Morris's human anatomy : a complete systematic treatise by English and American authors / ed. by C.M. Jackson eleven hundred and eighty two illustrations, three hundred and fifty eight printed in colors.

Contributors

Morris, Henry, Sir, 1844-1926
Jackson, Clarence Martin, 1875-1947
Augustus Long Health Sciences Library

Publication/Creation

Philadelphia : P. Blakiston's Son, [1914], [©1914]

Persistent URL

https://wellcomecollection.org/works/ad56hqjs

License and attribution

This material has been provided by the Augustus C. Long Health Sciences Library at Columbia University and Columbia University Libraries/Information Services, through the Medical Heritage Library. The original may be consulted at the the Augustus C. Long Health Sciences Library at Columbia University and Columbia University.
This work has been identified as being free of known restrictions under copyright law, including all related and neighbouring rights and is being made available under the Creative Commons, Public Domain Mark.

You can copy, modify, distribute and perform the work, even for commercial purposes, without asking permission.

wellcome collection

Wellcome Collection
183 Euston Road
London NW1 2BE UK
T +44 (0)20 7611 8722
E library@wellcomecollection.org
https://wellcomecollection.org

DUPLICATE
HX00013447

QM23 M83 1914
Columbia University
in the City of New York
College of Physicians and Surgeons
Library



Digitized by the Internet Archive
in 2010 with funding from
Columbia University Libraries

http://www.archive.org/details/morrisshumanana00morr

MORRIS'S

TREATISE ON ANATOMY

FIFTH EDITION

CONTRIBUTORS TO FIFTH EDITION

CHARLES R. BARDEEN, University of Wisconsin.
ELIOT R. CLARK, Johns Hopkins University.
IRVING HARDESTY, Tulane University of Louisiana.
C. M. JACKSON, University of Minnesota.
F. W. JONES, London School of Medicine for Women.
ABRAM T. KERR, Cornell University.
J. PLAYFAIR McMURRICH, University of Toronto.
JOHN MORLEY, Manchester University.
H. D. SENIOR, University and Bellevue Hospital Medical College., N. Y.
R. J. TERRY, Washington University, St. Louis.
PETER THOMPSON, University of Birmingham.
DAVID WATERSTON, King's College, London.

For arrangement of subjects and authors see page v.

THIS WORK IS ALSO PUBLISHED IN FIVE PARTS AS FOLLOWS:

PART I. Morphogenesis. Osteology. Articulations. Index. $1.50.
PART II. Muscles. Blood-Vascular System. Lymphatic System. Index. $2.50.
PART III. Nervous System. Special Sense Organs. Index. $2.00.
PART IV. Digestive System. Respiratory System. Skin, Mammary and Ductless Glands. Urogenital System. Index. $1.50.
PART V. Clinical and Topographical Anatomy. Index. $1.50.

MORRIS'S

HUMAN ANATOMY

A COMPLETE SYSTEMATIC TREATISE BY ENGLISH AND AMERICAN AUTHORS

EDITED BY

C. M. JACKSON, M. S., M. D.

PROFESSOR AND DIRECTOR OF THE DEPARTMENT OF ANATOMY,
UNIVERSITY OF MINNESOTA

ELEVEN HUNDRED AND EIGHTY TWO ILLUSTRATIONS
THREE HUNDRED AND FIFTY EIGHT PRINTED IN COLOURS

FIFTH EDITION, REVISED AND LARGELY REWRITTEN

PHILADELPHIA
P. BLAKISTON'S SON & CO.
1012 WALNUT STREET

Copyright, 1914, by P. Blakiston's Son & Co.

QM23
M83
1914

THE·MAPLE·PRESS·YORK·PA

ARRANGEMENT OF SUBJECTS AND AUTHORS

The names of the more recent of those who wrote or revised articles for previous editions have been retained in the following list in order that due credit should be given them for the work done and for their share in the great success which Morris's "Anatomy" has achieved.

MORPHOGENESIS. Revised and largely rewritten for the fifth edition by C. M. Jackson, M.S., M.D., Professor of Anatomy in the University of Minnesota. Originally written by J. Playfair McMurrich, A.M., Ph.D., Professor of Anatomy, University of Toronto.

OSTEOLOGY. Revised for the third, fourth and fifth editions by Peter Thompson, M.D., Professor of Anatomy, University of Birmingham; Member of Anatomical Society of Great Britain. This article was originally written by Sir John Bland Sutton, F.R.C.S.

ARTICULATIONS. Revised for the fifth edition by Frederic Wood Jones, D.Sc., M.B., B.S. (Lond.), M.R.C.S., L.R.C.P., Head of the Department of Anatomy and Lecturer in the London School of Medicine for Women. Originally written by Sir Henry Morris, A.M., M.B.

MUSCLES. Rewritten and revised for the fourth and fifth editions by Charles R. Bardeen, A.B., M.D., Professor of Anatomy in the University of Wisconsin; Member Association of American Anatomists; Member of Editorial Board of "American Journal of Anatomy."

BLOOD-VASCULAR SYSTEM. Revised and in part rewritten by Harold D. Senior, M.B., F.R.C.S., Professor of Anatomy, University and Bellevue Hospital Medical College. The section on Blood-vessels was formerly revised by Florence R. Sabin, B.S., M.D., Associate Professor of Anatomy, Johns Hopkins University.

LYMPHATIC SYSTEM. Revised and partly rewritten for the fifth edition by Eliot R. Clark, A.B., M.D., Associate in Anatomy, Johns Hopkins University. Revised for previous edition by Florence R. Sabin, B.S., M.D.

NERVOUS SYSTEM. Revised and largely rewritten for the fourth and fifth editions by Irving Hardesty, A.B., Ph.D., Professor of Anatomy, Tulane University, Louisiana; Member Association of American Anatomists.

SPECIAL SENSE ORGANS. Revised for the fifth edition by David Waterston, M.A., M.D., F.R.C.S., Professor of Anatomy in the University of London. In the earlier edition, the Ear, Nose, Tongue were revised by Abram T. Kerr, B.S., M.D.

DIGESTIVE SYSTEM. Revised and largely rewritten for the fifth edition by C. M. Jackson, M.S., M.D., Professor of Anatomy, University of Minnesota. Revised for the fourth edition by G. Carl Huber, M.D.

RESPIRATORY SYSTEM. Revised for the fourth and fifth editions by R. J. Terry, A.B., M.D., Professor of Anatomy, Washington University, St. Louis; Member Association of American Anatomists.

UROGENITAL SYSTEM. Revised for the fourth and fifth editions by J. Playfair McMurrich, A.M., Ph.D., Professor of Anatomy, University of Toronto; Member Association of American Anatomists.

THE SKIN AND MAMMARY GLAND; THE DUCTLESS GLANDS. By Abram T. Kerr, B.S., M.D., Professor of Anatomy, Cornell University; Member Association of American Anatomists, etc. The article on the Ductless Glands was originally written by G. Carl Huber, M.D.

CLINICAL AND TOPOGRAPHICAL ANATOMY. By John Morley, Ch.M., F.R.C.S., Honorary Surgeon, Ancoats Hospital, Manchester, and Lecturer in Clinical Anatomy, Manchester University. Originally written by W. H. A. Jacobson, F.R.C.S.

EDITOR'S PREFACE TO THE FIFTH EDITION

One criticism upon most of the current text-books of human anatomy is that they are too extensive for the beginner. Much precious time is wasted by him in floundering through a mass of details which obscure the fundamental facts. And yet it is important to have these details conveniently accessible for both present and future reference. To meet this difficulty, the attempt is made in this edition to discriminate systematically in the use of sizes of type. The larger type is used for the more fundamental facts, which should be mastered first, and the smaller type for details. While it has been found difficult to apply this principle uniformly through the various sections, it is hoped that the plan, even though but imperfectly realized, will prove useful to the beginner.

In the illustrations of the bones, as heretofore, the origins of muscles are indicated by red lines, the insertions by blue lines, and the attachments of ligaments by dotted black lines.

While the authors of the present edition are for the most part the same as in the previous edition, a few changes have been made as noted under the preceding section, "Arrangement of Subjects and Authors." Owing to the retirement of the distinguished originator and former editor of this work, Sir Henry Morris, and of Professor McMurrich as co-editor, the responsibility for the general supervision of the fifth revision has fallen to the present editor.

Each author is alone responsible for the subject-matter of the article following his name. Care has been exercised on the part of the editor, however, to make the whole uniform, complete and systematic.

As to nomenclature, the Anglicised form of the BNA has been continued, excepting those cases where the Latin form is adopted into English (e. g., most of the muscles), and rare cases where the BNA term seems undesirable. As a rule, the Anglicised form where first used is followed by the BNA Latin term *in brackets*, except where the two are practically identical. For convenience of reference, some of the commoner synonyms of the old nomenclature are also added in parenthesis.

The previous edition of Morris's Anatomy was the first general text-book of anatomy in English to adopt the BNA. During the past few years the merit of this system of nomenclature has become so widely recognized that it is now very generally accepted among the English-speaking nations. Lack of space forbids the enumeration here of the many advantages of this system, not the least of which is the reduction of some 30,000 anatomical terms (including synonyms) to 5000. The comparatively few defects of the BNA will doubtless be remedied by revision (preferably through the International Anatomical Congress). For a full discussion of the BNA system, with complete list of the Latin terms and English equivalents, the reader is referred to the excellent work on the BNA by Professor L. F. Barker, of Johns Hopkins University.

In addition to the bibliographical references scattered throughout the text, a brief list is given at the close of each section. These brief lists of carefully selected references are intended merely as a guide to put the student "on track" of the original literature.

In addition to a thorough revision of the various sections, there has also been a rearrangement of a part of the subject matter in the present edition. The Teeth have been transferred from the section on Osteology to the Digestive System. The Tongue and Nose are transferred to the Digestive System and Respiratory System, respectively, excepting those portions forming the organs of Taste and Smell, which have been retained in the section on Special Sense Organs. The Pelvic Outlet has been discontinued as a separate section, the subject matter being divided between Musculature and Clinical and Topographical Anatomy. The Ductless Glands have been included in the section with the Skin and Mammary Glands.

Due credit has been given throughout the book wherever illustrations have been taken, or modified, from other works. Special acknowledgment should be made of our indebtedness to the works of Toldt, Rauber-Kopsch, Poirier and Charpy, Henle and Spalteholz.

The number of figures in the present edition has been increased about one hundred and sixty and in addition many of the older figures have been improved or replaced. For the generosity of the publishers in this connection, and for the hearty coöperation of the contributors in the revision of the various sections, the editor desires to express his deep indebtedness. Valuable assistance has been rendered by Mr. Walter E. Camp in the reading of proof and preparation of the index.

C. M. Jackson.

Minneapolis.

CONTENTS

PAGE

INTRODUCTION 1

BY C. M. JACKSON, M.S., M.D.

SECTION I

MORPHOGENESIS

BY C. M. JACKSON, M.S., M.D.

PAGE

Segmentation of the Ovum 9
Embryonic Disc and Derivatives 10
Metamerism 15
Branchiomerism 16
Viscera and Limbs 18
Prenatal Growth 22
Variability 25
References 25

SECTION II

OSTEOLOGY

BY PETER THOMPSON, M.D.

The Skeleton 27
I. The Axial Skeleton 29
A. The Vertebral Column 29
The Cervical Vertebræ 31
The Thoracic Vertebræ 36
The Lumbar Vertebræ 37
The Sacrum 39
The Coccygeal Vertebræ 42
The Vertebral Column as a Whole 43
B. Bones of the Skull 51
The Occipital 51
The Parietal 57
The Frontal 59
The Sphenoid 62
The Sphenoidal Conchæ 67
The Epipteric and Wormian Bones 68
The Temporal Bone 68
The Tympanum 77
The Osseous Labyrinth 80
The Ethmoid 81
The Inferior Nasal Concha 84
The Lacrimal Bone 85
The Vomer 85
The Nasal Bones 86
The Maxilla or Upper Jaw 87
The Palate Bone 91
The Zygomatic or Malar Bone 93
The Mandible or Lower Jaw 95
The Hyoid Bone 99
The Skull as a Whole 100
The Orbits 109
The Nasal Fossæ 110
The Interior of the Skull 112
The Morphology of the Skull 117
The Skull at Birth 120
C. The Thorax 126
The Ribs 126
The Sternum 132
The Thorax as a Whole 138
II. The Appendicular Skeleton 139
A. Bones of the Upper Extremity. 139
The Clavicle 139
The Scapula 141
The Humerus 146
The Radius 152
The Ulna 155
The Carpus 159
The Metacarpals 164
The Phalanges 167
B. Bones of the Lower Extremity 169
The Coxal Bone 169
The Pelvis 175
The Femur or Thigh Bone 178
The Patella 184
The Tibia 185
The Fibula 189
The Tarsus 191
The Metatarsus 200
The Phalanges 203
The Bones of the Foot 205
Homology of the Bones of the Extremities 206
References 209

SECTION III

THE ARTICULATIONS

By F. W. Jones, D. Sc., M. B., M. R. C. S., L. R. C. P.

	PAGE
Constituents of an Articulation	211
Classification of Articulations	212
Development and Morphology	213
Movements of Joints	214
Articulations of the Skull	215
Mandibular Articulation	215
Ligaments and Joints between the Skull and Vertebral Column	218
Articulations of Atlas with Occiput	218
Articulations between Atlas and Epistropheus	220
Ligaments uniting the Occiput and Epistropheus	223
Articulations of the Trunk	224
1. The Articulations of the Vertebral Column	225
a. The Bodies of the Vertebræ	225
b. The Articular Processes	228
c. The Laminæ	229
d. The Spinous Processes	229
e. The Transverse Processes	231
2. Sacro-vertebral Articulations	232
3. Articulations of the Pelvis	234
4. Articulations of the Ribs with the Vertebræ	241
5. Articulations at the Front of the Thorax	244
Movements of the Thorax	247
The Articulations of the Upper Extremity	248
1. Sterno-costo-clavicular Articulation	248
2. Scapulo-clavicular Union	250
3. Shoulder-joint	253
4. Elbow-joint	258
5. Union of Radius with Ulna	261
6. Radio-carpal Articulation	265
7. Carpal Joints	268
8. Carpo-metacarpal Joints	272
9. Intermetacarpal Articulations	273
10. Metacarpo-phalangeal Joints	274
11. Interphalangeal Articulations	276
The Articulations of the Lower Limb	276
1. Hip-joint	276
2. Knee-joint	284
3. Tibio-fibular Union	295
4. Ankle-joint	297
5. Tarsal Joints	301
a. The Talo-calcaneal Union	301
b. Articulations of Anterior Part of Tarsus	303
c. Medio-tarsal or Transverse Tarsal Joints	305
6. Tarso-metatarsal Articulations	307
7. Intermetatarsal Articulations	309
8. Metatarso-phalangeal Articulations	310
9. Interphalangeal Joints	310
References	311

SECTION IV

THE MUSCULATURE

By C. R. Bardeen, A.B., M.D.

General Remarks on Muscles	313
Muscle Fasciæ	313
Gross Structure	314
Finer Structure of Muscles	315
Tendons	317
Synovial Bursæ	318
Synovial Sheaths	318
Nerves and Vessels	318
Nomenclature	319
Variation	320
Physiology	320
I. Musculature of the Head and Neck and Shoulder Girdle	323
Physiological and Morphological	323
1. Facialis Musculature	329
2. Cranio-mandibular Musculature	338
3. Supra-hyoid Musculature	343
4. Muscles of the Tongue	345
5. Superficial Shoulder Girdle Musculature	347
6. Infrahyoid Muscles	350
7. Scalene Musculature	353
8. Prevertebral Musculature	355
9. Anterior and Lateral Intertransverse Muscles	356
10. Deep Musculature of the Shoulder Girdle	356
II. Musculature of the Upper Limb	360
A. Musculature of the Shoulder	363
B. Pectoral Muscles and Axillary Fascia	370
C. Musculature of the Arm	374
1. Dorsal or Extensor Group	377
2. Ventral or Flexor Group	379
D. Musculature of the Forearm and Hand	383
1. Dorsal-Radial Division	387
a. Superficial Layer	387
b. Deep Layer	392
2. Ulno-Volar Division	395
a. First Layer	395
b. Second Layer	399
c. Third Layer	401
d. Fourth Layer	402
3. Musculature of the Hand	403
III. Spinal Musculature	410
A. Superficial Lateral Dorsal System	414
B. Deep Lateral Dorsal Muscles	417
C. Superficial Medial Dorsal System	417

PAGE

D. Deep Medial Dorsal System.. 417
E. Suboccipital Muscles..... 419
IV. Thoracic-abdominal Musculature. 422
A. Ventral Division..... 430
B. Lateral Division..... 431
1. Serratus Group..... 431
2. External Oblique Group.... 432
3. Internal Oblique Group.... 433
4. Transverse Group..... 434
C. Lumbar Muscle..... 436
D. Diaphragm..... 436
V. Musculature of the Pelvic Outlet. 439
A. Muscles of the Pelvic Diaphragm, Coccyx and Anus.. 448
B. Muscles of the Urogenital Diaphragm..... 449
C. External Genital Muscles..... 450
VI. Musculature of the Lower Limb.. 452
A. Musculature of the Hip..... 454
1. Ilio-femoral Musculature... 454
a. Anterior Group..... 455
b. Posterior Group..... 457
2. Ischio-pubo-femoral Musculature of the Hip..... 463
B. Musculature of the Thigh..... 464
1. Anterior Group..... 468
2. Medial (Adductor) Group.. 471
3. Posterior (Hamstring) Group..... 474
C. Musculature of the Leg..... 477
1. Muscles of the Front of the Leg..... 480
2. Lateral Musculature of the Leg..... 483
3. Musculature of the Back of the Leg..... 484
D. Muscles of the Foot..... 491
1. Muscle of the Dorsum of the Foot..... 492
2. Muscles of the Sole..... 493
Muscles Grouped According to Function 500
References..... 506

SECTION V

BLOOD-VASCULAR SYSTEM

By Harold D. Senior, M.B., M.D.

A. The Heart and Pericardium..... 508
1. The Heart..... 508
Exterior of the Heart..... 509
Atrial Portion..... 511
Atrio-Ventricular Valves..... 515
Ventricular Portion..... 516
Semilunar Valves..... 517
Architecture of the Heart..... 518
Vessels and Nerves..... 519
2. The Pericardium..... 522
3. Surface Relations..... 523
4. Morphogenesis..... 523
B. The Arteries and Veins..... 527
1. Pulmonary Arteries and Veins... 528
2. The Systemic Arteries..... 529
The Aorta..... 529
Innominate Artery..... 532
Branches..... 532
Common Carotid Arteries..... 533
External Carotid Artery..... 536
Branches..... 536
Internal Carotid Artery..... 549
Branches..... 552
Subclavian Artery..... 556
Branches..... 558
Axillary Artery..... 569
Branches..... 570
Brachial Artery..... 573
Branches..... 575
Ulnar Artery..... 576
Branches..... 577
Superficial Volar Arch..... 582
Branches..... 582
Radial Artery..... 582
Branches..... 583
Deep Volar Arch..... 586
Branches..... 586
Descending or Thoracic Aorta.. 586
Visceral Branches..... 588
Parietal Branches..... 588
Abdominal Aorta..... 590
Parietal Branches..... 592
Visceral Branches..... 593
Terminal Branches..... 603
Middle Sacral Artery..... 603
Common Iliac Arteries..... 603
Hypogastric Artery..... 605
Parietal Branches..... 606
Visceral Branches..... 609
External Iliac Artery..... 614
Branches..... 614
Femoral Artery..... 616
Branches..... 618
Popliteal Artery..... 621
Branches..... 622
Posterior Tibial Artery..... 624
Branches..... 626
Lateral Plantar Artery..... 627
Branches..... 628
Medial Plantar Artery..... 629
Branches..... 629
Anterior Tibial Artery..... 629
Branches..... 630
Dorsalis Pedis Artery..... 632
Branches..... 632
Morphogenesis and Variations of the Arteries..... 633
a. Arteries of the Head and Trunk..... 633
b. Arteries of the Extremities 639
3. The Systemic Veins..... 640
Veins Emptying into the Vena Cava Superior..... 641
Veins of the Head and Neck..... 642
Superficial Veins of the Head and Neck..... 643
Deep Veins of the Head and Neck..... 648
Veins of the Thorax..... 662
Superficial Veins of the Thorax. 662
Deep Veins of the Thorax..... 662
Veins of the Upper Extremity... 667
Superficial Veins of Upper Extremity..... 667
Deep Veins of Upper Extremity 670
Veins Emptying into the Vena Cava Inferior..... 672
Portal Vein and its Tributaries. 675
Common Iliac Veins..... 679
Hypogastric Vein..... 679

PAGE

External Iliac Vein 683
Superficial Veins of Abdominal Wall 683
Veins of the Lower Extremity ... 683
Superficial Veins of Lower Extremity 684
Deep Veins of Lower Extremity 686
Morphogenesis and Variations of the Veins 690
a. Vena Cava Superior and Tributaries 690
b. Vena Cava Inferior and Tributaries 693
c. Portal System 694
The Fœtal Circulation 695
References 696

SECTION VI

THE LYMPHATIC SYSTEM

By Eliot R. Clark, A.B., M.D.

I. General Anatomy of the Lymphatic System 697
1. Lymphatic Capillaries 697
2. Lymphatic Vessels 702
3. Lymphoid Organs 704
4. Development of the Lymphatic System 706
II. Special Anatomy of the Lymphatic System 709
A. Lymphatics of the Head and Neck 709
1. Superficial Nodes of Head and Neck 709
2. Lymphatic Vessels of the Face 712
3. Deep Lymphatic Nodes of the Head and Neck 714
4. Deep Lymphatic Vessels of the Head and Neck 714
B. Lymphatics of the Upper Extremity 719
1. Lymphatic Nodes of the Upper Extremity 719
2. Lymphatic Vessels of the Upper Extremity 721
C. Lymphatics of the Thorax 723
1. Superficial Lymphatic Vessels of the Thorax 723
2. Lymphatic Nodes of the Thorax 724
3. Deep Lymphatics of the Thorax 725
Thoracic Duct 726
Right Collecting Ducts 728
Deep Lymphatic Vessels 728
D. Lymphatics of Abdomen and Pelvis 730
1. Lymphatic Nodes of the Abdomen and Pelvis 730
2. Lymphatic Vessels of the Abdominal Walls 733
3. Visceral Lymphatic Vessels of the Abdomen and Pelvis ... 733
Lymphatics of Alimentary Tract 733
Lymphatics of Excretory Organs 737
Lymphatics of Reproductive Organs 742
E. Lymphatics of the Lower Extremity 746
1. Lymphatic Nodes of the Lower Extremity 746
2. Lymphatic Vessels of the Lower Extremity 748
References 750

SECTION VII

THE NERVOUS SYSTEM

By Irving Hardesty, A.B., Ph.D.

General Considerations 751
Central Nervous System 770
I. Spinal Cord 771
External Morphology 771
Internal Structure 775
II. Brain or Encephalon 792
General Topography 793
Rhombencephalon 799
1. Medulla Oblongata 799
2. Pons Varolii 804
3. Cerebellum 804
Cerebrum 833
1. Mesencephalon (Mid-brain). 833
2. Prosencephalon (Fore-brain) 843
A. Diencephalon(Inter-brain) 843
B. Telencephalon(End-brain) 847
III. General Summary of Principal Conduction Paths of Nervous System 895
IV. Meninges 908
The Peripheral Nervous System 924
I. Cranial Nerves 927
Olfactory Nerves 929
Optic Nerves 930
Oculo-motor Nerves 931
Trochlear Nerves 933
Abducens Nerves 934
Trigeminal Nerves 934
Masticator Nerves 942
Facial Nerves 943
Glosso-palatine Nerves 946
Vestibular Nerves 949
Cochlear Nerves 950
Glosso-pharyngeal Nerves 951
Hypoglossal Nerves 952
Vagus Nerves 954
Spinal Accessory Nerves 958
Gangliated Cephalic Plexus 959
II. Spinal Nerves 964
A. Posterior Primary Divisions ... 970

PAGE
1. Cervical Nerves 971
2. Thoracic Nerves 971
3. Lumbar Nerves 973
4. Sacral Nerves 973
B. Anterior Primary Divisions 973
1. Cervical Nerves 974
Cervical Plexus 974
Brachial Plexus 980
2. Thoracic Nerves 994
3. Lumbar Nerves 996
Lumbo-sacral Plexus 996
Lumbar Plexus 998
Lumbo-sacral Trunk 1005
4. Sacral Nerves 1006
Sacral Plexus 1006
Pudendal Plexus 1016
Coccygeal Plexus 1018
III. Distribution of the Cutaneous Branches 1018
Cutaneous Areas of Scalp 1018
Cutaneous Areas of Face 1018
PAGE
Cutaneous Areas of Neck 1019
Cutaneous Areas of Trunk 1020
Cutaneous Areas of Limbs 1020
The Sympathetic System 1026
Sympathetic Trunks 1032
Cephalic and Cervical Portions of the Sympathetic Trunk 1033
1. Superior Cervical Ganglion 1035
2. Middle Cervical Ganglion 1036
3. Inferior Cervical Ganglion 1036
Thoracic Portion of Sympathetic Trunk 1037
Lumbar Portion of Sympathetic Trunk 1039
Sacral Portion of Sympathetic Trunk. 1040
Great Prevertebral Plexuses 1040
1. Cardiac Plexus 1041
2. Cœliac Plexus 1043
3. Hypogastric Plexus 1045
References 1047

SECTION VIII

SPECIAL SENSE ORGANS

By David Waterston, M.A., M.D., F.R.C.S.

General Considerations 1049
I. Olfactory Organ 1049
II. Organ of Taste 1051
III. The Eye 1051
General Surface View 1052
Examination of Eyeball 1055
Cavity of Orbit 1066
General Arrangement 1066
Optic Nerve 1073
Blood-vessels and Nerves of Orbit 1074
Eyelids 1076
Lacrimal Apparatus 1079
Development of the Eye 1080
The Ear 1082
External Ear 1082
Middle Ear 1086
Internal Ear 1092
Development of the Ear 1096
References 1098

SECTION IX

THE DIGESTIVE SYSTEM

By. C. M. Jackson, M.S., M.D.

The Mouth 1100
The Lips and Cheeks 1102
The Palate 1104
The Tongue 1106
The Salivary Glands 1113
The Teeth 1117
The Pharynx 1128
The Œsophagus 1138
The Abdomen 1142
The Peritoneum 1145
The Stomach 1151
The Small Intestine 1161
The Duodenum 1161
The Jejunum and Ileum 1165
The Large Intestine 1170
The Liver 1180
The Bile Passages 1186
The Pancreas 1192
References 1197

SECTION X

THE RESPIRATORY SYSTEM

By R. J. Terry, A.B., M.D.

The Nose 1200
The Larynx 1209
Cartilages of Larynx 1209
Joints and Membranes of Larynx 1213
Muscles of Larynx 1218
Cavity of Larynx and Mucosa 1220
The Trachea and Bronchi 1225
The Lungs 1228
The Thoracic Cavity 1235
The Pleuræ 1236
Mediastinal Septum 1239
References 1240

SECTION XI

UROGENITAL SYSTEM

By J. Playfair McMurrich, A.M., Ph.D.

	PAGE
The Urinary Apparatus	1241
The Kidneys	1241
The Ureters	1247
The Urinary Bladder	1249
The Male Reproductive Organs	1253
The Testes and Their Appendages	1254
The Scrotum	1254
The Testes and Epididymis	1255
The Ductus Deferentes and Seminal Vesicles	1257
The Spermatic Cord	1259
The Penis	1260
The Male Urethra	1262
The Prostate	1264
The Bulbo-urethral Glands	1265
The Female Reproductive Organs	1265
The Ovaries	1268
The Tubæ Uterinæ	1269
The Uterus	1271
The Vagina	1274
Female External Genitalia and Urethra	1276
Development of the Reproductive Organs	1278
References	1280

SECTION XII

THE SKIN, MAMMARY AND DUCTLESS GLANDS

By Abram T. Kerr, B.S., M.D.

The Skin	1281
Appendages of the Skin	1290
Hairs	1290
Nails	1293
Cutaneous Glands	1296
Mammary Glands	1299
The Ductless Glands	1306
The Spleen	1306
The Thyreoid Gland	1312
Parathyreoid Glands	1318
Thymus	1319
Suprarenal Glands	1323
Glomus Caroticum	1327
Aortic Paraganglia	1329
Glomus Coccygeum	1329
References	1329

SECTION XIII

CLINICAL AND TOPOGRAPHICAL ANATOMY

By John Morley, Ch.M., F.R.C.S.

The Head	1331
The Cranium	1333
The Bony Sinuses	1335
Cranio-cerebral Topography	1338
The Hypophysis Cerebri	1342
The Face	1342
The Orbit and Eye	1346
The Mouth	1349
The Nose	1352
The Neck	1354
The Thorax	1363
The Abdomen	1370
The Pelvis	1382
Male Pelvis	1382
Female Pelvis	1391
Hernia	1394
Inguinal Hernia	1394
Femoral Hernia	1398
Umbilical Hernia	1402
The Back	1403
The Upper Extremity	1409
The Shoulder and Arm	1409
The Elbow	1417
The Forearm	1419
The Wrist and Hand	1424
The Lower Extremity	1434
The Hip and Thigh	1434
The Knee	1444
Popliteal Space	1451
The Leg	1453
The Ankle	1459
The Foot	1464
Arches of the Foot	1468

Index 1471

INTRODUCTION

By C. M. JACKSON, M.S., M.D.

PROFESSOR OF ANATOMY, UNIVERSITY OF MINNESOTA.

ANATOMY, as the term is usually employed, denotes the study of the structure of the human body. Properly, however, it has a much wider significance, including within its scope not man alone, but all animal forms, and, indeed, plant forms as well; so that, when its application is limited to man, it should be qualified by the adjective human. *Human Anatomy*, then, is the study of the structure of the human body, and stands in contrast to, or rather in correlation with, *Human Physiology*, which treats of the functions of the human body, the two sciences, Anatomy and Physiology, including the complete study of man's organization and functional activities.

In the early history of the sciences these terms sufficed for all practical needs, but as knowledge grew, specialization of necessity resulted and new terms were from time to time introduced to designate special lines of anatomical inquiry. With the improvement of the microscope a new field of anatomy was opened up and the science of *Histology* came into existence, assuming control over that portion of Anatomy which dealt with the minuter details of structure. So, too, the study of the development of the various organs gradually assumed the dignity of a more or less independent study known as *Embryology*, and the study of the structural changes due to disease was included in the science of *Pathology;* so that the term Anatomy is sometimes limited to the study of the macroscopic structure of normal adult organisms.

It is clear, however, that the lines of separation between Anatomy, Histology, Embryology, and Pathology are entirely arbitrary. Microscopic anatomy necessarily grades off into macroscopic anatomy; the development of an organism is a progressive process and the later embryonic or fœtal stages shade gradually into the adult; and structural anomalies lead insensibly from the normal to the pathological domains. Furthermore it is found that in its individual development the organism passes through stages corresponding to those of its ancestry in evolution; in other words, Ontogeny repeats Phylogeny. A comprehensive study of Anatomy must therefore include more or less of the other sciences, and since an appreciation of the significance of structural details can only be obtained by combining the studies of Anatomy, including Histology and Embryology, and since, further, much light may be thrown on the significance of embryological stages by comparative studies, Anatomy, Embryology, and Comparative Anatomy form a triumvirate of sciences by which the structure of an organism, the significance of that structure, and the laws which determine it are elucidated. For this combination it is convenient to have a single term, and that which is used is *Morphology*, a word meaning literally the science of form.

In morphological comparisons, the term *homology* denotes similarity of structure, due to a common origin in the evolution of organs or parts; while *analogy* denotes merely physiological correspondence in function. Thus the arm of man and the wing of a bird are homologous, but not analogous, structures; on the other hand, the wing of a bird and the wing of an insect are analgous, but not homologous. *Serial homology* refers to corresponding parts in successive segments of the body.

Nomenclature.—Formerly there was much confusion in the anatomical nomenclature, due to the multiplicity of names and the lack of uniformity in using them. Various names were applied to the same organs and great diversity of usage prevailed, not only between various countries, but also even among authors of the same country. Recently, however, a great improvement has been made by the general adoption of an international system of anatomical nomen-

clature. This system was first adopted by the German Anatomical Society at a meeting in Basel, in 1895, and is hence called the Basel Nomina Anatomica, or briefly, the BNA. The BNA provides each term in Latin form, which is especially desirable for international usage. Each nation, however, is expected to translate the terms into its own language, wherever it is deemed preferable for everyday usage. Thus in the present work the Anglicised form of the BNA is generally used. Where not identical, however, the Latin form is added once for each term in a place convenient for reference, and is designated by enclosure in brackets [ ]. Where necessary the older terms have also been added as synonyms.

The Commission by whom the BNA was prepared included eminent anatomists representing various European nations. The work of the Commission was very thorough and careful, and extended through a period of six years. Among the guiding principles in the difficult task of selecting the most suitable terms were the following: (1) Each part should have one name only. (2) The names should be as short and simple as possible. (3) Related structures should have similar names. (4) Adjectives should be in opposing pairs. A few exceptions were found necessary, however.

On account of its obvious merits, the BNA system has been generally adopted throughout the civilised world, and the results are very satisfactory. Comparatively few new terms have been thereby introduced, over 4000 of the 4500 names in the BNA corresponding almost exactly to older terms already in use by the English-speaking nations. Certain minor defects in the system have been criticised; but these are outweighed by the advantages of this uniform system.

Abbreviations.—Certain frequently used words in the BNA are abbreviated as follows: a., arteria (plural, aa., arteriæ); b., bursa; g., ganglion; gl., glandula; lig., ligamentum (plural, ligg., ligamenta); m., musculus (plural, mm., musculi); n., nervus (plural, nn., nervi); oss., ossis (or ossium); proc., processus; r., ramus (plural, rr., rami); v., vena (plural, vv., venæ).

Terms of position and direction.—The exact meaning of certain fundamental terms used in anatomical description must be clearly understood and kept in mind. In defining these terms, it is supposed that the human body is in an upright position, with arms at the sides and palms to the front.

The three **fundamental planes** of the body are the sagittal, the transverse and the frontal. The vertical plane through the longitudinal axis of the trunk, dividing the body into right and left halves, is the *median* or *mid-sagittal* plane; and any plane parallel to this is a *sagittal* plane. Any vertical plane at right angles to a sagittal plane, and dividing the body into front and rear portions is a *frontal* (or coronal) plane. A plane across the body at right angles to sagittal and coronal planes is a *transverse* or *horizontal* plane.

Terms pertaining to the front of the body are *anterior* or *ventral*; to the rear, *posterior* or *dorsal*; upper is designated as *superior* or *cranial*; and lower as *inferior* or *caudal*.

The term *medial* means nearer the mid-sagittal plane, and *lateral*, further from that plane. These terms should be carefully distinguished from internal (inner) and external (outer), which were formerly synonymous with them. *Internal*, as now used (BNA), means deeper, i. e., nearer the central axis of the body or part; while *external* refers to structures more superficial in position. *Proximal*, in describing a limb, refers to position nearer the trunk; while *distal* refers to a more peripheral position.

Adverbial forms are also employed, e. g., anteriorly or ventrally (forward, before); posteriorly or dorsally (backward, behind); superiorly or cranially (upward, above); and inferiorly or caudally (downward, below).

It should also be noted that the terms ventral, dorsal, cranial and caudal are independent of the body posture, and therefore apply equally well to corresponding surfaces of vertebrates in general with horizontal body axis. On this account these terms are preferable, and will doubtless ultimately supplant the terms anterior, posterior, superior and inferior.

The discrimination in the use of several similar terms of the BNA should also receive attention. Thus *medianus* (median) refers to the median plane. *Medialis* (medial) means nearer the median plane and is opposed to lateral, as above stated. *Medius* (middle) is used to designate a position between anterior and posterior, or between internal and external. Between medialis and lateralis, however, the term *intermedius* is used. Finally, *transversalis* means transverse to the body axis; *transversus*, transverse to an organ or part; and *transversarius*, pertaining to some other structure which is transverse.

Parts of the body.—The primary divisions of the human body (fig. 1) are the head, neck, trunk and extremities. The *head* [caput] includes *cranium* and *face* [facies]. The *neck* [collum] connects head and trunk. The *trunk* [truncus] includes *thorax*, *abdomen*, and *pelvis*. The *upper extremity* [extremitas superior] includes *arm* [brachium], *forearm* [antibrachium], and *hand* [manus]. The

lower extremity [extremitas inferior] includes *thigh* [femur], *leg* [crus], and *foot* [pes].

Each of the parts mentioned has further subdivisions, as indicated in fig. 1. The cranium includes: *crown* [vertex]; *back* of the head [occiput]; *frontal* region [sinciput], including *forehead* [frons]; *temples* [tempora]; *ears* [aures], including *auricles* [auriculæ].

FIG. 1.—PARTS OF THE HUMAN BODY. A, Posterior view. B, Anterior view.

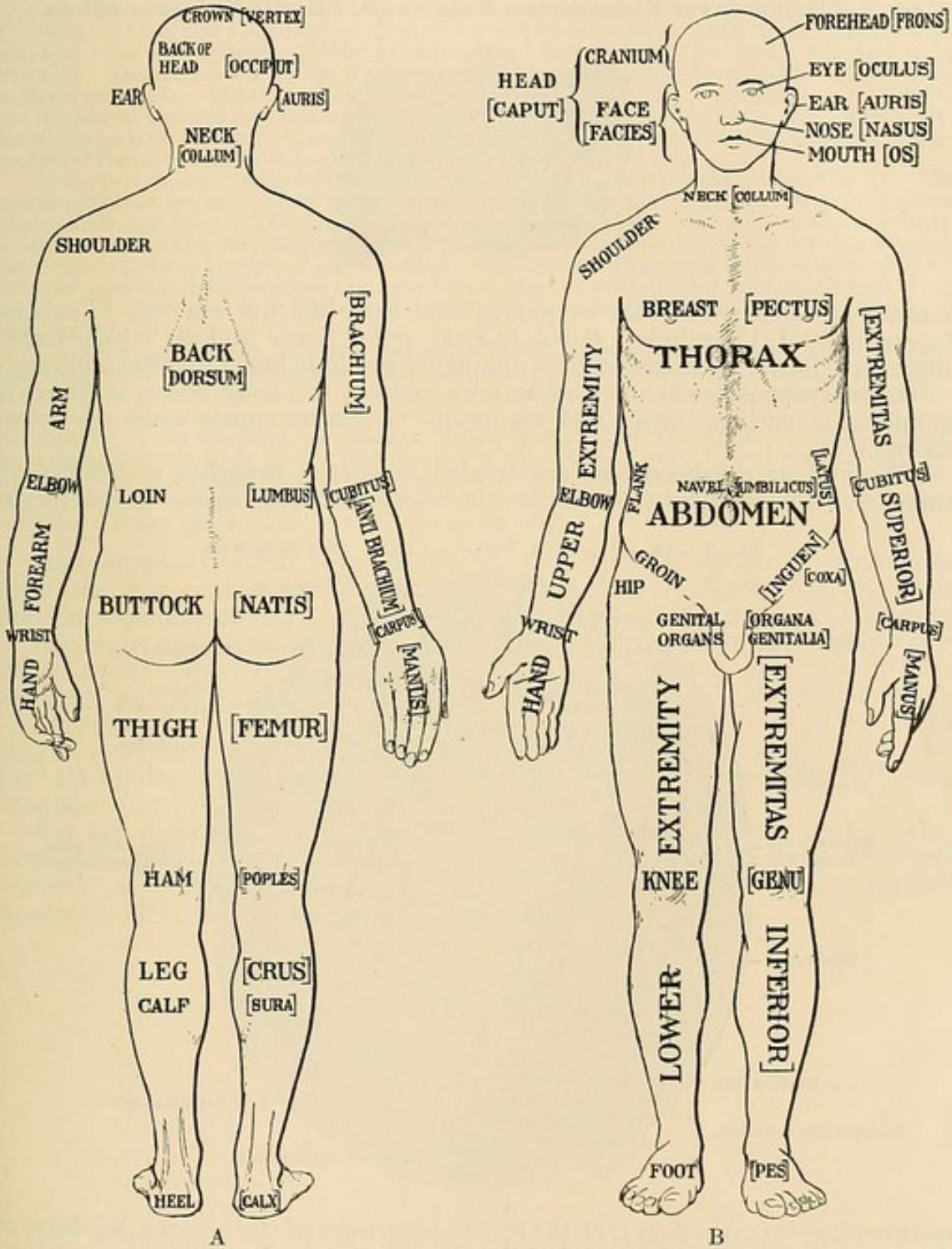

The face includes the regions of the *eye* [oculus], *nose* [nasus], and *mouth* [os], the subdivisions of which will be given later under the appropriate sections.

The thorax includes: *breast* [pectus]; *mammary gland* [mamma]; and *thoracic cavity* [cavum thoracis]. The *back* [dorsum] includes the vertebral column [columna vertebralis]. The abdomen includes: *navel* [umbilicus]; *flank* [latus]; *groin* [inguen]; *loin* [lumbus]; and the *abdominal cavity* [cavum abdominis]. The pelvis includes: *pelvic cavity* [cavum pelvis]; *genital organs* [organa genitalia],

buttocks [nates], separated by a cleft [crena ani] at the *anus*. The *hip* [coxa] connects the pelvis with the lower extremity.

In the lower extremity, the thigh is joined to the leg by the *knee* [genu]. The foot includes: *heel* [calx]; *sole* [planta]; *instep* [tarsus]; *metatarsus;* and five *toes* [digiti I–V], including the *great toe* [hallux] and *little toe* [digitus minimus].

The upper extremity is joined to the thorax by the *shoulder*. The arm is joined to the forearm at the *elbow* [cubitus]. The hand includes: *wrist* [carpus];

FIG. 2.—SECTION OF THE EPIDERMIS OF A FINGER, FROM A HUMAN EMBRYO OF 10.2 CM.

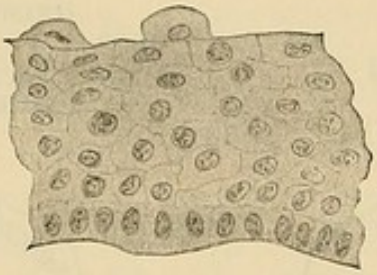

metacarpus, with *palm* [vola or palma] and *back* [dorsum manus]. The five *fingers* [digiti I–V] include: *thumb* [pollex], *index* finger [index]; *middle* finger [digitus medius]; *ring* finger [digitus annularis] and *little* finger [digitus minimus].

Organ-systems.—Each of the various parts of the body above outlined is composed of various *organs*, and the groups of related organs make up *organ-systems*.

The various organ-systems are treated as special branches of descriptive anatomy. The study of the *bones* is called *osteology;* of the *ligaments* and *joints*,

FIG. 3.—DIAGRAM OF A TYPICAL CELL. (Szymonowicz.)

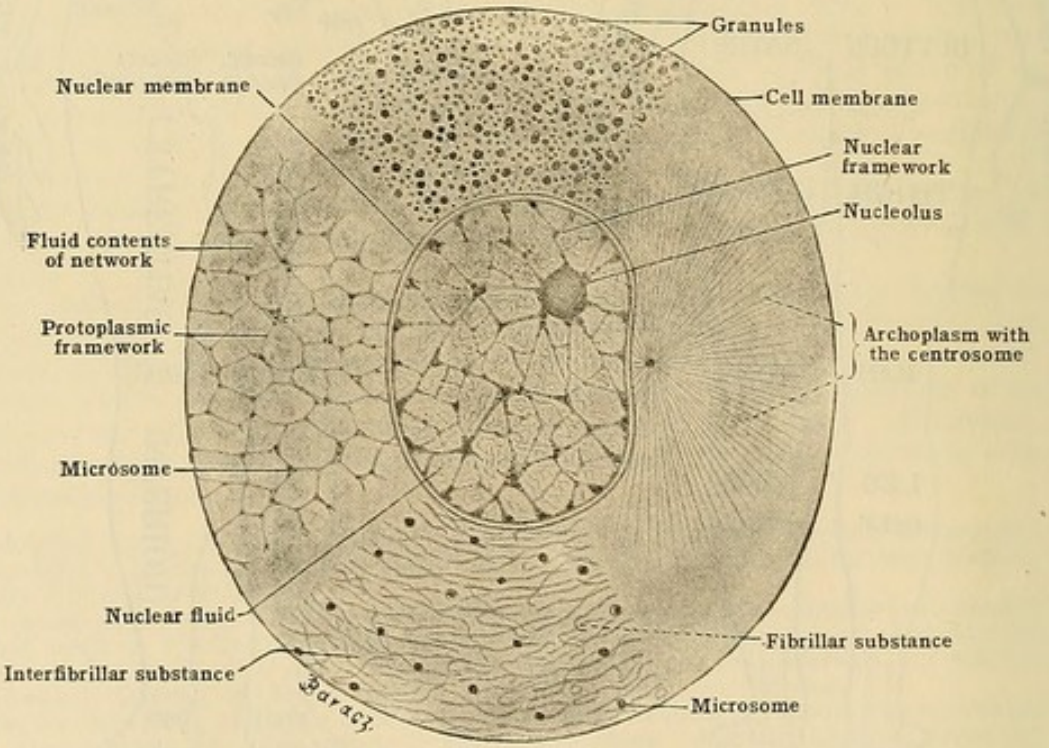

syndesmology (or arthrology); of the *vessels, angiology;* of the *muscles, myology;* of the *nervous system, neurology;* and of the *viscera, splanchnology*. Further subdivisions are also made. The viscera, for example, include the *digestive* tract, *respiratory* tract, *urogenital* tract, etc.

Tissues and cells.—The body, as above stated, has various parts, each of which may be subdivided into its component systems and organs. A further analysis reveals a continued series of structural units of gradually decreasing complexity. Thus each organ is found to consist of a number of *tissues* (epithelial, connective, muscular or nervous). Finally, each tissue is composed of a group of similar units called *cells* (figs. 2, 3) which are the ultimate structural units

of the body. The body may therefore be regarded as composed of myriads of cell units, organized into units of gradually increasing complexity, very much as a social community is composed of individuals organized into trades, municipalities, etc.

Most of the individual tissues can be recognized by their gross appearance. In fact, the principal tissues were first demonstrated by Bichat through skilful dissection, maceration, etc., and without the aid of the microscope. The cellular structure of the tissues was later discovered by Schwann in 1839.

Each cell (fig. 3) is composed of a material called *protoplasm*, a viscid substance variable in appearance and exceedingly complex in chemical composition. It readily breaks down into simpler chemical compounds, whereby energy (chiefly in the form of heat and mechanical energy) is liberated. It has also the power of absorbing nutritive material to build up and replace what was lost. Its decomposition results from stimuli of various kinds, and hence it is said to be irritable. The mechanical energy which it liberates is manifested by its contractility, especially in the muscle cells. It excretes the waste products produced by its decomposition. Each cell has the power, under favourable conditions, of reproducing itself by division. Protoplasm presents, in short, all the forms of activity manifested by the body as a whole; and, indeed, the activities of the body are the sum of the activities of its constituent cells.

In the protoplasm of each cell is a specially differentiated portion, the *nucleus* (fig. 3). The nucleus plays an important part in regulating the activities of the *cytoplasm*, the general protoplasm of the cell body. The nucleus differs from the cytoplasm both structurally and chemically, and contains a very important substance, *chromatin*, which during cell division is aggregated into a definite number of masses called *chromosomes*. The cytoplasm of actively growing cells also contains the *archoplasm* and *centrosome*, structures of importance in the process of cell division. Further details concerning the cells and tissues may be found in the text-books of cytology and histology.

In earlier days Human Anatomy was almost entirely a descriptive science, but little attention being paid to the significance of structure, except in so far as it could be correlated with physiological phenomena as they were at the time understood. In recent years attention has been largely paid to the morphology of the human body and much valuable information as to the meaning of the structure and relations of the various organs has resulted. Since the form and structure of the body are the final result of a series of complicated developmental changes, the science of Embryology has greatly contributed to our present knowledge of human Morphology; and, accordingly, a brief sketch of some of the more important phases of morphogenesis will form a fitting introduction to the study of the adult.

References.—*General:* For looking up the literature upon any anatomical topic, the best guide is the "Jahresbericht ueber die Fortschritte der Anatomie und Entwicklungsgeschichte," which contains classified titles and brief abstracts of the more important papers in gross anatomy, histology and embryology. Other useful aids are the "Zentralblatt fuer normale Anatomie," the "Index Medicus" and the catalogue of the Surgeon Genera 's Library of the War Dep't. (Washington, D. C.). The latter two contain titles only, but cover the whole field of medicine. The "Concilium Bibliographicum" also provides a convenient card-index system of references for the biological sciences, including Anatomy.

For *nomenclature:* His, Archiv f. Anat., 1895 (BNA system); Barker, Anatomical Nomenclature. *Cells and tissues:* Wilson, The Cell; Hertwig, Zelle und Gewebe (also English transl.); Schaefer, Microscopic Anatomy (in Quain's Anatomy, 11th ed.); Heidenhain, Plasma und Zelle.

SECTION I

MORPHOGENESIS

REVISED FOR THE FIFTH EDITION

BY C. M. JACKSON, M.S., M.D.

PROFESSOR OF ANATOMY IN THE UNIVERSITY OF MINNESOTA

CHANGE is a fundamental characteristic of all living things. The human body during its life cycle accordingly passes through various phases of form and structure. In the earliest embryonic phases of development the changes are very rapid, decreasing in rapidity during the later fœtal stages, but continuing at a diminishing rate throughout infancy, childhood and youth up to the adult. Following the acme of maturity, changes continue which lead gradually to senescence and final death of the body.

This cycle of change in the body depends upon similar changes in its various component organs, each having its own characteristic life cycle. In a few of the organs this cycle is very short, as in some of the organs of the embryo (e. g., mesonephros). Other organs persist only during childhood (e. g., thymus); while the majority continue, with varying degrees of change, throughout postnatal life. The final death of the body is due to the breakdown of some of the essential organs.

A further analysis reveals the fact that the characteristic life cycles of the organs depend ultimately upon similar changes in their constituent tissues and cells. Every cell has a definite life cycle, an early period characterised by rapid and vigourous changes, later periods of differentiation and maturity, followed by stages of degeneration and death. This cycle of cell changes has been designated by Minot as *cytomorphosis*.

Growth.—Associated with the process of cell differentiation (cytomorphosis), and even more important as a factor in the morphogenesis of the body, is the process of *growth*. The developmental changes in form and structure of the body are due largely to the unequal growth of its various parts. Growth, like other changes in the body and its parts, depends ultimately upon the characteristics of the constituent cells.

FIG. 4.—THE OVUM OF A NEW-BORN CHILD, WITH FOLLICLE CELLS. (After Mertens.)

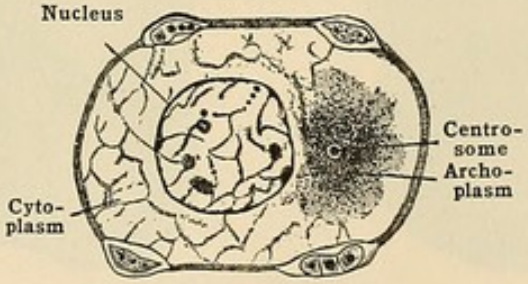

The cell changes during growth may be grouped under two heads. The first, or growth proper, involves merely the *enlargement* (hypertrophy) of the individual cells and intercellular products. The second includes the *multiplication* (hyperplasia) of the cells, which is accomplished by mitotic division. Cell division is necessary in cell growth, for otherwise the cell would soon reach a size where its surface (for nutritive, respiratory and excretory purposes) would be inadequate for its mass. In general, however, cell division is most active in the earlier embryonic periods, during which the cells remain small. Later, cell division diminishes or ceases, and growth is due chiefly to enlargement of the cells already present. It is also during the later period, when the cells have ceased rapid division, that the process of cell differentiation and tissue formation is most marked.

The principle of the *ratio of surface to mass* often applies to the growing organs as well as to the individual cells. To maintain the necessary ratio, the surface area is increased by the formation, through localised unequal growth, of *projections* (e. g., villi or folds) or *invaginations* (e. g., glands) from surfaces. Innumerable modifications of this principle occur throughout the process of morphogenesis.

FIG. 5.—OVUM FROM OVARY OF A WOMAN THIRTY YEARS OF AGE. *cr*, corona radiata. *n*, nucleus. *y*, yolk. *p*, clear protoplasmic zone, *ps*, perivitelline space. *zp*, zona pellucida. (McMurrich's Embryology, from Nagel.)

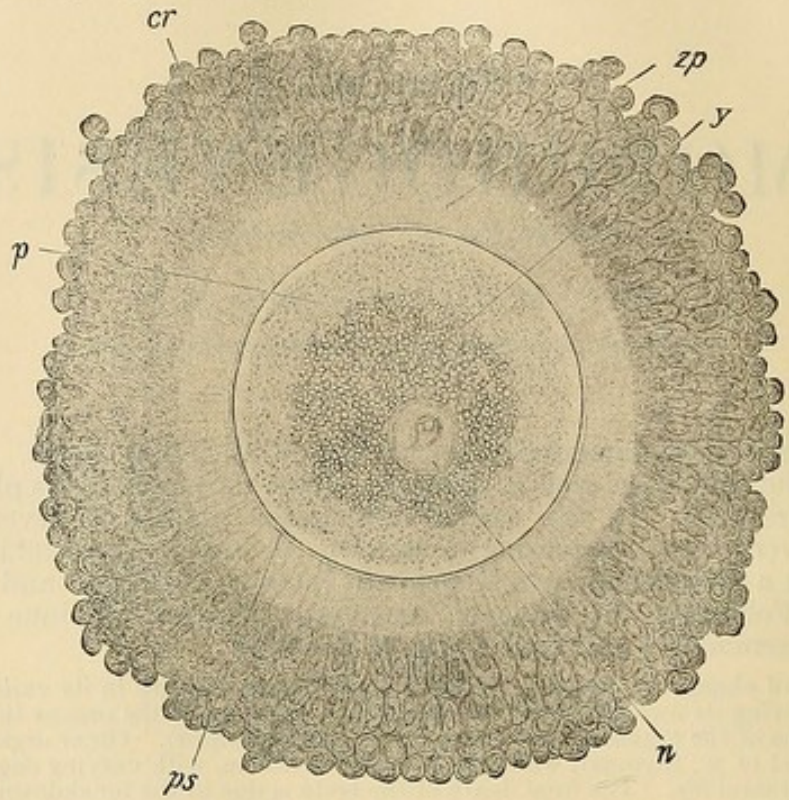

FIG. 6.—STAGES OF SEGMENTATION IN THE OVUM OF THE MOUSE. *x*, polar body. (McMurrich's Embryology, from Sobotta.)

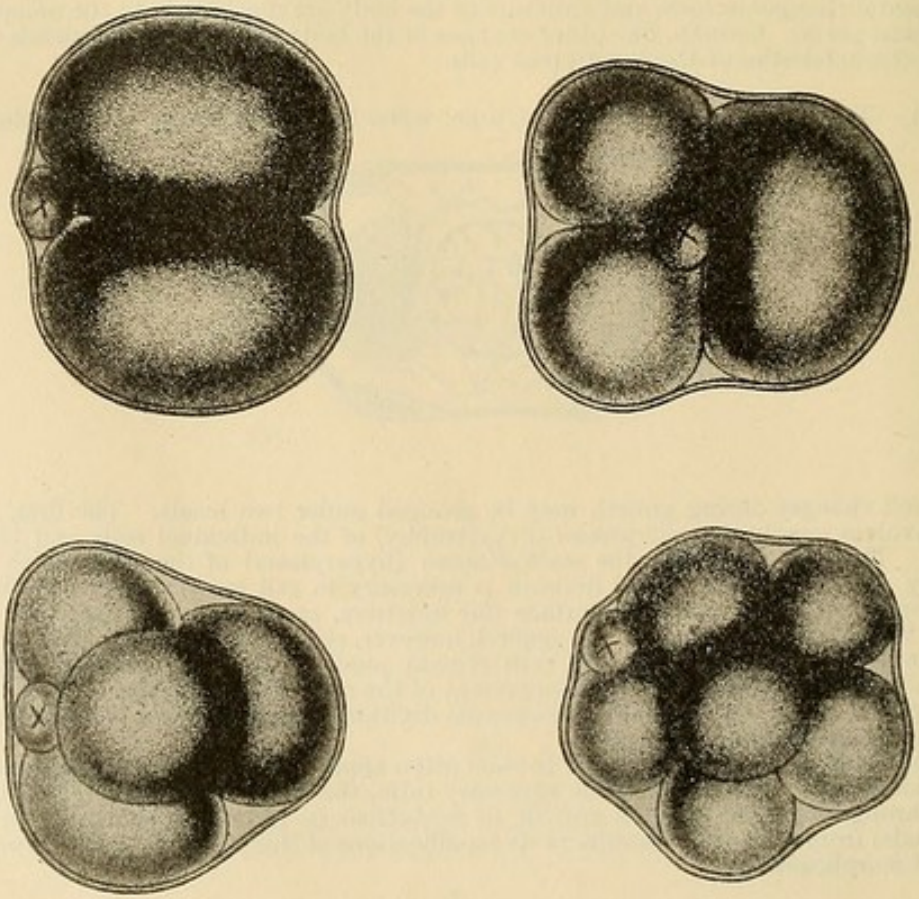

While the present work deals primarily with the adult human organism in the stage of maturity, reference is made also to its changes according to age. Although these changes for the various systems of organs are described under the appropriate sections, it is desirable to consider first some of the more fundamental features pertaining to the body as a whole. This applies particularly to the earlier embryonic period, which includes the more general phases of morphogenesis. No attempt will be made to describe fully the process of development, the details of which are to be found in text-books of embryology.

Segmentation of the ovum.—The human body, like all living organisms, arises from a single cell, the egg-cell or *ovum*. An early stage in the development of the ovum is shown in fig. 4, and a later stage, approaching maturity, in fig. 5. The mature human ovum is about 0.2 mm. in diameter. In the uterine (Fallopian) tube, the fertilised ovum undergoes segmentation, the various stages of which are represented in figs. 6 and 7.

FIG. 7.—DIAGRAM OF SECTION THROUGH A MAMMALIAN OVUM AT THE MORULA STAGE.

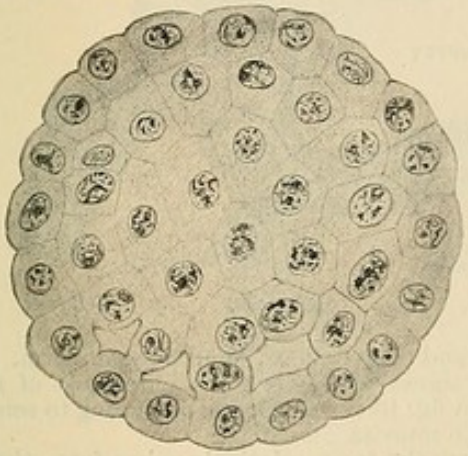

FIG. 8.—DIAGRAM OF SECTION OF A MAMMALIAN OVUM SHOWING THE INNER CELL MASS.

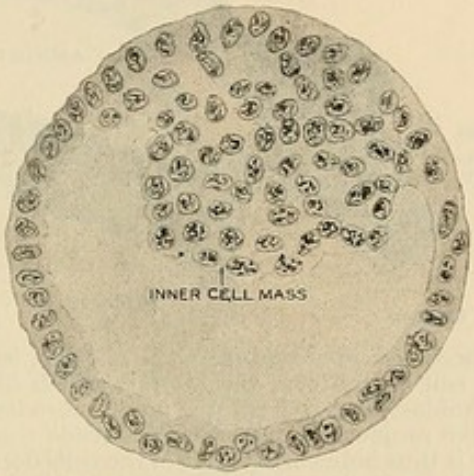

While the processes of maturation, fertilisation and segmentation have not as yet been observed in the human ovum, the evidence of comparative anatomy makes it very probable that in all essential respects these processes are like those found in other mammals. As a result of the successive divisions of the ovum in segmentation, a spherical mass of cells, the *morula* (fig. 7) is formed. In this mass, an excentric cavity forms (fig. 8) whereby the mass is transformed into a hollow vesicle. The wall of this vesicle is probably formed throughout the greater part of its extent by a single layer of cells; but at one point of the circumference there is a group of cells termed the *inner cell mass* (fig. 8). Probably about this time the ovum enters the uterine cavity, and through the activity of the outer layer of cells (*trophoblast*) becomes embedded in the uterine mucosa.

Formation of the embryonic disc and germ layers.—In the earliest human embryos which have been described, development has already proceeded beyond

FIG. 9.—DIAGRAM SHOWING THE RELATIONS OF THE GERM LAYERS IN AN EARLY EMBRYO. *Ac*, amniotic cavity, lined by ectoderm. *D*, yolk-sac, lined by endoderm (*En*). *Me,Me'*, mesoderm, *C*, extra-embryonic cœlom. *B*, chorion. *T*, trophoblast. (McMurrich.)

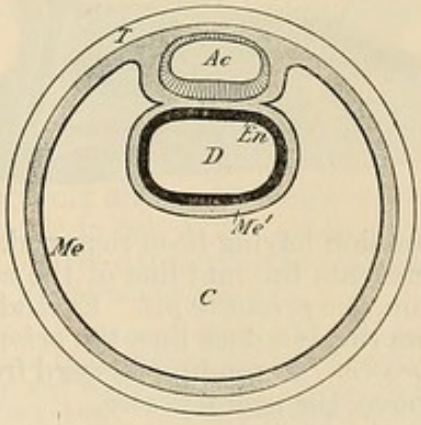

the stage represented by fig. 8, and has reached that of fig. 9. Within the inner cell mass, two cavities have appeared. The more superficial (ac) is the *amniotic*

cavity; the deeper (D) is the cavity of the *yolk-sac;* while between them is a plate of cells forming the *embryonic disc.* The embryonic disc (figs. 9 and 10) contains three layers of cells,—the fundamental *germ layers,—ectoderm* (Ec), *endoderm* (En), and *mesoderm.*

The germ layers of the embryonic disc are of prime importance in the development of the body. From the *ectoderm,* which lies next to the amniotic cavity and represents the upper (later outer) germ layer, are derived the epidermis and the entire nervous system. From the *endoderm,* which lies next to the yolk-sac, and represents the lower (later inner) germ layer, is derived the epithelial lining of the digestive mucosa and its derivatives. From the *mesoderm,* or middle germ layer, is differentiated the remainder of the body, including the skeletal and supporting tissues, vascular system, muscle and most of the urogenital organs.

The germ layers also extend beyond the embryonic disc, as shown in figs. 9 and 10. The *yolk-sac* is made up of a lining of endoderm and an outer layer of mesoderm. The *amnion,* which

FIG. 10.—DIAGRAM OF SECTION OF A MAMMALIAN OVUM SHOWING THE EMBRYONIC DISC, AMNIOTIC CAVITY AND THE GERM LAYERS.

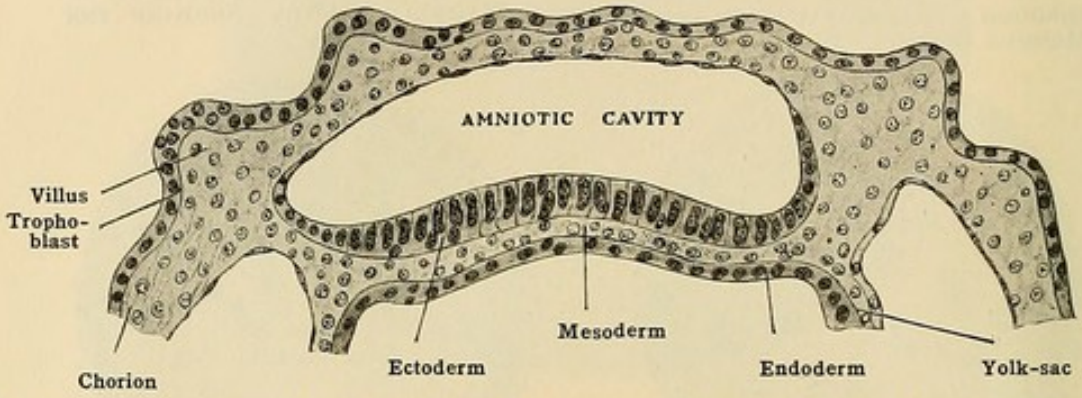

later becomes separated from the chorion, is composed of mesoderm lined by endoderm. The outer cell layers form the *chorion,* which likewise shows two layers, the outermost of which (trophoblast) is ectoderm, the inner, mesoderm. In fig. 10 the chorion is beginning to send out root-like projections (villi) which invade the uterine mucosa.

It is thus noteworthy that of the cells derived from the ovum relatively only a few—those of the embryonic disc—enter directly into the formation of the body. The yolk-sac, a rudimentary organ of phylogenetic significance, is later chiefly absorbed, although the proximal portion may enter slightly into the formation of the intestinal wall. The amnion is a protective membrane, while the chorion forms the fœtal part of the placenta.

Development of the embryonic disc.—When first formed, the surface of the embryonic disc shows no trace of differentiation. A slightly later but still comparatively early stage in its development is shown in fig. 11. It is here

FIG. 11.—MODEL SHOWING THE EMBRYONIC DISC FROM AN EMBRYO 1.17 MM. IN LENGTH. Viewed from above and laterally, the roof of the amniotic cavity having been removed. *n,* primitive pit (neurenteric canal). *pg,* primitive groove. *mg,* neural groove. *b,* body-stalk. (McMurrich, from Frassi.)

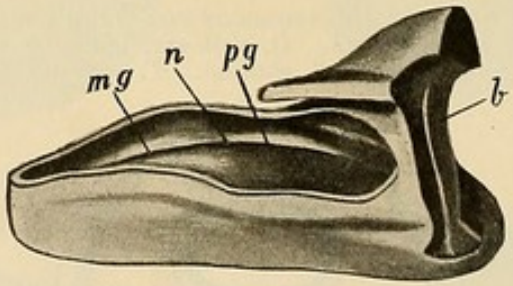

viewed from above, the amnion having been removed. The disc is an elliptical plate, whose long axis represents the mid-line of the embryo. Near the center is a small rounded depression, the *primitive pit.* Extending backward (toward the tail end of the embryo) from this is a dark line, the *primitive streak,* corresponding to a groove, the *primitive groove.* Extending forward from the primitive pit is an indistinct wide shallow groove, the *neural groove.*

At an earlier stage, the primitive streak extends further forward, possibly to the anterior end of the embryonic disc (Spee). The primitive streak and groove probably correspond to the

fused lips of a primitive blastopore. They represent a centre of proliferation from which the mesoderm is budded off from the ectoderm and spreads out to form the middle germ layer of the embryonic disc.

At the anterior end of the primitive streak this proliferation extends forward as a plate of cells, the so-called '*head process*.' The axial portion of this process is the anlage of the *notochord*, the embryonic skeletal axis. It contains a canal, which opens into the primitive pit. The notochordal anlage soon fuses with the underlying endoderm, and its canal forms the transient *neurenteric canal*.

In the mid-line anterior to the primitive streak there appears the shallow *neural groove* (fig. 11), corresponding to a thickened plate of ectodermic cells, the *neural plate*. The neural groove is slightly forked at its posterior extremity, in the region of the *primitive node* (Hensen's node), which forms the dorsal lip of the primitive pit. As development proceeds, the neural plate extends posteriorly, and the primitive pit is accordingly shifted backward, the corresponding part of the primitive groove being converted into 'head process.' The primitive streak thus becomes progressively shortened (cf. figs. 11 and 13).

FIG. 12.—TOPOGRAPHY OF THE EMBRYONIC DISC. DIAGRAM OF RELATIONS AT THE LENGTH OF ABOUT 1 MM. *ng*, neural groove. *pn*, primitive node. *pp*, primitive pit. *U*, upper limb. *L*, lower limb.

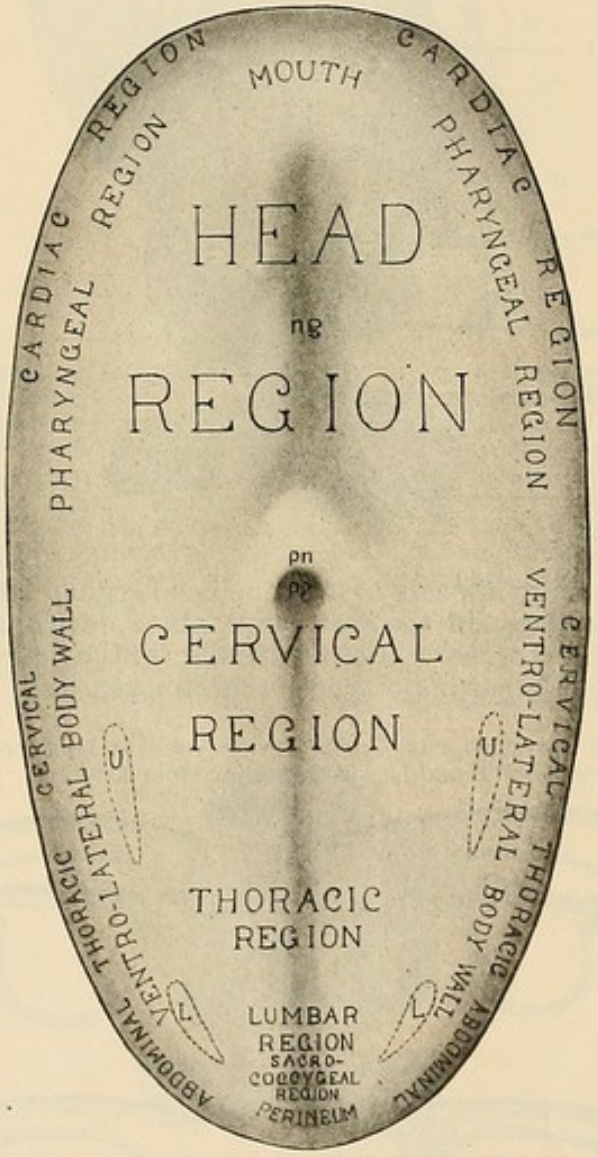

Topography of the embryonic disc.—Although only slight signs of differentiation are visible in the embryonic disc at the stage shown in fig. 11, it is already possible to map out more or less definite areas corresponding to all the various regions of the future body, as shown in fig. 12.

Beginning anteriorly, the head region is relatively enormous in size, occupying at this time the entire portion in front of the primitive pit and forming about half of the entire disc. The cervical, thoracic, lumbar and sacro-coccygeal regions appear successively smaller, approaching the posterior end ('tail bud') of the primitive streak. It is also a striking fact that the future dorsal region of the body wall, corresponding to the central portion of the disc, along each side of the mid-line, is now larger than the ventro-lateral regions, which occupy a relatively narrow area around the periphery of the disc.

The topography of the germinal areas in the embryonic disc shown in fig. 12 is based partly upon a study of the succeeding stages of development, and partly upon the results of experiments upon the germinal disc in lower forms, especially in the chick (Assheton, Peebles, Kopsch).

Law of developmental direction.—In the relative size of the various embryonic areas is foreshadowed what may be termed the law of direction in development. In general it is found that development (including growth and differentiation) in

FIG. 13.—HUMAN EMBRYO 1.54 mm. long. Viewed from above, the roof of the amniotic cavity having been removed. (Minot, after Graf Spee.)

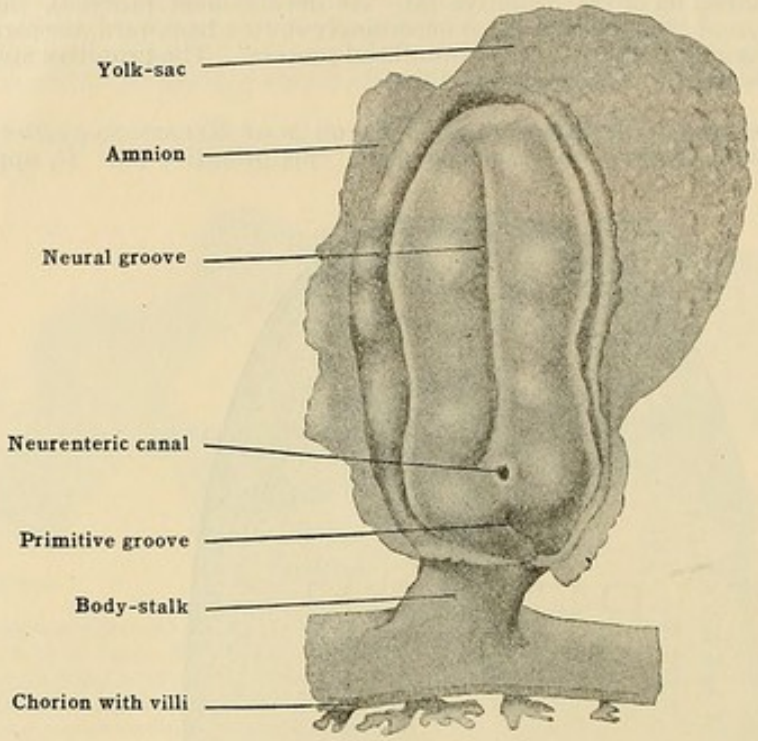

the long axis of the body appears first in the head region and progresses toward the tail region. Similarly in the transverse plane development begins in the mid-dorsal region and progresses latero-ventrally (in the limbs, proximo-distally). These principles are of great importance in morphogenesis.

FIG. 14.—DIAGRAMS SHOWING THE CONSTRICTION OF THE EMBRYO FROM THE YOLK-SAC. *A* and *C*, longitudinal sections; *B* and *D*, corresponding cross-sections. (McMurrich.)

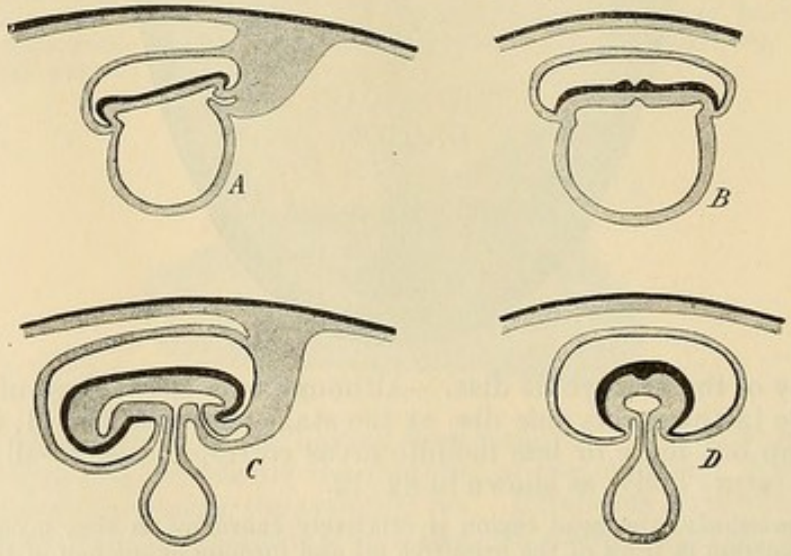

The law of developmental direction is also probably of phylogenetic significance. The *cranio-caudal* direction of development is in accordance with the theory that the head is the most primitive portion of the body, and hence precocious in development. The trunk is perhaps a secondary acquisition, hence arising as an extension of the primitive head region.

The *dorso-ventral* direction of development, together with the plate-like form of the embryonic disc, has a different phylogenetic significance. Both are probably inherited from an ancestral type with a yolk-laden ovum. In such an ovum, with the meroblastic type of segmentation, the flattened embryonic disc gradually spreads from the dorsal surface in a ventral direction around the underlying yolk-mass.

Derivation of body tube from embryonic disc.—The primary result of the precocious growth in the dorsal region of the embryonic disc is the conversion of the disc into the body tube, curved ventrally in its long axis (fig. 14).

FIG. 15.—PORTION OF CROSS SECTION OF THE EMBRYO SHOWN IN FIG. 13. *ch*, notochord. *ct*, somatic mesoderm. *df*, splanchnic mesoderm. *g*, junction of extra-embryonic somatic and splanchnic mesoderm. *ek*, ectoderm. *en*, endoderm. *me*, embryonic mesoderm. *f*, neural groove, *p*, beginning of embryonic cœlom (pericardial cavity). (Minot, after Graf Spee.)

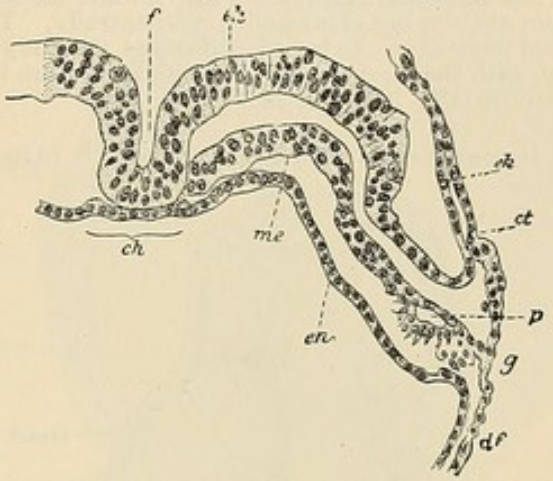

As a result of the more rapid expansion of the germ layers (especially the ectoderm) near the mid-line, the dorsal surface of the embryonic disc in general becomes convex, with a depression laterally (where growth is less rapid) forming a groove at the line of attachment of the amnion (figs. 11, 12, 13, 14 B). The unequal growth in the germ layers is clearly evident in the cross section shown in fig. 15. By a continuation of this process, the margins of the embryonic disc become still further depressed and finally folded in ventrally so as to transform the disc into a tube (fig. 14 D). Similarly, by a more rapid expansion of the dorsal layer of the disc in the longitudinal axis, the head and tail ends of the disc are folded and tucked in ventrally, and the primitive body tube is thus correspondingly curved in its long axis (figs. 14 A, 14 C).

FIG. 16.—MODEL OF HUMAN EMBRYO 1.8 MM. LONG. Viewed from above, the roof of the amniotic cavity having veen removed. Near the caudal end of the neural groove, the primitive pit (opening of neurenteric canal) is visible. The primitive somites are appearing in the occipital region, the fourth corresponding to the boundary between head and neck. (McMurrich, from Keibel and Elze.)

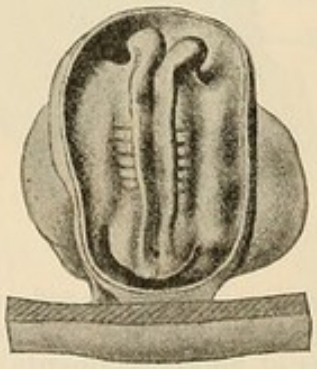

The embryonic disc is thus converted into a tube composed of an outer layer of ectoderm, a middle layer of mesoderm and an inner layer of endoderm. The yolk-sac now presents an expanded *yolk-vesicle* lined by endoderm which is still continuous through the constricted *yolk-stalk* with the endoderm lining the primitive *enteric cavity* (fig. 14 C). The enteric cavity (or archenteron) has a blind tubular prolongation (fore gut) into the head region, and another (hind gut) into the tail region. From the latter a slender diverticulum, the *allantois*, extends into the body stalk (later the umbilical cord). The allantois is an organ of phylogenetic importance, with which the urinary bladder is later connected.

Formation of the neural tube.—The principle of unequal growth applies to the formation not only of the body as a whole, but also of its constituent parts. Thus the anlage of the nervous system arises from the ectoderm as a wide groove

whose edges (neural ridges) by local growth are folded upward so as to meet in the mid-line where they fuse, thus transforming the groove into the *neural tube* (figs. 11, 12, 13, 15, 16, 17, 18).

The closure begins, not at the anterior end (as might be expected from the general law of cranio-caudal development), but in the cervical region, extending forward into the brain region, and backward along the spinal cord. Thus the extreme ends (anterior and posterior neuropores) are the last to close.

The precocious and energetic growth of the neural anlage is largely responsible for the ventral flexure of the embryonic body axis, especially in the head region, where the flexures of the brain are very conspicuous (figs. 22, 26).

With the closure of the neural tube dorsally and of the alimentary canal ventrally the human embryo assumes the typical vertebrate form. The cylindrical body wall now encloses two tubes (neural and enteric) with the longitudinal axis (notochord) between them (figs. 18, 24).

After the embryonic disc has been transformed into a tube, the body of the human embryo in cross section appears not circular but elongated dorso-ventrally. This is the typical form for vertebrates with horizontal body axis. In later fœtal stages, the body becomes more rounded in cross section, and finally, with the assumption of the erect posture in postnatal life, becomes decidedly flattened dorso-ventrally (figs. 20, 21).

FIG. 17.—A HUMAN EMBRYO 2.5 MM. IN LENGTH. (After Kollmann.)

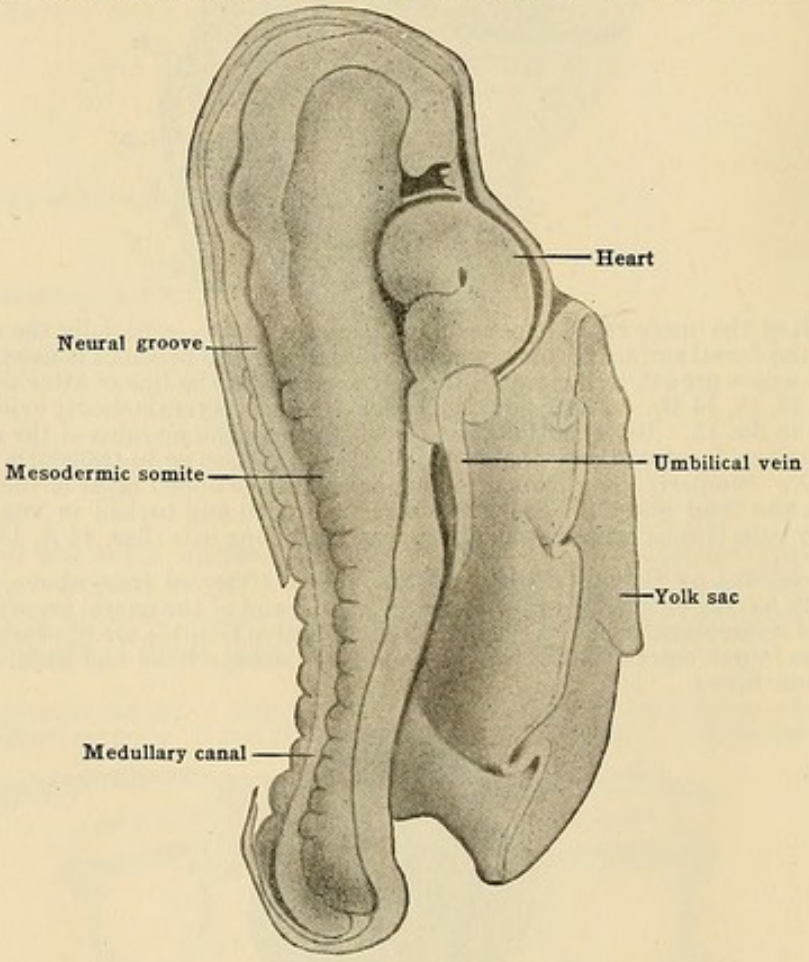

Development of the mesoderm.—The mesodermic layer on each side of the notochord in the embryonic disc develops in two divisions. The medial (or dorsal) divisions form a series of hollow segments, the *somites* (figs. 16, 17, 18). The lateral (later ventral) divisions each split into an upper (outer) or somatic layer and a lower (inner) or visceral layer. When the embryonic disc becomes folded, the corresponding somatic and visceral layers unite ventrally and enclose between them the common *cœlom* or primitive body cavity (fig. 18).

[As previously noted, the mesoderm arises chiefly from the lateral portions of the 'head process.' A comparatively early stage before the appearance of the somites is shown in cross section in fig. 15. The somites appear first in the occipital region, and rapidly differentiate successively in the cranio-caudal direction (figs. 16, 17, 22). In embryos 7 or 8 mm. in length, about 40 somites may be distinguished, 3 to 5 occipital, 8 cervical, 12 thoracic, 5 lumbar, 5 sacral and 5 or 6 coccygeal (in the rudimentary tail region).

The *cœlom* or body cavity is unsegmented. Two primitive pericardial cavities appear sepa-

rate at first, but soon fuse and unite with the general cœlom. Later the general cœlom becomes secondarily divided into the permanent pericardial, pleural and peritoneal cavities.

The outer layer of the lateral mesodermic division forms the somatic or parietal layer of the peritoneum, etc. The inner layer forms the visceral or splanchnic layer, and develops not only the serous membrane, but also the muscular and connective tissue of the walls of the alimentary canal and its derivatives.

Development of the somites. Metamerism.—The appearance of the somites marks the beginning of *metamerism*, the arrangement of the body in successive

FIG. 18.—DIAGRAM OF A CROSS SECTION OF A HUMAN EMBRYO.

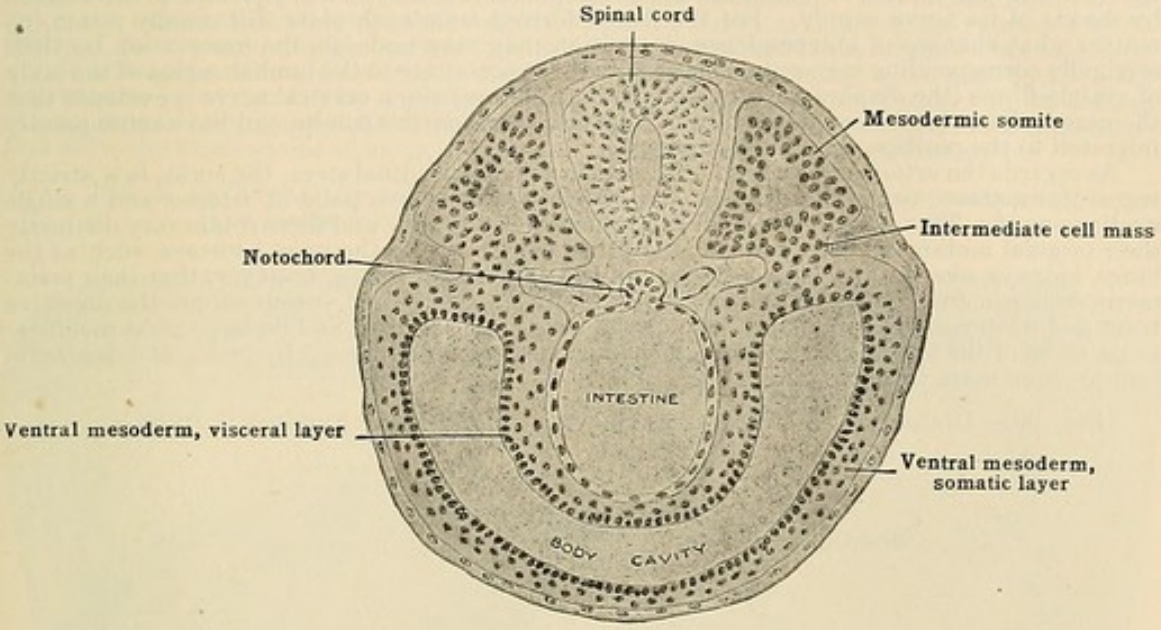

segments or metameres. Each somite develops a primitive muscle segment, *myotome*, and a skeletal segment, *sclerotome* (figs. 18, 19). Moreover, the corresponding nerves and blood-vessels likewise assume a metameric arrangement. This metamerism persists (more or less modified) in the adult neck and trunk.

The differentiation of the somites is illustrated by figs. 18 and 19. The medial wall of each somite forms the *sclerotome*. Its cells migrate to form the corresponding vertebra, rib, etc., as

FIG. 19.—DIAGRAMS ILLUSTRATING THE HISTORY OF THE MESODERM. *M*, myotome, *dM*, dorsal portion of myotome. *vM*, ventral portion of myotome. *SC*, sclerotome. *gr*, genital ridge. *Wd*, Wolffian duct. *Sm*, somatic layer of mesoderm. *vm*, visceral layer of mesoderm. *mr*, membrana reuniens. *I*, intestine. *N*, neural tube. (McMurrich.)

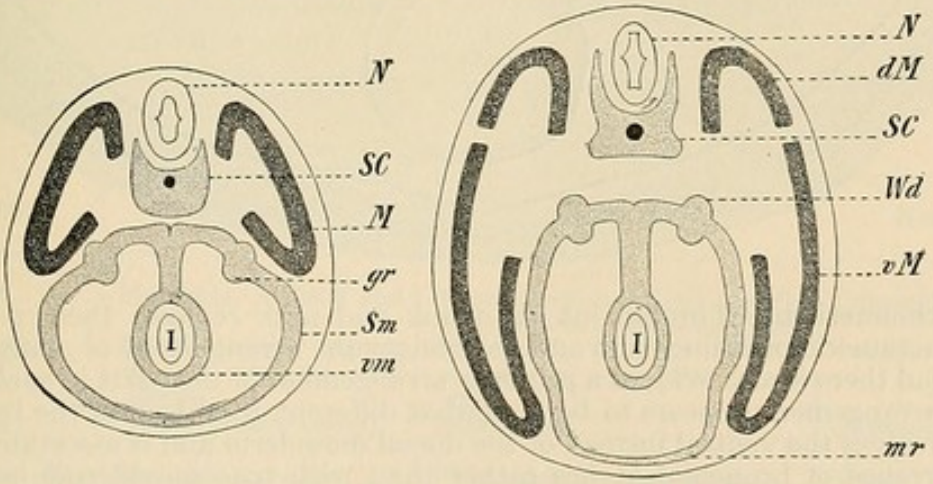

well as the *mesenchyme* forming the various connective tissues in this region. The remainder of the somite forms the *myotome*, from which the voluntary musculature of the trunk, the neck and (in part) the head is derived. The dorsal portions of the myotomes develop the muscle in the dorsal region of the trunk, while the ventral portions extend ventralward to form the musculature of the latero-ventral body walls (figs. 19, 20, 21, 23).

At the junction of the dorsal and ventral divisions of the mesoblast is a group of cells called the *intermediate cell mass*. This mass becomes segmented (corresponding to the somites) and

each segment, or *nephrotome*, gives rise to a portion of the *mesonephros*, the provisional kidney. Other cells of the mass become *mesenchyme*, which is converted into blood-vessels, connective tissue, etc.

As development proceeds, the metamerism of the muscles and arteries becomes more or less obscured, but that of the vertebræ and nerves is fully retained even in the adult. In the case of the muscle plates, from which all the voluntary musculature of the trunk is derived, great modifications occur. Extensive fusion of successive plates occurs, the intervening connective tissue disappearing more or less completely; associated with this fusion there is longitudinal and tangential splitting of the somites to form individual muscles; and portions of some of the plates may wander far from their original position. But notwithstanding these complicated changes, indications of the primary metameric arrangement of the muscle plates are abundant, and even in the most extreme cases of modification the developmental history of a muscle can be determined by means of its nerve supply. For the fibres derived from each plate will usually retain, no matter what changes of independence or position they may undergo, the innervation by their originally corresponding segmental nerve; so that the occurence in the lumbar region of the body of muscle-fibres (the diaphragm) supplied by nerve-fibres from a cervical nerve is evidence that the muscle-fibres have been derived from a cervical mesodermic somite and have subsequently migrated to the position they finally occupy.

As regards the arteries, they arise primarily from a longitudinal stem, the aorta, in a strictly segmental manner, each metamere having distributed to it two pairs of arteries and a single median one (fig. 20). One pair of arteries supplies the body wall, and these retain very distinctly their original metameric arrangement; the other pair passes to the paired viscera, such as the lungs, kidneys, ovaries (or testes), so many of the pairs disappearing, however, that their metameric arrangement is not very evident in the adult. The unpaired vessels supply the digestive tract and its unpaired appendages, such as the liver and pancreas, and undergo great modifications, those of the lower thoracic and lumbar regions becoming reduced by fusion and degeneration to three main trunks.

FIG. 20.—DIAGRAM OF A TRANSVERSE SECTION THROUGH THE ABDOMINAL REGION.

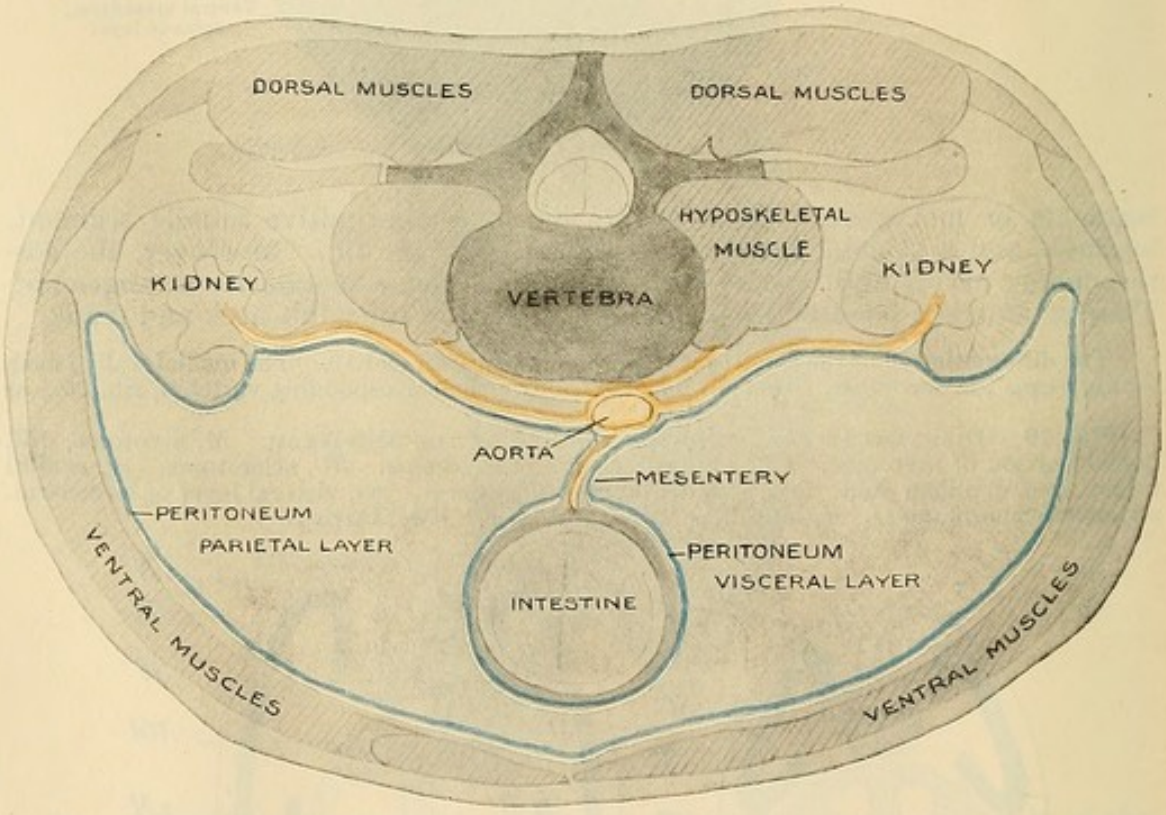

Branchiomerism.—Throughout the trunk and neck regions, then, a fundamental metameric plan underlies and determines the arrangement of many parts. In the head there is also evident a primary arrangement of the parts in succession; but this arrangement appears to be somewhat different from that of the trunk in that it involves the ventral instead of the dorsal mesoderm and is associated with the occurrence of branchial arches rather than with true mesodermic somites. It is consequently termed *branchiomerism*.

Not but that there are also indications of metamerism in the head, the muscles of the orbit, and the majority of the extrinsic muscles of the tongue, together with the nerves supplying these muscles, being apparently metameric structures, but the metamerism of this region of the body is largely overshadowed by the branchiomerism.

If an embryo of about the fifth week of development (fig. 22) be examined, there will be observed on the surface of the body in the pharyngeal region three or four linear depressions,

and sections will show that similar and corresponding grooves also occur upon the inner surface of the pharyngeal wall. These are the *branchial grooves*, and since they are four in number (with a rudimentary fifth) in the human embryo, they mark off five *branchial (or visceral) arches*, the first of which lies between the oral depression and the first branchial groove, while the fifth is situated behind the fourth groove. These branchial arches are so named because they represent the arches which (excepting the first) support the gills (branchiæ) in the lower vertebrates, the grooves representing the branchial slits, even although they do not become perforated in the human embryo.

Each *branchiomere* consists of an axial skeletal structure, of muscles which act on this skeleton, of a nerve which supplies the muscles and the neighbouring integument and mucous membrane, and of an artery which carries blood to all these structures. The arches, however, do not in the human embryo retain their original branchial function, but undergo extensive modifications, becoming adapted to various functions and showing less in the adult of their originally simple arrangement than do the metameres. Nevertheless no matter what modifications the musculature of any arch may undergo, it will retain its original innervation and, to a large extent, its relations to the skeletal elements of its arch; and even the arteries in their distribution show clear indications of being arranged in correspondence to the various arches.

FIG. 21.—DIAGRAM OF A TRANSVERSE SECTION THROUGH THE THORACIC REGION.
(The pleura is represented in blue and the pericardium in red.)

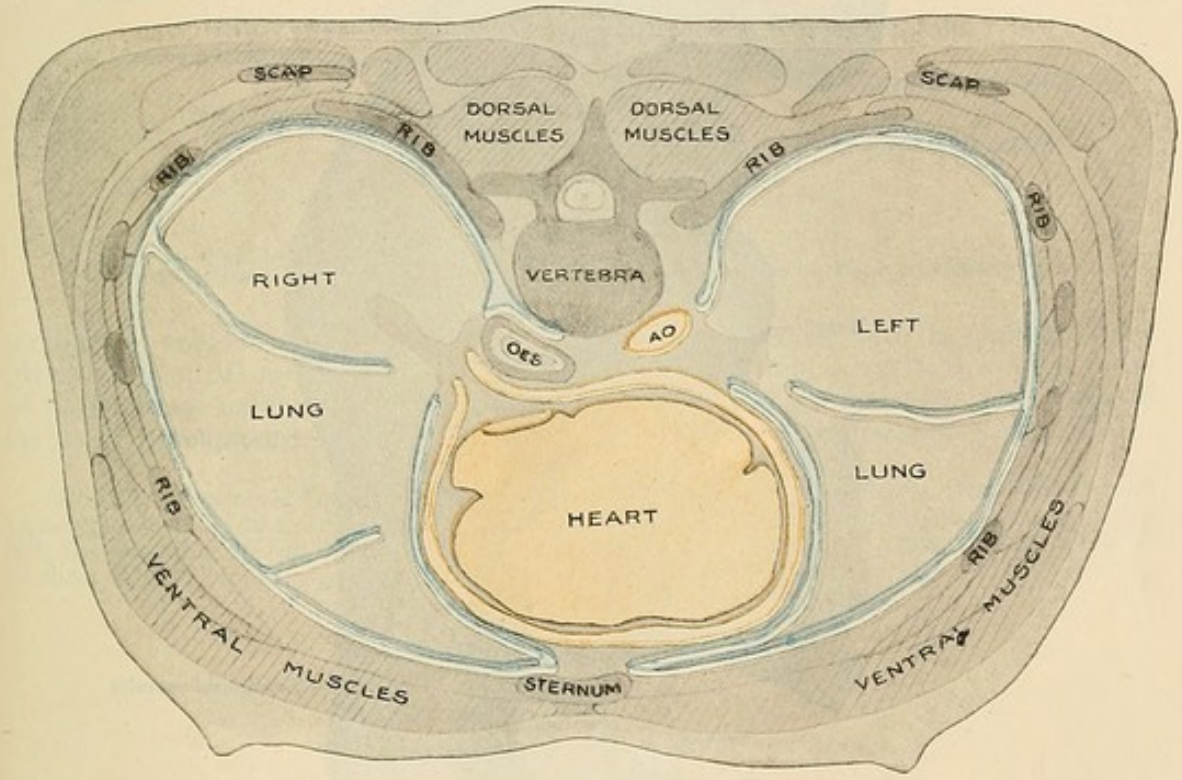

With respect to the fate of the various structures pertaining to each branchial arch, their general arrangement in the adult body may be stated in the following table:—

RELATIONS OF THE BRANCHIAL ARCHES IN THE ADULT

Arch	Skeleton	Muscles	Nerve
First arch.....	Mandible, malleus and incus.	Masticatory, mylohoid and digastric (ant.), tensor tympani.	Trigeminus.
Second arch.....	Hyoid (lesser cornu), styloid process and stapes.	Stylohyoid, digastric (post.), muscles of expression, stapedius.	Facialis.
Third arch.....	Hyoid (greater cornu)...	Pharyngeal.....	Glossopharyngeus.
Fourth and fifth arches.	Thyreoid cartilage.....	Pharyngeal and laryngeal.....	Vagus.

Branchial grooves.—Of the *external branchial grooves*, the first (lying between mandibular and hyoid arches) becomes deepened to form the *external auditory meatus*, the margins becoming elevated to form the *auricle* (fig. 26). The region corresponding to the second, third and fourth external grooves becomes depressed, forming the *sinus cervicalis*, which soon closes up and disappears.

The *internal branchial grooves* or pouches communicate with the pharyngeal cavity and are

lined with endoderm. The first internal groove becomes transformed into the *auditory* (Eustachian) *tube, tympanic cavity,* etc. The second internal groove persists in part as the fossa of the *palatine tonsil.* The third and fourth grooves are probably represented in part by the *vallecula* and *recessus piriformis,* detached portions of their lining endoderm giving rise to the *thymus, parathyreoid glands,* etc. The rudimentary fifth groove is said to give rise to the *ultimobranchial body,* a structure of uncertain significance (fig. 27).

Development of the face.—The facial region is at first relatively small. It includes the sense organs (eye, ear, nose) and mouth region. Some of the more important developmental features may be briefly mentioned. In an embryo of the sixth week (fig. 28) the wide mouth aperture is seen to be bounded below (posteriorly) by the lower (*mandibular*) portion of the

FIG. 22.—HUMAN EMBRYO OF 4.2 MM., SHOWING THREE BRANCHIAL GROOVES. (After His.)

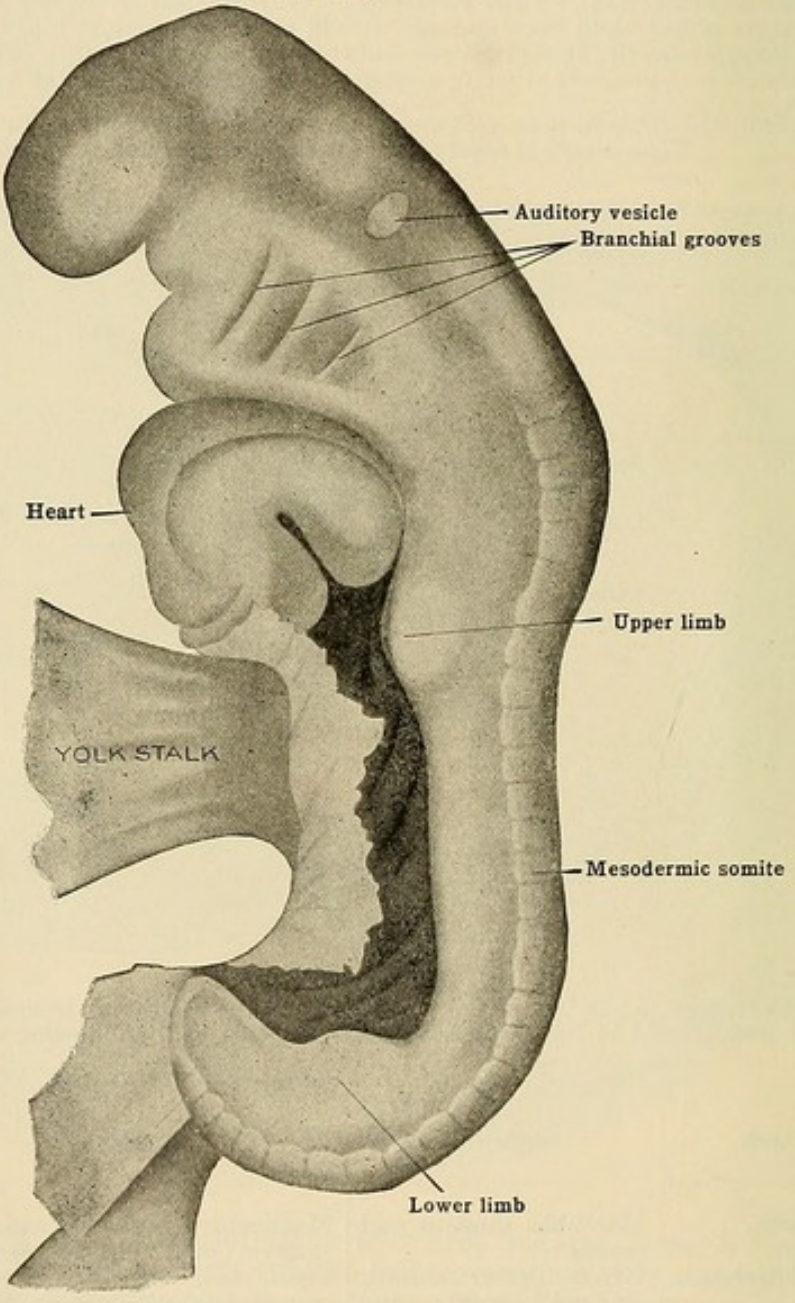

first arch, laterally by the upper (*maxillary*) process of the first arch. Above it is bounded by a median plate, the *nasal process,* which on either side forms a protuberance, the *globular process.* Lateral to the globular process is a rounded depression, the *nasal pit.* The maxillary process extends forward and fuses with the globular process to form the upper jaw region (failure to unite resulting in the malformation known as 'hare-lip'). The nose is at first broad, due to the width of the nasal process, which later becomes the nasal septum (fig. 29). The nasal pits deepen and later acquire openings into the primitive mouth cavity.

The viscera.—The structures so far considered belong, for the most part, to the body wall; it remains to consider the general plan of arrangement of the viscera. It has been pointed out that the body may be regarded as a cylinder enclosing two tubes, one of which constitutes the central nervous system and the

other the digestive tract. The latter may be regarded as being primarily a straight tube traversing lengthwise the body cavity enclosed by the body wall (figs. 18, 20). The layers of both the visceral and somatic plates which im-

FIG. 23.—SAGITTAL SECTION SHOWING THE PRIMITIVE PERICARDIAL AND CŒLOMIC COMMUNICATION, SEPTUM TRANSVERSUM, LIVER, ETC., IN A HUMAN EMBRYO OF 3 MM. (After Kollmann, from a model by His.)

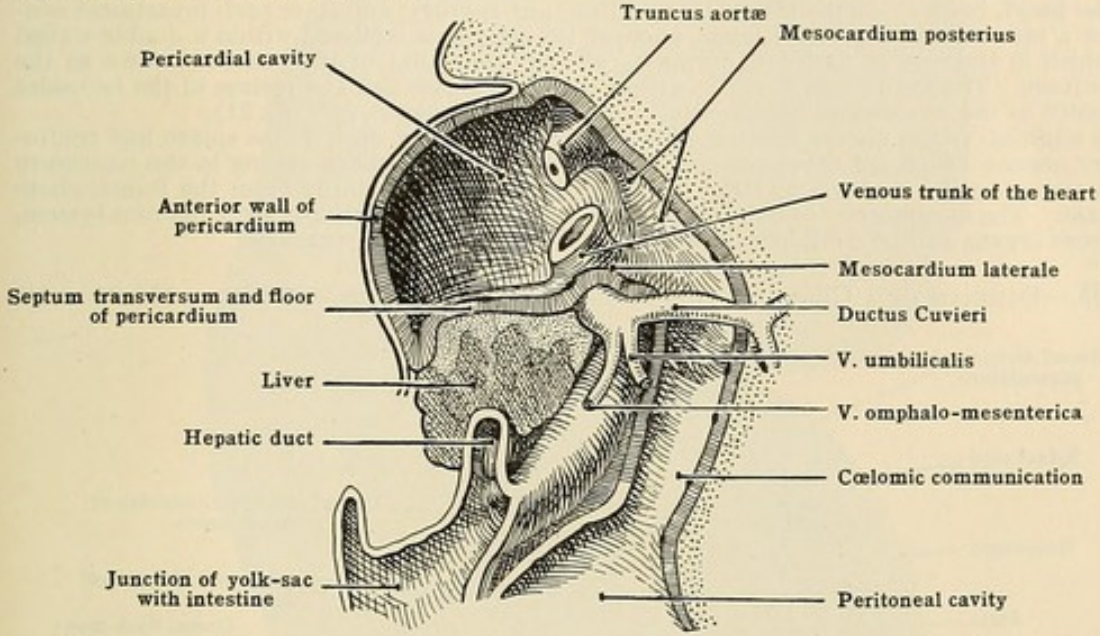

mediately enclose the body cavity become transformed into a characteristic pleuro-peritoneal membrane. Near the mid-dorsal line, a vertical double plate of peritoneum extends ventrally connecting the somatic (parietal) and visceral layers of peritoneum, and constituting what is termed the *mesentery* (fig. 20).

FIG. 24.—DIAGRAM ILLUSTRATING THE RECESSION OF THE DIAPHRAGM (SEPTUM TRANSVERSUM) IN THE HUMAN EMBRYO. On the right are indicated the vertebral levels; on the left, the position of the septum transversum in a series of embryos from 2 mm. (XII) to 24 mm. (VI) in length. *pp*, pleuro-peritoneal cavity. (Mall.)

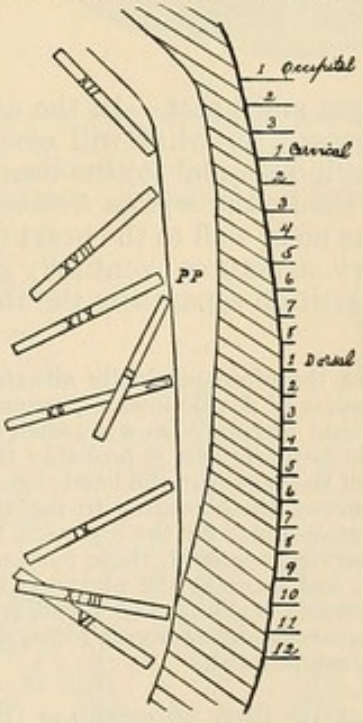

As development proceeds the digestive tract grows in length more rapidly than the cavity which contains it, and so gradually becomes thrown into numerous coils in the abdominal region, these changes leading to numerous modifications of the original arrangement of the mesentery. These will be described later on in the section on the digestive system. Several outgrowths also arise from the primitive digestive tract, to form important organs, such as the lungs,

the liver, the pancreas and the urinary bladder; and, with the exception of the bladder, each of these becomes completely invested by primitive peritoneum. In the case of the liver this original condition is practically retained, but the investment of the pancreas later becomes a partial one on account of the modifications which ensue in the mesentery. The bladder has only a portion of its surface in contact with the peritoneum, but the investment of the lungs remains complete, each lung, indeed, appropriating to itself the entire visceral layer of its half of the thorax, with the exception of a small ventral portion which forms the investment of the heart. Furthermore, the cavities which surround each of the three organs named, the two lungs and the heart, become completely separated from one another; and since each investment consists of a visceral and a parietal layer, each of the organs is enclosed within a double-walled sac, which in the case of each lung forms its *pleura*, while that of the heart is known as the *pericardium*. The spaces which occur within the thorax between the pleuræ of the two sides are known as the *mediastina*, which include the heart, œsophagus, etc. (fig 21).

In addition to the viscera mentioned there are some organs, such as the spleen and genito-urinary organs, which are developments of the mesoderm, the spleen arising in the mesentery which passes to the stomach and the genito-urinary organs primarily from the intermediate cell mass. The morphogeny of these structures and also of the vascular system, nervous system, and sense organs will be considered later in connection with their structure.

FIG. 25.—DIAGRAM OF A CROSS SECTION OF THE EMBRYONIC BODY AND LIMB. (McMurrich, after Kollman.)

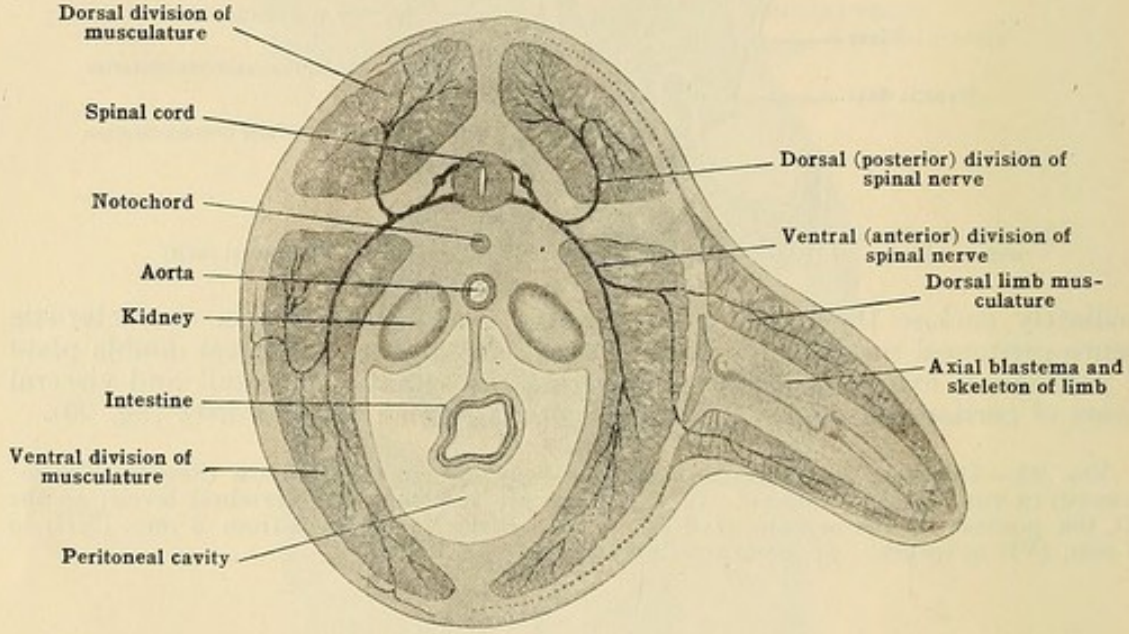

Recession of the diaphragm and heart.—In the early stages of development the heart is situated far forward, in what will eventually be the pharyngeal region (figs. 12, 17). Just behind (caudal to) the heart, between it and the yolk-sac, is a plate of connective tissue, the *septum transversum*, which serves for the passage of large veins from the body wall to the heart (figs. 17, 23). This septum together with certain accessory structures eventually gives rise to the diaphragm, which becomes a complete partition separating the thoracic and abdominal portions of the body cavity.

The diaphragm and heart are therefore originally situated far above (cranial to) their final position and recede in the course of development, producing an elongation of the vessels and nerves associated with them and forcing downward such organs as the stomach and liver (fig. 24). The chief factor in this displacement is probably the ventral head flexion and the precocious growth and expansion of the organs in the head region. The effects of this recession are especially noticeable in the nerves, these passing to the various organs concerned arising from a much higher level than that occupied by the organs. The nerve to the diaphragm, for instance, comes from the fourth cervical segment, those passing to the cardiac and pulmonary plexuses from the cervical region, and those to the plexus in relation with the stomach, liver and adjacent organs from the thoracic region. The blood-vessels, however, may shift their origins from the main trunks by successive anastomotic roots, so that in general they keep pace with the viscera in the migration caudalward.

The limbs.—Each limb at its first appearance (fig. 22) is a flat, plate-like outgrowth from the side of the body, and consists of an axial mass (blastema) of mesodermic tissue from which the limb skeleton will develop, and, surrounding this, a layer, also of mesodermic tissue, from which the muscles and blood-vessels will arise. It is as yet uncertain whether the muscle blastema is derived from the myotomes (as in lower vertebrates) or whether it develops from the mesenchyme.

FIG. 26.—LATERAL VIEW OF A HUMAN EMBRYO 18 MM. LONG, SHOWING THE DEVELOPMENT OF THE EXTREMITIES. M, mandibular arch.

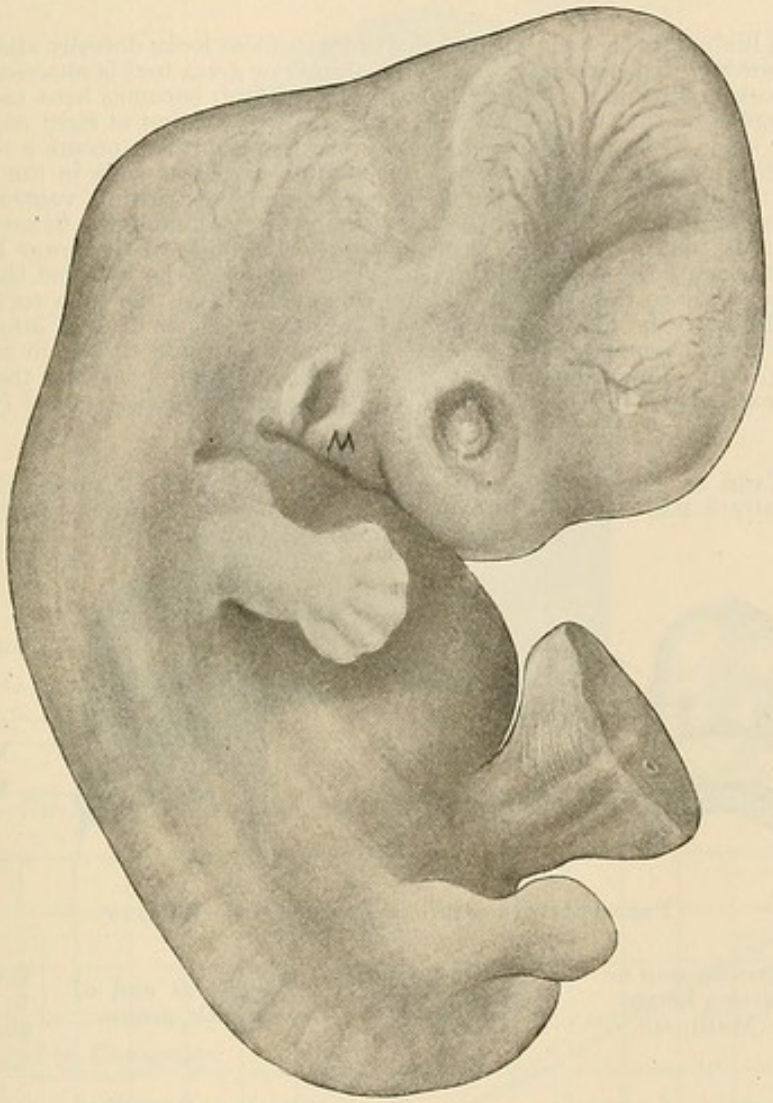

FIG. 27.—DIAGRAM TO SHOW THE DERIVATIVES OF THE BRANCHIAL CLEFTS. I*e*, II*e*, III*e*, IV*e*, V*e*, external branchial grooves. I*i*, II*i*, III*i*, IV*i*, V*i*, internal branchial grooves. Tons., palatine tonsil. *Ep III*, *Ep* IV, epithelial bodies. *Ub*, ultimobranchial body. *Th.*, thyreoid gland. *D.th. gl.*, ductus thyreoglossus. (Modified rom Keibel and Mall.)

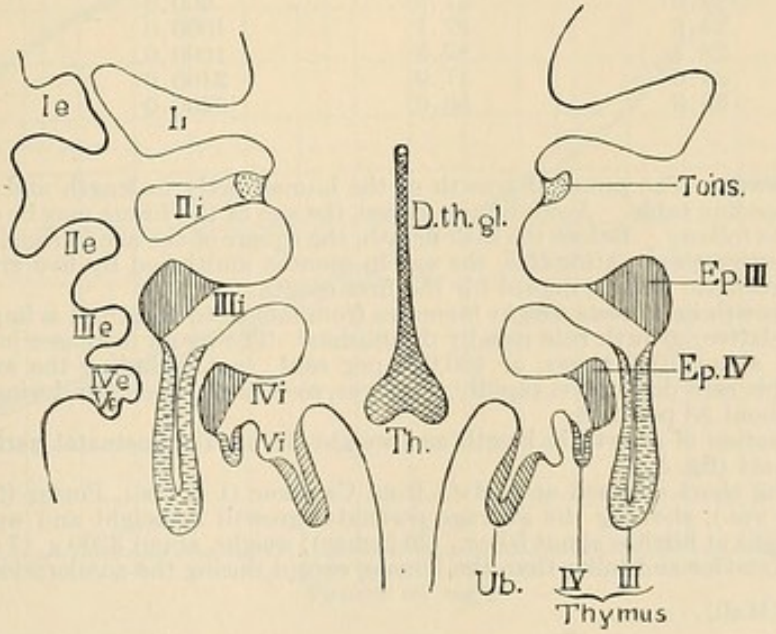

As the muscles become differentiated, nerves grow to them from a definite number of spinal segments (fig. 25).

At first each limb plate is so placed that one of its surfaces looks dorsally and the other ventrally, and one border (that corresponding to the thumb or great toe) is anterior (i. e., cranial) and the other posterior (caudal). Later, however, each limb becomes bent caudally through about ninety degrees, so that the limbs whose long axes were at first at right angles to the long axis of the body come to lie parallel to that axis. In addition there occurs a rotation of each fore-limb in such a manner that the thumb turns latero-dorsally, while in the lower limb the direction of the movement is exactly the opposite, the great toe turning ventro-medially. As a result there is an apparent reversal of the surfaces in the two limbs, the flexor muscles of the arm reaching on the surface which is directed anteriorly, while in the lower limb the corresponding muscles occupy the posterior surface. The dorsum of the foot and the great toe side correspond respectively to the back and thumb side of the hand, the tibia corresponds to the radius and the fibula to the ulna. The limb anlage soon becomes divided into three primary segments. The distal segment (hand or foot) is a flattened rounded disc, in which the digits soon appear (fig. 26). The proximal portion forms the forearm or leg and the arm or thigh. In general, the extremities follow the law of cranio-caudal and dorso-ventral (proximo-distal) development.

FIG. 28A.—FACE OF HUMAN EMBRYO OF ABOUT 8 MM. (His.)

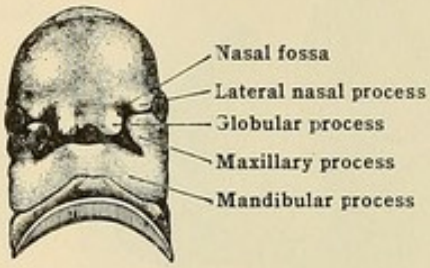

FIG. 28B.—FACE OF HUMAN EMBRYO AT STAGE SLIGHTLY LATER THAN 28A. (After Kallius.)

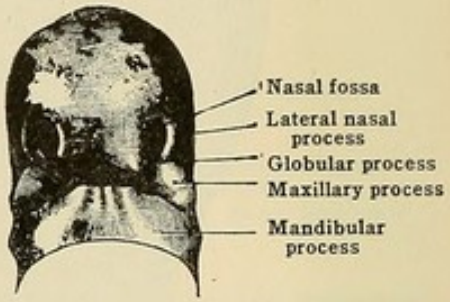

PRENATAL GROWTH IN LENGTH AND WEIGHT

Age in lunar months	Crown-rump or sitting height (Mall), cm.	Crown-heel or standing height (Mall), cm.	Weight at end of month, grams	Ratio of increase to weight at beginning of month
0	(diameter of ovum =0.2 mm.)	.....	(Ovum = 0.000004 g.)	.....
I	0.25	0.25	0.004	999.0
II	2.5	3.0	2.0	499.0
III	6.8	9.8	24.0	11.0
IV	12.1	18.0	120.0	4.0
V	16.7	25.0	330.0	1.75
VI	21.0	31.5	600.0	0.82
VII	24.5	37.1	1000.0	0.67
VIII	28.4	42.5	1600.0	0.60
IX	31.6	47.0	2400.0	0.50
*X	33.6	50.0	3200.0	0.33

Prenatal growth.—The prenatal growth of the human body in length and weight is indicated in the preceding table. According to Hasse, the age of the fœtus may be estimated from its total length as follows. Before the fifth month, the square of the age in (lunar) months gives the length in centimetres. After this, the age in months multiplied by five gives the length. This gives approximate results, except for the first month.

While the growth in *absolute* weight increases from month to month, it is important to note that the real (relative) growth rate rapidly diminishes. The ovum increases in weight during the first month about 1000 times, or 100,000 per cent. (not including the extra-embryonic structures). This rate diminishes rapidly, however, so that the increase during the last fœtal month is only about 33 per cent.

The continuation of growth in length and weight during the **postnatal period** is shown in the following chart (fig. 30).

The following chart is based upon data from Camerer (1–5 yrs.), Porter (6–17 yrs.), and Roberts (18–20 yrs.), showing the average postnatal growth in height and weight by sexes. The average height at birth is about 50 cm. (20 inches); weight, about 3200 g. (7 pounds). The male is slightly heavier and taller than the female, except during the acceleration at the period

* 270 days (Mall).

FIG. 29.—FACE OF A HUMAN EMBRYO AFTER COMPLETION OF THE UPPER JAW. (McMurrich from His.)

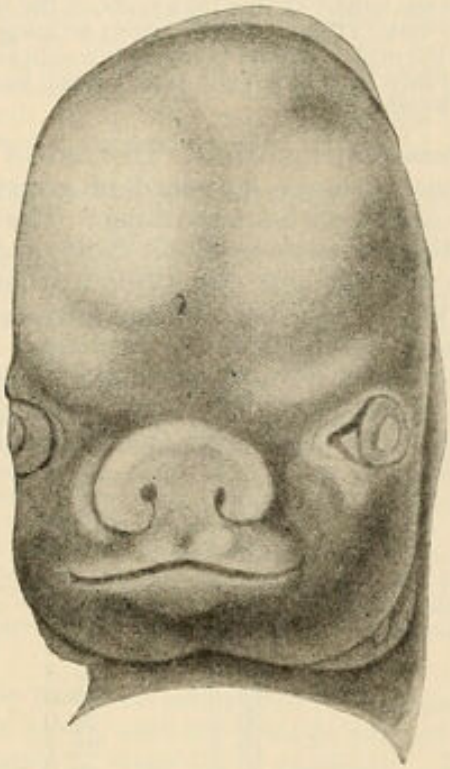

FIG. 30.—CHART SHOWING AVERAGE POSTNATAL GROWTH IN HEIGHT AND WEIGHT.

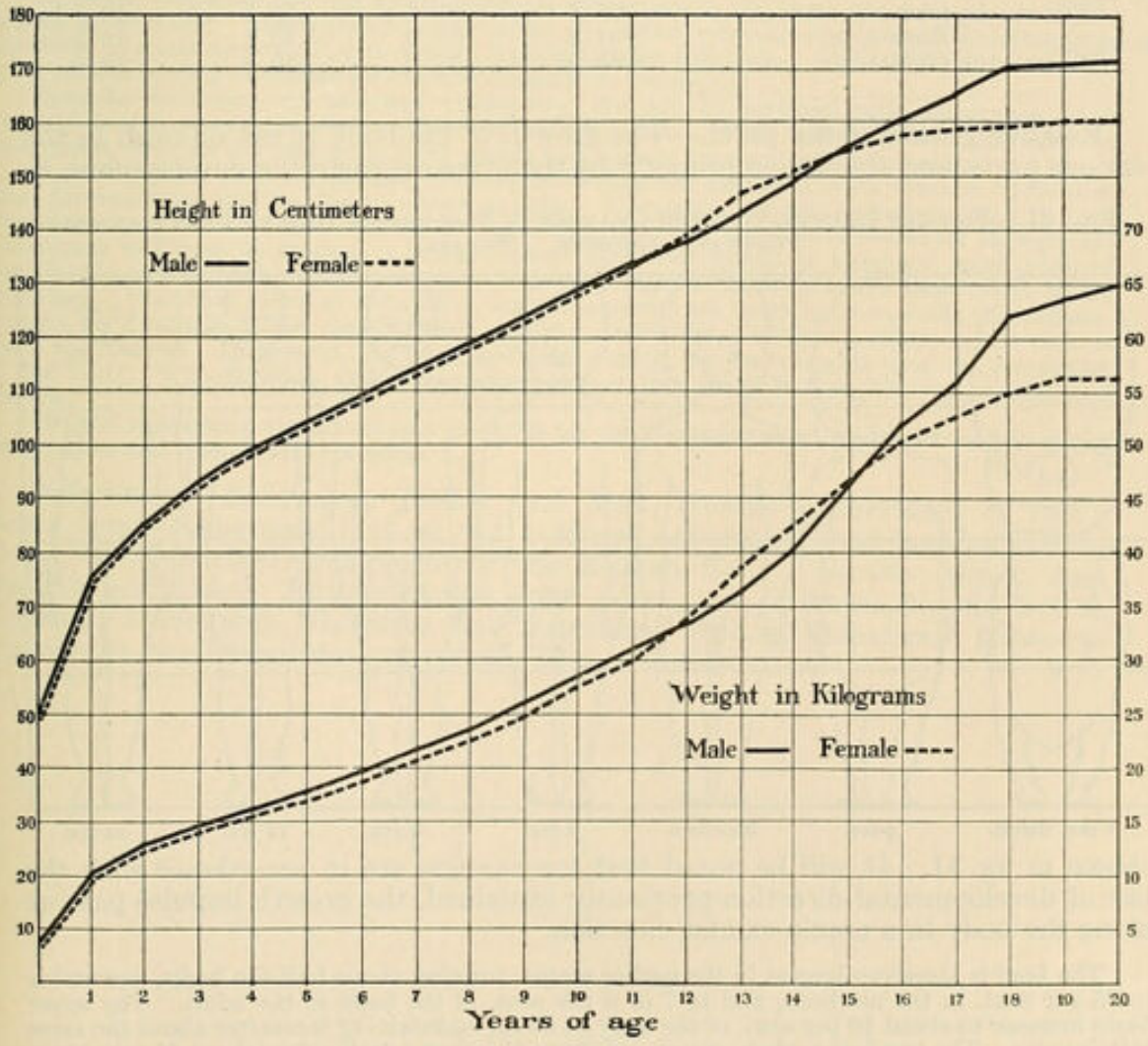

of puberty. Puberty occurs earlier in the female, so that between the ages of 12 and 15 the girls exceed the boys in average height and weight. With the exception of this period of acceleration, the (relative) growth rate in general diminishes steadily from birth, and has practically ceased at 20 years. The average height at this time is about 160 cm. (5 ft., 3 in.) in the female, and 170 cm. (5 ft., 7 in.) in the male; average weight, about 56 kilograms (126 lbs.) in the female, and 65 kilograms (146 lbs.) in the male. Under favourable conditions, growth in height may continue slowly up to about 25 years, and in weight even longer; but in old age there is a slight decrease in both height and weight.

The following measurements (from Holt, "Diseases of Infancy and Childhood" may be taken as a normal average standard of growth during the first three years. The weights are taken without clothing. The height is taken by placing the baby on a perfectly flat surface like a table, and having some one hold the child's knee down so that he lies out straight, then taking a tape-measure and measuring from the top of his head to the bottom of his foot, holding the tape line absolutely straight. The chest is measured by means of a tape line passed directly over the nipples around the child's body and midway between full inspiration and full expiration. The head measurement is taken directly around the circumference of the head, over the forehead and occipital bone.

		Weight, pounds	Height, inches	Chest, inches	Head, inches
Birth	Boys	7.55	20.6	13.4	13.9
	Girls	7.16	20.5	13.0	13.5
6 months	Boys	16.0	25.4	16.5	17.0
	Girls	15.5	25.0	16.1	16.6
12 months	Boys	20.5	29.0	18.0	18.0
	Girls	19.8	28.7	17.4	17.6
18 months	Boys	22.8	30.0	18.5	18.5
	Girls	22.0	29.7	18.0	18.0
2 Years	Boys	26.5	32.5	19.0	18.9
	Girls	25.5	32.5	18.5	18.6
3 Years	Boys	31.2	35.0	20.1	19.3
	Girls	30.0	35.0	19.8	19.0

Relative growth of the parts.—The growth of the body is not uniform in the various parts, and changes in proportions therefore occur during development, as

FIG. 31.—FIGURES ILLUSTRATING THE CHANGES IN PROPORTION DURING PRENATAL AND POSTNATAL GROWTH. (STRATZ.)

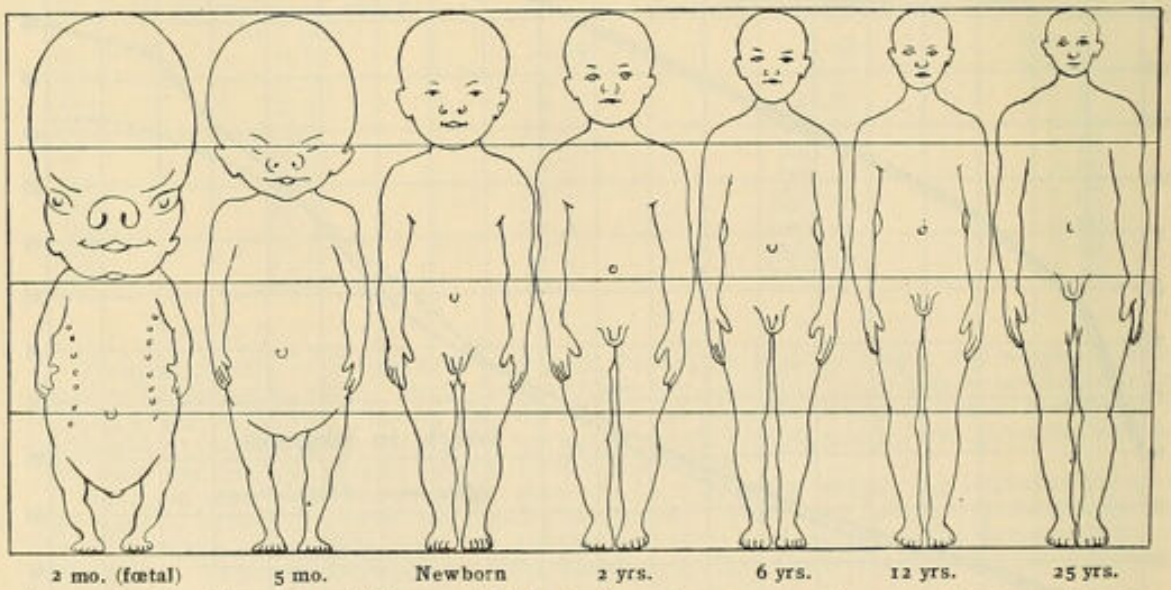

shown in fig. 31. It will be noted that the changes are in accordance with the law of developmental direction previously explained, the growth impulse passing along the body in a cranio-caudal direction.

The *head* is therefore largest in the earlier stages, forming about half the body, decreasing to 25 per cent. in the newborn, and to 7 or 8 per cent. of the body in the adult. The *upper limbs* increase to about 10 per cent. of the body at birth, maintaining thereafter about the same relative size. The *trunk* as a whole remains of about the same relative size (about 45 per cent.),

although the thoracic portion reaches its maximum in the earlier stages, and the pelvic portion not until adult life. The *lower limbs*, like the pelvis, develop slowly, forming about 20 per cent. of the body at birth and reaching 35 per cent. in the adult.

Relative growth of the systems.—There is also a marked difference in the relative growth of the various systems. Data for the *skin* and *skeleton* are somewhat scanty and unsatisfactory. The *musculature*, however, is relatively small in the embryo, increasing to about 25 per cent. of the body in the newborn, and to 40 or 45 per cent. in the adult. The visceral group (including brain and spinal cord), on the other hand, is relatively largest in the early embryo, decreasing from about 35 per cent. of the body to about 24 per cent. in the newborn and to about 10 per cent. in the adult.

Relative growth of the organs.—While in general, the individual organs follow the course of relative growth of the visceral group, each organ has its own characteristic course of growth. As a rule, after its appearance in the embryo, each organ increases more or less rapidly to its maximum relative size, after which, although increasing in *absolute* size, it decreases in *relative* size through subsequent prenatal and postnatal life up to the adult.

Thus the *brain* in the embryo of the second month forms more than 20 per cent. of the body, but steadily declines to about 13 or 14 per cent. in the newborn, and about 2 per cent. in the adult. The *spinal cord* and *eyeballs* have a similar course of growth. The *heart* declines from about 5 per cent. of the body in the embryo of the second month to about .75 per cent. in the newborn and .46 per cent. in the adult. The *liver* decreases from a maximum of nearly 10 per cent. in the third month to 5 per cent. in the newborn and 2.7 per cent in the adult. The *suprarenal glands* decrease from about .46 per cent. of the body in the third month to .23 per cent. in the newborn and .01 per cent. in the adult. The *lungs* decrease from 3.3 per cent. in the fourth month to about 2 per cent. of the body at birth and 1 per cent. (bloodless weight) in the adult. The *kidneys* reach a maximum of about 1 per cent. of the body toward the end of the fœtal period, decreasing to about .46 per cent. in the adult. The *thymus*, *thyroid*, *spleen* and *alimentary canal* likewise reach their maximum slowly, being probably relatively largest about the time of birth. The *ovary* and *testis*, however, appear to be relatively largest during the prenatal period.

Variability.—It must be borne in mind that all statements concerning structure refer to the *average* or *norm*, and are always subject to variation. This is therefore a topic of importance to students of anatomy. Variations are classified as either *germinal* or *somatic*.

Germinal variations are due to fundamental differences in the germ plasm, and are transmitted by heredity. These include many of the characters whereby one individual differs from another. Variations according to sex are included under this class. Variations inherited from more or less remote ancestors are termed *atavistic* or *reversional*.

Somatic variations, or 'acquired characters,' are due to environmental influences, such as nutrition, temperature, shelter, disease, training, etc. While somatic variations may be very great, they do not affect the germ plasm and are not transmitted by heredity.

In many cases it is exceedingly difficult to distinguish germinal from somatic variations Size, for example, may be due to either or both. Moreover, somatic variations may be produced at any time after the fertilisation of the ovum. Very slight environmental changes are sometimes sufficient to produce a marked effect upon the delicately balanced mechanism of the developing embryo. Malformations and pathological conditions are thus often to be explained. As to the *extent* of variability, some characters are much more variable than others. Height, for example, is less variable than weight. Moreover, variability differs in the various parts and organs. In general, the head and head organs are less variable than the remainder of the body. The skeleton and musculature appear less variable than the integument and viscera.

Details concerning variations and methods for their measurement may be found in works on genetics and biometrical statistics.

References.—*Embryology:* Keibel and Mall, Human Embryology (2 vols.); Bryce, Quain's Anatomy, 11th ed., vol. 1; Minot, Laboratory Text-book of Embryology; McMurrich, Development of the Human Body. *Growth:* Minot, Age, Growth, and Death; Jackson, Amer. Jour. Anat., vol. 9; Anat. Record, vol. 3. *Heredity:* Davenport, Heredity and Eugenics; Walter, Genetics. *Biometry:* Davenport, Statistical Methods; Yule, Theory of Statistics.

SECTION II

OSTEOLOGY

REVISED FOR THE FIFTH EDITION

BY PETER THOMPSON, M.D.,

PROFESSOR OF ANATOMY IN THE UNIVERSITY OF BIRMINGHAM; EXAMINER IN ANATOMY, THE UNIVERSITY OF CAMBRIDGE; FORMERLY EXAMINER IN ANATOMY FOR THE UNIVERSITIES OF LONDON, ABERDEEN, MANCHESTER, DUBLIN AND FOR THE CONJOINT BOARD OF ENGLAND

THE SKELETON

THE skeleton forms the solid framework of the body, and is composed of bones, and in certain parts, of pieces of cartilage. The various bones and cartilages are united by means of ligaments, and are so arranged as to give the body definite shape, protect from injury the more important delicate organs, and afford attachment to the muscles by which the various movements are accomplished.

In its widest acceptance, the term **skeleton** includes all parts of the framework, whether internal or external, and as in many of the lower animals there are, in addition to the deeper osseous parts, hardened structures associated with the integument, it is convenient to refer to the two groups as **endoskeleton** and **exoskeleton** or **dermal skeleton,** respectively. All vertebrate—i. e., back-boned—animals possess an endoskeleton, and many of them a well-developed exoskeleton also, but in mammals, the highest group of vertebrates, the external skeleton, when it exists, plays a relatively subordinate part. In most of the invertebrates the endoskeleton is absent and the dermal skeleton alone is found.

In man by far the greater part of the endoskeleton is formed of bone, a tissue of definite chemical composition, being formed mainly of a gelatine basis strongly impregnated with lime salts.

The number of bones in the skeleton varies at different ages, some, which are originally quite independent, becoming united as age advances. They are arranged in an **axial set,** which includes the vertebral column, the skull, the ribs, and the sternum, and an **appendicular set,** belonging to the limbs. The following table shows the number of bones usually distinct in middle life, excluding the auditory ossicles:—

		Bones.
Axial Skeleton	The vertebral column	26
	The skull	23
	The ribs and sternum	25
Appendicular Skeleton	The upper limbs	64
	The lower limbs	62
	Total	200

Several of the skull bones are **compound,** i. e., in the immature skeleton they consist of separate elements which ultimately unite to form a single bone. In order to comprehend the nature of such bones it is advantageous to study them in the various stages through which they pass in the process of development in the fœtus and the child.

It follows, therefore, that to appreciate the **morphology** of the skeleton—i. e., the history of the osteological units of which it is composed—the **osteogenesis** or mode of development of the bones must be studied, as well as their **topography** or position.

Some bones arise by **ossification in membrane,** others in **cartilage.** In the embryo, many portions of the skeleton are represented by cartilage which may become infiltrated by lime salts —**calcification.** This earthy material is taken up and redeposited in a regular manner—**ossification.** Portions of the original cartilage persist at the articular ends of bones, and, in

young bones, at the **epiphysial** lines, i. e., the lines of junction of the main part of a bone with the extremities or epiphyses. Long bones increase in length at the **epiphysial cartilages,** and increase in thickness by ossification of the deeper layers of the investing membrane or **periosteum.** These processes—intracartilaginous and intramembranous ossification—proceed concurrently in the limb-bones of a young and growing mammal.

There is no bone in the human skeleton which, though pre-formed in cartilage, is perfected in this tissue. The ossification is completed in membrane. On the other hand, there are numerous instances in the skull, of bones the ossification of which begins in, and is perfected by, the intramembranous method. Ossification in a few instances commences in membrane, but later invades tracts of cartilage; occasionally the process begins in the **perichondrium** and remains restricted to it, never invading the underlying cartilage, which gradually disappears as the result of continued pressure exerted upon it by the growing bone. The vomer and nasal bones are the best examples of this mode of development. Further details of development and ossification are included in the description of each bone.

The **limb-bones** differ in several important particulars from those of the skull. Some of the long bones have many centres of ossification, but these have not the same significance as those of the skull. It is convenient to group the centres into two sets, **primary** and **secondary.** The **primary** nucleus of a long bone appears quite early in fœtal life, and the main part (shaft) thus formed is called the **diaphysis.** In only three instances does a **secondary** centre appear before birth, e. g., the lower end of the femur, the head of the tibia, and occasionally the head of the humerus. Many **primary** ossific nuclei appear after birth, e. g., those for the carpal bones, the cuneiform and navicular bones of the foot, the coracoid process of the scapula, and for the third, fourth, and fifth pieces of the sternum.

When a bone ossifies from one nucleus only, this nucleus may appear before or after birth. Examples: the talus (astragalus) at the seventh month of fœtal life, and the lesser multangular (trapezoid) at the eighth year. When a bone possesses one or more secondary centres, the primary nucleus, as a rule, appears early. Examples: the femur, humerus, phalanges, and the calcaneus.

Secondary centres which remain for a time distinct from the main portion of a bone are termed **epiphyses.** An epiphysis may arise from a single nucleus, as is the case at the lower end of the femur, or from several, as at the upper end of the humerus. Prominences about the ends of long bones may be capped by separate epiphyses, as illustrated at the upper end of the femur.

According to Professor F. G. Parsons, there are at least three kinds of epiphyses:—(1) Those which appear at the articular ends of long bones, which, since they transmit the weight of the body from bone to bone, may be termed *pressure* epiphyses. (2) Those which appear as knob-like processes, where important muscles are attached to bones; and as these are concerned with the pull of muscles, they may be described as *traction* epiphyses. (3) The third kind includes those epiphyses which represent parts of the skeleton at one time of functional importance but which, having lost their function, have now become fused with neighbouring bones and only appear as separate ossifications in early life. These may be termed *atavistic* epiphyses and include such epiphyses as the tuberosity of the ischium, the representative of the hypoischium of reptiles.

The epiphyses of bones seem to follow certain rules, thus:—

1. Those epiphyses whose centres of ossification appear last are the first to unite with the shaft. There is one exception, however, to this statement, viz., the upper end of the fibula, which is the last to unite with the shaft, although its centre appears two years after that for the lower end. This may perhaps be accounted for by the rudimentary nature of the proximal end of the fibula in man and many other mammals.

2. The epiphysis toward which the nutrient artery is directed is the first to be united with the shaft. It is also found that while the increase in length of the long bones takes place at the epiphysial cartilages, the growth takes place more rapidly and is continued for a longer period at the end where the epiphysis is the last to unite. It follows, therefore, that the shifting of the investing periosteum, which results from these two factors, leads to obliquity of the vascular canal by drawing the proximal portion of the nutrient artery toward the more rapidly growing end. Moreover, when a bone has only one epiphysis, the nutrient artery will be directed toward the extremity which has no epiphysis.

3. The centres of ossification appear earliest in those epiphyses which bear the largest relative proportion to the shafts of the bones to which they belong.

4. When an epiphysis ossifies from more than one centre, the various nuclei coalesce before the shaft and epiphysis consolidate, e. g., the upper end of the humerus.

On section, the shaft of a fœtal long bone is seen to be occupied by red marrow lodged in bony cells which do not present any definite arrangement. In an adult the central portion of the shaft is filled with fat or marrow held together by a delicate reticulum of connective tissue, whence the space is known as the **medullary cavity.** The expanded ends of the bones contain a network of cancellous tissue, the intervals being filled with red marrow. This cancellous tissue differs from that of the fœtal bone in being arranged in a definite manner according to the direction of **pressure** exerted by the weight of the body, and the **tension** produced by the muscles. The arrangement of the cancelli in consequence of the mechanical conditions to which bones are subject is noticed in the description of a vertebra, the femur, and the humerus.

Bones are divisible into four classes:—**long, short, flat,** and **irregular.** The **long bones,** found chiefly in the limbs, form a system of levers sustaining the weight of the trunk and providing the means of locomotion. The **short bones,** illustrated by those of the carpus and tarsus, are found mainly where compactness, elasticity, and limited motion are the principal requirements. **Flat bones** confer protection or provide broad surfaces for muscular attachment, as in the case of the cranial bones and the shoulder-blade. Lastly, the **irregular** or **mixed bones** constitute a group of peculiar form, often very complex, which cannot be included under either of the preceding heads. These are the vertebræ, sacrum, coccyx, and many of the bones of the skull.

The **shafts** of long bones at the time of birth are mainly cylindrical and free from ridges. The majority of the lines and ridges so conspicuous on the shafts of long bones in adults are due to the ossification of muscle-attachments. The more developed the muscles, the better marked the ridges become.

The surfaces of bones are variously modified by environing conditions. Pressure at the extremities causes enlargement, and movement renders them smooth. The two causes combined produce an articular surface. When rounded and supported upon a constricted portion of bone, an articular surface is termed a **head,** sometimes a **condyle;** when depressed, a **glenoid fossa.** Blunt, non-articular processes are called **tuberosities;** smaller ones, **tubercles;** sharp projections, **spines.** Slightly elevated ridges of bones are **crests;** when narrow and pronounced, **lines** and

FIG. 32.—THE TIBIA AND FIBULA IN SECTION TO SHOW THE EPIPHYSES.

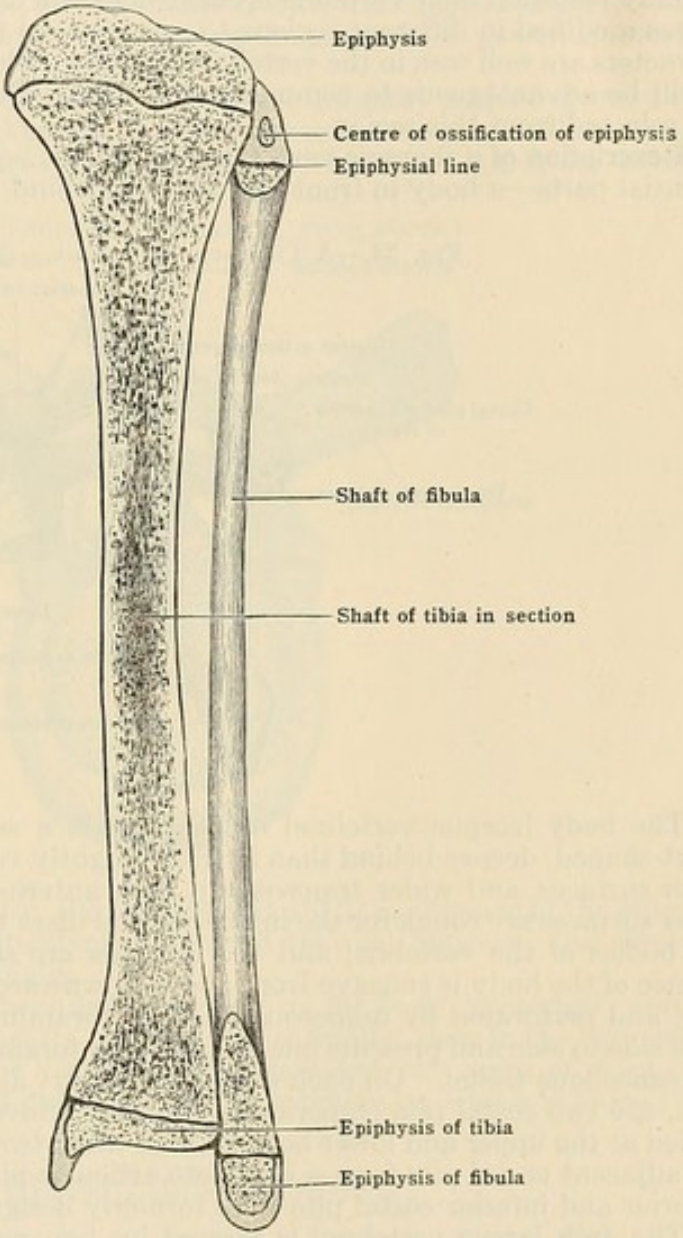

borders. A shallow depression is a **fossa;** when narrow and deep, a **groove;** a perforation is usually called a **foramen.**

In addition to these, other terms are employed which do not require any explanation, such as **canal, notch** or **incisura, sulcus** or **furrow,** and the like.

I. THE AXIAL SKELETON

A. THE VERTEBRAL COLUMN

The **vertebral column** [columna vertebralis] consists of a series of bones called **vertebræ,** closely connected by means of fibrous and elastic structures, which allow of a certain but limited amount of motion between them. In the young

subject the vertebræ are thirty-three in number. Of these, the upper twenty-four remain separate throughout life, and are distinguished as **movable** or **true vertebræ.** The succeeding five vertebræ become consolidated in the adult to form one mass, called the **sacrum,** and at the terminal part of the column are four rudimentary vertebræ, which also tend to become united as age advances, to form the **coccyx.** The lower nine vertebræ thus lose their mobility as individual bones, and are accordingly known as the **fixed** or **false vertebræ.** Of the true vertebræ, the first seven are called **cervical** [cervicales], the succeeding twelve **thoracic** [thoracales] or **dorsal,** and the remaining five **lumbar** [lumbales].

Although the vertebræ of the different regions of the column differ markedly in many respects, each vertebra is constructed on a common plan, which is more or less modified in different regions to meet special requirements. The essential characters are well seen in the vertebræ near the middle of the thoracic region, and it will be advantageous to commence the study of the vertebral structures with one selected from this region.

Description of a thoracic vertebra (figs. 33, 34).—The vertebra consists of two essential parts—a body in front and an arch behind.

FIG. 33.—A THORACIC VERTEBRA. (Side view.)

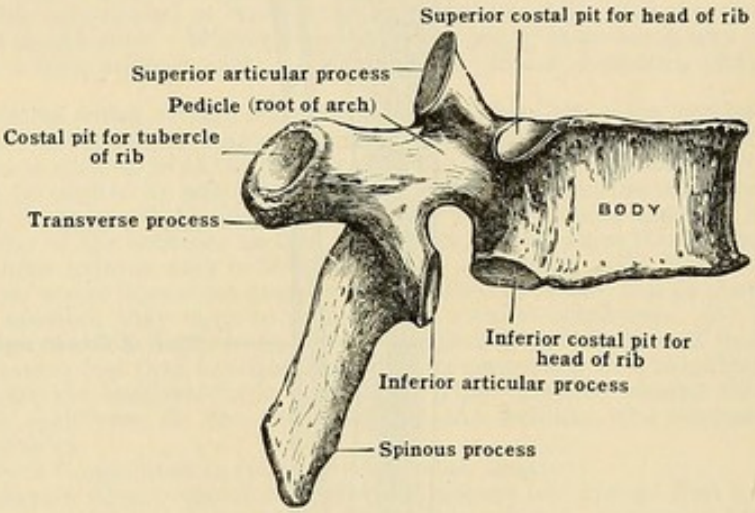

The **body** [corpus vertebræ] or **centrum** is a solid disc of bone, somewhat heart-shaped, deeper behind than in front, slightly concave on its superior and inferior surfaces, and wider transversely than antero-posteriorly. The upper and lower surfaces are rough for the intervertebral discs which are interposed between the bodies of the vertebræ, and the margins are slightly lipped. The circumference of the body is concave from above downward in front, convex fron side to side, and perforated by numerous vascular foramina. Posteriorly it is concave from side to side and presents one or two large foramina for the exit of veins from the cancellous tissue. On each side of the body, at the place where it joins the arch, are two costal pits (superior and inferior) [fovea costalis superior; inferior] placed at the upper and lower borders, and when two vertebræ are superimposed, the adjacent costal pits form a complete articular pit for the head of a rib. The superior and inferior costal pits were formerly designated as "demi-facets."

The **arch** [arcus vertebræ] is formed by two pedicles and two laminæ, and supports seven processes—one spinous, two transverse, and four articular. The pedicles or **roots** of the vertebral arch [radices arcus vertebræ] are two short, constricted columns of bone, projecting horizontally backward from the posterior surface of the body. The concavities on the upper and lower borders of each pedicle, of which the lower is much the deeper, are named **vertebral notches** [incisurae], and when two vertebræ are in position, the notches are converted into **intervertebral foramina** for the transmission of the spinal nerves and blood-vessels.

The **laminæ** are two broad plates of bone which connect the spinous process with the roots (pedicles) and complete the arch posteriorly. The superior border and the lower part of the anterior surface of each lamina is rough for the insertion of the ligamenta flava. The upper part of the anterior surface is smooth where it forms the posterior boundary of the vertebral canal. When articulated, the

laminæ in the thoracic region are imbricated or sloped, one pair over the other, somewhat like tiles on a roof.

The **spinous process** [processus spinosus], long and three-sided, projects backward and downward from the centre of the arch and terminates in a slight tubercle. It gives attachment by its prominent borders to the interspinous ligaments and by its free extremity to the supraspinous ligament. It serves mainly as a process for muscular attachment.

The **transverse processes** [processus transversus] are two in number and extend laterally from the arch at the junction of the pedicles and laminæ. They are long, thick, backwardly directed columns of bone terminating in a clubbed extremity, on each of which is a costal pit for articulation with the tubercle of a rib. The transverse processes, in addition to supporting the ribs, afford powerful leverage to muscles.

The **articular processes,** two superior and two inferior, project upward and downward opposite the attachments of the transverse processes. The superior are flat and bear facets or surfaces [facies articulares superiores] which are directed

FIG. 34.—A THORACIC VERTEBRA. (From above.)

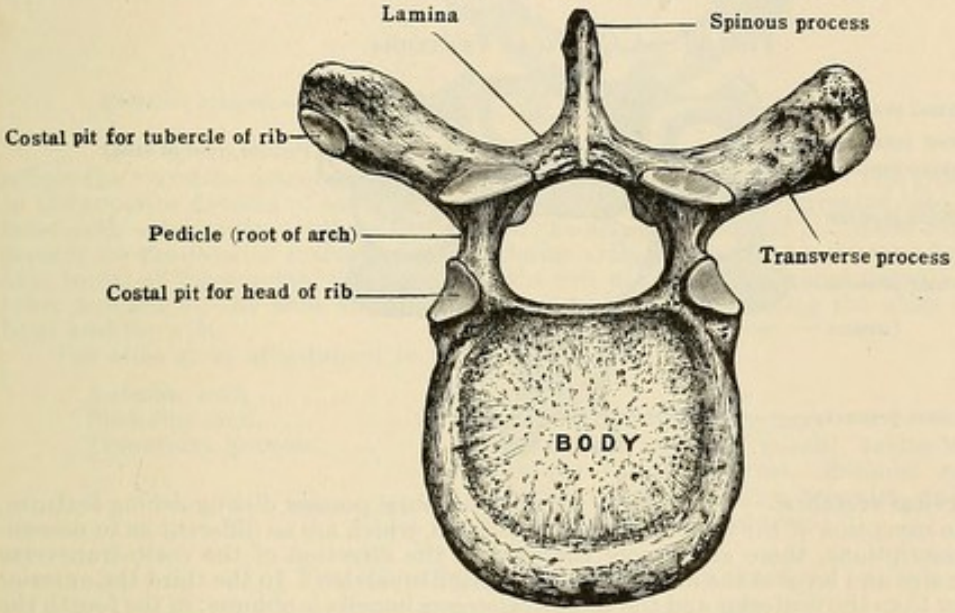

upward, backward, and laterally, and are situated a little in advance of the inferior, the facets of which [facies articulares inferiores] are oval, concave, and directed downward, forward, and medially.

The **vertebral foramen** is bounded anteriorly by the body, posteriorly and on each side by the arch. It is nearly circular, and is smaller than in the cervical or the lumbar region. When the vertebræ are articulated, the series of rings constitute the **spinal** or **vertebral** canal [canalis vertebralis], in which is lodged the spinal cord.

THE CERVICAL VERTEBRÆ

A typical cervical vertebra (from the third to the sixth inclusive) presents the following characteristics (fig. 35):—The **body** is smaller than in other regions of the column and is of oval shape with the long axis transverse. The lateral margins of the upper surface are raised into prominent lips, so that the surface is concave from side to side; it is also sloped downward in front. The inferior surface, on the contrary, projects downward in front and is rounded off at the sides to receive the corresponding lips of the adjacent vertebra. It is concave anteroposteriorly and convex in an opposite direction.

The **roots** (pedicles) are directed laterally and backward and spring from the body about midway between the upper and lower borders. The superior and inferior notches are nearly equal in depth, but the inferior are usually somewhat deeper. The **laminæ** are long, narrow, and slender. The **spinous process** is short and bifid at the free extremity.

Articular processes.—Both the superior and inferior articular processes are situated at the junction of the root with the lamina and they form the upper and lower extremities of a small column of bone. The articular surfaces are oblique and nearly flat, the superior looking backward and upward, and the inferior forward and downward.

The **transverse process** presents near its base a round **costo-transverse foramen** [foramen transversarium] for the transmission of the vertebral artery, vein, and a plexus of sympathetic nerves. Moreover, each process is deeply grooved above for a spinal nerve, and is bifid at its free extremity, terminating in two tubercles—anterior and posterior. The **costo-transverse foramen** is very characteristic of a cervical vertebra. It is bounded medially by the pedicle, posteriorly by the transverse process (which corresponds to the transverse process of a thoracic vertebra), anteriorly by the costal process (which corresponds to the rib in the thoracic region), and laterally by the costo-transverse lamella. The latter is a bar of bone joining the two processes and directed obliquely upward and forward in the upper vertebræ and horizontally in the lower. The **vertebral foramen** is triangular with rounded angles, and is larger than in the thoracic or lumbra vertebræ.

FIG. 35.—A CERVICAL VERTEBRA.

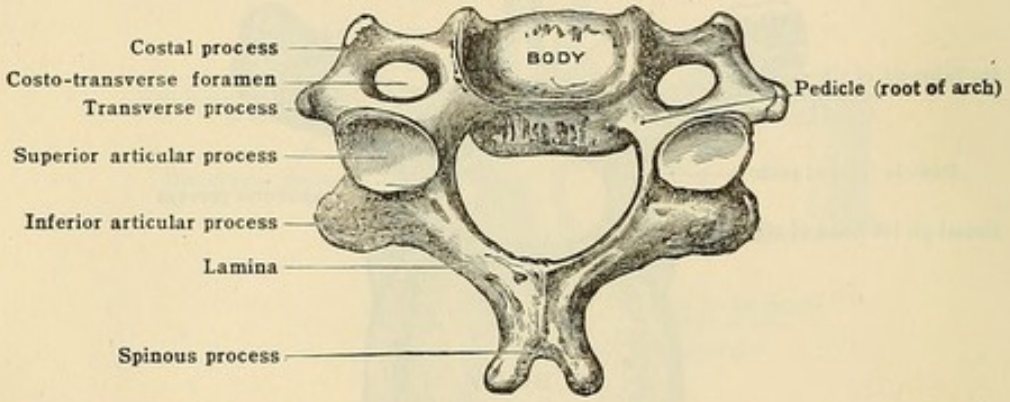

Peculiar cervical vertebræ.—The various cervical vertebræ possess distinguishing features, though, with the exception of the first, second, and seventh, which are so different as to necessitate separate descriptions, these are largely confined to the direction of the costo-transverse lamella, and the size and level of the anterior and posterior tubercles. In the third the anterior tubercle is higher than the posterior and the costo-transverse lamella is oblique; in the fourth the anterior tubercle is elongated vertically, so that its lower end is nearly on a level with the posterior, though the lamella still remains oblique. In the fifth and sixth they are nearly on the same level, but in the latter the anterior tubercle is markedly developed to form the **carotid tubercle.**

THE ATLAS OR FIRST CERVICAL VERTEBRA

This vertebra (fig. 36) is remarkable in that it has neither body nor spinous process. It has the form of an irregular ring, and consists of two thick portions, the **lateral masses,** united in front and behind by bony arches. The **anterior arch** joins the lateral masses in front and constitutes about one-fifth of the entire circumference of the ring. On its anterior surface it presents a **tubercle** for the attachment of the *longus colli* muscle and the anterior longitudinal ligament, and on its posterior surface a circular facet [fovea dentis] for articulation with the odontoid process [dens] of the axis. The upper and lower borders serve for the attachment of ligaments uniting the atlas to the occipital bone and axis respectively.

The **lateral masses** are thick and strong, supporting the articular processes above and below and extending laterally into the transverse processes. The superior articular surfaces are elongated, deeply concave, and converge in front. Directed upward and medially they receive the condyles of the occipital bone, and occasionally each presents two oval facets united by an isthmus. The inferior articular surfaces are circular and almost flat; they are directed downward and medially and articulate with the axis. The articular processes, like the superior articular processes of the axis, differ from those of other vertebræ in being situated in front of the places of exit of the spinal nerves.

Between the upper and lower articular surfaces on the inside of the ring are two smooth rounded **tubercles,** one on each side, to which the transverse ligament is attached. This liga-

ment divides the interior of the ring into a smaller anterior part for the dens of the axis, and a larger posterior part, corresponding to the foramina of other vertebræ, for the spinal cord and its membranes.

The **transverse processes** are large and extend farther outward than those of the vertebræ immediately below. They are flattened from above downward and each is perforated by a large **costo-transverse** foramen; the extremity is not bifid, but, on the contrary, is broad and rough for the attachment of numerous muscles. The **posterior arch** unites the lateral masses behind and forms about two-fifths of the entire circumference. It presents in the middle line a rough elevation or tubercle representing a rudimentary spinous process. At its junction with the lateral mass on the superior surface is a deep **groove,** the **sulcus arteriæ vertebralis,** which

Fig. 36.—The First Cervical Vertebra or Atlas.

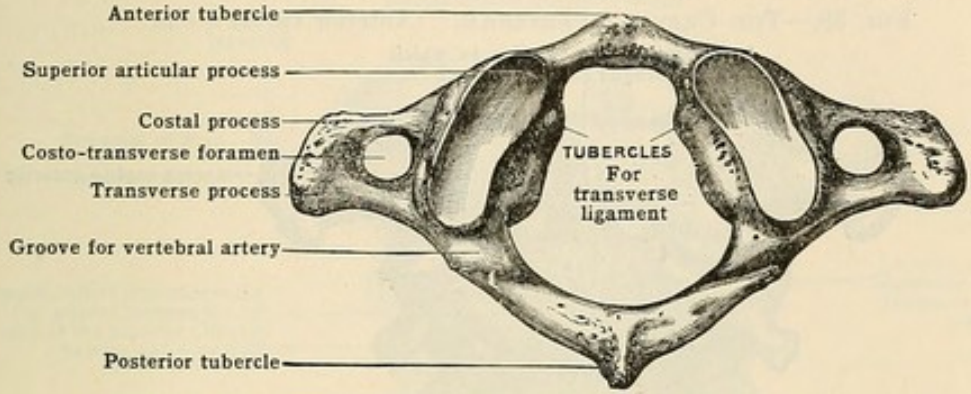

lodges the vertebral artery and the sub-occipital (first spinal) nerve. The groove corresponds to the superior notches of other vertebræ and occasionally it is converted into a foramen by a bony arch—the ossified oblique ligament of the atlas. A similar but much shallower notch is present on the inferior surface of the posterior arch, and, with a corresponding notch on the axis, forms an intervertebral foramen for the exit of the second spinal nerve. The upper and lower surfaces of the arch afford attachment to ligaments uniting the atlas to the occipital bone and the axis.

The atlas gives attachment to the following muscles:—

Anterior arch	Longus colli.
Posterior arch	Rectus capitis posterior minor.
Transverse process	Rectus capitis anterior (minor), rectus capitis lateralis, obliquus capitis inferior, obliquus capitis superior, splenius cervicis, levator scapulæ, and intertransversarii, anterior and posterior.

Fig. 37.—The Epistropheus or Axis.

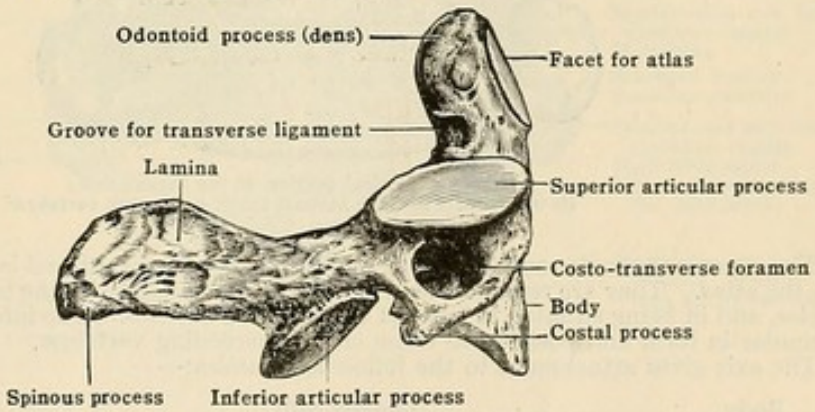

The Epistropheus (Axis)

The **epistropheus** (axis) (fig. 37) is the thickest and strongest of the bones of this region, and is so named from forming a pivot on which the atlas rotates, carrying the head. It is easily recognised by the rounded **dens** (odontoid process) which surmounts the upper surface of the **body.** This process, which represents the displaced body of the atlas, is large, blunt, and tooth-like, and bears on its anterior surface an oval facet for articulation with the anterior arch of the atlas; posteriorly it presents a smooth groove which receives the transverse ligament. To the apex a thin narrow fibrous band (the apical dental ligament) is attached, and on each side of the apex is a rough surface for the attachment of the alar

ligaments which connect it with the occipital bone. The enlarged part of the process is sometimes termed the **head,** and the constricted basal part the **neck.** The inferior surface of the body resembles that of the succeeding vertebræ and is concave from front to back and slightly convex from side to side. Its anterior surface is marked by a median ridge separating two lateral depressions for the insertion of the *longus colli.*

The **roots** (pedicles) are stout and broad; the **laminæ** are thick and prismatic; the **spinous process** is large and strong, deeply concave on its under surface, and markedly bifid; the **transverse processes** are small, not bifurcated and not grooved. The costo-transverse foramen is directed very obliquely upward and laterally and the costal process is larger than the transverse.

FIG. 38.—THE CERVICAL VERTEBRÆ. (Anterior view.)

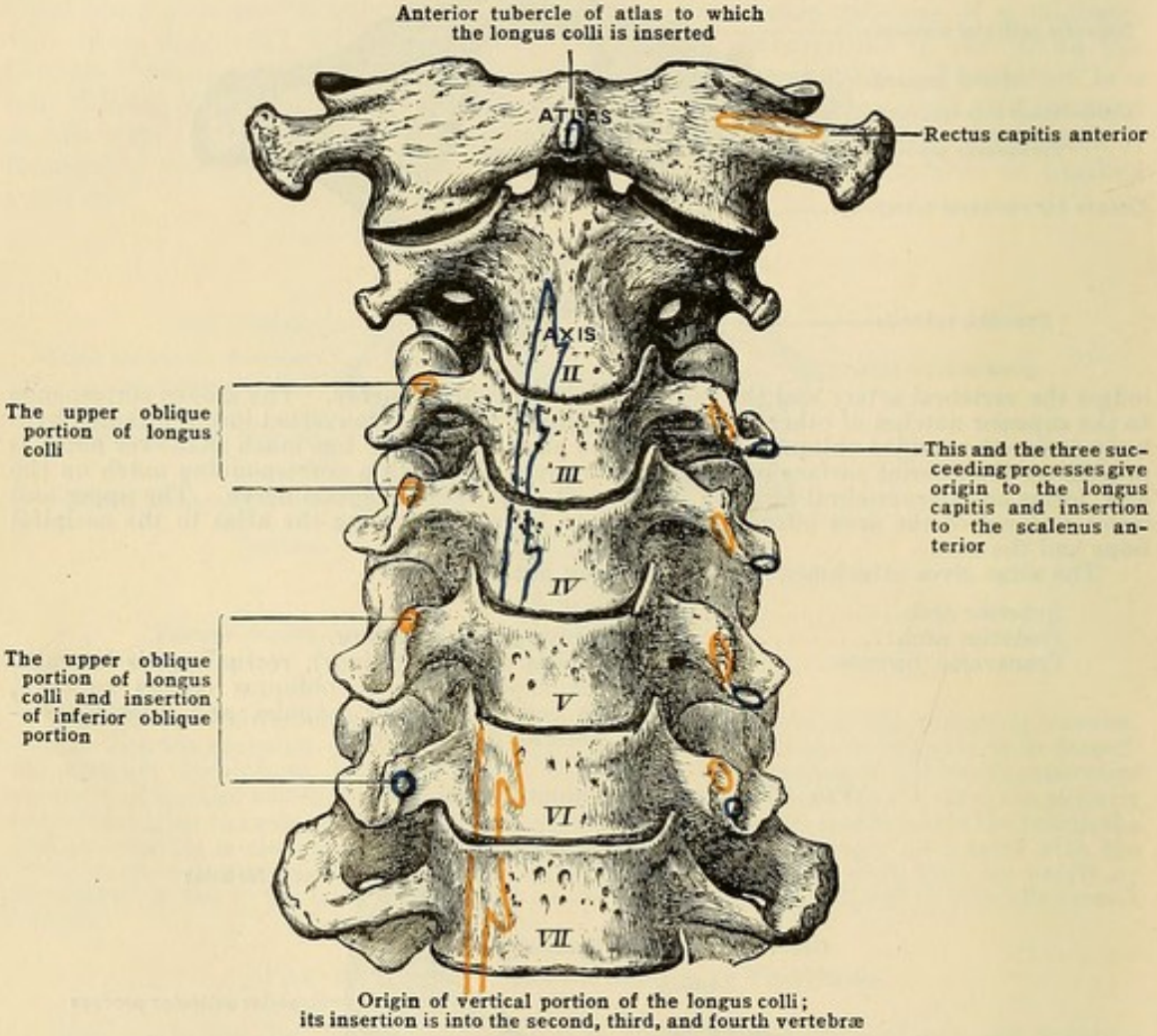

The **superior articular surfaces** are oval, and directed upward and laterally for articulation with the atlas. They are remarkable in being supported partly by the body, and partly by the pedicles, and in being situated in front of the superior notches. The **inferior articular surfaces** are similar in form and position to those of the succeeding vertebræ.

The axis gives attachment to the following muscles:—

Body	Longus colli.
Spinous process	Obliquus capitis inferior, rectus capitis posterior major semispinalis cervicis, interspinales, multifidus.
Transverse process	Splenius cervicis, intertransversarii, levator scapulæ, longissimus (transversalis) cervicis, scalenus medius.

THE SEVENTH CERVICAL VERTEBRA

Situated at the junction of the cervical and thoracic regions of the vertebral column, the seventh cervical vertebra (figs. 38, 39) may be described as a transitional vertebra—i. e., possessing certain features characteristic of both regions.

The **spinous process** is longer than that of any of the other cervical vertebræ. It is not bifurcated, but ends in a broad tubercle projecting beneath the skin,

whence the name **vertebra prominens** has been applied to this bone. The **transverse process** is massive; the costal element of the process is very small, but, on the other hand, the posterior or vertebral part of the process is large and becoming more like the transverse process of a thoracic vertebra.

The costo-transverse foramen is the smallest of the series and may be absent. It does not, as a rule, transmit the vertebral artery, but frequently gives passage to a vein. Occasionally the costal process is segmented off and constitutes a cervical rib. The body sometimes bears on each side near the lower border a costal pit for the head of the first rib. When this is present, there is usually a well-developed cervical rib.

FIG. 39.—THE CERVICAL VERTEBRÆ. (Posterior view.)

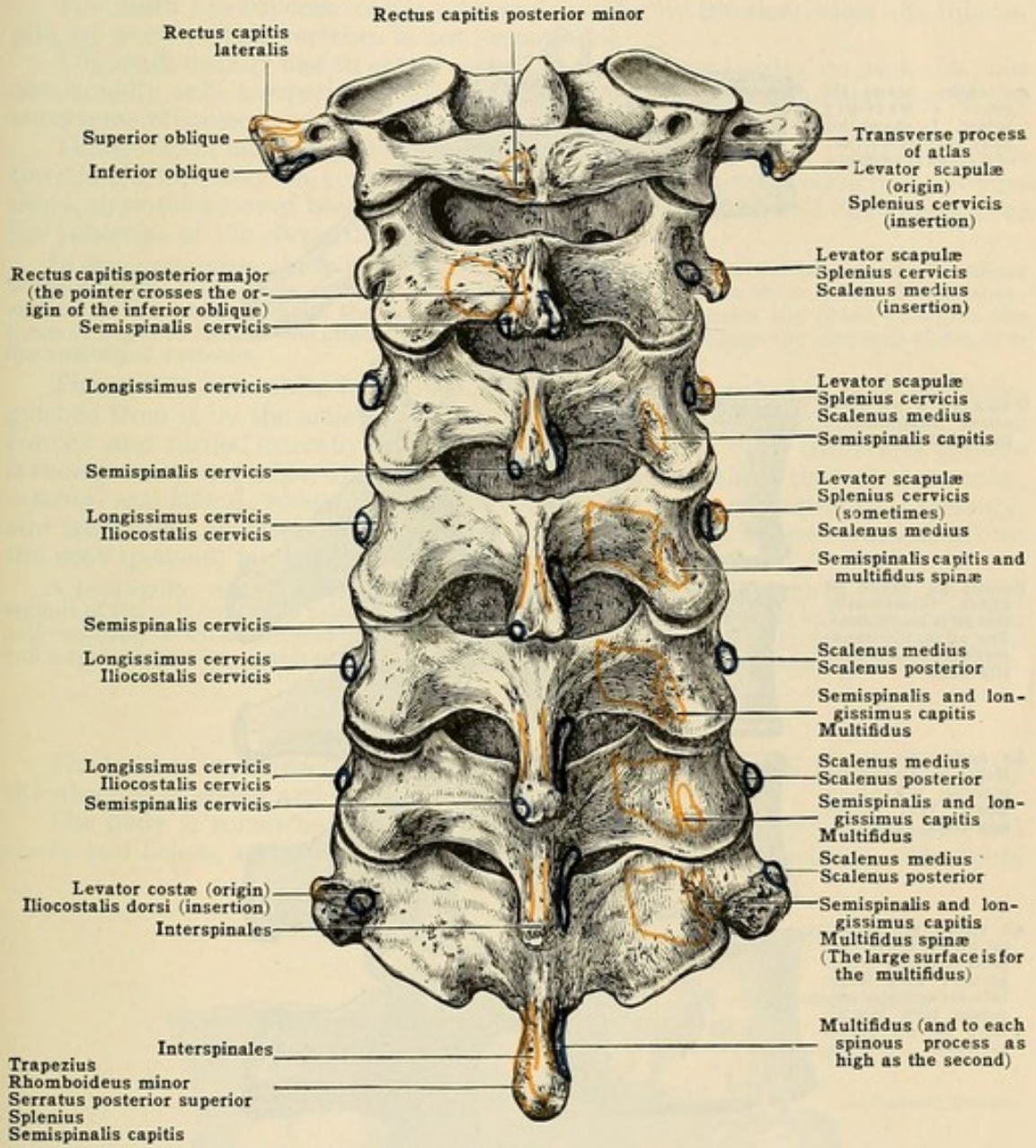

The seventh cervical vertebra gives attachment to the following muscles:—

Body.....Longus colli.
Spinous process.....Trapezius, rhomboideus minor, serratus posterior superior, splenius capitis, multifidus, interspinales, semispinalis dorsi.
Transverse process.....Intertransversarii, levator costæ, scalenus posterior, iliocostalis dorsi (musculus accessorius), scalenus medius, semispinalis capitis (complexus).
Articular process.....Multifidus, longissimus capitis (trachelomastoid).

The cervical vertebræ exhibit great variation in regard to the extremities of their spinous processes. As a rule among Europeans, the second, third, fourth, and fifth vertebræ possess bifid spines. The sixth and seventh exhibit a tendency to bifurcate, their tips presenting two small lateral tubercles; sometimes the sixth has a bifid spine, and more rarely the seventh pre-

sents the same condition. Occasionally all the cervical spines, with the exception of the second, are non-bifid, and even in the axis the bifurcation is not extensive. In the lower races of men the cervical spines are relatively shorter and more stunted than in Europeans generally and, as a rule, are simple. The only cervical vertebra which presents a bifid spine in all races is the axis; even this may be non-bifid in the Negro, and occasionally in the European. (Owen, Turner, Cunningham.)

The laminæ of the lower cervical vertebræ frequently present posteriorly distinct tubercles from which fasciculi of the *multifidus* muscle arise. They are usually confined to the sixth and seventh vertebræ, but are fairly frequent on the fifth, and are occasionally seen on the fourth.

FIG. 40.—PECULIAR THORACIC VERTEBRÆ.

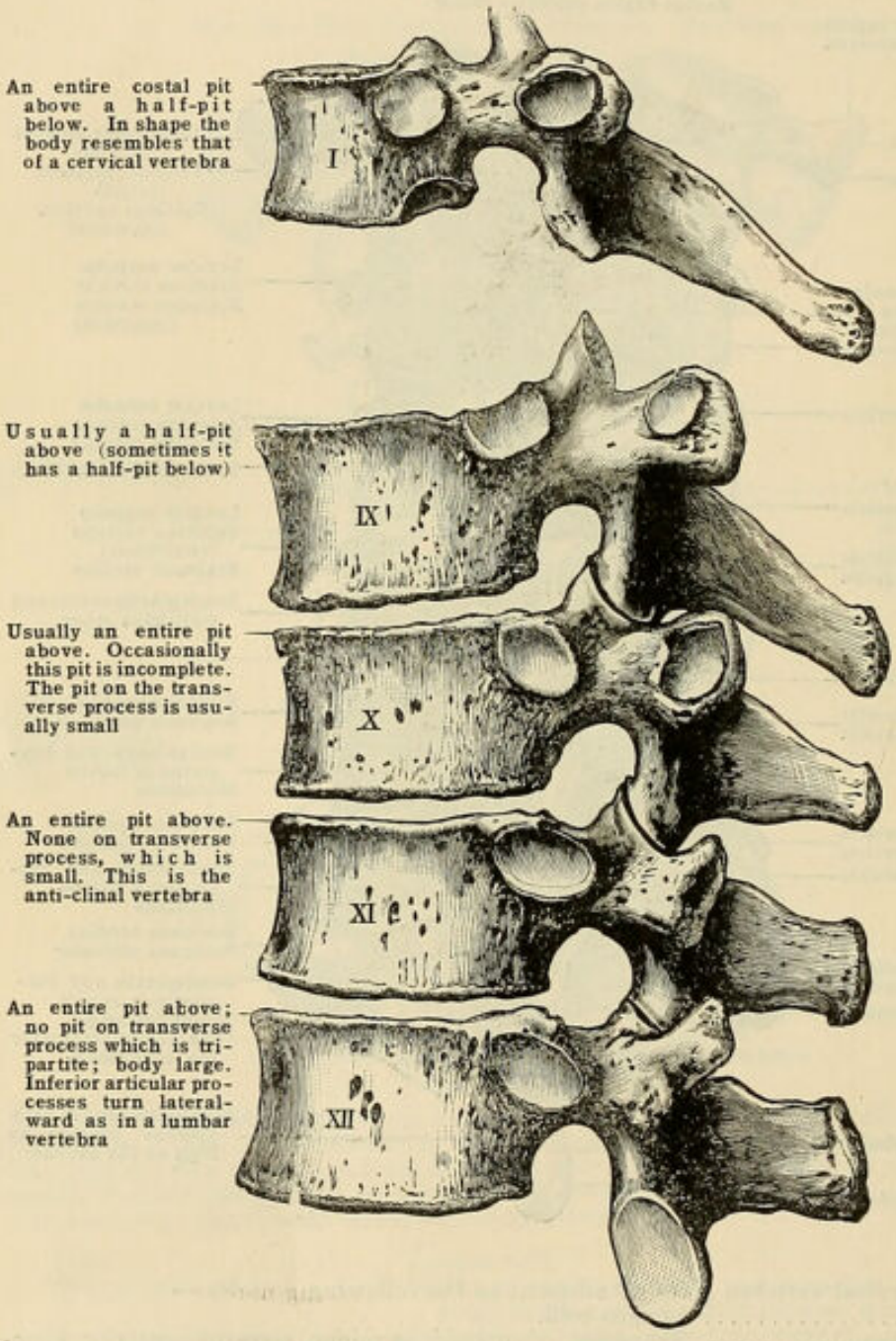

THE THORACIC VERTEBRÆ

The general characters of the thoracic (or dorsal) vertebræ have already been considered. Their most distinguishing features are the **pits** on the **transverse processes** and sides of the **bodies** for the **tubercles** and **heads of the ribs** respectively.

Peculiar thoracic vertebræ.—Several vertebræ in this series differ from the typical example. The exceptional ones are—the **first, ninth, tenth, eleventh,** and **twelfth** (fig. 40).

The **first** thoracic vertebra is a transitional vertebra. The **body** in its general conformation approaches very closely the seventh cervical, in that the greatest diameter is transverse, its upper surface is concave from side to side, and its lateral margins bear two prominent lips. On each side is an entire pit, close to the upper border, for the head of the first rib, and a very small pit (inferior costal pit) below for the head of the second rib. The **spinous process** is thick, strong, almost horizontal and usually more prominent than that of the seventh cervical, an important point to remember when counting the spines in the living subject. Occasionally the transverse process is perforated near the root.

The **ninth** has superior costal pits, and usually no inferior; when the inferior pits are present, this vertebra is not exceptional.

The **tenth** usually has an entire costal pit at its upper border, on each side, but occasionally only a superior costal pit. It has no lower pits and the pits on the transverse processes are usually small.

The **eleventh** has a large body resembling a lumbar vertebra. The pits are on the pedicles and they are complete and of large size. The transverse processes are short, show evidence of becoming broken up into three parts, and have no pits for the tubercles of the eleventh pair of ribs.

In many mammals, the spines of the anterior vertebræ are directed backward, and those of the posterior directed forward, whilst in the centre of the column there is usually one spine vertical. The latter is called the anti-clinal vertebra, and indicates the point at which the thoracic begin to assume the characters of lumbar vertebræ. In man the eleventh thoracic is the anti-clinal vertebra.

The **twelfth** resembles in general characters the eleventh, but may be distinguished from it by the articular surfaces on the inferior articular processes being convex and turned laterally as in the lumbar vertebræ. The transverse process is rudimentary and tripartite, presenting for examination three tubercles, *superior*, *inferior*, and *lateral*, which correspond respectively to the mammillary, accessory, and transverse processes of the lumbar vertebra. There is one complete pit on the root (pedicle) for the head of the twelfth rib.

A peculiarity, more frequent in the thoracic and lumbar than in the cervical and sacral regions of the column, is the existence of a half-vertebra. Such specimens have a wedge-shaped half-centrum, to which are attached a lamina, a transverse, superior, and inferior articular, and half a spinous process. As a rule, a half-vertebra is ankylosed to the vertebræ above and below.

THE LUMBAR VERTEBRÆ

The **lumbar vertebræ** (figs. 41, 42) are distinguished by their large size and by the absence of costal articular surfaces.

The **body** is somewhat reniform, with the greatest diameter transverse, flat above and below, and generally slightly deeper in front than behind. The **roots**

FIG. 41.—A LUMBAR VERTEBRA. (Side view.)

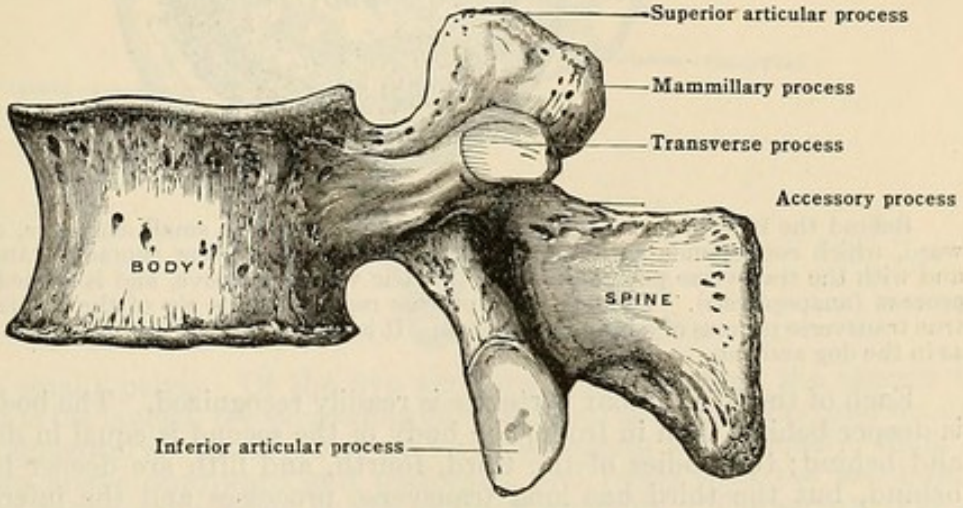

(pedicles) are strong and directed straight backward, and the lower vertebral notches are deep and large. The **laminæ** are shorter and thicker than those of the thoracic or cervical vertebræ, and the **vertebral foramen** is triangular, wider than in the thoracic, but smaller than in the cervical region. The **spinous process**,

thick, broad, and somewhat quadrilateral, projects horizontally backward. It is thicker below than above and terminates in a rough posterior edge. The **articular processes** are thick and strong. The superior articular surface is concave and directed backward and medially; the inferior is convex and looks forward and laterally. The superior pair are more widely separated than the inferior pair and embrace the inferior articular processes of the vertebra above. The posterior margin of each superior articular process is surmounted by the **mammillary process** or tubercle (metapophysis) which corresponds to the superior tubercle of the transverse process of the last thoracic vertebra. In man the mammillary tubercles are rudimentary, but in some animals they attain large proportions, as in the kangaroo and armadillo. The **transverse processes** are long, slender, somewhat spatula-shaped, compressed from before backward, and directed laterally and a little backward. They are longest in the third vertebra and diminish in the fourth, second, and fifth, in this order, to the first, in which they are shortest of all. Their extremities are in series with the lateral tubercles of the transverse processes of the twelfth thoracic vertebra and also with the ribs. With the latter the so-called transverse processes in the lumbar region are homologous, and hence they are sometimes called the **costal processes.** Occasionally the costal element differentiates and becomes a well-developed lumbar rib.

FIG. 42.—A LUMBAR VERTEBRA.
(Showing the compound nature of the transverse process. Upper view.)

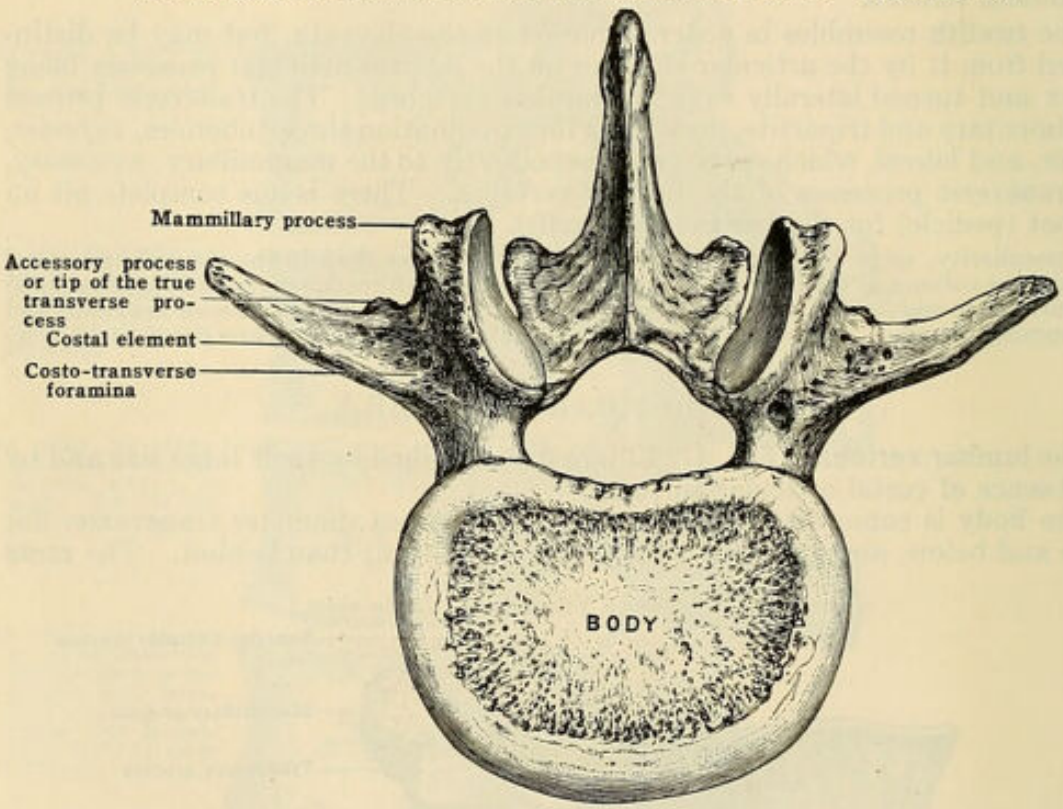

Behind the base of each transverse or costal process is a small eminence, directed downward, which corresponds with the inferior tubercle of the lower thoracic transverse process, and with the transverse processes of the thoracic vertebræ above, and is named the **accessory process** (anapophysis). The accessory process represents the tip of the partially suppressed true transverse process of a lumbar vertebra. It is well developed in some of the lower animals, as in the dog and cat.

Each of the five lumbar vertebræ is readily recognized. The body of the first is deeper behind than in front; the body of the second is equal in depth in front and behind; the bodies of the third, fourth, and fifth are deeper in front than behind, but the third has long transverse processes and the inferior articular processes are not widely separated. The fourth has shorter transverse processes and the inferior articular processes are placed more widely apart. The fifth lumbar vertebra deviates in some of its features so widely from the other members of the series that special prominence must now be given them.

The **fifth lumbar vertebra** is massive, and the **body** is much thicker in front

than behind in consequence of being bevelled off to form with the sacrum the *sacro-vertebral angle.* The **transverse processes** are short, thick, conical, and spring from the body as well as from the roots of the arch. They are very strong for the attachment of the ilio-lumbar ligaments. The **spinous process** is smaller than that of any of the other lumbar vertebræ; the **laminæ** project into the vertebral foramen on each side; and the **roots** are stout and flattened from above downward. The **inferior articular processes** are separated to such a degree as to be wider apart than the superior, and they articulate with the first sacral vertebra.

The **roots** of the arch in this vertebra are liable to a remarkable deviation from the conditions found in other parts of the spine. The peculiarity consists of a complete solution in the continuity of the arch immediately behind the superior articular processes. In such specimens the anterior part consists of the body carrying the roots, transverse and superior articular processes; whilst the posterior segment is composed of the laminæ, spine, and inferior articular processes. The posterior segment of the ring of this vertebra may even consist of two pieces. There is reason to believe that this abnormality of the fifth lumbar vertebra occurs in five per cent. of all subjects examined. Sir William Turner, in his report on the human skeletons in the Challenger Reports, found seven examples among thirty skeletons examined. The skeletons in which this occurred were:—a Malay, an Andamanese, a Chinese, two Bushmen, an Eskimo, and a Negro. Turner has also seen it in the skeleton of a Sandwich Islander. A similar condition is occasionally met with either unilaterally or bilaterally in the thoracic vertebræ.

THE SACRUM

The five sacral vertebræ (figs. 43, 44) are united in the adult to form the **os sacrum,** a large, curved, triangular bone, firmly wedged between the innominate bones, and completing, together with the coccyx, the posterior boundary of the

FIG. 43.—THE SACRUM AND COCCYX. (Anterior view.)

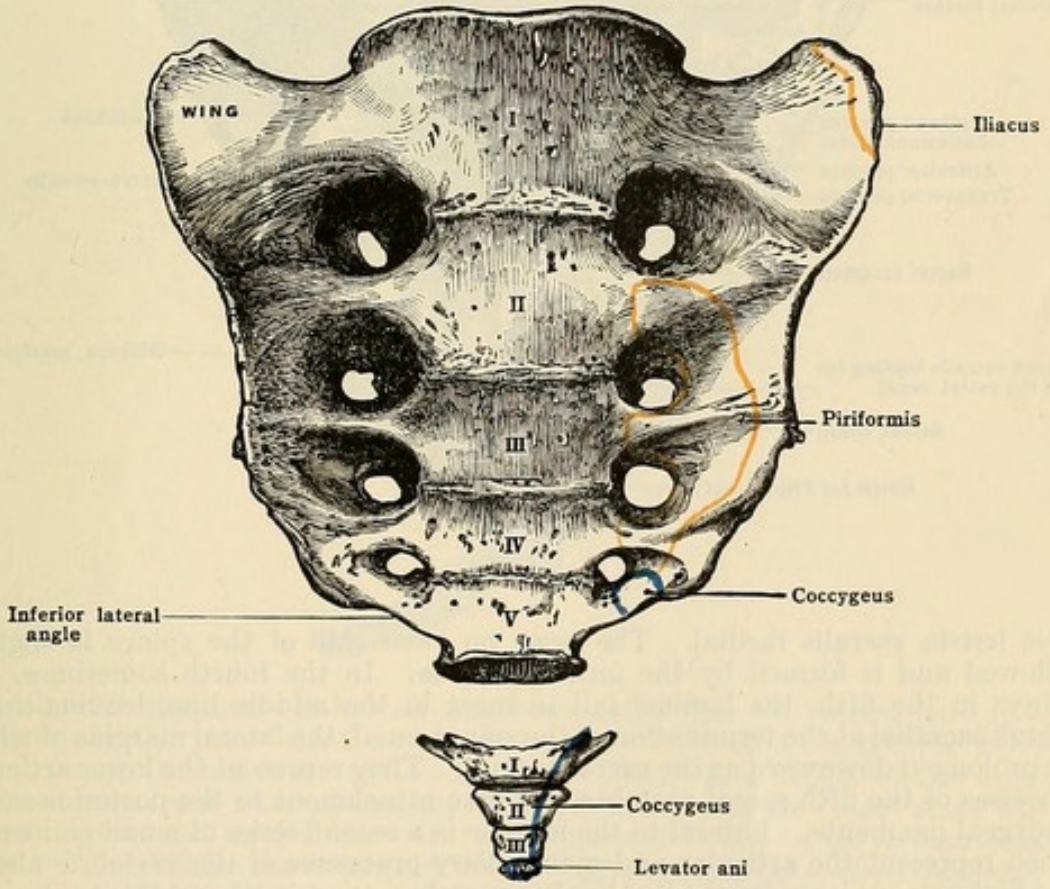

minor (or small) pelvis. Of the five vertebræ which compose the sacrum the uppermost is the largest, the succeeding ones become rapidly smaller, and the fifth is quite rudimentary. In the erect posture the sacrum lies obliquely, being directed from above downward and backward, and forms with the last lumbar vertebra an anterior projection known as the **promontory.** The sacrum presents for examination a pelvic and a dorsal surface, two lateral margins, a base, and an apex.

Surfaces.—The **pelvic surface,** directed downward and forward, is smooth, concave from above downward and slightly from side to side. It is crossed in the

middle by four transverse ridges [lineæ transversæ] which represent the ossified intervertebral discs and separate the bodies of the five sacral vertebræ. Of the bodies, the first and second are nearly equal in size and are larger than the third, fourth, and fifth, which, in vertical depth, are also nearly equal to each other. At the extremities of the transverse ridges on each side are four openings, called the **anterior sacral foramina,** which correspond to the intervertebral foramina in other regions of the column, and transmit the anterior divisions of the first four sacral nerves; they are also traversed by branches of the lateral sacral arteries. The foramina are separated by wide processes, representing the costal processes of the vertebræ, which unite laterally to form the **lateral portion** (or mass) [pars lateralis]. The latter is grooved for the sacral nerves, and rough opposite the second, third, and fourth sacral vertebræ, for the origin of the *piriformis* muscle. The lateral part of the fifth sacral vertebra gives insertion to fibres of the *coccygeus*.

The **dorsal surface** is strongly convex and rough. The middle line is occupied by four eminences representing the somewhat suppressed **spinous processes.** Of these the first is the largest, the second and third may be confluent, and the fourth is often absent. The processes are united to form an irregular ridge or

FIG. 44.—THE SACRUM. (Posterior view.)

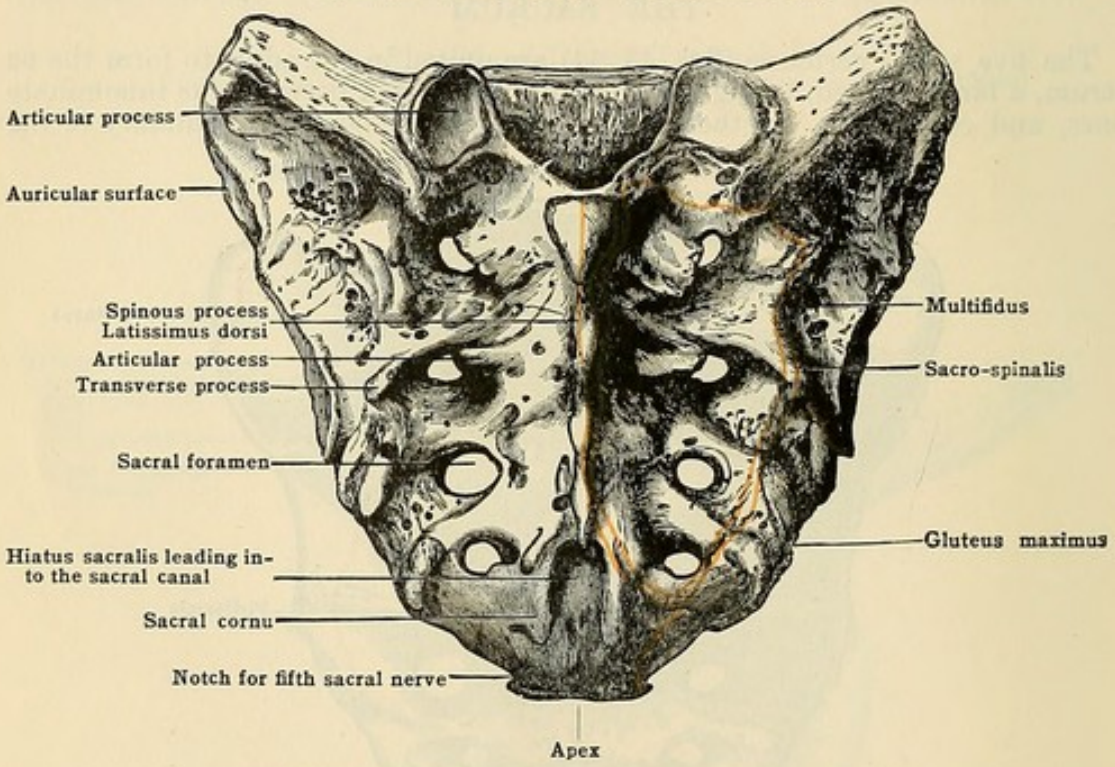

crest [crista sacralis media]. The bone on each side of the spines is slightly hollowed and is formed by the united **laminæ**. In the fourth sometimes, but always in the fifth, the laminæ fail to meet in the middle line, leaving a gap [**hiatus sacralis**] at the termination of the spinal canal, the lateral margins of which are prolonged downward as the **sacral cornua.** They represent the lower articular processes of the fifth sacral vertebra and give attachment to the posterior sacro-coccygeal ligaments. Lateral to the laminæ is a second series of small eminences which represent the **articular** and **mammillary processes** of the vertebræ above. The first pair are large for the last lumbar vertebra, the second and third are small, and the fourth and fifth are inconspicuous. Together they form a pair of irregular ridges [cristæ sacrales articulares].

Immediately lateral to the articular processes are the **posterior sacral foramina,** four on each side; they are smaller than the anterior, and give exit to the posterior primary divisions of the first four sacral nerves. Lateral to the foramina on each side are five elevations representing the **transverse processes.** The first pair, situated at the junction of the posterior surface with the base, are large and conspicuous, and serve all for the attachment of ligaments and muscles.

Together they form on each side of the sacrum an irregular ridge [crista sacralis lateralis]. The space between the spinous and transverse processes presents a shallow concavity known as the **sacral groove,** continuous above with the vertebral groove of the movable part of the column, and, like it, lodging the *multifidus* muscle. Bridging across the groove and attached to the sacral spines medially, and to the lower and back part of the sacrum laterally, is the flat tendon of origin of the *sacro-spinalis* (*erector spinæ*). The *gluteus maximus* takes origin from the back of the lower two pieces of the sacrum.

The **base** or upper surface of the sacrum bears considerable resemblance to the upper surface of the fifth lumbar vertebra. It presents in the middle the body, of a reniform shape, posterior to which is the upper end of the sacral canal bounded by two laminæ. On each side of the canal are two articular processes bearing well-marked mammillary tubercles. The conjoined transverse and costal processes form on each side a broad surface, the wing or **ala** of the sacrum, continuous with the iliac fossa of the hip bone, and giving attachment to a few fibres of the *iliacus*.

FIG. 45.—LEFT LATERAL VIEW OF SACRUM AND COCCYX.

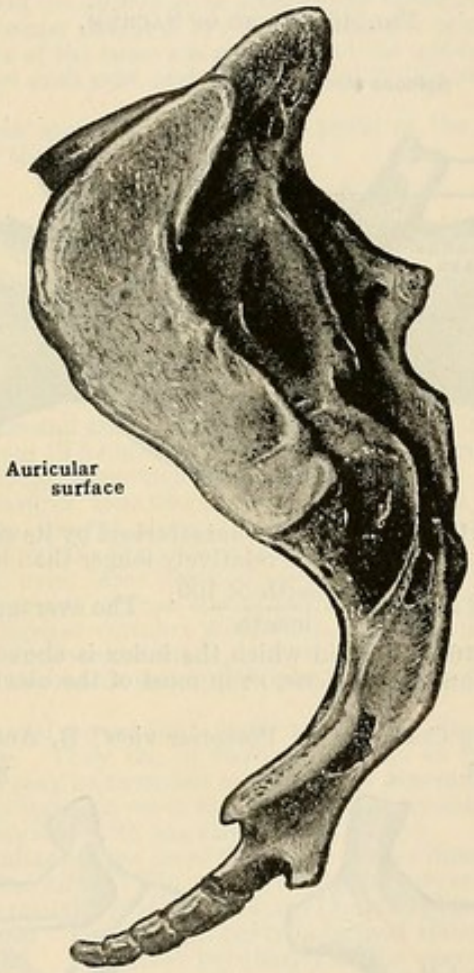

The lateral margins.—It has already been noted that the lateral portion of the sacrum is the part lateral to the foramina. It is broad and thick above, where it forms the ala, but narrowed below. The lateral aspect of the upper part presents in front a broad irregular surface, covered in the recent state with fibro-cartilage, which articulates with the ilium and is known as the **auricular surface.** It is bounded posteriorly by some rough depressions for the attachment of the posterior sacro-iliac ligaments. Below the auricular surface, the lateral margin is rough for the sacro-tuberous (greater) and sacro-spinous (lesser sacro-sciatic) ligaments, and terminates in the projection known as the **inferior lateral angle.** Immediately below the angle is a notch, converted into a foramen by the transverse process of the first coccygeal vertebra, and a ligament connecting this with the inferior lateral angle of the sacrum. Through this foramen passes the anterior branch of the fifth sacral nerve.

The **apex** is directed downward and forward and is formed by the inferior aspect of the body of the fifth sacral vertebra. It is transversely oval and

articulates by means of an intervertebral disc with the coccyx. In advanced life the apex of the sacrum becomes united to the coccyx by bone.

The **sacral canal** is the continuation of the spinal canal through the sacrum. Like the bone, it is curved and triangular in form at the base and flattened toward the apex. It terminates at the hiatus sacralis between the sacral cornua, where the laminæ of the fourth and fifth sacral vertebræ are incomplete. The canal opens on the surface by the anterior and posterior sacral foramina and lodges the lower branches of the cauda equina, the filum terminale, and the lower extremity of the dura and arachnoid. The sub-dural and sub-arachnoid spaces extend downward within the canal as far as the body of the third sacral vertebra.

Differences in the two sexes.—The sacrum of the female is usually broader in proportion to its length, much less curved, and directed more obliquely backward than in the male. The curvature of the female sacrum belongs chiefly to the lower part of the bone, whereas in the male it is equally distributed over its whole length; but the curvature is subject to considerable variation in different skeletons.

FIG. 46.—BASE OF SACRUM.

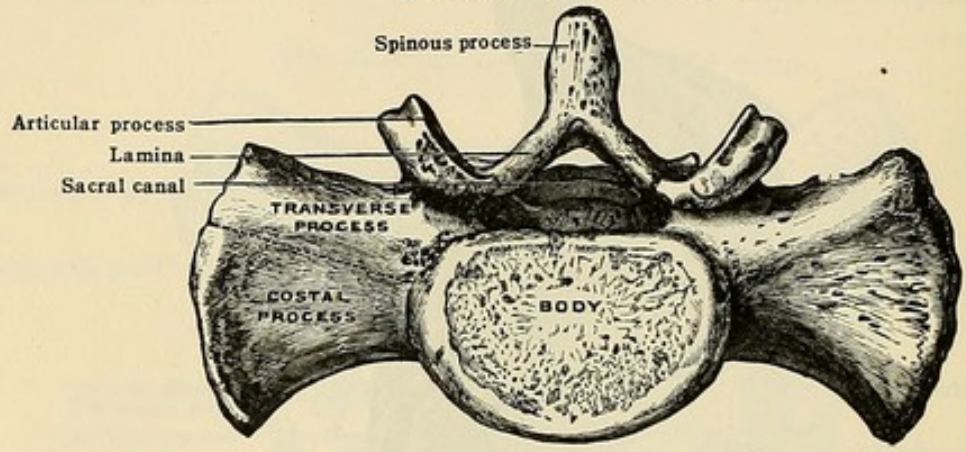

Racial differences.—The human sacrum is characterised by its great breadth in comparison with its length, though in the lower races it is relatively longer than in the higher. The proportion is expressed by the *sacral index* $= \frac{\text{breadth} \times 100}{\text{length}}$. The average sacral index in the British male is 112, in the female 116. Sacra in which the index is above 100 are *platyhieric*, as in Europeans; those under 100 are *dolichohieric*, as in most of the black races (Sir W. Turner).

FIG. 47.—THE COCCYX. A. Posterior view; B. Anterior view.

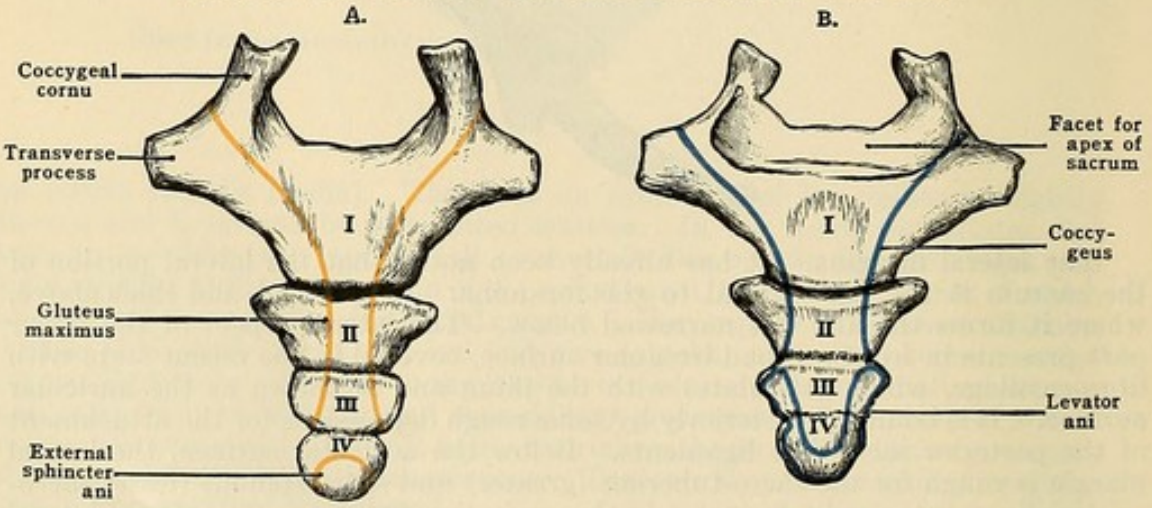

THE COCCYGEAL VERTEBRÆ

The four coccygeal vertebræ are united in the adult to form the **coccyx** [os coccygis] (fig. 47). While four is the usual number of these rudimentary vertebræ, occasionally there are five, and rarely three. In middle life the first piece is usually separate, and the original division of the remaining portion of the coccyx

into three parts is indicated by transverse grooves. In advanced life the pieces of the coccyx, having previously united to form one bone, may also become joined to the sacrum.

The **first** piece of the coccyx is much broader than the others. It consists of a body, transverse processes, and rudiments of a neural arch. The body presents on its upper surface an oval facet for articulation with the apex of the sacrum. On each side of the body a **transverse process** projects laterally and is joined either by ligament or bone to the inferior lateral angle of the sacrum, forming a foramen for the anterior division of the fifth sacral nerve. From the posterior surface of the body two long **coccygeal cornua** project upward and are connected to the sacral cornua by the posterior sacro-coccygeal ligaments, enclosing on each side an aperture —the last intervertebral foramen—for the exit of the fifth sacral nerve. The coccygeal cornua represent the roots and superior articular processes of the first coccygeal vertebra.

The **second** piece of the coccyx is much smaller than the first, and consists of a body, traces of transverse processes, and a neural arch, in the form of slight tubercles at the sides and on the posterior aspect of the body.

The **third** and **fourth** pieces of the coccyx, smaller than the second piece, are mere nodules of bone, corresponding solely to vertebral bodies.

The **anterior surface** of the coccyx gives attachment to the anterior sacro-coccygeal ligament and near the tip to the *levator ani;* it is in relation with the posterior surface of the rectum.

The **posterior surface** of the coccyx is convex, and the upper three pieces afford attachment to the *gluteus maximus* on each side, and the last piece to the coccygeal portion of the *sphincter ani externus.*

The **lateral margins** are thin, and receive parts of the sacro-sciatic ligaments, of the *coccygei* muscles, and of the *levatores ani.*

THE VERTEBRAL COLUMN AS A WHOLE

The vertebral column (fig. 48) is the central axis of the skeleton and is situated in the median line at the posterior aspect of the trunk. Superiorly it supports the skull; laterally it gives attachment to the ribs, through which it receives the weight of the upper limbs, and inferiorly it is supported by the hip bones, by which the weight of the trunk is transmitted to the lower limbs. Its length varies in different skeletons, but on an average it measures about 70 cm. (28 in.) in the male and about 2.5 cm. (1 in.) less in the female. To the entire length the cervical region contributes 12.5 cm. (5 in.), the thoracic 27.5 cm. (11 in.), the lumbar 17.5 cm. (7 in.), and the sacro-coccygeal portion the remaining 12.5 cm. (5 in.). The vertebral column presents a series of curvatures, four when viewed in profile and one when viewed from the front or back. The former are directed alternately forward and backward, and are named, from the regions of the column in which they occur, **cervical, thoracic, lumbar,** and **sacral.** The fifth curve is **lateral,** being in most cases directed toward the right side.

The cervical, thoracic and lumbar curvatures pass imperceptibly into one another, but at the junction of the last lumbar vertebra with the sacrum a well-marked angle occurs, known as the **sacro-vertebral** or **lumbo-sacral** angle, with the result that the promontory of the sacrum overhangs the cavity of the minor (small)pelvis and forms a portion of the superior aperture of the small pelvis.

The thoracic and sacral curves have their concavities directed forward and are developed during intra-uterine life. They are in obvious relation to two great cavities of the trunk, thoracic and pelvic, and may be regarded as **primary** or **accommodation** curves, for the thoracic and pelvic viscera. The thoracic curve extends from the second to the twelfth thoracic vertebra and the sacral curve coincides with the sacrum and coccyx.

The cervical and lumbar curves have their convexities directed forward, and are developed during the first year after birth. They are essentially curves of **compensation,** necessary for the maintenance of the upright posture, and are brought about by modifications in the shape of the intervertebral discs. The cervical curve is formed about the third month, or as soon as the infant can sit upright. The great peculiarity of the curve is that it is never consolidated, being present when the body is placed in the erect position and obliterated by bending the head down upon the chest. The lumbar curve is developed about the end of the first year or when the child begins to walk, but is not consolidated until adult life. (Symington.) The cervical curve extends from the atlas to the second thoracic vertebra, and the lumbar curve from the twelfth thoracic to the promontory of the sacrum.

The lateral curve is situated in the upper thoracic region, and when directed to the right is probably associated with the greater use made of the right hand. This curve, however, is particularly liable to modification in different occupations and in different races.

Viewed from the front, the vertebral column presents a series of **pyramids** due to the successive increase and decrease in size of the bodies. These become broader from the axis to the first thoracic vertebra and then decrease to the fourth thoracic. The first pyramid therefore includes all the cervical vertebræ except the atlas, and has the apex directed upward and its base downward, whilst the second is inverted and formed by the first four thoracic vertebræ. The third pyramid, much the longest, is the result of the increase in size from the fourth thoracic to the fifth lumbar vertebra, and the fourth, which is inverted, is produced by the rapid contraction of the sacral and coccygeal vertebræ.

Viewed from behind, the spinous processes project in the middle line, and the transverse processes as two lateral rows. Of the spines, those of the axis, seventh cervical, first thoracic, and the lumbar vertebræ appear most prominent. On each side is the **vertebral groove,** the floor of which is formed in the cervical and lumbar regions by the laminæ and articular processes,

FIG. 48.—VERTEBRAL COLUMN. (Lateral view.)

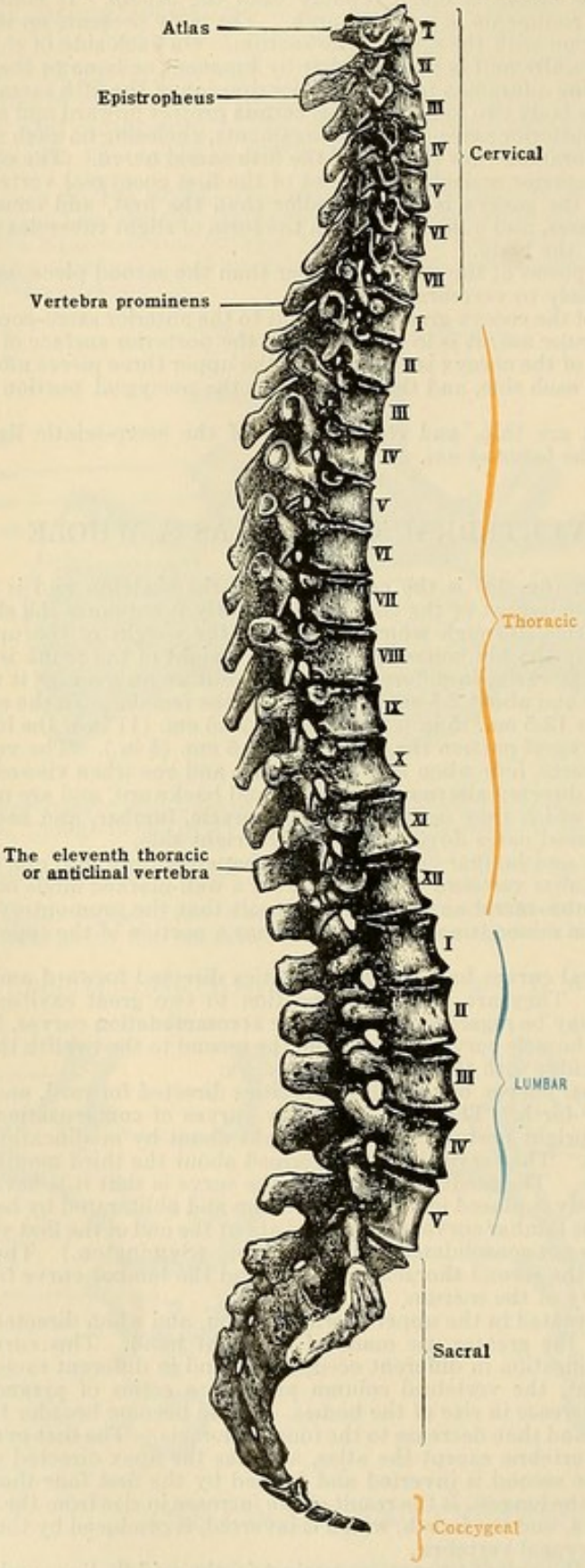

and in the thoracic region, by the laminæ and transverse processes. The transverse processes project laterally for a considerable distance in the atlas, first thoracic, and the middle of the lumbar series; they are shortest in the third cervical and the twelfth thoracic.

In the lateral view, the intervertebral foramina appear oval in shape, and are small in the cervical, larger in the thoracic, and largest in the lumbar region.

Structure of a vertebra.—The bodies of the vertebræ are largely composed of cancellous tissue, with a thin outer covering of compact tissue. In a vertical section through the centrum

FIG. 49.—A DIVIDED THORACIC VERTEBRA. (After Turner.)

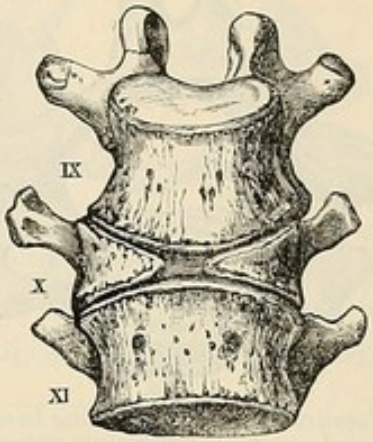

the fibres of the cancellous tissue are seen to be arranged vertically and horizontally, the vertical fibres being curved with their concavities directed toward the centre of the bone. The horizontal fibres are slightly curved parallel with the upper and lower surfaces, and have their convexities toward the centre of the bone. They are not so well defined as the vertical set. (Wagstaffe.)

Ossification.—The vertebræ in general.—The ossification of each vertebra takes place in cartilage from three primary and five secondary centres. The three primary centres

FIG. 50.—A VERTEBRAL CENTRUM IN SECTION TO SHOW THE PRESSURE CURVES.

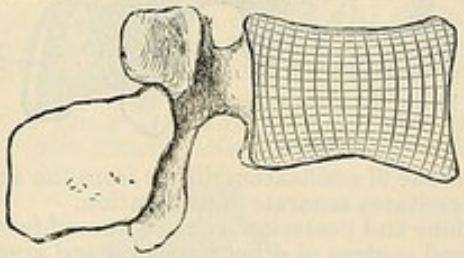

appear, one in the body and two in the arch, about the seventh week of intra-uterine life. In the thoracic region the nucleus for the body appears first, but in the cervical region it is preceded by the centres for the arch. The nucleus for the body soon becomes bilobed, and this condition is sometimes so pronounced as to give rise to the appearance of two distinct nuclei. Indeed, the nucleus is very rarely double and the two parts of the body may remain separate throughout life (fig. 49). The bilateral character of the nucleus is further emphasised by the occasional formation of half-vertebræ. The lateral centres are deposited near the bases of the

FIG. 51.—A VERTEBRA AT BIRTH.

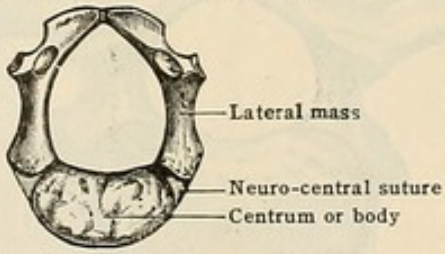

superior articular processes and give rise to the roots, laminæ, articular, and the greater parts of the transverse and spinous processes.

At birth a typical vertebra consists of three osseous pieces—a body and two lateral masses, which constitute the arch, the parts being joined together by hyaline cartilage. The line of union of the lateral portion with the body is known as the *neuro-central suture*, and is not actually obliterated for several years after birth. In the thoracic region the central ossification does not pass beyond the point with which the head of the rib articulates, and leaves a portion of the body on each side formed from the lateral ossification. A thoracic vertebra at the fifth year shows

that the pits for the heads of the ribs are situated behind the neuro-central suture, which is directed obliquely backward and medially. The laminæ unite during the first year after birth; and by the gradual extension of ossification into the various processes, the vertebræ have attained almost their full size by the time of puberty. Subsequently the secondary centres appear in the cartilaginous extremities of the spinous and transverse processes, and in the carti-

Fig. 52.—Cervical Vertebra showing the Epiphysial Plate on the Upper Surface of the Body.

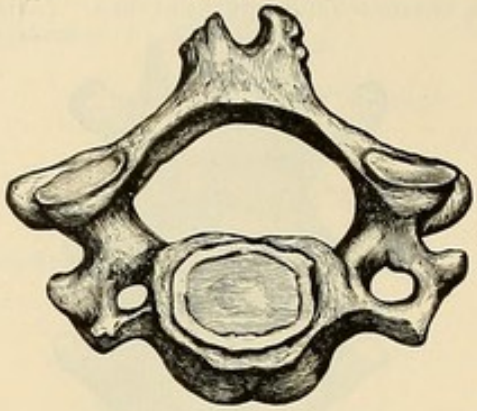

lage on the upper and lower surfaces of the bodies, forming in each vertebra two annular plates, thickest at the circumference and gradually thinning toward the central deficiency. The epiphyses appear from the fifteenth to the twentieth year and join with the vertebra by the twenty-fifth year.

Fig. 53.—Lumbar Vertebra at the Eighteenth Year with Secondary Centres.

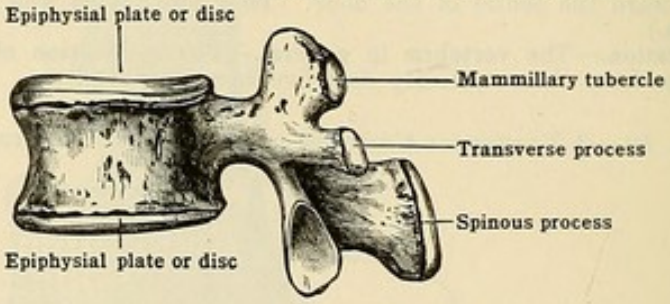

In several vertebræ the mode of ossification differs from the account given above—in some cases considerably—and necessitates separate consideration.

Atlas.—The lateral portions and posterior arch are formed from two centres of ossification, which correspond to the lateral centres of other vertebræ and appear about the seventh week.

Fig. 54.—Upper Thoracic Vertebra with an Epiphysial Plate Removed and Drawn at the Side.

The plate shows the characteristic deficiency in the centre. (Natural size.)

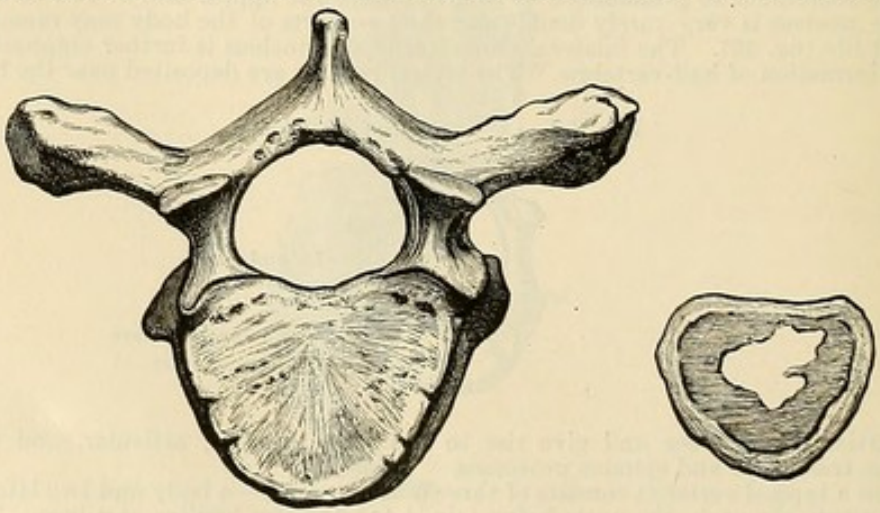

The anterior arch is ossified from one centre, which, however, does not appear until a few months after birth. Union of the lateral parts occurs posteriorly in the third year, being sometimes preceded by the appearance of a secondary centre of ossification in the intervening cartilage, and the union of the lateral parts with the anterior arch occurs about the sixth year.

Epistropheus.—The arch, and the processes associated with it, are formed from two lateral centres which appear, like those in the other vertebræ, about the seventh week. The common piece of cartilage which precedes the body and dens is ossified from four (or five) centres, one (or two) for the body of the axis, in the fourth month, two, laterally disposed, for the dens, a

FIG. 55.—IMMATURE ATLAS. (Third year.)

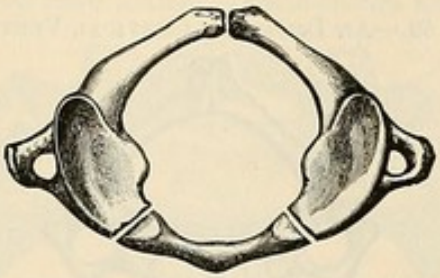

few weeks later, and one, for the apex of the dens, in the second year. The two collateral centres for the main part of the dens soon coalesce, so that at birth the axis consists of four osseous pieces —two lateral portions which constitute the arch, the body, and the dens, surmounted by a piece of cartilage. During the third or fourth year the dens joins with the body, the line of

FIG. 56.—DEVELOPMENT OF THE EPISTROPHEUS.

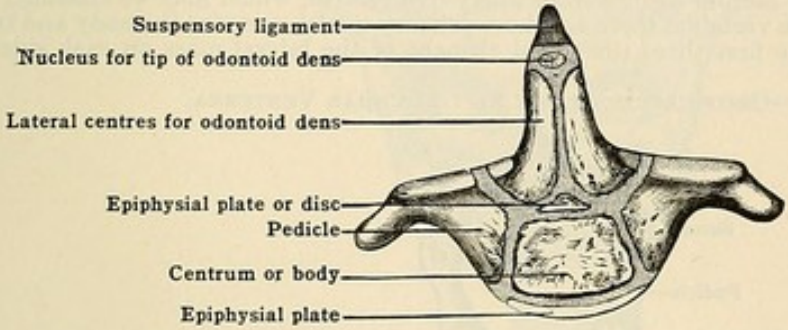

union being indicated even in advanced life by a small disc of cartilage, and the arch unites in front and behind about the same time or a little later. The apical nucleus of the dens, which represents an epiphysis, joins the main part about the twelfth year and in the seventeenth year

FIG. 57.—THE EPISTROPHEUS AT FOUR YEARS OF AGE, SHOWING THE SIZE AND EXTENT OF THE DENS. (Natural size.)

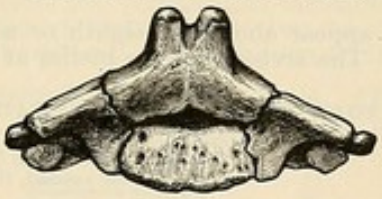

an epiphysial plate appears for the lower surface of the body. There are also rudiments, adjoining the cartilaginous disc, of the upper epiphysial plate of the body.

Cervical vertebræ.—In the cervical vertebræ the lateral centres form a larger share of the body than in the vertebræ of other regions, and the neuro-central suture runs almost in a sag-

FIG. 58.—THE EPISTROPHEUS (FROM AN ADULT) IN SAGITTAL SECTION.

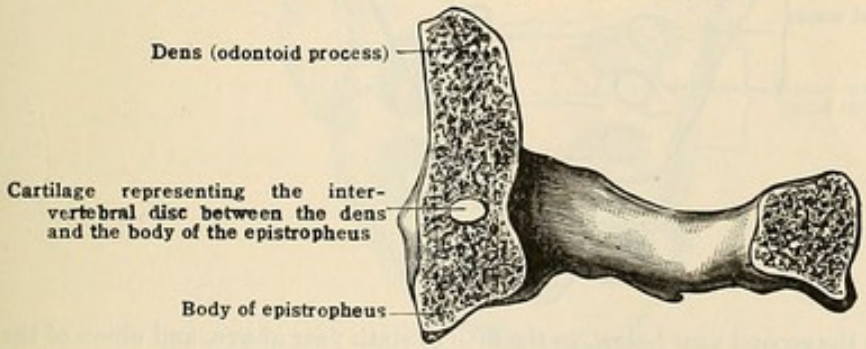

ittal direction. The sixth, seventh, and even the fifth have additional centres which appear before birth for the anterior or costal divisions of the transverse processes. In the other cervical vertebræ the costal processes are ossified by extension of the lateral nuclei. The costal processes of the seventh cervical sometimes remain separate, constituting cervical ribs.

Lumbar vertebræ.—In the lumbar vertebræ the neuro-central suture is almost transverse, and to the usual number of centres of ossification, two other epiphyses for the mammillary tubercles are added, the centres appearing about puberty. The transverse process of the first lumbar vertebra is occasionally developed from an independent centre.

The fifth lumbar exhibits in some cases a special mode of ossification in the arch. Instead of two centres, there are four—one on each side for the root, transverse process, and supe-

FIG. 59.—AN IMMATURE CERVICAL VERTEBRA.

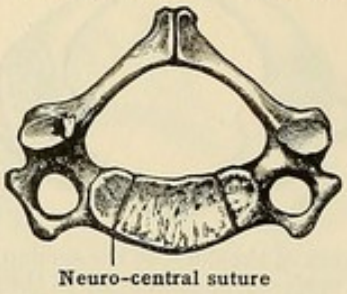

rior articular process, and another on each side for the lamina, inferior articular process, and the lateral half of the spinous process (fig. 60). There may be failure of union of roots with the laminæ or of the laminæ with one another.

Sacral vertebræ.—The sacrum ossifies from thirty-five centres, which may be classified as follows:—In each of the five vertebræ there are three primary nuclei—one for the body and two for the arch; in each of the first three the costal element of the lateral mass on each side is

FIG. 60.—OSSIFICATION OF THE FIFTH LUMBAR VERTEBRA.

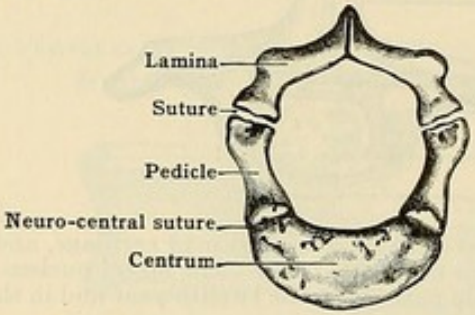

formed from a separate nucleus; associated with each body are two epiphysial plates; and on each lateral margin are two irregular epiphyses, one for the auricular surface and another for the rough edge below.

The centres for the bodies appear about the eighth or ninth week and for the vertebral arches about the sixth month. The arches join the bodies at different times in the different

FIG. 61.—SACRUM AT BIRTH TO SHOW CENTRES OF OSSIFICATION. (Enlarged one-third.)

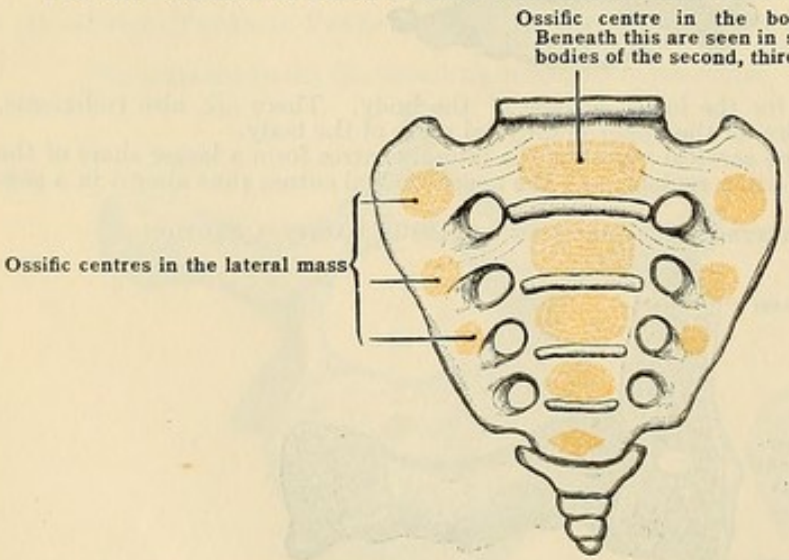

vertebræ, ranging from the second year below, to the fifth or sixth year above, and union of the laminæ takes place behind some years later, from about the ninth to the fifteenth year.

The centres for the costal elements appear outside the anterior sacral foramina, from the fifth to the seventh month, and these unite with the bodies somewhat later than the arches.

The centres for the epiphysial plates appear about the fifteenth year, and for the auricular epiphyses and the edges below, from the eighteenth to the twentieth year.

Consolidation begins soon after puberty by fusion of the costal processes, and this is followed by ossification from below upward in the intervertebral discs, resulting in the union of the adjacent bodies and the epiphysial plates, the ossific union of the first and second being completed by the twenty-fifth year or a little later. The marginal epiphyses are also united to the

FIG. 62.—THE SACRUM AT FOUR YEARS OF AGE (B). THE FIGURE AT THE TOP (A) SHOWS THE BASE DRAWN FROM ABOVE. (Three-fourths natural size.)

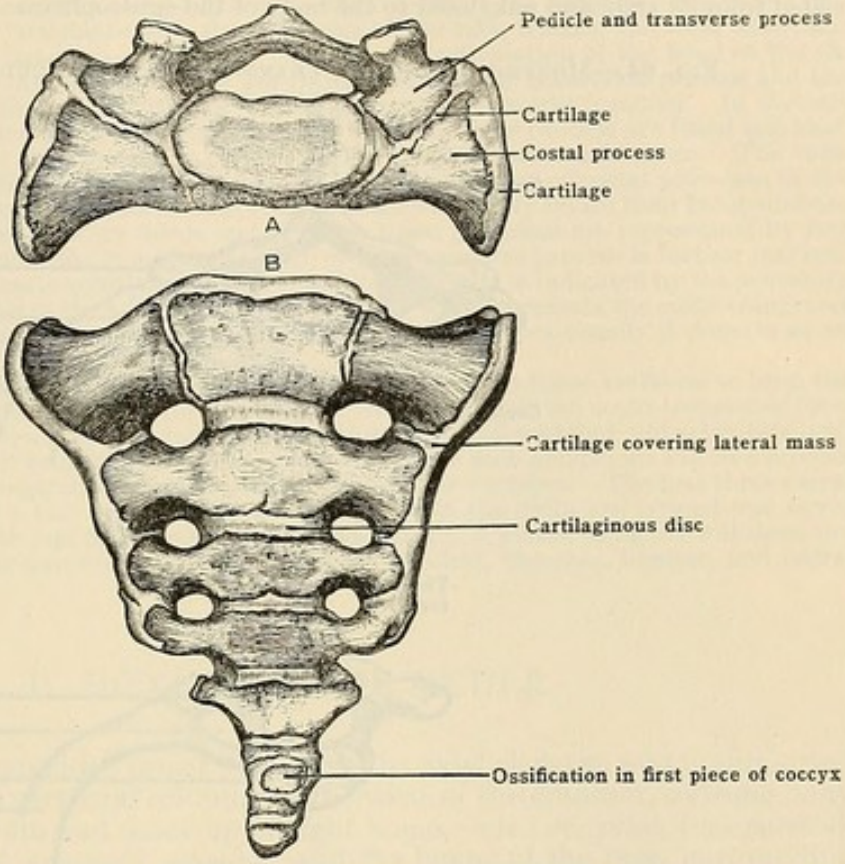

sacrum by the twenty-fifth year. Even in advanced life intervertebral discs persist in the more central parts of the bone and can be well seen in sections.

Coccygeal vertebræ.—The coccygeal vertebræ are cartilaginous at birth and each is usually ossified from a single centre, though there may be two for the first piece. Ossification begins soon after birth in the first segment, and in the second from the fifth to the tenth year.

FIG. 63.—SACRUM AT ABOUT TWENTY-TWO YEARS. (Three-fifths natural size.)

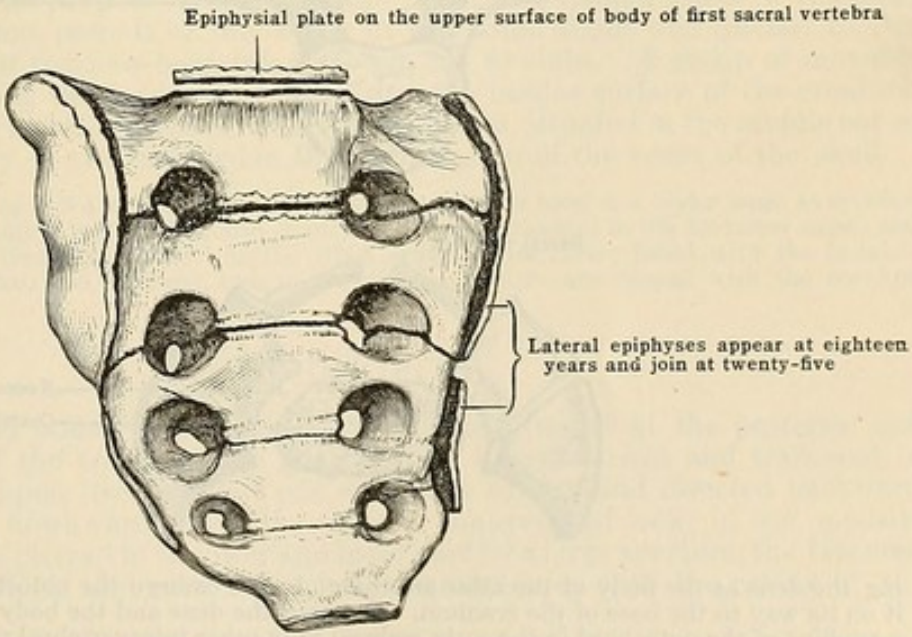

The centres for the third and fourth segments appear just before, and after, puberty respectively. As age advances the various pieces become united with each other, the three lower uniting before middle life and the upper somewhat later. In advanced life the coccyx may join with the sacrum, the union occurring earlier and more frequently in the male than in the female.

The Serial Morphology of the Vertebræ

Although at first sight many of the vertebræ exhibit peculiarities, nevertheless a study of the mode by which they develop, and their variations, indicates the serial homology of the constituent parts of the vertebræ in each region of the column.

The body (centrum) of the vertebra is that part which immediately surrounds the notochord. This part is present in all the vertebræ of man, but the centrum of the atlas is dissociated from its arch, and ankylosed to the body of the epistropheus. The reasons for regard-

FIG. 64.—MORPHOLOGY OF THE TRANSVERSE AND ARTICULAR PROCESSES.

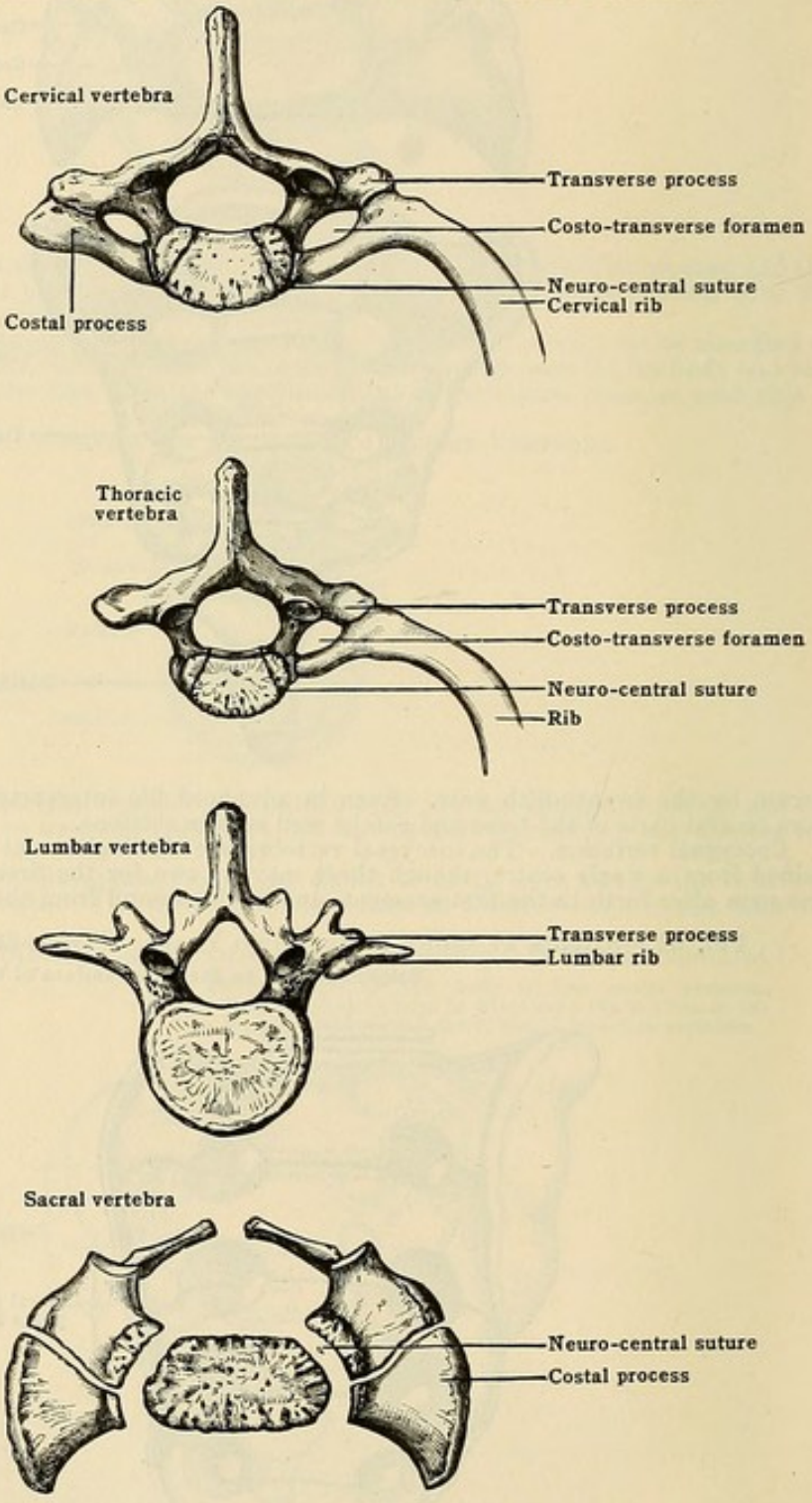

ing the dens as the body of the atlas are these: In the embryo the notochord passes through it on its way to the base of the cranium. Between the dens and the body of the axis there is a swelling of the notochord in the early embryo as in other intervertebral regions. This swelling is later indicated by a small intervertebral disc hidden in the bone, but persistent even in old age. Moreover, the dens ossifies from primary centres, and in chelonians it remains as a separate ossicle throughout life; in Ornithorhynchus it remains distinct for a long time, and it has been found separate even in an adult man. Lastly, in man and many mammals, an epi-

physial plate develops between it and the body of the axis. The anterior arch of the atlas represents a cartilaginous *hypochordal bar*, which is present in the early stages of development of the vertebræ, but disappears in all but the atlas in the ossification of the body.

The *arches* and *spinous processes* are easily recognised throughout the various parts of the column in which complete vertebræ are present.

The *articular processes* or *zygapophyses* are of no morphological value, and do not require consideration here.

The *transverse processes* offer more difficulty. They occur in the simplest form in the thoracic series. Here they articulate with the tubercles of the ribs, whence the term *tubercular processes* or *diapophyses* has been given them (the place of articulation of the head of the rib with the vertebra is the *capitular process* or *parapophysis*), and the transverse process and the neck of the rib enclose an arterial foramen named the costo-transverse foramen. In the cervical region the costal element (*pleurapophysis*) and the transverse process are fused together, and the conjoint process thus formed is pierced by the costo-transverse foramen. The compound nature of the process is indicated by the fact that the anterior or costal processes in the lower cervical vertebræ arise from additional centres and occasionally retain their independence as cervical ribs, and in Sauropsida (birds and reptiles) these processes are represented by free ribs. In the lumbar region, the compound nature of the transverse process is further marked. The true transverse process is greatly suppressed, and its extremity is indicated by the accessory tubercle. Anterior to this in the adult vertebræ a group of holes represents the costo-transverse foramen, and the portion in front of this is the costal element. Occasionally it persists as an independent ossicle, the lumbar rib.

In the sacral series the costal elements are coalesced in the first three vertebræ to form the greater portion of the lateral portion for articulation with the ilium, the costo-transverse foramina being completely obscured. In rare instances the first sacral vertebra will articulate with the ilium on one side, but remain free on the other, and under such conditions the free process exactly resembles the elongated transverse process of a lumbar vertebra. The first three sacral vertebræ which develop costal processes for articulation with the ilium are termed *true sacral* vertebræ, while the fourth and fifth are termed *pseudo-sacral*. A glance at fig. 64 will show the homology of the various parts of a vertebra from the cervical, thoracic, lumbar, and sacral regions.

B. BONES OF THE SKULL

The skull is the expanded upper portion of the axial skeleton and is supported on the summit of the vertebral column. It consists of the **cranium,** a strong bony case enclosing the brain and made up of eight bones—viz., *occipital*, two *parietal*, *frontal*, two *temporal*, *sphenoid*, *ethmoid;* and the **bones of the face,** surrounding the mouth and nose, and forming with the cranium the orbital cavity for the reception of the eye. The bones of the face are fourteen in number—viz., two *maxillæ*, two *zygomatic* (*malar*), two *nasal*, two *lacrimal*, two *palate*, two *inferior conchæ* (*turbinates*), the *mandible*, and the *vomer*. All the bones enumerated above, with the exception of the mandible, are united by suture and are therefore immovable. The proportion between the facial and cranial parts of the skull varies at different periods of life, being in the adult about one (facial) to two (cranial), and in the new-born infant about one to eight. A group of movable bones, comprising the *hyoid*, suspended from the basilar surface of the cranium, and three small bones, the *incus*, *malleus*, and *stapes*, situated in the middle ear or tympanic cavity, is also included in the enumeration of the bones of the skull.

According to the BNA nomenclature, the term *cranium* is used in a wider sense as synonymous with *skull*, and is subdivided into *cranium cerebrale* (cranium in the narrower sense) and *cranium viscerale* (facial skeleton). In the BNA, seven bones above listed with the facial,—two inferior conchæ, two lacrimal, two nasal and the vomer—are classed with the cranium cerebrale.

THE OCCIPITAL

The **occipital bone** [os occipitale] (fig. 65) is situated at the posterior and inferior part of the cranium. In general form it is flattened and trapezoid in shape, curved upon itself so that one surface is convex and directed backward and somewhat downward, while the other is concave and looks in the opposite direction. It is pierced in its lower and front part by a large aperture, the **foramen magnum,** by which the vertebral canal communicates with the cavity of the cranium.

The occipital bone is divisible into four parts, **basilar, squamous,** and two **condylar,** so arranged around the foramen magnum that the basilar part lies in front, the condylar parts on either side, and the squamous part above and behind.

Speaking generally, this division corresponds to the four separate parts of which the bone consists at the time of birth (fig. 69), known as the **basi-occipital, supra-occipital,** and **ex-occipital.** In early life these parts fuse together, the lines of junction of the supra-occipital and ex-occipitals extending lateralward from the posterior margin of the foramen magnum, and those of the ex-occipitals and basi-occipital passing through the condyles near their anterior extremities. It must be noted, however, that the upper portion of the squamous part represents an additional bone, the **interparietal.**

The **squamous part** [squama occipitalis] (supra-occipital and interparietal) presents on its convex **posterior surface,** and midway between the superior angle and the posterior margin of the foramen magnum, a prominent tubercle known as the **external occipital protuberance,** from which a vertical ridge—the **external occipital crest**—runs downward and forward as far as the foramen. The protuberance and crest give attachment to the ligamentum nuchæ.

FIG. 65.—THE OCCIPITAL. (External view.)

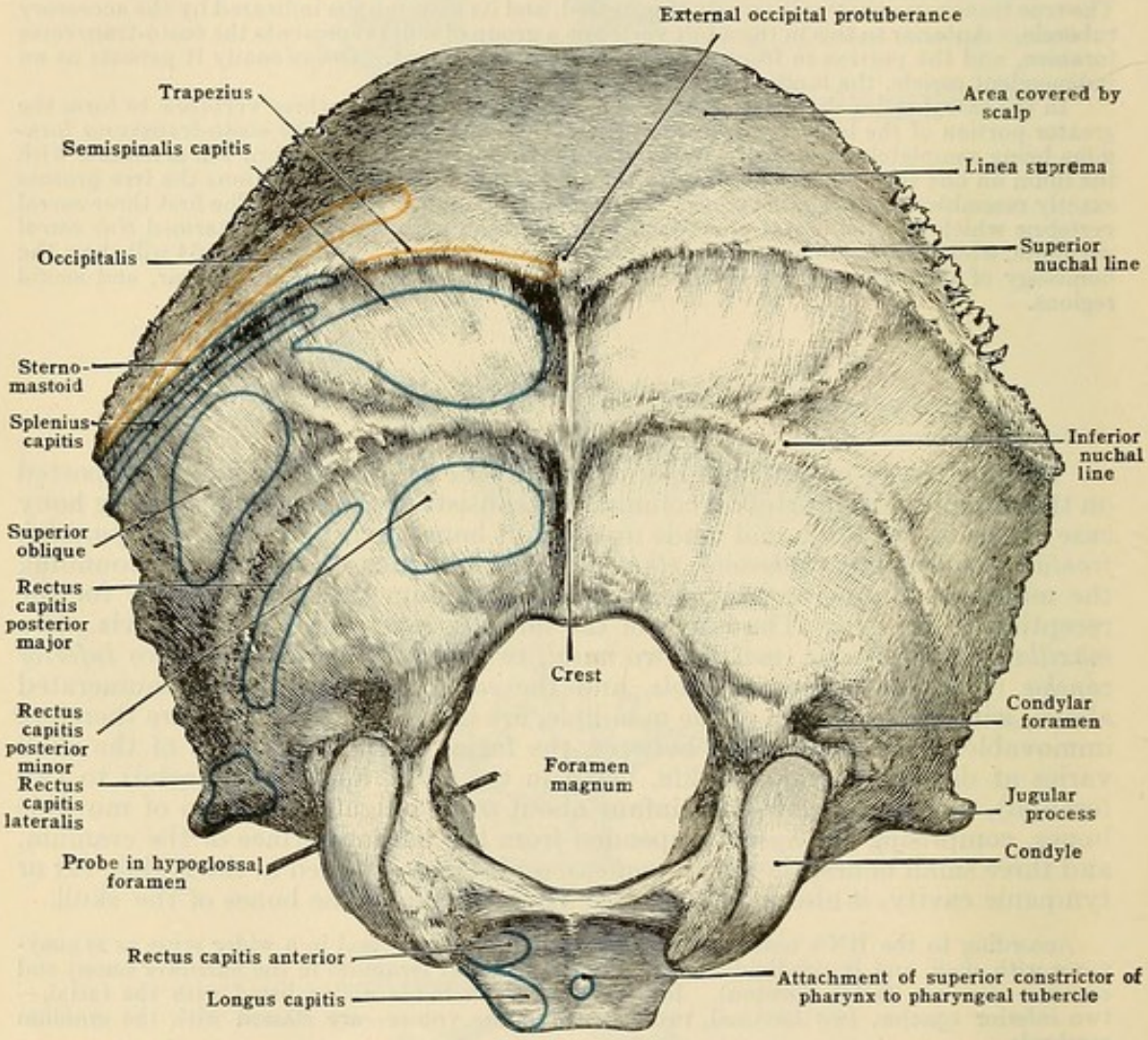

Arching lateralward on each side from the external occipital protuberance toward the lateral angle of the bone is a semicircular ridge, the **superior nuchal line** [linea nuchæ superior], which divides the surface into two parts—an upper [planum occipitale] and a lower [planum nuchale]. Above this line, a second less distinctly marked ridge—the **highest nuchal line** [linea nuchæ suprema]—is usually seen. It is the most curved of the three lines on this surface and gives attachment to the epicranial aponeuosis and to a few fibres of the *occipitalis* muscle. Between the superior and highest curved lines is a narrow crescentic area in which the bone is smoother and denser than the rest of the surface, whilst the part of the bone above the linea suprema is convex and covered by the scalp.

The lower part of the surface is very uneven and subdivided into an upper and a lower area by the **inferior nuchal line,** which runs laterally from the middle of the crest to the jugular process.

The curved lines and the areas thus mapped out between and below them give attachment to several muscles. To the superior nuchal line are attached, medially the *trapezius*, and laterally the *occipitalis* and *sterno-cleido-mastoid;* the area between the superior and inferior curved lines receives the *semispinalis capitis* (*complexus*) medially, and *splenius capitis* and *obliquus capitis superior* laterally; the inferior nuchal line and the area below it afford insertion to the *rectus capitis posterior minor* and *major*.

The **anterior** or **cerebral surface** is deeply concave and marked by two grooved ridges which cross one another and divide the surface into four fossæ of which the two upper, triangular in form, lodge the occipital lobes of the cerebrum, and the two lower, more quadrilateral in outline, the lobes of the cerebellum. The vertical ridge extends from the superior angle to the foramen magnum and the transverse ridge from one lateral angle to the other, the point of intersection being indicated by the **internal occipital protuberance** [eminentia cruciata]. The

FIG. 66.—OCCIPITAL BONE, CEREBRAL SURFACE.

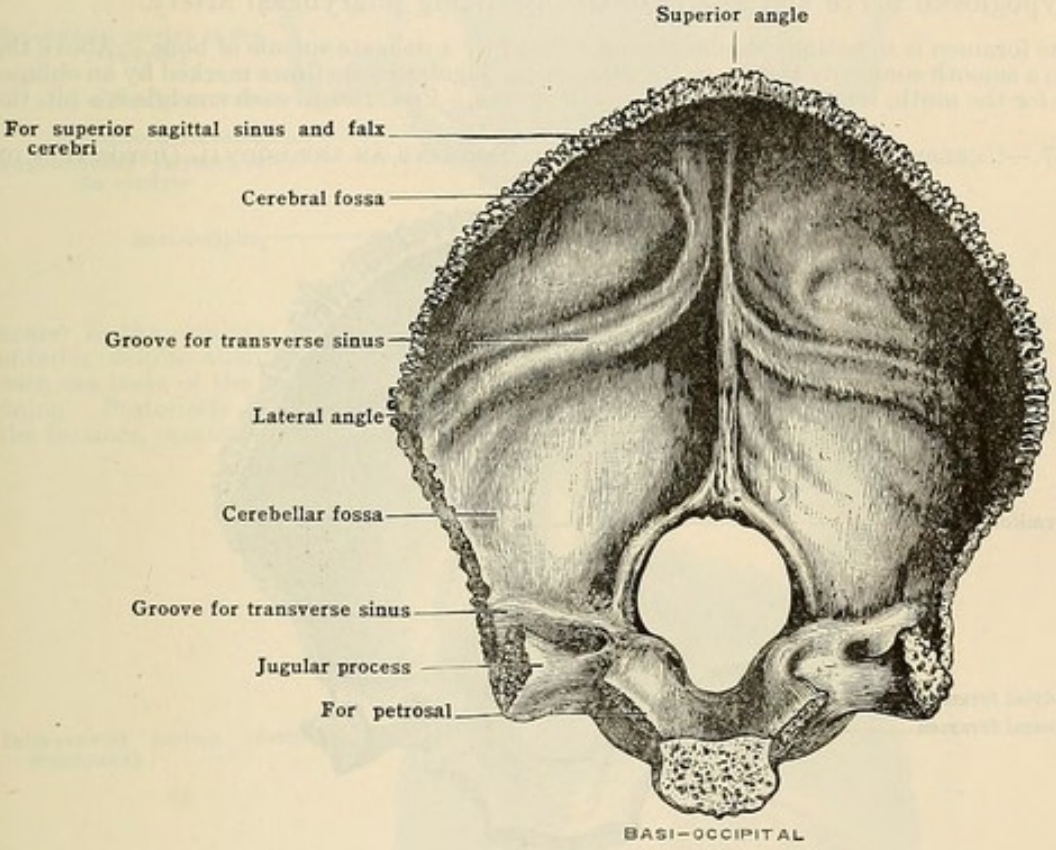

upper part of the vertical ridge is grooved [sulcus sagittalis] for the superior sagittal (*longitudinal*) sinus and gives attachment, by its margins, to the falx cerebri; the lower part is sharp and known as the **internal occipital crest,** and affords attachment to the falx cerebelli. Approaching the foramen magnum the ridge divides, and the two parts become lost upon its margin. The angle of divergence sometimes presents a shallow fossa for the extremity of the vermis of the cerebellum, and is called the **vermiform fossa.** The two parts of the transverse ridge are deeply grooved [sulcus transversus] for the transverse (*lateral*) sinuses, and the margins of the groove give attachment to the tentorium cerebelli. To one side of the internal occipital protuberance is a wide space, where the vertical groove is continued into one of the lateral grooves (more frequently the right), and this is termed the torcular Herophili; it is sometimes exactly in the middle line.

The squamous portion has three angles and four borders. The **superior angle** forming the summit of the bone is received into the space formed by the union of the two parietals. The **lateral angles** are very obtuse and correspond in situation with the lateral ends of the transverse ridges. Above the lateral angle on each side the margin is deeply serrated, forming the **lambdoid** or **superior border** which extends to the superior angle and articulates with the posterior border of the parietal in the lambdoid suture. The **mastoid** or **inferior border** extends

from the lateral angle to the jugular process and articulates with the mastoid portion of the temporal.

The **condylar** or **lateral portions** [partes laterales] (ex-occipitals) form the lateral boundaries of the foramen magnum and bear the condyles on their inferior surfaces. The **condyles** are two convex oval processes of bone with smooth articular surfaces, covered with cartilage in the recent state, for the superior articular processes of the atlas. They converge in front, and are somewhat everted. Their margins give attachment to the capsular ligaments of the occipito-atlantal joints and on the medial side of each is a prominent tubercle for the alar (lateral odontoid) ligament. The anterior extremities of the condyles extend beyond the ex-occipitals on the basi-occipital portion of the bone. The **hypoglossal** (anterior condyloid) **foramen** or **canal** [canalis hypoglossi] perforates the bone at the base of the condyle, and is directed from the interior of the cranium, just above the foramen magnum, forward and laterally; it transmits the hypoglossal nerve and a twig of the ascending pharyngeal artery.

The foramen is sometimes double, being divided by a delicate spicule of bone. Above the canal is a smooth convexity known as the **tuberculum jugulare** sometimes marked by an oblique groove for the ninth, tenth and eleventh cranial nerves. Posterior to each condyle is a pit, the

FIG. 67.—CEREBRAL SURFACE OF THE OCCIPITAL, SHOWING AN OCCASIONAL DISPOSITION OF THE CHANNELS.

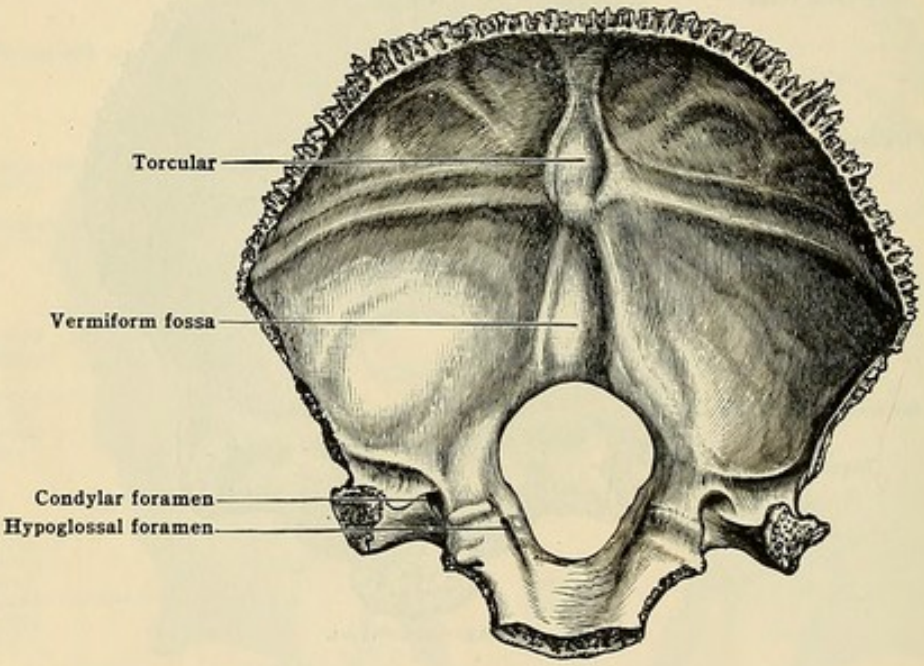

condylar fossa, which receives the hinder edge of the superior articular process of the atlas when the head is extended. The floor of the depression is occasionally perforated by the **condylar** (posterior condyloid) **canal** or **foramen** [canalis condyloideus], which transmits a vein from the transverse sinus. Projecting laterally opposite the condyle is a quadrilateral portion of bone known as the **jugular process,** the extremity of which is rough for articulation with the jugular facet on the petrous portion of the temporal bone. Up to twenty-five years the bones are united here by means of cartilage; about this age ossification of the cartilage takes place, and the jugular process thus becomes fused with the petrosal. Its anterior border is deeply notched to form the posterior boundary of the jugular foramen, and the notch is directly continuous with a groove on the upper surface which lodges the termination of the transverse sinus. In or near the groove is seen the inner opening of the condylar foramen. The lower surface of the process gives attachment to the *rectus capitis lateralis* and the oblique occipito-atlantal ligament. Occasionally the mastoid air cells extend into this process and rarely a process of bone, representing the *paramastoid process* of many mammals, projects downward from its under aspect and may be so long as to join or articulate with the transverse process of the atlas.

The **basilar portion** (basi-occipital) is a quadrilateral plate of bone projecting forward and upward in front of the foramen magnum. Its superior surface presents a deep groove—the **basilar groove** [clivus]; it supports the medulla oblongata and gives attachment to the tectorial membrane (occipito-axial ligament). The lower surface presents in the middle line a small elevation known as the **pharyngeal tubercle** for the attachment of the fibrous raphé of the pharynx, and immediately in front of the tubercle there is frequently a shallow

fossa—the **scaphoid fossa**—which originally received the primitive anterior extremity of the foregut.

On each side of the middle line are impressions for the insertions of the *longus capitis* (*rectus capitis anterior major*) and *rectus capitis anterior* (*minor*), the impression for the latter being

FIG. 68.—THE FORAMEN MAGNUM AT THE SIXTH YEAR.

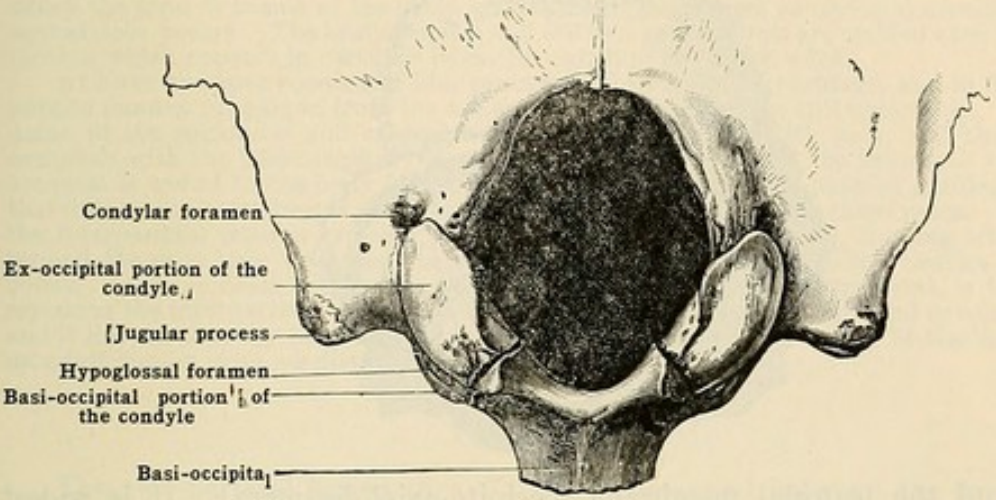

nearer to the condyle, and near the foramen magnum this surface gives attachment to the anterior occipito-atlantal ligament. Anteriorly the basilar process articulates by synchondrosis with the body of the sphenoid up to twenty years of age, after which there is complete bony union. Posteriorly it presents a smooth rounded border forming the anterior boundary of the foramen magnum. It gives attachment to the apical odontoid ligament, and above this

FIG. 69.—THE OCCIPITAL AT BIRTH. (Anterior view.)

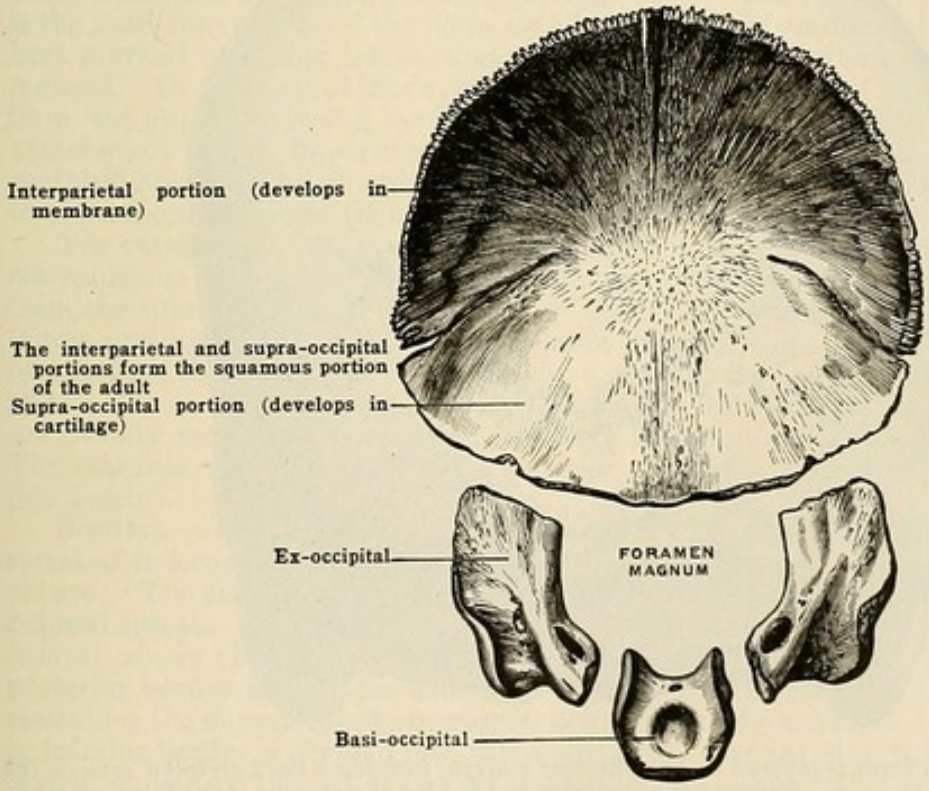

to the ascending portion of the crucial ligament. In the occipital bone at the sixth year the lateral extremities of this border are enlarged to form the basilar portion of the condyles. The lateral borders are rough below for articulation with the petrous portion of the temporal bones, but above, on either side of the basilar groove, is a half-groove, which, with a similar half-groove on the petrous portion of the temporal bone, lodges the inferior petrosal sinus.

The **foramen magnum** is oval in shape, with its long axis in a sagittal direction. It transmits the medulla oblongata and its membranes, the accessory nerves (spinal portions), the vertebral arteries, the anterior and posterior spinal

Fig. 70.—The Occipital with a Separate Interparietal.

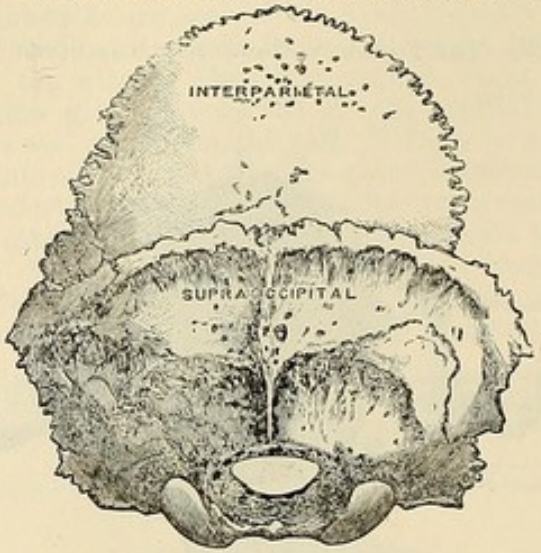

arteries, and the tectorial membrane (occipito-axial ligament). It is widest behind, where it transmits the medulla, and is narrower in front, where it is encroached upon by the condyles.

Fig. 71.—Skull showing a Pre-interparietal Bone (P.I.).

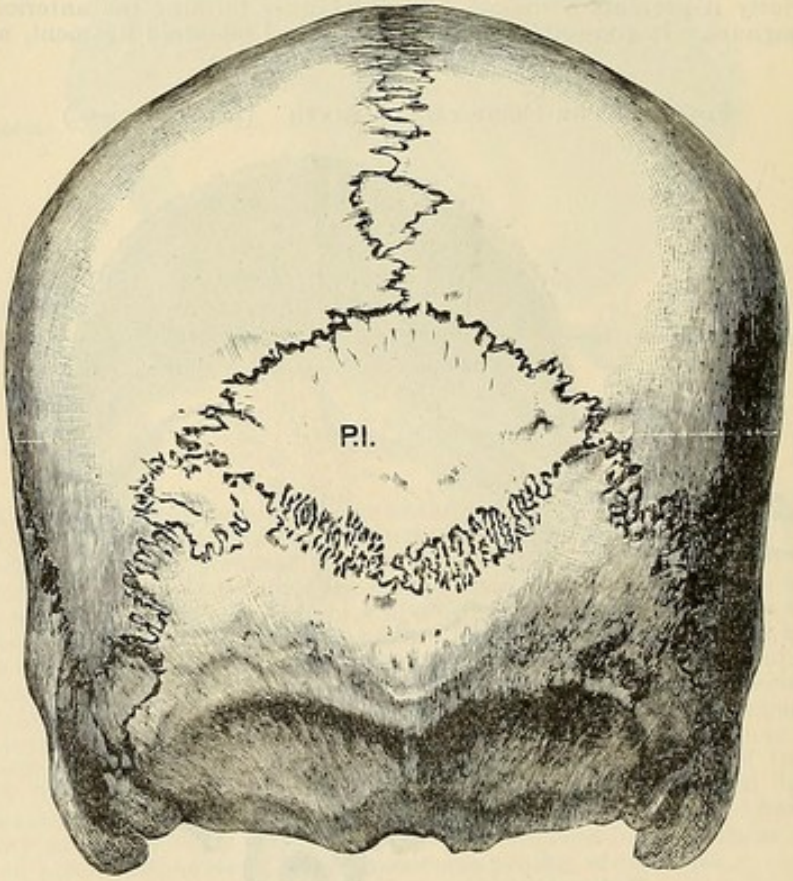

Occasionally a facet is present on the anterior margin, forming a *third occipital condyle* for articulation with the dens. Between the condyles and behind the margin of the foramen magnum the posterior occipito-atlantal ligament obtains attachment.

Blood-supply.—The occipital bone receives its blood-supply from the occipital, posterior auricular, middle meningeal, vertebral and the ascending pharyngeal arteries.

Articulations.—The occipital bone is connected by suture with the two parietals, the two temporals, and the sphenoid; the condyles articulate with the atlas, and exceptionally the occipital articulates with the dens of the epistropheus by means of the third occipital condyle.

Ossification.—The occipital bone develops in four pieces. The squamous portion is ossified from four centres, arranged in two pairs, which appear about the eighth week. The upper pair are deposited in membrane, and this part of the squamous portion represents the interparietal bone of many animals. The lower pair, deposited in cartilage, form the true supra-occipital element, and the four parts quickly coalesce near the situation of the future occipital protuberance. For many weeks two deep lateral fissures separate the interparietal and supraoccipital portions, and a membranous space extending from the centre of the squamous portion to the foramen magnum partially separates the lateral portions of the supra-occipital. This space is occupied later by a spicule of bone, and is of interest as being the opening through which the form of hernia of the brain and its meninges, known as occipital meningocele or encephalocele, occurs. The basi-occipital and the two ex-occipitals are ossified each from a single nucleus which appears in cartilage from the eighth to the tenth week.

At birth the bone consists of four parts united by strips of cartilage, and in the squamous portion fissures running in from the upper and lateral angles are still noticeable. The osseous union of the squamous and ex-occipital is completed in the fifth year, and that of the ex-occipitals with the basi-occipital before the seventh year. Up to the twentieth year the basi-occipital is united to the body of the sphenoid by an intervening piece of cartilage, but about that date ossific union begins and is completed in the course of two or three years. Occasionally the interparietal portion remains separate throughout life (fig. 70), forming what has been termed the *inca bone*, or it may be represented by numerous detached ossicles or Wormian bones. In some cases a large Wormian bone, named the pre-interparietal, is found, partly replacing the interparietal bone (fig. 71). A pre-interparietal bone is found in some mammals, and it has occasionally been observed in the human fœtal skull. In fig. 71 the bone is seen in an adult human skull—a distinctly rare condition.

THE PARIETAL

The two **parietal bones** (figs. 72, 73), interposed between the frontal before and the occipital behind, form a large portion of the roof and sides of the cranium. Each parietal bone [os parietale] is quadrilateral in form, convex externally, concave internally, and each presents for examination two surfaces, four borders, and four angles.

The **parietal surface** is smooth and is crossed, just below the middle, by two curved lines known as the **temporal lines.** The superior line gives attachment to the temporal fascia; the lower, frequently the better marked, limits the origin of the *temporal* muscle; whilst the narrow part of the surface enclosed between them is smooth and more polished than the rest. Immediately above the ridges is the most convex part of the bone, termed the **parietal eminence** [tuber parietale], best marked in young bones, and indicating the point where ossification commenced. Of the two divisions on the parietal surface marked off by the temporal lines, the upper is covered by the scalp, and the lower, somewhat striated, affords attachment to the *temporal* muscle. Close to the upper border and near to the occipital angle is a small opening—the **parietal foramen**—which transmits a vein to the superior sagittal (*longitudinal*) sinus.

The **cerebral surface** is marked with depressions corresponding to the cerebral convolutions and by numerous deep furrows, running upward and backward from the sphenoidal angle and the lower border, for the middle meningeal vessels (sinus and artery). A shallow depression running close to the superior border forms, with the one of the opposite side, a channel for the superior sagittal sinus, at the side of which are small irregular pits for the Pacchionian bodies; the pits are usually present in adult skulls, but are best marked in those of old persons. The margins of the groove for the superior sagittal sinus give attachment to the falx cerebri.

Borders.—The **sagittal** or **superior border,** the longest and thickest, is deeply serrated to articulate with the opposite parietal, with which it forms the **sagittal suture.** The **frontal** or **anterior border** articulates with the frontal to form the **coronal suture.** It is deeply serrated and bevelled, so that it is overlapped by the frontal above, but overlaps the edge of that bone below. The **occipital** or **posterior border** articulates with the occipital to form the **lambdoid suture,** and resembles the superior and anterior in being markedly serrated. The **squamosal** or **inferior border** is divided into three portions:—the anterior, thin and bevelled, is overlapped by the tip of the great wing of the sphenoid; the middle portion, arched and also bevelled, is overlapped by the squamous part of the temporal; and the posterior portion, thick and serrated, articulates with the mastoid portion of the temporal bone.

Angles.—The **frontal** or **anterior superior,** almost a right angle, occupies that part of the bone which at birth is membranous and forms part of the anterior

fontanelle. The **sphenoidal** or **anterior inferior** angle is thin and prolonged downward to articulate with the tip of the great wing of the sphenoid. Its inner surface is marked by a deep groove, sometimes converted into a canal for a short

FIG. 72.—THE LEFT PARIETAL. (Outer surface.)

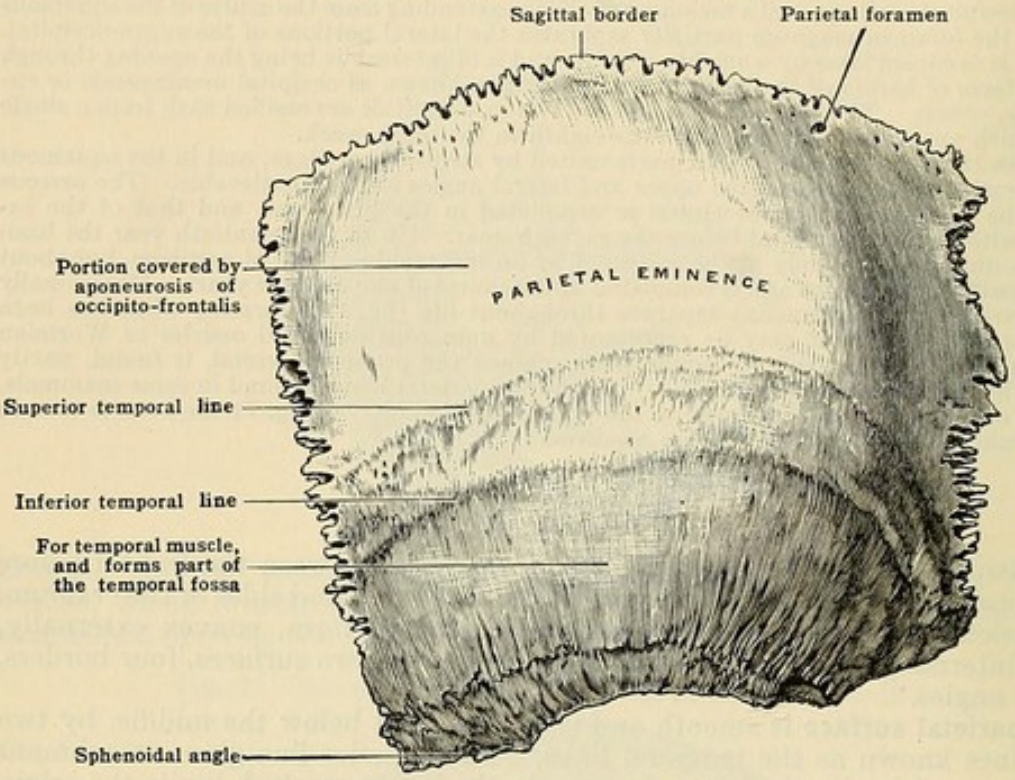

FIG. 73.—THE LEFT PARIETAL. (Inner surface.)

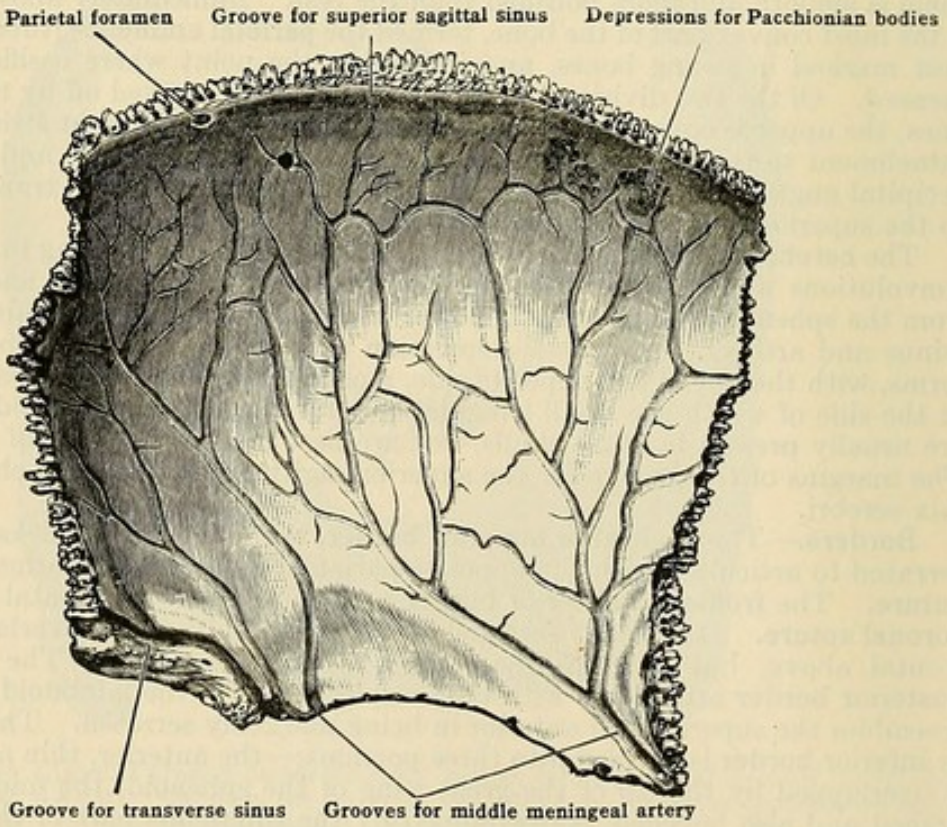

distance, for the middle meningeal vessels (chiefly for the sinus). The **occipital** or **posterior superior** angle is obtuse and occupies that part which during fœtal life enters into formation of the posterior fontanelle. The **mastoid** or **posterior**

inferior angle is thick and articulates with the mastoid portion of the temporal bone. Its inner surface presents a shallow groove which lodges a part of the transverse (lateral) sinus.

Blood-supply.—The parietal bone receives its blood-supply from the middle meningeal, occipital, and supra-orbital arteries.

Articulations.—The parietal articulates with the occipital, frontal, sphenoid, temporal, its fellow of the opposite side, and the epipteric bone when present. Occasionally the temporal and epipteric bones exclude the parietal from articulation with the great wing of the sphenoid.

Ossification.—The parietal ossifies from a single nucleus which appears in the outer layer of the membranous wall of the skull about the seventh week. The ossification radiates in such a way as to leave a cleft at the upper part of the bone in front of the occipital angle, the

FIG. 74.—UNUSUAL FORM OF PARIETAL EXHIBITING A HORIZONTAL SUTURE SEPARATING THE BONE INTO TWO PIECES, UPPER AND LOWER.

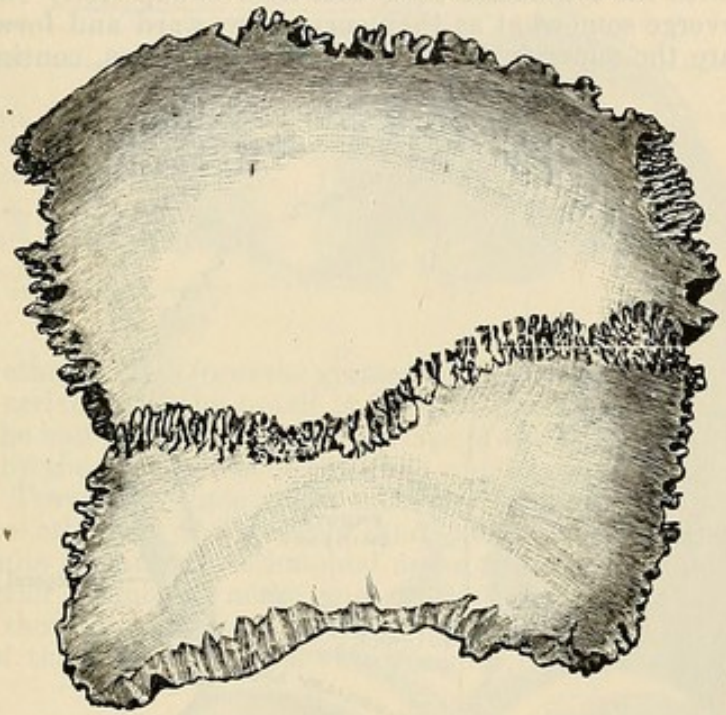

cleft of the two side forming a lozenge-shaped space across the sagittal suture known as the **sagittal fontanelle.** This is usually closed about the fifth month of intra-uterine life, but traces may sometimes be recognised at the time of birth, and the parietal foramina are to be regarded as remains of the cleft. According to Dr. A. W. W. Lea, a well-developed sagittal fontanelle is present in 4.4 per cent. of infants at birth. In such cases it closes within the first two months of life, but at times it may remain open for at least eight months after birth and possibly longer.

Rarely the parietal bone is composed of two pieces (fig. 74), one above the other, and separated by an antero-posterior suture (sub-sagittal suture), more or less parallel with the sagittal suture. In such cases the parietal is ossified from two centres of ossification.

THE FRONTAL

The **frontal bone** [os frontale] closes the cranium in front and is situated above the skeleton of the face. It consists of two portions—a **frontal** (*vertical*) **portion** [squama frontalis], forming the convexity of the forehead, and an **orbital** (*horizontal*) **portion,** which enters into formation of the roof of each orbit.

Frontal (*vertical*) **portion.**—The **frontal surface** is smooth and convex, and usually presents in the middle line above the root of the nose some traces of the suture which in young subjects traverses the bone from the upper to the lower part. This suture, known as the **frontal** or **metopic suture,** indicates the line of junction of the two lateral halves of which the bone consists at the time of birth; in the adult the suture is usually obliterated except at its lowest part. On each side is a rounded elevation, the **frontal eminence** [tuber frontale], very prominent in young bones, below which is a shallow groove, the **sulcus transversus,** separating the frontal eminence from the **superciliary arch.** The latter forms an arched projection above the margin of the orbit and corresponds to an air-cavity within the bone known as the **frontal sinus;** it gives attachment to the *orbicularis oculi* and the *corrugator* muscles. The ridges of the two sides converge toward the

median line, but are separated by a smooth surface called the **glabella** (nasal eminence). Below the arch the bone presents a sharp curved margin, the **supra-orbital border,** forming the upper boundary of the circumference of the orbit and separating the frontal from the orbital portion of the bone. At the junction of its medial and intermediate third is a notch, sometimes converted into a foramen, and known as the **supra-orbital notch** or **foramen;** it transmits the supra-orbital nerve, artery, and vein, and at the bottom of the notch is a small opening for a vein of the diploe which terminates in the supra-orbital. Sometimes, a second less marked notch is present, medial to the supra-orbital, and known as the **frontal notch;** it transmits one of the divisions of the supra-orbital nerve. The extremities of the supra-orbital border are directed downward and form the **medial** and **zygomatic** (**lateral angular**) **processes.** The prominent zygomatic process articulates with the zygomatic bone and receives superiorly two well-marked lines which converge somewhat as they curve downward and forward across the bone. These are the **superior** and **inferior temporal lines,** continuous with the

FIG. 75.—THE FRONTAL. (Anterior view.)

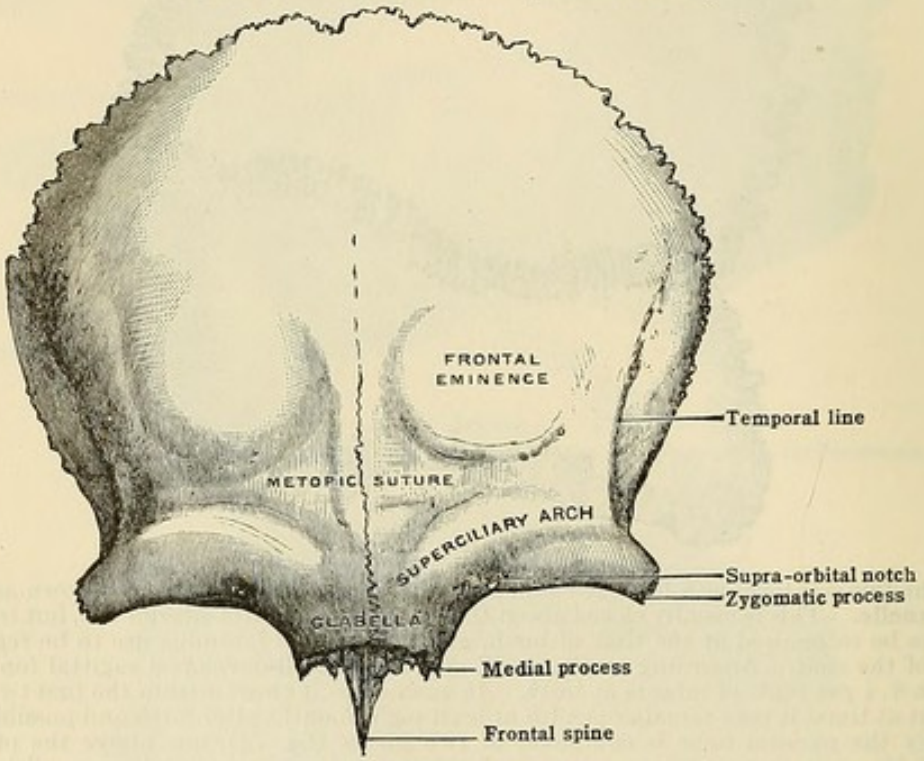

temporal lines on the parietal bone, the upper giving attachment to the temporal fascia and the lower to the temporal muscle. Behind the lines is a slight concavity which forms part of the floor of the temporal fossa and gives origin to the *temporal* muscle. The medial angular processes articulate with the lacrimals and form the lateral limits of the **nasal notch,** bounded in front by a rough, semilunar surface which articulates with the upper ends of the nasal bones and the frontal (nasal) processes of the maxillæ.

In the concavity of the notch lies the **nasal portion** of the frontal, which projects somewhat beneath the nasal bones and the nasal processes of the maxillæ. It is divisible into three parts: —a median **frontal** (nasal) **spine,** which descends in the nasal septum between the crest of the nasal bones in front and the vertical plate of the ethmoid behind, and, on the posterior aspect of the process, two **alæ,** one on either side of the median ridge from which the frontal (nasal) spine is continued. Each ala forms a small grooved surface which enters into the formation of the roof of the nasal fossa.

The **cerebral surface** presents in the middle line a vertical groove—the **sagittal sulcus**—which descends from the middle of the upper margin and lodges the superior sagittal (longitudinal) sinus. Below, the groove is succeeded by the **frontal crest,** which terminates near the lower margin at a small notch, converted into a foramen by articulation with the ethmoid.

The foramen is called the **foramen cæcum,** and is generally closed below, but sometimes transmits a vein from the nasal fossæ to the superior sagittal (longitudinal) sinus. The frontal crest serves for the attachment of the anterior part of the falx cerebri. On each side of the middle line the bone is deeply concave, presenting depressions for the cerebral convolutions and numerous small furrows which, running medially from the lateral margin, lodge branches of the middle meningeal vessels. At the upper part of the surface, on either side of the frontal sulcus, are some depressions for Pacchionian bodies.

The **horizontal portion** consists of two somewhat triangular plates of bone called the **orbital plates,** which, separated from one another by the **ethmoidal**

FIG. 76.—THE FRONTAL BONE. (Inferior view.)

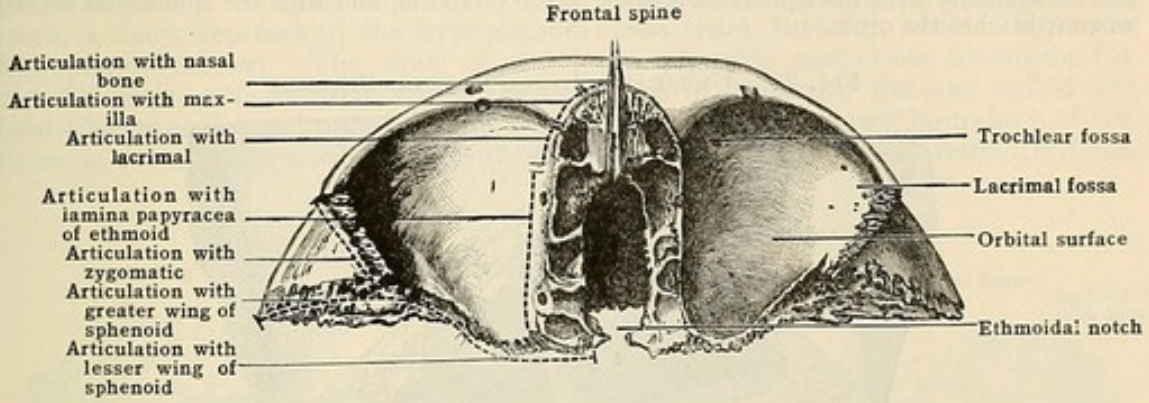

notch [incisura ethmoidalis], form the greater part of the roof of each orbit. When the bones are articulated, the notch is filled up by the cribriform plate of the ethmoid, and the half-cells on the upper surface of the lateral mass of the ethmoid are completed by the depressions or half-cells which occupy the irregular margins of the notch. Traversing these edges transversely are two grooves which complete, with the ethmoid, the **anterior** and **posterior ethmoidal canals.** The anterior transmits the anterior ethmoidal nerve and vessels; the posterior transmits the posterior ethmoidal nerve and vessels, and both canals open on the medial wall of the orbit. Farther forward, on either side of the nasal spine, are the openings of the **frontal sinuses,** two irregular cavities which extend within

FIG. 77.—THE FRONTAL BONE AT BIRTH.

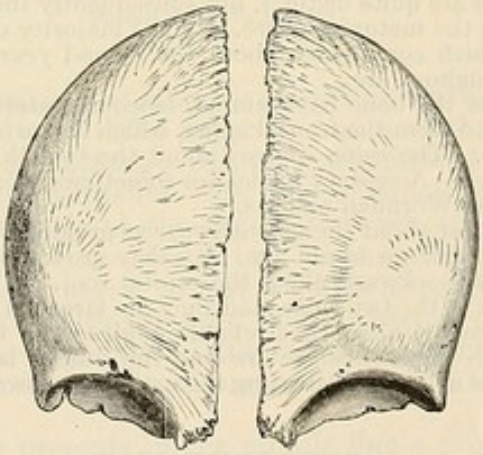

the bone for a variable distance and give rise to the superciliary arches (ridges). Each is lined by mucous membrane and communicates with the nasal fossa by means of a passage called the infundibulum.

The **inferior surface** of each orbital plate, smooth and concave, presents immediately behind the lateral angular process the **lacrimal fossa,** for the lacrimal gland. Close to the medial angular process is a depression called the **trochlear fossa** [fovea trochlearis], which gives attachment to the cartilaginous pulley for the *superior oblique* muscle. The **superior surface** of each plate is convex and strongly marked by eminences and depressions for the convolutions on the orbital surface of the cerebrum.

Borders.—The articular border of the frontal portion (**parietal margin**) forms a little more than a semicircle. It is thick, strongly serrated, and bevelled so as to overlap the parietal above and to be overlapped by the edge of that bone below. The border is continued inferiorly into a triangular rough surface on either side, which articulates with the great wing of the sphenoid. The posterior border of the orbital portion is thin and articulated with the lesser wing of the sphenoid.

Blood-supply.—The blood-vessels for the supply of the vertical portion are derived from the frontal and supra-orbital arteries, which enter on the outer surface, and from the middle and small meningeal, which enter on the cerebral surface. The horizontal portion receives branches from the ethmoidal, and other branches of the ophthalmic, as well as from the meningeal.

Articulations.—The frontal articulates with the parietal, sphenoid, ethmoid, lacrimal, zygomatic (malar), maxilla, and nasal bones. Also, with the epipteric bones when present, and occasionally with the squamous portion of the temporal, and with the sphenoidal concha when it reaches the orbit.

FIG. 78.—UNUSUALLY LARGE FRONTAL SINUSES.

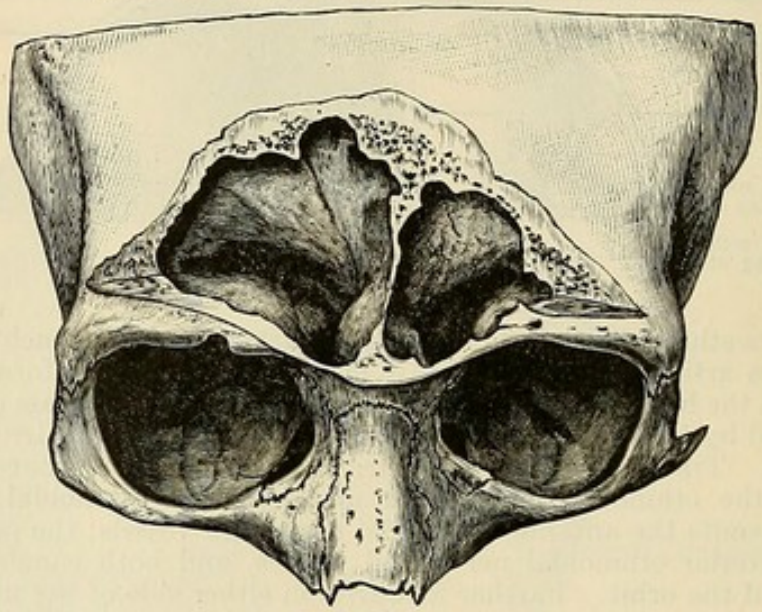

Ossification.—The frontal is ossified from two nuclei deposited in the outer layer of the membranous wall of the cranium, in the situations ultimately known as the frontal eminences. These nuclei appear about the eighth week, and ossification spreads quickly through the membrane. At birth the bones are quite distinct, but subsequently they articulate with each other in the median line to form the metopic suture. In the majority of cases the suture is obliterated by osseous union, which commences about the second year, though in a few cases the bones remain distinct throughout life.

After the two halves of the bone have united, osseous material is deposited at the lower end of the metopic suture to form the frontal spine, which is one of the distinguishing features of the human frontal bone. The spine appears about the twelfth year, and soon consolidates with the frontal bone above. Accessory nuclei are sometimes seen between this bone and the lacrimal and may persist as Wormian ossicles.

The frontal sinuses appear about the seventh year as prolongations upward from the hiatus semilunaris and increase in size up to old age. As they grow they extend in three directions, viz., upward, laterally, and backward along the orbital roof. A bony septum, usually complete, separates the sinuses of the two sides, and they are larger in the male than in the female. The superciliary arches are not altogether reliable guides as to the size of the sinuses, since examples are seen in which the arches are low and the sinuses large. In fig. 78 an example of unusually large sinuses is figured, illustrating the extension upward, laterally, and backward.

THE SPHENOID

The **sphenoid** [os sphenoidale] (figs. 79, 80, 81, 82) is situated in the base of the skull and takes part in the formation of the floor of the anterior, middle, and posterior cranial fossæ, of the temporal and nasal fossæ, and of the cavity of the orbit. It is very irregular in shape and is described as consisting of a central part or **body,** two pairs of lateral expansions called the **great** and **small wings,** and a pair of processes which project downward, called the **pterygoid processes.**

The **body,** irregularly cuboidal in shape, is hollowed out into two large cavities known as the **sphenoidal sinuses,** separated by a thin **sphenoidal septum** and opening in front by two large apertures into the nasal fossæ. The **superior sur-**

face presents the following points for examination: In front is seen a prominent spine, the **ethmoidal spine,** which articulates with the hinder edge of the cribriform plate of the ethmoid. The surface behind this is smooth and frequently presents two longitudinal grooves, one on either side of the median line, for the olfactory bulbs; it is limited posteriorly by a ridge, the **limbus sphenoidalis,** which forms the anterior border of the narrow transverse **optic groove** [sulcus chiasmatis], above and behind which lies the optic commissure. The groove terminates on each side in the **optic foramen,** which perforates the root of the small wing and transmits the optic nerve and the ophthalmic artery. Behind the optic groove is the **tuberculum sellæ,** indicating the line of junction of the two parts of which the body is formed (pre- and post-sphenoid); and still further back, a deep depression, the **hypophyseal fossa** [sella turcica], which lodges the hypophysis cerebri. The floor of the fossa presents numerous foramina for blood-vessels, and at birth the superior orifice of a narrow passage called the **basi-pharyngeal canal** opens on the tuberculum. The posterior boundary of the fossa is formed by a quadrilateral plate of bone, the **dorsum sellæ** (dorsum

FIG. 79.—THE SPHENOID, FROM ABOVE.

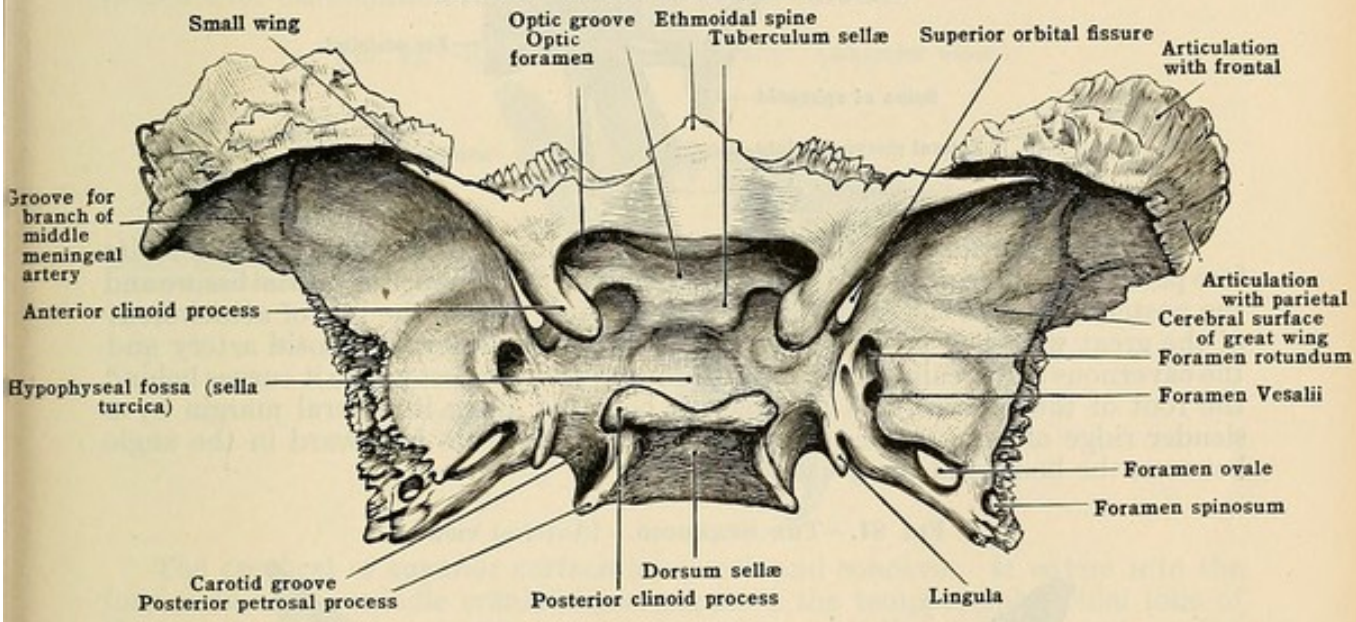

ephippii), the posterior surface of which is sloped in continuation with the basilar groove of the occipital bone. The superior angles of the plate are surmounted by the **posterior clinoid processes,** which give attachment to the tentorium cerebelli and the interclinoid ligaments. Below the clinoid process, on each side of the dorsum sellæ (sometimes at the suture between the sphenoid and apex of petrosal), a notch is seen, converted into a foramen by the dura mater, for the passage of the sixth cranial nerve, and at the inferior angle the **posterior petrosal process,** which articulates with the apex of the petrous portion of the temporal bone, forming the inner boundary of the **foramen lacerum.** The dorsum sellæ is slightly concave posteriorly (the clivus) and supports the pons Varolii and the basilar artery.

The **inferior surface** presents in the middle line a prominent ridge known as the **rostrum,** which is received into a deep depression between the alæ of the vomer. On each side is the **vaginal process** of the medial pterygoid plate, directed horizontally and medially, which, with the alæ of the vomer, covers the greater part of this surface. The remainder is rough and clothed by the mucous membrane of the roof of the pharynx.

The **anterior surface** is divided into two lateral halves by the **sphenoidal crest,** a vertical ridge of bone continuous above with the ethmoidal spine, below with the rostrum, and articulating in front with the perpendicular plate of the ethmoid. The surface on each side presents a rough lateral margin for articulation with the lateral mass of the ethmoid and the orbital process of the palate bone. Elsewhere it is smooth, and enters into the formation of the roof of the

nasal fossæ, presenting superiorly the irregular apertures of the sphenoidal sinuses.

The body is not hollowed until after the sixth year, but from that time the sinuses increase in size as age advances. Except for the apertures just mentioned, they are closed below and in front by the two **sphenoidal conchæ** (turbinate bones), originally distinct, but in the adult usually incorporated with the sphenoid.

The **posterior surface** is united to the basilar process of the occipital, up to the twentieth year, by a disc of hyaline cartilage forming a synchondrosis, but afterward this becomes ossified and the two bones then form one piece.

FIG. 80.—THE LEFT HALF OF THE SPHENOID.

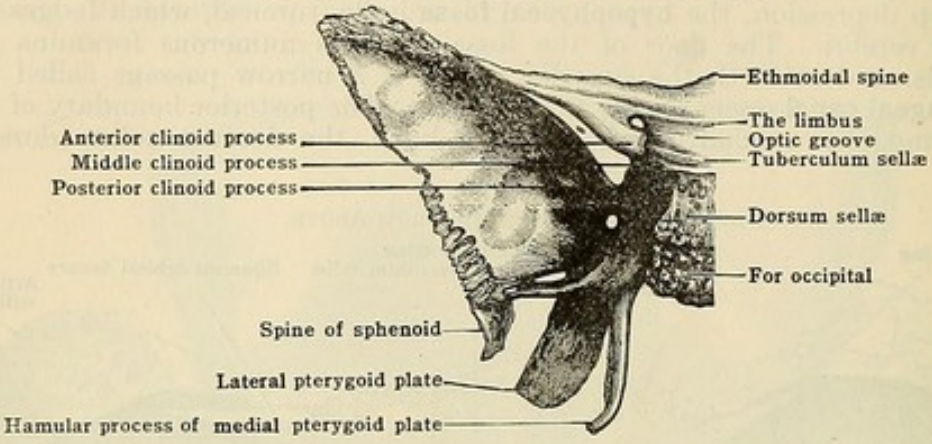

The **lateral surface** of the body gives attachment to the two wings, and its fore part is free where it forms the medial boundary of the superior orbital fissure and the posterior part of the medial wall of the orbit. Above the line of attachment of the great wing is a broad groove which lodges the internal carotid artery and the cavernous sinus, called the **carotid** groove. It is deepest where it curves behind the root of the process, and this part is bounded along its lateral margin by a slender ridge of bone named the **lingula,** which projects backward in the angle between the body and the great wing.

FIG. 81.—THE SPHENOID. (Anterior view.)

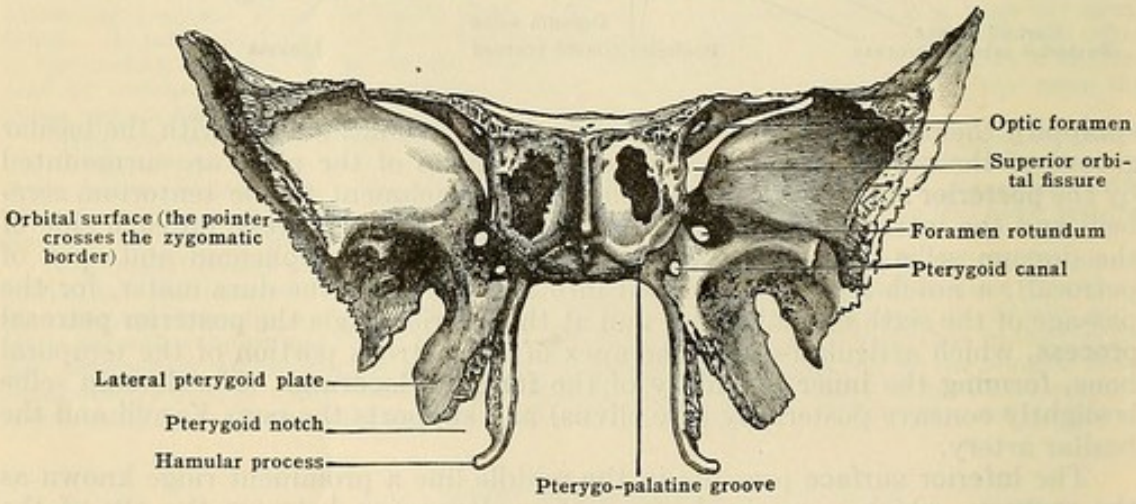

The **small** or **orbital wings** [alæ parvæ] are two thin, triangular plates of bone extending nearly horizontally and laterally on a level with the front part of the upper surface of the body. Each arises medially by two processes or roots, the upper thin and flat, the lower thick and rounded.

Near the junction of the lower root with the body is a small tubercle for the attachment of the common tendon of three ocular muscles—viz., the *superior, medial,* and upper head of *lateral rectus*—and between the two roots is the **optic foramen.** The lateral extremity, slender and pointed, approaches the great wing, but, as a rule, does not actually touch it. The superior surface, smooth and slightly concave, forms the posterior part of the anterior fossa of the cranium. The inferior surface constitutes a portion of the roof of each orbit and overhangs

the **superior orbital** (or **sphenoidal**) **fissure,** the elongated opening between the small and great wings. The anterior border is serrated for articulation with the orbital plate of the frontal, and the posterior border, smooth and rounded, is received into the Sylvian fissure of the cerebrum. Moreover, the posterior border forms the boundary between the anterior and middle cranial fossæ and is prolonged at its medial extremity to form the **anterior clinoid process,** which gives attachment to the tentorium cerebelli and the interclinoid ligaments. Between the tuberculum sellæ and the anterior clinoid process is a semicircular notch which represents the termination of the carotid groove. It is sometimes converted into a foramen, the **carotico-clinoid foramen,** by a spicule of bone which bridges across from the anterior clinoid to the **middle clinoid process;** the latter is a small tubercle frequently seen on each side, in front of the hypophyseal fossa, and slightly posterior to the tuberculum sellæ; the foramen transmits the internal carotid artery, and the spicule of bone which may complete the foramen is formed by ossification of the carotico-clinoid ligament.

The **great** or **temporal wings** [alæ magnæ], arising from the lateral surface of the body, extend laterally and then upward and forward. The posterior part is placed horizontally and projects backward into the angle between the squamous and petrous portions of the temporal bone. From the under aspect of its pointed extremity the **spine,** which is grooved medially by the chorda tympani nerve (Lucas), projects downward. The spine serves for the attachment of the spheno-mandibular ligament and a few fibres of the *tensor veli palatini*. Each wing presents for examination four surfaces and four borders.

FIG. 82.—RIGHT HALF OF SPHENOID. (Anterior view.)

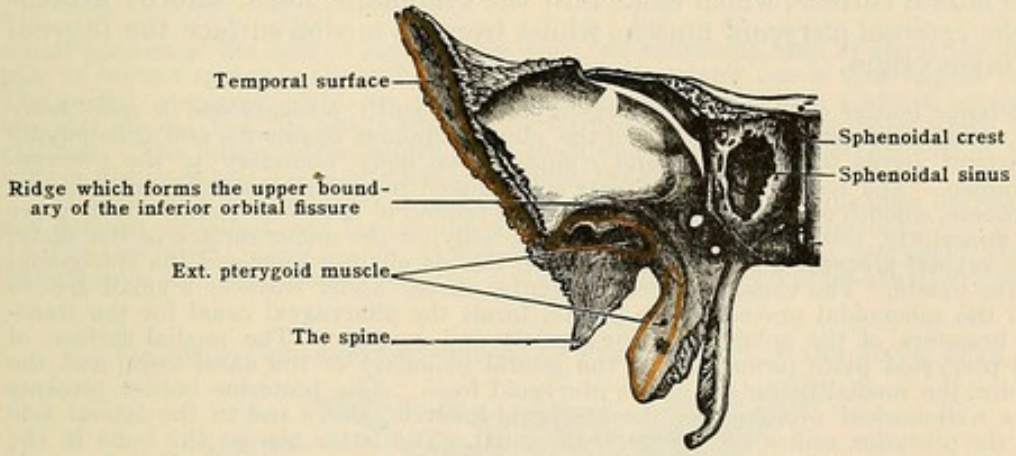

The **cerebral** or **superior surface** is smooth and concave. It enters into the formation of the middle cranial fossa, supports the temporo-sphenoidal lobe of the cerebrum, and presents several foramina. At the anterior and medial part is the **foramen rotundum** for the second division of the fifth nerve, and behind and lateral to it, near the posterior margin of the great wing, is the large **foramen ovale,** transmitting the third division of the fifth, the small meningeal artery, and an emissary vein from the cavernous sinus.

Behind and lateral to the foramen ovale is the small circular **foramen spinosum,** sometimes incomplete, for the passage of the middle meningeal vessels, and the recurrent branch of the third division of the fifth. Between the foramen ovale and the foramen rotundum is the inconstant **foramen Vesalii,** which transmits a small emissary vein from the cavernous sinus; and on the plate of bone, behind and medial to the foramen ovale (spheno-petrosal lamina), a minute canal is occasionally seen—the **canaliculus innominatus**—through which the small superficial petrosal nerve escapes from the skull. When the canaliculus is absent, the nerve passes through the foramen ovale.

The **anterior surface** looks medially and forward and consists of two divisions—a quadrilateral or **orbital** surface, which forms the chief part of the lateral wall of the orbit, and a smaller, inferior or **spheno-maxillary** surface, situated above the pterygoid process and perforated by the foramen rotundum; this inferior part forms the posterior wall of the pterygo-palatine fossa.

The lateral or **squamo-zygomatic surface** is divided by a prominent **infra-temporal ridge** into a superior portion, which forms part of the temporal fossa and affords attachment to the *temporal* muscle, and an inferior part, which looks downward into the zygomatic fossa and gives attachment to the *external pterygoid* muscle; the inferior part joins the lateral surface of the lateral pterygoid plate, and presents the inferior orifices of the foramen ovale, foramen spinosum, and foramen of Vesalius.

Borders.—The **posterior border** extends from the body to the spine. By its lateral third it articulates with the petrous portion of the temporal bone, whilst the medial two-thirds form the anterior boundary of the foramen lacerum. The **squamosal border** is serrated behind and bevelled in front for articulation with the squamous portion of the temporal bone, whilst its upper extremity, or summit, is bevelled on its inner aspect, for the anterior inferior angle of the parietal. Immediately in front of the upper extremity is a rough, triangular, sutural area for the frontal, the sides of which are formed by the upper margins of the superior, anterior, and lateral surfaces respectively. The **zygomatic** or **anterior border** separates the orbital and temporal surfaces and articulates with the zygomatic, and by its lower angle, in many skulls, also with the maxilla. Below the anterior border is a short horizontal ridge, non-articular, which separates the spheno-maxillary and zygomatic surfaces. Above and medially, where the orbital and cerebral surfaces meet, is the sharp **medial border,** which forms the lower boundary of the **superior orbital fissure,** serving for the passage of the third, fourth, three branches of the first division of the fifth, and the sixth cranial nerves, the orbital branch of the middle meningeal artery, a recurrent branch from the lacrimal artery, some twigs from the cavernous plexus of the sympathetic, and one or two ophthalmic veins. Near the middle of the border is a small tubercle for the origin of the lower head of the *lateral rectus* muscle.

The **pterygoid processes** project downward from the junction of the body and the great wings. Each consists of two plates, one shorter and broader, the **lateral pterygoid plate** [lamina lateralis], the other longer and narrower, the **medial pterygoid plate** [lamina medialis]. They are united in front, but diverge behind so as to enclose between them the **pterygoid fossa** in which lie the *internal pterygoid* and *tensor palati* muscles. The lateral pterygoid plate is turned a little laterally and by its lateral surface, which looks into the zygomatic fossa, affords attachment to the *external pterygoid* muscle, whilst from its medial surface the *internal pterygoid* takes origin.

The posterior border of the lateral pterygoid plate frequently presents one or more bony projections, which represent ossified parts of the pterygo-spinous ligaments, and occasionally one may extend across to the spine and complete the bony boundary of the pterygo-spinous foramen. The medial pterygoid plate is prolonged below into a slender, hook-like or **hamular process,** smooth on the under aspect for the tendon of the *tensor palati,* which plays round it. Superiorly, the medial plate extends medially on the under surface of the body, forming the **vaginal process,** which articulates with the ala of the vomer and the sphenoidal process of the palate. The vaginal process presents, on the under surface, a small groove which, with the sphenoidal process of the palate, forms the **pharyngeal canal** for the transmission of branches of the spheno-palatine vessels and ganglion. The medial surface of the medial pterygoid plate forms part of the lateral boundary of the nasal fossa, and the lateral surface, the medial boundary of the pterygoid fossa. The posterior border presents superiorly a well-marked prominence, the **pterygoid tubercle,** above and to the lateral side of which is the posterior orifice of the **pterygoid canal.** The latter pierces the bone in the sagittal direction at the root of the medial pterygoid plate and transmits the Vidian vessels and nerve. Some distance below the tubercle is a projection, called the **processus tubarius,** which supports the cartilage of the tuba auditiva (Eustachian tube). From the lower third of the posterior border and from the hamular process, the *superior constrictor* of the pharynx takes origin, and from the depression known as the **scaphoid fossa,** situated in the upper part of the recess between the two pterygoid plates, the *tensor palati* arises.

FIG. 83.—THE SPHENOID AT BIRTH.

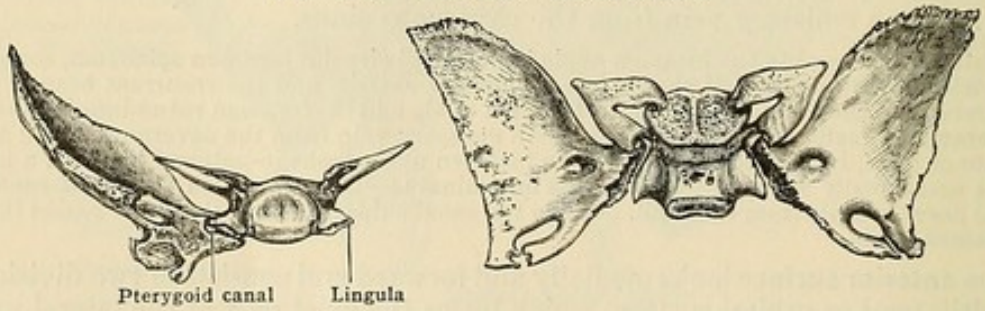

In front, the two plates are joined above, but diverge below, leaving a gap—the **pterygoid notch**—occupied, in the articulated skull, by the pyramidal process of the palate. Superiorly, they form a triangular surface which looks into the pterygo-palatine fossa and presents the anterior orifice of the pterygoid canal. The anterior border of the medial pterygoid plate articulates with the posterior border of the vertical plate of the palate.

Blood-supply.—The sphenoid is supplied by branches of the middle and small meningeal arteries, the deep temporal and other branches of the internal maxillary artery—viz., the Vidian and spheno-palatine. The body of the bone also receives twigs from the internal carotid.

Articulations.—The sphenoid articulates with all the bones of the cranium—viz., occipital,

parietal, frontal, ethmoid, temporal, and sphenoidal conchæ. Also with the palate, vomer, zygomatic, epipteric bone when present, and occasionally with the maxilla.

Ossification.—The sphenoid is divided, up to the seventh or eighth month of intra-uterine life, into an anterior or **pre-sphenoid** portion, including the part of the body in front of the tuberculum sellæ and the small wings, and a **post-sphenoid** portion, the part behind the tuberculum sellæ including the hypophyseal fossa and the great wings. The two portions of the body join together before birth, but in many animals the division is persistent throughout life.

The pre-sphenoid portion ossifies in cartilage from four centres, one of which gives rise to each lesser wing (**orbito-sphenoid**) and a pair to the body of the pre-sphenoid.

In the formation of the post-sphenoidal portion both cartilage and membrane bone participate, the pterygoid plates being formed in membrane, while the rest of the portion, together with the hamular process, ossifies from cartilage. (Fawcett.) At about the eighth week a

FIG. 84.—THE JUGUM SPHENOIDALE.



centre appears at the base of each greater wing (**ali-sphenoid**), and at about the same time a pair of centres appear in the body (**basi-sphenoid**) and later one in each lingula (**sphenotic**). The medial pterygoid plates are pre-formed in cartilage, in which a centre appears for the hamular process, but the rest of the plate is formed from membrane bone which invests the cartilage. The lateral plate is formed in membrane and a considerable part of the greater wing is also membranous in origin (see epipteric bone).

At birth the bone consists of three pieces. The median piece includes the basi-sphenoid and lingulæ, conjoined with the pre-sphenoid, carrying the orbito-sphenoids.

The two lateral pieces are the ali-sphenoids, carrying the medial pterygoid plates. The dorsum sellæ is cartilaginous. A canal, known as the **basi-pharyngeal canal,** extends into the

FIG. 85.—THE INFERIOR SURFACE OF PRE-SPHENOID AT THE SIXTH YEAR.

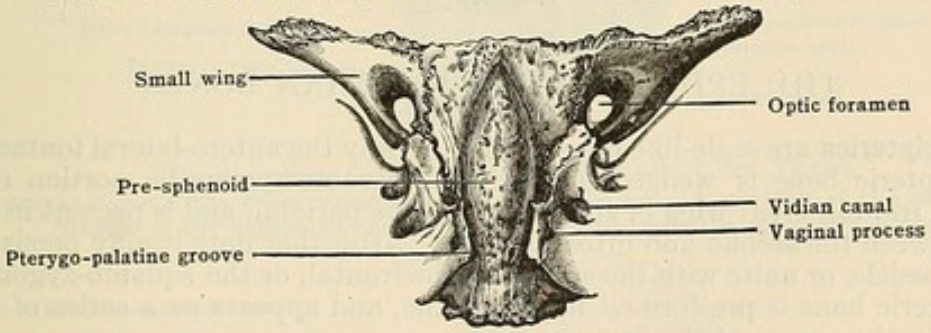

body from the sella turcica and sometimes reaches its under surface. It contains a process of dura mater, and represents the remains of the canal in the base of the cranium, through which the diverticulum of Rathke extended upward to form part of the hypophysis.

The great wings are joined to the lingulæ by cartilage, but in the course of the first year bony union takes place. About the same time the orbito-sphenoids meet and fuse in the middle line to form the **jugum sphenoidale,** which thus excludes the anterior part of the pre-sphenoid from the cranial cavity. For some years the body of the pre-sphenoid is broad and rounded inferiorly (fig. 85). The posterior clinoid processes chondrify separately, a fact which throws some light on the occasional absence of these processes.

THE SPHENOIDAL CONCHÆ

The **sphenoidal conchæ** (or **turbinate bones;** bones of Bertin) (figs. 86, 87) may be obtained as distinct ossicles about the fifth year, and resemble in shape two hollow cones flattened in three planes. At this date each is wedged in between the under surface of the pre-sphenoid and the orbital and sphenoidal processes of the palate bone, with the apex of the cone directed backward as far as the vaginal process of the medial pterygoid plate. Of its three surfaces, the lateral is in relation with the pterygo-palatine fossa, and occasionally extends upward between the sphenoid and the lamina papyracea of the ethmoid, to appear on the medial wall of the orbit (fig. 105). The inferior surface forms the upper boundary of the spheno-palatine foramen and enters into formation of the posterior part of the roof of the nasal fossa. The

superior surface lies flattened against the under surface of the pre-sphenoid, whilst the base of the cone is in contact with the lateral mass of the ethmoid.

The deposits of earthy matter from which the sphenoidal conchæ are formed appear at the fifth month. At birth each forms a small triangular lamina in the perichondrium of the ethmo-vomerine plate near its junction with the presphenoid, and partially encloses a small recess from the mucous membrane of the nose, which becomes the sphenoidal sinus. By the third year the bone has surrounded the sinus, forming an osseous capsule, conical in shape, the circular orifice which represents the base becoming the sphenoidal foramen. As the cavity enlarges the medial wall is absorbed, and the medial wall of the sinus is then formed by the pre-sphenoid.

FIG. 86.—THE SPHENOIDAL CONCHA AT THE SIXTH YEAR.



The bones are subsequently ankylosed in many skulls with the ethmoid, whence they are often regarded as parts of that bone. More frequently they fuse with the pre-sphenoid, and less frequently with the palate bones. After the twelfth year they can rarely be separated from the skull without damage. In many disarticulated skulls they are so broken up that a portion is found on the sphenoid, fragments on the palate bones, and the remainder attached to the ethmoid. Sometimes, even in old skulls, they are represented by a very thin triangular plate on each side of the rostrum of the sphenoid (fig. 87).

FIG. 87.—THE SPHENOIDAL CONCHÆ FROM AN OLD SKULL.

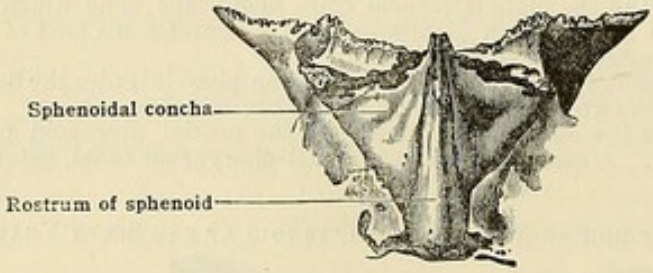

THE EPIPTERIC AND WORMIAN BONES

The **epipterics** are scale-like bones which occupy the antero-lateral fontanelles. Each epipteric bone is wedged between the squamo-zygomatic portion of the temporal, frontal, great wing of sphenoid, and the parietal, and is present in most skulls between the second and fifteenth year. After that date it may persist as a separate ossicle, or unite with the sphenoid, the frontal, or the squamo-zygomatic. The epipteric bone is pre-formed in membrane, and appears as a series of bony granules in the course of the first year.

The **Wormian** or **sutural bones** [ossa suturarum] are small, irregularly shaped ossicles, often found in the sutures of the cranium, especially those in relation with the parietal bones. They sometimes occur in great numbers; as many as a hundred have been counted in one skull. They are rarely present in the sutures of the face.

THE TEMPORAL BONE

The **temporal bone** [os temporale], situated at the side and the base of the cranium, contains the organ of hearing and articulates with the lower jaw. It is usually divided into three parts—viz., the **squamous portion,** forming the anterior and superior part of the bone, thin and expanded and prolonged externally into the zygomatic process; the **mastoid portion,** the thick conical posterior part, behind the external aperture of the ear; and a pyramidal projection named the **petrous portion,** situated in a plane below and to the medial side of the two parts already mentioned, and forming part of the base of the skull.

When it is considered in reference to its mode of development, the temporal bone is found to be built up of three parts (figs. 88, 89, 90), which, however, do not altogether correspond to the arbitrary divisions of the adult bone. The three parts are named **squamosal, petrosal,**

and **tympanic,** and a knowledge of their arrangement in the early stages of growth greatly facilitates the study of the fully formed bone.

The more important division of the temporal bone is the petrous portion. It is pyramidal in shape, and contains the essential part of the organ of hearing,

FIG. 88.—THE TEMPORAL BONE AT BIRTH.

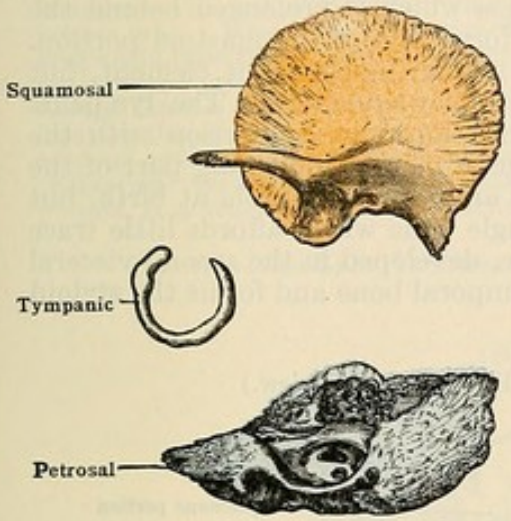

FIG. 89.—TEMPORAL BONE AT BIRTH. (Inner view.)

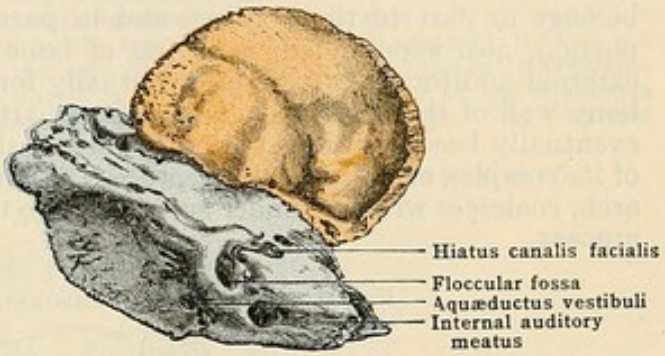

FIG. 90.—THE TEMPORAL BONE AT BIRTH. (Outer view.)

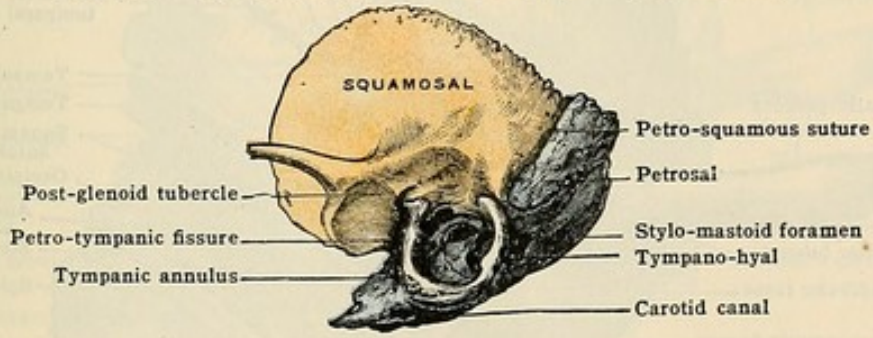

FIG. 91.—RIGHT TEMPORAL BONE AT ABOUT SIX YEARS.
The tympanic plate has been separated and drawn below. A portion of the post-auditory process of the squamosal has been removed to show the mastoid antrum.

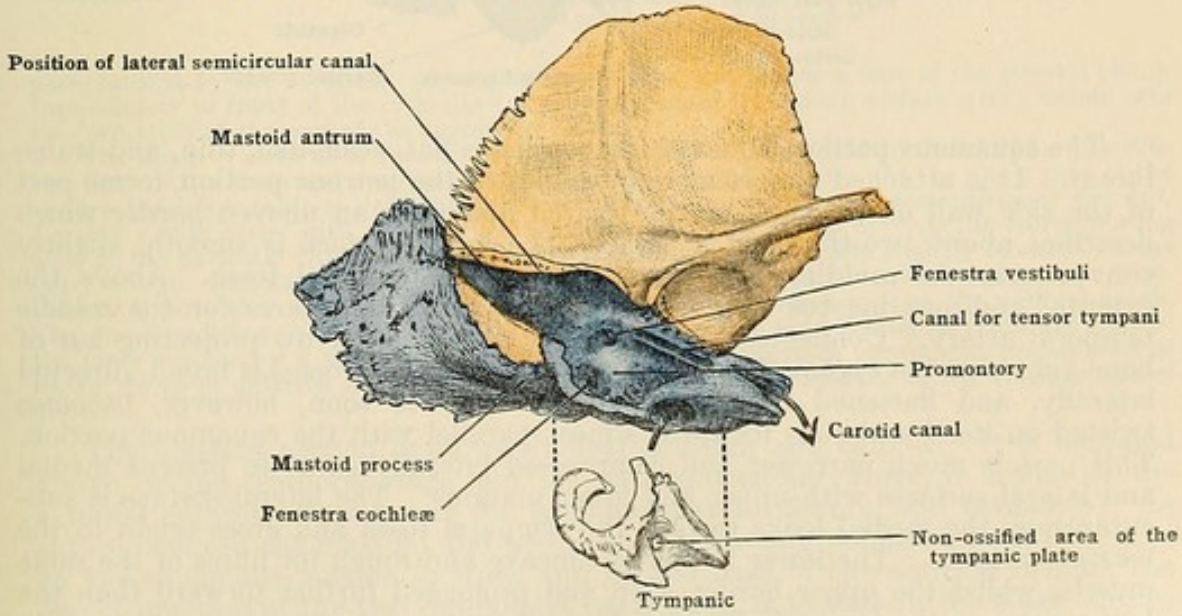

around which it is developed as a cartilaginous capsule. This is known as the **periotic capsule** or **petrosal** element, and its **base** abuts on the outer aspect of the

cranium, where it forms a large part of the so-called mastoid portion of the temporal bone. Besides containing the internal ear, it bears on its cranial side a foramen for the seventh and eighth cranial nerves (internal auditory meatus), and on its outer side two openings—the fenestra vestibuli and fenestra cochleæ (fig. 91). The **squamosal** is a superadded element and is formed as a membrane bone in the lateral wall of the cranium. It is especially developed in man in consequence of the large size of the brain, and forms the squamous division of the adult bone, and by a triangular shaped process which is prolonged behind the aperture of the ear it also contributes to the formation of the mastoid portion. It is obvious, therefore, that the mastoid is not an independent element, but belongs in part to the petrous, and in part to the squamous. The **tympanic** portion, also superadded, is a ring of bone developed in connection with the external auditory meatus, and eventually forms a plate constituting part of the bony wall of this passage. These three parts are easily separable at birth, but eventually become firmly united to form a single bone which affords little trace of its complex origin. Lastly a process of bone, developed in the second visceral arch, coalesces with the under surface of the temporal bone and forms the **styloid process.**

FIG. 92.—THE LEFT TEMPORAL BONE. (Outer view.)

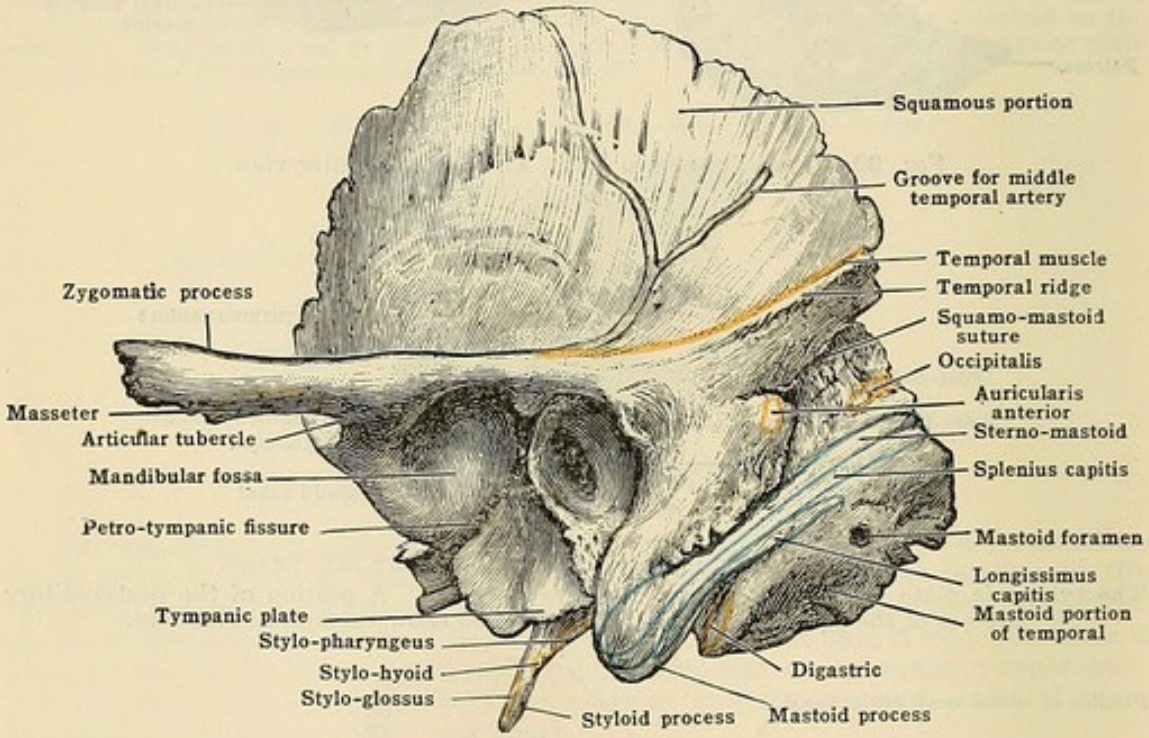

The **squamous portion** [squama temporalis] is flat, scale-like, thin, and translucent. It is attached almost at right angles to the petrous portion, forms part of the side wall of the skull and is limited above by an uneven border which describes about two-thirds of a circle. The outer surface is smooth, slightly convex near the middle, and forms part of the temporal fossa. Above the external auditory meatus it presents a nearly vertical groove for the middle temporal artery. Connected with its lower part is a narrow projecting bar of bone known as the **zygomatic process.** At its base the process is broad, directed laterally, and flattened from above downward. It soon, however, becomes twisted on itself and runs forward, almost parallel with the squamous portion. This part is much narrower and compressed laterally so as to present medial and lateral surfaces with upper and lower margins. The lateral surface is subcutaneous; the medial looks toward the temporal fossa and gives origin to the *masseter* muscle. The lower border is concave and rough for fibres of the same muscle, whilst the upper border, thin and prolonged further forward than the lower, receives the temporal fascia. The extremity of the process is serrated for articulation with the zygomatic bone. At its base the zygomatic process presents three roots—anterior, middle, and posterior.

The anterior, continuous with the lower border, is short, broad, convex, and directed medially to terminate in the **articular tubercle,** which is covered with cartilage in the recent state, for articulation with the condyle of the lower jaw. The middle root, sometimes very prominent, forms the **post-glenoid process.** It separates the articular portion of the mandibular fossa from the external auditory meatus and is situated immediately in front of the **petro-tympanic** (**Glaserian**) fissure. The posterior root, prolonged from the upper border, is strongly marked and extends backward as a ridge above the external auditory meatus. It is called the **temporal ridge** (supra-mastoid crest), and marks the arbitrary line of division between the squamous and mastoid portions of the adult bone. It forms part of the posterior boundary of the temporal fossa, from which, as well as from the ridge, fibres of the *temporal* muscle arise. Where the anterior root joins the zygomatic process is a slight tubercle—the **preglenoid tubercle**—for the attachment of the temporo-mandibular ligament, and between the anterior and middle roots is a deep oval depression, forming the part of the mandibular fossa for the condyle of the lower jaw. The **mandibular fossa** is a considerable hollow, bounded in front by the articular tubercle and behind by the tympanic plate which separates it from the external auditory meatus. It is divided into two parts by a narrow slit—the **petro-tympanic** (**Glaserian**) **fissure.** The anterior part [facies articularis], which belongs to the squamous portion, is articular, and, like the articular tubercle, is coated with cartilage. The posterior

FIG. 93.—THE LEFT TEMPORAL BONE. (Seen from the inner side and above.)

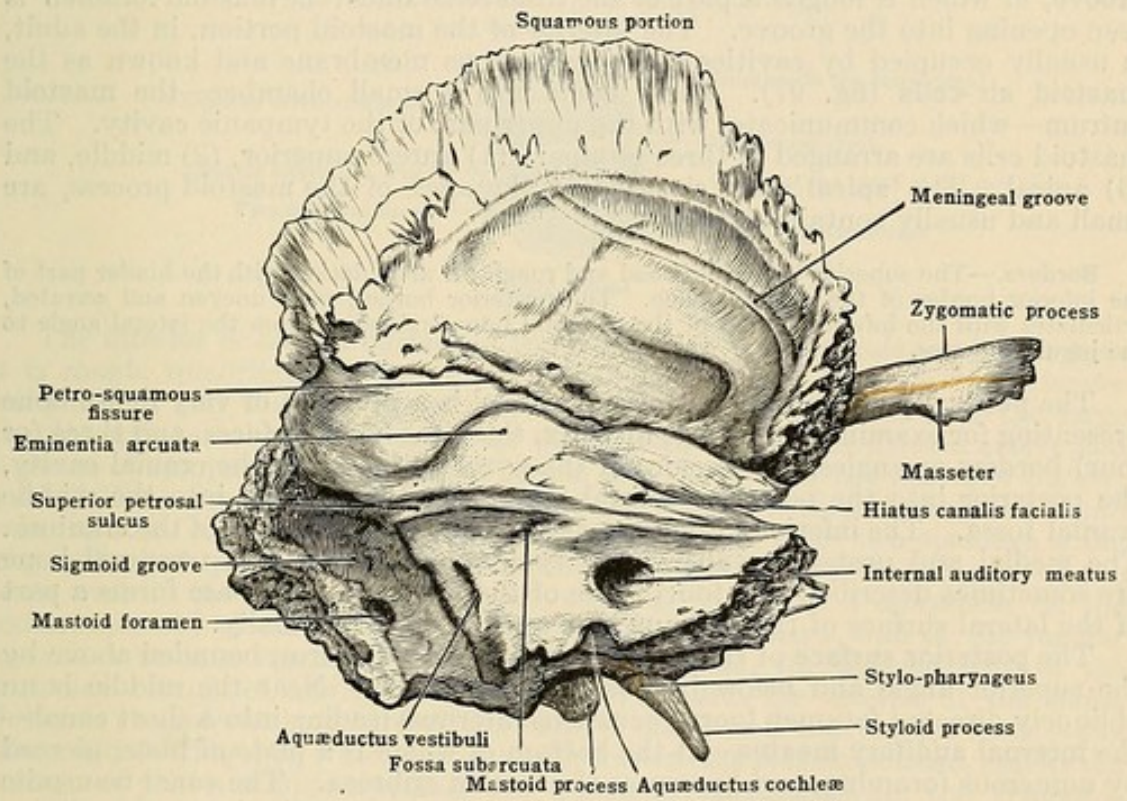

part, formed by the tympanic plate, is non-articular and lodges a lobe of the parotid gland. Immediately in front of the articular tubercle is a small triangular surface which enters into the formation of the roof of the zygomatic fossa.

The inner or *cerebral surface* of the squamous portion is marked by furrows for the convolutions of the brain and grooves for the middle meningeal vessels. At the upper part of the surface the inner table is deficient and the outer table is prolonged some distance upward, forming a thin scale, with the bevelled surface looking inward to overlap the corresponding edge of the parietal. Anteriorly the border is thicker, serrated, and slightly bevelled on the outer side for articulation with the posterior border of the great wing of the sphenoid. Posteriorly it joins the rough serrated margin of the mastoid portion to form the parietal notch. The line separating the squamous from the petrous portion is indicated at the lower part of the inner surface by a narrow cleft, the internal **petro-squamous suture,** the appearance of which varies in different bones according to the degree of persistence of the original line of division.

The **mastoid portion** [pars mastoidea] is rough and convex. It is bounded above by the temporal ridge and the parieto-mastoid suture; in front, by the external auditory meatus and the **tympano-mastoid** fissure; and behind, by the suture between the mastoid and occipital. As already pointed out, it is formed by the squamous portion in front and by the base of the petrosal behind, the line of junction of the two component parts being indicated on the outer surface by the **external petro-squamous suture** (squamo-mastoid). The appearance of the suture varies, being in some bones scarcely distinguishable, in others, a series

of irregular depressions, whilst occasionally it is present as a well-marked fissure (fig. 92) directed obliquely downward and forward. The mastoid portion is prolonged downward behind the external acoustic meatus into a nipple-shaped projection, the **mastoid process,** the tip of which points forward as well as downward. The process is marked, on its medial surface, by a deep groove, the **mastoid notch** (digastric fossa), for the origin of the *digastric* muscle, and again medially by the **occipital groove** for the occipital artery.

The outer surface is perforated by numerous foramina, one, of large size, being usually situated near the posterior border and called the **mastoid foramen.** It transmits a vein to the transverse (lateral) sinus and the mastoid branch of the occipital artery. The mastoid portion gives attachment externally to the *auricularis posterior* (*retrahens aurem*) and *occipitalis*, and, along with the mastoid process, to the *sterno-mastoid*, *splenius capitis*, and *longissimus capitis* (*trachelo-mastoid*). Projecting from the postero-superior margin of the external auditory meatus there is frequently a small tubercle—the **supra-meatal spine**—behind which the surface is depressed to form the **mastoid (supra-meatal) fossa.**

The inner surface of the mastoid portion presents a deep curved **sigmoid groove,** in which is lodged a part of the transverse sinus; the mastoid foramen is seen opening into the groove. The interior of the mastoid portion, in the adult, is usually occupied by cavities lined by mucous membrane and known as the **mastoid air-cells** (fig. 97). These open into a small chamber—the **mastoid antrum**—which communicates with the upper part of the tympanic cavity. The mastoid cells are arranged in three groups: (1) antero-superior, (2) middle, and (3) apical. The apical cells, situated at the apex of the mastoid process, are small and usually contain marrow.

Borders.—The superior border is broad and rough for articulation with the hinder part of the inferior border of the parietal bone. The posterior border, very uneven and serrated, articulates with the inferior border of the occipital bone, extending from the lateral angle to the jugular process.

The **petrous portion** [pars petrosa; pyramis] is a pyramid of very dense bone presenting for examination a base, an apex, three (or four) surfaces, and three (or four) borders or angles. Two sides of the pyramid look into the cranial cavity, the posterior into the posterior cranial fossa, and the anterior into the middle cranial fossa. The inferior surface appears on the under surface of the cranium. The medial and posterior walls of the tympanic cavity in the temporal bone are sometimes described as a fourth side of the pyramid. The base forms a part of the lateral surface of the cranium; the apex is placed medially.

The **posterior surface** of the pyramid is triangular in form, bounded above by the superior angle and below by the posterior angle Near the middle is an obliquely directed foramen [porus acusticus internus] leading into a short canal—the **internal auditory meatus**—at the bottom of which is a plate of bone, pierced by numerous foramina, and known as the **lamina cribrosa.** The canal transmits the facial and auditory nerves, the pars intermedia, and the internal auditory artery. The bottom of the internal auditory meatus can be most advantageously studied in a temporal bone at about the time of birth, when the canal is shallow and the openings relatively wide.

The fundus of the meatus is divided by a transverse ridge of bone, the *transverse crest*, into a superior and inferior fossa. Of these, the superior is the smaller, and presents anteriorly the beginning of the **facial canal** (aqueduct of Fallopius), which transmits the seventh nerve. The rest of the surface above the crest is dotted with small foramina (the superior vestibular area) which transmit nerve-twigs to the recessus ellipticus (fovea hemielliptica) and the ampullæ of the superior and lateral semicircular canals (vestibular division of the auditory nerve). Below the crest there are two depressions and an opening. Of these, an anterior curled tract (the spiral cribriform tract) with a central foramen (foramen centrale cochleare) marks the base of the cochlea; the central foramen indicates the orifice of the canal of the modiolus, and the smaller foramina transmit the cochlear twigs of the auditory nerve. The posterior opening (foramen singulare) is for the nerve to the ampulla of the posterior semicircular canal. The middle depression (inferior vestibular area) is dotted with minute foramina for the nerve-twigs to the saccule, which is lodged in the recessus sphæricus (fovea hemisphærica). The inferior fossa is subdivided by a low vertical crest. The fossa in front of the crest is the *fossula cochlearis*, and the recess behind it is the *fossula vestibularis*.

Behind and lateral to the meatus is a narrow fissure, the **aquæductus vestibuli,** covered by a scale of bone. In the fissure lies the ductus endolymphaticus, a small arteriole and venule, and a process of connective tissue which unites the dura mater to the sheath of the internal ear. Occasionally a bristle can be passed through it into the vestibule. Near the upper margin, and opposite a point about midway between the meatus and the aqueduct of the vesti-

bule, is an irregular opening, the **fossa subarcuata,** the remains of the **floccular fossa,** a conspicuous depression in the fœtal bone. In the adult the depression usually lodges a process of dura mater and transmits a small vein, though in some bones it is almost obliterated.

The **anterior surface** of the pyramid, sloping downward and forward, forms the back part of the floor of the middle fossa of the cranium.

Upon the anterior surface of the pyramid will be found the following points of interest, proceeding from the apex toward the base of the pyramid:—(1) a shallow **trigeminal impression** for the semilunar (Gasserian) ganglion of the trigeminal nerve; (2) two small grooves running backward and laterally toward two small foramina overhung by a thin osseous lip, the larger and medial of which, known as the **hiatus canalis facialis,** transmits the great superficial petrosal nerve and the petrosal branch of the middle meningeal artery, whilst the smaller and lateral foramen is for the small superficial petrosal nerve; (3) behind and lateral to these is an eminence—the **eminentia arcuata**—best seen in young bones, corresponding to the superior semicircular canal in the interior; (4) still more laterally is a thin transulcent plate of bone, roofing in the tympanic cavity, and named the tegmen tympani.

FIG. 94.—THE FORAMINA IN THE FUNDUS OF THE LEFT INTERNAL AUDITORY MEATUS OF A CHILD AT BIRTH (†). (Diagrammatic.)

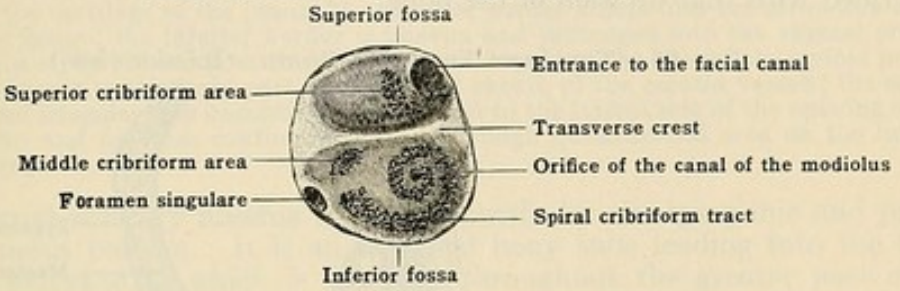

The **inferior** or **basilar surface** of the pyramid is very irregular. At the apex it is rough, quadrilateral, and gives attachment to the *tensor tympani, levator veli palatini,* and the pharyngeal aponeurosis. Behind this are seen the large circular orifice of the **carotid canal** for the transmission of the carotid artery and a plexus of sympathetic nerves, and on the same level, near the posterior border, a small three-sided depression, the **canaliculus cochleæ,** which transmits a small vein from the cochlea to the internal jugular. Behind these two openings is the large elliptical **jugular fossa** which forms the anterior and lateral part of the bony wall of the jugular foramen, in which is contained a dilatation on the commencement of the internal jugular vein; on the lateral wall of the jugular fossa is a minute foramen, the **mastoid canaliculus,** for the entrance of the auricular branch of the vagus (Arnold's nerve) into the interior of the bone. Between the inferior aperture of the carotid canal and the jugular fossa is the sharp **carotid ridge,** on which is a small depression, the **fossula petrosa,** and at the bottom of this a minute opening, the **tympanic canaliculus,** for the tympanic branch of the glosso-pharyngeal or Jacobson's nerve, and the small tympanic branch from the ascending pharyngeal artery. Behind the fossa is the rough **jugular surface** for articulation with the jugular process of the occipital bone, on the lateral side of which is the prominent cylindrical spur known as the **styloid process** with the **stylo-mastoid** foramen at its base. The facial nerve, and sometimes the auricular branch of the vagus, leave the skull, and the stylo-mastoid artery enters it by this foramen. Running backward from the foramen are the mastoid and occipital grooves already described.

The **tympanic surface** of the pyramid, forming the medial and posterior walls [paries labyrinthica] of the tympanic cavity, is shown by removing the tympanic plate (fig. 91). It presents near the base an excavation, known as the **tympanic** or **mastoid antrum,** covered by the triangular part of the squamous below and behind the temporal line. The opening of the antrum into the tympanic cavity is situated immediately above the **fenestra vestibuli,** an oval-shaped opening which receives the base of the stapes; below the fenestra vestibuli is a convex projection or **promontory,** marked by grooves for the tympanic plexus of nerves and containing the commencement of the first turn of the cochlea. In the lower and posterior part of the promontory is the **fenestra cochleæ,** closed in the recent state by the **secondary** membrane of the tympanum. Running downward and forward from the front of the fenestra vestibuli is a thin curved plate of bone [**septum canalis musculotubarii**], separating two grooves converted

into canals by the overlying tympanic plate. The lower is the groove for the **Eustachian tube** [semicanalis tubæ auditivæ], the communicating passage between the tympanum and the pharynx; the upper is the **semicanalis m. tensoris tympani,** and the lateral apertures of both canals are visible in the retiring angle, between the petrous and squamous portions of the bone.

The **apex** of the pyramid is truncated and presents the medial opening of the carotid canal. The latter commences on the inferior surface, and, after ascending for a short distance, turns forward and medially, tunnelling the bone as far as the apex, and finally opens into the upper part of the **foramen lacerum** formed between the temporal and sphenoid bones. One or two minute openings in the wall of the carotid canal, known as the **carotico-tympanic canaliculi,** transmit communicating twigs between the carotid and tympanic plexuses. The upper part of the apex is joined by cartilage to the posterior petrosal process of the sphenoid.

The **base** is the part of the pyramid which appears laterally at the side of the cranium and takes part in the formation of the mastoid portion. It is described with that division of the bone.

FIG. 95.—THE LEFT TEMPORAL BONE. (Inferior view.)

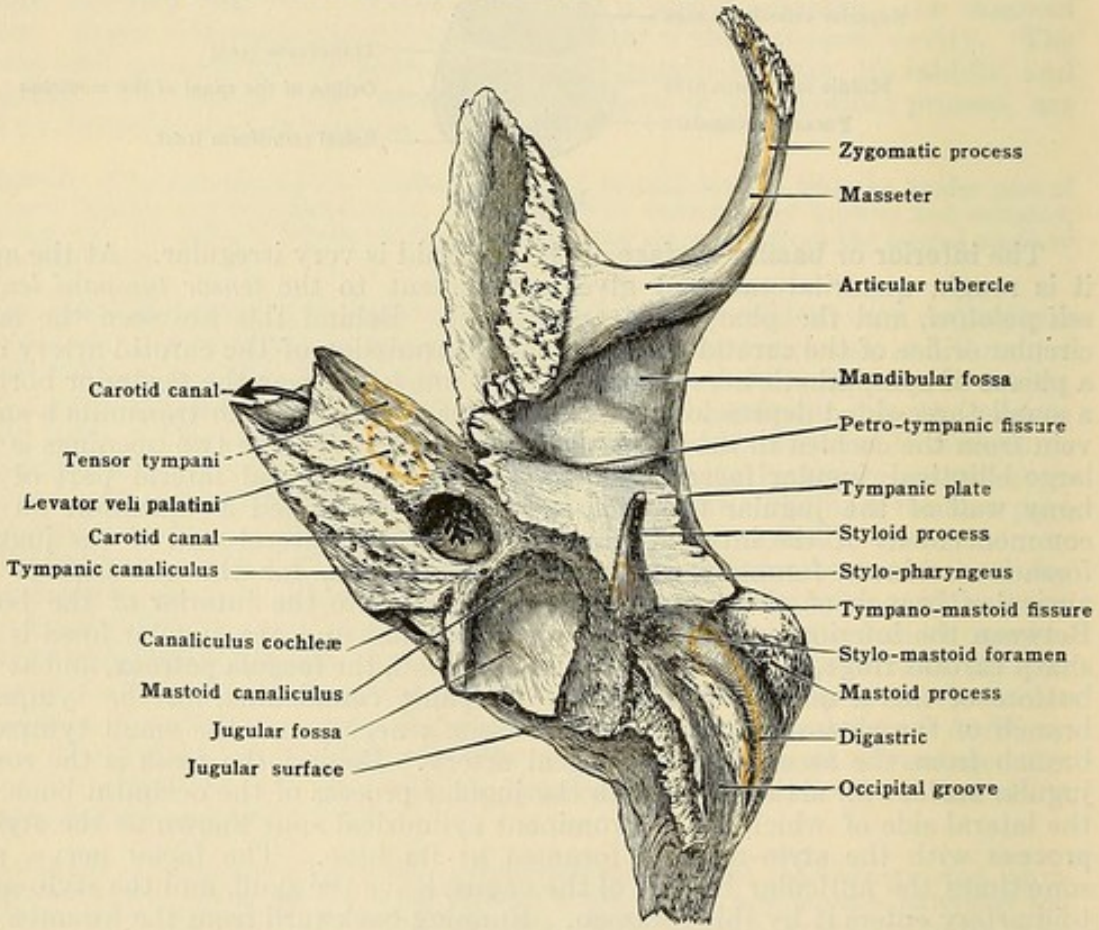

Angles.—The **superior angle** (border) of the pyramid is the longest and separates the posterior from the anterior surface. It is grooved for the superior petrosal sinus, gives attachment to the tentorium cerebelli, and presents near the apex a semilunar notch upon which the fifth cranial nerve lies. Near its medial end there is often a small projection for the attachment of the petro-sphenoidal ligament, which arches over the inferior petrosal sinus and the sixth nerve. The **posterior angle** separates the posterior from the inferior surface, and when articulated with the occipital, forms the groove for the inferior petrosal sinus, and completes the **jugular foramen** formed by the temporal in front and on the lateral side, and by the occipital behind and on the medial side. The jugular foramen is divisible into three compartments: an anterior for the inferior petrosal sinus, a middle for the glossopharyngeal, vagus and accessory cranial nerves, and a posterior for the internal jugular vein and some meningeal branches from the occipital and ascending pharyngeal arteries. The **anterior angle** is the shortest and consists of two parts, one joined to the squamous in the petro-squamous suture and a small free part internally which articulates with the sphenoid. A fourth or inferior border may be distinguished, which runs along the line of junction with the tympanic plate and is continued on to the rough area below the apex.

The **tympanic portion** [pars tympanica] is quadrilateral in form, hollowed out above and behind, and nearly flat, or somewhat concave, in front and below. It forms the whole of the anterior and inferior walls, and part of the posterior wall, of the external auditory meatus, and is separated behind from the mastoid process by the **tympano-mastoid** (auricular) fissure through which the auricular branch of the vagus in some cases leaves the bone.

In front it is separated by the **petro-tympanic** fissure from the squamous portion. Through the petro-tympanic fissure the tympanic branch of the internal maxillary artery and the so-called laxator tympani pass. The processus gracilis of the malleus is lodged within it, and a narrow subdivision at its inner end, known as the **canal of Huguier,** transmits the chorda tympani nerve. The tympanic part presents for examination two surfaces and four borders.

The **antero-inferior surface,** directed downward and forward, lodges part of the parotid gland. Near the middle it is usually very thin, and sometimes presents a small foramen (the foramen of Huschke), which represents a non-ossified portion of the plate. The **postero-superior surface** looks into the external auditory meatus and tympanic cavity, and at its medial end is a narrow groove, the **sulcus tympanicus,** deficient above, which receives the membrana tympani.

The **lateral border** is rough and everted, forming the **external auditory process** for the attachment of the cartilage of the pinna; the **superior border** enters into the formation of the petro-tympanic fissure; the **inferior border** is uneven and prolonged into the **vaginal process** [vagina processus styloidei] which surrounds the lateral aspect of the base of the styloid process and gives attachment to the front part of the fascial sheath of the carotid vessels; the **medial border,** short and irregular, lies immediately below and to the lateral side of the opening of the Eustachian tube, and becomes continuous with the rough quadrilateral area on the inferior aspect of the apex.

The **external auditory meatus** is formed partly by the tympanic and partly by the squamous portion. It is an elliptical bony tube leading into the tympanum, the extrance of which is bounded throughout the greater part of its circumference by the external auditory process of the tympanic plate. Above, the entrance is limited by the temporal ridge or posterior root of the zygomatic process.

The **styloid process** is a slender, cylindrical spur of bone fused with the inferior aspect of the temporal immediately in front of the stylo-mastoid foramen. It consists of two parts, **basal** (tympano-hyal), which in the adult lies under cover of the tympanic plate, and a **projecting** portion (stylo-hyal), which varies in length from five to fifty millimetres. When short, it is hidden by the vaginal process, but, on the other hand, it may reach to the hyoid bone. The projecting portion gives attachment to three muscles and two ligaments.

The *stylo-pharyngeus* arises near the base from the medial and slightly from the posterior aspect; the *stylo-hyoid* from the posterior and lateral aspect near the middle; and the *stylo-glossus* from the front near the tip. The tip is continuous with the stylo-hyoid ligament, which runs down to the lesser cornu of the hyoid bone. A band of fibrous tissue—the stylo-mandibular ligament—passes from the process below the origin of the stylo-glossus to the angle of the lower jaw.

Blood-supply.—The arteries supplying the temporal bone are derived from various sources. The chief are:—

Stylo-mastoid from posterior auricular: it enters the stylo-mastoid foramen.

Anterior tympanic from internal maxillary: it passes through the petro-tympanic fissure.

Superficial petrosal from middle meningeal: transmitted by the hiatus canalis facialis.

Carotico-tympanic from internal carotid whilst in the carotid canal.

Internal auditory from the basilar: it enters the internal auditory meatus, and is distributed to the cochlea and vestibule.

Other less important twigs are furnished by the middle meningeal, the meningeal branches of the occipital, and by the ascending pharyngeal artery. The squamous portion is supplied, on its internal surface, by the middle meningeal, and externally by the branches of the deep temporal from the internal maxillary.

Articulations.—The temporal bone articulates with the occipital, parietal, sphenoid, zygomatic, and, by a movable joint, with the mandible. Occasionally the squamous portion presents a process which articulates with the frontal. A **fronto-squamosal** suture is common in the skulls of the lower races of men, and is normal in the skulls of the chimpanzee, gorilla, and gibbon.

Ossification.—Of the three parts which constitute the temporal bone at birth, the squamosal and tympanic develop in membrane and the petrosal in cartilage. The squamosal is formed from one centre, which appears as early as the eighth week, and ossification extends into the zygomatic process, which grows concurrently with the squamosal. At first the tympanic border is nearly straight, but soon assumes its characteristic horseshoe shape. At birth the post-glenoid tubercle is conspicuous, and at the hinder end of the squamosal there is a process which comes into relation with the mastoid antrum The centre for the tympanic element appears about the twelfth week. At birth it forms an incomplete ring, open above, and slightly ankylosed to the lower border of the squamosal. The anterior extremity terminates

in a small irregular process, and the medial aspect presents, in the lower half of its circumference, a groove for the reception of the tympanic membrane.

Up to the middle of the fifth month the periotic capsule is cartilaginous; it then ossifies so rapidly that by the end of the sixth month its chief portion is converted into porous bone. The ossific material is deposited in four centres, or groups of centres, named according to their relation to the ear-capsule in its embryonic position.

The nuclei are deposited in the following order:—

1. The **opisthotic** appears at the end of the fifth month. The osseous material is seen first on the promontory, and it quickly surrounds the fenestra cochleæ from above downward, and forms the floor of the vestibule, the lower part of the fenestra vestibuli, and the internal auditory meatus; it also invests the cochlea. Subsequently a plate of bone arises from it to surround the internal carotid artery and form the floor of the tympanum.

2. The **prootic** nucleus is deposited behind the internal auditory meatus near the medial limb of the superior semicircular canal. It covers in a part of the cochlea, the vestibule, and the internal auditory meatus, completes the fenestra vestibuli, and invests the superior semicircular canal.

3. The **pterotic** nucleus ossifies the tegmen tympani and covers in the lateral semicircular canal; the ossific matter is first deposited over the lateral limb of this canal.

4. The **epiotic,** often double, is the last to appear, and is first seen at the most posterior part of the posterior semicircular canal.

At birth the bone is of loose and open texture, thus offering a striking contrast to the dense and ivory-like petrosal of the adult. It also differs from the adult bone in several other particulars. The floccular fossa is widely open and conspicuous. Voltolini has pointed out that a small canal leads from the floor of the floccular fossa and opens posteriorly on the mastoid surface of the bone; it may open in the mastoid antrum. The hiatus canalis facialis is unclosed

FIG. 96.—TEMPORAL BONE AT THE SIXTH YEAR.

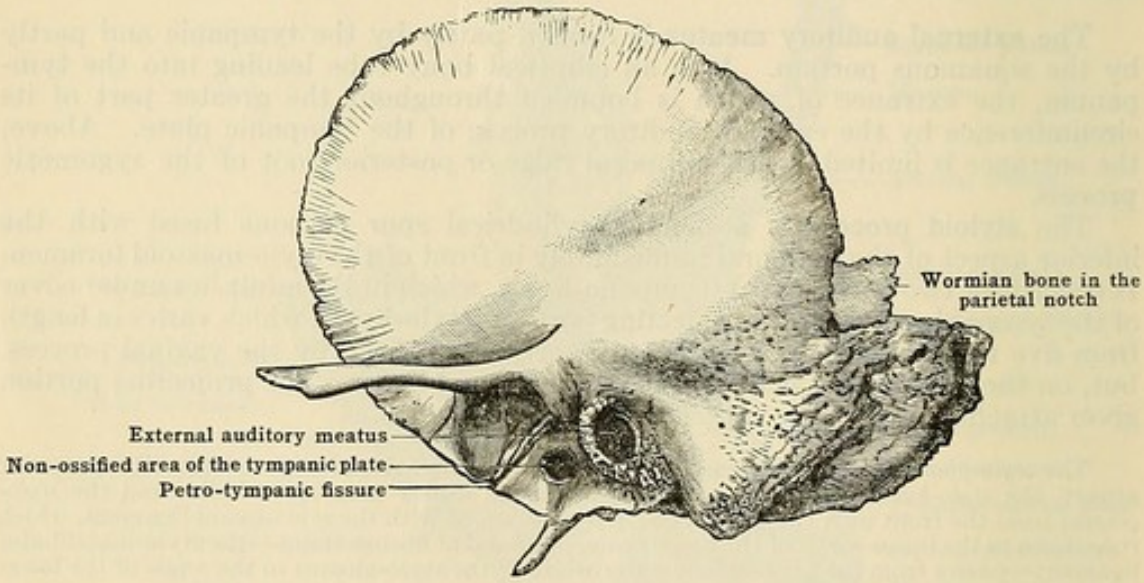

and the tympanum is filled with gelatinous connective tissue. The mastoid process is not developed, and the jugular fossa is a shallow depression.

After birth the parts grow rapidly. The tympanum becomes permeated with air, the various elements fuse, and the tympanic annulus grows rapidly and forms the tympanic plate. Development of the tympanic plate takes place by an outgrowth of bone from the lateral aspect of the tympanic annulus. This outgrowth takes place most rapidly from the tubercles or spines at its upper extremities, and in consequence of the slow growth of the lower segment a deep notch is formed; gradually the tubercles coalesce, lateral to the notch, so as to enclose a foramen which persists until puberty, and sometimes even in the adult. In most skulls a cleft capable of receiving the nail remains between the tympanic element and the mastoid process; this is the tympano-mastoid fissure. The anterior portion of the tympanic plate forms with the inferior border of the squamosal a cleft known as the petro-tympanic fissure, which is subsequently encroached upon by the growth of the petrosal. As the tympanic plate increases in size it joins the lateral wall of the carotid canal and presents a prominent lower edge, known as the vaginal process (sheath of the styloid).

The **mastoid process** becomes distinct about the first year, coincident with the obliteration of the petro-squamous suture, and increases in thickness by deposit from the periosteum. According to most writers, the process becomes pneumatic about the time of puberty, but it has been shown by Young and Milligan that the mastoid air-cells develop at a much earlier period than is usually supposed. These writers have described specimens in which the air-cells were present, as small pit-like diverticula from the mastoid antrum, in a nine months' fœtus and in an infant one year old. In old skulls the air-cells may extend into the jugular process of the occipital bone.

At birth the mastoid antrum is relatively large and bounded laterally by a thin plate of bone belonging to the squamosal (post-auditory process). As the mastoid increases in thickness the antrum comes to lie at a greater depth from the surface and becomes relatively smaller.

The styloid process is ossified in cartilage from two centres, one of which appears at the base in the tympano-hyal before birth. This soon joins with the temporal bone, and in the second year a centre appears for the stylo-hyal, which, however, remains very small until puberty. In the adult it usually becomes firmly united with the tympano-hyal, but it may remain permanently separate.

THE TYMPANUM

The **tympanum** (middle ear) includes a cavity [cavum tympani] of irregular form in the temporal bone, situated over the jugular fossa, between the petrous portion medially and the tympanic and squamous portions laterally. When fully developed, it is completely surrounded by bone except where it communicates with the external auditory meatus, and presents for examination six walls—lateral, medial, posterior, anterior, superior (roof), and inferior (floor). The lateral and medial walls are flat, but the remainder are curved, so that they run into adjoining surfaces, without their limits being sharply indicated.

The **roof** or tegmen tympani [paries tegmentalis] is a translucent plate of bone, forming part of the superior surface of the petrous portion and separating the tympanum from the middle fossa of the skull. The **floor** [paries jugularis] is the plate of bone which forms the roof of the jugular fossa.

The **medial wall** [paries labyrinthica] is formed by the tympanic surface of the petrous portion. In the angle between it and the roof is a horizontal ridge which extends backward as far as the posterior wall and then turns downward in the angle between the medial and posterior walls. This is the **facial (Fallopian) canal,** and is occupied by the facial nerve. The other features of this surface—viz., the **fenestra vestibuli,** the **fenestra cochleæ,** and the **promontory**—have previously been described with the anterior surface of the petrous portion of the temporal bone.

The **posterior wall** [paries mastoidea] of the tympanum is also formed by the anterior surface of the petrous portion. At the superior and lateral angle of this wall an opening

FIG. 97.—THE MEDIAL WALL OF THE TYMPANUM.

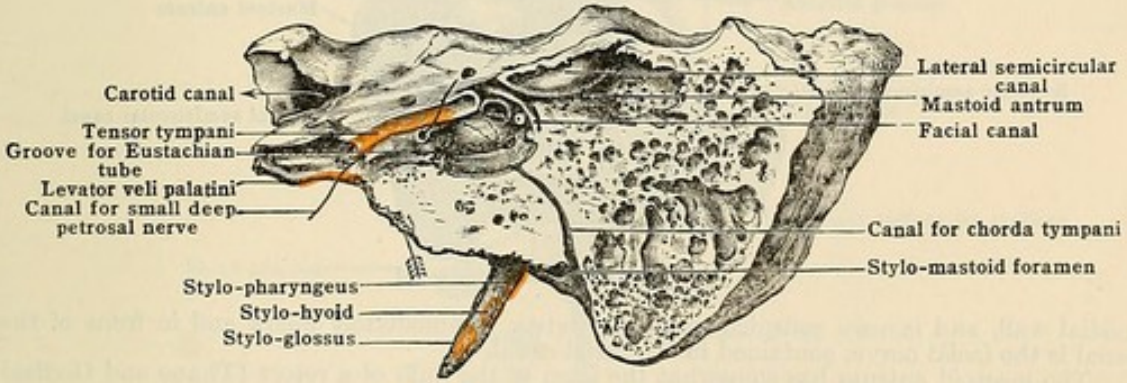

leads into the **mastoid antrum.** Immediately below this opening there is a small hollow cone, the **pyramidal eminence,** the cavity of which is continuous with the descending limb of the facial canal. The cavity is occupied by the *stapedius* and the tendon of the muscle emerges at the apex. One or more bony spicules often connect the apex of the pyramid with the promontory.

The roof and floor converge toward the **anterior extremity** of the tympanum, which is, in consequence, very low; it is occupied by two semicanals, the lower for the Eustachian tube, the upper for the *tensor tympani* muscle. These channels are sometimes described together as the **canalis musculo-tubarius.** In carefully prepared bones the upper semicanal is a small horizontal hollow cone (anterior pyramid), 12 mm. in length; the apex is just in front of the fenestra vestibuli, and is perforated to permit the passage of the tendon of the muscle. As a rule, the thin walls of the canal are damaged, and represented merely by a thin ridge of bone. The posterior portion of this ridge projects into the tympanum, and is known as the **processus cochleariformis.** The thin septum between the semicanal for the tensor tympani and the tube is pierced by a minute opening which transmits the small deep petrosal nerve.

The **lateral wall** [paries membranacea] is occupied mainly by the external auditory meatus. This opening is closed in the recent state by the tympanic membrane. The rim of bone to which the membrane is attached is incomplete above, and the defect is known as the **tympanic notch (notch of Rivinus).** Anterior to this notch, in the angle between the squamous portion and the tympanic plate, is the **petro-tympanic (Glaserian) fissure,** and the small passage which transmits the chorda tympani nerve, known as the **canal of Huguier.**

Up to this point the description of the middle ear conforms to that in general usage. But Young and Milligan have laid stress on the fact that the middle ear is really a cleft, named by them the "*middle-ear cleft,*" which intervenes between the periotic capsule, on the one hand, and the squamo-zygomatic and tympanic elements of the temporal bone on the other. This cleft, as development proceeds, gives rise to three cavities:—(1) the mastoid antrum; (2)

tympanum; and (3) the Eustachian tube. They point out that "the cleft is primarily continuous, and however much it may be altered in shape and modified in parts to form these three cavities, that continuity is never lost." It will be clear that the mastoid antrum, according to this view, is not an outgrowth from the tympanum, but is simply the lateral end of the middle-ear cleft.

The tympanic cavity may be divided into three parts. The part below the level of the superior margin of the external auditory meatus is the **tympanum proper**; the portion above this level is the **epitympanic recess** or **attic**; it receives the head of the malleus, the body of the incus, and leads posteriorly into the recess known as the **mastoid antrum.** The third part is the downward extension known as the **hypotympanic recess.**

The tympanic or mastoid antrum.—The air-cells which in the adult are found in the interior of the mastoid portion of the temporal bone open into a small cavity termed the **mastoid antrum.** This is an air-chamber, communicating with the attic of the tympanum, and separated from the middle cranial fossa by the posterior portion of the tegmen tympani. The floor is formed by the mastoid portion of the petrosal, and the lateral wall by the squamosal, below the temporal ridge. In children the outer wall is exceedingly thin, but in the adult it is of considerable thickness. The **lateral semicircular canal** projects into the antrum on its

FIG. 98.—TEMPORAL BONE AT BIRTH DISSECTED FROM ABOVE AND BEHIND TO SHOW THE SEMICIRCULAR CANALS AND THE MASTOID ANTRUM. (Enlarged ½.)

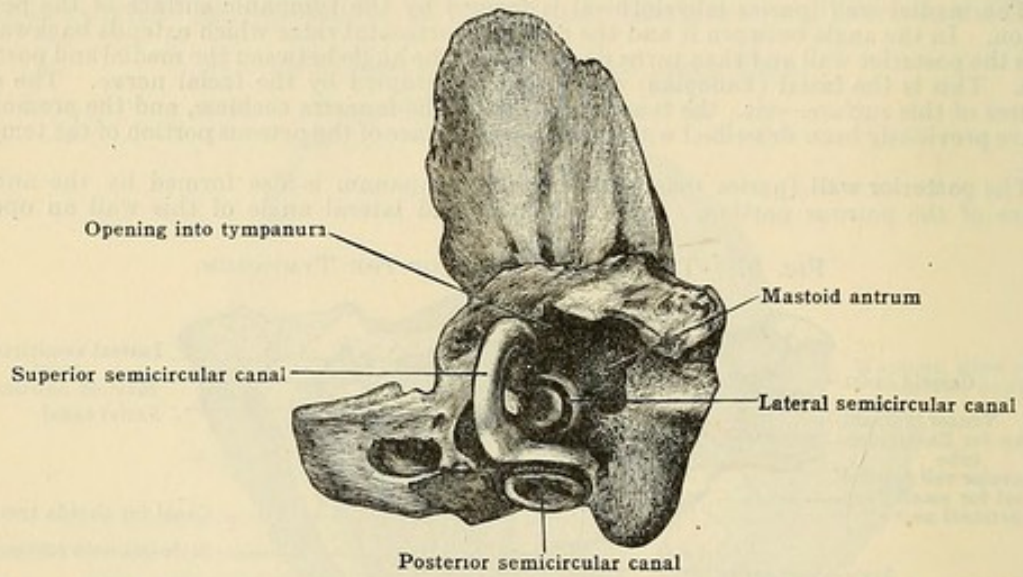

medial wall, and is very conspicuous in the fœtus. Immediately below and in front of the canal is the facial nerve, contained in the facial canal.

The mastoid antrum has somewhat the form of the bulb of a retort (Thane and Godlee) compressed laterally, and opening by its narrowed neck into the attic or epitympanic recess. Its dimensions vary at different periods of life. It is well developed at birth, attains its maximum size about the third year, and diminishes somewhat up to adult life. In the adult the plate of bone which forms the lateral wall of the antrum is 12 to 18 mm. (½ to ¾ in.) in thickness, whereas at birth it is about 1.8 mm. ($\frac{1}{15}$ in.) or less. The deposition of bone laterally occurs, therefore, at average rate of nearly 1 mm. a year in thickness. In the adult the antrum is about 12 mm. (½ in.) from front to back, 9 mm. (⅜ in.) from above downward, and 4.5 mm. ($\frac{3}{15}$ in.) from side to side.

A canal occasionally leads from the mastoid antrum through the petrous bone to open in the recess which indicates the position of the floccular fossa; it is termed the petro-mastoid canal. (Gruber.)

The facial (Fallopian) canal.—This canal begins at the anterior angle of the superior fossa of the internal auditory meatus, and passes forward and laterally above the vestibular portion of the internal ear for a distance of 1.5–2.0 mm. At the lateral end of this portion of its course it becomes dilated to accommodate the geniculate ganglion, and then turns abruptly backward and runs in a horizontal ridge on the medial wall of the tympanum, lying in the angle between it and the tegmen tympani, immediately above the fenestra vestibuli, and extending as far backward as the entrance to the mastoid antrum. Here it comes into contact with the inferior aspect of the projection formed by the lateral semicircular canal, and then turns vertically downward, running in the angle between the medial and posterior walls of the tympanum to terminate at the stylo-mastoid foramen.

The canal is traversed by the facial nerve. Numerous openings exist in the walls of this passage. At its abrupt bend, or **genu,** the greater and smaller superficial petrosal nerves escape from, and a branch from the middle meningeal artery enters, the canal, and in the vertical part of its course the cavity of the pyramid opens into it. There is also a small orifice by which the auricular branch of the vagus joins the facial, and near its termination the **iter chordæ posterius** for the chorda tympani nerve leads from it into the tympanum.

The small bones of the tympanum.—These bones, the malleus, incus and stapes, are contained in the upper part of the tympanic cavity. Together they form a jointed column of bone connecting the membrana tympani with the fenestra vestibuli.

The malleus.—This is the most external of the auditory ossicles, and lies in relation with the tympanic membrane. Its upper portion, or **head,** is lodged in the epitympanic recess. It is of rounded shape, and presents posteriorly an elliptical depression for articulation with the incus. Below the head is a constricted portion or **neck,** from which three processes diverge. The largest is the **handle** or **manubrium,** which is slightly twisted and flattened. It forms an obtuse angle with the head of the bone, and lies between the membrana tympani and the mucous membrane covering its inner surface. The *tensor tympani* tendon is inserted into the manubrium near its junction with the neck on the medial side.

FIG. 99.—THE BONES OF THE EAR. (Modified from Henle.)

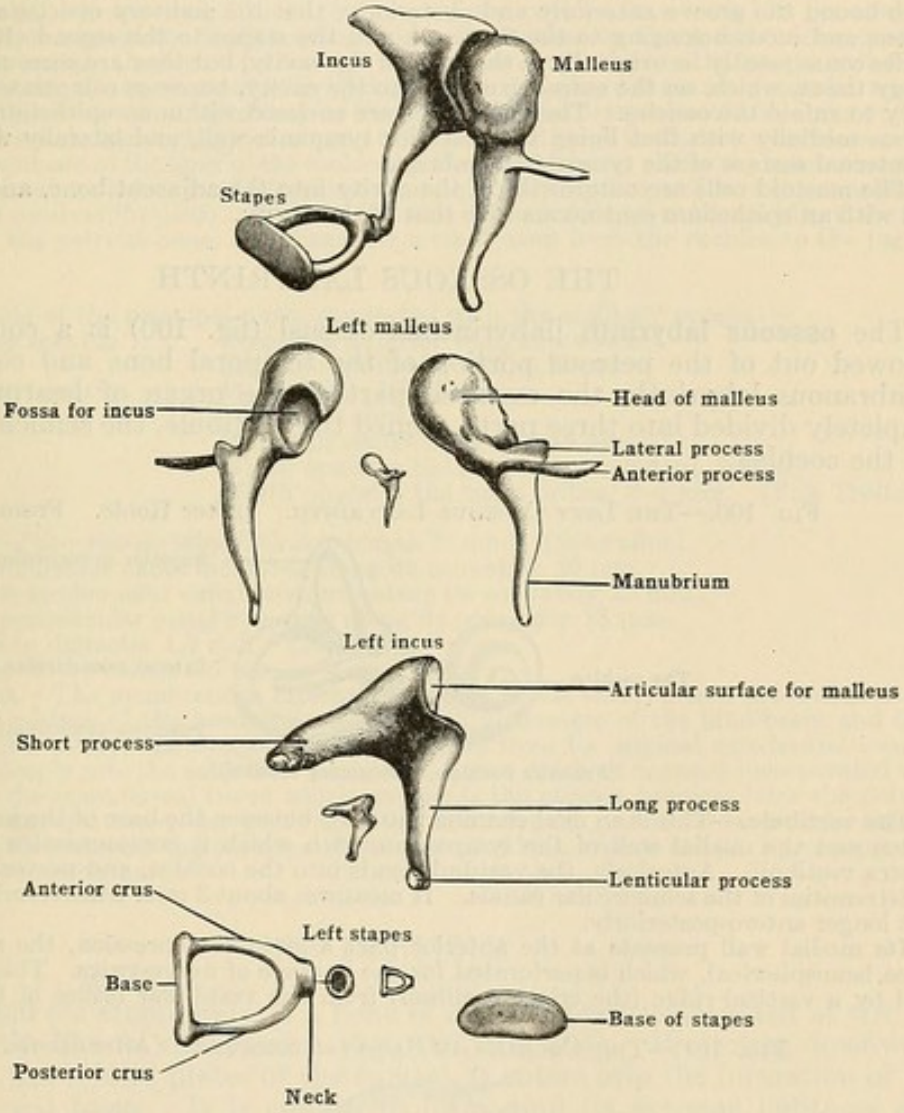

The **anterior process** (processus gracilis or Folii) is a long, slender, delicate spiculum of bone (rarely seen of full length except in the fœtus), projecting nearly at right angles to the anterior aspect of the neck, and extending obliquely downward. It lies in the petro-tympanic fissure, and in the adult usually becomes converted into connective tissue, except a small basal stump. The **lateral process** is a conical projection from the lateral aspect of the base of the manubrium. Its apex is connected to the upper part of the tympanic membrane, and its base receives the lateral ligament of the malleus. The malleus also gives attachment to a superior ligament and an anterior ligament, the latter of which was formerly described as the *laxator tympani* muscle.

The incus.—This bone is situated between the malleus externally and the stapes internally. It presents for examination a body and two processes. The **body** is deeply excavated anteriorly for the reception of the head of the malleus. The **short process** projects backward, and is connected by means of ligamentous fibres to the posterior wall of the tympanum, near the entrance to the mastoid antrum. The **long process** is slender, and directed downward and inward, and lies parallel with the manubrium of the malleus. On the medial aspect of the distal extremity of this process is the **lenticular process** (orbicular tubercle), separate in early life, but

subsequently joined to the process by a narrow neck. Its free surface articulates with the head of the stapes.

The **stapes** is the innermost ossicle. It has a **head** directed horizontally outward, capped at its outer extremity by a disc resembling the head of the radius. The cup-shaped depression receives the lenticular process of the incus. The **base** occupies the fenestra vestibuli, and like this opening, the inferior border is straight, and the superior curved. The base is connected with the head by means of two **crura**, and a narrow piece of bone called the neck. Of the two crura, the anterior is the shorter and straighter. The crura with the base form a stirrup-shaped arch, of which the inner margin presents a groove for the reception of the membrane stretched across the hollow of the stapes. In the early embryo this hollow is traversed by the stapedial artery. The **neck** is very short, and receives on its posterior border the tendon of the *stapedius* muscle.

Development.—The tympanic cavity represents the upper extremity of the first endodermal branchial groove, which becomes converted into a blind pouch, the communication of which with the pharyngeal cavity is the tuba auditiva (Eustachian tube). The thin membrane which separates the endodermal from the ectodermal groove becomes the tympanic membrane, and it is from the upper extremities of the axial skeletons of the first and second branchial arches, which bound the groove anteriorly and posteriorly, that the auditory ossicles are formed, the malleus and incus belonging to the first arch and the stapes to the second (Reichert). The ossicles consequently lie originally in the walls of the cavity, but they are surrounded by a loose spongy tissue, which, on the entrance of air into the cavity, becomes compressed, allowing the cavity to enfold the ossicles. These therefore are enclosed within an epithelium which is continuous medially with that lining the posterior tympanic wall, and laterally with that lining the internal surface of the tympanic membrane.

The mastoid cells are outgrowths of the cavity into the adjacent bone, and are therefore lined with an epithelium continuous with that of the cavity.

THE OSSEOUS LABYRINTH

The **osseous labyrinth** [labyrinthus osseus] (fig. 100) is a complex cavity hollowed out of the petrous portion of the temporal bone and containing the membranous labyrinth, the essential part of the organ of hearing. It is incompletely divided into three parts, named the vestibule, the semicircular canals, and the cochlea.

FIG. 100.—THE LEFT OSSEOUS LABYRINTH. (After Henle. From a cast.)

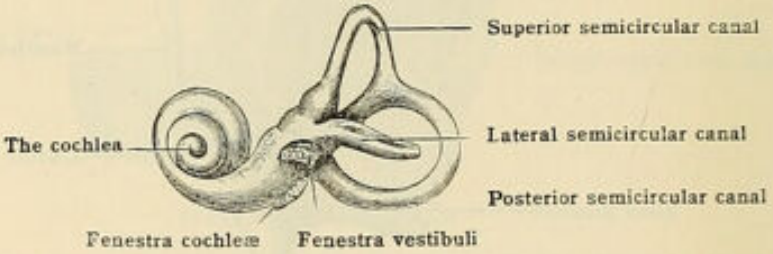

The vestibule.—This is an oval chamber situated between the base of the internal auditory meatus and the medial wall of the tympanum, with which it communicates by way of the fenestra vestibuli. Anteriorly, the vestibule leads into the cochlea, and posteriorly it receives the extremities of the semicircular canals. It measures about 3 mm. transversely, and is somewhat longer antero-posteriorly.

Its medial wall presents at the anterior part a circular depression, the **spherical recess** (fovea hemispherica), which is perforated for the passage of nerve-twigs. This recess is separated by a vertical ridge (the **crista vestibuli**) from the vestibular orifice of the **aquæductus**

FIG. 101.—THE COCHLEA IN SAGITTAL SECTION. (After Henle.)

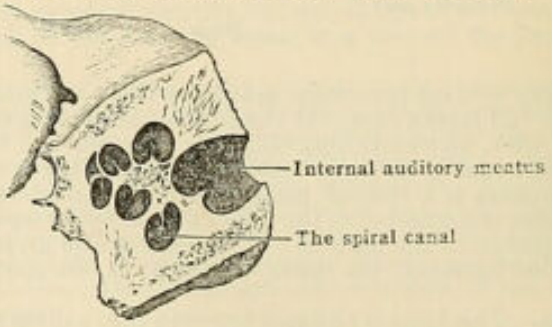

vestibuli, which passes obliquely backward to open on the posterior surface of the petrosal. The roof contains an oval depression—the **elliptical recess** (fovea hemielliptica).

The **semicircular canals** are three in number. Arranged in different planes, each forms about two-thirds of a circle. One extremity of each canal is dilated to form an **ampulla.**

The **superior canal** lies transversely to the long axis of the petrosal, and is nearly vertical;

its highest limb makes a projection on the superior surface of the bone. The ampulla is at the lateral end; the medial end opens into the vestibule conjointly with the superior limb of the posterior canal.

The **posterior canal** is nearly vertical and lies in a plane nearly parallel to the posterior surface of the petrosal. It is the longest of the three; its upper extremity joins the medial limb of the superior canal, and opens in common with it into the vestibule. The lower is the ampullated end.

The **lateral canal** is placed horizontally and arches laterally; its lateral limb forms a prominence in the mastoid antrum. This canal is the shortest; its ampulla is at the lateral end near the fenestra vestibuli.

The cochlea.—This is a cone-shaped cavity lying with its base upon the internal auditory meatus, and the apex directed forward and laterally. It measures about five millimetres in length, and the diameter of its base is about the same. The centre of this cavity is occupied by a column of bone—the **modiolus**—around which a canal is wound in a spiral manner, making about two and a half turns. This is the **spiral canal** of the cochlea; its first turn is the largest and forms a bulging, the **promontory,** on the medial wall of the tympanum.

Projecting into the canal throughout its entire length there is a horizontal, shelf-like lamella, the **lamina spiralis,** which terminates at the apex of the cochlea in a hook-like process, the **hamulus.** The free edge of the lamina spiralis gives attachment to the membranous cochlea, a canal having in section the form of a triangle whose base is attached to the lateral wall of the spiral canal. By this the spiral canal is divided into a portion above the lamina spiralis, termed the **scala vestibuli,** which communicates at its lower end with the osseous vestibule, and a portion below, termed the **scala tympani,** which abuts at its lower end upon the fenestra cochleæ. The two scalæ communicate at the apex of the cochlea by the **helicotrema.** Near the commencement of the scala tympani, and close to the fenestra rotunda, is the cochlear orifice of the **canaliculus cochleæ** (ductus perilymphaticus). In the adult this opens below, near the middle of the posterior border of the petrous bone, and transmits a small vein from the cochlea to the jugular fossa.

Measurements of the principal parts connected with the auditory organs:—

Internal auditory meatus.....	Length of anterior wall, 13–14 mm.
	Length of posterior wall, 6.7 mm.
External auditory meatus.....	14–16 mm. (Gruber.)
Tympanum.....	Length, 13 mm.
	Height in centre of cavity, 15 mm.
	Width opposite the membrana tympani, 2 mm.
	Width opposite the tubal orifice, 3–4 mm. (Von Tröltsch.)

The capsule of the osseous labyrinth is in length 22 mm. (Schwalbe.)
Superior semicircular canal measures along its convexity 20 mm.
The posterior semicircular canal measures along its convexity 22 mm.
The lateral semicircular canal measures along its convexity 15 mm.
The canal is in diameter 1.5 mm. (Huschke.)
The ampulla of the canal, 2.5 mm.

Development.—The membranous internal ear arises in the embryo as a depression of the ectoderm of the surface of the head opposite the fifth neuromere of the hind-brain and later becomes a sac-like cavity, the otocyst, which separates from its original ectodermal connections and sinks deeply into the subjacent mesoderm, a part of which becomes incorporated with it. The rest of the mesodermal tissue which surrounds the otocyst becomes later the petrous portion of the temporal bone, the perilymph and the internal periosteal layer; the osseous labyrinth is therefore merely the portions of the petrous which enclose the cavity occupied by the membranous internal ear.

THE ETHMOID

The **ethmoid** [os ethmoidale] is a bone of delicate texture, situated at the anterior part of the base of the cranium (figs. 102, 103, 104). Projecting downward from between the orbital plates of the frontal, it enters into the formation of the orbital and nasal fossæ. It is cubical in form, and its extreme lightness and delicacy are due to an arrangement of very thin plates of bone surrounding irregular spaces known as air-cells. The ethmoid consists of four parts: the horizontal or cribriform plate, the ethmoidal labyrinth on each side, and a perpendicular plate.

The **cribriform plate** [lamina cribrosa] forms part of the anterior cranial fossa, and is received into the ethmoidal notch of the frontal bone. It presents on its upper surface, in the median line, the intra-cranial portion of the perpendicular plate, known as the **crista galli,** a thick, vertical, triangular process with the highest point in front, and a sloping border behind which gives attachment to the falx cerebri. The anterior border is short and in its lower part broadens out to form two **alar processes** which articulate with the frontal bone and complete the **foramen cæcum.** The crista galli is continuous behind with a median ridge, and on each side of the middle line is a groove which lodges the olfactory bulb.

The cribriform plate is pierced, on each side, by numerous foramina, arranged in two or three rows, which transmit the filaments of the olfactory nerves descending from the bulb. Those in the middle of the groove are few and are simple perforations, through which pass the nerves to the roof of the nose; the medial and lateral series are more numerous and constitute the upper ends of small canals, which subdivide as they course downward to the upper parts of the septum and the lateral wall of the nasal fossa. At the front part of the cribriform plate is a narrow longitudinal slit, on each side of the crista galli, which transmits the anterior ethmoidal (nasal) branch of the ophthalmic division of the fifth nerve. The posterior border articulates with the ethmoidal spine of the sphenoid.

FIG. 102.—SECTION THROUGH THE NASAL FOSSA TO SHOW THE MESETHMOID (LAMINA PERPENDICULARIS).

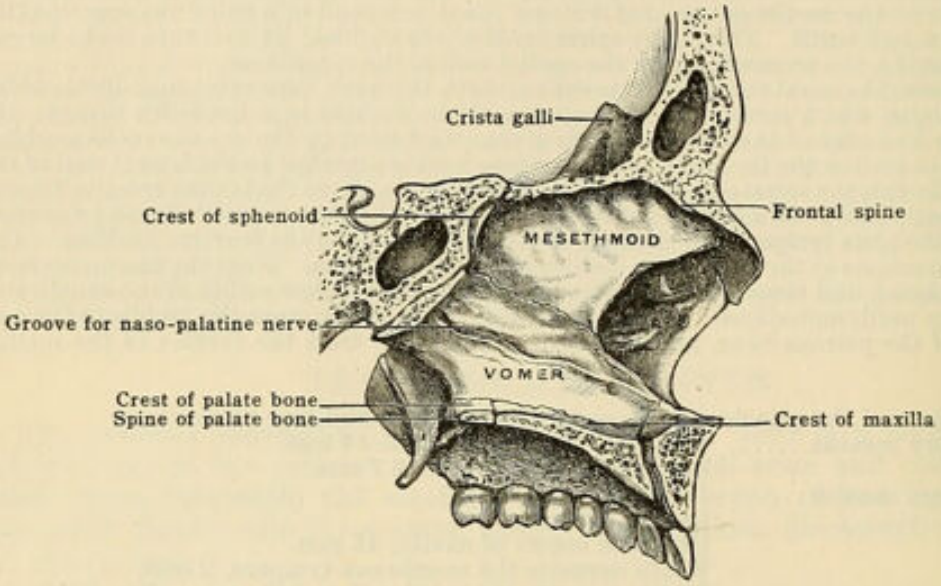

The **perpendicular plate** (mesethmoid) [lamina perpendicularis is directly continuous with the crista galli on the under aspect of the cribriform plate, so that the two plates cross each other at right angles. The larger part of the perpendicular plate is below the point of intersection and forms the upper third of the septum of the nose. It is quadrangular in form with unequal sides.

FIG. 103.—THE ETHMOID. (Lateral view.)

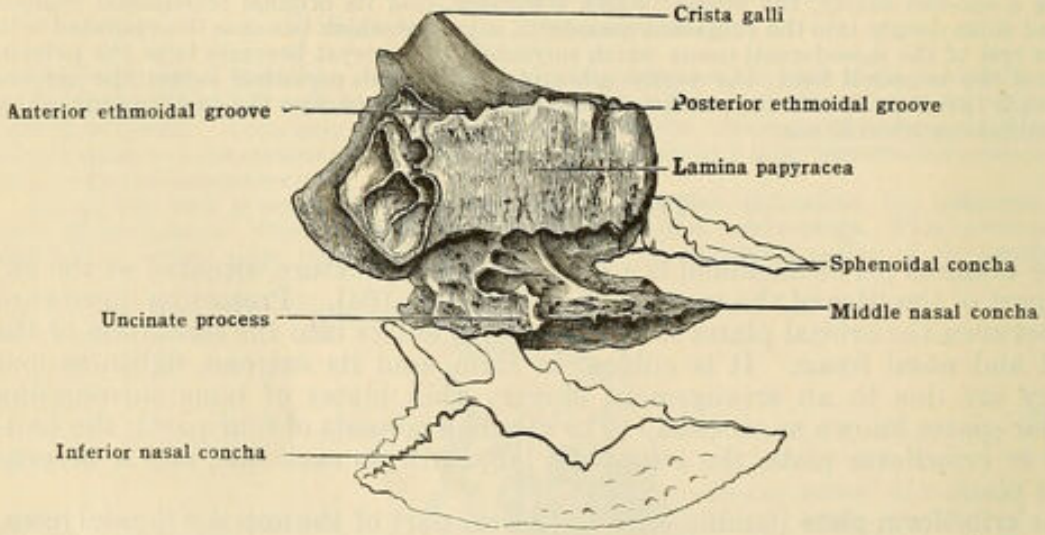

The anterior border articulates with the spine of the frontal and the crest of the nasal bones. The inferior border articulates in front with the septal cartilage of the nose and behind with the anterior margin of the vomer. The posterior margin is very thin and articulates with the crest of the sphenoid. This plate, which is generally deflected a little to one side, presents above a number of grooves and minute canals which lead from the inner set of foramina in the cribriform plate and transmit the olfactory nerves to the septum.

The **labyrinth** (lateral mass) is oblong in shape and suspended from the under aspect of the lateral part of the cribriform plate. It consists of two scroll-like

pieces of bone, the **superior** and **middle nasal conchæ** (turbinate bones), and encloses numerous irregularly shaped spaces, known as the **ethmoidal cells.** These are arranged in three sets—anterior, middle, and posterior ethmoidal cells —and, in the recent state, are lined with prolongations of the nasal mucous membrane. Laterally the labyrinth presents a thin, smooth, quadrilateral plate of bone—the **lamina papyracea** (os planum)—which closes in the middle and posterior ethmoidal cells and forms a large part of the medial wall of the orbit.

By its anterior border it articulates with the lacrimal, and by its posterior border with the sphenoid; the inferior border articulates with the medial margin of the orbital plate of the maxilla and the orbital process of the palate bone, whilst the superior border articulates with the horizontal plate of the frontal. Two notches in the superior border lead into grooves running horizontally across the lateral mass to the cribriform plate, which complete, with the frontal bone, the **ethmoidal canals.** The anterior canal transmits the anterior ethmoidal vessels and (nasal) nerve; the posterior transmits the posterior ethmoidal vessels and nerve.

FIG. 104.—SECTION THROUGH THE NASAL FOSSA TO SHOW THE LABYRINTH OF THE ETHMOID. It shows also the lateral wall of the left nasal fossa.

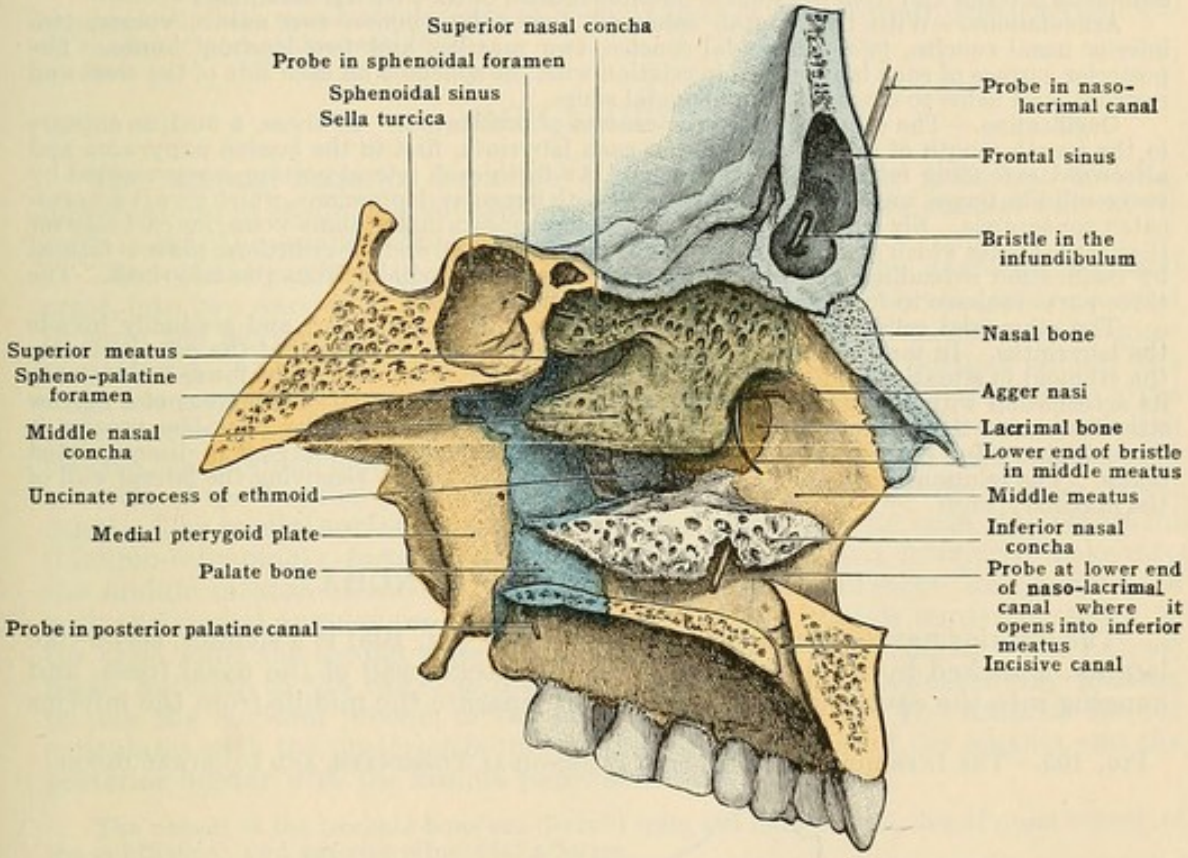

At the lower part of the lateral surface is a deep groove, which belongs to the middle meatus of the nose, and is bounded below by the thick curved margin of the inferior nasal concha. Anteriorly the middle meatus receives the **infundibulum,** a sinuous passage which descends from the frontal sinus through the anterior part of the labyrinth. The anterior ethmoidal cells open into the lower part of the infundibulum, and in this way communicate with the nose, whereas the middle ethmoidal cells open directly into the middle or horizontal part of the meatus. In front of the lamina papyracea are seen a few broken cells, which extend under, and are completed by, the lacrimal bone and the frontal process of the maxilla; from this part of the labyrinth an irregular lamina, known as the **uncinate process,** projects downward and backward. The uncinate process articulates with the ethmoidal process of the inferior nasal concha and forms a small part of the medial wall of the maxillary sinus.

Medially the labyrinth takes part in the formation of the lateral wall of the nasal fossa, and presents the **superior** and **middle nasal conchæ** (turbinate processes), continuous anteriorly, but separated behind by a space directed forward from the posterior margin. This channel is the **superior meatus** of the nose and communicates with the posterior ethmoidal cells. The conchæ are covered

in the recent state with mucous membrane and present numerous foramina for blood-vessels and, above, grooves for twigs of the olfactory nerves. Each concha has an attached upper border and a free, slightly convoluted, lower border, and in the case of the middle concha, the lower margin has already been noticed on the outer aspect, where it overhangs the middle meatus of the nose. The posterior extremity of the labyrinth articulates with the anterior surface of the body of the sphenoid and is commonly united with the sphenoidal concha.

A rounded prominence on the lateral wall of the middle meatus is known as the **bulla ethmoidalis.** Antero-inferior to the bulla is a large semilunar depression [hiatus semilunaris] which corresponds to the lower aperture of the infundibulum.

Many of the ethmoidal cells are imperfect and are completed by adjacent bones. Those along the superior edge of the lateral mass are the **fronto-ethmoidal;** those at the anterior border, usually two in number, are known as **lacrimo-ethmoidal.** Those along the lower edge of the lamina papyracea are the **maxillo-ethmoidal;** and posteriorly, are the **spheno-ethmoidal,** completed by the sphenoidal concha, and a **palato-ethmoidal** cell. The anterior extremity presents one or two incomplete cells closed by the nasal process of the maxilla.

Blood-supply.—The ethmoid receives its **blood-supply** from the anterior and posterior ethmoidal arteries and from the spheno-palatine branch of the internal maxillary.

Articulations.—With the frontal, sphenoid, two palate bones, two nasals, vomer, two inferior nasal conchæ, two sphenoidal conchæ, two maxillæ, and two lacrimal bones. The posterior surface of each labyrinth is in relation with the sphenoid on each side of the crest and rostrum, and helps to close in the sphenoidal sinus.

Ossification.—The ethmoid has three centres of ossification. Of these, a nucleus appears in the fourth month of intra-uterine life in each labyrinth, first in the lamina papyracea and afterward extending into the middle concha. At birth each lateral portion is represented by two scroll-like bones, very delicate and covered with irregular depressions, which give it a worm-eaten appearance. Six months after birth a nucleus appears in the ethmo-vomerine cartilage for the vertical plate which gradually extends into the crista galli, and the cribriform plate is formed by ossification extending laterally from this centre, and medially from the labyrinth. The three parts coalesce to form one piece in the fifth or sixth year.

The ethmoidal cells make their appearance about the third year, and gradually invade the labyrinths. In many places there is so much absorption of bone that the cells perforate the ethmoid in situations where it is overlapped by other bones. Along the lower border, near its articulation with the maxilla, the absorption leads to the partial detachment of a narrow strip known as the uncinate process. Sometimes a second but smaller hook-like process is formed, above and anterior to this, so fragile that it is difficult to preserve it in disarticulated bones. The relations of the uncinate process are best studied by removing the lateral wall of the maxillary sinus.

THE INFERIOR NASAL CONCHA

The **inferior nasal concha** (inferior turbinate) (fig. 105) is a slender, scroll-like lamina, attached by its upper margin to the lateral wall of the nasal fossa, and hanging into the cavity in such a way as to separate the middle from the inferior

FIG. 105.—THE INFERIOR CONCHA, ADULT SPHENOIDAL TURBINATE, AND LACRIMAL BONES.

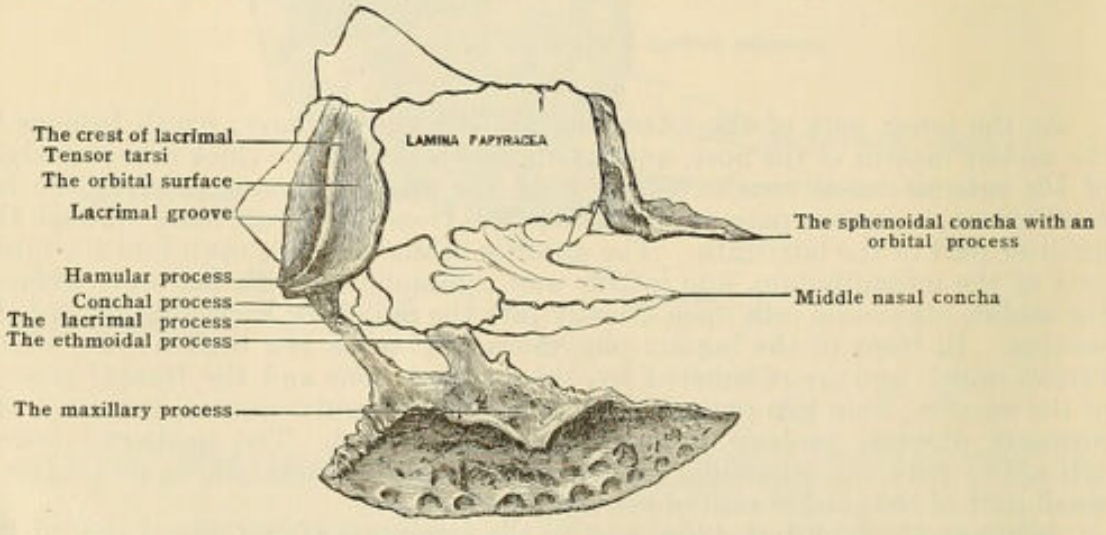

meatus of the nose. It may be regarded as a dismemberment of the ethmoidal labyrinth, with which it is closely related. It presents for examination two surfaces, two borders, and two extremities.

The **lateral surface** is concave, looks toward the lateral wall of the nasal fossa,

and is overhung by the **maxillary process.** The **medial surface** is convex, pitted with depressions, and grooved for vessels, which, for the most part, run longitudinally. The **superior** or **attached border** articulates in front with the conchal crest of the maxilla, then ascends to form the **lacrimal process,** which articulates with the lacrimal bone and forms part of the wall of the lacrimal canal. Behind this, it is turned downward to form the maxillary process, already mentioned, which overhangs the orifice of the maxillary sinus and serves to fix the bone firmly to the lateral wall of the nasal fossa. The projection behind the maxillary process is the **ethmoidal process,** joined in the articulated skull with the uncinate process of the ethmoid across the opening of the maxillary sinus. Posteriorly the upper border articulates with the conchal crest of the palate. The **inferior border** is free, rounded, and somewhat thickened. The **anterior extremity** is blunt and flattened, and broader than the **posterior extremity,** which is elongated, narrow, and pointed.

Articulations.—With the maxilla, lacrimal, palate, and ethmoid.

Ossification.—The inferior nasal concha is ossified in cartilage from a single nucleus which appears in the fifth month of intra-uterine life. At birth it is a relatively large bone and fills up the lower part of the nasal fossa.

THE LACRIMAL

The **lacrimal bone** [os lacrimale] (fig. 105) is extremely thin and delicate, quadrilateral in shape, and situated at the anterior part of the medial wall of the orbit. It is the smallest of the facial bones.

The **orbital surface** is divided by a vertical ridge, the **posterior lacrimal crest,** into two unequal portions. The anterior, smaller portion is deeply grooved to form the **lacrimal groove,** which lodges the lacrimal sac and forms the commencement of the canal for the naso-lacrimal duct. The portion behind the ridge is smooth, and forms part of the medial wall of the orbit. The ridge gives origin to the *orbicularis oculi* (*pars lacrimalis*) muscle and ends below in a hook-like process, the lacrimal hamulus, which curves forward to articulate with the lacrimal tubercle of the maxilla and completes the superior orifice of the naso-lacrimal canal. The **medial surface** is in relation with the two anterior cells of the ethmoid (lacrimo-ethmoidal), forms part of the infundibulum, and inferiorly looks into the middle meatus of the nose. The **superior border** is short, and articulates with the medial angular process of the frontal. The **inferior border** posterior to the crest joins the medial edge of the orbital plate of the maxilla. The narrow piece, anterior to the ridge, is prolonged downward as the **descending process** to join the lacrimal process of the inferior nasal concha. The **anterior border** articulates with the posterior border of the frontal process of the maxilla and the **posterior border** with the lamina papyracea of the ethmoid.

The vessels of the lacrimal bone are derived from the infra-orbital, dorsal nasal branch of the ophthalmic, and anterior ethmoidal arteries.

Articulations.—The lacrimal articulates with the ethmoid, maxilla, frontal, and inferior nasal concha.

Ossification.—This bone arises in the membrane overlying the cartilage of the fronto-nasal plate, and in its mode of ossification is very variable. As a rule, it is formed from a single nucleus which appears in the third or fourth month of intra-uterine life. Not infrequently, the hamulus is a separate element, and occasionally the bone is divided by a horizontal cleft, a process of the lamina papyracea projecting between the two halves to join the frontal process of the maxilla. More rarely the bone is represented by a group of detached ossicles resembling Wormian bones.

The hamular process is regarded as representing the remains of the facial part of the lacrimal seen in lower animals.

THE VOMER

The **vomer** (fig. 106) (ploughshare bone) is an unpaired flat bone, which lies in the median plane and forms the lower part of the nasal septum. It is thin and irregularly quadrilateral in form, and is usually bent somewhat to one side, though the deflection rarely involves the posterior margin. Each **lateral surface** is covered in the recent state by the mucous membrane of the nasal cavity, and is traversed by a narrow but well-marked groove, which lodges the naso-palatine nerve from the spheno-palatine ganglion.

The **superior border,** by far the thickest part of the bone, is expanded laterally into two **alæ.** The groove between them receives the rostrum of the sphenoid, and the margin of each ala comes into contact with the sphenoidal process of the palate and the vaginal process of the medial pterygoid plate. The **inferior border** is uneven and lies in the groove formed by the crests of the maxillary and palate bones of the two sides. The **anterior border** slopes downward and forward and is grooved below for the septal cartilage of the nose; above it is united with the perpendicular plate of the ethmoid. The **posterior border,** smooth, rounded, and covered by mucus membrane, separates the posterior nares. The anterior and inferior borders meet at the anterior extremity of the bone which forms a short vertical ridge behind the incisor crest of the maxillæ. From near the anterior extremity, a small projection passes downward between the incisive foramina.

FIG. 106.—THE VOMER. (Side view.)

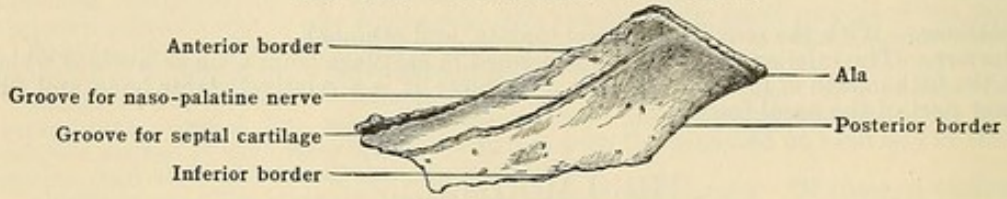

Blood-supply.—The arterial supply of the vomer is derived from the anterior and posterior ethmoidal and the spheno-palatine arteries. Branches are also derived from the posterior palatine through the foramen incisivum.

Ossification.—The vomer is ossified from two centres which appear about the eighth week in the membrane investing the ethmo-vomerine cartilage. The two lamellæ unite below during the third month and form a shallow bony trough in which the cartilage lies. In the process of growth the lamellæ extend upward and forward and gradually fuse to form a rectangular plate of bone, the cartilage enclosed between them undergoing absorption at the same time. The alæ on the superior margin and the groove in front are evidence of the original bilaminar condition.

THE NASAL

The **nasal** (figs. 107 and 108) are two small oblong bones situated at the upper part of the face and forming the bridge of the nose. Each bone is thicker and narrower above, thinner and broader below, and presents for examination two surfaces and four borders.

FIG. 107.—THE LEFT NASAL BONE, FACIAL SURFACE.

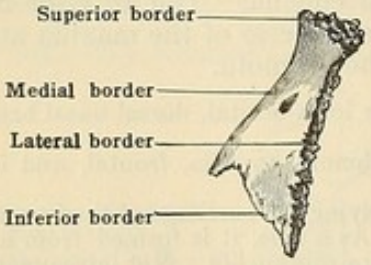

FIG. 108.—THE LEFT NASAL BONE, NASAL SURFACE.

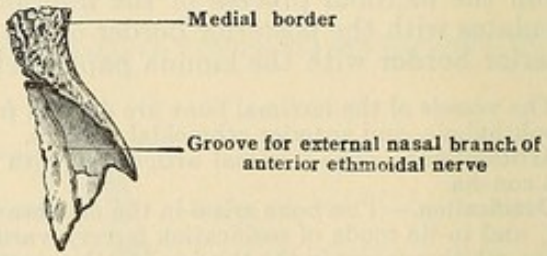

The **facial surface** is concave from above downward, convex from side to side, and near the centre is perforated by a small foramen, which transmits a small tributary to the facial vein. The posterior or **nasal surface,** covered in the recent state by mucous membrane, is concave laterally, and traversed by a longitudinal groove [sulcus ethmoidalis] for the anterior ethmoidal branch of the ophthalmic division of the fifth nerve. The short **superior border** is thick and serrated for articulation with the medial part of the nasal notch of the frontal. The **inferior border** is thin, and serves for the attachment of the lateral nasal cartilage. It is notched for the external nasal branch of the anterior ethmoidal nerve. The nasal bones of the two sides are united by their **medial borders,** forming the internasal suture. The contiguous borders are prolonged backward to form a crest which rests on the frontal spine and the anterior border of the perpendicular plate of the ethmoid. The **lateral border** articulates with the frontal process of the maxilla.

Blood-supply.—Arteries are supplied to this bone by the nasal branch of the ophthalmic, the frontal, the angular, and the anterior ethmoidal arteries.

Articulations.—With the frontal, maxilla, ethmoid, and its fellow of the opposite side.

Ossification.—Each nasal bone is developed from a single centre which appears about the eighth week in the membrane overlying the fronto-nasal cartilage. The cartilage, which is continuous with the ethmoid cartilage above and the lateral cartilage of the nose below, subsequently undergoes absorption as a result of the pressure caused by the expanding bone. At birth the nasal bones are nearly as wide as they are long, whereas in the adult the length is three times greater than the width.

THE MAXILLA

The **maxilla** or upper jaw-bone (figs. 109, 110, 111) is one of the largest and most important of the bones of the face. It supports the maxillary teeth and takes part in the formation of the orbit, the hard palate, and the nasal fossa. It is divisible into a **body** and four processes, of which two—the **frontal** and **zygomatic**—belong to the upper part, and the **palatine** and **alveolar** to the lower part of the bone.

The **body** is somewhat pyramidal in shape and hollowed by a large cavity known as the **sinus maxillaris** (antrum of Highmore), lined by mucous membrane in the recent state, and opening at the base of the pyramid into the nasal cavity, the zygomatic process forming the apex. The **anterior** (or facial) **surface** looks forward and outward and is marked at its lower part by a series of eminences which indicate the positions of the fangs of the teeth. The eminence produced by the fang of the canine tooth is very prominent and separates two fossæ. That on the medial side is the **incisive fossa,** and gives origin to the *alar* and *transverse portions* of the *nasalis,* and just above the socket of the lateral incisor tooth, to a slip of the *orbicularis oris;* on the lateral side is the **canine fossa,** from which the *caninus* (*levator anguli oris*) arises. Above the canine fossa, and close to the margin of the orbit, is the **infra-orbital foramen,** through which the terminal branches of the infra-orbital nerve and vessels emerge, and from the ridge immediately above the foramen the *quadratus labii superioris* takes origin. The medial margin of the anterior surface is deeply concave, forming the **nasal notch,** and is prolonged below into the **anterior nasal spine.**

A ridge of bone extending upward from the socket of the first molar tooth separates the anterior from the **infratemporal** (zygomatic) **surface.** This latter surface is convex and presents near the middle the orifices of the **posterior alveolar canals,** transmitting the posterior alveolar vessels and nerves. The posterior inferior angle, known as the **tuberosity** [tuber maxillare], is rough and is most prominent after eruption of the wisdom tooth. It gives attachment to a few fibres of the *internal pterygoid* muscle and articulates with the tuberosity of the palate.

The **orbital surface** [planum orbitale] is smooth, irregularly triangular, and forms the greater part of the floor of the orbit.

Anteriorly, it is rounded and reaches the orbital circumference for a short distance at the root of the nasal process; laterally is the rough surface for the zygomatic bone. The posterior border, smooth and rounded, forms the inferior boundary of the inferior orbital fissure. The medial border is nearly straight and presents behind the frontal process, a smooth rounded angle forming part of the circumference of the orbital orifice of the naso-lacrimal canal, and a notch which receives the lacrimal bone. The rest of the medial border is rough for articulation with the lamina papyracea of the ethmoid and orbital process of the palate bone.

The orbital surface is traversed by the **infra-orbital groove,** which, commencing at the posterior border, deepens as it passes forward and finally becomes closed in to form the **infra-orbital canal.** It transmits the second division of the fifth nerve and the infra-orbital vessels and terminates on the anterior surface immediately below the margin of the orbit. From the infra-orbital, other canals —the **anterior** and **middle alveolar**—run downward in the wall of the antrum and transmit the anterior and middle alveolar vessels and nerves. Lateral to the commencement of the lacrimal canal is a shallow depression for the origin of the *inferior oblique.*

The **nasal surface** takes part in the formation of the lateral wall of the nasal fossa. It presents a large irregular aperture which leads into the antrum and, immediately in front of this, the **lacrimal groove,** directed downward, backward, and laterally into the inferior meatus of the nose. The groove is converted

into a canal by the lacrimal and inferior nasal concha and transmits the naso-lacrimal duct.

In front of the groove is a smooth surface crossed obliquely by a ridge, the **conchal crest**, for articulation with the inferior nasal concha. The surface below the crest is smooth, concave, and belongs to the inferior meatus; the surface above the crest extends on to the lower part of the frontal process and forms the wall of the atrium of the middle meatus. Behind the opening of the antrum the surface is rough for articulation with the vertical plate of the palate bone, and crossing it obliquely is a smooth groove converted by the palate into the **pterygo-palatine canal** for the passage of the (descending) palatine nerves and the descending palatine artery.

FIG. 109.—THE LEFT MAXILLA. (Outer view.)

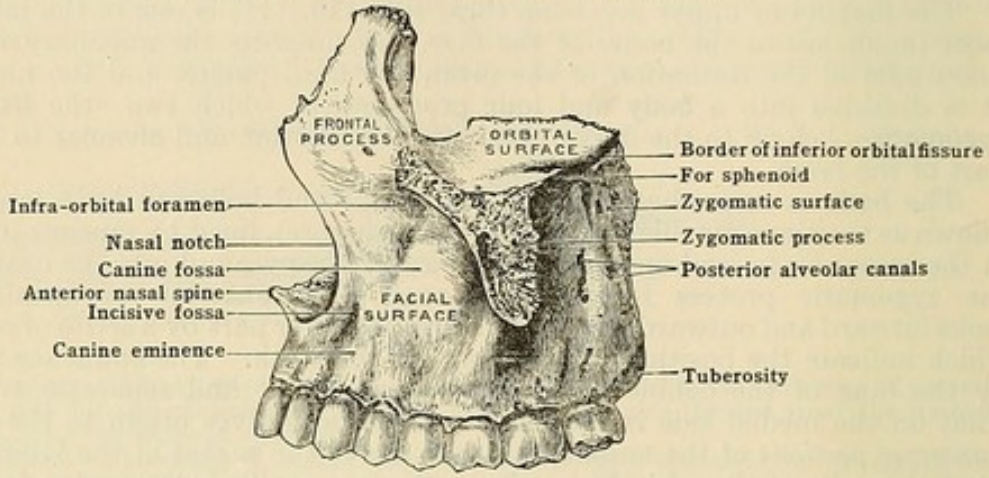

The **frontal process,** somewhat triangular in shape, rises vertically from the **angle** of the maxilla. Its lateral surface is continuous with the anterior surface of the body, and gives attachment to the *orbicularis oculi*, the medial palpebral ligament and the *quadratus labii superioris* (*caput angulare*). The medial surface forms part of the lateral boundary of the nasal fossa and is crossed obliquely by a low ridge, known as the **agger nasi,** limiting the atrium of the middle meatus.

The hinder part of this surface rests on the anterior extremity of the labyrinth of the ethmoid and completes the maxillo-ethmoidal cells. The superior border articulates with the frontal; the anterior border articulates with the nasal bone; the posterior border is thick and vertically grooved, in continuation with the lacrimal groove, and lodges the lacrimal sac. The medial margin of the groove articulates with the lacrimal bone, and the junction of its lateral margin with the orbital surface is indicated by the **lacrimal tubercle.**

FIG. 110.—THE LEFT MAXILLA. (Inner view.)

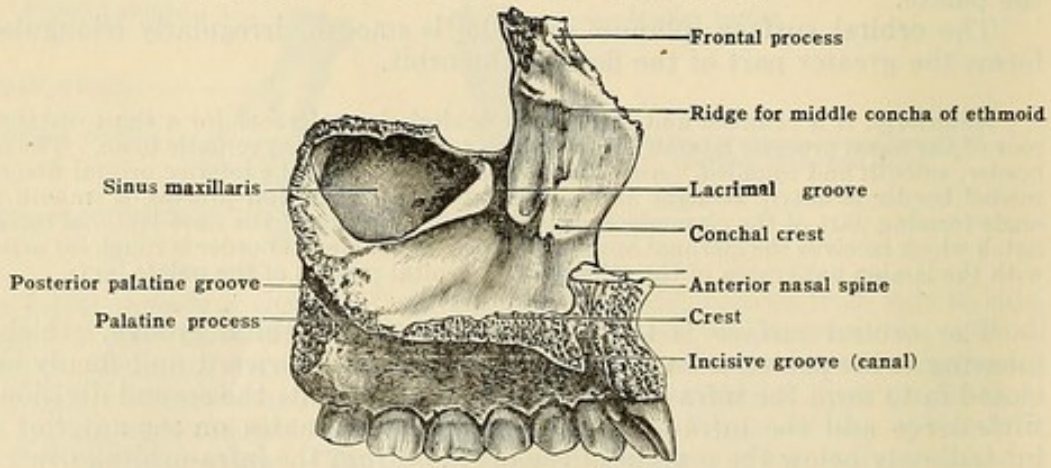

The **zygomatic process,** rough and triangular, forms the summit of the prominent ridge of bone separating the anterior and infratemporal surfaces. It articulates above with the zygomatic, and from its inferior angle a few fibres of the *masseter* take origin. The anterior and posterior surfaces are continuous with the anterior and infratemporal surfaces of the body.

The **palatine process** projects horizontally from the medial surface and, with the corresponding process of the opposite side, forms about three-fourths of the hard palate. The superior surface is smooth, concave from side to side, and

constitutes the larger part of the floor of the nasal fossa. The inferior surface is vaulted, rough, and perforated with foramina for nutrient vessels. Near its lateral margin is a longitudinal groove for the transmission of the vessels and nerves which issue at the posterior palatine canal and course along the lower aspect of the palate. When the bones of the two sides are placed in apposition, a large orifice may be seen in the middle line immediately behind the incisor teeth. This is the **incisive foramen,** at the bottom of which are four foramina. Two are small and arranged one behind the other exactly in the **meso-palatine suture.** These are the **foramina of Scarpa** and transmit the naso-palatine nerves, the left

FIG. 111.—SECTION OF MAXILLÆ TO SHOW THE FLOOR OF THE MAXILLARY ANTRUM. (Reduced ¼.)

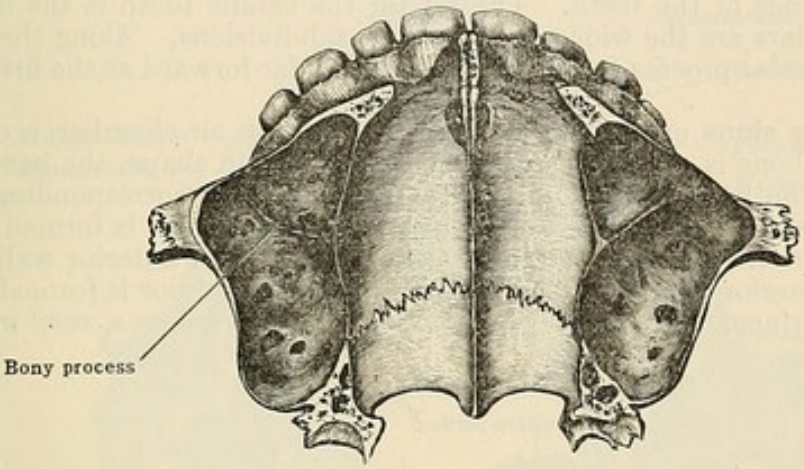

passing through the anterior and the right through the posterior aperture. The lateral and larger orifices are the **foramina of Stenson,** representing the lower apertures of two passages by which the nose communicates with the mouth; they transmit some terminal branches of the descending palatine artery to the nasal fossæ, and lodge recesses of the nasal mucous membrane and remnants of Jacobson's organs.

FIG. 112.—MAXILLA AND ZYGOMATIC BONE, TO SHOW MUSCULAR ATTACHMENTS. (Poirier.)

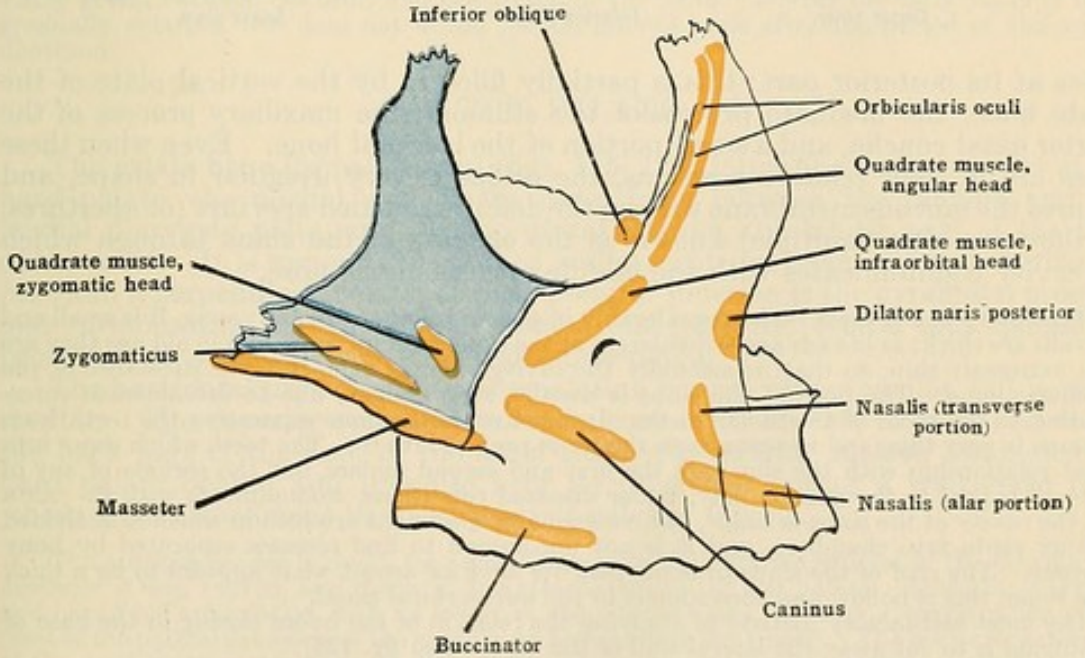

Running laterally from the incisive foramen to the space between the second incisor and canine tooth, an indistinct suture may sometimes be seen, indicating the line of junction of the maxillary and pre-maxillary portions of the bone. The **premaxilla** or incisive bone is the part which bears the incisor teeth and in some animals exists throughout life as an independent element. The posterior border of the palate process is rough and serrated for articulation with

the horizontal plate of the palate bone which completes the hard palate. The medial border joins with its fellow to form the **nasal crest** upon which the vomer is received. The more elevated anterior portion of this border is known as the **incisor crest,** and is continued forward into the **anterior nasal spine.** The septal cartilage of the nose rests on its summit and the anterior extremity of the vomer lies immediately behind it. At the side of the incisor crest is seen the upper aperture of the canal leading from the nose to the mouth (Stenson's canal), which in its course downward becomes a groove by a deficiency of its medial wall. Thus when the two bones are articulated a canal is formed (incisive) with the lower ends of two canals opening into it.

The **alevolar process** is crescentic in shape, spongy in texture, and presents cavities [alveoli dentales] in which the upper teeth are lodged. When complete there are eight tooth-cavities (alveoli), with wide mouths, gradually narrowing as they pass into the substance of the bone, and forming exact impressions of the corresponding fangs of the teeth. The pit for the canine tooth is the deepest; those for the molars are the widest, and present subdivisions. Along the lateral aspect of the alveolar process the *buccinator* arises as far forward as the first molar tooth.

The **maxillary sinus** or antrum of Highmore, as the air-chamber occupying the body of the bone is called, is somewhat pyramidal in shape, the **base** being represented by the nasal or mediai surface, and the **apex** corresponding to the zygomatic process. In addition it has four walls: the superior is formed by the orbital plate, and the inferior by the alveolar ridge. The anterior wall corresponds to the anterior surface of the maxilla, and the posterior is formed by the infratemporal surface. The medial boundary or base presents a very irregular

FIG. 113.—THE MAXILLA AT BIRTH.

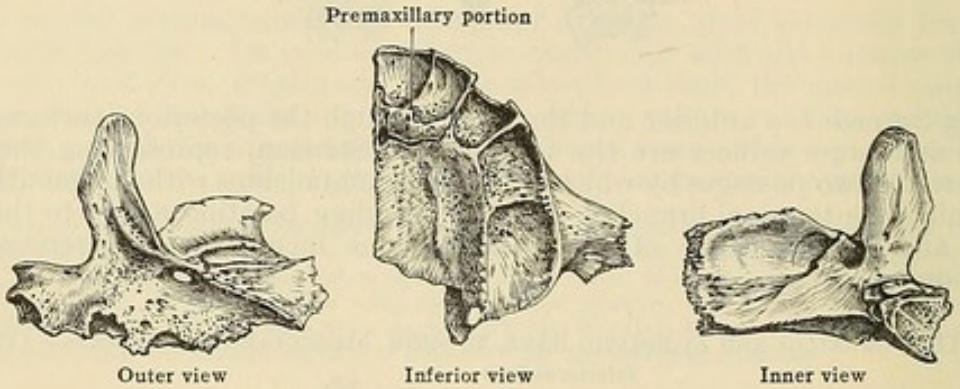

orifice at its posterior part; this is partially filled in by the vertical plate of the palate bone, the uncinate process of the ethmoid, the maxillary process of the inferior nasal concha, and a small portion of the lacrimal bone. Even when these bones are in their relative positions, the orifice is very irregular in shape, and requires the mucous membrane to form the definite rounded aperture (or apertures, for they are often multiple) known as the **opening of the sinus** through which the cavity communicates with the middle meatus of the nose.

The cavity of the sinus varies considerably in size and shape. In the young, it is small and the walls are thick: as life advances it enlarges at the expense of its walls, and in old age they are often extremely thin, so that occasionally the cavity extends even into the substance of the zygomatic bone. The floor of the sinus is usually very uneven, due to prominences corresponding to the roots of the molar teeth. In most cases the bone separating the teeth from the sinus is very thin, and in some cases the roots project into it. The teeth which come into closest relationship with the sinus are the first and second molars, but the sockets of any of the teeth lodged in the maxilla may, under diseased conditions, communicate with it. As a rule, the cavity of the sinus is single, but occasionally specimens are seen in which it is divided by bony septa into chambers, and it is not uncommon to find recesses separated by bony processes. The roof of the sinus presents near its anterior aspect what appears to be a thick rib of bone; this is hollow and corresponds to the infra-orbital canal.

The most satisfactory method of studying the relation of the bones closing in the base of the antrum is to cut away the lateral wall of the cavity (see fig. 128).

Blood-supply.—The maxilla is a very vascular bone and its arteries are numerous and large. They are derived from the infra-orbital, alveolar, descending palatine, spheno-palatine, ethmoidal, frontal, nasal, and facial vessels.

Articulations.—With the frontal, nasal, lacrimal, ethmoid, palate, vomer, zygomatic, inferior nasal concha and its fellow of the opposite side. Occasionally it articulates with the great wing, and the pterygoid process, of the sphenoid.

Ossification.—The maxilla is developed from several centres which are deposited in membrane during the second month of intrauterine life. Several pieces are formed which speedily fuse, so that at birth, with the exception of the incisor fissure separating the maxilla from the premaxilla, there is no trace of the composite character of the bone. The centres of ossification comprise—(1) the **malar,** which gives rise to the portion of bone outside the infra-orbital canal; (2) the **maxillary,** from which the greater part of the body and the frontal process are developed; (3) the **palatine,** forming the hinder three-fourths of the palatal process and adjoining part of the nasal wall; (4) the **premaxillary,** giving rise to the independent premaxillary bone (os incisivum), which lodges the incisor teeth and completes the anterior fourth of the hard palate. In the early stages of growth the premaxilla may consist of two pieces arising from two centres of ossification which Albrecht has named as follows:—the *endognathion*, or medial division for

FIG. 114.—MAXILLÆ AT THE END OF THE FIRST DENTITION IN BOTH OF WHICH THE SUTURES BETWEEN MAXILLA AND PREMAXILLA, AND BETWEEN THE TWO PARTS OF THE PREMAXILLA, ARE SEEN.

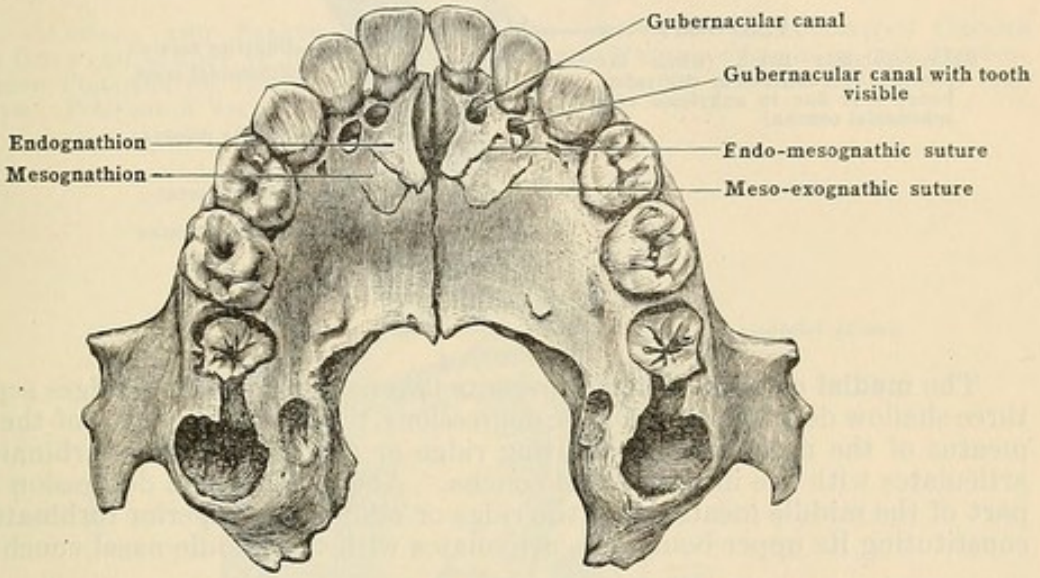

the central incisor, and the *mesognathion*, or lateral division for the lateral incisor; the rest of the maxilla is named the *exognathion;* (5) the **prepalatine,** corresponding to the **infra-vomerine** centre of Rambaud and Renault, forms a portion of bone interposed between the premaxillary in front and the palatine process behind. It gives rise to a part of the nasal surface and completes the medial wall of the incisive canal.

At birth the sinus is narrow from side to side and does not extend laterally to any appreciable extent between the orbit and the alveoli of the teeth. During the early years of life it gradually enlarges, but does not attain its full growth until after the period of the second dentition.

THE PALATE

The **palate bone** [os palatinum] (figs. 115, 116) forms the posterior part of the hard palate, the medial wall of the nasal fossa between the maxilla and the medial pterygoid plate, and, by its orbital process, the hinder part of the floor of the orbit. It is somewhat L-shaped and presents for examination a **horizontal** part and a **perpendicular** part; at their point of junction is the **pyramidal process,** and surmounting the top of the vertical plate are the **orbital** and **sphenoidal** processes, separated by the **spheno-palatine notch.**

The **horizontal** part resembles the palatine process ofthe maxilla, but is much shorter. The **superior surface** is smooth, concave from side to side, and forms the back part of the floor of the nasal fossa; the **inferior surface** completes the hard palate behind and presents near its prosterior border a transverse ridge which gives attachment to the *tensor veli palatini* muscle.

The anterior border is rough for articulation with the palatine process of the maxilla; the posterior is free, curved, and sharp, giving attachment to the soft palate. Medially it is thick and broad for articulation with its fellow of the opposite side, forming a continuation of the crest of the palatal processes of the maxillæ and supporting the vomer. The posterior extremity of the crest is the **posterior nasal spine,** from which the *azygos uvulæ* arises. Laterally, at its junction with the perpendicular part, it is grooved by the lower end of the pterygo-palatine canal.

The **perpendicular** part is longer and thinner than the horizontal plate. The **lateral surface** is in relation with the maxilla and is divided into two parts by

a vertical groove which forms with the maxilla the **pterygo-palatine canal** for the transmission of the anterior palatine nerve and the descending palatine artery. The part of the surface in front of the groove articulates with the nasal surface of the maxilla and overlaps the orifice of the antrum by the **maxillary process,** a variable projection on the anterior border. Behind the groove the surface is rough for articulation with the maxilla below and the medial pterygoid plate above.

FIG. 115.—PALATE BONE (LEFT). (Medial view.)

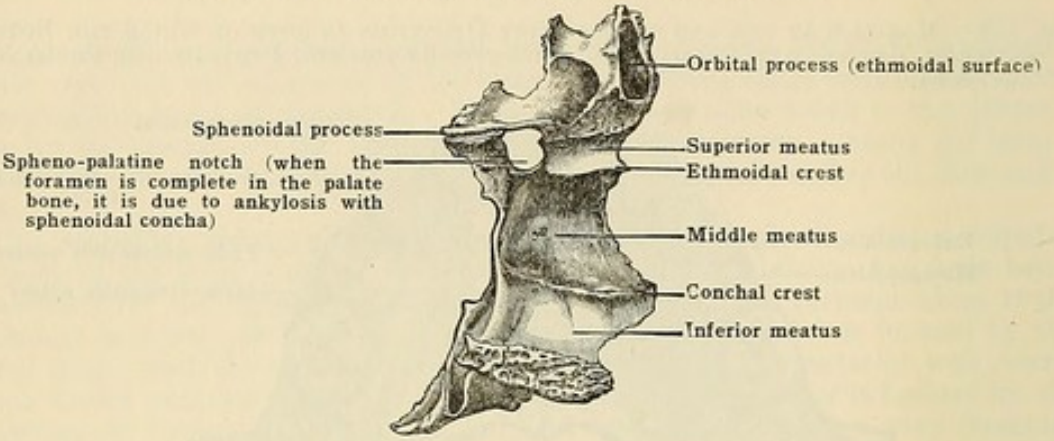

The **medial** or **nasal surface** presents two nearly horizontal ridges separating three shallow depressions. Of the depressions, the lower forms part of the inferior meatus of the nose, and the limiting ridge or **conchal** (**inferior turbinate**) **crest** articulates with the inferior nasal concha. Above this is the depression forming part of the middle meatus, and the ridge or **ethmoidal** (**superior turbinate**) **crest,** constituting its upper boundary, articulates with the middle nasal concha.

FIG. 116.—PALATE BONE. (Posterior view.)

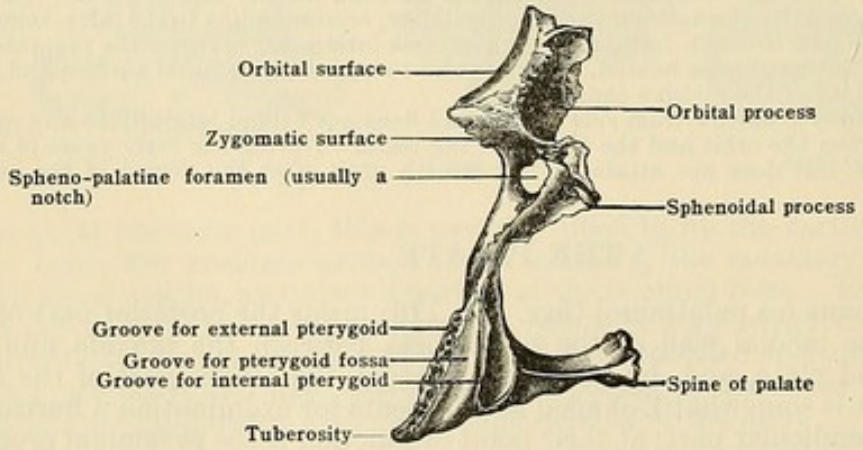

The upper groove is narrower and deeper than the other two and forms a large part of the superior meatus of the nose. The anterior border of the vertical plate is thin and bears the **maxillary process,** a tongue-like piece of bone, which extends over the opening of the maxillary sinus from behind. This border is continuous above with the orbital process. The posterior border is rough and articulates with the anterior border of the medial pterygoid plate. It is continuous superiorly with the sphenoidal process.

The **pyramidal process** or **tuberosity** fits into the notch between the lower extremities of the pterygoid plates and presents posteriorly three grooves. The middle, smooth and concave, completes the pterygoid fossa, and gives origin to a few fibres of the *internal pterygoid;* the medial and lateral grooves are rough for articulation with the anterior border of the corresponding pterygoid plate. Inferiorly, close to its junction with the horizontal plate, are the openings of the **greater palatine** and **smaller palatine canals,** of which the latter are the smaller and less constant; they transmit the palatine nerves. Medially the pyramidal process gives origin to a few fibres of the *superior constrictor* of the pharynx, and laterally a small part appears in the zygomatic fossa between the tuberosity of the maxilla and the pterygoid process of the sphenoid.

The **sphenoidal process,** the smaller of the two processes surmounting the vertical part, curves upward and medially and presents three surfaces and two borders. The **superior surface** is in contact with the body of the sphenoid, and the top of the medial pterygoid plate, where it completes the **pharyngeal** canal. The **medial** or **inferior surface** forms part of the lateral

wall and roof of the nasal fossa, and at its medial end touches the ala of the vomer. The **lateral surface** looks forward and laterally into the pterygo-palatine (spheno-maxillary) fossa. Of the two borders,the posterior is thin and articulates with the medial pterygoid plate; the anterior border forms the posterior boundary of the **spheno-palatine** foramen.

The **orbital process** is somewhat pyramidal in shape, and presents for examination five surfaces, three of which—the posterior, anterior, and medial—are articular and the rest non-articular. The **posterior** or **sphenoidal surface** is small and joins the anterior surface of the body of the sphenoid; the **medial** or **ethmoidal** articulates with the labyrinth of the ethmoid; and the **anterior** or **maxillary,** which is continuous with the lateral surface of the perpendicular part, is joined with the maxilla. Of the two non-articular surfaces, the **superior** or **orbital,** directed upward and laterally, is slightly concave, and forms the posterior angle of the floor of the orbit; the **lateral** or **zygomatic,** smooth and directed lateral, looks into the pterygo-palatine (spheno-maxillary) and zygomatic fossæ, and forms the anterior boundary of the spheno-palatine foramen. The process is usually hollow and the cavity completes one of the posterior ethmoidal cells or communicates with the sphenoidal sinus.

FIG. 117.—MAXILLA AND PALATE BONES SHOWING HOW THE INFRA-ORBITAL GROOVE RUNS OUTWARD ALMOST AT RIGHT ANGLES FROM THE NEIGHBOURHOOD OF THE SPHENO-PALATINE FORAMEN ON THE BACK OF THE MAXILLA AND THE ORBITAL PROCESS OF THE PALATE. POSTERIOR VIEW. (E. Fawcett.)

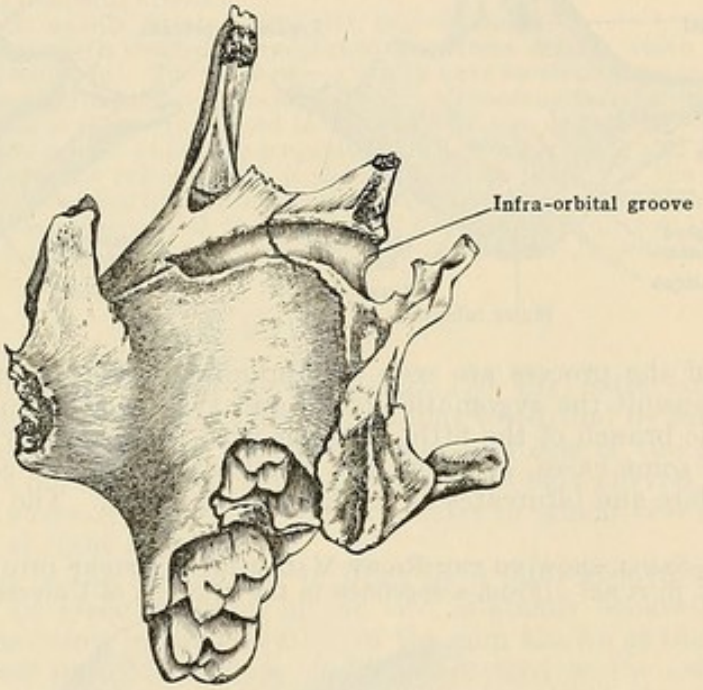

Between the orbital and sphenoidal processes is the **spheno-palatine notch,** converted by the body of the sphenoid, into a complete foramen. It leads from the pterygo-palatine fossa into the back part of the nasal cavity close to its roof, and transmits the medial branches from the spheno-palatine ganglion and the spheno-palatine vessels.

Blood-supply.—The palate bone receives branches from the descending palatine and the spheno-palatine arteries.

Articulations.—With the sphenoid, maxilla, vomer, inferior nasal concha, ethmoid, and its fellow of the opposite side.

Ossification.—The palate is ossified in membrane from a single centre which appears about the eighth week at the angle between the horizontal and perpendicular parts. At birth the two parts are nearly equal in length, but as the nasal fossæ increase in vertical depth, the perpendicular part is lengthened until it becomes about twice as long as the horizontal part.

THE ZYGOMATIC

The **zygomatic** [os zygomaticum] or **malar bone** (fig. 118) forms the prominence known as the cheek and joins the zygomatic process of the temporal with the maxilla. It is quadrangular in form with the angles directed vertically and horizontally. The **malar** (or external) **surface** is convex and presents one or two small orifices for the transmission of the zygomatico-facial nerves and vessels. It is largely covered by the *orbicularis oculi* and near the middle is slightly elevated to form the **malar tuberosity,** which gives origin to the *zygomaticus* and *zygomatic head* of quadrate muscle of upper lip.

The **temporal** (or internal) **surface** is concave and looks into the temporal and infratemporal fossæ; it is excluded from the orbit by a prominent curved plate

of bone, the **orbital process,** which forms the anterior boundary of the temporal fossa. The upper part gives origin to a few fibres of the *temporal* muscle, while at the lower part is a large rough area for articulation with the zygomatic process of the maxilla.

The **orbital process** is placed at right angles to the remaining part of the bone and forms the anterior portion of the lateral wall of the orbit. On the **orbital**

FIG. 118.—THE LEFT ZYGOMATIC BONE.
A, the malar surface. B, the temporal and orbital surfaces.

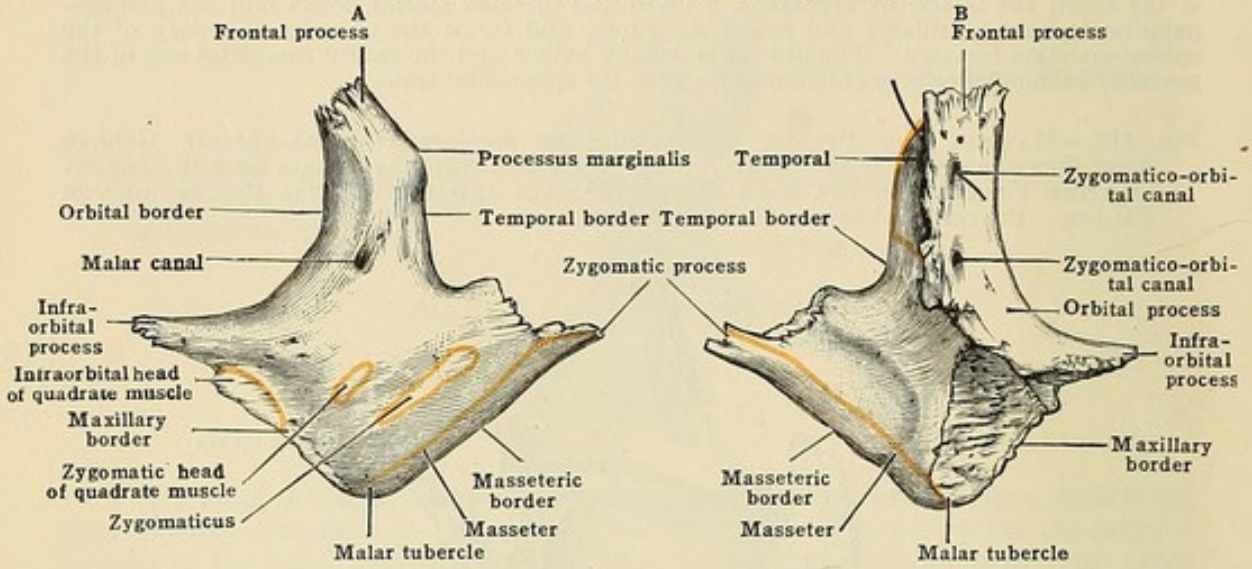

surface of the process are seen the foramina of two **zygomatico-orbital canals,** which transmit the zygomatico-facial and zygomatico-temporal branches of the zygomatic branch of the fifth, together with two small arteries from the lacrimal. In some cases, however, the canal is single at its commencement on the orbital plate and bifurcates as it traverses the bone. The rough free edge of the

FIG. 119.—SKULL SHOWING THE RIGHT MALAR BONE DIVIDED INTO TWO PARTS BY A HORIZONTAL SUTURE. (From a specimen in the Museum of University College, London.)

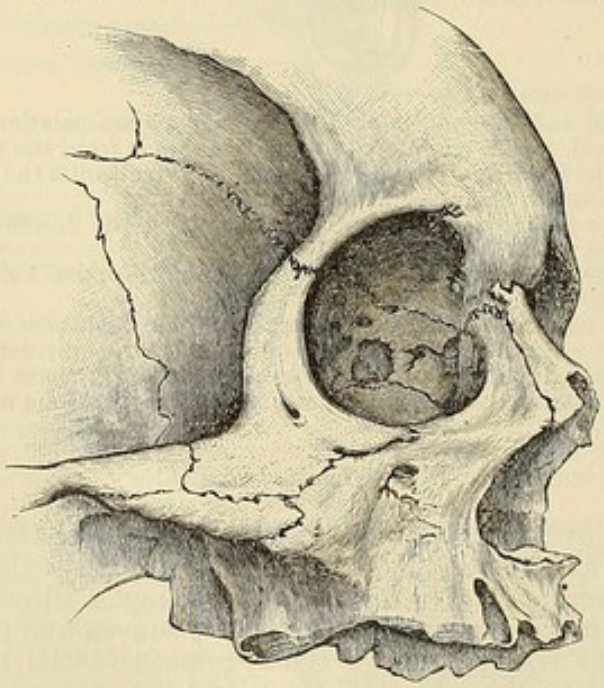

process articulates above with the zygomatic border of the great wing of the sphenoid, and below with the maxilla. When the orbital process is large, it excludes the great wing of the sphenoid from articulation with the maxilla, and the border then presents near the middle a short, non-serrated portion

which closes the anterior extremity of the inferior orbital (spheno-maxillary) fissure.

All the four angles of the zygomatic bone have distinguishing features. The superior, forming the **fronto-sphenoidal process,** is the most prominent, and is serrated for articulation with the zygomatic process of the frontal; the anterior or **infra-orbital process,** sharp and pointed, articulates with the maxilla and occasionally forms the superior boundary of the infra-orbital foramen; the posterior or **temporal process** is blunt and serrated mainly on its medial aspect for articulation with the zygomatic process of the temporal; the inferior angle, blunt and rounded, is known as the **malar tubercle.**

Of the four borders, the **orbital** is the longest and extends from the fronto-sphenoidal to the infra-orbital process. It is thick, rounded, and forms more than one-third of the circumference of the orbit; the **temporal border,** extending from the fronto-sphenoidal to the temporal process, is sinuously curved and gives attachment to the temporal fascia. Near the frontal angle is usually seen a slight elevation, the **processus marginalis,** to which a strong slip of the fascia is attached; the **masseteric** border, thick and rough, completes the lower edge of the zygomatic arch and gives origin to the anterior fibres of the *masseter;* the **maxillary** border, rough and concave, is connected by suture with the maxilla, and near the margin of the orbit gives origin to the infra-orbital head of the *quadratus labii superioris.*

Blood-supply.—The arteries of the zygomatic are derived from the infra-orbital, lacrimal, transverse facial, and deep temporal arteries.

Articulations.—With the maxilla, frontal, temporal, and sphenoid.

Ossification.—The zygomatic is ossified in membrane from three centres which appear in the eighth week of intra-uterine life. The three pieces, which have received the names of *premalar, postmalar,* and *hypomalar,* unite about the fifth month. Occasionally the primary nuclei fail to coalesce, and the bone is then represented in the adult by two or three portions separated by sutures. In those cases in which the premalar and postmalar unite and the hypomalar remains distinct, the suture is horizontal; if the independent portion is the premalar, then the suture is vertical. The bipartite zygomatic has been observed in skulls obtained from at least a dozen different races of mankind, but because of the greater frequency in which it occurs in the crania of the Japanese (seven per cent.), the name of *os Japonicum* has been given to it.

THE MANDIBLE

The **mandible** [mandibula] or lower jaw-bone (figs. 120, 121) is the largest and strongest bone of the face. It supports the mandibular teeth, and by means of a pair of condyles, moves on the skull at the mandibular fossæ of the temporal bones. It consists of a horizontal portion—the **body**—strongly curved, so as to somewhat resemble in shape a horseshoe, from the ends of which two branches or **rami** ascend almost at right angles.

The **body** is marked in the middle line in front by a faint groove which indicates the **symphysis** or place of union of the two originally separate halves of the bone. This ends below in the elevation of the chin known as the **mental protuberance,** the lowest part of which is slightly depressed in the centre and raised on each side to form the **mental tubercle.** Each half of the mandible presents two surfaces and two borders. On the **lateral surface,** at the side of the symphysis, and below the incisor teeth, is a shallow depression, the **incisor fossa,** from which the *mentalis* and *the incisivus labii inferioris* muscle arise; and more laterally, opposite the second bicuspid tooth, and midway between the upper and lower margins, is the **mental foramen,** which transmits the mental nerve and vessels. Below the foramen is the **oblique line,** extending backward and upward from the mental tubercle to the anterior border of the ramus; it divides the body into an upper or **alveolar** part and a lower or **basilar** part, and affords attachment to the *quadratus labii inferioris* and the *triangularis oris.*

The **medial surface** presents at the back of the symphysis four small projections, called the **mental spine** (genial tubercles). These are usually arranged in two pairs, one above the other; the upper comprising a pair of prominent spines, gives origin to the *genio-glossi,* and the lower, represented in some bones by a median ridge or only a slight roughness, gives origin to the *genio-hyoid* muscles. At the side of the symphysis near the inferior margin is an oval depression, the **digastric fossa,** for the insertion of the *digastric* muscle. Commencing below the mental spine, and extending upward and backward to the ramus, is the **mylo-hyoid line,** which becomes more prominent as it approaches the alveolar border; it gives attachment along its whole length to the *mylo-hyoid* muscle, at its posterior fifth to the *superior constrictor* of the pharynx, and at the posterior extremity to the pterygo-mandibular raphe. Above this line at the side of the symphysis is a smooth depression [fovea sublingualis] for the sublingual gland, and below it, farther back, is another for the submaxillary gland.

The **alveolar part** or superior border is hollowed out into eight sockets or alveoli. These are conical in shape and form an exact counterpart of the roots of the teeth which they contain. From the lateral aspect of the alveolar process, as far forward as the first molar tooth, the *buccinator* muscle takes origin.

The **base** or inferior border is thick and rounded. In the anterior part of its extent it gives attachment to the *platysma*, and near its junction with the ramus is a groove for the external maxillary artery which here turns upward into the face.

The **ramus** is thinner than the body and quadrilateral in shape. The lateral surface is flat, gives insertion to the *masseter*, and at the lower part is marked by several oblique ridges for the attachment of tendinous bundles in the substance of the muscle. The medial surface presents near the middle the **mandibular** (inferior dental) **foramen,** leading into the **mandibular** (inferior dental) **canal** which traverses the bone and terminates at the mental foramen on the lateral surface of the body. From the canal, which in its posterior two-thirds is nearer to the medial, and in its anterior third nearer to the lateral, surface of the mandible,

FIG. 120.—THE MANDIBLE. (Lateral view.)

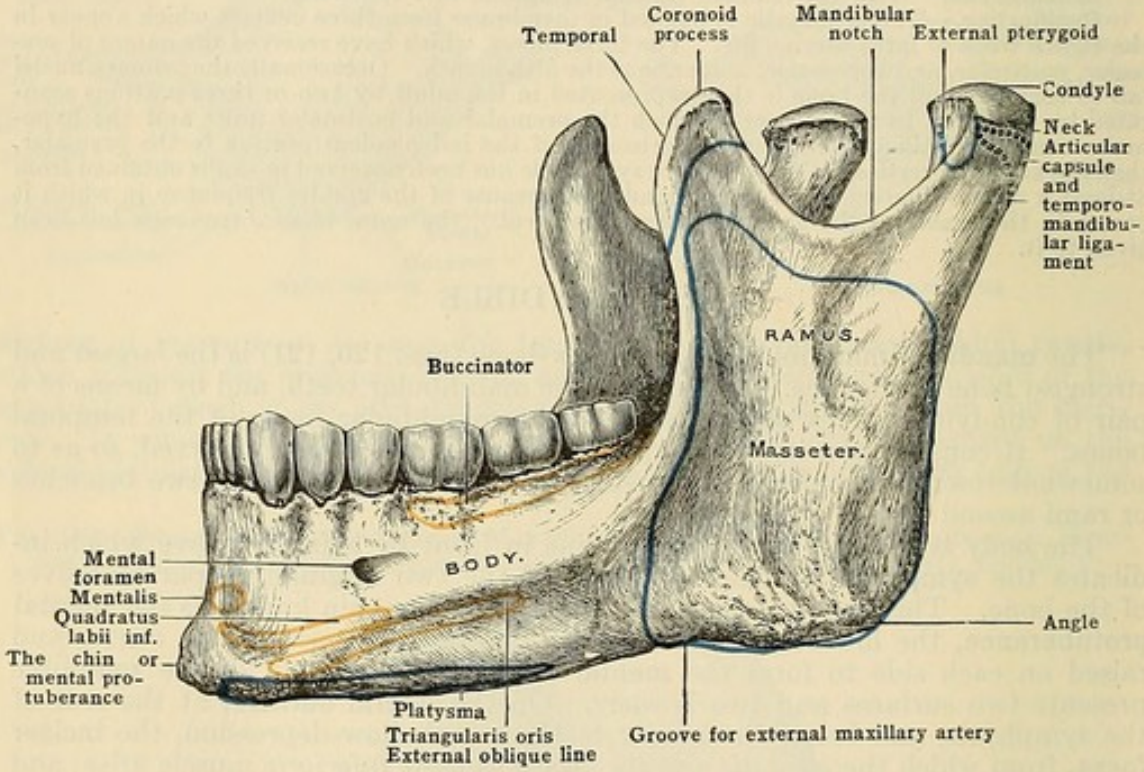

a series of small channels pass upward to the sockets of the posterior teeth and transmit branches of the inferior alveolar (dental) vessels and nerve; in front of the mental foramen a continuation of the canal extends forward and conveys the vessels and nerves to the canine and incisor teeth. The mandibular foramen is bounded medially by a sharp margin forming the **lingula** (mandibular spine), which gives attachment to the spheno-mandibular ligament.

The posterior margin of the lingula is notched. This notch forms the commencement of a groove, the **mylo-hyoid groove** [sulcus mylohyoideus], which runs obliquely downward and forward and lodges the mylo-hyoid nerve and artery, and, in the embryo, Meckel's cartilage. Behind the spine is a rough area for the insertion of the *internal pterygoid* muscle.

The posterior border of the ramus is thick and rounded, and in meeting the inferior border of the ramus forms the **angle** of the jaw, which is rough, obtuse, usually everted, and about 122° in the adult; the angle gives attachment to the stylo-mandibular ligament. The inferior border is thick, rounded, and continuous with the base. The anterior border is continuous with the oblique line, whilst the upper border presents two processes separated by a deep concavity, the **mandibular** (sigmoid) **notch.** Of the processes, the anterior is the **coronoid;** the posterior, the **condylar.**

The **condylar process** consists of the **condyle** [capitulum mandibulæ] and the narrowed portion by which it is supported, the **neck.** The **condyle** is oval in shape, with its long axis transverse to the upper border of the ramus, but oblique with regard to the median axis of the skull, so that the lateral extremity, which presents the **condylar tubercle** for the temporo-mandibular ligament of the temporo-mandibular articulation, is a little more forward than the medial extremity. The convex surface of the condyle is covered with cartilage in the recent

FIG. 121.—THE MANDIBLE. (Medial view.)

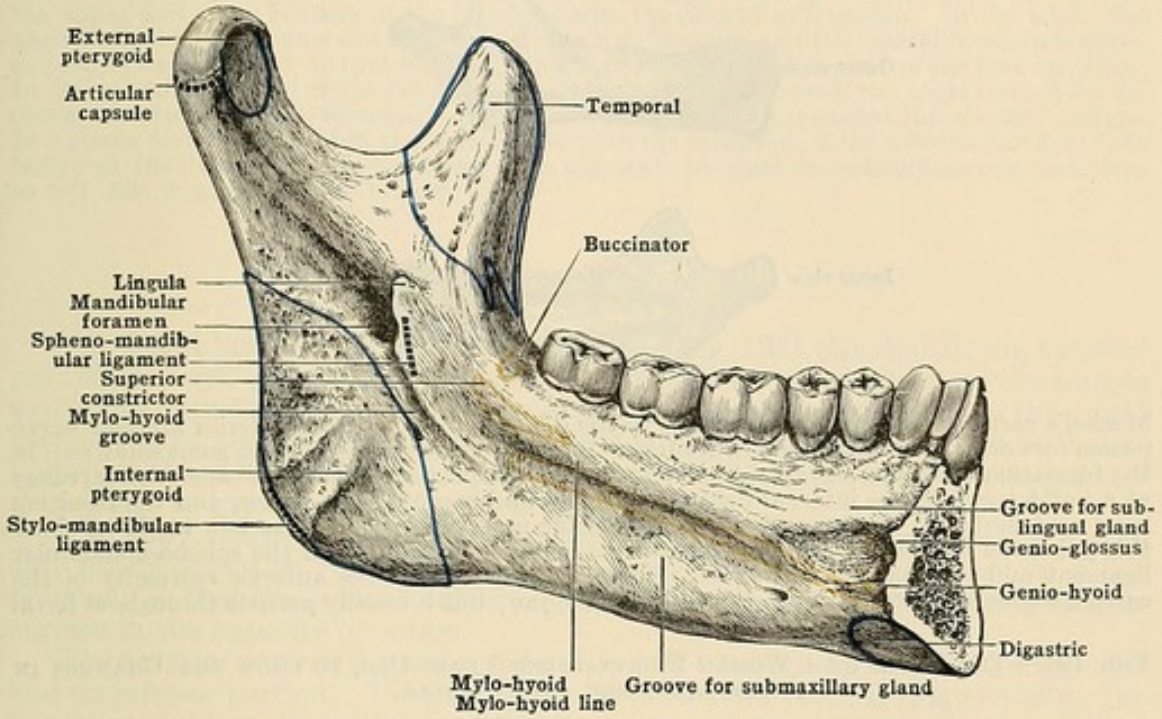

state, and rests in the mandibular fossa; the **neck** is flattened from before backward, and presents, in front, a depression [fovea pterygoidea] for the insertion of the *external pterygoid* muscle.

The **coronoid process,** flattened and triangular, is continued upward from the anterior part of the ramus. The lateral surface is smooth and gives insertion to the *temporal* and *masseter* muscles; the medial surface is marked by a ridge which descends from the tip and becomes continuous with the posterior part of the mylo-hyoid line. On the medial surface, as well as on the tip of the coronoid

FIG 122—MANDIBLE SHOWING RELATIONS OF MECKEL'S CARTILAGE IN HUMAN FŒTUS OF 8 CM. CROWN-RUMP LENGTH. (After Kollmann, Handatlas der Entwickelungsgeschichte.)

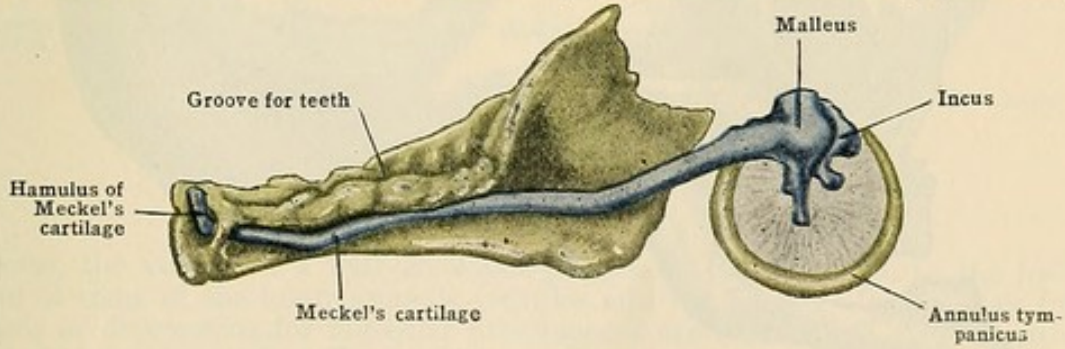

process, the *temporal* muscle is inserted. The **mandibular notch,** the deep semilunar excavation separating the coronoid from the condylar process, is crossed by the masseteric nerve and vessels.

Blood-supply.—Compared with other bones, the superficial parts of the mandible are not so freely supplied with blood. The chief artery is the inferior alveolar which runs in the mandibular canal, and hence, as the bone is exposed to injury and sometimes actually laid bare in its alveolar portion, it often necroses, especially if the artery is involved at the same time.

Ossification.—The mandible is mainly formed by ossification in the fibrous tissue investing the cartilage of the first branchial arch or Meckel's cartilage, although a small portion of the cartilage itself is directly converted into bone.

It is now generally admitted that the lower jaw is developed in membrane as a single skeletal element. The centre of ossification appears in the outer aspect of Meckel's cartilage and gives rise to the bony plate known as the *dentary*. This plate extends forward right up to the middle line in front, and from it a shelf grows upward for the support of the tooth germs.

FIG. 123.—THE MANDIBLE AT BIRTH.

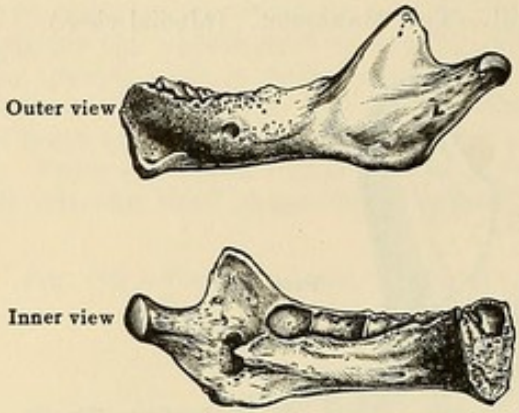

Meckel's cartilage lies below and medial to the dentary plate, and the inferior alveolar nerve passes forward between the two structures. Meckel's cartilage itself takes some small part in the formation of the lower jaw. Ossification from the primary nucleus invades the cartilage at a point opposite the interval between the first and second tooth germs, and the resulting bone contributes to the formation of the alveolar margin opposite these two teeth. Behind this point the cartilage atrophies except in so far as it helps to form the spheno-mandibular ligament and the malleus and incus. Behind the symphysis the anterior extremity of the cartilage does not enter into the formation of the jaw, but it usually persists throughout fœtal

FIG. 124.—THE SKULL OF A WOMAN EIGHTY-THREE YEARS OLD, TO SHOW THE CHANGES IN THE MANDIBLE AND MAXILLA.

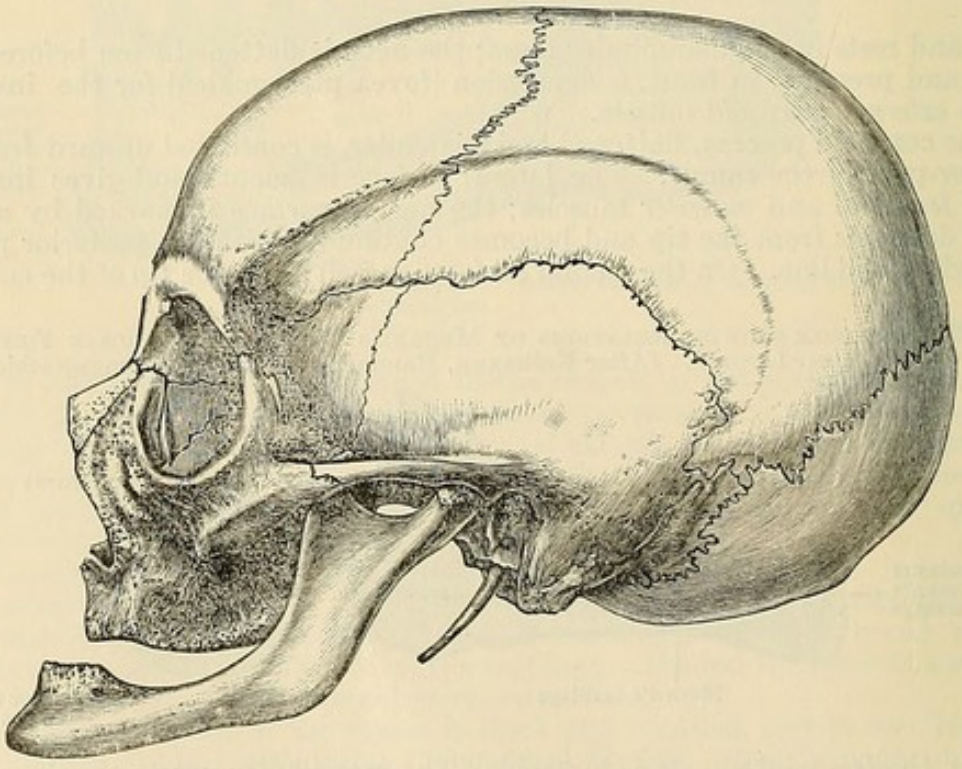

life as one or two small, rounded, cartilaginous masses. Occasionally they become ossified and give rise to accessory ossicles in this situation. The lamella of bone situated on the medial side of Meckel's cartilage, corresponding to the distinct splenial element in some animals, arises in man as an extension from the dentary element.

In connection with the condylar and coronoid processes, cartilaginous masses are developed. These do not, however, indicate separate elements, but are adaptations to the growth of the lower jaw. They are ossified by an extension from the surrounding membrane bone.

The process of ossification of the lower jaw commences very early, between the sixth and eighth week, and proceeds rapidly, so that by the fourth month the various parts are formed.

Age-changes.—At birth the mandible is represented by two nearly horizontal troughs of bone, lodging unerupted teeth, and joined at the symphysis by fibrous tissue. The body is mainly alveolar, the basal part being but little developed; the condyle and the upper edge of the symphysis are nearly on a level; the mental foramen is nearer the lower than the upper margin, and the angle is about 175°. The inferior alveolar nerve lies in a shallow groove between the splenial and dentary plates.

During the first year osseous union of the two halves takes place from below upward, but is not complete until the second year. After the first dentition, the ramus forms with the body of the mandible an angle of about 140°, and the mental foramen is situated midway between the upper and lower borders of the bone opposite the second milk-molar. In the adult, the angle formed by the ramus and body is nearer to a right angle, and the mental foramen is opposite the second bicuspid, so that its relative position remains unaltered after the first dentition. In old age, after the fall of the teeth, the alveolar margin is absorbed, the angle formed by the ramus and body is again increased, and the mental foramen approaches the alveolar margin. In a young and vigorous adult the mandible is, with the exception of the petrous portion of the temporal, the densest bone in the skeleton; in old age it becomes exceedingly porous, and often so soft that it may easily be broken.

THE HYOID BONE

The **hyoid bone** [os hyoideum] or os linguæ (fig. 125), situated in the anterior part of the neck between the chin and the thyreoid cartilage, supports the tongue and gives attachment to numerous muscles. It is suspended from the lower extremities of the styloid processes of the temporal bones by two slender bands known as the **stylo-hyoid ligaments,** and is divisible into a **body** and two pairs of processes, the **greater** and **lesser cornua.**

The **body,** constituting the central portion of the bone, is transversely placed and quadrilateral in form. It is compressed from before backward and lies obliquely so that the anterior surface looks upward and forward and the posterior surface in the opposite direction.

The **anterior surface** is convex and divided by a horizontal ridge into a superior and an inferior portion. Frequently it also presents a vertical ridge crossing the former at right angles, and just above the point of intersection is the **glosso-hyal**

FIG. 125.—THE HYOID BONE. A, MALE, B, FEMALE (Natural Size)

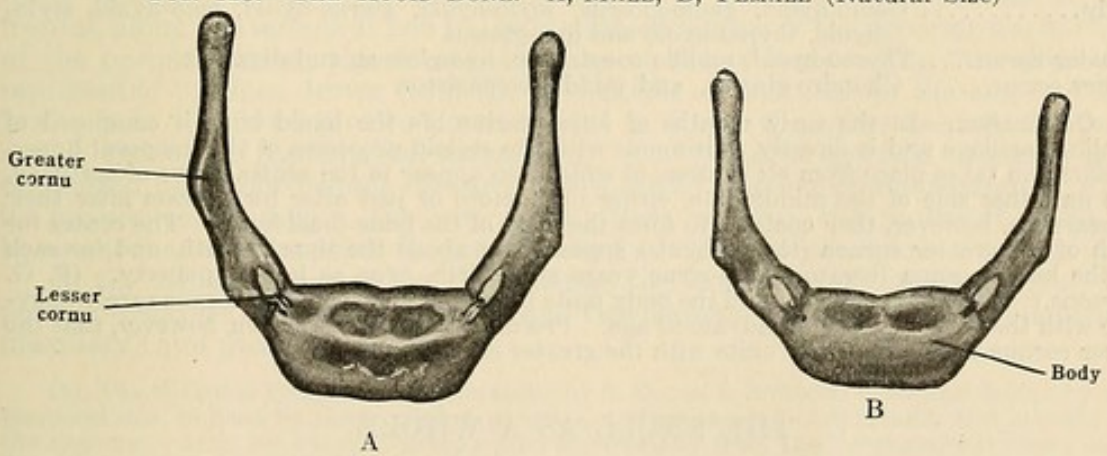

process, the vestige of a well-developed process in this situation in the hyoid bone of some of the lower animals (reptiles and the horse). In this way four spaces or depressions for muscular attachments are marked off, two on either side of the middle line. The **posterior surface** is deeply concave and separated from the epiglottis by the thyreo-hyoid membrane, and by some loose areolar tissue. The membrane passes upward from the thyreoid cartilage to be attached to the **superior border,** and interposed between it and the concavity on the back of the body is a small synovial bursa. The **inferior border,** thicker than the upper, gives insertion to muscles. The **lateral borders** are partly in relation with the greater cornua, with which they are connected, up to middle life, by synchondrosis, but after this period, usually by bone.

The **greater cornua** projects upward and backward from the sides of the body. They are flattened from above downward, thicker near their origin, and terminate posteriorly in a rounded tubercle to which the thyreo-hyoid ligament is attached.

The **lesser cornua** are small conical processes projecting upward and backward opposite the lines of junction between the body and the greater cornua, and by their apices give attachment to the stylo-hyoid ligaments; they are connected to the body by fibrous tissue. Professor Parsons has shown that a joint with a synovial cavity is common between the smaller and geater cornua. The lesser cornua are sometimes partly or even completely cartilaginous in the adult.

FIG. 126.—HYOID BONE ENLARGED TO SHOW MUSCULAR ATTACHMENTS. (After F. G. Parsons.)

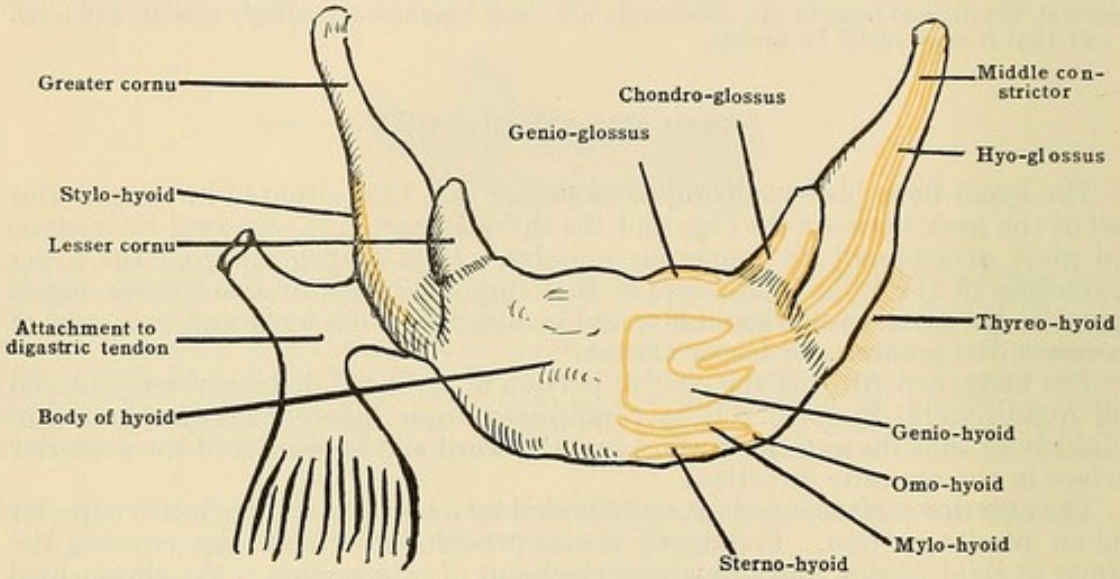

The **muscles** attached to each half of the hyoid bone may be enumerated as follows:—

Body..... Genio-hyoid, genio-glossus, mylo-hyoid, sterno-hyoid, omo-hyoid, stylo-hyoid, thyreo-hyoid and hyo-glossus.
Greater cornu.....Thyreo-hyoid, middle constrictor, hyo-glossus, and digastric.
Lesser cornu..... Chondro-glossus, and middle constrictor.

Ossification.—In the early months of intra-uterine life the hyoid bone is composed of hyaline cartilage and is directly continuous with the styloid processes of the temporal bones. Ossification takes place from six centres, of which two appear in the central piece of cartilage, one on either side of the middle line, either just before or just after birth; soon after their appearance, however, they coalesce to form the body of the bone (basi-hyal). The centre for each of the greater cornua (thyreo-hyals) appears just about the time of birth, and for each of the lesser cornua (cerato-hyals) some years after birth, even as late as puberty. (F. G. Parsons.) The greater cornua and the body unite in middle life; the lesser cornua rarely ankylose with the body and only in advanced age. Professor Parsons has shown, however, that the lesser cornua more frequently unite with the greater cornua.

THE SKULL AS A WHOLE

The skull, formed by the union of the cranial and facial bones already described, may now be considered as a whole. Taking a general view, it is spheroidal in shape, smooth above, compressed from side to side, flattened and uneven below, and divisible into six regions: a superior region or vertex, a posterior or occipital region, an anterior or frontal region, an inferior region or base, and two lateral regions.

(1) THE SUPERIOR REGION

Viewed from above (*norma verticalis*) the skull presents an oval outline with the broader end behind, and includes the **frontal, parietals,** and the **interparietal** portion of the **occipital.** In a skull of average width the zygomatic arches are visible, but in very broad skulls they are obscured.

The **sutures** of the vertex are:—

The **metopic,** which is, in most skulls, merely a median fissure in the frontal bone just above the **glabella;** occasionally it involves the whole length of the bone. It is due to the persistence of the fissure normally separating the two halves of the bone in the infant.

The **sagittal** is situated between the two parietals, and extends from the bregma to the lambda.

The **coronal** lies between the frontal and parietals, and extends from pterion to pterion.

The **lambdoid** is formed by the parietals and interparietal portion of the occipital. It extends from asterion to asterion.

The **occipital** suture is only present when the interparietal exists as a separate element (figs. 70 and 71).

The more important points are:—

The **bregma,** which indicates the situation of the frontal (greater) fontanelle, and marks the confluence of the coronal, the sagittal, and, when present, the metopic sutures.

The **lambda,** where the sagittal enters the lambdoid suture; it marks the situation of the occipital (lesser) fontanelle.

The **obelion,** a little anterior to the lambda, is usually indicated by a median or two lateral foramina.

(2) The Posterior Region

Viewed from behind (*norma occipitalis*) the skull is somewhat pentagonal in form. Of the five angles, the superior or median is situated in the line of the sagittal suture; the two upper lateral angles coincide with the parietal eminences and the two lower with the mastoid processes of the temporal bones. Of the sides, four are somewhat rounded, and one, forming the basal line, running between the mastoid processes, is flattened.

The centre is occupied by the lambda, and radiating from this point are three sutures, the **sagittal,** and the two parts of the **lambdoid.** Each half of the lambdoid suture bifurcates at the mastoid portion of the temporal bone, the two divisions constituting the **parieto-mastoid** and **occipito-mastoid** sutures; the point of bifurcation is known as the **asterion.**

In the lower part of the view is seen the **external occipital protuberance** (inion), the occipital crest, and the three pairs of nuchal lines, which give it a rough and uneven appearance. The **occipital point** is the point of the occiput furthest from the glabella in the median plane. It is situated above the external occipital protuberance.

(3) The Lateral Region

The **lateral region** (*norma lateralis*) (fig. 127) is somewhat triangular in shape, being bounded above by a line extending from the zygomatic process of the frontal, along the temporal line to the lateral extremity of the superior nuchal line of the occipital bone; this forms the base of the triangle. The two sides are represented by lines drawn from the extremities of the base to the angle of the jaw. It is divisible into two portions, one in front, the other behind, the eminentia articularis [tuberculum articulare]. The posterior portion presents, in a horizontal line from behind forward, the mastoid portion of the temporal, with its process and foramen, the external auditory meatus, the centre of which is known as the **auricular point,** the mandibular fossa, and the condyle of the mandible.

In the anterior portion are three fossæ, (a) temporal, (b) infratemporal, (c) pterygo-palatine (spheno-maxillary), and two fissures, the inferior orbital (spheno-maxillary) and pterygo-palatine.

(a) The **temporal fossa,** somewhat semilunar in shape, is bounded *above* and *behind* by the temporal line, in *front* by the frontal, zygomatic, and great wing of sphenoid, and *laterally* by the zygomatic arch, by which it is separated superficially from the infratemporal fossa; more deeply the infratemporal ridge separates the two fossæ.

The fossa is formed by parts of five bones, the zygomatic, temporal, parietal, frontal, great wing of sphenoid, and is traversed by six sutures, coronal, spheno-zygomatic, spheno-squamosal, spheno-parietal, squamosal, and spheno-frontal. The point where the temporal ridge is crossed by the coronal suture is the **stephanion,** and the region where the frontal, sphenoid, temporal, and parietal meet is the **pterion.** The latter is frequently occupied in the adult by the **epipteric** bone.

The temporal fossa is concave in front, convex behind, filled by the temporal muscle, and roofed in by a strong glistening aponeurosis, the **temporal fascia,** which serves to bind down the muscle.

(b) The **infratemporal fossa** (zygomatic fossa), irregular in shape, is situated below and to the medial side of the zygoma, covered in part by the ramus of the mandible. It is bounded *in front* by the lower part of the medial surface of the zygomatic, and by the infratemporal surface of the maxilla, on which are seen the orifices of the posterior superior alveolar canals; *behind* by the posterior border of the lateral pterygoid plate, the spine of the sphenoid, and the articular tubercle; *above* by the infratemporal ridge, a small part of the squamous portion of

the temporal, the great wing of the sphenoid perforated by the foramen ovale and foramen spinosum; *below* by the alveolar border of the maxilla; *laterally* by the ramus of the mandible and the zygoma formed by zygomatic and temporal; *medially* by the lateral pterygoid plate, a line from which to the spine of the sphenoid separates the infratemporal fossa from the base of the skull. It contains the lower part of the temporal muscle and the coronoid process of the mandible, the external and internal pterygoids, the internal maxillary vessels, and the mandibular division of the fifth nerve with numerous branches. At its upper and medial part are seen the inferior orbital and pterygo-palatine fissures.

The **inferior orbital** (or spheno-maxillary) **fissure** is horizontal in position, and lies between the maxilla and the great wing of the sphenoid; laterally it is usually completed by the zygomatic, though in some cases the sphenoid joins the maxilla, and in this way excludes the zygomatic bone from the fissure; medially it is terminated by the infratemporal surface of the orbital process of the palate bone. Through this fissure the orbit communicates with the pterygo-palatine (spheno-maxillary), infratemporal, and temporal fossæ. It transmits the infra-orbital nerve and vessels, the zygomatic nerve, ascending branches from the spheno-palatine ganglion to the orbit, and a communicating vein from the ophthalmic to the pterygoid plexus.

FIG. 127.—THE SKULL. (Norma lateralis.)

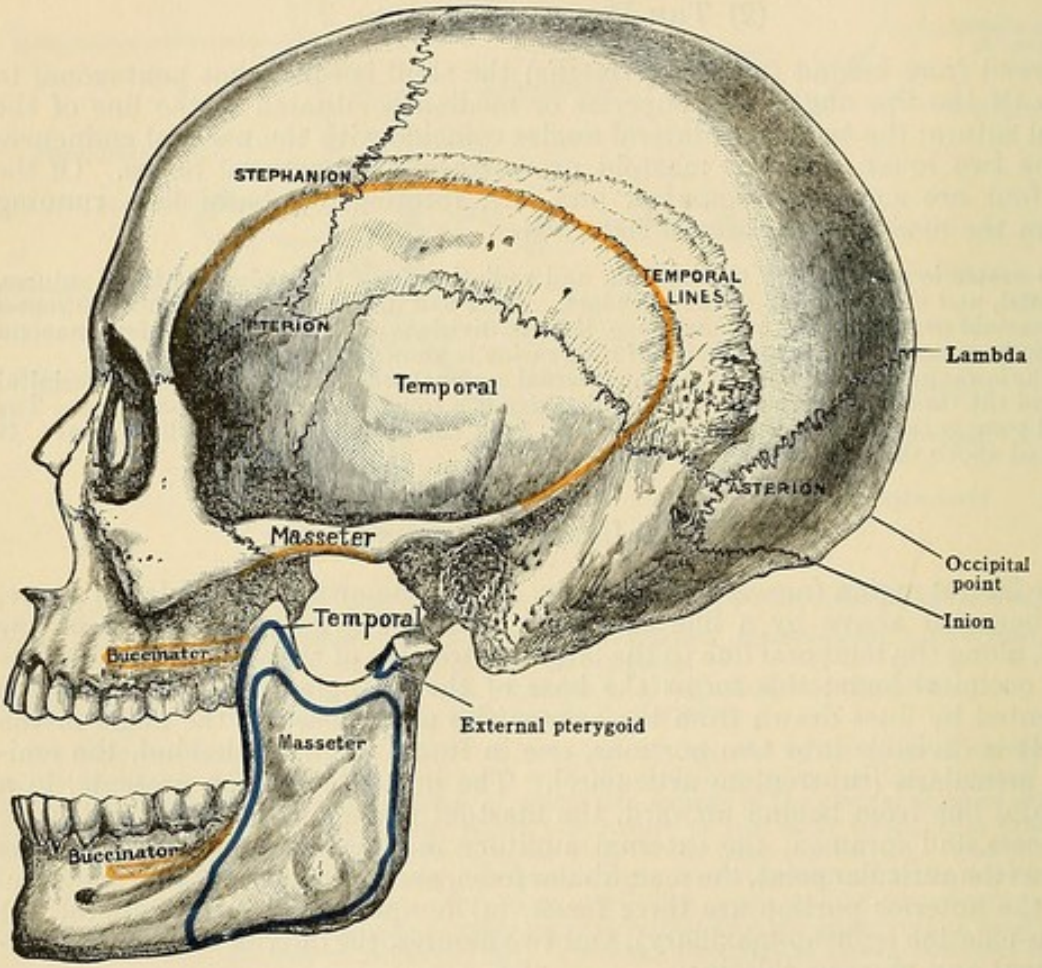

The **pterygo-palatine** (pterygo-maxillary) **fissure** forms a right angle with the inferior orbital fissure and is situated between the maxilla and the anterior border of the pterygoid process of the sphenoid. At its lower angle, where the two lips of the fissure approximate, the lateral pterygoid plate occasionally articulates with the maxilla, but they are usually separated by a thin portion of the pyramidal process of the palate. The pterygo-palatine fissure, which serves to connect the infratemporal fossa with the pterygo-palatine fossa, is bounded medially by the perpendicular part of the palate; it transmits branches of the internal maxillary artery, and the corresponding veins, to and from the pterygo-palatine fossa.

(c) The **pterygo-palatine** (spheno-maxillary) **fossa** is a small space, of the form of an inverted pyramid, situated at the angle of junction of the inferior orbital (spheno-maxillary) with the pterygo-palatine (pterygo-maxillary) fissure, below the apex of the orbit. It is bounded *in front* by the infratemporal surface of the maxilla; *behind*, by the base of the pterygoid process and the lower part of the anterior surface of the great wing of the sphenoid; medially by the perpendicular part of the palate with its orbital and sphenoidal processes; *above* by the lower surface of the body of the sphenoid. Three fissures terminate in it—viz., the superior orbital, pterygo-palatine, and inferior orbital; through the superior orbital fissure it communicates with the cranium, through the pterygo-palatine fissure with the infratemporal fossa, through the inferior orbital fissure with the orbit, and through the spheno-palatine foramen on the medial wall it communicates with the upper and back part of the nasal fossa. In-

cluding the **spheno-palatine** foramen six foramina open into the fossa. Of these, three are on the posterior wall: enumerated from without inward, and from above downward, they are the **foramen rotundum,** the **pterygoid** (Vidian) **canal,** and the **pharyngeal** (pterygo-palatine) **canal.** The apex of the pyramid leads below into the **pterygo-palatine canal** and the **accessory palatine canals** which branch from it; and anteriorly is the orifice of the **infra-orbital canal.** The fossa contains the spheno-palatine ganglion, the maxillary nerve, and the terminal part of the internal maxillary artery, and the various foramina and canals in relation with the fossa serve for the transmission of the numerous branches which these vessels and nerves give off.

FIG. 128.—A SECTION OF THE SKULL SHOWING THE MEDIAL WALL OF THE ORBIT, THE MEDIAL WALL OF THE ANTRUM, AND THE PTERYGO-PALATINE FOSSA.

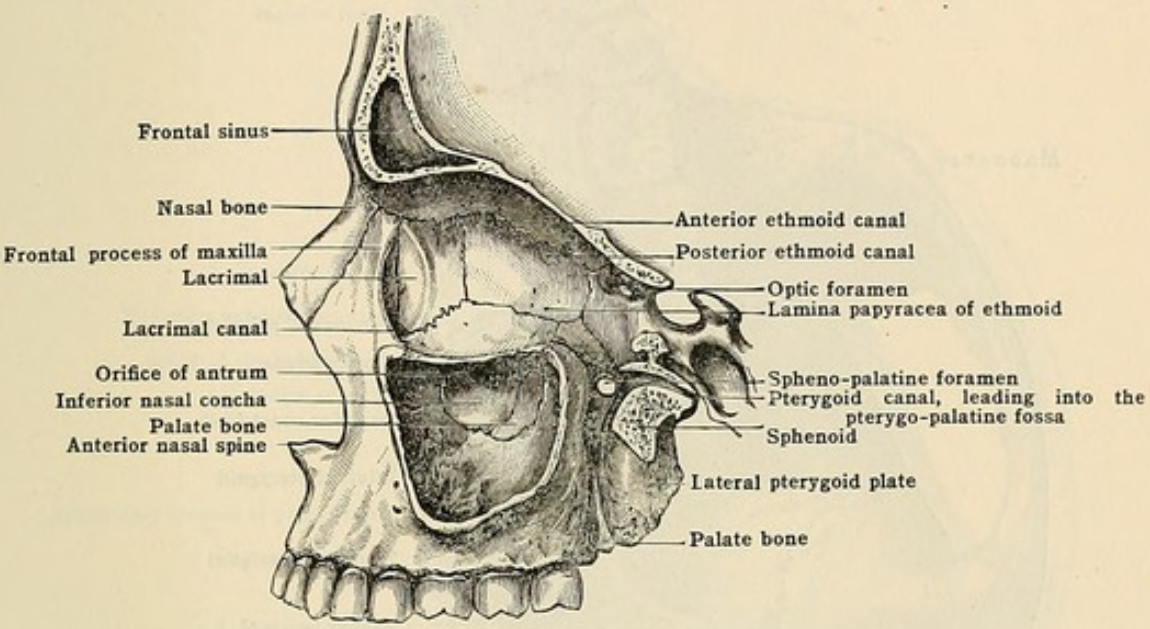

(4) INFERIOR REGION OR EXTERNAL BASE OF SKULL

The **external base** of the skull (*norma basilaris*) (figs. 130, 131) extends from the incisor teeth to the occipital protuberance, and is bounded on each side by the alveolar arch, the zygomatic, the zygoma, the temporal, and the superior nuchal line of the occipital bone. It is very uneven and, excluding the lower jaw, divisible into three portions: (a) anterior, (b) middle or subcranial, and (c) posterior or suboccipital.

FIG. 129.—HARD PALATE OF A CHILD FIVE YEARS OLD.

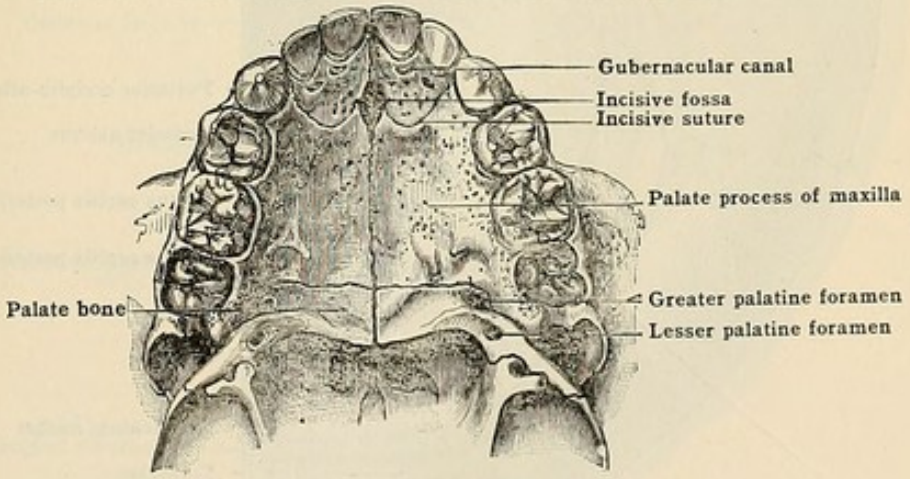

(a) The **anterior division** consists of the hard palate, the alveolar arch, and the choanæ (posterior nares).

When the skull is inverted, the hard palate stands at a higher level than the rest, and is bounded anteriorly and laterally by the alveolar ridges containing the teeth. The bones appearing in the intermediate space are the premaxillary and palatine portions of the maxillæ and the horizontal parts of the palate bones.

FIG. 130.—THE SKULL. (Norma basilaris.)

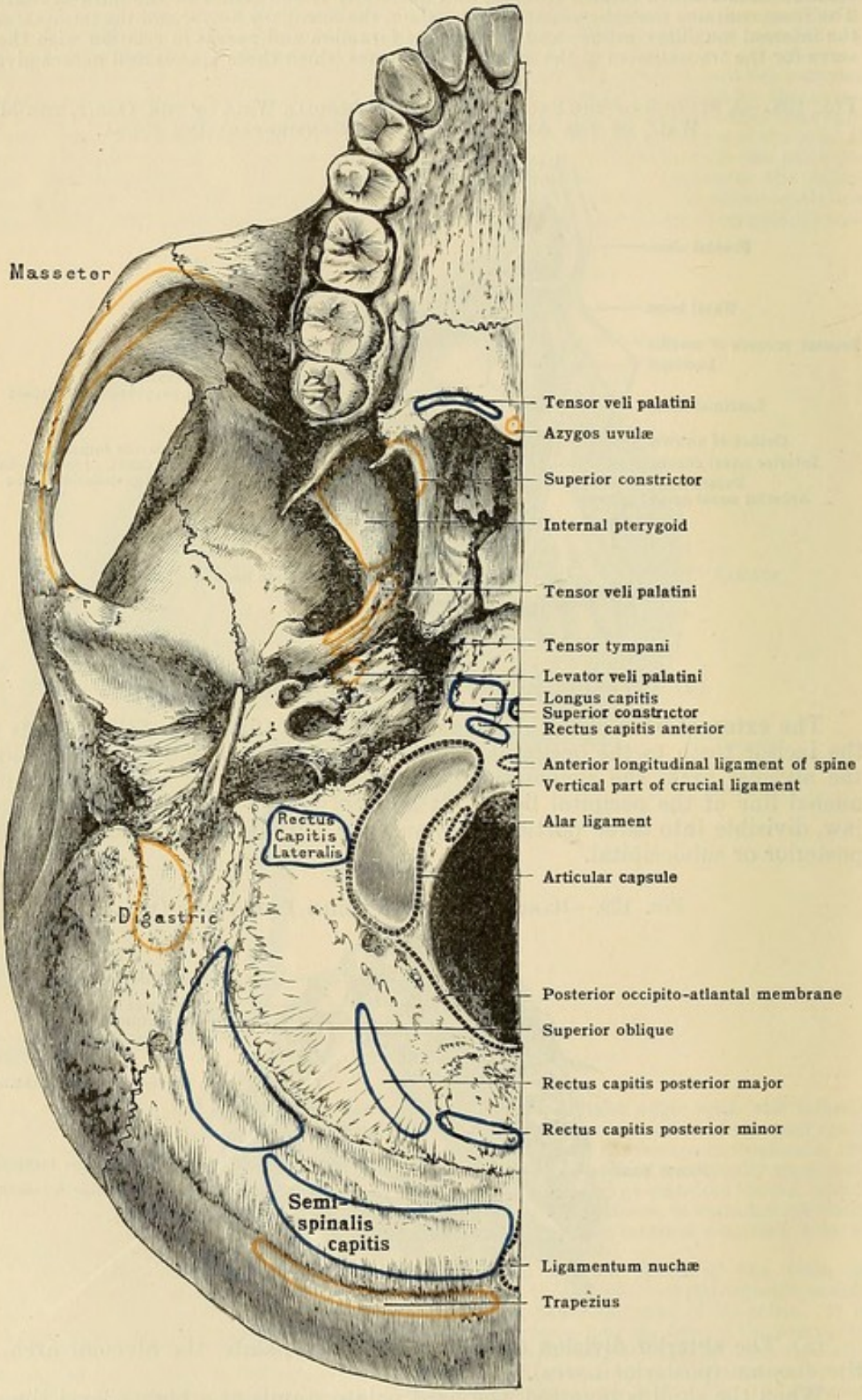

FIG. 131.—THE SKULL. (Norma basilaris.)

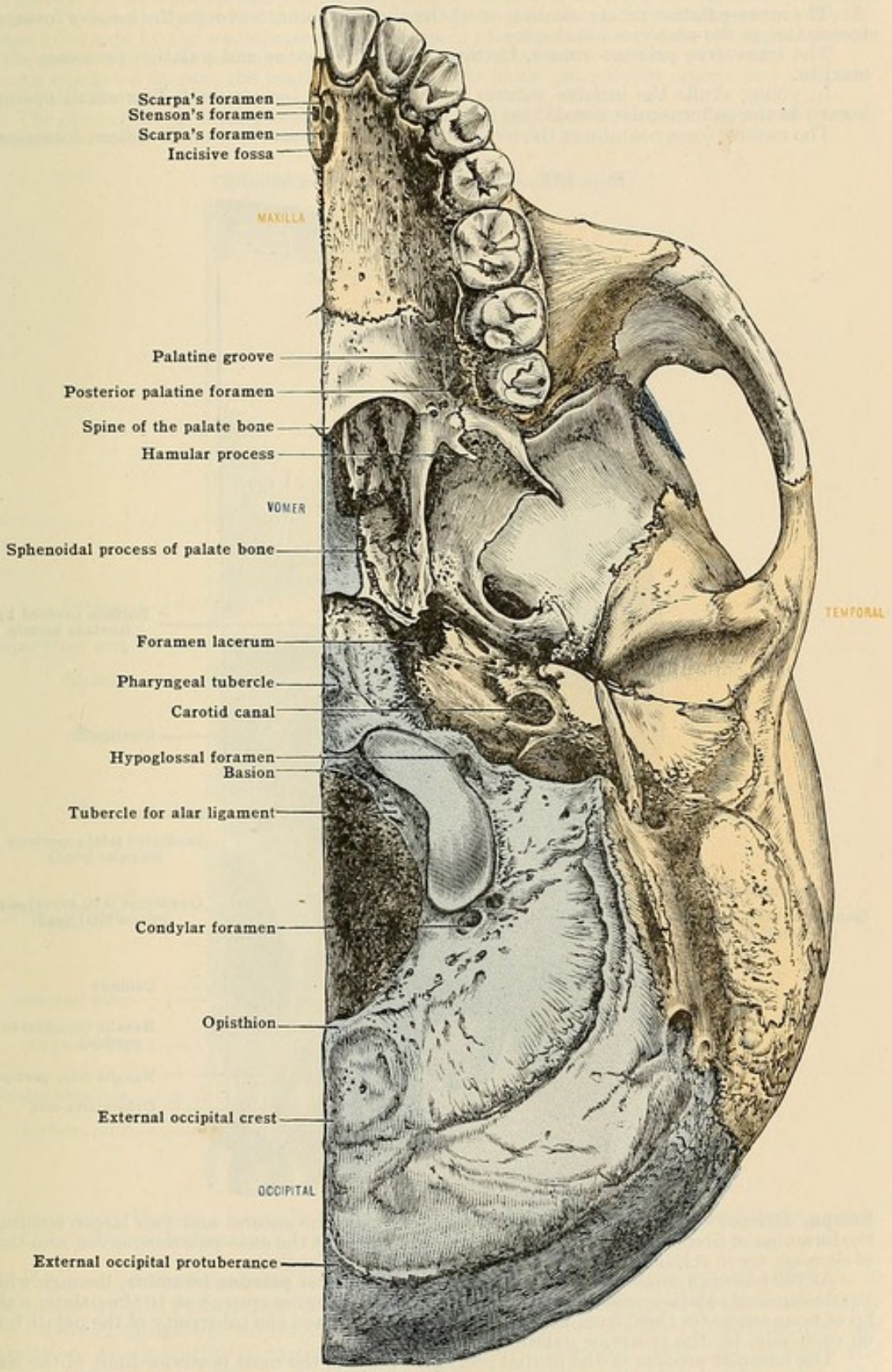

They are rough for the attachment of the muco-periosteum, and near the posterior margin is the ridge for the fibrous expansion of the *tensor veli palatini*. The following points are readily recognised (fig. 129):—

The **meso-palatine suture** commences at the alveolar point, traverses the incisive fossa, and terminates at the posterior nasal spine.

The **transverse palatine suture,** between the palate bones and palatine processes of the maxillæ.

In young skulls the **incisive sutures,** and behind the incisor teeth four small openings known as the **gubernacular canals** (see figs. 114 and 129).

The incisive fossa containing the termination of four canals: two small orifices, **foramina of**

FIG. 132.—THE SKULL. (Norma facialis.)

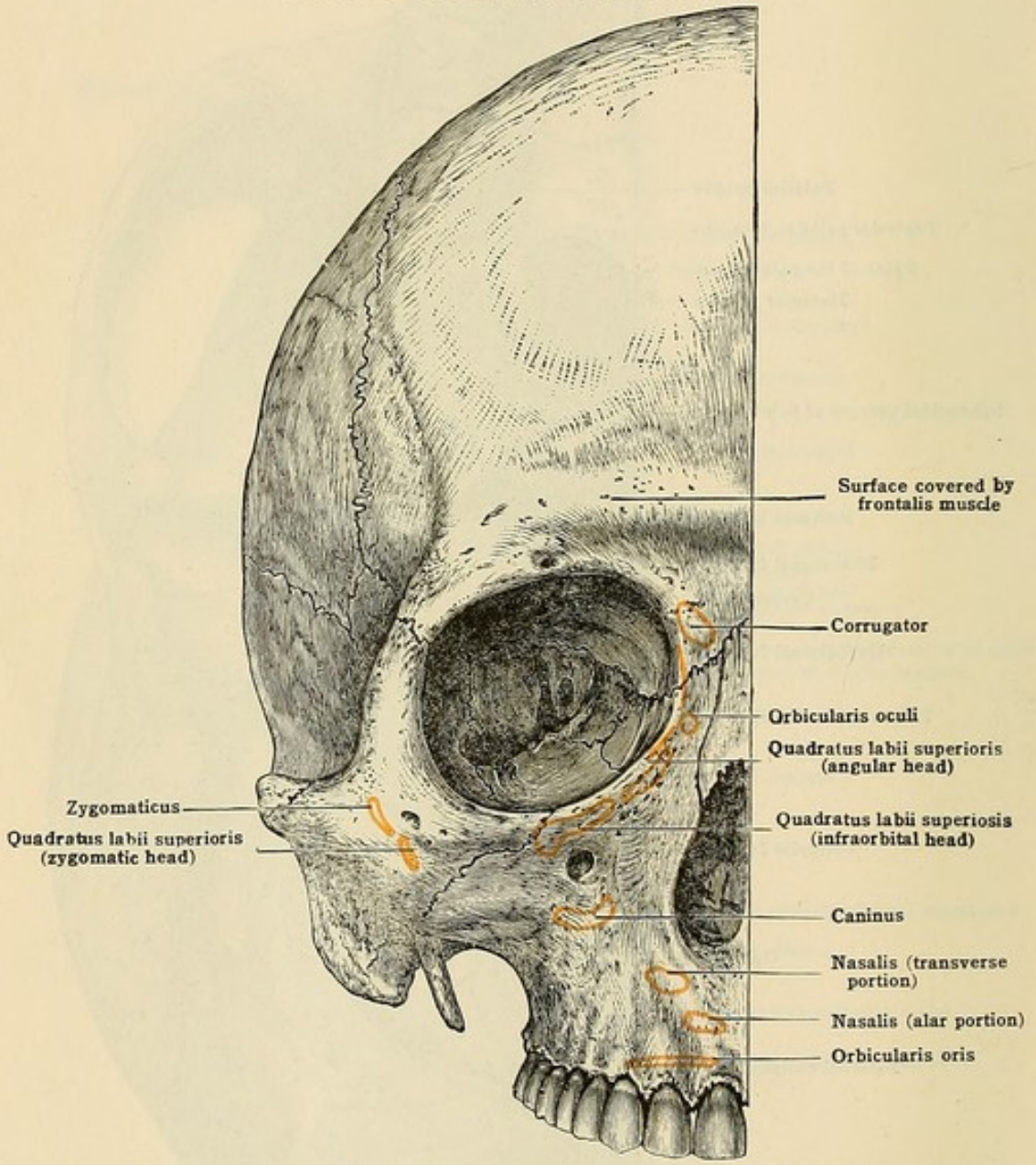

Scarpa, situated one behind the other in the meso-palatine suture; and two larger openings, the **foramina of Stenson.** The foramina of Scarpa transmit the naso-palatine nerves, and those of Stenson are in relation (embryonic) with the organs of Jacobson.

At the posterior angles of the hard palate are the **greater palatine foramina,** through which the descending palatine vessels and the anterior palatine nerves emerge on to the palate; a thin lip of bone separates them from the **lesser palatine foramen** in the tuberosity of the palate bone on each side, for the posterior palatine nerve.

The **hamular process** of the medial pterygoid plate is the most posterior limit of the hard palate.

At the posterior extremity of each alveolar ridge is the **tuberosity** of the maxilla, and between it and the palate bone is a foramen (variable in size and sometimes absent), the **middle palatine foramen,** for the middle palatine nerve. This foramen is often included under the lesser palatine foramina (BNA).

Behind the hard palate are the **choanæ** (posterior nares), separated from each other by the vomer. Each is bounded laterally by the medial pterygoid plate; below by the horizontal plate of the palate bone; above by the under surface of the body of the sphenoid, with the ala of the vomer and a portion of the sphenoidal process of the palate bone.

Lateral to the choanæ there is on each side a vertical fossa lying between the pterygoid plates. It extends upward to the under surface of the great wings of the sphenoid; it is completed anteriorly by the coalescence of the pterygoid plates and below by the pyramidal process of the palate bone. It contains the following points of interest:—

An elongated furrow, the **scaphoid fossa,** for the *tensor veli palatini* muscle and the cartilage of the Eustachian tube.

The general cavity of the **pterygoid fossa** which lodges the *tensor veli palatini* and *internal pterygoid* muscles.

FIG. 133.—THE SKULL. (Norma facialis.)

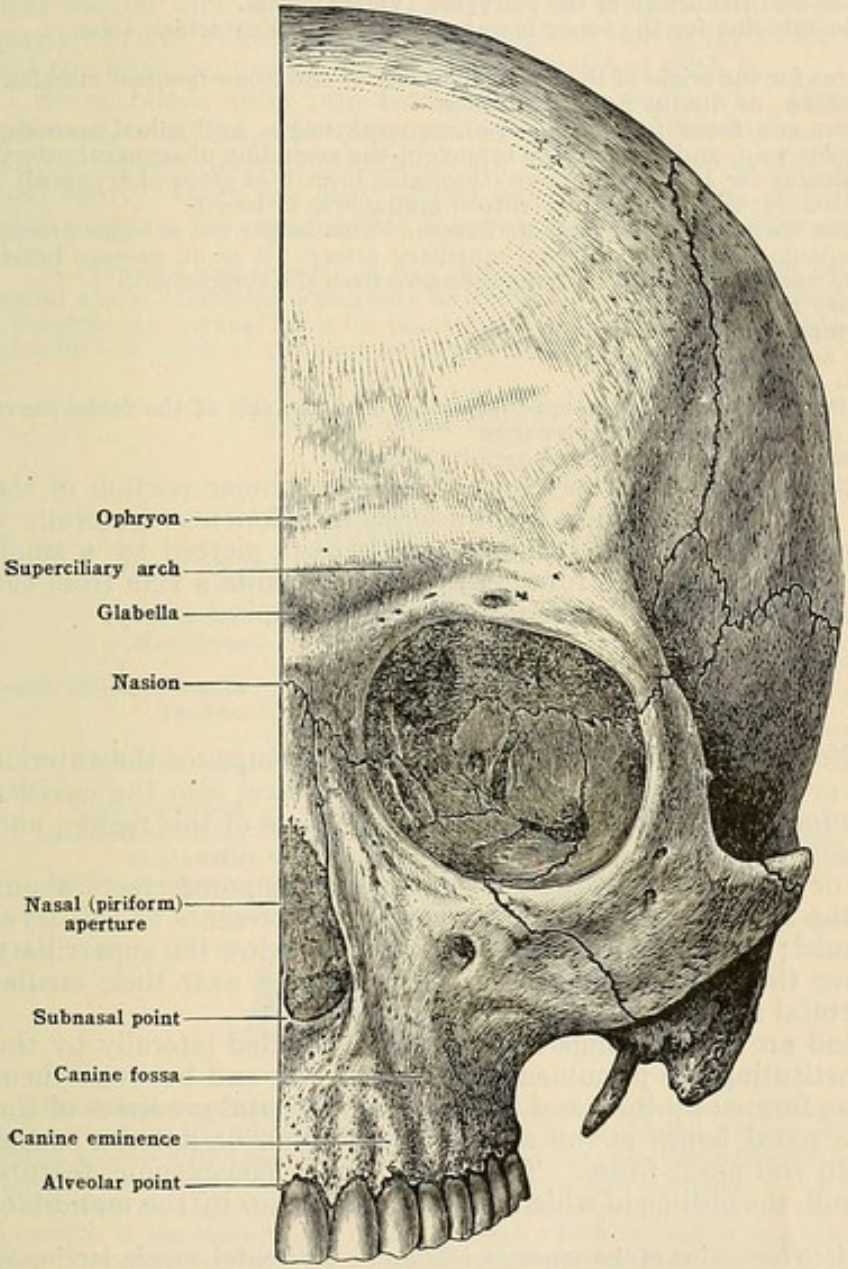

Frequently there is a notch in the lateral pterygoid plate close beside the foramen ovale. The posterior termination of the **pterygoid (Vidian) canal.**

If a line be drawn across the base of the skull from one preglenoid tubercle to the other, it will fall immediately behind the lateral pterygoid plate and bisect the foramen spinosum on each side. A second transverse line, drawn across the **opisthion** or posterior margin of the foramen magnum, will fall behind the mastoid processes. The space between these arbitrary lines may be called the *subcranial region;* that behind the second line, the *suboccipital region.*

(b) The **subcranial region** is separated from the infratemporal fossa by a line drawn from the posterior margin of the lateral pterygoid plate to the spine of the

sphenoid. It is formed by the inferior surface of the basilar process of the occipital and the body of the sphenoid, the petrous portion of the temporal bone, a small piece of the squamosal portion, the posterior part of the great wing of the sphenoid, and the condylar portions of the occipital bone. It presents the following points for examination (Figs. 95, 131):—

The pharyngeal tubercle.

The **foramen magnum** and the **occipital condyles.** The most anterior point of the foramen is termed the **basion,** and the most posterior point the **opisthion.**

On each side will be seen:—The **hypoglossal foramen** for the hypoglossal nerve and a meningeal branch of the ascending pharyngeal artery.

The **condylar fossa** with the condylar foramen (this foramen is not constant).

The under aspect of the **jugular process,** from which the *rectus capitis lateralis* takes origin.

The **foramen lacerum** and the orifice of the **pterygoid (Vidian) canal.**

The **canalis musculo-tubarius** for the *tensor tympani* muscle and Eustachian tube.

The **carotid canal.**

The quadrilateral area for the origin of the *levator veli palatini* and *tensor tympani* muscles.

The **canaliculus cochleæ,** or ductus perilymphaticus.

The **jugular foramen** and **fossa** for the glosso-pharyngeal, vagus, and spinal accessory nerves, the internal jugular vein, and a meningeal branch of the ascending pharyngeal artery.

The **tympanic canaliculus** for Jacobson's nerve (tympanic branch of glossopharyngeal).

The **spine** of the sphenoid; this is sometimes fifteen millimetres in length.

The **mandibular fossa** with the **petro-tympanic fissure.** This lodges the anterior process of the malleus, the tympanic twig of the internal maxillary artery. A small passage beside it, the **canal of Huguier,** conducts the chorda tympani nerve from the tympanum.

The **external auditory meatus.**

The **auricular** or **tympano-mastoid fissure.**

The **tympanic plate** and vaginal process.

The **styloid process.**

The **stylo-mastoid foramen** for the stylo-mastoid artery and the exit of the facial nerve and, in some cases, the auricular branch of the vagus.

The **mastoid process** with the digastric and occipital grooves.

(c) The **suboccipital region** is largely formed by the tabular portion of the occipital bone with its ridges and areas for muscular attachment. Laterally a small part of the mastoid portion of the temporal is seen, pierced by a small foramen, of variable size, the **mastoid foramen,** which transmits a vein from the transverse (lateral) sinus and a meningeal branch of the occipital artery.

(5) The Anterior Region

The **anterior region** (*norma facialis*) (figs. 132, 133) comprises the anterior end of the cranium or forehead, and the skeleton of the face; also the cavities known as the **orbits,** formed by the junction of the two parts of this region, and the **nasal fossæ,** situated on either side of the septum of the nose.

The upper part or forehead, narrowest between the temporal crests about half an inch above the zygomatic processes of the frontal, presents at this level the two **transverse sulci;** above are the **frontal eminences,** below the **superciliary arches,** and still lower the supra-orbital margins, interrupted near their medial ends by the supra-orbital notches.

Below the forehead are the openings of the **orbits,** bounded laterally by the zygomatic bones constituting the prominences of the cheeks, and between them the bridge of the nose, formed by the nasal bones and the frontal processes of the maxillæ. Below the nasal bones is the **apertura piriformis** or **anterior nasal aperture,** leading into the nasal fossæ. The teeth form a conspicuous feature in this view of the skull, the outline of which is completed below by the mandible.

The **bones** entering into formation of the *norma facialis* are:—the frontal, nasals, lacrimals, orbital surfaces of the small and the great wings, and a portion of the body of the sphenoid, the laminæ papyraceæ of the ethmoids, the orbital processes of the palate bones, the zygomatics, maxillæ, inferior nasal conchæ, and the mandible.

The **sutures** are numerous, and for the most part unimportant:—

The **transverse** suture (fig. 133) extends from one zygomatic process of the frontal to the other. The upper part of the suture is formed by the frontal bone; below are the zygomatic, great and small wings of the sphenoid, lamina papyracea, lacrimal, maxillary, and nasal bones. A portion of this complex suture, lying between the sphenoidal and frontal bones, appears in the anterior cranial fossa.

Other fissures are the internasal, naso-maxillary, inter-maxillary and zygomatico-maxillary. The small sutures seen in the orbit are described with that cavity.

The **foramina** are:—the supra-orbital, infra-orbital, optic, zygomatico-facial, and mental; the naso-lacrimal canal; the ethmoidal canals; and the inferior and superior orbital fissures.

The following points may also be noticed:—
The **glabella,** a smooth space between the converging superciliary arches.
The **ophryon,** the most anterior point of the metopic suture.
The **nasion,** the middle of the naso-frontal suture.
The **subnasal point,** the middle of the inferior border of the pyriform aperture at the base of the nasal spine.
The **alveolar point,** the centre of the anterior margin of the upper alveolar arch.

THE ORBITS

The **orbits** [orbitæ] (fig. 134) are two cavities of pyramidal shape, with their bases directed forward and laterally and their apices backward and medially; their medial walls are nearly parallel, but their lateral walls diverge so as to be nearly at right angles to each other. Each cavity forms a socket for the eyeball and the muscles, nerves, and vessels associated with it.

Seven bones enter into formation of its walls, viz., the frontal, zygomatic, sphenoid, ethmoid, lacrimal, palate, and maxilla; but as three of these—the frontal, sphenoid, and ethmoid—are single median bones which form parts of each cavity, there are only eleven bones represented in the two orbits. Each orbit presents for examination four walls, a circumference or base, and an apex.

The **superior wall or roof,** vaulted and smooth, is formed mainly by the orbital plate of the frontal and is completed posteriorly by the small wing of the sphenoid. At the lateral angle it presents the **lacrimal fossa** for the lacrimal gland, and at the medial angle a depression or a spine for the pulley of the *superior oblique* muscle.

FIG. 134.—THE MEDIAL WALL OF THE ORBIT.

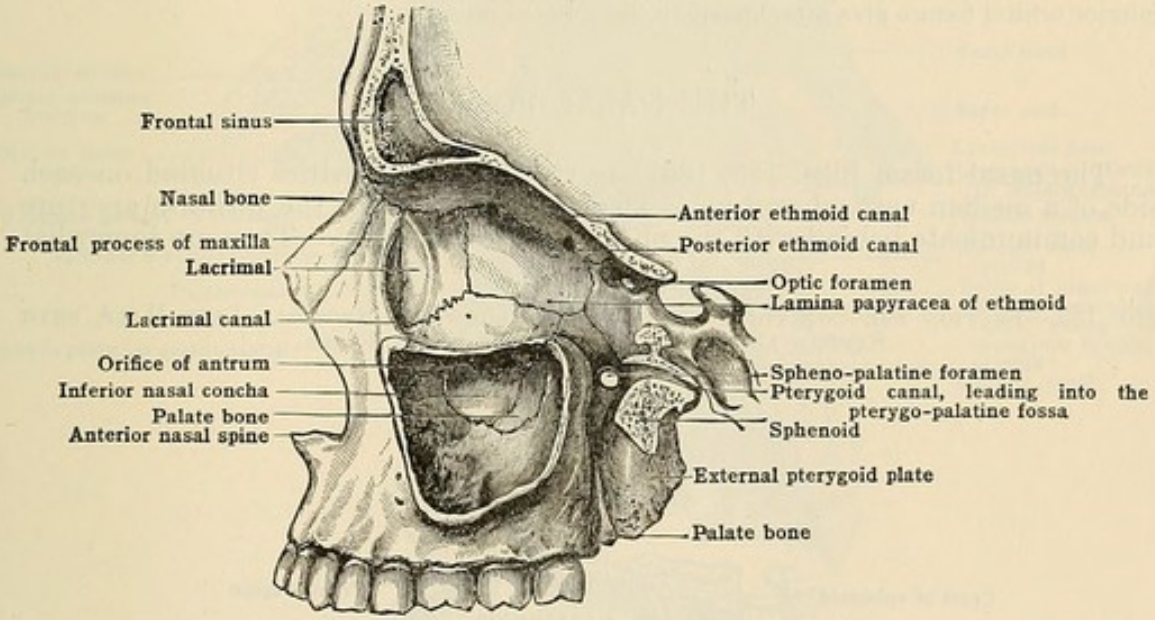

The **inferior wall or floor** is directed upward and laterally and is not so large as the roof. It is formed by the orbital plate of the maxilla, the orbital process of the zygomatic, and the orbital process of the palate bone. At its medial angle it presents the naso-lacrimal canal, and near this, a depression for the origin of the *inferior oblique* muscle. It is marked near the middle by a furrow for the infra-orbital artery and the second division of the fifth nerve, terminating anteriorly in the infra-orbital canal, through which the nerve and artery emerge on the face. Near the commencement of the canal a narrow passage, the anterior alveolar canal, runs forward and downward in the anterior wall of the antrum, transmitting nerves and vessels to the incisor and canine teeth.

The **lateral wall,** directed forward and medially, is formed by the orbital surface of the great wing of the sphenoid, and the zygomatic. Between it and the roof, near the apex, is the **superior orbital** (sphenoidal) **fissure,** by means of which the third, fourth, ophthalmic division of the fifth, and sixth nerves enter the orbit from the cranial cavity; it also transmits some filaments from the cavernous plexus of the sympathetic, the orbital branch of the middle meningeal artery, recurrent branches of the lacrimal artery, and an ophthalmic vein. The lower margin of the fissure presents near the middle a small tubercle, from which the inferior head of the *lateral rectus* muscle arises. Between the lateral wall and the floor, near the apex, is the **inferior orbital** (spheno-maxillary) **fissure,** through which the second division of the fifth and the infra-orbital vessels pass from the pterygo-palatine fossa to enter the infra-orbital groove. At the anterior margin of the fissure the sphenoid occasionally articulates with the maxilla, but

the two are usually separated by the orbital plate of the zygomatic, and on the latter are seen the orifices of the zygomatico-temporal and zygomatico-facial canals, which traverse the zygomatic bone. The commencement of the zygomatico-temporal canal is sometimes seen in the spheno-zygomatic suture connecting the sphenoid and zygomatic bones.

The **medial wall,** narrow and nearly vertical, is formed from before backward by the frontal process of the maxilla, the lacrimal, the lamina papyracea of the ethmoid, and the body of the sphenoid. At the junction of the medial wall with the roof, and in the suture between the ethmoid and frontal, are seen the orifices of the **anterior** and **posterior ethmoidal canals,** the anterior, transmitting the anterior ethmoidal vessels and nerve; and the posterior, the posterior vessels and nerve. Anteriorly is the **lacrimal groove** for the lacrimal sac, and behind this the **lacrimal crest,** from which the *tensor tarsi* arises. The medial wall, which is the smallest of the four, is traversed by three vertical sutures:—one between the frontal process of the maxilla and the lacrimal, a second between lacrimal and lamina papyracea, and a third between the lamina papyracea and the sphenoid. Occasionally the sphenoidal concha appears in the orbit between the ethmoid and the body of the sphenoid.

The **apex** of each orbit corresponds to the **optic foramen,** a circular orifice which transmits the optic nerve and ophthalmic artery. The **base** or circumference is quadrilateral in form and is bounded by the frontal bone above, the frontal process of the maxilla and the medial angular process of the frontal on the medial side, the zygomatic bone and the zygomatic process of the frontal on the lateral side, and by the zygomatic and the body of the maxilla below. The following points may also be noted:—The suture between the zygomatic process of the frontal bone and the zygomatic; the supra-orbital notch (sometimes a complete foramen); the suture between the frontal bone and the frontal process of the maxilla; and in the lower segment, the zygomatico-maxillary suture.

The orbit communicates with the cranial cavity by the optic foramen and superior orbital fissure; with the nasal fossa, by means of the naso-lacrimal canal; with the zygomatic and pterygo-palatine fossæ, by the inferior orbital fissure. In addition to these large openings, the orbit has five other foramina—the infra-orbital, zygomatico-orbital, and the anterior and posterior ethmoidal canals—opening into it or leading from it.

The following **muscles** arise within the **orbit:**—the *four recti*, the *superior oblique*, and *levator palpebræ superioris*, near the apex; the *inferior oblique* on the floor of the orbit lateral to the naso-lacrimal canal; and the *tensor tarsi* from the lacrimal crest. The margins of the inferior orbital fissure give attachment to the *orbitalis* muscle.

THE NASAL FOSSÆ

The **nasal fossæ** (figs. 135, 136) are two irregular cavities situated on each side of a median vertical septum. They open in front by the piriform aperture and communicate behind with the pharynx by the choanæ. They are somewhat

FIG. 135.—SECTION THROUGH THE NASAL FOSSA TO SHOW THE SEPTUM. LEFT HALF, WITH SEPTUM LOOKING TOWARD RIGHT NASAL FOSSA.

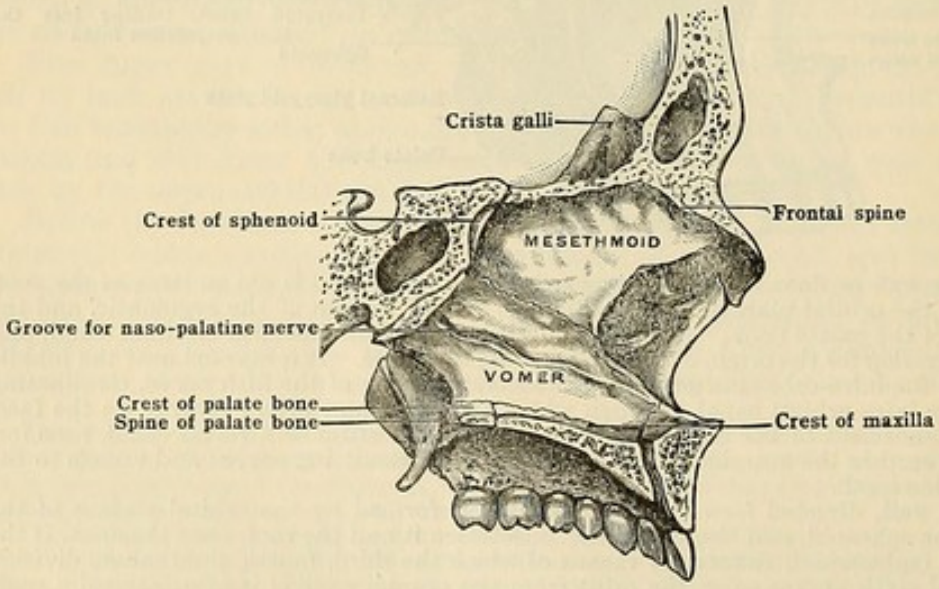

oblong in transverse section, and extend vertically from the anterior part of the base of the cranium above to the superior surface of the hard palate below. Their transverse extent is very limited, especially in the upper part. Each fossa presents for examination a roof, floor, medial and lateral walls, and communicates with the sinuses of the frontal, sphenoid, maxilla, and ethmoid bones.

The **roof** is horizontal in the middle, but sloped downward in front and behind. The anterior slope is formed by the posterior surface of the nasal bone and the nasal process of the frontal; the horizontal portion corresponds to the cribriform plate of the ethmoid and the sphenoidal concha; the posterior slope is formed by the inferior surface of the body of the sphenoid, the ala of the vomer, and a small portion of the sphenoidal process of the palate. The sphenoidal sinus opens at the upper and back part of the roof into the spheno-ethmoidal recess, above the superior meatus.

The **floor** is concave from side to side, and in the transverse diameter wider than the roof. It is formed mainly by the palatine process of the maxilla and completed posteriorly by the horizontal part of the palate bone. Near its anterior extremity, close to the septum, is the **incisive canal.**

The **septum** or medial wall is formed by the perpendicular plate of the ethmoid, the vomer, the rostrum of the sphenoid, the crest of the nasal bones, the frontal spine, and the median crest formed by the apposition of the palatine processes of the maxillæ and the horizontal parts of the palate bones. The anterior border has a triangular outline limited above by the perpendicular plate of the ethmoid and below by the vomer, and in the recent state the deficiency is filled up by the septal cartilage of the nose. The posterior border is formed by the

FIG. 136.—SECTION THROUGH THE NASAL FOSSA TO SHOW THE LATERAL WALL WITH THE MEATUSES.

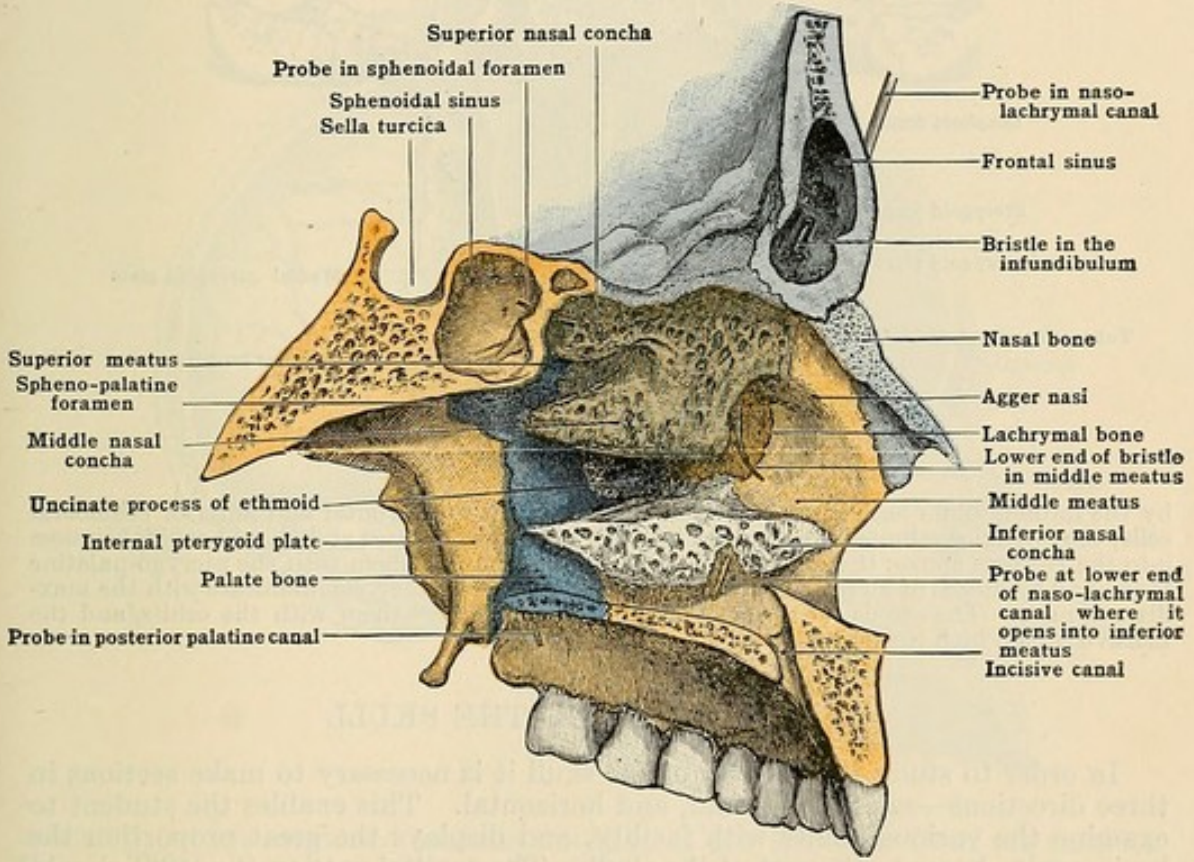

pharyngeal edge of the vomer, which separates the two choanæ. The septum, which is usually deflected from the middle line to one side or the other, is occasionally perforated, and in some cases a strip of cartilage, continuous with the triangular cartilage, extends backward between the vomer and perpendicular plate of the ethmoid (*posterior* or *sphenoidal process*).

The **lateral wall** is the most extensive and the most complicated on account of the formation of the meatuses of the nose. It is formed by the frontal process and the medial surface of the maxilla, the lacrimal, the superior and inferior conchæ of the ethmoid, the inferior nasal concha, the vertical part of the palate bone, and the medial surface of the medial pterygoid plate. The three conchæ, which project medially, overhang the three recesses known as the **meatuses** of the nose. The **superior meatus,** the shortest of the three, is situated between the superior and middle nasal conchæ, and into it open the orifice of the **posterior ethmoidal cells** and the **spheno-palatine foramen.** The **middle meatus** lies between the middle and inferior conchæ. At its fore part it communicates with the frontal sinus by means of the **infundibulum,** and near the middle with the **maxillary sinus** (**antrum**); the communication with the sinus is very irregular and sometimes represented by more than one opening (fig. 136). Two sets of **ethmoidal cells**—the **middle** and **anterior**—also open into the middle meatus, the anterior in common with the infundibulum, the middle on an elevation known as the **bulla ethmoidalis.** The **inferior meatus,** longer than either of the preceding, is situated between the inferior nasal concha and the floor of the fossa, and presents, near the anterior part, the lower orifice of the canal for the **naso-lacrimal duct.**

The **nasal fossæ** open on the face by means of the **apertura piriformis,** a heart-shaped or piriform opening whose long axis is vertical and whose broad end is below. The orifice is bounded above by the lower borders of the nasal bones, laterally by the maxillæ, inferiorly by the premaxillary portions of the maxillæ, and in the recent state the orifice is divided by the septal cartilage. Below, where the lateral margins slope inward to meet in the middle line, is the **anterior nasal spine.**

The **choanæ** (posterior nares) are bounded superiorly by the alæ of the vomer, the sphenoidal processes of the palate, and the inferior surface of the body of the sphenoid; laterally by the lateral pterygoid plates; and inferiorly by the posterior edge of the horizontal plates of the palate bones. They are separated from each other by the posterior border of the vomer.

The nasal fossæ communicate with all the more important fossæ and the air-sinuses of the skull. By means of the foramina in the roof they are in connection with the cranial cavity;

FIG. 137.—THE CHOANÆ. Veiwed from behind.

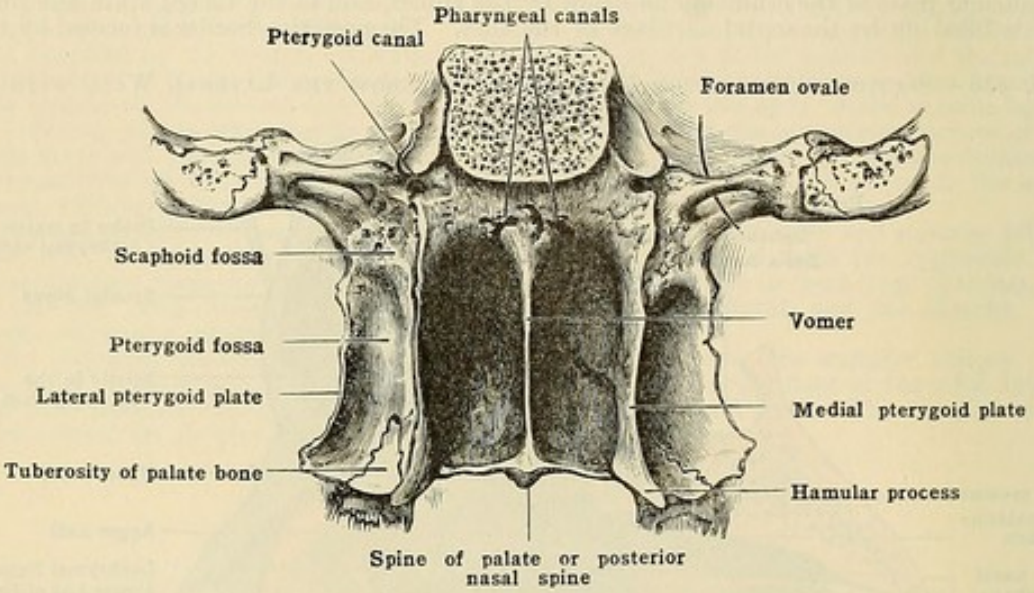

by the infundibulum each fossa is in communication with the frontal and anterior ethmoidal cells; the posterior ethmoidal cells open into the superior meatuses and the sphenoidal sinuses into the recesses above; the spheno-palatine foramina connect them with the pterygo-palatine fossæ, and by means of an irregular orifice in each lateral wall they communicate with the maxillary sinuses. The canals for the naso-lacrimal ducts connect them with the orbits, and the incisive canals with the oral cavity.

THE INTERIOR OF THE SKULL

In order to study the interior of the skull it is necessary to make sections in three directions—sagittal, coronal, and horizontal. This enables the student to examine the various points with facility, and displays the great proportion the brain cavity bears to the rest of the skull. The **sagittal section** (fig. 138) should be made slightly to one side of the median line, in order to preserve the nasal septum. The black line (fig. 138) drawn from the **basion** (anterior margin of the foramen magnum) to the **gonion** (the anterior extremity of the sphenoid) represents the **basi-cranial axis;** whilst the line drawn from the **gonion** to the **subnasal point** lies in the **basi-facial axis.** These two axes form an angle termed the **cranio-facial,** which is useful in making comparative measurements of crania. A line prolonged vertically upward from the **basion** will strike the **bregma.** This is the **basi-bregmatic** axis, and gives the greatest height of the cranial cavity. A line drawn from the **ophryon** to the **occipital point** indicates the greatest length of the cranium.

Near its middle, the cranial cavity is encroached upon by the petrous portion of the temporal bone on each side; the walls are channelled vertically by narrow grooves for the middle and small meningeal vessels, and toward the base and at the vertex are broader furrows for the venous sinuses.

The **coronal** section is most instructive when made in the **basi-bregmatic axis.** The section will pass through the petrous portion on each side in such a way as to traverse the external auditory passage and expose the tympanum and vestibule, and will also partially traverse the internal auditory meatus. Such

a section will divide the parietal bones slightly posterior to the parietal eminences, and a line drawn transversely across the section at the mid-point will give the greatest transverse measurement of the cranial cavity. A skull divided in this way facilitates the examination of the parts about the choanæ (posterior nares).

The **horizontal section** (figs. 139, 140) of the skull should be made through a line extending from the **ophryon** to the **occipital point,** passing laterally a few millimetres above the **pterion** on each side. It is of great advantage to study the various parts on the floor of the cranial cavity in a second skull in which the dura mater and its various processes have not been removed.

The **floor** [basis cranii interna] of the cranial cavity presents three irregular depressions termed the anterior, middle, and posterior fossæ (figs. 139 and 140).

The Anterior Cranial Fossa.—The floor of this fossa is on a higher level than the rest of the cranial floor. It is formed by the horizontal plate of the frontal bone, the cribriform plate of the ethmoid, and the lesser wings of the

Fig. 138.—The Skull in Sagittal Section.

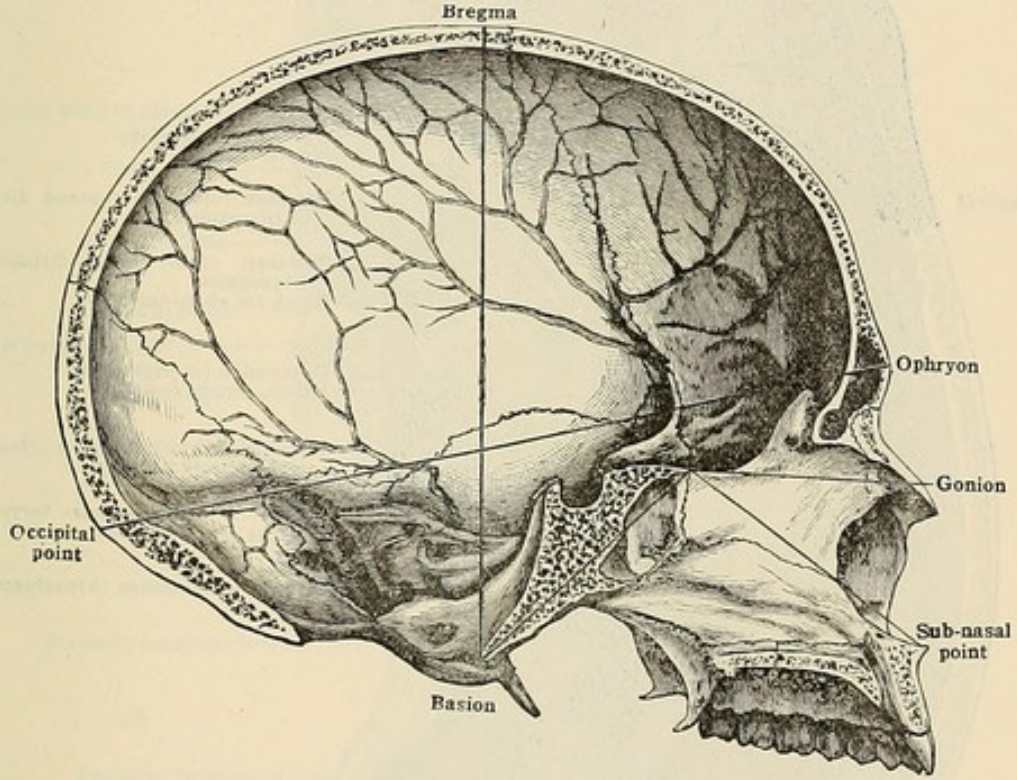

sphenoid, which meet and exclude the body of the sphenoid from the anterior fossa. The free margins of the lesser wings and the anterior margin of the optic groove mark the limits of this fossa posteriorly. The central portion is depressed on each side of the crista galli, presents the numerous apertures of the cribriform plate, and takes part in the formation of the roof of the nasal fossæ; laterally, the floor of the anterior cranial fossa is convex; it forms the roof of the orbits, and is marked by irregular furrows. It supports the frontal lobes of the cerebrum. The **sutures** traversing the floor of the fossa are the fronto-ethmoidal, forming three sides of a rectangle, that portion of the transverse facial suture which traverses the roof of the orbit, and the ethmo-sphenoidal suture, the centre of which corresponds to the **gonion.** The other points of interest in the fossa are:—

A groove for the superior sagittal sinus.
The **foramen cæcum** which frequently transmits a small vein to the nasal cavity.
The **crista galli.**
The **ethmoidal fissure** for the anterior ethmoidal branch of the fifth nerve.
The cranial orifice of the **anterior ethmoidal canal,** transmitting the anterior ethmoidal branch of the fifth nerve, and a meningeal branch of the anterior ethmoidal artery.
The cranial orifice of the **posterior ethmoidal canal,** transmitting a meningeal branch of the posterior ethmoidal artery.
The **ethmoidal spine** of the sphenoid.
Furrows for meningeal vessels.

FIG. 139.—THE SKULL IN HORIZONTAL SECTION.

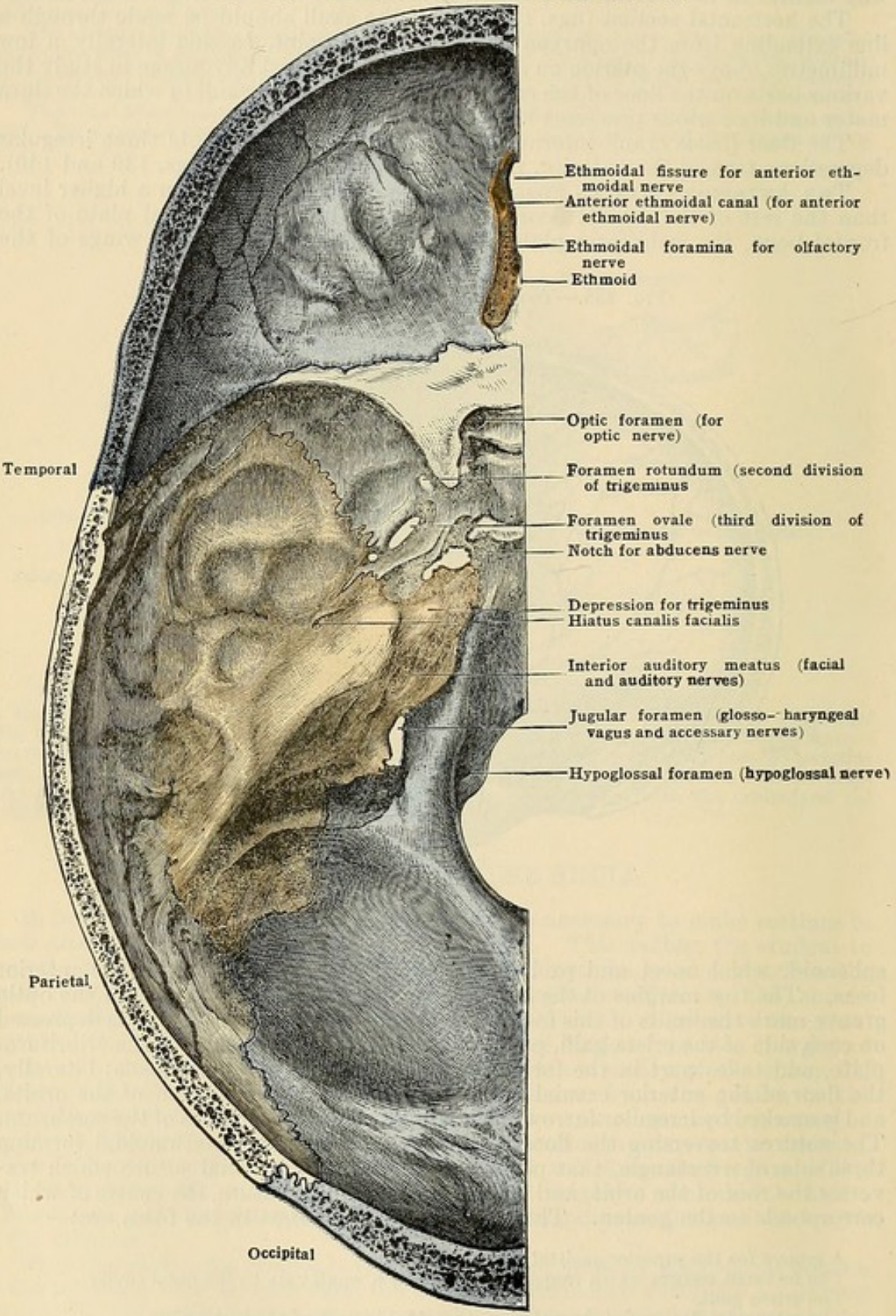

FIG. 140.—THE SKULL IN HORIZONTAL SECTION.

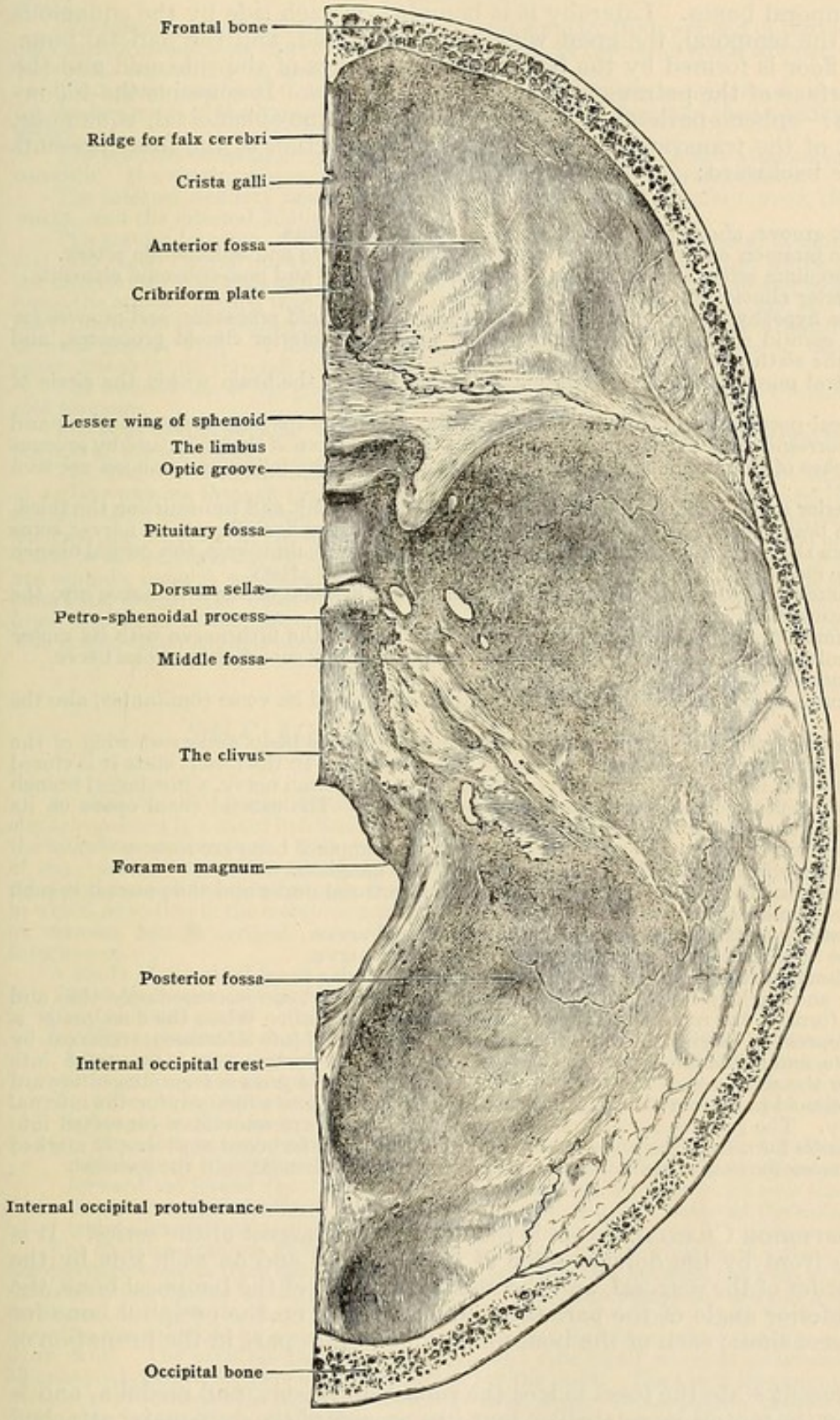

The Middle Cranial Fossa, situated on a lower level than the anterior, consists of a central and two lateral portions. In front it is limited by the posterior borders of the lesser wings of the sphenoid and the anterior margin of the optic groove, behind by the dorsum sellæ and the upper angle of the petrous portion of both temporal bones. Laterally it is bounded on each side by the squamous portion of the temporal, the great wing of the sphenoid, and the parietal bone, whilst the floor is formed by the body and great wings of the sphenoid and the anterior surface of the petrous portion of the temporals. It contains the following sutures:—spheno-parietal, petro-sphenoidal, squamo-sphenoidal, squamous, and a part of the transverse suture. The central portion of the fossa presents from before backward:

The **optic groove,** above and behind which is the optic chiasma.

The **optic foramen** on each side, transmitting the optic nerve and ophthalmic artery.

The **tuberculum sellæ,** indicating the line of junction of pre- and post-sphenoid elements.

The **anterior clinoid processes.**

The **fossa hypophyseos** or **sella turcica,** with the **middle clinoid processes,** and grooves for the internal carotid arteries. The **dorsum sellæ,** with the **posterior clinoid processes,** and notches for the sixth pair of cranial nerves.

The central portion is in direct relation with the parts of the brain within the circle of Willis.

The lateral portions are of considerable depth and marked by numerous elevations and depressions corresponding to the convolutions of the temporal lobes of the brain, and by grooves for the branches of the middle and small meningeal vessels. The following foramina are seen on each side:—

The **superior orbital** (sphenoidal) **fissure,** leading into the orbit and transmitting the third, fourth, three branches of the ophthalmic division of the fifth and sixth cranial nerves, some filaments from the cavernous plexus of the sympathetic, an ophthalmic vein, the orbital branch of the middle meningeal, and a recurrent branch of the lacrimal artery.

The **foramen rotundum,** for the passage of the second division of the fifth nerve into the pterygo-palatine fossa.

The **foramen ovale,** which transmits the third division of the fifth nerve with its motor root (mandibular nerve), the small meningeal artery, and the small superficial petrosal nerve.

The **foramen Vesalii** (not always present) for a small vein.

The **foramen spinosum,** for the middle meningeal artery and its venæ comitantes; also the N. spinosus.

The **foramen lacerum** is the irregular aperture between the body and great wing of the sphenoid, and the apex of the petrous portion of the temporal. In the recent state it is closed below by a layer of fibro-cartilage which is perforated by the Vidian nerve, a meningeal branch of the ascending pharyngeal artery, and an emissary vein. The carotid canal opens on its lateral wall and the pterygoid (Vidian) canal in front.

On the anterior surface of the petrous portion of the temporal bone are seen:—

A depression which lodges the semilunar (Gasserian) ganglion.

The **hiatus canalis facialis** for the great superficial petrosal nerve and the petrosal branch of the middle meningeal artery.

The **accessory hiatus** for the small superficial petrosal nerve.

A minute foramen for the external superficial petrosal nerve.

The **eminentia arcuata,** formed by the superior semicircular canal.

Anterior and slightly lateral to the eminentia arcuata the bone is exceedingly thin and translucent, forming the roof of the tympanum (tegmen tympani). When the dura mater is *in situ,* the depression lodging the semilunar ganglion is converted into a foramen, traversed by the fifth nerve, and in the same way the notch on the side of the dorsum sellæ is converted into a foramen for the sixth nerve. In many skulls the middle clinoid process is prolonged toward the anterior clinoid process, with which it may be joined to complete a foramen for the internal carotid artery. The grooves for the middle meningeal vessels are sometimes converted into canals or tunnels for a short distance, especially in old skulls. The bones most deeply marked are the squamous portion of temporal, the great wing of the sphenoid, and the parietal.

The Posterior Cranial Fossa is the deepest and largest of the series. It is bounded in front by the dorsum sellæ of the sphenoid and on each side by the superior border of the petrosal, and the mastoid portion of the temporal bone, the posterior inferior angle of the parietal, and the groove on the occipital bone for the transverse sinus; each of the bones mentioned takes part in the formation of its floor.

In the recent state the fossa lodges the cerebellum, pons, and medulla, and is roofed in by the tentorium cerebelli, a tent-like process of the dura mater attached to the ridges limiting the fossa above. It communicates with the general cranial cavity by means of the **foramen ovale of Pacchionius,** a large opening bounded in front by the clivus (basilar groove) and behind by the anterior free edge of the tentorium.

The posterior fossa is marked by several **sutures,** viz., petro-occipital, occipito-mastoid, parieto-mastoid, and in young skulls the basilar (occipito-sphenoidal). In addition, the following points may be noted:—

The **clivus,** extending from the dorsum sellæ to the anterior margin of the foramen magnum, and in relation with the basilar artery, the pons, the medulla, the sixth nerves, and the basilar sinus.

The **foramen magnum,** occupied in the recent state by the lower end of the medulla oblongata and its membranes, the vertebral, anterior spinal and posterior spinal arteries, the accessory (eleventh) cranial nerves, and the tectorial membrane.

The **hypoglossal canal** (foramen), sometimes divided by a spicule of bone into two divisions, for the two parts of the hypoglossal nerve and a meningeal branch of the ascending pharyngeal artery.

The **internal occipital crest,** behind the foramen magnum, for the attachment of the falx cerebelli. It sometimes presents a depression known as the **vermiform fossa.**

The **internal auditory meatus,** for the seventh and eighth cranial nerves, the pars intermedia, and the internal auditory vessels.

The **jugular foramen** (foramen lacerum posterius), somewhat pyriform in shape, and divisible into three compartments. The anterior division, placed somewhat medially, transmits the inferior petrosal sinus and is sometimes completely separated by an intra-jugular process of bone; the middle division transmits three cranial nerves, the ninth, tenth, and eleventh; and, in the posterior division, placed somewhat laterally, the transverse sinus becomes continuous with the internal jugular vein. A meningeal branch of the ascending pharyngeal or occipital artery enters the cranium through this division of the foramen.

The termination of the groove for the transverse sinus with the internal orifice of the **mastoid foramen.**

The **aquæductus vestibuli** and the **fossa subarcuata,** on the posterior surface of the petrous portion of the temporal.

The cranium of an average European has a *capacity* of 1450 c.c. The *circumference,* taken in a plane passing through the ophryon in front, the occipital point behind, and the pterion at the side, is 52 cm. The *length* from the ophryon to the occipital point is 17 cm., and the width between the parietals at the level of the zygomata is 12.5 cm. The proportion of the greatest width to the length is known as the *cephalic index,* i. e., index of breadth. A skull with an average cephalic index is *mesaticephalic.* When the index is above the average, it is *brachycephalic* (short and broad), and when below the average, *dolichocephalic* (long and narrow). The *height* from the basion to the bregma is nearly the same as the width at the level of the zygomata. The cranio-facial angle is about 96°.

THE MORPHOLOGY OF THE SKULL

In man the skull during development passes through three stages. At first the brain vesicles are enclosed in a sac of indifferent tissue which ultimately becomes tough and fibrous to form the **membranous cranium.** This, in turn, is partly converted into the membrane or roof bones of the cranium, whilst the remainder is represented in the adult by the dura mater. At the sides and base of the membranous cranium, however, cartilage is deposited, **chondro-cranium,** in which, as well as in the membranous tracts, osseous tissue appears in due course. Eventually, as **osseous box** is formed, consisting of membrane bones and cartilage bones intricately interwoven.

A study of the skull in the chondral stage is very instructive. It consists of two parts: (1) The skull proper and (2) the appendicular elements.

(1) The **skull proper** consists of three regions:—

(*a*) The **notochordal** region, which ultimately gives rise to the chief parts of the occipital bone and a part of the sphenoid. It is named notochordal because the notochord runs in it as far as the anterior extremity, i. e., the level of the fossa hypophyseos (sella turcica.)

(*b*) Anterior to the notochordal is the **trabecular region,** from which the remainder of the sphenoid is developed.

(*c*) The most anterior part of the prechordal portion of the base is the **ethmo-vomerine region,** from which the nasal septum and its cartilages arise. These three parts continue forward the line of the vertebral axis, and constitute a *cranio-facial axis* terminating, in front, in the premaxillæ. Finally, wedged in on each side, between the notochordal and trabecular regions, is the complicated **periotic capsule.**

The **chondro-cranium** at the third month presents the following parts. Seen from above, the cartilage extends from the cranial base to a spot midway between the base and the vertex, shading off indefinitely on the membranous wall. The oval masses on each side are the **periotic cartilages,** in which the fossæ subarcuatæ are conspicuous objects. Each periotic cartilage is joined to the sphenoid by a strip, termed the **sphenotic cartilage,** which usually persists in the adult skull. The cartilage for the orbito-sphenoid (the small wing) is co-extensive with the ali-sphenoid, and forms part of the lateral wall of the skull. The snout-like appearance of the anterior part of the skull is caused by the **fronto-nasal** plate. On each side of the ethmo-vomerine plate, near its anterior termination, are two small concave pieces of cartilage for Jacobson's organs. They are sometimes referred to as the ploughshare cartilages, owing to their shape. Further details are given in fig. 141.

(2) The **appendicular elements** of the skull are a number of cartilaginous rods surrounding the visceral cavity—i. e., nose, mouth, and pharynx—which undergo a remarkable metamorphosis, and are represented in the adult by the *ear bones,* the *styloid process,* and the *hyoid bone.*

FIG. 141.—MODEL OF THE CHONDRO-CRANIUM OF A HUMAN FŒTUS 8 CM. IN LENGTH. Cartilage in Blue. Viewed from Above. (After O. Hertwig.)

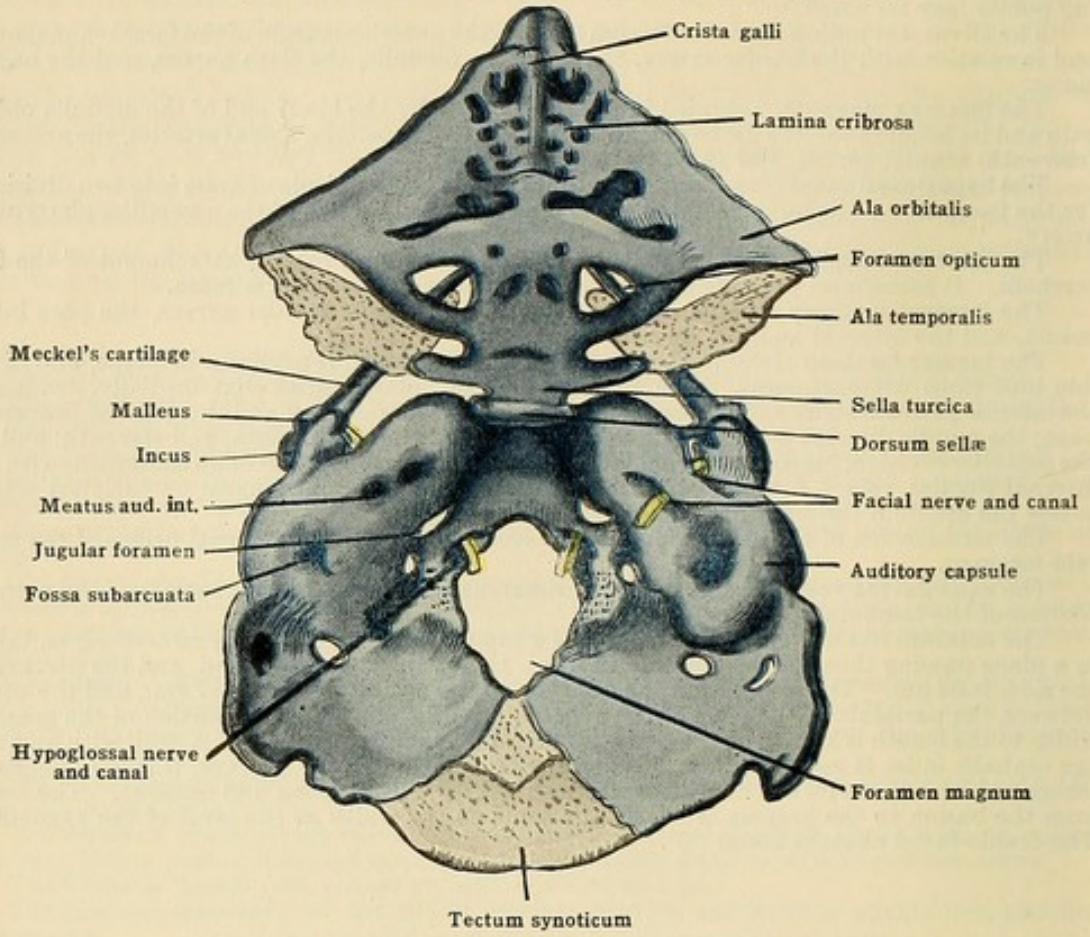

FIG. 142.—AN ENLARGED PORTION OF THE SAME MODEL OF THE CHONDRO-CRANIUM AS SHOWN IN FIG. 141. VIEWED FROM THE RIGHT SIDE, SHOWING THE SKELETON OF THE AUDITORY REGION. Cartilage in Blue. (After O. Hertwig.)

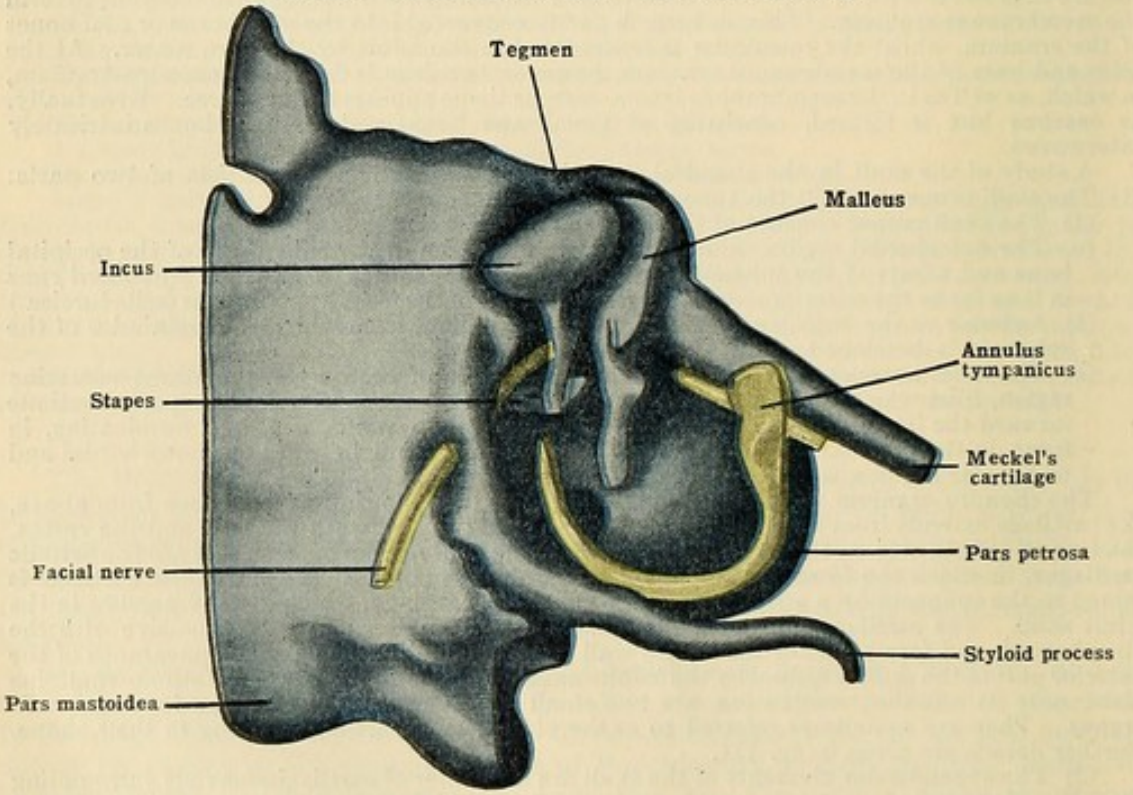

Metamorphosis of the Branchial or Visceral Bars

These rods of cartilage are named, f om before backward, the **mandibular, hyoid,** and **thyreoid** bars. They may with care be easily dissected in the fœtus between the third and fourth months. Their metamorphosis is as follows:—

The two extremities of the **mandibular bar** (cartilago Meckelii) ossify; the distal end ultimately forms a portion of the mandible near to the symphysis (see p. 98); the proximal end ossifies as the **malleus** and **incus.** The intermediate portion disappears; the only vestige is a band of fibrous tissue, the spheno-mandibular ligament, extending from the spine of the sphenoid to the spine of the mandible.

In the connective tissue surrounding the bar there appear, however, ossifications, one of which invests the bar to form the dentary plate; while a second, situated more proximally, forms the tympanic bone.

The **hyoid bar** fuses distally with the thyreoid bar, and forms part of the **hyoid bone.** Its proximal end becomes the **stapes,** the **tympano-hyal** portion of the styloid process (fused with the petro-mastoid), and the **stylo-hyal** or free portion of the process. The succeeding portion (**epi-hyal segment**) is represented in the adult by the stylo-hyoid ligament, and the lowest segment, or **cerato-hyal,** by the small cornu of the hyoid.

The **thyreoid bar** forms the great cornu of the hyoid bone (**thyreo-hyal**). The body of the hyoid (**basi-hyal**) is regarded as representing the fused ventral ends of the hyoidean and thyreoidean arches.

In addition to these structures ossifications occur in the connective tissue of the maxillary process, a structure which may be regarded as forming the anterior part of the first branchial arch, and in the fronto-nasal process. The ossifications in the maxillary process give rise to the pterygoid (medial pterygoid process of the sphenoid), the palate, the maxilla, and the zygomatic, while that in the fronto-nasal process forms the premaxilla.

The bony elements of the head may therefore be arranged, according to their origin, in the following table:—

I. Basilar Bones Developed in the Cartilaginous Cranium

Basi-occipital.....Basilar portion of the occipital bone.
Exoccipitals.....Condylar parts of the occipital bone.
Supra-occipital.....Lower part of the squamous portion of the occipital.
Basi-sphenoid } .....Constituting the body of the sphenoid.
Pre-sphenoid }
Ali-sphenoids.....Greater wings and lateral pterygoid plates.
Orbito-sphenoids.....Lesser wings.
Petro-mastoids.....Petrous and mastoid portions (excepting post-auditory processes) of the temporal bones.

II. Roof Bones Developed in the Membranous Cranium

Squamosals.....Squamous portions of temporals.
Parietals.....The two parietal bones.
Frontals.....United to form a median frontal bone.
Interparietal.....Upper part of squamous portion of occipital.
Epipterics.....The epipteric bones.

III. Bones of the Nasal Region

Mesethmoid.....Vertical plate of ethmoid developed in the cartilage of the cranio-facial axis.
Ethmo-turbinals.....Superior and inferior conchal processes of ethmoid.
Maxillo-turbinals.....The inferior nasal conchæ.
Cribriform lamina.....Cribriform plate of ethmoid.
These elements are developed in the cartilage of the lateral nasal process.
Sphenoidal turbinals.....Sphenoidal conchæ. These are derivatives of the ethmo-turbinals.
Lacrimals.....The lacrimal bones } Developed in the membrane over
Nasals.....The nasal bones } the lateral nasal process.
Vomer.....The vomer. Ossified in the membrane investing the cartilage of the cranio-facial axis.

IV. Facial Bones

Maxillæ.....The maxillæ..... } Developed in the connective tissue
Zygomatics.....The zygomatic bones } of the maxillary process.
Premaxillæ.....The incisor parts of the maxillæ. Formed at the anterior extremity of the cranio-facial axis in the tissue of the fronto-nasal process (proc. globulares).

V. Appendicular Elements (Bones of the Visceral Arches)

(A) *Cartilaginous*

Malleus, Incus, and Stapes.....The ossicula auditus.
Mento-Meckelian portion of the lower jaw.....Small part on either side near to the symphysis menti.
Tympano-hyals and Stylo-hyals.....Styloid processes of the temporal bones.
Epihyals.....Stylo-hyoid ligaments.
Cerato-hyals.....Lesser cornua of hyoid bone.
Thyreo-hyals.....Greater cornua of hyoid bone.
Basi-hyals.....Body of hyoid bone.

(B) *Membranous*

Mandible.....The lower jaw excluding a small portion near symphysis.
Tympanics.....The tympanic plates.
Pterygoids.....The medial pterygoid plates.
Palatals.....The palate bones.

The Skull at Birth

The skull at birth presents, when compared with the adult skull, several important and interesting features. Its peculiarities may be considered under three headings:—The peculiarities of the fœtal skull as a whole; the construction of the individual bones; the remnants of the chondral skull.

(1) *The General Characters of the Fœtal Skull*

The most striking features of the skull at birth are, its relatively large size in comparison with the body, and the predominance of the cranial over the facial portion of the skull (8 to 1); the latter is, in fact, very small.

Fig. 143.—The Cranium at Birth. (Viewed from above.)

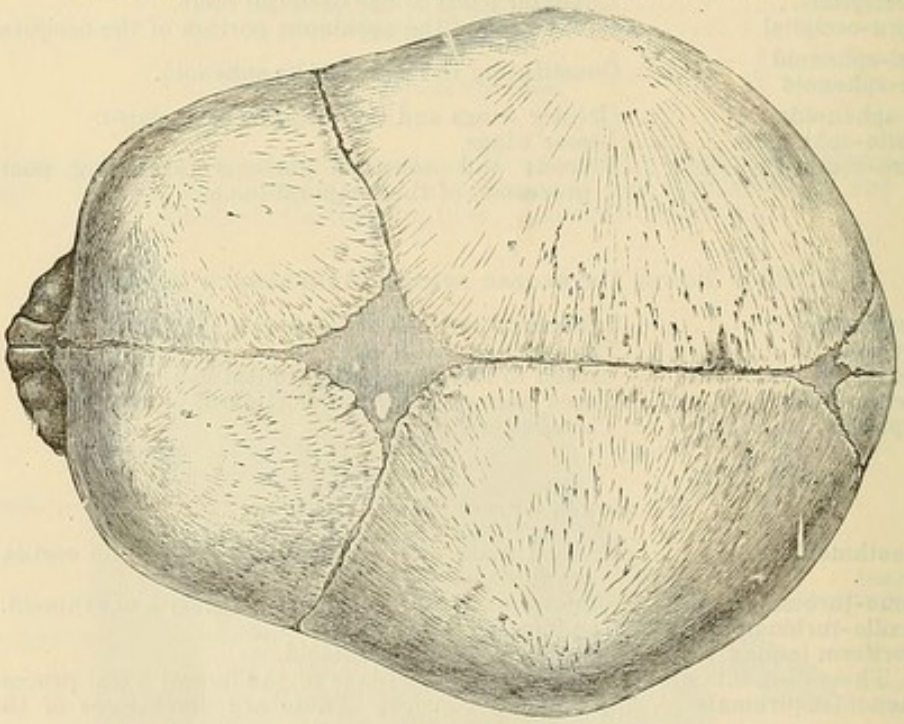

The frontal and parietal eminences are large and conspicuous; the sutures are absent; the adjacent margins of the bones of the vault are separated by septa of fibrous tissue continuous with the dura mater internally and the pericranium externally; hence it is difficult to separate the roof bones from the underlying dura mater, each being lodged, as it were, in a dense membranous sac. The bones of the vault consist of a single layer without any diploë, and their cranial surfaces present no digital impressions. Six membranous spaces exist, named fontanelles: two are median, the frontal [fonticulus frontalis; major] being anterior and the occipital [fonticulus occipitalis; minor] posterior. Two exist on each side, termed anterior [fonticulus sphenoidalis] and posterior [fonticulus mastoideus] lateral fontanelles. Each angle of the parietal bones is in relation with a fontanelle. The anterior fontanelle is lozenge-shaped, the posterior triangular. The lateral fontanelles are irregular in outline. The lateral fontanelles close soon after birth; the occipital fontanelle closes in the first year, and the frontal during the second year.

Turning to the base of the skull, the most striking points are the absence of the mastoid processes, and the large angle which the pterygoid plates form with the skull-base, whereas in the adult it is almost a right angle. The base of the skull is relatively short, and the lower border of the mental symphysis is on a level with the occipital condyles.

The facial skeleton is relatively small in consequence of the small size of the nasal fossæ, the small size of the maxillary sinus, and the rudimentary condition of the alveolar borders

FIG. 144.—THE CRANIUM AT BIRTH. (Lateral view.)

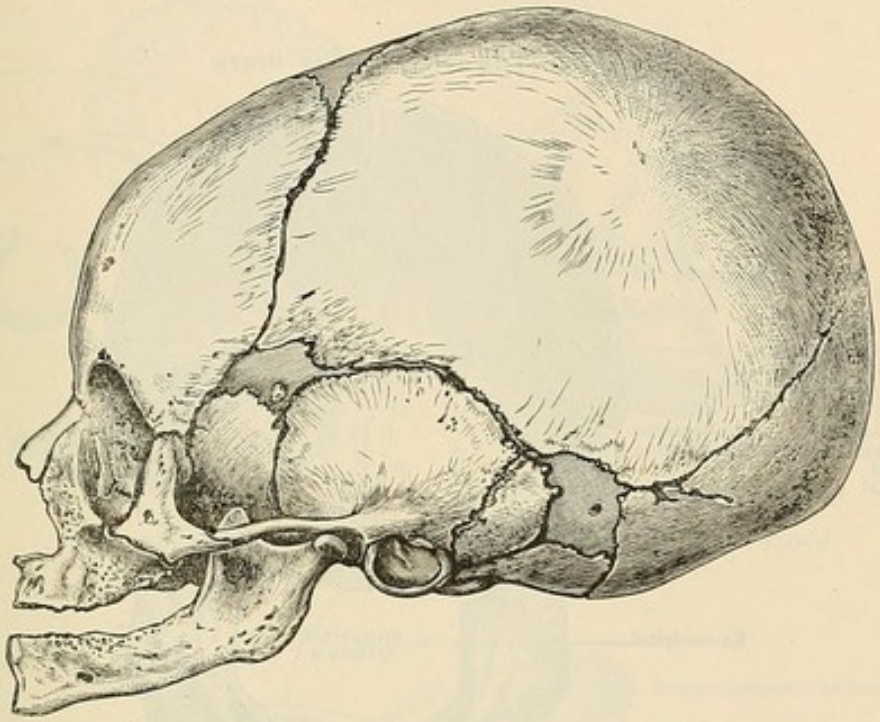

of the maxillæ and mandible; the nasal fossæ are as wide as they are high, and are almost filled with the conchæ.

Growth takes place rapidly in the first seven years after birth. There is a second period of rapid growth at puberty, when the air sinuses develop, and this affects especially the face and frontal portion of the cranium.

FIG. 145.—THE CRANIUM AT BIRTH IN SAGITTAL SECTION. (Sphenoidal concha indicated by a *)

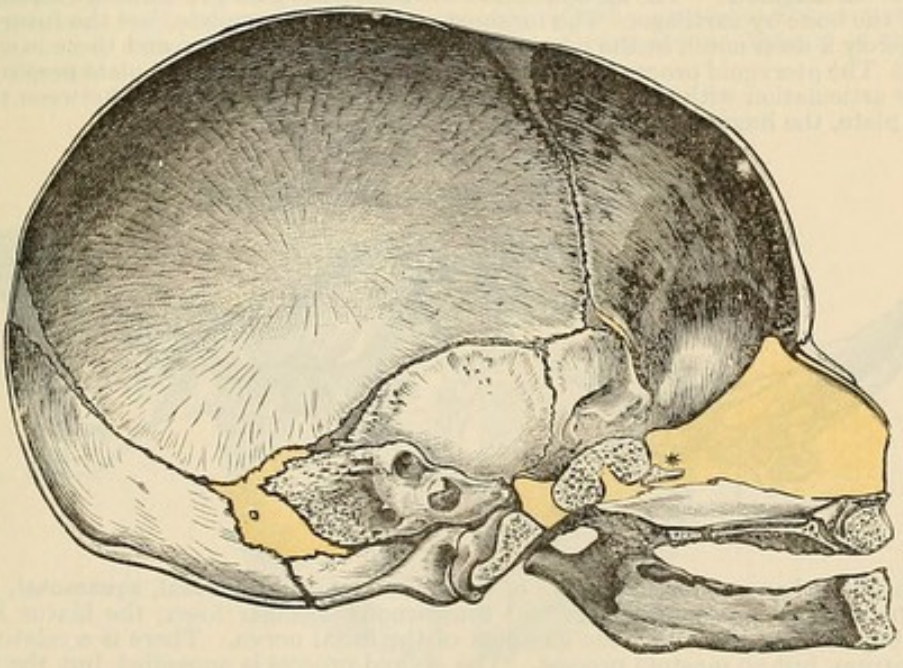

(2) *The Peculiarity of Individual Bones at Birth*

The **occipital bone** consists of four distinct parts, which have already been described. Compared with the adult bone, the following are the most important points of distinction:—There is no **pharyngeal tubercle** or **jugular process**; the squamous portion presents two deep fissures separating the interparietal from the supra-occipital portion and extending medially

as far as the occipital protuberance. The grooves for the transverse (lateral) sinuses are absent.

The **sphenoid** in a macerated fœtal skull falls into three pieces: (1) united **pre-** and **post-sphenoids, orbito-sphenoids,** and **lingulæ,** and (2 and 3) the **ali-sphenoids.** The **pre-sphenoid** is quite solid and connected with the ethmo-vomerine cartilage, and presents no traces of the air sinuses which occupy this part in the adult skull. The pre-sphenoid by its upper surface forms part of the anterior cranial fossa, from which it is subsequently excluded by the growth of the orbito-sphenoids. The optic foramina are large and triangular in shape. The **lingulæ**

FIG. 146.—THE OCCIPITAL AT BIRTH.

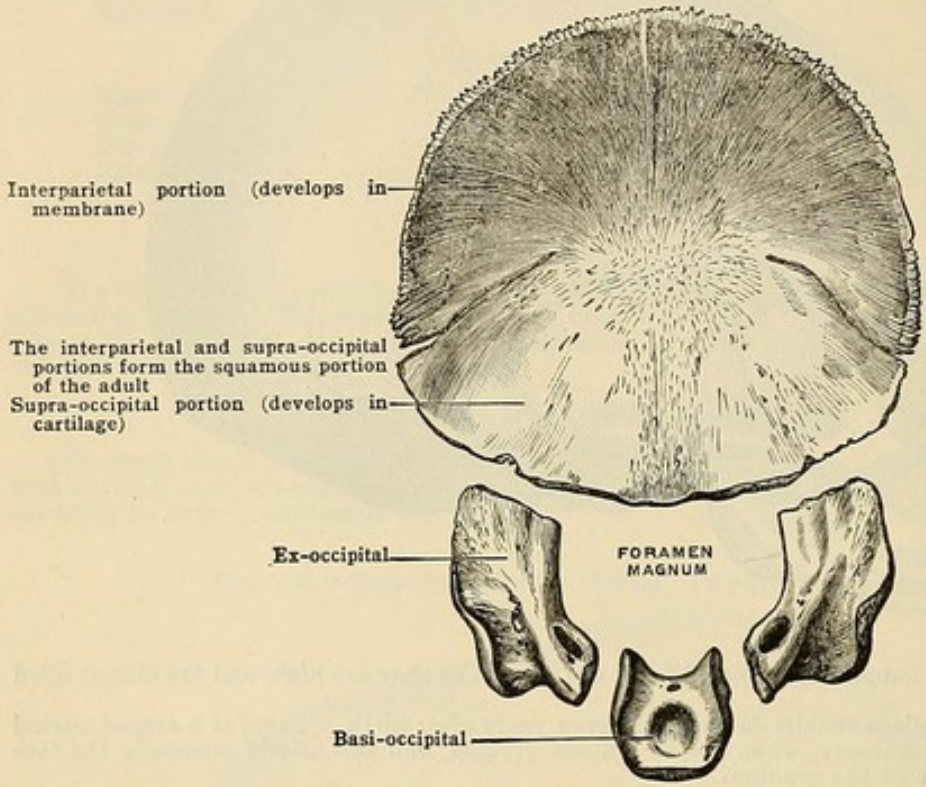

stand out from the basi-sphenoid as two lateral buttresses, and at the tuberculum sellæ is the **basi-pharyngeal canal,** which in the recent bone is occupied by fibrous tissue. The **dorsum sellæ** is still cartilaginous. The **ali-sphenoids** with the pterygoid processes are separated from the rest of the bone by cartilage. The foramen rotundum is complete, but the future foramen ovale is merely a deep notch in the posterior border of the great wing, and there is no foramen spinosum. The pterygoid processes are short, and each medial pterygoid plate presents a broad surface for articulation with the lingula. The **pterygoid canal** is a groove between the medial pterygoid plate, the lingula, and great wing.

FIG. 147.—THE SPHENOID AT BIRTH.

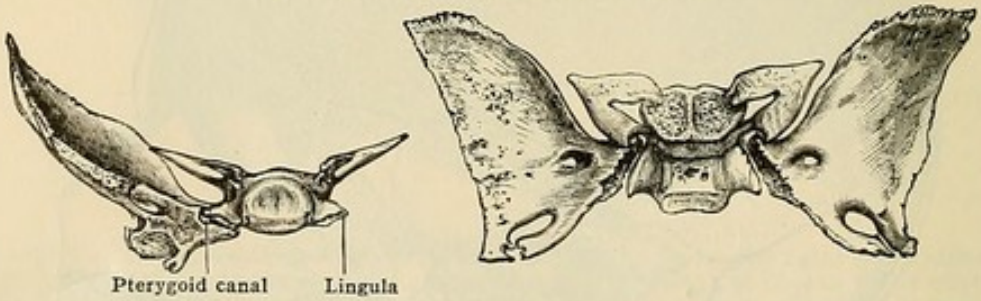

The **temporal bone** at birth consists of three elements, the **petrosal, squamosal,** and **tympanic.** The **petrosal** presents a large and conspicuous floccular fossa; the hiatus Fallopii is a shallow bay lodging the geniculate ganglion of the facial nerve. There is a relatively large mastoid antrum, but no mastoid process. The styloid process is unossified, but the **tympano-hyal** may be detected as a minute rounded nodule of bone near the stylo-mastoid foramen.

The **squamosal** has a very shallow mandibular fossa and a relatively large post-glenoid tubercle. The posterior part of the inferior border is prolonged downward into an uncinate process (*post-auditory process*) which closes the mastoid antrum laterally.

The **tympanic** bone or annulus is a delicate, horseshoe-shaped ossicle, attached by its anterior and posterior extremities to the inferior border of the squamosal.

The **ear-bones** are chiefly of interest from their size, for they are as large at birth as in the adult. The anterior process (Folian process) may be 2 cm. in length.

FIG 148.—THE TEMPORAL BONE AT BIRTH.

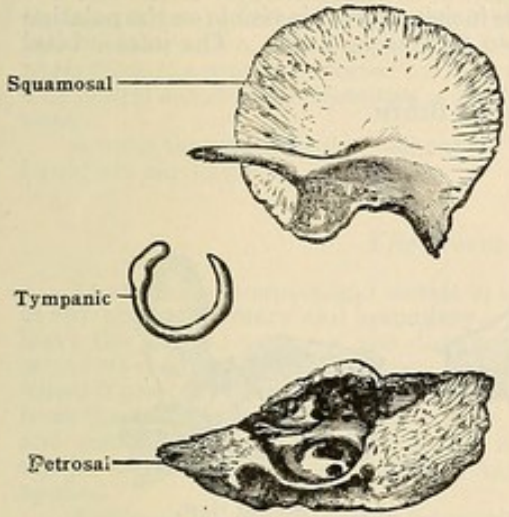

FIG. 149.—TEMPORAL BONE AT BIRTH. (Medial view.)

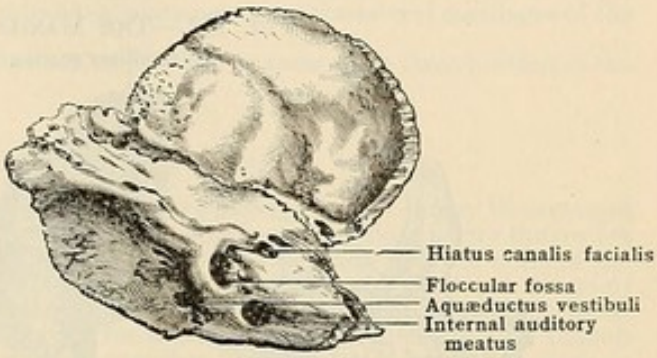

FIG. 150.—THE TEMPORAL BONE AT BIRTH. (Lateral view.)

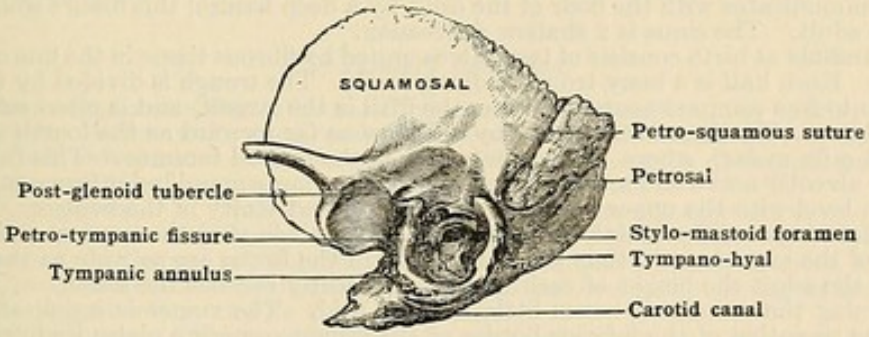

The **frontal** consists of two bones separated by a median vertical (metopic) suture. The frontal eminence is very pronounced, but the superciliary arches and frontal sinuses are wanting. The frontal spine, which later becomes one of the most conspicuous features of this bone, is absent. There is no temporal line.

FIG. 151.—THE FRONTAL BONE AT BIRTH.

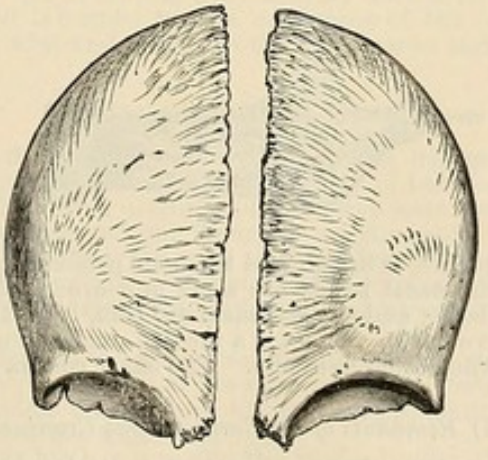

The **parietal** is simply a quadrilateral lamina of bone, concave on its inner and convex on the outer surface. The parietal eminence, which indicates the spot in which the ossification of the bone commenced, is large and prominent. The grooves for blood-sinuses, as in other cranial

bones, are absent. Each angle of the parietal is in relation with a fontanelle. As in the adult, the anterior inferior angle of the bone is prolonged downward toward the ali-sphenoid.

The **ethmoid** consists of two lateral portions separated by the still cartilaginous ethmo-vomerine plate. The ethmoid cells are represented by shallow depressions, and the uncinate process is undeveloped.

The **sphenoidal conchæ** are two small triangular pieces of bone lying in the perichondrium on each side of the ethmo-vomerine plate near its junction with the pre-sphenoid. (Indicated by the * in fig. 145.)

The **maxilla** presents the following characters:—The incisive suture is visible on the palatine aspect of the bone. The alveolar border presents five sockets for teeth. The infra-orbital

FIG. 152.—THE MAXILLA AT BIRTH.

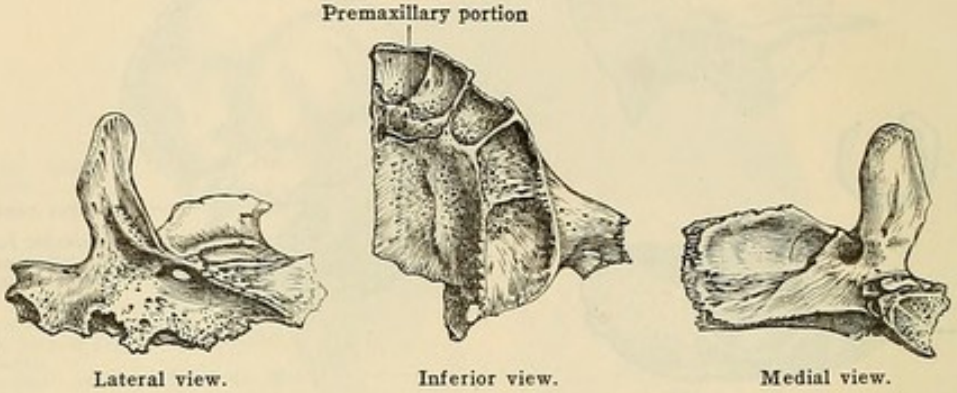

foramen communicates with the floor of the orbit by a deep fissure; this fissure sometimes persists in the adult. The sinus is a shallow depression.

The **mandible** at birth consists of two halves united by fibrous tissue in the line of the future symphysis. Each half is a bony trough lodging teeth. The trough is divided by thin osseous partitions into five compartments: of these, the fifth is the largest, and is often subdivided by a ridge of bone. The floor is traversed by a furrow as far forward as the fourth socket (that for the first milk molar), where it turns outward at the mental foramen. This furrow lodges the inferior alveolar nerve and artery, which enter by the large mandibular foramen. The condyle is on a level with the upper border of the anterior extremity of the bone.

The **palate bones** differ mainly from those in the adult in that the vertical and horizontal plates are of the same length; thus the nasal fossæ in the fœtus are as wide as they are high, whereas in the adult the height of each nasal fossa greatly exceeds the width.

Concerning the remaining bones little need be said. The vomer is a delicate trough of bone for the reception of the inferior border of the ethmo-vomerine plate; its inferior border,

FIG. 153.—THE MANDIBLE AT BIRTH.

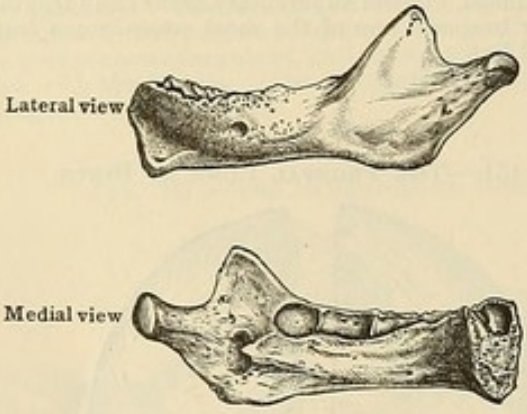

which rests upon the hard palate, is broad, and the bone presents quite a different appearance from that in the adult. The **nasal bones** are short and broad; the **zygomatics** and **inferior conchæ** are relatively very large; and the **lacrimals** are thin, frail, and delicate lamellæ.

The **hyoid** consists of five parts. There is a median nucleus for the basi-hyal, and one on each side for the greater cornua (thyreo-hyals). The lesser cornua are cartilaginous.

(3) *Remnants of the Cartilaginous Cranium*

It has already been pointed out that at an early date the base of the skull and the face are represented by hyaline cartilage, which for the most part is replaced by bone before birth. Even at birth remnants of this primitive chondral skull are abundant. In the cranium, cartilaginous tracts exist between the various portions of the occipital bone, as well as at the line of

junction of the occipital with the petrosal and sphenoid. The dorsum sellæ is entirely cartilaginous at birth, and the last portion of this cartilage disappears with the ankylosis of the basi-occipital and basi-sphenoid about the twentieth year. A strip of cartilage unites the ali-sphenoids with the lingulæ, and for at least a year after birth this cartilage is continuous with that which throughout life occupies the foramen lacerum. A strip of cartilage exists along the posterior border of the orbito-sphenoid, and not unfrequently extends lateralward to the pterion. In the adult skull it is replaced by ligamentous tissue.

The ethmo-vomerine plate is entirely cartilaginous, and near the end of the nose supports the lateral nasal cartilages, remnants of the fronto-nasal plate. The fate of the ethmo-vomerine plate is instructive. The upper part is ossified to form the mesethmoid; the lower part atrophies from the pressure exerted by the vomer; the anterior end remains as the septal cartilage. The lateral snout-like extremities of the fronto-nasal plate persist as the lateral cartilages of the nose.

Among the appendicular elements of the skull, the styloid process and a large portion of the hyoid are cartilaginous at birth.

The Nerve-foramina of the Skull

The various foramina and canals in the skull which give passage to nerves may be arranged in two groups, **primary** and **secondary.** **Primary** foramina indicate the spots where the nerves leave the general cavity of the dura mater, and as this membrane indicates the limit of the primitive cranium, a cranial nerve, in a morphological sense, becomes extra-cranial at the point where it pierces this membrane. In consequence of the complicated and extraordinary modifications the vertebrate skull has undergone, many nerves traverse, in the adult skull, bony tunnels and canals which are not represented in the less complex skulls of low vertebrates, such as sharks and rays. To such foramina and canals the terms **secondary** or **adventitious** may be applied.

Nerve-foramina are further interesting in that they occupy sutures, or indicate the points of union of two or more ossific centres. To this rule the foramen rotundum is the only exception in the human skull.

The Primary Foramina

1. **Foramen magnum.**—This is bounded by four distinct centres, the supra-, basi-, and two ex-occipitals. It transmits the accessory (eleventh) pair of cranial nerves, the vertebral arteries and their anterior and posterior spinal branches, the medulla oblongata and its membranes, and the membrana tectoria.

2. **The hypoglossal.**—At birth this is a deep notch in the anterior extremity of the ex-occipital, and becomes a complete foramen when the basi- and ex-occipitals fuse. Occasionally it may be complete in the ex-occipital, but it indicates accurately the line of union of these two elements of the occipital bone. It transmits the hypoglossal nerve, the meningeal branch of the ascending pharyngeal artery, and its venæ comitantes.

3. **Jugular foramen.**—This occupies the petro-occipital suture, and is formed by the basi- and ex-occipital in conjunction with the petrosal. It transmits the glosso-pharyngeal, vagus, and accessory nerves, a meningeal branch of the ascending pharyngeal artery, and receives the transverse and inferior petrosal sinuses.

4. **Auditory.**—This marks the point of confluence of the groups of centres termed pro-otic and opisthotic. It transmits the facial and auditory nerves, the pars intermedia, and the auditory twig of the basilar artery.

5. **Trigeminal.**—This is only a foramen when the dura mater is present in the skull. It is a notch at the apex of the petrosal converted into a foramen by the tentorium. The main trunk of the trigeminal nerve, with the small motor root (masticator nerve), traverses it.

6. **Petro-sphenoidal.**—This is a notch between the side of the dorsum sellæ and apex of the petrosal which becomes converted into a foramen by dura mater.

7. **Optic.**—This foramen is formed by the confluence of the orbito- and pre-sphenoidal centres. It opens into the orbit and transmits the optic nerve and ophthalmic artery.

The Secondary Nerve-foramina

Foramina transmitting the various subdivisions of the trigeminal nerve.—The primary foramen of exit for the trigeminal nerve is formed partly of bone and partly of membrane at the apex of the petrosal. The three divisions of the nerve issue through secondary foramina.

(*a*) The **superior orbital** (sphenoidal) fissure is an elongated chink, bounded above by the orbital wing and below by the great wing of the sphenoid, medially by the body of the sphenoid, and laterally by the frontal. It opens into the orbit, and transmits the third, fourth, first (ophthalmic) division of the trigeminal and abducens nerves, also the ophthalmic vein or veins.

(*b*) The **foramen rotundum** is the only exception to the rule relating to the formation of nerve-foramina; it is probably a segment of the superior orbital fissure. The foramen is really a canal running from the middle cranial fossa to the pterygo-palatine fossa, and transmits the second or maxillary division of the trigeminal.

(*c*) The **foramen ovale** at birth is a gap in the hinder border of the great wing (ali-sphenoid) of the sphenoid, and is converted into a foramen by the petrosal; subsequently it becomes complete in the sphenoid. It transmits the third or mandibular division of the trigeminal and the small or motor root, the small superficial petrosal nerve (which occasionally passes through a separate foramen), and the small meningeal artery with its venæ comitantes.

The ethmoidal canals.—These commence in the suture between the lamina papyracea and the frontal bone, and traverse the space between the upper surface of the lateral mass of the ethmoid and the horizontal plate of the frontal, to emerge on the cribriform plate; they are situated outside the dura mater. The anterior foramen transmits the anterior ethmoidal branch of the ophthalmic, which subsequently gains the nasal cavity by passing through the ethmoidal fissure by the side of the crista galli.

The **infra-orbital canal** indicates the line of confluence of the maxillary and malar centres of the maxilla; occasionally it is completed by the zygomatic; rarely it is incomplete above, and communicates by a narrow fissure with the orbit. It lodges the infra-orbital nerve and artery.

The **zygomatico-temporal foramen** is situated in the suture between the zygomatic and the greater wing of the sphenoid (ali-sphenoid); it transmits the temporal branch of the zygomatic nerve and a branch of the lacrimal artery. In the adult this foramen may be wholly confined to the zygomatic bone.

The **zygomatico-facial canals** traverse the zygomatic bone, and indicate the line of confluence of the two chief centres for this bone. The facial twigs of the zygomatic nerve issue from them accompanied by arterial twigs.

The **spheno-palatine foramen** is a deep groove between the orbital and sphenoidal processes of the palate bone, converted into a foramen by the sphenoidal concha. It is traversed by the naso-palatine nerve and artery as they enter the nasal from the pterygo-palatine fossa.

Scarpa's foramina are two minute openings in the meso-palatine suture where it is in relation with the incisive fossa. They are traversed by the naso-palatine nerves.

The **pharyngeal foramen** is situated between the sphenoidal process of the palate bone, the medial pterygoid plate of the sphenoid, and the sphenoidal concha. The pharyngeal branch of the spheno-palatine ganglion and a branch of the spheno-palatine artery pass through it.

The **pterygoid** (Vidian) **canal** is trumpet-shaped: the narrower end is situated in the foramen lacerum; the broader orifice opens on the posterior wall of the pteryo-palatine fossa. The canal is 10 mm. long; in the fœtal skull it is a chink between the base of the medial pterygoid plate, the ali-sphenoid, and the lingula of the sphenoid. The canal is traversed by the Vidian branch of the spheno-palatine ganglion and the Vidian artery.

The **posterior** (greater) **palatine canal** is a passage left between the maxilla, the vertical plate and tuberosity of the palate bone and the medial pterygoid plate; it commences on the hard palate by the greater palatine foramen. The descending palatine nerve and artery traverse this canal. Several foramina open from it. In the suture between the vertical plate of the palate bone and the maxilla, two small openings allow minute nerves to issue for the middle and inferior nasal conchæ. In the fissures between the tuberosities of the palate and maxillæ, and the pterygoid plates, the posterior and middle palatine nerves issue. These are sometimes called the posterior and middle (smaller) palatine canals.

The **mandibular** or **inferior dental canal** runs in the mandible between the dentary and Meckel's cartilage of the mandible. The posterior orifice of the canal is the mandibular (inferior dental) foramen; the anterior orifice is the mental foramen. The inferior alveolar nerve and artery enter the canal at its posterior orifice; the mental foramen allows the mental nerve to escape from the canal accompanied by the mental artery.

Foramina transmitting the facial nerve and its branches.—The main trunk of the facial enters the internal auditory meatus and traverses the facial canal. In the early embryo the nerve lies on the petrosal, and is not covered in with bone until the fifth month of fœtal life. The terminal orifice, the **stylo-mastoid foramen,** is situated between the tympanic, tympano-hyal, and epiotic elements of the complex temporal bone.

The **'iter chordæ posterius'** is a chink between the squamosal and the tympanic elements, and allows the chorda tympani nerve to enter the tympanum. The fissure of exit for this nerve is the subdivision of the petro-tympanic fissure termed the canal of Huguier, or **'iter chordæ anterius.'** The **petro-tympanic fissure** lies between the tympanic plate and the squamosal. It transmits the tympanic branch of the internal maxillary artery, and lodges the anterior process of the malleus.

The **inferior orbital** (spheno-maxillary) fissure is situated between the posterior border of the orbital plate of the maxilla and a smooth ridge on the orbital surface of the great wing of the sphenoid. It transmits the superior maxillary division (second) of the fifth nerve, the zygomatic nerve, branches of the spheno-palatine ganglion to the orbit, and a communicating vein from the ophthalmic to the pterygoid plexus.

C. THE THORAX

The **thorax** is a bony cage formed by the thoracic vertebræ already described, the ribs with their costal cartilages, and the sternum.

THE RIBS

The **ribs** [costæ] (figs. 154, 155) twelve in number on each side, constitute a series of narrow, flattened bones, extending from the sides of the thoracic vertebræ toward the median line on the anterior aspect of the trunk. The anterior ends of the first seven pairs are connected, by means of their costal cartilages, with the sides of the sternum, and on this account the first seven ribs on each side are

termed **true** or sternal ribs. The remaining five pairs, known as **false** or asternal ribs, may be arranged in two sets:—one, including the eighth, ninth, and tenth ribs, in which the cartilages of the anterior extremities are connected together, and the other, including the eleventh and twelfth, in which the anterior extremities, tipped with cartilage, are free. The eleventh and twelfth are known, in consequence, as the **floating** ribs. Thus, the first seven are **vertebro-sternal;** the eighth, ninth, and tenth, **vertebro-chondral;** the eleventh and twelfth, **vertebral** ribs.

The ribs increase in length from the first to the seventh, and decrease from the seventh to the twelfth. They also vary in their direction, the upper ones being less oblique than the lower. The obliquity is greatest at the ninth rib and gradually decreases from the ninth to the twelfth.

Typical characters of a rib (fig. 154).—The seventh is regarded as the most typical rib. It presents for examination a vertebral extremity or **head;** a narrow portion or **neck;** a **sternal** extremity; and an intermediate portion, the **body** or **shaft.**

The **head** [capitulum costæ] presents an **articular surface** made up of two articular facets separated by a horizontal crest [crista capituli]. The crest is connected by an interarticular ligament with an intervertebral disc, and the facets articulate with the costal pits on the sides of the bodies of two vertebræ (sixth and seventh). As a rule, the lower facet is the larger, and articulates with the thoracic vertebra, to which the rib corresponds in number. This is the primary facet, and is the one represented in those ribs which possess only a single facet on the rib-head. The anterior margin is lipped for the attachment of the radiate ligament.

The **neck** [collum costæ] is that portion of the rib extending from the head to the **tubercle.** It is flattened from before backward and the posterior surface is in relation with the transverse process of the lower of the two vertebræ with which the head articulates; it forms the anterior boundary of the **costo-transverse foramen,** and is rough where it is attached to the neck (middle costo-transverse) ligament. The anterior surface is flat and smooth. The superior border of the neck, continuous with the corresponding border of the shaft, presents a rough crest [crista colli] for the anterior costo-transverse ligament. The inferior border of the neck is rounded and continuous with the ridge of the **costal groove.** This difference in the relation of the neck, to the upper and lower borders of the rib-shaft, is useful in determining to which side a rib belongs.

The **tubercle,** situated behind at the junction of the neck with the shaft, consists of an upper and lateral part, rough for the attachment of the posterior costo-transverse ligament, and a lower and medial part, bearing a facet for articulation with a pit near the tip of the transverse process. The tubercle projects below the lower edge of the rib to form a crest, marking the beginning of the costal groove.

The **body** is strongly curved and presents for examination two surfaces and two borders. At first the curve is in the same plane as the neck, but it quickly turns forward at a spot on the posterior surface of the shaft known as the **angle,** where it gives attachment to the *ilio-costalis* muscle and some of its subdivisions. The rib has also a second or upward curve, beginning at the angle. These curves are expressed by describing the main curve as disposed around a vertical, and the second or upward curve around a second transverse axis.

When a rib, except the first, second, and twelfth, is laid with its lower border upon the table, the rib-head rises and the rib touches the table at two places, viz., at the anterior end, and in the neighbourhood of the angle.

Besides the two curves now described, the rib is slightly twisted on itself, so that the surfaces which look medially and laterally behind are placed obliquely in front and look downward as well as medially, and upward as well as laterally.

The external surface of the rib is convex, and gives attachment to muscles. Near its anterior extremity it forms a somewhat abrupt curve, indicated by a ridge on the bone, which gives attachment to the *serratus anterior* (*magnus*) muscle, and is sometimes called the **anterior angle.**

The internal surface is concave and presents near its inferior border the **costal groove** [sulcus costæ]. The groove is best marked near the angle, and gradually becomes shallower toward the anterior extremity of the rib, where it is finally lost; it lodges the intercostal vessels and nerve. The ridge limiting the

groove above is continuous with the inferior border of the neck of the rib, and gives attachment to the *internal intercostal* muscle.

The superior border is rounded, and affords attachment to the *internal* and *external intercostal* muscles. The inferior border commences abruptly near the angle, and gives attachment to the *external intercostal* muscle.

The **sternal** end of the shaft is cupped for the reception of the costal cartilage.

FIG. 154.—THE SEVENTH RIB OF THE LEFT SIDE. (Seen from below.)

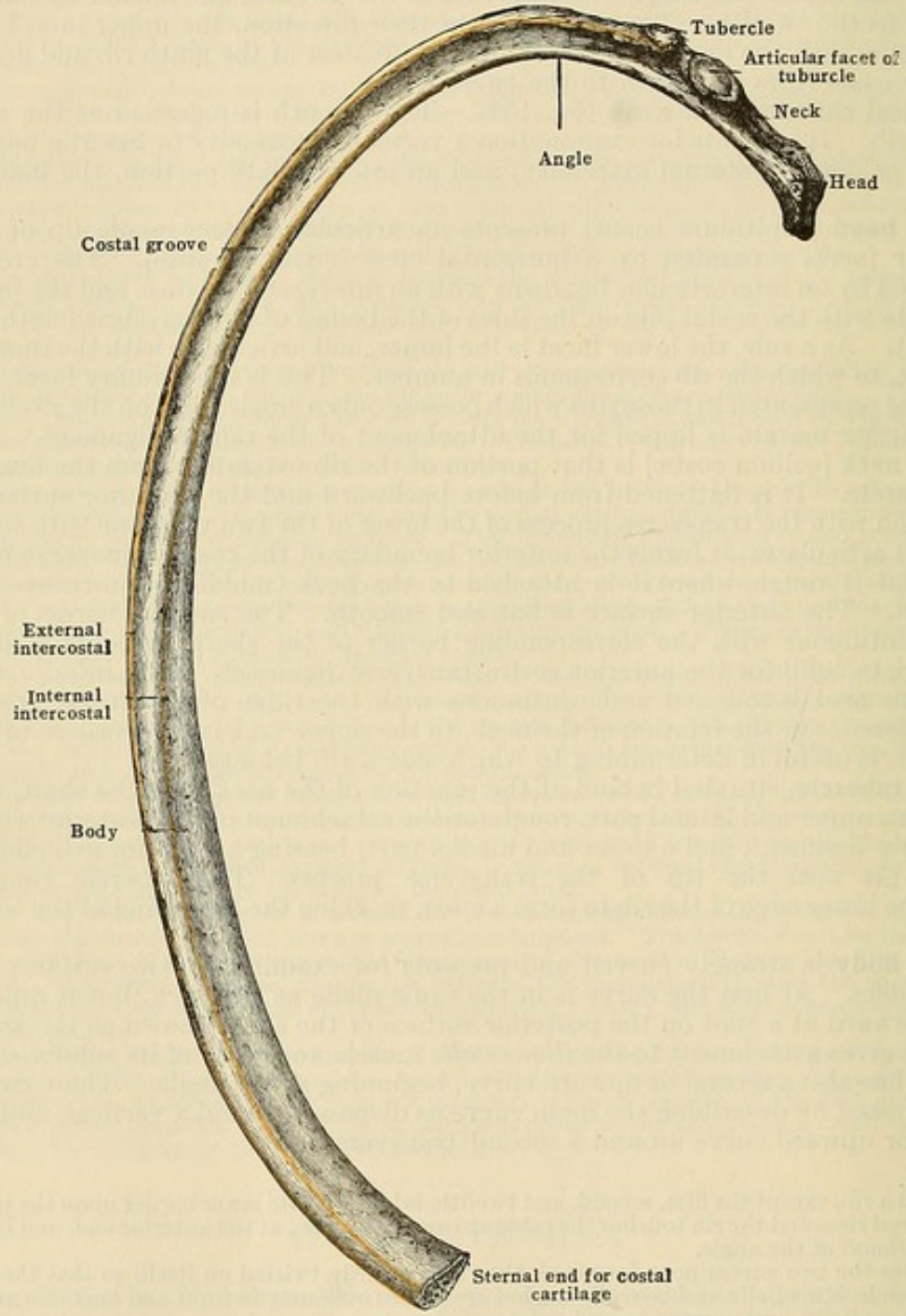

Blood-supply.—The ribs are very vascular and derive numerous branches from the intercostal arteries. The branches in the shaft run toward the vertebral end, whilst those in the head and neck run, as a rule, toward the shaft. In the neighbourhood of the tuberosity the vessels do not seem to have any constant arrangement.

Peculiar ribs (figs. 155, 156).—Several of the ribs present certain peculiarities and differ in many particulars from the general description given above. These are the first, second, tenth, eleventh, and twelfth.

The **first rib** is the broadest, flattest, strongest, shortest, and most curved of all the series. It is not twisted, and is so placed that its superior surface looks forward as well as upward, and its inferior surface backward as well as downward. The head is small, and as a rule is furnished

with only one articular facet. The neck, longer than that of most of the ribs, is slender and rounded. The tubercle is large and prominent. The shaft lies for its whole extent nearly in one plane, has no angle, and is curved in one direction only, i. e., around a vertical axis. The superior surface presents two shallow grooves, separated near the inner border by a rough surface (**scalene tubercle** or tubercle of Lisfranc) for the *scalenus anterior* muscle. The groove in front of this surface is for the subclavian vein, and the groove behind it is for the subclavian artery and a nerve trunk passing to the brachial plexus. Between the groove for the artery and the tubercle is a rough surface for the insertion of the *scalenus medius*, and between the groove and the outer margin is an area for the origin of the *serratus anterior* (*magnus*). The inferior surface is uniformly flat and lacks a subcostal groove. By the lateral portion, which is rough, it gives attachment to the internal intercostal muscle; the remainder of the inferior surface is in relation to pleura and lung. The lateral border is thick and rounded, and gives attachment to the *external intercostal* muscle, whilst the medial border, thin, sharp, and concave, receives the attachment of the fascia (Sibson's) covering the dome of the pleura. The anterior extremity is thick and broad, and its upper margin, as well as the cartilage to which it is joined, afford attachment to the costo-clavicular ligament and the *subclavius* muscle. The costal cartilage of this rib is directly united to the manubrium sterni, and occasionally the cartilage and the adjoining part of the anterior extremity of the rib are replaced by fibrous tissue.

FIG. 155.—FIRST AND SECOND RIBS. (Viewed from above.)

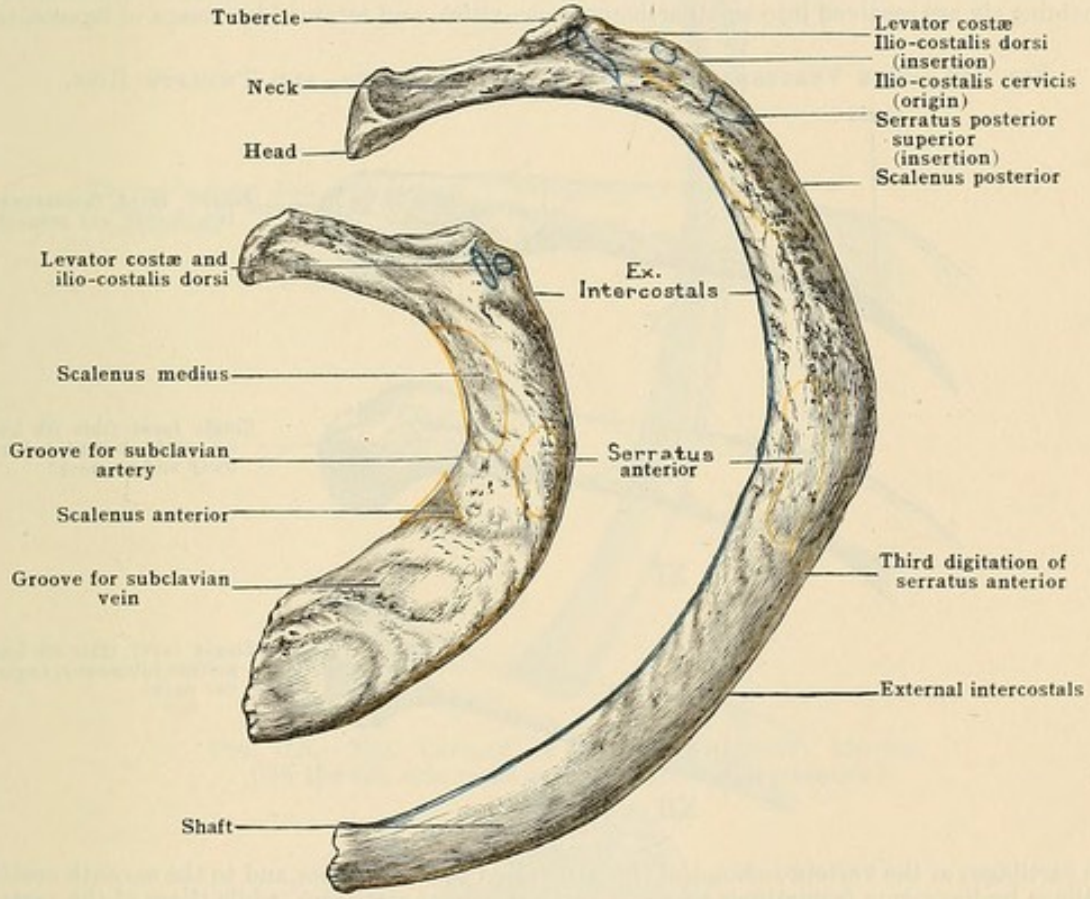

The rib derives its nutrition mainly from the superior intercostal branch of the subclavian artery.

The **second rib** is much longer than the first, and although like it in being strongly curved round a vertical axis, in its form and general characters there is a closer resemblance to the ribs lower down in the series. The head is round and presents two facets, the costal groove is present, though faintly marked, and an angle is situated near the tubercle. The specially distinguishing feature of the rib, however, is a well-marked tuberosity on its outer surface somewhat near the middle, for the origin of a part of the first digitation, and the whole of the second digitation of the *serratus anterior* (*magnus*). Between the tuberosity and the tubercle the outer surface is smooth and rounded and gives attachment to the *scalenus posterior*, the *serratus posterior superior*, the *ilio-costalis cervicis* (*cervicalis ascendens*), and the *ilio-costalis dorsi* (*accessorius*). The internal surface is smooth and in relation to the pleura. The borders give attachment to the *intercostal* muscles, the upper, to those of the first space, the lower, to those of the second. The shaft of the second rib is not twisted on its own axis, so that both ends can lie flat on the table. The second rib receives vessels from the superior intercostal branch of the subclavian artery and the first aortic intercostal.

The **tenth rib** is distinguished by a single facet on the head for articulation with the body of the tenth thoracic vertebra. Occasionally there are two facets, in which case the rib articulates also with the ninth thoracic vertebra. The tenth rib, like the ribs immediately above, is long, curved, presents a deep costal groove, a well-marked tuberosity and an angle. It may

be noted, however, that the distance between the tubercle and the angle in this rib is greater than in the ribs above. Speaking generally, the distance between these points increases from above downward—a disposition which is useful in at once determining if any given rib belongs to the upper or lower end of the series.

The **eleventh rib** is peculiar in that it has a single facet on the head, a feebly marked angle some distance from the head, a shallow costal groove, no tubercle, and no neck. The tubercle is sometimes represented by a slight elevation or roughness without any articular facet. The anterior extremity is pointed.

The **twelfth rib** has a large head furnished with one facet for articulation with the root (pedicle) of the twelfth thoracic vertebra. The shaft is narrow and extremely variable in length (3 to 20 cm.). It is usually somewhat longer than the first rib, but it may be shorter. There is no tubercle, no angle, no neck, no costal groove. The anterior extremity is pointed. Posteriorly, the upper border is smooth and somewhat rounded; the lower border is sharp and rough.

The **costal cartilages** are bars of hyaline cartilage attached to the anterior extremities of the ribs, and may be regarded as representing **unossified epiphyses.** Like the shaft of a rib, each cartilage has an outer and inner surface. The outer surfaces give origin and insertion to large muscles, and the inner surfaces, from the second to the sixth inclusive, are in relation with the *transversus thoracis* (*triangularis sterni*). The upper and lower borders serve for the attachment of the *internal intercostal* muscles. The upper seven cartilages, and occasionally the eighth, are connected with the sternum. Of these, the first fuses with the manubrium sterni and the remaining six are received into small articular concavities, and retained by means of ligaments.

FIG. 156.—THE VERTEBRAL ENDS OF TENTH, ELEVENTH, AND TWELFTH RIBS.

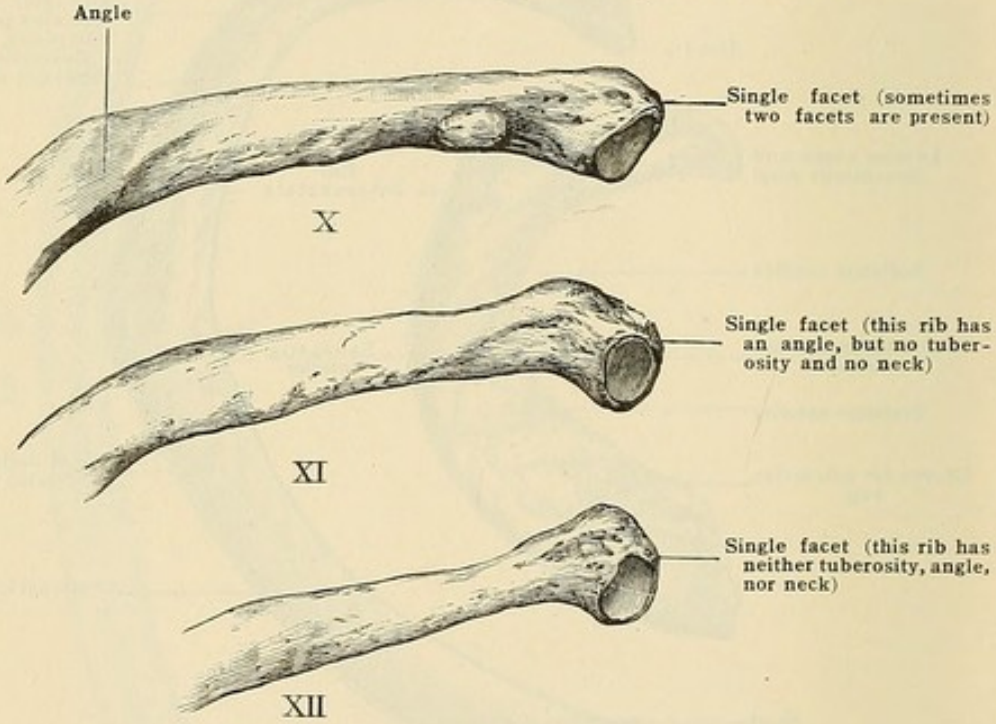

The cartilages of the vertebro-chondral ribs are united to one another and to the seventh costal cartilage by ligaments (sometimes by short vertical bars of cartilage), while those of the vertebral ribs form no such attachment, but lie between the abdominal muscles. The inner surfaces of the lower six costal cartilages afford attachment to the *diaphragm* and the *transversalis* muscle.

Each of the second, third, fourth, and fifth costal cartilages articulates with the side of the sternum, at a point corresponding to the junction of two sternebræ. The sixth and seventh (and eighth when this reaches the sternum) are arranged irregularly. As a rule, the sixth lies in a recess at the side of the fifth sternebra; the seventh corresponds to the line of junction of the meso- and metasternum; and the eighth articulates with the metasternum (see figs. 158, 161).

Blood-supply.—The costal cartilages derive their blood-supply from the terminal twigs of the aortic intercostals and from the internal mammary arteries.

Ossification.—At the eighth week of intra-uterine life the ribs are cartilaginous. About this date a nucleus appears near the angle of each rib, and spreads with great rapidity along the shaft, and by the fourth month reaches as far as the costal cartilage. At this date the length of rib-shaft bears the same proportion to that of the costal cartilage as in adult life. Whilst the ribs are in a cartilaginous condition, the first eight reach to the side of the sternum, and even after ossification has taken place, the costal cartilage of the eighth rib, in many instances, retains its articulation with the sternum up to as late as the eighth month (fig. 158). This relationship may persist through life, but usually the cartilage retrogresses, and is replaced by ligamentous tissue. About the fifteenth year a secondary centre appears for the head of each rib, and a little later one makes its appearance for the tubercle, except in the eleventh and twelfth ribs. Frequently epiphyses are developed on both parts of the tubercle (see figs. 159 and 160). The

epiphyses fuse with the ribs about the twenty-third year. The rib-shaft increases in length mainly at its line of junction with the costal cartilage.

Variations in the Number and Shape of the Ribs

The ribs may be increased in number by addition either at the cervical or lumbar end of the series, but it is extremely rare to find an additional rib or pair of ribs in both the cervical and lumbar regions in the same subject.

FIG. 157.—RIB AT PUBERTY.

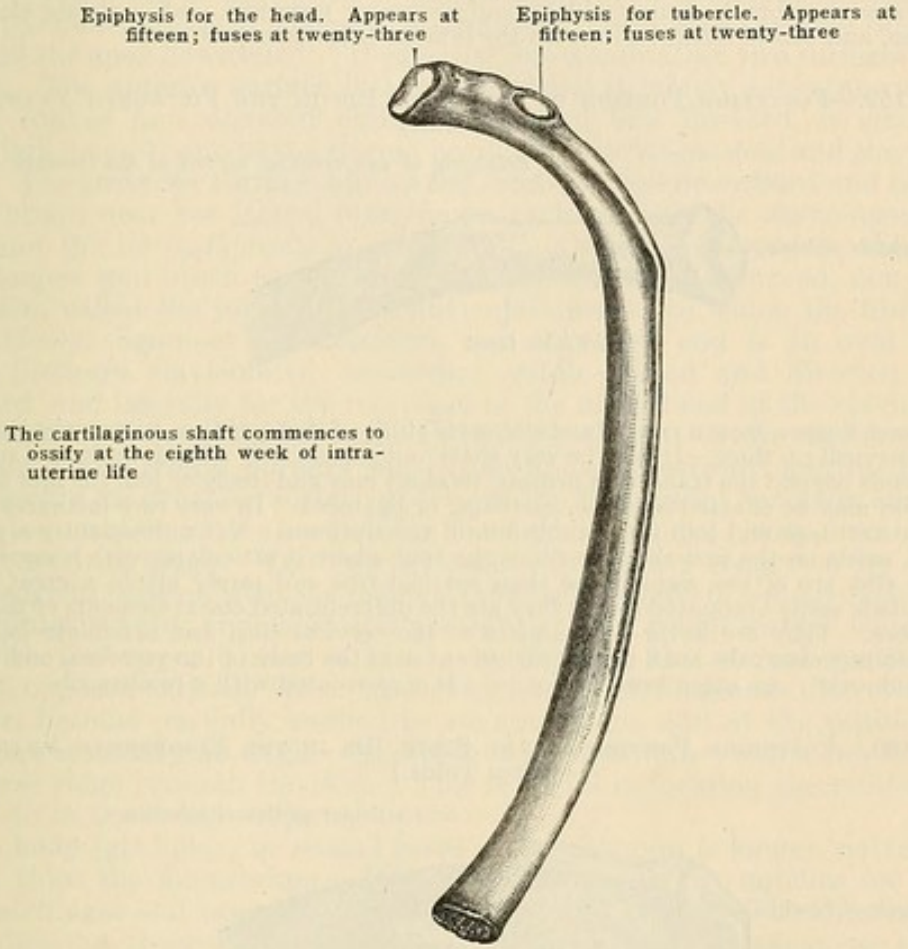

FIG. 158.—THE THORAX AT THE EIGHTH FŒTAL MONTH.
(On the left side eight cartilages reach the sternum.)

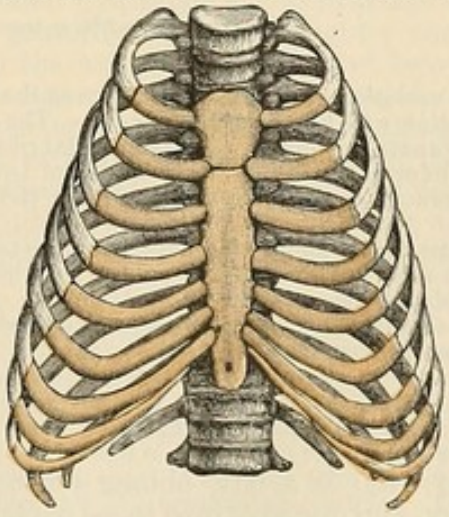

Cervical ribs are fairly common; as a rule, they are of small size and rarely extend more than a few millimeters beyond the extremity of the transverse process (see p. 35). Rarely they exceed such insignificant proportions and reach as far as the sternum; between these two extremes many varieties occur. In one case Turner was able to make a thorough dissection of a specimen in which a complete cervical rib existed. Its head articulated with the body of the

seventh cervical vertebra and had a radiate ligament. The tubercle was well developed, and articulated with the transverse process. The costal cartilage blended with that of the first thoracic rib, and gave attachment to the costo-clavicular ligament. Between it and the first thoracic rib there was a well-marked intercostal space occupied by intercostal muscles. It received the attachment of the *scalenus anterior* and *medius* muscles, and it was crossed by the subclavian artery and vein. The nerves of the intercostal space were supplied by the eighth cervical and first thoracic. The artery of the space was derived from the deep cervical, which, with the superior intercostal, arose from the root of the vertebral. The head of the first thoracic rib in this specimen articulated with the seventh cervical, as well as with the first thoracic vertebra. An interesting fact is also recorded in the careful account of this specimen. There was no movable twelfth thoracic rib on the same side as this well-developed cervical rib, and the twelfth thoracic vertebra had mammillary and accessory processes, and a strong elongated costal process, and was in linear series with the lumbar transverse processes.

FIG. 159.—POSTERIOR PORTION OF THE SIXTH RIB IN THE FIFTEENTH YEAR. (After Toldt.)

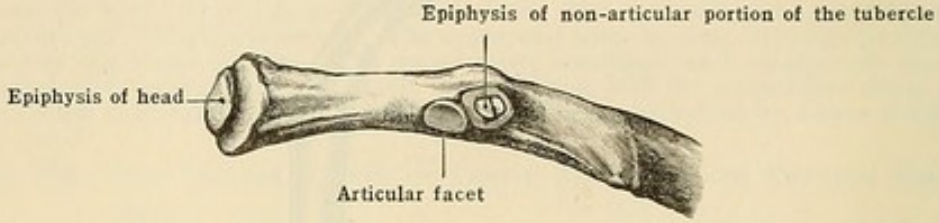

Gruber and Turner, from a careful and elaborate study of this question, summarise the variations in the cervical rib thus:—It may be very short and possess only a head, neck, and tubercle. When it extends beyond the transverse process, its shaft may end freely or join the first thoracic rib: this union may be effected by bone, cartilage, or ligament. In very rare instances it may have a costal cartilage and join the manubrium of the sternum. Not unfrequently a process, or eminence, exists on the first thoracic rib at the spot where it articulates with a cervical rib.

Lumbar ribs are of less significance than cervical ribs and rarely attain a great length. Their presence is easily accounted for, as they are the differentiated costal elements of the transverse processes. They are never so complete as the cervical ribs, and articulate only with the transverse processes; the head never reaches as far as the body of the vertebra, and there is no neck or tubercle. An extra *levator costæ* muscle is associated with a lumbar rib.

FIG. 160.—POSTERIOR PORTION OF THE SIXTH RIB IN THE EIGHTEENTH YEAR. (After Toldt.)

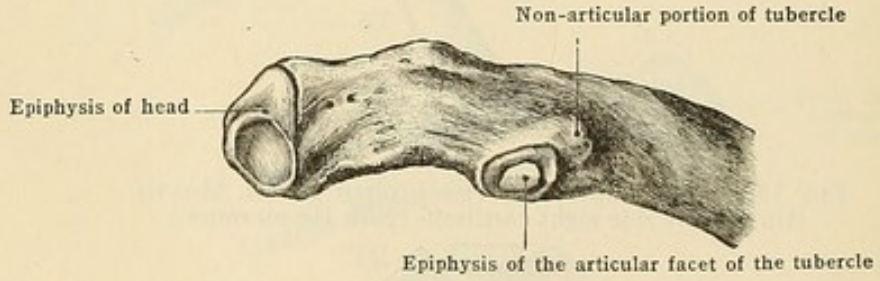

Not the least interesting variation of a rib is that known as the **bicipital rib.** This condition is seen exclusively in connection with the **first thoracic rib.** The vertebral end consists of two limbs which lie in different transverse planes. These bicipital ribs have been especially studied in whales and man. This abnormality is due to the fusion of two ribs, either of a cervical rib with the shaft of the first thoracic; or the more common form, the fusion of the first and second true ribs.

Among unusual variations of ribs should be mentioned the replacement of the costal cartilage and a portion of the rib-shaft by fibrous tissue, a process which occurs normally in the case of the eighth rib during its development.

Sometimes the shafts of two or more ribs may become united by small quadrilateral plates of bone extending across the intercostal spaces.

THE STERNUM

The **sternum** (figs. 161, 162) is a flat, oblong plate of bone, situated in the anterior wall of the thorax, and divisible into three parts, called respectively—(1) the **manubrium sterni** (presternum), (2) the **gladiolus** (mesosternum), constituting the **body** of the bone, and (3) the **xiphoid** (or ensiform) **process** (metasternum). In the young subject it consists of six pieces or segment (sternebræ). Of these, the first remains separate throughout life and forms the manubrium; the suc-

ceeding four segments fuse together, forming the body; whilst the lowest segment, also distinct until middle life, is represented by the xiphoid process.

In its natural position the sternum is inclined obliquely from above downward and forward, and corresponds in length to the spine from the third to the ninth thoracic vertebra. It is not of equal width throughout, being broader above at the manubrium and narrow at the junction of this piece with the body. Toward the lower part of the body the sternum again widens, and then suddenly contracts at its junction with the xiphoid process which constitutes the narrowest part.

The **manubrium** or first piece of the sternum forms the broadest and thickest part of the bone, and is of a somewhat triangular form with the base directed upward and the apex downward. It presents for examination two surfaces and four borders. The **anterior surface** [planum sternale] is largely subcutaneous. It is slightly convex and directed obliquely upward and forward, is smooth and gives origin on each side to the sternal head of the *sterno-mastoid* and the *pectoralis major*. The **posterior surface,** almost flat, and directed downward and backward, affords origin near the lateral margins on each side, to the *sterno-hyoid* muscle above and the *sterno-thyreoid* muscle below. Of the four borders, the **superior** is the longest and much the thickest. In the middle is a curved, non-articular depression, called the **jugular** (interclavicular) **notch,** to which the fibres of the interclavicular ligament are attached, and at either end is an oval articular surface [incisura clavicularis], somewhat saddle-shaped and directed upward, backward, and laterally for the reception of the medial end of the clavicle. The circumference of the articular surface gives attachment to the sterno-clavicular ligaments. The **lateral borders** slope from above downward and medially and each presents an irregular surface above for the first costal cartilage and a small facet below, which, with an adjoining facet on the body, forms a notch for the second costal cartilage. The two articular surfaces are separated by a narrow curved edge in relation with the *internal intercostal* muscle of the first space. The **lower border** is thick and short and presents an oval rough surface which articulates with the upper border of the body, forming the **sternal synchondrosis.** The two opposed surfaces are separated by a fibro-cartilaginous disc, which may, however, become partially ossified in advanced age, and at the position of the joint there is usually an angle—the **angle of the sternum**—which can be felt as a transverse ridge beneath the skin. This is useful in locating the position of the second rib in the living subject.

The **body** (gladiolus) or second piece of the sternum is longer, narrower, and thinner than the manubrium. It is widest opposite the notches for the fifth costal cartilages and becomes narrower above and below. The **anterior surface** is flat, directed upward and forward, and marked by three transverse elevations which indicate the lines of junction of its four component parts. It gives attachment on each side to fibres of the *pectoralis major*, and occasionally presents a foramen—the **sternal foramen**—situated at the junction of the third and fourth pieces of the bone. The **posterior surface** is slightly concave, marked by lines corresponding to those on the anterior surface, and below gives attachment on each side to fibres of the *transversus thoracis* (*triangularis sterni*). The **lateral borders** present four whole notches [incisuræ costæ] and two half-notches on each side, which articulate with the costal cartilages of the second to the seventh ribs inclusive; the two half-notches are completed by corresponding notches on the manubrium and the xiphoid process. Between the articular depressions the lateral border is curved and in relation to the *internal intercostal* muscles.

In order to appreciate the nature of these articular notches, it is advantageous to study the sternum in a young subject. Each typical **sternebra** presents four angles at each of which is a demi-notch. Between every two sternebræ there is an intersternebral disc so that when in position, each notch for a costal cartilage is formed by a sternebra above and below and an intersternebral disc in the middle, thus repeating the relation of the rib-head to the vertebral centre. Later in life these fuse more or less together, except in the case of the first and second sternebræ, which usually remain separate to the end of life. The first (pre-sternum) is the most modified of all the sternebræ, and differs from them in the fact that the costal cartilage of the first rib is continuous with it, and in fact that it supports the clavicles. Occasionally a rounded pisiform bone is seen on each side, medial to the articular notch for the clavicle; these are the **supra-sternal** bones.

The **superior border** of the sternal body presents an oval facet for articulation (synchondrosis) with the manubrium. The **inferior border** is short and articu-

lated with the xiphoid process, forming the meso-metasternal joint, the two opposed surfaces being separated by a layer of cartilage so long as they are not united by bone.

The **xiphoid** (ensiform) **process** is the thin, elongated process projecting downward between the cartilages of the seventh ribs. It is the least developed

FIG. 161.—THE STERNUM. (Anterior view.)

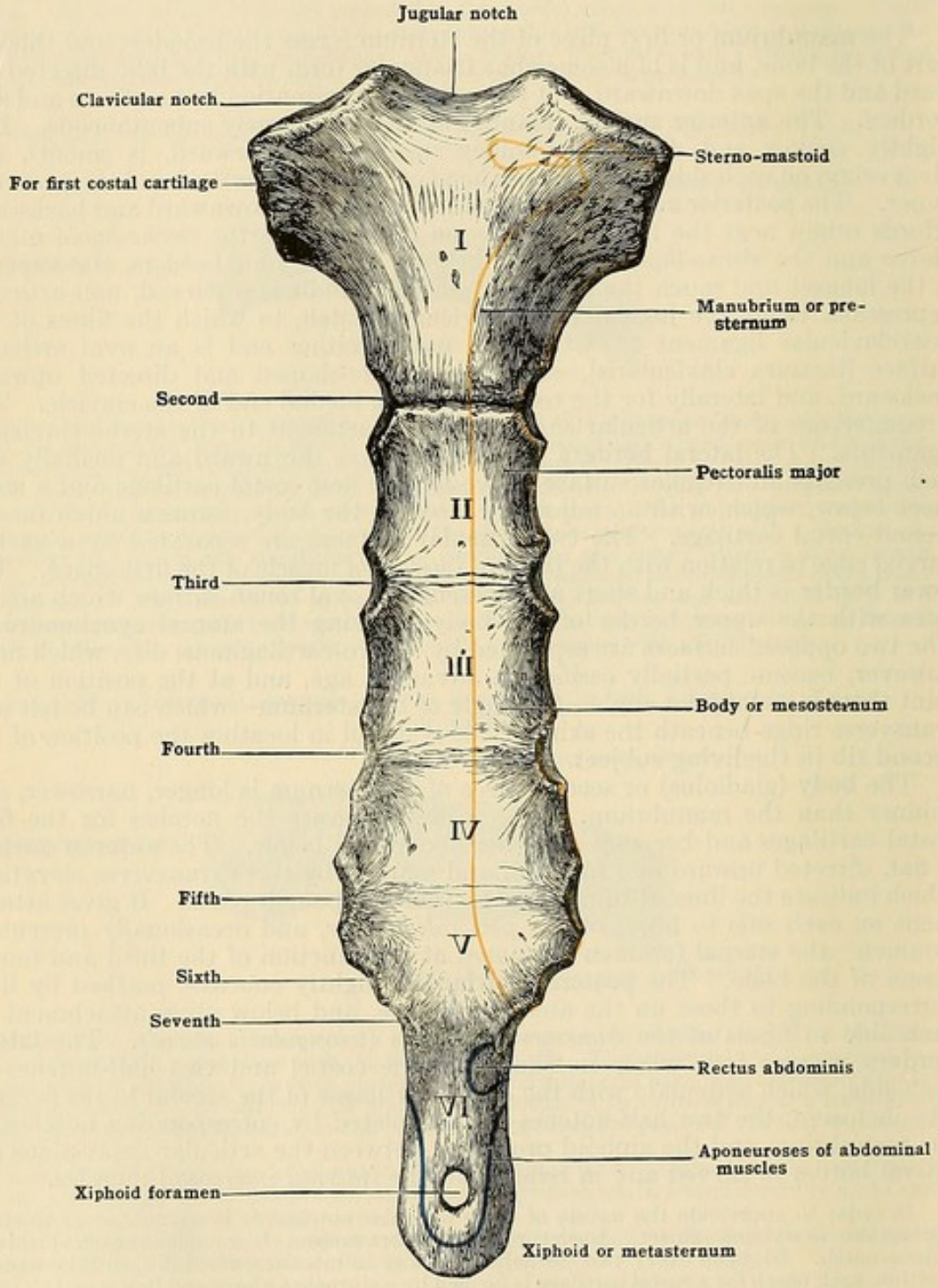

part of the sternum and is subject to many variations in form, being sometimes pointed, broad and thin, occasionally bifid or perforated by a foramen, and sometimes bent forward, backward, or deflected to one side. In structure it is cartilaginous in early life, partially ossified in the adult, but in old age it tends to become ossified throughout and to fuse with the body.

The **anterior surface** of the xiphoid process gives attachment to a few fibres of the *rectus abdominis* muscle and the chondro-xiphoid ligament, the **posterior surface** to the sternal fibres of the *diaphragm*, and the lowest fibres of the *transversus thoracis* (*triangularis sterni*), whilst

the lateral margins receive the aponeuroses of the abdominal muscles. Its tip is directly continuous with the linea alba.

Differences according to sex.—The sternum differs somewhat in the two sexes. The female sternum is relatively shorter, the diminution being almost confined to the body. In the male the body is more than twice as long as the manubrium, whereas in the female it is usually less than twice the length of the first piece.

FIG. 162.—THE STERNUM. (Posterior view.)

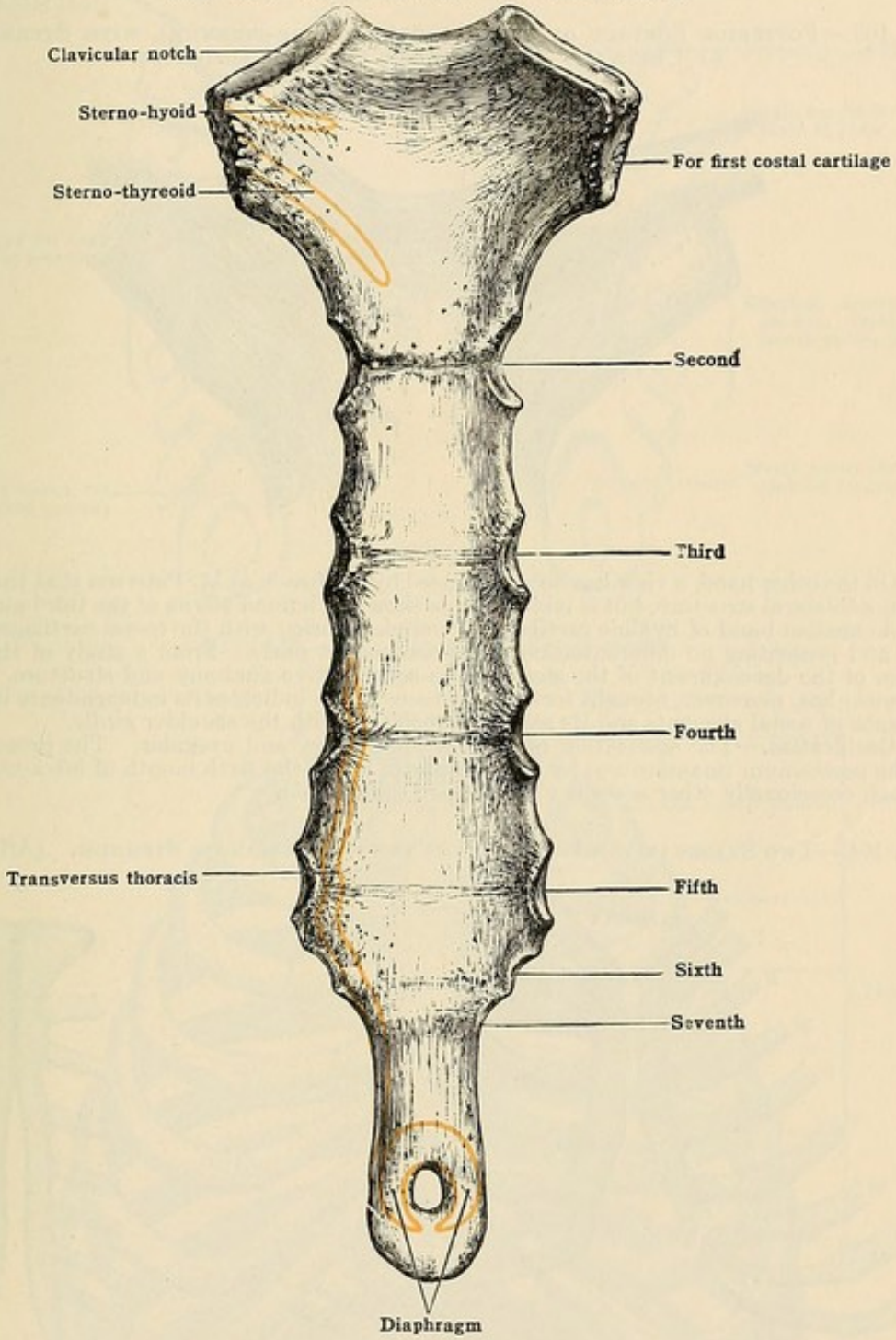

Structurally the sternum is composed of cancellous tissue covered with an outer layer of compact tissue. Its **arterial supply** is derived mainly from the sternal and perforating branches of the internal mammary.

Development of the sternum.—The osseous sternum is preceded by a continuous or non-segmented central sternal cartilage formed in the following way When the cartilaginous ribs first appear in the embryo, their anterior or ventral ends fuse together on either side of the middle line. For some time a median fissure is present, bordered by two sagittally directed strips of cartilage with each of which at first nine ribs are joined. As development proceeds the two strips come into contact in the middle line and fuse from before backward to form a median sternal cartilage. The eighth cartilage generally loses its sternal attachment, although in some cases it remains permanently articulated with the side of the ensiform process. The ninth

costal cartilage becomes subdivided, one part remaining attached to the sternum and forming the xiphoid process, whilst the end still continuous with the rib acquires a new attachment to the eighth cartilage. The ends adherent to the sternum may remain separate and give rise to a bifid xiphoid process, though much more frequently they unite, leaving a small foramen.

At first, therefore, the sternum and costal cartilages are continuous. A joint soon forms between the presternum and mesosternum, and others between the costal cartilages and the sternum (except in the case of the first) quickly follow. The division of the mesosternum into segments is a still later formation and arises during the process of ossification.

Fig. 163.—Posterior Surface of the Manubrium (Pre-sternum), with Sternal Ends of Clavicles and the First Costal Cartilages.

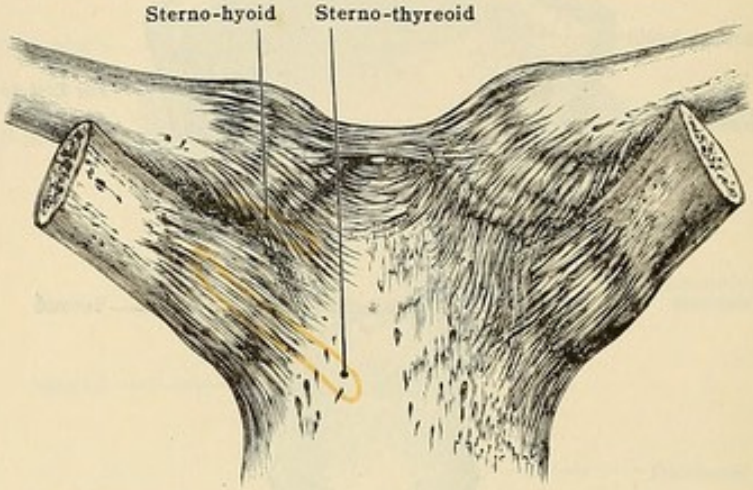

On the other hand, a view has been advanced by Professor A. M. Paterson that the sternum is not a bilateral structure, but is laid down, as shown in human sterna of the third month, as a simple median band of hyaline cartilage, in complete fusion with the costal cartilages on each side and presenting no differentiation of its component parts. From a study of the earliest stages of the development of the sternum, its comparative anatomy and structure, Professor Paterson has, moreover, brought forward evidence which indicates its independence in the first instance of costal elements and its genetic association with the shoulder girdle.

Ossification.—The ossification of the sternum is slow and irregular. The process begins in the presternum (manubrium) by a single centre about the sixth month of intra-uterine life, though occasionally other accessory centres are superadded.

Fig. 164.—Two Stages in the Formation of the Cartilaginous Sternum. (After Ruge.)

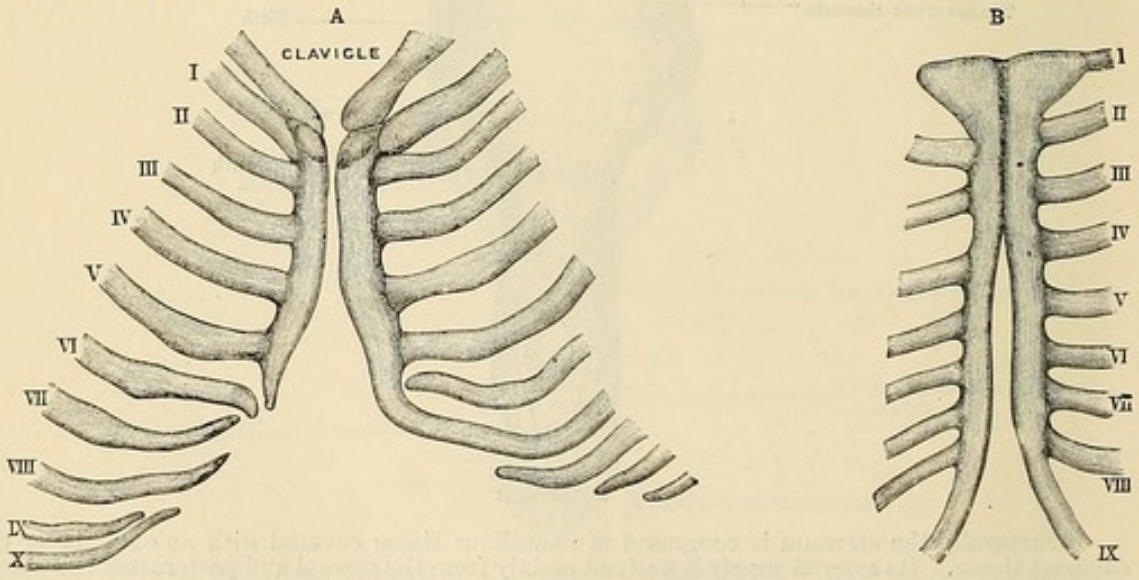

The mesosternum (body) usually ossifies from seven centres. The upper segment ossifies from a single median nucleus about the eighth month, and below this, three pairs of ossific nuclei appear, which may remain for a long time separate. Of these, two pairs for the second and third segments are visible at birth, and those for the lower segment make their appearance toward the end of the first year. The various lateral centres unite in pairs, so that at the sixth year the sternum consists of six sternebræ, the lowest (metasternum) being cartilaginous. Very often, however, there are only four centres of ossification in the gladiolus, as shown in fig. 165. Gradually the four pieces representing the mesosternum fuse with one another, and

FIG. 165.—OSSIFICATION OF THE STERNUM.

A, common arrangement of the ossific centres. B, showing accessory centre in the manubrium sterni, and bilateral centres in the second, third, and fourth pieces of the body.

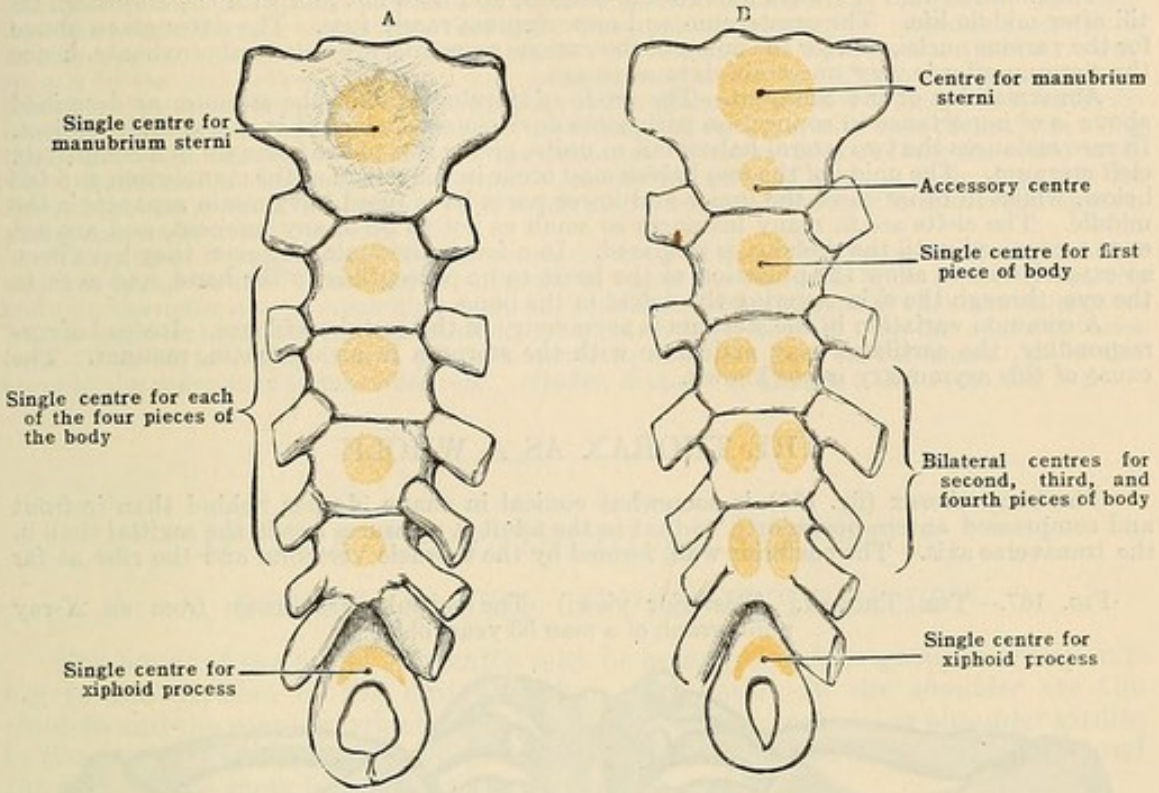

FIG. 166.—THE THORAX. (Front view.)

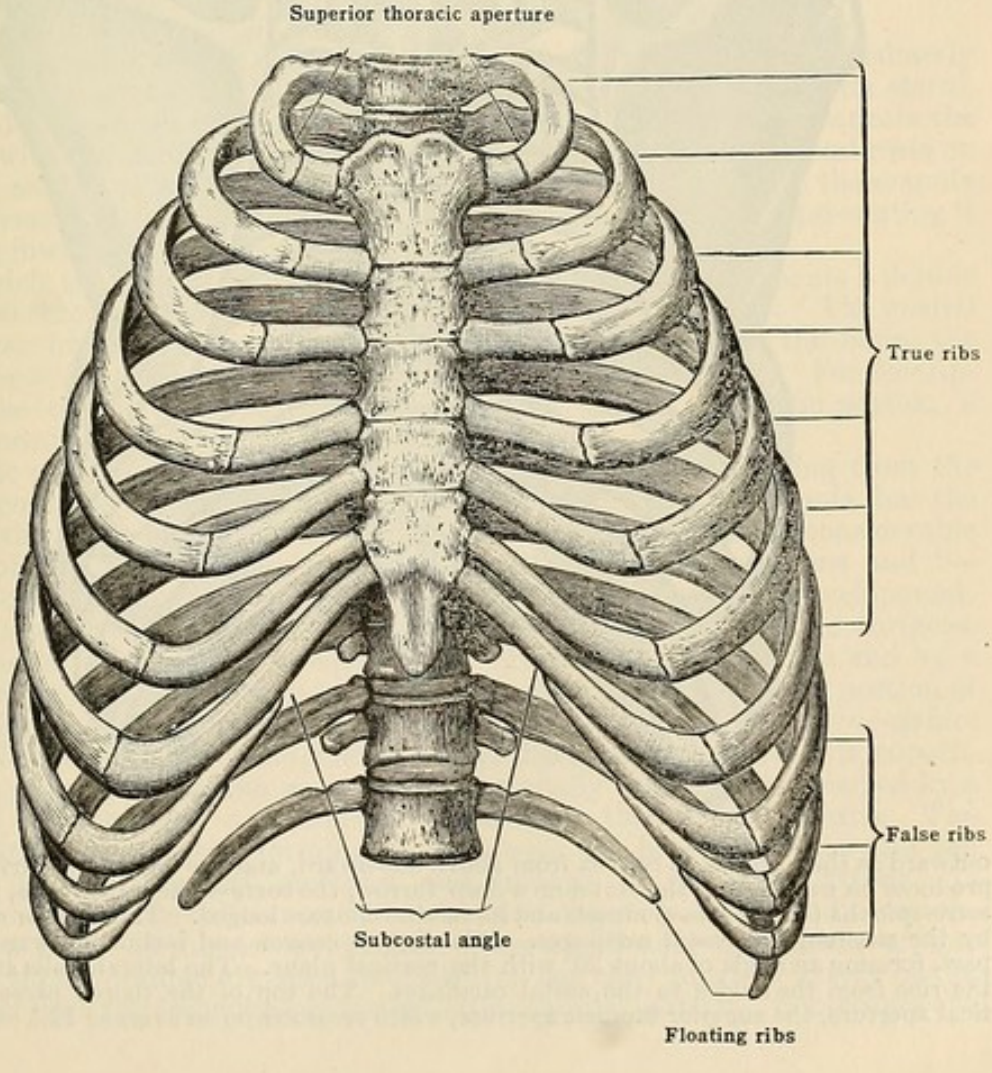

at twenty-five they form a single piece, but exhibit, even in advanced life, traces of their original separation. A sternal foramen is usually the result of non-union across the middle line or a defect of ossification.

The metasternum is always imperfectly ossified, and does not join with the mesosternum till after middle life. The presternum and mesosternum rarely fuse. The dates given above for the various nuclei, and for the union of the various segments, are merely approximate, hence the sternum affords very uncertain data as to age.

Abnormalities of the Sternum.—The mode of development of the sternum as described above is of importance in connection with some deviations to which it is occasionally subject. In rare instances the two lateral halves fail to unite, giving rise to the anomaly of a completely cleft sternum. The union of the two halves may occur in the region of the manubrium and fail below, whilst in other cases the upper and lower parts have fused but remain separate in the middle. The clefts are in many instances so small as not to be of any moment, and are not even recognised until the skeleton is prepared. In a few individuals, however, they have been so extensive as to allow the pulsation of the heart to be perceptible to the hand, and even to the eye, through the skin covering the defect in the bone.

A common variation in the sternum is asymmetry of the costal cartilages. Instead of corresponding, the cartilages may articulate with the sternum in an alternating manner. The cause of this asymmetry is not known.

THE THORAX AS A WHOLE

The bony thorax (fig. 166) is somewhat conical in shape, deeper behind than in front and compressed antero-posteriorly, so that in the adult it measures less in the sagittal than in the transverse axis. The **posterior** wall, formed by the thoracic vertebræ and the ribs as far

FIG. 167.—THE THORAX. (Posterior view.) The scapulæ are drawn from an *X*-ray photograph of a man 33 years old.

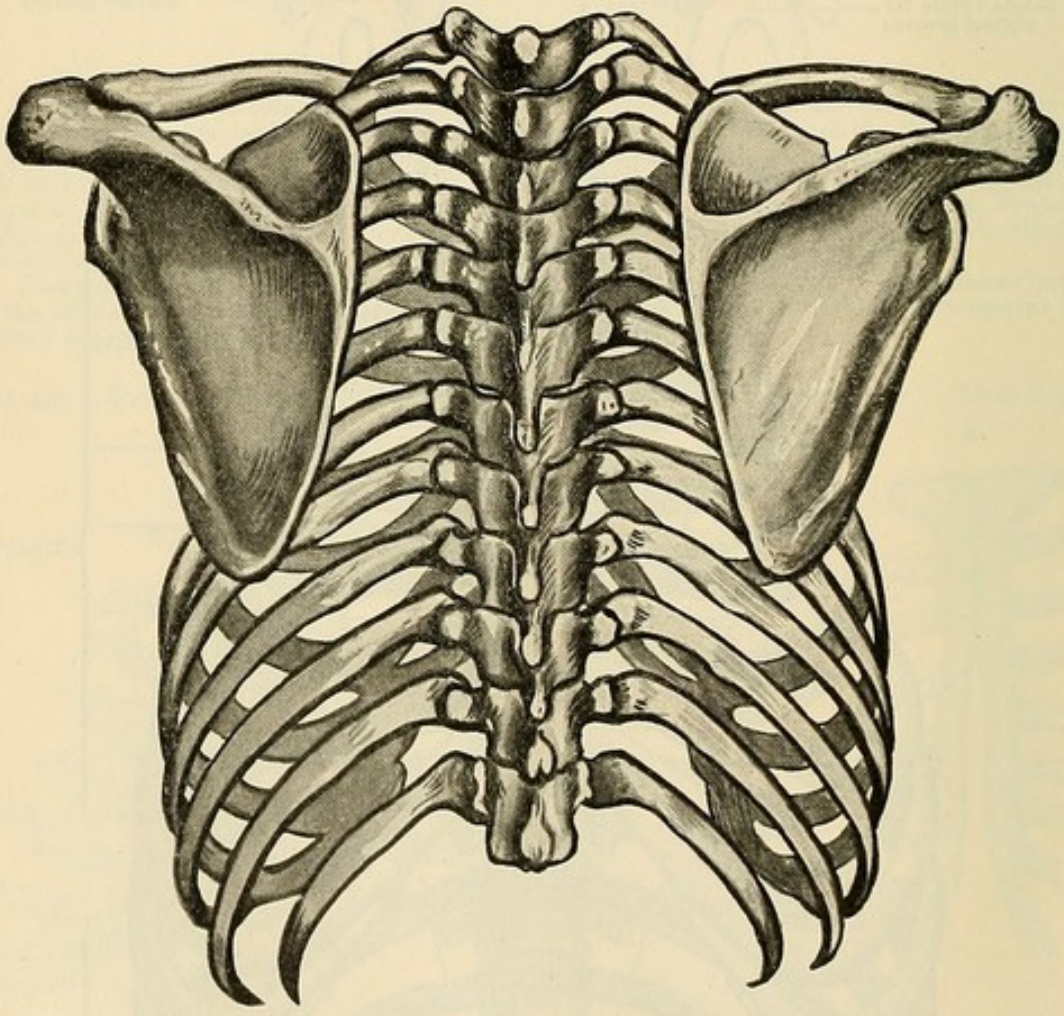

outward as their angles, is convex from above downward, and the backward curve of the ribs produces on each side of the vertebræ a deep furrow, the **costo-vertebral groove,** in which the *sacro-spinalis* (*erector spinæ*) muscle and its subdivisions are lodged. The **anterior** wall is formed by the sternum and costal cartilages. It is slightly convex and inclined forward in its lower part, forming an angle of about 20° with the vertical plane. The **lateral** walls are formed by the ribs from the angles to the costal cartilages. The top of the thorax presents an elliptical aperture, the **superior thoracic aperture,** which measures on an average 12.5 centimetres (5

inches) transversely and 6.2 centimetres (2½ inches) in its sagittal axis. It is bounded by the first thoracic vertebra behind, the upper margin of the manubrium sterni in front, and the first rib on each side. As the upper margin of the manubrium sterni is oftenest on a level with the disc between the second and third thoracic vertebræ, it follows that the plane of the opening is directed obliquely upward and forward. The angle of the sternum (*angulus Ludovici*) is usually opposite the body of the fifth thoracic vertebra and the xiphi-sternal junction corresponds to the disc between the ninth and tenth thoracic vertebræ. The lower aperture of the thorax is very irregular, and is formed by the twelfth thoracic vertebra behind, the twelfth ribs laterally, and in front by two curved lines, ascending one on either side from the last rib, along the costal margin to the lower border of the gladiolus. The two borders form the **costal arch,** which in the median line below the sternum forms the **infrasternal angle.** From this angle the xiphoid process projects downward. The intervals between the ribs are the **intercostal spaces,** and are eleven in number on each side.

The ratio of the sagittal and the transverse diameter of the thorax forms the **thoracic index,** which is higher in the female and in children, in whom the thorax is more rounded. In the embryo, the index is very much higher, the sagittal diameter being greater than the transverse. In the early embryo, the index is nearly 200; at birth it is about 90. In the adults it varies from 70 to 75, averaging 2 or 3 per cent. lower in the male than in the female. It is also lower in the negro than in the white race. (Rodes, Zeitschr. f. Morph. u. Anthrop., Bd. 9.)

II. THE APPENDICULAR SKELETON

A. BONES OF THE UPPER EXTREMITY

The bones of the upper extremity may be arranged in four groups corresponding to the division of the limb into four segments. In the *shoulder* are the clavicle and the scapula, which together constitute the pectoral or shoulder girdle; in the *arm* is the humerus; in the *forearm* are the radius and ulna; and in the *hand* the carpus, the metacarpus, and the phalanges.

THE CLAVICLE

The **clavicle** [clavicula] or collar bone (figs. 168, 169) is situated immediately above the first rib and extends from the upper border of the manubrium sterni, laterally and backward to the acromion process of the scapula. It connects the upper limb with the trunk, and is so arranged that whilst the medial end rests on the sternum and first costal cartilage, the lateral end is associated with the scapula in all its movements, supporting it firmly in its various positions and preventing it from falling inward on the thorax.

The clavicle is a long bone, and when viewed from the front presents a double curvature, so that it somewhat resembles in shape the italic letter *f*. The medial curve, convex forward, extends over two-thirds of the length of the bone; the lateral, concave forward, is smaller and confined to the lateral part. For descriptive purposes the clavicle may be divided into a medial prismatic portion, a lateral flattened portion, and two extremities.

Prismatic portion.—The medial two-thirds of the bone, extending from the sternal extremity to a point opposite the coracoid process of the scapula, has the form of a triangular prism. This portion, however, is subject to considerable variations of form, being more cylindrical in ill-developed specimens and becoming almost quadrangular when associated with great muscular development. In a typical specimen it is marked by three borders separating three surfaces. Of these, the **anterior surface** is convex and divided near the sternal end by a prominent ridge into two parts, a lower, giving origin to the clavicular portion of the *pectoralis major;* an upper, for the clavicular portion of the *sterno-cleido-mastoid.* Near the middle of the shaft the ridge disappears, the surface is smooth, and is covered by the *platysma myoides.* Occasionally this surface is pierced by a small canal, transmitting a cutaneous nerve from the cervical plexus. The **posterior surface** is concave, forming an arch over the brachial plexus and the subclavian artery, broadest medially and smooth in its whole extent. It gives origin near the sternal extremity to a part of the *sterno-hyoid* and occasionally to a few fibres of the *sterno-thyreoid.* Somewhere near the middle of this surface is a small foramen, directed laterally, for the chief nutrient artery of the bone, derived from the transverse scapular (suprascapular) artery. Sometimes the

foramen is situated on the inferior surface of the bone, in the subclavian groove. On the **inferior surface** near the sternal end is a rough area, the **costal tuberosity,** about three-quarters of an inch in length, for the attachment of the costo-clavicular ligament, by which the clavicle is fixed to the first rib. More laterally is a longitudinal groove for the *subclavius*, bordered by two lips, to which the sheath of the muscle is attached. To the posterior of the two lips the layer of deep cervical fascia which binds down the posterior belly of the omo-hyoid to the clavicle is also attached.

Of the three **borders,** the **superior** separates the anterior and posterior surfaces. Beginning at the sternal end, it is well-marked, becomes rounded and indistinct in the middle, whilst laterally it is continuous with the posterior border of the outer third. The **posterior border** separates the inferior and posterior surfaces and forms the posterior lip of the subclavian

FIG. 168.—THE LEFT CLAVICLE. (Superior surface.)

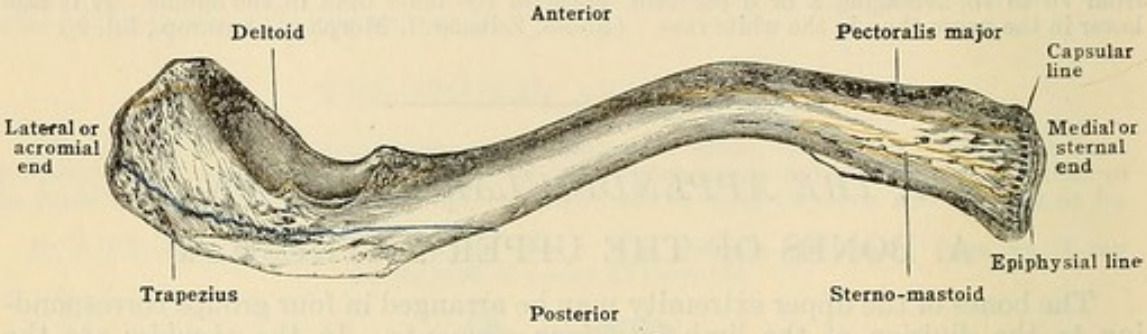

groove. It begins at the costal tuberosity and can be traced laterally as far as the coracoid tubercle, an eminence on the under aspect of the bone near the junction of prismatic and flattened portions. The **anterior border** is continuous with the anterior border of the flattened portion and separates the anterior and inferior surfaces. Medially, it forms the lower boundary of the elliptical area for the origin of the *pectoralis major*, and approaches the posterior border. Near the middle of the bone it coincides with the anterior lip of the subclavian groove.

Flattened portion.—The lateral third of the bone, extending from a point opposite the coracoid process of the scapula to the acromial extremity, is flat-

FIG. 169.—THE LEFT CLAVICLE. (Inferior surface.)

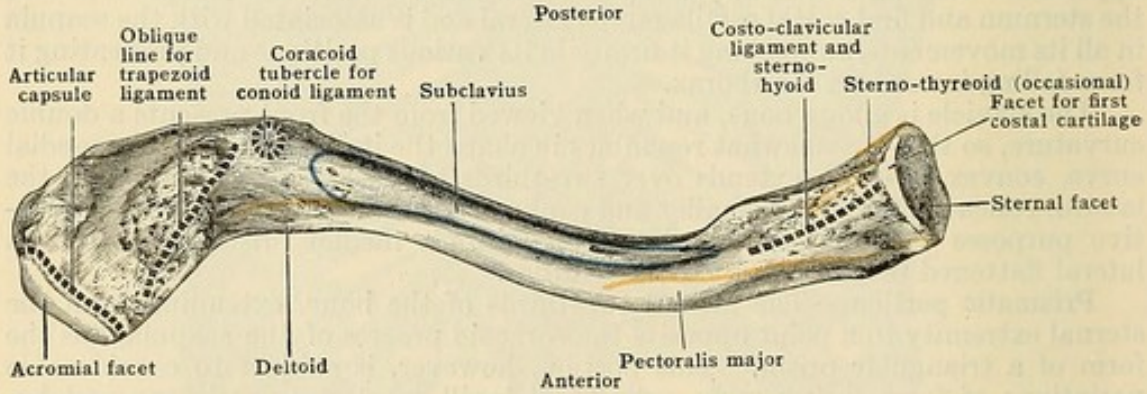

tened from above downward and presents two surfaces and two borders. The **superior surface** is rough and looks directly upward and gives attachment to the *trapezius* behind and the *deltoid* in front; between the two areas the surface is subcutaneous. On the **inferior surface,** near the posterior border, is a rough elevation, the **coracoid** (conoid) **tubercle;** it overhangs the coracoid process and gives attachment to the conoid ligament. From the coracoid tubercle, a prominent ridge, the **trapezoid** or **oblique line,** runs laterally and forward to near the lateral end of the bone. To it the trapezoid ligament is attached. The conoid and trapezoid ligaments are the two parts of the coraco-clavicular ligament which binds the clavicle down to the coracoid process.

The **anterior border** is sharp, gives origin to the *deltoid* muscle, and frequently presents near the junction of the flattened and prismatic portions a projection known as the **deltoid tubercle.** The **posterior border** is thick and rounded, and receives the insertion of the upper fibres of the *trapezius*.

Extremities.—The **sternal extremity** of the clavicle presents a triangular articular surface, directed medially, downward, and a little forward, slightly concave from before backward and convex from above downward, which articulates with a facet on the upper border of the manubrium sterni through an interposed interarticular fibro-cartilage.

Of the three angles, one is above and two below. The *postero-inferior angle* is prolonged backward, and so renders this surface considerably larger than that with which it articulates; the *superior angle* receives the attachment of the upper part of the fibro-cartilage. The lower part of the surface is continuous with a facet on the under aspect of the bone, medial to the costal tuberosity, for the first costal cartilage. The circumference of the extremity is rough, and gives attachment to the interclavicular ligament above and the anterior and posterior sterno-clavicular ligaments in front and behind.

The **acromial extremity** presents a smooth, oval, articular facet, flattened or convex, directed slightly downward for the acromion; its border is rough, for the attachment of the capsule of the acromio-clavicular joint.

Structure.—The clavicle consists externally of a compact layer of bone, much thicker in the middle and thinning out gradually toward the two extremities. There is no true medullary

FIG. 170.—THE STERNAL ENDS OF TWO CLAVICLES WITH EPIPHYSES.
A, right clavicle from below and behind. B, left clavicle from below and behind.
(From Royal College of Surgeons Museum.)

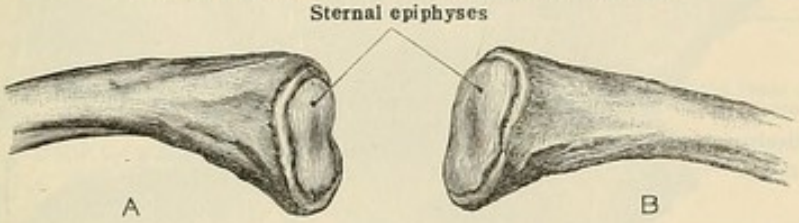

cavity, for the interior is occupied from end to end by cancellous tissue, the amount in the various parts of the bone being in inverse proportion to the thickness of the outer compact shell

Ossification.—From observations made by F. P. Mall, D. C. L. Fitzwilliams, and E. Fawcett it seems almost certain that there are two centres of ossification of the shaft of the clavicle, at the juncture of the middle and lateral thirds. They appear very early, about the fifth week of embryonic life, and rapidly fuse. The ossific process extends medially and laterally along the shaft toward the medial and lateral extremities, respectively. About the eighteenth year a secondary centre appears at the sternal end and forms a small epiphysis which joins the shaft about the twenty-fifth year.

THE SCAPULA

The **scapula** (figs. 171, 172) is a large flat bone, triangular in shape, situated on the dorsal aspect of the thorax, between the levels of the second and seventh ribs. Attached to the trunk by means of the clavicle and various muscles it articulates with the lateral end of the clavicle at the acromio-clavicular joint, and with the humerus at the shoulder-joint. The greater part of the bone consists of a triangular plate known as the *body,* from which two processes are prolonged: one anterior in position, is the *coracoid;* the other, posterior in position, is the *spine,* which is continued laterally into the *acromion.*

The body presents for examination two surfaces, three borders, and three angles. The **costal** (anterior) **surface,** or venter, looks considerably medialward, is deeply concave, forming the **subscapular fossa,** and marked by several oblique lines which commence at the posterior border and pass obliquely upward and laterally; these lines or ridges divide the surface into several shallow grooves, from which the *subscapularis* takes origin, whilst the ridges give attachment to the tendinous intersections of that muscle. The lateral third of the surface is smooth and overlapped by the subscapularis, whilst medially are two small flat areas in front of the upper and lower angles respectively, but excluded from the subscapular fossa by fairly definite lines and joined by a ridge which runs close to the vertebral border. The ridge and its terminal areas serve for the insertion of the *serratus anterior (magnus).*

The **dorsal** (posterior) **surface** is generally convex and divided by a prominent plate of bone—the **spine**—into two unequal parts. The hollow above the spine is the **supraspinous fossa** and lodges the *supraspinatus* muscle. The part below

the spine is the **infraspinous fossa;** it is three times as large as the supraspinous fossa, is alternately concave and convex, and gives origin to the *infraspinatus.* The muscle is attached to its medial three-fourths and covers the lateral fourth, without taking origin from it.

The infraspinous fossa does not extend as far as the axillary border, but is limited laterally by a ridge—**the oblique line**—which runs from the glenoid cavity—the large articular surface for the head of the humerus—downward and backward to join the posterior border a short distance above the inferior angle. This line, which gives attachment to a stout aponeurosis, cuts off an elongated surface, narrow above for the origin of the *teres minor,* and crossed near its middle by a groove for the circumflex (dorsal) artery of the scapula; below, the surface is broader for the origin of the *teres major* and occasionally a few fibres of the *latissimus dorsi.* The two areas are separated by a line which gives attachment to an aponeurotic septum situated between the two teres muscles.

FIG. 171.—THE LEFT SCAPULA. (Dorsal surface.)

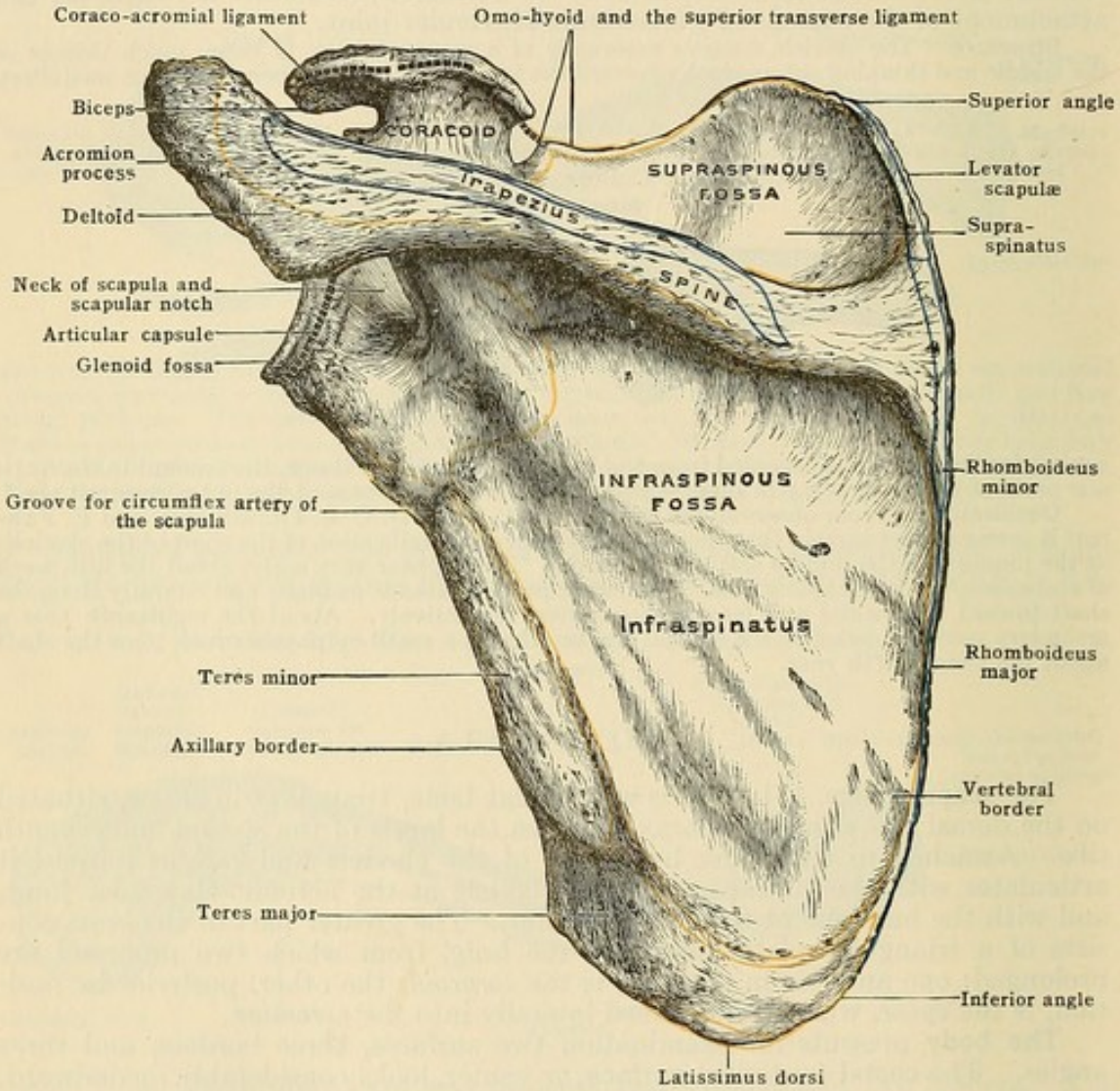

The supra- and infraspinous fossæ communicate through the **great scapular notch** at the lateral border of the spine, and through the notch the suprascapular nerve and transverse scapular artery are transmitted from one fossa to the other.

Borders.—The three borders of the scapula are named superior, vertebral, and axillary. The **superior** is short and thin and extends from the upper angle to the coracoid process. Laterally it presents a deep depression, the **scapular notch,** to the extremities of which the superior transverse ligament is attached.

Not infrequently the notch is replaced by a **scapular foramen,** and it is interesting to note that a bony foramen occurs normally in some animals, notably the great ant-eater (*Myrmecophaga jubata*). The notch or foramen transmits the suprascapular nerve, whilst the transverse scapular artery usually passes over the ligament. From the adjacent margins of the notch and from the ligament the posterior belly of the *omo-hyoid* takes origin.

The **vertebral border** (sometimes called the base) is the longest, and extends from the upper or medial to the lower angle of the bone. It is divisible into three parts, to each of which a muscle is attached: an upper portion, extending from the medial (superior) angle to the spine, for the insertion of the *levator scapulæ;* a middle portion, opposite the smooth triangular area at the commencement of the spine, for the *rhomboideus minor;* and the lowest and longest portion, extending below this as far as the inferior angle, for the *rhomboideus major,* the attachment of which takes place through the medium of a fibrous arch.

The **axillary border** is the thickest, and extends from the lower margin of the glenoid cavity to the inferior angle of the bone. Near its junction with the glenoid cavity there is a rough surface, about 2.5 cm. (1 in.) in length the **infraglenoid tubercle,** from which the long head of the *triceps* arises, and below

FIG. 172.—THE LEFT SCAPULA. (Ventral surface.)

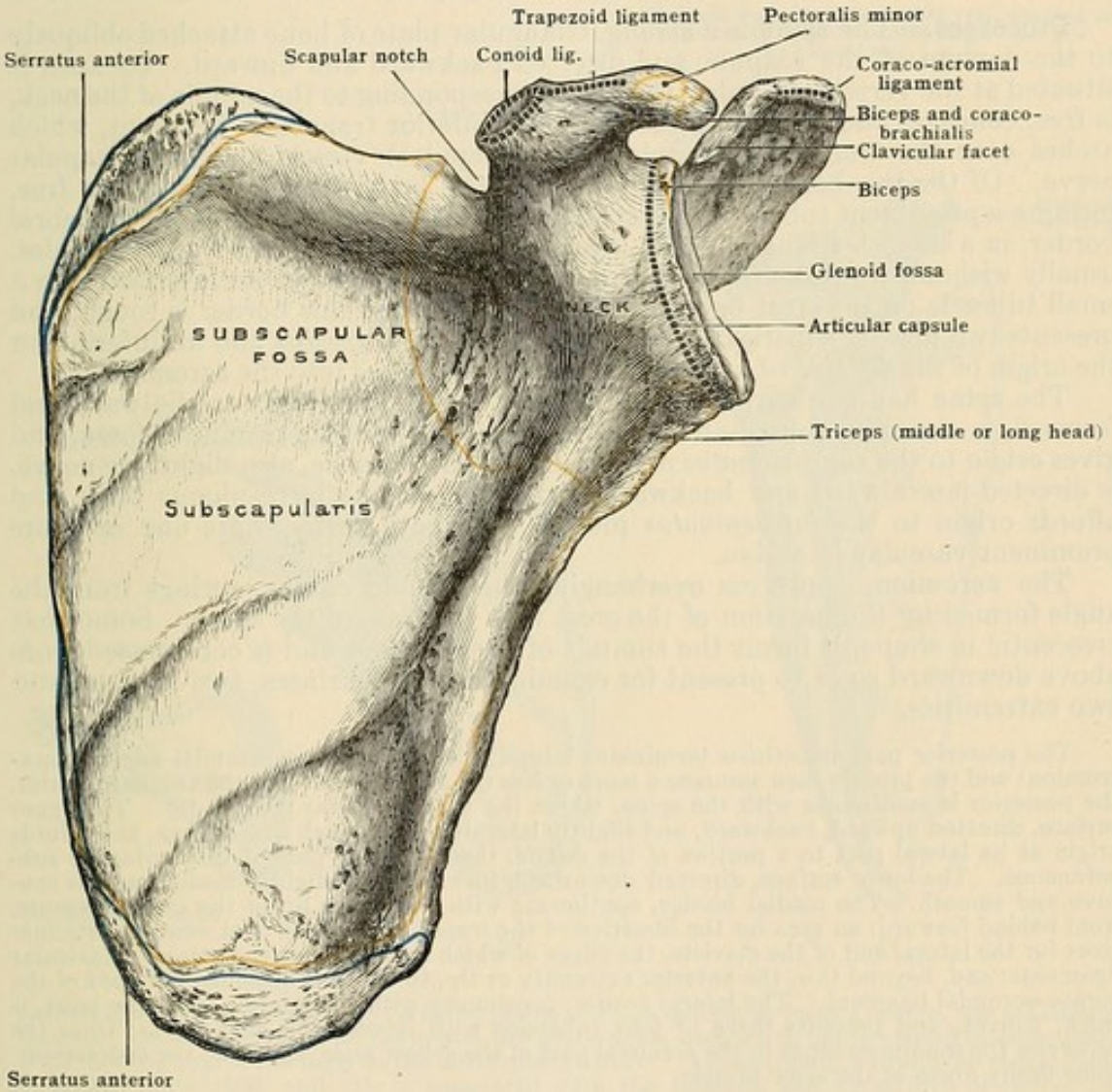

the tubercle is the groove for the circumflex (dorsal) artery of the scapula. The upper two-thirds of the border is deeply grooved on the ventral aspect and gives origin to a considerable part of the *subscapularis.*

Angles.—The three angles are named medial, inferior, and lateral.

The **medial** (or superior) **angle,** forming the highest part of the body, is thin, smooth, and either rounded or approximating a right angle. It is formed by the junction of the superior and vertebral borders and gives insertion to a few fibres of the *levator scapulæ.* The **inferior angle,** constituting the lowest part of the body, is thick, rounded, and rough. It is formed by the junction of axillary and vertebral borders, gives origin to the *teres major,* and is crossed horizontally by the upper part of the *latissimus dorsi,* the latter occasionally receiving from it a small slip of fleshy fibres.

The **lateral angle** forms the expanded portion of the bone known as the **head,** bearing the **glenoid cavity,** and supported by a somewhat constricted **neck.** The

glenoid cavity is a wide, shallow, pyriform, articular surface for the head of the humerus, directed forward and laterally, with the apex above and the broad end below. Its margin is raised, and affords attachment to the glenoid ligament, which deepens its concavity. The margin is not, however, of equal prominence throughout, being somewhat defective where it is overarched by the acromion, notched anteriorly, and emphasised above to form a small eminence, the **supra-glenoid tubercle,** for the attachment of the long head of the *biceps.*

The circumference and adjoining part of the neck give attachment to the articular capsule of the shoulder-joint, and the anterior border to the three accessory ligaments of the capsule, known as the superior, middle, and inferior gleno-humeral folds. The superior fold (Flood's ligament) is attached above the notch near the upper end; of the two remaining folds, which together constitute Schlemm's ligament, the middle is attached immediately above the notch and the inferior below the notch. In the recent state the glenoid fossa is covered with hyaline cartilage. The **neck** is more prominent behind than before and below than above, where it supports the coracoid process. It is not separated by any definite boundary from the body.

Processes.—The **spine** is a strong, triangular plate of bone attached obliquely to the dorsum of the scapula and directed backward and upward. Its apex is situated at the vertebral border; the base, corresponding to the middle of the neck, is free, concave, and gives attachment to the inferior transverse ligament, which arches over the transverse scapular (suprascapular) vessels and suprascapular nerve. Of the two borders, one is joined to the body, whilst the other is free, forming a prominent subcutaneous **crest.** The latter commences at the vertebral border, in a smooth triangular area, over which the tendon of the *trapezius* glides, usually without the intervention of a bursa, as it passes to its insertion into a small tubercle on the crest beyond. Further laterally, this border is rough, and presents two lips—a superior for the insertion of the *trapezius* and an inferior for the origin of the *deltoid.* Laterally the crest is continued into the **acromion.**

The **spine** has two surfaces, the superior, which also looks medialward and forward, is concave, contributes to the formation of the supraspinous fossa, and gives origin to the *supraspinatus* muscle; the inferior surface, also slightly concave, is directed lateralward and backward, forms part of the infraspinous fossa, and affords origin to the *infraspinatus* muscle. On both surfaces are one or more prominent vascular foramina.

The **acromion,** a process overhanging the glenoid cavity, springs from the angle formed by the junction of the crest with the base of the spine. Somewhat crescentic in shape, it forms the summit of the shoulder and is compressed from above downward so as to present for examination two surfaces, two borders, and two extremities.

The posterior part sometimes terminates laterally in a prominent **acromial angle** (meta-cromion) and the process then assumes a more or less triangular form. Of the two extremities, the posterior is continuous with the spine, whilst the anterior forms the free tip. The upper surface, directed upward, backward, and slightly lateralward, is rough and convex, and affords origin at its lateral part to a portion of the *deltoid;* the remaining part of this surface is sub-cutaneous. The lower surface, directed downward, forward, and slightly medialward, is con-cave and smooth. The medial border, continuous with the upper lip of the crest, presents, from behind forward, an area for the insertion of the *trapezius;* a small, oval, concave articular facet for the lateral end of the clavicle, the edges of which are rough for the acromio-clavicular ligaments; and, beyond this, the anterior extremity or tip, to which is attached the apex of the coraco-acromial ligament. The lateral border, continuous with the inferior lip of the crest, is thick, convex, and presents three or four tubercles with intervening depressions; from the tubercles the tendinous septa in the acromial part of the *deltoid* arise, and from the depressions, some fleshy fibres of the same muscle.

Projecting upward from the neck of the scapula is the **coracoid process,** bent finger-like, pointing forward and laterally. It consists of two parts, ascending and horizontal, arranged at almost a right angle to each other.

The *ascending part* arises by a wide root, extends upward and medially for a short distance, and is compressed from before backward; it is continuous above with the horizontal part and below with the neck of the scapula; the lateral border lies above the glenoid cavity and gives attachment to the coraco-humeral ligament; the medial border, which forms the lateral boundary of the scapular notch, gives attachment to the conoid ligament above and the transverse liga-ment below. Its anterior and posterior surfaces are in relation with the *subscapularis* and *supraspinatus* respectively. The *horizontal part* of the process runs forward and lateralward; it is compressed from above downward so as to present two borders, two surfaces, and a free extremity. The medial border gives insertion along its anterior half to the *pectoralis minor* and nearer the base to the costo-coracoid membrane; the lateral border is rough for the coraco-acromial and coraco-humeral ligaments; the upper surface is irregular and gives insertion in

front to the *pectoralis minor*, and behind to the trapezoid ligament; the inferior surface is smooth and directed toward the glenoid cavity, which it overhangs; the free extremity or apex gives origin to the conjoined *coraco-brachialis* and short head of the *biceps*.

The greater part of the body of the scapula and the central parts of the spinous process are thin and transparent. The coracoid and acromion processes, the crest of the spine and inferior angle, the head, neck, and axillary border, are thick and opaque. The young bone consists of two layers of compact tissue with an intervening cancellous layer, but in the transparent parts of the adult bone the middle layer has disappeared. The vascular foramina on the costal surface transmit twigs from the subscapular and transverse scapular (suprascapular) arteries; those in the infraspinous fossa, twigs from the circumflex (dorsal) and transverse scapular (suprascapular) arteries, the latter also giving off vessels which enter the foramina in the supraspinous fossa. The acromion is supplied by branches from the thoraco-acromial (acromiothoracic) artery.

The line of attachment of the spinous process to the dorsum of the scapula is known as the **morphological axis,** and the obtuse angle in the subscapular fossa opposite the spine as the

FIG. 173.—OSSIFICATION OF THE SCAPULA.

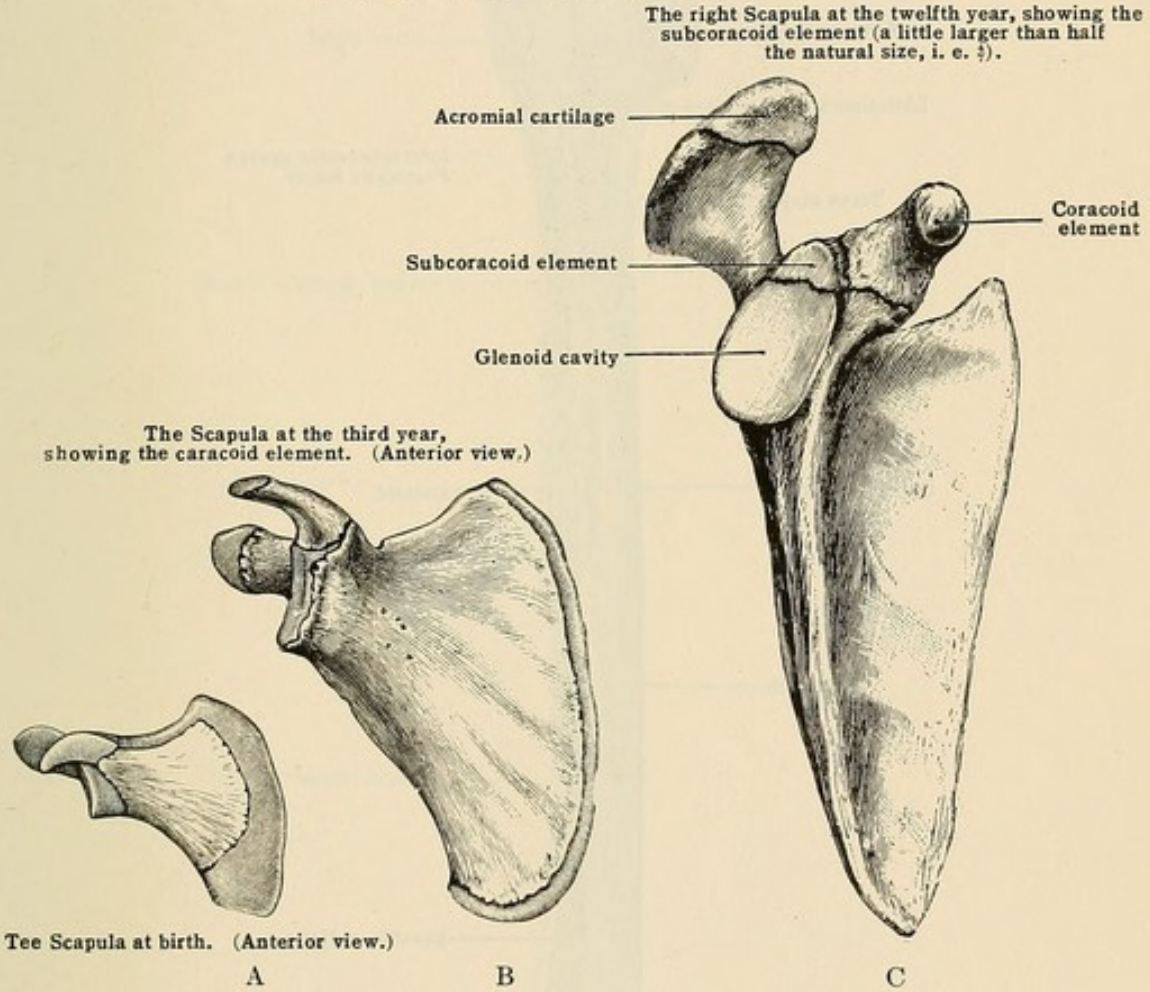

subscapular angle. From the axis three plates of bone radiate as from a centre, the **prescapula** forward, the **mesoscapula** laterally, and the **postscapula** backward, being named in accordance with the long axis of the body in the horizontal position. In the human subject the postscapula is greatly developed, and this is associated with the freedom and versatility of movement possessed by the upper limb.

Ossification.—The scapula is ossified from nine centres. Of these, two (for the body of the scapula and the coracoid) may be considered as **primary,** and the remainder as **secondary.** The centre for the body appears in a plate of cartilage near the neck of the scapula about the eighth week of intra-uterine life, and quickly forms a triangular plate of bone, from which the spine appears as a slight ridge about the middle of the third month. At birth the glenoid fossa and part of the scapular neck, the acromion and coracoid processes, the vertebral border and inferior angle, are cartilaginous. During the first year a nucleus appears for the coracoid, and at the tenth year a second centre appears for the base of the coracoid and the upper part of the glenoid cavity (subcoracoid, fig. 173).

During the fifteenth year the coracoid unites with the scapula, and about this time the other secondary centres appear. Two nuclei are deposited in the acromial cartilage, and fuse to form the acromion, which joins the spine at the twentieth year. The union of spine and acromion may be fibrous, hence the latter is sometimes found separate in macerated specimens. The cartilage along the vertebral border ossifies from two centres, one in the middle, and another at the inferior angle. A thin lamina is added along the upper surface of the coracoid process and

occasionally another at the margin of the glenoid cavity. These epiphyses join by the twenty-fifth year.

The occurrence of a special primary centre for the coracoid process is of morphological importance in that the process is the representative of what in the lower vertebrates is a distinct *coracoid bone*. This primarily takes part in the formation of the glenoid cavity and extends medially to articulate with the sternum. In man and all the higher mammals only the lateral portion of the bone persists.

THE HUMERUS

The **humerus** (figs. 174, 175, 176) is the longest and largest bone of the upper limb, and extends from the shoulder above, where it articulates with the scapula,

FIG. 174.—THE LEFT HUMERUS. (Anterior view.)

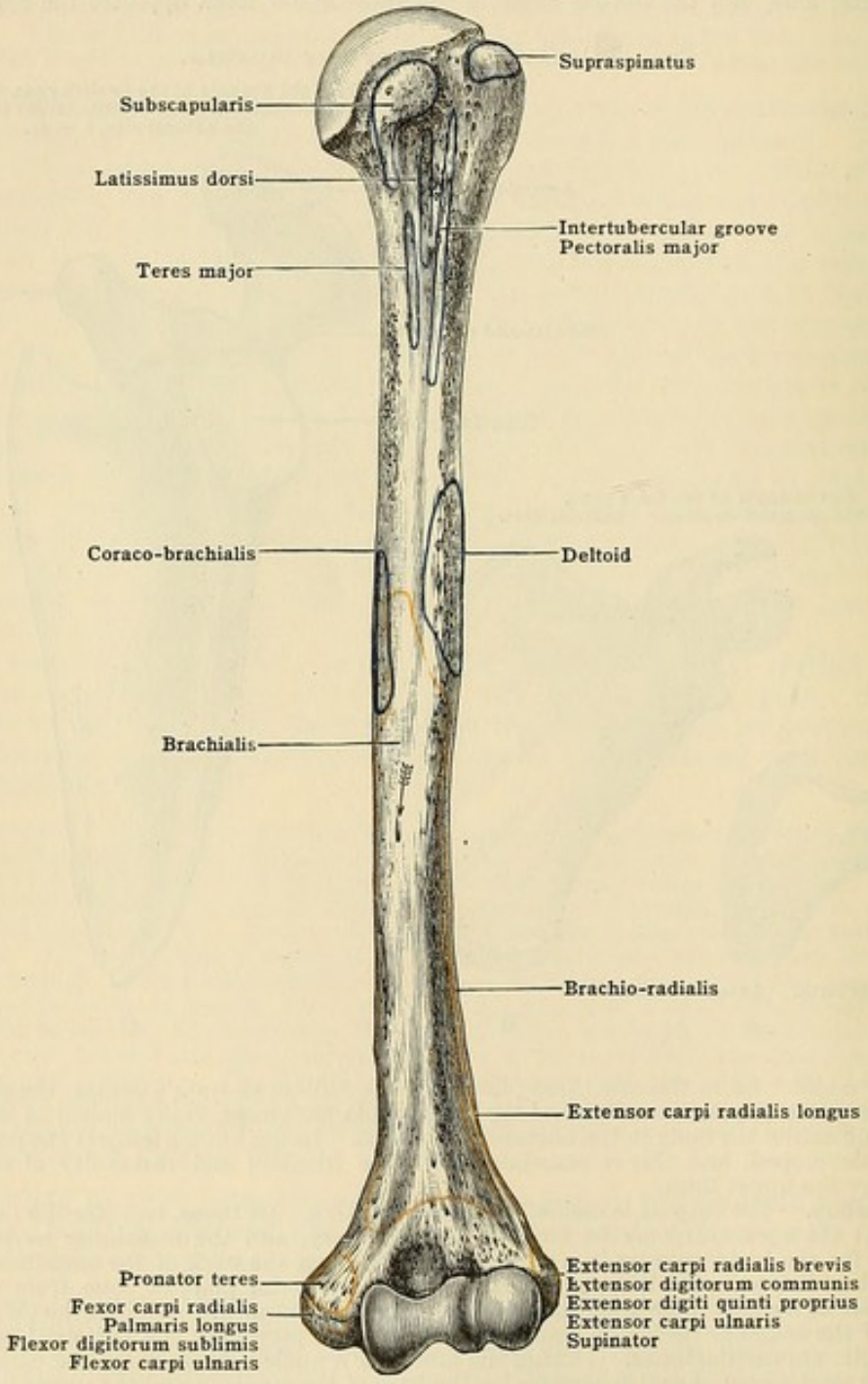

to the elbow [cubitus] below, where it articulates with the two bones of the forearm [anti-brachium]. It is divisible into a shaft and two extremities; the *upper* extremity includes the head [caput], neck [collum], and two tuberosities—great and small; the *lower* extremity includes the articular surface with the surmounting fossæ in front and behind, and the two epicondyles.

Upper extremity.—The **head** forms a nearly hemispherical articular surface, cartilage-clad in the recent state and directed upward, medially, and backward toward the glenoid cavity. Below the head the bone is rough and somewhat constricted, constituting the **anatomical neck,** best marked superiorly, where it forms a groove separating the articular surface from the two tuberosities. The circumference of the neck gives attachment to the capsule of the shoulder-joint and the gleno-humeral folds, the upper of which is received into a depression near the top of the intertubercular (bicipital) groove. The lowest part of the capsule

FIG. 175.—THE LEFT HUMERUS. (Posterior view.)

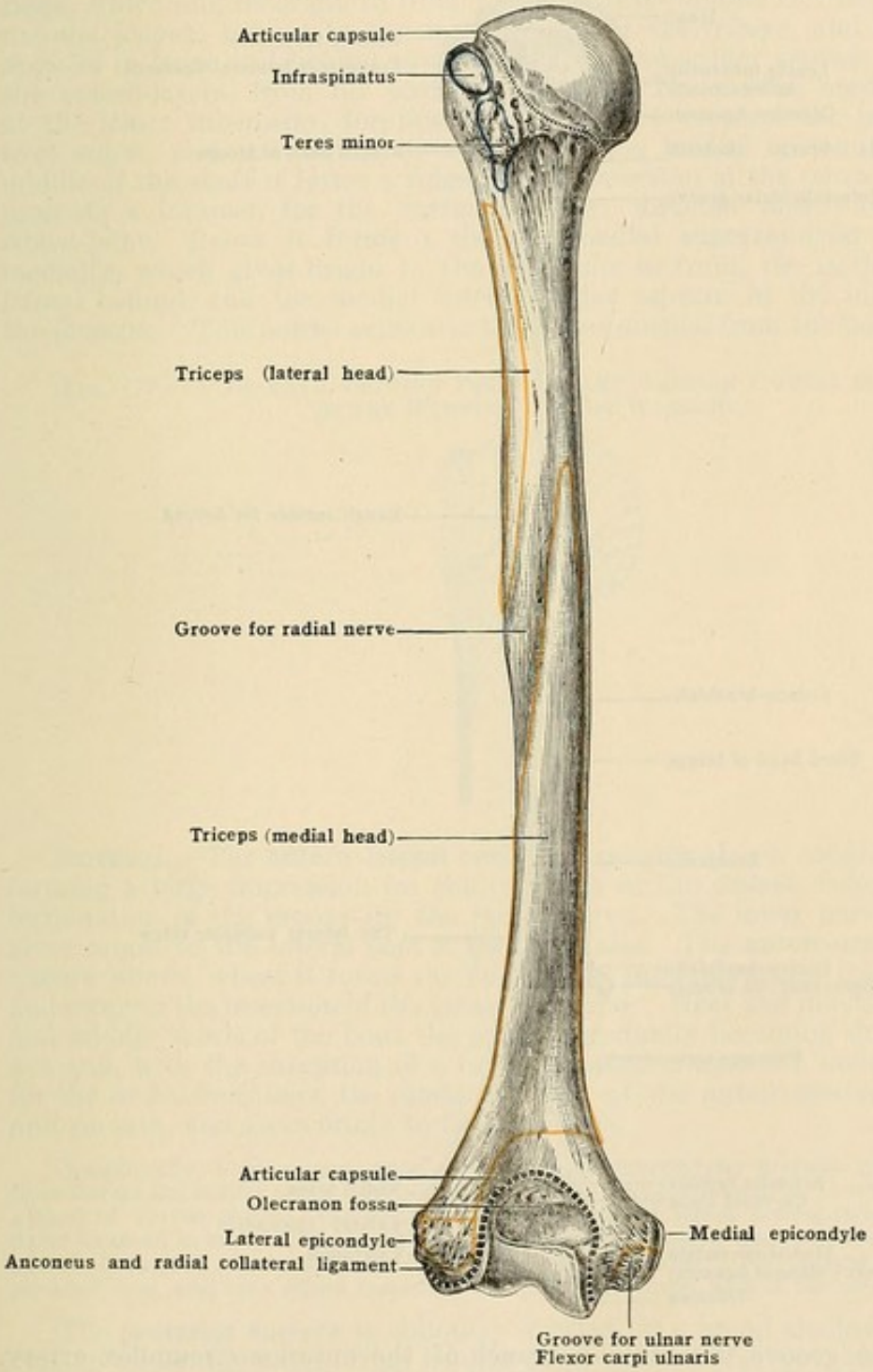

descends upon the humerus some distance from the articular margin. Laterally and in front of the head are the two tuberosities, separated by a deep furrow. The **greater tuberosity** [tuberculum majus], lateral in position and reaching higher than the **lesser tuberosity** [tuberculum minus], is marked by three facets for the insertion of muscles: an upper one for the *supraspinatus*, a middle for the *in-*

fraspinatus, and a lower for the *teres minor*. The **lesser tuberosity** is situated in front of the head and is the more prominent of the two; it receives the insertion of the *subscapularis*. The furrow between the tuberosities lodges the long tendon of the biceps and forms the commencement of the **intertubercular** (bicipital) **groove,** which extends downward along the shaft of the humerus. Between the tuberosities the transverse humeral ligament converts the upper end of the groove into a canal. In addition to the long tendon of the biceps and its tube of synovial

FIG. 176.—THE LEFT HUMERUS WITH A SUPRACONDYLOID PROCESS AND SOME IRREGULAR MUSCLE ATTACHMENTS. (Anterior view.)

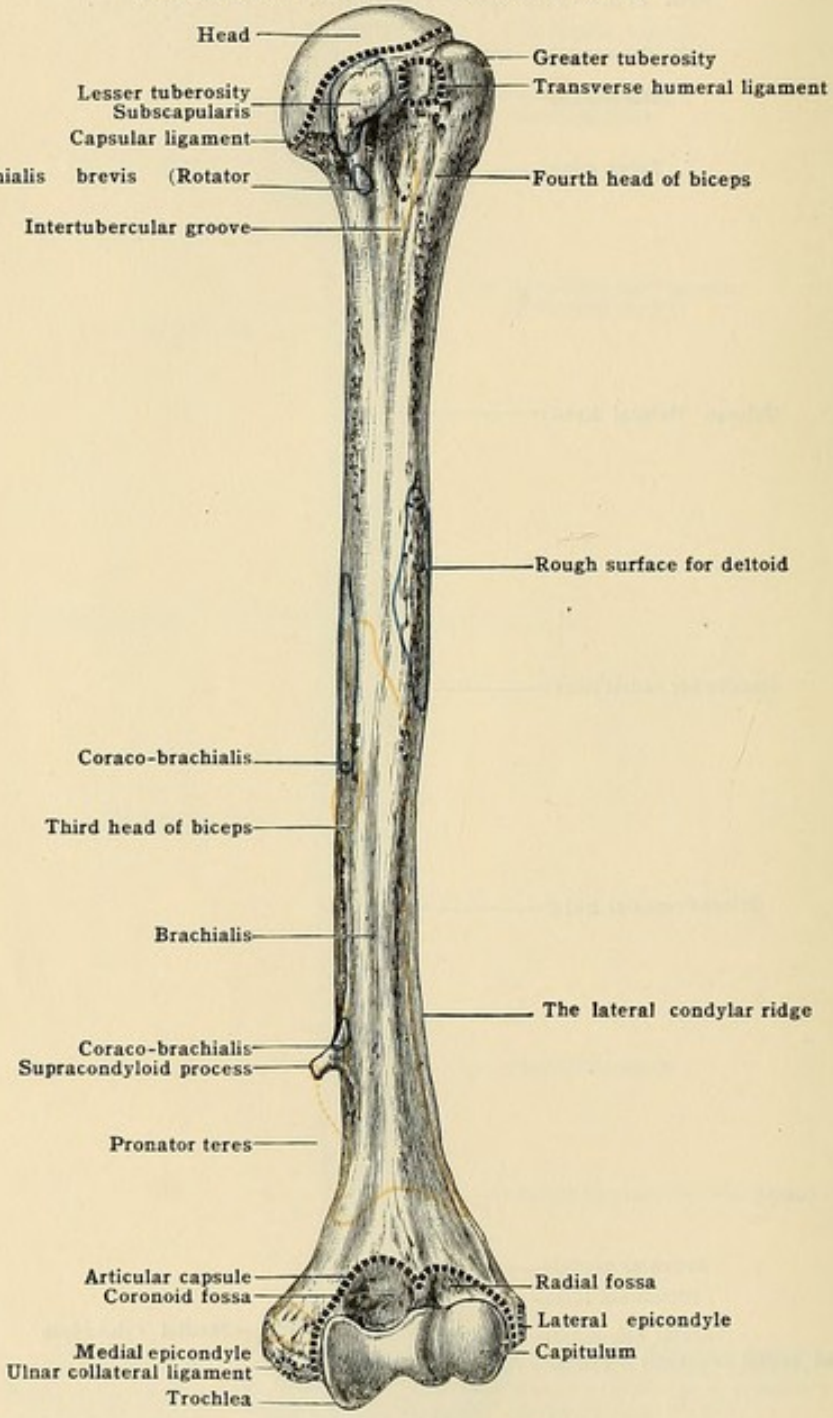

membrane, the groove transmits a branch of the anterior circumflex artery. Immediately below the two tuberosities the bone becomes contracted and forms the **surgical neck.**

The **shaft** or **body** [corpus humeri] is somewhat cylindrical above, flattened and prismatic below. Three borders and three surfaces may be recognised.

Borders.—The **anterior border** commences above at the greater tuberosity, and its upper part, forming the **crest** of this tuberosity [crista tuberculi majoris],

receives the *pectoralis major*. In the middle of the shaft it is rough and prominent and gives insertion to fibres of the *deltoid;* below it is smooth and rounded, giving origin to fibres of the *brachialis*, and finally it passes along lateral to the coronoid fossa to become continuous with the ridge separating the capitulum and trochlea. It separates the antero-medial from the antero-lateral surface. The **lateral margin** extends from the lower and posterior part of the greater tuberosity to the lateral epicondyle. Smooth and indistinct above, it gives attachment to the *teres minor* and the lateral head of the *triceps;* it is interrupted in the middle by the **groove for the radial nerve** (musculo-spiral groove), but the lower third becomes prominent and curved laterally to form the **lateral supracondylar ridge,** which affords origin in front to the *brachio-radialis* and the *extensor carpi radialis longus;* behind to the medial head of the *triceps*, and between these muscles in front and behind to the lateral intermuscular septum. It separates the antero-lateral from the posterior surface. The **medial border** commences at the lesser tuberosity, forming its **crest** which receives the insertion of the *teres major*, and continuing downward to the medial epicondyle. Near the middle of the shaft it forms a ridge for the insertion of the *coraco-brachialis* and presents a foramen for the nutrient artery, directed downward toward the elbow-joint. Below it forms a distinct **medial supracondylar ridge,** curved medially, which gives origin to the *brachialis* in front, the medial head of the *triceps* behind, and the medial intermuscular septum in the interval between the muscles. This border separates the antero-medial from the posterior surface.

FIG. 177.—A DIAGRAM SHOWING PRESSURE AND TENSION CURVES IN THE HEAD OF THE HUMERUS. (After Wagstaffe.)



Surfaces.—The **antero-lateral surface** is smooth above, rough in the middle, forming a large impression for the insertion of the *deltoid*, below which is the termination of the groove for the radial nerve. The lower part of the surface gives origin to the lateral part of the *brachialis*. The **antero-medial surface** is narrow above, where it forms the floor of the intertubercular (bicipital) groove, and receives the insertion of the *latissimus dorsi*. Near the junction of the upper and middle thirds of the bone the groove, gradually becoming shallower, widens out and, with the exception of a rough impression near the middle of the shaft for the *coraco-brachialis*, the remaining part of the antero-medial surface is flat and smooth, and gives origin to the *brachialis*.

Occasionally, a prominent spine of bone, the **supracondylar process,** projects downward from the medial border about 5 cm. (2 in.) above the medial epicondyle, to which it is joined by a band of fibrous tissue. Through the ring thus formed, which corresponds to the supracondylar foraman in many of the lower animals, the median nerve and brachial artery are transmitted, though in some cases it is occupied by the nerve alone. The process gives origin to the *pronator teres*, and may afford insertion to a persistent lower part of the *coraco-brachialis*.

The **posterior surface** is obliquely divided by a broad shallow groove, which runs in a spiral direction from behind downward and forward and transmits the radial (musculo-spiral) nerve and the profunda artery. The lateral part of the surface above the groove gives attachment to the lateral head, and the part below the groove, to the medial head of the *triceps*.

The **lower extremity** of the humerus is flattened from before backward, and terminates below in a sloping articular surface, subdivided by a low ridge into the

trochlea and the **capitulum.** The **trochlea** is the pulley-like surface which extends over the end of the bone for articulation with the semilunar notch (great sigmoid cavity) of the ulna. It is constricted in the centre and expanded laterally to form two prominent edges, the medial of which is thicker, descends lower, and forms a marked projection; the lateral edge is narrow and corresponds to the interval between the ulna and radius. Above the trochlea are two fossæ: on the anterior surface is the **coronoid fossa,** an oval pit which receives the coronoid process of

FIG. 178.—OSSIFICATION OF THE HUMERUS; THE FIGURE ALSO SHOWS THE RELATIONS OF THE EPIPHYSIAL AND CAPSULAR LINES

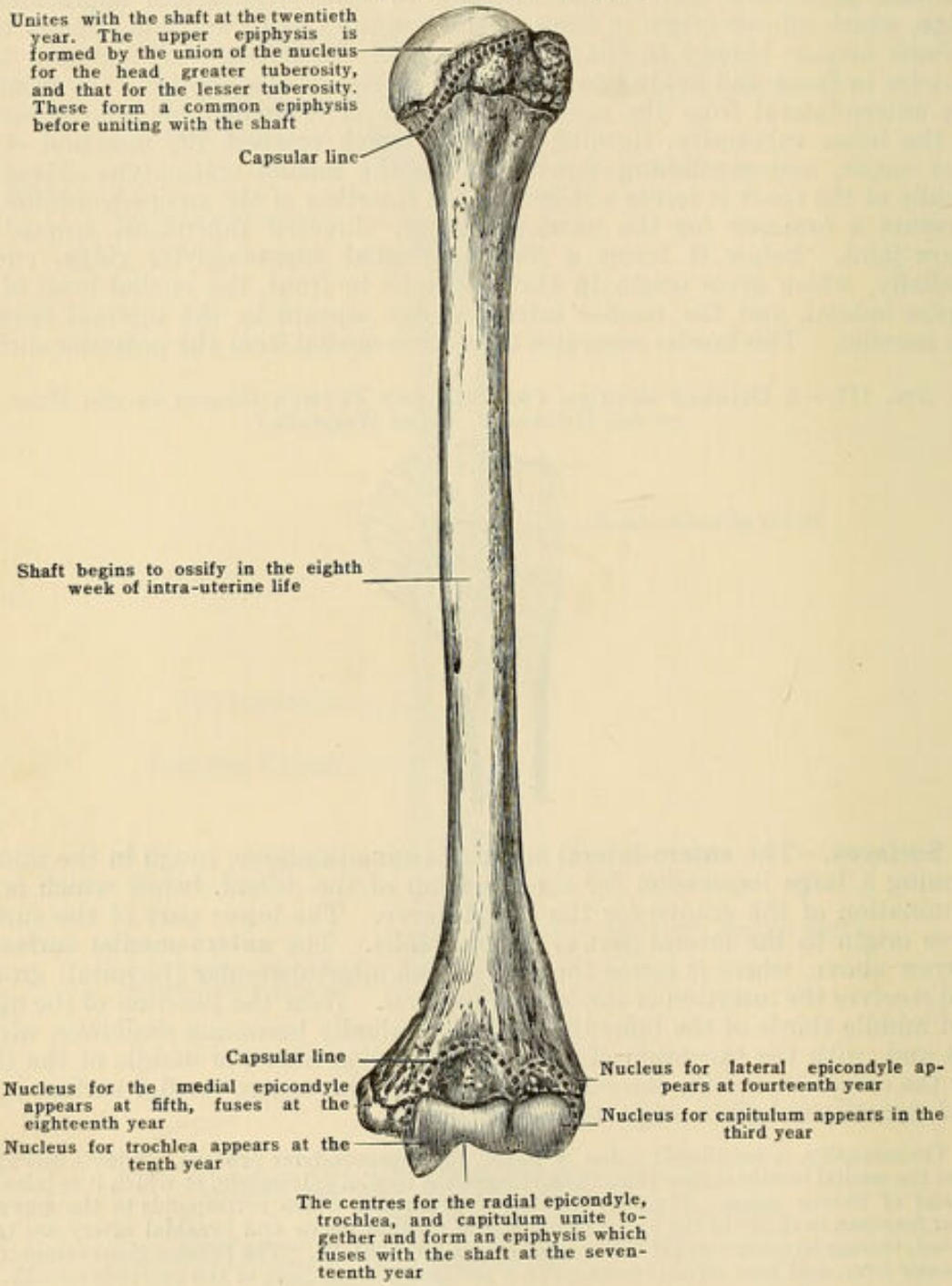

the ulna when the forearm is flexed; on the posterior aspect is the **olecranon fossa,** a deep hollow for the reception of the anterior extremity of the olecranon in extension of the forearm. These fossæ are usually separated by a thin, translucent plate of bone, sometimes merely by fibrous tissue, so that in macerated specimens a perforation, the **supratrochlear foramen,** exists. The **capitulum,** or radial head, is much smaller than the trochlea, somewhat globular in shape, and limited to the anterior and inferior surfaces of the extremity. It articulates with the con-

cavity on the summit of the radius. The **radial fossa** is a slight depression on the front of the bone, immediately above the capitulum, which receives the anterior edge of the head of the radius in complete flexion of the forearm, whilst between the capitulum and the trochlea is a shallow groove occupied by the medial margin of the head of the radius.

In the recent state the inferior articular surface is covered with cartilage, the fossæ are lined by synovial membrane, and their margins give attachment to the capsule of the elbow-joint. Projecting on either side from the lower end of the humerus are the two **epicondyles.** The medial one is large and by far the more prominent of the two, rough in front and below, smooth behind, where there is a shallow groove for the ulnar nerve. The rough area serves for origin of the *pronator teres* above, the common tendon of origin of the *flexor carpi radialis, palmaris longus, flexor digitorum sublimis* and *flexor carpi ulnaris* in the middle, and the ulnar collateral ligament below. The lateral epicondyle is flat and irregular. Above, it gives attachment to a common tendon of origin of the *extensor carpi radialis brevis, extensor digitorum communis, extensor quinti digiti proprius, extensor carpi ulnaris,* and *supinator;* to a depression near the outer margin of the capitulum, the radial collateral ligament is attached, and from an area below and behind, the *anconeus* takes origin.

Architecture.—The interior of the shaft of the humerus is hollowed out by a large medullary canal, whereas the extremities are composed of cancellated tissue invested by a thin compact layer. The arrangement of the cancellous tissue at the upper end of the humerus is shown in fig. 177. The lamellæ converge to the axis of the bone and form a series of superimposed arches which reach upward as far as the epiphysial line. In the epiphyses the spongy tissue forms a fine network, the lamellæ resulting from "pressure" being directed at right angles to the articular surface of the head and to the great tuberosity.

Blood-supply.—The foramina which cluster round the circumference of the head and tuberosities transmit branches from the transverse scapular (suprascapular) and anterior and posterior circumflex arteries. At the top of the intertubercular groove is a large nutrient foramen

FIG. 179.—THE HEAD OF THE HUMERUS AT THE SIXTH YEAR. (In section.)

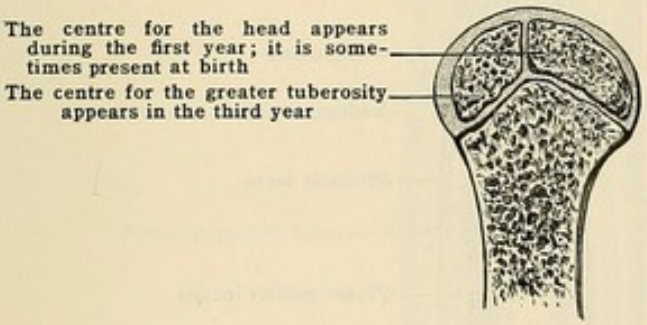

for a branch of the anterior circumflex artery which supplies the head. The nutrient artery of the shaft is derived from the brachial, and in many cases, an additional branch, derived from the profunda artery, enters the foramen in the groove for the radial nerve (musculo-spiral groove). The lower extremity is nourished by branches derived from the profunda (superior profunda), the superior and inferior ulnar collateral (inferior profunda and anastomotic), and the recurrent branches of the radial, ulnar, and interosseous arteries.

Ossification.—The humerus is ossified from one primary centre (diaphysial) and six secondary centres (epiphysial). The centre for the shaft appears about the eighth week of intrauterine life and grows very rapidly. At birth only the two extremities are cartilaginous, and these ossify in the following manner: Single centres appear for the head in the first year, for the greater tuberosity in the third year, and for the lesser tuberosity in the fifth year, though sometimes the latter ossifies by an extension from the greater tuberosity. These three nuclei coalesce at six years to form a single epiphysis, which joins the shaft about the twentieth year.

The inferior extremity ossifies from four centres: one for the capitulum appears in the third year, a second for the medial epicondyle in the fifth year, a third for the trochlea in the tenth year, and a fourth for the lateral epicondyle in the fourteenth year. The nuclei for the capitulum, trochlea, and lateral epicondyle coalesce to form a single epiphysis which joins the shaft in the seventeenth year. The nucleus of the medial epicondyle joins the shaft independently at the age of eighteen years.

A study of the upper end of the humeral shaft before its union with the epiphysis is of interest in relation to what is known as the neck of the humerus. The term neck is applied to three parts of this bone. The *anatomical* neck is the constriction to which the articular capsule is mainly attached, and its position is accurately indicated by the groove which lies internal to the tuberosities. The upper extremity of the humeral shaft, before its union with the epiphysis, terminates in a low three-sided pyramid, the surfaces of which are separated from one another by ridges. The medial of these three surfaces underlies the head of the bone, and the two lateral surfaces underlie the tuberosities. The part supporting the head constitutes the *morphological* neck of the humerus, whilst the *surgical* neck is the indefinite area below the tuberosities where the bone is liable to fracture.

THE RADIUS

The **radius** (figs. 180–185) is the lateral and shorter of the two bones of the forearm. Above, it articulates with the humerus; below, with the carpus; and on the medial side with the ulna. It presents for examination a shaft and two extremities.

The **upper extremity,** smaller than the lower, includes the head, neck, and tuberosity. The **head** [capitulum], covered with cartilage in the recent state, is a circular disc forming the expanded, articular end of the bone. Superiorly it presents the capitular depression [fovea capituli] for the reception of the capitulum

FIG. 180.—THE LEFT ULNA AND RADIUS. (Antero-medial view.)

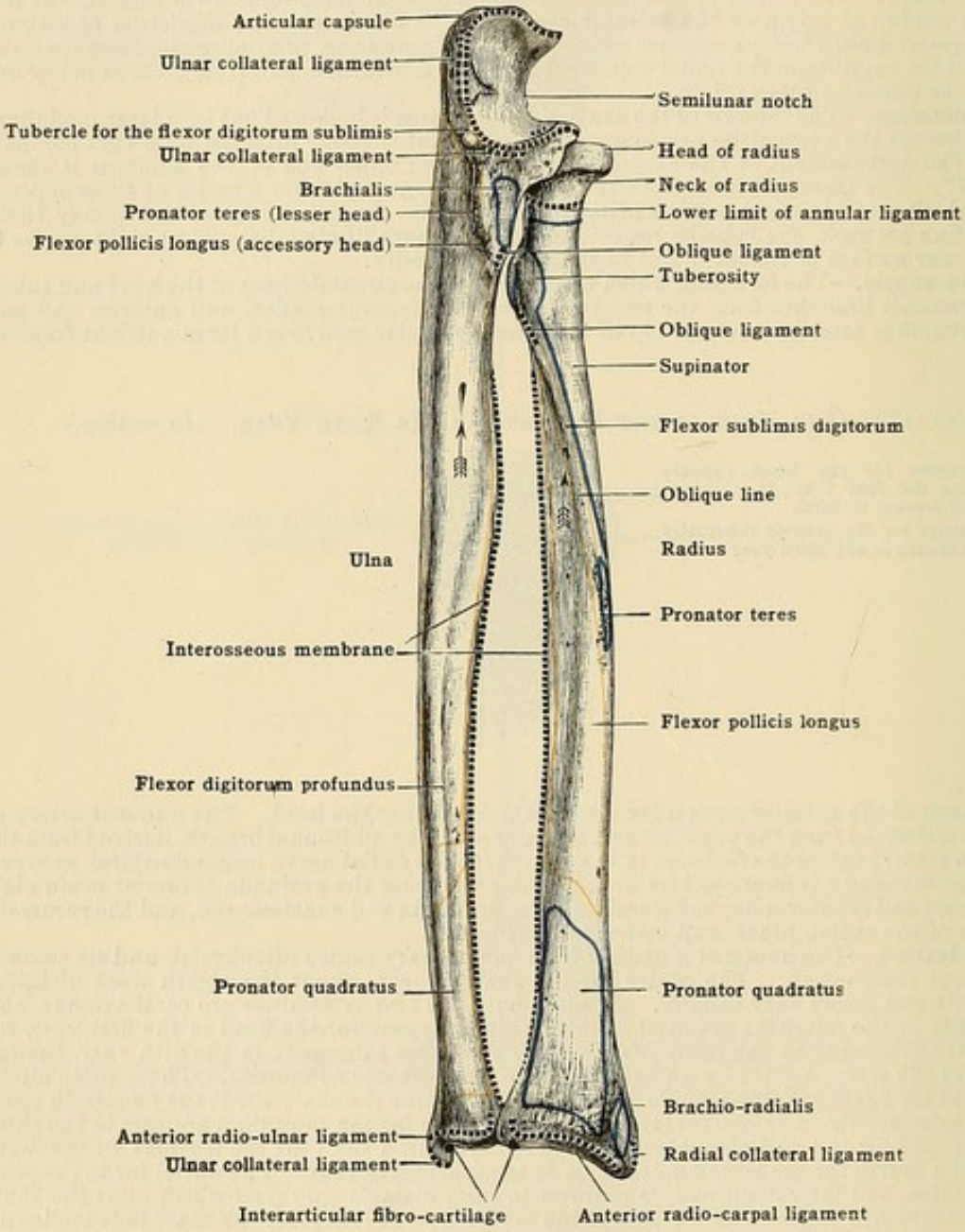

of the humerus; its circumference [circumferentia articularis], deeper on the medial aspect, articulates with the radial notch (lesser sigmoid cavity) of the ulna, and is narrow elsewhere for the annular ligament by which it is embraced. Below the head is a short cylindrical portion of bone, somewhat constricted, and known as the **neck.** The upper part is surrounded by the ligament which embraces the head, and below this it gives insertion antero-laterally to the *supinator.* Below the neck, at the antero-medial aspect of the bone, is an oval eminence, the radial **tuberosity,** divisible into two parts: a rough posterior portion for the insertion of

the tendon of the *biceps*, and a smooth anterior surface in relation with a bursa which is situated between the tendon and the tuberosity.

The **body** [corpus radii] or **shaft** is somewhat prismatic in form, gradually increasing in size from the upper to the lower end, and slightly curved so as to be concave toward the ulna. Three borders and three surfaces may be recognised. Of the borders, the medial or **interosseous crest** [crista interossea] is best marked. Commencing at the posterior edge of the tuberosity, its first part is round and indistinct, and receives the attachment of the oblique cord of the radius; it is con-

FIG. 181.—THE LEFT ULNA AND RADIUS. (Postero-lateral view.)

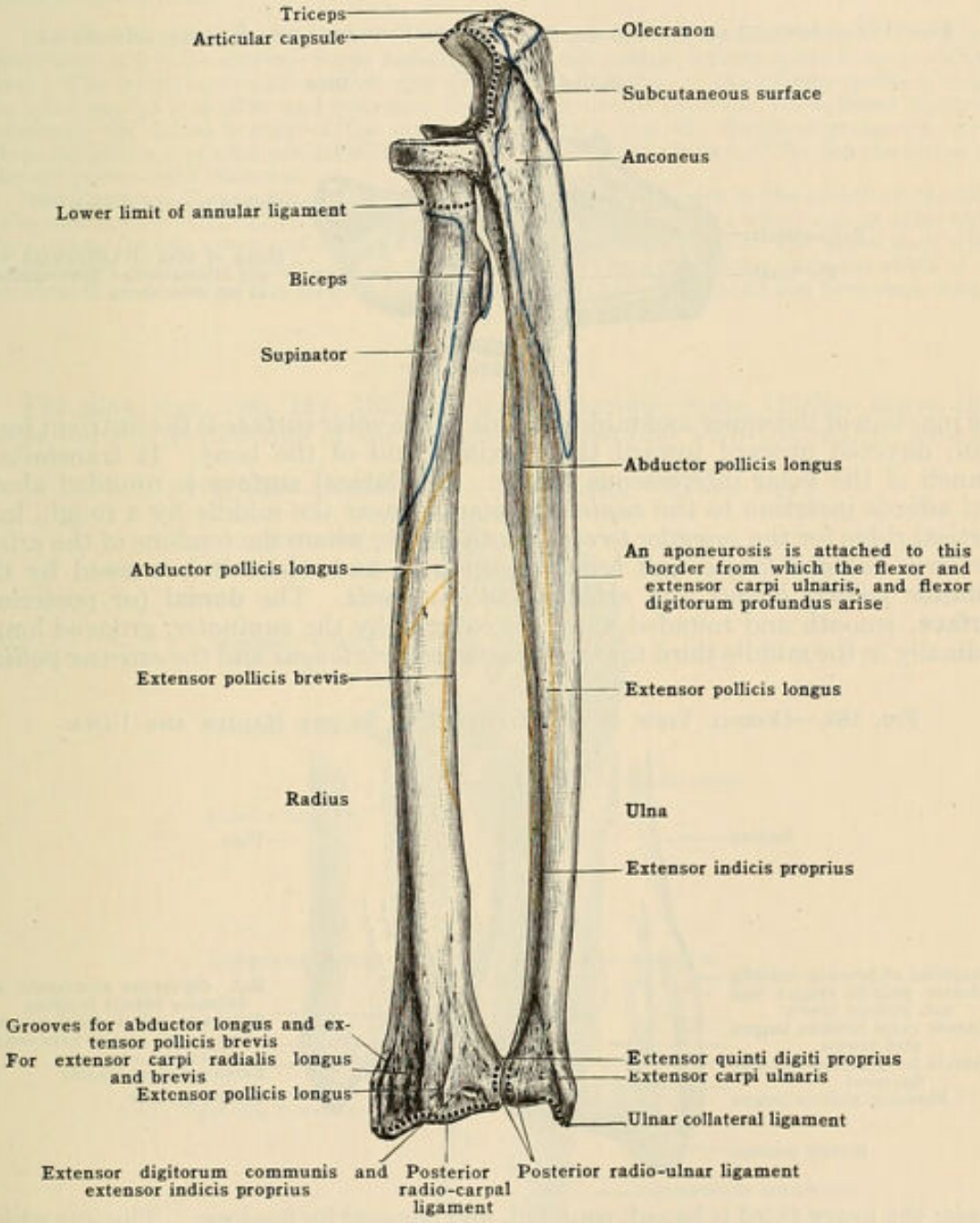

tinued as a sharp ridge which divides near the lower extremity to become continuous with the anterior and posterior margins of the ulnar notch (sigmoid cavity). The prominent ridge and the posterior of the two lower lines give attachment to the interosseous membrane, whilst the triangular surface above the ulnar notch receives a part of the *pronator quadratus*. The interosseous crest separates the volar from the dorsal surface. The **volar border** [margo volaris] runs from the tuberosity obliquely downward to the lateral side of the bone and then descends vertically to the anterior border of the styloid process. The upper third, consti-

tuting the **oblique line** of the radius, gives origin to the radial head of the *flexor digitorum sublimis*, limits the insertion of the *supinator* above, and the origin of the *flexor pollicis longus* below. The volar border separates the volar from the lateral surface. The **dorsal border** extends from the back of the tuberosity to the prominent middle tubercle on the posterior aspect of the lower extremity. Separating the lateral from the dorsal surface, it is well marked in the middle third, but becomes indistinct above and below.

Surfaces.—The **volar** (or anterior) **surface** is narrow and concave above; broad, flat, and smooth below. The upper two-thirds is occupied chiefly by the *flexor pollicis longus* and a little less than the lower third by the *pronator quadratus*. Near

FIG. 182.—ARTICULAR FACETS ON THE LOWER END OF LEFT RADIUS AND ULNA.

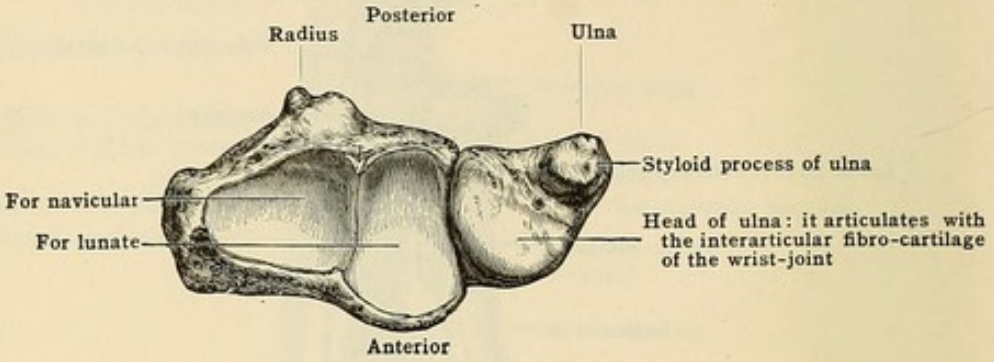

the junction of the upper and middle thirds of the volar surface is the nutrient foramen, directed upward toward the proximal end of the bone. It transmits a branch of the volar interosseous artery. The **lateral surface** is rounded above and affords insertion to the *supinator;* marked near the middle by a rough, low, vertical ridge for the *pronator teres;* smooth below, where the tendons of the *extensor carpi radialis longus* and *brevis* lie upon it, and where it is crossed by the *abductor pollicis longus* and *extensor pollicis brevis*. The **dorsal** (or posterior) **surface,** smooth and rounded above, is covered by the *supinator;* grooved longitudinally in the middle third for the *abductor pollicis longus* and the *extensor pollicis*

FIG. 183.—DORSAL VIEW OF THE LOWER END OF THE RADIUS AND ULNA.

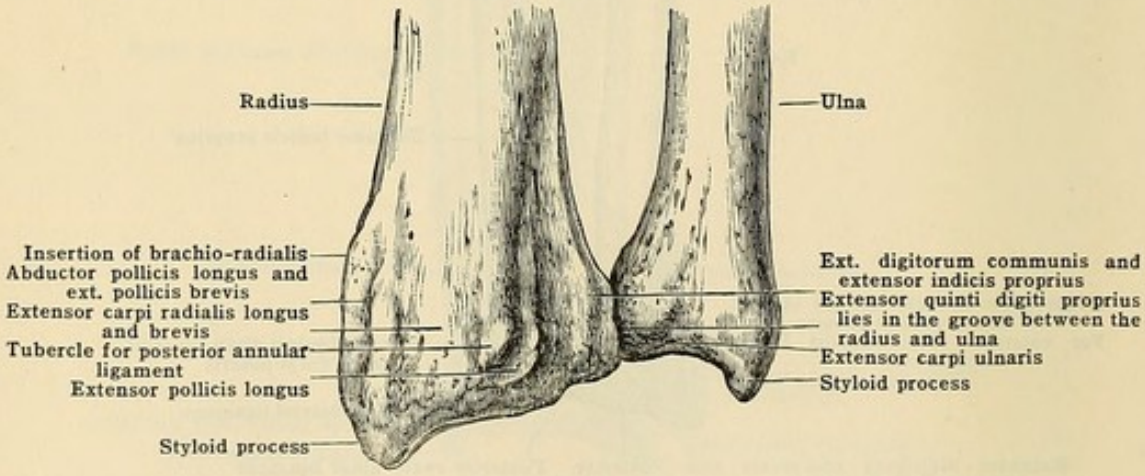

brevis; the lower third is broad, rounded, and covered by tendons. The line which forms the upper limit of the impression for the *abductor pollicis longus* is known as the **posterior oblique line.**

The **lower extremity** of the radius is quadrilateral; its **carpal surface** [facies articularis carpea] is articular and divided by a ridge into a medial quadrilateral portion, concave for articulation with the lunate bone; and a lateral triangular portion, extending onto the styloid process for articulation with the navicular (scaphoid) bone. The medial surface, also articular, presents the **ulnar notch** (sigmoid cavity) for the reception of the rounded margin of the head of the ulna. To the border separating the ulnar and carpal articular surfaces the base of the

articular disc is attached, and to the anterior and posterior borders, the anterior and posterior radio-ulnar ligaments respectively. The **anterior surface** is raised into a prominent area for the anterior ligament of the wrist-joint. The **lateral surface** is represented by the **styloid process,** a blunt pyramidal eminence, to the base of which the *brachio-radialis* is inserted, whilst the tip serves for the attachment of the radial (external) collateral ligament of the wrist. Its lateral surface is marked by two shallow furrows for the tendons of the *abductor pollicis longus* and *extensor pollicis brevis*. The **posterior surface** is convex, and marked by three prominent ridges separating three furrows. The posterior annular ligament is attached to these ridges, thus forming with the bone a series of tunnels for the passage of tendons.

The most lateral is broad, shallow, and frequently subdivided by a low ridge. The lateral subdivision is for the *extensor carpi radialis longus*, the medial for the *extensor carpi radialis brevis*. The middle groove is narrow and deep for the tendon of the *extensor pollicis longus*. The most medial is shallow and transmits the *extensor indicis proprius*, the *extensor digitorum communis*, the dorsal branch of the interosseous artery, and the dorsal interosseous nerve. When the radius and ulna are articulated, an additional groove is formed for the tendon of the *extensor quinti digiti proprius*.

Ossification.—The radius is ossified from a centre which appears in the middle of the shaft in the eighth week of intra-uterine life and from two epiphysial centres which appear after birth. The nucleus for the lower end appears in the second year, and that for the upper end, which forms simply the disc-shaped head, in the fifth year. The head unites with the shaft at the seventeenth year, whilst the inferior epiphysis and the shaft join about the twentieth year.

THE ULNA

The **ulna** (figs. 180, 181, 189) is a long, prismatic bone, thicker above than below, on the medial side of the forearm and parallel with the radius, which it

FIG. 184.—UPPER END OF LEFT ULNA. (Lateral view.)

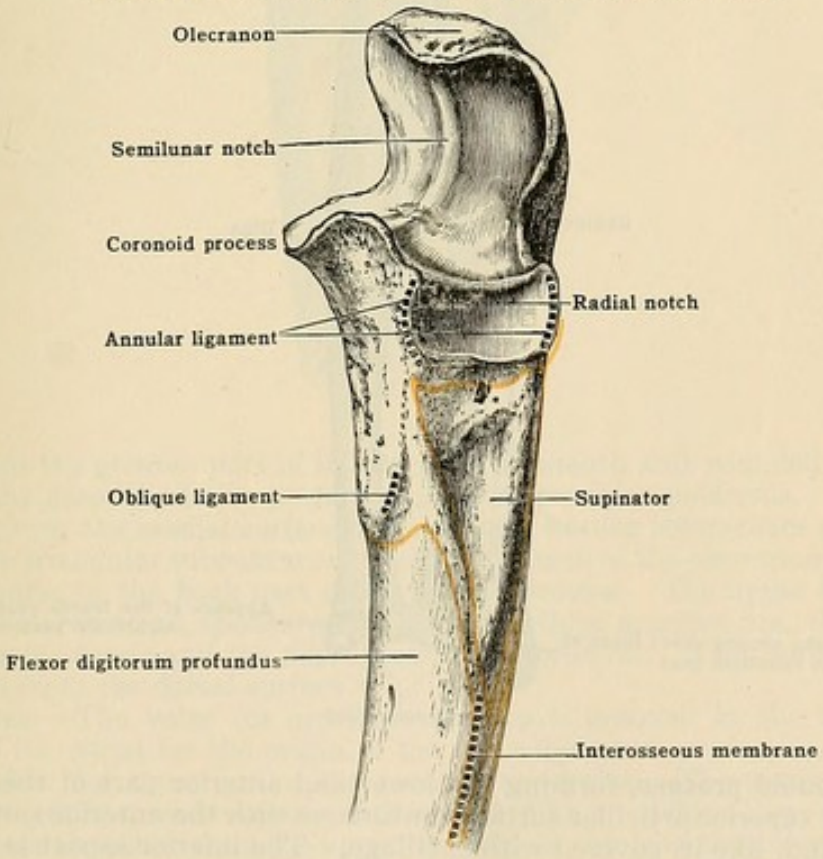

exceeds in length by the extent of the olecranon process. It articulates at the upper end with the humerus, at the lower end indirectly with the carpus, and on the lateral side with the radius. It is divisible into a shaft and two extremities.

The **upper extremity** is of irregular shape and forms the thickest and strongest part of the bone. The superior articular surface is concave from above downward, convex from side to side, and transversely constricted near the middle. It belongs

partly to the **olecranon,** the thick upward projection from the shaft, and partly to the **coronoid process,** which projects horizontally forward from the front of the ulna. This semilunar excavation forms the **semilunar notch** (greater sigmoid cavity) and articulates with the trochlear surface of the humerus. The **olecranon** is the large curved eminence forming the highest part of the bone.

The superior surface of the olecranon, uneven and somewhat quadrilateral in shape, receives behind, where there is a rough impression, the insertion of the *triceps*, and along the anterior margin the articular capsule of the elbow-joint. The posterior surface, smooth and triangular in outline, is separated from the skin by a bursa. The anterior surface, covered with cartilage in the recent state, is directed downward and forward, and its margins give attachment to the articular capsule of the elbow-joint. This surface, as already noticed, forms the upper and back part of the semilunar notch. On the medial surface of the olecranon is a tubercle for the origin of the ulnar head of the *flexor carpi ulnaris*, and in front of this a fasciculus of the ulnar collateral ligament of the elbow-joint is attached to the bone; the lateral surface is rough, concave, and gives insertion to a part of the *anconeus*. The extremity of the olecranon lies during extension of the elbow in the olecranon fossa of the humerus.

FIG. 185.—OSSIFICATION OF THE RADIUS AND ULNA; THE FIGURE ALSO SHOWS THE RELATIONS OF THE EPIPHYSIAL AND CAPSULAR LINES.

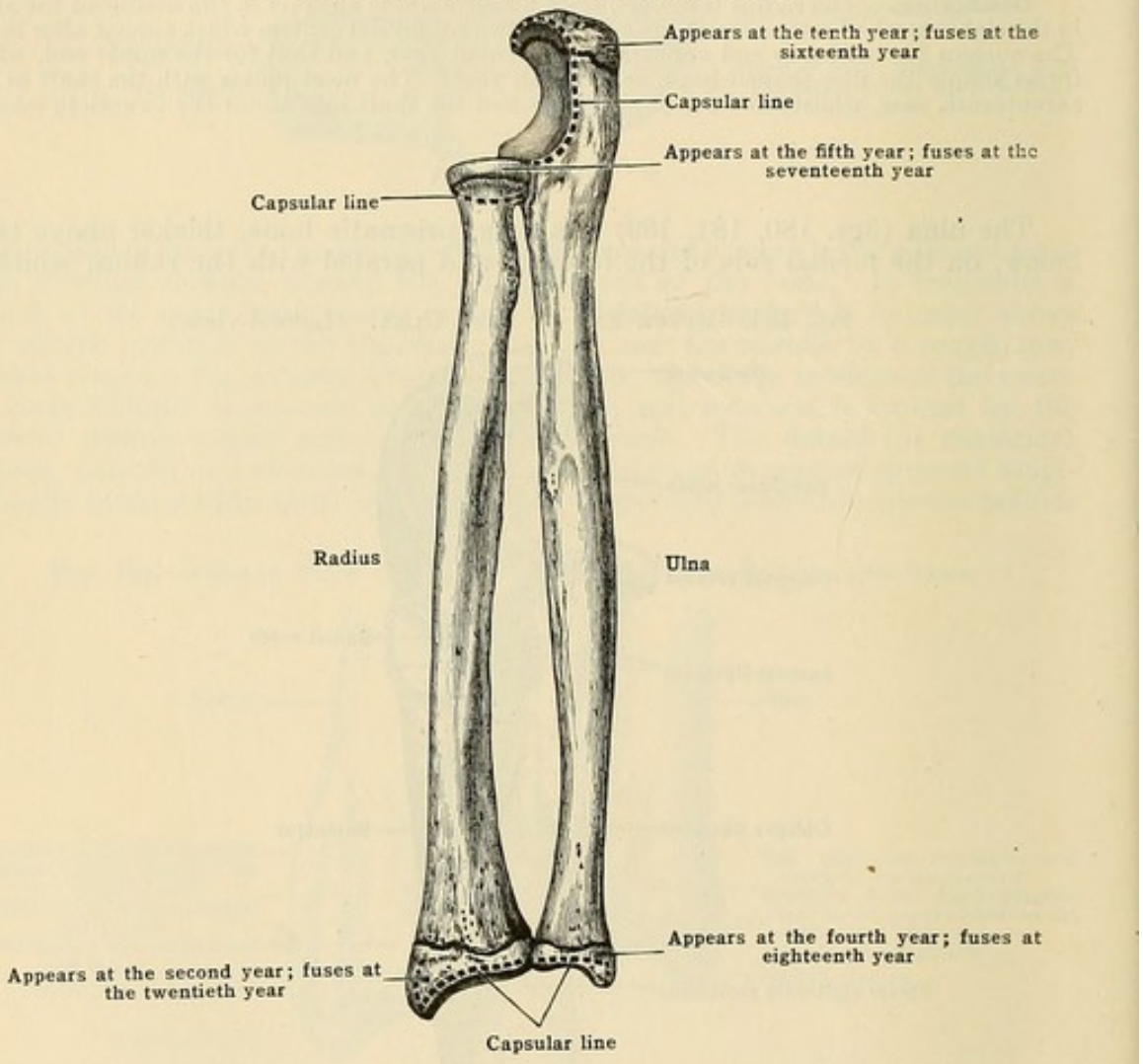

The **coronoid process,** forming the lower and anterior part of the semilunar notch, has a superior articular surface continuous with the anterior surface of the olecranon, and, like it, covered with cartilage. The inferior aspect is rough and concave, and gives insertion to the *brachialis*.

It is continuous with the volar surface of the shaft, and near the junction of the two is a rough eminence, named the **tuberosity of the ulna,** which receives the attachment of the oblique cord of the radius and the insertion of the *brachialis*. The medial side presents above a smooth tubercle for the origin of the ulnar portion of the *flexor digitorum sublimis*, and a ridge below for the lesser head of the *pronator teres* and the rounded accessory bundle of the *flexor pollicis longus*, whilst immediately behind the sublimis tubercle there is a triangular depressed surface for the upper fibres of the *flexor digitorum profundus*.

On the lateral surface is the **radial notch** (lesser sigmoid cavity), an oblong articular surface which articulates with the circumference of the head of the radius, the anterior and posterior margins of which afford attachment to the annular ligament and the radial collateral ligament of the elbow-joint. In flexion of the elbow the tip of the process is received into the coronoid fossa of the humerus.

The **body** [corpus ulnæ] or **shaft** throughout the greater part of its extent is three-sided, but tapers toward the lower extremity, where it becomes smooth and rounded. It has three borders and three surfaces. Of the three borders, the **lateral,** the **interosseous crest,** is best marked. In the middle three-fifths of the shaft it is sharp and prominent, but becomes indistinct below; above it is continued by two lines which pass to the anterior and posterior extremities of the radial notch and enclose a depressed triangular area (bicipital hollow), the fore part of which lodges the tuberosity of the radius and the insertion of the biceps tendon during pronation of the hand, while from the posterior part the *supinator* takes origin. The **interosseous crest** separates the volar from the dorsal surface and gives attachment by the lower four-fifths of its extent to the interosseous membrane. The **volar border** is directly continuous with the medial edge of the rough surface for the brachialis and terminates inferiorly in front of the styloid process.

FIG. 186.—UPPER END OF ULNA SHOWING TWO EPIPHYSES. (E. Fawcett.)

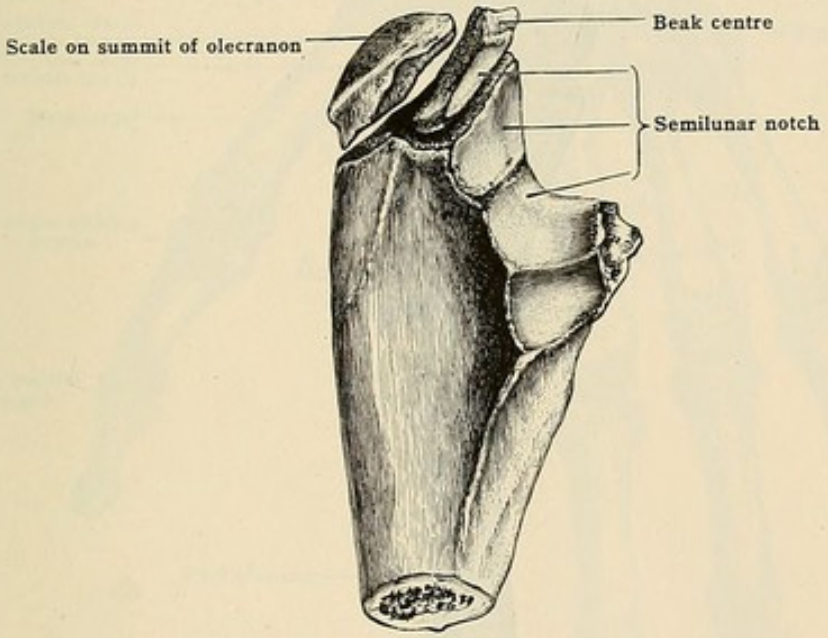

Throughout the greater part of its extent it is smooth and rounded, and affords origin to the *flexor digitorum profundus* and the *pronator quadratus.* It separates the volar from the medial surface. The **dorsal border** commences above at the apex of the triangular subcutaneous area on the back of the olecranon, and takes a sinuous course to the back part of the styloid process. The upper three-fourths gives attachment to an aponeurosis common to three muscles, viz., the *flexor* and *extensor carpi ulnaris* and the *flexor digitorum profundus.* This border separates the medial from the dorsal surface.

Surfaces.—The **volar** (or anterior) **surface** is grooved in the upper three-fourths of its extent for the origin of the *flexor digitorum profundus,* narrow and convex below, for the origin of the *pronator quadratus.* The upper limit of the area for the latter muscle is sometimes indicated by an oblique line—the **pronator ridge.** Near the junction of the upper and middle thirds of the anterior surface is the nutrient foramen, directed upward toward the proximal end of the bone. It transmits a branch of the volar interosseous artery. The **medial surface,** smooth and rounded, gives attachment, on the upper two-thirds, to the *flexor digitorum profundus,* whereas the lower third is subcutaneous. The **dorsal** (or posterior) **surface,** directed laterally as well as backward, presents at its upper part the **oblique line** of the ulna running from the posterior extremity of the radial notch to the dorsal border.

The oblique line gives attachment to a few fibres of the *supinator* and marks off the posterior surface into two unequal parts. That above the line, much the smaller of the two, receives the insertion of the *anconeus*. The more extensive part below is subdivided by a vertical ridge into a medial portion, smooth, and covered by the *extensor carpi ulnaris*, and a lateral portion which gives origin to three muscles, viz., the *abductor pollicis longus*, the *extensor pollicis longus* and the *extensor indicis proprius*, from above downward.

The **lower extremity** of the ulna is of small size and consists of two parts, the **head** and the **styloid process**, separated from each other on the inferior surface by a groove into which the apex of the articular disc is inserted. That part of the head adjacent to the groove is semilunar in shape and plays upon the articular disc which thus excludes the ulna from the radio-carpal or wrist-joint. The margin of the head is also semilunar, and is received into the ulnar notch of the radius. The **styloid process** projects from the medial and back part of the bone, and appears as a continuation of the dorsal border. To its rounded summit the ulnar collateral ligament of the wrist-joint is attached, and its dorsal surface is grooved for the passage of the tendon of the *extensor carpi ulnaris*. Immediately above the articular margin of the head the anterior and posterior radio-ulnar ligaments are attached in front and behind.

FIG. 187.—THE LEFT RADIUS AND ULNA IN PRONATION. (Anterior view.)

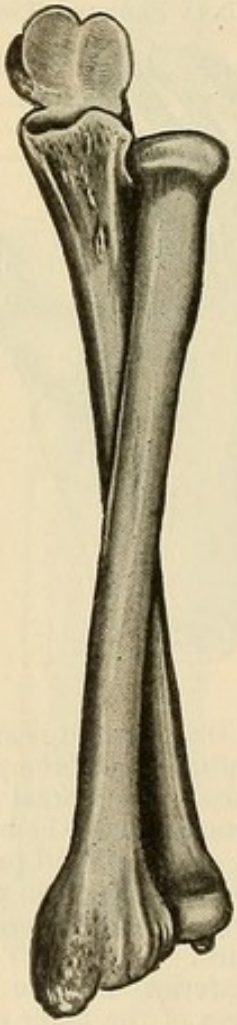

Ossification.—The ulna is ossified from three centres. The primary nucleus appears near the middle of the shaft in the eighth week of intra-uterine life. At birth the inferior extremity and the greater portion of the olecranon are cartilaginous. The nucleus for the lower end appears during the fourth year and the epiphysis joins with the shaft from the eighteenth to the twentieth year. The greater part of the olecranon is ossified from the shaft, but an epiphysis is subsequently formed from a nucleus which appears in the tenth year.

The epiphysis varies in size, and may be either scale-like and form a thin plate on the summit, or involve the upper fourth of the olecranon and the corresponding articular surface. In the latter case the epiphysis is probably composed of two parts fused together: (1) The scale on the summit of the olecranon process, and (2) the beak centre which enters into the formation of the upper end of the semilunar notch (see fig. 186). The epiphysis unites to the shaft in the sixteenth or seventeenth year.

THE CARPUS

The **carpus** (figs. 188, 189) consists of eight bones, arranged in two rows, four bones in each row. Enumerated from the radial to the ulnar side, the bones of the proximal row are named **navicular** (scaphoid), **lunate** (semilunar), **triquetral** (cuneiform), and **pisiform;** those of the distal row, **greater multangular** (trapezium), **lesser multangular** (trapezoid), **capitate** (os magnum), and **hamate** (unciform).

When the bones of the carpus are articulated, they form a mass somewhat quadrangular in outline, wider below than above, and with the long diameter transverse. The dorsal surface is convex and the volar surface concave from side to side. The concavity is increased by four prominences, which project forward, one

FIG. 188.—BONES OF THE LEFT HAND. (Dorsal surface.)

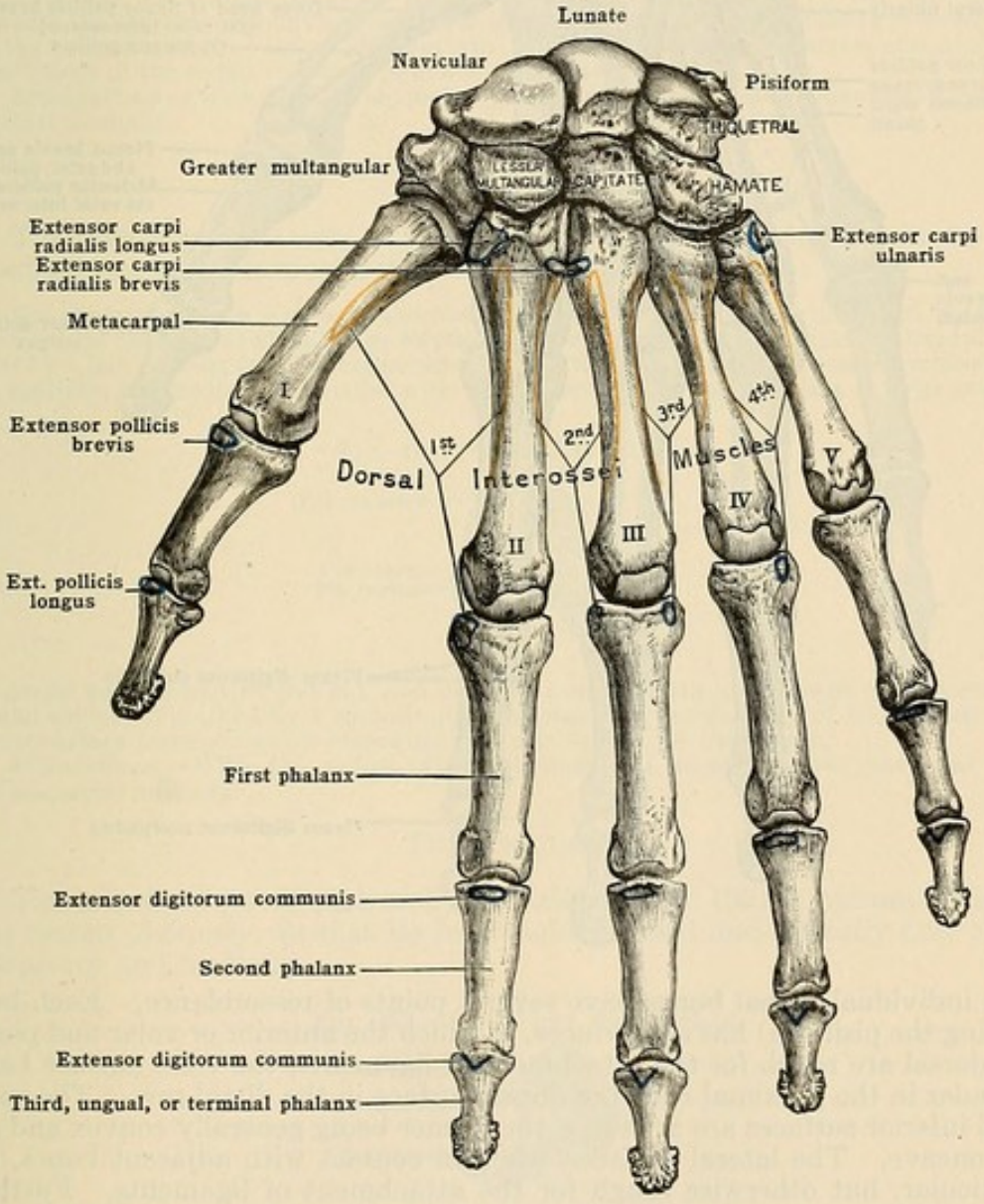

from each extremity of each row. On the radial side are the tuberosity of the navicular and the ridge of the greater multangular; on the ulnar side, the pisiform and the hook of the hamate. Stretched transversely between these prominences, in the recent state, is the transverse carpal ligament forming a canal for the passage of the flexor tendons and the median nerve into the palm of the hand. The proximal border of the carpus is convex and articulates with the distal end of the radius and the articular disc. The pisiform, however, takes no share in this articulation, being attached to the volar surface of the triquetral. The distal border forms an undulating articular surface for the bases of the metacarpal bones. The

line of articulation between the two rows of the carpus is concavo-convex from side to side, the lateral part of the navicular being received into the concavity formed by the greater multangular, lesser multangular, and capitate, and the capitate and hamate into that formed by the navicular, lunate, and triquetral bones.

FIG. 189.—BONES OF THE LEFT HAND. (Volar surface.)

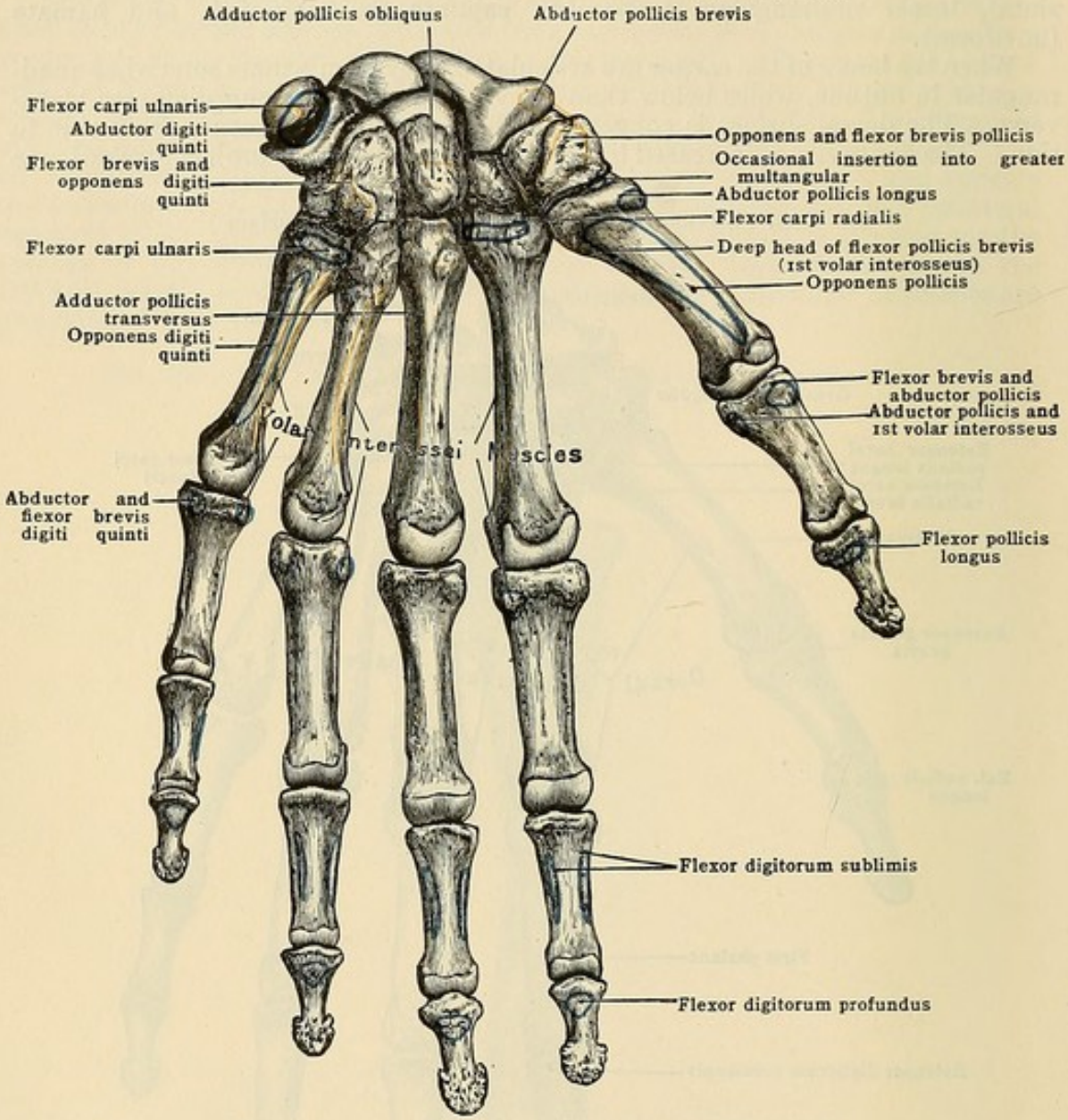

The individual carpal bones have several points of resemblance. Each bone (excepting the pisiform) has six surfaces, of which the anterior or volar and posterior or dorsal are rough for the attachment of ligaments, the volar surface being the broader in the proximal row, the dorsal surface in the distal row. The superior and inferior surfaces are articular, the former being generally convex and the latter concave. The lateral surfaces, when in contact with adjacent bones, are also articular, but otherwise rough for the attachment of ligaments. Further, the whole of the carpus is cartilaginous at birth and each bone is ossified from a single centre.

THE NAVICULAR

The **navicular** [os naviculare] or scaphoid (fig. 190) is the largest bone of the proximal row, and so disposed that its long axis runs obliquely downward and lateralward.

The **superior surface** is convex and somewhat triangular in shape for articulation with the lateral facet on the distal end of the radius. The **inferior surface,** smooth and convex, is divided

into two parts by a ridge running from before backward. The lateral part articulates with the greater multangular, the medial with the lesser multangular. The **volar surface,** rough and concave above, is elevated below into a prominent **tubercle** for the attachment of the transverse carpal ligament and the *abductor pollicis brevis*. The **dorsal surface** is narrow, being reduced

FIG. 190.—THE LEFT NAVICULAR.

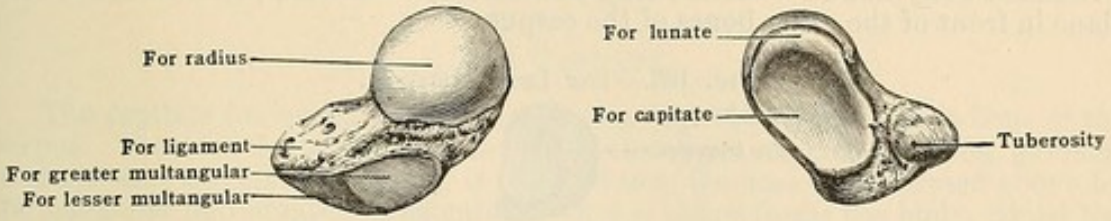

to a groove running the whole length of the bone; it is rough and serves for the attachment of the dorsal radio-carpal ligament. The **medial surface** is occupied by two articular facets, of which the upper is crescentic in shape for the lunate bone, whilst the lower is deeply concave for the reception of the head of the capitate. The **lateral surface** is narrow and rough for the attachment of the radial collateral ligament of the wrist-joint.

Articulations.—With the radius above, greater and lesser multangular below, lunate and capitate medially.

THE LUNATE

The **lunate** [os lunatum] or semilunar (fig. 191), placed in the middle of the proximal row of the carpus, is markedly crescentic in outline.

The **superior surface** is smooth and convex and articulates with the medial of the two facets on the distal end of the radius. The **inferior surface** presents a deep concavity divided into two parts by a line running from before backward. Of these, the lateral and larger articulates with the capitate; the medial and smaller with the hamate. The **volar surface** is large and convex,

FIG. 191.—THE LEFT LUNATE.

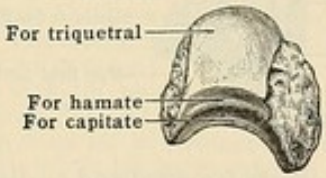

the **dorsal surface** narrow and flat, and both are rough for the attachment of ligaments. The **medial surface** is marked by a smooth quadrilateral facet for the base of the triquetral. The **lateral surface** forms a narrow crescentic articular surface for the lunate.

Articulations.—With the radius above, capitate and hamate below, navicular laterally and triquetral medially.

THE TRIQUETRAL

The **triquetral** [os triquetrum] or cuneiform (fig. 192) is pyramidal in shape and placed obliquely, so that its base looks upward and laterally and the apex downward and medially.

FIG. 192.—THE LEFT TRIQUETRAL.

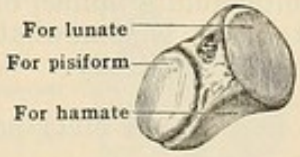

The **superior surface** presents laterally near the base a small, convex articular facet which plays upon the articular disc interposed between it and the distal end of the ulna, and medially a rough non-articular portion for ligaments. The **inferior surface** forms a large, triangular undulating facet for articulation with the hamate. The **volar surface** can be readily recognised by the conspicuous oval facet near the apex for the pisiform bone. The **dorsal surface** is rough for the attachment of ligaments. The **medial** and **lateral surfaces** are represented by the base and the apex of the pyramid. The base is marked by a flat quadrilateral facet for the lunate. The apex forms the lowest part of the bone and is roughened for the attachment of the ulnar collateral ligament of the wrist.

Articulations.—With the pisiform in front, lunate laterally, hamate below, articular disc above.

The Pisiform

The **pisiform** [os pisiforme] (fig. 193), the smallest of the carpal bones, is in many of its characters a complete contrast to the rest of the series. It deviates from the general type in its shape, size, position, use, and development. Forming a rounded bony nodule with the long axis directed vertically, it is situated on a plane in front of the other bones of the carpus.

Fig. 193.—The Left Pisiform.



On the **dorsal surface** is a single articular facet for the triquetral which reaches to the upper end of the bone, but leaves a free non-articular portion below. The **volar surface,** rough and rounded, gives attachment to the transverse carpal ligament, the *flexor carpi ulnaris*, the *abductor quinti digiti*, the piso-metacarpal and the piso-hamate ligaments. The median and lateral surfaces are also rough and the lateral presents a shallow groove for the ulnar artery. It is usually considered that the pisiform is a sesamoid bone developed in the tendon of the *flexor carpi ulnaris*, though by some writers it is regarded as part of a rudimentary digit.

The Greater Multangular

The **greater multangular** [os multangulum majus] or trapezium (fig. 194), situated between the navicular and first metacarpal, is oblong in form with the lower angle prolonged downward and medially.

Fig. 194.—The Left Greater Multangular.

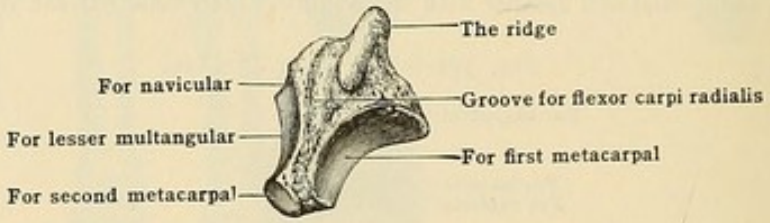

The **superior surface** is concave and directed upward and medially for articulation with the lateral of the two facets on the distal surface of the navicular, and on the **inferior surface** is a saddle-shaped facet for the base of the first metacarpal. The **volar surface** presents a prominent ridge with a deep groove on its medial side which transmits the tendon of the *flexor carpi radialis*. The **ridge** gives attachment to the transverse carpal ligament, the *abductor pollicis brevis*, the *opponens pollicis*, and occasionally a tendinous slip of insertion of the *abductor pollicis longus*. The **dorsal** and **lateral surfaces** are rough for ligaments. The **medial surface** is divided into two parts by a horizontal ridge. The upper and larger portion is concave and articulates with the lesser multangular; the lower—a small flat facet on the projecting lower angle—articulates with the base of the second metarcarpal.

Articulations.—With the navicular above, first metacarpal below, the lesser multangular and second metacarpal on the medial side.

The Lesser Multangular

The **lesser multangular** [os multangulum minus] or trapezoid (fig. 195), the smallest of the bones in the distal row, is somewhat wedge-shaped, with the broader end dorsally and the narrow end ventrally.

Fig. 195.—The Left Lesser Multangular.

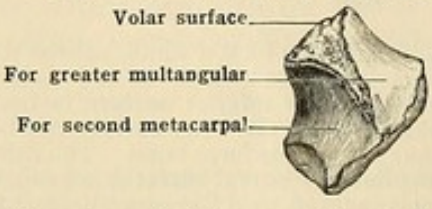

The **superior** surface is marked by a small, quadrilateral, concave facet, for the media of the two facets on the lower surface of the navicular. The **inferior surface** is convex from side to side and concave from before backward, forming a saddle-shaped articular surface for the base of the second metacarpal. Of the **volar** and **dorsal surfaces,** the former is narrow and rough,

the latter broad and rounded, constituting the widest surface of the bone, and both are rough for the attachment of ligaments. The **lateral surface** slopes downward and medially and is convex for articulation with the corresponding surface of the greater multangular. On the **medial surface** in front is a smooth flat facet for the capitate; elsewhere it is rough for ligaments.

Articulations.—With the navicular above, second metacarpal below, greater multangular laterally, and the capitate medially.

The Capitate

The **capitate** [os capitatum] or os magnum (fig. 196) is the largest bone of the carpus. Situated in the centre of the wrist, the upper expanded portion, globular in shape and known as the **head,** is received into the concavity formed above by the navicular and lunate. The cubical portion below forms the **body,** whilst the intermediate constricted part is distinguished as the **neck.**

Fig. 196.—The Left Capitate.

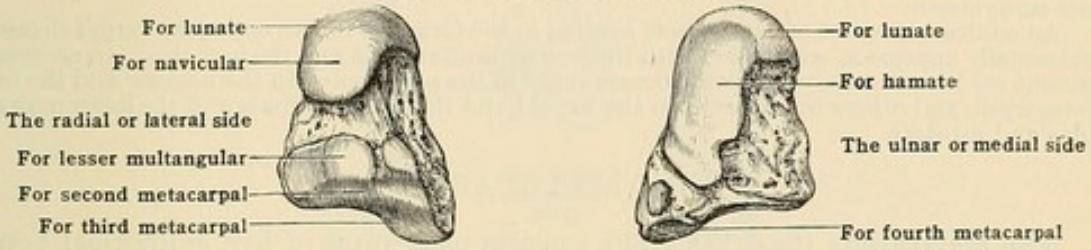

Of the six surfaces, the **superior** is smooth and convex, elongated from before backward for articulation with the concavity of the lunate bone. The **inferior surface** is divided into three unequal parts by two ridges. The middle portion, much the larger, articulates with the base of the third metacarpal; the lateral, narrow and concave, looks lateral as well as downward to articulate with the second metacarpal, whilst the medial portion is a small facet, placed on the projecting angle of the bone dorsally, for the fourth metacarpal bone. The **volar surface** is convex and rough, giving origin to fibres of the oblique *adductor pollicis;* the **dorsal surface** is broad and deeply concave. The **lateral surface** presents, from above downward:—(1) a smooth convex surface, forming the outer aspect of the head, with the superior surface of which it is continuous, for articulation with the navicular; (2) a groove representing the neck, indented for ligaments; (3) a small facet, flat and smooth, for articulation with the lesser multangular. Behind this facet is a rough area for attachment of an interosseous ligament. The **medial surface** has extending along its whole hinder margin an oblong articular surface for the hamate; the lower part of this smooth area sometimes forms a detached facet. The volar part of the surface is rough for an interosseous ligament.

Articulations.—With the lunate and navicular above, second, third, and fourth metacarpals below, lesser multangular laterally, and hamate medially.

The Hamate

The **hamate** [os hamatum] or unciform (fig. 197) is a large wedge-shaped bone, bearing a hook-like process, situated between the capitate and triquetral, with the base directed downward and resting on the two medial metacarpals.

Fig. 197.—The Left Hamate.

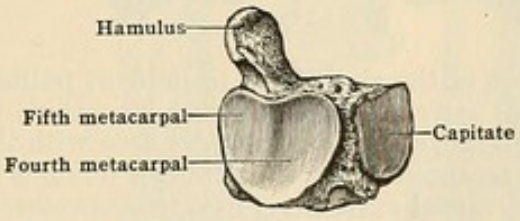

The apex of the wedge forms the narrow **superior surface,** directed upward and laterally for articulation with the lunate. The **inferior surface** or base is divided by a ridge into two quadrilateral facets for the fourth and fifth metacarpal bones. The **volar surface** is triangular in outline and presents at its lower part a prominent **hamulus** (unciform process), a hook-like eminence, projecting forward and curved toward the carpal canal. It is flattened from side to side so as to present two surfaces, two borders, and a free extremity. To the latter the transverse carpal ligament and the *flexor carpi ulnaris* (by means of the piso-hamate ligament) are attached, whilst the medial surface affords origin to the *flexor brevis* and the *opponens digiti quinti.* The lateral surface is concave and in relation to the flexor tendons. The **dorsal surface** is triangular and rough for ligaments. The **lateral surface** has extending along its upper and

hinder edges a long flat surface, wider above than below, for articulation with the capitate. In front of this articular facet the surface is rough for the attachment of an interosseous ligament. The **medial surface** is oblong and undulating, i. e., concavo-convex from base to apex, for articulation with the triquetral.

Articulations.—With the triquetral, lunate, capitate, and the fourth and fifth metacarpal bones.

Ossification of the Carpal Bones

Capitate	first year	Greater multangular	fifth year
Hamate	second year	Navicular	sixth year
Triquetral	third year	Lesser multangular	eighth year
Lunate	fourth year	Pisiform	twelfth year

Additional carpal elements are occasionally met with. The **os centrale** occurs normally in the carpus of many mammals, and in the human fœtus of two months it is present as a small cartilaginous nodule which soon becomes fused with the cartilage of the navicular. Failure of fusion, with subsequent ossification of the nodule, leads to the formation of an os centrale in the human carpus which is then found on the dorsal aspect, between the navicular, capitate, and lesser multangular. In most individuals, however, it coalesces with the navicular or undergoes suppression.

An additional centre of ossification, leading to the formation of an accessory carpal element, occasionally appears in connection with the greater multangular and the hamate. An accessory element (*os Vesalianum*) also occurs occasionally in the angle between the hamate and the fifth metacarpal, and others occur between the second and third metacarpals and the lesser multangular and capitate.

THE METACARPALS

The **metacarpus** (figs. 188, 189) consists of a series of five cylindrical bones [ossa metacarpalia], well described as 'long bones in miniature.' Articulated with the carpus above, they descend, slightly diverging from each other, to support the fingers, and are numbered from the lateral to the medial side. With the exception of the first, which in some respects resembles a phalanx, they conform to a general type.

A typical metacarpal bone presents for examination a shaft and two extremities. The **body** or **shaft** is prismatic and curved so as to be slightly convex toward the back of the hand. Of the three surfaces, two are **lateral** in position,

Fig. 198.—The First (Left) Metacarpal.

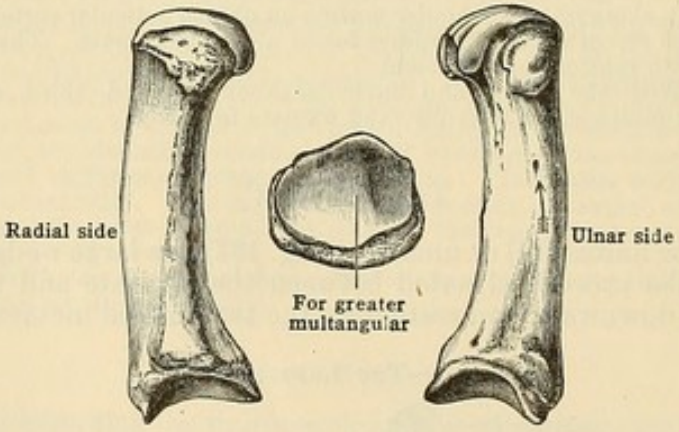

separated in the middle part of the shaft by a prominent palmar ridge, and concave for the attachment of *interosseous* muscles. The third or **dorsal surface** presents for examination a large, smooth, triangular area with the base below and apex above, covered in the recent state by the extensor tendons of the fingers, and two sloping areas, near the carpal extremity, also for *interosseous* muscles. The triangular area is bounded by two lines, which commence below in two dorsal tubercles, and, passing upward, converge to form a median ridge situated between the sloping areas on either side. A little above or below the middle of the shaft, and near the volar border, is the medullary foramen, entering the bone obliquely upward. The **base** or carpal extremity, broader behind than in front, is quadrilateral, and both palmar and dorsal surfaces are rough for ligaments; it articulates above with the carpus and on each side with the adjacent metacarpal bones. The **head** [capitulum] or digital extremity presents a large rounded articular surface, extending further on the palmar than on the dorsal aspect, for

articulation with the base of the first phalanx. The volar surface is grooved for the flexor tendons and raised on each side into an articular eminence. On each side of the head is a prominent tubercle, and immediately in front of this a well-marked fossa, to both of which the collateral ligament of the metacarpo-phalangeal joint is attached.

FIG. 199.—THE SECOND (LEFT) METACARPAL.

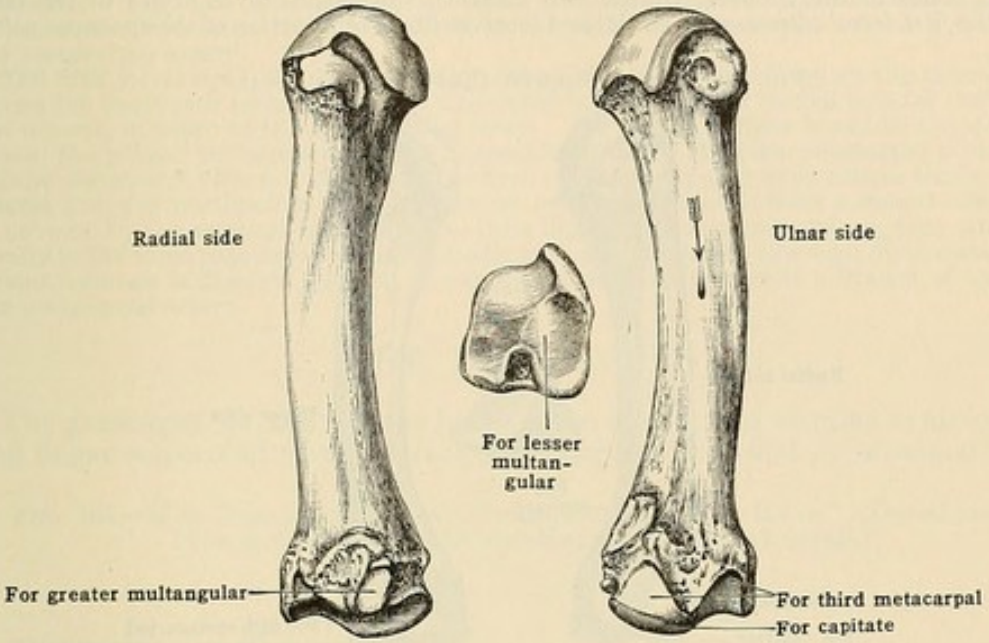

The second is the longest of all the metacarpal bones, and the third, fourth, and fifth successively decrease in length. The several metacarpals possess distinctive characters by which they are readily identified.

The **first metacarpal** (fig. 198) is the shortest and widest of the series. Diverging from the carpus more widely than any of the others the **palmar surface** is directed medially and marked

FIG. 200.—THE THIRD (LEFT) METACARPAL.

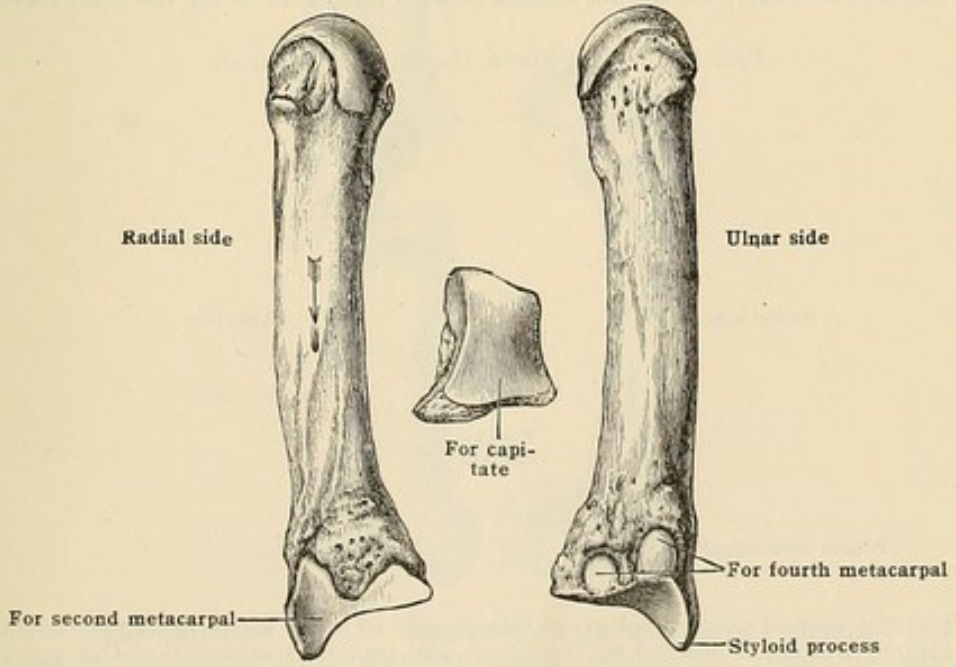

by a ridge placed nearer to the medial border. The lateral portion of the surface slopes gently to the lateral border and gives attachment to the *opponens pollicis;* the medial portion, the smaller of the two, slopes more abruptly to the medial border, is in relation to the deep head of the *flexor pollicis brevis,* and presents the nutrient foramen, directed downward toward the head of the bone and transmitting a branch of the arteria princeps pollicis. The **dorsal surface,** wide and flattened, is in relation to the tendons of the *extensor pollicis longus* and *brevis.*

The **base** presents a saddle-shaped articular surface for the greater multangular, prolonged in front into a thin process. There are no lateral facets, but laterally a small tubercle receives the insertion of the *abductor pollicis longus*. Medially is a rough area from which fibres of the inner head of the *flexor pollicis brevis* take origin. The margin of the articular surface gives attachment to the articular capsule of the carpo-metacarpal joint. The inferior extremity or **head** is rounded and articular, for the base of the first phalanx; the greatest diameter is from side to side and the surface is less convex than the corresponding surface of the other metacarpal bones. On the volar surface it presents two articular eminences corresponding to the two sesamoid bones of the thumb. Of the two margins, the medial gives origin to the lateral head of the *first dorsal interosseous*, the lateral receives fibres of insertion of the *opponens pollicis*.

FIG. 201.—THE FOURTH (LEFT) METACARPAL.

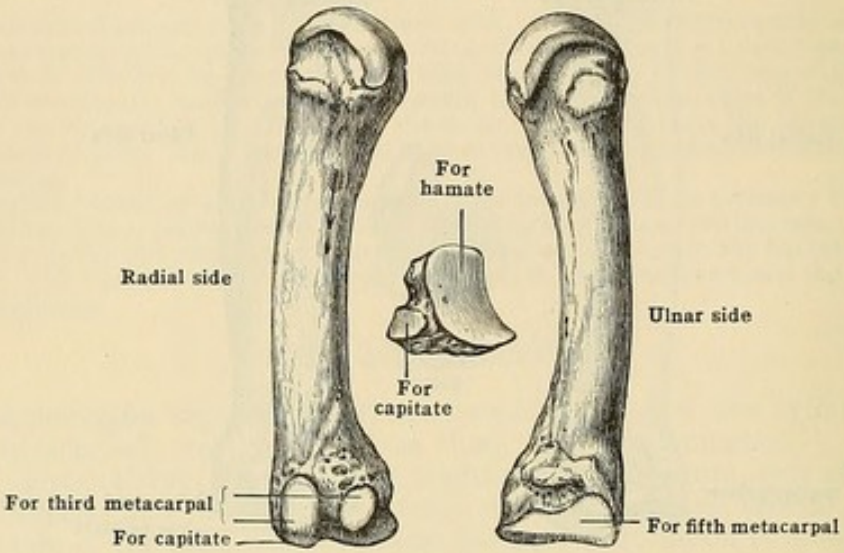

The second metacarpal (fig. 199).—The distinctive features of the four remaining metacarpals are almost exclusively confined to the carpal extremities. The second is easily recognised by its deeply cleft base. The terminal surface presents three articular facets, arranged as follows, from lateral to medial border:—(1) a small oval facet for the greater multangular; (2) a hollow for the lesser multangular; and (3) an elongated ridge for the capitate. The dorsal surface is rough for the insertions of the *extensor carpi radialis longus* and a part of the *extensor carpi radialis brevis;* the palmar surface receives the insertion of the *flexor carpi radialis* and gives origin to a few fibres of the *oblique adductor pollicis*. The lateral aspect of the extremity is rough and non-articular; the medial surface bears a bilobed facet for the third metacarpal.

FIG. 202.—THE FIFTH (LEFT) METACARPAL.

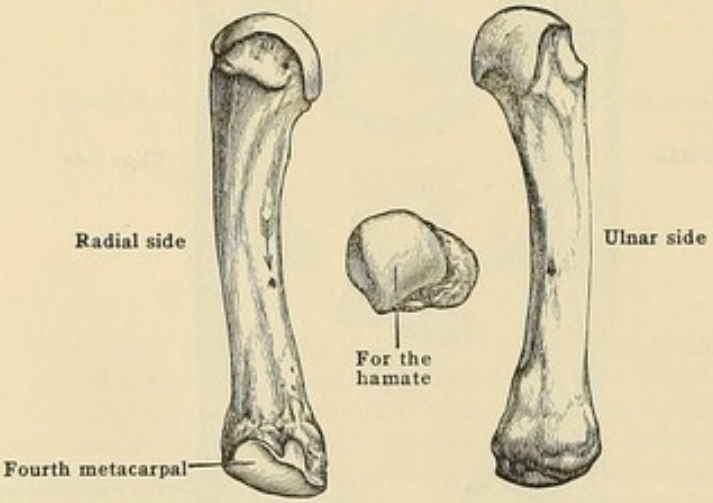

The shaft of the second metacarpal gives attachment to three *interosseous* muscles, and the nutrient foramen, directed upward on the ulnar side, transmits a branch of the second volar metacarpal artery.

The **third metacarpal** (fig. 200) is distinguished by the prominent **styloid process** projecting upward from the lateral and posterior angle of the base. Immediately below it, on the dorsal surface, is a rough impression for the *extensor carpi radialis brevis*. The carpal surface is concave behind and convex in front, and articulates with the middle of the three facets on the inferior surface of the capitate. On the lateral side is a bilobed articular facet for the second metacarpal, and on the medial side two small oval facets for the fourth metacarpal. The volar aspect of the base is rough and gives attachment to fibres of the *oblique adductor pollicis* and

sometimes a slip of insertion of the *flexor carpi radialis*. The shaft of the third metacarpal serves for the origin of the transverse *adductor pollicis* and two *interosseous* muscles. The nutrient foramen is directed upward on the radial side and transmits a branch of the second volar metacarpal artery.

The **fourth metacarpal** (fig. 201) has a small base. The carpal surface presents two facets: a medial, large and flat, for articulation with the hamate, and a small facet, at the lateral and posterior angle, for the capitate. On the lateral side are two small oval facets for the corresponding surfaces on the third metacarpal and a single concave facet on the medial side for the fifth metacarpal. The shaft of the fourth metacarpal gives attachment to three *interosseous* muscles, and the nutrient foramen, directed upward on the radial side, transmits a branch of the third volar metacarpal artery.

The **fifth metacarpal** (fig. 202) is distinguished by a semilunar facet on the lateral side of the base for the fourth metacarpal, and a rounded tubercle on the medial side for the *extensor carpi ulnaris*, in place of the usual medial facet. The carpal surface is saddle-shaped for the hamate; the palmar surface is rough for ligaments including the piso-metacarpal prolongation from the *flexor carpi ulnaris*. The dorsal surface of the shaft presents an *oblique line* separating a lateral concave portion for the fourth dorsal *interosseous* muscle from a smooth medial portion covered by the extensor tendons of the little finger. The palmar surface gives attachment laterally to the third palmar *interosseous* muscle and medially to the *opponens digiti quinti*. The nutrient foramen is directed upward on the radial side and transmits a branch of the fourth volar metacarpal artery.

THE PHALANGES

The **phalanges** (fig. 203) are the bones of the fingers, and number in all fourteen. Each finger consists of three phalanges distinguished as first or proximal, second

FIG. 203.—THE PHALANGES OF THE THIRD DIGIT OF THE HAND. (Dorsal view.)
[The arrows indicate the direction of the nutrient canals.]

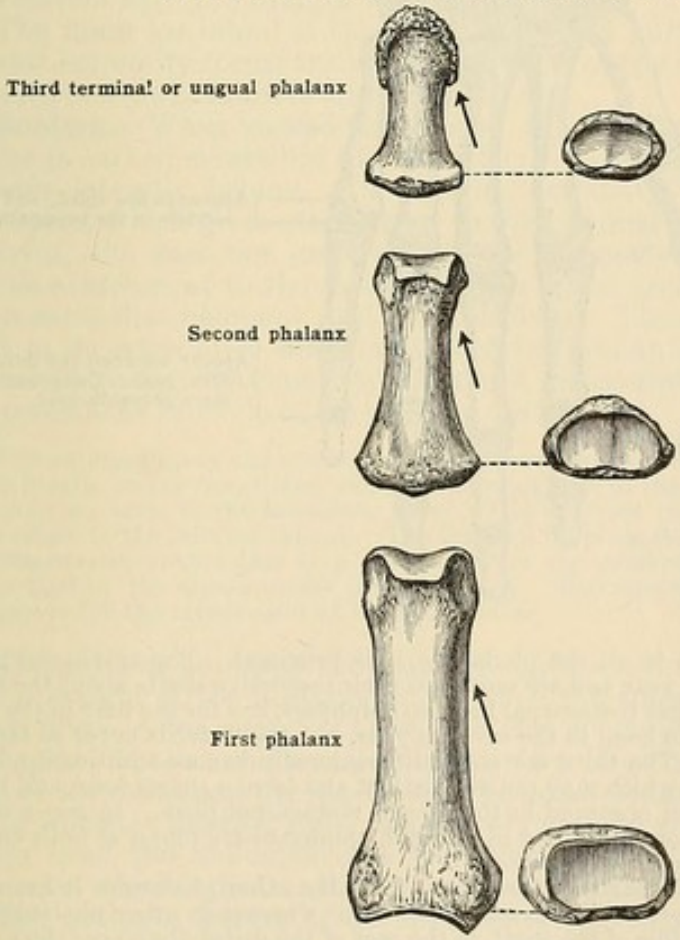

or middle, and third or distal. In the thumb, the second phalanx is wanting. Arranged in horizontal rows, the phalanges of each row resemble one another and differ from those of the other two rows. In all the phalanges the nutrient canal is directed downward, toward the distal extremity.

First phalanx.—The shaft of a phalanx from the first row is flat on the palmar surface, smooth and rounded on the dorsal surface, i. e., semi-cylindrical in shape. The borders of the palmar surface are rough for the attachment of the sheaths of the flexor tendons. The base or metacarpal extremity presents a single concave articular surface, oval in shape, for the

convex head of the metacarpal bone. The distal extremity forms a pulley-like surface, grooved in the centre and elevated at each side to form two miniature condyles, for articulation with the base of a second phalanx.

Second phalanx.—The second phalanges are four in number and are shorter than those of the first row, which they closely resemble in form. They are distinguished, however, by the articular surface on the proximal extremity, which presents two shallow depressions, separated by a ridge and corresponding to the two condyles of the first phalanx. The distal end for the base of the third phalanx is trochlear or pulley-like, but smaller than that of the first phalanx. The palmar surface of the shaft presents on each side an impression for the tendon of the *flexor digitorum sublimis*, and the dorsal aspect of the base is marked by a projection for the insertion of the *extensor digitorum communis*.

Third phalanx.—A third phalanx is readily recognised by its small size. The proximal end is identical in shape with that of a second phalanx, and bears a depression in front for the tendon of the *flexor digitorum profundus*. The free, flattened and expanded distal extremity presents on its palmar surface a rough semilunar elevation for the support of the pulp of the finger. The somewhat horseshoe-shaped free extremity is known as the **ungual tuberosity** [tuberositas unguicularis], and the bone is accordingly referred to as the **ungual phalanx.**

Ossification of the Metacarpus and Phalanges

Each of the metacarpal bones and phalanges is ossified from a primary centre for the greater part of the bone, and from one epiphysial centre. The primary nucleus appears from the eighth to the tenth week of intra-uterine life. In four metacarpal bones the epiphysis is distal, whilst

Fig. 204.—Ossification of the Metacarpals and Phalanges.

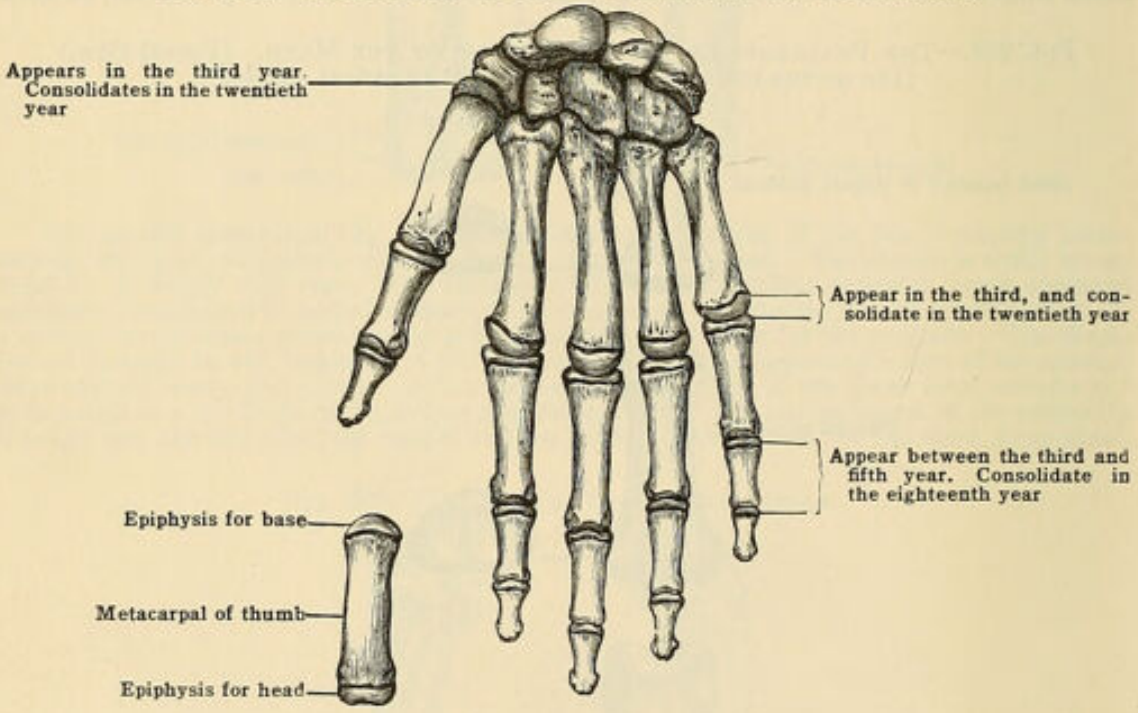

in the first metacarpal bone, and in all the phalanges, it is proximal. The epiphysial nuclei appear from the third to the fifth year and are united to their respective shafts about the twentieth year. In many cases the first metacarpal has two epiphyses, one for the base in the third year and an additional one for the head in the seventh year, but the latter is never so large as in the other metacarpal bones. The third metacarpal occasionally has an additional nucleus for the prominent styloid process which may remain distinct and form a *styloid bone*, and traces of a proximal epiphysis have been observed in the second metacarpal bone. In many of the Cetacea (whales, dolphins, and porpoises) and in the seal, epiphyses are found at both ends of the metacarpal bones and phalanges (Flower).

The ossification of a terminal phalanx is peculiar. Like the other phalanges, it has a primary nucleus and a secondary nucleus for an epiphysis. But whereas in other phalanges the primary centre appears in the middle of the shaft, in the case of the distal phalanges the earthy matter is deposited in the free extremity.

Sesamoid Bones

The sesamoid bones are small and rounded and occur imbedded in certain tendons where they exert a considerable amount of pressure on subjacent bony structures. In the hand five sesamoid bones are of almost constant occurrence, namely, two over the metacarpo-phalangeal joint of the thumb in the tendons of the flexor pollicis brevis, one over the interphalangeal joint of the thumb, and one over the metacarpo-phalangeal joints of the second and fifth fingers.

Occasionally sesamoids occur over the metacarpo-phalangeal joint of the third and fourth digits, and an additional one may occur over that of the fifth.

Very rarely a sesamoid is developed in the tendon of the biceps over the tuberosity of the radius.

B. THE BONES OF THE LOWER EXTREMITY

The bones of the lower extremity may be arranged in four groups corresponding to the division of the limb into the *hip*, *thigh*, *leg*, and *foot*. In the *hip* is the coxal or hip-bone, which constitutes the pelvic girdle [cingulum extremitatis inferioris], and contributes to the formation of the pelvis; in the *thigh* is the femur; in the *leg*, the tibia and fibula, and in the *foot* the tarsus, metatarsus, and phalanges. Associated with the lower end of the femur is a large sesamoid bone, the patella or knee-cap.

THE COXAL BONE

The **coxal** (innominate) **bone** or hip-bone [os coxæ] (figs. 205, 206) is a large, irregularly shaped bone articulated behind with the sacrum, and in front with its fellow of the opposite side, the two bones forming the anterior and side walls of the pelvis. The coxal bone consists of three parts, named **ilium, ischium,** and **pubis,** which, though separate in early life, are firmly united in the adult. The three parts meet together and form the **acetabulum** (or cotyloid fossa), a large, cup-like socket situated near the middle of the lateral surface of the bone for articulation with the head of the femur.

The **ilium** [os ilium] is the upper expanded portion of the bone, and by its inferior extremity forms the upper two-fifths of the acetabulum. It presents for examination three borders and two surfaces.

Borders.—When viewed from above, the thick **crest** [crista iliaca] or superior border is curved somewhat like the letter *f*, being concave medially in front and concave laterally behind. Its anterior extremity forms the **anterior superior iliac spine,** which gives attachment to the inguinal (Poupart's) ligament and the *sartorius;* the posterior extremity forms the **posterior superior iliac spine** and affords attachment to the sacro-tuberous (great sacro-sciatic) ligament, the posterior sacro-iliac ligament, and the *multifidus*. The crest is narrow in the middle, thick at its extremities, and may be divided into an inner lip, an outer lip, and an intermediate line. About two and a half inches from the anterior superior spine is a prominent tubercle on its external lip.

The external lip of the crest gives attachment in front to the *tensor fasciæ latæ;* along its whole length, to the *fascia lata;* along its anterior half to the *external oblique;* and behind this, for about an inch, to the *latissimus dorsi*. The anterior two-thirds of the intermediate line gives origin to the *internal oblique*. The internal lip gives origin, by its anterior two-thirds, to the *transversus;* behind this is a small area for the *quadratus lumborum*, and the remainder is occupied by the *sacro-spinalis* (*erector spinæ*). The internal lip, in the anterior two-thirds, also serves for the attachment of the iliac fascia.

The **anterior border** of the ilium extends from the **anterior superior iliac spine** to the margin of the acetabulum. Below the spine is a prominent notch from which fibres of the *sartorius* arise, and this is succeeded by the **anterior inferior iliac spine,** smaller and less prominent than the superior, to which the straight head of the *rectus* and the ilio-femoral ligament are attached. On the medial side of the anterior inferior spine is a broad, shallow groove for the *ilio-psoas* as it passes from the abdomen into the thigh, limited below by the **ilio-pectineal** eminence, which indicates the point of union of the ilium and pubis.

The **posterior border** of the ilium presents the **posterior superior iliac spine,** and below this, a shallow notch terminating in the **posterior inferior iliac spine** which corresponds to the posterior extremity of the auricular surface and gives attachment to a portion of the sacro-tuberous (great sacro-sciatic) ligament. Below the spine the posterior border of the ilium forms the upper limit of the greater sciatic notch.

Surfaces.—The **external surface** or **dorsum** is concave behind, convex in front, limited above by the thick superior border or **crest,** and traversed by three gluteal lines.

The **posterior gluteal line** commences at the crest about two inches from the posterior superior iliac spine and curves downward to the upper margin of the **greater sciatic notch.** The space included between this ridge and the crest affords origin at its upper part to the *gluteus maximus*, and at its lower part, to a few fibres of the *piriformis*, while the intermediate portion is smooth and free from muscular attachment. The **anterior gluteal line** begins at the crest, one inch behind its anterior superior iliac spine, and curves across the dorsum to terminate near the lower end of the superior line, at the upper margin of the greater sciatic notch. The surface of bone between this line and the crest is for the origin of the *gluteus medius*. The **inferior gluteal line** commences at the notch immediately below the anterior

FIG. 205.—THE LEFT COXAL OR HIP-BONE. (Lateral view.)

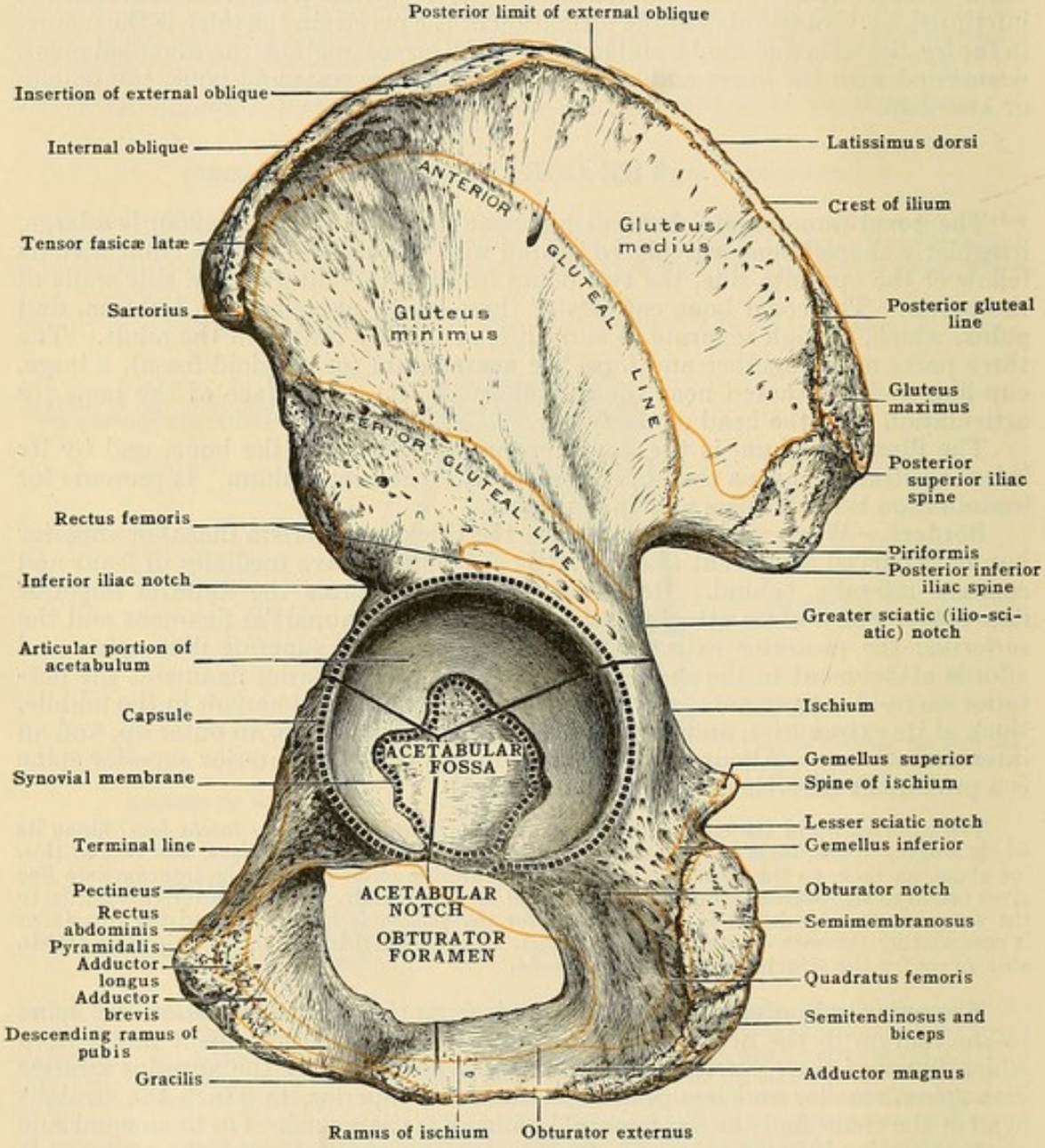

superior iliac spine and terminates posteriorly at the front part of the greater sciatic notch. The space between the anterior and inferior gluteal lines, with the exception of a small area adjacent to the anterior end of the spine for the *tensor fasciæ latæ*, gives origin to the *gluteus minimus*. Between the inferior gluteal line and the margin of the acetabulum the surface affords attachment to the capsule of the hip-joint, and on a rough area (sometimes a depression) toward its anterior part, to the *reflected tendon of the rectus femoris*.

The **internal surface** presents in front a smooth concave portion termed the **iliac fossa,** which lodges the *iliacus* muscle. The fossa is limited below by linea arcuata, the iliac portion of the terminal (ilio-pectineal) line. This is a rounded border separating the fossa from a portion of the internal surface below the line, which gives attachment to the *obturator internus* and enters into the formation of the minor (true) pelvis. Behind the iliac fossa the bone is uneven and presents

an auricular surface, covered with cartilage in the recent state, for articulation with the lateral aspect of the upper portion of the sacrum; above the auricular surface are some depressions for the posterior sacro-iliac ligaments and a rough area reaching as high as the crest, from which parts of the *sacro-spinalis* (*erector spinæ*) and *multifidus* take origin. The rough surface above the auricular facet is known as the **tuberosity of the ilium.**

The **ischium** [os ischii] consists of a body, a tuberosity, and a ramus. The **body,** which has somewhat the form of a triangular pyramid, enters superiorly into

FIG. 206.—THE LEFT COXAL OR HIP-BONE. (Medial aspect.)

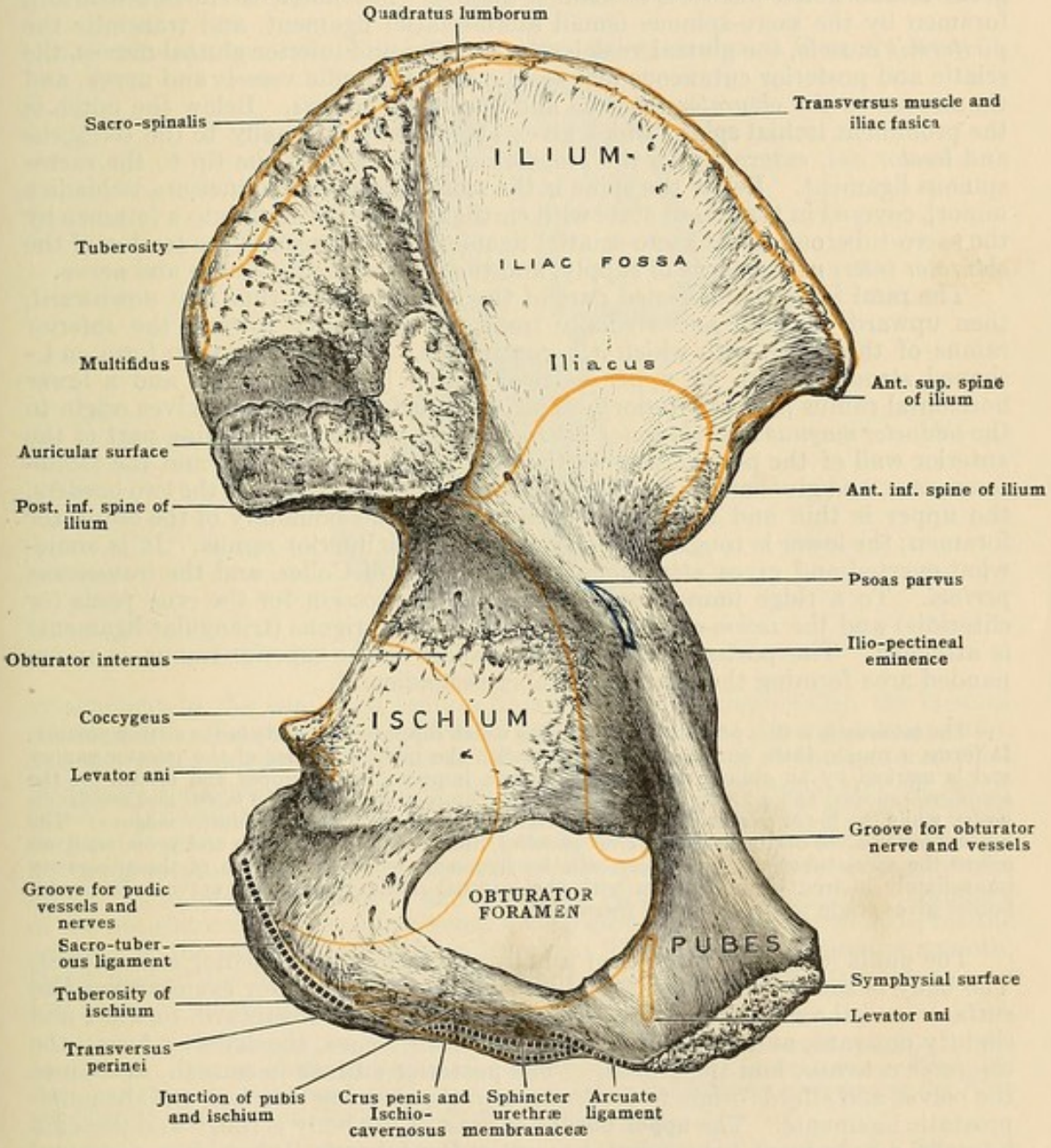

the formation of the acetabulum, to which it contributes a little more than two-fifths, and forms the chief part of the non-articular portion or floor. The **inner surface** forms part of the minor (true) pelvis and gives origin to the *obturator internus.* It is continuous with the ilium a little below the terminal (ilio-pectineal) line, and with the pubis in front, the line of junction with the latter being frequently indicated in the adult bone by a rough line extending from the ilio-pectineal eminence to the margin of the obturator foramen. The **outer surface** includes the portion of the acetabulum formed by the ischium. The **posterior surface** is broad and bounded laterally by the margin of the acetabulum and behind

by the posterior border. The capsule of the hip-joint is attached to the lateral part and the *piriformis*, the great sciatic and posterior cutaneous nerves, the inferior gluteal (sciatic) artery, and the nerve to the *quadratus femoris* lie on the surface as they leave the pelvis. Inferiorly this surface is limited by the **obturator groove,** which receives the posterior fleshy border of the *obturator externus* when the thigh is flexed. Of the three borders, the **external,** forming the prominent rim of the acetabulum, separates the posterior from the external surface and gives attachment to the glenoid lip. The **inner border** is sharp and forms the lateral boundary of the obturator foramen. The **posterior border** is continuous with the posterior border of the ilium, with which it joins to complete the margin of the **great sciatic notch** [incisura ischiadica major]. The notch is converted into a foramen by the sacro-spinous (small sacro-sciatic) ligament, and transmits the *piriformis* muscle, the gluteal vessels, the superior and inferior gluteal nerves, the sciatic and posterior cutaneous nerves, the internal pudic vessels and nerve, and the nerves to the *obturator internus* and *quadratus femoris*. Below the notch is the prominent **ischial spine,** which gives attachment internally to the *coccygeus* and *levator ani*, externally to the *gemellus superior*, and at the tip to the sacro-spinous ligament. Below the spine is the **small sciatic notch** [incisura ischiadica minor], covered in the recent state with cartilage, and converted into a foramen by the sacro-tuberous (great sacro-sciatic) ligament. It transmits the tendon of the *obturator internus*, its nerve of supply, and the internal pudic vessels and nerve.

The **rami** form the flattened part of the ischium which runs first downward, then upward, forward and medially from the tuberosity toward the inferior ramus of the pubis, with which it is continuous. The **rami** together form an L-shaped structure with an upper vertical ramus [ramus superior] and a lower horizontal ramus [ramus inferior]. The outer surface of the rami gives origin to the *adductor magnus* and *obturator externus;* the inner surface, forming part of the anterior wall of the pelvis, receives the crus penis (or clitoridis) and the *ischio-cavernosus*, and gives origin to a part of the *obturator internus*. Of the two borders, the upper is thin and sharp, and forms part of the boundary of the obturator foramen; the lower is rough and corresponds to the inferior ramus. It is somewhat everted and gives attachment to the fascia of Colles, and the *transversus perinei*. To a ridge immediately above the impression for the crus penis (or clitoridis) and the *ischio-cavernosus*, the urogenital trigone (triangular ligament) is attached. The posterior and inferior aspect of the superior ramus is an expanded area forming the **tuberosity** [tuber ischiadicum].

The **tuberosity** is that portion of the ischium which supports the body in the sitting posture. It forms a rough, thick eminence continuous with the inferior border of the inferior ramus, and is marked by an oblique line separating two impressions, an upper and lateral for the *semimembranosus*, and a lower and medial for the common tendon of the *biceps* and *semitendinosus*, while the lower part is markedly uneven and gives origin to the *adductor magnus*. The upper border gives origin to the *inferior gemellus;* the inner border, sharp and prominent, receives the sacro-tuberous (great sacro-sciatic) ligament, while the surface of the tuberosity immediately in front is in relation with the internal pudic vessels and nerve. The outer border gives origin to the *quadratus femoris*.

The **pubis** [os pubis] consists of a **body** and two **rami**—superior and inferior. The **body** is somewhat quadrilateral in shape and presents for examination two surfaces and three borders. The **anterior surface** looks downward, forward and slightly outward, and gives origin to the *adductor longus*, the *adductor brevis*, the *obturator externus*, and the *gracilis*. The **posterior surface** is smooth, looks into the pelvis, and affords origin to the *levator ani*, the *obturator internus*, and the pubo-prostatic ligaments. The **upper border** or crest of the body is rough and presents laterally a prominent bony point, known as the **tubercle** [tuberculum pubicum] or spine, for the attachment of the inguinal (Poupart's) ligament. The upper border extends from the pubic tubercle medialward to the upper end of the symphysis, with which it forms the *angle* of the pubis. The upper border is a short horizontal ridge, which gives attachment to the *rectus abdominis* and *pyramidalis*. The **medial border** is oval in shape, rough, and articular, forming with the bone of the opposite side the *symphysis pubis* [facies symphyseos]. The **lateral border** is sharp and forms part of the boundary of the obturator foramen.

The **inferior ramus,** like the inferior ramus of the ischium, with which it is continuous, is thin and flattened. To its **anterior surface** are attached the

adductor brevis, *adductor magnus*, and *obturator externus*. The **posterior surface** is smooth and gives attachment to the *crus penis* or *clitoridis*, the *sphincter urethræ* (urogenitalis), the *obturator internus*, and the urogenital trigone (triangular ligament). The **lateral border** forms part of the circumference of the obturator foramen, and the **medial border** forms part of the pubic arch and gives attachment to the *gracilis*.

The **superior ramus** extends from the body of the pubis to the ilium, forming by its lateral extremity the anterior one-fifth of the articular surface of the acetabulum. It is prismatic in shape and increases in size as it passes laterally. Above it presents a sharp ridge, the **pecten** or pubic portion of the terminal (ilio-pectineal) line continuous with the iliac portion at the ilio-pectineal eminence, and affording

FIG. 207.—AN IMMATURE COXAL (INNOMINATE) BONE, SHOWING A COTYLOID BONE.

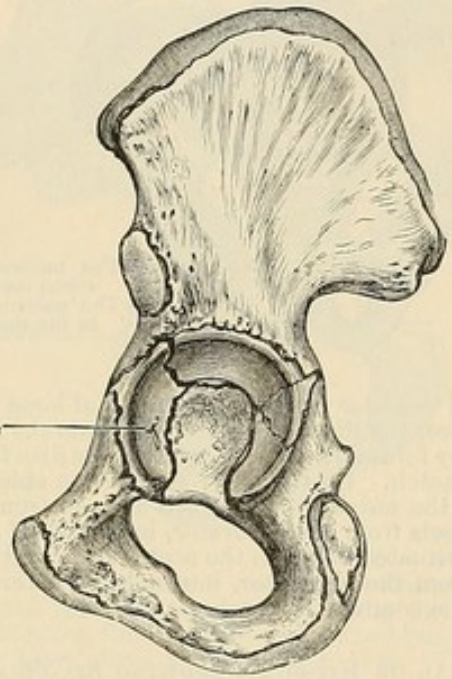

attachment to the conjoined tendon [falx aponeurotica inguinalis], the lacunar (Gimbernat's) ligament, the reflected inguinal ligament (fascia triangularis), and the pubic portion of the fascia lata; the iliac portion of the terminal (ilio-pectineal) line gives attachment to the *psoas minor*, the iliac fascia, and the pelvic fascia. Immediately in front of the pubic portion of the line is the **pectineal surface**; it gives origin at its posterior part to the *pectineus*, and is limited below by the **obturator crest**, which extends from the pubic tubercle to the acetabular notch. The **inferior surface** of the ascending ramus forms the upper boundary of the obturator foramen and presents a deep groove [sulcus obturatorius] for the passage of the obturator vessels and nerve. The **posterior surface** is smooth, forms part of the anterior wall of the pelvic cavity, and gives attachment to a few fibres of the *obturator internus*.

According to the BNA, the body [corpus ossis pubis] is the portion corresponding to the acetabulum. The remainder of the bone is described as consisting of the ramus superior and the ramus inferior, which meet at the symphysis. Thus the divisions according to the BNA are different from those in the description above given.

The **acetabulum** is a circular depression in which the head of the femur is lodged and consists of an articular and a non-articular portion. The articular portion is circumferential and semilunar in shape [facies lunata], with the deficiency in the lower segment. One-fifth of the acetabulum is formed by the pubis, two-fifths by the ischium, and the remaining two-fifths are formed by the ilium. In rare instances the pubis may be excluded by a fourth element, the **cotyloid bone.** The non-articular portion [fossa acetabuli] is formed mainly by the ischium, and is continuous below with the margin of the obturator foramen. The articular portion presents a lateral rim to which the glenoid lip is attached, and a medial margin to which the synovial membrane which excludes

the ligamentum teres from the synovial cavity is connected. The opposite extremities of the articular lunate surface which limit the **acetabular notch** are united by the transverse ligament, and through the **acetabular foramen** thus formed a nerve and vessels enter the joint.

The **obturator** (thyreoid) **foramen** is situated between the ischium and pubis. Its margins are thin, and serve for the attachment of the obturator membrane. At the upper and posterior angle it is deeply grooved for the passage of the obturator vessels and nerve.

FIG. 208.—THE PELVIS OF A FŒTUS AT BIRTH, TO SHOW THE THREE PORTIONS OF THE COXAL BONES.

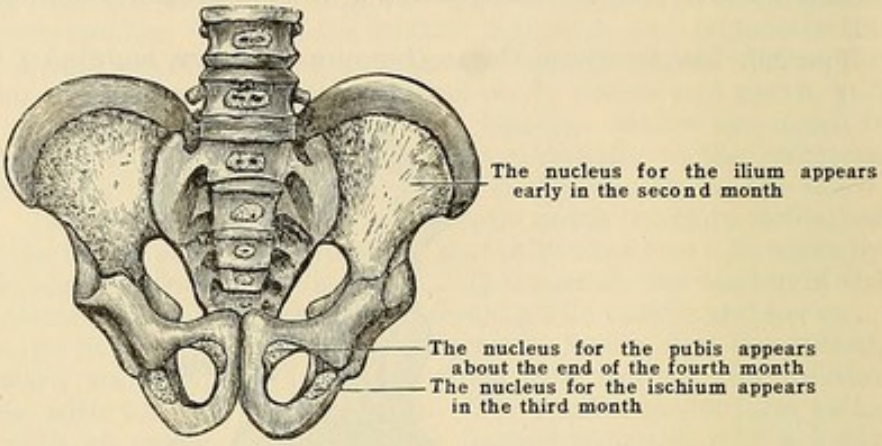

Blood-supply.—The chief vascular foramina of the coxal bone are found where the bone is thickest. On the inner surface, the ilium receives twigs from the ilio-lumbar, deep circumflex iliac, and obturator arteries, by foramina near the crest, in the iliac fossa, and below the terminal line near the greater sciatic notch. On the outer surface the chief foramina are found below the inferior gluteal line and the nutrient vessels are derived from the gluteal arteries. The ischium receives nutrient vessels from the obturator, internal and external circumflex arteries, and the largest foramina are situated between the acetabulum and the ischial tuberosity. The pubis is supplied by twigs from the obturator, internal and external circumflex arteries, and from the pubic branches of the common femoral artery.

FIG. 209.—COXAL OR HIP-BONE, SHOWING SECONDARY CENTRES.

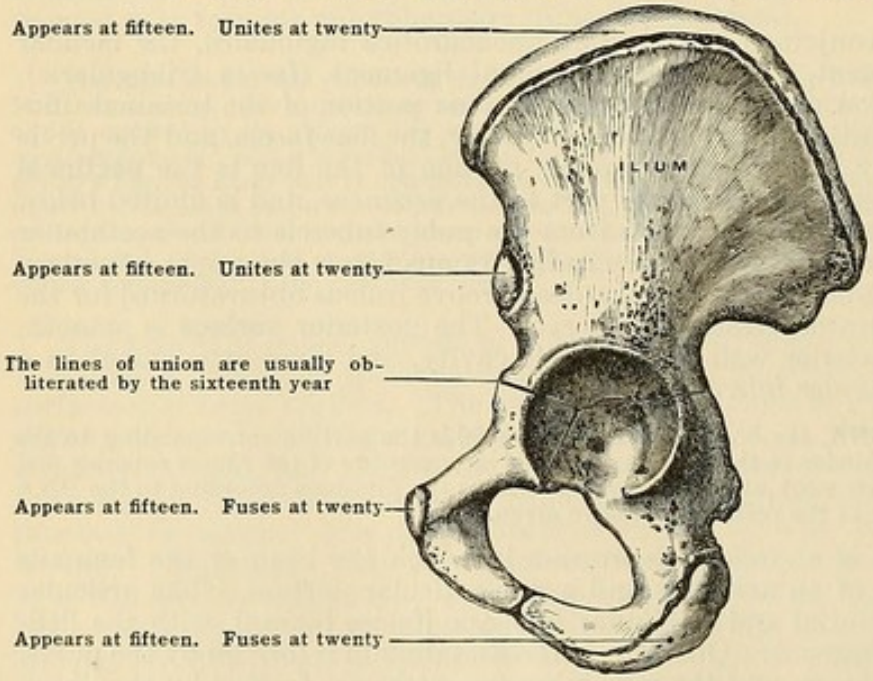

Ossification.—The cartilaginous representative of the hip-bone consists of three distinct portions, an **iliac,** an **ischiatic,** and a **pubic** portion; the iliac and ischiatic portions first unite and later the pubic portion, so that eventually there is found a single cartilaginous mass. Early in the second month a centre of ossification appears above the acetabulum for the ilium. A little later a second nucleus appears below the cavity for the ischium, and this is followed in the fourth month by a deposit in the pubic portion of the cartilage. At birth, the three nuclei

are of considerable size, but are surrounded by relatively wide tracts of cartilage; ossification has, however, extended into the margin of the acetabulum. In the eighth year the rami of the pubis and ischium become united by bone, and in the twelfth year the triradiate cartilage which separates the three segments of the bone in the acetabulum begins to ossify from several centres. Of these, one is more constant than the others and is known as the acetabular nucleus. The triangular piece of bone to which it gives rise is regarded as the representative of the *cotyloid* or acetabular bone, constantly present in a few mammals. It is situated at the medial part of the acetabulum and is of such a size as to exclude entirely the pubis from the cavity. With this bone, however, it eventually fuses, and afterward becomes joined with the ilium and

FIG. 210.—COXAL OR HIP-BONE (INNER SURFACE) AT THE EIGHTH YEAR.

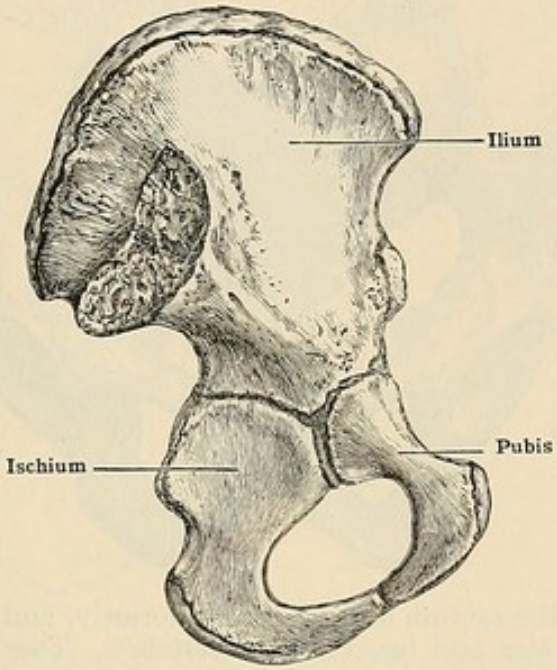

ischium, so that by the eighteenth or twentieth year the several parts of the acetabulum have become united. In the fifteenth year other centres appear in the cartilage of the crest of the ilium, the anterior inferior iliac spine, the tuberosity of the ischium, and the pubic pecten. The epiphyses fuse with the main bone about the twentieth year. The fibrous tissue connected with the tubercle of the pubis represents the epipubic bones of marsupials.

THE PELVIS

The **pelvis** (figs. 211, 212, 213, 214) is composed of four bones: the two coxal or hip-bones, the sacrum, and the coccyx. The hip-bones form the lateral and anterior boundaries, meeting each other in front to form the pubic symphysis [symphysis ossium pubis]; posteriorly they are separated by the sacrum. The interior of the pelvis is divided into the **major** and **minor** pelvic cavity.

The **major** (or false) **pelvis** is that part of the cavity which lies above the terminal (iliopectineal) lines and between the iliac fossæ. This part belongs really to the abdomen, and is in relation with the hypogastric and iliac regions.

The **minor** (or true) **pelvis** is situated below the terminal (ilio-pectineal) lines. The upper circumference, known as the **superior aperture** (inlet or brim) of the pelvis, is bounded anteriorly by the tubercle and pecten of the pubis on each side, posteriorly by the anterior margin of the base of the sacrum, and laterally by the terminal lines. The inlet in normal pelves is heart-shaped, being obtusely pointed in front; posteriorly it is encroached upon by the promontory of the sacrum. It has three principal **diameters**; of these, the antero-posterior, called the **conjugate** diameter [conjugata], is measured from the **sacro-vertebral angle** to the symphysis. The **transverse** diameter represents the greatest width of the pelvic cavity. The **oblique** diameter is measured from the sacro-iliac synchondrosis of one side to the ilio-pectineal eminence of the other.

The **cavity** of the minor (true) pelvis is bounded in front by the pubes, behind by the sacrum and coccyx, and laterally by a smooth wall of bone formed in part by the ilium and in part by the ischium. The cavity is shallow in front, where it is formed by the pubes, and is deepest posteriorly.

The **inferior aperture,** or outlet, of the minor pelvis is very irregular, and encroached upon by three bony processes: the posterior process is the coccyx, and the two lateral processes are the ischial tuberosities. They separate three notches. The anterior notch is the **pubic arch,** and is bounded on each side by the conjoined rami of the pubes and ischium. Each of the two remaining gaps, bounded by the

Fig. 211.—The Male Pelvis.

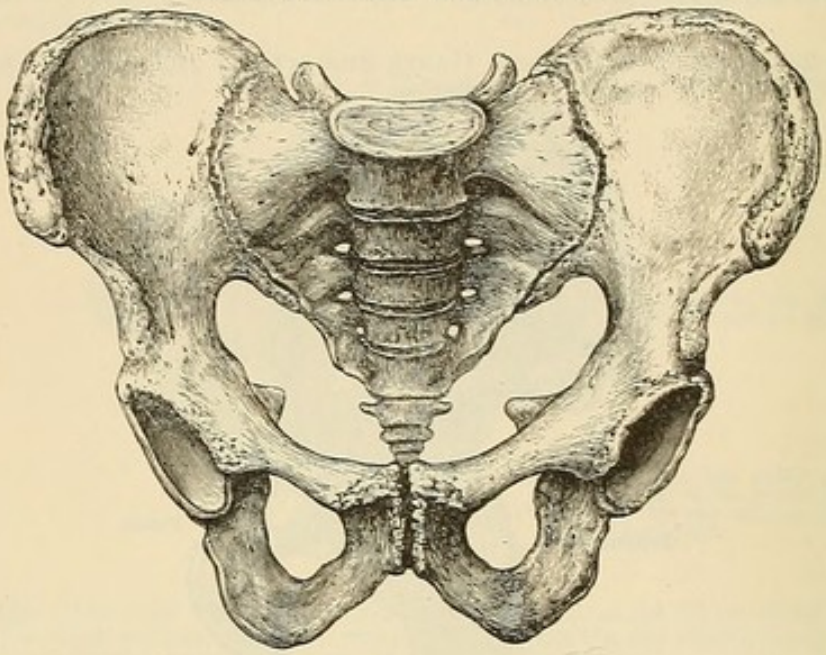

ischium anteriorly, the sacrum and coccyx posteriorly, and the ilium above, corresponds to the greater and lesser sciatic notches. These are converted into foramina by the sacro-tuberous (great sacro-sciatic) and sacro-spinous (small sacro-sciatic) ligaments.

The position of the pelvis.—In the erect position of the skeleton the plane of the pelvic inlet forms an angle with the horizontal plane, which varies in individuals from 50° to 60°.

Fig. 212.—The Female Pelvis.

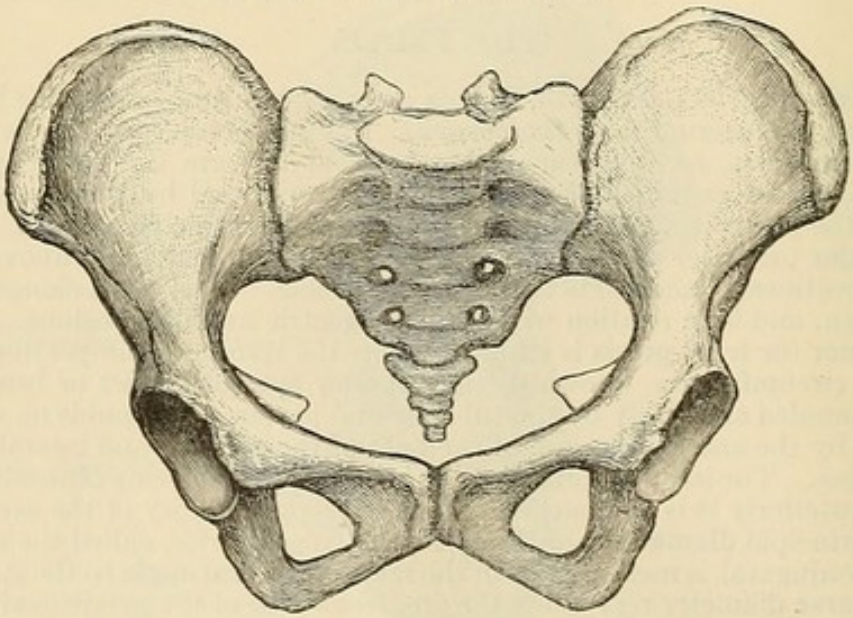

The base of the sacrum in an average pelvis lies nearly ten centimetres (four inches) above the upper margin of the symphysis pubis.

The axis of the pelvis.—This is an imaginary curved line drawn through the minor pelvis at right angles to the planes of the **inlet, cavity,** and **outlet** through their central points.

As the posterior wall, formed by sacrum and coccyx, is nearly five inches long and concave, and the anterior wall at the symphysis pubis one one and a half to two inches long, it follows that the axis must be curved.

The average measurements of the diameters of the minor pelvis in the three planes are given below:—

	Conjugate or Antero-posterior.	Oblique.	Transverse.
Inlet	4½ inches (10.6 cm.)	5 inches (12.5 cm.)	5¼ inches (13.0 cm.)
Cavity	4¾ " (11.8 cm.)	5¼ " (13.0 cm.)	4¾ " (11.8 cm.)
Outlet	3¾ " (9.0 cm.)	4½ " (11.2 cm.)	4¼ " (10.6 cm.)

Fig. 213.—Male Pelvis. (Lateral view.)

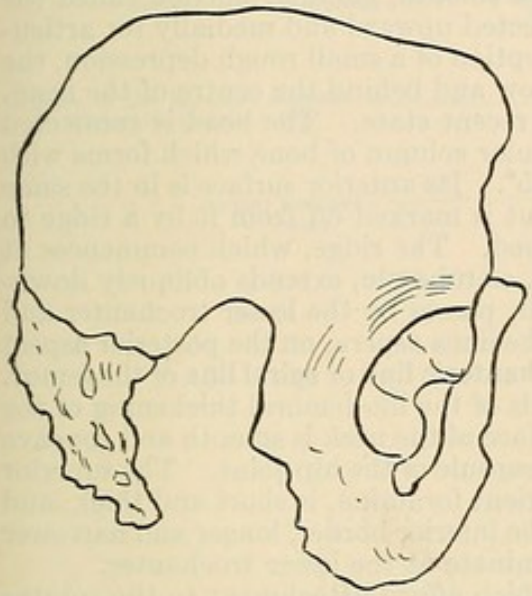

Fig. 214.—Female Pelvis. (Lateral view.)

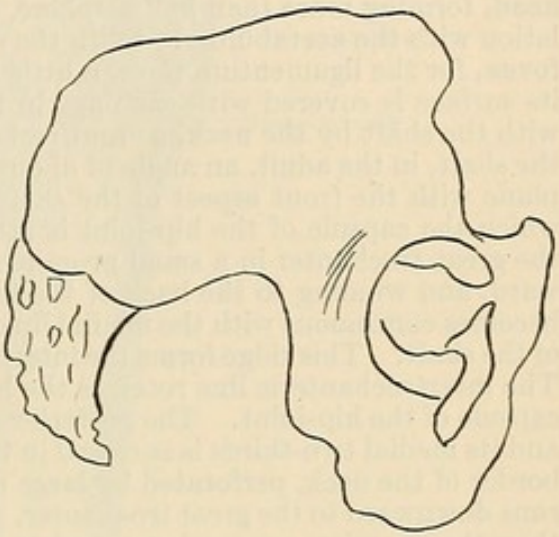

There is, however, a difference between the sexes, the diameters of the male pelvis in general averaging slightly less, and those of the female slightly greater than the figures above given.

Differences according to sex.—There is a marked difference in the size and form of the male and female pelvis, the pecularities of the latter being necessary to qualify it for its functions in parturition. The various points of divergence may be tabulated as follows:—

Male.	Female.
Bones heavier and rougher.	Bones more slender.
Ilia less vertical.	Ilia more vertical.
Iliac fossæ deeper.	Iliac fossæ shallower.
Major pelvis relatively wider.	Major pelvis relatively narrower.
Minor pelvis deeper.	Minor pelvis shallower.
" " narrower.	" " wider.
Superior aperture more heart-shaped.	Superior aperture more oval.
Symphysis deeper.	Symphysis shallower.
Tuberosities of ischia inflexed.	Tuberosities of ischia everted.
Pubic angle narrow and pointed.	Pubic arch wider and more rounded.
Margins of ischio-pubic rami more everted.	Margins of ischio-pubic rami less everted.
Obturator foramen oval.	Obturator foramen triangular.
Sacrum narrower and more curved.	Sacrum wider and less curved.
Capacity of minor pelvis less.	Capacity of minor pelvis greater.

The sexual characters of the pelvis as shown by A. Thomson are manifest as early as the fourth month of fœtal life.

Quite recently attention has been drawn by D. Derry to some special points in which the os coxæ differ in the two sexes, and two figures are shown here in which one of these points is clearly brought out. It will be seen that the great sciatic notch is larger in the female, and that the sacrum projects less forward at its apex. Moreover the facies auricularis is smaller whilst below and in front of this surface, the *sulcus preauricularis*, a depression for the attachment of the *ligamenta sacroiliaca anteriora*, is usually more pronounced.

In comparison with the pelves of lower animals, which, speaking generally, are elongated and narrow, the human pelvis is characterised by its breadth, shallowness, and great capacity. Differences are also to be recognised in the form of the pelvis in the various races of mankind, the most important being the relation of the antero-posterior to the transverse diameter, measured at the inlet. This is expressed by the *pelvic index* $= \frac{100 \times \text{conjugate diameter}}{\text{transverse diameter}}$.

In the average European male the index is about 80; in the lower races of mankind, 90 to 95. Pelves with an index below 90 are *platypellic*, from 90 to 95 are *mesatipellic*, and above 95 *dolichopellic*. (Sir William Turner.)

THE FEMUR

The **femur** or thigh bone (figs. 215, 216) is the largest and longest bone in the skeleton, and transmits the entire weight of the trunk from the hip to the tibia. In the erect posture it inclines from above downward and medially, approaching at the lower extremity its fellow of the opposite side, but separated from it above by the width of the true pelvis. It presents for examination a superior extremity, including the head, neck, and two trochanters, an inferior extremity, expanded laterally into two condyles, and a shaft.

The **upper extremity** is surmounted by a smooth, globular portion called the **head,** forming more than half a sphere, directed upward and medially for articulation with the acetabulum. With the exception of a small rough depression, the **fovea,** for the ligamentum teres, a little below and behind the centre of the head, its surface is covered with cartilage in the recent state. The head is connected with the shaft by the **neck,** a stout rectangular column of bone which forms with the shaft, in the adult, an angle of about 125°. Its anterior surface is in the same plane with the front aspect of the shaft, but is marked off from it by a ridge to which the capsule of the hip-joint is attached. The ridge, which commences at the great trochanter in a small prominence, or **tubercle,** extends obliquely downward, and winding to the back of the femur, passes by the lesser trochanter and becomes continuous with the medial lip of the linea aspera, on the posterior aspect of the shaft. This ridge forms the **intertrochanteric line** or **spiral line** of the femur. The intertrochanteric line receives the bands of the ilio-femoral thickening of the capsule of the hip-joint. The posterior surface of the neck is smooth and concave and its medial two-thirds is enclosed in the capsule of the hip-joint. The superior border of the neck, perforated by large nutrient foramina, is short and thick, and runs downward to the great trochanter. The inferior border, longer and narrower than the superior, curves downward to terminate at the lesser trochanter.

The **trochanters** are the prominences which afford attachment to the rotator muscles of the thigh; they are two in number—great and lesser.

The **great trochanter** is a thick, quadrilateral process surmounting the junction of the neck with the shaft, and presents for examination two surfaces and four borders. The lateral surface is broad, rough, and continuous with the lateral surface of the shaft. It is marked by a diagonal ridge running from the postero-superior to the antero-inferior angle, which receives the insertion of the *gluteus medius.* The ridge divides the surface into two triangular areas: an upper, covered by the *gluteus medius,* and occasionally separated from it by a bursa, and a lower, covered by a bursa to permit the free gliding of the tendon of the *gluteus maximus.* Of the **medial** surface the lower and anterior portion is joined with the rest of the bone; the upper and posterior portion is free, concave, and presents a deep depression, the **trochanteric** or **digital fossa,** which receives the tendon of the *obturator externus.* The fore part of the surface is marked by an impression for the insertion of the *obturator internus* and two *gemelli.*

Of the four borders, the superior, thick and free, presents near the centre an oval mark for the insertion of the *piriformis;* the anterior border, broad and irregular, receives the *gluteus minimus;* the posterior border, thick and rounded, is continuous with the **intertrochanteric crest,** the prominent ridge uniting the two trochanters behind. Above the middle of this line is an elevation, termed the **tubercle of the quadratus,** for the attachment of the upper part of the *quadratus femoris.* The inferior border corresponds with the line of junction of the base of the trochanter with the shaft; it is marked by a prominent ridge for the origin of the upper part of the *vastus lateralis.*

The **lesser trochanter** is a conical eminence projecting medially from the posterior and medial aspect of the bone, where the neck is continuous with the shaft. Its summit is rough and gives attachment to the tendon of the *ilio-psoas.* The fibres of the *iliacus* extend beyond the trochanter and are inserted into the surface of the shaft immediately below.

The **body** or **shaft** of the femur is almost cylindrical, but is slightly flattened in front and strengthened behind by a projecting longitudinal ridge, the **linea aspera,** for the origin and insertion of muscles. The linea aspera extends along the middle third of the shaft and presents a medial lip and a lateral lip separated by a narrow interval. When followed into the upper third of the shaft, the three parts diverge. The lateral lip becomes continuous with the **gluteal tuberosity** and ends at the base of the great trochanter. The ridge affords insertion to the *gluteus maximus,*

FIG. 215.—THE LEFT FEMUR. (Anterior view.)

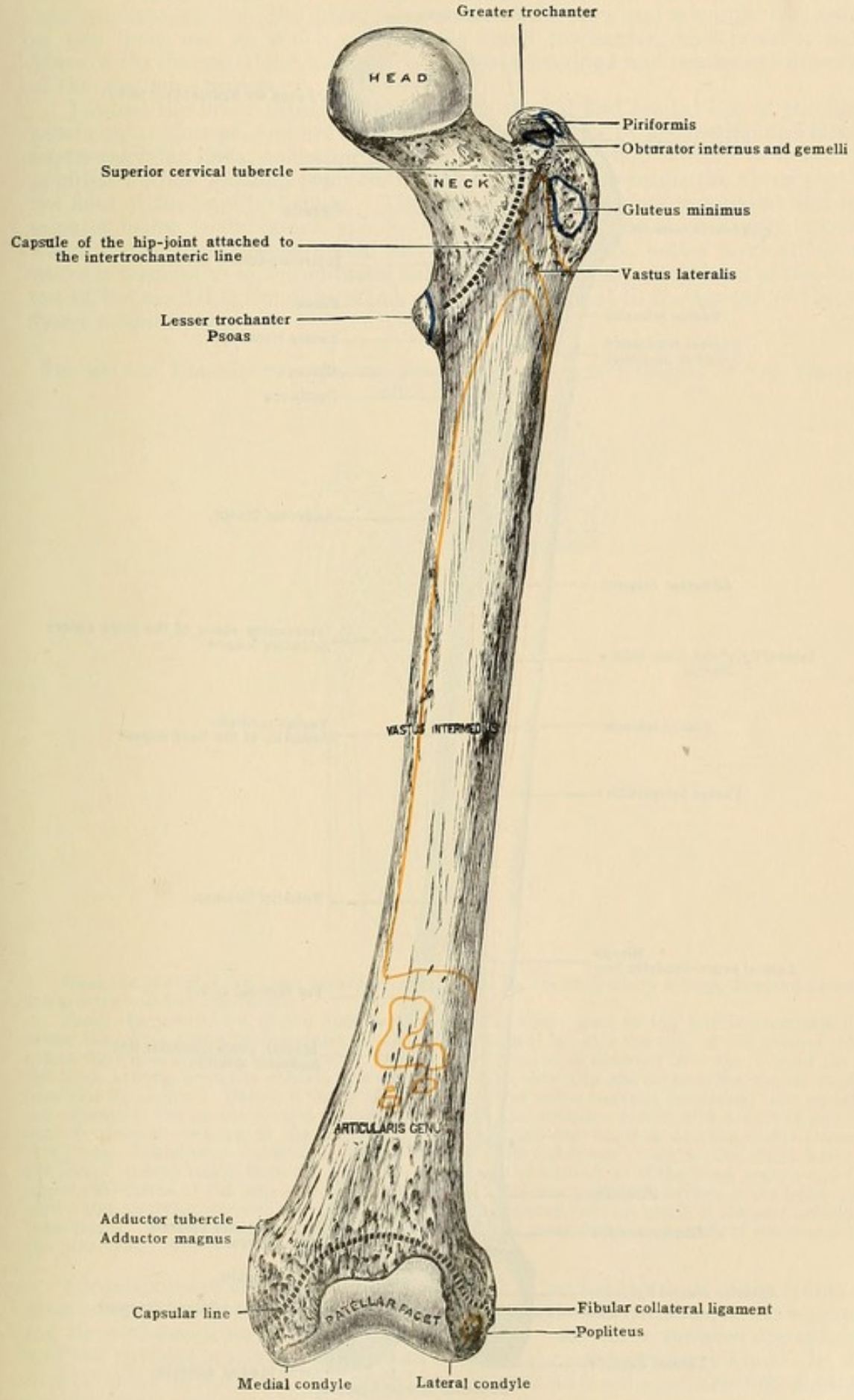

FIG. 216.—THE LEFT FEMUR. (Posterior view.)

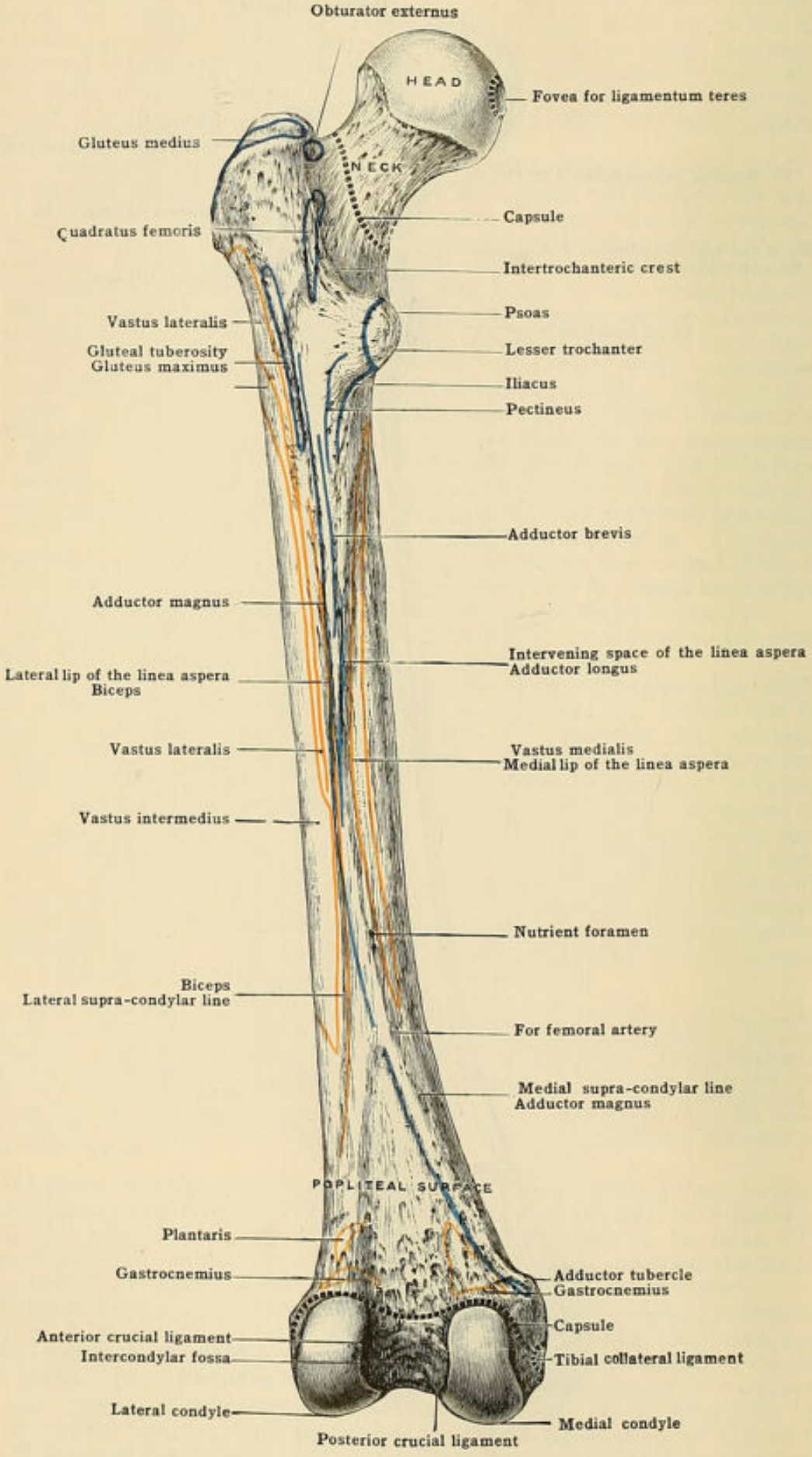

and when very prominent is termed the **third trochanter.** The medial lip curves medialward below the lesser trochanter, where it becomes continuous with the intertrochanteric line; the intervening portion bifurcates and is continued upward as two lines, one of which ends at the small trochanter, and receives some fibres of the *iliacus*, whilst the other is the **linea pectinea** and marks the insertion of the pectineus muscle.

Toward the lower third of the shaft the medial and lateral lips of the linea aspera again diverge, and are prolonged to the condyles by the **medial** and **lateral supra-condylar lines,** enclosing between them a triangular surface of bone, the popliteal surface [**planum popliteum**] of the femur, which forms the upper part of the floor of the popliteal space. The lateral line is the more prominent and terminates below in the lateral epicondyle. The medial one is interrupted above, where the femoral vessels are in relation with the bone, better marked below, where it terminates in the **adductor tubercle,** a small sharp projection at the summit of the medial epicondyle, which affords attachment to the tendon of the *adductor magnus.*

FIG. 217.—A DIAGRAM TO SHOW THE PRESSURE AND TENSION CURVES OF THE FEMUR. (After Wagstaffe.)

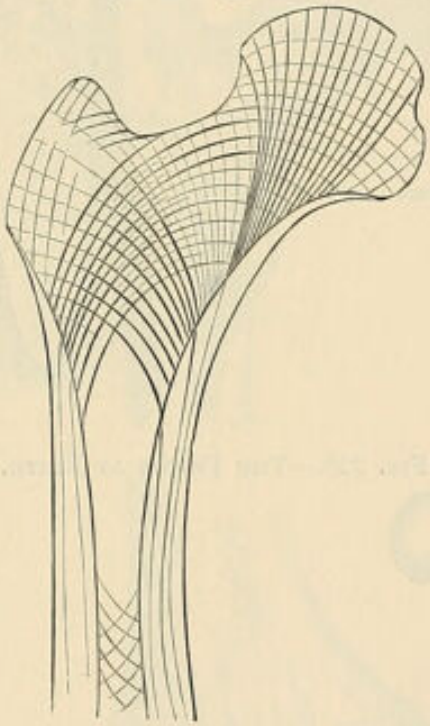

Near the centre of the linea aspera is the foramen for the medullary artery, directed upward toward the head of the bone.

From the medial lip of the linea aspera and the lower part of the intertrochanteric line arises the *vastus medialis* (internus), and from the lateral lip and the side of the gluteal ridge arises the *vastus lateralis* (externus). The *adductor magnus* is inserted into the medial lip of the linea aspera, from the medial side of the gluteal tuberosity above, and the medial supra-condylar line below. Between the *adductor magnus* and *vastus medialis* (internus) four muscles are attached: the *pectineus* and *iliacus* above, then the *adductor brevis,* and lowest of all, the *adductor longus.* Above, in the interval between the *adductor magnus* and the *vastus lateralis* (externus), the *gluteus maximus* is inserted; in the interval lower down is the short head of the *biceps,* taking origin from the lower two-thirds of the lateral lip of the linea aspera and the upper two-thirds of the lateral supra-condylar line. On the popliteal surface of the bone, just above the condyles, are two rough areas from which fibres of the two heads of the *gastrocnemius* take origin. Above the area for the lateral head of the gastrocnemius is a slight roughness for the *plantaris.*

For purposes of description it is convenient to regard the shaft of the femur as presenting anterior, medial, and lateral surfaces, although definite borders separating the surfaces from one another do not exist. All three surfaces are smooth and the anterior is not separated from the lateral by ridges of any kind. In the middle third of the shaft the medial and lateral surfaces approach one another behind, being separated by the linea aspera.

The shaft is overlapped on its medial side by the *vastus medialis* (internus), and on its lateral side by the *vastus lateralis* (externus). The upper three-fourths of the anterior and lateral surfaces afford origin to the *vastus intermedius* (crureus), and the lower fourth of the anterior surface, to the *articularis genu* (sub-crureus). The medial surface is free from muscular attachment.

FIG. 218.—TRANSVERSE SECTION OF SHAFT OF FEMUR TO SHOW THE MEDULLARY CAVITY.

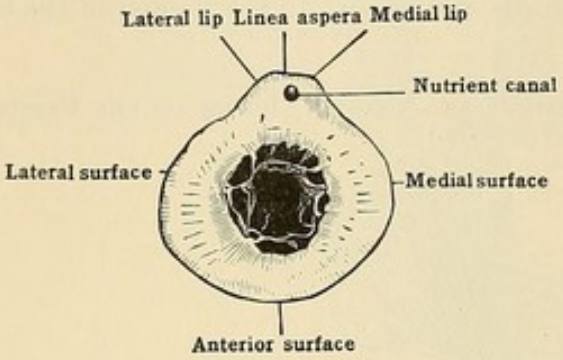

FIG. 219.—SECTION OF UPPER END OF FEMUR TO SHOW THE CALCAR FEMORALE.

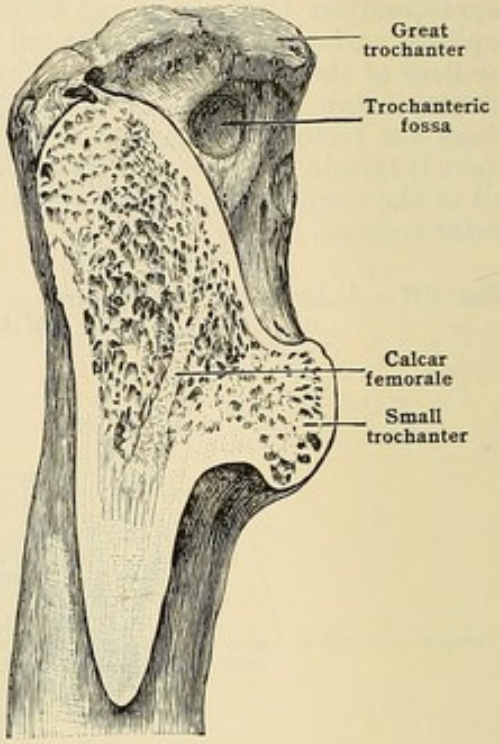

FIG. 220.—THE FEMUR AT BIRTH.

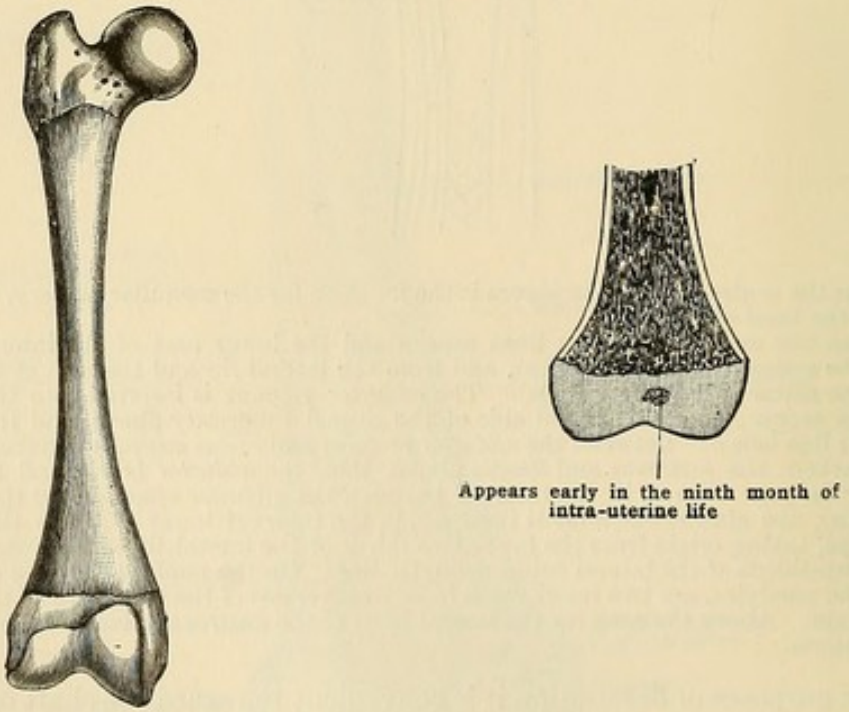

The **lower extremity** presents two cartilage-covered eminences or **condyles,** separated behind by the **intercondyloid fossa.** The lateral condyle is wider than its fellow and more prominent anteriorly; the medial condyle is narrower, more prominent, and longer, to compensate for the obliquity of the shaft. When the femur is in the natural position, the inferior surfaces of the condyles are on the

same plane, and almost parallel, for articulation with the upper surfaces on the head of the tibia. The two condyles are continuous in front, forming a smooth trochlear surface [facies patellaris] for articulation with the patella. This surface presents a median vertical groove and two convexities, the lateral of which is wider, more prominent, and prolonged farther upward. The patellar surface is faintly marked off from the tibial articular surfaces by two irregular grooves, best seen while the lower end is still coated with cartilage. The lateral groove commences on the medial margin of the lateral condyle near the front of the intercondylar fossa, and extends obliquely forward to the lateral margin of the bone. The general direction of the medial groove is from front to back, turning medially in front and extending backward as a faint ridge which marks off from the

FIG. 221.—THE LEFT FEMUR AT THE TWENTIETH YEAR. (Posterior view.)
The figure shows the relations of the epiphysial and capsular lines.

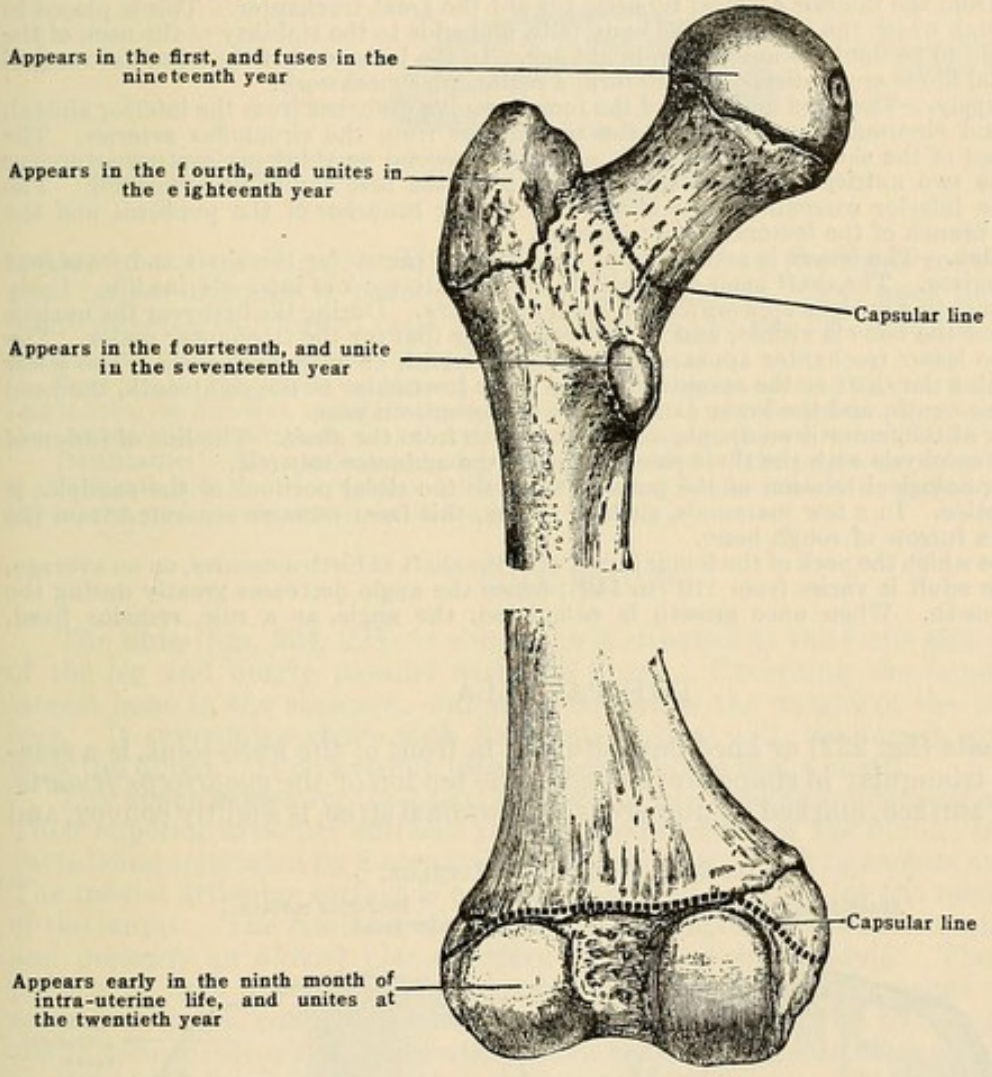

rest of the medial condyle a narrow semilunar facet for articulation with the medial perpendicular facet of the patella in extreme flexion. The grooves receive the semilunar menisci in the extended position of the joint. The tibial surfaces are almost parallel except in front, where the medial turns laterally to become continuous with the patellar surface.

The opposed surfaces of the two condyles form the boundaries of the intercondylar fossa and give attachment to the crucial ligaments which are lodged within it. The posterior crucial ligament is attached to the fore part of the lateral surface of the medial condyle and the anterior crucial ligament to the back part of the medial surface of the lateral condyle. The two remaining surfaces of the condyles are broad and convex, and each presents an **epicondyle** (tuberosity) for the attachment of lateral ligaments. The medial epicondyle, the larger of the two, is surmounted by the adductor tubercle, behind which is an impression for

the medial head of the *gastrocnemius* on the upper aspect of the condyle; below and behind the lateral epicondyle is a deep groove which receives the tendon of the *popliteus* muscle when the knee is flexed, and its anterior end terminates in a pit from which the tendon takes origin. Above the lateral epicondyle is a rough impression for the lateral head of the *gastrocnemius*.

The interior of the shaft of the femur is hollowed out by a large medullary canal, and the extremities are composed of cancellated tissue invested by a thin compact layer. The arrangement of the cancelli in the upper end of the bone forms a good illustration of the effect produced by the mechanical conditions to which bones are subject. In the upper end of the bone the cancellous tissue is arranged in divergent curves. One system springs from the lower part of the neck and upper end of the shaft medially and spreads into the great trochanter ('pressure lamellæ'). A second system springs from the lateral part of the shaft and arches upward into the neck and head ('tension lamellæ'), crossing the former almost at right angles. A second set of pressure lamellæ springs from the lower thick wall of the neck, and extends into the upper part of the head to end perpendicularly in the articular surface mainly along the lines of greatest pressure. A nearly vertical plate of compact tissue (**calcar femorale**) projects into the neck of the bone from the inferior cervical tubercle toward the great trochanter. This is placed in the line through which the weight of the body falls, and adds to the stability of the neck of the bone; it is said to be liable to absorption in old age. In the lower end of the bone the vertical and horizontal fibres are so disposed as to form a rectangular meshwork.

Blood-supply.—The head and neck of the femur receive branches from the inferior gluteal, obturator, and circumflex arteries, and the trochanters from the circumflex arteries. The nutrient vessel of the shaft is derived from either the second or third perforating artery, or there may be two nutrient vessels arising usually from the first and third perforating. The vessels of the inferior extremity arise from the articular branches of the popliteal and the anastomotic branch of the femoral (supremagenu).

Ossification.—The femur is ossified from one primary centre for the shaft and from four epiphysial centres. The shaft begins to ossify in the seventh week of intra-uterine life. Early in the ninth month a nucleus appears for the lower extremity. During the first year the nucleus for the head of the bone is visible, and in the fourth year that for the trochanter major. The centre for the lesser trochanter appears about the thirteenth or fourteenth year. The lesser trochanter joins the shaft at the seventeenth, the great trochanter at the eighteenth, the head about the nineteenth, and the lower extremity at the twentieth year.

The neck of the femur is an *apophysis*, or outgrowth from the shaft. The line of fusion of the condylar epiphysis with the shaft passes through the adductor tubercle.

The morphological relation of the patellar facet to the tibial portions of the condyles is worthy of notice. In a few mammals, such as the ox, this facet remains separated from the condyles by a furrow of rough bone.

The angle which the neck of the femur forms with the shaft at birth measures, on an average, 160°. In the adult it varies from 110° to 140°; hence the angle decreases greatly during the period of growth. When once growth is completed, the angle, as a rule, remains fixed. (Humphry.)

THE PATELLA

The **patella** (fig. 222) or knee-pan, situated in front of the knee-joint, is a sesamoid bone, triangular in shape, developed in the tendon of the *quadriceps femoris*. Its **anterior surface,** marked by numerous longitudinal striæ, is slightly convex, and

FIG. 222.—THE LEFT PATELLA.

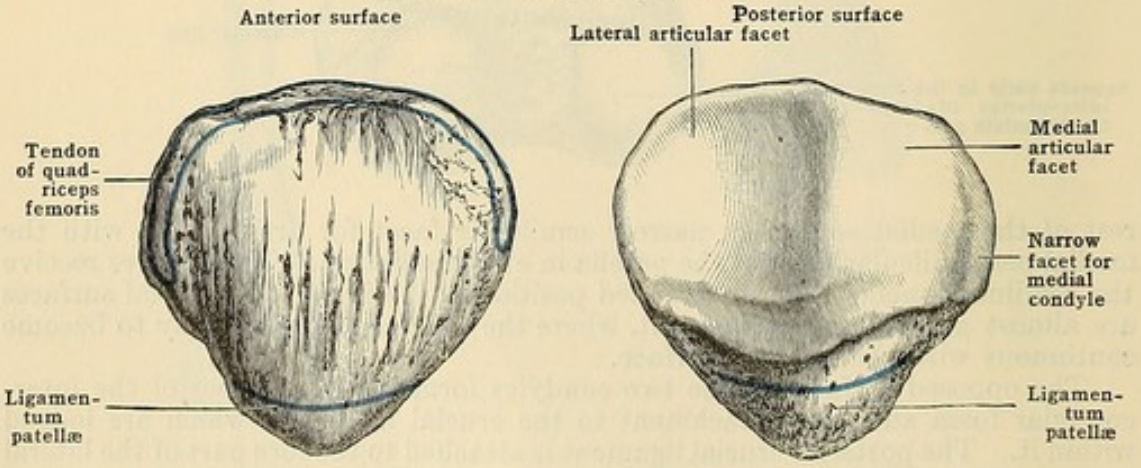

perforated by small openings which transmit nutrient vessels to the interior of the bone. It is covered in the recent state by a few fibres prolonged from the common tendon of insertion (supra-patellar tendon) of the *quadriceps femoris*, into the ligamentum patellæ (infra-patellar tendon), and is separated from the skin by one

or more bursæ. The **posterior surface** is largely articular, covered with cartilage in the recent state, and divided by a slightly marked vertical ridge, corresponding to the groove on the trochlear surface of the femur, into a lateral larger portion for the lateral condyle, and a medial smaller portion for the medial condyle. Close to the medial edge a faint vertical ridge sometimes marks off a narrow articular facet, for the lateral margin of the medial condyle of the femur in extreme flexion of the leg. Below the articular surface is a rough, non-articular depression, giving attachment to the ligamentum patellæ, and separated by a mass of fat from the head of the tibia.

The **base** or superior border is broad, sloped from behind downward and forward, and affords attachment, except near the posterior margin, to the common

FIG. 223.—THE SUPERIOR BORDER OR BASE OF THE LEFT PATELLA.

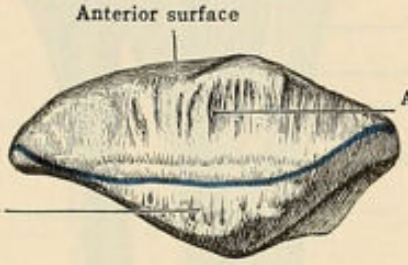

tendon of the *quadriceps*. The **borders,** thinner than the base, converge to the apex below, and receive parts of the two *vasti* muscles. The **apex** forms a blunt point directed downward, and gives attachment to the ligamentum patellæ, by which the patella is attached to the tibia.

Structurally the patella consists of dense cancellous tissue covered by a thin compact layer, and it receives nutrient vessels from the articular branch of the suprema genu (anastomotic), the anterior tibial recurrent, and the inferior articular branches of the popliteal.

Ossification.—The cartilaginous deposit in the tendon of the *quadriceps* muscle takes place in the fourth month of intra-uterine life. Ossification begins from a single centre during the third year, and is completed about the age of puberty.

THE TIBIA

The **tibia** (figs. 224, 225) or shin-bone is situated at the front and medial side of the leg and nearly parallel with the fibula. Excepting the femur, it is the largest bone in the skeleton, and alone transmits the weight of the trunk to the foot. It articulates above with the femur, below with the tarsus, and laterally with the fibula. It is divisible into two extremities and a shaft.

The **upper extremity** (or head) consists of two lateral eminences, or **condyles.** Their superior articular surfaces receive the condyles of the femur, the articular parts being separated by a non-articular interval, to which ligaments are attached. The medial articular surface is oval in shape and concave for the medial condyle of the femur. The lateral articular surface is smaller, somewhat circular in shape, and presents an almost plane surface for the lateral condyle. The peripheral portion of each articular surface is overlaid by a fibro-cartilaginous meniscus of semilunar shape, connected with the margins of the condyles by bands of fibrous tissue termed coronary ligaments. Each semilunar meniscus is attached firmly to the rough interval separating the articular surfaces. This interval is broad and depressed in front, **the anterior intercondyloid fossa,** where it affords attachment to the anterior extremities of the medial and lateral menisci and the anterior crucial ligament; elevated in the middle to form the **intercondyloid eminence** or spine of the tibia, a prominent eminence, presenting at its summit two compressed **intercondyloid tubercles,** on to which the condylar articular surfaces are prolonged; the posterior aspect of the base of the eminence affords attachment to the posterior extremities of the lateral and medial semilunar menisci, and limits a deep notch, inclined toward the medial condyle, known as the **posterior intercondyloid fossa** or popliteal notch. It separates the condyles on the posterior aspect of the head and gives attachment to the posterior crucial ligament, and part of the posterior ligament of the knee-joint. Anteriorly, the two condyles are confluent, and form a somewhat flattened surface of triangular outline, the apex of which forms the **tuberosity** of the tibia. The tuberosity is divisible into two parts. The upper

part, rounded and smooth, receives the attachment of the ligamentum patellæ. The lower part is rough, and into its lateral edges prolongations of the ligamentum patellæ are inserted. A prominent bursa intervenes between the ligament and the anterior aspect of the upper extremity of the bone.

FIG. 224.—THE LEFT TIBIA AND FIBULA. (Anterior view.)

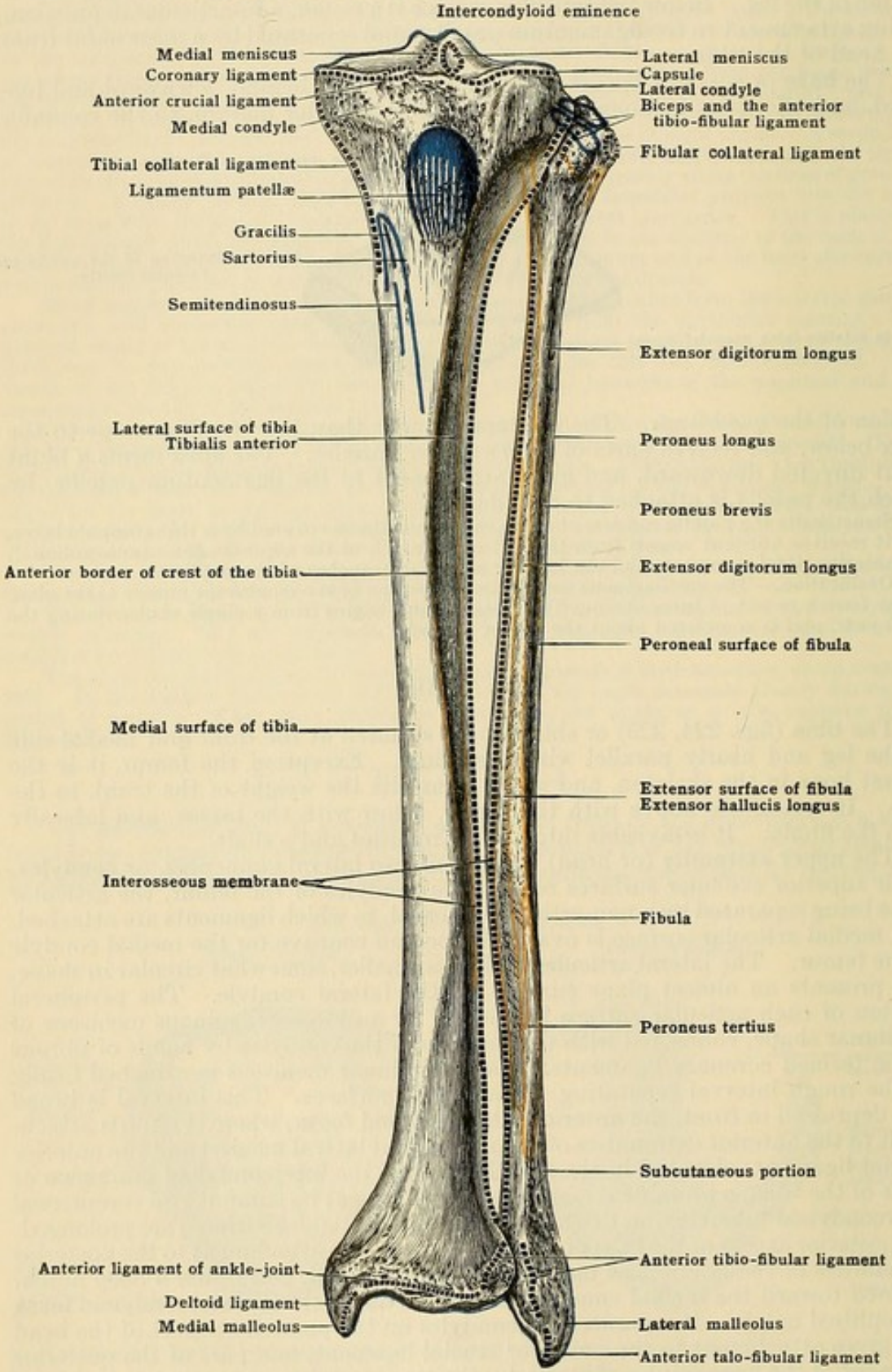

The medial condyle is less prominent though more extensive than the lateral, and near the posterior part of its circumference is a deep horizontal groove for the attachment of the central portion of the *semimembranosus* tendon. The margins of this groove, and the surface

of bone below, give attachment to the tibial (internal) lateral ligament of the knee. On the under aspect of the lateral condyle is a rounded articular facet for the head of the fibula, flat and nearly circular in outline, directed downward, backward, and laterally. The circumference of the facet is rough and gives attachment to the ligaments of the superior tibio-fibular joint, while above and in front of the facet, at the junction of the anterior and lateral surfaces

FIG. 225.—THE LEFT TIBIA AND FIBULA. (Posterior view.)

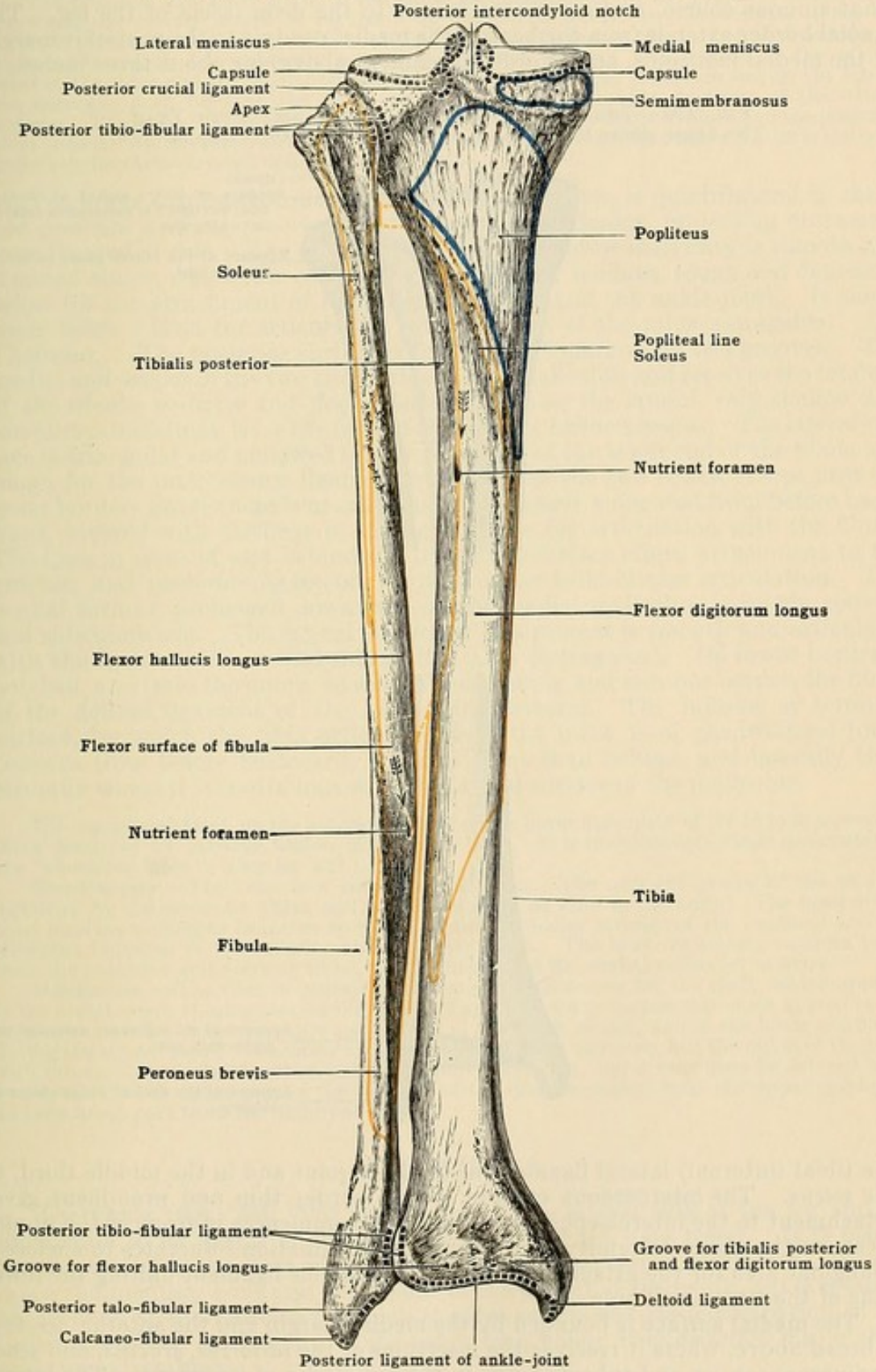

of the condyle, is a ridge for the ilio-tibial band. A slip from the tendon of the *biceps* and parts of the *extensor longus digitorum* and *peroneus longus* muscles are attached to the head below the ilio-tibial band.

The **shaft** or body [corpus] of the tibia, thick and prismatic above, becomes thinner as it descends for about two-thirds of its length, and then gradually expands toward its lower extremity. It presents for examination three borders and three surfaces. The **anterior border** is very prominent and known as the **anterior crest** of the tibia. It commences above on the lateral edge of the tuberosity and terminates below at the anterior margin of the medial malleolus. It runs a somewhat sinuous course, and gives attachment to the deep fascia of the leg. The **medial border** extends from the back of the medial condyle to the posterior margin of the medial malleolus, and affords attachment above, for about three inches, to

FIG. 226.—THE TIBIA AND FIBULA AT THE SIXTEENTH YEAR.
The figure shows the relations of the epiphysial and capsular lines.

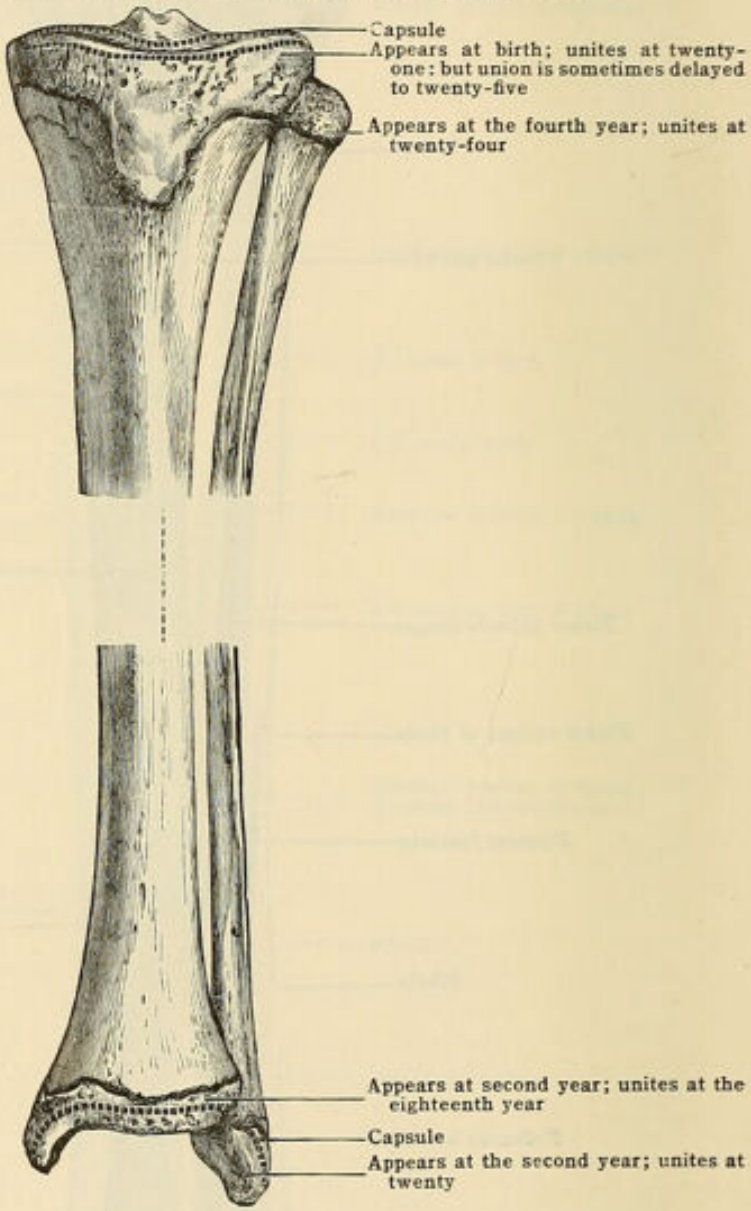

the tibial (internal) lateral ligament of the knee-joint and in the middle third, to the *soleus*. The **interosseous crest** or lateral border, thin and prominent, gives attachment to the interosseous membrane. It commences in front of the fibular facet, on the upper extremity, and toward its termination bifurcates to enclose a triangular area for the attachment of the interosseous ligament uniting the lower ends of the tibia and fibula.

The **medial surface** is bounded by the medial margin and the anterior crest; it is broad above, where it receives the insertions of the *sartorius*, *gracilis*, and *semitendinosus;* convex and subcutaneous in the remainder of its extent. The **lateral surface** lies between the crest of the tibia and the interosseous crest. The upper two-thirds presents a hollow for the origin of the *tibialis anterior;* the rest of the

surface is convex and covered by the extensor tendons and the anterior tibial vessels. The **posterior surface** is limited by the interosseous crest and the medial border. The upper part is crossed obliquely by a rough **popliteal line,** extending from the fibular facet on the lateral condyle to the medial border, a little above the middle of the bone.

The popliteal line gives origin to the *soleus* and attachment to the popliteal fascia, while the triangular surface above is occupied by the *popliteus* muscle. Descending along the posterior surface from near the middle of the popliteal line is a vertical ridge, well marked at its commencement, but gradually becoming indistinct below. The portion of the surface between the ridge and the medial border gives origin to the *flexor digitorum longus;* the lateral and narrower part, between the ridge and the interosseous border, to fibres of the *tibialis posterior.* The lower third of the posterior surface is covered by flexor tendons and the posterior tibial vessels. Immediately below the popliteal line and near the interosseous border is the large medullary foramen directed obliquely downward.

The **lower extremity,** much smaller than the upper, is quadrilateral in shape and presents a strong process called the **medial malleolus,** projecting downward from its medial side. The anterior surface of the lower extremity is smooth and rounded above, where it is covered by the extensor tendons, rough and depressed below for the attachment of the anterior ligament of the ankle-joint. It sometimes bears a facet for articulation with the neck of the talus (astragalus). (A. Thomson.) The posterior surface is rough and is marked by two grooves. The medial and deeper of the two encroaches on the malleolus, and receives the tendons of the *tibialis posterior* and *flexor digitorum longus;* the lateral, very shallow and sometimes indistinct, is for the tendon of the *flexor hallucis longus.* The lateral surface is triangular and hollowed for the reception of the lower end of the fibula and rough for the interosseous ligament which unites the two bones, except near the lower border, where there is usually a narrow surface, elongated from before backward, covered with cartilage in the recent state for articulation with the fibula. The lines in front of and behind the triangular surface afford attachment to the anterior and posterior ligaments of the inferior tibio-fibular articulation. The medial surface, prolonged downward on the medial malleolus, is rough, convex, and subcutaneous. The lateral surface of this process is smooth and articulates with the facet on the medial side of the talus (astragalus). Its lower border is notched, and from the notch, as well as from the tip and anterior border, the fibres of the deltoid ligament of the ankle-joint descend. The inferior or terminal surface, by which the tibia articulates with the talus, is of quadrilateral form, concave from before backward, wider in front than behind, and laterally than medially where it is continuous with the lateral surface of the malleolus.

The occasional facet on the anterior surface of the lower extremity of the tibia is a pressure facet, produced by extreme flexion of the ankle joint. It is therefore sometimes designated as the "squatting facet." (See fig. 333.)

Blood-supply.—The tibia is a very vascular bone. The nutrient artery of the shaft is furnished by the posterior tibial, and is the largest of its kind in the body. The head of the bone receives numerous branches from the inferior articular arteries of the popliteal and the recurrent branches of the anterior and posterior tibial. The lower extremity receives twigs from the posterior and anterior tibial, the peroneal, and the medial malleolar arteries.

Ossification.—The tibia is ossified from one principal centre for the shaft, which appears in the eighth week of intra-uterine life, and two epiphyses, the centres for which appear in the cartilaginous head of the bone toward the end of the ninth month, and in the lower extremity during the second year. The latter unites with the shaft at eighteen, but the union of the head with the shaft does not take place until the twenty-first year, and it may even be delayed until twenty-five. The upper part of the tubercle of the tibia is ossified from the upper epiphysis, and the lower part from the diaphysis.

THE FIBULA

The **fibula** (figs. 224, 225) is situated on the lateral side of the leg and, in proportion to its length is the most slender of all the long bones. It is placed nearly parallel to the tibia with which it is connected above and below. In man it is a rudimentary bone and bears none of the weight of the trunk, but is retained on account of the muscles to which it gives origin and its participation in the formation of the ankle-joint. Like other long bones, it is divisible into a shaft and two extremities.

The **head** [capitulum fibulæ], or upper extremity, is a rounded prominence. Its upper surface presents laterally a rough eminence for the attachment of the

biceps tendon and the fibular (long external) collateral ligament of the knee-joint, medially it presents a round or oval facet [facies articularis capituli], directed upward, forward, and medially, for articulation with the lateral condyle (tuberosity) of the tibia. The margin of the facet gives attachment to the articular capsule of the superior tibio-fibular articulation. Posteriorly, the head rises into a pointed **apex** (styloid process), which affords attachment to the short lateral ligament of the knee-joint, and on the lateral side, to part of the *biceps* tendon.

The posterior aspect of the head gives attachment to the *soleus*, the lateral aspect, extending also in front of the eminence for the *biceps*, to the *peroneus longus;* from the anterior aspect fibres of the *extensor digitorum longus* arise, whilst the medial side lies adjacent to the tibia.

The **shaft** [corpus fibulæ], in its upper three-fourths, is quadrangular, possessing four borders and four surfaces, whereas its lower fourth is flattened from side to side, so as to be somewhat triangular. The borders and surfaces vary exceedingly so that their description is difficult. The **anterior crest** (or antero-lateral border) commences in front of the head and terminates below by dividing to enclose a subcutaneous surface, triangular in shape, immediately above the

FIG. 227.—THE UPPER END OF THE LEFT FIBULA TO SHOW MUSCULAR AND LIGAMENTOUS ATTACHMENTS × 2. (G. J. Jenkins.)

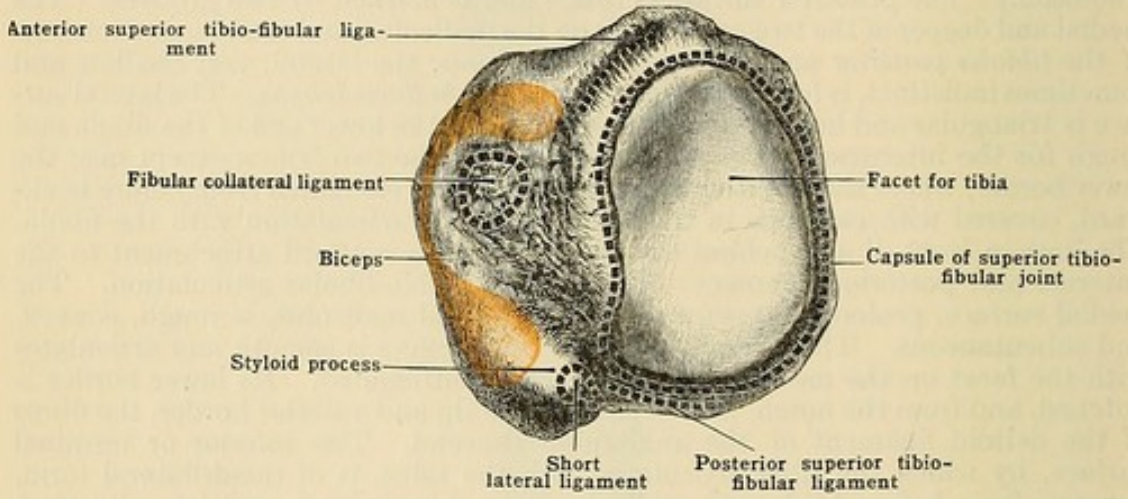

lateral malleolus. It gives attachment to a septum separating the extensor muscles in front from the peronei muscles on the lateral aspect. The **interosseous crest** (or antero-medial border), so named from giving attachment to the interosseous membrane, also commences in front of the head, close to the anterior crest, and terminates below by dividing to enclose a rough triangular area immediately above the facet for the *talus* (*astragalus*); this area gives attachment to the inferior interosseous ligament, and may present at its lower end a narrow facet for articulation with the tibia. The **medial crest** (or postero-medial border), sometimes described as the **oblique line** of the fibula, commences at the medial side of the head and terminates below by joining the interosseous crest, in the lower fourth of the shaft. It gives attachment to an aponeurosis separating the *tibialis posterior* from the *soleus* and *flexor hallucis longus*. The **lateral crest** (or postero-lateral border) runs from the back of the head to the medial border of the peroneal groove on the back of the lower extremity; it gives attachment to the fascia separating the peronei from the flexor muscles.

The **anterior** or **extensor surface** is the interval between the interosseous and anterior crests. In the upper third it is extremely narrow, but broadens out below, where it is slightly grooved longitudinally. It affords origin to three muscles: laterally, in the upper two-thirds, to the *extensor digitorum longus*, and, in the lower third, to the *peroneus tertius;* medially, in the middle third, also to the *extensor hallucis longus*. The **medial surface,** situated between the interosseous and medial crests, is narrow above and below, and broadest in the middle. It is grooved and sometimes crossed obliquely by a prominent ridge, the **secondary oblique line** of the fibula; the surface gives origin to the *tibialis posterior*, and the ridge to a tendinous septum in the substance of the muscle. The **posterior surface**

is the interval between the medial and lateral crests, and is somewhat twisted so as to look backward above and medially below. It serves, in its upper third, for the origin of the *soleus*, and in its lower two-thirds for the *flexor hallucis longus*. Near the middle of the surface is the medullary foramen, directed downward toward the ankle. The **lateral surface,** situated between the anterior and lateral crests, is also somewhat twisted, looking laterally above and backward below, where it is continuous with the groove on the back of the lateral malleolus. The surface is often deeply grooved and is occupied by the *peroneus longus* in the upper two-thirds and by the *peroneus brevis* in the lower two-thirds.

The **lateral malleolus** or lower extremity is pyramidal in form, somewhat flattened from side to side, and joined by its base to the shaft. It is longer, more prominent, and descends lower than the medial malleolus. Its lateral surface is convex, subcutaneous, and continuous with the triangular subcutaneous surface on the shaft, immediately above. The medial surface is divided into an anterior and upper area [facies articularis malleoli], triangular in outline and convex from above downward for articulation with the lateral side of the talus (astragalus), and a lower and posterior excavated area, the **digital fossa,** in which are attached the transverse inferior tibio-fibular ligament and the posterior talo-fibular (posterior fasciculus of the external lateral) ligament of the ankle. The anterior border is rough and gives attachment to the anterior talo-fibular (anterior fasciculus of the external lateral) ligament of the ankle, and the anterior inferior tibio-fibular ligament. The posterior border is grooved for the peronei tendons, and near its upper part gives attachment to the posterior inferior tibio-fibular ligament. The apex or summit of the process affords attachment to the calcaneo-fibular (middle fasciculus of the external lateral) ligament of the ankle.

Blood-supply.—The shaft of the fibula receives its nutrient artery from the peroneal branch of the posterior tibial. The head is nourished by branches from the inferior lateral articular branch of the popliteal artery, and the lateral malleolus is supplied mainly by the peroneal, and its perforating and malleolar branches.

Ossification.—The shaft of the fibula commences to ossify in the eighth week of intra-uterine life. A nucleus appears for the lower extremity in the second year, and one in the upper extremity during the fourth or fifth year. The lower extremity fuses with the shaft about twenty, but the upper extremity remains separate until the twenty-second year or even later.

It is interesting, in connection with the times of appearance of the two epiphyses of the fibula, to note that the ossification of the lower epiphysis is contrary to the general rule—viz., that the epiphysis toward which the nutrient artery is directed is the last to undergo ossification. This is perhaps explained by the rudimentary nature of the upper extremity. In birds the head of the bone is large and enters into the formation of the knee-joint; and in human embryos, during the second month, the fibula is quite close up to the femur.

The human fibula is characterised by the length of its malleolus, for in no other vertebrate does this process descend so far below the level of the tibial malleolus. On the other hand, in the majority of mammals the tibial descends to a lower level than the fibular malleolus. In the human embryo of the third month, the lateral is equal in length to the medial malleolus. At the fifth month the lateral malleolus exceeds the medial by 1.5 mm.; at birth, the lateral malleolus is still longer; and by the second year it assumes its adult proportion.

THE TARSUS

The **tarsal bones** [ossa tarsi] (figs. 228, 229) are grouped in two rows:—a proximal row, consisting of the **talus** and **calcaneus,** and a distal row, consisting of four bones which, enumerated from tibial side, are the **first, second,** and **third cuneiform** bones and the **cuboid.** Interposed between the two rows on the tibial side of the foot is a single bone, the **navicular;** on the fibular side the proximal and distal rows come into contact.

Compared with the carpus, the tarsal bones present fewer common characters, and greater diversity of size and form, in consequence of the modifications for supporting the weight of the trunk. On each, however, six surfaces can generally be recognised, articular when in contact with neighbouring bones, elsewhere subcutaneous or rough for the attachment of ligaments. As regards ossification, they correspond in the main with that of the bones of the carpus. Each tarsal bone is ossified from a single centre, but the calcaneus has, in addition, an epiphysis for a large part of its posterior extremity, and the talus, an occasional centre for the os trigonum.

The Talus

The **talus** (or astragalus) (figs. 230, 231) is, next to the calcaneus, the largest of the bones of the tarsus. Above it supports the tibia, below it rests on the calcaneus, at the sides it articulates with the two malleoli, and in front it is received into the navicular. For descriptive purposes, it may be divided into a **head, neck,** and **body.**

Fig. 228.—The Left Foot. (Superior surface.)

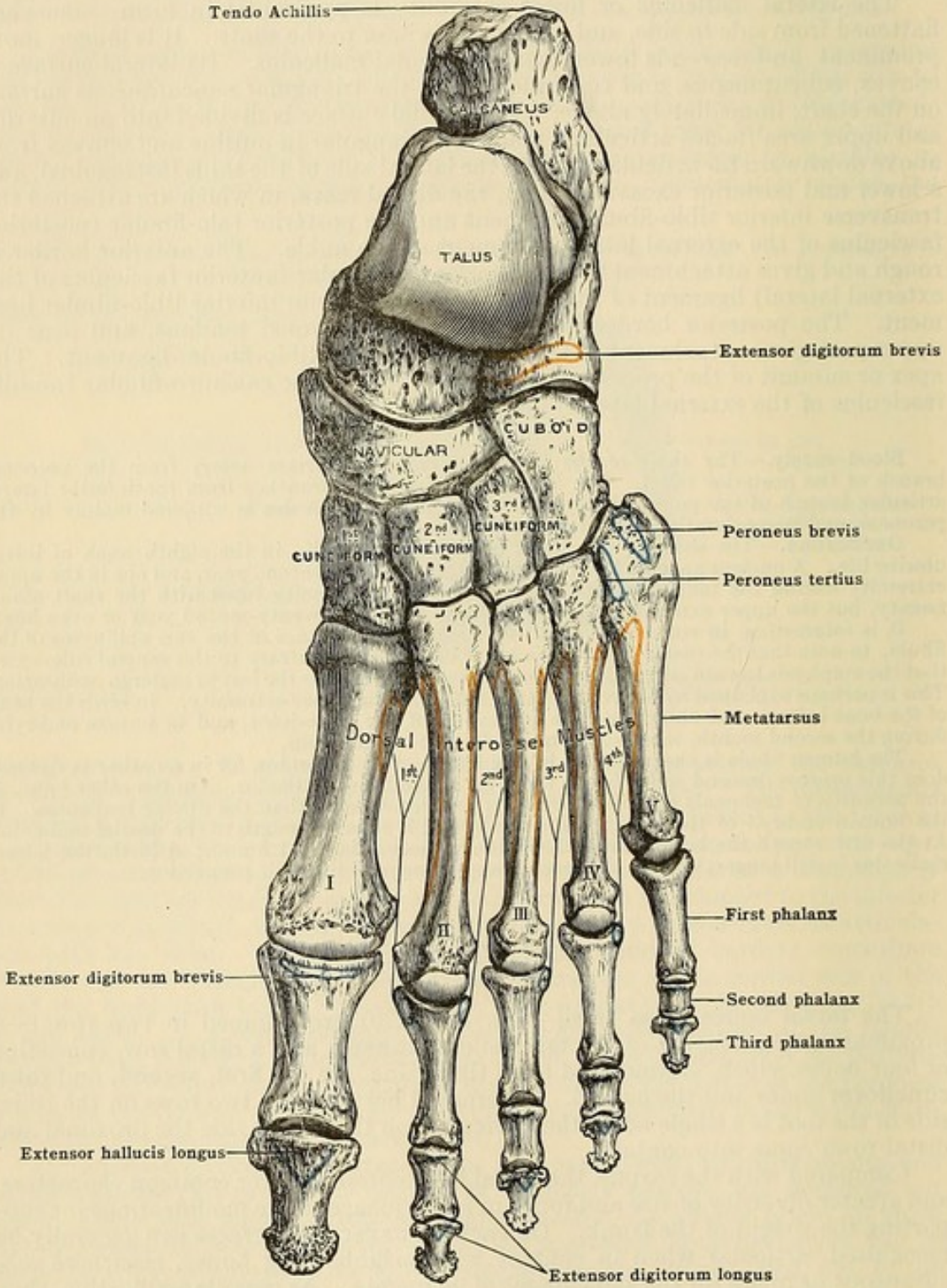

The **body** is somewhat quadrilateral in shape. The **upper surface** presents a broad, smooth surface for the tibia, slightly concave from side to side, convex from before backward, and wider in front than behind. The diminution in width posteriorly is associated with an obliquity of the lateral margin, which is directed medially as well as backward and downward. The **inferior surface** is occupied by a transversely disposed oblong facet [facies articularis calcanea

posterior], deeply concave from side to side, which articulates with a corresponding surface on the calcaneus. Of the malleolar surfaces, the lateral is almost entirely occupied by a large triangular facet, broad above, where it is continuous with the superior surface, concave from above downward, for articulation with the lateral malleolus; on the **medial malleolar surface** is a pyriform facet continuous with the superior surface, broad in front and narrow behind, which articulates with the medial malleolus. Below this facet the medial surface is rough for the attachment of the deep fibres of the deltoid (internal lateral) ligament of the ankle. The

FIG. 229.—THE LEFT FOOT. (Plantar surface.)

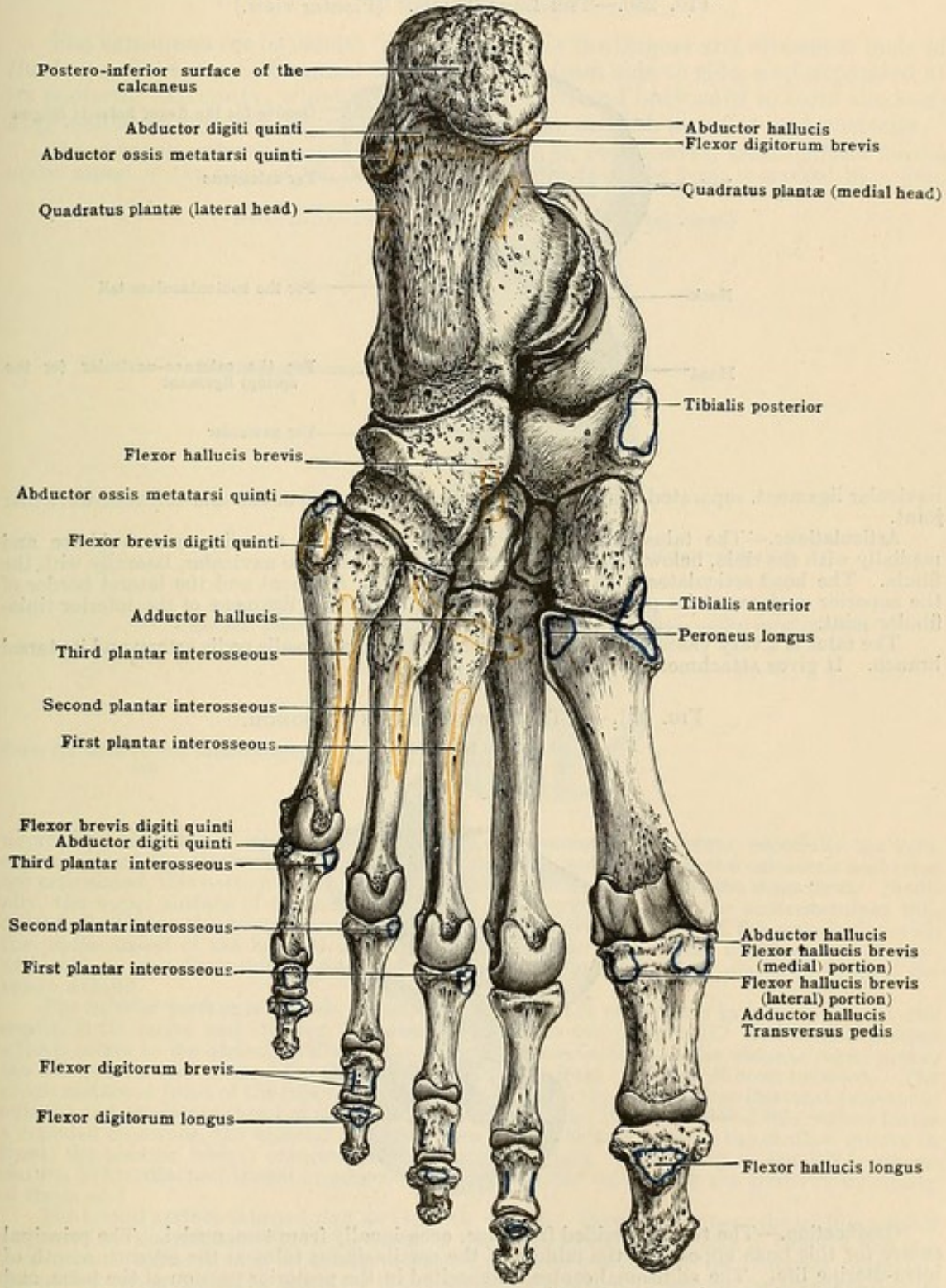

superior surface and the two malleolar surfaces together constitute the **trochlea**. The **posterior surface** is of small extent and marked by a groove which lodges the tendon of the *flexor hallucis longus*. Bounding the groove on either side are two tubercles, of which the lateral [processus posterior tali] is usually the more prominent, for attachment of the posterior talo-fibular ligament of the ankle-joint; the medial tubercle gives attachment to the medial talo-calcaneal ligament. Continuous with the anterior aspect of the body is the **neck**, a con-

stricted part of the bone supporting the head. Above it is rough, and perforated by numerous vascular foramina. Below, it presents a deep groove [sulcus tali], directed from behind forward and lateralward. When the talus is articulated with the calcaneus, this furrow is converted into a canal [sinus tarsi] in which is lodged the interosseous talo-calcaneal ligament. The **head** is the rounded anterior end of the bone, and its large articular surface is divisible into three parts: in front, a smooth, oval convex area, directed downward and forward for the navicular bone; below, an elongated facet, convex from front to back, for articulation with the sustentaculum tali of the calcaneus; and between these, is a small facet which rests on the calcaneo-

FIG. 230.—THE LEFT TALUS. (Plantar view.)

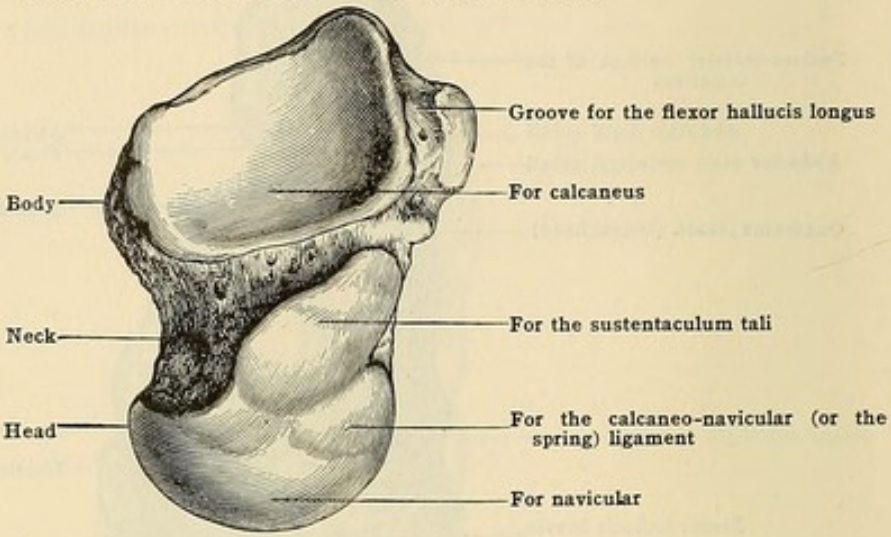

navicular ligament, separated from it by the synovial membrane of the talo-calcaneo-navicular joint.

Articulations.—The talus articulates with four bones and two ligaments. Above and medially with the tibia, below with the calcaneus, in front with the navicular, laterally with the fibula. The head articulates with the calcaneo-navicular ligament and the lateral border of the superior surface, at its posterior part, with the transverse ligament of the inferior tibio-fibular joint.

The talus is a very vascular bone and is nourished by the dorsalis pedis artery and its tarsal branch. It gives attachment to no muscles.

FIG. 231.—A TALUS WITH THE OS TRIGONUM.

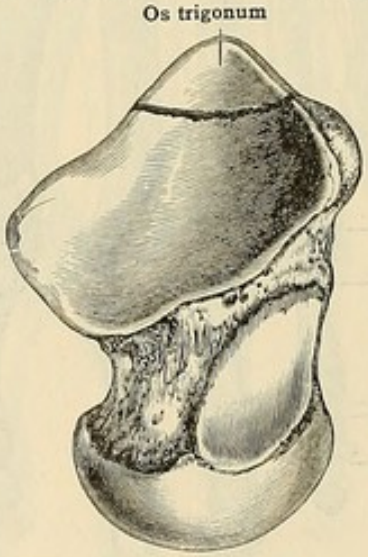

Ossification.—The talus is ossified from one, occasionally from two, nuclei. The principal centre for this bone appears in the middle of the cartilaginous talus at the seventh month of intra-uterine life. The additional centre is deposited in the posterior portion of the bone, and forms the lateral posterior tubercle which may remain separate from the rest of the bone and form the **os trigonum.** At birth, the talus presents some important peculiarities in the disposition of the articular facet on the tibial side of its body, and in the obliquity of its neck. If, in the adult talus, a line be drawn through the middle of the superior trochlear surface parallel with its medial border, and a second line be drawn along the lateral side of the neck of the bone so as to intersect the first, the angle formed by these two lines will express the obliquity of the neck of the bone. This in the adult varies greatly, but the average may be taken as 10°. In the

fœtus at birth the angle averages 35°, whilst in a young orang it measures 45°. In the normal adult talus the articular surface on the tibial side is limited to the body of the bone. In the fœtal talus it extends for some distane on to the neck, and sometimes reaches almost as far forward as the navicular facet on the head of the bone. This disposition of the medial malleolar facet is a characteristic feature of the talus in the chimpanzee and the orang. It is related to the inverted position of the foot which is found in the human fœtus almost up to the period of birth, and is of interest to the surgeon in connection with some varieties of club-foot. (Shattock and Parker.)

The Calcaneus

The **calcaneus** (or os calcis) (figs. 232, 233) is the largest and strongest bone of the foot. It is of an elongated form, flattened from side to side, and expanded at its posterior extremity, which projects downward and backward to form the heel. It presents six surfaces, superior, inferior lateral, medial, anterior and posterior.

The **superior surface** presents in the middle a large, oval, convex, articular facet for the under aspect of the body of the talus. In front of the facet the bone is marked by a deep

Fig. 232.—The Left Calcaneus. (Dorsal view.)

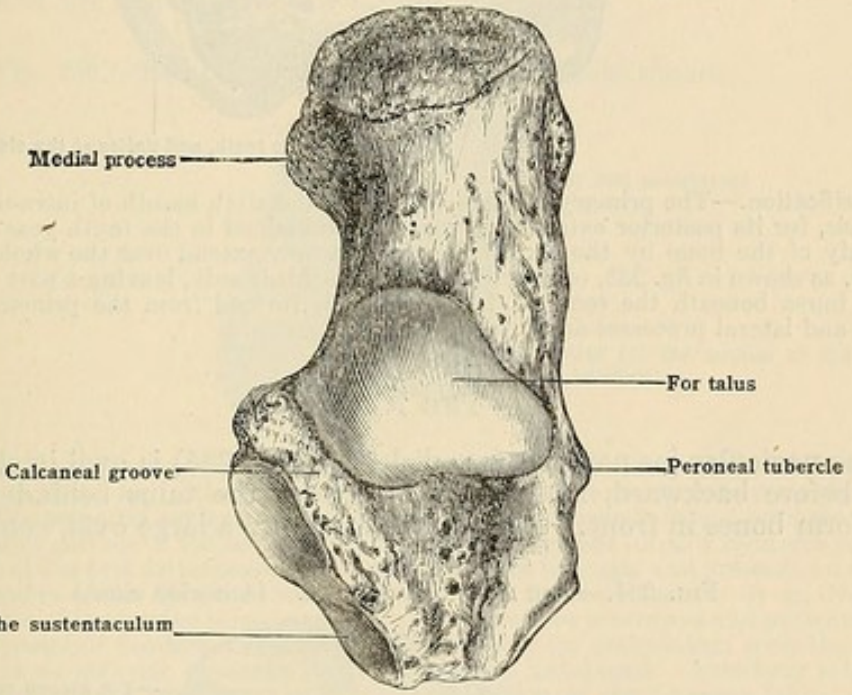

depression, the floor of which is rough for the attachment of ligaments, especially the talo-calcaneal, and the origin of the *extensor digitorum brevis* muscle; when the calcaneus and talus are articulated, this portion of the bone forms the floor of a cavity called the **sinus tarsi.** Medially, the upper surface of the bone presents a well-marked process, the **sustentaculum tali,** furnished with an elongated concave facet, occasionally divided into two, for articulation with the under aspect of the head of the talus. The posterior part of the upper surface is non-articular, convex from side to side, and in relation with a mass of fat placed in front of the tendo Achillis.

The **inferior surface** is narrow, rough, uneven, and ends posteriorly in two **processes:** the **medial** is the larger and broader, the **lateral** is narrower but prominent. The medial process affords origin to the *abductor hallucis*, the *flexor digitorum brevis*, and the *abductor digiti quinti;* the last muscle also arises from the lateral process and from the ridge of bone between. The rough surface in front of the tubercles gives attachment to the long plantar ligament (calcaneo-cuboid) and the lateral head of the *quadratus plantæ*. Near its anterior end this surface forms a rounded eminence, the **anterior tubercle,** from which (as well as from the shallow groove in front) the plantar (short) calcaneo-cuboid ligament arises. (According to the BNA nomenclature, the medial and lateral processes belong to the *tuber calcanei* or the posterior extremity of the bone.)

The **lateral surface** is broad, flat, and slightly convex. It represents near the middle a small eminence for the calcaneo-fibular ligament of the ankle-joint. Below and in front of this is a well-marked tubercle—the **trochlear process** [processus trochlearis] (or peroneal tubercle), separating two grooves, the upper for the *peroneus brevis* and the lower for the *peroneus longus*.

The **medial surface** is deeply concave, the hollow being increased by the prominent medial process behind and the overhanging **sustentaculum tali** in front. The latter forms a prominence of bone projecting horizontally, concave and articular above, grooved below for the tendon of the *flexor hallucis longus*, and giving attachment to a slip of the tendon of the *tibialis posterior*, the inferior calcaneo-navicular ligament, and some fibres of the deltoid ligament of the ankle-joint. The hollow below the process receives the plantar vessels and nerves and its lower part gives attachment to the medial head of the *quadratus plantæ*.

The **anterior surface** is somewhat quadrilateral in outline with rounded angles, and presents a saddle-shaped articular surface for the cuboid.

The **posterior surface** is oval in shape, rough, and convex. It is divided into three parts:—an upper, smooth and separated by a bursa from the tendo Achillis; a middle part giving attachment to the *tendo Achillis* and the *plantaris*, and a lower part in relation to the skin and fat of the heel. The expanded posterior extremity of the bone is known as the **tuber calcanei.**

Articulations.—The calcaneus articulates with two bones, the talus above and the cuboid in front.

Blood-supply.—The calcaneus is nourished by numerous branches from the posterior tibial and the medial and lateral malleolar arteries. They enter the bone chiefly on the inferior and medial surfaces.

FIG. 233.—THE CALCANEUS AT THE FIFTEENTH YEAR, SHOWING THE EPIPHYSIS.

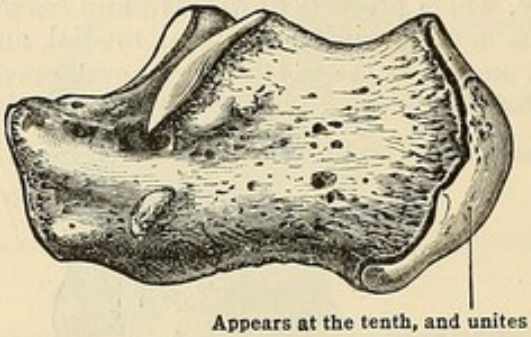

Ossification.—The primary nucleus appears in the sixth month of intra-uterine life. The epiphysis, for its posterior extremity, begins to be ossified in the tenth year and is united to the body of the bone by the sixteenth year. It may extend over the whole of the posterior surface, as shown in fig. 233, or over the lower two-thirds only, leaving a part above in relation to the bursa beneath the tendo Achillis, which is formed from the primary nucleus. The medial and lateral processes are formed by the epiphysis.

THE NAVICULAR

The **navicular** [os naviculare pedis] (figs. 234, 235) is oval in shape, flattened from before backward, and situated between the talus behind and the three cuneiform bones in front. It is characterised by a large oval, concave, articular

FIG. 234.—THE LEFT NAVICULAR. (Anterior view.)

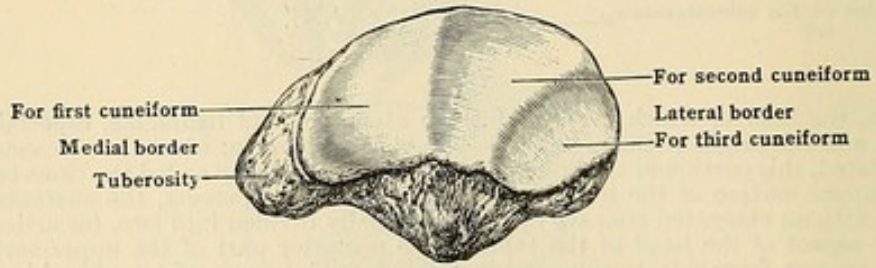

facet on the **posterior surface,** which receives the head of the talus; a broad, rough, rounded eminence on the **medial surface,** named the **tuberosity** of the navicular, the lower part of which projects downward and gives insertion to the tendon of

FIG. 235.—THE LEFT NAVICULAR, SHOWING A FACET FOR THE CUBOID.

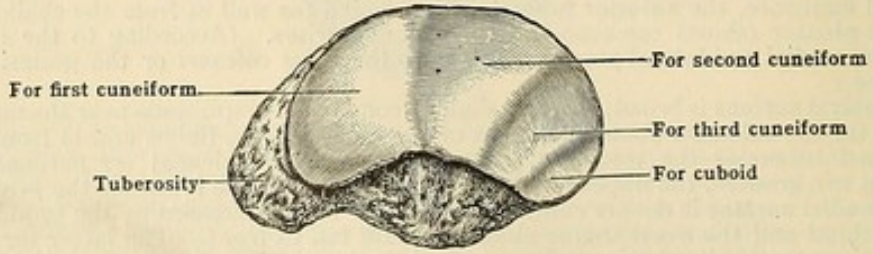

the *tibialis posterior;* and an oblong-shaped **anterior surface,** convex and divided by two vertical ridges into three facets which articulate with the three cuneiform bones. The **superior** (dorsal) **surface** is rough, convex, and slopes downward to

the tuberosity; the **inferior** (plantar) **surface** is irregular and rough for the attachment of the inferior calcaneo-navicular ligament, and the **lateral surface** is rough and sometimes presents a small articular surface for the cuboid.

Articulations.—With the talus behind, with the three cuneiform bones in front, and occasionally with the cuboid on its lateral aspect.

Ossification.—The nucleus for the navicular appears in the course of the fourth year. The tuberosity of the navicular, into which the *tibialis posterior* acquires its main insertion, occasionally develops separately, and sometimes remains distinct from the rest of the bone.

The Cuneiform Bones

Of the three cuneiform bones, the first is the largest, the second is the smallest, and the third intermediate in size. They are wedge-shaped bones placed between the navicular and the first, second and third metatarsal bones. Posteriorly, the ends of the bones lie in the same transverse line, but in front, the first and third project farther forward than the second, and form the sides of a deep recess into which the base of the second metatarsal bone is received.

Fig. 236.—The Left First Cuneiform. (Medial surface.)

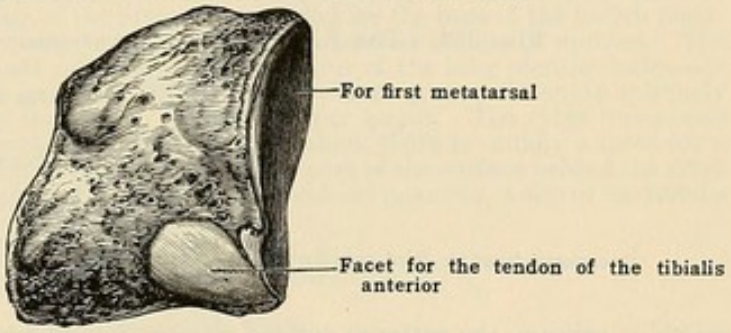

The **first cuneiform** [os cuneiforme primum] (figs. 236, 237) is distinguished by its large size and by the fact that when articulated, the base of the wedge is directed downward and the apex upward. The **posterior surface** is concave and pyriform for articulation with the medial facet on the anterior surface of the navicular. The **anterior surface** forms a reniform articular facet for the base of the first metatarsal. The **medial surface** is rough, and presents an oblique groove for the tendon of the *tibialis anterior;* this groove is limited inferiorly by an oval facet into which a portion of the tendon is inserted. The **lateral surface** is concave and presents along its superior and posterior borders a reversed **L**-shaped facet for articulation with the second cuneiform, and, at its anterior extremity, with the second metatarsal. Anteriorly it is rough for ligaments. The **inferior surface** is rough for the insertion of the *peroneus longus*, *tibialis anterior*, and (usually) the *tibialis posterior*. The **superior surface** is the narrow part of the wedge and is directed upward.

Fig 237.—The Left First Cuneiform. (Lateral aspect.)

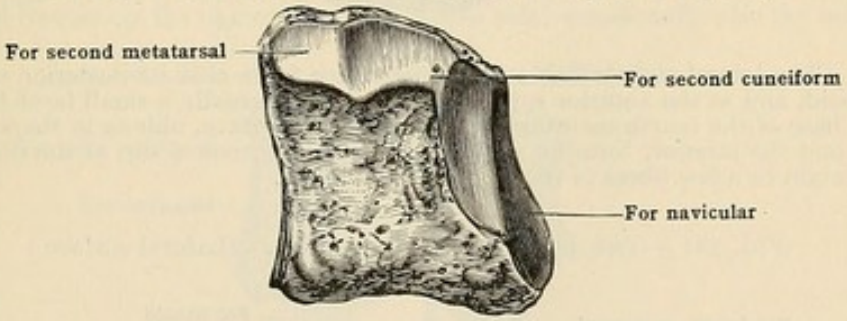

Articulations.—With the navicular behind, second cuneiform and second metatarsal on its lateral side, and first metatarsal in front.

Ossification.—From a single nucleus which appears in the course of the third year.

The **second cuneiform** [os cuneiforme secundum] (figs. 238, 239) is placed with the broad extremity upward and the narrow end downward, and is readily recognised by its nearly square base. The **posterior surface,** triangular and concave, articulates with the middle facet on the anterior surface of the navicular. The **anterior surface,** also triangular, but narrower than the posterior surface, articulates with the base of the second metatarsal. The **medial surface** has a reversed **L**-shaped facet running along its superior and posterior margins for articulation with the corresponding facet on the first cuneiform, and is rough elsewhere for the

attachment of ligaments. On the **lateral surface** near its posterior border is a vertical facet, sometimes bilobed, for the third cuneiform, and occasionally a second facet at the anterior inferior angle. The **superior surface** forms the square-cut base of the wedge and is rough for the attachment of ligaments. The **inferior surface** is sharp and rough for ligaments and a slip of the tendon of the *tibialis posterior*.

FIG. 238.—THE LEFT SECOND CUNEIFORM. (Medial surface.)



Articulations.—With the navicular behind, second metatarsal in front, third cuneiform on the lateral side, and first cuneiform on the medial side.

Ossification.—From a single nucleus which appears in the fourth year.

The **third cuneiform bone** (figs. 240, 241) also placed with the broad end directed upward and the narrow end downward, is distinguished by the oblong shape of its base. Like the

FIG. 239.—THE LEFT SECOND CUNEIFORM. (Lateral surface.)

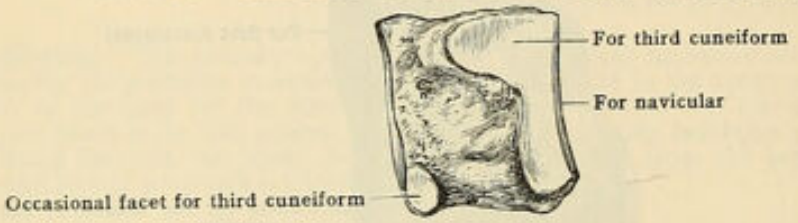

second cuneiform, the **posterior surface** presents a triangular facet for the navicular; and the **anterior surface** a triangular facet, longer and narrower, for the third metatarsal. The **medial surface** has a large facet extending along the posterior border for the second cuneiform, and along the anterior border a narrow irregular facet for the lateral side of the base of the second metatarsal. Occasionally, a small facet is present near the anterior inferior angle for the second

FIG. 240.—THE LEFT THIRD CUNEIFORM. (Medial surface.)

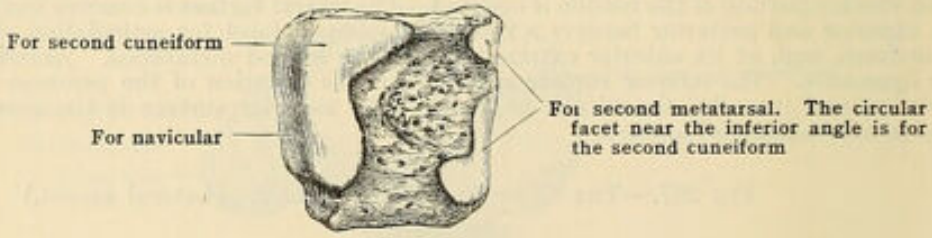

cuneiform. The **lateral surface** has a large distinctive facet near its posterior superior angle for the cuboid, and at the anterior superior angle there is usually a small facet for the medial side of the base of the fourth metatarsal. The **superior surface,** oblong in shape, is rough for ligaments, and the **inferior,** forming a rounded margin, receives a slip of the *tibialis posterior* and gives origin to a few fibres of the *flexor hallucis brevis*.

FIG. 241.—THE LEFT THIRD CUNEIFORM. (Lateral surface.)

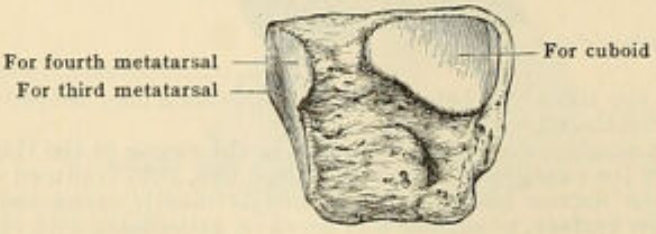

Articulations.—With the navicular behind, third metartarsal in front, cuboid and fourth metatarsal on the lateral side, second cuneiform and second metatarsal on the medial side.

Ossification.—A single nucleus appears in the course of the first year.

The Cuboid

The **cuboid** (figs. 242, 243, 244), irregularly cubical in shape, is placed on the lateral aspect of the foot, forming a continuous line with the calcaneus and the fourth and fifth metatarsals.

Its **posterior surface** is somewhat quadrangular with rounded angles and presents a saddle-shaped articular surface for the calcaneus. Its lower and medial angle is somewhat prolonged backward beneath the sustentaculum tali (calcaneal process of the cuboid), an arrangement to oppose the upward or outward movement of the bone. This process occasionally terminates

Fig. 242.—The Left Cuboid. (Medial view.)

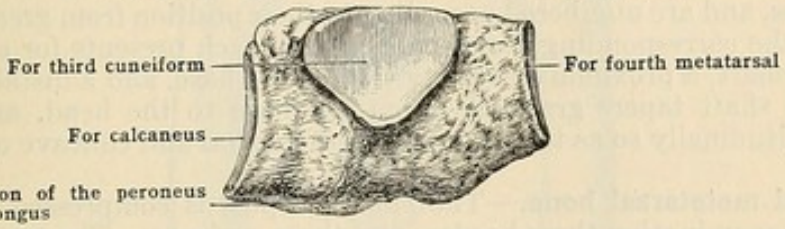

in a rounded facet which plays on the head of the talus lateral to the facet for the calcaneo navicular ligament. The **anterior surface** is smaller and divided by a vertical ridge into two articular facets, a lateral for the base of the fifth, and a medial for the base of the fourth metatarsal. The **superior surface** is rough, non-articular, and directed obliquely upward. The **inferior surface** presents a prominent ridge for the attachment of the long plantar (calcaneo-cuboid) ligament, in front of which is a deep groove—the **peroneal groove**—running obliquely forward and medially and lodging the tendon of the *peroneus longus*. The ridge terminates laterally in an eminence, the **tuberosity** of the cuboid, on which there is usually a facet for a sesamoid bone of the tendon contained in the groove. The part of the surface behind the ridge is rough for the attachment of the plantar (short) calcaneo-cuboid ligament, a slip of the *tibialis posterior*, and a few fibres of the *flexor hallucis brevis*.

Fig. 243.—The Left Cuboid. (Medial view.)

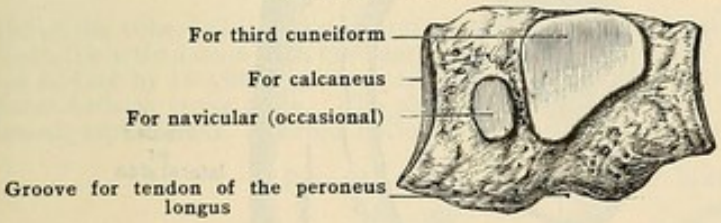

The **medial surface** presents, near its middle and upper part, an oval facet for articulation with the third cuneiform bone (fig. 242); behind this, a second facet for the navicular is frequently seen (fig. 243). Generally the two facets are confluent and then form an elliptical surface (fig. 244). The remainder of this surface is rough for the attachment of strong interosseous ligaments.

The **lateral surface,** the smallest and narrowest of all the surfaces, presents a deep notch which leads into the peroneal groove.

Articulations.—With the calcaneus behind, fourth and fifth metatarsals in front, third cuneiform and frequently the navicular on the medial side; occasionally also the talus.

Fig. 244.—The Left Cuboid. (Medial view.)

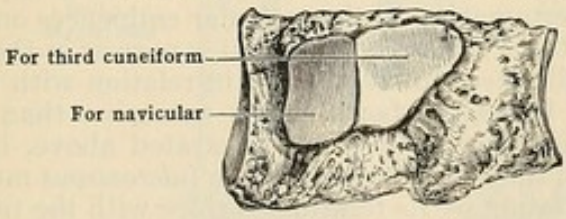

Ossification.—The cuboid is ossified from a single nucleus which appears about the time of birth.

Accessory tarsal elements.—As in the carpus, a number of additional elements may occur in the tarsus. The most frequent of these is the **os trigonum,** which has already been noticed. Next in frequency is an additional first cuneiform, resulting from the ossification of the plantar half of that bone independently of the dorsal half, so that the bone is represented by a plantar and a dorsal first cuneiform. Other additional elements may occasionally occur at the upper posterior angle of the sustentaculum tali; at the anterior superior angle of the calcaneus, between that bone and the navicular; in the angle between the first cuneiform and the first and second metatarsals; and in the fibular angle between the fifth metatarsal and the cuboid (**os Vesalianum**).

The fibular portion of the navicular is sometimes united to the cuboid and quite separate from the rest of the navicular, the cuboid in such cases articulating with the talus. This condition suggests the recognition of the fibular portion of the navicular as a distinct accessory tarsal element, the *cuboides secundarium*, though it has not yet been observed as an independent bone in the human foot.

THE METATARSUS

The **metatarsus** [ossa metatarsalia] consists of a series of five somewhat cylindrical bones. Articulated with the tarsus behind, they extend forward, nearly parallel with each other, to their anterior extremities, which articulate with the toes, and are numbered according to their position from great toe to small toe. Like the corresponding bones in the hand, each presents for examination a three-sided shaft, a proximal extremity termed the base, and a distal extremity or head. The shaft tapers gradually from the base to the head, and is slightly curved longitudinally so as to be convex on the dorsal and concave on the plantar aspect.

A typical metatarsal bone.—The **shaft** [corpus] is compressed laterally and presents for examination three borders and three surfaces. The two **borders,** distinguished as **medial** and **lateral,** are sharp and commence behind, one on each side of the dorsal aspect of the tarsal extremity, and, gradually approaching in the middle of the shaft, separate at the anterior end to terminate in the corresponding

FIG. 245.—THE FIRST (LEFT) METATARSAL.

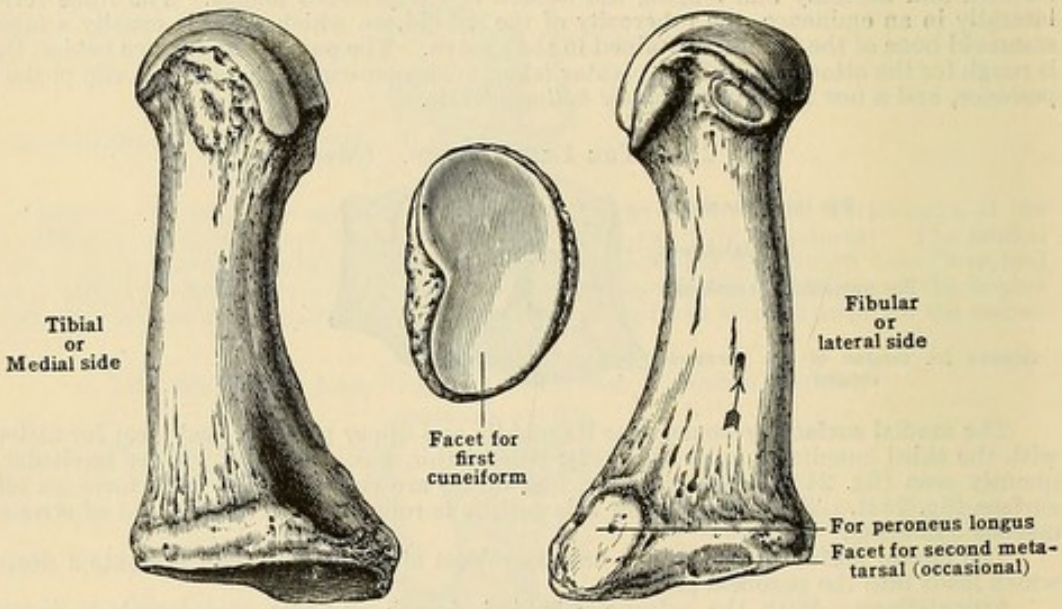

tubercles. The **inferior border** is thick and rounded and extends from the under aspect of the tarsal extremity to near the anterior end of the bone, where it bifurcates, the two divisions terminating in the articular eminences on the plantar aspect of the head. Of the three surfaces, the **dorsal** is narrow in the middle and wider at either end. It is directed upward and is in relation with the extensor tendons. The **medial** and **lateral surfaces,** more extensive than the dorsal, corresponding with the interosseous spaces, are separated above, but meet together at the inferior border; they afford origin to the *interosseous* muscles. The **base** is wedge-shaped, articulating by its terminal surface with the tarsus, and on each side with the adjacent metatarsal bones. The dorsal and plantar surfaces are rough for the attachment of ligaments. The **head** presents a semicircular articular surface for the base of the first phalanx, and on each side a depression, surmounted by a tubercle, for the attachment of the lateral ligaments of the metatarso-phalangeal joint. The inferior surface of the head is grooved for the passage of the flexor tendons and is bounded by two eminences continuous with the terminal articular surface.

The several metatarsals possess distinctive characters by which they can be readily recognised.

The **first metatarsal** (fig. 245) is the most modified of all the metatarsal bones, and deviates widely from the general description given above. It is the shortest, the thickest, the strongest, and most massive of the series. The **base** presents a large reniform, slightly concave facet for the first cuneiform and projects downward into the sole to form the **tuberosity,** a rough eminence into which the *peroneus longus* and a slip of the *tibialis anterior* are inserted. A little

FIG. 246.—THE SECOND (LEFT) METATARSAL.

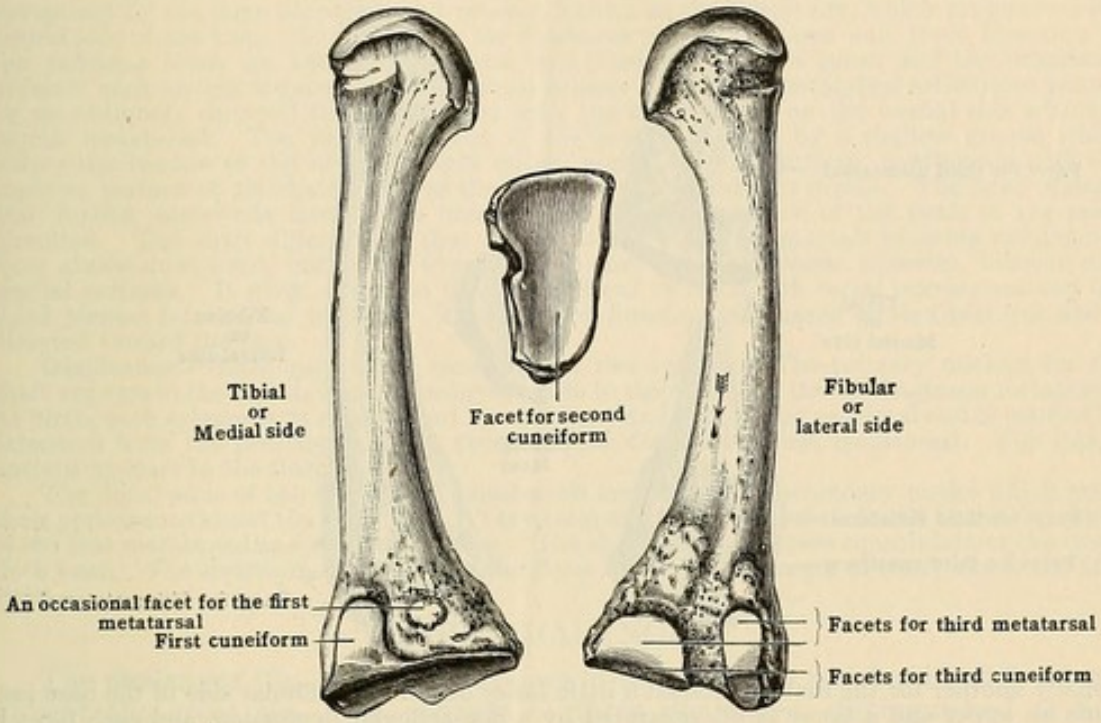

above the tuberosity, on its lateral side, there is occasionally a shallow, but easily recognised facet, for articulation with the base of the second metatarsal. The **head** is marked on the plantar surface by two deep grooves, separated by a ridge, in which the two sesamoid bones of the *flexor hallucis brevis* glide. The **shaft** is markedly prismatic. The **dorsal surface** is smooth, broad, and convex, directed obliquely upward; the **plantar surface** is concave longitudinally

FIG. 247.—THE THIRD (LEFT) METATARSAL.

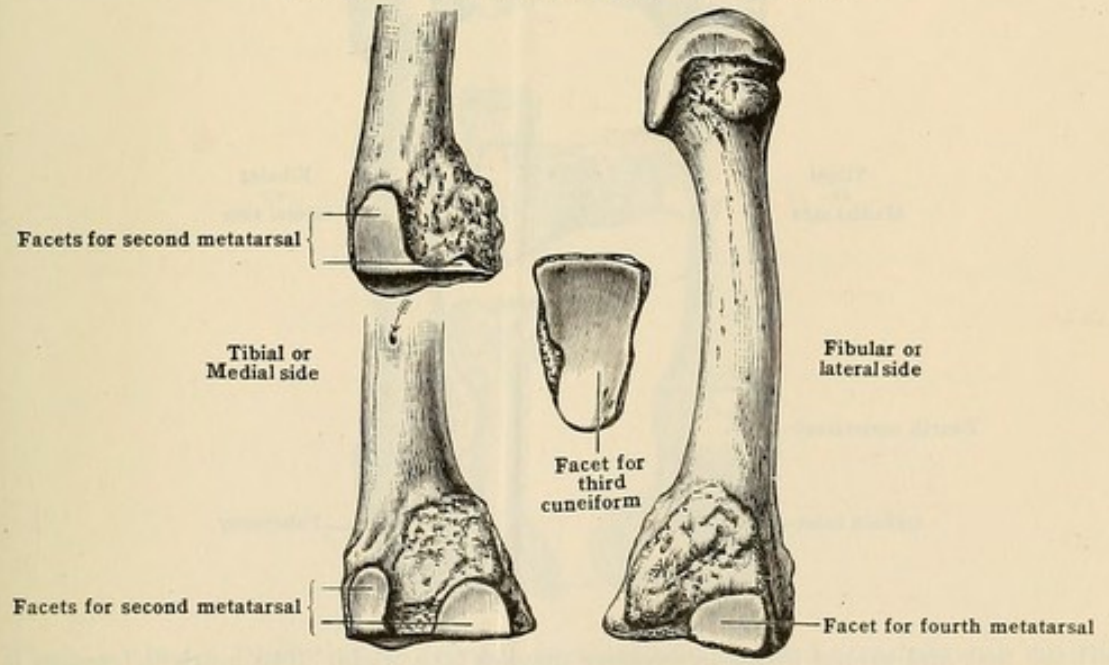

and covered by the *flexor hallucis longus* and *brevis*, whilst the **lateral surface** is triangular in outline, almost vertical, and in relation with the first *dorsal interosseous* and *adductor hallucis obliquus*. A few fibres of the medial head of the first *dorsal interosseous* occasionally arise from the hinder part of the surface adjoining the base, or from the border separating the lateral from the dorsal surface. Somewhere near the middle of the shaft, and on its fibular side, is the nutrient foramen, directed toward the head of the bone.

The **second metatarsal** (fig. 246) is the longest of the series. Its base is prolonged backward to occupy the space between the first and third cuneiform, and accordingly it is marked by facets for articulation with each of these bones. The tarsal surface is triangular in outline, with the base above and apex below, and articulates with the second cuneiform bone. On the tibial side of the base, near the upper angle, is a small facet for the first cuneiform, and occa-

FIG. 248.—THE FOURTH (LEFT) METATARSAL.

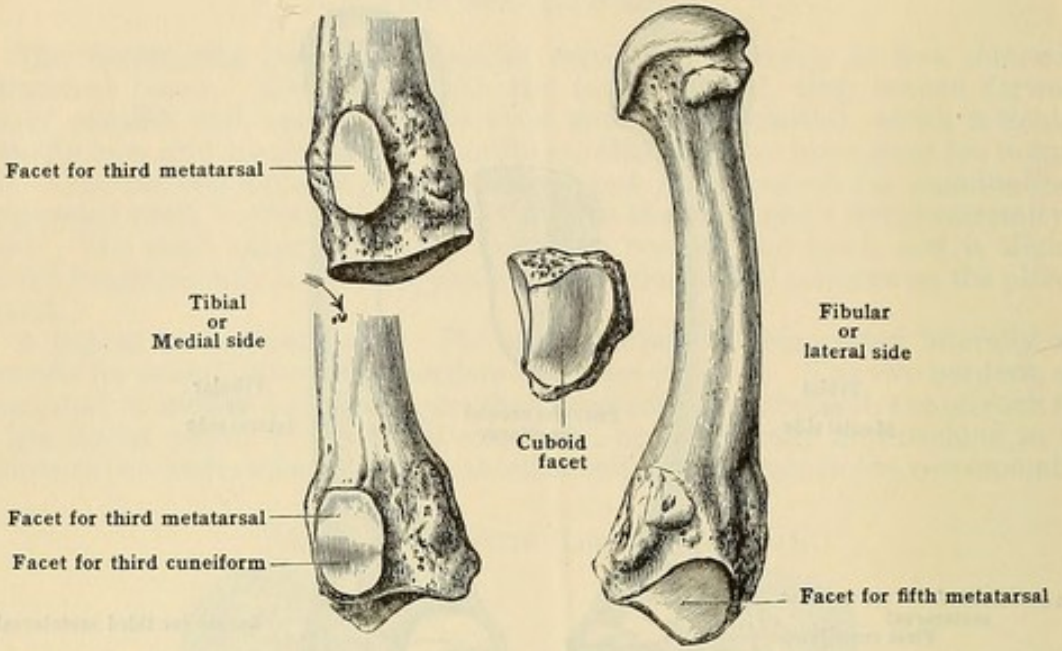

sionally another for the first metatarsal a little lower down. The fibular side of the base presents an upper and a lower facet, separated by a non-articular depression, and each facet is divided by a vertical ridge into two, thus making four in all. The two posterior facets articulate with the third cuneiform and the two anterior with the third metatarsal. The base gives attachment to a slip of the *tibialis posterior* and the *adductor hallucis obliquus*, whilst from the

FIG. 249.—THE FIFTH (LEFT) METATARSAL.

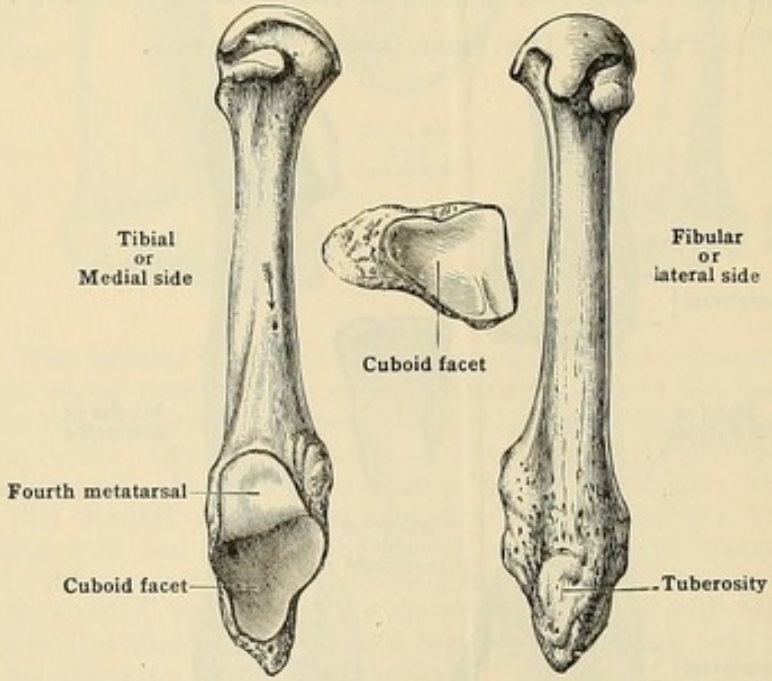

shaft the first and second *dorsal interosseous* muscles take origin. The nutrient foramen is situated on the fibular side of the shaft near the middle and is directed toward the base of the bone.

The **third metatarsal** (fig. 247), a little shorter than the second, articulates by the triangular surface of its base with the third cuneiform. On the medial side are two small facets, one below the other, for the second metatarsal, and on the lateral side, a single large facet for the fourth metatarsal. The base gives attachment to a slip of the *tibialis posterior* and the *adductor hallucis obliquus*, and from the shaft three *interosseous* muscles take origin. The nutrient foramen is situated on the tibial side of the shaft and is directed toward the base.

The **fourth metatarsal** (fig. 248), smaller in size than the preceding, is distinguished by the quadrilateral facet on the base, for the cuboid. The medial side presents a large facet divided by a ridge into an anterior portion for articulation with the third metatarsal and a posterior portion for the third cuneiform. Occasionally the cuneiform part of the facet is wanting. On the lateral side of the base is a single facet for articulation with the fifth metatarsal.

The **fifth metatarsal** (fig. 249), is shorter than the fourth, but longer than the first. It is recognised by the large nipple-shaped process, known as the **tuberosity,** which projects on the lateral side of the base. It constitutes the hindmost part of the bone and gives insertion to the *peroneus brevis* on the dorsal aspect, and *flexor brevis digiti quinti* and the occasional *abductor ossis metatarsi quinti* on the plantar aspect. The fifth metatarsal articulates behind by an obliquely directed triangular facet with the cuboid, and on the medial side with the fourth metatarsal. The plantar aspect of the base is marked by a shallow groove which lodges the tendon of the *abductor digiti quinti*, and the dorsal surface, continuous with the superior surface of the shaft, receives the insertion of the *peroneus tertius*. The **head** is small and turned somewhat laterally in consequence of the curvature of the shaft in the same direction. The **shaft** differs from that of any of the other metatarsals in being compressed from above downward, instead of from side to side, so as to present superior, inferior, and medial surfaces. It gives origin to the lateral head of the fourth *dorsal interosseous* and the third *plantar interosseous* muscles. The nutrient foramen is situated on its tibial side and is directed toward the base.

Ossification.—Each metatarsal ossifies from two centres. The primary nucleus for the shaft appears in the eighth week of embryonic life in the middle of the cartilaginous metatarsal. At birth, each extremity is represented by cartilage, and that at the proximal end is ossified by extension from the primary nucleus, except in the case of the first metatarsal. For this, a nucleus appears in the third year.

The distal ends of the four lateral metatarsals are ossified by secondary nuclei which make their appearance about the third year. Very frequently an epiphysis is found at the distal end of the first metatarsal as well as at its base. The shafts and epiphyses consolidate at the twentieth year. The sesamoids belonging to the *flexor hallucis brevis* begin to ossify about the fifth year.

THE PHALANGES

The **phalanges** (fig. 250) are the bones of the toes, and number in all fourteen. Except the great toe, each consists of three phalanges, distinguished as first (proximal), second and third (distal); in the great toe the second phalanx is absent.

FIG. 250.—THE PHALANGES OF THE MIDDLE TOE.

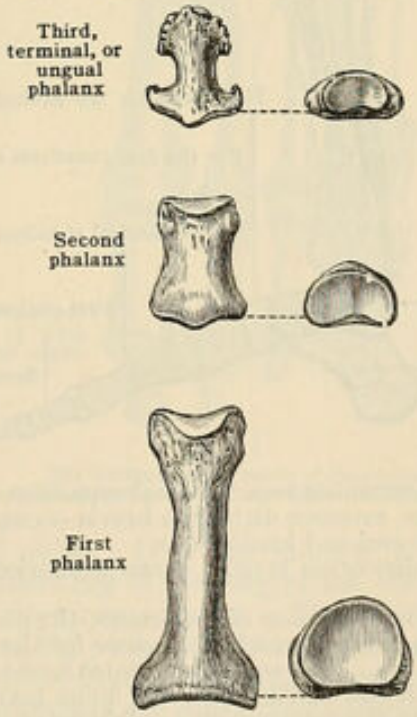

There is thus a similarity as regards number and general arrangement with the phalanges of the fingers. With the exception of the phalanges of the great toe, which are larger than those of the thumb, the bones of the toes are smaller and more rudimentary than the corresponding bones of the fingers. In all the phalanges, the nutrient foramen is directed toward the distal extremity.

The phalanges of the **first row** are constricted in the middle and expanded at either extremity. The shafts are narrow and laterally compressed, rounded on the dorsal and concave

on the plantar aspects. The base of each presents a single oval concave facet for the convex head of the corresponding metatarsal, whilst the head forms a pulley-like surface [trochlea phalangis], grooved in the centre and elevated on each side for the second phalanx.

The phalanges of the **second row** are stunted, insignificant bones. Their shafts, besides being much shorter, are flatter than those of the first row. The **bases** have two depressions, separated by a vertical ridge, and the heads present **trochlear** surfaces for the ungual phalanges.

The **third,** or **ungual** phalanges are easily recognised. The bases articulate with the second phalanges; the shafts are expanded, forming the ungual tuberosities which support the nails, and their plantar surfaces are rough where they come into relation with the pulp of the digits.

The muscles attached to the various phalanges may be tabulated thus:—

The **first phalanx of the hallux** gives insertion to the flexor hallucis brevis; abductor hallucis; adductor hallucis transversus and obliquus; extensor digitorum brevis.

The **first phalanx of second toe:** The first and second dorsal interosseous.

The **first phalanx of third toe:** Third dorsal interosseous; first plantar interosseous.

The **first phalanx of fourth toe:** Second plantar interosseous; fourth dorsal interosseous.

The **first phalanx of fifth toe:** Third plantar interosseous; flexor digiti quinti brevis; and abductor digiti quinti.

The **terminal phalanx of hallux:** Flexor hallucis longus; extensor hallucis longus.

FIG. 251.—A LONGITUDINAL SECTION OF THE BONES OF THE LOWER LIMB AT BIRTH.

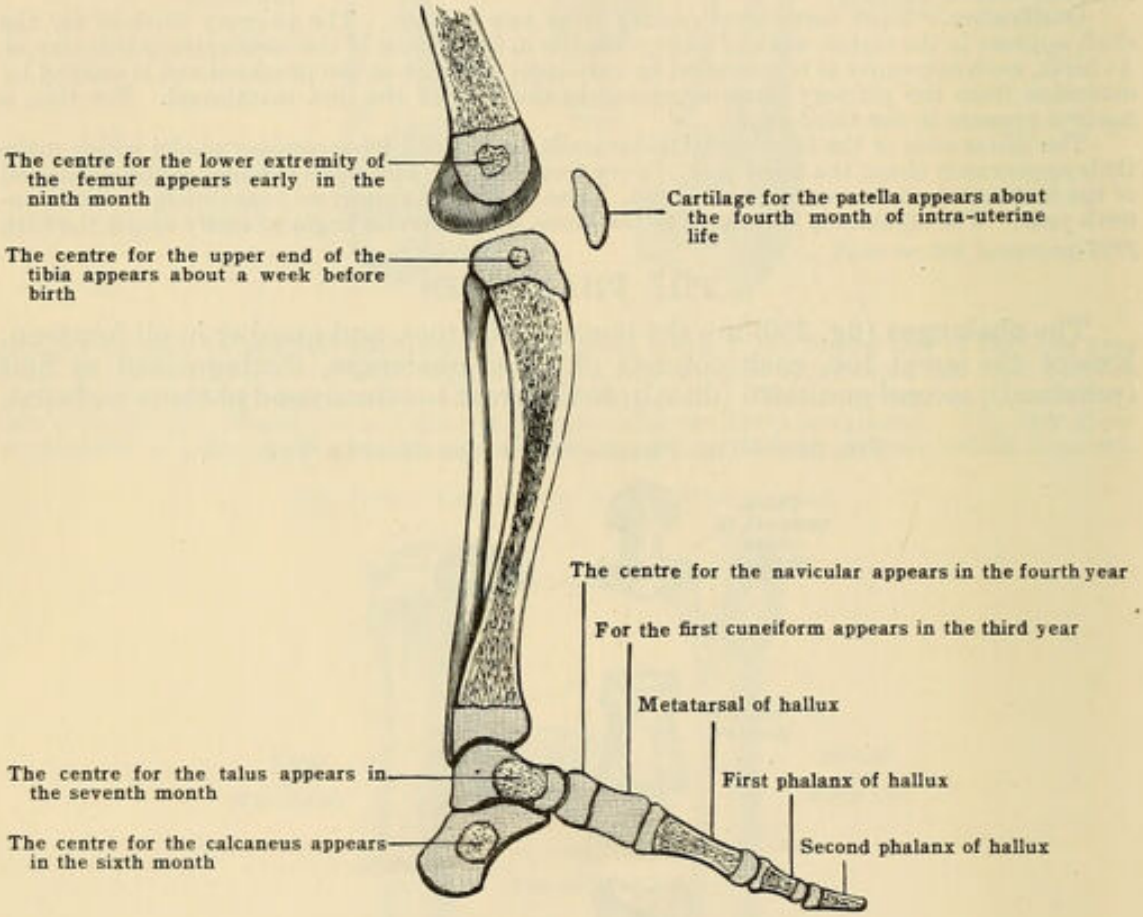

The **second phalanges of the remaining toes:** Dorsal expansion of the extensor tendons, including extensor digitorum longus, extensor digitorum brevis (except in the case of the fifth toe), and expansions from the interossei and lumbricales.

The **third phalanges:** Flexor digitorum longus; dorsal expansion of the extensor tendon with the associated muscles.

Ossification.—Like the corresponding bones of the fingers, the phalanges of the toes ossify from a primary and a secondary nucleus. In each, the centre for the shaft appears during the eighth or ninth week of embryonic life. The secondary centre forms a scale-like epiphysis for the proximal end between the fourth and eighth years, and union takes place in the eighteenth or nineteenth year—i. e., earlier than the corresponding epiphyses in the fingers. The primary centres for the third phalanges appear at the distal extremities of the bones.

SESAMOID BONES

In the foot a pair of sesamoid bones is constant over the metatarso-phalangeal joint of the great toe in the tendons of the flexor hallucis brevis. One sometimes occurs over the inter-phalangeal joint of the same toe and over the metatarso-phalangeal joints of the second and fifth and rarely of the third and fourth toes.

A sesamoid also occurs in the tendon of the peroneus longus, where it glides over the groove in the cuboid; another may be found, especially in later life, in the tendon of the tibialis anterior over the first cuneiform bone, and another in the tendon of the tibialis posterior over the medial surface of the head of the talus. Further a sesamoid, the fabella, sometimes occurs in the lateral head of the gastrocnemius, and another may be found in the tendon of the ilio-psoas over the pubis.

BONES OF THE FOOT AS A WHOLE

Although the foot is constructed on the same general plan as the hand, there is a marked difference in its architecture to qualify it for the different functions which it is called upon to perform. When in the erect posture, the foot forms a firm basis of support for the rest of the body, and the bones are arranged in an elliptical arch, supported on two pillars, a posterior or *calcaneal* pillar and an

FIG. 252.—THE SECONDARY OSSIFIC CENTRES OF THE FOOT.

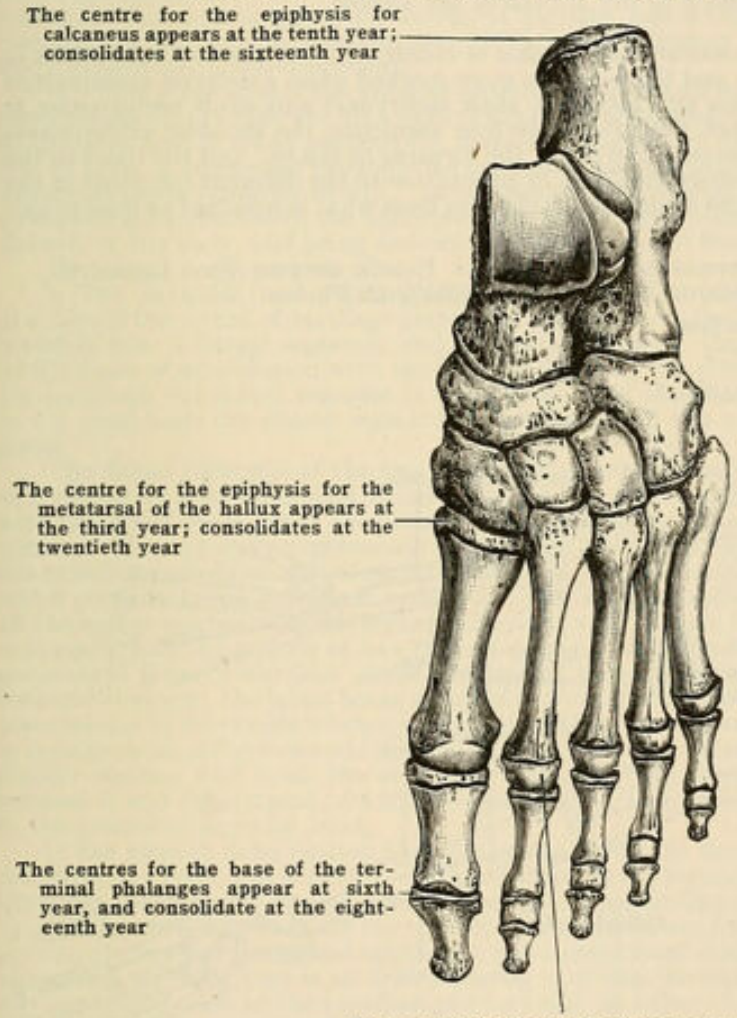

anterior or *metatarsal* pillar. It is convenient, however, to regard the anterior part of the arch as consisting of two segments, corresponding to the medial and lateral borders of the foot respectively. The medial segment is made up of the three metatarsal bones, the three cuneiform, the navicular, and talus; the lateral segment is made up of the fourth and fifth metatarsal bones, the cuboid, and the calcaneus, and both segments are supported behind on a common *calcaneal* pillar. The division corresponds to a difference in function of the two longitudinal arches. Both are intimately concerned in ordinary locomotion. In addition, the medial, characterised by its great curvature and remarkable elasticity, sustains the more violent concussions in jumping and similar actions, whereas the lateral, less curved, more rigid, and less elastic arch forms, with the pillars in front and behind, a firm basis of support in the upright posture.

Both arches are completed and maintained by strong ligaments and tendons. The weakest part is the joint between the talus and navicular bone, and special

provision is accordingly made, by the addition of a strong calcaneo-navicular ligament, for the support of the head of the talus. This ligament is in turn supported by its union with the deltoid ligament of the ankle, and by the tendon of the *tibialis posterior* which passes beneath it to its insertion.

Besides being arched longitudinally, the foot presents a transverse arch formed by the metatarsal bones in front and the distal row of the tarsus behind. It is produced by the marked elevation of the central portion of the medial longitudinal arch above the ground, whereas the lateral longitudinal arch is much less raised, and at its anterior end becomes almost horizontal. Both the longitudinal and transverse arches serve the double purpose of increasing the strength and elasticity of the foot and of providing a hollow in which the muscles, nerves, and vessels of the sole may lie protected from pressure.

Homology of the Bones of the Limbs

That there is a general correspondence in the plan of construction of the two extremities is apparent to a superficial observer, and this becomes more marked when a detailed examination of the individual bones, their forms and relations, their embryonic and adult peculiarities, is systematically carried out. In each limb there are four segments, the shoulder girdle corresponding to the pelvic girdle, the arm to the thigh, the forearm to the leg, and the hand to the foot. These parts have been variously modified, in adaptation to the different functions of the two limbs, particularly as regards the deviations or changes from what is regarded as their primi-

FIG. 253.—DIAGRAMMATIC REPRESENTATION OF THE BONES OF THE TWO LIMBS, TO SHOW HOMOLOGOUS PARTS. (Modified from Flower.)

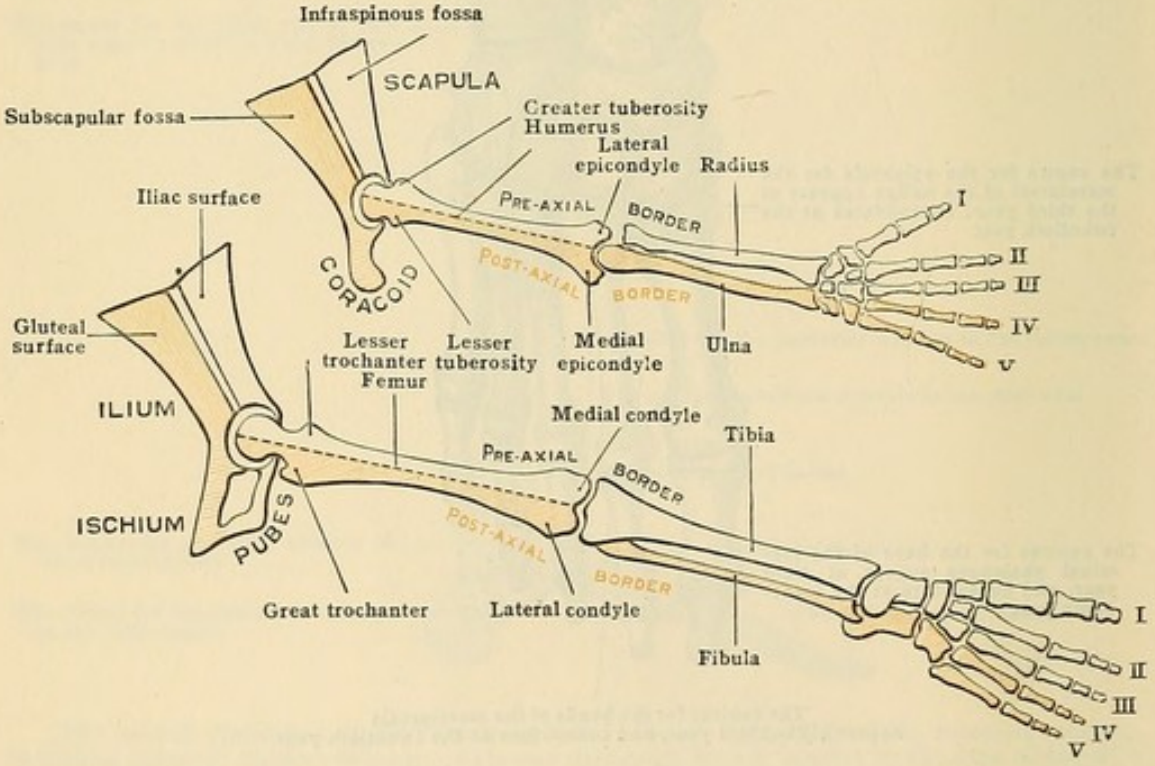

tive position, and as a knowledge of these changes is essential to a clear understanding of the homologous bones, it will be advantageous to refer briefly to the relations of the limbs in the earliest stages of development.

The limbs first appear as flattened, bud-like outgrowths from the sides of the trunk. Each presents a *dorsal* or *extensor* surface, and a *ventral* or *flexor* surface, as well as two borders, an *anterior*, or *cephalic*, directed toward the head end of the embryo, and a *posterior* or *caudal*, directed toward the tail end. In reference to the axis of the limb itself, the borders have been called *pre-axial* and *post-axial*, respectively. When, somewhat later, the various divisions of the limb make their appearance, it is seen that the greater tuberosity, the lateral epicondyle, the radius, and the thumb lie on the pre-axial border of the anterior extremity, and the small trochanter, the medial condyle, the tibia, and the great toe on the pre-axial border of the posterior extremity. Further on the post-axial border of the anterior extremity are seen the lesser tuberosity, the medial epicondyle, the ulna, and little finger, whilst on the corresponding border of the posterior limb are the great trochanter, the lateral condyle, the fibula, and the little toe. The parts now enumerated on the corresponding borders of the two limbs must therefore be regarded as serially homologous (fig. 253).

It is necessary to trace next the further changes which take place in the segments of the limbs up to the time when they assume their permanent positions. They may be arranged in stages as follows:—

(1) Each segment of the limb is bent upon the one above it. The humerus and femur remain unchanged. The forearm segment, however, is bent so that the ventral surface looks medially and the dorsal surface laterally. Moreover, the joints between these segments—i. e., elbow and knee—form marked projections. The terminal segments (hand and foot) are bent in the opposite direction to the middle one, so that the primitive position is retained, and the ends of the digits directed laterally. It will be noticed that in this series of changes the relations of the pre-axial and post-axial borders of the limbs remain as before.

(2) This stage consists in a rotation of the whole limb from the proximal end, though in an exactly opposite direction in each case. The anterior extremity is rotated *backward* so that the humerus lies parallel with the trunk; the elbow is directed toward the caudal end, the pre-axial (radial) border becomes lateral, and the post-axial border medial. The ends of the digits point backward. The posterior extremity undergoes a rotation *forward* to the same extent, so that the femur is also nearly parallel with the trunk; the knee is directed toward the head end, the pre-axial (tibial) border becomes medial, and the post-axial border lateral. The tibia and fibula are parallel, the ends of the digits are directed forward, the great toe is on the pre-axial and the little toe on the post-axial border of the limb, and in this position the posterior extremity remains, the changes being finally completed by the extension of the limb at the hip-joint as the body attains its full development.

(3) This stage affects the anterior extremity alone and consists in a rotation of the radius, carrying the hand round the ulna so that the digits are brought round from the back to the front of the limb, and in many animals the manus is thus placed permanently in the prone position. But in man, in whom the capacity for pronation and supination is highly developed, the hand can assume either position at will. In his case the final change is the extension which takes place at the shoulder-joint with the assumption of the upright posture, the limb dropping loosely at the side of the body, and being endowed with the greatest freedom of movement.

Homological comparison of—

I. The shoulder and pelvic girdles.—Primarily the lateral half of each girdle consists of a curved bar or rod of cartilage placed at right angles to the longitudinal axis of the trunk and divisible into a dorsal segment, and a ventral segment, the point of division corresponding to the place of articulation with the limb-stalk—i. e., the glenoid and acetabular cavities. In the fore-limb the dorsal segment is the scapula, and the ventral segment the coracoid, whilst in the hind-limb the dorsal segment is the ilium and the ventral segment the ischium and pubis.

The dorsal segments of the two girdles—i. e., scapula and ilium—are accordingly regarded as homologous bones, the chief difference being that whereas the scapula is free from articulation with the vertebral column, the ilium is firmly jointed to the rib elements (lateral mass) of the sacrum. But the correspondence is not quite so clear with regard to the ventral segments. In the primitive condition the coracoid articulates with the side of the sternum, an arrangement which persists throughout life in certain animals, such as reptiles and Ornithorhynchus. But in all the higher mammals it undergoes reduction, withdrawing from the side of the sternum, and eventually forming a more or less rudimentary process attached to the scapula. In the more generalised form of shoulder girdle the ventral bar is double, consisting of coracoid and pre-coracoid elements, the latter being situated in front and almost parallel with the coracoid. The pre-coracoid in mammals is largely replaced by the development over it of the clavicle, a dermal or membranous splint-bone which eventually invades the underlying cartilage. Parts, however, remain distinct and form the sternal epiphysis of the clavicle, the inter-articular cartilage between it and the sternum, the supra-sternal bones, and the inconstant inter-articular cartilage in the acromio-clavicular joint.

It has already been noticed that in the hip girdle the ventral segment also consists of two elements, the pubis and ischium. Both take part in the formation of the acetabular cavity, and the pubis meets in the ventral median line the corresponding segment of the opposite side.

It is generally agreed that the coracoid and ischium are homologous structures. The pubic portion of the ventral segment appears to correspond most closely with the pre-coracoid element of reptiles, so that there is no true homologue of the clavicle in the pelvis. If, however, the clavicle corresponds to the reptilian pre-coracoid, as believed by many anatomists, it then becomes the representative of the pubis.

From a consideration of the condition in cranio-cleido-dysostosis, Mr. Fitzwilliams has put forward the following views regarding the homology of the shoulder girdle:—Coracoid bar is represented by (a) medial two-thirds of clavicle; (b) coraco-clavicular ligaments; and (c) sub-coracoid centre of coracoid process. The clavicula, a membranous bone, is represented by the lateral third of adult clavicle. The pre-coracoid bar is represented by:—(a) the coracoid process (less the sub-coracoid centre); and (b) the costo-coracoid ligament. The epi-coracoid is represented by the meniscus of the sterno-clavicular joint.

Moreover, it is possible to establish a comparison between the individual parts of the ilium and scapula. A reference to fig. 253 shows that both the scapula and ilium may be resolved into three-sided prismatic rods, each of which has three surfaces and three borders. In the primitive position of the limb one surface—the *internal*—is turned toward the vertebral column, the remaining surfaces are *external*, and named *pre-axial* and *post-axial*, corresponding to the borders of the limb. The borders separating the internal from the external surfaces are antero-internal (terminating in the acromion or pubis) and postero-internal (terminating in the coracoid or ischium). The two external surfaces are separated by a ridge, terminating below at the upper margin of the glenoid cavity or acetabulum (glenoid and cotyloid borders).

The primitive arrangement is lost by the marked growth of the borders of the rods leading to the formation of fossæ and by the rotation of each rod, the scapula *laterally* and the ilium *medially*, in association with the rotation which takes place in the free part of the limb, so that

the inner surface of the one comes to correspond with the outer surface of the other. It results that the primitive vertebral surface of the scapula is now the pre-scapular or supraspinous fossa, and the corresponding surface in the ilium is the sacral, which, on account of its close connection with the vertebral column, undergoes but little change in position. Further, the primitive pre-axial surfaces are the infraspinous fossa and the iliac fossa, which accordingly are to be regarded as homologous, as well as the two post-axial surfaces, the subscapular fossa and the dorsum ilii. The correspondence between the various parts of the scapula and ilium is shown in the appended table (after Flower).

	Scapula	Primitive Arrangement	Ilium
I. Surfaces:	Supraspinous fossa.	Vertebral.	Sacral surface.
	Infraspinous fossa.	Pre-axial.	Iliac fossa.
	Subscapular fossa.	Post-axial.	Gluteal surface.
II. Borders:	Axillary or glenoid.	External.	Cotyloid or anterior border.
	Spine.	Antero-internal.	Terminal line.
	Superior or coracoid.	Postero-internal.	Posterior border.
	Base.	Dorsal extremity.	Crest of ilium.

II. Bones of the arm and thigh, forearm, and leg.—It has already been pointed out in describing the deviation of the limbs from the primitive position that the humerus corresponds to the femur, the radius to the tibia, and the ulna to the fibula; also that in consequence of the rotation backward of the fore-limb, and forward of the hind-limb, the lateral side of the humerus corresponds with the medial side of the femur, the radial border of the forearm to the tibial border of the leg, and the ulnar (border of the forearm) to the fibular border of the leg. The corresponding parts are tabulated below:—

Fore-Limb	Hind-Limb
Humerus	Femur
Greater tuberosity	Lesser Trochanter
Lesser tuberosity	Great Trochanter
Lateral epicondyle and capitulum	Medial Condyle
Medial epicondyle and trochlea	Lateral Condyle
Radius	Tibia
Ulna	Fibula
Not represented	Patella

III. Bones of the hand and foot.—It is obvious that the carpus and tarsus, the metacarpus and metatarsus, and the various digits, commencing at the thumb, in the hand, and at the great toe, in the foot, are serially homologous.

Fig. 254.—Dorsal Surface of the Right Manus of a Water-tortoise, *Chelydra serpentina*. (After Gegenbaur.)

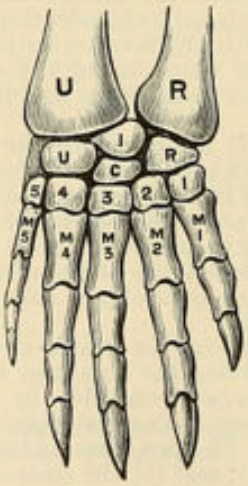

In order to trace the correspondence between the various elements of the carpus and tarsus it is convenient to refer in the first place to the primitive type of hand and foot as found in the water-tortoise and the lizard (fig. 254). In each segment nine elements may be recognised, arranged in a proximal row of three, named respectively *radiale* or *tibiale*, *intermedium*, and *ulnare*, or *fibulare*, a distal row of five *carpalia*, or *tarsalia*, numbered from one to five, commencing at the pre-axial border, and between the two rows an *os centrale*.

In man the carpus is derived from the typical form in the following manner: The radiale forms the navicular, intermedium the lunate, and the ulnare, the triquetral; carpale I forms the greater multangular, carpale II the lesser multangular, carpale III the capitate, whilst carpalia IV and V coalesce to form the hamate. The os centrale is present in the human carpus at an early stage, but in the second month it joins the navicular. It is occasionally separate—a normal arrangement in most of the primates.

In the tarsus, the tibiale and intermedium coalesce to form the talus, and the fibulare becomes the calcaneus. It is interesting to note that although in the human subject there are three bones in the first row of the carpus and two in the first row of the tarsus, in carnivores the navicular and lunate are united to form a naviculo-lunate bone—the homologue of the talus. In the human tarsus the intermedium occasionally remains distinct as the *os trigonum*.

Tarsale I forms the first cuneiform, tarsale II the second cuneiform, tarsale III the third cuneiform, and tarsale IV and V are joined to form the cuboid. The os centrale forms the navicular.

In addition to the carpal and tarsal elements enumerated above, brief mention must now be made of the sesamoid bones of the two segments, which are regarded by many anatomists as vestiges of suppressed digits. In the hand are the **ulnar** and **radial sesamoids,** the ulnar being represented by the pisiform and the radial probably by the tuberosity of the navicular. (In the mole and other allied species with fossorial habits, the radial sesamoid is greatly developed to form a sickle-shaped bone which has received the name of *os falciforme*.)

The corresponding structures in the foot are the **tibial** and **fibular sesamoids,** the tibial being most nearly represented by the tuberosity of the navicular and the fibular by the tuber of the calcaneus.

TABLE SHOWING THE HOMOLOGOUS BONES OF THE CARPUS AND TARSUS. (*After G. D. Thane in Quain's Anatomy.*)

CARPUS	PRIMITIVE NAMES		TARSUS
Triquetral	Ulnare	Fibulare	Calcaneus
Pisiform	Ulnar sesamoid	Fibular sesamoid	
Lunate	Intermedium	Intermedium	Talus
Navicular	Radiale	Tibiale	
	Radial sesamoid	Tibial sesamoid	Navicular
	Centrale	Centrale	
Greater multangular	Carpale I	Tarsale I	First cuneiform
Lesser multangular	" II	" II	Second cuneiform
Capitate	" III	" III	Third cuneiform
Hamate	" IV	" IV	Cuboid
	" V	" V	

References.—For the *development* of the skeleton, consult the bibliography in Bardeen's article in Keibel and Mall's 'Human Embryology,' Vol. 1. For further references concerning the *adult structure* and *morphology* of the skeleton, the sections on osteology in the larger works on human anatomy by Quain, von Bardeleben, Rauber-Kopsch. Poirier-Charpy, etc., should be consulted. References to the most recent literature may be found in Schwalbe's Jahresbericht, the Index Medicus, and in the various anatomical journals.

SECTION III

THE ARTICULATIONS

Revised for the Fifth Edition

By FREDERIC WOOD JONES, D.Sc., M.B., B.S.(Lond.), M.R.C.S., L.R.C.P.

Head of the Department of Anatomy and Lecturer in the London School of Medicine for Women.

THE CONSTITUENTS OF AN ARTICULATION

THE section devoted to the Articulations or Joints deals with the union of the various and dissimilar parts of the human skeleton. The following structures enter into the formation of joints.

Bones constitute the basis of most joints. The long bones articulate by their ends, the flat by their edges, and the short at various parts on their surfaces. The articular ends are usually expanded, and are composed of cancellous tissue, surrounded by a dense and strong shell of compact tissue.

This shell has no Haversian canals (the vessels of the cancellous tissue turn back and do not perforate it), or large lacunæ, and no canaliculi, and is thus well adapted to bear pressure. This "osteoid" layer may represent in part calcified cartilage rather than true bone.

The **cartilage** which covers the articular ends of the bones is called **articular,** and is of the **hyaline variety.** It is firmly implanted on the bone by one surface, while the other is smooth, polished, and free, thus reducing friction to a minimum, while its slight elasticity tends to break jars. It ends abruptly at the edge of the articulation, and is thickest over the areas of greatest pressure.

Another form of cartilage, the **white fibrous,** is also found in joints:—

(i) As *interarticular cartilage* in diarthrodial joints—viz., in the knee, mandibular, sterno-clavicular, radio-carpal, and occasionally in the acromio-clavicular joint. It is interposed between the ends of the bones, partially or completely dividing the synovial cavity into two. It serves to adjust dissimilar bony surfaces, adding to the security of, while it increases the extent of motion at, the joint; it also acts as a buffer to break shocks.

(ii) As *circumferential* or marginal fibro-cartilages, which serve to deepen the sockets for the reception of the heads of bones—e. g., the glenoid ligaments of the shoulder and hip.

Another form of marginal plate is seen in the accessory volar ligaments of the fingers and toes, which deepen the articulations of the phalanges and add to their security.

(iii) As *connecting fibro-cartilage.* The more pliant and elastic is the more cellular form, and is found in the intervertebral discs; while the less yielding and more fibrous form is seen in the sacro-iliac and pubic articulations, where there is little or no movement.

The **ligaments** which bind the bones together are strong bands of white fibrous tissue, forming a more or less perfect capsule [capsula articularis], round the articulation. They are pliant but inextensile, varying in shape, strength, and thickness according to the kind of articulation into which they enter. They are closely connected with the periosteum of the bones they unite. In some cases—as the ligamenta flava which unite parts not in contact—they are formed of yellow elastic tissue.

The **synovial membrane** [stratum synoviale] lines the interior of the fibrous ligaments, thus excluding them, as well as the cushions or pads of fatty tissue situate within and the tendons which perforate the fibrous capsule, from the articular cavity. It is a thin, delicate membrane, frequently forming folds and fringes which project into the cavity of the joint; or, as in the knee, stretches across the cavity, forming a so-called synovial ligament. In these folds are often found pads of fatty tissue, which fill up interstices, and form soft cushions between the contiguous bones. The amount of fat that is normally present within a joint varies greatly. It is an old observation that although there is always fat in the hip-

and knee-joints, there is usually none within the shoulder-joint. Sometimes these fringes become villous and pedunculated, and cause pain on movement of the joints. They contain fibro-fatty tissue, with an isolated cartilage cell or two. The synovial membrane is well supplied with blood, especially near the margins of the articular cartilages and in the fringes. It secretes a thick, glairy fluid like white of egg, called synovia, which lubricates the joint. Another variety of synovial membrane is seen in the bursæ, which are interposed between various moving surfaces. In some instances bursæ in the neighbourhood of a joint may communicate with the synovial cavity of that joint.

CLASSIFICATION OF ARTICULATIONS

Joints may be classified:—(*a*) From an anatomical point of view, with regard to the substances and the arrangement of the substances by which the constituent parts are united. (*b*) From a physiological standpoint, with regard to the greater or smaller mobility at the seat of union. (*c*) From a physical standpoint, either the shapes of the portions in contact being mainly considered or the axes round which movement can occur. Or again (*d*) a combination of the preceding methods may be adopted, and this is the plan most generally followed. None of the classifications hitherto used is quite satisfactory, but perhaps, on the whole, that suggested by Prof. Alex. Macalister is the least open to objection, and therefore with slight modification it is utilised here.

There are three chief groups of joints:—

1. *Synarthroses.* In joints of this class the bones are united by fibrous tissue.
2. *Synchondroses.* Or joints in which the uniting substance intervening between the bones is cartilage.
3. *Diarthroses.* The constituent parts of joints of this class are (*a*) two or more bones each covered by articular hyaline cartilage; (*b*) a fibrous capsule uniting the bones, and (*c*) a synovial membrane which lines the fibrous capsule and covers any part of bone enclosed in the capsule and not covered with articular cartilage. An interarticular plate of cartilage may or may not be present.

Synarthroses.—
- (*a*) *Sutures* or immovable joints, in which the fibrous tissue between the bones is too small in amount to allow movement.
  - (1) *Harmonic.* The edges of the bones are comparatively smooth and are in even apposition, e. g., vertical plate of palate and maxilla.
  - (2) *Squamous.* The margin of one bone overlaps the other, e. g., temporal and parietal.
  - (3) *Serrate.* The opposed edges interlock by processes tapering to a point.
  - (4) *Dentate.* The opposed edges are dovetailed, e. g., occipital and parietal.
  - (5) *Limbous.* The opposed edges alternately overlap, e. g., parietal and frontal.
  - (6) *Schindylesis.* A ridge or flattened process is received into a corresponding socket, e. g., rostrum of sphenoid and vomer.
  - (7) *Gomphosis.* A peg-like process is lodged in a corresponding socket, e. g., the fangs of the teeth.
- (*b*) *Syndesmoses.* Movable joints in which the fibrous tissue between bones or cartilages is sufficiently lax to allow movement between the connected parts, e. g., thyreo-hyoid membrane. Interosseous membranes of forearm and leg.

2. **Synchondroses.**—In all synchondroses a certain amount of movement is possible, and they are often called amphiarthroses.
   - (1) *True synchondroses.* The cartilage connecting the bones is the remains of the bar in which the bones were ossified, e. g., occipito-sphenoidal joint.
   - (2) *False synchondroses.* The plate of cartilage intervening between and connecting the bones is fibro-cartilage and is not part of the cartilage in which the bones were ossified, but is developed separately, e. g., intervertebral joint and pubic symphysis. The articular end of each bone may be covered with hyaline cartilage and there may be a more or less well-marked cavity in the intervening plate of fibro-cartilage.
3. **Diarthroses.**—In diarthrodial joints the surfaces in contact may be equal and similar or unequal and dissimilar. In the former case the joints are homomorphic; in the latter, heteromorphic.
   - (A) *Homomorphic.*
     - (*a*) *Plane or arthrodial.* Flat surfaces, admitting gliding movement, e. g., intercarpal and acromio-clavicular joints.
     - (*b*) *Ephippial.* Saddle-shaped surfaces placed at right angles to each other, admitting free movement in all directions, e. g., metacarpo-phalangeal joint of thumb.

(B) *Heteromorphic.*

(*a*) *Enarthrodial.* Ball-and-socket, allowing the most free movement, e. g., hip- and shoulder-joints.

(*b*) *Condylarthroses.* The convex surface is ellipsoidal, and fits into a corresponding concavity, e. g., wrist and metacarpo-phalangeal joints.

(*c*) *Ginglymi.* One surface consists of two conjoined condyles or of a segment of a cone or cylinder, and the opposite surface has a reciprocal contour. In these joints movement is only permitted round one axis, which may be transverse; e. g., elbow, ankle; or it may be vertical, in which case the joint is trochoid; e. g., odontoid process of axis with atlas, radius with ulna.

Such a classification should be considered as being purely academic and the student must always remember that it is not enough to discuss a joint by assigning it to a particular class in any scheme; for he must be familiar with the actual conditions present in every joint. No classification, however perfect, must be taken as final, and each joint should be studied as a separate thing altogether apart from any general systematic arrangement.

DEVELOPMENT AND MORPHOLOGY OF JOINTS

The arrangement of the various parts which constitute an articulation is best appreciated by a study of the development of the various types of joints. In this way it is easy to recognise a primitive condition typical of each class; but it must be remembered that various modifications take place during growth, that these modifications vary in the individual joints, and produce adult departures from the primitive arrangement which are peculiar to each joint and which must be studied separately.

In the case of bones ossifying in membrane the articulation will be a **suture,** the ossifications from neighbouring centres extending until they practically come into contact.

FIG. 255.—DEVELOPMENT OF JOINTS

A. Stage in which primary embryonic tissue separates the developing cartilages.

B. Primary embryonic tissue transformed into cartilage (synchondrosis), or fibrous connective tissue (syndesmosis).

C. Degeneration of embryonic tissue with production of a joint cavity (diarthrosis).

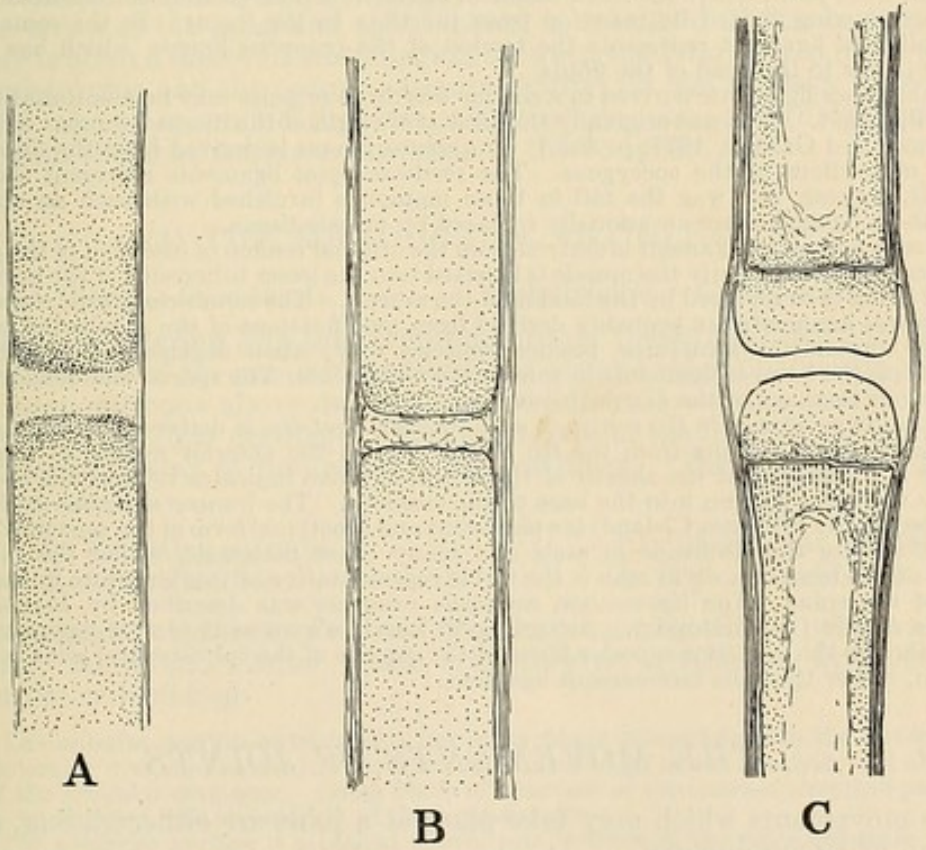

[With cartilage bones the articulation may be either a syndesmosis, a synchondrosis, or a diarthrosis. The embryonic tissue in which the cartilage is to develop is at first continuous; centres of chondrification, corresponding in number to the bony elements which are destined to be formed, appearing in it. As the chondrifications approach each other a small portion of the primary embryonic tissue persists between them (fig. 255), and it is the subsequent fate of this intermediate tissue that determines the nature of the articulation.

(1) When the ossification of the cartilage occurs to form the articulating bones, the intermediate tissue may undergo transformation into cartilage (fig. 255), a **synchondrosis** being thus produced. (2) Or the intermediate tissue may be converted into fibrous connective-tissue

(fig. 255), the result being a **syndesmosis.** (3) Or, finally, the central portion of the intermediate tissue may degenerate, so that an articular cavity is produced, the peripheral portions being converted into connective tissue, forming a sleeve-like capsule surrounding the cavity, continuous at either extremity with the periosteum of the articulating bones (fig. 255). This is the articular capsule, and the connective-tissue cells arranging themselves in a layer upon its inner surface give rise to a synovial membrane. As the result of these processes a **diarthrosis** is produced, and from its mode of formation it is clear that the cavity of such an articulation is completely closed.

In a typical diarthrosis there is therefore a ligamentous capsule which entirely encloses the joint cavity, which is continuous with the periosteum of the bones entering into the articulation but which is not attached to nor reflected onto the cartilaginous ends of the bones which constitute the articulating surfaces. Such a capsule constitutes the primitive bond between the articulating bones and furnishes a complete lubricating bag in which these smooth cartilaginous ends glide over one another. This primitive capsule, however, becomes modified in most adult joints, (1) by unequal development of various parts of the capsule; and (2) by the more or less complete incorporation of other structures which are developmentally separate from the capsule. Under the first heading come specially thickened bands which may be so distinctly marked off from the rest of the capsule as to be named as separate ligaments (e. g., the temporo-mandibular ligament of the mandibular joint). Again certain thickened bands of capsule may, with alteration of joint contour, take up anatomical positions which are apparently separated from the rest of the capsule; advanced examples of this process are, in all probability, seen in the ligamentum teres of the hip-joint and the crucial ligaments of the knee. Under the second heading comes a series of ligaments derived from a great variety of sources; the most common origin being from the divorced or rearranged tendons of the muscles around the joint.

Muscles arising from, or inserted into, bones in the immediate vicinity of a joint tend to become metamorphosed into tendon near their attachments, and a comprehensive study of **myology** in low vertebrate forms indicates that there is associated with this tissue-change a tendency for the muscle to alter its point of attachment; hence a muscle originally inserted below a joint may eventually come to have its insertion above the joint. In the same way, a muscle arising above a joint may, as a result of altered environment, shift its origin to some point below the joint. To this change of position the term **migration of muscles** has been applied. In many instances a portion of the muscle equivalent to the distance between the original and the acquired attachment persists as a fibrous band and fulfils the function of a ligament. This is well seen in the knee-joint, where the *tibial collateral* ligament is derived from the adductor magnus, this muscle having shifted its insertion from the tibia to the femur. In the same way the *fibular collateral* ligament represents the tendon of the peroneus longus, which has migrated from the femur to the head of the fibula.

Among other ligaments derived in a similar way from muscles may be mentioned the *sacro-tuberous* ligament. This was originally the tendon of origin of the biceps femoris. (H. Morris, Med. Times and Gazette, 1877, p. 361.) The *sacro-spinous* is derived from the fibrous retrogression of portions of the coccygeus. The *sacro-coccygeal* ligaments represent the muscles which lift, depress, and wag the tail in those mammals furnished with such an appendage; indeed, these ligaments are occasionally replaced by muscle-tissue.

The *coraco-humeral* ligament is derived from the original tendon of insertion of the pectoralis minor, and not unfrequently the muscle is inserted into the lesser tuberosity of the humerus, the ligament being then replaced by the tendon of the muscle. The *coraco-clavicular*, *rhomboid*, and *gleno-humeral* ligaments are probably derived from modifications of the subclavius muscle.

Other anatomical structures besides muscles may, when degenerated or functionally altered, form the basis of ligaments in connection with joints. The *spheno-mandibular* ligament is the fibrous remnant of the cartilaginous mandibular bar.

The pulpy substance in the centre of each *intervertebral disc* is derived from the notochord; the *apical ligament* passing from the tip of the dens to the anterior margin of the foramen magnum is a remnant of the sheath of the notochord, and indicates its position as it passed from the vertebral column into the base of the cranium. The *transverse ligament* of the atlas (as pointed out by Professor Cleland) is a persistent and functional form of the posterior conjugal ligament uniting the rib-heads in seals and many other mammals, whilst the *interosseous ligament* of the head of a rib in man is the feeble representative of this structure in the thoracic region of the spine. The *ligamentum conjugale costarum* was described by Mayer in 1834 (Müller's Archiv für Anatomie). According to Luschka's account of this ligament it would seem as though the posterior superior fibres of the capsule of the costo-central joint represented it in man, rather than the interosseous ligament.

THE MOVEMENTS OF JOINTS

The movements which may take place at a joint are either gliding, angular, rotatory, or circumductory.

The **gliding** motion is the simplest, and is common to all diarthrodial joints; it consists of a simple sliding of the apposed surfaces of the bones upon one another, without angular or rotatory motion. It is the only kind of motion permitted in the carpal and tarsal joints, and in those between the articular processes of the vertebræ.

The **angular** motion is more elaborate, and increases or diminishes the angle between different parts. There are four varieties, viz., *flexion* and *extension*, which bend or straighten the various joints, and take place in a forward and backward direction (in a perfect hinge-joint this is the only motion permitted); and *adduction* and *abduction*, which, except in the case of the fingers and toes, signifies an approach to, or deviation from, the median plane of the body. In the

case of the hand, the line to or from which adduction and abduction are made is drawn through the middle finger, while in the foot it is through the second toe.

Rotation is the revolution of a bone about its own axis without much change of position. It is only seen in enarthrodial and trochoidal joints. The knee also permits of slight rotation in certain positions, which is a distinctive feature of this articulation.

Circumduction is the movement compounded of the four angular movements in quick succession, by which the moving bone describes a cone, the proximal end of the bone forming the apex, while the distal end describes the base of the cone. It is seen in the hip and shoulder, as well as in the carpo-metacarpal joint of the thumb, which thus approximates to the ball-and-socket joint.

In some situations where a variety of motion is required, strength, security, and celerity are obtained by the combination of two or more joints, each allowing a different class of action, as in the case of the wrist, the ankle, and the head with the spine. Many of the long muscles, which pass over two or more joints, act on all, so tending to co-ordinate their movements and enabling them to be produced with the least expenditure of power. Muscles also act as elastic ligaments to the joints; and when acting as such, are diffusers and combiners, not producers of movement; the short muscles producing movement, the long diffusing it, and thus allowing the short muscles to act on more than one joint.

Muscles are so disposed at their attachments near the joints as never to strain the ligaments by tending to pull the bones apart, but, on the contrary, they add to the security of the joint by bracing the bones firmly together during their action.

The articulations may be divided for convenience of description into those: 1. of the SKULL; 2. of the TRUNK; 3. of the UPPER LIMB; and 4. of the LOWER LIMB.

THE ARTICULATIONS OF THE SKULL

The movable articulations of the skull comprise (1) the mandibular; and (2) those between the skull and the vertebral column, namely (*a*) between the occiput and atlas; (*b*) between the atlas and epistropheus (axis); and (*c*) the ligaments which connect the occiput and epistropheus.

The union of the atlas and epistropheus is described in this section because, (1) there is often a direct communication between the synovial cavity of the transverse epistrophic and the occipito-atlantal joints; (2) the rotatory movements of the head take place around the dens (odontoid process); and (3) important ligaments from the dens pass over the atlas to the occiput.

(1) THE MANDIBULAR ARTICULATION

Class.—*Diarthrosis.* **Subdivision.**—*Condylarthrosis.*

The parts entering into the formation of this joint (figs. 256, 257) are:—the anterior portion of the mandibular fossa and glenoid ridge (eminentia articularis) of the temporal bone above, and the condyle of the lower jaw below. Both are covered with articular cartilage, which extends over the front of the glenoid ridge to facilitate the play of the interarticular cartilage. The ligaments which unite the bones are:

1. Articular capsule.
2. Articular disc.
3. Spheno-mandibular.
4. Stylo-mandibular.

The **articular capsule** is often described as consisting of four portions, anterior, posterior, lateral and medial, which are, however, continuous with one another around the articulation.

1. The **anterior portion** consists of a few stray fibres connected with the anterior margin of the articular disc, and attached below to the anterior edge of the condyle, and above to the front of the articular eminence. Some fibres of insertion of the *external pterygoid* pass between them to be inserted into the margin of the articular disc.

2. The **posterior portion** is attached above, just in front of the *petro-tympanic* (*Glaserian*) fissure, and is inserted into the back of the jaw just below its neck.

3. The **lateral portion** or **temporo-mandibular** (external lateral) **ligament** (fig. 256) is the strongest part of the capsule. It is broader above, where it is attached to the lower edge of the zygoma in nearly its whole length, as well as to the tubercle at the point where the two roots of the zygoma meet. It is inclined downward and backward, to be inserted into the condyle and neck of the mandible laterally. Its fibres diminish in obliquity and strength from before backward, those coming from the tubercle being short and nearly vertical.

4. The **medial portion** (or short internal lateral ligament) (fig. 257) consists of well-defined fibres, having a broad attachment, above to the lateral side of the spine of the sphenoid and medial edge of the mandibular fossa; and below, a narrow insertion to the medial side of the neck

of the condyle. Fatty and cellular tissue separate it from the spheno-mandibular ligament which is medial to it.

The **articular disc** (fig. 258) is an oval plate of fibro-cartilage interposed between and adapted to the two articular surfaces. It is thinner at the centre than at the circumference, and is thicker behind, where it covers the thin bone at the bottom of the mandibular fossa which separates it from the dura mater, than in front, where it covers the articular eminence.

FIG. 256.—LATERAL VIEW OF THE MANDIBULAR JOINT.

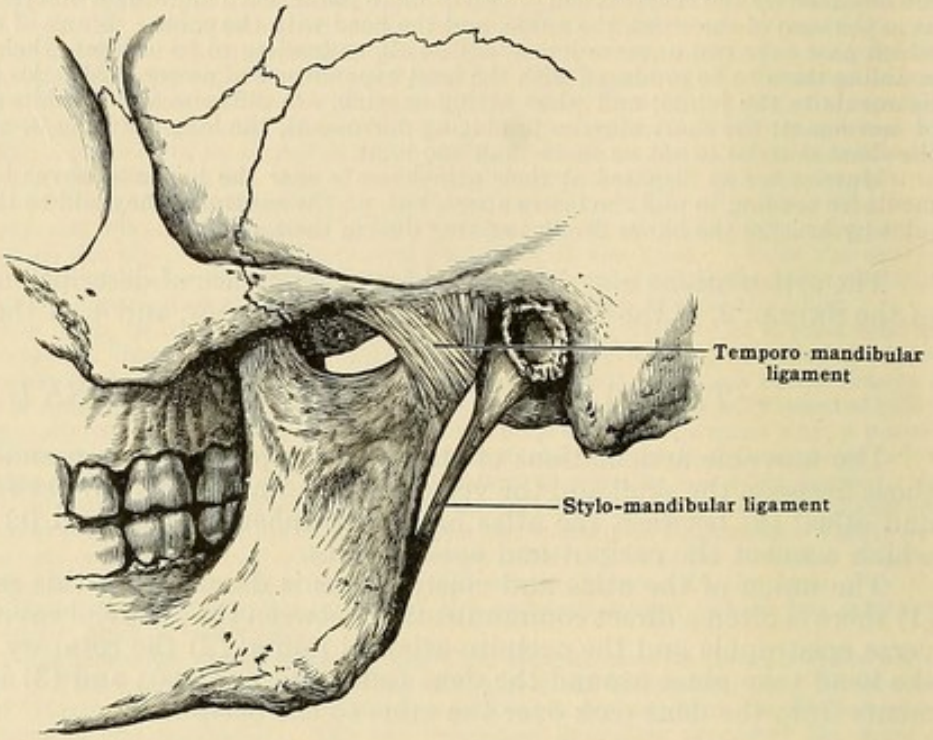

FIG. 257.—MEDIAL VIEW OF THE MANDIBULAR JOINT.

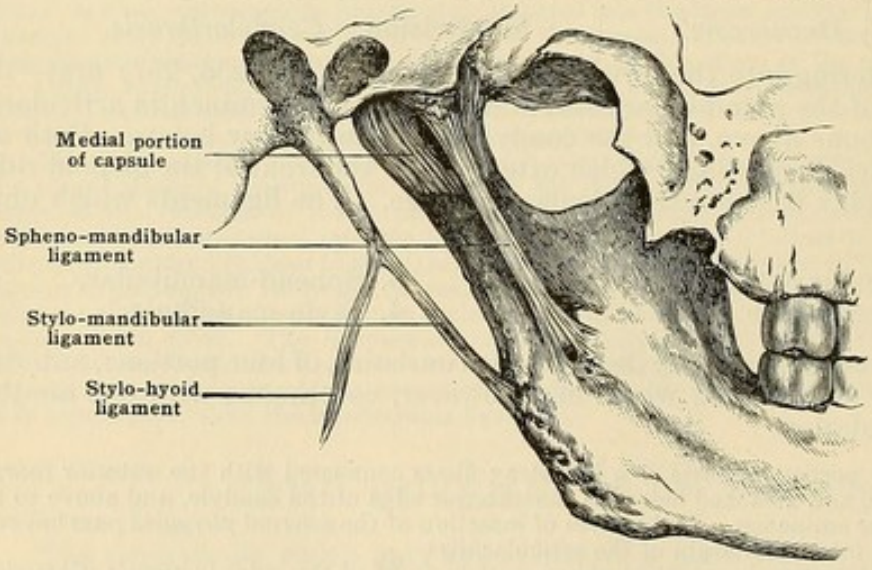

Its *inferior surface* is concave and fits on to the condyle of the lower jaw; while its *superior surface* is concavo-convex from before backward, and is in contact with the articular surface of the temporal bone. It divides the joint into two separate synovial cavities, but is occasionally perforated in the centre, and thus allows them to communicate. It is connected with the articular capsule at its circumference, and has some fibres of the *external pterygoid* muscle inserted into its anterior margin.

There are usually two **synovial membranes** (fig. 258), the superior being the larger and looser, passing down from the margin of the articular surface above, to the upper surface of the articular disc below; the lower and smaller one passes

from the articular disc above to the condyle of the jaw below, extending somewhat further down behind than in front. When the disc is perforated, the two sacs communicate.

The **spheno-mandibular ligament** (long internal lateral) (fig. 257) is a thin, loose band, situated some little distance from the joint. It is attached above to the spine of the sphenoid and contiguous part of the temporal bone, and is inserted into the lingula of the lower jaw.

It covers the upper end of the mylo-hyoid groove, and is here pierced by the *mylo-hyoid* nerve. Its origin is a little medial to, and immediately behind, the origin of the medial portion of the capsule. It is separated from the joint and ramus of the jaw by the *external pterygoid* muscle, the *internal maxillary* artery and vein, the *inferior alveolar (dental)* nerve and artery, the *auriculo-temporal* nerve, and the *middle meningeal* artery. It is really the fibrous remnant of a part of the mandibular (Meckelian) bar.

The **stylo-mandibular ligament** (stylo-maxillary) (figs. 256 and 257) is a process of the deep cervical fascia extending from near the tip of the styloid process to the angle and posterior border of the ramus of the jaw, between the *masseter* and *internal pterygoid* muscles. It separates the parotid from the submaxillary gland, and gives origin to some fibres of the *stylo-glossus* muscle.

FIG. 258.—SAGITTAL SECTION THROUGH THE CONDYLE OF JAW TO SHOW THE TWO SYNOVIAL SACS AND THE ARTICULAR DISC.

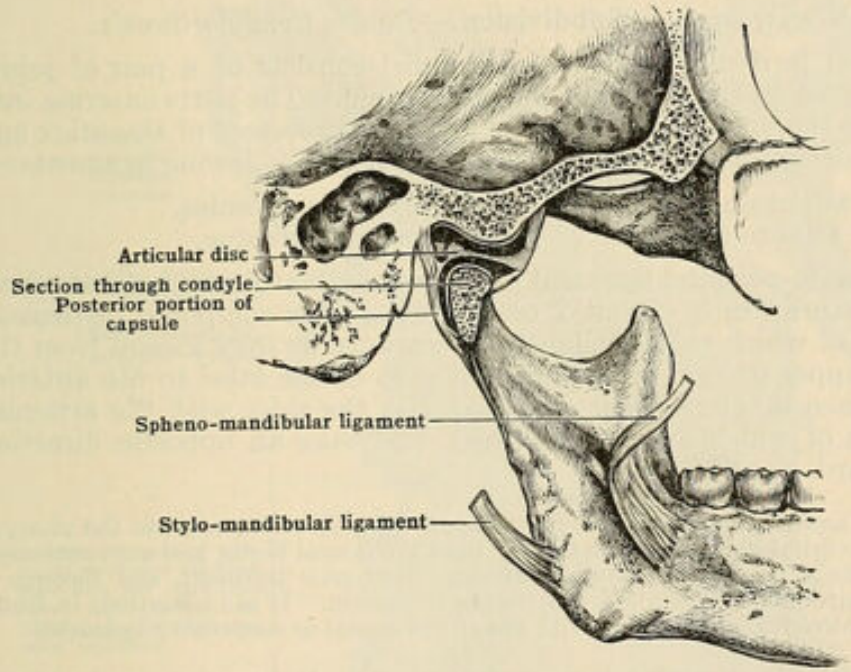

The **arterial supply** of the mandibular joint is derived from the temporal, middle meningeal and ascending pharyngeal arteries, and from the latter by its branches to the Eustachian tube.

The **nerves** are derived from the masseteric and auriculo-temporal.

Movements.—The chief movement of this joint is of (i) a **ginglymoid** or **hinge character,** accompanied by a slight gliding action, as in opening or shutting the mouth. In the opening movement the condyle turns like a hinge on the articular disc, while at the same time the articular disc, together with the condyle, glides forward so as to rise upon the eminentia articularis, reaching as far as the anterior edge of the eminence, which is coated with articular cartilage to receive it; but the condyle never reaches quite so far as the summit of the eminence. Should the condyle, however, by excessive movement (as in a convulsive yawn), glide over the summit, it slips into the zygomatic fossa, the mandible is dislocated, and the posterior portion of the capsule is torn. In the shutting movement the condyle revolves back again, and the articular disc glides back, carrying the condyle with it. This combination of the hinge and gliding motions gives a tearing as well as a cutting action to the incisor teeth, without any extra muscular exertion.

There is (ii) a **horizontal gliding action** in an antero-posterior direction, by which the lower teeth are thrust forward and drawn back again: this takes place almost entirely in the upper compartment, because of the closer connection of the articular disc with the condyle than with the squamosal bone, and also because of the insertion of the *external pterygoid* into both bone and cartilage. In these two sets of movements the joints of both sides are simultaneously and similarly engaged.

The third form of movement is called (iii) the **oblique rotatory,** and is that by which the grinding and chewing actions are performed. It consists in a rotation of the condyle about

the vertical axis of its neck in the lower compartment, while the cartilage glides obliquely forward and inward on one side, and backward and inward on the other, upon the articular surface of the squamosal bones, each side acting alternately. If the symphysis be simply moved from the centre to one side and back again, and not from side to side as in grinding, the condyle of that side moves round the vertical axis of its neck, and the opposite condyle and cartilage glide forward and inward upon the mandibular fossa. But in the ordinary grinding movement, one condyle advances and the other recedes, and then the first recedes while the other advances, slight rotation taking place in each joint meanwhile.

Relations.—The chief relations are: Behind, and overlapping the lateral side, the parotid gland. Laterally, the superficial temporal artery. Medially, the internal maxillary artery and auriculo-temporal nerve. In front, the nerve to the masseter muscle.

Muscles acting on the joint.—*Elevators of the mandible.*—temporals, masseters, int. pterygoids.

Depressors.—Mylo-hyoids, digastrics, genio-hyoid, muscles connecting the hyoid bone to lower points. Ext. pterygoids. The weight of the jaw.

Protractors.—Ext. pterygoids, superficial layer of masseters, anterior fibres of temporals.

Retractors.—Posterior fibres of temporals, slightly by the int. pterygoids and deep layer of the masseters.

(2) THE LIGAMENTS AND JOINTS BETWEEN THE SKULL AND VERTEBRAL COLUMN, AND BETWEEN THE ATLAS AND EPISTROPHEUS

(*a*) The Articulation of the Atlas with the Occiput

Class.—*Diarthrosis.* **Subdivision.**—*Double Condylarthrosis.*

This articulation [articulatio atlanto-occipitalis] consists of a pair of joints symmetrically situated on either side of the middle line. The parts entering into their formation are the cup-shaped superior articular processes of the atlas and the condyles of the occipital bone. They are united by the following ligaments:—

1. Anterior atlanto-occipital.
2. Posterior atlanto-occipital.
3. Two articular capsules.
4. Two anterior oblique.

The **anterior atlanto-occipital ligament** [membrana atlanto-occipitalis anterior] (fig. 259) is less than an inch (about 2 cm.) wide, and is composed of densely woven fibres, most of which radiate slightly lateralward as they ascend from the front surface and upper margin of the anterior arch of the atlas to the anterior border of the foramen magnum; it is continuous at the sides with the articular capsules, the fibres of which overlap its edges, and take an opposite direction medially and upward.

The central fibres ascend vertically from the anterior tubercle of the atlas to the pharyngeal tubercle on the occipital bone; they are thicker than the lateral fibres, and are continuous below with the superficial part of the anterior atlanto-epistrophic ligament, and through it with the anterior longitudinal ligament of the vertebral column. It is in relation, in front, with the *recti capitis anteriores;* and behind, with the apical dental or suspensory ligament.

The **posterior atlanto-occipital ligament** (fig. 260) is broader, more membranous, and not so strong as the anterior. It extends from the posterior surface and upper border of the posterior arch of the atlas to the posterior margin of the foramen magnum from condyle to condyle; being incomplete on either side for the passage of the *vertebral artery* into, and *suboccipital nerve* out of, the canal. It is somewhat thickened in the middle line by fibres, which pass from the posterior tubercle of the atlas to the lower end of the occipital crest.

It is not tightly stretched between the bones, nor does it limit their movements; it corresponds with the position of the ligamenta flava, but has no elastic tissue in its composition. It is in relation in front with the dura mater, which is firmly attached to it; and behind with the *recti capitis posteriores minores*, and enters into the floor of the suboccipital triangle. Its lateral margins, which do not reach the occipital bone but terminate on the posterior end of the superior articular processes of the atlas, form the so-called *oblique ligaments of the atlas.* The lateral margins of these ligaments are free and they form the posterior boundaries of the apertures through which the vertebral arteries enter and the suboccipital nerves leave the vertebral canal.

The **atlanto-occipital articular capsules** (figs. 259 and 260) are very distinct and strongly marked, except on the medial side, where they are thin and formed only of short membranous fibres. They are lax, and do not add much to the security of the joint.

In front, the capsule descends upon the atlas, to be attached, some distance below the articular margin, to the front surface of the lateral mass and to the base of the transverse process; these fibres take an oblique course upward and medialward, overlapping the anterior atlanto-occipital. At the sides and behind, the capsule is attached above to the margins of the occipital condyles; below, it skirts the medial edge of the foramen for the vertebral artery, and behind is attached to the prominent tubercle overhanging the groove for that vessel; these latter fibres are strengthened by a band running obliquely upward and medialward to the posterior margin of the foramen magnum.

The **anterior oblique** or **lateral occipito-atlantal ligament** is an accessory band which strengthens the capsule laterally (fig. 259). It is an oblique, thick band of fibres, sometimes quite separate and distinct from the rest, passing upward and medialward from the upper surface of the transverse process beyond the costo-transverse foramen to the jugular process of the occipital bone.

The **synovial membrane** of these joints occasionally communicates with the synovial sac between the dens (odontoid process) and the transverse ligament.

The **arterial** supply is derived from twigs of the vertebral, and occasionally from twigs from the meningeal branches of the ascending pharyngeal.

FIG. 259.—ANTERIOR VIEW OF THE UPPER END OF THE VERTEBRAL COLUMN.

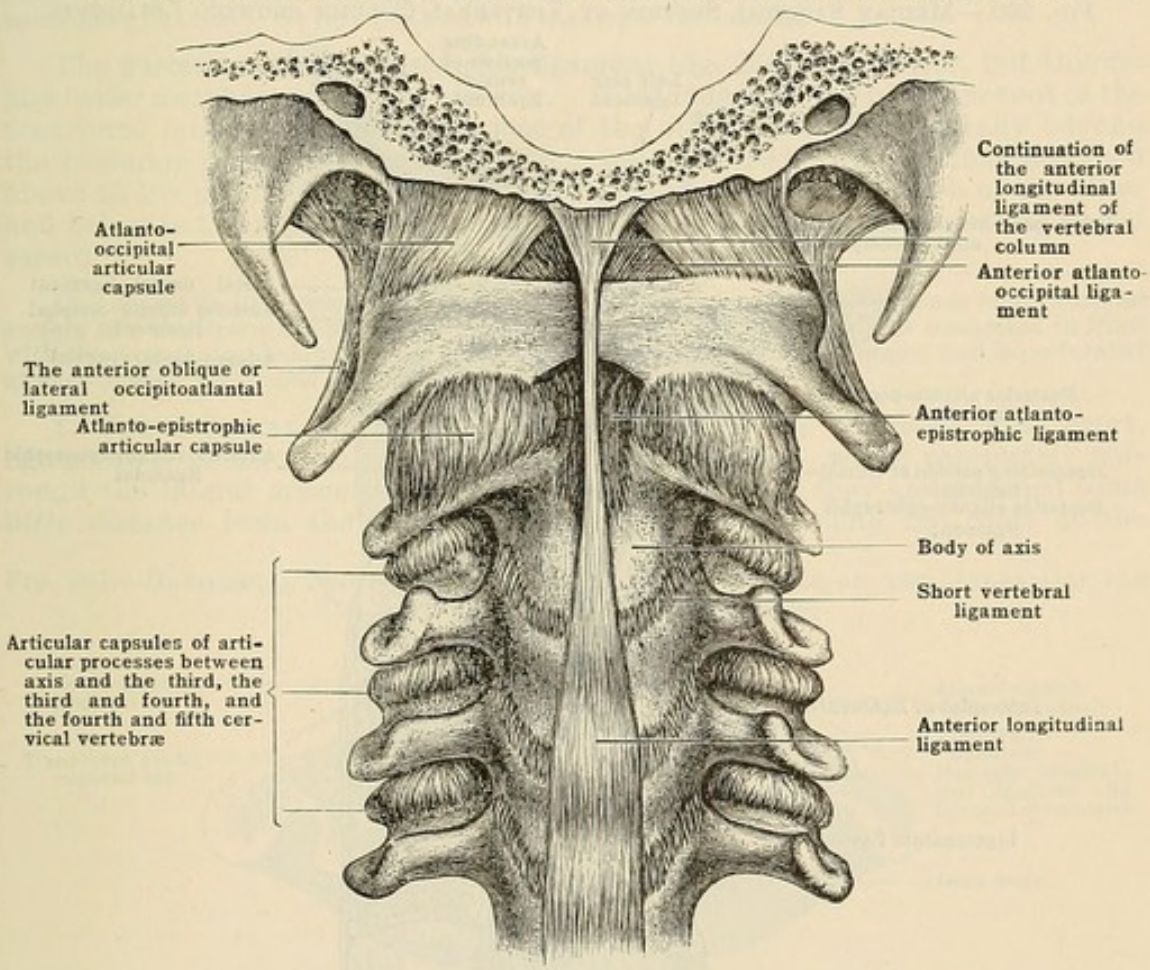

The nerve-supply comes from the anterior division of the suboccipital nerve.

Movements.—By the symmetrical and bilateral arrangement of these joints, security and strength are gained at the expense of a very small amount of actual articular surface; the basis of support and the area of action being equal to the width between the most distant borders of the joint.

The principal movement permitted at these joints is of a ginglymoid character, producing flexion and extension upon a transverse axis drawn across the condyles at their slightly constricted parts.

In flexion, the forehead and chin drop, and what is called the nodding movement is made; in extension, the chin is elevated and the forehead recedes.

There is also a slight amount of gliding movement, either **directly lateral,** the lateral edge of one condyle sinking a little within the lateral edge of the socket of the atlas, and that of the opposite condyle projecting to a corresponding degree. The head is thus tilted to one side, and it is even possible that the weight of the skull may be borne almost entirely on one joint, the articular surfaces of the other being thrown out of contact.

Or the movement may be **obliquely lateral,** when the lower side of the head will be a trifle

in advance of the elevated side. In this motion, which takes place on the antero-posterior axis, one condyle advances slightly and approaches the middle line, while the other recedes. This is of the nature of rotation, though there is no true rotation round a vertical axis possible between the occiput and atlas.

These lateral movements are checked by the alar ligaments and the lateral part of the capsules; extension is checked by the anterior atlanto-occipital and anterior oblique ligaments, and flexion by the posterior part of the capsule and the tectorial membrane.

Muscles acting upon the occipito-atlantal joint.—Flexion whereby the chin is approximated toward the sternum is produced by the weight of the anterior part of the head and by all muscles which are attached to the hyoid bone or to the bones of the skull in front of a transverse axis between the two condyles. These muscles take their fixed point below either from the vertebral column, the sternum, or the bones of the shoulder girdle. Before those connected with the mandible can act that bone must be fixed by the muscles of mastication which, therefore, also take part in the movements. It must be noted that the sterno-mastoid muscles are powerful flexors, although a part of their insertion is behind the transverse axis between the two condyles.

Extension is due to the action of muscles or portions of muscles inserted into the skull behind the transverse axis above mentioned, and connected below either with the vertebral column, shoulder girdle, or sternum.

Lateral movement is produced by the anterior and posterior groups of muscles on the same side acting simultaneously and aided by the rectus capitis lateralis of that side.

FIG. 260.—MEDIAN SAGITTAL SECTION OF VERTEBRAL COLUMN SHOWING LIGAMENTS.

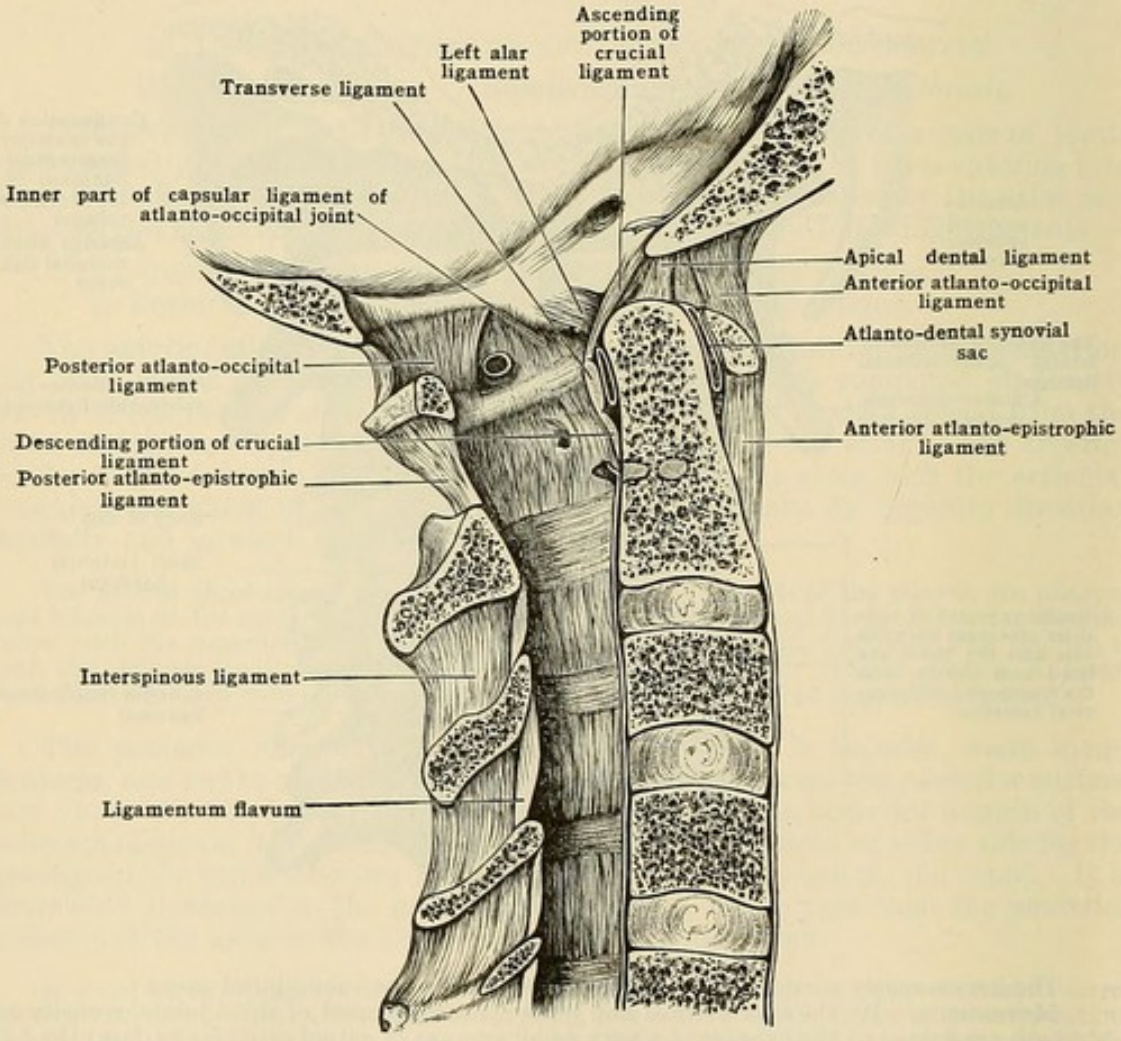

(*b*) THE ARTICULATIONS BETWEEN THE ATLAS AND EPISTROPHEUS (AXIS).

1. THE LATERAL ATLANTO-EPISTROPHIC JOINTS. { **Class.**—*Diarthrosis.* **Subdivision.**—*Arthrodia.*
2. THE CENTRAL ATLANTO-EPISTROPHIC JOINT OR THE ATLANTO-DENTAL. { **Class.**—*Diarthrosis.* **Subdivision.**—*Trochoides.*

The bones that enter into the formation of the lateral joints are the inferior articular processes of the atlas and the superior of the epistropheus (axis); the central joint is formed by the dens (odontoid process) articulating in front with the atlas, and behind with the transverse ligament.

The ligaments which unite the epistropheus and atlas are:—

1. The anterior atlanto-epistrophic.
2. The posterior atlanto-epistrophic.
3. Two articular capsules (for lateral joints).
4. The transverse ligament.

5. The atlanto-dental articular capsule.

The **anterior atlanto-epistrophic ligament** (figs. 259 and 260) is a narrow but strong membrane filling up the interval between the lateral joints. It is attached above to the front surface and lower border of the anterior arch of the atlas, and below to the transverse ridge on the front of the body of the epistropheus. Its fibres are vertical, and are thickened in the median line by a dense band which is a continuation upward of the anterior longitudinal ligament of the vertebral column.

This band is fixed above to the anterior tubercle of the atlas, where it becomes continuous with the central part of the anterior atlanto-occipital ligament (fig. 259); it is sometimes separated by an interval from the deeper ligament, and is often described as the superficial atlanto-epistrophic ligament. It is in relation with the *longus colli* muscle.

The **posterior atlanto-epistrophic ligament** (fig. 260) is a deeper, but thinner and looser membrane than the anterior. It extends from the posterior root of the transverse process of one side to that of the other, projecting laterally beyond the posterior part of the capsules which are connected with it. It is attached above to the posterior surface and lower edge of the posterior arch of the atlas, and below to the superior edge of the laminæ of the epistropheus on their dorsal aspect.

It is denser and stronger in the median line, and has a layer of elastic tissue on its anterior surface like the ligamenta flava, to which it corresponds in position. It is connected in front with the dura mater; behind, it is in relation with the *inferior oblique* muscles, and is perforated at each side by the *second cervical* nerve.

1. The Lateral Atlanto-epistrophic Joints are provided with short, ligamentous fibres, forming **articular capsules** (fig. 259), which completely surround the lateral articular facets. Lateral to the canal they are attached some little distance from the articular margins, extending along the roots of the

Fig. 261.—Horizontal Section through the Lateral Masses of the Atlas and the Top of the Dens (Odontoid Process).

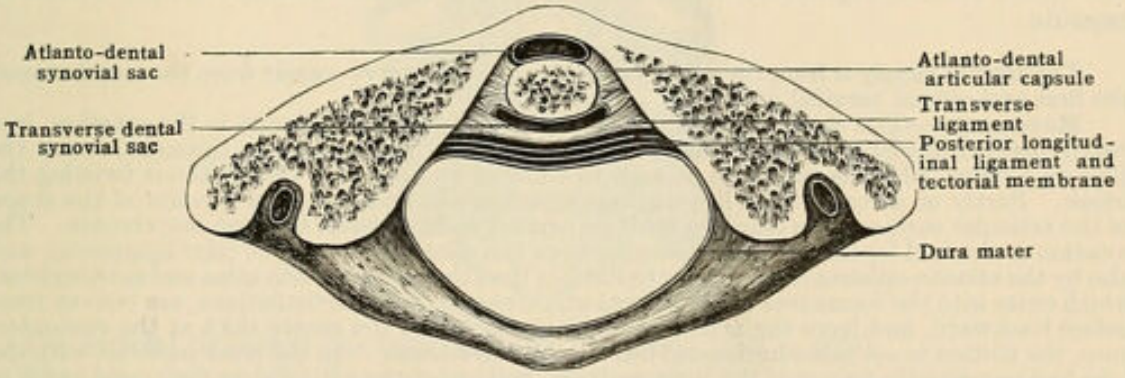

transverse processes of the epistropheus nearly to the tips, but between the roots they skirt the medial edge of the costo-transverse foramina. They are strengthened in front and behind by the atlanto-epistrophic ligaments.

Medially each capsule is thinner, and attached close to the articular margins, being strengthened behind by a strong band of slightly oblique fibres passing upward along the lateral edge of the tectorial membrane from the body of the epistropheus to the lateral mass of the atlas behind the transverse ligament; some of these fibres pass on, thickening and blending with the atlanto-occipital capsule, to be inserted into the margin of the foramen magnum. This band is sometimes called the **accessory band** (fig. 263).

There is a **synovial membrane** for each joint.

2. The Central Atlanto-epistrophic Joint, although usually described as one, is composed of two articulations, which are quite separate from one another:

an anterior between the dens and the arch of the atlas, and a posterior between the dens and the transverse ligament.

The **transverse ligament** (figs. 260, 261, and 263) is one of the most important structures in the body, for on its integrity and that of the alar ligaments our lives largely depend. It is a thick and very strong band, as dense and closely woven as fibro-cartilage, about a quarter of an inch (6 mm.) deep at the sides, and somewhat more in the middle line. Attached at each end to a tubercle on the inner side of the lateral mass of the atlas, it crosses the ring of this bone in a curved manner, so as to have the concavity forward; thus dividing the ring into a smaller anterior portion for the dens and a larger posterior part for the spinal cord and its membranes, and the spinal accessory nerves.

It is flattened from before backward, being smooth in front, and covered by synovial membrane to allow it to glide freely over the posterior facet of the dens. Where it is attached to the atlas it is smooth and well rounded off to provide an easy floor of communication between the transverso-dental and occipito-atlantal joints.

To its posterior surface is added, in the middle line, a strong fasciculus of vertical fibres, passing upward from the root of the dens to the basilar border of the foramen magnum on its cranial aspect. Some of these fibres are derived from the transverse ligament. These vertical fibres give the transverse ligament a cruciform appearance; hence the name, the **crucial ligament** (figs. 260 and 263) applied to the whole.

The **atlanto-dental articular capsule** (fig. 261) is a tough, loose membrane, completely surrounding the apposed articular surfaces of the atlas and dens.

At the dens it blends above with the front of the alar and central occipito-odontoid ligaments, and arises also along the sides of the articular facet as far as the neck of the dens; the fibres are thick, and blend with the capsules of the lateral joint. At the atlas they are attached to the non-articular part of the anterior arch in front of the tubercles for the transverse ligament, blending, above and below the borders of the bone, with the anterior atlanto-occipital and atlanto-epistrophic ligaments, as well as with the medial portion of the articular capsules. It holds the dens to the anterior arch of the atlas after all the other ligaments have been divided.

The **synovial membranes** (figs. 260 and 261) are two in number:—one for the joint between the dens and atlas; and another (transverso-dental) for that between the transverse ligament and the dens. This last often communicates with the atlanto-occipital articulations; it is closed in by membranous tissue between the borders of the transverse ligament and the margin of the facet on the dens, and is separated from the front sac by the atlanto-dental articular capsule.

The **arterial supply** is from the vertebral artery, and the **nerve-supply** from the loop between the first and second cervical nerves.

Movements.—The chief and characteristic movement at these joints is the rotation, in a nearly horizontal plane, of the collar formed by the atlas and transverse ligament, round the dens as a pivot, which is extensive enough to allow of an all-round view without twisting the trunk. Partly on account of its ligamentous attachments, and partly on account of the shape of the articular surfaces, the cranium must be carried with the atlas in these movements. The rotation is checked by the ligaments passing from the dens to the occiput (alar ligaments), and also by the atlanto-epistrophic. Owing to the fact that the facets of both atlas and epistropheus, which enter into the formation of the lateral atlanto-epistrophic articulations, are convex from before backward, and have the articular cartilage thicker in the centre than at the circumference, the motion is not quite horizontal but slightly curvilinear. In the erect position, with the face looking directly forward, the most convex portions of the articular surfaces are alone in contact, there being a considerable interval between the edges; during rotation, therefore, the prominent portions of the condyles of the atlas descend upon those of the epistropheus, diminishing the space between the bones, slackening the ligaments, and thus increasing the amount of rotation, without sacrificing the security of the joint in the central position.

Besides rotation, forward and backward movements and some lateral flexion are permitted between the atlas and epistropheus, even to a greater extent than in most of the other vertebral joints.

The muscles acting upon the atlanto-epistrophic joints.—The muscles capable of producing rotation at the atlanto-epistrophic joints are those which take origin from near the mesial plane either in front or behind and which are attached above either to the atlas or the skull, lateral to the atlanto-epistrophic joints. When the muscles which lie at the back of the joint on one side act they will turn the head to the same side and will be aided by the muscles in front on the opposite side. If the muscles in front and behind on the same side act simultaneously, they will pull down the head to that side and will be aided by muscles which pass more or less vertically from the transverse process of the atlas to points below.

(*c*) The Ligaments uniting the Occiput and Epistropheus

The following ligaments unite bones not in contact, and are to be seen from the interior of the canal after removing the posterior arches of the epistropheus and atlas and posterior ring of the foramen magnum:—

1. The tectorial membrane.
2. The crucial ligament.
3. Two alar (or check) ligaments.
4. The apical dental ligament.

The **tectorial membrane** (occipito-cervical ligament) (figs. 261, 262, and 263) consists of a very strong band of fibres, connected below to the upper part of the body of the third vertebra and lower part of the body of the epistropheus as far as the root of the dens. It is narrow below, but widens out as it ascends, to be fastened to the basilar groove of the occiput. Laterally, it is connected with the accessory fibres of the atlanto-epistrophic capsule. It is really only the upward prolongation of the deep stratum of the posterior longitudinal ligament, the superficial fibres of which run on to the occipital bone without touching the epistropheus, thus giving rise to two strata. It is in relation in front with the crucial ligament.

Fig. 262.—The Superficial Layer of the Posterior Longitudinal Vertebral Ligament has been Removed to show its Deep or Short Fibres. These Deep Fibres form the Tectorial Membrane. Viewed from behind.

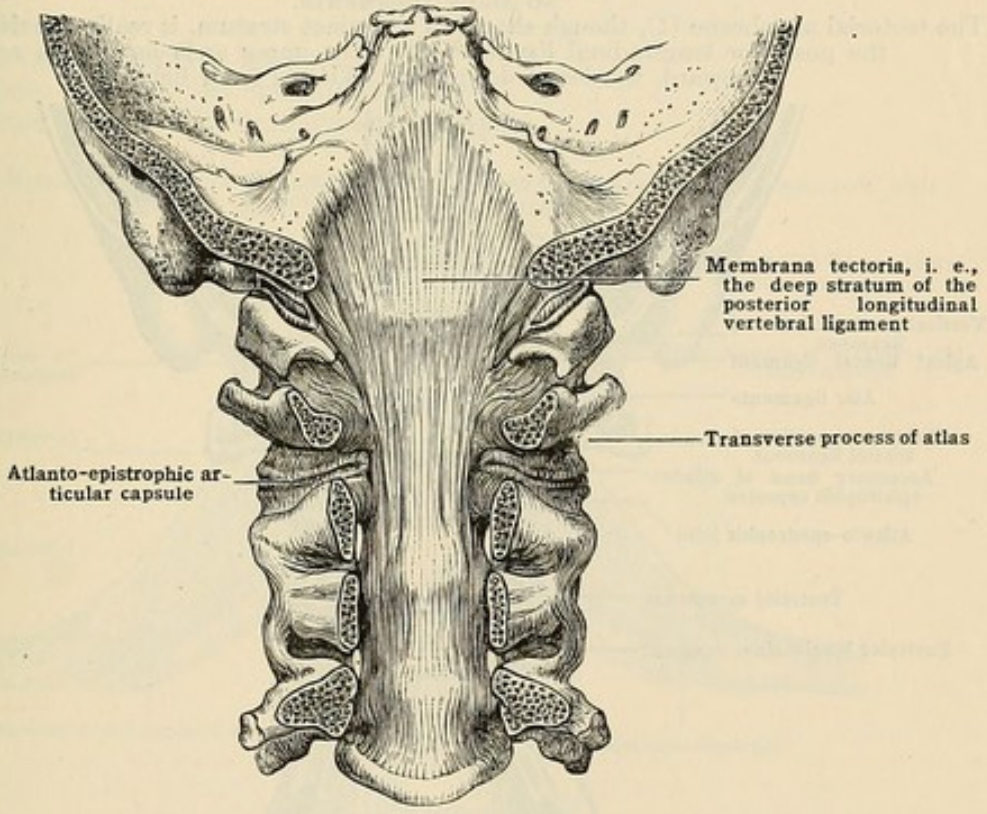

The **crucial ligament** has been already described (see p. 222).

The **alar** (or check) **ligaments** (figs. 260 and 263) are two strong rounded cords, which extend from the sides of the apex of the dens, transversely lateralward to the medial edge of the anterior portion of the occipital condyles.

They are to be seen immediately above the upper border of the transverse ligament, which they cross obliquely owing to its forward curve at its attachments to the atlas. Some of their fibres occasionally run across the middle line from one alar ligament to the other. At the dens they are connected with the atlanto-dental capsule, and at the condyles they strengthen the atlanto-occipital articular capsule.

The **apical dental** or suspensory ligament (figs. 260 and 263) consists of a slender band of fibres ascending from the summit of the dens to the lower surface of the occipital bone, close to the foramen magnum. It is best seen from the front, after removing the anterior atlanto-occipital ligament, or from behind by drawing aside the crucial ligament.

The apical ligament is tightened by extension and relaxed by flexion or nodding; the alar ligaments not only limit the rotatory movements of the head and atlas upon the epistropheus, but by binding the occiput to the pivot, round which rotation occurs, they steady the head and prevent its undue lateral inclination upon the vertebral column. (See TRANSVERSE LIGAMENT, p. 222.)

By experiments, it has been proved that the head, when placed so that the orbits look a little upward, is poised upon the occipital condyles in a line drawn a little in front of their middle; the amount of elevation varies slightly in different cases, but the balance is always to be obtained in the human body—it is one of the characteristics of the human figure. It serves to maintain the head erect without undue muscular effort, or a strong ligamentum nuchæ and prominent dorsal spines such as are seen in the lower animals. Disturb this balance, and let the muscles cease to act, the head will either drop forward or backward according as the centre of gravity is in front or behind the balance line. The ligaments which pass over the dens to the occiput are not quite tight when the head is erect, and only become so when the head is flexed; if this were not so, no flexion would be allowed; thus, muscular action, and not ligamentous tension, is employed to steady the head in the erect position. It is through the combination of the joints of the atlas and epistropheus, and occiput and epistropheus (consisting of two pairs of joints placed symmetrically on either side of the median line, while through the median line there passes a pivot, also with a pair of joints), that the head enjoys such freedom and celerity of action, remarkable strength, and almost absolute security against violence, which could only be obtained by a ball-and socket joint; but the ordinary ball-and-socket joints are too prone to dislocations by even moderate twists to be reliable enough when the life of the individual depends on the perfection of the articulation: hence the importance of this combination of joints.

FIG. 263.—CORONAL SECTION OF THE VERTEBRAL COLUMN AND THE OCCIPITAL BONE TO SHOW LIGAMENTS.

(The tectorial membrane (1), though shown as a distinct stratum, is really the deeper part of the posterior longitudinal ligament (2). The upper ends have been reflected upward, the lower downward. Viewed from behind.)

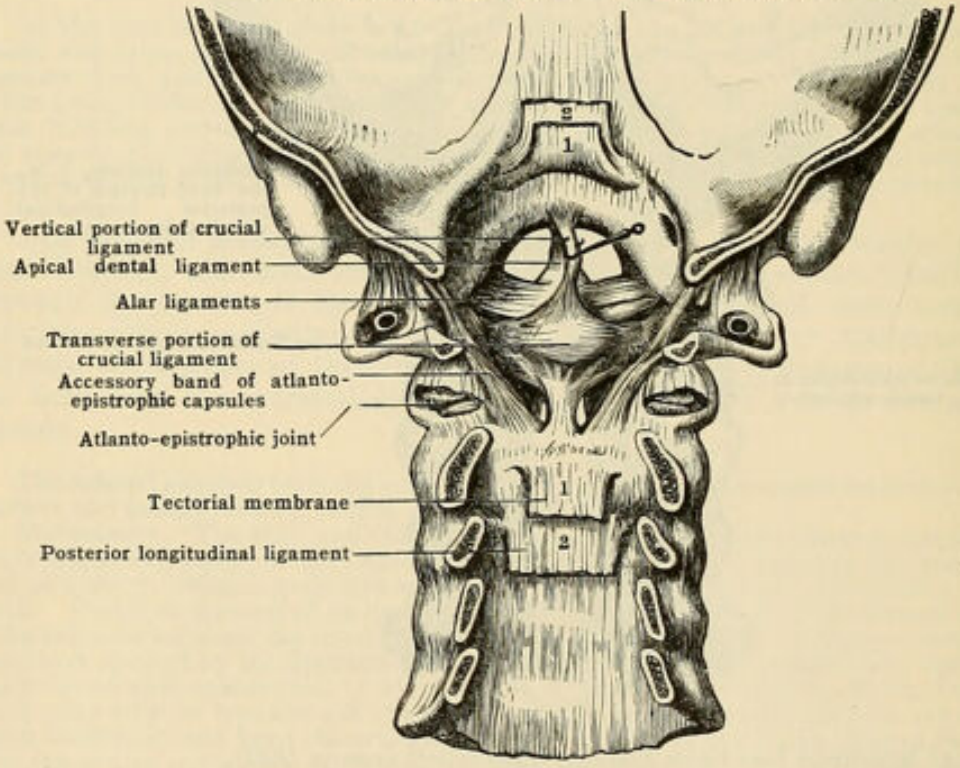

THE ARTICULATIONS OF THE TRUNK

These may be divided into the following sets:—

1. Those of the vertebral column. Joints and ligaments connecting:
   - (*a*) The bodies.
   - (*b*) The articular processes.
   - (*c*) The laminæ.
   - (*d*) The spinous processes.
   - (*e*) The transverse processes.
2. Vertebral column with the pelvis.
3. Pelvis.
   - (*a*) Sacro-iliac
   - (*b*) Sacro-coccygeal.
   - (*c*) Intercoccygeal.
   - (*d*) Symphysis pubis.

4. Ribs with the vertebral column.
5. The articulations at the front of the thorax.

   (*a*) Costal cartilages with the sternum.
   (*b*) Costal cartilages with the ribs.
   (*c*) Sternal.
   (*d*) Certain costal cartilages with each other.

1. THE ARTICULATIONS OF THE VERTEBRAL COLUMN

There are two distinct sets of articulations in the vertebral column:—

(*a*) Those between the bodies and intervertebral discs which form synchondroses and which are amphiarthrodial as regards movement.
(*b*) Those between the articular processes which form arthrodial joints.

The ligaments which unite the various parts may also be divided into two sets, viz.—**immediate,** or those that bind together parts which are in contact; and **intermediate,** or those that bind together parts which are not in contact.

Immediate.
(*a*) Those between the bodies and discs.
(*b*) Those between the articular processes.

Intermediate.
(*c*) Those between the laminæ.
(*d*) Those between the spinous processes.
(*e*) Those between the transverse processes.

FIG. 264.—HORIZONTAL SECTION THROUGH AN INTERVERTEBRAL FIBRO-CARTILAGE AND THE CORRESPONDING RIBS.

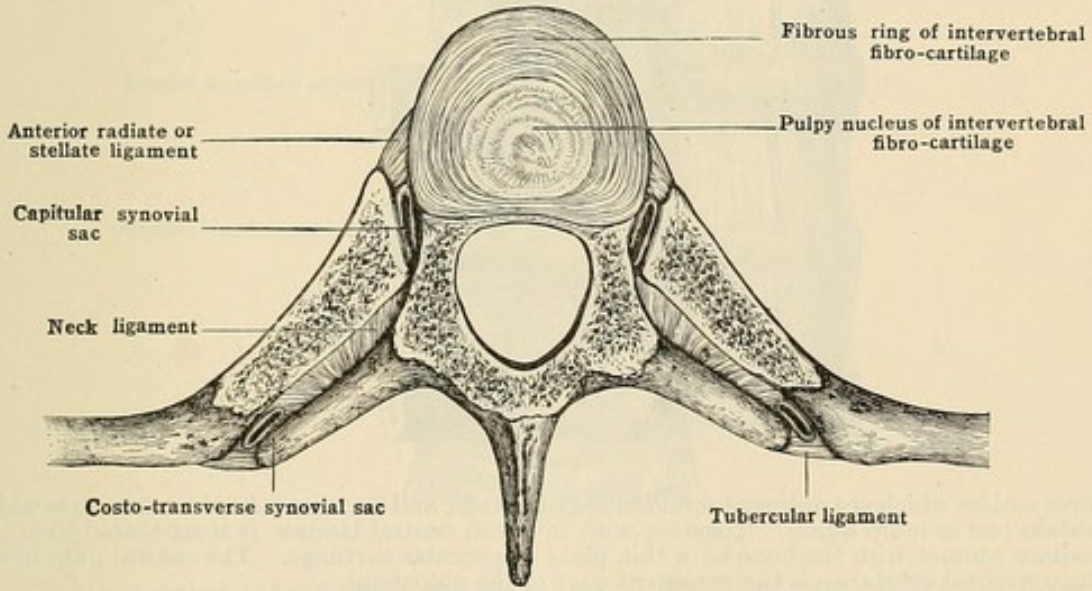

(*a*) THE ARTICULATIONS OF THE BODIES OF THE VERTEBRÆ

Class.—*False Synchondrosis.*

The ligaments which unite the bodies of the vertebræ are:—

Intervertebral fibro-cartilages.	Anterior longitudinal.
Short lateral ligaments.	Posterior longitudinal.

The **intervertebral fibro-cartilages** (figs. 260 and 264) are tough, but elastic and compressible discs of composite structure, which serve as the chief bond of union between the vertebræ. They are twenty-three in number, and are interposed between the bodies of all the vertebræ from the epistropheus to the sacrum (figs. 260 and 271). Similar discs are found between the segments of the sacrum and coccyx in the younger stages of life, but they undergo ossification at their surfaces and often throughout their whole extent.

Each disc is composed of two portions—a circumferential laminar, and a central pulpy portion; the former tightly surrounds and braces in the latter, and forms somewhat more than half the disc. The **fibrous ring** [annulus fibrosus] or laminar portion consists of alternating layers of fibrous tissue and fibro-cartilage; the component fibres of these layers are firmly connected with two vertebræ, those of one passing obliquely down and to the right, those of the next down and to the left, making an ×-shaped arrangement of the alternate layers. A few of the superficial lamellæ project beyond the edges of the bodies, their fibres being connected with the edges of the anterior and lateral surfaces; and some do not completely surround the rest, but terminate at the intervertebral foramina, so that on horizontal section the circumferential portion is seen to be thinner posteriorly. The more central lamellæ are incomplete, less firm, and not so distinct as the rest; and as they near the pulp they gradually assume its characters, becoming more fibro-cartilaginous and less fibrous, and have cartilage cells in their structure.

The **pulpy nucleus** [nucleus pulposus] or central portion is situated somewhat behind the centre of the disc, forming a ball of very elastic and tightly compressed material, which bulges freely when the confining pressure of the laminar portion is removed by either horizontal or vertical section. Thus, it has a constant tendency to spring out of its confinement in the direction of least resistance, and constitutes a pivot round which the bodies of the vertebræ can twist, tilt, or incline. It is yellowish in colour, and is composed of fine white and elastic

FIG. 265.—THE ANTERIOR LONGITUDINAL LIGAMENT, THE RADIATE, THE INTERARTICULAR, AND THE ANTERIOR COSTO-TRANSVERSE LIGAMENTS.

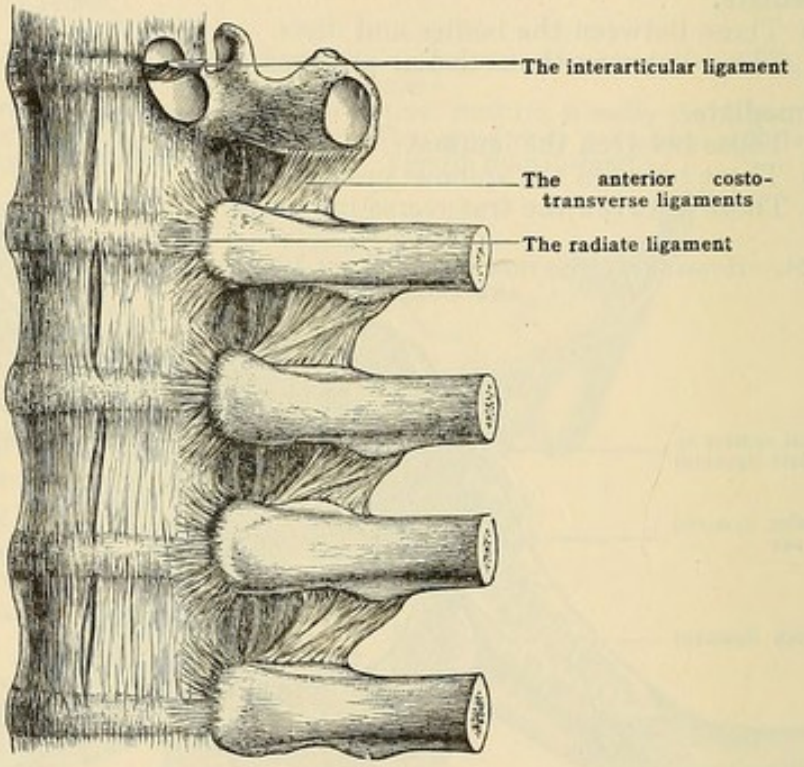

fibres amidst which are ordinary connective-tissue cells, and peculiar cells of various sizes which contain one or more nuclei. Together with the most central laminæ, it is separated from immediate contact with the bone by a thin plate of articular cartilage. The central pulp of the intervertebral substance is the persistent part of the notochord.

The intervertebral substances vary in shape with the bodies of the vertebræ they unite, and are widest and thickest in the lumbar region. In the cervical and lumbar regions they are thicker in front than behind, and *cause* the convexity forward of the cervical, and *increase* that of the lumbar; the curve in the thoracic region, almost entirely due to the shape of the bodies, is, however, somewhat increased by the discs. Without the discs the column loses a quarter of its length, and assumes a curve with the concavity forward, most marked a little below the mid-thoracic region. Such is the curve of old age, which is due to the shrinking and drying up of the intervertebral substances. The disc between the epistropheus and third cervical is the thinnest of all (fig. 260); that between the fifth lumbar and sacrum is the thickest, and is much thicker in front than behind (fig. 271). The intervertebral discs are in relation, in front with the anterior longitudinal ligament; behind, with the posterior longitudinal ligament; laterally, with the short lateral; and in the thoracic region, with the interarticular and radiate ligaments.

In the cervical region lateral diarthrodial joints are placed one on each side of the intervertebral discs. They are of small extent and are confined to the intervals between the prominent lateral lips of the upper surface of the body below and the bevelled lateral edges of the lower surface of the body above. Situated in front of the issuing spinal nerves and between those parts of the bodies formed from the neural arches, they are homologous with the joints between the atlas and epistropheus, and between the atlas and occipital bone.

The **anterior longitudinal ligament** (figs. 259 and 265) commences as a narrow band attached to the inferior surface of the occipital bone in the median line, just in front of the atlanto-occipital ligament, of which it forms the thickened central portion. Attached firmly to the tubercle of the atlas, it passes down as the central portion of the atlanto-epistrophic ligament, in the mid-line, to the front of the body of the epistropheus. It now begins to widen out as it descends, until it is nearly two inches (5 cm.) wide in the lumbar region. Below, it is fixed to the upper segment of the sacrum, becoming lost in periosteum about the middle of that bone; but is again distinguishable in front of the sacro-coccygeal joint, as the anterior sacro-coccygeal ligament.

Its structure is bright, pearly-white, and glistening. Its lateral borders are separated from the lateral bands by clefts through which blood-vessels pass; they are frequently indistinct and are best marked in the thoracic region. It is thickest in the thoracic region, and thicker in the lumbar than the cervical. It is firmly connected with the bodies of the vertebræ, and is composed of longitudinal fibres, of which the superficial extend over several, while the deeper pass over only two or three vertebræ. It is connected with the tendinous expansion of the pre-vertebral muscles in the cervical, and the crura of the diaphragm are closely attached to it in the lumbar region.

FIG. 266.—POSTERIOR LONGITUDINAL LIGAMENT. (Thoracic region.)
(Pedicles cut through, and posterior arches of vertebræ removed.)

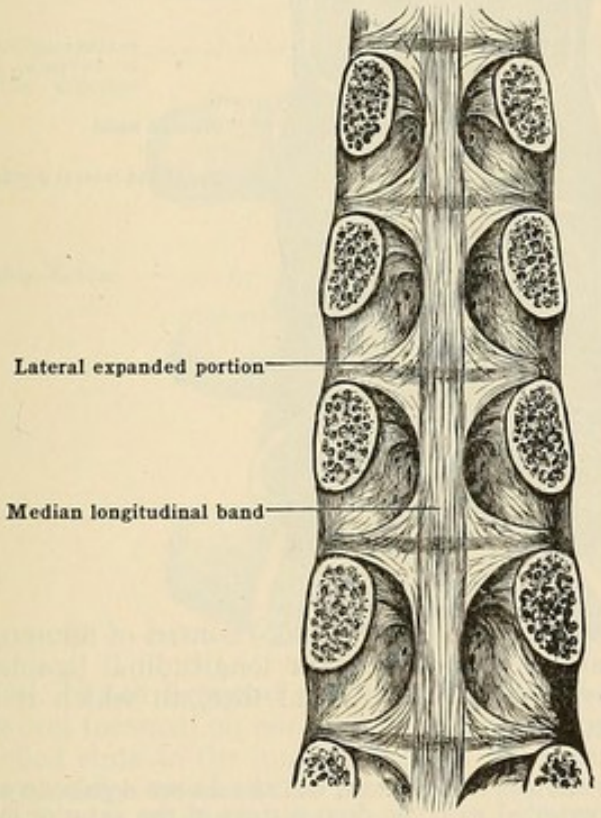

The **posterior longitudinal ligament** (figs. 263, 266, 267, and 274) extends from the occipital bone to the coccyx. It is wider above than below, and commences by a broad attachment to the cranial surface of the basi-occipital. In the cervical region it is of nearly uniform width, and extends completely across the bodies of the vertebræ, upon which it rests quite flat. It does, however, extend slightly further laterally on each side opposite the intervertebral discs. In the thoracic and lumbar regions it is distinctly dentated, being broader over the intervertebral substances and the edges of the bones than over the middle of the bodies, where it is a narrow band stretched over the bones without resting on them, the anterior internal vertebral venous plexus being interposed. The narrow median portion consists of longitudinal fibres, some of which are superficial and pass over several vertebræ; and others are deeper, and extend only from one vertebra to the next but one below.

The dentated or broader portions (fig. 267) are formed by oblique fibres which, springing from the bodies near the intervertebral foramina, take a curved course downward and back-

ward over an intervertebral fibro-cartilage, and reach the narrow portion of the ligament on the centre of the vertebra next below; they then diverge to pass over another intervertebral dics to end on the body of the vertebra beyond, near the intervertebral notch. They thus pass over two discs and three vertebræ. Deeper still are other fibres thickening these expansions of the longitudinal ligament, and extending from one bone to the next.

The last well-marked expansion is situated between the first two segments of the sacrum: below this, the ligament becomes a delicate central band with rudimentary expansions, being more pronounced again over the sacro-coccygeal joint, and losing itself in the ligamentous tissue at the back of the coccyx. The dura mater is tightly attached to it at the margin of the foramen magnum and behind the bodies of the upper cervical vertebræ, but is separated from it in the rest of its extent by loose cellular tissue which becomes condensed in the sacral region to form the sacro-dural ligament. The filum terminale becomes blended with it at the lower part of the sacrum and back of the coccyx.

Fig. 267.—Posterior Longitudinal Ligament. (Lumbar region.)

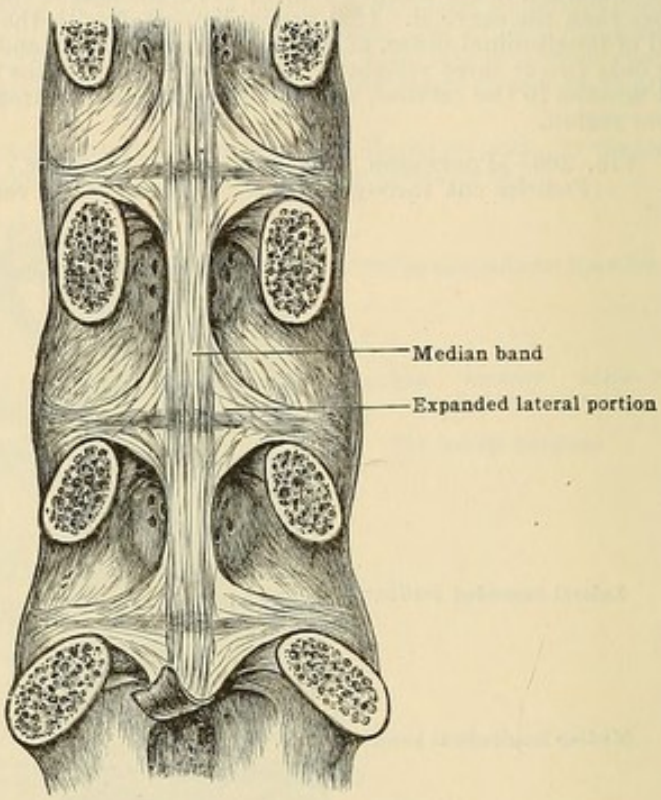

The **lateral** (or short) **vertebral ligaments** (fig. 265) consist of numerous short fibres situated between the anterior and posterior longitudinal ligaments, and passing from one vertebra over the intervertebral disc, to which it is firmly adherent, to the next vertebra below.

The more superficial fibres are more or less vertical, but the deeper decussate and have a crucial arrangement. They are connected with the deep surface of the anterior longitudinal ligament, and so tie it to the edges of the bodies of the vertebræ and to the intervertebral discs. They blend behind with the expansions of the posterior longitudinal ligament, and so complete the casing round each amphiarthrodial joint. In the thoracic region, they overlie the radiate ligament, and in the lumbar they radiate toward the transverse processes. In the cervical region they are less well marked.

(*b*) The Ligaments Connecting the Articular Processes

Class.—*Diarthrosis.* **Subdivision.**—*Arthrodia.*

The **articular capsules** (fig. 259) which unite these processes are composed partly of yellow elastic tissue and partly of white fibrous tissue. In the cervical region only the medial side of the capsule is formed by the ligamenta flava, which in the thoracic and lumbar regions, however, extend anteriorly to the margins of the intervertebral foramina.

The part formed of white fibrous tissue consists of short, well-marked fibres, which in the cervical region pass obliquely downward and forward over the joint, between the articular proc-

esses and the posterior roots of the transverse processes of two contiguous vertebræ. In the thoracic region the fibres are shorter, and vertical in direction, and are attached to the bases of the transverse processes; in the lumbar, they are obliquely transverse. The articular capsules in the cervical region are the most lax, those in the lumbar region are rather tighter, and those in the thoracic region are the tightest.

There is one **synovial membrane** to each capsule.

(*c*) The Ligaments uniting the Laminæ

The **ligamenta flava** (fig. 268) are thick plates of closely woven yellow elastic tissue, interposed between the laminæ of two adjacent vertebræ. The first connects the epistropheus with the third cervical, and the last the fifth lumbar with

Fig. 268.—Ligamenta Flava in the Lumbar Region, seen from within the Vertebral Canal.

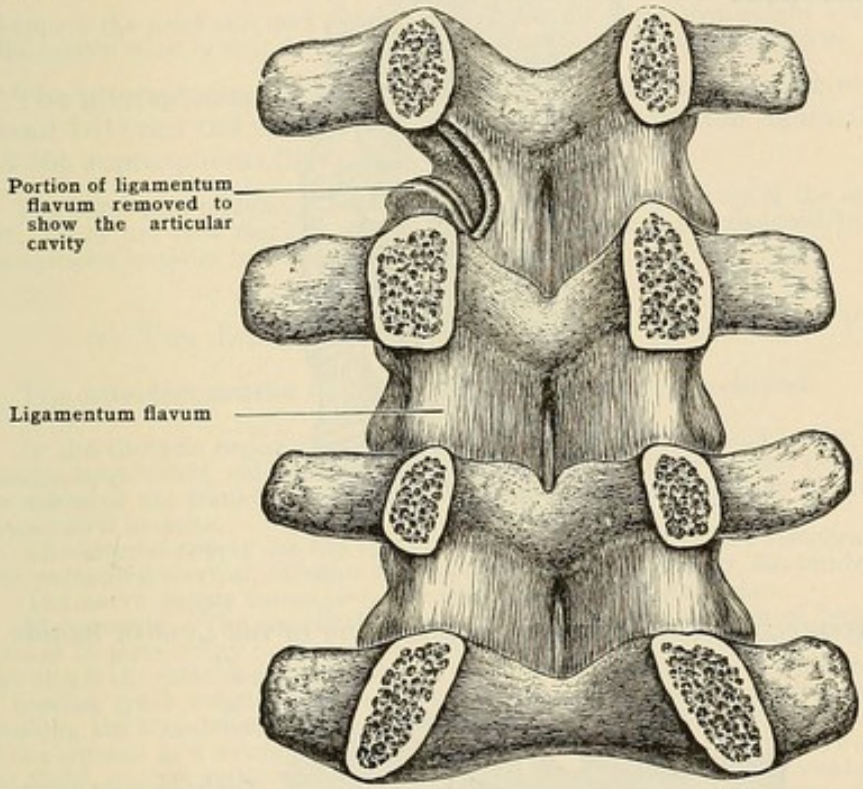

the sacrum. Each ligament extends from the medial and posterior edge of the intervertebral foramen on one side to a corresponding point on the other; above, it is attached close to the inner margin of the inferior articular process and to a well-marked ridge on the inner surface of the laminæ as far as the root of the spine; below, it is fixed close to the inner margin of the superior articular process and to the dorsal aspect of the upper edge of the laminæ.

Thus each ligamentum flavum, besides filling up the interlaminar space, enters into the formation of two articular capsules; they do so to a greater extent in the thoracic and lumbar regions than in the cervical, where the articular processes are placed wider apart. When seen from the front after removing the bodies of the vertebræ, they are concave from side to side, but convex from above downward; they make a more decided transverse curve than the arches between which they are placed. This concavity is more marked in the thoracic, and still more in the lumbar region than in the cervical; in the lumbar region the ligamenta flava extend a short distance between the roots of the spinous process, blending with the interspinous ligament, and making a median sulcus when seen from the front; there is, however, no separation between the two parts. In the cervical region, where the spines are bifid, there is a median fissure in the yellow tissue which is filled up by fibro-areolar tissue. The ligaments are thickest and strongest in the lumbar region; narrow but strong in the thoracic; thinner, broader, and more membranous in the cervical region.

(*d*) The Ligaments connecting the Spinous Processes

These include supraspinous ligament, interspinous ligaments, and the ligamentum nuchæ.

The **supraspinous ligament** (fig. 270) extends without interruption as a well-marked band of longitudinal fibres along the tips of the spines of the vertebræ from that of the seventh cervical downward till it ends on the median sacral crest.

FIG. 269.—SIDE VIEW OF LIGAMENTUM NUCHÆ.

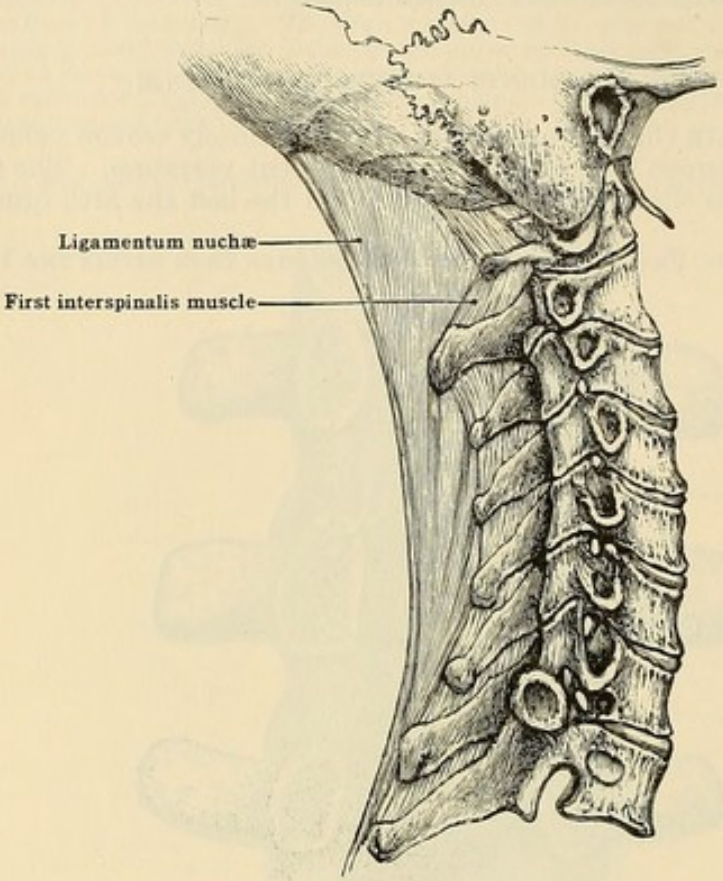

FIG. 270.—THE INTERSPINOUS AND SUPRASPINOUS LIGAMENTS IN THE LUMBAR REGION.

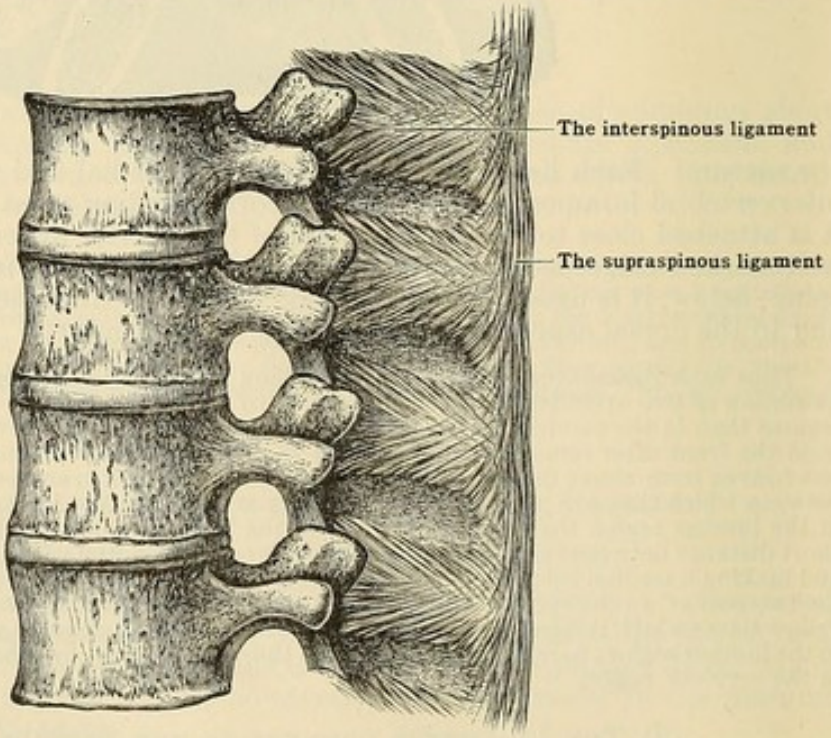

Its more superficial fibres are much longer than the deep. The deeper fibres pass over adjacent spines only, while the superficial overlie several. It is connected laterally with the aponeurotic structures of the back; indeed, in the lumbar region, where it is well marked, it

appears to result from the interweaving of the tendinous fibres of the several muscles which are attached to the tips of the spinous processes. In the dorsal region it is a round slender cord which is put on the stretch in flexion and relaxed in extension of the back.

The **ligamentum nuchæ,** or the posterior cervical ligament (fig. 269), is the continuation in the neck of the supraspinous ligament, from which, however, it differs considerably. It is a slender vertical septum of an elongated triangular form, extending from the seventh cervical vertebra to the external protuberance and the crest of the occipital bone. Its anterior border is firmly attached to the tips of the spines of all the cervical vertebræ, including the posterior tubercle of the atlas, as well as to the occiput. Its posterior border gives origin to the trapezii, with the tendinous fibres of which muscle it blends. Its lateral, triangular surfaces afford numerous points of attachment for the posterior muscles of the head and neck.

In man it is rudimentary, and consists of elastic and white fibrous tissues. As seen in the horse, elephant, ox, and other pronograde mammals, it is a great and important elastic ligament, which even reaches along the thoracic part of the spinal column. In these animals it serves to support the head and neck, which otherwise from their own weight would hang down. Its rudimentary state in man is the direct consequence of his erect position.

The **interspinous ligaments** (fig. 270) are thin membranous structures which extend between the spines, and are connected with the ligamenta flava in front, and the supraspinous ligament behind.

The fibres pass obliquely from the root of one spine to the tip of the next; they thus decussate. They are best marked in the lumbar region, and are replaced by the well-developed *interspinales* muscles in the cervical region.

(*e*) The Ligaments connecting the Transverse Processes

The **intertransverse ligaments** are but poorly developed.

In the thoracic region they form small rounded bundles, and in the lumbar they are flat membranous bands, unimportant as bonds of union. They consist of fibres passing between the apices of the transverse processes. In the cervical region they are replaced by the *intertransversarii* muscles.

The **arterial supply** for the column comes from twigs of the vertebral, ascending pharyngeal, ascending cervical, superior and aortic intercostals, lumbar, ilio-lumbar, and lateral sacral.

The **nerve-supply** comes from the spinal nerves of each region.

Movements.—The vertebral column is so formed of a number of bones and intervertebral discs as to serve many purposes. It is the axis of the skeleton; upon it the skull is supported; and with it the cavities of the trunk and the limbs are connected. As a fixed column it is capable of bearing great weight, and, through the elastic intervertebral substances, of resisting and breaking the transmission of shocks. Moreover, it is flexible. Now, the range of movements of the column as a whole is very considerable; but the movements between any two vertebræ are slight, so that motions of the spine may take place without any change in the shape of the column, and without any marked disturbance in the relative positions of the vertebræ. It is about the pulpy part of the intervertebral discs, which form a central elastic pivot or ball, upon which the middle of the vertebræ rest, that these movements take place.

The amount of motion is everywhere limited by the common vertebral ligaments, but it depends partly upon the width of the bodies of the vertebræ, and partly upon the depth of the discs, so that in the loins, where the bodies are large and wide, and the discs very thick, free motion is permitted; in the cervical region, though the discs are thinner, yet, as the bodies are smaller, almost equally free motion is allowed. As the ball-like pulpy part of the intervertebral disc is the centre of movement of each vertebra, it is obvious that the motion would be of a rolling character in any direction but for the articular processes, which serve also to give steadiness to the column and to assist in bearing the superincumbent weight. Were it not for these processes, the column, instead of being steady, endowed with the capacity of movement by muscular agency, would be tottering, requiring muscles to steady it. The influence of the articular processes in limiting the direction of inclination will appear from a study of the movements in the three regions of the spine.

In the **neck** all movements are permitted and are free, except between the second and third cervical vertebræ, where they are slight, owing to the shallow intervertebral disc and the great prolongation of the anterior lip of the inferior surface of the body of the epistropheus, which checks forward flexion considerably. On the whole, however, extension and lateral inclination are more free and extensive in this than in any other region of the column, whilst flexion is more limited than in the lumbar region. Rotatory movements are also free, but take place, on account of the position and inclination of the articular facets, not, as in the thoracic region, round a vertical axis, but round an oblique axis, the articular process of one side gliding upward and forward and that of the opposite side downward and backward.

In the **thoracic region,** especially near its middle, antero-posterior flexion and extension are very slight; and, as the concavity of the curve here is forward, the flat and nearly vertical surfaces of the articular processes prevent anything like sliding in a curvilinear manner of the

one set of processes over the sharp upper edges of the other, which would be necessary for forward flexion. A fair amount of lateral inclination would be permitted but for the impediment offered by the ribs; while the position and direction of the articular processes allows rotation round a vertical axis which passes through the centres of the bodies of the vertebræ. This rotation is not very great, and is freer in the upper than in the lower part of the thoracic region.

In the **lumbar region,** extension and flexion are very free, especially between the third and fourth and fourth and fifth vertebræ, where the lumbar curve is sharpest; lateral inclination is also very free between these same vertebræ. It has been stated that the shape and position of the articular processes of the lumbar and the lower two or three dorsal are such as to prevent any rotation in these regions; but, owing to the fact that the inferior articular processes are not tightly embraced by the superior, so that the two sets of articular processes are not in contact on both sides of the bodies at the same time, there is always some space in which horizontal motion can occur round an axis drawn through the central part of the bodies and intervertebral discs, but it is very slight. Thus, the motions are most free in those regions of the column which have a convex curve forward, due to the shape of the intervertebral discs, where there are no bony walls surrounding solid viscera, where the spinal canal is largest and its contents are less firmly attached, and where the pedicles and articular processes are more nearly on a transverse level with the posterior surface of the bodies of the vertebræ.

Nor must the uses of the ligamenta flava be forgotten: these useful structures—(1) complete the roofing-in of the vertebral canal, and yet at the same time permit an ever-changing variation in the width of the interlaminar spaces in flexion and extension; (2) they also restore the articulating surfaces to their normal position with regard to each other after movements of the column; (3) and by forming the medial portion of each articular capsule, they take the place of muscle in preventing it from being nipped between the articular surfaces during movement.

Muscles which take part in the movements of the vertebral column.—Flexors: When acting with their fellows of the opposite side. Rectus abdominis, infra-hyoid muscles (slightly) sterno-mastoid, external oblique, internal oblique, intercostals, scalenus anterior, psoas major and minor, longus colli, longus capitis (rectus capitis anterior major).

Extensors: When acting with their fellows of the opposite side. Sacro-spinalis, quadratus lumborum, semispinalis, multifidus, rotatores, interspinales, serrati posteriores, the splenius, and with the scapula fixed the levator scapulæ and the upper fibres of the trapezius.

Muscles which help to incline the column to their own side.—Sacro-spinalis, quadratus lumborum, semispinalis, multifidus, the intercostals helping to fix the ribs, the external and internal oblique muscles, levatores costarum, serrati posteriores, the scalenes, splenius cervicis, longus colli (oblique part), rotatores, intertransversales, psoas, and with the scapula fixed the levator scapulæ and the upper and lower fibres of the trapezius.

Muscles which rotate the column and turn the body to their own side.—Splenius cervicis, internal oblique (the ribs being fixed), serratus posterior inferior, and with the scapula fixed the lower fibres of the trapezius.

Muscles which rotate the column and turn the body to the opposite side.—Multifidus, semispinalis, external oblique, the lower oblique fibres of the longus colli, and with the scapula and humerus fixed the latissimus dorsi and trapezius.

2. THE SACRO-VERTEBRAL ARTICULATIONS

(*a*) **Class.**—*False Synchondrosis.*

(*b*) **Class.**—*Diarthrosis.* **Subdivision.**—*Arthrodia.*

As in the intervertebral articulations, so in the union of the first portion of the sacrum with the last lumbar vertebra, there are two sets of joints—viz. (*a*) a synchondrosis, between the bodies and intervertebral disc; and (*b*) a pair of arthrodial joints, between the articular processes. The union is effected by the following ligaments, which are common to the vertebral column:—(i) anterior, and (ii) posterior longitudinal; (iii) lateral or short vertebral; (iv) capsular; (v) ligamenta flava; (vi) supraspinous and (vii) interspinous ligaments. Two special accessory ligaments on either side, viz., the sacro-lumbar and the ilio-lumbar, connect the pelvis with the fourth and fifth lumbar vertebræ.

The **sacro-lumbar ligament** (fig. 271) is strong, and triangular in shape. Its apex is above and medial, being attached to the whole of the lower border and front surface of the transverse process of the fifth lumbar vertebra, as well as to the pedicle and body. It is intimately blended with the *ilio-lumbar ligament.* Below, it has a wide, fan-shaped attachment, extending from the edge of the ilio-lumbar ligament forward to the brim of the true pelvis; blending with the periosteum on the base of the sacrum and in the iliac fossa, and with the superior sacro-iliac ligament.

By its sharp medial border it limits laterally the foramen for the *last lumbar nerve.* It is pierced by two large foramina, which transmit arteries to the sacro-iliac synchondrosis. This ligament is in series with the intertransverse ligaments of the spinal column. It is sometimes described as a part of the ilio-lumbar ligament.

The **ilio-lumbar ligament** (fig. 271) is a strong, dense, triangular ligament connecting the fourth and fifth lumbar vertebræ with the iliac crest.

It springs from the front surface of the transverse process of the fifth lumbar vertebra as far as the body, by a strong fasciculus from the posterior surface of the process near the tip, and also from the front surface and lower edge of the transverse process and pedicle of the fourth lumbar vertebra, as far medialward as the body. Between these two lumbar vertebræ it is inseparable from the intertransverse ligament.

At its origin from the transverse process of the fifth lumbar vertebra it is closely interwoven with the sacro-lumbar ligament, and some of its fibres spread downward on to the body of the fifth vertebra, while others ascend to the disc above. At the pelvis it is attached to the inner lip of the crest of the ilium for about two inches (5 cm.). The highest fibres at the column form the upper edge of the ligament at the pelvis, those which come from the posterior portion of the transverse process of the fifth lumbar vertebra forming the lower, while the fibres from the front of the same process pass nearly horizontally lateralward. Near the column the surfaces

FIG. 271.—ANTERIOR VIEW OF THE LIGAMENTS BETWEEN VERTEBRÆ AND PELVIS.

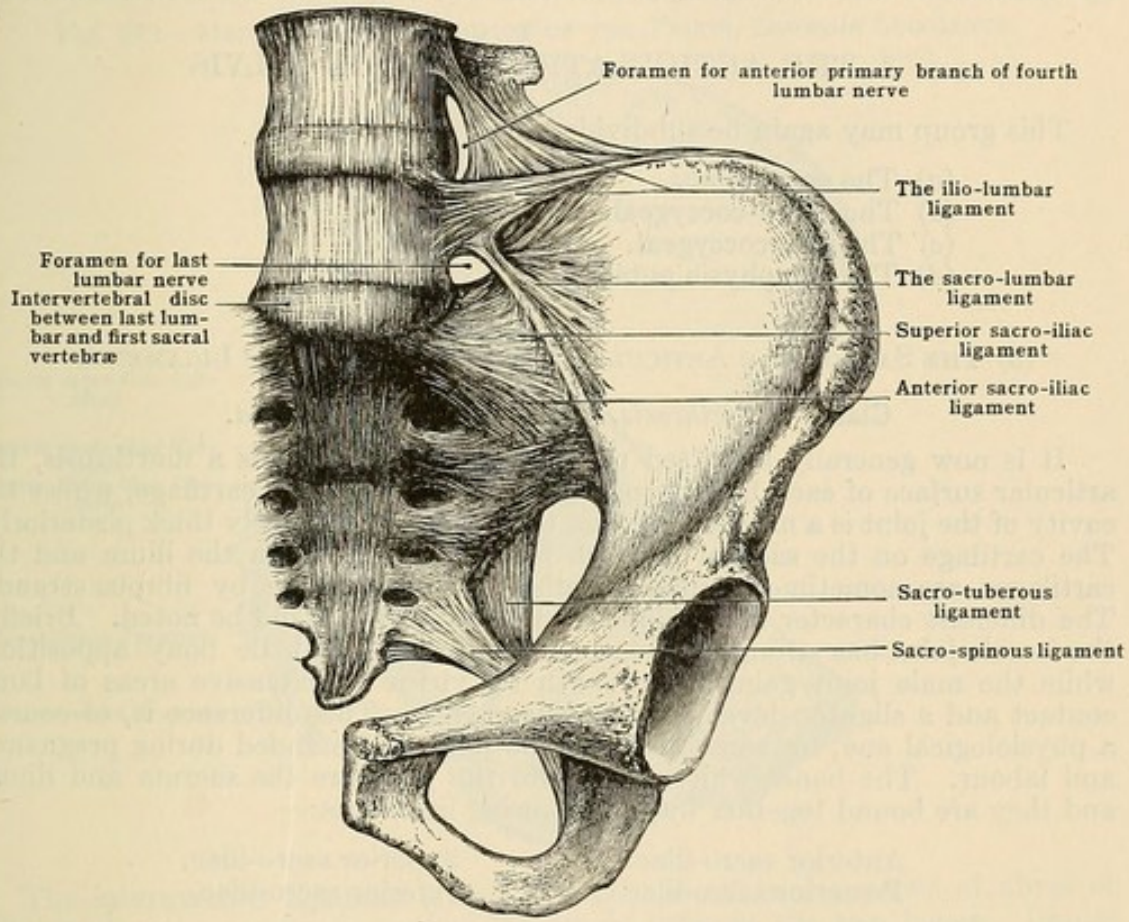

look directly backward and forward, but at the ilium the ligament gets somewhat twisted, so that the posterior surface looks a little upward, and the anterior looks a little downward. The anterior surface forms part of the posterior boundary of the major (false) pelvis, and overlies the upper part of the posterior sacro-iliac ligament; the posterior surface forms part of the floor of the spinal groove, and gives origin to the *multifidus* muscle. Of the borders, the upper is oblique, has the anterior lamella of the lumbar fascia attached to it, and gives origin to the *quadratus lumborum;* the lower is horizontal, and is adjacent to the upper edge of the sacro-lumbar ligament; while the medial is crescentic, and forms the lateral boundary of a foramen through which the *fourth lumbar* nerve passes.

The **arterial supply** is very free, and comes from the last lumbar, ilio-lumbar, and lateral sacral.

The **nerve-supply** is from the sympathetic, as well as from twigs from the fourth and fifth lumbar nerves.

Movements.—The angle formed by the sacrum with the spinal column is called the sacro-vertebral angle. The pelvic inclination does not depend entirely upon this angle, but in great part upon the obliquity of the coxal (innominate) bones to the sacrum, so that in males in whom the average pelvic obliquity is a little greater, the average sacro-vertebral angle is considerably less than in females.

The sacro-vertebral angle in the male shows that there is a greater and more sudden change in direction at the sacro-vertebral union than in the female. A part of this change in direction is due to the greater thickness in the anterior part of the intervertebral fibro-cartilage between the last lumbar vertebra and the sacrum. Owing to the greater thickness of the intervertebral

disc here than elsewhere, the movements permitted at this joint are very free, being freer than those between any two lumbar vertebræ. As the diameter of the two contiguous bones is less in the sagittal than in the frontal plane, the forward and backward motions are much freer than those from side to side. The backward and forward motions take place every time the sitting is exchanged for the standing position, and the standing for the sitting posture; in rising, the back is extended on the sacrum at the sacro-lumbar union; in sitting down it is flexed.

The articular processes provide for the gliding movement incidental to the extension, flexion, and lateral movements; they also allow some horizontal movement, necessary for the rotation of the vertebral column on the pelvis, or pelvis on the column. The inferior articular processes of the fifth differ considerably from the inferior processes in the rest of the lumbar vertebræ, and in direction they resemble somewhat those of the cervical vertebræ; while the superior articular processes of the sacrum differ in a similar degree from the superior processes of the lumbar vertebræ. This difference allows for the freer rotation which occurs at this joint.

The sacro-vertebral angle averages 117° in the male, and 130° in the female; while the pelvic inclination averages 155° in the male, and 150° in the female.

As already stated, the movements at the sacro-vertebral joint are the same as those in other parts of the spinal column, but more extensive, and the muscles which produce the movements are those mentioned in the preceding groups which cross the plane of the articulation.

3. THE ARTICULATIONS OF THE PELVIS

This group may again be subdivided into—

(*a*) The **sacro-iliac.**
(*b*) The **sacro-coccygeal.**
(*c*) The **intercoccygeal.**
(*d*) The **symphysis pubis.**

(*a*) The Sacro-iliac Articulation and Sacro-sciatic Ligaments

Class.—*Diarthrosis.* **Subdivision.**—*Arthrodia.*

It is now generally admitted that the sacro-iliac joint is a diarthrosis, the articular surface of each bone being covered with a layer of cartilage, whilst the cavity of the joint is a narrow cleft and the capsule is extremely thick posteriorly. The cartilage on the sacrum is much thicker than that on the ilium and the cartilages are sometimes bound together here and there by fibrous strands. The different character of the joint in the two sexes should be noted. Briefly, the female joint has strong ligamentous bonds with but little bony apposition, while the male joint gains its strength by virtue of extensive areas of bony contact and a slighter development of ligaments. This difference is, of course, a physiological one; for some laxity of the joint is demanded during pregnancy and labour. The bones which enter into the joint are the sacrum and ilium, and they are bound together by the following ligaments:—

Anterior sacro-iliac.	Superior sacro-iliac.
Posterior sacro-iliac.	Inferior sacro-iliac.

Interosseous.

The **anterior sacro-iliac ligament** (figs. 271 and 272) consists of well-marked glistening fibres which pass above into the superior, and below into the inferior, ligaments. It extends from the first three bones of the sacrum to the ilium between the brim of the pelvis minor and the great sciatic notch, blending with the periosteum of the sacrum and ilium as it passes away from the united edges of the bones.

The **superior sacro-iliac ligament** (figs. 271 and 272) extends across the upper margins of the joint, from the ala of the sacrum to the iliac fossa, being well marked along the brim of the pelvis, where it is thickened by some closely packed fibres. Behind, it is far stronger, especially beneath the transverse process of the fifth lumbar vertebra. This ligament is connected with the strong sacro-lumbar ligament, which spreads lateralward and forward over the joint to reach the iliac fossa and terminal line. By some authors it is described as a part of the ilio-lumbar ligament.

The **posterior sacro-iliac ligament** is extremely strong and consists essentially of two sets of fibres, deep and superficial. The deep fibres (short posterior sacro-iliac ligament) pass downward and medialward from the rough area of the

ilium behind the auricular surface to the back of the lateral mass of the sacrum, both lateral to and between the upper foramina and to the upper sacral articular process, and the area between it and the first sacral foramen. The deepest fibres of this group constitute the so-called interosseous ligament. The more superficial fibres (long posterior sacro-iliac ligament) are oblique or vertical, and pass from the posterior superior iliac spine to the second, third, and fourth tubercles on the back of the sacrum, a more or less well-defined band which goes to the third and fourth sacral tubercles being called sometimes the oblique sacro-iliac band and sometimes the long straight band.

The **inferior sacro-iliac ligament** (fig. 272) is covered behind by the upper end of the sacro-tuberous ligament; it consists of strong fibres extending from the lateral border of the sacrum below the articular facet to the posterior iliac spines; some of the fibres are attached to the deep surface of the ilium and join the interosseous ligament.

FIG. 272.—MEDIAN SAGITTAL SECTION OF THE PELVIS, SHOWING LIGAMENTS.

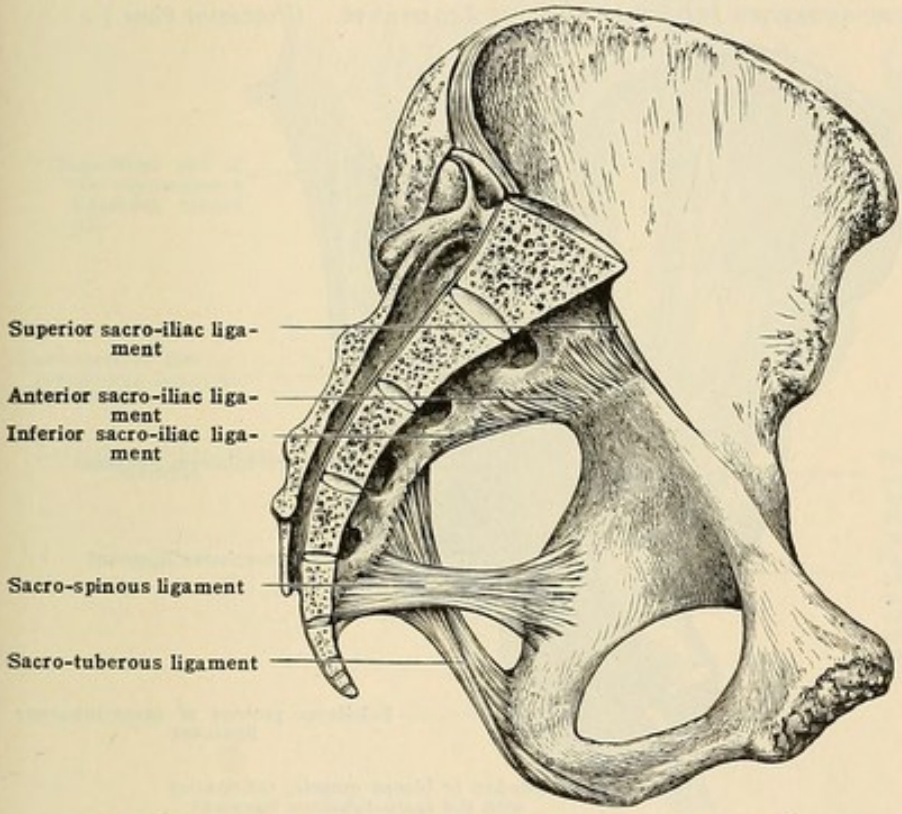

The **interosseous ligament** is the strongest of all, and consists of fibres of different lengths passing in various directions between the two bones. Immediately above the interspinous notch of the ilium the fibres of this ligament are very strong, and form an open network, in the interstices of which is a quantity of fat in which the articular vessels ramify.

The ear-shaped **cartilaginous plate,** which unites the bones firmly, is accurately applied to the auricular surfaces of the sacrum and ilium. It is about one-twelfth of an inch (2 mm.) thick in the centre, but becomes thinner toward the edges. Though closely adherent to the bones, it tears away from one entirely, or from both partially, on the application of violence, sometimes breaking irregularly so that the greater portion remains connected with one bone, leaving the other bone rough and bare. It is usually one mass, and is only occasionally formed of two plates with a synovial cavity between them.

Because of the occasional presence of a more or less extensive synovial cavity within the fibro-cartilage, and also of a synovial lining to the ligaments passing in front and behind the articulation, the term 'diarthro-amphiarthrosis' has been given to this joint, and also to the symphysis pubis. Testut mentions certain folds of synovial membrane filling up gaps which here and there occur at the margin of the fibro-cartilage but they are not usually seen.

The **sacro-tuberous** (great sciatic) **ligament** (figs. 271, 272, and 273) is attached above to the posterior extremity of the crest of the ilium and the lateral aspect of the posterior iliac spines. From this attachment some of its fibres

pass downward and backward to be attached to the lateral borders and posterior surfaces of the lower three sacral vertebræ and upper two segments of the coccyx; while others, after passing for a certain distance backward, curve forward and downward to the ischium, forming the anterior free margin of the ligament where it limits posteriorly the sciatic foramina. These fibres are joined by others which arise from the posterior surfaces of the lower three sacral vertebræ and upper pieces of the coccyx. At the ischium it is fixed to the medial border of the tuberosity, and sends a thin sharp process upward along the ramus of the ischium which is called the **falciform process** (fig. 273), and is a prolongation of the posterior edge of the ligament.

A great many fibres pass on directly into the tendon of the biceps muscle, so that traction on this muscle braces up the whole ligament, and the coccyx is thus made to move on the sacrum. The ligament may not unfairly be described as a tendinous expansion of the muscle, whereby its action is extended and a more advantageous leverage given. It is broad and flat at its attached ends, but narrower and thicker in the centre, looking like two triangular expansions

FIG. 273.—SACRO-TUBEROUS AND SACRO-SPINOUS LIGAMENTS. (Posterior view.)

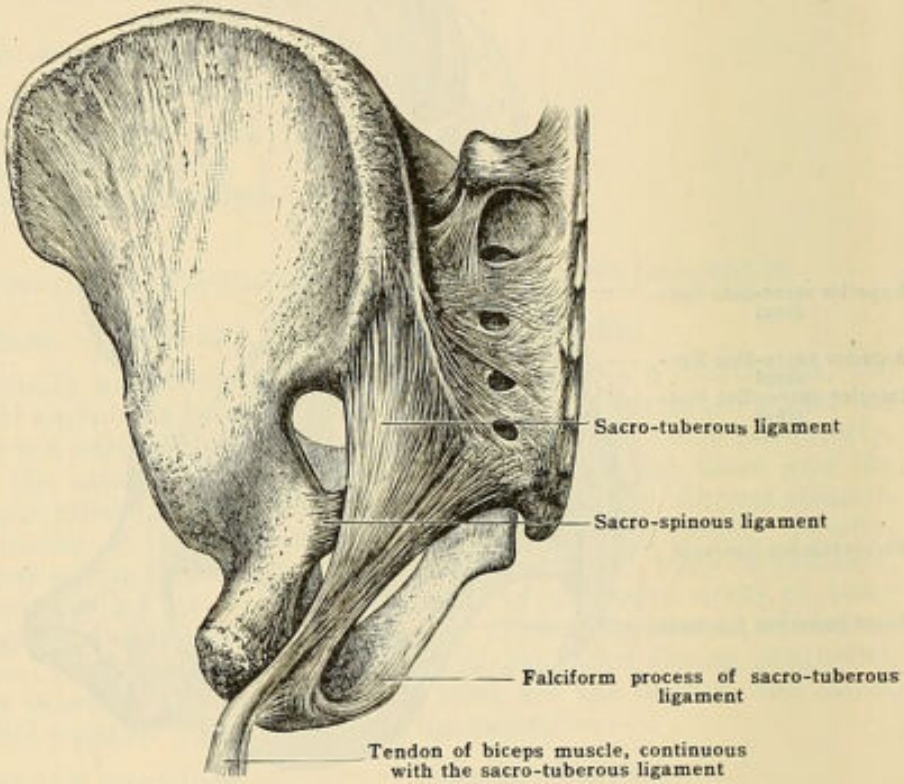

joined by a flat band, the larger triangle being at the ilium, and the smaller at the ischium The fibres of the ligament are twisted upon its axis at the narrow part, so that some of the superior fibres pass to the lower border.

The posterior surface gives origin to the *gluteus maximus* muscle, and on it ramify the loop; from the posterior branches of the sacral nerves; its anterior surface is closely connected at its origin ,with the sacro-spinous ligament, and some fibres of the *piriformis* muscle arise from its below the *obturator internus* passes out of the pelvis under its cover, and the *internal pudic vessels and nerve* pass in. At the ilium, its posterior edge is continuous with the vertebra. aponeurosis; while to the anterior edge is attached the thick fascia covering the gluteus mediusl The obturator fascia is attached to its falciform edge. It is pierced by the *coccygeal branches of the inferior gluteal (sciatic) artery* and the *inferior clunial (perforating cutaneous) nerve* from the *second* and *third sacral.*

The **sacro-spinous** (small sciatic) **ligament** (figs. 271, 272, and 273) is triangular and thin, springing by a broad base from the lateral border of the sacrum and coccyx, from the front of the sacrum both above and below the level of the fourth sacral foramen, and from the coccyx nearly as far as its tip. By its apex it is attached to the front surface and the borders of the ischial spine as far outward as its base. Its fibres decussate so that the lower ones at the coccyx become the highest at the ischial spine; muscular fibres are often seen intermingled with the ligamentous.

The sacro-spinous ligament is situated in front of the sacro-tuberous ligament, with which it is closely connected at the sacrum, and separates the greater from the lesser sciatic foramen.

Its front surface gives attachment to the *coccygeus* muscle, which overlies it. Behind, it is connected with, and hidden by, the sacro-tuberous ligament, so that only the lateral inch or less (2 cm.) and a small part of its attachment to the coccyx can be seen; the *internal pudic* nerve also passes over the posterior surface.

The **arterial supply** of the sacro-iliac joint comes from the superior gluteal, ilio-lumbar, and lateral sacral.

The **nerve-supply** is from the superior gluteal, sacral plexus, and external twigs of the posterior divisions of the first and second sacral nerves.

Movements.—Recent investigations have shown that in spite of the interlocking of the articular surfaces and the strong ligaments connecting the bones together a slight amount of movement, both a gliding and rotatory, does occur at the sacro-iliac joint. The gliding movement is both up and down, and forward and backward, and the latter is associated with a slight rotation round a transverse axis which passes through the upper tubercles on the back of the sacrum. The movement is but small in extent, nevertheless as the base of the sacrum moves

FIG. 274.—LIGAMENTS CONNECTING SACRUM AND COCCYX POSTERIORLY.

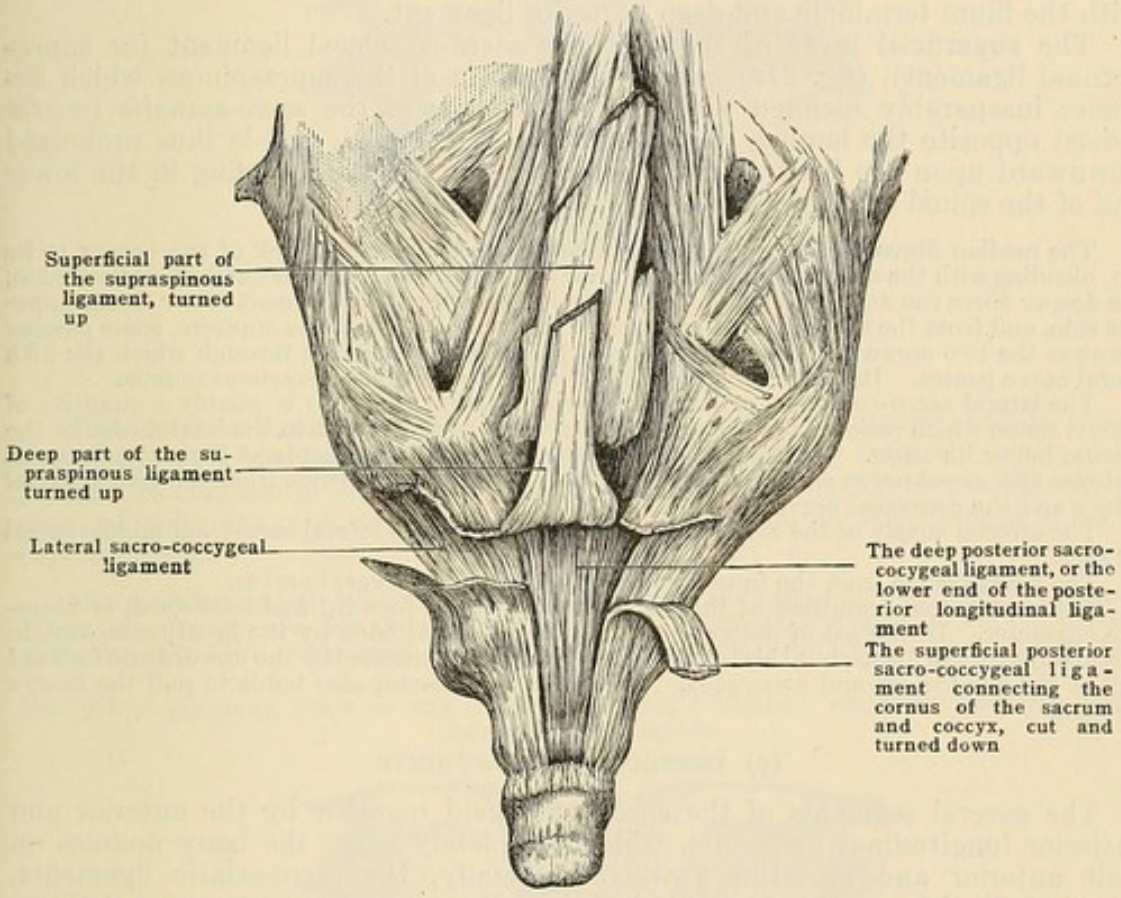

downward and forward the conjugate (antero-posterior) diameter of the pelvic inlet is diminished and at the same time, as the coccyx moves up and back, the conjugate diameter of the outlet is increased. This rotatory movement is limited principally by the sacro-sciatic (sacro-tuberous and sacro-spinous) ligaments which prevent any extensive upward and backward movement of the coccyx and lower part of the sacrum.

Downward displacement of the sacrum when the body is in the sitting posture is prevented not only by the surrounding ligaments, but also by the wedge-like character of the sacrum, which is broader above than below. Downward and forward displacement of the sacrum in the erect posture is prevented by the ligaments and more particularly by the posterior sacro-iliac bands, while backward displacement would be hindered by the breadth of the anterior as contrasted with the posterior part of the sacrum as well as by the anterior ligaments.

Relations.—The sacro-iliac joint is in relation above with psoas and iliacus. In front it is in relation at its upper part with the hypogastric vessels and obturator nerve, and at its lower part with the piriformis muscle.

(*b*) THE SACRO-COCCYGEAL ARTICULATION

Class.—*False Synchondrosis.*

The last piece of the sacrum and first piece of the coccyx enter into this union [symphysis sacrococcygea] and are bound together by the following ligaments:—

Anterior sacro-coccygeal. Deep posterior sacro-coccygeal.
Superficial posterior sacro-coccygeal. Lateral sacro-coccygeal.
Intervertebral substance.

The **intervertebral fibro-cartilage** is a small oval disc, three-quarters of an inch (about 2 cm.) wide, and a little less from before backward, closely connected with the surrounding ligaments. It resembles the other discs in structure, but is softer and more jelly-like, though the laminæ of the fibrous portion are well marked.

The **anterior sacro-coccygeal ligament** is a prolongation of the glistening fibrous structure on the front of the sacrum. It is really the lower extremity of the anterior longitudinal ligament, which is thicker over this joint than over the central part of either of the bones.

The **posterior sacro-coccygeal ligament** (fig. 274) is divided into two layers of which one (the **deep**) is a direct continuation of the posterior longitudinal ligament of the column, consisting of a narrow band of closely packed fibres, which become blended at the lower border of the first segment of the coccyx with the filum terminale and deep posterior ligament.

The **superficial layer** of the posterior sacro-coccygeal ligament (or supracornual ligament), (fig. 274) is the prolongation of the supraspinous which becomes inseparably blended with the aponeurosis of the *sacro-spinalis* (*erector spinæ*) opposite the laminæ of the third sacral vertebra, and is thus prolonged downward upon the back of the coccyx, passing over and roofing in the lower end of the spinal canal where the laminæ are deficient.

The median fibres (the **supraspinous ligament**) extend over the back of the coccyx to its tip, blending with the deep fibres of the posterior sacro-coccygeal ligament and filum terminale; the deeper fibres run across from the stunted laminæ on one side to the next below on the opposite side, and from the sacral cornua on one side to the coccygeal on the opposite, some passing between the two cornua of the same side, and bridging the aperture through which the fifth sacral nerve passes. Its posterior surface gives origin to the *gluteus maximus* muscle.

The **lateral sacro-coccygeal** or **intertransverse ligament** (fig. 274) is merely a quantity of fibrous tissue which passes from the transverse process of the coccyx to the lateral edge of the sacrum below its angle. It is connected with the sacrosciatic ligaments at their attachments, and the *fifth sacral* nerve escapes behind it. It is perforated by twigs from the lateral sacral artery and the coccygeal nerve.

The **arterial supply** of the sacro-coccygeal joint is from the lateral sacral and middle sacral arteries.

The **nerves** come from the fourth and fifth sacral and coccygeal nerves.

The **movements** permitted at this joint are of a simple forward and backward, or hinge-like character. In the act of defecation, the bone is pushed back by the fæcal mass, and, in parturition, by the fœtus; but this backward movement is controlled by the upward and forward pull of the levator ani and coccygeus. The external sphincter also tends to pull the coccyx forward.

(*c*) Intercoccygeal Joints

The several segments of the coccyx are held together by the anterior and posterior longitudinal ligaments, which completely cover the bony nodules on their anterior and posterior aspects. Laterally, the sacro-sciatic ligaments, being attached to nearly the whole length of the coccyx, serve to connect them. Between the first and second pieces of the coccyx there is a very perfect amphiarthrodial joint, with a well-marked intervertebral substance.

Movements.—But little movement occurs as a rule at the sacro-coccygeal and intercoccygeal joints, but when the head of the child is passing through the pelvic outlet at birth, the tip of the coccyx is displaced backward, it may be to the extent of one inch.

(*d*) The Symphysis Pubis

Class.—*False Synchondrosis.*

The bones entering into this joint are the pubic portions of the hip-bones. This joint is shorter and broader in the female than in the male. The ligaments, which completely surround the articulation, are:—

Superior.	Anterior.
Arcuate.	Posterior.

Interpubic cartilage.

The **superior ligament** (figs. 275 and 276) is a well-marked stratum of yellowish fibres which extends lateralward along the crest of the pubis on each side, blending in the middle line with the interosseous cartilage.

It is continuous in front with the deep traverse fibres of the anterior ligament, and behind with the posterior ligament. It gives origin to the *rectus abdominis* tendon.

The **posterior ligament** (fig. 277) is slight, and, excepting above and below, consists of little more than thickened periosteum.

Near the upper part is a band of strong fibres, reaching the whole width of the pubic bones, and continuous with the thickened periosteal fibres along the terminal line. Below, many of the upper and superficial fibres of the arcuate ligament ascend over the back of the joint, and interlace across the median line with fibres from the opposite side nearly as high as the middle of the symphysis.

FIG. 275.—ANTERIOR VIEW OF THE SYMPHYSIS PUBIS (MALE), SHOWING THE DECUSSATION OF THE FIBRES OF THE ANTERIOR LIGAMENT.

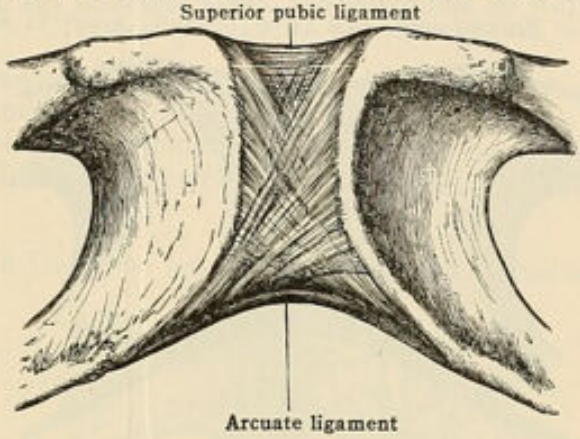

The **anterior ligament** (figs. 275 and 276) is thick and strong, and is closely connected with the fascial covering of the muscles arising from the body of the pubis. It consists of several strata of thick, decussating fibres of different degrees of obliquity, the superficial being the most oblique, and extending lowest over the joint.

The most superficial descending fibres extend from the upper border of the pubis, cross others from the opposite side about the middle of the symphysis, and are attached to the ramus of the opposite bone. The most superficial ascending fibres come from the arcuate ligament,

FIG. 276.—ANTERIOR VIEW OF THE SYMPHYSIS PUBIS (FEMALE), SHOWING GREATER WIDTH BETWEEN THE BONES.

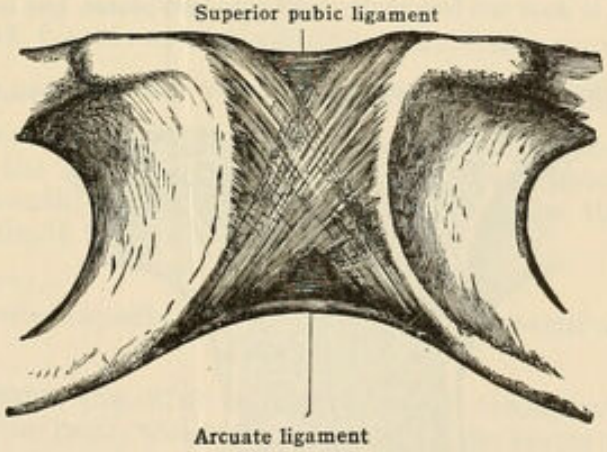

arch upward, and decussate with other fibres across the middle line, and are lost on the opposite side beneath the descending set. There is another deeper set of descending fibres which arise below the angle, but do not descend so far as the superficial; and a deeper set of ascending, which decussate, and reach higher than the superficial set, and are connected with the arcuate ligament. Some few transverse fibres pass from side to side, especially above and below the points of decussation.

The **arcuate** (inferior or subpubic) **ligament** (figs. 275, 276, and 277) is a thick, arch-like band of closely packed fibres which fills up the angle between the pubic rami, and forms a smooth, rounded summit to the pubic arch. On section, it is yellowish in colour and three-eighths of an inch (1 cm.) thick in the middle line; it is inseparably connected with the interpubic cartilage.

Both on the front and back aspects of the joint it gives off decussating fibres, which, by their interlacement over the anterior and posterior ligaments of the symphysis, add very materially to its security. In fact, the ligament may be said to split superiorly into two layers, one passing over the front, and the other over the back, of the articulation.

The **interpubic fibro-cartilage** varies in thickness in different subjects, but is thicker in the female than in the male. It is thicker in front than behind, and projects beyond the edges of the bones, especially posteriorly (see fig. 277), blending intimately with the ligaments at its margins. It is sometimes uninterruptedly woven throughout, but at others has an elongated narrow fissure, partially dividing the cartilage into two plates, with a little fluid in the interspace

FIG. 277.—POSTERIOR VIEW OF THE SYMPHYSIS PUBIS, SHOWING THE DECUSSATION OF THE FIBRES FROM THE ARCUATE LIGAMENT.

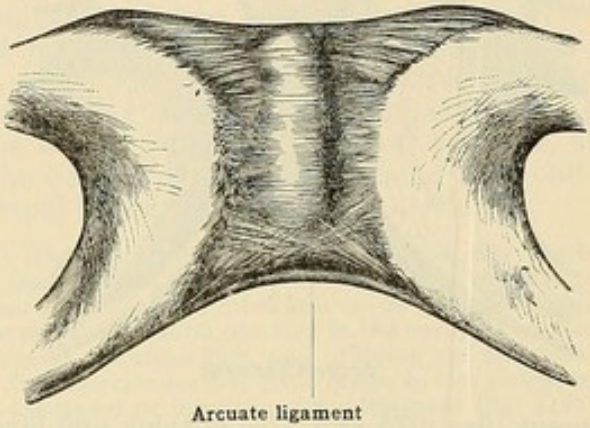

(fig. 278). This is situated toward the upper and posterior aspects, but does not usually reach either; it generally extends about half the length of the cartilage.

When this cavity is large, especially if it reaches or approaches very near to the circumference of the cartilage (which, however, it very rarely does), it is thought by some anatomists that it more nearly resembles a diarthrodial than an amphiarthrodial joint, and it is then classed with the sacro-iliac joint under similar conditions, as 'diarthroamphiarthrosis.' The interosseous cartilage is intimately adherent to the layer of hyaline cartilage which covers the medial surface of each pubic bone; the osseous surface is ridged to give a firmer attachment; and, on forcing the bones apart, it does not frequently split into two plates, but is torn from the bone on one side or the other.

FIG. 278.—SECTION OF SYMPHYSIS TO SHOW THE SYNOVIAL CAVITY.

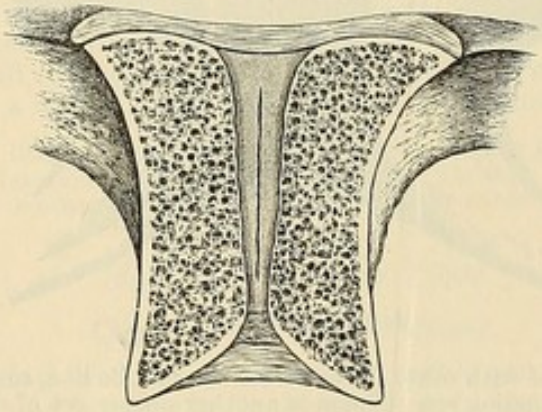

The **arterial supply** of the interpubic joint is from twigs of the internal pudic, pubic branches of the obturator and epigastric, and ascending branches of the internal circumflex and superficial external pudic.

The **nerve-supply** has not been satisfactorily made out, but it probably comes, in part, from the internal pudic and in part from the ilio-hypogastric and ilio-inguinal.

The **movements** amount only to a slight yielding of the cartilage; neither muscular force nor extrinsic forces produce any appreciable movement in the ordinary condition. Occasionally, as the result of child-bearing, the joint becomes unnaturally loose, and then walking and standing are painfully unsteady. It is known that, during pregnancy and parturition, the

symphyseal cartilage becomes softer and more vascular, so as to permit the temporary enlargement of the pelvis; but it must be remembered that the fibres of the oblique muscles decussate and thus, during labour, while they force the head of the fœtus down, they strengthen the joint by bracing the bones more tightly together.

Relations.—The interpubic joint is in relation above with the linea alba. Behind with the prostate and the anterior border of the bladder. In front with the suspensory ligament of the penis or clitoris and below with the dorsal vein of the penis or clitoris and the upper border of the urogenital trigone (triangular ligament).

4. THE COSTO-VERTEBRAL ARTICULATIONS

These consist of two sets, viz.:—

(*a*) The **capitular** (costo-central): i. e., the articulation of the head of the rib with the vertebræ.

(*b*) The **costo-transverse,** or the articulation of the tubercle (of each of the first ten ribs) with the transverse process of the lower of the two vertebræ, with which the head of the rib articulates: i. e., the one bearing its own number, as the first rib with the first thoracic vertebra, the second rib with the second thoracic vertebra, and so on.

FIG. 279.—THE CAPSULAR LIGAMENTS OF THE COSTO-VERTEBRAL JOINTS.

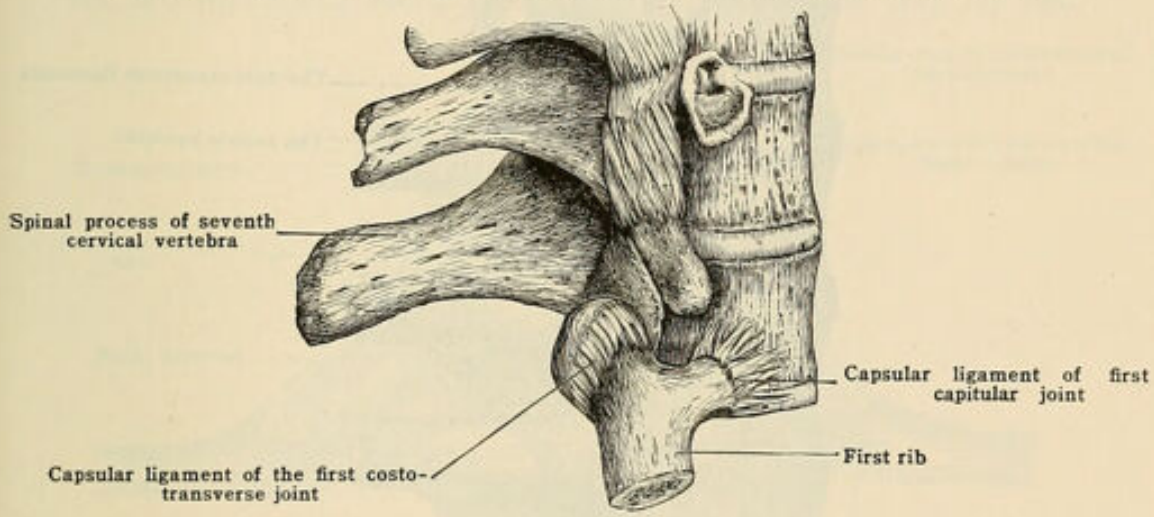

(*a*) THE CAPITULAR (COSTO-CENTRAL) ARTICULATION

Class.—*Diarthrosis.* **Subdivision.**—*Condylarthrosis.*

It is a very perfect joint, into the formation of which the head of the rib and two vertebræ, with the intervertebral disc between them, enter. In the case of the first, tenth, eleventh, and twelfth ribs, it is formed by the head of the rib articulating with a single vertebra.

The **ligaments** are:—

Articular capsule. Interarticular.

Radiate.

The **articular capsule** (fig. 279) consists of short, strong, woolly fibres, completely surrounding the joint, which are attached to the bones and intervertebral substances, a little beyond their articular margins.

At its upper part it reaches through the intervertebral foramen toward the back of the bodies of the vertebræ, being strengthened here by fibres which at intervals connect the anterior with the posterior longitudinal ligaments. The lower fibres extend downward nearly to the demi-facet (costal pit) of the rib below; behind, it is continuous with the neck ligament, and in front is overlaid by the radiate.

The **interarticular ligament** (fig. 280) consists of short, strong fibres, closely interwoven with the outermost ring of the intervertebral disc, and attached to the transverse ridge separating the articular facets on the head of the rib. It completely divides the articulations into two parts, but does not brace the rib tightly to the spine, being loose enough to allow a moderate amount of rotation

on its own axis. There is no interarticular ligament in the costo-vertebral joints of the first, tenth, eleventh, and twelfth ribs.

The **radiate** (or stellate) **ligament,** a thickening of the anterior part of the capsule (figs. 280 and 281), is the most striking of all, and consists of bright, pearly-white fibres attached to the anterior surface, and upper and lower borders of the neck of the rib, a little way beyond the articular facet; from this they radiate upward, forward, and downward, so as to form a continuous layer of distinct and sharply defined fibres.

The middle fibres run straight forward to be attached to the intervertebral disc; the upper ascend to the lower half of the lateral surface of the vertebra above, and the lower descend to the upper half of the vertebra below. The radiate ligament is overlapped on the vertebral bodies by the lateral (short) vertebral ligaments.

In the case of the first, tenth, eleventh, and twelfth ribs, each of which articulates with one vertebra, the ligament is not quite so distinctly radiate, but even in these the ascending fibres reach the vertebra above that with which the rib articulates.

FIG. 280.—SHOWING THE ANTERIOR LONGITUDINAL LIGAMENT, AND THE CONNECTION OF THE RIBS WITH THE VERTEBRÆ.

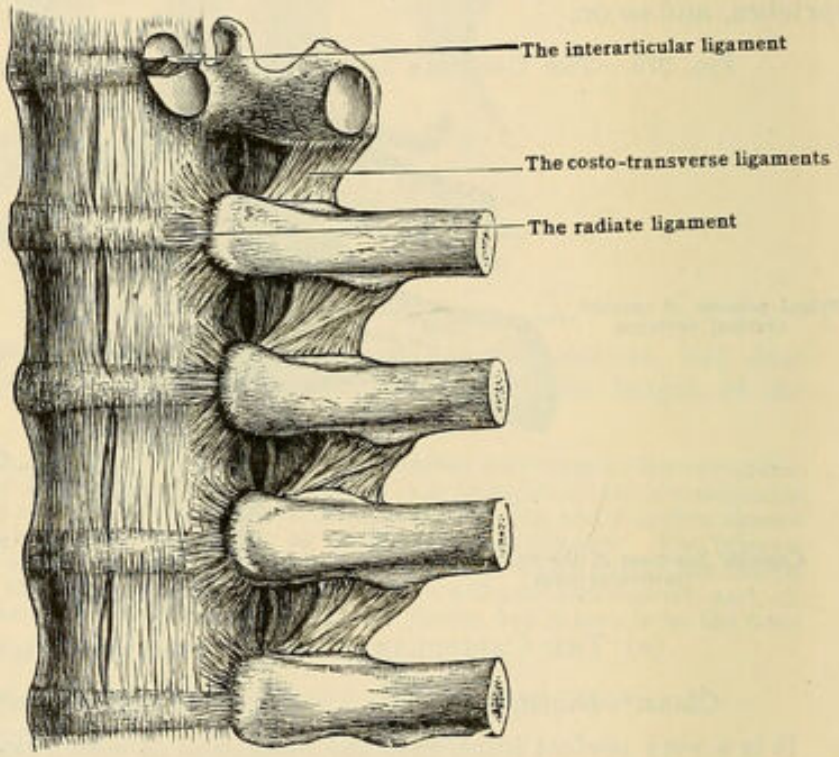

The **synovial membranes** (fig. 281) consist of two closed sacs which do not communicate: one above, and the other below, the interarticular ligament. In the case of the first, tenth, eleventh, and twelfth articulations, there is but one synovial membrane, as these joints have no interarticular ligament.

The **arterial supply** is from the intercostal arteries, the twigs piercing the radiate and capsular ligaments.

The **nerve-supply** comes from the anterior primary branches of the intercostal nerves.

These joints approach most nearly in their movements to the condylarthroses.

The **movements** are ginglymoid in character, consisting of a slight degree of elevation and depression around an obliquely horizontal axis corresponding with the interarticular ligament; there is also a slight amount of forward and backward gliding; and a slight degree of screwing or rotatory movement is also possible. There is a considerable difference in the degree of mobility of the different ribs, for while the first rib is almost immobile except in a very deep inspiration, the mobility of the others increases from the second to the last; the two floating ribs being the most mobile of all. The head of the rib is the most fixed point of the costal arch, and upon it the whole arch rotates; the interarticular ligament allows only a very limited amount of flexion and extension (i. e., elevation and depression), and of gliding. Gliding is checked by the radiate ligament.

In inspiration, the rib is elevated, and glides forward in its socket, too great elevation being checked not only by the ligaments, but also by the overhanging upper edge of the cavity itself. In expiration, the rib is depressed, and glides backward in its cavity.

(*b*) The Costo-transverse Articulation

Class.—*Diarthrosis.* **Subdivision.**—*Arthrodia.*

This joint is formed by the tubercle of the rib articulating with the anterior part of the tip of the transverse process. The eleventh and twelfth ribs are devoid of these joints, for the tubercles of these ribs are absent, and the transverse processes of the eleventh and twelfth thoracic vertebræ are rudimentary.

The ligaments of the union are:—

Articular capsule.	Tubercular ligament.
Neck ligament.	Costo-transverse ligaments.

The **articular capsule** (figs. 279 and 281) forms a thin, loose, fibrous envelope to the synovial membrane. Its fibres are attached to the bones just beyond the articular margins, and are thickest below, where they are not strengthened by any other structure. It is connected medially with the neck ligament, above with the costo-transverse, and laterally with the tubercular (posterior costo-transverse) ligaments. The **eleventh** and **twelfth ribs** are unprovided with costo-transverse capsules.

Fig. 281.—Horizontal Section through the Intervertebral Disc and Ribs.

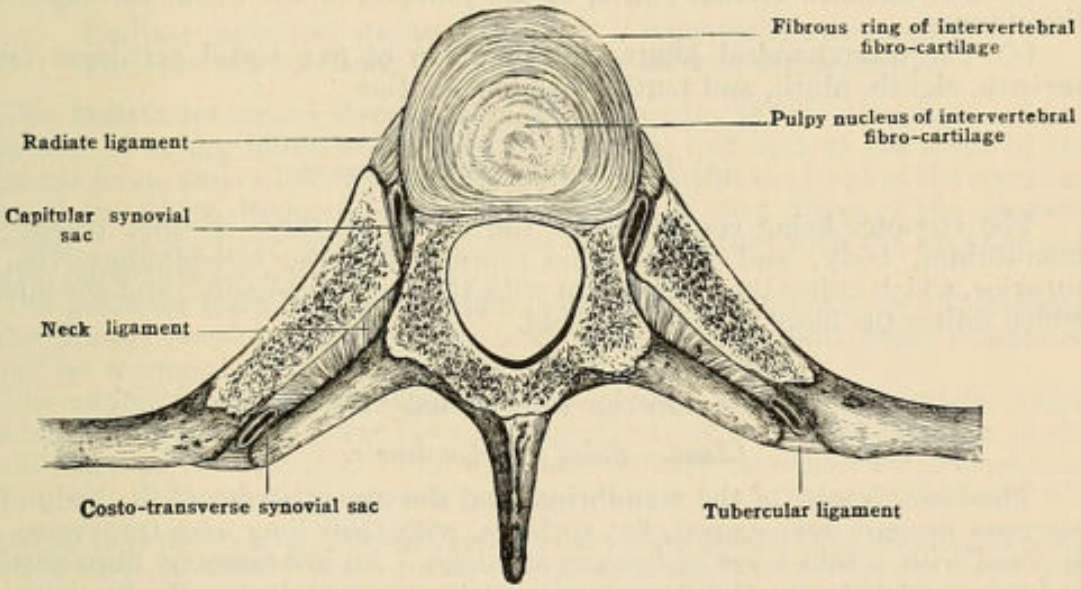

The **neck ligament** [lig. colli costæ] (middle costo-transverse, or interosseous ligament) (fig. 281), consists of short fibres passing between the back of the neck of the rib and front of the transverse process, with which the tubercle articulates. It extends from the capsule of the capitular joint to that of the costo-transverse. It is best seen on horizontal section through the bones. In the **eleventh** and **twelfth** ribs this ligament is rudimentary.

The **tubercular ligament** (posterior costo-transverse) (fig. 281) is a short but thick, strong, and broad ligament, which extends laterally and upward from the extremity of the transverse process to the non-articular surface of the tubercle of the corresponding rib. The **eleventh** and **twelfth** ribs have no posterior ligament.

The (superior) **costo-transverse ligament** (fig. 280) is a strong, broad band of fibres which ascends laterally from the **crest** on the upper border of the neck of the rib, to the lower border of the transverse process above. A few scattered posterior fibres pass upward and medially from the neck to the transverse process. The costo-transverse ligament is subdivided into a stronger anterior portion (anterior costo-transverse ligament) best seen from the front (fig. 280), and a weaker posterior portion (posterior costo-transverse ligament). Its medial border bounds the foramen through which the posterior branches of the intercostal vessels and nerves pass. To the lateral border is attached the thin aponeu-

rosis covering the *external intercostals*. Its anterior surface is in relation with the intercostal vessels and nerve; the posterior with the *longissimus dorsi*. The first rib has no (superior) costo-transverse ligament.

The **synovial membrane** (fig. 281) is a single sac.

The **arterial** and **nerve supplies** come from the posterior branches of the intercostal arteries and nerves.

The **movements** which take place at these joints are limited to a gliding of the tubercle of the rib upon the transverse process. The exact position of the facet on the transverse process varies slightly from above downward, being placed higher on the processes of the lower vertebræ. The plane of movement in most of the costo-transverse joints is inclined upward and backward in inspiration, and downward and forward in expiration. The point round which these movements occur is the head of the rib, so that the tubercle of the rib glides upon the transverse process in the circumference of a circle, the centre of which is at the capitular joint.

5. THE ARTICULATIONS AT THE FRONT OF THE THORAX

These may be divided into four sets, viz.:—

(*a*) The **intersternal joints,** or the union of the several parts of the sternum with one another.

(*b*) The **costo-chondral joints,** or the union of the ribs with their costal cartilages.

(*c*) The **chondro-sternal joints,** or the junction of the costal cartilages with the sternum.

(*d*) The **interchondral joints,** or the union of five costal cartilages (sixth, seventh, eighth, ninth, and tenth) with one another.

(*a*) The Intersternal Joints

The sternum being composed, in the adult, of three distinct pieces—the manubrium, body, and the xiphoid process—has two articulations, viz., the superior, which unites the manubrium with the body (gladiolus), and the inferior, which unites the body with the xiphoid.

1. The Superior Intersternal Articulation

Class.—*False Synchondrosis.*

The lower border of the manubrium and the upper border of the body of the sternum present oval-shaped, flat surfaces, with their long axes transverse, and covered with a thin layer of hyaline cartilage. An **interosseous fibro-cartilage** is interposed between the bony surfaces: it corresponds exactly in shape and intimately adheres to them. At each lateral border this fibro-cartilage enters into the formation of the second chondro-sternal articulation (fig. 282).

In consistence it varies, being in some cases uniform throughout, in others softer in the centre than at the circumference, and in others again an oval-shaped synovial cavity is found toward its anterior part. When such a cavity exists in the fibro-cartilage this joint has a remote resemblance to the diarthroses, and is classed, with the sacro-iliac joint and the symphysis pubis under similar conditions, as 'diarthro-amphiarthrosis.'

The periosteum passes uninterruptedly over the joint from one segment of the sternum to the other, forming a kind of capsular ligament [membrana sterni]. This capsule is strengthened, especially on its posterior aspect, by longitudinal ligamentous fibres as well as by the radiating and decussating fibres of the chondro-sternal ligaments.

In some instances the fibro-cartilage is replaced by short bundles of fibrous tissue which unite the cartilage-coated articular bony surfaces.

2. The Inferior Intersternal Articulation

Class.—*False Synchondrosis.*

The gladiolus is joined to the xiphoid cartilage by a thick investing membrane, by anterior and posterior longitudinal fibres, and by radiating fibres of the sixth and seventh chondro-sternal ligaments. The **costo-xiphoid ligament** also connects the xiphoid with the anterior surface of the sixth and seventh costal cartilages, and thus indirectly with the gladiolus; and some fine fibro-areolar tissue also connects the xiphoid with the back of the seventh costal cartilage.

The junction of the xiphoid with the sternum is on a level somewhat posterior to the junction of the seventh costal cartilage with the sternum. The union is a synchondrosis, each bone being covered by hyaline cartilage which is connected with the intervening fibro-cartilage plate.

(*b*) The Costo-chondral Joints

Class.—*Synarthrosis.*

The extremity of the costal cartilage is received into a cup-shaped depression at the end of the rib, which is somewhat larger than the cartilage. The two are joined together by the continuity of the investing membranes, the periosteum of the rib being continuous with the perichondrium of the cartilage.

(*c*) The Sterno-costal Articulations

Class.—*Diarthrosis.* **Subdivision**—*Ginglymus.*

These articulations are between the lateral borders of the sternum and the ends of the costal cartilages. The union of the first rib with the sternum is *synchondrodial*, and therefore forms an exception to the others. From the second to the seventh inclusive, the articulations have the following ligaments, which together form a complete capsule:—

Radiate (anterior) sterno-costal.	Superior sterno-costal.
Posterior sterno-costal.	Inferior sterno-costal.

The **radiate** (anterior) **sterno-costal ligament** (fig. 282) is a triangular band composed of strong fibres which cover the medial half-inch of the front of the costal cartilage, and radiate upward and downward upon the front of the sternum. Some of the fibres decussate across the middle line with fibres of the opposite ligament. At its upper and lower borders it is in contact with the superior and inferior ligaments respectively.

The **posterior sterno-costal ligament** consists of little more than a thickening of the fibrous envelopes of the bone and cartilage, the joint being completed behind by a continuity of perichondrium with periosteum.

The **superior** and **inferior ligaments** are strong, well-marked bands, which pass from the upper and lower borders respectively of the costal cartilage to the lateral edges of the sternum. The sixth and seventh cartilages are so close that the superior ligament of the seventh is blended with the inferior of the sixth rib.

Deeper than the fibres of these ligaments are short fibres passing from the margins of the sternal facets to the edges of the facets on the cartilages; they are most distinct in the front and lower part of the joint, and may encroach so much upon the synovial cavity as to reduce it to a very small size, or almost obliterate it. This occurs mostly in the case of the sixth and seventh joints, especially the latter.

The **interarticular ligament** (fig. 282) is by no means constant, but is usually present in the second joint on one, if not on both sides of the same subject. It consists of a strong transverse bundle of fibres passing from the ridge on the facet on the cartilage to the fibrous substance between the manubrium and body; sometimes the upper part of the synovial cavity is partially or entirely obliterated by short, fine, ligamentous fibres.

The **costo-xiphoid ligament** (fig. 282) is a strong flat band of fibres passing obliquely upward and laterally from the front surface of the xiphoid cartilage to the anterior surface of the sternal end of the seventh costal cartilage, and most frequently to that of the sixth also.

Synovial membranes.—The union of the first cartilage with the sternum being synchondrodial, it has no synovial membrane; the second has usually two, separated by the interarticular ligament. The rest usually have one synovial membrane, which may occasionally be subdivided into two (fig. 282).

The **arterial supply** is derived from perforating branches of the internal mammary; and the **nerves** come from the anterior branches of the intercostals.

Movements.—Excepting the first, the chondro-sternal joints are ginglymoid, but the motion of which they are capable is very limited. It consists of a hinge-like action in two directions: first, there is a slight amount of elevation and depression which takes place round a transverse axis, and, secondly, there is some forward and backward movement round an obliquely vertical axis. In inspiration the cartilage is elevated, the lowest part of its articular facet is pressed into the sternal socket, and the sternum is thrust forward so that the upper

and front edges of the articular surfaces separate a little; in expiration the reverse movement takes place. Thus the two extremities of the costal arches move in their respective sockets in opposite directions.

This difference results necessarily from the fact that the costal arch moves upon the vertebral column, and, having been elevated, it in its turn raises the sternum by pushing it upward and forward.

The costo-xiphoid ligament tends to prevent the xiphoid cartilage from being drawn backward by the action of the diaphragm.

FIG. 282.—THE ARTICULATION AT THE FRONT OF THE THORAX.
(Left side, showing ligaments; right side, the synovial cavities.)

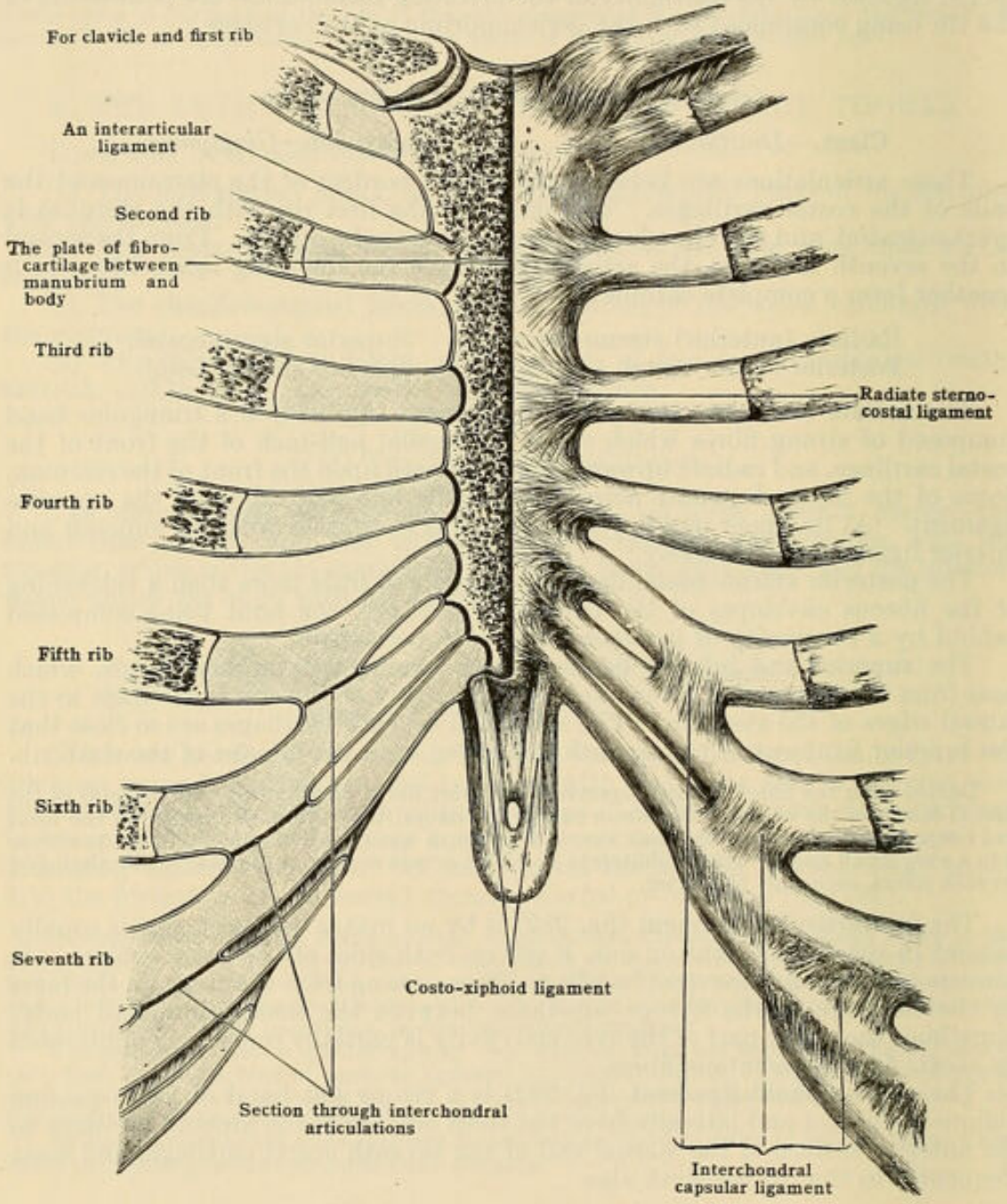

(*d*) THE INTERCHONDRAL ARTICULATIONS

Class.—*Diarthrosis.* **Subdivision.**—*Arthrodia.*

A little in front of the point where the costal cartilages bend upward toward the median line the sixth is united with the seventh, the seventh with the eighth, the eighth with the ninth, and the ninth with the tenth.

At this point each of the cartilages from the sixth to the ninth inclusive is deeper than elsewhere, owing to the projection downward from its lower edge of a broad blunt process, which comes into contact with the cartilage next below. Each of the apposed surfaces is smooth,

and they are connected at their margins by ligamentous tissue, which forms a complete capsule for the articulation, and is lined by a synovial membrane (fig. 282). The largest of these cavities is between the seventh and eighth; those between the eighth and ninth, and ninth and tenth, are smaller, and are not free to play upon each other in the whole of their extent, being held together by ligamentous tissue at their anterior margins. Sometimes this fibrous tissue completely obliterates the synovial cavity.

The **arteries** are derived from the musculo-phrenic, and the **nerves** from the intercostals.

Movements.—By means of the costal cartilages and interchondral joints, strength with elasticity is given to the wall of the trunk at a part where the cartilages are the only firm structures in its composition; while a slight gliding movement is permitted between the costal cartilages themselves, which takes place round an axis corresponding to the long axis of the cartilages. By this means, the outward projection of the lower part of the thoracic wall is increased by deep inspiration.

MOVEMENTS OF THE THORAX AS A WHOLE

Before describing these movements as a whole, it must be premised that there are somt few modifications in the movements of certain ribs resulting from their shape. Thus the firs rib (and to a less extent the second also), which is flat on its upper and lower surfaces, revolves on a transverse axis drawn through the costo-vertebral and costo-transverse joints. During inspiration and expiration, the anterior extremities of the first pair of costal arches play up and down, the tubercles and the heads of the ribs acting in a hinge-like manner, the latter having also a slight screwing motion. By this movement the anterior ends of the costal arches are simply raised or depressed, and the sternum pushed a little forward; it may be likened to the movement of a pump-handle, as in fig. 283, *a*, *b*.

The movements of the other ribs, particularly in the mid-region of the thorax, are more complex, for, besides the elevation of the anterior extremities, the bodies and angles of the

FIG. 283.—DIAGRAM OF AXIS OF RIB-MOVEMENT. (After Kirkes.)

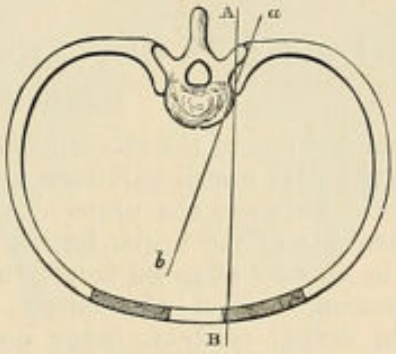

ribs rise nearly as much as the extremities themselves. In this movement the tubercles of the ribs glide upward and backward in inspiration, and downward and forward in expiration; and the movement may be likened to that of a bucket handle, as in fig. 283, A, B.

During inspiration, the cavity of the thorax is increased in every direction. The **antero-posterior diameter** is increased by the thrusting forward of the sternum, caused by the elevation of the costal cartilages and fore part of the ribs, whereby they are brought to nearly the same level as the heads of the ribs. The **transverse diameter** is increased: (i) Behind, by the elevation of the middle part of the ribs; for when at rest the mid-part of the rib is on a lower level than either the costo-vertebral or chondro-sternal articulations. Owing to this obliquity the transverse diameter is increased when the rib is raised, and the increase is proportionate to the degree of obliquity. (ii) By the eversion of the lower border of the costal arch, which turns outward as the arch is raised. (iii) The transverse diameter is increased in front by the abduction of the anterior extremity of the rib at the same time as it is elevated and thrust forward.

The increase in the **vertical diameter** of the thorax is due to the elevation of the ribs, especially the upper ones, and the consequent widening of the intercostal spaces; but the chief increase in this direction is due to the descent of the diaphragm.

The greatest increase both in the antero-posterior and transverse diameters takes place where the ribs are longest, most oblique, and most curved at their angles, and where the bulkiest part of the lung is enclosed. This is on a level with the sixth, seventh, and eighth ribs.

At the lower part of the thorax, where the ribs have no relation to the lungs, and do not affect respiration directly by their movements, it is important that the costal arches should be thrown well outward in order to counteract the compression of the abdominal viscera by the contraction of the diaphragm.

By widening and steadying the lower part of the thorax during inspiration, the attachments of the muscular fibres of the diaphragm are widened, and their power increased.

Muscles which take part in the movements of inspiration.—(*a*) *Ordinary inspiration;* The scalenes, serratus posterior superior, the external and internal (?) intercostals, the diaphragm; the quadratus lumborum and serratus posterior inferior fixing the lower ribs, possibly the posterior fibres of the external oblique also helping to fix the lower ribs. (*b*) *Extraordinary inspiration:* The superior extremities are raised and fixed. The cervical part of the vertebral column and the head are extended, and in addition to the muscles of ordinary inspiration, the following

muscles also come into play: The pectoralis minor, the muscles which extend the head and the cervical part of the vertebral column, the sterno-mastoid and the supra- and infra-hyoid muscles, the lower fibres of the pectoralis major, some of the lower fibres of the serratus anterior, and, when the clavicle is fixed, the subclavius.

Expiration is produced by the elasticity of the lungs and the weight of the thorax, aided by the elastic reaction and contraction of the external and internal oblique muscles, the recti and pyramidales, the transversus abdominis, and the levatores ani and coccygei. In forcible expiration all muscles which depress the ribs and reduce the dimensions of the abdomen are thrown into action. The internal intercostals probably tend to contract the thorax, excepting the parts between the costal cartilages, which tend to expand the thorax.

THE ARTICULATIONS OF THE UPPER EXTREMITY

The articulations of the upper extremity are the following:—

1. The **sterno-costo-clavicular.**
2. The **scapulo-clavicular union.**
3. The **shoulder-joint.**
4. The **elbow-joint.**
5. The **radio-ulnar union.**
6. The **radio-carpal** or **wrist-joint.**
7. The **carpal joints.**
8. The **carpo-metacarpal joints.**
9. The **intermetacarpal joints.**
10. The **metacarpo-phalangeal joints.**
11. The **interphalangeal joints.**

1. THE STERNO-COSTO-CLAVICULAR ARTICULATION

Class.—*Diarthrosis.* **Subdivision.**—*Condylarthrosis.*

At this joint the large medial end of the clavicle is united to the superior angle of the manubrium sterni, the first costal cartilage also assisting to support the clavicle. It is the only joint between the upper extremity and the trunk, and takes part in all the movements of the upper limb. Looking at the bones, one would say that they were in no way adapted to articulate with one another, and yet they assist in constructing a joint of security, strength, and importance. The bones are nowhere in actual contact, being completely separated by an articular disc. The interval between the joints of the two sides varies from one inch to an inch and a half (2.5–4 cm.). The ligaments of this joint are:—

(1) Articular capsule.
(2) Interclavicular.
(3) Articular disc.
(4) Costo-clavicular.

The **articular capsule** (fig. 284) consists of fibres, having varying directions and being of various strength and thickness, which completely surround the articulation, and are firmly connected with the edges of the interarticular fibro-cartilage.

The fibres at the back of the joint, sometimes styled the **posterior sterno-clavicular ligament,** are stronger than those in front or below, and consist of two sets: a superficial, passing upward and laterally from the manubrium sterni, to the projecting posterior edge of the end of the clavicle, a few being prolonged onward upon the posterior surface of the bone. A deeper set of fibres, especially thick and numerous below the clavicle, connect the interarticular cartilage with the clavicle and with the sternum, but do not extend from one bone to the other. The fibres in front, the **anterior sterno-clavicular ligament,** are well marked, but more lax and less tough than the posterior, and are overlaid by the tendinous sternal origin of the *sterno-mastoid*, the fibres of which run parallel to those of the ligament. They extend obliquely upward and laterally from the margin of the sternal facet to the anterior surface of the clavicle some little distance from the articular margin. The fibres which cover in the joint **below** are short, woolly, and consist more of fibro-areolar tissue than true fibrous tissue; they extend from the upper border of the first costal cartilage to the lower border of the clavicle just lateral to the articular margin, and fill up the gap between it and the costo-clavicular ligament. The **superior portion** consists of short tough fibres passing from the sternum to the articular disc; and of others welding the fibro-cartilage to the upper edge of the clavicle, only a few of them passing from the clavicle direct to the sternum.

The **interclavicular ligament** (fig. 284) is a strong, concave band, materially strengthening the superior portion of the capsule. It is nearly a quarter of an

inch (6 mm.) deep with the concavity upward, its upper border tapering to a narrow, almost sharp edge. It is connected with the posterior superior angle of the sternal extremity of each clavicle, and with the fibres which weld the inter-articular cartilage to the clavicle; and then passes across from clavicle to clavicle along the posterior aspect of the upper border of the manubrium sterni. The lowest fibres are attached to the sternum, and join the posterior fibres of the capsule of each joint. In the middle line, between the ligament and the sternum, there is an aperture for the passage of a small artery and vein.

In addition to the interclavicular ligament Mr. Carwardine ("Journal of Anatomy and Physiology," vol. 7, new series, p. 232) has described a special band of the upper portion of the sterno-clavicular capsule which he proposes to name the 'suprasternal ligament.' It descends from the upper border of the sternal end of the clavicle to the upper border of the sternum, and is of special importance as it encloses the **suprasternal bones**, when these rudiments are present.

The **costo-clavicular** or rhomboid **ligament** (fig. 284) is a strong dense band, composed of fine fibres massed together into a membranous structure. It extends from the upper (medial) border of the first costal cartilage (and rib),

FIG. 284.—POSTERIOR VIEW OF THE STERNO-COSTO-CLAVICULAR JOINT.

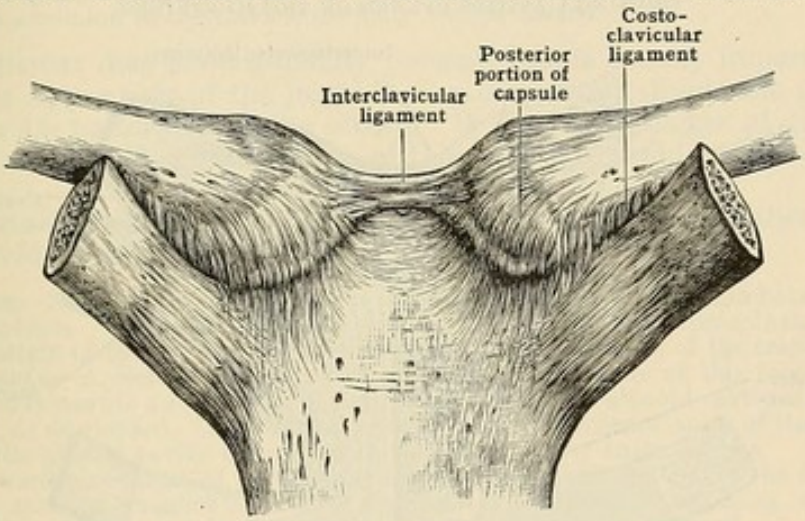

upward, backward, and distinctly laterally to the costal tuberosity on the under surface of the medial extremity of the clavicle, to which it is attached just lateral to the lower part of the capsule. Frequently some of the lateral fibres pass upward and medially behind the rest, and give the appearance of decussating. It is from half to three-quarters of an inch (1.5–2 cm.) broad.

The **articular disc** (fig. 285) is a flattened disc of nearly the same size and outline as the medial articular end of the clavicle, which it fairly accurately fits. It is attached above to the upper border of the posterior edge of the clavicle; and below to the cartilage of the first rib at its union with the sternum, where it assists in forming the socket for the clavicle. At its circumference it is connected with the articular capsule, and this connection is very strong behind, and still stronger above, where it is blended with the interclavicular ligament.

It is usually thinnest below, where it is connected with the costal cartilage. It varies in thickness in different parts, sometimes being thinner in the centre than at the circumference sometimes the reverse, and is occasionally perforated in the centre. It divides the joint into two compartments.

There are two **synovial membranes** (fig. 285); a lateral one, which is reflected from the clavicle and capsule over the lateral aspect of the disc and is looser than the medial one; the medial is reflected from the sternum over the medial side of the articular disc, costal cartilage, and capsule. Occasionally a communication takes place between them.

The **arterial supply** is derived from branches—(1) from the internal mammary; (2) from the superior thoracic branch of the axillary; (3) twigs of a muscular branch often arising from the subclavian artery pass over the interclavicular notch; (4) twigs of the transverse scapular (suprascapular) artery.

The **nerve-supply** is derived from the nerve to the *subclavius* and sternal descending branch of the cervical plexus.

Relations.—In front of the joint is the sternal head of the sterno-mastoid. Behind it are the sterno-hyoid and sterno-thyreoid muscles. Still further back, on the right side, are the innominate and internal mammary arteries, and, on the left side, the left common carotid, the left subclavian, and the internal mammary arteries. Above and behind, between the sterno-mastoid and sterno-hyoid muscles, the anterior jugular vein passes back and laterally toward the posterior triangle.

The **movements** permitted at this joint are various though limited, owing to the capsular ligament being moderately tense in every position of the clavicle. Motion takes place in nearly every direction—viz., upward, downward, forward, backward, and in a circumductory manner. The upward and downward motions occur between the clavicle and the articular disc; during elevation of the arm the upper edge of the clavicle with its attached articular disc is pressed into the sternal socket, and the lower edge glides away from the disc; during depression of the limb, the lower edge of the clavicle presses on to the disc, while the rest of the articular surface of the clavicle inclines laterally, bringing with it to a slight degree the upper edge of the articular disc. These movements occur on an antero-posterior axis drawn through the outer compartment of the joint. The forward and backward motions take place between the articular disc and sternum, the clavicle with the disc gliding backward upon the sternum when the shoulder is brought forward, and forward when the shoulder is forced backward; these movements occur round an axis drawn nearly vertically through the sternal socket.

FIG. 285.—ANTERIOR VIEW OF STERNO-COSTO-CLAVICULAR JOINT, WITH SECTION SHOWING CAVITIES OPENED ON THE RIGHT SIDE.

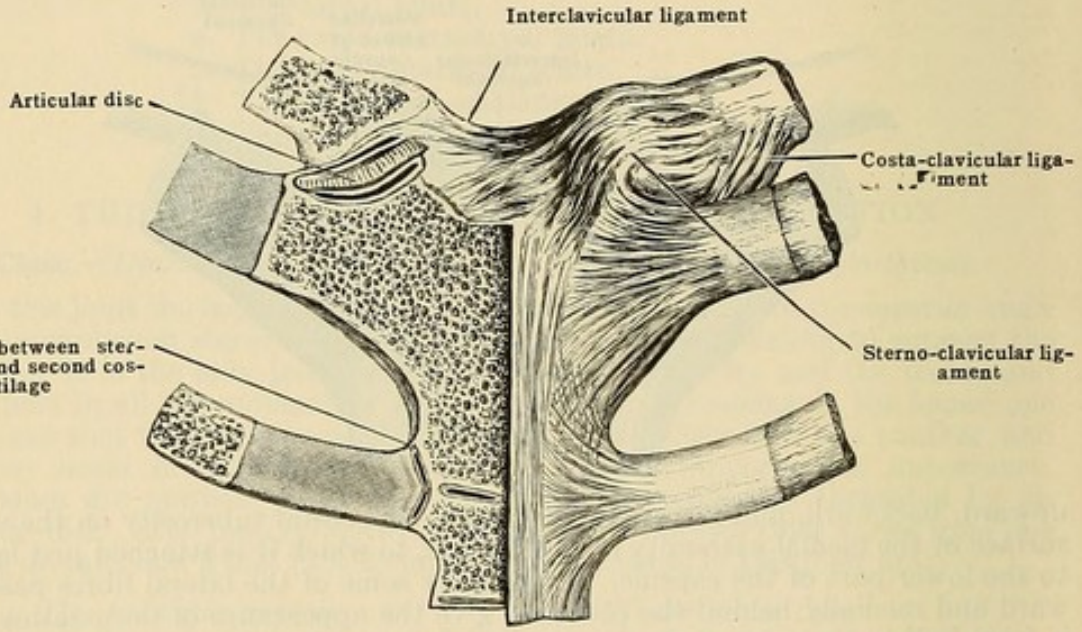

The articular disc serves materially to bind the bones together, and to prevent the media and upward displacements of the clavicle. It also forms an elastic buffer which tends to break shocks. The capsule, by being moderately tight, tends to limit movements in all directions, while the interclavicular ligament is a safeguard against upward displacement during depression of the arm. The costo-clavicular ligament prevents dislocation upward during elevation of the arm, and resists displacements backward.

Muscles which move the clavicle at the sterno-clavicular joint.—*Elevators.*—Trapezius, clavicular part of sterno-mastoid, levator scapulæ, omo-hyoid, rhomboids.

Depressors.—Subclavius, pectoralis minor, lower fibres of trapezius and serratus anterior (magnus). Depression is aided by the weight of the upper extremity.

Protractors.—Pectoralis major and minor. Serratus anterior (magnus).

Retractors.—Latissimus dorsi, trapezius.

2. THE SCAPULO-CLAVICULAR UNION

The scapula is connected with the clavicle by a synovial joint with its ligaments at the acromio-clavicular articulation; and also by a set of ligaments passing between the coracoid process and the clavicle. So that we have to consider—

(*a*) The **acromio-clavicular articulation.**

(*b*) The **coraco-clavicular ligaments.**

(*c*) The **proper scapular ligaments** are also best described in this section—viz., the **coraco-acromial** and **transverse.**

(*a*) The Acromio-clavicular Joint

Class.—*Diarthrosis.* **Subdivision.**—*Arthrodia.*

The acromio-clavicular joint is surrounded by an articular capsule and frequently contains an articular disc.

The **articular capsule** (figs. 287 and 290) completely surrounds the articular margins, and is composed of strong, coarse fibres arranged in parallel fasciculi, of fairly uniform thickness, which are attached to the borders as well as the surfaces of the bones. It is somewhat lax in all positions of the joint, so that the clavicle is not tightly braced to the acromion. The fibres extend three-quarters of an inch (2 cm.) along the clavicle posteriorly, but only a quarter of an inch (6 mm.) anteriorly. Superiorly, they are attached to an oblique line joining these two points, while inferiorly they reach to the ridge for the trapezoid ligament with which they blend.

At the acromion they extend half way across the upper and lower surfaces, but at the anterior and posterior limits of the joint they are attached close to the articular facet. The anterior fibres become blended with the insertion of the coraco-acromial ligament. The fibres are strengthened above by the aponeuroses of the *trapezius* and *deltoid* muscles; and all run from the acromion to the clavicle medially and backward.

The **articular disc** is occasionally present, but is usually imperfect, only occupying the upper part of the joint; it may completely divide the joint into two cavities, or be perforated in the centre. It is usually thicker at the edge than in the centre, and some of the fibres of the articular capsule are blended with its edges.

The **synovial membrane** lining the joint is occasionally either partially or entirely divided into two by the articular disc.

Relations.—Superiorly skin and fascia and the tendinous intersection between the deltoid and the trapezius. Inferiorly, the coraco-acromial ligament and supraspinatus. Anteriorly, part of the origin of the deltoid. Posteriorly, part of the insertion of the trapezius.

Movements.—A certain amount of gliding movement occurs at this joint, but the most important movement is a rotation of the scapula whereby the glenoid cavity is turned forward and upward, or downward. As these movements occur the inferior angle of the scapula moves forward as the glenoid cavity turns upward and the superior angle recedes.

The forward movement of the inferior angle is produced mainly by the inferior fibres of the serratus anterior (magnus), aided by the inferior fibres of the trapezius, and it is by this movement that the arm is raised above the level of the shoulder forward.

The reverse movement is produced mainly by the rhomboideus major aided by the latissimus dorsi.

(*b*) The Coraco-clavicular Union

The **coraco-clavicular ligament** (figs. 286, 287, and 290) consists of two parts, the conoid and the trapezoid ligaments.

The **conoid ligament** is the medial and posterior portion, and passes upward and laterally from the coracoid process to the clavicle.

It is a very strong and coarsely fasciculated band of triangular shape, the apex being fixed to the medial and posterior edge of the root of the coracoid process just in front of the scapular notch, some fibres joining the transverse ligament. Its base is at the clavicle, where it widens out, to be attached to the posterior edge of the inferior surface, as well as to the coracoid tubercle. It is easily separated from the trapezoid, without being absolutely distinct. A small bursa often exists between it and the coracoid process; medially, some of the fibres of the *subclavius* muscle are often attached to it.

The **trapezoid ligament** is the anterior and lateral portion of the coraco-clavicular ligament. It is a strong, flat, quadrilateral plane of closely woven fibres, the surfaces of which look upward and medially toward the clavicle, and downward and laterally over the upper surface of the coracoid process.

At the coracoid it is attached for about an inch (2.5 cm.) to a rough ridge which runs forward from the angle, along the anterior border of the process. At the clavicle it is attached to the oblique ridge which runs laterally and forward from the coracoid tubercle, reaching as far as, and blending with the inferior part of the acromio-clavicular ligament. Its anterior edge is free, and overlies the coraco-acromial ligament; the posterior edge is shorter than the anterior, and is in contact with the posterior and lateral portion of the conoid ligament.

The **arterial supply** is derived from the transverse scapular (suprascapular), acromial branches of the thoraco-acromial, and the anterior circumflex.

The **nerve-supply** is derived from the suprascapular and axillary (circumflex) nerves.

Movements.—In the movements of the shoulder girdle, the scapula moves upon the lateral end of the clavicle, and the clavicle, in turn, carried by the uniting ligaments, moves upon the sternum; so that the entire scapula moves in the arc of a circle whose centre is at the sterno-clavicular joint, and whose radius is the clavicle. The scapula, in moving upon the clavicle, also moves upon the thorax forward and backward, upward and downward, and also in a rotatory direction upon an axis drawn at right angles to the centre of the bone. Throughout these movements the inferior angle and base of the scapula are kept in contact with the ribs by the

FIG. 286.—ANTERIOR VIEW OF SHOULDER, SHOWING ALSO CORACO-CLAVICULAR AND CORACO-ACROMIAL LIGAMENTS.

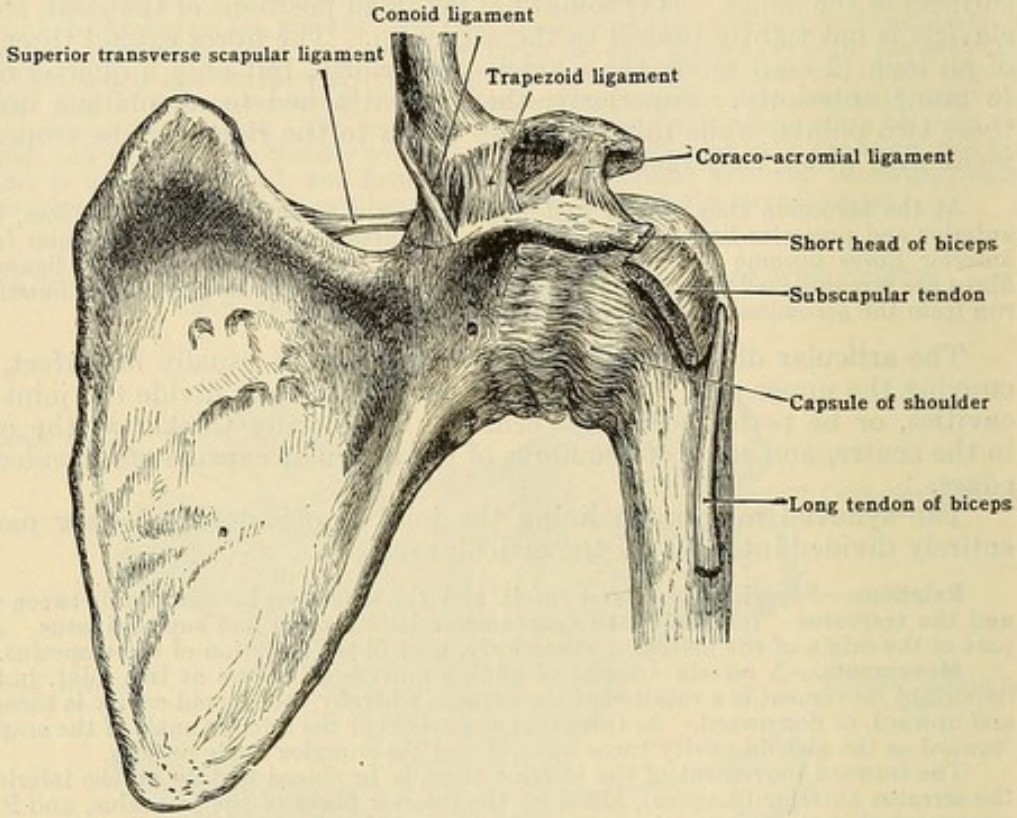

latissimus dorsi, which straps down the former, and the *rhomboids* and *serratus anterior* (*magnus*), which brace down the latter. The glenoid cavity could not have preserved its obliquely forward direction had there been no acromio-clavicular joint, but would have shifted round a vertical axis, and thus the shoulder would have pointed medialward when the scapula was advanced, and lateralward when it was drawn backward. By means of the acromio-clavicular joint, the scapula can be forcibly advanced upon the thorax, the glenoid cavity all the time keeping its face duly forward. Thus the muscles of the shoulder and forearm can be with advantage combined, as, for example, in giving a direct blow. The acromio-clavicular joint also permits the lower angle of the scapula to be retained in contact with the chest wall during the rising and falling of the shoulder, the scapula turning in a hinge-like manner round the horizontal axis of the joint.

There are no actions in which the scapula moves on a fixed clavicle, or the clavicle on a fixed scapula; the two bones, bound together by their connecting ligament, must move in unison.

(*c*) THE PROPER SCAPULAR LIGAMENTS

There are three proper ligaments of the scapula, which pass between different portions of the bone, viz.—

Coraco-acromial. Superior transverse.
Inferior transverse.

The **coraco-acromial ligament** (figs. 286 and 290) is a flat, triangular band with a broad base, attached to the lateral border of the coracoid process, and a blunt apex which is fixed to the tip of the acromion. It is made up of two broad marginal bands, and a smaller and thinner intervening portion. The **anterior band,** which arises from the anterior portion of the coracoid process, is the stronger, and some of its marginal fibres can often be traced into the short head of the biceps, which can then make tense this edge of the ligament. The **posterior band,** coming from the posterior part of the coracoid process, is also strong.

The intermediate part, of variable extent, is thin and membranous, containing but few ligamentous fibres; it is often incomplete near the coracoid process, leaving a small gap (fig. 286).

The superior surface of the ligament looks upward and a little forward, and is covered by the *deltoid* muscle; the inferior looks downward and a little backward, and is separated from the capsule of the shoulder-joint by a bursa and the tendons of the *supraspinatus* and *subscapularis* muscles. At the coracoid process it overlies the coraco-humeral ligament. It is barely one-third of an inch (8 mm.) above the capsule of the shoulder, and in the undissected state there is scarcely a quarter of an inch (6 mm.) interval. The anterior band projects over the centre of the head of the humerus, and is continued into a tough fascia under the deltoid; the posterior band is continuous with the fascia over the supraspinatus muscle. It binds the

FIG. 287.—POSTERIOR VIEW OF THE SHOULDER-JOINT, SHOWING ALSO THE ACROMIO-CLAVICULAR JOINT AND THE SPECIAL LIGAMENTS OF THE SCAPULA.

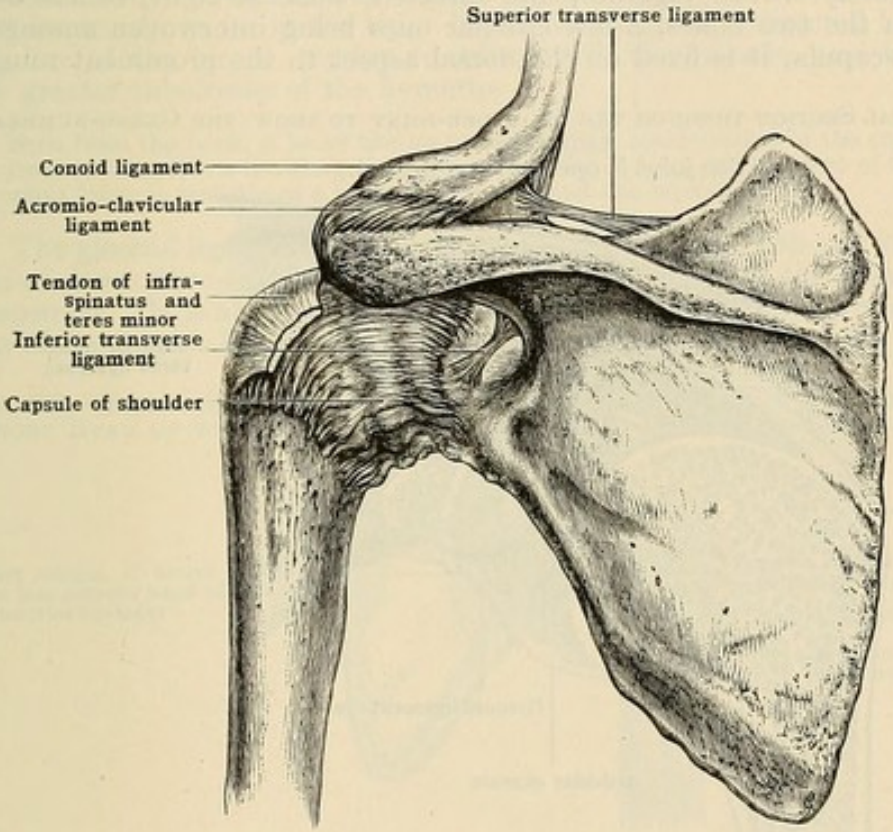

two processes firmly together, and so strengthens each; it holds the deltoid off the capsule of the shoulder, and protects the joint from slight injuries directed downward and backward against it.

The **superior transverse** (coracoid, or suprascapular) **ligament** (figs. 286, 287, and 288) is a small triangular band of fibrous tissue, the surfaces of which look forward and backward; and its edges, which are thin and sharp, are turned upward and downward. It continues the superior border of the scapula, bridging over the scapular notch.

It is broader medially, where it springs from the upper border of the scapula on its dorsal surface; and narrow laterally, where it is attached to the base of the coracoid process; some of its fibres are inserted under the edge of the trapezoid ligament, and others pass upward with the conoid to reach the clavicle. The *transverse scapular* (*suprascapular*) *artery* passes over it, and the *suprascapular nerve* beneath it. Medially, some fibres of the *omo-hyoid* muscle arise from it.

The **inferior transverse** (spino-glenoid) **ligament** (fig. 287) reaches from the lateral border of the spine of the scapula to the margin of the glenoid cavity, and so forms a foramen under which the *transverse scapular* (*suprascapular*) *vessels* and *suprascapular nerve* gain the infraspinous fossa. It is usually a weak membranous structure with but few ligamentous fibres.

3. THE SHOULDER-JOINT

Class.—*Diarthrosis.* **Subdivision.**—*Enarthrodia.*

The shoulder [articulatio humeri] is one of the most perfect and most movable

of joints, the large upper end of the humerus playing upon the shallow glenoid cavity. Like the hip, it is a ball-and-socket joint. It is retained in position much less by ligaments than by muscles, and, owing to the looseness of its capsule, as well as to all the other conditions of its construction and position, it is exceedingly liable to be displaced; on the other hand, it is sheltered from violence by the two projecting processes—the acromion and coracoid.

The ligaments of the shoulder-joint are:—

Articular capsule.	Coraco-humeral.
Gleno-humeral.	Glenoid:

The **articular capsule** (figs. 286, 287, and 288) is a loose sac, insufficient in itself to maintain the bones in contact. It consists of fairly distinct but not coarse fibres, closely woven together, and directed, some straight, others obliquely, between the two bones, a few circular ones being interwoven amongst them. At the scapula, it is fixed on the dorsal aspect to the prominent rough

FIG. 288.—VERTICAL SECTION THROUGH THE SHOULDER-JOINT TO SHOW THE GLENO-HUMERAL LIGAMENT.
(The joint is opened from behind.)

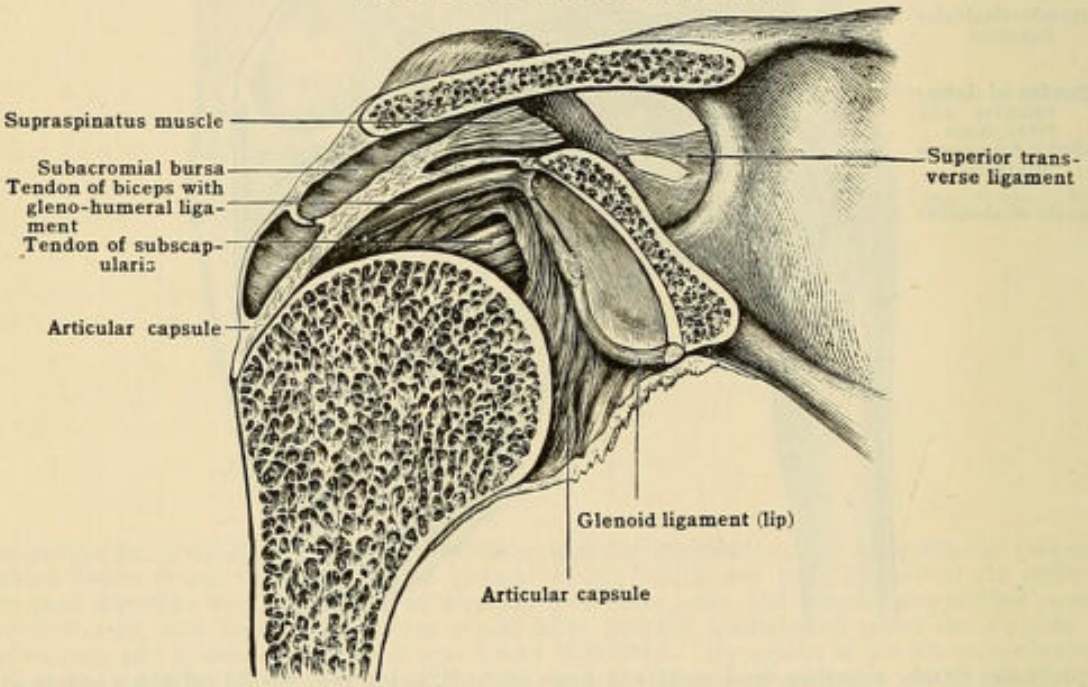

surface around the margin of the glenoid cavity, reaching as far as the neck of the bone. Superiorly, it is attached to the root of the coracoid process; anteriorly, to the ventral surface, at a variable distance from the articular margin, often reaching half an inch (12 mm.) upon the neck of the bone, and thus allowing the formation of a pouch; it may not, however, extend for more than a quarter of an inch (6 mm.) beyond the articular margin; inferiorly, it blends with the origin of the long head of the triceps. At the humerus, the superior half is fixed to the anatomical neck, sending a prolongation downward between the two tuberosities which attenuates as it descends, and covers the transverse humeral ligament. The lower half of the capsule descends upon the humerus further from the articular margin, some of the deeper fibres being reflected upward so as to be attached close to the articular edge, thus forming a kind of fibrous investment for the neck of the humerus. This ligament is more uniform in thickness than that of the hip.

Gleno-humeral bands of the capsule (figs. 288 and 289).—There are three accessory bands, known as the *superior*, *middle* and *inferior gleno-humeral bands*, which project toward the interior of the joint from the fore part of the capsule and are consequently best seen when the joint is opened from behind.

The **middle** band reaches from the anterior margin of the glenoid cavity along the lower border of the subscapularis tendon to the lower border of the lesser tuberosity, and the **inferior** band from the inferior part of the glenoid cavity to the inferior part of the neck of the humerus.

The **superior** band, known also as the **gleno-humeral ligament,** runs from the edge of the glenoid cavity at the root of the coracoid process, just medial to the origin of the long tendon of the biceps, and, passing laterally and downward at an acute angle to the tendon, for which it forms a slight groove or sulcus, is fixed to a depression, the fovea capitis humeri, above the lesser tuberosity of the humerus. It is a thin, ribbon-like band, of which the superior surface is attached to the capsule, while the inferior is free and turned toward the joint. In the fœtus it is often, and in the adult occasionally, quite free from the capsule, and may be as thick as the long tendon of the biceps (fig. 289).

The tendons of the *supra-* and *infra-spinatus, teres minor,* and *subscapularis* muscles strengthen and support the capsule, especially near their points of insertion, and can be with difficulty dissected off from it. The long head of the *triceps* supports and strengthens the capsule below. The capsule also receives an upward slip from the *pectoralis major.* The *supraspinatus* often sends a slip into the capsule from its upper edge (fig. 288).

The **coraco-humeral ligament** (fig. 290) is a strong broad band, which is attached above to the lateral edge of the root and horizontal limb of the coracoid process nearly as far as the tip. From this origin it is directed backward along the line of the biceps tendon to blend with the capsule, and is inserted into the greater tuberosity of the humerus.

Seen from the back, it looks like an uninterrupted continuation of the capsule, while from the front it looks like a fan-shaped prolongation from it overlying the rest of the ligament. At its origin there is sometimes a bursa between it and the capsule.

The **glenoid ligament** or **lip** [labrum glenoidale] (figs. 288 and 292) is a narrow rim of dense fibro-cartilage, which surrounds the edge of the glenoid socket and deepens it. It is about a quarter of an inch (6 mm.) wide above and below, but less at its sides. Its peripheral edge is inseparably welded, near the bone, with

FIG. 289.—FŒTAL SHOULDER-JOINT, SHOWING THE GLENO-HUMERAL LIGAMENT, AND ALSO THE SHORT HEAD OF THE BICEPS, BEING CONTINUOUS WITH THE CORACO-ACROMIAL LIGAMENT.

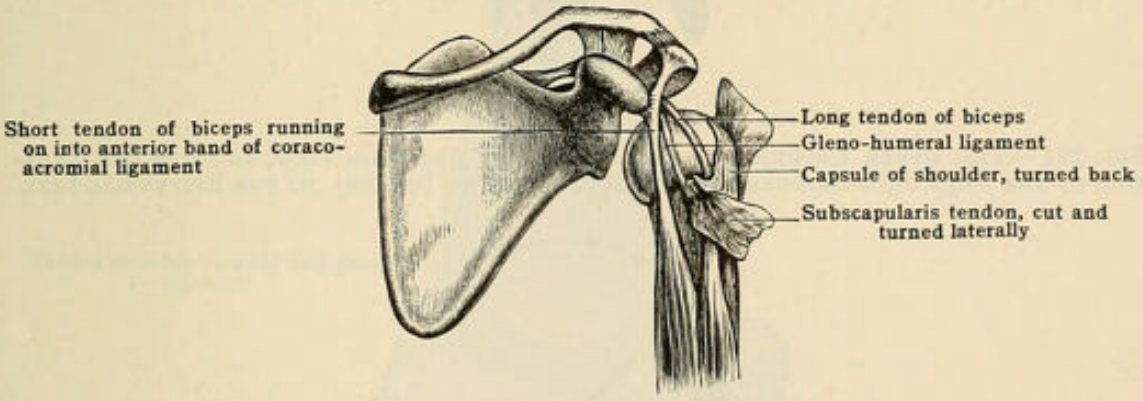

the articular capsule. Its structure is almost entirely fibrous, with but few cartilage cells intermixed. At the upper part of the fossa the **biceps tendon** is prolonged into the glenoid ligament, the tendon usually dividing and sending fibres right and left into the ligament, which may wind round nearly the whole circumference of the socket. It may, however, send fibres into one side only, usually into the lateral.

The **articular cartilage** covering the glenoid fossa is thicker at the circumference than in the centre, thus tending to deepen the cavity. It is usually thickest at the lower part of the fossa; over the head of the humerus the cartilage is thickest at and below the centre.

The **synovial membrane** lines the glenoid ligament, and is then reflected over the capsule as far as its attachment to the humerus, from which it ascends as far as the edge of the articular cartilage. The tendon of the *biceps* receives a long tubular sheath, which is continuous with the synovial membrane, both at its attached extremity and at the bicipital groove, but is free in the rest of its extent. The synovial cavity almost always communicates with the bursa under the *subscapularis,* and sometimes with one under the infraspinatus muscle.

It also sends a pouch-like prolongation beneath the coracoid process when the fibrous capsule is attached wide of the margin of the glenoid fossa. A few fringes are seen near the edge of the glenoid cavity, and there is often one which runs down the medial edge of the biceps tendon, extending slightly below it and making a slight groove for the tendon to lie in.

The **transverse humeral ligament** (fig. 290) is so closely connected with the capsule of the shoulder that, although it is a proper ligament of the humerus, it may well be described here. It is a strong band of fibrous tissue, which extends

FIG. 290.—LATERAL VIEW OF THE SHOULDER-JOINT, SHOWING THE CORACO-HUMERAL AND TRANSVERSE HUMERAL LIGAMENTS.

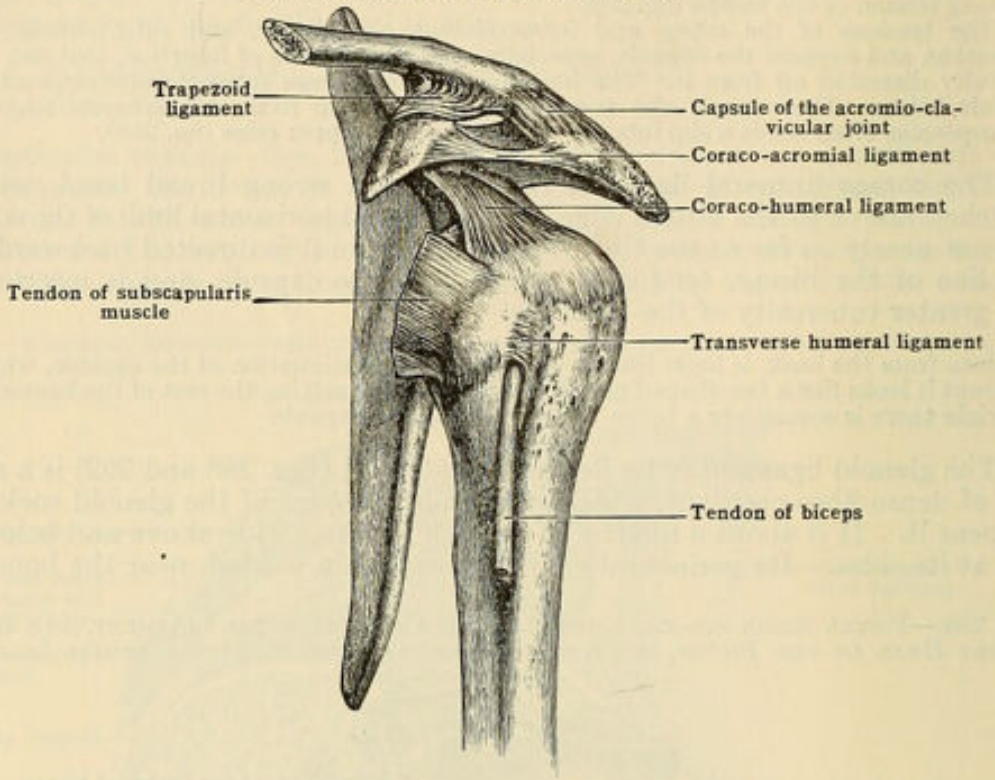

FIG. 291.—THE UPPER EXTREMITY OF THE HUMERUS, ANTERIOR VIEW, TO SHOW THE RELATION OF THE ARTICULAR CAPSULE OF THE SHOULDER-JOINT (IN RED) TO THE EPIPHYSIAL LINE.

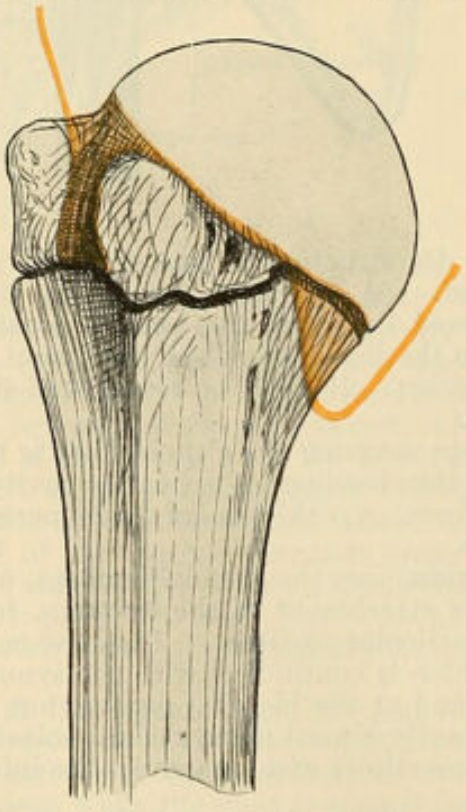

between the two tuberosities, roofing in the intertubercular (bicipital) groove. It is covered by a thin expansion of the capsule. It is limited to the portion of the bone above the line of the epiphysis.

Relations.—The following muscles are in contact with the capsule of the shoulder-joint. In front, the subscapularis; above, the supraspinatus; above and behind, the infraspinatus; behind, the teres minor; below, the long head of the triceps and the teres major. In the interval between the subscapularis and the supraspinatus the subacromial bursa is close to the capsule and occasionally its cavity communicates with the cavity of the joint.

The axillary (circumflex) nerve and posterior circumflex artery pass beneath the capsule in the interval between the long head of the triceps, the humerus, and the teres major. When the arm is abducted, the long head of the triceps and the teres major are drawn into closer relation with the capsule and help to prevent dislocation of the humerus.

The axillary vessels, the great nerves of the axilla, the short head of the biceps, and the coraco-brachialis are separated from the joint by the subscapularis, whilst the deltoid forms a kind of cap, which extends from the front to the back over the more immediate relations.

The arterial supply is derived from the transverse scapular (suprascapular), anterior and posterior circumflex, subscapular, circumflex scapular (dorsalis scapulæ), and a branch from the second portion of the axillary artery.

The **nerve-supply** is derived from the suprascapular, by branches in both fossæ; and from the axillary (circumflex) and subscapular nerves.

The **movements** of the shoulder-joint consist of flexion, extension, adduction, abduction, rotation and circumduction.

Flexion is the swinging forward, extension the swinging backward, of the humerus; abduction is the raising of the arm from, and adduction depression of the arm to, the side. In flexion and extension the head of the humerus moves upon the centre of the glenoid fossa round an

FIG. 292.—BICEPS TENDON, BIFURCATING AND BLENDING ON EACH SIDE WITH THE GLENOID LIGAMENT.

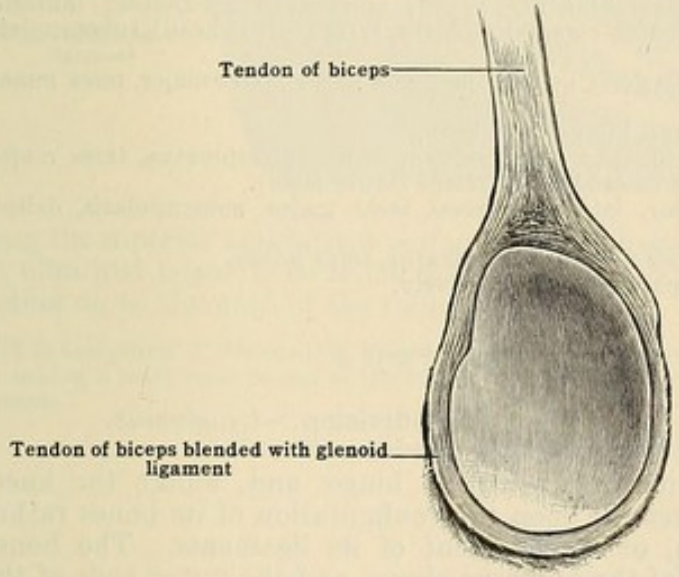

oblique line corresponding to the axis of the head and neck of the humerus, flexion being more free than extension, and in extreme flexion the scapula follows the head of the humerus, so as to keep the articular surfaces in apposition. In extension the scapula moves much less, if at all.

In abduction and adduction the scapula is fixed, and the humerus rolls up and down upon the glenoid fossa; during abduction the head descends until it projects beyond the lower edge of the glenoid cavity, and the greater tuberosity impinges against the arch of the acromion; during adduction, the head of the humerus ascends in its socket, the arm at length reaches the side, and the capsule is completely relaxed.

In circumduction, the humerus, by passing quickly through these movements, describes a cone, whose apex is at the shoulder-joint, and the base at the distal extremity of the bone or limb.

Rotation takes place round a vertical axis drawn through the extremities of the humerus from the centre of the head to the inner condyle; in rotation forward (that is, medialward) the head of the bone rolls back in the socket as the great tuberosity and shaft are turned forward; in rotation backward (that is, lateralward) the head of the bone glides forward, and the tuberosity and shaft of the humerus are turned backward, i. e., lateralward.

Great freedom of movement is permitted at the shoulder, and this is increased by the mobility of the scapula. Restraint is scarcely exercised at all upon the movements of the shoulder by the ligaments, but chiefly by the muscles of the joint.

In abduction, the lower part of the capsule is somewhat, and in extreme abduction considerably, tightened; and in rotation medialward and lateralward, the upper part of the capsule is made tense, as is also, in the latter movement, the coraco-humeral ligament.

The movements of abduction and extension have a most decided and definite resistance offered to them other than by muscles and ligaments, for the greater tuberosity of the humerus, by striking against the acromion process and coraco-acromial ligament, stops short any further advance of the bone in these directions, and thus abduction ceases altogether as soon as the arm

is raised to a right angle with the trunk, and extension shortly after the humerus passes the line of the trunk.

Further elevation of the arm beyond the right angle, in the abducted or extended position, is effected by the rotation of the scapula round its own axis by the action of the trapezius and serratus anterior muscles upon the sterno-clavicular and acromio-clavicular joints respectively.

The acromion and coracoid process, together with the coraco-acromial ligament, form an arch, which is separated by a bursa and the tendon of the *supraspinatus* from the capsule of the shoulder. Beneath this arch the movements of the joint take place, and against it the head and tuberosities are pressed when the weight of the trunk is supported by the arms; the greater tuberosity and the upper part of the shaft impinge upon it when abduction and extension are carried to their fullest extent.

No description of the shoulder-joint would be complete without a short notice of the peculiar relation which the biceps tendon bears to the joint. It passes over the head of the humerus a little to the medial side of its summit, and lies free within the capsule, surrounded only by a tubular process of synovial membrane. It is flat, with the surfaces looking upward and downward, until it reaches the intertubercular (bicipital) groove, when it assumes a rounded form. It strengthens the articulation along the same course as the coraco-humeral ligament, and tends to prevent the head of the humerus from being pulled upward too forcibly against the inferior surface of the acromion. It also serves the purpose of a ligament by steadying the head of the humerus in various movements of the arm and forearm, and to this end is let into a groove at the upper end of the bone, from which it cannot escape on account of the abutting tuberosities and the strong transverse humeral ligament which binds it down. Further, it acts like the four shoulder muscles which pass over the capsule, to keep the head of the humerus against the glenoid socket; and, moreover, it resists the tendency of the *pectoralis major* and *latissimus dorsi* muscles, in certain actions when the arm is away from the side of the body, to pull the head of the humerus below the lower edge of the cavity.

Muscles which act upon the shoulder-joint.—*Flexors or protractors.*—Deltoid (anterior fibres), pectoralis major (clavicular fibres), coraco-brachialis, biceps (short head), subscapularis (upper fibres).

Extensors or retractors.—Latissimus dorsi, deltoid (posterior fibres), teres major, teres minor, infraspinatus (lower fibres).

Abductors.—Deltoid, supraspinatus, biceps (long head).

Adductors.—Pectoralis major, latissimus dorsi, subscapularis, infraspinatus, teres major, teres minor, coraco-brachialis, biceps (short head), triceps (lower head).

Medial rotators.—Pectoralis major, latissimus dorsi, teres major, subscapularis, deltoid (anterior fibres).

Lateral rotators.—Deltoid (posterior fibres), infraspinatus, teres minor.

Circumductors.—The above groups acting consecutively.

4. THE ELBOW-JOINT

Class.—*Diarthrosis.* **Subdivision.**—*Ginglymus.*

The elbow [articulatio cubiti] is a complete hinge, and, unlike the knee, depends for its security and strength upon the configuration of its bones rather than on the number, strength, or arrangement of its ligaments. The bones composing it are the lower end of the humerus above, and the upper ends of the radius and ulna below; the articular surface of the humerus being received partly within the semilunar notch (great sigmoid cavity) of the ulna, and partly upon the cup-shaped area (fovea) of the radial head. The ligaments form one large and capacious capsule [capsula articularis], which, by blending with the annular ligament, and then passing on to be attached to the neck of the radius, embraces the elbow and the superior radio-ulnar joints, uniting them into one. Laterally, it is considerably strengthened by superadded fibres arising from the epicondyles of the humerus and inseparably connected with the capsule. For convenience of description it will be spoken of as consisting of four portions:—

Anterior.	Medial.
Posterior.	Lateral.

The **anterior portion** (fig. 293) is attached to the front of the humerus above the articular surface and coronoid fossa, in an inverted **V**-shaped manner, to two very faintly marked ridges which start from the front of the medial and lateral epicondyles, and meet a variable distance above the coronoid fossa. Below, it is fixed, just beyond the articular margin, to the front of the coronoid process and it is intimately blended with the front of the annular ligament, a few fibres passing on to the neck of the radius.

It varies in strength and thickness, being sometimes so thin as barely to cover the synovial membrane; at others, thick and strong, and formed of coarse decussating fibres, the majority of which descend from the medial side laterally to the radius.

The **posterior portion** (fig. 294), thin and membranous, is attached superiorly to the humerus, in much the same inverted **V**-shaped way as the anterior; ascending from the medial epicondyle, along the medial side of the olecranon fossa nearly to the top; then, crossing the bottom of the fossa, it descends on the lateral side, skirting the lateral margin of the trochlear surface, and turns laterally along the posterior edge of the capitulum. Inferiorly, it is attached to a slight groove

FIG. 293.—MEDIAL VIEW OF THE ELBOW-JOINT.

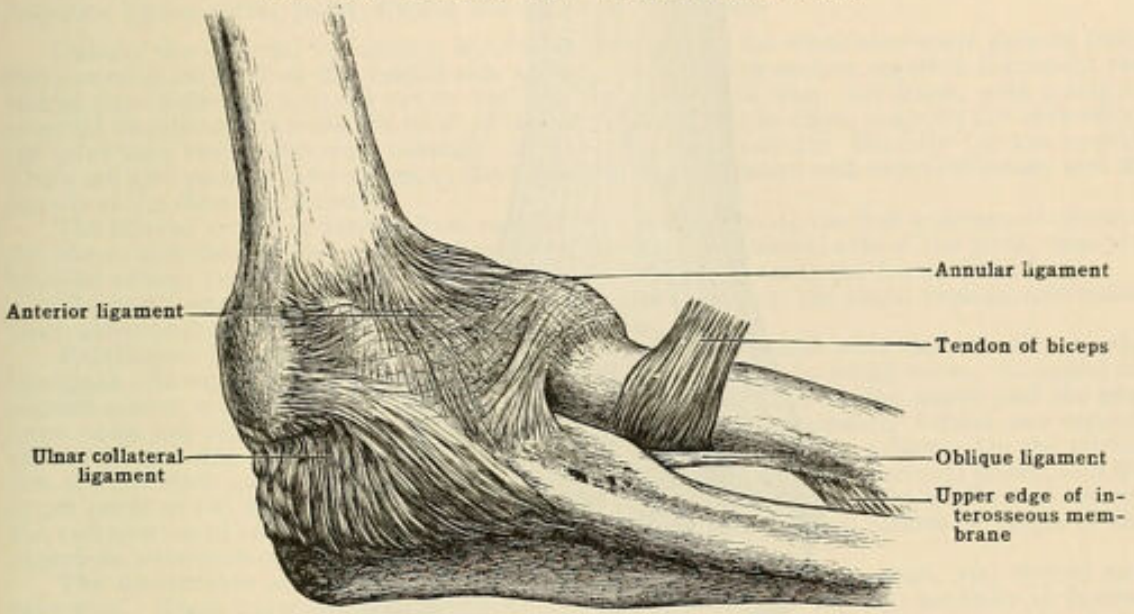

along the superior and lateral surfaces of the olecranon, and the rough surface of the ulna just beyond the radial notch, and to the annular ligament, a few fibres passing on to the neck of the radius.

It is composed of decussating fibres, most of which pass vertically or obliquely downward, a few taking a transverse course at the summit of the olecranon fossa where the ligament is usually thinnest.

FIG. 294.—LATERAL VIEW OF THE ELBOW-JOINT.

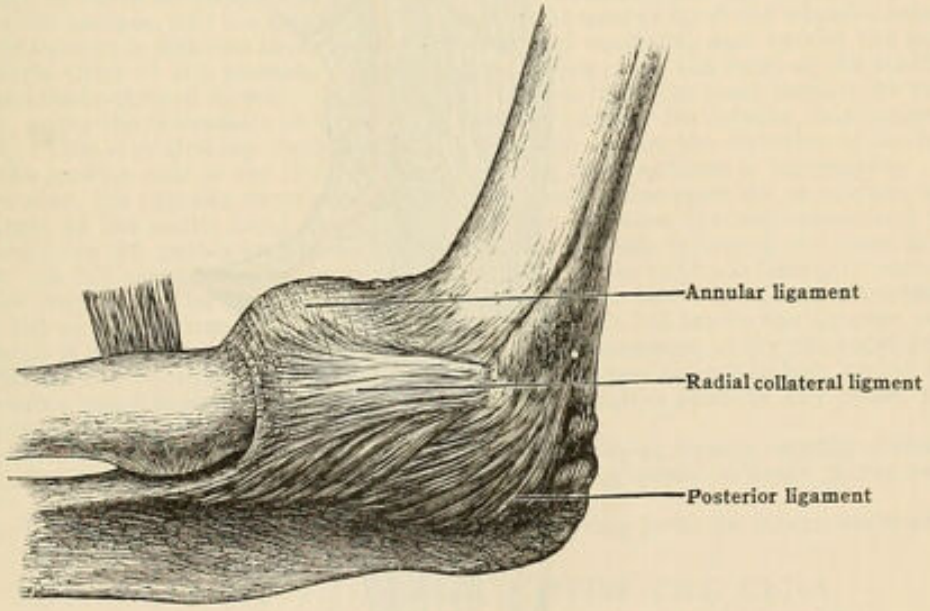

The **medial portion,** the **ulnar collateral ligament** (fig. 293), is thicker, stronger, and denser than either the anterior or posterior portions. It is triangular in form, its apex being attached to the anterior and under aspect of the medial epicondyle, and to the condyloid edge of the groove between the trochlea and the condyle. The fibres radiate downward from this attachment, the anterior passing forward to be fixed to the rough overhanging medial edge of the coronoid

process; the middle descend less obliquely to a ridge running between the coronoid and olecranon processes, while the posterior pass obliquely backward to the medial edge of the olecranon just beyond the articular margin.

FIG. 295.—LOWER EXTREMITY OF THE HUMERUS, TO SHOW THE RELATION OF THE ARTICULAR CAPSULE OF THE ELBOW-JOINT (IN RED) TO THE EPIPHYSIAL LINES.

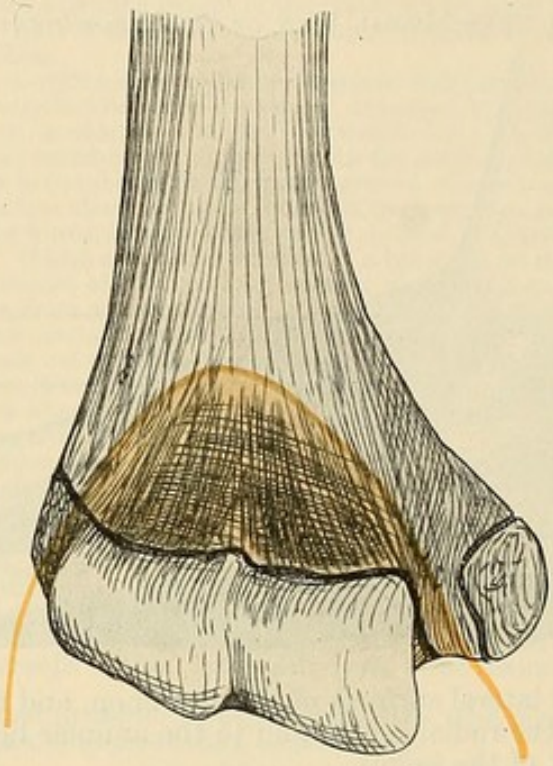

FIG. 296.—THE UPPER EXTREMITY OF THE ULNA, TO SHOW THE RELATION OF THE ARTICULAR CAPSULE OF THE ELBOW-JOINT (IN RED) TO THE EPIPHYSIAL LINES.

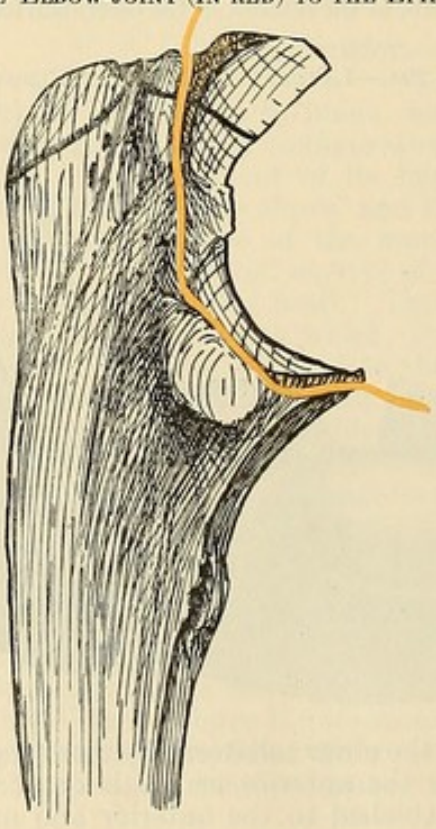

An oblique band (the oblique ligament of Sir Astley Cooper) connects the margin of the olecranon process with the margin of the coronoid process. It lies superficial to the posterior fibres of the ulnar collateral ligament. The anterior fibres are the thickest, strongest, and most pronounced.

The **lateral portion,** the **radial collateral ligament** (fig. 294), is attached above to the lower part of the lateral epicondyle, and from this the fibres radiate to their attachment into the lateral side of the annular ligament, a few fibres being prolonged to reach the neck of the radius. The anterior fibres reach further forward than the posterior do behind. It is strong and well-marked, but less so than the medial portion.

The **synovial membrane** lines the whole of the capsule, and extends into the superior radio-ulnar joint, lining the annular ligament.

Outside the synovial membrane, but inside the capsule, are often seen some pads of fatty tissue; one is situated on the medial side at the base of the olecranon, another is seen on the lateral side projecting into the cavity between the radius and ulna; this latter, with a fold of synovial membrane opposite the front of the lateral lip of the trochlea, suggests the division of the joint into two parts—one medially for the ulna, and another laterally for the radius. There are also pads of fatty tissue at the bottom of the olecranon and coronoid fossæ, and at the tip of the olecranon process.

The **arterial supply** is derived from each of the vessels forming the free anastomosis around the elbow, and there is also a special branch to the front and lateral side of the joint, from the brachial artery, and the arterial branch to the *brachialis* also feeds the front of the joint.

The **nerve-supply** comes chiefly from the musculo-cutaneous; the ulnar, median, and radial (musculo-spiral) also give filaments to the joint.

Relations.—In front of the joint, and in immediate relation with the capsule, are the brachialis, the superficial and deep branches of the radial (musculo-spiral) nerve, the radial recurrent artery, and the brachio-radialis. The brachial artery, the median nerve, and the pronator teres are separated from the capsule by the brachialis. Directly behind the capsule are the triceps, the anconeus, and the posterior interosseous recurrent artery. On the medial side are the ulnar nerve, the superior ulnar collateral (posterior ulnar recurrent) artery, and the upper parts of the flexor carpi ulnaris and flexor digitorum sublimis. On the lateral side lie the extensor carpi radialis longus and the upper part of the common tendon of origin of the superficial extensors of the wrist and fingers.

The **movements** permitted at the elbow are those of a true hinge joint, viz., flexion and extension. These movements are oblique, so that the forearm is inclined medially in flexion, and laterally in extension; they are limited by the contact respectively of the coronoid and olecranon processes of the ulna with their corresponding fossæ on the humerus, and their extent is determined by the relative proportion between the length of the processes and depth of the fossæ which receive them, rather than by the tension of the ligaments, or the bulk of the soft parts over them. The anterior and posterior portions of the capsule, together with the corresponding portions of the collateral ligament, are not put on the stretch during flexion and extension; but, although they may assist in checking the velocity, and thus prevent undue force of impact, they do not control or determine the extent of these movements. The limit of extension is reached when the ulna is nearly in a straight line with the humerus; and the limit of flexion when the ulna describes an angle of from 30° to 40° with the humerus.

The obliquity of these movements is due to the lateral inclination of the upper and back part of the trochlear surface, and the greater prominence of the medial lip of the trochlea below; thus the plane of motion is directed from behind forward and medially, and carries the hand toward the middle third of the clavicle. The obliquity of the joint, the twist of the shaft of the humerus, and the backward direction of its head, all tend to bring the hand toward the midline of the body, under the immediate observation of the eye, whether for defence, employment, or nourishment. This is in striking contrast to the lower limb, where the direction of the foot diverges from the median axis of the trunk, thus preventing awkwardness in locomotion. In flexion and extension, the cup-like depression of the radial head glides upon the capitulum, and the medial margin of the radial head travels in the groove between the capitulum and the trochlea. This allows the radius to rotate upon the humerus while following the ulna in all its movements. In full extension and supination, the head of the radius is barely in contact with the inferior surface of the capitulum, and projects so much backward that its posterior margin can be felt as a prominence at the back of the elbow. In full flexion the anterior edge of the radial head is received into, and checked against, the depression above the capitulum; while in mid-flexion the cup-like depression is fairly received upon the capitulum, and in this position, the radius being more completely steadied by the humerus than in any other, pronation and supination take place most perfectly.

Muscles which act upon the elbow-joint.—*Flexors.*—Brachialis, biceps, brachio-radialis, pronator teres, flexor carpi radialis, palmaris longus, flexor digitorum sublimis, flexor carpi ulnaris.

Extensors.—Triceps, anconeus, and the muscles which spring from the lateral epicondyle

5. THE UNION OF THE RADIUS WITH THE ULNA

The radius is firmly united to the ulna by two joints, and an intermediate fibrous union, viz.:—

(*a*) **The superior radio-ulnar**—whereat the head of the radius *rotates* within the radial notch and annular ligament.

(*b*) The **union of the shafts**—the **mid radio-ulnar union.**

(*c*) The **inferior radio-ulnar**—whereat the lower end of the radius *rolls round* the head of the ulna.

(*a*) The Superior Radio-ulnar Joint

Class.—*Diarthrosis.* **Subdivision.**—*Trochoides.*

The bones which enter into this joint (which is often included with the elbow-joint) are, the ulna by its radial notch and the radius by the smooth vertical border or rim on its head. There is but one ligament special to the joint, viz.:—

Annular.

The **annular ligament** consists of bands of strong fibres, somewhat thicker than the capsule of the elbow-joint, which encircle the head of the radius, retaining it against the side of the ulna. The bulk of these fibres forms about three-fourths of a circle, and they are attached to the anterior and posterior margins of the radial notch; some few are continued round below the radial notch, and form a complete ligamentous circle.

The ligament is inseparably connected along its upper edge and lateral (i. e., its non-articular) surface with the anterior, posterior, and lateral portions of the capsule of the elbow, a few of the fibres of these portions, especially of the lateral, descending to be attached to the neck of the radius. The lower part of the articulation is covered in anteriorly, posteriorly, and laterally by a thin independent membranous layer, which passes from the lower edge of the annular ligament to the neck of the radius, strengthened on the lateral side by those fibres passing down from the capsule. They are loose enough to allow the bone to rotate upon its

Fig. 297.—Annular Ligament.
(The head of the radius removed to show the membranous connection of this ligament with the radius.)

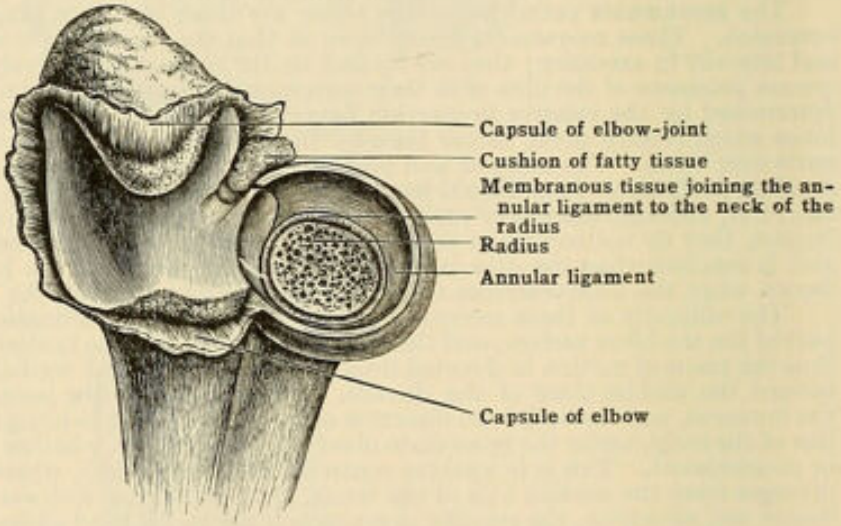

own axis (fig. 297). Medially and below the cavity is closed in by a loose membrane, the ligamentum quadratum, which passes from the lower border of the radial notch to the neck of the radius.

The **synovial membrane** is the same as that of the elbow-joint, and, after lining the annular ligament, passes on to the neck of the radius, and thence up to the lower margin of the articular cartilage.

The **arterial** and **nerve-supply** are the same as those to the lateral part of the elbow-joint.
Relations.—Behind lies the anconeus and in front the lateral border of the brachialis.

(*b*) The Mid Radio-ulnar Union

Class.—*Synarthrosis.* **Subdivision.**—*Syndesmosis.*

There are two interosseous ligaments which pass betweeen the shafts of the bones and unite them firmly together, viz.:—

Oblique cord. Interosseous membrane.

The **oblique cord** [chorda obliqua] (figs. 293 and 298) is a fairly strong, narrow band, which passes from the lower end of the rough lateral border of the coronoid

process, downward and laterally to be attached to the posterior edge of the lower end of the tuberosity of the radius and the vertical ridge running from it to the medial border of the bone.

Some of its fibres blend with the fibres of insertion of the biceps tendon; behind, it is in close contact with the *supinator;* below, a thin membrane passes off from it to the upper edge of the interosseous membrane; the posterior interosseous vessels pass in the space between it and the interosseous membrane; occasionally a slip is continued into the annular ligament of the superior radio-ulnar articulation (see fig. 298).

The **interosseous membrane** (fig. 293) is attached to the ulna at the lowest part of the ridge in front of the depression for the supinator, and along the whole length of the interosseous border as far as the inferior radio-ulnar articulation, approaching the front of the bone in the lower part of its attachment. To the radius it is attached along the interosseous border, from an inch (2.5 cm.) below the tuberosity to the ulnar notch for the lower end of the ulna.

It is strongest and broadest in the centre, where the fibres are dense and closely packed; it is also well marked beneath the *pronator quadratus*, and thickens considerably at the lower end, forming a strong band of union between the two bones. Its fibres pass chiefly downward and medially, from the radius to the ulna, though some take the opposite direction; at the lower end some are transverse. On the posterior surface are one or two bands, which pass downward and laterally from the ulna to the radius, and frequently there is a strong bundle as large as the

FIG. 298.—UPPER PORTIONS OF LEFT ULNA AND RADIUS, TO SHOW AN OCCASIONAL SLIP FROM THE OBLIQUE CORD TO THE LOWER PART OF THE ANNULAR LIGAMENT. This condition is present in the spider monkey (*Ateles*), which has no external thumb but only rudimentary bones of one.

(From a dissection by Mr. W. Pearson, Royal College of Surgeons, England.)

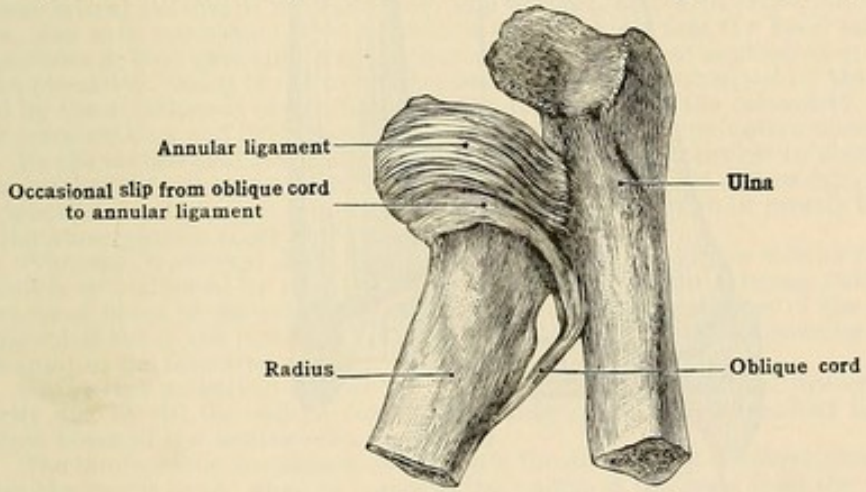

oblique cord; this, which may be called the **inferior oblique ligament** (fig. 303), stretches from the ulna, an inch and a half above its lower extremity, downward and laterally to the ridge above and behind the ulnar notch of the radius.

At its attachment to the bones, the interosseous membrane blends with the periosteum. Its upper border is connected with the oblique cord by a thin membrane, which is pierced by the posterior interosseous vessels; and the lower border, which stretches across between the two bones just above the inferior radio-ulnar articulation, assists in completing the capsule of that joint. Its anterior surface is in relation with the *flexor digitorum profundus and flexor pollicis longus* in the upper three-quarters, the lower fourth being in relation with the *pronator quadratus.* The anterior interosseous vessels and nerve descend along the middle of the membrane, the artery being bound down to it. About an inch from the lower end it is pierced by the anterior interosseous artery. The posterior surface is in relation with the *supinator, abductor pollicis longus* (*extensor ossis metacarpi pollicis*), *extensor pollicis longus* and *brevis*, and the *extensor indicis proprius;* at its lower part, also with the posterior branch of the anterior interosseous artery, and the deep branch of the radial nerve (posterior interosseous).

(*c*) THE INFERIOR RADIO-ULNAR JOINT

Class.—*Diarthrosis.* **Subdivision.**—*Trochoides.*

This is, in one respect, the reverse of the superior; for the radius, instead of presenting a circular head to rotate upon the facet on the ulna, presents a concave facet which rolls round the ulna. The articulation may be said to consist of two

parts at right angles to each other; one between the radius and ulna, and the other between the ulna and the articular disc (triangular fibro-cartilage).

The ligaments are:—

Anterior radio-ulnar. Posterior radio-ulnar.

Articular disc.

The **articular disc** (triangular fibro-cartilage) (figs. 303 and 304) assists the radius in forming an arch under which is received the first row of carpal bones. Its base is attached to the margin of the radius, separating the ulnar notch from the articular surface for the carpus, while its apex is fixed to the fossa at the base of the styloid process of the ulna. It gradually and uniformly diminishes in width from base to apex, becoming rounded where it is fixed to the ulna; it is joined by fibres of the ulnar collateral ligament of the wrist.

The articular disc is about three-eighths of an inch (1 cm.) wide, and the same from base to apex; thicker at the circumference than in the centre; smooth and concave above to adapt itself to the ulna, and smooth and slightly concave below to fit over the triquetral bone. Its anterior and posterior borders are united to the anterior and posterior radio-ulnar and radio-carpal ligaments. It is the most important structure in the inferior radio-carpal articulation, as it is a very firm bond of union between the lower ends of the bones, and serves to limit their movements upon one another more than any other structure in either the upper or lower radio-ulnar joints. Its structure is fibrous at the circumference, while in the centre there is a preponderance of cells. It differs from all other fibro-cartilages in entering into two distinct articulations; and separates entirely the synovial membrane of the radio-ulnar joint from that of the wrist.

Fig. 299.—Lower Extremities of the Radius and Ulna to Show the Relation of the Articular Capsule of the Wrist Joint (in red) to the Epiphysial Lines. Note the upward extension of the membrana sacciformis.

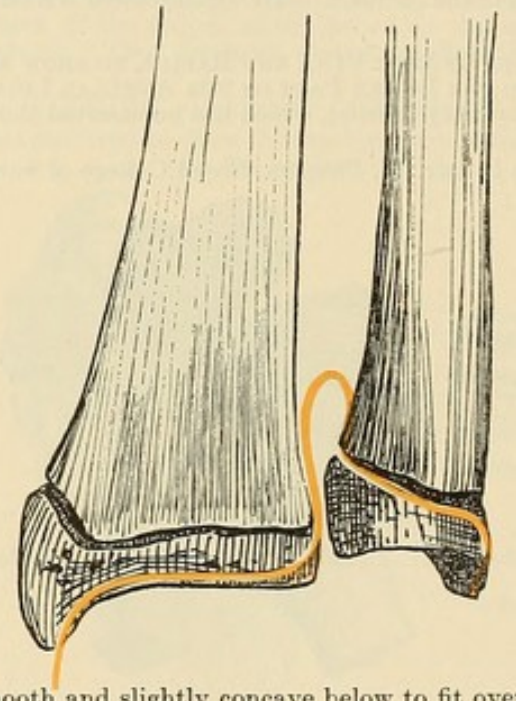

The lower end of the **interosseous membrane** extends between the ulna and radius immediately above their points of contact. Transverse fibres between the two bones form a sort of arch above the concave articular facet of the radius, and, joining the anterior and posterior radio-ulnar ligaments, complete the **articular capsule** of the inferior radio-ulnar joint. The ligaments represent merely thickenings of the capsule.

The **anterior radio-ulnar ligament** (fig. 300) is attached by one end to the anterior edge of the ulnar notch of the radius, and by the other to the rough bone above the articular surface of the ulna as far medially as the notch, as well as into the anterior margin of the trianguar cartilage from base to apex.

The **posterior radio-ulnar ligament** (fig. 301) is similarly attached to the posterior margin of the ulnar notch at one end, and at the other to the rough bone above the articular surface of the extremity of the ulna as far medially as the groove for the *extensor carpi ulnaris*, with the sheath of which it is connected, as well as into the whole length of the posterior margin of the articular disc. Both the radio-ulnar ligaments consist of thin, almost scattered, fibres.

The **synovial membrane,** sometimes called **the membrana sacciformis,** is large and loose in proportion to the size of the joint. It is not only interposed between the radial and ulnar articular surfaces, but lines the terminal articular surface of the ulna and the upper surface of the articular disc.

The **arterial supply** is derived from the volar interosseous artery and branches of the volar carpal rete.

The **nerve-supply** comes from the volar interosseous of the median, and the deep branch of the radial (posterior interosseous).

Relations.—Behind lies the tendon of the extensor digiti quinti proprius and in front the flexor digitorum profundus.

The movements of the radius.—The upper end of the radius rotates upon an axis drawn through its own head and neck within the collar formed by the radial notch and the annular ligament, while the lower end, retained in position by the articular disc, rolls round the head of the ulna. This rotation is called *pronation*, when the radius from a position nearly parallel to the ulna turns medialward so as to lie obliquely across it; and *supination*, when the radius turns back again, so as to uncross and lie nearly parallel with the ulna. In these movements the radius carries with it the hand, which rotates on an axis passing along the ulnar side of the hand; thus, the hand when pronated lies with its dorsum upward, as in playing the piano, while when supinated, the palm lies upward—the attitude of a beggar asking alms. Ward thus expresses the relations of the two extremities of the radius in pronation and supination: 'The head of the radius is so disposed in relation to the sigmoid cavity (ulnar notch) at the lower end that the axis of the former if prolonged falls upon the centre of the circle of which the latter is a segment;' the axis thus passes through the lower end of the ulna at a point at which the articular disc is attached, and if prolonged further, passes through the ring finger. Thus the radius describes, in rotating, a blunt-pointed cone whose apex is the centre of the radial head, and whose base is at the wrist; partial rotation of the bone being unaccompanied by any hinge-like or antero-posterior motion of its head, and pronation and supination occurring without disturbance to the parallelism of the bones at the superior radio-ulnar joint. Associated with this rotation in the ordinary way, there is some rotation of the humero-ulnar shaft, which causes lateral shifting of the hand from side to side; thus, with pronation there is some abduction, and with supination some adduction combined, so that the hand can keep on the same superficies in both pronation and supination. The power of supination in man is much greater than pronation, owing to the immense power and leverage obtained by the curve of the radius, and by the attachment of the biceps tendon to the back of the tuberosity. For this reason all our screw-driving and boring tools are made to be used by supination movements.

In the undissected state, the amount of rotation it is possible to obtain is about 135°, so that neither the palm nor the fore part of the lower end of the radius can be turned completely in opposite directions; yet in the living subject this amount can be greatly increased by rotation of the humero-ulnar shaft at the shoulder-joint.

Pronation is checked in the living subject by (a) the posterior inferior radio-ulnar ligament, which is strengthened by the connection of the sheath of the extensor tendons with it; (b) the lowermost fibres of the interosseous membrane; (c) the back part of the ulnar collateral and adjacent fibres of the posterior ligament of the wrist, and (d) the meeting of the soft parts on the front of the forearm.

Supination is checked mainly (a) by the medial ulnar collateral ligaments of the wrist, but partly also by (b) the oblique cord; (c) the anterior inferior radio-ulnar ligament, and (d) the lowest fibres of the interosseous membrane.

The interosseous membrane serves, from the direction of its fibres downward and medially from the radius to the ulna, to transmit the weight of the body from the ulna to the radius in the extended position of the elbow, as in pushing forward with the arms extended, or in supporting one's own weight on the hands, the ulna being in intimate contact with the humerus, but not at all with the carpus; while the area of contact of the radius with the humerus is small, and that of the radius with the carpus large. Hence the weight transmitted by the ulna is communicated to the radius by the tightening of the interosseous membrane. Conversely, in falls upon the hand with the arm extended, the interosseous membrane acts as a sling to break the violence of the shock, and prevents the whole force of the impact from expending itself directly upon the capitulum.

Muscles which act upon the radio-ulnar joints.—*Pronators.*—Pronator teres, pronator quadratus, flexor carpi radialis, palmaris longus.

Supinators.—Biceps, supinator, extensor pollicis longus.

The brachio-radialis is chiefly a flexor of the elbow-joint, but it takes part in the initiation of the movement of supination when the hand is fully pronated and of pronation when the hand is fully supinated.

6. THE RADIO-CARPAL OR WRIST-JOINT

Class.—*Diarthrosis.* **Subdivision.**—*Condylarthrosis.*

The wrist-joint is formed by the union of the radius and articular disc above, articulating with the navicular, lunate, and triquetral bones below; the ulna being excluded by the intervention of the articular disc. The radius and disc together present a smooth surface, slightly concave both from before backward, and from side to side, whilst the three bones of the carpus present a smooth,

convex surface, made uniformly even by the interosseous ligaments which bind them together.

The capsule of the wrist-joint has been usually described as four separate ligaments, and it will be convenient for the sake of a complete description to follow this method; but it must be understood that these four portions are continuous around the joint, extending from styloid process to styloid process on both its aspects.

The four portions are:—

Volar radio-carpal.	Ulnar collateral.
Dorsal radio-carpal.	Radial collateral.

The **volar** (or anterior) **radio-carpal** (fig. 300) is a thick strong ligament, attached superiorly to the radius immediately above the anterior margin of the terminal articular facet, to the curved ridge at the root of the styloid process of the radius, and to the anterior margin of the articular disc, blending with some fibres of the capsule of the inferior radio-ulnar joint. It passes downward and in a medial direction to be attached to both rows of carpal bones, especially the second, and to the volar intercarpal ligament.

FIG. 300.—ANTERIOR VIEW OF WRIST.

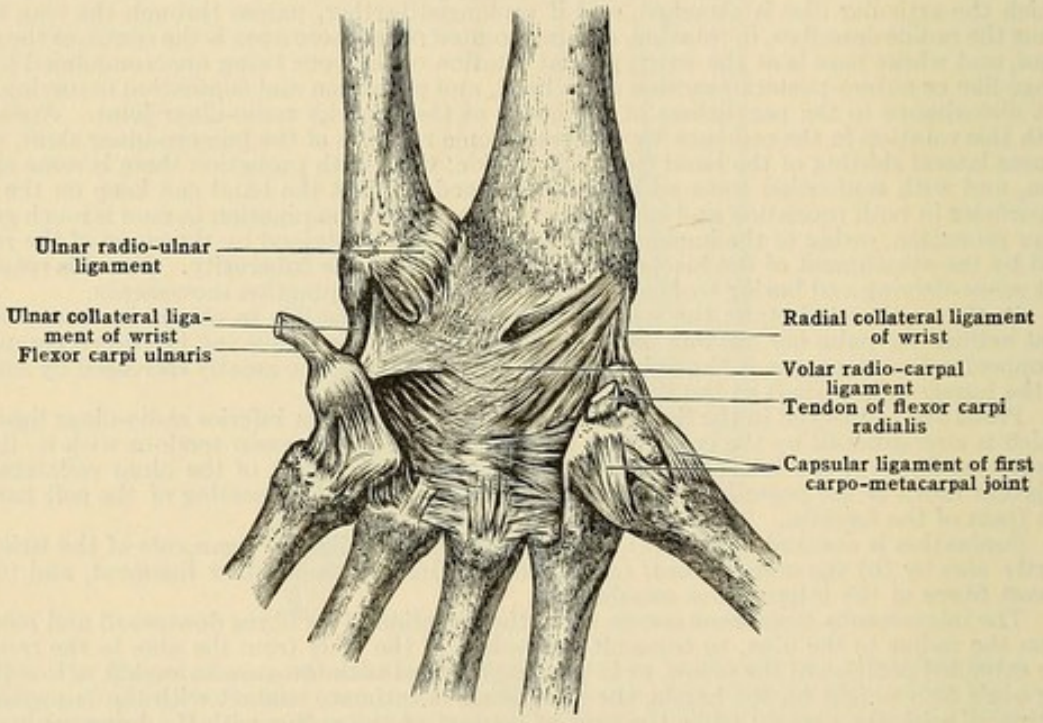

The strongest and most oblique fibres arise from the root of the styloid process of the radius, and pass obliquely over the navicular, with which only a few fibres are connected, to be inserted into the lunate, capitate, and triquetral bones. Another set, less oblique, passes from the margin of the facet for the lunate to be attached to the adjacent parts of the capitate, hamate, and triquetral bones. Between the two sets of fibres, small vessels pass into the joint.

The **dorsal** (or posterior) **radio-carpal ligament** (fig. 301) is attached above to the dorsal edge of the lower end of the radius, the back of the styloid process, and the posterior margin of the fibro-cartilage. It passes downward and in a medial direction to be connected with the first row of the carpal bones, chiefly with the lunate and triquetral, and the dorsal intercarpal ligament. This ligament is thin and membranous.

It is strengthened by (i) strong fibres passing from the back of the articular disc where they are blended with the posterior inferior radio-ulnar ligament, and, from the edge of the radius just behind the ulnar notch, to the triquetral bone; (ii) from the ridge and groove for the extensor pollicis longus to the back of the lunate and triquetral bones; and (iii) from the groove for the radial extensors to the back of the navicular and lunate. It is in relation with, and strengthened by, the extensor tendons which pass over it.

The **ulnar collateral ligament** (fig. 301) is fan-shaped, with its apex above, at the styloid process of the ulna, to which it is attached on all sides, blending with

the apex of the articular disc. Some of the fibres pass forward and laterally to the base of the pisiform bone and to the medial part of the upper border of the transverse carpal ligament, where it is attached to the pisiform bone; they form a thick, rounded fasciculus on the front of the wrist. Other fibres descend vertically to the medial side of the triquetral bone, and others again laterally to the dorsal surface of the triquetral. The tendon of the *extensor carpi ulnaris* is posterior to, and passes over, part of the fibres of the ligament.

The **radial collateral ligament** (fig. 300) consists of fibres which radiate from the fore part and tip of the styloid process of the radius. Some pass downward and medially, in front, to the navicular and adjacent edge of the capitate; some downward, a little forward and medially, to the tubercle of the navicular and ridge of the greater multangular; and others downward and laterally to the rough dorsal surface of the navicular.

The fibres of this ligament are not so long and strong, nor do they radiate so much as those of the ulnar collateral ligament. It is in relation with the *radial artery*, and the *abductor pollicis longus* (*extensor ossis metacarpi pollicis*) and *extensor pollicis brevis*, the artery separating the tendons from the ligament.

FIG. 301.—POSTERIOR VIEW OF WRIST.

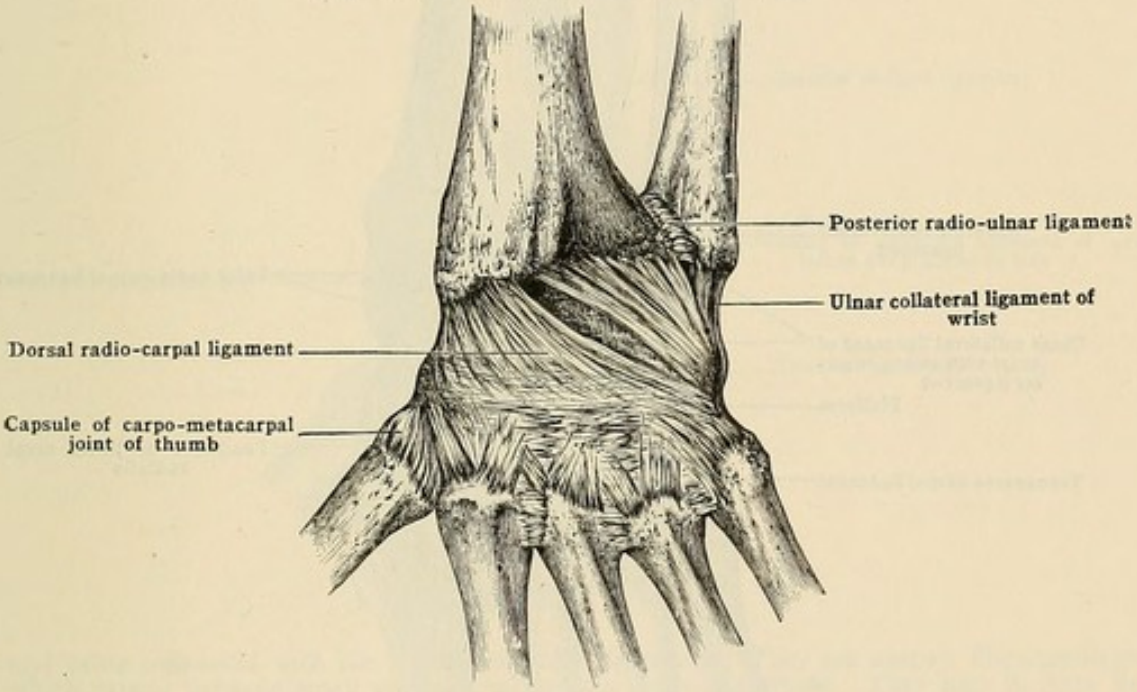

The **synovial membrane** is extensive, but does not usually communicate with the synovial membrane of the inferior radio-ulnar joint, being shut out by the articular disc. It is also excluded, in almost every instance, from that of the carpal joints by the interosseous ligaments between the first row of carpal bones. The styloid process of the radius is cartilage-covered medially, and forms part of the articular cavity, while that of the ulna does not.

The **arterial supply** is derived from the anterior and posterior carpal rami, the dorsal division of the volar interosseous, and from twigs direct from the radial and ulnar arteries.

The **nerve-supply** is derived from the ulnar and median in front, and the deep branch of the radial (posterior interosseous) behind.

Relations.—In front of the radio-carpal joint are the tendons of the flexor muscles of the wrist and fingers, the synovial sheaths associated with them, the radial and ulnar arteries, and the median and ulnar nerves.

Behind the joint are the majority of the tendons of the extensor muscles of the wrist and fingers, with their synovial sheaths, the terminal part of the anterior and posterior interosseous arteries, and the deep branch of the radial nerve (posterior interosseous). On the radial side lie the tendons of the abductor pollicis longus (*extensor ossis metacarpi pollicis*) and the extensor pollicis brevis. On the ulnar side the joint is subcutaneous and it is crossed by the dorsal cutaneous branch of the ulnar nerve.

Movements.—The wrist is a condyloid joint, the carpus forming the condyle. It allows of movements upon a transverse axis, i. e., flexion and extension; and around an antero-posterior axis, i. e., abduction and adduction; together with a combination of these in quick succes-

sion—circumduction. Lacking only rotation on a vertical axis, it thus possesses most of the movements of a ball-and-socket joint, without the weakness and liability to dislocation which are peculiar to these joints. This deficiency of rotation is compensated for by the movements of the radius at the radio-ulnar joints, viz., supination and pronation. Its strength depends chiefly upon the number of tendons which pass over it, and the close connection which exists between the fibrous tissue of their sheaths and the capsule of the wrist; also upon the proximity of the medio-carpal and carpo-metacarpal joints, which permits shocks and jars to be shared and distributed between them; another source of strength is the absence of any long bone on the distal side of the joint. In flexion and extension the carpus rolls backward and forward, respectively, beneath the arch formed by the radius and articular disc; flexion being limited by the dorsal ligament and dorsal portions of the collateral; extension by the volar, and volar portions of the collateral ligaments. In adduction and abduction the carpal bones glide from the ulnar to the radial side and from the radial to the ulnar side, respectively. Abduction is more limited than adduction, and is checked by the ulnar collateral ligament and by contact of the styloid process of the radius with the greater multangular; adduction is checked by the radial collateral ligament alone. One reason for adduction being more free than abduction is that the ulna does

FIG. 302.—FRONT OF WRIST WITH TRANSVERSE CARPAL LIGAMENT.

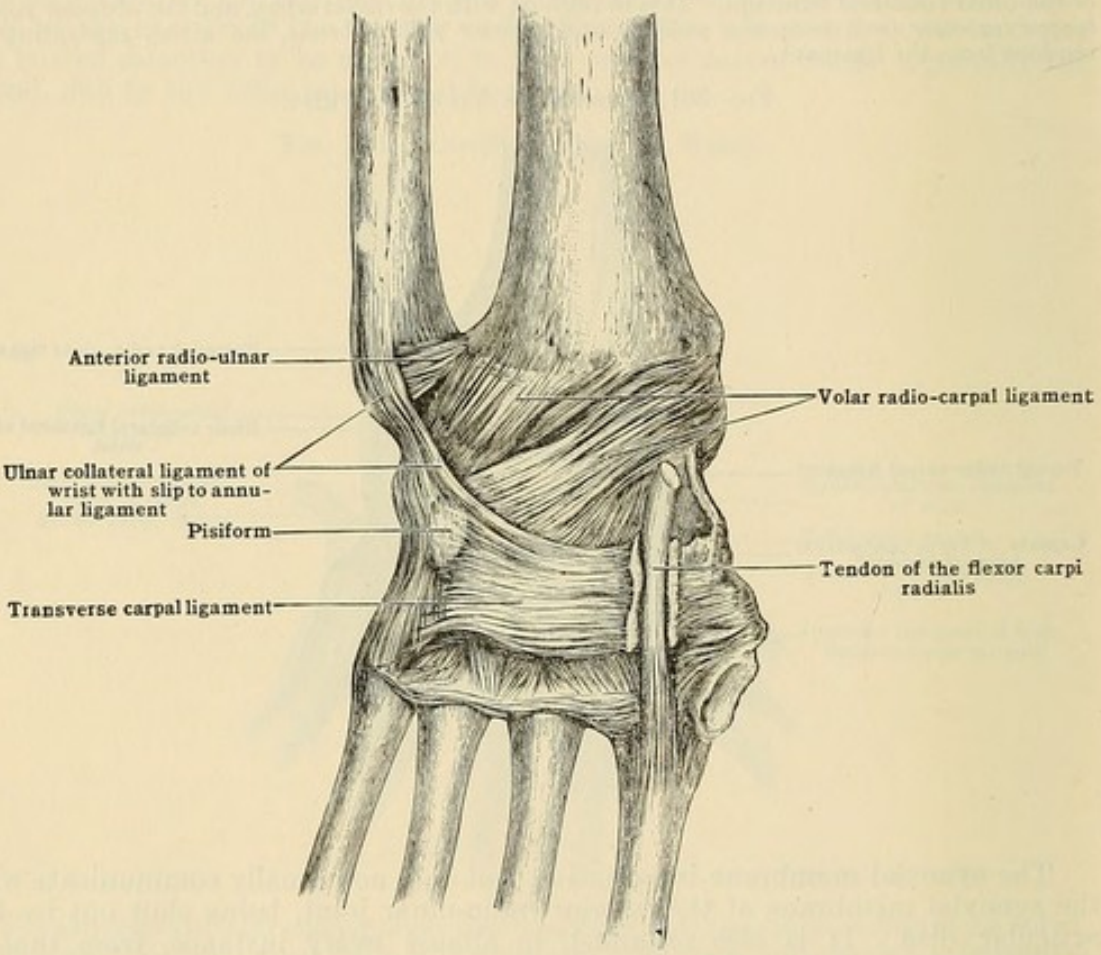

not reach so low down as the radius, and the yielding articular disc allows of greater movement upward of the ulnar end of the carpus. In circumduction the hand moves so as to describe a cone, the apex of which is at the wrist. These movements are made more easy and extensive by the slight gliding of the carpal bones upon one another, and the comparatively free motion at the medio-carpal joint. The oblique direction of the fibres of the collateral ligaments prevents any rotation at the radio-carpal joint, while it permits considerable freedom of abduction and adduction.

Muscles which act upon the radio-carpal joint.—*Flexors.*—The flexors of the carpus and the long flexors of the fingers and the thumb, and the palmaris longus. *Extensors.*—The extensors of the carpus and fingers. *Abductors.*—Extensor carpi radialis longus, the abductor pollicis longus (extensor ossis metacarpi pollicis. *Adductors.*—Flexor carpi ulnaris, extensor carpi ulnaris.

7. THE CARPAL JOINTS

The joints of the carpus may be subdivided into—

(*a*) The **joints of the first row.**
(*b*) The **joints of the second row.**
(*c*) The **medio-carpal,** or junction of the two rows with each other.

(*a*) The Joints of the First Row of Carpal Bones

Class.—*Diarthrosis.* **Subdivision.**—*Arthrodia.*

The bones of the first row, the pisiform excepted, are united by two sets of ligaments and two interosseous fibro-cartilages.

Dorsal. Volar.

Interosseous.

The **two dorsal intercarpal ligaments** extend transversely between the bones, and connect the navicular with the lunate, and the lunate with the triquetral. Their posterior surfaces are in contact with the posterior ligament of the wrist.

The **two volar intercarpal ligaments** extend nearly transversely between the bones connecting the navicular with the lunate, and the lunate with the triquetral. They are stronger than the dorsal ligaments, and are placed beneath the anterior ligament of the wrist.

The **two interosseous intercarpal ligaments** (fig. 304) are interposed between the navicular and lunate, and the lunate and triquetral bones, reaching from the dorsal to the volar surfaces,

Fig. 303.—Posterior View of the Wrist, with Capsule cut to show Articular Surfaces.

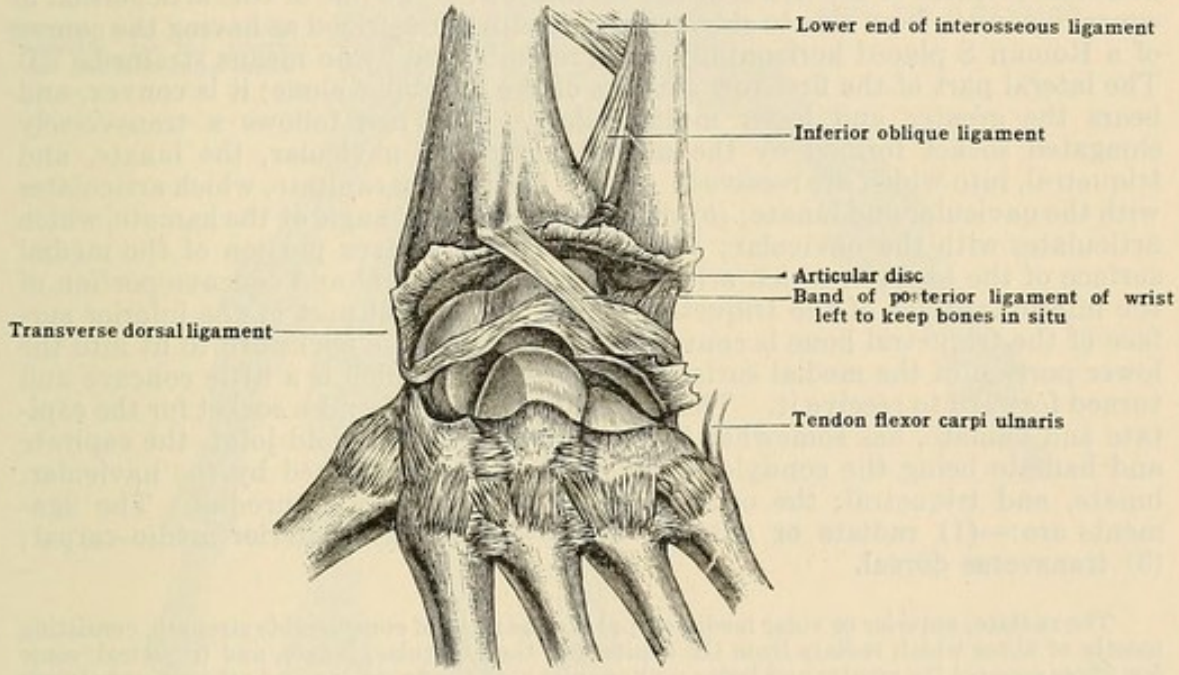

and being connected with the dorsal and volar ligaments. They are narrow fibro-cartilages which extend between small portions only of the osseous surfaces. They help to form the convex carpal surface of the radio-carpal joint, and are somewhat wedge-shaped, their bases being toward the wrist, and their thin edges between the adjacent articular surfaces of the bones.

The **synovial membrane** is a prolongation from that of the medio-carpal joint.

The **arterial** and **nerve-supplies** are the same as for the medio-carpal joint.

The Joint of the Pisiform Bone with the Triquetral

This is an arthrodial joint which has a loose fibrous **capsule** attached to both the pisiform and triquetral bones just beyond the margins of their articular surfaces.

It is lined by a separate synovial membrane. Two strong rounded or flattened bands pass downward from the pisiform, one to the process of the hamate [lig. pisohamatum], and the other [lig. pisometacarpeum] to the bases of the third to fifth metacarpals; these are regarded as prolongations of the tendon of the *flexor carpi ulnaris*, and the pisiform bone may be looked upon in the light of a sesamoid bone developed in that tendon.

(*b*) The Joints of the Second Row of Carpal Bones

Class.—*Diarthrosis.* **Subdivision.**—*Arthrodia.*

The four bones of this row are united by three dorsal, three palmar, and three interosseous ligaments.

The **three dorsal ligaments** (fig. 303) extend transversely and connect the greater with the lesser multangular, the lesser multangular with the capitate, and the capitate with the hamate.

The **three volar ligaments** are stronger than the dorsal, and are deeply placed beneath the mass of flexor tendons; they extend transversely between the bones in a similar manner to the dorsal ligaments.

Three interosseous ligaments connect the bones of the lower row of the carpus together. Two are connected with the capitate, one uniting it with the hamate (fig. 304) and the other binding it to the lesser multangular. The third ligament joins the greater and lesser multangular.

The **synovial membrane** is a prolongation of that lining the medio-carpal joint.

The **arterial** and **nerve-supplies** are the same as for the medio-carpal joint.

(*c*) The Medio-carpal Joint, or the Union of the Two Rows of the Carpus with each other

(I) **Class.**—*Diarthrosis.* **Subdivision.**—*Arthrodia.*
(II) **Class.**—*Diarthrosis.* **Subdivision.**—*Condylarthrosis.*

The inferior surfaces of the bones of the first row are adapted to the superior articular surfaces of the bones of the second row. The line of this articulation is concavo-convex from side to side, and is sometimes described as having the course of a Roman S placed horizontally, ∽, a resemblance by no means strained. (i) The lateral part of the first row consists of the navicular alone; it is convex, and bears the greater and lesser multangulars. (ii) Then follows a transversely elongated socket formed by the medial part of the navicular, the lunate, and triquetral, into which are received—(*a*) the head of the capitate, which articulates with the navicular and lunate; (*b*) the upper and lateral angle of the hamate, which articulates with the navicular; and (*c*) the upper convex portion of the medial surface of the hamate, which articulates with the lateral and concave portion of the inferior surface of the triquetral. (iii) The medial part of the inferior surface of the triquetral bone is convex, and turned a little backward to fit into the lower portion of the medial surface of the hamate, which is a little concave and turned forward to receive it. The central part, which forms a socket for the capitate and hamate, has somewhat the character of a condyloid joint, the capitate and hamate being the condyle, to fit into the cavity formed by the navicular, lunate, and triquetral; the other portions are typically arthrodial. The ligaments are:—(1) **radiate or anterior medio-carpal;** (2) **posterior medio-carpal;** (3) **transverse dorsal.**

The **radiate,** anterior or volar medio-carpal is a ligament of considerable strength, consisting mostly of fibres which radiate from the capitate to the navicular, lunate, and triquetral; some few fibres connect the greater and lesser multangular with the navicular, and others pass between the hamate and triquetral. It is covered over and thickened by fibrous tissue derived from the sheaths of the flexor tendons and the fibres of origin of the small muscles of the thumb and little finger.

The posterior or **dorsal medio-carpal ligament,** consists of fibres passing obliquely from the bones of the first row to those of the second. It is stronger on the ulnar side than on the radial, but is not so strong as the volar ligament.

The **transverse dorsal ligament** (fig. 303) is an additional band, well marked and often of considerable strength, which passes across the head of the capitate from the navicular to the triquetral bone; besides binding down the head of the capitate, it serves to fix the upper and lateral angle of the hamate in the socket formed by the first row.

The dorsal ligaments, like the volar, are strengthened by a quantity of fibrous tissue belonging to the sheaths of the extensor tendons, and by an extension of some of the fibres of the capsule of the wrist. There are no proper collateral medio-carpal ligaments; they are but prolongations of the collateral ligaments of the wrist.

The **synovial membrane** (fig. 304) of the carpus is common to all the joints of the carpus, and extends to the bases of the four medial metacarpal bones. Thus, besides lining the inter- or medio-carpal joint, it sends two processes upward between the three bones of the first row, and three downward between the contiguous surfaces of the lesser and greater multangular, the lesser multangular and capitate, and capitate and hamate. From these latter, prolongations extend to the four medial carpo-metacarpal joints and the three intermetacarpal joints.

The **arterial supply** is derived from—(*a*) the volar and dorsal carpal rami of the radial and ulnar arteries; (*b*) the carpal branch of the volar interosseous; (*c*) the recurrent branches from the deep palmar arch. The terminal twigs of the volar and dorsal interosseous arteries supply the joint on its dorsal aspect.

The **nerve-supply** comes from the ulnar on the ulnar side, the median on the radial side, and the deep branch of the radial (posterior interosseous) behind.

Relations.—The relations of this joint are practically the same as those of the radio-carpal joint, except that the flexor carpi ulnaris does not cross the front, the ulnar artery is separated

from it by the transverse carpal ligament, and the radial artery passes across its lateral border instead of in front.

The **movements** of the carpal articulations between bones of the same row are very limited and consist only of slight gliding upon one another; but, slight as they are, they give elasticity to the carpus to break the jars and shocks which result from blows or falls upon the hand.

The movements of one row of bones upon the other at the medio-carpal joint are more extensive, especially in the direction of flexion and extension, so that the hand enjoys a greater range of these movements than is permitted at the wrist-joint alone. At the wrist, extension is more free than flexion; but this is balanced by the greater freedom of flexion than of extension at the medio-carpal joint, and by flexion at the carpo-metacarpal joint, so that on the whole the range of flexion of the hand is greater than that of extension.

FIG. 304.—SYNOVIAL MEMBRANES OF WRIST, HAND, AND FINGERS.

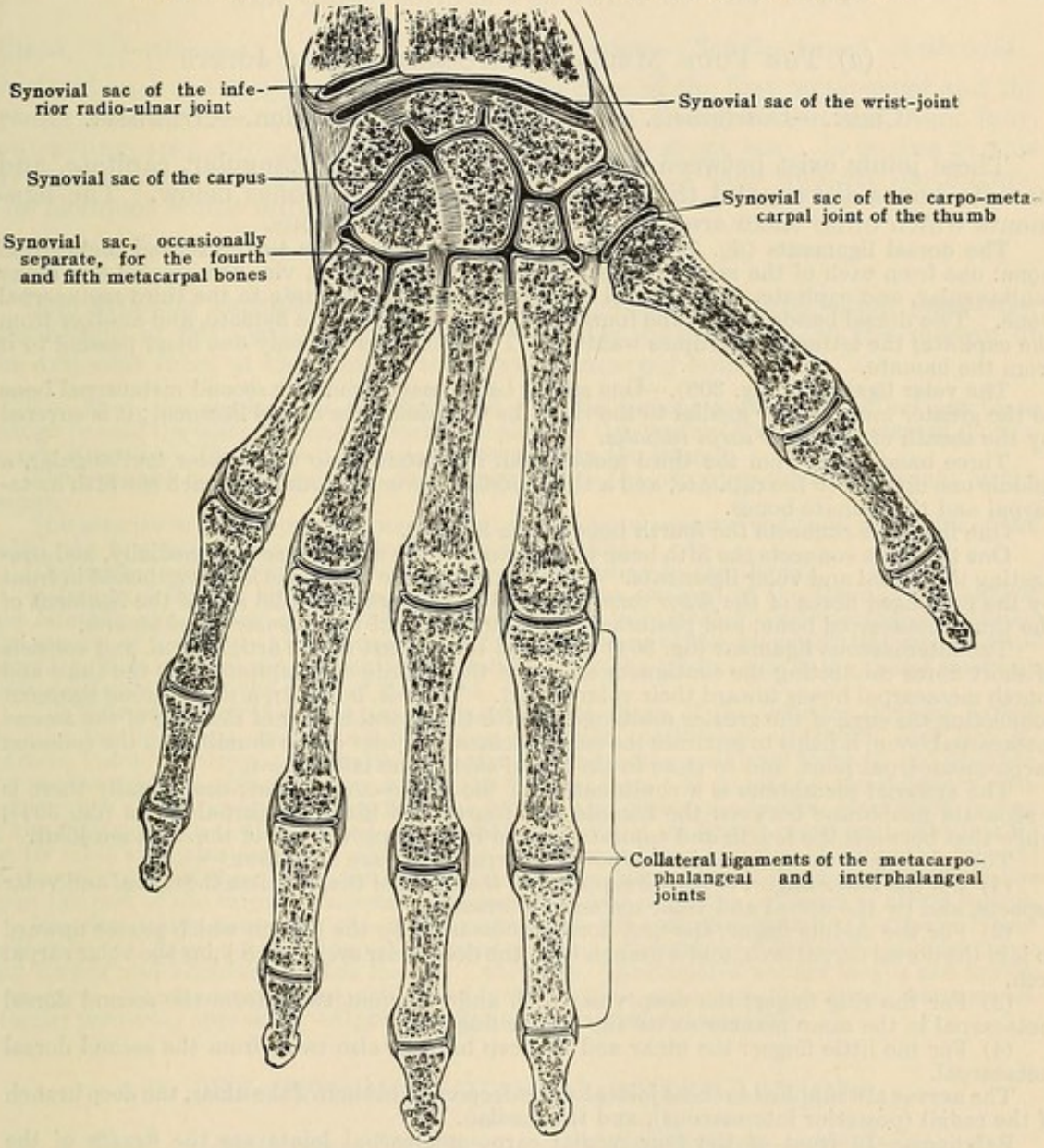

A slight amount of side to side motion accompanied by a limited degree of rotation also takes place; this rotation consists in the head of the capitate and the superior and lateral angle of the hamate bone rotating in the socket formed by the three bones of the upper row, and in a gliding forward and backward of the greater and lesser multangular upon the navicular.

In addition to the ligaments, the undulating outline and the variety of shapes of the apposed facets render this joint very secure.

Bearing in mind the mobility of this medio-carpal joint and of the carpo-metacarpal, we see at once the reason for the radial and ulnar flexors and extensors of the carpus being prolonged down to their insertion into the base of the metacarpus, for they produce the combined effect of motion at each of the three transverse articulations:—(1) at the wrist; (2) at the medio-carpal; (3) at the carpo-metacarpal joints.

Muscles which act upon the mid-carpal joint.—The muscles which act upon this joint are the same as those which act upon the radio-carpal joint, except the flexor carpi ulnaris, which is inserted into the pisiform bone.

8. THE CARPO-METACARPAL JOINTS

These may be divided into two sets, namely:—

(*a*) The **carpo-metacarpal joints of the four medial fingers.**
(*b*) The **carpo-metacarpal joints of the thumb.**

The inferior surfaces of the bones of the second row of the carpus present a composite surface for the four medial metacarpal bones; the greater multangular presents in addition a distinct and separate saddle-shaped surface for the base of the metacarpal bone of the thumb.

(*a*) The Four Medial Carpo-metacarpal Joints

Class.—*Diarthrosis.* **Subdivision.**—*Arthrodia.*

These joints exist between the greater and lesser multangular, capitate, and hamate bones above, and the four medial metacarpal bones below. The ligaments which unite them are, dorsal, volar, and interosseous.

The dorsal ligaments (fig. 303).—Three dorsal ligaments pass to the second metacarpal bone: one from each of the carpal bones with which it articulates, viz., the greater and lesser multangular, and capitate. Two dorsal bands pass from the capitate to the third metacarpal bone. Two dorsal bands pass to the fourth bone: viz., one from the hamate, and another from the capitate; the latter is sometimes wanting. The fifth bone has only one band passing to it from the hamate.

The volar ligaments (fig. 300).—One strong band passes from the second metacarpal bone to the greater multangular medial to the ridge for the transverse carpal ligament; it is covered by the sheath of the *flexor carpi radialis.*

Three bands pass from the third metacarpal: one laterally to the greater multangular, a middle one upward to the capitate, and a third medially over the fourth to reach the fifth metacarpal and the hamate bones.

One ligament connects the fourth bone to the hamate.

One ligament connects the fifth bone to the hamate, the fibres extending medially, and connecting the dorsal and volar ligaments. The ligament to the fifth bone is strengthened in front by the prolonged fibres of the *flexor carpi ulnaris* and the strong medial slip of the ligament of the third metacarpal bone; and posteriorly, by the tendon of the *extensor carpi ulnaris.*

The **interosseous ligament** (fig. 304) is limited to one part of the articulation, and consists of short fibres connecting the contiguous angles of the hamate and capitate with the third and fourth metacarpal bones toward their volar aspect. There is, however, a thick strong ligament connecting the edge of the greater multangular with the lateral border of the base of the second metacarpal bone; it helps to separate the carpo-metacarpal joint of the thumb from the common carpo-metacarpal joint, and to close in the radial side of the latter joint.

The **synovial membrane** is a continuation of the medio-carpal joint; occasionally there is a separate membrane between the hamate and fourth and fifth metacarpal bones (fig. 304); while that between the fourth and capitate is lined by the synovial sac of the common joint.

The **arteries** to the four medial carpo-metacarpal joints are as follows:—

(1) For the index finger: twigs are supplied by the trunk of the radial on the dorsal and volar aspects, and by the dorsal and volar metacarpal branches.

(2) For the middle finger: the first dorsal metacarpal by the branch which passes upward to join the dorsal carpal arch, and a branch from the deep volar arch which joins the volar carpal arch.

(3) For the ring finger: the deep volar arch and recurrent twigs from the second dorsal metacarpal in the same manner as for the middle finger.

(4) For the little finger: the ulnar and its deep branch; also twigs from the second dorsal metacarpal.

The **nerves** are supplied to these joints by the deep volar branch of the ulnar, the deep branch of the radial (posterior interosseous), and the median.

Relations.—In front of the four medial carpo-metacarpal joints are the flexors of the fingers with their synovial sheath. The flexor carpi radialis crossing in front of the lateral part of the joint and the fibres of the oblique adductor pollicis which spring from the capitate and lesser multangular are also anterior relations. Behind the joints are the extensors of the wrist and fingers with their synovial sheaths and the dorsal metacarpal arteries. At the lateral border of the joints between the index and lesser multangular lies the radial artery.

The **movements** permitted at these joints, though slight, serve to increase those of the medio-carpal and wrist-joints. The joint between the fifth metacarpal and the hamate bones approaches somewhat in shape and mobility the first carpo-metacarpal joint; it has a greater range of flexion and extension, but its side to side movement is nearly as limited as that of the three other metacarpal bones; the process of the hamate bone limits its flexion. Motion toward the ulnar side is checked by the strong palmar band which unites the base of the fifth metacarpal to the base of the third, and the strong transverse ligament at the head of the bones. The mobility of the second, third, and fourth metacarpal bones is very limited, and consists almost entirely of a slight gliding upon the carpal bones, i. e., flexion and extension; that of the third and fourth bones is extremely slight, as there is no long flexor attached to either; but,

owing to the close connection of the bases of the metacarpal bones, the radial and ulnar flexors and extensors of the carpus act on all by their pull on the particular bone into which they are inserted.

Abduction, or movement toward the radial side, is prevented by the impaction of the second bone against the greater multangular; a little adduction is permitted, and is favoured by the slope given to the hamate and fifth metacarpal bones.

There is also a slight gliding between the fourth and fifth bones, when the concavity they present toward the palm is deepened to form the 'cup of Diogenes.'

Muscles which act upon the four medial carpo-metacarpal joints are the flexors and extensors of the wrist and fingers, except the flexor carpi ulnaris.

(*b*) The Carpo-metacarpal Joint of the Thumb

Class.—*Diarthrosis.* **Subdivision.**—*Saddle-shaped Arthrodia.*

The bones entering into this joint are the base of the first metacarpal and the greater multangular. The first metacarpal bone diverges from the other four, contrasting very strongly with the position of the great toe. It is due to this divergence that the thumb is able to be opposed to each and all the fingers. The ligament which unites the bones is the

Articular capsule.

The **articular capsule** (figs. 300 and 301) consists of fibres which pass from the margin of the articular facet on the greater multangular, to the margin of the articular facet at the base of the first metacarpal bone.

The fibres are stronger on the dorsal than on the palmar aspect. They are not tense enough to hold the bones in close contact, so that while they restrict they do not prevent motion in any direction. The medial fibres are stronger than the lateral.

The **synovial membrane** is lax, and distinct from the other synovial membranes of the carpus.

The **arteries** of the carpo-metacarpal joint of the thumb are derived from the trunk of the radial, the first volar metacarpal, and the dorsalis pollicis.

The **nerves** are supplied by the branches of the median to the thumb.

Relations.—Behind are the long and short extensor tendons of the thumb, and behind and laterally the tendon of the abductor pollicis longus (extensor ossis metacarpi pollicis). The tendon of the flexor pollicis longus is in front and fibres of the flexor pollicis brevis and opponens pollicis muscles are also anterior relations. To the medial side is the radial artery as it passes forward into the palm of the hand.

The **movements** of this joint are regulated by the shape of the articular surfaces, rather than by the ligaments, and consist of flexion, extension, abduction, adduction, and circumduction, but not rotation. In flexion and extension the metacarpal bone slides to and fro upon the multangular; in abduction and adduction it slides from side to side or, more correctly, revolves upon the antero-posterior axis of the joint. The power of opposing the thumb to any of the fingers is due to the forward and medial obliquity of its flexion movement, which is by far its most extensive motion. Abduction is very free, while adduction is limited on account of the proximity of the second metacarpal bone. The movement of the greater multangular upon the rest of the carpus somewhat increases the range of all the movements of the thumb.

Muscles which act upon the carpo-metacarpal joint of the thumb.—*Flexors.*—Flexor pollicis brevis, flexor pollicis longus, opponens pollicis. *Extensors.*—Extensores pollicis brevis and longus and abductor pollicis longus. *Abductors.*—Abductores pollicis longus and brevis. *Adductors.*—The transverse and oblique adductor pollicis, opponens, first dorsal interosseous. *Muscles producing opposition.*—Opponens, flexor brevis, oblique adductor.

9. THE INTERMETACARPAL ARTICULATIONS

Class.—*Diarthrosis.* **Subdivision.**—*Arthrodia.*

The metacarpal of the thumb is not connected with any other metacarpal bone. The second, third, fourth, and fifth metacarpal bones are in actual contact at their bases, and are held firmly together by the following ligaments (in addition to the articular capsule):—

Dorsal. Volar.
Interosseous ligaments.

The **dorsal ligaments** (fig. 302) are layers of variable thickness of strong, short fibres, which pass transversely from bone to bone, filling up the irregularities on the dorsal surfaces.

The **volar ligaments** are transverse layers of ligamentous tissue passing from bone to bone; they cannot be well differentiated from the other ligaments and fibrous tissue covering the bones.

The **interosseous ligaments** (fig. 304) pass between the apposed surfaces of the bones, and are attached to the distal sides of the articular facets, so as to close in the synovial cavities on

this aspect; where there are two articular facets, the fibres extend upward between them nearly as far as their carpal facets. That between the fourth and fifth is the weakest.

The **synovial membrane** is prolonged downward from the common carpal sac.

The **arteries** to the intermetacarpal joints are twigs from the volar and dorsal metacarpal arteries; the twigs pass upward between the interosseous muscles.

The **nerves** are derived from the ulnar and the deep branch of radial (posterior interosseous).

The Union of the Heads of the Metacarpal Bones

The distal extremities of these bones are connected together on their palmar aspects by what is called the **transverse ligament** [lig. capitulorum]. This consists of three short bands of fibrous tissue, which unite the second and third, third and fourth, and the fourth and fifth bones. They are rather more than 6 mm. ($\frac{1}{4}$ in.) deep, and rather less in width, and limit the distance to which the metacarpal bones can be separated. They are continuous above with the fascia covering the interosseous muscles; below, they are connected with the subcutaneous tissue of the web of the hand. They are on a level with the front surface of the bones, and are blended on either side with the edges of the glenoid ligament in front, with the lateral ligaments

Fig. 305.—Anterior and Posterior Views of Ligaments of the Fingers.

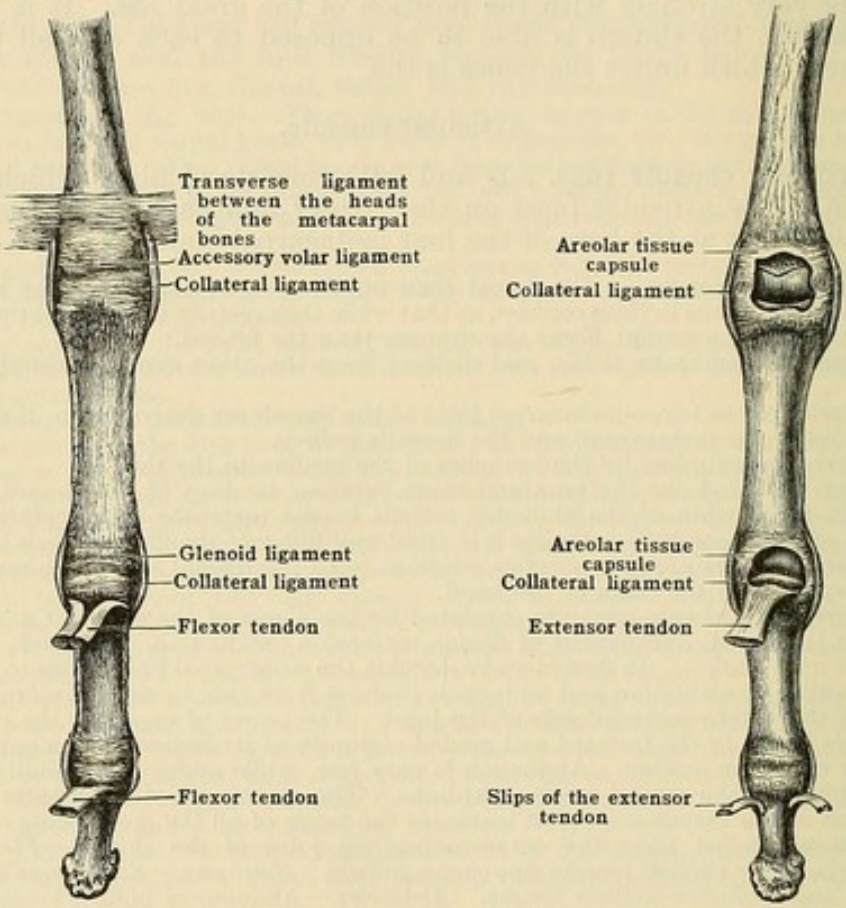

of the metacarpo-phalangeal joint, and also with the sheaths of the tendons. In front, a *lumbrical* muscle passes with the digital arteries and nerves; while behind, the *interossei* muscles pass to their insertions.

10. THE METACARPO-PHALANGEAL JOINTS

(*a*) The Metacarpo-phalangeal Joints of the Four Medial Fingers

Class.—*Diarthrosis.* **Subdivision.**—*Condylarthrosis.*

In these joints the cup-shaped extremity of the base of the first phalanx fits on to the rounded head of the metacarpal bone, and is united by the following ligaments (in addition to the articular capsule):—

Collateral. Volar accessory.

The **volar accessory** (or glenoid) **ligament** (fig. 305) is a fibro-cartilaginous plate which seems more intended to increase the depth of the phalangeal articular facet in front, than to unite the two bones. It is much more firmly attached to the margin of the phalanx than to the metacarpal bone, being only loosely connected with the palmar surface of the latter by some loose areolar tissue which covers in the synovial membrane, here prolonged some little distance upon the surface of the bone. At the sides, it is connected with the collateral ligaments and the

transverse metacarpal ligament. It corresponds to the sesamoid bones of the thumb; a sesamoid bone sometimes exists at the medial border of the joint of the little finger.

The **collateral ligaments** (304 and 305) are strong and firmly connect the bones with one another; each is attached above to the corresponding tubercle, and to a depression in front of the tubercle, of the metacarpal bone. From this point the fibres spread widely as they descend on either side of the base of the phalanx; the anterior fibres are connected with the glenoid ligament; the posterior blend with the tendinous expansion at the back of the joint.

The joint is covered in **posteriorly** by the expansion of the extensor tendon, and some loose areolar tissue passing from its under surface to the bones (fig. 305).

The **synovial membrane** is loose and capacious, and invests the inner surface of the ligaments which connect the bones.

The **arteries** come from the digital or volar metacarpal vessels of the deep arch.

The **nerves** are derived from the digital branches, or from twigs of the branches of the ulnar to the interosseous muscles.

Relations.—I. The metacarpo-phalangeal joints of the middle three digits. In front, the tendons of the flexor profundus and flexor sublimis digitorum. On the radial side, a lumbrical, an interosseous muscle, and digital nerves and vessels; on the ulnar side, an interosseous muscle and digital vessels and nerves. Behind, the common extensor tendon and in the case of the index digit the tendon of the extensor indicis.

II. The metacarpo-phalangeal joint of the little finger. In front, the flexor quinti digiti brevis and the tendons of the flexor profundus and sublimis digitorum muscle which go to this digit. Behind, the extensor digiti quinti to a slip of the extensor digitorum communis sometimes. On the radial side, a lumbrical, the third palmar interosseous muscle, digital vessels and nerves. On the ulnar side, digital vessels and nerves.

The **movements** permitted at these joints are flexion, extension, abduction, adduction, and circumduction. Flexion is the most free of all and may be continued until the phalanx is at a right angle with the metacarpal bone. It is on this account that the articular surface of the head of the bone is prolonged so much further on the palmar aspect, and that the synovial membrane is here so loose and ample. Extension is the most limited of the movements, and can only be carried to a little beyond the straight line. Abduction and adduction are fairly free, but not so free as flexion. Flexion is associated with adduction, and extension with abduction. This may be proved by opening the hand, when the fingers involuntarily separate as they extend, while in closing the fist they come together again. The free abduction, adduction, and circumduction which are permitted at these joints are due to the fact that the long axes of the articular facets are at right angles to one another.

Muscles acting on the middle three digits.—*Flexors.*—Flexor digitorum profundus, flexor digitorum sublimis. *Extensors.*—Extensor digitorum communis and on the index digit the extensor indicis. *Abductors.*—Dorsal interossei. *Adductors.*—Volar interossei.

Muscles acting on the metacarpo-phalangeal joint of the little finger.—*Flexors.*—Flexor quinti digiti brevis, flexor digitorum sublimis, flexor digitorum profundus. *Extensors.*—Extensor digitorum communis, extensor quinti digiti. *Abductor.*—Abductor quinti digiti. *Adductor.*—Third volar interosseous.

(*b*) The Metacarpo-phalangeal Joint of the Thumb

Class.—*Diarthrosis.* **Subdivision.**—*Condylarthrosis.*

The head of the metacarpal bone of the thumb differs considerably from the corresponding ends of the metacarpal bones of the fingers. It is less convex, wider from side to side, the palmar edge of the articular surface is raised and irregular, and here on either side of the median line are the two facets for the sesamoid bones. The base of the first phalanx of the thumb, too, is more like the base of the second phalanx of one of the other fingers. The ligaments are:—

Collateral. Dorsal.
Articular capsule.

The **collateral ligaments** are short, strong bands of fibres, which radiate from depressions on either side of the head of the metacarpal bone to the base of the first phalanx and sesamoid bones. As they descend they pass a little forward, so that the greater number are inserted in front of the centre of motion.

The **dorsal ligament** consists of scattered fibres which pass across the joint from one collateral ligament to the other, completing the **articular capsule** and protecting the synovial sac.

The **sesamoid bones** are two in number, situated on either side of the middle line, and connected together by strong transverse fibres which form the floor of the groove for the *long flexor tendon;* they are connected with the base of the phalanx and head of the metacarpal bone by strong fibres. Anteriorly they give attachment to the short muscles of the thumb, and posteriorly are smooth for the purpose of gliding over the facets. The collateral ligaments are partly inserted into their sides.

The **arteries** and **nerves** come from the digital branches of the thumb.

Relations.—Of the metacarpo-phalangeal joint of the thumb: In front and externally abductor pollicis brevis and superficial head of flexor pollicis brevis. In front and medially oblique and transverse adductors and deep head of flexor pollicis brevis. Directly in front flexor pollicis longus and terminal branches of first volar metacarpal artery. Behind, extensor pollicis brevis and longus tendons. On either side, the dorsal digital vessels and the digital nerves.

The **movements** are chiefly flexion and extension, very little side to side movement being permitted, and that only when the joint is slightly bent. Thus this joint more nearly approaches the simple hinge character than the corresponding articulations of the fingers. The thumb gets its freedom of motion at the carpo-metacarpal joint; the fingers get theirs at the metacarpo-phalangeal, but they are not endowed with so much freedom as the thumb enjoys.

Muscles which act upon the metacarpo-phalangeal joint of the thumb.—*Flexors.*—Flexor pollicis brevis, flexor pollicis longus. *Extensors.*—Extensor pollicis brevis, extensor pollicis longus.

11. THE INTERPHALANGEAL ARTICULATIONS

Class.—*Diarthrosis.* **Subdivision.**—*Ginglymus.*

The ligaments which unite the phalanges of the thumb and of the fingers are (in addition to the articular capsule):—

Accessory volar. Collateral.

The **accessory volar** (or glenoid) **ligament** (fig. 305), sometimes called the sesamoid body, is very firmly connected with the base of the distal bone, and loosely, by means of fibro-areolar tissue, with the head of the proximal one. It blends with the collateral ligaments at the sides, and over it pass the flexor tendons. Occasionally a sesamoid bone is developed in the cartilage of the interphalangeal joint of the thumb.

The **collateral ligaments** (figs. 304 and 305) are strong bands which are attached to the rough depressions on the sides of the upper phalanx, and to the projecting margins of the lower phalanx of each joint. They are tense in every position, and entirely prevent any side to side motion; they are connected posteriorly with the expansion of the extensor tendon.

Dorsally (fig. 305) the joint is covered in by the deep surface of the extensor tendon, and a little fibro-areolar tissue extends from the tendon, and thickens the posterior portion of the synovial sac, completing the **articular capsule.**

The **synovial membrane** is loose and ample, and extends upward a little way along the shaft of the proximal bone.

The **arteries** and **nerves** come from their respective digital branches.

The **relations** of the interphalangeal joints are the flexor and extensor tendons and the digital vessels and nerves.

The **movements** are limited to flexion and extension. Flexion is more free, and can be continued till one bone is at a right angle to the other, and is most free at the junction of the first and second bones; the second phalanx can be flexed on the first through 110° to 115° when the latter is not flexed. The greater freedom of flexion is due to the greater extent of the articular surface in front of the heads of the proximal bones, and to the direction of the fibres of the collateral ligaments, which pass a little forward to their insertion into the distal bone.

The muscles which act upon the interphalangeal joints are the extensors and flexors of the digits.

THE ARTICULATIONS OF THE LOWER LIMB

The articulations of the lower limb are the following:—

1. The **hip-joint.**
2. The **knee-joint.**
3. The **tibio-fibular union.**
4. The **ankle-joint.**
5. The **tarsal joints.**
6. The **tarso-metatarsal joints.**
7. The **intermetatarsal joints.**
8. The **metatarso-phalangeal joints.**
9. The **interphalangeal joints.**

1. THE HIP-JOINT

Class.—*Diarthrosis.* **Subdivision.**—*Enarthrodia.*

The hip is the most typical example of a ball-and-socket joint in the body, the round head of the femur being received into the cup-shaped cavity of the acetabulum. Both articular surfaces are coated with cartilage, that covering the head of the femur being thicker above where it has to bear the weight of the body, and thinning out to a mere edge below; the pit for the ligamentum teres is the only part uncoated, but the cartilage is somewhat heaped up around its margin. Covering the acetabulum, the cartilage is horseshoe-shaped, and thicker above than below, being deficient over the depression at the bottom of the acetabulum,

where a mass of fatty tissue—the so-called synovial or Haversian gland—is lodged.

The ligaments of the joint are:—

Articular capsule.	Ligamentum teres.
Transverse.	Glenoid lip.

The **articular capsule** is one of the strongest ligaments in the body. It is large and somewhat loose, so that in every position of the body some portion of it is relaxed. At the **pelvis** it is attached, superiorly, to the base of the anterior inferior iliac spine; curving backward, it becomes blended with the deep surface of the reflected tendon of the *rectus femoris;* posteriorly, it is attached a few millimetres from the acetabular rim; and below, to the upper edge of the groove between the acetabulum and tuberosity of the ischium. Thus it reaches the

FIG. 306.—ANTERIOR VIEW OF THE ARTICULAR CAPSULE OF THE HIP-JOINT.

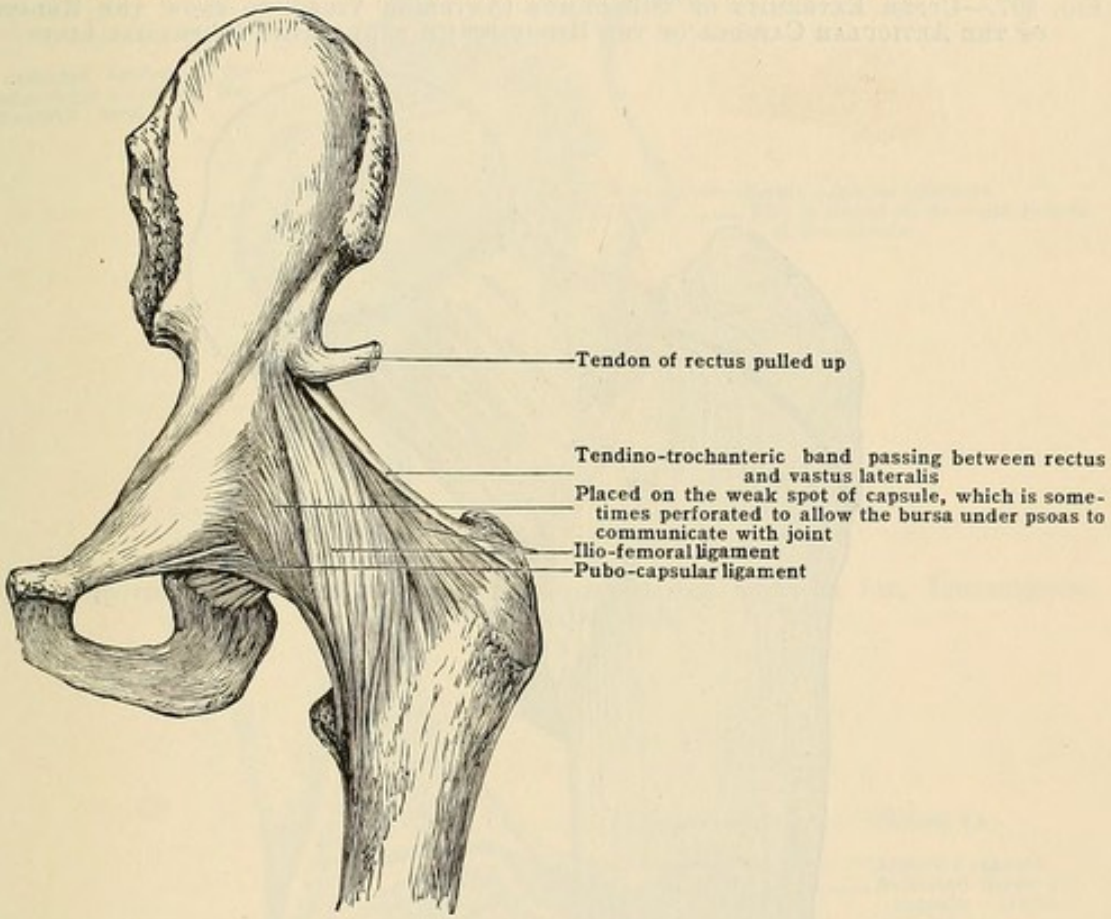

transverse ligament, being firmly blended with its outer surface, and frequently sends fibres beyond the notch to blend with the obturator membrane. Anteriorly it is attached to the pubis near the obturator notch, to the ilio-pectineal eminence and thence backward to the base of the inferior iliac spine.

A thin strong stratum is given off from its superficial aspect behind; this extends beneath the gluteus minimus and small rotators, to be attached above to the dorsum of the ilium higher than the reflected tendon of the rectus, and posteriorly to the ilium and ischium nearly as far as the sciatic notch. As this expansion passes over the long tendon of the *rectus,* the tendon may be described as being in part contained within the substance of the capsule.

At the **femur,** the capsule is fixed to the anterior portion of the upper border of the great trochanter and to the cervical tubercle. Thence it runs down, the intertrochanteric line as far as the medial border of the femur, where it is on a level with the lower part of the lesser trochanter. It then runs upward and backward along an oblique line about 1.6 cm. ($\frac{2}{3}$ in.) in front of the lesser trochanter, and continues its ascent along the back of the neck nearly parallel to the intertrochanteric crest, and from 12 to 16 mm. ($\frac{1}{2}$ to $\frac{2}{3}$ in.) above it; finally, it passes along the medial side of the trochanteric fossa to reach the anterior superior angle of the great trochanter.

On laying open the capsule, some of the deeper fibres are seen reflected upward along the neck of the femur, to be attached much nearer the head: these are the **retinacula.** One corresponds to the upper, and another to the lower, part of the intertrochanteric line; a third is seen at the upper and back part of the neck. They form flat bands,which lie on the femoral neck.

Superadded to the capsule, and considerably strengthening it, are three auxiliary bands, whose fibres are intimately blended with, and in fact form part of, the capsule, viz., the ilio-femoral, ischio-capsular, and pubo-capsular ligaments.

The **ilio-femoral ligament** (fig. 306) is the longest, widest, and strongest of the bands. It is of triangular shape, with the apex attached above to a curved line on the ilium immediately below and behind the anterior inferior spine, and its base below to the anterior edge of the greater trochanter and to the spiral line as far as the medial border of the shaft. The highest or most lateral fibres are coarse, almost straight, and shorter than the rest; the most medial fibres are also thick and strong, but oblique. This varying obliquity of the fibres, and their accumulation at the borders, explain why this band has been described as the **Y**-shaped ligament; but it

FIG. 307.—UPPER EXTREMITY OF THE FEMUR (ANTERIOR VIEW), TO SNOW THE RELATION OF THE ARTICULAR CAPSULE OF THE HIP-JOINT (IN RED) TO THE EPIPHYSIAL LINES.

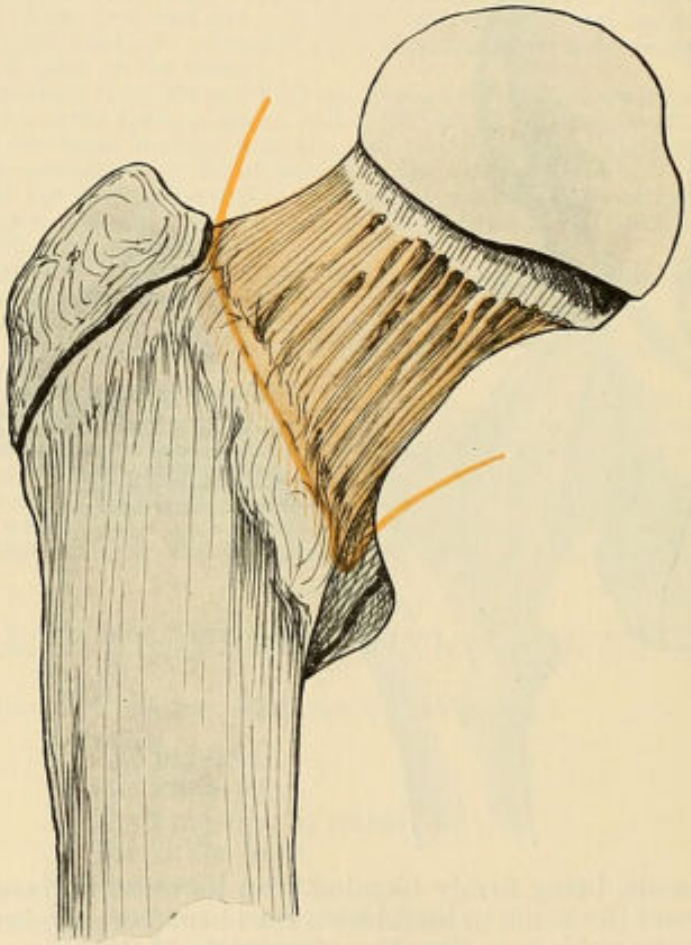

should be noted that the **Y** is inverted. About the centre of its base, near the femoral attachment, is an aperture transmitting an articular twig from the ascending branch of the external circumflex artery.

The **ischio-capsular ligament** (fig. 308) is formed of very strong fibres attached all along the upper border of the groove for the external obturator, and to the ischial margin of the acetabulum above the groove. The highest of these incline a little upward as they pass laterally to be fixed to the greater trochanter in front of the insertion of the piriformis tendon, while the other fibres curve more and more upward as they pass laterally to their insertion at the inner side of the trochanteric fossa, blending with the insertion of the external rotator tendons. When the joint is in flexion, these fibres pass in nearly straight lines to their femoral attachment, and spread out uniformly over the head of the femur; but in extension they wind over the back of the femur in a zonular manner [zona orbicularis], embracing the posterior aspect of the neck of the femur.

The **pubo-capsular (pectineo-femoral) band** (fig. 306) is a distinct but narrow set of fibres which are individually less marked than the fibres of the other two bands; they are fixed above to the obturator crest and to the anterior border of the ilio-pectineal eminence, reaching as far down as the pubic end of the acetabular notch. Below, they reach the neck of the femur, and are fixed above and behind the lowermost fibres of the ilio-femoral band, with which they blend.

In **thickness** and strength the capsule varies greatly; thus, if two lines be drawn, one from the anterior inferior spine to the medial border of the femur near the lesser trochanter, and the other from the anterior part of the groove for the

FIG. 308.—POSTERIOR VIEW OF THE ARTICULAR CAPSULE OF THE HIP-JOINT.

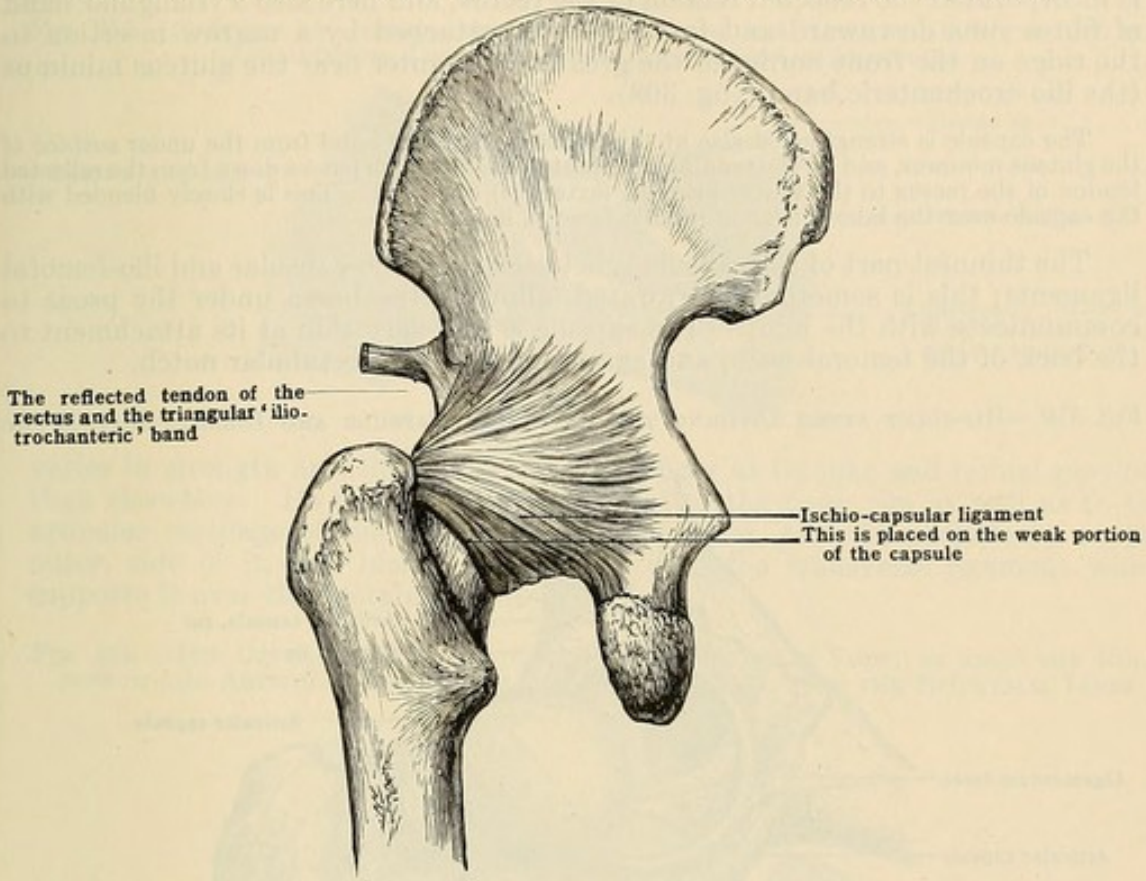

FIG. 309.—SECTION THROUGH THE HIP-JOINT, SHOWING THE GLENOID LIP, LIGAMENTUM TERES, AND RETINACULA.

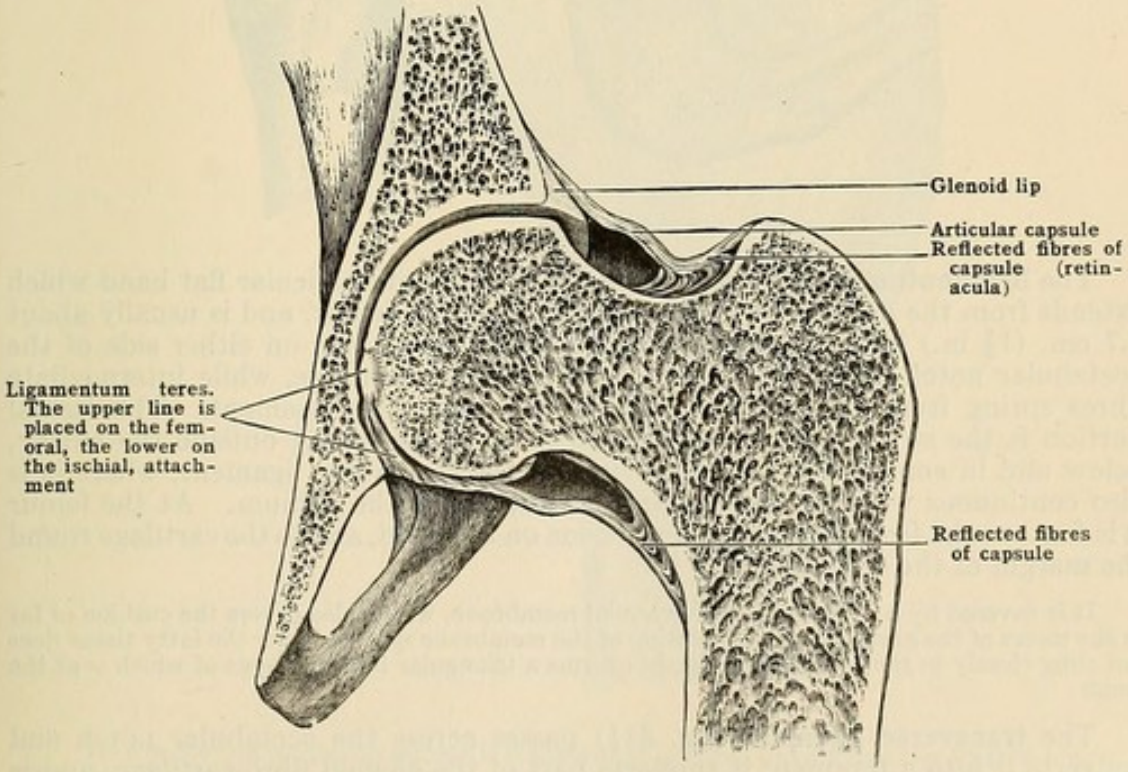

external obturator to the trochanteric fossa, all the ligament between these lines on the lateral and upper aspects of the joint is very thick and strong, while that below and to the medial side, except at the narrow pubo-capsular ligament, is

thin and weak, so that the head of the bone can be seen through it. The capsule is thickest in the course of the ilio-femoral ligament, toward the lateral part of which it measures over 6 mm. ($\frac{1}{4}$ in.). Between the ilio-femoral and ischio-capsular ligaments the capsule is very strong, and with it here, near the acetabulum, is incorporated the reflected tendon of the rectus, and here also a triangular band of fibres runs downward and forward to be attached by a narrow insertion to the ridge on the front border of the greater trochanter near the gluteus minimus (the **ilio-trochanteric band**) (fig. 308).

The capsule is strengthened also at this point by a strong band from the under surface of the gluteus minimus, and by the **tendino-trochanteric band** which passes down from the reflected tendon of the rectus to the vastus lateralis (externus) (fig. 306). This is closely blended with the capsule near the lateral edge of the ilio-femoral ligament.

The thinnest part of the capsule is between the pubo-capsular and ilio-femoral ligaments; this is sometimes perforated, allowing the bursa under the psoas to communicate with the joint. The capsule is also very thin at its attachment to the back of the femoral neck, and again opposite the acetabular notch.

FIG. 310.—HIP-JOINT AFTER DIVIDING THE ARTICULAR CAPSULE AND DISARTICULATING THE FEMUR.

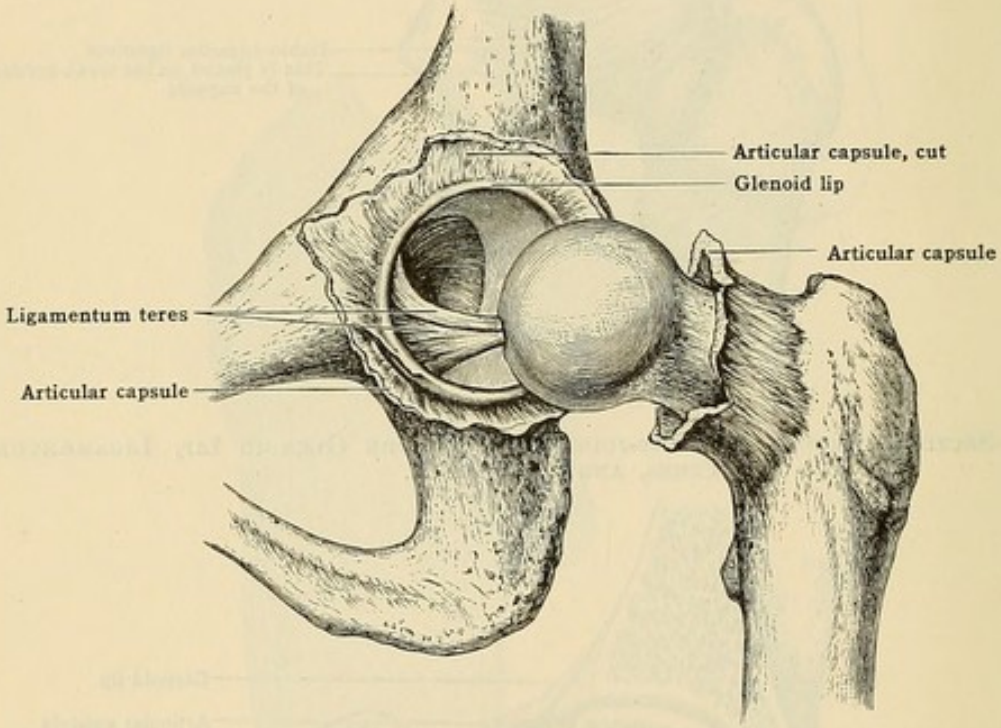

The **ligamentum teres** (figs. 309 and 310) is an interarticular flat band which extends from the acetabular fossa to the head of the femur, and is usually about 3.7 cm. ($1\frac{1}{2}$ in.) long. It has two bony attachments, one on either side of the acetabular notch immediately below the articular cartilage, while intermediate fibres spring from the lower surface of the transverse ligament. The ischial portion is the stronger, and has several of its fibres arising outside the cavity, below and in connection with the origin of the transverse ligament, where it is also continuous with the capsule and periosteum of the ischium. At the femur it is fixed to the front part of the depression on the head, and to the cartilage round the margin of the depression.

It is covered by a prolongation of synovial membrane, which also covers the cushion of fat in the recess of the acetabulum; the portion of the membrane reflected over the fatty tissue does not cling closely to the round ligament, but forms a triangular fold, the apex of which is at the femur.

The **transverse ligament** (fig. 311) passes across the acetabular notch and converts it into a foramen; it supports part of the glenoid fibro-cartilage, and is connected with the ligamentum teres and the capsule. It is composed of decussating fibres, which arise from the margin of the acetabulum on either side of the notch, those coming from the pubis being more superficial, and passing to form

the deep part of the ligament at the ischium, while those superficial at the ischium are deep at the pubis. It thus completes the rim of the acetabulum.

The glenoid lip (cotyloid fibro-cartilage) (figs. 309 and 310) is a yellowish-white structure, which deepens the acetabulum by surmounting its margin. It

FIG. 311.—PORTIONS OF ISCHIUM AND PUBIS, SHOWING THE ACETABULAR NOTCH AND THE LIGAMENTUM TERES ATTACHED OUTSIDE THE ACETABULUM.

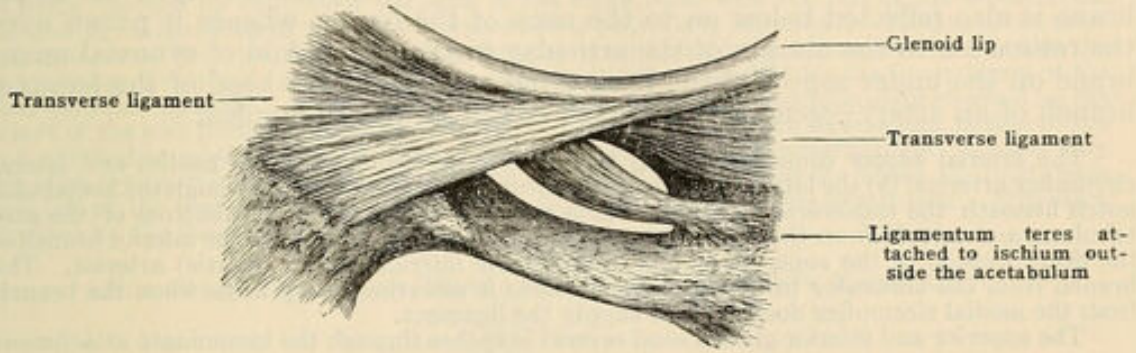

varies in strength and thickness, but is stronger at its iliac and ischial portions than elsewhere. Its base is broad and fixed to the bony rim as well as to the articular cartilage of the acetabulum on the inner, and the periosteum on the outer, side of it, and blends inseparably with the transverse ligament which supports it over the acetabular notch.

FIG. 312.—THE UPPER EXTREMITY OF THE FEMUR (POSTERIOR VIEW), TO SHOW THE RELATION OF THE ARTICULAR CAPSULE OF THE HIP-JOINT (IN RED) TO THE EPIPHYSIAL LINES.

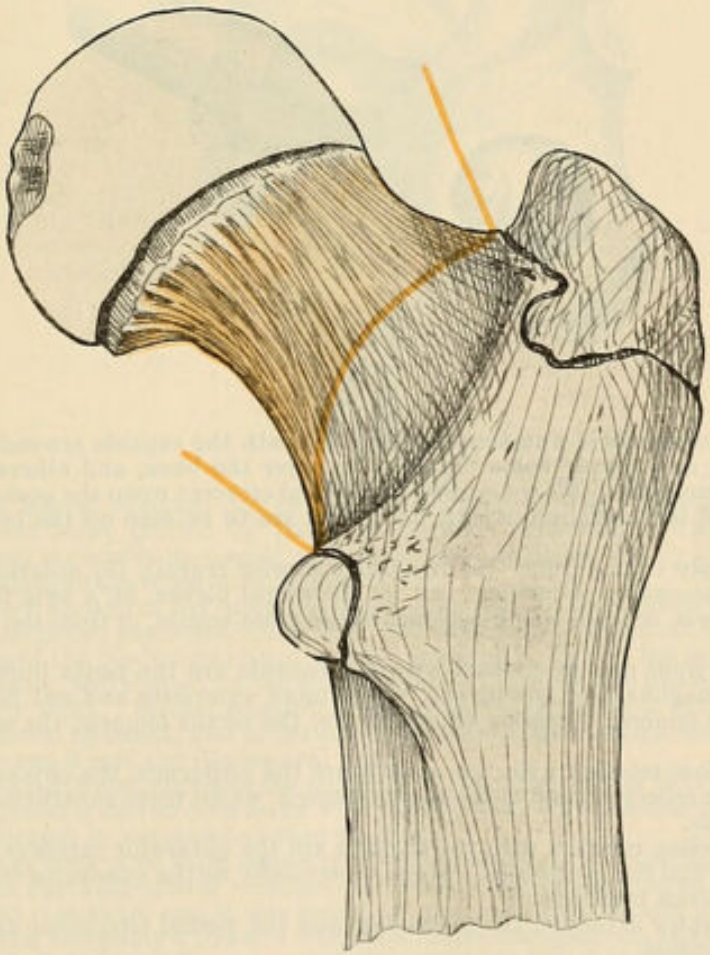

Its free margin is thin; on section it is somewhat lunated, having its outer surface convex and its articular face concave and very smooth in adaptation to the head of the bone, which it tightly embraces a little beyond its greatest circumference. It somewhat contracts the aperture of the acetabulum, and retains the head of the femur within its grasp after division of the muscles and capsular ligament. It is covered on both aspects by synovial membrane.

The **synovial membrane** lines the capsule and both surfaces of the glenoid lip, and passes over the border of the acetabulum to reach and cover the fatty cushion it contains. The part covering the fatty cushion is unusually thick, and is attached round the edges of the rough bony surface on which the cushion rests. The membrane is loosely reflected off this on to the ligamentum teres, along which it is prolonged to the head of the femur; thus the fibres of the round ligament are shut out from the joint cavity. From the capsule the synovial membrane is also reflected below on to the neck of the femur, whence it passes over the retinacula to the margin of the articular cartilage. A fold of synovial membrane on the under aspect of the neck often conveys to the head of the femur a branch of an artery—generally a branch of the medial circumflex.

The **arterial supply** comes from—(*a*) the transverse branches of the medial and lateral circumflex arteries; (*b*) the lateral branch of the obturator sends a branch through the acetabular notch beneath the transverse ligament, which ramifies in the fat at the bottom of the acetabulum, and travels down the round ligament to the head of the femur; (*c*) the inferior branch of the deep division of the superior gluteal; and (*d*) the inferior gluteal (sciatic) arteries. The branch from the obturator to the ligamentum teres is sometimes very large when the branch from the medial circumflex does not also supply the ligament.

The superior and inferior gluteal send several branches through the innominate attachment

FIG. 313.—LIGAMENTUM TERES, LAX IN FLEXION.

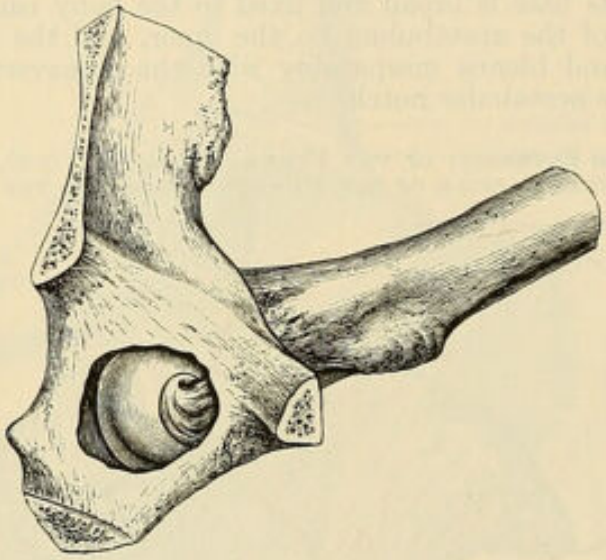

of the articular capsule: these anastomose freely beneath the capsule around the outer aspect of the acetabulum, and supply some branches to enter the bone, and others which enter the substance of the glenoid lip. There is quite an arterial crescent upon the posterior and postero-superior portions of the acetabulum; but no vessels are to be seen on the inner aspect of the glenoid lip.

The **nerve-supply** comes from—(*a*) femoral (anterior crural), (*b*) anterior division of the obturator, (*c*) the accessory obturator, and (*d*) the sacral plexus, by a twig from the nerve to the quadratus femoris, or from the upper part of the great sciatic, or from the lower part of the sacral plexus.

Relations.—In *front* and in contact with the capsule are the psoas bursa, the tendinous part of the psoas magnus, and the iliacus. Still more anteriorly and not in contact are the femoral artery, the femoral (anterior crural) nerve, the rectus femoris, the sartorius, and the tensor fasciæ latæ.

Above and in close relation with the capsule are the piriformis, the obturator internus and the gemelli, and the reflected head of the rectus femoris, whilst more superficially lie the gluteus minimus and medius.

Behind and in close relation with the capsule are the obturator externus, the gemelli and obturator internus, and the piriformis. More superficially lie the quadratus femoris, the sciatic nerves, and the gluteus maximus.

Below the obturator externus, the pectineus, and the medial circumflex artery are in close relation with the capsule.

The movements.—The hip-joint, like the shoulder, is a ball-and-socket joint, but with a much more complete socket and a corresponding limitation of movement. Each variety of movement is permitted, viz., flexion, extension, abduction, adduction, circumduction, and rotation; and any two or more of these movements not being antagonistic can be combined, i. e., flexion or extension associated with abduction or adduction can be combined with rotation in or out.

It results from the obliquity of the neck of the femur that the movements of the head in the acetabulum are always more or less of a rotatory character. This is more especially the case during flexion and extension, and two results follow from it. First, the bearing surfaces of the femur and acetabulum preserve their apposition to each other, so that the amount of articular surface of the head in the acetabulum does not sensibly diminish *pari passu* with the transit of the joint from the extended to the flexed position, as would necessarily be the case if the movement of the femoral head, like that of the thigh itself, was simply angular, instead of rotatory and angular. Secondly, as rotation of the head can continue until the ligaments are tight without being checked by contact of the neck of the thigh bone with the rim of the acetabulum, flexion of the thigh so far as the joint is concerned is practically unlimited. Flexion is the most important, most frequent, and most extensive movement, and in the dissected limb, before the ligaments are disturbed, can be carried to 160°, and is then checked by the lower fibres of the ischio-capsular ligament. In the living subject simple flexion can continue until checked by the contact of the soft parts at the groin, if the knee be bent; if the knee be straight, flexion of the hip is checked in most persons by the hamstring muscles at nearly a right angle. This is very evident on trying to touch the ground with the fingers without bending the knees, the chief strain being felt at the popliteal space. This is due to the shortness of the hamstrings. Extension is limited by the ilio-femoral ligament.

FIG. 314.—LIGAMENTUM TERES, VERY LAX IN COMPLETE EXTENSION.

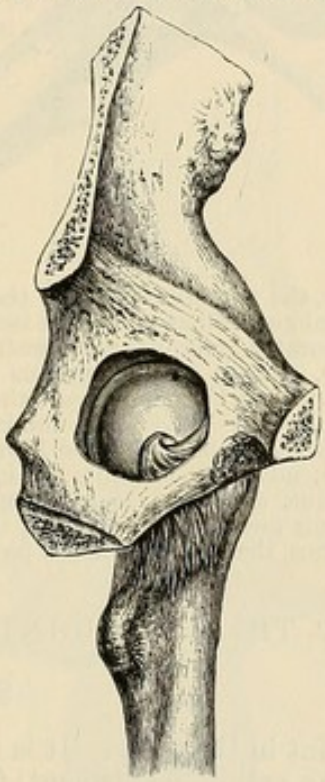

Abduction and lateral rotation can be performed freely in every position of flexion and extension—abduction being limited by the pubo-capsular ligament; lateral rotation by the ilio-femoral ligament, especially its medial portion, during extension; but by the lateral portion, as well as by the ligamentum teres, during flexion.

Adduction is very limited in the extended thigh on account of the contact with the opposite limb. In the slightly flexed position adduction is more free than in extension, and is then limited by the lateral fibres of the ilio-femoral band and the superior portion of the capsule. In flexion the range is still greater, and limited by the ischio-capsular ligament, the ligamentum teres being also rendered nearly tight. Medial rotation in the extended position is limited by the lower fibres of the ilio-femoral ligament; and in flexion by the ischio-capsular ligament and the portion of the capsule between it and the ilio-femoral band.

The ilio-femoral band also prevents the tendency of the trunk to roll backward on the thigh bones in the erect posture, and so does away with the necessity for muscular power for this purpose; it is put on stretch in the stand-at-ease position.

The ligamentum teres is of little use in resisting violence or in imparting strength to the joint. It assists in checking lateral rotation, and adduction during flexion. A ligament can only be of use when it is tight, and it was found by trephining the bottom of the acetabulum, removing the fat, and threading a piece of whipcord round the ligament, that the ligament was slack in simple flexion, and very loose in complete extension, but that its most slack condition was in abduction. It is tightest in flexion combined with adduction and lateral rotation and almost as tight in flexion with lateral rotation alone, and in flexion with adduction alone (figs. 313–315).

Muscles which act upon the hip-joint.—*Flexors.*—The psoas and iliacus, the rectus femoris, the pectineus, the adductors, the sartorius, the tensor fasciæ latæ, and the gluteus medius.

FIG. 315.—LIGAMENTUM TERES, DRAWN TIGHT IN FLEXION COMBINED WITH LATERAL ROTATION AND ADDUCTION.

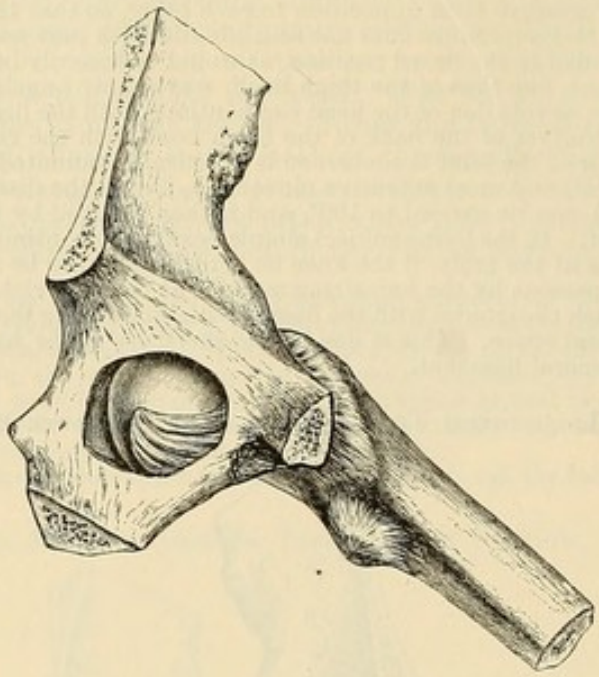

Extensors.—The gluteus maximus, the posterior fibres of the glutei medius and minimus, the biceps, the semitendinosus, the semimembranosus, and the ischial fibres of the adductor magnus; also (slightly) the piriformis, obturator internus and gemelli. *Abductors.*—Gluteus maximus (upper fibres), tensor fasciæ latæ, gluteus medius, gluteus minimus, and, when the joint is flexed, the piriformis, obturator internus, the gemelli, and the sartorius also become abductors. *Adductors.*—Adductores magnus, longus, brevis, and minimus, semitendinosus, biceps, the gracilis, the pectineus, the quadratus femoris, and the lower fibres of the gluteus maximus. *Medial rotators.*—Psoas (slightly), adductor magnus, semimembranosus, the anterior fibres of the gluteus medius and minimus, and the tensor fasciæ latæ. *Lateral rotators.*—Gluteus maximus, posterior fibres of gluteus medius and minimus, the adductors, obturator externus, quadratus femoris, obturator internus, the gemelli, and the piriformis when the joint is extended.

2. THE KNEE-JOINT

Class.—*Diarthrosis.* **Subdivision.**—*Ginglymus.*

The knee is the largest joint in the body. It is rightly described as a ginglymoid joint, but there is also an arthrodial element; for, in addition to flexion and extension, there is a sliding backward and forward of the tibia upon the femoral condyles, as well as slight rotation round a vertical axis. It is one of the most superficial, and, as far as adaptation of the bony surfaces goes, one of the weakest joints, for in no position are the bones in more than partial contact. Its strength lies in the number, size, and arrangement of the ligaments, and the powerful muscles and fascial expansions which pass over the articulation and enable it to withstand the leverage of the two longest bones in the body. It may be said to consist of two articulations with a common synovial membrane—the patello-femoral and the tibio-femoral, the latter being double. It is composed of the condyles and trochlear surface of the femur, the condyles of the tibia, and the patella, united by the following ligaments, which may be divided into an external and internal set:—

EXTERNAL	INTERNAL
(1) Fibrous expansion of the extensors.	(1) Anterior crucial.
(2) Articular capsule.	(2) Posterior crucial.
(3) Oblique popliteal ligament.	(3) Medial meniscus.
(4) Fibular collateral.	(4) Lateral meniscus.
(5) Tibial collateral.	(5) Coronary.
(6) Ligamentum patellæ	(6) Transverse.

External Ligaments

Superficial to the fibrous expansion of the quadriceps extensor tendons the fascia lata of the thigh covers the front and sides of the knee-joint.

The deep fascia of the thigh, as it descends to its attachment to the tuberosity and oblique lines of the tibia, not only overlies but blends with the fibrous expansion of the extensor tendons. The oblique lines of the tibia curve upward and backward from the tuberosity on each side to the postero-lateral part of the condyles. The process of fascia attached to the lateral ridge of the tibia and to the head of the fibula descends from the tensor fasciæ latæ and is very thick and strong. It is firmly blended with the tendinous fibres of the vastus lateralis. The fascia lata, on the medial side of the patella, besides being attached to the medial oblique ridge of the tibia, sends some longitudinal fibres lower down to become blended with the fibrous expansion of the sartorius. The fascia is much thinner on the medial side of the patella than on the lateral, and blends much less with the tendon of the vastus medialis than the lateral part of the fascia does with the vastus lateralis. A thin layer of the fascia lata in the form of transverse or arciform fibres passes over the front of the joint. These fibres are specially well marked over the ligamentum patellæ, and blend here with the central portion of the quadriceps extensor fibres.

Fig. 316.—The Lower Extremity of the Femur (Posterior View), to show the Relation of the Articular Capsule of the Knee-joint (in red) to the Epiphysial Line.

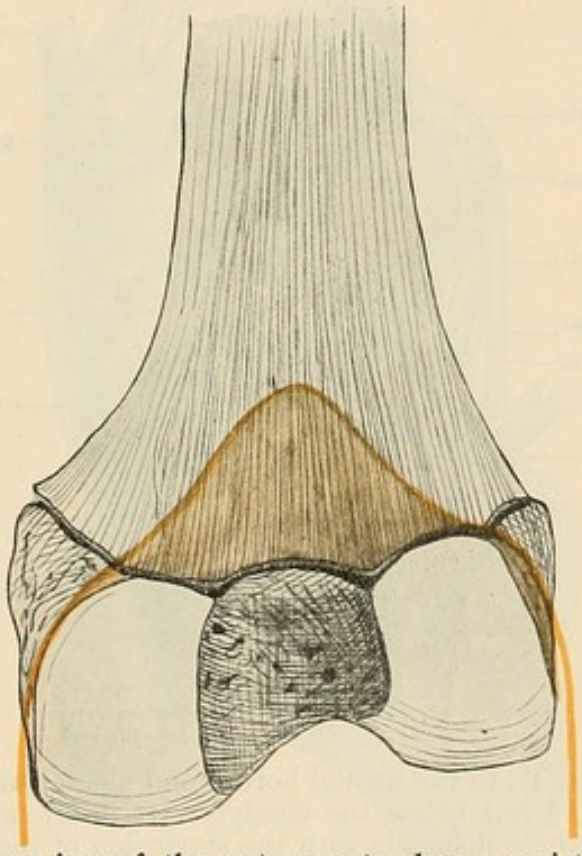

The **fibrous expansion of the extensor tendons** consists—(1) of a central portion, densely thick and strong, 3.7 cm. ($1\frac{1}{2}$ in.) broad, which is inserted into the anterior two-thirds of the upper border of the patella, many of its superficial fibres passing over the subcutaneous surface of the bone into the ligamentum patellæ; (2) of two side portions thinner, but strong.

The side portions are inserted into the patella along its upper border on either side of the central portion and also into its medial and lateral borders, nearer the anterior than the posterior surface, as low down as the attachment of the ligamentum patellæ; passing thence along the sides of the ligamentum patellæ to the tibia, they are attached to the oblique lines which extend from the tuberosity to the medial and lateral condyles, and reach as far as the tibial and fibular collateral ligaments. On the lateral side, the fibres blend with the ilio-tibial band of the fascia lata, and on the medial they extend below the oblique line to blend with the periosteum of the shaft. Thus there is a large hood spread over the whole of the front of the joint, investing the patella, and reaching from the sides of the ligamentum patellæ to the collateral ligaments, attached below to the tibia, and separated everywhere from the synovial membrane by a layer of fatty tissue.

The **ligamentum patellæ** (fig. 320) is the continuation in line of the central portion of the conjoined tendon, some fibres of which are prolonged over the front

of the patella into the ligament. It is an extremely strong, flat band, attached above to the lower border of the patella; below, it is fixed to the lower part of the tuberosity and upper part of the crest of the tibia, somewhat obliquely, being prolonged downward further on the lateral side, so that this border is fully 2.5 cm. (1 in.) longer than the medial, which measures 6.7 cm. (2½ in.) in length. Behind, it is in contact with a mass of fat which separates it from the synovial membrane, and a small bursa intervenes between it and the head of the tibia. In front, a large bursa separates it from the subcutaneous tissue, and at the sides it is continuous with the fibrous expansion of the extensors.

The **tibial** (internal) **collateral ligament** (fig. 317) is a strong, flat band, which extends from the depression on the tubercle on the medial side of the medial

FIG. 317.—POSTERIOR VIEW OF THE KNEE-JOINT.

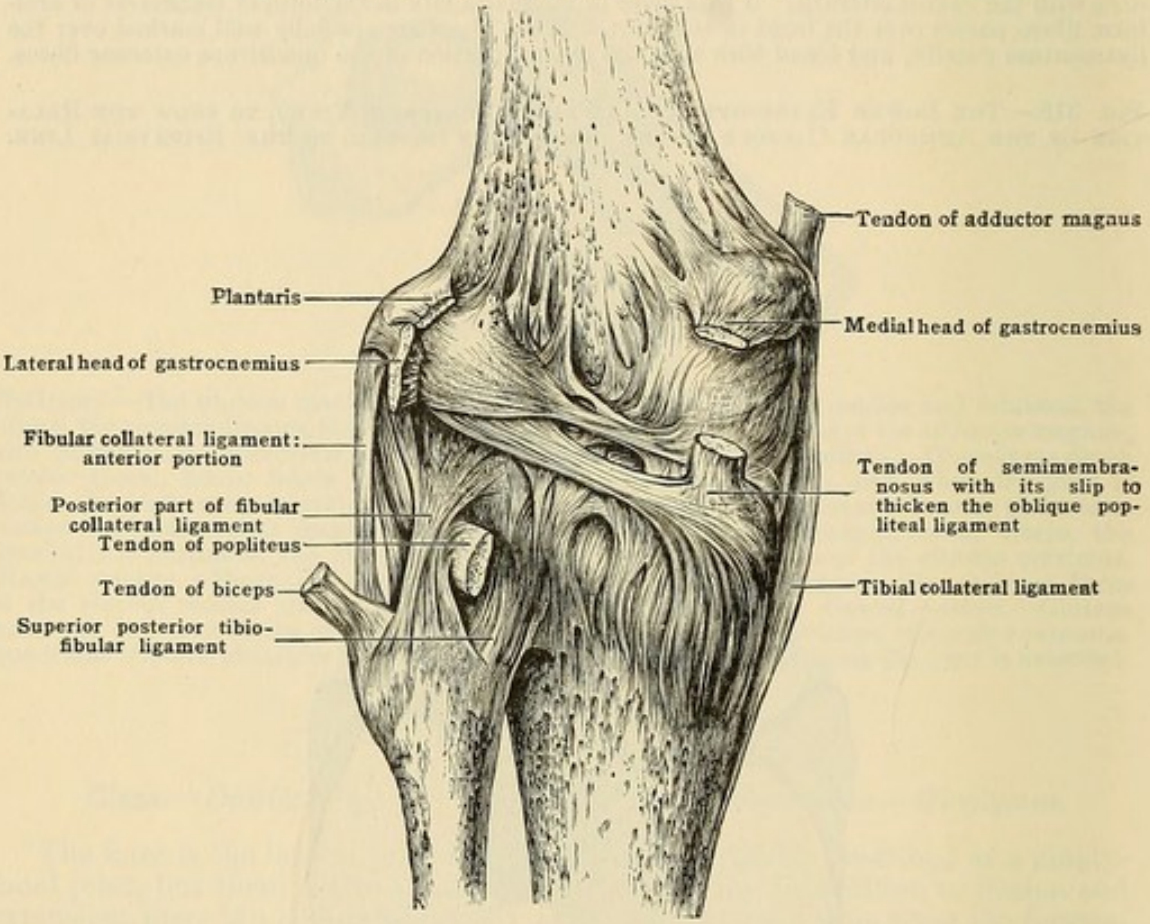

epicondyle of the femur, to the medial border and medial surface of the shaft of the tibia, 3.7 cm. (1½ in.) below the condyle. It is 8.7 cm. (3½ in.) long, well defined anteriorly, where it blends with the expansion of the conjoined extensor tendons; but not so well defined posteriorly, where it merges into the oblique popliteal ligament.

Some of the lower fibres blend with the descending portion of the *semimembranosus* tendon, Its deep surface is firmly adherent to the edge of the medial meniscus and coronary ligament. while part of the *semimembranosus tendon* and *inferior medial articular vessels* and *nerve* pass between it and the bone. Superficially, a bursa separates it from the tendons of the *gracilis* and *semitendinosus* muscles and from the aponeurosis of the *sartorius* muscle.

The **fibular** (external) **collateral ligament** (fig. 317) consists of two portions: the **anterior,** which is the longer and better marked, is a strong, rounded cord, about 5 cm. (2 in.) long, attached above to the tubercle on the lateral side of the lateral epicondyle of the femur, just below and in front of the origin of the lateral head of the *gastrocnemius*, whilst the *tendon* of the *popliteus* arises from the groove below and in front of it. Below, it is fixed to the middle of the lateral surface of the head of the fibula, 1.25 cm.(½) in. or more anterior to the apex.

Superficially is the tendon of the *biceps*, which splits to embrace its lower extremity; while beneath it pass the *popliteus tendon* in its sheath, and the *inferior lateral articular vessels* and *nerve*.

Some fibres of the peroneus longus occasionally arise from the lower end of the ligament. The posterior portion is 8 mm. (⅓ in.) behind the anterior. It is broader and less defined; fixed below to the apex of the fibula, it inclines upward and somewhat backward, and ties down the *popliteus* against the lateral condyle of the tibia, blending beneath the lateral head of the *gastrocnemius* with the oblique popliteal ligament of the knee, of which it is really a portion.

The **oblique popliteal ligament** or ligamentum Winslowii (fig. 317) is a broad dense structure of interlacing fibres, with large orifices for vessels and nerves. It is attached above to the femur close to the articular margins of the condyles, stretching across the upper margin of the intercondyloid fossa, to which it is connected by fibro-fatty tissue; it thus reaches across from the tibial to the fibular collateral ligaments. Below, it is fixed to the border of the lateral condyle of the tibia, to the bone just below the posterior intercondyloid notch, and to the shaft of the tibia below the medial condyle, blending with the descending slip of the *semimembranosus* and tibial collateral ligament.

Superficially, an oblique fasciculus from the *semimembranosus* runs across the centre, passing upward and laterally from near the back part of the medial condyle of the tibia to the lateral

FIG. 318.—THE LOWER EXTREMITY OF THE FEMUR (ANTERIOR VIEW) TO SHOW THE RELATION OF THE ARTICULAR CAPSULE OF THE KNEE-JOINT (IN RED) TO THE EPIPHYSIAL LINE.

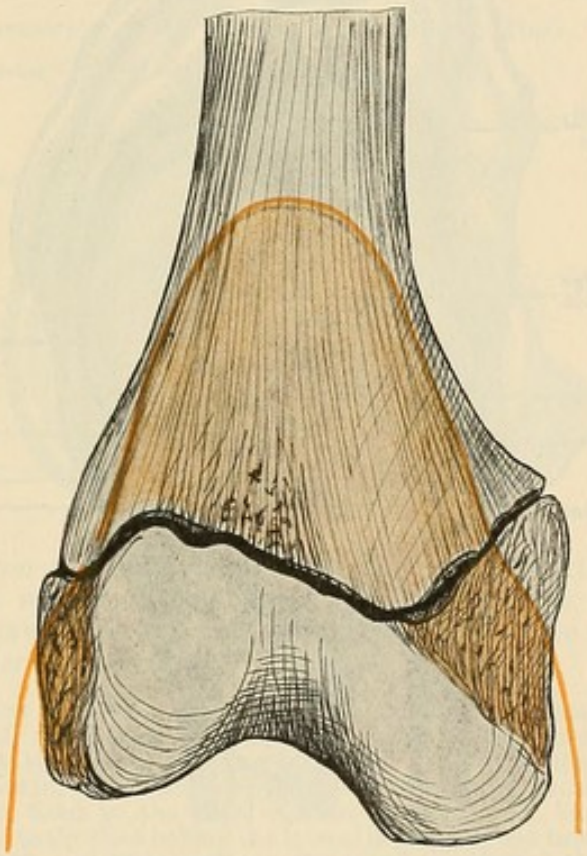

epicondyle of the femur, where it joins the lateral head of the gastrocnemius, a sesamoid plate being sometimes developed at the point of junction. This slip greatly strengthens the oblique popliteal ligament, of which, if not the chief constituent, it is at least a very important part.

Its deep surface is closely connected with the semilunar menisci (especially the medial) and coronary ligaments, and in the interval between the cartilages with the posterior crucial ligament and fibro-fatty tissue within the joint. Superficially it forms part of the floor of the popliteal space. A special band, the arcuate ligament, is sometimes found extending from the lateral epicondyle to the oblique ligament.

The **articular capsule** (fig. 319) is thin but strong, covering the synovial membrane, and looking like a loose sac. It is attached to the femur near the articular margin on the medial side, but further away on the lateral; it passes beneath the fibular collateral ligament to join the sheath of the *popliteus*. Medially it joins the tibial collateral ligament. Below, it is fixed to the upper as well as the medial and lateral borders of the patella and the anterior border of the head of the tibia. It is strengthened superficially between the femur and patella by an expansion from the *articularis genu* (*sub-crureus*) and is separated from

the fibrous expansion of the extensor tendon by a layer of fatty tissue. The synovial membrane lines its deep surface, and holds it against the borders of the semilunar menisci; it is also attached to the coronary ligaments.

Internal Ligaments

The **anterior crucial ligament** (figs. 319 and 320) is strong and cord-like. It is attached to the medial half of the fossa in front of the intercondyloid eminence of the tibia, and to the lateral border of the medial articular facet as far back as the medial intercondyloid tubercle. It passes upward, backward, and laterally to the back part of the medial surface of the lateral condyle of the femur. To

Fig. 319.—Anterior View of the Internal Ligaments of the Knee-joint.

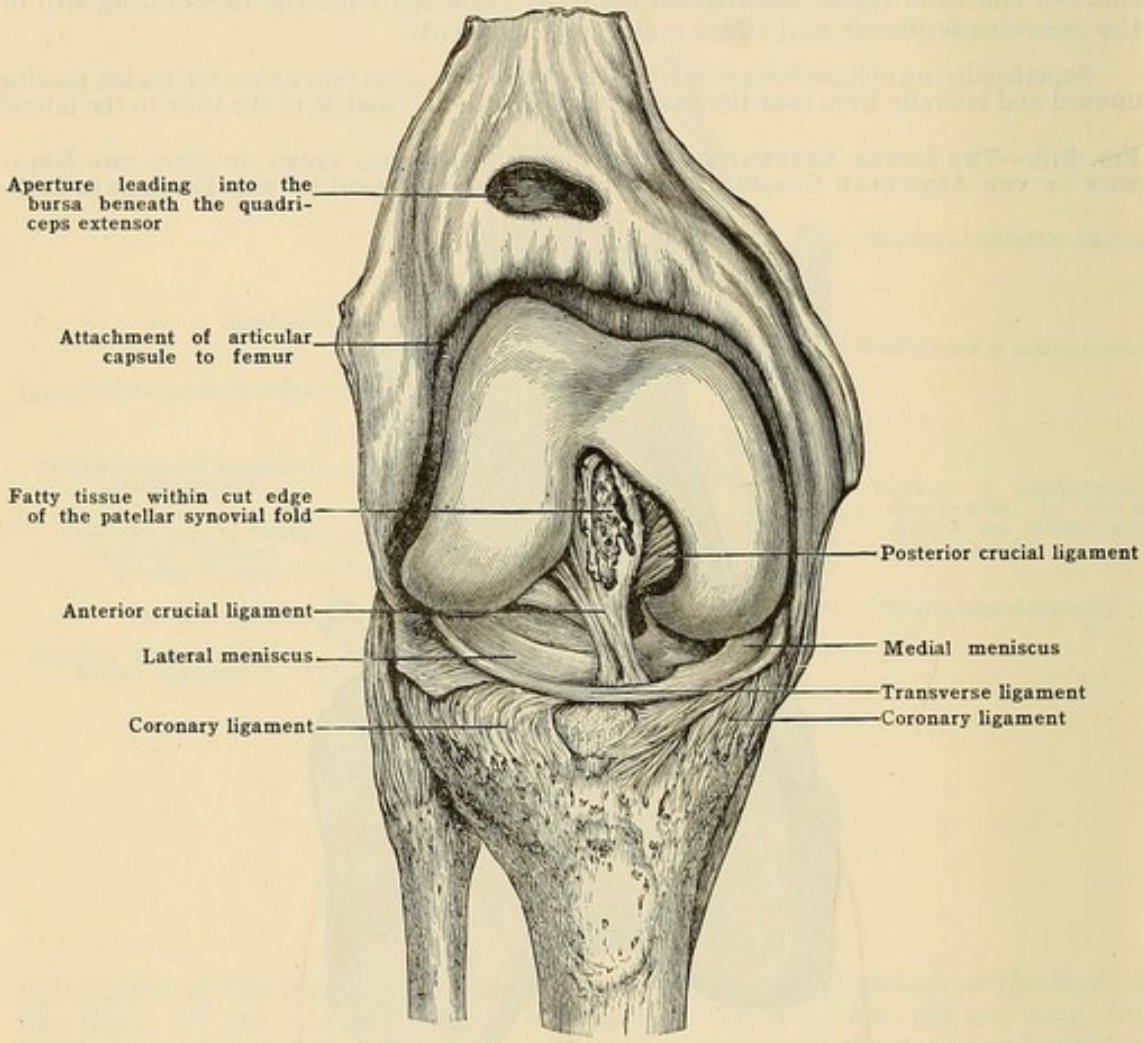

the tibia, it is fixed behind the anterior extremity of the medial semilunar meniscus. Behind and to the lateral side it has the anterior extremity of the lateral meniscus, a few fibres of which blend with the lateral edge of the ligament.

Its anterior fibres at the tibial end are strongest and longest, being fixed highest on the femur; while the posterior, springing from the intercondyloid eminence, are shorter and more oblique. Near the spine, a slip is sometimes given off to the posterior crucial ligament.

The **posterior crucial ligament** (fig. 319, 320, and 322) is stronger and less oblique than the anterior. It is fixed below to the greater portion of the fossa behind the intercondyloid eminence of the tibia, especially the lateral and posterior portion, and then medially along the posterior intercondyloid fossa; being joined by fibres which arise between the intercondyloid tubercles, it ascends to the anterior part of the lateral surface of the medial condyle of the femur, having a wide crescentic attachment 1.5 cm. ($\frac{3}{5}$ in.) in extent just above the articular surface.

Behind, it is connected at the tibia directly with the posterior ligament, and a little higher up by means of a quantity of interposed areolar tissue. In front it rests upon the posterior

horn of the medial semilunar meniscus, and receives a large slip from the lateral meniscus, which ascends along it, either in front or behind, to the femur; higher up in front it is connected with the anterior crucial ligament.

Until they rise above the intercondyloid eminence of the tibia the two crucial ligaments are closely bound together, so that no interspace exists between their tibial attachments and the point of decussation; the only space between them is therefore a V-shaped one corresponding to the upper half of their X-shaped arrangement, and this is a mere chink in the undissected state, and can be seen from the front only, owing to the fatty tissue beneath the synovial membrane which surrounds their femoral attachment.

The interarticular **menisci** or semilunar fibro-cartilages (figs. 319 and 320) are two crescentic discs resting upon the circumferential portions of the articular facets of the tibia, and moving with the tibia upon the femur. They somewhat deepen the tibial articular surfaces, and are dense and compact in structure, becoming looser and more fibrous near their extremities, where they are firmly fixed in front of and behind the intercondyloid eminence of the tibia. The circumferential border of each is convex, thick, and somewhat loosely attached to the borders of the condyles of the tibia by the coronary ligaments and the reflexion of the synovial membrane. The inner border is concave, thin, and free. Half an inch (1.3 cm.) broad at the widest part, they taper somewhat toward their

FIG. 320.—STRUCTURES LYING ON THE HEAD OF THE TIBIA. (Right knee.)

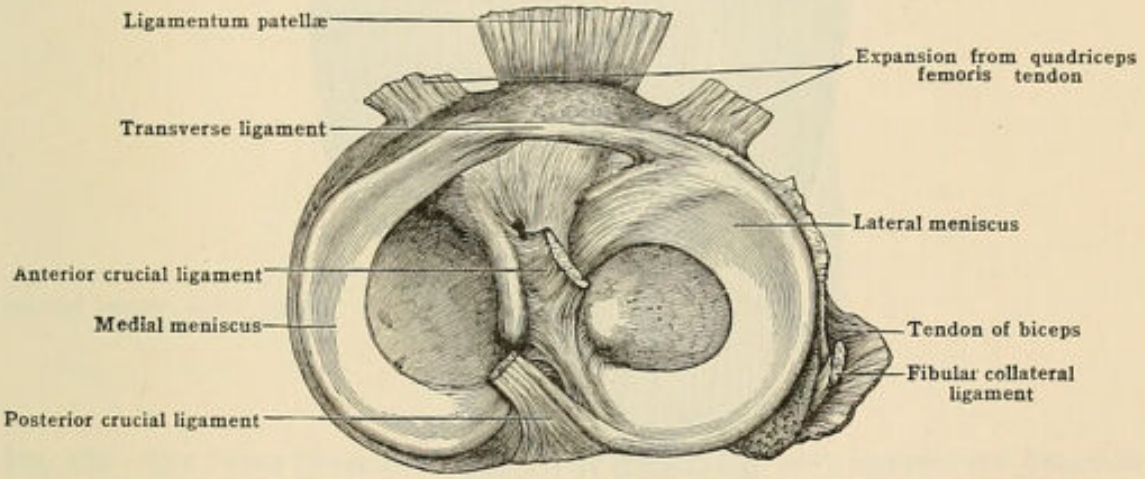

extremities, and cover rather less than two-thirds of the articular facets of the tibia. Their upper surfaces are slightly concave, and fit on to the femoral condyles, while the lower are flat and rest on the head of the tibia; both surfaces are smooth and covered by synovial membrane.

The **lateral meniscus** (fig. 320) is nearly circular in form and less firmly fixed than the medial, and consequently slides more freely upon the tibia. Its anterior cornu is attached to a narrow depression along the lateral articular facet, just in front of the lateral intercondyloid tubercle of the tibia, close to, and on the lateral side of, the anterior crucial ligament; a small slip from the cornu is often fixed to the tibia in front of the crucial ligament. The posterior cornu is firmly attached to the tibia behind the lateral intercondyloid tubercle, blending with the posterior crucial ligament, and giving off a well-marked fasciculus, which runs up along the anterior border of the ligament to be attached to the femur (ligament of Wrisberg). It also sends a narrow slip into the back part of the anterior crucial ligament. Its outer border is grooved toward its posterior part by the *popliteus* tendon, which is held to it by fibrous tissue and synovial membrane, and separates it from the fibular collateral ligament. From its anterior border is given off the transverse ligament.

The **medial meniscus** (fig. 320) is a segment of a larger circle than the lateral, and has an outline more oval than circular. Its anterior cornu is wide, and has a broad and oblique attachment to the anterior margin of the head of the tibia. It reaches from the margin of the condyle toward the middle of the fossa in front of the intercondyloid eminence, being altogether in front of the anterior crucial ligament. The posterior cornu is firmly fixed by a broad insertion in an antero-posterior line along the medial side of the posterior intercondyloid fossa, from the medial tubercle to the posterior margin of the head of the tibia. Its convex border is connected with the tibial collateral ligament and the *semimembranosus* tendon.

The **transverse ligament** (figs. 319 and 320) is a rounded, slender, short cord, which extends from the convex border of the lateral meniscus to the concave border or anterior cornu of the medial, near which it is sometimes attached to the bone. It is an accessory band of the lateral meniscus, and is situated beneath the synovial membrane.

The **coronary ligaments** (fig. 319) connect the margins of the semilunar discs with the head of the tibia. The lateral is much more lax than the medial, permitting the lateral disc to change its position more freely than the medial. They are not in reality separate structures, but consist of fibres of the several surrounding ligaments of the knee-joint which become attached to the margins of the discs as they pass over them.

The **synovial membrane** (fig. 324) of the knee forms the largest synovial sac in the body. Bulging upward from the patella, it follows the capsule of the joint into a large *cul-de-sac* beneath the tendon of the extensor muscles on the front of the femur. It reaches some distance beyond the articular surface of the bone, and communicates very frequently with a large bursa interposed between the tendon and the femur above the line of attachment of the articular capsule. After investing the circumference of the lower end of the femur, it is reflected upon the

FIG. 321.—THE UPPER EXTREMITY OF THE TIBIA (ANTERIOR VIEW), TO SHOW THE RELATION OF THE ARTICULAR CAPSULE OF THE KNEE-JOINT (IN RED) TO THE EPIPHYSIAL LINE.

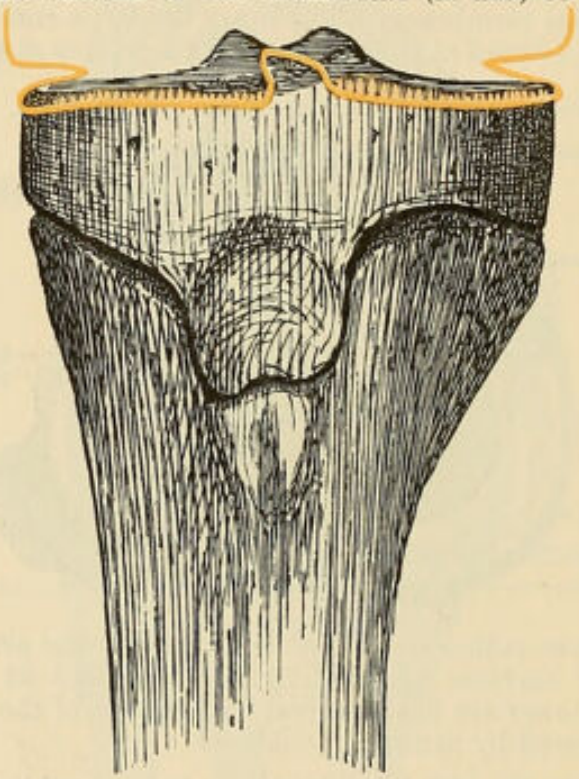

fibrous envelope of the joint formed by the capsular, posterior, and collateral ligaments.

The synovial membrane covers a great portion of the crucial ligaments, but leaves uncovered the back of the posterior crucial where the latter is connected with the posterior ligament, and the lower part of both crucial ligaments where they are united. Thus the ligaments are completely shut out of the synovial cavity. Along the fibrous envelope the synovial membrane is conducted down to the semilunar menisci, over both surfaces of which it passes, and is reflected off the under surface on to the coronary ligaments, and thence down to the head of the tibia, around the circumference of which it extends a short way. It dips down between the external meniscus and the head of the tibia as low as the superior tibio-fibular ligament, reaching inward nearly as far as the intercondyloid notch, and forming a bursa for the play of the popliteal tendon.

At the back of the joint two pouches are prolonged beneath the muscles, one on each side between the condyle of the femur and the origin of the gastrocnemius. Large processes of synovial membrane also project into the joint, and being occupied by fat serve as padding to fill up spaces. The chief of these processes, the **patellar synovial fold** (ligamentum mucosum) (figs. 322 and 324), springs from the infrapatellar fatty mass. This so-called ligament is the central portion of the large process of synovial membrane, of which the alar folds form the free margins. It extends from the fatty mass, below the patella, backward and upward to the intercondyloid notch of the femur, where it is attached in front of the anterior crucial, and lateral to the posterior crucial ligament. Near the femur it is thin and transparent, consisting of a double fold of synovial membrane, but near the patella it contains some fatty tissue. Its anterior or upper edge is free, and fully 2.5 cm. (an inch) long; the posterior or lower edge is half the length, and is attached to the crucial ligaments above, but is free below.

Passing backward from the capsule on each side of the patella is a prominent crescentic fold formed by reduplications of the synovial membrane—these are the **alar folds** (fig. 322). Their free margins are concave and thin, and are lost below in the patellar fold. There is a slight fossa above and another below each ligament.

FIG. 322.—ANTERIOR VIEW OF THE KNEE-JOINT, SHOWING THE SYNOVIAL LIGAMENTS. (Anterior portion of capsule with the extensor tendon thrown downward.)

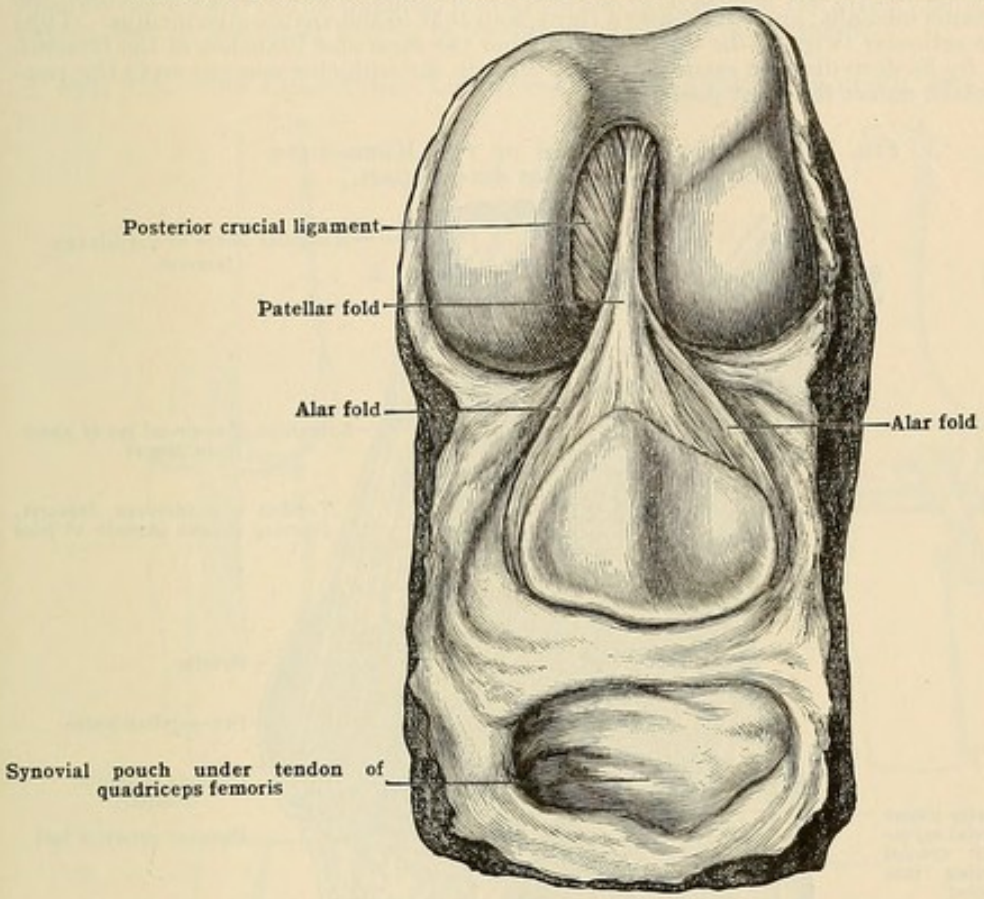

FIG. 323.—THE UPPER EXTREMITY OF THE TIBIA (POSTERIOR VIEW), TO SHOW THE RELATION OF THE ARTICULAR CAPSULE OF THE KNEE-JOINT (IN RED) TO THE EPIPHYSIAL LINE.

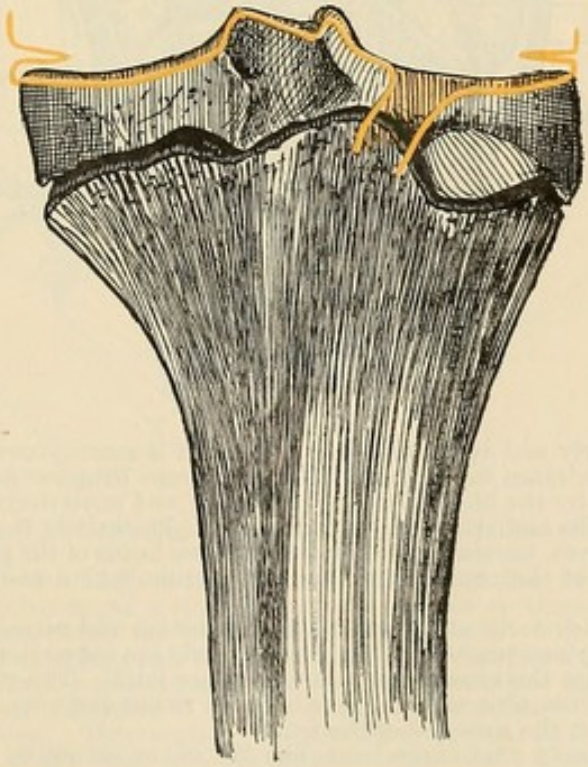

The **arterial supply** is derived from the art. genu suprema (anastomotica); the superior and inferior medial and lateral articular; the medial articular; the descending branch of the lateral circumflex; the anterior recurrent branch from the anterior tibial; and the posterior tibial recurrent.

The **nerve-supply** comes from the great sciatic, femoral, and obturator sources. The **great sciatic** gives off the tibial and common peroneal; the tibial sends two, sometimes three branches—one with the medial articular artery; one with the inferior medial, and sometimes one with the superior medial articular artery; the common peroneal gives a branch which accompanies the superior, and another which accompanies the inferior articular artery, and a recurrent branch which follows the course of the anterior recurrent branch of the anterior tibial artery. The **femoral** sends an articular branch from the nerve to the vastus lateralis; a second from the nerve to the vastus medialis; and sometimes a third from that to the vastus intermedius. Thus there are three articular twigs to the knee derived from the muscular branches of the femoral. The **obturator** by its deep division sends a branch through the adductor magnus on to the popliteal artery, which enters the joint posteriorly.

FIG. 324.—SAGITTAL SECTION OF THE KNEE-JOINT.
(The bones are somewhat drawn apart.)

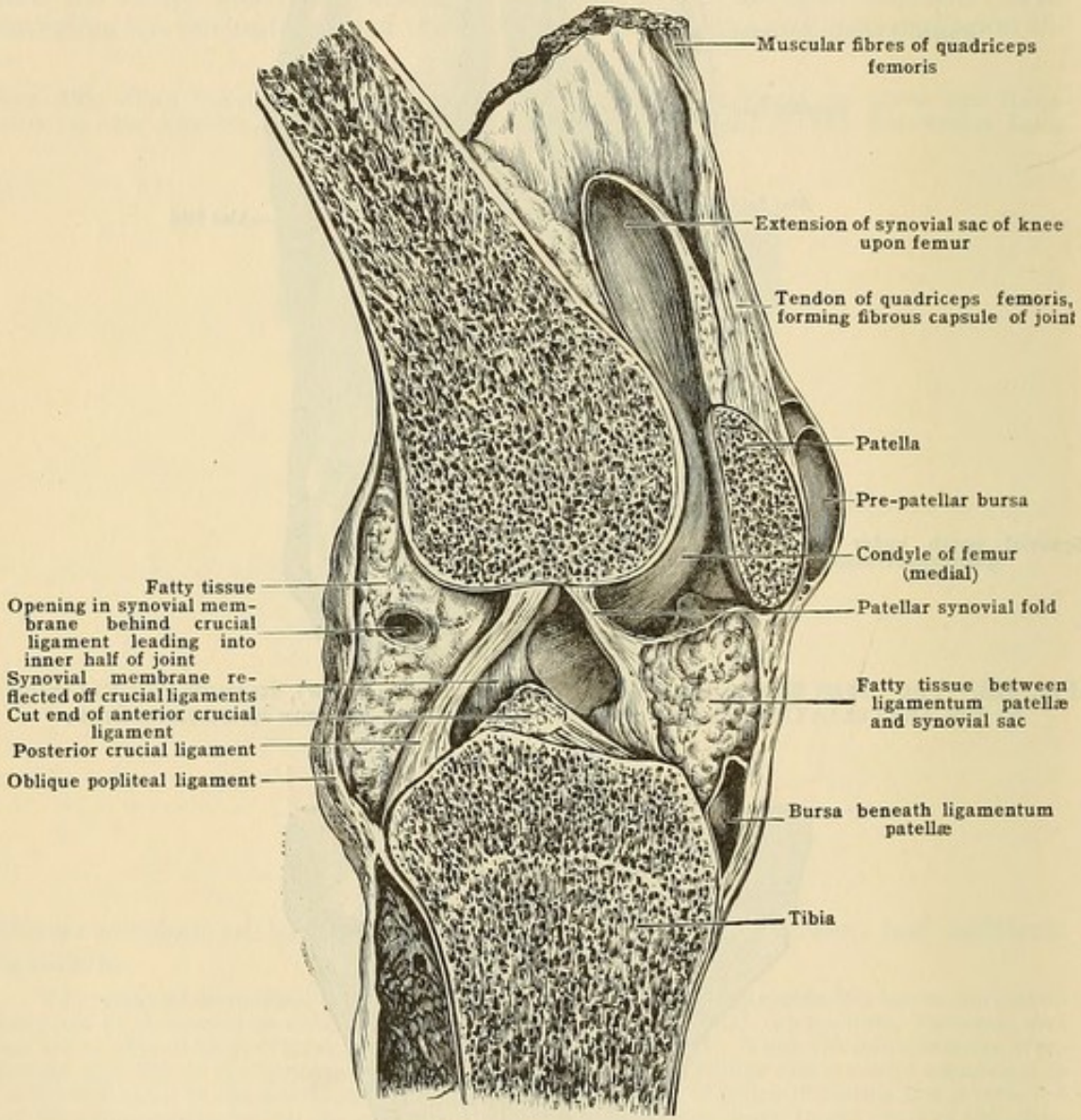

Relations.—Anteriorly and at the sides the knee-joint is merely covered and protected by skin, fascia, and the tendinous expansions of the quadriceps extensor muscle. Laterally and posteriorly it is crossed by the biceps tendon. Medially and posteriorly lie the sartorius and the tendons of the gracilis and semitendinosus muscles. Posteriorly it is in relation with the popliteal vessels and nerves, the semimembranosus, the two heads of the gastrocnemius, and the plantaris. The tendon of the popliteus pierces the capsule behind and medial to the biceps tendon.

The **movements** which occur at the knee-joint are flexion and extension, with some slight amount of rotation in the bent position. These movements are not so simple as the corresponding ones at the elbow, for the knee is not a simple hinge joint. The movements of rotation instead of occurring between tibia and fibula, as between radius and ulna, are movements of the tibia with the fibula upon the condyles of the femur.

The knee differs from a true hinge joint, like the elbow or ankle, in the following particulars:—

1. The points of contact of the femur with the tibia are constantly changing. Thus, in

the flexed position, the posterior part of the articular surface of the tibia is in contact with the rounded back part of the femoral condyles; in the semiflexed position the middle parts of the tibial facets articulate with the anterior rounded part of the condyles; while in the fully extended position the anterior and middle parts of the tibial facets are in contact with the anterior flattened portion of the condyles. So with the patella: in extreme flexion the medial articular facet rests on the lateral part of the medial condyle of the femur; in flexion the upper pair of facets rests on the lower part of the trochlear surface of the femur; in mid-flexion the middle pair rests on the middle of the trochlear surface; while in extension the lower pair of facets on the patella rests on the upper portion of the trochlear surface of the femur.

FIG. 325.—THE COLLATERAL LIGAMENTS OF THE KNEE IN FLEXION AND EXTENSION.

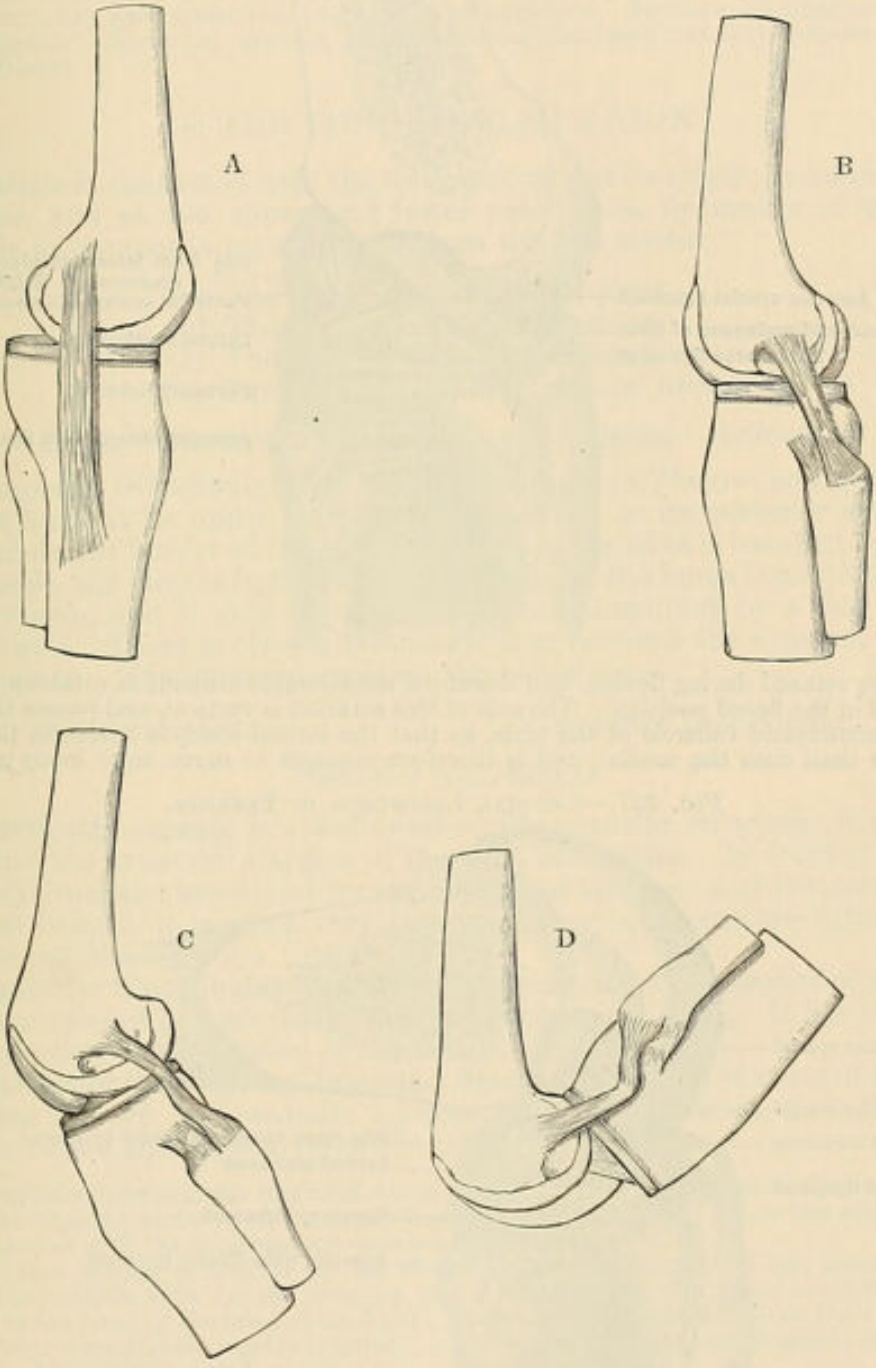

This difference may be described as the shifting of the points of contact of the articular surface.

2. It differs from a true hinge in that, in passing from a state of extension to one of flexion, the tibia does not revolve round a single transverse axis drawn through the lower end of the femur, as the ulna does round the lower end of the humerus. The articular surface of the tibia slides forward in extension and backward in flexion; thus the axis round which the tibia revolves upon the femur is a shifting one, as is seen by reference to fig. 325, B, C, D.

3. Another point of difference is that extension is accompanied by lateral rotation, and flexion by medial rotation. This rotation occurs round a vertical axis drawn through the middle of the lateral condyle of the femur and the lateral condyle of the tibia, and is most marked at the termination of extension and at the commencement of flexion. This rotation of the leg at the knee is a true rotation about a vertical axis, and thus differs from the obliquity of the flexion

and extension movements at the elbow which is due to the oblique direction of the articular surfaces of the bones.

4. The **antero-posterior spiral curve** of the femoral condyles is such that the anterior part is an arc of a greater circle than the posterior; hence certain ligaments which are tightened during

FIG. 326.—SECTION OF KNEE, SHOWING CRUCIAL LIGAMENTS IN EXTENSION.

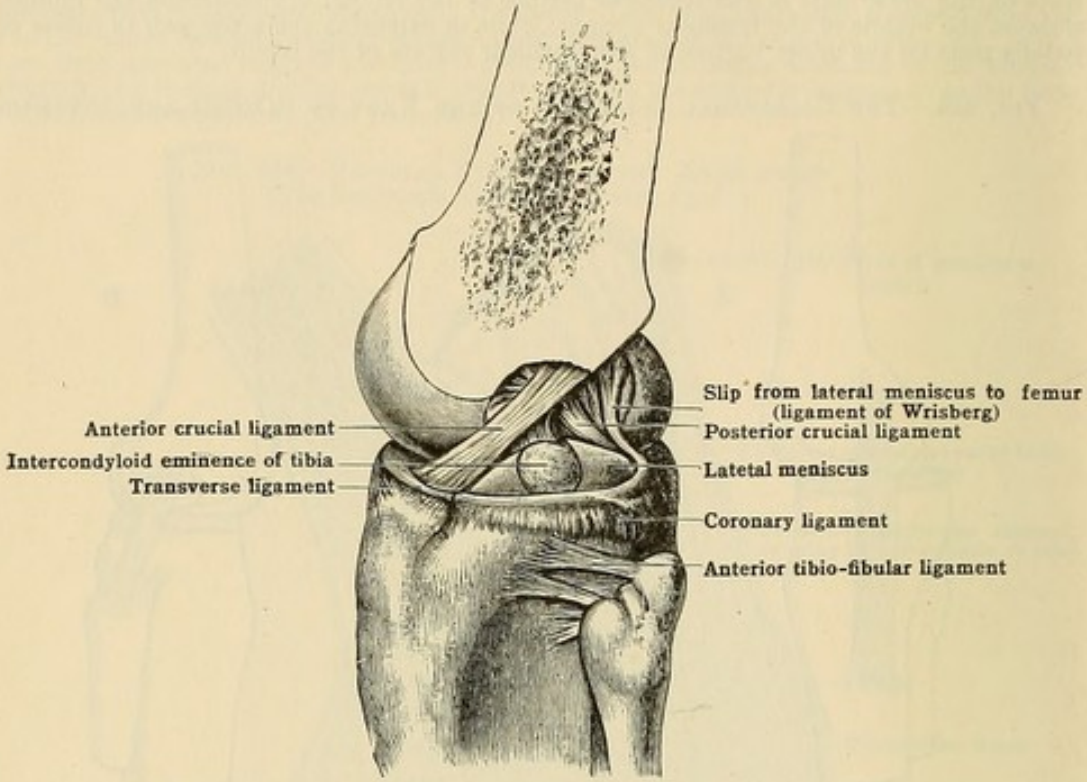

extension are relaxed during flexion, and thereby a considerable amount of rotatory movement is permitted in the flexed position. The axis of this rotation is vertical, and passes through the medial intercondyloid tubercle of the tibia, so that the lateral condyle moves in the arc of a larger circle than does the medial, and is therefore required to move more freely and easily;

FIG. 327.—CRUCIAL LIGAMENTS IN FLEXION.

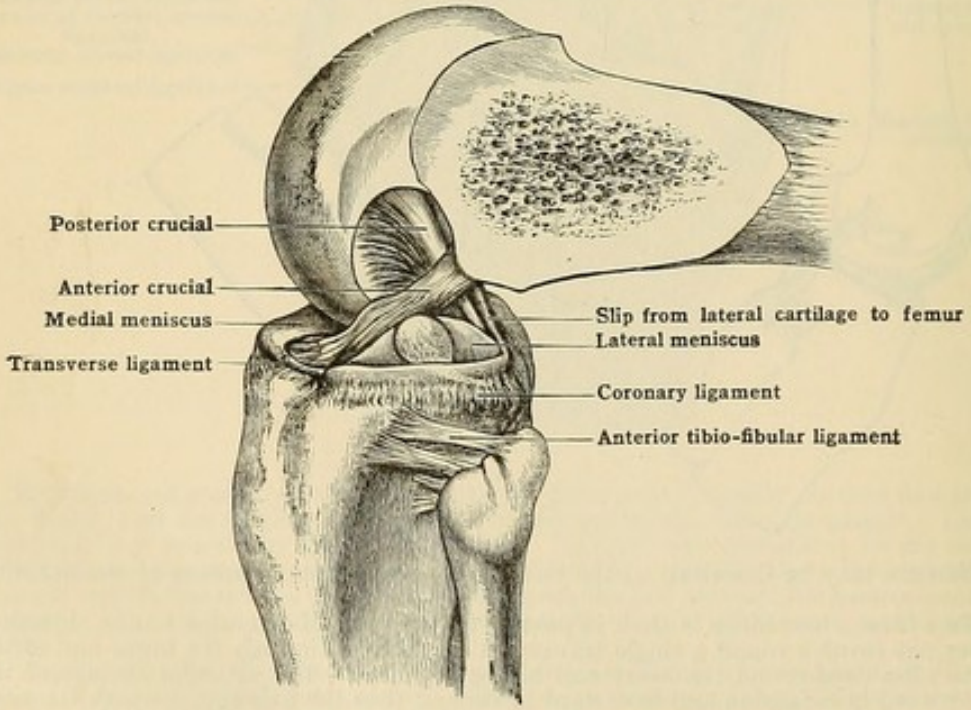

hence the shape of the lateral articular facet and the loose connection of the lateral meniscus which is adapted to it.

In **extension,** all the ligaments are on the stretch with the exception of the ligamentum patellæ and front of the capsule. Extension is checked by both the crucial ligaments and the collateral ligaments (figs. 325, A, B, and 326).

In **flexion** the ligamentum patellæ and anterior portion of the capsule are on the stretch; so also is the posterior crucial in extreme flexion, though it is not quite tight in the semiflexed state of the joint. All the other ligaments are relaxed (fig. 325, C, D), although the relaxation of the anterior crucial ligament is slight in extreme flexion (fig. 327). Flexion is only checked during life by the contact of the soft parts, i. e., the calf with the back of the thigh.

Rotation medially is checked by the anterior crucial ligament; the collateral ligaments being loose.

Rotation laterally is checked by the collateral ligaments; the crucial ligaments have no controlling effect on it, as they are untwisted by it.

Sliding movements are checked by the crucial and collateral ligaments—sliding forward especially by the anterior, and sliding backward by the posterior crucial.

Muscles which act upon the knee-joint.—*Flexors.*—Biceps, semimembranosus, semitendinosus, sartorius, gastrocnemius, plantaris, and popliteus. *Extensor.*—Quadriceps extensor. **Medial** *Rotators.*—Sartorius, gracilis, semitendinosus, semimembranosus, popliteus. **Lateral** *Rotator.*—Biceps.

3. THE TIBIO-FIBULAR UNION

The fibula is connected with the tibia throughout its length by an interosseous membrane, and at the upper and lower extremities by means of two joints. Very little movement is permitted between the two bones.

(*a*) The **superior tibio-fibular joint.**
(*b*) The **middle tibio-fibular union.**
(*c*) The **inferior tibio-fibular joint.**

(*a*) The Superior Tibio-fibular Joint

Class.—*Diarthrosis.* **Subdivision.**—*Arthrodia.*

The superior tibio-fibular joint is about 6 mm.($\frac{1}{4}$ in.) below, and quite distinct from, the knee at its upper and anterior part; but at its posterior and superior aspect, where the border of the lateral condyle of the tibia is bevelled by the popliteus muscle, the joint is in the closest proximity to the bursa beneath the tendon of that muscle, and is only separated from the knee-joint by a thin septum of areolar tissue. There is often a communication between the synovial cavities of the two joints. The ligaments uniting the bones are:—

Articular capsule. Anterior tibio-fibular.
Posterior tibio-fibular.

The **articular capsule** is a well-marked fibro-areolar structure; it is attached close round the articular margins of the tibia and fibula. In front it is shut off completely from the knee-joint by the capsule of the knee and the coronary ligament; but behind, it is often very thin, and may communicate with the bursa under the popliteus tendon.

The **anterior tibio-fibular (capitular) ligament** (fig. 326) consists of a few fibres which pass upward and medially from the fibula to the tibia. It lies beneath the anterior portion of the tendon of the biceps.

The **posterior tibio-fibular (capitular) ligament** (fig. 317) consists of a few fibres which pass upward and medially between the adjacent bones, from the head of the fibula to the lateral condyle of the tibia.

The **superior interosseous ligament** consists of a mass of dense yellow fibroareolar tissue, binding the opposed surfaces of the bones together for 2 cm. ($\frac{3}{4}$ in.) below the articular facets. It is continuous with the interosseous membrane along the tibia.

The **biceps tendon** is divided by the fibular collateral ligament of the knee; of the two divisions the anterior is by far the stronger, and is inserted into the lateral condyle of the tibia as well as to the front of the head of the fibula, and thus the muscle, acting on both bones, tends to brace them more tightly together; indeed, it holds the bones strongly together after all other connections have been severed.

The **synovial membrane** which lines the joint sometimes communicates with the knee-joint through the bursa beneath the popliteus tendon.

The **arterial supply** is from the inferior lateral articular and recurrent tibial arteries.

The **nerve-supply** is from the inferior lateral articular, and also from the recurrent branch of the common peroneal.

Relations.—In front, the upper ends of the tibialis anterior, the extensor digitorum longus, and the peroneus longus. Behind, the tendon of the popliteus overlapped by the lateral head of the gastrocnemius. Laterally, the biceps tendon and the common peroneal nerve. Below and medially, the anterior tibial vessels.

The **movements** are but slight, and consist merely of a gliding of the two bones upon each other. The joint is so constructed that the fibula gives some support to the tibia in transmitting

the weight to the foot. The articular facet of the tibia overhangs, and is received upon the articular facet of the head of the fibula in an oblique plane. This joint allows of slight yielding of the lateral malleolus during flexion and extension of the ankle-joint, the whole fibula gliding slightly upward in flexion, and downward in extension, of the ankle.

(*b*) The Middle Tibio-fibular Union

Class.—*Synarthrosis.* **Subdivision.**—*Syndesmosis.*

The **interosseous membrane** is attached along the lateral border of the tibia and the interosseous border of the fibula. It is deficient above for about 2.5 cm. (1 in.) or more, measured from the under aspect of the superior joint. Its upper border is concave, and over it pass the anterior tibial vessels.

The membrane consists of a thin aponeurotic and translucent lamina, formed of oblique fine fibres, some of which run from the tibia to the fibula, and some from the fibula to the tibia, but all are inclined downward. They are best marked at their attachment to the bones, and gradually grow denser and thicker as they approach the inferior interosseous ligament. The chief use of the membrane is to afford a surface for the origin of muscles. It is continuous below with the inferior interosseous ligament.

In front of the interosseous membrane lie the tibialis anterior, the extensor digitorum longus, the extensor hallucis longus, and the anterior tibial vessels and nerves. Behind it is in relation with the tibialis posterior, the flexor hallucis longus, and the peroneal artery.

Fig. 328.—Lower Ends of Left Tibia and Fibula, showing the Ligaments. The synovial fold between these bones has been removed to show the transverse ligament forming part of the capsule of the joint, and the deeper fibres of the anterior lateral malleolar ligament which come into contact with the talus.
(From a dissection by Mr. W. Pearson, of the Royal College of Surgeons' Museum.)

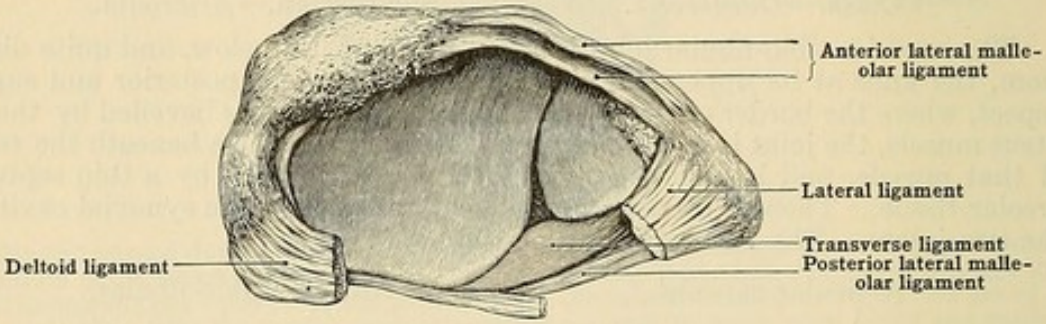

(*c*) The Inferior Tibio-fibular Articulation

Class.—*Diarthrosis.* **Subdivision.**—*Arthrodia.*

This junction is formed by the lower ends of the tibia and fibula. The rough triangular surface on each of these bones formed by the bifurcation of their interosseous lines is closely and firmly united by the inferior interosseous ligament. The fibula is in actual contact with the tibia by an articular facet, which is small in size, crescentic in shape, and continuous with the articular facet of the malleolus.

The ligaments which unite the bones are:—

1. Anterior lateral malleolar ligament.
2. Posterior lateral malleolar ligament.
3. Transverse ligament.
4. Inferior interosseous ligament.

The **anterior lateral malleolar ligament** (anterior inferior tibio-fibular ligament) (figs. 328 and 334) is a strong triangular band about 2 cm. ($\frac{3}{4}$ in.) wide, and is attached to the lower extremity of the tibia at its anterior and lateral angle, close to the margin of the facet for the talus and passes downward and

laterally to the anterior border and contiguous surface of the lower end of the fibula, some fibres passing along the edge nearly as far as the origin of the anterior talo-fibular ligament.

The fibres increase in length from above downward. In front it is in relation with the *peroneus tertius* and deep fascia of the leg, and gives origin to fibres of the anterior ligament of the ankle-joint. Behind, it lies in contact with the interosseous ligament, and comes into contact with the articular surface of the talus (see figs. 328 and 329).

The **posterior lateral malleolar ligament** (figs. 328 and 334) is very similar to the anterior, extending from the posterior and lateral angle of the lower end of the tibia downward and laterally to the lowest 1.5 cm. ($\frac{1}{2}$ in.) of the border separating the medial from the posterior surface of the shaft of the fibula, and to the upper part of the posterior border of the lateral malleolus. It is in relation in front with the interosseous ligament; below, it touches the transverse ligament.

The **inferior interosseous ligament** is a dense mass of short, felt-like fibres, passing transversely between and firmly uniting the opposed rough triangular surfaces at the lower ends of the

FIG. 329.—RIGHT ANKLE-JOINT, SHOWING THE LIGAMENTS.
(From dissection by Mr. W. Pearson, of the Royal College of Surgeons' Museum.)

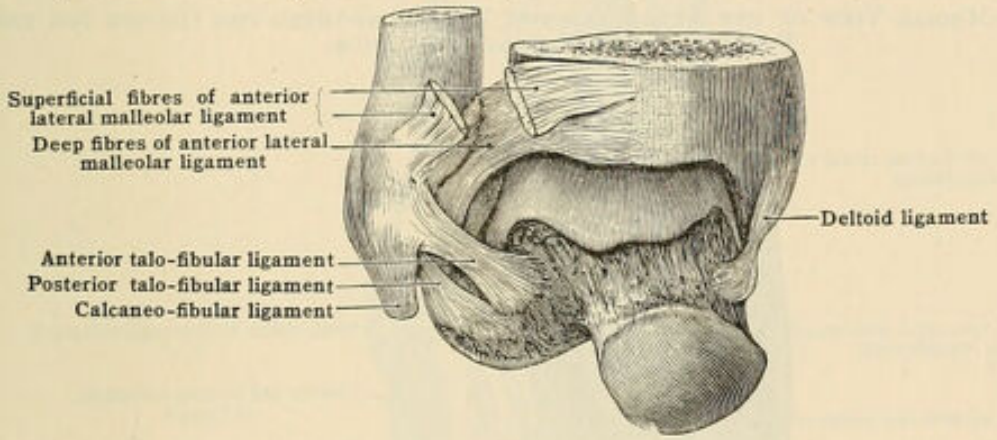

tibia and fibula, except for 1 cm. ($\frac{3}{8}$ in.) at the extremity, where there is a synovial cavity. It extends from the anterior to the posterior lateral malleolar ligaments, reaching upward 4 cm. ($1\frac{1}{2}$ in.) in front, but only half this height behind.

The **transverse ligament** (fig. 331) is a strong rounded band, attached to nearly the whole length of the inferior border of the posterior surface of the tibia, just above the articular facet for the talus. It then inclines a little forward and downward, to be attached to the medial surface of the lateral malleolus, just above the fossa, and into the upper part of the fossa itself.

The **synovial membrane** is continuous with that of the ankle-joint; it projects upward between the bones beyond their articular facets as high as the inferior interosseous ligament.

The **nerve-supply** is the same as that of the ankle-joint; the **arterial** supply is from the peroneal and the anterior peroneal, and sometimes from the anterior tibial, or its lateral malleolar branch.

Relations.—In front of the inferior tibio-fibular joint are the anterior peroneal artery and the tendon of the peroneus tertius, and behind it are the posterior peroneal artery and the pad of fat which lies in front of the tendo Achillis.

The **movement** permitted at this joint is a mere gliding, chiefly in an upward and downward direction, of the fibula on the tibia. The bones are firmly braced together and yet form a slightly yielding arch, thus allowing a slight side to side expansion during extreme flexion, when the broad part of the talus is brought under the arch, by the upward gliding of the fibula on the tibia. To this end the direction of the fibres of the lateral malleolar ligaments is downward from tibia to fibula. This mechanical arrangement secures perfect contact of the articular surfaces of the ankle-joint in all positions of the foot.

4. THE ANKLE-JOINT

Class.—*Diarthrosis.* **Subdivision.**—*Ginglymus.*

The ankle [articulatio talo-cruralis] is a perfect ginglymus or hinge joint. The bones which enter into its formation are: the lower extremity and medial malleolus of the tibia, and the lateral malleolus of the fibula, above; and the upper

and lateral articular surfaces of the talus (astragalus) below. The ligaments (supplementing the articular capsule) uniting the bones are:—

Anterior.	Deltoid.
Posterior.	Lateral ligament.

The **anterior ligament** (fig. 334) is a thin, membranous structure, which completes the capsule in front of the joint. It is attached above to the anterior border of the medial malleolus, to a crest of bone just above the transverse groove at the lower end of the tibia, to the anterior lateral malleolar ligament, and to the anterior border of the lateral malleolus. Below, it is attached to the rough upper surface of the neck of the talus (astragalus). Medially it is thicker, and is fixed to the talus close to the facet for the medial malleolus, being continuous with the deltoid ligament, and passing forward to blend with the talo-navicular ligament. Laterally it is attached to the talus, just below and in front of the angle between the superior and lateral facets, close to their edges, and joins the anterior talo-fibular ligament.

It is in relation, in front with the *tibialis anterior* muscle, the anterior tibial vessels and nerve, the *extensor tendons of the toes*, and the *peroneus tertius;* and behind with a mass of fat and synovial membrane.

FIG. 330.—MEDIAL VIEW OF THE ANKLE AND THE TARSUS, SHOWING THE GROOVE FOR THE TENDON OF THE TIBIALIS POSTERIOR.

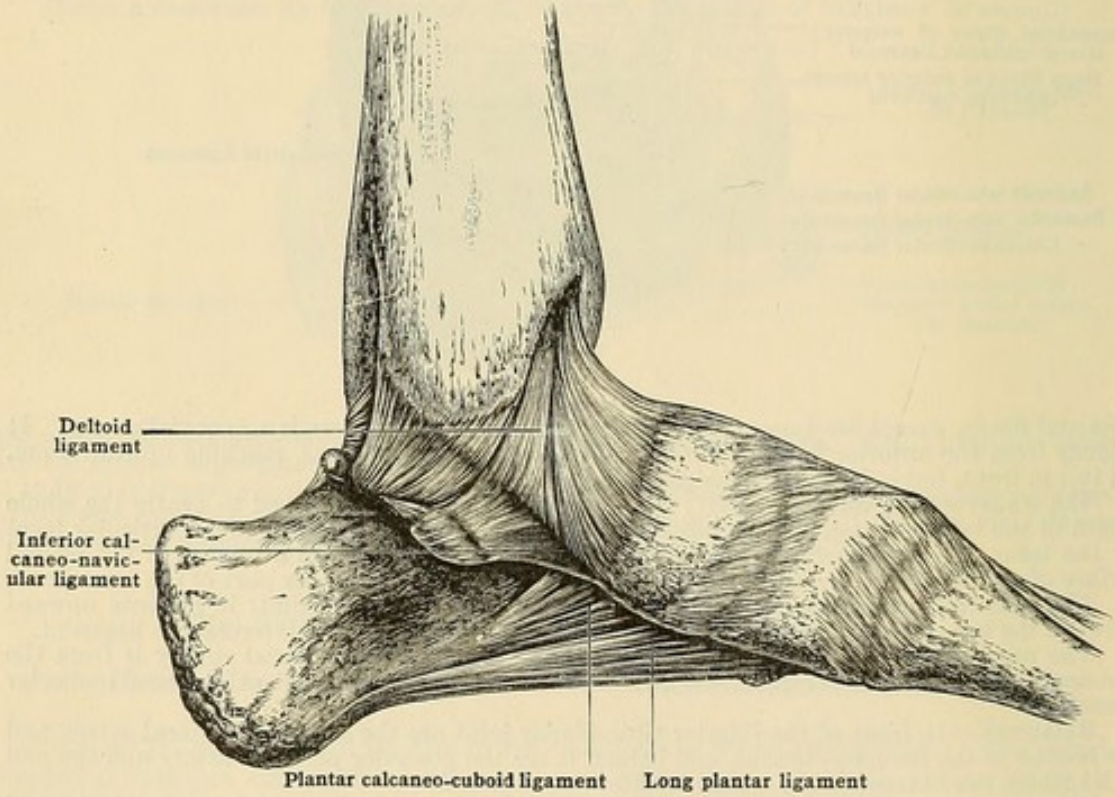

The **posterior ligament** (fig. 331) is a very thin and disconnected membranous structure, connected above with the lateral malleolus, medial to the peroneal groove; to the posterior margin of the lower end of the tibia lateral to the groove for the tibialis posterior; and to the posterior lateral malleolar ligament. Below, it is attached to the posterior surface of the talus from the deltoid to the lateral ligaments. The passage of the flexor hallucis longus tendon over the back of the joint serves the purpose of a much stronger posterior ligament.

The **deltoid ligament** (fig. 330) is attached superiorly to the medial malleolus along its lower border, and to its anterior surface superficial to the anterior ligament; some very strong fibres are fixed to the notch in the lower border of the malleolus, and, getting attachment below to the rough depression on the medial side of the talus, form a **deep** portion to the ligament. The ligament radiates; the posterior fibres are short, and incline a little backward to be fixed to the rough medial surface of the talus, close to the superior articular facet, and into the

tubercle to the medial side of the flexor hallucis longus groove. The fibres next in front are numerous and form a thick and strong mass, filling up the rough depression on the medial surface of the talus, whilst some pass over the talo-calcaneal joint to the upper and medial border of the sustentaculum tali. The fibres which are connected above with the anterior surface of the malleolus pass downward and somewhat forward to be attached to the navicular and to the margin of the calcaneo-navicular ligament.

The **lateral ligament** (figs. 329 and 334) consists of three distinct slips (fasciculi). The **anterior talo-fibular ligament** (anterior fasciculus), is ribbon-like and passes from the anterior border of the lateral malleolus near the tip to the rough surface of the talus in front of the lateral facet, and overhanging the sinus pedis. The **calcaneo-fibular ligament** (middle fasciculus), is a strong roundish bundle, which extends downward and somewhat backward from the anterior border of the lateral malleolus close to the attachment of the anterior fasciculus, and from the lateral surface of the malleolus, just in front of the apex, to a tubercle on the middle of the lateral surface of the calcaneum. The **posterior talo-**

FIG. 331.—LIGAMENTS SEEN FROM THE BACK OF THE ANKLE-JOINT.

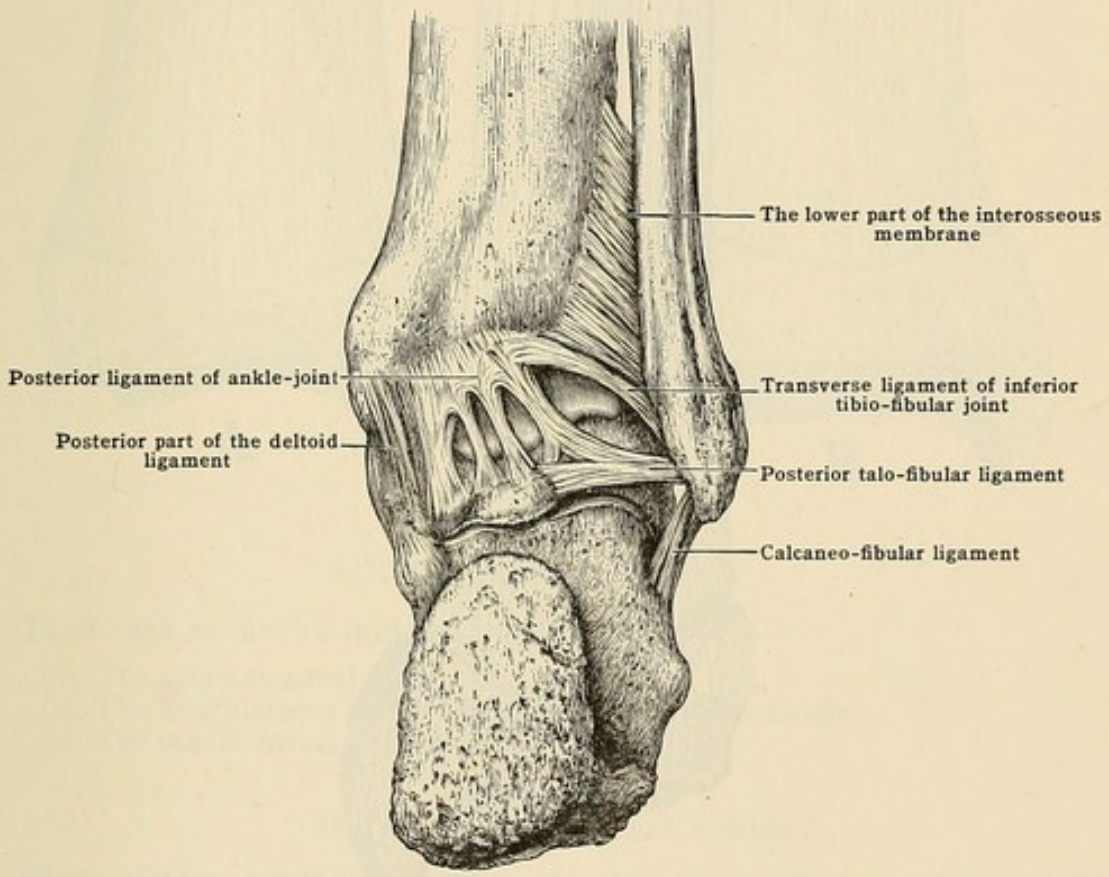

fibular ligament (posterior fasciculus), is almost horizontal; it is a strong, thick band attached at one end to the posterior border of the malleolus, and slightly to the fossa on the medial surface; and at the other end to the talus, behind the articular facet for the fibula, as well as to a tubercle on the lateral side of the groove for the *flexor hallucis longus*.

The middle fasciculus is covered by the tendons of the *peronei longus* and *brevis;* and in extension, the posterior fasciculus is received into the pit on the medial surface of the lateral malleolus.

The **synovial membrane** is very extensive. Besides lining the ligaments of the ankle, it extends upward between the tibia and fibula, forming a short *cul-de-sac* as far as the interosseous ligament. Upon the anterior and posterior ligaments it is very loose, and extends beyond the limits of the articulation. It is said to contain more synovia than any other joint.

The **nerve-supply** is from the saphenous, posterior tibial, and the lateral division of the anterior tibial.

The **arterial supply** comes from the anterior tibial, the anterior peroneal, the lateral malleolar, the posterior tibial, and posterior peroneal.

Relations.—In front and in contact with the anterior ligament, from medial to lateral aspects, are the tendons of the tibialis anterior, the tendon of the extensor hallucis longus, the anterior tibial vessels, the anterior tibial nerve, the tendons of the extensor digitorum longus, and the tendon of the peroneus tertius. To the medial side of the tibialis anterior and to the lateral side of the peroneus tertius the joint is subcutaneous anteriorly. Behind and laterally are the tendons of the peroneus longus and brevis. Behind and medially, from medial to lateral side, are the tendon of the tibialis posterior, the tendon of the flexor digitorum longus, the posterior tibial vessels, the posterior tibial nerve, and the tendon of the flexor hallucis longus. Directly behind is a pad of fat which intervenes between the tendo Achillis and the joint. Below and on the lateral side, crossing the middle fasciculus of the lateral ligament, are the tendons of the peroneus longus and brevis. Below and on the medial side, crossing the deltoid ligament, are the tendons of the tibialis posterior and the flexor digitorum longus.

Movements.—This being a true hinge joint, flexion and extension are the only movements of which it is capable, there being no side to side motion, except in extreme extension, when the narrowest part of the talus is thrust forward into the widest part of the tibio-fibular arch.

FIG. 332.—THE LOWER EXTREMITY OF THE TIBIA (ANTERIOR VIEW), TO SHOW THE RELATION OF THE ARTICULAR CAPSULE OF THE ANKLE-JOINT (IN RED) TO THE EPIPHYSIAL LINE.

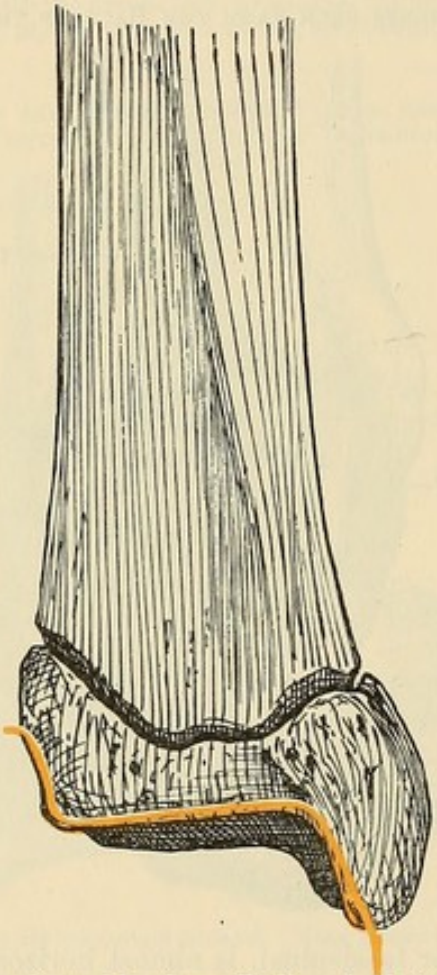

In flexion the talus is tightly embraced by the malleoli, and side to side movement is impossible. Flexion of the ankle-joint is limited by:—(i) nearly the whole of the fibres of the deltoid ligament, none but the most anterior being relaxed; (ii) the posterior and middle portions of the lateral ligament, especially the posterior; (iii) the posterior ligament of the ankle. It is also limited by the neck of the talus abutting on the edge of the tibia.

In most European ankle-joints the anterior edge of the lower end of the tibia is kept from actual contact with the neck of the talus in positions of extreme flexion by the intervention of a pad of fat situated beneath the anterior extension of the anterior ligament. In races which adopt a squatting posture, however, an actual articulation may be developed between these two bony surfaces, a facet being present both upon the anterior margin of the tibia and upon the neck of the talus. These facets are known as "squatting facets" (fig. 333, A) and are of common occurrence in ancient bones and in the bones of modern oriental people.

Extension of the ankle-joint is limited by:—(i) the anterior fibres of the deltoid ligament; (ii) the anterior and middle portions of the lateral ligament; (iii) the medial and stronger fibres of the anterior ligament. It is also limited by the posterior portion of the talus meeting with the tibia. Thus the middle portion of the lateral ligament is always on the stretch, owing to its obliquely backward direction, whereby it limits flexion; and its attachment to the fibula in front of the malleolar apex, whereby it prevents over-extension as soon as the foot begins to twist

medialward. This medial twisting, or adduction of the foot, is partly due to the greater posterior length of the medial border of the superior articular surface of the talus, and to the less proportionate height posteriorly of the lateral border of that surface, but chiefly to the side to side movement in the talo-calcaneal joints. Flexion and extension take place round a transverse axis drawn through the body of the talus. The movement is not in a direct antero-posterior plane, but on a plane inclined forward and laterally from the middle of the astragalus to the intermetatarsal joint of the second and third toes.

Muscles which act on the ankle-joint.—*Flexors.*—Tibialis anterior, extensor hallucis longus, extensor digitorum longus, peroneus tertius. *Extensors.*—Tibialis posterior, flexor digitorum longus, flexor hallucis longus, peroneus longus, peroneus brevis, soleus, gastrocnemius, plantaris.

FIG. 333.—ANTERIOR ASPECT OF THE LOWER EXTREMITY OF THE TIBIA.

In *A*, the articular surface is prolonged upward in front, forming a "squatting facet" which articulates with a corresponding facet on the neck of the talus. In *B* (the usual condition) the articular surface is confined to the lower aspect of the bone.

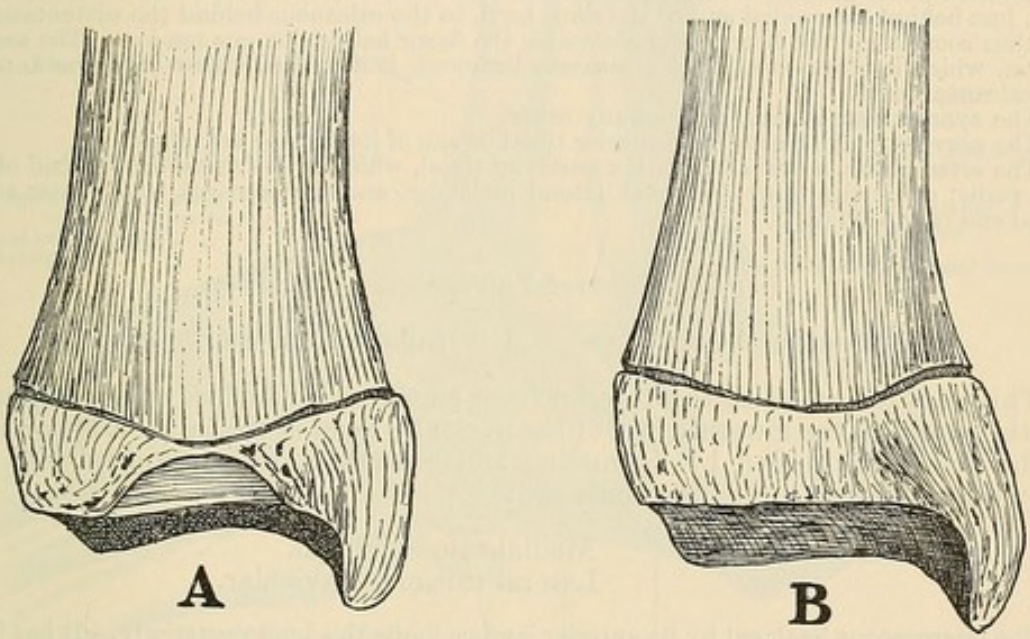

5. THE TARSAL JOINTS

These may be divided into the following sub-groups:—

(*a*) The **talo-calcaneal union.**
(*b*) The **articulations of the anterior portion of the tarsus.**
(*c*) The **medio-tarsal joint.**

(*a*) THE TALO-CALCANEAL UNION

There are two joints which enter into this union—viz., an anterior and a posterior.

(i) *The Posterior Talo-calcaneal Joint*

Class.—*Diarthrosis.* **Subdivision.**—*Arthrodia.*

The calcaneus articulates with the talus by two joints, the anterior and posterior: the former communicates with the medio-tarsal; the posterior is separate and complete in itself. At the latter joint the two bones are united by an articular capsule with the following ligaments:—

Interosseous.	Lateral talo-calcaneal.
Posterior talo-calcaneal.	Medial talo-calcaneal.

The **interosseous ligament** (figs. 334 and 335) is a strong band connecting the apposed surfaces of the calcaneus and talus along their oblique grooves. It is composed of several vertical laminæ of fibres, with some fatty tissue in between.

It is better marked, deeper, and broader laterally. Strong laminæ extend from the rough inferior and lateral surfaces of the neck of the talus to the rough superior surface of the calcaneus anteriorly, forming the posterior boundary of the anterior talo-calcaneal joint; these have been described as the **anterior (interosseous) ligament.** The posterior laminæ extend from the roof of the sinus pedis to the calcaneus immediately in front of the lateral facet, thus forming the anterior part of the capsule of the posterior joint.

The **lateral talo-calcaneal ligament** (fig. 334) extends from the groove just below and in front of the lateral articular facet of the talus, to the calcaneus some little distance from the articular margin. Its fibres are nearly parallel with those of the calcaneo-fibular ligament of the ankle, which passes over it and adds to its strength. It fills up the interval between the calcaneo-fibular and anterior talo-fibular ligaments, a considerable bundle of its fibres blending with the anterior border of the calcaneo-fibular.

The **posterior talo-calcaneal ligament** passes from the lateral tubercle of the talus and lower edge of the groove for the flexor hallucis longus to the calcaneus, a variable distance from the articular margin.

The **medial talo-calcaneal ligament** includes two portions. The first is a narrow band of well-marked fibres passing obliquely downward and forward from the medial tubercle of the talus, just behind the medial end of the sinus tarsi, to the calcaneus behind the sustentaculum tali, thus completing the floor of the groove for the flexor hallucis longus tendon. The second portion, which is often considered a separate ligament, is described below with the anterior talo-calcaneal joint.

The **synovial sac** is distinct from any other.

The **nerve-supply** is from the posterior tibial or one of its plantar branches.

The **arteries** are, a branch from the posterior tibial, which enters at the medial end of the sinus pedis; and twigs from the tarsal, lateral malleolar, and the peroneal, which enter at the lateral end of the sinus.

(ii) *The Anterior Talo-calcaneal Joint*

Class.—*Diarthrosis.* **Subdivision.**—*Arthrodia.*

This joint is formed by the anterior facet on the upper surface of the calcaneus and the facets on the lower surface of the neck and head of the talus; it is bounded on the sides and behind by ligaments, and communicates anteriorly with the talo-navicular joint. The ligaments are:—

Interosseous. Medial talo-calcaneal. Lateral calcaneo-navicular.

The **interosseous ligament** by its anterior laminæ limits this joint posteriorly. It has been already described.

The **medial talo-calcaneal** ligament (second portion; see above) consists of short fibres attached above to the medial surface of the neck of the talus, and below to the upper edge of the free border of the sustentaculum tali, blending posteriorly with the medial extremityof the interosseous ligament, and anteriorly with the upper border of the plantar calcaneo-navicular ligament. It is strengthened by the deltoid ligament, the anterior fibres of which are also attached to the plantar calcaneo-navicular ligament.

The **lateral calcaneo-navicular** (figs. 334 and 335) limits this, as well as the talo-navicular joint, on the lateral side. It is a strong, well-marked band, extending from the rough upper surface of the calcaneus, lateral to the anterior facet, to a slight groove on the lateral surface of the navicular near the posterior margin. It blends below with the plantar calcaneo-navicular, and above with the talo-navicular ligament. Its fibres run obliquely forward and medially. The deltoid ligament and middle fasciculus of the lateral ligament of the ankle-joint also add to the security of these two joints, and assist in limiting movements between the bones by passing over the talus to the calcaneus.

The **synovial membrane** is the same as that of the talo-navicular joint. The **arteries** and **nerves** are derived from the same sources as those of the medio-tarsal joints.

The **movements** of which these two joints are capable are adduction and abduction, with some amount of rotation. Adduction, or inclination of the sole medialward, is combined with some medial rotation of the toes, and some lateral rotation of the heel; while abduction, or inclination of the foot lateralward, is associated with turning of the toes laterally and the heel medially. Thus the variety and the range of movements of the foot on the leg, which at the ankle are almost limited to flexion and extension, are increased. The cuboid moves with the calcaneus, while the navicular revolves on the head of the talus.

In walking, the heel is first placed on the ground; the foot is slightly adducted; but as the body swings forward, first the lateral then the medial toes touch the ground, the talus presses against the navicular and sinks upon the plantar calcaneo-navicular ligament; the foot then becomes slightly abducted. When the foot is firmly placed on the ground, the weight is transmitted to it obliquely downward and medially, so that if the ligaments between the calcaneus and talus did not check abduction, medial displacement of the talus from the tibio-fibular arch would only be prevented by the tendons passing round the medial ankle (especially the *tibialis posterior*). If the ligaments be too weak to limit abduction, the weight of the body increases it, and forces the medial malleolus and talus downward and medially, giving rise to flat foot.

The advantages of the obliquity and peculiar arrangement of the posterior talo-calcaneal articulation are seen in walking:—(i) for the posterior facet of the calcaneus receives

the whole weight of the body when the heel is first placed on the ground; (ii) by the upward pressure of this facet against the talus it transfers the weight to the ball of the toes as the heel is raised, the posterior edge of the sustentaculum tali and the anterior and lateral part of the upper surface of the calcaneus preventing the talus from being displaced too far forward by the superincumbent weight; and (iii) the calcaneus serves to suspend the talus when, with the heel raised by muscular action, the other foot is being swung forward.

FIG. 334.—LATERAL VIEW OF THE LIGAMENTS OF THE FOOT AND ANKLE.

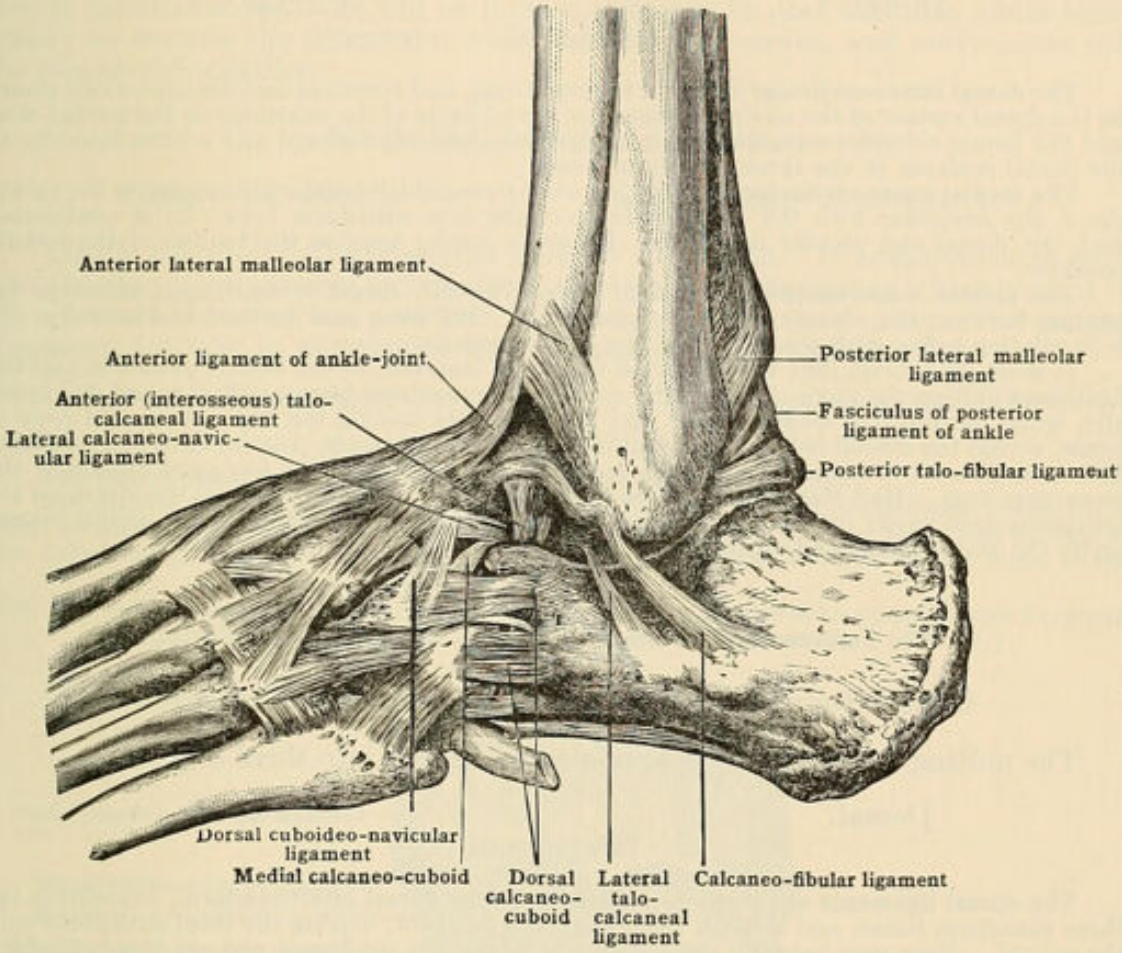

(*b*) THE ARTICULATIONS OF THE ANTERIOR PART OF THE TARSUS

These include (i) the cuboideo-navicular; (ii) cuneo-navicular; (iii) inter-cuneiform; and (iv) cuneo-cuboid joints.

(i) *The Cuboideo-navicular Union*

Class.—*Diarthrosis.* **Subdivision.**—*Arthrodia.*

The joint cavity is only occasionally present and this joint is often included in the transverse tarsal.

The ligaments which unite the cuboid and navicular are:—

Dorsal. Plantar. Interosseous.

The **dorsal cuboideo-navicular ligament** (fig. 334) runs forward and laterally from the lateral end of the dorsal surface of the navicular to the middle third of the medial border of the cuboid on its dorsal aspect, passing over the posterior lateral angle of the third cuneiform bone. It is wider laterally.

The **plantar cuboideo-navicular ligament** is a well-marked strong band, which runs forward and laterally, from the plantar surface of the navicular to the depression on the medial surface of the cuboid, and slightly into the plantar surface just below it.

The **interosseous cuboideo-navicular ligament** is a strong band which passes between the apposed surfaces of these bones from the dorsal to the plantar ligaments. Some of its posterior fibres reach the plantar surface of the foot behind the cuboideo-navicular ligament, and radiate laterally and backward over the medial border of the cuboid to blend with the anterior extremity of the plantar calcaneo-cuboid ligament.

(ii) *The Cuneo-navicular Articulation*

Class.—*Diarthrosis.* **Subdivision.**—*Arthrodia.*

The ligaments uniting the navicular with the three cuneiform bones are:—

Dorsal. Plantar.
Medial.

The **dorsal cuneo-navicular ligament** is very strong, and stretches as a continuous structure on the dorsal surface of the navicular, between the tubercle of the navicular on the medial side, and the dorsal cuboideo-navicular ligament laterally, passing forward and a little laterally to the dorsal surfaces of the three cuneiform bones.

The **medial cuneo-navicular ligament** is a very strong thick band which connects the tubercle of the navicular with the medial surface of the first cuneiform bone. It is continuous with the dorsal and plantar ligaments. Its lower border touches the tendon of the *tibialis posterior*.

The **plantar cuneo-navicular ligament** forms, like the dorsal, a continuous structure extending between the plantar surfaces of the bones. Its fibres pass forward and laterally. It is in relation below with the tendon of the *tibialis posterior*.

It must be noticed that the expanded tendon of insertion of the *tibialis posterior*, and the ligaments uniting the navicular with the cuboid and cuneiform bones, pass forward and laterally, while the *peroneus longus* tendon and the ligaments uniting the first and second rows of bones, except the medial half of the dorsal talo-navicular ligaments, pass forward and medially. This arrangement is admirably adapted to preserve the arches of the foot, and especially the transverse arch. Had these tendons and ligaments run directly forward, all the strain on the transverse arch would have fallen on the interosseous ligaments, but as it is, the arch is braced up by the above-mentioned structures.

(iii) *The Intercuneiform and* (iv) *The Cuneo-cuboid Articulations*

Class.—*Diarthrosis.* **Subdivision**—*Arthrodia.*

The uniting ligaments of these bones are divided into three sets:—

Dorsal. Plantar.
Interosseous.

The **dorsal ligaments** are three in number, two, the **dorsal intercuneiform,** connecting the three cuneiform bones, and a third, the dorsal **cuneo-cuboid,** uniting the third cuneiform with the cuboid. They pass between the contiguous margins of the bones, and are blended behind with the dorsal ligaments of the cuboideo-navicular and cuneo-navicular joints.

The **plantar ligaments** are two in number: a very strong one, the **plantar intercuneiform,** passes laterally and forward from the lateral side of the base of the first cuneiform to the apex of the second cuneiform, winding somewhat to its lateral side. The second, the **plantar cuneo-cuboid,** connects the apex of the third cuneiform with the anterior half of the medial surface of the cuboid along its plantar border, joining with the plantar cuboideo-navicular ligament behind.

The **interosseous ligaments** are three in number. They are strong and deep masses of ligamentous tissue which connect the second cuneiform with the first and third cuneiform bones, and the third cuneiform with the cuboid; occupying all the non-articular portions of the apposed surfaces of the bones. The ligaments extend the whole vertical depth between the second cuneiform and the third, and the third cuneiform and the cuboid, and blend with the dorsal and plantar ligaments; they are situated in front of the articular facets, and completely shut off the synovial cavity behind from that in front. The ligament between the first and second cuneiform bones occupies the inferior and anterior two-thirds of the apposed surfaces, and does not generally extend high enough to separate the synovial cavity of the anterior tarsal joint from that of the second and third metatarsal and cuneiform bones. If it does extend to the dorsal surface, it divides the facets completely from one another, making a seventh synovial sac in the foot.

The **synovial cavity** will be described later on.

The **arterial supply** is from the metatarsal and plantar arteries.

The **nerves** are derived from the deep peroneal and medial and lateral plantar.

The **movement** permitted in these joints is very limited, and exists only for the purpose of adding to the general pliancy and elasticity of the tarsus without allowing any sensible alteration in the position of the different parts of the foot, as the medio-tarsal and talo-calcaneal joints do. It is simply a gliding motion, and either deepens or widens the transverse arch. The third cuneiform being wedged in between the others is less movable, and so forms a pivot upon which the rest can move. The movement is more produced by the weight of the body than by direct muscular action; and of the muscles attached to this part of the tarsus, all deepen the arch save the tibialis anterior, which pulls the first cuneiform up, and so tends to widen it.

(c) The Transverse Tarsal Joints

The articulations of the anterior and posterior portions of the tarsus, although in the same transverse line, consist of two separate joints, viz., (i) a medial, the talo-navicular, which communicates with the anterior talo-calcaneal articulation; and (ii) a lateral, the calcaneo-cuboid, which is complete in itself. The movements of the anterior upon the posterior portions of the foot take place at these joints simultaneously. It will be most convenient to deal with the joints separately as regards the ligaments; while the arteries, nerves, and movements will be considered together.

(i) *The Talo-navicular Articulation*

Class.—*Diarthrosis.* **Subdivision.**—*Enarthrodia.*

This is the only ball-and-socket joint in the tarsus. It communicates with the anterior talo-calcaneal articulation, and two of the ligaments which close it in do not touch the talus, but pass from the calcaneus to the navicular. The uniting ligaments include, in addition to the articular capsule, the following:—

Lateral calcaneo-navicular. Plantar calcaneo-navicular
Talo-navicular.

The **lateral calcaneo-navicular** has been already described (p. 302).

The **plantar calcaneo-navicular ligament** (figs. 335 and 336) is an exceedingly dense, thick plate of fibro-elastic tissue. It extends from the sustentaculum tali and the under surface of the calcaneus in front of a ridge curving laterally to the anterior tubercle of that bone, to the

Fig. 335.—View of the Foot from above, with the Talus removed to show the Plantar and Lateral Calcaneo-navicular Ligaments

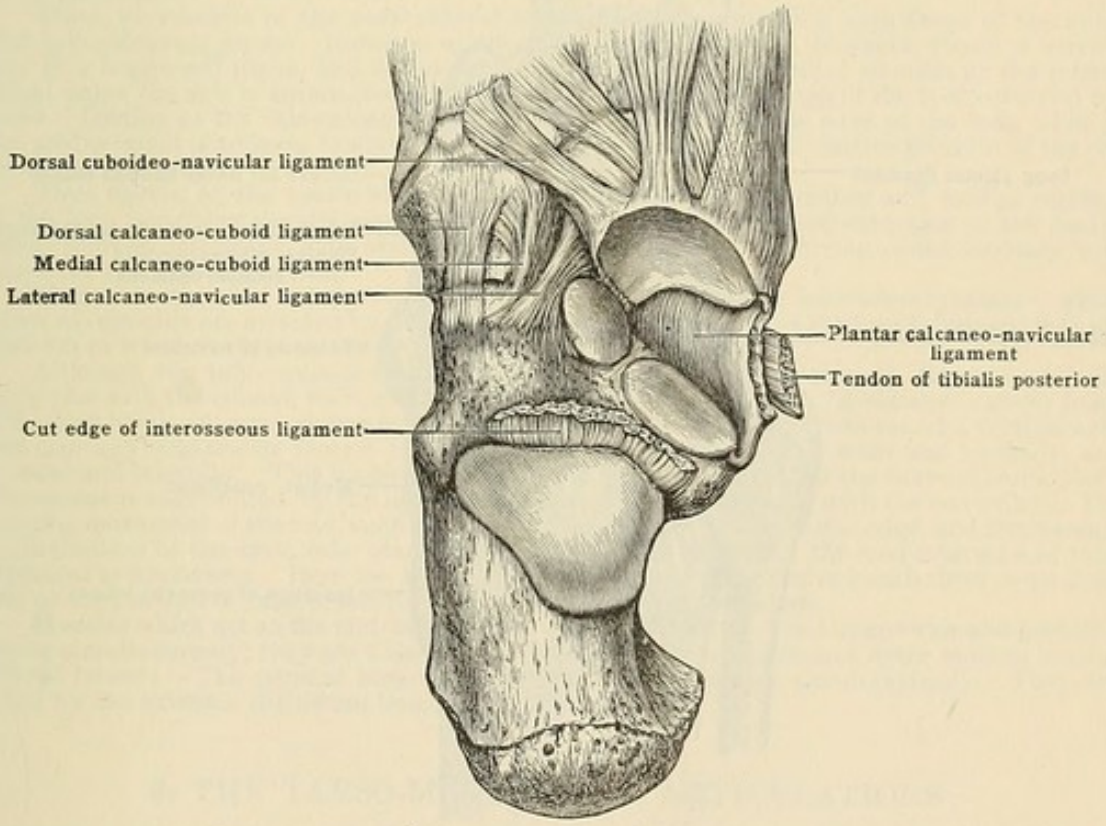

whole width of the inferior surface of the navicular, and also to the medial surface of the navicular behind the tubercle. Medially it is blended with the anterior portion of the deltoid ligament of the ankle, and laterally with the lower border of the lateral calcaneo-navicular ligament. It is thickest along the medial border. Its upper surface loses the well-marked fibrous appearance which the ligament has in the sole, and becomes smooth and faceted. In contact with the under surface of the ligament the tendon of the *tibialis posterior* passes, giving considerable support to the head of the talus by assisting the power and protecting the spring of the ligament. The fibres of the ligament run forward and medially. On account of its elasticity it is sometimes termed the **spring ligament.**

The **talo-navicular ligament** is a broad, thin, but well-marked layer of fibres which passes from the dorsal and lateral surfaces of the neck of the talus to the whole length of the dorsal surface of the navicular. Many of the fibres converge to their insertion on the navicular. The fibres low down on the lateral side blend a little way from their origin with the upper edge of the lateral calcaneo-navicular ligament, and then pass forward and medially to the navicular; those next above pass obliquely and with a distinct twist over the upper and lateral side of the head of the talus to the centre of the dorsum of the navicular, overlapping fibres from the medial side of the talus as well as some from the anterior ligament of the ankle-joint.

Synovial membrane.—The talo-navicular is lined by the same synovial membrane as the anterior talo-calcaneal joint.

(ii) *The Calcaneo-cuboid Articulation*

Class.—*Diarthrosis.* **Subdivision.**—*Saddle-shaped Arthrodia.*

The ligaments which are supplementary to the articular capsule and unite the bones forming the outer part of the medio-tarsal joint are:—

Medial calcaneo-cuboid.	Dorsal calcaneo-cuboid.
Long plantar.	Plantar calcaneo-cuboid.

The **medial calcaneo-cuboid ligament** (fig. 335) is a strong band of fibres attached to the calcaneus along the medial part of the non-articular ridge above the articular facet for the cuboid, and also to the upper part of the medial surface close to the articular margin, and passes forward to be attached to the depression on the medial surface of the cuboid, and also to the rough angle

FIG. 336.—LIGAMENTS OF THE SOLE OF THE LEFT FOOT.

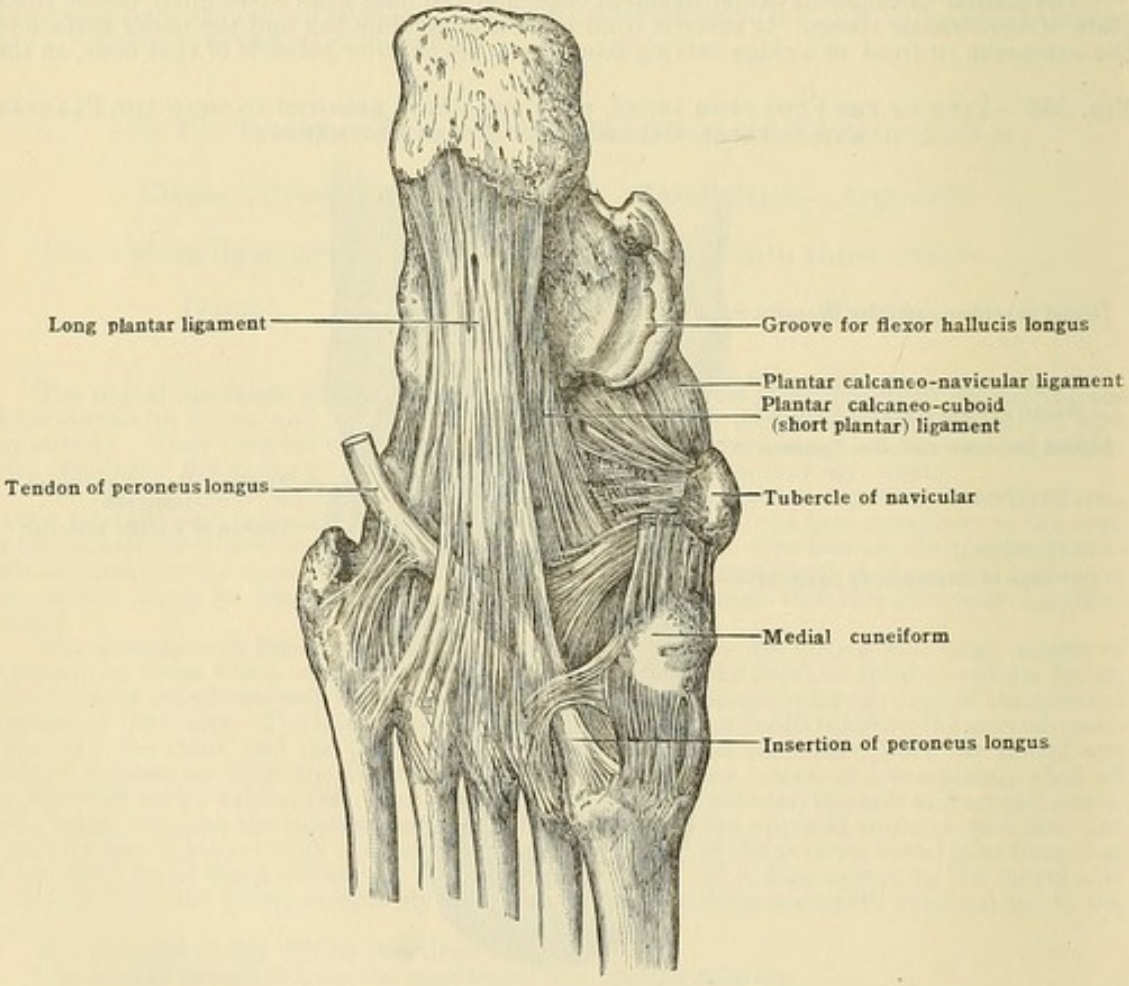

between the medial and inferior surfaces. At the calcaneus this ligament is closely connected with the lateral calcaneo-navicular ligament. Toward the sole it is connected with the plantar calcaneo-cuboid ligament, and superiorly with the dorsal calcaneo-cuboid.

The **dorsal calcaneo-cuboid** (fig. 335) is attached to the dorsal surfaces of the two bones, extending low down laterally to blend with the lateral part of the plantar calcaneo-cuboid ligament. Over the medial half, or more, the ligament stretches some distance beyond the margins of the articular surfaces, reaching well forward upon the cuboid to be attached about midway between its anterior and posterior borders; but toward the lateral side, the ligament is much shorter, and is attached to the cuboid behind its tubercle.

The **long plantar ligament** (fig. 336) is a strong, dense band of fibres which is attached posteriorly to the whole of the inferior surface of the calcaneus between the posterior tubercles and the rounded eminence (the anterior tubercle) at the anterior end of the bone. Most of its fibres pass directly forward, and are fixed to the lateral two-thirds or more of the oblique ridge behind the peroneal groove on the cuboid, while some pass further forward and medially, expanding into a broad layer, and are inserted into the bases of the second, third, fourth, and medial half of the fifth metatarsal bones. This anterior expanded portion completes the canal for the *peroneus longus tendon*, and from its under surface arise the *oblique adductor hallucis* and the *flexor quinti digiti brevis* muscles.

The **plantar calcaneo-cuboid** (short plantar) (fig. 336) is attached to the rounded eminence (anterior tubercle) at the anterior end of the under surface of the calcaneus, and to the bone in front of it, and then takes an oblique course forward and medially, and is attached to the whole of the depressed inferior surface of the cuboid behind the oblique ridge, except its lateral angle. It is strongest near its lateral edge, and is formed by dense strong fibres.

The **synovial membrane** is distinct from that of any other tarsal joint.

The **arterial supply** of the medio-tarsal joints is from the anterior tibial, from the tarsal and metatarsal branches of the dorsalis pedis, and from the plantar arteries.

The **nerve-supply** of the medio-tarsal joints is from the lateral division of the deep peroneal, and occasionally from the superficial peroneal or lateral plantar.

Relations.—On the *dorsal aspect* of the mid-tarsal joint lie the tendons of the tibialis anterior, extensor hallucis longus, extensor digitorum longus, and peroneus tertius, the muscular part of the extensor digitorum brevis, the dorsalis pedis artery, and the anterior tibial nerve. On its *plantar aspect* are the tendons of the flexor digitorum longus and hallucis longus, quadratus plantæ (accessorius), and the medial and lateral plantar vessels and nerves. It is crossed laterally by the tendons of the peroneus longus and brevis and medially by the tendon of the tibialis posterior.

The **movements** which take place at the medio-tarsal joints are mainly flexion and extension, with superadded side-to-side and rotatory movements. Flexion at these joints is simultaneous with extension of the ankle, and *vice versa*. Flexion and extension do not take place upon a transverse, but round an oblique, axis which passes from the medial to the lateral side, and somewhat backward and downward through the talus and calcaneus.

Combined with flexion and extension is also some rotatory motion round an antero-posterior axis which turns the medial or lateral border of the foot upward. There is also a fair amount of side-to-side motion whereby the foot can be inclined medially (i. e., adducted) or laterally (i. e., abducted).

These movements of the medio-tarsal joint occur in conjunction with those of the ankle and talo-calcaneal joints. Rotation at the talo-calcaneal joint is, however, round a vertical axis in a horizontal plane, and so turns the toes medially or laterally; whereas at the medio-tarsal union the axis is antero-posterior and the medial or lateral edge of the foot is turned upward. Gliding at the talo-calcaneal joint elevates or depresses the edge of the foot, while at the medio-tarsal it adducts or abducts the toes without altering the relative position of the calcaneus to the talus.

Thus flexion at the medio-tarsal joint is associated with adduction and medial rotation of the foot, occurring simultaneously with extension of the ankle; and extension at the medio-tarsal joint is associated with abduction and lateral rotation, occurring simultaneously with flexion of the ankle.

Flexion and medial rotation are far more free than extension and lateral rotation, which latter movements are arrested by the ligaments of the sole as soon as the foot is brought into the position in which it rests on the ground.

Although the talo-navicular is a ball-and-socket joint, yet, owing to the union of the navicular with the cuboid, its movements are limited by the shape of the calcaneo-cuboid joint; this latter being concavo-convex from above downward, prevents rotation round a vertical axis, and also any side-to-side motion except in a direction obliquely downward and medially, and upward and laterally. This is also the direction of freest movement at the talo-navicular joint. Movement is also limited by the ligamentous union of the calcaneus with the navicular. The twisting movement of the foot, such as turning it upon its medial or lateral edge, and the increase or diminution of the arch, take place at the tarsal joints, especially the medio-tarsal and talo-calcaneal articulations. Here too those changes occur which, owing to paralysis of some muscles or contraction of others, result in talipes equino-varus, or valgus.

Muscles which act on the mid-tarsal joint.—*Medial rotators.*—Tibialis anterior and posterior acting simultaneously; they are aided by the flexor digitorum longus and flexor hallucis longus. *Lateral rotators.*—The peronei longus, brevis, and tertius, acting simultaneously. They are aided by the extensor digitorum longus.

6. THE TARSO-METATARSAL ARTICULATIONS

There may be said to be three articulations between the tarsus and metatarsus, viz.:—

(*a*) The medial, between the first cuneiform and first metatarsal bones.

(*b*) The intermediate, between the three cuneiform and second and third metatarsal bones.

(*c*) The lateral, or cubo-metatarsal, between the cuboid and fourth and fifth metatarsal bones.

(*a*) The Medial Tarso-metatarsal Joint

Class.—*Diarthrosis.* **Subdivision.**—*Arthrodia.*

A complete **articular capsule** unites the first metatarsal with the first cuneiform, the fibres of which are very thick on the inferior and medial aspects; those on the lateral side pass from behind forward in the interval between the interosseous ligaments which connect the two bones forming this joint with the second metatarsal. The ligament on the plantar aspect is by far the strongest, and blends at the cuneiform bone with the cuneo-navicular ligament.

(*b*) The Intermediate Tarso-metatarsal Joint

Class.—*Diarthrosis.* **Subdivision.**—*Arthrodia.*

Into this union there enter the three cuneiform and second and third metatarsal bones, which are bound together by the following ligaments (supplementary to the articular capsule): dorsal, plantar, interosseous.

The dorsal ligaments.—1. Some short fibres cross obliquely from the lateral edge of the first cuneiform bone to the medial border of the base of the second metatarsal bone; they take the place of a dorsal metatarsal ligament, which is wanting between the first and second metatarsal bones.

2. Between the second cuneiform and the base of the second metatarsal bone some fibres run directly forward.

3. The third cuneiform is connected with (1) the lateral corner of the second metatarsal bone by a narrow band passing obliquely medially; (2) with the third metatarsal by fibres passing directly forward; and (3) with the fourth metatarsal by a short band passing obliquely laterally to the medial edge of its base.

The plantar ligaments.—A strong ligament unites the first cuneiform and the bases of the second and third metatarsal bones. The *tibialis posterior* is inserted into these bones close beside it. Other slender ligaments connect the second cuneiform with the second, and the third cuneiform with the third metatarsal bones.

The interosseous ligaments.—(1) A strong broad interosseous ligament extends between the lateral surface of the first cuneiform and the medial surface of the base of the second metatarsal bone. It is attached to both bones below and in front of the articular facets, and separates the intermediate from the medial tarso-metatarsal joint. (2) A second band is attached behind to a fossa on the anterior and lateral edge of the third cuneiform and to the interosseous ligament between it and the cuboid, and passes horizontally forward to be attached to the whole depth of the fourth metatarsal bone behind its medial facet, and to the opposed surfaces of the third and fourth below the articular facets upon their sides. It separates the middle tarso-metatarsal, and intermetatarsal between the third and fourth bones, from the cubo-metatarsal joint. It is more firmly connected with the third bone than with the fourth. (3) A slender ligament composed only of a few fibres often passes from a small tubercle on the medial and anterior edge of the third cuneiform to a groove on the lateral edge of the second metatarsal bone between the two facets upon their sides.

The **synovial membrane** is prolonged forward from that of the naviculari-cuneiform and inter-cuneiform articulations.

The **arteries for the tarso-metatarsal joints** are derived:—(1) for the medial, from the dorsalis pedis and medial plantar; (2) for the rest, twigs from the arcuate and deep plantar arch.

The **nerve-supply** comes from the deep peroneal and plantar nerves.

The **movements** permitted at these joints are flexion and extension of the metatarsus on the tarsus; and at the medial and lateral divisions, slight adduction and abduction. In the lateral, the side-to-side motion is freer than in the medial joint, and freest between the fifth metatarsal bone and the cuboid. In the medial joint, flexion is combined with slight abduction and extension with abduction.

There is also a little gliding, which allows the transverse arch to be increased or diminished in depth; the medial and lateral two bones sliding downward, and the two middle a little upward, when the arch is increased; and *vice versa* when the arch is flattened.

(*c*) The Lateral or Cubo-metatarsal Joint

Class.—*Diarthrosis.* **Subdivision.**—*Arthrodia.*

The bones comprising this joint are the fourth and fifth metatarsal and the anterior surface of the cuboid, firmly connected on all sides by the articular capsule, strengthened by the following ligaments:—

Dorsal. Plantar. Interosseous.

The **plantar cubo-metatarsal ligament** is a broad, well-marked ligament, which extends from the cuboid behind to the bases of the fourth and fifth metatarsal bones in front. It is

continuous along the groove at the base of the fifth metatarsal bone with the dorsal ligament, and as it passes round the lateral border of the foot it is somewhat thickened, and may be described as the **lateral cubo-metatarsal ligament.** On its medial side it joins the interosseous ligaments, thus completing the capsule below. It is not a thick structure, and to see it the long plantar ligament, the peroneus longus, and lateral slip of the tibialis posterior must be removed; the attachment of these structures to the fourth and fifth metatarsal bones considerably assists to unite them with the tarsus.

The **dorsal cubo-metatarsal ligament** is composed of fibres which pass obliquely outward and forward from the cuboid to the bases of the fourth and fifth metatarsal bones. They complete the capsule above, and are continuous laterally with the lateral cubo-metatarsal ligament.

The **interosseous ligament** shuts off the cubo-metatarsal from the middle tarso-metatarsal joint. It is attached to the third cuneiform behind, and to the whole depth of the fourth metatarsal behind its medial facet, and to the apposed surfaces of the third and fourth bones below their articular facets. It is continuous below with the plantar ligament.

The **synovial membrane** is separate from the other synovial sacs of the tarsus, and is continued between the fourth and fifth metatarsal bones.

Relations.—The line of the tarso-metatarsal joints is crossed dorsally by the tendons of the long and short extensor muscles of the toes and the tendon of the peroneus tertius. On the plantar aspect it is in relation with the oblique adductor of the great toe, the short flexor of the great toe, the lateral plantar artery, and the tendon of the peroneus longus. Its medial end is subcutaneous except that it is crossed, near the plantar surface, by a slip of the tendon of the tibialis anterior, and its lateral end is crossed by the tendon of the peroneus brevis.

FIG. 337.—SECTION TO SHOW THE SYNOVIAL CAVITIES OF THE FOOT.

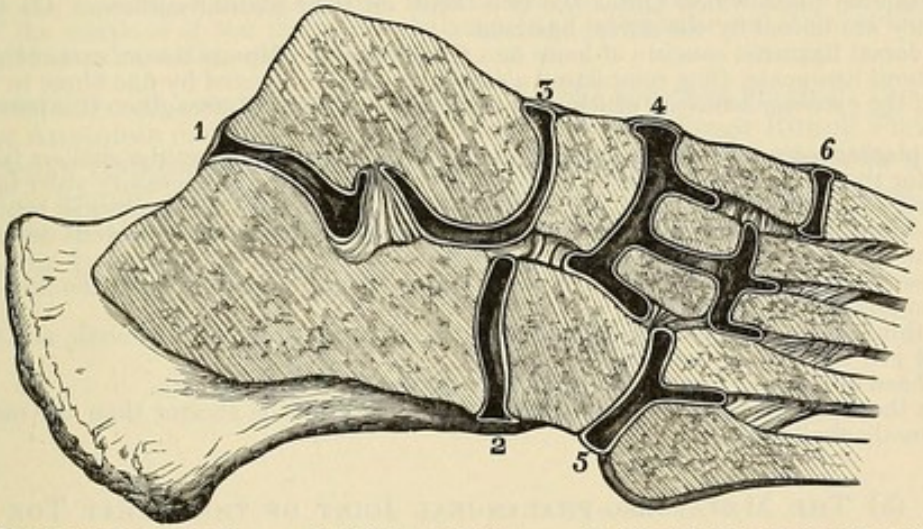

1. Posterior talo-calcaneal. 2. Calcaneo-cuboid. 3. Anterior talo-calcaneo-navicular.
4. Tarsal. 5. Cubo-metatarsal. 6. First metatarso-cuneiform.

7. THE INTERMETATARSAL ARTICULATIONS

Class.—*Diarthrosis.* **Subdivision.**—*Arthrodia.*

The bases of the metatarsal bones are firmly held in position by dorsal, plantar, and interosseous ligaments, supplementing the articular capsules. The first occasionally articulates by means of a distinct facet with the second metatarsal (figs. 245 and 246).

The **dorsal ligaments** are broad, membranous bands passing between the four lateral toes on their dorsal aspect; but in place of one between the first and second metatarsal bones, a ligament extends from the first cuneiform to the base of the second metatarsal bone.

The **plantar ligaments** are strong, thick, well-marked ligaments which connect the bones on their plantar aspect.

The **interosseous ligaments** are three in number, very strong, and are situated at the points of union of the shaft with the bases of the bones, and fill up the sulci on their sides. They limit the synovial cavities in front of the synovial facets.

The common **synovial membrane** of the tarsus extends between the second and third, and third and fourth bones; that of the cubo-metatarsal joint extending between the fourth and fifth.

The **arterial** and **nerve-supply** is the same as for the tarso-metatarsal joints.

The **movements** consist merely of gliding, so as to allow the raising or widening of the transverse arch. Considerable flexibility and elasticity are thus given to the anterior part of the foot, enabling it to become moulded to the irregularities of the ground.

THE UNION OF THE HEADS OF THE METATARSAL BONES

The **heads of the metatarsal bones** are connected on their plantar aspect by the **transverse ligament** [Ligg. capitulorum transversa], consisting of four bands

of fibres passing transversely from bone to bone, blending with the fibro-cartilaginous or sesamoid plates of the metatarso-phalangeal joints, and the sheaths of the flexor tendons where they are connected with the fibro-cartilages. It differs from the corresponding ligament in the hand by having a band from the first to the second metatarsal bone.

8. THE METATARSO-PHALANGEAL ARTICULATIONS

(*a*) The Metatarso-phalangeal Joints of the Four Lateral Toes

Class.—*Diarthrosis.* **Subdivision.**—*Condylarthrosis.*

These joints are formed by the concave proximal ends of the first phalanges articulating with the rounded heads of the metatarsal bones, and united by articular capsules strengthened by the following ligaments:—

Collateral. Dorsal. Plantar accessory.

The two **collateral ligaments** are strong bands passing from a ridge on each side of the head of the metatarsal bone to the sides of the proximal end of the first phalanx, and also to the sides of the sesamoid plate which unites the two bones on their plantar surfaces. On the dorsal aspect they are united by the dorsal ligament.

The **dorsal ligament** consists of loose fine fibres of areolo-fibrous tissue, extending between the collateral ligaments, thus completing a capsule. It is connected by fine fibres to the under surface of the extensor tendons, which pass over and considerably strengthen this portion of the capsule.

The **plantar accessory ligament** or sesamoid plate helps to deepen the shallow facet of the phalanx for the head of the metatarsal bone, and corresponds to the accessory volar ligament of the fingers. It is firmly connected to the collateral ligaments and the transverse ligament, and is grooved inferiorly where the flexor tendons pass over it. It serves to prevent dorsal dislocation of the phalanx.

The second metatarso-phalangeal joint is 6 mm. ($\frac{1}{4}$ in.) in front of both the first and third metatarso-phalangeal joints.

The third metatarso-phalangeal joint is 6 mm. ($\frac{1}{4}$ in.) in front of the fourth, and the fourth 9 mm. ($\frac{3}{8}$ in.) in front of the fifth.

The head of the fifth metatarsal is in line with the neck of the fourth.

Thus the lateral side of the longitudinal arch of the foot is shorter than the medial, it is also distinctly shallower.

(*b*) The Metatarso-phalangeal Joint of the Great Toe

The metatarso-phalangeal joint of the great toe differs from the rest in the following particulars:—

(1) The bones are on a larger scale, and the articular surfaces are more extensive.

(2) There are two grooves on the plantar surface of the metatarsal bone, one on each side of the median line, for the sesamoid bones.

(3) The sesamoid bones replace the accessory plantar ligament (sesamoid plate). They are two small hemispherical bones developed in the tendons of the flexor hallucis brevis, convex below, but flat above where they play in grooves on the head of the metatarsal bone; they are united by a strong transverse ligamentous band, which is smooth below and forms part of the channel along which the long flexor tendon plays. They are firmly united to the base of the phalanx by strong short fibres, but to the metatarsal bone they are joined by somewhat looser fibres. At the sides they are connected with the collateral ligaments and the sheath of the flexor tendon. They provide shifting leverage for the *flexor hallucis brevis* as well as for the *flexor hallucis longus*.

The **arteries** come from the digital and metatarsal branches; and the **nerves** from the cutaneous digital, or from small twigs of the nerves to the interossei muscles.

The **movements** permitted are: flexion, extension, abduction, adduction, and circumduction.

Flexion is more free than extension, and is limited by the extensor tendons and dorsal ligaments; extension is limited by the flexor tendons, the plantar fibres of the collateral ligaments, and the sesamoid plates. The side-to-side motion is possible from the shape of the bony surfaces, but is very limited, being most marked in the great toe. It is limited by the collateral ligaments and sesamoid plates.

9. THE INTERPHALANGEAL JOINTS

Class.—*Diarthrosis.* **Subdivision.**—*Ginglymus.*

The articulations between the first and second and second and third phalanges of the toes are similar to those of the fingers, with this important difference, that

the bones are smaller and the joints, especially between the second and third phalanges, are often ankylosed. The ligaments which unite them include, in addition to the articular capsule:—

Collateral. Dorsal. Accessory plantar.

The **two collateral ligaments** are well marked, and pass on each side of the joints from a little rough depression on the head of the proximal, to a rough border on the side of the base of the distal phalanx of the joint.

The **dorsal ligament** is thin and membranous, and extends across the joint from one collateral ligament to the other beneath the extensor tendon, with the deep surface of which it is connected and by which it is strengthened.

The **accessory plantar ligament** covers in the joint on the plantar surface. It is a fibro-cartilaginous plate, connected at the sides with the collateral ligaments, and with the bones by short ligamentous fibres; the plantar surface is smooth, and grooved for the flexor tendons.

The **arteries** and **nerves** are derived from the corresponding digital branches.

The only **movements** permitted at these joints are flexion and extension.

At the interphalangeal joint of the great toe there is very frequently a small sesamoid bone which plays on the plantar surface of the first phalanx, in the same way as the sesamoid bones of the metatarso-phalangeal joint play upon the plantar surface of the head of the metatarsal bone.

Relations of the muscles acting on the metatarso-phalangeal and interphalangeal joints of the foot.—If the student will refer to the accounts given of the relations of the corresponding joints in the hand and of the actions of the muscles upon those joints, and if he contrasts and compares the muscles of the hand with those of the foot, he will readily be able to construct tables of the relations of the metatarso-phalangeal and interphalangeal joints of the foot, and tables of the muscles acting upon the joints.

References.—A complete bibliography for the joints is given in the "Handbuch der Anatomie und Mechanik der Gelenke," by Professor Rudolf Fick (in von Bardeleben's Handbuch der Anatomie). References are also given in the larger works on human anatomy by Quain, Rauber-Kopsch, Poirier-Charpy, etc. References to the most recent literature may be found in Schwalbe's Jahresbericht, the Index Medicus and the various anatomical journals.

SECTION IV

THE MUSCULATURE

REVISED FOR THE FIFTH EDITION

BY C. R. BARDEEN, A.B., M.D.

PROFESSOR OF ANATOMY IN THE UNIVERSITY OF WISCONSIN

MUSCLES, the movements of which are under the control of the will, almost completely envelope the skeletal framework of the body; close in the oral, abdominal, and pelvic cavities; separate the thoracic from the abdominal cavity; surround the pharynx and the upper portion of the œsophagus; and are found connected with the eye, ear, larynx, and other organs. They constitute about two-fifths to three-sevenths of the weight of the body.

In this section an account is given of the gross anatomy of the musculature attached to the skeleton and the skin, with the exception of certain of the muscles which are more conveniently treated in connection with the organs to which they are appended. Thus, the muscles of the eye, the ear, the pharynx, the larynx, and the intrinsic muscles of the tongue are described in the sections devoted to those structures.

Relations to the skin.—Beneath the skin is a sheet of connective tissue, the **tela subcutanea.** In this, in some regions of the body (the head, neck, and palm), thin, flat, **subcutaneous muscles** are embedded. Superficial muscles of this kind constitute a **panniculus carnosus,** much more extensive in the lower mammals than in man. The tela subcutanea is separated from the more deeply seated musculature by areolar tissue, which, in most places, is loose in texture over the muscles. In some regions, as over the upper part of the back, the tela subcutanea is firmly united to the underlying musculature and is less freely movable. In the tela subcutanea more or less fat is usually embedded. This constitutes the **panniculus adiposus,** which varies greatly in thickness in different parts of the body. As a rule, it is much more developed over muscles than over those regions where bone and joints lie beneath the skin. From the tela subcutanea of the eyelids, penis, and scrotum fat is absent. The deeper layer of the tela subcutanea is more or less free from fat, and in it run the main trunks of the cutaneous nerves and vessels. In some regions, as over the lower part of the abdomen, one or more fibrous membranes are differentiated in this deeper layer.

To the tela subcutanea the term **superficial fascia** has been commonly applied, but since this leads to a confusion with the superficial fasciæ which immediately invest the muscles, it seems better to restrict the term fascia to the membranes connected with the muscular system, and to use the term **tela subcutanea** for the layer of connective tissue which underlies the skin and is continuous over the whole surface of the body.

In several places where the skin overlies bony prominences well-marked **synovial bursæ,** or sacs (**bursæ mucosæ**), are developed in the tela subcutanea.

Since the skin and the subcutaneous tissue must be removed in order to study the muscles of various regions, the tela subcutanea and subcutaneous bursæ may be conveniently described in connection with the muscles, and brief references will, therefore, be made to them in connection with the musculature of various regions.

Muscle fasciæ.—The musculature of the body, with the exception of some of the subcutaneous muscles, is ensheathed by fibrous tissue, which, in certain regions forms distinct membranes, while in other regions it is delicate and not clearly to be distinguished from the superficial connective tissue of the muscles, the perimy-

sium externum. The membranes, or **muscle fasciæ,** are united to various parts of the skeleton, either directly or by means of intermuscular septa, and, where strong, keep the underlying musculature in place. In some regions they are united to the muscles; in others they are separated from the underlying musculature by loose areolar tissue, which allows free movement between the surface of the muscles and the overlying fascia. The best example of a strong fascia of this nature is that which envelopes the extensor muscles of the thigh. Where the fasciæ are well developed, the main bundles of constituent fibres take a course directly or obliquely transverse to the direction of the underlying muscles. They may be composed of several successive layers of fibrous tissue, the fibres of one layer taking a different direction from those of the next layer.

The **function** of the fasciæ is the mechanical one of restraining or modifying muscle action. The direction of the main component fibre-bundles indicates the direction of the greatest stress to which the fasciæ are subjected. Indirectly the fasciæ promote the circulation of the blood and lymph in places where the vessels lie between the contracting muscles and the overlying fascia.

Intermuscular septa.—Muscle fasciæ enclose not only the external layer of the musculature of the body, but also the various groups of more deeply seated muscles. In addition, between the individual muscles, and between the different layers and groups of muscles, there intervenes a greater or less amount of connective tissue, sometimes loose in texture, sometimes dense in structure. In these intermuscular septa run the chief nerves and blood-vessels of the region in which the musculature lies.

Gross structure of the muscles.—The muscles are composed of bundles of reddish fibres surrounded by a greater or less extent of white and glistening connective tissue. They are attached by prolongations of this tissue in the form of **tendons** or **aponeuroses** usually to the bony skeleton, but also in places to cartilages, as in the thorax and larynx; to the skin, as in the face; to mucous membranes, as in the tongue and cheeks; to the tendons of other muscles, as in the case of the lumbrical muscles; to muscle fasciæ, as in the case of the oblique and transverse muscles of the abdomen; and to other structures, as, for instance, to the eyeball.

The fleshy portion of the muscle is called the **belly.** The belly is usually attached at one extremity to a portion of the skeleton or to some other structure which serves as a support for its action on the structures to which its other extremity is attached. The attachment to the more fixed part is called the **origin** of the muscle; the attachment to the structure chiefly acted on is called the **insertion.** Thus the origin of the biceps muscle, the chief flexor of the forearm at the elbow, is from the scapula; the insertion is into the radius and into the fascia of the forearm. The part of the muscle attached to the origin is called the **head** of the muscle. The part attached to the insertion is sometimes called the **tail,** but this term is much less frequently used than the former.

The muscles vary greatly in **size** and **form.** Thus the stapedius muscle of the middle ear is a slender little structure, only a few millimetres long, while the gluteus maximus muscle of the hip is a large, rhomboid structure often several centimetres thick and with a surface area of over 500 square centimetres. The length of a muscle from origin to insertion may be much less than the width of the muscle, as in the intercostal muscles; or much greater than the width, as in most of the long muscles of the limbs. The thickness of a muscle is usually less than the width—so much so in some instances that the muscle is described as flat, sheet-like, or ribbon-like; while in other instances the belly is cylindrical. In flat muscles the general outline is usually quadrilateral or triangular. In triangular muscles in most instances one angle of the triangle marks the insertion of the muscle, while the opposite side marks the origin. In cylindrical muscles the belly usually has a somewhat fusiform shape, and grows smaller both toward the origin and the insertion of the muscle.

Some muscles are divided by tendons transverse to the long axis of the muscle. When one such tendon exists, the muscle is called **digastric** (fig. 348); when several, **polygastric,** e. g., rectus abdominis (fig. 388).

Two muscle masses with separate origins may have a common insertion. Such muscles are usually designated **bicipital** muscles (biceps muscles of the arm and thigh). Other muscles have three heads (the triceps muscle of the arm) or four (the quadriceps muscle of the thigh). In the latter case special names are given

to the four parts or muscles which constitute the quadriceps as a whole. In addition to these comparatively simple compound muscles there are others in which the various component fasciculi and the tendons of origin and insertion are numerous and complexly interrelated. The intrinsic muscles of the back offer good illustrations of muscles of this nature.

In addition to muscles with distinct regions of origin and insertion, there are a few voluntary muscles which surround hollow viscera or their orifices and have a circular or tube-like form (sphincter muscles, voluntary muscles of the œsophagus, etc.).

Number of muscles.—A logical constancy does not appear always to have been followed in the commonly accepted division of the musculature into muscles individually designated. Most of the muscles are symmetrically placed in pairs, one on each side of the body. Authors not only vary in the extent to which they carry the subdivisions of the musculature on each side of the body into individual muscles, but also in describing muscles placed near the median line either as single muscles with bilateral halves or as paired muscles. In addition some muscles are not constantly present, and there are differences of opinion as to which of these less constant muscles should be classed with the normal musculature. The BNA recognises 347 paired and two unpaired skeletal muscles, and 47 paired and two unpaired muscles belonging to the visceral system and organs of special sense. Of the skeletal muscles the head has 25 paired and one unpaired; the neck 16 paired; the back 112 paired; the thorax 52 paired, one unpaired; the abdomen and pelvis 8 paired; the upper extremity, 52 paired; the lower extremity, 62 paired (Eisler).

Finer structure of muscles.—While no attempt can be made here to describe in detail the finer microscopic features of muscle structure, some of the more general features of muscle architecture may be briefly mentioned.

The contractile cells of voluntary muscle are long, slender, multinucleated **'fibres,'** the protoplasm of which exhibits both cross and longitudinal striation. The longitudinal striation is due to the presence of fibrils situated in the sarcoplasma. The cross striation is due to alternate segments of singly and doubly refracting substance in these fibrils. The length of these fibres in the human body varies from a few millimetres to sixteen centimetres or more, and the thickness from ten to eighty microns. Each muscle-fibre is surrounded by an especially differentiated sheath, the **sarcolemma.** Outside of this is a layer of delicate connective tissue, the **perimysium internum** or **endomysium,** the fibres of which are in part inserted into the sarcolemma. This connective tissue, which is especially developed at the ends of the fibres, serves to attach them either directly to the structures on which the muscle acts or to the skeletal framework of the muscle.

In the simplest mammalian muscles the muscle-fibres take a parallel course from tendon to tendon, and are not definitely bound into secondary groups. An example may be seen in fig. 338, a, which represents two segments of the rectus abdominis muscle of a mouse. More often, however, the individual fibres do not run the entire distance from tendon to tendon, but instead they interdigitate, and the interdigitating fibres are bound up into secondary and tertiary anastomosing fibre-bundles by connective tissue, in which there is usually a considerable amount of elastic tissue. Fig. 338, b, represents diagrammatically this interdigitation of fibre-bundles as seen in the abdominal musculature of one of the larger mammals.

In most of the flat muscles of the body the fibre-bundles either take a nearly parallel course from tendon to tendon or they converge from the tendon of origin toward the tendon of insertion (see fig. 338, c–e). The greater the distance from tendon to tendon, the more marked is the interdigitation of the constituent fibre-bundles.

In elongated muscles the tendons of origin and insertion may either arise near the extremities of the muscle or may extend for a considerable distance on the surface or within the substance of the muscle. In the former case the belly of the muscle is composed of bundles of interdigitating fibres which take a course parallel with the long axis of the muscle. This is shown diagrammatically in fig. 338, f. An example may be seen in the sartorius muscle of the thigh (fig. 411). When the tendons extend far on the surface or within the substance of the muscle, the constituent fibre-bundles take a course oblique to the long axis of the muscle. When they take a course from a tendon of origin on one side toward a tendon of insertion on the other, the muscle is called **unipenniform** (see fig. 338, g, and the extensor digitorum longus, fig. 415). In other instances the fibre-bundles converge from two sides toward a central tendon. Such a muscle is called **bipenniform** (see fig. 338, h, and the flexor hallucis longus, fig. 416). When there are several tendons in the muscle between which the fibre-bundles run obliquely, the muscle is called **multipenniform.** In **fusiform** muscles the tendons usually either embrace the extremity of the muscle like a hollow cone, or they extend far on the surface or within the substance of the muscle. In such muscles the fibre-bundles take a curved course from one tendon to the other. The bundles which arise highest on one tendon are inserted highest on the other, and the fibre-bundles of lowest origin have the lowest insertion. This structure is diagrammatically shown in fig. 338, i. A good example may be found in the rectus femoris muscle (fig. 411).

Many other arrangements of the fibre-bundles are found, and the arrangements here shown may be variously combined. In most muscles the architecture is decidedly complex. In the

more complex muscles dense connective-tissue septa, or intramuscular fasciæ, serve to separate different regions of the muscle from one another. In general there are groups of muscle fibre-bundles surrounded by a greater amount of connective tissue, or perimysium internum, than that surrounding the individual fibre-bundles, and the latter are surrounded by a denser connective

FIG. 338.—DIAGRAMMATIC OUTLINES TO ILLUSTRATE VARIOUS TYPES OF MUSCLE ARCHITECTURE AND THE RELATIONS OF THE MAIN NERVE BRANCHES TO THE FIBRE-BUNDLES OF THE MUSCLE.

a. Two segments of the rectus abdominis muscle of a small mammal. b. Portion of sheet-like muscle with two nerve-branches and intramuscular nerve plexus. c. Typical quadrilateral muscle with nerve passing across the muscle about midway between the tendons. d and e. Two triangular muscles with different types of innervation. f. Long ribbon-like muscle with interdigitating fibre-bundles. g. Unipenniform muscle. h. Bipenniform muscle. i. Typical fusiform muscle. The main intramuscular nerve-branches are distributed to the fibre-bundles about midway between their origins and insertions. N. nerve.

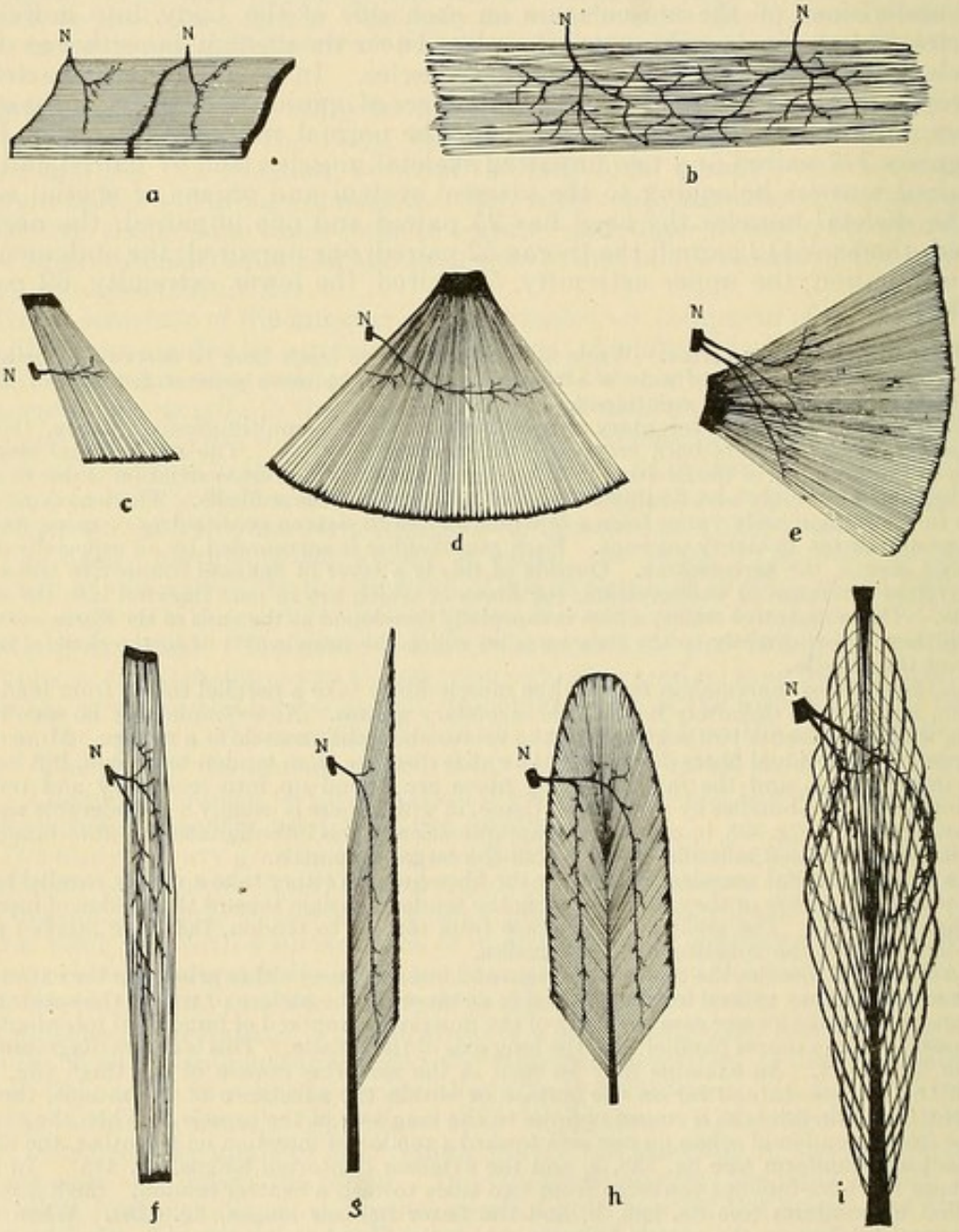

tissue than that surrounding the component muscle-fibres. The muscles are surrounded externally by a more or less dense sheet of connective tissue called the **perimysium externum**, or epimysium, which is continuous with the connective tissue within the muscle, the perimysium internum. In the following pages 'muscle fibre-bundle' is used to denote small groups of muscle-fibres, 'fasciculus' to denote large, more or less isolated, groups of fibre-bundles.

Embryonic development of muscles.—The voluntary muscles are of mesodermal origin. The muscles of the trunk arise chiefly from the myotomes, those of the head and limbs chiefly from the mesenchyme in these regions. New muscle fibres are formed mainly before birth. After birth, growth of muscles depends on growth of individual muscle fibres.

Tendons.—Muscles vary not only in general form and in the relations of the constituent fibre-bundles to the intrinsic skeletal framework, but also in the mode of attachment to the parts on which they act. In many instances the fibre-bundles impinge, perpendicularly or obliquely, directly upon a bone or cartilage. The tendinous tissue arising from the fibre-bundles of the muscle here is attached to the periosteum or perichondrium or to the bone directly. A broad attachment is thus offered the muscle. Instances of this mode of attachment may be seen in the attachment of the intercostal muscles and of many of the muscles attached to the shoulder and hip girdles.

In the case of most thin, flat muscles the muscle is continued at one or both extremities into thin, tendinous sheets called **aponeuroses,** composed of connective tissue. Well-marked instances may be seen in the transverse muscle of the abdomen (fig. 390), and the trapezius and latissimus dorsi muscles of the back (fig. 355). The extent of development of these aponeuroses is generally inversely proportional to the development of the muscle—the more extensively developed the muscle is in a given individual, the less extensive the aponeurotic sheet.*

Most muscles are continued at one or both extremities into dense, tendinous bands which may be comparatively short and thick, like the tendon of Achilles (fig. 413), or very long and narrow, like the tendon of the palmaris longus (fig. 370). In this latter case the tendon represents in part the remnants of musculature more highly developed in the lower vertebrates. In most instances, however, the tendons are structures specifically differentiated for definite functions and are composed of bundles of parallel connective-tissue fibrils held together by an interlacing fibrous-tissue framework. The tendons usually contain a relatively small amount of elastic tissue.

The tendons are attached to the skeleton early in embryonic development. As the bones enlarge the tendons become in part incorporated in the substance of the bone and ossified.

In some tendons **sesamoid bones** are developed in the neighbourhood of joints over which the tendons pass. Examples of these are the patella at the knee-joint (fig. 412) and the sesamoid bones of the thumb and great toe.

Where muscles or tendons closely envelope a joint, there is usually formed a close union between the connective tissue of the capsule of the joint and that of the muscle or the tendon. Special bands may develop in the direction of the pull of the muscle (lig. popliteum obliquum).

Where tendons run for some distance across or beneath a fascia, they are usually either bound to the fascia by a special investment, as near the wrist and knee (fig. 366 and fig. 414), or are fused with the fascia, as in the case of the iliotibial band. Fibrous tracts in the fascia may indicate stress under muscle contraction (the lacertus fibrosus of the fascia of the forearm).

Often in broad aponeurotic attachments of muscles there is formed in the tendon near the attachment a fibrous archway [**arcus tendineus**] for the passage of blood-vessels, nerves, muscles, or tendons. The tendinous arch is either fastened at both ends to the bone, or at one end it is connected with a joint capsule or other membrane. The dorsal attachment of the diaphragm (fig. 391) and that of the adductor magnus to the femur (fig. 409) offer good examples of tendon arches.

In digastric and polygastric muscles the transverse tendons which separate the bellies are often composed of narrow, incomplete bands of fibrous tissue. Such a transverse band is called an **inscriptio tendinea** (see RECTUS ABDOMINIS MUSCLE, fig. 388).

Tendon sheaths.—The tendons are held in place by sheaths composed of dense connective tissue. These sheaths vary in different regions. In the most complete form they confine tendons in osseous grooves which they convert into osteofibrous canals on the flexor surface of the digits. The sheath is here called a **vagina fibrosa tendinis.** It is strengthened by tendinous bands (**vaginal ligaments**). In other regions special dense bands or ligaments, **retinacula tendinum,** confine a series of tendons in place, as at the ankle (fig. 417), or fasciæ may be modified for this purpose, as at the back of the wrist (fig. 366). A tendinous loop,

* The terms fascia and aponeurosis are often loosely and interchangeably used. It seems best to make a distinction by restricting the term fascia to membranous sheets of investment, and aponeurosis to broad tendons. The latter may, however, be inserted into and form a part of the former.

annulus fibrosus, may hold a tendon in place, as, for instance, the trochlea of the tendon of the superior oblique muscle of the eye.

Synovial bursæ [bursæ mucosæ].—Where there is freedom of action between muscles and tendons and the surrounding parts, there intervenes a loose connective tissue. In regions where the pressure is great or considerable friction would result were these conditions retained, there are developed special cavities with smooth surfaces and containing fluid. Most of these bursæ are developed from the intervening connective tissue at a period in embryonic life preceding muscular activity, but special bursæ may later be developed as the result of unusual pressure or muscular activity after birth. An instance of a bursa lying in a region of friction may be seen in the bursa intervening between the tendinous posterior surface of the ilio-psoas muscle and the ilio-femoral ligament. As an instance of a bursa lying in a region of intermittent pressure may be cited that between the tendon of Achilles and the calcaneus.

Most synovial bursæ intervene between a tendon and a bone, a tendon and a ligament, or between two tendons (**subtendinous bursæ mucosæ**). Others lie between two muscles, a muscle and some skeletal part, or between a muscle and a tendon (**submuscular bursæ mucosæ**); or below a fascia (**subfascial bursæ mucosæ**). Subcutaneous bursæ have been referred to in connection with the tela subcutanea (see p. 313). Most bursæ are developed near joints. The bursæ may so expand during active life that they come to communicate with other bursæ or with a neighbouring joint cavity.

Synovial sheaths [vaginæ mucosæ tendinum].—Synovial sheaths are developed about tendons where the latter are confined in osteo-fibrous canals, as in the fingers. The wall of the canal and the enclosed tendon, or tendons, are each covered by a smooth membrane which at the extremities of the canal is reflected from the wall to the tendon. Between the membrane covering the tendon and that lining the canal is a synovial cavity. An interesting feature of these tendon-sheaths is the presence of **mesotendons,** delicate bands of vascular connective tissue which run in places from the osseous groove to the tendon and carry blood-vessels and nerves.

Trochleæ.—Where a tendon passes at an angle about a bone, the tissue in the groove in which the tendon runs frequently is composed of hyaline cartilage instead of bone. An example may be seen in the trochlear process of the calcaneus.

Nerves.—To each muscle of the body a nerve containing motor and sensory fibres is distributed. A few muscles receive two or more nerves. Sherrington has estimated that in the muscle-nerves of the cat two-fifths of the fibres are sensory and three-fifths motor.

The muscles of the head and in part those of the neck are supplied by branches of the cranial nerves. The intrinsic muscles of the neck, back, thorax, and abdomen are supplied by branches which arise fairly directly from the spinal nerves. The muscles of the limbs are supplied by branches from nerve-trunks which arise from plexuses formed by the spinal nerves in the regions near which the limbs are attached.

The main nerve-trunks lie beneath the superficial muscles. They usually run in the intermuscular septa which separate the deeper groups of muscles from one another and from the superficial muscles. The nerve-branches which enter a given muscle usually pass in where the larger intramuscular septa approach the surface of the muscle, and then ramify through the perimysium internum, the smaller branches being distributed in the finer layers of connective tissue which surround and separate the primary muscle fibre-bundles, to the constituent muscle-fibres of which terminal branches are given. Special sensory end organs are distributed chiefly in the large intramuscular septa, in the tendons and in the muscles near the tendons. Simple sensory endings are found on the muscle fibres.

The size of a nerve supplying a muscle is not proportional to the size of the latter, but rather to the complexity of movements in which the muscle plays a part.

Muscles receive their nerve supply early in development. During later development the muscle may wander a considerable distance from its place of origin and carry its nerve with it. The diaphragm, innervated by cervical nerves, is a good example.

The distribution of the motor nerves varies according to the architecture of the muscle, but in general it appears that the nerves are so distributed as to carry the main branches of distribution most directly to the middle of the constituent fibre-bundles. This is seen most clearly in muscles with comparatively short fibre-bundles, where the individual muscle-fibres run nearly or quite the entire distance from tendon to tendon (fig. 338 a, c, d, e, g, h, and i). When the distance is long, a marked plexiform arrangement is found (fig. 338, b and f). To each muscle

fibre there is distributed a terminal nerve-fibre which passes through the sarcolemma and ends in a motor end organ (muscle plate). Occasionally there are two such nerve-fibres to one muscle-fibre.

Vessels.—The muscles are richly supplied with blood. In many instances the larger blood-vessels accompany the larger nerve-trunks as they enter the muscle, and their primary branches are distributed in the larger intramuscular septa. Often, however, the main blood-vessels approach a muscle from a direction different from that taken by the nerves. Each muscle has, however, its own blood supply. There is little anastomosis between the blood-vessels of a muscle and those of a neighbouring structure, but the anastomosis between the vessels within the muscle is exceedingly rich. Veins, as a rule, accompany all but the smallest arteries within the muscle. The veins are richly supplied with valves, so that muscle contraction promotes the flow of blood through the muscle. Rich capillary plexuses surround the muscle-fibres. The capillaries are of unusually small diameter.

During contraction, the blood is forced from the muscles; during expansion it rushes in through dilated arteries which furnish five or six times as much blood to muscles during exercise as that supplied to them during rest.

The connective-tissue sheaths, the larger intramuscular septa, and the tendons of muscles are richly supplied with lymphatics. There are no lymphatics within the muscle bundles or in small muscles.

Nomenclature.—The names of the various muscles and their classification are less satisfactory than is desirable. The muscular system was first carefully studied in the human body, and names based sometimes upon the shape, structure, size, or position, at other times upon the supposed function or other associated facts, were applied to the muscles found in various regions. Sometimes two or more names were applied to a muscle to indicate several of these factors. Thus *trapezius* and *triangularis* indicate the shape of the corresponding muscles; *biceps* or *triceps* indicates the origin by two or three heads; *rectus*, *obliquus*, and *transversus* represent the direction taken by a muscle or its constituent fibre-bundles; *magnus* and *minimus* indicate size; *sublimis* (superficial) and *profundus* (deep) represent the relative positions occupied; *sterno-cleido-mastoid* indicates structures to which the muscle is attached; *flexor* and *extensor* indicate function; and *sartorius* indicates that the corresponding muscle was supposed to be of use to tailors.

Since careful study has been devoted to the comparative anatomy of the muscles in various vertebrates, it has become apparent that a simple and more consistent nomenclature applicable to corresponding muscles found in various animals would be of great value. A satisfactory nomenclature of this sort has not, however, as yet been devised and adopted in comparative anatomy, and the established usage of the terms now familiarly applied to the muscles of the human body makes it seem improbable that even if such a system were devised for comparative anatomy it could be brought into extensive use in human anatomy. For many of the muscles in the human body various synonyms have been in use in different countries. The Anatomical Congress assembled at Basel in 1895, to simplify the nomenclature of human anatomy, adopted in large part the terms in familiar use in England and America. In the following pages the terms approved by the Congress will be employed, but where they differ materially from those previously in use, the synonym will be given in parentheses.

Classification.—The muscles are usually treated strictly according to the region of the body in which they are found. This method of consideration is still of value in a dissector's guide and in text-books of topographical anatomy. But in studying the muscles scientifically it is of importance also to consider them in their more fundamental genetic relationships to one another and to the nervous system. Embryology and comparative anatomy have proved of the greatest value in revealing these relationships. Studies of this nature have revealed well-marked relationships in the adult human musculature which are of practical as well as scientific importance The voluntary musculature may be broadly divided into that of the skeletal axis, the limbs, and the visceral orifices. The musculature of each of these divisions has a different and in general simpler form in the lower than in the higher vertebrates, and in the embryos of the higher vertebrates than in the adult. The musculature of the spinal region of the body axis of fishes, the tailed amphibia, and all vertebrate embryos is metamerically segmented; that is, it is divided along the axis of the body into a series of components corresponding with the segmentation of the vertebral column. Although marked alterations take place in the subsequent ontogenetic differentiation in higher vertebrates, traces of this primitive segmentation are still to be found in the adult; in man, for instance, in the intercostal muscles and the segments of the rectus abdominis. In the region of the head conditions are complex, owing to the concurrent presence of muscles which primitively correspond in nature with the segmental spinal musculature, and muscles non-segmental in character, which surround the visceral orfices. This also is true of the anus and external genitalia, where, however, the conditions are simpler. Embryology and comparative anatomy have done much to clear up puzzling features in both regions.

The muscles of the limbs are metamerically arranged in no adult vertebrate. In some of the lower forms a series of axial muscle segments, myotomes, furnishes material from which the

musculature of the limbs is differentiated. In the mammals this appears not to be the case, and the muscles are differentiated from the non-segmental tissue of the limb-buds.

Where mammalian musculature is primitively segmental, each segment becomes associated with a corresponding spinal nerve or, in the head, with a nerve which corresponds in series with a spinal nerve. Even when subsequent differentiation brings about marked alterations in the axial musculature, the nerves maintain to a considerable degree a segmental distribution.

Into each of the limbs, where the intrinsic musculature is at no time segmental, there extends during embryonic development a series of segmental spinal nerves, so that in them, as in the region of the body axis, a certain segmentation in the nerve-supply can be made out in the adult. That part of the limb nearest the head in early embryonic development has its muscles supplied by the most cranial, that part nearest the caudal extremity of the body by the most caudal, of the nerves which supply the limb musculature. There is here, however, considerable overlapping of the segmental areas.

Variation.—In man some variation in the arrangement of the muscles is met with in every individual, and often marked deviations from the normal conditions are found. The muscles vary in their mode of origin or insertion, and in the extent to which muscles of a given group are fused with one another or to which the chief parts of a complex muscle are isolated from one another. Some muscles, like the palmaris longus and the plantaris, are frequently entirely absent, and other muscles generally absent are frequently present.

In addition to these frequent variations there are others so rare that many authors prefer to speak of them as anomalies rather than variations. Sometimes muscles may be found doubled by longitudinal division, or two or more muscles normally present may be fused into a single indivisible muscle. Occasionally there occur muscles constantly present in some of the lower animals, but normally not met with in the human body (anomalies of reversion or of convergence). In such instances the muscle may be normally represented by a tendon or fascia. At times the anomalies are supposed to be not a reversion to an ancestral condition, but a distinct step in advance. This, however, is difficult to prove. At other times no phylogenetic relation is apparent, and the anomaly is looked upon as a monstrous sport or as the result of some pathological condition.

The nerve-supply of the muscles is of value in the study of muscle variations. There is, however, not infrequent variation in the nerves with relation to the supply of the muscles.

Physiology.—From the standpoint of morphology the muscles are grouped according to their intimate relations to one another and to the peripheral nerves, relations, as noted above, that are made more clear by a study of comparative anatomy and embryology. From the physiological aspect a different grouping of the muscles is required, because muscles belonging morphologically in one group may have different physiological functions in the animal body. The chief features of the mechanical action of muscles may be briefly considered here.

Most muscles act on the bones as levers. In physics three types of levers are recognised In levers of the first type (fig. 339, I) the fulcrum (F) lies between the place where power (P) is exerted on the lever and the point of resistance or load (L). Levers of this kind are frequently met with in the body. A good example is seen in the attachment of the skull to the vertebral column. The fulcrum lies at the region of attachment; the weight of the skull tends to bend the head forward, while the force exerted by the dorsal muscles of the neck serve to keep the head upright or to bend it back.

In levers of the second class (fig. 339 II) the point on which power is exerted moves through a greater distance than the point of resistance. Speed of movement is thus sacrificed to power. Levers of this type are exceedingly rare in the animal body. An example in the human body is the foot when the body is raised on the toes.

In levers of the third class (fig. 339, III) the point on which force is exerted moves a less distance than the point of resistance. Power is thus sacrificed to speed. This is the common form of leverage found in the body. A good example is found in the action of the muscles which flex the forearm on the arm. The region in which the biceps and brachialis are attached is but a short distance from the elbow-joint or fulcrum, while the hand may be looked upon as the region of resistance to the force exerted. A movement of the point P through a short distance will cause L to move through a great distance.

The more the angle between a muscle or its tendon and the bone on which it acts approaches a right angle, the greater is the power of movement exerted by the muscle. The arm in fig. 339, III, is in the position of greatest advantage for the action of the biceps on the forearm. All boys know that it is easier to 'chin' oneself after the arm is partly bent than when hanging

straight from a bar. Many of the muscles run nearly parallel with the parts on which they act, but the tendons before their attachment are usually either carried over a bony prominence or some fascia or ligament acts as a pulley so that the tendon is inserted at an oblique angle. At other times a process for the attachment of the tendon projects from the bone and causes the force of the contracting muscle to be more advantageously exerted on the bone. It may, of course, readily be seen that the greater the distance of the attachment of a muscle from the joint over which it acts, the greater will be the power exerted by the muscle.

In considering the movements of the body, it is convenient to recognise two groups, simple and complex. To the former, which alone can be considered in a text-book of anatomy, belong such movements as flexion, extension, adduction, rotation, etc., while to the latter belong those associated movements which give rise to changes in the positions of the body as a whole or of extensive regions of the body.

In **flexion** the extremities of the trunk or limbs or special portions of these regions are bent near to one another; in **extension** the reverse movement is brought about. The parts are straightened or even bent beyond the straight position (over-extension).

FIG. 339.—THREE DIAGRAMS (AFTER TESTUT) TO ILLUSTRATE DIFFERENT TYPES OF LEVERS IN THEIR RELATIONS TO THE MECHANICAL ACTION OF THE MUSCLES.

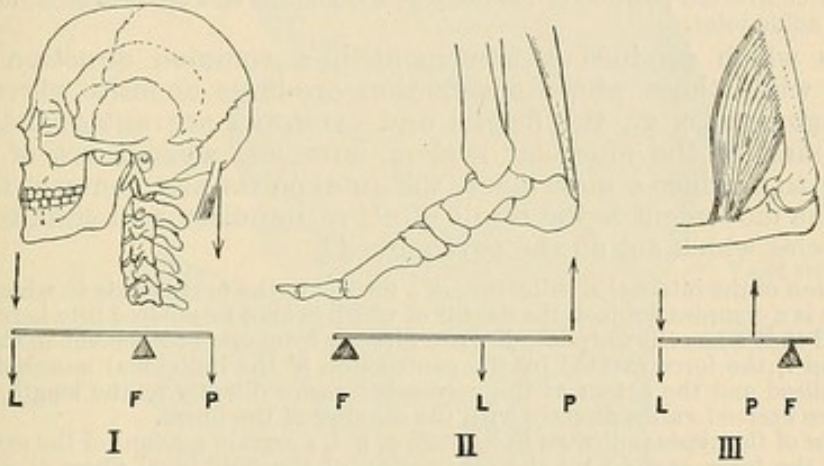

In **abduction** transverse movements are made, a part being bent away from the median line of the body or limb; in **adduction** the reverse movement is brought about.

In **rotation** a part is turned on its longitudinal axis. The rotation of the femur at the hip-joint is called medial rotation when the toes are turned medialward, lateral rotation when the toes are turned lateralward. Rotation at the shoulder-joint is called medial when the thumb is turned forward and medialward toward the body, lateral when the reverse movement takes place. These movements are also carried out at the elbow-joint, but here medial rotation is called **pronation**, lateral rotation, **supination**. Fick prefers these terms also for the rotation at other joints as at the shoulder, hip and knee.

At the shoulder-joint the swinging of the arm toward the back is called extension; toward the front, flexion; and from the side, abduction. Moving the arm toward the mid-dorsal or mid-ventral line is called adduction.

Taking the body as a whole the musculature may be divided into two main divisions, an *expander division* and a *contractor division*. In general the extensors, abductors and lateral rotators expand, the flexors, adductors and medial rotators contract.

In the most expanded condition the head and spine are extended or even slightly hyper-extended (flexed dorsally), and the limbs project laterally from the body with the backs of the hands and feet facing dorsalward, the palms and soles ventralward, and the digits spread out. In the fully formed human body it is not possible to put the lower extremity in the completely expanded position, although it is in this position early in embryonic development. As development proceeds the lower extremity is adducted and rotated medialward and the girdle is so fixed that full abduction becomes no longer possible. In many of the lower vertebrates full abduction is possible throughout life in the lower extremities just as it is throughout life in the upper extremities in man. Full extension of the spinal column in man is also hindered in the thoracic region by the thorax, and in the sacro-coccygeal region by the osseous union of the vertebræ with one another as well as by the attachment of the hip girdles. The lumbar region in man is in a condition of permanent hyper-extension.

In the fully contracted condition the head and spinal column are strongly flexed, and the digits are adducted, the various segments of the limbs are flexed and the limbs are adducted, flexed and rotated medialward toward the middle of the trunk. The body approaches a ball in form. It is the position taken by a gymnast when turning a somerset in the air, and is in marked contrast to the fully expanded condition which would be assumed could man fly like a bat or glide like a flying squirrel.

In general, the muscles which tend to put the body or a part of the body into the expanded position form a distinct group as contrasted with those which tend to put the body into the contracted position. The chief musculature which extends the head and trunk lies dorso-lateral to the spinal column and is supplied by the dorsal divisions of the spinal nerves. The chief musculature which flexes the head and trunk lies ventro-lateral to the spinal column and is supplied by ventro-lateral divisions of the spinal nerves. The chief muscles which abduct, extend and rotate the limbs lateralward arise during embryonic development on the dorsal sides of the limb buds and are innervated by branches from the dorsal sides of the brachial and lumbo-sacral nerve plexus. The chief muscles which flex, adduct and rotate the limbs medialward arise on the ventral sides of the limb buds and are supplied by nerves which arise from the ventral sides of the limb plexuses. To these general rules there are some exceptions, the most marked of which is at the hip-joint where rotation of the girdle has brought about a condition in which the primitive action of the flexor and extensor groups is partly reversed. The chief flexors (the ilio-psoas and rectus femoris) belong to the dorsal division and some of the chief extensors (the hamstring muscles) belong to the ventral division. At the ankle-joint the exception is more apparent than real. What is usually called flexion at the ankle-joint is really hyper-extension and the reverse movement is the nearest we can come to real flexion. In the extremely contracted position of the body as a whole the feet are extended (flexed plantarward) at the ankle-joint.

Muscles which produce a movement in a common direction are called **synergists,** while those whose contraction produces opposite movements are called **antagonists;** e. g., the flexors and extensors are antagonists. In the actual working of the muscular system, however, when a set of muscles is contracting to produce a movement, the antagonists also contract to a certain degree. The movement is the result of nerve impulses sent simultaneously to all the muscles which act on the part moved.

The relation of the internal architecture of a muscle to the movements to which its contraction gives rise is a complex subject, the details of which cannot be entered into here. In general it may be said that when the fibre-bundles run directly from one attachment to the other, as in fig. 338, a and f, the force exerted by the contraction of the individual muscle-fibres is most efficiently utilised and the extent of the movement varies directly as the length of the fibres, while the force exerted varies directly with the number of the fibres.

In muscles of the types indicated in fig. 338, g, h, i, a certain amount of the extent of movement and of the force exerted by the contraction of the individual fibres is not effectively exerted on the parts moved by the muscles, as may be seen by applying to this action the laws of the parallelogram of forces. In such muscles, however, the great number of short muscle-fibres composing them makes possible the exertion of great power with some loss of speed of contraction in the muscle as a whole.

The direction of the movements which result from muscular contraction is in large part determined by the shape of the articular surfaces, none of which are to be looked upon as simple fulcra, but instead, during a given movement, the fulcrum shifts from one region to another of the joint.

In different muscles the extent of contraction of the constituent fibre-bundles during activity varies considerably. While usually the length of the contracted fibre-bundles is half that of those in the extended state, the amount of shortening in some muscles is only 25 to 35 per cent.

Functional activity is necessary for the full development or for the maintenance of development in muscles. Muscles atrophy if their nerve supply is injured or if they are passively prevented from contracting.

Order of treatment.—The muscles and fasciæ are here treated in the following order:—(1) those of the head and neck and shoulder girdle (p. 323); (2) those of the upper extremity (p. 360); (3) those of the back (p. 410); (4) those of the thorax and abdomen (p. 422); (5) those of the pelvic outlet (p. 439); (6) those of the lower extremity (p. 452). The reason for taking up the musculature in the order named is, that during embryonic development musculature belonging primitively to the head comes to overlap that of the neck; that of the neck spreads over the region of the back and thorax, and becomes attached to the shoulder girdle; that of the arm extends over the region of the thorax, abdomen, and back; that of the back partially over the region of the thorax; while that of the abdomen enters into intimate relation with the pelvic girdle. So far as practicable the musculature of these various regions will be taken up according to fundamental morphological relationships.

Since a morphological grouping of the muscles does not accord perfectly with a physiological grouping, there is given at the end of this section a table showing what muscles are concerned in performing the simpler voluntary movements.

The topographical relations of the muscles in various regions of the body are illustrated in the series of cross-sections given for each region.

Tables illustrating the relations of the central nervous system and the peripheral nerves to the muscles are given in the section on the nervous system (Section VI).

FIG. 340.—HUMAN EMBRYO (LR) 42 MM. LONG. (After His.)

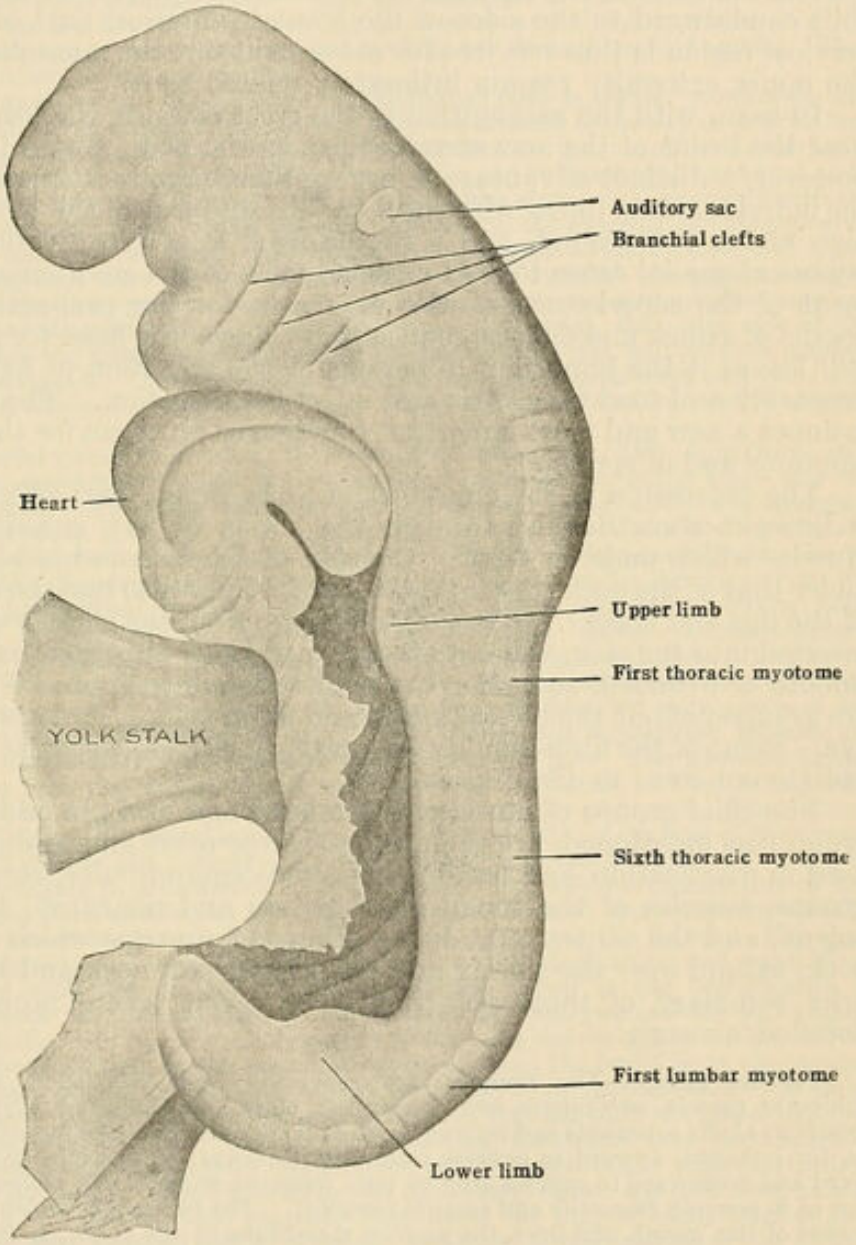

I. MUSCULATURE OF THE HEAD, NECK AND SHOULDER GIRDLE

PHYSIOLOGICAL AND MORPHOLOGICAL ASPECTS

The head, situated at the anterior end of the trunk in bilaterally symmetrical animals, is primitively that part of the body first brought into contact with new surroundings as the animal moves forward. We therefore find developed here the most highly differentiated organs of special sense, those of vision, hearing, and smell, through which the animal is put in touch with an environment more or less removed from immediate contact with the body. In connection with these

organs of special sense, the brain is developed. In most animals the head also is the chief organ for the prehension of food and for attack and defense. The neck is a part of the trunk differentiated to give freedom to the movements of the head. The forelimbs, relatively unimportant as the forefins in the fishes, become important organs of locomotion in the land animals. In the fishes there is no true neck, but the forefins are developed at the sides of the cervical part of the trunk. In the higher vertebrates the forelimbs are also first differentiated at the sides of the cervical region (fig. 340) but, as embryonic development goes on, they shift caudalward to the sides of the cranial (anterior) part of the thorax. The cervical region is thus left free for movement but the musculature and nerves of the upper extremity remain intimately related to it.

In man, with the assumption of the erect posture, the head no longer has to bear the brunt of the new surroundings as the body moves forward. There is, however, a distinct advantage in having those organs of special sense, which put the individual into touch with the more distant parts of the environment, situated high above the ground, and a motile neck is of great value in directing the organs of special sense toward various parts of the environment. The development of the superior extremities as organs for the prehension of food and as organs of attack and defense reduces the value of the head for these purposes, but still leaves it the important functions of the reception of food and air and the preparation of food for gastric and intestinal digestion. The head, furthermore, assumes a new and most important function as an organ for the expression of the emotions and of speech.

The expression of the emotions, such as anger, fear, affection and the like,* is brought about largely through the action of flat, subcutaneous "facialis" muscles which underlie most of the skin of the face and head and extend down under that of the neck (figs. 341 and 344). They also line the mucous membrane of the lips and cheeks. Most of them arise from the surface of the skull and are inserted into the skin, which they pull in various directions causing it to become smooth or wrinkled, according to the direction of the pull. The various muscles are grouped about the buccal, nasal and aural orifices and about the orbit of the eye. Some of the fibre-bundles are arranged so as to constrict the orifices, others radiate out so as to dilate them.

The chief groups of muscles of the head and neck, in addition to the facialis group just mentioned, are the muscles of the orbit and middle ear, the muscles used in mastication and swallowing (cranio-mandibular, supra- and infrahyoid groups, muscles of the tongue, soft palate and pharynx), the muscles of the larynx, and the ventral and dorsal groups of muscles which lie in the region of neck, extend over the thorax and move the head, neck and shoulder girdle. A brief summary of these groups will be given before proceeding to a more detailed account.

Facialis group.—The muscles are especially well developed about the mouth, a sphincter muscle (*orbicularis oris*) serving to close, the radiating muscles to open the lips (*quadratus labii superioris* and *inferioris*), to pull the corners of the mouth in various directions, as, for instance, upward to express bitterness (*caninus*) or pleasure (*zygomaticus*), or lateralward and downward to express grief or pain (*risorius, triangularis, platysma*) or to protrude the lips as in pouting (*mentalis* and *incisive* muscles). The *buccinator*, which radiates out from the corner of the mouth and lines the mucous membrane of the cheek, is used in mastication and whistling.

About the **orbit** and in the **eyelids** a circular musculature (*orbicularis oculi*) is broadly developed. It is used to close the eyes, and to contract the skin about the orbit. Associated with the orbicularis are muscles which produce perpendicular furrows in the skin of the forehead above the nose (*procerus, corrugator*). The skin is drawn upward from the orbit and horizontal furrows are caused in the skin of the forehead by muscles attached to the **scalp** (epicranius). Two of these muscles, the *occipitales*, arise one on each side from the occipital bone and are attached to an aponeurosis which lies beneath the scalp to which it is firmly united. Two of the muscles, the *frontales*, extend one on each side from this aponeurosis to the skin above the eyebrows.

About the **nasal orifices** there are weak constrictors (*alar part* of the *nasalis, depressor alæ nasi*) and dilators (*dilator naris anterior* and *posterior, transverse part* of the *nasalis, angular head* of the *quadratus labii superioris*). From the **ear** (auricle) three flat muscles radiate, one backward (*auricularis posterior*), one upward (*auricularis superior*) and one forward (*auricularis anterior*). These muscles are seldom functionally developed. They pull the auricle in their respective directions. They may be looked upon as (primitively) dilators of the aural orifice. On the cartilage of the auricle are several rudimentary "intrinsic" muscles which may be looked upon as remnants of a constrictor of this orifice.

*See Darwin: The Expression of the Emotions in Man and Animals.

In the **orbital cavity** there are six muscles which are attached to and move the eyeball and one muscle (the *levator palpebræ superioris*) which extends into and raises the upper lid (fig. 341). Of the muscles which move the eyeball five arise like the levator of the lid, from the back of the orbit. Four of these, the *rectus muscles*, are inserted respectively into the superior, inferior, medial and lateral sides of the eyeball and direct the pupil upward, downward, medialward and lateralward. One, the *superior oblique*, sends a tendon through a loop at the upper, front part of the nasal side of the orbit and thence to the upper surface of the eyeball. Another muscle, the *inferior oblique*, arises from the nasal side of the front of the lower part of the orbit and is attached to the lower part of the eyeball. The oblique muscles prevent the rectus muscles from rotating the eyeball. These muscles are supplied by the third, fourth and sixth cranial nerves. They are described in the section on the eye, p. 1067. In the **middle ear** are two small muscles (the *tensor tympani* and the *stapedius*) attached respectively to the malleus and stapes and supplied by fifth and seventh cranial nerves. They are described in the section on the ear, p. 1091.

Mastication and swallowing.—The complex musculature used in biting, masticating and swallowing food is used also in speech in conjunction with the muscles of the larynx and the lips. The two movable bones of the skull concerned with these functions are the mandible and the hyoid bone. The mandible articulates with the skull on each side, just in front of the external auditory meatus. The hyoid bone is connected on each side by the stylo-hyoid ligament with the styloid process of the temporal bone, which descends just behind the external auditory meatus. A powerful group of muscles, the **cranio-mandibular** *muscles* (figs. 344, 345, 346, 347 c), or muscles of mastication, arise from the temporal fossa (*temporal* muscle), the zygomatic arch (*masseter* muscle) and the pterygoid process (*external* and *internal pterygoid* muscles) and are inserted into the coronoid process of the mandible (*temporal* muscle), the outer side of the ramus (*masseter* muscle), the inner side of the ramus (*internal* pterygoid), and into the condyle of the jaw (*external pterygoid*). These muscles raise the jaw, move it forward and from side to side, and are used in biting and chewing the food. They are innervated by the fifth cranial (masticator) nerve.

Another less powerful group of muscles, the **suprahyoid** group (fig. 348), is divisible into two subdivisions, **hyo-mandibular** which extends in front between the hyoid bone and the ramus of the jaw (anterior belly of the *digastric*, *genio-hyoid*, *mylo-hyoid*) and a **hyo-temporal** group which extends between the hyoid bone and the temporal bone back of the external auditory meatus (*stylo-hyoid*, posterior belly of the *digastric*). Two of the hyo-mandibular muscles (the anterior belly of the digastric and the mylo-hyoid) are innervated by the trigeminal; the genio-hyoid by the hypoglossal nerve. The two hyo-temporal muscles (posterior belly of the digastric and stylo-hyoid) are innervated by the facial nerve. Morphologically therefore, as indicated by this innervation, the muscles of this group are diverse. Physiologically they are closely united. The group, acting as a whole, elevates the hyoid bone and with this the larynx and the tongue. If, however, the hyoid bone be fixed by contraction of the neck muscles (infrahyoid muscles) attached to its lower border, the suprahyoid muscles act as antagonists of the cranio-mandibular muscles and depress the jaw. The hyo-mandibular muscles form, together with the tongue, the muscular floor of the mouth. When acting with the hyo-temporal muscles they help the tongue to pass food into the pharynx. When acting alone the hyo-mandibular muscles draw forward the hyoid bone and with it the base of the tongue and the larynx and thus open the passage from the pharynx into the œsophagus. The two hyo-temporal muscles, acting in conjunction with the middle and inferior constrictors of the pharynx, draw the hyoid bone and larynx backward, as well as upward, and thus constrict the pharynx while giving free passage for air from the naso-pharynx into the larynx. The chief functions of the suprahyoid group are, therefore, to play a part in deglutition and respiration.

Closely associated with the muscles of the suprahyoid group in the performance of these important functions are the muscles of the tongue, the pharynx and the soft palate. The bulk of the **tongue** (fig. 349) is made up of muscles which have their origin on each side from the inner surface of the front part of the mandible (*genio-glossus*), the hyoid bone (*hyo-glossus* and *chondro-glossus*) and the styloid process of the temporal bone (*stylo-glossus*). Muscles also connect the tongue with the palate (*glosso-palatinus*) and with the pharynx (*glosso-pharyngeus*). These muscles, together with intrinsic longitudinal, transverse and perpendicular fibre-bundles, enable the tongue to perform the complex activities associated with mastication and swallowing and with speech. During mastication the tongue passes the food from side to side between the teeth. When the food has been masticated the tongue forms a bolus of it and then this is passed into the pharynx by a sudden elevation of the dorsum of the tongue produced in part by the muscles of the tongue, in part by the suprahyoid group of muscles. The muscles of the tongue are described on p. 345.

The **pharynx** is the dilated upper part of the alimentary canal into which open the Eustachian tubes, the nasal passages, the mouth and the larynx. The walls of the side and back of the pharynx are composed mainly of muscular tissue. The chief muscles are three "**constrictor**" muscles on each side, a *superior*, a *middle* and an *inferior*, and an elevator and dilator, the *stylo-pharyngeus* (fig. 894). The three constrictor muscles are attached to the median raphe* which extends in front of the spinal column from the base of the occipital bone to the sixth cervical vertebra. The *superior constrictor* muscle is attached to the pterygoid process, the pterygo-mandibular ligament, the mandible and the side of the root of the tongue (fig. 343); the *middle constrictor* to the hyoid bone; and the *inferior constrictor* to the larynx. These muscles constrict the pharyngeal orifice and thus force food into the œsophagus. The *stylo-pharyngeal* muscle, which extends from the styloid process into the lateral wall of the pharynx, serves to

*The attachments to the raphe are usually spoken of as the insertions, those to the bones in front as the origins of these muscles. The raphe is, however, a more fixed structure than most of the structures to which the constrictors are attached in front.

elevate and dilate the pharynx and elevate the larynx. The muscles of the pharynx are described on page 1134.

The orifices of the various passages into the pharynx are dilated or constricted by muscular action. The orifices of the nasal passages, the Eustachian tubes, and the mouth are controlled mainly by the musculature of the soft palate and pharynx. The orifice of the larynx is controlled by special muscles which act in conjunction with those of the suprahyoid group, the tongue, and the pharynx.

The **soft palate** is a muscular partition which is continued backward from the hard palate between the buccal cavity and the naso-pharyngeal orifice and then bends downward between the back part of the mouth and the nasal part of the pharynx, terminating in a median projection, the uvula. Above, on each side, back of the fold of tissue (*plica salpingo-palatinus*) which descends from the ventral border of the orifice of the Eustachian tube and which marks laterally the passage from the nose into the pharynx, there is a muscle, the *levator veli palatini* (fig. 343). This arises from the petrous portion of the temporal bone and from the Eustachian tube descends to the middle of the side of the soft palate and then spreads out broadly on its dorsal side. The muscle from each side interdigitates to some extent with that of the other side. These muscles raise the soft palate toward the upper part of the posterior wall of the naso-pharynx and thus shut off the nose from the buccal portion of the pharynx during deglutition. The sides of this portion of the pharynx are, meanwhile, constricted by the superior constrictors of the pharynx and by the pharyno-palatinus muscles described below. Contraction of the levator veli palatini tends to cause folds of tissue to close firmly the opening of the Eustachian tube. This is counteracted by the *tensor veli palatini* muscles (fig. 343). One of these arises on each side from the pterygoid region of the sphenoid bone, and is inserted into the anterior part of the soft palate by a tendon which passes beneath the hamular process of the pterygoid process. Contraction of this pair of muscles flattens the anterior part of the soft palate and exerts a traction which dilates the orifice of the Eustachian tube. Most authorities state that the Eustachian tube is thus opened each time we swallow. As air is admitted into the middle ear the tensor tympani muscle contracts so as to prevent too sudden an effect on the ear drum (Jonnesco.)

Dorsal to the fibres of the elevator of the palate in the soft palate next the median line on each side there extends from the hard palate into the uvula a small muscle, the *muscle of the uvula*, which lifts the tip of this and shortens the soft palate from front to back thus enlarging the opening from the mouth into the pharynx. On each side of the uvula the posterior edge of the soft palate is continued backward and downward into a fold, the *arcus pharyngo-palatinus*, which contains a muscle, the *pharyngo-palatinus* (fig. 865). This arises from the soft palate, passes downward and backward on the inner side of the lateral wall of the pharynx and divides into two fasciculi, one of which is attached to the larynx, the other to the median raphe. The muscle constricts the pharynx at the junction between the nasal and buccal portions and elevates the larynx. As the bolus of food is passed from the dorsum of the tongue into the pharynx the bucco-pharyngeal opening is dilated by the contraction of the elevators of the palate and uvular muscles and the opening into the naso-pharynx is closed not only by the soft palate being raised against the posterior wall of the naso-pharynx but also by the lateral folds raised on each side by the pharyngo-palatinus against t he uvula. Meanwhile the larynx is raised by the pharyngo-palatinus and the stylo-pharyngeus, as well as by the suprahyoid muscles, and carried forward by the hyo-mandibular subdivision of the latter muscles so that the opening from the pharynx into the œsophagus is dilated for the passage of food. At the same time the opening into the larynx is constricted from above, the larynx being carried forward beneath the tongue so that the epiglottis slants somewhat backward. This backward slant is aided by the constriction of the thyreo-hyoid muscle which raises the thyreoid cartilage toward the hyoid bone and by the stylo-glossus muscle which pulls the tongue backward over the larynx. The opening into the larynx is constricted at the sides and behind by the contraction of muscles which run in the aryepiglottic folds and by the thyreo-arytenoid and transverse arytenoid muscles. At the end of deglutition the larynx is pulled back from beneath the base of the tongue by the middle and inferior constrictors of the pharynx and the opening is again dilated. The buccal cavity may be shut off from the pharynx by the action of the muscles which pass in the glosso-palatal folds from the soft palate to the mouth in front of the tonsils. These *glosso-palatal* muscles elevate the folds in which they lie, depress the soft palate, and, if the dorsum of the tongue be raised, shut off the buccal cavity. The muscles of the soft palate are described on p. 1134.

The uvular muscle, the levator veli palaini, the glosso-palatinus and the pharyngo-palatinus muscles are supplied by the pharyngeal plexus. The tensor veli palatini is supplied by the mandibular division of the fifth nerve. The pharyngeal muscles are supplied by the glosso-pharyngeal, the vagus, and the spinal accessory cranial nerves.

The **larynx** lies in the neck, but since the intrinsic muscles of the larynx from the standpoint of embryology and comparative anatomy belong with the musculature of the head, it is convenient to refer to them briefly here rather than to treat of them with the intrinsic muscles of the neck. A full description of the laryngeal muscles is given in the section on the larynx (fig. 981). They develop from tissue which corresponds with that which in fishes gives rise to the muscles of the gills and are innervated by the nerves which in the fishes innervate the gills, the tenth pair (vagus) of cranial nerves. The movements of the laryngeal cartilages are such as to approximate or draw apart the vocal cords and to loosen or make them tense. The approximation of the vocal cords is produced by the rotation medialward of the vocal processes of the arytenoid cartilages brought about by the *lateral crico-arytenoid* and *transverse arytenoid* muscles. The drawing apart of the vocal cords is produced by the *posterior crico-arytenoids*. The vocal cords are made long, thin and tense by the *crico-thyreoid*. They are shortened and thickened by the *thyreo-arytenoid* (externus) and the *vocalis*. The inferior laryngeal branch of

the vagus supplies all the muscles but the crico-thyreoid. This is supplied by the superior laryngeal branch of the vagus.

Metamerism.—The muscles thus far considered are essentially visceral muscles, although all are composed of striated muscle cells and all are more or less directly under the control of the will. From the morphological standpoint the muscles of the orbit, the tensor tympani, the muscles of mastication, the hyo-mandibular muscles and the muscles of the tongue have been grouped with the ordinary voluntary skeletal muscles while the facialis musculature, the stapedius, the hyo-temporal muscles and the muscles of the soft palate, pharynx and larynx are looked upon as of a more purely visceral origin. A primitive characteristic of the voluntary skeletal muscles is metameric segmentation. This is maintained through life in the trunk musculature of fishes and of tailed amphibia and is passed through as a temporary stage in all the higher vertebrates. The embryonic segmented muscles are called myotomes (see fig. 340). In some regions the metamerism is retained throughout life even in the higher forms, as, for instance, in the intercostal muscles and the intertransverse muscles. But for the most part the primitive metamerism is so lost during the differentiation of the definitive trunk musculature that only traces of it remain here and there as, for instance, in the segments of the rectus abdominis muscle. In the lower forms the myotomes give rise during embryonic development to material utilized in the formation of the limb musculature, but even in the fishes all traces of trunk metamerism are lost in the differentiated limb musculature and in the higher forms, as in man, the limb musculature appears to differentiate directly from the unsegmented tissue in the limb-buds. In the head the musculature is differentiated directly, as in the limbs, without undergoing a preliminary metameric or myotomic stage. Attempts have been made to show that in primitive forms the cranial voluntary skeletal musculature, in the narrower morphological sense mentioned above, passes through a metameric stage comparable with the myotomic metamerism of the trunk. This attempt has been partially successful as regards the development of the muscles of the eye in some of the lower forms. There is also good evidence that the spinal region of the skull and associated structures represent a part of the metameric trunk fused with a more primitive head so that the musculature of the tongue and the hyo-mandibular muscles belongs morphologically with the primitively metameric trunk musculature. The rest of the cranial musculature gives little evidence of a primitive metameric segmentation and hence is probably to be classed morphologically with the unsegmented visceral musculature.

Of the **muscles of the neck,** the most superficial, the **platysma** (fig. 341), is a subcutaneous muscle belonging to the facialis group of the head from which it grows down during embryonic development. It is supplied by the seventh cranial (facial) nerve. It extends from the corner of the mouth and the side of the mandible over the clavicle. It depresses the corner of the mouth, wrinkles up the skin of the neck and aids the circulation by relieving pressure on the underlying veins.

Beneath the platysma there lies a layer composed of two flat muscles (fig. 344) which extend from the base of the skull behind the ear to the shoulder girdle. One of these muscles, the **sterno-cleido-mastoid,** arises in front from the sternum and clavicle and is inserted into the mastoid process of the temporal bone and the skull behind this. The other, the **trapezius,** arises from the base of the skull, and from the ligamentum nuchæ and vertebral spines of the cervical and thoracic regions, and is inserted into the spine of the scapula, the acromion and the lateral third of the clavicle. These two muscles constitute the **superficial shoulder-girdle musculature.** They extend the head, bend it toward the same side and rotate it toward the opposite side. The sterno-cleido-mastoid and the upper part of the trapezius raise the shoulder girdle and thorax and hence are of use in forced inspiration. The trapezius draws the scapula toward the spine and rotates the inferior angle of the scapula lateralward. The lower part of the trapezius acting alone draws the scapula downward and dorsalward while rotating the inferior angle lateralward. The trapezius is therefore used when the arm is raised high or carried backward. The two muscles of this group are innervated partly by the spinal accessory, and partly by the ventral divisions of the second, third and fourth cranial nerves. They represent in part musculature which in the lower vertebrates is associated with the visceral musculature of the gills (hence the innervation by the spinal accessory, a derivative of the vagus nerve) and in part metameric musculature of the second, third, and fourth cervical segments. During embryonic development this musculature therefore spreads out widely from its origin, the upper cervical region. The lower part of the trapezius varies greatly in the extent of its development caudalward. It may reach only half way down the thoracic region or it may extend into the lumbar region. The deeper musculature of the neck is derived from the cervical myotomes.

The primitive segmental musculature of the neck, like that of the whole trunk, becomes divided at an early embryonic stage into two divisions, a dorsal, supplied by the dorsal divisions of the spinal nerves, and a ventro-lateral supplied by the ventral divisions. The trapezius, although it covers the intrinsic dorsal musculature of the cervical region, insofar as it is of cervical origin, belongs to the ventro-lateral musculature and is derived, apparently, from the first three cervical myotomes. There is also a deeper layer of muscles attached to the shoulder girdle which arise from the ventro-lateral divisions of the lower five or six cervical myotomes but which, with one exception, the *levator scapulæ* (fig. 353), wander over the thorax during embryonic development. This group is described below as the deep shoulder-girdle musculature. The rest of the muscles derived from the ventro-lateral divisions of the cervical myotomes are divisible into three groups, the infra-hyoid, the scalene and the prevertebral.

The **infra-hyoid** group lies at the front of the neck, superficial to the larynx and trachea (fig. 348), and is composed of four flat muscles, the *sterno-hyoid, sterno-thyreoid, thyreo-hyoid* and *omo-hyoid* (scapulo-hyoid), the names of which indicate the origin and insertion. The chief function of this group of muscles is to depress the hyoid bone, the larynx and the associated structures. When the supra-hyoid group of muscles contracts at the same time, the infra-hyoid muscles help to depress the lower jaw, or if this in turn is fixed by the cranio-mandibular group, to flex the head. The muscles of this group are derived from the ventral portions

of the first three cervical myotomes and are innervated by the first three cervical nerves through the ansa hypoglossi. The primitive segmental origin of these muscles is frequently indicated by transverse tendons (inscriptiones tendineæ). They correspond morphologically with the rectus abdominis musculature.

The **scalene** group (fig. 352) lies at the side of the neck and extends to the first and second ribs from the transverse processes of the lower six cervical vertebræ. The muscles of this group bend the neck toward the side, or if the neck be fixed, elevate the thorax. They come from the lateral parts of the ventro-lateral divisions of the lower five cervical myotomes and are innervated by the lower five cervical nerves. They correspond morphologically with the intercostal and with the lateral abdominal musculature.

The **prevertebral** group lies back of the pharynx and œsophagus and in front of the bodies and transverse processes of the cervical vertebræ. The muscles of this group arise not only from the transverse processes and bodies of the cervical vertebræ, but also in part from the bodies of the first three thoracic vertebræ and are inserted in part into the cervical vertebræ (*longus colli*) and in part into the base of the occipital bone (*longus capitis*). This musculature flexes the neck and the head. When acting on one side it rotates the head toward the same side. It is innervated by the first six cervical nerves.

The deep shoulder-girdle musculature.—This becomes differentiated from the ventro-lateral divisions of the lower five or six cervical myotomes. Like the muscles of the superficial layer those of the deeper layer spread out widely from their origin. There are four muscles in the deeper group, all of which become attached to the dorsal border of the scapula. Of these, one, the *levator scapulæ* (fig. 353), remains in the cervical region, extending from the upper cervical transverse processes to the medial angle of the scapula. Two, the *rhomboids* (fig. 353), extend over the intrinsic dorsal musculature and are attached to the upper thoracic and lower cervical vertebral spines; while the fourth, the *serratus anterior* (fig. 354), extends over the side of the upper part of the thorax beneath the scapula and is attached to the first nine ribs. These muscles all, however, through their innervation, reveal in the adult their primitive cervical origin. They are supplied by branches from the third to the seventh cervical nerves. The levator scapulæ elevates the scapula, the rhomboid muscles retract it and the serratus anterior draws it forward. The levator and rhomboid muscles rotate the shoulder girdle so as to depress the shoulder, the serratus anterior, like the trapezius, rotates it so as to raise the shoulder. The two former muscles are an aid in extending the arm, the latter in flexing and abducting it. When the group, as a whole, contracts action is exerted on the ribs so that the group is of use in forced inspiration.

The **intrinsic dorsal musculature** of the neck, innervated by the dorsal divisions of the cervical nerves, is separated from the scalene muscles by the levator scapulæ. Dorsally it is covered by the trapezius and the rhomboid muscles. It is to be looked upon as a specialized portion of the system of intrinsic dorsal muscles which extend from the sacrum to the base of the skull on each side of the vertebral column. The primary function of this muscle system is to extend and to rotate the spine and the skull. In the thoracic region three main subdivisions may be recognised, a lateral, the *ilio-costal;* an intermediate, the *longissimus;* and a medial, the *transverse-spinal* group (fig. 381). In the cervical region these three groups may likewise be recognised and, in addition, there is a superficial group, the *splenius* (fig. 380), not represented in the lower thoracic region. The splenius arises from the upper thoracic and lower cervicla spines and is inserted into the transverse processes of the upper cervical vertebræ and into the mastoid processes of the temporal bone and the neighbouring part of the occipital. It acts with the sterno-cleido-mastoid, by which it is crossed near the head, in extending the head, bending it toward the side, but tends to rotate it toward the same side instead of toward the opposite side. Laterally beneath the splenius the *ilio-costalis cervicis* extends from the upper part of the thorax to the transverse processes of the sixth to the fourth cervical vertebræ, and the *longissimus cervicis* and *capitis* extend from the same region to the transverse processes of the mid-cervical vertebræ and to the mastoid process of the temporal bone (fig. 381). These muscles likewise extend and bend the head and neck laterally and rotate it toward the same side. Medially on each side the strong *semispinalis capitis* (fig. 381), arises from the upper thoracic and the lower cervical vertebræ, spreads out and is inserted into the squamous portion of the occipital bone. It is a powerful extensor of the head. Beneath it numerous fasciculi extend from the transverse processes to the spines of the cervical vertebræ. These fasciculi, the more superficial of which are the longest, constitute the *semispinales cervicis, multifidus,* and *rotatores* muscles. They extend and rotate the neck.

Between the successive spines and the transverse process there are **short muscles** (*interspinales, intertransversares*). The *rectus capitis anterior* and the *rectus capitis lateralis* between the transverse process of the atlas and the lateral part of the occipital belong with the latter series.

Between the base of the skull behind and the first two vertebræ there are four deep-seated specialized muscles which constitute the **suboccipital group** (fig. 382). The *rectus capitis posterior major* and *minor* spread out respectively from the spines of the atlas and epistropheus and are inserted beneath the inferior nuchal line of the occipital. The *obliquus capitis inferior* arises from the spine of the epistropheus and is inserted into the transverse process of the atlas; the *obliquus capitis superior* arises from this and is inserted into the lateral part of the inferior nuchal line of the occipital. These muscles extend and rotate the head. A detailed description of the intrinsic muscles of the back is given on page 410.

The **muscle fasciæ** in the head and neck are well developed in connection with most of the groups of muscles except the facialis group and are described in detail in connection with each of these groups. In the head we may here call attention merely to the dense temporal fascia which covers over the temporal fossa and hides from view the temporal muscle. In the neck the fasciæ are of considerable practical importance. It is convenient to think of them as divisible into several layers although the various layers fuse to some extent. The external layer (fig. 350) may be looked upon as completely ensheathing the neck and as dividing on each

side into two layers which ensheath the sterno-cleido-mastoid and trapezius muscles. As a free fascia it is attached to the lower jaw, to the clavicle and sternum, and to the hyoid bone which divides it into a submaxillary and an infra-hyoid portion. It is connected with the fibrous sheath of the parotid and submaxillary glands. The middle layer of cervical fascia is composed of two laminæ, one extending between the sterno-hyoid and omo-hyoid and another more delicate one beneath this, ensheathing the thyreo-hyoid and sterno-thyreoid muscles and fused with the fibrous sheath which encloses the carotid artery, internal jugular vein and the vagus nerve. The deeper muscles of the side and front of the neck and the intrinsic muscles of the back of the neck are likewise ensheathed by muscle fasciæ.

Of the various groups of muscles mentioned above, some, for the sake of convenience, are treated in connection with the organs to which they belong. Thus the muscles of the eye and ear are taken up in Section VIII; those of the palate, pharynx and larynx in Sections IX and X; the deep dorsal musculature of the neck will be taken up in the section on the intrinsic muscles of the back, p. 410, The remaining groups of muscles will be taken up in the following order:—

1. The facial group p. 329.
2. The cranio-mandibular group p. 338.
3. The supra-hyoid musculature p. 343.
4. The muscles of the tongue p. 345.
5. The superficial shoulder-girdle musculature p. 347.
6. The infra-hyoid musculature p. 350.
7. The scalene musculature p. 353.
8. The prevertebral musculature p. 355.
9. Anterior and lateral intertransverse muscles p. 356.
10. Deep musculature of the shoulder girdle p. 356.*

1. THE FACIALIS MUSCULATURE

(Figs. 341, 344)

The muscles of this group are intimately connected with the scalp, with the skin of the face and neck, and with the mucous membrane lining the lips and the cheeks. Most of the muscles have an osseous origin and a cutaneous insertion, but there are exceptions. Both origin and insertion may be cutaneous, or the attachment may be to an aponeurosis instead of directly to the skin. The deeper musculature about the mouth is attached to the mucous membrane.

The muscles are composed of interdigitating muscle-fibres which are grouped in bundles that take a nearly parallel or slightly converging course and give rise to thin muscle-sheets. The extent of development of the various muscles of the group and their independence varies greatly in different individuals.

The region from which the facial musculature originates in the embryo is, in the main at least, that of the hyoid arch immediately below the ear. From here the musculature spreads with the development of the facial nerve, dorsally to the occipital region behind the ear, distally over the neck, ventrally over the face, and upward toward the eye, forehead, and the side of the skull. The course of the development is indicated by the branches of the facial nerve. A somewhat similar phylogenetic development is indicated by conditions found in the inferior mammals and lower vertebrates. According to Ruge and Gegenbaur, the facial musculature is to be looked upon as derived from two muscle-sheets, of which in man the deeper has disappeared in the region of the neck while it is differentiated into the deeper facial muscles in the region of the head. The deeper layer of transverse fibres in the neck, the *sphincter colli*, is found in several of the mammals. The complex development of the facial muscles in man is characteristic of the human species, and is associated with the use of these muscles as a means of expression of the emotions, a physiological function superadded to the primitive function of opening and closing visceral orifices. There is much individual variation in the differentiation of the muscles.

Fasciæ.—The skin of the head and neck is, in most regions, firmly fused with the **tela subcutanea.** This is composed of a dense fibrous tissue united by a looser areolar tissue to the underlying structures. But a slight amount of fat is embedded in the subcutaneous tissue of the scalp, forehead, and nose. Considerable fat may be embedded in the region of the cheeks, the back of the neck, and the under surface of the chin (double chin). The constantly repeated action of various muscles of the facialis group usually results by middle life in the production of permanent wrinkles due to alterations in the structure of the tela subcutanea and the cutis.

The subcutaneous muscles of the cranial vault and the neck are invested with fascial membranes. That covering the cranial musculature externally is firmly fused to the subcutane-

* The pectoral muscles and the latissimus dorsi, which extend from the skeleton of the limb to the front and side of the thorax and the lower part of the back, arise from the limb-bud during embryonic development, are innervated through the brachial plexus, and will, therefore, be taken up in considering the intrinsic musculature of the upper limb, p. 360.

ous tissue of the scalp. That covering the subcutaneous muscle of the neck is less firmly fused with the subcutaneous tissue. In the facial region the more superficial muscles are so closely embedded in the subcutaneous tissue that no distinct fasciæ intervening between the muscles and the skin can, as a rule, be distinguished. Of the deeper muscles of the facialis group, the buccinator alone possesses a distinct fascia. This muscle lies upon the mucous membrane of the lateral wall of the mouth, and is covered externally by a fascia continued into the fascia investing the superior constrictor of the pharynx.

Bursæ.—Bursa subcutanea prementalis. Between the periosteum at the tip of the chin and the overlying tissue. **Bursa subcutanea prominentiæ laryngeæ.** In front of the junction of the right and left laminæ of the thyreoid cartilage.

FIG. 341.—THE SUPERFICIAL MUSCLES OF THE HEAD AND NECK.

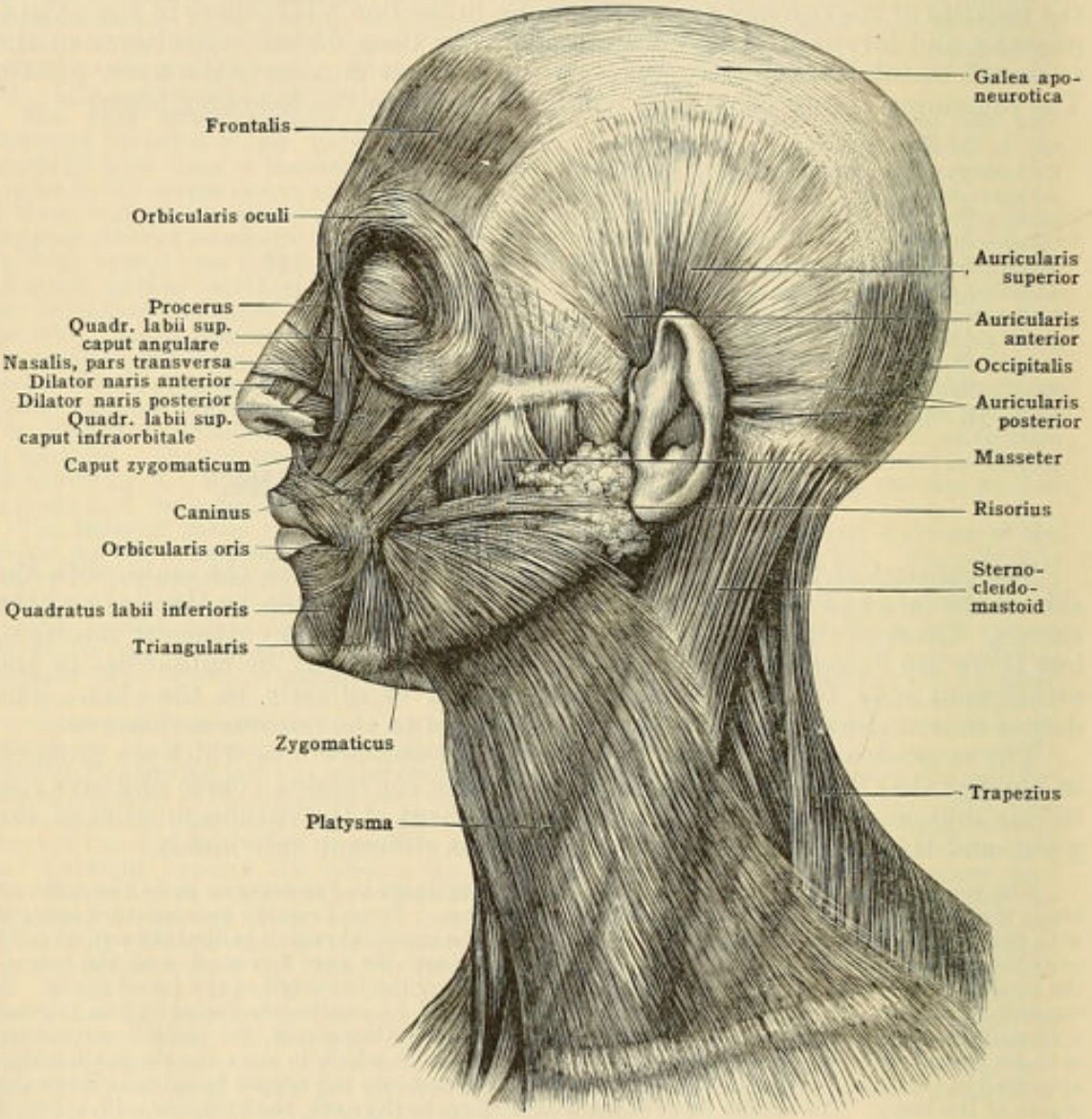

MUSCLES

The muscles of the facialis group may be conveniently subdivided as follows:—(*a*) **Cervical:** the platysma. (*b*) **Oral:** the orbicularis oris and the incisivus labii superioris and inferioris; the quadratus labii superioris and inferioris; the caninus, zygomaticus, risorius, and triangularis; and the buccinator. (*c*) **Mental.** (*d*) **Nasal:** the nasalis, depressor septi, and the dilatores naris. (*e*) **Periorbital:** the orbicularis oculi, corrugator, and procerus. (*f*) **Epicranial:** the frontalis and occipitalis, with the galea aponeurotica. (*g*) **Auricular:** anterior, superior, and posterior. With these the temporalis superficialis is also described.

(*a*) CERVICAL MUSCLE

The **platysma** is a large, thin, quadrangular muscle which runs obliquely from the chin, the corner of the mouth, and the lower part of the cheek across the

mandible and the neck to the proximal part of the thorax and shoulder. The muscles of each side interdigitate across the chin. A short distance below the chin, in the neck, the ventral margins diverge (fig. 341).

Origin.—From the tela subcutanea by somewhat scattered bundles—(1) along a line extending from the cartilage of the second rib to the acromion, and (2) along the dorsal margin of the muscle.

Insertion.—Into—(1) the mental protuberance of the mandible and the inferior margin of the mandible; and (2) into the skin of the lower part of the cheek and at the corner of the mouth, where it fuses more or less with the quadratus labii inferioris and the orbicularis oris.

Nerve-supply.—The cervical branch (ramus colli) of the seventh cranial nerve forms beneath the muscle a plexus to which the cutaneus colli nerve contributes sensory branches.

Relations.—The muscle is situated beneath the panniculus adiposus, to which in the neck it is not very firmly attached. For the most part it is separated from the external layer of the cervical fascia by loose areolar tissue. The main cutaneous rami of the cervical plexus and the external jugular vein lie beneath the muscle.

Action.—It wrinkles up the skin of the neck, depresses the corner of the mouth, and thus plays a part in expression of sadness, fright, and suffering. It aids the circulation by relieving pressure on the underlying veins.

Variations.—Either the facial or the distal development of the muscle may be more extensive than that described above. On the other hand, it may be less developed than usual, and rarely it is absent. Accessory slips have been seen going to the zygoma, the auricle, or the mastoid process, etc., and to the clavicle and sternum. Rarely a deep transverse layer is found in man.

FIG. 342.—DIAGRAM TO ILLUSTRATE THE ARCHITECTURE OF THE ORBICULARIS ORIS. (After T. D. Thane.)

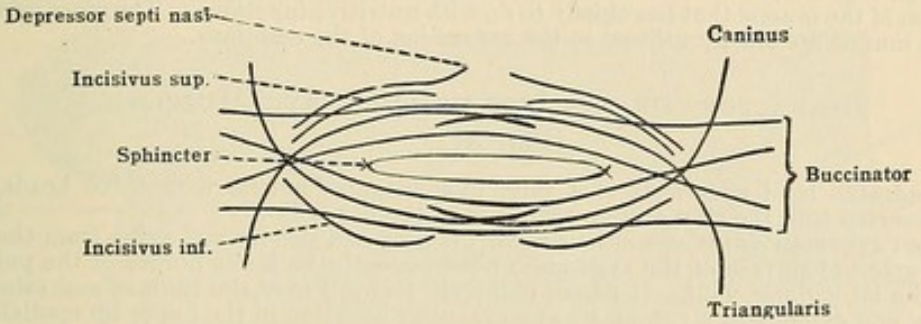

(*b*) ORAL MUSCLES

The muscles of the mouth belonging to the facialis system include several *intralabial* muscles:—a sphincter, the **orbicularis oris;** a transverse, the **compressor labii;** and four deep submucous muscles which pass from the sides of the lips to the alveolar juga of the upper canine and lower lateral incisor teeth, the **incisivi labii superioris** and **inferioris.** From each corner of the mouth there radiate out several muscles; the **caninus** and **zygomaticus** upward to the maxilla and zygomatic bone; the **risorius** lateralward over the cheek; the **platysma** and the **triangularis** downward over the side of the jaw; and the **buccinator,** lateralward over the side of the oral cavity. From each of these fibre-bundles are continued into the more peripheral and superficial portions of the orbicularis. In addition to these muscles there are two retractors or quadrate muscles, one of which, the **quadratus labii superioris,** extends from the upper lip medial to the angle to the bridge of the nose, the lower margin of the orbit, and the zygomatic bone; while the other, the **quadratus labii inferioris,** extends from a corresponding position in the lower lip to the side of the chin. The orbicularis oris, compressor labii, and incisive muscles close the lips; the other muscles open them and pull them in various directions. The buccinator, however, plays a part in the closing of the mouth by offering support for the orbicularis.

INTRALABIAL MUSCLES

The **orbicularis oris** (figs. 308, 341, 342, 343) is a complex muscle which surrounds the oral orifice and forms the chief intrinsic musculature of the lips. Immediately about the orifice, and on the deep surface of the muscle, is a fairly well-defined sphincter, although at the corners of the mouth the fibre-bundles of one lip cross those of the other and are inserted into the mucosa, and to a less extent into the skin. In the mid-line the fibre-bundles end partly in the perimysium, partly in the skin. About this sphincter area and between its outer margin and

the skin is a complex musculature comprised partly of fibre-bundles prolonged from the muscles which radiate from the corners of the mouth. The more superficial portion of the muscle in the upper lip is composed of fibre-bundles from the triangularis (depressor anguli oris), the more superficial portion of that in the lower lip by fibre-bundles from the caninus (levator anguli oris). These fibre-bundles form commissures at the angles of the mouth and extend toward the median line, where many of them interdigitate with those of the opposite side, and are attached to the skin of the lips. The deeper portions are partly formed by fibre-bundles prolonged from the buccinator, the mandibular fibre-bundles of the latter muscle going mainly to the upper lip, the maxillary fibre-bundles mainly to the lower lip. These fibre-bundles are attached chiefly to the mucosa, near the corners of the mouth.

The **compressor labii,** or muscle of Klein, is composed of bundles of fibres which take a course transverse to those of the orbicularis, and pass obliquely from the skin surrounding the oral orifice toward the mucosa which bounds its inner margin. It is said to be best marked in infants.

The **incisivus labii superioris** is a small muscle-bundle which passes from the alveolar jugum of the upper canine tooth to the back of the orbicularis near the corner of the mouth.

The **incisivus labii inferioris** passes similarly from the alveolar jugum of the lower lateral incisor tooth to the back of the orbicularis in the lower lip.

Nerve-supply.—These muscles are supplied by the buccal branches of the facial nerve which enter the orbicularis on the lateral border.

Relations.—The main mass of intrinsic musculature of the lips is placed slightly nearer the mucosa than the skin. On its deep surface lie the labial arteries.

Action.—The orbicularis draws the upper lip downward, the lower lip upward. The incisive muscles draw the corners of the lips medialward, and the compressor flattens the lips. Together they serve to close the mouth. Acting separately they may draw different parts of it in the directions indicated by their structure. The circumferential portion of the orbicularis acting with the incisive muscles makes the lips protrude. The central portion of the orbicularis draws the lips together, and when the buccinator also acts, draws them against the teeth. It is this portion of the muscle that has chiefly to do with nutritive functions. The more peripheral parts of the muscle are chiefly utilised in the expression of the emotions.

Retractors of the Lips or Quadrate Muscles
(Fig. 341)

The **quadratus labii superioris** is a thin, quadrangular muscle with three heads, all of which are inserted into the skin and musculature of the upper lip.

The **caput zygomaticum** (zygomaticus minor) is long and slender and arises from the lower part of the external surface of the zygomatic bone beneath the lower border of the palpebral portion of the orbicularis oculi. It passes obliquely forward over the caninus and orbicularis oris muscles, and extends to a cutaneous and muscular insertion in the upper lip medial to the corner of the mouth. It lies medial to the zygomaticus.

The **caput infraorbitale** (levator labii superioris), a broad, flat muscle, arises from the infra-orbital margin of the maxilla, where it is concealed by the orbicularis oculi. It extends obliquely forward over the caninus and beneath the caput angulare to the skin and musculature of the lateral half of the upper lip.

The **caput angulare** (levator labii superioris alæque nasi) arises from the root of the nose, where it is fused with the frontalis. As it descends it divides into two fasciculi, one of which is attached to the skin and the alar cartilage of the nose; the other passes obliquely downward over the caput infraorbitale to the skin and musculature of the lateral half of the upper lip.

Nerve-supply.—The zygomatic ramus of the seventh nerve sends branches to enter the deep surface of each of the divisions of the muscle.

Actions.—It raises the lateral half of the upper lip and the wing of the nose. It is of value in inspiration, serves to express the emotion of discontent, and comes into play in violent weeping.

Variations.—The caput zygomaticum is often absent. It may be fused with the zygomaticus (major). It may be doubled. Its origin may extend to neighbouring structures. The other heads, though more stable, vary considerably, especially in the extent of their fusion with neighbouring muscles.

The **quadratus labii inferioris** (depressor labii inferioris) is a thin, rhomboid muscle which arises below the canine and bicuspid teeth from the base of the mandible, between the mental protuberance and the mental foramen, and extends obliquely upward in a medial direction to the orbicularis oris, through which its fibre-bundles pass. Its more medial fibres cross at their insertion with those of the muscle of the other side. It is attached to the skin and mucosa of the lower lip. It is essentially a part of the platysma, and is superficially united to the skin except where covered by the triangularis (depressor anguli oris). It crosses the mental vessels and nerves and a part of the mentalis (levator menti).

Nerve-supply.—The mandibular branch of the facial sends twigs into its deep surface near the lateral border.

Action.—It draws down and everts the lower lip. It is an antagonist of the mentalis (levator menti). It plays a part in the expression of terror, irony, great anger, and similar emotions.

Muscles of the Angle of the Mouth
(Figs. 341, 342, 344, 345)

The **caninus** (levator anguli oris) is a flat, quadrilateral muscle which arises from the canine fossa of the maxilla and runs beneath the quadratus (levator) labii superioris to the corner of

the mouth, where it becomes attached to the skin and sends some fasciculi into the orbicularis of the lower lip. Between the caninus and the quadratus labii superioris there is a certain amount of fatty areolar tissue through which the infraorbital vessels and nerves run. Its deep surface extends over the canine fossa, the buccinator muscle, and the mucosa of the lip. The external maxillary (facial) artery passes over its inferior extremity.

The **zygomaticus** (z. major) is a long, ribbon-shaped muscle which arises by short tendinous processes from the zygomatic bone near the temporal suture under cover of the orbicularis oculi. It passes obliquely to the corner of the mouth, where it is attached to the skin and mucosa. The body of the muscle is subcutaneous and is usually surrounded by fat. It crosses the masseter and buccinator muscles and the anterior facial vein.

The **risorius** is a thin, triangular, subcutaneous muscle which extends across the middle of the cheek and lies in a more superficial plane than the platysma, with which it is often fused. It arises from the tela subcutanea above the parotid fascia. Its fibres converge across the masseter muscle toward the angle of the mouth and are attached to the skin and mucosa in this vicinity. It lies above the anterior facial vein and external maxillary artery.

The **platysma** has been described above.

The **triangularis** (depressor anguli oris) is a broad, flat, well-developed, subcutaneous muscle which arises from the base and external surface of the body of the mandible below the canine, bicuspid, and first molar teeth. From here its fibres converge toward the corner of the mouth, where they are in part inserted into the skin and in part are continued into the orbicularis oris of the upper lip. It overlies the buccinator and the quadratus (depressor) labii inferioris muscles. Not infrequently (58 out of 92 bodies—LeDouble) some fasciculi are continued into

FIG. 343. (AFTER EISLER.) BUCCINATOR MUSCLE AND PTERYGOMANDIBULAR RAPHE, AS SEEN FROM THE BUCCAL SIDE.

The alveolar processes of both jaws have been removed in the region of the molar teeth. The soft palate and its muscles have been removed.

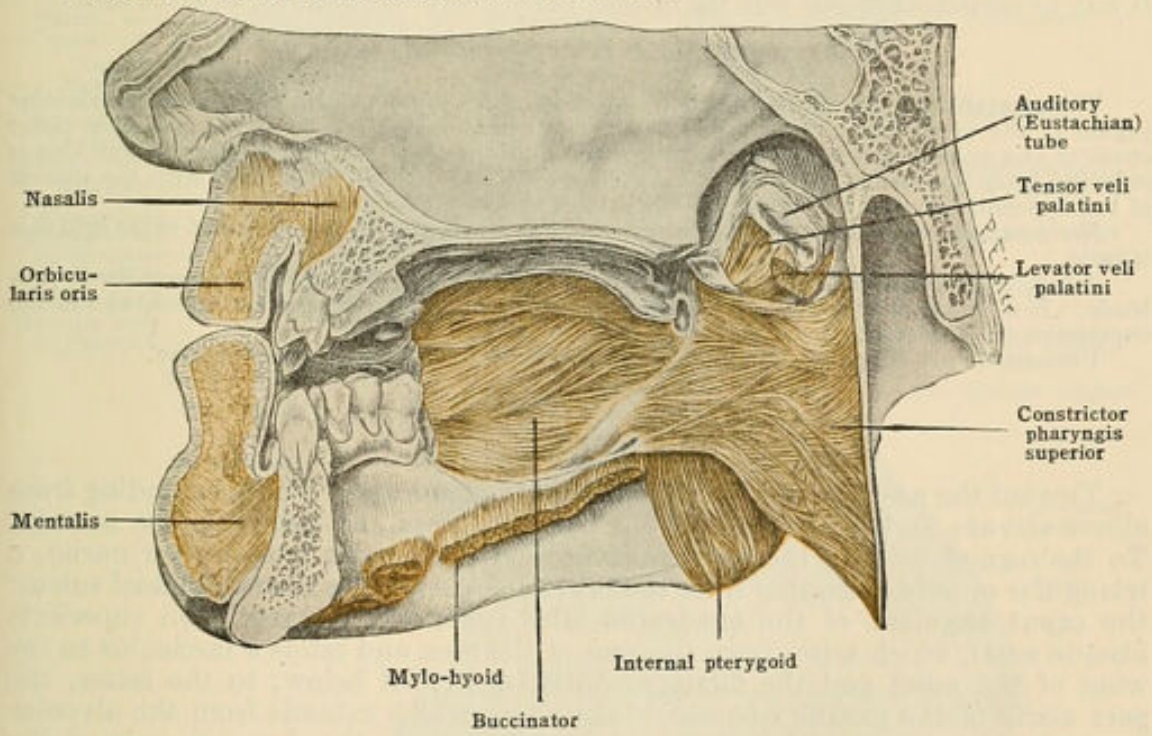

the neck as the **transversus menti,** a fibro-muscular band formed by the interdigitation of the slips prolonged from each side below the chin and superficial to the platysma. Santorini described the *transversus menti* as an independent though inconstant muscle. According to Eisler the true transversus menti muscle is to be distinguished from aberrent slips of the triangularis or of the platysma in this region. In one instance Eisler found a slender nerve emerging through the platysma and passing to this muscle.

Nerve-supply.—The zygomatic branch of the seventh nerve supplies the canine (levator anguli oris) and zygomatic (major) muscles. Branches enter the middle of the deep surface of the latter muscle and the superficial surface of the former near its lateral border. The risorius is supplied by branches from the buccal rami of the seventh nerve, which enter its deep surface. The triangularis (depressor anguli oris) is supplied by the buccal branch through branches which enter its deep surface near the posterior margin.

Action.—The caninus (levator anguli oris) and zygomatic (z. major) muscles raise the corner of the mouth, the former at the same time drawing it medially, the latter, laterally. The caninus gives rise to expression of bitterness or menace. The zygomaticus is active in smiling or laughing. When contracted greatly it elevates the cheek and the lower eyelid and produces crow's-foot wrinkles at the corner of the eye. The risorius draws the angle of the mouth laterally. In spite of its name it is not used to express pleasure, but instead gives rise to an expression of pain. The triangularis (depressor anguli oris) depresses the corner of the mouth and draws it laterally, giving rise to the expression of grief.

Variations.—The risorius is very inconstant in its development, and in its relations to neighbouring muscles, and is not infrequently quite small. The zygomaticus is rarely absent Its origin may extend to the temporal or masseteric fasciæ. It may be doubled throughout its length or at one extremity. Frequently the triangularis is divided into three fasciculi.

The **buccinator** (fig. 343) arises from—(1) the molar portion of the alveolar process of the maxilla; (2) the buccinator crest of the mandible, and (3) the pterygo-mandibular raphe of the bucco-pharyngeal fascia. This narrow fibrous band, which separates the buccinator from the superior constrictor of the pharynx, extends from the pterygoid hamulus to the buccinator crest of the mandible. The fibre-bundles are divisible into four sets. The most cranial extend directly into the orbicularis of the upper lip. The next pass through the commissure at the corner of the lips into the orbicularis of the lower lip; the third through the commissure into the orbicularis of the upper lip, and the fourth directly into the orbicularis of the lower lip. The muscle is attached chiefly to the mucosa of the lips near the angle of the mouth. Some fibre-bundles extend to the more medial portion of the mucosa and some through the orbicularis to the skin.

Nerve-supply.—By the buccal branch of the facial nerve through filaments which enter the posterior half of its outer surface.

Relations.—The muscle is covered externally by the thin bucco-pharyngeal fascia; internally by the mucosa of the mouth. Above its outer surface lie the zygomatic (z. major), risorius, and masseter muscles. Between the last and the buccinator lies a large pad of fat (the buccal fat pad). The parotid duct passes forward over the muscle, and slightly in front of its centre pierces it and passes into the mouth. It is crossed by the external maxillary (facial) artery and anterior facial vein and by the buccal artery and nerve.

Actions.—It draws the corner of the mouth laterally, pulls the lips against the teeth, and flattens the cheek. It is of use in mastication, swallowing, whistling, and blowing wind-instruments.

Variations.—Occasionally it consists of two laminæ, a condition found in many mammals. It may be continuous in part with the superior constrictor of the pharynx, as in the cat.

(*c*) MENTAL MUSCLE

The **mentalis** (levator menti) (fig. 343) is a short, thick muscle which arises from the alveolar jugum of the lower lateral incisor tooth and the neighbouring region of the mandible under cover of the quadratus (depressor) labii inferioris and beneath the oral mucosa, where this is reflected from the lips to the gums. It extends to the chin, where it is fused with the muscle of the opposite side and is attached to the skin of the chin.

Nerve-supply.—The mandibular branch of the seventh nerve sends terminal twigs into this muscle.

Actions.—It draws up the skin of the chin and thus indirectly causes the lower lip to protrude. It is of use in articulation, in forcing bits of food from between the gums, and in the expression of various emotions (muscle of pride).

Variations.—It varies greatly in size and generally is fused with the platysma.

(*d*) NASAL MUSCLES
(Figs. 341 and 344)

Toward the nasal apertures several muscles converge. Those extending from above elevate and dilate, those from below depress and contract, the nostrils. To the former belongs the **pars transversa** of the **nasalis** (compressor naris), a triangular muscle extending from the bridge of the nose to the naso-labial sulcus; the **caput angulare** of the **quadratus labii superioris** (levator labii superioris alæque nasi), which arises from the root of the nose and sends a fasciculus to the wing of the nose; and the **dilatores naris,** described below; to the latter, the **pars alaris** of the **nasalis** (depressor alæ nasi), which extends from the alveolar juga of the upper lateral incisor and canine teeth to the dorsal margin of the nostril; and the small **depressor septi nasi.**

The **nasalis** consists of two parts, the pars transversa and the pars alaris. The **pars transversa** (compressor naris) is triangular. It lies on the side of the nose above the wing. Its fibre-bundles arise from an aponeurosis which overlies the bridge of the nose, is adherent to the skin, and is not closely attached to the underlying cartilage. From this aponeurosis the fibre-bundles converge toward the back of the wing, where they are attached to the skin along the line which separates the wing from the cheek (naso-labial sulcus). Its insertion is covered by the nasal process of the caput angulare (levator labii superioris alæque nasi) of the quadratus labii superioris (p. 332), with which its fibres interdigitate. An attachment (origin) is also described by many as taking place in the lower part of the canine fossa of the maxilla.

The **pars alaris** (depressor alæ nasi) (fig. 343), is a small quadrangular muscle situated below the aperture of the nose, between this and the alveolar portion of the maxilla. It is covered by the mucosa of the gum, by the orbicularis oris and the quadratus (levator) labii superioris, and laterally is fused with the pars transversa (compressor naris). It arises from the alveolar juga of the lateral incisor and the canine teeth. Its fibre-bundles extend vertically to the skin of the dorsal margin of the nostril, from the dorsal part of the cartilage of the wing to the septum

The **depressor septi** is a flat, triangular muscle which extends from the orbicularis oris to the lower edge of the nasal septum. It may arise from the jugum alveolare of the medial incisor.

The **dilator naris posterior** is a thin, triangular muscle which lies on the side of the wing of the nose. It arises from the skin of the naso-labial groove and is attached to the inferior border of the wing of the nose.

The **dilator naris anterior** is a very small, thin muscle which runs from the lower margin of the cartilage at the front of the wing of the nose to the skin. It is not usually clearly marked.

Nerve-supply.—The muscles of this group are supplied by the infra-orbital and buccal branches of the facial nerve.

Actions.—The transverse portion of the nasalis (compressor naris) acts with the angular head (levator labii superioris alæque nasi) of the quadratus labii superioris in drawing lateral-

FIG. 344.—THE DEEPER MUSCLES OF THE FACE AND NECK.

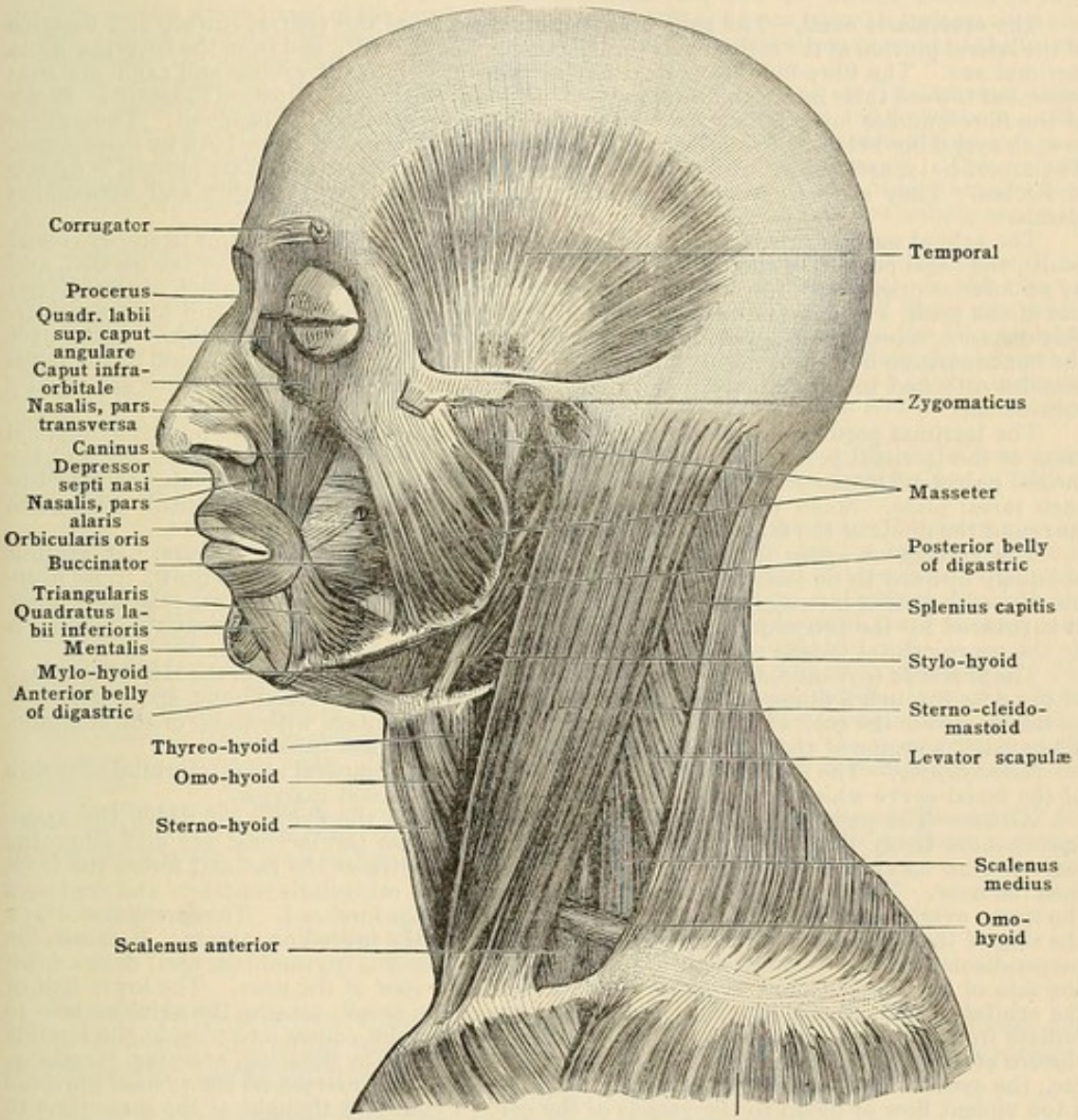

ward and up the lateral margin of the wings of the nose, and gives rise to the expression of sensuality. (Poirier.) This accords with the electrical experiments of Duchenne. However, acting in conjunction with the alar portion, the transverse portion of the nasalis may constrict the nostrils. The alar portion (depressor alæ nasi) of the nasalis and the depressor septi nasi draw down the nostril. The former tends to contract it from side to side, the latter from front to back, and at the same time to depress the tip of the nose. They play a part in the expression of anger and of pain. The functions of the other muscles are indicated by their names.

Variations.—The muscles of the nose vary considerably in extent of development, and one or more may be absent. Authors differ considerably in their description of several of the muscles. The **anomalus** is a longitudinal muscle strip occasionally found running from the frontal process to the body of the maxilla near the lateral margin of the nasal aperture.

(*e*) PERIORBITAL MUSCLES

(Figs. 341, 344)

The muscles which encircle the orbit constrict the entrance of the orbit so as to shut out light and protect the eye against foreign bodies. To these belong

the orbicularis oculi, the corrugator, and the procerus. The **orbicularis oculi** is a large, flat, elliptical muscle which lies in the eyelids and over the bone surrounding the orbit. **Three parts** are recognised, a **palpebral**, an **orbital** and a **lacrimal.** The quadrangular **corrugator** extends from the nasal portion of the frontal bone to the skin of the middle half of the eyebrow; the narrow **procerus** (pyramidalis nasi) from the bridge of the nose to the skin at the root. The muscles which have an antagonistic action are the levator palpebræ superioris and the epicranius. The levator palpebræ is described in the chapter on the EYE (see Section VIII), the epicranius in the following subsection.

The **orbicularis oculi.**—The **palpebral portion** arises from the ventral surface and margins of the lateral portion of the medial palpebral ligament (tendo oculi), and from the covering of the lacrimal sac. The fibre-bundles spread out as they pass into the eyelids and again are concentrated toward their insertion into the outer surface of the lateral palpebral ligament. Many of the fibre-bundles interdigitate here without being inserted into the ligament. The muscle in each eyelid lies between the tarsal plate and the skin, separated from both by loose tissue. The superficial muscle-fibres nearest the margin of the lids constitute the ciliary muscle, or muscle of Riolan. They are very small fibres and probably act on the eyelashes and Meibomian glands.

The **orbital portion** arises by a superior origin from the medial palpebral ligament (tendo oculi), the nasal portion of the frontal bone, and the anterior lacrimal crest of the maxilla, and by an inferior origin from the medial palpebral ligament and the medial portion of the inferior rim of the orbit. The fibre-bundles form a flat ring which surrounds the orbit for a considerable distance, especially inferiorly. The muscle is adherent to the overlying skin. It lies over the bones surrounding the margin of the orbit and over the attachments of several of the facial muscles attached to these bones. With these muscles some of the fibre-bundles are usually continuous.

The **lacrimal portion** (tensor tarsi or Horner's muscle) arises from the posterior lacrimal crest of the lacrimal bone and passes down on the dorsal surface of the lacrimal sac and the medial palpebral ligament (tendo oculi). It bifurcates and furnishes a fasciculus attached to each tarsal plate. Some of the fibre-bundles surround the lacrimal canaliculi and some surround the ducts of the tarsal glands and the roots of the eyelashes.

The **corrugator** arises from the frontal bone near the fronto-nasal suture. It extends obliquely upward to be inserted into the skin of the middle half of the eyebrow. The fibre-bundles of insertion interdigitate with those of the frontalis. The muscle lies relatively deep. It is covered by the procerus (pyramidalis nasi), the frontalis, and the orbicularis. Under it lie the supra-orbital vessels and nerves.

The **procerus** (pyramidalis nasi) overlies the nasal bone. It arises from the lateral cartilage of the nose through a fibrous membrane and also directly from the nasal bone, and is attached to the skin over the root of the nose, where its fibres interdigitate with those of the frontalis. The medial margins of the muscles on each side are more or less fused.

Nerve-supply.—The muscles of this group are supplied by temporal and infraorbital branches of the facial nerve which enter the deep surfaces near the lateral margins.

Action.—The palpebral portion of the orbicularis closes the eyelids, of which the upper moves more freely than the lower. It also serves to dilate the lacrimal sac and allow the tears to flow away readily. The tensor tarsi probably contracts the sac and forces the tears into the nose. The upper half of the orbital portion of the orbicularis contracts and depresses the tissue overhanging the orbit, and stretches the skin of the forehead. The corrugator draws the skin of the brow downward and medially, thus aiding the preceding muscle. It causes the perpendicular furrows characteristic of frowning. The procerus (pyramidalis nasi) draws down the skin of the forehead and wrinkles the skin across the root of the nose. The lower half of the orbital portion of the orbicularis raises the skin of the cheek, causing the wrinkles seen to radiate from the corner of the eye. The whole set of muscles comes into play in the forcible closure of the eyes. In case of violent expiratory efforts, as in shouting, sneezing, coughing, etc., the eye is thus usually forcibly closed. The pressure thus exerted on the eyeball prevents a too violent flow of blood to the vessels of the eye. Pressure is thought at the same time to be exerted on the lacrimal gland so as to cause the excessive flow of tears often experienced at such times.

Variations.—The muscles of this group vary in extent and differentiation, and may be more or less fused with one another or with neighbouring muscles. The orbital portion of the orbicularis, the corrugator, and the procerus have been found absent.

(*f*) THE EPICRANIAL MUSCULATURE

(Fig. 341)

The **epicranius** (occipito-frontalis) is formed of the two **frontal** muscles, which lie on each side of the forehead, the two **occipital** muscles, which occupy corresponding positions on the occipital bone, and of the epicranial aponeurosis, the **galea aponeurotica,** which extends between these. The occipital muscles arise from the supreme nuchal line and are inserted into the galea aponeurotica. The frontal muscles arise from the latter and are inserted into the skin near the eyebrows. The chief function of these muscles is to elevate the brows. The

muscles and the intervening aponeurosis lie between two layers of fascia, the external of which is fused to the skin, while the internal moves freely over the periosteum, to which it is loosely attached. Hæmorrhages and abscesses spread freely between the deep layer of fascia and the periosteum.

The **frontalis** is a large, thin muscle with convex upper and concave lower border. It arises from the epicranial aponeurosis midway between the coronal suture and the orbital arch, and is inserted into the skin of the eyebrow and of the root of the nose. The medial fibre-bundles take a sagittal direction; the lateral converge obliquely toward the brow. The medial margins of the muscles of each side are approximated near the attachment. The more medial fibre-bundles are continuous with those of the procerus (pyramidalis nasi) and the angular portion (levator labii superioris alæque nasi) of the quadratus labii superioris; the more lateral interlace with those of the corrugator and orbicularis muscles. The branches of the vessels and nerves of the frontal region pierce the muscle and are distributed between it and the skin.

The **occipitalis,** flat and quadrangular, lies on the occipital bone above the supreme nuchal line. It rises by tendinous fibres from the lateral two-thirds of this line and from the posterior part of the mastoid process of the temporal bone, and is inserted into the epicranial aponeurosis. The medial fibre-bundles run sagitally, while the lateral run obliquely forward. The occipital artery and nerve lie between the muscle and the skin. The lateral border of the muscle comes in contact with the posterior auricular muscle. The muscles of each side are usually separated by a strip of aponeurosis.

The **galea aponeurotica** (epicranial aponeurosis) is a fibrous membrane which extends between the occipital muscles and from them anteriorly to the frontal muscles. In the area between these two sets of muscles it is composed largely of sagitally running fibres into which coronal fibres radiate from the region of the muscles of the ear. Between the two occipital muscles the aponeurosis is attached to the supreme nuchal line and external occipital protuberance. Laterally the fascia covering it is continued as a special investment of the auricular muscles, beyond which it is attached to the mastoid process, the zygoma, and to the external cervical and the masseteric fasciæ.

Nerve-supply.—The frontalis is supplied by the temporal branches of the facial nerve, the occipitalis by the posterior auricular branch. The branches enter the deep surface of each of these muscles near its lateral border.

Action.—The occipitalis serves to draw back and to fix and make tense the epicranial aponeurosis. The frontalis, with its aponeurotic extremity fixed, elevates the brows and throws the skin of the forehead into transverse wrinkles as in the expression of attention, surprise, or horror. When both muscles contract forcibly there is, in addition, a tendency to make the hair stand on end because the hair-bulbs of the occipital region slant forward, those of the frontal region backward. The frontalis when fixed below pulls the scalp forward.

Variations.—The occipitalis is occasionally absent, a condition normal in ruminants. The muscles of the two sides may be fused in the median line (normal in dogs). It may be fused with the posterior auricular. The frontalis is rarely missing. The frontalis may send slips to the medial or lateral angles or the orbital arch of the frontal bone, to the nasal process of the maxilla or to the nasal bone. The fibre-bundles of the frontalis may interdigitate across the median line.

The **transversus nuchæ,** or occipitalis minor, is a small muscle, frequently present (27 per cent., Le Double), which runs from the occipital protuberance toward the posterior auricular muscle, with which it may be fused. It may lie over or under the trapezius.

(*g*) AURICULAR MUSCLES
(Fig. 341)

The intrinsic muscles of the auricle are described in Section VIII. There are three 'extrinsic' auricular muscles which converge from regions anterior, superior, and posterior to the auricle and are inserted into it.

The **auricularis anterior** (attrahens aurem) is a small, flat, triangular muscle which arises between the two layers of the fascia of the galea aponeurotica, extends over the zygomatic arch, and is attached to the ventral end of the helix. The fibre-bundles converge from the origin toward a tendon of insertion. The area of origin of this muscle is often marked by a fibrous band tangential to its component fibres. From this band muscle fibre-bundles radiate out toward the frontal region of the skull. To the muscle formed of these radiating fibres the names **epicranio-temporalis** (Henle), **temporalis superficialis** (Sappey) and **auriculo-frontalis** (Gegenbaur) have been given.

The **auricularis superior** (attollens aurem) is a large, thin, triangurar muscle which, from its tendinous insertion on the eminence of the triangular fossa of the ear, radiates upward into the fascia of the galea aponeurotica, between the layers of which it takes oigin near the temporal ridge. It lies over the temporal fascia and the periosteum of the parietal bone.

The **auricularis posterior** (retrahens aurem) is a thin, band-like muscle which extends over the insertion of the sterno-cleido-mastoid from the base of the mastoid process and the aponeurosis of the sterno-cleido-mastoid muscle to the convexity of the concha, where it has a tendinous insertion. It is usually composed of two fasciculi, and is contained between two layers of fascia derived from the galea aponeurotica.

Nerve-supply.—The auricularis anterior and superior are supplied by the temporal branch of the facial, the auricularis superior and posterior by the posterior auricular branch. The twigs of supply run to the deep surface of the muscles.

Relations.—The superficial ascending branch of the auriculo-temporal nerve usually runs superficial to the anterior and superior auricular muscles. The superficial temporal vessels run at first beneath these muscles and the lateral expansion of the galea aponeurotica, then between the two fascial layers which enclose the muscles. Their branches of distribution finally come to lie between the muscles and aponeurosis and the skin. The posterior auricular artery and nerve usually run under cover of the auricularis posterior.

Action.—The anterior muscle is a protractor, the superior an elevator, and the posterior a retractor of the ear, but usually in man they are inactive.

Variations.—These muscles vary much in development. The most constant of them is the superior. The posterior frequently is increased in size and may be fused with the occipitalis, which originally was probably an ear muscle. From the anterior muscle a special deep fasciculus is occasionally isolated. Each of the muscles is occasionally, though rarely, absent, the anterior most frequently. An inferior auricular muscle is very rarely found in man, though present in many of the lower mammals. A slip of the posterior auricular may run beneath the ear to the parotid fascia.

FIG. 345.—THE TEMPORAL MUSCLE.

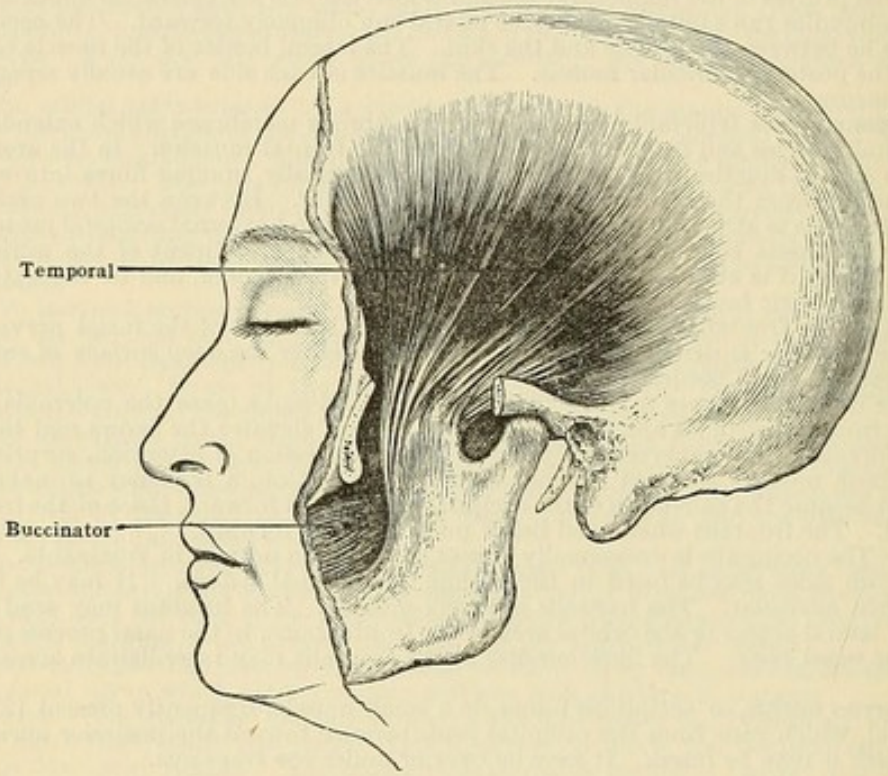

2. CRANIO-MANDIBULAR MUSCULATURE

(Figs. 344, 345, 346, and 347)

The cranio-mandibular muscles, or muscles of mastication, pass from the base of the skull to the lower jaw. They are represented in the selachians by a single muscle mass, the adductor mandibulæ (Gegenbaur), but in the higher vertebrates this muscle mass becomes variously subdivided during embryonic development. The muscles are innervated by the masticator nerve (motor root of the trigeminal cranial nerve, the nerve of the mandibular arch). In man four muscles are recognised, the temporal, masseter, and internal and external pterygoids.

The **temporal** and **masseter** muscles are situated on the lateral surface of the skull, partly under cover of muscles of the facialis group. The **temporal** muscle (fig. 345), which resembles the quadrant of a circle, arises from the temporal fossa and is inserted into the coronoid process of the mandible; the thick, quadrilateral **masseter** (fig. 344) muscle arises from the zygomatic arch and is inserted into the lateral surface of the ramus and angle of the mandible. The **pterygoids** (fig. 346) are more deeply seated. The cone-shaped **external pterygoid** arises from the lateral side of the pterygoid process and lower surface of the great wing of the sphenoid and is inserted into the condyloid process of the mandible and the capsule of the joint. The thick, quadrilateral **internal pterygoid** parallels the masseter. It arises from the pterygoid fossa of the sphenoid and is inserted into the inner side of the angle of the mandible. It will be noted that the tem-

poral, masseter, and internal pterygoid muscles have approximately vertical axes of contraction and adduct the lower jaw, while the external pterygoid has an approximately horizontal axis of contraction and draws the jaw forward and, when acting on one side, toward the opposite side.

FIG. 346.—THE PTERYGOID MUSCLES.

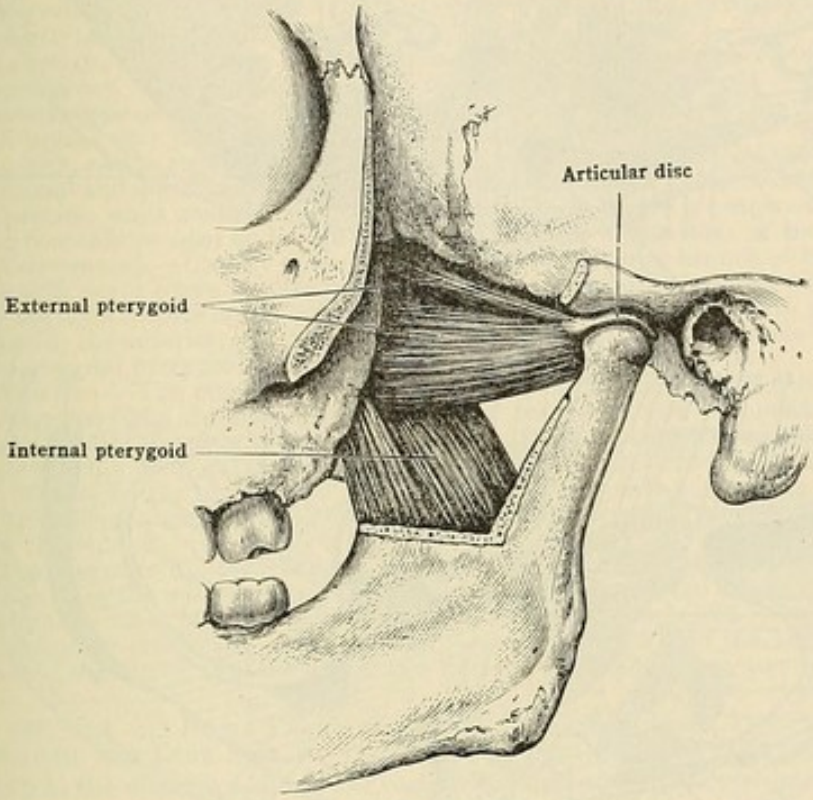

FASCIÆ

The **temporal fascia** arises from the temporal line of the frontal bone and from the superior temporal line of the parietal and the periosteum immediately below this. It extends to the zygomatic arch. In its inferior quarter the fascia divides into two lamellæ, one of which passes to the outer, the other to the inner, surface of the arch, but at the superior margin of the arch these two lamellæ are united by dense fibrous tissue. Between the two lamellæ above the arch lies a fatty areolar tissue in which the middle temporal artery often runs. The outer surface of the fascia is covered by the superficial temporal and anterior and superior auricular muscles, and by a thin layer of fascia from the galea aponeurotica, with which, toward the zygomatic arch, it becomes merged. The superficial temporal artery and auriculo-temporal nerve cross it.

The **masseteric fascia** represents essentially a continuation of the temporal fascia from the inferior margin of the zygomatic arch over the masseter muscle which it covers. It is less thick than the temporal fascia, but is firm and strong. It is attached dorsally to the dorsal margin of the mandible, inferiorly to the inferior margin, and ventrally to the body and to the ventral margin of the ramus and the coronoid process of the mandible. In part it extends over the fat pad of the cheek to the buccinator fascia. The parotid gland, covered by the parotid extension of the external cervical fascia, extends over the posterior portion of this fascia. The **parotid fascia** becomes fused to its external surface at the anterior margin of the gland. Over it lie the parotid duct, the transverse facial artery, branches of the facial nerve, the zygomaticus (major), risorius, and platysma muscles.

The pterygoid muscles are each surrounded by a delicate membrane. In addition an **interpterygoid fascia** separates the two muscles. This arises from the sphenoidal spine and follows the internal surface of the external pterygoid to the mandible. Medially it is attached to the lateral lamella of the pterygoid process; posteriorly and laterally it presents a free margin which forms with the neck of the mandibular condyle, an orifice for the passage of the internal maxillary artery, the auriculo-temporal nerve, and several veins. Its posterior margin is strengthened into the spheno-mandibular ligament, which runs from the spine of the sphenoid to the lingula of the mandible.

The pharyngeal region is separated from the pterygoid by a dense membrane, the **lateral pharyngeal fascia.** This extends from the depth of the pterygoid fossa to the prevertebral fascia, and separates the tensor veli palatini from the internal pterygoid muscle. It is attached above along a line extending from the external margin of the carotid canal to the internal margin of the oval foramen.

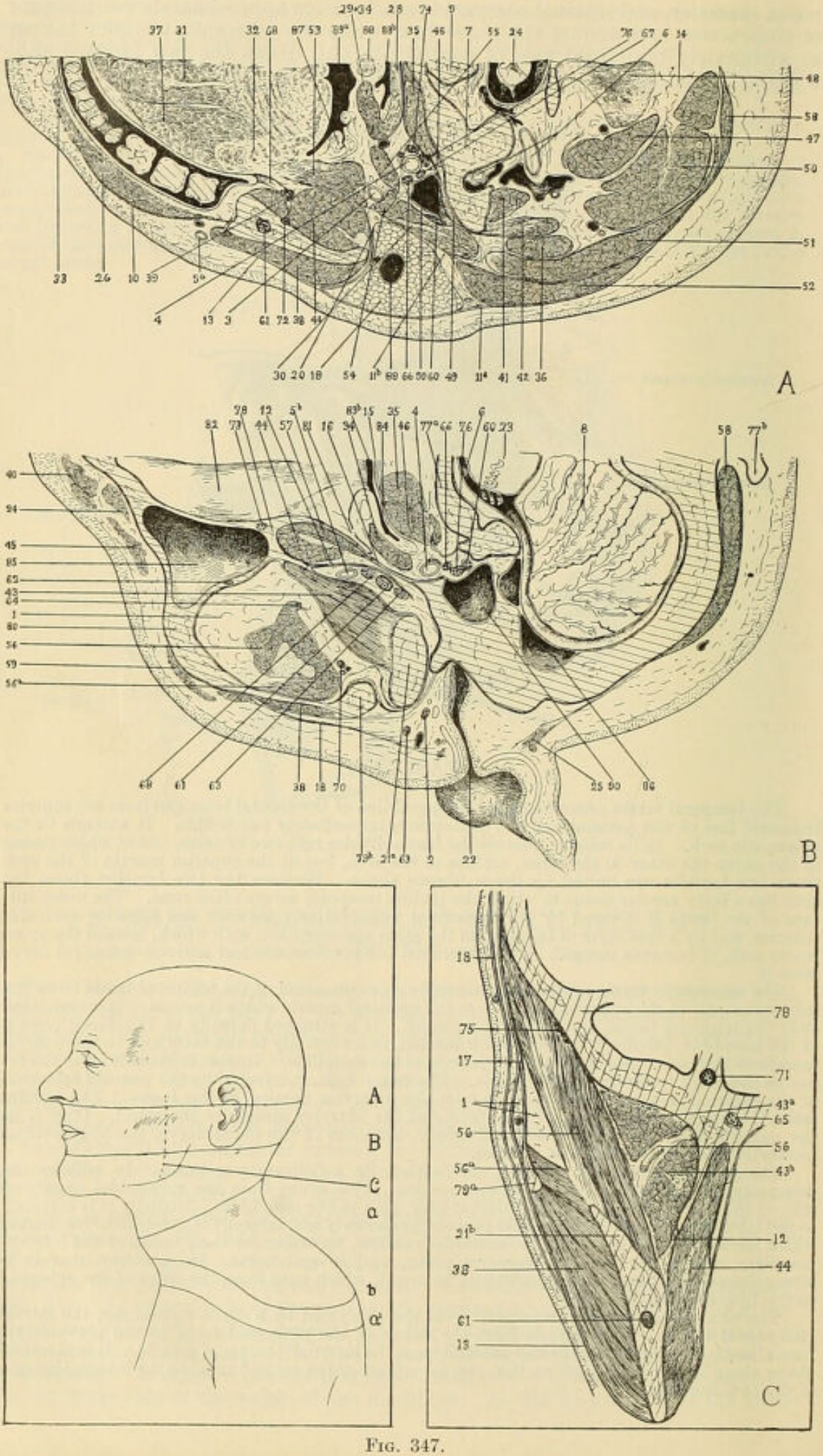

FIG. 347.

The **sigmoidal septum** is a thin membrane which occupies the incisura mandibulæ and separates the masseter from the external pterygoid muscle.

MUSCLES

The **temporalis** (fig. 345).—**Origin.**—(1) From the whole of the temporal fossa, with the exception of that part formed by the body and temporal process of the zygomatic (malar) bone; and (2) from the fascia covering the fossa. **Insertion** is into the tip, dorsal and ventral borders, and the whole internal surface of the coronoid process of the mandible and the ventral portion of the medial surface of the ramus.

In *structure*, the muscle is thin near its superior margin, but becomes thick as its insertion is approached. The fibre-bundles arising from the medial surface of the fossa and from the fascia converge upon the medial and lateral surfaces and the margins of a thick, broad tendon which begins very high in the muscle, becomes visible laterally some distance above the zygomatic arch, and is inserted into the tip, edges, and internal surface of the coronoid process. On the ventral and dorsal margins of the tendon the insertion of fibre-bundles continues to the coronoid process, while medially the insertion of the fibre-bundles is continued on the medial surface of the coronoid process and often on the ramus as far as the body of the bone.

Nerve-supply.—Usually three branches from the anterior branch of the mandibular division of the fifth nerve curve upward over the temporal surface of the great wing of the sphenoid and enter the deep surface of the muscle. The posterior and middle nerves pass above the external pterygoid; the anterior, which springs from the buccinator nerve, passes between the two heads of the external pterygoid before curving upward.

Relations.—The muscle is covered by the temporal fascia and the zygomatic arch. Below the temporal fossa the pterygoid muscles and the buccinator lie medial to it. The temporal fossa in front of the muscle is filled with a fatty areolar tissue and this also extends between the muscle and the temporal fascia. Fatty tissue likewise lies between the muscle and the buccinator. Medial to the muscle run the deep temporal vessels and nerves, the buccinator nerve and the spheno-mandibular ligament. The masseteric nerve passes lateralward behind and below the tendon.

The **masseter** (fig. 343) is composed of two layers. The **superficial layer** arises by an aponeurosis from the anterior two-thirds of the lower border of the zygomatic (malar) bone. The fibre-bundles arise from the deep surface of this aponeurosis and its tendinous prolongations pass obliquely downward and backward, and are inserted into the lower half of the external surface of the ramus, into the angle, and into the neighbouring portion of the body of the man-

---

FIG. 347.*—A AND B ARE TRANSVERSE SECTIONS AND C (AFTER TESTUT), A FRONTAL SECTION THROUGH THE LEFT SIDE OF THE HEAD, IN THE REGIONS INDICATED IN THE DIAGRAM.

a and *b* in the diagram indicate the regions through which pass sections A and B, fig. 351; and a^1, section A, fig. 357.

1. Adipose tissue. 2. Arteria temporalis superficialis. 3. A. carotis externa. 4. A. carotis interna. 5*a*. A. maxillaris externa (facial). 5*b*. A. maxillaris interna. 6. A. vertebralis. 7. Atlas. 8. Cerebellum. 9. Epistropheus (axis). 10. Fascia buccopharyngea. 11. F. cervicalis, *a* (superficial layer), *b*, deep parotid process. 12. F. interpterygoidea. 13. F. masseterica. 14. F. nuchæ. 15. F. pharyngobasilaris. 16. F. pharyngis lateralis. 17. F. temporalis. 18. Galea aponeurotica. 19. Glandula parotica. 20. Ligamentum stylomandibularis. 21*a*. Mandible, capitulum; *b*, coronoid process. 22. Meatus acusticus ext. 23. Medulla oblongata. 24. Medulla spinalis (spinal cord). 25. Musculus auricularis posterior (retractor auris). 26. M. buccinator. 27. M. caninus (levator anguli oris). 28. M. constrictor pharyngis medius. 29. M. constrictor pharyngis superior. 30. M. digastricus. 31. M. genio-glossus. 32. M. hyo-glossus. 33. M. incisivus labii inferioris. 34. M. levator veli palatini. 35. M. longus capitis (rectus capitis anticus major). 36. M. longissimus capitis (trachelo-mastoid). 37. M. longitudinalis inferior. 38. M. masseter. 39. M. mylo-hyoideus. 40. M. nasalis (alar portion). 41. M. obliquus capitis inferior. 42. M. obliquus capitis superior. 43. M. pterygoideus externus —*a*, superior fasciculus; *b*, inferior fasciculus. 44. M. pterygoideus internus. 45. M. quadratus (levator) labii superioris. 46. M. rectus capitis anterior (minor). 47. M. rectus capitis posterior major. 48. M. rectus capitis posterior minor. 49. M. rectus capitis lateralis. 50. M. semispinalis capitis (complexus). 51. M. splenius capitis. 52. M. sterno-cleido-mastoideus. 53. M. stylo-glossus. 54. M. stylo-hyoideus. 55. M. stylo-pharyngeus. 56. M. temporalis (*a*, fasciculus from zygoma). 57. M. tensor veli palatini. 58. M. trapezius. 59. M. zygomaticus (major). 60. Nervus accessorius (spinal accessory). 61. N. alveolaris inferior (dental). 62. N. alveolaris posterior superior (dental). 63. N. auriculo-temporalis. 64. N. buccinatorius. 65. N. canalis pterygoidei (Vidian nerve). 66. N. glosso-pharyngeus. 67. N. hypoglossus. 68. N. lingualis. 69. N. mandibularis. 70. N. masseteric nerve. 71. N. maxillary nerve. 72. N. mylohyoid nerve. 73. N. palatinus. 74. Sympathetic trunk. 75. N. temporalis profundus. 76. N. vagus. 77. Os occipitale—*a*, basilar portion; *b*, external protuberance. 78. Os sphenoidale. 79. Os temporale—*a*, processus zygomaticus; *b*, tubercle. 80. Os zygomaticum (malar). 81. Pharyngeal orifice of tuba auditiva (Eustachian tube). 82. Palatum durum (hard palate). 83. Pharynx—*a*, oral portion; *b*, nasal portion. 84. Pharyngeal recess. 85. Sinus maxillaris (antrum of Highmore). 86. Sinus transversus (lateral). 87. Tonsila palatina. 88. Uvula. 89. Vena facialis posterior (temporomaxillary). 90. V. jugularis interna.

* This and the following series of cross-sections are taken from a thin, not very muscular, adult male. The fasciæ are represented in most instances disproportionately thick.

dible—the more anterior directly, the posterior by means of an aponeurosis. The **deep layer** arises from the lower border and internal surface of the zygomatic arch. The fibre-bundles pass nearly vertically downward, and are inserted upon the upper half of the external surface of the ramus. The origin and insertion are by tendinous bands, to which the fibre-bundles are attached in a multipenniform manner. The two layers are fused near the origin and insertion and in front. From the temporal surface of the zygomatic bone and the neighbouring part of the deep layer of the temporal fascia there arises a fasciculus which is separated by a pad of fat from the main body of the temporal muscle, and is inserted into the lateral surface of the lower extremity of the tendon of the temporal muscle and into the ventro-lateral surface of the tip of the coronoid process. This fasciculus, sometimes described as a part of the temporal muscle, is innervated by the masseteric nerve.

Nerve-supply.—The branch arises in common with the posterior nerve to the temporal muscle from the motor root of the trigeminal (the masticator nerve). It passes above the external pterygoid, through the mandibular (sigmoid) notch, and enters the deep surface of the muscle near the dorsal margin.

Relations.—It is covered by the masseteric fascia (see above). It lies upon the ramus of the jaw and ventrally is separated by a pad of fat from the buccinator muscle. At the mandibular (sigmoid) notch the sigmoid septum separates it from the external pterygoid muscle. The parotid gland partly overlaps its posterior border.

The **pterygoideus externus** (figs. 343–346) consists of two fasciculi. Each is thick and triangular. The superior is flattened in a horizontal, the inferior in a vertical, plane. At their origin they are separated by a narrow cleft. Near the insertion they become more or less fused. The **superior fasciculus** arises by short tendinous processes from the infratemporal (pterygoid) crest and from the neighbouring portion of the under surface of the great wing of the sphenoid. Its fibre-bundles converge toward the insertion, which takes place by short tendinous processes into—(1) the capsular ligament in front of the articular disc and (2) the upper third of the front of the neck of the condyle. The **inferior fasciculus** is the larger. It arises by short tendinous processes from the lateral surface of the lateral lamina of the pterygoid process, from the pyramidal process of the palate bone, and from the adjacent portions of the maxillary tuberosity. The fibre-bundles converge toward their insertion into a depression on the front of the neck of the condyle.

Nerve-supply.—A branch from the masticator nerve (motor root of the trigeminus) approaches the muscle near the upper border of the medial surface of the superior fasciculus and gives branches to both portions.

Relations.—It is partly covered by the maxillary fasciculus of the internal pterygoid and by the temporal and masseter muscles. Medial to it lies the chief fasciculus of the internal pterygoid muscle. The masseteric and the posterior and middle temporal nerves usually pass above the muscle, the anterior temporal and the buccinator nerves and frequently the internal maxillary artery between the two fasciculi. The internal maxillary vessels usually pass below the lower border of the muscle and across its external surface; and the auriculo-temporal, lingual, and inferior alveolar (dental) nerves cross the deep surface of the muscle.

The **pterygoideus internus** (fig. 346).—*Origin.*—From (1) the pterygoid fossa, and (2) from the maxillary tuberosity and the pyramidal process of the palatine, where these adjoin.

Structure and Insertion.—From the medial and lateral laminæ of the pterygoid process there arise aponeuroses and from the palatine bone at the lower margin of the fossa, and from the maxillary tuberosity and palatine bone in front of the external pterygoid, there arise short tendons. From these aponeuroses and tendons and directly from the fossa the fibre-bundles take a nearly parallel course downward, backward, and outward, and are inserted in part in a multi-penniform manner into the lower half of the internal surface of the ramus of the mandible. The insertion extends to the mylo-hyoid ridge. The muscle is divided at its origin into two fasciculi by the distal margin of the external pterygoid.

Nerve-supply.—The internal pterygoid nerve arises from the back of the mandibular nerve near the foramen ovale. It passes near or through the otic ganglion, and thence to the medial surface of the muscle near the dorsal edge. Both the buccinator and lingual nerves are also described as sending filaments to this muscle.

Relations.—Laterally the muscle is covered by the interpterygoid fascia and the sphenomandibular ligament, the external pterygoid, temporal, and masseter muscles, and the ramus of the mandible. The inferior alveolar (dental) and lingual nerves and the corresponding vessels run across this surface. Medial to the muscle lie the lateral pharyngeal fascia, the tensor veli palatini muscle, and the superior constrictor of the pharynx.

Action.—The muscles of this group adduct the lower jaw and serve to carry it forward and backward and from side to side. The elevation is produced by the masseter, temporal, and internal pterygoid muscles. The suprahyoid muscles and the external pterygoid are the feeble antagonists. The forward movement of the jaw is produced by the simultaneous action of the two external pterygoids (slightly by the superficial layer of the masseter, and the anterior fibres of the temporal) while the inferior posterior portions of the temporal muscles carry the jaw at the temporo-discoidal joint somewhat backward. Oblique lateral rotatory movements are produced chiefly by the action of one of the external pterygoids. The alternate action of these two msucles associated with the elevating action of the other muscles of the group, gives rise to the grinding movement of the molar teeth. Purely lateral movements of the jaw may be produced by the internal pterygoids, acting alternately. Lord (Anat. Rec., vol. 7, p. 355, 1913) states that in ordinary opening of the mouth the external pterygoids pull the articular discs and condyles forward while the jaw rotates about an axis passing through the insertions of the stylo-mandibular ligaments.

Variations.—The temporal muscle may have a more extensive cranial origin than usual. It may be formed of two superimposed layers. It may be more or less fused with the external pterygoid, or send a fasciculus to the coronoid process. The masseter may be completely

divided into two fasciculi, a condition normal in many mammals. A special fasciculus may arise from the temporo-mandibular articulation or from the zygomatic (malar) bone. Its deepest fibres may be fused with the temporal muscle. The two fasciculi of the external pterygoid may be distinct, as in the horse. It has been seen fused with the temporal and with the digastric muscle. The internal pterygoid may send a fasciculus to the masseter. It may give origin to the stylo-glossus. Inconstant fasciculi (*accessory pterygoids*) extending from the body of the sphenoid to the pterygoid process represent perhaps remnants of the muscles which act on the movable pterygoids possessed by many inferior vertebrates.

3. SUPRAHYOID MUSCULATURE

(Fig. 348)

From the hyoid bone there extend to the base of the skull on each side four muscles which form a fairly well-defined group. They are situated external to

FIG. 348.—ANTERIOR AND LATERAL CERVICAL MUSCLES.

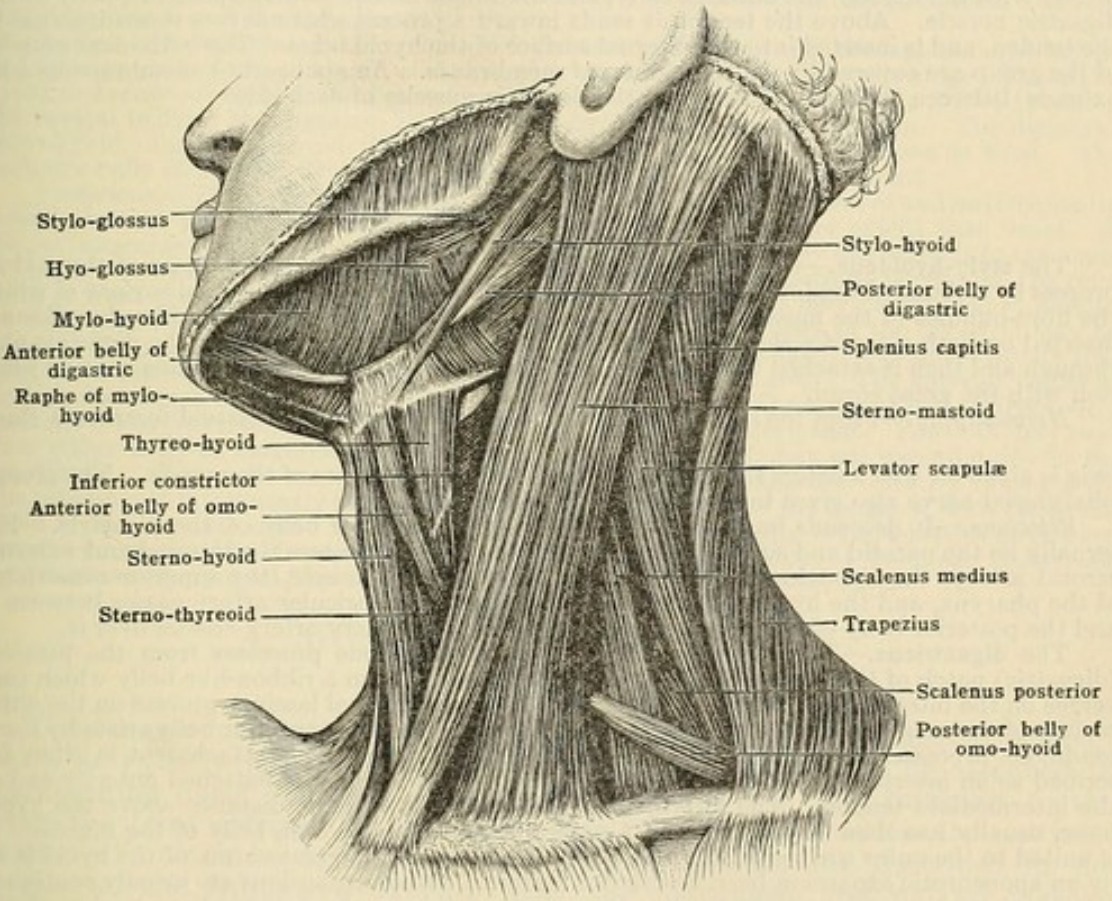

the musculature of the tongue and pharynx. They elevate the hyoid bone and larynx and depress the mandible. The most superficial of the group is the slender, fusiform **stylo-hyoid,** which arises from the styloid process of the temporal bone and is inserted into the body of the hyoid. Immediately behind this is the flattened posterior belly of the **digastric,** which extends from its origin in the mastoid notch to a tendon that runs between two divisions of the tendon of the stylo-hyoid and is attached to the hyoid bone by an aponeurotic process. From the digastric tendon the flat, triangular anterior belly is continued to the back of the ventral portion of the inferior margin of the mandible. Internal to this anterior belly the thin, quadrangular **mylo-hyoid** arises from the inner surface of the body of the mandible and is inserted into a median raphe extending from the mandible to the hyoid. Still more internally the triangular **genio-hyoid** extends from the hyoid to the mental spine of the mandible. The last two muscles form the muscular floor of the mouth. The motor innervation of the posterior belly

of the digastric and of the stylo-hyoid is from the seventh cranial nerve, the sensory innervation probably from the glosso-pharyngeal cranial nerve. The mylo-hyoid and the anterior belly of the digastric are supplied by the masticator (fifth) cranial nerve; the genio-hyoid from the hypoglossal by a branch, the fibres of which are possibly derived through anastomosis from the first cervical nerve.

From the morphological standpoint, therefore, the stylo-hyoid and the posterior belly of the digastric belong to the facialis group; the anterior belly of the digastric and the mylo-hyoid to the group of mandibular muscles, and the genio-hyoid to the muscles of the tongue innervated by the hypoglossal, or, if we consider the nerve-fibres of the nerve to the genio-hyoid as derived from the first cervical nerve, to the same group as the infra-hyoid muscles. It is convenient, however, to follow the usual custom of considering these muscles as a suprahyoid group.

FASCIÆ

The muscles of this group lie internal to that portion of the external cervical fascia which extends above the hyoid bone. This fascia, which is described on p. 347, comes into contact merely with the tendon, the anterior belly, and to a slight extent with the posterior belly of the digastric muscle. Above the tendon it sends inward a process which curves down internal to the tendon, and is inserted into the external surface of the hyoid bone. The individual muscles of the group are covered by delicate adherent membranes. An aponeurotic membrane usually extends between the anterior bellies of the digastric muscles of each side.

MUSCLES
(Fig. 348)

The **stylo-hyoideus.**—*Origin.*—From the lateral and dorsal part of the base of the styloid process by a rounded tendon which soon becomes a hollow cone to the internal surface of which the fibre-bundles of the muscle are attached. *Structure and Insertion.*—The fibre-bundles are inserted on both sides of a slender tendon which divides to let the tendon of the digastric pass through and then is attached to the ventral surface of the body of the hyoid bone near its junction with the great cornu.

Nerve-supply.—From the facial nerve as it emerges from the stylo-mastoid foramen a small twig is given off which enters the proximal third of the deep surface of the muscle. The glosso-pharyngeal nerve also gives to it a small twig, probably sensory.

Relations.—It descends immediately in front of the posterior belly of the digastric. Externally lie the parotid and submaxillary glands. Medially it crosses the internal and external carotid artery, the hypoglossal nerve, the stylo-pharyngeus muscle, the superior constrictor of the pharynx, and the hyo-glossus muscle. The posterior auricular artery passes between it and the posterior belly of the digastric and the external maxillary artery crosses over it.

The **digastricus.**—The **posterior belly** arises by tendinous processes from the mastoid (digastric) notch of the temporal bone. The fibre-bundles form a ribbon-like belly which converges on the intermediate tendon. This begins as a semiconical laminar process on the outer surface of the muscle a short distance above the hyoid bone. The **anterior belly** arises by short tendinous processes from the digastric fossa of the mandible. This attachment is often described as an insertion. The fibres converge on both surfaces of the flattened anterior end of the intermediate tendon. The **intermediate tendon** lies a variable distance above the hyoid bone, usually less than a centimetre. It curves upward toward each belly of the muscle. It is united to the outer surface of the body and to the base of the great cornu of the hyoid bone by an aponeurotic expansion from its inferior margin. Other expansions are usually continued into the interdigastric aponeurotic membrane. Occasionally the intermediate tendon of the digastric is bound to the hyoid bone by a fibrous loop which allows the tendon free play.

Nerve-supply.—The facial nerve near the stylo-mastoid foramen gives off a branch which enters the proximal third of the anterior margin of the muscle. From this a ramus may be continued through the muscle to the glosso-pharyngeal nerve. The anterior belly is supplied by a branch of the nerve to the mylo-hyoid muscle. This enters the middle of the lateral part of the deep surface. Very rarely the vagus may supply the anterior belly, the hypoglossal, the posterior belly.

Relations.—The posterior belly of the digastric lies internal to the mastoid process and the longissimus capitis (trachelo-mastoid), splenius, and sterno-cleido-mastoid muscles. Posteriorly near its origin are the rectus capitis lateralis and obliquus cap. sup. muscles, the occipital artery and the spinal accessory nerve. It helps to form the deep wall of the cavity in which the parotid gland is placed. Internally it crosses the origin of the styloid muscles, the carotid arteries, the internal jugular vein, and the twelfth cranial nerve. The intermediate tendon of insertion lies below the inferior margin of the submaxillary gland, and crosses the hyo-glossus and mylo-hyoid muscles. The relations to the stylo-hyoid muscle have been described above. The anterior belly lies on the mylo-hyoid and is covered by the external cervical fascia and the platysma.

The **mylo-hyoideus.**—*Origin.*—From the mylo-hyoid ridge of the mandible. *Structure and Insertion.*—Its fibre-bundles take an oblique course and are inserted into—(1) a median raphe extending from the middle of the ventral surface of the hyoid bone nearly or quite to the

dorsal surface of the inferior margin of the mandible, and (2) into the ventral surface of the hyoid bone. Some of the fibre-bundles may cross the median line. The muscles of the two sides form a sheet with a downward convexity which lies between the inner surface of the body of the mandible and the hyoid bone. On the diaphragm thus formed rests the tongue.

Nerve-supply.—From the mylo-hyoid branch of the inferior alveolar (dental) nerve several filaments enter the under surface of the muscle.

Relations.—The mylo-hyoid muscle is covered externally by the submaxillary gland, the anterior belly of the digastric, and the external cervical fascia. It is crossed by the submental artery. With the genio-hyoid and the genio-glossus muscles it helps to bound a compartment in which are lodged the sublingual gland, the duct of Wharton, and the deep portion of the submaxillary gland. Its deep surface also faces the stylo-glossus and hyo-glossus muscles, the lingual and hypoglossal nerves, and to a slight extent the buccal mucosa.

The **genio-hyoideus** (fig. 349).—*Origin.*—By short tendinous fibres from the mental spine of the mandible. *Structure and Insertion.*—The fibre-bundles diverge and are inserted into the ventral surface of the body of the hyoid bone. Usually a special fasciculus goes to the great cornu of the hyoid bone.

Nerve-supply.—The hypoglossal nerve sends a filament to the middle third of the deep surface of the muscle. The nerve-fibres are thought to be derived chiefly from the first cervical nerve.

Relations.—It lies between the genio-glossus and mylo-hyoid muscles. It adjoins its fellow of the opposite side and is often fused with it. Lateral to it lie the sublingual and submaxillary glands and the hypoglossal nerve.

Action.—The muscles of this group all elevate the hyoid bone and, through this, the larynx and inferior part of the pharynx, and thus play a part in the act of swallowing. The stylo-hyoid and posterior belly of the digastric serve also to draw the hyoid bone in a dorsal direction; the ventral belly of the digastric and the genio-hyoid, in a ventral direction. The digastric, genio-hyoid, and mylo-hyoid depress the mandible, when the hyoid bone is fixed. The posterior belly of the digastric has a slight power to bend the head backward.

Variations.—The stylo-hyoid tendon frequently passes entirely in front of and less frequently entirely behind the digastric muscle. Its insertion may be of greater extent than usual. A special fasciculus to the lesser cornu is not very infrequent; more rarely one extends to the angle of the jaw or to other regions. The muscle may arise from the petrous portion of the temporal or from the occipital bone, as in some lower vertebrates. It may be doubled or absent, or fused with the posterior belly of the digastric. The anterior belly of the digastric may be missing; the posterior belly may be inserted into the angle of the jaw. The intermediate tendons of the digastric of each side may be connected by a fibrous arch. The anterior bellies of the muscles of each side may be united by a fasciculus or fused. The anterior belly is frequently doubled. The posterior belly may be divided by a tendinous inscription. Fasciculi may pass from either belly to neighbouring structures. The mylo-hyoid may not extend quite to the hyoid bone. It may be more or less fused with neighbouring muscles. Rarely it is absent. The genio-hyoid is frequently more or less fused with the muscles of the tongue or with the genio-hyoid of the opposite side. A considerable number of infrequently found muscles have been described superficial to the stylo-hyoid and digastric muscles. Most of them are innervated by the glosso-pharyngeal nerve or by the facial nerve.

4. MUSCLES OF THE TONGUE

(Fig. 349)

The tongue is a flexible organ, composed chiefly of various muscles, some of which lie entirely within its substance, while others extend to be attached to neighbouring parts of the skeleton. To the former the term **intrinsic,** to the latter the term **extrinsic,** is frequently applied. In this section the extrinsic muscle will alone be taken up. The intrinsic muscles are described in the section on the DIGESTIVE SYSTEM. Certain pharyngeal and palatal muscles which are continued into the tongue are described in connection with the pharynx. The extrinsic musculature of the tongue is concealed below by the suprahyoid musculature and the sublingual gland. It is covered on the free surface of the tongue by the mucosa.

The musculature of the tongue is supplied by the hypoglossal nerve, which is in series with the motor roots of the spinal nerves. It is, primitively at least, derived from the ventral portion of myotomes in series with the spinal myotomes.

Four extrinsic muscles are recognised on each side. The **stylo-glossus** is a slender muscle, which arises from the styloid process and is inserted into the side of the tongue. It is cylindrical near its origin, flat and triangular near its insertion. The thin, quadrilateral **hyo-glossus** arises from the body and great cornu of the hyoid bone and is inserted into the dorsum of the tongue. The **chondro-glossus** arises from the lesser cornu of the hyoid bone and joins the superior and inferior longitudinal muscles of the tongue. The **genio-glossus** (genio-hyo-glossus), which forms the main part of the body of the tongue, arises from the mental spine of the mandible, from which the fibre-bundles radiate out toward the whole length of the dorsum of the tongue and to the hyoid bone.

Under the mucous membrane of the tongue is a dense layer of fibrous tissue, the **lingual fascia.** In the body of the tongue there is a sagittal **septum linguæ,** which separates the two genio-glossus muscles. A transverse fibrous lamella, the **hyo-glossal membrane,** helps to unite the tongue to the hyoid bone. Delicate membranes invest the free portions of the extrinsic muscles of the tongue.

MUSCLES

The **stylo-glossus.**—This *arises* from the front of the lower end of the styloid process of the temporal bone and from the upper part of the stylo-mandibular ligament. *Insertion.*—It runs obliquely downward, forward, and medially, with slightly diverging fibre-bundles, to the lateral margin of the tongue, where it gives rise near the anterior pillar of the fauces to two fasciculi. The larger, lateral, longitudinal fasciculus runs superficially along the lateral margin of the tongue to the tip. The fibre-bundles are attached to the overlying mucosa and underlying musculature. The smaller, inferior, transverse fasciculus gives rise to diverging fibre-bundles which pass medially through the hyo-glossus into the base of the tongue. The most posterior of these diverging bundles may extend to the hyoid bone.

The **hyo-glossus.**—This *arises* from—(1) the lateral part of the ventral surface of the body of the hyoid bone and (2) from the upper border of the great cornu. The fibre-bundles take a nearly parallel course upward, diverging, however, slightly. Near the upper margin of the back

FIG. 349.—SIDE VIEW OF THE MUSCLES OF THE TONGUE.

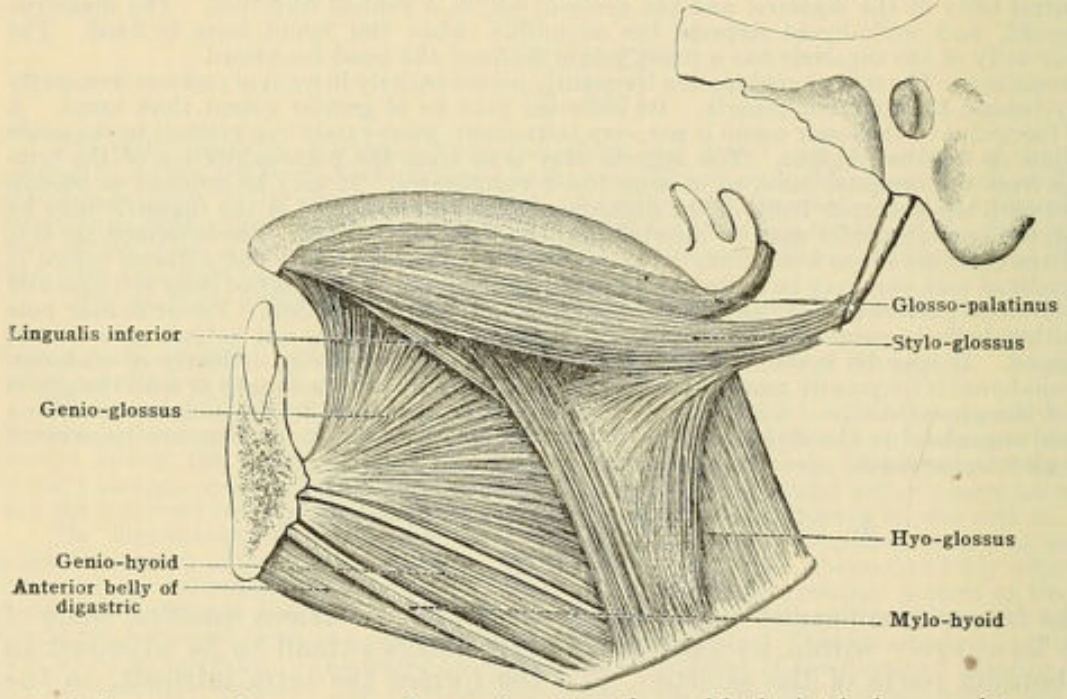

part of the tongue they curve medianward and interlace with the intrinsic musculature of this region. The dorsal fibre-bundles pass transversely, the middle obliquely, the ventral longitudinally. They are inserted into the fibrous tissue which forms the skeletal framework of the tongue.

The **chondro-glossus** is a small muscle which arises from the lesser cornu of the hyoid bone and gives rise to fasciculi which join the longitudinalis inferior and the longitudinalis superior of the tongue described in Section IX.

The **genio-glossus.**—This *arises* from the mental (genial) spine of the mandible partly directly, partly by means of a short, triangular tendon. The more inferior fibre-bundles radiate toward the tip of the tongue; the intermediate extend directly toward the dorsum of the tongue, where they are *inserted* into the lingual fascia and skeletal framework. The inferior curve back to be inserted on the median part of the superior border of the hyoid bone.

Nerve-supply.—Twigs from the hypoglossal nerve enter the lateral surfaces of the muscles of this group.

Action.—The chief of the muscles, the genio-glossus, performs various services according to the part which contracts. The anterior portion serves to withdraw the tongue into the mouth and depress the tip; the middle portion to draw the base of the tongue forward, depress the median portion of the tongue, and make the tongue protrude from the mouth; the inferior fibres to elevate the hyoid bone and carry it forward. The stylo-glossus retracts the tongue, elevates its margin, and raises the hyoid bone and base of the tongue. The hyo-glossus draws down the sides of the tongue and is also a retractor. The chondro-glossus aids in both these movements.

Relations.—The main portion of the tongue is composed of the two genio-glossus muscles, which are separated in the median line by the lingual septum. The genio-glossus is covered inferiorly by the genio-hyoid and the mylo-hyoid muscles; along the lateral margin of the tongue by the glosso-palatinus, the stylo-glossus, the longitudinalis inferior, and the glosso-pharyngeus

muscles; and posteriorly by the hyo-glossus, and the chondro-glossus. Below it forms a part of the medial wall of the space in which the sublingual gland is lodged. Over the dorsum and tip of the tongue it is covered by the mucosa. This likewise covers laterally, in the region of the base of the tongue, the stylo-glossus, hyo-glossus, and the longitudinalis inferior. The lingual artery runs between the hyo-glossus and the genio-glossus, and along the boundary between the longitudinalis inferior and the genio-glossus to the tip of the tongue. The lingual vein, which lies lateral to the hyo-glossus muscle, takes a similar although much more irregular course. The glosso-pharyngeal nerve passes down medial to the stylo-glossus muscle to the root of the tongue. The lingual nerve passes along the lateral margin of the tongue external to the stylo-glossus, hyo-glossus, and inferior longitudinal muscles. The hypoglossal nerve lies lateral to the inferior portion of the hyo-glossus muscle and then sinks into the genio-glossus.

The hyo-glossus muscle is covered laterally below the free portion of the tongue by the mylo-hyoid, digastric, and stylo-hyoid muscles and by the deep part of the submaxillary gland. Medially it covers in part the middle constrictor of the pharynx.

The stylo-glossus muscle above the tongue lies medial to the stylo-hyoid and the internal pterygoid muscles and the parotid gland, and between the internal and external carotid arteries. It lies lateral to the superior constrictor of the pharynx.

Variations.—The genio-glossus often sends a slip to the epiglottis (**levator epiglottidis**). It may send some bundles into the superior constrictor of the pharynx (**genio-pharyngeus**) or to the stylo-hyoid ligament. Various parts of the muscle may be more or less isolated. Of these, a fasciculus from the mental (genial) spine to the tip of the tongue is the most frequent (**longitudinalis linguæ inferior medius**). The hyo-glossus exhibits considerable variation in structure. Some authors consider the chondro-glossus but a portion of this muscle, while Poirier considers it merely the origin of the longitudinalis inferior. The stylo-glossus may be absent on one side or on both. Its origin varies considerably and may be from the angle of the jaw. The muscle may be doubled.

5. SUPERFICIAL MUSCULATURE OF THE SHOULDER GIRDLE AND THE EXTERNAL CERVICAL FASCIA

(Figs. 348, 355)

The **sterno-cleido-mastoid** is a strong, band-shaped muscle, bifurcated below, which arises from the medial third of the clavicle and the front of the manubrium and is inserted into the mastoid process of the temporal bone and the neighbouring part of the occipital. The large, flat, triangular **trapezius** arises from the occipital bone and the spines of the cervical and thoracic vertebræ and is inserted into the lateral third of the clavicle and into the acromion and spine of the scapula. The two muscles lie in a well defined layer of fascia which ensheaths the neck beneath the platysma, the external cervical fascia. Both muscles bend the head and neck toward the shoulder, rotate and extend the head, and raise the shoulder. The sterno-cleido-mastoid also elevates the thorax and flexes the neck.

These two superficially placed muscles represent differentiated portions of a musculature found in elasmobranchs and in the amphibia and all higher vertebrates. In sharks this musculature is associated with the musculature of the branchial arches, and, like them, is innervated by the vagus nerve. In the higher vertebrates it is innervated by the vagus or by the spinal accessory nerve, developed in connection with the vagus. To this innervation by a cranial nerve, innervation by cervical nerves is added in those higher vertebrates in which the musculature is more extensively developed. In the human embryo the muscles migrate from their origin in the upper lateral cervical region to the positions found in the adult.

FASCIÆ

The **fasciæ** of the neck and the relations of the muscles are shown in cross-section in figs. 347, and 351.

The tela subcutanea of the head and neck in the upper dorsal region is thick, fibrous, and closely adherent to the underlying muscle fascia. Ventrally in the cervical region it contains the platysma.

The **external cervical fascia** (fig. 350) lies beneath the subcutaneous tissue and the platysma, completely invests the neck and extends cranialward over the parotid gland to the zygoma and the masseteric fascia. The trapezius lies between two closely adherent laminæ of the fascia. From the ventral margin of the trapezius it is continued as a thin but strong membrane across the posterior triangle of the neck, between this muscle and the sterno- cleido-mastoid, and is attached below to the clavicle. It invests the sterno-cleido-mastoid with two adherent laminæ and extends from the ventral margin of this muscle across the anterior triangle to the mid-line where it is continued into that of the opposite side. In this triangle the fascia is bound to the hyoid bone, and is thus divided into a submaxillary and an infrahyoid portion. The **infrahyoid portion** is simple and is attached below to the front of the manubrium. The **submaxillary portion** is attached to the inferior margin of the mandible. It covers the submaxillary gland, and along the inferior margin gives rise to a strong, membranous process which passes inward below the gland and, after extending around the tendon of the digastric muscle, becomes united

to the superior margin of the hyoid bone. This process ventrally becomes fused with the perimysium of the ventral belly of the digastric. Dorsally it extends over the posterior end of the submaxillary gland and becomes attached to the angle of the jaw. Here it is strengthened by fibrous tissue which extends in from the ventral margin of the sterno-cleido-mastoid and serves to separate the parotid from the submaxillary gland. This 'mandibular process' is continued into the stylo-mandibular ligament.

FIG. 350.—FASCIÆ OF THE NECK. (After Eisler.) The superficial fascia has been removed in places in order to show the deeper fasciæ; the sterno-cleido-mastoid has been partly removed; the submaxillary gland, almost wholly; the parotid gland, as far as the duct.

1. Submaxillary space. 2. Parotid space. 3. Sterno-cleido-mastoid. 4 Supra-clavicular fossa. 5. Supra-sternal space. 6. External jugular vein. 7. Anterior jugular vein. 8. Median colli vein. 9. N occipitalis minor. 10. N. auricularis magnus. 11. Deltoid. 12. Proc. coracoideus. 13. Fascia coraco-clavicularis.

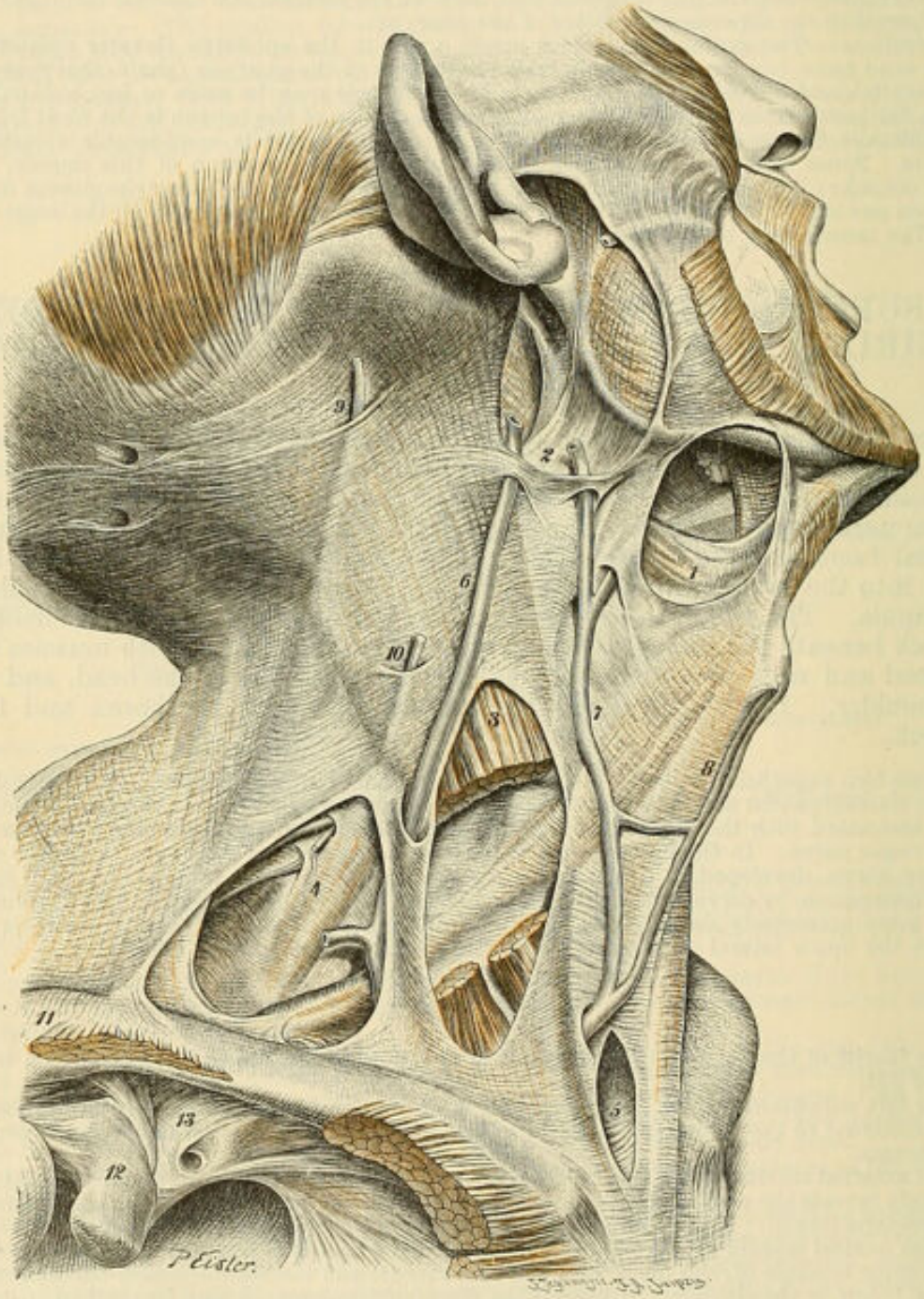

The **parotid gland** is enclosed between two laminæ of the external cervical fascia. These are continued over the gland from the fascial investment of the sterno-cleido-mastoid, and unite ventrally to become fused to the masseteric fascia along the anterior margin of the gland. They unite below the inferior margin of the gland, and are continued into the mandibular process mentioned above. The external layer, which is the thicker and stronger, is attached above to the cartilage of the auditory canal and to the zygoma. The inner lamina is attached above

to the base of the temporal bone. It is incomplete and is more or less fused to the posterior belly of the digastric muscle, the styloid process, and the muscles arising from this process. Between the styloid process and the angle of the jaw this lamina is strengthened to form the stylo-mandibular ligament.

In the back, beyond the spine of the scapula, the fascia arising from the investing adherent fascial sheath of the trapezius muscle is continued laterally across the fascia investing the infraspinatus muscle, and becomes fused with the most superficial layer of this fascia and more distally with that of the latissimus dorsi muscle. Near this lateral line of fusion it is usually closely adherent to the tela subcutanea.

MUSCLES

The **sterno-cleido-mastoideus** (fig. 348).—*Origin.*—By a medial (sternal) head from the front of the manubrium and by a lateral (clavicular) head from the upper border of the median third of the clavicle. Between the two origins there intervenes a triangular area covered by the external cervical fascia. Its *insertion* is—(1) on the anterior border and outer surface of the mastoid process, and (2) on the lateral half of the superior nuchal line of the occipital bone.

Structure.—The tendons are comparatively short, the longest being that on the anterior surface of the sternal attachment. The fibre-bundles of the muscle take a nearly parallel course from origin to insertion. Five fasciculi may be more or less clearly recognised. In a superficial layer—(1) a superficial sterno-mastoid; (2) a sterno-occipital; and (3) a cleido-occipital. In a deep layer—(4) a deep sterno-mastoid and (5) a cleido-mastoid.

Nerve-supply.—(1) From the spinal accessory nerve, which gives it branches during its course through the deep portion of the muscle, and (2) by branches from the anterior primary divisions of the second and third (?) cervical nerves. These branches enter the deep surface of the upper half of the muscle.

Action.—To bend the head and neck toward the shoulder and rotate the head toward the opposite side. When both muscles act, the neck is flexed toward the thorax and the chin is raised; or, with fixed head, the sternum is raised, as in forced respiration. When the head is bent back, the two muscles may further increase the hyperextension.

Relations.—The muscle and its sheath are covered externally by the tela subcutanea, which here contains the platysma and the external jugular vein, as well as the superficial branches of the cervical plexus. Beneath the muscle lie the sterno-hyoid, sterno-thyreoid, omo-hyoid, levator scapulæ, scaleni, splenius, and digastric muscles, the cervical plexus, the common carotid artery, internal jugular vein, and the vagus nerve. The spinal accessory nerve usually runs through its deep cleido-mastoid portion.

Variations.—There is considerable variation in the extent of independence of the main fasciculi of the muscle. In many of the lower animals the cleido-mastoid portion of the muscle is quite distinct from the sterno-mastoid portion, and this condition is frequently found in man. The cleido-occipital portion of the muscle is that most frequently absent (Wood found it present in 37 out of 102 instances). The clavicular portion of the muscle varies greatly in width. The sternal head has been seen to extend as far as the attachment of the fifth rib. Slips from the muscle may pass to various neighbouring structures. The main fasciculi of the muscle may be doubled. Sometimes one or more tendinous inscriptions cross a part or the whole of the superficial layer of the muscle.

The **trapezius** (fig. 355).—*Origin.*—By a flat aponeurosis from the superior nuchal line and external protuberance of the occipital bone, the ligamentum nuchæ, and the vertebral spines and supraspinous ligament from the seventh cervical to the twelfth thoracic vertebra. The aponeuroses of the right and left muscles are continuous across the middle line. Between the middle of the ligamentum nuchæ and the second thoracic vertebra, the aponeuroses give rise to an extensive quadrilateral tendinous area. At the distal extremity of the muscle they are also well developed.

Structure and Insertion.—The superior fibre-bundles pass obliquely downward, lateralward, and forward to the postero-superior aspect of the lateral third of the clavicle; the middle fibre-bundles, transversely to the medial edge of the acromion and the upper border of the spine of the scapula; the lower fibre-bundles, obliquely upward and laterally to terminate through a flat, triangular tendon on a tubercle at the medial end of the spine of the scapula.

Nerve-supply.—The external branch of the spinal accessory nerve descends for a distance near the superior border of the trapezius muscle and then along the ventral surface. Soon it gives rise to ascending branches for the superior portion of the muscle and descending branches for the middle and inferior portions. The main branches of distribution run about midway between the origin and insertion of the fibre-bundles. The branches from the second (?), third and fourth cervical nerves anastomose with the trunk of the spinal accessory, sometimes as it passes along the margin of the muscle, at other times within the substance of the upper portion of the muscle.

Action.—When the whole muscle contracts, it draws the scapula toward the spine and turns it so that the inferior angle points laterally, the lateral angle upward. In addition the upper portion draws the point of the shoulder upward, and with the scapula fixed extends the head, bends the neck toward the same side, and turns the face to the opposite side. The lower portion of the muscle tends to draw the scapula downward and inward and at the same time to rotate the inferior angle of the scapula outward.

Relations.—It is covered merely by skin and fascia. It lies external to the semispinalis, splenii, rhomboidei, latissimus dorsi, levator scapulæ, supraspinatus, and a small portion of the infraspinatus muscles.

Variations.—The lower limit of attachment of the muscle may be as high as the fourth thoracic vertebra. The right and left muscles are seldom symmetrical. The upper attachment may not extend to the skull. The clavicular attachment may be much more extensive

than normal or may be missing. The attachments to the scapula show considerable variations. Occasionally the cervical and thoracic portions are separate, a condition normal in many mammals. Ventrally the trapezius may become continuous with the sterno-cleido-mastoid in the neck, or send a fasciculus to it or to the sternum. Aberrant fasciculi are not infrequent. Rarely a transverse tendinous inscription is found in the cervical or in the thoracic portion of the muscle. Sometimes a fasciculus is sent into the deltoid. The innervation of either the sterno-cleido-mastoid or the trapezius may be by cervical nerves only. The *omo-cervicalis* (*levator claviculæ*) is a fasciculus frequent in the lower mammals, but rarely found in man. It usually extends from the acromial end of the clavicle to the atlas and axis, but may extend to more distal cervical vertebræ. It is innervated by a ramus from the cervical branches to the trapezius. The *supra-clavicularis proprius* is a muscle rarely found. It extends on the cranial surface of the clavicle from the sternal to the acromial end and is innervated by the third cervical nerve. It is said to make tense the superficial layer of the cervical fascia.

A **bursa** is often found between the base of the spine of the scapula and the tendon of insertion of the thoracic portion of the trapezius. Another bursa is also frequently found between the insertion of the transverse portion and the supraspinous fascia.

6. INFRAHYOID MUSCULATURE

(Figs. 348 and 351)

The four infrahyoid muscles constitute a well-defined group of muscles which depress the hyoid bone, the larynx, and the associated structures. They lie beneath the sterno-cleido-mastoid muscle and the external cervical fascia. Two strata may be recognised. In the superficial stratum are comprised the **omo-hyoid,** a narrow, ribbon-like digastric muscle which arises from the superior margin of the scapula and is inserted into the hyoid bone; and the thin, quadrangular **sterno-hyoid,** which arises from the superior margin of the sternum and the medial end of the clavicle and is inserted into the hyoid bone. Between these two muscles is an aponeurotic membrane which constitutes the main part of the middle layer of the cervical fascia, and represents possibly a retrograde portion of a single muscle, of which the two above named are but the ventral and dorsal margins. Beneath this superficial musculature the thin, quadrangular **thyreo-hyoid** descends from the hyoid bone to the thyreoid cartilage, and the ribbon-like **sterno-thyreoid** arises from the dorsal surface of the manubrium and is inserted into the thyreoid cartilage.

All these muscles are supplied by branches from the ansa hypoglossi. The nerve-fibres arise from the first three cervical nerves.

The muscles of this group are derived from the ventral portions of the ventro-lateral divisions of the first three cervical myotomes, and correspond with the rectus abdominis muscle, which is derived from the ventral portions of the eighth to the twelfth thoracic myotomes. This musculature is characterised by metameric segmentation, which may be more or less obscured, and by a general longitudinal direction taken by the component fibre-bundles. The course of the fibres in the omo-hyoid may be looked upon as a secondary condition due to the shifting laterally of the distal attachment of the muscle. Musculature of this nature is not derived from the lower cervical and upper thoracic myotomes in man, but in some of the lower vertebrates it forms a continuous ventral band. Even in man occasional traces of this ventral musculature may, however, be seen as muscular and aponeurotic slips on the upper part of the thoracic wall, above the ribs and the aponeurosis of the external intercostal muscles.

FASCIA

(Figs. 351 and 357)

The **middle cervical fascia** is composed of two laminæ. Of these, the superficial, which ensheaths the sterno-hyoid and omo-hyoid muscles and fills in the intervening area, is much the stronger and better differentiated. The more delicate deep lamina ensheaths the thyreo-hyoid and sterno-thyreoid muscles, and laterally extends out to become fused with the superficial lamina. It is also more or less closely bound to the sheath which covers the internal jugular vein, carotid artery, and vagus nerve.

The middle cervical fascia is attached above to the hyoid bone. Beyond the lateral edge of the omo-hyoid it becomes fused with the deep lamina of the external layer of the cervical fascia, beneath the sterno-cleido-mastoid. Posterior to this muscle it usually terminates along the cranial margin of the omo-hyoid in the areolar tissue of the neck. Its distal attachment takes place into the dorsal surface of the upper margin of the sternum, and from here a process is sent over the left innominate vein to the pericardium. Lateral to the sternum the fascia is attached for some distance to the inner margin of the clavicle, and gives rise to processes, one of which extends to the fascia of the subclavius muscle, while the others pass on each side of the subclavian vein to the first rib. Still more laterally the fascia is fused along the lower margin of the scapular belly of the omo-hyoid to the underlying dense, fatty areolar tissue.

MUSCLES

(Figs. 348 and 351)

The **sterno-hyoideus.**—*Origin.*—From (1) the deep surface of the medial extremity of the clavicle; (2) the costo-clavicular (rhomboid) ligament; and (3) the neighbouring part of the sternum. The origin may extend to the cartilage of the first rib. *Structure and insertion*—The fibre-bundles take a nearly parallel course upward. The muscle belly, however, contract. slightly in width and increases slightly in thickness and slants somewhat toward the median line. The insertion takes place directly upon the inferior margin of the body of the hyoid lateral to the mid-line. Not infrequently a tendinous inscription near the junction of the middle and inferior thirds more or less completely divides the muscle into two portions. A second inscription is sometimes found at the level of the oblique line of the thyreoid cartilage. *Nerve-supply.*—One or more branches from the ansa hypoglossi enter the lateral margin of the muscle. Frequently one goes to the upper third, another to the lower third, of the muscle.

The **omo-hyoideus.**—*Origin.*—From the superior margin of the scapula near, and occasionally also from, the superior transverse ligament of the scapula. *Insertion.*—The lower border of the hyoid bone lateral to the sterno-hyoid muscle. *Structure.*—The inferior belly of the muscle near its origin is thick and fleshy. It contracts as it passes ventrally across the posterior triangle of the neck. Beneath the sterno-cleido-mastoid it is attached to a short tendon from which, as it bends upward toward the hyoid bone, the superior belly takes origin and thence expands toward the insertion. The tendon of attachment is short. The fibre-bundles of both bellies take a nearly parallel course. The central tendon of the muscle is held in place by a strong process in the middle layer of the cervical fascia. This process is attached to the dorsal surface of the clavicle and to the first rib. *Nerve-supply.*—The superior belly is supplied by a branch which enters its deep surface near the medial margin somewhat below the centre; the inferior by a branch which enters the proximal third of its deep surface. These branches arise from the ansa hypoglossi.

The **sterno-thyreoideus.**—*Origin.*—Partly directly, partly by tendinous fibres, from—(1) the dorsal surface of the manubrium from the middle line to the notch for the first rib; (2) the dorsal surface of the cartilage of the first rib. Occasionally also from the back of the cartilage of the second rib or from the clavicle. *Structure and insertion.*—The fibre-bundles take a nearly parallel course upward and slightly lateralward. The muscle is inserted by short tendinous fibres into the oblique line on the lamina of the thyreoid cartilage. A transverse tendinous inscription near the upper border of the interclavicular ligament not infrequently divides the belly of the muscle more or less completely into two parts. Sometimes a second transverse inscription is found at the level of the lower margin of the thyreoid cartilage. *Nerve-supply.*—By one or two branches from the ansa hypoglossi, which enter the ventral surface of the muscle near the lateral margin. One branch usually goes to the upper, another to the lower, third of the muscle.

The **thyreo-hyoideus.**—*Origin.*—From the oblique line on the lamina of the thyreoid cartilage. *Structure and insertion.*—The fibre-bundles take a parallel course and are inserted on the inferior margin of the lateral third of the body of the hyoid bone and the external surface of the great cornu. Many fibre-bundles are continuous with those of the sterno-thyreoid. *Nerve-supply.*—By a branch of the hypoglossal which enters the muscle near the middle of its lateral border. The fibres are said to be derived from the first cervical nerve.

Action.—The sterno-hyoid and omo-hyoid depress the hyoid bone; the sterno-thyreoid depresses the thyreoid cartilage; and the thyreoid-hyoid approximates the bone to the cartilage. The omo-hyoid tends to draw the hyoid bone somewhat laterally. In this it is aided by the posterior belly of the digastric and the stylo-hyoid and is opposed by the sterno-thyreoid and thyreo-hyoid muscles, and the anterior belly of the digastric.

Relations.—The muscles of this group lie beneath the external cervical fascia. The sterno-cleido-mastoid muscle crosses the omo-hyoid, the sterno-hyoid, and sterno-thyreoid muscles. The latter two muscles extend for a distance behind the manubrium of the sternum. The omo-hyoid is partly covered by the trapezius, crosses the scalene muscles, the brachial plexus, the internal jugular vein, carotid artery, and the sterno-thyreoid and thyreo-hyoid muscles. The sterno-hyoid extends over the sterno-thyreoid muscle, the thyreoid gland, crico-thyreoid muscle, and the thyreoid cartilage. The sterno-thyreoid lies over the innominate vein, the trachea, and thyreoid gland. It is partly covered by the sterno-hyoid and omo-hyoid muscles. The thyreo-hyoid is largely covered by the omo-hyoid and sterno-hyoid muscles, and lies upon the hyo-thyreoid membrane and the upper part of the thyreoid cartilage.

Variations.—The muscles vary in extent of development and may be more or less fused with one another. The sternal attachment of the sterno-hyoid is more frequently absent than the clavicular attachment. The region between the omo-hyoid and sterno-hyoid may be composed of muscle instead of fascia. Each of the muscles may be longitudinally divided into two distinct fasciculi, may send fasciculi to one another or to the middle layer of the cervical fascia, or may have an abnormal origin or insertion. The omo-hyoid is the one of the group most frequently absent. One of the bellies is much more frequently absent than both. The intermediate tendon of the omo-hyoid may be reduced to a tendinous inscription or even disappear entirely. The distal attachment may take place on the scapular spine, the acromion, the coracoid process, or even the first rib or clavicle. An extra fasciculus from the clavicle is found in 3 per cent. of instances. (Le Double.). Not very infrequently a muscle innervated by a branch of the *descendens hypoglossi* is found extending from the sternum to the clavicle behind the origin of the sterno-cleido-mastoid. It may also extend from the sternum or clavicle in various directions upward toward the head.

FIG. 351, A and B.—TRANSVERSE SECTIONS THROUGH THE LEFT SIDE OF THE NECK AND SHOULDER IN THE REGIONS INDICATED IN THE DIAGRAM.

a and *b* in the diagram indicate sections A and B of fig. 347 (p. 340). *a*, that of section A, fig. 357 (p. 366).

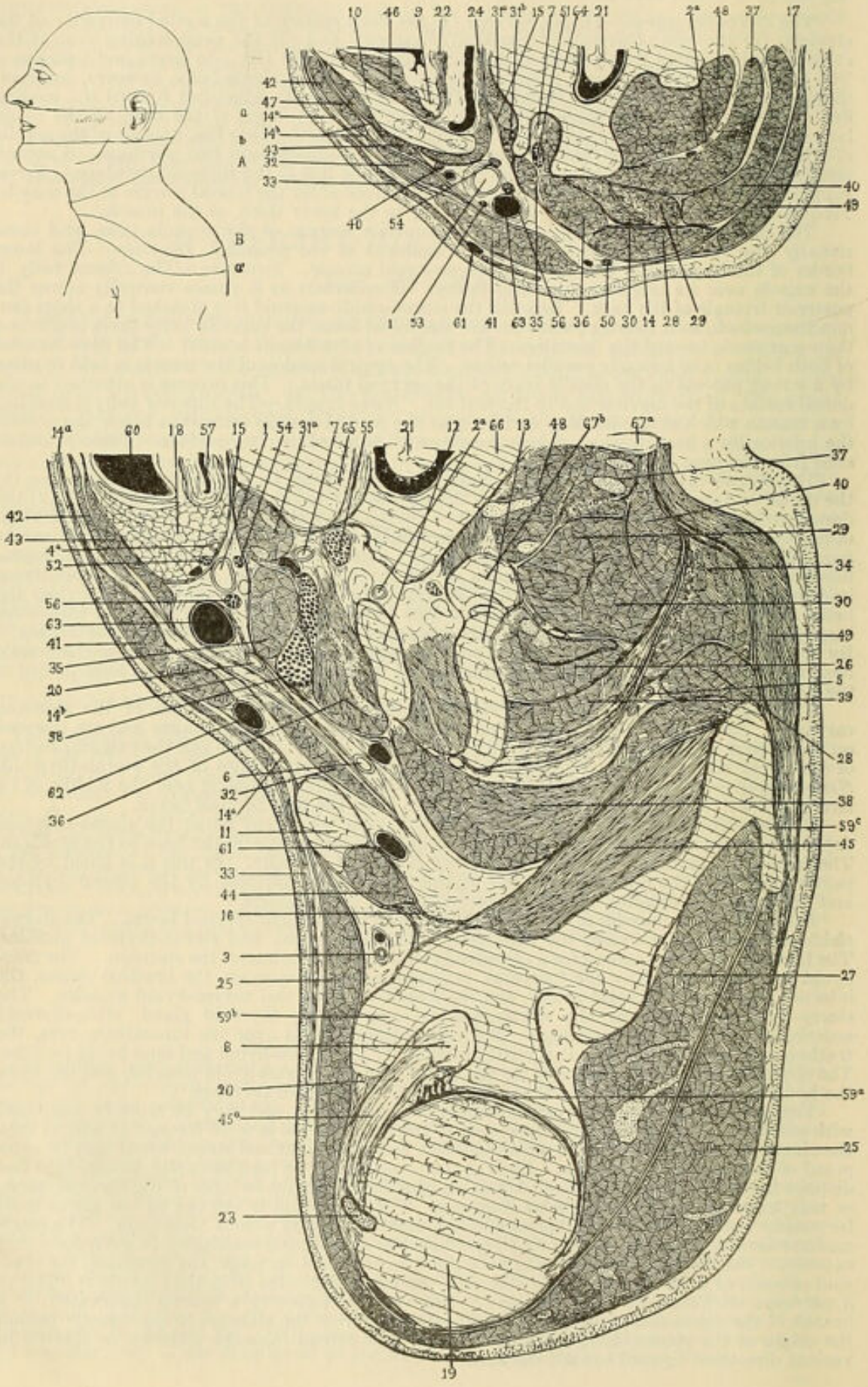

BURSÆ

The **bursa m. sterno-hyoidei** is in constantly found between the lower margin of the hyoid bone and median hyo-thyreoid ligament and the sterno-hyoid muscle and external cervical fascia. It is better developed in men than in women and is found either on each side of the median line or fused in the median line.

The **bursa m. thyreo-hyoidei** is frequently found between the greater cornu of the hyoid bone and hyo-thyreoid membrane and the thyreo-hyoid muscle.

7. SCALENE MUSCULATURE

(Figs. 348 and 352)

The three muscles which form this group constitute a triangular mass which extends in front of the levator scapulæ and intrinsic dorsal musculature and behind the prevertebral musculature from the first two ribs to the transverse processes of the cervical vertebræ. They cover laterally the apex of the pleural cavity. They bend the neck and fix the first two ribs or raise the thorax. In front lies the **scalenus anterior,** which extends from the first rib to the fourth to sixth vertebræ. Behind this the **scalenus medius** extends from the first rib to the lower six vertebræ. The most dorsal of the group, the **scalenus posterior,** extends from the second rib to the fifth and sixth vertebræ.

These muscles are supplied by direct branches of the cervical nerves. They are probably derived from the lateral portions of the cervical myotomes. According to Gegenbaur, the two more ventral are homologous with intercostal muscles, the dorsal with the levatores costarum. It is to be noted, however, that the anterior muscle lies in front of the brachial plexus, i. e., in a position similar to that of the subcostal musculature. The scalene musculature is morphologically closely related to the deep shoulder-girdle musculature, p. 356.

FASCIA

(Figs. 351, 357)

From the front of the bodies of the cervical vertebræ the prevertebral fascia is continued laterally over the longus colli and the scalene muscles, and extends dorsally into the fascia covering the levator scapulæ. Between the muscles fascial processes are sent in to become attached to the cervical vertebræ. Inferiorly the fascia extends to the outer surface of the thorax.

MUSCLES

(Fig. 352)

The **scalenus anterior.**—This *arises* from the ventral part of the inferior border of the transverse processes of the fourth, fifth, and sixth cervical vertebræ, usually also from the third, rarely from the seventh, by means of long, slender tendinous processes. From each tendon arises a fasciculus composed of nearly parallel fibre-bundles. The fasciculi soon fuse to form a muscle belly which contracts somewhat toward the insertion. This takes place by means of

1. Arteria carotis communis. 2*a*. A. cervicalis profunda. 2*b*. A. cervicalis superficialis 3. A. thoracoacromialis (acromial branch). 4*a*. A. thyreoidea inferior. 4*b*. A. thyreoidea superior. 5. A. transversa colli. 6. A. transversa scapulæ. 7. A. vertebralis. 8. Bursa m. subscapularis. 9. Cartilago arytenoidea. 10. Cartilago thyreoidea. 11. Clavicle. 12. Costa I. 13. Costa II. 14. Fascia cervicalis—*a*, superficial layer; *b*, middle layer. 15. Deep or prevertebral layer. 16. Fascia coraco clavicularis. 17. Fascia nuchæ. 18. Glandula thyreoidea. 19. Humerus. 20. Ligamentum coracohumerale. 21. Medulla spinalis (spinal cord). 22. Musculus arytenoideus transversus. 23. M. biceps brachii, tendon long head. 24. M. constrictor pharyngis inferior. 25. M. deltoideus. 26. M. llio-costalis. 27. M. infraspinatus. 28. M. levator scapulæ. 29. M. longissimus capitis (trachelo-mastoid). 30. M. longissimus cervicis. 31*a*. M. longus colli. 31*b*. M. longus capitis (rectus capitis anticus major). 32. M. omo-hyoideus. 33. M. platysma. 34. M. rhomboideus minor. 35. M. scalenus anterior. 36. M. scalenus medius. 37. M. semispinalis capitis (complexus). 38. M. serratus anterior. 39. M. serratus posterior superior. 40. M. splenius. 41. M. sterno-cleido-mastoideus. 42. M. sterno-hyoideus. 43. M. sterno-thyreoideus. 44. M. subclavius. 45. M. subscapularis; *a*, tendon. 46. M. thyreo-arytenoideus (and vocalis). 47. M. thyreo-hyoideus. 48. M. transverso-spinales. 49. M. trapezius. 50. Nervous accessorius. 51. N. cervicalis IV. 52. N. laryngeus inferior. 53. N. descendens hypoglossi. 54. Sympathetic trunk. 55. N. thoracalis I. 56. N. vagus. 57. Œsophagus. 58. Plexus brachialis. 59. Scapula—*a*, glenoid cavity; *b*, coracoid process; *c*, spine. 60. Trachea. 61. Vena transversa colli. 62. V. jugularis externa. 63. V. jugularis interna. 64. Vertebra cervicalis V. 65. Vertebra cervicalis VII. 66. Vertebra thoracalis I, arch. 67. Vertebra thoracalis II—*a*, spine; *b*, transverse process.

a tendon which sends a fibrous lamina a short distance upward on the outer surface of the muscle. The tendon is *inserted* into the scalene tubercle on the upper surface of the body of the first rib.

The **scalenus medius.**—This *arises* usually from the third to the seventh, sometimes from all seven or from merely the last four or five cervical vertebræ. The origin takes place from the posterior part of the lateral border of the transverse processes by means of a slender tendon from each of the upper and directly by a muscular fasciculus from each of the lower vertebræ. The fasciculi become combined into a compact muscle belly which is *inserted* in a manner similar to the scalenus anterior into the upper surface of the first rib behind the subclavian groove. The insertion usually extends to the second rib.

The **scalenus posterior** *arises* by short tendons from the posterior tubercles of the transverse processes of the fifth and sixth cervical vertebræ. The origin may extend as high as the fourth vertebra, or as low as the seventh. It is *inserted* by a short tendon into the lateral surface of the second rib. Occasionally it extends to the third rib.

FIG. 352.—THE DEEP VENTRAL MUSCLES OF THE NECK.

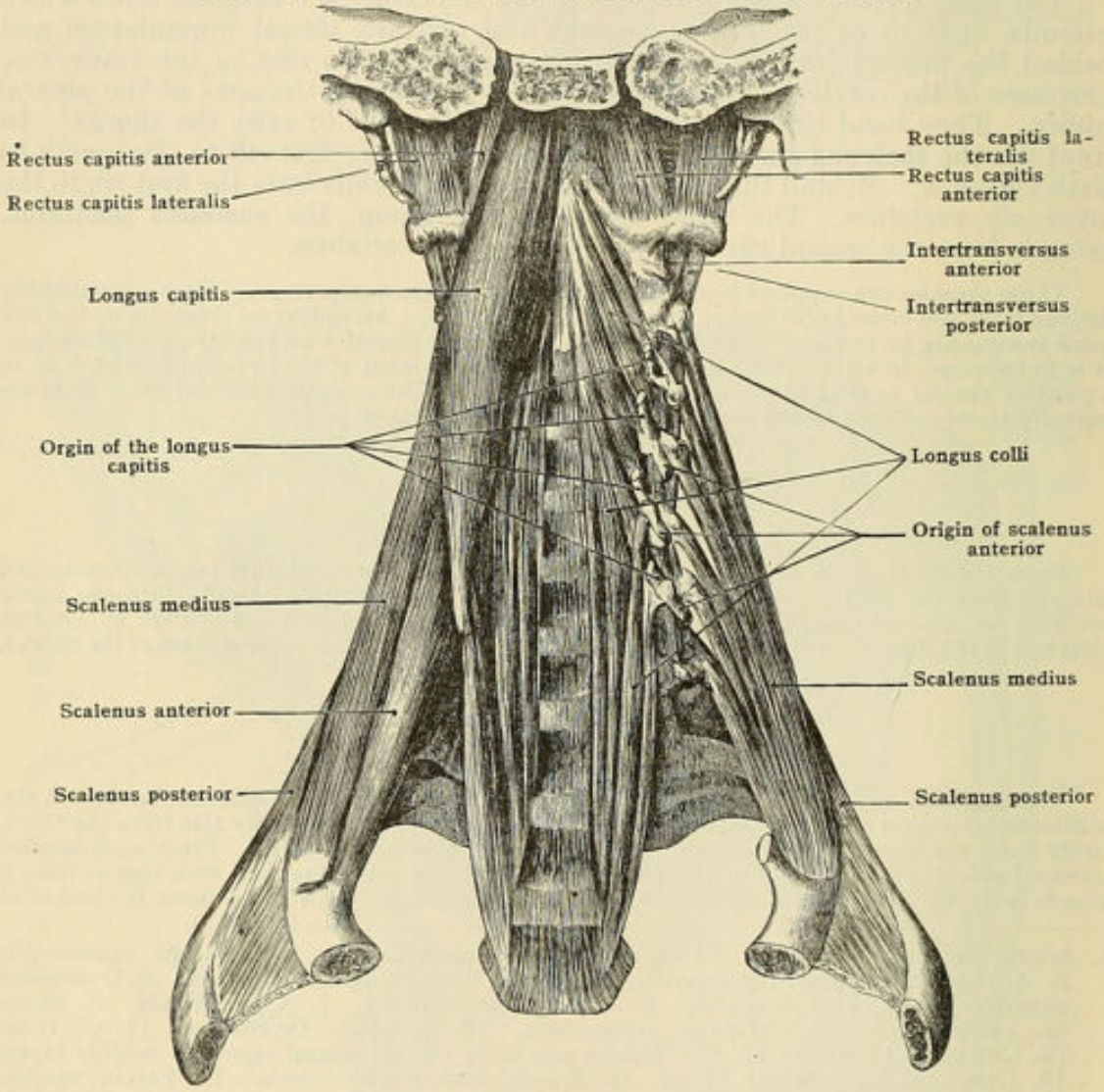

Nerve-supply.—The scalenus anterior is innervated by branches from the fifth, sixth, and seventh cervical nerves; the middle by the fourth, fifth, sixth, seventh, and eighth cervical nerves; the posterior by the seventh or eighth nerves.

Action.—With the thorax fixed the scalene muscles bend the neck to the side and slightly forward and turn it slightly toward the opposite side. With the neck fixed they serve to lift the first two ribs and are of use in enforced inspiration. In quiet inspiration they serve to fix the first two ribs.

Relations.—The longus colli lies medial to the scalenus anterior. Dorsally the scalene muscles; medially the pharynx, thyreoid gland, and trachea; ventro-laterally the sterno-cleido-mastoid, infra-hyoid, and subclavius muscles and the clavicle bound a space filled with dense fatty areolar tissue in which are contained the subclavian and carotid arteries, the subclavian and internal jugular veins, the vagus, phrenic, and sympathetic nerves, and numerous smaller blood-vessels and nerves. The main branches of the lower five cervical nerves pass laterally between the scalenus anterior and medius. The subclavian artery passes behind, the subclavian vein in front, of the attachment of the scalenus anterior. The scalenus medius above and the scalenus posterior below enter into relations dorsally with the levator scapulæ and the intrinsic dorsal musculature, from which they are separated by fascial septa.

Variations.—The scaleni present numerous variations in the extent of the costal and vertebral attachments. The degree of fusion of the various fasciculi likewise varies so much that different authors have described varying numbers of muscles into which the scalenus mass should be subdivided. A muscle frequently present is the **scalenus minimus.** This arises from the anterior tubercle of the sixth or sixth and seventh cervical vertebræ, and is inserted into the first rib behind the sulcus for the subclavian artery. It sends a process (Sibson's fascia) to the pleural cupola and serves to make the pleura tense. Zuckerkandl found it in 22 out of 60 bodies on both sides; 12 times on the right side only, 9 times on the left. It is innervated by the eighth cervical nerve. When absent, a ligamentous band takes its place. An *intertransversarius lateralis longus*, may extend from the posterior tubercles of the 3–5 transverse processes to the tip of the seventh transverse process and divide the muscle fasciculi near their origin into dorsal and ventral divisions.

8. THE PREVERTEBRAL MUSCULATURE

(Fig. 352)

This deep-seated musculature extends along the ventro-lateral surfaces of the three upper thoracic and the cervical vertebræ to the skull. It is composed of two muscles. The **longus colli** arises from the bodies of the three thoracic and from the bodies and transverse processes of the third to the sixth cervical vertebræ, and is inserted into transverse processes and bodies of the cervical vertebræ. The **longus capitis** (rectus capitis anterior major) arises from the transverse processes of the fourth, fifth, and sixth cervical vertebræ, and is inserted into the basilar process of the occipital bone. These muscles flex, abduct, and rotate the head and neck. All of them are supplied by direct branches from the anterior divisions of the cervical nerves. They are probably specialised from the ventro-lateral portions of the cervical myotomes. Similar muscles are found in all vertebrates with well-developed necks. The rectus capitis anterior (minor) represents an anterior cervical intertransverse muscle.

FASCIA

(Figs. 351, 357)

The muscles are firmly bound to the vertebral column by the prevertebral fascia described in connection with the scalene muscles and by the septa which extend in between the muscles of this group and between them and the scalenus anterior.

MUSCLES

(Fig. 352)

The **longus colli.**—This muscle may be compared to a triangle, the base of which extends from the anterior tubercle of the atlas to the body of the third thoracic vertebra and the apex of which is the transverse process of the fifth cervical vertebra. The complex construction of the muscle makes it advisable to consider it as divided into three parts.

The **supero-lateral portion** consists of fasciculi which arise from the anterior tubercles of the transverse processes of the third, fourth, fifth, and sixth cervical vertebræ and from the body of the third thoracic and become fused into a belly which is inserted into the anterior tubercle of the atlas.

The **median portion** is formed of muscle fasciculi which arise from the antero-lateral parts of the bodies of the first three thoracic vertebræ and the last three cervical vertebræ by tendinous processes. These fasciculi fuse into a belly which terminates by three flat tendinous fasciculi on the antero-lateral surfaces of the bodies of the second, third, and fourth cervical vertebræ.

The **infero-lateral portion** is applied to the inferior lateral surface of the median portion. It arises from the lateral parts of the bodies of the first three thoracic vertebræ and is inserted by tendinous processes into the transverse processes of the fifth and sixth cervical vertebræ.

Nerve-supply.—By branches from the second to sixth cervical nerves which send rami to the various constituent fasciculi of the muscle.

The **longus capitis** (rectus capitis anterior major).—*Origin.*—By cylindrical tendons from the tips of the anterior tubercles of the third, fourth fifth, and sixth cervical vertebræ. The tendons send up aponeurotic expansions on the outside of the fasciculi, which arise from them. These fasciculi fuse into a dense muscular belly to which is usually added a fasciculus from the longus colli. The *insertion* takes place into the impression on the inferior surface of the basilar portion of the occipital bone, extending lateral to the pharyngeal tubercle outward and forward. The insertion of the fibre-bundles from the third vertebra is direct; the other fibre-bundles are inserted largely into a tendinous lamina which covers the middle of the ventral surface of the muscle and from which, in turn, other fibre-bundles arise. It is an incomplete digastric muscle. *Nerve-supply.*—The first, second, third, and fourth cervical nerves send branches into the ventral surface of the muscle.

Actions.—The longus colli serves to bend the neck forward; the supero-lateral portion, when acting on one side only, serves slightly to bend the neck toward that side and to rotate it; the infero-lateral portion serves especially to prevent hyperextension. The longus capitis bends the head forward; one side acting alone rotates the head toward that side.

Variations.—There is considerable variation in the number of vertebræ to which the tendons of origin and insertion of the longus colli and longus capitis may be attached and in the extent of fusion of the different fasciculi composing them. There may be fusion with the scalenus anterior. The *atlantico-basilaris internus* in 4 per cent. of cases extends from the anterior tubercle of the atlas to the base of the skull.

9. ANTERIOR AND LATERAL INTERTRANSVERSE MUSCLES

(Fig. 352)

The **anterior intertransverse** muscles extend successively between the anterior tubercles of the cervical vertebræ. They lie in front of the anterior divisions of the cervical nerves and are supplied by branches from these divisions. They are usually more or less bound up with the insertions of the scalene and prevertebral muscles into these tubercles. The muscle between the atlas and epistropheus is frequently missing; when present, it passes in front of the lateral articulation between these vertebræ. The rectus capitis anterior (minor) may be considered a continuation of the series. The lowest muscle may extend between the seventh cervical vertebra and the first rib. The **lateral intertransverse** muscles lie immediately behind the ventral divisions of the spinal nerves and lateral to the dorsal divisions and are supplied by branches from the ventral divisions. The rectus capitis lateralis belongs to this series. The **rectus capitis anterior** (minor) arises from the lateral mass of the atlas and is inserted into the base of the occipital bone. The **rectus capitis lateralis** runs from the transverse process of the atlas to the lateral part of the occipital. For the posterior intertransverse muscles see p. 417.

The **rectus capitis anterior** (minor).—This *arises* from the upper surface of the lateral mass of the atlas in front of the articular process and partly from the neighbouring transverse process. From a tendon the fibre-bundles extend in a nearly parallel direction upward and medially to be *inserted* on the inferior surface of the basilar portion of the occipital bone in front of the condyle *Nerve-supply.*—From the first (and second) cervical nerves. *Action.*—The rectus capitis anterior (minor) serve to bend the head forward and, when the muscles on one side only are contracted, to rotate the head toward the same side.

Relations.—The muscles of this group are closely applied to the vertebral column. Between the fascia covering them and the fascia surrounding the pharynx which lies in front is a region in which merely a slight amount of loose areolar tissue is found. Dorso-medially the longus colli below and the longus capitis above help to bound the space in which the chief vessels and nerves extend between the thorax and the head.

The rectus capitis lateralis (fig. 352).—*Origin.*—From the upper surface of the transverse process of the atlas.

Structure and insertion.—The fibre-bundles give rise to a quadrilateral sheet which passes upward to be inserted on the under surface of the pars lateralis of the occipital bone.

Nerve-supply.—The ventral branch of the suboccipital (first cervical) nerve gives twigs to its ventral surface.

Action.—To flex the head laterally.

Relations.—In front lie the anterior primary division of the suboccipital nerve and the internal jugular vein. Behind the muscle lie the superior oblique and the longissimus capitis (trachelo-mastoid) muscles and the atlanto-occipital joint.

10. DEEP MUSCULATURE OF THE SHOULDER GIRDLE

(Figs. 348, 353, 354, 388)

To this group belong four muscles which arise in the lateral cervical region during embryonic development and become secondarily attached to the vertebral margin of the scapula. One of these muscles, the band-like **levator scapulæ** (fig. 353), remains in the cervical region. It extends beneath the sterno-cleido-mastoid, the trapezius, and the intervening fascia from the transverse processes of the first four cervical vertebræ to the medial angle of the scapula. A second, the large, quadrilateral **serratus anterior** (magnus) (fig. 354), comes to lie beneath the blade of the scapula and wanders with this to the thoracic region. It arises, in the adult, from the first nine ribs and is inserted into the vertebral margin of the scapula. The flat, quadrangular **rhomboideus major** and **rhomboideus**

minor (fig. 353) arise from the spines of the last cervical and first four or five thoracic vertebræ, pass obliquely downward across the deep dorsal muscles beneath the trapezius and are inserted into the vertebral margin of the scapula. The third to the seventh cervical nerves supply this set of

FIG. 353.—THE LEVATOR SCAPULÆ AND RHOMBOIDEI.

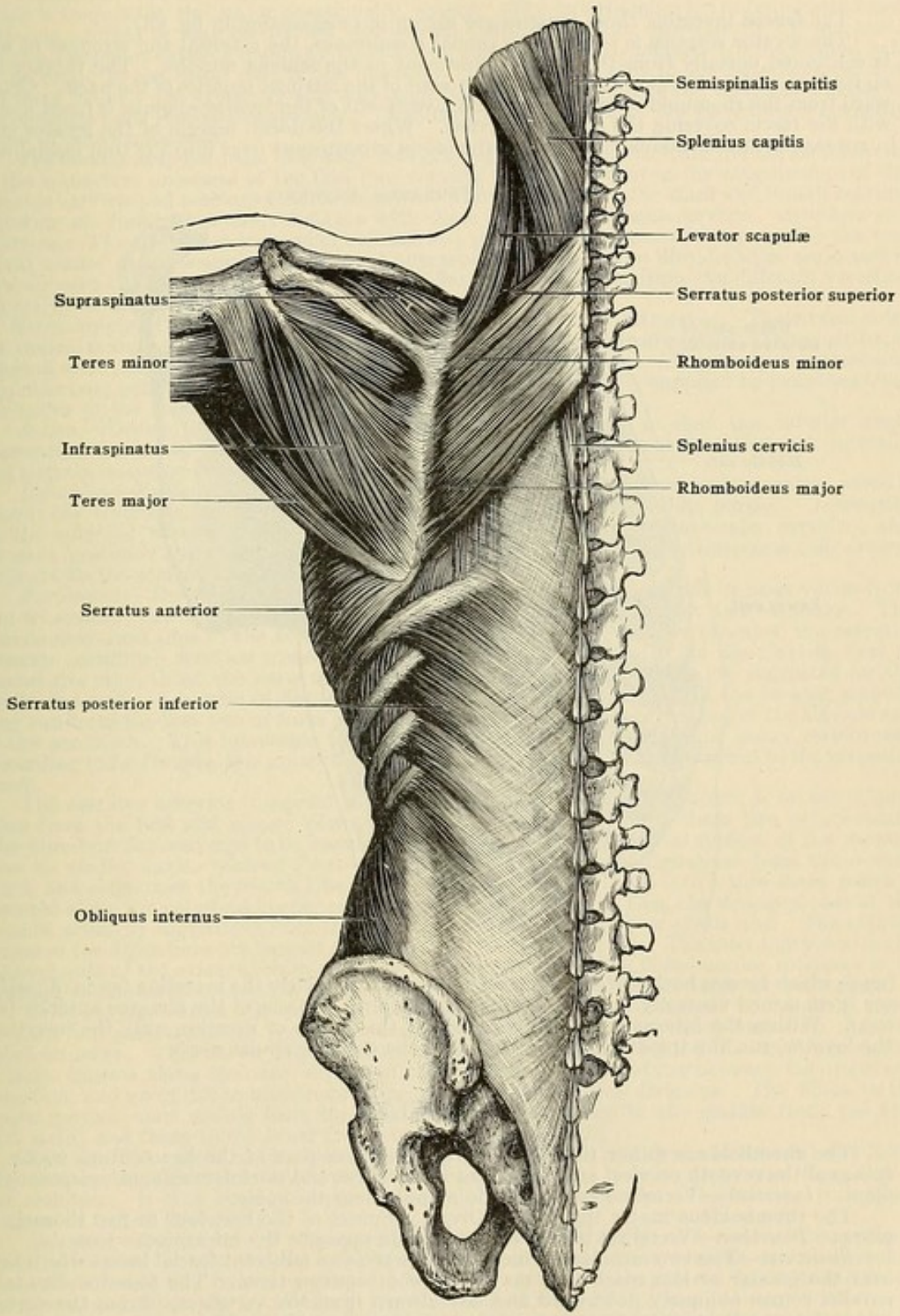

muscles. The levator scapulæ is supplied by the third and fourth cervical nerves, the rhomboids by the fifth (dorsal scapular), the serratus anterior by the fifth to the seventh (long thoracic nerve). The muscles of this group elevate the scapula, rotate it, and draw it backward (rhomboidei) or forward (serratus anterior). When all contract together they raise the thorax.

The levator scapulæ and the serratus anterior (magnus) are two differentiated parts of a muscle which is a continous mass in many of the lower mammals. A muscle corresponding to the rhomboideus is found in some of the reptiles and many of the higher vertebrates. In some of the mammals it has a more extensive cervical attachment than in man.

FASCIÆ

The **fasciæ** investing these muscles are shown in cross-section in fig. 357.

The levator scapulæ is invested by fascial membranes, the external and stronger of which is continued dorsally from the fascial investment of the scalene muscles. The thinner layer on its deep surface lies next the fascial investment of the intrinsic muscles of the back. Cranialward from the rhomboid muscles the fascial investment of the levator scapulæ is fused dorsally with the fascia covering the splenius cervicis. Where the dorsal margin of the levator comes in contact with the rhomboideus minor, the fascia is continued over into the thin fascial membrane which invests both surfaces of the rhomboidei. Similarly the investing fascia of the levator is continued ventrally into the fascia investing both surfaces of the serratus anterior (magnus). Within the internal fascial investment of this group of muscles, near the insertion of the levator, run the transversa colli artery and the dorsal scapular nerve.

FIG. 354.—SERRATUS ANTERIOR.

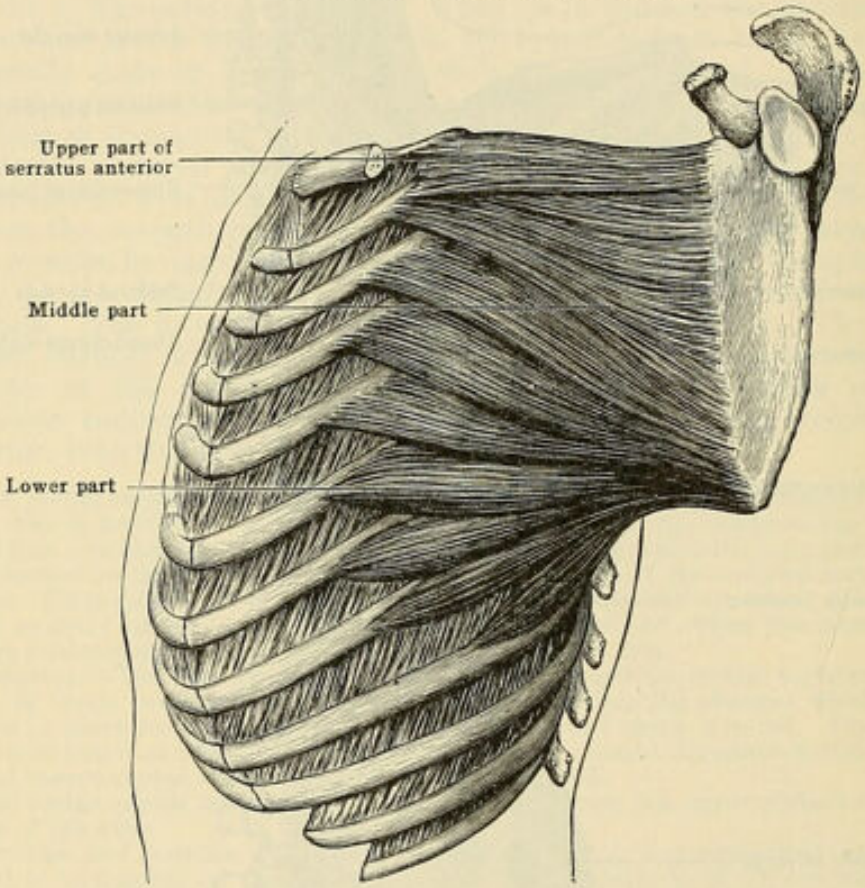

MUSCLES

The **rhomboideus minor** (fig. 353).—*Origin.*—Lower part of the ligamentum nuchæ, the spines of the seventh cervical and first thoracic vertebræ, and the intervening supraspinous ligament. *Insertion.*—Vertebral border of the scapula near the spine.

The **rhomboideus major** (fig. 353).—*Origin.*—Spines of the first four or five thoracic vertebræ. *Insertion.*—Vertebral border of the scapula opposite the infraspinous fossa.

Structure.—The two muscles are included between two adherent fascial layers which bridge over the greater or less space that may intervene between them. The fibre-bundles take a parallel course obliquely downward and lateralward from the vertebræ. From the vertebral spines the muscles arise by an aponeurosis which varies in width. The attachment to the scapula is by short tendinous processes. The attachment of the rhomboideus major is firmest toward the inferior angle of the scapula.

Nerve-supply.—The dorsal scapular nerve, which usually arises chiefly from the fifth cervical nerve, enters the superior margin of the rhomboideus minor and then courses distally near the deep ventral surface of the two muscles and about midway between the tendons of origin and insertion.

Action.—The two muscles draw the scapula upward and medialward toward the spine and rotate it so as to depress the shoulder.

Relations.—Over the muscles lies the trapezius. Under them lie the serratus posterior superior and the splenius cervicis, the longissimus dorsi, the ilio-costalis, serratus posterior superior and external intercostal muscles. The descending ramus of the transversa colli artery descends on the deep surface. Blood-vessels for the trapezius pass to this muscle between the two rhomboids.

Variations.—There is much variation in the extent of the vertebral attachment. The minor is frequently, the major occasionally, absent. The two rhomboids are frequently fused with one another or may be divided into several distinct fasciculi. Frequently (80 per cent., Balli) a fasciculus extends obliquely on the deep surface of the R. major from the cranial part of the origin to the distal part of the insertion. Slips may be sent to the latissimus dorsi or the teres major. An accessory slip may pass between the trapezius and splenius muscles to the occipital bone (**occipito-scapularis**). A muscle corresponding to this fasciculus is normally found in many mammals.

The **levator scapulæ** (figs. 353, 388).—*Origin.*—By short tendons from the dorsal tubercles of the transverse processes of the first four cervical vertebræ, between the attachments of the splenius cervicis and scalenus medius muscles. The tendons from the third and fourth cervical vertebræ are fused for a short distance with those of the longissimus cervicis. *Structure and insertion.*—The fibres run in parallel bundles in a dorso-lateral direction downward to the vertebral border of the scapula opposite the supraspinous fossa. The fibre-bundles are inserted directly into the periosteum. As a rule, the flat fasciculi arising from the different vertebræ are easily separated.

Nerve-supply.—By rami chiefly from the third and fourth cervical nerves. These rami enter the ventral margin of the muscle and extend obliquely across the dorsal surface of the constituent fasciculi about midway between the tendons of origin and insertion. Frequently anastomosing branches pass between the nerves. The lowest fasciculus is usually supplied by branches from the nerve to the rhomboid muscles (dorsal scapular).

Action.—Draws the scapula upward and tends to rotate it so that the inferior angle approaches the spine. When the scapula is fixed, the muscle serves to bend the neck laterally and slightly to rotate it toward the same side and extend it.

Relations.—Externally the sterno-cleido-mastoid and, in part, the splenius capitis cover it above; the trapezius, below; and the external cervical fascia, its middle portion. Internally lie the splenius cervicis, longissimus and iliocostalis cervicis (transversalis cervicis), and serratus posterior superior muscles and the ramus descendens of the transversa colli artery. In front lie the scalene muscles.

Variations.—The number of cervical vertebræ from which the muscle springs varies from two to seven. The most constant are the slips of origin from the first two vertebræ. The muscle may send slips to the temporal or the occiptal bone or to the trapezius, the serratus anterior (magnus), serratus posterior superior, and other muscles, or to the clavicle, first or second rib, etc. Often the parts of the muscle running to each vertebra are separated for the whole distance. A bundle of fibres that appears to be a detached slip of the levator scapulæ may run from the first two or from lower cervical vertebræ to the lateral end of the clavicle and to the acromion. This represents the **levator claviculæ** found normally in many vertebrates. According to Le Double, it is innervated by a branch from the cervical branches to the trapezius group.

The **serratus anterior** (magnus) (figs. 354, 388).—*First Part.*—The origin is by two digitations from the first and second ribs and from a fibrous arch uniting these two attachments. The fibre-bundles converge to be inserted on an oval space on the costal surface of the scapula near its medial angle. *Second Part.*—This arises by two or three digitations from the second, third, and sometimes the fourth ribs. The fibre-bundles spread out into a thin sheet which is inserted along the vertebral border of the scapula. *Third Part.*—This, the strongest part of the muscle, arises by digitations from the fourth or fifth to the eighth or ninth ribs. The attachments of the digitations are longest on the upper border of each rib. The interdigitate with the attachments of the external oblique muscle of the abdomen. The fibre-bundles converge to be inserted on the large oval space on the costal surface near the inferior angle of the scapula.

Nerve-supply.—From the proximal portions of the anterior divisions of the fifth, sixth, seventh, and sometimes the eighth cervical nerves branches arise which fuse into the long thoracic nerve. This nerve usually passes laterally through or behind the scalenus medius muscle, courses along the outer surface of the serratus anterior midway between the origin and insertion, and gives rise to numerous twigs to supply the various divisions. The fibres to the upper portion come mainly from the fifth cervical nerve; those to the middle from the fifth and sixth; and those to the lower from the sixth and seventh.

Action.—The muscle holds the scapula against the thorax and draws it forward and laterally and, by its highly developed inferior portion, rotates the bone so as to raise the point of the shoulder. It is of especial importance in abduction of the arm. It also aids, to a slight degree, in forced inspiration.

Relations.—Superficial to the muscle lie the pectoralis major and minor, subscapularis, teres major, and latissimus dorsi muscles, the subclavian and axillary vessels, and the brachial plexus. Between the latissimus dorsi and pectoral muscles it is covered by skin and fascia inferiorly, and superiorly by the fatty areolar tissue of the axillary fossa. Under it lie the external intercostal, serratus posterior superior, and the lower extremity of the scalenus medius and posterior muscles.

Variations.—The digitations may extend to the tenth or only to the seventh rib. The muscle may be continuous with the levator scapulæ as it is in the carnivora, or some of its upper digitations may be wanting. Slips may be continued into neighbouring muscles. The lower digitations may be partially replaced by digitations innervated by intercostal nerves.

II. MUSCULATURE OF THE UPPER LIMB

The upper limbs in man, relieved of the function of locomotion which is their chief office in most of the lower mammals, have become endowed with great

FIG. 355.—FIRST LAYER OF MUSCLES OF THE BACK.

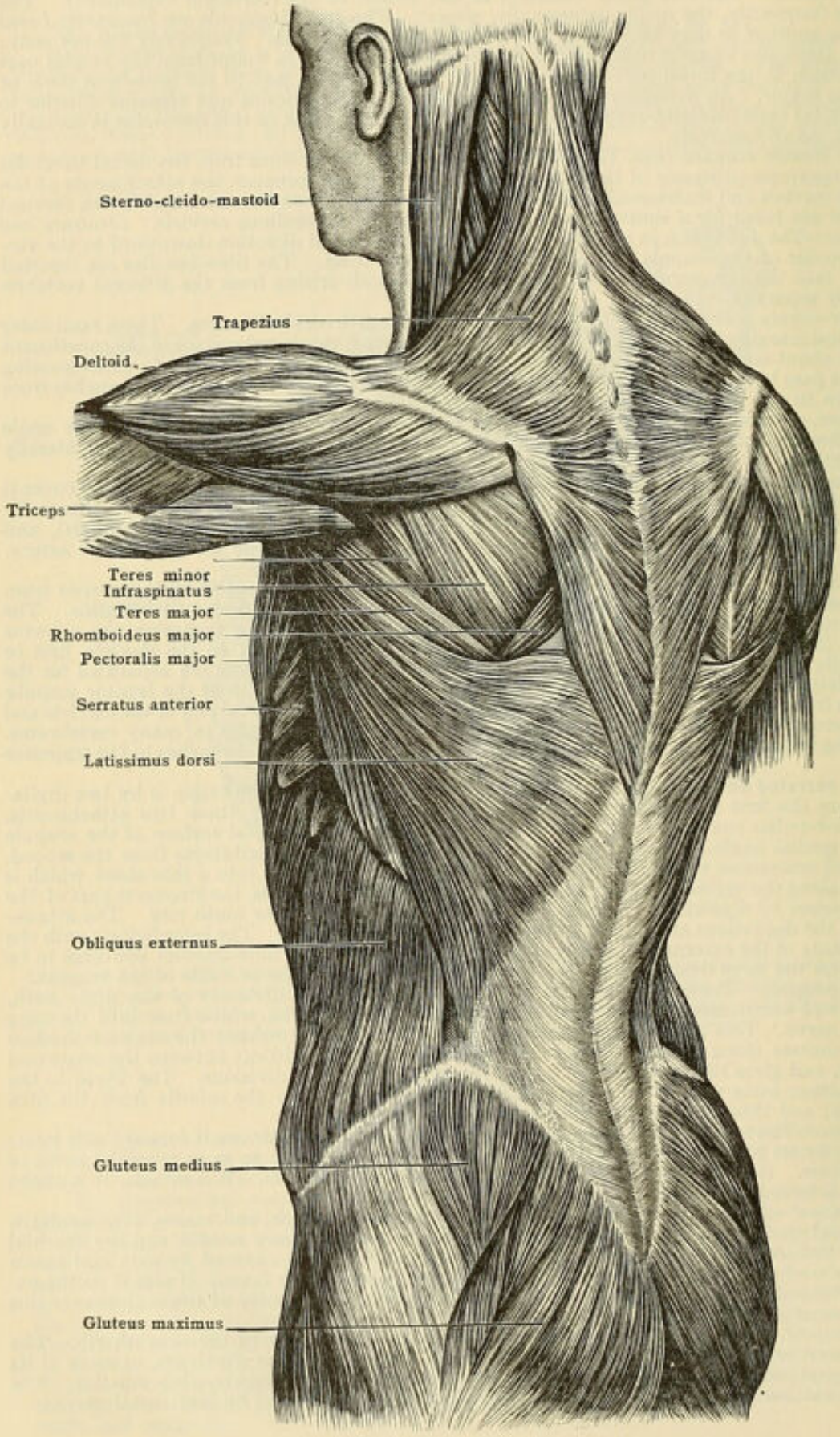

freedom of movement which permits their developing many important functions. Primitively of value in climbing, in seizing food, preparing it for eating and carrying it to the mouth, in attack and defense, their importance has been greatly increased through the invention and use of tools, at first simple but constantly increasing in complexity. They are also used as a means of social expression, as seen primitively in the shrugging of the shoulders, or in the varied movements of the arms which accompany heated discourse, and as finally developed in the art of writing. In order to understand the muscles which are called into play in the performance of these varied functions it is necessary to consider the various types of movement which take place at each of the joints. Since, however, most muscles act on more than one joint and the different parts of a muscle may act differently on the same joint, it is convenient to take up the muscles of each region of the limb in groups, based not so much upon the action of the muscles on any one joint as upon the development of the group and the innervation of the muscles composing it.

Movement of the scapula is of essential importance in the movements of the arm. The scapula is kept against the thorax by muscular attachments and atmospheric pressure, but it may be moved forward, backward, upward, and downward, and may be rotated so that the glenoid fossa, with which the head of the humerus articulates, is pointed forward when the arms are carried forward, lateralward when the arms are abducted, upward when the arms are raised high and somewhat downward when the arms are carried backward, thus greatly increasing the extent of movement in these various directions. The acromio-clavicular, and sterno-clavicular joints both allow limited movements in various directions so that they resemble physiologically limited ball and socket joints. The part played by the superficial and deep shoulder-girdle muscles in the various movements has been described above, p. 356, in connection with these groups of muscles. The action of these muscles is aided by the "pectoral muscles," (figs. 360, 388) and by the latissimus dorsi (fig. 355) described below. These muscles depress the scapula*

At the humero-scapular or shoulder-joint the arm may be carried outward or abducted, bodyward or adducted, forward or flexed and backward or extended. The last is much more limited in degree than the other two. The arm may also be partially rotated at this joint. These various movements are brought about by the scapulo-humeral muscles (figs. 355, 356, 363) and by the latissimus dorsi (fig. 355) and the pectoralis major, (fig. 360) assisted by the muscles of the arm which arise from the scapula. They are produced in association with the movements of the scapula described above. At the ulno-humeral joint the movements are relatively simple, consisting of flexion and extension. Extension is produced at the elbow by the dorsal muscles of the arm (fig. 363), flexion is produced not only by the ventral muscles of the arm, which are inserted into the radius and ulna (fig. 364), but also by the more superficial of both the main groups of muscles of the forearm. The pronation of the forearm, whereby the palm is turned downward, and supination, whereby it is turned upward, take place in the joints between the radius and ulna at each extremity and between the radius and the lower end of the humerus. At the upper radio-ulnar joint the radius is turned on its long axis, at the lower joint it is carried about the lower end of the ulna. Pronation is produced chiefly by muscles belonging to the ulno-volar group of forearm muscles (fig. 370); supination is produced by the biceps of the arm (fig. 364) in conjunction with some of the muscles of the radio-dorsal group of the forearm (fig. 367). At the wrist joints (radio-carpal, intercarpal), the movements are those of flexion, extension, radial abduction and ulnar abduction. Volar flexion takes place chiefly at the radio-carpal joint, dorsal flexion at the intercarpal joint (Frohse). Extension is produced by those muscles of the radio-dorsal group of the forearm, which send tendons to the wrist and digits, flexion by the corresponding muscles of the ulno-volar group, radial abduction is produced by the radial carpal extensors (fig. 367), and flexor ulnar abduction by the ulnar carpal extensor and flexor (fig. 370). The varied movements of the thumb and fingers, flexion, extension, abduction, and adduction are produced partly by muscles of the two chief groups of forearm muscles, partly by the intrinsic muscles of the hand. Of chief interest here are the free movements of the metacarpal of the thumb and the limited movements of the other metacarpals, that of the little fingers being the most movable, as seen in spreading or cupping the hand. In flexion and extension of the metacarpal of the thumb the movement is such as to bring the thumb into opposition to the fingers. In the metacarpo-phalangeal joints those of the fingers admit of much greater freedom of movement, flexion, extension, abduction, and adduction, than that of the thumb. The interphalangeal joints are pure hinge joints and permit merely flexion and extension.

Divisions.—The muscles described in this section as the muscles of the upper limb are all differentiated from the blastema of the embryonic limb bud. Most of them are differentiated in connection with the skeleton of the limb and extend between the various bones which compose it, but a few grow out from the limb bud over the trunk and become secondarily attached at one extremity to the trunk, while the other extremity remains attached to the skeleton of the limb. Thus the pectoral muscles (fig. 360), extend from the limb bud over the front of the thorax and the latissimus dorsi extends over the side and back of the trunk

* The upper sternal part of the pectoralis major, however, acting alone elevates the scapula. and the glenoid fossa, the latissimus dorsi draws the scapula backward, the pectoral muscles draw it forward.

as far as the iliac crest (fig. 355). The muscles of the limb may be divided into two great divisions, a dorsal division, innervated by nerves arising from the back of the brachial plexus (supra- and subscapular, axillary and radial nerves) and a ventral division innervated by nerves arising from the front of the plexus (subclavian, anterior thoracic, musculo-cutaneous, median and ulnar). The former, which correspond with the musculature on the back of the shark's fin, are in the main extensors; the latter, which correspond with the musculature on the front of the shark's fin are in the main flexors. The bellies of the muscles of each division are found in the region of the shoulder and thorax, the arm, the forearm, and the hand.

The **shoulder muscles** belong to the dorsal division. They arise from the lateral third of the clavicle and from both surfaces of the scapula and are inserted into the upper part of the humerus. They include the *deltoid* (fig. 355), the chief abductor of the arm; the *supraspinatus*, the *infraspinatus* and the *teres minor* (fig. 363), all lateral rotators; the *subscapularis* (fig. 356), the chief medial rotator; and the *teres major* (fig. 355), a medial rotator and adductor. With these may be classed the *latissimus dorsi* (a medial rotator, adductor and extensor) (fig. 355), which arises from the dorsolumbar fascia and the crest of the ilium and is inserted into the upper part of the shaft of the humerus. These muscles are supplied by the suprascapular, the subscapular, and the axillary nerves.

The **pectoral group** belongs to the ventral division. It includes the *pectoralis major* (fig. 360), a powerful flexor and adductor of the arm arising from the anterior chest wall and inserted into the shaft of the humerus; the *pectoralis minor* (fig. 388), which arises from the chest wall and is inserted into the coracoid process of the scapula, and the *subclavius* (fig. 361), which extends from the first rib to the clavicle. These muscles are supplied by the subclavian and the anterior thoracic nerves.

In the **arm** the **dorsal division** is represented by the triceps and anconeus, (fig. 363). The *triceps* arises from the scapula and the back of the humerus and is inserted into the olecranon process of the ulna. The *anconeus* arises from the radial epicondyle of the humerus and is inserted into the olecranon process. Both muscles extend the forearm. The triceps also adducts the arm. They are supplied by the radial nerve.

The **ventral division** is made up of the coraco-brachialis (fig. 365); the biceps (fig. 364); and the brachialis (fig. 365). The *coraco-brachialis* (fig. 365), arises from the tip of the coracoid process of the clavicle and is inserted into the shaft of the humerus. It adducts and flexes the arm. The *biceps* (fig. 364), arises by a short head from the coracoid process and by a long head from the scapula above the glenoid fossa and is inserted into the radius and the fascia of the forearm. It flexes and supinates the forearm. The long head is an abductor, the short head an adductor and flexor of the arm. The *brachialis* (fig. 365), arises from the lower part of the shaft of the humerus and is inserted into the ulna. It is a flexor of the forearm.

The two main divisions of the musculature of the **forearm** give rise to the prominences on each side of the elbow-joint. Their peculiar arrangement with respect to the humerus is because in man, as in most tetrapods, the normal position of the forearm is one of pronation and in this position the back of the forearm is in line with the radial epicondyle, the front with the ulnar epicondyle. The dorsal or extensor muscles, springing from the lower end of the humerus (fig. 367), get the most direct purchase when attached to the radial epicondyle, and the ventral or flexor muscles (fig. 370), the most direct purchase when attached to the ulnar epicondyle. The two divisions of the musculature may therefore here be designated the radio-dorsal and the ulno-volar or volar divisions. The main bulk of the musculature is found in the upper part of the forearm. At the wrist numerous tendons pass over to the wrist, palm and digits. This arrangement facilitates movement of the hand.

The muscles of the **dorsal division** (figs. 367, 368, 369), are divisible into two groups, a superficial and a deep group. Those of the superficial group arise from the radial side of the lower end of the humerus and are inserted into the dorsal end of the radius (*brachio-radialis*), the radial and ulnar sides of the metacarpus (*extensor carpi radialis longus* and *brevis* and *extensor carpi ulnaris*) and into the backs of the digits (*extensores digitorum*). The deeper muscles arise chiefly from

the ulna and are inserted into the radius (*supinator*), the thumb (*abductor pollicis longus, extensor pollicis longus* and *brevis*) and index-finger (*extensor indicis proprius*, fig. 369). All are supplied by the radial nerve. The chief function of the brachio-radialis is to flex the forearm. The chief functions of the other muscles are indicated by their names.

The **volar musculature** (figs. 370, 371, 372, 375) arises from the medial side of the lower end of the humerus and from the front of the radius and ulna and is divisible into four planes. The muscles of the most superficial plane, *pronator teres, flexor carpi radialis, palmaris longus*, and *flexor carpi ulnaris*, arise from the humerus and are inserted respectively into the radius, the radial side of the metacarpus, the palmar fascia and the ulnar side of the metacarpus. In the second layer the *flexor digitorum sublimis* arises from the humerus and the upper part of the radius and ulna and sends tendons to the second row of phalanges of the fingers. In the third layer the *flexor digitorum profundus* and *flexor pollicis longus* arise from the radius and ulna and send tendons to the terminal row of phalanges. In the fourth layer a single muscle, the *pronator quadratus* (fig. 377), extends in the lower part of the forearm from the radius to the ulna. These muscles are supplied mainly by branches of the median nerve but the ulnar nerve supplies the flexor carpi ulnaris and a part of the flexor profundus digitorum. The chief functions of these muscles are indicated by their names.

In the **hand** (figs. 368, 375, 376, 377, 379) there are several sets of intrinsic muscles. About the metacarpal of the thumb is grouped a set of muscles which arise from the carpus and metacarpus and are inserted into the metacarpal and first phalanx of the thumb (*flexor brevis pollicis, opponens pollicis, abductor pollicis brevis, adductor pollicis*). A similar set of muscles is grouped about the metacarpal of the little finger (*abductor digiti quinti, opponens digiti quinti, flexor brevis digiti quinti*). These sets of muscles give rise respectively to the thenar and hypothenar eminences. Between the metacarpals two sets of *interosseous* muscles arise; a *volar*, adductor toward the middle finger and a *dorsal*, abductor group. They are inserted into the sides of the bases of the first row of phalanges and into the extensor tendons. They also flex the first row of phalanges and extend the other two rows. From the tendons of the deep flexor muscle of the fingers, a series of *lumbrical* muscles extends to the radial sides of the extensor tendons. They flex the first row of phalanges and extend the other two. Over the thenar eminence there is a subcutaneous muscle, the *palmaris brevis*. The muscles of the hand are supplied by the ulnar nerve, with the exception of the two more radial *lumbricals* and the *abductor, opponens*, and *flexor brevis* of the thumb, which are supplied by the median nerve.

Fasciæ.—The muscle fasciæ of the upper extremities are well developed. The deltoid and latissimus dorsi are contained in a fascial sheet which extends between them. The deeper muscles which arise from the scapula are covered by strong fasciæ. Of the pectoral muscles the pectoralis major is covered by a delicate fascia, while the subclavius and pectoralis minor are contained within the dense *costo-coracoid membrane* (fig. 358) which extends into the fascia covering the axillary fossa. The latter (fig. 359), is thin and is intimately fused to the tela subcutanea. The muscles of the arm are enveloped in a cylindrical sheath which in the lower half of the arm is united to the humerus by intermuscular septa.

In the forearm near the wrist and on the back of the hand the tela subcutanea contains little fat. The antibrachial fascia forms a cylindrical enclosure for the muscles of the forearm. Near the wrist it becomes strengthened dorsally to form the dorsal ligament of the carpus (posterior annular ligament). This ligament converts the grooves on the back of the radius into canals for the tendons of the extensors of the wrist and fingers. On the back of the hand and fingers the fascia is intimately connected with these tendons. On the volar side near the wrist the fascia is strengthened to form the volar ligament of the carpus. Beneath the ligament lies the transverse ligament of the carpus which extends from the pisiform and hamate bones to the tuberosities of the navicular and greater multangular bones. It completes an osteo-fibrous canal for the tendons of the long flexors of the fingers. On the palm of the hand the fascia is firmly bound to the bones by intermuscular septa, which separate the thenar and hypothenar regions from a central palmar region. On the volar sides of the fingers the fascia forms the vaginal ligaments of the flexor tendons.

A. MUSCULATURE OF THE SHOULDER

(Figs. 355, 356, 357, 363, 388)

The muscles belonging to this group are the deltoid, the teres minor, the infra- and supraspinatus, the latissimus dorsi, the teres major, and the subscapularis.

The **deltoid** (fig. 355) is a large, shield-shaped muscle which covers the shoulder. It arises from the spine of the scapula, the acromion, and lateral third of the clavicle and is inserted into the deltoid tubercle of the humerus. It abducts the arm.

The teres minor, infra- and supraspinatus form a group of muscles (fig. 363) which arise from the back of the scapula, pass over the capsule of the shoulder-joint, to which their tendons are adherent, and, under cover of the deltoid, are inserted into the top and the dorsal margin of the great tubercle of the humerus. The band-like **teres minor** arises from the upper two-thirds of the axillary border of the scapula, and has the lowest insertion on the tubercle. The triangular **infraspinatus** (fig. 363) arises from the whole infraspinous fossa except the axillary border, and is inserted above the teres minor. The pyramidal **supraspinatus** (fig. 363) arises under cover of the trapezius from the supraspinous fossa, and has the highest insertion on the tubercle. The teres minor, supraspinatus and infraspinatus act as lateral rotators of the arm, the supraspinatus also as an abductor.

The latissimus dorsi, the teres major, and the subscapularis form a group of muscles attached to the lesser tubercle of the humerus and to the crest which

FIG. 356.—FRONT VIEW OF THE SCAPULAR MUSCLES.

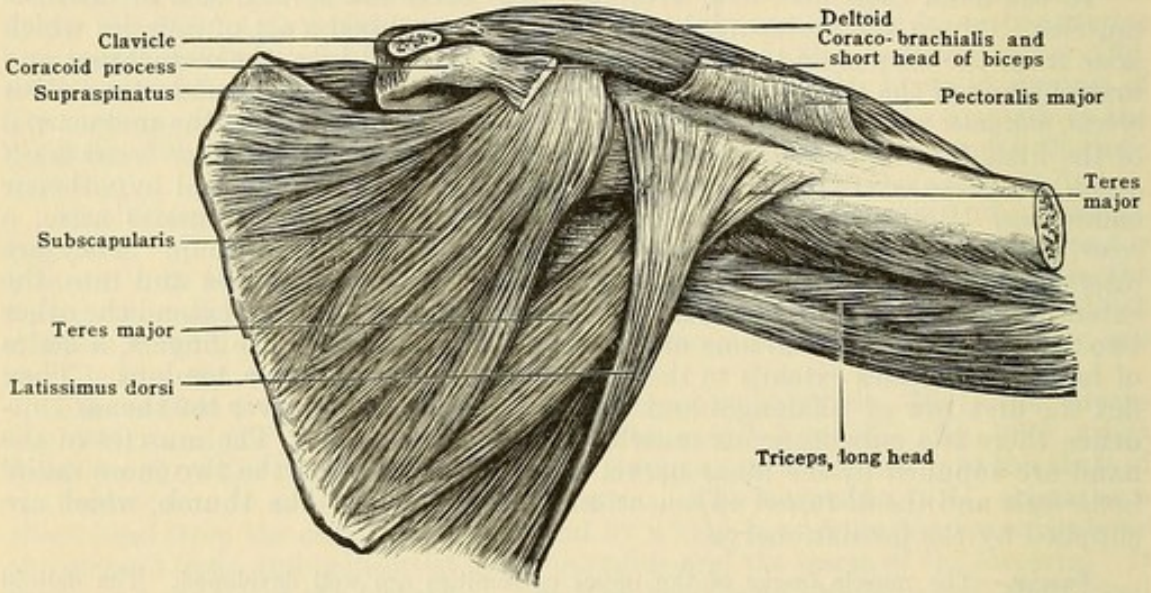

extends distally from this on the medial side of the intertubercular (bicipital) groove. The **latissimus dorsi** (figs. 355, 356) is a large, flat, triangular muscle, which arises from an aponeurosis covering the lumbar and the lower half of the thoracic regions of the back and from the posterior part of the iliac crest, and is inserted into the intertubercular (bicipital) groove. The **teres major** (figs. 355, 356) is a thick, ribbon-shaped muscle which arises from the dorsal surface of the inferior angle of the scapula and is inserted behind the latissimus dorsi into the distal two-thirds of the crest of the small tubercle of the humerus. The **subscapularis** (fig. 355) is a thick, triangular muscle which extends from the subscapular fossa to the small tubercle of the humerus. These muscles adduct the arm and rotate it medialward. The latissmus dorsi is also the chief extensor of the arm.

Near their humeral attachments these two groups of muscles are separated below by the long head of the triceps. The supraspinatus is separated from the subscapularis by the base of the coracoid process and by the intertubercular (bicipital) groove. The tendons of the latissimus dorsi, teres major, and subscapularis are crossed ventrally by the main vessels and nerves of the arm and by the short head of the biceps and the coraco-brachialis.

The supra- and infraspinatus muscles are supplied by the suprascapular nerve. The deltoid and the teres minor are supplied by the axillary (circumflex). The subscapularis, the teres major, and the latissimus dorsi are supplied by subscapular nerves. That to the latissimus dorsi is called the dorsal thoracic nerve.

The deltoid in many of the mammals and the lower vertebrates is represented by separate scapulo-humeral and cleido-humeral portions. The cleido-mastoid in some mammals is continued into the deltoid. The teres minor, which is innervated by the same nerve, may be looked upon as a derivative of the deltoid, although in man it is anatomically more intimately connected with the infraspinatus. The teres major may be looked upon as a specialised portion of the more primitive latissimus dorsi. The comparative anatomy of the shoulder muscles throughout the vertebrate series is a somewhat intricate subject, owing to the great variations exhibited in the form and attachment of the shoulder girdle.

The muscles of this group show more or less marked resemblances to certain muscles of the lower limb. The deltoid and the teres minor probably represent the tensor fasciæ latæ, the gluteal fascia, and the upper part of the gluteus maximus; the latissimus dorsi and teres major, the lower portion of the gluteus maximus; and the subscapularis, the gluteus medius and minimus, and the piriformis. The subscapular and axillary nerves, which supply the arm muscles mentioned, therefore represent in the main the nerves to the gluteal muscles, and the gluteal branch of the posterior cutaneous nerve of the thigh. The infraspinatus muscle probably represents the iliacus; the supraspinatus possibly the pectineus muscle of the lower limb.

FASCIÆ

(Figs. 351, 357, 359, 362)

The **tela subcutanea** covering the regions occupied by these muscles contains considerable fat. In most regions it is not readily separable into two distinct layers. In the neighbourhood of the shoulder-joint it is adherent to the underlying musculature and the axillary fasciæ. Over the acromion there is a well-marked subcutaneous bursa, **bursa subcutanea acromialis.**

Muscle fasciæ.—The deltoid and latissimus dorsi muscles are throughout the greater part of their extent superficially placed. They are covered by an adherent fascial layer, which, above, is attached to the clavicle and to the spine of the scapula. Ventrally it is continued over and fuses with the fascia covering the pectoralis major, serratus anterior, and external oblique muscles. On the back it extends as a thin sheet between the dorsal margin of the deltoid and the upper margin of the latissimus dorsi, and is continued dorsally into the fascial investment of the rhomboid muscles. The lateral fascial extension of the trapezius becomes fused to the dorsal surface of this sheet. Toward the armpit the fascial investment of the deltoid and latissimus dorsi muscles is continued into the axillary fascia, and on the back of the arm it is continued into the fascial investment of the triceps.

The supraspinatus muscle lies beneath the trapezius. It is covered by a dense adherent fascial layer which is separated from the trapezius by loose connective tissue which usually contains a considerable amount of fat.

The infraspinatus and the two teres muscles lie beneath the musculo-fascial layer composed of the deltoid, the latissimus dorsi, and the fascial sheet described above. Each of the three muscles has a special fascial investment which is bound to the scapula about the region of attachment of the muscle to the bone. Where two of the muscles adjoin, their fasciæ gives rise to intermuscular septa. Septa of this nature are found between the infraspinatus and each of the teres muscles, and between the teres minor and the teres major. The intermuscular septum between the infraspinatus and teres minor muscles is often incomplete. The fascia covering the teres major is so delicate as hardly to deserve the name, except near the origin of the muscle. Near the spine the fascia covering the deep surface of the deltoid is often fused to that covering the infraspinatus.

The subscapularis muscle is invested by a moderately dense fascia which is bound to the scapula along the periphery of the attachment of the muscle. For a short distance this fascia is fused with the fascial investment of the teres major near the origin of the latter muscle, so that an intermuscular septum is formed. From the ventro-lateral margin of the fascia covering the subscapularis muscle a sheet of fascia is continued below the axillary fascia into the fascia covering the serratus anterior (magnus).

MUSCLES

The **deltoideus** (figs. 355, 356, 360).—*Origin.*—Fleshy from the lateral border and upper surface of the acromion and from the ventral border and upper surface of the lateral third of the clavicle, and tendinous from the spine of the scapula. Some fibre-bundles also at times arise from the deep fascia of the muscle where it overlies and is fused to the fascia of the infraspinatus muscle near the spine.

Insertion.—Into the deltoid tuberosity of the humerus by a strong tendon arising from numerous tendinous bands within the muscle (fig. 364).

Structure.—In structure the deltoid muscle is complex. Three portions may be recognised:—a clavicular, an acromial, and a spinous. The first and last are composed of long fibre-bundles which take a slightly converging course and are inserted by aponeurotic tendons respectively on the front and back of the V-shaped area of insertion of the muscle. The acromial portion, on the other hand, is multipenniform in composition. Four or five tendinous expansions descend into the muscle from the acromion, and three up into the muscle from the tendon of insertion. From the acromion and from the descending tendinous processes fibre-bundles run to be inserted on the sides of the ascending processes and into the tendons of insertion of the clavicular and spinous portions of the muscle.

Nerve-supply.—The axillary (circumflex) nerve passes across the costal surface of the muscle near the tendon of insertion and gives off rami which enter lateral to the middle of the muscle. The nerve fibres are derived from the (fourth), fifth, and sixth cervical nerves.

Action.—When the whole muscle contracts, the arm is abducted (raised laterally) to a

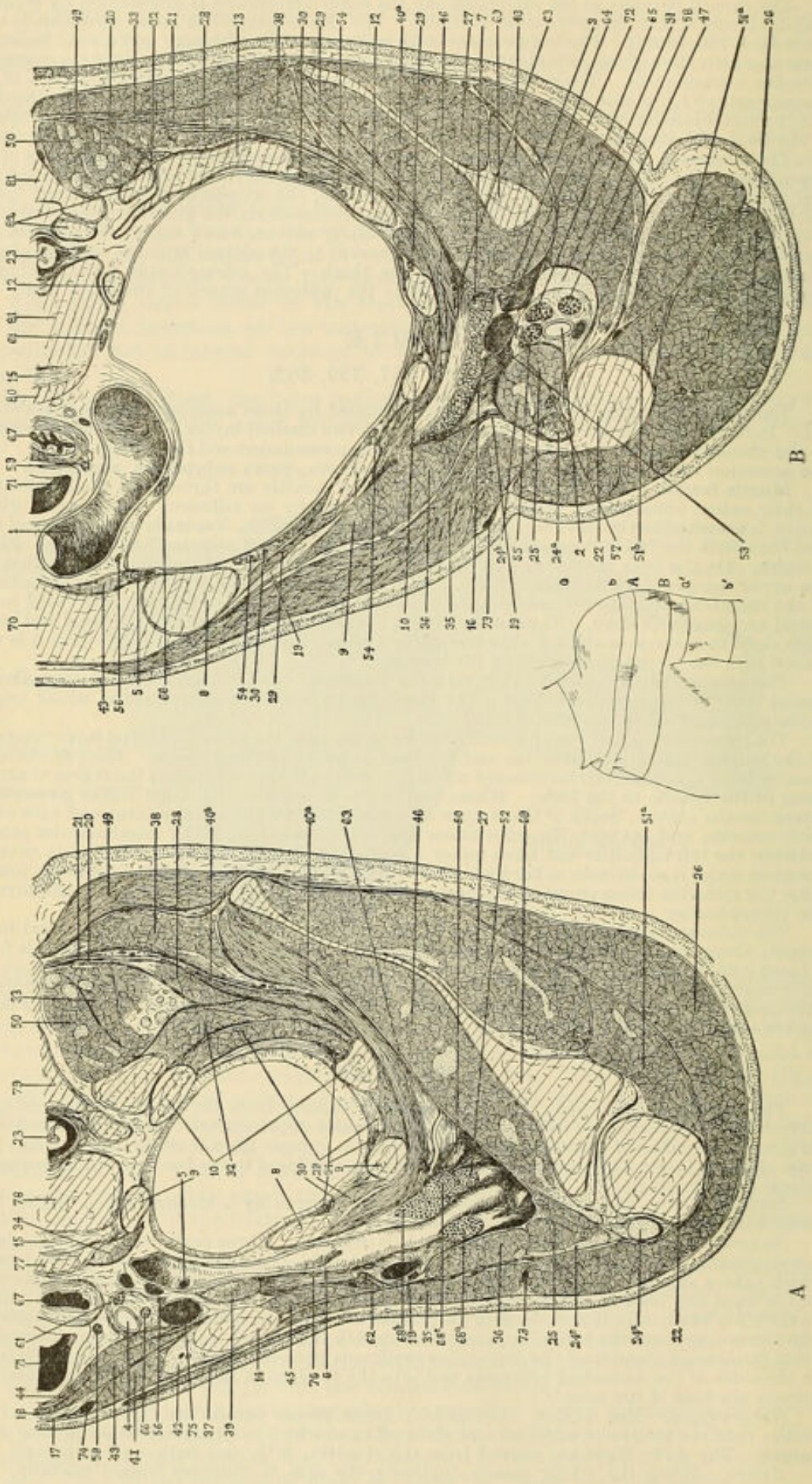

FIG. 357

horizontal position. When the clavicular and acromial parts act, the arm is raised and flexed (brought forward toward the chest). When the acromial and spinous parts act, the arm is raised and extended (carried toward the back), but in this instance the arm is not brought to a level with the shoulder-joint, but only about 45° from the hanging position. The inferior part of the serratus anterior and the trapezius act in conjunction with the deltoid in abduction. Abduction is greatest when the arm is rotated lateralward. The ventral portion rotates the arm medially, the dorsal portion laterally. When the arm is fixed, the deltoid tends to carry the inferior angle of the scapula toward the spinal column and away from the thorax.

Relations.—On its ventral border the deltoid is in contact with the pectoralis major muscle. Near the clavicle the cephalic vein and a small artery pass between the two muscles. Its dorsal border is continued into a dense fascial sheet which overlies the infraspinatus muscle. Its tendon of insertion passes between the biceps and triceps muscles. The deltoid overlies the coracoid process and upper extremity of the humerus, the coraco-clavicular and coraco-acromial ligaments, and the insertions of the supraspinatus, infraspinatus, and teres minor muscles, the origins of the biceps and coraco-brachialis, and a part of the long and lateral heads of the triceps. Beneath it run the posterior circumflex artery and axillary (circumflex) nerve.

Variations.—The clavicular portion is frequently separate from the rest of the muscle. The three portions may be distinctly separate—a condition normal in some of the lower mammals. The clavicular and acromial portions have been found missing. The deep portion of the muscle may be separated as a distinct layer and inserted either into the capsule of the joint or into the humerus. Accessory fasciculi may pass into the muscle from the fascia over the infraspinatus and from the vertebral and axillary borders of the scapula. Not infrequently fasciculi are continued into the muscle from the trapezius—a condition normal in animals with ill-developed clavicles. An accessory tendon of insertion may extend to the radial side of the forearm. Bundles of fibres from the axillary border of the scapula have been seen to cross the deep surface of the deltoid and be inserted into the deltoid fascia. The deltoid may be fused with neighbouring muscles, the pectoralis major, trapezius, infraspinatus, brachialis, brachio-radialis.

The **teres minor** (fig. 363).—*Origin.*—From the upper two-thirds of the axillary border of the infraspinous fossa, and from the septa lying between it and the infraspinatus on the one side and the teres major and subscapularis on the other. The origin is in part fleshy, in part from an aponeurotic band on its ventral surface toward the subscapularis muscle.

Structure and insertion.—The fibre-bundles from this origin take a slightly converging course toward a tendon of insertion which extends for some distance on the dorsal surface of the muscle. The muscle is adherent to the capsule of the joint, and terminates on the inferior of the three facets of the great tubercle of the humerus and the postero-lateral aspect of that bone for two or three centimetres below the facet.

Nerve-supply.—From a branch of the axillary (circumflex) nerve which enters the muscle on its lateral margin about midway between its extremities. A 'ganglion' is usually found upon this nerve. A branch from the nerve to the teres major has also been reported. The nerve fibres are derived from the fifth cervical nerve.

Action.—It acts conjointly with the infraspinatus to rotate the arm laterally. It is a flexor when the arm is down and an extensor when it is abducted. It is also an adductor.

Relations.—The muscle is in part covered by the deltoid. Ventrally it enters into relations with the long head of the triceps, the teres major, and the subscapularis. Superiorly, the circumflex (dorsal) scapular vessels run between it and the axillary border of the scapula.

FIG. 357. A AND B.—TRANSVERSE SECTIONS THROUGH THE LEFT SHOULDER IN THE REGIONS INDICATED IN THE DIAGRAM.

In the neighbourhood of the brachial plexus in each section some of the adipose and lymphatic tissue has been removed. In section B the fascia covering the apex of the axillary fossa is thus revealed from above. *a* and *b* in the diagram indicate the regions through which pass sections A and B, fig. 351 (p. 352); *a'* and *b'*, the regions through which pass sections A and B, fig. 362 (p. 375).

1. Aorta. 2. Arteria brachialis. 3. A. circumflexa scapulæ (dorsalis scapulæ). 4. A. carotis communis. 5. A. mammaria interna. 6. A. subclavia. 7. A. thoracalis lateralis (long thoracic). 8. Costa I. 9. Costa II. 10. Costa III. 11. Costa IV. 12. Costa V. 13. Costa VI. 14. Clavicle. 15. Fibrocartilago intervertebralis (intervertebral disc). 16. Fascia axillaris. 17. Fascia cervicalis (superficial layer). 18. Middle layer. 19. F. coraco-clavicularis. 20. F. lumbo-dorsalis. 21. Fascia of posterior serrati. 22. Humerus. 23. Medulla spinalis (spinal cord). 24. Musculus biceps—*a*, long head; *b*, short head; *c*, tendon of short head. 25. M. coraco-brachialis. 26. M. deltoideus. 27. M. infraspinatus. 28. M. ilio-costalis dorsi (accessorius). 29. M. intercostales externi. 30. M. intercostales interni. 31. M. latissimus dorsi, tendon. 32. M. levator costæ. 33. M. longissimus dorsi. 34. M. longus colli. 35. M. pectoralis major. 36. M. pectoralis minor. 37. M. platysma. 38. M. rhomboideus major. 39. M. scalenus anterior. 40*a*. M. serratus anterior. 40*b*, M. serratus posterior superior. 41. M. sterno-mastoideus. 42. M. cleido-mastoideus. insertion. 43. M. sterno-hyoideus. 44. M. sterno-thyreoideus. 45. M. subclavius. 46. M. subscapularis. 47. M. teres major. 48. M. teres minor. 49. M. trapezius. 50. M. transverso-spinales. 51. M. triceps—*a*, long head; *b*, lateral head. 52. Nervus axillaris 53. N. cutaneus antebrachii medialis (internal cutaneous). 54. *a*–*e*, Nn. intercostales I–V. 55. N. medianus. 56. N. phrenicus. 57. N. musculocutaneus. 58. N. radialis (musculo-spiral). 59. N. recurrens. 60. N. subscapularis. 61. Sympathetic trunk. 62. N. thoracalis anterior. 63. N. thoracalis longus. 64. N. thoracodorsalis (long subscapular). 65. N. ulnaris. 66. N. vagus. 67. Œsophagus. 68. Plexus brachialis—*a*, lateral fasciculus; *b*, medial; *c*, posterior. 69. Scapula. 70. Sternum. 71. Trachea. 72. Venæ brachiales. 73. V. cephalica. 74. V. jugularis anterior. 75. V. jugularis inferior. 76. V. subclavia. 77. Vertebra I. 78. Vertebra II. 79. Vertebra III. 80. Vertebra IV. 81. Vertebra V. 82. Vertebra VI.

Variations.—Aside from its frequent fusion with the infraspinatus, there has also been reported an isolation of a special fasciculus to the subtubercular attachment.

The **infraspinatus** (fig. 363).—*Origin.*—From the vertebral three-fourths of the infraspinous fossa, from the under surface of the spine, from the enveloping fascia and from intermuscular septa between it and the two teres muscles.

Structure and insertion.—The fibre-bundles converge toward the lateral angle of the scapula to be attached to a deep-seated tendon which is adherent to the capsule of the joint and is attached to the middle facet of the great tubercle. The fibre-bundles arising from the inferior surface of the spine and the fascia near this form a distinct fasciculus which descends on and covers the tendon of insertion.

Nerve-supply.—From the suprascapular nerve, which passes beneath the supraspinatus muscle and enters the deep surface of the infraspinatus in the lateral part of the midde third of its upper margin. From here rami spread out toward the vertebral border of the muscle and toward the humeral insertion. The nerve fibres are derived from the fifth and sixth cervical nerves.

Action.—This muscle is the chief lateral rotator of the arm, a movement that can be carried through 90°. The upper part of the muscle is an abductor, the lower part an adductor of the arm. The muscle is also a flexor.

Relations.—The deltoid and trapezius, and sometimes the latissimus dorsi muscles, cover a portion of the dorsal surface. Over most of it extends the complex fascia described above. Laterally it adjoins the teres minor and major muscles. Under the muscle lie the transverse (suprascapular) and circumflex (dorsal) scapular vessels.

Variations.—These are rare, aside from a greater or less independence of the bundles arising from the spine and a greater or less complete fusion with the teres minor. A fasciculus has been seen extending to the muscle from the deltoid.

The **supraspinatus** (fig. 363).—*Origin.*—Fleshy from the medial two-thirds of the supraspinous fossa and from the deep surface of the enveloping fascia near the vertebral end.

Structure and insertion.—The fibre-bundles converge upon a deep-seated tendon nearly to its attachment into the highest of the three facets on the great tubercle of the humerus.

Nerve-supply.—Two branches from the suprascapular nerve enter the middle third of the deep surface of the muscle. The nerve fibres are derived from the fifth cervical nerve.

Action.—It aids the deltoid in abducting the arm. It is also a weak lateral rotator and flexor. It keeps the head of the humerus in place during abduction of the arm.

Relations.—The muscle is covered by the trapezius, the acromion, and the coraco-acromial ligament. Beyond the base of the spine of the scapula it comes into contact with the infraspinatus muscle. Beneath the muscle pass the suprascapular nerve and transverse scapular (suprascapular) vessels.

Variations.—The muscle shows slight variations. Its tendon may be fused with that of the infraspinatus. Its belly may be reinforced by fibre-bundles from the coraco-acromial ligament.

The **latissimus dorsi** (figs. 355, 356, 387, 388).—*Origin.*—(1) From an aponeurosis attached to the spines and interspinous ligaments of the five or six last thoracic and the upper lumbar vertebræ, to the lumbo-dorsal fascia, and to the posterior third of the external lip of the crest of the ilium; (2) from the external surface and upper margin of the last three or four ribs by muscular slips which interdigitate with those of the external oblique. In the lumbar region the aponeuroses of the right and left muscles are connected by fibrous fasciculi which cross the mid-dorsal line above the supraspinous ligament.

Structure and insertion.—From this extensive area of the origin fibre-bundles converge toward the tendon of insertion. In the region of the dorsal wall of the axillary fossa the muscle is concentrated into a thick, ribbon-like band which winds about the teres major and passes to the ventral surface of that muscle. As this takes place the fibre-bundles become applied to each surface of a flat tendon, which, after emerging from the muscle, is six to eight cm. long and three to five cm. broad, and is inserted into the ventral side of the crest of the lesser tubercle of the humerus and into the depth of the intertubercular (bicipital) groove immediately ventral to the tendon of the teres major. With this it is more or less closely bound, although between the tendons there lies a serous bursa. Some of the fasciculi of the tendon extend to the crest of the greater tubercle. Frequently a tendon slip passes from the inferior margin of the tendon to the tendon on the posterior surface of the long head of the triceps or into the brachial fascia (see *latissimo-condyloideus*, p. 379).

Like the teres major, with which it is closely associated, the latissimus dorsi muscle undergoes a torsion between its origin and its insertion, so that the dorsal surface of the muscle is continued into the ventral surface of the tendon and the most cranially situated of the fibre-bundles are most distally attached to the humerus, and *vice versa*. The muscle either directly or through its fascial extension is often adherent to the inferior angle of the scapula.

Nerve-supply.—From the dorsal thoracic (long subscapular) nerve (from the sixth, seventh and eighth cervical nerves). This nerve, which may arise in conjunction with the axillary nerve, passes to the deep surface of the muscle in the lower part of the axilla, and here gives rise to rami which diverge as the muscle expands toward its tendons of origin. Though soon embedded in the muscle substance, two main branches may be followed for a considerable distance near the deep surface of the muscle. One usually extends near the lateral, the other near the superior, border of the muscle, and from these large rami pass into the intervening region. Branches of the dorsal thoracic artery and vein accompany the nerve.

Action.—With the trunk fixed, the latissimus dorsi draws the raised arm down and backward and rotates it medialward (swimming movement). When the arm is hanging by the side, the action of the muscle is on the scapula. The upper third of the muscle draws the scapula toward the spine, the inferior two-thirds depress the shoulder. When the humerus is fixed, the latissimus serves to lift the trunk and pelvis forward, as in climbing. It also aids in forced inspiration through its costal attachments.

Relations.—The trapezius covers a small portion of the muscle in the mid-thoracic region of the back. Over a large area it is subcutaneous, and its fascial investment is adherent to the skin. As it winds about the teres major its tendon comes to lie behind the coraco-brachialis muscle. The main nerves and vessels of the arm here pass across its ventral surface. The muscle covers in part the rhomboideus major, the infraspinatus, teres major, serratus posterior inferior, the lower ribs, the external intercostal muscles, the dorsal border of the external and internal oblique muscles, and the lower dorsal part of the serratus anterior (magnus).

Variations.—It may show considerable variation in the extent of its fleshy portion and in the attachment of its aponeurosis to the vertebral column, crest of the ilium, the ribs, and the scapula. Its origin may be merely from the ribs. It may be divided into separate fasciculi. Frequently a fasciculus arises from the inferior angle of the scapula. The muscle is often intimately united to the teres major. For an account of the muscular slip which extends from the latissimus dorsi across the axillary fossa to the tendon of the pectoralis major near the intertubercular (bicipital) groove see the latter muscle (p. 374); and for the slip continued from the tendon of the latissimus dorsi to the olecranon see the TRICEPS MUSCLE (p. 379).

The **teres major** (figs. 356, 388).—*Origin.*—Directly from the dorsal surface of the inferior angle of the scapula and from the septa which lie between this muscle and the subscapularis, teres minor, and infraspinatus muscles.

Insertion.—For about five or six cm. from the lower border of the small tubercle of the humerus, along the medial lip of the intertubercular (bicipital) groove. Proximally the fibre-bundles are attached directly to the tubercle; more distally the attachment is by means of a flat tendon which extends for some distance on the dorsal surface of the muscle.

Structure.—The nearly parallel fibre-bundles pass upward in a spiral direction so that the muscle undergoes a torsion on its axis. The fibre-bundles which have the highest attachment to the scapula have the lowest humeral attachment, and *vice versa*.

Nerve-supply.—By a branch of the lower subscapular nerve which enters the muscle near the middle of its scapular border. The nerve fibres are derived from the fifth, sixth (and seventh) cervical nerves.

Action.—It aids the latissimus dorsi in adducting the arm, and in some positions of the arm acts as a medial rotator and as an extensor.

Relations.—Dorsally the muscle is covered by the latissimus dorsi and by the fascia which extends from this muscle to the deltoid and rhomboid muscles. It is also crossed by the long head of the triceps. Its lower border and ventral surface are largely covered by the latissimus dorsi and its tendon. Its upper border helps to bound a triangular space the other sides of which are the borders of the scapula and the humerus. In front lies the subscapularis, and behind, the teres minor. Across this space passes the long head of the triceps. Lateral to this head lie the humeral circumflex vessels and axillary (circumflex) nerve; and medial, the circumflex (dorsal) scapular artery.

Variations.—The teres major may be connected with the latissimus dorsi by a fasciculus, or it may be fused with that muscle or its tendon. Slips have also been seen extending to the triceps and into the fascia of the arm. The muscle is rarely absent.

The **subscapularis** (figs. 356, 388).—*Origin.*—The fibre-bundles spring—(1) directly and by means of tendinous bands from the costal surface of the scapula, except near the neck and at the upper and lower angles; and (2) from intermuscular septa between it and the teres major and teres minor muscles.

Insertion.—The tendon of insertion as it passes over the capsule of the joint is intimately bound to this. It is inserted into the lesser tubercle of the humerus and into the shaft immediately below this.

Structure.—The fibre-bundles arising from the tendinous bands attached to the bone converge upon several tendinous laminæ which extend into the muscle from the tendon of insertion, thus forming small penniform fasciculi. The fibre-bundles arising directly from the bone converge toward the extremities of the tendinous laminæ, thus forming triangular bundles interdigitating with the penniform fasciculi. The fasciculus which arises highest on the axillary border goes directly to the humerus.

Nerve-supply.—By two or three subscapular branches from the back of the brachial plexus. One or more of these may arise in association with the axillary (circumflex) nerve. From the main nerves rami spread out to enter the ventral surface of the muscle near the junction of the lateral and middle thirds. The nerve fibres come from the fifth and sixth cervical nerves.

Action.—It is the chief medial rotator of the arm. It strengthens the shoulder-joint by drawing the humerus against the glenoid cavity. It is an extensor when the arm is at the side, a flexor when the arm is abducted. The upper portion of the muscle, however, acts as a flexor in both positions. The upper part acts as an abductor but when the arm is abducted the muscle is an adductor.

Relations.—Ventrally it forms the greater part of the posterior wall of the axillary fossa, and enters into relation with the serratus anterior (magnus) and the combined tendon of the coraco-brachialis and biceps. On it lie the axillary vessels, the brachial plexus, and numerous lymph-vessels and glands. At its lateral border lie the teres major, the humeral circumflex vessels, axillary (circumflex) nerve, and circumflex (dorsal) scapular vessels. Behind it lie the long head of the triceps and the teres minor muscle.

Variations.—It may be divided into several distinct segments. A fasciculus may be sent to the tendon of the latissimus dorsi and another to the brachial fascia. The **subscapularis minor** arises from the axillary border of the scapula and is inserted into the articular capsule (capsular ligament) of the shoulder-joint or into the crest of the lesser tubercle of the humerus.

BURSÆ

B. subacromialis.—A large bursa, nearly constantly found, between the acromion and coraco-acromial ligament and the insertion of the supraspinatus muscle and capsule of the joint.

Processes extend over the greater and lesser tubercles.

B. supracoracoidea.—A bursa sometimes found between the coracoid process and the clavicle and the deltoid muscle.

B. m. subscapularis.—Between the glenoid border of the scapula and the subscapularis muscle. Communicates with the joint cavity. A small portion of this bursa may be isolated adjacent to the base of the coracoid process (*b. subcoracoidea*).

B. m. infraspinati.—Between the tendon of the infraspinatus and the capsule of the joint or the great tubercle.

B. m. latissimi dorsi.—Constant between the tendons of the latissimus dorsi and the teres major.

B. m. teretis majoris.—Under the insertion of the tendon of the teres major muscle.

B. PECTORAL MUSCLES AND AXILLARY FASCIA

(Figs. 357, 358, 360, 361, 388)

The muscles belonging to this group are the pectoralis major, pectoralis minor, and the subclavius. Of these, the largest and most superficial is the

FIG. 358.—DEEP FASCIA OF THE BREAST. (AFTER EISLER). THE PECTORALIS MAJOR HAS BEEN IN LARGE PART REMOVED. 1, DELTOID; 2, PECTORALIS MAJOR, ABDOMINAL PART; 3, PECTORALIS MINOR; 4, CORACO-BRACHIALIS.

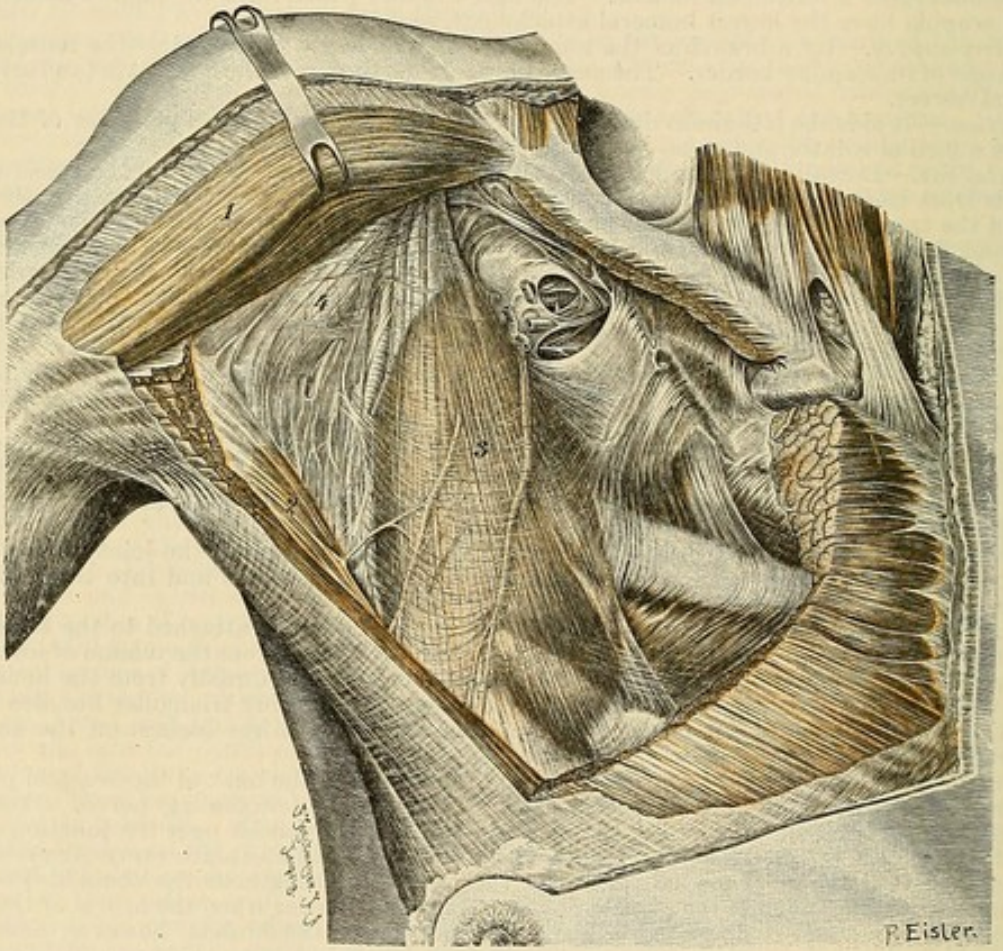

triangular **pectoralis major** (fig. 360), which arises from the second to the sixth ribs, the sternum, and the medial half of the clavicle and is inserted into the crest of the greater tubercle of the humerus (pectoral ridge). Its lateral margin adjoins the ventral margin of the deltoid. Beneath this muscle the much smaller triangular **pectoralis minor** (fig. 388) extends from near the ends of the second, third, fourth, and fifth ribs to the tip of the coracoid process, while the small **subclavius** (fig. 361) extends from the first rib upward and lateralward to the clavicle.

The pectoral muscles and the subclavius play a part in forced inspiration. The pectoralis major also serves to adduct and flex the arm and rotate it medialward.

Of the muscles included in this group, the two pectoral muscles are morphologically the most closely related. They receive a nerve-supply from the same set of nerves, the anterior thoracic With them the subclavius, which has a separate nerve of its own, is closely associated. Cor-

responding musculature, although variously modified in different forms, is found throughout the vertebrate series. In the lower forms it seems to be differentiated directly from the segmental trunk musculature and secondarily attached to the shoulder girdle, like the superficial and deep musculature of the shoulder girdle previously described. In man, however, the muscle mass from which these muscles arise is at all times in intimate union with the skeleton of the upper limb, and the nerves which supply it are in much more intimate union with the brachial plexus than are those of the shoulder-girdle muscles. For these reasons the three muscles are classed with the intrinsic muscles of the arm. They have no certain representatives in the lower limb, although the clavicular portion of the pectoralis major is considered by some to represent certain adductor muscles of the thigh. Possibly they correspond in their embryonic origin with the obturator internus group of the lower limb.

In many of the mammals a subcutaneous muscle arises from the pectoral muscle mass and extends over the axilla and the trunk. In man this musculature is frequently represented by abnormal slips of muscles, of which the 'axillary arch' and possibly the 'sternalis' are representatives. A list of some of the abnormal muscles which are innervated from the anterior thoracic nerves and are evidently derivatives of the pectoral muscle mass is given at the end of this section

FIG. 359.—(AFTER EISLER). FASCIA OF THE AXILLARY FOSSA.

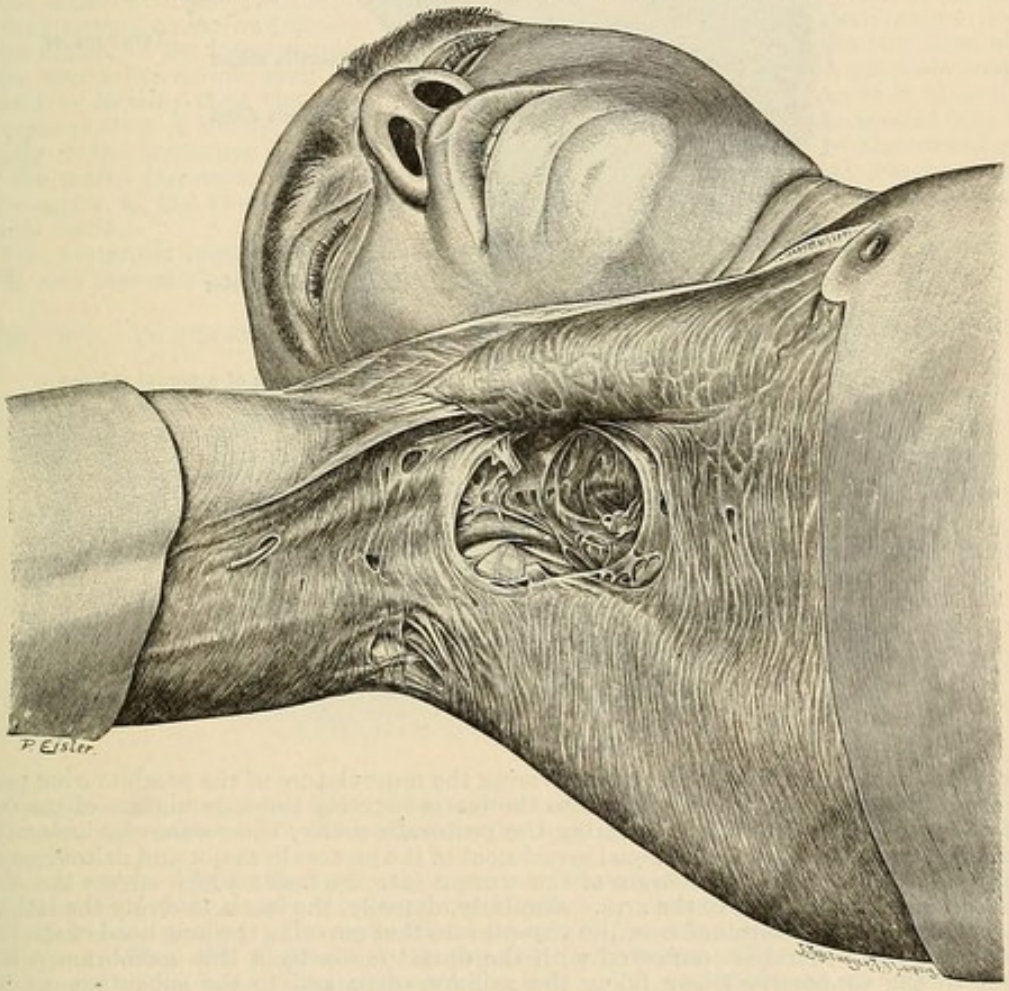

FASCIÆ

In the **tela subcutanea** of the pectoral region the mammary gland is embedded between two layers which ensheath the gland and are connected by dense fibre-bands. To a greater or less extent the platysma extends into the tela of this region from above the clavicle.

Muscle fasciæ.—The pectoralis major is invested with a thin, adherent membrane, **fascia pectoralis,** attached to the clavicle and the sternum and continued into the fascial investment of the external oblique, the serratus anterior (magnus), and the deltoid muscles, and in to the axillary fascia. More important is the **coraco-clavicular** (**costo-coracoid**) **fascia** fig. 358. This arises from two fascial sheets which invest the subclavius muscle and are attached to the clavicle. From the inferior margin of this muscle the membrane is continued to the superior margin of the pectoralis minor. Between the coracoid process and the first costal cartilage it is strengthened to form the **costo-coracoid ligament.** Between this and the pectoralis minor it is thin. At the superior margin of this muscle it again divides to form two adherent fascial sheets, which, at the axillary margin of the muscle, once more unite to form a firm membrane continued into the fascial investment of the coraco-brachialis and short head of the biceps and into the axillary fascia. Above, dorsally, the membrane is adherent to the sheath of the axillary vessels and nerves.

Axillary fascia (fig. 359).—The arm-pit, or **axillary fossa,** is a pyramidal space bounded by the pectoralis major and minor and coraco-brachialis muscles in front; by the latissimus

dorsi, teres major, and subscapularis muscles behind; by the subscapularis muscle toward the joint; and by the serratus anterior (magnus) toward the thoracic wall. In the groove between the coraco-brachialis and the subscapularis and tendons of the latissimus dorsi and teres major muscles run the main nerves and vessels of the arm. These are surrounded by a considerable amount of connective tissue in which numerous blood- and lymph-vessels, lymph-nodes, nerves, and masses of fat are embedded.

FIG. 360.—THE PECTORALIS MAJOR AND DELTOID.

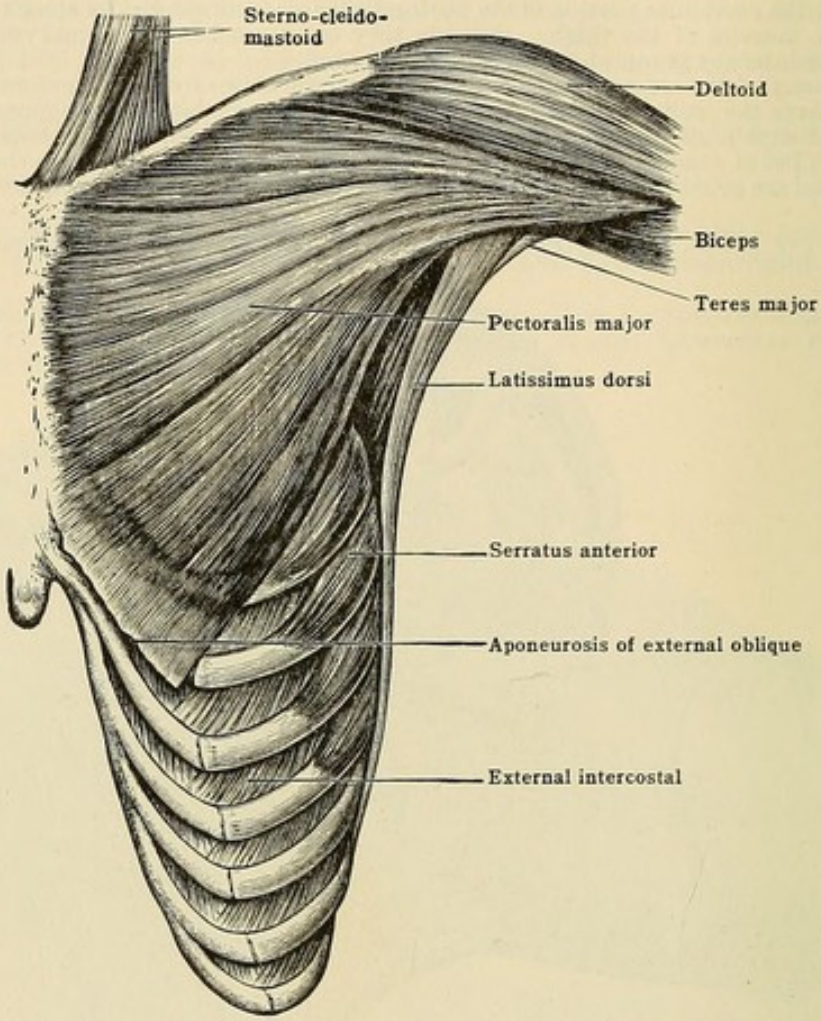

Over this connective tissue the fascia covering the musculature of the neighbouring portion of the shoulder and thorax is continued into the fascia covering the musculature of the medial side of the arm. Thus the fascia covering the pectoralis minor, the coraco-clavicular fascia, strengthened by a reflection of the fascial investment of the pectoralis major and deltoid muscles is continued across the ventral margin of the arm-pit into the fascia which covers the coraco-brachialis and biceps muscles in the arm. Similarly, dorsally, the fascia covering the latissimus dorsi and teres major is continued over the arm-pit into that covering the long head of the triceps in the arm. The ventral is connected with the dorsal fascia by a thin membrane which is adherent to the connective tissue filling the axillary space and to the subcutaneous tissue. On the trunk this membrane, the **fascia axillaris,** becomes fused below the axillary fossa with the fascia of the serratus anterior (magnus). In the arm it becomes fused with the fascia over the biceps muscle. Owing to its adherence to the skin and the connective tissue of the axillary fossa, investigators have dissected out and figured the axillary fascia in different ways.

MUSCLES

The **pectoralis major** (fig. 360).—*Origin.*—(1) From the medial half of the clavicle; (2) from the side and front of the sternum as far as the sixth costal cartilage; (3) from the front of the cartilages of the second to the sixth ribs; and (4) from the upper part of the aponeurosis of the external oblique where this extends over the rectus abdominis muscle. The costal origin may in part take place from the osseous extremities of the sixth and seventh ribs.

Insertion.—Crest of the greater tubercle (outer lip of the bicipital groove) of the humerus from the tubercle to the insertion of the deltoid (fig. 174). Some of the tendon fibres are also continued into the tendon of the deltoid and adjacent fibrous septa and into the fibrous lining of the intertubercular sulcus.

Structure.—The muscle is divisible into a series of overlapping layers spread out like a fan. Of these, the clavicular portion forms the most cranial and superficial layer, and the portion of the muscle springing from the aponeurosis of the external oblique, the most caudal and deepest layer. This last layer has a special tendon, while the other layers are inserted into a combined

tendon lying ventral to this. The two tendons are continuous at their distal margins. (W. H. Lewis.)

Nerve-supply.—From the external and internal anterior thoracic nerves, branches of which enter the sterno-costal portion of the muscle about midway between the tendons of origin and insertion, and the clavicular portion in the proximal third. The nerve fibres are derived from the (fifth), sixth, seventh and eighth cervical and first thoracic nerves.

Action.—With the thorax fixed, the muscle adducts and flexes the arm and rotates it medialward. The clavicular portion draws the arm forward, upward, and medialward; the sterno-costal portion draws the arm downward, medialward, and forward. When the arm is pendent, the upper portion elevates, the lower depresses, the shoulder. With the arm fixed, the muscle draws the chest upward toward it. It is of value in forced inspiration.

Relations.—It lies over the coracoid process, the subclavius, pectoralis minor, intercostal, and serratus anterior (magnus) muscles, the coraco-clavicular (costo-coracoid) fascia, and the thoraco-acromial vessels. It forms the main part of the ventral wall of the axillary fossa, and laterally it enters into relation with the deltoid, biceps, and coraco-brachialis muscles.

Variations.—In considering variations the muscle may be looked upon as composed of four portions—a clavicular, a sternal, a costal, and an abdominal, the last being that portion which arises from the aponeurosis of the external oblique. These portions vary in the extent of their attachments and in the degree of separation which they present. The abdominal portion may extend to the umbilicus. Huntington considers this portion a derivative of the panicular muscle of the lower mammals. On the sternum the muscles of the two sides may decussate across the middle line. The sterno-costal portions of the muscle are more frequently deficient or missing than the clavicular, but in rare cases the entire muscle is absent. The clavicular portion of the muscle may be fused with the deltoid. The sterno-costal may extend laterally to the latissimus dorsi. There may be an intimate fusion of the abdominal portion with the rectus abdominis or the external oblique. Sometimes a slip may run from the pectoralis major to the biceps, the pectoralis minor, coracoid process, capsule of the joint, or brachial fascia.

The **pectoralis minor** (fig. 388).—*Origin.*—By aponeurotic slips from the second, third, fourth, and fifth ribs near the costal cartilages.

FIG. 361.—THE SUBCLAVIUS AND THE UPPER PORTION OF THE SERRATUS ANTERIOR.

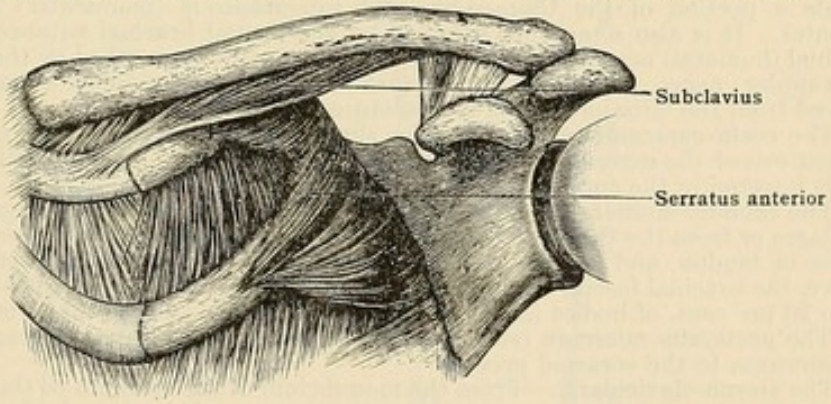

Structure and insertion.—The fibre-bundles converge upward and outward to a flattened tendon which is attached to the medial border and upper surface of the coracoid process of the scapula.

Nerve-supply.—From the internal anterior thoracic nerve which enters the upper part of the middle third of the deep surface by several branches. Some of the branches extend through to the pectoralis major. The nerve fibres arise from the seventh and eighth cervical nerves.

Action.—When the thorax is fixed, the pectoralis minor pulls the scapula forward, the lateral angle of the bone downward, and the inferior angle dorsalward and upward. When the scapula is fixed, the muscle aids in forced inspiration.

Relations.—It is covered by the pectoralis major. Near its insertion the fibrous investment of the chief nerves and vessels of the arm is adherent to its enveloping fascia.

Variations.—The origin may extend to the sixth rib or may be reduced to one or two ribs. In the primates below man the insertion of the muscle takes place normally into the humerus. In man its insertion may be continued (in more than 15 per cent. of bodies—Wood) over the coracoid process to the coraco-acromial or coraco-humeral ligaments, to the tendon of the subscapularis muscle, or to the great tubercle of the humerus. It may be divided into two superimposed fasciculi. Fasciculi may extend from the muscle to the subclavius or the pectoralis major.

The **subclavius** (fig. 361).—*Origin.*—From a flat tendon attached to the first rib and its cartilage near their junction.

Structure and insertion.—The fibre-bundles arise in a penniform manner from the tendon of origin which extends for some distance along the lower border of the muscle. They are inserted in a groove which lies on the lower surface of the clavicle between the costal tuberosity and the coracoid tuberosity. The medial fibre-bundles are inserted directly, the lateral by a strong tendon.

Nerve-supply.—By a branch which arises usually from the fifth or fifth and sixth cervical nerves and enters the middle of the back part of the muscle.

Action.—When the first rib is fixed, the subclavius depresses the clavicle and the point of

the shoulder. When the clavicle is fixed, the muscle aids in forced inspiration. It also serves to keep the clavicle against the sternum.

Relations.—It is concealed by the clavicle and pectoralis major muscle. Behind it lie the subclavian vessels and the brachial plexus.

Variations.—It may be replaced by a ligament or by a pectoralis minimus muscle (see below). It may be doubled or may be inserted into the coracoid process, coraco-acromial ligament, the acromion, or the humerus. The *subclavius posticus* arises near the subclavius, passes backward over the subclavian vessels and brachial plexus and is inserted into the cranial margin of the scapula near the base of the coracoid process.

Abnormal Muscles of the Pectoral Group

The following muscles are usually innervated by the anterior thoracic nerves and are probably generally abnormal derivatives of the pectoral mass. Frequently they represent muscles normally found in lower mammals.

The **sternalis.**—A flat muscle somewhat frequently seen on the surface of the pectoralis major, usually nearly parallel to the sternum. It arises from the sheath of the rectus and from some of the costal cartilages (third to seventh) and terminates on the sterno-cleido-mastoid, on the sternum, or on the fascia covering the pectoralis major. When present on both sides, the two muscles may be fused across the sternum. This muscle is found in 4 per cent. of normal individuals and 48 per cent. of anencephalic monsters. (Eisler.) Rarely, corresponding muscle slips have been found innervated by the intercostal nerves. These probably represent remains of a thoracic 'rectus' muscle.

The **pectoro-dorsalis (axillary arch).**—This muscle in its most complete form extends from the tendon of the pectoralis major over the axillary fossa to the tendon of the latissimus dorsi, to the fascia covering the latissimus dorsi, to the teres major or even more distally. It may, however, be more or less fused with either of the last two muscles mentioned, and it presents a great variety of forms. It may extend from the latissimus dorsi to the brachial fascia over the coraco-brachialis or biceps, to the long tendon of the biceps, to the axillary fascia, to the axillary margin of the pectoralis minor, or to the coracoid process, etc. It is found in about 7 per cent. of bodies. (Le Double.) When supplied from the anterior thoracic nerves, it probably represents a portion of the thoraco-humeral subcutaneous (pannicular) muscle of the lower primates. It is also sometimes supplied by the medial brachial cutaneous or the intercosto-brachial (humeral) nerve and frequently is partly or wholly supplied by the dorsal thoracic (long subscapular) nerve. The part of the muscle supplied by the dorsal thoracic nerve is probably derived from the latissimus dorsi musculature.

The **costo-coracoideus.**—A muscular slip which arises from one or more ribs or from the aponeurosis of the external oblique between the pectoralis major and latissimus dorsi muscles, and is inserted in the coracoid process.

The **chondro-humeralis** (epitrochlearis).—This is a slip which springs from one or two rib cartilages or from the thoraco-abdominal fascia beneath the pectoralis major, or from its lower border or tendon, and extends on the medial side of the arm to the intertubercular (bicipital) groove, the brachial fascia, the intermuscular septum, or the medial epicondyle. It is found in 12 to 20 per cent. of bodies (Le Double), and occurs normally in many of the lower mammals.

The **pectoralis minimus (sterno-chondro-scapularis).**—From the cartilage of the first rib and sternum to the coracoid process.

The **sterno-clavicularis.**—From the manubrium of the sternum to the clavicle between the pectoralis major and the coraco-clavicular (costo-coracoid) fascia. In 2 per cent. to 3 per cent of bodies. (Gruber.)

The **scapulo-clavicularis.**—From the coracoid process of the scapula to the outer third of the clavicle.

The **infra-clavicularis.**—From above the clavicular part of the pectoralis major to the fascia over the deltoid.

Bursæ

B. m. pectoralis majoris.—Between the tendon of insertion of the pectoralis major and the long head of the biceps. Frequent.

C. MUSCULATURE OF THE ARM

(Figs. 355, 356, 362, 363, 364, 365, 367, 370, 372)

The muscles included in this section are the triceps and anconeus, coraco-brachialis, biceps, and brachialis. The *triceps* and *anconeus* (fig. 363) constitute a mass of musculature extending along the back of the arm from the scapula and humerus to the olecranon of the ulna. The *coraco-brachialis*, *biceps*, and *brachialis* (figs. 364, 365) constitute a similar mass of musculature extending along the front of the arm from the scapula and the humerus to the humerus, and to the radius and ulna near the elbow. In the upper half of the arm the two groups are separated on the lateral side of the arm by the deltoid, pectoralis major, teres minor, supra- and infraspinatus muscles, and by the greater tubercle of the humerus. On the medial side they are separated the by chief nerves and blood-

FIG. 362, A–D.—TRANSVERSE SECTIONS THROUGH THE LEFT ARM IN THE REGIONS SHOWN IN THE DIAGRAM.

a and *b* in the diagram indicate the regions through which pass sections A and B, fig. 351 (p. 352); *a'* and *b'*, the regions through which pass sections A and B, fig. 357 (p. 366); and a^{11} the region through which passes section A, fig. 366 (p. 385).

1. Arteria brachialis. 2. Bursa subcutanea olecrani. 3. Fascia brachialis. 4. Humerus. 5. Musculus anconeus. 6. M. biceps—*a*, long head; *b*, short head; *c*, tendon of insertion. 7. M. brachialis. 8. M. brachio-radialis. 9. M. coraco-brachialis. 10. M. deltoideus. 11. M. extensor carpi radialis brevis. 12. M. extensor carpi radialis longus. 13 M. extensor digitorum communis. 14. M. flexor carpi radialis. 15. M. flexor carpi ulnaris.. 16. M. flexor digitorum sublimis. 17. M. flexor digitorum profundus. 18. M. palmaris longus. 19. M. pronator teres. 20. M. triceps—*a*, lateral head; *b*, long head; *c*, medial head. 21*a*. N. cutaneus antibrachii medialis (internal cutaneous). 21*b*. N. cutaneus antibrachii dorsalis. 22. N. musculo-cutaneus. 23. N. medianus. 24. N. radialis—*a*, muscular branch. 25. N. ulnaris. 26. Lymphatic gland. 27. Olecranon. 28. Septum intermusculare laterale. 29. Septum intermusculare mediale. 30. Vena cephalica. 31. V. basilica. 32. Vv. brachiales.

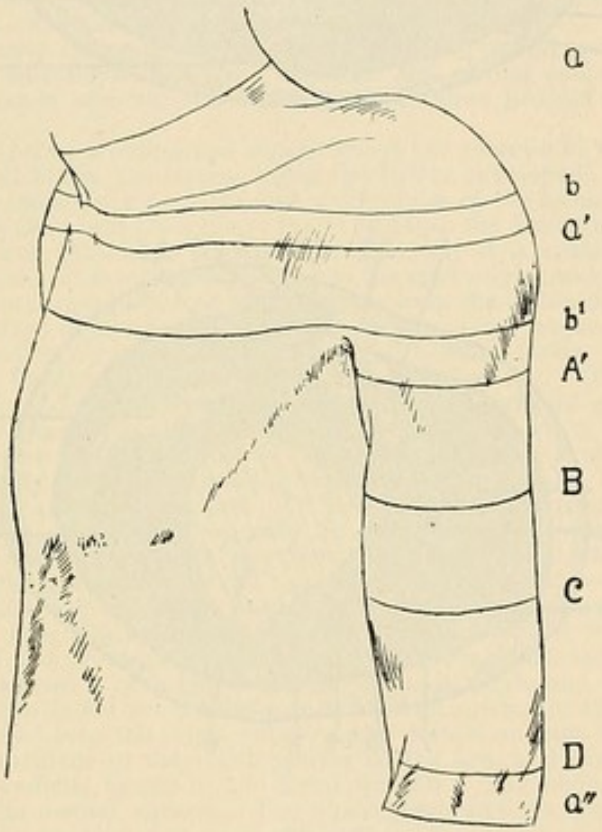

A

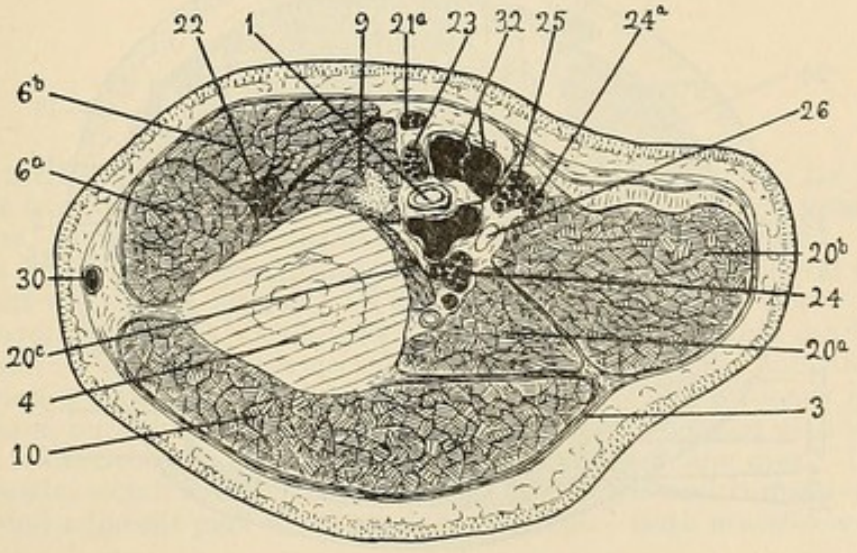

B

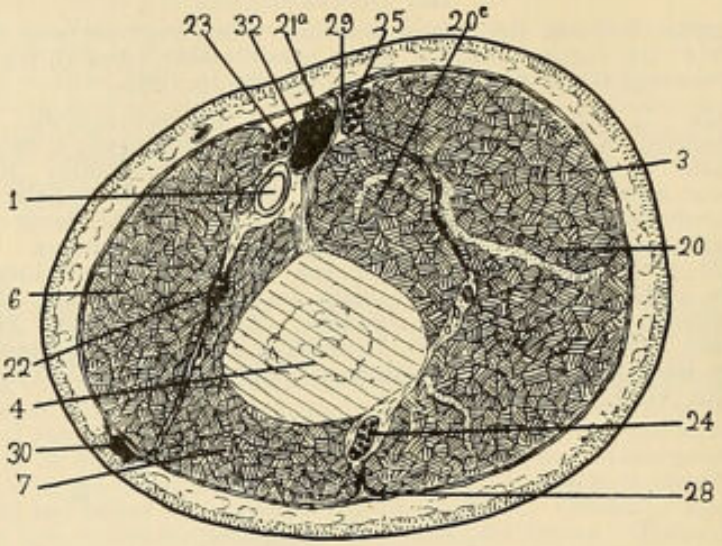
23
32
21a
29
25
20c
3
1
20
6
22
4
24
30
7
28

C

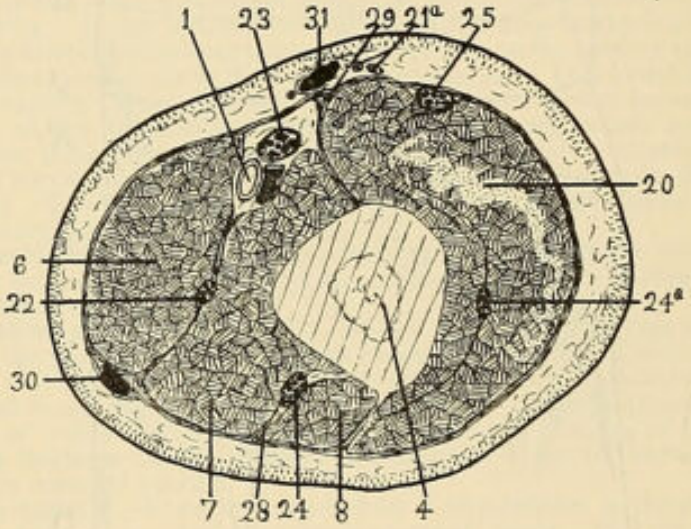
1
23
31
29
21a
25
20
6
22
24a
30
7
28
24
8
4

D

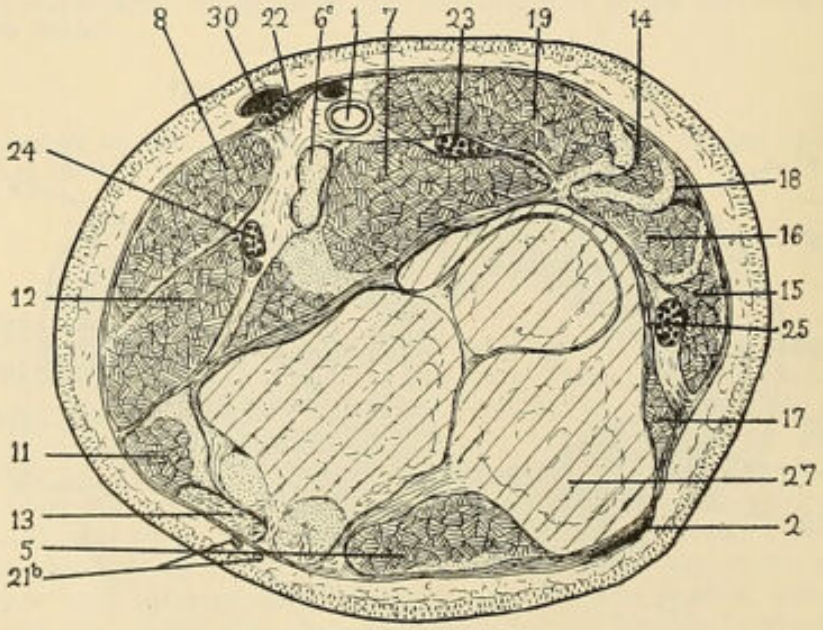
8
30
22
6c
1
7
23
19
14
24
18
16
12
15
25
17
11
27
13
2
5
21b

vessels of the arm and by the tendons of the latissimus dorsi, teres major, and subscapularis muscles. In the distal half of the arm they are separated medially by the medial intermuscular septum (described below) and by the medial epicondyle and the ulno-volar group of muscles of the forearm. On the lateral side of the arm they are separated by the lateral intermuscular septum, by the lateral epicondyle, and by the brachio-radialis and the extensor muscles of the forearm which take origin from the lateral epicondyle.

FASCIÆ

The **fasciæ** and the general relations of the muscles of the arm are shown in the cross-sections in fig. 362.

The **tela subcutanea** of the arm is fairly well developed and contains a considerable amount of fat, especially near the shoulder. It is but loosely bound to the muscle fascia, except near the insertion of the deltoid, where the union may be more intimate.

Bursæ.—B. subcutanea epicondyli lateralis.—Between the lateral epicondyle and the skin. Rare. **B. subcutanea epicondyli medialis.**—Between the medial epicondyle and the skin. Inconstant. **B. subcutanea olecrani.**—Between the olecranon process of the ulna and the skin. Nearly constant.

The **brachial fascia** forms a cylindrical sheath about the muscles of the arm. It contains circular and longitudinal fibres, the former being the better developed. The fascia is strong over the dorsal muscles, especially near the two epicondyles of the humerus. Proximally the fascia of the arm is continued into the axillary fascia and into the fascial investment of the pectoralis major, deltoid, and latissimus dorsi muscles; distally it is continued into the fascial investment of the forearm. It is intimately bound to the epicondyles and to the dorsal surface of the olecranon. It is separated by loose areolar tissue from the bellies of the muscles which it covers. From the tendons of the deltoid, pectoralis major, teres major, and latissimus dorsi muscles, however, fibrous bundles are continued into the brachial fascia. There are a number of orifices in the fascia for the passage of nerves and blood-vessels. Of these, the largest is that for the basilic vein and two or three large branches of the medial antibrachial (internal) cutaneous nerve. This lies on the ulnar margin of the arm in the lower third. On the radial margin lie the cephalic vein in a double fold of the fascia, orifices for branches of the musculocutaneous nerve, and more dorsally orifices for branches of the radial. From the fascia septa descend between the muscles which it invests. Of these septa, the most important are the medial and lateral intermuscular septa, which separate the dorsal group of muscles from the ventral in the distal half of the arm. The **medial intermuscular septum** is the stronger. It is attached to the medial epicondyle and to the medial margin of the humerus proximal to this. It is continued proximally into the tendon of insertion of the coraco-brachialis and the investing fascia of this muscle. Into it longitudinal bundles of fibres descend from the tendon. It separates the brachialis and pronator teres muscles from the medial head of the triceps. The **lateral intermuscular septum** is attached to the lateral epicondyle and to the lateral margin of the humerus. It is continued proximally into the dorsal surface of the tendon of insertion of the deltoid muscle, and into the septa between the deltoid and the triceps. It separates the triceps from the brachialis in the third quarter of the arm and from the brachio-radialis and extensor carpi radialis longus in the distal quarter. The median nerve and brachial vessels lie in front of the medial septum. The ulnar nerve and the superior ulnar collateral (inferior profunda) artery are bound to its dorsal surface.

MUSCLES

1. Dorsal or Extensor Group

Two muscles are included in this group, the triceps brachii and the anconeus. The **triceps** is a complex muscle in which proximally three heads, a long or scapular, a lateral humeral, and a medial humeral, may be distinguished. The long head arises from the infraglenoid tuberosity of the scapula, the lateral head from the humerus above and laterally to the groove for the radial nerve (musculospiral groove), the medial head from the lower half and medial margin of the posterior surface of the humerus. Distally these heads fuse and are inserted by a common tendon into the olecranon of the ulna. The **anconeus** lies chiefly in the forearm, but physiologically and morphologically it belongs with the triceps, and hence is described in connection with the muscles of the arm. It is a triangular muscle, which arises from the lateral epicondyle and is inserted into the olecranon and adjacent part of the shaft of the ulna. Both muscles are supplied

by branches of the radial (musculo-spiral) nerve. They extend the forearm. The long head is also an adductor of the arm.

The triceps, variously modified, is found in the amphibia and all higher vertebrates. The anconeus is found in the prosimians and all higher forms. The triceps muscle is homologous with the quadriceps of the thigh. The long head is equivalent to the rectus femoris. The anconeus is not represented in the lower limb.

The **triceps brachii** (figs. 355, 356, 363).—The **long head** *arises* from the infraglenoid tuberosity of the scapula by a strong, broad tendon, some of the fibres of which are connected with the inferior portion of the capsule of the shoulder-joint. The tendon soon divides into two lamellæ, which extend distally, one a short distance on the deep surface, the other much farther

Fig. 363.—Dorsal View of the Scapular Muscles and Triceps.

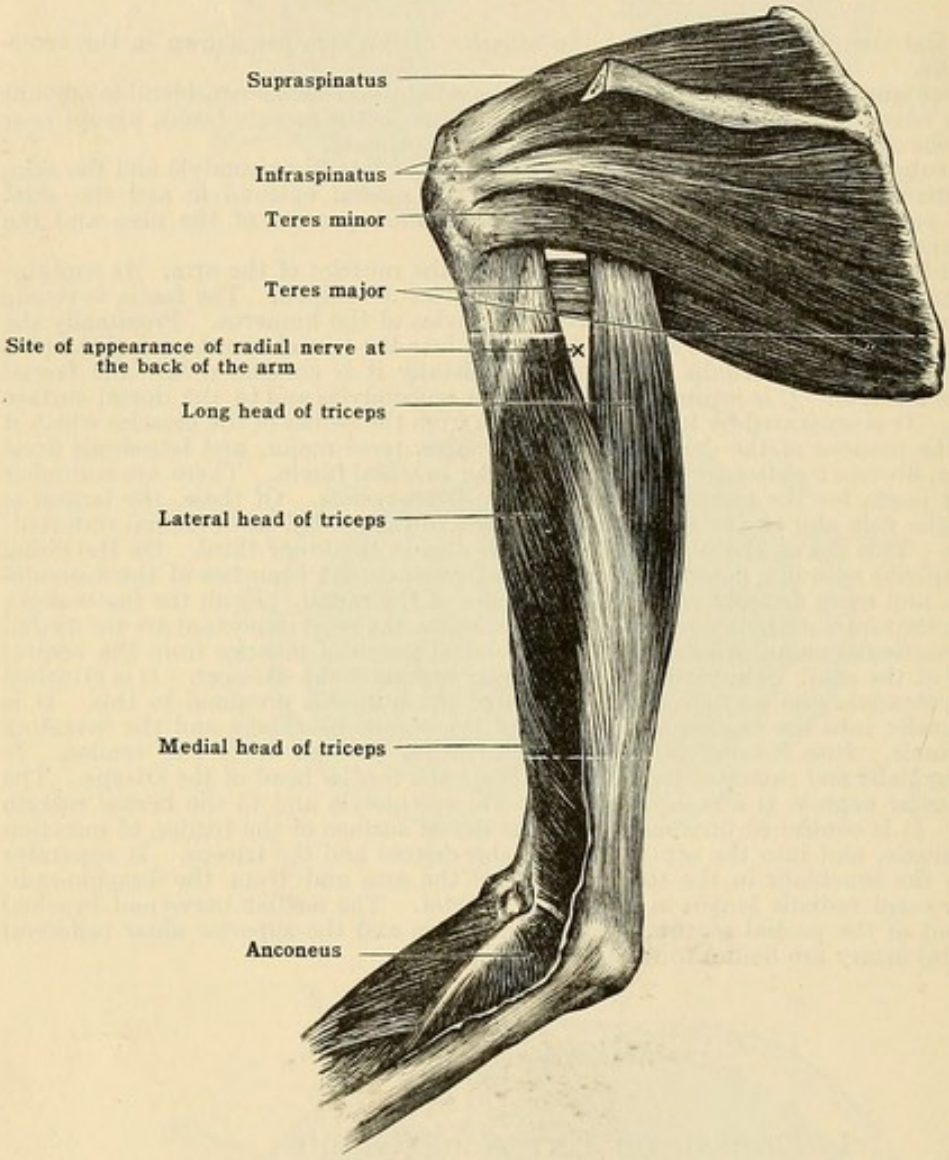

on the superficial surface of this head. The parallel fibre-bundles which arise from these lamellæ form a thick muscle-band which twists upon itself so that the ventral surface at the origin becomes dorso-medial at the insertion. At the insertion the long head becomes applied to an aponeurosis which extends upward from the main tendon of insertion of the triceps. The fibre-bundles extend for some distance on the medial side of this tendon and terminate about three-fourths of the way down the arm.

The **lateral head** has a tendinous *origin* from the superior lateral portion of the posterior surface of the humerus along a line extending from the insertion of the teres minor as far as the groove for the radial (musculo-spiral) nerve, and from the aponeurotic arch formed by the lateral intermuscular septum as it crosses this groove. The constituent fibre-bundles descend, the superior vertically, the inferior obliquely, to be inserted on the dorsal and ventral surfaces of the proximo-lateral margin of the common tendon of insertion of the triceps.

The **medial head** has a fleshy *origin* from the posterior surface of the humerus below the radial (musculo-spiral) groove and from the dorsal surfaces of the medial and lateral intermuscular septa. The greater part of the fibre-bundles arising from this extensive area are inserted into the deep surface of the common tendon, but some extend directly to the olecranon and the articular capsule of the elbow. The slip attached to the capsule is sometimes called the **subanconeus** muscle.

Insertion.—The tendon of insertion of the triceps forms a flat band covering the dorsal surface of the distal two-fifths of the muscle. It also extends proximally between the long and lateral heads and on the deep surface of the former. This tendon is inserted into the olecranon and laterally, by a prolongation over the anconeus, into the dorsal fascia of the forearm.

Nerve-supply.—From the radial (musculo-spiral) nerve. The branch to the long head arises in the arm-pit and enters that margin of the muscle which is prolonged down from the lateral edge of the tendon, but which, because of the torsion of the muscle, comes to lie on the medial side. The nerve usually enters through several rami about the middle of the free portion of the long head. Somewhat more distally the radial nerve gives off a branch that enters, by two or three branches, the proximal portion of the medial head. A similar branch is given to the lateral head and other branches are given to the lateral and medial heads from that portion of the radial (musculo-spiral) nerve lying in the radial (musculo-spiral) groove. The nerve fibres arise from the sixth, seventh, and eighth cervical nerves.

Relations.—Near the shoulder the triceps is covered by the deltoid muscle. The long head passes between the teres major and teres minor muscles. The circumflex (dorsal) scapular vessels here pass medial, the circumflex humeral vessels and the axillary (circumflex) nerve lateral, to this head. More distally the muscle lies beneath the brachial fascia. It covers the radial groove of the humerus, in which run the radial (musculo-spiral) nerve and (superior) profunda brachii artery. Ventro-lateral to the muscle lie the deltoid, brachialis, brachio-radialis, and extensor carpi radialis muscles; ventro-medial, the coraco-brachialis, biceps, and brachialis muscles.

Action.—It extends the forearm. The leverage is of such a nature that force is sacrificed for speed of movement. The long head of the triceps also serves to extend and to adduct the arm and to hold the head of the humerus in the glenoid cavity.

Variations.—The scapular attachment may extend for a considerable distance down the axillary border of the scapula. Each of the heads may be more or less fused with neighbouring muscles. Frequently a fourth head is found. This may arise from the humerus, from the axillary margin of the scapula, from the capsule of the shoulder-joint, from the coracoid process, or from the tendon of the latissimus dorsi.

The *latissimo-condyloideus* (dorso-epitrochlearis).—This muscle is found in about 5 per cent. of bodies. When well developed, it extends from the tendon of the latissimus dorsi to the brachial fascia, the triceps muscle, the shaft of the humerus, the lateral epicondyle, the olecranon, or the fascia of the forearm. It is innervated by a branch of the radial (musculo-spiral) nerve. It is a muscle normally present in some one of the forms above mentioned or in some similar form, in a large number of the inferior mammals. In the human body it is normally represented by a fascial slip from the tendon of the latissimus to the long head of the triceps or the brachial fascia.

The **anconeus.**—*Origin.*—By a short narrow tendon from the distal part of the back of the lateral epicondyle and the adjacent part of the capsular ligament of the elbow-joint.

Structure and insertion.—The tendon of origin is prolonged on the deep surface and lateral border of the muscle. From this the fibre-bundles spread, the proximal transversely, the more distal obliquely, to be inserted into the radial side of the olecranon and an adjacent impression on the shaft of the ulna. Its superior fibre-bundles are usually continuous with those of the medial head of the triceps.

Nerve-supply.—By a long branch which arises in the radial (musculo-spiral) groove from the radial (musculo-spiral) nerve, passes through the medial head of the triceps, to which it gives branches, and enters the proximal border of the anconeus. The nerve fibres arise from the seventh and eighth cervical nerves.

Action.—It aids the triceps in extending the forearm and draws the ulna laterally in pronation of the hand.

Relations.—The muscle lies immediately beneath the antibrachial fascia. It extends over the head of the supinator (brevis) and the elbow-joint and upper radio-ulnar joint.

Variations.—The extent of fusion of the muscle with the medial head of the triceps varies a good deal. It may also be fused with the extensor carpi ulnaris. It has been reported missing.

BURSÆ

B. intratendinea olecrani.—Within the tendon of the triceps near its insertion. More frequent than the following:—

B. subtendinea olecrani.—Between the tendon of the triceps and the olecranon and dorsal ligament of the elbow-joint. Inconstant.

B. epicondyli medialis dorsalis.—Between the medial epicondyle, the edge of the triceps, and the ulnar nerve. Rare.

B. m. anconei.—Between the tendon of origin of the muscle and the head of the radius. Frequent.

2. Ventral or Flexor Group

(Figs. 364, 365, 370, 372)

The muscles of this group are the coraco-brachialis, the biceps, and the brachialis. The **coraco-brachialis** (fig. 365) is a band-like muscle which arises from the coracoid process and is inserted into the middle third of the shaft of the humerus. The **biceps** (fig. 364) arises by two heads: a short head, closely associated with the coraco-brachialis, from the coracoid process; a long head, by an

extended tendon, from the supraglenoid tuberosity of the scapula. The fusiform belly which arises from the fusion of these two heads is inserted into the radius and into the fascia of the forearm. The **brachialis** (fig. 365) extends under cover of the biceps from the lower three-fifths of the shaft of the humerus to the coronoid process of the ulna. The muscles of this group are supplied by the musculo-cutaneous nerve. The brachialis also usually receives a branch from the radial nerve. The coraco-brachialis and short head of the biceps flex and adduct the arm at the shoulder; the biceps and brachialis flex the forearm at the elbow. The long head of the biceps abducts the arm at the shoulder.

FIG. 364.—SUPERFICIAL MUSCLES OF THE FRONT OF THE ARM.

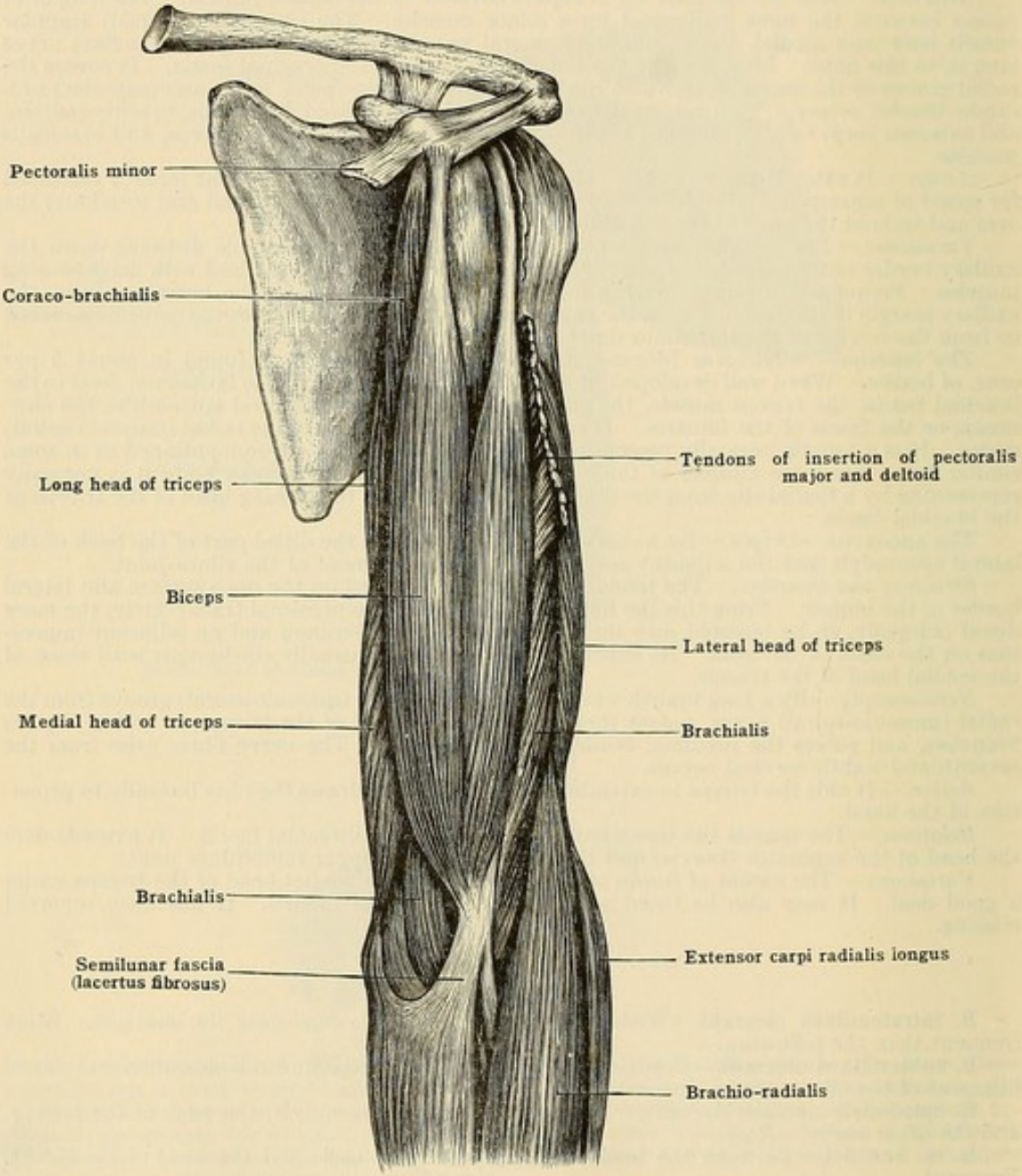

The muscles of this group are found in most of the limbed vertebrates. In many of the lower forms the coraco-brachialis, which appears farther down in the vertebrate series than the biceps, has a more extensive insertion than in man. It may extend to the ulna (lizards) and may be subdivided into various muscles which correspond with the adductors of the thigh. The biceps, the place of which is taken in the lower vertebrates by a coraco-radial muscle, in most of the mammals presents two heads, the more lateral of which is attached by a tendon to the scapula above the shoulder-joint. This long tendon of the biceps lies primitively outside the capsule of the shoulder-joint, but in some of the higher mammals has come to lie within the capsule. In the biceps four elements may be recognised:—a coraco-radial, coraco-ulnar, gleno-radial, and gleno-ulnar. (Krause.) The development of these elements varies in different mammals

The coraco-brachialis (fig. 365).—*Origin.*—(1) By a short tendon from the tip of the coracoid process of the scapula and (2) from the tendon of the short head of the biceps.

Insertion.—(1) By means of a strong tendon into the medial surface of the humerus immediately proximal to the middle of the shaft, and (2) often above this also into an aponeurotic band which extends from the tendon along the medial margin of the humerus, arches over the tendons of the latissimus dorsi and teres major, and is attached to the lesser tubercle of the humerus. When the attachment to the tubercle does not take place, the band becomes closely applied to the deep surface of the muscle.

Structure.—From the tendons of origin, which are usually closely associated, the fibre-bundles take an oblique, nearly parallel, course and are attached to the aponeurotic band above

FIG. 365.—DEEP MUSCLES OF THE FRONT OF THE ARM.

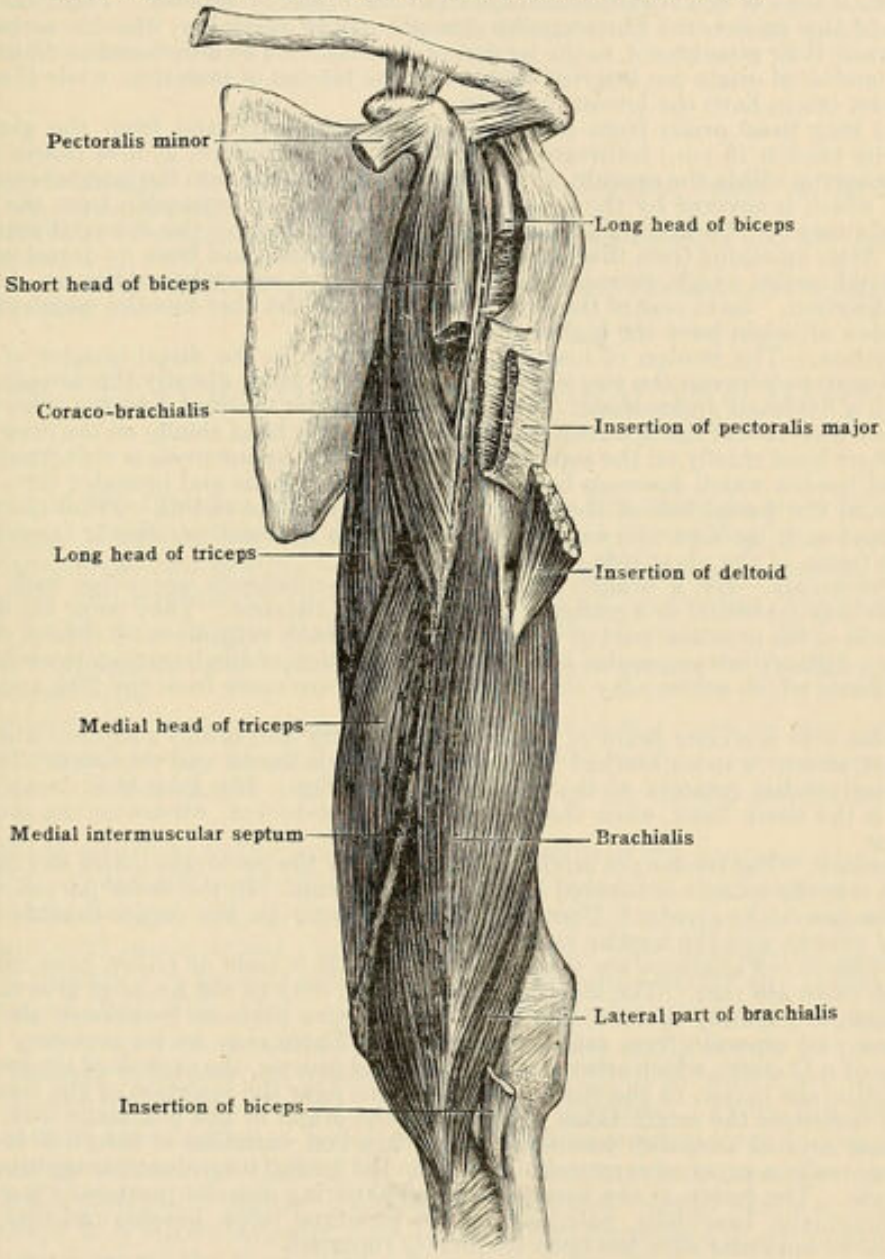

mentioned and to both surfaces of the flat tendon of insertion. This extends high into the muscle. The belly of the muscle usually shows some separation into a superficial and a deep portion, between which runs the musculo-cutaneous nerve. When this separation is well marked, the tendon of origin of the superior fasciculus may be distinct from that of the inferior fasciculus and the short head of the biceps, and the tendon of insertion may give a separate lamina to each fasciculus.

Nerve-supply.—A branch of the musculo-cutaneous nerve, or of the brachial plexus near the origin of this nerve, enters the upper third of the medial border of the muscle, and passes across the constituent fibre-bundles about midway between their attachments. The nerve fibres arise from the sixth and seventh cervical nerves.

Action.—Adducts and flexes the arm at the shoulder and helps to keep the head of the humerus in the glenoid fossa. When the arm has been rotated lateralward, it acts as a medial rotator.

Relations.—The coraco-brachialis is largely covered by the deltoid and pectoralis major muscles. Below the inferior border of the latter it becomes superficial. Near its origin it lies

between the pectoralis minor and the subscapularis muscles. More distally it lies medial to the humerus and in front of the chief brachial vessels and nerves. The musculo-cutaneous nerve usually runs through it.

Variations.—The humeral insertion of the muscle varies considerably. According to Wood, the coraco-brachialis consists primitively of three parts, which arise from the coracoid process and are inserted respectively into the upper, the middle, and the distal part of the humerus along the medial side. The superior division is most deeply, the inferior the most superficially, placed. In man the muscle is composed of parts of the middle and inferior divisions. The inferior division may be completely developed as far as the medial epicondyle. The superior division of the muscle is occasionally found. Slips from the coraco-brachialis to the brachialis have been seen. Complete absence of the muscle has been recorded.

The **biceps brachii** (figs. 364, 370).—The **short head** *arises* by a flat tendon closely associated with that of the coraco-brachialis from the coracoid process. From the dorso-medial surface of this tendon the fibre-bundles descend nearly vertically, though increasing in number, toward their attachment to the tendon of insertion. The fibre-bundles which arise highest on the tendon of origin are inserted highest on the tendon of insertion, while those which have the lowest origin have the lowest insertion.

The **long head** *arises* from the supraglenoid tuberosity and from the glenoid ligament by a long tendon (9 cm.) bifurcated at its origin. The tendon at first passes over the head of the humerus within the capsule of the joint, and then passes into the intertubercular (bicipital) groove, which is covered by the capsule of the joint and an expansion from the tendon of the pectoralis major. To this point the tendon is surrounded by the synovial membrane of the joint. After emerging from this the tendon slowly expands and from its dorsal concave surface arise fibre-bundles which, increasing in number, extend, somewhat obliquely, toward the tendon of insertion. As in case of the short head, here also the fibre-bundles which arise highest on the tendon of origin have the highest insertion.

Insertion.—The tendon of insertion begins usually in the distal quarter of the arm as a vertical septum between the two heads of the muscle. More distally this broadens out on each side into a flattened aponeurosis. The fibre-bundles are inserted into the sides of the septum and on each surface of the aponeurosis—those of the long head chiefly on the deep surface, those of the short head chiefly on the superficial surface. The aponeurosis is continued into a strong, flattened tendon which descends between the brachio-radialis and pronator teres muscles to be inserted on the dorsal half of the bicipital tuberosity of the radius. From the medial border of the tendon an aponeurotic expansion, the **lacertus fibrosus** (semilunar fascia), is continued into the fascia of the ulnar side of the forearm.

Nerve-supply.—By a branch from the musculo-cutaneous nerve for each head. These branches may be bound in a common trunk for some distance. They enter the deep surface of the muscle in the proximal part of the middle third of each belly often by several rami. Usually there is a distinct intramuscular fissure for the reception of the branches to each head and the blood-vessels which accompany them. The nerve fibres come from the fifth and sixth cervical nerves.

Action.—It is a chief flexor of the arm at the elbow and is also a supinator of the forearm. This last action is most marked when the forearm is flexed and pronated. Both heads are flexors and medial rotators of the arm at the shoulder. The long head is an abductor and so also is the short head when the arm is greatly abducted, otherwise the short head is an adductor.

Relations.—The tendons of origin are concealed by the pectoralis major and deltoid muscles. Beyond this the muscle is covered by the fascia brachii. In the lower part of the arm it lies upon the brachialis muscle. Upon the medial margin lie the coraco-brachialis muscle, the brachial vessels. and the median nerve.

Variations.—Variations are frequent. The whole muscle or either head may be missing, but such cases are rare. The long head may extend only to the bicipital groove. Frequently the muscle is partially divided into the four primitive portions mentioned above. The two heads may be separate from origin to insertion. There may be an accessory head (1 in 10 subjects—Le Double) which arises from the coracoid process, the capsule of the joint, the tendon of the pectoralis major, or the shaft of the humerus near the insertion of the coraco-brachialis. In most instances the origin takes place above the origin of the brachialis from the humerus. Sometimes several accessory heads are seen. Marked variation of insertion is less frequent, but occasionally a supernumerary slip may go to the medial intermuscular septum or the medial epicondyle. The fusion of the biceps with neighbouring muscles (pectoralis major and minor, coraco-brachialis, brachialis, palmaris longus, pronator teres, brachio-radialis) by means of tendinous or muscular slips has been frequently reported.

The **brachialis** (fig. 365).—*Origin.*—(1) From the distal three-fifths of the front of the humerus, (2) from the medial intermuscular septum, and (3) from the lateral intermuscular septum proximal to the heads of the brachio-radialis and extensor carpi radialis longus. Proximally it sends up a pointed process on the lateral side of the insertion of the deltoid and another between the insertions of the deltoid and the coraco-brachialis. Distally the area of origin stops a little above the capitulum and the trochlea.

Structure and Insertion.—The fibre-bundles arise directly from this area of origin, except near the insertion of the deltoid and on the medial margin, where tendinous bands are developed. The fibre-bundles descend, the middle vertically, the medial obliquely lateralward, the lateral still more obliquely medialward. The tendon of insertion appears on the dorsal side of the lateral edge of the muscle in its lower fourth. Continuous with this stronger lateral portion of the tendon more distally a thinner band appears upon the ventral surface of the muscle above the joint. The tendon becomes thick as it passes distally, is closely united to the capsule of the elbow-joint, and is attached to the ulnar tuberosity. In addition to the main tendon, some of the deeper fibre-bundles of the muscle and some of those coming from the lateral intermuscular septum are attached by short tendinous bands to the coronoid process.

Nerve-supply.—From the musculo-cutaneous nerve by a branch which enters the ventral surface of the muscle near the junction of the upper and middle thirds of the medial border. In addition the radial (musculo-spiral) nerve usually sends a small branch into the distal lateral portion of the muscle. A branch from the median nerve frequently supplies the medial side of the muscle near the elbow-joint (Frohse).

Action.—To flex the forearm.

Relations.—It lies behind the biceps, on each side of which it projects. The distal lateral portion of the muscle is grooved by the brachio-radialis, which here is closely applied to it. The radial (musculo-spiral) nerve runs between these two muscles. On the medial side run the brachial vessels and median nerve.

Variations.—It may be divided into two distinct heads continuous with the projections on each side of the deltoid tuberosity. A great number of supernumerary slips have been recorded. These may be attached to the radius, ulna, fascia of the forearm, capsule of the joint, brachio-radialis, and extensor carpi radialis muscles. It may be partially fused with neighbouring muscles. It has also been reported absent.

Bursæ

B. m. coraco-brachialis.—Between the subscapularis muscle, the tendon of the coraco-brachialis, and the coracoid process. Frequent.

B. bicipito-radialis.—Between the ventral half of the radial tuberosity and the tendon of the biceps. Constant.

B. cubitalis interossea.—Between the tendon of the biceps and the ulna and the neighbouring muscles. Frequent.

D. MUSCULATURE OF THE FOREARM AND HAND

(Figs. 366–379)

The muscles of the forearm arise in part from the humerus, in part from the radius and ulna. Their bellies lie chiefly in the proximal half of the forearm. They are divisible into two groups:—a radio-dorsal, composed of extensors of the hand and fingers and supinators of the forearm; and an ulno-volar, composed of flexors of the hand and fingers and pronators of the forearm. The brachio-radialis, which belongs morphologically with the former group, is physiologically a flexor of the forearm.

The two groups are separated on the medial side of the back of the forearm by the dorsal margin of the ulna (figs. 366, 369). Ventrally they are separated by the insertions of the biceps and brachialis and by an intermuscular septum (figs. 366, 370).

In the **hand,** in addition to the tendons of the muscles of the forearm mentioned above (fig. 376), there are several sets of intrinsic muscles. About the metacarpal of the thumb (figs. 375, 376, 377) is grouped a set of muscles which arise from the carpus and metacarpus and are inserted into the metacarpal and first phalanx of the thumb. A similar set of muscles is grouped about the metacarpal of the little finger (figs. 375, 376). These sets of muscles give rise respectively to the thenar and hypothenar eminences. Between the metacarpals lies a series of dorsal and palmar interosseous muscles (figs. 377, 378, 379) which are inserted into the first row of phalanges and into the extensor tendons. From the tendons of the deep flexor of the fingers a series of lumbrical muscles passes to the radial side of the extensor tendons (figs. 373, 375). These various muscles abduct, adduct, flex, and extend the digits. In addition to these deeper skeletal muscles of the hand there is a subcutaneous muscle over the hypothenar eminence (fig. 375). Of the muscles of the hand, all are supplied by the ulnar nerve except most of those of the thumb and the two more radial lumbricals, which are supplied by the median nerve.

An arrangement of the muscles of the forearm in which the dorsal extensor-supinator musculature extends proximally on the radial side of the arm to the distal extremity of the humerus, and the volar flexor-pronator musculature similarly on the ulnar side, is characteristic of all limbed vertebrates and is associated with the pronate position of the forelimb characteristic of quadrupeds. In amphibia and reptiles the musculature terminates distally on the carpus and in the aponeuroses of the hand. In the higher forms special tendons are differentiated for those muscles of the forearm which act on the fingers. On the back of the hand in many vertebrates short extensor muscles are found running from the carpus to the phalanges. On the volar surface a complex musculature is found in all forms which have freely movable fingers. In animals which walk on the ends of the fingers, especially in the hoofed animals, the intrinsic musculature of the hand is greatly reduced. The phylogenetic development of the muscles of

the forearm and hand is too complex a subject to be briefly summarised. The phylogeny of the forearm flexors and the palmar musculature has been studied by McMurrich. In his papers a summary of the literature on the subject may be found.

FASCIÆ

The **fasciæ** and the general relations of the musculature of the forearm and hand may be followed in the cross-sections fig. 366.

The **tela subcutanea** contains a moderate amount of fat in the upper part of the forearm. This grows less in amount as the wrist is approached. On the back of the hand it contains little fat. In the palm and on the volar surface of the fingers a moderate amount of fat is embedded between dense vertical bundles of fibres which unite the skin to the fascia. Except on the volar surface of the hand and on the backs of the terminal phalanges, the tela is but loosely united to the underlying fascia.

The **bursa subcutanea olecrani** lies over the dorsal surface of the olecranon. Subcutaneous bursæ are also frequently found over the knuckles (**b. subcutaneæ metacarpophalangeæ dorsales**) and the proximal joints of the fingers (**b. subcutaneæ digitorum dorsales**).

The **antibrachial fascia** encloses the muscles of the forearm in a cylindrical sheath, composed in the main of circular fibre-bundles, but strengthened by longitudinal and oblique bundles extending in from the epicondyles of the humerus, the olecranon, the lacertus fibrosus of the biceps, and the tendon of the triceps. The fascia of the forearm is attached to the dorsal surface of the olecranon and to the subcutaneous margin of the ulna. Above, it is continued into the fascia of the arm; below, into the fascia of the hand. From the antibrachial fascia in the upper half of the forearm a fibrous septum extends between the radio-dorsal and the ulno-volar muscle group to the radius. In the radial septum below the elbow a branch of communication extends between the superficial and deep veins of the arm. That part of the fascia overlying the radio-dorsal group of muscles is much denser than that covering the volar group, except where the latter is strengthened by the lacertus fibrosus. In addition to the main radial septum other septa descend between the underlying muscles from the antibrachial fascia. These septa are best marked near the attachment of the muscles to the humerus. Here the fascia is firmly fused to the muscles.

Dorsally the antibrachial fascia is strengthened at the wrist by transverse fibres which extend from the radius to the styloid process of the ulna, the triquetrum (cuneiform), and pisiform, and give rise to the **dorsal ligament of the carpus** (posterior annular ligament). From this ligament septa descend to the radius and ulna and convert the grooves in these bones into osteo-fibrous canals which lodge the tendons of the various muscles extending to the wrist and hand.

On the **back of the hand** there is spread a fascia composed of two thin fascial sheets between which the extensor tendons are contained. Between the tendons these sheets are more or less fused. On the backs of the fingers the fascia blends with the extensor tendons and the associated aponeurotic expansions from the interosseous and lumbrical muscles. Between the fingers it is continued into the transverse fasciculi of the palmar aponeurosis. At the sides of the hand the fascia is continued into the thenar and hypothenar fasciæ. Each dorsal interosseous muscle is covered by a special fascial membrane which is separated by loose tissue from the fascia investing the extensor tendons.

FIG. 366, A–H.—TRANSVERSE SECTIONS THROUGH THE LEFT FOREARM AND HAND.

H. Transverse section through the first phalanx of the middle finger, diagrammatic, with the cavity of the synovial sheath of the flexor tendons distended.

The regions through which these sections pass are indicated in the diagram. *c* and *d* in the diagram show the regions through which pass sections C and D, fig. 362 (p. 375).

1. Aponeurosis palmaris. 2. Arteria radialis. 3. A. ulnaris. 4. Bursa bicipito-radialis. 5 Discus articularis. 6. Ligamentum carpale dorsale. 7. L. carpi transversum. 8. L. carpi volare. 9. Fascia antibrachii. 10. Musculus abductor pollicis brevis. 11. M. abductor pollicis longus—a, tendon. 12. M. abductor digiti quinti. 13. M. adductor pollicis. 14. M. anconeus. 15. M. biceps, tendon. 16. M. brachialis, tendon. 17. M. brachio-radialis—a, tendon. 18. M. extensor carpi radialis brevis—a, tendon. 19. M. extensor carpi radialis longus—a, tendon. 20. M. extensor carpi ulnaris. 21. M. extensor digitorum communis—a, tendon for second finger; b, tendon for the third finger; c, tendon for fourth finger; d, tendon for fifth finger; e, digital aponeurosis. 22. M. extensor digiti quinti proprius. 23. M. extensor indicis proprius. 24. M. extensor pollicis brevis —a, tendon. 25. M. extensor pollicis longus—a, tendon. 26. M. flexor carpi radialis—a, tendon. 27. M. flexor carpi ulnaris—a, tendon. 28. M. flexor digitorum profundus—a, tendon for second finger; b, tendon for third finger; c, tendon for fourth finger; d, tendon for fifth finger. 29. M. flexor digitorum sublimis—a, tendon for second finger; b, tendon for third finger; c, tendon for fourth finger; d. tendon for fifth finger. 30. M. flexor digiti quinti brevis. 31. M. flexor pollicis brevis. 32. M. flexor pollicis longus—a, tendon. 33. M. interossei dorsales. 34. M. interossei volares. 35. M. lumbricales. 36. M. opponens pollicis. 37. M. opponens digiti quinti. 38. M. palmaris brevis. 39. M. palmaris longus—a, tendon. 40. M. pronator quadratus. 41. M. pronator teres. 42. M. supinator. 43. N. cutaneus antibrachii lateralis. 44. N. medianus. 45. N. radialis—a, deep radial nerve; b, superficial radial nerve. 46. N. ulnaris. 47. Os capitatum (magnum). 48. Os hamatum (unciform). 49. Os lunatum (semilunar). 50. Os metacarpale, I. 51. Os metacarpale, II. 52. Os metacarpale, III. 53. Os metacarpale, IV. 54. Os metacarpale, V. 55. Os multangulum majus (trapezium). 56. Os naviculare. 57. Ossa sesamoidea of fifth digit. 58. Radius. 59. Ulna. 60. Vagina fibrosa (tendon-sheath) of the long digital flexors. 61. Vagina fibrosa (tendon-sheath) of the flexor pollicis longus. 62. Vagina fibrosa (tendon-sheath in digit). 63. Vena cephalica.

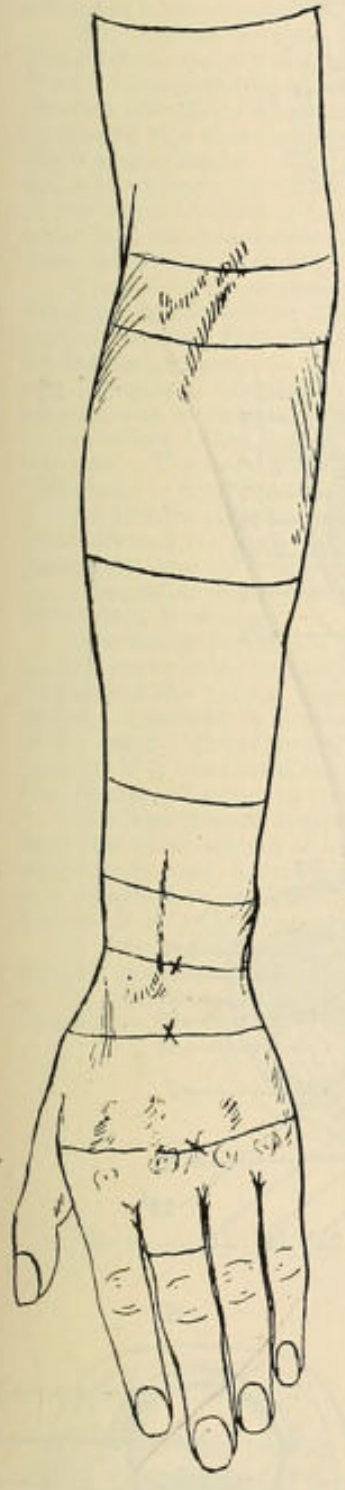
c
d
A
B
C
D
E
F
G
H

A

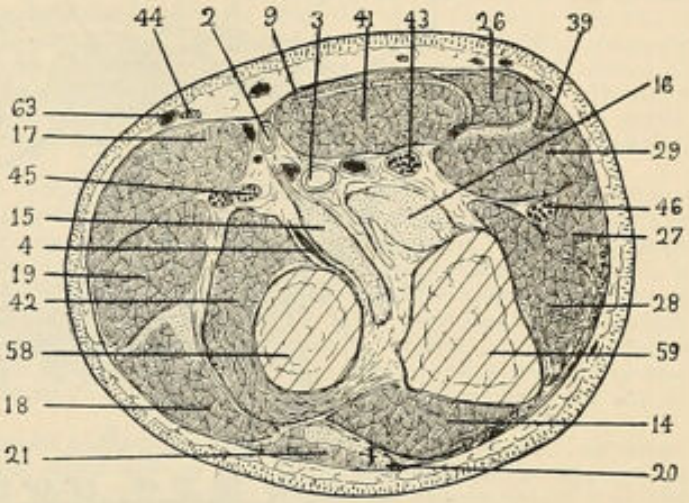
44
2
9
3
41
43
26
39
16
63
17
45
29
15
46
4
27
19
42
28
58
59
18
14
21
20

B

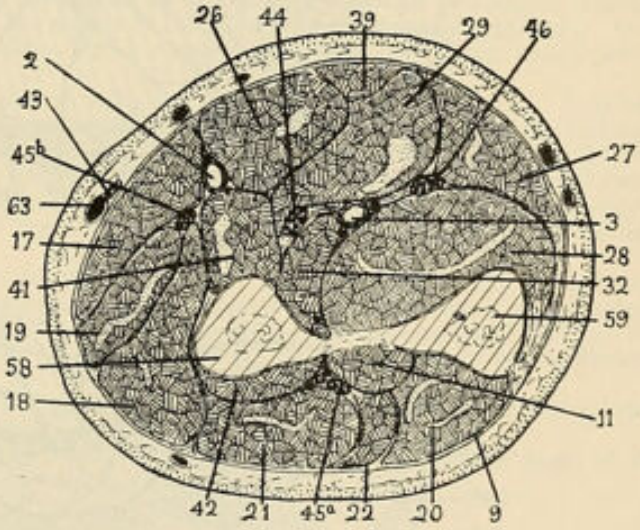
26
44
39
29
46
2
43
45b
27
63
3
17
28
41
32
19
59
58
18
11
42
21
45a
22
20
9

C

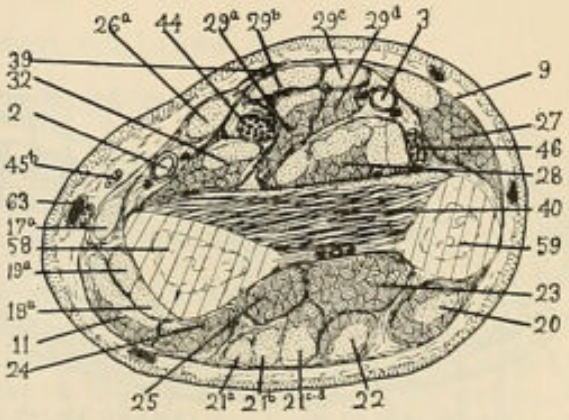
26a
44
29a
29b
29c
29d
3
39
9
32
27
2
46
45b
28
63
40
17c
58
59
19a
23
18c
20
11
24
25
21a
21b
21c
22

D

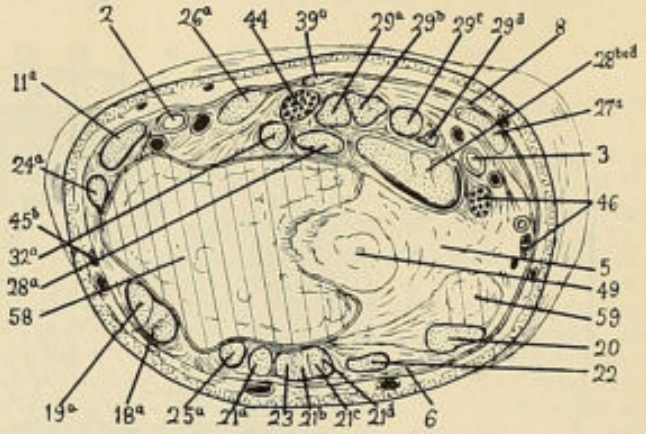
2
26a
44
39a
29a 29b 29c 29d
8
28b+d
11a
27a
24a
3
46
45b
32a
28a
58
5
49
59
20
22
19a
18a
25a
21a
23
21b
21c
21d
6

E

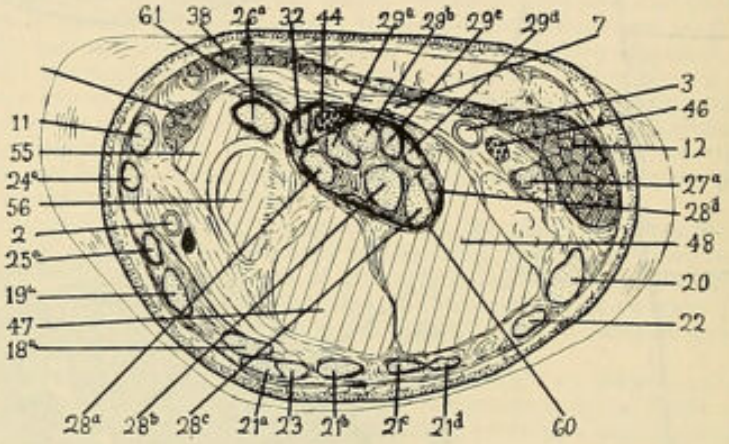
61
38
26a
32
44
29a 29b 29c 29d
7
3
46
11
55
24c
56
2
25c
19c
47
18c
12
27a
28d
48
20
22
28a
28b
28c
21a
23
21b
21c
21d
60

F

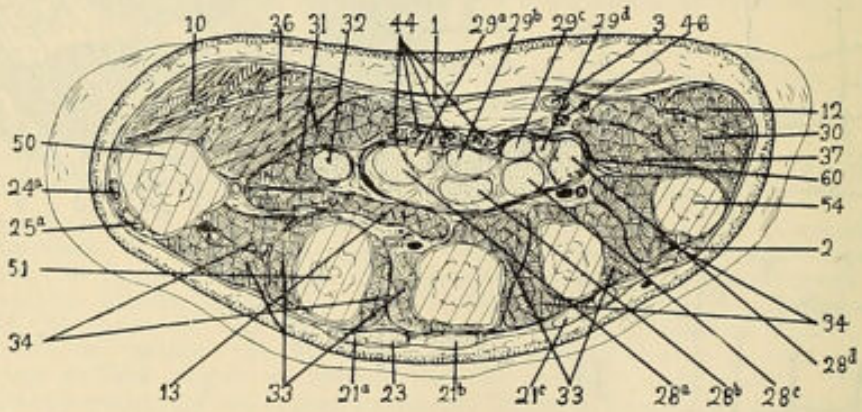
10
36
31
32
44
1
29a 29b 29c 29d
3
46
12
30
37
60
54
2
34
28d
50
24a
25a
51
34
13
33
21a
23
21b
21c
33
28a
28b
28c

G

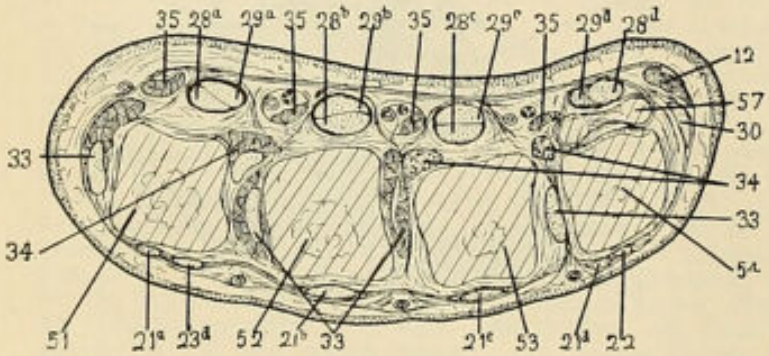
35
28a
29a
35
28b
29b
35
28c
29c
35
29d
28d
12
57
30
34
33
54
33
34
51
21a
23d
52
21b
33
21c
53
21d
22

H

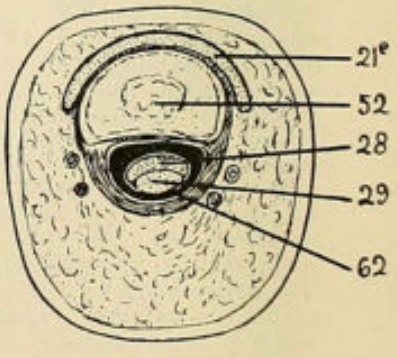
21e
52
28
29
62

On the **volar side of the forearm** for some distance above the wrist the tendons of the flexor carpi radialis, the palmaris longus, and the flexor carpi ulnaris run between two layers of the fascia. The fascia is much strengthened at the wrist by transverse fibres which give rise to the **volar ligament of the carpus.** Beneath it lies the **transverse ligament of the carpus** (anterior annular ligament). This dense band is broader than the volar ligament but like it extends from the pisiform bone and the hamulus of the hamatum (unciform) to the tuberosity of the navicular and the tuberosity of the greater multangular (trapezium). It serves to complete an osteo-fibrous canal through which pass the flexor tendons of the fingers. Between the two ligaments which are partially fused with one another run the ulnar artery and nerve.

On the **palm of the hand** the ensheathing fascia presents three distinct areas—a central, a lateral, and a medial.

The central portion, the **palmar aponeurosis,** is composed chiefly of bundles of fibrous tissue which radiate superficially toward the fingers from the tendon of the palmaris longus or from a corresponding region of the forearm fascia when this muscle is absent. Between these bundles are others which arise from the transverse ligament. The deep surface of the fascia is composed of a thin incomplete layer of transverse fibres which continue the transverse fibres of the forearm fascia. Near the capitula of the metacarpals this layer becomes much stronger and constitutes a ligamentous band (**superficial transverse ligament** of Poirier). Near the bases of the digits bundles of transverse fibres (**fasciculi transversi**) lie in the webs of the fingers and constitute an incomplete transverse ligament separated by a distinct interval from the superficial transverse ligament.

From the palmar aponeurosis processes are sent in toward the deeper structures. Of these, the most important are those continued into a fibrous sheath which surrounds the space containing the long flexor tendons and the lumbrical muscles. This dense fibrous sheath is united by fibrous processes to the third, fourth, and fifth metacarpals. As the flexor tendons diverge and the ends of the metacarpals are approached, numerous processes descend from the palmar aponeurosis to the transverse capitular ligament. These hold the tendons in place. On the volar surface of the fingers the fascia serves to complete osteo-fibrous canals for the long flexor tendons. The ventral surface of the first and second phalanges of each finger is slightly grooved. The fascia is firmly united on each side to the margin of the groove, and over the groove forms a semicylindrical, strong, fibrous sheath, the **vaginal ligament** of the finger. This sheath is strengthened by transverse bands over the bases of the first and second phalanges (**annular ligaments**) and by cruciate bands over the shafts of the phalanges (**cruciate ligaments**). Over the interphalangeal joints the sheath is thin, but is strengthened by crucial bands which permit of freedom of motion.

The **thenar fascia** is a thin membrane covering the short muscles of the thumb. It is continued above into the fascia of the forearm, medially is fused with the tendon of the palmaris longus and the palmar aponeurosis, and extends as a septum to be attached to the third metacarpal. Laterally it is attached to the first metacarpal and is continued into the dorsal fascia of the hand. It is fused with an aponeurosis from the tendon of the abductor pollicis longus. Distally it is continued into the vaginal ligament of the long flexor of the thumb. Superficially it is closely adherent to the skin.

The **hypothenar fascia** invests the palmar muscles of the little finger. It is continued from the ulnar margin of the fifth metacarpal over the muscles of the little finger to the palmar aponeurosis, and, by means of a septum, to the radial side of the fifth metacarpal. Proximally, it is attached to the hamatum (unciform) and extends into the fascia of the forearm, distally, it extends into the vaginal ligament of the tendon of the fifth digit.

A deeply seated suprametacarpal fascial layer, or **deep palmar fascia,** covers the interosseous muscles and is attached to the volar surface of the metacarpal bones.

In addition to the fasciæ mentioned, intermuscular septa serve to separate more or less completely the various intrinsic muscles of the hand.

MUSCLES

1. Radio-Dorsal Division

The muscles of this group lie in two chief layers, a superficial and a deep.

a. Superficial Layer

(Figs. 367, 370, 371)

The muscles of this layer, closely associated at their origins, extend from the radial side of the distal end of the humerus to the distal extremity of the radius, the carpus, and the fingers. They are divisible into a radial, an intermediate, and an ulnar set.

Radial set.—To this belong three muscles, the brachio-radialis, extensor carpi radialis longus and brevis. The **brachio-radialis** (fig. 370), a forearm flexor, is a superficial fusiform muscle which arises from the lateral epicondylar ridge of the humerus and is inserted into the base of the styloid process of the radius. The **extensor carpi radialis longus** (fig. 371) is a narrow, fusiform muscle which extends

along the radial margin of the forearm, partly under cover of the brachio-radialis. It arises from the lateral epicondylar ridge of the humerus, and is inserted into the second metacarpal bone. The **extensor carpi radialis brevis** (fig. 367) is a band-like muscle more dorsally placed than the last at the radial side of the arm. It arises from the lateral epicondyle and is inserted into the bases of the second and third metacarpals. These muscles are supplied by branches of the radial nerve which arise proximal to the passage of the deep radial (posterior interosseous) through the supinator muscle. Distally this set of muscles is separated from the intermediate set by the long abductor and the extensors of the thumb, which pass from an origin under the latter set over the tendons of the radial extensors to the thumb.

The **intermediate set.**—This consists of the thick, flattened **extensor digitorum communis** and the slender **extensor digiti quinti proprius** (fig. 367). They arise from the lateral epicondyle, and are inserted into the backs of the fingers.

The **ulnar set** consists of one muscle, the fusiform **extensor carpi ulnaris,** which arises from the lateral epicondyle of the humerus and is inserted into the back of the base of the fifth metacarpal.

The intermediate and ulnar sets of muscles are supplied by branches from the ramus profundus of the radial nerve after this has passed through the supinator muscle.

In the leg the lateral set of the superficial layer is represented by the tibialis anterior. The intermediate set is represented by the long extensors of the toes. The single muscle which constitutes the medial set is represented by the peroneal muscles.

The brachio-radialis (supinator radii longus) (figs. 367, 370).—*Origin.*—From the upper two-thirds of the lateral epicondylar ridge of the humerus and from the front of the lateral intermuscular septum.

Insertion.—Into the lateral side of the base of the styloid process of the radius.

Structure.—The constituent fibre-bundles arise directly from the septum and by short tendinous bands from the epicondylar ridge, extend downward and ventrally, and terminate in a penniform manner on a tendon which extends high on the deep surface of the muscle. This tendon becomes free about the middle of the forearm as a broad, flat band. This becomes narrow as the tendon winds about the radius from the volar to the lateral surface. Before its insertion it expands laterally and is connected with neighbouring ligaments. The free surface of the muscle faces laterally at its origin, but, owing to the torsion, ventrally in the forearm. The tendon, however, is turned again so that at the insertion it faces laterally once more.

Nerve-supply.—From a branch of the radial nerve (musculo-spiral) which enters the proximal third of the muscle on its deep surface. The nerve fibres arise from the fifth and sixth cervical nerves.

Action.—To flex the forearm. This action is strongest when the forearm is pronated. It acts as a supinator only when the arm is extended and pronated. It then serves to put the arm in a state of semi-pronation. When the forearm is flexed, it acts as a pronator.

Relations.—The muscle is superficially placed on the ventro-lateral surface of the forearm. Its tendon of insertion, however, is covered by the long abductor and the short extensor of the thumb. Near its origin (fig. 367) it lies lateral to the brachialis. In the intervening tissue run the radial nerve and the terminal branch of the profunda brachii artery. Dorsally and laterally lies the medial head of the triceps. More distally the muscle overlies the extensor carpi radialis longus. It crosses the supinator, pronator teres, and flexor pollicis longus muscles. Beneath its medial edge lie the radial vessels and nerve.

Variations.—The humeral origin may extend half-way up the shaft. The radial insertion may be as high as the middle of the shaft or descend to the lesser multangular, navicular, or third metacarpal. In about 7 per cent. of bodies (Le Double) the tendon of insertion divides into two or three slips which are inserted on the styloid process of the radius. Occasionally the radial nerve passes between these slips. An accessory slip may pass to the fascia of the forearm. The muscle may be doubled throughout its length and it may be missing. It may be connected by accessory slips with neighbouring muscles, the deltoid, brachialis, long abductor of the thumb, or long radial carpal extensor. The slip most frequently found goes to the brachialis.

The extensor carpi radialis longus (figs. 367, 368, 371.)—*Origin.*—From the lower third of the lateral epicondylar ridge, the lateral intermuscular septum, and from the front of the tendons of the extensor carpi radialis brevis and the extensor communis digitorum which arise from the lateral epicondyle.

Structure and insertion.—The fibre-bundles are inserted in a penniform manner on both surfaces of a tendon which first appears on the lateral border of the deep surface of the muscle, becomes free above the middle of the forearm, and descends, closely applied to the tendon of the short radial carpal extensor, to the second compartment beneath the dorsal carpal ligament, through which it passes to its insertion into the base of the second metacarpal near the radial border. The outer surface of the muscle faces at first laterally, then ventrally.

Nerve-supply.—By one or two branches which arise from the radial (musculo-spiral) nerve as it passes between the brachialis and brachio-radialis. The nerve enters the deep surface of the muscle in the proximal third. The nerve fibres arise from the (fifth), sixth and seventh cervical nerves.

Action.—To extend and abduct the hand. It steadies the wrist when the flexors act on

the fingers. It is a flexor of the forearm; a supinator when the forearm is extended, a pronator when it is flexed.

Relations.—It is covered by the brachio-radialis near the elbow. Below it becomes superficial except where crossed by the tendons of the muscles of the thumb. (For the relations to the short radial carpal extensor see below.)

FIG. 367.—MUSCLES OF THE RADIAL SIDE AND THE BACK OF THE FOREARM.

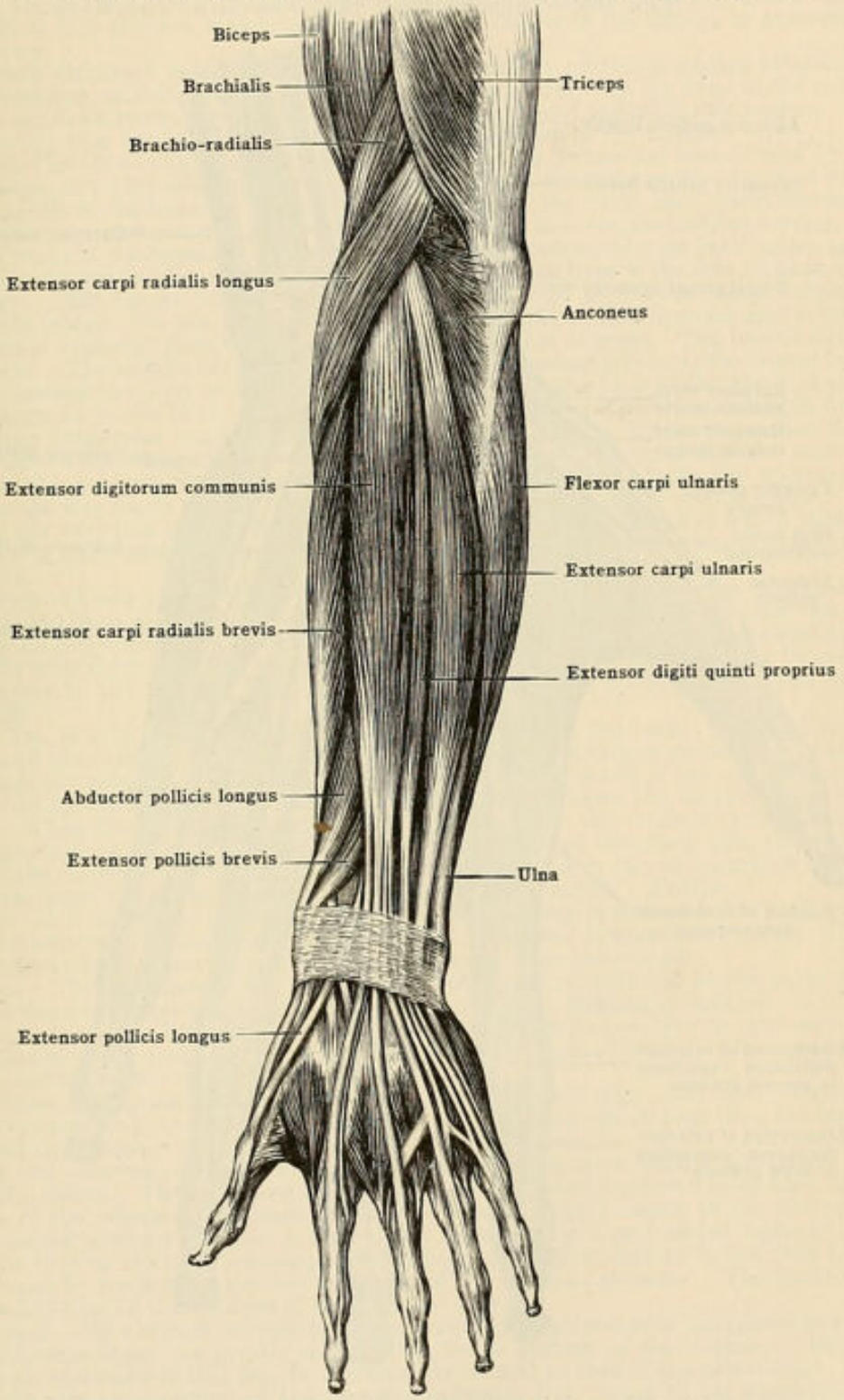

Variations.—The humeral attachment may be more extensive than that indicated above. The tendon of insertion may send a band to the third or to the fourth metacarpal or to the multangulum majus (trapezium). The muscle may be fused, partly or completely, with the short radial extensor. It may send a slip to the abductor pollicis longus or to some of the interossei.

The extensor carpi radialis brevis (figs. 367, 368).—*Origin.*—From a band which descends on its deep surface from the common extensor tendon attached to the lateral epicondyle, from the intermuscular septa surrounding its head, and from the radial collateral ligament of the elbow-joint.

Structure and insertion.—The fibre-bundles converge obliquely toward a tendon which appears high up on the dorso-lateral surface of the muscle. Toward the lower third of the forearm this tendon becomes a free, strong band closely applied to the under surface of the tendon of the long radial extensor, and with this passes through the second compartment beneath the dorsal ligament of the carpus, diverging as it does so toward its insertion into the back of the bases of the second and third metacarpal bones.

FIG. 368.—TENDONS UPON THE DORSUM OF THE HAND.

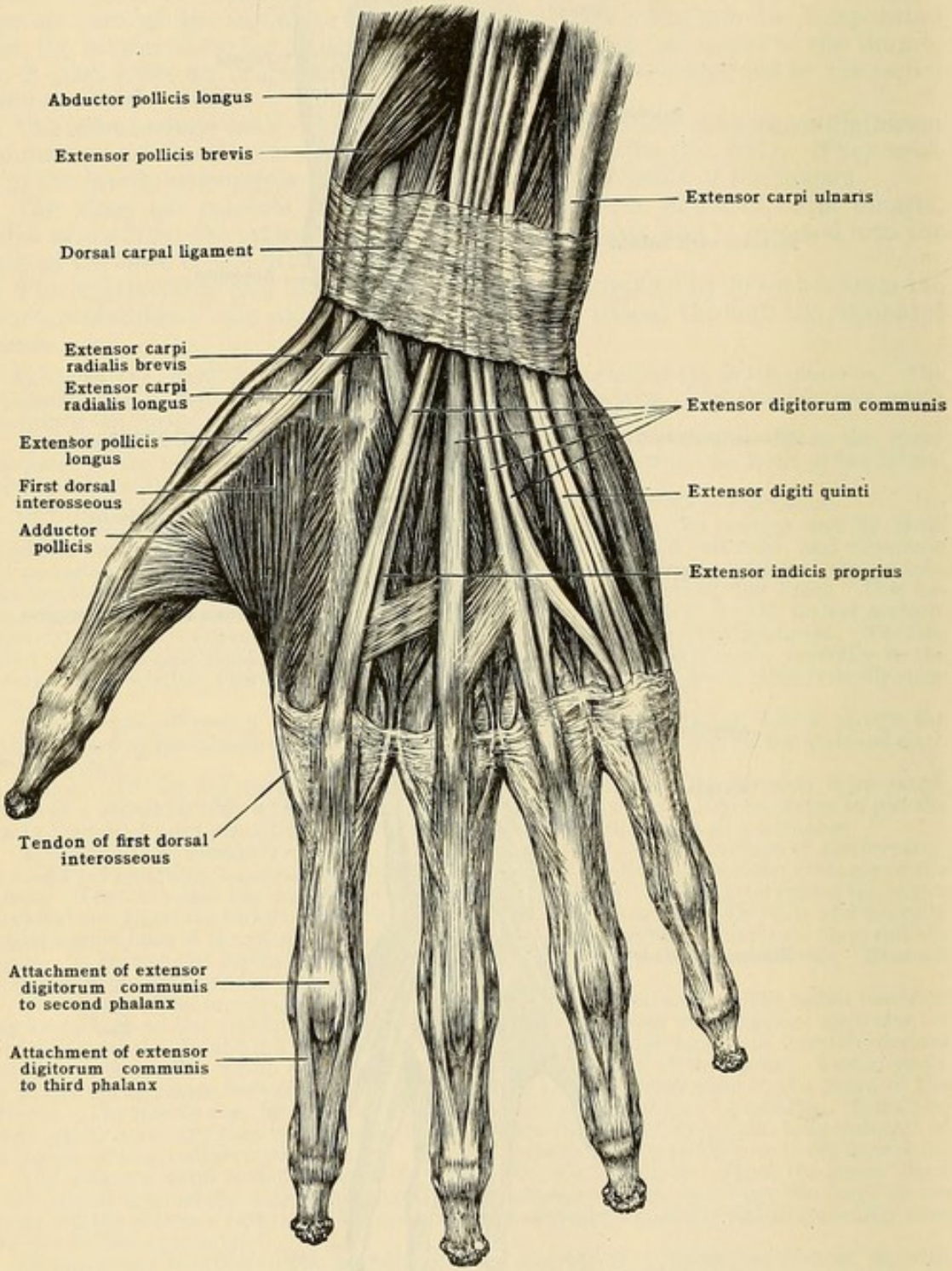

Nerve-supply.—A branch is supplied to the muscle from the deep radial (posterior interosseous) nerve before this enters the supinator (brevis). The branch enters the middle third of the medial margin of the muscle by several rami. The nerve fibres arise from the (fifth), sixth and seventh cervical nerves.

Action.—To extend the hand and, to a slight extent, to flex the forearm.

Relations.—In its proximal portion the muscle is placed with a medial surface toward the common extensor, a deep toward the supinator (brevis) and pronator teres, and a dorso-lateral toward the long radial extensor. More distally the muscle and its tendon become flattened about the radius and partly covered by the long radial extensor and its tendon.

In the distal quarter of the forearm the tendons of these two muscles are crossed by the long abductor and the short extensor of the thumb. Beneath the dorsal carpal ligament the tendon of the short radial extensor is crossed by the tendon of the long extensor of the thumb.

Variations.—The tendon often sends no slip to the second metacarpal. Fusion of the two radial extensors is frequent. The fused muscle may have from one to four tendons. The **extensor carpi radialis intermedius** of Wood is a muscle which arises, rarely directly from the humerus, but not infrequently as a slip from one or both radial extensors. It is inserted into the second or third metacarpal bone or into both. The **extensor carpi radialis accessorius** is a muscle which has an origin like the extensor intermedius, but which terminates on the base of the metacarpal or first phalanx of the thumb, the short abductor of the thumb, or some neighbouring structure.

The extensor digitorum communis (figs. 367, 368).—*Origin.*—From a tendon attached to the lateral epicondyle, and from intermuscular septa which lie between the head of the muscle and the short radial extensor, the extensor of the little finger, and the supinator muscle.

Insertion.—By four tendons into the bases of the phalanges of the fingers.

Structure.—The fibre-bundles arise from the interior of the pyramidal case formed by the tendon, the fascia, and intermuscular septa, and pass distally to converge on four tendons which begin in the middle of the forearm, become free a little above the wrist, pass under the dorsal carpal ligament in a groove common to them and the tendon of the extensor indicis proprius, and diverge to the backs of the fingers. Opposite the metacarpo-phalangeal joint each tendon gives rise on its under surface to a band which becomes attached to the base of the first phalanx of its respective digit. The tendon is also closely bound to the joint by fibrous bands connected with the palmar fascia. On the dorsum of the first phalanx the tendon expands and is bound to an aponeurotic extension from the interosseous and lumbrical muscles. The tendon divides into three bands. The middle band passes to the base of the second phalanx, the lateral bands pass laterally around the joint to be inserted into the back of the base of the third phalanx. The lateral bands are bound to the second joint by a thin layer of transverse and oblique fibres.

An obliquely transverse band usually passes from the tendon of the index to that of the middle finger above the heads of the metacarpals. The tendon to the index finger is united to the tendon of the extensor indicis proprius opposite the metacarpo-phalangeal articulation. The tendon to the ring finger usually sends a slip to join the tendon of the middle finger. The fourth tendon lies near that of the ring finger and divides into two slips, one of which joins the tendon of the ring finger and one goes to the little finger to join the tendon of the extensor digiti quinti proprius.

Nerve-supply.—From a branch which arises from the deep radial (posterior interosseous) nerve as it emerges from the supinator (brevis) muscle. From this several twigs enter the deep surface of the middle third of the belly. Often the nerve is bound up with the nerve to the extensor of the little finger and the ulnar extensor. On the other hand, there may be several separate branches to the muscle. The nerve fibres arise from the sixth, seventh, and eighth cervical nerves.

Action.—The muscle extends the two terminal phalanges on the basal, the basal on the metacarpus, and the hand at the wrist. The extensor action is strongest on the first phalanx. The cross-bands between the tendons hinder the independent extension of the middle and ring fingers, while the special extensors of the index and little fingers makes the movements of these fingers freer. When the hand is abducted toward the radial side, the extensor muscles tend to draw the fingers ulnarward. When the hand is abducted toward the ulnar side, the muscles tend to draw the fingers toward the thumb. When the hand is in the mid-position the ring finger and little finger are abducted and the index-finger is adducted. (Frohse.)

Relations.—It is superficially placed. Under it lie the deep muscles of the back of the forearm, the interosseous vessels, and the deep radial (posterior interosseous) nerve. It lies between the short radial carpal extensor and the extensor of the little finger.

Variations.—There is considerable variation in the extent of isolation of the parts going to the various fingers. That to the index-finger is the one most frequently isolated. At times the tendon to the index or little finger may be wanting. More frequently one or more of the tendons subdivides to be attached to two or more fingers or to the thumb. The connections between the tendons on the back of the hand vary greatly.

The extensor digiti quinti proprius (extensor minimi digiti) (figs. 367, 368).—*Origin.*—Chiefly from the septum between it and the common extensor, but also in part from the septum between it and the extensor ulnaris and from the overlying fascia.

Structure and insertion.—The fibre-bundles descend in a narrow band which begins near the neck of the radius. They are inserted into the side of a tendon which begins high on the ulnar margin of the muscle. The most distal fibre-bundles extend nearly to the wrist-joint. The tendon passes through the fifth compartment beneath the dorsal carpal ligament, and extends on the back of the fifth metacarpal to the base of the first phalanx of the little finger, where it is joined by a slip from the fourth tendon of the common extensor. The insertion of the tendon is like that of the tendons of the common extensor.

Nerve-supply.—By a branch or branches from the deep radial (posterior interosseous) nerve. The nerve filaments enter the middle third of the fleshy portion of the muscle on its deep surface. The innervation of this muscle is intimately related to that of the preceding.

Action.—It acts as a portion of the common extensor, but, owing to its separation, independent movement of the little finger is possible.

Relations.—It lies between the common extensor and the ulnar extensor and upon the deep muscles of the back of the forearm.

Variations.—Absence is not very frequent; blending with the common extensor is frequent. Its tendon often divides into two or more slips. The belly may also be doubled. It may have a supplementary origin from the ulna. A tendon slip to the ring-finger is frequently found.

The extensor carpi ulnaris (figs. 367, 368).—*Origin.*—By two heads: one from the inferior dorsal portion of the epicondyle by an aponeurotic band attached below the tendon of the

common extensor, from the enveloping fascia, and from the septa between it and the extensor digiti quinti, anconeus, and supinator (brevis); the other from the proximal three-fourths of the dorsal border of the ulna.

Structure and insertion.—The fibre-bundles descend in an osteo-fascial compartment bounded by the dorsal surface of the ulna, the fascia of the forearm, the dense fascia overlying the ulnar origin of the muscles of the thumb, and the origin of the extensor indicis. The tendon commences high in the muscle and appears on the radial border of the middle third of the back of its belly. The fibre-bundles are inserted in a penniform manner on the ulnar border and deep surface of the tendon as far as the wrist. Here the tendon enters the sixth osteo-fibrous canal beneath the dorsal carpal ligament in a special groove on the outer side of the styloid process of the ulna. It is inserted into the base of the fifth metacarpal.

Nerve-supply.—By a branch which arises from the deep radial (posterior interosseous) nerve as this emerges from the supinator (brevis) muscle. Several filaments enter the deep surface of the muscle in the middle third. The nerve fibres arise from the sixth, seventh and eighth cervical nerves.

Action.—To extend and abduct the hand ulnarward.

Relations.—It occupies a superficial position on the ulnar side of the extensors of the forearm. Beneath it lie the deep muscles of the back of the forearm and the posterior surface of the ulna.

Variations.—It may receive a slip from the triceps or be fused with the anconeus or with the extensor of the little finger. More frequently it is doubled, partially or completely. An accessory tendon may go to the first phalanx of the little finger, to the head of the fifth metacarpal, to the fourth metacarpal, to the extensor tendon of the little finger, or to the fascia over the opponens digiti quinti. The muscle may be reduced to a fibrous band. The **ulnaris digiti quinti** is a rare muscle arising from the dorsal surface of the ulna and inserted into the base of the first phalanx of the little finger. It may be represented by a fasciculus or an extra tendon from the ulnar extensor.

b. Deep Layer

(Fig. 369)

The muscles of this group extend from the ulna to the radius, thumb, and index-finger. They are the supinator, abductor pollicis longus, extensor pollicis longus and brevis, and extensor indicis proprius. The **supinator** is a rhomboid muscle which arises from the lateral epicondyle of the humerus and the supinator crest of the ulna winds laterally around the radius and is inserted into its volar surface. The **abductor pollicis longus** is a fusiform muscle which arises from the middle third of the ulna, the interosseous membrane, and the radius, and is inserted into the base of the first metacarpal. The **extensor pollicis brevis** arises from the radius distal to the preceding muscle, and is inserted into the base of the first phalanx of the thumb. The **extensor pollicis longus** is a narrow muscle which arises from the middle third of the dorsal surface of the ulna and is inserted into the base of the second phalanx of the thumb. The **extensor indicis proprius** is a narrow, fusiform muscle arising from the shaft of the ulna and inserted into the dorsal aponeurosis of the index-finger. These muscles are supplied from branches of the deep radial (posterior interosseous) nerve while this is passing through or after its exit from the supinator.

The extensor pollicis longus is represented by the extensor hallucis longus of the leg. The abductor pollicis longus and extensor pollicis brevis are represented by the abnormal abductor hallucis longus and extensor primi internodii hallucis muscles, the rudiments of which are perhaps normally present in the tibialis anterior. The supinator and the extensor indicis muscles are not represented in the leg. On the other hand, the extensor digitorum brevis, normal in the foot, is only occasionally found on the back of the hand.

The supinator (brevis) (figs. 366, 369, 372).—*Origin.*—From (1) the inferior dorsal portion of the lateral epicondyle by a tendinous band which is adherent to the deep surface of the tendons of origin of the radial and common extensors and to the radial collateral ligament of the joint; and (2) the ulna by a superficial aponeurosis and by fibre-bundles attached directly to the depression below the radial notch and to the supinator crest.

Insertion.—The lateral and volar surfaces of the radius from the tuberosity to the attachment of the pronator teres.

Structure.—From their origin the fibre-bundles descend spirally in a muscular sheet which enwraps the radius (fig. 366). The attachment extends to the oblique line. The muscle is divided into a superficial and a deep plane by a septum in which the deep radial (posterior interosseous) nerve runs. The radial attachments of these two portions are separated by an osseous area into which no fibre-bundles are inserted. The fibre-bundles of the superficial layer have a much more vertical course and are longer than those of the deep layer.

Nerve-supply.—By branches which arise from the deep radial (posterior interosseous) nerve before it passes between the two layers of the supinator muscle. The nerve fibres arise from the fifth, sixth, and seventh cervical nerves.

Action.—To supinate the forearm.

Relations.—The supinator is covered by the superficial group of extensor muscles above described and by the anconeus.

Variations.—The extent of separation of the muscles into two portions varies. Accessory fasciculi of origin are not uncommon. These may spring from the annular ligament, **tensor ligamenti annularis anterior** (5 per cent. or more of bodies—Le Double), the lateral epicondyle, the tendon of the biceps, the tuberosity of the radius, etc. A sesamoid bone may lie in the tendon of origin. The **tensor ligamenti annularis posterior** is a slip generally present and often independent of the supinator. It runs from the ulna behind the radial notch to the annular ligament of the radio-ulnar joint.

The abductor pollicis longus (extensor ossis metacarpi pollicis) (fig. 369).—*Origin.*—From (1) the lateral margin of the dorsal surface of the ulna in the proximal portion of the middle third,

FIG. 369.—THE DEEP MUSCLES OF THE BACK OF THE FOREARM.

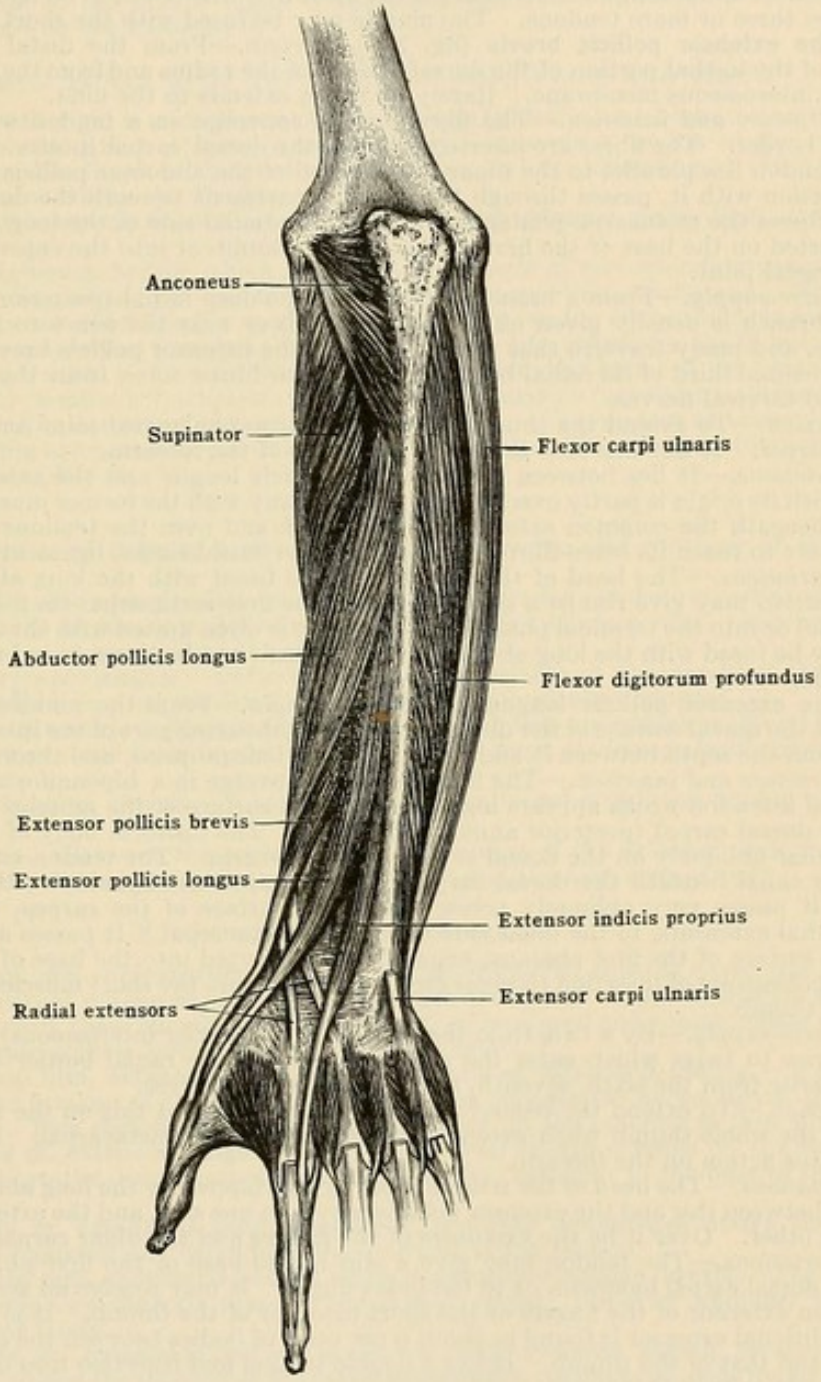

and the adjacent interosseous membrane, (2) the dorsal surface of the radius distal and medial to the attachment of the supinator, and (3) at times, from the septa lying between it and the supinator, extensor carpi ulnaris, and extensor pollicis longus.

Structure and insertion.—The fibre-bundles from this extensive area of origin converge in a bipenniform manner upon a tendon which appears as an aponeurosis on the deep surface of the muscle about the middle of the forearm. The tendon as it descends becomes rounded. The insertion of fibre-bundles continues nearly to the wrist. Here, together with the tendon of the short extensor, it enters the first osteo-fibrous canal beneath the dorsal carpal ligament upon the lateral surface of the distal extremity of the radius. Upon leaving this canal the tendon extends to be inserted on the radial side of the base of the first metacarpal bone.

Nerve-supply.—By one or more branches from the deep radial (posterior interosseous) nerve

after it has emerged from the supinator. The branches enter the muscle on the superficial surface in the proximal third. The nerve fibres come from the sixth, seventh (and eighth) cervical nerves.

Action.—It carries the first metacarpal radialward and forward. At the height of its contraction it flexes and abducts the hand at the wrist.

Relations.—Near its origin the muscle is covered by the superficial extensors of the forearm. More distally, accompanied by the short extensor, it passes radially, becomes superficial, and crosses the tendons of the two radial carpal extensors.

Variations.—The muscle or its tendon may be doubled. An accessory tendon may be applied to the multangulum majus (trapezium), the transverse ligament of the carpus, the superficial muscles of the thenar eminence, or the first metacarpal. Of these, the attachment to the short abductor and short flexor is the most frequent (7 out of 36 bodies—Wood). There may be three or more tendons. The muscle may be fused with the short extensor.

The extensor pollicis brevis (fig. 369).—*Origin.*—From the distal part of the middle third of the medial portion of the dorsal surface of the radius and from the neighbouring portion of the interosseous membrane. Rarely its origin extends to the ulna.

Structure and insertion.—The fibre-bundles converge on a tendon which appears on the radial border. The fibres are inserted as far as the dorsal carpal (posterior annular) ligament. The tendon lies parallel to the ulnar side of that of the abductor pollicis longus, and, in close connection with it, passes through the first compartment beneath the dorsal carpal ligament, and crosses the metacarpo-phalangeal joint on the radial side of the long extensor tendon. It is inserted on the base of the first phalanx of the thumb or into the capsule of the metacarpo-phalangeal joint.

Nerve-supply.—From a branch derived from the deep radial (posterior interosseous) nerve. This branch is usually given off in common with or near the nerve to the abductor pollicis longus, and many traverse that muscle to reach the extensor pollicis brevis, which it enters in the proximal third of its radial border. The nerve fibres come from the sixth, seventh (and eighth) cervical nerves.

Action.—To extend the thumb at the metacarpo-phalangeal joint and to abduct the first metacarpal. It likewise acts as a weak supinator of the forearm.

Relations.—It lies between the abductor pollicis longus and the extensor pollicis longus, by which its origin is partly overlapped. In company with the former muscle it passes medially from beneath the common extensor of the fingers and over the tendons of the radial carpal extensors to reach its osteo-fibrous canal under the dorsal carpal ligament.

Variations.—The head of the muscle may be fused with the long abductor. Its tendon of insertion may give rise to a slip inserted on the first metacarpal (in 2 out of 85 bodies—Le Double) or into the terminal phalanx. Its tendon is often united with that of the long extensor. It may be fused with the long abductor of the thumb and has been found missing. It may be doubled.

The extensor pollicis longus (fig. 369).—*Origin.*—From the middle third of the lateral part of the dorsal surface of the ulna; from the neighbouring part of the interosseous membrane; and from the septa between it and the extensor indicis proprius, and the extensor carpi ulnaris.

Structure and insertion.—The fibre-bundles converge in a bipenniform manner on the two sides of a tendon which appears high on the dorsal surface of the muscle. They extend as far as the dorsal carpal (posterior annular) ligament. The fusiform body of the muscle descends somewhat obliquely on the dorsal surface of the forearm. The tendon enters the third osteo-fibrous canal beneath the dorsal carpal (posterior annular) ligament. On emerging from the canal it passes very obliquely across the dorsal surface of the carpus, over the tendons of the radial extensors, to the ulnar side of the first metacarpal. It passes along this and on the dorsal surface of the first phalanx, expands to be inserted into the base of the second phalanx. The aponeurosis of insertion receives tendinous slips from the short muscles of the volar surface of the thumb.

Nerve-supply.—By a twig from the deep radial (posterior interosseous) nerve. The branch gives rise to twigs which enter the proximal third of the radial border of the muscle. The fibres arise from the sixth, seventh, and eighth cervical nerves.

Action.—To extend the second phalanx on the first, and this on the metacarpal. It also draws the whole thumb when extended toward the second metacarpal. It may have a slight supinator action on the forearm.

Relations.—The head of the muscle is partly overlapped by the long abductor of the thumb. It lies between this and the extensor pollicis brevis on one side, and the extensor indicis proprius on the other. Over it lie the extensors of the fingers and the ulnar carpal extensor.

Variations.—The tendon may give a slip to the base of the first phalanx of the thumb, to the dorsal carpal ligament, or to the index finger. It may receive an accessory slip from the common extensor of the fingers or the short extensor of the thumb. It is frequently doubled. An additional extensor is found in about 6 per cent. of bodies between the extensor of the index finger and that of the thumb. It has a double tendon and insertion into both digits (**extensor communis pollicis et indicis**).

The extensor indicis proprius (fig. 369).—*Origin.*—From the proximal part of the distal third of the posterior surface of the ulna, medial and distal to that of the preceding muscle, from the adjacent interosseous membrane, and from the septum between it and the extensor pollicis longus.

Structure and insertion.—The fibre-bundles are inserted on a tendon which first appears on the radial border of the muscle. The insertion of fibre-bundles extends nearly to the dorsal carpal (posterior annular) ligament. Here the tendon passes beneath that of the extensor of the little finger and enters the fourth osteo-fibrous canal beneath the lateral tendons of the common extensor. It passes across the wrist beneath the tendon from the extensor communis to the index finger, and is inserted on the ulnar side of this into the dorsal aponeurosis of the index finger opposite the base of the first phalanx.

Nerve-supply.—By a twig from the deep radial (posterior interosseous) nerve. This twig enters the proximal third of the radial border of the muscle. It frequently arises from a branch to the extensor pollicis longus. The nerve fibres come from the sixth, seventh, eighth cervical nerves.

Action.—To extend the first phalanx on the metacarpal. Like the common extensor it has a limited action on the two terminal phalanges. It also adducts the index finger and is a weak supinator of the forearm.

Relations.—It is covered by the superficial extensor group.

Variations.—These are frequent. It may be absent. There may be two heads, or the muscle may be completely doubled. It may receive an accessory slip from the ulna or the carpus. The tendon may give accessory slips to the middle finger, the ring finger, or the thumb. The accessory tendon to the middle finger is the most frequent. The tendon to the index finger may be inserted on the metacarpus.

Abnormal Muscles of the Back of the Wrist and Hand

The **extensor medii digiti** is a small muscle which arises from the ulna beneath the extensor of the index finger, with which it is more or less fused. It sends a tendon to the extensor aponeurosis of the middle finger or slips both to this finger and the index finger. It is present in about 10 per cent. of bodies (Le Double).

The **extensor digiti annularis** is a muscle similar to the extensor medii digiti, but much rarer.

The **extensor digitorum brevis,** which resembles the muscle of corresponding name on the dorsum of the foot, may have from one to four fasciculi, but most frequently one. The most common fasciculus is one which sends a tendon to the extensor tendon of the index finger. One for the middle finger is nearly as frequent. Others are rare. A fasciculus for the thumb has not been reported. (Le Double.) The fasciculi usually arise from the bones of the ulnar half of the carpus—lunatum (semilunar), triquetrum (cuneiform), hamatum (unciform), and capitatum (magnum), and from the dorsal ligaments uniting these bones. The tendons are inserted either into the corresponding extensor tendons or into the metacarpals. The muscle is found in about 10 per cent. of bodies (Wood).

Bursæ

B. m. extensoris carpi radialis brevis.—Between the tendon and the base of the third metacarpal.

B. m. abductoris pollicis longi.—Between the tendons of the long and short radial extensors and the tendons of the abductor pollicis longus and extensor pollicis brevis. Another bursa lies beneath the tendon of insertion of the abductor.

B. intermetacarpo-phalangeæ.—Between the lateral surfaces of the heads of the metacarpal bones of neighbouring fingers dorsal to the transverse capitular ligament.

B. tendinum m. extensoris digitorum communis.—Small bursæ are sometimes found beneath the tendons to the index and little fingers near where they begin to diverge from the common tendon.

B. m. extensoris carpi ulnaris.—A small bursa may be found under the tendon of origin of this muscle.

B. m. supinatoris.—Between the supinator and the tendon of the extensor muscles.

B. m. extensoris pollicis longi.—Between the tendon and the first metacarpal.

Synovial Tendon-sheaths

Vagina tendinum mm. extensorum carpi radialium.—Synovial sheaths cover the tendons of the two radial carpal extensors as they pass beneath the dorsal carpal (posterior annular) ligament. In the adult these sheaths usually are more or less fused and communicate with the sheath of the extensor pollicis longus where this crosses them.

Vagina tendinum mm. extensoris digitorum communis et extensoris indicis.—A synovial sheath surrounds the tendons of these muscles as they pass beneath the dorsal carpal (posterior annular) ligament. This sheath extends for some distance on the tendons as they diverge.

Vagina tendinis m. extensoris digiti quinti.—A synovial sheath extends on the tendon of this muscle from above the dorsal carpal (posterior annular) ligament to the base of the metacarpal.

Vagina tendinis m. extensoris carpi ulnaris.—This sheath commences above the carpal (posterior annular) ligament and extends to the insertion of the tendon.

Vagina tendinum mm. abductoris pollicis longi et extensoris pollicis brevis.—The sheaths which surround these two tendons beneath the dorsal carpal (posterior annular) ligament usually communicate freely.

Vagina tendinis m. extensoris pollicis longi.—A long synovial sheath surrounds this tendon. Where it crosses the tendons of the radial extensors, a communication is found with the sheath of the latter.

2. Ulno-Volar Division

The muscles on the volar side of the forearm lie in four layers.

a. First Layer

(Fig. 370)

Of the four muscles of associated ulnar epicondylar origin which constitute this layer the **pronator teres** is a strong, band-like muscle which is inserted into

the lateral surface of the middle third of the shaft of the radius; the fusiform **flexor carpi radialis** sends a tendon to the base of the second metacarpal; the slender **palmaris longus** is inserted into the palmar fascia; and the medially situated, fusiform **flexor carpi ulnaris** into the pisiform bone and the palmar fascia. The pronator teres is the most powerful pronator of the forearm. When

FIG. 370.—FRONT OF THE FOREARM: FIRST LAYER OF MUSCLES.

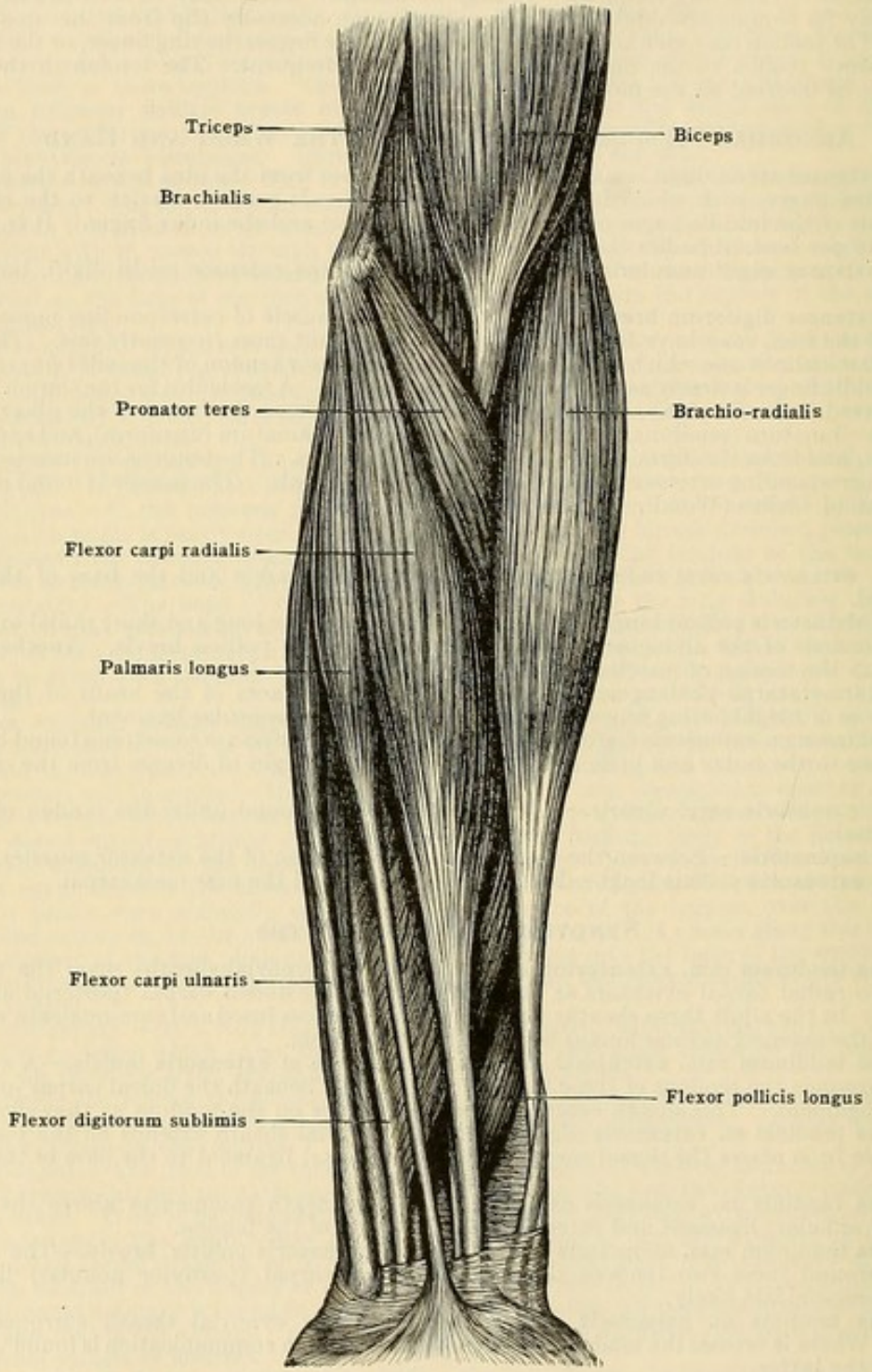

the hand is slightly flexed the ulnar carpal flexor abducts ulnarward. When the hand is greatly flexed lateral movement is difficult. The ulnar flexor is supplied by the ulnar nerve, the other muscles by the median.

The pronator teres probably corresponds with the popliteus of the leg. The flexor carpi radialis and flexor carpi ulnaris probably represent in the main the two heads of the gastrocnemius; and the palmaris longus, the plantaris.

The pronator teres (fig. 370).—*Origin.*—By two heads:—(1) The *humeral* or chief head arises by a tendon from the superior half of the ventral surface of the medial epicondyle and directly from the overlying fascia and from the intermuscular septa between it and the medial

head of the triceps and the flexor carpi radialis. (2) The *ulnar*, deep or accessory, head arises by an aponeurotic band attached to the inner border of the coronoid process medial to the tendon of the brachialis. Between the humeral and ulnar heads is a fibrous arch beneath which the median nerve passes.

Structure and insertion.—The fibre-bundles of the humeral head are inserted in a penniform manner on a tendon which begins near the middle of the belly of the muscle on the superficial

FIG. 371.—FRONT OF THE FOREARM: SECOND LAYER OF MUSCLES.

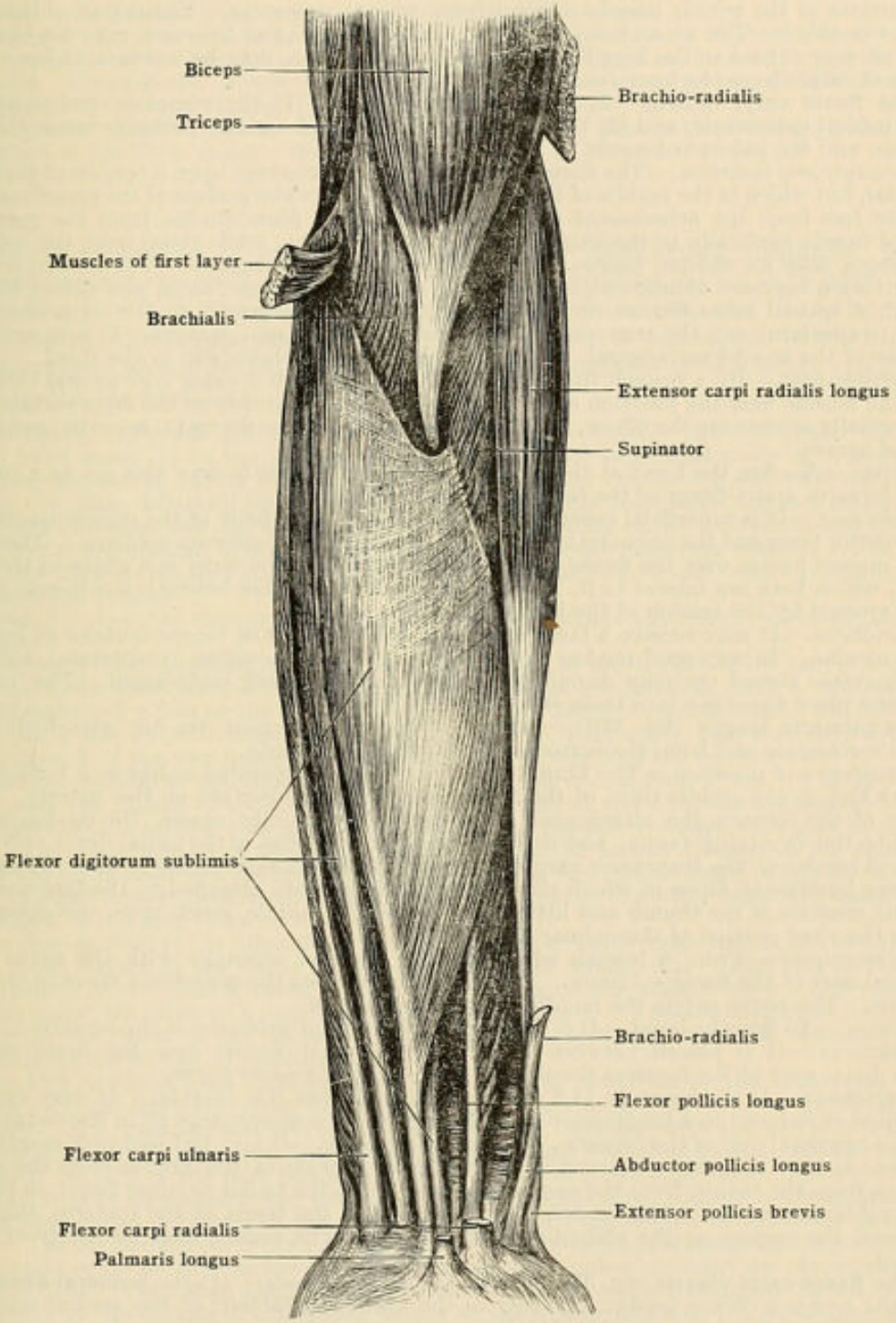

surface along the radial border. The tendon gradually becomes broader, winds about the volar surface of the radius, and is inserted into the middle third of its lateral surface. The attachment of fibre-bundles continues nearly to this insertion. The fibre-bundles of the ulnar head form a slender fasciculus which is inserted into the radial side of the deep surface of the humeral head.

Nerve-supply.—By a branch derived from the median nerve before it passes between the two heads of the muscle. The nerve enters the proximal part of the middle third of the main belly of the muscle on its deep surface near the radial border. The branch to the ulnar head usually enters this portion of the muscle somewhat proximal to its fusion with the humeral head. The nerve fibres arise from the sixth and seventh cervical nerves.

Action.—To pronate and flex the forearm.

Relations.—The muscle is superficially placed. Near its origin it is covered by the lacertus fibrosus of the biceps, and near its insertion by the radial vessels and nerve and the brachio-radialis and radial extensor muscles. It is the most radial of the group of muscles under consideration. The radial border helps to bound an angular space, the cubital fossa, in which lie the brachial vessels, median nerve, and the tendon of the biceps. The median nerve passes between its humeral and ulnar heads. The muscle overlies the supinator, the brachialis, and the radial origin of the flexor digitorum sublimis muscles and the ulnar artery.

Variations.—Supplementary fasciculi may arise from the humerus, the medial intermuscular septum of the arm, the flexor carpi radialis, the flexor sublimis, or the brachialis muscles. The two portions of the muscle may be distinct from origin to insertion. Either part of the muscle may be doubled. The ulnar head may be absent. The radial insertion may be extensive. Fasciculi may extend to the long flexor of the thumb. There may be a sesamoid bone in the tendon of origin from the humerus.

The flexor carpi radialis (fig. 370).—*Origin.*—From (1) the common tendon attached to the medial epicondyle; and (2) the septa between its head and the pronator teres, the flexor sublimis, and the palmaris longus.

Structure and insertion.—The fibre-bundles descend to converge upon a tendon at first intramuscular, but which in the middle of the arm appears on the volar surface of the muscle and soon becomes free from the attachment of fibre-bundles. The fibre-bundles from the epicondyle descend nearly vertically to the front and sides of the tendon, while those from the intermuscular septa take an oblique course to the deep surface of the tendon. The tendon is at first flat, but soon becomes cylindrical, bound to the superficial muscle fascia, and enters the hand through a special osteo-fibrous canal formed mainly by the groove in the os multangulum majus (trapezium) and the transverse carpal (anterior annular) ligament. It is inserted into the base of the second metacarpal. It usually also sends a tendon slip to the third.

Nerve-supply.—By a branch from the median nerve which divides into several twigs that enter the muscle near the junction of its proximal and middle thirds on the deep surface. The nerve usually arises near the elbow. The nerve fibres arise from the sixth, seventh (and eighth) cervical nerves.

Action.—To flex the hand at the wrist. To a slight extent it may also act as a pronator of the forearm and a flexor of the forearm on the arm.

Relations.—It is superficial except near its insertion. The belly of the muscle lies between the pronator teres and the palmaris longus and upon the flexor digitorum sublimis. The tendon of the muscle passes over the flexor pollicis longus, and near the wrist is a guide to the radial artery, which here lies lateral to it. In the hand the tendon lies beneath the thenar muscles and is crossed by the tendon of the long flexor of the thumb.

Variations.—It may receive a fasciculus from the brachialis or biceps muscles or from the radius or ulna. It may send tendon slips to the multangulum majus (trapezium), navicular, the transverse carpal (anterior annular) ligament, or the fourth metacarpal. The insertion may take place variously into these structures.

The palmaris longus (fig. 370).—*Origin.*—From the common tendon attached to the medial epicondyle and from the surrounding intermuscular septa.

Structure and insertion.—The fibre-bundles take a nearly parallel course to a tendon which appears high in the middle third of the forearm on the volar surface of the muscle. In the middle of the forearm the attachment of fibre-bundles usually ceases, the tendon becomes bound to the overlying fascia, and descends parallel with that of the radial flexor. Near the proximal border of the transverse carpal (anterior annular) ligament the tendon expands into radiating bundles of fibres of which the medial and lateral are attached to the fascia over the intrinsic muscles of the thumb and little finger, while the middle, much more developed, constitute the chief portion of the palmar aponeurosis.

Nerve-supply.—From a branch which usually arises in company with the nerve to the proximal part of the flexor sublimis. It frequently traverses the superficial fibres of the flexor sublimis. The nerve enters the middle third of the muscle.

Action.—To flex the hand. It is also a weak flexor and pronator of the forearm.

Relations.—It is placed between the radial and ulnar flexors over the flexor sublimis. In the distal part of the forearm the tendon lies over the median nerve.

Variations.—It is absent in 11.2 per cent. of instances (Le Double). It may be highly developed or reduced to a tendinous band. The belly of the muscle may lie in the distal instead of in the proximal part of the forearm. It may be digastric. It may be fused with neighbouring muscles. It may arise from the medial intermuscular septum of the arm or from the lacertus fibrosus, from the radius, from the coronoid process, from the radial or ulnar flexor, or from the flexor sublimis muscles. The tendon may terminate in the fascia of the forearm, the thenar eminence, the carpus, or the abductor of the thumb. The muscle may be partly or wholly doubled.

The flexor carpi ulnaris (fig. 370).—*Origin.*—By two heads:—(1) the **humeral head** arises from the common flexor tendon attached to the lower ventral part of the medial epicondyle Fibre-bundles of this head are also attached to the surrounding intermuscular septa and the deep fascia of the forearm. (2) The **ulnar head** arises by short tendinous fibres from the medial side of the olecranon and by an aponeurotic band common to it and the flexor digitorum profundus from the upper two-thirds of the dorsal border of the ulna. Proximally the two heads of the muscle are united by a fibrous arch extending from the olecranon to the medial epicondyle. Beneath this band pass the ulnar nerve and the dorsal recurrent ulnar artery. (See EPITROCHLEO-OLECRANONIS, p. 402.)

Structure and insertion.—The fibre-bundles of the humeral head descend nearly vertically, those of the ulnar head obliquely distally in a radial direction. They are inserted in a penniform manner on a tendon which appears in the proximal part of the middle third of the belly of the muscle on the radial margin of the deep surface, and in the distal third of the forearm forms the radial border of the muscle. On the ulnar side the insertion of fibre-bundles continues nearly

to the pisiform bone. The insertion of the tendon takes place chiefly into the pisiform bone, but from it tendinous bundles extend to the palmar aponeurosis, volar ligament of the carpus, to the pisohamate ligament (pisi-unciform), and to the bases of the fifth, fourth, and third metacarpals.

Nerve-supply.—From two or three branches of the ulnar nerve, the most proximal of which arises near the elbow-joint. These branches, which may arise by a single trunk, enter the deep surface of the proximal third of the muscle and send long twigs distally across the middle third of the constituent fibre-bundles. The nerve fibres arise from the seventh and eighth cervical and first thoracic nerves.

Action.—To flex the hand and to abduct the hand ulnarward.

Relations.—It is superficially placed. Its aponeurotic origin is adherent to the fascia of the forearm. It lies medial to the palmaris longus and flexor sublimis and upon the flexor profundus. Beneath the muscle lies the ulnar nerve. The ulnar artery extends along the radial border of the tendon near the wrist.

Variations.—These are rare. Slips from the tendon may pass to the metacarpo-phalangeal articulation of the little finger. (See, however, ABNORMAL MUSCLES, p. 402.)

b. SECOND LAYER

This is composed of one muscle, the **flexor digitorum sublimis,** which, although in part covered by the muscles of the preceding layer, is in part superficial. It arises from the medial epicondyle of the humerus, and from the radius and the ulna, and sends tendons to the second row of phalanges of the fingers. It corresponds probably with the soleus and the tendons of the flexor digitorum brevis in the leg and foot.

The flexor digitorum sublimis (figs. 371, 373, 375).—*Origin.*—By two heads: the **ulnar or chief head** arises (1) by the tendon common to it and the superficial group of muscles from the medial epicondyle, and by short tendinous bands from the ventral surface of the epicondyle; (2) from the ulnar collateral ligament of the elbow, the ulnar tuberosity, the medial border of the coronoid process, and the inferior extremity of the tendon of the brachialis; and (3) from the intermuscular septum between the flexor sublimis and the overlying muscles. The **radial head** arises from an oblique line on the volar surface of the radius, and from the middle third of the anterior border.

Insertion.—Into the sides of the volar surface of the shafts of the second row of phalanges of the fingers.

Structure.—The fibre-bundles of the ulnar head and the upper part of the radial head converge, the ulnar fibre-bundles nearly vertically, the radial obliquely, to form a common belly the deep surface of which on the ulnar side is backed by a dense tendinous band. On the radial side of this a less dense membrane covers over an oval canal which passes distally along the line of junction of the two heads and lodges the ulnar artery and the median nerve.

The fibre-bundles of the ulnar head form a superficial and a deep group. The superficial portion near the middle of the forearm divides into a lateral and a medial division, the former being inserted on a tendon that goes to the middle and the latter on one that goes to the ring finger. The fibre-bundles of the radial head join with the lateral division of the superficial layer of the ulnar head and are inserted on the tendon of the middle finger nearly as far as the wrist. A small muscle fasciculus of the superficial portion of the ulnar head is usually united by a tendon to the long flexor of the thumb.

The deep portion of the ulnar head about the middle of the forearm terminates in large part on the volar surface of the dense tendinous band above mentioned. From this in turn two muscle bellies arise. One of these is inserted in a bipenniform manner on a tendon going to the index finger, the other on a tendon going to the little finger. A muscle fasciculus also usually passes from the region of the tendon band to that portion of the superficial fasciculus which terminates on the tendon of the ring finger.

The four tendons pass together through the carpal canal under the transverse carpal (anterior annular) ligament, those to the middle and ring fingers lying at first superficial to the other two. The tendons then diverge, and each tendon, together with and above a tendon of the flexor profundus, passes over the metacarpo-phalangeal joint into an osteo-fibrous canal on the palmar surface of the first phalanx of the finger for which it is destined. Here the tendon becomes flattened about the round tendon of the flexor profundus. Opposite the middle of the phalanx the tendon divides into two slips, between which the tendon of the flexor profundus passes. The divided halves of the sublimis tendon fold about the profundus tendon so that their lateral edges come to meet in the mid-line beneath this tendon opposite the phalangeal joint (figs. 375, 376). They then again separate, extend distally, and are attached one on each side into a ridge at the middle of the lateral border of the second phalanx. The tendons are also attached by **vincula tendinum,** a **ligamentum breve,** between the tendon and the head of the first phalanx and the joint, and a **ligamentum longum,** between the tendon and the volar surface of the first phalanx.

Nerve-supply.—Before the median nerve passes between the two heads of the pronator teres a branch arises which accompanies the nerve through the pronator and sends several branches into the proximal third of the ulnar head of the muscle. As the median nerve passes beneath the muscle, one or more branches are given to the radial head, and a long branch is given to the fasciculus of the second and from this one to that of the fifth digit. Occasionally, the median nerve in the distal third of the forearm gives rise to branches for these fasciculi. The nerve fibres arise from the seventh and eighth cervical and first thoracic nerves.

Action.—Chiefly to flex the second phalanx of each finger on the first; secondarily, to flex the fingers on the hand and the hand on the forearm.

Relations.—The belly of the muscle is covered by the pronator teres, flexor carpi radialis, and palmaris longus, but is superficial along a narrow strip between the flexor carpi ulnaris and the palmaris longus, and on each side of the tendon of the flexor carpi radialis. The muscle rests on the flexor pollicis longus and flexor digitorum profundus, the median nerve (see description given above) and ulnar vessels. The median nerve emerges from beneath the radial border of the muscle in the lower third of the forearm. In the palm the tendons lie beneath the

FIG. 372.—FRONT OF THE FOREARM: THIRD LAYER OF MUSCLES.

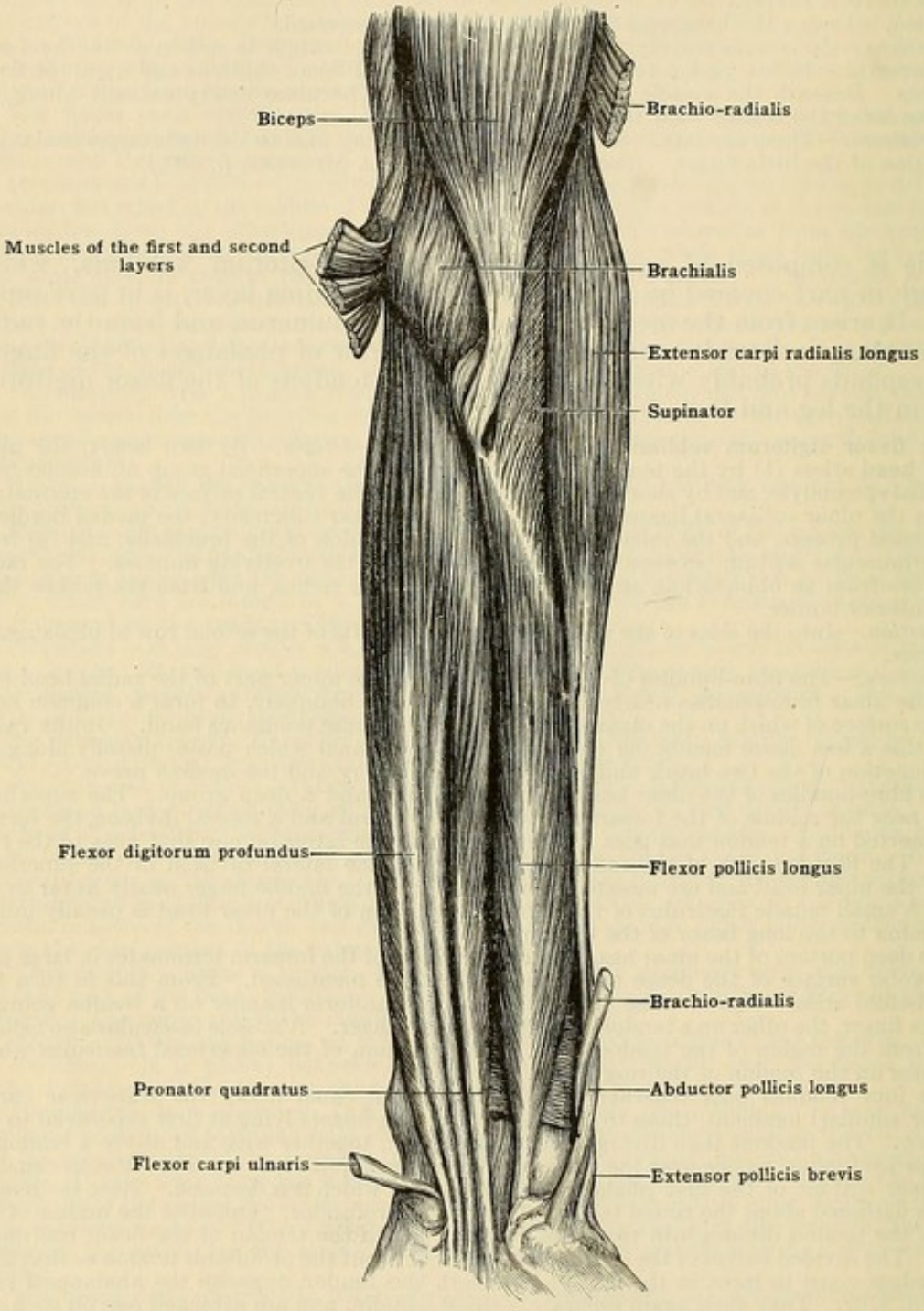

palmar aponeurosis, the superficial palmar arch, and the branches of the median nerve, while they lie in front of the tendons of the flexor profundus, with which they are closely associated into a common bundle by loose fibrous tissue. The digital relations of the tendons are described above.

Variations.—The whole muscle may be rendered digastric by a transverse tendon. A fasciculus of the flexor sublimis may replace the palmaris longus or the two may coexist. A fasciculus may terminate in the fascia of the forearm or in the transverse carpal ligament, the palmar aponeurosis, etc. Various parts of the muscle may be absent or more independent than usual. The extent of the radial attachment varies greatly and may be missing. A special fasciculus may be received from the coronoid process of the ulna. A fasciculus may be sent to the flexor profundus or to other muscles. There may be some fusion with neighbouring muscles.

c. Third Layer

(Figs. 372–376)

The two muscles which constitute this layer may be looked upon as differentiated from a single deep flexor muscle. The **flexor digitorum profundus** is a strong, broad muscle which arises from the upper three-fourths of the volar surface of the ulna and gives rise to tendons which are inserted into the bases of the third row of phalanges of the fingers. The **flexor pollicis longus,** likewise broad and flat, arises from the volar surface of the radius and is inserted into the base of the second phalanx of the thumb. Both muscles are supplied by the median nerve and the flexor profundus is also supplied by the ulnar nerve.

These muscles correspond to the flexor digitorum longus and the flexor hallucis longus of the leg.

The flexor digitorum profundus (figs. 372–376).—*Origin.*—(1) Through an aponeurotic septum between it and the flexor carpi ulnaris from the dorsal border of the ulna; (2) directly from the proximal two-thirds of the medial surface and the proximal three-fourths of the volar surface of the ulna and from the adjacent interosseous membrane; and (3) inconstantly, from a small area on the radius below the bicipital tuberosity.

Structure and insertion.—The fibre-bundles descend nearly vertically and give rise to a common belly which soon divides into four portions, each of which is attached about midway down the forearm in a semipenniform manner to the dorsal surface of a tendon. The attachment of fibre-bundles continues nearly to the wrist. The digital divisions of the muscle vary in the height to which they extend. That belonging to the index finger is usually the one most exten-

Fig. 373.—Insertions of the Tendons of the Muscles which act on the Finger. (After Toldt, Atlas of Human Anatomy, Rebman, London and New York.)

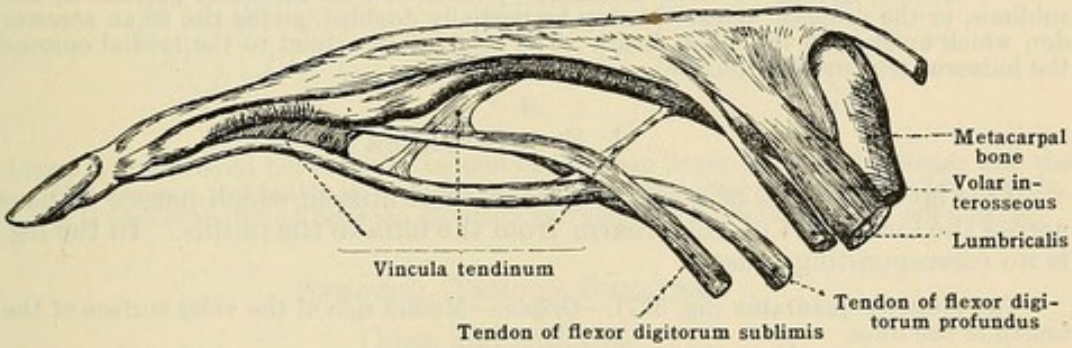

sively isolated, and that to the little finger is the next most so. The tendons pass side by side under the transverse carpal (anterior annular) ligament, and then diverge to the bases of the fingers. At the metacarpo-phalangeal joints, they enter the osteo-fibrous canals described above (p. 387). On the volar surface of the first phalanx each tendon passes through the slit in the sublimis tendon. The tendon then is continued over the second phalanx to the base of the third. **Vincula tendinum** are described passing to the capsule of the second interphalangeal joint (**ligamentum breve**) and to the tendon of the flexor sublimis (**ligamentum longum**). The lumbrical muscles arise from the tendons while they are in the palm.

Nerve-supply.—The interosseous branch of the median nerve arises usually before the nerve passes through the pronator teres and accompanies the main trunk. This branch as it passes beneath the flexor sublimis gives off a branch (or two) from which several twigs spring. These twigs enter the muscle near the radial border and pass in across the middle third of the constituent fibre-bundles of the fasciculi to the index and middle fingers. The ulnar nerve near the elbow gives rise to a branch which enters the volar surface of the muscle near the junction of the proximal and middle thirds of that portion of the belly, giving tendons to the ring and little fingers. There is some variation in the extent of the innervation by the branches of the ulnar and those of the median nerve. To a greater or less extent through anastomosis their territories overlap. The nerve fibres arise from the seventh and eighth cervical and first thoracic nerves.

Action.—To flex the terminal phalanx of each finger on the second and the second on the first, while that of the superficial flexor is to flex the second phalanx on the first. The action of the two flexors on the first phalanx is somewhat more limited. The interosseous muscles, aided by the lumbricals, are the chief flexors of the first row of phalanges. The flexor profundus acts, though not powerfully, as a flexor of the wrist.

Relations.—The flexor profundus muscle lies beneath the flexor sublimis and the flexor carpi ulnaris muscles, the median nerve, and the ulnar vessels and nerve. Under the muscle lie the ulna, the interosseous membrane, and the pronator quadratus muscle. Under the transverse carpal (anterior annular) ligament the tendons lie beneath those of the flexor sublimis in the same synovial sac. In the palm the tendons with the associated lumbrical muscles lie upon the interosseous muscles, the adductor of the thumb, and the deep palmar arch, and beneath the flexor sublimis tendons. For the relations to the synovial bursæ see p. 403.

Variations.—There is considerable variation in the extent of the radial origin and in the extent of the independence and fusion of the different fasciculi. In the prosimians a common tendon extends as far as the hand. The division in the higher forms is associated with refinement of movements of the fingers. One or more special fasciculi not infrequently join the muscle from the flexor sublimis, the flexor pollicis longus, the medial epicondyle, or the ulna. The **accessorius ad flexorem digitorum profundum** is a fasciculus which arises from the coronoid process of the ulna and sends a tendon to join the tendon of one of the fingers, most frequently the middle or index. It is found in 20 per cent. of bodies.

The flexor pollicis longus (fig. 372).—*Origin.*—The attachment extends along the oblique line and the ventral border of the radius from slightly below the bicipital tuberosity to within 5 cm. of the wrist. Medially it is continued into the interosseous membrane. Proximally the tendon frequently extends to the distal radial margin of the coronoid process of the ulna and gives rise to fibre-bundles connected with the muscle, as well as to a fasciculus of the flexor profundus.

Structure and insertion.—The fibre-bundles descend obliquely to be inserted in a penniform manner on a tendon which begins high up on the volar surface near the ulnar border of the muscle, and descends as a broad band which near the wrist becomes cylindroid. The insertion of fibres continues nearly to the point where the tendon passes under the transverse carpal ligament. Here the tendon enters the carpal canal radial to the tendons of the flexor profundus, and passes beneath the superficial head of the short flexor of the thumb, then between the thumb sesamoids into the osteo-fibrous canal of the thumb, in which it is continued to the base of the terminal phalanx.

Nerve-supply.—Usually from two branches of the volar interosseous ramus of the median nerve. These enter the proximal half of the ulnar margin of the muscle. The nerve fibres arise from the sixth, seventh (and eighth) cervical nerves.

Action.—It is a strong flexor of the second phalanx on the first and has less powerful action on the metacarpo-phalangeal joint and on the wrist.

Relations.—It lies beneath the flexor sublimis, the flexor carpi radialis and brachio-radialis muscles, and the radial artery. Near the wrist it crosses over the insertion of the pronator quadratus. In the hand the tendon runs beneath the opponens pollicis and the superficial head of the flexor brevis, and across the deep head of the latter.

Variations.—It may be fused or united by fasciculi with the flexor profundus, the flexor sublimis, or the pronator teres. It may be partially doubled, giving rise to an accessory tendon which extends to the index finger. The origin may extend to the medial epicondyle of the humerus (epitrochlear bundle).

d. Fourth Layer

This layer consists of a single quadrilateral muscle which passes transversely across the lower part of the forearm from the ulna to the radius. In the leg there is no corresponding muscle.

The pronator quadratus (fig. 377).—*Origin.*—Medial side of the volar surface of the lower fourth of the ulna.

Structure and insertion.—From the ulna a strong aponeurosis extends a third of the way across the volar surface of the muscle. From this membrane and from the bone fibre-bundles extend transversely to be inserted on the distal quarter of the volar surface of the radius and on the triangular area above the ulnar notch. The deeper fibre-bundles which arise directly from the ulna are inserted into the radius by means of an aponeurosis. The superficial and deep portions of the muscle are often separated. The muscle is thicker distally than proximally.

Nerve-supply.—The volar interosseous nerve descends along the interosseous membrane, passes behind the middle of the proximal margin of the muscle, and sends branches into its deep surface. The nerve fibres arise from the (sixth), seventh and eighth cervical and first thoracic nerves.

Action.—To pronate the forearm.

Relations.—The muscle lies immediately beneath the muscles of the third layer and upon the radius and ulna, the interosseous membrane, and radio-ulnar joint. The radial artery and ulnar nerve pass in front of it, the volar interosseous artery behind it.

Variations.—It may be missing or may extend further up the forearm than usual or down upon the carpus. It may be triangular or divided into parts the fibre-bundles of which take different directions. It may send fasciculi to the carpus or metacarpus or be fused with the flexor carpi radialis brevis (see below).

Abnormal Muscles of the Volar Side of the Forearm and Wrist

The epitrochleo-olecranonis (anconeus internus).—A muscle fasciculus, distinct from the distal margin of the triceps, which runs from the medial epicondyle to the olecranon over the groove for the ulnar nerve, by a branch of which it is supplied. It takes the place of the fibrous arch normally extending between the epicondylar and ulnar heads of the flexor carpi ulnaris. It occurs in about 25 per cent. of bodies (Testut), and represents an adductor of the olecranon of the lower mammals. Occasionally the medial head of the triceps may descend over the ulnar groove, but this forms another type of muscle variation.

The flexor carpi ulnaris brevis (ulno-carpeus).—An abnormal muscle which arises from the distal quarter of the volar surface of the ulna and is inserted into the hamatum (unciform), the pisiform, the abductor of the little finger, or the superior extremity of the fifth metacarpal.

The unci-pisiformis.—A short, thick band of muscle which runs from the pisiform to the tip of the hamulus of the os hamatum (unciform) parallel with the pisohamate (pisi-unciform) ligament. It is innervated by the ulnar nerve.

The flexor carpi radialis brevis (radio-carpeus).—An abnormal muscle found in about 5 per cent. of bodies (Le Double). It arises from the lateral or the volar surface of the distal half of the radius. Some of the fibre-bundles may spring from the pronator quadratus, the fascia of the forearm, or the ulna. It is inserted into the carpus or metacarpus, and occasionally even into the first phalanx of the index finger, etc. It is supplied by a branch of the volar interosseous nerve. It serves to flex the wrist. It is said to represent the tibialis posterior of the leg.

Bursæ

B. m. flexoris carpi ulnaris.—Between the tendon of this muscle and the pisiform bone.

B. m. flexoris carpi radialis.—Between the tendon of this muscle and the tubercle of the navicular bone.

Fig. 374.—Synovial Sheaths of the Tendons of the Long Flexors of the Fingers
A. Frequent type; B. normal type; C. fœtal type. (After Poirier and Charpy.)

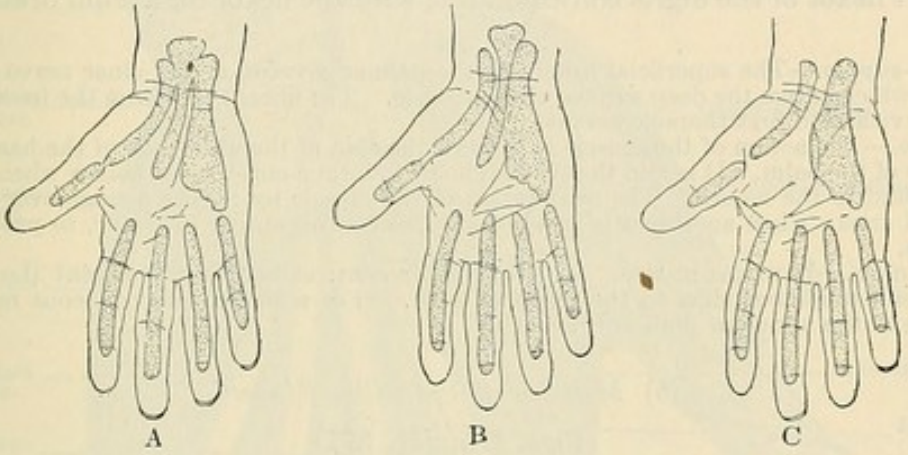

A bursa is often found between the tendon of the deep flexor of the index finger and the carpus. This bursa is frequently in communication with the radial and ulnar tendon sheaths.

A bursa is also often found between the deep and superficial tendons of the index finger.

Synovial Tendon Sheaths

(Figs. 366 and 374)

Vagina tendinis m. flexoris carpi radialis.—About the tendon as it passes beneath the transverse carpal ligament.

Vaginæ tendinum mm. flexorum digitorum.—The osteo-fibrous canals of the digits are lined by a synovial membrane which is reflected by means of a fold (cul-de-sac) to the tendons at each end and over the vincula tendinum, in which blood-vessels and nerves for the tendons are contained. The synovial cavity of the first and usually that of the fifth digit communicate with those of the palm.

In the wrist and palm two large synovial sacs may usually be recognized, although the number may be raised to five or reduced to one.

The radial sac, **vagina tendinis m. flexoris pollicis longi,** surrounds the long flexor tendon of the thumb in the wrist and palm and usually communicates with that of the thumb. In the palm a well-marked mesotendon usually extends to the deep ulnar side of the tendon from the parietal layer of the sheath.

The ulnar sac, **vagina tendinum mm. flexorum communium,** surrounds the tendons of the long flexors of the fingers. It begins proximal to the transverse carpal ligament and extends nearly or quite to the synovial sheath of the little finger on the ulnar side and on the radial side to the centre of the palm.

3. Musculature of the Hand

(Figs. 366, 368, 375–379)

The intrinsic muscles of the hand are taken up in the following groups:—

a The subcutaneous muscle of the palm.
b The muscles of the little finger.
c The muscles of the thumb.
d The lumbrical muscles.
e The interosseous muscles.

The ulnar nerve supplies the muscles of the little finger, the interossei, the medial lumbrical muscles, and two of the muscles of the thumb; the median nerve supplies most of the muscles of the thenar region and the lateral lumbrical muscles.

(*a*) *Subcutaneous Muscle*

(Fig. 375)

The **palmaris brevis** is a small, trapezoid sheet situated between the hypothenar fascia and the skin. It arises at the lateral edge of the palmar aponeurosis from tendinous slips which may be traced through the aponeurosis to the navicular and greater multangular. It is composed of nearly parallel fibre-bundles, and extends into the deep surface of the skin along the ulnar border of the palm. It is generally taken to be a subcutaneous muscle like the superficial muscles of the head and neck. It has, however, been suggested that it represents the remnants of a short flexor of the digits corresponding with the flexor digitorum brevis of the foot.

Nerve-supply.—The superficial branch of the palmar division of the ulnar nerve gives rise to a twig which enters the deep surface of the muscle. The fibres come from the (seventh and) eighth cervical and first thoracic nerves.

Action.—The action of the muscle is to draw the skin of the ulnar side of the hand toward the centre of the palm. It is said that it thus helps to form a cup-shaped hollow when the hand conveys fluid to the mouth. The contraction of the muscle by raising a ridge over the ulnar nerve and artery when an object is grasped hard serves, according to Henle, to protect these structures.

Variations.—It varies in size. In about 2 per cent. of bodies it is absent (Le Double). It may send tendinous slips to the pisiform bone. (For a thenar subcutaneous muscle, see variations of the abductor pollicis brevis.)

(*b*) *Muscles of the Little Finger*

(Figs. 375, 376, 377)

In the hypothenar eminence are three muscles, the abductor, the flexor brevis, and the opponens digiti quinti. The **abductor digiti quinti** is a flat, fusiform muscle which arises from the pisiform and is inserted into the ulnar border of the first phalanx and into the dorsal aponeurosis through which it helps to flex the first and extend the second and third phalanges of the little finger. The fusiform **flexor brevis** arises from the hamatum (unciform) and adjacent part of the transverse carpal (anterior annular) ligament and is *inserted into* the ulnar side of the base of the first phalanx. The triangular **opponens** likewise arises from the hamatum (unciform) and the transverse (anterior annular) ligament. It is inserted into the ulnar border and the head of the fifth metacarpal.

The abductor of the little finger corresponds with that of the little toe. A part of the opponens beneath the ulnar nerve corresponds with that of the little toe, while the more superficial portion is unrepresented in the foot. The flexor brevis of the little toe corresponds with a part of the deep portion of the opponens of the little finger. The flexor brevis of the little finger is unrepresented in the foot. (Cunningham.)

The abductor digiti quinti (figs. 375, 376).—*Origin.*—From the distal half of the pisiform, the ligaments between this and the hamatum, the tendon of the flexor carpi ulnaris, and often from the transverse carpal (anterior annular) ligament.

Structure and insertion.—The fibre-bundles descend vertically, at first increasing in number and then concentrated, toward two short tendons one of which is inserted into the ulnar border of the first phalanx of the little finger and the other into the aponeurosis of the extensor tendon of the little finger.

Nerve-supply.—From the deep palmar division of the ulnar nerve before it passes through the opponens, or from the superficial palmar branch, arise one or more twigs which enter the radial side of the muscle on its deep surface in the proximal third. The nerve fibres arise from the (seventh and) eighth cervical and first thoracic nerves.

Action.—To abduct the little finger, flex the first phalanx, and extend the last two.

Relations.—It overlies the opponens and flexor brevis. Superficially it is covered by fascia and the palmaris brevis muscle. Along the proximal part of its radial margin run the deep palmar branches of the ulnar artery and nerve.

Variations.—It may be missing or doubled. It may be fused with the short flexor or receive fasciculi from the palmaris longus, the ulnar flexor, the fascia of the forearm, etc.

The flexor digiti quinti brevis (figs. 376, 377).—*Origin.*—By a short tendon from the hook of the hamatum (unciform) and from the adjacent parts of the transverse carpal (anterior annular) ligament.

Structure and insertion.—The fibre-bundles take a nearly parallel course and are inserted

by a short tendon which is fused with that of the abductor and is inserted into the ulnar side of the base of the first phalanx of the little finger. A sesamoid bone may lie in the tendon.

Nerve-supply.—A branch from the superficial or deep palmar division of the ulnar nerve enters the deep surface of the muscle in its proximal half. The nerves to the abductor and flexor may arise in common from the ulnar. The nerve fibres arise from the (seventh and) eighth cervical and first thoracic nerves.

FIG. 375.—THE SUPERFICIAL MUSCLES OF THE PALM OF THE HAND.

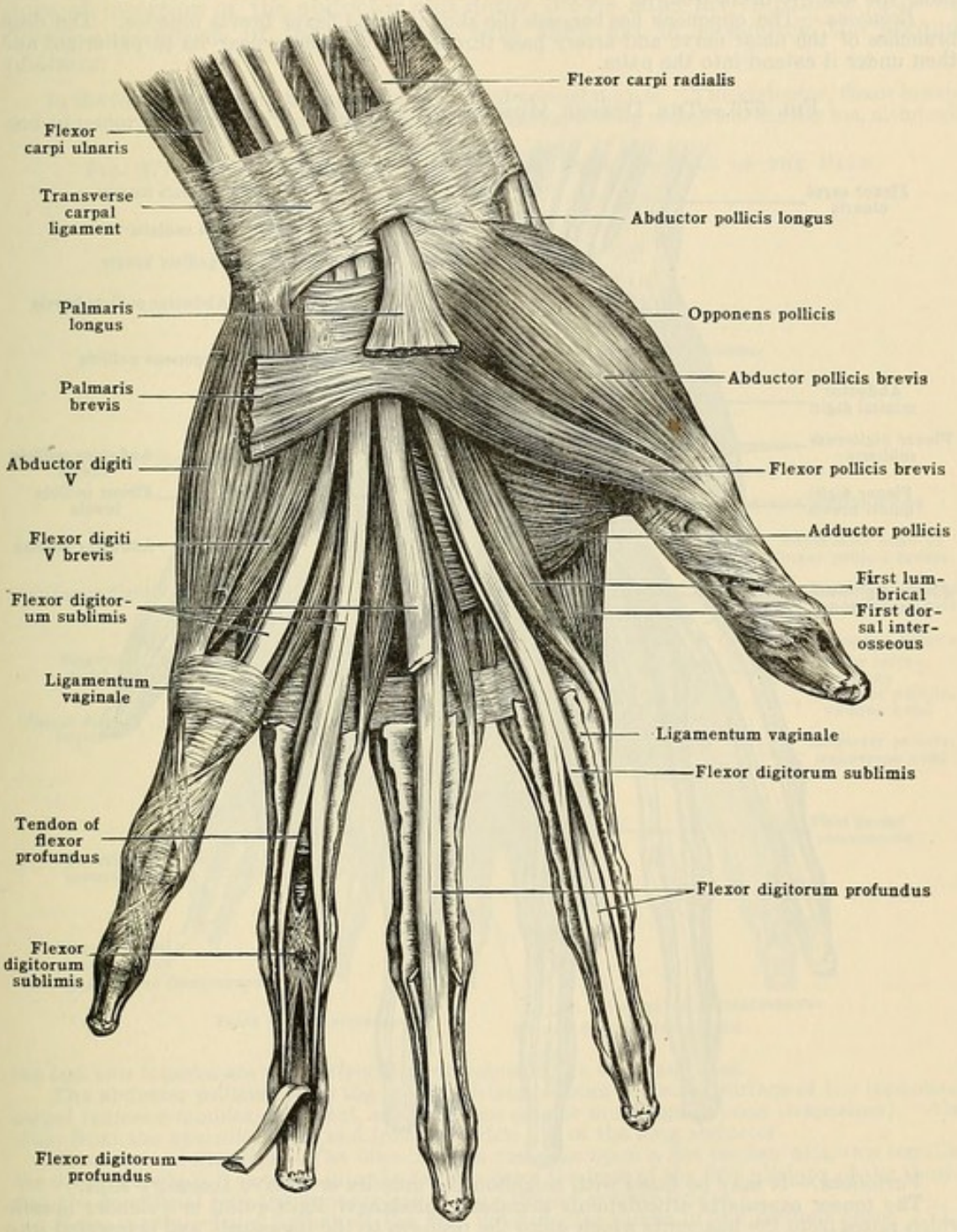

Action.—To flex the first phalanx of the little finger. When it sends a tendon slip to the aponeurosis of the extensor of the finger it helps to extend the two terminal phalanges.

Relations.—The muscle closely adjoins and is partly covered by the abductor. The palmaris brevis and the lateral volar digital artery to the fifth finger lie superficial to it. Under it lies the opponens.

Variations.—The muscle may be wanting or may be closely fused with the abductor or the opponens. It may receive an accessory slip from the forearm fascia. It may give a tendon slip to the extensor aponeurosis or to the head of the fifth metacarpal.

The opponens digiti quinti (fig. 377).—*Origin.*—Partly tendinous, from the distal ulnar border of the hook of the hamatum (unciform) and from the adjacent transverse carpal (anterior annular) ligament.

Structure and insertion.—The fibre-bundles diverge, the proximal short and horizontal, the distal long and oblique, and are inserted on the whole of the ulnar border and on a part of the head of the fifth metacarpal. Often the muscle is divisible into two portions between which the ulnar nerve runs.

Nerve-supply.—Before the deep palmar branch passes through the muscle it gives rise to a twig which enters its volar surface in the middle third near the ulnar margin. The nerve fibres arise from the (seventh and) eighth cervical and first thoracic nerves.

Action.—To flex, adduct, and slightly rotate the fifth metacarpal; as, for example, in 'cupping' the hand to drink from it.

Relations.—The opponens lies beneath the abductor and flexor brevis muscles. The deep branches of the ulnar nerve and artery pass through the opponens near its carpal origin and then under it extend into the palm.

FIG. 376.—THE DEEPER MUSCLES OF THE PALM OF THE HAND.

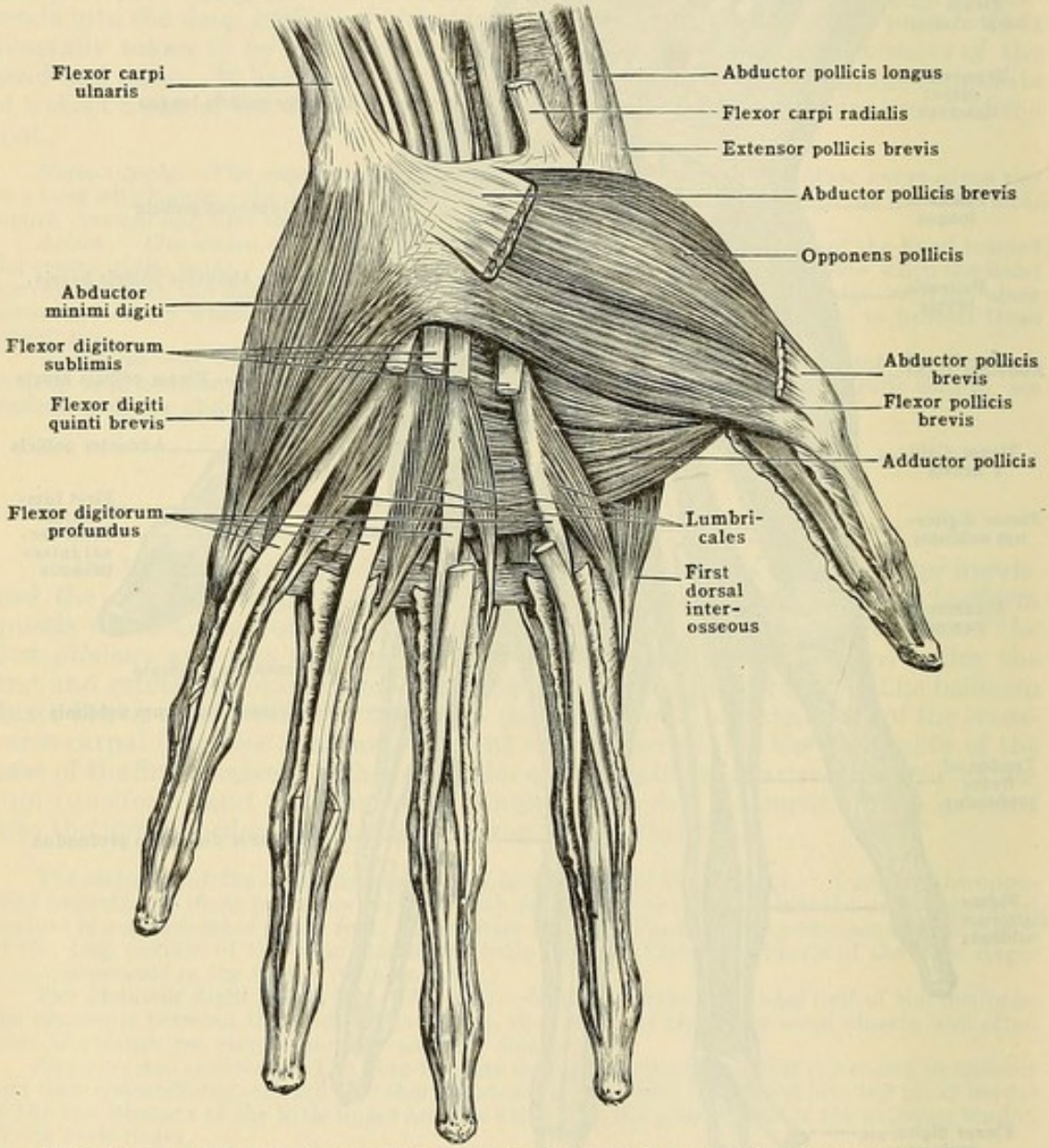

Variations.—It may be fused with neighbouring muscles or receive accessory slips.

The tensor capsularis articulationis metacarpo-phalangei digiti quinti is a slender muscle which arises from the ligaments which unite the pisiform to the hamatum, and is inserted into the volar surface of the metacarpo-phalangeal joint of the little finger.

(*c*) *Muscles of the Thumb*

(Figs. 375, 376, 377)

In the thenar region there are four muscles. Of these, the abductor pollicis brevis is the most superficial. Then come the opponens pollicis and the short flexor, and beneath the last the adductor pollicis. All are triangular in form. The **abductor pollicis brevis** arises from the radial side of the volar surface of the

carpus and is inserted into the radial side of the base of the first phalanx of the thumb. The **opponens** is a thick muscle extending from the transverse carpal (anterior annular) ligament to the radial side of the first metacarpal. The **flexor pollicis brevis** arises by two heads, a "deep" and a "superficial" from the carpus and is inserted into the radial side of the base of the first phalanx. The **adductor pollicis** arises from the carpus and the second and third metacarpals and is inserted into the ulnar side of the first phalanx of the thumb. From the tendons of insertion of the abductor and flexor brevis slips are continued into the dorsal aponeurosis of the thumb so that they aid in extending the second phalanx.

In the foot an opponens hallucis occurs as an abnormal muscle. The abductor, flexor brevis and adductor of the thumb are represented by the corresponding muscles of the big toe, although

FIG. 377.—THE PRONATOR QUADRATUS AND DEEP MUSCLES OF THE PALM.

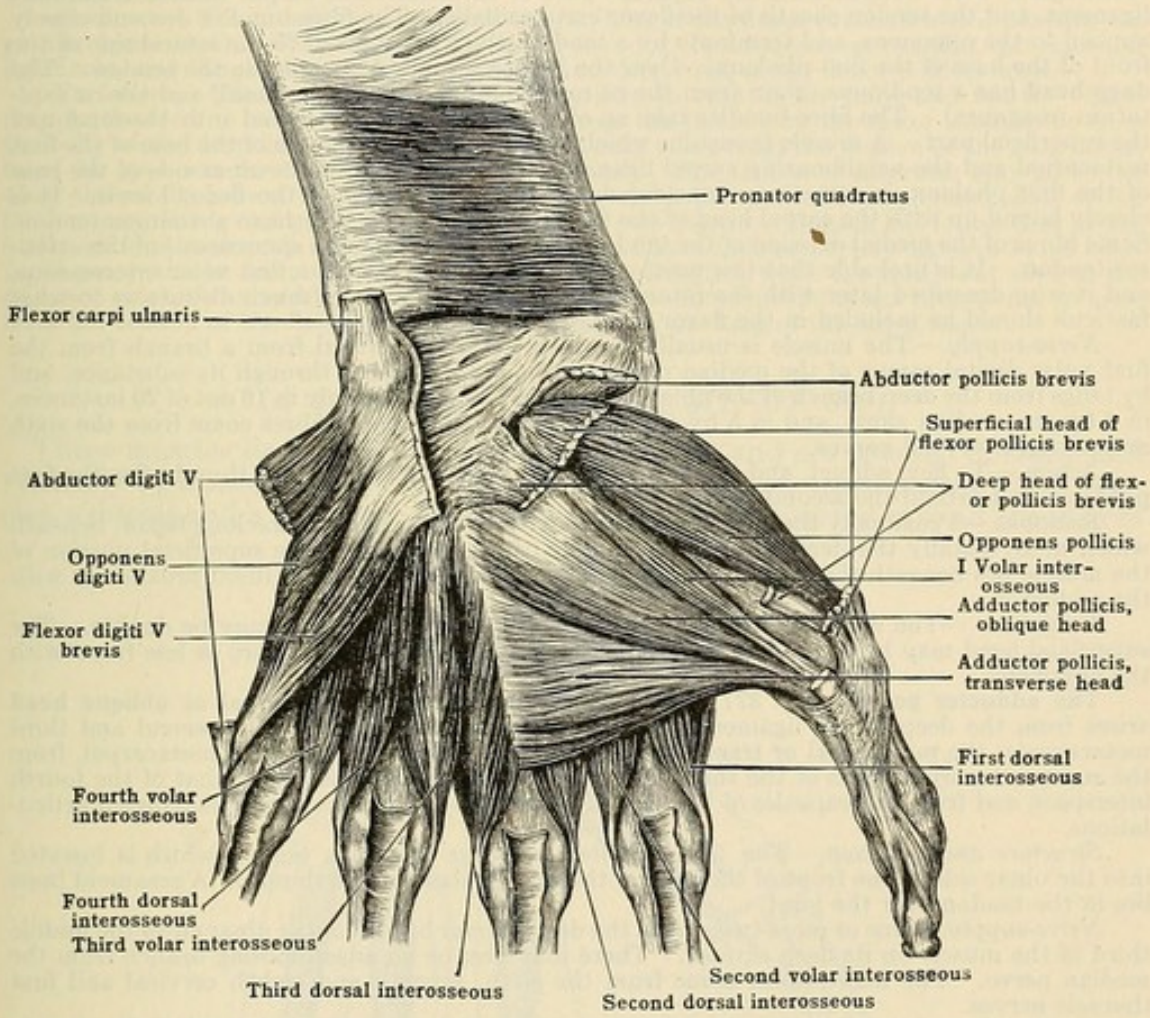

the last two muscles are not perfectly homologous in the hand and foot.

The abductor pollicis brevis (fig. 375).—*Origin.*—From the volar surface of the transverse carpal (anterior annular) ligament, and from the greater multangular bone (trapezium). Also often from the navicular bone and from a tendon slip of the long abductor.

Structure and insertion.—The fibre-bundles converge upon a flat tendon with two lamellæ, the deeper of which is inserted into the radial side of the base of the first phalanx of the thumb and the superficial into the aponeurosis of the extensor pollicis longus.

Nerve-supply.—By a branch of the first volar digital ramus of the median nerve. This branch passes over or through the flexor brevis and enters the muscle on the volar surface in the middle third near its ulnar border.

Action.—To abduct the thumb, flex the first phalanx, and extend the terminal phalanx.

Relations.—It lies beneath the thenar fascia lateral to the superficial head of the flexor brevis and over the opponens. The superficial volar artery usually perforates the muscle.

Variations.—It may be wanting or may be divided into two divisions. The origin may extend to the fascia of the forearm or styloid process of the radius. It may receive an accessory slip from the long radial extensor, the opponens, or the short extensor of the thumb. A *thenar subcutaneous muscle* is occasionally present. It is narrow, is closely associated with the short abductor of the thumb, and extends from the radial side of the base of the first metacarpal into the skin of the thenar eminence.

The opponens pollicis (fig. 377).—*Origin.*—From the volar surface of the transverse carpa (anterior annular) ligament and from the tubercle of the greater multangular bone (trapezium).

Structure and Insertion.—The fibre-bundles extend obliquely in a nearly parallel direction to their insertion along the whole lateral border of the volar surface of the shaft and the head of the first metacarpal.

Nerve-supply.—By a branch of the first volar digital ramus of the median nerve. This branch passes over or through the superficial division of the flexor brevis near the origin of the muscle. One or two twigs enter the deep surface of the proximal third of the opponens near its ulnar border. The nerve fibres arise from the sixth and seventh cervical nerves.

Action.—To flex, adduct, and rotate medialward the first metacarpal bone. The volar surface of the thumb is thus brought to face the volar surface of the other digits.

Relations.—It lies beneath the thenar fascia and the abductor brevis. The flexor brevis overlies its ulnar border.

Variations.—It may be absent or it may be divided into two heads. It is usually more or less fused with the short flexor.

The flexor pollicis brevis (figs. 376, 377).—The muscle is divided by the tendon of the long flexor into a superficial and a deep portion. The **superficial head** arises from the greater multangular bone (trapezium), the adjacent part of the transverse carpal (anterior annular) ligament, and the tendon sheath of the flexor carpi radialis. The fibre-bundles descend closely applied to the opponens, and terminate by a tendon which is attached to the lateral side of the front of the base of the first phalanx. Over the joint a sesamoid bone lies in the tendon. The **deep head** has a tendinous origin from the os multangulum minus (trapezoid) and the os capitatum (magnum). The fibre-bundles take an oblique course, to be inserted into the tendon of the superficial part. A muscle fasciculus which arises from the ulnar side of the base of the first metacarpal and the neighbouring carpal ligaments and is inserted on the ulnar side of the base of the first phalanx, is sometimes considered to be the deep head of the flexor brevis. It is closely bound up with the carpal head of the adductor pollicis and they have a common tendon. Some fibres of the medial division of the tendon may be traced into the aponeurosis of the extensor tendon. It is probable that this portion of the muscle represents a first volar interosseous, and it is so described later with the interosseous muscles. There is much dispute as to what fasciculi should be included in the flexor brevis.

Nerve-supply.—The muscle is usually supplied by twigs derived from a branch from the first volar digital ramus of the median nerve as this branch passes through its substance, and by twigs from the deep branch of the ulnar. Brookes found this supply in 19 out of 29 instances, in 5 by the median alone, and in 5 by the ulnar alone. The nerve fibres come from the sixth and seventh cervical nerves.

Action.—To flex, adduct, and rotate medialward the metacarpal of the thumb; flex the first phalanx; and extend the second phalanx.

Relations.—Proximally the short flexor is grooved for the tendon of the long flexor, beneath which more distally the deep head of the muscle passes laterally. The superficial portion of the muscle lies beneath the skin. The ulnar border of the deep head is fused proximally with the adductor.

Variations.—The deep head may be absent. Either or both heads may be double. The superficial head may be fused with the abductor brevis, and is usually more or less fused with the opponens.

The adductor pollicis (fig. 377).—*Origin.*—By two heads. The **carpal or oblique head** arises from the deep carpal ligaments, the capitatum and the bases of the second and third metacarpals; the **metacarpal or transverse head,** from the crest of the third metacarpal, from the suprametacarpal fascia of the third interspace, and sometimes also from that of the fourth interspace and from the capsules of the second, third, and fourth metacarpo-phalangeal articulations.

Structure and insertion.—The fibre-bundles converge toward a tendon which is inserted into the ulnar side of the front of the base of the first phalanx of the thumb. A sesamoid bone lies in the tendon over the joint.

Nerve-supply.—One or more twigs from the deep palmar branch of the ulnar enter the middle third of the muscle on its deep surface. There may also be an anastomosing branch from the median nerve. The nerve fibres come from the sixth, seventh and eighth cervical and first thoracic nerves.

Action.—To adduct and flex the first metacarpal and flex the first phalanx of the thumb. When the thumb is in an extreme position of apposition, it acts as an abductor.

Relations.—Superficial to the muscle lie some of the tendons of the deep flexor of the fingers and the first two lumbrical muscles. It extends over the two more lateral intermetacarpal spaces, and is in part subcutaneous on the dorsal surface. The deep palmar arch extends between the two heads and beneath the oblique head. The oblique head of the muscle is closely united to the first volar interosseous, so that the latter by some is considered a part of the adductor.

Variations.—The extent of the attachments of origin of the muscle vary considerably. The two heads of the muscle may be more or less completely separated from one another. Each may be divided into separate fasciculi.

(d) Lumbrical Muscles

From the deep flexor tendons in the palm of the hand arise the lumbrical muscles, four in number, which are attached by small tendons to the radial side of the extensor tendons (figs. 373, 375). These lumbrical muscles have homologues in the sole of the foot.

The **lumbricales** (figs. 375, 376).—*Origin.*—The two lateral arise from the radial side of the volar aspect of the first and second tendons of the flexor digitorum profundus; the two medial arise from the adjacent sides of the second and third and third and fourth tendons.

Structure and insertion.—The fibre-bundles of each muscle arise directly from the flexor tendons near the distal border of the transverse carpal (anterior annular) ligament. They converge as far as the metacarpo-phalangeal joint, upon a small tendon which begins about the middle of the muscle. The tendon passes out between the palmar aponeurosis and the transverse capitular ligament, winds about the metacarpo-phalangeal joint, expands, and is attached along the side of the first phalanx to the radial border of the tendon of the extensor digitorum communis.

Nerve-supply.—Branches from the median nerve enter the middle third of the radial border of the first two or three lumbrical muscles. The last one or two are supplied by branches from the deep volar branch of the ulnar nerve, which enter the middle third of the deep surface. The third lumbrical and sometimes one or more of the others may receive a branch from both nerves. The nerve fibres come from the eighth cervical and first thoracic nerves.

Action.—Together with the interosseous muscles they flex the basal phalanges on the metacarpal bones and extend the terminal and middle phalanges. They also adduct the fingers toward the thumb.

Relations.—The muscles run between the tendons of the flexor profundus and beneath the palmar aponeurosis. They lie upon the fascia covering the interosseous muscles, the capitular ligaments, and the septum over the adductor and deep head of the flexor pollicis brevis.

Variations.—These are very frequent, especially in case of the third and fourth. Each may be doubled or missing. They may arise from the tendons of the flexor sublimis or from the belly of the deep flexor. The first lumbrical may come from the tendon of the long flexor, from the opponens, or the metacarpal of the thumb. The tendon of insertion may go to the ulnar side of the base of the digit opposite that to which the tendon is usually attached, or the tendon may divide and go to the adjacent sides of two fingers. Kopsch has found that in 110 bodies all four lumbricals were inserted on the radial side of their respective digits in 39 per cent. In 35 per cent. the first, second, and fourth were so inserted, while the third sent slips to the adjacent sides of the middle and ring fingers. An accessory fasciculus has been found to arise from the tendon of the flexor pollicis longus and go to the base of the index finger.

(*e*) *Interosseous Muscles* (figs. 377, 378, 379)

These muscles lie between the metacarpal bones and are covered dorsally and ventrally by fasciæ attached to the metacarpals. In each interspace are two muscles, a dorsal and a palmar. The volar interossei are inserted into all the fingers

Fig. 378.—The Volar Interossei.

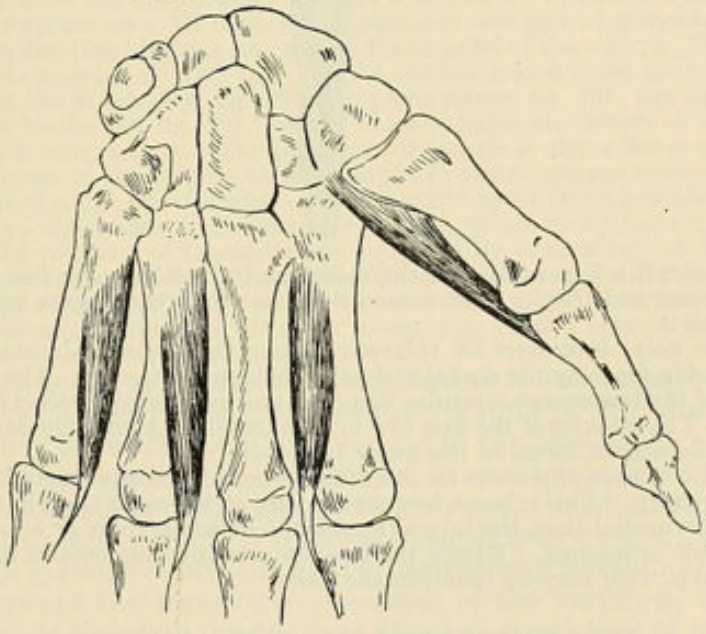

except the middle finger, and are adductors toward an axis passing through the middle finger; the dorsal interossei are inserted into both sides of the middle finger and into the radial side of the second and the ulnar side of the fourth finger, and are abductors. All also serve as flexors of the first row of phalanges and extensors of the second and third. In the foot the axis to and from which the interosseous muscles adduct and abduct the toes passes through the second toe.

The **interossei volares** arise from the sides toward the middle finger and the front of the shafts of the first, second, fourth, and fifth metacarpals. The first arises from near the base, the

others from three-fourths of the shaft. The fibre-bundles of each muscle converge in a penniform manner upon a tendon which is inserted into the aponeurosis of the digital extensor tendon and the base of the first phalanx on the middle finger side of the corresponding digit (see fig. 373). The first volar interosseous is often described as a division of the flexor pollicis brevis or of the adductor pollicis.

The **interossei dorsales** arise from the adjacent sides of the metacarpal bones in each interspace. On the sides nearest the middle finger they cover three-fourths of the bone, on the opposite sides much less. The fibre-bundles converge in a bipenniform manner upon a tendon which begins high in the muscle and is inserted into the aponeurosis of the extensor muscles and the base of the first phalanx on each side of the middle finger, on the thumb side of the index finger, and the ulnar side of the ring finger. The interosseous muscle in the first interspace is thick and strong and forms with the adductor pollicis the fleshy web between the base of the thumb and the palm.

Nerve-supply.—By branches of the deep palmar division of the ulnar nerve. As a rule, a branch to each volar interosseous enters the proximal third of the muscle. To each dorsal interosseous a branch is given which enters between the two heads. These branches may be variously combined before entering the interosseous muscles. The nerve fibres arise from the eighth cervical and first thoracic nerves.

FIG. 379.—THE DORSAL INTEROSSEI.

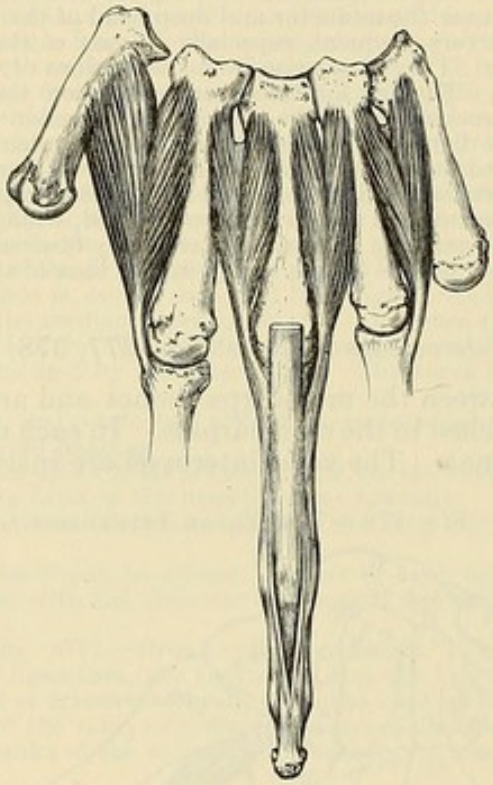

Action.—To move the fingers toward the radial and ulnar sides, to flex the first phalanx and extend the second and third. The volar interossei move the fingers toward the median axis, the dorsal from it.

Relations.—The volar interossei lie volarward from the dorsal interossei. The two sets of muscles are bound in place by the dorsal and volar metacarpal fasciæ. The tendons pass out on the dorsal side of the transverse capitular ligament and are closely applied to the metacarpophalangeal joints. The muscles of the first two interspaces lie immediately dorsal to the adductor of the thumb; the others dorsal to the flexor tendons.

Variations.—The tendon slip from an interosseous muscle to the base of the first phalanx of a digit may be missing. This is more frequent in case of the volar than in that of the dorsal interossei, and in the medial than the lateral muscles. Either a volar or a dorsal interosseous muscle may be double or missing. Rarely the insertions of the interosseous muscles characteristic of the foot (see p. 499) may be found in the hand.

III. SPINAL MUSCULATURE

(Figs. 380, 381, 382, 383)

The spinal (vertebral) column is of special interest as the segmented longitudinal axial support of the body which has given rise to the term "vertebrates" as applied to the class of animals of which man is the highest form. The segmentation in fishes permits the lateral movements of the body which are their chief means of propulsion. In the land vertebrates, with the exception of snakes, the limbs are developed as the chief organs of propulsion but flexibility of the column

is retained for the sake of freedom of movement. In man the spinal column, with the exception of the sacral region, may be readily extended (bent backward) and flexed (bent forward), abducted (bent to the side) and rotated. Freedom of movement is greatest in the cervical and lumbar regions and is restricted by the thorax in the thoracic region. The cervical region allows considerable flexion, extension and rotation, but a more limited abduction. In the thoracic region rotation and abduction are freer than flexion and extension. The lumbar region is that in which the chief flexion and extension of the trunk takes place, but abduction and rotation are limited, especially the latter. In the isolated articulated spinal column freedom of movement of the various parts depends chiefly upon the thickness and elasticity of the intervertebral discs, upon the conformation of the articular processes, and upon the elasticity or arrangement of the various ligaments uniting the vertebræ. In the living body freedom of movement is further restricted by the musculature and skeletal apparatus attached to the column. There is much individual variation in the flexibility of the vertebral column.

The various movements of the column are produced partly by muscles which act directly on it and partly by muscles which act on it through the head, thorax or pelvis. Most of the muscles which act on it directly belong to the intrinsic dorsal musculature; that is, to musculature which is derived from the dorsal divisions of the myotomes and is innervated by the dorsal divisions of the spinal nerves. This musculature extends from the sacrum to the skull and is closely applied on each side of the mid-dorsal line of the body to the backs of the vertebræ and the back of the thorax (fig. 381). Its chief function is to extend the spinal column and head, hence the old term applied to the superficial portion of this musculature "erector spinæ." During the development of the body, muscles belonging to the ventro-lateral thoracic musculature and to the upper extremity come to overlie in part the intrinsic dorsal musculature. The trapezius and rhomboid muscles which cover it in the cervical and thoracic regions, and the latissimus dorsi which covers it in the thoracic and lumbar regions belong to the shoulder girdle and arm and have already been described, p. 360. The serratus posterior superior, which overlaps it in the upper thoracic region, and the serratus posterior inferior, which overlaps it at the junction of the thoracic and lumbar regions, are derived from the intercostal musculature which is described below, p. 422 (fig. 380). All of these muscles are innervated by the ventro-lateral divisions of the spinal nerves. The levatores costarum (fig. 380), which extend from the transverse process of the thoracic vertebræ to the ribs, and which, in spite of their name, act chiefly on the spinal column, are derived from the external intercostal musculature and are innervated by the intercostal nerves.

Ventral to the spinal column and closely applied to it there are a few muscles, the chief function of which is to flex the column. All are supplied by branches from the ventro-lateral divisions of the spinal nerves. Of these the *longissimus colli* and *longissimus capitis* and *scalene* muscles have been described in connection with the muscles of the neck, p. 353. In the thoracic region there are no muscles of this type. In the lumbar region there are four muscles on each side, the pillars of the *diaphragm*, fig. 391, the *psoas minor*, fig. 391, the *psoas major*, fig. 391, and the *quadratus lumborum*, fig. 391. All of these muscles are flexors of the spine, except the quadratus, which is an extensor. The psoas major muscle is also a flexor of the thigh. Even more powerful flexors of the column than those above mentioned are some of those which work indirectly upon it through the leverage offered by the skull (sterno-cleido-mastoid described above, p. 347), and the thorax (the ventro-lateral abdominal musculature).

Abduction and rotation of the spine are produced by contraction of muscles on one side while the corresponding muscles on the other side are relaxed. See Table, p. 502.

In the present section we shall confine our attention to the intrinsic dorsal musculature, leaving for consideration elsewhere the other musculature which acts on the vertebral column.

The intrinsic dorsal musculature is attached to the sacrum, to the ilium, to the spines, transverse, and articular processes and laminæ of the lumbar, thoracic, and cervical vertebræ, to the backs of the ribs and to the base of the skull. Two great longitudinal subdivisions may be recognised, a lateral, supplied by lateral branches of the posterior divisions of the spinal nerves, and a medial, supplied by medial branches. The lateral portion is further divisible into a superficial division, consisting chiefly of systems of muscles extending laterally from the spines of the vertebræ upward toward the transverse processes of the vertebræ, the ribs, and the mastoid process of the skull; and a deep division, consisting of muscles which extend between successive transverse processes. The medial portion likewise consists of two parts; a superficial medial composed of fasciculi extending from inferior to superior spines, best developed in the dorsal region, and a deep portion consisting mainly of muscle fasciculi which pass from the transverse processes upward toward the spines of vertebræ situated more cranially. In the neck the more superficial extend to the base of the skull. Between the base of the skull and the first two vertebræ there are several specialised muscles. There is also frequently present the rudimentary *sacro-coccygeus posterior* described on p. 448, which represents an extension into the caudal region of the intrinsic dorsal musculature.

The **superficial lateral dorsal musculature** consists of the splenius and the sacro-spinalis. The **splenius** (fig. 380) is a flat, somewhat triangular muscle, which extends from the cervical and upper thoracic spines to the upper cervical transverse processes and to the mastoid process of the temporal bone and the neighbouring part of the occipital. The **sacro-spinalis** (erector spinæ) (fig. 381) is the name given to a mass of musculature which takes its origin from the ilium, the sacrum, and the lumbar spines. In the lumbar region this muscle divides into its two chief portions, the ilio-costalis and the longissimus. The *ilio-costalis* (fig. 382) is attached to the lumbar transverse processes and to the ribs near the angles, and is continued upward by accessory fasciculi along the back of the thorax to the transverse processes of the cervical vertebræ. The *longissimus* (fig. 382) extends upward between the ilio-costalis and the spines of the lumbar and thoracic vertebræ. It is attached to the transverse processes of the lumbar and thoracic vertebræ and to the ribs lateral to the transverse processes. It is continued to the transverse processes of the cervical vertebræ and to the skull by accessory muscle slips.

The **deep lateral dorsal musculature** consists of the **dorsal intertransverse** muscles. The intertransverse muscles are best developed in the cervical and lumbar regions. In the cervical region intertransverse muscles belonging to the dorsal musculature extend between the successive dorsal tubercles, while intertransverse muscles belonging to the ventral musculature extend between the ventral tubercles. The latter, as well as the rectus capitis anterior and rectus capitis lateralis, which belong in the series, have been described above (p. 356). In the lumbar region there are also two sets of intertransverse muscles, one belonging to the ventral and one to the dorsal musculature.

The **superficial medial dorsal musculature** consists of the spinalis dorsi and cervicis. The *spinalis dorsi* (fig. 381) is intimately fused with the longissimus. It extends from the lower to the upper thoracic spines, and is derived from the medial dorsal musculature. The inconstant *spinalis cervicis*, which extends from the upper thoracic to the lower cervical spines, is likewise derived from the medial dorsal musculature, but is less intimately related to the longissimus.

The **deep medial dorsal musculature** (fig. 383) lies in the groove between the transverse processes and the spines of the sacral, lumbar, thoracic, and cervical vertebræ. It extends from the sacrum to the skull, and is best developed in the lumbar and cervical regions. It is subdivided into a vertebro-occipital muscle (semispinalis capitis), a transverso-spinal group, and the interspinal muscles. The *semispinalis capitis* (complexus) (fig. 381) arises from the transverse processes of the third cervical to the sixth thoracic vertebræ and from the spines of the upper thoracic vertebræ and is inserted into the base of the skull. The *transverso-spinal* group (fig. 383) extends from the sacrum to the second cervical vertebra. It is more or less artificially divisible into several layers. In the superficial layer, the *semispinalis dorsi et cervicis*, which extends from the twelfth thoracic to the second cervical vertebra, the constituent fasciculi extend from the transverse process of one vertebra to the spine of a vertebra four to six segments above. In the middle layer, the *multifidus*, the fasciculi extend over from two to four vertebræ. In the deepest layer, the *rotatores*, the fasciculi extend to the next vertebra (short rotators) or to the second vertebra above (long rotators). The *interspinal* muscles extend between successive spines.

The muscles which pass from the first two vertebræ to the base of the skull behind, or *suboccipital muscles* (fig. 382), consist of the *rectus capitis posterior minor*, from the spine of the atlas to beneath the inferior nuchal line of the occipital and *rectus capitis posterior major*, from the spine of the epistropheus (axis) to beneath the inferior nuchal line, lateral to the preceding; of the *obliquus capitis inferior*, from the spine of the epistropheus (axis) to the transverse process of the atlas, and the *obliquus capitis superior*, from the transverse process of the atlas to the base of the lateral part of the inferior nuchal line of the occipital above the *rectus major*.

The primitive condition of the dorsal musculature is one of metameric segmentation. This is characteristic of fishes, many amphibia, and of the embryos of all higher vertebrates. In the tailless amphibia, however, a partial differentiation of the dorsal musculature takes place during embryonic development, and in all higher forms a differentiation takes place which corresponds in many ways to that described above for man. According to Favaro, the splenius is differentiatied from the medial dorsal system, but its innervation should place it with the lateral system. In the human embryo the dorsal segmental musculature extends into the tail region, but afterward here undergoes retrograde metamorphosis.

The intrinsic musculature of the back serves to extend, bend from side to side, and to rotate the spinal column and head. The muscles attached to the ribs depress the thorax.

FIG. 380.—THE THIRD AND FOURTH LAYERS OF THE MUSCLES OF THE BACK. (INTRINSIC DORSAL MUSCULATURE)

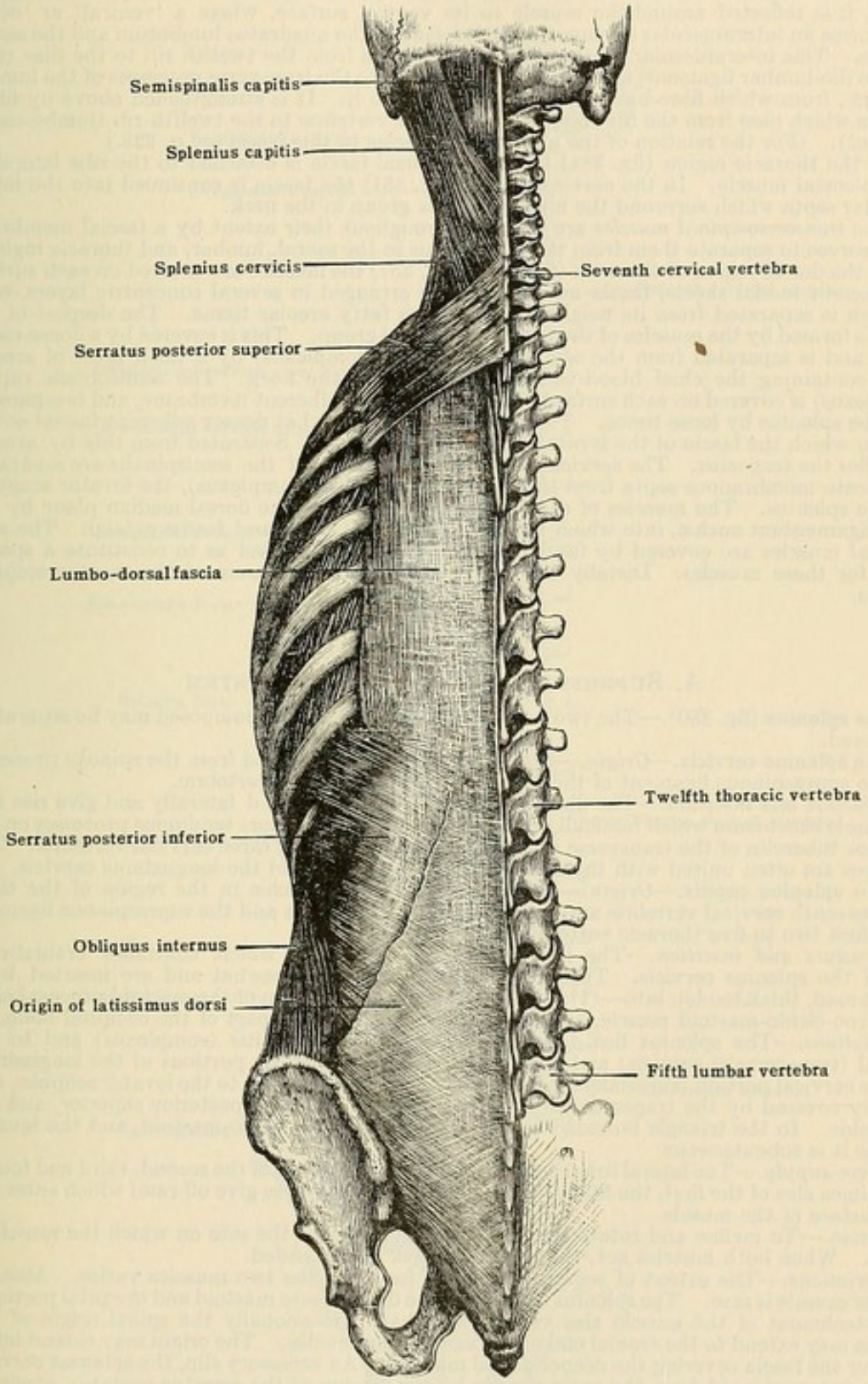

FASCIÆ

The **fasciæ** and the general relations of the muscles of the back may be followed in the cross-sections shown in figs. 347, 351, 357, 384, and 407.

The **tela subcutanea** of the upper dorsal region has been described in connection with the muscles of the shoulder girdle (p. 347). It is thick, fibrous, and adherent. In the lower dorsal

region it is somewhat less compact, but is thicker and contains more fat. It is usually divisible into two layers, of which the deeper is adherent to the lumbodorsal fascia.

The splenius (fig. 380) is enveloped in a thin, adherent fascial covering. The sacro-spinalis is covered by a fascia, the **fascia lumbo-dorsalis** (fig. 380), which inferiorly is attached to the iliac crest, the distal and lateral margins of the sacrum, and the sacral spines. In the lumbar and thoracic regions it is attached medially to the vertebral spines. Laterally, in the lumbar region, it is reflected around the muscle to its ventral surface, where a 'ventral' or 'deep' layer forms an intermuscular septum (fig. 384) between the quadratus lumborum and the sacro-spinalis. This intermuscular septum (fig. 383) extends from the twelfth rib to the iliac crest and the ilio-lumbar ligament, and is attached medially to the transverse processes of the lumbar vertebræ, from which fibre-bands extend laterally into it. It is strengthened above by fibre-bundles which pass from the first and second lumbar vertebræ to the twelfth rib (lumbo-costal ligament). (For the relation of the abdominal muscles to this fascia see p. 328.)

In the thoracic region (fig. 384) the lumbo-dorsal fascia is attached to the ribs lateral to the ilio-costal muscle. In the cervical region (fig. 351) the fascia is continued into the intermuscular septa which surround the muscles of this group in the neck.

The *transverso-spinal muscles* are covered throughout their extent by a fascial membrane which serves to separate them from the longissimus in the sacral, lumbar, and thoracic regions.

In the dorsal region of the neck (figs. 347, 351, 357) the muscles are covered on each surface by adherent fascial sheets, **fascia nuchæ**, and are arranged in several concentric layers, each of which is separated from its neighbours by dense fatty areolar tissue. The deepest of the layers is formed by the muscles of the transverso-spinal group. This is covered by a dense membrane, and is separated from the semispinalis capitis (complexus) by a thick layer of areolar tissue containing the chief blood-vessels and nerves of the neck. The semispinalis capitis (complexus) is covered on each surface by a more delicate adherent membrane, and is separated from the splenius by loose tissue. The splenius has a somewhat denser adherent fascial covering into which the fascia of the levator scapulæ is continued. Separated from this by areolar tissue lies the trapezius. The cervical and thoracic portions of the semispinalis are separated by delicate membranous septa from the semispinalis capitis (complexus), the levator scapulæ, and the splenius. The muscles of each side are separated in the dorsal median plane by the dense **ligamentum nuchæ,** into which the various cervical septa and fasciæ extend. The sub-occipital muscles are covered by fascial sheaths which are so fused as to constitute a special fascia for these muscles. Distally this is continued into the fascia of the transversospinal muscles.

MUSCLES

A. Superficial Lateral Dorsal System

The splenius (fig. 380).—The two parts of which this muscle is composed may be separately considered.

The splenius cervicis.—*Origin.*—By a narrow aponeurotic band from the spinous processes and the supraspinous ligament of the third to the sixth thoracic vertebræ.

Structure and insertion.—The fibre-bundles extend upward and laterally and give rise to a flat muscle sheet from which fasciculi arise that are inserted by short tendinous processes on the posterior tubercles of the transverse processes of the first two or three cervical vertebræ. The processes are often united with those of the levator scapulæ and the longissimus cervicis.

The splenius capitis.—*Origin.*—From the ligamentum nuchæ in the region of the third to the seventh cervical vertebræ and from the spinous processes and the supraspinous ligament of the first two to five thoracic vertebræ.

Structure and insertion.—The fibre-bundles form a sheet which continues cranialward that of the splenius cervicis. The fibre-bundles converge somewhat and are inserted by a short, broad, thick tendon into—(1) the back, the side, and the tip of the mastoid process below the sterno-cleido-mastoid muscle, and (2) into the neighbouring part of the occipital bone.

Relations.—The splenius lies dorsal to the semispinalis capitis (complexus) and to the cervical (transversalis cervicis) and the cranial (trachelo-mastoid) portions of the longissimus and the cervical portion (cervicalis ascendens) of the ilio-costalis and to the levator scapulæ, and is partly covered by the trapezius, sterno-cleido-mastoid, serratus posterior superior, and the rhomboids. In the triangle bounded by the trapezius, sterno-cleido-mastoid, and the levator scapulæ it is subcutaneous

Nerve-supply.—The lateral branches of the posterior divisions of the second, third and fourth (sometimes also of the first, the fifth and the sixth) cervical nerves give off rami which enter the deep surface of the muscle.

Action.—To incline and rotate the head and neck toward the side on which the muscle is placed. When both muscles act, the head and neck are extended.

Variations.—The extent of separation and of fusion of the two muscles varies. Absence of either muscle is rare. The splenius capitis may be divided into mastoid and occipital portions. The attachment of the muscle also varies somewhat. Occasionally the spinal origin of the splenius may extend to the cranial end of the ligamentum nuchæ. The origin may extend laterally over the fascia covering the deeper dorsal muscles. An accessory slip, the **splenius cervicis accessorius,** separated from the main muscle by the tendon of the serratus posterior superior, is frequently (8 per cent. of instances, LeDouble) found to run from the lower cervical or upper thoracic vertebræ to the transverse process of the atlas.

The sacro-spinalis (erector spinæ).—*Origin.*—(1) From a strong aponeurosis attached to the spines of the lumbar, and the sacral vertebræ, to the ligament passing from the sacrum to the coccyx, to the lateral sacral crest, the sacro-tuberous ligament, the long posterior sacro-iliac ligament, and to the dorsal fifth of the iliac crest; (2) directly from the iliac crest in front of and lateral to the attachment of the aponeurosis; and (3) from the short posterior sacro-iliac

ligaments. The aponeurosis covers the muscles of the sacral region and is there united to the overlying fascia by more or less dense areolar tissue. Opposite the iliac crest fibre-bundles begin to take origin from the lateral margin of the dorsal surface as well as from the deep or

FIG. 381.—THE FIFTH LAYER OF THE MUSCLES OF THE BACK.

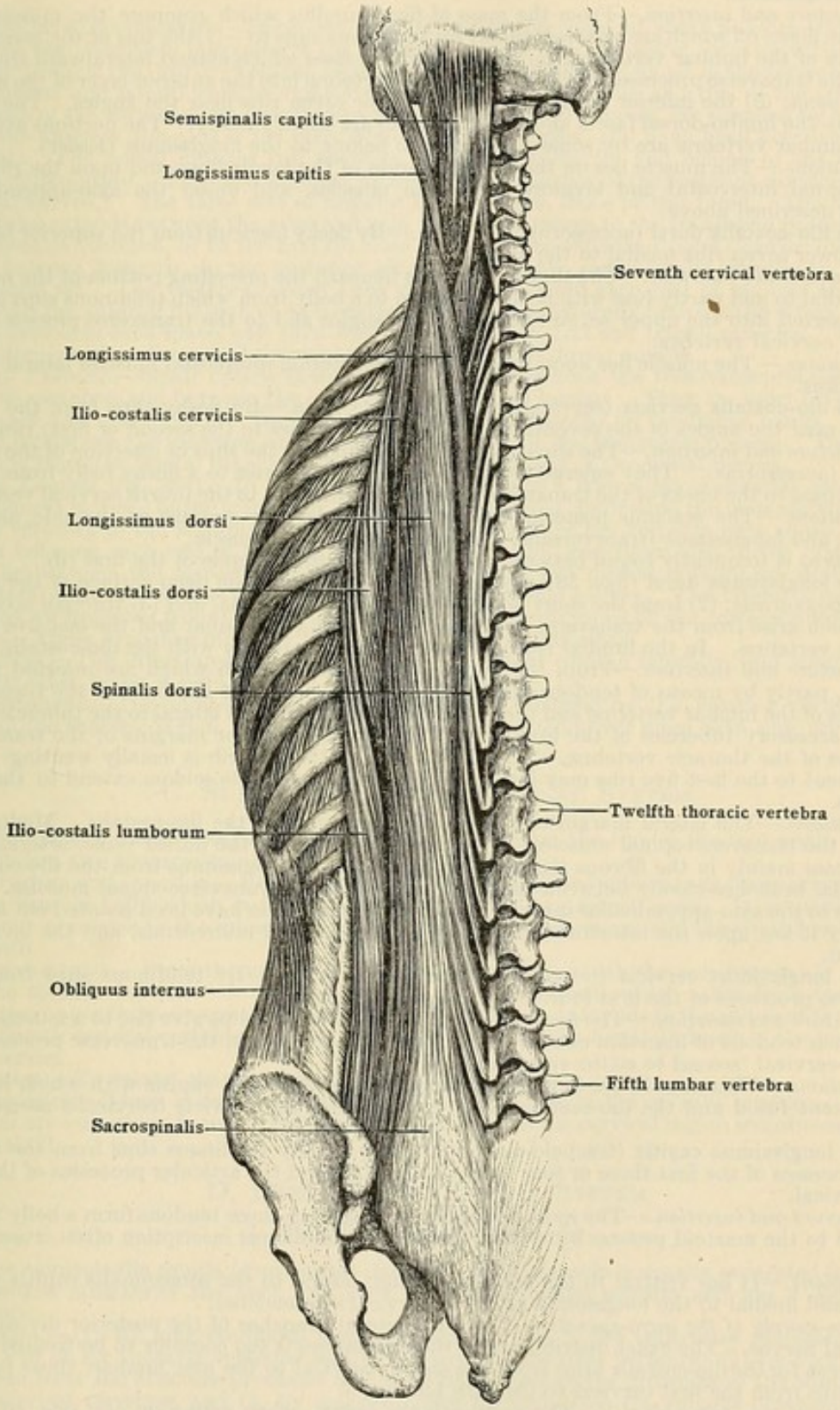

ventral surface of the aponeurosis of origin, and gradually the line of dorsal attachment extends medially until, in the lower thoracic region, the tendon becomes completely embedded in the muscle-fasciculi which take their origin from it. The aponeurosis, which is the strongest in the lower lumbar region, is composed chiefly of fibres which take a direction upward and somewhat lateralward.

In the lower lumbar region the sacro-spinalis (erector spinæ) muscle begins to show a distinct division into its two chief component parts, the ilio-costalis and the longissimus. The parts of which the ilio-costalis and longissimus are composed will be taken up separately.

The ilio-costalis lumborum (figs. 381, 382).—*Origin.*—(1) Chiefly from the back of the sacrospinal aponeurosis, medial to and cranialward from the iliac crest, and (2) from the iliac crest directly. The deep medial surface of the muscle is closely united in the lumbar region to the longissimus.

Structure and insertion.—From the mass of fibre-bundles which compose the muscle, fasciculi are given off which are attached chiefly by tendinous slips to—(1)the tips of the transverce processes of the lumbar vertebræ; (2) the fibrous processes which extend lateralward from the tips of the transverse processes of the upper lumbar vertebræ into the anterior layer of the lumbo-dorsal fascia; (3) the inferior margin of the last six or seven ribs near the angles. The insertions into the lumbo-dorsal fascia and the twelfth rib are usually fleshy. The portions attached to the lumbar vertebræ are by some considered to belong to the longissimus (Eisler).

Relations.—The muscle lies on the lateral margin of the longissimus and upon the ribs and the external intercostal and levatores costarum muscles, and under the axio-appendicular muscles described above.

The ilio-costalis dorsi (accessorius).—*Origin.*—By fleshy fasciculi from the superior borders of the lower seven ribs medial to the angles.

Structure and insertion.—The slips of origin lie beneath the preceding portion of the muscle, pass medial to and partly fuse with it, and give rise to a belly from which tendinous slips extend to be inserted into the upper seven ribs near their angles and to the transverse process of the seventh cervical vertebra.

Relations.—The muscle lies upon the ribs and the external intercostal muscles lateral to the longissimus.

The ilio-costalis cervicis (cervicalis ascendens).—*Origin.*—By fleshy slips from the upper borders near the angles of the seventh to the third (sometimes to the second or first) ribs.

Structure and insertion.—The slips of origin are covered by the slips of insertion of the dorsal portion (accessorius). They emerge medial to them and give rise to a fleshy belly from which tendons pass to the backs of the transverse processes of the sixth to the fourth cervical vertebræ.

Relations.—The scalenus posterior lies in front, the levator scapulæ at the side, and the splenius and longissimus (transversalis) cervicis medial to this muscle.

A *bursa* is frequently found between the muscle and the tubercle of the first rib.

The longissimus dorsi (figs. 381, 382).—*Origin.*—(1) From the deep surface of the sacro-spinal aponeurosis; (2) from the short posterior sacro-iliac ligaments; and (3) through accessory slips which arise from the transverse processes of the first two lumbar and the last five or six thoracic vertebræ. In the lumbar region it is fused dorso-laterally with the ilio-costalis.

Structure and insertion.—From the muscle mass arise fasciculi which are inserted partly directly, partly by means of tendons, into—(1) the lower border of the back of the transverse processes of the lumbar vertebræ and the inferior margins of the ribs lateral to the tubercles; and (2) the accessory tubercles of the lumbar and the tips and inferior margins of the transverse processes of the thoracic vertebræ. The attachment to the first rib is usually wanting. The attachment to the first five ribs may fail. The medial attachments seldom extend to the first vertebra.

Relations.—The lateral margin of the muscle is covered by the ilio-costalis. Medially it overlies the transverso-spinal muscles. The lateral branches of the dorsal veins, arteries, and nerves pass mainly in the fibrous tissue which separates the longissimus from the ilio-costalis, the medial branches chiefly between the longissimus and the transverso-spinal muscles. The relations to the axio-appendicular muscles and to the dorsal fascia have been pointed out above. Ventrally it lies upon the intertransverse muscles, the external intercostals, and the levatores costarum.

The longissimus cervicis (transversalis cervicis).—*Origin.*—By tendinous slips from the transverse processes of the first four to six thoracic vertebræ.

Structure and insertion.—The fasciculi which arise from these slips give rise to a muscle belly from which tendons of insertion extend to the posterior tubercles of the transverse processes of the mid-cervical (second to sixth) vertebræ.

Relations.—This muscle lies between the longissimus dorsi and capitis with which it is to some extent fused and the ilio-costalis dorsi (accessorius) and cervicis (cervicalis ascendens) muscles.

The longissimus capitis (trachelo-mastoid).—*Origin.*—By tendinous slips from the transverse processes of the first three or four thoracic vertebræ and the articular processes of the last four cervical.

Structure and insertion.—The muscle fasciculi arising from these tendons form a belly which is united to the mastoid process by a short tendon. A tendinous inscription often crosses the muscle.

Relations.—It lies ventral to the splenius capitis, lateral to the semispinalis capitis (complexus) and medial to the longissimus cervicis (cervicalis ascendens).

Nerve-supply of the sacro-spinalis.—From the lateral branches of the posterior divisions of the spinal nerves. The exact distribution of these branches is too complex to be treated here. The nerves for the ilio-costalis arise from the eighth cervical to the first lumbar, those for the longissimus from the first cervical to the fifth lumbar.

Action of the sacro-spinalis.—The sacro-spinalis serves, when acting on one side, to bend the spinal column toward that side, and when acting on both sides, to extend the spinal column. The cranial portions of the muscle serve to incline the head toward the same side, and when both muscles act they serve to extend the head. The ilio-costalis muscle has the greatest power for producing lateral inclination. The ilio-costalis lumborum depresses the ribs, while the ilio-costalis cervicis (cervicalis ascendens) may aid in elevating them. The spinalis muscle serves merely as an extensor.

Variations of the sacro-spinalis.—The slips of origin and insertion of the various parts of this muscle and the extent of fusion of the various parts vary greatly. Statistical data from which the most frequent conditions might be determined are wanting. Tendinous inscriptions may extend across the longissimus cervicis and other parts of the sacro-spinalis.

B. Deep Lateral Dorsal System

The intertransversarii.—These are vertical bands composed of short bundles which pass between the transverse processes of the cervical, lumbar, and the lower thoracic vertebræ.

(a) *Cervical* (fig. 349).—Ventral, lateral and dorsal muscles are found in the cervical region. The ventral and lateral muscles run between the ventral tubercles and tips of the transverse processes of the vertebræ, are homologous with the intercostal muscles, are supplied by branches from the anterior divisions of the corresponding spinal nerves, and have been described above (p. 356). The dorsal muscles run between the dorsal tubercles and belong to the intrinsic dorsal musculature. They are supplied by the lateral branches of the posterior divisions of the cervical nerves.* The three sets of muscles are, however, more or less fused. The first pair of muscles extends between the atlas and axis, the lowest passes to the transverse process of the first thoracic vertebra, or to the first rib close to this. The *obliquus capitis superior* (described later) belongs, however, to the posterior set of muscles, the *rectus capitis lateralis* (p. 356) to the lateral set. The vertebral artery runs vertically between each pair of muscles above the sixth, and the anterior division of each cervical nerve passes laterally between the artery and the dorsal muscle in each space, and then out between the ventral and lateral muscles. The posterior division of each cervical nerve passes medial to each dorsal muscle.

(b) *Thoracic.*—Small muscle fasciculi may extend between the transverse processes of the thoracic vertebræ and between the last thoracic and first lumbar. They are most frequent in the upper and lower thoracic regions. Often they are replaced by tendinous bands. In the second interspace the insertion may extend to the rib near the transverse process. The innervation is from the lateral branches of the posterior divisions of the spinal nerves.

(c) *Lumbar* (fig. 383).—In the lumbar region there is a lateral set of muscles connecting the adjacent margins of the transverse processes and a medial connecting the mammary tubercle of one vertebra to the mammary or the accessory tubercle of the vertebra next above. They extend between each two of the five lumbar vertebræ and sometimes also to the first sacral. They lie between the sacrospinalis and psoas muscles. The medial muscles are supplied by the lateral branches of the posterior divisions of the spinal nerves. The lateral muscles are supplied by branches from the junction between the two divisions of the corresponding spinal nerves. These branches probably belong to the anterior divisions.

Action.—The intertransverse muscles bend the spinal column laterally, and when acting on both sides, make it rigid.

Variations.—The number of intertransverse spaces occupied by the muscles varies, especially in the thoracic region. They may be doubled or extend over more than one interspace.

C. Superficial Medial Dorsal System

The spinalis dorsi.—*Origin.*—By tendinous bands from the tips of the two upper lumbar and the last two thoracic spines.

Structure and insertion.—From the deep surface of the tendinous bands there arises a long slender muscle belly which is fused laterally with the longissimus dorsi. It is attached by tendinous processes to the spines of the upper thoracic vertebræ, usually the second or third to the ninth.

Nerve-supply.—From the medial divisions of the sixth to ninth thoracic nerves.

The spinalis cervicis.—A muscle of inconstant development which arises from the spines of the two upper thoracic and two lower cervical vertebræ and extends to the spines of the second to the fourth cervical vertebræ. The nerve supply is from the dorsal divisions of the lower cervical nerves.

Action.—To extend the vertebral column.

Variation.—There is great variation in the development of the spinalis muscles. Similar fasciculi are sometimes found in the lumbar region and in the cervical region sometimes extend to the skull.

D. Deep Medial Dorsal System

1. *Vertebro-occipital Muscle*

The semispinalis capitis (complexus) (fig. 381).—This muscle is usually separated from the semispinalis muscles of the back and neck by a well-marked septum and has a distinctive structure.

Origin.—(1) By long tendinous fasciculi from the tips of the transverse processes of the upper five or six thoracic vertebræ and of the seventh cervical vertebra; (2) by short fleshy processes from the articular processes and bases of the transverse processes of the third to the sixth cervical vertebræ; and (3) by delicate fleshy fasciculi from the spinous processes of the upper thoracic vertebræ.

Structure and insertion.—The slightly diverging fibre-bundles form a long, flat belly which is inserted, partly by means of an aponeurosis which covers the muscle laterally, into the lower

* According to Lickley, both sets of cervical intertransverse muscles are supplied by the anterior divisions of the spinal nerves.

surface of the squamous portion of the occipital, between the superior and inferior nuchal lines. There is often a transverse tendinous inscription across the muscle opposite the sixth cervical vertebra, and less frequently one between the upper and middle thirds of the muscle. These

FIG. 382.—THE FIFTH LAYER OF THE MUSCLES OF THE BACK, AFTER SEPARATING THE LONGISSIMUS AND ILIO-COSTALIS DIVISIONS.

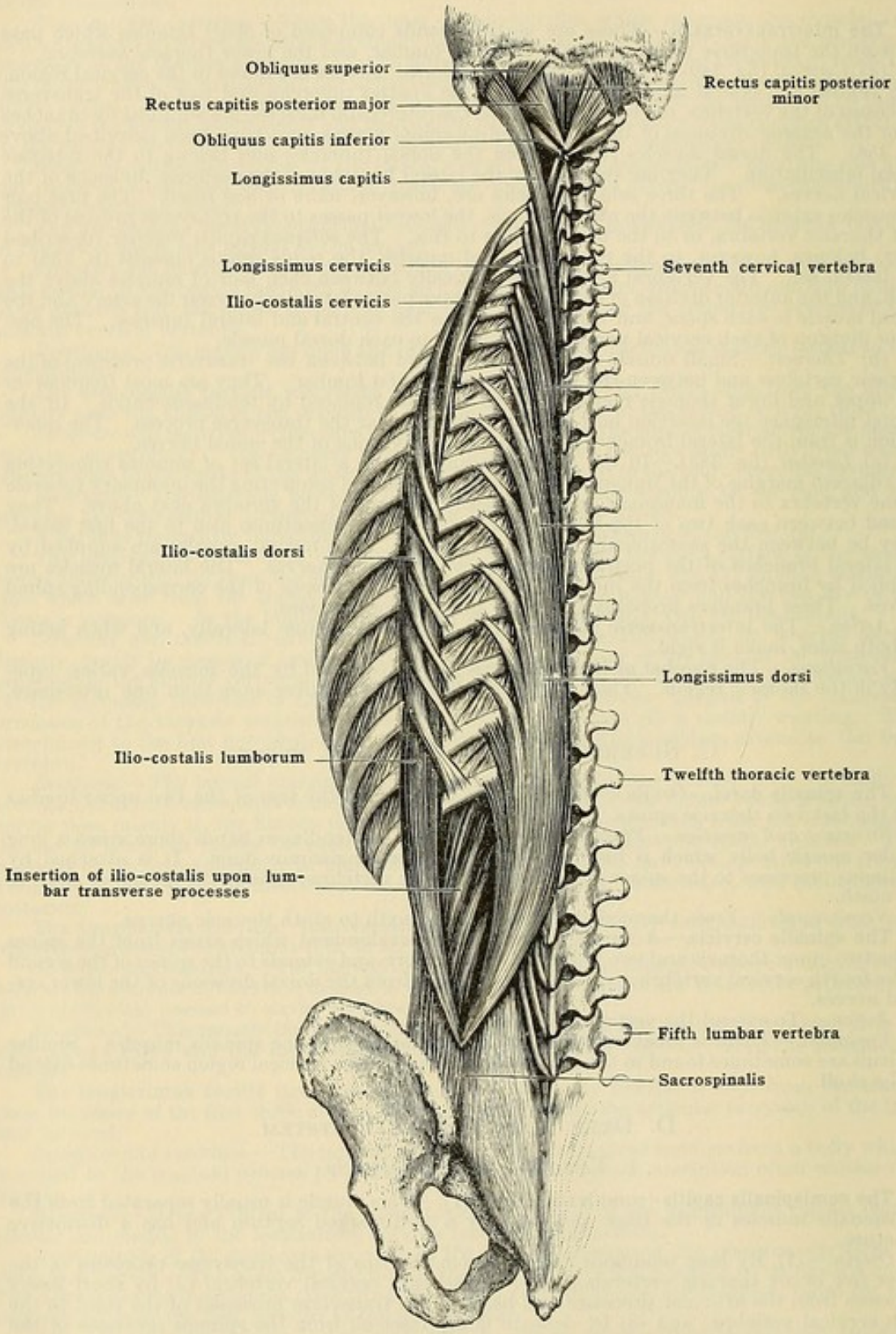

are best marked in the medial portion of the muscle, which comes from the thoracic vertebræ and is sometimes separately designated as the *spinalis capitis* (*biventer cervicis*).

Nerve-supply.—It is supplied chiefly by the medial branches of the posterior divisions of the first four or five cervical nerves. The muscle also gets some twigs from the lateral branches.

Relations.—It lies dorso-lateral to the suboccipital muscles and to the semispinalis cervicis. From this latter it is separated by a septum containing the descending branch of the occipital artery, the deep cervical artery, and the medial dorsal branches of the cervical nerves. It is covered laterally by the longissimus capitis (trachelo-mastoid), and dorsally by the splenius, and above the upper margin of the splenius by the trapezius.

Action.—To extend the head and to incline it slightly toward the same side.

Variations.—The origin of the muscle may extend to the eighth thoracic vertebra or merely to the first thoracic. It may be fused with the longissimus (transversalis) cervicis. A special fasciculus may run beneath the muscle from the upper thoracic vertebræ to the head. The origin from the spinous processes of the thoracic vertebræ is not constant. The part of the muscle arising from this origin may be looked upon as a spinalis capitis.

2. *Transverso-spinal Muscles*

The semispinalis dorsi et cervicis (fig. 383).—This superficial transverso-spinal muscle sheet extends from the twelfth thoracic to the second cervical vertebra. The fasciculi which compose it arise by short tendons from the backs of the transverse processes, and are inserted by short tendons into the spines.

The semispinalis dorsi.—*Origin.*—From the sixth to the tenth or twelfth thoracic vertebræ.

Insertion.—The upper four to six thoracic and the last two cervical vertebræ. The fasciculi extend over four to six vertebræ.

Nerve-supply.—Third to sixth thoracic.

The semispinalis cervicis.—*Origin.*—From the upper five or six thoracic vertebræ.

Insertion.—Into the fifth to the second cervical vertebræ. The fasciculi extend over four to five vertebræ.

Nerve-supply.—Third to sixth cervical.

Relations.—This muscle lies beneath the longissimus dorsi and the semispinalis capitis (complexus) and over the following musculature.

Variations.—A semispinalis lumborum is a muscle rarely found extending from the lumbar to the lower thoracic vertebræ.

The multifidus (fig. 383).—This second layer of transverso-spinal musculature extends from the sacrum to the second cervical vertebra. It is best developed in the lumbar region and least so in the thoracic.

Origin.—(1) From the groove on the back of the sacrum between the spines and the articular elevations, from the dorsal sacro-iliac ligaments, from the dorsal end of the iliac crest, and from the deep surface of the aponeurosis of the sacrospinal muscle; (2) from the mammary and accessory processes of the lumbar vertebræ; (3) from the backs of the transverse processes of the thoracic vertebræ; and (4) from the articular processes of the fourth to the seventh cervical vertebræ and the back of the transverse process of the seventh.

Insertion.—Spinous processes of the lumbar, thoracic, and lower six cervical vertebræ.

Structure.—The more superficial fasciculi arise by short tendinous processes, the deeper ones directly. The more superficial fasciculi extend to the fourth or fifth vertebra above, the middle to the third, and the deepest to the second above.

The rotatores.—These, the third layer of transverso-spinal muscles, extend from the sacrum to the second cervical vertebra. They are composed of short fleshy fasciculi which extend to the second vertebra above (*rotatores longi*) and to the first above (*rotatores breves*). The fasciculi arise from the back and upper borders of the transverse processes or their homologues, and are inserted into the laminæ of the preceding vertebræ. They are best developed in the thoracic region. Some authors consider the rotatores breves confined to the thoracic region. In the cervical region the fasciculi usually run from articular processes to the bases of the spines, in the lumbar region from the mammary processes to the caudal margin of the laminæ of the arches.

3. *The Interspinal Muscles*

The **interspinales** consist of short fasciculi which extend from the upper surface of the spine of each vertebra near its tip to the lower surface of the spine of the vertebra above. In the neck the muscles lie in pairs between the bifid extremities of the vertebræ. In the lumbar region they form broad bands attached to the whole length of the spinous processes and are separated by the interspinous ligaments. In the thoracic region they usually are undeveloped.

Nerve-supply of medial dorsal muscles.—These are all supplied by the medial branches of the posterior divisions of the spinal nerves.

Action of medial dorsal muscles.—These muscles extend the spinal column when acting on both sides. When acting on one side, they produce a movement of rotation toward the opposite side.

E. Suboccipital Muscles

(Figs. 382, 383)

The rectus capitis posterior major.—*Origin.*—From the upper surface of the spine of the epistropheus.

Structure and insertion.—The muscle-fibres diverge to form a broad triangular band which is inserted into the lateral half of the inferior nuchal line of the occipital bone and the area below it. Its insertion is immediately below that of the obliquus superior.

The rectus capitis posterior minor.—*Origin.*—From the upper part of the side of the posterior tubercle of the atlas.

Structure and insertion.—The fibre-bundles diverge to form a flat, triangular sheet inserted below the medial third of the inferior nuchal line of the occipital bone on the inferior surface of the squama occipitalis.

The obliquus capitis inferior.—*Origin.*—From the upper part of the side of the spine of the epistropheus (axis).

Structure and insertion.—The fibre-bundles form a fusiform belly which is inserted by a short tendon into the lower part of the tip of the transverse process of the atlas.

FIG. 383.—THE TRANSVERSO-SPINALIS.

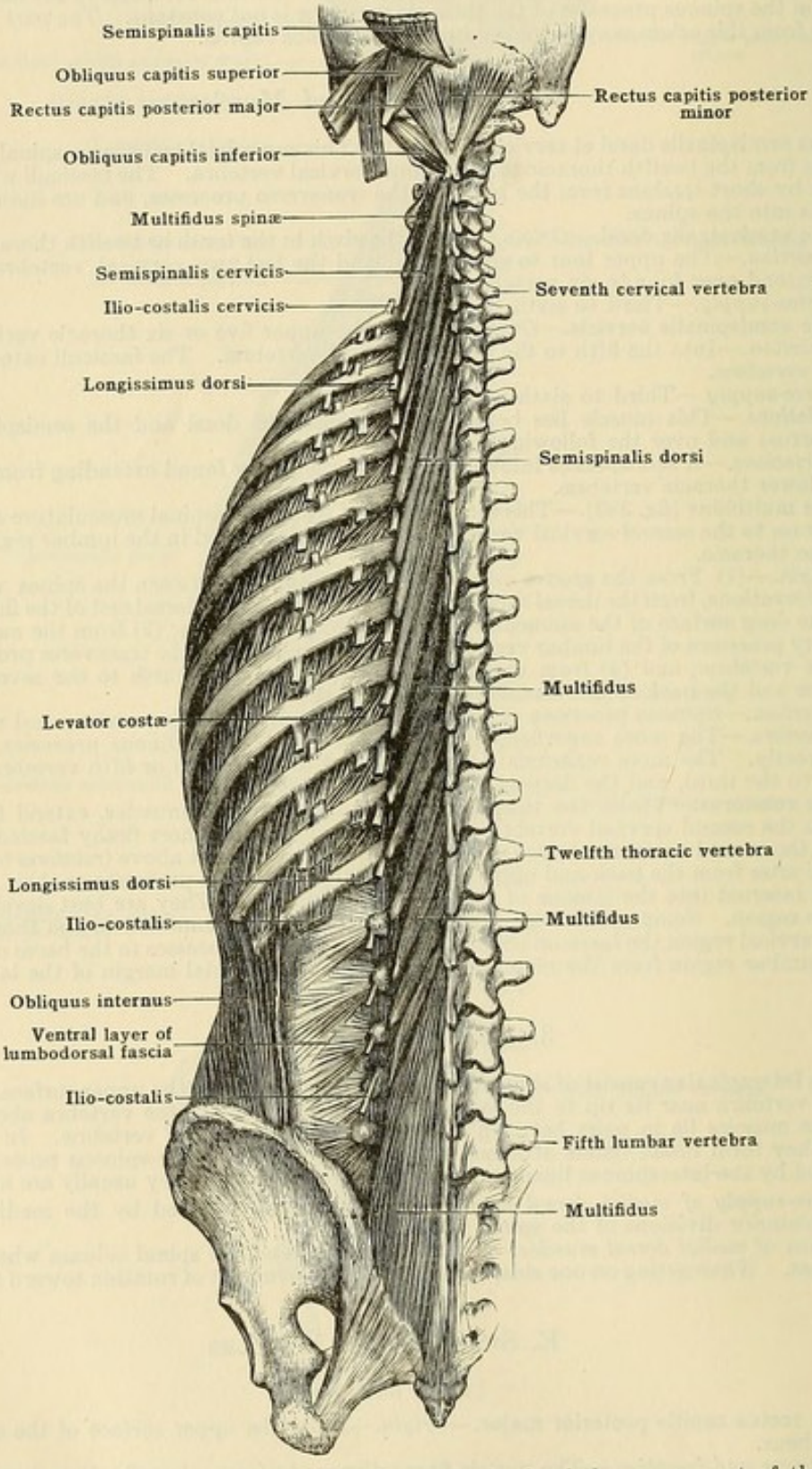

The obliquus capitis superior.—*Origin.*—From the back of the upper part of the transverse process of the atlas.

Structure and insertion.—The fibre-bundles diverge to form a flat, triangular muscle, inserted into the lateral third of the inferior nuchal line of the occipital bone, and above the lateral part of the insertion of the rectus capitis posterior major.

FIG. 384, A and B.—SECTIONS THROUGH THE LEFT SIDE OF THE TRUNK IN THE REGIONS SHOWN IN THE DIAGRAM.

The muscles of the body wall have been slightly pulled apart in order to reveal the relations of muscles, fasciæ, and aponeuroses. *a* and *b* in the diagram indicate sections A and B, fig. 351 (p. 352); a^2 and b^2, sections A and B, fig. 357 (p. 366); $a^{2'}$ and b^2, sections A and B, fig. 407 (p. 458):

1. Aorta. 2. Arteria mammaria interna. 3. Costa VI—a, cartilage. 4. Costa VII—a, cartilage. 5. Costa VIII. 6. Costa IX. 7. Costa X. 8. Costa XI. 9. Descending colon. 10. Diaphragm—a, costal portion; b, lumbar portion; c, sternal portion; d, centrum tendineum. 11. Fascia lumbodorsalis—a, anterior layer; b, posterior layer. 12. Fascia transversalis. 13. Flexura colica sinstra (splenic flexure). 14. Kidney. 15. Liver. 16. Linea alba. 17. Musculi intercostales externi—a, ligament. 18. Mm. intercostales interni. 19. M. ilio-costalis. 20. M. latissimus dorsi. 21. M. levator costæ. 22. M. longissimus dorsi. 23. M. obliquus abdominis externus. 24. M. obliquus abdominis internus. 25. M. psoas major. 26. M. quadratus lumborum. 27. M. rectus abdominis. 28. M. serratus posterior inferior. 29. M. subcostalis. 30. M. transversus thoracis. 31. M. transversus abdominis. 32. Mm. transverso-spinales. 33. M. trapezius. 34. Nervus lumbalis I. 35. N. thoracalis VI. 36. N. thoracalis VII. 37. N. thoracalis VIII. 38. N. thoracalis IX. 39. N. thoracalis X. 40. N. thoracalis XI. 41. N. thoracalis XII. 42. Sympathetic trunk—a, great splanchnic nerve. 43. Omentum majus. 44. Œsophagus. 45. Scarpa's fascia. 46. Spleen. 47. Stomach. 48. Ureter. 49. Vertebra lumbalis II. 50. Vert. lumbalis III. 51. Vert. thoracalis X.

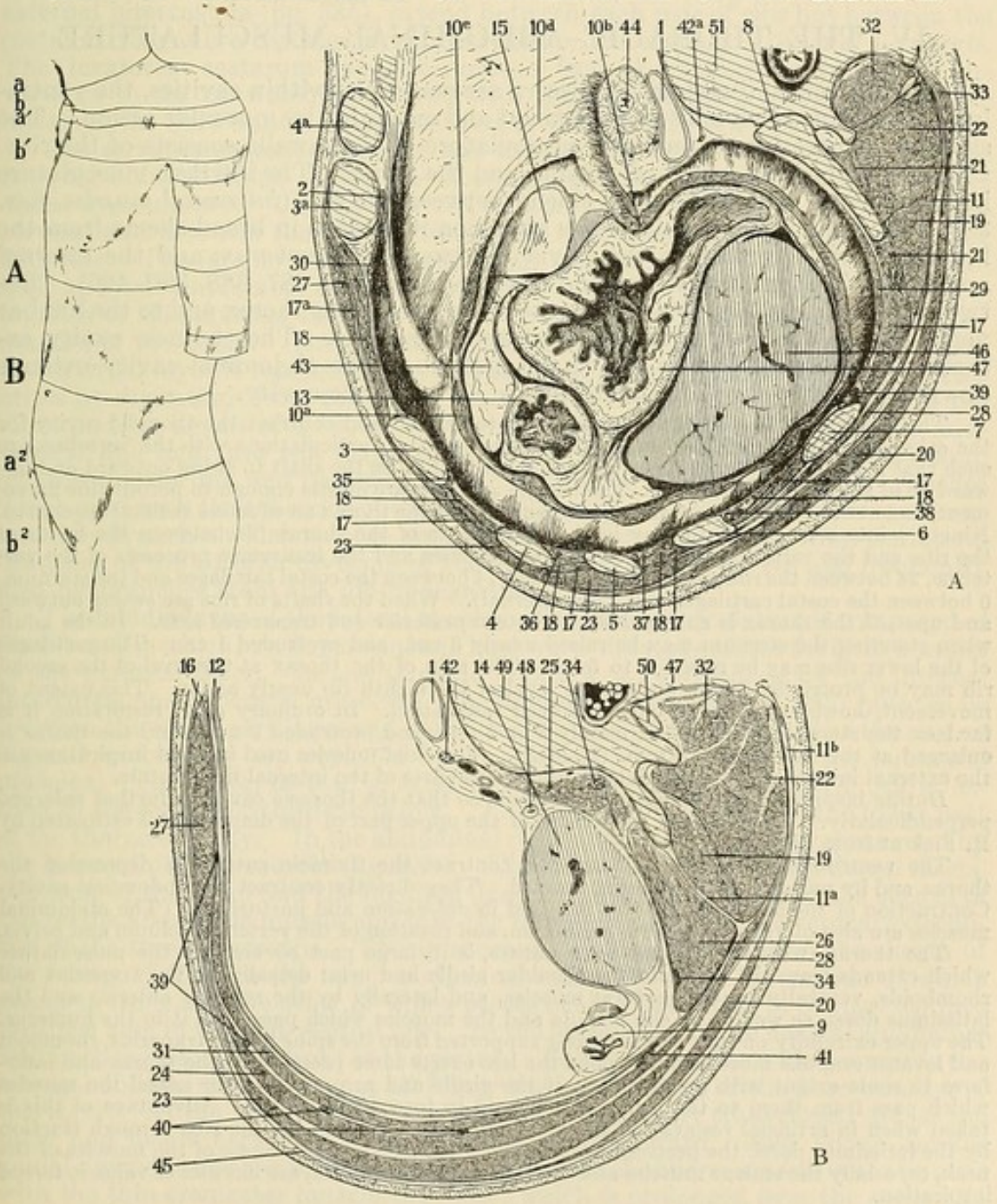

Nerve-supply.—These muscles are all supplied by the posterior branch of the suboccipital (first cervical) nerve. The branch to the two rectus muscles passes across the dorsal surface of the major rectus and supplies branches to the middle of the dorsal surface of each muscle. The branch to the superior oblique muscle enters the middle of the medial margin, that to the inferior oblique about the middle of its superior margin. The inferior oblique and major rectus muscles usually, the other muscles occasionally, receive branches from the second cervical nerve.

Relations.—The two oblique muscles with the rectus major serve to bound a small triangular space, the suboccipital triangle, through which pass the dorsal division of the suboccipital nerve and the vertebral artery. The two minor recti lie on the atlanto-occipital membrane in the upper part of the space bounded by the major recti. The muscles are covered medially by the semispinalis capitis (complexus), laterally by the longissimus and splenius capitis. In front of the two oblique muscles and the major rectus runs the vertebral artery. The great occipital nerve runs between the semispinalis capitis (complexus) and the inferior oblique and the two recti in a dense fatty connective tissue containing the extensive suboccipital venous plexus.

Action.—The rectus muscles and the superior oblique draw the head backward. The rectus major and the inferior oblique, when acting on one side, rotate the face toward that side.

Variations.—Each of these muscles may be doubled by longitudinal division. Accessory slips may connect the two recti with the semispinalis capitis. The **atlanto-mastoid** is a small muscle frequently found. It passes from the transverse process of the atlas to the mastoid process.

IV. THE THORACIC–ABDOMINAL MUSCULATURE

The thoracic and abdominal viscera are contained within cavities, the ventro-lateral walls of which may be contracted and expanded by muscular action. The skeletal support for the intrinsic musculature of these walls consists of the ribs, the sternum and the vertebral column and the pelvis. The intrinsic musculature in the thoracic walls is situated chiefly between the ribs (*intercostal muscles*, figs. 385, 386) while in the region of the abdomen it extends in broad sheets from the lower part of the thorax to the pelvis (the *quadratus lumborum* and the *external* and *internal oblique*, *transverse*, and *rectus* muscles, figs. 387, 388, 390, 406). Between the two cavities, attached to the lower part of the thorax and to the lumbar vertebræ lies the dome-shaped diaphragm (fig. 391). The thoracic cavity extends on each side slightly above the first rib. The abdominal cavity extends downward and backward into the pelvis, as the pelvic cavity.

The **function** of the intercostal muscles is to expand and contract the thoracic cavity for the sake of respiration. The shape of the ribs and their articulations with the vertebræ are such that a slight rotation of the neck of each rib will cause the shaft to swing outward and upward or in the reverse direction. The costal cartilages are elastic enough to permit this movement, and at the same time are strong enough to make the thorax an effective skeletal apparatus. Ninety joints are called into play in the movements of the thorax (24 between the heads of the ribs and the vertebræ, 20 between the tuberosities and the transverse processes of the vertebræ, 24 between the ribs and costal cartilages, 14 between the costal cartilages and the sternum, 6 between the costal cartilages and 2 intrasternal). When the shafts of ribs are swung outward and upward the thorax is enlarged in the antero-posterior and transverse axes. In the adult when standing the sternum may be raised nearly 3 cm., and protruded 1 cm. The cartilages of the lower ribs may be raised 4 to 5 cm. The side of the thorax at the level of the second rib may be protruded 3 cm., and at the level of the eighth rib nearly as far. This extent of movement, however, is found only in forced respiration. In ordinary quiet respiration it is far less, the sternum being raised merely 3 or 4 mm. and protruded 2 mm., and the thorax is enlarged at the side merely 5 mm. (R. Fick). The chief muscles used in quiet inspiration are the external intercostals and the intercartilaginous parts of the internal intercostals.

During inspiration the diaphragm contracts so that the thoracic cavity is further enlarged perpendicularly. The extent of movement of the upper part of the diaphragm is estimated by R. Fick at from 1½–3 cm.

The ventro-lateral abdominal muscles contract the thoracic cavity by depressing the thorax and by pushing the diaphragm upward. They directly contract the abdominal cavity. Contraction of the abdominal cavity is of aid in defecation and parturition. The abdominal muscles are also of value in flexion, abduction, and rotation of the vertebral column and pelvis.

The thorax, with its intrinsic musculature, is in large part covered by the musculature which extends from the trunk to the shoulder girdle and arm; dorsally by the trapezius and rhomboids, ventrally by the pectoral muscles, and laterally by the serratus anterior and the latissimus dorsi, as well as by the scapula and the muscles which pass from it to the humerus. The upper extremity on each side is largely supported from the spine by the trapezius, rhomboid and levator scapulæ muscles but it none the less exerts some pressure on the thorax and interferes to some extent with respiration. If the girdle and arm are fixed or raised the muscles which pass from them to the thorax are an aid in forced inspiration. Advantage of this is taken when in artificial respiration the arms are raised so as to lift the ribs through traction by the latissimus dorsi, the pectoralis muscles and the subclavius. Some of the muscles of the neck, especially the scalene muscles and the sterno-cleido-mastoid, are likewise of value in forced inspiration.

Expiration is produced not only by the part ofthe internal intercostals which lie between the bony ribs, and by the abdominal muscles, but also by the lumbar ilio-costales and by the quadratus lumborum.

The intrinsic muscles of the thorax and abdomen are derived from the twelve thoracic myotomes and the first one or two lumbar and are innervated by the corresponding nerves, while the musculature of the shoulder girdle and arm which covers the intrinsic muscles of the thorax is of cervical origin and is innervated by cervical nerves. The diaphragm is likewise of cervical origin and is innervated by the phrenic nerve from the cervical plexus.

The intrinsic muscles of the back extend over the thoracic musculature (external intercostals and levators of the ribs, fig. 383) and in turn are in part covered by muscles which extend dorsally from the thoracic region (posterior serrate muscles, fig. 380).

The intrinsic thoracic-abdominal muscles are composed laterally of three layers of sheet-like muscles.

In the **external layer** the fibre bundles run downward and ventralward. This layer is represented in the thoracic region by the external intercostal muscles, the levators of the ribs and the posterior serrate muscles. The fibre-bundles of the **external intercostals** (fig. 385), extend between each pair of ribs but between the costal cartilages are replaced by fibrous tissue, the *external intercostal ligaments.* The **levatores costarum** (fig. 383), extend from the transverse process of one vertebra to the rib which articulates with the next vertebra below and in some instances the fibre bundles are continued to the second rib below.

The **serratus posterior superior and inferior** (fig. 380), are derivatives of the external oblique which during development wander in part over the intrinsic dorsal musculature. The *superior serrate* arises from the spines of the last two cervical and first two thoracic vertebræ and is inserted into the second to the fifth ribs. The *inferior serrate* muscle arises from the spines of the last two thoracic and first two lumbar spines and is inserted into the last four ribs. The fibre-bundles of this muscles therefore take a direction opposite to that of the other muscles of the group. The muscles aid in inspiration. In the abdominal region the external layer is represented by the **external oblique** muscle (fig. 387). This arises by digitations from the last seven ribs and is inserted into the crest of the ilium and by means of a broad flat aponeurosis into the linea alba in the mid-ventral line and into the inguinal ligament below. The external intercostal, levatores costarum, and posterior serrate muscles are innervated from branches which arise near the tubercles of the ribs. The external oblique muscles are innervated by branches which in large part arise in conjunction with or from the lateral branches of the anterior divisions of the last seven thoracic nerves and frequently also by branches from the ilio-hypogastric.

The **middle layer** of the lateral thoraco-abdominal musculature is composed of fibre-bundles which run downward and backward obliquely across the fibre-bundles of the external layer. In the thoracic region it is represented by the internal intercostal and subcostal muscles. The **internal intercostal** (fig. 385) muscles lie between the costal cartilages and between the ribs as far dorsalward as the angles, beyond which they are replaced by membranous tissue and by the **subcostal muscles.** The latter, instead of extending from one rib to the next rib below, extend to the second or third rib below. They are best developed in the lower part of the thoracic cavity. In the abdominal region the middle layer is represented by the **internal oblique muscle** (fig. 388). This arises from the lumbo-dorsal fascia, the crest of the ilium and the inguinal ligament and is inserted into the sheath of the rectus abdominis muscle and into the inferior margins of the ventral extremities of the three lower ribs. The aponeurosis, which helps to form the sheath of the rectus, divides in the upper abdominal region into two layers, one of which passes in front and the other of which passes behind the rectus to be inserted into the linea alba in the mid-ventral line. In the lower third of the ventral abdominal wall both layers pass in front of the rectus. The fibre-bundles which compose the internal oblique muscles do not all follow the usual course of the fibre-bundles of this layer. At the level of the iliac crest they pass nearly transversely across the body and below here they slant downward and forward. Just above the inguinal ligament and medial to its centre the internal oblique muscle is continuous with the thin **cremaster muscle** (fig. 389), which is prolonged over the spermatic cord and the tunica vaginalis of the testis and epididymis in the male and over the

ligamentum teres in the female. The cremaster muscle is attached laterally to the inguinal ligament, medially to the outer layer of the sheath of the rectus near the insertion of the latter.

The **inner layer** of the thoraco-abdominal musculature is composed of fibre bundles which take a course transversely across the body. In the thoracic region it is represented by the **transversus thoracis** (fig. 386), a slightly developed muscle which arises from the costal cartilages of the third to sixth ribs and is inserted into the lower part of the sternum and into the xiphoid process. In the upper portion of the muscle the fibre-bundles extend obliquely downward and forward instead of transversely. In the abdomen this layer is represented by the **transversus abdominis** (fig. 390) which arises from the cartilages of the lower seven ribs, from the lumbo-dorsal fascia, the iliac crest and lateral part of the inguinal ligament and is inserted into the linea alba by means of an aponeurosis which lies behind the rectus in the upper two-thirds of the ventral wall of the abdomen and in front in the lower third. It is intimately fused with the aponeurosis of the internal oblique.

The main trunks of the anterior divisions of the last five or six thoracic nerves give rise to branches which supply the muscles both of the middle and inner layers of the lateral thoraco-abdominal musculature. In the abdominal region these trunks run in the main between the two layers. Some muscular branches are usually also supplied from the ilio-hypogastric and ilio-inguinal nerves. In the thoracic region the intercostal nerves run external to the subcostal muscles, through the substance of the costal part of the internal intercostal muscles, and internal to the parts of the internal intercostals which lie between the costal cartilages. Eisler includes the subcostal muscles and that part of the internal intercostals which lies internal to the nerve trunk, with the inner rather than with the middle layer of the thoracic musculature.

The **ventral part** of the muscular thoraco-abdominal wall is represented by a single muscle on each side, the rectus abdominis muscle, except just above the symphysis pubis where the rudimentary pyramidalis is usually found. The **rectus abdominis muscle** (fig. 388), is a band-like muscle which arises from the ventral surfaces of the fifth to the seventh costal cartilages and from the xiphoid process and is inserted into the superior ramus of the pubis. It is ensheathed by the aponeuroses of the lateral abdominal musculature described above. The component fibre-bundles run nearly parallel with the mid-sagittal line. Transverse inscriptions partially divide the muscles into segments. It is innervated by the last six or seven thoracic nerves. The **pyramidalis** (fig. 388) is a small muscle which arises from the superior pubic ramus and is inserted into the linea alba for about a third of the distance to the umbilicus.

The **lateral intertransverse muscles** of the lumbar region described on p. 417 probably belong to the ventro-lateral musculature of the trunk. The nerves supplying them come from the junction between the posterior and anterior divisions of the spinal nerves.

The **inguinal (Poupart's) ligament** and the **inguinal canal,** described in detail below, are of considerable practical interest because of the frequency of hernias in this region. In the quadrupeds the pressure of the weight of the abdominal viscera centres toward the umbilicus while in man it centres toward the ventral part of the line of attachment of the abdominal wall to the pelvis. The lower margin of the aponeurosis of the external oblique muscle is here strengthened to form the inguinal (Poupart's) ligament which extends from the anterior superior iliac spine to the pubic tubercle. Near the latter it is reflected (curves medialward) to the pubic crest forming the triangular **lacunar ligament** (Gimbernart's). The medial half of the inguinal ligament helps to bound a slit-like space, **inguinal canal** through which in the male the spermatic cord passes to the scrotum, and in the female, the round ligament passes to the labium majus. This canal begins on the inner side at the (internal) abdominal ring, which is situated above and medial to the centre of the inguinal ligament. The canal, which is about 4 cm. long, extends medialward and downward to the subcutaneous (external abdominal) ring, a slit-like opening in the aponeurosis of the external oblique just above the inguinal ligament. The canal is bounded ventrally by the aponeurosis of the ex-

ternal oblique and the cremaster muscle, below by the reflected portion of the inguinal ligament, dorsally by the transversalis fascia and above by the transversus, internal oblique, and cremaster muscles.

The **quadratus lumborum** (fig. 406), which extends from the twelfth rib to the ilium and ilio-lumbar ligament, is supplied by direct branches of the lumbar nerves in series with the nerves supplying the musculature of the abdominal wall. It will, therefore, be taken up with the intrinsic thoraco-abdominal muscles. It depresses the thorax and abducts and extends the spine. The psoas muscle, on on the other hand, which also lies at the back of the abdominal cavity, represents an extension of the intrinsic musculature of the limb to the spinal column (see p. 455).

The **diaphragm** (fig. 391), a dome-shaped muscle which is attached to the distal margin of the thorax and to the upper lumbar vertebræ, and separates the thoracic and abdominal cavities, arises in the embryo in the region of the neck, and maintains cervical relations through its innervation by the phrenic nerves, which spring one on each side usually from the third to fifth cervical nerves. It does not belong morphologically with the other muscles considered in this section, but is here included because of its physiological and anatomical relations and the convenience of treating it in connection with the intrinsic thoraco-abdominal muscles. A diaphragm completely separating the thoracic from the abdominal cavities is found only in the mammals. The central portion of the diaphragm is an aponeurosis or central tendon with a convex ventral and concave dorsal margin. Into this tendon is inserted the musculature which arises on each side from the xiphoid cartilage, the cartilages and tips of the last six or seven ribs and by means of three crura from the sides of the first four lumbar vertebræ.

In fishes and tailed amphibians the musculature of the body wall is composed of metamerically segmented musculature. In all higher vertebrates it is likewise at an early embryonic stage segmental, being composed of the ventro-lateral portions of the myotomes. The ventral ends of the myotomes give rise to a ventral longitudinal muscle which runs on each side of the body next the mid-line in front, and retains more or less of the primitive segmentation. The rectus abdominis and the infrahyoid muscles represent this system in man. Very frequently traces of the system may also be seen on the upper thoracic wall in the form of slender muscular and aponeurotic slips. The rectus muscle in man is usually developed from the last seven thoracic myotomes. The pyramidalis becomes split off from its lower end. The lateral part of the ventro-lateral portions of the thoracic myotomes usually gives rise to several strata of muscles which vary somewhat in different vertebrates, although quite similar among the mammals. In man the twelve thoracic and first two lumbar myotomes give rise to the lateral musculature of the thoraco-abdominal wall.

The quadratus lumborum represents the ventro-lateral portions of the lumbar myotomes with the exception of that portion of the first two which enter into the lateral abdominal musculature and of the fifth, which probably undergoes retrograde metamorphosis.

It will be noted that the abdominal wall is composed of musculature which has an origin chiefly from the thoracic myotomes. At an early stage of embryonic development both the thoracic and the abdominal viscera are covered by a non-muscular membrane. The myotomes extend into this from the thoracic region, and as the musculature is differentiated, it approaches the median line in front and extends distally to the pelvis. Owing to the rotation of the limbs the abdominal musculature is stretched ventrally over an area corresponding to the lumbar and sacral regions dorsally. The last part of the thoraco-abdominal wall to be furnished with musculature is that about the umbilicus. Occasionally the process fails to be completed in this region.

Each spinal nerve supplies primarily the musculature derived from the myotome which lay caudal to it, and at first the musculature lies wholly superficial to the nerves. With subsequent differentiation the metamerism is somewhat obscured by anastomosis of nerves and fusion of myotomes; and a part of the internal oblique layer and all the transverse layer of the lateral musculature comes to lie on the inner side of the main nerve-trunks.

FASCIÆ

The **fasciæ** and the topographical relations of the thoraco-abdominal muscles may be followed in the sections shown in figs. 357, 384, and 407.

Tela subcutanea.—As mentioned above, most of the intrinsic thoracic musculature is covered by other muscles, while the superficial layer of the abdominal musculature is subcutaneous. A panniculus adiposus, **Camper's fascia,** in which much fat may be deposited is usually easily distinguishable, especially in the lower part of the ventral wall of the abdomen, from a membranous fascial sheet which is loosely attached to the underlying fascial envelopment of the muscles. To this membrane has been applied the term **Scarpa's fascia.** Near the groin it is separated from the panniculus adiposus by blood-vessels and lymphatic glands. It is closely bound to the linea alba between the two rectus muscles, to the fibrous structures in front of the pubic bone, to the fascia lata below the inguinal ligament, and to the crest of the ilium.

Over the scrotum of the male and vulva of the female both layers of the tela subcutanea are continued. In the male the fat of the more superficial layer disappears and the two layers

blend with the fundiform (suspensory) ligament and fascia of the penis and the dartos and septum of the scrotum.

Muscle fasciæ and sheaths.—The posterior serrate muscles (fig. 380) are enveloped by two adherent layers of an aponeurotic sheet that extends as a single membrane between them and is attached lateralward to the ribs and medialward to the spines of the thoracic vertebræ. The membrane between the muscles may represent the rudiment of a primitive continuous muscle such as is found in some lower vertebrates. This membrane may usually be easily separated from the aponeurosis of the latissimus dorsi on its superficial surface and the lumbo-dorsal fascia beneath.

The intercostal muscles are covered by delicate, adherent membranes on each surface. The external intercostal muscles are continued as aponeurotic bands between the costal cartilages. These serve here as fasciæ for the internal intercostals.

FIG. 385.—THE INTERCOSTAL MUSCLES.

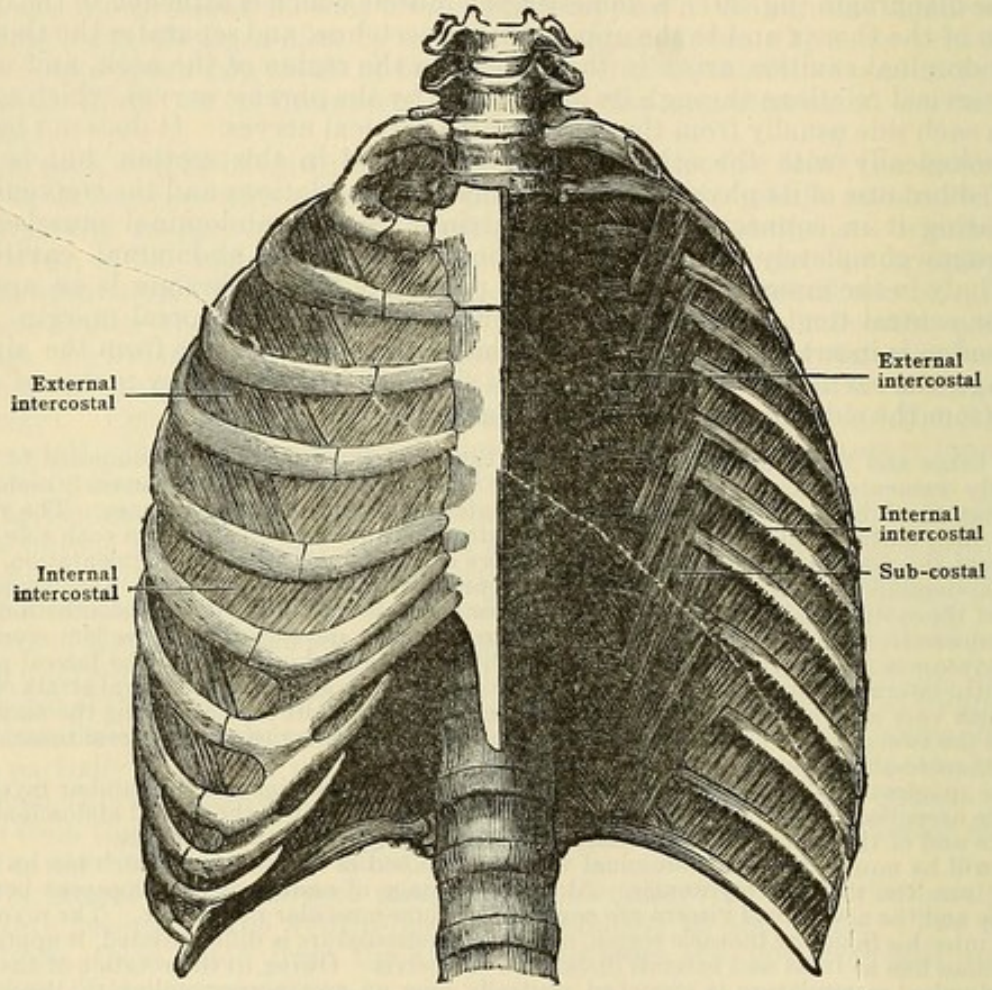

The external oblique muscle is covered externally by a dense, adherent membrane and internally by a more delicate membrane except where the muscle is attached to the ribs or fused with the external intercostal muscles. Ventrally and distally these membranes are fused beyond the fleshy portion of the muscle to the broad aponeurosis that serves to ensheath the rectus muscle and cover the lower part of the abdominal wall (fig. 389). Dorsally the membranes are in part attached to the ribs and in part are fused to form a membrane which becomes adherent to the deep surface of the latissimus dorsi in the thoracic region and to the lumbo-dorsal fascia in the lumbar region.

The internal oblique muscle and the transversus abdominis have similar membranous coverings which are fused to the aponeuroses of origin and insertion of these muscles. The membranes on the muscles are, however, much more delicate than that of the external oblique. More or less fusion between the two muscles with disappearance of the membranes covering the opposing surfaces takes place, especially in the lower part of the abdominal wall. The superficial muscle fasciæ of the external oblique and the fasciæ of the internal oblique are continued into the thin *cremasteric fascia* which covers the cremasteric muscle, spermatic cord and testis.

The diaphragm is covered on each surface by a more or less well-marked adherent membrane.

The **transversalis fascia** is a thin membrane which lies external to the peritoneum of the abdominal wall. It covers the peritoneal surface of the transversus muscle and its aponeurosis. Ventrally it is continued across the median line internal to the rectus abdominis. In the lumbar region the fascia divides at the lateral margin of the quadratus lumborum (fig. 384), one lamina of it passing dorsal to this muscle to be attached to the lumbo-dorsal fascia. The other lamina extends over the ventral surface of the quadratus and becomes fused with the psoas fascia. Proximally the transversalis fascia becomes fused with the fascial membrane adherent

to the diaphragm. In the region of the iliac fossa the transversalis fascia is reflected from the transversus muscle to the ilio-psoas fascia, with which it usually becomes fused. Sometimes, however, it may be traced as a very delicate membrane over the iliac artery and vein. As these vessels pass below the inguinal ligament a process from the transversalis fascia is usually reflected into their sheath.

The **sheath of the rectus** (figs. 384, 407) is formed externally in the upper portion of its extent by the aponeurosis of the external oblique which fuses distal to the costal margin with the external layer of the aponeurosis of the internal oblique. In the lower portion of the abdomen this fusion takes place nearer the linea alba than in the upper portion. In the lower third of its extent the rectus is covered ventrally by the fused aponeuroses of the two oblique muscles conjoined with that of the transversus. Internally the rectus is covered in the upper two-thirds of the abdomen by the inner layer of the aponeurosis of the internal oblique conjoined with that of the transversus and by the transversalis fascia. In the lower third of the abdomen the aponeurosis of the internal oblique, together with that of the transversus, passes in front of the rectus, leaving the rectus in this portion of its abdominal surface covered merely by the transversalis fascia and the peritoneum. The line which marks the lower limit of the dorsal ensheathment of the rectus by the aponeurosis of the transversus muscle is called the **linea semicircularis,**

FIG. 386.—THE MUSCLES ATTACHED TO THE BACK OF THE STERNUM.

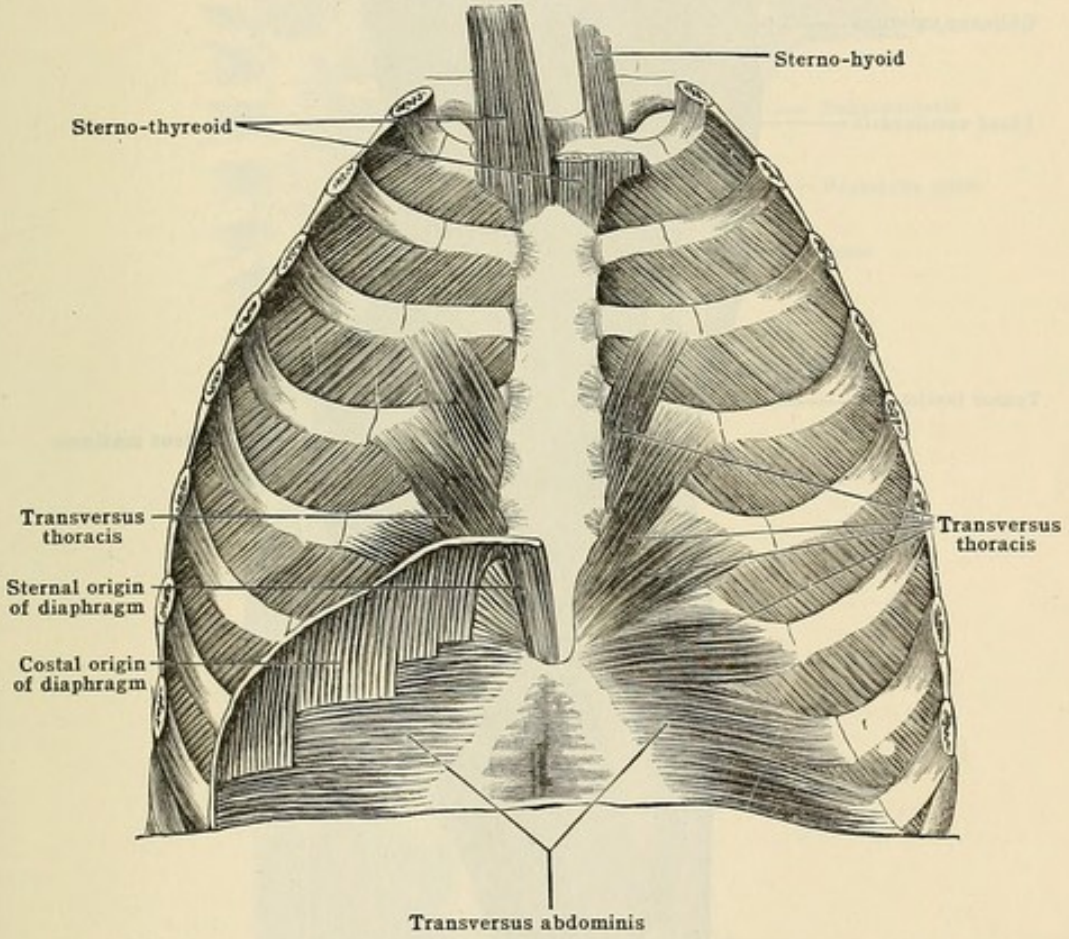

or fold of Douglas. Between the transversalis fascia and the rectus just above the pubis there is a space filled with loose connective tissue or with fat.

The pyramidalis lies beneath the ventral layer of the sheath of the rectus. From the latter it is sometimes separated by a distinct fascial layer.

Between the rectus muscles of each side the investing aponeuroses are firmly united into a dense tendinous band, the **linea alba** (fig. 389). This is broadest opposite the umbilicus. Above this it gradually grows narrower toward the xiphoid process to the ventral surface of which it is attached. From the tip of the xiphoid process it is often separated by a bursa. Toward the symphysis pubis it extends as a narrow line. Just above the symphysis it divides to be attached on each side to the tubercle (spine) of the pubis. Behind it broadens into the *adminiculum lineæ albæ* which is attached on each side to the pubis. The linea alba is composed mainly of the interlacing of the fibres which pass into it from the aponeurotic sheaths of the rectus abdominis. From it and Scarpa's fascia, a few centimetres above the symphysis, there arises a broad elastic band, the *fundiform ligament* (superficial suspensory ligament) of the penis, which sends a fasciculus on each side of the penis. Below the penis these fasciculi unite.* At the umbilicus there is a circular opening encircled by dense fibrous tissue and filled with a thick connective tissue, extending from the tela subcutanea to the subserosa.

* Alex. Hagenton has shown that the linea alba varies much in width. It is relatively wide in fat people and in fœtuses.

The *ventral layer* of the *lumbo-dorsal fascia* and its relations to the abdominal muscles also merit attention. This lies between the intrinsic dorsal musculature and the quadratus lumborum muscle and extends from the twelfth rib to the ilio-lumbar ligament. It is strengthened by the lumbo-costal ligament, which extends between the transverse processes of the first and

FIG. 387.—SUPERFICIAL MUSCULATURE OF ABDOMEN AND THIGH.

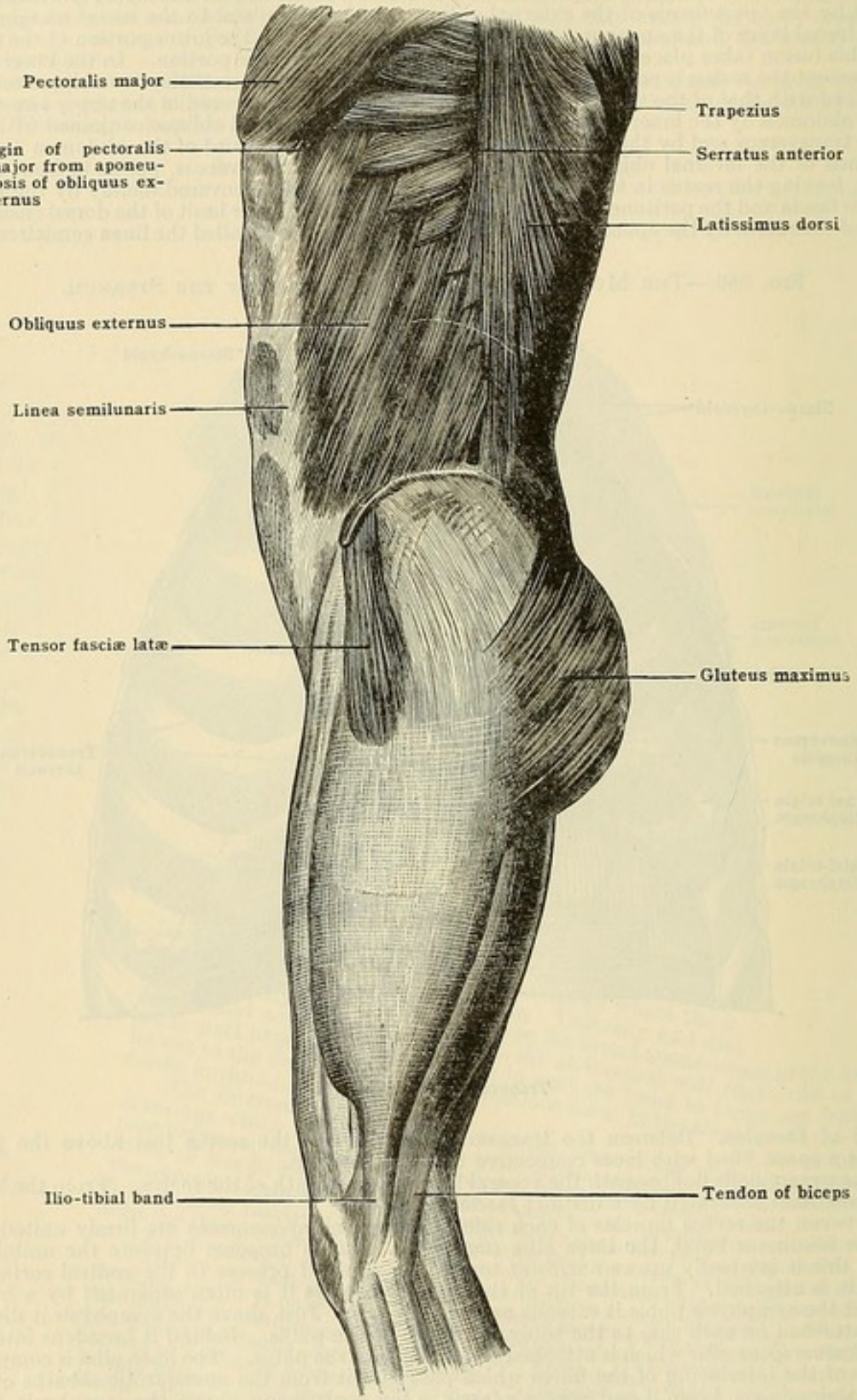

second lumbar vertebræ and the twelfth rib, and by fibrous processes which extend into it from the transverse processes of the lumbar vertebræ to which it is attached. With the lateral margin of this ventral layer the dorsal layer of the lumbo-dorsal fascia is fused. The dorsal aponeurosis of the transversus muscle is united to the lumbo-dorsal fascia at the line of junction of the ventral and dorsal layers. The internal oblique muscle, covered externally by a fascia continued dorsally from the external oblique, arises in part from the dorsal layer of the lumbo-dorsal fascia near the junction of the two layers.

The **inguinal ligament** (Poupart's ligament) (figs. 387, 389, 390) is a strong band which extends along the distal margin of the aponeurosis of the external oblique from the anterior superior iliac spine to the pubic tubercle. Internally the iliac fascia is fused to it. Distally the fascia lata of the thigh is attached to it. The deeper lateral abdominal muscles in part

FIG. 388.—THE PECTORALIS MINOR, OBLIQUUS INTERNUS, PYRAMIDALIS, AND RECTUS ABDOMINIS.

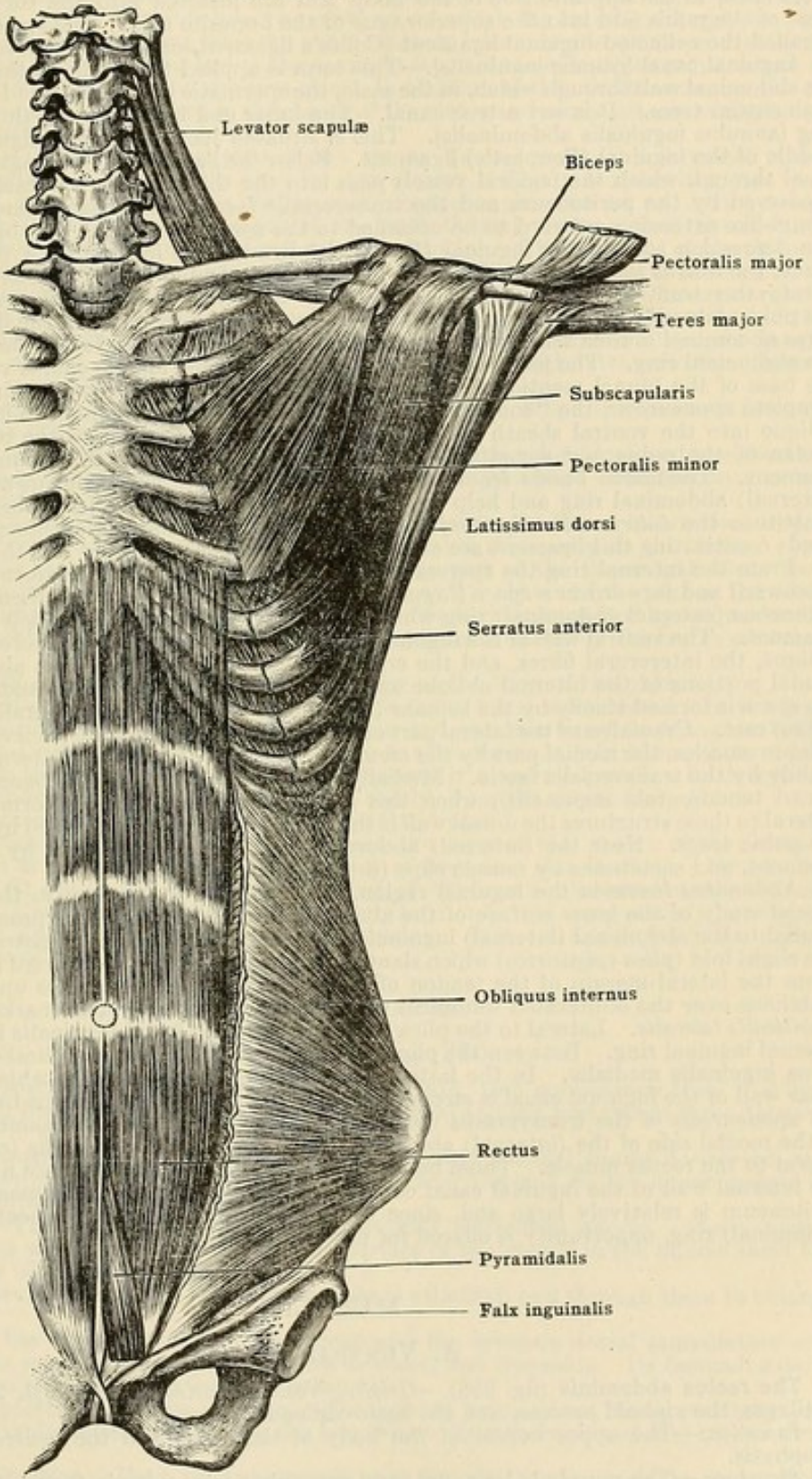

arise from it. Medially near the attachment of the ligament to the pubic tubercle (spine) diverging fibres are given off which pass inward and upward to the pecten (crest) of the pubis and give rise to the triangular **lacunar ligament** (Gimbernat's ligament). This is fused with the fascia of the pectineus muscle and bounds the femoral ring. Above the inguinal ligament near its medial extremity lies the external opening of the inguinal canal, the **subcutaneous** (external)

inguinal ring [annulus inguinalis subcutaneus]. This opening is formed by the diverging of the lower medial fibres which compose the aponeuroiss of the external oblique muscle. The superior fibres form the upper boundary, *superior crus*, of the ring and pass to the front of the symphysis pubis. The inferior fibres form the inferior boundary, *inferior crus*, of the ring and pass to the pubic tubercle (spine). Between these two fibre bands *intercrural* (intercolumnar) *fibres* arch about the lateral boundary of the ring and serve to strengthen the anterior and inferior walls of the inguinal canal. Some of the fibres of the superior crus, intermingled with other fibres cross to the opposite side of the body and are inserted into the tubercle (spine) and crest of the pubis and into the superior crus of the opposite side. The structure thus formed is called the **reflected inguinal ligament** (Colles's ligament, or triangular fascia).

Inguinal canal [canalis inguinalis].—This term is applied to the slit in the lower margin of the abdominal wall through which, in the male, the spermatic cord passes, and in the female, the ligamentum teres. It is not a true canal. The inner end begins at the (internal) **abdominal ring** [annulus inguinalis abdominalis]. This is situated just above and slightly medial to the middle of the inguinal (Poupart's) ligament. Below the ligament in this region lies the femoral canal through which the femoral vessels pass into the thigh. The (internal) abdominal ring is covered by the peritoneum and the transversalis fascia. The latter here sends a shallow funnel-like extension outward to be attached to the spermatic cord. The base of this funnel-like depression toward the inguinal (Poupart's) ligament is formed by a thickened band of tissue, the *tractus ilio-pubicus*. Medially and laterally the bundles of fibrous tissue which constitute this tract spread out fan-like, medially over the sheath of the rectus and toward the pubis, laterally over the transversus muscle and toward the crest of the ilium. The transverse abdominal muscle arises from the inguinal ligament nearly as far as the lateral margin of the abdominal ring. The fibre-bundles of this portion of the muscle course ventralward above the base of the funnel mentioned above and are inserted by tendons forming a more or less complete aponeurosis, the "conjoined tendon" [falx inguinalis], common to it and the internal oblique into the ventral sheath of the rectus abdominis muscle, into the tubercle, crest and pecten of the pubis and sometimes into the pectineal fascia or the lacunar (Gimbernat's) ligament. Tendinous bands from the transversalis muscle curve downward medial to the (internal) abdominal ring and help to strengthen the transversalis fascia here. These bands constitute the *interfoveolar ligament* [ligamentum interfoveolare, Hesselbachi]. The fibrous bands constituting this ligament are attached to the lacunar ligament and the pectineal fascia.

From the internal ring the spermatic cord (or in the female the ligamentum teres) passes downward and forward in a space (inguinal canal) about 4 cm. long and then through the subcutaneous (external abdominal) ring which has been described in connection with the inguinal ligament. The ventral wall of the inguinal canal is composed of the aponeurosis of the external oblique, the intercrural fibres, and the cremaster muscle. Laterally it is also covered by the caudal portions of the internal oblique and transversus muscles. The caudal wall or floor of the space is formed chiefly by the lacunar (Gimbernat's) ligament and laterally also by the ilio-pubic tract. Cranialward the lateral part of the space is covered by the transversus and internal oblique muscles, the medial part by the cremaster muscle. The dorsal (internal) wall is formed mainly by the transversalis fascia. Medially the lacunar (Gimbernat's) ligament and the conjoined tendon (falx inguinalis), when this is well developed, help to form the dorsal wall. Lateral to these structures the dorsal wall is thinner but may be strengthened by a well developed ilio-pubic tract. Near the (internal) abdominal ring it is strengthened by the interfoveolar ligament, and sometimes by muscle slips (interfoveolar muscle).

Abdominal fossæ in the inguinal region.—The hernias so frequent in this region make a special study of the inner surface of the abdominal wall of considerable practical importance. Medial to the abdominal (internal) inguinal ring the inferior internal epigastric vessels give rise to a slight fold (*plica epigastrica*) which slants medialward and upward toward the rectus muscle. From the lateral margin of the tendon of insertion of the rectus muscle upward toward the umbilicus over the obliterated umbilical artery there extends a better marked fold, the *plica umbilicalis lateralis*. Lateral to the plica epigastrica lies the **fovea inguinalis lateralis,** with the internal inguinal ring. Between the plica epigastrica and the plica umbilicalis lateralis lies the **fovea inguinalis medialis.** In the latter region the fascia transversalis which here forms the inner wall of the inguinal canal is strengthened by two longitudinal fibrous bands belonging to the aponeurosis of the transversalis muscle and described above, the ligament interfoveolare at the medial side of the (internal) abdominal ring, and the falx inguinalis (conjoined tendon) lateral to the rectus muscle. These bands vary in width. When they are narrow the part of the internal wall of the inguinal canal covered merely by the thin transversalis fascia and the peritoneum is relatively large and, since this region lies behind the subcutaneous (external abdominal) ring, opportunity is offered for direct inguinal hernia.

MUSCLES

A. Ventral Division

The rectus abdominis (fig. 388).—*Origin*—Ventral surface of the fifth to seventh costal cartilages, the xiphoid process, and the costo-xiphoid ligament.

Insertion.—The upper border of the body of the pubis and the ventral surface of the symphysis.

Structure.—The muscle is long, flat, and somewhat triangular in form. Cranialward it is broad and thin; caudalward it becomes thicker as it converges toward the insertion. The fibre-bundles of the muscle have a longitudinal course. It is crossed by several incomplete, zigzag, transverse tendinous bands, **inscriptiones tendineæ,** better developed on the ventral than on the dorsal surface of the muscle and intimately united to the ventral sheath of the rectus. One of these, corresponding segmentally to the tenth rib, is usually situated opposite the um-

bilicus. Another, corresponding to the ninth rib, is situated midway between this and the lower margin of the thoracic wall, and one corresponding to the seventh rib is found at the level of the xiphoid process. Between this and the one corresponding to the ninth rib an additional inscription is frequently found. Below the umbilicus an inscription corresponding with the eleventh rib is often found (30 per cent.). In these inscriptions many of the fibre-bundles have their origin and insertion. The thoracic attachments take place by means of band-like fasciculi which extend upward from the highest inscription, the fibre-bundles of these fasciculi being inserted by short tendinous bands. The pubic attachment of the muscle takes place by a short, thick tendon, usually divisible into two portions, of which the broader, lateral portion is inserted into a rough area extending from the pubic tubercle (spine) to the symphysis, while the more slender medial portion is attached to the fasciæ in front of the symphysis pubis, where its fibres interdigitate with those of the opposite side. In addition to the attachments mentioned, some of the fibre-bundles are attached to the sheath of the rectus and many, after interdigitating, terminate in the intramuscular framework.

Nerve-supply.—The anterior branches of the six or seven lowermost intercostal nerves enter the deep surface of the muscle near its lateral edge. The cutaneous branches pass obliquely through its substance, while the muscular branches give rise to an intramuscular plexus. As a rule, the chief ventral branch of the tenth thoracic nerve enters the substance of the muscle slightly below the umbilical transverse inscription. The branches of the eleventh and twelfth nerves enter at a lower level. The main branch of the ninth nerve enters slightly below the preumbilical inscription; the eighth nerve, between this and the lower margin of the thorax. Either the sixth or seventh nerve may supply the fasciculi of origin. In addition to the main branches other smaller branches of the nerves of the abdominal wall are also usually distributed to the muscle. Each segment, either directly or through intramuscular plexuses, has a supply from more than one spinal nerve.

Action.—To depress the thorax and flex the spinal column. When the thorax is fixed the rectus serves to flex the pelvis upon the trunk.

Relations.—It lies between the transversalis fascia and the tela subcutanea and is ensheathed by the aponeuroses of the lateral abdominal muscles, as above described. The epigastric artery runs on its deep surface.

Variations.—The rectus muscle varies in the number of its tendinous inscriptions and in the extent of its thoracic attachment. It may extend farther than usual on the thorax. Frequently aponeurotic slips or slips of muscle on the upper part of the thorax indicate a more primitive condition in which the muscle extended to the neck. Absence of a part or the whole of the muscle has been noted. The muscles of the two sides may be separated by a considerable interval in the neighbourhood of the umbilicus. The muscle is relatively thicker in men than in women.

The pyramidalis (fig. 388).—*Origin.*—Upper border of the body of the pubis.

Structure and insertion.—The fibre-bundles extend toward and are inserted into the linea alba for about a third of the distance to the umbilicus, and give rise to a flat, triangular belly.

Nerve-supply.—Usually through a branch of the twelfth thoracic, which may extend into the muscle through the rectus abdominis. Not infrequently a special branch extends into the muscle from the ilio-hypogastric or ilio-inguinal or, rarely, from the genito-femoral.

Action.—To draw down the linea alba in the median line.

Relations.—It lies between two laminæ of the anterior layer of the sheath of the rectus.

Variations.—It is missing in about 16 per cent. of instances (Le Double). Dwight has found it absent in 81 out of 450 males and in 60 out of 223 females dissected at the Harvard Medical School. It may extend upward to the umbilicus or be but very slightly developed. It may be double. In many of the mammals it is missing. It is well developed in the marsupials and monotremes.

B. Lateral Division

1. *Serratus Group* (fig. 380)

The serratus posterior superior.—*Origin.*—By a broad, thin aponeurosis from the ligamentum nuchæ and the spines of the last one or two cervical and the first two or three thoracic vertebræ.

Structure and insertion.—The fibre-bundles take a nearly parallel course downward and lateralward and give rise to a flat belly which ends by four fasciculi on the upper margin of the second to the fifth ribs, lateral to the ilio-costalis.

Nerve-supply.—Through branches from the first four intercostal nerves. These nerves give rise to a plexus which passes across the deep surface of the muscle in the middle third between the tendons of origin and insertion.

Action.—To elevate the ribs to which the muscle is attached, and through them to enlarge the thorax.

Relations.—It lies upon the wall of the thorax and the intrinsic dorsal musculature and beneath the levator scapulæ, rhomboids, serratus anterior, and trapezius. Its fasciculi extend on the ribs to those of the serratus anterior (magnus).

The serratus posterior inferior.—*Origin.*—Through an aponeurosis, fused medially and inferiorly with the lumbo-dorsal fascia, from the last two or three thoracic and first two or three lumbar spines.

Structure and insertion.—From the aponeurosis arise four flat bands which are successively attached to the inferior margins of the last four ribs, lateral to the ilio-costalis.

Nerve-supply.—From the ninth to eleventh intercostal nerves arise branches which form a plexus that extends across the deep surface of the muscle in the middle third between the tendons of origin and insertion.

Action.—To depress and draw outward the four lower ribs and through them to enlarge

the thorax. Together with the serratus posterior superior and the connecting aponeurotic fascia it aids in keeping the intrinsic dorsal muscles in place.

Relations.—It lies upon the intrinsic dorsal musculature, the lower dorsal part of the thorax, and the lumbo-dorsal fascia, and beneath the latissimus dorsi, the trapezius, and their aponeuroses.

Variations.—The fasciculi of both muscles vary in number and may be replaced by aponeurotic slips. Aberrant muscle fasciculi, **supracostales posteriores,** may be found in the fascia which connects the two muscles. In several of the lower mammals the two muscles are normally continuous.

2. *External Oblique Group*

The intercostales externi (fig. 385).—These muscles extend in the intercostal spaces from the tubercles of the ribs to the costal cartilagess. The intermediate muscles do not, however, often quite reach the cartilages. The first intercostal muscle may extend to the sternum. The others are continued through the intercostal region by thin aponeuroses, the **external intercostal ligaments,** the fibres of which have a direction corresponding to that of the muscle fibre-bundles. Dorsally the muscles are fused with the levatores, and ventrally the lower seven muscles are more or less fused with the corresponding fasciculi of the external oblique.

Origin.—From the lower margin of each rib external to the costal sulcus.

Structure and insertion.—The fibre-bundles take a parallel course obliquely forward and downward to the upper margin of the next rib. The proximal fibre-bundles are more oblique than the distal, and the muscles are best developed in the dorsal part of the intercostal spaces.

Nerve-supply.—By several branches from the corresponding intercostal nerves.

Action.—To elevate the ribs and enlarge the thorax.

Relations.—They are covered externally by the pectoral muscles, the serratus anterior, and serrati posteriores, the levatores costarum, the sacro-spinalis (erector spinæ), and the external oblique muscles. Internally they are separated by a slight amount of loose tissue from the internal intercostals, the membranes which continue these muscles medially, and from the subcostal muscles.

Variations.—When the twelfth rib is very small or is lacking, the eleventh intercostal muscle may be missing. When there is a supernumerary cervical or thirteenth thoracic rib, there may be an extra external intercostal muscle. Next to the first intercostal, the fourth most frequently reaches the sternum.

The levatores costarum (fig. 383).—These consist of a series of flat, triangular muscles, each of which *arises* from the tip and inferior margin of a transverse process and extends laterally with diverging fibre-bundles to be *inserted* into the dorsal surface of the rib below, from the tubercle to the angle. The first extends from the transverse process of the seventh cervical vertebra to the first rib. They increase successively in size from this to the last, which is attached to the twelfth rib. Those arising from the transverse processes of the eighth to the eleventh thoracic vertebræ send their more medial fibre-bundles across the rib below to join the lateral margin of the succeeding muscle (**levatores longi**). The levatores costarum are closely united to the external intercostals and are innervated by the intercostal nerves which pass forward in the corresponding intercostal spaces. The first muscle is innervated by the eighth cervical nerve.

Action.—To bend laterally and extend the spinal column.

Relations.—They are covered dorsally by the longissimus dorsi and the ilio-costalis.

Variations.—The first levator may be continued into the scalenus posterior. When greatly developed, the series of levators forms a serrate muscle.

The obliquus abdominis externus (fig. 387).—*Origin.*—By eight fleshy digitations from the external surface of the lower eight ribs immediately lateral to where they join the cartilages. The first five slips interdigitate with the serratus anterior (magnus), the last three with the latissimus dorsi.

Insertion.—(1) By a strong aponeurosis which extends over the rectus to the linea alba, where the more superficial fibres interdigitate across the median line, and to the inguinal (Poupart's) ligament; and (2) directly into the outer lip of the crest of the ilium. The aponeurosis over the rectus is usually partly fused with the aponeurosis of the internal oblique.

Structure.—The fibre-bundles which compose the flat fasciculi of origin diverge slightly as they pass forward and downward, and by fusion of their edges give rise to a flat sheet of muscle. The fasciculus taking origin from the fifth rib passes nearly directly ventrally, but the succeeding fasciculi incline somewhat downward, those from the seventh to the ninth ribs showing the greatest downward inclination. The lower margin of the fasciculus which arises from the seventh rib terminates opposite the umbilicus, that from the ninth rib extends toward the anterior superior spine of the ilium, and those from the last three ribs descend to the iliac crest. The first two fasciculi extend over the lateral margin of the rectus, the next two to its lateral edge. The fourth and fifth usually terminate along a line extending ventrally from the anterior superior iliac spine toward the rectus.

Nerve-supply.—The external oblique is supplied by rami from the lateral branches of the lower seven intercostal nerves and usually from the ilio-hypogastric as well. The rami of the first two or three nerves usually extend on the external surface of the muscle, while the others extend on the deep surface of the muscle as the cutaneous branches are passing through it toward the skin. The nerves of the external oblique take a more transverse direction than the fasciculi of the muscle. Thus the branch from the tenth intercostal nerve extends toward the umbilicus and that of the twelfth toward a point midway between the umbilicus and the symphysis pubis. The nerves have a segmental distribution corresponding with the primitive segmental condition of the muscle.

Action.—(1) To compress the abdomen; (2) to depress the thorax; (3) to flex the spinal

column; and (4) to rotate the column toward the opposite side. With the thorax fixed it serves to flex and rotate the pelvis.

Relations.—It lies superficial to the lower ventro-lateral margin of the thorax and the internal oblique muscle. It is partly covered by the latissimus dorsi muscle behind. Otherwise it is subcutaneous.

Variations.—It may have a more or less extensive origin from the ribs. Broad fasciculi not infrequently are separated by loose tissue from the main belly of the muscle either on its deep or superficial surface. Occasionally tendinous inscriptions are found. These transverse inscriptions are constant in many of the smaller mammals. The **supracostalis anterior** is a rare fasciculus sometimes found on the upper portion of the thoracic wall. It is usually supplied by branches of the upper thoracic nerves and seems to be a continuation upward of the external oblique muscle. In some prosimians the external oblique extends normally to the first or second rib.

3. *Internal Oblique Group*

The intercostales interni (figs. 385, 386, 388).—These extend in the intercostal spaces from the angles of the ribs to the sternal ends of the spaces. The upper and lower muscles are usually continued dorsally slightly beyond the angles of the ribs, while the intermediate muscles frequently do not quite reach them. Dorso-medially the internal intercostals are continued in

FIG. 389.—STRUCTURES OF INGUINAL REGION.

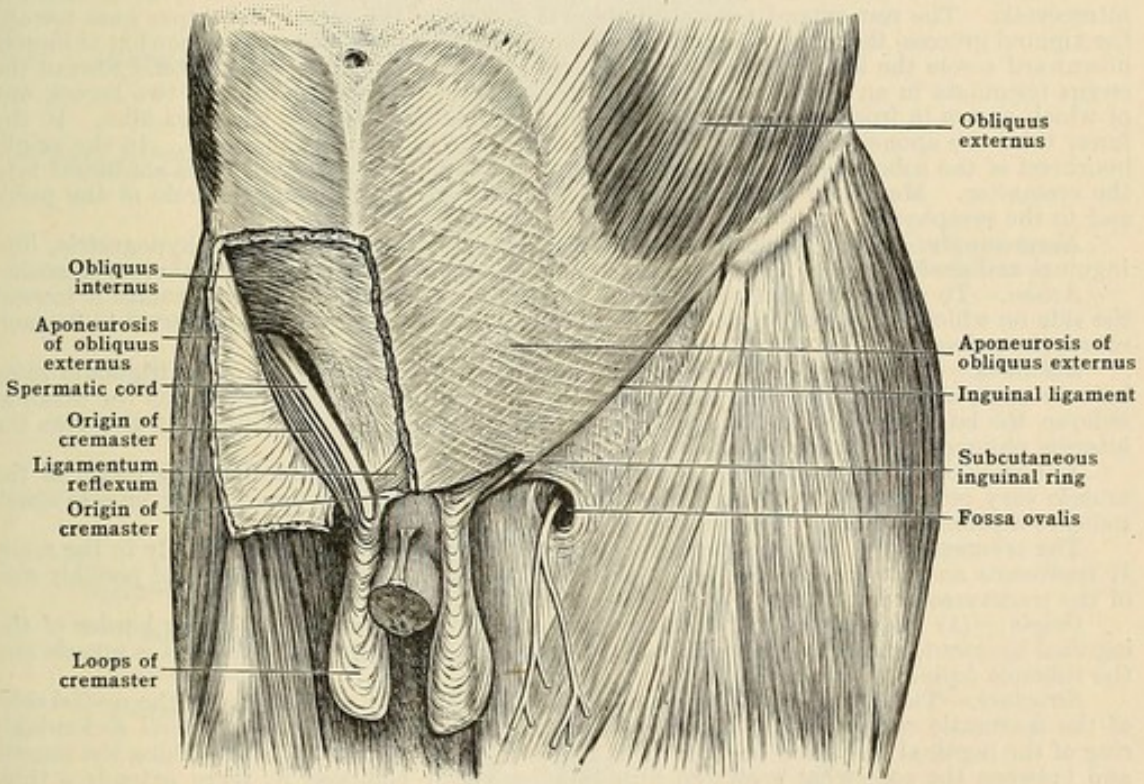

the form of thin fascial sheets across the inner surface of the external intercostals and become fused with the subcostals.

Origin.—Near the angles of the ribs they arise from the internal lip of the costal sulcus. More ventrally they arise mainly from the external lip of the sulcus, but also in part from the internal lip.

Structure and insertion.—The fibre-bundles take a parallel course downward and dorsalward to the upper margin of the rib below. They are less obliquely placed than those of the external intercostals. The muscles are thicker in front and grow thinner dorsally. They contain less fibrous tissue than the external intercostals.

Nerve-supply.—From numerous branches of the corresponding intercostal nerves.

Action.—Investigators disagree as to the functions. It is probable that the portions of the muscles between the ribs serve to contract, those between the costal cartilages to expand, the thorax.

Relations.—Between the ribs they are covered by the external intercostal muscles and between the costal cartilages by the external intercostal ligaments. Between the internal and external muscles there is some loose areolar tissue. Proximally, for a short distance, the intercostal nerve in each interspace runs between the external and internal intercostal muscles, but more distally it runs first in the substance of and then on the internal surface of the internal intercostal. Eisler distinguishes that portion of the internal intercostal muscle which lies external to the nerve as the intercostalis intermedius, that which lies internal as the true internal intercostal. The terminal branches of the first six nerves, however, pass through the muscle on their way to the skin, while the last six pass beneath the inferior margin of the thorax. Internal to the internal intercostal muscles lie the transversus (triangularis sterni) and sub-

costal muscles, the diaphragm, and the pleural membranes. The more distal internal intercostal muscles are continuous with the internal oblique and the subcostal muscles.

Variations.—The tenth and eleventh internal intercostal muscles normally are but slightly developed and often may be wanting. The internal intercostals of the first three spaces may extend to the vertebræ.

The subcostales (fig. 385).—These muscles are due to an extension over two or more intercostal spaces of those fibre-bundles of the internal intercostal muscles which lie in the proximal part of the interspaces. They arise near the angles of the ribs, and are usually well developed only in the lower part of the thorax. The component fibre-bundles keep the general direction of the internal intercostals, but they converge toward the tendons of insertion, which are attached in each case to the second or third rib below, between the angle and the neck.

Nerve-supply.—The main nerve of supply for each muscle comes from the intercostal nerve running below the rib from which the muscle takes origin.

Action.—To depress the ribs and contract the thorax.

Relations.—They lie on the inner side of the internal and external intercostals and the ribs, and are covered by the pleural membranes.

Variations.—They vary much in development. Next to the lower fasciculi, the fasciculi in the cranial part of the thorax are those usually best developed.

The obliquus abdominis internus (fig. 388).—*Origin.*—From the lumbo-dorsal fascia the intermediate lip of the ventral two-thirds of the iliac crest, and the lateral half of the inguinal ligament.

Structure and insertion.—From the origin the fibre-bundles radiate forward in a flat sheet. The most dorsal extend to the lower three ribs, where they become continuous with the internal intercostals. The rest extend toward the lateral margin of the rectus, the upper ones toward the xiphoid process, the intermediate toward the umbilicus, the lower ones somewhat obliquely downward across the lower part of the abdomen. The fibre-bundles which extend toward the rectus terminate in an aponeurosis which in its upper two-thirds divides into two layers, one of which passes in front of and the other behind the rectus muscle to the linea alba. In the lower third the aponeurosis passes as a single membrane in front of the rectus. In the neighbourhood of the subcutaneous inguinal (external abdominal) ring the muscle is continued into the cremaster. Medial to the ring some fasciculi are attached to the tubercle of the pubis and to the symphysis.

Nerve-supply.—From branches of the last three intercostal and the ilio-hypogastric, ilio-inguinal and genito-femoral (?) nerves as these pass between this muscle and the transversus.

Action.—To depress the thorax, flex the vertebral column, and bend and rotate it toward the side on which the muscle is placed. When the thorax is fixed, the muscle serves to flex and rotate the pelvis.

Relations.—It lies between the external oblique and the transversus. The **trigonum lumbale** (triangle of Petit) is an area, variable in size, between the posterior margin of the external oblique, the lateral margin of the latissimus dorsi, and the crest of the ilium. In this area the internal oblique is subcutaneous.

Variations.—The attachments and the extent of development of the fleshy part of the muscle vary considerably. Occasionally tendinous inscriptions are found in the muscle which indicate a primitive segmental condition.

The cremaster (fig. 389).—The cremaster muscle is found well developed only in the male. It represents an extension of the lower border of the internal oblique muscle and possibly also of the transverse over the testis and spermatic cord.

Origin.—(1) Lateral, thick and fleshy, from about the middle of the upper border of the inguinal ligament, and (2) medial, thin and tendinous, from the sheath of the rectus muscle and the tubercle (spine) of the pubis.

Structure.—The lateral head is applied to the lateral side, the medial head to the medial side, of the spermatic cord. Both pass with this through the subcutaneous (external abdominal) ring of the inguinal canal and become spread in loops over the testis. Ensheathing the muscle and between the somewhat scattered fibre-bundles which compose it, there extends a thin, membranous layer of connective tissue, the **cremasteric (Cowper's) fascia.**

Nerve-supply.—The genital nerve (external spermatic), usually joined by a ramus from the inguinal nerve, gives rise to branches which spread over the muscle.

Action.—To lift the testis toward the subcutaneous inguinal (external abdominal) ring.

Relations.—It is covered by the aponeurosis of the external oblique, the cremasteric fascia, the dartos, and the skin. It covers the spermatic cord and the testis.

Variations.—In the female the muscle is represented by a few fasciculi on the round ligament. It may arise wholly from the transversalis fascia or be somewhat fused with the transversus muscle. The latter condition is especially frequent in muscular individuals.

4. *Transversus Group*

The transversus thoracis (triangularis sterni) (fig. 386).—*Origin.*—By aponeurotic bands from the dorsal surface of the lower half of the body of the sternum and the xiphoid process.

Structure and insertion.—The muscle is composed of several flat, thin fasciculi, partly fibrous, more or less isolated, which are inserted by aponeurotic bands into the dorsal surface of the cartilages of the second or third to the sixth ribs, and occasionally also into the tips of the bony portions of the ribs. The lower fasciculus is closely related to the cranial margin of the transversus abdominis.

Nerve-supply.—By rami from the ventral portions of the second to the sixth intercostal nerves. These nerves give rise to a longitudinal plexus across the deep surface of the muscle near the middle of the constituent fasciculi.

Action.—To depress the ribs in expiration.

Relations.—The sternum, the costal cartilages, internal intercostal muscles, and the internal mammary vessels lie in front and the pleura and pericardium behind the muscle.

Variations.—It is an exceedingly variable muscle, both in the extent of its attachments and in the development of the individual fasciculi. The fasciculi vary in number from one to six. With this muscle Eisler would class the subcostal muscles and those portions of the internal intercostal muscles which lie internal to the intercostal nerves.

The transversus abdominis (figs. 386, 390).—*Origin.*—Directly from—(1) the inner side of the cartilages of the lower six ribs by dentations which interdigitate with the attachments of the diaphragm; (2) the internal lip of the iliac crest and lateral half of the inguinal ligament; and (3) through an aponeurosis from the lumbo-dorsal fascia.

Structure and insertion.—The fibre-bundles give rise to a broad, thin belly and take a nearly transverse course across the inner side of the abdominal wall. The most distal fibres, however, are inclined obliquely toward the pubis. The fleshy portion of the muscle terminates in a strong aponeurosis along a curved line, which extends above well under the rectus and emerges

FIG. 390.—TRANSVERSUS ABDOMINIS AND SHEATH OF RECTUS.

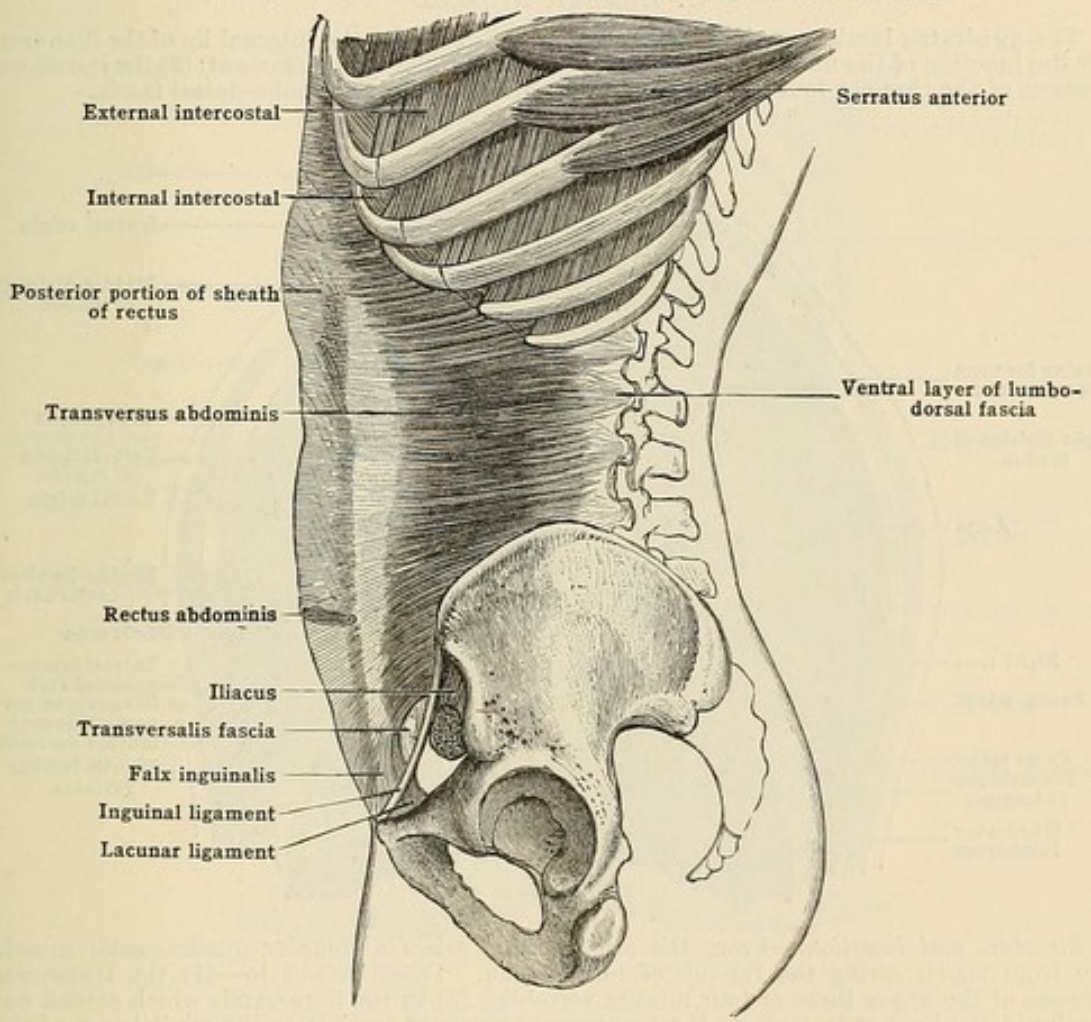

lateral to the rectus opposite the umbilicus, whence it extends toward the middle of the inguinal ligament. In the upper two-thirds of the abdomen the aponeurosis extends behind the rectus to the linea alba and fuses with the inner lamina of that of the internal oblique. In the lower third of the abdomen it extends in front of the rectus to the linea alba, and is here also fused with the aponeurosis of the internal oblique. Some of the fibres are continued into the aponeurosis of the muscle of the opposite side. The lower attachment of the muscle is somewhat more complex. The fibre-bundles here bend around the spermatic cord, on the medial side of which they are spread out to be attached to the lacunar (Gimbernat's) ligament and pectineal fascia, the pubis, and the sheath of the rectus. The attachment to the lacunar ligament and pectineal fascia takes place by means of an aponeurotic band, the more lateral fibres of which are dense and curve below the spermatic cord to the lacunar ligament and the pectineal fascia below this. This band is called the **interfoveolar ligament.** It is composed partly of bundles of fibres prolonged from the aponeurosis of the opposite transversus, and bounds the abdominal ring medially and below. Medially the transversus is united to the upper part of the os pubis, and to the sheath of the rectus by an aponeurotic band, the **falx inguinalis** (conjoined tendon). Between the interfoveolar ligament and the falx inguinalis the transversalis fascia forms the posterior wall of the inguinal canal. In this area a detached band of muscle-fibres is sometimes found. This is called the **musculus interfoveolaris.**

Nerve-supply.—The transversus is supplied with nerves by the last five or six thoracic and

the ilio-hypogastric, inguinal and genito-femoral nerves as these course forward between this muscle and the internal oblique.

Action.—The chief function is to compress the abdominal viscera. Through the portions extending between the lower margins of the thorax on each side it serves to contract the thorax and so may aid in expiration.

Relations.—It lies on the inner side of the lower ribs, the internal oblique and rectus muscles, and is covered on the deep surface by the transversalis fascia.

Variations.—It is very rarely absent. It shows considerable variation in the extent of its development. The **pubo-peritonealis** is a similar muscle which may pass from the pubic crest to the transversus near the umbilicus. The **pubo-transversalis** is a small muscle which may extend from the superior ramus of the pubis to the transversalis fascia near the abdominal inguinal ring. The **tensor laminæ posterioris vaginæ musculi recti abdominis,** essentially like the preceding, may extend from the inguinal ligament to the rectus sheath on the deep surface of the rectus muscle near the umbilicus. The **tensor laminæ posterioris vaginæ musculi recti et fasciæ transversalis abdominis** likewise extends from the transversalis fascia near the abdominal inguinal ring to the fold of Douglas.

C. Lumbar Muscle

The quadratus lumborum (fig. 406).—*Origin.*—From—(1) the internal lip of the iliac crest near the junction of the middle and dorsal thirds, and the iliolumbar ligament; (2) the transverse processes of the three or four lower lumbar vertebræ; and (3) the lumbo-dorsal fascia.

Fig. 391.—Diaphragm.

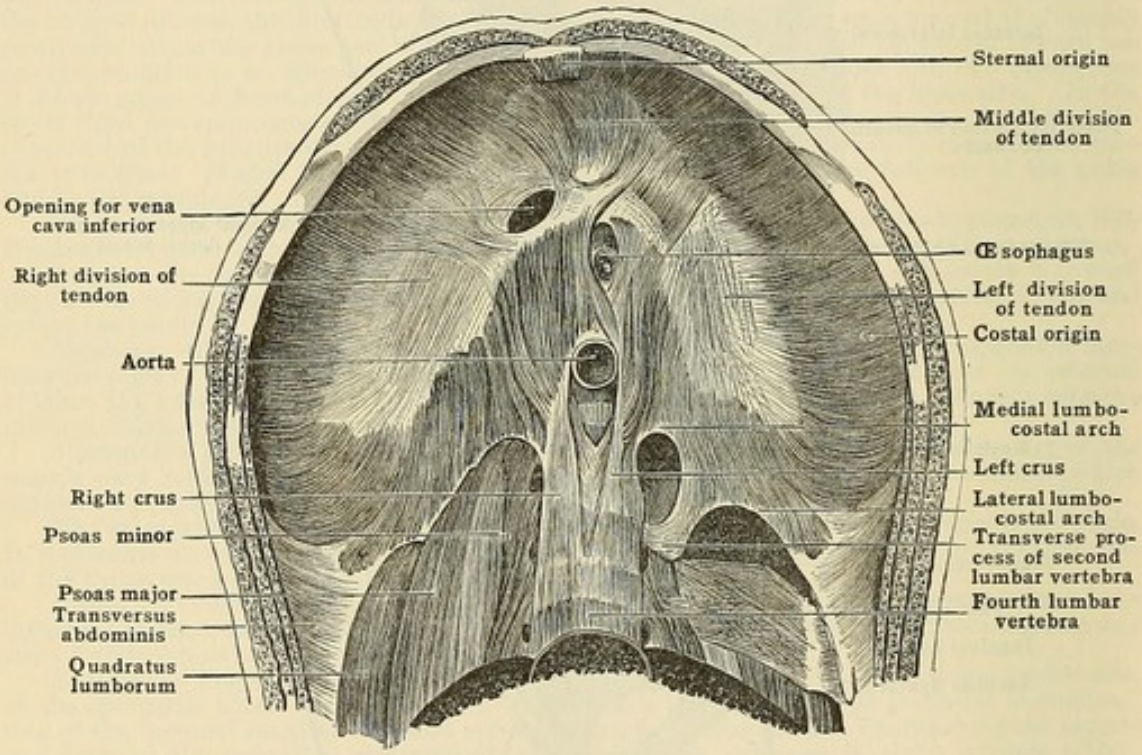

Structure and insertion.—From the origins there arises a complex quadrangular muscle belly from which spring the fasiculi of termination. These extend to—(1) the transverse processes of the upper three or four lumbar vertebræ; (2) to the fibre-bands which extend out laterally in the lumbar fascia from the transverse processes; and (3) to the medial part of the lower border of the twelfth rib.

Nerve-supply.—Through direct branches from the first three or four lumbar nerves.

Action.—It serves primarily to produce lateral flexion of the spinal column. When both muscles act together, they produce extension of the column. The muscle also serves to depress and fix the twelfth rib.

Relations.—It rests posteriorly on the lumbo-dorsal fascia and the transverse processes of the lumbar vertebræ. Its medial edge is partly covered by the psoas. In front of it also lie the kidney, the intestines, and the lumbar arteries and nerves. It is ensheathed by membranes continued over each surface from the transversalis fascia. Of these, the anterior is the better marked and is called the **lumbar fascia.**

Variations.—There is much individual variation in the internal structure of the muscle and in its attachments. Its insertion may extend to the eleventh rib.

The **psoas major** and **minor** belong essentially to the musculature of the lower limb and are there described (p. 455).

D. The Diaphragm

The diaphragm (figs. 386, 391).—This dome-shaped musculo-membranous sheet has, when seen from above, something of the outline of a kidney. It consists of a pair of muscles which arise one on each side from the thoracic wall and are inserted into a central tendon. Lateral

to the tendon the diaphragm projects higher into the thoracic cavity than in the central area. On the right, in moderate expiration, it extends in adults to the height of the medial extremity of the fifth rib, and on the left to the fifth interspace.

Origin.—On each side from—(1) the lower border and back of the xiphoid process and the adjacent aponeurosis of the transversus abdominis or from the tendinous arch extending from the tip of the xiphoid process to the cartilages of the fifth and sixth ribs, (*sternal portion*); (2) the lower border and inner surfaces of the cartilages of the seventh and eighth ribs, the cartilages and osseous extremity of the ninth rib and the osseous extremities of the last three ribs (*costal portion*); and (3) from the lumbar vertebræ (*lumbar portion*). The lumbar portion is divided somewhat irregularly into three crura, between which pass blood-vessels and nerves.

The **lateral crus** arises from the lateral surface of the bodies of the first two lumbar vertebræ and from fibrous thickenings of the fascia over the psoas and quadratus lumborum muscles. Of these, one, the **medial lumbo-costal arch** (internal arcuate ligament), extends from the body of the second lumbar vertebra to the transverse process of the same vertebra; the other, the **lateral lumbo-costal arch** (external arcuate ligament), extends from the tip of the transverse

FIG. 392.—THE PERINEAL MUSCLES IN THE FEMALE.

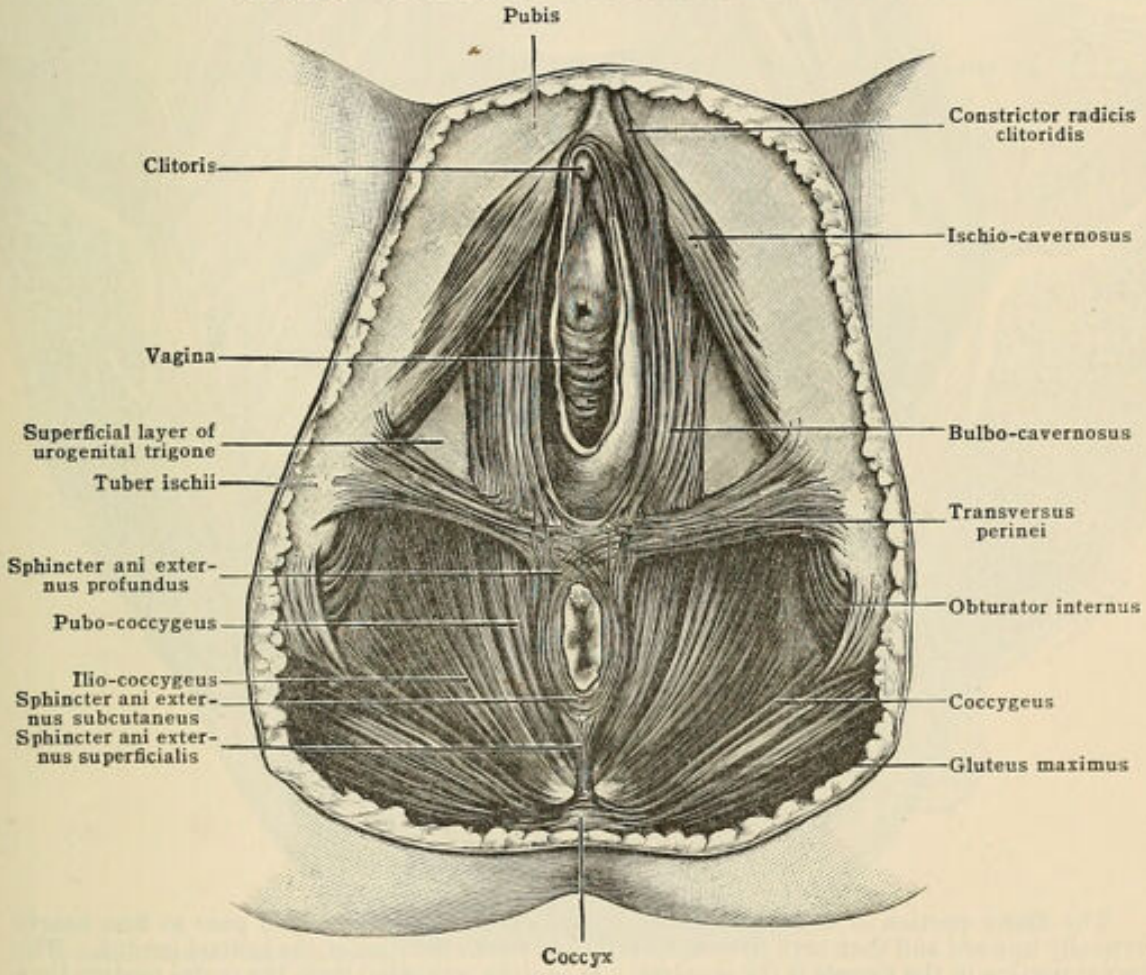

process of the second lumbar vertebra to the twelfth rib. The lateral crus is only inconstantly attached to this. The **intermediate crus** arises from the ventro-lateral surface of the body of the second lumbar vertebra from the sides of the bodies of the first two lumbar vertebræ and from the intervening discs. The **medial crus** arises from the front of the bodies of the third and the fourth lumbar vertebræ. On the left side it usually extends only to the third vertebra, and it does not always extend to the fourth on the right. The extremity and medial margin of this crus are tendinous, the lateral portion fleshy. On the second, third, and fourth, and the lower part of the first lumbar vertebræ the medial crus of each side is separated from its fellow by the **hiatus aorticus** (for the aorta and thoracic duct). Over the first lumbar vertebra they are fused by a process which extends from the right crus into the lower ventral surface of the left. Above here the right crus may be divided into two parts, one of which, fused with the left crus, passes on the left of the **hiatus œsophageus**, while the other passes on the right. Sometimes the hiatus œsophageus lies between the right and left crura. Frequently the left crus gives off a slip which passes to the ventral surface of the right below the hiatus.

The **costal portion** arises by a series of dentations which do not correspond perfectly in number with the ribs. Some costal cartilages have two dentations attached to them. It interdigitates with the transversus abdominis but in part arises from tendinous arches which bridge the origin of the transversus in the last three interspaces.

Structure and insertion.—The central tendon has somewhat the shape of a trifoliate leaf,

the place of the stem being taken by the region occupied by the vertebral column, one leaflet lying on each side of this and one in front. The ventral part is usually placed somewhat to the left and is more or less completely fused with the left leaflet. Between the ventral and the right leaflets there is a large opening through which passes the inferior vena cava, the **foramen venæ cavæ.** The leaflets are fused in front and behind this.

FIG. 393.—VENTRAL COCCYGEAL MUSCLES (After Eisler.)—1. M. sacrococcygeus anterior. 2. M. coccygeus. 3. M. piriformis. 4. M. obturator internus. 5. Fascia iliaca, above the iliopsoas. 6. Fibrocartilago intervertebralis lumbosacralis. 7. Ventral trunk of first sacral nerve. 8. Sacral plexus.

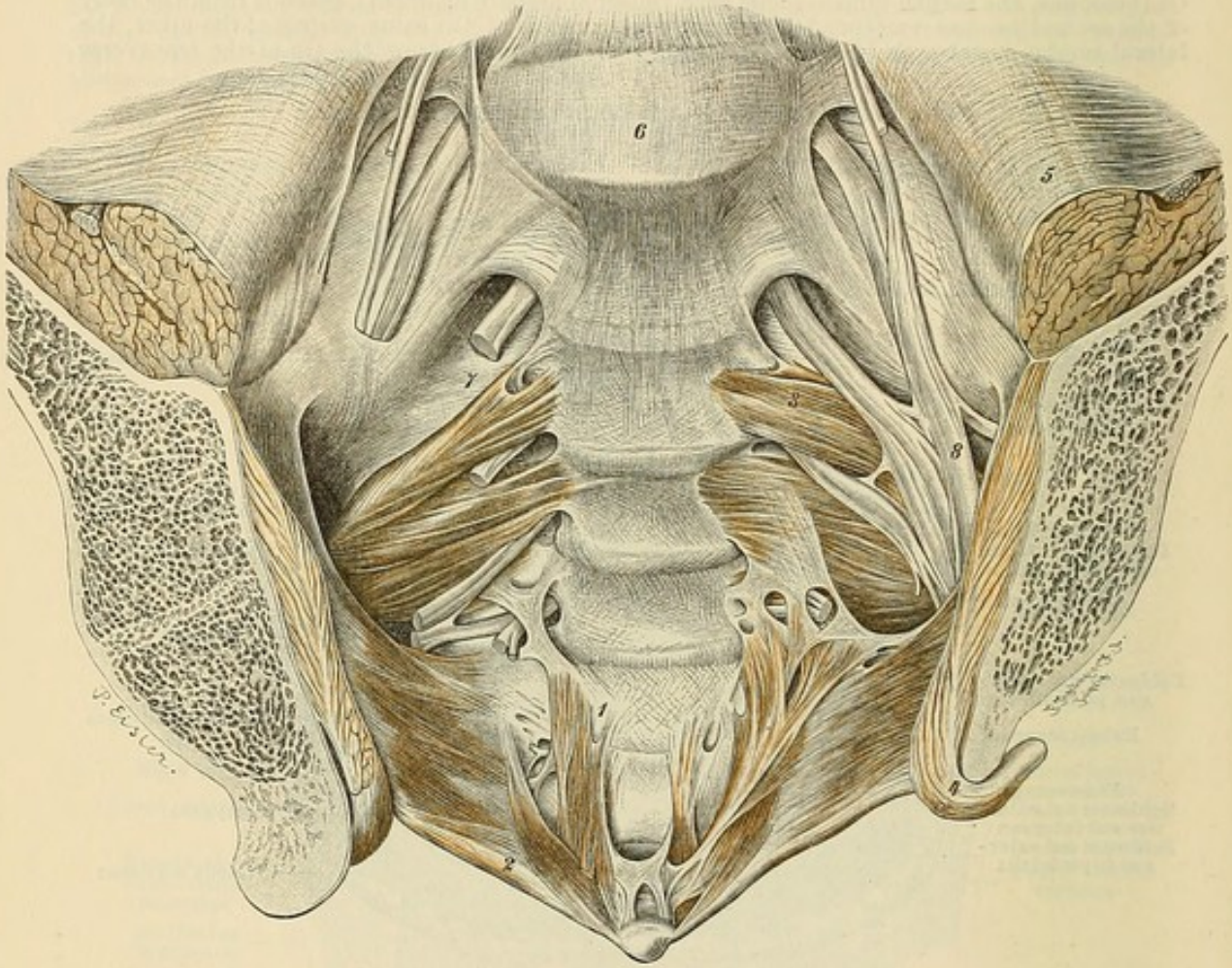

The fleshy portion of the muscle is composed of fibre-bundles which pass at first nearly vertically upward and then arch over to be attached to the margins of the central tendon. The sternal portion of the muscle is the shortest. It is often separated from the costal portion by a small space through which the superior epigastric vessels pass.

Nerve-supply.—From the phrenic nerves, one of which arises on each side from the third to the fifth cervical nerves. Each nerve penetrates the diaphragm lateral to the central tendon and breaks up into an extensive plexus on the inferior surface of the muscle. Some of the lower intercostal nerves also contribute to the sensory innervation of the margin of the muscle and possibly also slightly to the motor innervation. The sympathetic nerves furnish fibres for the blood-vessels.

Action.—To enlarge the thoracic cavity and thus cause inspiration. According to R. Fick, however, the diaphragm plays a less important part in inspiration than is usually assumed for it. The middle part of the central tendon is united to the pericardium and through this to the cervical fascia, and is, therefore, not very movable. In the contraction of the muscle it is the dorsal and lateral portions which in the main are flattened. The diaphragm aids in defecation, parturition and vomiting, by the pressure it exerts on the abdominal viscera. It also acts as a constrictor of the œsophagus.

Relations.—Above lie the heart and the lungs; below lie the liver, stomach, duodenum, pancreas, spleen, kidneys, and suprarenal bodies.

Variations.—The sternal portion of the muscle is frequently absent. Infrequently the diaphragm is incompletely developed dorsally on the left side. This condition is rarer on the right side. The extent of the various insertions of the diaphragm shows considerable individual differences. The vertebral portion of the muscle may be slightly fused with the psoas or with the quadratus lumborum. Some fusion of the ventral portion of the muscle with the transversus

thoracis has also been seen. Small fasciculi may pass to neighbouring structures: the œsophagus, stomach, liver, mesentery, etc. Muscle fasciculi are frequently found in the central tendon.

V. MUSCULATURE OF THE PELVIC OUTLET

In order to understand the musculature of the pelvic outlet it is necessary first to consider briefly the structure of the pelvis. It is bounded laterally and in front by the ilium below the terminal (ilio-pectineal) line, the ischium and the pubis, and by the obturator membrane and the sacro-spinous (small sciatic), sacro-tuberous (great sciatic) and the interpubic ligaments. The pubis, ischium and the obturator membrane are covered by the obturator internus muscle (figs. 392, 401) which here takes its origin and which converges toward and passes through the lesser sciatic notch on its way to its insertion on the great trochanter of the femur. The piriformis muscle (figs. 393, 396), which arises from the sides of the pelvic surface of

FIG. 394.—THE MALE PERINEUM. (Modified from Hirschfeld and Leveillé.)

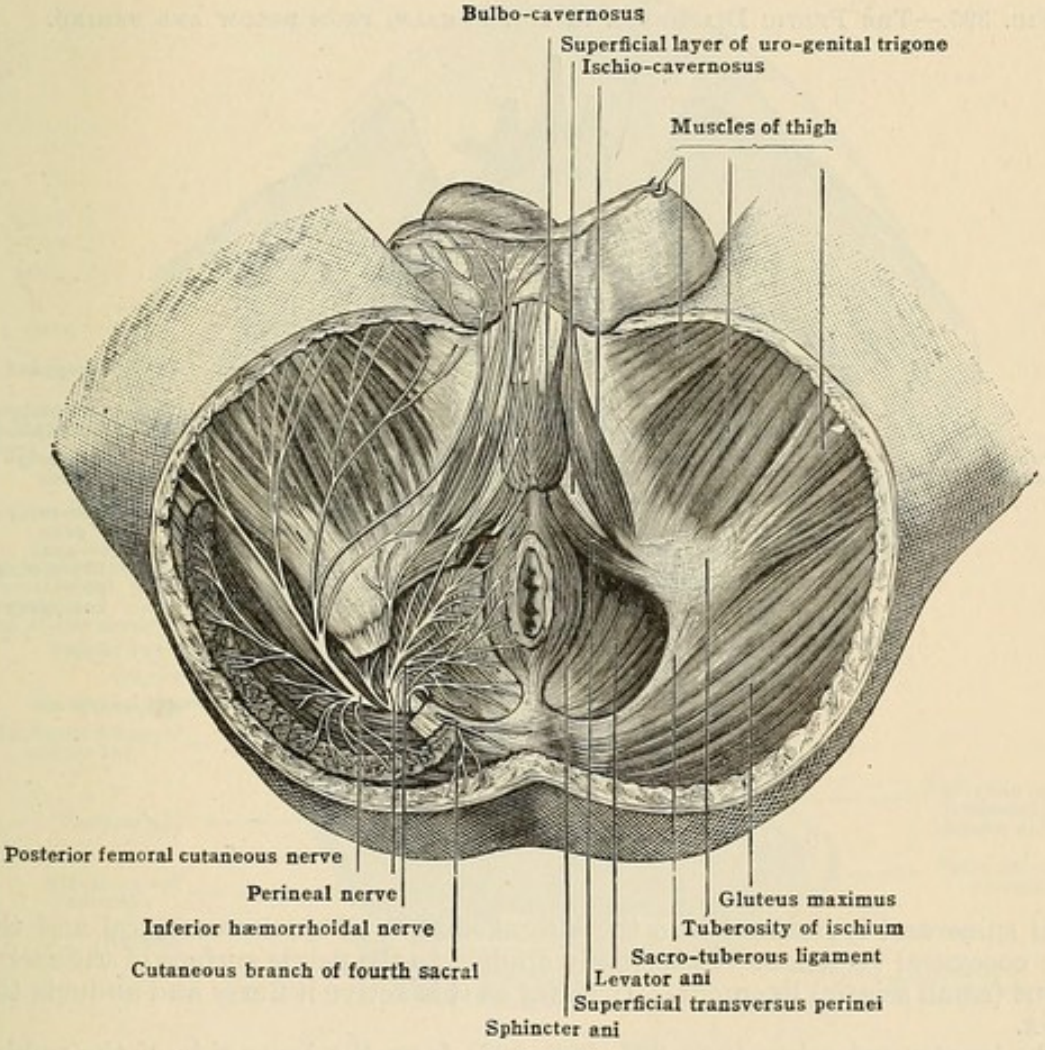

the sacrum, from the posterior border of the great sciatic notch and the neighbouring part of the sacro-tuberous (great sciatic) ligament nearly fills up the great sciatic notch on its way to its insertion on the great trochanter. The walls of the pelvis are thus padded by muscles which belong to the limb. The muscles are covered by fascia best developed over the obturator internus muscle as the *obturator fascia*. The gluteus maximus muscle (figs. 392, 394, 400, 401), which arises from the back of the ilium, the sacrum, and the coccyx, and is inserted into the femur and the fascia of the thigh overlaps to some extent the sacro-tuberous ligament, and in the standing position the tuberosity of the ischium so that its lower margin forms an accessory boundary to the pelvic outlet.

The outlet of the pelvis thus bounded by bone, ligaments and by muscles belonging to the lower extremity presents two triangles (figs. 392, 394), an anterior or urogenital triangle, with the base between the two ischial tuberosities and the apex below the symphysis pubis, and a posterior or rectal with the base between the ischial tuberosities and the apex at the coccyx which projects into it here. The outlet is closed by a special musculature divisible into three groups of muscles and fascia; those of the pelvic diaphragm and anus, those of the urogenital diaphragm, and those of the external genitalia.

The *pelvic diaphragm* [diaphragma pelvis] extends from the upper part of the pelvic surface of the pubis and ischium to the rectum which passes through it to be surrounded by the external sphincter. The urogenital trigone or *urogenital diaphragm* [diaphragma urogenitale] lies between the ischio-pubic rami superficial to the pelvic diaphragm and surrounds the membranous urethra and in the female also the vagina. The *external genital* muscles lie superficial to the trigone.

The muscles of the **pelvic diaphragm** are two in number on each side, the coccygeus, and the levator ani (figs. 395, 396, 397). The **coccygeus** arises from the

FIG. 395.—THE PELVIC DIAPHRAGM IN THE FEMALE, FROM BELOW AND BEHIND.

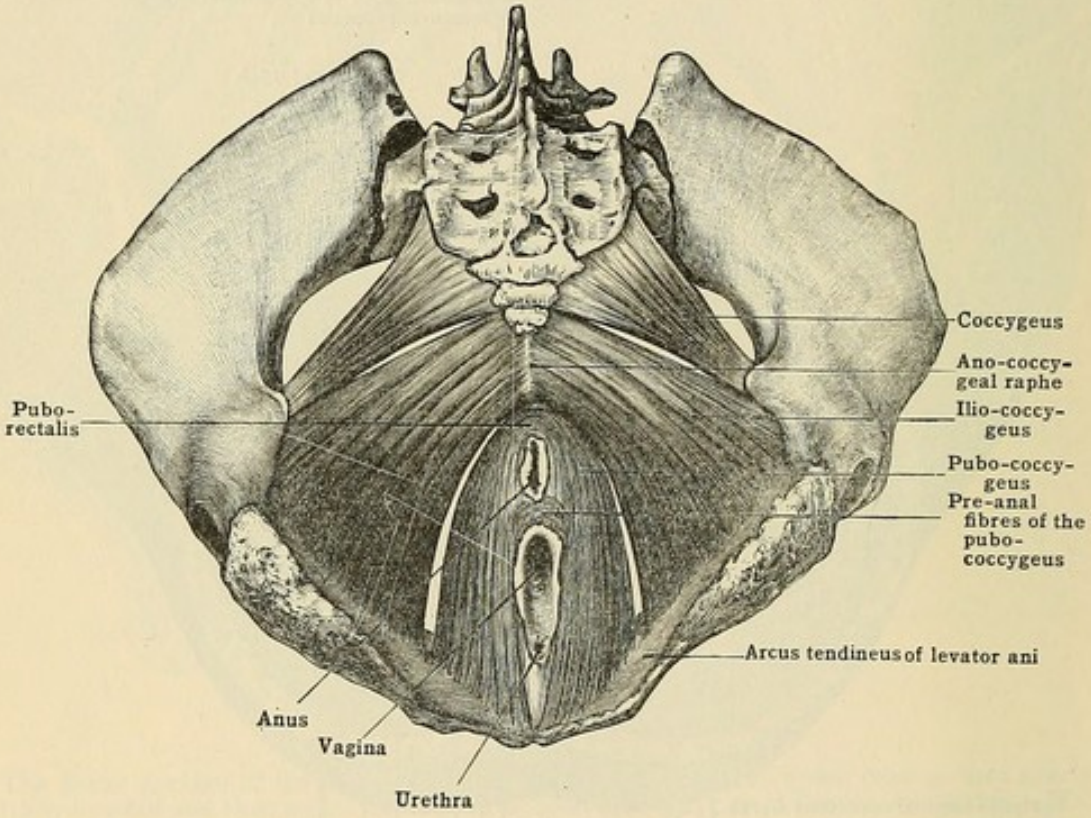

ischial spine and is inserted into the lateral margin of the lower sacral and the upper coccygeal vertebræ. It is closely applied to the pelvic surface of the sacrospinous (small sciatic) ligament. In so far as it is active it flexes and abducts the coccyx.

The **levator ani** arises (figs. 395, 396, 397) from the inner side of the pubis, along a line extending laterally from the inferior margin of the symphysis to the obturator canal, and from the obturator fascia along a line, the *arcus tendineus*, extending from the pubis to the spine of the ischium. The levator ani is inserted into the median raphe back of the anus, the ano-coccygeal raphe, into the tip and sides of the coccyx and into an aponeurosis, which is attached to the anterior sacrococcygeal ligament. It is divisible into three portions, a *pubo-coccygeal*, an *iliococcygeal*, and a *pubo-rectal*. The levator ani muscles of the two sides are separated by a slit which extends from the rectum to the symphysis pubis and in which in the male lie the lower part of the prostate, and the membranous urethra (fig. 396), and in the female the vagina and urethra (fig. 395). Back of the rectum some of the fibre-bundles from the muscles of the two sides interdigitate, while

others terminate in the ano-coccygeal raphe. A few fibre-bundles also interdigitate across the median line, in front of the rectum (pubo-coccygeal, fig. 395) and some are inserted into the walls of the rectum. The levator ani and coccygeal muscles of the two sides form a funnel-shaped muscular support for the pelvic viscera (fig. 399). When the abdomino-thoracic diaphragm contracts, as during inspiration, the pressure on the viscera is transmitted to the pelvic diaphragm which resists the pressure and elevates the viscera when the abdomino-thoracic diaphragm relaxes. The levator ani muscle also constricts the rectum and pulls it forward and in the female constricts the vagina from side to side.

As it passes through the pelvic diaphragm, the rectum for about two and a half centimetres is surrounded by a special **external sphincter** muscle (figs. 393, 394, 397), divisible into three concentric layers as described below. This muscle, especially differentiated from the primitive sphincter of the cloaca,

FIG. 396.—LATERAL VIEW OF MUSCLES OF THE FLOOR OF THE PELVIS.
(A portion of the ischial and pubic bones sawn away.)

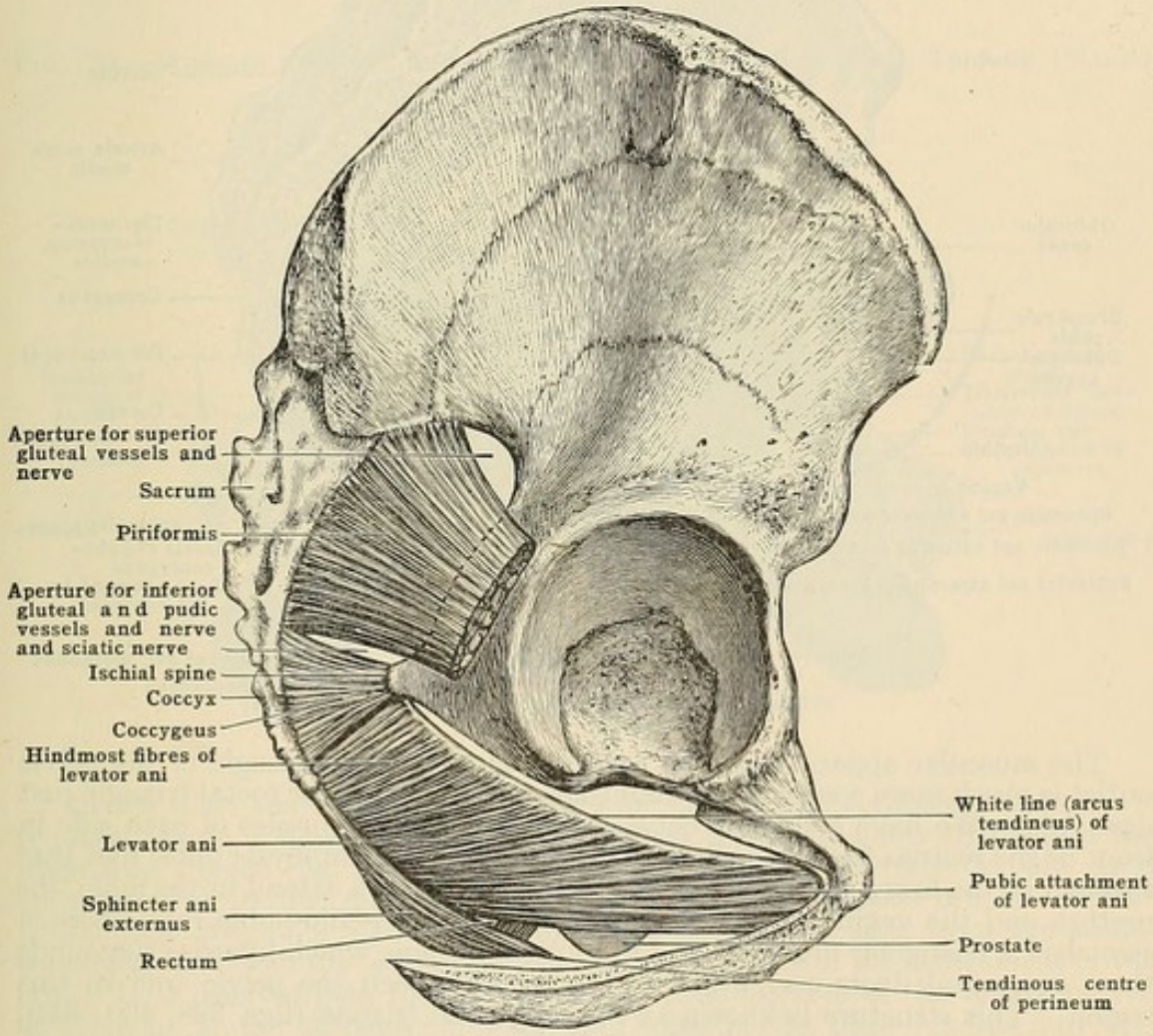

serves to close the rectum. It is supplemented by a sphincter of smooth muscle which lies immediately beneath the mucous membrane of the anus. It is attached behind to the coccygeus, and in front to the central tendon of the perineum described below.

The lateral origin of the levator ani, as above described and as shown in figs. 396 and 399, is considerably above the osseous and muscular margin of the pelvic outlet. The muscles of each side converge toward the post-anal region so that a space is left between the lateral wall of the pelvis, and the levator ani and external sphincter (fig. 399). This space, the **ischio-rectal fossa,** is filled with fat (fig. 400, 401, 402). It is deepened laterally by the lower margin of the gluteus maximus muscle (fig. 400). In the fascial canal (Alcock's canal) in the lateral wall of the

fossa run the internal pudic vessels and nerves (fig. 401). Above the pelvic diaphragm in the median part of the pelvic cavity are found the bladder, the ampulla of the rectum, and the prostate gland (in the male) or the vagina and uterus (in the female). Laterally on each side there is a subperitoneal space, filled with connective tissue and containing blood-vessels and nerves (fig. 402). Fasciæ invest each surface of the pelvic diaphragm (*diaphragmatic fascia*) and extend about the viscera (*endopelvic fascia*).

FIG. 397.—SAGITTAL SECTION OF THE PELVIS TO SHOW THE PELVIC DIAPHRAGM AND EXTERNAL SPHINCTER ANI.

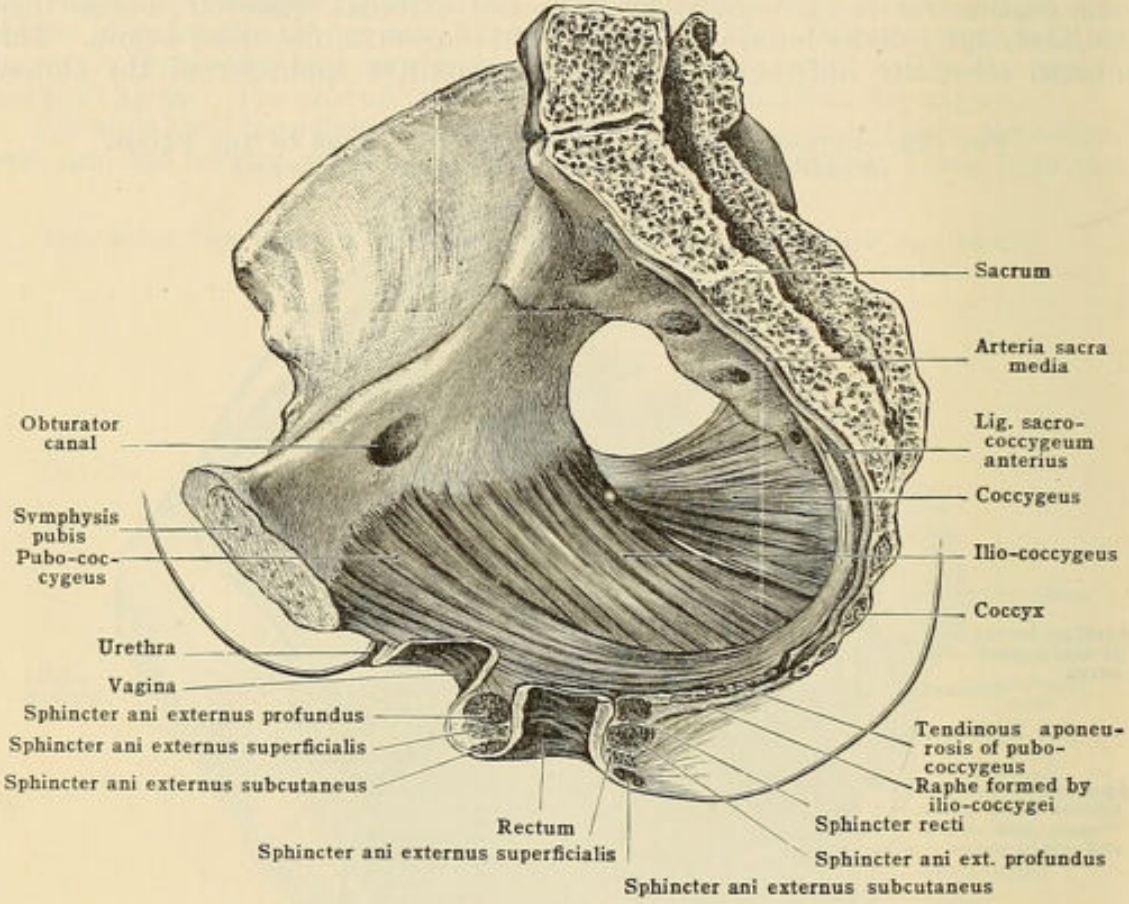

The muscular apparatus of the anterior or urogenital triangle of the pelvic outlet is much more complicated than that of the posterior or rectal triangle just described. We have seen that between the levator ani muscles of each side in front of the rectum there is a slit which extends to the symphysis pubis and that through it, the lower part of the prostate and the urethra extend in the male, the urethra and the vagina in the female. Between the ischio-pubic rami there is stretched a triangular muscular and fibrous membrane, which likewise surrounds these urogenital ducts and which serves to strengthen the pelvic wall in this region. This structure is known as the **urogenital trigone** (figs. 398, 400, 403). The musculature within it, called by Holl the accessory or urogenital diaphragm, includes two muscles (fig. 398), the sphincter urogenitalis (urethræ) and the deep transverse perineal muscle. The *sphincter* embraces the urethra and associated structures. The component fibre-bundles arise chiefly from the fibrous tissue in the angle beneath the symphysis pubis, but partly also from the descending pubic rami. They pass analward and medialward on each side of the urethra and then partly interdigitate across the median line, partly terminate in a median raphe. Some fibre-bundles embrace in the male the lower part of the prostate and Cowper's gland. In the female the fibre-bundles of the sphincter partly terminate in the wall of the vagina. Some of them are continued downward on each side of the vagina and interdigitate with fibre-bundles from the deep transverse perineal muscle. The *deep transverse perineal* muscle (fig. 398) arises on each side from the ischio-pubic ramus. It constitutes a flat band of muscle, the fibre-bundles of

which in part interdigitate across the median line, and in part are inserted into a median raphe.

The musculature of the urogenital diaphragm is enclosed between two well marked **fascial layers** (fig. 400, 403), the deep (superior) and superficial (inferior) layers of the urogenital trigone (triangular ligament). The anterior margins of the two fascial layers are fused to form the transverse ligament of the pelvis which extends between the inferior pubic rami, beneath the dorsal nerves and veins of the penis (clitoris). At the anal margin of the musculature these two layers are also fused with one another. The deep layer of the urogenital trigone forms the floor of the anterior recess of the ischio-rectal fossa (fig. 400).

Superficial to the urogenital trigone lie the external genitalia (figs. 392, 394). Voluntary muscle is here found in connection with the crura of the penis (clitoris) and the bulb of the penis (vestibule). Although the musculature in the two sexes is fundamentally similar, nevertheless, owing to the differences in the structure of the genitalia in the two sexes, it is convenient to take up first the external genital musculature in the male and then that in the female.

FIG. 398.—MUSCLES BETWEEN THE TWO LAYERS OF THE UROGENITAL TRIGONE (MALE.)

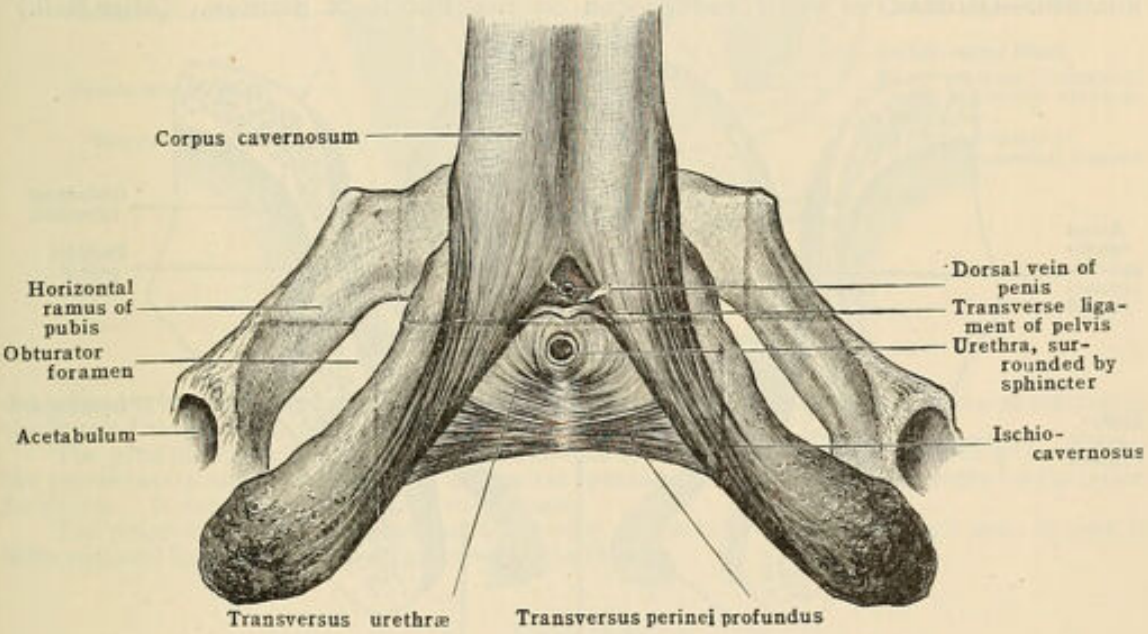

In the male the crus penis, the posterior part of the corpus cavernosum, is relatively large. It lies in the groove between the ischio-pubic ramus and the urogenital trigone (fig. 398), to the former of which it is firmly united. It is enwrapped on its free medial surface by the **ischio-cavernosus** muscle (erector penis) (figs. 398, 402). The fibre-bundles of this muscle arise from the ischial tuberosity and from the ischio-pubic ramus on each side of the attachment of the crus. It is inserted into the medial and ventral surfaces of the crus near the attachment of the suspensory ligament. Some of the fibre-bundles may frequently be traced to the dorsal surface of the root of the penis (levator penis muscle).

The corpus spongiosum [corpus cavernosum urethræ] terminates posteriorly in the bulb which lies on the urogenital trigone between the two crura (figs. 394, 402). It is united to the superficial layer of the trigone (fig. 402). It is enveloped by the **bulbo-cavernosus** muscle, composed of right and left halves united by a median raphe on the superficial surface of the bulb (fig. 394). Each half consists of several superimposed layers of fibre-bundles described below. The component fibre-bundles arise from the superficial layer of the urogenital trigone, from fibrous tissue on the dorsum of the bulb in the angle between the two crura, from the lateral surface of the corpus cavernosum penis in front of the ischio-cavernosus and from the dorsal surface of the penis. It is inserted into a tendinous structure situated in front of the anus, the central tendon of the perineum,

and into the median raphe on the free surface of the bulb. By its contraction the bulbo-cavernosus forces semen or urine from the bulbous part of the urethra.

The **superficial transverse muscle** of the perineum (figs. 392, 394) arises on each side from the ascending ramus of the ischium and is inserted into the central tendon of the perineum. It is frequently weakly developed. It acts with the deep transverse perineal muscle in fixing the perineum and thus offering support for the action of other muscles.

In the **female** (fig. 392) the *ischio-cavernosus* does not differ markedly from that in the male although usually it is smaller. The superficial transverse muscles are, on the other hand, usually relatively better developed. The central tendon of the perineum is likewise usually better developed in women and is more elastic, a characteristic of value in childbirth.

The chief difference in the musculature in the two sexes is found in the *bulbo-cavernosus* (fig. 392). This, in the female, arises from the back of the clitoris, the corpus cavernosum and the trigone. It covers the outer side of the bulb of the vestibule and the gland of Bartholin. It is inserted into the central tendon of the perineum. The chief function of the pair of muscles is to constrict the vagina.

The external genital muscles are covered by a deep layer of the tela subcutanea,

FIG. 399.—DIAGRAM TO SHOW THE FASCIÆ OF THE PELVIS IN SECTION. (After Holl.)

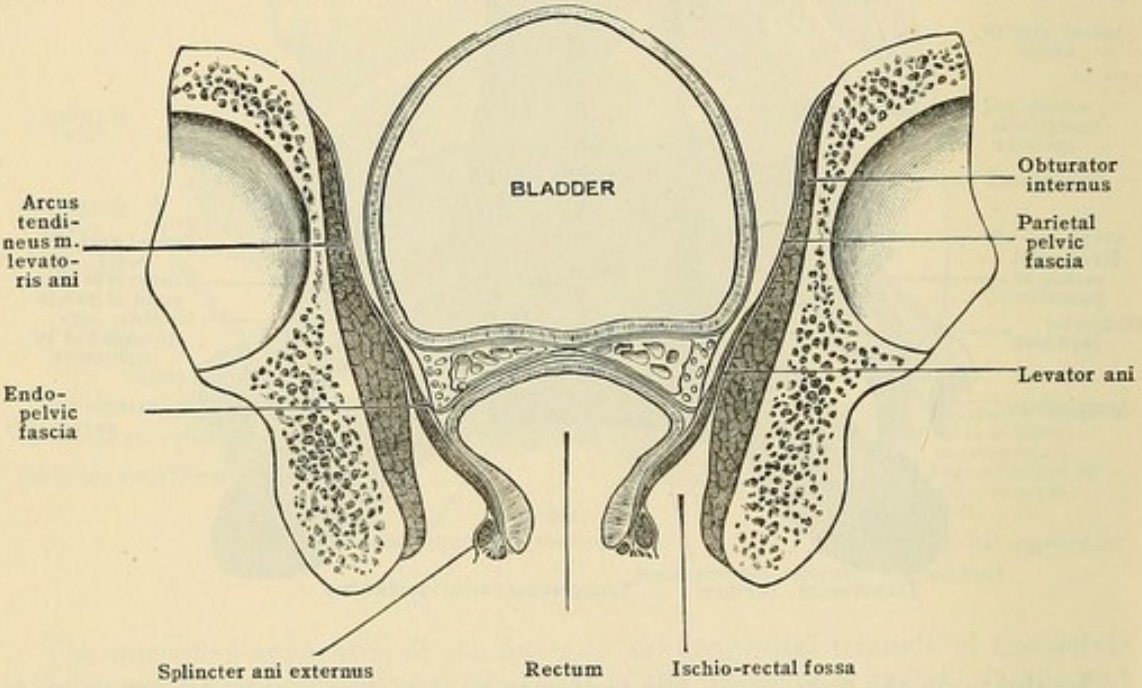

Colles' fascia, which is firmly fused with the two layers of the urogenital trigone at the anal margin of the latter.

MORPHOLOGICAL REMARKS

While the shoulder-girdle and the muscles which extend from this and from the trunk to the upper extremity are superficially placed with respect to the trunk, and do not interrupt the trunk musculature the reverse is true of the hip-girdle and the musculature of the lower extremity. The hip-girdle is firmly united to the spinal column at the sacrum. The muscles which arise from the trunk and are attached to the lower limbs are few in number compared with those of the upper extremity and, unlike the latter, are deeply placed. Thus the psoas major muscle (fig. 406) arises on each side of the lumbar region of the spinal column at the back of the abdominal cavity and is inserted into the femur and the piriformis (fig. 406) arises from the front of the sacrum at the back of the pelvic cavity and is inserted into the great trochanter of the femur. The skeleton and musculature of the lower extremity, furthermore, markedly interfere with the continuity of the trunk musculature which in the lower vertebrates and in the human embryo may be followed continuously to the caudal end. The interruption is much less marked behind than in front. The intrinsic dorsal spinal musculature extends well down over the back of the sacrum, but on the back of the lower end of the sacrum and on the back of the coccyx there is found merely the inconstant sacro-coccygeus posterior. Of the ventro-lateral musculature the musculature of the abdominal wall, as is indicated by its innervation, is derived from the lower thoracic and the first one or two lumbar myotomes; the quadratus lumborum, at the back of the abdominal cavity (fig. 406), from the first three or four lumbar myo-

tomes. Beyond here there is an interruption until we come to the musculature of the pelvic outlet which, in part, may be looked upon as modified trunk musculature belonging to the last three sacral myotomes. The intervening region is "cut out" for the reception of the base of the lower extremity.

It is of interest to note that more and more of the ventro-lateral wall of the trunk is "cut out" as the mid-ventral line is approached. Thus while the quadratus lumborum behind represents spinal segments as far caudal as the third or fourth lumbar, the rectus abdominis in front represents segments merely as far caudal as the twelfth thoracic. Similarly while the

FIG. 400.—SAGITTAL SECTION THROUGH THE UROGENITAL TRIGONE AND ISCHIO-RECTAL FOSSA TO THE LEFT OF THE MIDDLE LINE. (Diagrammatic.)

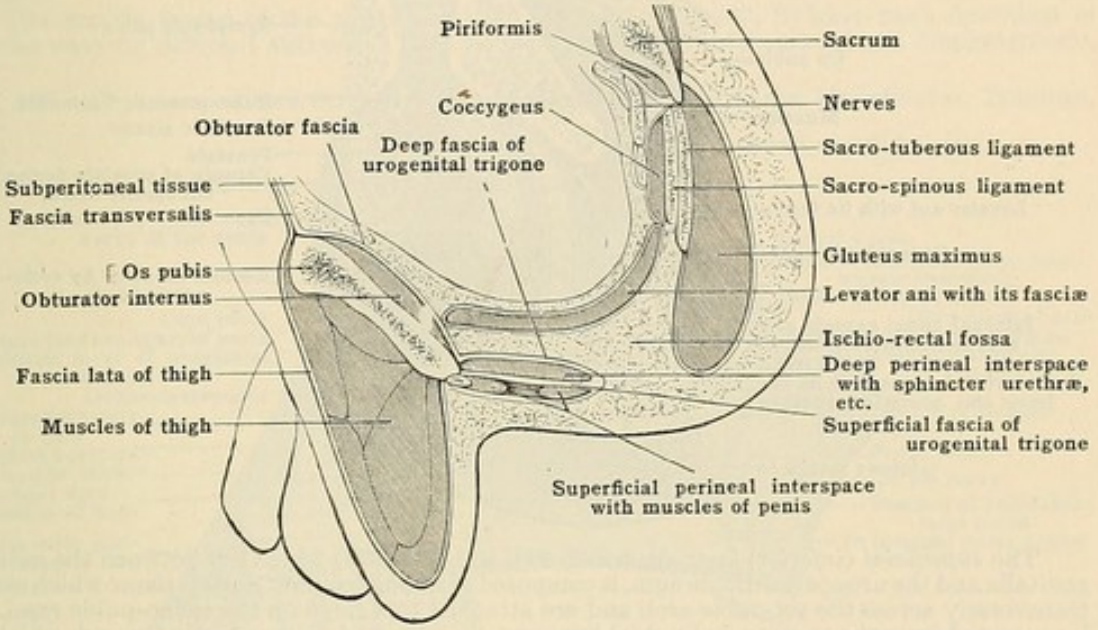

coccygeus at the back part of the pelvic outlet represents the third and fourth sacral segments, the levator ani at the front represents chiefly the fourth.

The musculature which in the tailed mammals is used to move the tail as well as to wall off the pelvic cavity and close rectal and urogenital openings, in man is modified wholly for the latter functions. It constitutes the pelvic diaphragm.

The musculature of the urogenital diaphragm of the external genitalia and anus in man is differentiated from the primitive sphincter of the cloaca.

FASCIÆ

The **tela subcutanea** in the male perineal region contains many bundles of smooth muscle fibres continuous with and similar to the dartos of the scrotum (corrugator cutis ani). At the sides where it passes over the lower margin of the gluteus maximus it contains a large amount of fat, but in the dorsal region over the coccyx and sacrum, as in the mid-perineal region, the fat is limited in amount. In the labia majora of the female perineum there is much fat in the tela subcutanea.

The **ischio-rectal fossa** (figs. 401, 402) is bounded laterally by the obturator internus muscle and fascia, the tuberosity of the ischium and the ischio-pubic ramus, medially by the levator ani and coccygeus muscles and fasciæ, ventrally by the dorsal aspect of the urogenital trigone and dorsally by the gluteus maximus muscle. An *anterior recess* extends forward well toward the body of the pubis between the levator ani, the ischio-pubic ramus and the urogenital trigone. A *posterior recess* may likewise be traced backward covered by the lower edge of the gluteus maximus (figs. 400, 401). The fossa is filled with loose fatty tissue continuous with that of the tela subcutanea. Through it pass the hæmorrhoidal, and long and short perineal branches of the pudic artery and nerve. The main trunks of these vessels and nerves lie in a special fascial compartment (Alcock's canal) in the lateral wall (fig. 401).

The external genital organs are covered by a special deep layer of the tela subcutanea, the **superficial perineal (Colles') fascia** (fig. 402). This is attached on each side to the lower margin of the ischio-pubic ramus and to the ischial tuberosity. At the posterior margin of the superficial transverse perineal muscle it fuses with the two fascial layers of the trigone. It is adherent to the central tendon of the perineum and to the raphe of the bulb. Anteriorly it is continuous with the deep layer of the tela subcutanea covering the scrotum, the penis, and the lower part of the abdominal wall. In rupture of the urethra urine is prevented, by the attachments of the tela, from getting further back than the posterior edge of the trigone, but anteriorly it may extend to the surface of the abdomen. Here it may extend upward for a considerable distance, but it is kept from the thighs by the attachment of the deep layer of the tela subcutanea (Scarpa's fascia) to the inguinal ligament. Beneath the superficial perineal fascia are found the crura of

the penis and their muscles, the bulb of the corpus spongiosum and its muscles, the superficial transverse perinei muscles, and the perineal vessels and nerves (fig. 402).

Muscle fasciæ.—The muscles of the urogenital diaphragm, the urogenital (urethral) sphincter and the transversus perinei profundus, are contained between two fascia layers which constitute the **superficial** (inferior) and **deep** (superior) **layers of the urogenital trigone** (the superficial or inferior and the deep or superior layers of the triangular ligament).

FIG. 401.—SECTION SHOWING THE ISCHIO-RECTAL FOSSA IN ITS RELATIONS TO THE PELVIC VISCERA.

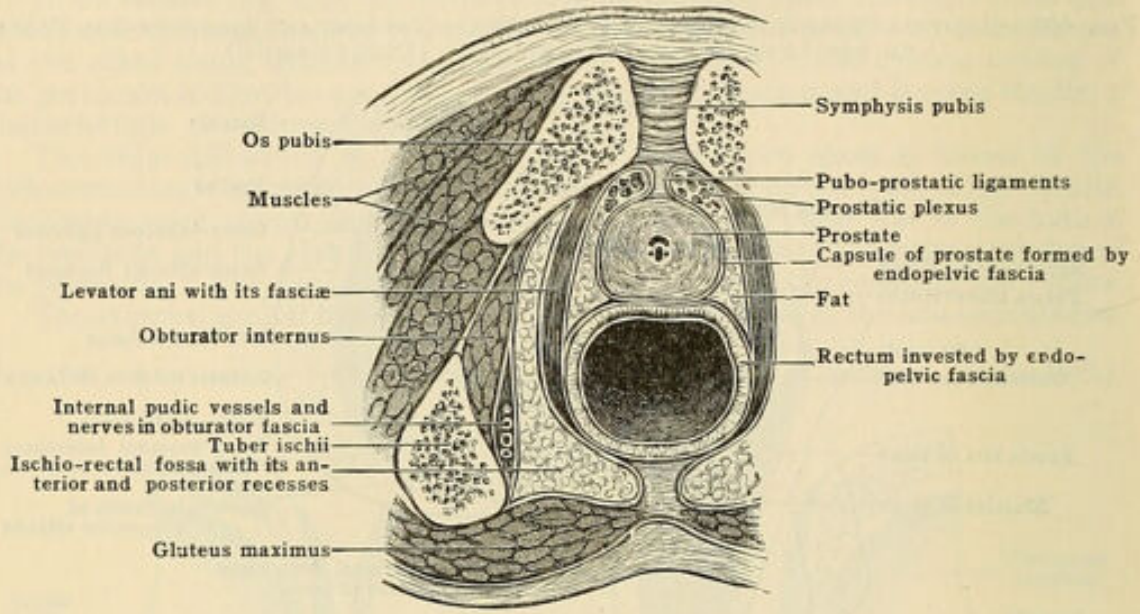

The *superficial (inferior) layer* (figs. 392, 394, 400, 402, 403) which lies between the external genitalia and the urogenital diaphragm, is composed of strong bands of fibrous tissue which extend transversely across the subpubic arch and are attached to a ridge on the ischio-pubic rami. It is separated from the arcuate (subpubic) ligament by a mass of fibrous tissue through which the dorsal veins and nerves of the penis (clitoris) run, and in which there is a venous plexus.

FIG. 402.—VERTICAL FRONTAL SECTION OF THE PELVIS, SHOWING FASCIÆ. (Modified from Braune.)

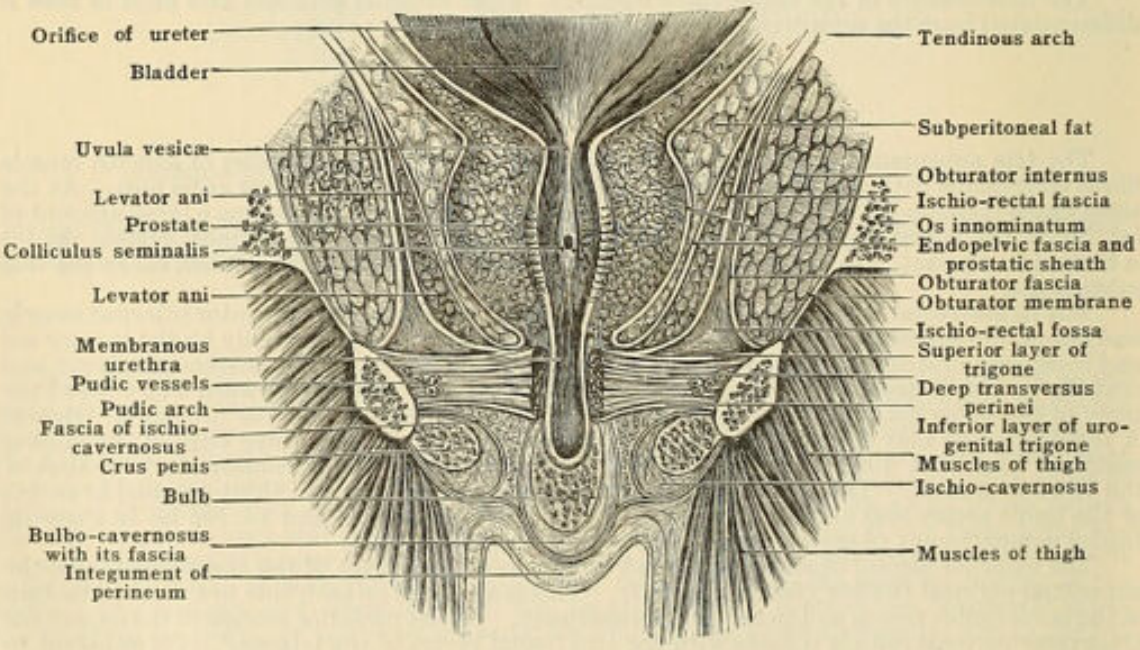

Beneath this tissue a fibrous band, the *transverse ligament* of the pubis, extends between the descending pubic rami. This represents a region of fusion of the deep and superficial layers of the fascia of the trigone. Posterior to the deep transverse muscle the two layers are likewise fused. The superficial layer is better developed in the front than in the back part of the space. It is pierced by the urethra (about 3 cm. below the symphysis) by the ducts of the bulbo-urethral

(Cowper's) glands, the arteries of the bulb, and the dorsal nerves and arteries of the penis. In the female it is pierced by the vagina as well as by the structures mentioned above.

Beneath the superficial layer of the fascia of the trigone, in addition to the muscles of the urogenital diaphragm, there are found the membranous urethra, the bulbo-urethral glands (Cowper's), the internal pudic arteries and the pudic nerves (in part).

The *deep (superior) layer of the urogenital trigone* (figs. 400, 402, 403) lies between the muscles of the urogenital diaphragm and the ischio-rectal fossa and levator ani. It may be looked upon as a continuation of the obturator fascia across the pubic arch. Posterior to the deep transverse perineal muscle it fuses with the superficial layer of the fascia of the urogenital trigone. In this region in the male it fuses with a fascial membrane, the *prostatico-perineal* fascia, which extends upward between the rectum and prostate, and is attached to the posterior wall of the latter. In the female it is fused with the fibrous tissue which lies between the vagina and the rectum.

The **muscle fasciæ of the pelvis** (figs. 399, 400, 401, 402, 407, B) have been described in various ways by different authors. They may be subdivided into parietal and diaphragmatic.

FIG. 403.—DIAGRAM OF THE SUPERFICIAL AND DEEP LAYERS OF THE UROGENITAL TRIGONE.

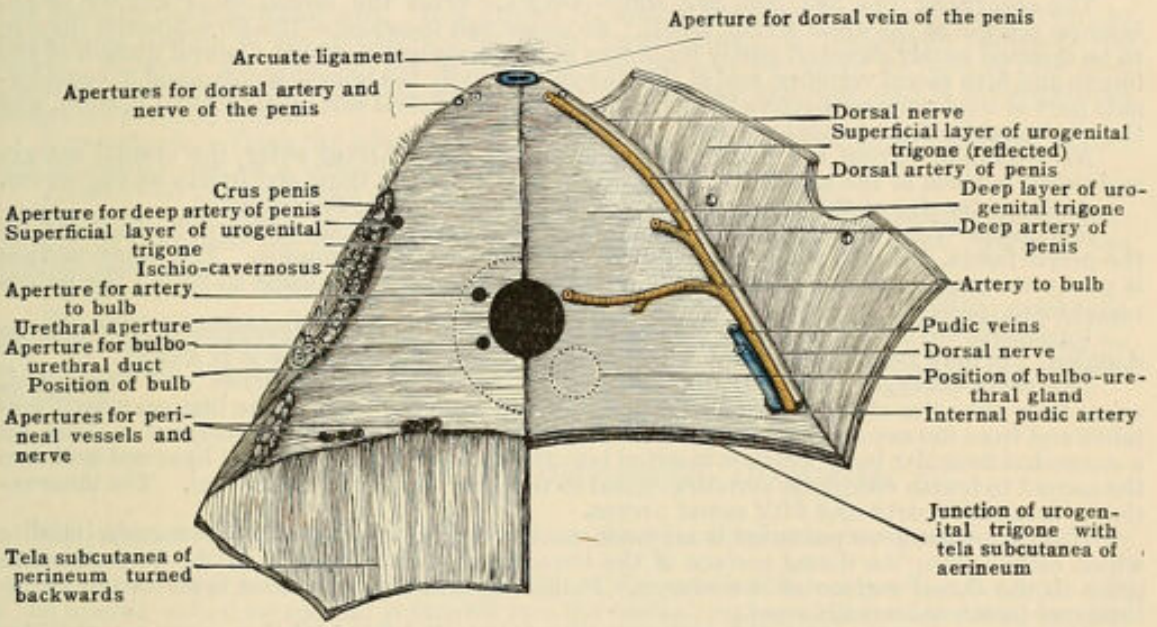

The **parietal fasciæ** (fig. 399) cover the muscles which extend from the interior of the pelvis to the thigh (the obturator internus and piriformis muscles). Above, the fascia on each side is attached to the linea terminalis and is continuous with the fascia transversalis and the iliac fascia. It is attached to the margins of the greater and lesser sciatic notches and to the ischio-pubic ramus and the body of the pubis. Between the ischio-pubic rami it is stretched across the subpubic arch and forms the superior or deep layer of the urogenital trigone described above. The portion of parietal pelvic fascia over the obturator internus muscle is called the obturator fascia.

The **diaphragmatic pelvic fasciæ** cover both surfaces of the pelvic diaphragm and are reflected upon the viscera. The fasciæ covering the two surfaces of the levator ani are attached to the parietal (obturator) fascia along the line of origin of the muscle.

The line of attachment of the levator ani divides the obturator fascia into two parts (fig. 399), a pelvic part above the line of attachment, covered by peritoneum, and an ischio-rectal part below the line of attachment. The latter bounds the lateral wall of the ischio-rectal fossa. The former part is much the thicker. It consists morphologically of two fused membranes, the obturator fascia proper and the aponeurosis of the ilio-coccygeal portion of the levator ani, which although usually fused with the obturator fascia, may frequently be traced to the terminal (ilio-pectineal) line from which in tailed mammals this portion of the levator takes origin. The two layers of fascia also become continuous at the medial margin of the muscle where this faces the urogenital passage (fig. 399). Posteriorly, the inner layer fuses with the tendinous insertion of the pubo-coccygeus portion of the muscle and the fasciæ of the muscles of each side are continuous. It also fuses with a fascia covering the coccygeus muscle.

The thin perineal layer of the levator fascia behind the rectum fuses with that of the opposite side and is attached to the coccyx and the ano-coccygeal raphe. About the anus it helps to form a covering for the external sphincter. Ventrally it is attached to the ischio-pubic rami. It forms the medial wall of the ischio-rectal fossa.

Endo-pelvic fascia (figs. 401, 402).—The peritoneum is reflected from the pelvic wall onto the viscera much higher up than the level at which the viscera are attached to the pelvic diaphragm. Between the pelvic fascia covering the deep surface of the pelvic diaphragm (levator ani and coccygeus muscles) and the peritoneum there is thus left a space, subperitoneal space (fig. 467 B). In the median plane in this region in the male are found the bladder, prostate, seminal vesicles, the ureter and ductus deferens in their course near the bladder, and the ampulla of the rectum. In the female we find here the bladder, the vagina, the uterus, and the ampulla of the rectum. Between these medially placed viscera and the lateral wall of the pelvis

there is an irregularly shaped space, *cavum pelvis subperitoneale*, bounded above by peritoneum, below by the fascia covering the pelvic diaphragm and filled with connective tissue of varying density. The tissue in this space in the female is continuous with that between the two peritoneal surfaces of the broad ligament. Between the viscera in the subperitoneal region and about their walls the connective tissue is more or less definitely condensed into membranes which constitute the endopelvic fascia, variously described by different authors. The fascia covering the pelvic diaphragm, especially that on the deep surface, is fused to the endopelvic fascia where the viscera pass through the pelvic diaphragm. In the connective tissue of the subperitoneal space are found the hypogastric artery and vein and their chief branches, and various visceral nerves. The subperitoneal space above the pelvic diaphragm is to be compared with the subcutaneous space below the pelvic diaphragm known as the ischio-rectal fossa and described above.

MUSCLES

A. Muscles of the Pelvic Diaphragm, Coccyx, and Anus

The **coccygeus** (figs. 393, 395, 397, 400).—*Origin.*—From the ischial spine and the neighbouring margin of the great sciatic notch. *Structure and insertion.*—The fibre-bundles diverge to be inserted partly directly, partly by means of an aponeurosis, into the lateral margin of the fourth and fifth sacral vertebræ and of the coccyx. Usually the muscle is composed in considerable part of tendinous connective tissue, especially on the dorsal side of the cranial portion, and the ventral side of the caudal portion.

Nerve-supply.—From the pudendal plexus several small nerves enter the cranial margin and pelvic surface of the muscle. They arise usually from the third and fourth sacral nerves.

Action.—Insofar as the muscle is active it flexes and abducts the coccyx.

Relations.—Ventrally the muscle bounds the pelvic cavity, from which it is separated by the pelvic fascia, beneath which runs the nerve to the levator ani muscle. The dorsal surface is partly covered by the sacro-spinous (lesser sciatic) ligament and helps to bound the ischio-rectal fossa (posterior recess).

Variations.—The muscle varies greatly in the extent of its fleshy development. It may be doubled. It may be partially fused with the levator ani. Occasionally it is absent.

The sacro-coccygeus anterior (fig. 393).—This inconstant muscle, when well developed, arises from the sides of the fourth and fifth sacral and from the front of the first coccygeal vertebra and from the sacro-spinous ligament. The short fibre-bundles which compose it make up a somewhat irregular belly which is inserted into the anterior sacro-coccygeal ligament and into the second to fourth coccygeal vertebræ dorsal to the insertion of the levator ani. The innervation is from the fourth and fifth sacral nerves.

The **sacrococcygeus posterior** is an inconstant muscle consisting of a few muscle bundles which extend from the dorsal surface of the lower sacral vertebræ or from the posterior iliac spine to the dorsal surface of the coccyx. It lies beneath the superficial layer of the sacro-tuberous (great sciatic) ligament.

The **levator ani** (figs. 392, 394, 395, 396, 399, 401) is divisible into three portions, the ilio-coccygeus, the pubo-coccygeus and the pubo-rectalis.

The *ilio-coccygeus* (fig. 397) *arises* from the ischial portion of the arcus tendineus (white line). This extends from the ischial spine and posterior part of the arcuate line to the superior ramus of the pubis near the obturator canal, curving downward for a variable distance below the obturator canal. The constituent fibre-bundles form a muscular sheet which is inserted into the side of the coccyx and into the median raphe (ano-coccygeal) which extends from the tip of the coccyx to the rectum. Many fibre-bundles cross the median line.

The *pubo-coccygeus* (figs. 395, 397) *arises* from the inner surface of the os pubis, along a line extending from the lower margin of the symphysis pubis to the obturator canal, and from the arcus tendineus as far backward as the origin of the ilio-coccygeus. The fibre-bundles form a sheet of muscle which passes backward, downward, and medialward past the urogenital organs and the rectum on each side and is *inserted* by means of an aponeurosis into the anterior sacro-coccygeal ligament. Back of the rectum some of the fibre-bundles of the muscle sheets of each side interdigitate across the median line. Some of the more superficial fibres are inserted into the deep part of the ano-coccygeal raphe. Some of the fibre-bundles which arise nearest the symphysis are inserted on each side into the rectum. The pubo-coccygeus lies to some extent on the pelvic surface of the insertion of the ilio-coccygeus.

The *pubo-rectalis* (fig. 395) *arises* (a) from the body and descending ramus of the pubis beneath the origin of the *pubo-coccygeus*, (b) from the neighbouring part of the obturator fascia and (c) from the fascia covering the pelvic surface of the urogenital trigone. The fibre-bundles form a thick band on each side of the rectum behind which those of each side are inserted into the ano-coccygeal raphe. Many fibre-bundles may be traced into the muscle of the opposite side. Some of the more superficial fibre-bundles are reflected medialward in front of rectum and may be followed into the superficial transverse perineal muscle, others may be followed into the sphincter ani externus, or even to the skin.

Nerve-supply.—By a special nerve which arises usually from the fourth sacral, runs across the pelvic surface of the muscle and gives a special branch to each portion.

Action.—To flex the coccyx, raise the anus and constrict the rectum. It resists the downward pressure which the thoraco-abdominal diaphragm exerts on the viscera during inspiration.

Relations.—Between the right and left muscles in front lie the urethra and the lower part of the prostate in the male, the urethra and vagina in the female. In the triangle between the ischio-pubic rami of each side lies the urogenital diaphragm separated from the pubo-rectal part of the muscle by the deep layer of the trigone from which some of the fibres of the latter arise. Back of the urogenital diaphragm the muscle helps to bound the ischio-rectal fossa.

Variations.—The muscle shows great individual variation in structure which causes it to be variously described by different authors.

The **sphincter ani externus** (figs. 392, 394, 396, 397, 399) is made up of bundles of muscle fibres which surround the anus for nearly two centimetres. It is elliptical in form. Behind the anus the fibre-bundles of each side in part interdigitate, forming a ring. They are attached to the skin, and in part are attached through a tendon, the *ligamentum ano-coccygeum*, to the back of the coccyx. In front of the anus the fibre-bundles also in part interdigitate with one another, in part are inserted into the skin and in part interdigitate with the fibre-bundles of the transverse perineal and bulbo-cavernosus muscles. At the point where these muscles meet, about two and a half centimetres in front of the anus, there may be a visible mass of fibrous tissue, the *central tendon of the perineum*, but this is not always distinct. It is usually better developed in the female than in the male perineum. The external sphincter is divisible into three portions, a subcutaneus, a superficial and a deep (fig. 397). The three parts are connected by fibre-bundles, and are not always distinct. The *subcutaneous division* is small and immediately encircles the anal orifice. The *superficial division* lies external to the subcutaneous ring and descends further toward the rectum. It is shown in figs. 392, 394. It is the only part attached to the coccyx. In front it is attached to the central tendon of the perineum, but some fibres are continued into the bulbo-cavernosus. The *deep portion* forms a heavy ring above the rectum beneath the superficial part. It is distinctly, though not completely, separated from the pubo-rectal portion of the levator ani by fascial tissue containing the inferior hæmorrhoidal vessels. Some of the fibre-bundles of the deep portion may be traced in front of the anus across the mid-line to the ascending ramus of the opposite side and form part of the superficial transverse perineal muscle.

Nerve-supply.—From the inferior hæmorrhoidal branches of the pudendal (internal pudic) and frequently also by a perineal branch from the fourth sacral.

Action.—To keep the anus closed.

Relations.—Externally it is surrounded by the fat of the ischio-rectal fossa, internally near the skin it surrounds the sphincter ani internus, composed of smooth muscle, deeper it lies next the mucous membrane, for a distance of two centimetres from the skin.

Variations.—The muscle shows considerable individual variation in structure.

The *recto-coccygeus* or muscle of Treitz, is a triangular bundle of smooth muscle fibres. The origin of the muscle is from the second and third coccygeal vertebræ. It is inserted by its apex into the posterior wall of the rectum and the perirectal fascia. It retracts and elevates the rectum.

B. Muscles of the Urogenital Diaphragm

The urogenital diaphragm is composed of two closely united muscles, the deep transverse perineal muscle and the urogenital sphincter.

The **transversus perinei profundus** (fig. 398) is a flat muscle which *arises* from the inner side of the inferior ischial ramus and is *inserted* into the median raphe. Many of the fibre-bundles interdigitate with those of the opposite side and some may be followed into the external sphincter of the anus and into the urogenital spincter and other perineal muscles.

Nerve-supply.—By the perineal branch of the pudendal (internal pudic).

Action.—The pair of muscles draw back and fix the central tendon of the perineum and thus give firm support for the action of the urogenital sphincter.

Relations.—The inferior surface is separated (often incompletely) by the inferior layer of the urogenital trigone from the superficial transverse perineal muscle. The superior surface is covered by the deep layer of the urogenital trigone, into which the superficial layer is reflected about the anal margin of the muscle.

Variations.—The muscle is variable in structure and may be absent. (It is more frequently absent in the female than in the male.)

The **sphincter urogenitalis** differs in the male and female owing to the passage of the vagina through the perineum in the latter. In each sex it is convenient to consider the muscle as divided into two parts, a peri-urethral and an infra-urethral (vaginal).

In the male (fig. 398) the peri-urethral part, the *m. sphincter urethræ membranaceæ* is composed of fibre-bundles which are circularly placed about the membraneous urethra. The more external fibre-bundles are attached to the crura of the penis near their junction, to the transverse ligament of the pubis and to the fasciæ of the trigone. Some of them partially ensheath the lower part of the prostate, and others envelop the bulbo-urethral (Cowper's) glands. Some of the fibre-bundles take a longitudinal course along the urethra. Bundles of smooth muscle fibres are intermingled with the striated, and the fibrous framework of the musculature is marked by the large amount of elastic tissue which it contains. The infra-urethral part, the *m. transversus urethræ*, is closely associated with the urethral part. The fibre-bundles arise on each side from the inferior ramus of the pubis. They pass for the greater part beneath the urethra and interdigitate with that of the opposite side or are inserted into a median raphe. A few fibre-bundles may pass above instead of below the urethra. The transverse urethral muscle, first described by Guthrie (On the anatomy and diseases of the neck of the bladder, London, 1834) is inconstant. Its existence as a normal constituent of the male perineal musculature has been disputed by Delbet (Poirier and Charpy) and others.

In the *female* the peri-urethral part, *sphincter urethræ*, differs in no essential respects from the corresponding muscle in the male. Some of the fibre-bundles form a true sphincter about the urethra. The *infra-urethral* part, on the other hand, seems to vary greatly in different individuals so that the descriptions given by different authors are somewhat contradictory. It is better developed in women who have not borne children than in those who have. It may be looked upon as composed of two portions, a *m. transversus vaginæ* and an *m. constrictor vaginæ*.

The *transversus vaginæ* arises from the ischio-pubic rami and is inserted into the lateral wall of the vagina. Some of the fibre-bundles pass above and some below the vagina. This muscle corresponds with the transversus urethræ of the male but is, apparently, seldom fully developed. The *m. constrictor vaginæ*, on the other hand, seems to be more constant. It is composed of fibre-bundles which embrace the lateral wall of the vagina and are inserted above into the peri-urethral framework, below into the raphe between the two deep transverse perineal muscles. Some of the fibre-bundles are attached to the vaginal wall. Some interdigitate with the sphincter urethræ, others with the deep transverse perineal muscle and with the transversus vaginæ.

Nerve-supply.—By a branch from the perineal nerve.

Action.—To compress or close the urethra and in the male to compress the prostate and Cowper's glands, in the female to compress the vagina and Bartholin's glands.

Relations.—On the pelvic side it is separated from the levator ani by the deep layer of the urogenital trigone, and on the perineal side it is separated from the superficial muscles by the superficial layer of the trigone. Toward the anus it is closely associated with the deep transverse perineal muscle. Venous plexuses are well developed near the sphincter urethræ in both sexes, but especially in the female.

FIG. 404.—BULBO-CAVERNOSUS IN THE MALE.

The two halves have been reflected from the median raphé, and the bulb turned downward after division of the corpus spongiosum. (The ischio-bulbosus is not present on the right side.)

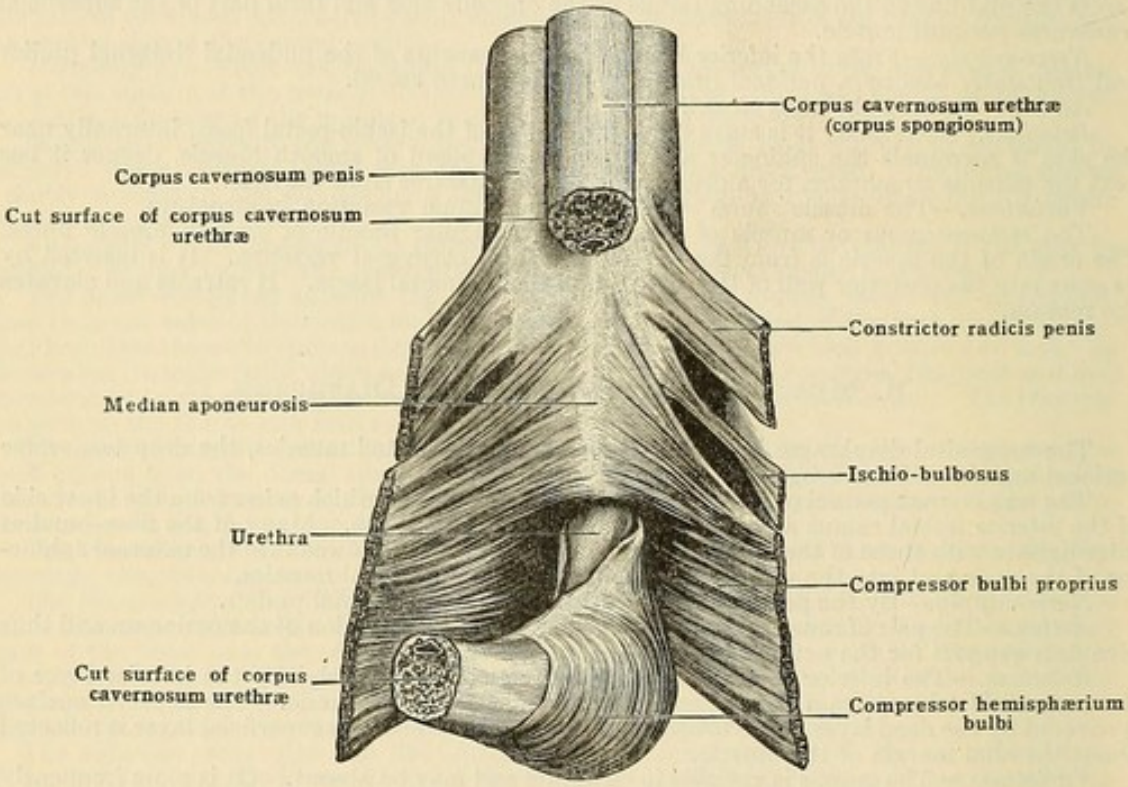

Variations.—It has already been pointed out that there is considerable variation in the muscles composing urogenital sphincter. Occasionally a rudimentary *ischio-pubicus* is found arising from the ischio-pubic ramus and terminating in a tendon which unites with that of the opposite side beneath the dorsal vein of the penis (clitoris). The tendon may be present as the transverse ligament of the pelvis when the muscle itself is absent. It represents the compressor of the dorsal vein found in lower mammals.

C. EXTERNAL GENITAL MUSCLES

The **bulbo-cavernosus** (figs. 394, 404) in the male ensheaths the bulb. The fibre-bundles *arise* from the dense tissue covering the corpus cavernosum at the root of the penis and from the subpubic connective tissue dorsal to the bulbar part of the urethra and are *inserted* into its median raphe on the ventral side of the bulb and into the central tendon of the perineum. Several parts may be more or less clearly distinguished.

1. *The constrictor radicis penis arises* usually from the lateral surface of the corpus cavernosum penis at the base of the penis, but may arise from the under surface or from the dorsal surface, or even from the suspensory ligament of the penis. The fibre-bundles pass obliquely backward and medialward and are *inserted* into the median raphe on the perineal surface of the bulb.

2. The *compressor bulbi proprius arises* (1) from a strong fibrous aponeurosis situated between the corpus spongiosum and the united crura of the penis and firmly adherent to the former, and (2) from the superficial layer of the trigone. The fibre-bundles ensheath the bulb and are *inserted* into the posterior part of the median raphe and into the central tendon of the

perineum. To a greater or less extent, depending on the development of the two muscles, the compressor covers the more posterior part of the constrictor.

3. The *compressor hemisphærium bulbi arises* from a tendon common to the muscles of the two sides on the dorsum of the bulbous part of the urethra near the membranous part. The fibre-bundles embrace the hemisphere of the bulb and are inserted into the median raphe. This muscle is covered by the preceding. It not only compresses the bulb, but also is a sphincter of the urethra.

4. The *ischio-bulbosus* is placed by Holl in this group. It *arises* from the pelvic surface of the tuberosity and of the inferior ramus of the ischium and when well developed is inserted into the median raphe, superficial to the compressor bulbi proprius or the constrictor radicis proprius. Frequently, however, it does not extend over the bulb but is *inserted* into the inferior surface of the corpus cavernosum. It is more frequently absent than present. (See fig. 404.)

Nerve-supply.—The perineal division of the pudic nerve sends several branches to the bulbo-cavernosus.

Action.—It compresses the bulb and at the same time the bulbous portion of the urethra. The turgescence of the penis is thus increased and urine or semen is expelled from this portion of the urethra.

Relations.—It lies beneath the skin and subcutaneous tissue.

Variations.—The muscle is variable in structure as is indicated by the different descriptions given by different authors. The *compressor venæ dorsalis* described by Houston is composed of

FIG. 405.—DIAGRAMMATIC REPRESENTATION OF THE PERINEAL STRUCTURES IN THE FEMALE.

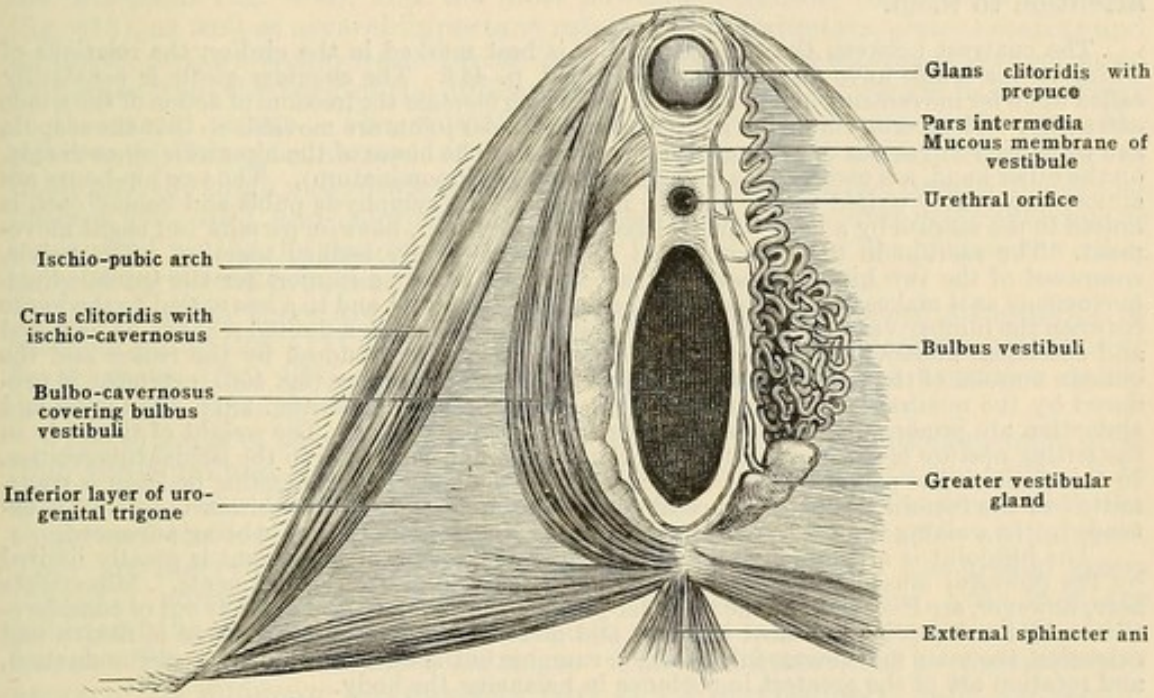

a few fasciculi which arise from the sheath of the corpus spongiosum, and from the median raphe and are united to those of the opposite side by a tendon which passes over the dorsal vein.

The *bulbo-cavernosus* (*sphincter vaginæ*) (fig. 392, 405) in the female arises (1) from fibrous tissue dorsal to the clitoris, (2) from the tunica fibrosa of the corpus cavernosum and from the superficial layer of the urogenital trigone in the angle between the crura of the clitoris. The fibre-bundles form a band of tissue about two centimetres wide at the side of the vagina and are inserted into the posterior part of the superficial (inferior) layer of the trigonum and into the central tendon of the perineum where some of the fibre-bundles interdigitate with those of other muscles attached here. The fibre-bundles arising from the back of the clitoris correspond with those of the constrictor radicis penis in the male. The other fibre-bundles correspond with those of the compressor bulbi proprius in the male.

Nerve-supply.—From the perineal division of the pudic.

Action.—To compress the vagina.

Relations.—It covers the bulb of the vestibule and the great vestibular gland (Bartholin's). It is covered by skin and superficial fascia.

The **ischio-cavernosus** (figs. 398, 405) (erector penis or clitoridis) *arises* from the pelvic surface of the tuberosity and inferior ramus of the ischium, back and on each side of the attachment of the crus. The fibre-bundles form a thin sheet which is spread over the crus into the medial and inferior surfaces of which it is *inserted* near the symphysis pubis. It is better developed in the male than in the female.

Nerve-supply.—By branches of the perineal nerve.

Action.—By constricting the crus to maintain turgescence of the penis or clitoris.

Relations.—Superficially it is covered by skin and subcutaneous tissue. Laterally it lies next the ischio-pubic ramus. Medially it bounds a space lying between the crus and the bulb and filled with fat.

Variations.—The muscle in the male is much larger than in the female. Some of the more anterior fibre-bundles may extend to the dorsal surface of the penis (clitoris) and form a *pubo-cavernosus* or levator penis muscle.

The **transversus perinei superficialis** (figs. 392, 394, 405) arises from the inferior ischial ramus. The fibre-bundles extend in front of the rectum superficial to the deep transverse muscle and are inserted into the central tendon of the perineum. Some cross to the opposite side. Some of the fibre-bundles are continuous with those of the external sphincter or of the pubo-rectalis of the opposite side.

Action.—It acts with the deep transverse muscle in fixing the central part of the perineum.

Nerve-supply.—By a branch from the perineal division of the pudic.

Variations.—It is frequently absent or poorly developed.

VI. THE MUSCULATURE OF THE LOWER LIMB

The lower limbs are used chiefly for the support and propulsion of the body. Variety of movement is subordinated to strength and precision. In contrast with the upper limbs, which perform a vast variety of complex movements under conscious control, the lower limbs are called upon to perform chiefly the relatively simple movements which are used in walking or running, without our paying much attention to them.

The contrast between the two extremities is best marked in the girdles, the relations of which to the trunk have already been described, p. 444. The shoulder girdle is constantly called upon for movements in various directions which increase the freedom of action of the whole extremity. The sterno-clavicular and acromio-clavicular joints are movable so that the scapula can be carried in various directions over the thorax. The bones of the hip-girdle on each side, on the other hand, are ossified into a single hip-bone (os innominatum). The two hip-bones are almost immovably united to one another in front by the symphysis pubis and behind each is united to the sacrum by a joint which, although a diarthrosis, likewise permits but slight movement. The sacrum in turn is composed of vertebræ firmly ossified together. The pelvis, composed of the two hip-bones and the sacrum forms a strong support for the trunk. Such movements as it makes are due chiefly to the lumbo-sacral joint and to a less extent to the joints between the lumbar vertebræ. These joints permit the pelvis, in a limited manner, to be flexed and extended, abducted, adducted, and rotated. Flexion is produced by the rectus and the oblique muscles of the abdomen (fig. 387) and by the psoas muscles (fig. 406), extension is produced by the quadratus lumborum (fig. 406) and the sacrospinalis (fig. 381). Rotation and abduction are produced when these muscles act on one side only. The weight of the body in the sitting posture is transmitted through the sacrum and hip-bones to the ischial tuberosities. In this position the pelvis is flexed. The weight of the body in the standing position is transmitted to the femora through the acetabulum on each side. In this position the pelvis is extended. In walking the pelvis is rotated forward toward the limb that is being advanced.

The hip-joint is a true ball-and-socket joint, but freedom of movement is greatly limited by the powerful musculature which surrounds it, as well as by the ligaments. Movements here, however, are freer than at the shoulder-joint, if the shoulder girdle be left out of consideration. At the hip-joint the most frequent and most free movements are those of flexion and extension, the main movements in walking or running; but abduction, adduction, circumduction, and rotation are of the greatest importance in balancing the body.

At the knee-joint the main movements are also those of flexion and extension and the musculature is so arranged that the chief flexors of the knee which lie at the back of the thigh are extensors of the hip (fig. 408) while the extensor musculature of the knee which lies at the front of the thigh flexes the hip (fig. 411). Flexion of the hip, however, through the action of gravity on the foot passively brings about flexion at the knee, while flexion of the knee likewise passively brings about flexion of the hip, since the flexed knee tends to swing forward. These passive movements, due to gravity, are of importance in walking. The gastrocnemius (fig. 413), the most powerful extensor of the ankle-joint, is also a powerful flexor of the knee-joint. At the knee-joint, in addition to flexion and extension, some rotation is possible, best marked when the knee is flexed. This rotation is of value in walking over rough ground in that it helps to accommodate the foot to the ground. It is also of value in sitting on a flat surface. While there is thus some rotation at the knee-joint not found at the elbow-joint, the free movement of the radius about the ulna which accompanies pronation and supination in the forearm, is unrepresented in the leg where the fibula is firmly united to the tibia at each end.

The joint between the bones of the leg and the tarsus permits merely of flexion and extension in contrast to the wrist-joint which also permits of adduction and abduction. Flexion and extension are also more limited at the ankle than at the wrist. On the other hand, the movements of inversion and eversion which take place in the intertarsal joints are not needed in the wrist because of the pronation and supination of the forearm. Inversion and eversion of the foot are of value in walking on rough ground.

The movements of the toes resemble those of the fingers except that they are, in most individuals, far more restricted. The greatest restriction is seen at the joint between the metatarsal of the big toe and the tarsus, as compared with that between the metatarsal of the thumb and the carpus.

The musculature of the inferior extremity, like that of the superior, can be divided according to its development and innervation into two great subdivisions

which correspond with the musculature on the dorsal and ventral sides of the (shark's fin. The dorsal musculature is supplied by nerve branches which arise from the back of the lumbo-dorsal plexus (femoral, gluteal, and peroneal nerves), the ventral musculature by branches which arise from the front of the plexus obturator and tibial nerves). Owing, however, to the rotation which the limb makes during embryonic development, the musculature which primitively lies on the dorsal side of the limb-bud comes to lie on the front and lateral side of the extremity and the musculature of the ventral side of the limb-bud comes to lie on the back and medial side of the extremity or in the sole of the foot. The side of the limb which primitively was toward the head becomes the medial side of the limb, and that which faced caudalward comes to lie laterally. While this makes the primitive relations of the musculature of the limb at first somewhat confusing, it is possible to approximate these primitive conditions by abducting the limb and rotating it so that the sole of the foot faces forward. An understanding of the innervation of the limb is thus greatly facilitated.

In the region of the hip the musculature of the **dorsal division** is that which arises from the spinal column and ilium and is inserted into the upper part of the femur and into the fascia of the thigh. It includes the chief flexor of the thigh, the *ilio-psoas* (fig. 406), and the most powerful extensor, the *gluteus maximus* (fig. 413), as well as several important rotators and abductors, *gluteus medius* and *minimus*, *piriformis* and *tensor fasciæ latæ* (fig. 408). The ilio-psoas is innervated by nerves from the back of the lumbar, the other muscles by nerves from the back of the sacral plexus. The musculature of the *ventral division* arises from the pubis and ischium, is inserted into the femur near the great trochanter and serves to adduct the thigh and rotate it lateralward, *obturator internus*, *gemelli*, *quadratus femoris* (fig. 408) and *obturator externus* (fig. 406). The obturator externus is innervated by the obturator nerve from the front of the lumbar plexus, the other muscles by special branches from the front of the sacral plexus.

In the thigh there are three well-marked groups of muscles, an anterior or extensor group (fig. 411), a medial or adductor group (fig. 411), and a posterior or flexor group (fig. 408). The anterior group belongs to the primitive dorsal division, the other two groups to the ventral division.

The muscles of the **anterior group** (fig. 411) the *sartorius* and *quadriceps* arise from the ilium and the shaft of the femur and are inserted into the tibia. The quadriceps flexes the thigh and extends the leg. The sartorius flexes both the thigh and the leg and rotates the former lateralward, the latter medialward. They are innervated by the femoral nerve. The muscles of the **medial group** (fig. 411), *gracilis*, *pectineus*, *adductor brevis*, *longus*, and *magnus*, arise from the pubis and the inferior ramus of the ischium and are inserted into the shaft of the femur. They adduct and flex the thigh. They are innervated by the obturator nerve. The adductor magnus gets part of its nerve-supply from the sciatic. The pectineus usually gets all or most of its supply from the femoral. The reasons for including it in this group are given below. The **posterior group** (fig. 408) consists of the *semitendinosus* and *semimembranosus*, which arise from the ischial tuberosity, and of the *biceps*, one head of which also arises from the ischial tuberosity while the other arises from the shaft of the femur. The semimembranosus and semitendinosus are inserted into the tibia, the biceps into the fibula. They are innervated by branches of the sciatic. They extend the thigh and flex the knee. The semitendinosus rotates the leg medialward, the biceps lateralward.

In the leg there are also three groups of muscles, an anterior, a lateral and a posterior. The two former belong to the dorsal division and are innervated by the peroneal nerve. The last belongs to the ventral division and is innervated by the tibial nerve. The muscles of the **anterior group** (fig. 415), the *tibialis anterior*, *extensor digitorum longus*, *peroneus tertius* and *extensor hallucis longus*, arise from the tibia and fibula and are inserted into first and fifth metatarsals and into the two distal rows of phalanges. They flex the ankle and extend the toes. The extensor digitorum longus and peroneus tertius evert the foot. The muscles of the **lateral group** (fig. 415), the *peroneus longus* and *brevis*, arise from the fibula. send tendons behind the lateral malleolus and are inserted respectively into the first and the fifth metatarsals. They extend and evert the foot. The **posterior group** (figs. 413, 416) may be separated into two subdivisions, a superficial and a deep. The *superficial subdivision* (fig. 413) consists of the *gastrocnemius*, which

arises from the two epicondyles of the femur, and the *soleus* which arises from the tibia and fibula. These powerful extensors of the ankle are inserted by means of the tendon of Achilles into the calcaneus. The gastrocnemius is a flexor of the knee as well as an extensor of the ankle. A rudimentary muscle, the *plantaris*, arises near the lateral head of the gastrocnemius and is inserted into the fibrous tissue of the heel.

The deep group (fig. 416) consists of one muscle, the *popliteus*, a medial rotator and flexor of the leg, which arises from the lateral condyle of the femur and is inserted into the tibia; and of three muscles, the *flexor digitorum longus*, *flexor hallucis longus* and *tibialis posterior*, which arise from the tibia and fibula, send tendons behind the medial malleolus and are inserted into the plantar surface of the tarsus and into the terminal phalanges of the toes. They invert the foot and flex the toes.

In the foot one muscle on the dorsum represents the primitive dorsal division, the *extensor digitorum brevis* (fig. 418), supplied by a branch from the peroneal nerve. On the other hand the primitive ventral division is well represented in the sole of the foot, not only by the muscles associated with the long flexor tendons, quadratus plantæ, lumbricales (fig. 420), but also by the short flexor of the toes (fig. 419), by the special musculature of the big and little toes (fig. 421) and by the interosseous muscles (fig. 422). The *flexor digitorum brevis* (fig. 419), the most superficial of these muscles, arises from the calcaneus and is inserted into the second row of phalanges of the four more lateral toes. The *quadratus plantæ* arises from the calcaneus and is inserted into the tendon of the long extensor of the toes. It makes the action of the tendon on the digits more direct. The four *lumbrical muscles* run from this tendon to the medial sides of the four lateral toes. They flex the digits. Of the intrinsic muscles of the great toe (figs. 419, 421), the *abductor* arises from the calcaneus; the *flexor brevis* from the cuneiform bones; and the *adductor*, by one head from the long plantar ligament, by the other from the capsules of the metatarso-phalangeal joints. All are inserted into the base of the first phalanx. Of the *muscles of the little toe* (figs. 419–421), the *abductor* arises from the calcaneus, the *flexor* and *opponens* from the cuboid. The two former are attached to the base of the first phalanx, the last to the fifth metatarsal. The *interosseous muscles* which arise between the metatarsals are so arranged that the three plantar abduct and the four dorsal adduct the four lateral toes to and from an axis passing through the second toe. The muscles of the sole of the foot which send tendons to the sides of the bases of the first row of phalanges help to flex the digits on the metatarsals and to extend the toes at the first row of interphalangeal joints. These are much less effective extensors of the phalanges than are the corresponding muscles of the hand and, unlike the latter, seem, in most individuals, to exert but little extensor action on the third row of phalanges. The muscles of the sole of the foot are supplied by the lateral and medial plantar branches of the tibial nerve.

The **muscle fasciæ** of the inferior extremity are well developed. The *fascia lata*, which encloses the musculature of the back of the hip and the musculature of the thigh, is especially strong on the lateral side where it includes the longitudinal bundles of fibres which compose the ilio-tibial band. From the fascia lata strong intermuscular septa extend on each side of the quadriceps group of muscles to the femur. Medially beneath the sartorius muscle (fig. 410), septa help to bound Hunter's canal in which lies the femoral artery on its way to the popliteal space behind the knee. In the leg there is likewise a strong cylindrical fascial sheath which encloses the musculature and sends septa on each side of the peroneal group to the fibula. A transverse septum also separates the deep from the superficial muscles of the calf. The fascia of the leg is especially well developed near the ankle where it helps to hold in place the tendons which pass from the muscles of the leg into the foot. Muscle fasciæ are well developed both on the dorsum and in the sole of the foot.

A. MUSCULATURE OF THE HIP

1. Ilio-Femoral Musculature

The iliac blade divides these muscles into an **anterior group** (ilio-psoas), supplied by nerves from the lumbar plexus, and a **posterior group** (the gluteal muscles, piriformis, and tensor fasciæ latæ, supplied by nerves from the sacral plexus.

In most of the limbed vertebrates these two groups of muscles are represented, but they present marked specific variations in the different forms. Primitively, the iliacus group lies on the proximal portion of the lateral surface of the ilium.

(*a*) Anterior Group
(Figs. 406, 411)

The fan-shaped **iliacus** muscle arises from the iliac fossa. The fusiform **psoas major** muscle arises from the sides of the last thoracic and of the lumbar vertebræ and extends along the medial margin of the iliacus muscle. The two muscles are inserted by a common tendon into the lesser trochanter of the femur. Together they constitute the **ilio-psoas** muscle. The small, flat, fusiform **psoas minor** lies on the medial surface of the psoas major and extends from the twelfth thoracic vertebra to the ilio-pectineal eminence. The ilio-psoas flexes the thigh at the hip and the pelvis on the trunk. The psoas minor aids in flexing the pelvis.

The ilio-psoas muscle arises in the human embryo from a blastema which at first surrounds the femoral nerve and later extends proximally over the ilium (iliacus) and toward the lumbar vertebræ (psoas). The iliacus is phylogenetically the more primitive. In the shoulder it is probably represented by the infraspinatus. The psoas minor is much better developed in many of the lower mammals than in man.

FASCIÆ

The **fasciæ** and the relations of these muscles are shown in figs. 384 and 407.

The iliac and psoas muscles are covered by a dense fascia which is but slightly adherent to the underlying muscles. It is best developed in the pelvic region, where it extends from the iliac crest and ilio-lumbar ligament to the iliac portion of the linea arcuata and is called the **iliac fascia**. Superiorly it is continued over the psoas muscle as the **psoas fascia** and is attached medially to the sacrum and the lumbar region of the spinal column. Laterally it unites with the lumbar fascia and superiorly it is strengthened to form the medial lumbo-costal arch (fig. 391). Infriorly the **ilio-pectineal fascia** extends over the ilio-psoas muscle to its femoral insertion. It is firmly united on each side of the muscle to the capsule of the hip-joint and to the femur. As it passes beneath the inguinal ligament it is united to this by tendinous processes. Beyond the ligament it is less dense than in the pelvic region.

MUSCLES

The psoas major (figs. 406, 411).—*Origin.*—(1) By a series of thick fasciculi from the intervertebral discs between the twelfth thoracic and the fifth lumbar vertebra, from the adjacent parts of the bodies of these vertebræ and from tendinous arches which bridge over the middle of the sides of the first four lumbar vertebræ; and (2) by a series of more slender fasciculi from the lower borders and ventral surfaces of the transverse processes of the lumbar vertebræ.

Structure and insertion.—From these origins parallel fibre-bundles descend nearly vertically and give rise to a fusiform muscle which lies at the side of the vertebral bodies and extends along the border of the true pelvis toward its insertion. A tendon arises deep in the muscle near the last lumbar vertebra, and becomes free on its dorso-lateral surface slightly above the inguinal (Poupart's) ligament. On the medial side the attachment of fibre-bundles continues to the insertion of the muscle into the small trochanter. The iliacus muscle is attached to the lateral side of the tendon from near the ilio-pectineal eminence downward.

Nerve-supply.—Delicate branches pass into the psoas muscle from the trunks which unite to form the femoral (anterior crural) nerve, i. e., from the fourth, third, second, and often the first lumbar nerves.

The iliacus (figs. 406, 411).—*Origin.*—(1) From the iliac crest, the ilio-lumbar ligament, and the greater part of the iliac fossa, the anterior sacro-iliac ligaments, and often from the sacrum, and (2) from the ventral border of the ilium between the two anterior spines.

Structure and insertion.—From these areas of origin the fibre-bundles pass to be inserted—(1) in a penniform manner on the lateral surface of the tendon which emerges from the psoas above the inguinal (Poupart's) ligament, and (2) directly on the femur immediately distal to the small trochanter. The lateral portion of the muscle arise from the ventral border of the ilium and is adherent to the direct tendon of the rectus femoris and the capsule of the hip-joint. It is sometimes more or less isolated (*m. iliacus minor, ilio-capsulo-trochantericus*, etc.).

Nerve-supply.—Nerve branches, often united in a plexiform manner, arise from the femoral (anterior crural) nerve and pass across the surface of the iliacus muscle about midway between the crest of the ilium and the combined ilio-psoas tendon. Special nerve branches are usually likewise distributed from the main trunk of the femoral nerve to the fleshy portion of the muscle which extends over the acetabulum and the head of the femur.

Relations.—The psoas major lies lateral to the lumbar vertebræ and in front of the quadratus lumborum and intertransverse muscles. The psoas minor passes downward across its ventral surface. Both psoas muscles are crossed by the crura of the diaphragm. The kidney with its adipose capsule lies lateral to them opposite the first two lumbar vertebræ. For the rest, their fascia is covered ventro-laterally by retro-intestinal and retro-peritoneal tissue in which the vena cava inferior runs in front of them on the right side, the inferior mesenteric vein in front of them on the left side, and the ureter, the spermatic or ovarian, and the renal and colic vessels on each side. The external iliac artery lies medial to the psoas major in the pelvis, and beyond the inguinal (Poupart's) ligament the femoral artery lies ventral to it. The lumbar plexus arises

between its origins from the vertebral bodies and discs and those from the transverse processes. The nerves springing from the lumbar plexus take courses subject to much individual variation through the muscle on the way to their destinations. Fasciculi of the muscle may thus be separated by the femoral (anterior crural) nerve or other branches of the lumbar plexus.

The iliacus muscle in the region of the pelvis is covered by retro-peritoneal fat. The psoas muscle crosses its medial margin and from between the two muscles the femoral nerve usually emerges to pass into the thigh above the iliacus. Beyond the inguinal ligament the iliacus lies in front of the capsule of the hip-joint and the straight tendon of the rectus femoris, and is crossed by the sartorius.

FIG. 406.—PSOAS, ILIACUS, AND QUADRATUS LUMBORUM.

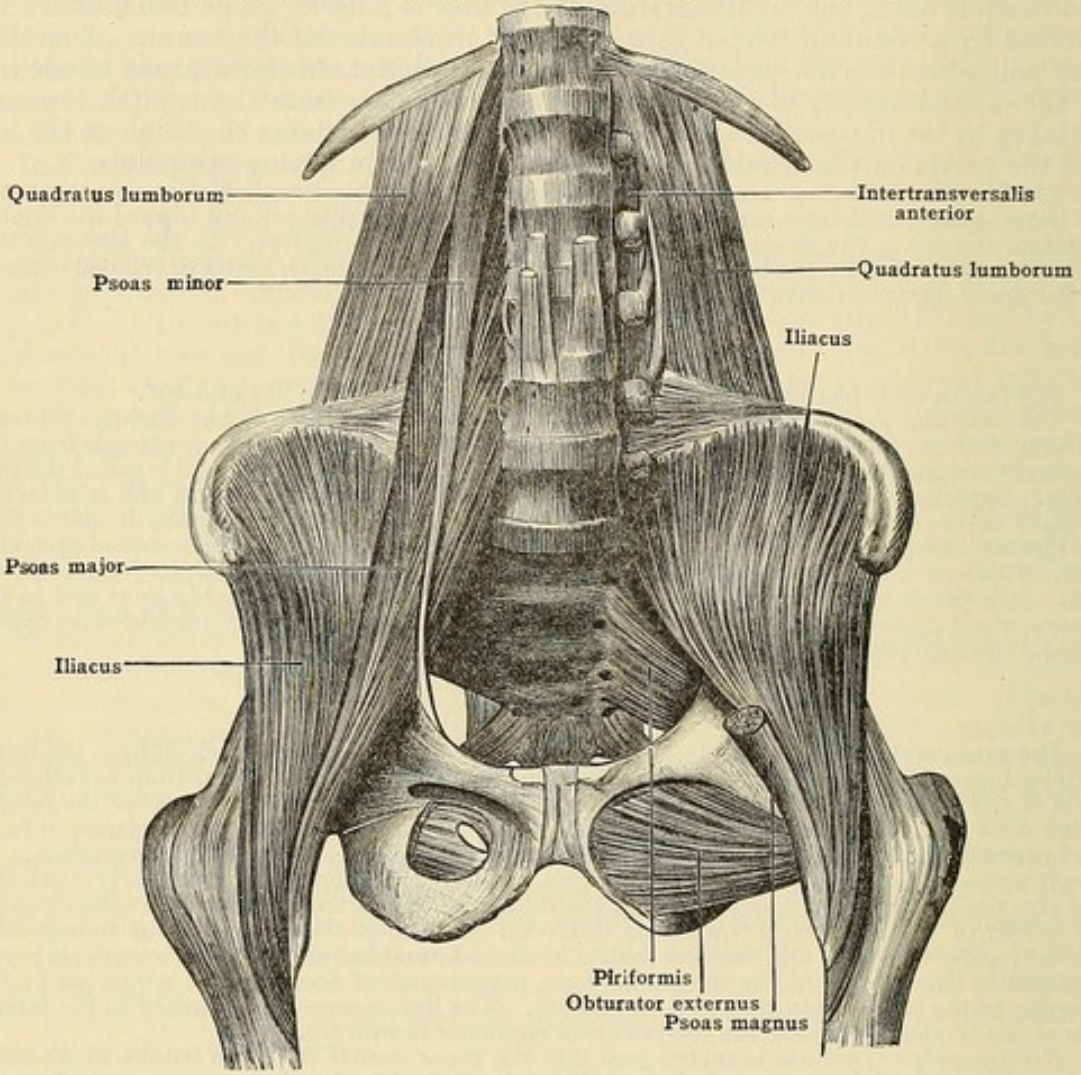

Action.—The ilio-psoas is a powerful flexor of the thigh at the hip and a weak medial rotator and adductor. It also serves to flex the lumbar region of the spine.

Variations.—The psoas muscle may be separated from the iliacus as far as the femoral insertion. The part of the psoas arising from the distal lumbar vertebræ may form a distinct muscle. Slips may pass from the psoas major to the psoas minor. A separate lamina of the iliacus muscle may be attached to the iliac fascia. From the anterior inferior iliac spine a small muscle slip may run to the intertrochanteric line or the ilio-femoral ligament. To this slip the term **iliacus minor** has been applied as well as to the larger fasciculus mentioned above.

The psoas minor (fig. 406).—*Origin.*—From the twelfth thoracic and first lumbar vertebræ and the intervening disc.

Structure and insertion.—The fibre-bundles pass to be attached as far as the level of the fifth lumbar vertebra to a flat tendon which appears about the mid-lumbar region and is inserted into the ilio-pectineal eminence. It is intimately united to the iliac fascia.

Nerve-supply.—The branch to the psoas minor arises usually from the first and second lumbar nerves, often in company with the genito-femoral (genito-crural).

Action.—To flex the pelvis.

Relations.—It is closely applied to the ventral surface of the psoas major.

Variations.—The muscle is inconstant in development and is frequently absent. Gruber has found it absent on both sides in 183 out of 450 bodies, on one side in 69.

BURSÆ

B. iliopectinea.—A large bursa between the ilio-psoas muscle, the ilio-pectineal eminence, and the capsule of the hip-joint. **B. iliaca subtendinea.**—A small bursa between the tendon of insertion of the ilio-psoas and the lesser trochanter.

(*b*) Posterior Group

(Figs. 387, 407, 408, 413)

The muscles of this group arise from the ilium and sacrum, cover the dorso-lateral surface of the hip, and are inserted into the great trochanter and shaft of the femur and into the ilio-tibial band. They lie in three planes. In the **first layer** (fig. 387) are the flat, quadrilateral **tensor fasciæ latæ,** which arises from the front of the crest of the ilium and is inserted into the ilio-tibial band, and the thick, rhomboid **gluteus maximus,** which arises from the dorsal portion of the iliac ala, the lumbo-dorsal fascia, the sacrum and coccyx, and the sacro-tuberous (great sacro-sciatic) ligament, and is inserted in part into the ilio-tibial band and in part into the back of the upper part of the shaft of the femur. The **ilio-tibial** band is a flat tendon which descends, closely fused with the fascia lata, to the lateral side of the upper extremity of the tibia. In the **second layer** (fig. 408) are the flat, thick, triangular **gluteus medius** and the 'pear-shaped' **piriformis** The former arises from the upper and back part of the outer surface of the ala of the ilium, the latter from the ventral surface of the sacrum and the posterior border of the great sciatic notch. Both are inserted into the top of the great trochanter. The **third layer** (fig. 409) is composed of the triangular **gluteus minimus,** which arises from the inferior ventral portion of the outer surface of the ala of the ilium, and is inserted into the front of the great trochanter of the femur.

The muscles of this group extend, flex, abduct, and rotate the thigh at the hip. The gluteus maximus and medius are in part extensors, the gluteus minimus and the tensor fasciæ latæ are flexors of the hip-joint. All the muscles serve to abduct, the gluteus maximus acting thus when the hip is flexed. When the thigh is extended the lower part of the gluteus maximus is an adductor. The gluteus maximus and posterior part of the gluteus medius and the piriformis act as lateral, the anterior part of the gluteus medius, the gluteus minimus, and the tensor fasciæ latæ as medial, rotators. The gluteus maximus and the tensor fasciæ latæ through the ilio-tibial band keep the extended knee-joint firm. The gluteus maximus is supplied by the inferior gluteal nerve, the piriformis by special nerves, and the other muscles of the group by the superior gluteal nerve. All these nerves arise from the upper part of the back of the sacral plexus.

The gluteus medius, gluteus minimus, and piriformis form a group of muscles which in the embryo have a common origin and are more or less fused in the adult. The gluteus maximus arises in two distinct, though associated, portions, and the tensor fasciæ latæ as another distinct portion. The two muscles, however, are probably to be considered as parts of a primitive caudo-pelvo-tibial musculature, while the gluteus medius group is represented in the lower forms by an ilio-femoral musculature. The former group is often closely associated with the extensor muscles of the thigh in the lower forms (frog), and in some of the lower mammals extends its insertion to the plantar fascia (ornithorhynchus). In the arm this group is perhaps represented by the deltoid, the latissimus dorsi, and the teres major, while the gluteus medius group is represented by the subscapularis.

FASCIÆ

The **tela subcutanea** of the gluteal region is very thick, contains much fat, and is often divisible into two layers, of which the deeper is closely adherent to the fascia lata and through this to the gluteus maximus. Over the great trochanter a subcutaneous bursa is usually found (**bursa trochanterica subcutanea**).

Muscle fascia.—The muscles of the hip and thigh are enclosed in a dense fascia, the **fascia lata** (figs. 387, 407). This arises from the tuber ischii, the sacro-tuberous (great sacro-sciatic) ligament, the back of the sacrum and the coccyx, the crest of the ilium, the inguinal (Poupart's) ligament, and the pubic and ischial rami, and extends to the tibia and the fascia covering the muscles of the leg. It is composed mainly of bundles of fibres running transversely to the long axis of the limb. In the region of the gluteal groove it is strengthened by a transverse fibrous band which arises from the tuberosity of the ischium and arches upward over the lower border of the gluteus maximus muscle.

In the region of the hip the fascia lata invests both surfaces of the tensor fasciæ latæ and the gluteus maximus, and is closely bound to these muscles through intramuscular septa. Between these two muscles the fascia covers the fascia of the gluteus medius, to which it is adherent near the iliac crest, but from which it is separated by loose tissue more distally. Anteriorly the fascia is fused with the ilio-pectineal fascia and the inguinal (Poupart's) ligament.

More distally the tendons of the tensor fasciæ latæ and of the superficial portion of the gluteus maximus become incorporated with the deep surface of the fascia lata and give rise to the **ilio-tibial band** [tractus iliotibialis].

FIG. 407, A and B.—TRANSVERSE SECTIONS THROUGH THE LEFT SIDE OF THE PELVIS IN THE REGIONS INDICATED IN THE DIAGRAM.

C. Section through the muscles of the left inguinal region parallel to the inguinal (Poupart's) ligament (after Spalteholz). *b* in the diagram indicates Section *B*, fig. 384, p. 421; *a'* and *b'* indicate sections *A* and *B*, fig. 410, p. 465. (For legends, see p. 459.)

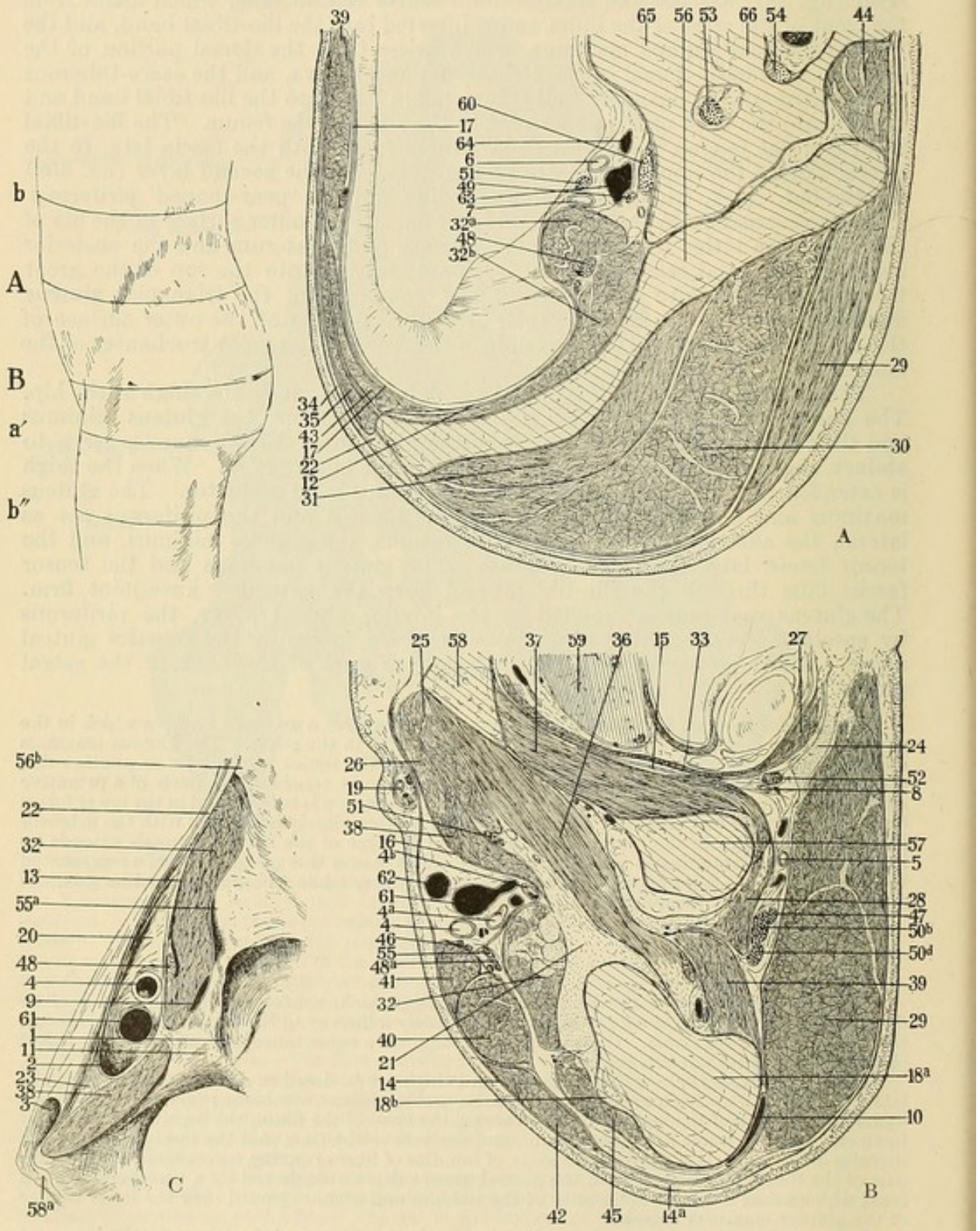

The gluteus medius and minimus muscles are invested by adherent fascial sheets which, ventrally between the two muscles, may be combined into an intermuscular septum or be so slightly developed that the muscles are fused. The fascial sheet covering the gluteus medius toward the iliac crest is fused with the deep surface of the fascia lata. This fusion results in the formation of septa between the gluteus medius and the gluteus maximus and tensor fasciæ latæ.

The piriformis in the pelvic cavity is covered on the anterior surface by a special slightly developed fascia. This fascia also covers the pelvic surface of the sacral plexus. Outside the pelvis the piriformis is covered by an adherent membrane which usually is separated by loose tissue from the surrounding structures.

MUSCLES

I. First Layer

The tensor fasciæ latæ (figs. 387, 411).—*Origin.*—(1) By a tendinous band from the external lip of the iliac crest, and the upper part of the notch between the anterior superior and anterior inferior spines of the ilium, and (2) from the septum between it and the gluteus medius.

Structure and insertion.—The nearly parallel fibre-bundles pass distally and laterally and are united to tendon fasciculi which become incorporated with the ilio-tibial band (tractus ilio-tibialis) about one-third of the way down the thigh.

Nerve-supply.—The superior gluteal nerve sends a branch through the ventral margin of the gluteus minimus to terminate in the middle third of the deep surface of the tensor fasciæ latæ near its dorsal border.

Action.—To rotate medially, flex, and abduct the thigh, and to make tense the fascia lata.

Relations.—It lies over the gluteus medius, the proximal part of the rectus femoris, and the vastus lateralis.

Variations.—It may be divided into two parts, one rising from the anterior superior spine, the other from the iliac crest. Accessory slips may arise from the inguinal ligament, the crest of the ilium, or the fascia over the lower part of the abdominal wall. Union of the muscle with the gluteus maximus has been observed, thus making a muscle much resembling the deltoid of the shoulder. By some the fascia lata between the tensor and the gluteus maximus is considered an atrophied part of a deltoid of the hip.

The gluteus maximus (figs. 387, 413).—*Origin.*—(1) From the dorsal fifth of the outer lip of the iliac crest, the outer surface of the ilium dorsal to the posterior gluteal line, the lumbo-dorsal fascia between the posterior superior spine of the ilium, and the side of the sacrum, and (2) from the lateral portions of the fourth and fifth sacral and the coccygeal vertebræ and from the back of the sacro-tuberous (great sacro-sciatic) ligament.

Insertion.—Into (1) the ilio-tibial band; (2) the gluteal tuberosity of the femur and the adjacent part of the tendinous origin of the vastus lateralis (fig. 407).

Structure.—The large fibre-bundles of which the muscle is composed take a somewhat parallel course from origin to insertion. From the areas of origin and the enveloping fascia fibrous bands extend into the muscle. The belly is divisible into two portions, a superficial and a deep. The division may be much more clearly recognised in the embryo than in the adult. The superficial portion is the larger, and includes all of that part of the muscle which springs from the ilium and the more superficial portion of that arising from the sacrum and the upper part of the coccyx. The deep portion includes that part of the muscle attached to the side of the sacrum and the coccyx, and to the sacro-tuberous ligament. The superficial portion and some of the fibre-bundles of the deep portion terminate in the ilio-tibial band along a line extending from the great trochanter to the end of the upper third of the femur. The deep portion is inserted chiefly by a flat tendon into the gluteal tuberosity, and also directly into the adjacent portion of the origin of the vastus lateralis.

Nerve-supply.—Two branches (inferior gluteal) arising from the sacral plexus either separately or united, are usually given to the muscle. One of these curves anteriorly across the deep surface of the proximal superficial portion of the muscle in the middle third between the tendons

---

1. Acetabulum. 2. Annulus femoralis. 3. Annulus inguinalis subcutaneous (ext. abdominal ring). 4. Arteria femoralis. 4*a*. A. profunda femoris. 4*b*. A. circumflexa femoris medialis. 5. A. glutea inferior. 6. A. hypogastrica (internal iliac). 7. A. iliaca externa. 8. A. pudena interna (pudic). 9. Bursa ilio-pectinea. 10. B. trochanterica m. glutæi maximi. 11. Eminentia iliopectinea. 12. Fascia iliaca. 13. F. ilio-pectinea. 14. F. lata—*a*, ilio-tibial band. 15. F. obturatoria. 16. F. pectinea. 17. F. transversalis. 18. Femur—*a*, trochanter major; *b*, trochanter minor. 19. Funiculus spermaticus (spermatic cord). 20.—Lacuna vasorum. 21. Ligamentum ilio-femorale. 22. L. inguinale (Poupart's ligament). 23. L. lacunare (Gimbernat's). 24. L. sacro-tuberosum (great sciatic). 25. Musculus adductor brevis. 26. M. adductor longus. 27. M. coccygeus. 28. M. gemellus inferior. 29. M. gluteus maximus. 30. M. gluteus medius. 31. M. gluteus minimus. 32. M. iliopsoas—*a*, psoas; *b*. iliacus. 33. M. levator ani. 34. M. obliquus abdominis externus, aponeurosis. 35. M. obliquus abdominis internus. 36. M. obturator externus. 37. M. obturator internus. 38. M. pectineus. 39. M. quadratus femoris. 40. M. rectus femoris. 41. M. sartorius. 42. M. tensor fasciæ latæ. 43. M. transversus abdominis. 44. M. transverso-spinales (multifidus). 45. M. vastus lateralis. 46. N. cutaneus femoris anterior (middle cutaneous). 47. N. cutaneous femoris posterior (small sciatic). 48. N. femoralis (anterior crural). 49. N. gluteus superior. 50. N. ischiadicus (great sciatic)—*a*, peronæus communis (external popliteal); *b*, tibialis (internal popliteal). 51. N. obturatorius. 52. N. pudendus. 53. N. sacralis I. 54. N. sacralis II. 55. N. saphenus. 56. Os ilium—*a*, spina anterior superior; *b*, spina anterior inferior. 57. Os ischium. 58. Os pubis—*a*, spina (tubercle). 59. Prostata. 60. Truncus lumbo-sacralis. 61. Vena femoralis. 62. V. saphena magna. 63. V. iliaca externa. 64. V. hypogastrica (internal iliac). 65. Vertebra sacralis I. 66. Vertebra sacralis II.

of origin and insertion, the other descends to enter the middle third of the distal deep portion of the muscle.

Action.—It is the most powerful extensor of the thigh. It also serves slightly to rotate the limb lateralward and to make tense the fascia lata, and through the ilio-tibial band to keep the extended knee-joint steady. When the thigh is extended the major part of the muscle is an adductor but the upper part is a weak abductor. The whole muscle is an abductor when the thigh is flexed. It is brought powerfully into play in climbing and in walking up hill.

FIG. 408.—THE LATERAL ROTATORS AND THE HAMSTRING MUSCLES.

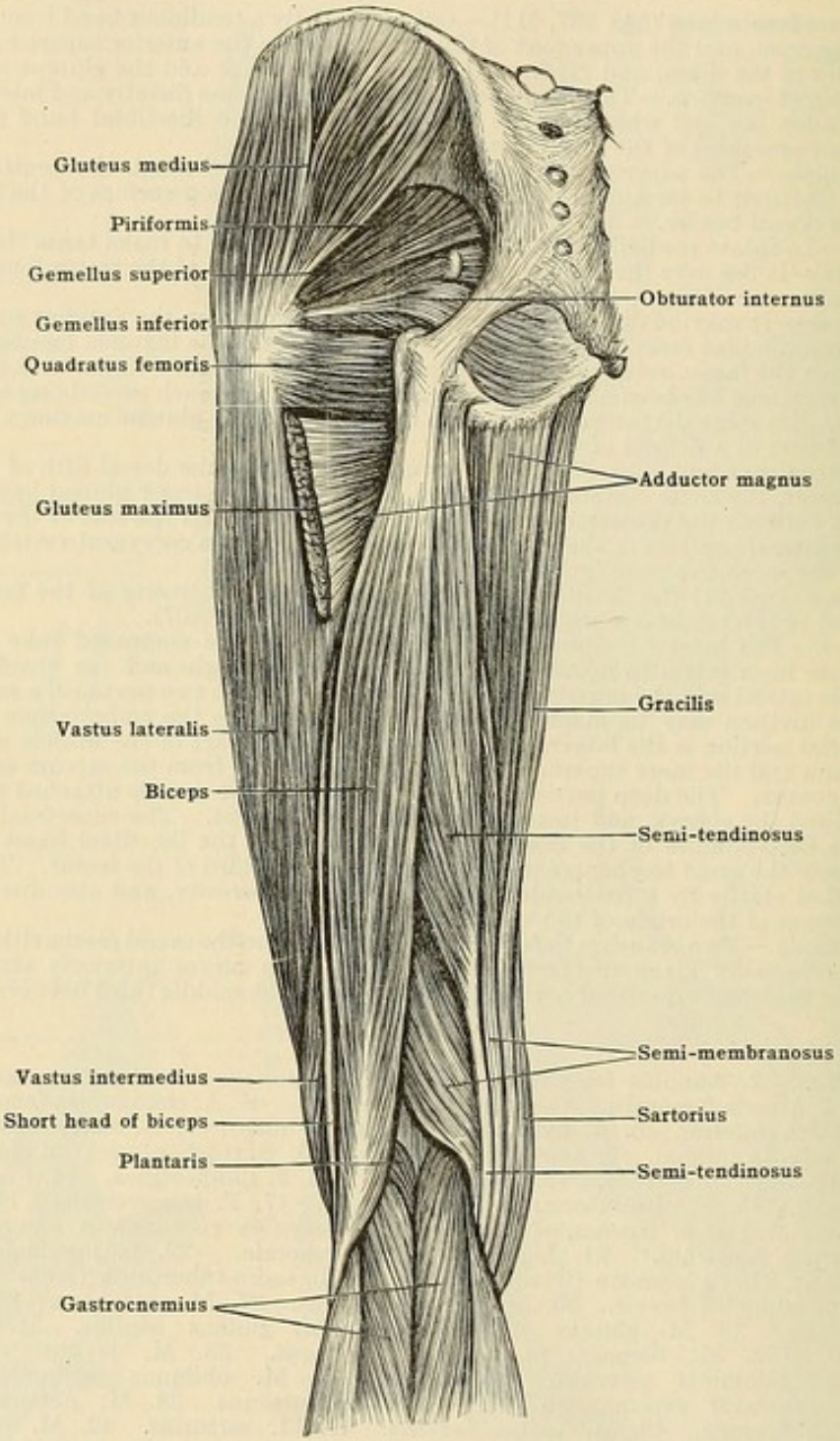

Relations.—It is covered by the fatty superficial tissue of the buttock. It extends over the posterior portion of the ilium, the lateral surface of the sacrum and coccyx, the sacro-tuberous ligament, and the great trochanter. It covers the tuber of the ischium in the standing but not in the sitting position. Immediately beneath the muscle lie portions of the gluteus medius, piriformis, obturator internus, gemelli, quadratus femoris, obturator externus, and hamstring muscles, and of the gluteal vessels and nerves and the sciatic nerve.

Variations.—Few anomalies are recorded. The deep distal portion of the muscle may be more isolated than normal in the adult. A special coccygeo-femoral muscle may run from the coccyx to the linea aspera, or from the sacro-tuberous ligament to the fascia of the leg. A

special fasciculus, the **ischio-femoralis**, may arise from the tuberosity of the ischium and become inserted into the lower border of the muscle near the great trochanter. The sacral, ischial, or coccygeal origin may be lacking, or the origin of the muscle may be from the sacrum only.

II. Second Layer

The muscles of this layer are the gluteus medius and the piriformis.

The gluteus medius (fig. 408).—*Origin.*—From (1) the ventral three-fourths of the iliac crest, and the outer surface of the ilium between the anterior and posterior gluteal lines and (2) the investing fascia.

Structure and insertion.—The fibre-bundles converge upon both surfaces of a broad tendon nearly to its insertion on an oblong impression on the postero-superior angle and the external surface of the great trochanter. The more posterior fibre-bundles of the superficial stratum of the ventral portion of the muscle cross obliquely those of the deeper dorsal portion near the tendon of insertion. From the tendon an aponeurotic extension is usually continued into the tendon of the vastus lateralis.

Nerve-supply.—From the superior gluteal nerve a branch passes to the dorsal portion of the muscle and one or more twigs of the branch to the tensor fasciæ latæ enter the ventral portion of the muscle. The branches enter the middle third of the muscle between its tendons of origin and insertion. The nerve-fibres arise usually from the fourth and fifth lumbar and first sacral nerves. The branch to the dorsal portion of the muscle has a lower spinal origin than those to the ventral portion.

Action.—To abduct the thigh. The anterior portion of the muscle is a flexor and a medial rotator, the posterior a lateral rotator and an extensor. When the muscle acts as a whole, it is a medial rotator.

Relations.—Upon the muscle lie the tensor fasciæ latæ and gluteus maximus muscles and the fascia lata; beneath it lie the gluteus minimus muscle, the superior gluteal nerve and vessels, and the great trochanter.

Variations.—It may be divided into two distinct portions, or it may be fused with the piriformis or the gluteus minimus or both. A special fasciculus may extend to the superior portion of the great trochanter.

The piriformis (fig. 408).—*Origin.*—From (1) the lateral part of the ventral surface of the second, third, and fourth sacral vertebræ; (2) the posterior border of the great sciatic notch; and (3) the deep surface of the sacro-tuberous (great sacro-sciatic) ligament near the sacrum.

Structure and insertion.—The fibre-bundles converge upon a tendon which is inserted upon the anterior and inner portion of the upper border of the great trochanter. The insertion of fibre-bundles continues nearly to the great trochanter. An accessory slip of insertion may pass to the gluteus minimus.

Nerve-supply.—From a nerve which arises either directly from the first or second sacral nerve or from a loop between them. The nerve enters the deep surface of the muscle in its middle third. There may be two or more nerves.

Action.—It is an extensor, abductor, and lateral rotator of the thigh. It causes medial rotation when the hip is flexed.

Relations.—Its ventral surface faces the sacral plexus, the rectum, and the hip-joint. It is covered dorsally by the gluteus maximus. It lies between the gluteus medius and the superior gemellus. Between the piriformis and the superior gemellus the sciatic nerve usually passes into the thigh. The superior gluteal nerve and vessels pass dorsally above its superior margin; the inferior nerve and vessels beneath its inferior margin.

Variations.—It is rarely absent. The origin may extend to the first sacral or to the fifth sacral vertebra and the coccyx. It may be fused with the gluteus medius or minimus or more rarely with the superior gemellus. Its tendon of insertion may be fused with that of the gluteus medius or the obturator internus. In about 20 per cent. of bodies it is divided partly or completely into two portions, between which the sciatic nerve or its peroneal (external popliteal) division usually passes. Rarely the tibial instead of the peroneal portion may pass between the two fasciculi, or the muscle may be divided into three or more fasciculi, between which the branches of the sciatic nerve pass.

III. Third Layer

The gluteus minimus (fig. 409).—*Origin.*—From the outer surface of the ilium between the anterior and inferior gluteal lines; (2) from the septum between it and the gluteus medius near the anterior superior iliac spine; and (3) from the capsule of the hip-joint.

Structure and insertion.—The fibre-bundles converge upon a tendon which appears on the middle of the ventral border and gradually spreads over the lateral surface. The muscle is thickest in front, where it is usually bound by an intermuscular septum to the gluteus medius. The tendon is inserted into the ventral surface of the great trochanter of the femur.

Nerve-supply.—From twigs of the branch of the superior gluteal nerve which goes to the tensor fasciæ latæ. These twigs enter the middle third of the muscle as the tensor branch passes across it.

Action.—To abduct the thigh and rotate it medialward. The anterior part of the muscle is a flexor, the posterior an extensor.

Relations.—It is covered by the gluteus medius and piriformis muscles. Beneath it lie the inferior part of the iliac ala, the hip-joint (to the capsular ligament of which it is bound), and the direct tendon of the rectus femoris muscle.

Variations.—It may be fused with the gluteus medius or the piriformis. It may send a slip to the fascia lata or the vastus lateralis. It may be divided into two distinct divisions,

an anterior and a posterior. Very frequently from the anterior margin of the muscle a special fasciculus is more or less isolated (the **scansorius,** invertor femoris, small anterior gluteal, etc.). The **accessorius of the gluteus minimus** is a small muscle fasciculus which may lie under cover of the gluteus minimus and extend to be inserted into the capsule of the hip-joint.

Bursæ

B. ischiadica m. glutei maximi.—A small inconstant bursa between the tuber ischii and the gluteus maximus muscle. **B. trochanterica m. glutei maximi.**—A large bursa constantly

Fig. 409—The Deep Muscles of the Back of the Thigh.

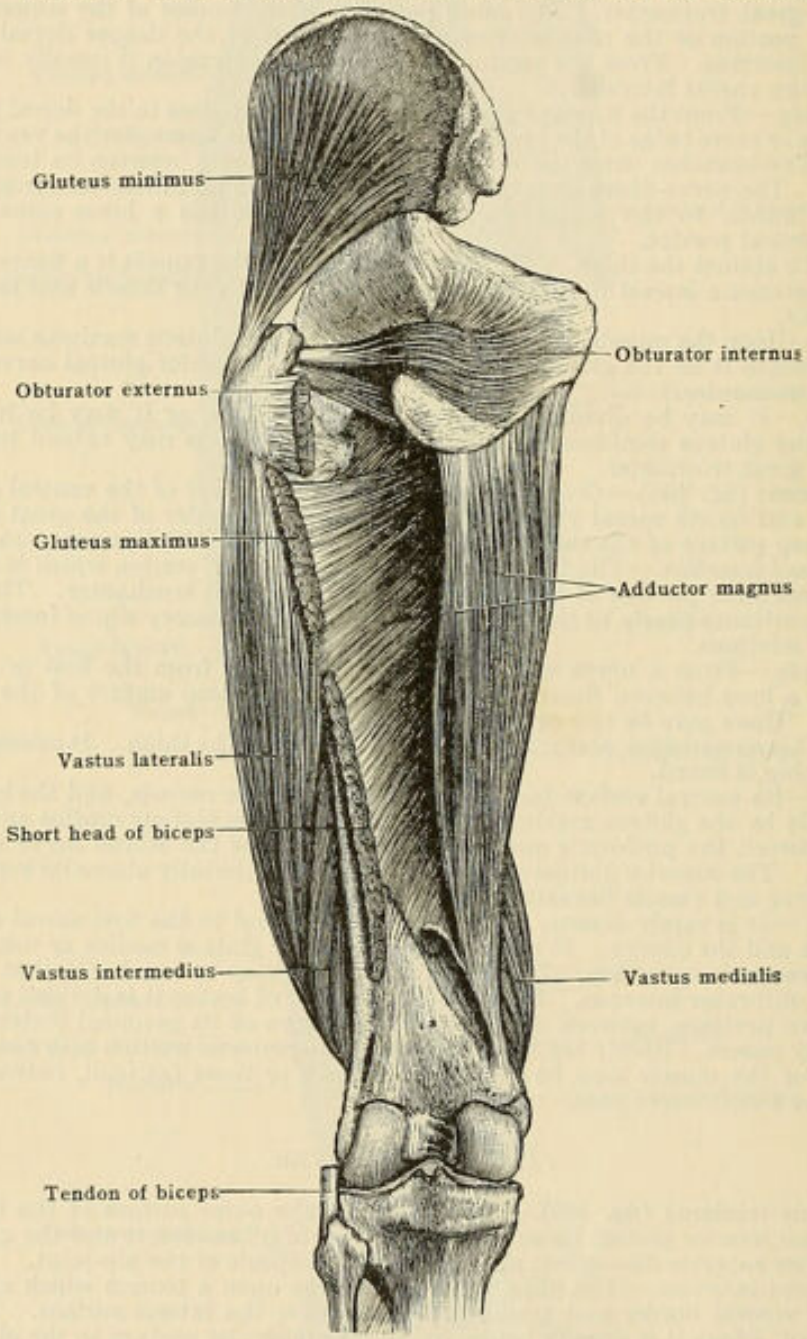

present between the fascial tendon of the gluteus maximus and the posterior lateral surface of the great trochanter and the origin of the vastus lateralis muscle. **B. gluteofemorales.**—Two or three small bursæ on each side of the tendon of attachment of the gluteus maximus to the femur. **B. trochanterica m. glutei medii anterior.**—A small bursa constantly present between the tendon of the gluteus medius muscle and the lateral surface of the great trochanter. **B. trochanterica m. glutei medii posterior.**—A small bursa frequently present between the tendons of the piriformis and the gluteus medius. **B. trochanterica m. glutei minimi.**—A fairly large bursa generally present between the margin of the great trochanter and the tendon of this muscle. **B. m. piriformis.**—A small bursa frequently present between the tendons of the piriformis and superior gemellus muscles and the femur.

2. Ischio-pubo-femoral Musculature of the Hip

The muscles belonging to this group (the obturator internus, the two gemelli, the quadratus femoris and the obturator externus, extend from the pubis and ischium across the back of the hip-joint to the great trochanter and the neighbouring part of the shaft of the femur. They are powerful lateral rotators of the thigh. The **obturator internus** (fig. 409), a large, flat, triangular muscle, arises from the pelvic surface of the innominate bone and from the obturator membrane. At the lesser sciatic notch its tendon is joined by the two **gemelli** (fig. 408), one of which arises on each side from the bony projections which make the notch, and the combined tendon is inserted into the trochanteric (digital) fossa. The **quadratus femoris** (fig. 408) passes from the tuber of the ischium to the femur behind and below the great trochanter. These muscles are supplied by special nerves which arise from the front of the sacral plexus and enter the deep surfaces of the muscles. A fifth muscle, attached to the greater trochanter and associated with this group, the **obturator externus,** is differentiated near the adductor muscles of the thigh and is supplied by a branch from the obturator nerve. It arises from the outer surface of the bones bounding the ventral two-thirds of the obturator foramen and is inserted by a tendon into the trochanteric (digital) fossa.

These muscles seem to have no certain representatives in the arm, where the shoulder-joint is entirely ensheathed by the dorsal musculature. It is possible that the pectoral group has a corresponding embryonic origin. The group is represented, with marked variations, in the lower extremities of amphibia and all higher vertebrates.

FASCIÆ

Within the pelvis the obturator internus lies on the obturator membrane. It is covered by the **obturator fascia,** which is attached to the body of the pubis, to the iliac portion of the arcuate line, to the ventral margin of the great sciatic notch, to the ischial spine, to the sacro-tuberous (great sacro-sciatic) ligament, and with the falciform process of that ligament, to the ischial and pubic rami. Near the upper part of the obturator foramen the fascia instead of being attached to bone is reflected over the muscle and attached to the obturator membrane. It here helps to bound the canal for the obturator vessels and nerve. The upper part of the fascia lies beneath the pelvic peritoneum and the levator ani. The lower part forms the outer boundary of the ischio-rectal fossa. The fascia is continued as a thin, adherent membrane over the obturator internus and the gemellus muscles to their attachment. The quadratus femoris is invested by a thin adherent fascial sheet.

MUSCLES

The obturator internus (fig. 409).—*Origin.*—From (1) the pelvic surface of the pubic rami near the obturator foramen; (2) the pelvic surface of the ischium between the foramen and the great sciatic notch; (3) the deep surface of the obturator internus fascia; (4) the fibrous arch which bounds the canal for the obturator vessels and nerve; and (5) the pelvic surface of the obturator membrane except in the lower part.

Structure and insertion.—From this extensive area of origin the fibre-bundles converge toward the lesser sciatic notch and become applied to the broad tendon of insertion. At the notch the muscle curves laterally and extends outward and upward to its insertion into the fore part of the trochanteric fossa of the femur. The tendon is formed of five or six bands which begin high in the muscle and converge into a common tendon situated on the deep surface of the muscle as the latter curves about the ischium. The tendon bands at first throw the tendon into folds which run in ridges in the fibro-cartilage which lines the notch. The attachment of fibre-bundles continues upon the dorsal surface of the tendon to half way between the lesser sciatic notch and the great trochanter.

Nerve-supply.—A special nerve to the obturator internus arises from the front of the sacral plexus, usually from the lumbo-sacral cord and the first and second sacral nerves. This nerve passes lateral to the sacro-spinous (lesser sciatic) ligament, then re-enters the pelvis through the lesser sciatic notch and sends out branches of distribution on the pelvic surface of the obturator internus.

Action.—This muscle with its two companions, the gemelli, is a powerful lateral rotator of the thigh. It is also an extensor and abductor when the thigh is bent at a right angle.

Relations.—The chief pelvic relations have been described in connection with the obturator fascia which completely covers the medial surface of the muscle. The muscle passes out between the two sacro-ischial (sacro-sciatic) ligaments. Outside the pelvis the gemellus muscles run on each side of the tendon, which is here closely applied to the capsule of the joint. Dorsal to it lie the gluteus maximus, the sacro-tuberous (great sacro-sciatic) ligament, the inferior gluteal (sciatic) vessels, and the sciatic and posterior cutaneous nerves. The nerve of the quadratus femoris runs beneath the obturator internus and gemellus muscles.

Variations.—It varies in the extent of its insertions. It may be divided into two parts,

a pubic and an ischial. Fasciculi may be sent to the postero-inferior part of the ilio-pectineal eminence, the tendon of the psoas minor, the tuber ischii, the sacro-tuberous (great sacro-sciatic) ligament, the ischial spine, etc.

The gemellus superior (fig. 408).—*Origin.*—From the outer surface of the ischial spine and the neighbouring edge of the lesser sciatic notch.

Structure and insertion.—The fibre-bundles encircle the upper border and ventral aspect of the tendon of the obturator internus. They are inserted into the upper border of this tendon, and sometimes also into the trochanteric fossa.

Nerve-supply.—From a small nerve which arises either directly from the plexus or as a branch of the nerve to the obturator internus or of that to the quadratus femoris. This nerve usually enters the deep surface of the muscle near the junction of its ischial and middle thirds.

Action.—It is essentially a part of the obturator internus.

Relations.—It lies between the piriformis and the tendon of the obturator internus. Proximally it adjoins its fellow beneath this tendon; distally, the two gemelli enclose the tendon in a musculo-tendinous sheath.

Variations.—It may be wanting or may have a more extensive origin than usual. It may be joined to the piriformis or to the gluteus minimus or be joined more closely than usual to the obturator tendon.

The gemellus inferior.—*Origin.*—From the upper part of the inner border of the tuberosity of the ischium, the sacro-tuberous (great sacro-sciatic) ligament and from the neighbouring edge of the lesser sciatic notch.

Structure and insertion.—The fibre-bundles converge upon the inferior border of the tendon of the obturator internus, and are inserted by tendon-fibres into this or into the great trochanter below the obturator internus tendon.

Nerve-supply.—From a branch of the nerve to the quadratus femoris. This branch enters the deep surface of the muscle near the junction of the ischial with the middle third.

Action.—It is essentially a part of the obturator internus.

Relations.—It lies between the quadratus femoris and the tendon of the obturator internus.

Variations.—It is rarely absent. It may be joined to the quadratus femoris. It is frequently closely bound up with the obturator internus. It may be doubled.

The quadratus femoris (fig. 408).—*Origin.*—From the upper part of the outer border of the tuber of the ischium.

Structure and insertion.—The fibre-bundles take a nearly parallel course and are inserted into the vertical ridge which terminates above on the inferior dorsal angle of the great trochanter.

Nerve-supply.—From a nerve which arises usually from the lumbo-sacral cord and the first sacral nerve and passes under the gemelli and the tendon of the obturator internus. The nerve enters the deep surface of the muscle near the junction of the ischial and middle thirds.

Action.—It is a powerful lateral rotator and a weak adductor of the thigh.

Relations.—It is covered by the gluteus maximus. Between this muscle and the quadratus femoris runs the sciatic nerve. The obturator externus muscle lies in front. The inferior gemellus extends along its superior border. The adductor minimus adjoins it distally.

Variations.—It is absent in from 1 to 2 per cent. of instances. (Schwalbe and Pfitzner.) It may be double near its femoral insertion. It may be fused with the inferior gemellus or the adductor magnus. It may send a fasciculus to the semimembranosus.

The **obturator externus** (figs. 407, 409).—*Origin.*—From the lateral surface of the pubic and ischial rami, where they bound the obturator foramen, and from the surface of the obturator membrane.

Structure and insertion.—Often the muscle is distally divided into three fasciculi, a superior from the superior pubic ramus, a middle from the inferior pubic ramus and the obturator membrane, and an inferior from the ischium. The fibre-bundles converge upon a tendon which is at first deeply buried, then appears on the lateral surface of the muscle and is continued as a rounded tendon over the capsule of the joint to its insertion into the dorsal part of the trochanteric fossa.

Nerve-supply.—The obturator nerve gives rise, usually in the obturator canal, to a branch which bifurcates to enter the superior border and ventral surface of the muscle in its middle third.

Action.—It is a powerful lateral rotator of the thigh and is also a weak adductor.

Relations.—It is covered by the pectineus, the ilio-psoas, and the adductor magnus muscles in front, and by the quadratus femoris behind near its insertion. It covers over the obturator membrane. The obturator nerve passes either above the muscle or through its upper portion.

Variations.—The reported variations are few. It may be joined by a slip from the adductor brevis.

Bursæ

B. m. obturatoris interni.—A fairly large bursa constantly present between the tendon of the obturator internus muscle and the lesser sciatic notch. It may extend on each side beneath the gemellus muscles. **B. m. quadrati femoris.**—A small bursa frequently found between this muscle and the small trochanter. **B. m. obturatoris externi.**—A bursa is sometimundes of between the tendon of this muscle and the capsule of the joint.

B. MUSCLES OF THE THIGH

In the thigh three groups of muscles may be recognised, an anterior or extensor (figs. 411, 412), a medial or adductor (figs. 409, 411, 412), and a posterior, flexor or hamstring group (figs. 408, 413).

FIG. 410, A–D.—TRANSVERSE SECTIONS THROUGH THE LEFT THIGH IN THE REGIONS INDICATED IN THE DIAGRAM.

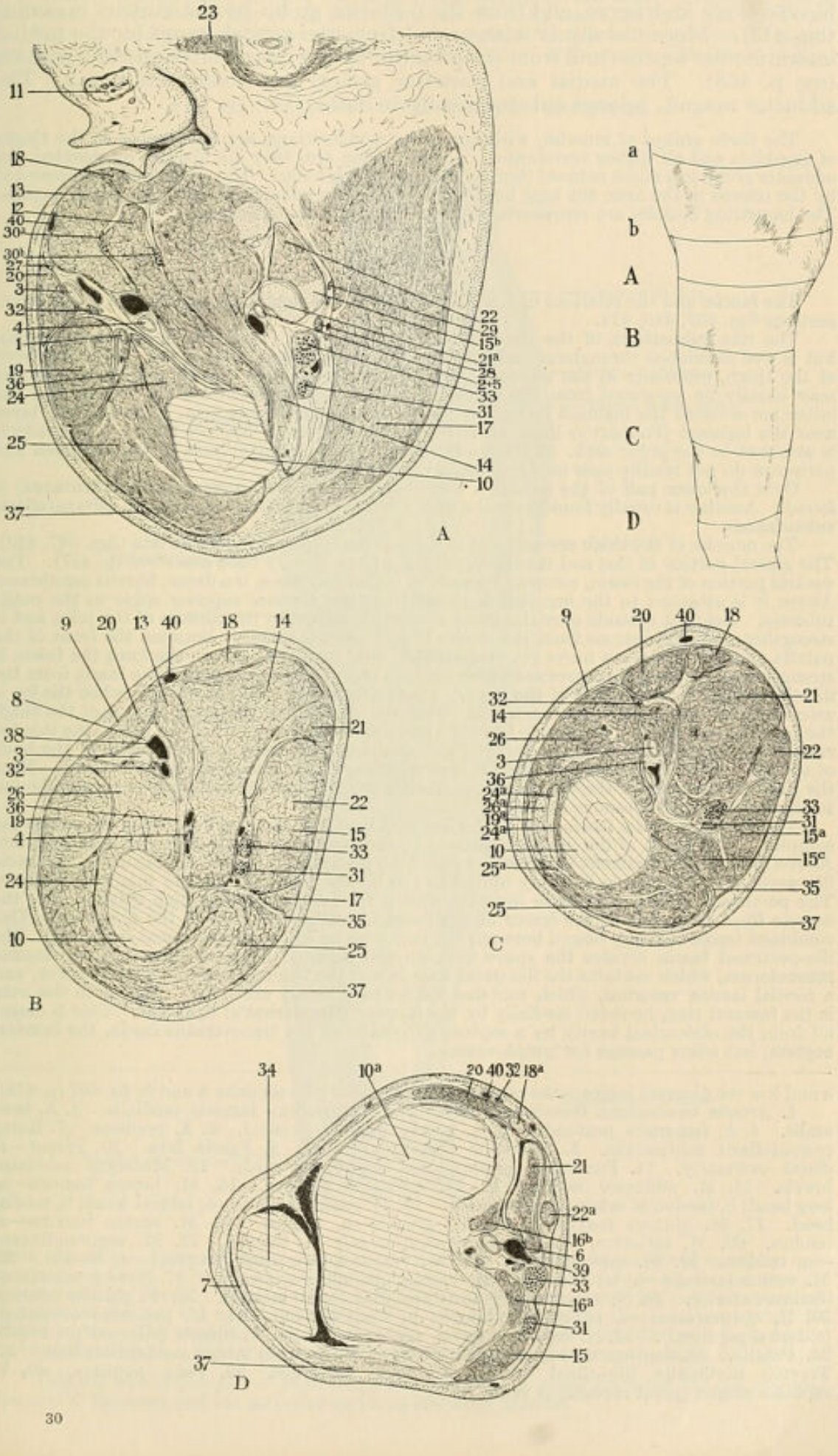

In the proximal part of the thigh the anterior group of muscles is separated from the medial group by the ilio-psoas muscle (fig. 411) and by the femoral blood-vessels and nerve, and from the posterior group by the gluteus maximus (fig. 413). More distally it is separated from the medial group by the medial intermuscular septum and from the posterior by the lateral intermuscular septum (see p. 468). The medial and posterior groups are closely associated. The adductor magnus belongs ontogenetically to both.

The three groups of muscles, with numerous modifications, are represented in the thighs of amphibia and all higher vertebrates. In the human arm they are likewise represented, the adductor group in a much reduced form by the coraco-brachialis. The quadriceps is represented by the triceps in the arm, the long head of the triceps corresponding with the rectus femoris. The hamstring muscles are represented by the biceps and the brachialis.

FASCIÆ

The **fasciæ** and the relations of the musculature of the thigh may be followed in the cross-sections figs. 407, 410, 414.

The **tela subcutanea** of the thigh varies considerably in thickness in different regions, but is well developed throughout and contains a considerable amount of fat. Over the front of the thigh, especially in the upper medial region, one or more deeper membranous layers may usually be separated from the superficial adipose layer. Between the former and the latter are situated the inguinal lymphatic nodes and the saphenous vein. The deepest layer near the inguinal (Poupart's) ligament is fused with the fascia lata (see below). Medially it is attached to the pubic arch. Thus fluids beneath the tela subcutanea of the abdomen and perineum do not readily pass into the region of the thigh.

Over the lower half of the patella a subcutaneous bursa (**b. præpatellaris subcutanea**) is found. Another is usually found over the upper end of the patellar ligament (**b. infrapatellaris subcutanea**).

The muscles of the thigh are enclosed in a dense fascial sheet, the **fascia lata** (figs. 387, 410). The gluteal portion of this and the ilio-tibial band have already been described (p. 457). The ventral portion of the fascia, composed chiefly of transverse fibres, is a dense, fibrous membrane. Above it is attached to the inguinal ligament from the anterior superior spine to the pubic tubercle. Below it extends over the knee, where it is united to the capsule of the joint and is strengthened by expansions from the vastus lateralis and medialis. Between the front of the patella and the fascia is a bursa (**b. præpatellaris subfascialis**). Above the knee the fascia is strengthened by an *arciform process* which extends obliquely distally across the fascia from the ilio-tibial band to the capsule of the knee. This gives rise to a fold in the skin when the leg is extended and the muscles are not tense. Over the medial and posterior regions of the thigh the fascia is less dense. It extends from the body and inferior ramus of the pubis, the inferior ramus and tuber of the ischium, and the sacro-tuberous ligament into the fascia of the back of the leg. Above the popliteal space it is strengthened by a transverse band of fibres. Near the knee the tendons of the quadriceps, sartorius, gracilis, and semitendinosus become bound to the fascia by membranous laminæ.

The relations of the fascia lata to the inguinal ligament and the iliac fascia are somewhat complex. The fascia of the ilio-psoas muscle extends over the muscle to its femoral insertion. Above the inguinal ligament this fascia is called the **fascia iliaca**; below the ligament, the **fascia ilio-pectinea.** This fascia is firmly united to the lateral extremity of the inguinal ligament. The pectineus muscle is likewise invested with a fascial membrane which extends over the muscle from the pubis to the femur and is fused laterally with that of the ilio-psoas. This combined fascia is firmly bound between the two muscles to the ilio-pectineal eminence. The ilio-pectineal fascia divides the space beneath the inguinal ligament into a lateral **lacuna musculorum,** which contains the ilio-psoas muscle and the femoral (anterior crural) nerve, and a medial **lacuna vasorum,** which contains the femoral artery and vein. Medial to the vein is the **femoral ring,** bounded medially by the **lacunar (Gimbernat's) ligament.** This is closed off from the abdominal cavity by a septum derived from the transversalis fascia, the **femoral septum,** but offers passage for lymph-vessels.

---

a and *b* in the diagram indicate the regions through which pass sections A and B, fig. 407 (p. 458);

1. Arteria circumflexa femoris lateralis. 2. A. circumflexa femoris medialis. 3. A. femoralis. 4. A. femoralis profunda. 5. A. glutea inferior (sciatic). 6. A. poplitea. 7. Bursa præpatellaris subfascialis. 8. Adductor (Hunter's) canal. 9. Fascia lata. 10. Femur—a, distal extremity. 11. Funiculus spermaticus (spermatic cord). 12. Musculus adductor brevis. 13. M. adductor longus. 14. M. adductor magnus. 15. M. biceps femoris—a, long head; b, tendon of origin; c, short head. 16. M. gastrocnemius—a, lateral head; b, medial head. 17. M. gluteus maximus. 18. M. gracilis—a, tendon. 19. M. rectus femoris—a, tendon. 20. M. sartorius. 21. M. semimembranosus—a, tendon. 22. M. semitendinosus—a, tendon. 23. M. sphincter ani. 24. M. vastus intermedius (crureus)—a, tendon. 25. M. vastus lateralis—a, tendon. 26. M. vastus medialis—a, tendon. 27. Nervus cutaneous femoris anterior. 28. N. cutaneous femoris posterior (small sciatic). 29. N. gluteus inferior. 30. N. obturatorius—a, superficial branch; b, deep branch. 31. N. peroneus communis (external popliteal). 32. N. saphenus (great saphenous). 33. N. tibialis (internal popliteal). 34. Patella. 35. Septum intermusculare laterale. 36. Septum intermusculare mediale. 37. Tractus iliotibialis (ilio-tibial band). 38. Vena femoralis. 39. Vena poplitea. 40. V. saphena magna (great saphenous vein).

Beyond the inguinal ligament the fasciæ of the ilio-psoas and pectineal muscles line a triangular space, the **ilio-pectineal fossa,*** through which run the femoral vessels (fig. 407). The sartorius muscle partly overlies the distal lateral margin of this fossa. The fascia lata is here reflected from the surface of the sartorius to the ilio-psoas fascia, and becomes fused with it. From the medial margin of the sartorius a process of the fascia is continued over the lateral and upper part of the fossa, and is attached to the inguinal and lacunar (Gimbernat's) liga-

FIG. 411.—MUSCLES OF THE FRONT OF THE THIGH.

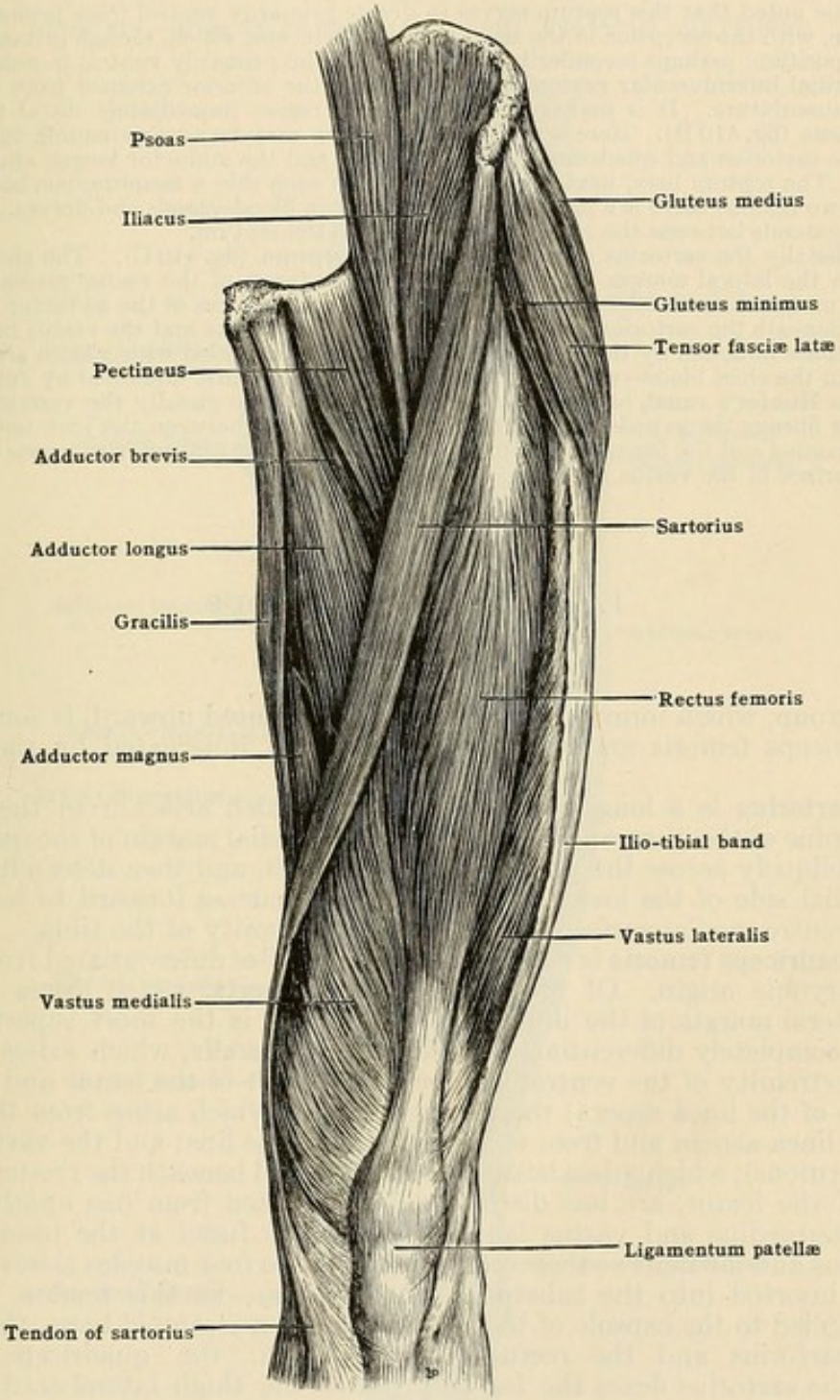

ments (fig. 389). Over the lower extremity of the fossa a process is continued medially into the pectineal fascia. On the medial margin of the fossa the fascia lata is continued directly into the pectineal fascia. The lateral concave margin of the fascia overlying the fossa is called the **falciform margin;** the upper extremity of this, the **superior cornu;** the distal extremity, the **inferior cornu.** The oval space bounded by the margo falciformis is called the **fossa ovalis** (saphenous opening). This is covered by the **fascia cribrosa,** which some consider a deep layer

* This lies within *Scarpa's triangle* [trigonum femorale], a space bounded by the inguinal (Poupart's) ligament and the sartorius and long adductor muscles.

of the tela subcutanea and others a portion of the fascia lata. This fascia cribrosa contains many openings for the passage of blood-vessels and lymphatics. The space which lies medial to the femoral vessels between the femoral ring and the fossa ovalis is called the **femoral canal** (crural canal).

From the fascia intermuscular septa descend in between the underlying muscles. Of these, the medial and lateral intermuscular septa are the best marked (fig. 410).

The **lateral intermuscular septum** separates the extensor muscles from the hamstring group. It extends from the tendon of the gluteus maximus to the lateral epicondyle. It is composed chiefly of longitudinal fibres and is thickest distally. The vastus lateralis is united to its ventro-lateral surface; the short head of the biceps, to its dorso-medial surface.

It will be noted that this septum serves to divide primarily ventral from primarily dorsal musculature, with the exception of the short head of the biceps, which, though primarily dorsal, occupies a position, perhaps secondarily acquired, with the primarily ventral muscles.

The **medial intermuscular septum** serves to divide the anterior extensor from the medial adductor musculature. It is perhaps simplest in the region immediately distal to the ilio-pectineal fossa (fig. 410 B). Here a well-marked septum may be seen extending to the femur between the sartorius and quadriceps on the one side, and the adductor longus and brevis on the other. The septum here, next the muscles, has on each side a membranous lamina. Between the two laminæ there is a looser tissue in which run blood-vessels and nerves. A fibrous membrane extends between the rectus and sartorius to the septum.

More distally the sartorius comes to overlie the septum (fig. 410 C). The sheath of the sartorius on the lateral margin becomes fused with the fascia of the vastus medialis, and on the medial margin to a membrane that covers the ventral surfaces of the adductor longus and magnus. Beneath the sartorius and between the adductor longus and the vastus medialis is a triangular space bounded by the sheaths of these muscles, and filled with a loose areolar tissue in which run the chief blood-vessels of the thigh. This space, first described by John Hunter, is known as **Hunter's canal,** or the **adductor canal.** Still more distally the vessels with their surrounding fibrous tissue pass through the hiatus tendineus, between the long tendon of the adductor magnus and the femur, to the back of the thigh. The septum here passes behind the posterior surface of the vastus medialis to the femur.

MUSCLES

1. The Anterior Group

(Figs. 411, 412)

This group, which forms a semi-conical mass pointed upward, is composed of the quadriceps femoris and the sartorius muscles, innervated by the femoral nerve.

The **sartorius** is a long, ribbon-like muscle which arises from the anterior superior spine of the ilium and extends along the medial margin of the quadriceps, passing obliquely across the upper part of the thigh, and then descending to the dorse-medial side of the knee, whence its tendon curves forward to be inserted into the ventro-medial surface of the superior extremity of the tibia.

The **quadriceps femoris** is composed of four muscles differentiated from a common embryonic origin. Of these, the **rectus femoris,** which arises from the ventro-lateral margin of the ilium by two tendons, is the most superficial and the most completely differentiated. The **vastus lateralis,** which arises from the superior extremity of the ventral surface of the shaft of the femur and from the lateral lip of the linea aspera; the **vastus medialis,** which arises from the medial lip of the linea aspera and from the intertrochanteric line; and the **vastus intermedius** (crureus), which arises between these two and beneath the rectus from the surface of the femur, are less distinctly differentiated from one another. The vastus intermedius and vastus lateralis are partly fused at the insertion, the intermedius and medialis at their origins. From the four muscles arises a tendon which is inserted into the tuberosity of the tibia. In this tendon, which is closely applied to the capsule of the knee-joint, lies a sesamoid bone, the patella.

The sartorius and the rectus flex the thigh; the quadriceps extends the leg; the sartorius flexes the leg and rotates the thigh lateralward and the leg medialward.

In the embryo the sartorius has an origin distinct from that of the quadriceps. In the anthropoid apes it is much more developed than in man.

In addition to supplying the muscles of this group, the femoral nerve also gives branches to the iliacus muscle (p. 455) and the pectineus muscle (p. 472).

The sartorius (fig. 411).—*Origin.*—From the anterior superior spine of the ilium and the area immediately below this.

Insertion.—Into the medial surface of the tibia near the tuberosity and into the neighbouring fascia of the leg.

Structure.—The muscle arises by short tendinous strands. The fibre-bundles take a nearly parallel course. The component muscle-fibres are said to be the longest in the body. Near the medial epicondyle of the femur the tendon of insertion makes its appearance on the deep aspect of the muscle. On the superficial surface of the tendon the muscle-fibres are inserted as far as the distal margin of the knee-joint. From there the tendon turns forward to its insertion.

Nerve-supply.—Usually two branches enter the deep surface of the proximal third of the sartorius. One or both of them may be bound up with an anterior cutaneous nerve passing

FIG. 412.—THE DEEP MUSCLES OF THE FRONT OF THE THIGH.

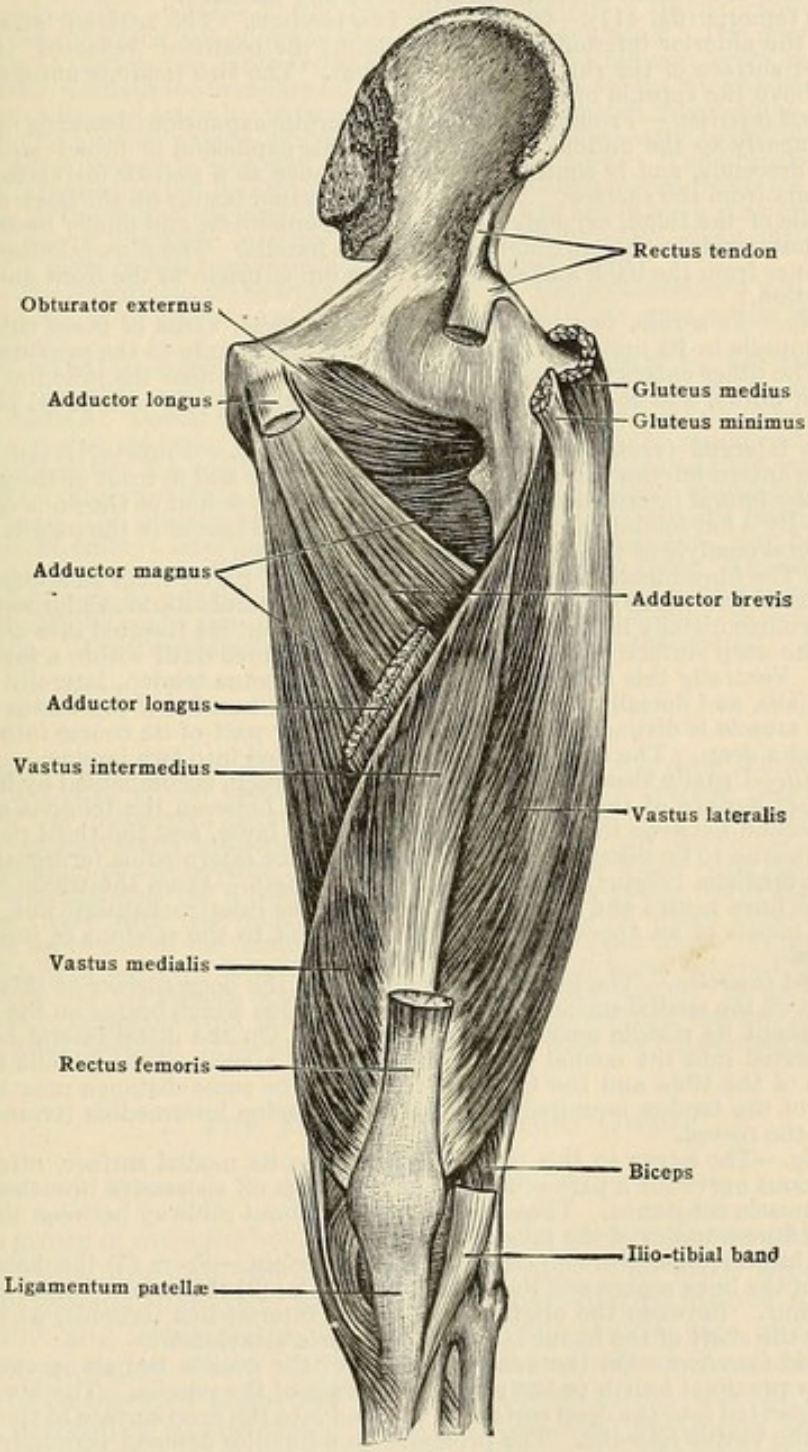

through the muscle. The first of the branches is distributed chiefly to the lateral and proximal, the second to the medial and distal, portions of the muscle. Within the muscle is a complex plexus.

Action.—(1) To flex the thigh at the hip, abduct and rotate it lateralward; (2) to flex the leg and rotate it slightly medialward; (3) to make tense the medial part of the fascia lata.

Relations.—The sartorius lies in a fascial canal bounded by the fascia lata and by intermuscular septa which descend from this. It crosses the rectus femoris, ilio-psoas, the adductor

longus and magnus, and the vastus medialis muscles, the femoral vessels and nerve, and the knee-joint. At its insertion its tendon covers the gracilis and semitendinosus.

Variations.—It may arise from the inguinal ligament or be inserted into the fascia lata, the medial epicondyle, or the capsule of the knee-joint. It may be longitudinally divided into two parts. The tendon of the secondary slip is in such instances usually attached to the capsule of the knee-joint, but sometimes is attached to the fascia over the vastus medialis or to the anterior wall of the adductor canal. More frequently the muscle is partly divided proximally or distally. The secondary tendon of origin may arise from the anterior inferior spine, the ilio-pectineal eminence, etc. The muscle is very rarely absent. It may be crossed by a tendinous inscription, or more rarely it is rendered digastric by an intervening tendon.

The quadriceps femoris (figs. 411, 412).—This, as pointed out above, is composed of the rectus femoris and the vastus lateralis, intermedius, and medialis.

The rectus femoris (fig. 411).—*Origin.*—By two tendons. The anterior 'straight' tendon is attached to the anterior inferior spine of the ilium; the posterior 'reflected' tendon to the postero-superior surface of the rim of the acetabulum. The two tendons unite so as to form a small arch above the capsule of the joint.

Structure and insertion.—From this arch an aponeurotic expansion descends upon the front of the muscle nearly to the middle of the thigh. This expansion is broad above, becomes narrower as it descends, and is continued a short distance as a narrow intramuscular tendon after it disappears from the surface. The tendon of insertion begins on the back of the muscle above the middle of the thigh, expands into a broad aponeurosis, and finally becomes a strong band which is inserted into the proximal border of the patella. The fibre-bundles pass in a bipenniform manner from the back and sides of the tendon of origin to the front and sides of the tendon of insertion.

Nerve-supply.—As a rule, two branches enter the muscle. One of these enters the deep surface of the muscle in its upper fourth, and is distributed mainly to the proximal part of the lateral half. The other enters the medial margin of the muscle near the junction of the proximal and middle thirds, and is distributed chiefly to the medial half and distal portion of the muscle.

The vastus lateralis (vastus externus) (fig. 412).—*Origin.*—From—(1) the shaft of the femur along the antero-inferior margin of the great trochanter and in front of the gluteal tuberosity; and (2) the lateral intermuscular septum along the upper half of the linea aspera.

Insertion.—By a flat tendon into—(1) the proximo-lateral border of the patella; and (2) the front of the lateral condyle of the tibia and the fascia of the leg.

Structure.—The fibre-bundles arise partly from the bone, partly from an aponeurosis which covers the proximal two-thirds of the muscle, and from the lateral intermuscular septum. They take a parallel course distally in a ventro-medial direction, and are inserted into an aponeurosis which lies on the deep surface of the muscle and receives fibres until within a few centimetres of the patella. Ventrally this aponeurosis fuses with the rectus tendon, laterally with that of the vastus medialis, and dorsally it receives some of the fibre-bundles of the vastus intermedius. Commonly the muscle is distinctly divisible for the greater part of its course into two sheets, a superficial and a deep. The deep sheet is often subdivided into two laminæ.

Nerve-supply.—Usually there are three nerves, one of which, accompanied by blood-vessels, runs on the inner surface of the superficial sheet midway between the tendons of origin and insertion, the second between the two laminæ of the deep layer, and the third passes through the innermost lamina to be distributed in part to the vastus intermedius (crureus) muscle.

The vastus medialis (vastus internus) (fig. 412).—*Origin.*—From the whole extent of the medial lip of the linea aspera and from the distal half of the intertrochanteric line. The origin takes place by means of an aponeurosis which is adherent to the tendons of insertion of the adductor muscles.

Structure and insertion.—The fibre-bundles arise from the deep surface of this aponeurosis and are inserted on the medial surface and margin of a tendon which begins on the deep surface of the muscle about its middle near the lateral margin. On the distal lateral border of the muscle it is inserted into the medial half of the proximal margin of the patella and into the medial condyle of the tibia and the fascia of the leg. For some distance near the knee the lateral margin of the tendon is united to those of the vastus intermedius (crureus), lateralis (externus) and the rectus.

Nerve-supply.—The nerve to this muscle descends on its medial surface, often bound up with the saphenous nerve for a part of its course. It gives off successive branches and finally sinks into the muscle substance. These branches enter about midway between the origin and insertion of the fibre-bundles of the muscle.

The vastus intermedius (crureus) (figs. 409, 412).—*Origin.*—From (1) the distal half of the lateral margin of the linea aspera and its lateral bifurcation; (2) the antero-lateral surface of the shaft of the femur. Between the origin of the vastus intermedius (crureus) and that of the vastus medialis the shaft of the femur is free from muscle attachment.

Structure and insertion.—On the ventral surface of the muscle lies an aponeurosis which extends from its proximal fourth to the proximal margin of the patella. The fibre-bundles of the muscle are inserted into the deep surface of this and into the deep surface of the aponeurosis of insertion of the vastus lateralis. The proximal fibre-bundles descend vertically, the medial and lateral, especially the latter, obliquely to their insertion. Medially the tendon is more or less fused with that of the vastus medialis, and laterally with that of the vastus lateralis. The muscle is composed of muscle lamellæ superimposed concentrically about the shaft of the femur. The deepest, most distal of these is called the **articularis genu** (subcrureus). The fibre-bundles of this layer are inserted into the capsule of the joint or into the superior margin of the patella.

Nerve-supply.—Several branches are usually distributed to this muscle. To the lateral region a branch from the nerve to the vastus lateralis is usually given; to the middle of the muscle another branch descends from the femoral (anterior crural) nerve; to the medial portion there extend several twigs from the nerve to the vastus medialis.

Tendon of the quadriceps.—The quadriceps tendon may be more or less distinctly divided into layers, of which the superficial layer belongs to the rectus, the deep to the vastus intermedius, and the intermediate to the vastus lateralis and medialis. Some of the more superficial fibres of the tendons of the two vasti, however, cross in front of the rectus tendon. The combined tendon of the quadriceps is in part attached to the superior and lateral margins of the patella, and in part extends over the patella into the patellar ligament. A part of the tendon fibres of the vastus lateralis and medialis run on each side of the patella to the ventral surface of the condyles of the tibia. These form the **retinacula patellæ mediale** and **laterale.** The medial is the broader and better developed. With the retinacula are included bundles of fibres which run from the epicondyles to the patella and into which some muscle fibre-bundles are inserted. From the apex of the patella to the tuberosity of the tibia the quadriceps tendon is continued as the **patellar ligament** (fig. 415).

Nerve-supply.—The relations of the branches of distribution to the various parts of the muscle have been pointed out above in connection with each head. The general relations of these branches of the femoral nerve are as follows:—From the femoral nerve near the proximal end of the vastus medialis the branches for the vastus lateralis, vastus intermedius (crureus), and rectus pass distally and laterally between the rectus and vastus intermedius (crureus) to be distributed to the muscles named, while the chief nerve for the vastus medialis descends on the medial side of this muscle in company with the saphenous nerve. The branches to the vastus lateralis and intermedius are commonly bound up in a single nerve-trunk for some distance. The branches to the rectus are usually bound up with this trunk for a shorter distance. The nerve to the vastus medialis may be united to this trunk for a slight distance, but more frequently it is more or less bound up with the saphenous nerve.

Action.—The quadriceps is the extensor of the leg. The rectus femoris also flexes the thigh at the hip and is a weak abductor of the thigh. The articularis genu makes tense the capsule of the knee-joint.

Relations.—The quadriceps is covered ventrally immediately by the fascia lata. The sartorius runs along its medial margin; the tensor fasciæ latæ lies over the proximal quarter of its lateral surface. Dorsal to the vastus lateralis lie the gluteus maximus and biceps; dorsomedial to the vastus medialis, the three adductor muscles and the semimembranosus. Next the vastus medialis lies the adductor canal with the femoral vessels and the saphenous nerve.

Variations.—The variations of this muscle, aside from a greater or less fusion of its parts, are not marked. The attachment of the rectus femoris to the anterior inferior spine, which takes place in the embryo later than its insertion above the acetabulum, may be wanting. On the other hand, this tendon may extend to the anterior superior spine. Occasionally the deep reflected tendon may be wanting. The **rectus accessorius** is a fasciculus rarely found, which arises by a tendon from the rim of the acetabulum and is inserted into the ventral edge of the vastus lateralis. It is innervated by a twig from the branch to the rectus.

Bursæ

B. m. recti femoris (superior).—A small bursa between the deep tendon of the rectus femoris and the edge of the acetabulum. Rare. **B. m. recti femoris (inferior).**—Between the tendon of the rectus and the combined tendon of the vastus lateralis and medialis. Occasional. **B. præpatellaris subtendinea.**—A bursa between the tendon of the quadriceps and the periosteum of the patella. Of the three præpatellar bursæ—the subcutaneous, subfascial, and subtendinous—as a rule only one occurs. When two or three exist, they usually communicate freely with one another. **B. suprapatellaris.**—A bursa between the anterior surface of the lower end of the femur and the tendon of the quadriceps. It usually communicates with the joint cavity. **B. infrapatellaris profunda.**—A bursa between the patellar ligament and the tibia. It seldom communicates with the joint cavity. **B. m. sartorii propria.**—A bursa, fairly large, between the tendon of the sartorius and the tendons of the semitendinosus and gracilis muscles. This usually communicates with the bursa anserina (see p. 474).

2. The Medial (Adductor) Group

(Figs. 409, 411, 412)

To this group of muscles belong the gracilis, the pectineus, the adductors brevis, longus, and magnus, and the obturator externus. The most superficial of the group is the **gracilis** (figs. 408, 411). This ribbon-shaped muscle arises from the inferior pubic and ischial rami, extends along the medial side of the thigh, and gives rise to a tendon which curves forward from behind the medial condyle of the femur to be inserted under the tendon of the sartorius into the medial side of the upper extremity of the tibia. The quadrilateral **pectineus** arises from the body and superior ramus of the pubis; the triangular **adductor longus** from the superior ramus medial to this (fig. 411). The pectineus is inserted into the pectineal line of the femur; the adductor longus into the middle third of the linea aspera. The triangular **adductor brevis** (fig. 412) arises from the inferior pubic ramus below the adductor longus. It is inserted into the pectineal line and the upper third of the linea aspera. The large, triangular **adductor magnus** (figs. 409, 412) arises from the inferior ramus and the tuber of the ischium and is

inserted behind the short and long adductors into the whole length of the linea aspera, and by a special tendon into the adductor tubercle of the femur. The deepest muscle of the group, the **obturator externus,** which arises from the outer surface of the bones bounding the ventral two-thirds of the obturator foramen, and is inserted by a tendon into the trochanteric (digital) fossa, has been described in connection with the ischio-pubo-femoral muscles of the hip.

All the muscles of this group adduct the thigh. The gracilis, obturator externus, adductor brevis and the lower part of the adductor magnus (when the thigh is extended) rotate it lateralward. The pectineus, adductor longus, and the adductor magnus rotate it medialward. Those attached to the pubis flex the thigh. The gracilis flexes the leg and rotates it medialward. The inferior part of the adductor magnus extends the thigh.

The muscles of this group are supplied by the obturator nerve, except the pectineus, which usually gets its whole supply from the femoral (anterior crural) nerve, and the adductor magnus, which gets a part of its supply from the sciatic nerve.

In embryonic development the pectineus arises in close conjunction with the obturator group, and in the adult it may get the whole or a part of its nerve-supply from the obturator nerve or from the accessory obturator nerve. In the lower mammals the nerve-supply may come from the femoral (anterior crural) or the obturator nerve or from both. It is not certain whether the innervation from the femoral nerve indicates that the muscle belongs phylogenetically, if not ontogenetically, with the primitive dorsal musculature of the limb. By some it is considered to be derived in part from the primitive dorsal, in part from the primitive ventral, musculature. The adductor magnus arises in the embryo as two distinct portions, one connected with the flexor group of muscles, the other with the adductor group. These two portions later become fused. Primitively the sciatic portion of the adductor magnus and the semimembranosus constitute a single medial flexor muscle.

The gracilis (figs. 408, 411).—*Origin.*—By a flat tendon from the medial margin of the inferior ramus of the pubis and the pubic extremity of the inferior ramus of the ischium.

Structure and insertion.—The nearly parallel fibre-bundles which arise between two laminæ of the tendon form a thin band of muscle which is narrower and thicker distally than proximally. They are inserted on a tendon which begins as an aponeurosis on the posterior border and medial surface of the muscle in the distal third of the thigh, becomes free as a rounded cord a little proximal to the medial condyle of the femur, runs behind the condyle, and then turns forward to be inserted by an expanded process into the tibia below the medial condyle.

Nerve-supply.—The nerve enters the deep surface of the muscle near the junction of the superior and middle thirds.

Action.—To adduct, flex and (slightly) rotate the thigh lateralward, and flex the leg. With the knee flexed, it acts as a medial rotator of the leg.

Relations.—It occupies a position beneath the fascia lata and superficial to the adductor brevis, longus, and magnus muscles. Distally the sartorius lies in front, the semimembranosus behind. Its tendon crosses the tibial collateral ligament of the knee-joint and the tendons of the semitendinosus and the semimembranosus, and is overlapped by that of the sartorius.

Variations.—The pubic origin of the muscle may be much reduced or may be double. Its tendon of insertion may give rise to an accessory fasciculus which extends distally in the leg. In some of the apes the tendon descends normally much farther down the leg than in man.

The pectineus (fig. 411.)—*Origin.*—(1) From the pecten (crest) of the os pubis, the bone in front of this, and the pectineal fascia near this origin; and (2) from the anterior margin of the obturator sulcus and from the pubo-capsular ligament. Laterally the two areas of origin are usually separated by most of the superior surface of the body of the pubis. Medially they come together.

Structure and insertion.—From each area of origin a separate lamina arises. The fibre-bundles of each layer take a nearly parallel course and terminate between two tendinous lamellæ which fuse to be inserted into the upper half of the pectineal line behind the small trochanter. The fibre-bundles of the superficial layer cross those of the deep slightly obliquely. The muscle faces ventrally at its origin, laterally at its insertion.

Nerve-supply.—From a branch of the femoral (anterior crural) nerve, which passes behind the femoral artery and vein and through the pectineal fascia to enter the ventral surface of the muscle. It may also be supplied by the accessory obturator nerve, when present, or by a branch from the obturator. When both the femoral (anterior crural) and obturator nerves supply this muscle, the femoral supplies the superficial, the obturator, the deep lamina (Paterson).

Action.—To flex and adduct the thigh (as in crossing the legs).

Relations.—It is covered by the pectineal fascia, lies between the ilio-psoas and the adductor longus muscles, and crosses the obturator externus and adductor brevis muscles, The medial circumflex artery runs between it and the ilio-psoas, the deep femoral artery between it and the adductor longus.

Variations.—The extent of the division of the pectineus into superficial and deep portions varies considerably. It may also be divided into a lateral and a medial division. Often the pectineus is fused with the adductor longus. It may receive an accessory fasciculus from the capsule of the hip-joint, the iliacus muscle, the obturator externus, or the adductor brevis muscles, or the small trochanter. It may send a fasciculus to the sartorius.

The adductor longus (fig. 411).—*Origin.*—From the medial corner of the superior ramus

of the pubis by a strong tendon which extends for some distance on the medial border of the muscle.

Structure and insertion.—From this tendon the fibre-bundles diverge toward their insertion.

FIG. 413.—SUPERFICIAL MUSCLES OF THE BACK OF THE THIGH AND LEG.

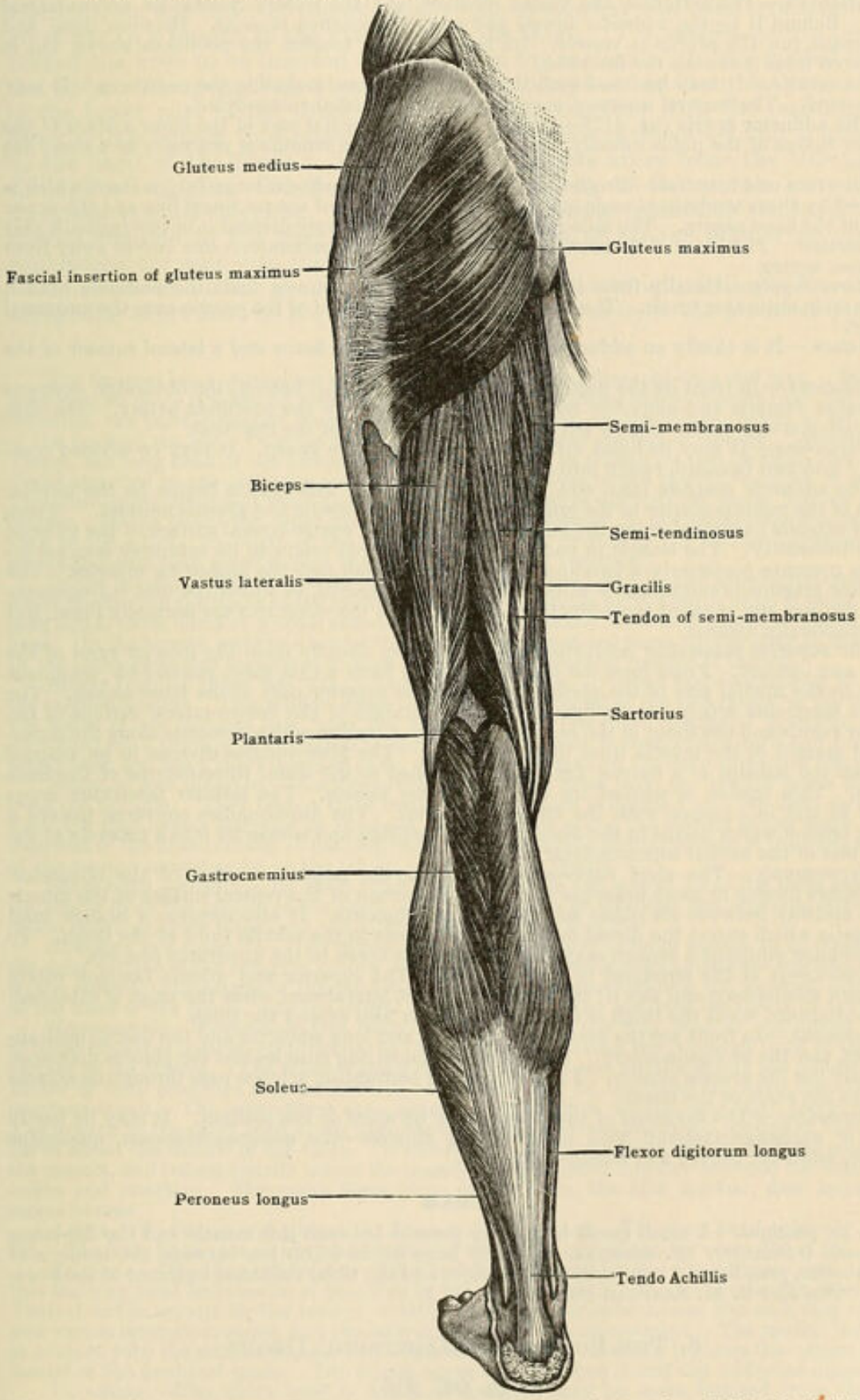

This takes place between two lamellæ of a short tendon attached to the middle third of the linea aspera. The tendon is usually fused to the medial intermuscular septum and sends an expansion to the long tendon of the adductor magnus.

Nerve-supply.—A branch from the anterior division of the main obturator trunk gives off several twigs which enter the middle third of the deep surface of the muscle. Occasionally a small branch from the femoral (anterior crural) nerve enters the muscle. This is probably sensory in nature.

Action.—To adduct and flex the thigh, and rotate it medialward.

Relations.—The sartorius, the vastus medialis, and the femoral vessels lie antero-lateral to it. Behind it lie the adductor brevis and adductor magnus muscles. Between these and the longus run the profunda vessels. Its lateral border touches the pectineus above, but is separated from it toward the insertion.

Variations.—It may be fused with the other adductors, including the pectineus. It may be doubled. The femoral insertion may extend to the medial epicondyle.

The adductor brevis (fig. 412).—*Origin.*—From the medial part of the outer surface of the inferior ramus of the pubis directly, and by means of short tendinous processes or a short flat tendon.

Structure and insertion.—From their origin the fibre-bundles diverge into a sheet which is inserted by short tendinous bands into the distal two-thirds of the pectineal line and the upper third of the linea aspera. The muscle is more or less completely divided into two fasciculi near its insertion. The place of division is near where the intertrochanteric line curves away from the linea aspera.

Nerve-supply.—Usually from the anterior but also sometimes from the posterior branch of the main obturator trunk. The rami enter the middle third of the muscle near the proximal border.

Action.—It is chiefly an adductor and to a less extent a flexor and a lateral rotator of the thigh.

Relations.—In front lie the pectineus and adductor longus; behind, the obturator externus quadratus femoris and adductor magnus. It is crossed by the profunda artery. The first perforating artery passes usually between the two fasciculi of the insertion.

Variations.—It may be fused with other members of the group. It may be divided completely into two fasciculi, rarely into three.

The **adductor magnus** (figs. 409, 412).—The *origin* of this muscle begins on the inferior ramus of the pubis posterior to the origins of the adductor brevis and gracilis muscles. From here it extends backward along the inferior margin of the ventro-lateral surface of the ischium to the tuberosity. The muscle in passing from this curved origin to its extensive femoral insertion presents posteriorly a longitudinal groove in which rest the hamstring muscles. The adductor magnus is composed of three superimposed fasciculi, of which the first is frequently fairly distinct and is called the **adductor minimus,** while the other two are normally fused, but are occasionally distinct.

The **superior fasciculus** (**adductor minimus**) *arises* directly from the inferior rami of the pubis and ischium. From here the fibres diverge to form a thin sheet *inserted* by tendinous bands to the medial side of the gluteal ridge and the superior part of the linea aspera. The **middle fasciculus** *arises* directly from the inferior margin of the ventro-lateral surface of the inferior ramus and the tuber of the ischium, and from a tendon which descends along the dorso-medial margin of the muscle from the tuber ischii. The fibre-bundles diverge to be *inserted* between the lamellæ of a narrow flat tendon attached to the distal three-fourths of the linea aspera. This tendon is pierced by the perforating vessels. The **inferior fasciculus** *arises* dorsal to and in common with the middle fasciculus. The fibre-bundles converge toward a strong tendon which begins in the distal third of the thigh and is *inserted* into a tubercle at the distal end of the medial supracondylar ridge.

Nerve-supply.—The chief nerve-supply is from the posterior ramus of the obturator. This enters by one or more branches the proximal portion of the ventral surface of the muscle about midway between its pubic and femoral attachments. It also receives a branch from the sciatic which enters the dorsal surface of the muscle in the middle third of the thigh. To the adductor minimus a branch may be sent from the nerve to the quadratus femoris.

Action.—It is the strongest of the adductors. The superior and middle fasciculi rotate the thigh medialward and flex it; the inferior rotate it lateralward when the thigh is extended, but medialward when the thigh is flexed. The latter also extend the thigh.

Relations.—In front are the pectineus, the short and long adductor and the vastus medialis muscles, and the profunda artery. Behind lie the hamstring muscles and the gluteus maximus. Medially lies the gracilis muscle. The femoral and perforating arteries pass through its attachment to the shaft of the femur.

Variations.—The divisions of the muscle may be more or less distinct. It may be partly fused or exchange fasciculi with neighbouring muscles—the semimembranosus, quadratus femoris, adductor brevis, and adductor longus.

Bursæ

B. m. pectinei.—A small bursa frequently present between this muscle and the ilio-psoas and small trochanter. **B. anserina.**—A fairly large bursa which lies between the tendons of the sartorius, gracilis, and semitendinosus muscles and the tibial collateral ligament of the knee-joint. (See also B. M. Sartorii Propria, p. 471.)

3. The Posterior (Hamstring) Group

(Figs. 408, 413)

The muscles of this group are the semitendinosus, semimembranosus, and biceps. They flex the leg and extend and adduct the thigh. The semitendinosus

and semimembranosus rotate the thigh and the leg medialward; the biceps, lateralward. The semitendinosus and the long head of the biceps constitute a superficial layer; the semimembranosus and the short head of the biceps a deep layer. The **semitendinosus** and the **long head of the biceps** arise by a common tendon from the tuber of the ischium. The somewhat fusiform semitendinosus gives rise to a tendon in the lower half of the thigh. The tendon curves forward behind the knee to be inserted under that of the sartorius into the medial side of the tibia. The penniform **short head of the biceps** arises from the linea aspera in the lower part of the thigh, and is inserted, together with the fusiform long head, into a tendon that passes over the lateral side of the knee and is attached to the head of the fibula. The **semimembranosus** arises from the tuber ischii through a long, flat, triangular tendon. The belly of the muscle increases in thickness toward the knee. It is inserted by a strong tendon on the back of the medial condyle of the tibia. From the tendons of all the hamstring muscles expansions are sent into the crural fascia.

The muscles of this group are all supplied by the tibial portion of the sciatic, except the short head of the biceps, which is supplied from the peroneal portion.

The femoral head of the biceps is characteristic of the anthropoid apes and man. In many mammals its place is taken by a slender muscle, the **tenuissimus,** which extends from the caudal vertebræ, the sacro-tuberous (great sacro-sciatic) ligament, or the gluteal fascia to the fascia of the back of the leg. In some forms this muscle is broad instead of slender. According to Testut, the long head of the biceps may be looked upon as arising by two fasciculi, one primitively attached to the posterior part of the ilium, the other to the caudal vertebræ or coccyx. The sacro-tuberous (great sacro-sciatic) ligament represents the reduced upper portion of this muscle. In the fœtus the origin of the muscle extends higher on the sacro-tuberous ligament than in the adult. In many of the lower mammals the origins of the semimembranosus and semitendinosus take place in part from the sacro-caudal vertebræ.

In the mammals below man the insertion of the biceps, gracilis, and semitendinosus takes place chiefly into the fascia of the back of the leg, and extends more distally than in man. This insertion of these flexor muscles is associated with a permanent position of flexion of the leg at the knee. In the human embryo likewise these muscles are inserted more distally than in the adult. In the lower primates the semimembranosus is chiefly a medial rotator of the leg.

Biceps femoris (Figs. 408, 413).—**Long head.**—*Origin.*—From a tendon common to it and the semitendinosus. This tendon arises from the more medial of the two facets on the back of the tuber of the ischium and from the sacro-tuberous (great sacro-sciatic) ligament. It is continued for a third of the distance to the knee as a septum between the biceps and the semitendinosus, and for a short distance as an aponeurotic sheath on the deep surface of the biceps.

Structure and insertion.—The fibre-bundles begin to arise from the tendon some distance from the ischium. They form a thick fusiform belly which is inserted into the deep surface of a tendon that begins laterally on the back of the muscle about the middle of the thigh. The insertion of the fibre-bundles of the long head continues on the medial margin of the deep surface of the tendon nearly as far as the lateral condyle of the femur.

Short head.—*Origin.*—By short tendinous fibres from the lateral lip of the linea aspera of the femur from the middle of the shaft to the bifurcation of this line, the proximal two-thirds of the supracondylar ridge, and the lateral intermuscular septum.

Structure and insertion.—The fibre-bundles take a nearly parallel course, to be inserted on the deep surface of the common tendon of insertion. The most distal fibres are inserted nearly to the skeletal attachment of the tendon. The tendon is inserted into the superior extremity of the head of the fibula, into the lateral condyle of the tibia, and into the fascia of the leg.

Nerve-supply.—Commonly two branches are given to the long head of the biceps. One of these branches is given off proximal to the ischium, and enters the proximal third of the deep surface of the muscle. The other is given off more distally and usually enters the middle third. Either or both branches may be doubled or the two may be combined for some distance in a common trunk. The nerve-fibres arise usually from the first, second, and third sacral nerves. The branch to the short head arises from the peroneal (external popliteal) portion of the sciatic nerve about the middle of the thigh. It enters the posterior surface near the lateral margin of the muscle, and passes distally across the muscle bundles about midway between the tendons of origin and insertion. The nerve-fibres come chiefly from the fifth lumbar, first and second sacral nerves.

Action.—To extend and adduct the thigh and flex the leg. The short head acts only on the leg. The long head acts as a lateral rotator of the thigh, and of the leg when flexed.

Relations.—The upper extremity of the muscle is covered by the gluteus maximus. Below this the long head and tendon of insertion lie beneath the fascia lata and overlie the short head. Ventral to the muscle lie the tendon of origin of the semimembranosus, the adductor magnus and vastus lateralis muscles, and the lateral head of the gastrocnemius. The medial border is in contact with the semitendinosus and semimembranosus. Distally it forms the upper lateral border of the popliteal space. The sciatic nerve runs between it and the adductor magnus.

Variations.—The short head is rarely absent. It may be more isolated from the long head than usual, and at times has a separate tendon of insertion. It may itself be divided into two distinct laminæ. Its origin may take place higher up on the femur than usual or from the fascia lata. Variations of this sort suggest the tenuissimus muscle of some of the lower mammals

(see above). The long head of the biceps may receive accessory fasciculi from the coccyx, sacrum, sacro-tuberous (great sacro-sciatic) ligament, tuber of the ischium, or the deep surface of the gluteus maximus. These fasciculi suggest the iliac and sacro-coccygeal origin of the muscle found in lower vertebrates (see above). Inferiorly, a muscle fasciculus may take the place of the fibrous prolongations from the tendon of the biceps into the sural fascia (the **tensores fasciæ suralis**). This may extend to the tendon of Achilles. The long head may have a tendinous inscription similar to that of the semitendinosus.

The **semitendinosus** (figs. 408, 413).—*Origin.*—Partly from a medio-dorsal facet on the distal margin of the tuber of the ischium by direct implantation of the fibre-bundles, and partly from the medial surface of the tendon common to it and the long head of the biceps.

Structure and insertion.—The fibre-bundles spread out to form a flat, fusiform belly which, about the middle of the thigh, again contracts toward the tendon of insertion. This begins on the medial margin and dorsal surface of the muscle, becomes free from the muscle slightly above the medial condyle of the femur, passes behind this and curves forward to be inserted by a triangular expansion into the proximal part of the medial surface of the tibia behind and distal to the insertion of the gracilis. An aponeurotic expansion is continued into the fascia of the leg. About the middle of the muscle a narrow irregular tendinous inscription more or less completely divides the belly into proximal and distal divisions.

Nerve-supply.—To the muscle two nerves are commonly given. One arises from the sciatic nerve or directly from the plexus, proximal to the tuber of the ischium, sometimes in company with a branch to the long head of the biceps. It enters the middle third of the deep surface of the proximal portion of the muscle. The other branch arises from the sciatic nerve, usually distal to the ischial tuber, sometimes in common with a nerve to the biceps or the semimembranosus. It enters about the middle of the deep surface of the distal half of the muscle. Either or both branches may be represented by two nerves. The nerve fibres of the first branch arise chiefly from the first and second sacral nerves, those of the second from the fifth lumbar and first sacral nerves.

Action.—To extend and adduct the thigh and rotate it medialward and to flex the leg, and with knee flexed, to rotate the leg medialward.

Relations.—It is covered by the gluteus maximus and fascia lata; on the lateral side lies the biceps; and in front, the semimembranosus and adductor magnus.

Variations.—It may be completely separated from the biceps at its origin. It may be fused with neighbouring muscles. There may be two tendinous inscriptions. It may have a femoral head (a condition characteristic of many birds). A muscle fasciculus may extend from the body of the muscle to the fascia of the back of the leg.

The **semimembranosus** (fig. 408).—*Origin.*—By a long, flat tendon which lies beneath the proximal half of the semitendinosus, and which arises from the more lateral of the two facets on the back of the tuber of the ischium, between the tendons of the biceps and the quadratus femoris. The tendon is at first adherent to the tendon of the adductor magnus in front and to that of the biceps and semitendinosus behind. It descends to the middle of the muscle.

Structure and insertion.—From both surfaces of the medial side and distal extremity of the tendon of origin fibre-bundles arise which take an oblique course to their insertion on the aponeurosis of the tendon of insertion. This appears on the deep surface and medial margin of the muscle opposite the end of the tendon of origin and descends on the medial side and deep surface of the muscle. Near the back of the medial condyle of the femur the insertion of muscle-fibres ceases and the tendon is inserted directly on the back of the medial condyle of the tibia, and by aponeurotic expansions into the capsule of the joint, into the lateral condyle of the femur, into the tibial collateral ligament, and into the fascia of the popliteus muscle.

Nerve-supply.—By several branches from the sciatic nerve, which usually arise from a common trunk in company with the branches to the adductor magnus. These branches enter the deep surface of the muscle about midway between the origin and insertion of the constituent fibre-bundles.

Action.—To flex the leg and rotate it medialward and to extend and adduct the thigh and rotate it medialward.

Relations.—It is covered by the gluteus maximus, the long head of the biceps, the semitendinosus, and the fascia lata. It lies dorsal to the quadratus femoris, the adductor magnus, and the knee-joint.

Variations.—It may be fused with the semitendinosus or the adductor magnus. It may be doubled. Its tendons may have a more extensive attachment than usual. The extent of the belly of the muscle varies considerably. A muscle fasciculus may be sent into the popliteal space. An extra head may arise from the ischial spine.

Bursæ

B. m. bicipitis femoris superior.—A fair-sized bursa which frequently lies between the tendon of origin of the long head of the biceps and semitendinosus and the tendon of the semimembranosus and the ischial tuber. **B. m. bicipitis femoris inferior.**—A small bursa which separates the tendon of insertion from the fibular collateral ligament of the knee-joint. **B. m. bicipitis gastrocnemialis.**—A bursa infrequently found between the tendon of the biceps and the tendons of origin of the lateral head of the gastrocnemius and the plantaris muscles. **B. m. semimembranosus.**—This is a large double bursa constantly present. One part extends between the semimembranosus, the medial head of the gastrocnemius, and the knee-joint. With the cavity of the joint it frequently communicates. The other part extends between the tendon of the semimembranosus and the medial condyle of the tibia.

C. MUSCULATURE OF THE LEG

(Figs. 413–422)

The musculature of the leg arises in part from the distal end of the femur, but in the main from the tibia and fibula. The muscle-bellies are best developed in the proximal half of the leg, where they give rise to the 'calf' behind and to less well-marked ventral and lateral protrusions. Toward the ankle the muscle-bellies give way to tendons which attach the muscles of the leg to the skeleton of the foot.

The musculature is divisible into an anterior, a lateral and a posterior group of muscles. The anterior and lateral groups are separated from one another by an intermuscular septum. The antero-lateral groups are separated from the posterior group by the tibia and fibula, the interosseous membrane, and by an intermuscular septum which extends from the lateral margin of the shaft of the fibula to the fascia enveloping the leg. Medially the separation is well marked by the broad medial surface of the tibia. Laterally the line of division is not so clearly marked externally. In the proximal part of the leg the dorsal musculature protrudes somewhat ventrally; in the distal part the lateral musculature passes dorsal to the lower end of the fibula. The posterior group is divided by a transverse septum into superficial and deep divisions.

While in the forearm the extensor-supinator muscles extend proximally on the radial side of the arm to the humerus, and the flexor-pronator muscles on the ulnar side, in the leg both of the corresponding sets of muscles extend primitively on the fibular side of the leg to the femur. In the higher vertebrates the superficial layer of the flexor musculature of the leg takes origin from both sides of the distal extremity of the femur, and the origin of the extensor musculature ceases to extend to the femur. The crural musculature is primitively inserted into the bones of the leg, the tarsus, and the aponeuroses of the foot. On the extensor side of the leg the musculature ultimately becomes attached wholly to the foot by means of tendons differentiated, in part at least, from the dorsal aponeurosis. The lateral portion of the extensor musculature, which primitively extends from the femur to the fibula, in the higher vertebrates extends from the fibula to the tarsus and metatarsus (peroneal musculature). On the flexor side of the leg the more superficial musculature maintains a tarsal attachment through the tendon of Achilles. The deeper musculature in part extends from the femur and fibula to the tibia, in part arises from the fibula and tibia, and is inserted into the metatarsus and the digits through tendons differentiated from the plantar aponeuroses. The musculature of the sole of the foot is highly developed in five-toed vertebrates, but in those which walk on the toes, and especially in hoofed animals, it is very greatly reduced.

FASCIÆ OF THE LEG

The **tela subcutanea** of the leg contains a considerable amount of fat where it overlies the muscles, but less where it overlies the bones and joints. Subcutaneous bursæ are found over the tuberosity of the tibia (**b. subcutanea tuberositatis tibiæ**) and over each of the malleoli (**b. subcutanea malleoli medialis et lateralis**). Over the dorsum of the foot the tela contains comparatively little fat, but on the sole of the foot and plantar surface of the toes it contains much fat interposed between dense fibrous tissue. The **b. subcutanea calcanea** lies beneath the tuber calcanei.

The **crural fascia,** or external layer of fascia of the leg, extends from the knee to the ankle. It forms an enveloping cone-like sheath for the muscles and is adherent to the periosteum of the medial surface of the tibia. It is formed of transverse, oblique, and longitudinal fibres and is thickest in front.

Ventrally the fascia of the thigh, to which the tendons of the quadriceps, sartorius, gracilis, semitendinosus, and biceps muscles and the ilio-tibial band are closely united, becomes attached with these tendons to the tibia and fibula. From these attachments, therefore, the fascia of the front of the leg may be said to arise. Into it extend processes from the tendons mentioned. Dorsally the fascia of the thigh is continued uninterruptedly into that of the leg. Distally the crural fascia is attached to the two malleoli and to the posterior surface of the calcaneus.

In the proximal part of the leg in front the underlying muscles in part take origin from the fascia; in other places the fascia is separated from the underlying muscles by loose tissue.

From the fascia two main intermuscular septa arise. One, the **anterior intermuscular septum,** extends between the extensor digitorum longus and peroneal muscles to the anterior crest of the fibula; the other, the **posterior intermuscular septum,** between the peroneal muscles and the soleus to the lateral crest of the fibula. These septa separate compartments for the anterior, lateral, and posterior groups of muscles.

As the heads of the gastrocnemius pass over the back of the knee they are held in place by a special deep lamina of the fascia lata, which distally becomes fused with the crural fascia (fig. 414 A).

FIG. 414, A–F.—TRANSVERSE SECTIONS THROUGH THE LEFT LEG IN THE REGIONS SHOWN IN THE DIAGRAM.

d In the diagram indicates the region through which passes section D, fig. 410 (p. 465); *a'*, *b'*, *c'*, *d'*, the regions through which pass sections A, B, C, D, fig. 417 (p. 488).

1. Arteria peronea. 2. A. poplitea. 3. A. tibialis anterior. 4. A. tibialis posterior. 5. Bursa anserina. 6. Bursa m. sartorii propria. 7. Fascia cruralis. 8. Fibula. 9. Ligamentum crurale transversum. 10. Lig. patellæ. 11. Membrana interossea. 12. Musculus biceps femoris—tendon. 13. M. extensor digitorum longus—a, tendon. 14. M. extensor hallucis longus. 15. M. flexor digitorum longus. 16. M. flexor hallucis longus. 17. M. gastrocnemius—a, lateral head; b, medial head. 18. M. gracilis, tendon. 19. M. peroneus brevis. 20. M. peroneus longus—a, tendon. 21. M. peroneus tertius. 22. M. plantaris—a, tendon. 23. M. popliteus. 24. M. sartorius, tendon. 25. M. semimembranosus, tendon. 26. M. semitendinosus, tendon. 27. M. soleus—a, fasciculus accessorius. 28. M. tibialis anterior—a, tendon. 29. M. tibialis posterior—a, tendon. 30. N. cutaneus suræ lateralis. 31. N. cutaneus suræ medialis. 32. N. peroneus communis (external popliteal). 33. N. peroneus profundus (anterior tibial). 34. N. peroneus superficiales (musculo-cutaneus). 35. N. plantaris lateralis (external plantar). 36. N. plantaris medialis (internal plantar). 37. N. suralis (external saphenous). 38. N. tibialis (posterior tibial). 39. Septum intermusculare (anterior). 40. S. intermusculare (posterior). 41. S. suræ transversum. 42. Tendo Achillis (calcanei). 43. Tibia. 44. Vena saphena magna. 45. V. saphena parva.

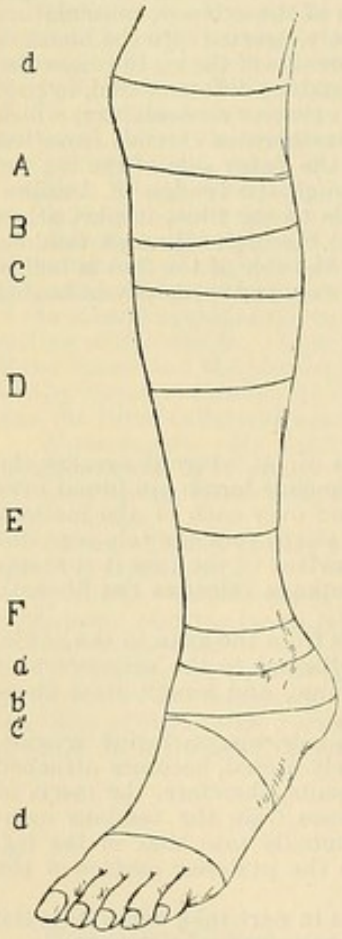

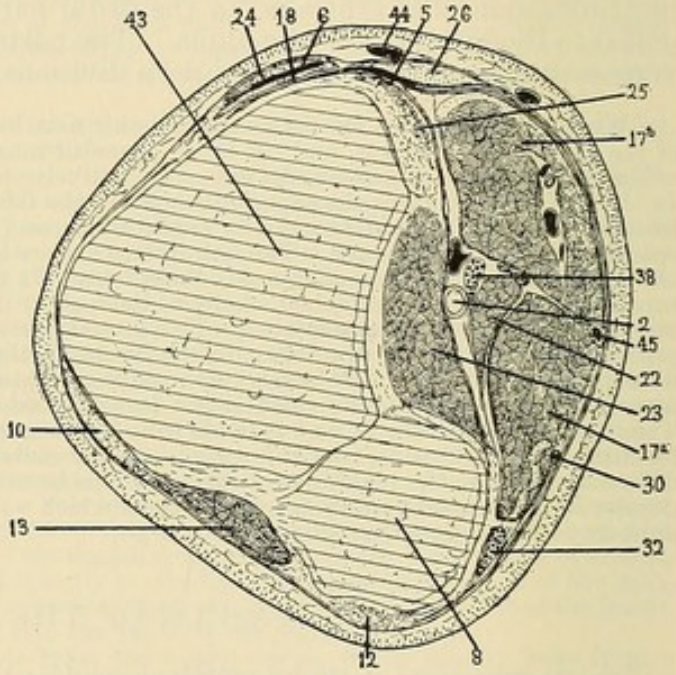

A

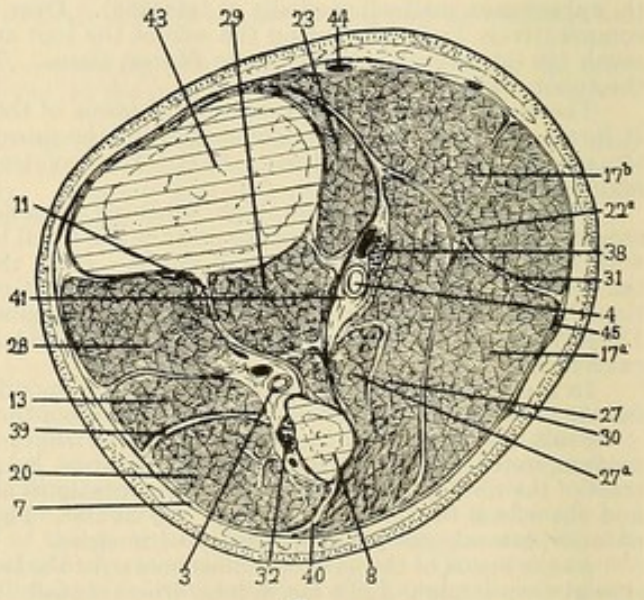

B

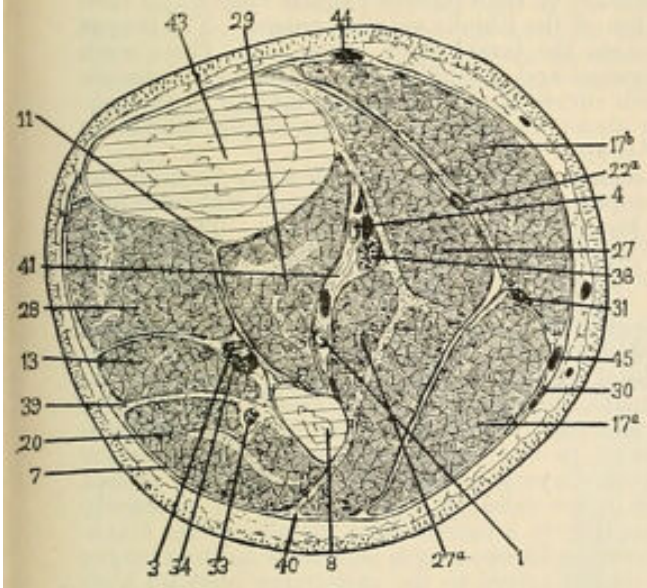

C

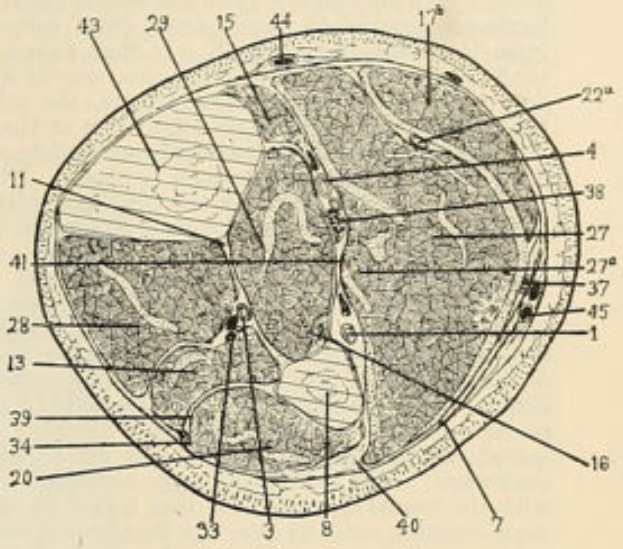

D

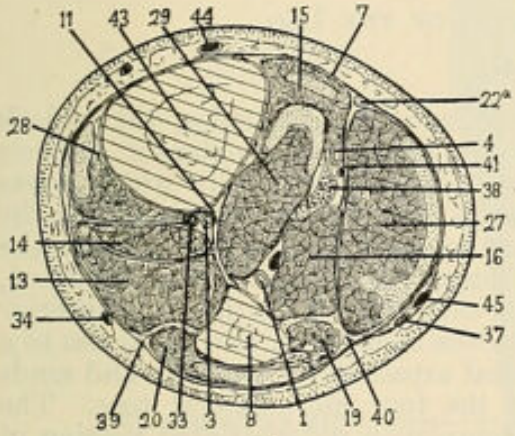

E

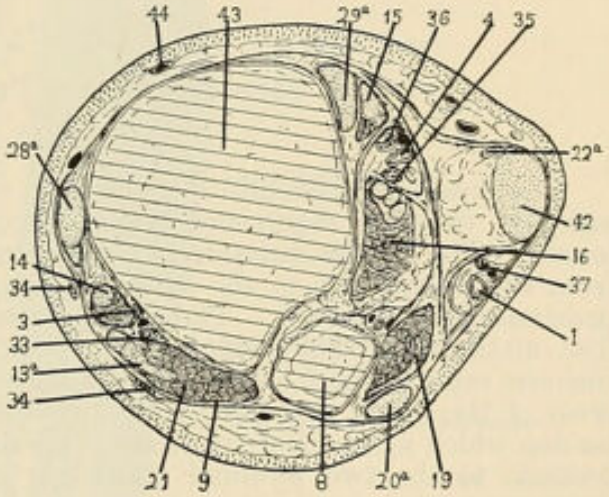

F

The semimembranosus has a special fascial investment which, on the back of the knee becomes bound on each side of the muscle and its tendon to the capsule of the joint. This fascia extends into a transverse septal membrane which is continued over the deep muscles of the back of the leg to the ankle. It is united on one side to the tibia, on the other to the fibula. Proximally the fibres are continued into it from the tendon of the semimembranosus. Over the back of the tibia the septum is interrupted by the attachment of the soleus to the popliteal line. Beyond the tibial origin of the soleus it is fused on the medial side of the flexor digitorum longus to the crural fascia.

In addition to the two intermuscular septa and the longitudinal transverse septum, other septa serve to separate the individual muscles of the different groups.

Above the ankle the fascia is enforced by bands of tissue so that ligaments are formed which serve to retain in position the various tendons which pass from the leg into the foot.

The **transverse crural ligament** (upper part of anterior annular ligament) (fig. 415) lies on the front of the lower part of the leg above the ankle. It is composed of fascia strengthened by transverse bundles which pass from the medial side of the tibia to the ventral margin of the fibula. From its deep surface a strong, broad septum descends to the tibia and divides the underlying space into two osteo-fibrous canals, a medial for the tibialis anterior and a lateral for the long extensor muscles. The lateral compartment is further subdivided by a slightly marked septum into a medial division for the extensor hallucis longus and a lateral for the extensor digitorum longus and the peroneus tertius.

The **cruciate ligament** (lower part of anterior annular ligament) (fig. 415) serves to hold the tendons of the anterior muscle group in place as they pass to the dorsum of the foot. In part it is formed by a dense fibrous band lying in the fascia over the ankle, in part of a ligament which passes from the bones of the ankle to the deep surface of this band. The superficial band is V-shaped. It arises from the lateral surface of the body of the calcaneus and passes across the dorsum of the foot, one arm of the V going to the medial malleolus, the other to the side of the foot, where it terminates in the fascia over the first cuneiform bone. The apex of the V lies over the tendons of the extensor digitorum longus and peroneus tertius muscles. The distal arm extends over the tendons of the extensor hallucis longus and tibialis anterior

muscles. The proximal arm passes over the tendon of the extensor hallucis longus and then divides into two layers, between which the tendon of the tibialis anterior passes. The deeper ligament mentioned above arises from deep within the tarsal sinus, some of its fibres even from the sustentaculum tali. It then passes forward and medially beneath the long extensor tendons, and divides into two parts, one of which curves about the medial margin of the tendon of the extensor digitorum longus, the other about the extensor hallucis longus tendon to the under surface of the proximal arm of the V-shaped band.

The **peroneal retinacula** are strengthened regions in the fascia which serve to hold the tendons of the peroneal muscles in place. The **superior** extends from the lateral malleolus into the fascia on the back of the leg, and to the lateral surface of the calcaneus. The **inferior** overlies the tendons on the lateral surface of the calcaneus, and is attached to this bone on each side of them. Between the tendons it sends a septum to the bone. It is connected with the superficial layer of the cruciate ligament.

The **laciniate ligament** (internal annular) (fig. 416) is found on the medial side of the ankle. Here the fascia is strengthened by fibre-bands which form a well-marked ligament that holds in place the tendons of the deep dorsal cruro-pedal muscles. This ligament extends from the dorsal and distal margins of the medial malleolus to the calcaneus. It is closely bound to the tibia and the talo-tibial (tibio-astragaloid) ligament until the tendon of the tibialis posterior is reached. It passes over this and becomes bound to the bony structures on the posterior margin of the tendon. From this attachment two layers, a deep and a superficial, extend backward. The superficial layer extends to the tuber calcanei, and is connected superiorly with the crural fascia. The deep layer, which represents a continuation distally of the transverse septum, extends over the tendons of the flexor digitorum longus and flexor hallucis longus to the medial surface of the calcaneus, and is closely united to the underlying bone on each side of these tendons, thus giving rise to osteo-fibrous canals.

MUSCLES

1. Muscles of thf Front of the Leg

(Figs. 415, 418)

The anterior musculature of the leg consists of four muscles, the tibialis anterior, extensor digitorum longus, peroneus tertius, and extensor hallucis longus. The **tibialis anterior** has a quadrangular prismatic belly which arises from the lateral side of the tibia and adjacent interosseous membrane in the proximal half of the leg. The tendon passes over the front of the tibia to the first metatarsal. The **extensor digitorum longus** is a transversely flattened, fusiform muscle, which arises from the superior extremity of the tibia, the anterior crest of the fibula, and the adjacent interosseous membrane, and gives rise to a tendon which passes over the front of the distal extremity of the tibia and sends tendons to the two terminal phalanges of the four more lateral toes. The **peroneus tertius** represents a more or less completely differentiated portion of the preceding muscle. Its tendon passes laterally through the same osteo-fibrous canal in the same synovial sheath and terminates on the fifth metatarsal. The **extensor hallucis longus** is a narrow muscle which arises from the distal half of the medial surface of the fibula and the interosseous membrane. Its tendon extends over the ankle to the great toe. The tendons of these muscles are held in place by the transverse and cruciate ligaments described above.

All the muscles of this group flex the foot. The extensors extend the toes; the peroneus tertius and the extensor digitorum longus evert the foot. The nerve supply is from the deep peroneal (anterior tibial) nerve.

The tibialis anterior is represented in the arm probably by the brachio-radialis and the two radial extensors; the extensor digitorum longus by the extensor digitorum communis and extensor digiti quinti proprius; and the extensor hallucis longus by the extensor pollicis longus. Two abnormal muscles not infrequently found, the abductor hallucis longus and extensor primi internodii hallucis, represent probably the corresponding normal muscles of the hand.

The tibialis anterior (fig. 415).—*Origin.*—From the distal surface of the lateral condyle of the tibia, and the lateral surface of the proximal half of the shaft of the tibia, the adjacent interosseous membrane, the overlying fascia near the condyle (tuberosity) of the tibia, and the intermuscular septum between it and the extensor digitorum longus.

Structure.—Bipenniform. The fibre-bundles converge upon a flat tendon which begins high in the muscle and emerges on the anterior margin of the muscle about the middle of the leg. On the deep surface the implantation of fibre-bundles continues to the transverse crural (anterior annular) ligament.

Insertion.—The tendon passes over the front of the tibia to the medial side of the foot, where it is inserted into the medial surface of the first cuneiform and the base of the first metatarsal.

Nerve-supply.—As a rule, a branch from the common peroneal (external popliteal) nerve enters the proximal portion of the muscle by several twigs, and another from the deep peroneal (anterior tibial) enters near the middle of the belly on the lateral edge.

Relations.—In the proximal half of the leg the extensor digitorum longus lies lateral to it; and between the two muscles, the anterior tibial artery and vein. It is covered by the crural fascia and rests on the interosseous membrane. Distally it lies over the extensor hallucis longus. The tendon passes in special compartments beneath the transverse and the cruciate (anterior annular) ligaments.

FIG. 415.—THE MUSCLES OF THE FRONT OF THE LEG.

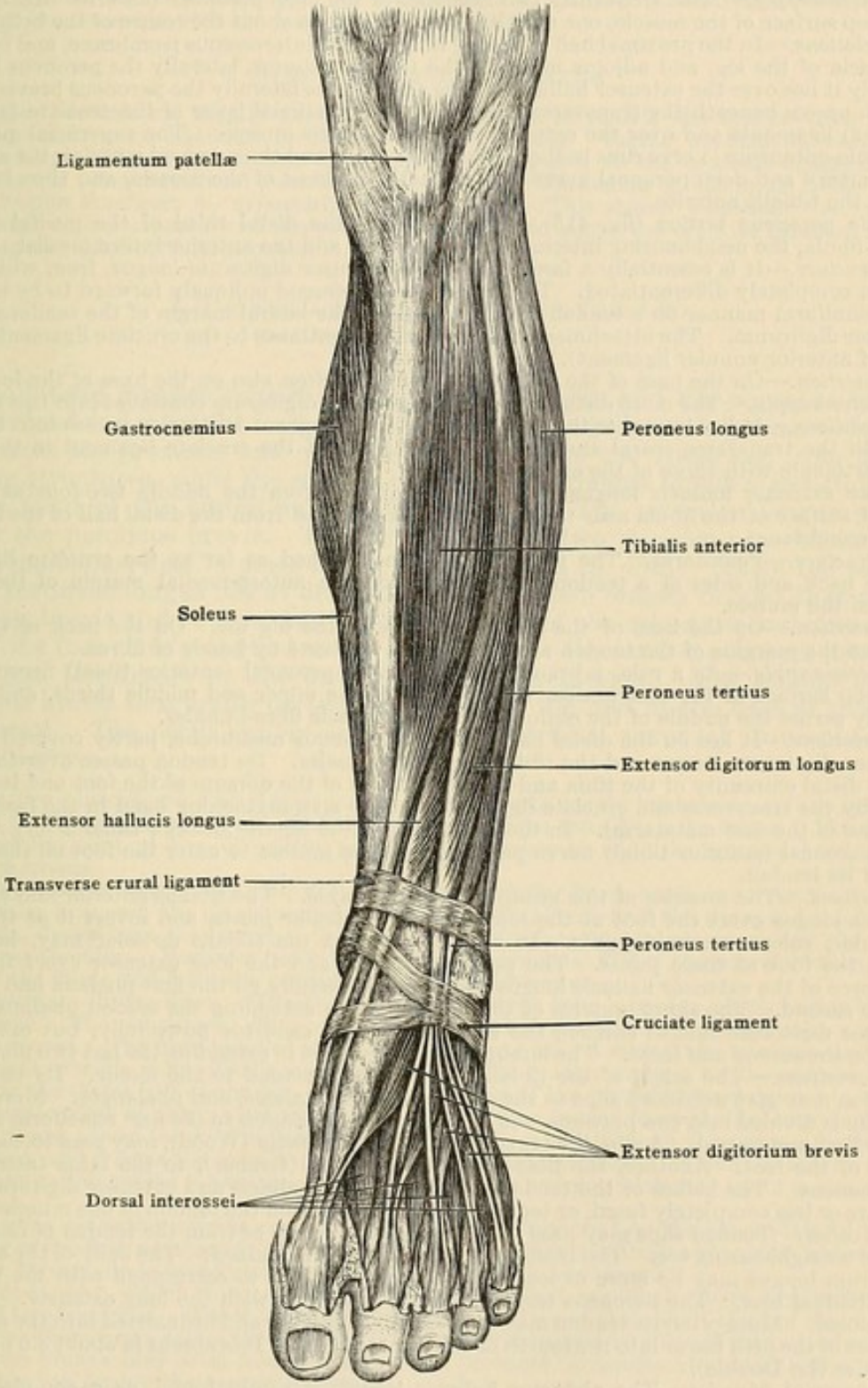

The extensor digitorum longus (fig. 415).—*Origin.*—From the lateral condyle of the tibia, the anterior crest (surface) of the fibula, the intermuscular membrane between it and the tibialis anterior, the lateral margin of the interosseous membrane, the septum between it and the peroneus longus, and the fascia of the leg near the tibial origin.

Structure.—Penniform. The fibre-bundles converge upon the posterior surface of a tendon which begins at the middle of the leg. The implantation of fibres continues nearly to the

ankle. Usually at the distal margin of the transverse (anterior annular) ligament the tendon divides into two parts which pass between the two layers of the cruciate (lower part of anterior annular) ligament, and then each divides again into two parts, thus giving rise to four slips, one for each of the four lateral toes.

Insertion.—Each tendon on the dorsal surface of the toe to which it goes divides into three fasciculi: an intermediate, which is attached to the dorsum of the base of the second phalanx; and two lateral, which converge to the dorsum of the base of the third phalanx. The margins of the tendon are also bound by fibrous tissue to the sides of the back of the first phalanx.

Nerve-supply.—Most frequently two branches of the deep peroneal (anterior tibial) enter the deep surface of the muscle, one near its tibial origin, one about the centre of the belly.

Relations.—In the proximal half of the leg it lies on the interosseous membrane, and beneath the fascia of the leg, and adjoins medially the tibialis anterior, laterally the peroneus longus. Distally it lies over the extensor hallucis longus and adjoins laterally the peroneus brevis. The tendon passes beneath the transverse crural and the superficial layer of the cruciate (anterior annular) ligaments and over the extensor digitorum brevis muscle. The superficial peroneal (musculo-cutaneous) nerve runs in the septum between it and the peroneal muscles; the anterior tibial artery and deep peroneal nerve pass beneath the head of the muscle, and then between it and the tibialis anterior.

The peroneus tertius (fig. 415).—*Origin.*—From the distal third of the medial surface of the fibula, the neighbouring interosseous membrane, and the anterior intermuscular septum.

Structure.—It is essentially a fasciculus of the extensor digitorum longus, from which it is seldom completely differentiated. The fibre-bundles descend obliquely forward to be inserted in a penniform manner on a tendon which runs along the lateral margin of the tendons of the extensor digitorum. The attachment of fibre-bundles continues to the cruciate ligament (lower part of anterior annular ligament).

Insertion.—On the base of the fifth metatarsal and often also on the base of the fourth.

Nerve-supply.—The more distal nerve to the extensor digitorum continues into this muscle.

Relations.—It lies lateral to the extensor digitorum longus. Its tendon passes into the foot beneath the transverse crural and the superficial layer of the cruciate ligament in the same compartments with those of the extensor longus.

The extensor hallucis longus (fig. 415).—*Origin.*—From the middle two-fourths of the medial surface of the fibula near the interosseous crest, and from the distal half of the interosseous membrane.

Structure.—Penniform. The fibre-bundles are attached as far as the cruciate ligament to the back and sides of a tendon which begins on the antero-medial margin of the distal third of the muscle.

Insertion.—On the base of the second phalanx of the big toe. On the back of the first phalanx the margins of the tendon are attached to the bone by bands of fibres.

Nerve-supply.—As a rule, a branch from the deep peroneal (anterior tibial) nerve enters the deep surface of the muscle near the junction of the upper and middle thirds, and passes distally across the middle of the obliquely running muscle fibre-bundles.

Relations.—It lies on the distal half of the interosseous membrane, partly covered by the extensor digitorum longus and the tibialis anterior muscles. Its tendon passes over the front of the distal extremity of the tibia and the medial side of the dorsum of the foot and is held in place by the transverse and cruciate ligaments and by a strengthening band in the fascia over the base of the first metatarsal. In the distal part of the leg the anterior tibial artery and the deep peroneal (anterior tibial) nerve pass beneath the muscle to enter the foot on the lateral side of its tendon.

Actions.—The muscles of this group all flex the ankle. The tibialis anterior and extensor hallucis longus evert the foot at the talo-calcaneo-navicular joints, and invert it at the talo-navicular, calcaneo-cuboid joints. In certain positions the tibialis anterior may, however, invert the foot at these joints. The peroneus tertius and the long extensor evert the foot. The force of the extensor hallucis longus is exerted powerfully on the first phalanx and weakly on the second. The short muscles of the big toe aid in extending the second phalanx. The extensor digitorum longus extends the first phalanx of each toe powerfully, but exerts less force on the second and third. The lumbrical muscles assist in extending the last two phalanges.

Variations.—The origin of the tibialis anterior may extend to the femur. Its tendon of insertion may give accessory slips to the cuneiforms, metatarsals, and phalanges. More rarely its belly is divided into two portions, one of which sends a tendon to the first cuneiform and one to the first metatarsal. A slip, the **tensor fasciæ dorsalis pedis** (Wood), may pass to the dorsal fascia of the foot. Another, the **tibio-astragalus anticus** (Gruber), to the talus (astragalus) or calcaneus. The bellies or the tendons of the extensor hallucis and extensor digitorum may be more or less completely fused, or tendon slips may pass from the tendon of one muscle to that of the other. Tendon slips may pass to the metatarsal bones or from the tendon of one toe to that of a neighbouring toe. The tendon to each toe may be doubled. The belly of the extensor digitorum longus may be more or less completely subdivided to correspond with the tendons to individual toes. The peroneus tertius is frequently fused with the long extensor. It may be doubled. More often its tendon may bifurcate or trifurcate and be inserted into the extensor tendons of the fifth toe or into the fourth or third metatarsal. It is absent in about 8.5 per cent. of bodies (Le Double).

Abnormal Muscles.—The **abductor hallucis longus** is rarely found as a completely independent muscle. It usually arises as a fasciculus of the extensor digitorum longus, extensor hallucis longus, or the tibialis anterior. It is inserted into the base of the first metatarsal. The **extensor primi internodii hallucis** (extensor hallucis brevis) has an origin similar to that of the long abductor above described. It is inserted into the dorsum of the base of the first phalanx of the big toe. It is not to be confounded with that portion of the extensor digitorum brevis connected with the great toe and also sometimes called the extensor hallucis brevis.

Bursæ

B. subtendinea m. tibialis anterioris.—A small bursa between the medial surface of the first cuneiform bone and the tendon of the tibialis anterior. **B. subtendinea m. extensoris hallucis longi.**—A small bursa beneath the tendon near the tarso-metatarsal articulation. It may communicate with the synovial sheath of the tendon. **B. sinus tarsi.**—A large bursa in the sinus tarsi and on the lateral surface of the neck of the talus (astragalus) beneath the tendons of the extensor digitorum longus and the fibrous bands between the talo-calcaneal and the cruciate ligaments. It extends back to the talo-crural, forward to the talo-navicular joint, and may communicate with the joint cavity of the latter.

Synovial Tendon-sheaths

Vagina tendinis m. tibialis anterioris.—This sheath surrounds the tendon from above the transverse crural ligament to the talo-navicular joint. **Vagina tendinis m. extensoris hallucis longi.**—The sheath begins above the proximal arm of the cruciate ligament, and ends near the tarso-metatarsal joint beneath a band-like thickening of the dorsal fascia of the foot. **Vagina tendinum m. extensoris digitorum longi.**—This sheath surrounds the tendons of the long digital extensor and the peroneus tertius from above the cruciate ligament to the middle of the third cuneiform bone.

2. Lateral Musculature of the Leg

(Figs. 416, 422)

The lateral muscles consist of the peroneus longus and the peroneus brevis. They extend and evert the foot. The thick prismatic belly of the **peroneus longus** arises from the proximal half of the lateral surface of the fibula and from neighbouring structures, while the smaller belly of the **peroneus brevis** arises from the middle third of the lateral surface of this bone. The peroneus longus partly covers the peroneus brevis. The tendons of the two muscles pass behind the lateral malleolus, held in place by special retinacula (p. 480). There the tendon of the peroneus longus lies at first lateral to and then crosses behind that of the peroneus brevis and curves about the lateral side of the calcaneus and across the sole of the foot closely applied to the cuboid and to the tarso-metatarsal articulations, and terminates on the base of the first metatarsal. The tendon of the peroneus brevis terminates on the lateral side of the foot at the base of the fifth metatarsal. The nerve supply is from the superficial peroneal (musculo-cutaneous) nerve.

The two muscles are probably represented in the arm by the extensor carpi ulnaris. In some of the lower animals the head of the peroneus longus extends to the femur. The fibular collateral ligament of the knee-joint probably represents in man the femoral head of the peroneus longus.

The peroneus longus (figs. 416, 422).—*Origin.*—Anterior head: tendinous from the anterior tibio-fibular ligament, the neighbouring part of the lateral condyle of the tibia, and the head of the fibula; fleshy from the proximal third of the anterior intermuscular septum and the crural fascia near the tibia. Posterior head: fleshy from the proximal half of the lateral surface of the shaft of the fibula and from the posterior intermuscular septum.

Structure.—Bipenniform. The fibre-bundles converge upon a tendon which begins high in the muscle. The constituent fibre-bundles of the anterior head are long and take a nearly vertical course. The fibre-bundles of the posterior head take a more oblique course and their attachment extends more distally on the tendon. The tendon emerges on the surface of the muscle in the distal half of the leg. The fibre-bundles of the posterior head extend to within a few centimetres of the lateral malleolus. The tendon passes through the retro-malleolar groove, passes across the lateral face of the calcaneus, to and through the peroneal groove of the cuboid, and crosses the second and third tarso-metatarsal joints. Where the tendon enters the groove in the cuboid it contains a fibro-cartilaginous nodule which may become a sesamoid bone.

Insertion.—On the inferior surface of the first cuneiform and on the supero-lateral border and base of the first metatarsal. From the region of the fibro-cartilaginous nodule above mentioned a fibrous slip is usually sent to the base of the fifth metatarsal.

Nerve-supply.—Most commonly the peroneal (external popliteal) nerve before dividing gives off two branches. One of these enters the deep surface of the middle third of the anterior head, the other passes across the middle third of the constituent bundles of the posterior head. The latter branch may arise from the superficial peroneal (musculo-cutaneous) nerve, and it may extend to supply the peroneus brevis.

The peroneus brevis (fig. 416).—*Origin.*—From the middle third of the lateral surface of the fibula; (2) from the septa which separate it from the anterior and posterior groups of muscles.

Structure.—Penniform. The fibre-bundles converge upon a tendon which begins high in the muscle and becomes visible on the lateral surface of the distal half of the belly. Behind the lateral malleolus the tendon becomes free, then passes forward below the malleolus and across the calcaneus and cuboid.

Insertion.—Into the tip of the tuberosity of the fifth metatarsal.

Nerve-supply.—The nerve arises from the superficial peroneal (musculo-cutaneous) nerve, or from a branch to the peroneus longus. It enters the proximal margin of the muscle and passes distally across its constituent fibre-bundles.

Relations.—The peroneal muscles in the leg are contained in a compartment bounded by the anterior and posterior intermuscular septa, by the fibula, and by the fascia of the leg. The peroneus longus to a considerable degree overlies the peroneus brevis. Beneath the upper part of the peroneus longus the peroneal (external popliteal) nerve bifurcates into its two chief branches. The deep peroneal (anterior tibial) nerve passes medially beneath the anterior head of the muscle. The superficial peroneal (musculo-cutaneous) nerve extends in the interval between the areas of the attachment of the two heads of the peroneus longus, and along the anterior margin of the peroneus brevis to the anterior intermuscular septum, through which it passes to its superficial distribution. The tendon of the peroneus longus at first lies lateral to and slightly overlaps that of the peroneus brevis. Toward the tip of the malleolus it lies almost directly posterior to this tendon. On the lateral surface of the calcaneus the tendon of the brevis lies superior to that of the longus, from which it is separated by a bony spine, the processus trochlearis of the calcaneus. The tendon of the longus is separated from the deep surface of the abductor of the little toe, and is held in place in the groove in the cuboid by the long plantar ligament.

Action.—The peroneus brevis everts the foot. The peroneus longus extends, abducts, and everts the foot, and supports the arch of the foot. The peroneus brevis also extends the foot when this is greatly flexed.

Variations.—The two peroneal muscles may be more or less fused. The origin of the peroneus longus may extend to the femur. The two heads of origin may be fused. Its tendon of insertion may send slips to the second, third, and rarely to the fourth and fifth metatarsals. The tendon may be united to that of the tibialis posterior (12 out of 45 bodies—Picou). Sesamoid cartilages or bones are occasionally found in the retro-malleolar and calcaneal portions of the tendon. The tendon of the peroneus brevis may send a slip to the second or third phalanx or to the head of the metatarsal of the fifth toe, to its extensor tendon, or to the cuboid. It may also send a fasciculus to the fourth metatarsal or the extensor tendon of the fourth toe.

Accessory peroneals.—Poirier considers these all varieties of a muscle which in its simplest form arises from the distal fourth of the fibula and is inserted by a tendon into the fifth toe. A corresponding muscle is normally found in many of the monkeys (**peroneus digiti quinti**). In man in one form or another it is a frequent anomaly. It may be so fused with the peroneus brevis that only its tendon of insertion is apparent. It may appear as a special muscle fasciculus of the peroneus longus or brevis. It may be merely a tendinous band, or it may be tendinous at origin and insertion, with an intermediate belly. Instead of being attached to the fifth toe, it may be inserted into the fifth metatarsal, the cuboid, the tendon of the peroneus longus, the calcaneus, lateral malleolus, or posterior talo-fibular ligament.

Synovial Tendon-sheaths

Vagina tendinum peroneorum communis.—There is a double sheath for the tendons of the peroneal muscles as they pass back of the lateral malleolus. From this region of union the sheath sends processes along each tendon proximally above the malleolus and distally over the lateral surface of the calcaneus. This process on the tendon of the peroneus longus often communicates with the following sheath. **Vagina tendinis m. peronæi longi plantaris.**—This sheath begins in the peroneal groove of the cuboid and ends near the medial border of the long plantar ligament.

3. Musculature of the Back of the Leg

a. Superficial Group (fig. 413)

To this group belong the gastrocnemius, soleus, and plantaris muscles. They extend the foot and flex the leg. The two ovoid heads of the **gastrocnemius** arise one on each side from above the condyles of the femur, extend about to the middle of the back of the leg, and are inserted into the posterior surface of the tendon of Achilles, and through this into the back of the calcaneus. The broad, flat, ovoid **soleus** arises beneath the gastrocnemius from the tibia and fibula, and is inserted into the deep surface of the tendon of Achilles as far as the ankle. The two heads of the gastrocnemius and the soleus constitute the **triceps suræ.** The **plantaris** is a slender muscle which passes along the medial margin of the lateral head of the gastrocnemius and beneath the medial head, where it gives rise to a slender tendon that runs between the gastrocnemius and soleus and along the medial margin of the tendon of Achilles to the fatty fibrous tissue of the heel. The nerve-supply is from the tibial nerve.

The muscles of this group have a common embryonic origin, and are first differentiated on the fibular side of the leg, whence they extend over the posterior tibial vessels and nerve to their medial attachments. The gastrocnemius corresponds with the flexor carpi radialis and ulnaris, the plantaris with the palmaris longus, the soleus with a portion of the flexor digitorum

sublimis of the forearm. In many of the monkeys and in the prosimians the plantaris is much more developed than in man.

The gastrocnemius (fig. 413).—**Medial head.**—*Origin.*—From a facet on the back of the medial condyle of the femur above the articular surface, from an area on the back of the femur superior and lateral to this, and from the femoral margin of the capsule of the knee-joint. **Lateral head.**—*Origin.*—From a facet on the proximal portion of the postero-lateral surface of the lateral condyle of the femur and from a rough area situated more medially and at a greater distance from the joint.

Structure and insertion.—The heads of the gastrocnemius are similar in structure. From the condylar facets there descend aponeurotic bands, one on the medial margin and the medial side of the posterior surface of the medial head, the other on the lateral margin and the lateral side of the posterior surface of the lateral head. These bands descend about two-thirds of the way down the muscle. In the tendon of the lateral head a sesamoid bone is frequently found. The fibre-bundles of the muscle pass obliquely from the supracondylar areas of origin and from the deep surface of the aponeurosis on each side to the tendon of insertion. This tendon begins as a septum between the two heads, and as a lamina on the deep surface of each head. The septum and laminæ soon fuse with the broad aponeurosis which covers the dorsal surface of the soleus. The attachment of fibre-bundles continues to about the middle of the back of the leg. The attachment of the medial head extends more distally than that of the lateral head. As a rule, the medial head is also the broader and thicker of the two.

The soleus.—*Origin.*—(1) By a fibular head from the back of the head and the proximal third of the posterior surface of the shaft of the fibula, and from the intermuscular septum between it and the peroneus longus; and (2) by a tibial head from the transverse septum over the distal margin of the popliteus, from the popliteal line, and from the middle third of the medial border of the tibia.

Structure and insertion.—From the fibular and tibial origins arise broad aponeuroses which unite proximally on the deep surface of the muscle so as to form a fibrous arch over the posterior tibial vessels and nerves. Distally they diverge and become more narrow, but the fibular aponeurosis is continued on the fibular side and the tibial aponeurosis on the tibial side of the muscle as far as the distal quarter of the leg. The main portion of the belly of the muscle is formed by fibre-bundles which arise from the posterior surface of these aponeuroses and pass obliquely to be inserted in a bipenniform manner on the deep surface of the tendon of Achilles. This tendon begins as a broad aponeurosis which covers the greater part of the posterior surface of the muscle, and gradually converges into a heavy fibrous band that is inserted into the calcaneus. The bundles of fibres of the tendon take a slightly spiral course. Those on the posterior surface run from the medial margin toward the lateral surface of the calcaneus; those on the anterior surface in a reverse direction. The attachment of the fibre-bundles continues to within a short distance of the heel. A few of the fibre-bundles arise directly from the fibula and the posterior intermuscular septum. On the deep surface of the belly of the muscle there is an **accessory fasciculus** which is formed by fibre-bundles that spring on each side from the anterior surface of the aponeuroses of origin of the muscle and have a bipenniform insertion on each side of a thin, oblique tendinous lamina which inferiorly becomes united to the deep surface of the tendon of Achilles.

The plantaris (fig. 413).—This muscle *arises* from the distal part of the lateral line of bifurcation of the linea aspera, in close association with the lateral head of the gastrocnemius. The fibre-bundles give rise to a flat, short, fusiform belly, and are united to a narrow tendon which extends along the medial edge of the tendon of Achilles to the lateral part of the dorsal surface of the calcaneus, where it *terminates* in the neighbouring fibrous tissue.

Nerve-supply.—From the tibial (internal popliteal) part of the sciatic nerve in the popliteal space nerves arise for each head of the gastrocnemius. Each nerve enters the middle third of the deep surface of the head near the proximal margin. The nerve-supply for the soleus is from two sources. One nerve arises in the popliteal space, often in company with the nerve to the lateral head of the gastrocnemius. It enters the posterior surface of the muscle near the proximal border and divides into two branches, one for each head of the muscle. The tibial (posterior tibial) nerve gives rise to a branch which, about half-way down the leg, enters the deep surface of the muscle and furnishes branches for the deep portion of the muscle on each side. The nerve-supply of the plantaris is by a branch from the tibial (internal popliteal) portion of the sciatic. This arises in the popliteal space and enters the deep surface of the muscle.

Relations.—The semimembranosus winds about the medial margin of the medial head of the gastrocnemius to its deep surface. The biceps passes to the lateral side of the lateral head of the gastrocnemius, and the plantaris along its medial margin. The semimembranosus and biceps above, the medial head of the gastrocnemius and the plantaris below, bound the popliteal space. The peroneal (external popliteal) nerve passes from the popliteal space obliquely across the plantaris and the lateral head of the gastrocnemius. The medial sural (short saphenous) nerve and the small saphenous vein pass between the heads of the gastrocnemius to the surface and thence to the lateral side of the ankle. From the peroneal (external popliteal) nerve in the popliteal space the lateral sural (communicans peronei) nerve extends distally over the calf. The (posterior) tibial nerve and posterior tibial artery and vein run between the two heads of the gastrocnemius, and then beneath the soleus to the medial side of the ankle. In the region of the tendon of Achilles a considerable space filled with fatty tissue intervenes between the tendon and the transverse septum.

Action.—The contraction of the triceps suræ produces extension, adduction, and inversion of the foot. The gastrocnemius is also a flexor of the leg. The plantaris has no known function in man. In some animals it is an extensor of the plantar fascia.

Variations.—There is considerable variation in the extent of the separation of the different parts of the triceps suræ. The tendons of the three heads may be separate nearly to the heel. Either or both heads of the gastrocnemius or the soleus may be doubled. A slip from the biceps

or semimembranosus, from the linea aspera, or popliteal space may join the triceps and give rise to a quadriceps suræ. On the other hand, one of the heads of the gastrocnemius or the tibial head of the soleus may be missing. A supernumerary fasciculus may extend from the deep surface of the soleus to the calcaneus. The plantaris is exceedingly variable in origin, structure, and insertion. The origin may be from the capsule of the knee-joint, the fascia of the leg, or from the tibia. Its tendon may terminate at almost any part of its course in neighbouring structures. It may be represented by a fibrous band. It is absent in about 7 per cent. of instances (Le Double).

Bursæ

B. m. gastrocnemii lateralis.—A bursa is often found between the tendon of the lateral head of the gastrocnemius and the capsule of the joint. It may communicate with the joint cavity. **B. m. gastrocnemii medialis.**—A bursa usually lies between the tendon of origin of the medial head of the gastrocnemius, the condyle of the humerus, and the capsule of the joint. Another bursa (b. m. semimembranosi) extends between the semimembranosus and the medial head of the gastrocnemius muscle. The two bursæ frequently communicate with one another and with the joint. **B. tendinis calcanei.**—This lies between the tendon of Achilles and the upper part of the back of the calcaneus. Between the back of the tendon and the crural fascia another bursa is frequently present.

b. Deep Group

The deep posterior musculature is separated from the superficial by the transverse septum described above (p. 479). The muscles covered by this septal fascia are the **popliteus,** the **flexor digitorum longus,** the **flexor hallucis longus,** and the **tibialis posterior.** An intermuscular septum between the popliteus and the tibialis posterior, and the attachment of the soleus to the popliteal line on the back of the tibia serve to separate the popliteus from the other deep posterior muscles which lie distal to this region and send tendons into the sole of the foot. The deep posterior musculature may thus be considered as divided into a proximal femoro-tibial and a distal cruro-pedal group. Both sets of muscles are supplied by branches of the tibial nerve.

Femoro-tibial Muscle

The popliteus (fig. 416).—A triangular muscle which *arises* from an ovoid facet at the inferior extremity of the groove on the outer side of the lateral condyle of the femur and is *inserted* into the proximal lip of the popliteal line of the tibia and the surface of the shaft of the tibia proximal to this. It rotates the leg medialward and flexes it.

Structure.—From the origin a broad tendon glides over the condyle within the capsule of the joint, then over the lateral fibro-cartilage and through a groove on the back of the tibio-fibular articulation. From both surfaces of this tendon, fibre-bundles diverge toward the area of insertion. The tendon is more or less intimately united to several structures with which it comes in contact about the joint. Rarely it contains a sesamoid bone. The fibres of insertion terminate in part in the fascia covering the muscle. The popliteus is homologous with the pronator teres of the arm, or, according to some investigators, with the deep portion of that muscle.

Nerve-supply.—A nerve which arises either independently or in conjunction with that to the posterior tibial muscle enters the popliteus near the middle of its distal edge. Sometimes a branch from the chief nerve to the knee-joint enters the proximal edge of the muscle.

Action.—To flex and rotate the leg medially.

Relations.—The popliteus lies within a compartment bounded by the transverse septum, the capsules of the knee and superior tibio-fibular joints, the back of the tibia, and a septum extending to the popliteal line (see above). On the transverse septum run the popliteal vessels and the tibial nerve. The proximal margin of the soleus overlaps the distal margin of the popliteus. The synovial membrane of the knee-joint sends a prolongation between its tendon and the back of the lateral condyle of the tibia.

Variations.—It is rarely absent. An accessory head may arise from the medial side of the lateral condyle or from some neighbouring structure. The **fibulo-tibialis** (peroneo-tibialis) is a small muscle found by Gruber in one body in seven. It arises from the medial side of the head of the fibula and is inserted into the posterior surface of the tibia beneath the popliteus.

Cruro-pedal Muscles (figs. 416, 420)

Of the three muscles of this group, the **flexor digitorum longus** lies on the tibial side of the leg, the **flexor hallucis longus** on the fibular side, and the **tibialis posterior** upon the interosseous membrane, partly covered by the other two

muscles, beneath the former of which it crosses, distally, to the tibial side of the leg. Septa separate the flexor muscles from the tibialis. The tendons of the three muscles pass behind the medial malleolus, held in place by the transverse septum and the deep layer of the laciniate (internal annular) ligament. They lie

FIG. 416.—THE DEEP MUSCLES OF THE BACK OF THE LEG.

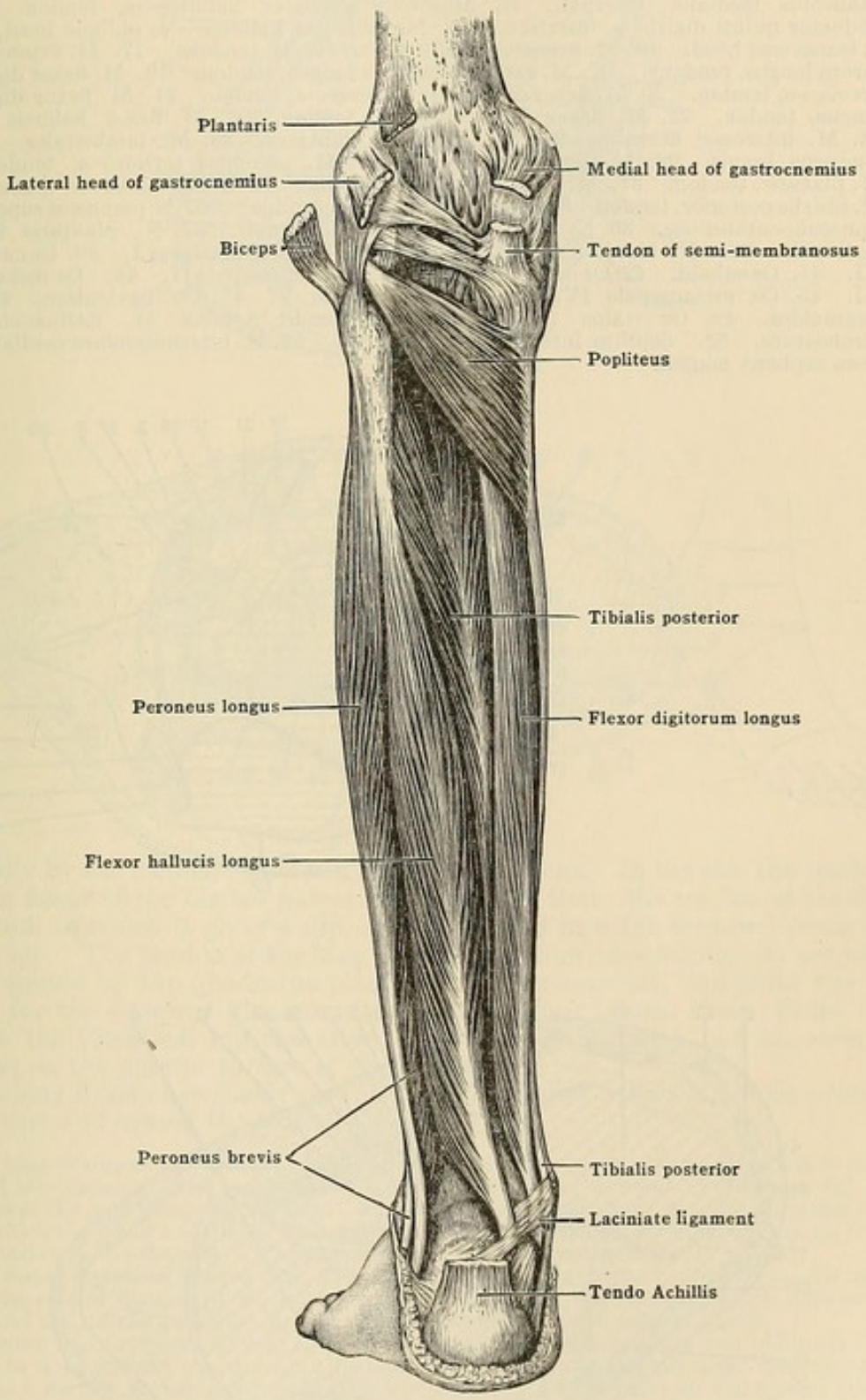

in compartments divided by septa which descend to the tibia. The compartment for the tibialis posterior is the most medial. It is partly overlapped by that for the flexor digitorum. At the ankle the tendon of the tibialis passes above, the tendon of the flexor digitorum medial to, and that of the flexor hallucis below, the sustentaculum tall, each in a separate osteo-fibrous canal bounded

FIG. 417. A–D.—TRANSVERSE SECTIONS THROUGH THE FOOT IN THE REGIONS SHOWN IN THE DIAGRAM.

f in the diagram indicates the region through which passes section F, fig. 414 (p. 478).

1. Arteria peronea. 2. A. plantaris medialis (internal). 3. A. plantaris lateralis (external). 4. A. tibialis anterior. 5. Aponeurosis plantaris. 6. Calcaneus. 7. Fascia pedis dorsalis. 8. F. plantaris—a, lateral; b, intermediate; c, medial. 9. Ligamentum cruciatum (anterior annular). 10. L. laciniatum (internal annular). 11. Malleolus lateralis (external). 12. Malleolus medialis (internal). 13. Musculus abductor hallucis—a, tendon. 14. M. abductor quinti digiti—a, insertion. 15. M. adductor hallucis— a, oblique head, origin; b, transverse head. 16. M. extensor digitorum brevis—a, tendons. 17. M. extensor digitorum longus, tendons. 18. M. extensor hallucis longus, tendon. 19. M. flexor digitorum brevis—a, tendon. 20. M. flexor digiti quinti brevis—a, tendon. 21. M. flexor digitorum longus, tendon. 22. M. flexor hallucis brevis tendon. 23. M. flexor hallucis longus. 24. M. interossei dorsales. 25. M. interossei plantares. 26. M. lumbricales. 27. M. peroneus brevis. 28. M. peroneus longus. 29. M. peroneus tertius—a, tendon. 30. M. planaris, tendon. 31. M. quadratus plantæ. 32. M. tibialis anterior, tendon. 33. M. tibialis posterior, tendon. 34. Nervus peroneus profundus. 35. N. peronæus superficialis (musculo-cutaneous). 36. N. plantaris medialis (internal). 37. N. plantaris lateralis (external). 38. N. suralis (external saphenous). 39. Os cuneiform I, 40. Os cuneiform III. 41. Os cuboid. 42. Os metacarpale I. 43. Os metacarpale II. 44. Os metacarpale III. 45. Os metacarpale IV. 46. Os metacarpale V. 47. Os naviculare. 48. Ossa sesamoidea. 49. Os talus (astragalus). 50. Tendo Achillis 51. Retinacula mm. peroneorum. 52. Septum intermusculare laterale. 53. S. intermusculare mediale. 54. Vena saphena magna.

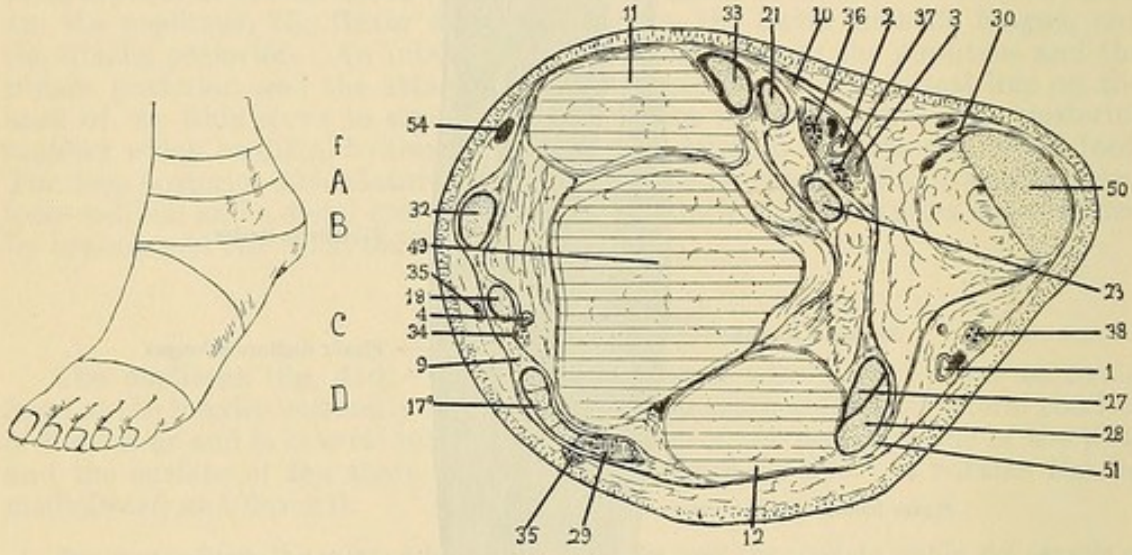

A

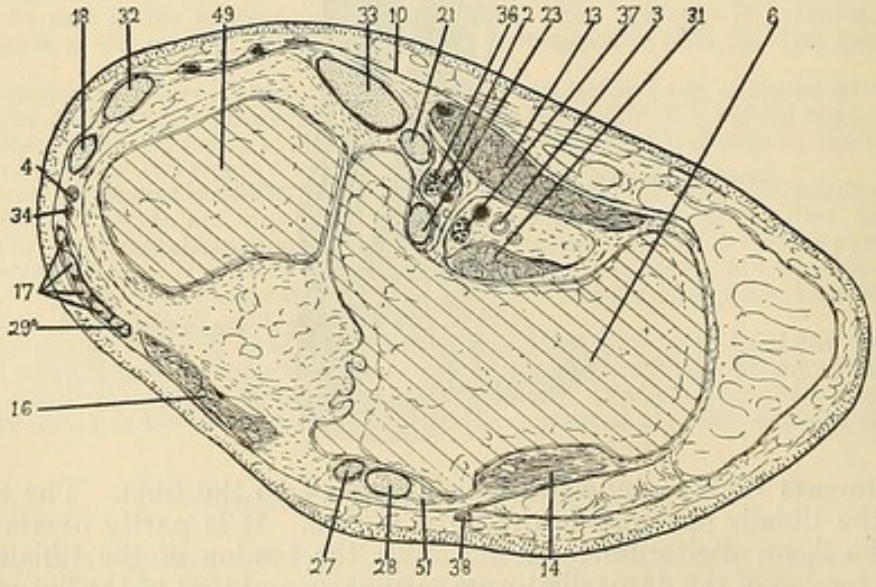

B

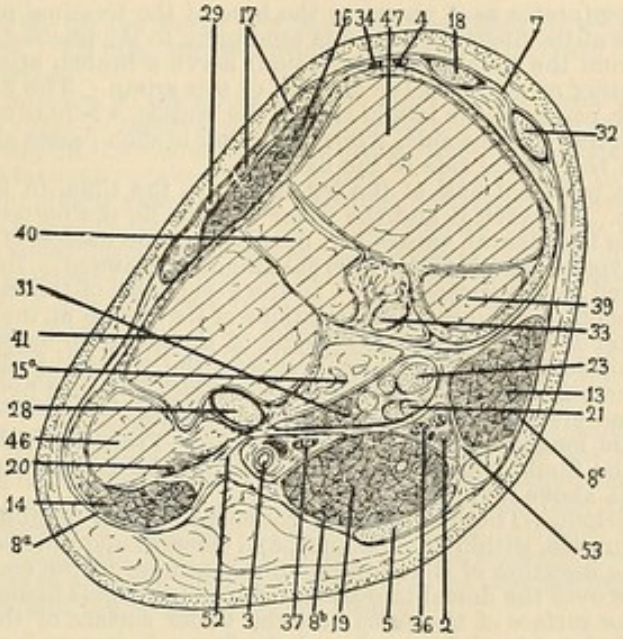

C

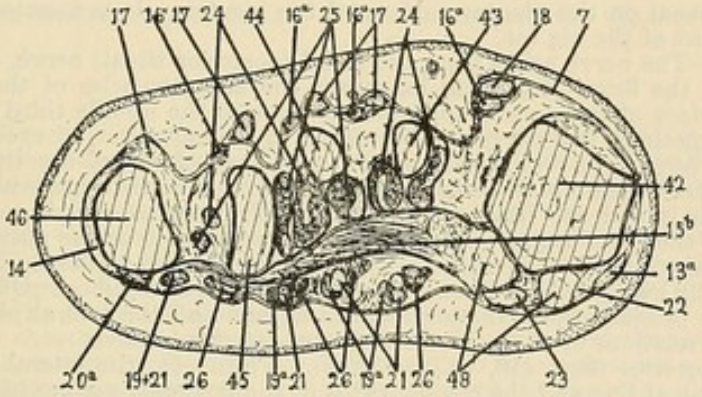

D

externally by the laciniate (internal annular) ligament. In the sole the tendon of the long flexor of the big toe passes under (deeper than) the tendon of the flexor digitorum, to which it gives a slip, and is inserted into the terminal phalanx of the big toe. The tendon of the long flexor of the toes passes obliquely across the sole, is joined by the quadratus plantæ (flexor accessorius), and gives rise to a tendon for the terminal phalanx of each of the four lateral toes. From these tendons the lumbrical muscles arise. The tibialis posterior has an extensive insertion on the plantar surface of the tarsus.

The long flexors act chiefly on the toes. Together with the tibialis posterior they invert and extend the foot.

The long flexors of the toes probably represent the flexor profundus and the flexor pollicis longus of the forearm. The tendons of the deep flexors of the forearm do not, however, cross like those of the long flexors of the toes. In the lower mammals there is much variation in the toes to which the tibial and fibular flexors are distributed. The tibialis posterior has no certain representative in the forearm. The rare ulno-carpeus may represent it.

The flexor digitorum longus (figs. 416, 420).—*Origin.*—From the popliteal line, the medial side of the second quarter of the dorsal surface of the tibia, the fibrous septum between the muscle and the tibialis posterior, and the fascia covering its proximal extremity.

Structure and insertion.—From these areas of origin the fibre-bundles run obliquely to be inserted in a penniform manner on a tendon which begins in the proximal quarter of the muscle as a narrow septum, and more distally becomes a strong band on the medial margin. The insertion of the fibre-bundles continues nearly to the medial malleolus. From here the tendon passes behind the medial malleolus, dorso-lateral to the tendon of the tibialis posterior, crosses the posterior talo-tibial ligament, and passes along the medial margin of the sustentaculum tali into the sole of the foot. Here it crosses the tendon of the flexor hallucis longus, from which it receives a tendinous slip, and divides into four parts, which pass to the second to the fifth toes. Each tendon is bound to the phalanges of the toe to which it passes by a fibrous sheath. Superficial to it in the sheath lies a tendon of the flexor digitorum brevis, which the

flexor longus tendon perforates as it passes to the base of the terminal phalanx. The tendon is connected, like those of the fingers, by vincula tendinum, to the phalanges of the toes.

Nerve-supply.—From the tibial (posterior tibial) nerve a branch arises, often in company with nerves to some other or others of the muscles of this group. The nerve divides into two branches, one of which passes to the lateral side of the muscle, where it extends along near the middle of the fibre-bundles of that side, while the other branch passes along near the middle of the fibre-bundles of the medial side of the muscle.

Relations.—In the proximal half of the leg it lies on the tibia, in the distal half on the posterior tibial muscle. Between it and the flexor hallucis lie the posterior tibial vessels and nerve. Near the ankle the plantar vessels and nerves cross the tendon of the muscle, separated from it by the deep layer of the laciniate (internal annular) ligament. In the upper two-thirds of its extent it is covered by the triceps suræ. In the lower third of the leg it emerges medial to the soleus and the tendon of Achilles. The relations of its tendon at the ankle have been described above. The tendon lies beneath the origin of the abductor hallucis muscle and in the sole is covered by the flexor digitorum brevis, crosses the tendon of the long flexor and the oblique adductor of the big toe and the interosseous muscles, is joined by the quadratus plantæ (flexor accessorius), and gives origin to the lumbrical muscles.

The flexor hallucis longus (figs. 416, 420).—*Origin.*—From the distal two-thirds of the posterior surface of the fibula, the septa between it and the tibialis posterior and peroneal muscles, and the fascia above its proximal extremity.

Structure and insertion.—The fibre-bundles converge upon a tendon which begins in the second quarter of the muscle, within its substance, and emerges upon the postero-medial margin in its distal half. The insertion of the fibre-bundles continues to the end of the tibia. From here the tendon passes over the dorsal talo-tibial (tibio-astragaloid) ligament, and through the groove on the posterior surface of the talus and the under surface of the sustentaculum tali, where it lies on the fibular side of the tendon of the flexor digitorum longus. It then crosses the deep surface of this tendon, to which it gives a slip, passes over the plantar surface of the medial head of the flexor hallucis brevis, and between the sesamoid bones of this muscle into the osteo-fibrous canal on the plantar surface of the big toe. It is inserted into the base of the terminal phalanx of the big toe.

Nerve-supply.—The nerve arises from the tibial (posterior tibial) nerve, often in company with the nerve to the flexor digitorum longus or the other muscles of the group. It runs along the deep surface of the muscle and sends twigs into the middle third of its constituent fibre-bundles. Sometimes two nerves are furnished to the muscle.

Relations.—It lies on the fibular side of the distal two-thirds of the leg. Proximally it diverges from the preceding muscle so as to disclose the tibialis posterior, which is more deeply situated. Between it and the tibialis posterior lie the peroneal vessels. Distally its tibial margin approaches the flexor digitorum longus, but between them lie the posterior tibial vessels and nerve. Lateral to it lie the peroneal muscles. It is covered in the leg by the soleus. In the distal part of the leg its tendon lies medial to the tendon of Achilles. On entering the foot the tendon crosses beneath the abductor hallucis muscle and the lateral plantar vessels and nerve. The other relations of the tendon have been described above.

The tibialis posterior (figs. 416, 422).—*Origin.*—From—(1) the lateral half of the distal margin of the popliteal line and the middle third of the posterior surface of the tibia; (2) the medial side of the head and of that part of the body of the fibula next the interosseous membrane in the proximal two-thirds; (3) from the whole of the proximal and the lateral portion of the distal part of the posterior surface of the interosseous membrane; and (4) from the septa between its proximal portion and the long flexor muscles.

Structure.—From this extensive area of origin the fibre-bundles converge upon a tendon which is at first deep seated within the muscle-belly, but about the middle of the leg emerges on the medial margin of the muscle. The fibular portion of the muscle is much more extensive than the tibial. The proximal fibres take a nearly perpendicular, the most distal (from the fibula) a nearly transverse, course. The insertion of fibres stops a little proximal to the medial malleolus. The tendon then extends to the medial side of the tendon of the long flexor of the toes, passes through the groove on the back of the malleolus, across the medial talo-tibial (tibio-astragaloid) ligament, and above the sustentaculum tali to the sole.

Insertion.—The tendon divides into two chief divisions, a deep and a superficial. (1) The deep portion becomes attached chiefly to the tubercle of the navicular bone, and usually in part also to the first cuneiform. (2) The superficial spreads out to be attached chiefly to the third cuneiform and the base of the fourth metatarsal, but also in part to the second cuneiform, to the capsule of the naviculo-cuneiform joint, to the sulcus of the cuboid, and usually also to the origin of the short flexor of the big toe and the base of the second metatarsal. Slips may, however, also be given to other structures. A sesamoid bone is usually found in the tendon either near the calcaneo-navicular ligament or the navicular bone.

Nerve-supply.—The nerve arises from the tibial (posterior tibial) in company often with branches to the other muscles of the group. It enters the posterior surface of the muscle in its proximal third, and gives off one or two branches for the tibial fasciculus. The main trunk descends across the middle third of the fasciculi arising from the fibula.

Relations.—The muscle covers the posterior surface of the interosseous membrane, and extends distally over the posterior surface of the tibia beneath the flexor digitorum longus. It is covered proximally by the soleus, distally by the two long digital flexors. The posterior tibial and peroneal arteries and the tibial (posterior tibial) nerve run upon its posterior surface. The tendon in the sole is under cover of the origin of the plantar muscles of the big toe.

Action.—The tibialis posterior adducts the foot and slightly inverts it. The flexor digitorum longus flexes the terminal phalanx on the second and the second on the first, and at the height of its contraction the first on the metatarsals. It also rotates medially to some extent the ends of the fourth and fifth toes, and inverts the foot. The flexor hallucis longus flexes

the second phalanx of the big toe on the first, and, less energetically, the first on the metatarsal. It also inverts the foot. All three muscles extend the foot. The flexor hallucis is the strongest of the three in this respect.

Variations.—The muscles of the group may be more or less fused with one another or be united by fasciculi. This is especially common between the two flexors of the toes. The individual muscles vary in development. The flexor digitorum longus may be more or less divided into separate fasciculi for the individual toes. The slip from the flexor hallucis longus to the flexor digitorum longus varies greatly in extent, but usually passes mainly to the second and third toes, more rarely to the second, third, and fourth, and very rarely to the fifth. In most of the apes the tibial flexor (flexor digitorum) sends tendons to the second and fifth, the fibular flexor (flexor hallucis) to the first, third, and fourth toes. This condition is also sometimes found in man. A slip may pass from the tendon of the flexor digitorum to that of the flexor hallucis longus. There may be a sesamoid bone in the tendon of the flexor hallucis longus as it passes over the talus (astragalus) and calcaneus. The tibialis posterior may be doubled. Aberrant fasciculi may arise from various regions on the back of the leg and join any one of the three muscles of the group.

Abnormal muscles.—**The soleus accessorius.**—Arises by a tendon from the head of the fibula beneath the soleus. It is usually a slender muscle inserted into the medial surface of calcaneus. **The tibialis secundus** (tensor of capsule of ankle-joint).—A small muscle which arises from the tibia beneath the flexor digitorum and is inserted into the capsule of the ankle-joint. **The fibulo-calcaneus medialis** (peroneo-calcaneus internus of MacAlister, flexor accessorius long. dig. long., etc.).—A fasciculus which arises from the lower third of the body of the fibula and gives rise to a tendon which passes beneath the laciniate ligament to the quadratus plantæ or to the tendon of the flexor digitorum longus.

Bursæ

B. subtendinea m. tibialis posterioris.—A small bursa between the navicular fibro-cartilage and the tendon.

Synovial Tendon-sheaths

Vagina m. flexoris digitorum longi.—The tendon is surrounded by a synovial sheath from the back of the medial malleolus to where it crosses the tendon of the flexor hallucis longus below the navicular bone. It may communicate with the sheath of the tibialis anterior or with that of the flexor hallucis longus. **Vaginæ tendinum digitales.**—The tendons of the long flexor, together with those of the short flexor, are surrounded by synovial sheaths from the heads of the metatarsals to the insertions of the tendons. In structure these resemble those of the fingers. **Vagina m. flexoris hallucis longi.**—The tendon is surrounded by a sheath from the back of the medial malleolus to the crossing of the tendon of the flexor digitorum longus. Another sheath surrounds the tendon from the middle of the first metatarsal to its insertion. **Vagina m. tibialis posterioris.**—The tendon is surrounded by a synovial sheath extending from a region proximal to the medial malleolus to the insertion of the tendon.

D. MUSCULATURE OF THE FOOT

On the dorsum of the foot there is a muscle not represented in the hand, the extensor digitorum brevis (fig. 418). In the sole of the foot there is a highly developed musculature which may be subdivided into the flexor digitorum brevis (fig. 419); the muscles connected with the long extensor of the toes, quadratus plantæ and lumbricales (fig. 420); the intrinsic muscles of the great toe, (figs. 419, 421); the intrinsic muscles of the little toe (figs. 419, 421); and the interosseous muscles (fig. 422). These muscles abduct and adduct the toes, flex them at the metacarpophalangeal joints and flex and extend them at the first row of interphalangeal joints. On the second row of interphalangeal joints they seem to exert relatively little action. All the movements, excepting flexion, are weak in most individuals. The extensor digitorum brevis is innervated by the deep peroneal (anterior tibial) nerve. The muscles of the sole of the foot are all innervated by the lateral (external) plantar, except the flexor digitorum brevis, the most medial of the lumbrical muscles, and the abductor and flexor brevis of the great toe, which are innervated by the medial (internal) plantar.

FASCIÆ

Tela subcutanea.—Over the dorsum of the foot the tela subcutanea contains little fat. On the sole of the foot and the plantar surface of the toes it contains much fat embedded in dense fibrous tissue.

Muscle fasciæ.—Over the dorsum of the foot a fascial membrane extends from the cruciate ligament mentioned above to the toes, where it is continued as fibrous sheaths for the extensor tendons. Laterally and medially it is continued into the plantar fascia. Where

it overlies skeletal structures it becomes adherent to them. In the main this fascial sheet is thin. Over the base of the first metatarsal it is strengthened by a band which runs from the medial side of this bone over the extensor tendons of the big toe to the base of the second metatarsal. The extensor digitorum brevis is covered by an adherent fascial sheet. The dorsal surface of each dorsal interosseous muscle is likewise covered by an adherent membrane.

The **plantar surface** of the foot is invested by a fascia in which three distinct regions may be observed, a central, a lateral, and a medial. The central region is greatly thickened by bands of fibrous tissue, the **plantar aponeurosis,** which diverge toward the toes from the medial half of the tuber calcanei. These bands become distinct from one another as the toes are approached, and each finally terminates partly in the skin over the head of the corresponding metatarsal and in the digital sheath of the flexor tendons. Some of the fibres are continued into the transverse capitular ligaments, the others extend through near the metatarsophalangeal articulation to the dorsum of the foot. Broader, thicker bands go to the three middle toes than to the big and little toes. At the margins of this central area some fibres radiate into the fascia of the lateral and medial area, some extend laterally into the skin, and some sink into the intermuscular septa described below. Near the toes well-marked transverse bundles of fibres may be seen between the digital bands. The central area of the plantar fascia is not densely adherent to the skin.

The digital sheaths of the flexor tendons of the toes correspond essentially with those previously described (p. 387) for the fingers.

The **medial plantar fascia** is thin and adherent to the skin. It extends between the central plantar and the dorsal fascia over the intrinsic muscles of the big toe. The **lateral plantar fascia** is thick and well developed near the heel, thin as the little toe is approached. A dense band, the **calcaneo-metatarsal ligament,** strengthens it between the calcaneus and the tuberosity of the fifth metatarsal.

At the junction of the lateral with the central region of the plantar fascia the **lateral intermuscular septum** sinks in to be attached to the first cuneiform, the navicular and the tendon of the posterior tibial. A similar **medial intermuscular septum** sinks in between the medial and central regions of the plantar fascia and is attached to the long plantar ligament, the tendon sheath of the peroneus longus and the base of the fifth metatarsal. The fascia of each of these regions in considerable part extends into these septa instead of becoming continuous across them.

The sole is thus divided into three great fascial compartments by these septa, a lateral, a central, and a medial. In the lateral lie the intrinsic pedal muscles of the little toe; in the medial, the abductor and the flexor brevis of the big toe and the distal end of the tendon of the flexor hallucis longus. The central compartment is subdivided by transverse septa into several sub-compartments. In the most superficial compartment lies the flexor digitorum brevis; in the second, the tendons of the flexor digitorum longus and its associated muscles, the quadratus plantæ (flexor accessorius) and the lumbrical muscles; in the third, the adductor muscles of the big toe; and in the fourth, the interosseous muscles.

The first two sub-compartments are most clearly marked in the region of the tarsus. Distally they become merged by the disappearance of the intervening transverse septum, and longitudinally subdivided by fibrous septa which serve to make a complete sheath over each digit for the flexor tendons. The sheath over the adductor muscle of the big toe is a thin membrane continued laterally from the medial intermuscular septum. Where the two heads of the adductor muscle advance upon their tendon of insertion, the medial septum has no skeletal attachment, so that the adductor sub-compartment of the middle fascial compartment communicates freely with the medial compartment. Over the cuneiform bones the tendon of the flexor hallucis longus passes from the long flexor region of the middle compartment into the medial compartment. Here the medial intermuscular septum divides into two layers, which form a sheath for the tendon as it passes to the plantar surface of the flexor hallucis brevis.

MUSCLES

1. Muscle of the Dorsum of the Foot

The extensor digitorum brevis (fig. 418).—This muscle is broad and thin, lies beneath the tendons of the long extensor muscle on the tarsus, lateral to the navicular and the head of the talus, and sends tendons to the four more medial toes. It arises from the calcaneus. Its nerve-supply is from the deep peroneal.

Origin.—From the lateral and superior surfaces of the body of the calcaneus and from the apex of the cruciate ligament.

Structure and insertion.—The fibre-bundles arise directly from the ligament, and by short tendinous bands from the bone. As they extend distally they become grouped into four bellies. Those of the most medial and largest belly, the **extensor hallucis brevis,** become inserted in a bipenniform manner on the lateral and medial margins of a tendon which begins opposite the cuboid. The insertion of fibre-bundles continues to the base of the first metatarsal. The insertion of the fibre-bundles of the other bellies, which are seldom so distinctly isolated as the first, takes place in a penniform manner into their respective tendons, but the exact mode of attachment is subject to great individual variations. The tendon of the first digit is inserted mainly into the middle of the back of the base of the first phalanx, but it is often also united to the tendon of the long extensor. The other three tendons are fused with the lateral margins of the corresponding tendons of the long extensor near the bases of the three middle digits. They also usually give slips to the bases of the first phalanges of the corresponding toes.

Nerve-supply.—The deep peroneal (anterior tibial) nerve, which, accompanied by the anterior tibial artery, passes beneath the medial belly of the muscle, gives off a branch which passes transversely across the middle of the deep surface of the muscle and sends twigs into it.

Relations.—It lies on the lateral side of the tarsus, beneath the long extensor tendons of the toes. The relations of its tendons have been described above.

Action.—It aids the long extensors in extending the first phalanx of each of the four medial digits. It has but a limited action on the second and third phalanges. It serves also to pull the ends of the toes to which its tendons go toward the little toe.

FIG. 418.—THE MUSCLE OF THE DORSUM OF THE FOOT.

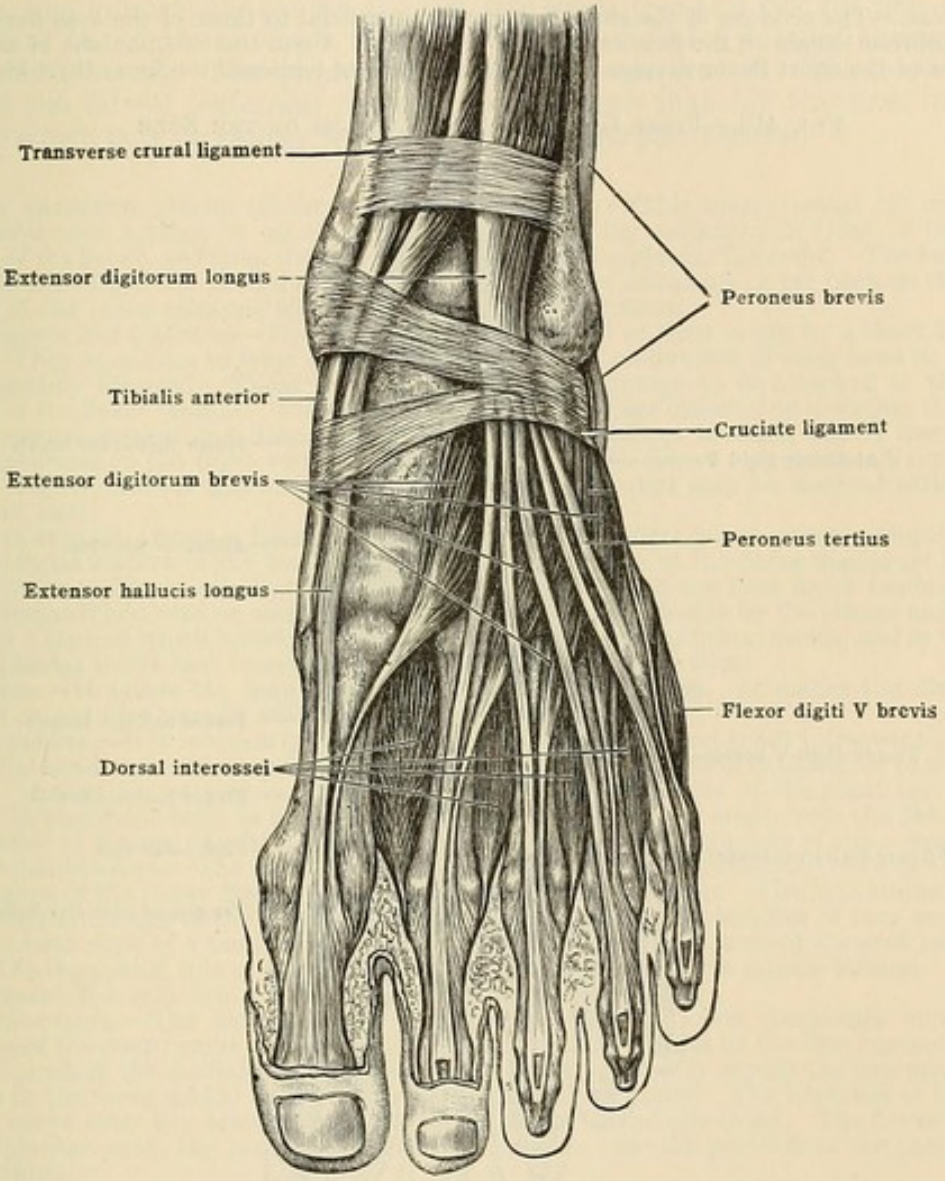

Variations.—The muscle shows great variation in development. Rarely the whole muscle, more frequently one or more of its digital divisions, may be missing. On the other hand, it may be more highly developed than usual. Accessory fasciculi vary greatly in origin and termination. Most frequently their tendons go to a metacarpo-phalangeal articulation or to the second or the fifth toe.

2. MUSCLES OF THE SOLE OF THE FOOT

a. FLEXOR DIGITORUM BREVIS (fig. 419)

The **flexor digitorum brevis,** the most superficially placed of the plantar muscles, lies in the mid-plantar region beneath the plantar fascia and over the tendons of the long flexor of the toes and its associated muscles. It arises from the calcaneus, and has a flat, elongated belly, which toward the middle of the sole is prolonged into four processes, each of which has a special tendon that is inserted into the second phalanx of one of the four lateral toes. The tendons of the muscle correspond to those of the flexor sublimis in the palm. The belly of the flexor

sublimis is supposed to be represented by the soleus. The nerve supply is from the medial (internal) plantar.

Origin.—From (1) the medial process of the tuber calcanei; (2) the posterior third of the plantar aponeurosis; and (3) the medial and lateral intermuscular septa.

Structure.—The constituent fibre-bundles pass distally in a compact mass. The tendons of insertion begin within the muscle substance, and as the fibre-bundles become inserted on them, the separate fasciculi become more and more distinct. The fasciculi for the second and third toes are larger and arise more superficially than those for the fourth and fifth toes. The fasciculus for the fifth toe is often very small, and its tendon takes an oblique course to the insertion.

Insertion.—The tendons of the short flexor pass superficial to those of the long flexor into the osteo-fibrous canals on the flexor surface of the digits. Upon the first phalanx of each toe the tendon of the short flexor divides and forms an opening (chiasma tendinis) through which

FIG. 419.—FIRST LAYER OF THE MUSCLES OF THE SOLE

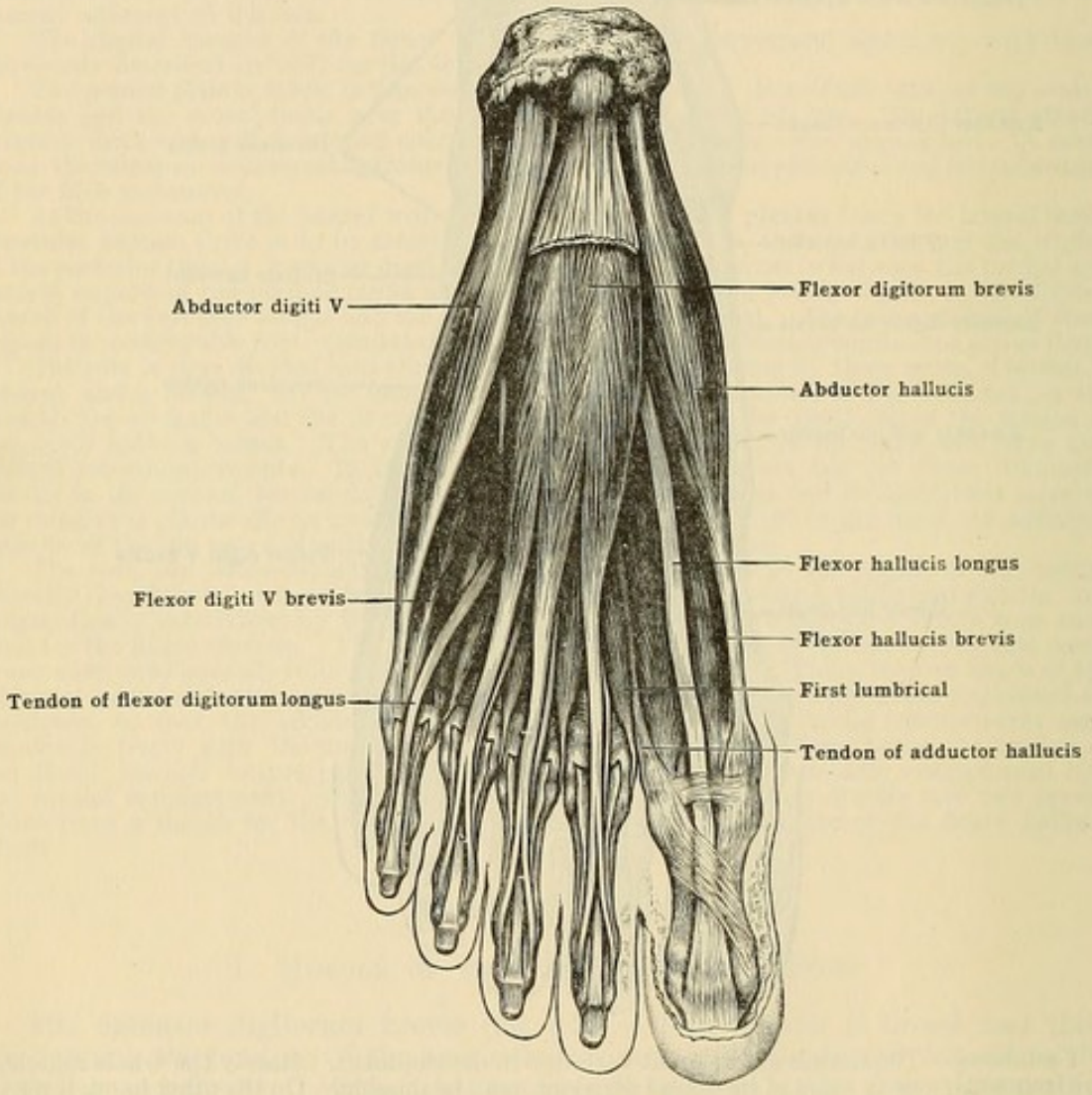

the tendon of the long flexor passes, while the tendon of the short flexor becomes attached to the base of the second phalanx. The arrangement is essentially like that described at length for the flexors of the fingers (p. 401).

Nerve-supply.—From the medial plantar nerve by a branch which enters the middle third of the deep surface near the medial margin of the muscle.

Action.—It is a strong flexor of the second row of phalanges.

Relations.—The short flexor is separated from the abductors of the big toe and little toe by strong intermuscular septa (p. 492), and from the long flexor tendons and the quadratus plantæ (flexor accessorius) by a transverse septum in which the lateral plantar vessels and nerve cross the foot. In its distal two-thirds it is separated from the plantar fascia by loose tissue.

Variations.—The muscle shows a tendency toward reduction, one or more of its fasciculi being frequently absent, and occasionally the whole muscle. The fasciculus for the fifth toe is absent in about 20 per cent. of bodies (Le Double). When a fasciculus is absent, its tendon is usually replaced by an accessory tendon from the long flexor. The muscle or its tendons may be more or less fused to the tendons of the flexor digitorum longus.

b. Muscles Attached to the Tendons of the Flexor Digitorum Longus (fig. 420)

The muscles belonging in this group are the **quadratus plantæ** (flexor accessorius), a flat, quadrangular, bicipital muscle which runs from the medial and plantar surface of the body of the calcaneus to the dorso-lateral margin and deep surface of the long flexor tendon; and the **lumbricales,** four slender bipinnate muscles which run from the medial sides of the digital slips of the tendon to the medial sides of the four more lateral toes. The quadratus aids the long flexor muscle; the lumbricales extend the last two phalanges and flex the first phalanx of each of the digits to which they pass. The lumbrical muscles correspond to those of the hand. The quadratus is not there represented. The nerve-supply is from the lateral (external) plantar nerve except that for the first lumbrical muscle which gets its supply from the medial (internal) plantar.

The quadratus plantæ (flexor accessorius) (fig. 420).—This muscle *arises* by two heads. The *lateral head* springs by an elongated tendon from the calcaneus in front of the lateral process of the tuber, and from the lateral margin of the long plantar ligament. The *medial head* arises directly from the medial surface of the body of the calcaneus as far back as the medial process of the tuber calcanei, and from neighbouring ligaments.

Structure and insertion.—The two heads are separated at their origin by a short triangular space. They soon fuse to form a single belly, but the fibre-bundles of each head in the main are separately inserted. Those from the lateral head diverge to be attached to the lateral margin of the flexor tendon. Those from the medial head are inserted on a tendon that begins on the medial margin and deep surface of this head, becomes broader, and is inserted as a flat aponeurosis on the deep surface of the flexor tendon. There are great individual variations in the structure of this muscle. The fibres of either part may be inserted with those of the other part.

Nerve-supply.—From a branch of the lateral plantar nerve which passes obliquely across the superficial surface of the muscle parallel with the tendon of the flexor digitorum longus.

Relations.—The muscle lies in a fascial compartment with the long flexor tendons. This compartment is bounded on each side by intermuscular septa, deeply by the tarsus, and plantarward by a septum which intervenes between it and the flexor digitorum brevis, and in which the lateral plantar nerve and vessels cross to the lateral side of the foot.

Action.—It assists the long flexor tendon in flexing the toes. It makes the direction of traction on the toes parallel with the long axis of the foot.

Variations.—It is frequently reduced in size. The lateral head is not infrequently missing, the medial head or the whole muscle much more rarely. The mode of attachment to the tendon varies. It may be inserted in part or wholly into the long flexor of the great toe. It may receive, in about one body in twenty (Wood), an accessory slip of origin from the fibula, one of the muscles of the leg, the fascia of the leg or foot, or the medial surface of the calcaneus, etc.

The lumbricales.—The three lateral muscles *arise* from the contiguous sides of the digital tendon-slips of the flexor digitorum longus in the angles of division. The first lumbrical arises on the medial margin of the tendon to the second toe. The fibre-bundles of each muscle converge on both sides of a tendon which becomes free near the metatarso-phalangeal joint and is *attached* to the medial side of the first phalanx of the toe to which the muscle belongs. A tendinous expansion is sent into the aponeurosis of the extensor muscle.

Nerve-supply.—The three lateral lumbrical muscles are most frequently supplied by branches of the deep ramus of the lateral plantar nerve, the medial by the first common plantar digital branch of the medial plantar nerve. The latter nerve may supply the two more medial muscles or the more medial muscles may receive a double supply. The branches of the lateral plantar nerve enter the deep surfaces of the muscles in the middle third. The branches of the medial plantar enter the medial borders of the muscles near the junction of the proximal and middle thirds.

Relations.—The lumbrical muscles lie in a plane with the long flexor tendons deeper than the flexor brevis tendons and superficial to the adductor hallucis. The deep branches of the lateral plantar nerve and vessels pass across their deep surface; superficial branches of both plantar nerves across the superficial surface.

Action.—To extend the last two phalanges of the toes and to flex the first.

Variations.—One or more of the muscles may be absent. Sometimes a muscle is doubled. This is more frequently the case with the third and fourth muscles. The first may arise wholly from the tendon of the posterior tibial muscle or from this and the long flexor of the big toe. The third lumbrical may arise from the flexor digitorum brevis. The second and fourth lumbricals may be inserted into the tendons of the flexor digitorum brevis.

c. Intrinsic Muscles of the Great Toe (figs. 419–421)

These muscles are the abductor, flexor brevis, and adductor. Of the three muscles, the first two lie in the medial fascial compartment, while the last lies in the middle compartment covered by the flexor digitorum longus and its associated muscles.

The **abductor hallucis** (fig. 419), the largest and most superficial of these muscles, lies on the border of the sole medial to the short flexor muscle. It passes from the calcaneus across the tendons of the long flexor muscles, and is inserted into the medial side of the base of the first phalanx of the great toe and into the medial side of the long extensor tendon. It is partly fused to the medial belly of the flexor hallucis brevis. The **flexor hallucis brevis** (fig. 421) is a bicaudal muscle which lies over the first metatarsal. It arises in the region of the cuneiform bones and is inserted on each side of the base of the first phalanx. Between

FIG. 420.—SECOND LAYER OF THE MUSCLES OF THE SOLE.

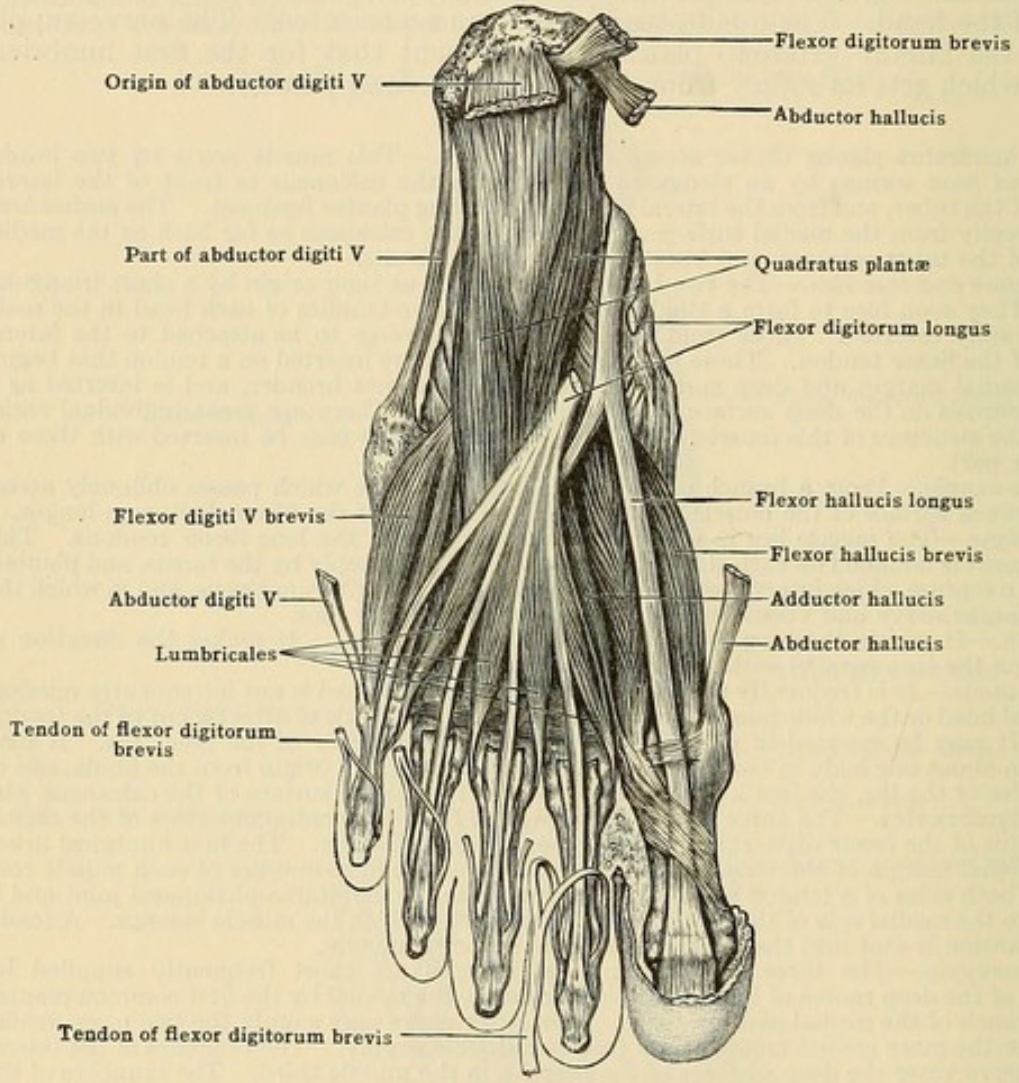

its two bellies and insertions runs the tendon of the long flexor of the great toe. Proximally and medially the flexor brevis is crossed by the abductor hallucis. Its tendons are fused with those of the abductor and the oblique head of the adductor. The **adductor hallucis** (fig. 421) is composed of two distinct heads, an oblique and a transverse. The oblique head extends from the long plantar ligament under cover of the tendons of the flexor digitorum longus and the lumbrical muscles to the lateral side of the base of the first phalanx of the great toe. Its tendon of insertion is joined by the transverse head, which arises from the capsules of the third to the fifth metatarso-phalangeal joints. Beneath the adductor lie the more medial interosseous muscles.

These muscles perform not only the functions indicated by their names, but also extend the second phalanx. They correspond fairly well with those of the thumb. The opponens is not normally present in the foot. The nerve supply for the adductor is from the lateral (external) plantar nerve; that for the other muscles is from the medial (internal) plantar.

The abductor hallucis (fig. 419).—*Origin.*—From (1) the medial process of the tuber calcanei; (2) the deep surface of the neighbouring plantar fascia; (3) the laciniate (internal

annular) ligament; (4) the septum between the muscle and the flexor digitorum brevis; and (5) a fibrous arch which extends on the deep surface of the muscle over the plantar vessels and nerves and the long flexor tendons from the calcaneus to the navicular bone.

Structure.—From the medial process of the tuber calcanei a tendinous band passes to the deep, lateral side of the muscle. Numerous tendinous bands arise from the other areas of origin. The fibre-bundles arise from these tendons and directly from the fibrous arch. They are attached in a penniform manner to numerous tendinous slips which extend far up in the muscle. These slips become gradually fused into a tendon which appears on the superficial plantar aspect of the muscle. Opposite the distal half of the first metatarsal bone the tendon leaves the belly of the muscle and becomes closely bound to the medial belly of the flexor hallucis brevis.

FIG. 421.—THIRD LAYER OF THE MUSCLES OF THE SOLE.

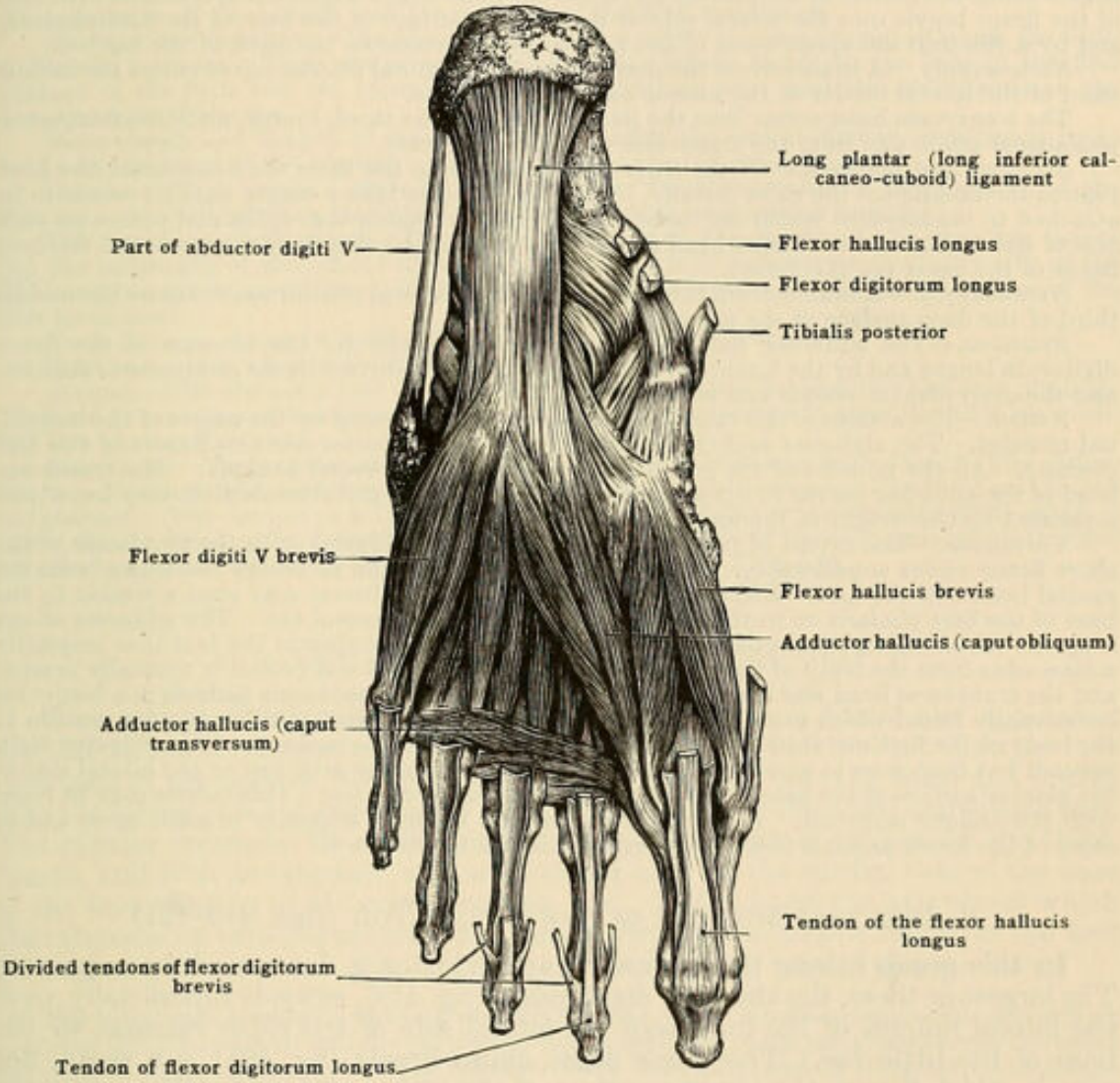

Insertion.—In conjunction with the tendon of the medial belly of the flexor brevis into the base of the first phalanx. It usually sends an expansion to the extensor tendon.

Nerve-supply.—A branch from the medial plantar nerve usually enters near the middle of the lateral border of the muscle.

Relations.—It is covered by the plantar fascia and is separated from the muscles of the median compartment by the medial intermuscular septum. It crosses the tendons of the tibialis anterior, tibialis posterior, flexor digitorum longus, and flexor hallucis longus muscles and the plantar vessels and nerves.

The flexor hallucis brevis (fig. 421).—*Origin.*—From a tendon attached to the first (internal), second and third cuneiform bones. The more lateral of its fibres are continued into the plantar calcaneo-cuboid ligament and the more medial into the expansion of the tendon of the posterior tibial muscle.

Structure and insertion.—The fibre-bundles give rise to two bellies, a medial and a lateral. Those of the medial belly pass obliquely medially to be inserted into the tendon of the abductor hallucis, and by a short tendon fused with this into the medial side of the plantar surface of the base of the first phalanx. This tendon contains a sesamoid bone. Those of the lateral converge upon the tendon of the oblique head of the adductor, and the two muscles are inserted by a common tendon, which contains a sesamoid bone, into the lateral side of the plantar surface of the base of the first phalanx.

Nerve-supply.—A branch from the medial plantar (or first plantar digital) nerve divides over the plantar surface of the muscle and gives a twig to each belly near the middle third. Rarely the lateral belly may receive a branch from the lateral plantar nerve.

Relations.—The abductor hallucis covers it medially; the tendon of the flexor hallucis longus passes between its two heads. Branches of the medial plantar vessels and nerve lie on its superficial surface.

The adductor hallucis (fig. 421).—The **oblique head.**—*Origin.*—From (1) the tuberosity of the cuboid and the sheath over the tendon of the peroneus longus muscle; (2) the plantar calcaneo-cuboid ligament; (3) the third cuneiform; (4) the bases of the second and third metatarsals and (5) a fibrous arch which extends from the plantar calcaneo-cuboid ligament to the interosseous fascia.

Structure and insertion.—From short tendon-slips the fibre-bundles pass forward to form a thick, fusiform belly which is attached in a bipenniform manner to a flat tendon. The tendon begins about the middle of the plantar surface of the muscle and is inserted in common with that of the flexor brevis into the lateral side of the plantar surface of the base of the first phalanx, and by a slip into the aponeurosis of the long extensor muscle on the back of the big toe.

Nerve-supply.—A branch from the deep ramus of the lateral plantar nerve enters the middle third of the lateral border of the muscle on its deep surface.

The **transverse head** *arises* from the joint-capsules of the third, fourth, and fifth metatarso-phalangeal joints and from the transverse capitular ligaments.

Structure and insertion.—Of the three fasciculi, that to the little toe lies nearest the heel, that to the middle toe the most distally. The fibre-bundles take a nearly parallel course to be attached to tendon-slips which are fused into a common tendon that splits and passes on each side of the tendon of the oblique head and is inserted into the sheath of the tendon of the long flexor of the great toe (Leboucq).

Nerve-supply.—A branch from the deep ramus of the lateral plantar nerve enters the middle third of the deep surface of the muscle.

Relations.—The adductor hallucis is crossed superficially by the tendons of the flexor digitorum longus and by the lumbrical muscles. On its deep surface lie the interosseous muscles, and the deep plantar vessels and nerves.

Action.—The actions of the muscles of this group are indicated by the names of the individual muscles. The abductor and the oblique head of the adductor are also flexors of the first phalanx. All the muscles of the group aid in extending the second phalanx. The transverse head of the adductor serves to draw together the heads of the metatarsals after they have been separated by the weight of the body during the tread.

Variations.—The extent of fusion of the abductor and adductor with the two heads of the short flexor varies considerably. The abductor may receive an accessory fasciculus from the medial border of the foot. Either the adductor or the flexor brevis may send a tendon to the base of the first phalanx or to the short flexor tendon of the second toe. The adductor shows frequent variations in relation to its metatarsal attachments, owing to the fact that originally a fasciculus from the body of the second (and third) metatarsal was probably normally present and the transverse head was more developed (Leboucq). The **opponens hallucis** is a fasciculus occasionally found which extends from the short flexor or the medial intermuscular septum to the body of the first metatarsal. This muscle is normal in some monkeys. An **adductor digiti secundi** has been seen to arise from various sources and become attached to the lateral side of the plantar surface of the base of the first phalanx of the second toe. This muscle may be fused with the oblique adductor. A corresponding muscle is found normally in some apes, and in some of the lower animals there is a special adductor for each toe.

d. Intrinsic Muscles of the Little Toe (figs. 419–421)

In this group belong three muscles, an abductor, a flexor and an opponens. The largest of these, the **abductor digiti quinti** (fig. 419), extends superficially over the lateral margin of the foot from the lateral side of the tuber calcanei to the base of the little toe. The **flexor digiti quinti brevis** (fig. 421) is a small, flat muscle which lies on the plantar surface of the fifth metatarsal. The **opponens** is a small muscle lying lateral to this. The two, which are often fused, arise from the cuboid. The flexor brevis is inserted into the plantar side of the base of the first phalanx of the little toe. The opponens is inserted into the lateral surface of the metatarsal. The abductor corresponds with the abductor of the little finger. The opponens and flexor brevis correspond probably with the deep part of the opponens of the little finger. The nerve supply is from the lateral plantar nerve.

The abductor digiti quinti (fig. 419).—*Origin.*—From (1) the lateral process of the tuber calcanei and the lateral and plantar surface of the body of the bone in front of this; (2) the lateral intermuscular septum; (3) the deep surface of the lateral plantar fascia, including the fibrous band extending from the calcaneus to the lateral side of the base of the fifth metatarsal bone.

Structure.—The fibre-bundles run obliquely to a flat tendon of insertion. This begins within the muscle near the calcaneo-cuboid joint, soon emerges on the medial side of the deep surface, and becomes free near the metatarso-phalangeal joint. Considerable individual variation in structure is found.

Insertion.—On the lateral surface of the first phalanx of the little toe and the metatarso-phalangeal capsule. Often a slip is sent to the extensor tendon. While usually the muscle

glides over the tuberosity of the fifth metatarsal, it frequently sends a second fasciculus to be attached to this bone (**abductor ossis metatarsi quinti**). A special fasciculus from the tuberosity often constitutes the lateral margin of the muscle.

Nerve-supply.—The nerve arises from the lateral plantar. It may be distributed either near the deep or the superficial surface of the muscle. The former appears to be the case when the muscle is slightly developed. The chief intramuscular branches then extend across the middle third of the constituent fibre-bundles near the deep surface. In case the calcaneo-metatarsal bundles are well developed, the nerve enters the proximal margin of the muscle and its chief branches extend across the middle third of the more superficial muscle-bundles, finally terminating in the distal margin of the muscle.

Relations.—It is ensheathed by the plantar fascia and the lateral intermuscular septum. It lies superficial to the quadratus plantæ (flexor accessorius), the opponens and flexor brevis of the little toe, the long plantar ligament, and the tendon of the peroneus longus muscle.

The flexor digiti quinti brevis (fig. 421).—*Origin.*—From the sheath of the peroneus longus, the tuberosity of the cuboid, and (3) the base of the fifth metatarsal.

Structure and insertion.—The fibre-bundles take a nearly parallel course, although the belly is slightly fusiform. They are attached by short tendinous bands to the base of the first phalanx of the little toe, the capsule of the corresponding joint, and the aponeurosis on the dorsal surface of the toe.

Nerve-supply.—A branch of the superficial ramus of the lateral plantar nerve sends twigs to the middle third of the plantar surface of this and the following muscle.

Relations.—It is covered medially by the plantar fascia, laterally by the abductor of the fifth toe. Medially it lies superficial to the third plantar interosseous muscle.

The opponens digiti quinti.—This muscle *arises* from the sheath of the peroneus longus and the tuberosity of the cuboid by a slender tendon which passes over the tuberosity of the fifth metatarsal and gives rise to fibre-bundles which are *inserted* on the lateral surface of the fifth metatarsal.

Nerve-supply.—From branches of the nerve to the flexor brevis.

Relations.—It is covered by the abductor of the fifth toe.

Actions.—The abductor and flexor brevis abduct the little toe and flex the first phalanx. They act as extensors of the second phalanx. The opponens serves to draw the little toe medially in a plantar direction.

Variations.—The muscles of this group may be more or less completely fused. The abductor, in addition to the variations mentioned above, may send tendons to the third and fourth metatarsals. The opponens is frequently missing. The **abductor accessorius digiti quinti** is a rare muscle which arises from the lateral process of the tuber of the calcaneus and is inserted into the lateral surface of the base of the first phalanx of the little toe.

e. The Interosseous Muscles (fig. 422)

Two groups of interosseous muscles are recognised, a dorsal and a plantar. The dorsal are the larger and fill the interspaces. The first two are inserted into each side of the base of the first phalanx of the second toe; the third and fourth into the lateral sides of the bases of the first phalanges of the third and fourth toes. The plantar interossei lie on the medial side of the ventral surfaces of the third, fourth, and fifth metatarsals, and are inserted each on the medial side of the base of the first phalanx of the corresponding toe. In the hand the axis about which the interosseous muscles are arranged passes through the middle finger, in the foot through the second toe. The nerve-supply is from the lateral plantar nerve.

The interossei dorsales.—Each of the three lateral dorsal interosseous muscles *arises* from—(1) the sides of the shaft and the plantar surface of the bases of the metatarsal bones bounding the space in which it lies; (2) from the fascia covering it dorsally; and (3) from fibrous prolongations from the long plantar ligament. The first has a similar origin except that it is attached medially to the base of the first metatarsal and to a fibrous arch extending from the base to the head.

Structure.—The component fibre-bundles of each muscle are inserted bipinnately on a tendon which begins high in the muscle and becomes free near the metatarso-phalangeal joint.

Insertion.—The first and second on each side of the base of the first phalanx of the second toe. The third and fourth on the lateral side of the bases of the proximal phalanges of the third and fourth toes. Each tendon is adherent to the capsule of the neighbouring joint. They send no well marked processes to the extensor tendons, as do those of the hand.

The interossei plantares.—Each plantar interosseus *arises*—(1) from the proximal third of the medial plantar surface of the shaft and from the base of the metatarsal on which it lies; and (2) from expansions of the long plantar ligament.

Structure and insertion.—The obliquely placed fibre-bundles are longer than those of the dorsal interossei, and are inserted in a tendon which lies near the medial border of the muscle, becomes free near the metatarso-phalangeal joint, and is inserted into a tubercle on the medial side of the base of the first phalanx of the digit to which it goes.

Nerve-supply.—From the deep branch of the lateral plantar nerve several rami are given off for the interossei. The nerve of each muscle enters the plantar surface in the proximal third. The interosseous muscles of the fourth interspace, however, are usually supplied by a branch from the superficial ramus of the lateral plantar nerve.

Relations.—The interosseous muscles are covered on the plantar surface by a thin fascia on which the deep branches of the lateral plantar nerve and vessels run. The first dorsal interosseous adjoins medially the flexor hallucis brevis and laterally on the plantar surface of the second metatarsal, adjoins the second dorsal interosseous. Dorsal and plantar interossei then alternate across the plantar surface of the foot until the fifth metatarsal is reached. Here the third plantar interosseous adjoins the flexor brevis of the little toe.

FIG. 422.—FOURTH LAYER OF THE MUSCLES OF THE SOLE.

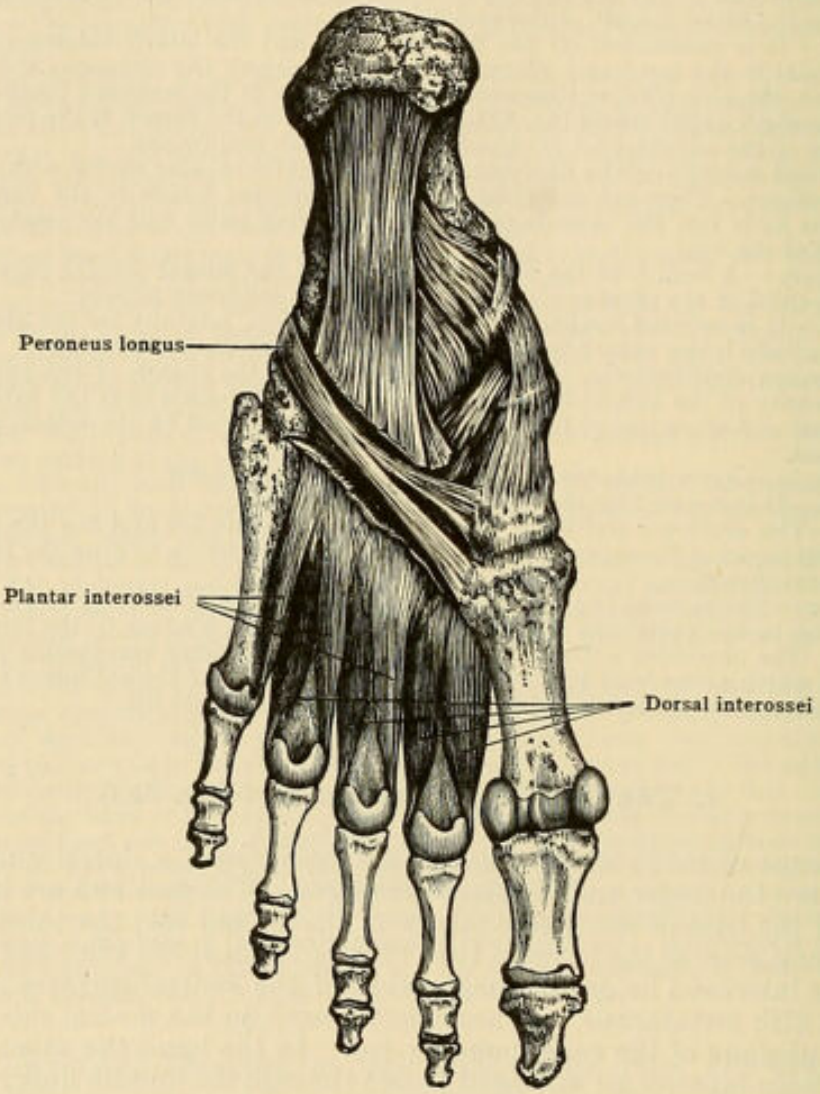

Action.—The chief axis of the foot may be taken to extend through the second toe. The dorsal interosseous muscles abduct—pull the digits to which they are attached away from this axis; the plantar interosseous muscles adduct—pull the digits toward the axis. The interossei all flex the first row of phalanges.

Variations.—The second dorsal interosseous may have no attachment to the third metatarsal.

BURSÆ

B. intermetatarsophalangeæ.—Four bursæ between the neighbouring sides of the heads of the metatarsal bones and dorsal to the transverse capitular ligaments. **B. mm. lumbricalium.**—Between the ends of the tendons of the lumbrical muscles and the transverse capitular ligaments. The three medial are more constant than the lateral.

For other bursæ in the foot, see pp. 483 and 491.

MUSCLES GROUPED ACCORDING TO FUNCTION

The exact functions of many of the muscles have not yet been decisively determined. Anatomical studies, the construction of mechanical models, the electrical stimulation of the musculature, and observation of the muscular activities of normal individuals and of individuals in whom given muscles or sets of muscles are absent or paralysed, have all proved valuable methods of investigation, but each method has its drawbacks, and knowledge of the part actually played by individual muscles in the normal activities of the body is as yet merely approxi-

mate. Owing to the influence of gravity, the relations of other muscles to the skeleton, and similar factors, a given muscle may perform functions which would not be deduced from a simple study of the relations of the muscle to the skeleton. Thus the iliacus serves to flex not only the hip, but also the knee, and the hamstring muscles may flex the hip while flexing the knee. The functions ascribed to various muscles in the following tables, although an attempt has been made to base them upon the more recent work on the action of the muscles, must be taken to be merely approximately correct. So far as possible the muscles are given in order of their power in effecting the various movements. In this we have utilized chiefly the work of R. Fick: "Anatomie und Mechanik der Gelenke unter Berücksichtigung der bewegenden Muskeln" in von Bardeleben's Handbuch der Anatomie des Menschen.

In this table have been included not only the voluntary muscles described in the preceding section, but also several described in other parts of the book.

1. Facial muscles.

These serve essentially to contract the various visceral orifices of the head or to retract the tissue surrounding them.

Ear.

Retractors: auricularis anterior, superior, and posterior.

Orbit.

(*a*) Retractor: Epicranius (occipito-frontalis). The levator palpebræ superioris, innervated by the third cranial nerve, serves to raise the upper lid of the eye.

(*b*) Contractors: orbicularis oculi, corrugator, and procerus.

Nasal orifice.

(*a*) Dilators: angular head of the quadratus labii superioris, transverse portion of the nasalis, and the dilatores naris.

(*b*) Contractors: pars alaris of the nasalis and the depressor septi nasi.

Oral orifice.

(*a*) Retractors:

Upward: zygomaticus, quadratus labii superioris, caninus.

Lateralward: zygomaticus, risorius, platysma, triangularis, buccinator.

Downward: triangularis, quadratus labii inferioris, platysma.

(*b*) Contractors: orbicularis oris, compressor labii, incisivus labii inferioris and superioris.

(*c*) Protractors of the lips: incisivus labii inferioris and superioris, mentalis.

2. Muscles acting on the eyeball (see Section on Eye).

To adduct the pupil: rectus medialis.

To abduct the pupil: rectus lateralis.

To direct the pupil upward: rectus superior, in association with the obliquus inferior.

To direct the pupil downward: rectus inferior, in association with the obliquus superior.

3. Muscles acting on the lower jaw.

(*a*) To raise it: masseter, temporal, internal pterygoid.

(*b*) To lower it: external pterygoid, digastric, mylo-hyoid, genio-hyoid, and the infrahyoid muscles. The weight of the jaw also plays a part in this movement.

(*c*) To protract it: external pterygoid, internal pterygoid, masseter and the anterior part of the temporal.

(*d*) To retract it: the inferior dorsal portion of the temporal and the digastric.

(*e*) To produce lateral movements: the external pterygoid acting on one side rotates the chin and carries the jaw toward the opposite side. The rotation may be aided by the digastric of the opposite side. The masseter draws it slightly toward the side on which the muscle lies. This action of the masseter is counterbalanced by the internal pterygoid (Riegner).

4. Muscles acting on the hyoid bone.

(*a*) To elevate it: digastric, stylo-hyoid, stylo-glossus, mylo-hyoid, genio-hyoid, genio-glossus, hyo-glossus, and the middle constrictor of the pharynx.

(*b*) To depress it: thyreo-hyoid, sterno-hyoid, omohyoid, sterno-thyreoid.

(*c*) To protract it: genio-glossus (inferior portion), genio-hyoid, anterior belly of digastric, and the mylo-hyoid.

(*d*) To retract it: posterior belly of digastric, stylo-hyoid, and the middle constrictor of the pharynx.

5. Muscles acting on the larynx (see Section IX).

(*a*) To elevate it: thyreo-hyoid, stylo-pharyngeus, pharyngo-palatinus, the inferior constrictor of the pharynx, and the elevators of the hyoid bone.

(*b*) To depress it: sterno-thyreoid, sterno-hyoid, and omo-hyoid.

(*c*) To approximate the vocal cords: crico-arytenoideus lateralis; vocalis; thyreo-arytenoideus, arytenoideus transversus.

(*d*) To make the vocal cord tense: crico-thyreoideus.

(*e*) To widen the rima glottidis: crico-arytenoideus posterior.

(*f*) To shorten and thicken the vocal cords: thyreo-arytenoideus (externus), vocalis.

(*g*) To constrict the aditus and vestibule of the larynx: aryepiglotticus, thyreo-arytenoideus.
(*h*) To widen the aditus and vestibule of the larynx: thyreo-epiglottideus

6. Muscles acting on the tongue (see Section IX).
(*a*) To elevate it: stylo-glossus (especially along the sides), glosso-palatinus, glosso-pharyngeus, and the elevators of the hyoid bone.
(*b*) To depress it: genio-glossus (in the centre), hyoglossus (at the sides), chondroglossus, and the depressors of the hyoid bone.
(*c*) To protrude it: genio-glossus (middle and inferior portions).
(*d*) To retract it: genio-glossus (anterior portion), stylo-glossus, chondro-glossus.
(*e*) To shorten it and make it bulge upwards: longitudinalis superior and inferior.
(*f*) To narrow it and make it bulge upwards: transversus linguæ.
(g) To flatten it: verticalis linguæ.
When the muscles work symmetrically, these movements are symmetrical; when they do not work symmetrically, the tongue is moved from side to side, rotated, etc.

7. Muscles acting on the palate and pharynx (see Section IX).
(*a*) To narrow the pharyngeal opening of the tuba auditiva (Eustachian tube): levator veli palatini.
(*b*) To widen the isthmus of the tuba: levator veli palatini.
(*c*) To open the tube: tensor veli palatini, pharyngo-palatinus.
(*d*) To raise and shorten the uvula: m. uvulæ.
(e) To depress the soft palate: glosso-palatinus, pharyngo-palatinus.
(*f*) To make tense the soft palate: tensor veli palatini.
(*g*) To lift the soft palate: levator veli palatini.
(*h*) To approximate the glosso-palatine arches (anterior pillars of the fauces): glosso-palatinus.
(*i*) To approximate the pharyngo-palatine arches (posterior pillars of the fauces): pharyngo-palatinus, superior constrictor of the pharynx.
(*j*) To constrict the pharynx: superior, middle, and inferior constrictors.
(*k*) To widen the pharynx: stylo-pharyngeus and the muscles which protract the hyoid bone.
(*l*) To elevate the pharynx: stylo-pharyngeus, pharyngo-palatinus.

8. Muscles acting on the head.
(*a*) To flex it: the supra- and infrahyoid muscles, rectus capitis anterior, longus capitis, rectus capitis lateralis.
(*b*) To extend it: sterno-cleido-mastoid, trapezius, splenius capitis, longissimus capitis, semispinalis capitis, obliquus capitis superior, rectus capitis posterior major and minor. When the hyoid bone and lower jaw are fixed by contraction of the hyomandibular and infrahyoid muscles, the posterior belly of the digastric aids the extensors of the head in opening the mouth.
(*c*) To bend it laterally: sterno-cleido-mastoid, rectus capitis lateralis, splenius capitis, longissimus capitis, semispinalis capitis, obliquus capitis superior.
(*d*) To rotate it: sterno-cleido-mastoid, trapezius, splenius capitis, longissimus capitis, semispinalis capitis, obliquus capitis superior and inferior, rectus capitis posterior major.

9. Muscles acting on the spinal column.
(*a*) To flex it: sterno-cleido-mastoid, longus colli, longus capitis, psoas major and minor, scaleni, rectus abdominis, obliquus abdominis externus and internus, the crura of the diaphragm, levator ani, and the coccygeus.
(*b*) To extend it: splenius capitis, splenius cervicis, spinalis, sacro-spinalis, semispinalis dorsi, cervicis and capitis, multifidus, rotatores, interspinales, intertransversarii, levatores costarum, quadratus lumborum.
(*c*) To bent it laterally and extend it: quadratus lumborum, splenius, iliocostalis, longissimus dorsi, cervicis and capitis, semispinales, multifidus, rotatores, levatores costarum, intertransversarii.
(*d*) To bend it laterally and flex it: scalene, sterno-cleido-mastoid, obliquus abdominis externus and internus, intercostales, psoas major and minor.
When the arm and shoulder girdle are fixed the trapezius, levator scapulæ, latissimus dorsi and rhomboids aid abduction.
(*e*) To rotate it to the right: r. internal oblique, l. external oblique, r. splenius, l. sterno-cleido-mastoid, r. longissimus capitis, r. ilio-costalis, l. semispinalis, l. multifidus, l. rotatores (except the lumbar), longus colli (r. above, l. below), l. serratus anterior and rhomboids, r. levatores costarum.

10. Muscles of respiration.
    Quiet inspiration: the external intercostals, intercartilaginous parts of internal intercostals, diaphragm.
    Enforced inspiration: in addition to the muscles mentioned above, the scaleni, sterno-cleido-mastoid, serratus posterior superior and inferior, rhomboids, serratus anterior, latissimus dorsi, subclavius, pectoralis major and minor, and the extensors of the spinal column, the trapezius and the levator scapuli.
    Quiet expiration: interosseous parts of internal intercostals, subcostales, and transversus thoracis.
    Enforced expiration: in addition to the muscles mentioned above, the abdominal muscles, ilio-costalis lumborum and dorsi, longissimus dorsi, and the quadratus lumborum.
    The chief muscles of respiration are the intercostals; the diaphragm plays a minor part (Fick).
11. Muscles acting on the abdomen.
    (*a*) Constriction of the abdominal cavity: obliquus abdominis externus and internus, the transversus and rectus abdominis, and the diaphragm, levator ani, and coccygeus.
    (*b*) Reduction of pressure in the abdominal cavity: the muscles of inspiration, with the exception of the diaphragm, serve to lessen the compression of the abdominal viscera.
12. Action of the muscles of the perineal region.
    (*a*) To close anal canal: sphincter ani externus.
    (*b*) To constrict the anal portion of the rectum: levator ani (pubo-coccygeal portion).
    (*c*) To constrict the bulbus urethræ and the corpus cavernosum urethræ (corpus spongiosum): bulbo-cavernosus.
    (*d*) To elevate the prostate gland: levator ani.
    (*e*) To constrict the vagina: bulbo-cavernosus, levator ani (pubo-coccygeal portion), constrictor vaginæ.
    (*f*) To cause erection of penis and clitoris: ischio-cavernosus, bulbo-cavernosus, and sphincter urethræ membranaceæ.
    (*g*) To compress the urethra and the bulbo-urethral (Cowper's) or the great vestibular (Bartholin's) gland: sphincter urethræ membranaceæ and the transversus perinei profundus.
    (*h*) To support and lift the pelvic floor: levator ani, coccygeus, transversus perinei profundus and superficialis.
13. Muscles acting on the shoulder-girdle.
    The two joints acted upon are the sterno-clavicular and the acromio-clavicular. The movements produced consist in lifting and lowering the scapula, carrying it forward and backward and rotating it.
    (*a*) Elevation: trapezius (upper portion), levator scapulæ, sterno-cleido-mastoid, rhomboidei, pectoralis major (upper sternal part), serratus anterior (middle portion), omo-hyoid.
    (*b*) Depression: trapezius (lower portion), pectoralis major (lower portion), pectoralis minor, subclavius, latissimus dorsi, serratus anterior (lower part). The weight of the limb is likewise a factor.
    (*c*) Forward movement: serratus anterior, pectorales major and minor.
    (*d*) Backward movement: trapezius, rhomboidei, latissimus dorsi.
    (*e*) Rotation:
        Associated with abduction of the arm: serratus anterior (inferior portion), trapezius.
        Associated with adduction of the arm: rhomboidei, pectoralis major (pectoral portion), latissimus dorsi, pectoralis minor, levator scapulæ.
14. Muscles acting on the arm at the shoulder-joint.
    (*a*) To flex it,
        When the arm is at the side: pectoralis major (upper part), deltoid (anterior part), short head of biceps, coracobrachialis, infraspinatus, long head of biceps, teres minor, subscapularis (upper part), supraspinatus.
        When the arm is abducted 60°: pectoralis major, deltoid, subscapularis, short head of biceps, coracobrachialis, long head of biceps, infraspinatus, supraspinatus.
        The movement is aided by the trapezius and the serratus anterior.
    (*b*) To extend it,
        When the arm is at the side: latissimus dorsi, deltoid (posterior part), teres major, subscapularis (lower part), triceps.
        When the arm is abducted 60°: latissimus dorsi, deltoid, teres major, triceps, teres minor.
        The upper and middle portions of the trapezius and the levator scapulæ play an important part in extension of the arm.
    (*c*) To abduct it,
        When the arm is at the side: deltoid, supraspinatus, long head of biceps, subscapularis, infraspinatus (upper part).
        When the arm is abducted 60°: deltoid, supraspinatus, infraspinatus (upper part), long head of biceps, short head of biceps.

The subscapularis is an adductor when the arm is abducted. The inferior part of the serratus anterior and the trapezius are important in abduction of the arm.

(*d*) To adduct it,

When the arm is at the side: pectoralis major, latissimus dorsi, deltoid (posterior and anterior parts), teres major, triceps, coracobrachialis, short head of biceps, teres minor, infraspinatus.

When the arm is abducted: pectoralis major, latissimus dorsi, teres major, triceps, subscapularis, deltoid (dorsal and ventral parts), coracobrachialis.

(*e*) To rotate it lateralward (supinate),

When the arm is at the side: infraspinatus (upper part), the dorsal part of the deltoid, teres minor, supraspinatus.

When the arm is abducted 60°: teres minor, infraspinatus, deltoid (dorsal part), coracobrachialis.

(*f*) To rotate it medialward (pronate).

With the arm at the side: latissimus dorsi, pectoralis major, subscapularis, deltoid (ventral part), long head of biceps, teres major, short head of biceps.

With the arm abducted 60°: latissimus dorsi, pectoralis major, subscapularis, teres major, deltoid (ventral part).

When the arms are raised high the power of rotation at the shoulder becomes slight.

15. Muscles acting on the forearm at the elbow-joint (arranged according to R. Fick).

(*a*) Flexion at elbow.

Forearm supinated: brachialis, long head of biceps, short head of biceps, brachio-radialis, pronator teres, extensor carpi radialis longus, flexor carpi radialis, extensor carpi radialis brevis, palmaris longus.

Forearm in mid-position or pronated: brachialis, long head of biceps, short head of biceps, brachio-radialis, extensor carpi radialis longus, pronator teres, flexor carpi radialis, extensor carpi radialis brevis, palmaris longus.

(*b*) Extension at elbow: triceps (lateral, medial, and long heads), anconeus.

(*c*) Pronation of forearm.

Forearm extended: flexor carpi radialis, pronator teres, pronator quadratus, palmaris longus.

Forearm at right angles: pronator teres, flexor carpi radialis, brachio-radialis, pronator quadratus, extensor carpi radialis longus, palmaris longus.

Forearm flexed: pronator teres, brachio-radialis, flexor carpi radialis, pronator quadratus, extensor carpi radialis longus, palmaris longus.

(*d*) Supination.

Forearm extended: short head of biceps, supinator, long head of biceps, brachio-radialis, extensor carpi radialis longus, abductor pollicis longus, extensor pollicis brevis, extensor pollicis longus, extensor indicis proprius.

Forearm at right angles: short head of biceps, long head of biceps, supinator, abductor pollicis longus, extensor pollicis brevis, brachio-radialis (in pronation), extensor pollicis longus, extensor indicis proprius.

Forearm flexed: short head of biceps, long head of biceps, supinator, abductor pollicis longus, extensor pollicis brevis, extensor pollicis longus, extensor indicis proprius.

16. Muscles acting on the hand at the wrist (arranged according to R. Fick).

(*a*) To flex it: flexor digitorum sublimis, flexor digitorum profundus, flexor carpi ulnaris, flexor pollicis longus, flexor carpi radialis, abductor pollicis longus, palmaris longus.

(*b*) To extend it: extensor digitorum communis, extensor carpi ulnaris, extensor carpi radialis longus and brevis, extensor indicis proprius, extensor pollicis longus.

(*c*) Radial abduction: extensor carpi radialis longus, extensor carpi radialis brevis, abductor pollicis longus, flexor carpi radialis, extensor indicis proprius, extensor pollicis longus, extensor pollicis brevis.

(*d*) Ulnar abduction: extensor carpi ulnaris, flexor carpi ulnaris.

17. Muscles acting on the palm:

(*a*) To flex the ulnar side: opponens, long and short flexors of the little finger.

(*b*) To extend the ulnar side: extensor carpi ulnaris, extensor digiti quinti.

(*c*) To adduct the ulnar side: third volar interosseous.

(*d*) To abduct the ulnar side: abductor digiti quinti.

For action on the radial side see "muscles acting on the thumb." Movements of the second, third and fourth metacarpals are produced by the long flexors and the dorsal interosseous muscles.

18. Muscles acting on the thumb.

(*a*) To oppose the thumb: adductor, opponens, flexor brevis, flexor longus, adductor brevis.

(*b*) To repose the thumb: long abductor, short extensor.

(*c*) To flex all joints: flexor pollicis longus; the carpo-metacarpal and metacarpo-phalangeal joints; flexor brevis, the adductors, abductor brevis; the carpo-metacarpal joints: opponens pollicis, abductor longus.

(*d*) To extend: all joints, extensor pollicis longus; the carpo-metacarpal and metacarpo-phalangeal joints, extensor pollicis brevis; the inter-phalangeal joint, abductor brevis, flexor brevis.

(*e*) To adduct: the adductor, flexor brevis, opponens, first dorsal interosseous, extensor longus.

(*f*) To abduct: the long and short abductors.

19. Muscles acting on the fingers.

(*a*) To flex: all the joints, flexor digitorum profundus; all but the last, flexor digitorum sublimis; the metacarpo-phalangeal joint only, flexor digiti quinti brevis, the lumbricales, and interossei.

(*b*) To extend the fingers: extensor digitorum communis, extensor indicis proprius, extensor digiti quinti proprius; to extend the two inter-phalangeal joints: the lumbricales, interossei, and frequently the flexor digiti quinti brevis.

(*c*) To abduct from the axis passing through the centre of the middle finger: dorsal interossei, first two lumbricales, abductor digiti quinti, the long extensor of the fingers.

(*d*) To adduct toward this axis: volar interossei, last two lumbricales, opponens and flexor digiti quinti brevis.

20. Muscles acting on the pelvis.

(*a*) To flex it: rectus abdominis, obliquus abdominis externus and internus, psoas major and minor.

(*b*) To extend it: sacro-spinalis, multifidus, latissimus dorsi and quadratus lumborum.

(*c*) To bend it laterally and rotate it: abdominal muscles, quadratus lumborum, psoas muscles, and latissimus dorsi acting on one side.

21. Muscles acting on the thigh at the hip-joint (arranged according to R. Fick).

(*a*) To flex it: ilio-psoas, rectus femoris, adductor longus, adductor brevis, obturator externus, tensor fasciæ latæ, pectineus, sartorius, gluteus minimus, adductor magnus (upper part), gracilis, quadratus femoris.

(*b*) To extend it: gluteus maximus, adductor magnus (posterior lower part), biceps, semitendinosus, semimembranosus, gluteus medius, piriformis, obturator internus.

(*c*) To adduct it: adductor magnus, gluteus maximus, adductor brevis, adductor longus, quadratus femoris, obturator externus, gracilis, adductor magnus (upper part), pectineus, biceps, semitendinosus, obturator internus and gemelli, semimembranosus.

(*d*) To abduct it: gluteus medius and minimus, the piriformis, rectus femoris, tensor fasciæ latæ, sartorius; and when the hip is flexed, the gluteus maximus, obturator internus, and gemelli.

(*e*) To rotate it medialward: gluteus medius (anterior portion), gluteus minimus, ilio-psoas, adductor magnus (upper part), pectineus, adductor longus, semitendinosus, semimembranosus, tensor fasciæ latæ.

(*f*) To rotate it lateralward: gluteus maximus, quadratus femoris, obturator internus, piriformis, rectus femoris, adductor brevis, adductor magnus (lower part), biceps, sartorius, obturator externus gracilis, gluteus medius (posterior part).

22. Muscles acting on the leg at the knee-joint (arranged according to R. Fick).

(*a*) To flex it: semimembranosus, semitendinosus, biceps, gastrocnemius, gracilis, sartorius, popliteus.

(*b*) To extend it: quadriceps femoris (the tensor fasciæ latæ and gluteus maximus through the ilio-tibial band keep the extended leg fixed).

(*c*) To rotate it medialward (when flexed): semimembranosus, semitendinosus, sartorius, popliteus, gracilis.

(*d*) To rotate it lateralward (when flexed): biceps, tensor fasciæ latæ.

23. Muscles acting on the foot at the ankle-joint (arranged according to R. Fick).

(*a*) To flex it: tibialis anterior, extensor digitorum longus, peroneus tertius, extensor hallucis longus.

(*b*) To extend it: gastrocnemius, soleus, flexor hallucis longus, peroneus longus, tibialis posterior, flexor digitorum longus, peroneus brevis.

(*c*) To invert the foot at the inferior articulation of the talus (art. talo-calcanea and talo-calcaneo-navicularis): gastrocnemius, soleus, tibialis posterior, flexor hallucis longus, flexor digitorum longus, tibialis anterior.

(*d*) To evert the foot at the inferior articulation of the talus: peroneus longus, peroneus brevis, extensor digitorum longus, peroneus tertius, extensor hallucis longus, tibialis anterior.

(*e*) To invert the foot at Chopart's (talo-navicular-calcaneo-cuboid) joint: tibialis anterior, tibialis posterior, flexor digitorum longus, flexor hallucis longus, extensor hallucis longus.

(*f*) To evert the foot at Chopart's joint: peroneus longus, peroneus brevis, extensor digitorum longus, peroneus tertius.

24. Muscles acting on the toes (arranged according to R. Fick).
   (*a*) To flex: all the joints, flexor hallucis longus, quadratus plantæ, and flexor digitorum longus; the first interphalangeal and the metatarsophalangeal joints of the four lateral toes, flexor digitorum brevis; the metacarpo-phalangeal joints, the lumbricales, interossei, abductor hallucis, adductor hallucis (oblique head), flexor hallucis brevis, abductor digiti quinti, flexor digiti quinti brevis.
   (*b*) To extend: all joints, extensor digitorum longus, extensor hallucis longus, extensor digitorum brevis; the interphalangeal joints, the lumbricales, and the adductors and abductors of the big and little toes.
   (*c*) To abduct from an axis passing through the second toe; abductor hallucis, dorsal interossei, abductor digiti quinti, first lumbrical.
   (*d*) To adduct toward this axis: adductores hallucis, plantar interossei, three more lateral lumbricals.
   (*e*) To draw together the ends of the metatarsals: the transverse head of the adductor of the big toe.

References.—For *development* of the muscular system, consult the list given by W. H. Lewis, Development of the Muscular System, in Keibel and Mall's Human Embryology; for *variations:* Le Double, Traité des variations du systeme musculaire de l'homme; for *action of muscles:* R. Fick, Handbuch der Anatomie und Mechanik der Gelenke unter Berücksichtigung der bewegenden Muskeln, in von Bardeleben's Handbuch, and H. Strasser, Lehrbuch der Muskel und Gelenkmechanik; for the *extremities:* Frohse und Fränkel, Die Muskeln des menschlichen Armes und Beines, in von Bardeleben's Handbuch; for the *head* and *trunk:* Eisler, Die Muskeln des Stammes, in von Bardeleben's Handbuch; for the *pelvis:* Holl, Die Muskeln und Fascien des Beckenausganges. Further references to the literature upon the muscular system may be found in Poirier-Charpy's Traité d'anatomie humaine.

Vessels

SECTION V

THE BLOOD-VASCULAR SYSTEM

REVISED FOR THE FIFTH EDITION

BY H. D. SENIOR, M.B., F.R.C.S.

PROFESSOR OF ANATOMY, NEW YORK UNIVERSITY

THE organs of circulation consist of a system of tubes or vessels which during life are filled with fluid constantly moving in one direction. The major portion of the system is concerned with the continuous distribution of blood throughout the body and is called the **hæmal or blood-vascular** system. A circumscribed part of the hæmal circulation is differentiated into a rhythmically contracting propulsory organ called the heart. The minor portion of the system is called the **lymphatic system.** The lymphatic vessels convey fluid, the lymph, from the tissues to the hæmal system.

The essential functions of the blood-vascular system are performed by the smallest of all the blood-vessels, the **capillaries** [vasa capillaria], which form a network pervading practically all the tissues of the body. Blood is carried to and from the capillaries by larger vessels called the **arteries** and **veins** respectively. The heart receives blood from the veins and propels it, in turn, into the arteries.

One of the primary functions of the blood is the transmission of oxygen from the atmosphere to the tissues. In order to do this the blood must of necessity pass through the respiratory organ before being delivered to the body at large. In gill-breathing vertebrates, the blood, having received oxygen in its passage through the gills, passes on directly to the tissues. The entire circuit is here accomplished by a single continuous chain of vessels in which capillaries occur twice, once in the gills and again in the organs and tissues in general. In man, as in other higher vertebrates, lungs assume the function of the gills. Having received oxygen in the lungs the blood is returned again to the heart before being redistributed throughout the body. There are thus in man two separate circuits or systems of blood-vessels, one traversing the lungs and a second ramifying throughout the body. The former is known as the **pulmonary** circulation; the latter as the **systemic.** Each has its own arteries, capillaries and veins; the heart is common to both. From the time of birth the heart is longitudinally divided into right and left halves, each of which contains its own independent stream of blood. The blood entering the left side of the heart has issued from the pulmonary circulation and is driven into the systemic; that in the right side, having traversed the systemic circuit, is returned again to the lungs.

The heart and blood-vessels have a continuous lining of flattened cells called endothelium; the hæmal system is, therefore, a closed circuit.* The main thickness of the heart, arteries and veins consists of additional tissue developed around the endothelial lining. It is due to this tissue that the blood is continuously delivered to and withdrawn from the capillaries under suitable pressure and velocity. The heart is mainly composed of rhythmically contracting muscle and its valves are so arranged that the contained blood is driven intermittently in one direction only. The walls of the largest arteries are formed to a great extent of elastic tissue, and, being constantly under tension from within, are instrumental in converting the stream, intermittently received from the heart, into a continuous flow. The walls of the medium sized to smallest arteries are mainly muscular. The smallest arteries are microscopic in size and known as **arterioles** [arteriolæ]. The muscular arteries are capable of general or local alterations of calibre regulated by the nervous system; they are thus largely concerned in the maintenance of the blood pressure and in the regulation of the volume of blood entering given localities under varying conditions. The veins have much thinner walls than the arteries; the blood in them is under low tension upon which they exercise little or no control.

When an artery divides, the combined calibre of its branches is greater than that of the vessel itself. Since the arteries divide repeatedly the bed of the blood-stream increases in proportion as the vessels diminish in size. The rate of increase, slow at first, becomes enormous in the arterioles. Conversely, the bed of flow undergoes contraction as the heart is approached from the venous side. The velocity of flow in the capillaries must necessarily be much lower

* In the spleen and bone marrow the blood-channels intermediate between the arteries and veins are possible exceptions to this statement, but the essential conditions here are still imperfectly understood.

than in the great arteries and veins. From the relative slowness of the blood flow in the systemic capillaries, it has been estimated that their total bed is eight hundred times greater than the bed of the main arterial stem.

Variations in the course and arrangement of the adult arteries and veins, originally studied by the surgeon for utilitarian purposes only, now furnish one of the most stimulating fields for anatomical research. Text-books can provide, at best, catalogues of the arrangement commonly found in the adult body and of the most ordinary variations. That no text-book description can fit any individual case in all particulars, and that unusual distribution of vessels does not necessarily shorten life are among the earliest lessons learned in the anatomical laboratory. The adult vascular pattern is derived from a symmetrical arrangement in the early embryo of which scarcely a trace remains. The intervening changes are so numerous and profound that the general uniformity of vascular distribution in different individuals is more remarkable than the occurrence of occasional wide variations from the usual type.

In early stages of development all vessels have a similar structure; they consist, in fact, of a single layer of endothelium. Some vessels, however, are larger than others; these act as arteries or veins (according to the direction of flow) while the smaller channels perform the office of capillaries. The early principal vessels do not necessarily persist, for many of these dwindle or are lost. New channels are meanwhile in continuous process of formation and some of these may, in turn, become main channels. It thus follows that the main vessels of the adult must be looked upon rather as selected channels through a plexus of possible pathways, than as separate entities which must necessarily conform to given rules of distribution and branching.

In time, no doubt, most of the commoner variations from the usual adult type will receive a rational explanation; at present enough has been done to indicate the value of the embryological method. The list of variations in the arteries and veins respectively is preceded by a brief account of the morphogenesis of these vessels.

In the case of the heart anomalies frequently result in early death, so that subjects of developmental irregularities are seldom seen in the anatomical laboratory. The anomalies usually consist in improper development of the septa which normally divide the heart and main arterial trunk into their pulmonary and systemic halves. A short account of the morphogenesis of the heart is appended to the description of the adult organ.

In the following section the heart and pericardium will first be considered followed by the arteries and veins.

A. THE HEART AND PERICARDIUM

1. THE HEART

The **heart** [cor] is a hollow organ principally composed of muscle, the **myocardium.** It is lined internally by **endocardium** which is continuous with the intima of the blood-vessels. Externally, it is covered by the **epicardium,** a serous membrane continuous with the serous lining of the pericardium. The form of the heart, when removed from the body without previous hardening, is that of a fairly regular truncated cone. The **base** [basis cordis] is poorly circumscribed but corresponds, in a general way, to the area occupied by the roots of the great vessels and the portion of the heart-wall between them. The base of the heart is held in position* chiefly by the great vessels, which are attached to the pericardium; the remainder of the organ is capable of free movement within the pericardial cavity.

The interior of the heart is longitudinally divided, into right and left cavities, by a septum passing from base to apex. Each cavity is subdivided into an **atrium** [atrium cordis] and a **ventricle** [ventriculus cordis], the former receiving the ultimate venous trunks and the latter giving rise to the main arteries. Thus the left atrium receives the four pulmonary veins, and the right atrium the superior and inferior vena cava and the coronary sinus; the aorta issues from the left ventricle and the pulmonary artery from the right. The ventricles, which constitute the major portion of the heart, may be recognised by their very thick walls. The atria have thinner walls and are less capacious than the ventricles; projecting from each is a diverticulum or **auricle** [auricula cordis]. The auricles (which receive their name from their resemblance to dog's ears) partially embrace the roots of the pulmonary artery and aorta.

Orientation of the heart.—The apex of the heart [apex cordis] points forward, to the left and downward. The base is directed backward, to the right and upward. The longitudinal axis of the heart forms an angle of about 40° with the horizontal plane and also with the median sagittal plane of the body.

* Not necessarily fixed, for during systole the base performs a greater excursion than does the apex.

The long axis of the heart is therefore slightly more horizontal than vertical, and slightly more antero-posterior than transverse. The atria are posterior to rather than above the ventricles. To arrive approximately at the longitudinal axis, it is necessary to select the central point of the base. By cutting the vessels short in several hearts, hardened by formalin before removal, a point immediately to the left of the left lower pulmonary vein was selected in determining the data above given. A steel pin was passed through this point to the apex cordis, and the angles controlled by frontal and transverse sections of the thorax. Mention of angular measurements of the axis of the heart could be found only in the text-books of Testut and Luschka; the former gives 40° to the horizontal plane, the latter 60° to the mid-sagittal. Luschka's angle appear to be too large; but further investigation in this direction is desirable.

FIG. 423.—STERNO-COSTAL SURFACE OF THE HEART.

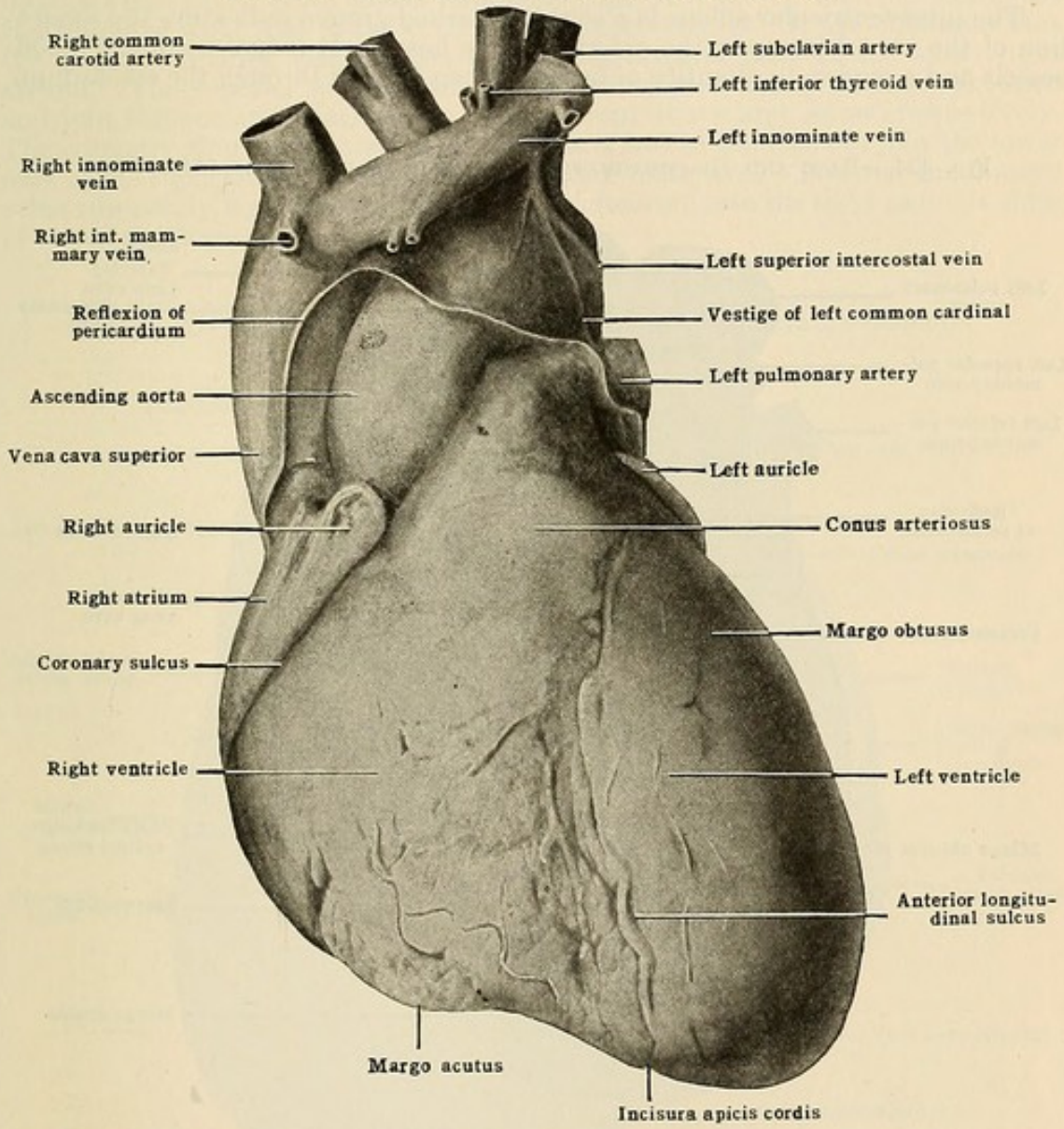

Size and weight.—In the adult the heart measures about 12.5 cm. (5 in.) from base to apex, 8.7 cm. (3½ in.) across where it is broadest, and 6.2 cm. (2½ in.) at its thickest portion. In the male its weight averages about 312 gm. (eleven ounces), and in the female about 255 gm. (nine ounces). It increases both in size and weight up to advanced life, the increase being most marked up to the age of twenty-nine years. The proportion of heart-weight to body-weight is about 1:205 in the adult.

EXTERIOR OF THE HEART

In hearts which have been hardened by injection before removal from the body, the regularity of the heart-cone is disturbed by a well-marked triangular facet, imparted by contact with the diaphragm. This facet is the **diaphragmatic surface** [facies diaphragmatica], which is directed downward and slightly backward (fig. 424). It ends abruptly along a sharp margin extending from the apex

toward the right. This margin is the **margo acutus** (fig. 423); it separates the diaphragmatic surface from the sternocostal surface. The other margin of the diaphragmatic surface is more rounded and shades gradually into the very wide margo obtusus (fig. 423), which passes almost insensibly into the sternocostal surface. The convex **sternocostal** surface [facies sternocostalis] (fig. 423), directed forward and somewhat upward and to the right, is triangular and bounded below by the margo acutus. To the left it goes over into the margo obtusus along a line extending from the apex of the heart to the root of the pulmonary artery. The **margo obtusus** corresponds to the rounded left side of the left ventricle.

The interventricular sulcus is a slightly marked groove indicating the separation of the ventricles upon the exterior of the heart. It lodges coronary blood-vessels and a moderate quantity of fat which can be seen through the epicardium.

FIG. 424.—BASE AND DIAPHRAGMATIC SURFACE OF THE HEART. (After His.)

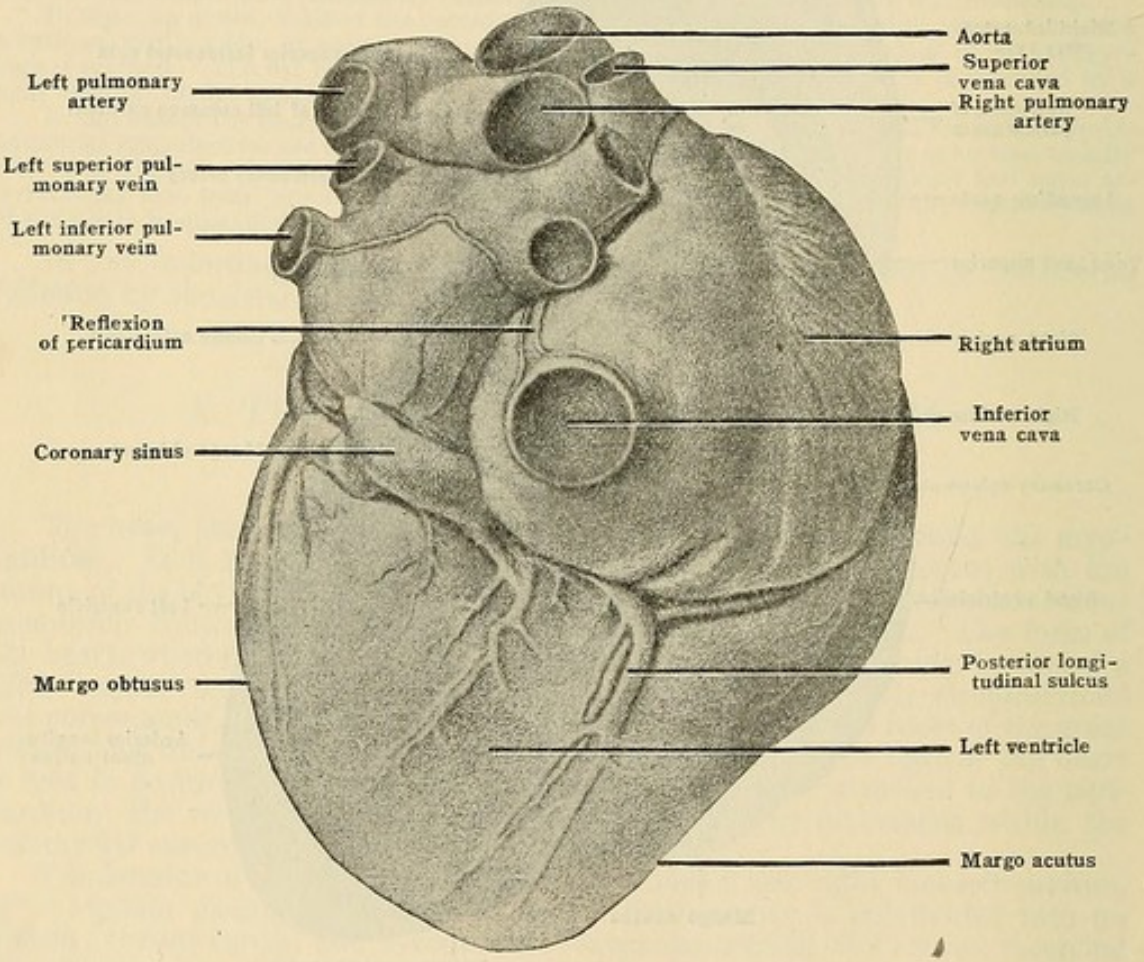

The anterior part of this groove, **sulcus longitudinalis anterior,** beginning posteriorly, runs obliquely over the upper part of the margo obtusus on to the sternocostal surface. Crossing the margo acutus to the right of the apex, it is continuous with the **sulcus longitudinalis posterior** upon the diaphragmatic surface. The diaphragmatic surface is formed about equally by the right and left ventricles, and the sterno-costal surface mainly by the right. Where the longitudinal sulcus crosses the margo acutus it produces a slight notch, the **incisura (apicis) cordis.**

The atria are separated externally from the ventricles by the **sulcus coronarius.** This is a horseshoe-shaped groove well marked below and laterally, and interrupted above by the roots of the pulmonary artery and aorta. It lodges the coronary sinus, smaller coronary vessels and fat.

ATRIAL PORTION

The **atrial portion of the heart** is situated behind, and slightly to the right of and above, the ventricular portion. The separation between the right and left atrium is not indicated behind except in distended hearts (such as that shown in fig. 424); in these it is marked by a slight groove connecting the left sides of the superior and inferior venæ cavæ. In front, the auricles are separated by the deep notch which lodges the aorta and pulmonary artery. A slight groove on the back of the right atrium which connects the right sides of the superior and inferior venæ cavæ, is the **sulcus terminalis** (figs. 424, 425). This represents the right limit of what was, in the embryo, the sinus venosus. It also indicates that the embryonic sinus venosus has become an integral part of the adult right atrium. The superior and inferior cavæ have each a nearly vertical direction and join the posterior part of the right atrium above and below, respectively. The coronary sinus runs downward, backward and to the right to join the lower part of the right atrium anterior to the inferior vena cava. The four pulmonary veins run nearly transversely and somewhat forward into the right and left sides of the left atrium.

FIG. 425.—ATRIA OPENED POSTERIORLY TO SHOW THE SEPTUM ATRIORUM.

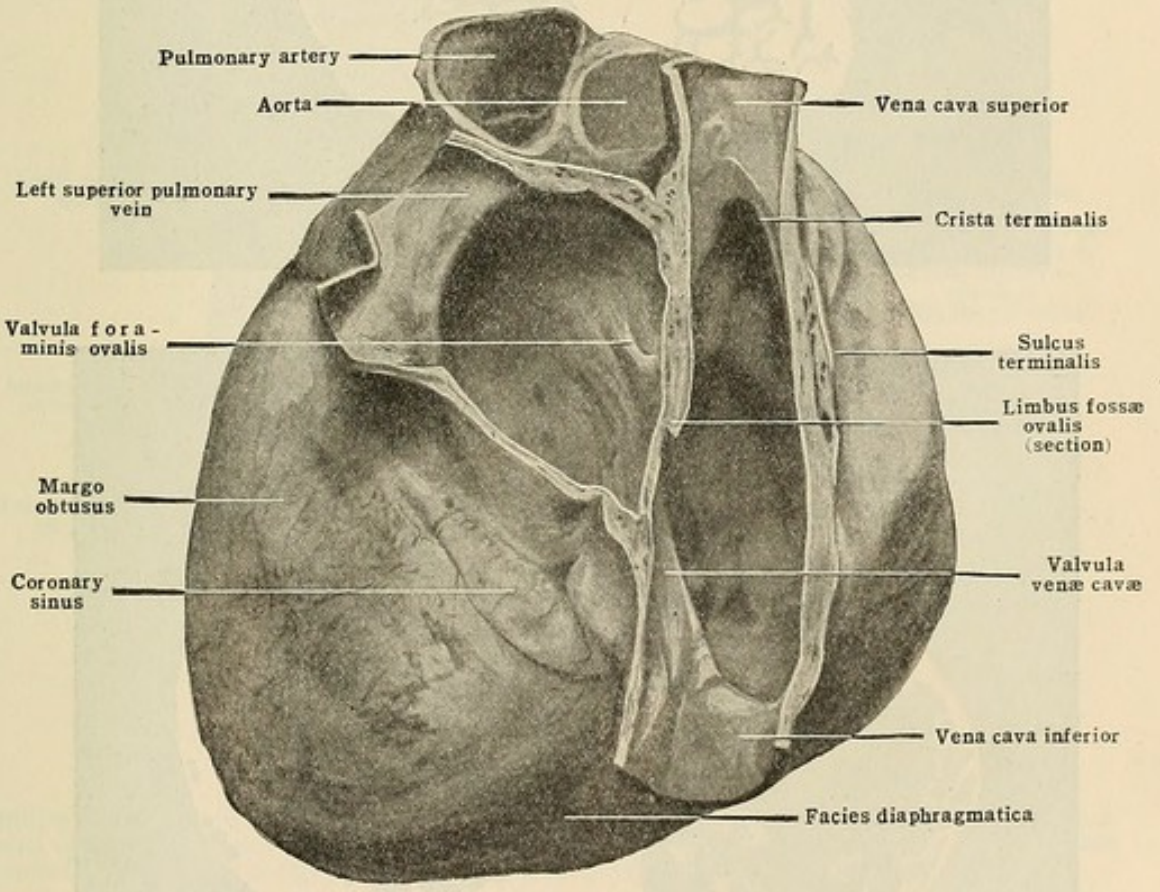

The interior of the atrial portion of the heart is divided into right and left cavities by the **septum atriorum.** This septum is a composite structure, having been developed (see morphogenesis of the heart) in two independent parts, each forming an incomplete septum in itself. The two incomplete septa, however, partly overlap one another so that, by the lateral fusion at the time of birth, they together produce the impervious structure of the adult heart (fig. 425). Of these septa, the first to be formed is the **membranous septum** [pars membranacea septi atriorum]. Later there is formed to the right of this the muscular septum, the margin of which forms, in the adult atrium, the greater part of the **limbus fossæ ovalis.** The margin of the membranous septum is recognizable as a fold

of endocardium on the septal wall of the left atrium; it is called the **valvula foraminis ovalis.**

Posteriorly into the **right atrium** [atrium dextrum (fig. 425)], above and below, respectively, open the superior and the inferior vena cava. Upon the septal wall, immediately above the inferior cava is the **fossa ovalis,** a depression of

FIG. 426.—SECTION OF THE VENTRICLES IN SYSTOLE AND DIASTOLE. (After Krehl.)

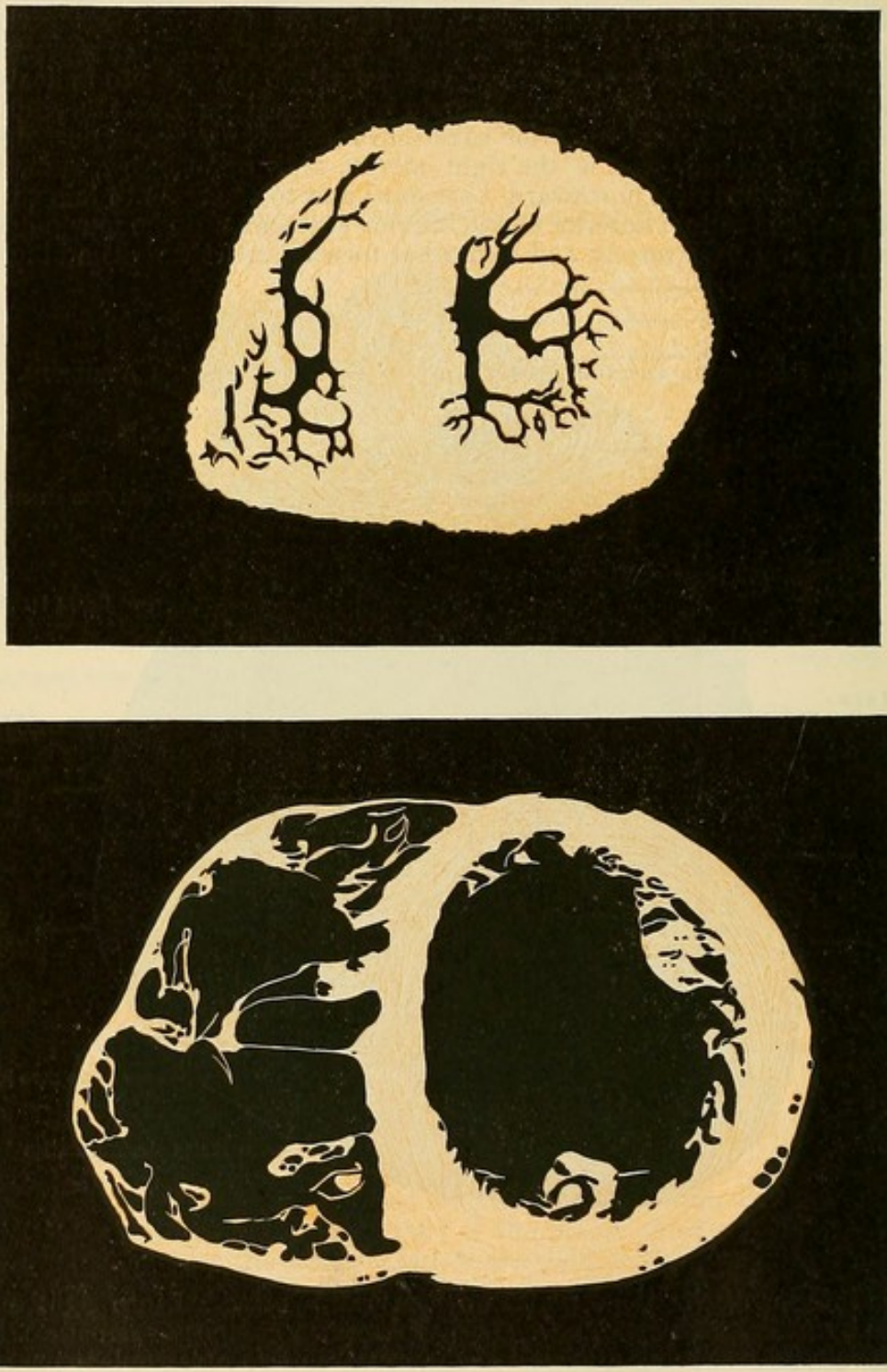

which the floor is formed by the membranous septum. Surrounding the fossa ovalis except below (indeed producing the fossa) is the limbus fossæ ovalis which is continuous anteriorly and below with the **valvula venæ cavæ** (inferioris Eustachii). Just anterior to the fossa ovalis is the orifice of the coronary sinus guarded by the **valvula sinus coronarii** (Thebesii) (fig. 428). Leading from the

front of the atrium forward and slightly downward and to the left is the **ostium venosum** (right atrio-ventricular orifice) guarded by the tricuspid valve. Above and behind this is the auricle, the exterior of which is in contact medially with the root of the aorta. To the right of the superior and inferior caval orifices there is a vertical ridge, the **crista terminalis,** which corresponds to the sulcus terminalis on the exterior (figs. 425, 428).

The portion of the atrium medial to the crista is smooth and is called the **sinus venarum;** in the embryo it is separated from the atrial cavity proper by the right and left sinus valves. The crista terminalis marks the original line of attachment of the right sinus valve. The valve itself has disappeared, except at the lower part where it persists as the caval and coronary valves. These valves vary in size considerably in different specimens, and are frequently netlike from numerous perforations.

The conversion of a portion of a single valve into two separate valves, which meet at an acute angle, is brought about by an attachment between the sinus valve and an embryonic structure called the sinus-septum. This septum is a ridge dividing the right horn of the sinus venosus from the transverse portion of the sinus (the coronary of the adult); it probably con-

FIG. 427.—THE INTERIOR OF THE VENTRICLES, ANTERIOR HALF. (After His.)

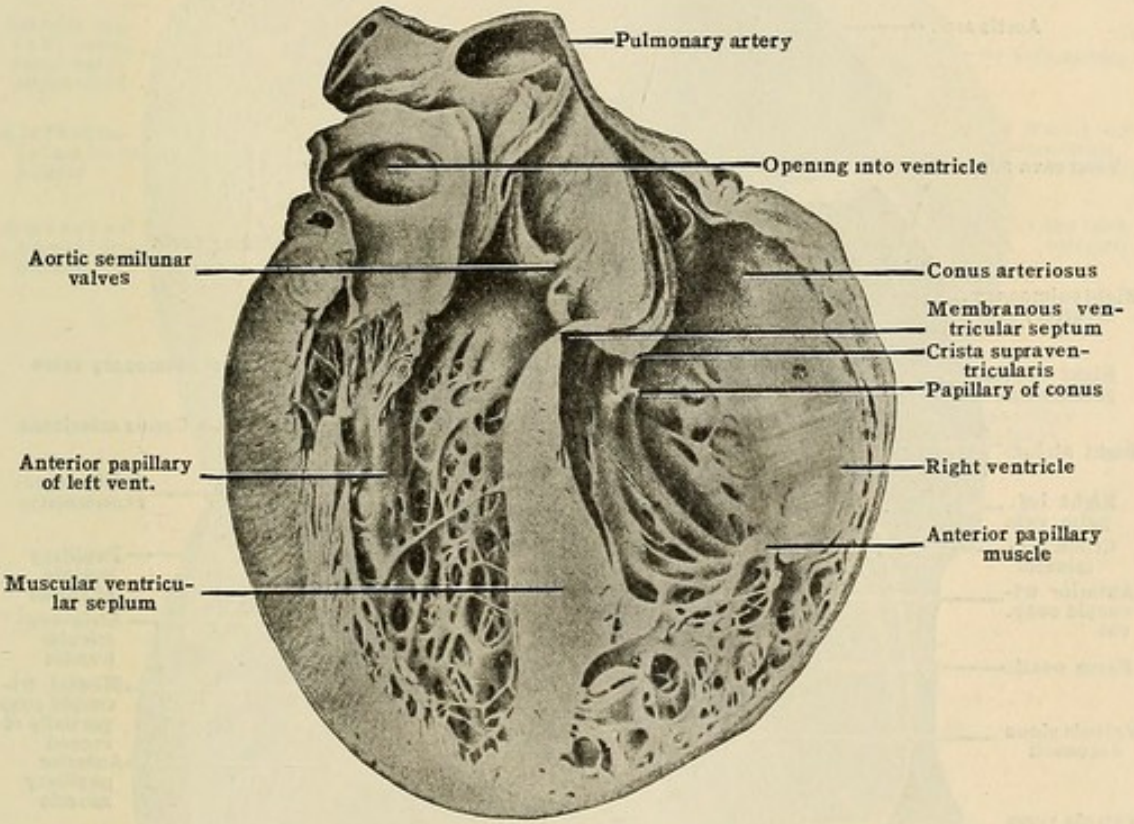

tributes somewhat to the formation of both the coronary and caval valves. The left sinus valve usually disappears by blending with the septum atriorum on which it unites with the limbus fossæ ovalis; it occasionally remains partially separate in the adult.

The interior of the right auricle and of the portion of the atrium lateral to the crista terminalis is thrown into ridges (**musculi pectinati**) by prominent bands of the atrial myocardium. The musculi pectinati end abruptly by joining the crista. The orifice of the superior cava has no valve and is directed downward and somewhat forward; below it, on the posterior wall of the atrium, there has been described a tubercle or ridge, the **tuberculum intervenosum** (Loweri).

Apart from the posterior circumference of the superior cava itself and the limbus fossæ ovalis, the human heart appears to contain nothing in this region that could be described as a tubercle. With regard to the segregation of the streams entering the fœtal right atrium from the superior and inferior cavæ, respectively, in which the tubercle of Lower has been supposed to participate, it is to be noted that the fossa ovalis is just above (almost within) the inferior

caval orifice. Also that the caval opening and the fossal ovalis (containing the fœtal foramen ovale) are, in hearts well hardened before removal, situated in a distinct diverticulum to the left of the remainder of the atrium. Between this diverticulum and the atrium proper, the caval valve and the limbus fossæ ovalis form a prominent flange, better marked in the fœtus than the adult. Opening into the right atrium, particularly upon the septal and right lateral walls, are numerous *foramina venarum minimarum* (Thebesii).

The **left atrium** [a. sinistrum] (fig. 425) is to the left and somewhat posterior to the right. It is behind the root of the aorta and its auricle is to the left of the

FIG. 428.—INTERIOR OF THE RIGHT ATRIUM AND VENTRICLE.

The atrio-ventricular bundle is dissected out.

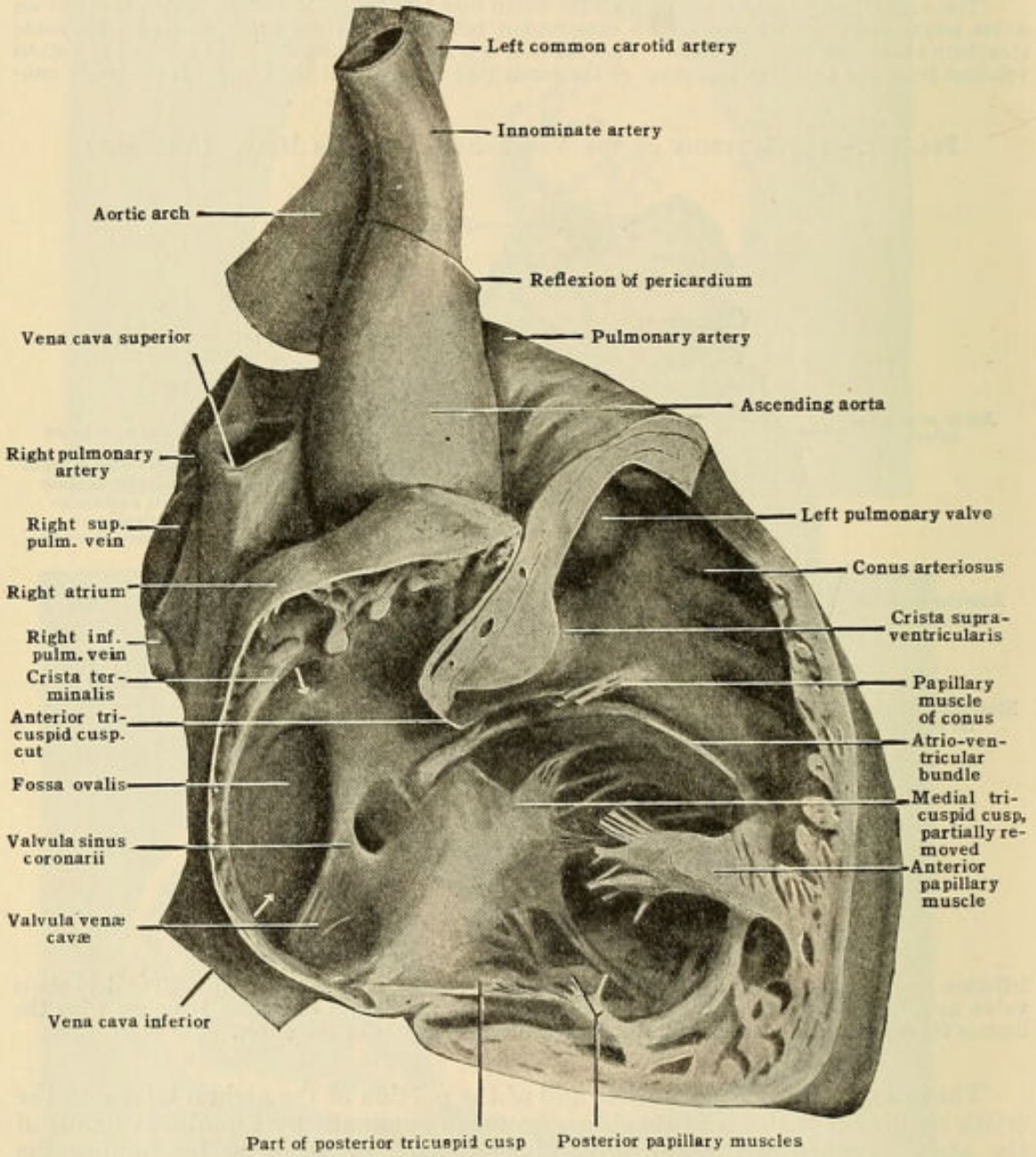

pulmonary root. Opening into it posteriorly on the right and left sides, respectively, are the right and left upper and lower pulmonary veins. The valvula foraminis ovalis forms a more or less distinct crescentic ridge on the septal wall (fig. 425). This may not be attached to the limbus fossæ ovalis, in which case there is a communication between the two atria. Absence of lateral adhesion between the two septa atriorum does not necessarily lead to admixture of arterial and venous blood during life. The left **ostium venosum** (atrio-ventricular orifice)

guarded by the mitral valve leads from the anterior part of the atrium forward and slightly downward and to the left. The interior of the left atrium is smooth except in the auricle, in which musculi pectinati are well marked.

FIG. 429.—LEFT VENTRICLE AND PART OF THE ATRIUM.
The aorta is opened through the anterior cusp of the mitral valve. The plainly visible left limb of the atrio-ventricular bundle has been accentuated.

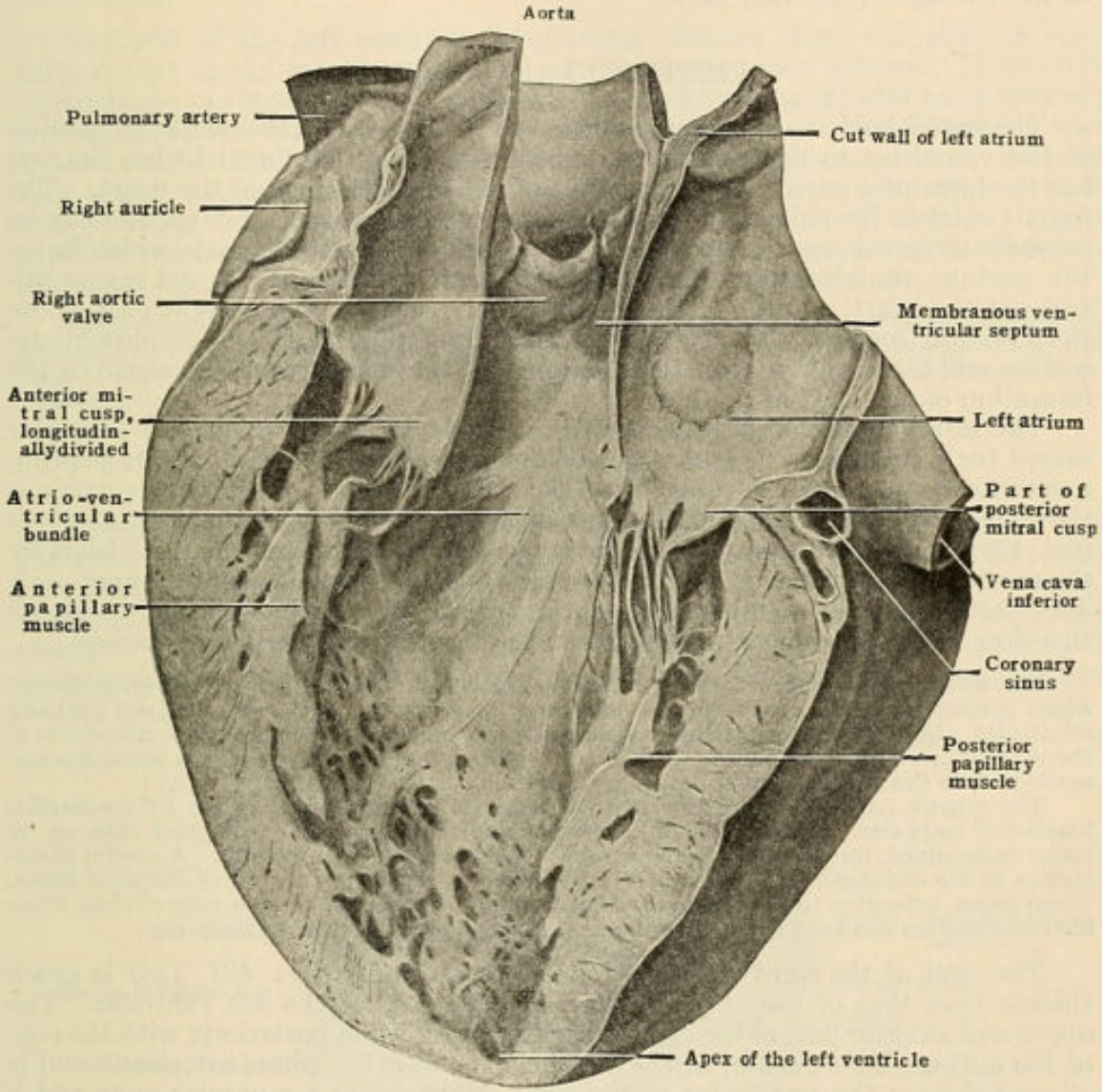

ATRIO-VENTRICULAR VALVES

The **atrio-ventricular valves** (figs. 427, 428, 429, 431) are attached around the venous ostia of the ventricles in such a way as to open freely into the ventricles, but to prevent regurgitation of the blood into the atria during ventricular systole. Each valve is continuous along its line of attachment, but its free edge is notched so as to produce an irregular margin; some of the notches are so deep as to partially divide the valve into cusps. The right atrio-ventricular valve is commonly divided by three deep notches into three cusps; this valve is therefore called the **tricuspid** [valvula tricuspidalis]. The left is similarly divided into two cusps and is called the **bicuspid** [v. bicuspidalis] or **mitral.** The depth of the notches, however, is very variable and there may be an increase or (more rarely) a diminution in the number of cusps; the addition of small subsidiary cusps is quite common. Each valve cusp is tied down to the **papillary muscles** [mm. papillares] of the ventricle by **chordæ tendineæ.** The latter are fibrous cords, generally branched, of varying thickness. The thinnest cords are attached to the free margin of the cusp; those of intermediate thickness to the ventricular surface a few millimetres from the margin, and the thickest to the ventricular surface

near the attached margin. The valves are smooth and glistening on the atrial aspect, but rough and fasciculated, from the attachment of the chordæ, on the ventricular. The cusps of the *mitral valve* are called *anterior* and *posterior;* those of the *tricuspid, anterior, posterior* and *medial.* Each cusp receives chordæ from more than one papillary muscle and each papillary muscle sends chordæ to more than one cusp. The chordæ tendineæ of the mitral valve are thicker than those of the tricuspid (figs. 428, 429).

VENTRICULAR PORTION

The **ventricles** form the greater portion of the heart. In the adult the relation of the ventricles to one another is as follows. The left [ventriculus sinister] has the form of a narrow cone, the apex of which is the apex of the heart. The right ventricle [ventriculus dexter] is crescentic in section and appears to be partially wrapped around the right or lower wall of the left ventricle which forms the septum ventriculorum (fig. 426). The **left ventricle** forms the margo obtusus of the heart, about half the diaphragmatic surface, and a slight part of the sterno-costal surface. The **right ventricle** forms about half the diaphragmatic surface and the major part of the sterno-costal surface; it takes no share in the formation of the apex of the heart.

The **interventricular septum** [septum ventriculorum] is thick and muscular except for a small area near the root of the aorta which is membranous [septum membranaceum ventriculorum]. The latter can be seen from the left ventricle in the angle between the attached edges of the right and posterior aortic valves (fig. 429). The membranous septum is partly concealed from the right heart by the medial cusp of the tricuspid valve which is attached to it near its upper part. The portion of the membranous septum above the medial tricuspid cusp is therefore atrio-ventricular, i. e., between the right atrium and left ventricle.

The membranous septum is the extreme lower part of the independent septum (s. aorticum) which divides the aortic root from the pulmonary artery and conus arteriosus (and partially subdivides, also, the right ventricle by separating the conus arteriosus from the remainder of the ventricle). The relation of the part of the aortic septum between the conus arteriosus and aortic root to the septum ventriculorum is beautifully shown by His, in fig. 427.

The greater part of the interior of the ventricles is thrown into ridges by myocardial bundles of large size. These fasciculi [**trabeculæ cordis**] either stand out in relief only, or, by being undermined, form bands covered except at either end by endothelium. A careful examination of the endocardium of fresh hearts will reveal a plexiform network of **Purkinje fibres.** These fibres, belonging to the atrio-ventricular conducting system, become very obvious when the endocardium has been exposed to the air long enough to become partially dry.

The wall of the **right ventricle** [ventriculus dexter] (figs. 427, 428) is much thicker than that of the atria, but less so than that of the left ventricle. The upper and anterior part of the right ventricle is in relation posteriorly with the root of the aorta. This portion of the ventricle is called the **conus arteriosus** and is separated from the remainder of the right ventricle by a muscular spur which extends from the back of the conus to the right venous ostium. The spur is the **crista supraventricularis;** its relation to the partition between the conus and aorta, and to the septum membranaceum, shows that it is the free edge of the embryonic aortic septum (see morphogenesis of the heart).

Two papillary muscles in the right ventricle are constant in position, the large **anterior papillary muscle,** and the small **papillary muscle of the conus** (Luschka). The anterior papillary is situated on the sterno-costal wall, near the junction of this with the septal wall. The papillary of the conus is placed just below the septal end of the crista supraventricularis. The **posterior papillary muscles** form an irregular group springing from the diaphragmatic wall. Some chordæ tendineæ stretch directly from the septal wall (with or without small muscular elevations at their bases) to the medial cusp of the tricuspid valve. The chordæ tendineæ from the anterior papillary go to the anterior and posterior cusps; those from the conus papillary to the medial and anterior, and those from the posterior papillary muscles to the medial and posterior cusps of the tricuspid valve, respectively.

There is frequently a band of myocardium extending from the septal wall of the right ventricle to the anterior papillary muscle near its middle. This is the **moderator band,** which contains a part of the right limb of the atrio-ventricular bundle. If the moderator band joins

the anterior papillary near its base, as it frequently does, it is difficult to distinguish it from the ordinary trabeculæ in this situation.

The term moderator band was originally applied to this bridge or band of muscle under the impression that it prevented overdistention of the ventricle. Subsequent discovery of the conducting system of the heart makes it plain that there is always a band conducting the right limb of the atrio-ventricular bundle from the septum to the anterior papillary muscle. Whether the band is isolated from the other trabeculæ, and therefore readily recognizable, appears to depend somewhat upon the relation of the base of the papillary muscle to the septum ventriculorum.

The wall of the **left ventricle** [ventriculus sinister] (figs. 427, 429) is very thick except at the extreme apex, and at the membranous septum. In the left ventricle are two large papillary muscles, generally known as **anterior** and **posterior**; both send chordæ tendineæ to each cusp of the mitral valve. On the septal wall of the ventricle the left limb of the atrio-ventricular bundle can usually be seen as a broad, flattened band beneath the endocardium. The band appears just below the septum membranaceum and divides into strands which go to the two papillary muscles. The strands in many places bridge across part of the ventricle to reach the papillary muscles covered only by tubes of endocardium.

These bridging strands connecting the papillary muscles with the septum ventriculorum, which were formerly called "false chordæ tendineæ," are exactly comparable to the moderator band of the right ventricle which occasionally consists of atrio-ventricular bundle and endocardium only.

SEMILUNAR VALVES

The **semilunar valves** [valvulæ semilunares] guard the arterial ostia of the ventricles. The aortic ostium is directed upward and slightly forward and to the right; the pulmonary backward and slightly upward and to the left. Each valve, of which there are three to each ostium, is a pocket-like fold of endocardium strengthened by fibrous tissue (fig. 430). The free edge of each valve is directed away from the ventricle, so that excess of pressure within the great vessels brings

FIG. 430.—INTERIOR VIEW OF THE AORTIC SEMILUNAR VALVES.

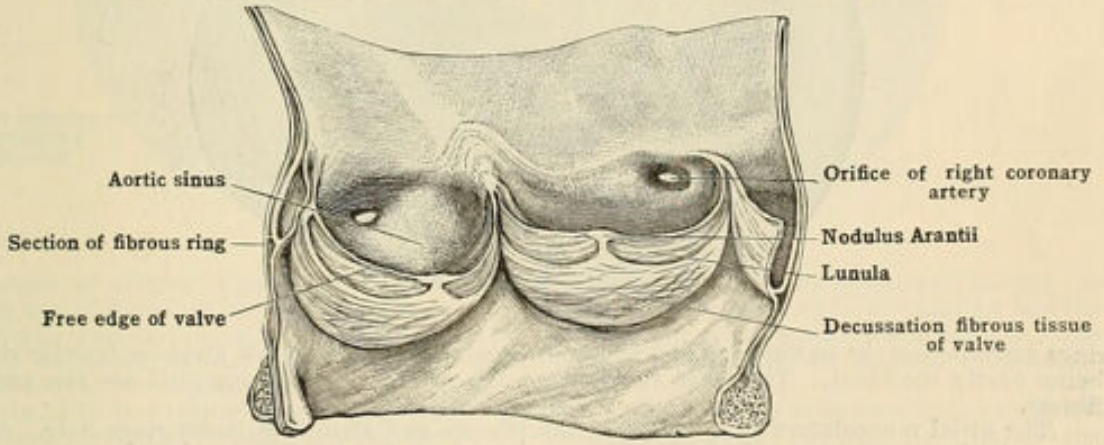

the three valves of either ostium into mutual apposition. In the middle of the free edge of each valve there is a small fibro-cartilaginous **nodule**; radiating from this toward the entire fundus, and along the extreme free edge of the valve, are fibrous thickenings. On either side of the nodule, between the thicker margin and fundus, the valve is thin over a crescentic area called the **lunula.**

The aortic valves are called the right, left, and posterior; the pulmonary valves, the right, left, and anterior.* The aortic semilunar valves are stronger than the pulmonary; opposite them there are three dilatations in the aortic wall, the aortic

* The BNA names of the aortic and pulmonary valves are not based upon their relative positions in the body. From transverse sections through the thorax (see any good atlas) it may be seen that one aortic valve is anterior, one pulmonary valve posterior, and the other aortic and pulmonary valves are right and left. If the removed heart is held so that the ventricles are on the right and left of the septum, respectively, the valves take the positions indicated by the BNA. The names given by the BNA to the valves, although conventional (like many other terms of orientation applied to parts of the heart), are convenient, particularly from a developmental standpoint.

sinuses [**sinus aortæ**] or sinuses of Valsalva. From the right and left sinuses the right and left coronary arteries, respectively, arise.

After ventricular systole the increased pressure in the great vessels distends the valves with blood. The noduli meet in the centre and the lunulæ, coming into mutual contact, produce a tri-radiate line of contact between the valves.

ARCHITECTURE OF THE MYOCARDIUM

In the adult heart the myocardium of the atria is separate from that of the ventricles. There is, between the atria and ventricles, a fibrous partition, the upper and lower surfaces of which give attachment to the muscle fibres of these cavities, respectively.

The **fibrous partition** (fig. 431) is thickest in the triangle formed by the meeting of the aortic, and right and left atrio-ventricular ostia. This interval is filled by a mass of fibrous tissue, which in the angles between the aortic and the left atrio-ventricular ostium forms two thickened triangular masses, the **trigona fibrosa.** The fibrous mass is continued to the pulmonary ostium as the **tendon of the conus.** Below the point of junction of the trigona and the tendon of the conus these structures blend with the septum membranaceum ventriculorum. The septum membranaceum, tendon of the conus, and part of the trigona are derived from the aortic septum (pp. 516, 527). The trigona give off laterally, on either side, atrio-ventricular rings which encircle the venous ostia and give attachment to the atrio-ventricular valves. There are also weak

FIG. 431.—BASE OF A WELL DEVELOPED HEART SHOWING THE COURSE OF THE SUPERFICIAL MUSCLE FIBRES.

From X to X′ around the front of the aorta indicates the course of the aortic septum. (Mall, ¾ nat. size.)

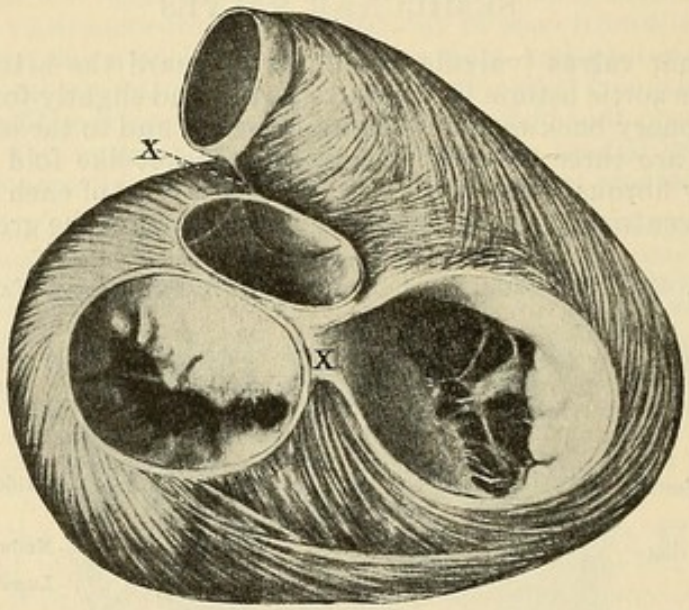

rings surrounding the pulmonary and aortic orifices; the aortic and left atrio-ventricular rings being partly confluent. The rings surrounding the arterial and venous ostia are the **annuli fibrosi.**

The **atrial musculature** is attached to the trigona and atrio-ventricular rings only. The superficial fibres are attached to both rings and either encircle both atria in one loop, or enter the septum and form a figure 8. The deeper fibres are attached to one ring and encircle one atrium only; some fibres encircle only the auricle.

The **ventricular musculature** is very complex and consists of numerous superimposed layers distinguished from one another by the direction taken by the muscle fibres. In a general way, the fibres of the deepest layer have a direction crossing those upon the surface of the same area at a right angle. The intervening layers of fibres pass through all stages of obliquity.

Recent work upon the origin and distribution of the ventricular fibres has resulted in the recognition of a certain uniformity of behavior, thus:—

1. All fibres arise from, and are inserted into, the fibrous partition at the base. The attachment may be directly to the trigona or annuli, or indirectly to them by means of the chordæ tendineæ and atrio-ventricular valves.

2. The more superficial fibres (fig. 432) tend to encircle the entire heart, passing over the longitudinal sulci. If they enter the septum they do so by passing into the vortex or whorl at the apex of the left ventricle. These fibres have always a definite direction upon the surface, i. e., from right to left upon the sterno-costal surface and from left to right on the diaphragmatic (fig. 431).

3. The deeper fibres all enter the septum in a direction oblique or perpendicular to its longitudinal axis. In addition they completely encircle one or both ventricles forming, in the latter case, double loops (fig. 433).

During systole, as a result of this arrangement:—(1) The papillary muscles and the longitudinal and antero-posterior axes of the ventricles are simultaneously shortened. (2) There is a movement of torsion or "wringing" which reduces the ventricular cavities to their minimum dimensions.

Conducting system.—Although the ordinary myocardium of the atria is distinct from that of the ventricles there is, at one place, a connection between them. This connection is by means of a small band of muscle which differs histologically from ordinary heart muscle. It is known as the **atrio-ventricular bundle,** and serves to transmit the atrial rhythm of contraction to the ventricles.

The atrio-ventricular bundle begins in the septal wall of the atrium a short distance in front of the coronary orifices (fig. 428). It has an expanded free end, the **atrio-ventricular node,** from which branches pass to be quickly lost in the atrial myocardium. The bundle passes forward covered by endocardium and by one or two millimetres of myocardium, and passes beneath the medial cusp of the tricuspid valve. In passing from the atrium to the ventricle, the bundle skirts the lower margin of the septum membranaceum. Immediately in front of the septum membranaceum it divides into a left and right limb, of which the former pierces the muscular interventricular septum. The right limb now passes beneath the crista supraventricularis and above the papillary muscle of the conus, giving off branches to the latter and to other small papillaries on the septum (fig. 428). Bending somewhat toward the apex, it enters the moderator band which conducts it to the large anterior papillary muscle. From here it passes along one of the trabeculæ connected with the sterno-costal wall of the ventricle, or in the wall itself, to reach the posterior papillary muscle or muscles. The right limb is compact and rounded and in the intact heart is usually invisible except, sometimes near the root of the moderator band or in the band itself.

The left limb of the bundle appears in the left ventricle a little below the septum membranaceum. It is a wide band immediately beneath the endocardium, which cannot usually be

FIG. 432.—DIAGRAM OF ONE ANTERIOR AND ONE POSTERIOR SUPERFICIAL BUNDLE OF CARDIAC MUSCLE FIBRES SEEN FROM BEHIND. (After MacCallum.)

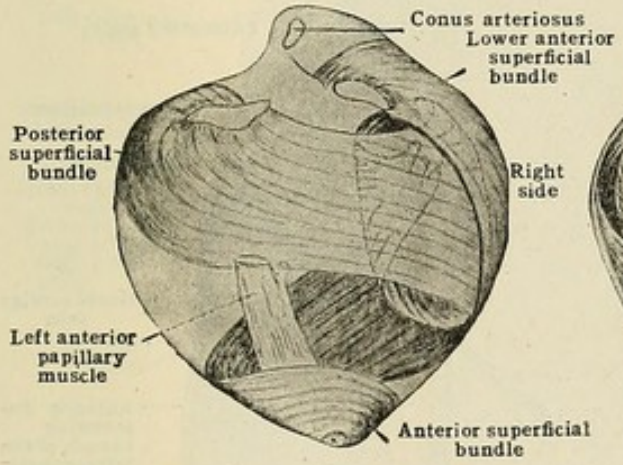

FIG. 433.—DIAGRAM OF A DEEPER BUNDLE OF MUSCLE FIBRES. (After MacCallum.)

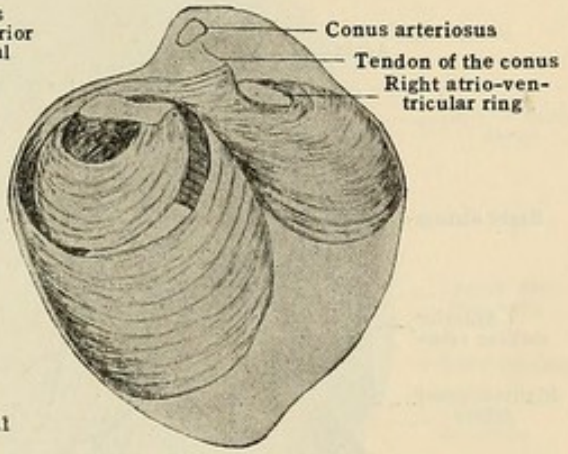

stripped off without injuring the bundle (fig. 429). It passes along the septal wall toward the apex and divides into two parts, which again subdivide to be distributed to the anterior and the posterior papillary muscles. The branches for the papillary muscles may reach them through thick trabeculæ, or they may form thin strands which, covered only by endocardium, bridge from septum to papillary muscle.

In addition to the comparatively distinct branches to the papillary muscles of both ventricles, the bundle gives off finer fibres which form a sub-endocardial plexus. This plexus, visible to the naked eye (p. 516) is made up of fibres having a structure similar to those of the ventricular portion of the bundle. The fibres were described by Purkinje as long ago as 1845,* but it was not until 1906, thirteen years after the discovery of the bundle by W. His, Jr., that Tawara† recognised their significance.

There is another node of muscle having characters similar to that of the conducting system, although not connected with it except by myocardium of the ordinary character. This is the sinus-node which is situated at the upper end of the crista terminalis of the right atrium. Unanimity is still lacking with regard to the physiological significance of this structure.

VESSELS AND NERVES OF THE HEART

The arteries.—The two coronary arteries arise from the right and left sinuses of the aorta.

The **right coronary** artery [a. coronaria dextra] passes forward between the pulmonary artery and the right atrium, and then follows the right coronary sulcus to the diaphragmatic surface of the heart (fig. 435), to anastomose with the left coronary artery. The **posterior descending** branch [ramus descendens posterior] arises at the posterior longitudinal sulcus. It

* Arch. f. Anat., Physiol. u. wissenschaftliche Medizin.

† Das Reitungssystem des Saügertierherzens, Fischer, Jena, 1906.

passes in the furrow between the ventricles toward the apex, near which it anastomoses with branches derived from the left coronary artery. In this course the right coronary artery supplies branches to the right atrium and roots of the pulmonary artery and aorta, as well as one that descends near the margo acutus (**right marginal**), and a second (**preventricular**) to the anterior wall of the right ventricle. It supplies both ventricles and the septum.

The **left coronary** artery [a. coronarius sinistra] passes for a short distance forward, between the pulmonary artery and the left auricle, and then divides into two principal branches, one of which runs in the anterior longitudinal sulcus to the apex of the heart, the **anterior descending** branch [r. descendens anterior], around which it sends branches to anastomose with the right coronary; whilst the other, the **circumflex** [ramus circumflexus], winds to the diaphragmatic surface in the coronary groove, to anastomose with the corresponding twigs of the right artery. In this course it gives off a branch which follows the margo obtusus (**left marginal**) as well as smaller branches to the left atrium, both ventricles, and the commencement of the aorta and pulmonary vessels.

FIG. 434.—STERNO-COSTAL SURFACE OF THE HEART, SHOWING ITS ARTERIES AND VEINS. (After Spalteholz.)

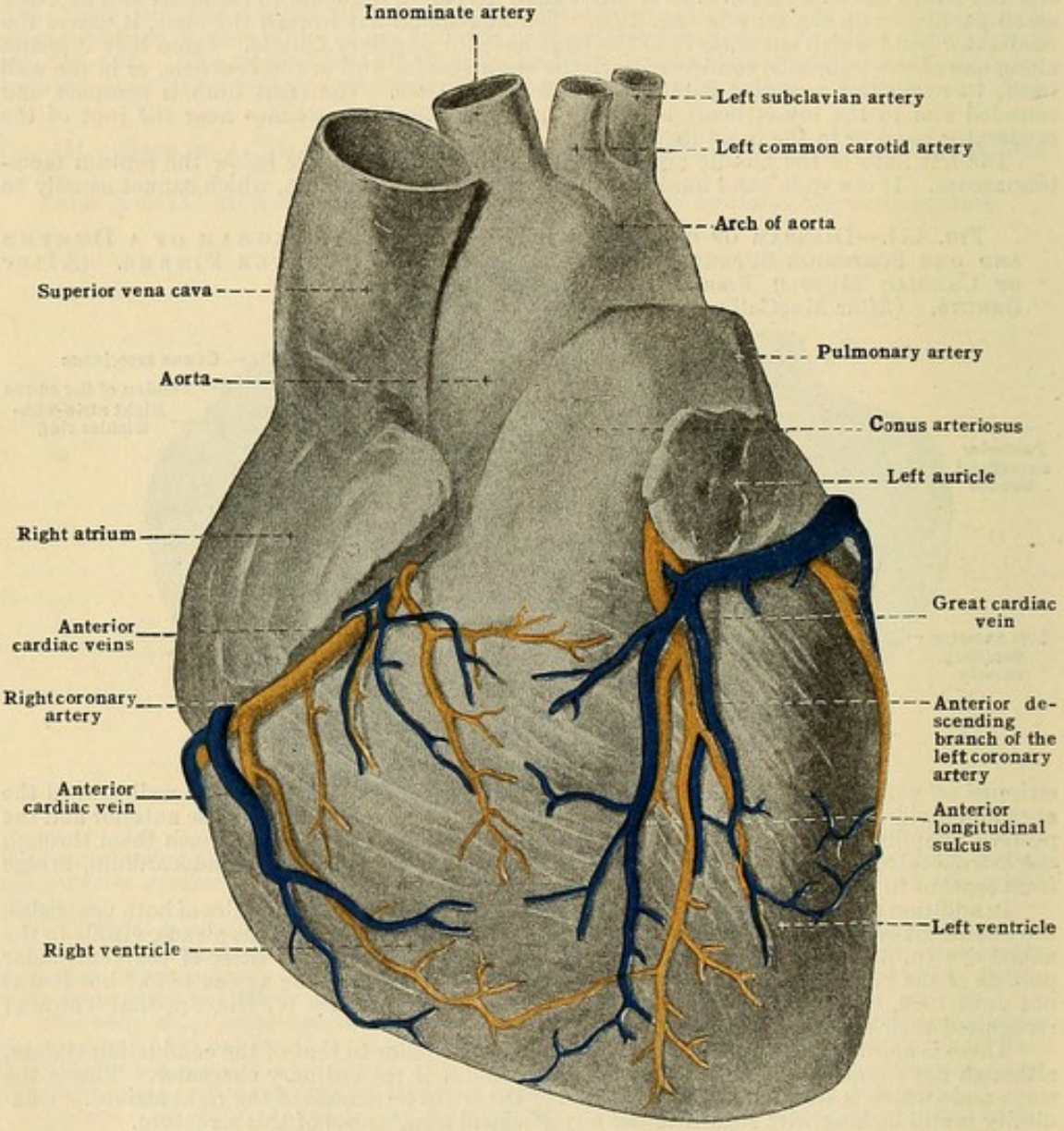

The **cardiac** or **coronary veins** accompany the coronary arteries and return the blood from the walls of the heart.

The **great cardiac** vein [v. cordis magna], (fig. 434) runs in the anterior longitudinal sulcus, passing round the left side of the heart in the coronary sulcus to terminate in the commencement of the coronary sinus. Its mouth is usually guarded by two valves, and it receives in its course the posterior vein of the left ventricle, with other smaller veins from the left atrium and ventricle, all of which are guarded by valves.

The **middle cardiac** vein (v. cordis media), sometimes the larger of the two chief veins, communicates with the foregoing at its commencement above the heart's apex. It ascends in the posterior longitudinal groove, receiving blood from the ventricular walls, and joins the coronary sinus through an orifice guarded by a single valve, close to its termination.

The **posterior vein of the left ventricle** [v. post. ventriculi sinistri], lies upon the posterior surface of the ventricle and, receiving branches from it, passes upward to terminate directly in the coronary sinus.

The **anterior cardiac** veins [vv. cordis anteriores] consist of several small branches from the front of the right ventricle, which vary in number and either open separately into the right atrium or join the lesser cardiac vein (fig. 434).

The **small cardiac** vein [v. cordis parva] is a small vessel which receives branches from both the right atrium and ventricle, and winds around the right side of the heart, in the coronary sulcus, to terminate in the coronary sinus.

The **coronary sinus** [sinus coronarius] (fig. 435) may be regarded as a much dilated terminal portion of the great cardiac vein. It is about 2.5 cm. (1 in.) in length, is covered by muscular fibres from the atrium, and lies in the coronary sulcus below the base of the heart. Its cardiac orifice, with the coronary (Thebesian) valve, has already been described. Besides the tributary veins already named, a small **oblique vein** [v. obliqua atrii sinistri] of the left atrium may some-

FIG. 435.—BASE AND DIAPHRAGMATIC SURFACE OF THE HEART, SHOWING ITS ARTERIES AND VEINS. (After Spalteholz.)

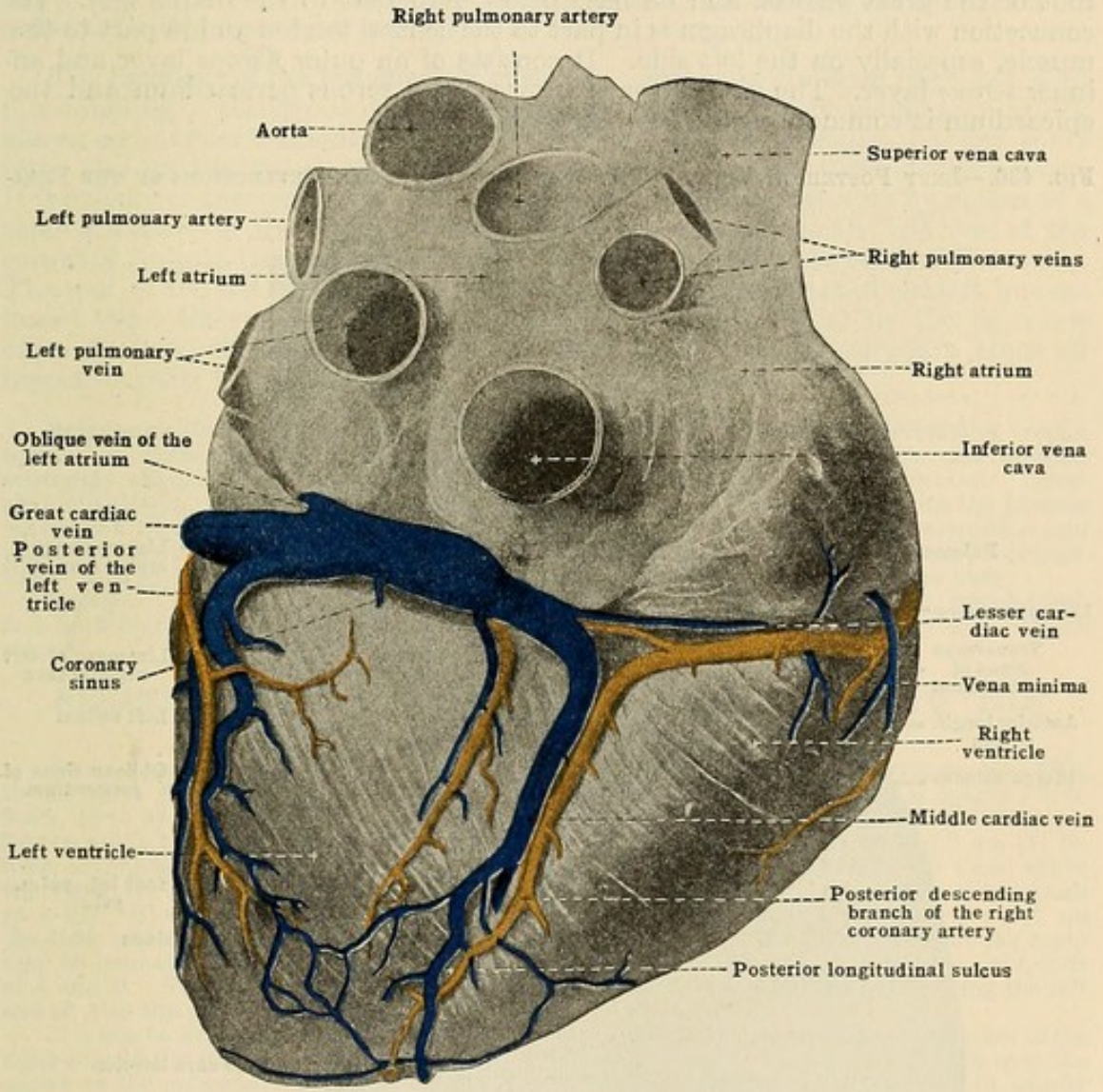

times be traced, on the back of the left atrium, from the ligament of the left vena cava (Marshall) to the sinus. This little vein, which is not always pervious or easy of demonstration, never possesses a valve at its orifice, and, like the coronary sinus, formed a part of the left superior vena cava of early fœtal life.

The **smallest cardiac** veins [vv. cordis minimæ] drain blood from septum and lateral walls of the atria, particularly the right; also from the conus arteriosus. They open directly into the right atrium.

Although *anastomoses* occur between the two coronary arteries, these are by no means extensive, and are not sufficient to allow of the establishment of a satisfactory collateral circulation in the case of the blocking of one coronary artery. Consequently such interference with the cardiac circulation produces rapid pathological changes in the heart musculature, provided it is sudden in occurrence. If the obliteration of the artery take place gradually, however, some relief may be afforded by the establishment of a collateral circulation through the venæ minimæ, which open out from both the atrial and ventricular cavities and communicate

with the finer branches of the cardiac veins, and also with the general capillary network in the heart's walls.

The **lymphatic** vessels of the heart pass chiefly through the anterior mediastinal lymph-nodes into the broncho-mediastinal trunk. (See Section VI.)

The **cardiac nerves,** derived from the vagus and the cervical sympathetic, descend into the superior mediastinum, passing in front of and behind the arch of the aorta; they unite in the formation of the superficial and deep cardiac plexuses. The superficial plexus lies above the right pulmonary artery as the latter passes beneath the aortic arch. The deep plexus lies between the trachea and the arch of the aorta, above the bifurcation of the pulmonary trunk. For the connections of the plexuses see section on NERVOUS SYSTEM.

2. THE PERICARDIUM

The **pericardium** is a cone-shaped, fibro-serous sac which surrounds the heart and contains a small amount of fluid [liquor pericardii]. Its apex is above at the root of the great vessels, and its base below, adherent to the diaphragm. Its connection with the diaphragm is in part to the central tendon and in part to the muscle, especially on the left side. It consists of an outer *fibrous* layer and an inner *serous* layer. The virtual space between the serous pericardium and the epicardium is commonly called the *pericardial cavity*.

FIG. 436.—LEFT POSTERIOR VIEW OF THE HEART TO SHOW THE REFLECTIONS OF THE PERICARDIUM.

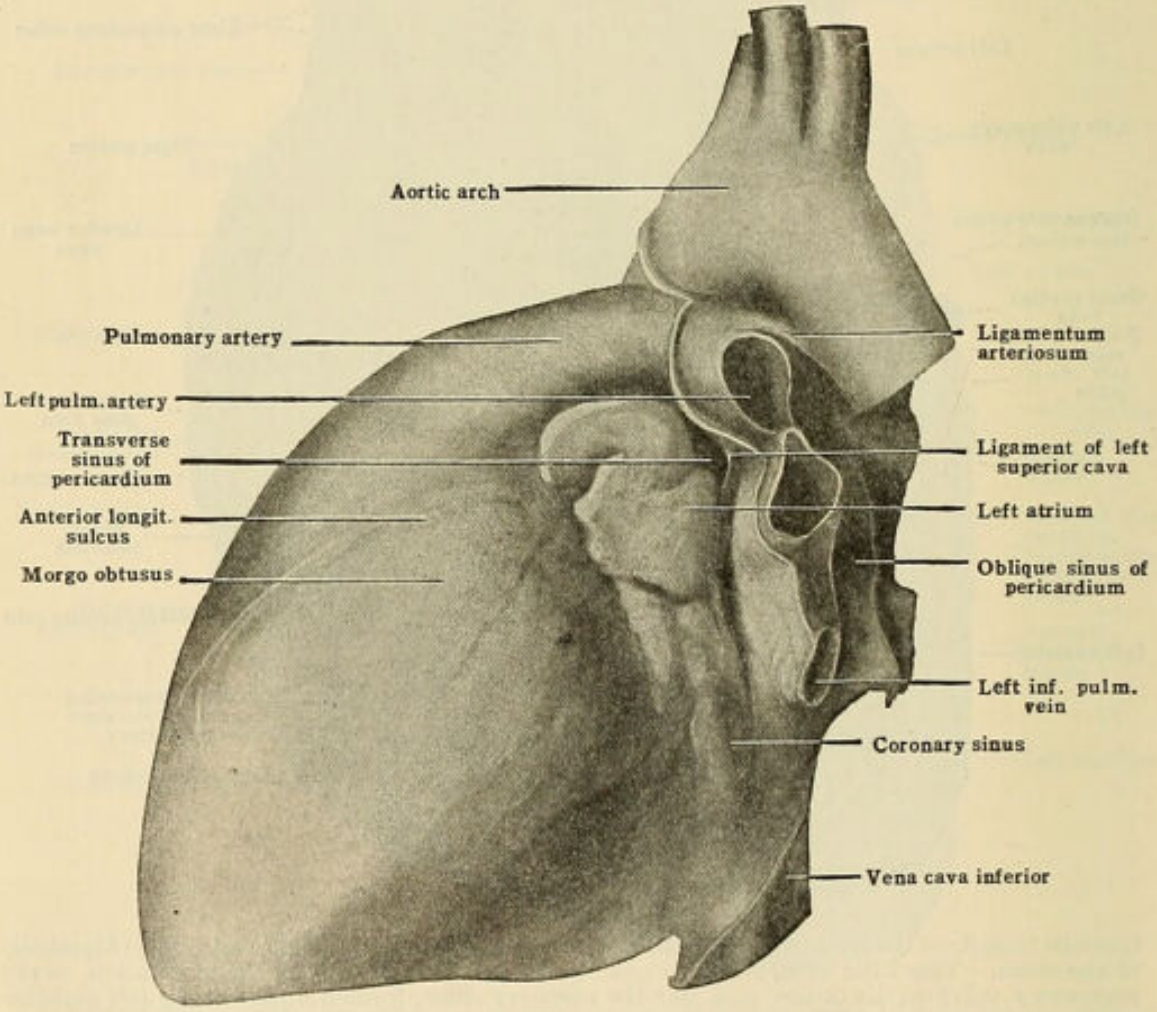

The **fibrous layer** is strong and inelastic, made of interlacing fibres. Its connection with the central tendon of the diaphragm is intimate, particularly in the region of the caval opening, but elsewhere it is attached loosely by means of areolar tissue. Above, it is lost on the sheaths of the great vessels, all of which receive distinct investments, with the single exception of the inferior vena cava, which pierces it from below. The aorta, superior vena cava, the pulmonary artery, and the four pulmonary veins, are all ensheathed in this manner. The pericardium is connected above with the deep cervical fascia. Two variable bands of fibrous tissue, the **sterno-pericardial ligaments** [ligg. sterno-pericardiaca], connect the front of the pericardium, above and below, with the posterior surface of the sternum.

The **serous layer** is smooth and glistening and consists of connective tissue, rich in elastic fibres, covered by endothelium. It lines the interior of the fibrous layer and is continuous with the epicardium or serous covering of the heart. The reflexion of the serous layer from the heart to the fibrous layer of the pericardium occurs at both the arterial and venous attachments of the heart. At the arterial attachment a simple tube of epicardium is reflected along the pulmonary artery and aorta. At the venous attachment the serous layer is reflected from the front of the pulmonary veins on the left, and from the front of these and from the roots of the venæ cavæ on the right. This reflexion is separated above from that around the aorta and pulmonary artery (figs. 424, 436). Around the lower margin of the left lower pulmonary vein (fig. 436) and the root of the inferior vena cava, this reflexion is continuous with an arched reflexion from the back of the atria (figs. 424, 436). The latter reflexion forms a pocket posterior to the atria which is sometimes called the *oblique sinus* of the pericardium.

Between the reflexions of the epicardium at the arterial and venous attachments of the heart there is a dorsal communication between the right and left sides of the pericardial cavity. This is the **transverse sinus** of the pericardium [s. transversus pericardii]; it passes behind the aorta and pulmonary artery and in front of the superior cava and left atrium.

During early embryonic life the sinus transversus is closed by the dorsal mesocardium (see p. 527). The primitive ventral mesocardium, which divides the right and left sides of the pericardial cavity ventrally, is lost very early.

The **ligament of the left superior cava** [lig. venæ cavæ sinistræ] (figs. 423, 436) is a doubling of the serous layer which passes between the left pulmonary artery above and the left superior pulmonary vein below. It contains, besides some fatty and areolar tissue, the shrunken remains of the left superior vena cava. It is usually connected above with the left superior intercostal vein by means of a small tributary of the latter. Passing from its lower end to the left end of the coronary sinus is the small **vena obliqua atrii sinistri** (oblique vein of Marshall). The root of the left superior intercostal (and the adjacent part of the left innominate) vein; the vein passing from the superior intercostal to the lig. venæ cavæ sinistræ; the oblique vein of the left atrium, and the coronary sinus all represent parts of the embryonic left vena cava superior.

Relations.—In front of the pericardium are found the thymus gland or its remains, areolar tissue, the sterno-pericardial ligaments, the left transversus thoracis muscle, the internal mammary vessels, the anterior margins of the pleural sac and lungs, and the sternum. Laterally, it is overlapped by the lungs with their pleural sacs, and it is in contact with the phrenic nerves and their accompanying vessels. Posteriorly, it is in relation with the œsophagus and vagus nerves, the descending aorta, the thoracic duct and vena azygos, and the roots of the lungs. Below it is separated by the diaphragm from the stomach and the left lobe of the liver.

Vessels.—The arteries of the pericardium are derived from the pericardiac, œsophageal, and bronchial branches of the thoracic aorta and from the internal mammary and phrenic arteries.

RELATIONS OF THE HEART AND PERICARDIUM TO THE THORACIC WALL

Heart (fig. 437 A and B).—The **base** of the heart corresponds *posteriorly* to the fifth, to the ninth thoracic vertebræ. *Anteriorly* the **apex** is in the fifth intercostal space, 7.5 to 8 cm. (3 to 3¼ in.) from the medan line. The **base** (above) corresponds to a line (A) drawn from a point 1 cm. (⅜ in.) below the second left chondro-costal articulation,and 3 cm (1⅛ in. from the median line, to another point (the same distance from the median line) 1 cm. above the right third chondro-sternal articulation. The **margo acutus**, or lower border corresponds to a line (B) drawn from the apex through the xiphi-sternal articulation, to a point on the sixth costal cartilage 2 cm. to the right of the median line. The **right border** of the heart may be indicated approximately by a line (slightly convex to the right) joining the right ends of A and B. The **left border** corresponds to a line (slightly convex to the left) joining the left end of A to the apex.

If a line be drawn from the upper margin of the left third chondro-sternal articulation to the right edge of the sternum in the fifth intercostal space, the upper end of the line will lie over the centre of the **pulmonary ostium,** and the lower two-thirds of it (approximately) will overlie the main axis of the **tricuspid ostium.** The **aortic ostium** is immediately to the left of the above line with its centre at the left edge of the sternum opposite the third space. The **mitral ostium** is very largely behind the third left interspace; its upper end is behind the third cartilage, its lower behind the left margin of the sternum opposite the fourth cartilage and space.

Of the **ostia** of the heart, the pulmonary is nearest the anterior thoracic wall, the aortic is slightly in advance of the mitral, and the tricuspid is the deepest of all.

The **pericardium** follows the heart closely. The upper end (apex) in the subject used in preparing fig. 437 extended up, behind the sternum, to the lower margin of the first costal cartilage on the right and the upper margin of the second on the left.

MORPHOGENESIS OF THE HEART AND PERICARDIUM

The heart is formed by the blending in the median line of two longitudinal endothelial tubes lying ventral to the fore-gut of the early embryo. Each tube is partially surrounded laterally by the splanchnic mesoderm which forms a septum between the right and left sides of

FIG. 437.—A, TELEROENTGENOGRAM OF A FORMALIN PREPARATION OF THE ANTERIOR THORACIC WALL WITH THE HEART, PERICARDIUM AND DIAPHRAGM IN SITU. (LE WALD, × ⅓). B, EXPLANATORY OUTLINE DRAWING, TRACED FROM THE NEGATIVE AND CONTROLLED BY STEREOSCOPIC VIEWS.

The ostia have been accurately fitted with wire rings. P, pulmonary ostium; *M*, mitral; *T*, tricuspid; aortic ostium is unlabelled; I–VII, right costal cartilages.

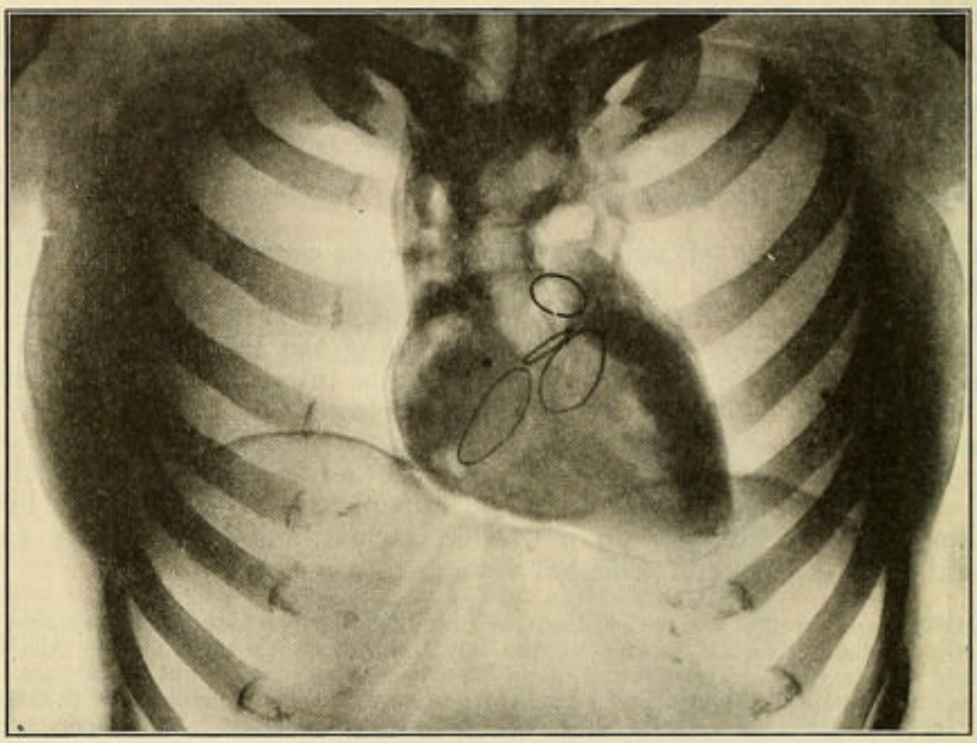

A

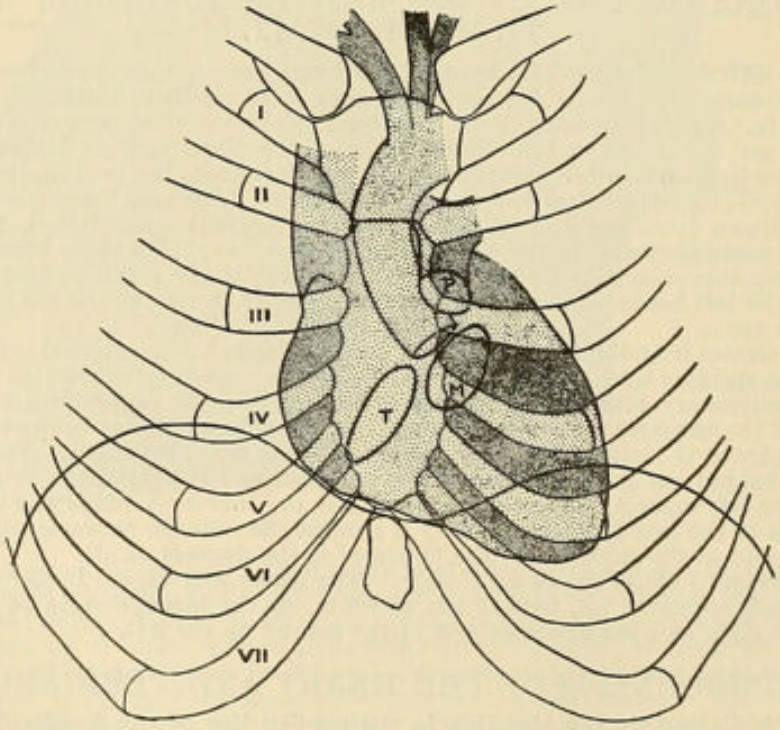

B

the cœlomic cavity. The blended endothelial tubes form the **endocardium.** The splanchnic mesoderm in relation to the endocardium becomes the **myoepicardium,** and the double layer connecting the heart dorsally and ventrally with the somatic mesoderm becomes the (temporary) dorsal and ventral mesocardia. The somatic mesoderm of the heart region becomes the **pericardium.**

The originally straight heart-tube grows rapidly and becomes tortuous on account of its increasing length between the limits assigned by its fixed arterial and venous ends. Its arterial end is continued into the truncus arteriosus, which is later divided into the pulmonary artery and the ascending aorta. Its venous end receives the vitelline and umbilical veins, and, later on, the common cardinals also. By the formation of a series of alternate bulgings and constrictions the heart becomes differentiated into the sinus venosus, atrium, ventricle and conus arteriosus, counting from the venous to the arterial end. These parts, after going through a process of progressive differentiation and shifting (fig. 438) take up relative positions somewhat approaching those of the adult.

FIG. 438.—MODELS SHOWING THE DEVELOPMENT OF THE HEART. (After His.)

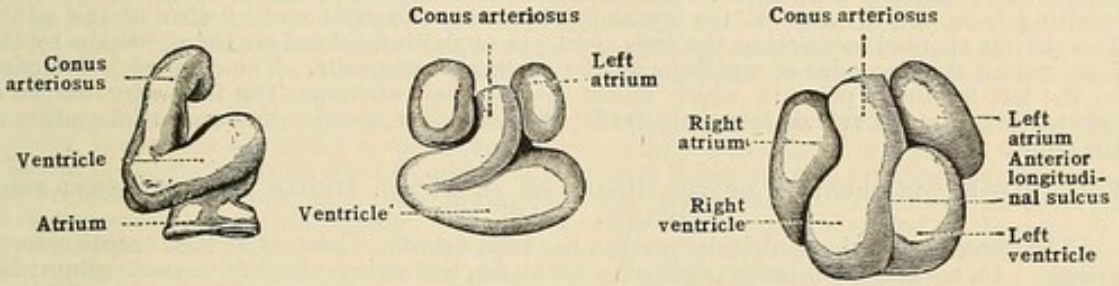

The sinus venosus lies on the dorsal wall of the atrium, and is composed of right and left horns united by a transverse portion. The sinus is separated from the atrium by a sagitally directed slit-like opening, guarded by right and left lateral valves which project into the atrium. The atrium is wide, being prolonged into a ventrally projecting pouch on either side, the future right and left auricles. The ventricle is situated caudal and somewhat ventral to the atrium. The right limb of the common ventricle, which leads into the conus arteriosus, is the future right ventricle; the left limb, connected with the atrium, is the future left ventricle. The

FIG. 439.—SAGITTAL SECTION THROUGH A RECONSTRUCTION OF THE HEART OF A 9 MM. HUMAN EMBRYO SEEN FROM THE LEFT SIDE. (Tandler, × 75.)

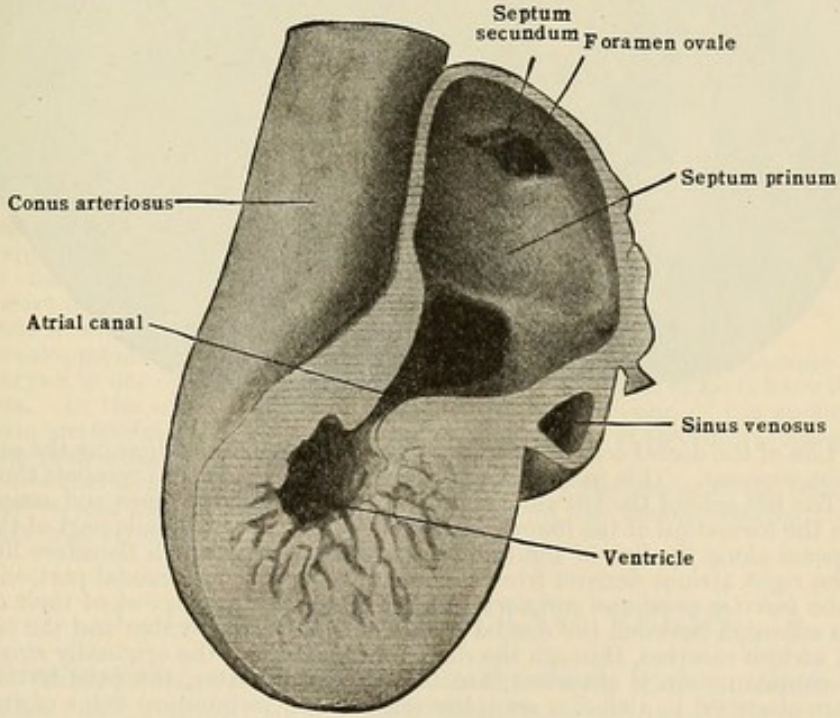

communication between the atrium and the ventricle, known as the atrial canal, is indicated on the exterior by a constriction; its interior consists of a transversely placed slit. The conus arteriosus is continued from the ventricle without obvious constriction and passes over into the truncus arteriosus.

The **sinus venosus** early loses its bilateral symmetry owing to the rapid enlargement of the right horn. This horn soon receives, through the proximal portion of the right vitelline vein (*inferior vena cava*), all the blood coming from the left vitelline and both umbilical veins. The right common cardinal also gains ascendency over the left and becomes the *superior vena cava.*

The left horn and transverse part, now only draining the dwindling left common cardinal, (*left superior cava*) and the coronary veins, become the *coronary sinus*. The right horn gradually becomes absorbed into the right end of the atrial cavity until the superior and inferior cavæ and the coronary sinus acquire separate openings into that chamber. Between the opening of the coronary sinus and that of the inferior cava there is a ridge, the sinus-septum (between the right horn and transverse parts of the sinus), which becomes attached to the lower part of the right sinus valve.

In the **atrium** a septum begins early to grow from the ventro-cephalic wall of the atrium, toward the atrial canal. As the interatrial communication around the edge of the septum (ostium primum) is becoming narrow, a perforation occurs near the attached margin of the septum (ostium secundum). This first septum (septum primum) is incomplete because when its edge reaches the atrial canal the atria still communicate through ostium secundum. To the right of the septum primum another septum (s. secundum) is formed later; this never stretches completely across the atrium and is rather a crescentic ridge than a true septum. Until the free edges of the two septa overlap one another there is a direct passage leading from one side of the atrium to the other; eventually they do overlap and the communication becomes oblique but persists until birth. (For adult relations of septa, see p. 511.) The cavities resulting from the division of the common atrium are the *right and left atria* of the adult. The oblique channel connecting the atria (foramen ovale) is bounded on the right side by the s. secundum the free edge of which forms the **limbus fossæ ovalis.** The channel is bounded on the left by the s. primum which slants into the left atrium. The free edge of the s. primum becomes the **valvula foraminis ovalis;** the remainder, the membranous atrial septum of the adult.

FIG. 440.—RECONSTRUCTION OF THE HEART OF AN 11 MM. HUMAN EMBRYO VIEWED FROM BELOW. (Mall, 50.)

The lower part of the ventricular portion has been cut off. Connective tissue septa colored yellow. *Ao*, aorta; *Ap*, anterior papillary muscle; *La*, left atrium; *Lo*, left venous ostium; *Lp*, large (anterior) papillary muscle of right ventricle; *Mpm*, medial papillary muscle; *PP*, posterior papillary muscle; *P*, pulmonary artery; *RA*, right atrium.

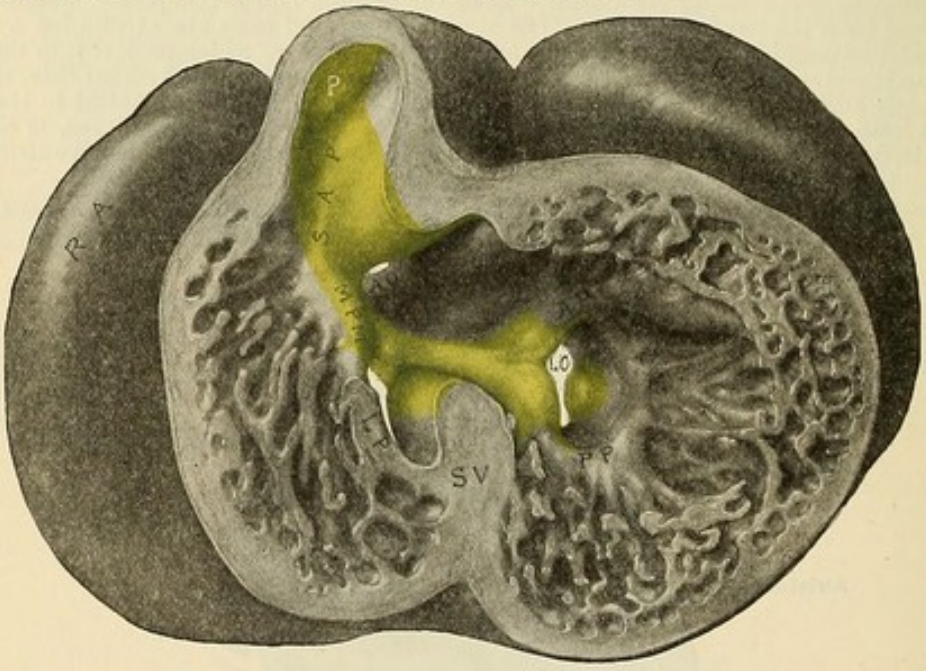

The portion of the dorsal wall of the right atrium immediately adjoining the septa is derived from the sinus venosus. This part of the atrium (the *sinus venarum*) receives the great venous openings. The left side of the left sinus-valve is attached to both septa and assists the septum secundum in the formation of the *limbus foraminis ovalis*. The cephalic part of the right sinus-valve disappears along the line of the (adult) *crista terminalis*, which therefore limits the right portion of the right atrium derived from the sinus venosus. The caudal portion of this valve persists as the *inferior caval and coronary valves*. These are drawn out of their original alignment by the adhesion between the caudal part of the right sinus-valve and the sinus-septum.

The left atrium receives, through the dorsal mesocardium, the originally single pulmonary vein. This common stem is absorbed into the atrial wall; later, the primitive right and left tributaries are absorbed in a similar way, leaving the four pulmonary veins of the adult opening separately into the left atrium. The area of the left atrium adjacent to the pulmonary veins, therefore, is not part of the original atrial wall.

The **ventricles** are divided by a septum (*s. musculare ventriculorum*) growing from the caudal wall of the common ventricular cavity toward the atrial canal. The canal moves to the right, and the dorsal part of the septum blends with the dorsal lip of the canal. The free ventral edge of the interventricular septum helps to bound the foramen through which blood from the left ventricle must enter the right on its way to the conus arteriosus. The foramen persists until (the free margin of the interventricular septum having been joined by the aortic septum) it becomes the circumference of the *aortic ostium*.

The aortic septum is a composite structure formed partly by a septum growing between the fourth and sixth pairs of aortic arches, and partly by swellings growing in the interior of the conus and truncus arteriosus. When fully formed it extends spirally along the truncus and conus, and enters the right half of the common ventricular cavity, where it joins the right side of the free edge of the interventricular septum. The septum is arranged in such a way that the blood from the left ventricle passes no longer through the right ventricle but along its own channel (*the aorta*) through the conus and truncus to the first four pairs of aortic arches. The blood from the right ventricle passes through *the pulmonary* division of the conus and truncus arteriosus, anterior and to the left of the aorta, into the sixth arches. Further differentiation brings about the external separation of the aorta from the pulmonary artery, but their common covering of epicardium persists as such in the adult. The lower end of the aortic septum persists in the adult as the *septum membranaceum ventriculorum* and the *crista supraventricularis*, the relations of which to the septum musculare are well shown in fig. 428. During the formation of the aortic septum four endocardial swellings appear at the distal part of the interior of the conus. These are arranged as smaller and larger opposite pairs; the smaller and larger swellings, therefore, alternating around the lumen. The larger pair of swellings assists (by partial blending) in the formation of the aortic septum. When the septum is complete, half of each of the larger swellings is contained in the aorta and half of each in the pulmonary artery. One of the smaller swellings remains in the aorta and one in the pulmonary artery, so that there are now three swellings in each vessel. Each of the six swellings becomes undermined to form a *semilunar valve* of the adult.

The atrio-ventricular valves.—The interior of the ventricular cavity, which is at first smooth, becomes undermined in an irregular way, to form a system of myocardial trabeculæ. The lips of the transversely directed atrial canal become thickened into prominent anterior and posterior endocardial cushions; these project into the ventricular cavity and become involved in its myocardial trabecular system. The atrial canal, which has now moved to the right, becomes divided sagittally, into *right and left venous ostia*, by the septum primum. The interventricular septum joins the ventricular side of the posterior endocardial cushion. The anterior and posterior endocardial cushions, where they blend with one another and with the septum primum on the medial side of each venous ostium, form an atrio-ventricular valve-cusp on either side, viz., the anterior cusp of the mitral in the left ostium, and the medial cusp of the tricuspid in the right. The posterior cusp of the mitral and the anterior and posterior of the tricuspid are formed later, partly, by lateral tubercles developing in either ostium, and partly by undermining of the ostia from the ventricular side. The atrial musculature extends into the atrio-ventricular valves and, until a late stage, is continuous with the trabecular system of the ventricles. Gradually, however, this connection between atrial and ventricular musculature is lost, leaving only the chordæ tendineæ connecting the papillary muscles with the valves Muscle is found at the basal region of the valve-cusps in the adult, and occasionally persists in the chordæ tendineæ.

The connection between the atrial and ventricular musculature is not confined to that occurring by means of the valves and trabecular system. The original myocardial connection between the atrial and ventricular portions of the heart remains complete until the embryo has reached the length of about 11 mm. From that time on the epicardium begins to blend with the fibrous annuli of the venous ostia. Meanwhile the atrial musculature rapidly loses its connection with that of the ventricles until they are connected in one place only, i. e., the site of the *atrio-ventricular bundle*.

The **pericardial cavity** is the original cephalic end of the intraembryonic cœlom. The somatic mesoderm of the pericardial region forms the adult *pericardium*. The splanchnic mesoderm persists only in the part which furnishes the *myo-epicardium*. The ventral and dorsal mesocardia, both of which are formed by the splanchnic mesoderm, are, in the main, transitory. The early disappearance of the ventral mesocardium unites the right and left sides of the pericardial cœlom ventral to the heart. The dorsal mesocardium persists at the arterial and venous ends of the heart only. The loss of the dorsal mesocardium between the latter points gives rise to the *sinus transversus pericardii* of the adult.

During development, the heart and pericardium migrate from a point opposite the cephalic end of the pharynx to one opposite the caudal end of the œsophagus; in fact, from the neck well into the thorax. In the adult, instead of being at the cephalic end of the cœlom, the heart and pericardium are contained between the right and left layers of the ventral mesentery of the œsophagus; the pericardial pleura of the adult.

The cranio-caudal migration is evidenced in the adult by the course of the recurrent and of the cardiac nerves, and also by the apparent migration of the vessels derived from some of the dorsal segmental arteries.

B. THE ARTERIES AND VEINS

The **arteries** [arteriæ], proportionately to their size, have much thicker walls than the veins. After death they retain their natural form, but are contracted and contain usually a small amount of pale clot. In a very general way the thickness of wall is proportional to calibre. Some arteries, however, are constantly thicker or thinner than could be predicted from size alone.

The larger arteries usually take a direct course and branch dichotomously. In descriptive anatomy if dichotomous branches are of nearly equal size it is common for each to take another name; if one branch preponderates in size, it is apt to retain the name of the parent trunk while the smaller is regarded as a collateral branch [vas collaterale]. There are numerous

exceptions to dichotomous branching; branches may run perpendicularly or recurrently to the vessel from which they arise; or several branches may arise simultaneously.

There is less tendency to anastomosis between large or medium sized arteries than in veins of corresponding magnitude. Anastomoses do occur, however, particularly in the form of arches, such as the palpebral, plantar and volar arches, or the arches between the intestinal arteries. This form of anastomosis is sometimes called inosculation. Between smaller arteries anastomosis is usually free as in the case, for instance, of the articular retia. In some organs anastomosis (excepting capillary) between neighbouring arteries can scarcely be said to exist at all; the a. centralis retinæ affords a good example of this, as do the arteries of the brain, spleen, and kidney; such arteries are called terminal.

The larger arteries are supplied by *vasa vasorum*, frequently arising from their own recurrent branches.

The **veins** [venæ] have thin walls, and after death are either collapsed or filled with clot or stained serum. They are characterized by the presence of valves and frequent anastomoses.

Frequent anastomoses occur between veins of all sizes; plexuses are common, such, for instance, those of the pelvis. *Venæ comitantes* are veins which, usually in pairs, accompany many arteries; they communicate with one another, around the artery, very freely. Veins do not primitively accompany arteries. In the case of the extremities the primitive veins are superficial. The deep veins of the limbs are of later formation and to them the superficial veins subsequently become tributary.

The veins from the stomach, spleen, pancreas and intestine are collected into a large trunk, the **portal vein.** This does not open into the inferior vena cava directly, but breaks up into numerous smaller vessels in the liver. From these the blood is returned, through the hepatic veins, to the inferior cava.

Many veins are provided with **valves,** the free borders of which are directed toward the heart. In the small veins the valves are single; in the larger veins they are usually double, rarely treble. Valves are much more numerous in the veins of infants than those of the adult, they seem to disappear progressively with advancing age. The venous valves are most numerous in the superficial veins, and in the deep veins of the extremities; in many veins of the head and neck they occur only at their point of termination in a larger trunk.

The cranial *venous sinuses* are modified veins, consisting of intima only which lines channels in the fibrous dura mater. The venous spaces in cavernous tissue, such as the corpora cavernosa, may be looked upon as specially modified veins.

The larger veins, like the arteries, have vasa vasorum.

The arteries and veins will be considered in the following order: 1, pulmonary artery and veins; 2, the systemic arteries; and, 3, the systemic veins. At the ends of the second and third divisions, the development and variations are considered.

1. THE PULMONARY ARTERY AND VEINS

The **pulmonary artery** [a. pulmonalis] (fig. 441) passes from the right ventricle to the lungs. It differs from all other arteries in the body in that it contains venous blood. It arises as a short, thick trunk from the **conus arteriosus** of the right ventricle, and, after a course of about 5 cm. (2 in.) within the pericardium, divides into a right and a left branch. These branches pass to the right and the left lung respectively.

The **trunk of the pulmonary artery** at its origin is on a plane anterior to the ascending aorta, and slightly overlaps that vessel. Thence it passes upward, backward, and to the left, forming a slight curve around the front and left side of the ascending portion of the aorta; and, having reached the concavity of the aortic arch, on a plane posterior to the ascending aorta, it divides into its right and left branches, which diverge from each other at an angle of about 130°. The division of the pulmonary artery occurs immediately to the left of the second left chondrosternal articulation.

In the fœtus, the pulmonary artery continues its course upward, backward, and to the left under the name of the **ductus arteriosus (Botalli),** and opens into the descending aorta just below the origin of the left subclavian artery. After birth, that portion of the pulmonary artery which extends to the aorta becomes obliterated, and remains merely as a fibrous cord, the **ligamentum arteriosum** (fig. 436).

Relations.—In front, the trunk of the pulmonary artery is covered by the remains of the thymus gland, and the pericardium. The artery lies, at its commencement, behind the upper margin of the third left chondro-sternal articulation. The right margin of the artery is behind the second piece of sternum but the greater part of the vessel is behind the medial end of the second intercostal space.

Behind, it lies successively upon the ascending aorta and the left atrium.

To the **right** are the ascending aorta, the right atrium, the right coronary artery, and the cardiac nerves.

To the **left** are the pericardium, the left pleura and lung, the left auricle, the left coronary artery, and the cardiac nerves.

The **right pulmonary artery** [ramus dexter] longer than the left, passes almost horizontally under the arch of the aorta to the root of the right lung, where it divides, either directly or after repeated division, into three branches, one for each lobe. These branches follow the course of the bronchi, dividing and subdividing for the supply of the lobules of the lung. The terminal branches do not anastomose with each other.

Relations.—In its course to the lung it has **in front** of it the ascending aorta, the superior vena cava, the phrenic nerve, the anterior pulmonary plexus, and the reflexion of the pleura. **Behind** are the right bronchus and the termination of the azygos vein. **Above** is the arch of the aorta, and **below** are the left atrium and the upper right pulmonary vein.

At the root of the lung it has the right bronchus **above** and **behind** it; the pulmonary veins **below** and in **front.** Crossing in front of it and the other structures forming the root of the lung are the phrenic nerve and the anterior pulmonary plexus; behind are the azygos vein, the vagus nerve, and the posterior pulmonary plexus.

The **left pulmonary artery,** shorter and slightly smaller than the right, passes in front of the descending aorta to the root of the left lung, where it divides into two branches for the supply of the upper and lower lobes respectively. These divide and subdivide as on the right side.

Relations.—At the root of the lung it has the left bronchus **behind** and also **below** it, in consequence of the more vertical direction taken by the left bronchus than by the right. **Below** and **in front** are the pulmonary veins, while passing from the artery and the upper left pulmonary vein is the ligament of the left superior cava. Crossing in front of it and the other structures forming the root of the lung are the phrenic nerve, the anterior pulmonary plexus, and the reflexion of the left pleura; crossing behind, are the descending aorta, the left vagus nerve, and the posterior pulmonary plexus.

The **pulmonary veins** [vv. pulmonales] (figs. 424, 441) return the aërated blood from the lungs to the heart. They are usually four in number, superior and inferior, of the right and left sides. Occasionally, however, there are three pulmonary veins on the right side, the result of the vein from the middle lobe of the right lung opening separately into the left atrium instead of joining as usual the upper of the two right pulmonary veins. The relations of the pulmonary veins to the pulmonary arteries and bronchi in the lungs are given with the anatomy of the lungs (Section X).

The pulmonary veins are about 15 mm. in length. In the pericardium the **right pulmonary veins** [vv. pulmonales dextræ] both pass behind the superior vena cava. The superior vein receives the vein from the right middle lobe and runs below and in front of the right pulmonary artery.

The **left pulmonary veins** [vv. pulmonales sinistræ] enter the left atrium about 3 cm. in front of the veins of the right side. The superior vein is below the left pulmonary artery.

2. THE SYSTEMIC ARTERIES

THE AORTA

The **aorta** (fig. 442) is the main systemic arterial trunk, and from it all the systemic arteries are derived. It begins at the left ventricle of the heart, and ascends near the anterior thoracic wall as high as the second right chondro-sternal articulation [**aorta ascendens**]. It then turns backward and to the left forming an arch [**arcus aortæ**] which reaches the posterior thoracic wall at the left side of the fourth thoracic vertebra. From here it runs downward along the vertebral column [**aorta descendens**] through the thorax and abdomen and ends by dividing, opposite the fourth lumbar vertebra, into the right and left common iliac arteries. From the point of bifurcation a small vessel, the middle sacral, is continued down the middle line in front of the sacrum and coccyx. The middle sacral represents the sacral and coccygeal aorta.

The Ascending Aorta

The **ascending aorta** [aorta ascendens] (fig. 442) begins at the upper part of the left ventricle, on a level with the third intercostal space, and ascends behind

the sternum to the upper border of the right second chondrosternal articulation. It measures about 5 to 5.5 cm. (2 to 2¼ in.), forming, as it ascends, a gentle curve with its convexity to the right. It is enclosed for the greater part of its length in the pericardium, being invested, together with the pulmonary artery, in a common sheath formed by the serous layer of that membrane. A dilatation known as the **bulbus aortæ** occurs immediately above the heart upon which are three localized bulgings, known as the **aortic sinuses** (sinuses of Valsalva); they are placed, one to the right, one to the left, and one posteriorly. From the right and left are derived the coronary arteries of the heart. (See HEART.)

FIG. 441.—THE GREAT VESSELS OF THE THORAX.
(Modified from a dissection in St. Bartholomew's Hospital Museum.)

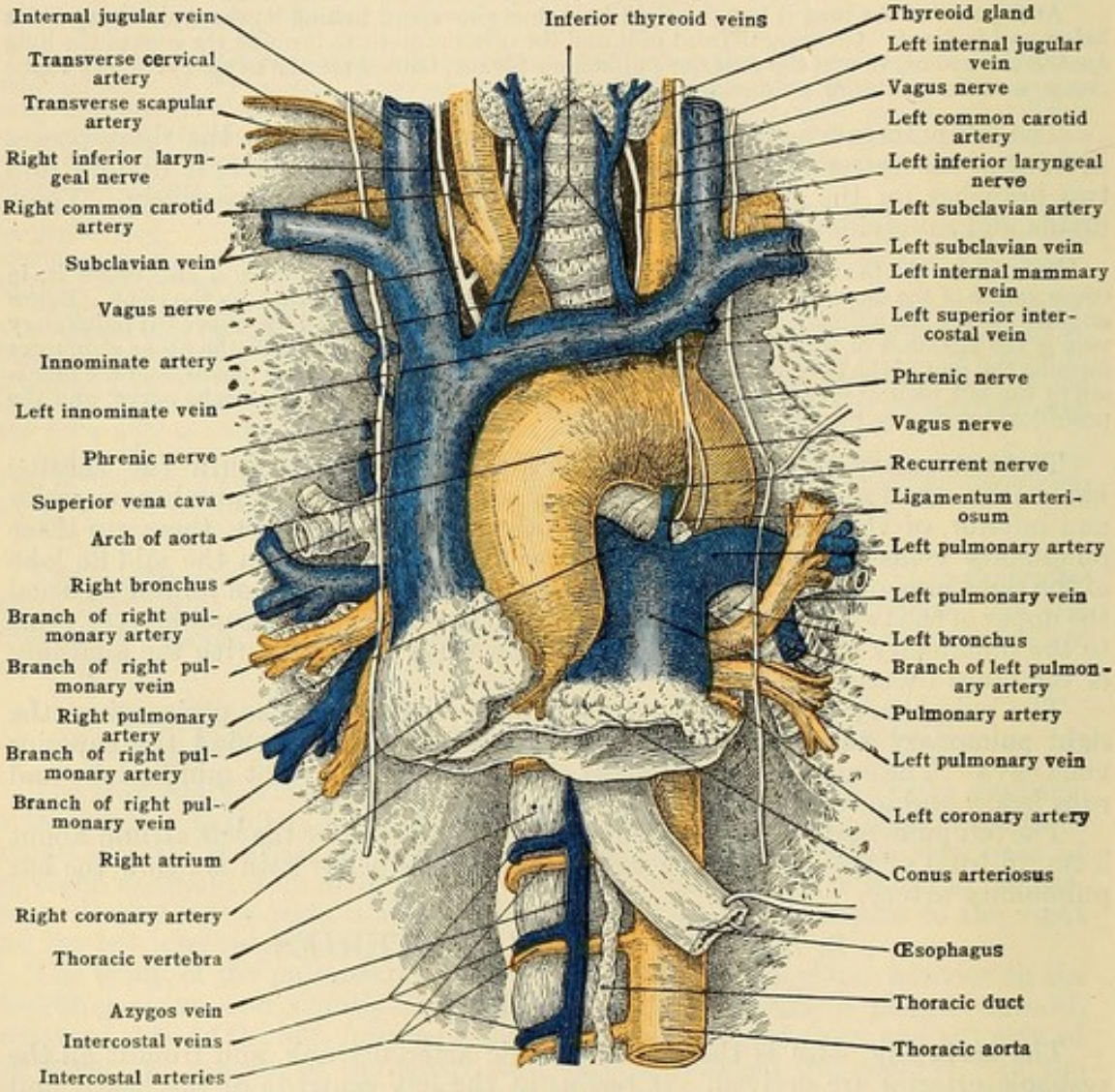

Relations.—In front, it is overlapped at its commencement by the right auricle, conut arteriosus and pulmonary artery. Higher up, as the pulmonary artery and auricle diverge, is is separated from the manubrium by the pericardium, the remains of the thymus gland, and by the loose tissue and fat in the superior mediastinum, and is here slightly overlapped by the right pleura and by the edge of the right lung in full inspiration. The root of the right coronary artery is also in front.

Behind are the left atrium of the heart, the right pulmonary artery, the right bronchus, and the anterior right deep cardiac nerves.

On the **right side** it is in contact, below with the right atrium, and above with the superior vena cava.

On the **left side** are the pulmonary artery and the branches of the right superficial cardiac nerves.

Branches.—The right and left coronary arteries have already been described (p. 519).

The ARCH OF THE AORTA

The **arch of the aorta** [arcus aortæ] (figs. 441, 442), extends in a gentle curve upward, backward, and to the left, from the level of the upper border of the

second right costal cartilage to the lower border of the fourth thoracic vertebra. Attached to the concavity of the arch, just beyond the origin of the left subclavian artery, is the **ligamentum arteriosum** (vestige of the dorsal part of the left sixth arch). Between the left subclavian artery and the ligamentum arteriosum there is sometimes a definite constriction of the arch (**isthmus aortæ**) situated opposite the third thoracic vertebra. When the isthmus is well marked, it is succeeded by a dilatation (**aortic spindle**) which begins in the neighbourhood of the ligamentum arteriosum and passes over into the descending aorta. Passing under the arch are the left bronchus, the right pulmonary artery, and the left recurrent (inferior laryngeal) nerve. It measures about 4.5 cm. ($1\frac{4}{5}$ in.).

FIG. 442.—THE THORACIC AND ABDOMINAL AORTA.

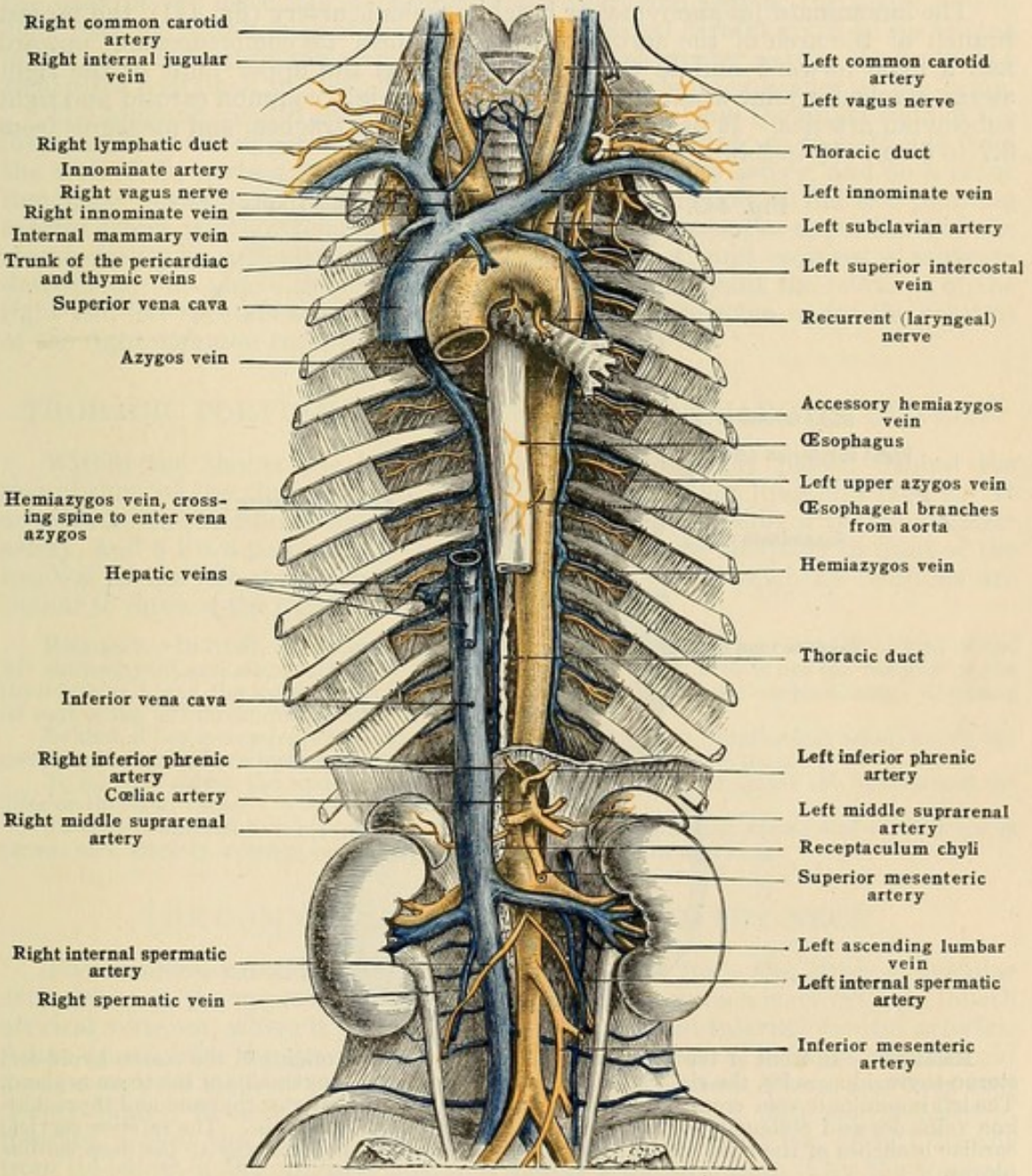

Relations.—In front and to the left, it is slightly overlapped by the right pleura and lung, and to a greater extent by the left pleura and lung. It is crossed in the following order from right to left, by the left phrenic nerve, by the cardiac branches of the vagus nerve, the cardiac branches of the sympathetic nerve, by the left vagus nerve, and by the left superior intercostal vein as it passes up to the left innominate vein.

Behind and to the right are the trachea, the œsophagus, the thoracic duct, the deep cardiac plexus which is situated on the trachea just above its bifurcation, and the left recurrent (inferior laryngeal) nerve.

Above it are the three chief branches for the head, neck, and upper extremities, namely, the innominate, the left carotid, and the left subclavian arteries, and the left innominate vein.

Below it—that is, in its concavity—are the bifurcation of the pulmonary artery, the left bronchus, the left recurrent (inferior laryngeal) nerve, the ligamentum arteriosum, the superficial cardiac plexus, two or more bronchial lymphatic glands, and the reflexion of the pericardium.

The **branches of the aortic arch** are:—the innominate, the left common carotid, and the left subclavian arteries. The innominate and left carotid arise close together—indeed, so close that, when seen from the interior of the aorta, the orifices appear merely separated by a thin septum. The left subclavian arises a little less close to the left carotid.

THE INNOMINATE ARTERY

The **innominate** [a. anonyma] or brachio-cephalic artery (fig. 441), the largest branch of the arch of the aorta, extends from near its commencement upward and a little forward and to the right, as high as the upper limit of the right sterno-clavicular joint where it bifurcates into the right common carotid and right subclavian arteries. It lies obliquely in front of the trachea, and measures from 3.7 to 5 cm. ($1\frac{1}{2}$ to 2 in.).

FIG. 443.—THE THYREOIDEA IMA. (After Henle.)

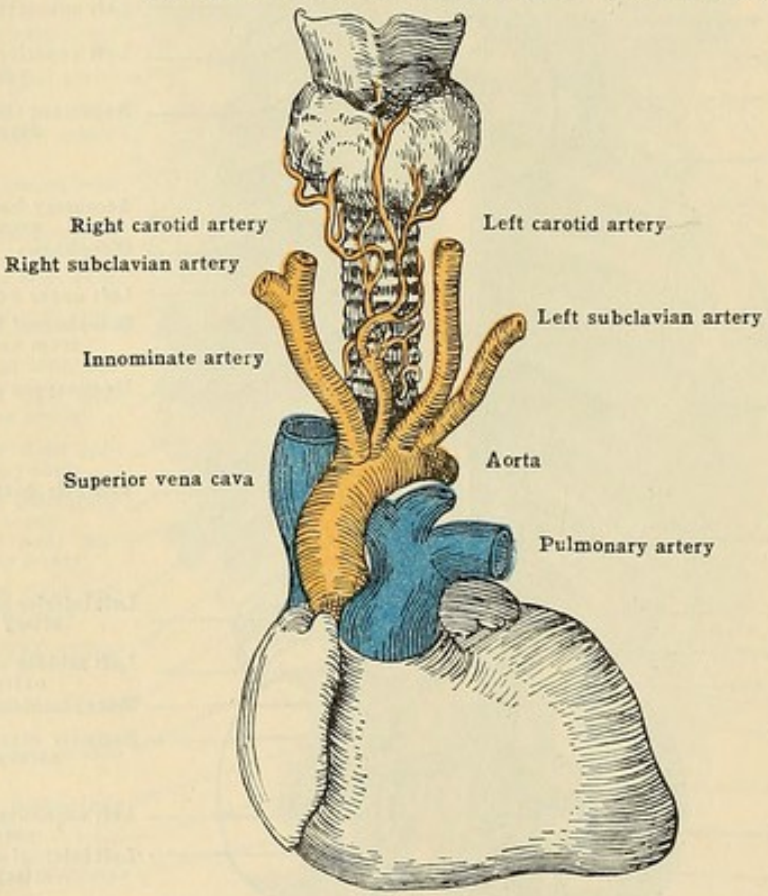

Relations.—In front of the artery are the manubrium, the origins of the sterno-hyoid and sterno-thyreoid muscles, the right sterno-clavicular joint, and the remains of the thymus gland. The left innominate vein crosses the root of the vessel, and the inferior thyreoid and thyreoidea ima veins descend obliquely over it to end in the left innominate vein. The inferior cervical cardiac branches of the right vagus nerve pass in front of it on their way to the deep cardiac plexus.

Behind, it lies on the trachea, crossing that tube obliquely from left to right, and coming into contact above with the right pleura.

To the **right side** are the right innominate vein, the right vagus, and the pleura.

To the **left side** are the left common carotid, the remains of the thymus gland, the right inferior thyreoid vein; and, higher, the trachea.

The **branches of the innominate artery** are:—(1) The right common carotid; and (2) the right subclavian. These are terminal branches. There are usually no collateral branches from this vessel, but at times the thyreoidea ima may arise from it.

The **thyreoida ima** artery, which occurs in about 10 per cent. of subjects, ascends on the front of the trachea to the thyreoid gland. It may be large in which case it might complicate the low operation of tracheotomy. It does not always arise from the innominate, but occasionally from the arch of the aorta (fig. 443) or from the right common carotid.

THE COMMON CAROTID ARTERIES

The **common carotid** arteries [aa. carotides communes] pass up deeply from the thorax on either side of the neck to about the level of the upper border of the thyreoid cartilage, where they divide into the external and internal carotid arteries. The **external carotid** supplies the structures at the upper part of the front and side of the neck, the larynx, pharynx, tongue, face, the upper part of the back of the neck, the structures in the pterygoid region, the scalp, and in chief part the membranes of the brain. The **internal carotid** gives off no branch in the neck, but enters the cranium and supplies the greater part of the brain, the structures contained in the orbit, and portions of the membranes of the brain.

The common carotid artery on the right side arises from the bifurcation of the innominate at the upper limit of the sterno-clavicular joint; on the left side from the arch of the aorta a little to the left of the innominate artery, and on a plane somewhat posterior to that vessel (fig. 441). The portion of the left common carotid artery which extends from the arch of the aorta to the upper limit of the sterno-clavicular articulation lies deeply in the chest, and requires a separate description; but above the level of the sterno-clavicular joint the relations of the right and left carotids are practically the same, and are given under the account of the right common carotid.

THORACIC PORTION OF THE LEFT COMMON CAROTID ARTERY

Within the thorax the left common carotid is deeply placed behind the manubrium of the sternum, and is overlapped by the left lung and pleura. It arises from the middle of the aortic arch, close to the left side of the innominate artery, and a little posterior to that vessel, and ascends obliquely in front of the trachea to the left sterno-clavicular articulation, above which its relations are similar to those of the right common carotid (fig. 442).

Relations.—In front, but at some little distance, are the manubrium and the origins of the left sterno-hyoid and sterno-thyreoid muscles, whilst in contact with it are the remains of the thymus gland, and the loose connective tissue and fat of the superior mediastinum. Crossing its root is the left innominate vein.

Behind, it lies successively upon the trachea the left recurrent (inferior laryngeal) nerve, the œsophagus (which here inclines a little to the left), and the thoracic duct.

To its **right side** is the root of the innominate artery, and higher up are the trachea and the inferior thyreoid veins.

To its **left side,** but on a posterior plane, are the left subclavian artery and the left vagus nerve; and, slightly overlapping it, the edge of the left pleura and lung.

THE COMMON CAROTID ARTERY IN THE NECK

The **common carotid artery in the neck** extends from the sterno-clavicular articulation to the upper border of the thyreoid cartilage on a level with the fourth cervical vertebra, where it divides into the external and internal carotid arteries. A line drawn from the sterno-clavicular joint to the interval between the mastoid process and the angle of the jaw would indicate its course. The artery is at first deeply placed beneath the sterno-mastoid, sterno-hyoid, and sterno-thyreoid muscles, and at the level of the top of the sternum is only 2 cm. ($\frac{3}{4}$ in.) distant from its fellow of the opposite side, and merely separated from it by the trachea. As the carotid arteries run up the neck, however, they diverge in the form of a V and become more superficial, though on a plane posterior to that in which they lie at the root of the neck, and are separated from each other by the larynx and pharynx. At their bifurcation they are about 6 cm. ($2\frac{1}{4}$ in.) apart. The common carotid is contained in a sheath of fascia common to it and the internal jugular vein and vagus nerve. The artery, vein, and nerve, however, are not in contact, but separated from one another by fibrous septa, which divide the common sheath into three compartments: one for the artery, one for the vein, and one

for the nerve. The vein, which is larger than the artery, lies to the lateral side, and somewhat overlaps it. The vagus nerve lies behind and between the two vessels. The artery on the right side measures about 9.5 cm. ($3\frac{3}{4}$ in.); on the left side, about 12 cm. ($4\frac{3}{4}$ in.) in length.

FIG. 444.—THE COLLATERAL CIRCULATION AFTER LIGATURE OF THE COMMON CAROTID AND SUBCLAVIAN ARTERIES.

(A ligature is placed on the common carotid and on the third portion of the subclavian artery.)

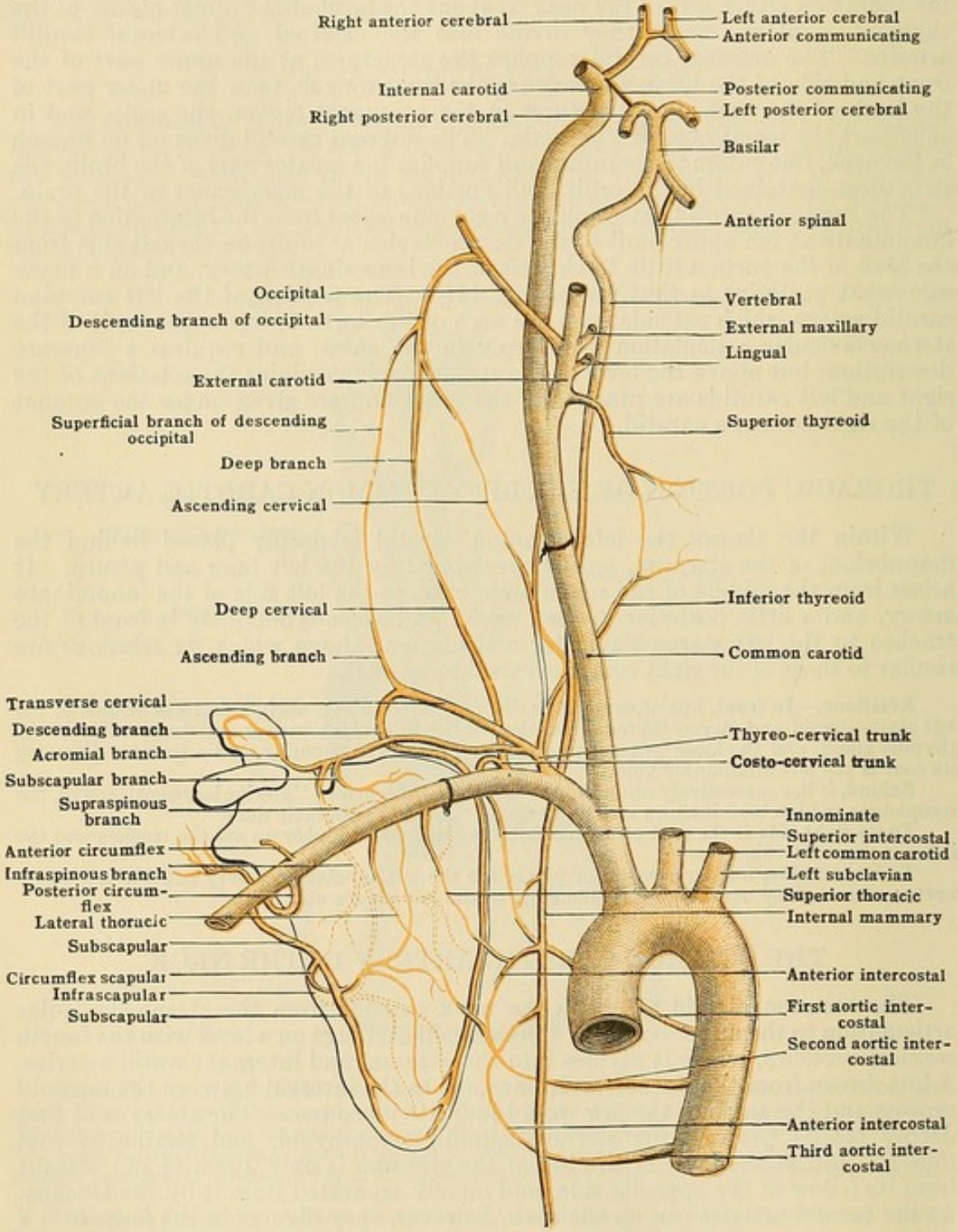

Relations.—In front the artery is covered by the skin, superficial fascia, platysma, and deep fascia, and is more or less overlapped by the sterno-mastoid muscle. At the lower part of the neck it is covered in addition by the sterno-hyoid and sterno-thyreoid muscles, and is crossed by the anterior jugular vein, and is often overlapped by the thyreoid gland. Opposite the cricoid cartilage it is crossed obliquely by the omo-hyoid muscle, and, above this spot, by the superior thyreoid vein, and the sterno-mastoid artery. Along the anterior border of the sterno-mastoid there is a communicating vein between the facial and anterior jugular veins, which, as it crosses the line of the carotid artery, is in danger of being wounded in the operation

of tying the carotid. The ramus descendens n. hypoglossi generally descends in front of the carotid sheath, being there joined by one or two communicating branches from the second and third cervical nerves. At times this nerve runs within the sheath. There are usually two lymphatic glands about the bifurcation of the artery. These are often found enlarged and infiltrated in cancer of the lip and tongue.

Behind, the common carotid lies on the longus colli and scalenus anterior below, and longus capitis (rectus capitis anterior major) above. Posterior to the artery, but in the same sheath, is the vagus nerve; and posterior to the sheath, the cervical sympathetic and the cervical

FIG. 445.—ARTERIES OF THE HEAD AND NECK. (After Toldt, "Atlas of Human Anatomy," Rebman, London and New York.)

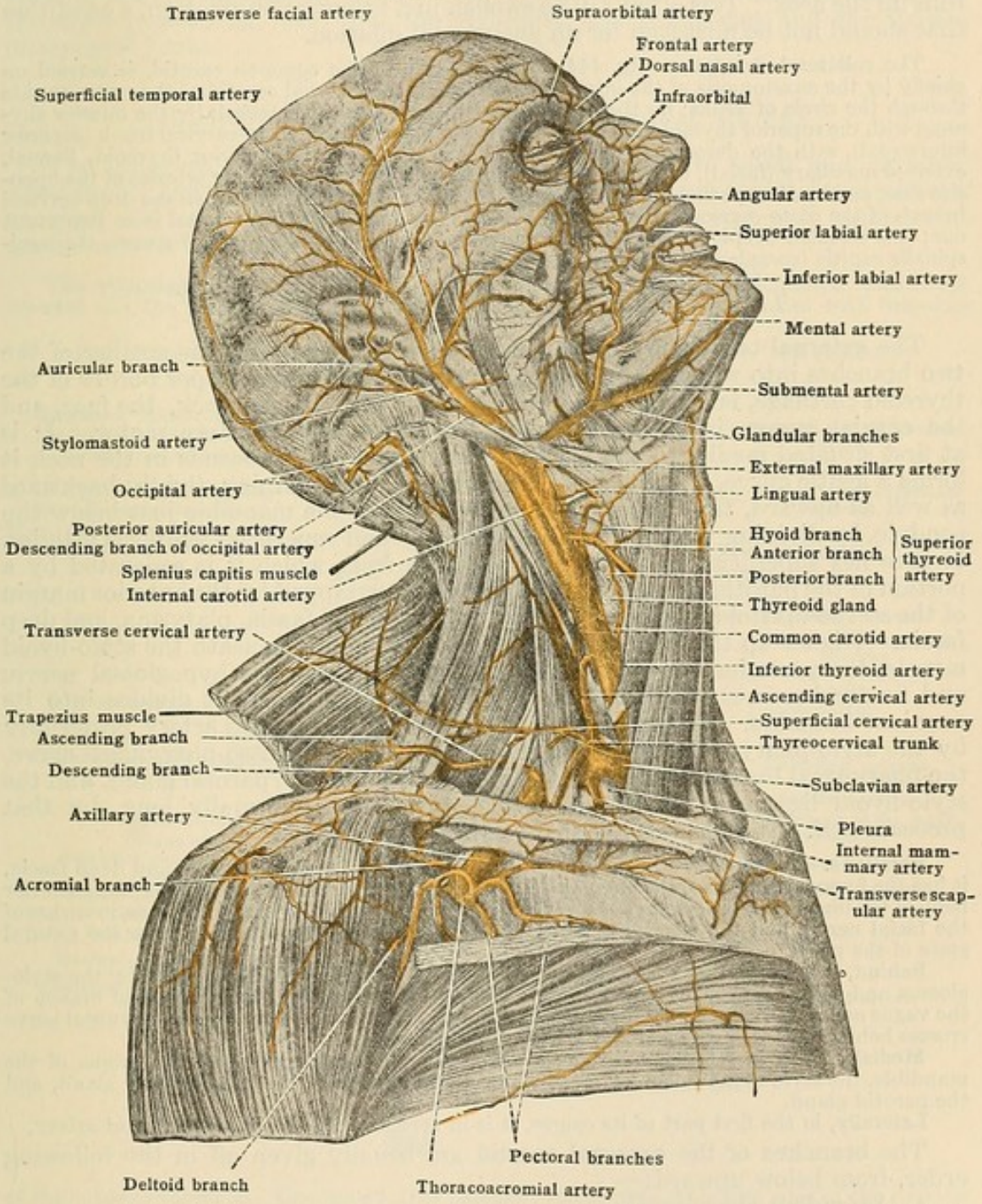

cardiac branches of the sympathetic and vagus nerves. At the lower part of the neck the inferior thyreoid artery courses obliquely behind the carotid, as does likewise the inferior (recurrent) laryngeal nerve.

Medially, from below upward, are the trachea and œsophagus, with the inferior (recurrent) laryngeal nerve in the groove between them, and the terminal branches of the inferior thyreoid artery, the lateral lobe of the thyreoid gland, the cricoid cartilage, the thyreoid cartilage, and the lower part of the pharynx. At the angle of bifurcation is the **carotid gland** [glomus caroticum].

Laterally are the internal jugular vein and the vagus nerve. On the right side, at the root of the neck, the vein diverges somewhat from the artery, leaving a space in which the vagus

nerve and vertebral artery are exposed. On the left side the vein approaches and somewhat overlaps the artery, thus leaving no interval corresponding to that on the right side.

The cricoid cartilage is, as a rule, taken as the centre of the incision in the operation for ligature of the common carotid artery. The incision is made in the line of the vessel parallel to the anterior margin of the sterno-mastoid muscle. The omo-hyoid forms one of the chief rallying points in the course of the operation for ligature of the artery above that muscle, the usual situation. The artery is found beating at the angle formed by the omo-hyoid with the sterno-mastoid.

Branches.—(1) External and (2) internal carotid arteries. The common carotid gives off no lateral branch, and consequently does not diminish in size as it runs up the neck. It is often a little swollen just below its bifurcation, a condition that should not be mistaken for an aneurismal dilation.

The **collateral circulation** (fig. 444), after ligature of the common carotid, is carried on chiefly by the anastomosis of the internal carotid with the internal carotid of the opposite side through the circle of Willis; by the vertebral with the opposite vertebral; by the inferior thyreoid with the superior thyreoid; by the deep cervical branch of the costo-cervical trunk (superior intercostal) with the descending branch of the occipital; by the superior thyreoid, lingual, external maxillary (facial), occipital, and temporal, with the corresponding arteries of the opposite side, and by the ophthalmic with the angular. The anastomosis between the deep cervical branch of the costo-cervical trunk with the descending branch of the occipital is an important one; it is situated deeply at the back of the neck, and is to be found lying between the semispinalis capitis (complexus) and cervicis muscles.

THE EXTERNAL CAROTID ARTERY

The **external carotid** artery [a. carotis externa] (fig. 445), the smaller of the two branches into which the common carotid divides at the upper border of the thyreoid cartilage, is distributed to the anterior part of the neck, the face, and the cranial region, including the skin, the bones, and the dura mater. It is at first situated medial to the internal carotid; but as it ascends in the neck it forms a gentle curve, with its convexity forward, and, running slightly backward as well as upward, terminates opposite the neck of the mandible just below the condyle, by dividing into the internal maxillary and superficial temporal arteries. It here lies superficial to the internal carotid, from which it is separated by a portion of the parotid gland. At its origin it is overlapped by the anterior margin of the sterno-mastoid, and is covered by the superficial fascia, platysma, and deep fascia. Higher up the neck it is deeply placed, passing beneath the stylo-hyoid muscle, the posterior belly of the digastric muscle, and the hypoglossal nerve; and finally becomes embedded in the parotid gland, where it divides into its terminal branches. It is separated from the internal carotid artery posteriorly by the stylo-pharyngeus and stylo-glossus muscles, the glosso-pharyngeal nerve, the pharyngeal branch of the vagus nerve, a portion of the parotid gland, and the stylo-hyoid ligament; or, if the styloid process is abnormally long, by that process itself. It measures about 6.5 cm. ($2\frac{3}{5}$ in.).

Relations.—In front, in addition to the skin, superficial fascia, platysma, and deep fascia, it has the hypoglossal nerve, the lingual, common facial and posterior facial veins, the posterior belly of the digastric and stylo-hyoid muscles, the superior cervical lymphatic glands, branches of the facial nerve, and the parotid gland. The sterno-mastoid also overlaps it in the natural state of the parts.

Behind, it is in relation with the internal carotid, from which it is separated by the stylo-glossus and stylo-pharyngeus muscles, the glosso-pharyngeal nerve, the pharyngeal branch of the vagus nerve, the stylo-hyoid ligament, and the parotid gland. The superior laryngeal nerve crosses behind both the external and internal carotid arteries.

Medially, it is in relation with the hyoid bone, the pharyngeal wall, the ramus of the mandible, the stylo-mandibular ligament which separates it from the submaxillary gland, and the parotid gland.

Laterally, in the first part of its course, it is in contact with the internal carotid artery.

The **branches of the external carotid** are usually given off in the following order, from below upward:—

1. Ascending pharyngeal.
2. Superior thyreoid.
3. Lingual.
4. External maxillary (facial).
5. Sternocleidomastoid.
6. Occipital.
7. Posterior auricular.
8. Superficial temporal.
9. Internal maxillary.

1. THE ASCENDING PHARYNGEAL ARTERY

The **ascending pharyngeal** artery [a. pharyngea ascendens] (fig. 446) is usually the first or second branch of the external carotid. Occasionally it comes off at the bifurcation of the common carotid from the common carotid itself. It is a long slender vessel which runs deeply seated up the neck to the base of the skull, having the walls of the pharynx and the tonsil **medially,** the internal carotid artery **laterally,** and the vertebral column, the longus capitis (rectus capitis anterior major), and the sympathetic nerve **posteriorly. In front** it is crossed by the stylo-glossus (fig. 446) and the stylo-pharyngeus muscles and the glosso-pharyngeal nerve.

Branches of the Ascending Pharyngeal Artery

The branches of the ascending pharyngeal artery are small and variable. They supply the longus and rectus capitis muscles, the upper cervical sympathetic ganglion and adjacent lymph-nodes, as well as the pharynx, soft palate, ear, cranial nerves, and meninges.

The **pharyngeal** branches [rami pharyngei] supply the superior and middle constrictor muscles and the mucous membrane lining them. These vessels anastomose with branches

Fig. 446.—Scheme of Right Ascending Pharyngeal Artery. (Walsham.)
The internal carotid artery is hooked aside.

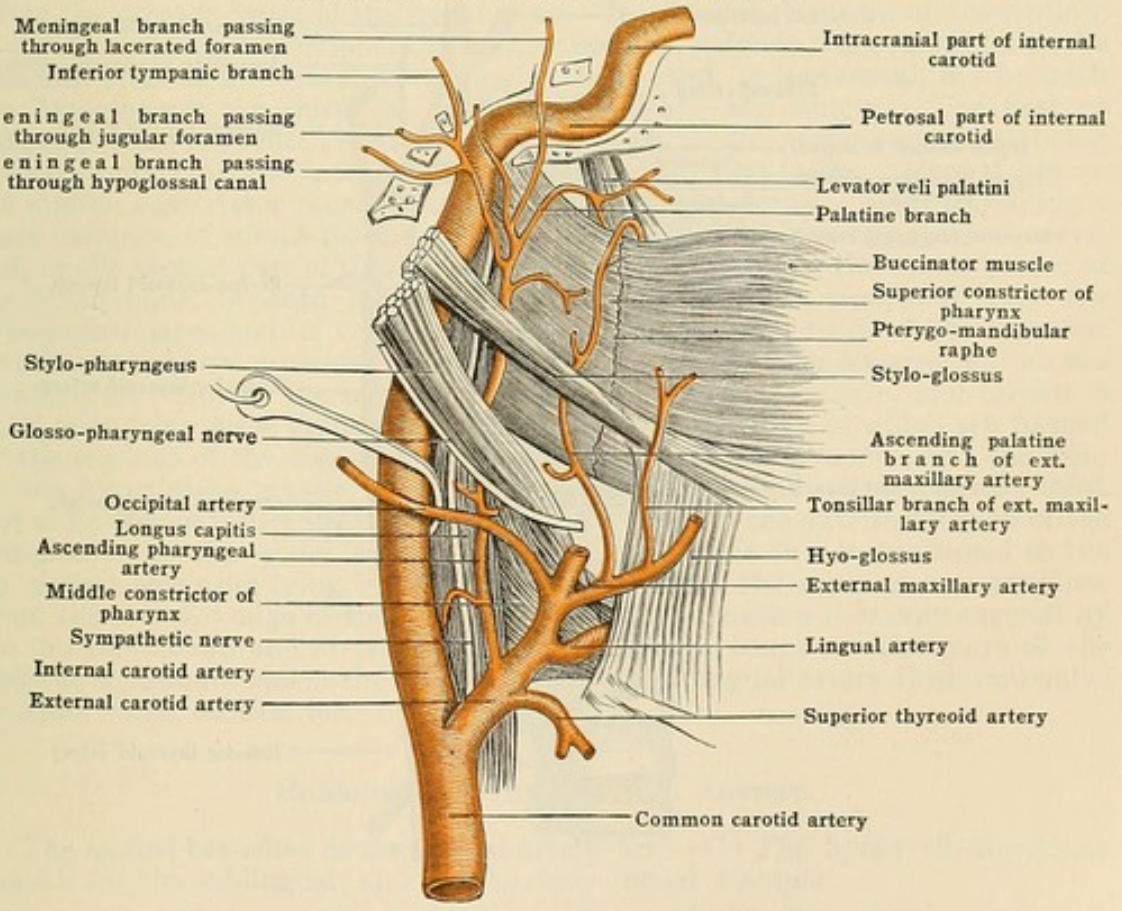

of the superior thyreoid. One branch (the **palatine**) passes over the upper edge of the superior constrictor to the soft palate and its muscles. This branch follows a course similar to that taken by the ascending palatine artery, and when the latter is small may take its place. It generally gives off small twigs to the Eustachian tube and tonsil. The **inferior tympanic** artery [a. tympanica inferior] accompanies the tympanic branch of the glosso-pharyngeal nerve through the tympanic canaliculus into the tympanum, and anastomoses with the other tympanic arteries. The **posterior meningeal** artery [a. meningea posterior] is distributed to the membranes of the brain. Some twigs pass with the jugular vein through the jugular foramen into the cranium, and supply the dura mater in the posterior fossa of the skull. Others occasionally reach the same fossa through the hypoglossal (anterior condyloid) canal in company with the hypoglossal nerve; while others pass through the cartilage of the lacerated foramen and supply the middle fossa of the skull.

2. THE SUPERIOR THYREOID ARTERY

The **superior thyreoid** artery [a. thyreoidea superior] (figs. 445, 447) arises from the front of the external carotid a little above the origin of that vessel, and, coursing forward, medially, and then downward, in a tortuous manner, supplies the depressor muscles of the hyoid bone, the larynx, the thyreoid gland, and the lower part of the pharynx. The artery at first runs forward and a little upward, just beneath the greater cornu of the hyoid bone. In this part of its course it lies in the superior carotid triangle, and is quite superficial, being covered only with the integument, fascia, and platysma. It next turns downward, and passes beneath the omo-hyoid, sterno-hyoid, and sterno-thyreoid muscles, and ends at the upper part of the thyreoid gland by breaking up into terminal glandular branches. The superior thyreoid vein passes beneath the artery on its way to the internal jugular vein. The superior thyreoid is the artery most commonly divided in cases of suicidal wounds of the throat.

Branches of the Superior Thyreoid Artery

The named **branches of the superior thyreoid artery** are:—(1) The hyoid; (2) the sterno-mastoid; (3) the superior laryngeal; (4) the crico-thyreoid; (5) anterior; (6) posterior; and (7) glandular.

Fig. 447.—Scheme of Left Superior Thyreoid Artery. (Walsham.)

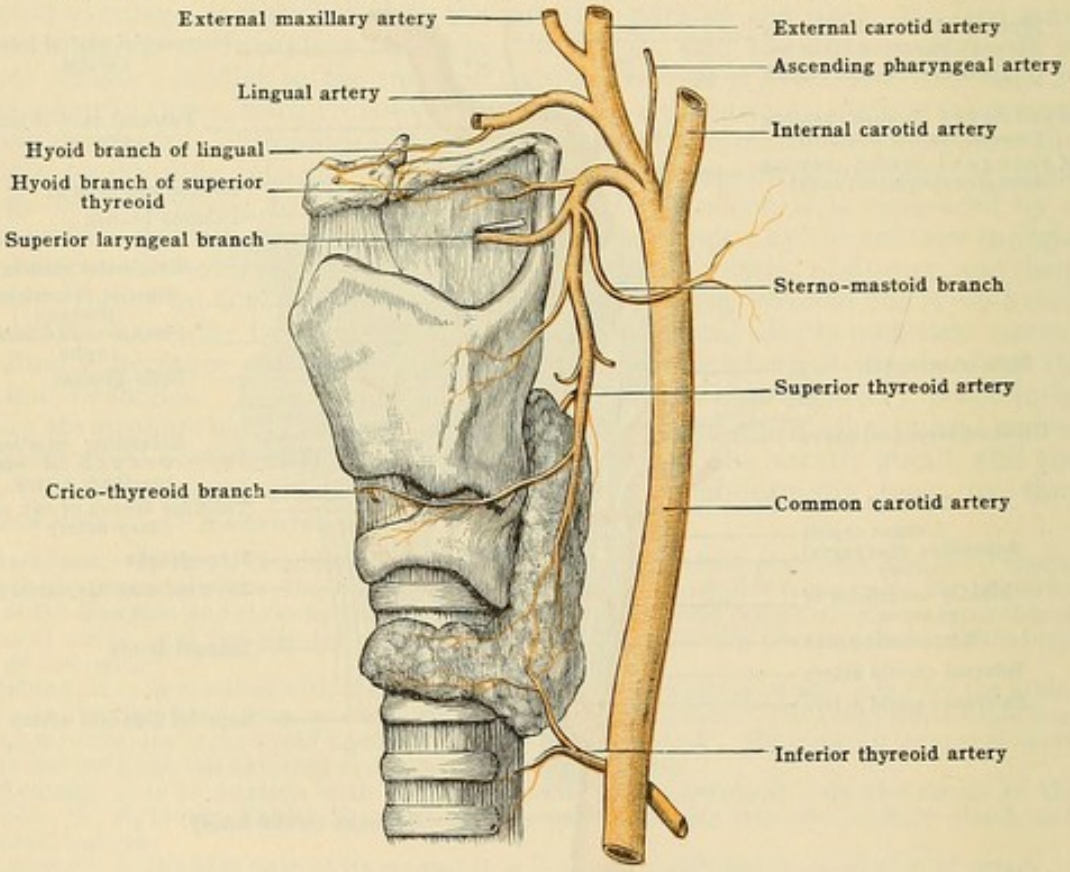

(1) The **hyoid** [ramus hyoideus] is usually a small twig which passes along the lower border of the hyoid bone, lying on the thyreo-hyoid membrane under cover of the thyreo-hyoid and sterno-hyoid muscles. It supplies the infra-hyoid bursa and the thyreo-hyoid muscle, and anastomoses with its fellow of the opposite side, and with the hyoid branch of the lingual. When the latter artery is small, the hyoid branch of the superior thyreoid is usually comparatively large, and *vice versa*.

(2) The **sterno-mastoid** [ramus sternocleidomastoideus] (fig. 447) courses downward and backward across the carotid sheath, and entering the sterno-mastoid supplies the middle portion of that muscle. It gives off slender twigs to the thyreo-hyoid, sterno-hyoid, and omo-hyoid muscles, and the platysma and integuments covering it. At times the vessel arises directly from the external carotid. It lies usually somewhere in the upper part of the incision for tying the common carotid above the omo-hyoid muscle.

(3) The **superior laryngeal** [a. laryngea superior] (fig. 447) passes medially beneath the

thyreo-hyoid muscle, and, perforating the thyreo-hyoid membrane along with the internal branch of the superior laryngeal nerve, supplies the intrinsic muscles and mucous lining of the larynx. Its further distribution within the larynx is given with the description of that organ. This branch sometimes arises from the external carotid direct. It may enter the larynx by passing through a foramen in the thyreoid cartilage.

(4) The **crico-thyreoid** [ramus cricothyreoideus] passes across the crico-thyreoid membrane immediately beneath the lower border of the thyreoid cartilage. It anastomoses with its fellow of the opposite side, and usually sends a small branch through the membrane into the interior of the larynx. Occasionally a considerable twig descends over the cricoid cartilage to enter the isthmus of the thyreoid gland. The crico-thyreoid has, however, frequently been seen of comparatively large size—once as large as the radial, and crossing the membrane obliquely. In order to avoid injuring the crico-thyreoid artery in the operation of laryngotomy, it is usual, if the operation has to be done in a hurry, to make the incision through the crico-thyreoid membrane in a transverse direction, and as near to the cricoid cartilage as possible.

(5) The **anterior** branch [ramus anterior] is the terminal branch supplying the isthmus and the neighbouring part of the lateral lobe of the thyreoid gland.

(6) The **posterior** branch [ramus posterior], the other terminal, supplies the posterior part of the lateral lobe, and sends branches to the inferior constrictor of the pharynx and to the œsophagus. It anastomoses with the ascending branches of the inferior thyreoid artery.

(7) The **glandular** branches [rami glandulares] are the ultimate twigs, arising from the anterior and posterior terminal branches, for the supply of the thyreoid gland.

3. THE LINGUAL ARTERY

The **lingual** artery [a. lingualis] (fig. 448) arises from the front of the external carotid, between the superior thyreoid and external maxillary (facial) arteries, often as a common trunk with the latter vessel, and nearly opposite or a little below the greater cornu of the hyoid bone. It may, for purposes of description, be divided into three portions: the **first,** or **oblique,** extends from its origin to the posterior edge of the hyo-glossus muscle; the **second,** or **horizontal,** lies beneath the hyo-glossus; the **third,** or **ascending**, beneath the tongue. The **first** or **oblique portion** is situated in the superior carotid triangle, and is superficial, being covered merely by the integument, platysma, and deep fascia. Here it lies on the middle constrictor muscle and superior laryngeal nerve. After ascending a short distance, it curves downward and forward beneath the hypoglossal nerve, and, in the **second part of its course,** runs horizontally along the upper border of the hyoid bone, beneath the hyo-glossus, by which it is separated from the hypoglossal nerve and its vena comitans, and the posterior belly of the digastric and the stylo-hyoid muscles. In this part of its course it lies successively on the middle constrictor of the pharynx and the genio-glossus muscle, and crosses a small triangular space known as 'Lesser's triangle,' the sides of which are formed by the tendons of the digastric, the base by the hypoglossal nerve, and the floor by the hyo-glossus muscle, in which situation it is usually tied. In the **third part of its course** it ascends tortuously, usually beneath the anterior margin of the hyo-glossus, to the under surface of the tongue, and is thence continued to the tip of that structure lying between the lingualis and the genio-glossus muscles. From the anterior edge of the hyo-glossus to its termination it is only covered by the mucous membrane of the under surface of the tongue. This part of the vessel is sometimes called the ranine artery. The lingual artery is accompanied by small venæ comitantes.

Branches of the Lingual Artery

The named **branches of the lingual artery** are:—(1) The hyoid; (2) the dorsal lingual; (3) the sublingual; and (4) the deep lingual (ranine).

(1) The **hyoid** branch [ramus hyoideus] (fig. 448) is a small vessel which arises from the first part of the lingual, and courses along the upper border of the hyoid bone, superficial to the hyo-glossus, but beneath the insertion of the posterior belly of the digastric and the stylo-hyoid. It anastomoses with its fellow of the opposite side, and with the hyoid branch of the superior thyreoid artery, and supplies the contiguous muscles.

(2) The **dorsalis linguæ** (fig. 448) arises from the second portion of the lingual artery, usually under cover of the posterior edge of the hyo-glossus muscle. It ascends to the back of the dorsum of the tongue, and, dividing into branches, supplies the mucous membrane on each side of the **V** formed by the vallate papillæ. It also supplies the pillars of the fauces and the tonsil, where it anastomoses with the other faucial and tonsillar arteries. Instead of a single artery, as above described, there may be several small vessels running directly to the parts mentioned. The artery anastomoses in the mucous membrane by very small branches with the

vessel of the opposite side; but the anastomosis is so minute that when one lingual artery is injected the injection merely passes across to the opposite side at the tip of the tongue; and when the tongue is divided accurately in the middle line, as in the removal of one-half of that organ, practically no hæmorrhage occurs.

(3) The **sublingual** artery [a. sublingualis] (fig. 448) usually comes off from the lingual at the anterior margin of the hyo-glossus. It passes beneath the mylo-hyoid to the sublingual gland, which it supplies, and finally it usually anastomoses with the submental artery, a branch of the external maxillary (facial). It also supplies branches to the side of the tongue, and gives off a terminal twig, which anastomoses beneath the mucous membrane of the floor of the mouth (to which it also gives twigs) with the artery of the opposite side. The **artery of the frænum** is usually derived from this vessel (fig. 448).

(4) The **deep lingual** [a. profunda linguæ], the termination of the lingual, courses forward beneath the mucous membrane, on the under surface of the tongue, to the tip. It lies lateral to the genio-glossus, between that muscle and the inferior lingualis, and is accompanied by the lingual vein and terminal branch of the lingual nerve. It follows a very tortuous course, so that it is not stretched when the tongue is protruded. Branches are given off from it to the contiguous muscles and mucous membrane. Near the tip of the tongue it communicates with its fellow of the opposite side, as shown by the fact that when the lingual artery of one side is injected, the injection fluid passes into the branches of the artery of the other side.

FIG. 448.—SCHEME OF THE RIGHT LINGUAL ARTERY. (Walsham.)

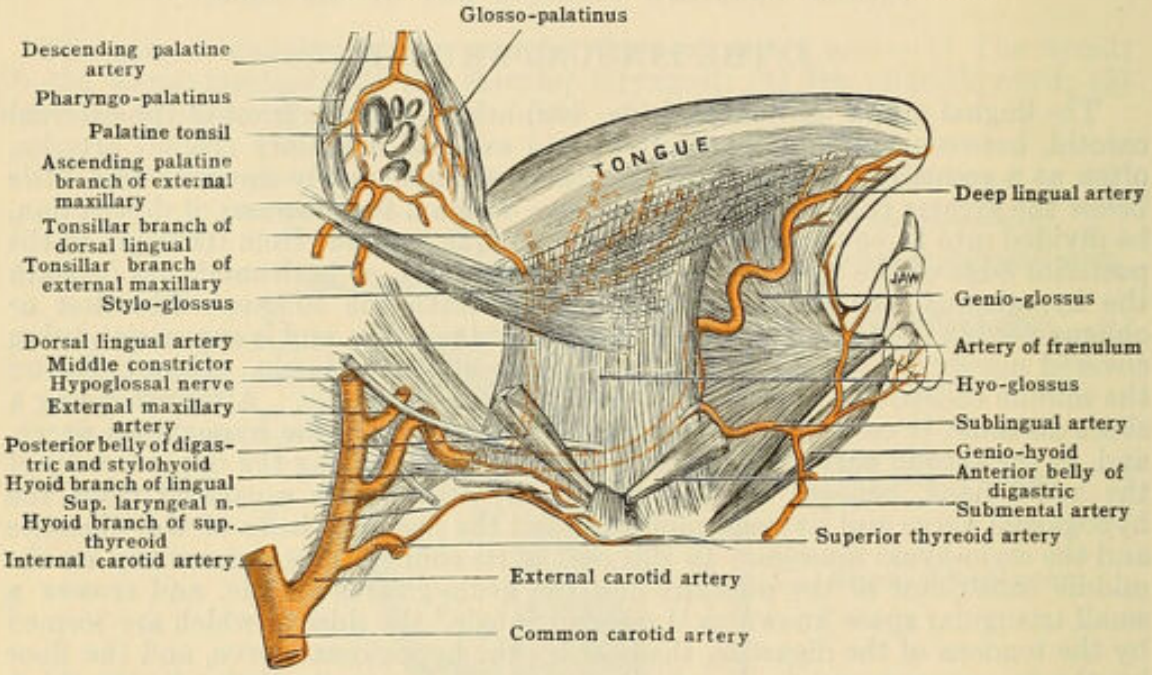

4. THE EXTERNAL MAXILLARY (FACIAL) ARTERY

The **external maxillary** or **facial** artery [a. maxillaris externa] (fig. 449) arises immediately above the lingual from the fore part of the external carotid, at times as a common trunk with the lingual. It courses forward and upward in a tortuous manner to the mandible, and, passing over the body of this bone at the anterior edge of the masseter muscle, winds obliquely upward and forward over the face to the medial angle of the eye, where it anastomoses, under the name of the **angular artery,** with the dorsal nasal branch of the ophthalmic. It is usually divided into two portions—the cervical and the facial.

The **cervical portion** (fig. 449) ascends tortuously from its origin from the external carotid upward and forward beneath the posterior belly of the digastric and stylo-hyoid muscles, and usually also beneath the hypoglossal nerve, and then, making a turn, runs horizontally forward for a short way beneath the jaw, either imbedded in or lying under the submaxillary gland. It has here the mylo-hyoid and stylo-glossus beneath it. On leaving the cover of the gland it forms a loop passing first downward and then upward over the lower border of the jaw immediately in front of the masseter muscle, where it is superficial, being merely covered by the integument and platysma. Here it can be felt beating, and can be readily compressed. In the above course it lies in the posterior part of the submaxillary triangle, and, in addition to the structures already mentioned as crossing it, is covered by the skin, superficial fascia, and platysma, and by one or two submaxillary lymphatic nodes. The vein is separated from the artery by the

submaxillary gland, the posterior belly of the diagastric muscle, the stylo-hyoid muscle, and the hypoglossal nerve.

The **facial portion** (fig. 449) of the external maxillary artery ascends tortuously forward toward the angle of the mouth, passing under the platysma (risorius), the zygomatic muscle, the zygomatic head of the quadratus labii superioris (zygomaticus minor), and the zygomatic and buccal branches of the facial nerve. It here lies upon the jaw and the buccinator muscle. Thence it courses upward by the side of the nose toward the medial angle of the eye, passing over or under the infraorbital and angular heads of the quadratus labii superioris, and under the infraorbital branches of the facial nerve. It lies on the caninus (levator anguli oris) and the infraorbital branches of the fifth nerve. The anterior facial vein takes a straighter course than the external maxillary artery, is separated from it by the zygomatic muscle, and lies lateral to it.

Branches of the External Maxillary Artery of the Neck

The **branches of the external maxillary artery in the neck** are:—(1) The ascending palatine; (2) the tonsillar; (3) the glandular; (4) the submental.

(1) The **ascending palatine** [a. palatina ascendens] (figs. 448, 449)—the first branch of the external maxillary, but often a distinct branch of the external carotid—ascends between the internal and external carotids, and then between the stylo-glossus and stylo-pharyngeus muscles, and on reaching the wall of the pharynx is continued upward between the superior constrictor and internal pterygoid muscles toward the base of the skull as high as the levator veli palatini, where it divides into two branches, a palatine and a tonsillar. One of these branches, the **palatine,** passes with the levator veli palatini over the curved upper margin of the superior constrictor to the soft palate, where it is distributed to the tissues constituting that structure, and anastomoses with its fellow of the opposite side and with the descending palatine branch of the internal maxillary, and the ascending pharyngeal, which vessel often to a great extent supplies the place of this artery. The other branch, the **tonsillar,** supplies the tonsil and the Eustachian tube, anastomosing with the tonsillar branch of the external maxillary (facial) and ascending pharyngeal arteries. The ascending palatine artery supplies the muscles between which it runs on its way to the palate.

(2) The **tonsillar** branch [ramus tonsillaris] (fig. 449) ascends between the stylo-glossus and internal pterygoid muscles to the level of the tonsil, where it perforates the superior constrictor muscle of the pharynx, and ends in the tonsil, anastomosing with the tonsillar branch of the ascending palatine and with the other tonsillar arteries (fig. 448). It gives branches also to the root of the tongue.

(3) The **glandular** branches [rami glandulares] are distributed to the submaxillary gland as the artery is passing through or beneath that structure. A small twig from one of these branches usually supplies the submaxillary (Wharton's) duct.

(4) The **submental** artery [a. submentalis] (fig. 449) comes off from the external maxillary as the latter vessel lies under cover of the submaxillary gland, and, passing forward on the mylo-hyoid muscle between the base of the jaw and the anterior belly of the digastricus, supplies these structures and the overlying platysma and integuments. It anastomoses with the sublingual artery. The external maxillary also supplies the adjacent muscles of the neck.

Branches of the External Maxillary Artery on the Face

From the **lateral** or **concave** side of the artery are given off branches which supply the masseter muscle and anastomose with the masseteric and buccinator branches of the internal maxillary artery, the transverse facial artery, and the infraorbital arteries.

From the **medial** or **convex** side the following larger and named vessels are given off:—(1) The inferior labial; (2) the superior labial; and (3) the angular.

(1) The **inferior labial** artery [a. labialis inferior] arises at the angle of the mouth and runs in the under lip within the substance of the orbicularis oris, close to the mucous membrane. It anastomoses with the artery of the other side. Frequently an additional branch passes from the external maxillary to the lower lip.

(2) The **superior labial** artery [a. labialis superior] arising from the facial a little higher than the inferior, passes forward beneath the zygomaticus, and then, like the inferior labial, courses tortuously along the lower margin of the upper lip between the orbicularis oris and the mucous membrane, about 1.2 cm. ($\frac{1}{2}$ in.) from the junction of the mucous membrane and the skin. It is usually larger than the inferior labial. It anastomoses with its fellow of the opposite side, and gives off a small artery to the septum—**arteria septi nasi.** Compression of this vessel will sometimes control hæmorrhage from the nose.

(3) The **angular** artery [a. angularis] (fig. 449) is the terminal branch of the external maxillary. It supplies the nose and anastomoses at the medial angle of the eye with the dorsal nasal branch of the ophthalmic. It is accompanied by the anterior descending vein from the scalp.

It lies to the medial side of the lacrimal sac and supplies that structure and the lower part of the orbicularis oculi, beneath which a branch anastomoses with the infraorbital artery. The situation of the artery to the medial side of the lacrimal sac should be borne in mind in opening a lacrimal abscess.

FIG. 449.—SCHEME OF THE RIGHT EXTERNAL MAXILLARY ARTERY. (Walsham.)

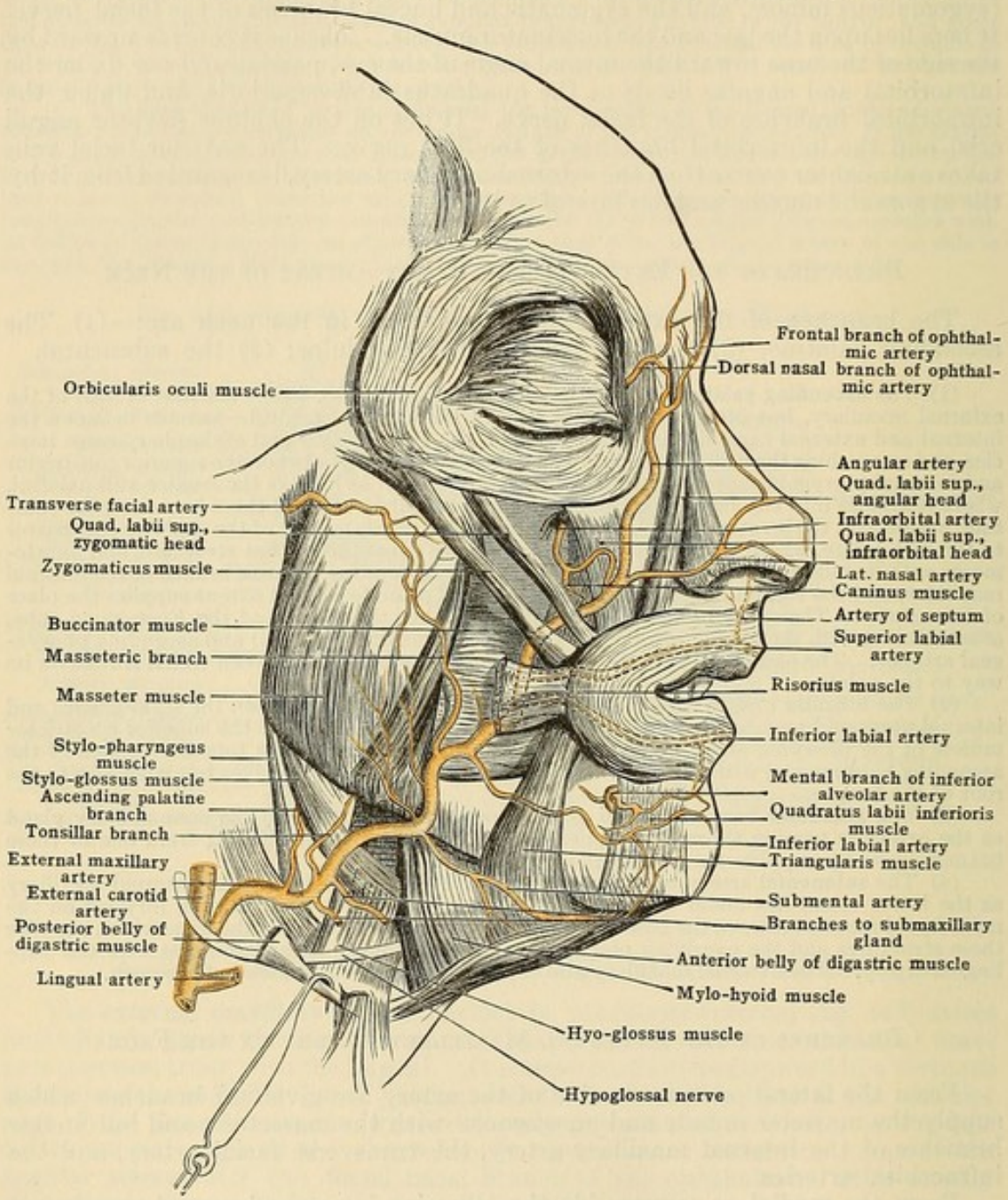

5. THE STERNOCLEIDOMASTOID

The **sternocleidomastoid** artery [a. sternocleidomastoidea] arises from the posterior side of the external carotid at the point where the carotid is crossed by the digastric muscle. It is distributed to the sternocleidomastoid muscle, and is frequently represented by one of the muscular branches of the occipital artery.

6. THE OCCIPITAL ARTERY

The **occipital** artery [a. occipitalis] (fig. 450) is usually a vessel of considerable size. It comes off from the posterior part of the external carotid opposite the external maxillary (facial), or else a little higher than that vessel. It then winds

upward and backward to the interval between the mastoid process of the temporal bone and transverse process of the atlas, and, after running horizontally backward in a groove on the mastoid portion of the temporal bone, again turns upward, and ends by ramifying in the scalp over the back of the skull, extending as far forward as the vertex.

The vessel may be divided into three parts—viz., that anterior to the sterno-mastoid muscle; that beneath the sterno-mastoid; and that posterior to the sterno-mastoid.

In the **first part of its course** the occipital artery is covered by the integuments and fascia, and is more or less overlapped by the posterior belly of the digastric muscle, the parotid gland, and posterior facial (temporo-maxillary) vein. It is crossed by the hypoglossal nerve as the latter winds forward over the carotid vessels to reach the tongue. It successively crosses in front of the internal carotid artery, the hypoglossal nerve, the vagus nerve, the internal jugular vein, and the spinal accessory nerve.

In the **second part of its course** it sinks deeply beneath the digastric muscle into the interval between the mastoid process of the temporal bone and the transverse process of the atlas. It is here covered by the sterno-mastoid, splenius capitis, and longissimus capitis muscles and by the origin of the digastric; and lies, first on the rectus capitis lateralis, which separates it from the vertebral artery, then in a groove, the occipital groove, on the mastoid portion of the temporal bone, and then on the insertion of the superior oblique muscle.

In the **third part of its course** it enters the triangular interval formed by the diverging borders of the splenius capitis and the superior nuchal line of the occipital bone. Here it lies beneath the integuments and the aponeurosis uniting the occipital attachments of the sterno-mastoid and trapezius, and rests upon the semi-spinalis capitis (complexus) just before the insertion of that muscle into the occipital bone. In company with the greater occipital nerve, it perforates either this aponeurosis, or less often the posterior belly of the epicranius (occipito-frontalis), and follows roughly, but in a tortuous course, the line of the lamboid suture, lying between the integument and the cranial aponeurosis. In the scalp it divides into several large branches, which ramify over the back of the skull and reach as far forward as the vertex. They anastomose with the corresponding branches of the opposite side, and with the posterior auricular and the superficial temporal arteries.

Branches of the Occipital Artery (Fig. 450)

The **branches of the occipital artery** are:—(1) The muscular; (2) the meningeal; (3) the auricular; (4) the mastoid; (5) the descending; (6) the occipital.

(1) The **muscular** branches [rami musculares] (fig. 450) supply the sternocleidomastoid and adjacent muscles. One of these branches may take the place of the sterno-mastoid branch of the external carotid. The hypoglossal nerve then, as a rule, loops round it instead of round the occipital.

(2) The **meningeal** branches [rami meningei] (fig. 450), one or more in number, are long slender vessels which leave the occipital artery as it crosses the internal jugular vein and, ascending along the vessel, pass with it through the jugular or hypoglossal foramen, and are distributed to the dura mater lining the posterior fossa of the skull.

(3) The **auricular** branch [ramus auricularis] ascends over the mastoid process to the back of the ear, and supplies the pinna and concha. It sometimes takes the place of the posterior auricular artery (fig. 450).

(4) The **mastoid** branch [ramus mastoideus] is a small twig that passes into the skull through the mastoid foramen, supplying the dura mater, the diploë, the walls of the transverse sinus, and the mastoid cells.

(5) The **descending** or **princeps cervicis** [ramus descendens] (fig. 450), the largest of the branches of the occipital, arises from that artery just before it emerges from beneath the splenius, and, descending for a short distance between the splenius and semi-spinalis capitis (complexus), divides into a superficial and a deep branch. The **superficial branch** perforates the splenius, supplies branches to the trapezius, and anastomoses with the ascending branch of the transverse cervical artery. The **deep branch** passes downward between the semi-spinalis capitis (complexus) and colli, and anastomoses with the deep cervical branch of the costo-cervical trunk and with branches of the vertebral. The anastomoses between the above-mentioned arteries form important collateral channels after ligature of the common carotid and subclavian arteries (fig. 444).

(6) The **occipital** or **terminal** branches [rami occipitales] (fig. 450), usually two in number, named from their position medial and lateral, ramify over the scalp, and have already been described. The medial branch generally gives off a twig which enters the parietal foramen (parietal artery) and is distributed to the dura mater. The occipital artery may also give off the stylo-mastoid, the posterior auricular, or the ascending pharyngeal arteries.

7. THE POSTERIOR AURICULAR ARTERY

The **posterior auricular** artery [a. auricularis posterior] (fig. 450) arises from the posterior part of the external carotid artery, usually immediately above the

posterior belly of the digastric, about the level of the tip of the styloid process. Occasionally it arises under cover of the digastric, quite close to, or as a common trunk with, or as a branch of, the occipital. It courses upward and backward in the parotid gland to the notch between the margin of the external auditory meatus and the mastoid process, where it divides into branches. In this course it rests on the styloid process, crosses the spinal accessory nerve, and is crossed by the facial nerve.

FIG. 450.—SCHEME OF LEFT OCCIPITAL AND POSTERIOR AURICULAR ARTERIES. (Walsham.)

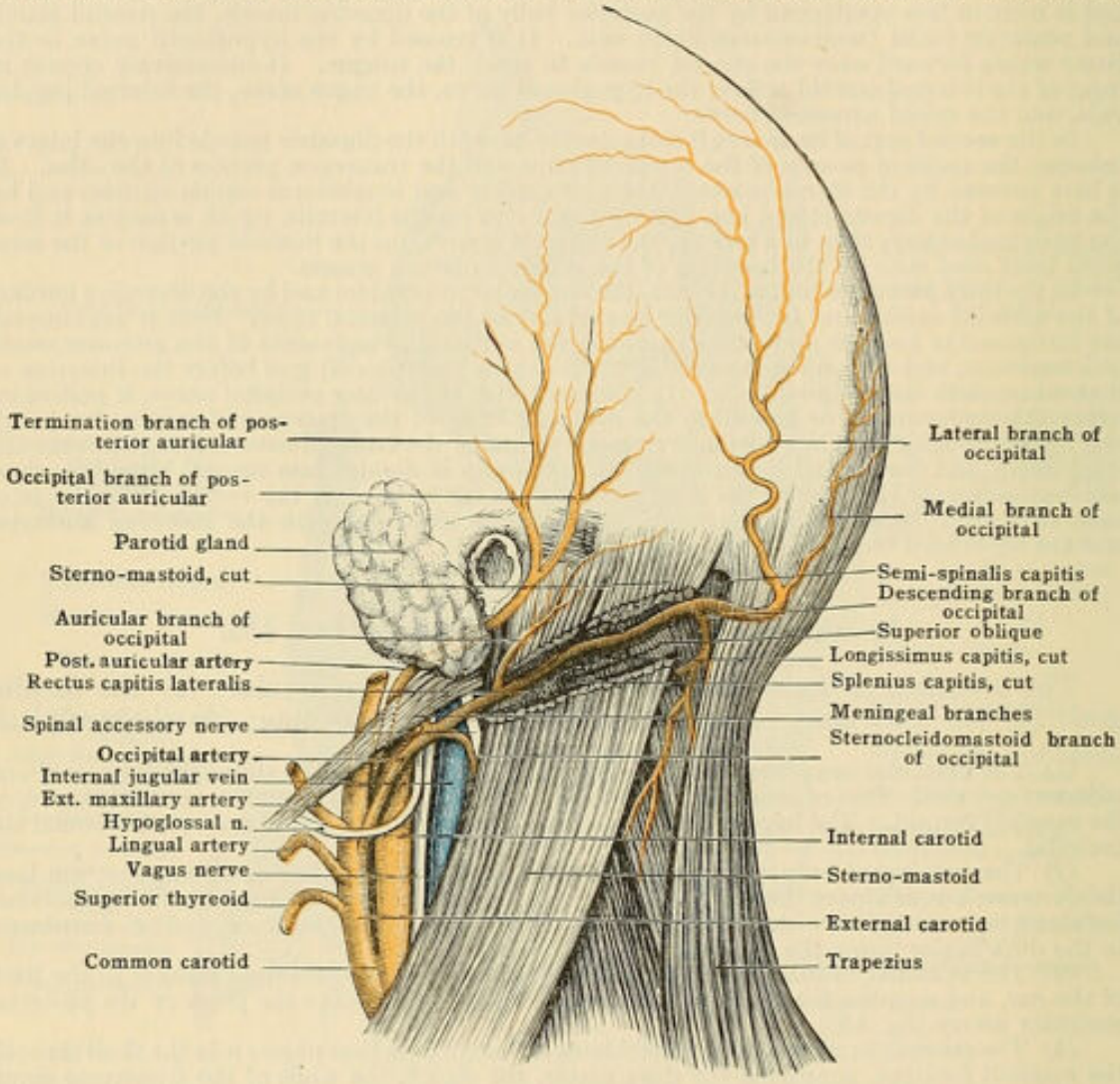

BRANCHES OF THE POSTERIOR AURICULAR ARTERY

The **branches of the posterior auricular artery** are:—(1) the stylo-mastoid; (2) the auricular; (3) the occipital (fig. 450).

The posterior auricular also gives branches to the parotid gland and the adjacent muscles, namely, the posterior belly of the digastric, the stylo-hyoid, and auricularis posterior (retrahens aurem).

(1) The **stylo-mastoid** artery [a. stylomastoidea] comes off from the posterior auricular artery just before it reaches the notch between the margin of the external auditory meatus and the mastoid process, and, following the facial nerve upward, enters the stylo-mastoid foramen in the temporal bone. In the facial canal (aqueduct of Fallopius) it gives off the following named twigs:—(*a*) **meatal,** to the external auditory meatus; (*b*) **mastoid** [rami mastoidei], to the mastoid cells and tympanic antrum; (*c*) **stapedic** [ramus stapedius], which runs forward to the stapedius muscle; (*d*) **posterior tympanic** [a. tympanica posterior], which anastomoses with the anterior tympanic branch of the internal maxillary, forming with it in the fœtus a vascular circle around the membrana tympani; (*e*) **vestibular,** to the vestibule and semicircular canals; and (*f*) **terminal,** a small twig which leaves the facial canal (by the hiatus) with the great superficial petrosal nerve, and anastomoses with the superior petrosal branch of the middle meningeal artery.

(2) The **auricular** branch [ramus auricularis] passes upward behind the ear and beneath the auricularis posterior (retrahens aurem), supplying the medial surface of the pinna and adjacent

skin. It anastomoses with the posterior branch of the superficial temporal artery. The branches to the pinna not only supply the back of that structure, but some perforate the cartilage, and others turn over its free margin to supply the lateral surface; there they anastomose with the anterior auricular branches from the temporal.

(3) The **occipital** branch [ramus occipitalis] passes upward and backward, crossing the aponeurotic insertion of the sterno-mastoid muscle. It gives a branch to the posterior belly of the epicranius (occipito-frontalis), and anastomoses with the occipital artery.

8. THE SUPERFICIAL TEMPORAL ARTERY

The **superficial temporal** artery [a. temporalis superficialis] (fig. 445), is the smaller of the two terminal divisions of the external carotid, though apparently the direct continuation of that vessel. It arises opposite the neck of the mandible and, under cover of the parotid gland, passes upward in the interval between the condyle and the external auditory meatus to the zygoma, lying on the capsule of the temporo-mandibular joint. Thence it ascends over the posterior zygomatic root and the temporal aponeurosis for about 4 or 5 cm. (1½ or 2 in.), and there divides into frontal and parietal branches. It is surrounded by a dense plexus of sympathetic nerves, and is accompanied by the auriculo-temporal nerve, which lies beneath and generally a little behind it. It is crossed by the temporal and zygomatic branches of the facial nerve, and by the auricularis anterior (attrahens aurem) muscle. As it crosses the zygoma it can be readily felt pulsating immediately in front of the ear, and in this situation can be compressed against the bone. It is here quite superficial, being merely covered by the integuments and a delicate prolongation from the cervical fascia (fig. 445).

Branches of the Superficial Temporal Artery

The **branches of the superficial temporal** artery are:—(1) The parotid; (2) the transverse facial; (3) the anterior auricular; (4) the zygomatico-orbital; (5) the middle temporal; (6) the frontal; (7) the parietal.

(1) The **parotid** branches [rami parotidei] are small twigs given off in the substance of the parotid gland.

(2) The **transverse facial** [a. transversa faciei] is the largest branch of the temporal. It sometimes arises from the external carotid as a common trunk with the temporal. It is at first deeply seated in the substance of the parotid gland, but soon emerging from the upper part of the anterior border of the gland known, courses transversely across the masseter muscle about a finger's breadth below the zygoma. The parotid duct runs below it, and the zygomatic (infraorbital) branches of the facial nerve above it. It supplies the parotid gland, the masseter muscle, and the skin of the face, and anastomoses with the infraorbital, the buccal, and the external maxillary (facial) arteries.

(3) The **anterior auricular** branches [rami auriculares anteriores] are three or four in number and supply the tragus, the pinna, and the lobule of the ear, and to some extent the external auditory meatus.

(4) The **zygomatico-orbital** artery [a. zygomaticoorbitalis] (fig. 445), at times a branch of the deep temporal, passes forward along the upper border of the zygoma in the fat between the superficial and deep layers of the temporal aponeurosis, and, after giving branches to the orbicularis oculi, sends one or more twigs into the orbit through foramina in the zygomatic (malar) bone to anastomose with the lacrimal and palpebral branches of the ophthalmic.

(5) The **middle temporal** artery [a. temporalis media] (fig. 453), arises just above the zygoma, and, perforating the temporal aponeurosis and temporal muscle, ascends on the squamous portion of the temporal bone, and anastomoses with the posterior deep temporal artery.

(6) The **frontal** or **anterior terminal** branch [ramus frontalis] ramifies tortuously in an upward and forward direction over the front part of the skull. It lies first between the skin and temporal fascia and then between the skin and epicranial aponeurosis. It supplies the anterior belly of the epicranius (occipito-frontalis) and the orbicularis oculi muscles, and anastomoses with the supraorbital and frontal branches of the ophthalmic, and with the corresponding artery of the opposite side. The secondary branches given off from this vessel to the scalp run from before backward.

(7) The **parietal** or **posterior terminal** branch [ramus parietalis] ramifies on the side of the head between the skin and temporal fascia. Its branches anastomose, in front with the anterior terminal branch; behind, with the posterior auricular and occipital arteries; and above, across the vertex of the skull, with the corresponding artery of the opposite side.

9. THE INTERNAL MAXILLARY ARTERY

The **internal maxillary** artery [a. maxillaris interna] (fig. 451) is the larger of the two terminal divisions of the external carotid. It arises opposite the neck of the mandible in the substance of the parotid gland, and, passing first between the mandible and the spheno-mandibular ligament and then between the external

and internal pterygoid muscles, sinks deeply into the pterygo-palatine (spheno-maxillary) fossa, and there breaks up into its terminal branches. It is divided into three portions: a mandibular, a pterygoid, and a pterygo-palatine.

(1) In the **first part of its course** (the **mandibular portion**) the artery lies between the neck of the mandible and the spheno-mandibular ligament, taking a horizontal course forward, nearly parallel to and a little below the auriculo-temporal nerve and the external pterygoid muscle. It is here embedded in the parotid gland, and usually crosses in front of the inferior alveolar (dental) nerve.

(2) In the **second part of its course** (the **pterygoid portion**) the artery may be placed superficial or deep to the external pterygoid muscle. In the first case it passes between the two pterygoid muscles and the ramus of the jaw, and then turns upward over the lateral surface of the external pterygoid, medial to the temporal muscle to gain the two heads of the external pterygoid, between which it

FIG. 451.—SCHEME OF LEFT INTERNAL MAXILLARY. (Walsham.)

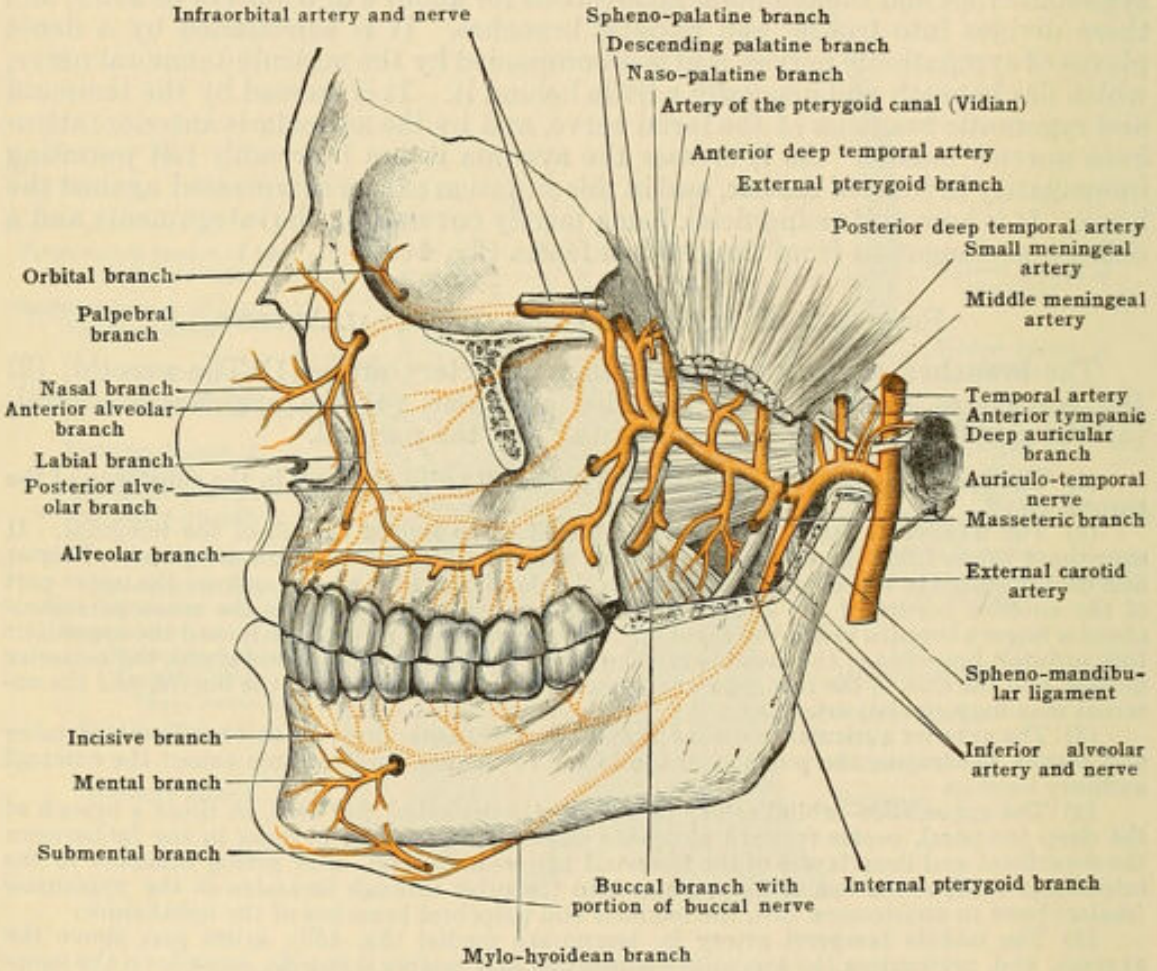

sinks into the pterygo-palatine fossa. In the second case it passes medial to the external pterygoid, and is covered by that muscle till it reaches the interval between its two heads, where it then often forms a projecting loop as it turns into the pterygo-palatine fossa.

(3) In the **third part of its course** (the **pterygo-palatine portion**) the artery lies in the pterygo-palatine fossa beneath the maxillary division of the fifth nerve and in close relationship with the spheno-palatine (Meckel's) ganglion, and there breaks up into its terminal branches.

BRANCHES OF THE INTERNAL MAXILLARY ARTERY

The **branches of the internal maxillary artery** are:—

(A) **From the first part:**—(1) The deep auricular; (2) the anterior tympanic; (3) the middle meningeal; (4) the inferior alveolar (dental); (5) the accessory meningeal (sometimes). All these vessels pass through bony or cartilaginous canals.

(B) **From the second part**:—(1) The masseteric; (2) the posterior deep temporal; (3) the pterygoid; (4) the buccal; and (5) the anterior deep temporal. All these branches supply muscles.

(C) **From the third part**:—(1) The posterior superior alveolar (dental); (2) the infra-orbital; (3) the descending palatine; (4) the a. canalis pterygoidei or Vidian; and (5) the spheno-palatine. All these branches pass through bony canals.

Branches of the First Part of the Internal Maxillary Artery

(1) The **deep auricular** artery [a. auricularis profunda] (fig. 451) passes upward in the substance of the parotid gland behind the capsule of the temporo-mandibular joint, and, perforating the bony or cartilaginous wall of the external auditory meatus, supplies the skin of that passage and the membrana tympani. It at times gives a branch to the joint as it passes behind the temporo-mandibular articular capsule.

Fig. 452.—The Middle Meningeal Artery within the Skull. (After Spalteholtz.)

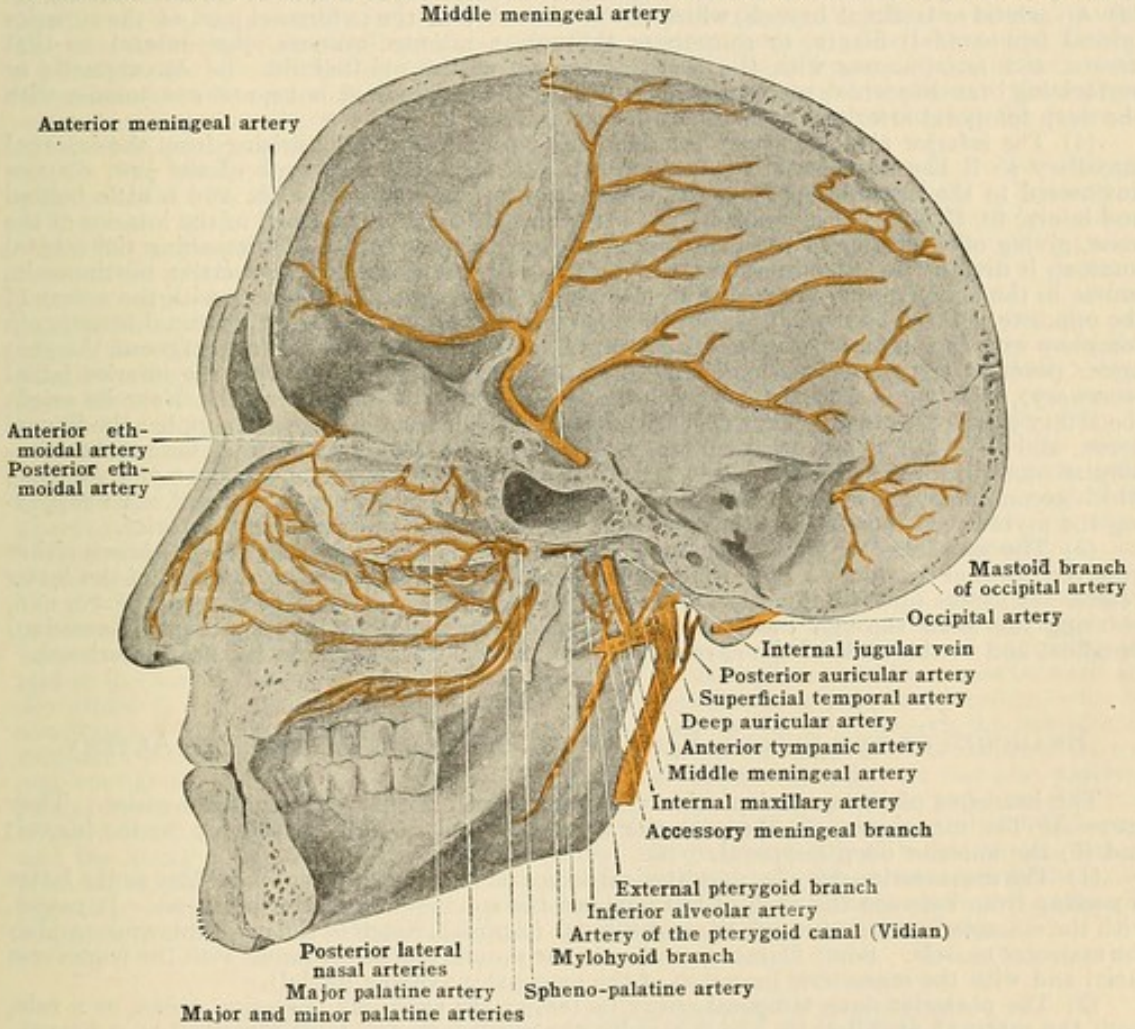

(2) The **anterior tympanic** artery [a. tympanica anterior] is a long slender vessel, which runs upward behind the condyle of the jaw to the petro-tympanic (Glaserian) fissure, through which it passes to the interior of the tympanum. Here it supplies the lining membrane of that cavity and anastomoses with the other tympanic arteries, forming with the posterior tympanic branch of the stylo-mastoid artery a vascular circle around the membrana tympani. This circle is more distinct in the fœtus than in the adult.

(3) The **middle meningeal** artery [a. meningea media] is the largest branch of the internal maxillary artery. It comes off from the vessel as it lies between the spheno-mandibular ligament and the ramus of the jaw, and under cover of the external pterygoid passes directly upward to the foramen spinosum, through which it enters the interior of the cranium. In this part of its course it is crossed by the chorda tympani nerve; and just before it enters the foramen is embraced by the two heads of origin of the auriculo-temporal nerve (fig. 451).

The trunk of the mandibular division of the fifth nerve, as it emerges from the foramen ovale, lies in front of the artery. As the artery passes upward it is surrounded by filaments of the sympathetic nerve, and is accompanied by two veins. On entering the skull it ramifies between the bone and dura mater, supplying both structures. It at first ascends for a short

distance in a groove on the greater wing of the sphenoid, and then divides into two branches, an anterior and a posterior.

The **anterior branch** passes upward, in the groove on the greater wing of the sphenoid, on to the parietal bone at its anterior and inferior angle; at this spot the groove becomes deepened and often bridged over by a thin plate of bone, being converted for 6 to 12 mm. (¼ to ½ in.) or more into a distinct canal. The situation of the artery is here indicated on the exterior of the skull by a spot 3.7 cm. (1½ in.) behind, and about 2.5 cm. (1 in.) above, the zygomatic process of the frontal bone. The anterior branch is continued along the anterior border of the parietal bone nearly as far as the superior sagittal sinus, and gives off in its course, but especially posteriorly, large branches which ramify in an upward and backward direction in grooves on the parietal bone (fig. 452).

The **posterior branch** passes backward over the squamous portion of the temporal bone; and thence on to the parietal bone, behind the anterior branch. This branch and its collaterals extend upward as far as the sagittal sinus, and backward as far as the transverse (lateral) sinus.

In addition to its terminal anterior, and terminal posterior branches, the middle meningeal gives off:—(*a*) **Ganglionic** branhecs to the semilunar (Gasserian) ganglion and its sheath of dura mater. (*b*) A **superficial petrosal** branch [ramus petrosus superficialis], which enters the hiatus of the facial canal in company with the large superficial petrosal nerve and anastomoses with the terminal branch of the stylo-mastoid artery. (*c*) A **superior tympanic** artery [a. tympanica superior], which enters the canal for the tensor tympani, and supplies that muscle. (*d*) An **orbital** or **lacrimal** branch, which enters the orbit at the outermost part of the superior orbital (sphenoidal) fissure, or sometimes through a minute foramen, just lateral to that fissure, and anastomoses with the lacrimal branch of the ophthalmic. (*e*) **Anastomotic** or **perforating** branches which pierce the greater wing of the sphenoid bone, and anastomose with the deep temporal arteries.

(4) The **inferior alveolar** artery [a. alveolaris inferior] (fig. 451), arising from the internal maxillary as it lies between the spheno-mandibular ligament and neck of the jaw, courses downward to the mandibular foramen, which it enters in company with, and a little behind and lateral to, the inferior alveolar nerve. It then passes along the canal in the interior of the bone, giving off branches to the molar, premolar, and canine teeth. On reaching the mental foramen it divides into two branches, the incisive and the mental. The **incisive** continues its course in the bone, supplies branches to the incisor teeth, and anastomoses with the artery of the opposite side. The **mental** branch [ramus mentalis] passes through the mental foramen in company with the mental branch of the inferior alveolar (dental) nerve, and emerges on the chin under cover of the quadratus labii inferioris. It anastomoses above with the inferior labial (coronary), and below with the submental, and also with the inferior labial. Near its origin the artery gives off (*a*) a **lingual** or **gustatory** branch, which accompanies and supplies the lingual nerve, and ends in the mucous membrane of the mouth; and, just before it enters the mandibular (dental) foramen in the lower jaw, (*b*) a **mylo-hyoidean** branch [ramus mylohyoideus], which accompanies the nerve of that name along the groove in the lower jaw, and, after supplying the mylo-hyoid muscle, anastomoses with the sublingual and submental arteries.

(5) The **accessory or small meningeal** branch [ramus meningeus accessoria] arises either from the internal maxillary a little in front of the middle meningeal, or as a branch of the latter vessel. It passes upward along the course of the mandibular division of the fifth nerve, and, entering the skull through the foramen ovale, is distributed to the semilunar (Gasserian) ganglion, and to the walls of the cavernous sinus and the dura mater in the neighbourhood.

Branches of the Second Part of the Internal Maxillary Artery

The branches of the second portion of the internal maxillary all supply muscles. They are:—(1) The masseteric; (2) the posterior deep temporal; (3) the pterygoid; (4) the buccal; and (5) the anterior deep temporal.

(1) The **masseteric** artery [a. masseterica] comes off from the internal maxillary as the latter is passing from between the neck of the jaw and the spheno-mandibular ligament. It passes, with the masseteric nerve through the mandibular (sigmoid) notch in the mandible and supplies the masseter muscle. Some filaments perforate the muscle and anastomose with the transverse facial and with the masseteric branches of the external maxillary (facial).

(2) The **posterior deep temporal** artery [a. temporalis profunda posterior] arises, as a rule, from the internal maxillary in common with the masseteric for a little beyond that branch. It passes upward beneath the temporal muscle in a slight groove on the anterior margin of the squamous portion of the temporal bone, supplying the temporal muscle, the pericranium and the external layer of the bone. It anastomoses with the other temporal arteries.

(3) The **pterygoid** branches [rami pterygoidei] are short trunks which pass into and supply the internal and external pterygoid muscles.

(4) The **buccal** artery [a. buccinatoria] (fig. 451) courses forward and downward with the buccal nerve to the buccinator muscle, lying in close contact with the medial side and anterior margin of the tendon of the temporal muscle and coronoid process of the lower jaw. It supplies the buccinator muscle and mucous membrane of the mouth, and anastomoses with the external maxillary (facial), transverse facial, and infraorbital arteries.

(5) The **anterior deep temporal** artery [a. temporalis profunda anterior] ascends beneath the temporal muscle in a slight groove on the greater wing of the sphenoid bone. It supplies the muscle, pericranium, and subjacent bone, and gives off small branches which pass through minute foramina in the zygomatic (malar) bone. Some of these last branches enter the orbit and anastomose with the lacrimal artery; others emerge on the face and anastomose with the transverse facial artery.

Branches of the Third Part of the Internal Maxillary Artery

The branches of the third part of the internal maxillary artery, like those of the first part, all pass through bony canals. They are the following:—(1) The posterior superior alveolar (dental); (2) the infraorbital; (3) the descending palatine; (4) the artery of the pterygoid canal (Vidian); and (5) the sphenopalatine.

(1) The **posterior superior alveolar (dental)** artery [a. alveolaris superior posterior] arises from the internal maxillary as the latter is passing into the pterygo-palatine (spheno-maxillary) fossa, and descends in a tortuous manner in a groove on the back of the body of the maxilla. It gives off branches to the maxillary sinus, to the molar and premolar teeth, the gums, and to the buccinator muscle.

(2) The **infraorbital** artery [a. infraorbitalis] arises from the internal maxillary, generally as a common trunk with the posterior alveolar (dental). It passes forward and a little upward through the pterygo-palatine (spheno-maxillary) fossa; then forward in company with the infraorbital branch of the fifth nerve, first along the groove, and then through the canal in the orbital plate of the maxilla; and finally, emerging on the face at the infraorbital foramen, under cover of the quadratus labii superioris, is distributed to the structures forming the upper lip, the lower eyelid, the lacrimal sac, and the side of the nose. It anastomoses with the superior labial (coronary) and angular branches of the external maxillary (facial), with the nasal and lacrimal branches of the ophthalmic, and with the transverse facial. It gives off small branches supplying the fat of the orbit and the inferior rectus and inferior oblique muscles. The **anterior superior alveolar** branch [a. alveolaris superior anterior] passes downward through a groove in the anterior wall of the maxilla, together with the anterior alveolar branch of the infraorbital nerve, and supplies branches to the incisor and canine teeth and the mucous membrane of the maxillary sinus. It has also **nasal** branches which pass through the foramina in the nasal process of the maxilla.

(3) The **descending palatine** artery [a. palatina descendens] descends in the pterygo-palatine canal with the anterior palatine branch of the spheno-palatine ganglion. On emerging on the palate at the greater (posterior) palatine foramen, it divides into the following branches: —(*a*) The **major palatine** artery [a. palatina major], which courses forward in the muco-periosteum at the junction of the hard palate with the alveolar process as far as the incisive (anterior palatine) foramen, where it anastomoses with the spheno-palatine artery; and (*b*) **minor palatine** arteries [aa. palatinæ minores], which pass backward and downward into the soft palate, contributing to the supply of that structure, and anastomosing with the ascending palatine artery. After the operation for cleft palate, serious hæmorrhage occasionally occurs from the descending palatine artery. The foramen is situated a little behind, and medial to, the last molar tooth, and almost immediately in front of the hamular process (fig. 452).

(4) The **arteria canalis pterygoidei or Vidian** artery is a long slender branch which passes backward through the pterygoid (Vidian) canal in company with the nerve of the same name into the cartilage of the lacerated foramen. It gives off branches which supply the roof of the pharynx, and anastomose with the ascending pharyngeal and spheno-palatine arteries; also a branch which is distributed to the Eustachian tube; and one which enters the tympanum, and anatomoses with the other tympanic arteries.

(5) The **spheno-palatine** [a. sphenopalatina], the terminal branch of the internal maxillary, passes with the naso-palatine branch of the spheno-palatine ganglion from the pterygo-palatine (spheno-maxillary) fossa into the nose through the spheno-palatine foramen. Crossing the roof of the nose in the muco-periosteum, it passes on to the septum, and then runs forward and downward in a groove on the vomer toward the incisive (anterior palatine) foramen, where it anastomoses with the anterior palatine artery, which enters the nose through the lateral compartment of that foramen (the canal of Stenson). In this course it gives off branches to the roof and contiguous portions of the pharynx, and to the sphenoidal cells. It has also **posterior lateral nasal** branches [aa. nasales post. laterales], which ramify over the nasal conchæ (turbinate bones) and lateral walls of the nose, and give twigs to the ethmoidal and frontal sinuses and the lining membrane of the maxillary sinus; and **posterior septal** branches [aa. nasales post. septi], which run upward and forward, giving small twigs to the mucous membrane covering the upper part of the septum, and which pass through the cribriform plate of the ethmoid, and anastomose with the ethmoidal arteries (perforating or meningeal branches).

THE INTERNAL CAROTID ARTERY

The **internal carotid** artery [a. carotis interna] (figs. 453 and 454) arises with the external carotid at the bifurcation of the common carotid, opposite the upper border of the thyreoid cartilage, on a level with the fourth cervical vertebra. It is at first placed a little lateral to the external carotid, but as it ascends in the neck the external carotid becomes more superficial and in front of the internal. The internal carotid passes up the neck, in front of the transverse processes of the upper cervical vertebræ, lying upon the longus capitis (rectus capitis ant. major), to the carotid foramen, thence through the carotid canal in the petrous portion of the temporal bone, making at first a forward and medial turn and then a second turn upward, and enters the cranium through the foramen lacerum. It makes a sigmoid curve on the side of the body of the sphenoid bone, and terminates, after perforating the dura mater, by dividing opposite the anterior clinoid processes

in the lateral fissure (fissure of Sylvius), into the anterior and middle cerebral arteries.

In its course up the neck it often forms one or more curves, especially in old people. Between the internal and the external carotids, at their angle of divergence, is situated the carotid body or gland [glomus caroticum].

The internal carotid is the continuation upward of the primitive dorsal aorta, and supplies the greater part of the brain, the contents of the orbit, and parts of the internal ear, forehead, and nose. It is divided into three portions:—(1) a cervical; (2) a petrosal; and (3) an intracranial.

1. The Cervical Portion

Relations.—In the neck (fig. 453) the artery is at first comparatively superficial, having in front of it, as it lies in the superior carotid triangle, the skin, superficial fascia, platysma and

Fig. 453.—The Carotid Arteries. (After Toldt, "Atlas of Human Anatomy," Rebman London and New York.)

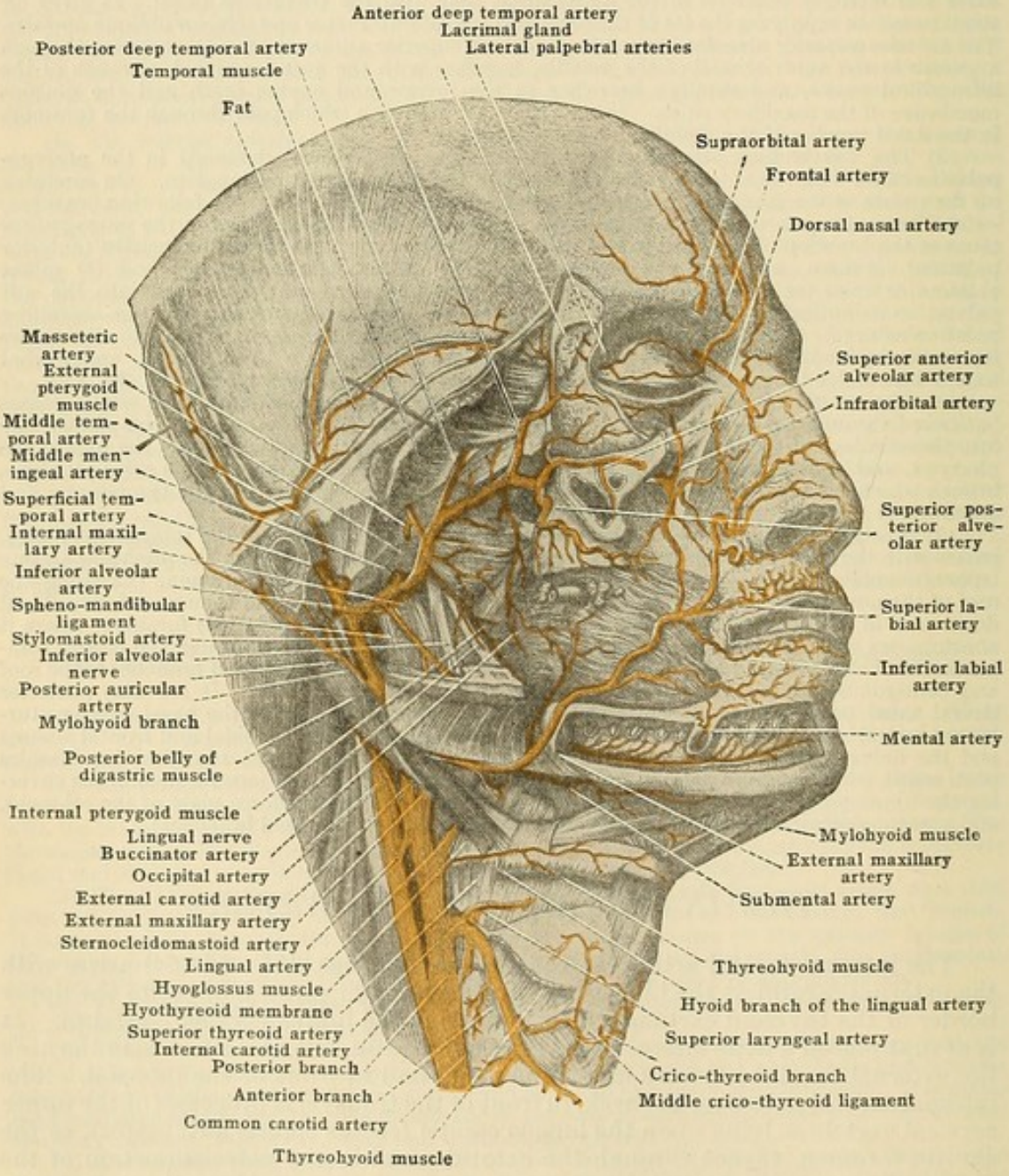

deep fascia, and the overlapping edge of the sterno-mastoid muscle. Higher up, as it sinks beneath the parotid gland, it becomes deeply placed, and is crossed by the posterior belly of the digastric and stylo-hyoid muscles, the hypoglossal nerve, and the occipital and posterior auricular arteries; whilst still higher it is separated from the external carotid artery, which here gets

in front of it, by the stylo-glossus and stylo-pharyngeus muscles, the glosso-pharyngeal nerve, the pharyngeal branch of the vagus nerve, and by the stylo-hyoid ligament.

Behind, it lies upon the longus capitis (rectus capitis anticus major), which separates it from the transverse processes of the three upper cervical vertebræ, on the superior cervical ganglion of the sympathetic nerve, and on the vagus nerve. Near the base of the skull, the hypoglossal, vagus, glosso-pharyngeal, and spinal accessory nerves cross obliquely behind it, separating it here from the internal jugular vein, which, as the artery is about to enter the carotid canal, also forms one of its posterior relations.

On its **lateral side** are the internal jugular vein and vagus nerve.

On its **medial side** it is in relation with the pharynx, the superior constrictor muscle separating it from the tonsil. The ascending pharyngeal and ascending palatine arteries, and at the base of the skull the Eustachian tube and levator palati muscles, are also medial to it.

2. The Petrosal Portion

The **petrosal portion** (fig. 454) is situated in the carotid canal in the petrous portion of the temporal bone. It is here separated from the walls of the canal by a prolongation downward of the dura mater. In this part of its course it first ascends in front of the tympanum and cochlea of the internal ear; it then turns forward and medially, lying a little medial to and behind the Eustachian tube, and enters the cranial cavity by turning upward through the fora-

Fig. 454.—The Internal Carotid Artery in the Canal. (After Spalteholz.)

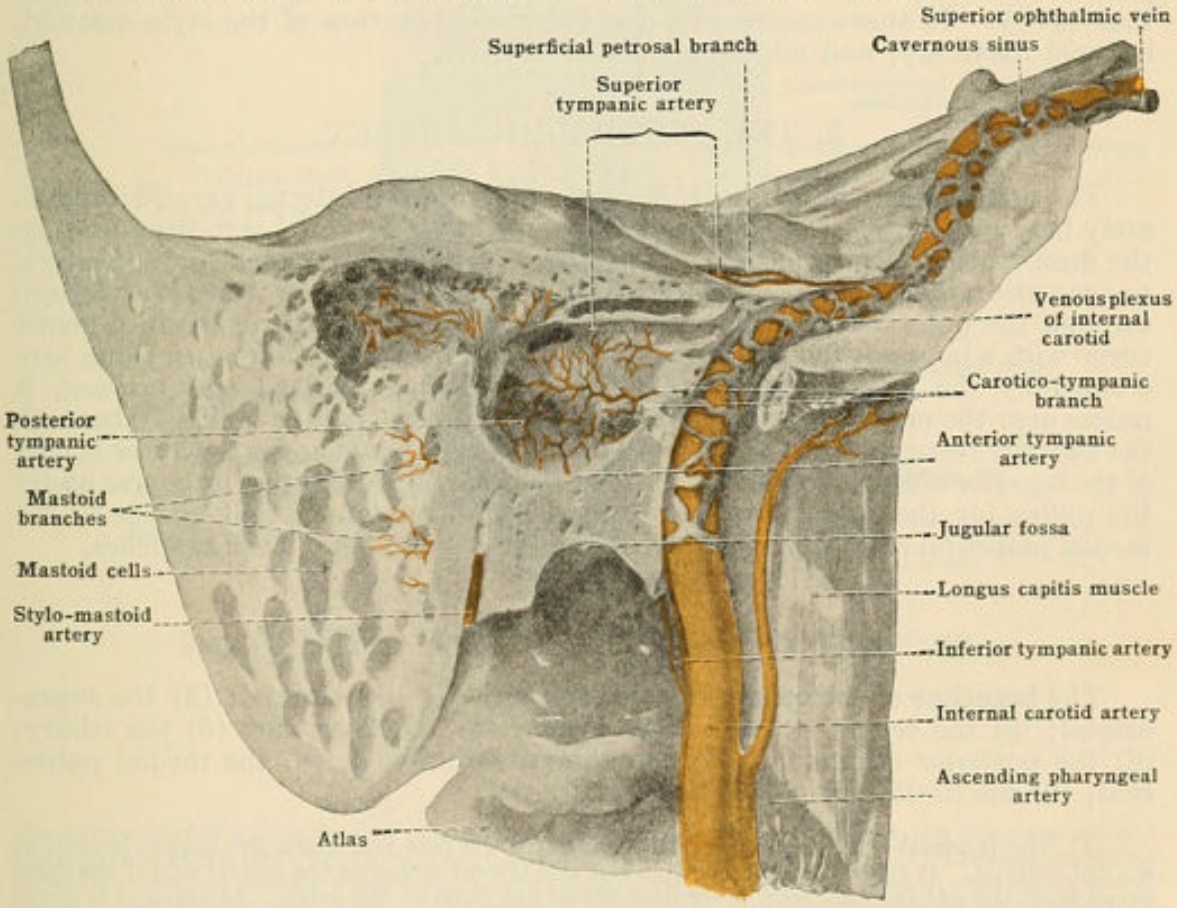

men lacerum, lying upon the lingula of the sphenoid bone. In this part of its course it is accompanied by the ascending branches from the superior cervical ganglion of the sympathetic. These form a plexus about the artery, but are situated chiefly on its lateral side. It is also surrounded by a number of small veins, which receive tributaries from the tympanum and open into the cavernous sinus and internal jugular vein.

3. The Intracranial Portion

On entering the cranium through the foramen lacerum, the internal carotid first ascends to reach the lateral part of the body of the sphenoid medial to the lingula. It then follows the carotid sulcus forward and slightly downward along the medial wall of the cavernous sinus (fig. 454). Here it has the sixth nerve immediately lateral to it, and is covered by the lining membrane of the sinus. Again turning upward, it pierces the dura mater on the medial side of the anterior clinoid process, and, passes between the second and third nerves to the anterior perforated substance. At the medial end of the lateral (Sylvian) fissure it pierces the arachnoid and divides into its two terminal branches, the anterior and middle cerebral. As it lies in the

foramen lacerum the artery is crossed on its lateral side by the great superficial petrosal nerve as the latter goes to join the great deep petrosal from the carotid plexus to form the nerve of the pterygoid canal (Vidian).

Branches of the Internal Carotid Artery

The **cervical portion** gives off no branch. The **petrosal portion** gives off the caroticotympanic. The **branches of the intracranial portion** are:—(2) ophthalmic; (3) posterior communicating; (4) chorioid; (5) anterior cerebral; (6) middle erebral.

As the internal carotid artery lies on the medial side of the cavernois sinus, it also gives off the following small branches—branches to the walls of the cavernous inus; to the pituitary body; to the semilunar (Gasserian) ganglion; to the dura mater. These anastomose with anterior branches of the middle meningeal.

1. THE CAROTICOTYMPANIC ARTERY

The **caroticotympanic** enters the tympanum through a small foramen in the posterior wall of the carotid canal, and contributes its quota to the blood-supply of that cavity. It anastomoses with the tympanic branches of the stylo-mastoid, internal maxillary, and middle meningeal arteries.

2. THE OPHTHALMIC ARTERY

The **ophthalmic** artery (fig. 455) comes off from the internal carotid immediately below the anterior clinoid process just as the latter vessel is passing through the dura matter. Entering the orbit through the optic foramen below and lateral to theo ptic nerve, it at once perforates the sheath of dura mater which is prolonged through the optic foramen on both artery and nerve. It then runs in a gentle curve with a lateral convexity below the optic nerve and lateral rectus, being here crossed by the naso-ciliary (nasal) nerve. Turning forward and upward, it passes over the optic nerve, to its medial side. Thence it runs obliquely beneath the superior rectus in front of the naso-ciliary (nasal) nerve under the lower border of the superior oblique, but above the medial rectus, and continues its course under the pulley for the superior oblique and reflected tendon of that muscle to the medial palpebral region, where it divides into the frontal and nasal branches.

Branches of the Ophthalmic Artery

The **branches of the ophthalmic artery** are:—(1) the lacrimal; (2) the supra-orbital; (3) the central artery of the retina; (4) the muscular; (5) the ciliary; (6) the posterior ethmoidal; (7) the anterior ethmoidal; (8) the medial palpebral; (9) the frontal; and (10) the dorsal nasal.

(1) The **lacrimal** artery [a. lacrimalis], is usually the first and often the largest branch of the ophthalmic. It arises between the superior and lateral rectus on the lateral side of the optic nerve from the ophthalmic, soon after that vessel has entered the orbit. At times it is given off from the ophthalmic outside the orbit, and then usually passes into that cavity through the superior orbital (sphenoidal) fissure. It runs forward along the lateral wall of the orbit with the lacrimal nerve, above the upper border of the lateral rectus, to the lacrimal gland, which it supplies. In this course it furnishes the following branches:—(*a*) **Recurrent,** one or more branches which pass backward through the superior orbital (sphenoidal) fissure, and anastomose with the lacrimal branch of the middle meningeal artery. The anastomosis is sometimes of large size, and then takes the chief share in the formation of the lacrimal artery. (*b*) **Muscular** branches, distributed chiefly to the lateral rectus. (*c*) **Zygomatic** branches—small twigs, which pass through the zygomatico-orbital (malar) canals, and anastomose with the orbital branch of the middle temporal, and with the transverse facial on the cheek. (*d*) **Lateral palpebral** arteries [aa. palpebrales laterales] which are distributed to the upper and lower eyelids and to the conjunctiva. (*e*) **Ciliary.** See Ciliary Arteries, page 553.

(2) The **supraorbital** artery [a. supraorbitalis] usually arises from the ophthalmic as the latter vessel is about to cross over the optic nerve. Passing upward to the medial side of the superior rectus and levator palpebræ, it runs along the upper surface of the latter muscle with the frontal nerve in the orbital fat, but beneath the periosteum, to the supraorbital notch. On emerging on the forehead beneath the orbicularis oculi, it divides into a superficial and deep branch, the former ramifies between the skin and epicranius (occipito-frontalis), the latter

between the epicranius and the pericranium. Both branches anastomose with the anterior branches of the superficial temporal, the angular branch of the external maxillary (facial), and the transverse facial artery. The branches of the supraorbital are:—(*a*) **periosteal,** to the periosteum of the roof of the orbit; (*b*) **muscular,** to the levator palpebræ and superior rectus; (*c*) **diploic,** given off as the artery is passing through the supraorbital notch and, entering a minute foramen at the bottom of the notch, is distributed to the diploë and frontal sinuses; (*d*) **trochlear,** to the pulley of the superior oblique; (*e*) **palpebral,** to the upper eyelid.

(3) The **arteria centralis retinæ,** a small but constant branch, comes off from the ophthalmic close to the optic foramen, and, perforating the optic nerve about 6 mm. (¼ in.) behind the globe, runs forward in (the substance of the nerve) to the eyeball, supplying the retina. Its further description is given in the section on the EYE.

(4) The **muscular** branches [rami musculares] are very variable in their origin and distribution. They may be roughly divided into superior and inferior sets. The superior or smaller set supply the superior oblique, the levator palpebræ, and superior rectus. The inferior pass forward, between the optic nerve and the inferior rectus, supplying that muscle, the medial rectus, and the inferior oblique. From the muscular branches are given off the anterior ciliary arteries. (See CILIARY ARTERIES.)

(5) The **ciliary arteries** are divided into three sets:—The **short posterior,** the **long posterior,** and the **anterior.** (i) The **short posterior** [aa. ciliares posteriores breves], five or six in number, come off chiefly from the ophthalmic as it is crossing the optic nerve. They run forward about

FIG. 455.—THE LEFT OPHTHALMIC ARTERY AND VEIN.

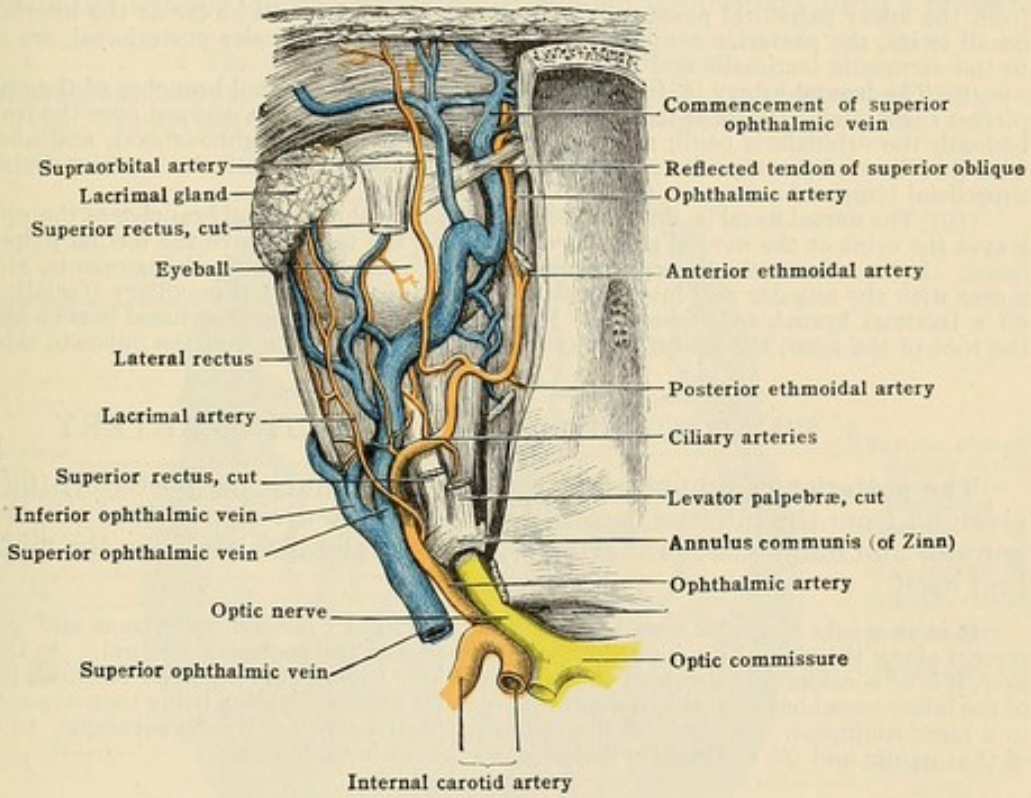

the nerve, dividing into twelve or fifteen small vessels, which perforate the sclerotic around the entrance of the optic nerve, and are distributed to the chorioid coat. (ii) The **long posterior** ciliary arteries [aa. ciliares posteriores longæ], usually two, sometimes three, in number, come off from the ophthalmic on either side of the optic nerve, and run forward with the short ciliary to the sclerotic. On piercing the sclerotic, they course forward, one on either side of the eyeball between the sclerotic and the chorioid to the ciliary processes and iris. Their further distribution is given under the anatomy of the EYE. (iii) The **anterior ciliary** arteries [aa. ciliares anteriores] are derived from the muscular branches and from the lacrimal. They run to the globe along the tendons of the recti, forming a zone of radiating vessels beneath the conjunctiva. Some of them, the **episcleral arteries** [aa. episclerales]; perforate the sclerotic about 6 mm. (¼ in.) behind the cornea, and supply the iris and ciliary processes. It is these vessels that are enlarged and congested in iritis, forming the circumcorneal zone of redness so characteristic of that disease. They then differ from the tortuous vessels of the conjunctiva in that they are straight and parallel. The remainder constitute the **anterior conjunctival** arteries [aa. conjunctivales anteriores].

(6) The **posterior ethmoidal** artery [a. ethmoidalis posterior] (fig. 455) runs medially between the superior oblique and medial rectus, and, leaving the orbit by the posterior ethmoidal canal, together with the posterior ethmoidal branch of the naso-ciliary (nasal) nerve, enters the posterior ethmoidal cells, whence it passes through a transverse slit-like aperture between the sphenoid bone and cribriform plate of the ethmoid bone into the cranium. It gives off (*a*) **ethmoidal** branches to the posterior ethmoidal cells; (*b*) **meningeal** branches to the dura mater lining the cribriform plate; and (*c*) **nasal** branches, which pass through the cribriform plate to

the superior meatus and upper spongy bones of the nose, and anastomose with the nasal branches of the spheno-palatine artery (fig. 452).

(7) The **anterior ethmoidal** artery [a. ethmoidalis anterior] (fig. 452), a larger branch than the posterior ethmoidal, arises in front of the latter, passes medially between the superior oblique and medial rectus, and, leaving the orbit through the anterior ethmoidal canal, in company with the anterior ethmoidal nerve, enters the cranial cavity. After running a short distance beneath the dura mater on the cribriform plate of the ethmoidal bone, it passes into the nose through the horizontal slit-like aperture by the side of the crista galli. Its terminal branch passes along the groove on the under surface of the nasal bone, and emerges on the nose between the bone and lateral cartilage, terminating in the skin of that organ. It gives off the following branches in its course:—(i) **Ethmoidal,** to the anterior ethmoidal cells; (ii) **anterior meningeal** artery, [a. meningea anterior] to the dura mater of the anterior fossa; (iii) **nasal,** to the middle meatus and anterior part of the nose; (iv) **frontal,** to the frontal sinuses; (v) **cutaneous,** or **terminal,** to the skin of the nose.

(8) The **medial palpebral** arteries [aa. palpebrales mediales] arise either separately or by a common trunk from the ophthalmic artery opposite the pulley for the superior oblique, just as the latter vessel is about to divide into its terminal branches. They pass, one above and one below, the medial palpebral ligament and then skirt along the upper and lower eyelids respectively, near the free margin between the palpebral tarsi and the orbicularis muscle, and form a **superior** and an **inferior tarsal arch** [arcus tarsus superior et inferior] by anastomosing with the lateral palpebral branches of the lacrimal. The upper also anastomoses with the supraorbital artery and orbital branch of the temporal artery; the lower with the infraorbital, the angular branch of the external maxillary (facial), and the transverse facial arteries. A branch from the lower palpebral passes with the ductus nasolacrimalis as far as the inferior meatus. Small twigs, the **posterior conjunctival** arteries [aa. conjunctivales posteriores], are also given to the caruncula lacrimalis and conjunctiva.

(9) The **frontal** artery [a. frontalis], the upper of the terminal branches of the ophthalmic, pierces the superior tarsus at the medial angle of the orbit, passes upward over the frontal bone beneath the orbicularis oculi, supplies the structures in its neighbourhood, and anastomoses with its fellow of the opposite side, with the supraorbital, and with the anterior division of the superficial temporal artery.

(10) The **dorsal nasal** [a. dorsalis nasi], the lower of the terminal branches of the ophthalmic, leaves the orbit at the medial angle by perforating the tarsus above the medial palpebral ligament. It then descends along the dorsum of the nose, beneath the integuments, and anastomoses with the angular and lateral nasal branches of the external maxillary (facial). It gives off a **lacrimal branch** as it crosses the lacrimal sac, and a **transverse nasal branch** as it crosses the root of the nose; the latter vessel anastomoses with its fellow of the opposite side.

3. THE POSTERIOR COMMUNICATING ARTERY

The **posterior communicating** artery [a. communicans posterior] (fig. 456) is given off from the internal carotid just before the division of that vessel into the anterior and middle cerebral arteries; occasionally it arises from the middle cerebral itself.

It is as a rule a slender vessel which runs backward over the optic tract and pedunculus cerebri along the side of the hippocampal gyrus to join the posterior cerebral. At times, however, it is of considerable size, and contributes chiefly to form the posterior cerebral, the portion of the latter vessel between the basilar and posterior communicating being then as a rule reduced to a mere rudiment. It gives off the following branches:—(*a*) the **hippocampal,** to the gyrus of that name; and (*b*) the **middle thalamic,** to the optic thalamus.

4. THE CHORIOID ARTERY

The **chorioid** artery [a. chorioidea] is a small but constant vessel which arises as a rule from the back part of the internal carotid just lateral to the origin of the posterior communicating.

It passes backward on the optic tract and the pedunculus cerebri, at first lying parallel and lateral to the posterior communicating artery. It then dips under the edge of the uncinate gyrus and, entering the chorioid fissure at the lower end of the inferior cornu of the lateral ventricle, ends in the chorioid plexus and supplies the hippocampus and fimbria.

5. THE ANTERIOR CEREBRAL ARTERY

The **anterior cerebral** artery [a. cerebri anterior] (figs. 456, 459), one of the terminal branches into which the internal carotid divides in the lateral fissure (fissure of Sylvius), supplies a part of the cortex of the frontal and parietal lobes of the brain and a small part of the basal ganglia. It passes at first anteriorly and medially across the anterior perforated substance between the olfactory and optic nerves to the longitudinal fissure where it approaches its fellow of the opposite side

and communicates with it by a short transverse trunk, about five mm. long, known as the **anterior communicating** artery [a. communicans anterior] (fig. 456). Onward from this point it runs side by side with its fellow in the longitudinal fissure round the genu of the corpus callosum; then, turning backward, it continues along the upper surface of that commissure, and, after giving off large branches to the frontal and parietal lobules, anastomoses with the posterior cerebral artery.

6. THE MIDDLE CEREBRAL ARTERY

The **middle cerebral** artery [a. cerebri media] (figs. 456, 460), the larger of the terminal divisions of the internal carotid, supplies the basal ganglia and a part of the cortex of the frontal and parietal lobes. It passes obliquely upward and lateralward into the lateral (Sylvian) fissure, and opposite the insula divides into cortical branches.

Circulus Arteriosus

The four arteries which supply the brain, namely, the two internal carotid arteries and the two vertebrals (which unite to form the basilar), form a remark-

Fig. 456.—The Arteries of the Brain.

(The cerebellum has been cut away on the left side to show the posterior part of the cerebrum. From a preparation in the Museum of St. Bartholomew's Hospital.)

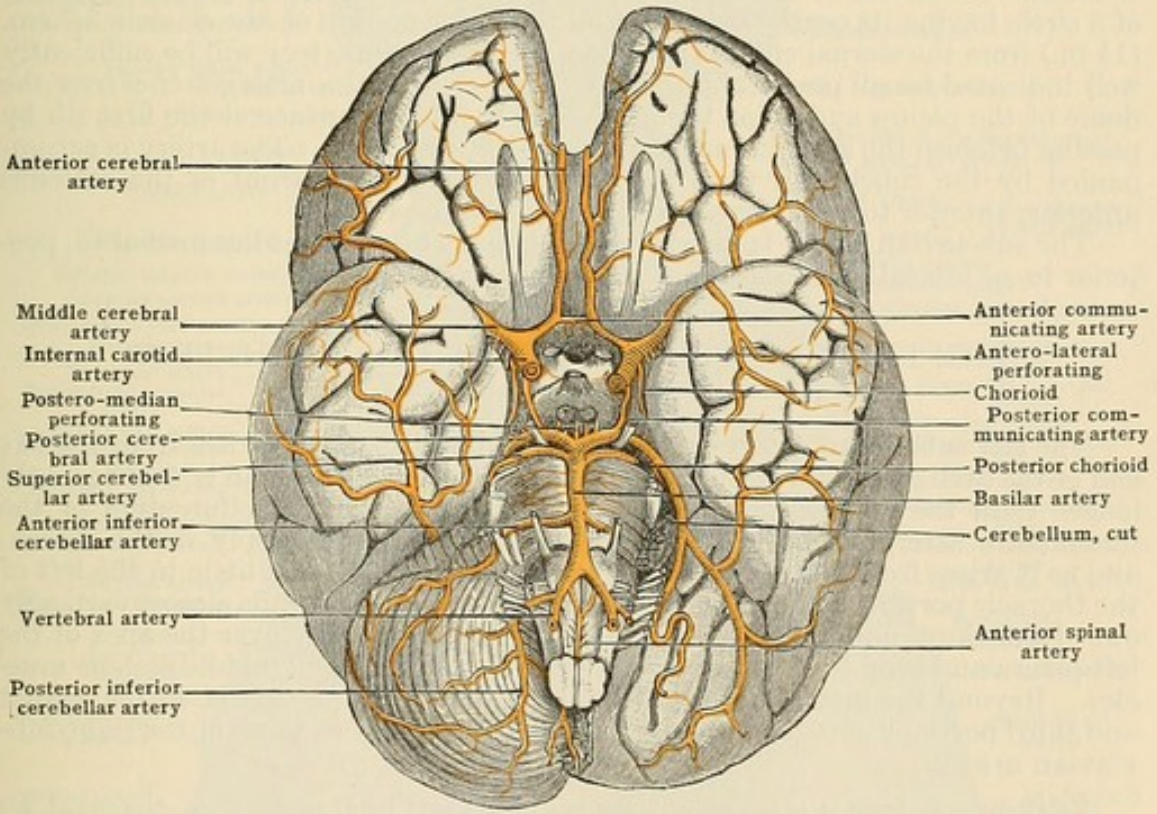

able anastomosis at the base of the brain known as the circle of Willis [circulus arteriosus (Willisi)]. This so-called circle, which has really the form of a heptagon, is formed, **in front,** by the anterior communicating artery uniting the anterior cerebral arteries of opposite sides; **laterally,** by the internal carotids and the posterior communicating arteries stretching between these and the posterior cerebrals; **behind,** by the two posterior cerebrals diverging from the bifurcation of the basilar artery (fig. 456).

This free anastomosis between the two internal carotid and the two vertebral arteries serves to equalise the flow of blood to the various portions of the brain; and, should one or more of the arteries entering into the formation of the circle be temporarily or permanently obstructed, it ensures a flow of blood to the otherwise deprived part through some of the collateral arteries. Thus, if one carotid or one vertebral is obstructed, the parts supplied by that vessel receive their blood through the circle from the remaining pervious vessels. Indeed, one vertebral artery alone has been found equal to the task of carrying sufficient blood for the supply of the

brain after ligature of both the carotids and the other vertebral artery. Further, the circle of Willis is the only medium of communication between the ganglionic or central and the peripheral or cortical branches of the cerebral arteries, and between the various ganglionic branches themselves. The ganglionic and the cortical branches form separate and distinct systems, and do not anastomose with each other; and the ganglionic, moreover, are so-called end-vessels, and do not anastomose with the neighbouring ganglionic branches. The three cerebral arteries, anterior, middle, and posterior may be regarded as branches of the circle of Willis. (For details concerning the distribution of the cerebral arteries see p. 562.)

THE SUBCLAVIAN ARTERY

The **subclavian artery** on the right side [a. subclavia dextra] arises at the bifurcation of the innominate opposite the upper limit of the right sterno-clavicular articulation. On the left side it arises from the arch of the aorta, and, as far as the medial border of the scalenus anterior, is situated deeply in the chest. The first portion of the left subclavian artery is described separately.

Beyond the medial border of the scalenus anterior the artery has the same relations on both sides. It courses from this point beneath the clavicle in a slight curve across the root of the neck to the lateral border of the first rib, there to end in the axillary artery. Thus the course of the artery in the neck will be indicated by a line drawn from the sterno-clavicular joint in a curve with its convexity upward to the middle of the clavicle. The height to which the artery rises in the neck varies. It is perhaps most commonly about 1.2 cm. ($\frac{1}{2}$ in.) above the clavicle. If the curved line above mentioned is drawn to represent part of the circumference of a circle having its center at a point on the lower margin of the clavicle 3.7 cm. ($1\frac{1}{2}$ in.) from the sternal end of that bone, the line of the artery will be sufficiently well indicated for all practical purposes. In its course the artery arches over the dome of the pleura and gains the groove on the upper surface of the first rib by passing between the scalenus anterior and medius muscles. The artery is accompanied by the subclavian vein, the latter vessel lying in front of the scalenus anterior, anterior to the artery, and on a slightly lower plane.

The subclavian artery is divided into three portions—as it lies medial to, posterior to, or lateral to, the scalenus anterior muscle.

THE FIRST OR THORACIC PORTION OF THE LEFT SUBCLAVIAN ARTERY

The **left subclavian** artery [a. subclavia sinistra] (fig. 457) arises from the left end of the arch of the aorta. The first part of the left subclavian is consequently longer than the first part of the right, which arises at the bifurcation of the innominate artery. The artery at its origin is situated deeply in the thorax, and as it arises from the aorta is on a plane posterior to and a little to the left of the thoracic portion of the left common carotid. It first ascends almost vertically out of the chest, and at the root of the neck curves laterally over the apex of the left pleura and lung to the interval between the anterior and middle scalene muscles. Beyond the medial border of the scalenus anterior—that is, in the second and third portions of its course—its relations are similar to those of the right subclavian artery.

Relations.—**In front** it is covered by the left pleura and lung, whilst more superficial are the sterno-thyreoid, sterno-hyoid, and sterno-mastoid muscles. It is crossed a little above its origin by the left innominate vein, and higher in the neck near the scalenus anterior by the internal jugular, vertebral, and subclavian veins. The phrenic nerve crosses the artery immediately medial to the scalenus anterior, and then descends parallel to it, but on an anterior plane, to cross the arch of the aorta. The vagus nerve descends parallel to the artery between it and the left common carotid, coming into contact with its anterior surface just before crossing the arch of the aorta. The left cervical cardiac nerves of the sympathetic also descend in front of it on their way to the cardiac plexus. The left *ansa subclavia* also loops in front of the subclavian artery. The left common carotid is situated anteriorly and to its right. The thoracic duct arches over the artery just medial to the scalenus anterior, to empty its contents into the confluence of the internal jugular and subclavian veins (fig. 442).

Behind and somewhat medial to it are the œsophagus, thoracic duct, inferior cervical ganglion of the sympathetic, longus colli muscle, and vertebral column. To some extent it is overlapped posteriorly by the left pleura and lung.

On its **right side** are the trachea and the inferior laryngeal nerve, and, higher up, the œsophagus and thoracic duct.

On its **left side** are the left pleura and lung.

Branches.—The vertebral, internal mammary, and thyreo-cervical trunk (thyreoid axis) usually arise from the first portion on the left side. (See p. 559.)

THE FIRST PORTION OF THE RIGHT SUBCLAVIAN ARTERY

The **first portion of the right subclavian artery** (fig. 457) extends from its origin at the bifurcation of the innominate, behind the upper margin of the right sterno-

FIG. 457.—THE SUBCLAVIAN ARTERY. (After Toldt, "Atlas of Human Anatomy," Rebman, London and New York.)

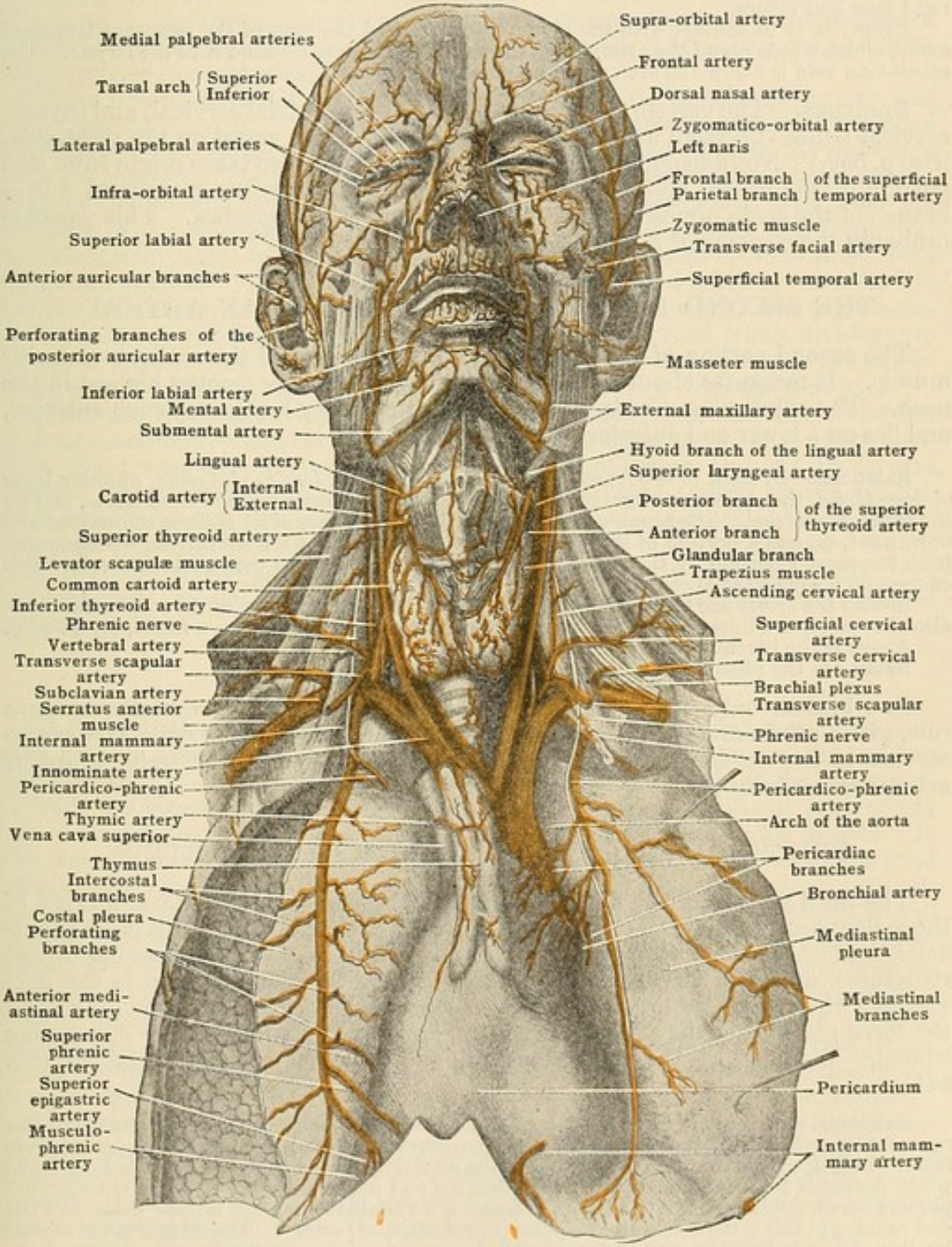

clavicular joint, upward and laterally in a gentle curve over the apex of the right lung and pleura to the medial border of the scalenus anterior. It measures about 3 cm. ($1\frac{1}{4}$ in.). In this course it ascends in the neck a variable distance above the clavicle, but is so deeply placed, so surrounded by important structures, and gives

off so many large branches, that it is now seldom or never selected for the application of a ligature.

Relations.—In front it is covered by the integuments, the superficial fascia, the platysma, the anterior layer of the deep fascia, the clavicular origin of the sterno-mastoid, the sterno-hyoid and sterno-thyreoid muscles, and the deep cervical fascia. It is crossed by the commencement of the innominate, by the internal jugular, and by the vertebral veins; and, in a medio-lateral direction, by the vagus and phrenic nerves, and the superior cardiac branches of the sympathetic nerve. A loop of the sympathetic nerve itself also crosses the artery, and forms with the trunk of the sympathetic a ring around the vessel known as the **ansa subclavia** (annulus of Vieussens).

Behind, but separated from the artery by a cellular interval, are the longus colli muscle, the transverse process of the seventh cervical or first thoracic vertebra, the main chain of the sympathetic nerve, the inferior cardiac nerves, the recurrent laryngeal nerve, and the apex of the right lung and pleura.

Below, it is in contact with the pleura and lung and the loop of the recurrent laryngeal nerve, which winds round the artery from the vagus and ascends behind it to the larynx. The subclavian vein is below the artery and on an anterior plane.

Branches.—The vertebral, internal mammary, superficial cervical, and thyreo-cervical trunk (thyreoid axis) arise from this part of the vessel on the right side. (See p. 559.) Not uncommonly a small aberrant artery also takes origin from this portion of the artery and descends to the left behind the œsophagus to join a branch of the aorta opposite the third or fourth thoracic vertebra. This vessel is probably the remains of the right dorsal aorta.

THE SECOND PORTION OF THE SUBCLAVIAN ARTERY

The **second portion of the subclavian artery** lies behind the scalenus anterior muscle. It measures about 2 cm. ($\frac{3}{4}$ in.) in length and here reaches highest in the neck. The subclavian vein is separated from the artery by the scalenus anterior, and lies on a lower and anterior plane (fig. 463).

Relations.—In front it is covered by the skin, superficial fascia, platysma, anterior layer of deep fascia, the clavicular origin of the sterno-mastoid, posterior layer of deep fascia, and by the scalenus anterior. The phrenic nerve—which, in consequence of its oblique course medially downward, crosses a portion of both the first and second part of the subclavian—is separated from the second portion by the scalenus anterior muscle, as is also the subclavian vein which courses on a somewhat lower plane.

Behind the artery are the apex of the pleura and lung, and a portion of the scalenus medius; also the scalenus minimus (partially or entirely fibrous, known as Sibson's fascia, see p. 355).

Above is the brachial plexus.

Below are the pleura and lung.

One **branch** only—the costo-cervical trunk (superior intercostal)—is, as a rule, given off from this portion of the subclavian; occasionally the transverse cervical or the descending branch of the transverse cervical (posterior scapular artery) arises from it.

THE THIRD PORTION OF THE SUBCLAVIAN ARTERY

The **third portion of the subclavian artery** extends from the lateral margin of the scalenus anterior muscle to the lateral border of the first rib. It is more superficial than either the first or second portions; it is in relation with less important structures, and as a rule gives off no branch, and for these reasons is the part selected when practicable for the application of a ligature. It is the longest of the three portions of the subclavian artery, and lies in a triangle—the subclavian triangle—bounded by the sterno-mastoid, the omo-hyoid, and the clavicle (fig. 445).

Relations.—In front it is covered by skin, superficial fascia, platysma, supra-clavicular nerves (descending superficial branches) of the cervical plexus; the anterior layer of deep fascia which descends from the omo-hyoid to the clavicle; and the posterior layer of deep fascia which descends from the omo-hyoid to the first rib and passes over the scalenus anterior and phrenic nerve. Between the two layers of fascia is a variable amount of cellular tissue and fat, and running in this is the transverse scapular (supra-scapular) artery. The subclavian is crossed by this artery unless the arm is drawn well downward. Close to the lateral margin of the sterno-mastoid, the external jugular vein pierces the fascia, and crosses the subclavian artery to open into the subclavian vein. As this vein lies between the two layers of fascia, it receives on its lateral side the transverse scapular (supra-scapular), transverse cervical, and other veins of the neck, which together form a plexus of large veins in front of the artery. The nerve to the subclavius, and, when present, the accessory branch from this nerve to the phrenic, also

here cross in front of the artery. In very muscular subjects the clavicular head of the sterno-mastoid may be larger than usual, and in such a case will form one of the coverings of the artery.

Behind, the artery is in contact with the scalenus medius, and with the lower trunk of the brachial plexus.

Below, the artery rests in the posterior of the two grooves on the upper surface of the first rib.

Above is the brachial plexus of nerves and the posterior belly of the omo-hyoid muscle. The trunk formed by the fifth and sixth cervical nerves is also above the artery, but on a somewhat anterior plane. It is close to the vessel, and has been mistaken for the artery in the application of a ligature.

As a rule there is no branch given off from the third portion of the subclavian. At times, however, the transverse cervical or the descending branch of the transverse cervical (posterior scapular artery) may arise from the third portion of the subclavian instead of from the thyreo-cervical trunk (thyreoid axis) and from the transverse cervical respectively, as here described.

There is considerable variation in the branches of the subclavian artery and Bean (Am. Jour. Anat., Vol. 4, p. 303) has shown that the branches are arranged in a different way on the two sides of the body. The usual form on the right side is for the vertebral, internal mammary, the superficial cervical and the common trunk of the inferior thyreoid and transverse scapular arteries to arise from the first part of the subclavian. In this case the ascending cervical is a branch of the inferior thyreoid, while the transverse cervical and costo-cervical arise from the second portion. There are no branches from the third portion. On the left side the usual form is for the vertebral and internal mammary, and thyreo-cervical trunk, to arise from the first part. The thyreo-cervical trunk divides into inferior thyreoid, transverse scapular, and transverse cervical arteries; the superficial cervical is absent, and the costo-cervical trunk arises from the first part.

There are three more types of origin of the branches; in one, the vertebral, internal mammary, costo-cervical, and inferior thyreoid come from the first part, while the transverse cervical arises from the second part, and the transverse scapular comes either from the third part or the axillary artery; in the second, the inferior thyreoid, transverse scapular and transverse cervical arise in a common stem from the first part; while in the third, which is the rarest form, the inferior thyreoid and superficial cervical arteries come by a common trunk from the first part, while the transverse scapular artery arises from the internal mammary.

1. THE VERTEBRAL ARTERY

The **vertebral** artery [a. vertebralis] (fig. 458) the first, largest, and most constant branch, arises from the upper and posterior part of the first portion of the subclavian, on the right side, about 2 cm. ($\frac{3}{4}$ in.) from the origin of the latter vessel from the innominate, on the left side, from the most prominent part of the arch of the subclavian, close to the medial edge of the scalenus anterior muscle. It first ascends vertically to the foramen transversarium of the sixth cervical vertebra, and, having passed through that foramen and those of the next succeeding cervical vertebræ as high as the epistropheus (axis), it turns laterally and then ascends to reach the foramen in the transverse process of the atlas; after passing through that foramen it turns backward behind the articular process, lying in the groove on the posterior arch of the atlas. It next pierces the posterior occipito-atlantoid membrane and the dura mater, and enters the cranium through the foramen magnum. Here it passes upward, at first lying by the side of the medulla, then in front of that structure, and terminates at the lower portion of the pons by anastomosing with the vertebral of the opposite side to form the basilar.

The vertebral artery may be divided for purposes of description into four parts: **the first,** or **cervical,** extending from its origin to the transverse process of the sixth cervical vertebra; the **second,** or **vertebral,** situated in the foramina transversaria; the **third,** or **occipital,** contained in the suboccipital triangle; and the **fourth,** or **intracranial,** within the cranium.

The first or cervical portion.—The artery here lies between the scalenus anterior and longus colli muscles. **In front** it is covered by the vertebral and internal jugular veins, and is crossed by the inferior thyreoid artery, and on the left side, in addition, by the thoracic duct, which runs over it medio-laterally. **Behind,** the artery lies on the transverse process of the seventh cervical vertebra and the sympathetic nerve. To its **medial side** is the longus colli. To its lateral

side is the scalenus anterior. It gives off as a rule no branch in this part of its course. Occasionally, however, a small branch passes into the foramen tranversarium of the seventh cervical vertebra.

The second or vertebral portion.—As the artery passes through the foramina transversaria, it is surriunded by a plexus of veins and by branches of the sympathetic nerve. The cervical nerves lie behind it. Between the transverse processes it is in contact with the intertransverse muscles.

The third or occipital portion.—The artery here lies in the suboccipital triangle, bounded by the superior oblique, inferior oblique, and rectus capitis posterior major muscles. As it winds round the groove on the atlas, it has the rectus capitis lateralis, the articular process, and the posterior occipito-atlantoid membrane **in front** of it; the superior oblique, the rectus capitis posterior major, and the semispinalis capitis (complexus) **behind** it. Separating it from the arch of the atlas, is the first cervical or suboccipital nerve.

The **fourth or intracranial portion** extends from the aperture in the dura mater to the lower border of the pons, where it pierces the arachnoid and unites with its fellow to form the basilar artery. It here winds round from the side to the front of the medulla, lying in the

FIG. 458.—SCHEME OF THE LEFT VERTEBRAL ARTERY. (Walsham.)
The internal jugular and vertebral veins are hooked aside to expose the artery.

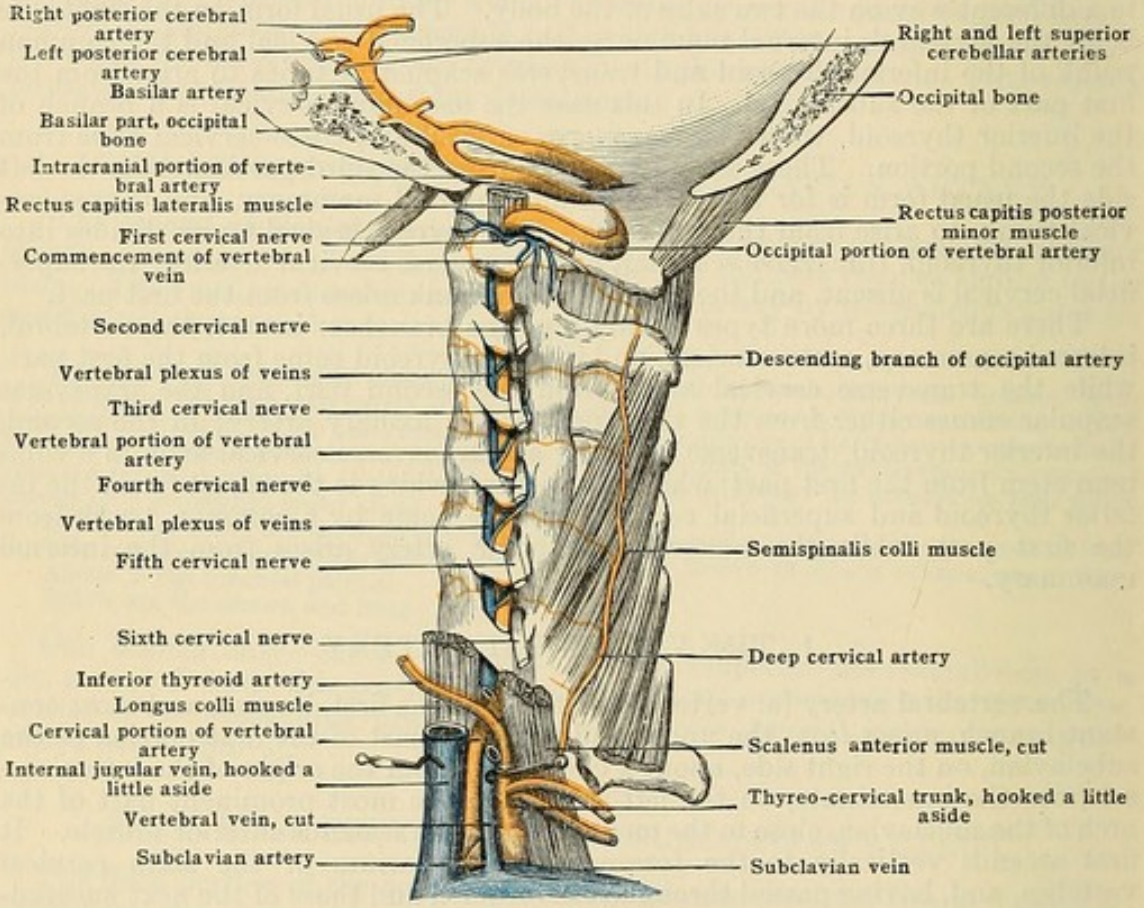

vertebral groove on the basilar part of the occipital bone. In this course it passes beneath the first process of the ligamentum denticulatum, and between the hypoglossal nerve in front, and the anterior roots of the suboccipital nerve behind.

BRANCHES OF THE VERTEBRAL ARTERY

The first part of the vertebral artery gives no branches. The second and third parts give off *muscular* branches to the semispinalis and posterior recti and oblique muscles. The second part also gives off five or six, (1) Spinal branches. The fourth part gives off the following: (2) Posterior meningeal; (3) posterior spinal; (4) anterior spinal; and (5) posterior inferior cerebellar.

(1) The **spinal** branches [rami spinales] run through the intervertebral foramina into the vertebral canal, and there divide into two branches: one of which ramifies on the backs of the bodies of the cervical vertebræ; while the other runs along the spinal nerves, supplies the cord and its membranes, and anastomoses with the arteries above and below.

(2) The **meningeal** [ramus meningeus] is a small branch given off as the vertebral artery pierces the dura mater to enter the cranium. It supplies the bone and dura mater of the posterior fossa of the skull, and anastomoses with the posterior meningeal branches derived from the occipital and ascending pharyngeal arteries. It gives branches to the falx cerebelli.

(3) The **posterior spinal** artery [a. spinalis posterior] runs downward obliquely along the side of the medulla to the back of the cord, down which it passes behind the roots of the spinal nerves, being reinforced by spinal branches accompanying these nerves, in the neck, the thoracic, and in the lumbar region. It can be traced as low as the end of the spinal cord.

(4) The **anterior spinal** artery [a. spinalis anterior] comes off from the vertebral a little below its termination in the basilar artery. Descending with a medial slant in front of the medulla, it unites on a level with the foramen magnum with its fellow of the opposite side. The single vessel thus formed runs downward in front of the spinal cord beneath the pia mater as far as the termination of the cord, being reinforced by the spinal branches on the way down. The spinal arteries are described in detail with the anatomy of the spinal cord.

(5) The **posterior inferior cerebellar** [a. cerebelli inferior posterior] (fig. 456)—the largest branch of the vertebral—arises from that vessel just before it joins its fellow to form the basilar artery. At times it may come off from the basilar itself. It runs, at first laterally across the restiform body between the origin of the vagus and hypoglossal nerves, and, descending toward the vallecula, there divides into two branches, medial and lateral. (*a*) The *medial branch* runs backward between the vermis and the lateral hemisphere of the cerebellum. It supplies the vermis, and anastomoses with the artery of the opposite side, and with the superior vermian of the superior cerebellar. (*b*) The *lateral branch* runs laterally and, ramifying over the under surface of the cerebellar hemisphere, supplies its cortex and anastomoses along its lateral margin with the superior cerebellar arteries.

From the undivided trunk of the posterior inferior cerebellar artery branches are given to the medulla oblongata, supplying the chorioid plexus and the fourth ventricle.

THE BASILAR ARTERY

The **basilar** artery [a. basilaris] is formed by the confluence of the right and left vertebral arteries, which meet at an acute angle at the lower border of the pons. It runs forward and upward in a slight groove in the middle line of the pons, and divides at the upper border of that structure at the level of the tentorial notch into the two posterior cerebral arteries, which take part in the formation of the circle of Willis (fig. 456).

Branches of the Basilar Artery

The **branches of the basilar artery** are:—1. Pontine; 2. internal auditory; 3. anterior inferior cerebellar; 4. superior cerebellar; 5. posterior cerebral.

(1) The **pontine** branches [rami ad pontem] are numerous small vessels which come off at right angles on either side of the basilar artery, and, passing laterally over the pons, supply that structure and adjacent parts of the brain.

(2) The **internal auditory** artery [a. auditiva interna], a long slender vessel, accompanies the auditory nerve into the internal auditory meatus (fig 514). It here lies between the facial and auditory nerves, and at the bottom of the meatus passes into the internal ear, and anastomoses with the other auditory arteries. (See Internal Ear.)

(3) The **anterior inferior cerebellar** [a. cerebelli inferior anterior] arises from the basilar soon after its origin, passes laterally and backward across the pons, and then over the brachium pontis to the front part of the under surface of the cerebellum. It anastomoses with the posterior inferior cerebellar artery (fig. 456).

(4) The **superior cerebellar** [a. cerebelli superior] comes off from the basilar immediately behind its bifurcation into the posterior cerebral arteries. It courses laterally and backward over the pons, in a curve roughly corresponding to that of the posterior cerebral artery, from which it is separated by the third cranial nerve; but, soon sinking into the groove between the pons and the pedunculus cerebri, it curves round the latter onto the upper surface of the cerebellum, lying nearly parallel to the fourth nerve. Here it divides into two branches medial and lateral. (*a*) The *medial branch* courses backward along the superior vermis, anastomosing with its fellow of the opposite side, and, at the posterior notch of the cerebellum, with the inferior vermian branch of the posterior inferior cerebellar artery. (*b*) The *lateral* runs to the circumference of the cerebellum, anastomosing with the lateral branch of the inferior posterior cerebellar artery.

Branches are given off from the main trunk of the superior cerebellar artery, or from its medial branch to the anterior velum (valve of Vieussens), the corpora quadrigemina, the pineal body, and the chorioid plexus.

(5). The **posterior cerebral** arteries [aa. cerebri posteriores] are the two terminal branches into which the basilar bifurcates at the upper border of the pons, immediately behind the posterior perforated substance. Each artery runs at first laterally and a little forward across the pedunculus cerebri immediately in front of the third nerve, which separates it from the superior cerebellar artery. After receiving the posterior communicating artery, which runs backward from the internal carotid, the posterior cerebral turns backward onto the under surface of the cerebral hemisphre, where it breaks up into branches for the supply of the temporal and occipital lobes.

The **branches of the posterior cerebral artery** are described below in connection with those of the other cerebral arteries.

Distribution of the Cerebral Arteries

Although the brain receives its blood supply from two distinct sources, namely, from the internal carotids and from the vertebrals, it is convenient to consider together the distribution of the various cerebral branches derived from these stems. The formation of the circulus arteriosus (circle of Willis) and the origin of the anterior, middle and posterior cerebral arteries has already been described (pp. 554, 561). The detailed distribution of these vessels will now be considered. In general, their branches may be divided into *central* or *ganglionic* and *peripheral* or *cortical*.

The **anterior cerebral artery** has but a limited **central** distribution. It gives off a few inconstant branches which enter the anterior perforated substance and supply the anterior end of the caudate nucleus. One or two of these run to the corpus callosum and septum pellucidum. The **anterior communicating** branch is a transverse trunk which connects the two arteries and thereby completes the circulus arteriosus in front. It lies in front of the optic chiasm, and varies considerably in length and size. It may give off some of the branches to the anterior perforated substance. The **cortical branches** supply the gyrus rectus, the olfactory lobe and a part of the orbital gyri on the ventral surface. On the medial surface branches supply the cortex as far back as the parieto-occipital fissure. These branches are given off as the artery

Fig. 459.—The Arteries of the Mesial Surface of the Brain. (After Spalteholz.)

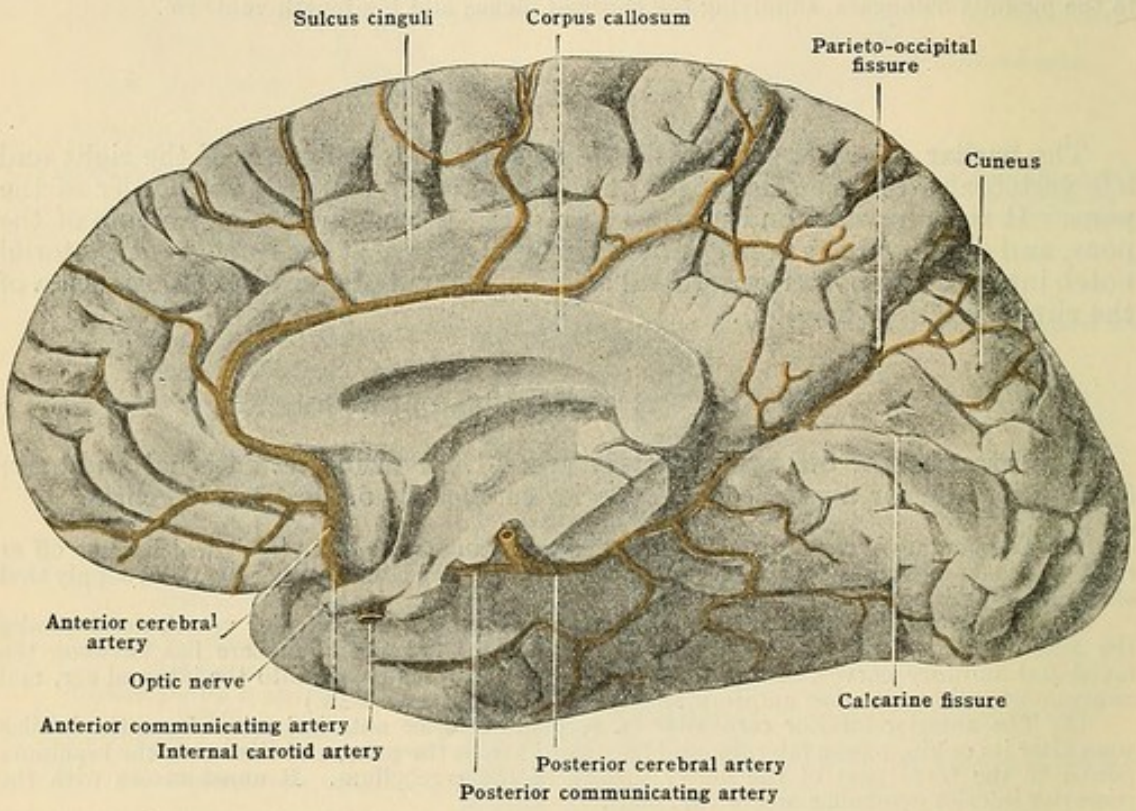

curves around the corpus callosum and some of them curve over onto the lateral surface and supply the superior and middle temporal convolutions. Branches from the anterior cerebral artery also supply the corpus callosum (fig. 459).

The **middle cerebral artery** gives off most of the branches to the basal ganglia and supplies the greater part of the lateral surface of the brain. It runs through the lateral fissure (fissure of Sylvius) (fig. 460). The *branches* of the middle cerebral include the following:

The **central branches** are:—(i) The **caudate,** two or three small branches, which arise from the medial aspect of the artery and pass through the medial part of the floor of the lateral fissure (fissure of Sylvius) to the head of the caudate nucleus. (ii) The **antero-lateral** are numerous small arteries which pass through the anterior perforated substance and supply the caudate nucleus (except its head), the internal capsule, and part of the optic thalamus. (iii) The **lenticulostriate,** a larger branch of the antero-lateral set, passes through a separate aperture in the lateral part of the anterior perforated substance, runs upward between the lenticular nucleus, which it supplies, and the external capsule, perforates the internal capsule, and terminates in the caudate nucleus. It has been so frequently found ruptured in apoplexy that it is called by Charcot the 'artery of cerebral hæmorrhages.' (iv) Sometimes a more or less distinct branch, called **lenticulo-optic,** is distributed to the lateral and hinder portion of the lenticular nucleus and the lateral portion of the optic thalamus.

The **cortical branches** come off opposite the insula. They supply the insula, the inferior frontal gyri, the central gyri (anterior and posterior), the parietal lobules, superior and inferior, the supra-marginal, angular, and superior temporal gyri.

The **posterior cerebral** give off both central and cortical branches. The **central branches** are the postero-median, posterior chorioid, and the postero-lateral. The **postero-median**

enter the posterior perforated substance and supply the medial portion of the optic thalamus, and the walls of the third ventricle; the **posterior chorioid** pass through the transverse fissure to the tela chorioidea (velum interpositum) and chorioid plexus; the **postero-lateral** run to the posterior part of the optic thalamus and give branches to the cerebral peduncles and the corpora quadrigemina.

The **cortical branches** of the posterior cerebral supply the entire occipital lobe and all of the temporal lobe except the superior temporal gyrus (fig. 459).

In regard to the cerebral arteries in general it may be said that there is no anastomosis between the cortical and central branches, the two forming distinct and separate systems. The cortical may or may not anastomose with each other, but the communication between the neighbouring cortical branches is seldom sufficient to maintain the nutrition of an area when the vessel that normally supplies it is obstructed. The central branches are so-called end-vessels and do not anastomose with each other. Hence obstruction of the middle cerebral artery leads to softening of the area supplied by its central branches, but not always to softening of the region supplied by its cortical branches. Indeed, the cortical region may escape completely, although the central area is irreparably disorganised. The gross anastomosis of the posterior cerebral with the anterior cerebral arteries through the circulus arteriosus has already been described. To sum up the distribution of the cerebral arteries, the branches of each are divided into the central, or ganglionic and the peripheral or cortical. The central branches arise at the commencement of the cerebral arteries about the circulus arteriosus whilst the cortical are derived chiefly from the termination of these vessels.

FIG. 460.—THE ARTERIES OF THE LATERAL SURFACE OF THE BRAIN. (After Toldt, "Atlas of Human Anatomy," Rebman, London and New York.)

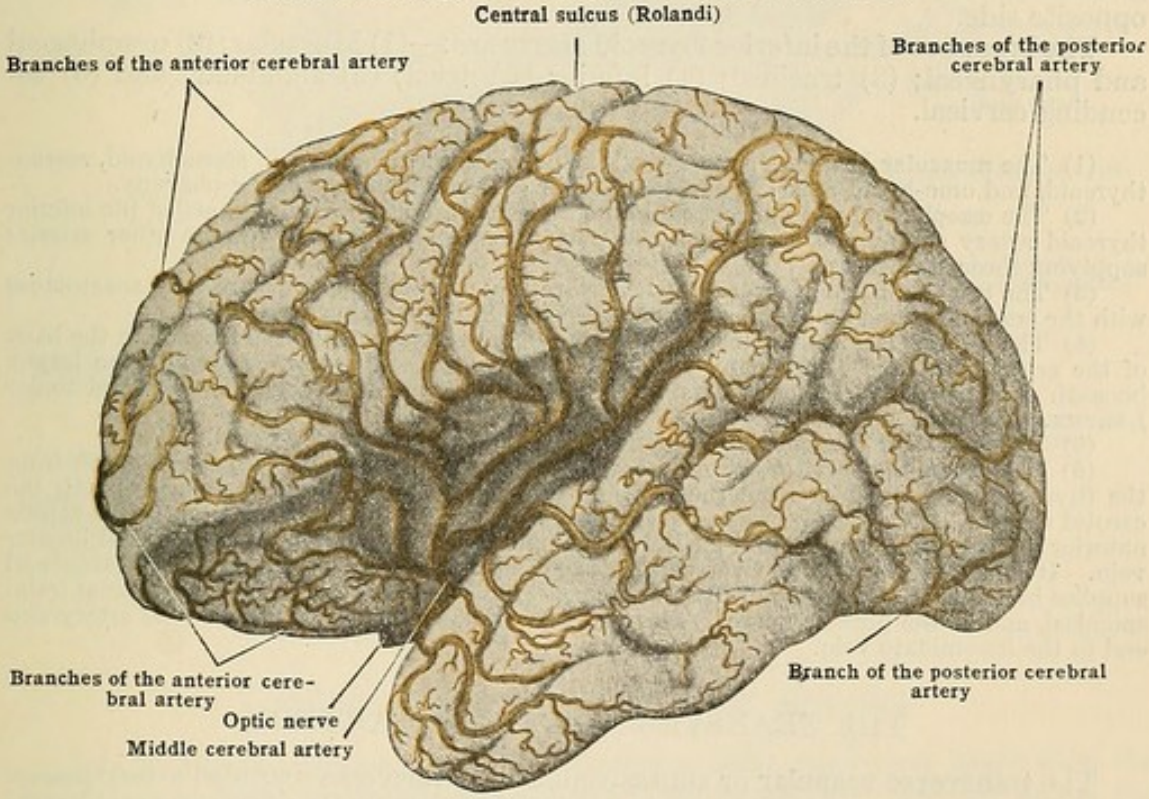

(A) The **central branches** are divided into four sets—two median and two lateral. 1. The **two median** are—(1) The **antero-median,** which arise from the anterior cerebral and the anterior communicating, and supply the fore end of the caudate nucleus, and (2) the **postero-median,** which arise from the posterior cerebral and supply the medial part of the optic thalamus and neighbouring wall of the third ventricle. 2. The **two lateral** are:—(1) The **antero-lateral** arise from the middle cerebral, and, passing through the anterior perforated substance, supply the lenticular nucleus, the posterior part of the caudate nucleus, the internal and external capsules, and the lateral part of the optic thalamus. (2) The **postero-lateral** arise from the posterior cerebral, and supply the hinder part of the optic thalamus, the pedunculus cerebri, and the corpora quadrigemina.

(B) The **cortical branches** ramify in the pia mater, giving off branches to the cortical substance, some of which extend through it to the underlying white substance.

It will be seen that the middle cerebral supplies the somæsthetic area of the cortex. It also supplies the cortical auditory centre, and, in part, the higher visual centre. The anterior cerebral supplies only a small part of the somæsthetic area, namely, the part of the leg centre that occupies the paracentral lobule and the highest part of the anterior central gyrus. The posterior cerebral supplies the visual path from the middle of the tract backward, and the half vision centre in the occipital lobe. It supplies also the corpora quadrigemina and the sensory part of the internal capsule.

The branches which supply the cerebellum and brain stem are given in connection with the vertebrals on page 561.

2. THE THYREOCERVICAL TRUNK

The **thyreocervical trunk** [truncus thyreocervicalis] or **thyreoid axis** arises from the upper and front part of the subclavian artery, usually opposite the internal mammary, and slightly medial to the scalenus anterior. It is a short thick trunk, and divides almost immediately into three radiating branches—namely, the **inferior thyreoid,** the **transverse scapular,** and the **transverse cervical** (figs. 444, 457). This is the usual form only on the left side (see page 559). It may give off also the **ascending cervical.**

THE INFERIOR THYREOID ARTERY

The **inferior thyreoid** artery [a. thyreoidea inferior] is the largest of the three branches into which the thyreocervical trunk (thyreoid axis) divides, and may arise in a common trunk with the transverse scapular, or as a branch of the subclavian. It ascends tortuously passing medially in front of the vertebral artery, the inferior laryngeal nerve and the longus colli muscle, and behind the common carotid and the sympathetic nerve or its middle cervical ganglion, to the thyreoid gland, where it anastomoses with the superior thyreoid artery and the artery of the opposite side.

The branches of the inferior thyreoid artery are:—(1) Muscular; (2) œsophageal and pharyngeal; (3) tracheal; (4) inferior laryngeal; (5) glandular; and (6) ascending cervical.

(1) The **muscular** branches supply the scalenus anterior, longus colli, sternohyoid, sternothyreoid, and omo-hyoid muscles, and the inferior constrictor muscle of the pharynx.

(2) The **œsophageal and pharyngeal** branches [rami œsophagei et pharyngei] of the inferior thyreoid artery supply the œsophagus and pharynx and anastomose with the other arteries supplying those structures.

(3) The **tracheal** branches [rami tracheales] ramify on the trachea, where they anastomose with the tracheal branches of the superior thyreoid and bronchial arteries.

(4) The **inferior laryngeal** artery [a. laryngea inferior] passes along the trachea to the back of the cricoid cartilage in company with the inferior laryngeal nerve. It enters the larynx beneath the inferior constrictor. Its further distribution in that organ is described under LARYNX.

(5) The **glandular** branches [rami glandulares] supply the thyreoid gland.

(6) The **ascending cervical** artery [a cervicalis ascendens] (figs. 444, 457) is given off from the thyreocervical trunk or from the inferior thyreoid as that vessel is passing beneath the carotid sheath. It ascends between the scalenus anterior and the longus capitis (rectus capitis anterior major), lying parallel and medial to the phrenic nerve and behind the internal jugular vein. It anastomoses with the vertebral, ascending pharyngeal, and occipital arteries, and supplies branches to the deep muscles of the neck [rami musculares], to the spinal canal [rami spinales], and to the phrenic nerve. Two veins accompany the ascending cervical artery and end in the innominate vein.

THE TRANSVERSE SCAPULAR ARTERY

The **transverse scapular** or suprascapular [a. transversa scapulæ] artery passes laterally across the root of the neck, lying first beneath the sterno-mastoid, and then in the subclavian triangle behind the clavicle and subcalvius muscle. At the lateral angle of this space it is joined by the suprascapular nerve, sinks beneath the posterior belly of the omo-hyoid, and passes over the ligament bridging the scapular notch, the nerve passing through the notch (fig. 461). It then ramifies in the supraspinous fossa of the scapula, and, winding downward round the base of the spine over the neck of the scapula, enters the infraspinous fossa, and terminates by anastomosing with the circumflex (dorsal) scapular artery, and the descending branch of the transverse cervical (posterior scapular) artery.

As it lies under cover of the sterno-mastoid muscle, it crosses the phrenic nerve and the scalenus anterior; and as it courses through the subclavian triangle, it is separated by the cervical fascia which descends from the omo-hyoid to the first rib, from the subclavian artery and brachial plexus of nerves. If this artery is seen in tying the subclavian it should not be injured, as it is one of the chief vessels by which the collateral circulation is carried on after ligature of the subclavian in the third part of its course. At the lateral part of the subclavian triangle it is covered by the trapezius, and after passing over the transverse scapular ligament it pierces the supraspinous fascia and passes beneath the supra-spinatus muscle, ramifying between it and the bone. In the infraspinous fossa it lies between the infra-spinatus and the bone. The artery is accompanied by two veins.

The **branches of the transverse scapular** are:—(1) the **nutrient,** to the clavicle; (2) the **acromial** [ramus acromialis] to the arterial rete or plexus on the acromial process, to reach which it pierces the trapezius; (3) the **articular,** to the acromio-clavicular joint and shoulder-joint; (4) the **subscapular,** given off as the artery is passing over the transverse scapular ligament, descends to the subscapular fossa between the subscapularis and the bone, and anastomoses with the infrascapular branch of the circumflex (dorsal) scapular artery, and with the subscapular and transverse cervical arteries; (5) the **supraspinous** branches, which ramify in the supraspinous fossa, and supply the supra-spinatus muscle and the periosteum, and the nutrient artery to the bone; (6) the **infraspinous** branches, which ramify in a similar way in the infraspinous fossa, giving off twigs to the infra-spinatus muscle, the periosteum, and the bone.

FIG. 461.—SCHEME OF ANASTOMOSES OF THE RIGHT SCAPULAR ARTERIES. (Walsham.)

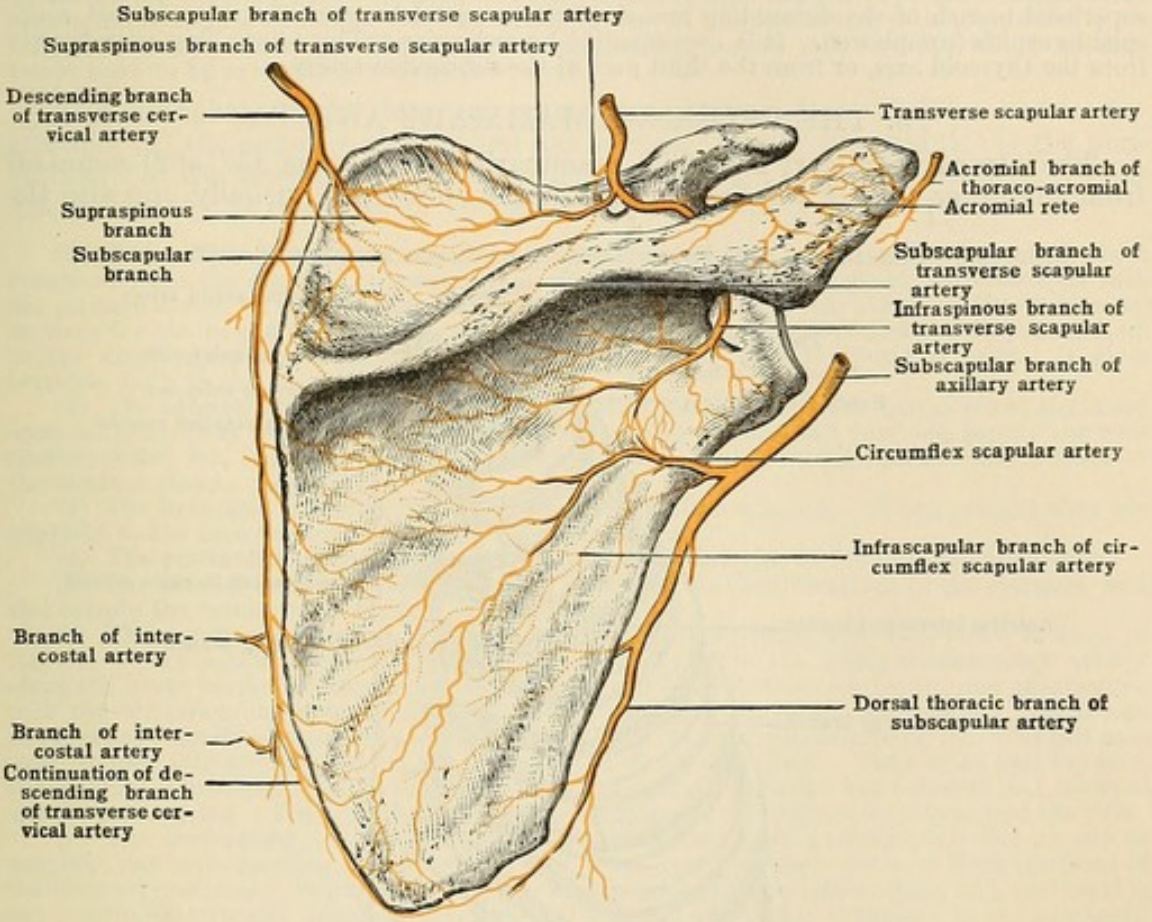

THE TRANSVERSE CERVICAL ARTERY

The **tranverse cervical** artery [a. transversa colli], somewhat larger than the transverse scapular (suprascapular), runs like the latter vessel laterally across the root of the neck, but on a slightly higher transverse plane, and a little above the clavicle. At its origin from the thyreo-cervical trunk (thyreoid axis) it lies under the sterno-mastoid; on leaving the cover of this muscle, it crosses the upper part of the subclavian triangle, lying here only beneath the platysma and cervical fascia; further laterally, it passes beneath the anterior margin of the trapezius and omo-hyoid muscle, and at the lateral margin of the levator scapulæ divides into a descending (posterior scapular) and an ascending (superficial cervical) branch. In this course it crosses the phrenic nerve, the scalenus anterior, the brachial plexus, and the scalenus medius. Sometimes it passes between the cords of the brachial plexus.

The **branches of the transverse cervical artery** are:—(1) a descending (posterior scapular); and (2) an ascending (or superficial) cervical. The descending branch occasionally arises from the third portion of the subclavian artery.

(1) The **descending branch,** or **posterior scapular** [ramus descendens] the apparent continuation of the transverse cervical artery, begins at the lateral border of the levator scapulæ, and, continuing its course beneath this muscle to the upper and posterior angle of the scapula, turns downward and skirts along the posterior border of the scapula, between the serratus anterior

(magnus) in front and the levator scapulæ and rhomboideus minor and major behind, to the inferior angle, where it anastomoses with the subscapular artery. It gives off the following branches:—(*a*) **Supraspinous,** which ramifies between the supraspinous muscle and the trapezius, and sends branches through the muscle into the fossa, to anastomose with the transverse scapular artery. (*b*) **Infraspinous** branches, one or more of which enter the infraspinous fossa, and anastomose with the circumflex (dorsal) scapular. (*c*) **Subscapular** branches, which enter the subscapular fossa, and anstomose with the branches of the transverse scapular and subscapular arteries. (*d*) **Muscular** branches, to the muscles between which it runs and to the latissimus dorsi. These branches anastomose with the posterior divisions of the intercostal arteries.

(2) The **ascending branch** or **superficial cervical artery** [r. ascendens], smaller than the descending branch, ascends under the anterior margin of the trapezius, lying upon the levator scapulæ and splenius muscles. It supplies branches to the trapezius, levator scapulæ, and splenius muscles, and the posterior chain of lymphatic glands. It anastomoses with the superficial branch of the descending branch of the occipital between the splenius and semi-spinalis capitis (complexus). It is accompanied by two veins. This artery may arise directly from the thyreoid axis, or from the third part of the subclavian artery.

3. THE INTERNAL MAMMARY ARTERY

The **internal mammary** artery [a. mammaria interna] (figs. 457, 462) comes off from the lower part of the first portion of the subclavian, usually opposite the

FIG. 462.—SCHEME OF THE RIGHT INTERNAL MAMMARY ARTERY. (Walsham.)

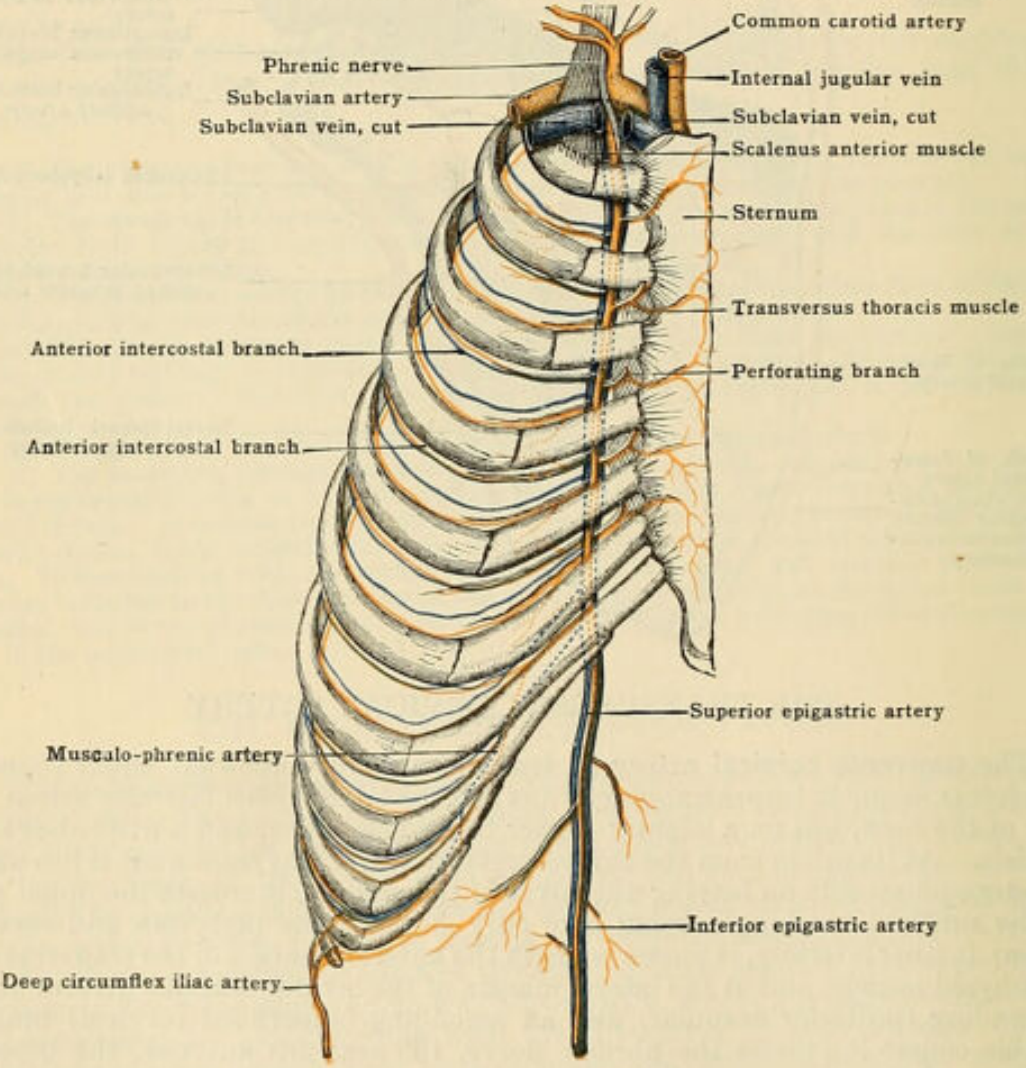

thyreo-cervical trunk (thyreoid axis), close to the medial edge of the scalenus anterior, occasionally opposite the vertebral, or at a spot between these two vessels. It descends with a slight inclination forward and medialward, under cover of the clavicle, and enters the thorax behind the cartilage of the first rib, and thence passes down behind the cartilages of the next succeeding ribs, about 1.2 cm. ($\frac{1}{2}$ in.) from the lateral margin of the sternum, to the sixth interspace, where it divides into the **superior epigastric** and **musculo-phrenic.** It is accompanied by two veins, which unite into one trunk behind the first intercostal muscle; this

passes to the medial side of the artery into the corresponding vena innominata, or occasionally on the right side into the vena cava superior direct. The artery may be divided into two portions, the *cervical* and the *thoracic*.

The **cervical portion** is covered by the sterno-mastoid muscle, subclavian vein, and internal jugular vein, and is crossed obliquely, in the latero-medial direction, by the phrenic nerve. It rests upon the pleura and courses around the upper part of the innominate vein. There is no branch from this part of the artery.

The **thoracic portion** lies behind the cartilages of the six upper ribs, and in the interspace between the ribs has in front of it the pectoralis major and the internal intercostal muscles and external intercostal ligaments. Behind, it is in contact above with the pleura, but it is separated from it lower down by slips of the transversus thoracis (triangularis sterni). On the left side, the artery between the fourth and sixth ribs may be said to be in the anterior mediastinum, the pleura here forming a notch for the heart. In the first, second, and third spaces the artery, if wounded, can be easily tied; but in the fourth space the operation is attended with more difficulty. The remaining spaces are so narrow that a portion of the cartilage would have to be removed to expose the vessel.

The **branches of the internal mammary artery** are:—(1) The pericardio-phrenic; (2) the anterior mediastinal and thymic; (3) the bronchial; (4) the pericardiac; (5) the sternal; (6) the anterior intercostals; (7) the perforating; (8) the lateral costal; (9) the superior epigastric; and (10) the musculo-phrenic.

(1) The **pericardio-phrenic** artery [a. pericaridiophrenica], is a long slender vessel which comes off from the internal mammary just after it has entered the chest, and descends with the phrenic nerve, at first between the pleura and innominate vein; then (on the right side) between the pleura and the vena cava superior; and lastly, between the pleura and the pericardium to the diaphragm, where it anastomoses with the other diaphragmatic arteries. It gives branches both to the pleura and pericardium.

(2) The **anterior mediastinal** and **thymic** arteries [aa. mediastinales anteriores et thymicæ] come off irregularly from the internal mammary. They are of small size, and supply the connective tissue, fat, and lymphatics in the superior and anterior mediastina and the remains of the thymus gland.

(3) The **bronchial** branches [rami bronchiales] are often wanting. When present they are supplied to the bronchi and the lower part of the trachea.

(4) The **pericardiac** branches are distributed to the anterior surface of the pericardium.

(5) The **sternal** branches [rami sternales] enter the nutrient foramina in the sternum, and also supply the transversus thoracis (triangularis sterni).

(6) The **anterior intercostal** branches [rami intercostales] (figs. 463, 478)—two in each of the five or six upper intercostal spaces—run laterally from the internal mammary artery, along the lower border of the rib above and the upper border of the rib below, and anastomose with the corresponding anterior and collateral branches of the aortic intercostals. Each pair of branches sometimes arises by a common trunk from the internal mammary, which in this case soon divides into an upper and a lower branch, as above described. They lie at first between the internal intercostal muscles and the pleura; afterward between the external and internal intercostal muscles. They supply the contiguous muscles, the pectoralis major, and the ribs.

(7) The **perforating** or **anterior perforating** branches [rami perforantes]—five or six in number, one corresponding to each of the five or six upper spaces—come off from the front of the internal mammary, between the superior and inferior anterior intercostals, and, perforating the internal intercostal muscles, pass forward between the costal cartilages to the pectoralis major, which they supply [*rami musculares*]. The terminal twigs perforate that muscle close to the sternum, and are distributed to the integument [*rami cutanei*]. The **second, third,** and **fourth perforating** supply the inner and deep surface of the mammary gland, and become greatly enlarged during lactation [*rami mammaria*]. They frequently require ligation in excision of the breast.

(8) The **lateral costal** branch [ramus costales lateralis] is given off close to the first rib, and descends behind the ribs just external to the costal cartilages. It anastomoses with the upper intercostal arteries. This vessel is often of insignificant size, or absent.

(9) The **superior epigastric** artery [a. epigastrica superior] (fig. 462), or medial terminal branch of the internal mammary artery, leaves the thorax behind the seventh costal cartilage by passing through the costo-xiphoid space in the diaphragm. It is the direct prolongation of the internal mammary downward. In the abdomen it descends behind the rectus muscle, between its posterior surface and its sheath, and, lower, entering the substance of the muscle, anastomoses with the inferior epigastric, a branch of the external iliac. It gives off the following small branches:—(*a*) The **phrenic,** to the diaphragm; (*b*) the **xiphoid,** which crosses in front of the xiphoid cartilage, and anastomoses with the artery of the opposite side; (*c*) the **cutaneous,** which perforate the anterior layer of the sheath of the rectus and supply the integuments; (*d*) the **muscular,** to the rectus muscle, some of which perforate the rectus sheath laterally, and are distributed to the oblique muscles; (*e*) the **hepatic** (on the right side only), which pass along the falciform ligament to the liver, and anastomose with the hepatic artery; (*f*) the **peritoneal,** which perforate the posterior layer of the sheath of the rectus, and ramify on the peritoneum.

(10) The **musculo-phrenic** artery [a. musculophrenica], or lateral terminal branch of the internal mammary artery, skirts laterally and downward behind the costal cartilages of the false ribs along the costal attachments of the diaphragm, which it perforates opposite the ninth rib. It terminates, much reduced in size, at the tenth or eleventh intercostal space by anastomosing with the ascending branch of the deep circumflex iliac artery. It gives off in its course the following small branches:—(*a*) The **phrenic** for the supply of the diaphragm; (*b*) the **anterior intercostals,** two in number for each of the lower five or six intercostal spaces, are dis-

tributed like those to the upper spaces, already described, and anastomose like them with the corresponding anterior branches of the lower aortic intercostals; (*c*) the **muscular** for the supply of the oblique muscles of the abdomen.

4. THE COSTO-CERVICAL TRUNK

The **costo-cervical trunk** [truncus costocervicalis] (figs. 444, 463) is a short stem which arises usually from the back part of the second portion of the subclavian artery, behind the scalenus anterior on the right side, but commonly just medial to that muscle on the left side. Its course is upward and backward above the dome of the pleura and then downward toward the thorax, before entering which it divides into its two terminal branches.

The **branches of the costo-cervical trunk** are:—(1) the superior intercostal and (2) the deep cervical.

(1) The **superior intercostal** [a. intercostalis suprema] (fig. 463) continues the direction of the costo-cervical trunk, passing downward into the thorax in front of the neck of the first rib. It sometimes terminates opposite the first intercostal space by becoming the first intercostal artery. Usually, however, it is prolonged downward over the neck of the second rib and supplies the second intercostal space in addition. It communicates with the highest aortic intercostal artery. As it crosses the neck of the first rib the superior intercostal lies anterior (ventral) to the first intercostal nerve and lateral to the superior thoracic ganglion of the sympathetic.

FIG. 463.—SCHEME OF THE RIGHT COSTO-CERVICAL TRUNK. (Walsham.)

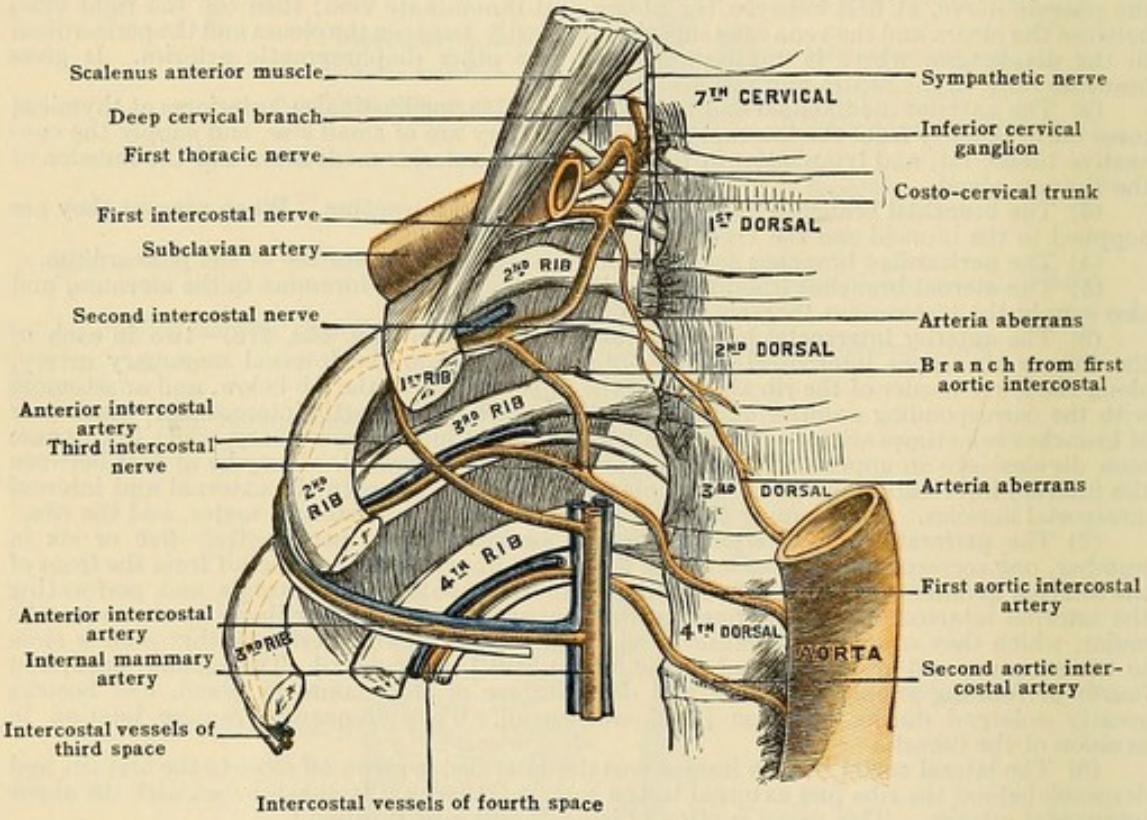

The branches to the first and second intercostal spaces resemble in course and distribution the succeeding intercostals derived from the thoracic aorta (see p. 588). Like the aortic intercostals they give off **dorsal** [rr. dorsales] and **spinal branches** [rr. spinales]. An **arteria aberrans**, when present, arises from the medial side of the right superior intercostal, or occasionally from the right subclavian itself. It descends as a slender vessel into the thorax, passing downward and medially behind the œsophagus as far as the third or fourth thoracic vertebra, where in some cases it anastomoses with a similar slender branch arising from the aorta below the ligamentum arteriosum. This anastomosis represents the remains of the embryonic right dorsal aortic arch, and it is by its occasional enlargement that the anomaly of the right subclavian artery rising from the descending portion of the aortic arch occurs (see p. 637).

(2) The **deep cervical** artery [a. cervicalis profunda] passes directly backward, first between the seventh and eighth cervical nerves, and then between the transverse process of the seventh cervical vertebra and the neck of the first rib, having the body of the seventh cervical vertebra to its medial side, and the intertransverse muscle to its lateral side. It then turns upward in the groove between the transverse and spinous processes of the cervical vertebræ lying upon the semispinalis colli. It is covered by the semispinalis capitis (complexus). Between these muscles it anastomoses with the deep branch of the descending branch (princeps cervicis) of the occipital artery. It gives off a spinal branch which enters the vertebral canal through the intervertebral foramen with the eighth cervical nerve.

THE AXILLARY ARTERY

The term axillary is applied to that portion of the main arterial stem of the upper limb that passes through the axillary fossa. The **axillary** artery [a. axillaris] (fig. 464) therefore is continuous with the subclavian above and with the brachial below. It extends from the lateral border of the first rib to the lower edge of the teres major muscle, and has the shoulder-joint and the neck of the humerus to its lateral side. When the arm is placed close to the side of the body, the artery forms a gentle curve with its convexity upward; but when the arm is carried out from the side at right angles to the trunk in the ordinary dissecting position, the vessel takes a nearly straight course, which will then be indicated by a line drawn from the middle of the clavicle to the groove on the medial side of the coraco-brachialis and biceps muscles. The axillary artery is at first deeply placed beneath the pectoral muscles, but in its lower third it is superficial, being covered

FIG. 464.—THE AXILLARY ARTERY. (After Spalteholz.)

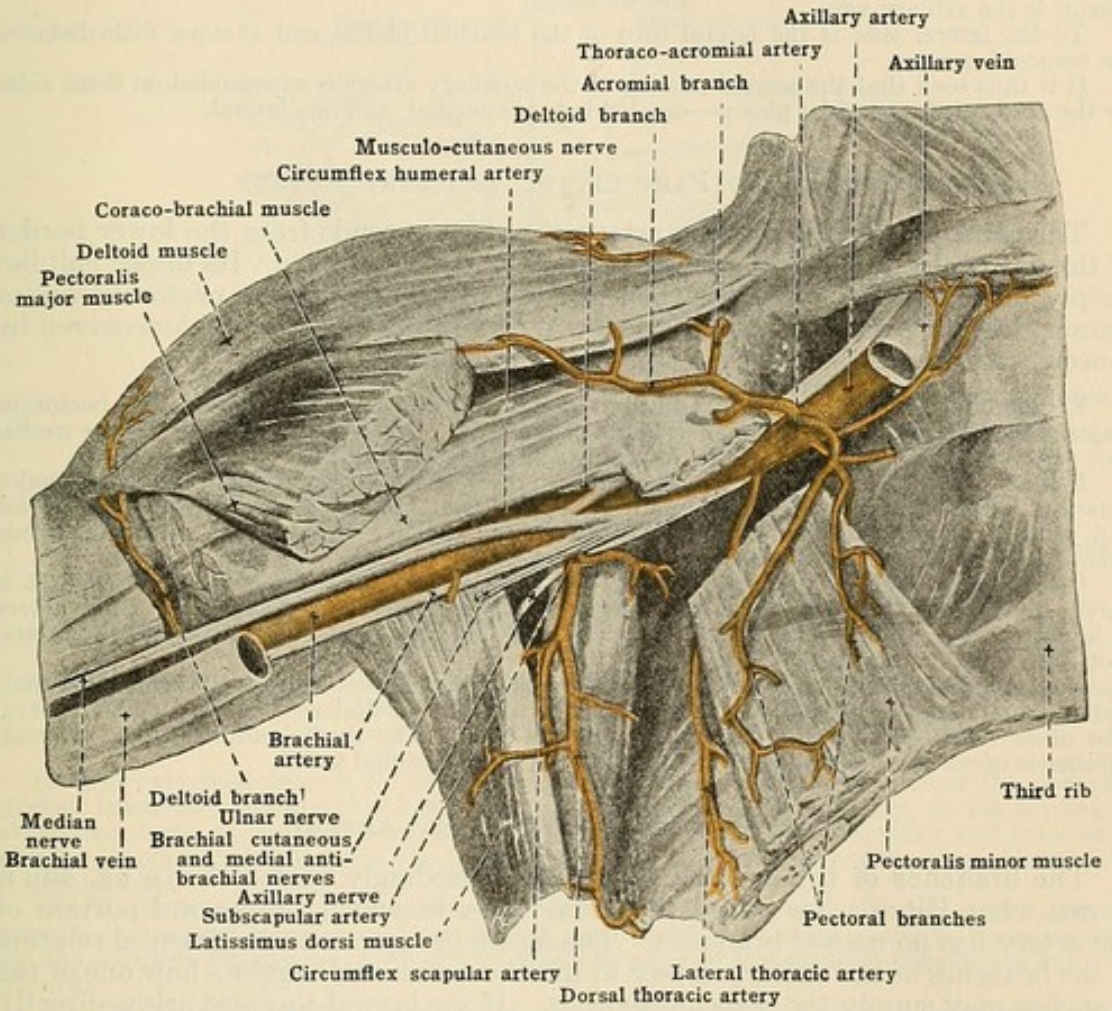

only by the skin and the superficial fascia and deep fascia. It is divided into three parts, first, second, and third, according as it lies respectively above, beneath, or below the pectoralis minor.

THE FIRST PART OF THE AXILLARY ARTERY

The **first part of the axillary artery** extends from the lateral border of the first rib to the upper border of the pectoralis minor. It measures about 2.5 cm. (1 in.) in length.

Relations.—**In front** it is covered by the skin, superficial fascia, lower part of the platysma, the deep fascia, the pectoralis major, the coraco-clavicular (costo-coracoid) fascia, the subclavius muscle and the clavicle when the arm hangs down by the side. The cephalic and thoraco-acromial veins, the external anterior thoracic nerve, and the axillary lymphatic trunk, cross over it. A layer of the deep cervical fascia which has passed under the clavicle also descends in front of it.

Behind, it rests upon the first intercostal space and first intercostal muscle, the first digitation and sometimes a portion of the second digitation of the serratus anterior (magnus) muscle, and a part of the second rib. The long thoracic nerve, on its way to the serratus anterior muscle, passes behind it.

To its **lateral side,** and somewhat on a higher plane, are the cords of the brachial plexus.

To its **medial side,** and on a slightly anterior plane, is the axillary vein. The internal anterior thoracic nerve courses between the vein and the artery.

The Second Part of the Axillary Artery

The **second part of the axillary artery** (fig. 464) lies beneath the pectoralis minor deep in the axilla. It measures 3 cm. (a little more than 1 in.) in length.

Relations.—In front, in addition to the pectoralis minor, it is covered by the pectoralis major and the integuments.

Behind, it is separated by a considerable interval, containing loose connective tissue and fat, from the subscapularis muscle; whilst behind, and in contact with it, is the posterior cord of the brachial plexus.

To the **medial side,** but separated from the artery by the medial cord of the brachial plexus, is the axillary vein.

To the **lateral side** is the lateral cord of the brachial plexus, and at some little distance the coracoid process.

It is thus seen that the second portion of the auxillary artery is surrounded on three sides by the cords of the brachial plexus—one behind, one medial, and one lateral.

The Third Part of the Axillary Artery

The **third part of the axillary artery** (fig. 464) extends from the lower border of the pectoralis minor to the lower border of the teres major. Its upper half lies deeply placed within the axilla, beneath the lower edge of the pectoralis major muscle, but its lower half is in the arm external to the axilla, and is uncovered by muscle. It measures about 7.5 cm. (3 in.) in length.

Relations.—In front it has, in addition to the skin and superficial fascia, the pectoralis major above, and lower down the deep fascia of the arm. It is crossed obliquely by the medial root of the median nerve and by the lateral brachial vena comitans.

Behind, it lies successively upon the subscapularis, the latissimus dorsi, and teres major muscles. From the first-named muscle it is separated at first by a considerable mass of fat and cellular tissue. The radial (musculo-spiral) and axillary (circumflex) nerves intervene between the artery and the muscles.

On its **lateral side** it is separated from the bone by the coraco-brachialis, by which it is partly overlapped, this muscle and the short head of the biceps serving as a guide to the artery in ligature. For a part of its course it has also the musculo-cutaneous nerve and the lateral root of the median nerve to its lateral side.

To its **medial side** it has the axillary vein, the ulnar nerve, the medial antibrachial (internal) and brachial (lesser internal) cutaneous nerves, and the medial root of the median nerve. The ulnar nerve is between the artery and the vein. The medial antibrachial (internal) cutaneous nerve is a little in front of the artery as well as medial to it.

Branches of the Axillary Artery

The **branches of the axillary artery** are exceedingly variable. In fig. 465 is shown what Hitzrot has found the usual type, in which the second portion of the artery has no named branches. The figure brings out the segmental relation of the branches of the axillary artery to the chest wall and suggests how one of the branches may supply the place of another. If the lateral thoracic arises directly from the axillary, it is generally from the second part as described below. In addition to the larger branches of the artery small twigs are supplied to the serratus anterior, coraco-brachialis, and subscapularis; also to the axillary lymph-nodes.

The **first part** gives off.—(1) The superior thoracic; and (2) the thoraco-acromial.

The **second part** gives off:—(3) The lateral thoracic.

The **third part** gives off:—(4) The subscapular; (5) the anterior humeral circumflex; and (6) the posterior humeral circumflex.

Branches of the Axillary Artery

1. The **superior thoracic** [a. thoracalis suprema] is variously given off from the axillary artery, usually either as a common trunk with the next branch, the

thoraco-acromial, or a little above. It passes behind the axillary vein across the first intercostal space, supplying the intercostal muscles and the upper portion of the serratus anterior, and anastomoses with the intercostal arteries. At times it sends a branch between the pectoralis major and minor, which then, as a rule, more or less takes the place of the pectoral branch of the thoraco-acromial (figs. 464 and 465).

2. The **thoraco-acromial** or **acromio-thoracic axis** [a. thoracoacromialis] arises from the front part of the axillary just above the upper border of the pectoralis minor. It is a short trunk, and, coming off from the front of the artery, pierces the coraco-clavicular fascia, and then divides into three or four small branches, named from their direction:—(*a*) the acromial; (*b*) the deltoid; (*c*) the pectoral, and (*d*) the clavicular.

FIG. 465.—THE BRANCHES OF THE AXILLARY ARTERY. (After Hitzrot.)
The numbers 1–5 indicate the intercostal spaces.

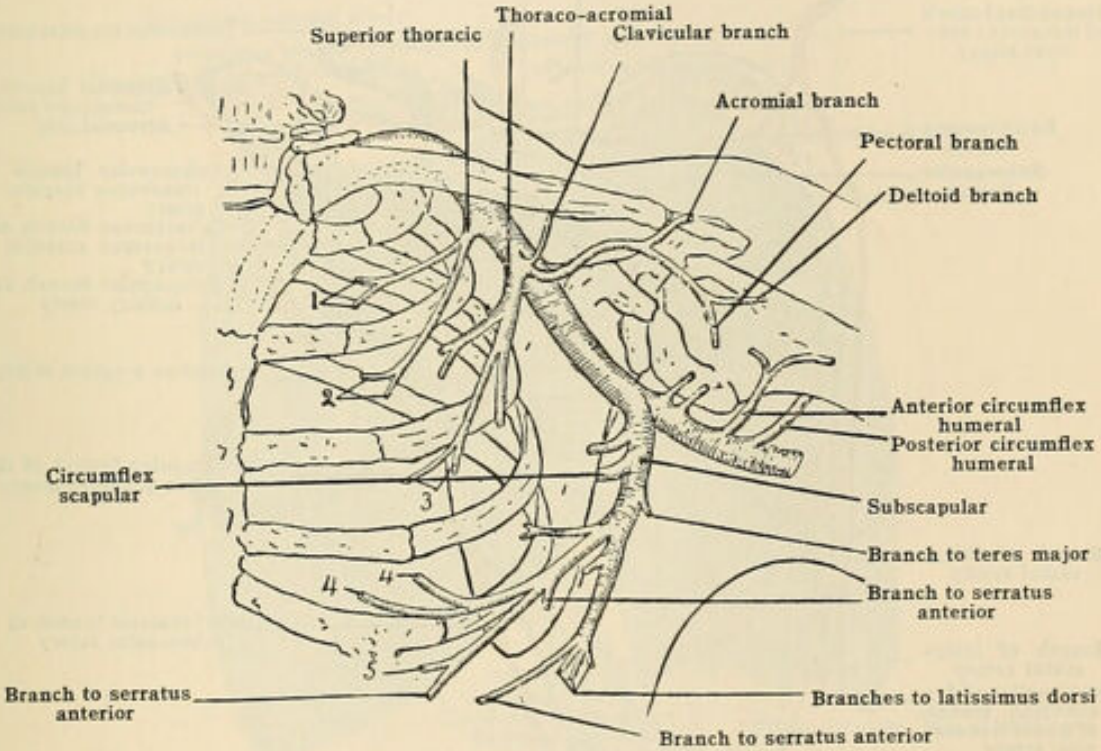

(*a*) The **acromial** branch [r. acromialis] or branches pass laterally across the coracoid process, frequently through the deltoid muscle, which they in part supply, to the acromion, where they form, by anastomosing with the anterior and posterior circumflex and transverse scapular (suprascapular) arteries, the so-called acromial rete, or plexus of vessels on the surface of that process.

(*b*) The **deltoid** branch [r. deltoideus] runs downward with the cephalic vein in the interval between the pectoralis major and the deltoid, and, supplying lateral offsets to these muscles and the adjacent integument, anastomoses with the anterior and posterior circumflex humeral arteries.

(*c*) The **pectoral** branch [r. pectoralis] passes between the pectoralis major and minor muscles, both of which it supplies. In the female, one or more branches which perforate the pectoralis major are often of large size, and supply the superimposed mammary gland.

(*d*) The **clavicular** branch passes upward beneath the clavicle, supplies the subclavius muscle, and anastomoses with the transverse scapular artery.

3. The **lateral thoracic** artery [a. thoracalis lateralis] descends along the lower border of the pectoralis minor, under cover of the pectoralis major, to the chest wall. It supplies both pectoral muscles and the serratus anterior (magnus), sends branches around the lower border of the pectoralis major to the mammary gland, and terminates in the intercostal muscles by anastomosing with the aortic intercostals and the internal mammary. It also furnishes branches to the lymph-nodes of the axillary fossa. The branches to the mammary gland in the female are often of large size.

4. The **subscapular** artery [a. subscapularis] is the largest branch of the axillary. It arises opposite the lower border of the subscapularis, and runs in a

downward and medial direction along the anterior border of that muscle under cover of the latissimus dorsi. It supplies the subscapularis, teres major, latissimus dorsi, and serratus anterior (magnus) muscles, and gives branches to the nodes in the axillary fossa. The course of this large vessel along the posterior border of the axillary fossa should be remembered in opening abscesses in the fossa, and in removing enlarged nodes from it. It is accompanied by two veins, which usually unite and then receive the circumflex (dorsal) scapular vein, and open as a single vein of large size either into the axillary or at the confluence of the medial brachial vena comitans with the basilic vein.

About 2.5 or 3.7 cm. (1 or 1½ in.) from its origin, the subscapular artery divides into two end branches, (1) the circumflex (dorsal) scapular, and (2) the dorsal thoracic.

FIG. 466.—THE ANASTOMOSES ABOUT THE SCAPULA.

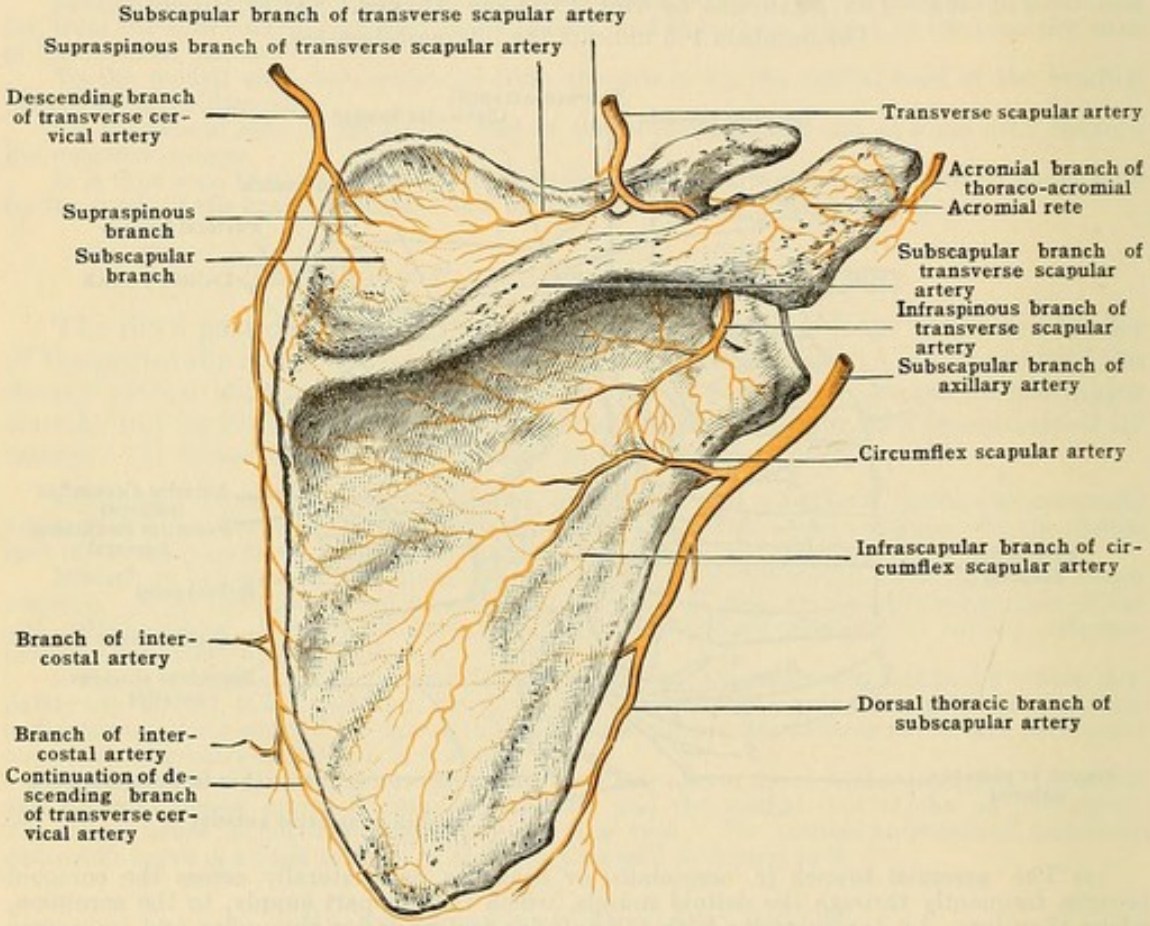

(1) The **circumflex scapular** artery [a. circumflexa scapulæ], or dorsal scapular, arising from the subscapular, usually at the point above mentioned, passes backward through the triangular space bounded by the subscapularis above, the teres major below, and the long head of the triceps laterally, and then between the teres minor and the axillary border of the scapula, which it commonly grooves. It thus reaches the infraspinous fossa, where, under cover of the infra-spinatus, it anastomoses with the transverse scapular (suprascapular) artery and the descending branch of the transverse cervical (posterior scapular) (fig. 466). As it passes through the triangular space, it gives off a ventral branch which ramifies between the subscapularis and the bone, supplying branches to the subscapularis, to the scapula, and to the shoulder-joint. A second branch is often given off near the triangular space and passes downward between the teres major and teres minor, supplying both muscles (fig. 467).

(2) The **dorsal thoracic** artery [a. thoracodorsalis] continues in the course of the subscapular as far as the angle of the scapula, where it anastomoses with the circumflex scapular, the descending branch of the transverse cervical (posterior scapular), the lateral thoracic, and intercostal arteries.

5. The **anterior circumflex humeral** artery [a. circumflexa humeri anterior], usually quite a small vessel, comes off from the lateral side of the axillary artery, generally opposite the posterior circumflex. It passes beneath the coracobrachialis and short and long heads of the biceps, winding transversely round the front of the surgical neck of the humerus, across the intertubercular (bicipital) groove, and anastomoses with the posterior circumflex and thoraco-acromial arteries. It gives off the following small branches:

(*a*) **The bicipital** or ascending, which runs up the intertubercular groove to supply the long tendon of the biceps and the shoulder-joint; and (*b*) a **pectoral** or descending branch, which runs downward along the insertion of the pectoralis major, and supplies the tendon of that muscle. The anterior circumflex artery, in consequence of its being close to the bone, is sometimes difficult to secure in the operation for excision of the shoulder-joint.

6. The **posterior circumflex humeral** artery [a. circumflexa humeri posterior] (fig. 467) arises from the posterior aspect of the axillary, just below the lower border of the subscapularis muscle. It passes through the quadrilateral space, bounded by the teres minor above, the latissimus dorsi and teres major below, the humerus laterally, and the long head of the triceps medially, and, winding round the back of the humerus beneath the deltoid, breaks up under cover of that muscle into a leash of branches, which for the most part enter its substance. The axillary (circumflex) nerve and two venæ comitantes run with it. It anastomoses with the anterior circumflex, the arteries on the acromion, and the profunda artery.

FIG. 467.—THE ARTERIES OF THE SHOULDER. (After Spalteholz.)

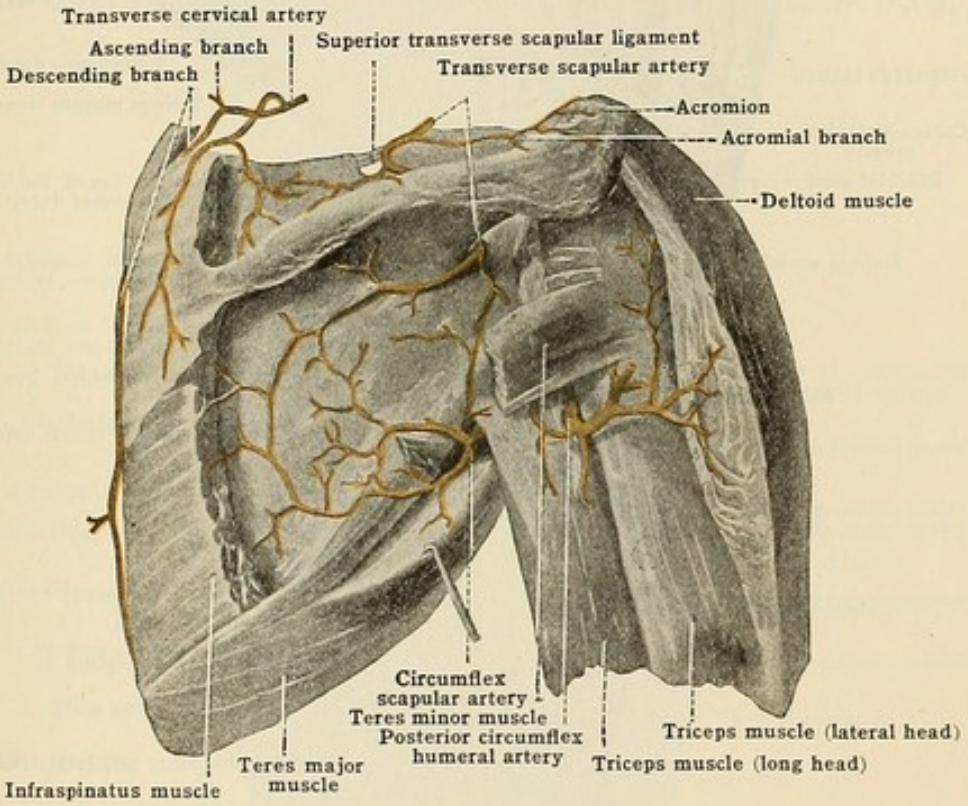

In addition to the leash of vessels to the deltoid, it gives off the following small branches:—(*a*) **nutrient,** to the greater tuberosity of the humerus; (*b*) **articular,** to the back of the shoulder-joint; (*c*) **acromial,** to the plexus on the acromion; and (*d*) **muscular,** to the teres minor and long and short heads of the triceps. One or more of these branches to the triceps descend either between the lateral and long head or in the substance of that muscle, to anastomose with an ascending branch from the profunda artery. It is by means of this anastomosis that the collateral circulation is chiefly carried on when the axillary or the brachial artery is tied between the origins of the posterior circumflex and profunda arteries.

THE BRACHIAL ARTERY

The **brachial** artery [a. brachialis] (fig. 468), the continuation of the axillary, extends from the lower border of the teres major to a little below the centre of the crease at the bend of the elbow, where it divides, opposite the junction of the head with the neck of the radius, into the radial and ulnar arteries. The artery is situated at first medial to the humerus; but as it passes down the arm it gradually gets in front of the bone, and at the bend of the elbow lies midway between the two epicondyles. Hence, in controlling hæmorrhage, the artery should be compressed laterally against the bone in its upper third, laterally and backward in its middle third, and directly backward in its lower third. Throughout the greater part of its course the artery is superficial, being merely overlapped slightly on

its lateral side by the coraco-brachialis and biceps muscles; but at the bend of the elbow it sinks deeply beneath the lacertus fibrosus of the biceps into the triangular interval (antecubital space) bounded on either side by the brachio-

FIG. 468.—THE BRACHIAL ARTERY. (After Toldt, "Atlas of Human Anatomy" Rebman, London and New York.)

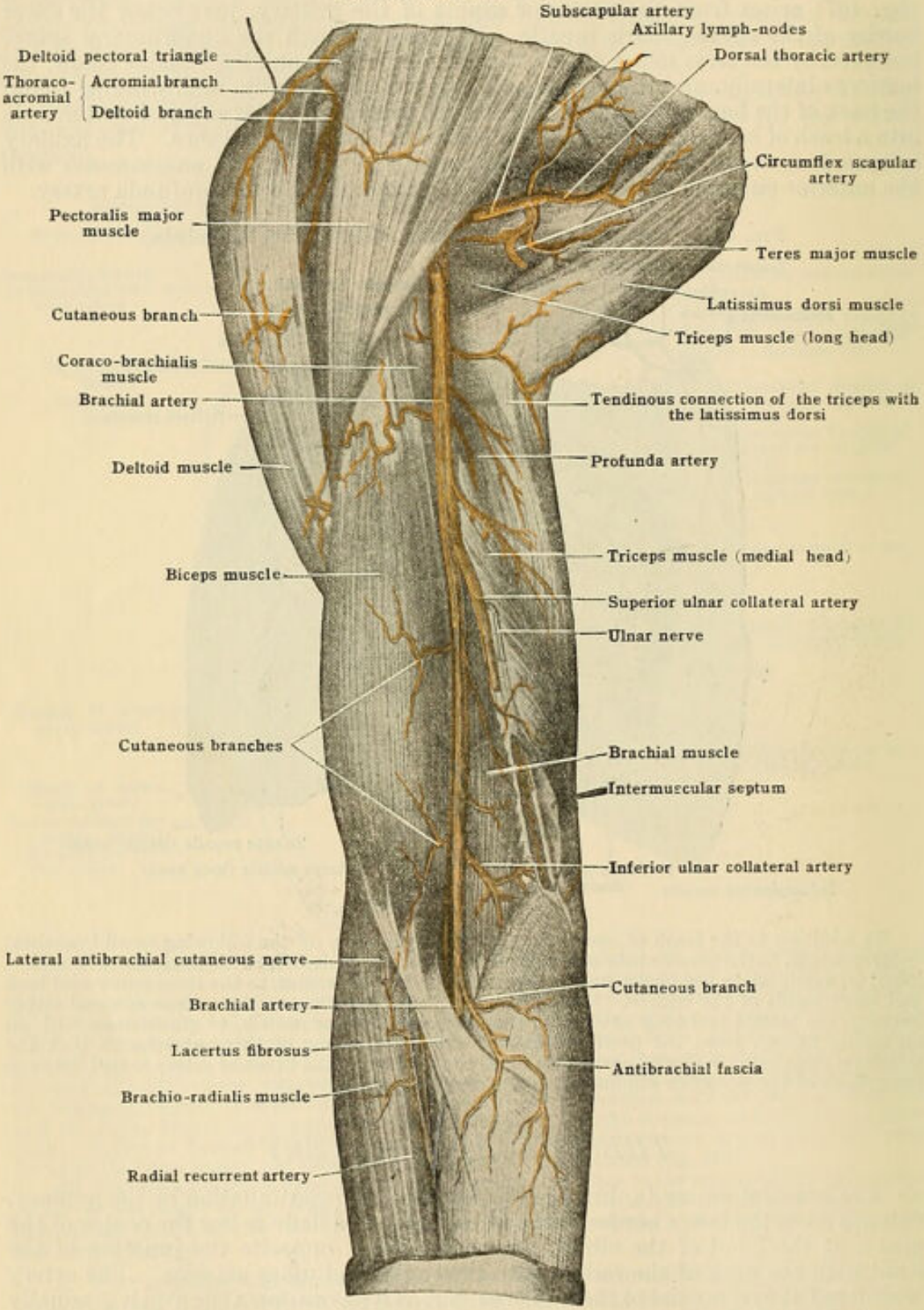

radialis and pronator teres, and at its bifurcation is more or less under cover of these muscles (fig. 469). The sheath of the brachial artery is closely incorporated with the fascia covering the biceps muscle, and it is for this reason that in the operation for ligaturing the vessel is apt to be retracted with the muscle.

A line drawn from the groove medial to the coraco-brachialis and biceps muscles to midway between the epicondyles of the humerus will indicate its course. It is accompanied by two veins which frequently communicate across the artery. In addition to the branches named below the brachial artery gives off numerous muscular branches and, occasionally, the nutrient artery to the humerus. The muscular branches usually come off from the lateral side of the artery; one in particular, which supplies the biceps muscle, is frequently of large size.

Relations.—In front, the artery is covered by the integument and superficial and deep fasciæ, and at the bend of the elbow by the lacertus fibrosus of the biceps, and in muscular subjects by the overlapping margins of the brachio-radialis and pronator teres. In the middle third of the arm it is crossed obliquely from the lateral to the medial side by the median nerve, and at the bend of the elbow by the median cubital vein, the bicipital fascia intervening (fig. 475).

Behind, it lies successively on the long head of the triceps (from which it is separated by the radial (musculo-spiral) nerve and profunda artery), on the medial head of the triceps, on the insertion of the coraco-brachialis, and thence to its bifurcation on the brachialis muscle.

FIG. 469.—THE BRACHIAL ARTERY AT THE BEND OF THE ELBOW, LEFT SIDE, FRONT VIEW. (From a mounted specimen in the Anatomical Department of Trinity College, Dublin.)

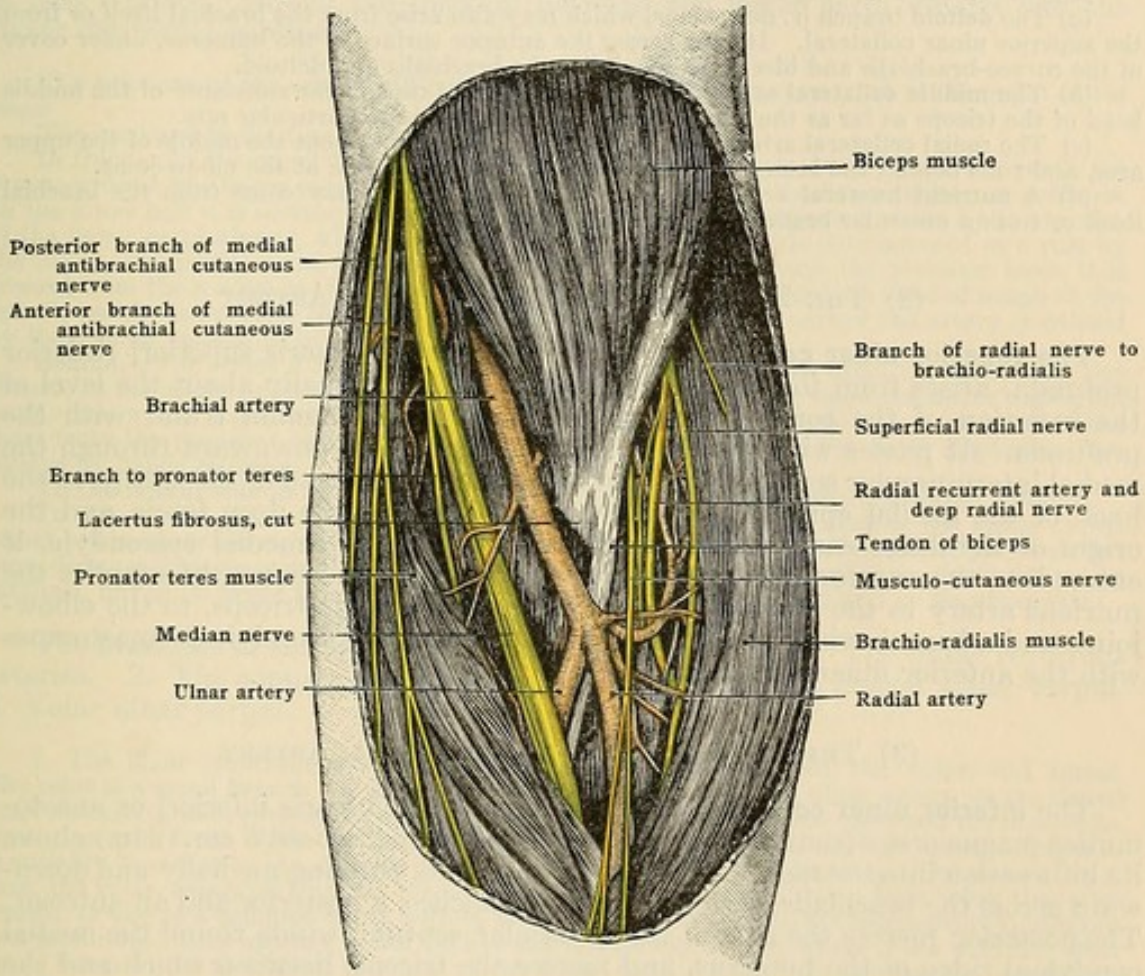

Lateral to the artery is the coraco-brachialis above, and the muscular belly of the biceps below, both of which slightly overlap the vessel, and at the bend of the elbow the tendon of the biceps. The lateral vena comitans is also to its lateral side. The median nerve is in close contact with the lateral side of the artery in the upper third of its course, but in the middle third crosses the artery obliquely to gain the medial side.

Medial to the artery in the upper part of its course are the medial antibrachial (internal) cutaneous and the ulnar nerves; the latter nerve, however, leaves the artery about the origin of the ulnar collateral (inferior profunda) branch, to make, with that vessel, for the medial epicondyle. Lower down, the medial antibrachial cutaneous nerve also leaves the artery, by piercing the deep fascia. The median nerve is in close contact with the medial side of the artery in its lower third and at the bend of the elbow. The basilic vein is superficial to it, and a little to its medial side in the greater part of its course, but separated from it by the deep fascia. The medial vena comitans runs along its medial side.

BRANCHES OF THE BRACHIAL ARTERY

The **branches of the brachial artery** are:—(1) The profunda brachii; (2) the superior ulnar collateral (inferior profunda); (3) the inferior ulnar collateral

(anastomotica magna); and (4) the terminal branches—the radial and ulnar arteries.

(1) The Profunda Artery

The **profunda brachii** (superior profunda) is the largest branch of the brachial. It arises from the medial and hinder aspect of that artery, a little below the inferior border of the tendon of the teres major. It at first lies to the medial side of the brachial, but soon passes behind that vessel, and, sinking between the medial and long heads of the triceps with the radial (musculo-spiral) nerve, curves around the humerus in the groove for the nerve, lying in contact with the bone between the medial and lateral heads of the triceps. On reaching the lateral supracondyloid ridge of the humerus it perforates the lateral intermuscular septum, and, continuing forward between the brachio-radialis and brachialis to the front of the lateral epicondyle, ends by anastomosing with the radial recurrent artery (figs. 468 and 474).

It gives off the following branches:—

(*a*) The **deltoid** branch [r. deltoideus] which may also arise from the brachial itself or from the superior ulnar collateral. It runs across the anterior surface of the humerus, under cover of the coraco-brachialis and biceps, and supplies the brachialis and deltoid.

(*b*) The **middle collateral** artery [a. collateralis media] runs in the substance of the middle head of the triceps as far as the elbow, where it terminates in the articular rete.

(*c*) The **radial collateral** artery [a. collateralis radialis] arises about the middle of the upper arm, and runs behind the lateral intermuscular septum to the rete at the elbow-joint.

(*d*) A **nutrient humeral** artery [a. nutritia humeri], which may come from the brachial itself or from a muscular branch, enters a canal in the humerus.

(2) The Superior Ulnar Collateral Artery

The **superior ulnar collateral** artery [a. collateralis ulnaris superior] (inferior profunda) arises from the medial side of the brachial, usually about the level of the insertion of the coraco-brachialis, at times as a common trunk with the profunda. It passes with the ulnar nerve medially and downward through the medial intermuscular septum, and then along the medial head of the triceps to the back of the medial epicondyle, where, under cover of the deep fascia and the origin of the flexor carpi ulnaris from the olecranon and medial epicondyle, it enters into the anastomoses around the elbow-joint. It frequently supplies the nutrient artery to the humerus. It gives branches to the triceps, to the elbow-joint, and a branch which passes in front of the medial epicondyle to anastomose with the anterior ulnar recurrent.

(3) The Inferior Ulnar Collateral Artery

The **inferior ulnar collateral** artery [a. collateralis ulnaris inferior] or anastomotica magna arises from the medial side of the brachial, about 5 cm. (2 in.) above its bifurcation into the radial and ulnar arteries, and, running medially and downward across the brachialis, divides into two branches, a posterior and an anterior. The **posterior** pierces the medial intermuscular septum, winds round the medial condyloid ridge of the humerus, and pierces the triceps, between which and the bone it anastomoses with the articular branch of the profunda artery, and to a lesser extent with the interosseous recurrent, forming an arterial arch or rete around the upper border of the olecranon fossa. The **anterior** branch passes medially and downward between the brachialis and pronator teres, and anastomoses in front of the medial epicondyle, but beneath the pronator teres, with the anterior ulnar recurrent. From this branch a small vessel passes down behind the medial epicondyle to anastomose with the posterior ulnar recurrent and superior ulnar collateral arteries (fig. 474).

THE ULNAR ARTERY

The **ulnar** artery [a. ulnaris] (fig. 470) the larger of the two terminal branches of the brachial, begins opposite the lower border of the head of the radius in the middle line of the forearm. Thence through the upper half of the forearm it runs

beneath the pronator teres and superficial flexor muscles, and, having reached the ulnar side of the arm about midway between the elbow and the wrist, it passes directly downward, being merely overlapped by the flexor carpi ulnaris. Crossing the transverse carpal (anterior annular) ligament immediately to the radial side of the pisiform bone, it enters the palm, where it divides into two branches, which enter respectively into the formation of the superficial and deep volar arches. The artery is accompanied by two veins, which anastomose with each other by frequent cross branches, and usually terminate in the brachial venæ comitantes. The ulnar nerve is at first some distance from the artery, but approaches the vessel at the junction of its upper and middle thirds, and then lies close to its medial or ulnar side. The course of the artery in the lower two-thirds of the forearm is indicated by a line drawn from the front of the medial epicondyle to the radial side of the pisiform bone; and in the upper third of the forearm by a line drawn in a gentle curve with its convexity to the medial side from 2.5 cm. (1 in.) below the centre of the bend of the elbow to a point in the former line at the junction of its upper with its middle third. The artery throughout its course is best reached through the interval between the flexor carpi ulnaris and the flexor digitorum sublimis.

The relations of the artery will be given in detail in the forearm, and in the palm of the hand.

The **relations in the forearm** are:—

In front.—In the upper half of the forearm the ulnar artery is deeply placed beneath the pronator teres, the flexor carpi radialis, the palmaris longus, and the flexor digitorum sublimis. In the lower half it is comparatively superficial, being merely overlapped above by the tendon of the flexor carpi ulnaris, whilst the last inch or so of the vessel is only covered as a rule by the skin and superficial and deep fasciæ. As the artery lies beneath the pronator teres, it is crossed from the medial to the lateral side by the median nerve, the deep head of origin of the muscle usually separating the nerve from the artery. The lower part of the artery is crossed by the palmar cutaneous branch of the ulnar nerve.

Behind.—For about 2.5 cm. (1 in.) of its course the artery lies upon the brachialis; but thence, as far as the transverse carpal (anterior annular) ligament, upon the flexor digitorum profundus, which separates it above from the interosseous membrane and bone, and at the wrist from the pronator quadratus. The artery is bound down to the flexor digitorum profundus by bands of fasciæ.

To the **lateral side** in the lower two-thirds of its course is the flexor digitorum sublimis.

To the **medial side** in the lower two-thirds is the flexor carpi ulnaris, the guide to the vessel. The ulnar nerve, as it enters the forearm from behind the medial epicondyle, is at first some distance from the artery, being separated from it in its upper third by the flexor digitorum sublimis, but in its lower two-thirds is in close contact with the vessel and on its ulnar side.

The **branches of the ulnar artery in the forearm** are:—1. The ulnar recurrent arteries. 2. The common interosseous. 3. Muscular. 4. Dorsal ulnar carpal. 5. Volar ulnar carpal.

1. The **ulnar recurrent** arteries [aa. recurrentes ulnares] are two, the volar, and dorsal. The *volar* is a small branch which arises from the medial side of the ulnar artery, or the dorsal ulnar recurrent, and, running between the lateral edge of the pronator teres and the brachialis, anastomoses in front of the medial epicondyle with the inferior and superior ulnar collaterals. It supplies branches to the muscles between which it runs, and to the skin. The *dorsal*, larger than the volar, comes off from the medial side of the ulnar artery, either a little below the latter branch, or else as a common trunk with it, and, passing between the flexores digitorum sublimis and profundus, turns upward to the back of the medial epicondyle, where it lies with the ulnar nerve between the two heads of origin of the flexor carpi ulnaris. It supplies the contiguous muscles—the flexor carpi ulnaris, the palmaris longus, and the flexores digitorum sublimis and profundus—the elbow-joint, and the ulnar nerve, and anastomoses with the inferior and superior ulnar collaterals, and with the interosseous recurrent forming the so-called rete olecrani.

2. The **common interosseous** artery [a. interossea communis] is a short thick trunk 1.2 cm. ($\frac{1}{2}$ in.) or so in length, which comes off from the lateral and back part of the ulnar artery about 2.5 cm. (1 in.) from its origin, and just before that artery is crossed by the median nerve. It passes backward and downward between the flexor pollicis longus and the flexor digitorum profundus, toward the triangular interval bounded by the upper border of the interosseous membrane, the oblique ligament, and the lateral border of the ulna, where it divides into the volar and dorsal interosseous arteries.

(*a*) The **volar interosseous** artery [a. interossea volaris], smaller than the dorsal, but apparently the direct continuation of the common trunk, courses downward in front of the interosseous membrane. It lies under cover of the overlapping edges of the flexor digitorum profundus and flexor pollicis longus, to both of which muscles it supplies branches. At the

upper border of the pronator quadratus it divides into two branches, an anterior terminal and a posterior terminal (fig. 473).

The volar interosseous artery is accompanied by two veins and by the deep branch of the median nerve which lies to its radial side. The artery is bound down to the interosseous membrane by aponeurotic fibres.

FIG. 470.—THE VOLAR ARTERIES OF THE FOREARM AND HAND. (After Toldt, "Atlas of Human Anatomy," Rebman, London and New York.)

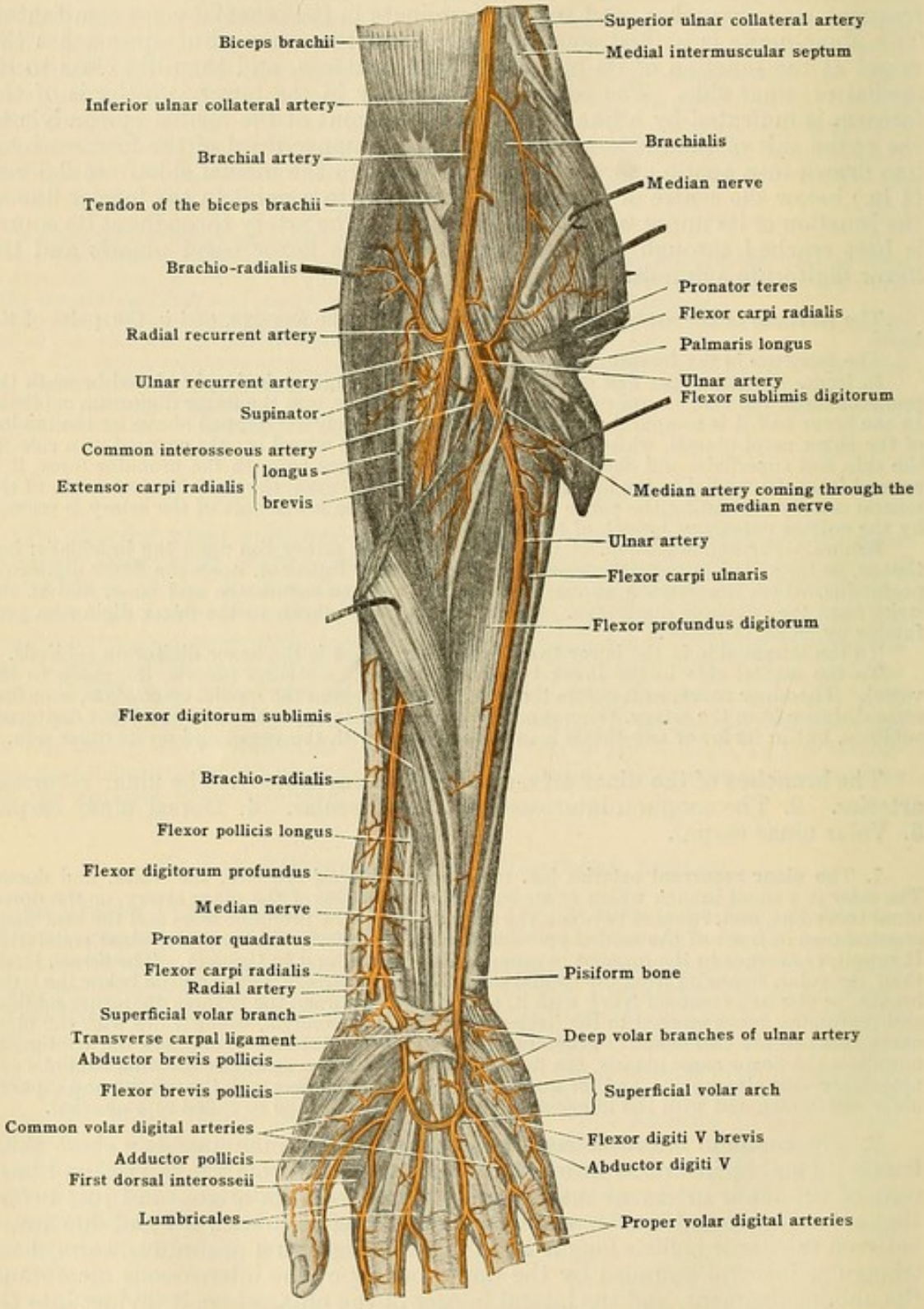

The **branches of the volar interosseous artery** are:—(i) The **median** artery [a. mediana] is a long slender vessel which arises from the volar interosseous immediately after the latter is given off from the common trunk. It passes forward between the flexor digitorum profundus and the flexor pollicis longus to the median nerve, with which it descends beneath the transverse carpal (anterior annular) ligament into the palm, and when of large size sometimes enters into the formation of the superficial palmar arch. At times the artery arises from the common

interosseous before its division. (ii) The **nutrient arteries** of the radius and ulna are usually derived from this vessel. (iii) The **volar terminal** division of the volar interosseous artery passes either in front of or behind the pronator quadratus, but in either case in front of the interosseous membrane, and anastomoses with the volar carpal branches of the radial and ulnar arteries, and with the recurrent branches from the deep volar arch, forming the so-called **volar carpal rete.** (iv) The **dorsal terminal,** the larger division, pierces the interosseous membrane, and continues its course downward behind the interosseous membrane, under cover of the extensor muscles, to the back of the wrist, where it ends by anastomosing with the dorsal

FIG. 471.—THE BACK OF THE LEFT FOREARM, WITH THE DORSAL INTEROSSEOUS ARTERY AND BRANCHES OF THE RADIAL AT THE BACK OF THE WRIST.
(From a dissection in the Hunterian Museum.)

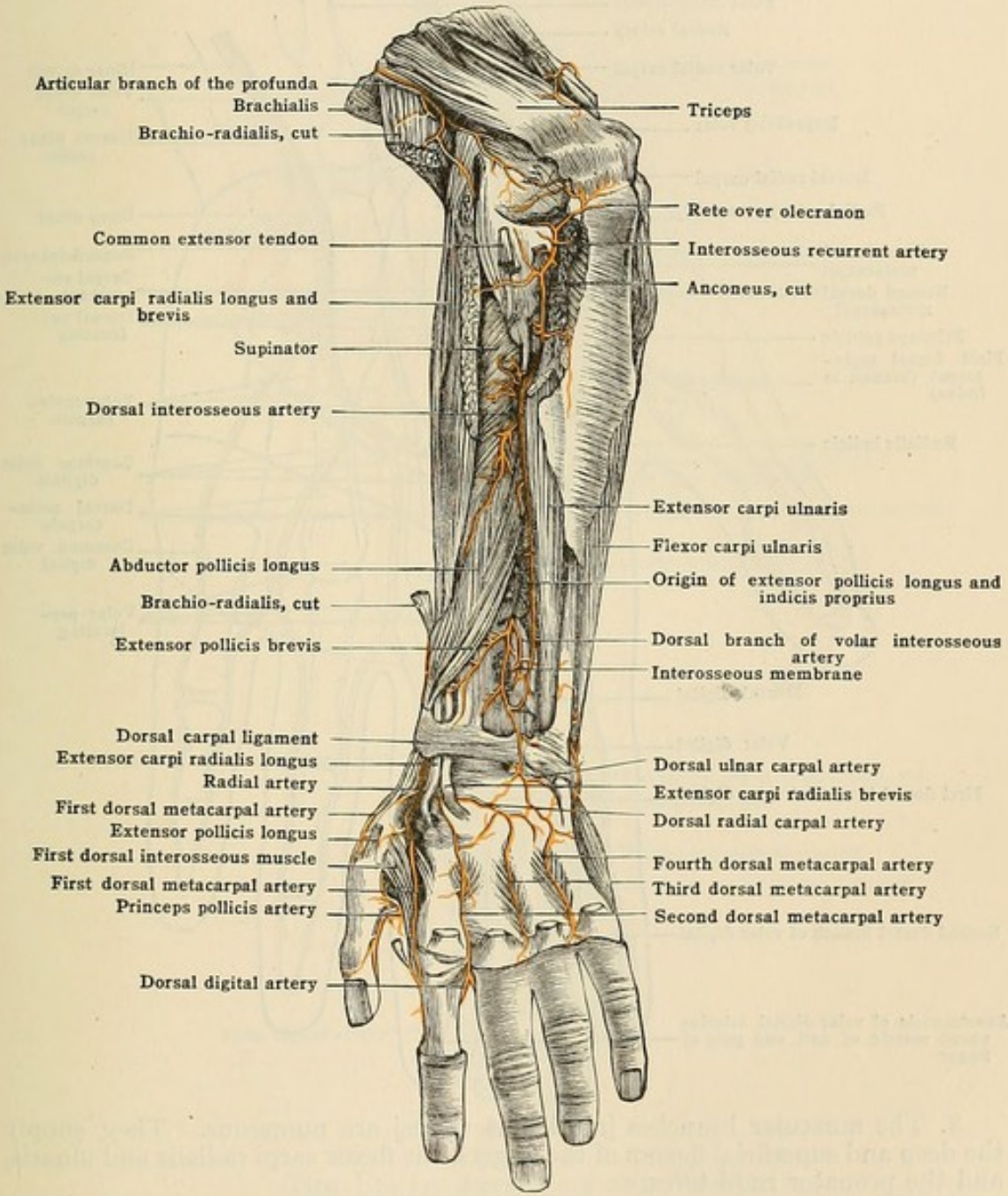

carpal branches of the radial and ulnar arteries, forming the so-called **dorsal carpal rete.** This branch anastomoses, as soon as it pierces the interosseous membrane, with the dorsal interosseous artery.

(*b*) The **dorsal interosseous** artery [a. interossea dorsalis], the larger division of the common interosseous, turns backward through the triangular interval bounded by the interosseous membrane below, the oblique ligament above, and the ulna on the medial side, and emerging at the back of the forearm between the abductor pollicis longus and the supinator, under cover of the superficial extensors of the forearm, descends between the superficial and the deep muscles, crossing in this course the abductor pollicis longus, the extensor pollicis brevis, the extensor pollicis longus, and the extensor indicis proprius (fig. 471). It anastomoses at the lower border

of this muscle and just above the wrist joint, with the dorsal branch of the volar interosseous which here, as above described, has perforated the interosseous membrane. It is separated from the deep radial nerve at first by the radius and supinator, and on the back of the forearm by the extensores pollicis longus and indicis proprius.

The chief branch of the dorsal interosseous artery, the **interosseous recurrent** artery [a. interossea recurrens] arises from the dorsal interosseous as the latter emerges from beneath the supinator. It runs upward between the anconeus and supinator, usually under cover of the former, to the interval between the lateral epicondyle and the olecranon, where it anastomoses with the profunda, inferior ulnar collateral, radial recurrent, and dorsal ulnar recurrent arteries, and gives branches to the retiform plexus over the olecranon—the rete olecrani.

FIG. 472.—ANASTOMOSES AND DISTRIBUTION OF THE ARTERIES OF THE HAND. (Walsham.)

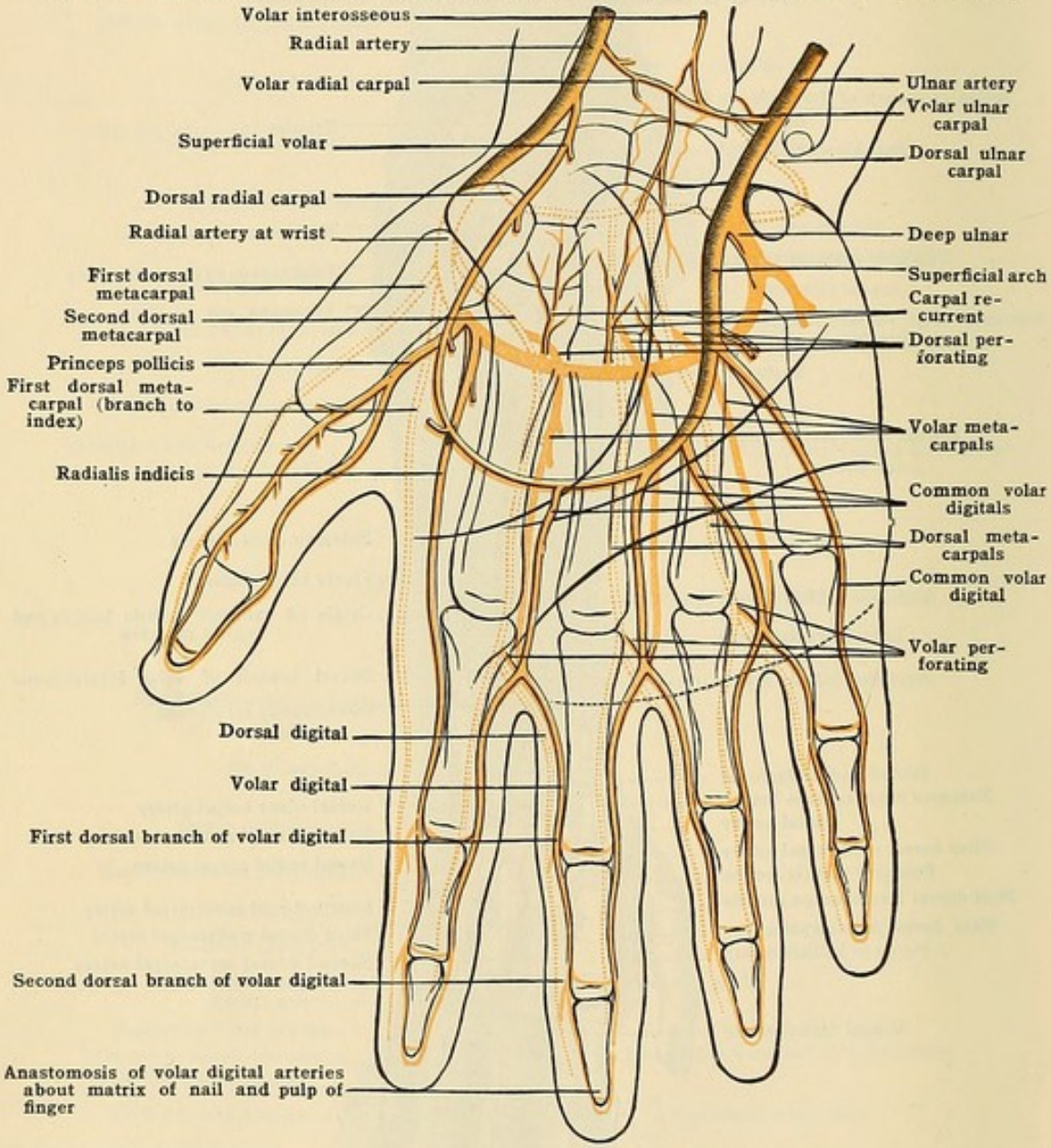

3. The **muscular** branches [rami musculares] are numerous. They supply the deep and superficial flexors of the fingers, the flexor carpi radialis and ulnaris, and the pronator radii teres.

4. The **dorsal ulnar carpal** [ramus carpeus dorsalis] comes off from the ulnar artery a little above the transverse carpal (anterior annular) ligament, and, winding medially round the end of the ulna or the ulnar collateral ligament of the wrist, beneath the flexor carpi ulnaris, ramifies on the back of the carpus beneath the extensor tendons. It forms by its anastomosis with the dorsal radial carpal, with the dorsal terminal branch of the volar interosseous and with the dorsal interosseous arteries a plexus or rete, the so-called dorsal carpal rete. The branches given off from this plexus or arch are described with the dorsal carpal branch of the radial artery.

5. The **volar ulnar carpal** [ramus carpeus volaris] is a small branch given off from the ulnar artery opposite the carpus. It passes beneath the flexor digitorum profundus to anastomose with the volar radial carpal, with terminal twigs of the volar branch of the volar interosseous, and with recurrent branches from the deep volar arch, forming an anastomotic arch across the front of the carpus—the **volar carpal arch** or **rete.**

FIG. 473.—THE ARTERIES OF THE RIGHT FOREARM AND THE DEEP VOLAR ARCH.

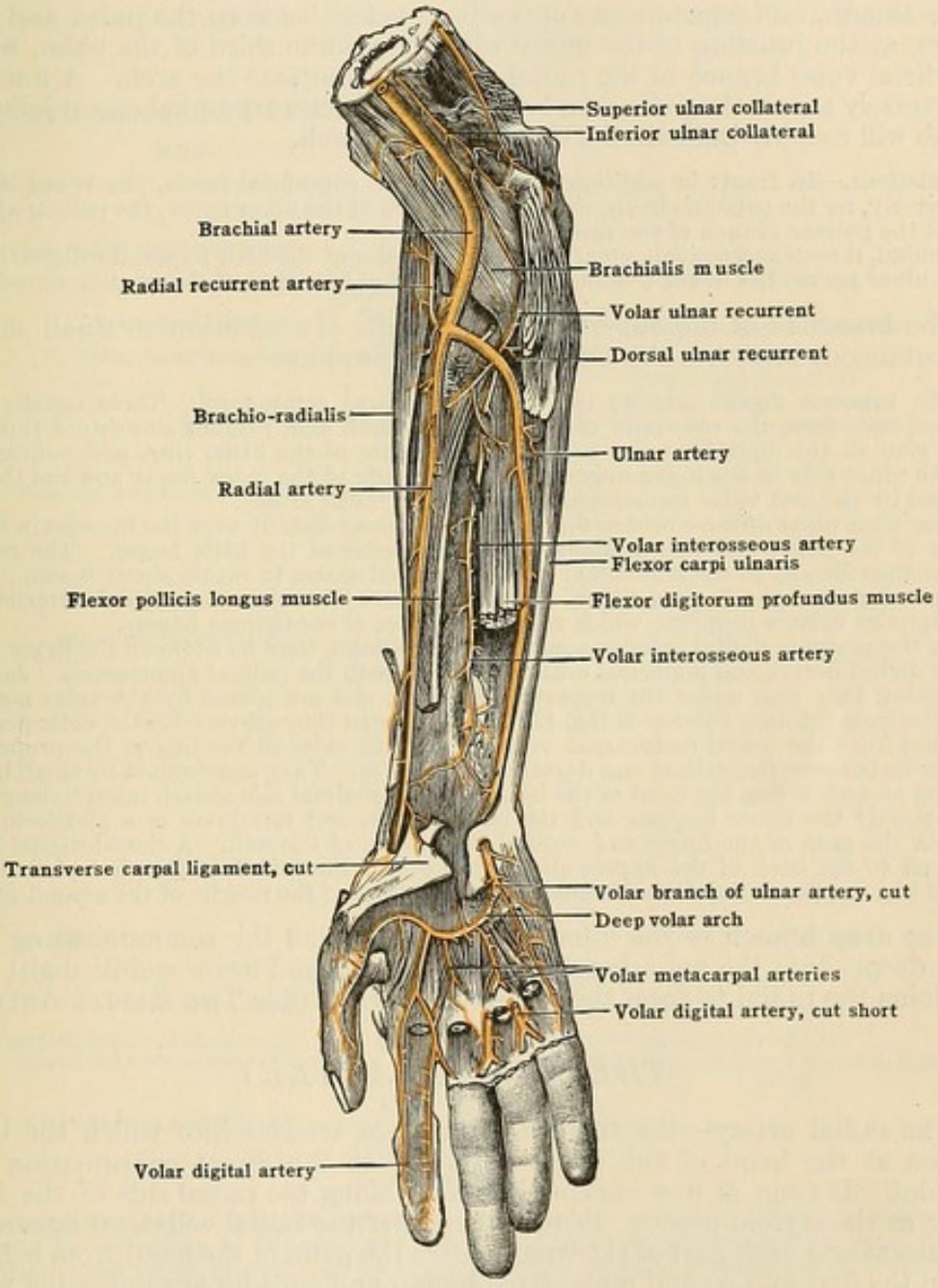

THE ULNAR ARTERY AT THE WRIST

The **ulnar artery at the wrist** may be said to extend from the upper to the lower border of the transverse carpal (anterior annular) ligament upon which it rests. It here lies immediately to the radial side of the pisiform bone, and to the ulnar side of the hook of the hamate (unciform), the two bones forming for the vessel a protecting channel, which is further converted into a short canal by the expansion of the flexor carpi ulnaris passing from the pisiform to the hook of the hamate (unciform). The ulnar nerve in this situation is immediately to the ulnar side of the artery.

The Ulnar Artery in the Palm (Superficial Volar Arch)

The ulnar artery, on entering the palm, divides into two branches, the superficial and deep.

The **superficial branch** (fig. 472), the direct continuation of the vessel, anastomoses with the superficial volar, a branch of the radial, forming what is then known as the **superficial volar arch.** After descending a short distance toward the cleft between the fourth and fifth fingers, it turns toward the thumb, forming a curve with its convexity toward the fingers and its concavity toward the muscles of the thumb, and anastomoses opposite the cleft between the index and middle fingers, at the junction of the upper with the middle third of the palm, with the superficial volar branch of the radial artery to complete the arch. A line drawn transversely across the palm on a level with the metacarpo-phalangeal joint of the thumb will roughly indicate the situation of the arch.

Relations.—In front: in addition to the skin and superficial fascia, the vessel is crossed successively, by the palmaris brevis, the palmar branch of the ulnar nerve, the palmar aponeurosis and the palmar branch of the median nerve.

Behind, it rests successively upon the short muscles of the little finger, the digital branches of the ulnar nerve, the flexor tendons, and the digital branches of the median nerve.

The **branches of the superficial volar arch.** In addition to small muscular and cutaneous branches the superficial volar supplies:—

The **common digital arteries** [aa. digitales volares communes]. These, usually four in number, arise from the convexity of the superficial arch and, running downward through the palm, give off the digital arteries proper to both sides of the little, ring, and middle fingers, and the ulnar side of the index finger. The radial side of the index finger and the thumb are supplied by the first volar metacarpal branch of the radial artery.

The most ulnar of the common digital arteries passes distally over the muscles in the ulnar border of the palm, and thence along the ulnar border of the little finger. The remaining arteries pass distally in the three ulnar intermetacarpal spaces to within about 6 mm. ($\frac{1}{4}$ in.) of the clefts between the fingers, where they divide into branches, the **digital arteries proper** [aa. digitales volares propriæ], which supply the sides of contiguous fingers.

As the common digital arteries pass through the palm, they lie between the flexor tendons, on the digital nerves and lumbrical muscles, and beneath the palmar aponeurosis. Just before bifurcating they pass under the transverse fasciculi, and are joined by the volar metacarpal branches from the deep volar arch (fig. 472). At this spot they also receive the volar perforating branches from the dorsal metacarpal vessels. On the sides of the fingers the proper digital arteries lie between the palmar and dorsal digital nerves. They anastomose by small branches, forming an arch across the front of the bones on the proximal side of each interphalangeal joint. They supply the flexor tendons and the integuments, and terminate in a plexiform manner beneath the pulp of the finger and around the matrix of the nail. A dorsal digital branch is given off to the back of the fingers about the level of the middle of the first phalanx, and a second but smaller dorsal digital branch about the level of the middle of the second phalanx.

The **deep branch** of the ulnar artery, also called the communicating artery, sinks deeply into the palm between the abductor and flexor quinti digiti brevis, and joins the radial to form the deep volar arch. (See The Radial Artery.)

THE RADIAL ARTERY

The **radial** artery—the smaller of the two arteries into which the brachial divides at the bend of the elbow—appears as the direct continuation of the brachial. It runs, at first curving laterally, along the radial side of the forearm as far as the styloid process, then, coiling over the radial collateral ligament and the lateral and back part of the wrist, enters the palm of the hand from behind between the first and second metacarpal bones, and ends by anastomosing with the deep branch of the ulnar to form the deep volar arch. Hence the artery is divisible into three parts: that in the forearm, that at the wrist, and that in the palm of the hand. The course of the artery is indicated by a line drawn from a point 2.5 cm. (1 in.) below the centre of the elbow to a point situated just medial to the styloid process of the radius.

I. The Radial Artery in the Forearm

In its course through the forearm (fig. 470) the radial artery is found in the most lateral of the intermuscular spaces, and it is only necessary to divide the

skin, superficial and deep fascia, to expose the vessel, and in addition in the upper third to separate the brachio-radialis from the pronator teres.

Relations.—In front, the artery is at first overlapped by the brachio-radialis, but for the rest of its course it is merely covered by the skin, superficial and deep fasciæ, by some cutaneous veins, and by cutaneous branches of the musculo-cutaneous nerve.

Behind, it lies successively from above downward on the tendon of the biceps, the supinator, from which it is separated by a layer of fat, the insertion of the pronator teres, the radial origin of the flexor digitorum sublimis, the flexor pollicis longus, the pronator quadratus, and the volar surface of the lower end of the radius. It is in this last situation, where the artery lies upon the bone and can therefore be easily pressed against it, that the pulse is usually felt.

FIG. 474.—DIAGRAM OF THE RELATION OF THE ARTERIES OF THE LEFT FOREARM TO THE BONES. (Walsham.)

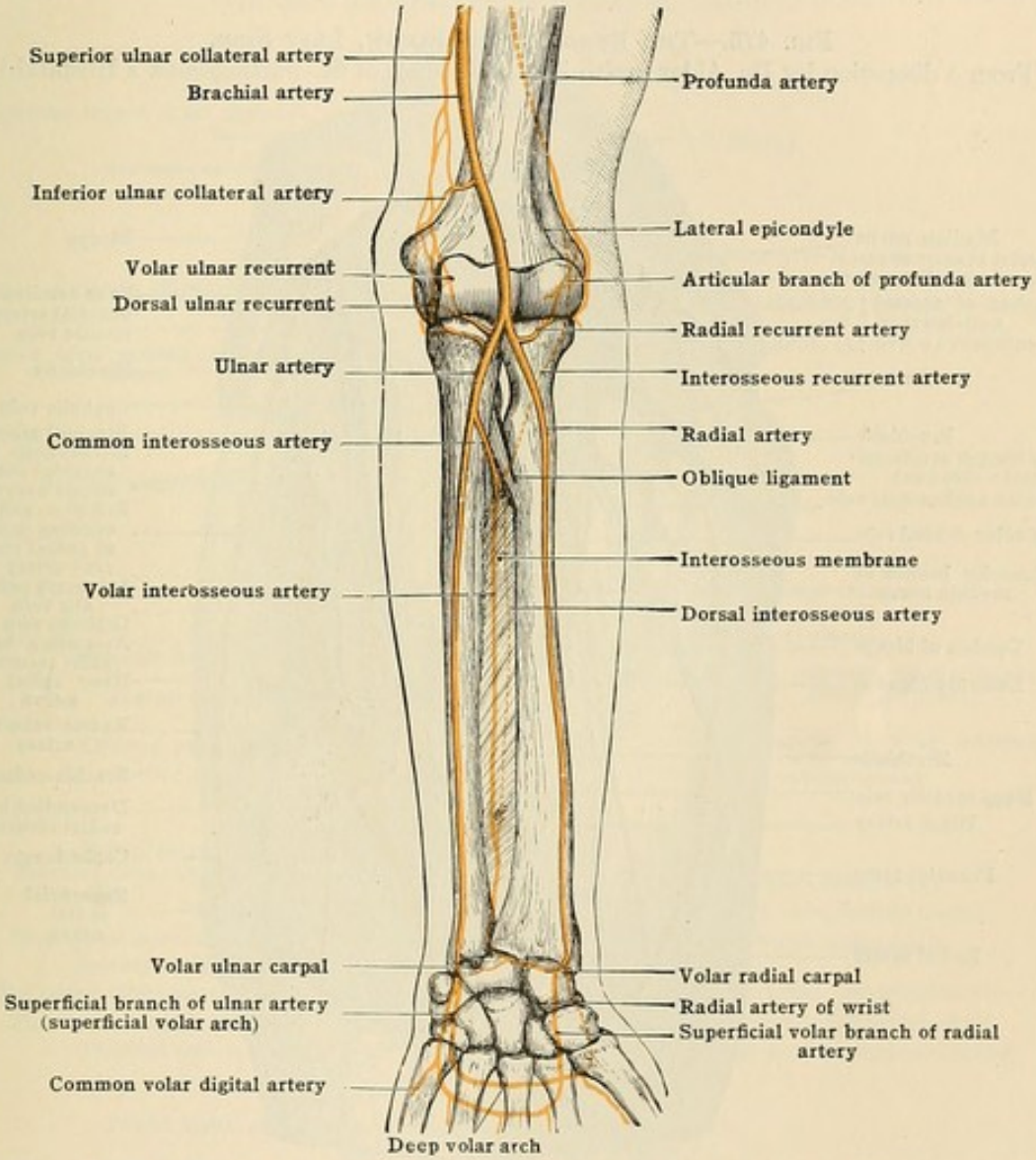

On its **lateral side** it has, throughout the whole of its course, the brachio-radialis muscle, the guide to the artery in ligature, and the lateral vena comitans; in its middle third, the superficial radial nerve as well. In its lower third the superficial radial nerve is to its lateral side, but separated from it by the brachio-radialis and fascia.

On its **medial side,** in the upper third is the pronator teres, in the lower third the tendon of the flexor carpi radialis, and throughout the whole of its course the medial vena comitans.

The **branches of the radial artery in the forearm** are:—(1) The radial recurrent; (2) the muscular; (3) the volar radial carpal; (4) the superficial volar.

(1) The **radial recurrent** [*a.* recurrens radialis] usually arises from the lateral side of the radial just below its origin from the brachial. It at first runs laterally on the supinator and then divides into three chief branches (fig. 475). One of these continues laterally through the fibres of the radial (musculo-spiral) nerve, or between the superficial (radial) and deep radial (posterior interosseous) nerves when the radial (musculo-spiral) divides higher than usual, into the brachio-radialis and extensor carpi radialis longus and brevis, and anastomoses with the interosseous recurrent. A second ascends between the brachialis and brachio-radialis, with the radial

(musculo-spiral) nerve, and anastomoses with the profunda artery. A third descends with the superficial radial nerve under cover of the brachio-radialis, supplying that muscle. The radial recurrent also gives off branches to the elbow-joint.

(2) The **muscular branches** [rami musculares] come off irregularly to supply the contiguous muscles on the lateral side of the forearm.

(3) The **volar radial carpal** branch [ramus carpeus volaris] arises from the medial side of the radial artery about the level of the lower border of the pronator quadratus. It crosses the front of the radius beneath the flexor muscles, and anastomoses with the volar carpal branch of the ulnar, forming the volar carpal rete. This plexus is joined above by terminal twigs from the volar interosseous artery, and below by recurrent branches from the deep volar arch. It supplies branches to the lower end of the radius, and to the wrist and carpal joints.

(4) The **superficial volar** branch [ramus volaris superficialis] leaves the radial artery as the latter vessel is about to turn over the radial collateral ligament to the back of the wrist. It courses forward over the short muscles of the ball of the thumb, and anastomoses with the superficial.

FIG. 475.—THE BEND OF THE ELBOW, LEFT SIDE.
(From a dissection by Dr. Alder Smith in the Museum of St. Bartholomew's Hospital.)

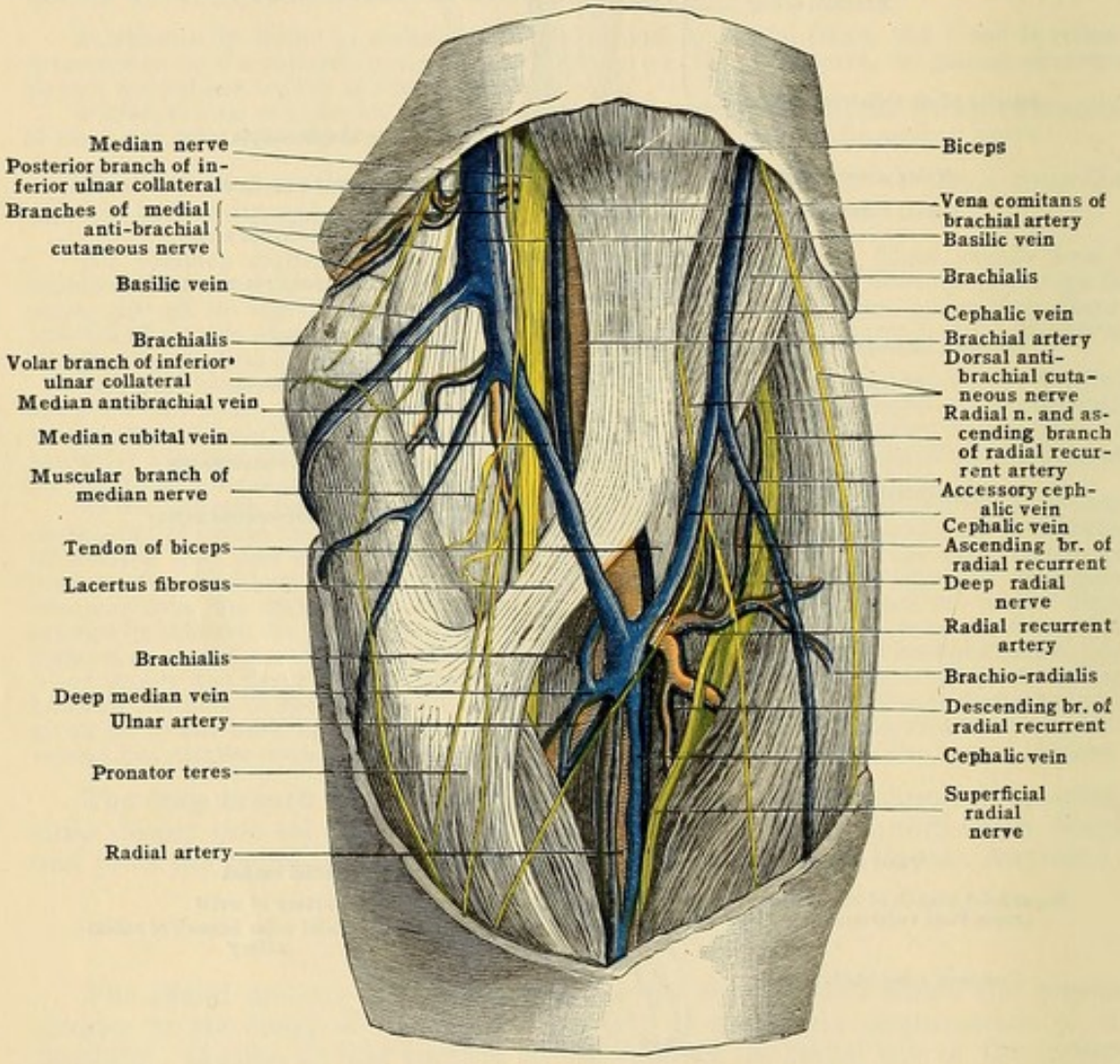

branch of the ulnar artery to complete the superficial volar arch. It supplies small branches to the muscles of the ball of the thumb, and frequently terminates in these muscles without joining the arch. Occasionally it passes beneath the abductor pollicis brevis.

II. THE RADIAL ARTERY AT THE WRIST

The radial artery at the wrist winds over the radial side of the carpus, under the extensor tendons of the thumb, from a spot a little below and medial to the styloid process of the radius to the base of the first interosseous space, where it sinks between the two heads of the first dorsal interosseous muscle into the palm, to form, by anastomosing with the deep branch of the ulnar artery, the deep volar arch. A line drawn from 1.2 cm. ($\frac{1}{2}$ in.) medial to the styloid process to the base of the first interosseous space, which can be distinctly felt on the back of the hand, will roughly indicate the course of the artery (fig. 476).

Relations.—The artery is covered successively by the abductor pollicis longus and extensor pollicis brevis, by branches of the superficial radial nerve and veins, and, just before it sinks between the two heads of the interosseous muscle, by the tendon of the extensor pollicis longus. The branches of the superficial radial nerve to the thumb and index finger cross it. It is at first somewhat deeply placed beneath the first-mentioned extensor muscles of the thumb; but subsequently it lies quite superficial, and can be felt pulsating in a little triangular depression bounded on either side by the extensores pollicis longus and brevis, and above by the lower end of the radius. The artery lies successively on the radial collateral ligament of the wrist, on the navicular (scaphoid), the greater multangular (trapezium), the base of the first metacarpal bone, and on the dorsal ligaments uniting these bones. It has usually with it two companion veins, and a few branches of the musculo-cutaneous nerve.

FIG. 476.—THE RADIAL ARTERY AT THE WRIST, LEFT FOREARM.
(From a dissection in the Hunterian Museum.)

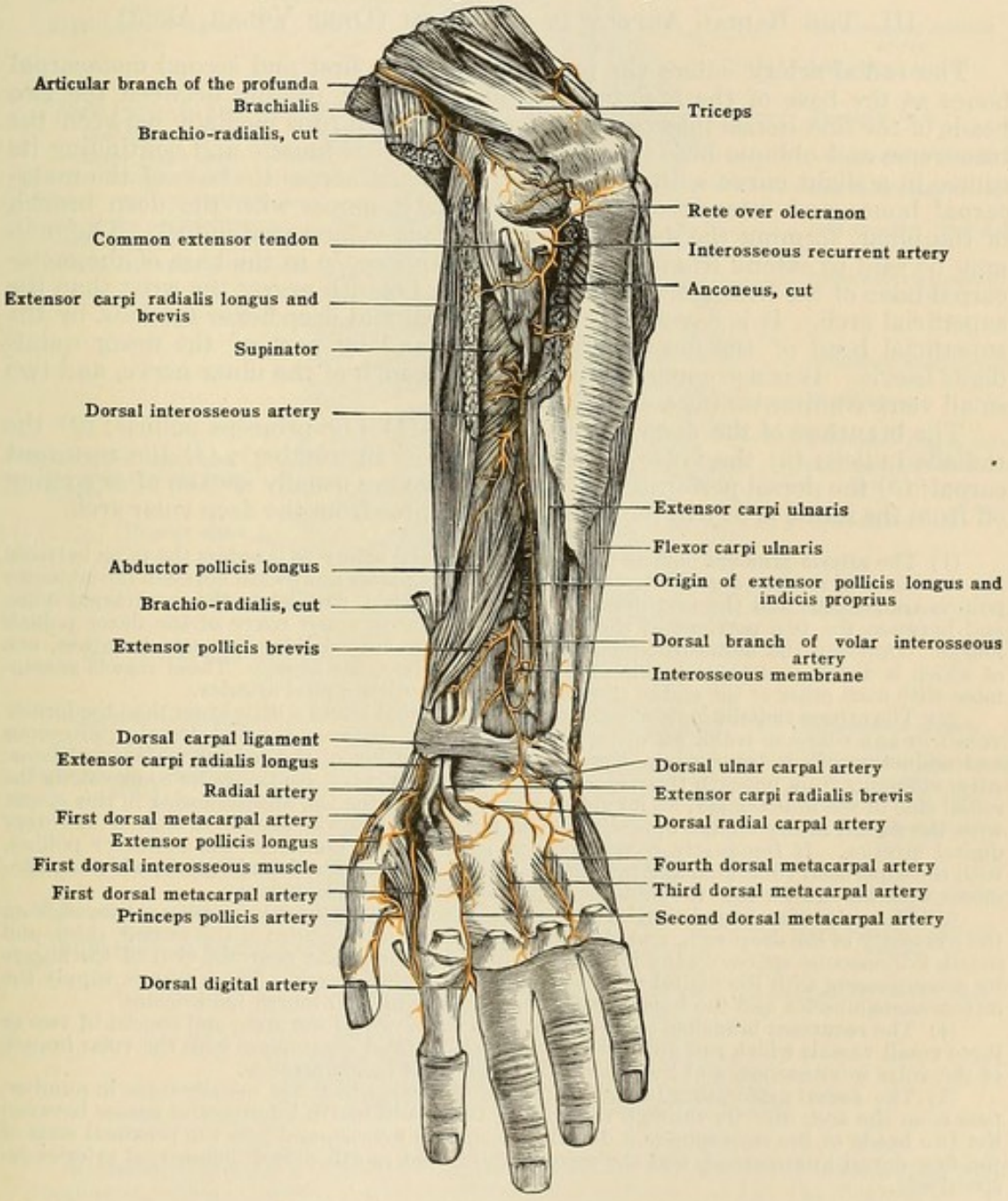

The **branches of the radial artery at the wrist** are:—(1) The dorsal radial carpal; (2) the first dorsal metacarpal.

(1) The **dorsal radial carpal** branch [ramus carpeus dorsalis] arises from the radial as the latter vessel passes under the abductor pollicis longus, and runs medially beneath the extensor carpi radialis longus and brevis, and the extensor pollicis longus, across the dorsal surface of the carpus, to anastomose with the dorsal ulnar carpal and with the terminal twigs of the posterior branch of the volar interosseous artery. This anastomosis is called the **dorsal carpal**

rete [rete carpi dorsale]. From this rete are given off the second, third, and fourth **dorsal metacarpal arteries** to the second, third, and fourth intermetacarpal spaces respectively. These vessels run downward on the dorsal interosseous muscles as far as the flexure of the fingers, and there divide into two branches (**dorsal digital**), which run along the sides of the contiguous fingers on their dorsal aspect. Near their proximal ends they anastomose with the dorsal **perforating branches of the deep volar arch.** Distally they are connected by **volar perforating** branches with the digital arteries or the corresponding spaces. The branches which run along the backs of the fingers anastomose with the dorsal branches of the first dorsal digital arteries derived from the volar common digital vessels (fig. 476).

(2) The **first dorsal metacarpal** (figs. 472, 476) is given off by the radial shortly before it passes between the two heads of the first dorsal interosseous muscle. It quickly divides into two branches which supply the dorsal surface of the thumb and the radial side of the index-finger toward its dorsal surface.

III. The Radial Artery in the Palm (Deep Volar Arch)

The radial artery enters the palm between the first and second metacarpal bones at the base of the first interosseous space, by passing between the two heads of the first dorsal interosseous muscle. It then runs medially between the transverse and oblique heads of the adductor pollicis muscle and continuing its course in a slight curve with the convexity forward, across the base of the metacarpal bones and interosseous muscles, it anastomoses with the deep branch of the ulnar, forming the **deep volar arch** [arcus volaris profundus]. The arch may be said to extend from the first interosseous space to the base of the metacarpal bone of the little finger, and is a finger's breadth nearer the wrist than the superficial arch. It is covered by the superficial and deep flexor tendons, by the superficial head of the flexor pollicis brevis, and by part of the flexor quinti digiti brevis. It is accompanied by the deep branch of the ulnar nerve, and two small venæ comitantes (figs. 472, 473).

The **branches of the deep volar arch** are:—(1) The princeps pollicis; (2) the radialis indicis; (5) the volar metacarpals (three in number); (4) the recurrent carpal; (3) the dorsal perforating. The first two are usually spoken of as coming off from the radial artery in the palm; the last three from the deep volar arch.

(1) The **arteria princeps pollicis** arises from the radial artery as it enters the palm between the two heads of the first dorsal interosseous muscle. It passes downward between the adductor pollicis transversus and the first dorsal interosseous muscle, parallel to the metacarpal bone, and between the two portions of the flexor pollicis brevis under cover of the flexor pollicis longus. Opposite the metacarpo-phalangeal joint it usually divides into two branches, one of which is distributed to each side of the thumb on its volar aspect. These vessels anastomose with each other at the end of the thumb, like the other digital arteries.

(2) The **arteria radialis indicis** comes off from the radial artery a little lower than the former vessel, or as a common trunk with it, and passes forward between the first dorsal interosseous and adductor pollicis transversus, parallel to the radial side of the second metacarpal bone. After emerging from beneath the adductor pollicis transversus it continues its course along the radial side of the index-finger, on its volar aspect, as far as the tip, anastomosing in this course with the digital artery on the opposite side of the finger in a way similar to that of the other digital arteries. It frequently communicates, at the lower border of the adductor pollicis, with the superficial volar arch and princeps pollicis. It gives off a dorsal branch, which anastomoses with the branch fron the first dorsal metacarpal to the index finger.

(3) The **volar metacarpal** arteries [aa. metacarpeæ volares], three in number, come off from the convexity of the deep arch, and, coursing downward in the centre of the second, third, and fourth interosseous spaces on the interosseous muscles, terminate near the cleft of the fingers by anastomosing with the digital arteries from the superficial arch. These vessels supply the interosseous muscles and the bones, and the second, third, and fourth lumbricales.

(4) The **recurrent branches** come off from the concavity of the arch, and consist of two or three small vessels which run upward toward the wrist, and anastomose with the volar branch of the volar interosseous, and the volar radial and ulnar carpal arteries.

(5) The **dorsal perforating** branches (rr. perforantes), which are usually three in number, pass from the arch directly through the second, third, and fourth interosseous spaces between the two heads of the corresponding dorsal interosseous muscle, and join the proximal ends of the first dorsal interosseous, and the second, third, and fourth dorsal metacarpal arteries respectively.

THE THORACIC AORTA

The **thoracic aorta** [aorta thoracalis] (fig. 477) is the thoracic portion of the aorta descendens. It extends from the termination of the aortic arch at the lower border of the body of the fourth thoracic vertebra to the lower border of the body of the twelfth thoracic vertebra, where it passes between the medial

crura of the diaphragm, and is thence continued under the name of the abdominal aorta. It is at first situated a little to the left of the vertebral column, but as it descends, approaches the front of the column, at the same time following the backward curve of the spine, and at the diaphragm is almost in the middle line. It lies in the posterior mediastinum, having the œsophagus at first a little to the right of it, then in front of it, and just above the tenth thoracic vertebra, where this tube pierces the diaphragm, a little to its left side.

FIG. 477.—THE ARCH OF THE AORTA, THE THORACIC AORTA, AND THE ABDOMINAL AORTA, WITH THE SUPERIOR AND INFERIOR VENA CAVA AND THE INNOMINATE AND AZYGOS VEINS.

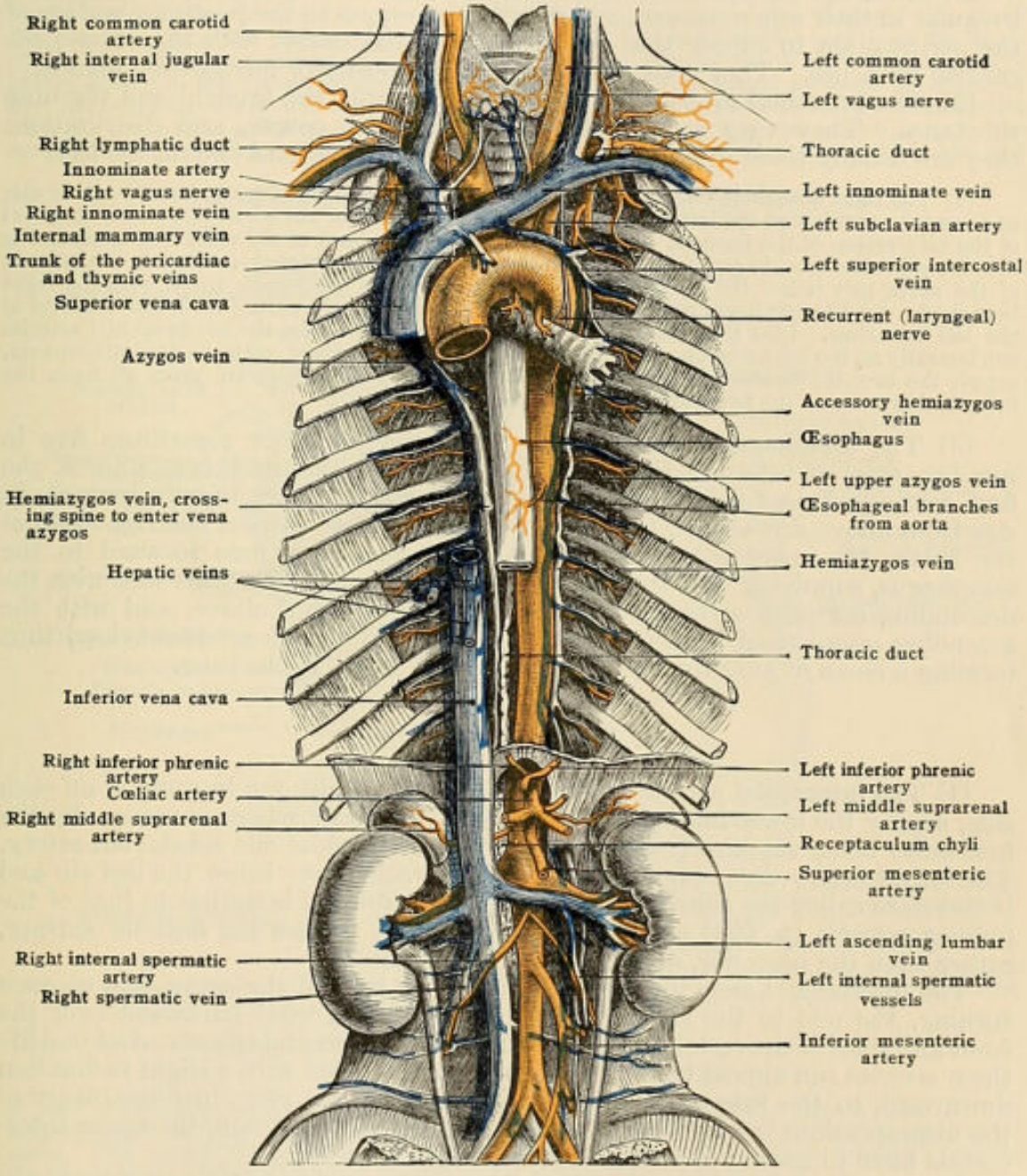

Relations.—**In front** it is crossed from above downward by the root of the left lung, by the œsophagus, which separates it from the pericardium and heart, and by the diaphragm.

Behind, it lies upon the lower seven thoracic vertebræ, and is crossed obliquely opposite the seventh or eighth thoracic vertebra by the the vena hemiazygos (azygos minor) and opposite the fifth or sixth vertebra by the accessory hemiazygos vein, or by one or more of the intercostal veins.

On the **right side** it has, above, the œsophagus and vertebral column; lower down the right pleura and lung. The vena azygos and thoracic duct also lie to the right, but on a somewhat posterior plane.

On the **left side** it has the left lung and pleura above, and the œsophagus below. The vena hemiazygos and the accessory hemiazygos vein are also to the left, but on a posterior plane.

Branches of the Thoracic Aorta

The **branches of the thoracic aorta** may be divided into the visceral and the parietal. The **visceral** are:—(1) The pericardiac; (2) the bronchial; and (3) the œsophageal. The **parietal** are:—(1) The intercostal; (2) the superior phrenic; and (3) the arteria aberrans.

A. Visceral Branches

(1) The **pericardiac** branches [rami pericardiaci]—two or three small branches, irregular in their origin, course, and distribution—pass to the posterior surface of the pericardium to supply that structure, and anastomose with the other pericardiac branches. They give small twigs to the posterior mediastinal glands.

(2) The **bronchial** arteries [aa. bronchiales] supply the bronchi and the lung substance. They vary considerably in their origin, course, and distribution; they are usually three in number—one on the right side, and two on the left.

(*a*) The **right bronchial** generally arises either from the first right aortic intercostal, or else as a common trunk with the left upper bronchial from the front of the aorta just below the level of the bifurcation of the trachea. It passes laterally on the back of the right bronchus, and is distributed to the bronchi and lung substance. (*b*) The **left upper bronchial** arises from the front of the aorta just below the bifurcation of the trachea, or as a common trunk with the right bronchial. (*c*) The **left lower bronchial** arises from the front of the aorta just below the level of the left bronchus. Like the corresponding artery on the right side, the left bronchial arteries run laterally on the left bronchus, and, after dividing and subdividing on the back of the bronchi, supply the bronchi themselves and the lung substance. Small twigs are given off from the bronchial arteries to the bronchial glands and to the œsophagus.

(3) The **œsophageal** arteries [aa. œsophageæ], four or sometimes five in number, arise at intervals from the front of the descending thoracic aorta, the first coming off just below the left lower bronchial. They usually increase in size from above downward, the upper coming off more toward the right side of the aorta, the lower more toward the left side. They pass forward to the œsophagus, supplying that tube and anastomosing with each other and with the descending œsophageal branches of the inferior thyreoid above, and with the ascending œsophageal branches of the phrenic and gastric arteries below, thus forming a chain of anastomoses along the whole length of the tube.

B. Parietal Branches

(1) The **intercostal** arteries [aa. intercostales], usually ten in number on each side, supply the lower intercostal spaces, the two upper spaces (occasionally the first only) being supplied from the costo-cervical trunk of the subclavian artery. The lowest artery accompanies the twelfth thoracic nerve below the last rib and is therefore called the **subcostal artery.** Its distribution is similar to that of the lumbar arteries (p. 593) except that it commonly crosses the anterior surface, rather than the posterior, of the quadratus lumborum.

The intercostals arise in pairs from the back part of the aorta, and at once turning, the one to the right, the other to the left, wind backward over the front and sides of the vertebral bodies to reach the intercostal spaces. In fœtal life these arteries run almost transversely backward, or even with a slight inclination downward, to the intercostal spaces; but after the first year, in consequence of the disproportionate growth of the aorta and vertebral column, the upper intercostals have to ascend to reach their respective spaces.

The arteries in their course around the vertebræ differ on the two sides of the body. On the **right side** the arteries—and especially the upper, in consequence of the aorta lying a little to the left side of the spine in the upper part of its course—are longer than the left. They wind over the front and right side of the vertebræ, being crossed by the thoracic duct and vena azygos (major), and covered by the right pleura and lung. The upper are also crossed by the œsophagus. They give off small branches to the bodies of the vertebræ and anterior longitudinal ligament. On the **left side,** as the intercostals wind around the sides of the bodies of the vertebræ, the lower are crossed by the vena hemiazygos (azygos minor), the two upper by the left superior intercostal vein, and the two next by

the accessory hemiazygos vein when this is present. They are all covered by the left pleura and lung (fig. 478).

The **branches of the intercostal arteries** are:—(a) anterior, (b) posterior.

(*a*) The **anterior** branches [rami anteriores] at first cross the intercostal space obliquely, in consequence of the downward direction of the ribs, toward the angle of the rib above, and thence are continued forward in the costal groove, and anastomose with the superior branches of the anterior intercostals from the internal mammary in the upper spaces, and from the musculo-phrenic in the lower spaces. They lie at first on the external intercostal muscles, being covered in front by the pleura and lung, the endothoracic fascia, and the subcostal muscles. Opposite the heads of the ribs they are crossed by the sympathetic nerve. At the angle of the ribs they pass under cover of the internal intercostal muscles, and thence to their termination lie between the two intercostal muscles. Their situation in the midspace as far as the angle of the rib should be remembered in performing paracentesis thoracis. To avoid the risk of injuring the vessels, the puncture should not be made further back than the angle of the ribs. They are accompanied by a nerve and vein, the vein lying above and the nerve below, except in the upper spaces, where the artery, having to ascend to reach the space, at first lies below the nerve which runs more horizontally. The uppermost branch anastomoses with the costo-cervical artery from the subclavian, and at times supplies almost entirely the second intercostal space. The arteries to the tenth and eleventh spaces on reaching the end

FIG. 478.—SCHEME OF INTERCOSTAL ARTERY. (Walsham.)

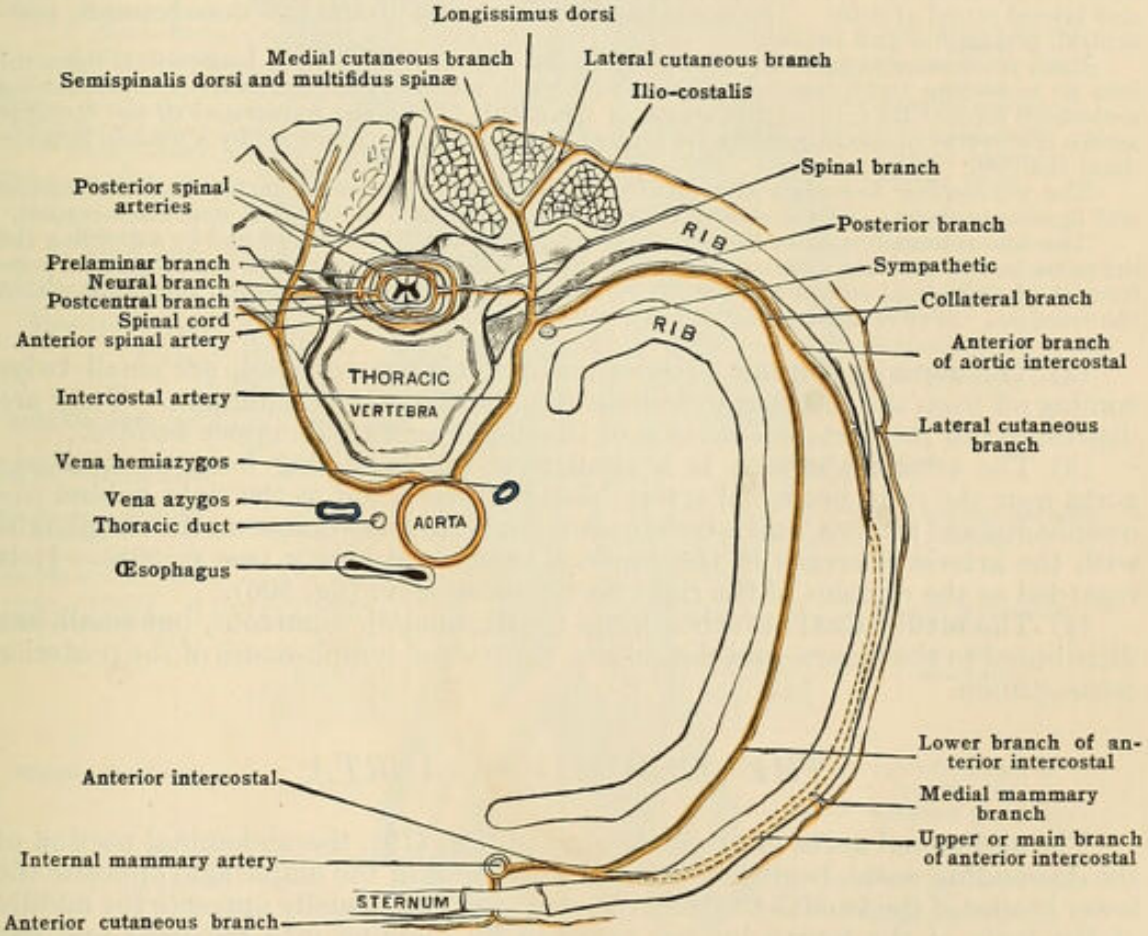

of their respective ribs pass between the abdominal muscles, and anastomose with the inf. epigastric artery from the external iliac, and with the lumbar arteries from the abdominal aorta. The artery beneath the twelfth rib anastomoses with the lumbar arteries and with the external circumflex iliac.

Each anterior branch gives off the following:—(i) The **collateral** branch which comes off near the angle of the rib and runs forward, between the external and internal intercostals, along the upper border of the lower rib enclosing the space. It is smaller than the main anterior branch and anastomoses with the lower anterior intercostal in each space. (ii) **Muscular** branches [rami musculares] supply the intercostal, pectoral and abdominal muscles. (iii) The **lateral cutaneous** branches [rami cutanei laterales], both pectoral and abdominal, run with the corresponding branches of the intercostal nerves through the external intercostal and serratus anterior muscles. They then divide into *anterior* and *posterior* branches which turn forward and backward, respectively, to supply the integument. The anterior branches from the third, fourth and fifth spaces supply *lateral mammary* branches [rr. mammarii laterales] to the lateral region of the breast. (iv) **Anterior cutaneous** branches [rami cutanei anteriores] pierce the external intercostal ligament and the pectoralis major just lateral to the sternum.

They are distributed to the skin and give *medial mammary* branches [rr. mammarii mediales] to the medial region of the breast.

(*b*) **The posterior** branches [rami posteriores].—These large branches are given off from the intercostals opposite the quadrilateral space bounded by the transverse process of the vertebra above, the neck of the rib below, the body of the vertebra medially, and the anterior costo-transverse ligament laterally. Passing backward toward this space with the dorsal branch of the corresponding intercostal nerve, they divide opposite the intervertebral foramen into a muscular and a spinal branch. (i) The **muscular** branch [r. muscularis] passes backward through the quadrilateral space, and soon subdivides into a medial and a lateral branch. The former passes between the longissimus dorsi and ilio-costalis, and, after supplying these muscles, gives off **medial cutaneous** branches [rr. cutanei mediales]. The latter branch pierces the multifidus spinæ, and, emerging between the longissimus dorsi and semispinalis dorsi near the spinous processes, gives off **lateral cutaneous** branches [rr. cutanei laterales]. It supplies the muscles in its course.

(ii) The **spinal** branch [r. spinalis] enters the intervertebral foramen with the spinal nerve of the corresponding segment. The disposition of the spinal branch is similar to that of the spinal branches entering the canalis vertebralis in other regions and may be described here:—

ARTERIES OF THE VERTEBRAL CANAL

Spinal arteries are derived from the vertebral, ascending cervical and costo-cervical arteries, from the dorsal rami of the intercostal (fig. 478) and lumbar arteries, and from the ilio-lumbar and lateral sacral arteries. The spinal branch in each case divides into three branches, post-central, prelaminar and neural.

Each *post-central* branch divides on the lateral part of the posterior longitudinal ligament into an ascending and a descending branch by which means a bilateral series of anastomosing arches are formed throughout the length of the canal. From the concavities of the opposite arches transverse connecting stems are formed which are again connected by a median longitudinal channel.

The *pre-laminar* branches also divide and form an anastomosis in front of the laminæ and ligamenta flava. This is similar in character to the post-central, but much less regular.

The *neural* branches enter the dura mater and are usually small and end by supplying the nerve roots. A variable number of these (5–10 on a side) are larger than the others and reinforce the longitudinal anterior and posterior spinal arteries given off from the vertebrals within the cranium. (For arteries of the spinal cord, see Section VII.)

(2) The **superior phrenic** arteries [aa. phrenicæ superiores], are small twigs coming off from the thoracic aorta immediately above the diaphragm. They are distributed to the vertebral portion of the diaphragm on its upper surface.

(3) The **arteria aberrans** is a small twig which, arising from the thoracic aorta near the right bronchial artery, passes upward and to the right behind the œsophagus and trachea, and is occasionally found to anastomose on the œsophagus with the arteria aberrans of the superior intercostal artery (see p. 568). It is regarded as the remains of the right aortic dorsal stem (fig. 506).

(4) The **mediastinal** branches [rami mediastinales], numerous, but small, are distributed to the pleura, and the vessels, nerves and lymph-nodes of the posterior mediastinum.

THE ABDOMINAL AORTA

The **abdominal aorta** [aorta abdominalis] (fig. 479), the abdominal portion of the descending aorta, begins at the aortic opening in the diaphragm opposite the lower broder of the twelfth thoracic vertebra, and ends usually opposite the middle of the body of the fourth lumbar vertebra by dividing into the right and left common iliac arteries. It is at first centrally placed between the medial crura of the diaphragm, but as it descends in front of the lumbar vertebræ it leaves the middle line, and, at its bifurcation, lies a little to the left side of the spine.

The place at which the aorta bifurcates may be somewhat roughly indicated on the surface of the abdomen by a point about 2.5 cm. (1 in.) below and a little to the left of the umbilicus. The level of its bifurcation may be more accurately determined by drawing a straight line across the front of the abdomen joining the highest points of the iliac crests.

The inferior vena cava, which accompanies the abdominal aorta, lies to its right side. Below, the vein is in contact with the artery and on a somewhat posterior plane; but above, it is separated from the aorta by the right medial crus of the diaphragm, and, in consequence of the caval opening in the diaphragm being placed further forward than the opening for the aorta, is on an anterior plane.

Relations.—In front, the aorta is successively crossed from above downward by the right lobe of the liver, the cœliac (solar) plexus, the lesser omentum, the termination of the œsophagus in the stomach, the ascending layer of the transverse meso-colon, the splenic vein or commencement of the portal vein, the pancreas, the left renal vein, the third portion of the duodenum, the mesentery, the aortic plexus of the sympathetic nerve, the internal spermatic or ovarian arteries, the inferior mesenteric artery, the median lumbar lymphatic nodes and lymphatic vessels, and the small intestines.

Of these structures the cœliac (solar) plexus, the aortic plexus, the splenic vein or the commencement of the portal vein, the pancreas, the left renal vein, the duodenum, the lymphatics, the spermatic or ovarian arteries, and the peritoneal reflexions are in contact with the aorta.

Behind, the aorta lies upon the bodies of the lumbar vertebræ and intervening intervertebral cartilages, the anterior longitudinal ligament, the origin of the left medial crus of the diaphragm, and the left lumbar veins.

FIG. 479.—THE ABDOMINAL AORTA AND ITS BRANCHES, WITH THE INFERIOR VENA CAVA AND ITS TRIBUTARIES.

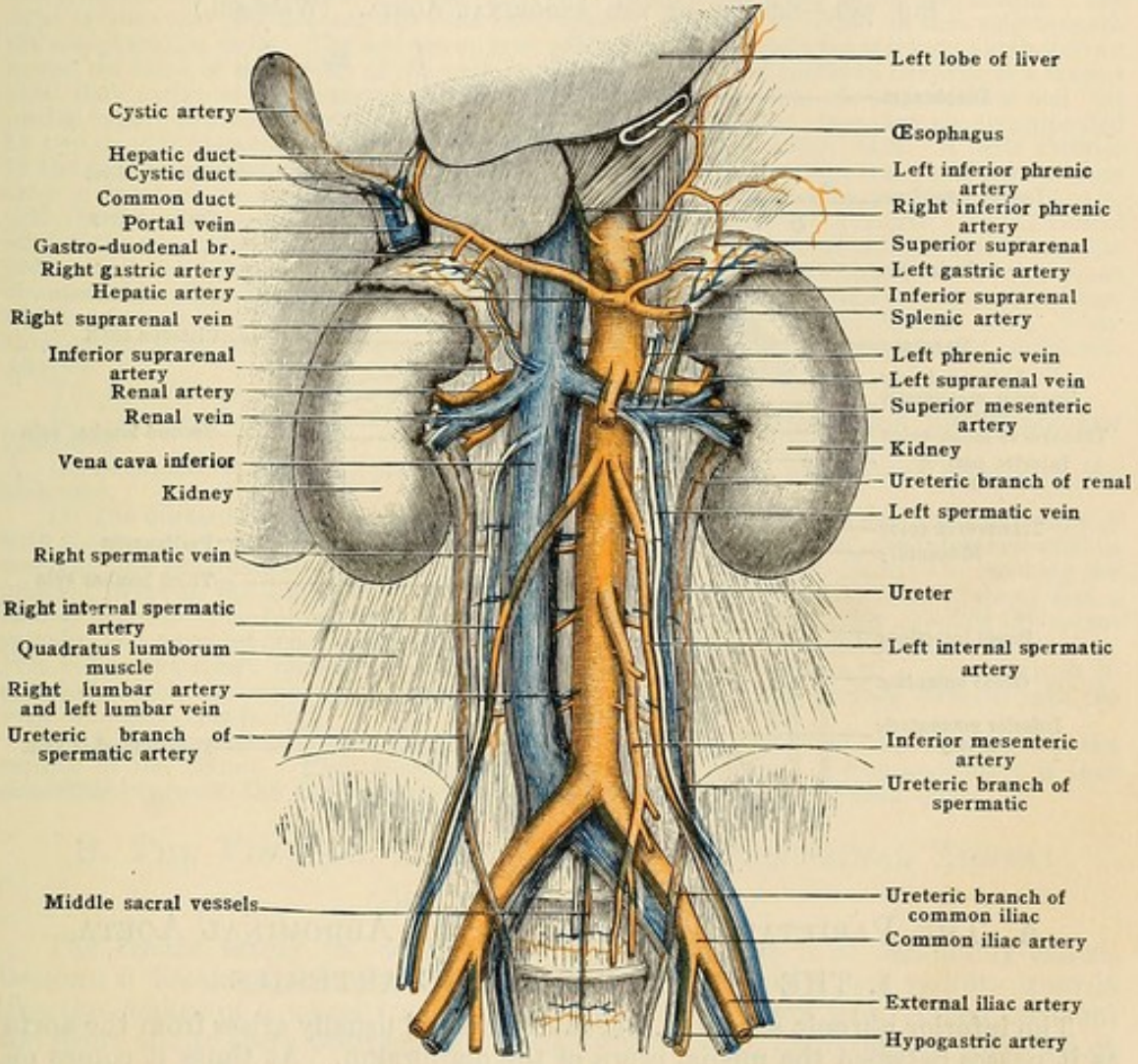

On the **right side** from above downward are the right medial crus of the diaphragm, the great splanchnic nerve, the caudate lobe of the liver, the receptaculum chyli and beginning of the thoracic duct (the two latter structures are on a posterior plane), the right cœliac (semilunar) ganglion, and the inferior vena cava.

On the **left side** are the left medial crus of the diaphragm, the left splanchnic nerve, and the left cœliac (semilunar) ganglion. The pancreas is also in contact with the aorta on the left side, and the small intestines are separated from it only by peritoneum.

BRANCHES OF THE ABDOMINAL AORTA

The **branches of the abdominal aorta** usually arise in the following order from above downward (figs. 479, 480):—

(1) Right and left inferior phrenic; (2) cœliac; (3) right and left middle suprarenal; (4) right and left first lumbar; (5) superior mesenteric; (6) right and

left renal; (7) right and left internal spermatic; (8) right and left second lumbar; (9) inferior mesenteric; (10) right and left third lumbar; (11) right and left fourth lumbar; (12) right and left common iliac; (13) middle sacral.

The above branches may be divided into the parietal, the visceral, and the terminal.

The **parietal branches** are distributed to the abdominal walls. They are the right and left phrenics, and the four right and left lumbars.

The **visceral branches** supply the viscera. Three of these are given off singly from the front of the aorta, namely, the cœliac, the superior mesenteric, and the inferior mesenteric; and three are given off in pairs, namely, the two suprarenals, the two renals, and the two spermatics.

The **terminal branches** are the middle sacral and the right and left common iliac arteries.

FIG. 480.—SCHEME OF THE ABDOMINAL AORTA. (Walsham.)

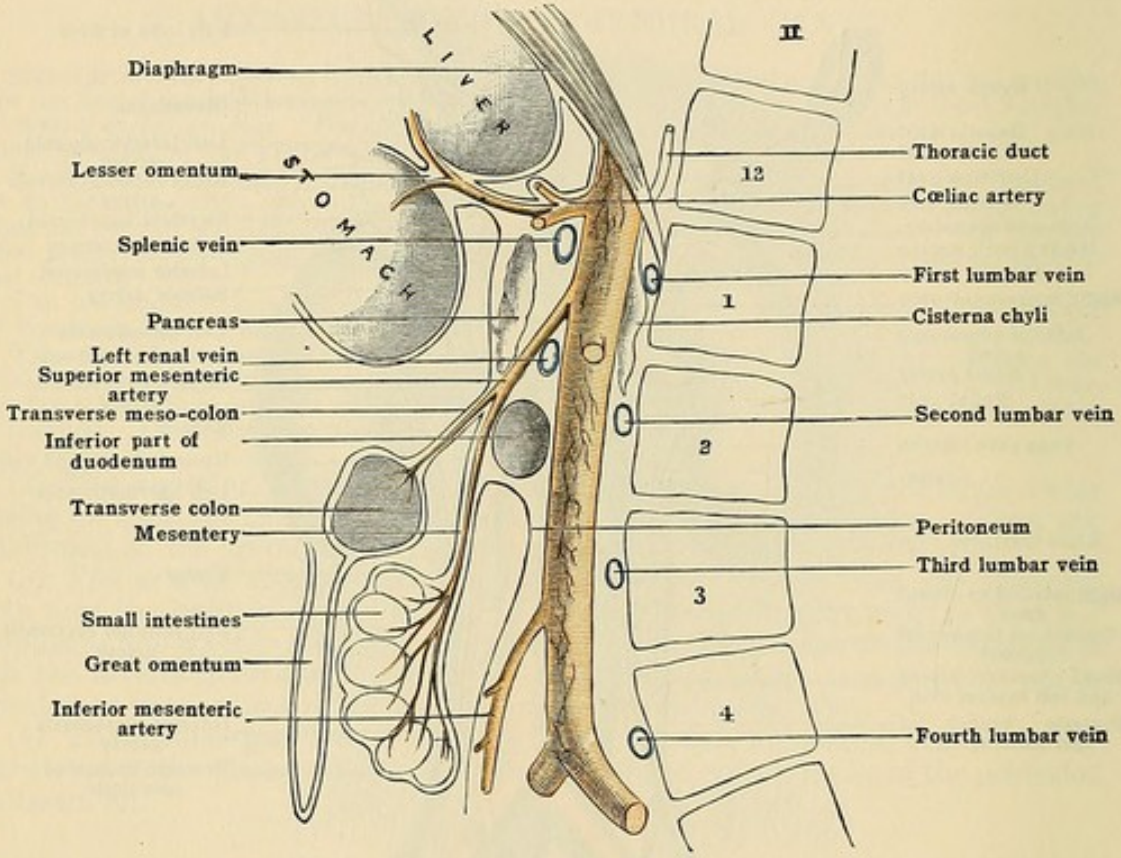

A. THE PARIETAL BRANCHES OF THE ABDOMINAL AORTA

1. THE INFERIOR PHRENIC ARTERIES

The **inferior phrenic** artery [a. phrenica inferior] usually arises from the aorta as it passes between the medial crura of the diaphragm. At times it comes off from the cœliac artery; or when it arises as two separate vessels, either the right or left vessel may come from this artery, or from other of the upper branches of the abdominal aorta.

The **right phrenic** passes (fig. 480) over the right medial crus of the diaphragm behind the vena cava, and then upward and to the right between the central and right leaflets of the central tendon of the muscle, where it divides into an **anterior** and a **posterior** branch. The former courses anteriorly and medially and anastomoses with the anterior branch of the left phrenic, with the musculo-phrenic branches of the internal mammary, and with the pericardio-phrenic arteries; the latter passes posteriorly and laterally toward the ribs, and anastomoses with the intercostal arteries. Besides the two terminal branches and branches for the supply of the diaphragm itself the right phrenic gives off the **right superior suprarenal** [ramus suprarenalis superior], to the right suprarenal gland, as well as branches to the vena cava, to the liver, and to the pericardium.

The **left phrenic** crosses the left medial crus of the diaphragm behind the œsophagus, and, like the right artery, divides into an anterior and posterior branch and gives off a left suprarenal branch. The distribution and anastamoses are similar on the two sides.

2. THE LUMBAR ARTERIES

The **lumbar** arteries [aa. lumbales] (fig. 479), usually eight in number, four on each side, come off in pairs from the posterior aspect of the abdominal aorta, opposite the bodies of the four upper lumbar vertebræ. A fifth pair of lumbar arteries, generally of small size, frequently arises from the middle sacral artery opposite the fifth lumbar vertebra. The lumbar arteries, which are rather longer on the right than on the left side, in consequence of the aorta lying a little to the left of the median line, wind more or less transversely around the bodies of the vertebræ to the space between the transverse processes, where they give off each a dorsal branch, and then, coursing forward between the abdominal muscles, terminate, by anastomosing with the other arteries of the abdominal wall.

Relations.—As they wind around the bodies of the vertebræ they pass beneath the chain of the sympathetic nerve trunk, and the upper two beneath the crura of the diaphragm. The right arteries also pass beneath the vena cava inferior, and the two upper on that side beneath the receptaculum chyli. The arteries on both sides then dip beneath the tendinous arch thrown across the sides of the bodies of the vertebræ by the psoas, and continue beneath this muscle until they arrive at the interval between the transverse processes of the vertebræ and the medial edge of the quadratus lumborum. While under cover of the psoas they are accompanied by two slender filaments of the sympathetic nerve and by the lumbar veins. A little anterior to the transverse processes they are crossed by branches of the lumbar plexus, and here usually cross in front of the ascending lumbar vein. They now pass behind the quadratus lumborum, with the exception sometimes of the last, which may pass in front of the muscle. At the lateral edge of the quadratus they run between the transversus and the internal oblique, and then, after perforating the internal oblique between the internal and external oblique. Finally, much diminished in size, they enter the rectus, and give off one or more anterior cutaneous branches, which accompany the last thoracic and the ilio-hypogastric nerves to the skin. They anastomose with the lower intercostals, ilio-lumbar, deep circumflex iliac, and inf. epigastric arteries.

The **branches of the lumbar arteries** are:—

(*a*) **Vertebral** branches which supply the bodies of the vertebræ and their connecting ligaments.

(*b*) **Muscular** branches to the psoas, quadratus lumborum, and oblique muscles of the abdomen.

(*c*) The **dorsal** branch [r. dorsalis]. This is of large size, and passes backward in company with the dorsal nerve between the transverse processes above and below, the intertransversalis medially and the quadratus lumborum laterally, to the muscles of the back. On reaching the interval between the longissimus dorsi and multifidus spinæ, it divides into a lateral and a medial branch. The former ends in the multifidus, the latter and larger supplies the sacrospinalis, and gives branches which accompany the termination of the dorsal nerves to the skin. Just before the artery passes between the transverse processes it gives off a **spinal** branch [r. spinalis], which accompanies the lumbar nerve through the intervertebral foramen into the vertebral canal (see p. 590).

(*d*) **Renal** branches of small size pass forward in front of the quadratus lumborum to the capsule of the kidney. They anastomose with the renal artery. A communication is thus established between the renal arteries and the arteries supplying the lumbar region.

B. The Visceral Branches of the Abdominal Aorta

THE CŒLIAC ARTERY

The **cœliac** artery [a. cœliaca]—or **cœliac axis,** as it is commonly called, because it breaks up simultaneously into three branches which radiate from it like the spokes of a wheel from the axle—is a short thick trunk given off from the front of the aorta between the medial crura of the diaphragm a little below the aortic opening. It passes horizontally forward above the upper margin of the pancreas for about half an inch, and then breaks up into three branches for the supply of the stomach, duodenum, spleen, pancreas, liver, and gall-bladder (fig. 481).

Relations.—**In front** is the lesser omentum; **behind,** the aorta; **above,** the right lobe of the liver; **below,** the pancreas; to the **right,** the right cœliac (semilunar) ganglion and caudate lobe of the liver; to the **left,** the left cœliac (semilunar) ganglion and the cardiac end of the stomach. It is closely surrounded by the dense cœliac (solar) plexus of sympathetic nerves.

Branches of the cœliac artery.—The cœliac artery divides into the left gastric, the hepatic, and the splenic arteries.

1. The Left Gastric Artery

The **left gastric** [a. gastrica sinistra] (fig. 481), the smallest of the three branches into which the cœliac artery divides, courses at first upward and to the

left toward the cardiac end of the stomach, where it turns sharply round, and then, following the lesser curvature of the stomach, descends from left to right toward the pylorus. It anastomoses with the right gastric branch of the hepatic artery, which has proceeded from the opposite direction, the two branches thus forming a continuous arterial arch corresponding to the lesser curvature of the stomach.

The artery at first lies behind the posterior layer of the omental bursa of peritoneum (fig. 480), but on reaching the cardiac end of the stomach it passes, between the layers of peritoneum reflected from the diaphragm onto the œsophagus, into the lesser omentum in which it then runs to its terminal anastomosis with the pyloric. It is surrounded by a plexus of sympathetic nerves.

It supplies both surfaces of the stomach around the lesser curvature and gives off small **œsophageal** branches [rami œsophagei] which anastomose with the œsophageal branches from the thoracic aorta.

FIG. 481.—THE CŒLIAC ARTERY AND ITS BRANCHES.

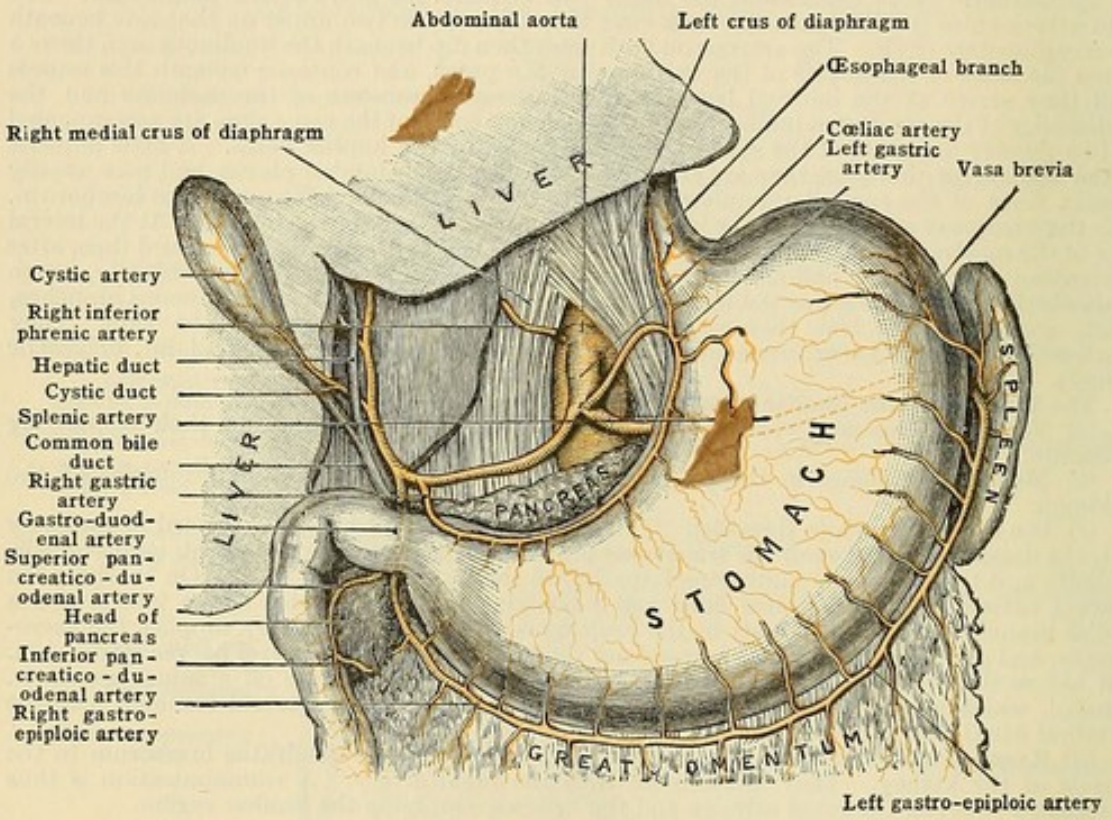

2. THE HEPATIC ARTERY

The **hepatic** artery [a. hepatica], the largest branch of the cœliac artery in the fœtus, but intermediate in the adult between the left gastric and the splenic, comes off on the right side of the cœliac artery, and, winding upward and to the right to the porta (portal fissure) of the liver, there breaks up into two chief branches for the supply of the right and left lobes of that organ. It at first courses forward and to the right along the upper border of the head of the pancreas, behind the posterior layer of the peritoneal omental bursa, to the upper margin of the duodenum, where it passes forward beneath the layer of peritoneum forming the floor of the epiploic foramen (of Winslow). It thus runs between the two layers of the lesser omentum, and ascends along with the hepatic duct which lies to its right, and with the portal vein which lies behind it (figs. 480, 481).

The **branches of the hepatic artery** are:—(1) The right gastric; (2) the gastro-duodenal; (3) the hepatic proper.

(1) The **right gastric** artery [a. gastrica dextra] comes off from the hepatic just as the latter vessel enters the lesser omentum, and, descending between the two layers of that fold of peritoneum to the pylorus, there turns to the left, and, ascending from right to left, anastomoses along the lesser curvature of the stomach, as already mentioned, with the left gastric artery, which descends from the opposite direction.

(2) The **gastro-duodenal** artery [a. gastroduodenalis] arises from the hepatic

a little beyond the pyloric. It descends behind the superior portion of the duodenum to the lower border of the pylorus, where it divides into the **right gastro-epiploic** and the **superior pancreatico-duodenal.** It varies from 1.2 to 2.5 cm. ($\frac{1}{2}$ to 1 in.) in length.

(*a*) The **right gastro-epiploic** artery [a. gastroepiploica dextra] passes from right to left along the greater curvature of the stomach between the layers of the great omentum, and anastomoses with the left gastro-epiploic branch of the splenic. From this anastomotic arch are given off:—(i) **Ascending** or **gastric** branches, which supply the anterior and posterior surfaces of the stomach, and anastomose with the descending gastric branches of the arteries along the lesser curvature. (ii) **Epiploic** [rami epiploici] or **omental branches**—long slender vessels which descend between the two anterior layers of the great omentum, and then, looping upward, anastomose with similar slender branches given off from the middle and left colic, and passing down in like manner between the two posterior layers of the great omentum.

(*b*) The **superior pancreatico-duodenal** [a. pancreaticoduodenalis superior]—the smaller division of the gastro-duodenal—arises from that vessel as it passes behind the first portion of the duodenum, and courses downward behind the peritoneum, in the anterior groove between the second portion of the duodenum and the pancreas, to anastomose with the inferior pancreatico-duodenal, a branch of the superior mesenteric. Both the inferior and superior pancreatico-duodenal give off **duodenal** [rami duodenales] and **pancreatic** branches [rami pancreatici] to supply these organs.

(3) The **hepatic artery proper** [a. hepatica propria] is the continuation of the hepatic after the gastro-duodenal has arisen. It ascends between the layers of the lesser omentum, preserving the relations of the main artery to the portal vein and common bile (and hepatic) duct, and divides, near the porta hepatis, into **right** and **left** branches.

(*a*) The **right** branch [r. dexter], given off at the porta (portal fissure) of the liver, runs to the right either behind the hepatic and cystic ducts, or between these strucures. At the right end of the porta it divides into or more branches, which again subdivided as they enter the liver substance for the supply of the right lobe. As it crosses the cystic duct it gives off the cystic artery.

The **cystic** artery [a. cystica] courses forward and downward through the angle formed by the union of the hepatic and cystic ducts, and just before it reaches the gall-bladder divides into a superficial and deep branch. The former breaks up into a number of small vessels, which ramify over the free surface of the gall-bladder beneath the peritoneal covering, and furnish branches to the muscular and mucous coats. The deep branch ramifies between the gall-bladder and the liver-substance, supplying each, and anastomosing with the superficial branch.

(*b*) The **left** branch [r. sinister], the smaller division of the hepatic artery, runs medialward toward the left end of the porta hepatis, and, after giving off a distinct branch to the caudate (Spigelian) lobe, enters the left lobe of the liver.

3. The Splenic Artery

The **splenic** artery [a. lienalis]—the largest branch of the cœliac artery—arises from the left side of the termination of that vessel below the left gastric, and passes along the upper border of the pancreas in a tortuous manner to the spleen. It at first lies behind the ascending layer of the transverse meso-colon, but on nearing the spleen enters the lieno-renal ligament, and there breaks up into numerous branches, which enter the hilus and supply the organ. In this course it crosses in front of the left medial crus of the diaphragm and the upper end of the left kidney and is placed above the splenic vein.

The **branches of the splenic artery** are:—(1) The pancreatic; (2) the left gastro-epiploic; (3) the vasa brevia; and (4) the terminal.

(1) The **pancreatic** branches (rami pancreatici) come off from the splenic at varying intervals as that vessel courses along the upper margin of the pancreas. They enter and supply the organ. One larger branch usually arises from the splenic about the junction of its middle with its left third. Entering the pancreas obliquely, it runs from left to right, commonly above, and a little behind, the pancreatic duct, which it supplies together with the substance of the organ.

(2) The **left gastro-epiploic** [a. gastroepiploica sinistra] arises from the splenic near the greater curvature and below the fundus of the stomach, and, passing between the anterior layers of the great omentum, descends along the greater curvature of the stomach from left to right, and anastomoses with the right gastro-epiploic. Like that vessel, it gives off **ascending or gastric** branches to the anterior and posterior surfaces of the stomach respectively, and long slender **descending epiploic** or **omental** branches to the great omentum which anastomose with like branches from the right and left colic arteries.

(3) The **vasa brevia** [aa. gastricæ breves] come off from the splenic just before it divides into its terminal branches, oftentimes from some of these terminal branches themselves. Passing from between the folds of the lieno-renal ligament into those of the gastro-lienal, they thus reach the fundus of the stomach, where, ramifying over both its anterior and posterior surfaces, they anastomose with the left gastric and left gastro-epiploic arteries.

(4) The **splenic** or **terminal** branches, five to eight or more in number, are given off from the splenic as it lies in the lieno-renal ligament, and, entering the spleen at the hilum, are distributed in the way mentioned in the description of that organ.

THE SUPERIOR MESENTERIC ARTERY

The **superior mesenteric artery** [a. mesenterica superior] is given off from the front of the aorta a little below the cœliac, which it nearly equals in size; sometimes it forms a common trunk with the cœliac. Lying at first behind the pancreas and splenic vein, it soon passes forward between the lower border of that gland and the upper border of the inferior portion of the duodenum, and, crossing in front of the duodenum, enters the mesentery, in which it runs from left to right, in the form of a curve with its convexity to the left, to the cæcum, where it anastomoses with its ileo-colic branch. Its vein lies to its right side above, having

FIG. 482.—THE SUPERIOR MESENTERIC ARTERY AND VEIN.
(The colon is turned up, and the small intestines are drawn over to the left side.)

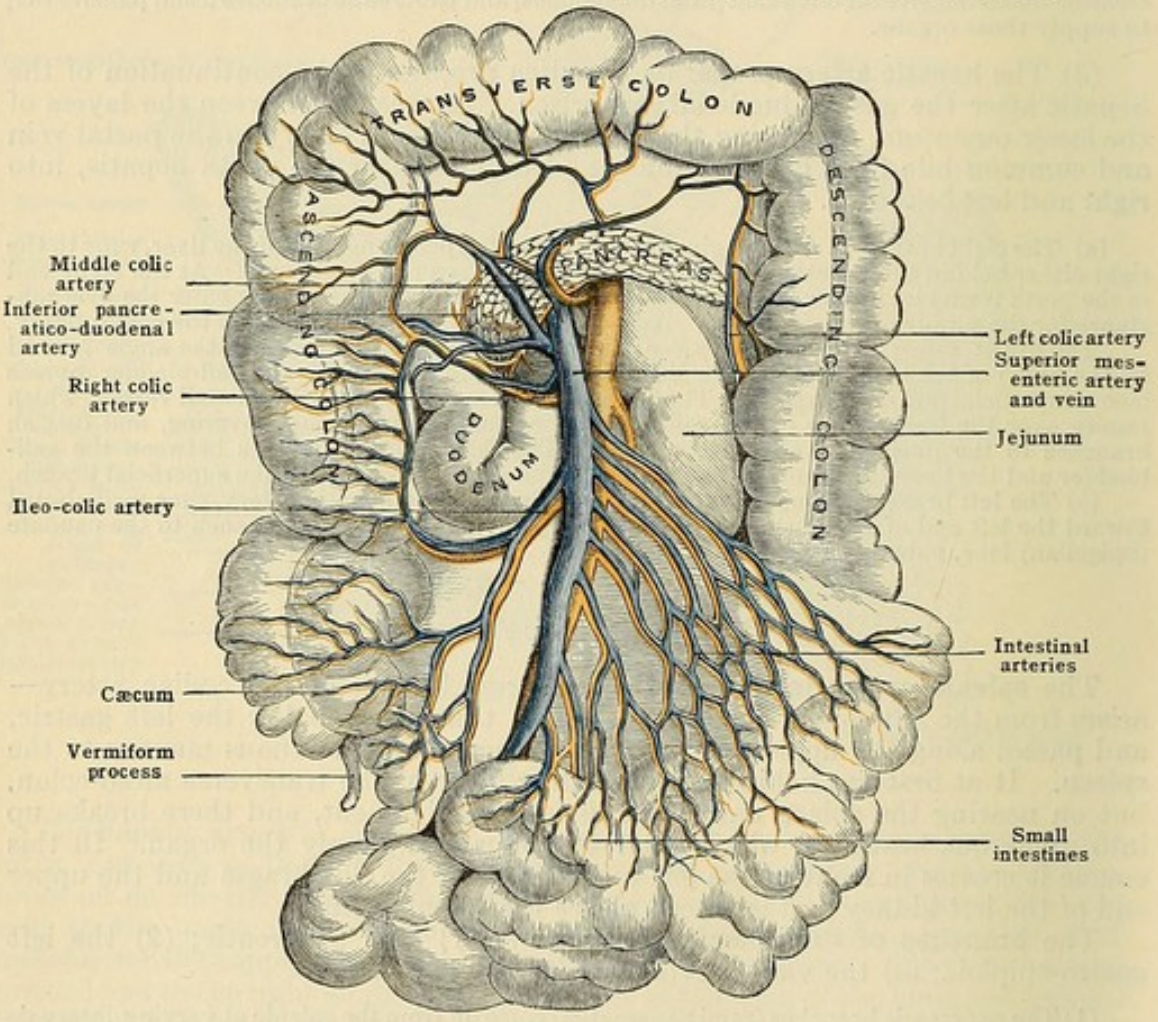

previously crossed obliquely in front of the artery from left to right. It is surrounded by the mesenteric plexus of nerves. The accessory portion of the head of the pancreas dips in behind the vessel.

The **branches of the superior mesenteric** are, in their *primitive* order:—(1) the inferior pancreatico-duodenal; (2) the intestinal arteries; (3) the ileo-colic; (4) the right colic; and (5) the middle colic.

(1) The **inferior pancreatico-duodenal** [a. pancreatico duodenalis inferior] arises either from the superior mesenteric as that vessel emerges from the contiguous margins of the pancreas and inferior part of the duodenum or from its first intestinal branch. Crossing behind the superior mesenteric vein, it courses upward and to the right between the head of the pancreas and the duodenum, and beneath the ascending layer of the transverse meso-colon, to anastomose with the superior pancreatico-duodenal.

(2) The **intestinal** arteries [aa. intestinales] arise from the convex side of the superior mesenteric, and, varying from twelve to sixteen in number, radiate in the mesentery, where

FIG. 483.—THE BLOOD-VESSELS OF THE ILEO-CÆCAL REGION. (From Kelly.)

(Arteries red, veins blue.) The peritoneal covering is removed so as to show the vessels more clearly. Above and to the right are seen the cut ends of the ileo-colic artery and vein. This artery gives off a branch to the ascending colon and a posterior and anterior cæcal artery, the latter descending through the ileo-colic fold. A short anastomosis connects the ileo-colic with the mesenteric. The artery of the vermiform process (appendix) is seen to arise from the posterior cæcal artery, 2 cm. above the ileum. It passes behind the ileum in the free border of the mesappendix and gives off five branches (long appendices have 8–12, short appendices, 2–3), which traverse the mesappendix at fairly regular intervals in the direction of the hilus of the appendix, where they divide into anterior and posterior branches. The branches in the mesappendix are sometimes seen to anastomose, forming loops of varying size. The terminal branch curves around the tip. The cæco-appendicular junction is supplied by a separate branch arising likewise from the posterior ileo-cæcal trunk. This branch may or may not anastomose with the proximal appendicular twig and while in some cases it supplies only the cæcum, in others, as in the present case, it sends a few delicate branches into the appendix. At the place where this cæco-appendicular artery crosses the ileo-cæcal fold it is seen to give off a delicate recurrent twig to this structure. Throughout their entire course the arteries are accompanied by veins.

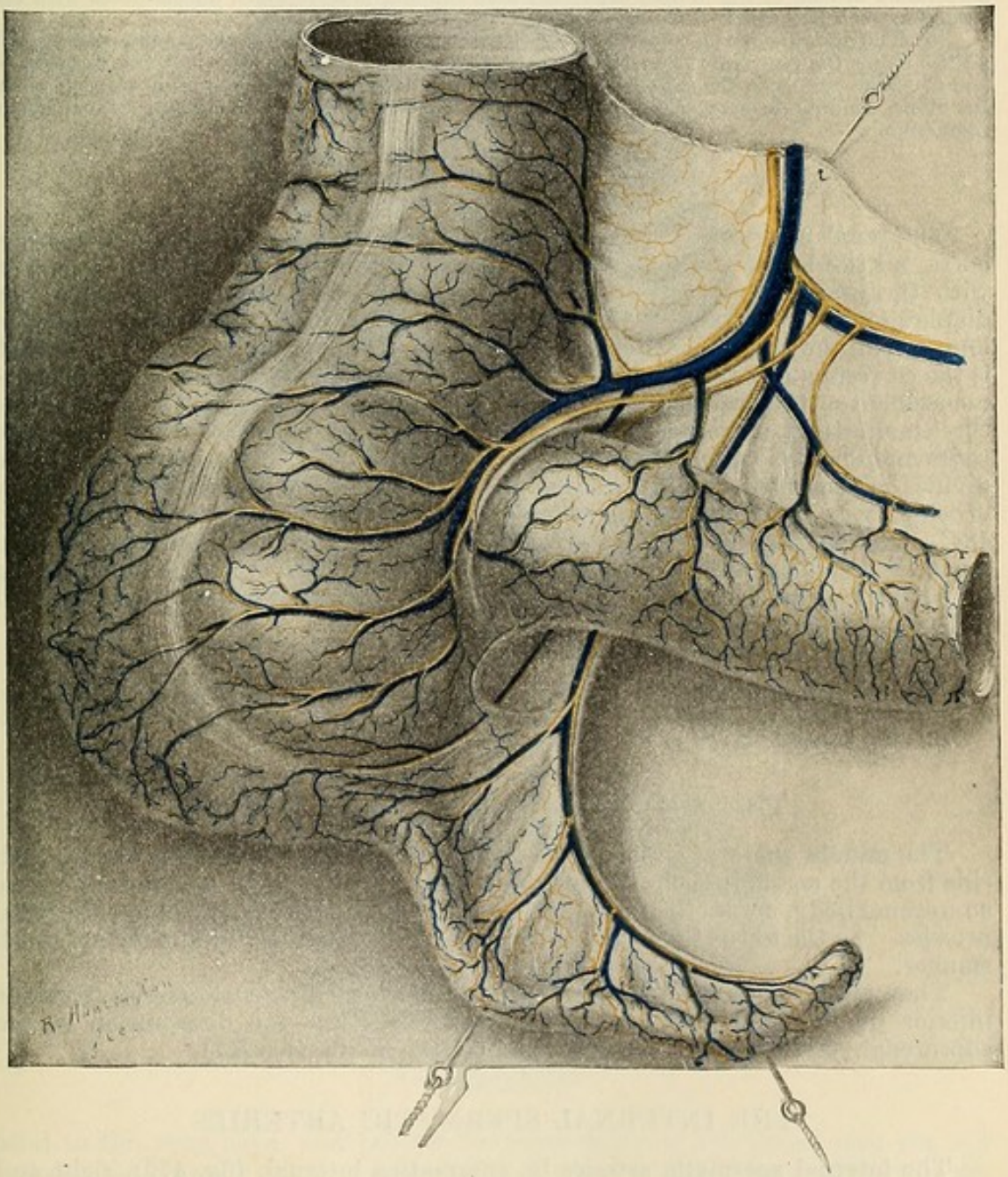

each divides into two branches, which inosculate with similar branches given off from the branch above and below. From the primary loops thus formed, secondary loops are derived in like manner, and from these tertiary, and at times quaternary, or even quinary loops. From the ultimate loops terminal **jejunal and iliac** branches [aa. jejunales et ilieæ] pass on to the muscular coat of the gut. These terminal vessels bifurcate, the two branches encircling the intestine, and thus forming with those above and below a series of vascular rings surrounding the small intestine throughout its whole length. The first intestial artery anastomoses with the pancreatico-duodenal arteries, and the last (the continuation of the main artery) with the ileo-colic. These branches of the superior mesenteric in their course to the intestine also supply the mesentery and the mesenteric glands.

(3) The **ileo-colic** [a. ileocolica] descends behind the peritoneum toward the cæcum, where it divides into a colic branch which tracks upward beneath the peritoneum to anastomose with the descending branch of the right colic; and into an iliac branch which passes between the layers of the mesentery and anastomoses with the termination of the superior mesenteric artery. Near the site of division the ileo-colic gives off anterior and posterior cæcal branches. From the latter of these arises a cæco-appendicular artery, to the cæcum and root of the vermiform process, and a main **appendicular** artery [a. appendicularis] (fig. 483).

(4) The **right colic** [a. colica dextra]—sometimes given off as a common trunk either with the middle colic or with the ileo-colic—passes to the right behind the peritoneum to the back of the ascending colon, where it divides into an ascending branch, which anastomoses with the descending branch of the middle colic, and a descending branch which anastomoses with the ascending or colic branch of the ileo-colic.

(5) The **middle colic** [a. colica media], arising from the concavity of the superior mesenteric a little below the pancreas, enters the transverse meso-colon, and divides into two branches—one of which passes to the left and anastomoses with the ascending branch of the left colic; the other, winding downward and to the right, anastomoses with the ascending branch of the right colic.

THE RENAL ARTERIES

The **renal** arteries [aa. renales] come off one on each side of the abdominal aorta, a little below the superior mesenteric and first lumbar arteries, on a level with the first lumbar vertebra. They pass laterally across the crura of the diaphragm to the kidneys, the right being on a slightly lower plane and somewhat longer than the left, and passing behind the inferior vena cava. In front of each is the corresponding renal vein, and behind, at the hilus of the kidney, is the commencement of the ureter. Each artery as it enters the hilus usually divides into three main stems, one of which passes toward the upper part of the pelvis, a second to its middle portion, and a third to its lower. Each of these primary stems then divides so that there result from seven to nine secondary branches, the majority of which pass anterior to the pelvis, while the remainder are posterior to it (fig. 484). No anastomoses take place between the branches of the anterior and posterior secondary stems and hence a longitudinal incision into the kidney along its curved border, half way between the anterior and posterior calices, will cut only terminal arteries.

The **branches of the renal arteries** are:—

(1) The **inferior suprarenal** [a. suprarenalis inferior] which ascends to the suprarenal body.
(2) The **capsular** or **peri-renal** branches to the capsule of the kidney and peri-renal fat.
(3) The **ureteral** branch to the upper end of the ureter.

THE MIDDLE SUPRARENAL ARTERIES

The **middle suprarenal** artery [a. suprarenalis media] comes off, one on each side from the aorta, just above the first lumbar artery, and passes laterally to the suprarenal body, across the medial crura of the diaphragm a little above the renal arteries. In the fœtus they equal the renals in size. In the adult they are much smaller.

They anastomose with the superior and inferior suprarenal arteries from the inferior phrenic and renal arteries respectively. For the distribution of the suprarenal vessels within the suprarenal bodies, see Section XII.

THE INTERNAL SPERMATIC ARTERIES

The **internal spermatic** arteries [a. spermatica interna], (fig. 479), right and left, come off from the front of the abdominal aorta. They diverge from each other as they descend over the aorta and psoas muscle to the abdominal inguinal (internal abdominal) ring, where they are joined by the ductus deferens, and, pass-

ing with it through the inguinal canal and out of the subcutaneous inguinal (external abdominal) ring, run downward into the scrotum in a tortuous course to the testes. They terminate in branches to the epididymis and body of those organs. Within the abdomen they lie beneath the peritoneum, and cross in their descent over the ureters and distal ends of the external iliac arteries; the right being super-

FIG. 484.—A. THE RENAL ARTERY AND THE DISTRIBUTION OF ITS BRANCHES IN RELATION TO THE PELVIS. B. TRANSVERSE SECTION THROUGH THE MIDDLE OF THE SAME KIDNEY. (After Brödel, Johns Hopkins Hospital Bulletin.)

a, renal artery; *a'* and *a''*, its anterior and posterior branches; *b*, branches to pyramids; *c*, line of division between anterior and posterior pyramids. The arrow and dotted line indicate the line of separation between the terminals of the anterior and posterior branches.

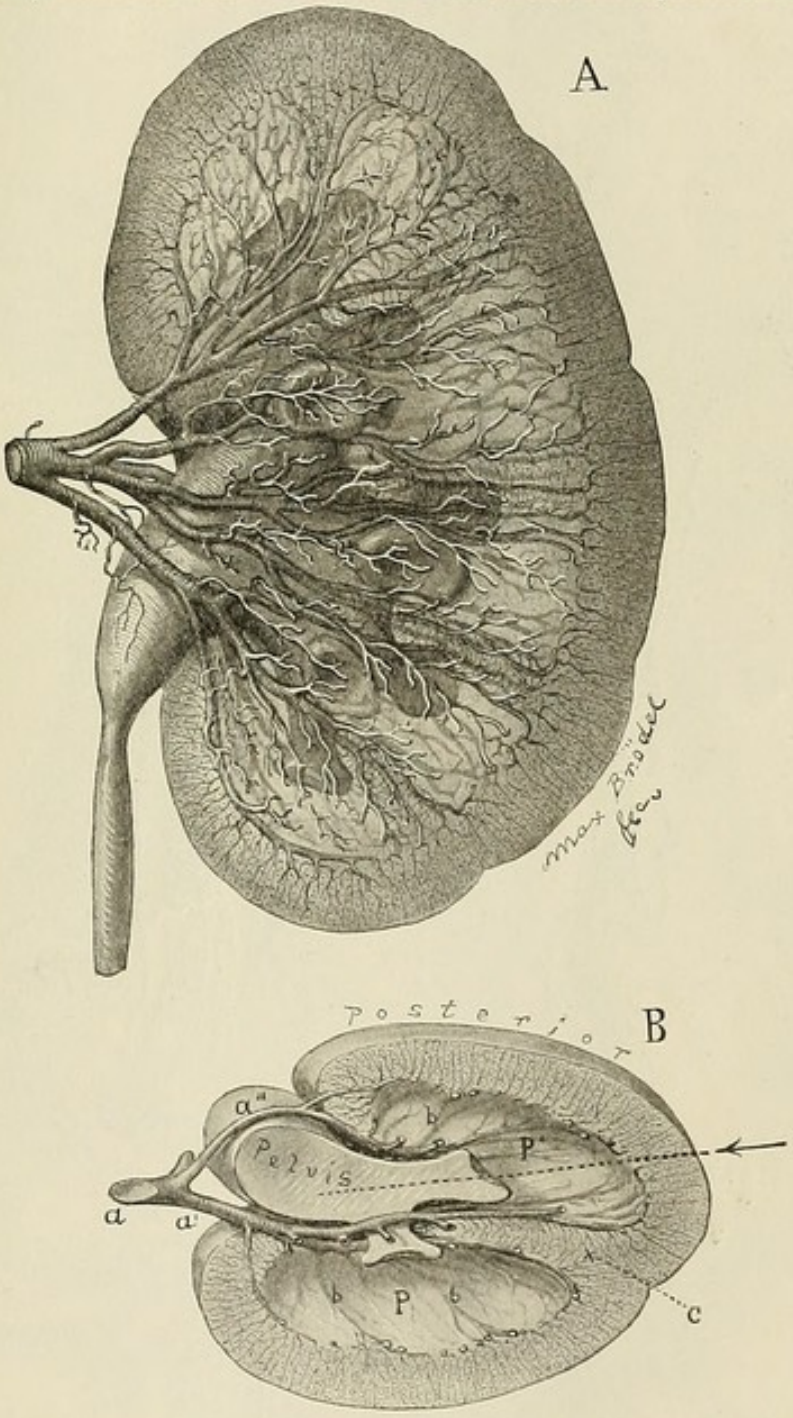

ficial to the vena cava, and behind the termination of the ileum; and the left beneath the sigmoid colon. In the inguinal canal and in the scrotum the spermatic veins lie in front of the artery, and the ductus deferens lies behind it.

In the fœtus these vessels pass in a transversely lateral direction to the testis, which in early fœtal life lies in the loin in front of the kidney; but as the testes

FIG. 485.—THE VASCULAR TRUNKS OF THE LOWER ABDOMEN. (From Kelly, by Brödel.)

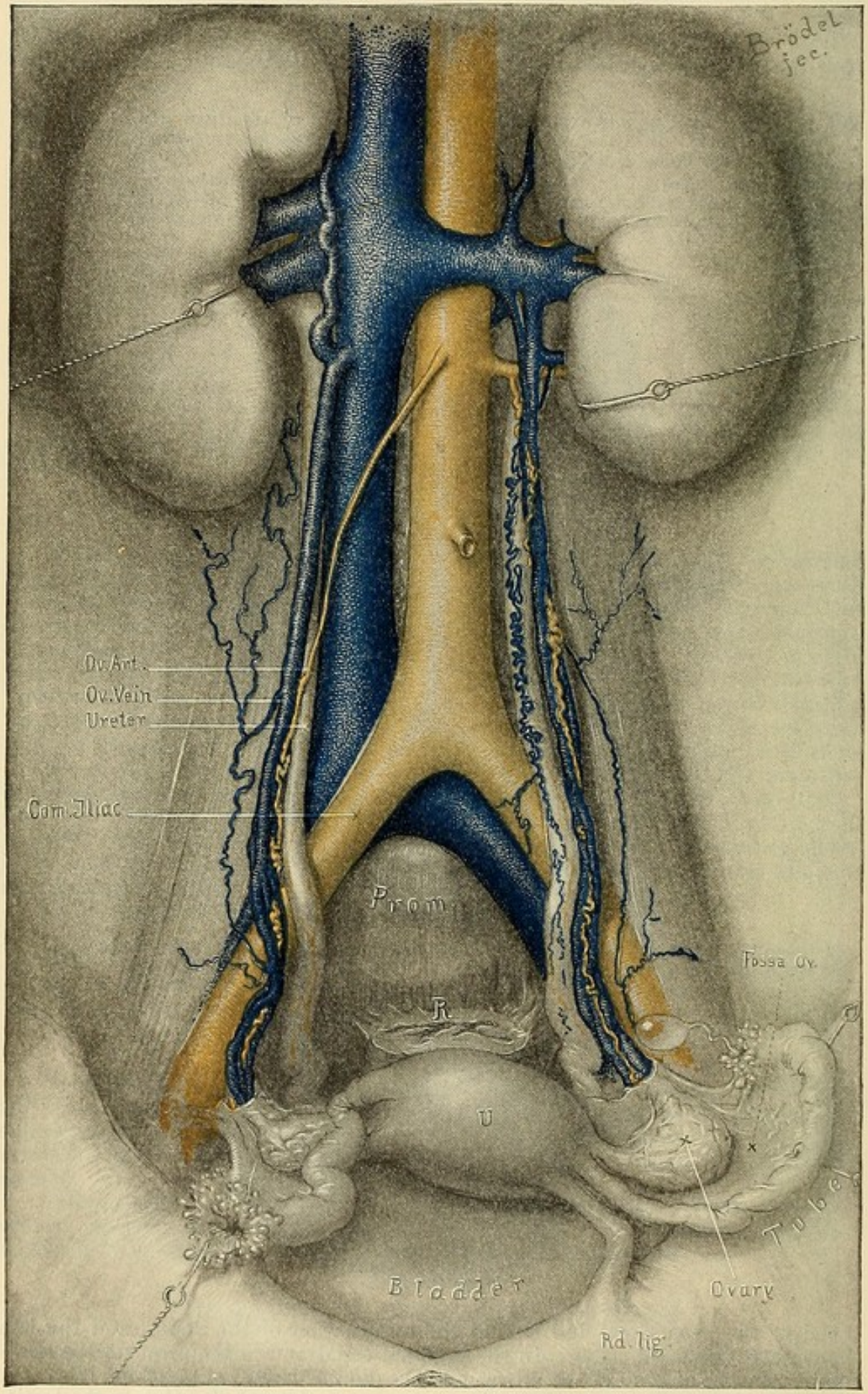

descend to the scrotum, the vessels become elongated, and are drawn with the testis into the scrotum.

The **branches of the internal spermatic artery** are:—(1) Ureteral; (2) cremasteric; (3) epididymal; and (4) testicular.

(1) The **ureteral** are small branches given off to the ureter as the spermatic artery crosses it. They anastomose with the other ureteral branches derived from the renal, common iliac, and vesical arteries.

(2) The **cremasteric** are small branches given off to the cremaster muscle; they anastomose with the cremasteric branch of the inf. epigastric.

FIG. 486.—THE OVARIAN VESSELS. (After Clark.)

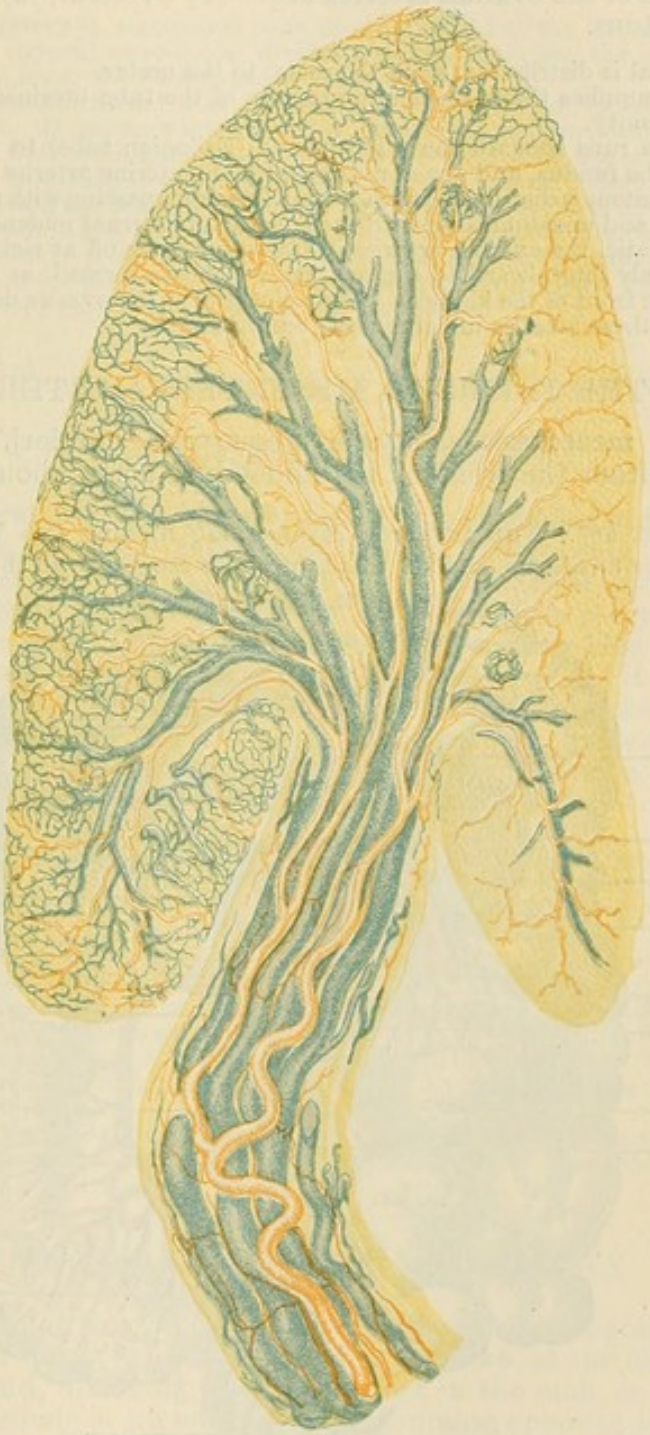

(3) The **epididynal** are distributed to the epididymic, and anastomose with the deferential artery.

(4) The **testicular** arteries [aa. testiculares] are the terminal branches of the spermatic; they perforate the tunica albuginea posteriorly, and are distributed to the body of the organ in the way mentioned in the section on the TESTIS.

The external spermatic artery is a branch of the inferior epigastric artery (p. 614).

THE OVARIAN ARTERIES

The **ovarian** arteries [aa. ovaricæ], are the homologues of the internal spermatic arteries in the male, and correspond in their relations in the upper part of their course. They diverge somewhat less, however, and, on reaching the level of the common iliac artery, turn medialward over that vessel and descend tortuously into the pelvis between the folds of the broad ligament to the ovaries. In the broad ligament the ovarian artery lies below the Fallopian tube, and on reaching the ovary turns backward and supplies that organ. In fig. 486 is shown how the artery enters the hilus of the ovary and breaks up into branches which determine the lobules of the organ.

The **branches of the ovarian arteries** are:—(1) Ureteral; (2) tubal; (3) uterine; and (4) ligamentous.

(1) The **ureteral** is distributed, as in the male, to the ureter.

(2) The **tubal** supplies the isthmus and ampulla of the tuba uterina (Fallopian tube) and its fimbriated extremity.

(3) The **uterine** runs beneath the tuba uterina (Fallopian tube) to the uterus, supplying the upper part of the fundus, and anastomosing with the uterine arteries from the hypogastric.

(4) The **ligamentous** is distributed to the round ligament, passing with that structure through the inguinal canal, and anastomosing with the superficial external pudendal artery.

Like the spermatic, the ovarian arteries in the fœtus come off at right angles to the aorta, and pass transversely lateralward to the ovaries, which are formed, as are the testes, in the right and left loin in front of the kidneys. They elongate as the ovaries descend into the pelvis. During pregnancy these arteries undergo great enlargement.

THE INFERIOR MESENTERIC ARTERY

The **inferior mesenteric** artery [a. mesenterica inferior], smaller than the superior, arises from the front of the abdominal aorta about 3.7 cm. (1½ in.)

FIG. 487.—THE INFERIOR MESENTERIC ARTERY AND VEIN.
(The colon is turned up, and the small intestines are drawn to the right side.)

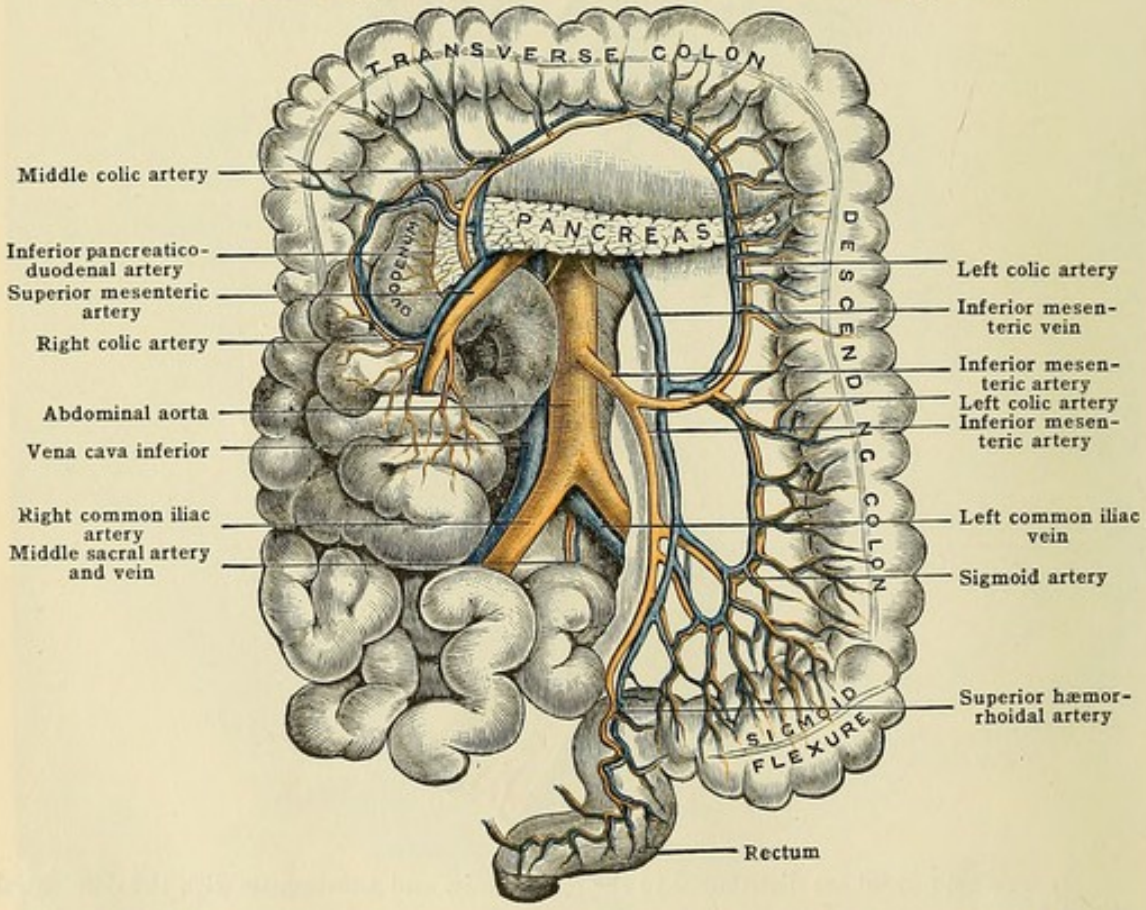

above the bifurcation of that vessel. It runs obliquely downward and to the left, behind the peritoneum, across the lower part of the abdominal aorta and then over the left psoas muscle and left common iliac artery. It descends into the

pelvis between the layers of the sigmoid meso-colon, and terminates on the rectum in the superior hæmorrhoidal artery. It supplies the lower half of the large intestine. Its vein lies at first close to the left side, but soon passes upward on the psoas, away from the artery, to end in the splenic vein (fig. 487).

The **branches of the inferior mesenteric** are:—(1) The left colic; (2) the sigmoid; and (3) the superior hæmorrhoidal.

(1) The **left colic** artery [a. colica sinistra] runs transversely to the left, beneath the peritoneum, and divides into two branches, one of which, entering the transverse meso-colon, ascends upward and to the right, to anastomose with the middle colic. The other descends, and, entering the sigmoid meso-colon anastomoses with the ascending branch of the sigmoid artery.

The distribution of this artery, and of the next, to the colon is similar to that of the colic branches of the superior mesenteric, and does not require a separate description. (See pp. 597, 598.)

(2) The **sigmoid artery** [a. sigmoidea] runs downward and to the left over the psoas muscle and, entering the sigmoid meso-colon, divides into two branches; the upper anastomosing with the left colic, the lower with the superior hæmorrhoidal.

(3) The **superior hæmorrhoidal** artery [a. hæmorrhoidalis superior] is the continued trunk of the inferior mesenteric. It descends into the pelvis, behind the rectum, between the layers of the sigmoid meso-colon. On reaching the wall of the bowel it bifurcates, one branch proceeding on either side of the gut, to within 10 or 12 cm. (4 or 5 in.) of the anus. Here each again divides, and the branches, piercing the muscular coat, descend between that coat and the mucous membrane, forming with each other, and with the middle hæmorrhoidal arteries—derived from the hypogastric (internal iliac)—a series of small vessels, running longitudinally to the rectum, and parallel to each other as far as the level of the internal sphincter, where, by their anastomosis, they form a series of loops around the lower part of the rectum.

C. The Terminal Branches of the Abdominal Aorta

THE MIDDLE SACRAL ARTERY

The **middle sacral** artery [a. sacralis media], is, anatomically, the continuation of the aorta. The coccygeal glomerulus [glomus coccygeum], in which it terminates, is believed to contain the rudiments of the caudal aorta. The artery extends from the bifurcation of the aorta to the tip of the coccyx. As it passes downward into the pelvis, it runs behind the left common iliac vein, the hypogastric plexus of the sympathetic nerve, and the peritoneum. It lies successively upon the intervertebral disc between the fourth and fifth lumbar vertebræ, the fifth lumbar vertebra, the intervertebral disc between that vertebra and the sacrum, and lower down upon the anterior surface of the sacrum and coccyx.

Branches.—The **branches of the middle sacral artery** are:—

(1) The **lowest lumbar** artery [a. lumbalis ima], which, when present, usually comes off from the middle sacral artery. Each vessel of this pair runs laterally beneath the common iliac artery and vein; and, after giving off a dorsal branch, ramifies over the lateral part of the sacrum, and ends in the iliacus muscle by anastomosing with the circumflex iliac artery. The **dorsal branch** passes to the back between the last lumbar vertebra and the sacrum and ramifies in the gluteus maximus, anastomosing with the lumbar arteries above, and the superior gluteal artery below.

(2) **Lateral sacral** branches, are usually four in number. They are serially homologous with the intercostal and lumbar arteries given off by the aorta. They run laterally, and anastomose with the lateral sacral branches of the hypogastric (internal iliac) artery. They give off small spinal branches, which pass through the sacral foramina, and supply the sacral canal and back of the sacrum.

(3) **Rectal** or **hæmorrhoidal** branches pass forward beneath the peritoneum or in the sigmoid meso-colon to the rectum, which they help to supply, and anastomose with the other hæmorrhoidal or rectal arteries.

THE COMMON ILIAC ARTERIES

The **common iliac** arteries [aa. iliacæ communes] arise opposite the left side of the middle of the body of the fourth lumbar vertebra, at the bifurcation of the abdominal aorta, and, diverging from each other in the male at about an angle of 60°, and in the female at an angle of 68°, terminate opposite the lumbo-sacral articulation by bifurcating into the external iliac, which is continued along the brim of the pelvis to the lower limb, and into the hypogastric (internal iliac), which passes through the superior aperture of the pelvis and descends into that cavity (fig. 488).

The relations differ slightly on the two sides, and may be considered separately.

FIG. 488.—THE RELATIONS OF THE COMMON ILIAC ARTERIES. (After Toldt, "Atlas of Human Anatomy," Rebman, London and New York.)

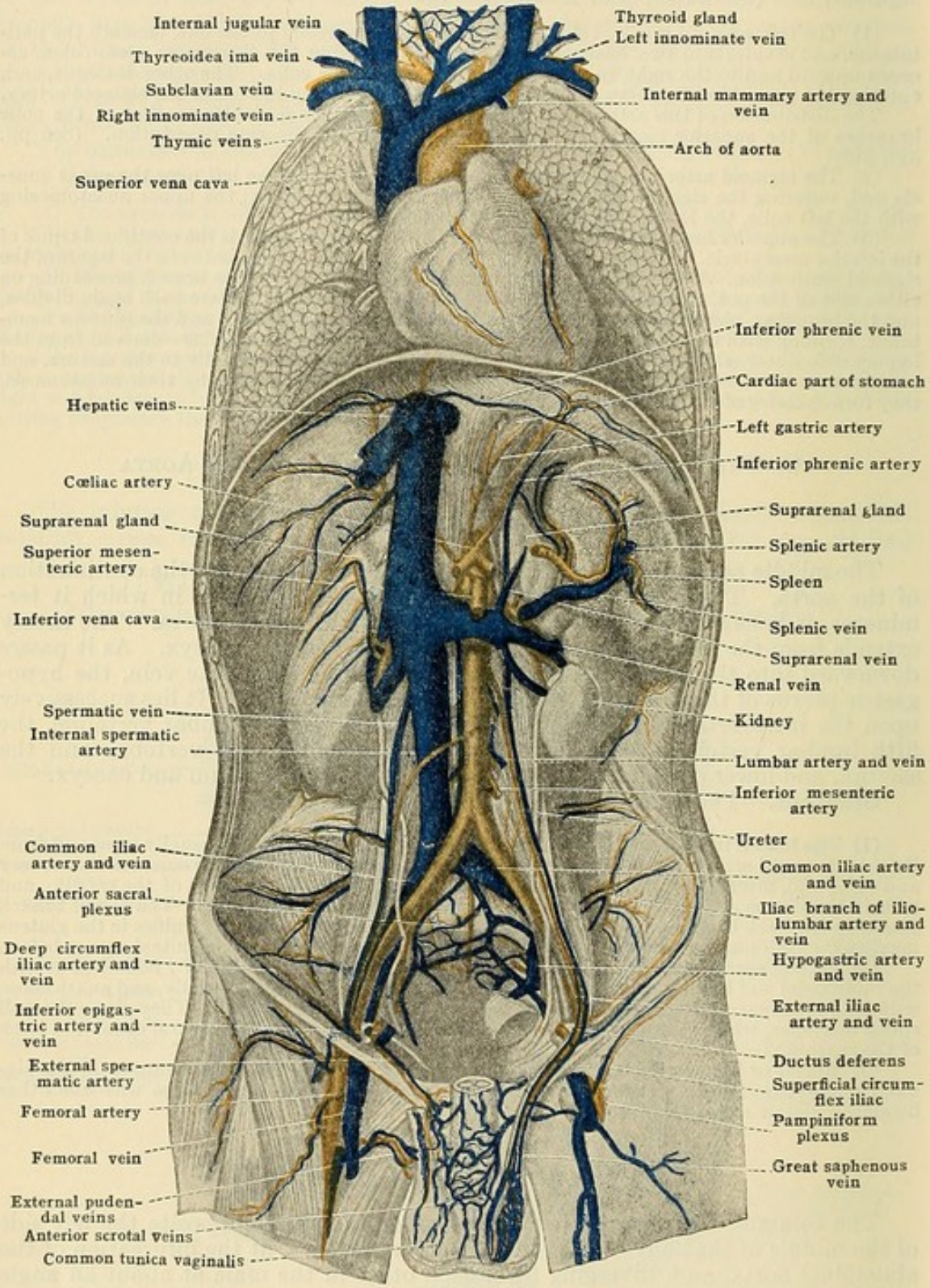

The Right Common Iliac Artery

The **right common iliac** measures about 5 cm. (2 in.) in length, and is rather longer than the left, in consequence of the aorta bifurcating a little to the left of the median line.

Relations.—In front it is covered by the peritoneum, and is crossed by the right ureter a little before its bifurcation, by the ovarian artery in the female, by the termination of the ileum, by the terminal branches of the superior mesenteric artery, and by branches of the sympathetic nerve descending to the hypogastric plexus.

Behind, it lies on the right common iliac vein, the end of the left common iliac vein, and the commencement of the inferior vena cava, which separate it from the fourth and fifth lumbar vertebræ and their intervening disc, the psoas muscle, and the sympathetic nerve; whilst still deeper in the groove between the fifth vertebra and the psoas are the lumbo-sacral trunk, the obturator nerve, and the ilio-lumbar artery.

To the **right side** are the beginning of the inferior vena cava, the end of the right common iliac vein, and the psoas muscle, which, however, is separated from the artery by the vena cava inferior at its upper part.

To the **left side** are the right common iliac vein, the termination of the left common iliac vein, and the hypogastric plexus.

The Left Common Iliac Artery

The **left common iliac** artery, 4 cm. (1½ in.) in length, is a little shorter and thicker than the right.

Relations.—In front it is covered by the peritoneum, which separates it from the intestines, and is crossed by the ureter, the ovarian artery in the female, branches of the sympathetic nerve descending to the hypogastric plexus, the termination of the inferior mesenteric artery, the sigmoid colon, and the sigmoid mesocolon.

Behind are the lower border of the body of the fourth lumbar vertebra, the disc between the fourth and fifth lumbar vertebra, the body of the fifth lumbar vertebra, and the disc between it and the sacrum. Crossing deeply behind the artery between the fifth lumbar vertebra and the psoas, is the obturator nerve, the lumbo-sacral trunk, and the ilio-lumbar artery.

To the **left side** is the psoas muscle.

To the **right side** are the left common iliac vein, the hypogastric plexus, and the middle sacral artery.

Collateral Circulation

The **collateral circulation** after obstruction or ligature of the common iliac artery is carried on chiefly (fig. 497) by the anastomosis of the middle sacral with the lateral sacral; the internal mammary with the epigastric; the lumbar arteries of the aorta with the ilio-lumbar and deep circumflex iliac; the pubic branch of the epigastric with the pubic branch of the obturator; the posterior branches of the sacral arteries with the superior gluteal (gluteal); the superior hæmorrhoidal from the inferior mesenteric, with the hæmorrhoidal branches of the hypogastric (internal iliac) and pudic; the ovarian arteries from the aorta with the uterine branches of the hypogastric (internal iliac); and by the anastomosis across the middle line of the pubic branch of the obturator with the like vessel of the opposite side; the lateral sacral with the opposite lateral sacral; and the vesical, hæmorrhoidal, uterine, and vaginal branches of the hypogastric with the corresponding branches of the opposite hypogastric (internal iliac).

Branches of the Common Iliac Artery

The **branches of the common iliac artery** are:—(1) The hypogastric (internal iliac); and (2) external iliac.

There are a few small, unimportant branches distributed to the peritoneum and subperitoneal fat. They anastomose with vessels given off from the lumbar, inferior phrenic, and renal arteries, forming a subperitoneal arterial anastomosis. The ureter receives small insignificant twigs as it crosses the artery. They anastomose with the ureteral arteries given off from the internal spermatic above, and with those derived from the vesical arteries below.

THE HYPOGASTRIC ARTERY

The **hypogastric** or **internal iliac** artery [a. hypogastrica], arises at the bifurcation of the common iliac opposite the lumbo-sacral articulation. It descends into the pelvis for about 3 cm. (1¼ in.) and then divides, opposite the upper margin of the great sciatic foramen, into an anterior and a posterior division. The *anterior division* commonly gives off the obturator, inferior gluteal, umbilical,

inferior vesical, deferential, middle hæmorrhoidal, uterine (in the female), and internal pudendal arteries. From the *posterior division* the ilio-lumbar, lateral sacral, and superior gluteal arteries arise. These vessels are classified, for description, as parietal and visceral.

In the adult the hypogastric is smaller than the external iliac; in the fœtus it is much larger and through it the fœtal blood is returned to the placenta. The adult hypogastric and common iliac arteries of either side represent the proximal portion of each of the embryonic umbilical arteries. The remainder of the umbilical artery within the body is represented by the umbilical branch of the hypogastric which runs to the navel. At birth, when the circulation in the umbilical cord ceases, the lumen of the umbilical branch of the hypogastric becomes obliterated except a small channel which remains pervious as the superior vesical of the adult.

Relations.—Behind, the hypogastric artery rests on the termination of the external iliac vein, the hypogastric vein, the medial margin of the psoas muscle, the lumbo-sacral trunk, the obturator nerve, and the sacrum.

In front, it is covered by the peritoneum, and is crossed by the ureter.

FIG. 489.—THE HYPOGASTRIC ARTERY. (After Henle.)

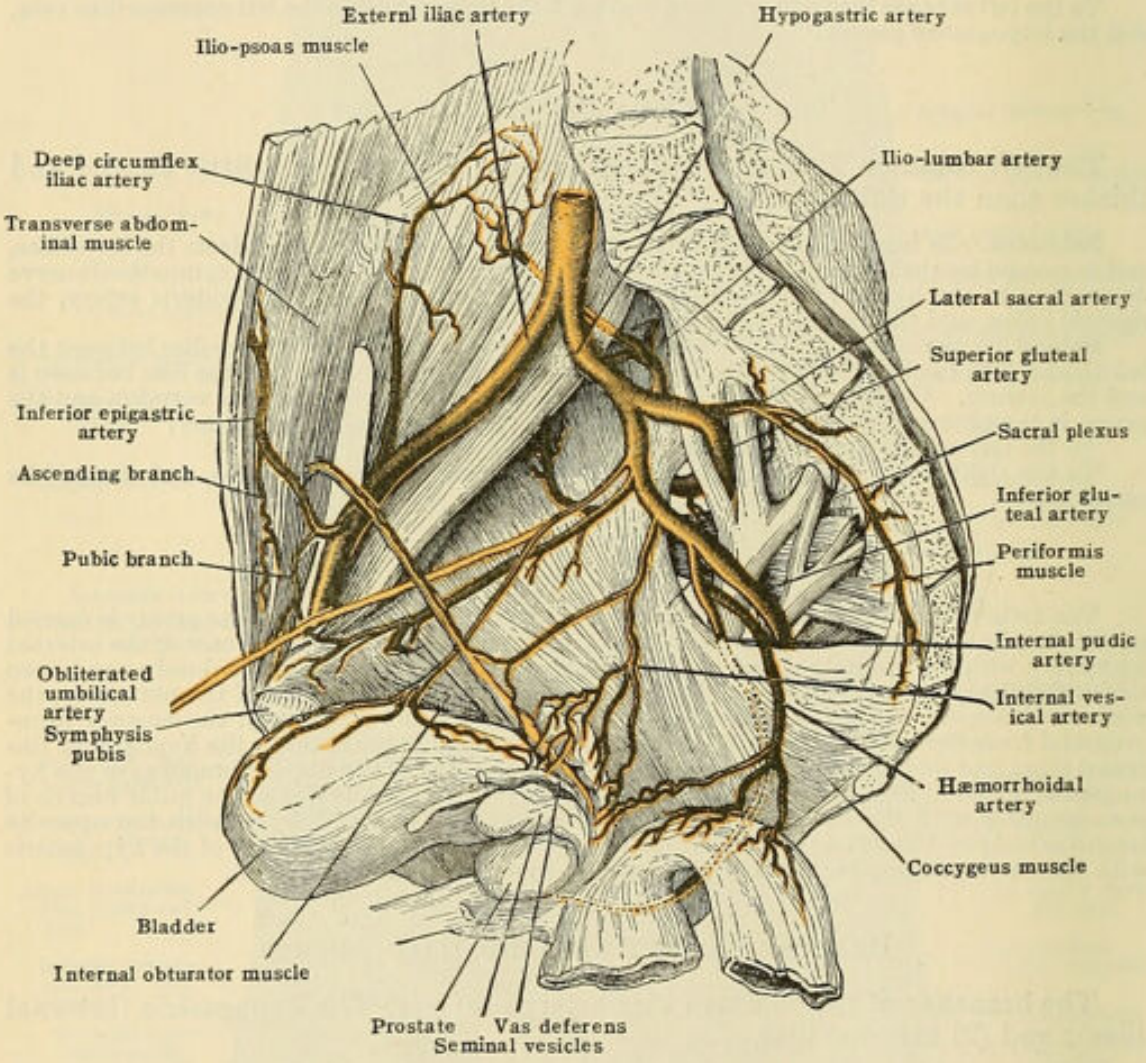

The **branches of the hypogastric artery** may be divided into parietal and visceral sets. The **parietal** branches are:—(1) The ilio-lumbar; (2) the lateral sacral; (3) the obturator; and (4) the gluteal arteries.

The **visceral** branches are:—(1) The umbilical; (2) the inferior vesical; (3) the middle hæmorrhoidal; (4) the uterine; and (5) the internal pudendal.

PARIETAL BRANCHES OF THE HYPOGASTRIC ARTERY

1. THE ILIO-LUMBAR ARTERY

The **ilio-lumbar** artery [a. iliolumbalis]—a short vessel coming off from the posterior part of the hypogastric artery—runs upward and laterally beneath the common iliac artery, first between the lumbo-sacral trunk and obturator nerve,

and then between the psoas muscles and the vertebral column. On reaching the superior aperture of the pelvis it divides into two branches, an iliac and a lumbar (fig. 489).

The **iliac** branch [ramus iliacus] passes laterally beneath the psoas and the femoral (anterior crural) nerve and, perforating the iliacus, ramifies in the iliac fossa between that muscle and the bone. It supplies a nutrient artery to the bone, and then breaks up into several branches which radiate from the parent trunk, upward toward the sacro-iliac synchondrosis, laterally toward the crest of the ilium, downward toward the anterior superior spine, and medially toward the pelvic cavity. The first anastomoses with the last lumbar; the second with the external circumflex and gluteal; the third with the deep circumflex iliac from the external iliac; the fourth with the iliac branch of the obturator. The **lumbar** branch [ramus lumbalis] ascends beneath the psoas, and, supplying that muscle and the quadratus lumborum, anastomoses with the last lumbar artery. It sends a **spinal** branch (ramus spinalis) into the vertebral canal through the intervertebral foramen between the last lumbar vertebra and the sacrum; this branch anastomoses with the other spinal arteries. The ilio-lumbar artery is serially homologous with the lumbar arteries. Hence the similarity in its course and distribution.

2. THE LATERAL SACRAL ARTERIES

The **lateral sacral** artery [a. sacralis lateralis], commonly arises as two vessels from the posterior division of the hypogastric. The **superior** artery, when two

FIG. 490.—THE GLUTEAL ARTERIES. (After Toldt, "Atlas of Human Anatomy," Rebman, London and New York.)

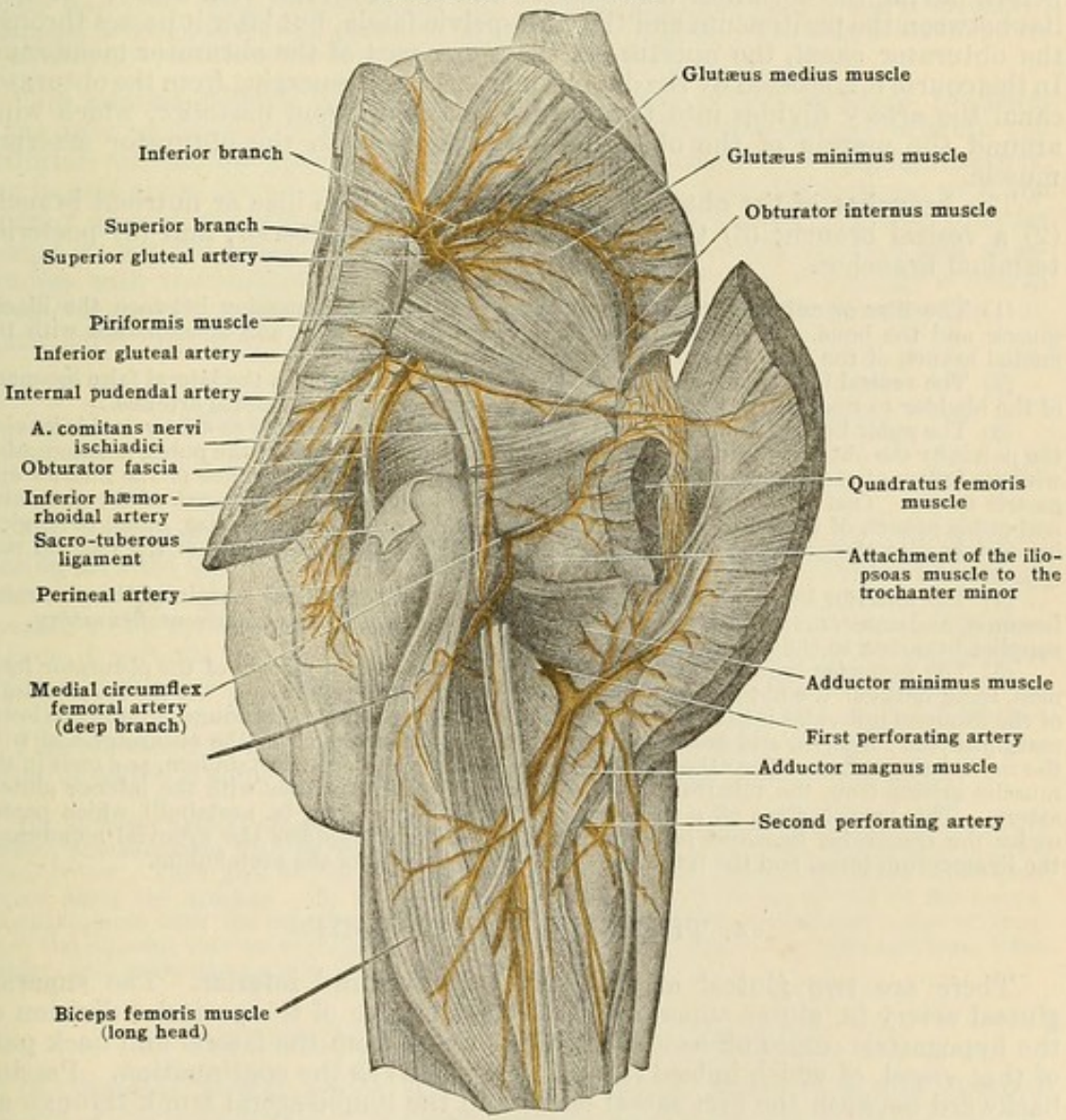

are present, runs downward and medially to the first anterior sacral foramen, through which it passes; and, after supplying the spinal membranes and anastomosing with the other spinal arteries, passes through the first posterior sacral

foramen, and is distributed to the skin over the back of the sacrum, there anastomosing with branches of the superior and inferior gluteal arteries. The **inferior lateral sacral** descends on the side of the sacrum, lateral to the sacral chain of the sympathetic, and medial to the anterior sacral foramina, crossing in its course the slips of origin of the piriformis muscle and the first anterior sacral nerve. On reaching the coccyx it anastomoses in front of that bone with the middle sacral artery, and with the inferior lateral sacral of the opposite side (fig. 489).

In this course it gives off:—**Spinal** branches [rami spinales], which enter the second, third and fourth anterior sacral foramina, and, after supplying the spinal membranes and anastomosing with each other, leave the spinal canal by the corresponding posterior sacral foramina, and are distributed to the muscle and skin over the back of the sacrum; and **rectal** branches which run forward to the rectum.

At times the lateral sacral arteries are exceedingly small, the spinal branches then coming chiefly from the middle sacral. The anastomosing branches between the lateral sacral and middle sacral are usually regarded as sacral arteries diminished in size, and serially homologous with the lumbar and intercostal arteries.

3. THE OBTURATOR ARTERY

The **obturator** artery [a. obturatoria], usually arises from the anterior division of the hypogastric. It runs forward and downward a little below the brim of the pelvis, having the obturator nerve above and the obturator vein below. It here lies between the peritoneum and the endo-pelvic fascia, but later it passes through the obturator canal, the aperture in the upper part of the obturator membrane. In this course it is crossed by the ductus deferens. On emerging from the obturator canal the artery divides into two branches, anterior and posterior, which wind around the margin of the obturator foramen beneath the obturator externus muscle.

The **branches of the obturator artery** are:—(1) The iliac or nutrient branch; (2) a vesical branch; (3) the pubic branch; (4) the anterior, and (5) posterior terminal branches.

(1) The **iliac or nutrient** branch ascends to the iliac fossa, passing between the iliacus muscle and the bone. It supplies a nutrient vessel to the ilium, and anastomoses with the medial branch of the iliac division of the ilio-lumbar artery.

(2) The **vesical** branch or branches are small vessels which run in the lateral false ligament of the bladder to that organ, where they anastomose with the other vesical arteries.

(3) The **pubic** branch [ramus pubicus] comes off from the obturator as that vessel is leaving the pelvis by the obturator canal. It runs upward and medially behind the pubis, anastomosing with its fellow of the opposite side of the body, and with the pubic branch of the inferior epigastric artery. One of the anastomosing channels between the pubic branch of the obturator and pubic branch of the inferior epigastric arteries is sometimes of large size, a fact of surgical interest in that the enlarged vessel may then run around the medial side of the femoral ring (pp. 615 and 636).

(4) The **anterior** branch [ramus anterior] runs around the medial margin of the obturator foramen, and anastomoses with the posterior branch and with the medial circumflex artery. It supplies branches to the obturator and adductor muscles.

(5) The **posterior** branch [ramus posterior] skirts the lateral margin of the obturator foramen, lying between the obturator externus and the obturator membrane. At the lower margin of the foramen it divides into two branches. One branch continues its course around the lower margin of the foramen, and anastomoses with the anterior branch of the obturator and with the medial circumflex. The other branch turns laterally below the acetabulum, and ends in the muscles arising from the tuberosity of the ischium. It anastomoses with the inferior gluteal artery. This branch gives off a small twig, the **acetabular** artery [a. acetabuli], which passes under the transverse ligament into the hip-joint, where it supplies the synovial membrane, the ligamentum teres, and the fat in the fossa at the bottom of the acetabulum.

4. THE GLUTEAL ARTERIES

There are two gluteal arteries, the **superior** and **inferior.** The **superior gluteal** artery [a. glutea superior], the largest branch of the posterior division of the hypogastric comes off as a short, thick trunk from the lateral and back part of that vessel, of which indeed it may be regarded as the continuation. Passing backward between the first sacral nerve and the lumbo-sacral trunk through an osseo-tendinous arch formed by the margin of the bone and the upper edge of the endo-pelvic fascia, it leaves the pelvis through the great sciatic foramen above the piriformis muscle in company with its vein and the superior gluteal nerve. At its exit posteriorly from the great sciatic foramen it lies under cover of the gluteus

maximus and beneath the superior gluteal vein, and in front of the superior gluteal nerve. It here breaks up into two chief branches, a superficial and a deep. Its emergence from the pelvis is indicated on the surface by a point situated at the junction of the posterior with the middle third of a line drawn from the anterior superior to the posterior superior spine of the ilium.

The **branches of the superior gluteal artery** are:—

(*a*) **Within the pelvis,** branches are distributed to the obturator internus, the piriformis, the levator ani, the coccygeus, and the pelvic bones.

(*b*) **External to the pelvis,** the artery divides into a superior and an inferior branch.

(i) The **superior** branch [ramus superior] breaks up into a number of large vessels for the supply of the upper portion of the gluteus maximus, some of them piercing the muscle and supplying the skin over it, and anastomosing with the posterior branches of the lateral sacral arteries; whilst one of larger size, emerging from the muscle near the iliac crest, anastomoses with the deep circumflex iliac artery. The lower branches to the muscle anastomose with branches of the inferior gluteal (sciatic).

(ii) The **inferior** branch [ramus inferior] subdivides into two branches—One skirts along the line of origin of the gluteus minimus (fig. 490), between the gluteus medius and the bone, and, emerging in front from beneath these muscles under cover of the tensor fasciæ latæ, anastomoses with the ascending branch of the lateral circumflex and the deep circumflex iliac arteries. The other passes forward between the gluteus medius and minimus, accompanied by the branch to the tensor fasciæ latæ of the inferior division of the superior gluteal nerve, toward the greater trochanter, where it anastomoses with the ascending branch of the lateral circumflex. It supplies branches to the contiguous muscles and to the hip-joint. The inferior branch before its division gives off the external nutrient artery of the ilium.

The **inferior gluteal** [a. glutea inferior], is one of the terminal branches of the anterior division of the hypogastric artery. It leaves the pelvis below the piriformis muscle, and immediately breaks up into a number of diverging branches. The largest enter the gluteus maximus muscle, where they anastomose with the superior gluteal branches. Others pass to the hip-joint and the deep muscles around it; a third group passes downward to the hamstring muscles and anastomoses with the medial and lateral circumflex and first perforating; a fourth slender branch, the **sciatic** artery [a. comitans n. ischiadici], accompanies the sciatic nerve (fig. 490).

Visceral Branches of the Hypogastric Artery

1. THE UMBILICAL ARTERY

The **umbilical** artery in the fœtus is the continuation of the hypogastric. Passing forward along the side of the pelvis, it runs beneath the lateral reflexion of peritoneum from the bladder, where, after giving off one or more vesical branches, it ceases to be pervious and passes on to the side and upper part of the bladder. Thence it ascends in the lateral umbilical fold, as a fibrous cord [ligamentum umbilicale laterale], to the umbilicus, where it is joined by its fellow of the opposite side. As it lies lateral to the bladder it is crossed by the ductus deferens.

The **branches of the umbilical artery** are:—(1) Superior vesical arteries, the lowest of which is sometimes called (2) the middle vesical artery (fig. 489).

The **superior vesical** arteries [aa. vesicales superiores] ramify over the upper surface of the bladder, anastomosing with the artery of the opposite side and with the middle and inferior vesical below. They give off the following branches:—(*a*) The **urachal** branches which pass upward along the urachus. (*b*) The **ureteric** branches pass to the lower end of the ureter, and anastomose with the other ureteric arteries. (*c*) The **middle vesical** may come off from one of the superior vesicals or from the umbilical. It is distributed to the sides and base of the bladder, and anastomoses with the other vesical arteries.

2. THE INFERIOR VESICAL ARTERY

The **inferior vesical** artery [a. vesicalis inferior] arises from the anterior division of the hypogastric, frequently in common with the middle hæmorrhoidal, and passes downward and medially to the fundus of the bladder, where it breaks up into branches which ramify over the lower part of the viscus. It gives off branches to the prostate, which supply that organ and anastomose with the arteries of the opposite side by means of descending arteries which pass through

the prostatic plexus of veins, but outside the capsule of the prostate, and with the inferior hæmorrhoidal branches of the internal pudic. At times one of these prostatic branches is of large size, and supplies certain of the parts normally supplied by the int. pudendal. It is then known as the **accessory pudendal** and most commonly terminates as the dorsal artery of the penis.

The inferior vesical usually gives off the **deferential, or artery of the ductus deferens** [a. deferentialis]. This vessel, which may come off from the superior vesical, divides, on the ductus deferens, into an ascending and a descending branch. The ascending branch follows the ductus through the inguinal canal to the testis, where it anastomoses with the internal spermatic artery. The descending branch passes downward to the dilated portion of the ductus and vesiculæ seminales.

3. THE MIDDLE HÆMORRHOIDAL ARTERY

The **middle hæmorrhoidal** artery [a. hæmorrhoidals media], variable in origin, perhaps most commonly arises from the anterior division of the hypogastric along with the inferior vesical. It runs medially to the side of the middle portion of the rectum, dividing into branches which anastomose above with the superior hæmorrhoidal derived from the inferior mesenteric, and below with the inferior hæmorrhoidal derived from branches of the internal pudendal. Its corresponding vein terminates in the inferior mesenteric vein. In the female it also sends branches to the vagina.

4. THE UTERINE ARTERY

The **uterine** artery [a. uterina], arises from the anterior division of the hypogastric close to or in conjunction with the middle hæmorrhoidal or inferior vesical. It runs downward and medially through the pelvic connective tissue, crossing the ureter about 12 mm. ($\frac{1}{2}$ in.) from the cervix uteri. It then turns upward and ascends in the parametrium between the layers of the broad ligament at the side of the uterus in a coiled and tortuous manner, and, after giving off a number of tortuous branches which ramify horizontally over the front and back of the uterus, supplying its substance, anastomoses with the uterine branch of the ovarian artery.

In addition to the branches to the uterus the **branches of the uterine artery** are:—(1) **Cervical.**—This branch comes off from the uterine as the latter artery crosses the ureter to turn upward on to the uterus. It is directed medially, and divides into three or four branches which pass on to the cervix at right angles to it; one branch anastomosing with its fellow of the opposite side in front and behind the neck, forming the so-called coronary artery of the cervix. (2) **Tubal** [ramus tubarius].—This courses along the lower surface of the tuba uterina (Fallopian tube) as far as its fimbriated extremity, and may also send a branch to the ligamentum teres. (3) **Ovarian** [ramus ovarii].—This runs along the attached border of the ovary, sending branches to that structure, and terminates by anastomosing widely with the ovarian artery. Usually the vaginal artery also arises from the uterine. (4) The **vaginal** artery [a. vaginalis] corresponds to the inferior vesical artery of the male, and may arise directly from the hypogastric artery, close to the origin of the uterine, or from the superior vesical. It passes medially, behind the ureter, to the upper part of the vagina, and sends numerous branches to that structure and also some to the posterior part of the fundus of the bladder.

The branches to the vagina tend to anastomose with one another and with the cervical branch of the uterine, to form a more or less perfect vertical stem in the median line of the vagina, both back and front. This stem is sometimes termed the **azygos artery of the vagina.** Branches also pass to the vagina from the middle hæmorrhoidal artery.

5. THE INTERNAL PUDENDAL ARTERY

The **internal pudendal** (pudic) artery [a. pudenda interna] (figs. 492, 493, 494) is one of the terminal branches of the anterior division of the hypogastric artery (the inferior gluteal being the other). It arises opposite the piriformis muscle and accompanies the inferior gluteal downward to the lower border of the great sciatic foramen. It leaves the pelvis between the piriformis and coccygeus and winds over the ischial spine to enter the ischio-rectal fossa through the small sciatic foramen. Running forward in the ischio-rectal fossa medial to the lower part of the obturator internus it ends by dividing into the **perineal artery** and the **artery of the penis** (or clitoris).

Relations.—*Within the pelvis*, the artery is anterior to the piriformis muscle and the sacral plexus of nerves, and lateral to the inferior gluteal artery. It passes between the piriformis and coccygeus, with the gluteal artery and pudendal nerve medial to it, and the nerve to the obturator internus lateral. The sciatic and posterior femoral cutaneous (lesser sciatic) nerves are still more lateral. *On the ischial spine* the artery retains its relations to the pudendal nerve (which often divides in this situation into its two terminal branches) and the nerve to the obturator internus. It is accompanied by venæ comitantes and covered by the gluteus maximus

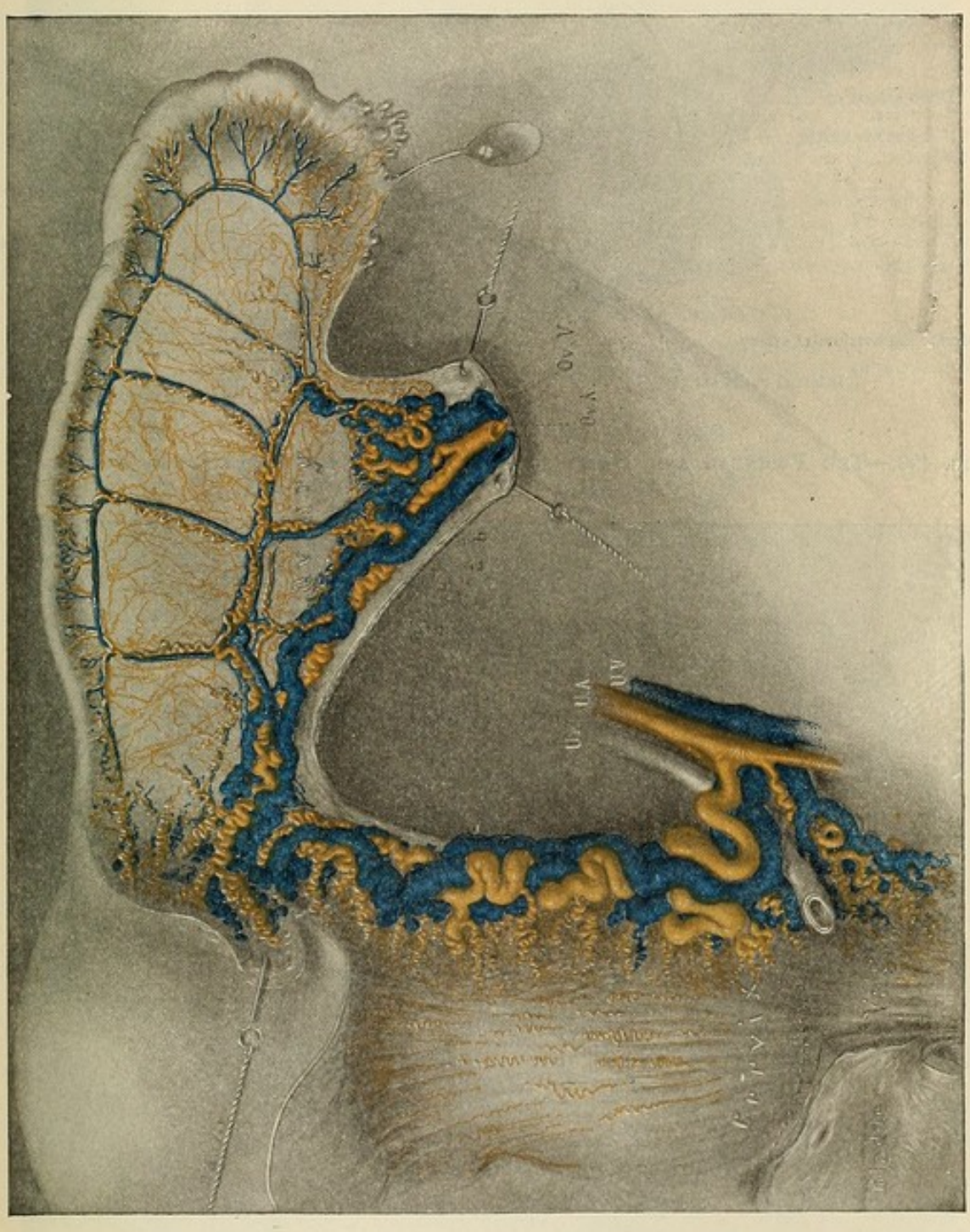

Fig. 491.—Scheme of the Ovarian and Uterine and Vaginal Arteries. (From Kelly, by Brödel.)

muscle. *In the ischio-rectal fossa* the artery is placed on the lateral wall about 3.5 cm. (1½ in.) above the tuberosity of the ischium. It is accompanied in a canal in the obturator fascia (Alcock's canal) by the dorsal nerve of the penis and the perineal nerve, which are respectively above and below the artery.

The **branches of the internal pudendal artery** are:—(1) Small branches to the gluteal region; (2) the inferior hæmorrhoidal arteries; and the terminal branches (3) perineal; and (4) artery to the penis or clitoris.

FIG. 492.—THE INTERNAL PUDENDAL ARTERY. (From Kelly, by Brödel.)

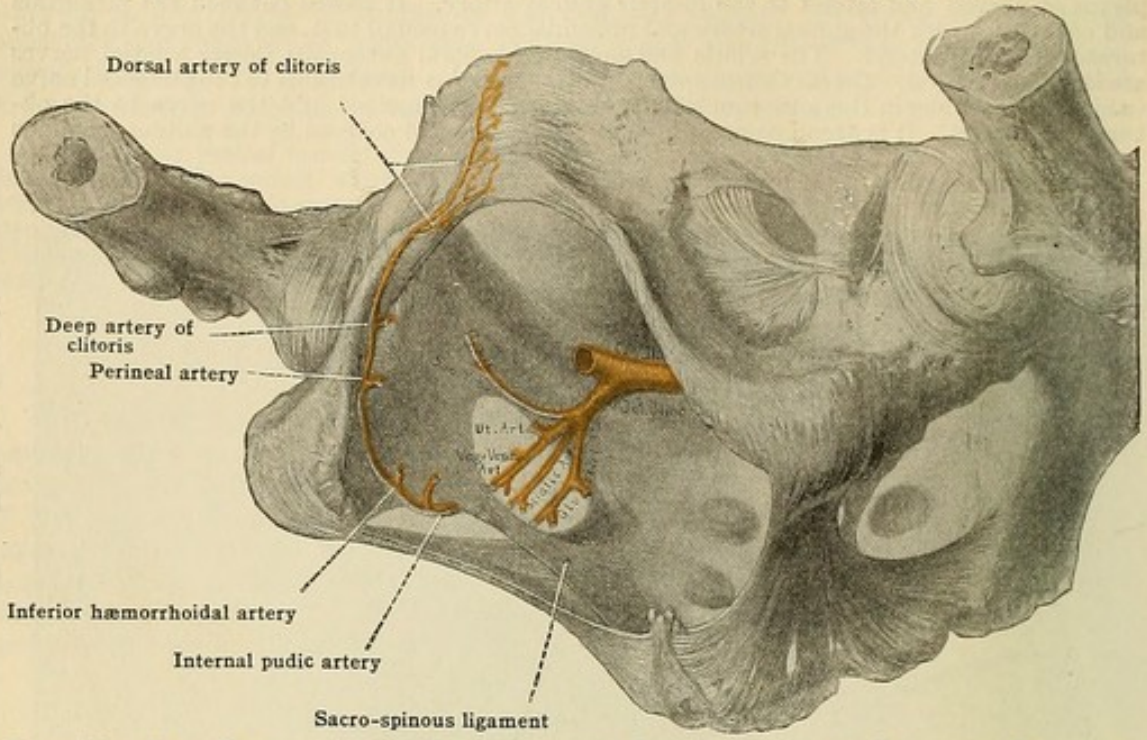

FIG. 493.—THE PERINEAL AND HÆMORRHOIDAL BRANCHES OF THE INTERNAL PUDENDAL ARTERIES. (From Kelly, by Brödel.)

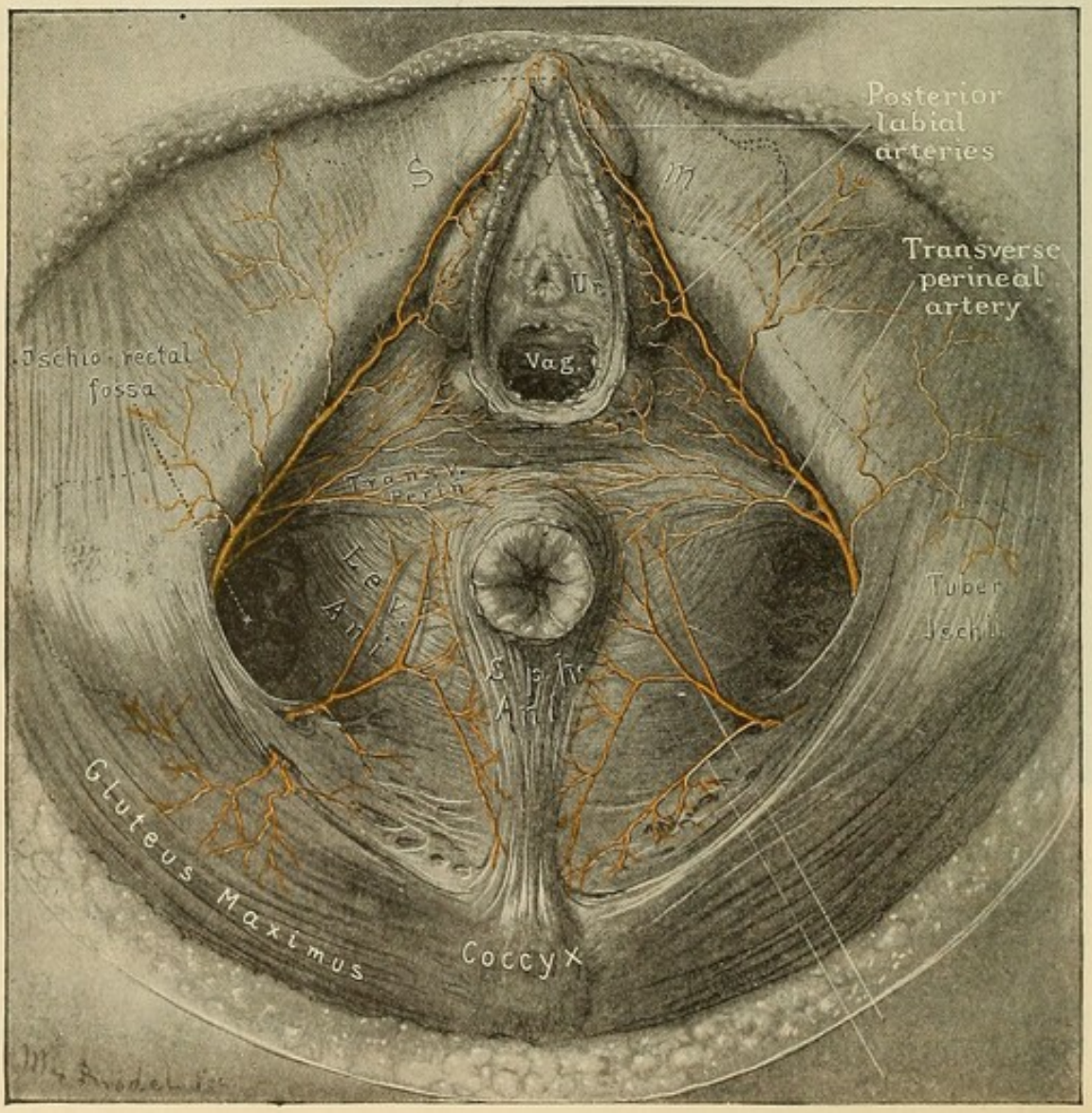

(1) The **branches of the gluteal region** are: (*a*) twigs to the gluteus maximus; (*b*) branches accompanying the nerve to the obturator internus; (*c*) a sacral branch which pierces the sacro-tuberous ligament, and anastomoses with the inferior gluteal artery.

(2) The **inferior hemorrhoidal** artery (a. hæmorrhoidalis inferior] (figs, 493, 494) arises at the posterior part of the ischio-rectal fossa and, perforating the obturator fascia, at once breaks up into several branches. These, running medially toward the anus, traverse the ischio-rectal fat and supply the fascia, skin and the levator ani and external sphincter muscles. The inferior hæmorrhoidal branches anastomose with those from the middle and superior hæmorrhoidal, and from the gluteal and perineal arteries.

(3) The **perineal** artery [a. perinei] (figs. 493, 494), one of the terminal arteries of the internal pudendal, arises at the anterior part of the ischio-rectal fossa. It pierces the base of the urogenital diaphragm (triangular ligament) anterior or posterior to the superficial transverse perineal muscle, and enters the space deep to Colles's fascia. Here it runs forward between the ischio- and bulbo-cavernosus muscles to the scrotum or labium majus and divides into numerous terminal branches. Immediately after piercing the diaphragm, the perineal artery gives off a constant **transverse perineal** branch which runs toward the median line along the superficial transverse perineal muscle. The terminal branches of the perineal are the **posterior scrotal or labial** arteries [aa. scrotales, or labiales posteriores] which ramify on the scrotum or labia majora (according to sex) and anastomose with external pudendal arteries.

(4) The **artery of the penis, or clitoris** [a. penis or clitoridis] (figs. 493, 494) pierces the free border of the urogenital diaphragm and runs forward between the layers of the diaphragm with the dorsal nerve of the penis along the inferior ramus of the pubis. It traverses the fibres of the deep transverse perineal muscle and of the sphincter of the membranous urethra and

FIG. 494.—THE ARTERIES OF THE MALE PERINÆUM.

On the right side Colles's fascia has been turned back to show the perineal artery. On the left side the perineal vessels have been cut away with the inferior layer of the urogenital diaphragm to show the artery of the penis.

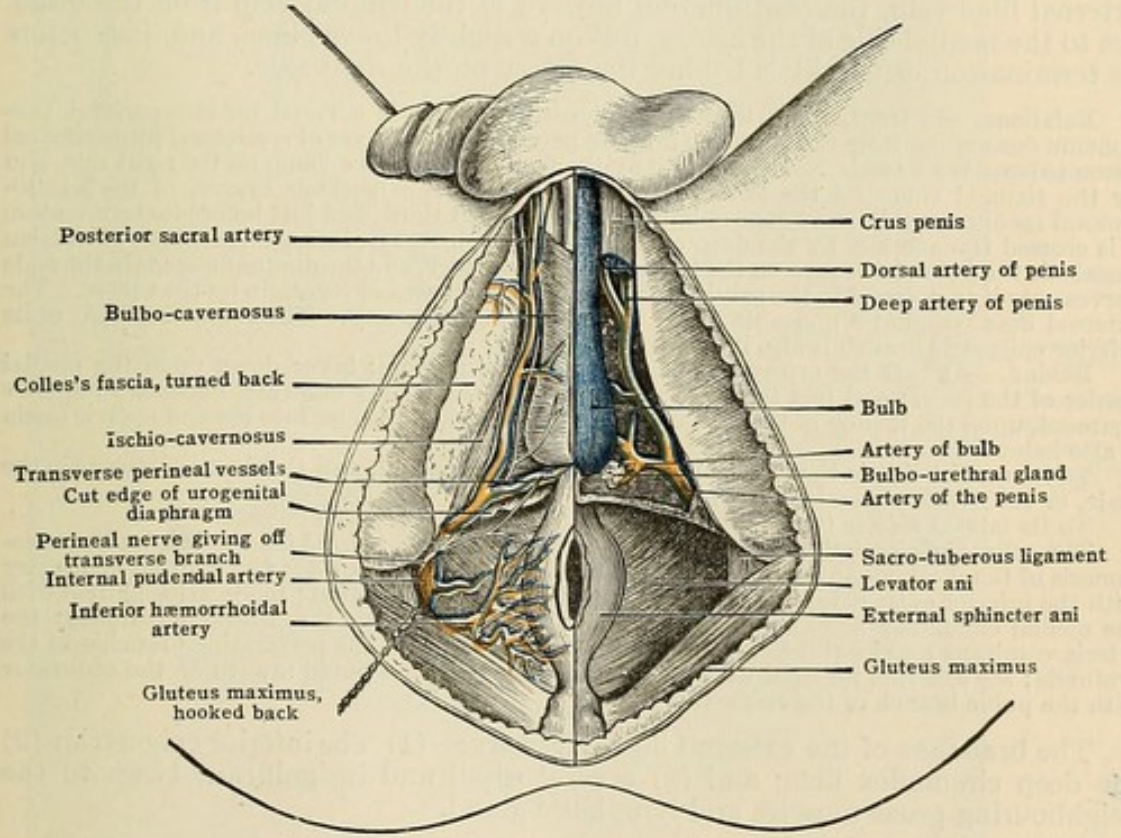

ends by dividing into deep and dorsal arteries of the penis, or clitoris, according to sex.

The **branches of the artery of the penis (or clitoris)** are: (*a*) The artery to the bulb; (*b*) the urethral artery; and (*c*) the terminal, deep artery of the penis or clitoris.

(*a*) The **artery of the bulb** [a. bulbi urethræ or vestibuli vaginæ] takes a medial direction through the fibres of the m. transversus perinei profundus. It then pierces the inferior fascia of the urogenital diaphragm to reach the bulb, the erectile tissue of which it supplies, in either sex. This vessel also supplies branches to the bulbo-urethral gland (Cowperi) or the gland of the vestibule (Bartholini).

The situation of the artery to the bulb should be remembered in performing the operation of lateral lithotomy, particularly as it may arise far back. When the artery arises, as it occasionally does, from the accessory pudendal it pierces the urogenital diaphragm further forward and is out of danger in the ordinary low operation.

(*b*) The **urethral** artery [a. urethralis] is a small branch which passes into the corpus spongiosum and anastomoses with branches from the artery of the bulb.

(*c*) The **deep artery of the penis or clitoris** [a. profunda penis or clitoridis], larger in the male sex, pierces the inferior layer of the urogenital diaphragm near the inferior ramus of the pubis. It enters the crus of the penis (fig. 494) or clitoris, and is distributed in the corpus cavernosum urethræ.

(*d*) The **dorsal artery of the penis or clitoris** [a. dorsalis penis or clitoridis] (figs. 492, 494), perforates the inferior fascia of the urogenital diaphragm near its apex. The dorsal nerve is lateral to the artery and both join the dorsal vein (which lies between the arteries of either side) on the dorsum of the penis or clitoris. The artery is much larger in the male than the female; in either sex it supplies the glans, corona, and prepuce and anastomoses with the external pudendal artery.

THE EXTERNAL ILIAC ARTERY

The **external iliac** artery [a. iliaca externa]—the larger in the adult of the two vessels into which the common iliac divides opposite the lumbo-sacral articulation—extends along the superior aperture of the pelvis, lying upon the medial border of the psoas muscle, to the lower margin of the inguinal ligament, where, midway between the anterior superior spine of the ilium and the symphysis pubis, it passes into the thigh, and takes the name of the femoral.

It measures 8.5 to 10 cm. (3½ to 4 in.) in length. The course of the vessel is indicated by a line drawn from 2.5 cm. (1 in.) below and a little to the left of the umbilicus to a spot midway between the symphysis pubis and the anterior superior spine of the ilium. If this line is divided into thirds, the lower two-thirds indicate the situation of the external iliac, the upper third the common iliac. The external iliac vein, the continuation upward of the femoral vein from the thigh, lies to the medial side of the artery, but on a slightly lower plane, and, just before its termination, gets a little behind the artery on the right side.

Relations.—In front, the artery together with the vein is covered by the parietal peritoneum descending from the abdomen into the pelvis, and by a layer of condensed subperitoneal tissue (Abernethy's fascia). It is crossed by the termination of the ileum on the right side, and by the sigmoid colon on the left. The external spermatic (genital) branch of the genito-femoral (genito-crural) nerve runs obliquely over its lower third, and just before its termination it is crossed transversely by the deep circumflex iliac vein. The internal spermatic or ovarian vessels lie for a short distance on the lower part of the artery, and the ductus deferens in the male curves over it to descend to the pelvis. It is sometimes crossed at its origin by the ureter. The external iliac lymphatic nodes lie along the course of the artery. The commencement of its inferior epigastric branch is also in front.

Behind.—At first the artery lies partly upon its own vein; lower down upon the medial border of the psoas; and just before it passes through the lacuna vasorum, beneath Poupart's ligament, upon the tendon of the psoas. The continuation of the iliac into the endo-pelvic fascia is also below it.

To its **medial side** is the external iliac vein, the peritoneum, and the ductus deferens in the male, or the ovarian vessels in the female.

To its **lateral side** is the psoas muscle and the iliac fascia.

The **collateral circulation** is carried on (fig. 497) when the external iliac is tied, by the anastomosis of the ilio-lumbar and lumbar arteries with the circumflex iliac; the internal mammary with the inferior epigastric; the obturator with the medial circumflex; the inferior gluteal with the medial circumflex and superior perforating; the gluteal with the lateral circumflex; the arteria comitans nervi ischiadici from the inferior gluteal, with the perforating branches of the profunda; the external pudenal with the internal pudendal; the pubic branch of the obturator with the pubic branch of the epigastric.

The **branches of the external iliac artery** are:—(1) The inferior epigastric; (2) the deep circumflex iliac; and (3) several small and insignificant twigs to the neighbouring psoas muscles and lymphatic gland.

(1) The Inferior Epigastric Artery

The **inferior** or **deep epigastric** artery [a. epigastrica inferior] (fig. 495) usually comes off from the external iliac just above the inguinal (Poupart's) ligament. Immediately after its origin, the ductus deferens in the male, and the round ligament in the female, loop around it on their way to the pelvis. It here lies medial to the abdominal inguinal (internal abdominal) ring, behind the inguinal canal, and a little above and lateral tc the femoral ring. Thence it ascends with a slightly medial direction passing above and to the lateral side of the subcutaneous inguinal (external abdominal) ring, lying between the fascia transversalis and the peritoneum. Having pierced the fascia transversalis at this point, it

passes in front of the linea semicircularis (Douglas' fold) and turns upward between the rectus and its sheath. Higher, it enters the substance of the muscle, and anastomoses with the superior epigastric, descending in the rectus from the internal mammary.

The situation of the artery between the two inguinal rings should be borne in mind in the operation for strangulated inguinal hernia, and its near proximity to the upper and lateral side of the femoral ring should not be forgotten in the operation for femoral hernia. The artery is accompanied by two veins which end in a single trunk before opening into the external iliac vein.

The **branches of the inferior epigastric** are small and include:—(*a*) The **external spermatic** [a. spermatica externa], which runs with the ductus through the inguinal canal, supplies the cremaster muscle, and anastomoses with the internal spermatic, external pudendal, and perineal arteries. In the female a corresponding artery [a. lig. teretis uteri] accompanies the round liga-

FIG. 495.—THE INFERIOR (DEEP) EPIGASTRIC ARTERY. (From Kelly, by Brödel).

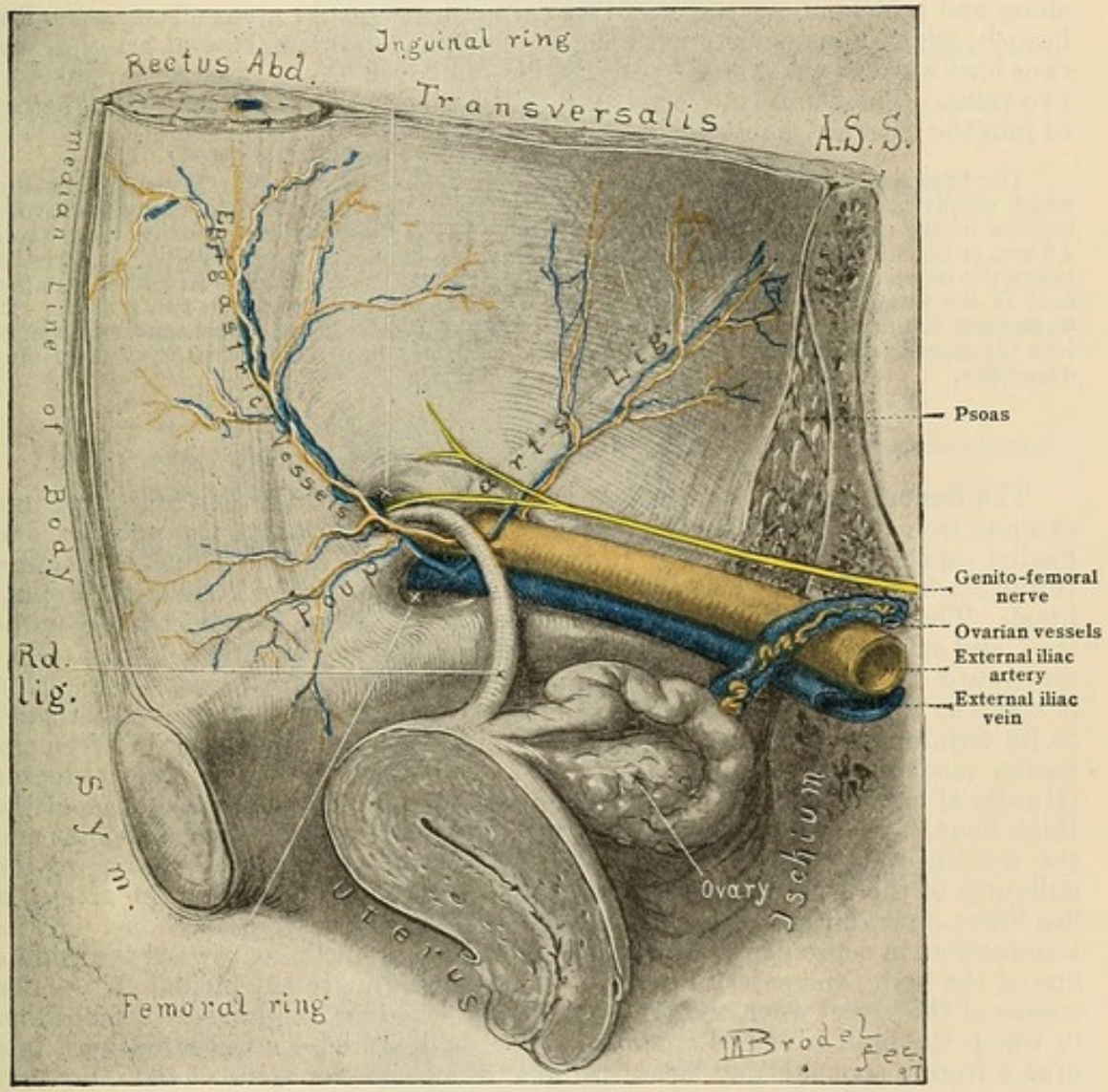

ment of the uterus through the inguinal canal and anastomoses in a similar manner. (*b*) The **pubic** [ramus pubicus], which passes below, or sometimes above, the femoral ring to the back of the pubis, where it anastomoses with the pubic branch of the obturator. This branch, though usually small, is occasionally considerably enlarged, when its exact course becomes of great interest to the surgeon. Thus it may descend immediately medial to the vein, and therefore lateral to the femoral ring, or it may course medially in front of the femoral ring and turn downward either behind the os pubis or immediately behind the free edge of the lacunar (Gimbernat's) ligament, in which situation it would be exposed to injury in the operation for the relief of a strangulated femoral hernia. In such cases the obturator may lose its connection with the hypogastric and actually arise from the inferior epigastric. Very rarely the inferior epigastric loses its connection with the external iliac and arises from the obturator. This abnormal origin of the obturator is said to occur once in every three subjects and a half; but the abnormal

artery only courses around the medial side of the ring—in which situation it is liable to injury in the operation for femoral hernia—in exceptional cases. According to Langton (Holden's 'Anatomy'), the chances are about seventy to one against this occurring. But even when it takes the abnormal course, it lies 3 mm. or so from the margin of the ring, and will probably escape injury in the division of the stricture if several short notches are made in place of a single and longer incision.

(2) The Deep Circumflex Iliac Artery

The **deep circumflex iliac** artery [a. circumflexa ilium profunda], arises from the lateral side of the external iliac artery either opposite the epigastric or a little below the origin of that vessel. It courses laterally just above the lower margin of Poupart's ligament, lying between the fascia transversalis and the peritoneum, or at times in a fibrous canal formed by the union of the fascia transversalis with the iliac fascia. Near the anterior superior spine of the ilium, it perforates the transversus, and then courses between that muscle and the internal oblique, along and a little above the crest of the ilium. It finally gives off an ascending branch, which anastomoses with the lumbar and lower intercostal arteries, and runs backward to anastomose with the ilio-lumbar artery. It is accompanied by two veins. These unite into one trunk, which then crosses the external iliac artery to join the external iliac vein.

The **branches of the deep circumflex iliac artery** are as follows:—(*a*) **Muscular** branches which supply the psoas, iliacus, sartorius, tensor fasciæ latæ, and the oblique and transverse muscles of the abdomen. One of these branches, larger than the rest, usually arises about 2.5 cm. (1 in.) behind the anterior superior spine of the ilium and ascends perpendicularly between the transversus muscle and the internal oblique. It has received no name but is important to the surgeon, as it indicates the intermuscular plane between the two muscles. (*b*) **Cutaneous** branches, which supply the skin over the course of the vessel, and anastomose with the superficial circumflex iliac, the superior gluteal, and the ascending branch of the lateral circumflex.

THE FEMORAL ARTERY

The **femoral** artery (fig. 496) is the continuation of the external iliac, and extends from the lower border of Poupart's ligament, down the anterior and medial aspect of the thigh, to the tendinous opening in the adductor magnus, through which it passes into the popliteal space, and is then known as the popliteal. The femoral artery is at first quite superficial, being merely covered by the skin, and superficial and deep fascia; but, after thus passing about 13 cm. (5 in.) downward through the space known as the femoral trigone (Scarpa's triangle), it sinks at the apex of that triangle beneath the sartorius muscle, and thence to its termination continues beneath the sartorius, coursing deeply between the vastus medialis and adductor muscles in the space known as the adductor (Hunter's) canal. It at first rests upon the brim of the pelvis and head of the thigh bone, from which it is merely separated by the capsule of the hip-joint and the tendon of the psoas. Here it can be readily compressed. Owing to the obliquity of the neck of the femur and the direct course taken by the artery, it lies lower down on muscles only, at some little distance from the bone. At its termination, in consequence of the shaft of the femur inclining toward the middle line of the body, the artery lies close to the bone, but to the medial side. The course of the vessel when the thigh is slightly flexed and abducted—the position in which the limb is placed when the vessel is ligatured—is indicated by a line drawn from a spot midway between the anterior superior spine of the ilium and the symphysis pubis to the adductor tubercle. When the thigh is in the extended position and parallel to its fellow, the course of the artery will correspond to a line drawn from the spot above mentioned to the medial border of the patella.

About 4–5 cm. (1½–2 in.) below the inguinal ligament the femoral artery gives off a large branch called the profunda femoris. The portion of the artery proximal to the origin of the profunda is sometimes called the *common femoral*, and the continuation of the vessel the *superficial femoral*.

The superficial femoral varies in length according to the distance that the profunda is given off from the common femoral below Poupart's ligament. As a rule, it measures 9 cm. (3½ in.), the common 4 cm. (1½ in.). But the profunda may come off 5 cm. (2 in.) or more below Poupart's ligament, in which case the superficial femoral will be shorter to this extent; or it may

come off less than 3.7 cm. (1½ in.) below Poupart's ligament, or even from the external iliac above Poupart's ligament, when the superficial will be longer than normal. The practical point to remember is that it is more usual to meet with a short than with a long common femoral and that if the superficial femoral is tied at the apex of the femoral trigone—i. e., the spot where the sartorius comes into contact with the adductor longus—there is nearly always a sufficient

FIG. 496.—THE FEMORAL ARTERY. (After Toldt, "Atlas of Human Anatomy," Rebman London and New York.)

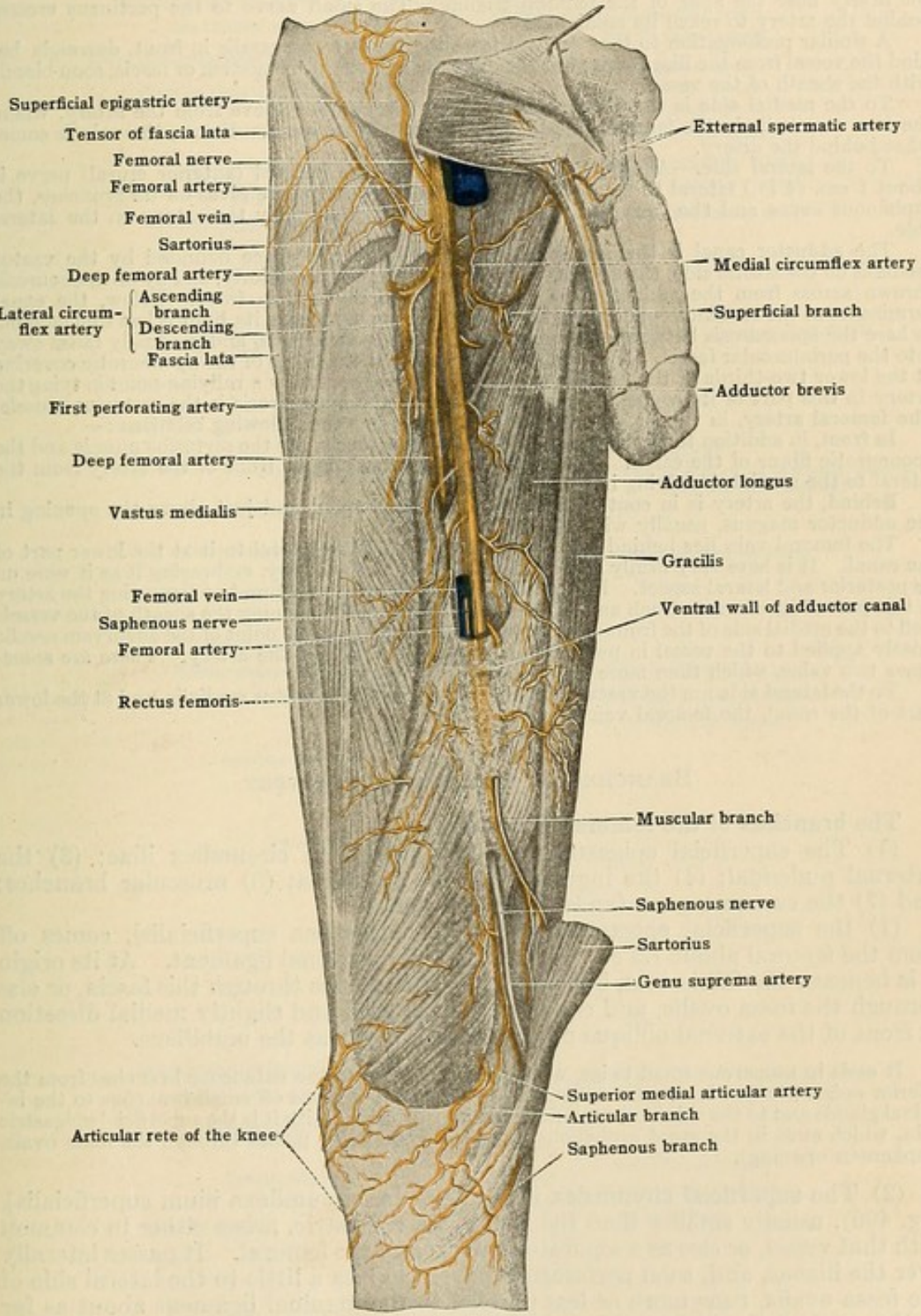

length of that vessel above the ligature to ensure a firm internal clot and consequently, as far as this point is concerned, a successful result.

The relations of the femoral artery in the femoral trigone.—**In front,** the femoral artery (fig. 496) is covered by the skin, the superficial fascia, the iliac portion of the fascia lata, and the lumbo-inguinal (crural) branch of the genito-femoral nerve. The superficial circumflex iliac vein, and sometimes the superficial epigastric vein, descend over the artery from the medial to

the lateral side. Just above the sartorius, the artery is crossed by the most medial of the anterior cutaneous branches of the femoral nerve. The fascia transversalis, which is continued downward into the thigh beneath the inguinal ligament, is also in anterior relation, but it soons becomes indistinguishable from the sheath of the vessel.

Behind, the artery rests from above upon the tendon of the psoas muscle, which separates it from the brim of the pelvis and capsule of the hip-joint; the pectineus, and adductor longus. The artery is partially separated from the pectineus by the femoral vein and the profunda vein and artery, and from the adductor longus by the femoral vein which is almost directly behind the artery near the apex of the femoral trigone. The small nerve to the pectineus crosses behind the artery to reach its medial side.

A similar prolongation to that derived from the fascia transversalis in front, descends behind the vessel from the iliac fascia; but this, like the anterior prolongation or fascia, soon blends with the sheath of the vessels.

To the **medial side** is the femoral vein. This is separated above from the artery, where the two vessels lie in the femoral sheath, by a thin fascial septum. Below, the vein is somewhat behind the artery.

To the **lateral side.**—Above, the common stem of the femoral (anterior crural) nerve is about 1 cm. (⅓ in.) lateral to the artery. When the femoral nerve gives off its branches, the saphenous nerve and the nerve to the vastus medialis accompany the artery on the lateral side.

The **adductor canal** is the somewhat triangularly shaped space bounded by the vastus medialis on the lateral side, the adductors longus and magnus posteriorly, and by an aponeurosis thrown across from the adductors to the vastus medially and in front. Below, the canal terminates at the tendinous opening in the adductor magnus; above, its limit is less well defined, as here the aponeurosis between the muscles becomes less tendinous, and gradually fades away into the perimuscular fascia. The transverse direction of the fibres of the aponeurotic covering at the lower two-thirds of the canal is characteristic, and serves as a rallying-point in tying the artery in this part of its course. Lying superficial to the aponeurosis is the sartorius muscle. **The femoral artery,** in the adductor (Hunter's) canal, has **the following relations:—**

In front, in addition to the skin, superficial and deep fascia, are the sartorius muscle and the aponeurotic fibres of the canal. The saphenous nerve crosses in front of the artery from the lateral to the medial side, lying in the wall of the canal.

Behind, the artery is in contact with the adductor longus, and just above the opening in the adductor magnus, usually with the latter muscle.

The femoral vein lies behind the artery, but gets a little lateral to it at the lower part of the canal. It is here very firmly and closely attached to the artery, embracing it as it were on its posterior and lateral aspect. Hence it is very liable to be punctured on ligaturing the artery in this part of its course. Such an accident is best avoided by opening the sheath of the vessels well to the medial side of the front of the artery, and by keeping the point of the aneurysm needle closely applied to the vessel in passing it between the vein and the artery. There are sometimes two veins, which then more or less surround the artery.

To the **lateral side** are the vastus medialis, the nerve to the vastus medialis, and at the lower part of the canal, the femoral vein.

Branches of the Femoral Artery

The **branches of the femoral artery** are:—

(1) The superficial epigastric; (2) the superficial circumflex iliac; (3) the external pudendal; (4) the inguinal; (5) the profunda; (6) muscular branches; and (7) the suprema genu (anastomotica magna).

(1) the **superficial epigastric** artery [a. epigastrica superficialis], comes off from the femoral about 1.2 cm. (½ in.) below the inguinal ligament. At its origin it is beneath the fascia lata, but almost at once passes through this fascia, or else through the fossa ovalis, and courses in an upward and slightly medial direction in front of the external oblique muscle almost as far as the umbilicus.

It ends in numerous small twigs, which anastomose with the cutaneous branches from the inferior epigastric and internal mammary. In its course it gives off small branches to the inguinal glands and to the skin and superficial fasciæ. Running with it is the superficial epigastric vein, which ends in the great saphenous just before the latter passes through the fossa ovalis (saphenous opening).

(2) The **superficial circumflex iliac** artery [a. circumflexa ilium superficialis], (fig. 496), usually smaller than the superficial epigastric, arises either in common with that vessel, or else as a separate branch from the femoral. It passes laterally over the iliacus, and, soon perforating the fascia lata a little to the lateral side of the fossa ovalis, runs more or less parallel to the inguinal ligament about as far as the crest of the ilium, where it ends in branches which anastomose with the deep circumflex iliac artery.

In its course it gives off branches to the iliacus and sartorius muscles, to the inguinal glands, and to the fascia and skin. Its companion vein ends in the great saphenous vein just before the latter passes through the fossa ovalis (saphenous opening).

(3) the **external pudendal** arteries [aa. pudendæ externæ], arise from the medial side of the femoral. Some of them pass either through the fascia lata, or

FIG. 497.—TO SHOW THE ANASTOMOSES OF THE ARTERIES OF THE LOWER EXTREMITY. (After Smith and Walsham.)

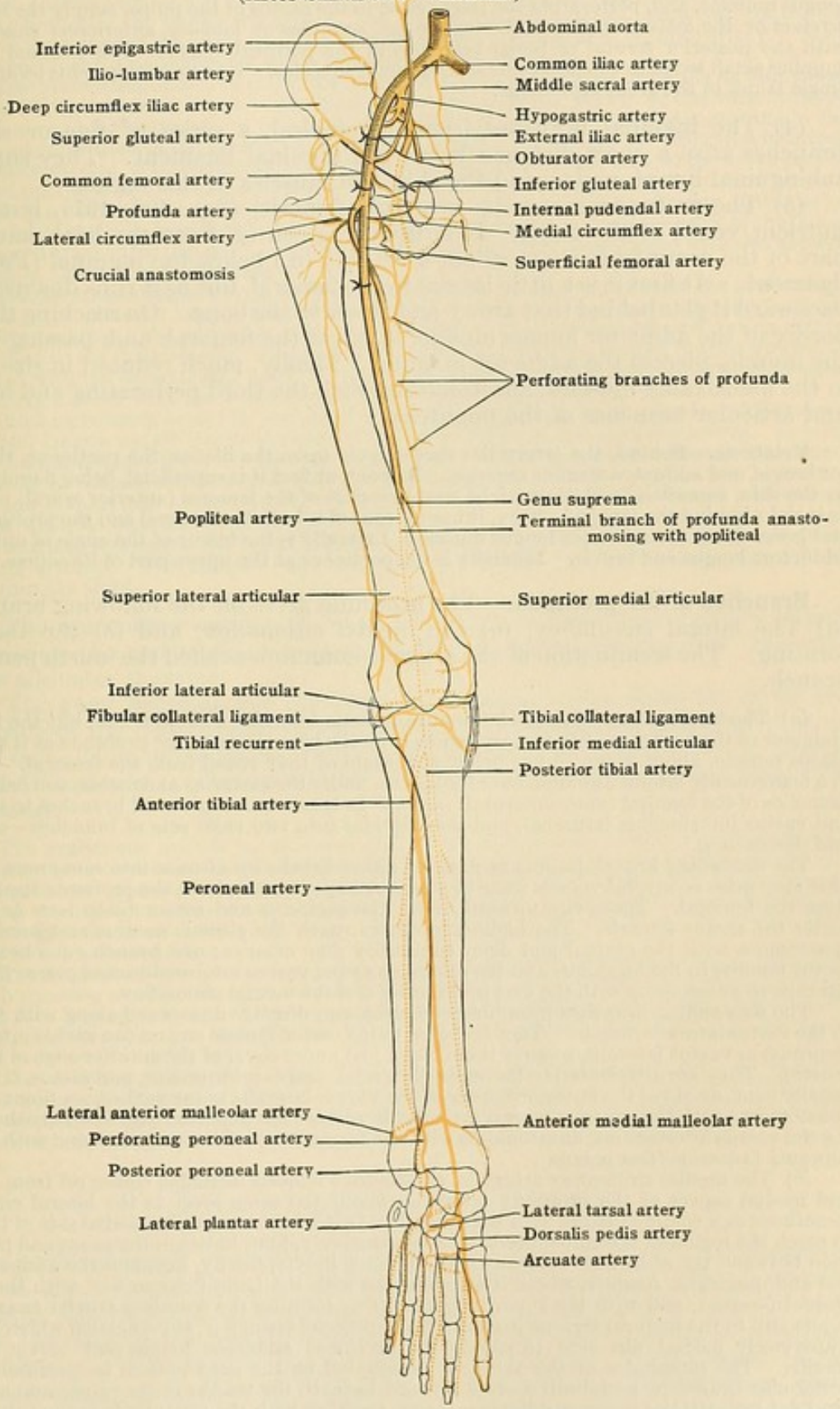

through the fascia covering the fossa ovalis (saphenous opening) and cross the spermatic cord in the male, or round ligament in the female, to reach and supply the integument above the pubes. One branch descends along the penis lateral

to the dorsal artery, with which, and with the corresponding artery of the opposite side, it anastomoses at the corona. In the female, this branch terminates in the preputium clitoridis, anastomosing with the dorsal artery of the clitoris.

Other branches run medially beneath the deep fascia, across the pectineus and adductor longus muscles, and, perforating the fascia close to the ramus of the pubis, supply the skin of the *scrotum* or the *labium majus*, in the female [aa. scrotales or labiales anteriores] anastomosing with the posterior scrotal or labial branches of the perineal artery. The external pudendal supplies small twigs to the pectineus and adductor muscles. Its companion veins terminate as a single trunk in the great saphenous.

(4) The **inguinal** branches [rami inguinales], a series of five or six small branches arise a short distance below the inguinal ligament. They supply the subinguinal lymph-nodes, and the skin and muscles in this region.

(5) The **profunda** artery [a. profunda femoris] (figs. 496, 497), is the chief nutrient vessel of the thigh. It is usually given off from the back and lateral part of the common femoral, about 4 cm. (1½ in.) below the inguinal (Poupart's) ligament. At first it is a little lateral to the femoral, but as it runs downward and backward it gets behind that artery and closer to the bone. On reaching the upper border of the adductor longus muscle, it leaves the femoral, and, passing beneath the muscle, pierces the adductor magnus. Finally, much reduced in size, it ends in the hamstraing muscles, anastomosing with the third perforating and muscular and articular branches of the popliteal.

Relations.—Behind, the artery lies successively upon the iliacus, the pectineus, the adductor brevis, and adductor magnus muscles. **In front,** at first it is superficial, being merely covered by the skin, superficial and deep fasciæ, and branches of the femoral (anterior crural) nerve; but as it sinks behind the femoral artery, it has in front of it both the femoral and the profunda veins and lower down the adductor longus muscle. **Laterally** is the femur at the angle of union of the adductors longus and brevis. **Medially** is the pectineus at the upper part of its course.

Branches of the profunda.—The profunda gives off the following branches:—(*a*) The lateral circumflex; (*b*) the medial circumflex; and (*c*) the three perforating. The termination of the artery is sometimes called the fourth perforating branch.

(*a*) The **lateral circumflex** [a circumflexa femoris lateralis] a short trunk, but the largest in diameter of the branches of the artery, arises from the lateral side of the profunda as it lies on the iliacus muscle, about 2 cm. (¾ in.) below the origin of that vessel from the femoral. It passes in a transversely lateral direction over the iliacus, under the sartorius and rectus, and between the branches of the femoral (anterior crural) nerve. In this course it gives off branches to the rectus and vastus intermedius (crureus), and then divides into two chief sets of branches—ascending and descending.

The **ascending** branch [ramus ascendeus] either breaks up at once into numerous branches or it may arise as several vessels some of which are apt to come from the profunda itself or even from the femoral. These run upward under the sartorius and tensor faciæ latæ or laterally under the rectus femoris. The highest branches reach the gluteus medius and minimus and anastomose with the gluteal and deep circumflex iliac arteries; one branch runs beneath the rectus femoris to the hip-joint, and the others cross the vastus intermedius and pierce the vastus lateralis to anastomose with the first perforating and the medial circumflex.

The **descending** branches [rami descendentes] run directly downward along with the nerve to the vastus lateralis muscle. They lie beneath the rectus muscle and on the vastus intermedius (crureus) or vastus lateralis, some of them being just under cover of the anterior edge of the latter muscle. They are distributed to the vastus lateralis, vastus intermedius, and rectus, one branch usually running along the anterior border of the vastus lateralis as far as the knee-joint, where it anastomoses with the superior lateral articular branch of the popliteal (fig. 499); another, entering the vastus intermedius, anastomoses with the termination of the profunda and with the genu suprema (anastomotica magna).

(*b*) The **medial circumflex** artery [a. circumflexa femoris medialis] comes off from the back and medial aspect of the profunda artery on about the same level as the lateral circumflex; sometimes as a common trunk with that vessel. As it winds around the medial side of the femur to reach the region of the trochanters, it lies successively, first, between the psoas and pectineus, then between the obturator externus and adductor brevis; finally, between the adductor magnus and quadratus femoris, where it anastomoses with the lateral circumflex, with the inferior gluteal (sciatic), and with the superior perforating, forming the so-called **crucial anastomosis.** While still in the femoral trgione it gives off a *superficial* branch [r. superficialis] which runs in a transversely medial direction to supply the pectineus adductor longus and brevis, and the gracilis. The remainder of the artery is designated as the *deep* branch [r. profundus]. An acetabular branch [r. acetabuli] courses upward beneath the tendon of the psoas, and enters the hip-joint beneath the transverse ligament, and, together with the articular branch of the obturator, supplies the fatty tissue in the acetabulum, and sends branches to the synovial membrane. The medial circumflex veins join the profunda vein.

(*c*) The **perforating arteries of the profunda** are so called because they perforate, in a more or less regular manner from above downward, certain of the adductor muscles. They form a series

of loops by anastomosing with one another (fig. 497), and with the superior gluteal, medial circumflex, and inferior gluteal arteries above, and with the muscular and articular branches of the popliteal below. They are distributed chiefly to the hamstring muscles, but send twigs along the lateral intermuscular septum to supply the integuments at the back and lateral parts of the thigh. Other branches perforate the lateral intermuscular septum and the short head of the biceps, and, entering the vastus intermedius (crureus) and vastus lateralis, anastomose with the descending branch of the lateral circumflex. All the perforating arteries, moreover, contribute to reinforce the artery of the sciatic nerve, a branch of the inferior gluteal (sciatic) artery. They are each accompanied by two veins which terminate in the profunda.

The **first perforating** artery [a. perforans prima] is given off from the profunda as that vessel sinks beneath the adductor longus. It either pierces the adductor brevis, or else runs between the pectineus and adductor brevis, and then passes through a small aponeurotic opening in the adductor magnus close to the medial lip of the linea aspera. In this course it supplies branches to the adductors, and, after perforating the adductor magnus, is distributed to the lower part of the gluteus maximus and the hamstring muscles, one branch commonly running upward beneath the gluteus maximus to anastomose with the lateral circumflex, medial circumflex, and inferior gluteal (sciatic) arteries, forming the **crucial anastomosis** at the junction of the neck of the femur with the great trochanter (fig. 497). A second branch descends to anastomose with the ascending branch of the second perforating.

The **second perforating** artery [a. perforans secunda] which is given off from the profunda as it lies behind the adductor longus, pierces the adductor brevis, and then passes through a second aponeurotic opening in the adductor magnus a little below that for the first perforating artery, and also close to the linea aspera. It supplies the hamstring muscles, sends a branch upward to anastomose with the descending branch of the first perforating, and another downward to anastomose in like manner with the ascending branch of the third perforating.

The **third perforating** artery [a. perforans tertia] also arises from the profunda as it lies under the adductor longus, usually about the level of the lower border of the adductor brevis. It turns beneath this border, and then, like the first and second perforating, passes through an aponeurotic opening in the adductor magnus close to the linea aspera. It also supplies the hamstring muscles, and divides into two branches, which anastomose above with the second perforating, and below with the termination of the profunda.

Two **nutrient arteries** to the femur [aa. nutritiæ femoris superior et inferior] arise from the perforating arteries. The superior generally arises from the first perforating, the inferior usually from the third.

(6) The **muscular** branches [rami musculares], of the femoral artery supply the sartorius, the rectus, the vastus medialis, the vastus intermedius (crureus), and the adductor muscles.

(7) The **genu suprema** (or anastomotica magna) arises from the front and medial side of the femoral just before the latter perforates the adductor magnus muscle, and almost immediately divides into branches, (*a*) saphenous, (*b*) muscular, and (*c*) articular. These branches may sometimes come off separately from the femoral.

(*a*) The **saphenous** branch [a. saphena] pierces the aponeurotic covering of the adductor canal, passes between the sartorius and gracilis muscles along with the saphenous nerve, and, perforating the deep fascia, supplies the skin of the upper and medial side of the leg and anastomoses with the inferior medial articular branch of the popliteal and the other vessels forming the plexus or rete at the medial side of the knee. In its course it gives twigs to the lower part of the sartorius and gracilis muscles.

(*b*) The **muscular** branches [rr. musculares] run downward in front of the adductor magnus tendon, burrowing amongst the fibres of the vastus medialis as far as the medial condyle. They break up into numerous twigs which supply the lower ends of the vasti muscles and adductor magnus. One branch runs laterally across the lower end of the femur to end in the vastus lateralis.

(*c*) The **articular** branches [rr. articulares] come off from the saphenous and muscular branches and enter the arterial rete on the medial and lateral sides of the knee. They anastamose with the medial and lateral superior articular branches of the popliteal and the anterior tibial recurrent and, like other vessels of the rete, supply branches to the joint.

THE POPLITEAL ARTERY

The **popliteal artery** [a. poplitea] (fig. 498) runs through the popliteal space or ham. It is a continuation of the femoral, and extends from the aponeurotic opening in the adductor magnus at the junction of the middle with the lower third of the thigh to the lower border of the popliteus muscle, where it terminates by dividing into the anterior and posterior tibial arteries. This division is on a level with the lower border of the tuberosity of the tibia. As the artery passes through the opening in the adductor magnus, it is accompanied by the popliteal vein, and at times by the branch of the obturator nerve to the knee-joint. The vein throughout is behind the artery, at first lying a little lateral to it, but as the vessels pass through the popliteal space the vein crosses obliquely over the artery,

and at the termination of the artery lies a little to its medial side. The tibial (internal popliteal) nerve is superficial to both artery and vein. As it enters the space it is well to the lateral side of the vessels, but as it descends it gradually approaches them, crosses behind them, and at the lower part of the space lies to their medial side. The artery in the whole of its course is deeply placed and covered by a considerable amount of fat and cellular tissue.

Relations (fig. 498).—**In front,** the artery lies successively on the popliteal surface of the femur (from which it is separated by a little fat and sometimes one or two small glands); on the posterior ligament of the knee; on the hinder edge of the articular surface of the head of the tibia; and on the popliteus muscle. From the latter muscle it is separated by the expansion from the semi-membranosus which covers the muscle, and is attached to the popliteal line on the tibia.

Behind, the artery is covered, above by the semi-membranosus; in the centre of the space by the skin, superficial and deep fascia; and below, by the medial head of the gastrocnemius. The popliteal vein is behind it in the whole of its course. The tibial (internal popliteal) nerve crosses behind it obliquely, from the lateral to the medial side, about the centre of the space. As the artery divides into the anterior and posterior tibial, it is crossed by the aponeurotic arch of the soleus which stretches between the tibial and fibular origins of that muscle.

To the **medial side** are the semi-membranosus above, and the medial head of the gastrocnemius and the tibial (internal popliteal) nerve below.

To the **lateral side** are the biceps and the tibial (internal popliteal) nerve above, and the lateral head of the gastrocnemius and the plantaris below.

Branches of the Popliteal Artery

The **branches of the popliteal** include the following:—(1) the sural; (2) the articular; and (3) the terminal.

(1) The **sural** arteries [aa. surales] arise irregularly from the popliteal and supply the muscles of the calf, sending branches upward to the muscles bounding the upper part of the popliteal space. From the sural arteries also arise the superficial sural or cutaneous branches which pass downward between the two heads of the gastrocnemius, and, perforating the deep fascia, supply the skin and fascia of the calf. A branch, usually of moderate size, accompanies the small saphenous vein, and is sometimes called the posterior saphenous artery.

(2) The **articular,** five in number, are divided into two superior (medial and lateral), two inferior (medial and lateral), and the middle or azygos. The superior and inferior come off transversely in pairs from either side of the popliteal, the superior above, the inferior below the joint. Winding round the bones to the front of the knee, they form—by anastomosing with each other and with the genu suprema (anastomotica magna), the termination of the profunda, the descending branch of the lateral circumflex, and the anterior tibial recurrent—a superficial and deep arterial rete (fig. 499). The superficial anastomosis or rete lies between the skin and fascia round about the patella (**patellar rete**), which it supplies, the larger branches entering it from above. The deep anastomosis or **articular rete** [rete articularis genu] lies on the surface of the bones around the articular surfaces of the femur and tibia, supplying branches to the contiguous bones and to the joints. The middle articular is a single short trunk coming off from the deep surface of the popliteal artery. It at once passes through the posterior ligament into the joint.

(*a*) The **superior lateral articular** artery [a. genu superior lateralis], the larger of the two superior articular branches, runs in a lateral direction above the lateral head of the gastrocnemius, and, passing beneath the biceps and through the lateral intermuscular septum and vastus lateralis, enters the substance of the vastus intermedius (crureus), and anastomoses, above with the descending branch of the lateral circumflex, below with the inferior lateral articular, and across the front of the femur with the superior medial articular, the genu suprema (anastomotica magna), and termination of the profunda, forming with them, as already described, the deep articular rete. Branches are given off to the patella, to the upper and lateral part of the joint, to the bone, and to the contiguous muscles.

(*b*) The **superior medial articular** artery [a. genu superior medialis] (fig. 499) runs medially just above the medial head of the gastrocnemius, beneath the semi-membranosus, and, after perforating the tendon of the adductor magnus, enters the substance of the vastus medialis. Here it anastomoses with the deep branch of the genu suprema (anastomotica magna) and termination of the profunda above, with the inferior medial articular below, and with the superior lateral articular across the front of the femur. It supplies small branches to the contiguous muscles, to the femur, to the patella, and to the joint.

(*c*) The **inferior medial articular** artery [a. genu inferior medialis], the larger of the two inferior articular arteries, passes in an obliquely medial direction across the popliteus, below the medial condyle (tuberosity) of the tibia and beneath the tibial collateral ligament to the front and

medial side of the knee-joint. Here it anastomoses (fig. 499), above with the superior medial articular and the superficial branch of the genu suprema (anastomotica magna), and across the front of the tibia with the inferior lateral articular. It supplies branches to the lower and medial part of the joint.

(*d*) The **inferior lateral articular** artery [a. genu inferior lateralis] passes laterally above the head of the fibula, along the tendon of the popliteus muscle, beneath the lateral head of the gastrocnemius, and then under the tendon of the biceps, and between the long and short fibular

FIG. 498.—RELATIONS OF THE POPLITEAL ARTERY TO BONES AND MUSCLES, LEFT SIDE.

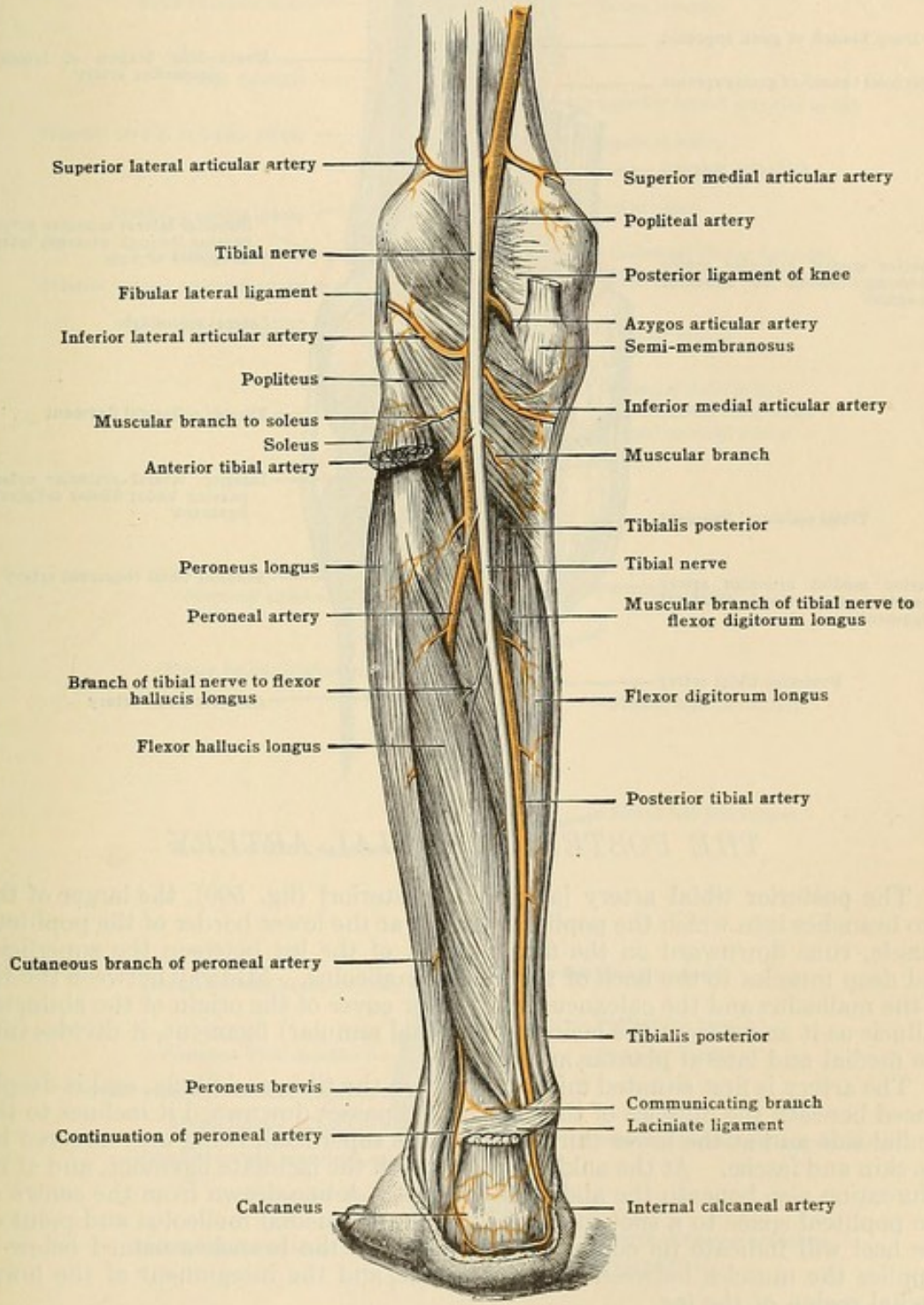

collateral ligaments. Then winding to the front of the joint, it anastomoses above with the superior lateral articular, below with the anterior tibial recurrent, and across the front of the tibia with the inferior medial articular. It also supplies branches to the lateral and lower part of the joint.

(*e*) The **middle or azygos articular** artery [a. genu media] arises from the deep surface of the popliteal artery, and passes, with the articular branch of the obturator nerve, through the

popliteal ligament, directly into the knee-joint, where it supplies the crucial ligaments, and the patellar synovial and alar folds. It anastomoses with the intrinsic branches of the other articular arteries.

(3) The **terminal branches** of the popliteal are the posterior and the anterior tibial arteries.

FIG. 499.—THE ANASTOMOSIS ABOUT THE LEFT KNEE-JOINT. (Walsham.)
(Semi-diagrammatic.)

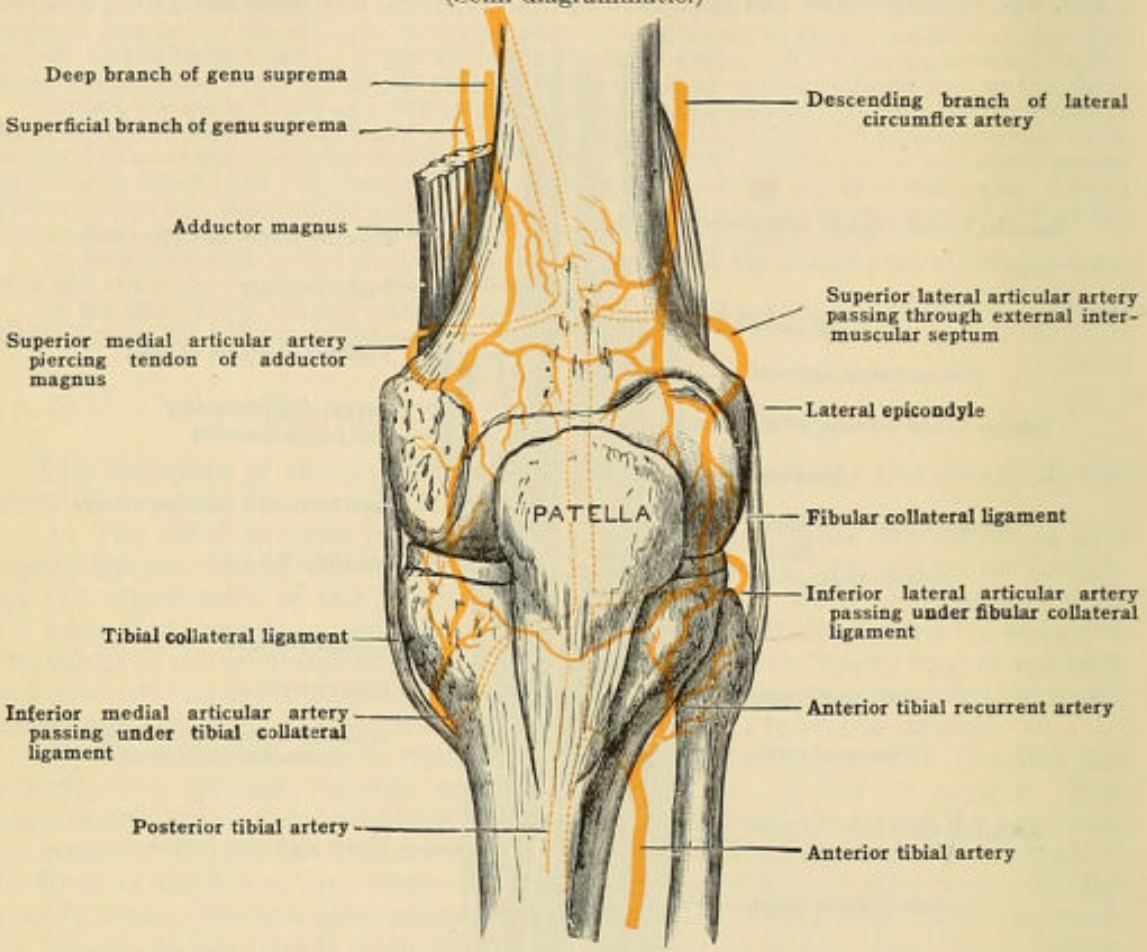

THE POSTERIOR TIBIAL ARTERY

The **posterior tibial** artery [a. tibialis posterior] (fig. 500), the larger of the two branches into which the popliteal divides at the lower border of the popliteus muscle, runs downward on the flexor aspect of the leg between the superficial and deep muscles to the back of the medial malleolus. Midway between the tip of the malleolus and the calcaneus, and under cover of the origin of the abductor hallucis as it arises from the laciniate (internal annular) ligament, it divides into the medial and lateral plantar arteries.

The artery is first situated midway between the tibia and fibula, and is deeply placed beneath the muscles of the calf. As it passes downward it inclines to the medial side and at the lower third of the leg is superficial, being only covered by the skin and fasciæ. At the ankle it lies beneath the laciniate ligament, and at its bifurcation also beneath the abductor hallucis. A line drawn from the centre of the popliteal space to a spot midway between the medial malleolus and point of the heel will indicate its course. In addition to the branches named below it supplies the muscles between which it passes, and the integument of the lower medial region of the leg.

Relations.—Anteriorly, from above downward, it lies successively on the tibialis posterior, the flexor digitorum longus, the posterior surface of the tibia, and the deltoid ligament of the ankle-joint.

Posteriorly, it is covered by the skin and fascia, the gastrocnemius and soleus, and the deep or intermuscular fascia of the leg, by which it is tightly bound down to the underlying muscles. It is crossed by the tibial nerve about 4 cm. ($1\frac{3}{4}$ in.) below its origin, after it has given off its

peroneal branch; the nerve first lies on the medial, and for the rest of its course on the lateral side of the vessel. It is accompanied by two veins, which send numerous anastomosing branches across it. In the lower third of the leg the artery is superficial, being covered only by the skin and by the superficial and deep fasciæ.

FIG. 500.—THE POPLITEAL, THE POSTERIOR TIBIAL, AND THE PERONEAL ARTERIES. (After Toldt, "Atlas of Human Anatomy," Rebman, London and New York.)

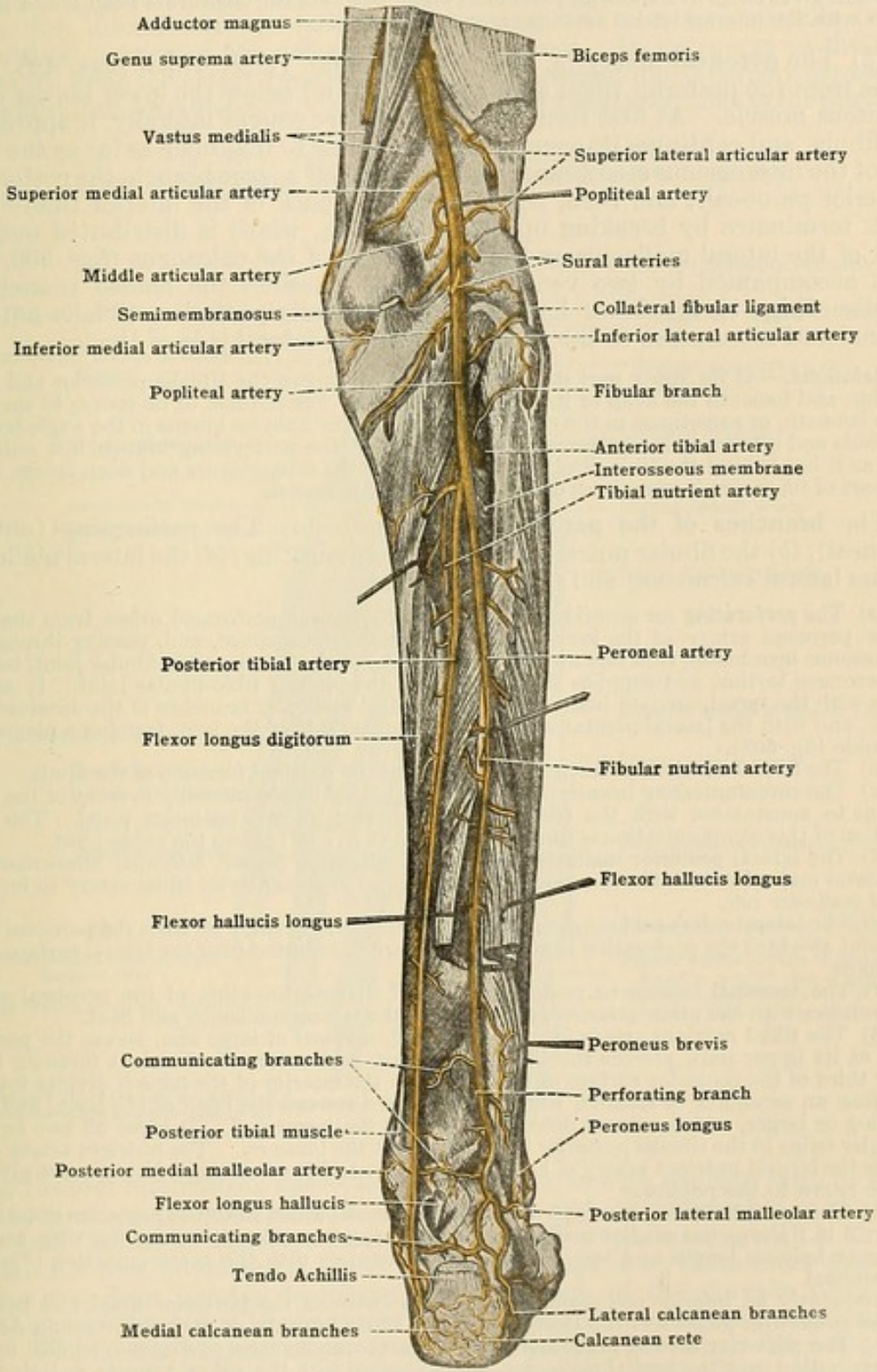

At the **medial malleolus** it lies beneath the laciniate (internal annular) ligament and abductor hallucis upon the deltoid ligament of the ankle-joint. Here it has the tibialis posterior and flexor digitorum longus in front of it, and the tibial nerve and the flexor hallucis longus behind and to its lateral side.

At times the tibial nerve divides higher than usual, when one branch lies on the medial side of the artery and the other branch on the lateral side.

The **branches of the posterior tibial artery** are:—(1) The fibular; (2) the peroneal; (3) the tibial nutrient; (4) the communicating; (5) the posterior medial malleolar; (6) the medial calcanean, and (7) the terminal, medial and lateral plantar.

(1) The **fibular** or superior fibular branch [ramus fibularis], which frequently arises from the beginning of the anterior tibial, runs upward and laterally toward the head of the fibula. It is small and gives twigs to the soleus, peroneus longus, and extensor digitorum longus, and anastomoses with the inferior lateral articular and the lateral sural arteries.

(2) The **peroneal** artery [a. peronea] is a large vessel which (figs. 498, 500), arises from the posterior tibial about 2.5 cm. (1 in.) below the lower border of the popliteus muscle. At first forming a gentle curve convex laterally, it approaches the fibula, and continues its course downward close to that bone as far as the lower end of the interosseous membrane, where it gives off a large branch, the perforating (anterior peroneal), and then, passing over the back of the inferior tibio-fibular joint, terminates by breaking up into a network, which is distributed over the back of the lateral malleolus and lateral surface of the calcaneus (figs. 500, 504). It is accompanied by two venæ comitantes. Besides the named branches it supplies twigs to the flexor hallucis longus, tibialis posterior, tibialis anterior, peronei and soleus; also to the integument on the lateral side of the leg.

Relations.—At its upper part it is deeply placed between the tibialis posterior and soleus muscles, and beneath the deep or intermuscular fascia. For the rest of its course to the ankle it lies beneath, or sometimes in the substance of, the flexor hallucis longus in the angle between the fibula and interosseous membrane. After giving off the perforating branch, it is only covered, as it lies behind the tibio-fibular articulation, by the integuments and deep fascia, and in this part of its course is sometimes called the **posterior peroneal.**

The **branches of the peroneal artery** are:—(*a*) The perforating (anterior peroneal); (*b*) the fibular nutrient; (*c*) the communicating; (*d*) the lateral malleolar; (*e*) the lateral calcanean; and (*f*) the terminal.

(*a*) The **perforating** (or anterior peroneal) branch [ramus perforans] arises from the front of the peroneal artery at the lower part of the interosseous space, and, passing through the interosseous membrane, runs downward over the front of the inferior tibio-fibular joint, beneath the peroneus tertius, and supplies this muscle and the inferior tibio-fibular joint. It anastomoses with the tarsal, arcuate (metatarsal) and lateral malleolar branches of the anterior tibial artery, and with the lateral plantar artery on the lateral side of the foot, forming a plexus over the ankle (fig. 503).

(*b*) The **fibular nutrient** [a. nutritia fibulæ] enters the nutrient foramen of the fibula.

(*c*) The **communicating** branch [ramus communicans] passes medially in front of the tendo Achillis to anastomose with the communicating branch of the posterior tibial. The usual situation of this communication is from 2.5 to 5 cm. (1 to 2 in.) above the ankle-joint.

(*d*) The **lateral posterior malleolar** artery [a. malleolaris poster. lateralis] anastomoses on the lateral malleolus with the anterior lateral malleolar of the anterior tibial artery to form the *lateral malleolar rete.*

(*e*) The **lateral calcaneal** branches [rami calcanei laterales] come off from the peroneal below the point at which the perforating is given off, and are distributed over the lateral surface of the calcaneus.

(*f*) The **terminal** branch or posterior peroneal, the continuation of the peroneal artery, anastomoses with the other arteries distributed to the lateral malleolus and heel.

(3) The **tibial nutrient** artery [a. nutritia tibiæ], a vessel of large size, leaves the posterior tibial at its upper part, pierces the tibialis posterior, and enters the nutrient foramen in the upper third of the posterior surface of the tibia. In the interior of the bone it divides into two branches: an ascending or smaller, which runs upward toward the head of the bone; and a descending or larger, which courses downward toward the lower end. It gives off two or three muscular twigs to the tibialis posterior before it enters the foramen. The nutrient artery of the tibia is the largest nutrient artery of bone in the body, and is accompanied by a nerve given off by the nerve to the popliteus.

(4) The **communicating** branch [ramus communicans] arises from the posterior tibial about 5 cm. (2 in.) above the medial malleolus, and, passing transversely across the tibia beneath the flexor hallucis longus and tendo Achillis, anastomoses with the communicating branch of the peroneal.

Frequently an inferior communicating branch between the posterior tibial and peroneal arteries is likewise present in the loose connective tissue beneath or behind the tendo Achillis.

(5) The **posterior medial malleolar** branch [ramus malleolaris posterior medialis] divides for distribution over the medial malleolus, anastomosing with the other arteries entering into the *medial malleolar rete* [rete malleolare mediale] which is formed over the portion of bone. In its course to the malleolus it runs beneath the flexor digitorum longus and tibialis posterior muscles.

(6) The **medial calcanean** branches [rami calcanei mediales] are distributed to the soft parts over the medial side of the calcaneus. These branches come off from the posterior tibial just before its bifurcation, and anastomose with the medial malleolar and peroneal arteries.

(7) The **terminal branches** are the lateral and medial plantar arteries.

THE LATERAL PLANTAR ARTERY

The **lateral plantar** artery [a. plantaris lateralis] (figs. 501, 502)—the larger of the two branches into which the posterior tibial divides beneath the laciniate (internal annular) ligament—passes at first laterally and forward across the sole of the foot to the base of the fifth metatarsal bone, where it bends medially, and still running forward sinks deeply into the foot and terminates at the proximal end of the first interosseous space by anastomosing with the deep plantar (communicating) branch of the dorsal artery of the foot. In its course to the fifth metatarsal bone the artery runs in a more or less straight line obliquely across the foot; whilst its deep portion, extending from the fifth metatarsal bone to the proximal

FIG. 501.—THE PLANTAR ARTERIES, LEFT FOOT.
(From a dissection in the Museum of St. Bartholomew's Hospital.)

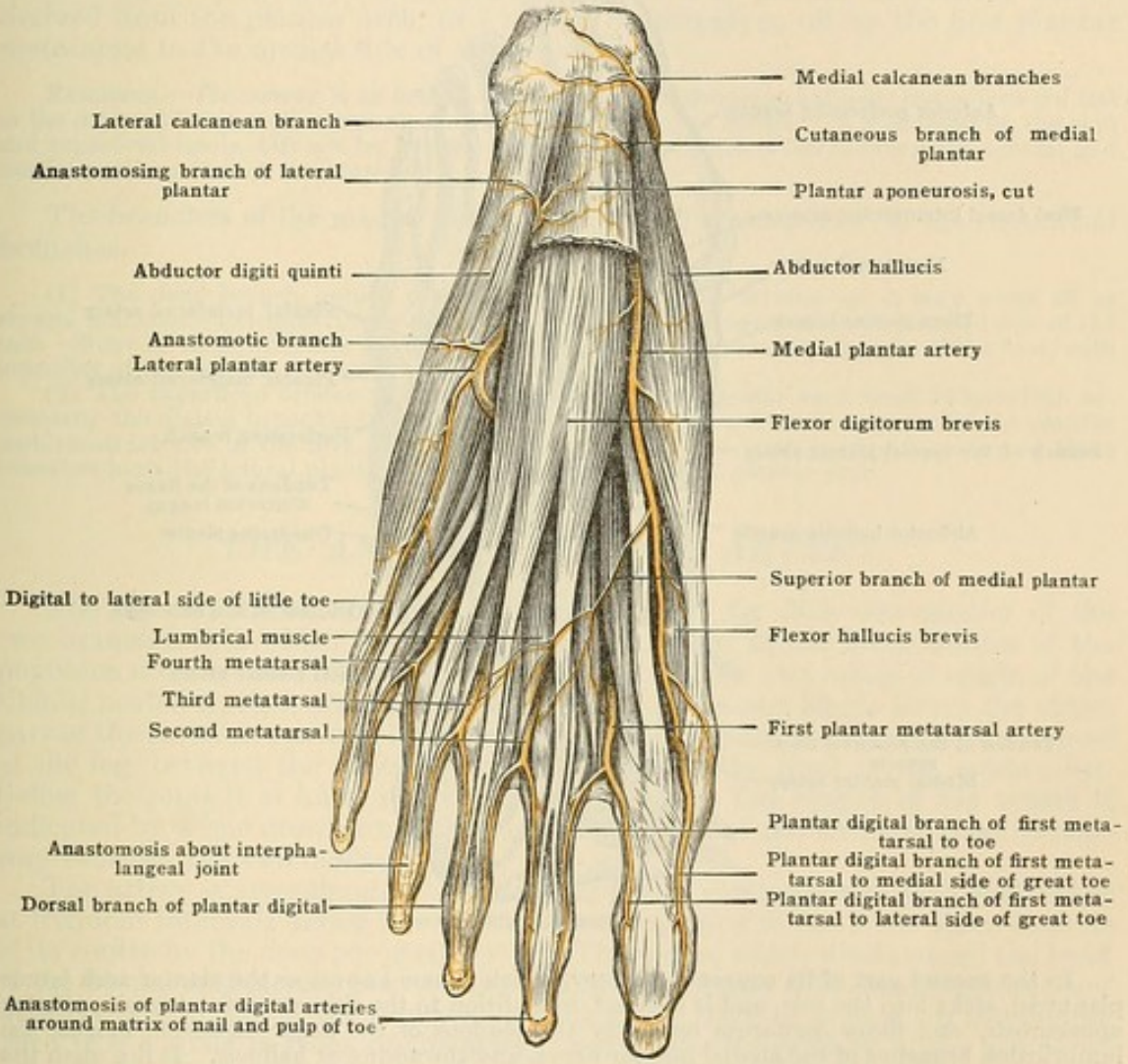

end of the first interosseous space, forms a slight curve with the convexity forward, and is known as the **plantar arch.** The plantar arch is comparable to the deep volar arch formed by the deep branch of the ulnar anastomosing with the radial through the first interosseous space. This homology is at times more complete in that the deep plantar (communicating) branch of the dorsalis pedis, the homologue of the radial in the upper limb, takes the chief share in forming the arch. The lateral plantar artery is accompanied by two veins. The course of the artery is indicated by a line drawn across the sole of the foot from a point midway between the tip of the medial malleolus and the medial tubercle of the calcaneus to the base of the fifth metatarsal bone, and thence to the lateral side of the base of the first metatarsal.

The lateral plantar artery, besides the branches named below gives twigs to supply the muscles between which it passes, and the tarsal joints. It also gives

branches to the integument of the lateral side of the sole, some of which anastomose with arteries on the lateral side of the dorsum.

Relations.—In the **first part of its course** from the medial malleolus to the base of the fifth metatarsal bone, the artery is covered successively by the abductor hallucis and the flexor digitorum brevis, by which it is separated from the plantar aponeurosis, and may be slightly overlapped in muscular subjects by the abductor quinti digiti. As it approches the base of the fifth metatarsal bone it lies, as it turns medially before sinking into the foot, in the interspace between the flexor digitorum brevis and the abductor quinti digiti, and is here covered only by the skin and superficial fascia and the plantar aponeurosis. It lies upon the calcaneus, the quadratus plantæ (flexor accessorius), and the flexor digiti quinti brevis. It is accompanied by the lateral plantar nerve, the smaller of the two divisions into which the tibial nerve divides. In this part of its course it gives off small branches to the contiguous muscles and to the heel.

FIG. 502.—PLANTAR ARTERIES (DEEP). (After Henle.)

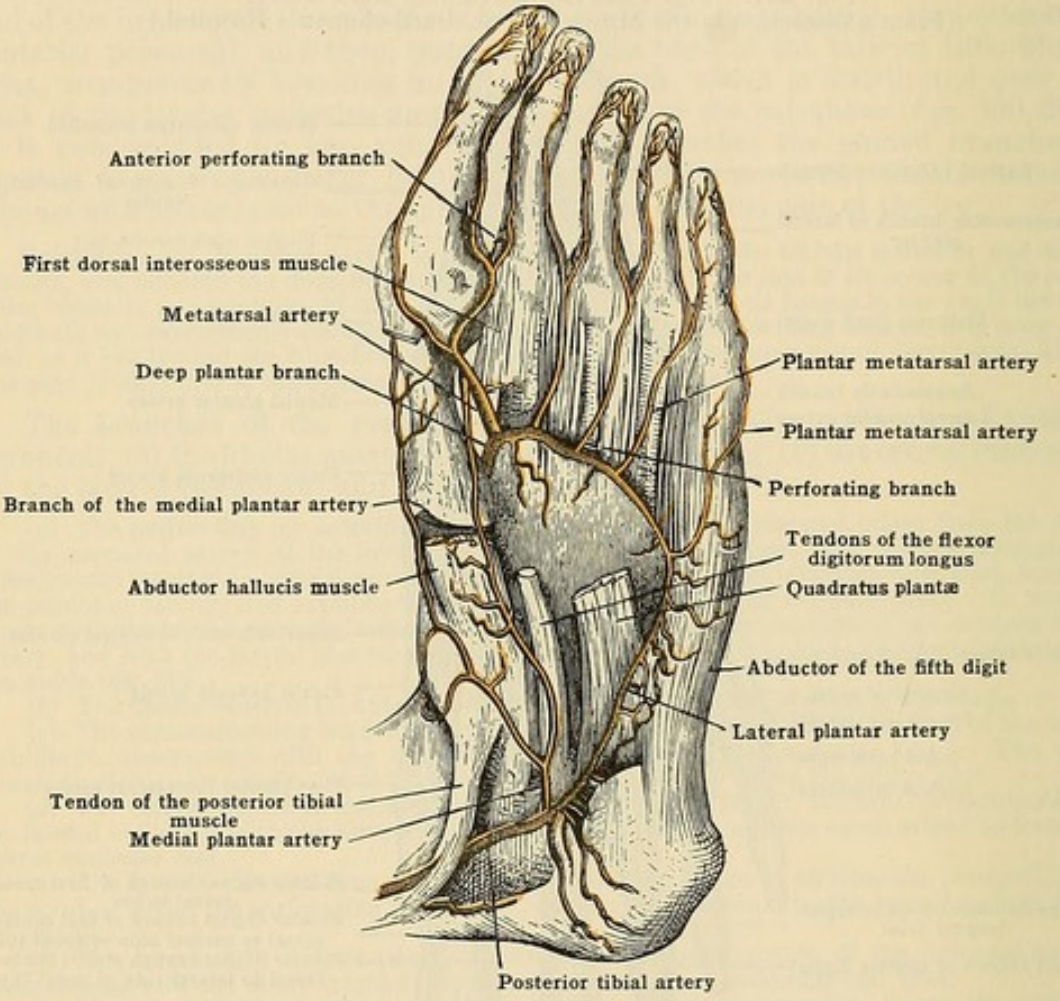

In the **second part of its course** the artery, which is here known as the **plantar arch** [arcus plantaris], sinks into the sole, and is covered, in addition to the skin, superficial fascia, plantar aponeurosis, and flexor digitorum brevis by the tendons of the flexor digitorum longus, the lumbricales, branches of the medial plantar nerve, and the adductor hallucis. It lies upon the proximal ends of the second, third, and fourth metatarsal bones and the corresponding interosseous muscles.

The **branches of the lateral plantar artery** are:—(1) Perforating; and (2) plantar metatarsal (digital).

(1) The **perforating** branches [rr. perforantes], three in numbers, ascend through the proximal end of the second, third, and fourth spaces, between the two heads of the correspondingly named dorsal interosseous muscles, and communicate with the proximal ends of the first, second, and third dorsal metatarsal (interosseous) arteries (fig. 502).

(2) The **plantar metatarsal** arteries [aa. metatarseæ plantares] are usually four in number, and pass forward in the four intermetatarsal spaces, which are numbered from the medial side. They rest upon the interosseous muscles of their spaces, and are at first under cover of the lumbricals, but as they approach the clefts of the toes each divides into two branches, the **plantar digital** arteries [aa. digitales plantares], which supply the contiguous sides of the toes. The plantar digital branch for the medial side of the great toe is usually given off by the first plantar metatarsal; that for the lateral side of the little toe is usually a separate branch from the lateral end of the plantar arch.

The plantar metatarsal arteries, immediately before they bifurcate, send to the dorsum of the foot a perforating branch each to the corresponding dorsal metatarsal arteries. They anastomose by many small twigs with the dorsal metatarsal arteries, which also run along the sides of the metatarsal bones, but more toward the dorsal aspect. Immediately above each phalangeal joint the plantar digital vessels communicate by cross branches, forming a rete for the supply of the articular end of the phalanges and the contiguous joints. At the distal end of the toes they also freely anastomose with each other, forming a rete beneath the pulp and around the matrix of the nail. The metatarsal and digital arteries are each accompanied by two small veins.

THE MEDIAL PLANTAR ARTERY

The **medial plantar** artery [a. plantaris medialis] (figs. 501, 502)—much the smaller of the two divisions into which the posterior tibial divides, passes forward along the medial side of the sole of the foot usually to the first interosseous space. Here it ends by anastomosing either with the first plantar metatarsal artery derived from the plantar arch, or with the branch given off by the first plantar metatarsal to the medial side of the great toe.

Relations.—The artery is at first under cover of the abductor hallucis, but afterward lies in the interval between that muscle and the flexor digitorum brevis. It is covered by the skin and superficial fascia, but not by the plantar aponeurosis, since it lies between the central and medial portions of that structure.

The **branches of the medial plantar** are:—(1) The deep and (2) the superficial branches.

(1) The **deep** branch [ramus profundus], which at once divides—or it may come off as several branches—to supply the muscles, articulations,and integument of the medial side of the sole. Some of these branches form an anastomosis around the medial margin of the foot, with branches of the dorsalis pedis.

(2) The **superficial** branch [ramus superficialis] breaks up into very small twigs which accompany the digital branches of the medial plantar nerves, and anastomose with the plantar metatarsal arteries in the first, second, and third spaces. At times a twig from one of these branches joins the lateral plantar artery to form a superficial plantar arch.

THE ANTERIOR TIBIAL ARTERY

The **anterior tibial** artery [a. tibialis anterior] fig. 503—the smaller of the two branches into which the popliteal artery divides at the lower border of the popliteus muscle—at first courses forward between the two heads of origin of the tibialis posterior, and, after passing between the tibia and fibula above the upper part of the interosseous membrane, runs downward on the front and lateral aspect of the leg, between the anterior muscles, as far as the front of the ankle-joint. Below the joint it is known as the dorsalis pedis. The **course of the vessel** is indicated by a line drawn from the front of the head of the fibula to a point midway between the two malleoli.

The artery is accompanied by two veins which communicate with each other at frequent intervals across it. It is also accompanied in the lower three-fourths of its course by the deep peroneal nerve. The nerve, which winds round the head of the fibula, and pierces the extensor digitorum longus, first comes into contact with the lateral side of the artery about the upper third of the leg; in the middle third it is a little in front of the artery, and in the lower third again lies to its lateral side. In addition to the named branches the anterior tibial artery supplies muscular twigs to the extensors of the toes and the tibialis anterior.

Relations.—The artery at first lies in the triangle formed by the two heads of the tibialis posterior and the popliteus muscle; and, as it passes above the interosseous membrane, it has the tibia on one side and the fibula on the other. It is separated from the deep peroneal (anterior tibial) nerve at its commencement by the neck of the fibula and the extensor digitorum longus. This arrangement is homologous with that met with in the forearm in the case of the posterior interosseous artery and deep radial (posterior interosseous) nerve.

Posteriorly in its course down the leg it lies in its upper two-thirds upon the interosseous membrane, to which it is closely bound by fibrous bands; and in its lower third upon the front of the tibia and the ankle-joint.

To its **medial side** along its upper two-thirds is the tibialis anterior muscle; but at the lower third it is crossed by the tendon of the extensor hallucis longus and then for the rest of its course has this tendon overlapping it or to its medial side.

On its **lateral side** it is in contact in its upper third with the extensor digitorum longus muscle; in its middle third with the extensor hallucis longus; but, as this muscle crosses to the medial side of the artery, the vessel usually for a very short part of its course comes again

into contact with the extensor digitorum longus. At the upper and lower thirds of its course on the front of the leg the artery has the deep peroneal (anterior tibial) nerve to its lateral side.

In front the artery is covered by the skin, superficial and deep fascia. In its upper two-thirds it is deeply placed in the cellular interval between the tibialis anterior on the medial side and the extensor digitorum longus and extensor hallucis longus on its lateral side; and in its lower third it is crossed in the latero-medial direction by the tendon of the extensor

FIG. 503.—THE ANTERIOR TIBIAL ARTERY, DORSAL ARTERY OF THE FOOT, AND PERFORATING (ANTERIOR) PERONEAL ARTERY, AND THEIR BRANCHES, LEFT SIDE.

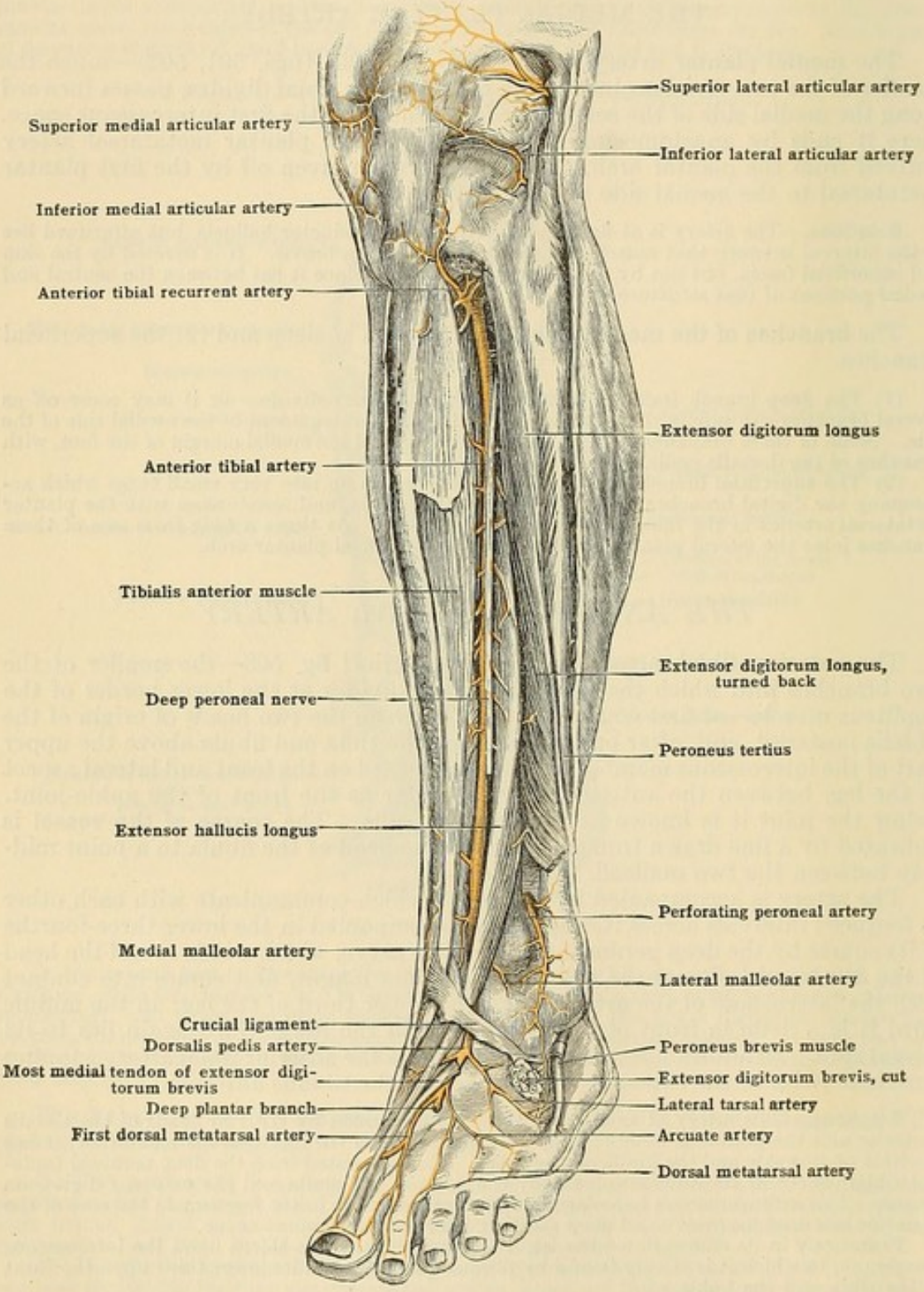

hallucis longus, and lies beneath the cruciate (anterior annular) ligament of the ankle-joint The deep peroneal nerve is usually in front of the artery in the middle third of the leg.

The **branches of the anterior tibial artery** are:—(1) The posterior tibial recurrent; (2) the anterior tibial recurrent; (3) the medial malleolar; and (4) the

FIG. 504.—SCHEME OF THE DISTRIBUTION AND ANASTOMOSES OF THE ARTERIES OF THE RIGHT FOOT. (Walsham.)

(The plantar arteries are shown in dotted outline; the dorsal in solid red.)

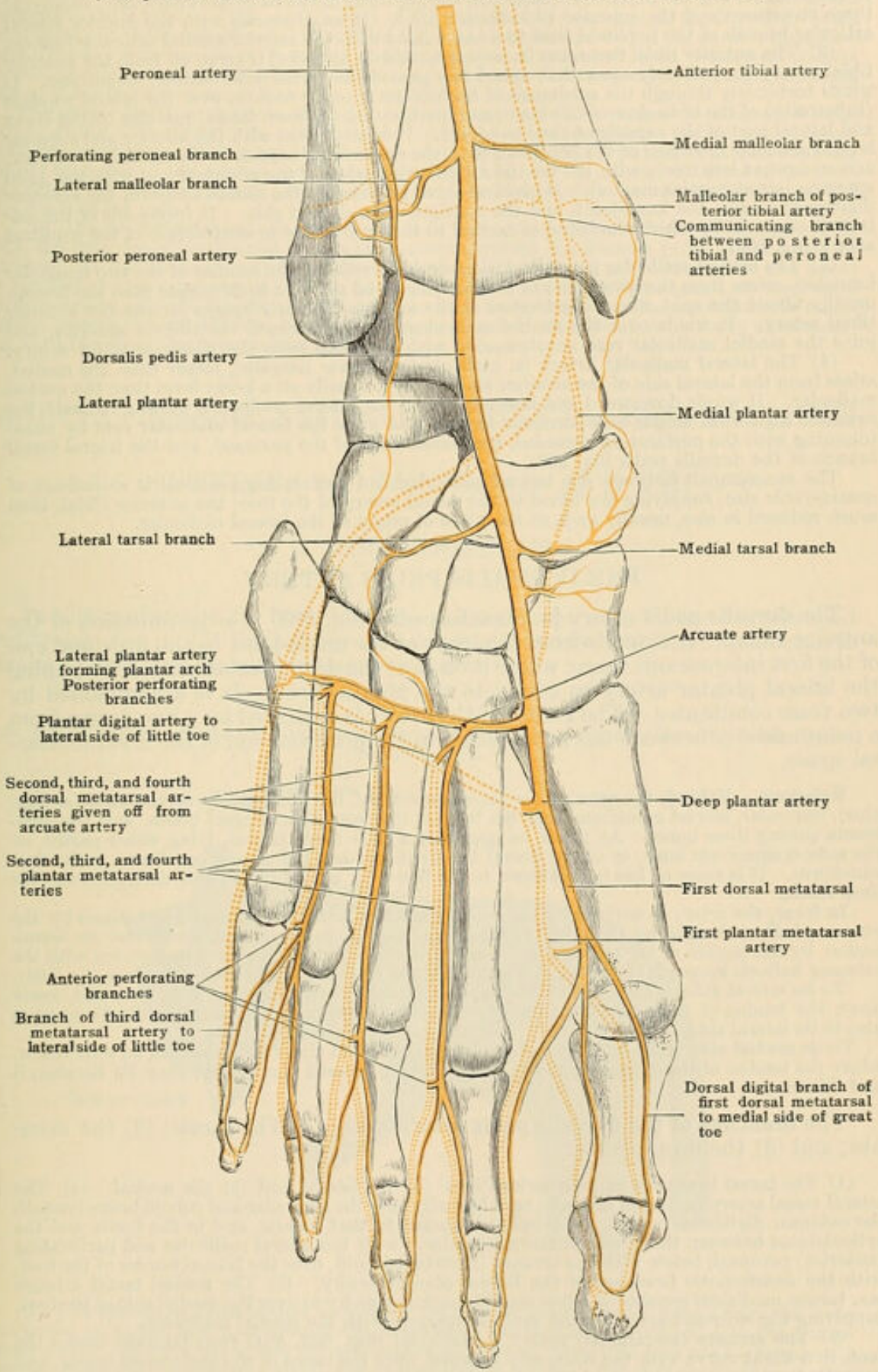

lateral malleolar. In addition, ten or twelve muscular branches are given off irregularly to the adjacent muscles along the artery.

(1) The **posterior tibial recurrent** artery [a. recurrens tibialis posterior] is occasionally absent. It ascends between the popliteus muscle and the popliteal ligament of the knee-joint, supplying these structures and the superior tibio-fibular joint. It anastomoses with the inferior lateral articular branch of the popliteal, and to a less extent with the inferior medial articular branch.

(2) The **anterior tibial recurrent** [a. recurrens tibialis anterior] is given off from the anterior tibial artery immediately after that vessel has passed above the interosseous membrane. It winds tortuously through the substance of the tibialis anterior muscle, over the lateral condyle (tuberosity) of the tibia close to the bone; and, perforating the deep fascia, ramifies on the lower and lateral part of the capsule of the knee-joint. It anastomoses with the inferior and superior lateral articular branches of the popliteal, with the descending branch of the lateral circumflex, and somewhat less freely with the medial articular branches of the popliteal and with the genu suprema (anastomotica magna). It gives off small branches to the tibialis anterior, the extensor digitorum longus, the knee-joint, and the contiguous fascia and skin. It forms one of the collateral channels by which the blood is carried to the limb below in obstruction of the popliteal artery (fig. 503).

(3) The **medial malleolar** [a. malleolaris anterior medialis], the smaller of the two malleolar branches, arises from the lower part of the anterior tibial artery a little higher than the lateral, usually about the spot where the tendon of the extensor hallucis longus crosses the anterior tibial artery. It winds over the medial malleolus, passing beneath the tibialis anterior, and joins the **medial malleolar rete** anastomosing with branches from the posterior tibial artery.

(4) The **lateral malleolar** artery [a. malleolaris anterior lateralis], larger than the medial, arises from the lateral side of the anterior tibial artery, usually on a lower level than the medial malleolar. It winds downward and laterally round the lateral malleolus, passing beneath the extensor digitorum longus and peroneus tertius, and joins the **lateral malleolar rete** by anastomosing with the perforating peroneal, the termination of the peroneal, and the lateral tarsal branch of the dorsalis pedis (fig. 503).

The anastomosis between the lateral malleolar and perforating peroneal is sometimes of considerable size, supplying the blood to the dorsal artery of the foot; the anterior tibial, then much reduced in size, usually ends at the place of origin of the lateral malleolar.

THE DORSALIS PEDIS ARTERY

The **dorsalis pedis** artery [a. dorsalis pedis] (fig. 503) is a continuation of the anterior tibial. It extends from the front of the ankle-joint to the proximal end of the first interosseous space, where it ends, as the deep plantar branch, by joining the lateral plantar artery to complete the plantar arch. It is accompanied by two venæ comitantes. The course of the artery is indicated by a line drawn from a point midway between the two malleoli to the proximal end of the first metatarsal space.

Relations.—Behind, the artery from above downward lies successively on the talus (astragalus), navicular, second cuneiform, and the base of the second metatarsal bones, and the ligaments uniting these bones. At times its course is a little more lateral, lying either partly on the second cuneiform bone, or on the dorsal ligaments uniting the second cuneiform to the first cuneiform. It is more or less bound down to the bones by aponeurotic fibres derived from the deep fascia.

In front, the artery is covered by the crucial (anterior annular) ligament, sometimes by the extensor hallucis longus, by the skin, the superficial and deep fascia, and, just before its termination, by the tendon of the extensor hallucis brevis. The angle formed by this tendon with the extensor hallucis longus is the best guide to finding the artery in the process of ligature (fig. 503).

To its **lateral side** is the most medial tendon of the extensor digitorum longus, and lower down the tendon of the extensor hallucis brevis. The deep peroneal (anterior tibial) nerve is also to its lateral side.

To its **medial side** is the extensor hallucis longus, except at times for about half an inch below, where the tendon of the extensor hallucis brevis, having crossed the artery, may lie between it and this tendon.

The **branches of the dorsalis pedis artery** are:—(1) The tarsal; (2) the arcuate; and (3) the deep plantar.

(1) The **tarsal branches** may be divided into (*a*) the lateral and (*b*) the medial. (*a*) The lateral tarsal artery [a. tarsea lateralis] runs laterally over the navicular and cuboid bones beneath the extensor digitorum brevis. It supplies branches to that muscle, and to the bones and the articulations between them, and anastomoses above with the lateral malleolar and perforating (anterior) peroneal, below with the arcuate (metatarsal) and, over the lateral border of the foot, with the anastomotic branches of the lateral plantar artery. (*b*) The **medial tarsal** arteries [aa. tarseæ mediales] consists of a few small branches which run over the medial side of the foot, supplying the skin and articulations, and anastomose with the medial malleolar.

(2) The **arcuate** (**metatarsal**) artery [a. arcuata] (figs. 503, 504) runs laterally across the foot, in a slight curve with the convexity forward, over the bases of the metatarsal bones, and beneath the extensor tendons and the extensor digitorum brevis. At the lateral border of the foot it anastomoses, with the lateral tarsal, and with branches of the lateral plantar.

From the convexity of the arch it gives off four **dorsal metatarsal** (interosseous) arteries, which run forward on the dorsal interosseous muscles in the centre of the four interosseous spaces to the cleft of the toes, where they bifurcate for the supply of the contiguous sides of the toes. The artery to the first space is large, and gives off the digital artery to the medial side of the great toe. This vessel continues the direction of the dorsalis pedis and is commonly known as the **dorsalis hallucis** artery. The most lateral of the interosseous branches gives off a small vessel for the supply of the lateral side of the little toe. At the proximal end of the second, third, and fourth interosseous spaces each artery receives a perforating branch from the lateral plantar artery, and immediately before they bifurcate a second perforating artery through the distal end of the interosseous space from the corresponding digital.

The **dorsal digital** arteries [aa. digitales dorsales], into which the dorsal metatarsal arteries divide at the cleft of the toes, run along the side of each toe toward the dorsal aspect, anastomosing with each other across the dorsum of the toes and by frequent branches with the digital branches of the plantar metatarsal arteries, which also run along the sides of the toes, but nearer the plantar surface. At the end of the toes they anastomose with each other around the quick of the nail.

(3) The **deep plantar** branch [ramus plantaris profundus] comes off from the dorsalis pedis with the first dorsal metatarsal (into which arteries indeed the dorsalis pedis may be said to divide). At the back of the first interosseous space it dips into the sole between the two heads of the first dorsal interosseous muscle, and communicates with the termination of the lateral plantar artery, completing the plantar arch, in a manner similar to that in which the radial artery, passing through the first dorsal interosseous muscle in the hand, completes by anastomosing with the ulnar the deep palmar arch.

MORPHOGENESIS AND VARIATIONS OF THE ARTERIES

A. ARTERIES OF THE HEAD AND TRUNK

1. MORPHOGENESIS

In conformity with the branchiomeric and metameric development of the head and trunk (see p. 15) the arteries are developed in two sets, the branchiomeric (aortic arches) and metameric (segmental arteries).

FIG. 505.—MODEL OF THE PHARYNX AND AORTIC ARCHES OF A HUMAN EMBRYO 5 MM. LONG. (Tandler, ×75.)

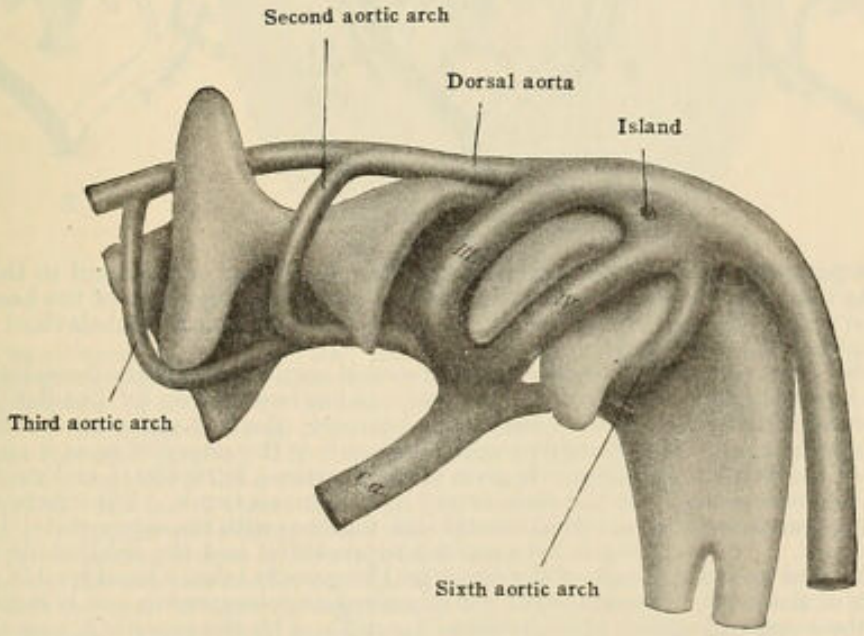

(1) **The system of aortic arches** consists of five pairs of arteries which spring from the ventral aorta, or aortæ, and pass around the pharynx in the branchial arches to join the paired dorsal aortæ. Some of the arches are very transitory, but all those that give rise to permanent vessels are present in embryos about five millimetres in length. Fig. 505 shows their distribution and rlations to the pharyngeal pouches at this stage; the arches which appear fifth in order are regarded as the sixth because (like the sixth arches in lung-fish and amphibia) they give

off the pulmonary arteries. The true fifth arches are probably not always developed, but when they occur they are later in development, imperfect, and very transitory. The dorsal aortæ, originally paired, are now united to form a single vessel as far forward as a place slightly caudal to the sixth arches.

During the separation of the heart into right and left halves (p 526.), the primitive ventral aorta is divided by the aortic septum into two vessels, the *main pulmonary artery* and the *ascending aorta* of the adult. The pulmonary trunk becomes connected with the sixth pair of arches only; the other arches then communicate, by means of the aorta, with the left ventricle. The further changes which occur in the arches to bring about the conditions found in the adult are shown diagrammatically in fig. 506. The right and left *pulmonary arteries* arise from the corresponding sixth arches. The portion of the sixth arch dorsal to the pulmonary artery disappears on the right, on the left it persists until birth as the *ductus arteriosus* (lig. arteriosum of the adult). The fourth arch, including the short ventral stem between the fourth and sixth arch, becomes the permanent *aortic arch* on the left side, and the *innominate* and proximal portion of the subclavian upon the right. The dorsal longitudinal stem disappears on both sides between the third and fourth arches, and on the right side from the sixth arch back to the unpaired dorsal aorta. A trace of the latter portion of the right dorsal stem frequently persists in the adult as a small vessel (*a. aberrans*) connecting the dorsal aorta, directly or indirectly, with the right subclavian artery (p. 590). The ventral stems between the fourth and third arches form the *common carotids;* those between the third and first become the *external carotids.* The *internal carotids* are formed by the third arches and the dorsal stems between the third and first arches. The first and second arches disappear early, contributing somewhat to the formation of the branches of the internal and external carotids.

FIG. 506.—DIAGRAMS SHOWING THE METHOD OF NORMAL DEVELOPMENT OF THE AORTIC ARCHES, AND INDICATING THE MECHANISM OF SOME VARIATIONS.)

The primitive aortic arches (1–6), and some of the cervical dorsal segmentals (V–VIII) are shown in all the diagrams but numbered in Y only. X., abnormal: the aortic arch is on the right; the left subclavian takes the dorsal course; the right vertebral arises direct from the aortic arch. Y., normal; Z., abnormal: the right subclavian arises from the sixth cervical dorsal segmental; the left from the sixth and seventh. A, ascending aorta; AA, aortic arch; AD, dorsal aorta; CC, common carotid; CE, external carotid; CI, internal carotid; D, ductus arteriosus; IN, innominate; S, subclavian; T, costo-cervical; V, vertebral.

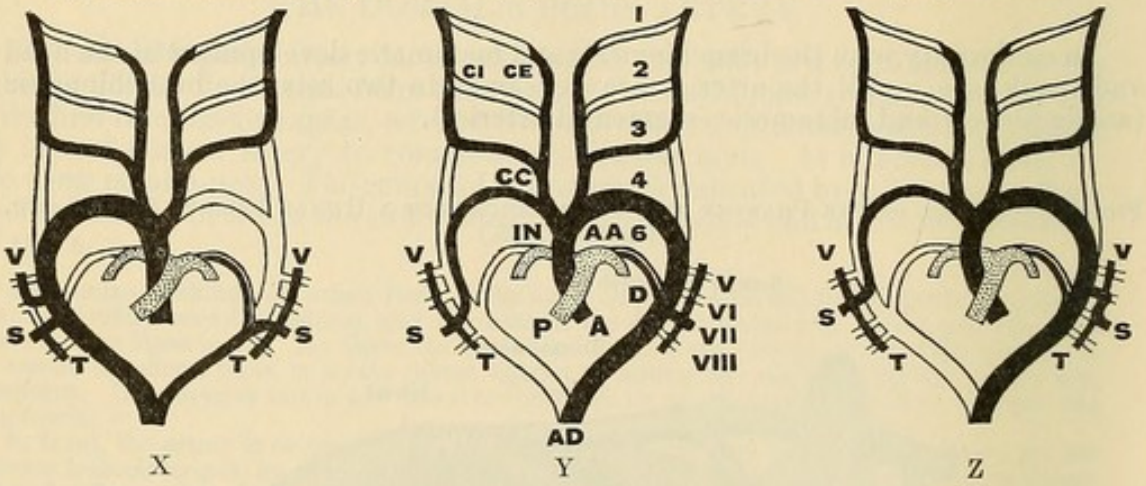

In early development the segmental arteries are caudally placed with regard to the aortic arch vessels. As the latter, however, become shifted following the migration of the heart from the neck into the thorax, the persistent seventh dorsal cervical segmental (subclavian) reaches the neighbourhood of the sixth aortic arch.

Little is known of the share taken by the first and second aortic arches in the formation of the branches of the internal and external carotid arteries. It has been shown by Tandler that the *internal maxillary* is primarily a branch of the internal carotid, (the first and second arches taking a share in its formation). The primitive vessel is known as the *stapedial* since it passes between the crura of the developing stapes. It gives off supraorbital, infraorbital, and mandibular branches; the latter two arising from the main artery by a common trunk. The common trunk is later joined by a branch from the external carotid and, together with the supraorbital, becomes the *middle meningeal.* An anastomosis between the supraorbital and the ophthalmic persists so that in the adult the anterior branch of the meningeal frequently takes a considerable share in the blood-supply of the orbit. The stapedial trunk undergoes retrogression and is represented in the adult by the *carotico-tympanic* of the internal carotid and by the *superior tympanic* of the middle meningeal. The infraorbital branch of the stapedial becomes the second and third parts of the internal maxillary and gives off branches accordingly. The mandibular branch becomes the *inferior alveolar* of the adult.

(2) **The segmental system** (fig. 507) consists of arteries primarily arising from the aorta in three longitudinal series, dorsal, lateral, and ventral on either side. The segmental arrangement is much less perfect in the ventral and lateral groups than in the dorsal. So much so, in fact, that the term segmental is used for the ventral and lateral groups rather as a matter

of convenience than as indicating a strict numerical correspondence between segments and vessels.

The **dorsal segmental arteries** primarily supply the central nervous system but later give off two sets of vessels to the body wall; these persist in the adult as the *anterior* and *posterior main branches of the intercostal and lumbar arteries.* The remainder of each segmental artery is represented in the adult by the *spinal ramus* which accompanies the corresponding nerve root through the intervertebral foramen. The tendency to form **intersegmental anastomoses** between these vessels (and their branches) gives rise to many of the important longitudinal stems of adult anatomy. Thus, the spinal ramus gives rise to a pre- and postneural anastomosing channel on either side, the (primarily paired) *anterior and posterior spinal arteries.* The anterior branches have each a longitudinal precostal anastomosis, and, as they grow forward with the developing body wall, their ends are connected to form the mammary anastomosis.

Between the posterior rami, a postcostal and a postvertebral anastomosis may be formed. In addition, the anterior rami give off lateral and anterior perforating branches (fig. 507).

Two dorsal segmental arteries have been recognized in the occipital region, the first disappears and the second, the *hypoglossus artery*, follows the hypoglossal nerve to the ventral surface of the brain where it is connected with the termination of the internal carotid of its own side by means of a longitudinal stem the *a. vertebralis cerebralis.* The hypoglossus artery, by shifting forward to the third aortic arch, itself acquires a secondary origin from the internal carotid.

In the *cervical region*, the spinal ramus of segmental cervical I forms the third, or suboccipital, part of the *vertebral artery.* Cervical segmentals I to VI lose their connection with the aorta and a postcostal anastomosis between them forms the second part of the same artery. The first part of the vertebral is formed by the posterior ramus of cervical VI and its precostal anastomosis with cervical VII (subclavian) (fig. 508).

FIG. 507.—SCHEME OF THE TYPICAL ARRANGEMENT OF THE BRANCHES OF THE AORTA. (After Quain.)

Longitudinal anastomoses: 1, precostal; 2, postcostal; 3 postvertebral; 4, preneural; 5, postneural; 6, mammary.

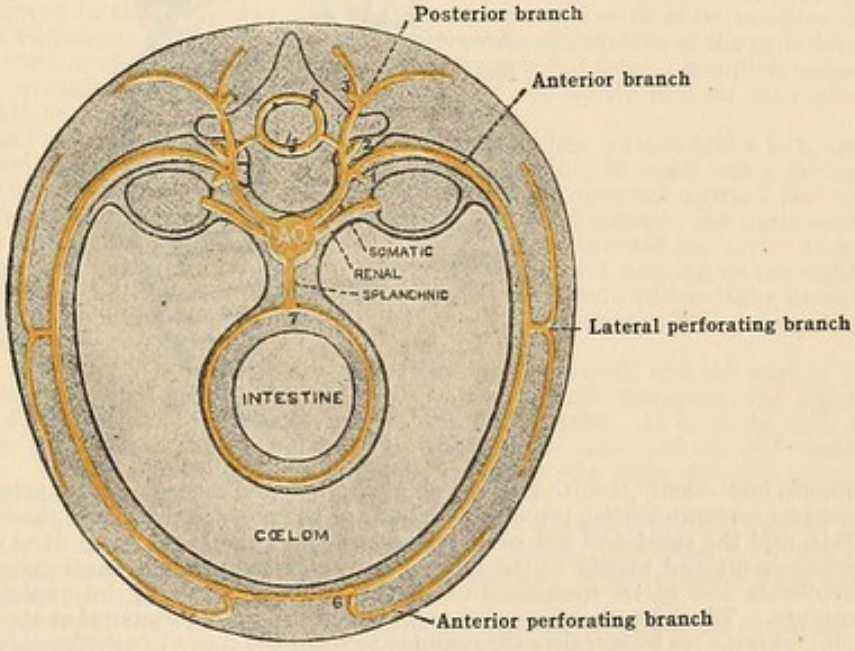

The anterior ramus of cervical VII forms the entire first part of the subclavian on the left, and the distal portion of it upon the right (see system of aortic arches). The second part of the subclavian is formed by the lateral branch of the anterior ramus of cervical VII, while the portion of the anterior ramus ventral to this becomes the root of the internal mammary. The anterior ramus of cervical VIII disappears, but the precostal anastomosis connecting it with the subclavian (cervical VII) persists to form the *costo-cervical* of the adult. The posterior ramus of cervical VIII forms the root of the *deep cervical*, and, by a postvertebral anastomosis with the other posterior cervical rami and with the occipital, forms the remainder of the deep cervical and the *descending branch of the occipital artery.*

In the *thoracic and lumbar regions*, the embryonic conditions very largely persist (fig. 508). The anterior rami of thoracic segmentals I and II, however, lose their connection with the aorta and, by a precostal anastomosis with cervical VIII, become secondarily connected (through the costo-cervical trunk) with the subclavian. The *superior intercostal* of the adult is thus formed. The fifth lumbar segmental apparently joins the umbilical artery (of the ventral segmental series) to form the external iliac which, in the adult, provides the chief arterial supply to the lower extremity. The inferior gluteal (sciatic), which is the primitive artery of supply for the lower extremity, if it is segmental at all, belongs to the sacral region. The free ends of the anterior rami of all the thoracic and the upper four lumbar segmentals become united, as they grow out with the body wall, to form the longitudinal mammary anastomosis (fig. 508). This anastomosis, by its connection with the anterior ramus of cervical

VII (subclavian) and with the anterior ramus of lumbar V (external iliac), forms the *internal mammary* (with its *superior epigastric* branch) and the *inferior (deep) epigastric* arteries of the adult.

In the sacral region, the adult shows evidence of segmental vessels in branches of the middle and lateral sacral arteries; the latter probably representing a precostal anastomosis. Whether the parietal branches may be derived directly from segmental sources, or whether they are vessels of new formation, has not been determined embryologically. The obturator would appear to be segmental for it contributes a branch to the mammary anastomosis which persists in the adult (pubic branches of obturator and inferior epigastric). If the connecting branch with the inferior epigastric is large, the obturator may lose its connection with the hypogastric, in which case the latter is said to arise from the former, or from the external iliac.

One of the most interesting of the longitudinal anastomoses in connection with the dorsal segmentals is the primitively bilateral preneural anastomosis extending ventral to the spinal cord and connected, beyond the first spinal segment, with each internal carotid by means of the right and left aa. cerebrales vertebrales. The hypoglossus artery (p. 635) having lost its connection with the internal carotid, leaves the spinal ramus of cervical I (third part of the subclavian) to take over the major share of the cerebral supply. A process of blending by anas-

FIG. 508.—DIAGRAM TO SHOW THE DEVELOPMENT OF THE ARTERIES OF THE TRUNK FROM THE AORTIC ARCHES AND SEGMENTAL ARTERIES.

The arteries which persist are black; those which degenerate are in outline; those newly formed are shaded. (After Mall.)

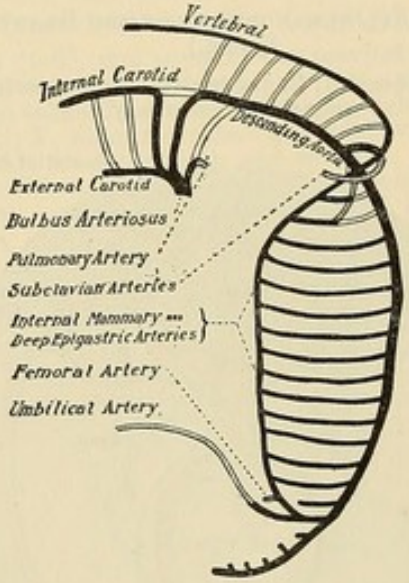

tomosis now occurs resulting in the single *basilar* and *anterior spinal* arteries of the adult. The *posterior communicating*, proximal portions of the *posterior cerebrals*, the fourth part of the vertebrals, and the right and left roots in the anterior spinals of the adult alone retain the primitive arrangement and testify to the double nature of the original anastomosis. Asymmetry in the vertebrals and other irregularities in the adult can usually be explained on developmental grounds. The postneural anastomosis, which joins the preneural at about the first cervical segment, retains its bilaterality throughout to form the paired *posterior spinal arteries* of the adult.

The **lateral segmental arteries** take origin from the aorta in series, intermediate in position between the dorsal and ventral segmentals. They reach their fullest development in embryos of about 8 mm., when they extend from the seventh cervical to the twelfth thoracic segment and supply the mesonephros. At this stage Broman found twenty arteries on each side, many of which were non-segmental. As the suprarenals and gonads develop, they each receive branches from several mesonephric arteries. The latter arteries now undergo rapid retrogression and the suprarenal and gonadic branches are shifted caudally through the mesonephric series to newly formed (non-segmental) arteries opposite the upper lumbar segments. Finally there remain three suprarenal arteries opposite the twelfth thoracic and first and second lumbar segments and a gonadic artery (*ovarian or internal spermatic* of the adult) opposite the third lumbar segment. All of these vessels now appear to be direct branches from the aorta. Of the three suprarenal branches, the upper and lower each gives a large branch to the diaphragm and kidney respectively and become the *inferior phrenic* and *renal arteries* of the adult. The middle becomes the *middle suprarenal* of the adult. Felix puts a somewhat different interpretation upon the origin of the vessels persisting in the lumbar region after the disappearance of the thoracic mesonephric arteries. He finds in an embryo of 18 mm. nine arteries on either side, extending from the ninth thoracic to the third lumbar segment, all of which he looks upon as mesonephric. These he classifies into three groups:—Cranial, which reach the mesonephros by passing dorsal to the suprarenal; caudal which pass ventral to the suprarenal, and middle which pass through it. Inasmuch as the arteries anastomose in the mesonephros there is great liability to variation in the number and position of the stems which persist in the adult. The suprarenal arteries

are usually derived from the caudal group, the renals from the caudal or middle and the spermatics from the middle. When accessory renals or spermatics occur in the adult their place of origin and course will generally indicate the group from which they are derived.

The **ventral segmental arteries** appear very early. In an embryo of seven somites (ca. 2 mm.) described by Dandy* there was a right and a left series of twelve arteries, each arising from the still ununited dorsal aortæ, the artery at the caudal end of each series being the umbilical, and the remainder vitelline arteries. In an embryo of 4.9 mm. (35 somites) described by Ingalls† the originally paired vitelline arteries had united (as had the dorsal aortæ in part) to form unpaired vessels. There were unpaired vessels as follows: one opposite the seventh cervical segment (cœliac); five opposite the first four thoracic (omphalo-mesenterics, united by a longitudinal anastomosis), and one vessel of doubtful significance opposite the fifth and sixth thoracic segments. The paired umbilical arteries were opposite the first lumbar segment. No other ventral arteries were present.

It has been found from more fully developed stages that the inferior mesenteric artery is distinguishable at a stage of 8 mm. opposite the second lumbar segment. Also that the ventral segmental vessels undergo a process of migration until they reach their definitive positions, i. e., the *cœliac* opposite the twelfth thoracic segment, the *superior mesenteric* opposite the first, the *inferior mesenteric* opposite the third, and the umbilicals opposite the fourth lumbar segments, respectively. The œsophageal arteries of the adult do not belong to this series; but seem to be vessels of later formation.

The *umbilical arteries*, by means of secondary anastomosis, move laterally upon the aorta so as to pass lateral to the Wolffian ducts instead of medial. The proximal portion of each umbilical artery becomes the *common iliac* of the adult; its continuation is represented by the *hypogastric* and its umbilical branch. The *external iliac* appears to be derived from the dorsal segmental artery of the fifth lumbar segment, and the parietal branches of the hypogastric from corresponding sacral segmentals acquired by anastomosis. How such anastomoses between the umbilicals and the dorsal segmentals come about has not been ascertained.

2. VARIATIONS

Aorta and pulmonary artery.—The variations met with in the arch of the aorta are usually to be explained as persistent fœtal conditions, and are often associated with abnormalities of the heart. Many of the variations are due to different modes of transformation of the primitive system of aortic arches. Since the aorta and pulmonary artery develop from a common conus and truncus arteriosus, irregular and imperfect development of the aortic septum may also produce numerous variations.

It has been seen that at one stage of development two fourth arches, a right and a left, are present, and such a condition is occasionally persistent in the adult. In such cases, owing to the portion of the aorta derived from the bulbus arteriosus being directed upward and to the right and the descending aorta lying in the left side of the vertebral column, the right arch passes from right to left behind the œsophagus, which thus seems to perforate the aortic arch.

Another variation occasionally seen is the occurrence of an aortic arch curving to the right instead of the left. This may be due to a persistence of the lower portion of the right dorsal longitudinal stem and the disappearance of the left, as shown in fig. 506; or it may be associated with a complete inversion of all the viscera, a *situs inversus*.

If the lower portion of the right dorsal longitudinal trunk should persist, and the part of it which normally forms the proximal part of the right subclavian should disappear, the right subclavian would arise from the descending portion of the aortic arch. It is to be noted that in such cases the subclavian passes behind the œsophagus and below the right inferior laryngeal nerve. Partial persistence of the lower portion of the right dorsal longitudinal trunk is represented in the arteria aberrans (see p. 590).

Another group of variations is based on the persistence of the ductus arteriosus, which is derived from the sixth aortic arch. With this group belong the cases in which the pulmonary artery arises from the aorta; that is, where the blood of the pulmonary arteries passes from the aorta through the ductus arteriosus.

Variations in the number and the position of the vessels arising from the arch are extremely great, and many of these conditions are found normally in other mammals or birds. There may be from one to six branches. The case of one branch is the normal in the horse. It involves the fusion of the two aortic stems and the shortening of the fourth arch so that the left subclavian joins with the common stem. The avian form with two innominate arteries is extremely rare. A more common form is the one found in most apes, in which the innominate and left carotid form one branch; in rare instances the three branches are the two subclavians and a general carotid artery. When there are more than three branches the vertebral arteries are added, or the extra branch may be the thyreoidea ima (fig. 443). The commonest form with four vessels is the one in which the left vertebral arises between the left carotid and subclavian. A rarer form is to be found when the order is right subclavian, right carotid, left carotid, and left subclavian. Where there are five arteries, the extra ones are the right subclavian and left vertebral. The case of six branches is due to the separate origin of both vertebrals and both subclavians. The manner in which the vertebral artery may arise from the adult aortic arch is indicated in fig. 506.

The **innominate artery** may be absent, or may give off additional branches (see AORTA). It may be longer than usual and, bending to the left, ascend in front of the trachea (or more rarely behind the trachea and œsophagus) to turn again to the right. The *thyroidea ima* has been referred to (p. 532).

Carotid arteries.—The *common carotid* may be absent or bifurcate higher or lower than usual.

* Am. Journ. Anat., Vol. 10, 1910.
† Arch. f. mikr. Anat., Bd. 70, 1907.

It may not bifurcate at all, in which case the branches usually arising from the external carotid are derived from the common. The ascending pharyngeal and superior thyreoid occasionally arise from an otherwise normal common carotid. Unusual origin of the common carotids has been referred to (see AORTA).

Branches of the carotid arteries.—The superior thyreoid, lingual and external maxillary sometimes have a common stem of origin. The *superior thyreoid* artery varies in size inversely with the inferior. The *external maxillary* occasionally terminates in its submental branch. In such cases the main supply of the face is taken over by an abnormally large dorsal nasal branch of the ophthalmic, or transverse facial branch of the temporal artery. The *occipital* sometimes arises from the internal carotid or from the ascending cervical. The *ascending pharyngeal* is very variable in its place of origin from the external carotid, it may arise from the common or internal.

Out of 447 arteries examined, the second portion of the *internal maxillary* passed lateral to the external pterygoid muscle in 55 per cent., and medial to it in 45 per cent. of cases. When medial to this muscle the internal maxillary sometimes passes medial to the inferior alveolar and lingual nerves and occasionally between them. The variability in the course of this artery appears to depend on a tendency to reduplication of the infraorbital branch of the *stapedial artery* (p. 634) in the neighbourhood of the mandibular nerve. Such a condition was found by Thyng in a 17 mm. human embryo. When the internal maxillary passes medial to the external pterygoid there is often a parallel anastomosing channel between the posterior deep temporal and buccal branches.

The *ophthalmic artery* may arise, wholly or in part, from the middle meningeal, or *vice versa*. This is due to the anastomosis between the supraorbital branch of the stapedial and the ophthalmic in the embryo.

Subclavian artery.—Irregularities of origin have been referred to (see AORTA).

The branches of the subclavian artery are very variable in their place of origin (p. 559). The *vertebral* may arise directly from the arch of the aorta (p. 537) or take an unusual course in the neck. It may enter the foramen transversarium of the fourth or fifth cervical vertebra instead of the sixth; this arises from substitution of an embryonic precostal anastomosis in these segments for the usual postcostal. By a converse substitution it may enter the seventh. The *aa. transversa colli and scapulæ* vary inversely in size. The *arteria aberrans* connecting the right subclavian with the dorsal aorta has been referred to (p. 634).

The **thoracic aorta.**—Transposition, and the arteria aberrans have been referred to above.

Branches of the thoracic aorta.—The *intercostal arteries* are liable to numerical variation, evidently owing to the occurrence of precostal intersegmental anastomoses between the embryonic dorsal segmentals. A common longitudinal stem may even take over the vessels of both sides. The *anterior spinal artery* usually shows lack of median symmetry which indicates the bilaterality of its origin (p. 636). The arrangement of the *bronchial arteries* is liable to much variation; this has not received adequate explanation.

The abdominal aorta sometimes divides as low as the fifth lumbar vertebra, occasionally higher than usual, depending upon the definitive position taken by the umbilical arteries (p. 637). Cases are on record of accessory pulmonary arteries arising by a single stem from the abdominal aorta, which passes into the thorax along the œsophagus. The aorta and vena cava inferior may be transposed either as a part of *situs inversus* or as an abnormality of the venous system.

Branches of the abdominal aorta.—The *lumbar arteries* are subject to the same type of variation as occurs in the intercostals. There may be a loop connecting the *cœliac* and *superior mesenteric* arteries. Any or all of the branches of the cœliac may arise from the superior mesenteric (cœlio-mesenteric in the latter case) or directly from the aorta. The instability of the cœliac and superior mesenteric branches is favored by the rapid cranio-caudal migration of the two trunks; intersegmental anastomosis, in some cases, may be a factor also. There is very great variation in the number of branches given off by the superior mesenteric and in the details of their arrangement. This is a natural result of the number of possible routes which may be taken by the blood; these resemble, in their variety, those of an embryonic circulation. The region of supply of the *inferior mesenteric artery* is sometimes taken over entirely or in part (e. g., middle colic) by the superior mesenteric. An *omphalo-mesenteric* artery, in rare cases, arises from the superior mesenteric or one of its branches. It passes to the navel and anastomoses with inferior epigastric and with the small arteries accompanying the round ligament of the liver or the urachus.

Accessory renal arteries are very common; as many as six have been recorded. These may arise from the aorta, middle sacral, inferior phrenic, middle suprarenal or internal spermatic. According to Felix, these are to be regarded as persistent mesonephric arteries. Those arising above the regular renal frequently enter the kidney dorsal to the hilum. Those below it are more apt to be ventrally placed.

Nearly all possible varieties of origin are met with in the *inferior phrenic*, *middle suprarenal*, *internal spermatic* and *accessory renal* arteries which find explanation in the caudal migration of, and anastomosis between, the embryonic representatives of these vessels. The occasional origin of the inferior phrenic from the cœliac (or its branches) or from the superior mesenteric; of the internal spermatic or the middle suprarenal from the lumbar arteries, or of an accessory renal from the inferior mesenteric must be taken as indicating embryonic anastomoses between the dorsal, lateral, or ventral segmental arteries, as the case may be.

The iliac and hypogastric arteries.—The length of the *common iliac* depends upon the site of aortic bifurcation (p. 590); also upon the site of division of the common iliac into external iliac and hypogastric. If these spring directly from the aorta (as they do in rare cases) the common iliac is absent. The trunk formed by the common iliac and *hypogastric* is the proximal portion of the embryonic umbilical artery. The manner in which this takes over a dorsal segmental artery (probably the fifth lumbar) to become the *external iliac* is not sufficiently undersood to account for variations in this region.

The *branches of the hypogastric artery* show great variation in their origin, and there is frequently no separation of the hypogastric into anterior and posterior divisions. Rarely the branches all take origin from the external iliac, in which case the hypogastric (as such) is absent. The *obturator artery* may arise from the inferior epigastric, or *vice versa* (p. 615). The *arteria comitans n. ischiadici* may be larger than usual and form a very pronounced anastomosis with the popliteal. In rare cases the main blood-supply of the lower limb is thus derived from the *inferior gluteal* which is the primitive embryonic condition (p. 640). The *vesical* and *vaginal* arteries are liable to variation in their relative areas of distribution. The *internal pudendal* is sometimes small and may terminate as the *perineal artery*, in these cases the urogenital region is supplied largely by the *accessory pudendal* (p. 610).

B. ARTERIES OF THE EXTREMITIES

1. MORPHOGENESIS

The arteries of the adult extremities represent surviving channels resulting from the selection of a chosen path traversing the perineural arterial plexuses of the early embryonic limb.

At present there is little unanimity of opinion as to whether the pattern of the developing nerve trunks is specifically reproduced by the primitive arterial plexuses or whether the undoubted similarity between the two is of a more general nature. There occurs in either extremity one case in which an artery of fundamental importance follows a course practically independent of nerve distribution. The volar interosseous, in the forearm, and the peroneal, in the leg, are accompanied by insignificant nerves (n. to pronator quadratus, and n. to flexor hallucis longus respectively) which, moreover, do not extend the full length of the arteries in question.

The blood of a developing limb, having traversed the proximal segment by means of the arterial plexus around a single nerve, has the choice of several possible paths by which to reach the digits. The selected channel becomes, for the time, the principal artery of the distal segment. This presently gives way to a second favoured route, which may persist or again give way to a third. Thus, finally, the adult arrangement is established. This process of alternation is the cause of many of the commoner variations for, if it does not proceed to its usual termination, a small vessel, commonly rated as a branch, may testify to its earlier importance by appearing as one of the chief vessels of the part.

In the **upper extremity** the blood first traverses the peri-median plexus (which becomes later the axillo-brachial trunk) and flows to the digits mainly by the volar interosseous route. Next the volar interosseous dwindles in favour of the median. The median afterward relinquishes its function to the radial and ulnar.

In the **lower extremity** the main blood-flow at first follows the peri-sciatic plexus from which it is delivered to the digits chiefly by the peroneal artery. The peroneal artery passes from the sole to the dorsum of the foot through the sinus pedis, and from here supplies the digits. The anterior and posterior tibial are at first small, the latter supplying the plantar digital arteries. At a stage of 10 millimetres the femoral artery is represented by a peri-saphenous plexus which anastomoses with the peri-sciatic plexus near the knee. The peri-femoral plexus rapidly consolidates into the femoral and genu suprema arteries. The femoral later takes over the poplileal as its direct continuation, and the origin of the genu suprema marks the boundary between the femoral and ischiadic zones of the main trunk. Finally the peroneal gives place to the anterior and posterior tibial arteries. The portion of the peroneal perforating the tarsus disappears. In so doing it leaves the original termination of the peroneal artery connected with the dorsalis pedis to become the arcuate branch of the latter.

2. VARIATIONS

The variations of the arteries of the **upper extremity** may be divided into two categories, A certain number of them, particularly those occurring in the forearm and hand, are directly traceable to the unusual persistence of one or more of the embryonic channels; or, when variation involves magnitude only, to reciprocal variations in the size of the normal vessels. The commoner and more important variations of the arterial distribution, however, arise in a manner much less susceptible to ready explanation. They depend, in fact, upon variations in the course taken by the single or double route which, surviving from the intricacies of the peri-median plexus, persists to maturity. These will be referred to later.

The *volar interosseous* artery may be unusually large. It may reinforce a deficient radia or ulnar through the volar carpal artery, or its dorsal carpal branch may join the radial at the back of the wrist. In very rare cases the volar interosseous, together with a large ulnar artery, replaces the radial altogether.

A large *median artery* may participate in the palmar supply of the fingers, either by joining the superficial volar arch or (the arch being absent) by breaking directly into digital branches. The median, when large, occasionally replaces the ulnar, very rarely the radial, and frequently the superficial volar.

The *superficial volar arch* may be small, with compensation by the deep, or absent. In the latter case the digital arteries may come directly from the ulnar and radial, ulnar and median or median and radial. In the absence of the superficial volar, which is very frequent, the superficial arch is completed by the princeps pollicis or the volaris radialis indicis.

Cases are on record in which the ulnar artery, arising in the middle of the arm passes behind the medial epicondyle to follow the nerve in the forearm as usual. The ulnar artery here replaces the superior ulnar collateral and the ulnar recurrent. This anomaly is explained in a striking way by the account given by de Vriese of the development of the vessels of the upper extremity.

Several important variations in the distribution of the main vessels belong to the second category. It is not uncommon for *two arteries* to arise from the primitive peri-median plexus of the arm. In such cases one artery usually takes a course dorsal to the median nerve, i. e., it is crossed medio-laterally by the medial head of the nerve and in the contrary direction by the nerve itself. Its course corresponds to that taken by the ordinary axillo-brachial trunk; it is known as the *deep brachial* artery. The other vessel takes a course ventral to the median, nerve, and is known as the *superficial brachial*. The superficial brachial may join its companion artery, at or above the elbow, or one of the forearm vessels arising from it. In either case the superficial brachial is referred to as a *"vas aberrans."* Persistence of the superficial brachial further operates as a frequent cause of abnormality in the forearm in that it is often continued directly into one or more of the chief arteries of the latter, the deep brachial taking the remainder. This condition is classified as a high origin of the radial, ulnar, etc., as the case may be.

There is another type of variation belonging to the same category. In this, *one large artery* only occurs above the elbow which, instead of following the normal course of the brachial, passes, entirely or in part, ventral to the median nerve. In the first case this vessel represents the superficial brachial, the deep being absent. In the second it corresponds in its upper part to the deep brachial and in its lower to the superficial, the two components varying in inverse proportion.

E. Müller*, who has made a study of the variations belonging to this category, classifies the abnormal artery occurring in cases of vas aberrans, of high origin of forearm-vessels, and of single abnormal brachial, according to the proportion of superficial brachial present in any particular example, as a. brachialis superficialis superior media, inferior, or ima. In an embryo of 11.7 millimetres he found a system of arterial channels in relation with the median nerve out of which any variation of this category might have been produced during further development.

In cases in which the superficial brachial alone persists, the branches of the axillary (and sometimes the profunda brachii and superior ulnar collateral) arise from a common (deep brachial) trunk called the *profunda axillaris*. In cases in which the deep and superficial brachial co-exist examples of continuation of the superficial brachial into the radial are rather common, continuation into the ulnar less so. Continuation of the superficial brachial into the median, interosseous, or of posterior interosseous arteries occasionally occur, but they are rare. In any case of high origin a cross branch may connect the high vessel with the deep brachial in the neighbourhood of the elbow. The ulnar artery when arising high is often superficial to the forearm flexors (a fact which has not been explained on embryological grounds), the interosseous arising from the radial.

The variations occurring in the arteries of the **lower extremity** are usually compensatory, or due to persistence of alternative embryonic channels. The sciatic (inferior gluteal) very rarely persists as the main artery of supply. In such cases the small femoral ends as the *genu suprema* which then appears to be a branch of the profunda.

The *profunda* is irregular; its origin may occur anywhere between the inguinal ligament and a point four inches below it. The *median* or *lateral circumflex* may arise from the femoral. The branches of the latter commonly arise separately from the profunda, or from the femoral. The *popliteal* does not vary much in its point of division. High division is commoner than low, but is never higher than the lower epiphyseal line of the femur.

The *anterior tibial* may be small and only reach the middle or lower part of the leg. In such cases an enlarged anterior peroneal may end as the dorsalis pedis, or the dorsal metatarsal arteries may be supplied from the plantar arch. Cases in which the anterior peroneal supplies the dorsum of the foot do not represent a direct inheritance of the embryonic method by which the peroneal artery performs this office. The embryonic route of the peroneal to the dorsum of the foot is transtarsal. The anterior tibial artery may reach the extensor surface of the leg by accompanying the peroneal nerve. This case, like that of the ulnar artery passing around the medial epicondyle, is interesting in connection with the work of de Vriese.

The *posterior tibial* artery may be absent or small, the peroneal replacing it, or reinforcing it by means of the ramus communicans. Absence of the *peroneal* has been recorded by Otto and W. Krause, but these cases are explained by Barkow as being suppression of the posterior tibial artery between the origin of the peroneal and the communicating branch (Quain).

The *lateral plantar* is sometimes very small, in which case the plantar arch may be supplied by a large deep plantar. In rare cases there is a superficial plantar arch as in the embryo.

3. THE SYSTEMIC VEINS

The **systemic veins** are naturally divided into three groups—(1) the veins of the heart; (2) the vena cava superior and its tributaries, namely the veins of the head, neck, upper extremity, and thorax; and (3) the vena cava inferior and its tributaries, namely, the portal system, and the veins of the abdomen, pelvis, and lower extremity.

* E. Müller, Anat. Hefte, No. 22, 1903.

I. THE VEINS OF THE HEART

The veins of the heart have already been described (p. 520).

II. THE VENA CAVA SUPERIOR AND ITS TRIBUTARIES

THE VENA CAVA SUPERIOR

The **vena cava superior** (fig. 509) carries to the heart the blood returned from the head and neck and upper extremities through the right and left innominate veins, and from the walls of the thorax, either directly through the azygos vein, or indirectly through the innominate veins. It is formed (fig. 509) by the confluence of the right and left innominate veins behind the first right sterno-chondral articulation. Descending from its origin in a gentle curve with its convexity to the right and in a direction slightly backward behind the sternal end of the first and second intercostal spaces and second costal cartilage, it terminates in the right atrium of the heart on a level with the third right costal cartilage in front and the seventh thoracic vertebra behind. It measures about 7 to 8 cm. (3 in.) in length. A little more than its lower half (4 cm.) is contained within the pericardium, the serous layer of that membrane being reflected obliquely over it immediately below the spot where it is joined by the vena azygos, and on a lower level than the reflexion of the pericardium on the aorta. The superior vena cava contains no valves.

Relations.—In front, in addition to the first and second intercostal spaces and the second costal cartilage, it is covered by the remains of the thymus gland, the intrathoracic fascia, and the pericardium, and is overlapped by the right pleura and lung.

Behind (fig. 509) are the vena azygos (major), the right bronchus, the right pulmonary artery, and the superior right pulmonary vein; and below, the fibrous layer of the pericardium. The serous layer is reflected over the front and sides of the vessel, but not over its posterior part.

To the **right side** are the right lung and pleura and the phrenic nerve.

To the **left side** are the innominate artery and the ascending aorta.

Tributaries.—In addition to the right and left innominate veins and the vena azygos it receives small veins from the mediastinum and pericardium.

THE INNOMINATE VEINS

The **innominate** or brachio-cephalic veins [vv. anonymæ] return the blood from the head and neck and upper extremity. They are formed on each side by the confluence of the internal jugular and subclavian veins behind the sternal end of the clavicle. They terminate behind the first costal cartilage on the right side by uniting to form the vena cava superior. The innominate veins have no valves.

The **right innominate** vein [v. anonyma dextra] (fig. 509) measures about 2 to 3 cm. (1 to 1½ in.) in length, and descends from its origin behind the sternal end of the clavicle, very slightly forward and medially, along the right side of the subclavian and innominate arteries, to its junction with the left vein behind the first costal cartilage close to the sternum. It is superficial to the innominate artery.

Relations.—In front are the origins of the sterno-hyoid and sterno-thyreoid muscles, the clavicle, the first costal cartilage, and the remains of the thymus gland.

Behind are the pleura and lung.

To the **right** are the right pleura and lung and the phrenic nerve.

To the **left** (fig. 509) are the right subclavian artery, the innominate artery, the right vagus nerve, and the trachea.

The **left innominate** vein [v. anonyma sinistra] (fig. 509) measures 6 to 7.5 cm. (2½ to 3 in.) in length, and extends from its origin behind the sternal end of the left clavicle obliquely across the three main branches of the arch of the aorta, to unite with the right innominate vein behind the cartilage of the first rib close to the sternum to form the vena cava superior. In this course it runs from left to right with an inclination downward and slightly backward. A line drawn obliquely across the upper half of the manubrium of the sternum, from the sterno-

clavicular articulation on the left side to the lower border of the first costal cartilage at its junction with the sternum on the right side, will indicate its course. The left innominate vein is on a level with the top of the sternum at birth.

Relations.—In front, in addition to the manubrium of the sternum, it has the origins of the sterno-hyoid and sterno-thyreoid muscles, and the remains of the thymus gland, the sternal end of the left clavicle, and the sterno-clavicular articulation.

Behind are the three chief arteries arising from the arch of the aorta, the trachea, and the left phrenic and left vagus nerves.

Below it is the arch of the aorta.

Above it are the cervical fascia, the inferior thyreoid, and thyreoidea ima veins.

Tributaries.—In addition to the internal jugular and subclavian veins, by the confluence of which the innominate veins are formed, each vein receives on its upper aspect the vertebral, the deep cervical, and inferior thyreoid veins; and

FIG. 509.—THE VENA CAVA SUPERIOR AND THE INNOMINATE VEINS.
(Modified from a dissection in St. Bartholomew's Hospital Museum.)

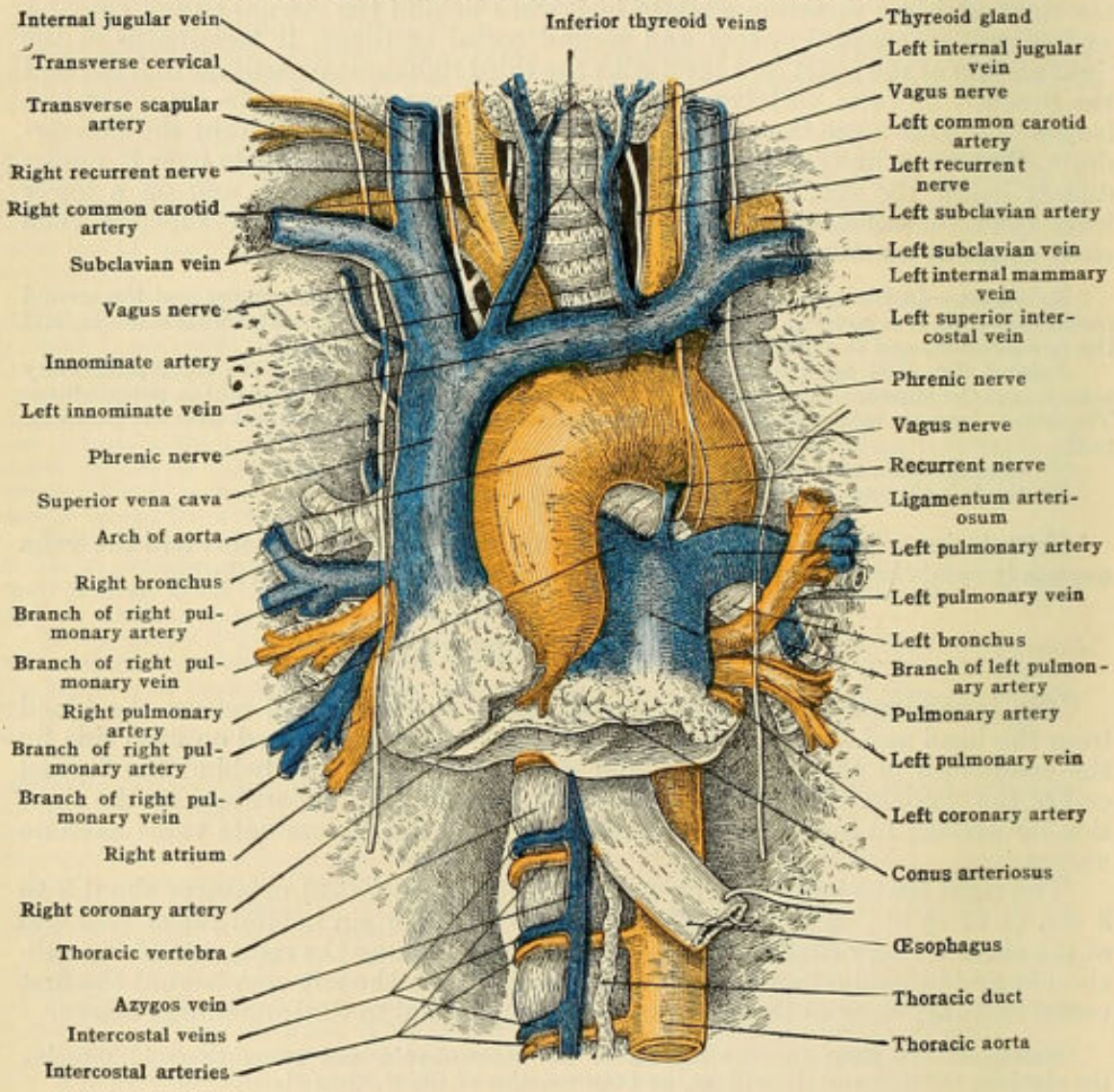

on its lower aspect the internal mammary vein. The left vein, moreover, is joined by the thyreoidea ima, the left superior intercostal, and by the thymic, tracheal, œsophageal, superior phrenic, anterior mediastinal, and pericardiac veins. At the confluence of the internal jugular and subclavian veins on the right side the three lymphatic trunks or the right lymphatic duct open; on the left side the thoracic duct.

THE VEINS OF THE HEAD AND NECK

The **veins of the head and neck** may be divided for purposes of description into the **superficial,** which return the blood from the external parts of the head and

neck; and the **deep,** which return the blood from the deeper structures. All the veins, whether superficial or deep, terminate in the internal jugular or subclavian, or open directly into the innominate veins at the root of the neck. Through the latter all the blood from the head and neck ultimately passes on its way to the heart.

THE SUPERFICIAL VEINS OF THE HEAD AND NECK

The venous blood from the anterior part of the scalp and integument of the face is returned, through the **anterior and posterior facial** veins, to the **common facial,** a tributary of the internal jugular vein. From the posterior part of the scalp and from the integument of the neck venous blood is returned, through the **external jugular** and its tributaries, to the subclavian vein.

A. The Anterior Facial Vein

The **anterior facial** vein [v. facialis anterior] (fig. 510) begins a little below the medial end of the eyebrow where it is formed by the union of the frontal and

Fig. 510.—The Superficial Veins of the Face and Scalp. (After Quain.)

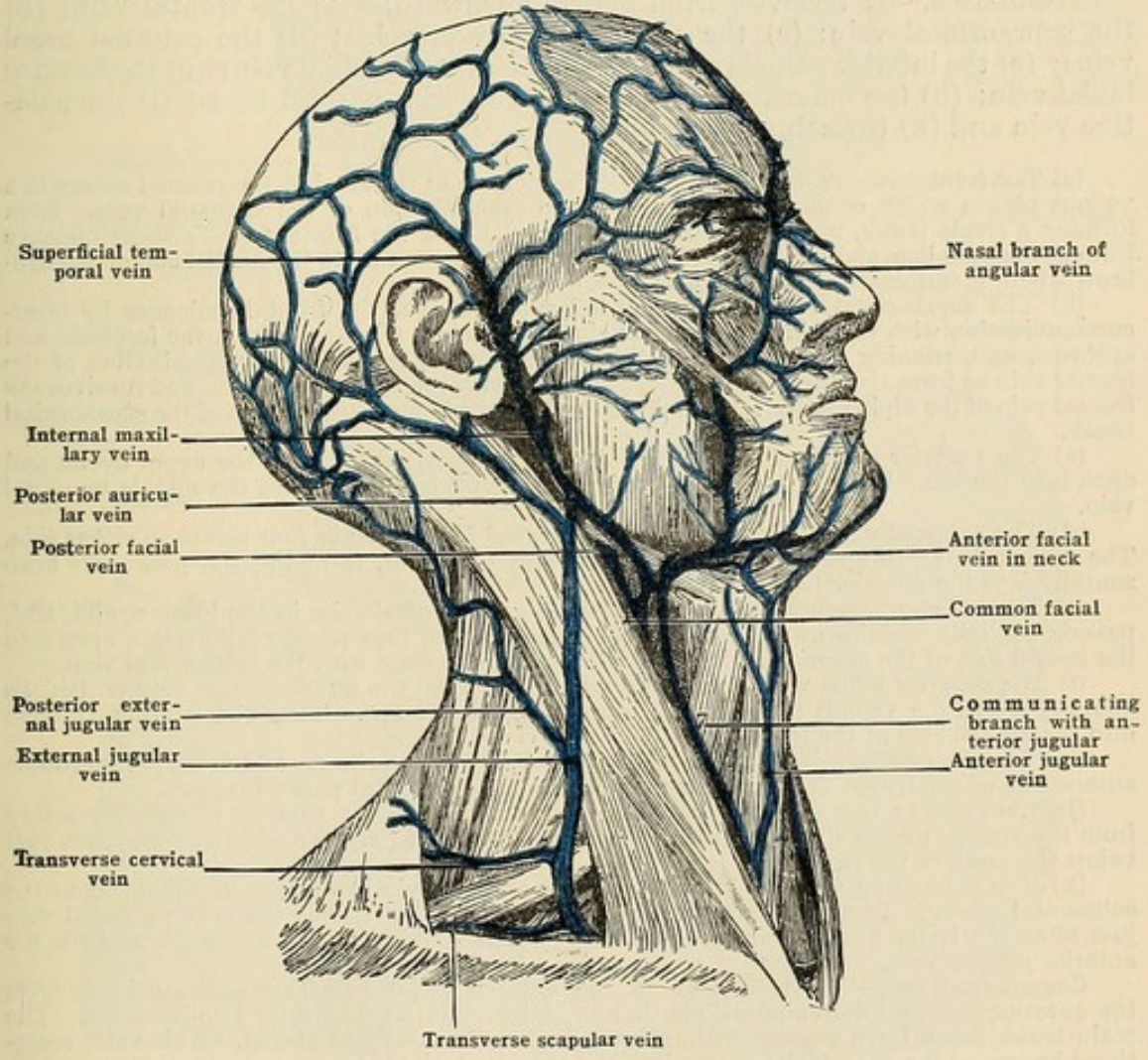

supraorbital veins. It descends near the medial angle of the orbit, and then by the side of the nose to the cheek, which it crosses obliquely, to the anterior edge of the masseter muscle. Thence it passes through the digastric triangle to the upper border of the hyoid bone, where it terminates in the common facial vein. In this course it is reinforced by numerous collateral veins, and gradually increases in size. It has, moreover, numerous communications with the deep veins. The portion of this vein above the lower margin of the orbit is called the **angular** [v.

angularis]. In the remainder of its course over the face and neck it is termed the **anterior facial** vein.

The angular vein skirts around the medial margin of the orbit, lying with the angular artery on the frontal (nasal) process of the maxillary bone slightly medial to the lacrimal sac. Branches pass from the posterior part of the angular vein into the orbit to join the ophthalmic.

The angular, the facial, and the ophthalmic veins contain no valves. The blood, therefore, can pass either forward from the ophthalmic into the angular, or backward through the facial and angular into the ophthalmic, and so on to the cavernous and other venous sinuses of the cranium. Hence in certain tumours in the orbit and cranium, the congestion of the angular and facial veins; and the danger in facial carbuncle and anthrax of septic thrombi spreading backward through the angular and ophthalmic veins to the cranial sinuses.

The anterior facial vein runs in a more or less direct line behind its corresponding artery, the external maxillary (facial), which itself pursues a tortuous course. It usually passes deep to the zygomatic muscle, the zygomatic head of the quadratus labii superioris, and the risorius, but superficial to the other muscles. At the anterior edge of the masseter it meets the external maxillary artery, lying immediately posterior to it. In the neck it lies beneath the platysma and cervical fascia, and is usually separated from the external maxillary artery by the submaxillary gland and the stylo-hyoid and posterior belly of the digastric muscles, below which it is joined by the posterior facial, to form the **common facial** vein.

Tributaries.—It receives, from above downward:—(a) the frontal vein; (b) the supraorbital vein; (c) the superior palpebral veins; (d) the external nasal veins; (e) the inferior palpebral veins; (f) the superior labial vein; (g) the inferior labial vein; (h) the masseteric veins; (i) the anterior parotid veins; (j) the palatine vein and (k) the submental vein.

(a) The **frontal** vein [v. frontalis] (fig. 510) begins about the level of the coronal suture in a venous plexus which communicates with the anterior division of the temporal vein. Soon forming a single trunk, it passes vertically downward over the frontal bone, a short distance from the middle line and parallel to its fellow of the opposite side, to the medial end of the eyebrow where it terminates in the angular vein.

(b) The **supraorbital** vein [v. supraorbitalis] begins over the frontal eminence by intercommunication with the middle temporal vein. It receives tributaries from the forehead and eyebrow, and, running obliquely, medially and downward, opens into the termination of the frontal vein to form the angular. It communicates with the ophthalmic vein, and receives the frontal vein of the diploë as the latter vein issues from the bone at the bottom of the supraorbital notch.

(c) The **superior palpebral** veins [vv. palpebrales superiores] arise in the upper eyelid and open into the lateral side of the angular vein. They communicate with the middle temporal vein.

(d) The **external nasal** veins [vv. nasales externæ] form three or four stems on either side. The upper veins run upward into the angular and the lower, from the ala, pass more horizontally into the anterior facial vein.

(e) The **inferior palpebral** veins [vv. palpebrales inferiores] arise in the lower eyelid, and, passing medially and downward over the cheek from which they receive tributaries, open into the lateral side of the anterior facial vein. They communicate with the infraorbital vein.

(f) The **superior labial** vein [v. labialis superior] and (g) the **inferior labial** vein [v. labialis inferior] arise from venous plexuses in the upper and lower lips. They run laterally to open into the medial side of the facial vein.

(h) The **masseteric** veins [vv. massetericæ] and (i) the **anterior parotid** veins [vv. parotidæ anteriores], of small size, drain the cheek over the masseteric and parotid regions.

(j) The **palatine** vein [v. palatina] accompanies the ascending palatine or tonsillar artery from the venous plexus about the tonsil and soft palate, and joins the anterior facial vein just below the body of the mandible.

(k) The **submental** vein [v. submentalis] lies on the mylo-hyoid muscle superficial to the submental artery. Running back in the submental triangle, it joins the anterior facial vein just after the latter has passed over the body of the mandible. It communicates with the anterior jugular vein.

Communications.—The tributaries of the anterior facial vein communicate freely with the anterior and middle temporal, ophthalmic, infraorbital and anterior jugular veins. The main trunk has a large **communicating branch with the pterygoid plexus.** This vein, sometimes known as the deep facial, opens into the anterior facial below the zygomatic bone under cover of the zygomaticus muscle.

B. The Posterior Facial Vein

The **posterior facial** (temporo-maxillary) vein [v. facialis posterior] is formed in in the region of the root of the zygoma by the union of the superficial and middle temporal veins. It passes downward behind the ramus of the mandible

through the substance of the parotid gland—here lying lateral to the superficial temporal and external carotid arteries. At the angle of the mandible it runs medially and somewhat forward, and, passing either deep or superficial to the stylo-hyoid and digastric muscles, joins the anterior facial to form the common facial vein.

The **tributaries** received by the posterior facial vein are:—(a) the superficial

FIG. 511.—THE VEINS OF THE HEAD, NECK, AND AXILLA. (After Toldt, "Atlas of Human Anatomy," Rebman, London and New York.)

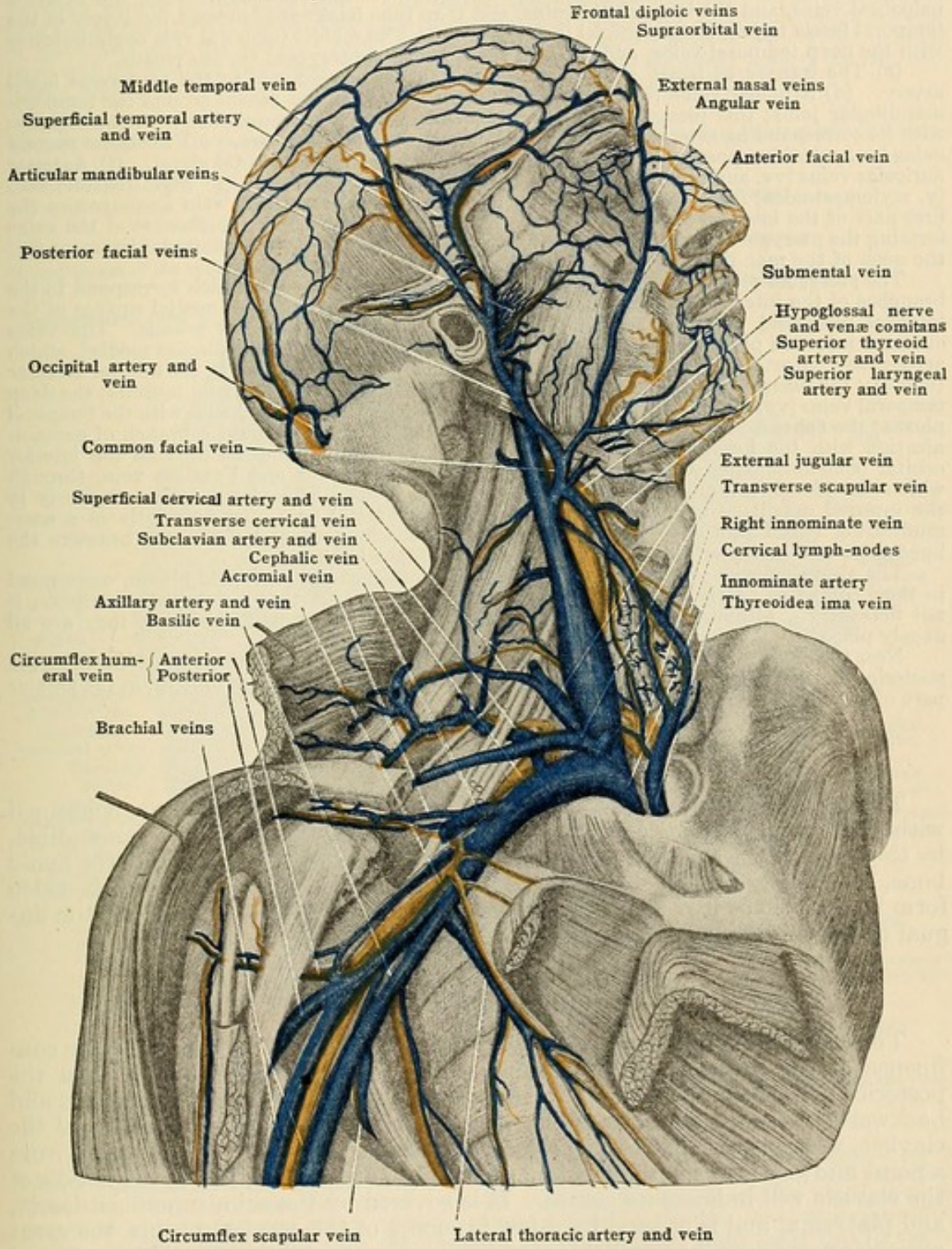

temporal veins; (b) the middle temporal vein; (c) the transverse facial vein; (d) the articular veins; (e) the posterior parotid veins; (f) the anterior auricular veins; (g) the stylo-mastoid vein; and (h) the internal maxillary vein through which occurs the principal drainage of the pterygoid plexus.

(a) The **superficial temporal** vein [v. temporalis superficialis] returns the blood from the parietal region of the scalp. It is formed by the union of an anterior and a posterior branch: the former communicates with the supraorbital and frontal veins; the latter with the posterior auricular and occipital veins and the temporal vein of the opposite side. These branches lie superficial to the corresponding branches of the superficial temporal artery, which they roughly though not accurately follow. Like the artery, they lie between the skin and the cranial aponeurosis, and descend over the temporal fascia to unite a little above the zygoma, and just in front of the auricle of the ear, to form the superficial temporal trunk. The vein thus formed continues its course downward with the trunk of the temporal artery, and opposite the zygoma is joined by the middle temporal vein to form the common temporal vein.

(b) The **middle temporal** vein [v. temporalis media] corresponds with the orbital branch of the temporal artery, and communicates in front with the ophthalmic vein, the external palpebral veins, and the infraorbital veins, and then runs backward between the layers of the temporal fascia to join the superficial temporal vein. The middle temporal vein communicates with the deep temporal veins, and through them with the pterygoid venous plexus.

(c) The **transverse facial** vein [v. transversa faciei] corresponds to the transverse facial artery. (d) **Articular** veins [vv. articulares mandibulæ] form the plexus around the temporomandibular joint; this plexus receives the **tympanic** veins [vv. tympanicæ], which, together with its corresponding artery, passes through the petrotympanic fissure. (e) **Posterior parotid** veins [vv. parotideæ posteriores] emerge from the substance of the parotid gland. (f) **Anterior auricular** veins [vv. auriculares anteriores], from the auricle of the ear. (g) **Stylo-mastoid** vein [v. stylomastoidea] from the facial canal. (h) The **internal maxillary** vein accompanies the first part of the internal maxillary artery. It begins at the posterior confluence of the veins forming the pterygoid plexus, and passes backward between the stylo-mandibular ligament and the neck of the mandible. It ends by joining the posterior facial vein.

The **pterygoid plexus** [plexus pterygoideus] is formed by the veins which correspond to the branches of the internal maxillary artery. It is situated, partly on the medial surface of the internal pterygoid muscle, and partly around the external pterygoid muscle. The veins entering into this plexus are:—the two **middle meningeal** veins [vv. meningeæ mediæ], which accompany the artery of that name; the **posterior superior alveolar** (dental); the **inferior alveolar** (dental); the **masseteric**; the **buccal**; the **pterygoid** veins from the pterygoid muscles; the **deep temporal** veins [vv. temporales profundæ], by which the plexus communicates with the temporal plexus; the **spheno-palatine** vein; the **infraorbital**; the **superior palatine**; a branch of communication with the lower branch of the **ophthalmic** vein, which courses through the inferior orbital (spheno-maxillary) fissure; and the **rete foraminis ovalis** and **Vesalian** vein, through which the plexus communicates with the cavernous sinus. The plexus ends posteriorly in the internal maxillary vein, which joins the posterior facial vein, and anteriorly in a communicating vessel (the deep facial vein), which passes forward and downward between the buccinator and masseter muscles to join the anterior facial vein.

The above-mentioned veins, forming by their confluence the pterygoid plexus, correspond in their course so nearly with that of their companion arteries that a detailed description is not necessary. Although for convenience described with the superficial veins, they are all deeply placed.

Near the angle of the mandible there is almost always a communicating branch between the posterior facial and the external jugular veins. When large, this branch may drain the greater part of the blood from the posterior facial.

C. The Common Facial Vein

The **common facial** vein [v. facialis communis] is a short thick stem contained within the carotid triangle. It is formed, just below the angle of the mandible, by the union of the anterior and posterior facial veins. It ends opposite the hyoid bone, by opening into the internal jugular vein. In addition to the vessels which form it, sometimes it receives the superior thyreoid, the pharyngeal, and the lingual or the sublingual veins.

D. The External Jugular Vein

The **external jugular** vein [v. jugularis externa] (fig. 510) is formed by the confluence of the posterior auricular and a short communicating trunk from the posterior facial near the angle of the mandible. It runs obliquely downward and backward across the sterno-mastoid muscle to a point opposite the middle of the clavicle, where it terminates as a rule in the subclavian vein. A line drawn from a point midway between the mastoid process and angle of the jaw to the middle of the clavicle will indicate its course. It is covered by the skin, superficial fascia, and platysma, and is crossed by a few branches of the cervical plexus, the great auricular nerve running parallel to it at the upper part of the neck. It is separated from the sterno-mastoid by the anterior layer of the deep cervical fascia.

Just above the clavicle it perforates the cervical fascia, by which it is prevented from readily collapsing, the fascia being attached to its walls. It then opens into the subclavian vein, occasionally into the internal jugular, or into the confluence of the subclavian and internal jugular

veins. It contains a pair of valves about 2.5 to 5 cm. (1 to 2 in.) above the clavicle, and a second pair where it enters the subclavian vein. Neither of these valves is sufficient to prevent the blood from regurgitating, or injections from passing from the larger vein into the external jugular.

Tributaries and communications.—These include;—(a) The posterior auricular vein; (b) the occipital vein; (c) a branch of communication with the posterior facial vein; (d) the posterior external jugular vein; (e) the transverse scapular vein; and (f) the anterior jugular vein.

(*a*) The **posterior auricular** vein [v. auricularis posterior] begins in a venous plexus on the posterior part of the parietal bone. This plexus communicates with the vein of the opposite side across the sagittal suture, and with the posterior branch of the superficial temporal vein in front, and with the occipital vein behind. It descends over the back part of the parietal bone and the mastoid process of the temporal bone, lying with its artery behind the ear, and joins a branch from the posterior facial vein to form the external jugular.

FIG. 512.—THE VEINS OF THE FACE. (After Toldt, "Atlas of Human Anatomy," Rebman, London and New York.)

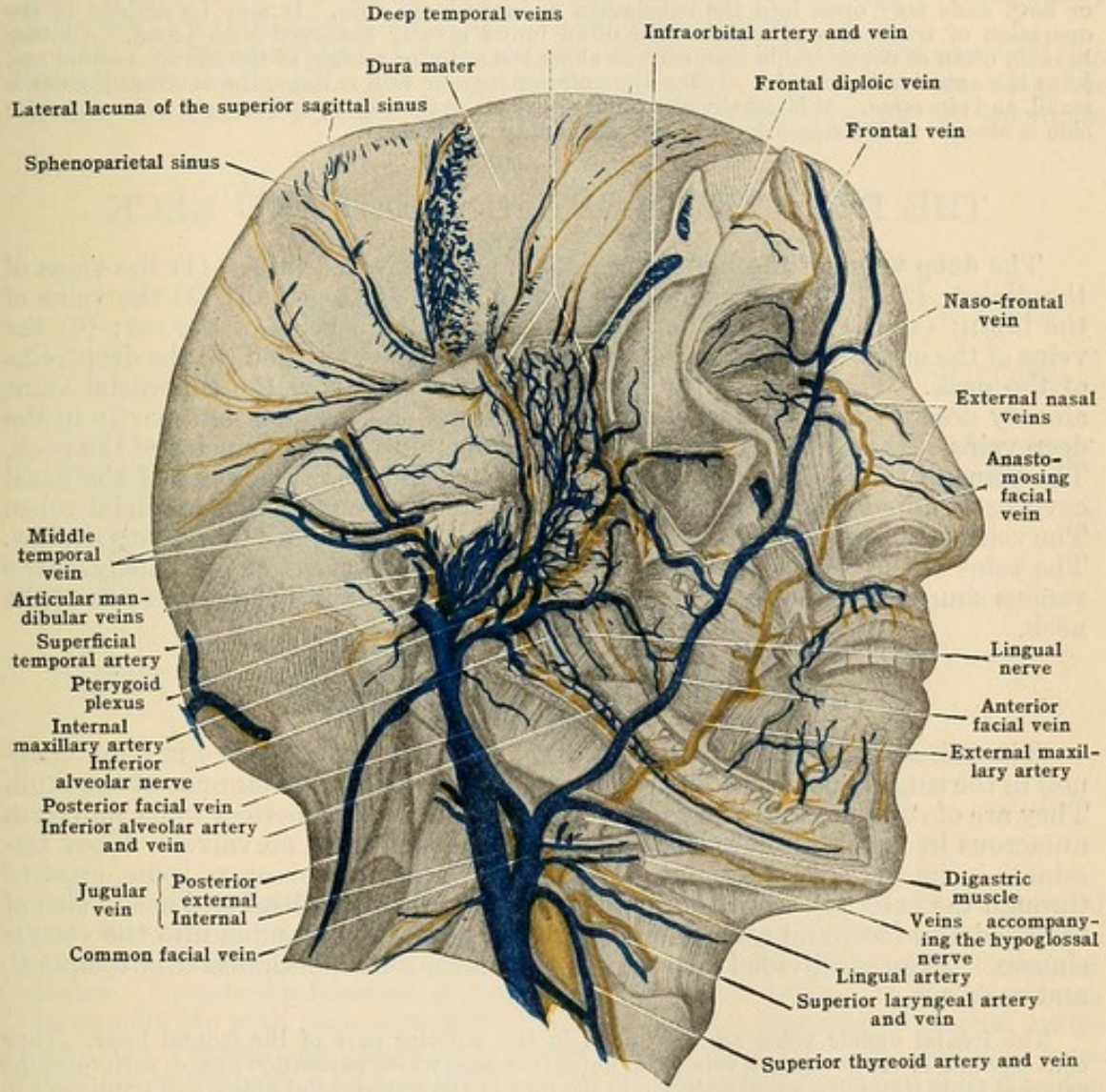

(*b*) The **occipital** vein [v. occipitalis] begins at the back of the skull in a venous plexus which anastomoses with the posterior auricular and the posterior branch of the superficial temporal veins. It passes downward over the occipital bone, and usually perforates the trapezius with the occipital artery, to join a plexus drained by the deep crevical and vertebral veins. It also communicates with the posterior auricular, and in many cases this forms the chief path of drainage. One of its branches, usually the most lateral, receives a **mastoid emissary** vein [emissarium mastoideum] which issues through the mastoid foramen of the temporal bone, and in this way forms a communication with the transverse sinus.

(*c*) The branch of **communication with the posterior facial** vein occurs a short distance below the point at which the posterior facial receives the internal maxillary vein. It is very constant and is placed immediately behind the angle of the mandible. Through it the external jugular

usually receives a considerable proportion of the blood returning from the temporal and pterygoid regions.

(*d*) The **posterior external jugular** vein (fig. 512) descends from the upper and back part of the neck, receiving small tributaries from the superficial structures and muscles. At times it communicates with the occipital, or may appear as a continuation of that vein. It opens into the external jugular as the latter vein is leaving the sterno-mastoid muscle.

(*e*) The **transverse scapular** vein [v. transversa scapulæ] corresponds to the transverse scapular (suprascapular) artery. If double, these venæ comitantes usually form one trunk before they open into the external jugular vein. They contain well-marked valves.

(*f*) The **anterior jugular vein** [v. jugularis anterior] begins below the chin by communicating with the mental, submental, inferior labial, and inferior hyoid veins. It descends a little lateral to the middle line, receiving branches from the superficial structures at the front and side of the neck, and occasionally a branch from the larynx and thyreoid body. Just above the clavicle it turns laterally, and, piercing the fascia, passes beneath the sterno-mastoid muscle and opens into the external jugular vein just before the latter joins the subclavian; at times it opens into the subclavian vein itself. In its course down the neck it communicates with the external jugular; and, as it turns laterally beneath the sterno-mastoid, sends a branch across the trachea, between the layers of cervical fascia, to join the anterior jugular of the opposite side. This communicating vein, the **jugular venous arch** [arcus venosus juguli], may open directly into the external jugular or into the internal jugular vein; occasionally one or both ends may open into the subclavian or innominate vein. It may be divided in the operation of tracheotomy, and is then often found greatly engorged with blood. Another branch, often of considerable size, courses along the anterior margin of the sterno-mastoid and joins the anterior facial vein. When the anterior jugular vein is large, the external jugular is small, and *vice versa*. It is usually also of large size when the corresponding vein on the opposite side is absent, as is frequently the case. It contains no valves.

THE DEEP VEINS OF THE HEAD AND NECK

The **deep veins of the head and neck** may be divided into:—(1) the veins of the diploë; (2) the venous sinuses of the dura mater encephali; (3) the veins of the brain; (4) the veins of the nasal cavities; (5) the veins of the ear; (6) the veins of the orbit; (7) the veins of the pharynx and larynx; and (8) the deep veins of the neck. The veins of the diploë terminate partly in the superficial veins already described, partly in the venous sinuses of the cranium, and partly in the deep veins of the neck. The venous sinuses open into the deep veins of the neck. The veins of the brain terminate in the venous sinuses. The veins of the nasal cavities terminate partly in the deep, and to some extent in the superficial veins. The veins of the ear join both the superficial and deep veins and the venous sinuses. The veins of the orbit terminate partly in the superficial veins, but chiefly in the venous sinuses. The veins of the pharynx and larynx enter the deep veins of the neck.

1. THE VEINS OF THE DIPLOE

The **veins of the diploë** [venæ diploicæ] (fig. 513) are contained in bony channels in the cancellous tissue between the external and internal laminae of the skull. They are of comparatively large size, with very thin and imperfect walls, and form numerous irregular communicating channels. They have no valves. They terminate in four or five main and descending channels, which open, some outward through the external cranial lamina into some of the superficial and deep veins of the head and face, and some inward through the internal lamina into the venous sinuses. They are divided into the frontal, anterior temporal, posterior temporal, and occipital.

The **frontal diploic veins** are contained in the anterior part of the frontal bone. They converge anteriorly to a single vein [v. diploica frontalis] which passes downward, perforates the external table through a small aperture in the roof of the supraorbital notch, and terminates in the supraorbital vein. They also communicate with the superior sagittal sinus.

The **anterior temporal** [v. diploica temporalis ant.] are contained in the posterior part of the frontal and in the anterior part of the parietal bone. They pass downward, and end, partly in the deep temporal veins by perforating the greater wing of the sphenoid bone, and partly in the spheno-parietal sinus.

The **posterior temporal** [v. diploica temporalis post.] ramifies in the parietal bone, and, coursing downward to the posterior inferior angle of that bone, passes either through a foramen in its inner table, or through the mastoid foramen into the transverse sinus.

The **occipital** [v. diploica occipitalis] ramifies chiefly in the occipital bone, and opens into the occipital vein or into the transverse sinus.

The diploic veins freely anastomose with one another in the adult; but in the fœtus, before the bones have united, each system of veins is distinct.

2. THE VENOUS SINUSES OF THE DURA MATER

The **venous sinuses of the dura mater** [sinus duræ matris] are endothelially lined blood-spaces, situated between the periosteal and meningeal layers of the dura mater. They are the channels by which the blood is conveyed from the cerebral veins, and from some of the veins of the meninges and diploë, into the veins of the neck. The sinuses at the base of the skull also carry the chief part of the blood from the orbit and eyeball to the jugular veins. At certain spots the sinuses communicate with the superficial veins by small vessels known as the emissary veins, which run through foramina in the cranial bones.

The venous sinuses are sixteen in number, six being median and unpaired, the remaining ten consisting of five lateral pairs. The median sinuses are:—(1) the superior sagittal; (2) the inferior sagittal; (3) the straight; (4) the occipital; (5) the circular; and (6) the basilar plexus. The lateral and paired sinuses are:—(7) the two transverse; (8) the two superior petrosal; (9) the two inferior petrosal; (10) the two cavernous; and (11) the two spheno-parietal. Occasionally there are two additional sinuses, the two petro-squamous.

(1) The **superior sagittal** (or longitudinal) **sinus** [sinus sagittalis superior] (fig. 515) lies in the median groove on the inner surface of the cranium along the attached margin of the falx cerebri. It extends from the foramen cæcum to the

FIG. 513.—THE VEINS OF THE DIPLOË.
(From a specimen in St. Bartholomew's Hospital Museum.)

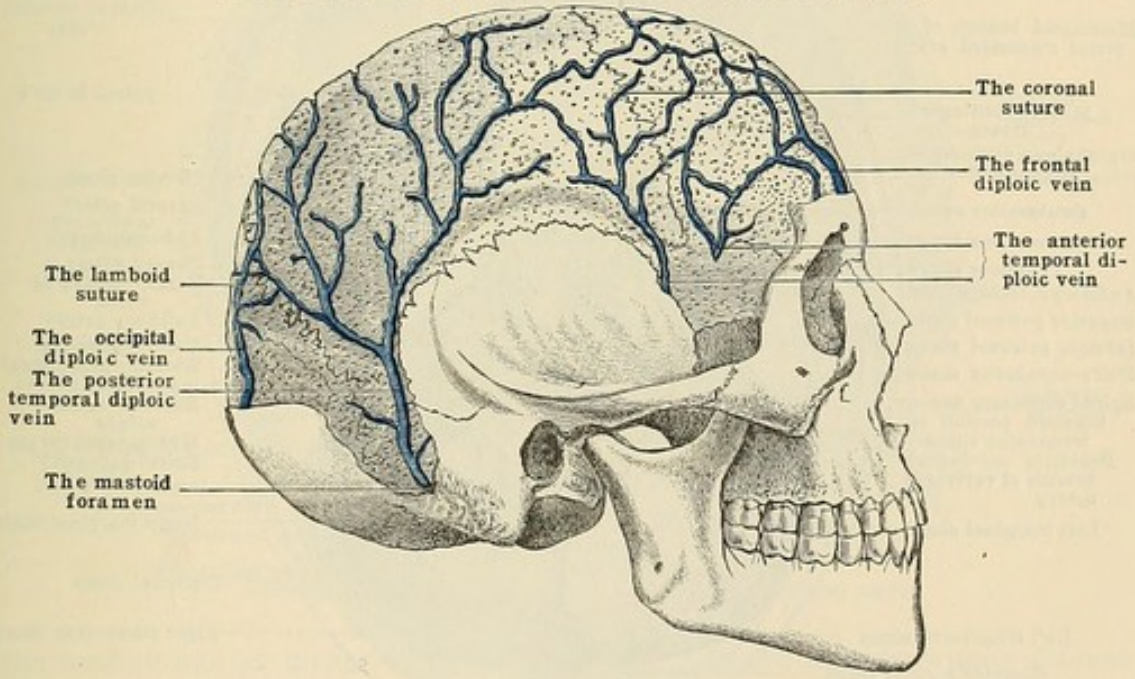

internal occipital protuberance. It grooves from before backward the frontal bone, the contiguous sagittal margins of the parietal bones, and the squamous portion of the occipital bone In the fœtus, and occasionally in the adult, it communicates (through the foramen cæcum) with the nasal veins. It communicates throughout life with each superficial temporal vein by means of a **parietal emissary** vein [emissarium parietale] which passes through the parietal foraman. It is triangular on section, the base of the triangle corresponding to the bone. Crossing it are a number of fibrous bands known as the *chords of Willis*, and projecting into it in places are the arachnoidal (Pacchionian) granulations. The parts of the sinus into which the arachnoidal granulations project are irregular lateral diverticula from the main channel known as the *lacunæ laterales* (fig. 517). In front the sinus is quite small, but it increases greatly in calibre as it runs backward. It receives at intervals the superior cortical cerebral veins and the veins from the falx. The former, for the most part, open into it in the direction opposite to that in which the blood is flowing in the sinus. They pass for some distance in the walls of the sinus before opening into it. Posteriorly, at the internal occipital protuberance, the superior sagittal sinus usually turns sharply to

the right, and ends in the right transverse (lateral) sinus; the straight sinus then usually terminates in the left transverse (lateral) sinus.

Occasionally, however, the superior sagittal sinus ends in the left transverse sinus, the straight then passing into the right. At the angle of union between the superior sagittal sinus and the transverse sinus into which it empties there is a dilation, the **confluens sinuum** or torcular Herophili. At this point there is a communication between the right and left transverse sinuses. In some cases the communication is so free that the blood from the sagittal sinus flows almost equally into each transverse sinus. The confluens may communicate with the occipital vein through the **occipital emissary** vein [emissarium occipitale], which, when present passes through a minute foramen in the occipital protuberance.

(2) The **inferior sagittal** (or longitudinal) **sinus** [sinus sagittalis inferior] (fig. 515) is situated at the free margin of the falx cerebri. Beginning about the junction of the anterior with the middle third of the falx, it is continued backward along the concave or lower margin of that process to the junction of the falx with the tentorium, where it ends in the straight sinus. The sinus is cylindrical in

FIG. 514.—THE VENOUS SINUSES.
(From a dissection by W. J. Walsham in St. Bartholomew's Hospital Museum.)

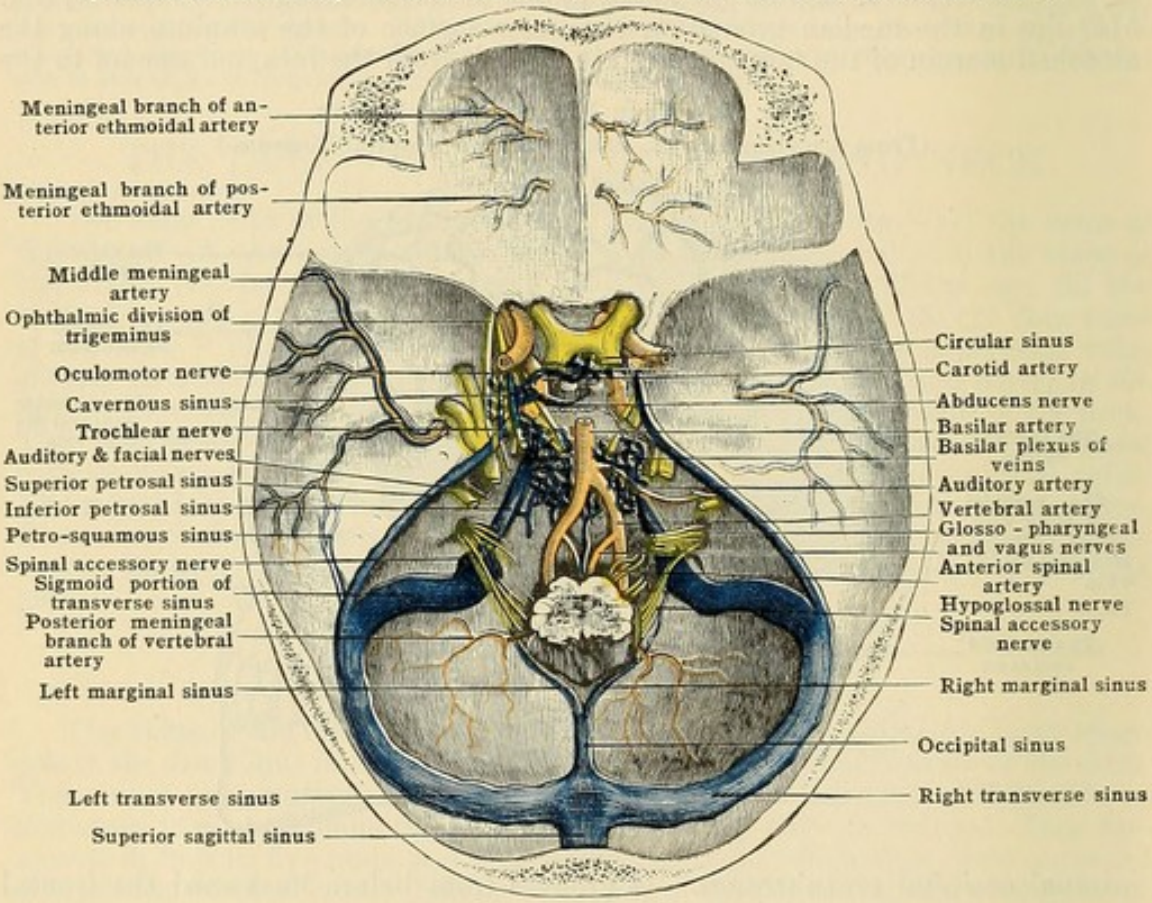

shape and of small size, and receives some of the inferior frontal veins of the brain, some of the veins from the medial surface of the brain, and some of the veins of the falx.

(3) The **straight sinus** [sinus rectus] lies along the junction of the falx cerebri with the tentorium cerebelli. It is formed by the union of the great cerebral vein (of Galen) and the inferior sagittal sinus. It receives in its course branches from the tentorium cerebelli and from the upper surface of the cerebellum. It runs downward and backward to the internal occipital protuberance, where it ends in the transverse sinus opposite to that joined by the superior sagittal sinus. On section it is triangular in shape, with its apex upward.

(4) The **occipital sinus** [sinus occipitalis] (fig. 514) ascends at the attached margin of the falx cerebelli, along the lower half of the squamous portion of the occipital bone from near the posterior margin of the foramen magnum to the internal occipital protuberance. It usually begins in a right and a left branch, known as the **marginal sinuses.** These proceed from the termination of each

transverse sinus, run around the foramen magnum, where they communicate with the venous vertebral retia, and unite at a variable distance from the internal occipital protuberance to form the single occipital sinus. Sometimes they remain separate as far as the occipital protuberance, then forming two occipital sinuses. One of the two marginal sinuses may be much smaller than the other, or be entirely absent. At the point where the marginal sinuses unite to form the single occipital sinus, there is a communication with the venous vertebral retia. The occipital sinus ends in the confluens sinuum. It receives in its course veins from the tentorium cerebelli, and from the inferior surface of the cerebellum. It communicates through the plexus of veins which surrounds the hypoglossal nerve [**rete canalis hypoglossi**] in the hypoglossal (anterior condyloid) canal with the vertebral vein and the longitudinal vertebral venous sinuses.

(5) The **circular sinus** [sinus circularis] (fig. 516) encircles the hypophysis cerebri. It consists of the two cavernous sinuses and their communications across

FIG. 515.—THE VENOUS SINUSES. (Longitudinal section.)

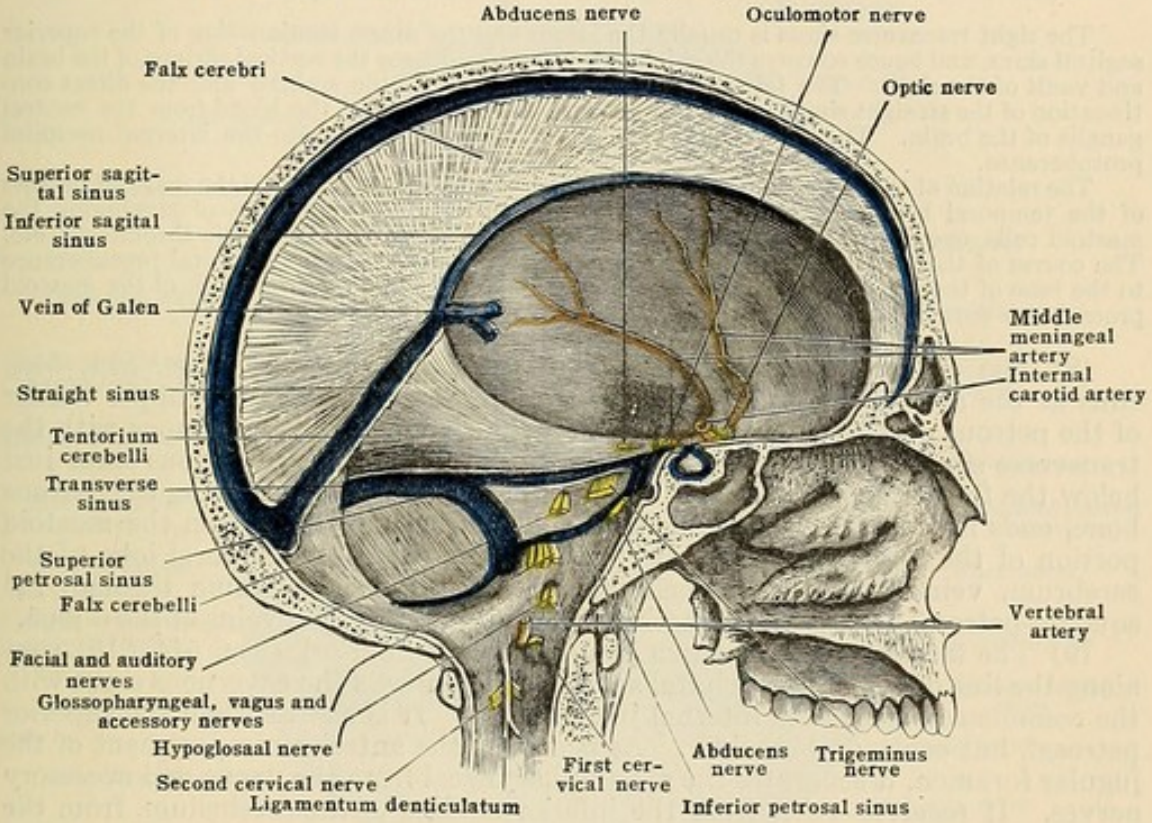

the median line by means of the **anterior and posterior intercavernous sinuses.** The intercavernous sinuses are small and cross the median line in front of and behind the hypophysis, respectively.

(6) The **basilar plexus** [plexus basilaris] is a venous plexus in the substance of the dura mater over the basilar part of the occipital bone. It extends from the cavernous sinus to the margin of the foramen magnum below. It communicates laterally with the inferior petrosal sinus, and inferiorly with the internal vertebral venous plexuses. One of the larger of the irregular venous channels forming the plexus passes transversely from one inferior petrosal sinus to the other. This venous plexus is serially homologous with the longitudinal vertebral venous sinuses on the posterior surfaces of the bodies of the vertebræ.

(7) The **transverse** (or lateral) **sinus** [sinus transversus] (figs. 514, 516) extends from the internal occipital protuberance to the jugular foramen. In this course it lies in the groove (which has been named after it) along the squamous portion of the occipital bone, the posterior inferior angle of the parietal bone, the mastoid portion of the temporal bone, and the jugular process of the occipital bone. It at first runs laterally and forward horizontally between the two layers of the tentorium cerebelli, following the curve of the groove on the occipital and on the mastoid angle of the parietal bone. On reaching the groove in the mas-

toid portion of the temporal bone it leaves the tentorium and curves medially and downward and then forward over the jugular process of the occipital bone, and ends in the posterior compartment of the jugular fossa in the superior bulb of the internal jugular vein. The S-shaped part of the sinus which lies on the mastoid portion of the temporal and jugular portion of the occipital bone is sometimes known as the **sigmoid sinus.** The transverse sinus receives the **internal auditory** veins [vv. auditivæ internæ] from the labyrinth, which emerge from the internal auditory meatus. It also receives veins from the temporal lobe of the cerebrum, some of the superior and inferior cerebellar veins, some of the veins of the medulla and pons, the occipital, and the posterior temporal and occipital veins of the diploë. At the point where it leaves the tentorium it drains the superior petrosal sinus and, when present, the petro-squamous sinus. It communicates with the occipital and vertebral veins through the mastoid and posterior condyloid foramina by means of the **mastoid** and **condyloid** emissary veins. As the transverse sinus lies between the layers of the tentorium it is on section prismatic in shape. The sigmoid portion is semicylindrical.

The **right** transverse sinus is usually the larger and the direct continuation of the superior sagittal sinus, and hence conveys the chief part of the blood from the cortical surface of the brain and vault of the skull. The **left** transverse sinus is usually the smaller and the direct continuation of the straight sinus, and hence returns the chief part of the blood from the central ganglia of the brain. The right and left sinuses communicate opposite the internal occipital protuberance.

The relation of the lateral sinus to the outside of the skull, especially to the mastoid process of the temporal bone, is of importance with reference to the operations of trephining the mastoid cells, opening the tympanum, and exposing the sinus itself, in septic thrombosis, etc. The course of the sinus corresponds to a line drawn from the external occipital protuberance to the base of the mastoid process, or to the asterion, and thence over the back of the mastoid process in a curved line toward its apex.

(8) The **superior petrosal sinus** [sinus petrosus superior] (figs. 514, 515) runs at the attached margin of the tentorium cerebelli, along the upper border of the petrous portion of the temporal bone. It connects the cavernous with the transverse sinus. Leaving the lateral and back part of the cavernous sinus just below the fourth nerve, it crosses the fifth nerve, and, after grooving the petrous bone, ends in the transverse sinus as the latter turns downward on the mastoid portion of the temporal bone. It receives veins from the temporal lobe of the cerebrum, veins from the cerebellum, veins from the tympanum through the squamo-petrosal fissure, and sometimes the anterior temporal veins of the diploë.

(9) The **inferior petrosal sinus** [sinus petrosus inferior] (figs. 514, 516) runs along the line of the petro-occipital suture, and connects the cavernous sinus with the commencement of the internal jugular vein. It is shorter than the superior petrosal, but considerably wider. As it crosses the anterior compartment of the jugular foramen, it separates the glosso-pharyngeal from the vagus and accessory nerves. It receives veins from the inferior surface of the cerebellum, from the medulla and pons, and from the internal ear. The last, the **vein of the cochlear canaliculus** [v. canaliculi cochleæ], issues through the canaliculus cochleæ.

(10) The **cavernous sinus** [sinus cavernosus] (fig. 516) is an irregularly shaped venous space situated between the meningeal and periosteal layers of the dura mater on the side of the body of the sphenoid bone. It extends from the medial end of the superior orbital (sphenoidal) fissure in front to the apex of the petrous bone behind. Its lateral wall is the more distinct, and contains the third and fourth nerves, and the ophthalmic division of the fifth nerve. The nerves take the above-mentioned order from above downward, and in the medio-lateral direction. The internal carotid artery and the sixth nerve also pass through the sinus, being separated from the blood by the endothelial lining. The right and left cavernous sinuses communicate across the middle line with the opposite sinus in front and behind the hypophysis cerebri as before mentioned.

The cavernous sinus is traversed by numerous trabeculæ or fibrous bands, so that there is no central space, but rather a number of endothelial-lined irregular lacunar cavities communicating one another. Hence its name cavernous, from its resemblance to cavernous tissue. **In front** it receives the ophthalmic vein, with which it is practically continuous, and just above the third nerve the spheno-parietal sinus. **Medially** it communicates with the opposite sinus, and **posteriorly** it ends in the superior and inferior petrosal sinuses. It also receives veins from the inferior surface of the frontal lobe of the brain, and some of the middle cerebral veins. Through the Vesalian vein, which runs in a minute foramen in the spinous process of

the sphenoid bone, the sinus communicates with the pterygoid plexus of veins; through the **venous plexus around the petrosal portion of the internal carotid** [plexus venosus caroticus internus], with the internal jugular vein; and through a venous rete which leaves the cranium by the foramen ovale [rete foraminis ovalis] and by small veins passing through the foramen lacerum medium, with the pterygoid and pharyngeal plexuses.

(11) The **spheno-parietal sinus** [sinus sphenoparietalis] runs in a slight groove on the under surface of the lesser wing of the sphenoid bone. It originates in one of the meningeal veins near the apex of the lesser wing, and, running medially, passes through the sphenoidal fold of dura mater above the third nerve into the front part of the cavernous sinus. It generally receives the anterior temporal veins from the diploë.

FIG. 516.—THE VENOUS SINUSES AT THE BASE OF THE BRAIN. The dura mater has not been removed. (After Toldt, "Atlas of Human Anatomy," Rebman, London and New York.)

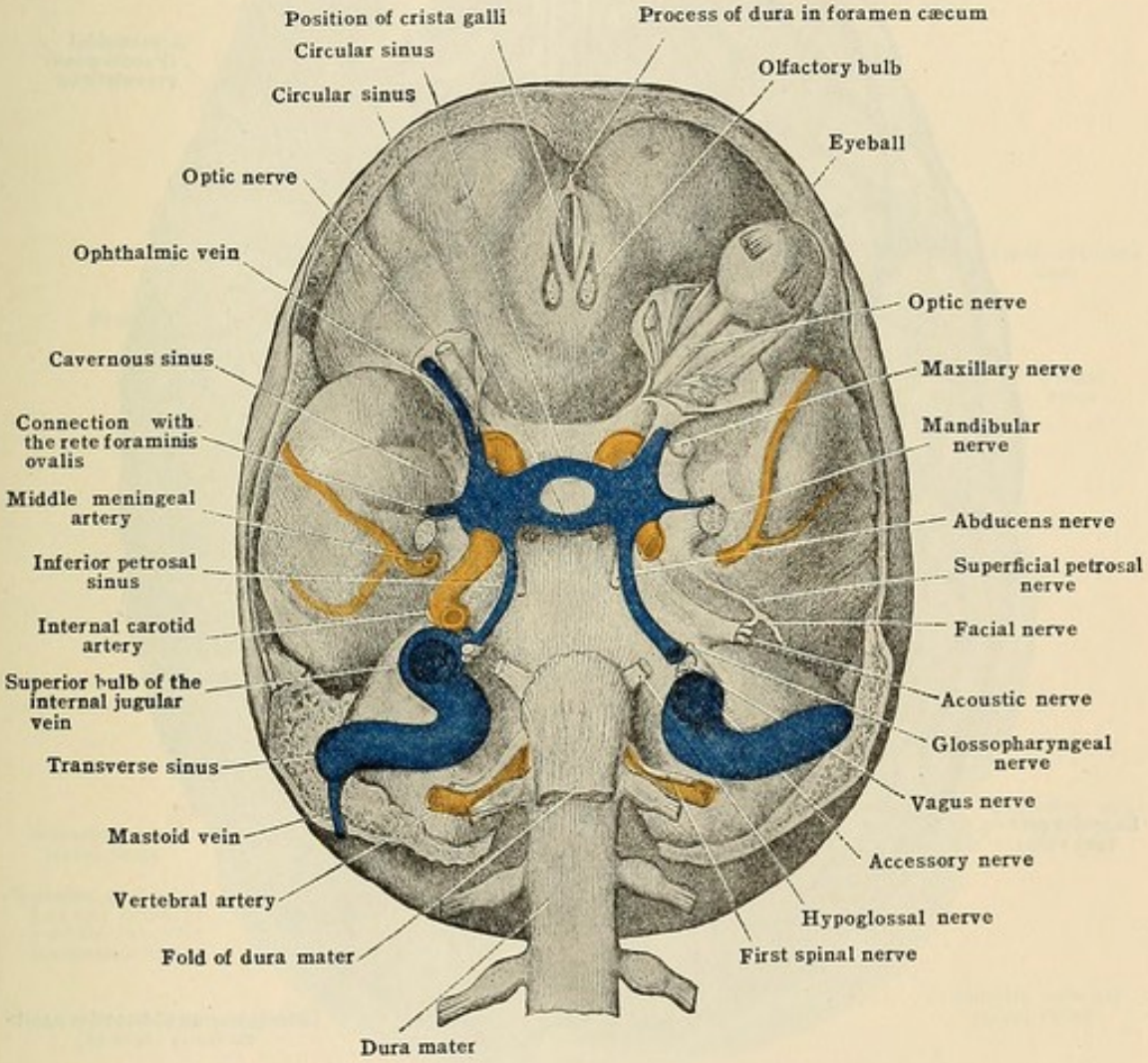

The **petro-squamous sinus** is occasionally present. It lies in a groove along the junction of the petrous and squamous portions of the temporal bone. It opens posteriorly into the transverse sinus at the spot where the latter enters on its sigmoid course. In front it sometimes, though very rarely, passes through a foramen in the squamous portion of the temporal bone between the mandibular fossa and the external auditory meatus into the temporal vein.

3. THE VEINS OF THE BRAIN

The **veins of the brain** present the following peculiarities:—(*a*) They do not accompany the cerebral arteries. (*b*) Ascending veins do not, as in other situations, run with descending arteries, but with ascending arteries, and *vice versa*. (*c*) The deep veins do not freely communicate. (*d*) The veins have very thin walls, no muscular coat, and no valves. (*e*) The veins opening into the sagittal, and some of those opening into the transverse (lateral) sinus pour in their blood in a direction opposite to the current in the sinuses, so impeding the flow in both

vein and sinus. (*f*) The flow of blood in the sinuses is further retarded by the trabeculæ stretching across their lumen, and in the sagittal sinus by the blood having to ascend, when the body is erect, through the anterior half of its course.

The veins of the brain may be divided into the **cerebral** and the **cerebellar.**

FIG. 517.—THE VEINS OF THE BRAIN, SUPERIOR SURFACE. (After Toldt, "Atlas of Human Anatomy," Rebman, London and New York.)

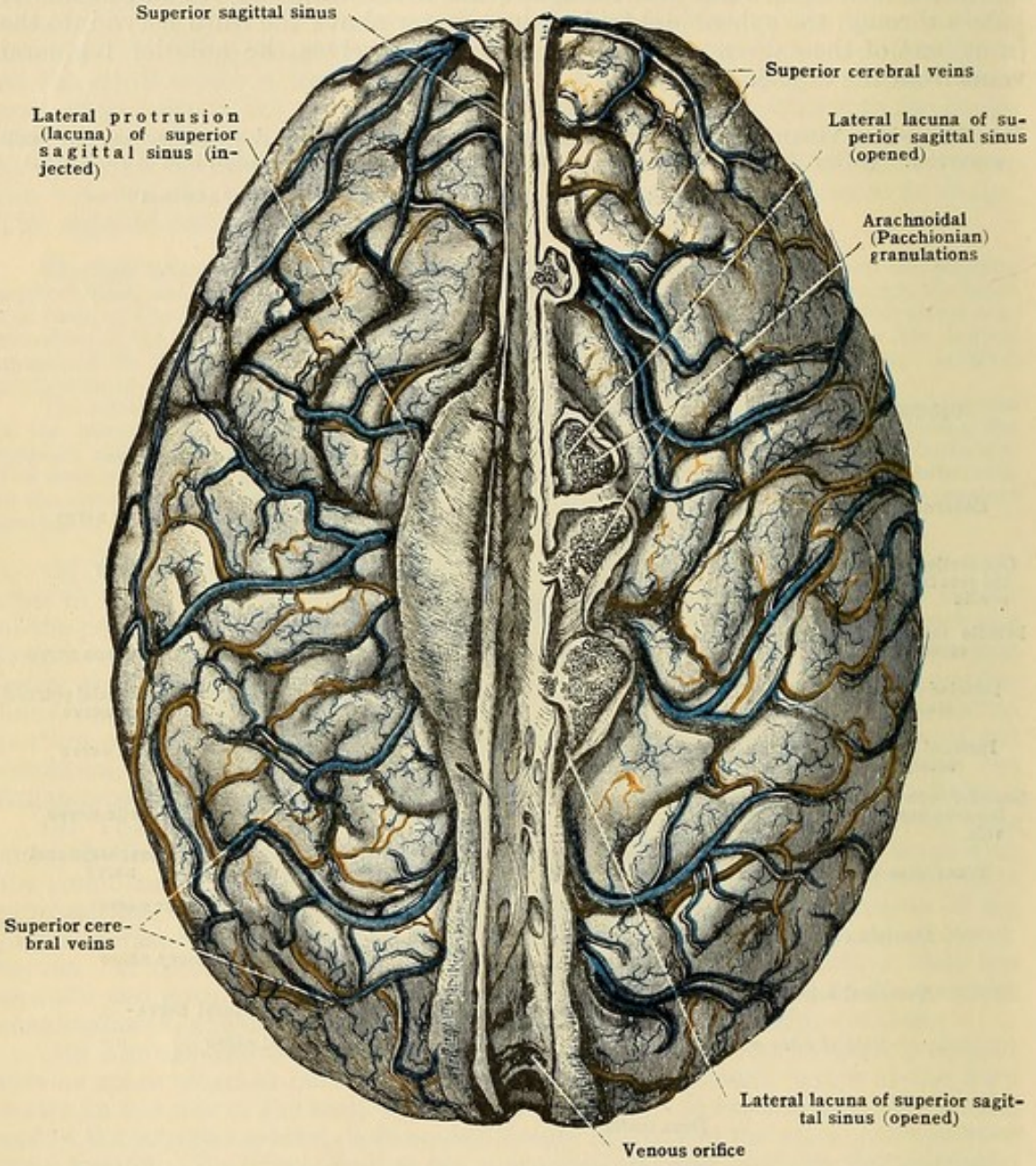

THE CEREBRAL VEINS

The **cerebral** veins, like the cerebral arteries, may be divided into the **cortical** and the **central.**

The **cortical** or **superficial** veins ramify on the surface of the brain and return the blood from the cortical substance into the venous sinuses. They lie for the most part in the sulci between the gyri, but some pass over the gyri from one sulcus to another. They consist of two sets: a superior and an inferior.

(1) The **superior cerebral** veins [venæ cerebri superiores] (fig. 517), some eight to twelve in number on each side, are formed by the union of branches from the convex and medial surfaces of the cerebrum. Those from the convex surface pass medially and forward toward the longitudinal fissure, where they are joined by the branches coming from the medial surface. After receiving a sheath from the arachnoid, they enter obliquely into the superior sagittal

sinus, running for some distance in its walls. These veins freely communicate with each other, thus differing from the cortical arteries. They also communicate with the inferior cortical veins. They may be roughly divided into (*a*) frontal; (*b*) paracentral; (*c*) central; (*d*) occipital.

(2) The **inferior cerebral** veins [venæ cerebri inferiores] (fig. 518), ramify on the base of the hemisphere and the lower part of its lateral surface. Those on the inferior surface of the frontal lobe pass, in part into the inferior sagittal sinus, and in part into the cavernous sinus. Those on the temporal lobe enter in part into the superior petrosal sinus, and in part into the transverse sinus, passing into the latter from before backward. A large vein from the occipital lobe winds over the cerebral peduncle and joins the great cerebral vein (of Galen) just before the latter enters the straight sinus. One of the inferior cortical veins is called the **middle cerebral** vein [v. cerebri media]; it runs in the lateral fissure (of Sylvius) and ends in the cavernous sinus. This vein is sometimes called the superficial Sylvian vein. Another, the great anasto-

FIG. 518.—THE VEINS OF THE BRAIN, INFERIOR SURFACE. (After Toldt, "Atlas of Human Anatomy," Rebman, London and New York.)

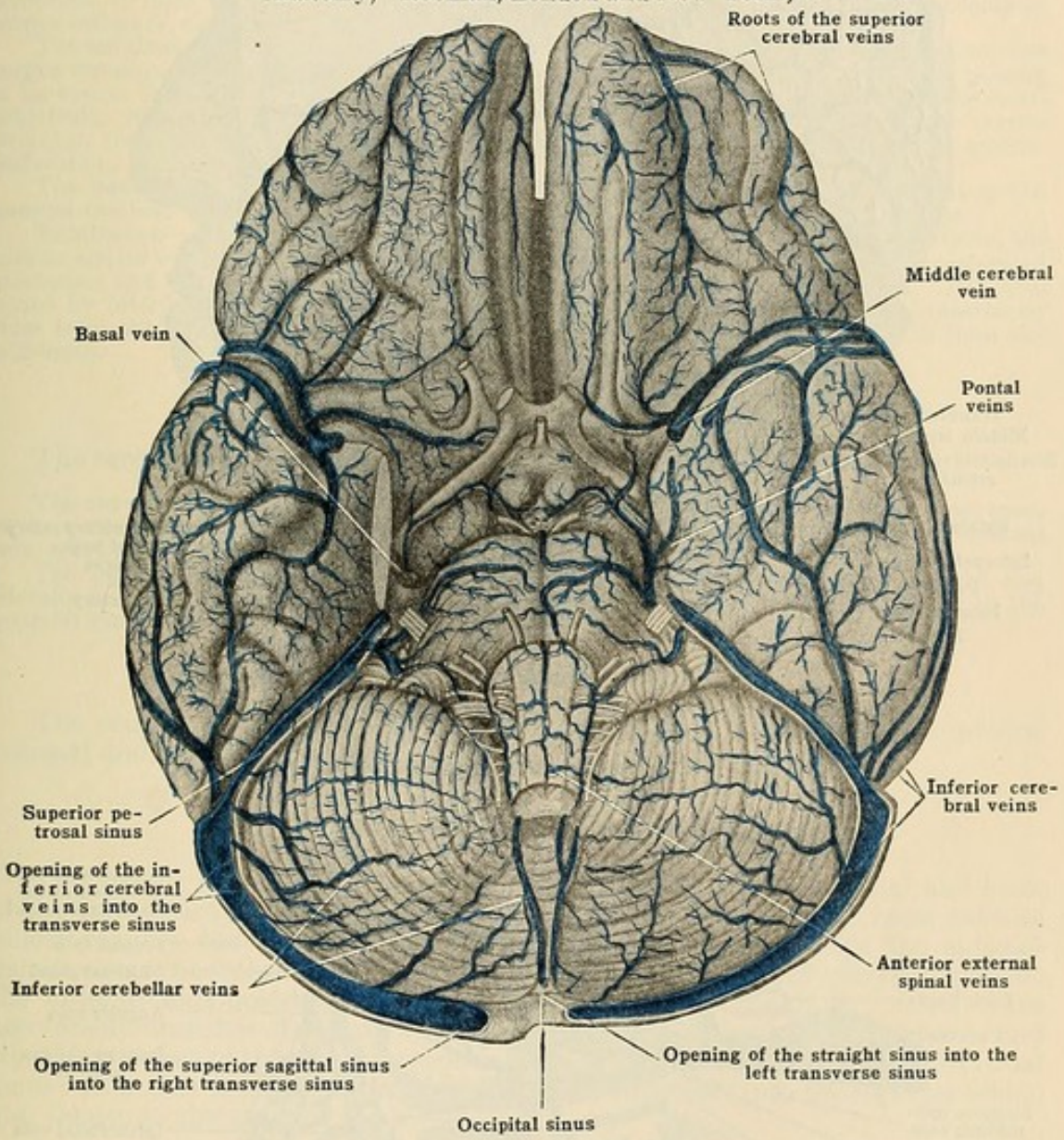

mosing vein of Trolard, a branch of the middle cerebral, establishes a communication between the superior sagittal and cavernous sinuses by anastomosing with one of the superior cortical veins. A second anastomotic vein, that of Labbé, is also a tributary of the middle cerebral, and connects the veins over the temporal lobe with the transverse sinus.

A small inferior cerebral vein, the **ophthalmomeningeal vein,** establishes a communication between the cerebral veins and those of the orbit. It communicates with the veins of the base and is usually drained by the superior ophthalmic vein. It occasionally opens into the superior petrosal sinus.

The **central** or **deep** (ganglionic) veins return blood from the internal parts of the cerebrum, and converge to the great cerebral vein.

FIG. 519.—THE VEINS OF THE BRAIN, LATERAL SURFACE. (After Toldt, "Atlas of Human Anatomy," London and New York.)

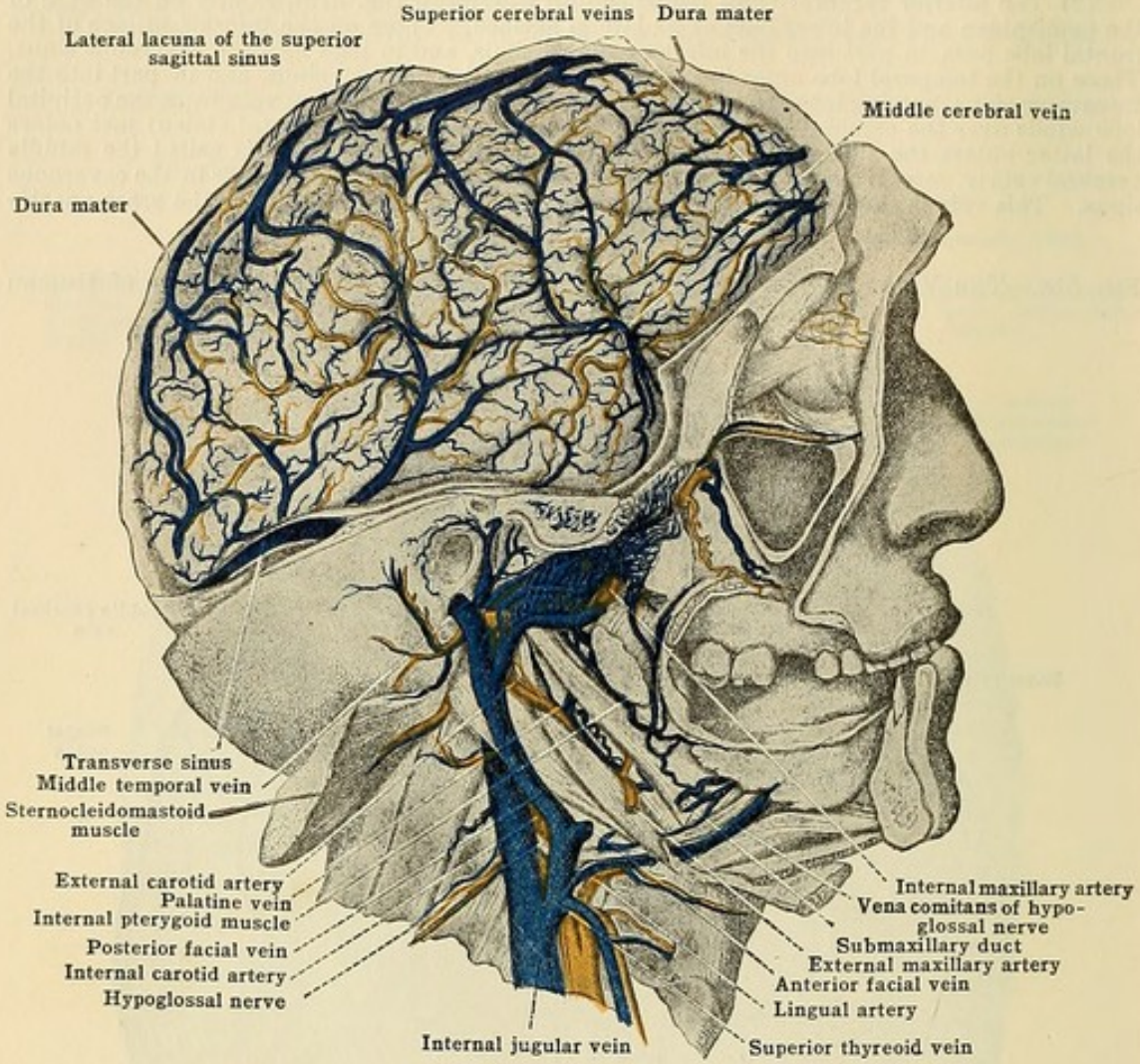

FIG. 520.—THE OPHTHALMIC VEINS. (After Quain.)

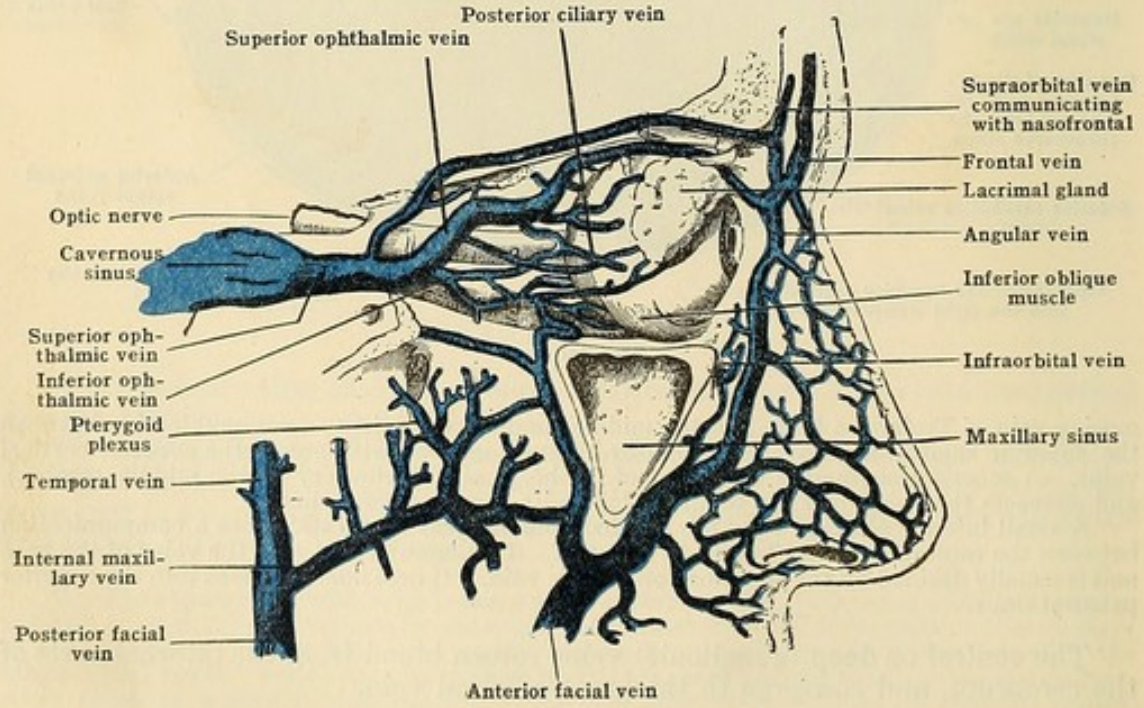

(3) The **internal cerebral** veins [vv. cerebri internæ] are two large venous trunks (the venæ Galeni) which leave the brain at the transverse fissure, that is, between the splenium of the corpus callosum and the corpora quadrigemina. In this region they unite to form the **great cerebral** vein [v. cerebri magna, Galeni], which opens into the anterior end of the straight sinus. The internal cerebral veins are formed by the union of the chorioid vein with the vena terminalis near the interventricular foramen. From this spot they run backward parallel to each other, between the layers of the tela chorioidea, and terminate in the way above mentioned.

Tributaries of the internal cerebral veins.—In addition to the vena terminalis and the chorioidal, the internal cerebral veins also receive the basal vein, the veins of the thalmus, the vein of the chorioid plexus of the third ventricle, and veins from the corpus callosum, the pineal body, the corpora quadrigemina, and posterior horn of the lateral ventricle. The united trunk, or great cerebral vein, receives veins from the upper surface of the cerebellum, and one of the posterior inferior cerebral veins.

The **chorioid** vein [v. chorioidea] runs with the chorioid plexus. It begins in the inferior cornu of the lateral ventricle, and ascends on the lateral side of the chorioid plexus along the margin of the tela chorioidea to the interventricular foramen, where it unites with the vena terminalis to form the internal cerebral vein. It receives tributaries from the hippocampus, corpus callosum, and fornix.

The **terminal** vein (or vein of the corpus striatum) [v. terminalis], formed by veins from the corpus striatum and thalamus, runs forward in the groove between those structures, passing in its course beneath the stria terminalis, and joins the chorioid (choroid) vein at the interventricular foramen. **Tributaries.**—It receives, in addition to the veins from the corpus striatum, thalamus and fornix, the **vena septi pellucidi** which receives blood from the septum pellucidum, and anterior cornu of the lateral ventricle.

The **basal** vein [v. basalis], runs backward over the cerebral peduncle, and enters the internal cerebral vein near the union of that vessel with the vein of the opposite side.

Tributaries.—A vein, the deep Sylvian, from the insula and surrounding convlutions; the inferior striate veins from the corpus striatum, which they leave through the anterior perforated substance; and the anterior cerebral veins from the front of the corpus callosum. It is also joined by interpenduncular veins from the structures in the interpeduncular space; ventricular veins from the inferior cornu of the lateral ventricle; and by mesencephalic veins from the mid-brain.

The Cerebellar Veins

The **cerebellar** veins are divided into the **superior** and **inferior.**

The **superior** [vv. cerebelli superiores] ramify on the upper surface of the cerebellum; some of them run medially over the superior vermis to join the straight sinus and great cerebral vein; others run laterally to the transverse and superior petrosal sinuses.

The **inferior** [vv. cerebelli inferiores], larger than the superior, run, some forward and laterally to the inferior petrosal and transverse sinuses, and others directly backward to the occipital sinus.

The Veins of the Medulla and Pons

The veins from the **medulla oblongata** and the **pons** terminate in the inferior petrosal and transverse sinuses.

4. THE VEINS OF THE NASAL CAVITIES

The venous plexuses on the inferior nasal concha (turbinate bone) and back of the septum are described with the Nose. The veins leaving the nasal cavities follow roughly the course of their corresponding arteries. Thus the spheno-palatine veins pass through the spheno-palatine foramen into the pterygoid plexus; the anterior and posterior ethmoidal veins join the ophthalmic. Small veins accompany branches of the external maxillary artery through the nasal bones and frontal processes of the maxillary bones, and end in the angular and anterior facial veins; and other small veins pass from the nose anteriorly into the superior labial, and thence to the anterior facial.

5. THE VEINS OF THE EAR

The veins from the external ear and external auditory meatus join the posterior facial and posterior auricular veins. The veins from the tympanum open into the superior petrosal sinus and posterior facial vein. The blood from the labyrinth flows chiefly through the **internal auditory** veins [vv. auditivæ internæ], which lie with the internal auditory artery in the internal auditory meatus, and enters the transverse or inferior petrosal sinus. Some of the blood from the labyrinth, however, passes through the vestibular vein which lies in the aquæductus

vestibuli, into the inferior petrosal sinus. Some also passes through the **vena canaliculi cochleæ** which traverses the canal of the same name and empties into the commencement of the internal jugular vein.

6. THE VEINS OF THE ORBIT

The blood from the eyeball and orbit is returned by the superior ophthalmic vein into the cavernous sinus. This vein and its tributaries have no valves, and communicate with the frontal, supraorbital, inferior cerebral, and other veins. Hence under certain conditions, as from pressure on the cavernous sinus, the blood

FIG. 521.—THE VEINS OF THE ORBIT.

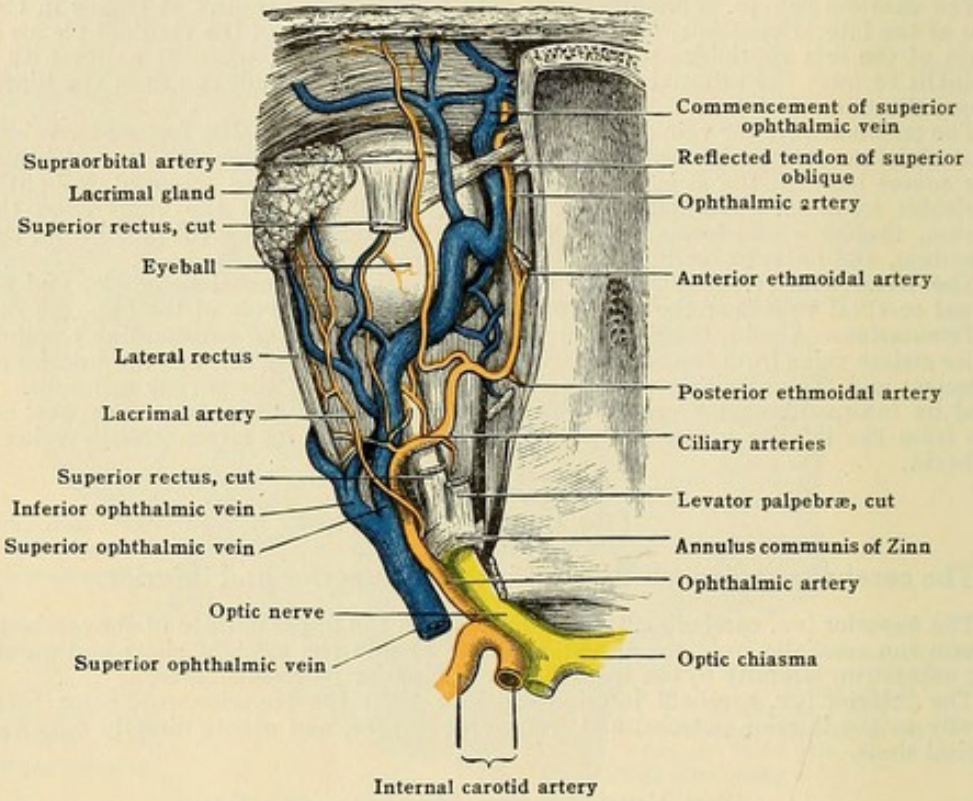

may flow in the contrary direction to the normal—i. e., from behind forward into the frontal and supraorbital, and thence through the angular vein into the anterior facial; or upward into the cerebral venous system. In this way pressure on the retinal veins is quickly relieved, and little or no distension occurs in cases of obstruction in the cavernous sinus.

The **superior ophthalmic** vein [v. ophthalmica superior] begins at the medial angle of the eyelid by a free communication with the frontal, supraorbital, and angular veins, and thence runs backward and laterally with the ophthalmic artery across the optic nerve to the medial end of the superior orbital (sphenoidal) fissure, where it is usually joined by the inferior ophthalmic vein. It then passes backward between the two heads of the lateral rectus muscle below the sixth nerve, leaves the orbit through the medial end of the superior orbital (sphenoidal) fissure and enters the front part of the cavernous sinus. In this course it lies anterior and superficial to the ophthalmic artery.

Tributaries.—(1) The naso-frontal vein; (2) the superior muscular veins; (3) the veins of the lids and conjunctiva; (4) the ciliary veins; (5) the anterior and posterior ethmoidal veins; (6) the lacrimal vein; (7) the central vein of the retina; and (8) the inferior ophthalmic vein.

(1) The **naso-frontal** vein [v. naso-frontalis] begins by a free communication with the supra-orbital vein and enters the orbit through the frontal notch or foramen. It frequently joins the superior ophthalmic vein quite far back in the orbit (see fig. 520).

(2) The **muscular** veins [vv. musculares] are derived from the levator palpebræ, superior rectus, superior oblique, and medial rectus.

(3) The **palpebral** and **conjunctival** veins [vv. palpebrales; vv. conjunctivales ant. et post.], both anterior and posterior, open into the superior ophthalmic.

(4) The **ciliary** veins, the veins of the eyeball, are divided into two sets. An **anterior** [vv. ciliares ant.] emerge from the eyeball with the anterior ciliary arteries, and open

into the muscular veins returning the blood from the four recti. They form a circumcorneal ring of **episcleral** veins [vv. episclerales]. The **posterior set,** which drain the **venæ vorticosæ,** leave the globe midway between the cornea and the entrance of the optic nerve. The latter veins are four or five in number, the upper ending in the superior, the lower in the inferior ophthalmic vein (fig. 520).

(5) The **anterior and posterior ethmoidal** veins [vv. ethmoidales ant. et post.), correspond in their course with the arteries of the same name. They enter the orbit through the anterior and posterior ethmoidal foramina, and join either the ophthalmic direct, or one or other of the superior muscular branches.

(6) The **lacrimal** vein [v. lacrimalis] returns the blood from the lacrimal gland, and corresponds in its course to the lacrimal artery.

(7) The **central vein of the retina** [v. centralis retinæ] runs with the central artery in the optic nerve. It joins the superior ophthalmic at the back of the orbit.

(8) The **inferior ophthalmic** vein [v. ophthalmica inferior], smaller than the superior, is formed near the front of the orbit by the confluence of the inferior muscular with the lower posterior ciliary veins. It runs backward below the optic nerve, along the floor of the orbit, and either joins the superior ophthalmic vein, or opens separately into the cavernous sinus. A large communicating branch passes downward through the inferior orbital (spheno-maxillary) fissure to join the pterygoid plexus of veins. It receives muscular twigs from the inferior and lateral rectus and from the inferior oblique, and some posteior ciliary veins.

7. THE VEINS OF THE PHARYNX AND LARYNX

The **pharyngeal** veins [vv. pharyngeæ] are arranged in the form of a plexus, between the constrictor muscles and the pharyngeal or prevertebral fascia. The **pharyngeal plexus** receives branches from the mucous membrane, the pterygoid canal [vv. canalis pterygoidei] from the soft palate, the Eustachian tube and the anterior recti and longus colli muscles. Above, it communicates with the pterygoid plexus of veins; below it drains into the internal jugular vein.

The **veins of the larynx** end partly in the **superior laryngeal** vein [v. laryngea superior], which opens into the internal jugular vein, and partly in the **inferior laryngeal** vein [v. laryngea inferior], which terminates in the plexus thyroideus impar. The laryngeal plexus of veins communicates with the pharyngeal plexus.

8. THE DEEP VEINS OF THE NECK

The **deep veins of the neck** include the internal jugular, vertebral, deep cervical, erior thyreoid, thyreoidea ima, thymic, tracheal, and œsophageal veins.

The Internal Jugular Vein

The **internal jugular** vein [v. jugularis interna] begins at the jugular fossa, and is the continuation of the transverse sinus. It passes down the neck, in company first with the internal carotid artery and then with the common carotid artery, to a point a little lateral to the sterno-clavicular articulation, where it joins the subclavian to form the innominate vein. At its commencement in the larger, posterior and lateral part of the jugular foramen, it is somewhat dilated, forming the **superior bulb** of the jugular vein [bulbus v. jugularis superior] (fig. 522). This dilated part of the internal jugular vein lies in the jugular fossa of the temporal bone and is therefore in immediate relation to the floor of the tympanum. At first the internal jugular lies in front of the rectus capitis lateralis, and behind the internal carotid artery, from which it is separated by the hypoglossal, glossopharyngeal, and vagus nerves, and by the carotid plexus of the sympathetic. As it descends it passes gradually to the lateral side of the internal carotid, and retains this relation as far as the upper border of the thyreoid cartilage. Thence it runs to its termination along the lateral side of the common carotid artery, being contained in the same sheath with it and the vagus nerve, but separated from these structures by a distinct septum. The vein generally overlaps the artery in front. About 2.5 cm. (1 in.) above its termination it contains a pair of imperfect valves below which a second dilation usually occurs in the vein. This, **the inferior bulb** [bulbus v. jugularis inferior], extends as low as the junction of the internal jugular with the subclavian. It not infrequently receives the termination of the external jugular vein.

Tributaries.—At the superior bulb the internal jugular vein receives the inferior petrosal sinus; the vein of the cochlear canaliculus, and a meningeal

vein; opposite the angle of the jaw, veins from the pharyngeal plexus, and often a communicating branch from the external jugular vein; opposite the bifurcation of the carotid it is joined by the common facial, and a little lower down by the lingual, sternomastoid, and the superior thyreoid veins. At the level of the cricoid cartilage by the middle thyreoid when this vein is present.

The inferior petrosal sinus is described with the other sinuses of the brain (p. 652); the pharyngeal plexus with the veins of the pharynx (see p. 659); and the common facial vein with the superficial veins of the scalp and face (p. 646).

The **lingual** vein [v. lingualis], begins near the tip of the tongue, where it accompanies the arteria profunda linguæ. It lies at first beneath the mucous membrane covering the under surface of the tongue. It then passes backward medial to the hyo-glossus, and in company with the lingual artery. After receiving the **sublingual** vein [v. sublingualis] and the **dorsal**

FIG. 522.—THE INTERNAL JUGULAR VEIN. (After Henle).

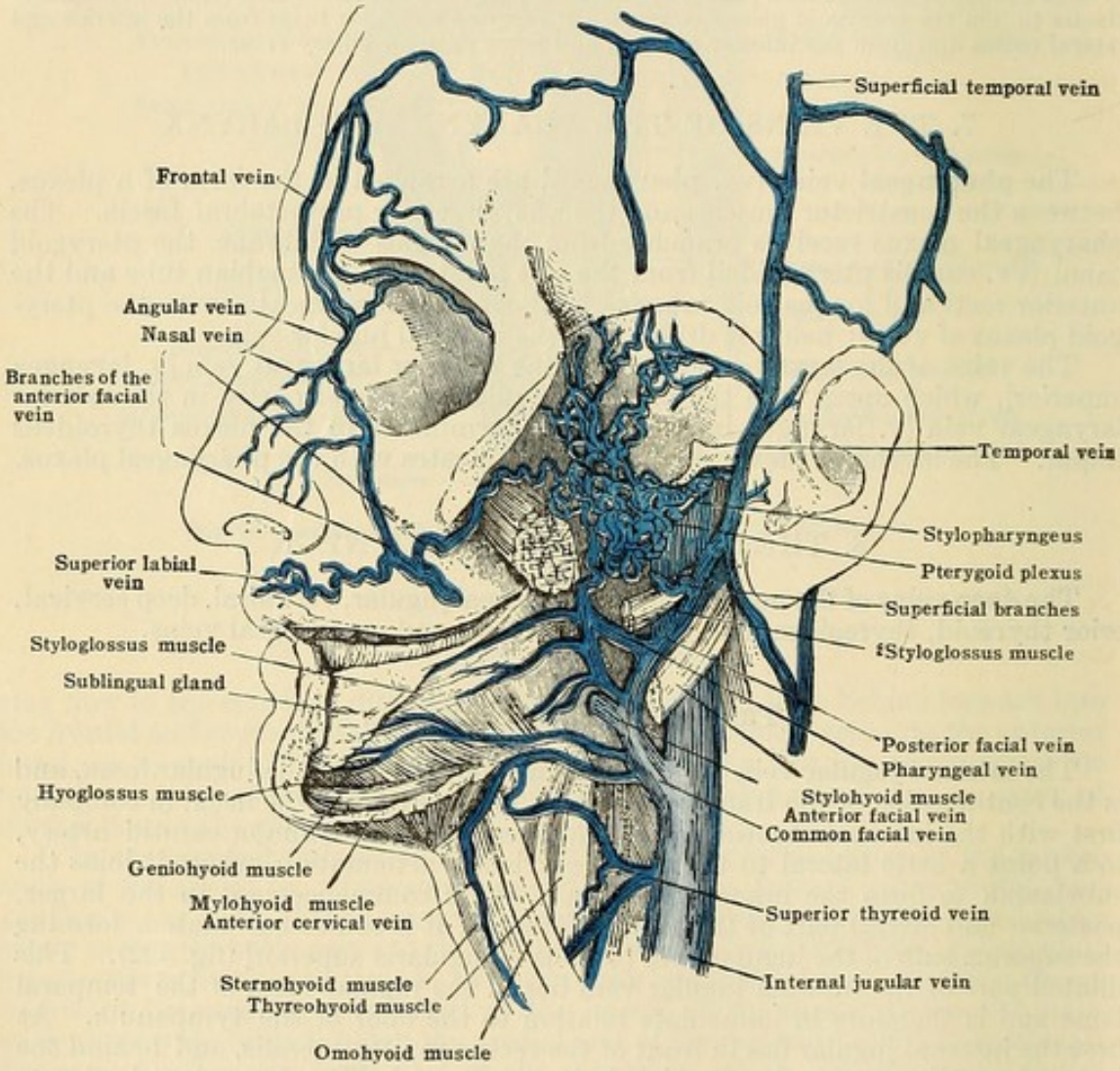

lingual veins [vv. dorsales linguæ], which roughly correspond to their respective arteries, it is joined by the small **v. comitans nervi hypoglossi** which follows the upper border of the hypoglossal nerve. The trunk finally crosses the common carotid artery and opens into the internal jugular vein. The lingual vein communicates with the pharyngeal veins and with tributaries of the anterior facial. It occasionally terminates in the posterior or in the common facial vein. The **sternomastoid** vein [v. sternocleidomastoidea] accompanies the artery of the same name and empties into the internal jugular.

The **superior thyreoid** vein [v. thyreoidea superior] emerges from the upper part of the thyreoid gland, in which it freely anastomoses with the other thyreoid veins. This anastomosis, the **plexus thyreoideus impar,** occurs both in the substance of the organ and on its surface beneath the capsule. The vein then passes upward and laterally into the internal jugular vein, crossing the common carotid artery in its course. At times it forms a common trunk with the common facial vein. Its **tributaries** are the sterno-hyoid, sterno-thyreoid, and thyreo-hyoid veins from the muscles bearing those names; and the crico-thyreoid and superior laryngeal veins which correspond with the crico-thyreoid and superior laryngeal arteries respectively. These require no special description.

A separate vein frequently passes out from the capsule of the thyreoid gland near the lower part of the lateral lobe, crosses the common carotid, and opens into the main superior thyreoid vein or into the internal jugular vein a little below the cricoid cartilage. In the former case it is regarded as part of the superior thyreoid vein system; in the latter it is generally known as the **middle thyreoid** vein.

The Vertebral Vein

The **vertebral** vein [v. vertebralis] does not accompany the vertebral artery in its fourth stage, that is, within the skull, but begins in the posterior vertebral venous plexus of the suboccipital triangle. It then enters the foramen in the transverse process of the altas, and passes with the vertebral artery through the foramina in the transverse processes of the cervical vertebræ, forming a plexus around the artery. On leaving the transverse process of the sixth cervical vertebra it crosses in front of the subclavian artery and opens into the innominate vein. It has one or two semilunar valves at its entrance into the innominate vein. In the suboccipital triangle it communicates with the internal vertebral venous plexuses, with the deep cervical, and occipital veins, and is joined by veins from the recti and oblique muscles and the pericranium.

Tributaries.—As it passes down the neck it receives (1) intervertebral veins, which issue along with the cervical nerves, from the spinal canal; (2) tributaries from the anterior and posterior vertebral venous plexus from the bodies of the cervical vertebræ and their transverse processes; and (3) tributaries from the deep cervical muscles. Just before it terminates in the innominate it is joined by (4) the anterior vertebral vein, a small vein which accompanies the ascending cervical artery, and, sometimes, by the deep cervical vein.

The Deep Cervical Vein

The **deep cervical** vein [v. cervicalis profunda], larger than the vertebral, passes down the neck posterior to the cervical transverse processes. It corresponds to the deep cervical artery from which it is separated by the semispinalis cervicis muscle.

It begins in the posterior vertebral venous plexus and receives tributaries from the deep muscles of the neck. It communicates with, or entirely drains, the occipital vein by a branch which perforates the trapezius muscle. The deep cervical vein then passes forward beneath the transverse process of the seventh cervical vertebra to open into the innominate vein near the vertebral, or into the latter near its termination. Its orifice is guarded by a pair of valves.

The Inferior Thyreoid and Thyreoidea Ima Veins

The **inferior thyreoid** veins [vv. thyreoidea inferiores] descend from the lower part of the thyreoid gland obliquely lateralward to the innominate veins. The **right vein** crosses the innominate artery just before its bifurcation, and ends in the right innominate vein a little above the superior vena cava. It receives inferior laryngeal veins and veins from the trachea, and has valves at its termination in the innominate. The **left vein** passes obliquely over the trachea behind the sterno-thyreoid muscle, and opens into the left innominate vein. It also receives laryngeal and tracheal veins, and sometimes the thyreoidea ima; it is guarded by valves where it opens into the innominate trunk.

The **thyreoidea ima** vein [v. thyreoidea ima] is single and placed approximately in the median line. It begins in the thyreoid isthmus from the plexus thyreoideus impar, runs downward upon the anterior surface of the trachea, and opens into the left innominate vein or into the left inferior thyreoid.

The Thymic, Tracheal and Œsophageal Veins

These small veins usually open into the left innominate vein. The **thymic veins** [vv. thymicæ], small in the adult, open into the left innominate or into the inferior thyreoid or thyreoidea ima vein. The **tracheal** veins [vv. tracheales] anastomose with the laryngeal and bronchial veins. The **œsophageal** veins [vv. œsophageæ] from the upper part of the œsophagus, anastomose with the lower œsophageal veins and with the pharyngeal plexus.

THE VEINS OF THE THORAX

THE SUPERFICIAL VEINS OF THE THORAX

The **superficial veins** of the front of the thorax can be seen in fig. 537. They form a plexus over the entire chest which the portion over the mammary gland is called the mammary plexus. The laterally placed lateral thoracic and costo-axillary veins drain the mammary plexus and communicate with the thoraco-epigastric vein. These three veins terminate in the axillary vein (p. 671). The veins nearer the median line are drained by the internal mammary vein and its anterior intercostal and superior epigastric tributaries. The veins over the entire thorax are in free communication with the superficial veins of the abdominal wall (p. 683).

THE DEEP VEINS OF THE THORAX

The **deep veins of the thorax** are:—the pulmonary veins, and the vena cava superior and its innominate and other tributaries. Of these veins, the pulmonary, the vena cava superior, and the innominate veins have already been described, as have the tributaries of the latter arising in the neck.

The following veins are described below:—(1) The azygos and ascending lumbar veins, which discharge their blood into the vena cava superior; (2) the veins of the vertebral column, which are tributary to the azygos veins through the intercostals; (3) the internal mammary veins, and (4) the superior phrenic, anterior mediastinal and pericardiac veins, all of which open into the innominate veins.

I. THE AZYGOS AND ASCENDING LUMBAR VEINS

The azygos veins are longitudinal veins, the remnants of the posterior cardinals, which are the main collecting trunks for the posterior part of the body in the embryo. They lie along the sides of the thoracic vertebræ, and collect the blood from the intercostal veins; they are the upward continuation of longitudinal anastomotic trunks, the **ascending lumbar veins** which take origin in the abdomen. The azygos veins are three in number, the azygos (azygos major) on the right side, and the hemiazygos (azygos minor) and accessory hemiazygos (azygos tertia) on the left.

The **azygos** vein [v. azygos] begins in the abdomen as a continuation upward of the ascending lumbar vein. Through this means it connects with the iliac veins and it has also an anastomosis with the vena cava inferior which may become very important in cases of obstruction of the vena cava. It runs up through the posterior mediastinum on the right side of the front of the bodies of the thoracic vertebræ as high as the fourth thoracic vertebra, in this part of its course lying to the right of the aorta and thoracic duct; it then curves forward over the root of the right lung, and opens into the vena cava superior immediately before the latter pierces the pericardium.

It usually contains an imperfect pair of valves at the point where it turns forward from the fourth thoracic vertebra to arch over the root of the lung; and still more imperfect valves are found at varying intervals lower down the vein.

It receives the intercostal veins of the right side, except the first two or three. These veins (usually excepting the first) are collected into a common trunk before joining the azygos vein. It also receives the hemiazygos and accessory hemiazygos, the right posterior bronchial vein, and small œsophageal and posterior mediastinal veins.

The **hemiazygos** vein [v. hemiazygos] begins in the abdomen by communicating, like the azygos vein, with the ascending lumbar vein of its own side. It courses up the posterior mediastinum to the left of the bodies of the lower thoracic vertebræ as high as the eighth or ninth, where it turns obliquely to the right, and, crossing in front of the vertebral column behind the aorta and the œsophagus, opens into the vena azygos. In its course it crosses over three or four of the lower left intercostal arteries, and is covered by the pleura.

Tributaries.—(1) The lower four or five left intercostal veins; (2) the lower end of the accessory hemiazygos vein (sometimes); (3) small left mediastinal veins; and (4) the lower left œsophageal veins.

The **accessory hemiazygos** [v. azygos accessoria] varies considerably in size, position, and arrangement, and is often continuous with, or drained by, the left superior intercostal vein. It lies in the posterior mediastinum by the left side of the bodies of the fifth, sixth, and seventh or eighth thoracic vertebræ, and is more

FIG. 523.—THE SUPERIOR AND INFERIOR VENÆ CAVÆ, THE INNOMINATE VEINS, AND THE AZYGOS VEINS.

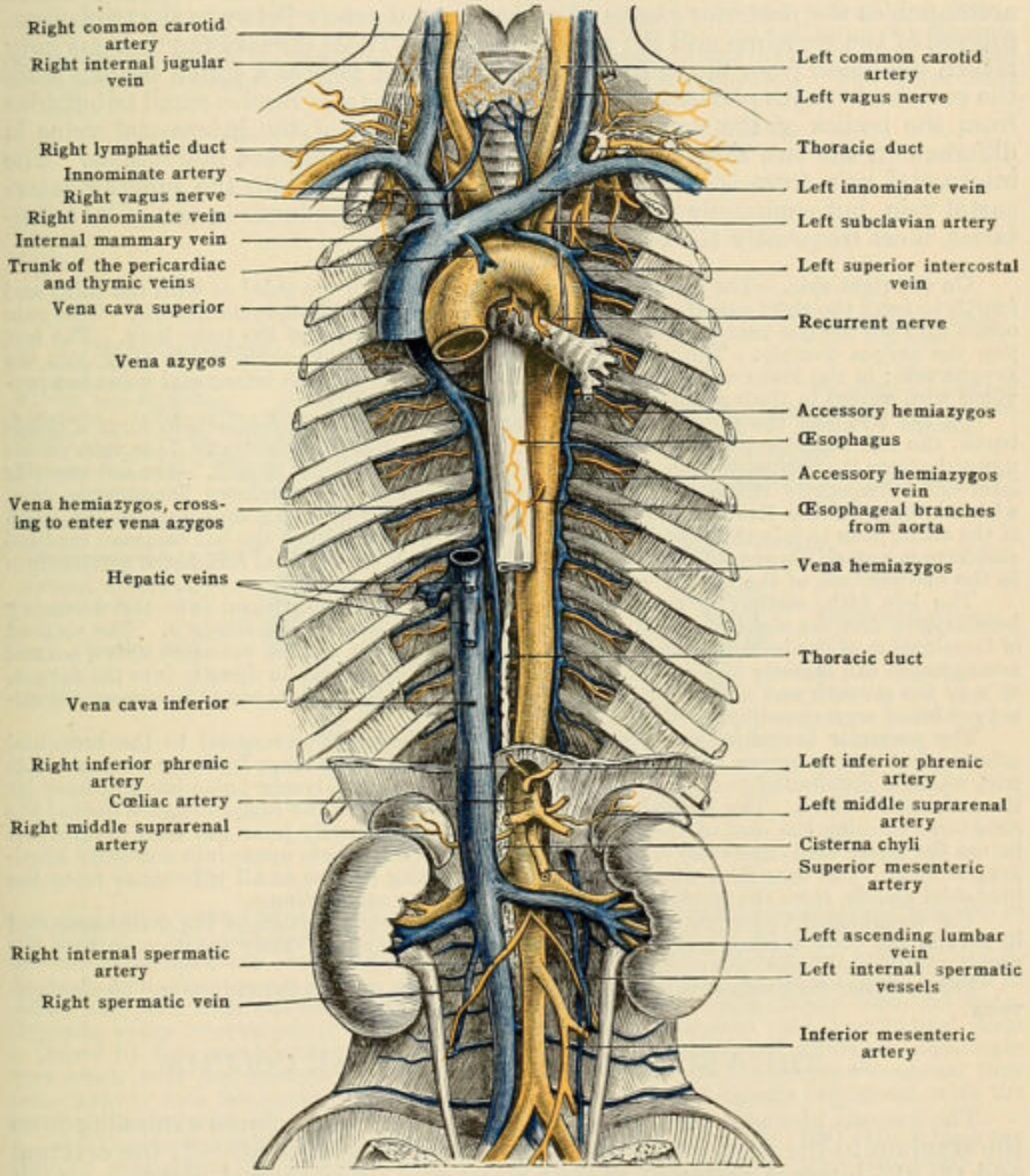

or less vertical in direction. It communicates above with the left superior intercostal vein, and below either joins the hemiazygos or passes obliquely across the seventh or eighth thoracic vertebra to join the azygos vein. It crosses the corresponding left intercostal arteries, and is covered by the pleura.

Tributaries.—(1) The fourth, fifth, sixth, seventh, and sometimes the eighth intercostal veins; and (2) the left posterior bronchial vein.

The **ascending lumbar** vein [v. lumbalis ascendens] begins, on either side, in the neighbourhood of the sacral promontory. It is here in free communication, by

means of the anterior sacral plexus, with the middle and lateral sacral veins, and with the common iliac, hypogastric and ilio-lumbar veins. It ascends in front of the lumbar transverse processes communicating with the lumbar veins, the vena cava inferior and, usually, with the renal vein. The right vein enters the thorax between the aorta and the right medial crus of the diaphragm, and is continued upward as the vena azygos. The left vein pierces the left medial crus and becomes the hemiazygos.

The intercostal veins [vv. intercostales].—The intercostal veins are twelve in number on each side, the last one being subcostal. They correspond to the intercostal arteries. There is one vein to each artery, the vein lying above the artery whilst in the intercostal space. Each vein receives a dorsal tributary which accompanies the posterior ramus of an intercostal artery between the transverse process of the vertebræ and the neck of the rib. These dorsal branches not only return the blood from the muscles of the back, but receive a spinal branch from the vertebral venous plexuses. The intercostal veins also receive small tributaries from the bodies of the vertebræ. The termination of the intercostal veins is different on the two sides and also varies greatly in different individuals. The intercostal vein from the first space on either side may join the superior intercostal vein, but commonly opens directly into the innominate or one of its tributaries, most frequently the vertebral.

On the right side.—The second intercostal vein joins with the third or with the third and fourth to form the **right superior intercostal** vein [v. intercostalis suprema dextra]. This vein opens into the azygos vein as the latter is arching over the root of the right lung. The rest join the azygos directly. The upper of these have well-marked valves where they join the azygos vein; in the lower veins these valves are imperfect. All the intercostal veins are provided with valves in their course between the muscles.

On the **left side** the second intercostal vein joins the third and fourth to form a single trunk, the **left superior intercostal** vein [v. intercostalis suprema sinistra]. This vein passes upward across the arch of the aorta and opens into the left innominate vein. The left superior intercostal frequently communicates at its lower end with the accessory hemiazygos vein, which is occasionally tributary to it. In most cases a small tributary runs up over the front of the aortic arch to join the superior intercostal vein; it is a vestige of the left common cardinal and from it a small fibrous cord can often be traced through the vestigial fold of the pericardium to the oblique vein of the left atrium (p. 523).

The left fifth, sixth and seventh intercostal veins commonly open into the accessory hemiazygos, and the eighth or ninth and succeeding veins into the hemiazygos. The method of termination of the intercostal veins of the left side is subject to such variation that a normal arrangement can scarcely be said to exist at all. The eighth may open directly into the azygos, as may the seventh and ninth or even more of the veins; the hemiazygos and accessory hemiazygos being correspondingly reduced in size.

The **posterior bronchial** veins [vv. bronchiales posteriores] correspond to the bronchial arteries, but do not return the whole of the blood carried to the lungs by those vessels—that part which is distributed to the smaller bronchial tubes and the alveolæ being brought back by the pulmonary veins. The posterior bronchial veins issue from the lung substance behind the structures forming the root of the lung. The right vein generally joins the vena azygos just before the latter vein enters the superior vena cava. The left vein opens into accessory hemiazygos vein. The bronchial veins at the root of the lung receive small tributaries from the bronchial glands, from the trachea, and from the posterior mediastinum.

The **œsophageal** veins [vv. œsophageæ] from the thoracic portion of the œsophagus end in part in the vena azygos, and in part in the vena hemiazygos. They anastomose with the upper œsophageal veins, and with the coronary vein.

The **posterior mediastinal** veins, small and numerous, open into the azygos and hemiazygos veins.

2. THE VEINS OF THE VERTEBRAL COLUMN

The venous plexuses around and within the vertebral column extending from the cranium to the coccyx may be divided into two categories:—(1) the **external** and (2) the **internal vertebral venous plexuses.** The external plexuses consist of two parts, the *anterior vertebral venous plexuses* situated on the anterior aspect of the vertebral bodies and the *posterior vertebral venous plexuses* ramifying over the posterior aspect of the vertebral arches, spines, and transverse processes. The internal plexuses consist of *two longitudinal venous sinuses* situated between the vertebræ and the posterior longitudinal ligament, and of two *vertebral venous retia* placed immediately external to the dura mater. The sinuses of the internal plexuses communicate freely with one another and with the internal retia and external plexuses. They receive the external spinal veins and the *basivertebral veins* from the bodies of the vertebræ. The venous circulation of the vertebral

column is drained by the vertebral, intercostal, lumbar and sacral veins either directly or by means of (3) the **intervertebral** veins.

1. The **external vertebral venous plexuses** [plexus venosi vertebrales externi] include the following:

(*a*) The **anterior vertebral venous plexuses** [plexus venosi vertebrales anteriores] (fig. 524) consist of small veins ramifying in front of the bodies of the vertebræ. These veins communicate with the basivertebral veins and are larger in the cervical region than elsewhere.

(*b*) The **posterior vertebral venous plexuses** [plexus venosi vertebrales posteriores] (fig. 524) are situated around the transverse, articular, spinous processes and laminæ of the vertebræ. Communications take place between the plexuses of each segment and with the veins of the neighbouring muscles and integuments. Branches are also sent, through the ligamenta flava, to the internal vertebral venous plexuses, and, between the transverse processes, to the intervertebral veins.

2. The **internal vertebral venous plexuses** [plexus venosi vertebrales interni] (fig. 524):—

(*a*) The two **longitudinal vertebral sinuses** [sinus vertebrales longitudinales] run throughout the entire length of the vertebral canal. They are situated behind the bodies of the vertebræ on either side, between the bone and the posterior longitudinal ligament. The sinuses have

FIG. 524.—THE VEINS OF THE VERTEBRAL COLUMN.

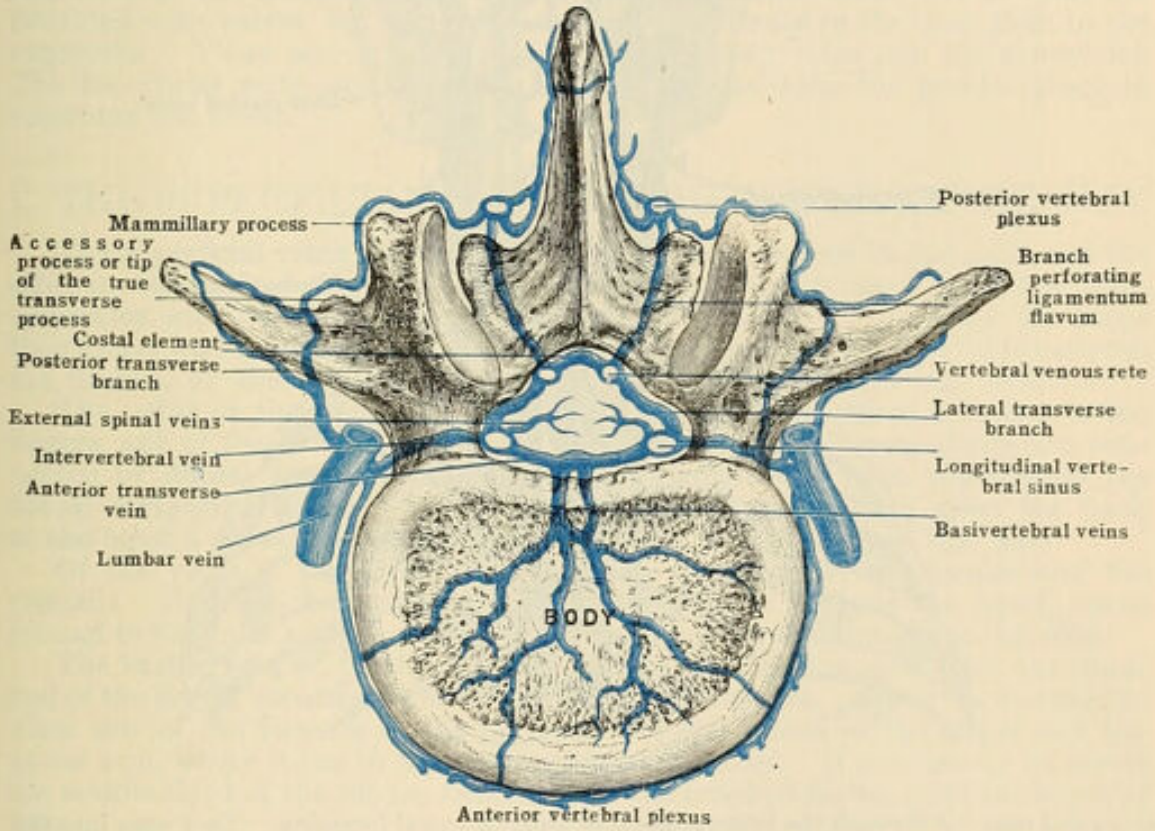

extremely thin walls, and their interior is made irregular by numerous folds but no true valves are present. The calibre of the longitudinal sinuses is reduced by constrictions opposite the intervertebral discs; the constrictions alternating with dilatations opposite the vertebral bodies. At each dilatation there occurs a cross communication between the longitudinal sinuses of either side, and each receives a basivertebral vein from the corresponding vertebral body. Opposite every intervertebral foramen and anterior sacral foramen each longitudinal sinus is joined by the corresponding intervertebral vein. The longitudinal sinuses communicate very freely with one another, and with the vertebral retia. At the foramen magnum they communicate with the basilar plexus and, by means of the **rete canalis hypoglossi,** with the internal jugular vein.

(*b*) The **venous rete of the vertebræ** [retia venosa vertebrarum] (fig. 524) extend from the foramen magnum to the coccyx. They consist of two main retia situated posteriorly and laterally to the dura between the latter and the vertebral arch. They communicate very freely with one another across the median line; with the posterior external plexus by means of twigs perforating the ligamenta flava; and with the longitudinal vertebral sinuses by means of lateral branches. At the foramen magnum they communicate with the occipital sinus.

(*c*) The **external spinal** veins consist of two sets—anterior and posterior—which are drained by means of veins following the nerve roots, into the internal vertebral venous plexus.

The **anterior external spinal** veins [vv. spinales externæ anteriores] form a tortuous anastomosing vessel in the region of the anterior median fissure.

The **posterior external spinal** veins [vv. spinales externæ posteriores], smaller than the anterior run longitudinally on the posterior surface of the cord.

The external spinal veins form a wide-meshed plexus in the pia mater which drains the **internal spinal** veins [vv. spinales internæ] (see SPINAL CORD).

(*d*) The **basivertebral** veins [vv. basivertebrales] (fig. 524) collect the blood from the cancellous tissue of the bodies of the vertebræ, and consist of a tunica intima only. They take a radial direction converging to the transverse vessels connecting the longitudinal vertebral sinuses. They communicate with the anterior external plexus and with the intercostal veins.

3 The **intevertebral** veins [vv. intervetebrales] (fig. 524), emerge from each longitudinal

FIG. 525.—THE VERTEBRAL VENOUS PLEXUSES. (After Henle.)

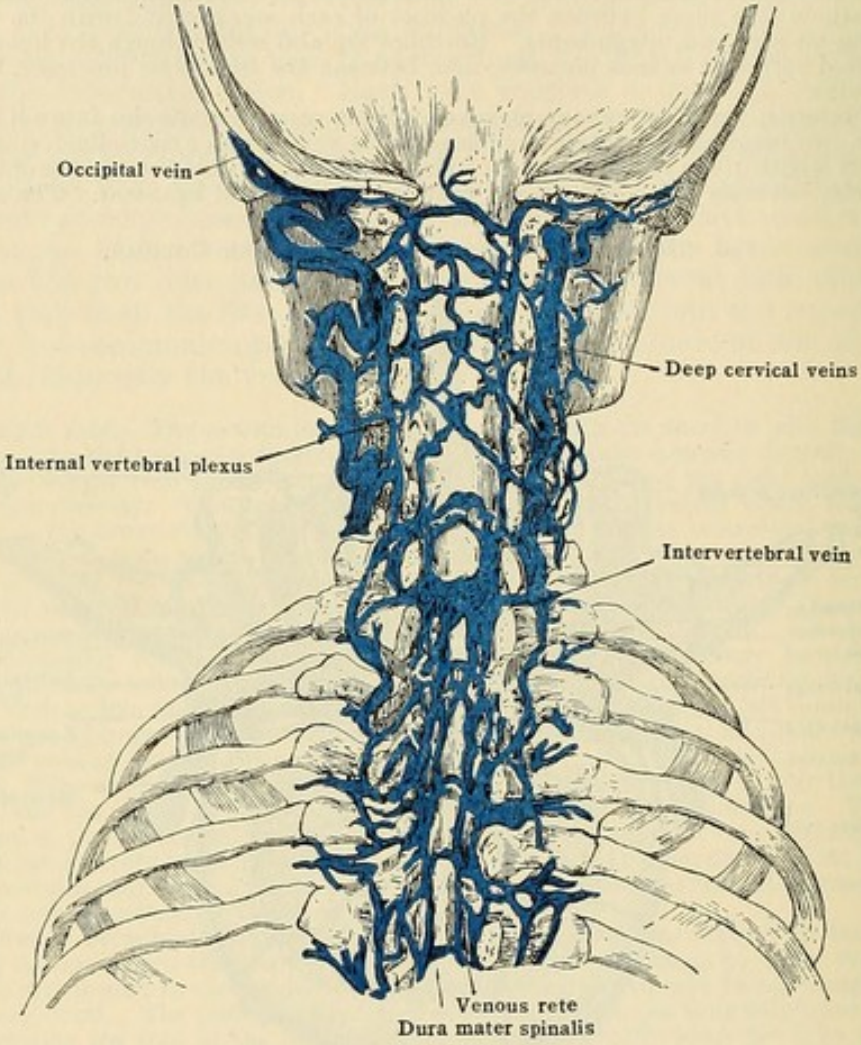

sinus and pass out through the intervertebral or anterior sacral foramina. They open into the vertebral, intercostal, lumbar or sacral veins according to region and receive numerous tributaries from the anterior and posterior external vertebral venous plexuses. They are instrumental in draining the venous system of the vertebral column and spinal cord.

3. THE INTERNAL MAMMARY VEIN

The internal mammary vein [v. mammaria interna] is formed by the union of the venæ comitantes corresponding to the superior epigastric and musculo-phrenic arteries. The right and left internal mammary veins pass upward, in company with the corresponding arteries, to open into the right and left innominate respectively.

Tributaries.—In addition to the superficial veins of the thorax, the internal mammary veins receive the anterior intercostal, anterior bronchial and pericardiac veins.

The **superior epigastric** vein [v. epigastrica superior] assists in the drainage of the subcutaneous abdominal veins [vv. subcutaneæ abdominis].

The **anterior bronchial** veins [vv. bronchiales anteriores] arise in the bronchial walls and communicate with the tracheal and posterior bronchial veins.

4. THE SUPERIOR PHRENIC, ANTERIOR MEDIASTINAL, AND PERICARDIAC VEINS

The **superior phrenic** [vv. phrenicæ superiores], the **anterior mediastinal** [vv mediastinales anteriores], and pericardiac [vv. pericardiacæ] veins are small vessels, corresponding to the arteries of those names. They pass over the arch of the aorta and open into the lower and anterior part of the left innominate.

THE VEINS OF THE UPPER EXTREMITY

The **veins of the upper limb** consist of two sets—a **superficial** and a **deep.** The superficial veins ramify in the subcutaneous tissue above the deep fascia, and they do not accompany arteries. The deep veins accompany the arteries, and have practically the same relations as those vessels. The superficial and deep veins communicate at frequent intervals through the intermuscular veins which run between the muscles and perforate the deep fascia. Both sets of veins are provided with valves, but the valves are more numerous in the deep than in the superficial. There are usually valves where the deep veins join the superficial. The superficial veins are larger than the deep, and take the greater share in returning the blood.

I. THE SUPERFICIAL VEINS OF THE UPPER EXTREMITY

The **superficial veins** begin in two irregular plexuses, one in the palm and the other on the back of the hand. The plexus in the palm is much finer, and communicates with the superficial volar veins of the fingers. The latter discharge their blood into the dorsal venous rete by means of the veins of the folds between the fingers, or the **intercapitular** veins [vv. intercapitulares] (fig. 426).

The veins of the back of the hand begin in a longitudinal plexus over the fingers, and at the bases of the fingers the veins of the adjacent digits are connected by **digital venous arches** [arcus venosi digitales], from which arise the **dorsal metacarpal** veins [vv. metacarpeæ dorsales]; these form upon the back of the hand a **dorsal venous rete** [rete venosum dorsale manus] (fig. 427).

Of the veins of the arm, two stand out prominently, the basilic and the cephalic. Both of these arise from the veins of the back of the hand, curve around to the volar surface of the forearm, and pass to the upper arm (fig. 426).

The **basilic** vein [v. basilica],* arises on the back of the hand from the ulnar end of the dorsal venous rete, which usually forms an arch. It curves around the ulnar side of the forearm to the volar surface and passes to the elbow and the upper arm, where it lies in the median bicipital sulcus. It extends up to about the middle third of the sulcus, and, piercing the brachial fascia, joins the brachial vein.

The **cephalic** vein [v. cephalica],* begins at the radial end of the dorsal venous rete or arch and curves around the radial border of the forearm to the volar surface not far above the thumb. It passes to the elbow and the upper arm, but, unlike the basilic, it maintains its superficial course up to the shoulder, lying first in the lateral bicipital sulcus and then in the groove between the pectoralis major and the deltoid. Just below the clavicle it turns into the depth, and empties into the axillary vein.

In the forearm plexus one or more longitudinal veins besides these are usually distinct. One lateral to the cephalic is known as the **accessory cephalic** [v. cephalica accessoria] (formerly the radial) vein; one near the centre is known as the **median antibrachial** [v. mediana antibrachii], (formerly the anterior ulnar) vein.

At the elbow there is usually an oblique connecting branch, the **median cubital** vein [v. mediana cubiti] (formerly termed median basilic) which extends

* The basilic vein here described corresponds to the posterior ulnar and basilic; the cephalic corresponds to the median, median cephalic and cephalic of the older terminology employed in English text-books. The BNA terminology has the great advantage that it can be readily used to described any form of venous pattern. The English terminology applies only to cases in which the M-shaped arrangement occurs upon the volar surface of the elbow. Berry and Newton find the latter arrangement in only 13 per cent. out of 300 cases examined.

from the cephalic up to the basilic. In some cases this anastomosis is made by a division of the **median antibrachial** into two branches, a **median cephalic** and

FIG. 526.—THE SUPERFICIAL VEINS OF THE ARM AND FOREARM. (After Toldt, "Atlas of Human Anatomy," Rebman, uondon and New York.)

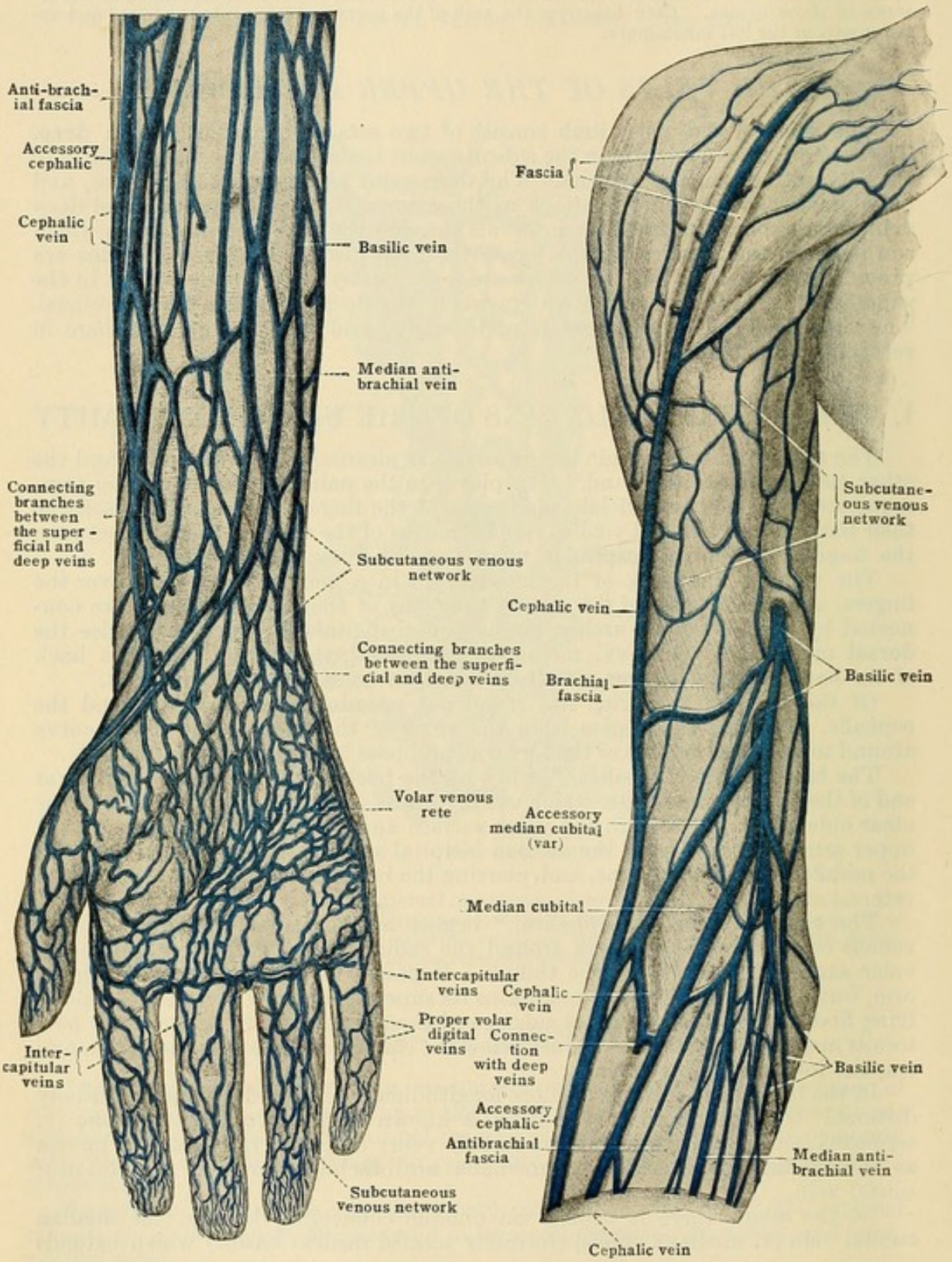

NOTE.—In the limb here represented the direct venous channel on the radial side of the forearm, the accessory cephalic (formerly radial) vein, is continued directly into the cephalic above the elbow. The cephalic in the forearm (formerly median) is mainly drained by the basilic through the median antecubital. The vein opposite the bend of the elbow, which usually forms the segment of the cephalic formerly known as the median cephalic vein, is here a small channel draining into an accessory median cubital. The basilic vein of the forearm (formerly posterior ulnar) is represented by a plexus of small venous channels.

median basilic. Occasionally the cephalic in the upper arm is reduced to a small tributary, which takes the course of the cephalic in the forearm, but bends ulnarward at the elbow to form the basilic. Numerous connections occur between the deep and the superficial veins at the elbow.

The superficial plexus of veins in the upper arm consists of small vessels that pass to the cephalic vein.

FIG. 527.—VEINS OF THE BACK OF THE FOREARM. (After Toldt, "Atlas of Human Anatomy," Rebman, London and New York.)

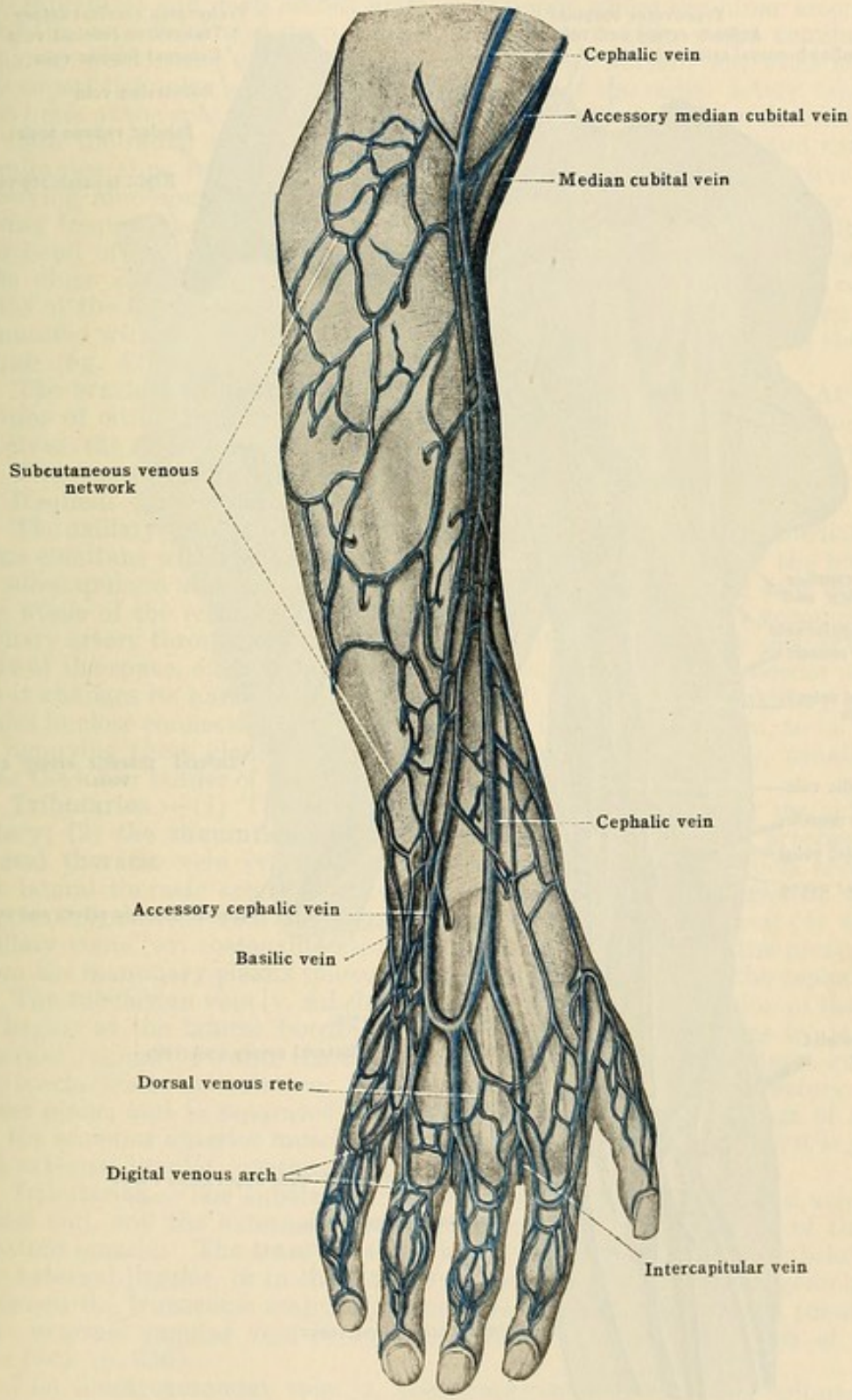

II. THE DEEP VEINS OF THE UPPER EXTREMITY

The **deep veins of the upper extremity** accompany their corresponding arteries. There are two veins to each artery below the level of the axilla, known as the venæ comitantes. The deep veins all contain numerous valves, and

FIG. 528.—DEEP VEINS OF THE ARM AND AXILLA. (After Toldt, "Atlas of Human Anatomy," Rebman, London and New York.)

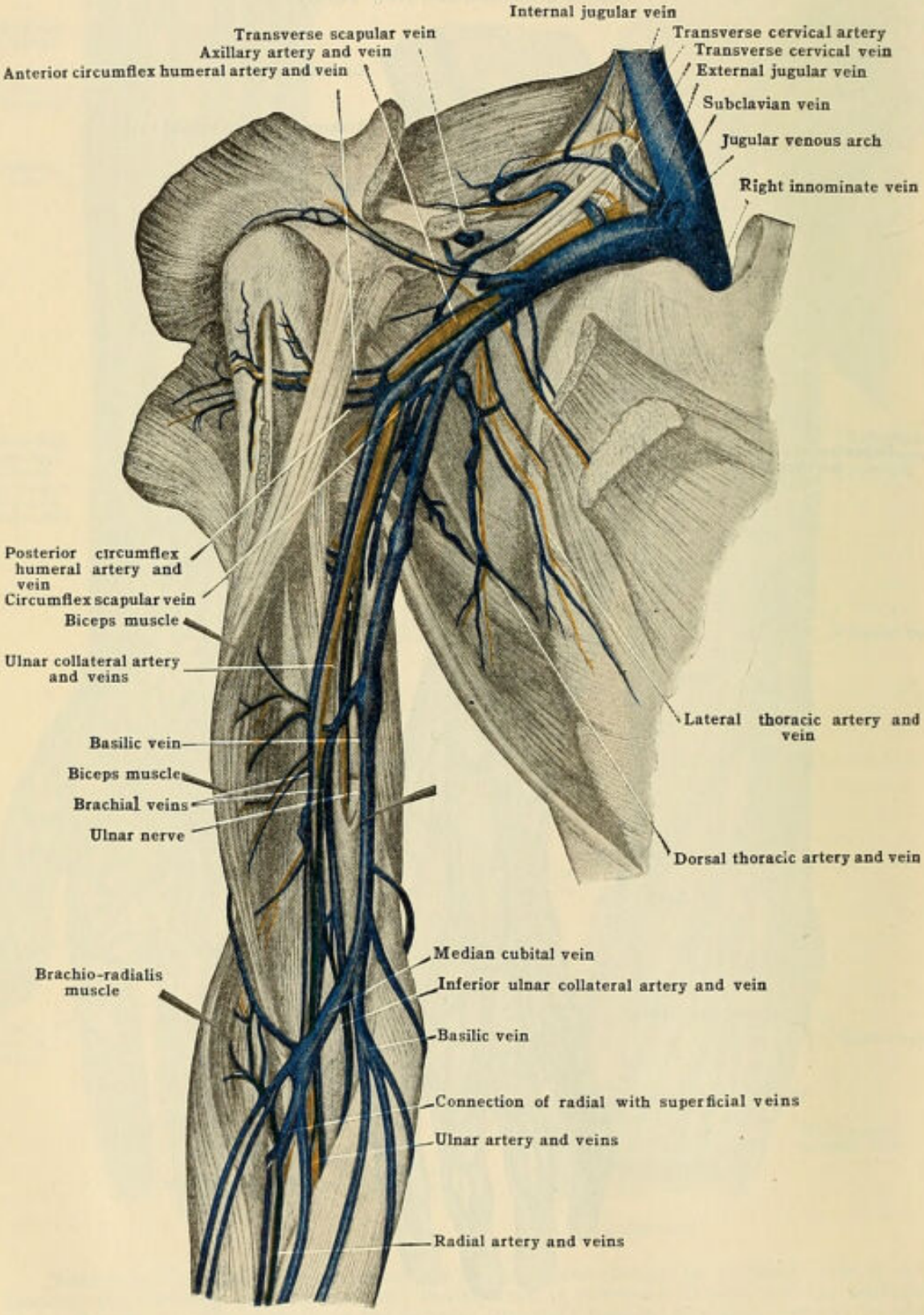

communicate at frequent intervals through intermuscular veins with the superficial vessels.

Beginning at the fingers, two minute **proper volar digital** veins [venæ digitales volares propriæ], accompany each digital artery along the sides of the fingers, and uniting at the cleft, form **common volar digital** veins [vv. digitales volares communes], which join the venæ comitantes of the arteries, forming the superficial palmar arch. In like manner the veins accompanying the arteries forming the deep arch receive tributaries, **the volar metacarpal** veins [vv. metacarpeæ volares], corresponding to the branches of that arch. A **superficial** and a **deep volar venous arch** [arcus volaris venosi superficialis et profundus] are thus formed accompanying the arterial arches. The venæ comitantes from the ulnar side of the superficial and deep arches unite at the spot where the ulnar artery divides into the superficial and deep branch to form two **ulnar venæ comitantes** [vv. ulnares]; whilst those on the radial side of the superficial and deep arch accompany the superficial volar artery and the termination of the radial artery respectively, and unite at the spot where the superficial volar is given off from the radial artery, to form the **radial venæ comitantes** [vv. radiales]. The ulnar and radial venæ comitantes thus formed course up the forearm with their respective arteries, receiving numerous tributaries from the muscles amongst which they run, and giving frequent communications to the superficial veins. They finally unite at the bend of the elbow to form the **brachial venæ comitantes** [vv. brachiales]. The ulnar venæ comitantes receive, before joining the radial, the companion veins of the interosseous arteries. At the bend of the elbow the deep veins are connected with the basilic or with the median antibrachial vein by a short, thick trunk (fig. 528).

The **brachial venæ comitantes** accompany the brachial artery. At the lower border of either the teres major or subscapularis muscle, the more medial vein receives the more lateral and the basilic vein, to form a single axillary vein.

The venæ comitantes of the arteries of the arm anastomose with one another by frequent cross branches.

The **axillary** vein [v. axillaris], is formed by the junction of the medial brachial vena comitans with the basilic vein at the lower border of either the teres major or subscapularis muscle. It is a vessel of large size, conveying as it does nearly the whole of the returned blood from the upper extremity. It accompanies the axillary artery through the axillary fossa, lying to its medial side and, at the upper part of the space, on a slightly posterior plane. At the lateral border of the first rib it changes its name to the subclavian. It has one or two axillary lymphatic nodes in close connection with it, and is liable, if care is not taken, to be wounded in removing these glands. The vein contains a pair of valves, usually placed near the lower border of the subscapularis muscle.

Tributaries:—(1) The **subscapular** veins which accompany the subscapular artery; (2) the **circumflex** veins accompanying the circumflex arteries; (3) the **lateral thoracic** vein [v. thoracalis lateralis] a large vein which accompanies the lateral thoracic artery and receives numerous **thoraco-epigastric** veins [vv. thoracoepigastricæ] from the epigastric and lower thoracic regions; (4) the **costo-axillary** veins [vv. costoaxillares] the radicles of which arise in the pectoral region from the **mammary plexus** [plexus venosus mamillæ]; and (5) the **cephalic** vein.

The **subclavian** vein [v. subclavii] (fig. 528), is the continuation of the axillary. It begins at the lateral border of the first rib, and terminates by joining the internal jugular to form the innominate vein opposite the lateral end of the sterno-clavicular articulation. It lies anterior to the subclavian artery and on a lower plane, and is separated from the artery in the second part of its course by the scalenus anterior muscle. The subclavian vein, just before it is joined by the external jugular, contains a pair of valves.

Tributaries.—The subclavian vein receives the thoracoacromial vein near its distal end, and the external jugular vein near the lateral border of the sterno-mastoid muscle. The transverse cervical veins terminate in the subclavian near the external jugular, or in the latter vein, or in a plexiform arrangement formed between the transverse scapular, transverse cervical and external jugular veins. The external jugular vein is described with the superficial veins of the head and neck (p. 646).

The **thoracoacromial** vein [v. thoracoacromialis], receiving tributaries corresponding to the branches of the artery of the same name, terminates near the lateral border of the first rib.

The **transverse cervical** veins [vv. transversæ colli] receive tributaries corresponding in distribution to the branches of the transverse cervical artery. They emerge from beneath the trapezius muscle, cross the posterior triangle, and usually terminate in the subclavian vein. They usually terminate as a single vein the orifice of which is guarded by a pair of valves. Occasionally the cephalic vein, or a branch from the cephalic (the jugulo-cephalic), passes over the clavicle to the subclavian.

III. THE VENA CAVA INFERIOR AND ITS TRIBUTARIES

All the veins of the abdomen, pelvis, and lower extremities, with the exception of the superior epigastric (p. 666), and ascending lumbar vein (p. 521), which join with the superior caval system, enter directly or indirectly into the vena cava inferior. The veins corresponding to the parietal branches of the abdominal aorta, except the middle sacral vein, open directly into the vena cava inferior; the middle sacral vein only indirectly through the left common iliac vein. Of the visceral veins corresponding to the visceral branches of the abdominal aorta, those which return the blood from the stomach, intestines, pancreas, and the spleen end in a common trunk called the portal vein.

The portal vein [vena portæ] enters the liver and there breaks up into a network of smaller vessels somewhat after the manner of an artery. This network contains venous blood, and is moulded upon the tissue-elements of the organ itself. The smaller vessels consist, like capillaries (from which they differ in developmental history) of intima only; they are called **sinusoids.** The venous blood is returned from the sinusoidal plexus by the hepatic veins which open into the vena cava inferior as that vessel lies in the fossa venæ cavæ of the liver.

Of the other visceral veins, both renals, the right suprarenal, and the right spermatic or ovarian open directly into the vena cava inferior; whilst the left suprarenal and left spermatic or ovarian are drained through the left renal.

Two of the superficial veins of the lower part of the anterior abdominal wall, the superficial epigastric and superficial circumflex iliac, enter the great saphenous vein; and two of the deep veins from the like situation, the inferior epigastric and deep circumflex iliac, enter the external iliac vein. The blood in these vessels, however, can flow upward as well as in the normally downward direction. In obstruction of the vena cava inferior they become greatly enlarged, and form, with the superior epigastric vein and with other superficial veins of the thorax with which they anastomose, one of the chief channels for the return of the blood from the lower limbs.

The veins of the pelvis, which receive the veins from the perinæum and gluteal region, join the hypogastric vein.

THE VENA CAVA INFERIOR

The **vena cava inferior** (fig. 529) is the large vessel which returns the blood from the lower extremities and the abdomen and pelvis. It is formed by the confluence of the right and left common iliac veins opposite the body of the fifth lumbar vertebra, ascends in front of the lumbar vertebræ to the right of the abdominal aorta, passes through the caval opening in the diaphragm, and ends in the lower and back part of the right atrium of the heart on a level with the lower border of the ninth thoracic vertebra. At its origin it lies behind the right common iliac artery on a plane posterior to the aorta, but as it ascends it passes slightly forward and to the right, reaching a plane anterior to the aorta, and becoming separated from that artery by the right medial crus of the diaphragm and the caudate lobe of the liver. While in contact with the liver it lies in a deep groove [fossa venæ cavæ] on the posterior surface of that organ, the groove being often converted into a distinct canal by a thin portion of the hepatic substance bridging across it. As it passes through the diaphragm its walls are attached to the tendinous margins of the caval opening, and are thus held apart when the muscle contracts. On the thoracic side of the diaphragm it lies for about 1.2 cm. ($\frac{1}{2}$ in.) within the pericardium, the serous layer of that membrane being reflected over it.

Relations.—**In front** it is covered by the peritoneum, and crossed by the right spermatic artery, branches of the aortic plexus of the sympathetic, the transverse colon, the root of the mesentery, the duodenum, the head of the pancreas, the portal vein, and the liver. The median group of the lumbar lymphatic nodes are also in front of it below, and at its commencement the right common iliac artery rests upon it.

Behind, it lies on the lumbar vertebræ, the right lumbar arteries, the right renal artery, the right cœliac (semilunar) ganglion, and the right medial crus of the diaphragm.

To the **right** are the peritoneum, liver, and psoas muscle.

To the **left** is the aorta, and higher up the right medial crus of the diaphragm.

Tributaries.—The vena cava inferior receives the following veins:—(1) the renal veins; (2) the right suprarenal vein; (3) the right spermatic or the right

FIG. 529.—THE ABDOMINAL AORTA AND VENA CAVA INFERIOR.

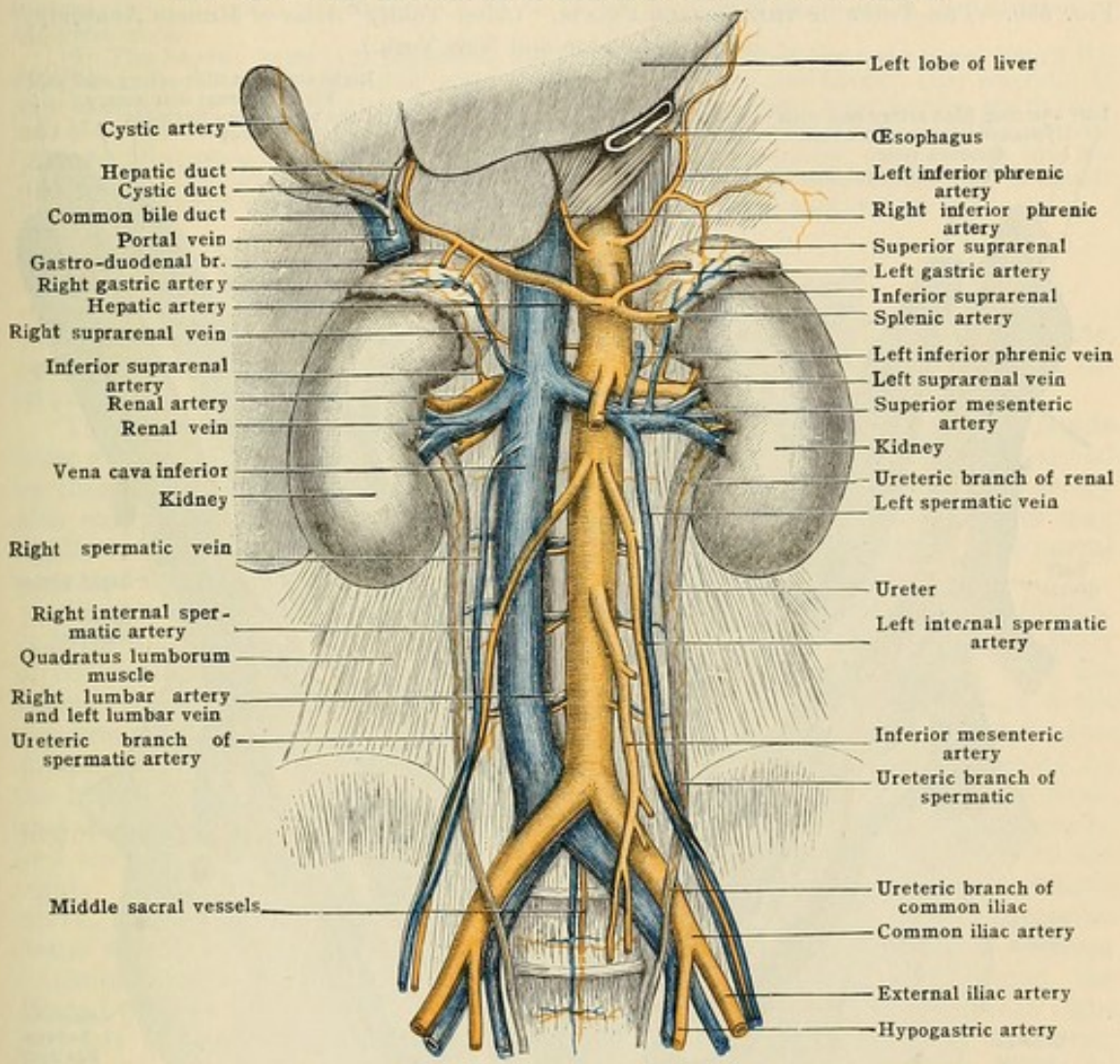

ovarian vein; (4) the lumbar veins; (5) the inferior phrenic veins; (6) the hepatic veins; and (7) the right and left common iliac veins.

(1) The **renal** veins [vv. renales] (fig. 529) return the blood from the kidneys. They are short but thick trunks, and open into the vena cava nearly at right angles to that vessel. The vein on the left side, like the kidney, is a little higher than on the right, and is also longer, in consequence of its having to cross the aorta.

Each renal vein lies in front of its corresponding artery. The left vein crosses in front of the aorta, just below the origin of the superior mesenteric artery. It is covered by the inferior portion of the duodenum, and receives the left spermatic, or the left ovarian in the female, and usually the left suprarenal, and sometimes the left phrenic. There are rudiments of valves in each vein where it joins the vena cava. Those on the right side, however, are less well marked.

(2) **The suprarenal** veins [vv. suprarenales] (fig. 529).—There is usually only one suprarenal vein on each side to return the blood brought to the suprarenal body by the three suprarenal arteries. On the **right side** the vein opens directly into the vena cava, above the opening of the right renal vein. On the **left side,** it opens into the left renal.

(3) The **spermatic** veins [vv. spermaticæ] (fig. 529) return the blood from the testis. They begin by the confluence of small branches from the body of the testis and epididymis. As they proceed up the spermatic cord, in front of the internal spermatic artery and ductus deferens, they become dilated and plexiform, constituting the **pampiniform plexus** [plexus pampiniformis] (fig. 541). After passing through the subcutaneous inguinal ring, the inguinal canal, and the abdominal inguinal ring, the plexus communicates with the inferior epigastric vein and is continued as two veins. Along with the artery the veins pass up beneath the peritoneum, and on the left side also beneath the sigmoid colon, across the psoas muscle and ureter. They receive small tributaries from the ureter and peritoneum, and proceed as a single trunk, on the right side to the vena cava inferior, and on the left side to the left renal vein. There are commonly a number of imperfect valves in the spermatic plexus and a perfect pair at the termination of each spermatic vein. On the left side, however, the terminal valve may be wanting.

FIG. 530.—THE VEINS OF THE FEMALE PELVIS. (After Toldt, "Atlas of Human Anatomy," Rebman, London and New York.)

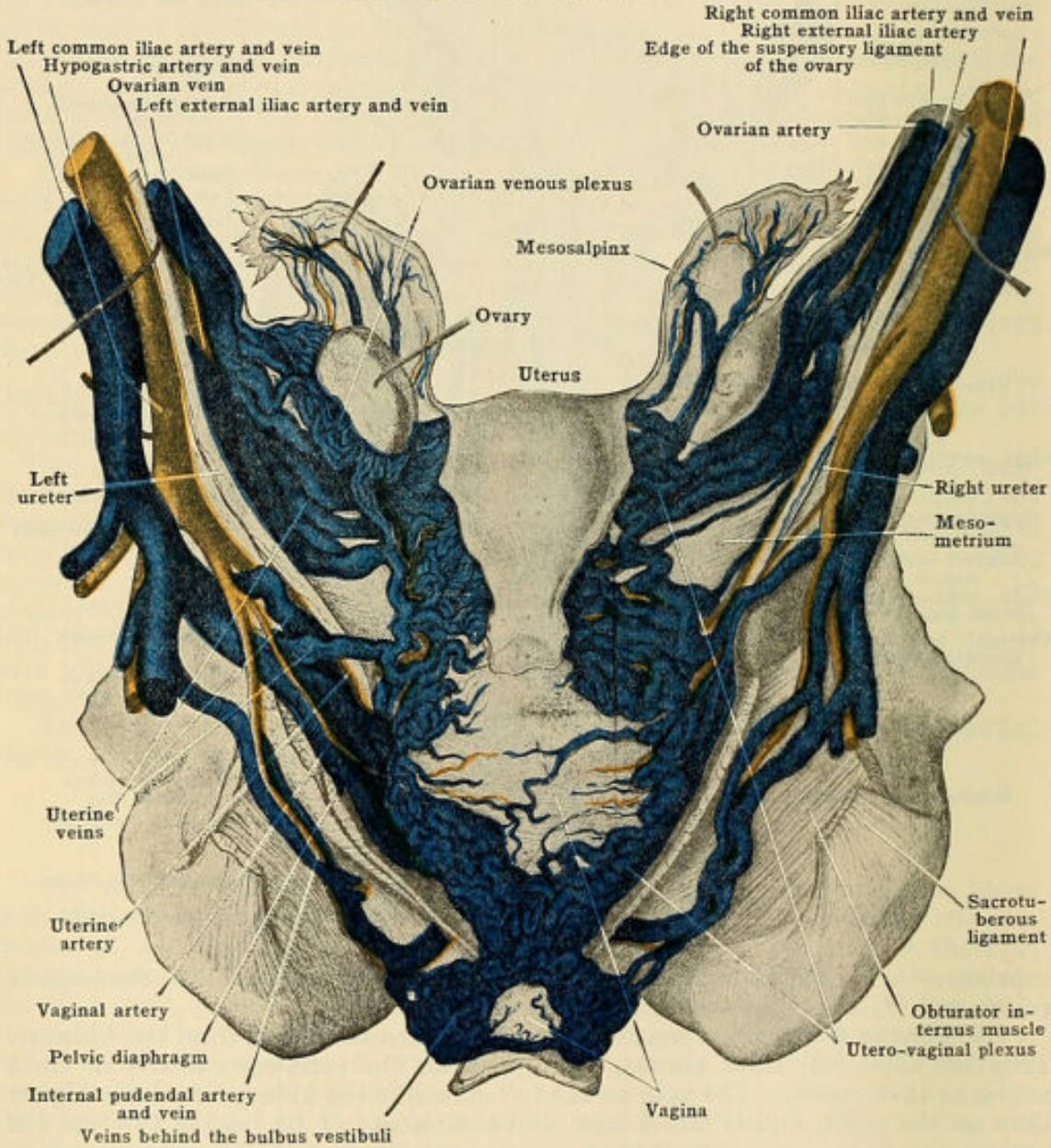

The **ovarian** veins [vv. ovaricæ] begin at the plexus pampiniformis near the ovary, between the layers of the broad ligament. This plexus is larger than in the male and communicates freely with the utero-vaginal plexus of veins, and with the plexus of veins which extends from the hilus of the ovary into the ovarian ligament (fig. 486). After passing from between the layers of the broad ligament, the plexus unites to form at first two and then a single vessel, which accompanies the ovarian artery, following a course similar to that of the spermatic veins in the male. The right ovarian veins open into the vena cava inferior, the left into the left renal. They usually contain imperfect valves in their plexiform part, and a perfect valve where they join the vena cava and renal vein respectively.

(4) The **lumbar** veins [vv. lumbales], four to five on either side accompany the lumbar arteries and collect venous blood from the muscles of the back and abdomen. They terminate by passing beneath the tendinous arches of the psoas major, along the sides of the lumbar vertebræ, and opening into the vena cava inferior. The veins of the left side are longer than those of the right and pass behind the aorta. Each vein receives a dorsal tributary corresponding in distribution to the dorsal branch of the lumbar artery. Between the dorsal tributaries and the posterior vertebral venous plexus there occurs a free communication. There is also an anastomosis between the main lumbar veins and the anterior vertebral venous plexus around the bodies and transverse processes of the lumbar vertebræ. By means of these communications the intervertebral veins, the internal and external vertebral and spinal plexuses are partly drained. In addition to these anastomoses the lumbar veins are connected with one another and with common iliac, hypogastric, ilio-lumbar, renal, azygos and hemiazygos veins by means of the *ascending lumbar vein* (p. 663).

(5) The **inferior phrenic** veins [v. phrenica inferior] follow the course of the inferior phrenic arteries; the right opens into the vena cava direct; the left into the suprarenal, the left renal, or the vena cava.

(6) The **hepatic** veins [vv. hepaticæ], the largest tributaries of the vena cava, return the blood from the liver. Commencing in the substance of the liver (see LIVER), they converge as they approach its posterior surface, and unite to form two or there large trunks, which open into the vena cava as it lies in the fossa venæ cavæ. Some smaller vessels from the caudate lobe, and other parts of the liver in the nighbourhood of the caval fossa, open directly into the vena cava. The hepatic veins contain no valves, but, in consequence of opening obliquely into the vena cava, a semilunar fold occurs at the lower magin of each orifice.

THE PORTAL VEIN

The veins corresponding to the inferior mesenteric, the superior mesenteric, and to some of the branches of the cœliac artery, do not join the vena cava inferior direct, but unite to form a common trunk—the **portal vein.**

This vein enters the liver, and breaks up in its substance into **sinusoids** from which the blood is again ultimately collected by the hepatic veins, and carried by them into the vena cava inferior. The terminal branches of the hepatic artery also empty into the hepatic sinusoids, and their blood likewise finds its way finally into the hepatic veins, and thence into the vena cava inferior. The portal vein and its tributaries have no valves.

The **portal** vein [v. portæ] (fig. 531), is a thick trunk 7 or 8 cm. (3 in.) in length. It is formed behind the head of the pancreas, opposite the right side of the body of the second lumbar vertebra, by the union of the superior mesenteric with the splenic veins. It passes upward and to the right behind the superior part of the duodenum, and then between the layers of the lesser omentum. In the latter situation it passes in front of the foramen epiploicum and is accompanied by the hepatic artery and the hepatic duct. Finally it enters the porta of the liver, and there divides into a right and a left branch. In this course the hepatic artery and the common bile duct are in front, the former to the left, the latter to the right. It is surrounded by branches of the hepatic plexus of the sympathetic nerve, and by numerous lymphatic vessels and some glands. The connective tissue sheath enclosing these structures is called the **fibrous capsule of Glisson** [capsula fibrosa, Glissoni]. Just before it divides it is somewhat dilated, the dilated portion being called the **sinus of the portal vein.** The division into right and left branches takes place toward the right end of the porta of the liver. The **right branch** is shorter and thicker than the left, and supplies the right lobe of the liver and a branch to the quadrate lobe. The **left branch** is longer and smaller than the right, and supplies the left lobe, and gives a branch to the caudate (Spigelian) and quadrate lobes. It is joined, as it crosses the left sagittal fossa, by a fibrous cord, known as the **ligamentum teres hepatis** (obliterated **vena umbilicalis**), and posteriorly by a second fibrous cord, the **ligamentum venosum** (oblietrated **ductus venosus**). The position of the original course of the umbilical vein across the left portal is marked, in adult life, by a dilation of the latter vein, called the **umbilical recess.**

Tributaries.—The pyloric, the coronary (gastric), the cystic, the superior mesenteric, and the splenic.

The **pyloric** vein begins near the pylorus in the lesser curve of the stomach, and, running from left to right with the right gastric artery, opens directly into the lower part of the portal vein. It receives branches from the pancreas and duodenum.

The **coronary** vein [v. coronaria ventriculi] (fig. 533) runs with the left gastric artery at first from right to left, among the lesser curvature of the stomach, toward the cardiac end, and then, turning to the right, passes across the spine from left to right to end in the portal trunk a

FIG. 531.—THE PORTAL VEIN. (From Kelly, by Brödel.)

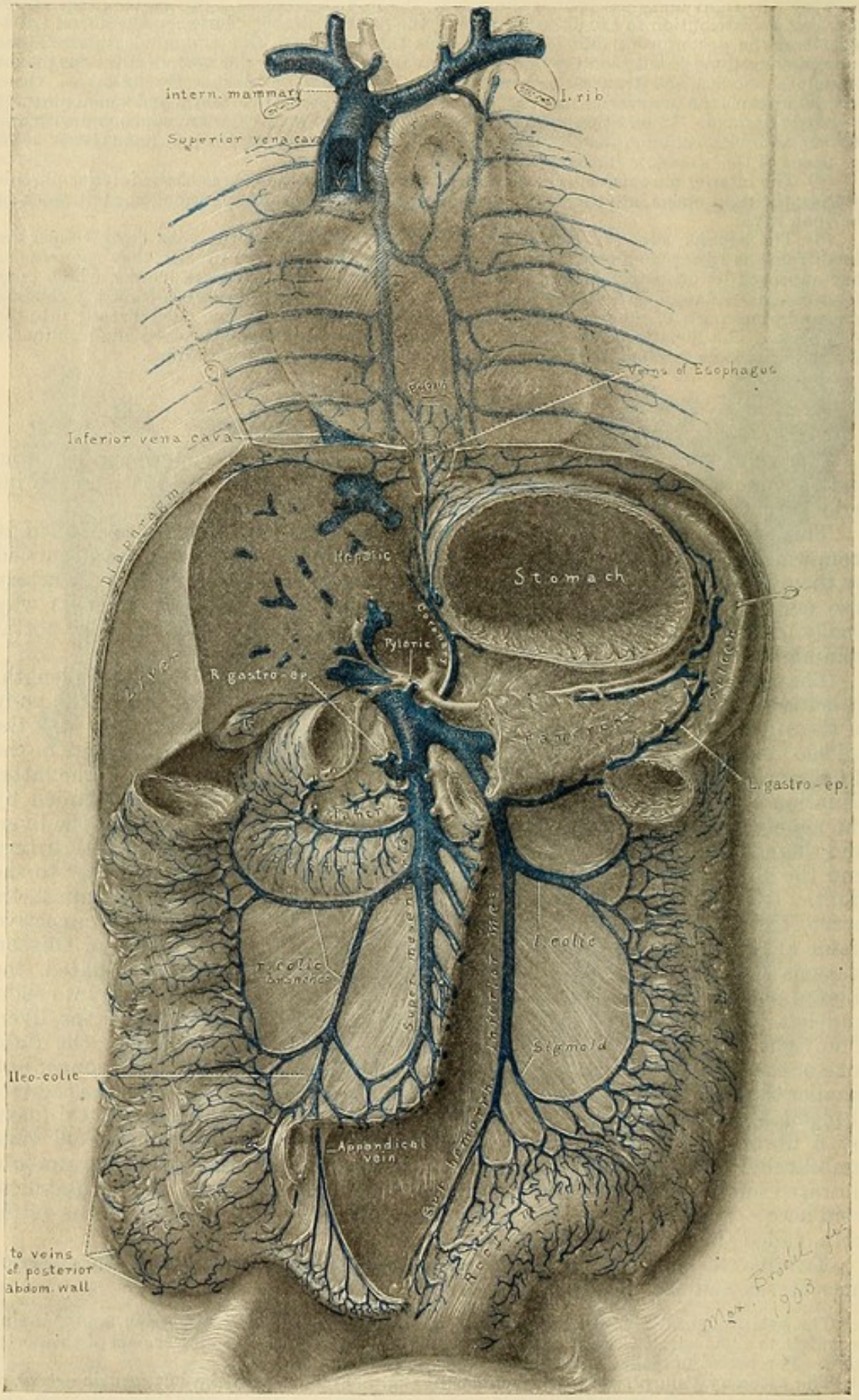

little higher than the pyloric vein. At the cardiac end of the stomach it receives small branches from the œsophagus.

The **cystic** vein [v. cystica] (fig. 533) returns the blood from the gall-bladder. It usually opens into the right branch of the portal vein.

The **superior mesenteric** vein [v. mesenterica superior] (fig. 534) begins in tributaries which correspond with the branches of the superior mesenteric artery. It courses upward a little in front and to the right of the artery, passing with that vessel from between the layers of the mesentery. It passes in front of the inferior portion of the duodenum, and behind the pancreas, where it joins the splenic vein to form the portal trunk (fig. 531).

Tributaries.—In addition to the tributaries corresponding to the branches of the superior mesenteric artery—viz. the *ileo-colica*, *colica dextra*, *colica media*, and *venæ intestinales* (fig. 534)—it receives the **right gastro-epiploic** and the **pancreatico-duodenal veins** just before its termination in the portal vein.

The **right gastro-epiploic** vein [v. gastroepiploica dextra] (fig. 533) accompanies the artery of that name. It runs from left to right along the greater curvature of the stomach, receiving branches from the anterior and posterior surfaces of that viscus, and from the great omentum, and, passing behind the superior portion of the duodenum, ends in the superior mesenteric vein just before that vessel joins the portal trunk.

FIG. 532.—THE PORTAL VEIN WITHIN THE LIVER. (After Rex.)

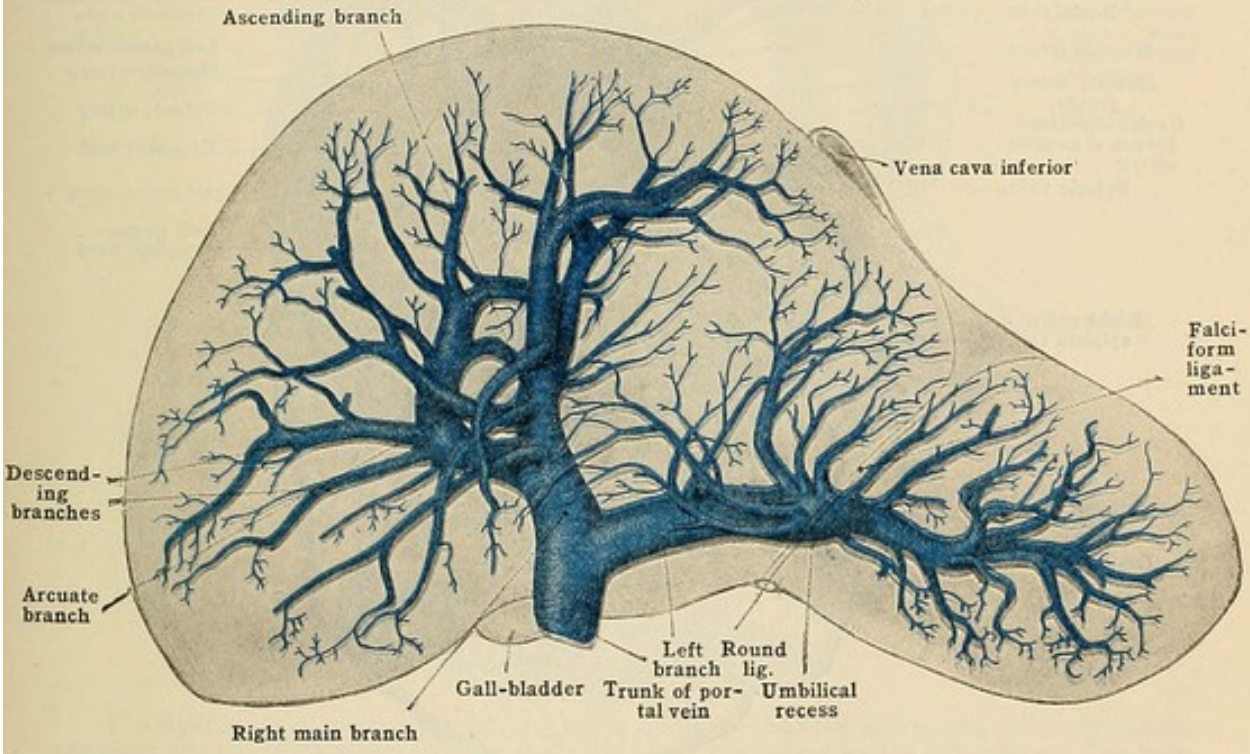

The **pancreatio-duodenal** veins [vv. pancreatico-duodenales] (fig. 531) run with the superior and inferior pancreatico-duodenal arteries between the head of the pancreas and the second portion of the duodenum. They receive **pancreatic** and **duodenal** veins [vv. pancreaticæ et duodenales] and are collected into a single stem which follows the inferior pancreatico-duodenal artery and ends in the superior mesenteric vein a little below the right gastro-epiploic vein.

The **splenic** vein [v. lienalis] (fig. 531) issues as several large branches from the hilus of the spleen. These soon unite to form a large trunk, which passes across the aorta and spine in company with the splenic artery, below which it lies, to join at nearly a right angle the superior mesenteric vein. In this course it lies behind the pancreas; and at its union with the superior mesenteric to form the vena portæ in front of the vena cava inferior.

Tributaries.—It receives the **short gastric** veins [vv. gastricæ breves], from the fundus of the stomach, the **left gastro-epiploic** vein, and the **inferior mesenteric** vein. As it lies in contact with the pancreas it receives some small **pancreatic** veins [vv. pancreaticæ].

The **left gastro-epiploic** vein [v. gastroepiploica sinistra] (fig. 533) accompanies the left gastro-epiploic artery. It runs from right to left along the greater curvature of the stomach, receives branches from the stomach and omentum, and opens into the commencement of the splenic vein.

The **inferior mesenteric** vein [v. mesenterica inferior] (fig. 531) begins at the rectum as the superior hæmorrhoidal vein. This emerges from the hæmorrhoidal plexus in which it communicates freely with the middle and inferior hæmorrhoidal veins. It passes out of the pelvis with the inferior mesenteric artery; but, after receiving the **sigmoid** and **left colic** veins [vv. sigmoideæ et v. colica sinistra] which accompany the arteries of the same names, it leaves the artery and runs upward on the psoas to the left of the aorta and behind the peritoneum. On approaching the pancreas it turns medially, and passes obliquely behind that gland to join the splenic vein just before the latter unites with the superior mesenteric to form the vena portæ.

FIG. 533.—THE VEINS OF THE STOMACH AND THE PORTAL VEIN.
(From a dissection by W. J. Walsham.)

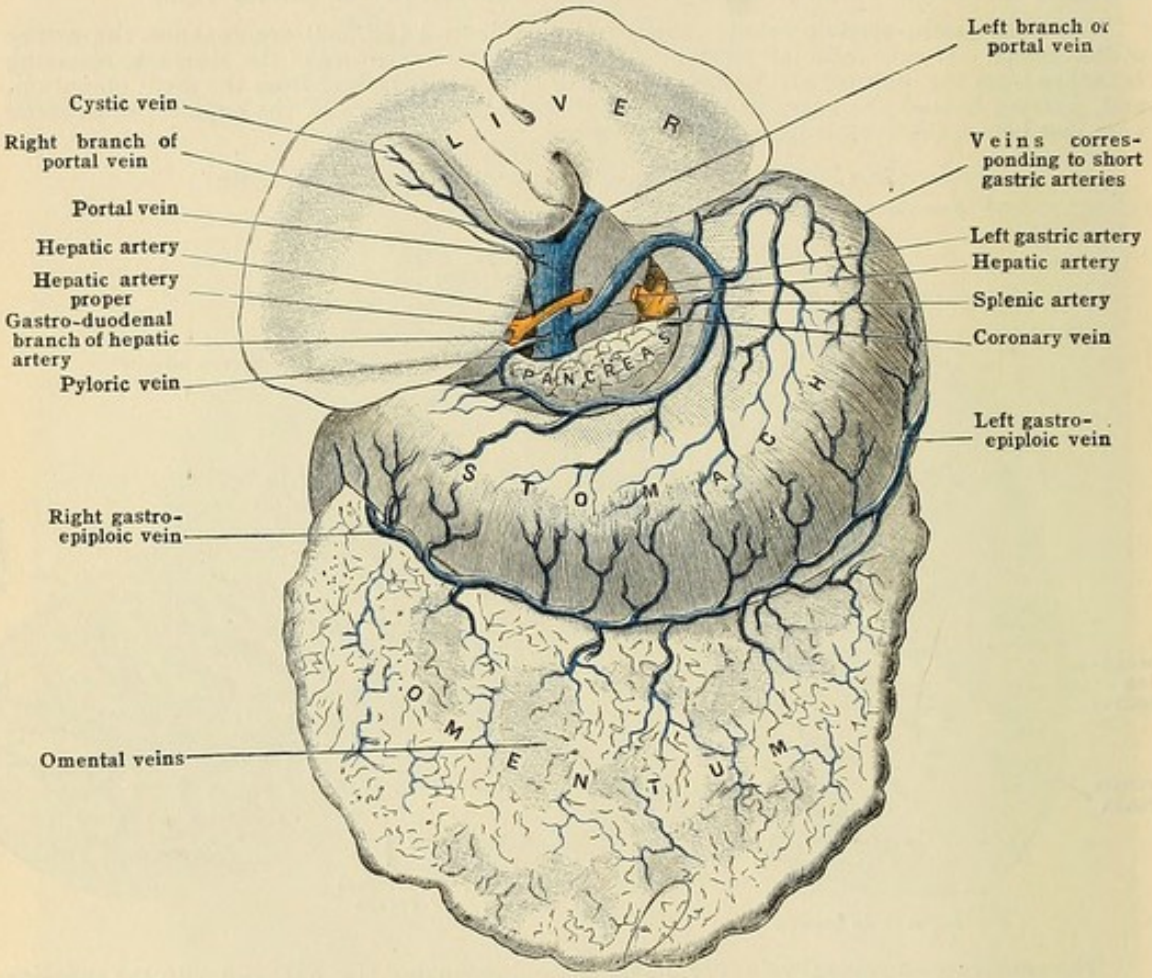

The adult portal vein and its tributaries contain no valves, a circumstance which adversely affects the circulation of blood within this system. The liability to excessive pressure in the most dependent part of the portal system is evidenced by the great frequency of the condition known as piles, due to dilatation of the veins of the internal hæmorrhoidal plexus. In early life valves are present in the veins of the stomach and of the intestinal wall but these undergo retrogression.

The accessory portal veins.—Since the blood returning from the abdominal portion of the digestive tract and spleen must pass through the hepatic capillaries before returning to the heart, extensive obliteration of these capillaries, such as occurs in certain diseases of the liver, would prevent the return of the portal blood to the heart were it not for anastomoses between tributaries of the portal vein and those of the caval systems, constituting what have been termed accessory portal veins. Some of the more important of these are—(1) between the branches of the coronary vein of the stomach and the œsophageal veins which open into the vena azygos; (2) between the **parumbilical** veins [vv. parumbilicales], which communicate with the portal vein above and descend upon the ligamentum teres to the anterior abdominal wall to anastomose with the superior and inferior epigastric and superior vesical veins; (3) between the superior and middle hæmorrhoidal veins, the latter opening into the hypogastric, and (4) between a wide-meshed retro-peritoneal plexus of veins which communicates with the portal vessels over the posterior surface of the liver and the veins of the pancreas, duodenum and ascending and descending colon on the portal side, and with the phrenic and azygos veins on the systemic.

THE COMMON ILIAC VEINS

The **common iliac** veins [vv. iliacæ communes], (fig. 536) are formed opposite the sacro-iliac articulation by the confluence of the external iliac and hypogastric (internal iliac) veins. They converge as they ascend, and unite opposite the upper border of the fifth lumbar vertebra and a little to the right of the median line to form the vena cava inferior.

FIG. 534.—THE SUPERIOR MESENTERIC VEIN.
(The colon is turned up, and the small intestines are drawn over to the left side.)

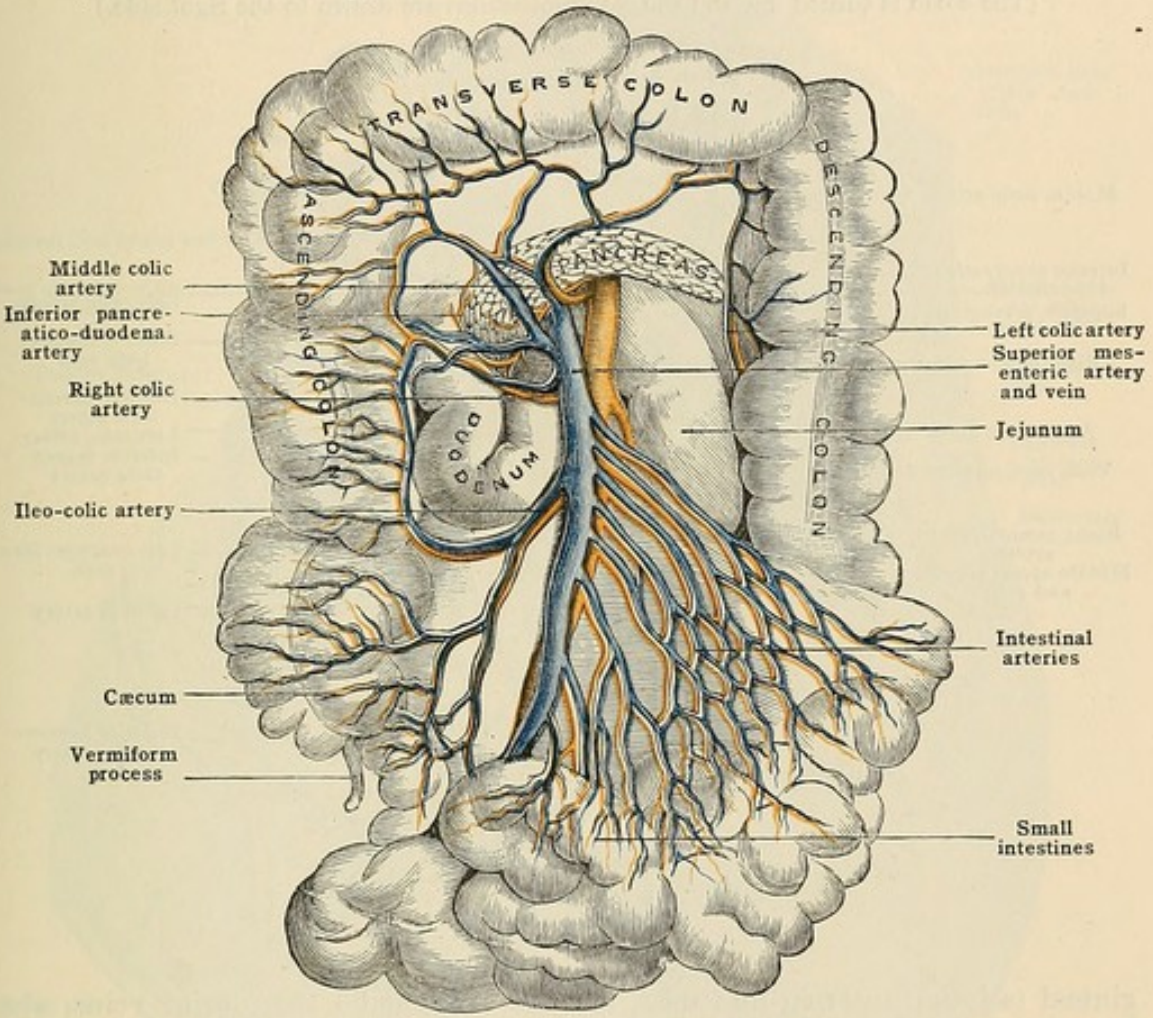

The **right** vein, shorter and more vertical in direction than the left, passes obliquely behind the right common iliac artery to its lateral side, where it is joined by the left common iliac vein.

The **left** vein lies to the medial side of the left common iliac artery, and, after crossing in front of the promontory of the sacrum and the fifth lumbar vertebra below the bifurcation of the aorta, passes beneath the right common iliac artery to join the right vein and form the vena cava inferior. The left vein may contain an imperfect valve.

Tributary.—The ilio-lumbar veins may enter the lower part of the common iliac, or open into the hypogastric vein. The left vein receives the middle sacral vein.

The **middle sacral** vein [v. sacralis media] opens usually as a single trunk into the left common liiac vein. The venæ comitantes which form it ascend on either side of the middle sacral artery in front of the sacrum. They communicate with the lateral sacral veins, forming the **anterior sacral plexus** [plexus sacralis anterior] which receives the sacral intervertebral veins, and anastomoses freely with the neighbouring lumbar and pelvic veins. Below, the middle sacral veins communicate with the hæmorrhoidal veins.

THE HYPOGASTRIC VEIN

The **hypogastric** (**internal iliac**) vein [v. hypogastrica] (fig. 536) is formed by the confluence of the veins (except the umbilical) corresponding to the branches

of the hypogastric artery. It varies considerably in length, but is usually quite a short trunk, extending from the upper part of the great sciatic foramen to the sacro-liac articulation, where it joins the external iliac to form the common iliac vein. It lies behind and a little medial to the hypogastric artery. It contains no valve.

Tributaries.—The hypogastric vein receives directly or indirectly the following vessels; the superior gluteal, ilio-lumbar, lateral sacral, obturator, inferior

FIG. 535.—THE INFERIOR MESENTERIC VEIN.
(The colon is turned up, and the small intestines are drawn to the right side.)

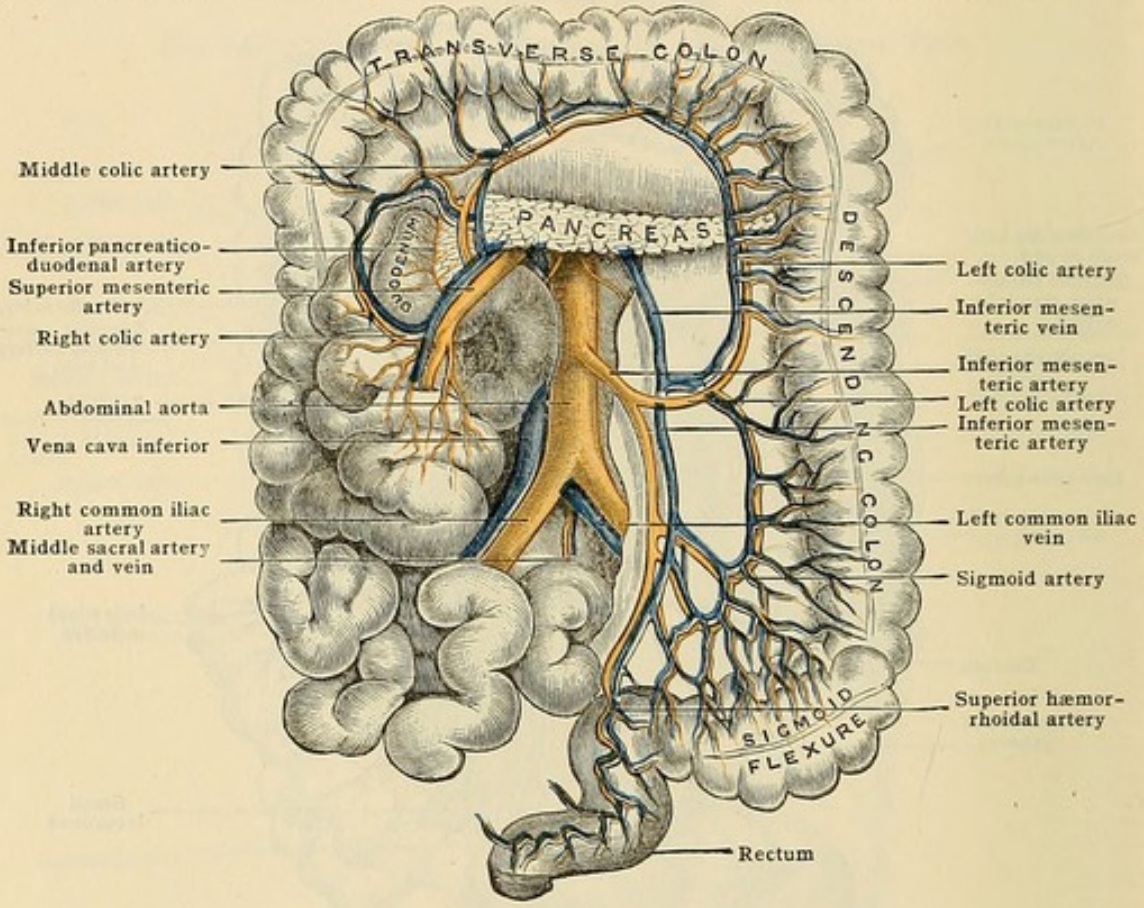

gluteal (sciatic), internal pudendal, and (in the female) the uterine veins; also branches from the pudendal, vesical, and hæmorrhoidal plexuses. The **single umbilical vein**—the vein corresponding to the right and left hypogastric arteries and their continuation, the umbilical arteries—does not enter the pelvis, but, leaving the umbilical arteries at the navel, passes along the falciform ligament to the liver. After birth it is converted into the ligamentum teres hepatis. (See PORTAL VEIN, p. 675.)

The **superior gluteal** veins [vv. gluteæ superiores] accompany the superior gluteal artery and, passing through the upper part of the great sciatic foramen, open into the hypogastric vein near its termination, either separately or as a single trunk.

The **ilio-lumbar** veins [vv. ilio lumbales] open into the hypogastric a little higher than the superior gluteal. At times they join the common iliac vein.

The **lateral sacral** veins [vv. sacrales laterales] (fig. 536) join the superior gluteal or the hypogastric at or about the same situation as the gluteal. They form with the middle sacral veins a plexus in front of the sacrum, which receives tributaries from the sacral canal.

The **obturator** vein [v. obturatoria] (fig. 536), which lies below the obturator artery as it crosses the side of the pelvis, opens into the front of the hypogastric vein a little below the superior gluteal. Its branches correspond to those of the artery.

The **inferior gluteal** veins [vv. gluteæ inferiores] accompany the inferior gluteal (sciatic) artery, and, as a rule, unite to form a single trunk before joining the hypogastric a little below the obturator vein.

All the above veins so closely follow the ramifications of their respective arteries that no further special description of them is required. They all contain valves.

The **internal pudendal** vein [v. pudenda interna] (fig. 536) begins at the termination of the deep veins of the penis [vv. profundæ penis] which issue from the corpus coavernosum penis with the artery of that body. These veins communicate with the dorsal vein at the root of the penis In its course the internal pudendal vein runs with the internal pudendal artery, receiving tributaries corresponding to the branches of that vessel. It terminates in the lower part of the hypogastric vein.

FIG. 536.—THE VEINS OF THE PELVIS, MALE. (After Toldt, "Atlas of Human Anatomy," Rebman, London and New York.)

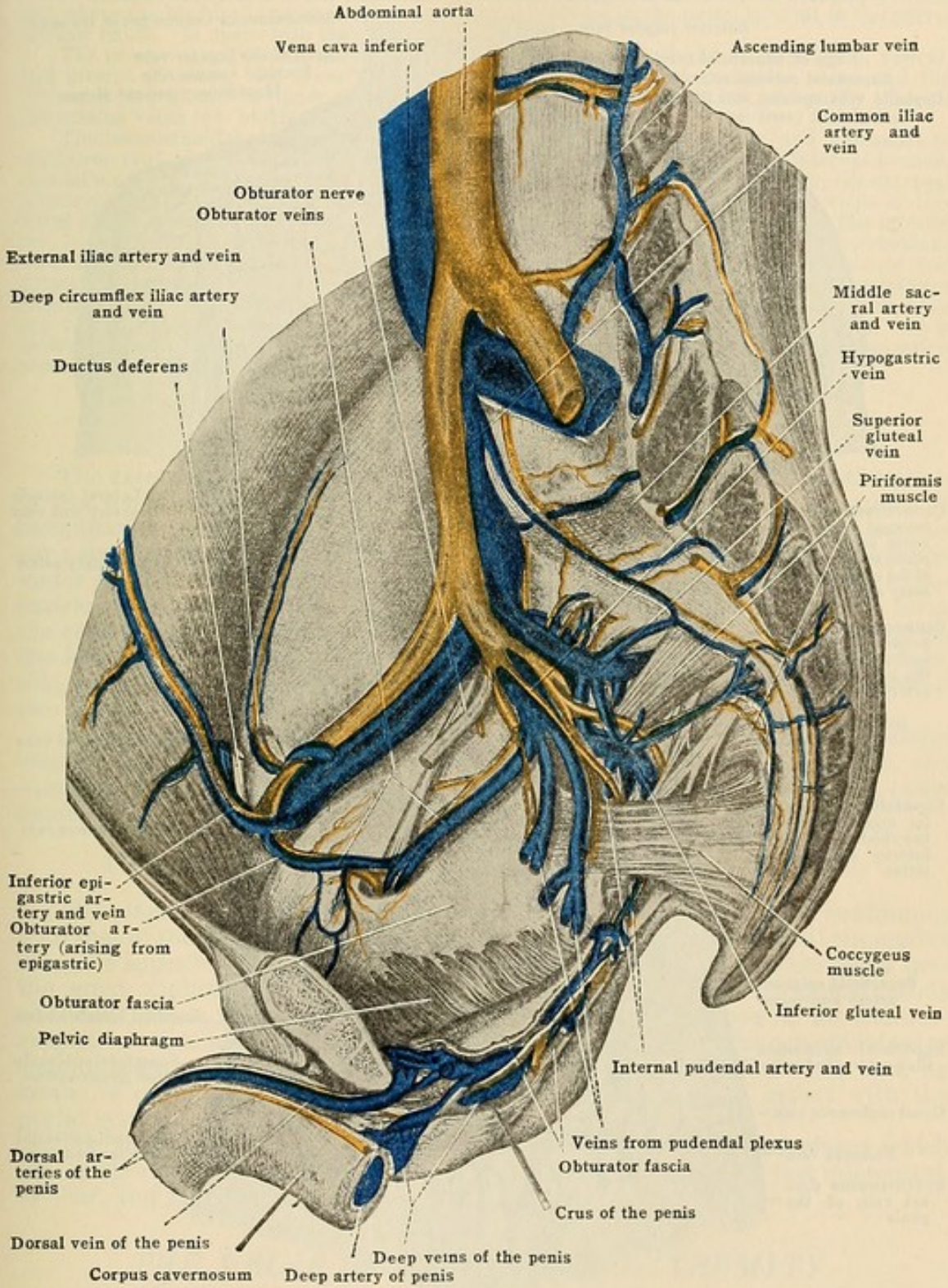

The **dorsal vein of the penis** [v. dorsalis penis] (fig. 536) begins in a plexus around the corona glandis, then runs along the centre of the dorsum of the penis between the two dorsal arteries. In this course it receives large tributaries from the interior of the organ, which, emerging for the most part between the corpus cavernosum urethræ and corpus cavernosum penis, wind obliquely over the lateral surface of the latter structure to the dorsum of the penis to end in the dorsal vein. At the root of the penis the dorsal vein communicates with the subcutaneous veins of the dorsum of the penis and, leaving the arteries, passes straight backward between the two layers of the fundiform (suspensory) ligament. It then goes between the subpubic linament

and the upper part of the fascia of the urogenital diaphragm (fig. 542). Here it bifurcates, each branch passing backward and downward to the pudendal plexus of veins. At times the dorsal vein begins as two branches, which run between the dorsal arteries and only unite to form a single trunk about 3.7 cm. (1½ in.) from the symphysis. After dividing into a right and a left branch within the pelvis, each vessel generally communicates with the obturator vein by a branch passing over the back of the pubis to the obturator foramen.

FIG. 537.—THE SUBCUTANEOUS ARTERIES AND VEINS OF THE ANTERIOR BODY WALL. (After Toldt, "Atlas of Human Anatomy," Rebman, London and New York.)

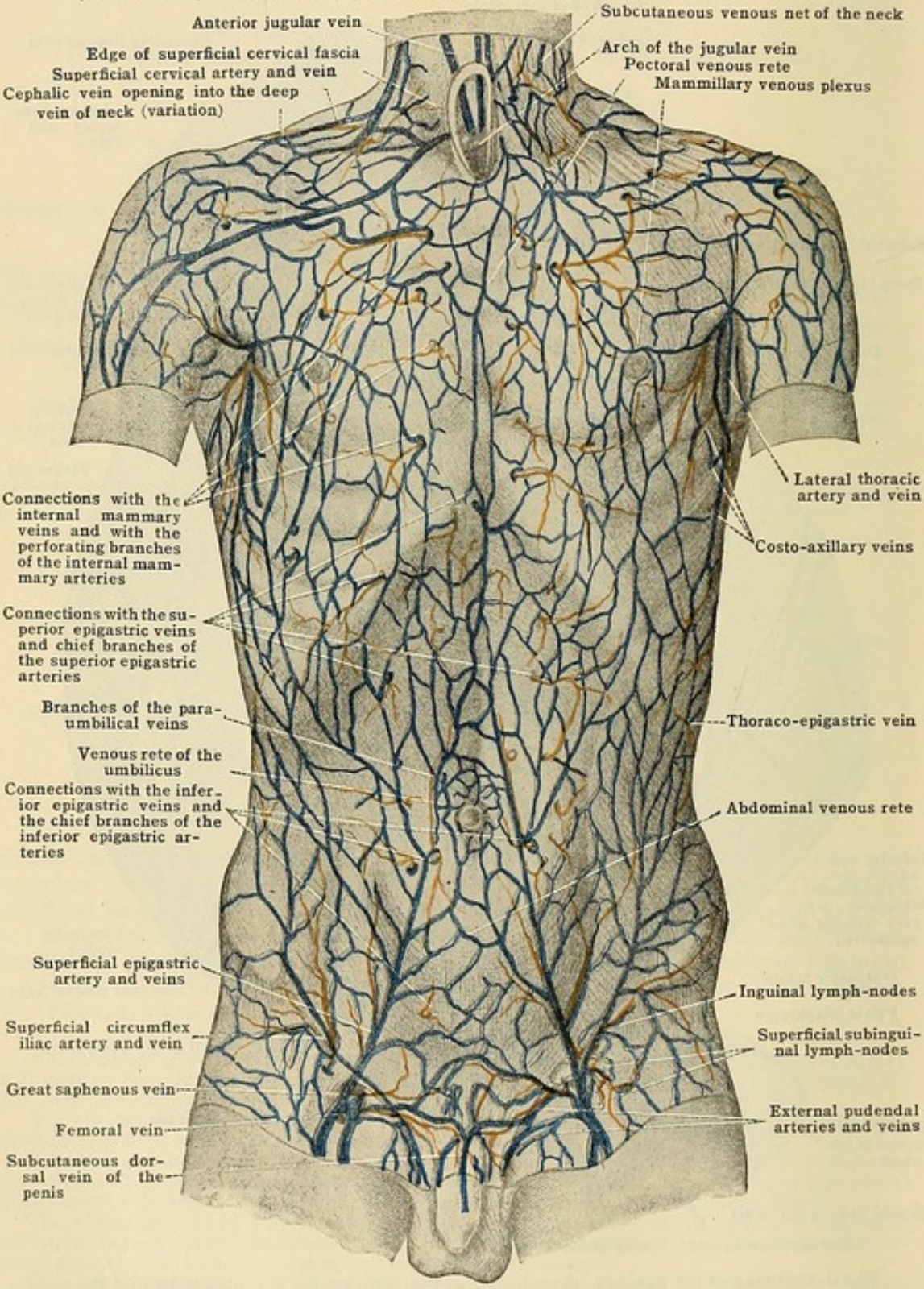

The **pudendal plexus** [plexus pudendalis] surrounds the prostate and the neck and fundus of the bladder. It receives in front the right and left divisions of the dorsal veins of the penis, and communicates with the posterior scrotal veins [vv. scrotales posteriores] and with the hæmorrhoidal plexus. The prostatic veins and the vesical plexus open into it, and it also communicates with the internal pudendal vein. The veins forming the plexus are of large size, especially in old men, in whom they often become varicose, and contain phleboliths, or vein-stones

The plexus is surrounded by a kind of capsule formed by the superior fascia of the pelvic diaphragm. It terminates in a single stem on each side which opens into the hypogastric vein.

In the female the smaller pudendal plexus surrounds the urethra and receives the **dorsal and deep veins of the clitoris** [vv. dorsales et profundæ clitoridis], veins from the vestibule, and the **posterior labial** veins [vv. labiales posteriores]. It communicates freely with the utero-vaginal plexus and is drained by the hypogastric veins.

The **vesical plexus** [plexus vesicalis] surrounds the apex, the sides, and the anterior and posterior surfaces of the bladder. It is situated between the muscular coat and the peritoneum, and where the bladder is uncovered by peritoneum external to the muscular coat in the pelvic cellular tissue. It opens into the pudendal plexus.

The **utero-vaginal plexus** [plexus uterovaginalis] connects with the hæmorrhoidal, vesical, and uterine plexuses. Its lower part drains through the internal pudendal veins and the pudendal plexus, and its upper protion largely through the ovarian veins, and partly through the **uterine veins** [vv. uterinæ] to the hypogastric (fig. 530).

The **hæmorrhoidal plexus** [plexus hæmorrhoidalis] surrounds the rectum, and is situated at the lower part of that tube. It consists of two portions, one of which, the internal hæmorrhoidal plexus, is situated between the muscular and mucous coats, while the other, the external hæmorrhoidal plexus, rests upon the outer surface of the muscular coat. The veins of this latter plexus terminate in the inferior, middle, and superior hæmorrhoidal veins. The **inferior** [vv. hæmorrhoidales inferiores] join the internal pudendal; the **middle** [v. hæmorrhoidalis media] accompanies the middle hæmorrhoidal artery and opens into the hypogastric and superior hæmorrhoidal veins; the **superior** (p. 678) forms the commencement of the inferior mesenteric vein, and through this the blood gains the portal vein. None of these veins have any valves, hence the enlargement of the inferior hæmorrhoidal veins, when the portal vein is obstructed, as in cirrhosis of the liver. Through the hæmorrhoidal veins a free communication is established between the systemic and portal system of veins.

THE EXTERNAL ILIAC VEIN

The **external iliac** vein [v. iliaca externa] (fig. 536), is the upward continuation of the femoral. Beginning at the lower border of the inguinal ligament, it accompanies the external iliac artery medially upward along the brim of the minor pelvis, lying at first on the superior ramus of the pubis, and then on the psoas major muscle. It terminates by joining the hypogastric vein behind the hypogastric artery, opposite the lower border of the sacro-iliac articulation, to form the common iliac vein. It lies at first medial to the external iliac artery, and on the left side remains medial to the artery throughout its course. On the right side, however, as it ascends, it gradually gets behind the artery. It contains one or two valves.

In addition to the femoral, the external iliac receives the **inferior epigastric** vein [v. epigastrica inferior] (fig. 536) and the deep circumflex iliac vein [v. circumflexa ilium profunda] (fig. 541), which accompany the arteries of the same name.

THE SUPERFICIAL VEINS OF THE ABDOMINAL WALL

The plexus of superficial veins of the anterior abdominal wall is continuous with that of the thorax (fig. 537). Its main channels are the superficial circumflex iliac, the superficial epigastric, and the external pudendal, all of which open into the great saphenous vein. These communicate, by means of subcutaneous abdominal veins, with the superior epigastric vein, and, by means of the thoraco-epigastric veins, with the lateral thoracic and costo-axillary. The superficial veins communicate very freely with the deeper veins of the abdominal wall, and, by means of parumbilical veins, they communicate to a slighter extent with the portal system.

The superficial veins of the lumbar region form an abundant plexus which drains through the dorsal and lateral perforating branches of the intercostal, lumbar, and sacral veins.

THE VEINS OF THE LOWER EXTREMITY

The **veins of the lower extremity** are divided into the superficial and the deep. The **superficial** veins lie in the subcutaneous tissue superficial to the deep fascia, through which they receive numerous communicating branches from the deep veins. They are collected chiefly into two main trunks, which, beginning on the foot, extend upward, one, the great saphenous, lying antero-medially, and the

other, the small saphenous, postero-laterally. The former finally joins the femoral vein by passing through the deep fascia at the groin; the latter, the popliteal by perforating the fascia at the ham. The **deep** veins, on the other hand, accompany their corresponding arteries. All the veins of the lower limb have valves which are more numerous than in the veins of the upper extremity and in the deep than in the superficial veins.

I. THE SUPERFICIAL VEINS OF THE LOWER EXTREMITY

The **superficial veins of the lower limb** begin in the plexuses of the foot. The **dorsal digital** veins [vv. digitales pedis dorsales] collect blood from the dorsal surfaces of the toes and unite in pairs, around each cleft, to form the **dorsal metatarsal** veins [vv. metatarseæ dorsales pedis]. The dorsal metatarsal veins, of which the first and fifth are larger than the others, join the **dorsal venous arch** [arcus venosus dorsalis pedis]. This arch is convex toward the toes and crosses near the bases of the metatarsal bones. From the medial and lateral ends of the arch the great and small saphenous veins, respectively, take origin. The area of the dorsum of the foot contained between the arch and the two saphenous veins is covered by the **dorsal venous rete** [rete venosum dorsale pedis] which extends as high as the ankle-joint (fig. 539).

On the plantar surface the **plantar digital** veins [vv. digitales plantares] return the venous blood to the clefts of the toes and unite to form the **common digital** veins [vv. digitales communes pedis]. The common digital veins join freely with one another on the sole to form the **plantar venous rete** [rete venosum plantare]. There are numerous communications between the superficial veins of the dorsum and sole. These occur both in the clefts of the toes, by means of the **intercapitular** veins [vv. intercapitulares], and around the margins of the foot. Communications between the superficial and deep veins of the foot are very free (fig. 540).

The **great** (or internal) **saphenous** vein [v. saphena magna] (fig. 538) commences as the medial end of the dorsal venous arch, and, after receiving branches from the sole which join it by turning over the medial border of the foot, passes upward in front of the medial malleolus, and then obliquely upward and backward about a finger's breadth from the posterior border of the tibia in company with the saphenous nerve, which becomes superficial just below the knee. Continuing its course upward, it passes behind the medial epicondyle, and then runs upward on the medial side of the front of the thigh to about 3.7 cm. ($1\frac{1}{4}$ in.) below the inguinal ligament, where it dips through the fossa ovalis (saphenous opening) in the fascia lata, and ends in the femoral vein.

Tributaries.—In its course up the leg and thigh it receives numerous unnamed cutaneous tributaries. As it passes up the thigh it often receives a large vein, the femoro-popliteal which communicates with the small saphenous, and several of the cutaneous veins on the lateral part of the thigh, and a second vein, the **accessory saphenous** [v. saphena accessoria], formed by the union of the cutaneous veins from the medial and back part of the thigh (fig. 538). The great saphenous vein contains from ten to twenty valves.

Immediately before entering the fossa ovalis the great saphenous vein receives the superficial epigastric, superficial circumflex iliac, and external pudendal veins, though any of these veins—or all of them—may pierce the fascia separately and enter the femoral vein.

The **superficial epigastric** vein [v. epigastrica superficialis] anastomoses with the superficial abdominal, and parumbilical veins.

The **superficial circumflex iliac** vein [v. circumflex ilium superficialis] anastomoses with the thoraco-epigastric and the superficial circumflex iliac veins.

The **external pudendal** veins [vv. pudendæ externæ] collect venous blood from the **anterior scrotal or labial** veins, which anastomose with the posterior scrotal or labial veins, and from the **subcutaneous veins of the dorsum of the penis** [vv. dorsales penis subcutaneæ].

The small **saphenous** vein [v. saphena parva] (fig. 539) begins at the lateral end of the venous arch on the dorsum of the foot. After receiving branches from the sole, which turn over the lateral border of the foot, it passes behind the lateral malleolus, and then upward and, lying at first along the lateral side of the tendo Achillis, afterward along the back of the calf, in company with the sural (short saphenous) nerve, to about the lower part of the centre of the popliteal space, where it perforates the deep fascia, and, sinking between the two heads of the gastrocnemius, opens into the popliteal vein.

Tributaries.—As it passes up the calf between the superficial and deep fascia, it receives numerous cutaneous veins from the heel, and the lateral side and back part of the leg, and

FIG. 538.—THE SUPERFICIAL VEINS AND LYMPHATICS OF THE LEFT LOWER LIMB. (Walsham.)

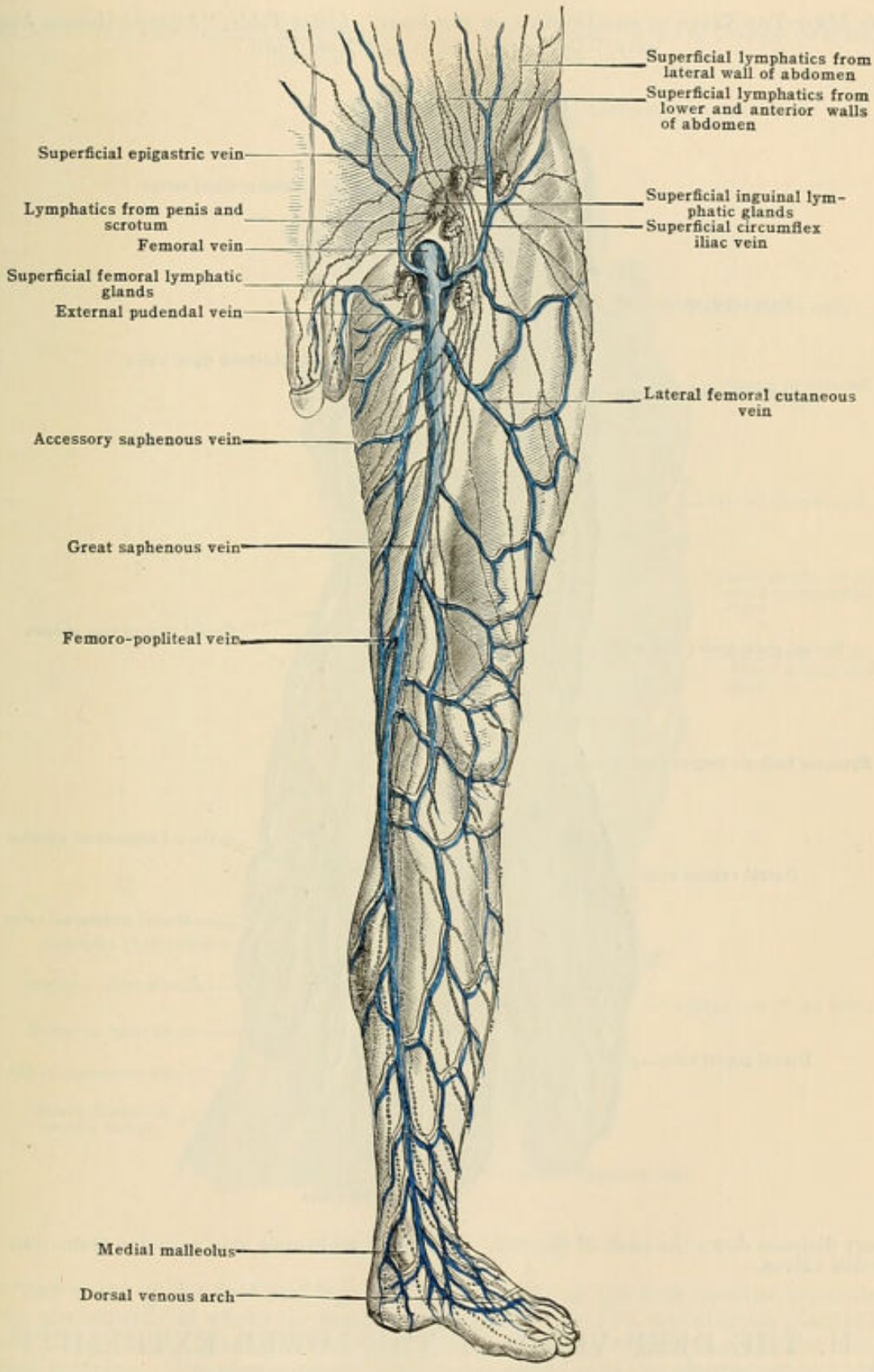

communicates at intervals, through transverse or intermuscular branches, with the deep veins accompanying the peroneal artery. Just before perforating the deep fascia, it receives a large descending branch, the **vena femoropoplitea,** from the lower and back part of the thigh. This

communicates with a plexus of veins upon the posterior and lateral regions of the thigh and with the great saphenous. In many cases the small saphenous vein is entirely drained, by means of the femoro-popliteal, into the great saphenous. Under these circumstances the usual place of termination of the small saphenous is marked by a small vein opening into the popliteal. A small offshoot from the inferior sural branch of the popliteal artery accompanies this vein for a

FIG. 539.—THE VEINS OF THE DORSUM OF THE FOOT. (After Toldt, "Atlas of Human Anatomy," Rebman, London and New York.)

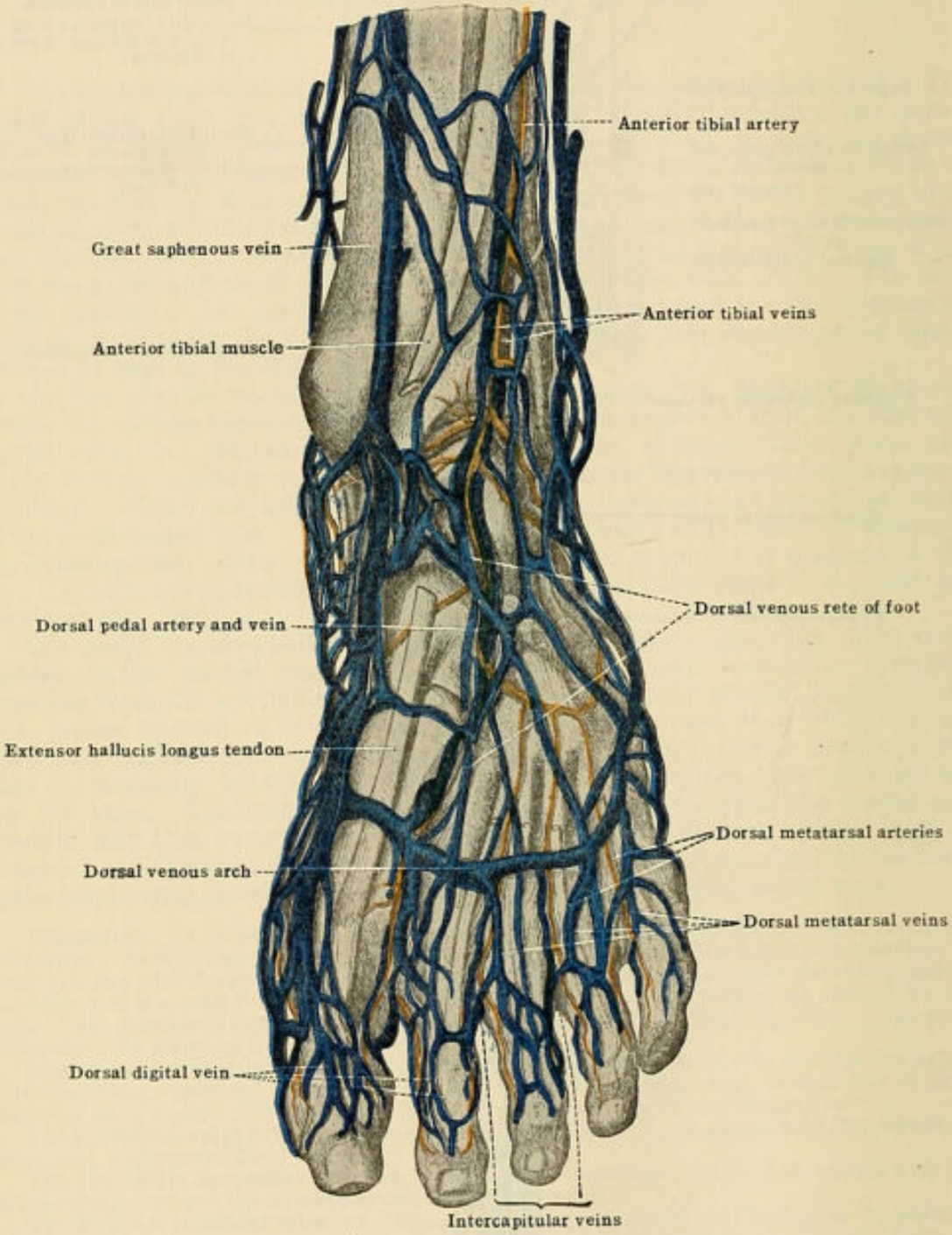

short distance down the back of the calf. The small saphenous vein contains from nine to twelve valves.

II. THE DEEP VEINS OF THE LOWER EXTREMITY

The **deep veins of the lower extremity** accompany the arteries, and have received corresponding names. From the foot to the knee there are two veins to each artery. These veins run on either side of the corresponding artery, and com-

municate at frequent intervals with each other across it. They are known as the venæ comitantes. From the knee upward there is a single main vein to each artery, except at the back of the thigh and in the gluteal region, where there are commonly two.

FIG. 540.—THE VEINS OF THE SOLE OF THE FOOT. (After Toldt, "Atlas of Human Anatomy," Rebman, London and New York.)

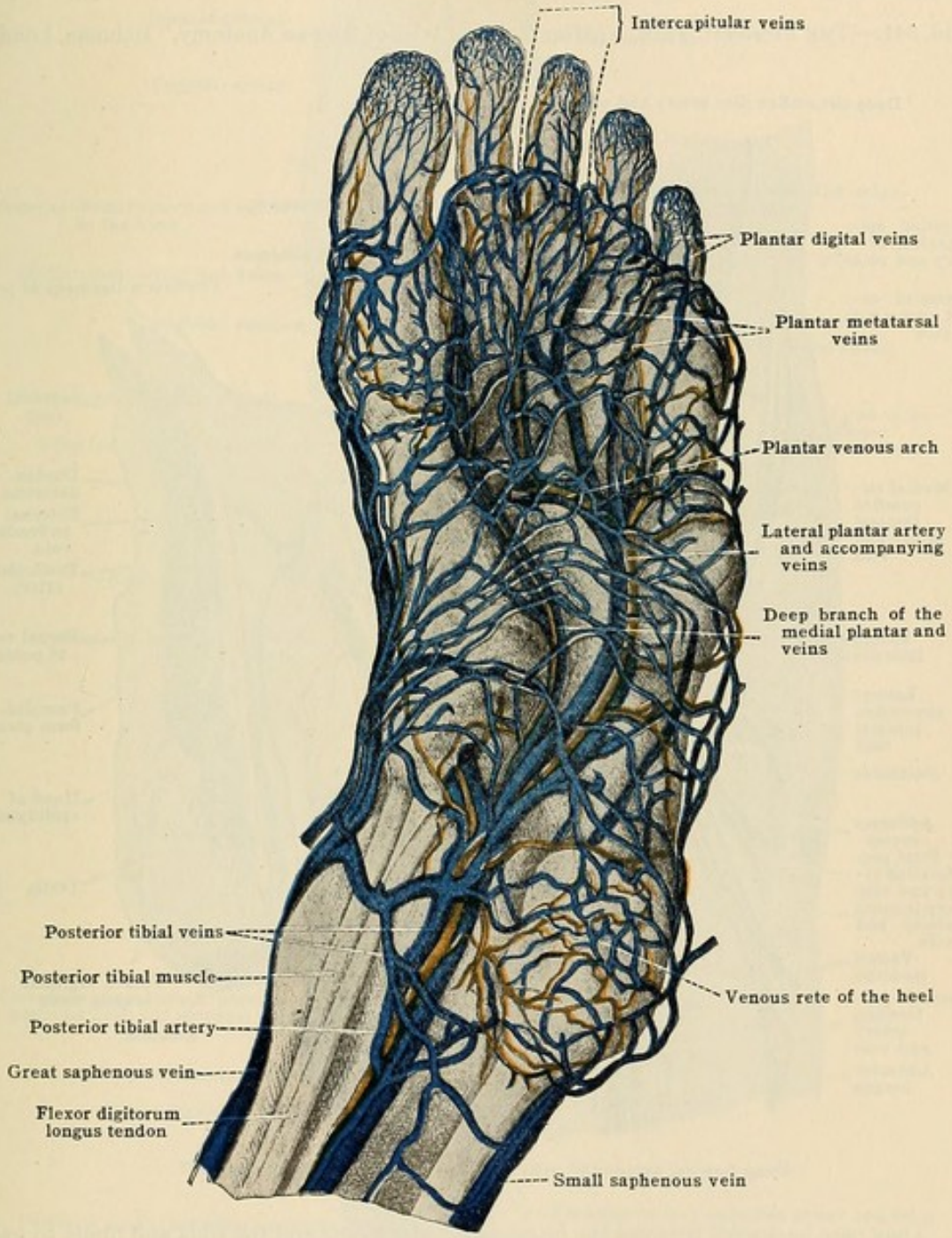

The veins of the foot and leg.—The deep veins of the foot become separated from the superficial where the **plantar metatarsal** veins [vv. metatarseæ plantares] leave the plantar digital and intercapitular veins to accompany the plantar metatarsal arteries. The plantar metatarsal veins empty into the **plantar venous arch** [arcus venosus plantaris] which accompanies the arterial plantar arch in the depth of the sole. (fig. 540)

The **posterior tibial** veins [vv. tibiales posteriores] drain the plantar venous arch and the superficial rete (fig 542).

They follow the posterior tibial artery up the leg, receiving tributaries corresponding to its branches, the largest of which are the **peroneal veins** [vv. peroneæ]. They unite with the anterior tibial venæ comitantes at the lower border of the popliteus muscle.

The **anterior tibial** veins [vv. tibiales anteriores] begin in the dorsal venous rete and accompany the anterior tibial artery up the leg receiving tributaries corresponding to branches of the artery.

FIG. 541.—THE FEMORAL VEIN. (After Toldt, "Atlas of Human Anatomy," Rebman, London and New York.)

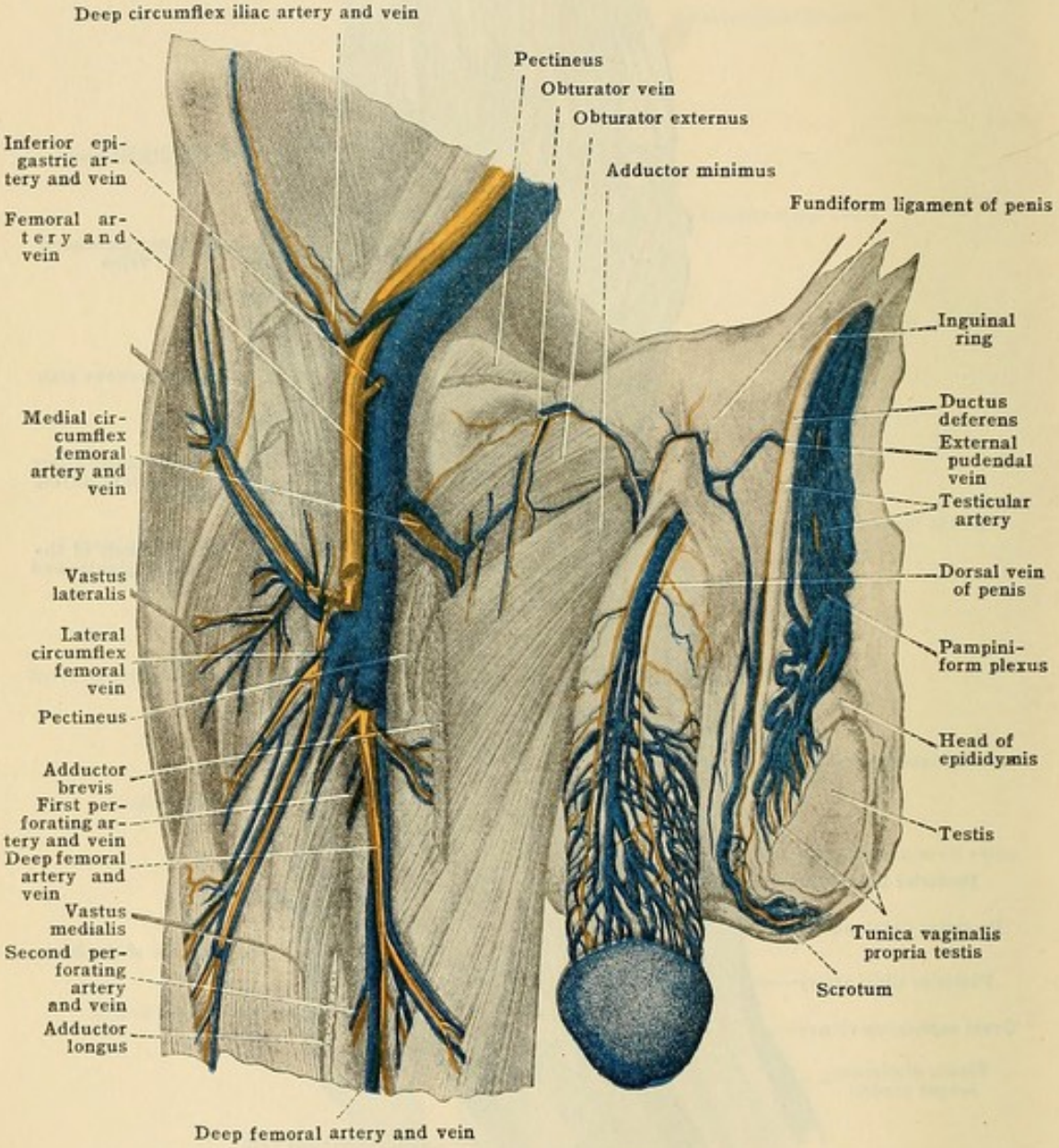

They pass backward between the interosseous membrane and the tibia and fibula to unite with the posterior tibial veins. The posterior and anterior tibial veins unite at the lower border of the popliteus muscle to form the popliteal vein.

All these veins contain numerous valves, and communicate, by means of intermuscular branches, with the superficial veins.

The **popliteal** vein [v. poplitea] (fig. 542), is formed by the confluence of the venæ comitantes of the anterior and posterior tibial arteries at the lower border of the popliteus, and extends upward to the opening in the adductor magnus at the junction of the middle and lower third of the thigh, where it changes its name to femoral.

It accompanies the popliteal artery, lying superficial to it in the whole of its course, and tightly bound down to it by its fascial sheath. At the lower part of the space it is a little medial to the artery, but, crossing the vessel obliquely as it ascends, lies a little lateral to it at the upper part of the space. The tibial (internal popliteal) nerve lies superficial to the vein, being lateral to it above, then posterior to it, and then a little to its medial side. The popliteal vein contains two or three valves.

FIG. 542.—THE DEEP VEINS OF THE LEG. (After Toldt, "Atlas of Human Anatomy," Rebman. London and New York.)

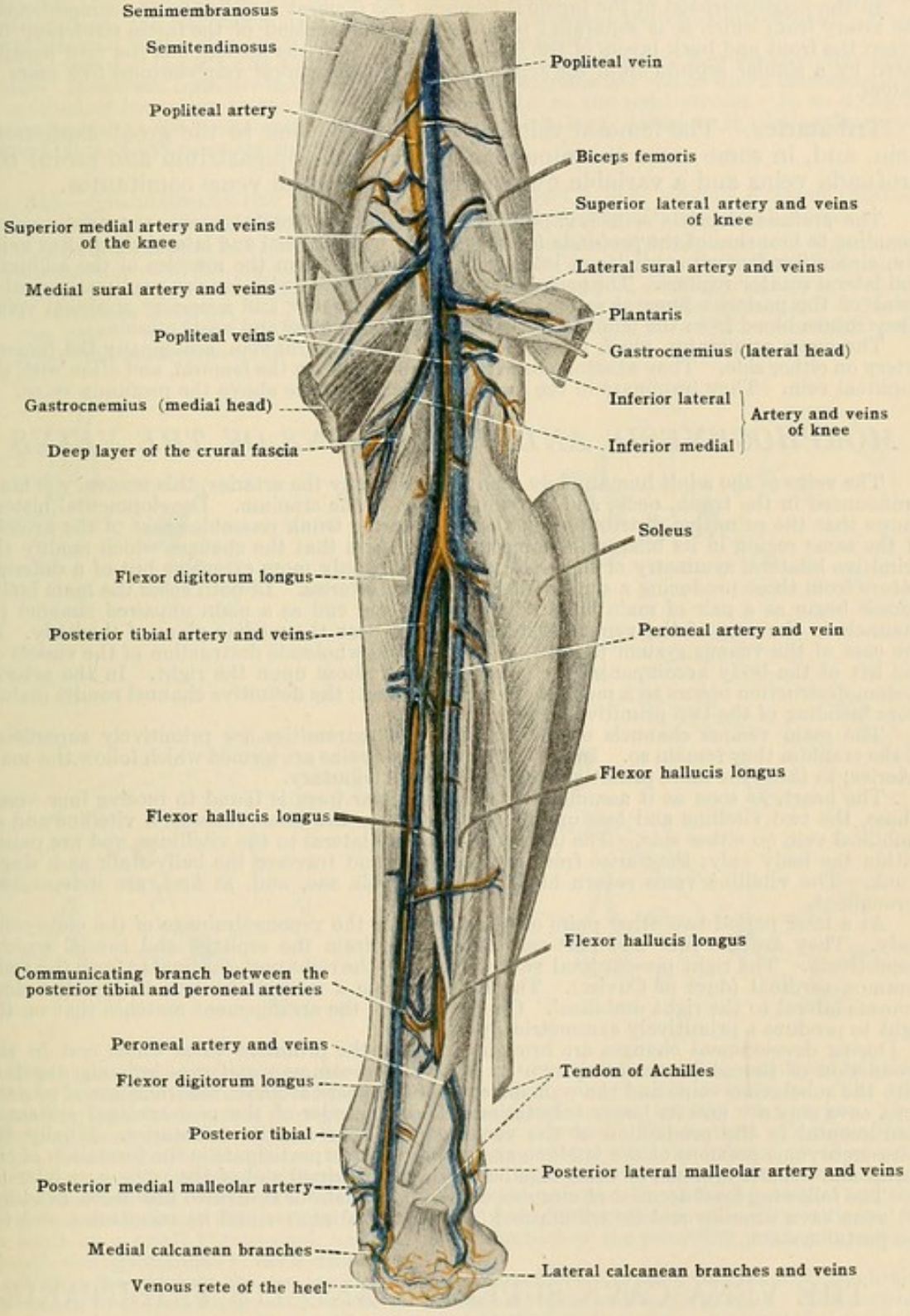

The popliteal receives the small saphenous vein. It is also joined on its lateral and medial sides by the *accessory popliteal* veins [vv. popliteæ accessoriæ] which form common trunks of termination of the sural and articular veins of the respective sides. The medial vein receives in addition, through a plexus extending as high as the opening in the adductor magnus, the veins accompanying the a. genu suprema.

The **femoral** vein [v. femoralis], the continuation of the popliteal upward, extends from the tendinous opening in the adductor magnus to the inguinal ligament. In this course its relations are similar to those of the femoral artery. As the vein passes through the adductor canal, it lies behind and a little lateral to the artery. At the apex of the femoral trigone (Scarpa's triangle) it is still posterior to the artery, but gradually passes to the medial side as it ascends through the trigone (fig. 541).

In the neighbourhood of the inguinal ligament the femoral vein lies on the same plane as the artery from which it is separated by a delicate prolongation of the fascia stretching between the front and back layers of the femoral sheath. On the medial side the vein is separated by a similar septum from the femoral canal. The femoral vein contains five pairs of valves.

Tributaries.—The femoral vein receives (in addition to the great saphenous vein, and, in some cases the superficial veins of the epigastrium and groin) the profunda veins and a variable number of small femoral venæ comitantes.

The **profunda femoris** veins [vv. profundæ femoris] arise from the venæ comitantes corresponding to branches of the profunda femoris artery. The **medial and lateral circumflex** veins [vv. circumflex femoris mediales et laterales] collect blood from the muscles of the adductor and lateral rotator regions. The **perforating** veins anastomose with femoro-popliteal and other veins of the posterior femoral region, and with the circumflex and accessory popliteal veins. They return blood from the femur and the adductor, hamstring and vasti muscles.

The **venæ comitantes,** much smaller than the main femoral vein, accompany the femoral artery on either side. They anastomose with one another, with the femoral, and often with the popliteal vein. They terminate in the femoral a short distance above the profunda veins.

MORPHOGENESIS AND VARIATIONS OF THE VEINS

The veins of the adult human body tend to accompany the arteries; this tendency is more pronounced in the trunk, neck, and extremities than in the cranium. Developmental history shows that the primitive distribution of the veins of the trunk resembles that of the arteries of the same region in its bilateral symmetry only. Also that the changes which modify the primitive bilateral symmetry of the chief veins are not only more extensive but of a different nature from those producing a similar effect upon the arteries. In both cases the main body-vessels begin as a pair of main longitudinal trunks and end as a main unpaired channel (or channels in the case of the venous system) situated near the median plane of the body. In the case of the venous system the change results from wholesale destruction of the vessels on the left of the body accompanied by enlargement of those upon the right. In the arterial system destruction occurs to a much more limited extent; the definitive channel results mainly from blending of the two primitive aortæ.

The main venous channels of the cranium and extremities are primitively superficial; in the cranium they remain so. In the extremities new veins are formed which follow the main arteries; to these the more primitive channels become tributary.

The heart, as soon as it assumes the simple tubular form is found to receive four veins. These, the two vitelline and two umbilical veins, enter the sinus venosus, a vitelline and an umbilical vein on either side. The umbilical veins are lateral to the vitellines, and are paired within the body only; they arise from the placenta, and traverse the belly-stalk as a single trunk. The vitelline veins return blood from the yolk sac, and, at first, are independent throughout.

At a later period two other pairs of veins arise for the venous drainage of the embryonic body. They are the pre- and post-cardinals which drain the cephalic and caudal regions respectively. The right pre-cardinal vein unites with the right post-cardinal to form the right common cardinal (duct of Cuvier). The latter runs in a medial direction to join the sinus venosus lateral to the right umbilical. On the left side the arrangement matches that on the right to produce a primitively symmetrical pattern.

During development changes are brought about in the primitive veins which end in the production of the adult venous system as follows: the common and pre-cardinals, together with the subclavian veins and the cephalic ends of the post-cardinals, are transformed into the vena cava superior and its larger tributaries. The remainder of the post-cardinal system is instrumental in the production of the vena cava inferior and its tributaries. Finally the intra-embryonic portions of the vitelline and umbilical veins participate in the formation of the portal and hepatic systems of veins together with the proximal end of the vena cava inferior.

The following brief account of morphogenesis and variations is divided into three headings (1) vena cava superior and its tributaries; (2) vena cava inferior and its tributaries, and (3) the portal system.

A. THE VENA CAVA SUPERIOR AND ITS TRIBUTARIES

1. MORPHOGENESIS

The **pre-cardinal** veins at first return blood from the head only, but as the heart recedes into the thorax the cardinal veins migrate with it. In so doing the common cardinals lag somewhat behind and in consequence their direction, primitively transverse, approaches the lon-

gitudinal. The pre-cardinals, which have increased in relative length, now course symmetrically along the neck into the thorax. At a stage of 16 mm., the definitive subclavian vein has migrated from the common to the pre-cardinal, which henceforth receives the main venous flow from the upper extremity as well as from the head. The symmetrical arrangement of the cardinal veins is disturbed at a stage of about 18 mm., by the development of a transverse connection between the right and left pre-cardinals (fig. 544). This connection, the left innominate vein, arises, probably, by the development of cross-anastomoses uniting the lateral veins draining the developing thymus and thyreoid glands. On the right side of the embryo the veins of the adult are now recognisable as follows:—the vein (pre- and common cardinal) extending from the left innominate to the heart becomes the vena cava superior. The pre-cardinal, from the left innominate to the subclavian, becomes the right innominate. From the subclavian to the cranium it becomes the internal jugular.

The vessel of the left side corresponding to the vena cava superior now rapidly diminishes in size. It extends from the left innominate vein (the extreme left end of which corresponds in its method of formation to the entire right innominate) to the right atrium. In so doing it passes ventral to the aortic arch and the foot of the left lung, dorsal to the left artium, and through part of the coronary sulcus.

FIG. 543.—SEMIDIAGRAMMATIC RECONSTRUCTIONS OF THE CRANIAL VENOUS SYSTEM. (MALL.) A, 4 WEEKS; B, 5TH WEEK; C, BEGINNING OF 3rd MONTH; D, AN OLDER FŒTUS.

A.c.v; pre-cardinal vein; A.V., otic vesicle; Inf.Pet., inferior petrosal sinus; L., eye; O.V., superior ophthalmic vein; S.L.S., superior sagittal sinus; S.P.S. sphenoparietal sinus; S.R., sinus rectus; S.S., middle cerebral vein; T.H., confluens sinuum; V., semilunar ganglion; V.C.A., v. cerebralis anterior; V.J., internal jugular vein; V.C.L., v. capitis lateralis; V.C.M. or sup. pet., v. cerebralis media and superior petrosal sinus; V.C.P. or L.S., v. cerebralis posterior and transverse sinus.

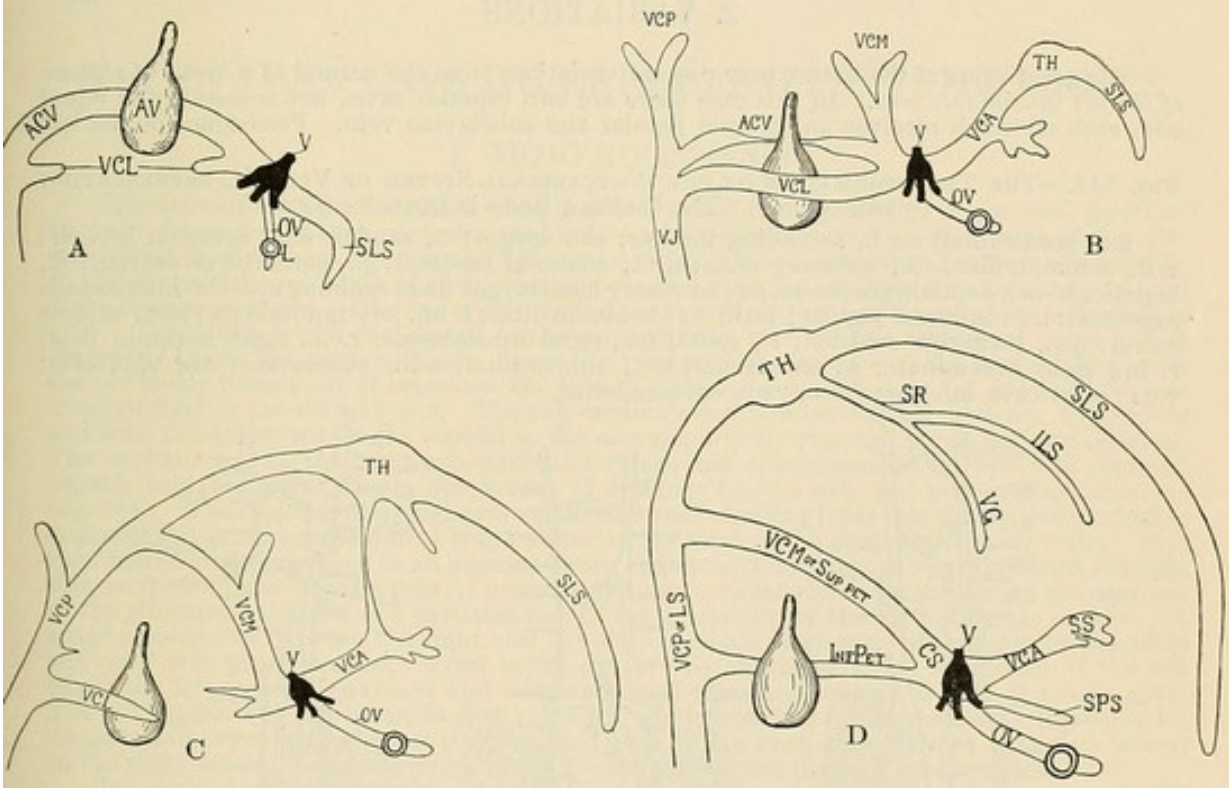

The segmental veins draining the second, third and fourth intercostal spaces of the left side open, by a common stem formed by the left pre-cardinal, into the left innominate. The corresponding segmental veins of the right side open, by a common stem, into the vena azygos. The collecting stem, on either side, is the *vena intercostais suprema*. The method of origin of the azygos, hemiazygos and accessory hemiazygos veins is treated with the inferior caval system. Below the superior intercostal tributary, the left superior cava is lost to within a short distance of the sinus venosus. Here its lower end persists as the oblique vein of the left atrium and the left end of the coronary sinus. The former course of the left superior cava is often indicated in the adult by a small fibrous cord, uniting the extremities of the persisting veins and passing through the ligamentum v. cavæ sinistræ (p. 523).

Within the cranium the pre-cardinal veins are primitively in close contact with the brain and medial to the semilunar, acustico-facial, glossopharyngeal and vagus ganglia. The portion of each vein extending from the semilunar ganglion to the facial canal (its exit from the cranium) early becomes involved in a process of anastomosis-migration which eventually places it lateral to the ganglia and to the otocyst. The new vein formed in the latter situation is called the vena capitis lateralis (fig. 543). The portion of the pre-cardinal vein which remains medial to the semilunar ganglion persists as the adult *cavernous sinus* and receives a primitive vein (v. cerebralis anterior) which drains the orbit and the mid- and forebrain. The forebrain tributaries of

the right and left v. cerebralis anterior unite to from a median vein, the definitive *superior sagittal sinus*, which at first drains into the cavernous sinus. There are two other primitive cerebral veins; the v. cerebralis media and v. cerebralis posterior. The first receives blood from the cerebellar region and drains into the cavernous sinus. The second, the v. cerebralis posterior, also receives blood from the hind-brain and, leaving the skull through the jugular foramen, joins the pre-cardinal (internal jugular) vein in the neck. Several changes occur from now on (fig. 543) which bring about the definitive relations of the dural sinuses and transfer the main venous exit from the stylomastoid to the jugular foramen. The right v. cerebralis posterior joins the superior sagittal sinus and this becomes the *right transverse sinus*. The left v. cerebralis posterior communicates with the junction of the superior sagittal and right transverse sinuses (now the *confluens sinuum*) and becomes *the left transverse sinus*. The confluens receives the sinus rectus, which forms its adult connections with the *inferior petrosal sinus* and *great cerebral vein*. The v. cerebralis media joins the transverse sinus to become the *superior petrosal sinus*. The latter forms a new (intracranial) means of drainage for the cavernous sinus and its tributaries. The original drainage channel of the cavernous sinus (v. capitis lateralis), having been supplanted, disappears. The *superior cerebral veins* drain into the superior sagittal sinus. The remaining portion of the interrupted v. cerebralis anterior drains the *middle cerebral vein* and *spheno-parietal sinus*. The *inferior petrosal sinus* arises *de novo*.

In the **upper extremity** the venous drainage is at first superficial and opens into the post-cardinal and umbilical veins. The ulnar limb of the loop-like early venous channel (marginal vein) becomes the *primitive ulnar vein*, but does not open into the pre-cardinal until a stage later than that of 10 millimetres. The primitive ulnar forms the *basilic, part of the brachial*, the *axillary*, and *subclavian* veins. It receives the large thoraco-epigastric trunk. The *cephalic vein*, which at first joins the external jugular, is of secondary formation. The venæ comitantes are formed later still.

2. VARIATIONS

The **great veins of the thorax** may present variations from the normal as a result of *absence of the left innominate vein*. In this case there are two superior cavæ, not necessarily of equal size, each of which receives an internal jugular and subclavian vein. Persistence of the left

FIG. 544.—THE TRANSFORMATION OF THE POSTCARDINAL SYSTEM OF VEINS, C REPRESENTING THE ADULT. The Wolffian Body is Dotted. (Lewis.)

a.c., precardinal; as. l., ascending lumbar; az., azygos; c., caudal; c.h., common hepatic; c. il., common iliac; c.s., coronary sinus; d.C., common cardinal; g., spermatic or ovarian; h., hepatic; h.-az., hemiazygos; h.-az. ac., accessory hemiazygos (here draining into the intercostalis suprema); i. j., internal jugular; l.c.i., left common iliac; l. in., left innominate; m.s., middle sacral; p.c., posterior cardinal; r., renal; r.a., renal anastomosis; r.c.i., right common iliac; r. in., right innominate; s., suprarenal; s-c., subcardinal; s-cl., subclavian; s.l., sinusoids; v.c.i., vena cava inferior; v.c.s., vena cava superior.

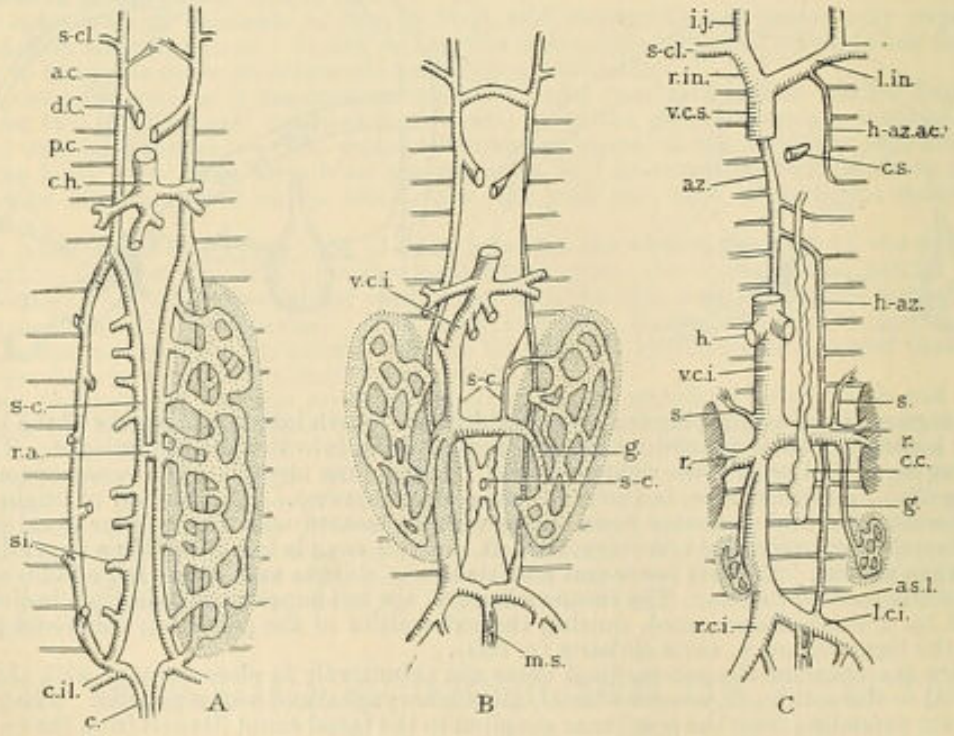

vena cava superior without failure of the left innominate may occur in three classes of cases: (*a*) In which both cavæ are present, equal in size or asymmetrical. (*b*) In which the *left cava only* occurs, associated with situs inversus. (*c*) In which the *left cava only* is present, *without situs inversus*. The left vena cava superior, when present, crosses in front of the aortic arch and

enters the right atrium by way of the coronary sinus, collecting the coronary veins. Cases are on record of a left superior cava terminating in the left atrium.

The azygos veins.—Variations of these veins and of the intercostal veins have been dealt with on pp. 663–664. For their morphogenesis, see under vena cava inferior.

The veins of the neck, face, and scalp.—These veins have so many variations in detail that it is difficult, in the case of some veins, to assign their normal distribution. The *external jugular*, for instance, is usually described in English text-books as a tributary of the subclavian vein; it is assigned by the BNA to the internal jugular. It is frequently found to open into the angle between the two, or, forming a plexus with its tributaries, drain into both. The origin of the external jugular vein is also exceedingly variable. The external jugular may be small, or absent, in which case the *anterior jugular* is large. The reverse may be the case since the external jugular frequently receives the *posterior*, and sometimes the *common facial*. Fortunately venous variations are not of prime surgical importance.

Veins of the cranium.—The *venous sinuses* of the dura mater are not subject to important variations. Variations in the relative size of the *transverse sinuses* have been referred to on p. 651. The *petro-squamous sinus*, occasionally present, is described on p. 653. The *occipital* and *inferior sagittal sinuses* are frequently absent.

The *cerebral veins* are liable to great variation in detail: the *great cerebral vein* may be absent, as a single trunk, in which case the *internal cerebral veins* open directly into the sinus rectus. The *middle cerebral vein* may open into the sphenoparietal, or superior petrosal sinus or into the basilar plexus.

Veins of the upper extremity.—The subclavian vein is occasionally posterior to the artery, or splits to enclose the latter and the anterior scalenus. Either case represents a partial retention of the early condition in which the vein passes behind the brachial plexus. Variations in the *superficial veins* have been referred to on p. 668. The question of the most common distribution of these vessels has lately been fully reviewed by Berry and Newton. The *cephalic vein* occasionally opens into the external jugular by persistence of the embryonic jugulo-cephalic vein.

B. THE VENA CAVA INFERIOR AND ITS TRIBUTARIES

1. MORPHOGENESIS

The right and left **post-cardinal** veins (fig. 544) are at first symetrical in size and position. Early in development each posterior cardinal vein becomes involved in the growth of the corresponding mesonephros, and the original venous channel is converted into a system of sinusoids. In the sinusoidal circulation of each mesonephros two main longitudinal venous channels soon make their appearance. One lies ventro-medial to the mesonephros and is called the *sub-cardinal* vein. The other, which lies dorsal to the mesonephros, receives the segmental veins and is frequently called the post-cardinal. Since the mesonephric segment of the post-cardinal vein has obviously passed out of existence, the vein in question (unlabelled in fig. 544) will be here distinguished as the *dorsal trunk*. The sub-cardinals communicate freely between themselves and with the dorsal trunks, lie ventral to the mesonephric arteries, and are at first symmetrical. The cephalic end of the right sub-cardinal now acquires a communication with the common hepatic vein, thus providing a new means of drainage for the sub- and post-cardinal systems (fig. 544). The rapidly enlarging main venous channel resulting from this alternative method of drainage follows the right dorsal trunk as far as the level of the permanent renal veins. It is then transferred, by means to an anastomosing channel, to the right sub-cardinal and, through this, to the common hepatic vein; it becomes the *vena cava inferior*. From now on the portions of the sub-cardinal veins not participating in the formation of the cava dwindle rapidly. A cross anastomosis between the right and left sub-cardinals persists as the portion of the adult left *renal vein* which crosses ventral to the aorta. By means of it the remainder of the left renal; the left *internal spermatic* and left *suprarenal* veins are connected with the vena cava. The left lumbar and left common iliac veins are also transferred to the vena cava, probably by direct anastomosis with the left post-cardinal vein. The vena cava inferior is at first lateral to the right ureter, its transference to the medial side occurs through anastomosis.

The portion of the right posterior cardinal vein above the mesonephric region, together with its continuation into the dorsal trunk, becomes the *azygos* vein (fig. 544). The corresponding vessel upon the left side is transformed into the *accessory hemiazygos* and *hemiazygos* veins. The hemiazygos vein is drained into the azygos by means of an anastomosing channel which may also drain the accessory hemiazygos. The variability of the means of drainage of the accessory hemiazygos vein, by means of anastomosing channels, is referred to on p. 663. The *ascending lumbar* veins are anastomosing channels of new formation.

In the **lower extremity,** as in the upper, the original superficial plexus is gradually drained by a loop-like marginal vein. The fibular limb of this loop, the primitive fibular vein, becomes *small saphenous;* it follows the sciatic nerve and opens into the post-cardinal. The next vein to be developed is the *great saphenous;* the small saphenous is transferred to this by an anastomosing vein which is usually present in the adult—the *femoropopliteal* vein. The deep veins are of later formation. The drainage of the small saphenous is usually taken over by the popliteal vein.

2. VARIATIONS

In determining the probable embryonic cause of variations of the vena cava inferior the possibility of abnormal persistence of the sub-cardinal veins must be remembered. The position of transverse anastomoses with regard to the aorta is often the key to diagnosis. Instruc-

tive cases of abnormalities of the vena cava inferior have recently been published by v. Alten and by Neuberger (see References). Both articles contain bibliographies. The chief variations are as follows:—

(1) The inferior vena cava, in cases of transposition of the viscera, may lie on the left side of the aorta. (2) Without transposition it may also lie to the left of the aorta, crossing to the right to gain the caval opening immediately below the diaphragm, or after receiving the left renal vein. (3) It may be double, the left cava than usually passing across the aorta into the right after receiving the left renal vein. A communication between the right and left veins in the position of the normal left common iliac vein may or may not then exist. (4) The inferior vena cava may be absent, the blood from the lower extremities passing by a large vein in the position of the ascending lumbar and azygos veins through the diaphragm to open into the superior vena cava. The hepatic veins then open directly into the right atrium through the normal caval opening in the diaphragm. (5) The inferior vena cava may receive the left spermatic vein. (6) It may receive a left accessory renal vein passing behind the aorta, and into this the usual tributaries of the left renal vein may open. (7) It may receive several accessory renal veins; as many as seven on each side have been met with. (8) The lumbar veins may enter it on one or both sides as a common trunk.

The variations in the veins of the lower extremity are for the most part unimportant. They have been mentioned in the description of the corresponding veins.

3. THE PORTAL SYSTEM OF VEINS

The portal system arises by transformations in the vitelline and umbilical veins. The proximal ends of the vitelline veins, where they lie between the umbilicals, are early enveloped in, and invaded by, the growing liver. The columns of liver cells, while not penetrating the endothelium, subject the vitelline veins to a process of fenestration by which the original channels are subdivided into innumerable smaller vessels or sinusoids. The *sinusoids* arising from the two vitelline veins intercommunicate to form one continuous network in which the vessels are larger in the afferent (portal) and efferent (hepatic) areas than in the intermediate zone.

FIG. 545.—SEMIDIAGRAMMATIC RECONSTRUCTIONS OF THE VEINS OF THE LIVER, VENTRAL ASPECT (MALL). A, EMBRYO OF 4.5 MM. LONG; B, 4 MM. (MORE ADVANCED THAN A); C, 7 MM.
d.v., ductus venosus; I., intestine; L., liver; m., superior mesenteric (continued as portal) vein; r.a., ramus angularis; r. a′., right branch of portal vein; r.h.d., right hepatic vein; r.h.s., left hepatic vein; r.u., recessus umbilicalis; u.v., left umbilical vein (the right umbilical vein is not labelled); v.o.m., vitelline veins.

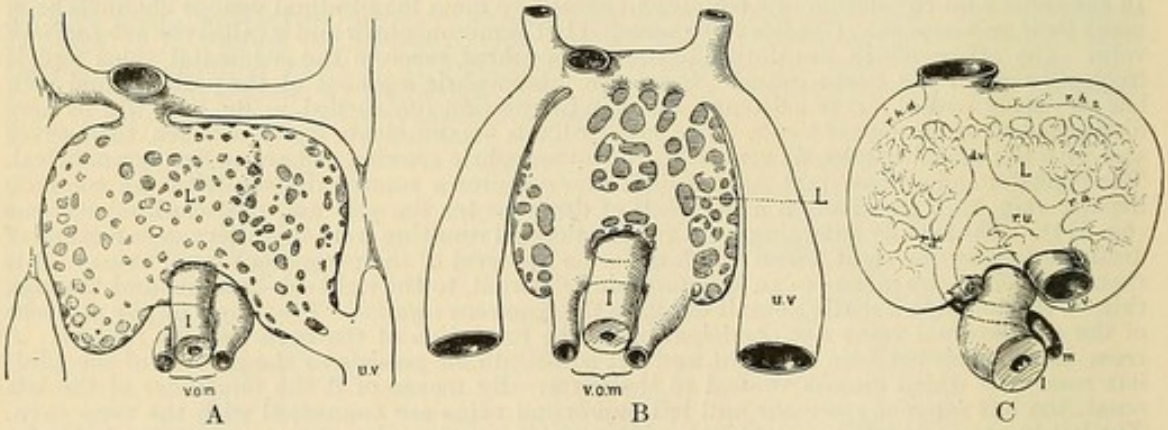

The two umbilical veins now form communications with the portal area of the sinusoidal network and eventually lose their original connections with the sinus venosus (fig. 545). The fate of the umbilical veins differs on the two sides; the right degenerates, from the sinus venosus to the common umbilical vein, and leaves the left to receive all the blood flowing from the placenta. The left, having lost its connection with the sinus venosus, discharges its blood partly into the portal sinusoidal zone, and partly, by means of the newly formed direct channel, the *ductus venosus*, into the right vitelline (fig. 545).

The hepatic end of the right vitelline vein enlarges considerably, for the left vitelline loses its original connection with the sinus venosus. It transmits blood both from the sinusoids and from the ductus venosus to the sinus venosus, and is called the common hepatic.

The vitelline veins are not only connected within the liver, but their distal ends become united upon the yolk-stalk to form a single trunk. A third communication between them is effected by a transverse vessel passing dorsal to the duodenum. The portion of the right vitelline below the transverse vessel disappears, as does the portion of the left between it and the liver. A tortuous vitelline vein is thus produced which enters the liver by passing dorsal to the intestine from left to right. This vessel is joined, to the left of the intestine, by the superior mesenteric vein and, dorsal to it, by the splenic. When the portion of the vitelline below the termination of the superior mesenteric finally disappears the vessel extending from the splenic vein to the liver becomes the portal vein of the adult.

Important variations of the portal system are rarely found in the adult. The mechanism of anomalies found in the embryo have been investigated by Begg (Amer. Jour. Anat., Vol. 13).

FŒTAL CIRCULATION

The changes which accompany the transformation of the fœtal type of circulation into that of the adult are initiated by the first inspiration. Prior to this act the functions of external respiration and digestion are performed by the

FIG. 546.—THE HEART, WITH THE ARCH OF THE AORTA, THE PULMONARY ARTERY, THE DUCTUS ARTERIOSUS, AND THE VESSELS CONCERNED IN THE FŒTAL CIRCULATION.
(From a preparation of a fœtus in the Museum of St. Bartholomew's Hospital.)

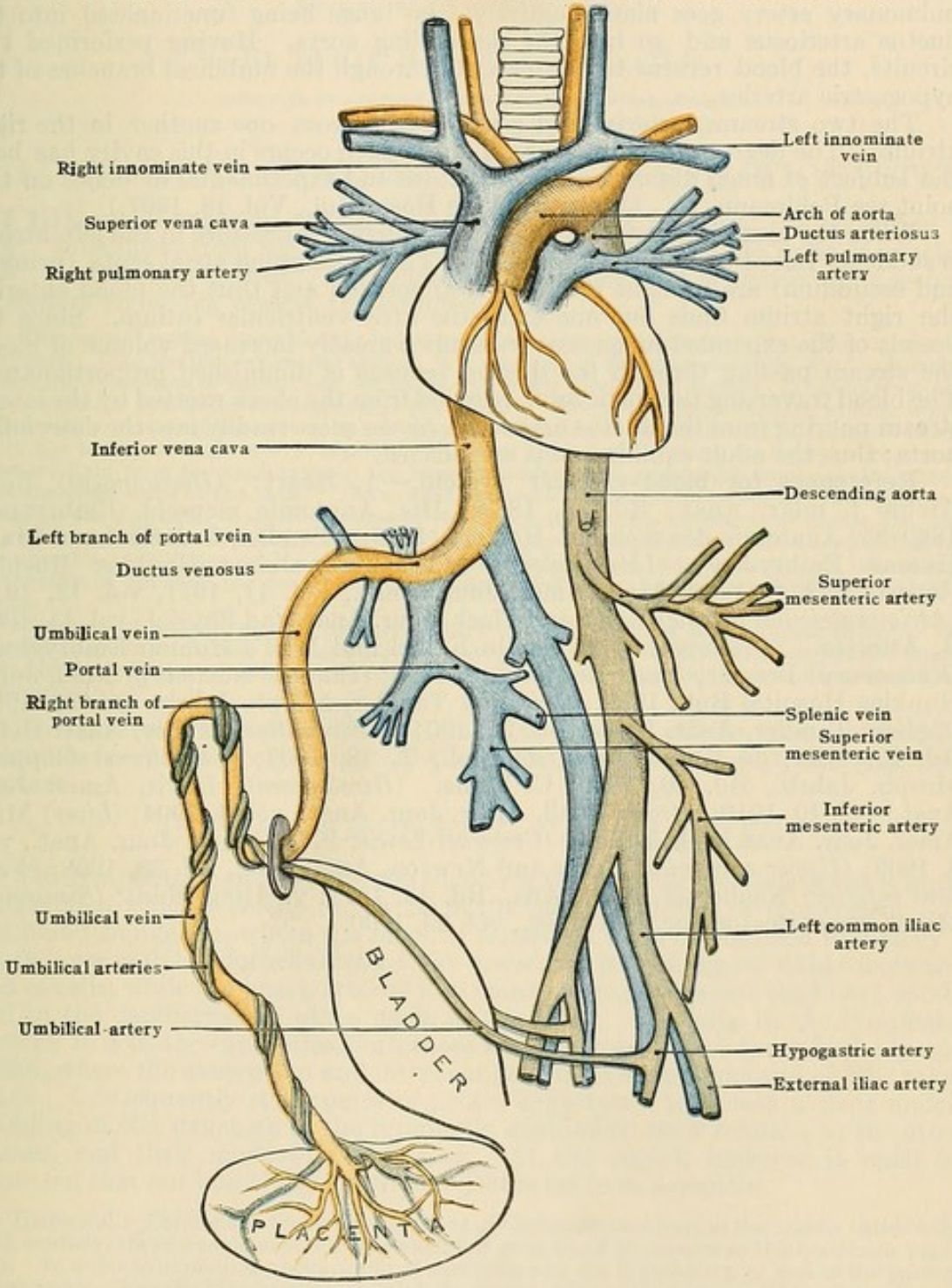

mother; the fœtal venous blood passing to the placenta through the umbilical arteries and returning through the umbilical vein.

At the time of birth the right and left chambers of the heart communicate only by means of an oblique passage between the overlapping atrial septa (p. 511). The pulmonary artery and descending aorta communicate by means of the ductus arteriosus (p. 508).

Arterial blood, transmitted from the placenta through the umbilical vein, passes almost entirely by way of the ductus venosus to the vena cava inferior. From here it passes through the right atrium; then, obliquely between the atrial septa into the left atrium, from which it passes through the left ventricle and into the ascending aorta. Escaping largely through the branches of the aortic arch, it is distributed to the head and upper extremities, and returned to the vena cava superior. Having reached the right atrium it passes, to the right of the stream from the vena cava inferior (p. 513), through the atrio-ventricular ostium into the right ventricle. The blood issuing from the right ventricle into the pulmonary artery goes almost entirely (the lungs being functionless) into the ductus arteriosus and so into the descending aorta. Having performed two circuits, the blood returns to the placenta through the umbilical branches of the hypogastric arteries.

The two streams, arterial and semi-venous, cross one another in the right atrium. The degree of intermixture, if any, which occurs in this cavity has been the subject of much discussion; for literature and experimental evidence on this point see Pohlmann, A. (Johns Hopkins Hosp. Bul., Vol. 18, 1907.)

When the lungs assume their function at birth the pressure in the left atrium is suddenly raised by an inrush of blood. The overlapping atrial septa (primum and secundum) are brought into lateral apposition and thus the blood entering the right atrium finds but one exit—the atrio-ventricular ostium. Since the vessels of the expanded lungs now transmit a greatly increased volume of blood, the stream passing through the ductus venosus is diminished proportionately. The blood traversing the aortic arch, released from the check exerted by the lateral stream pouring from the ductus arteriosus, passes more readily into the descending aorta; thus the adult equilibrium is established.

References for blood-vascular system.—A. **Heart:** (*Development*) Born, Archiv f. mikr. Anat., Bd. 33, 1889; His, Anatomie menschl. Embryonen, 1880–85, Anatomie des menschl. Herzens, 1886; Tandler, in Keibel and Mall's Human Embryology. (*Morphology*) MacCallum, Johns Hopkins Hospital Reports, vol. 9, 1900; Mall, Amer. Jour. Anat., vol. 11, 1911, vol. 13, 1912; (*Atrio-ventricular bundle*) Keith and Flack, Jour. Anat. and Physiol., vol. 41, 1907. B. **Arteries.** (*Development*) Evans, in Keibel and Mall's Human Embryology; (*Pulmonary*) Bremer, Anat. Rec., vol. 3, 1908; (*Internal mammary*) Mall, Johns Hopkins Hospital Bul., 1898; (*Cephalic*) Tandler, Morph. Jahrb., Bd. 30, 1902; (*Cœliac*) Tandler, Anat. Hefte, Bd. 25, 1904; (*Extremities*) Müller, Anat. Hefte, Bd. 22, 1903; de Vriese, Arch. de Biol., T. 18, 1902; (*Variations*) Göppert, Morph. Jahrb., Bd. 40, 1909; C. **Veins.** (*Development*) Davis, Amer. Jour. Anat., vol. 10, 1910; (*Brain*) Mall, Amer. Jour. Anat., vol. 4, 1904; (*Liver*) Mall, Amer. Jour. Anat., vol. 5, 1905; (*Cervical*) Lewis, F. T., Amer. Jour. Anat., vol. 9, 1909; (*Upper extremity*) Berry and Newton, Anat. Anz., Bd. 33, 1908; (*Vena cava inferior*) Neuberger, Anat. Anz., Bd. 43, 1913; v. Alten (ibid); (*Sinusoids*) Minot, Proc. Boston Soc. Nat. Hist., vol. 29, 1900.

SECTION VI

THE LYMPHATIC SYSTEM

REVISED FOR THE FIFTH EDITION

BY ELIOT R. CLARK, A.B., M.D.

ASSOCIATE IN ANATOMY, JOHNS HOPKINS MEDICAL SCHOOL

I. GENERAL ANATOMY OF THE LYMPHATIC SYSTEM

THE blood-vascular system has, as a part of its function, the collection of substances from the various tissues of the body which are to be conducted to the other tissues. In carrying on this function it is assisted by a second system of collecting vessels, the lymphatics.

This second system resembles the blood-vascular system in many ways, but differs markedly in others. Like the blood-vascular system, it is made up of minute endothelial-lined capillaries, where the absorption of substances occurs, and of larger conducting vessels. It differs from the blood-vascular system in two important particulars. While the blood-vascular system is provided with a pumping mechanism by which its fluid content is driven through a complete circuit from the heart, through artery, capillary, vein and back to the heart, the lymphatics merely conduct fluid *from* the capillaries to the larger vessels, which eventually empty their contents into the large veins of the neck. The second important difference between the two systems is found in the presence, along the course of the lymphatic vessels, of glands or nodes (fig. 553) [lymphoglandulæ] in which the vessels branch out into lymph capillaries. These are lined, as are the absorbing capillaries, with a single layer of endothelial cells, thus permitting an interchange of substances between the contents of the lymph capillaries and the lymphoid tissue around them.

Our present knowledge does not permit an exact statement of the complete extent of the lymphatic system. While, in a general way, the lymphatics may be said to be present wherever blood-capillaries occur, there are certain tissues where lymphatics have not been definitely demonstrated.

The general constitution of the lymphatic system will be considered under three heads—(1) the capillaries, (2) the collecting vessels and (3) the lymphoid organs.

1. *THE LYMPHATIC CAPILLARIES*

The lymphatic capillary, like the blood-capillary, is the portion of the lymphatic system which is chiefly concerned in the specific function of this system. In the blood-capillaries, where the blood is separated from the outside tissues by a single layer of flat endothelial cells, there occurs the interchange of fluid substances and of cells, while the heart, arteries and veins serve to transport the blood, modified in the capillaries, to other parts of the body. Similarly in the lymphatic system, it is in the capillaries, both those most peripheral and those in the lymph nodes, where the absorption and interchange of fluid substances and of cells takes place. Consequently it becomes of prime importance to obtain a clear understanding of the structure of the lymphatic capillaries, their relation to the other tissues, and their mode of functioning. At the outset, however, it must be admitted that our knowledge on this subject is far from complete.

Historical.—Previous to the development of microscopic anatomy, in the middle third of the 19th century, there was no accurate knowledge of such small structures as the lymphatic capillary. In order to explain the absorption of substances by the lymphatics, as well as the passage of substances from the blood-vessels through the tissues, various theories were invented. Prominent among such theories was that of the "vasa serosa," of H. Boerhaave and other 18th century anatomists and physiologists, which was perhaps most elaborately developed by Bichat, 1801–03. According to this theory there are two sets of minute vessels, too small for the passage of cellular elements. The one set leads from the blood-capillaries onto the various surfaces of the body and into the loose spaces in the tissues—the "exhalants." The other set leads from the body surfaces (including the serous cavities) and the loose spaces in the tissues to the lymphatics—the "inhalants" or "absorbants," which take in fluids by a sucking action.

This theory was somewhat shaken by the discovery of Magendie, in the first decade of the 19th century, that absorption may take place by the veins, as well as the lymphatics, and by the criticism of early 19th century anatomists who developed the technic of injection of lymphatics to a high point.

Our present conception of the lymphatic capillaries may be said to have started with Kölliker who, in 1846, saw, with the aid of the microscope, the lymphatic capillaries in the transparent tails of living frog larvae. He found them to be definite structures made up of a thin wall, from which projected fine-pointed processes, and in which were nuclei. Like Schwann who, in 1837, had studied the blood-capillaries in the tail of the frog larva, he erroneously supposed that the fine processes of the lymphatic capillaries were continuous with similar processes of the surrounding connective-tissue cells. Since, according to the conception current at the time, cells were thought to be hollow structures, with a membranous wall and fluid content, it was concluded that the mode of transmission of fluid from blood to lymphatic capillary took place through canaliculi inside these cells. This conception was elaborated by Virchow, in his Cellular-Pathologie.

In 1862 von Recklinghausen by means of the silver nitrate staining method discovered that the lymphatic vessels are lined with an endothelium made up of flattened cells whose outlines show as fine dark lines after this treatment. Again, however, as a result of the eagerness to find open passages through the tissues from blood to lymphatic capillary, an erroneous interpretation was made. von Recklinghausen held that the unstained parts outside the lymph vessels represent a system of irregularly shaped lymph-canaliculi ("Saftkanälchen") which are in open communication on the one hand with the blood-capillaries, and on the other with the lymphatics This conclusion has since been disproved by numerous investigators.

In a second series of observations, von Recklinghausen brought evidence in favor of open communications between the lymphatics and the peritoneal cavity. He watched, under the microscope, the passage into lymphatics, through minute openings, of milk, placed on a portion of the central tendon of the diaphragm. These minute openings he termed "stomata." Cohnheim described similar though smaller openings in blood-capillaries, and His described them in other lymphatic capillaries. Arnold termed the openings in the vessels "stigmata," as distinguished from the openings into the peritoneal cavity, or "stomata."

With the advent into microscopical technic of the various dyes for staining cell-nuclei and protoplasm, and the more precise methods for making histological studies, the endothelial wall of the lymphatic capillary has been definitely established, although much remains to be learned concerning the differences between the lymphatics of the various tissues.

Moreover, recent investigators have failed to find open connections between the lumen of the lymphatic vessel and the tissue outside. Kolossow failed to find the "stomata" of von Recklinghausen and the "stigmata" of Cohnheim, His and Arnold. The "stomata" have been carefully studied by a number of other recent investigators. All agree in finding a complete endothelial lining for the lymphatic capillaries lying underneath the peritoneum and pleura, with no openings or "stomata." Careful studies of the lymphatic capillaries in the transparent tails of living frog larvae, which may be clearly seen with the higher magnifications of the microscope, show that the endothelial lining of these capillaries is complete, with no trace of an opening into the spaces in the tissue outside (E. R. Clark).

Form.—The shape of the lymphatic capillaries has been found to vary enormously in the different parts of the body, where they have been studied. In general they form richly anastomosing plexuses, from which may extend cul-de-sacs, which end blindly. Such cul-de-sacs are especially noticeable in the dermal papillæ, in the filiform papillæ of the tongue, and in the intestinal villi. The plexuses are often present in two layers—a superficial and a deep. The vessels of the superficial plexus are of smaller calibre than those of the deep. These two sets of plexuses are particularly well seen in the skin and the gastro-intestinal tract. In relation to the blood-capillaries, the lymphatic capillaries are generally the more deeply placed.

In calibre, unlike the comparatively uniform diameter of blood-capillaries, the lymphatics vary enormously. In the same capillary a very narrow part may be succeeded by a very wide one (figs. 547, 548). Teichmann found lymphatic capillaries varying in diameter from a few thousandths of a millimetre to one millimetre. In the capsule of the spleen of the cow some measured more than 1.5 mm.! The capillaries are without valves.

Activity.—That the lymphatic endothelium is not exclusively a passive membrane has been shown by Clark in studies on the lymphatics in the transparent tails of living frog larvæ. The lymphatics here are seen to send out protoplasmic processes which, somewhat like an amœba, actively take into the interior of the lymphatic red blood-cells accidentally forced from the blood-capillaries into the tissue-spaces.

The mode of passage of leucocytes into or out of the lymphatics offers no such difficulties as that of the fluids, for they are able, through their power of amœboid movement, to pass independently through the endothelium—a process first directly observed by Cohnheim.

1. The Extent and Character of Lymphatic Capillaries

The *skin* over the entire surface of the body is richly provided with lymphatic capillaries. They form two sets of plexuses in the dermis, a superficial and a deep. The superficial set sends out blind cul-de-sacs into the dermal papillæ. The richest skin plexuses are found in the scrotum, the palms of the hand and palmar side of the fingers and in the soles of the feet and plantar side of the toes. In the loose *subcutaneous* fascia, according to Teichmann, there are present only the larger collecting vessels, with no lymphatic capillaries. Lymphatic capillaries of the *scrotum* are shown in Fig. 547.

The *conjuntiva*, both the sclerotic and corneal, is supplied with a rich plexus of capillaries, which are narrower in the corneal than in the sclerotic portion. At the corneal border the

capillaries form a fairly regular ring which has been called by Teichmann a circulus lymphaticus.

At the various *orifices* of the body, the skin plexuses go over into the mucous plexuses, forming anastomoses with them. Throughout the entire *alimentary tract*, including the nasal cavities, the lymphatic capillaries form extensive plexuses which are in many places divided into a superficial plexus in the mucosa and a deeper plexus in the submucosa. In portions provided with a peritoneal covering, there is a third rich subserous plexus. In the tongue and the small intestine the plexus in the mucosa sends out blind cul-de-sacs; in the tongue into the filiform papillæ; in the small intestine into the villi. Where muscle is present along the alimentary tract, the lymphatics pass between the muscle bundles, but form no plexuses around them.

The lining of the *tracheal* and *bronchial passages* is supplied with a double plexus of lymphatic capillaries, a mucous and a submucous set, which vary in richness according to the looseness of the tissue. In the smaller bronchi but a single layer of capillaries is present, and, according to Miller, no capillaries are present around the air cells. Plexuses surround the pul-

FIG. 547.—THE LYMPHATICS OF THE SCROTUM. (After Teichmann.) Showing the transition of the capillaries to the vessels with valves (*a*, *a*, *a*).

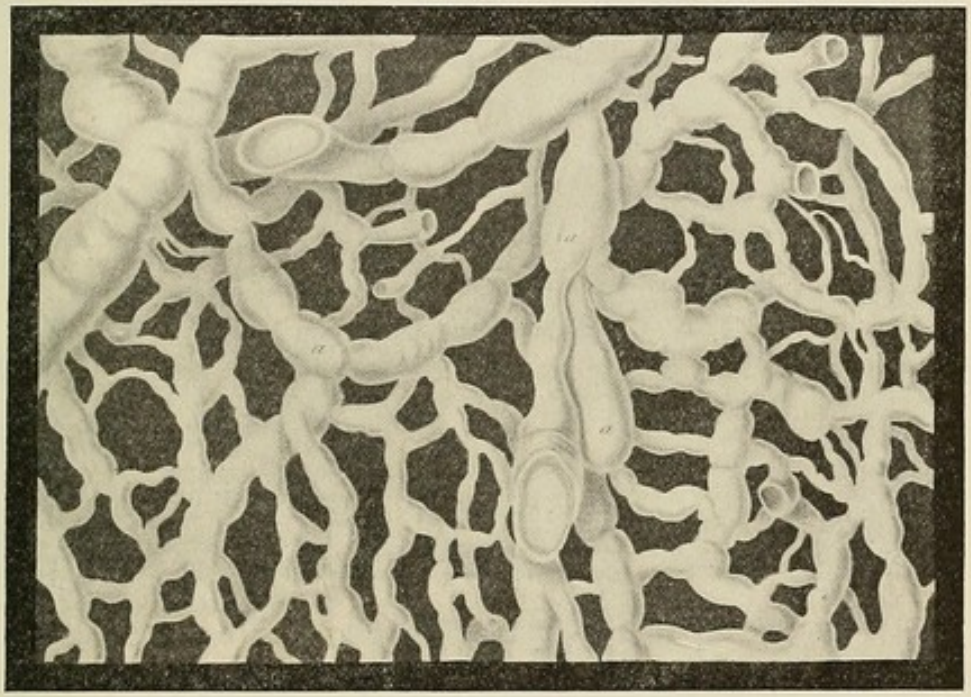

monary arteries and veins. Under the *pleura* lie rich plexuses which connect with the deeper lymphatics around the veins only in places where the veins reach the surface of the lung.

Concerning the arrangement of the lymphatic capillaries in the *glands* derived from the alimentary tract much remains to be learned.

The *salivary glands* have been recently studied anew by Aagaard, who has found lymphatic capillaries accompanying the blood-vessels into the interior of the lobules, and forming here irregular plexuses.

The *thyreoid gland* contains lymphatic plexuses which lie in relation to the colloid-containing alveoli. Direct connection between the lymphatics and the alveoli has lately been described by Matzunaga, but this observation needs verification. The lymphatics are apparently concerned in the absorption of the colloidal secretion, for traces of it have been found in the lymphatics draining the gland.

Concerning the lymphatics of the *parathyreoids* nothing is known.

The course of the lymphatics draining the *thymus* has been recently described, but the nature of the capillaries in this gland is unknown.

The lymphatic capillaries of the *liver* are of great importance, for the lymph which flows from this organ forms a very considerable part of the total lymph which is collected into the thoracic duct. And yet very little is definitely known about the nature and distribution of the lymphatic capillaries in the interior of the organ. In the capsule there is a rich plexus, lying under the peritoneum, in which very large widenings have been described (called by Teichmann "Lymphbehälter"). In the interior rich plexuses surround the branches of the hepatic artery and portal vein (fig. 549), and plexuses have been described accompanying the branches of the portal vein into the lobules.

The linings of the large *bile-ducts* and the *gall-bladder* are provided with a submucous network of lymphatics (Sudler and Clermont). The gall-bladder has also a rich subserous plexus.

Concerning the lymphatic capillaries of the *pancreas* Bartels notes briefly that they form richly branched plexuses in the interlobular connective tissues, which surround larger or smaller parts of whole lobules, not the single gland elements.

The mucous lining of the *genito-urinary tract*, wherever it has been carefully studied

has been found provided with plexuses of lymphatics. In the *bladder* they form a rich plexus of irregular capillaries which lie immediately under the almost intracpithelial blood-capillaries. They connect, through the muscular layer, with a subserous plexus. The lymphatic plexus of the *urethra* anastomoses with the capillaries of the base of the bladder. and in the male with those of the glans penis. The lymphatic capillaries of the ductus deferens and of the seminal vesicles have not been studied. In the *prostate* (Camineti) the lymphatics form rich plexuses surrounding the glands, which connect with a very wide meshed subcapsular plexus, surrounding the entire gland.

In the *testis* there is a rich superficial plexus, lying directly beneath the tunica albuginea. Concerning the deep lymphatics of the testis there has been much dispute. Ludwig and Thomsa

FIG. 548.—SURFACE VIEW AND SECTION OF LYMPH-NODES OF THE INTESTINE. A. Solitary follicle. B. Peyer's patch. (After Teichmann.)

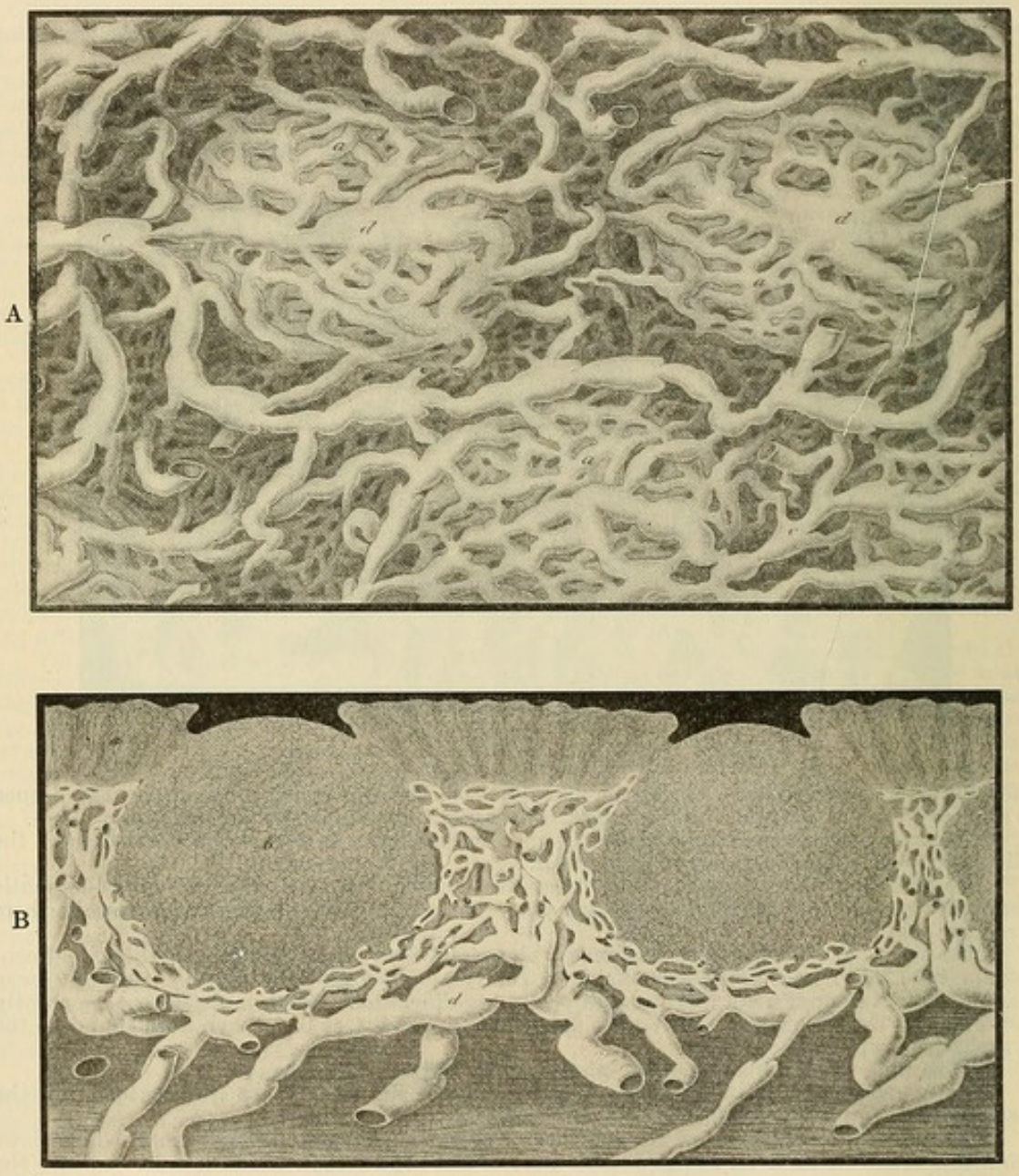

found the lymphatic capillaries going over into lacunæ, without endothelium. This has been disputed by Tommasi and Gerster, who find, in the septa, capillaries with endothelial wall, which they consider the beginnings of the lymphatics.

In the female, lymphatic plexuses have been found in the mucosa of *vagina* and *hymen*, anastomosing with those of the vulva. In the *uterus*, capillaries in the mucosa are very difficult to demonstrate. Definite lymphatics, however, have been found passing through the muscularis, and under the peritoneum a rich subserous plexus of capillaries is present. In the pregnant uterus these subserous capillaries are much distended (Schick). The *Fallopian tubes* are provided with lymphatics, but they have not been carefully described.

The *ovary* has a rich superficial lymphatic plexus. In the interior of the gland, according to His, the capillaries form networks in the connective-tissue framework. In the tunica externa of the follicles there is a rich plexus.

The *kidney* has two sets of lymphatics, a superficial, capsular set, and a deep set. The capsular set is divided into two layers, one lying directly beneath the peritoneum made up of a wide meshed plexus, and the other in the fibrous capsule of the kidney, with finer capillaries and narrower meshes, which anastomose with the deeper capillaries. The lymphatic capillaries of the kidney parenchyma have recently been described by Kumita. He found rich plexuses in both cortex and medulla, surrounding the straight and convoluted tubules, the loops of Henle and the collecting tubules. He also found a plexus surrounding and accompanying the blood-vessels into the interior of the glomeruli.

The lymphatic capillaries of the *adrenal* have also been described recently by Kumita. His results agree with those of Stilling, who studied the lymphatics of the adrenal of horse, cow and calf. Like the kidney, the adrenal possesses a superficial and a deep set. The superficial set

FIG. 549.—LYMPHATIC PLEXUS AROUND THE PORTAL VEIN IN AN ADULT MAN. (After Teichmann.) Showing the supporting relation of the vein.

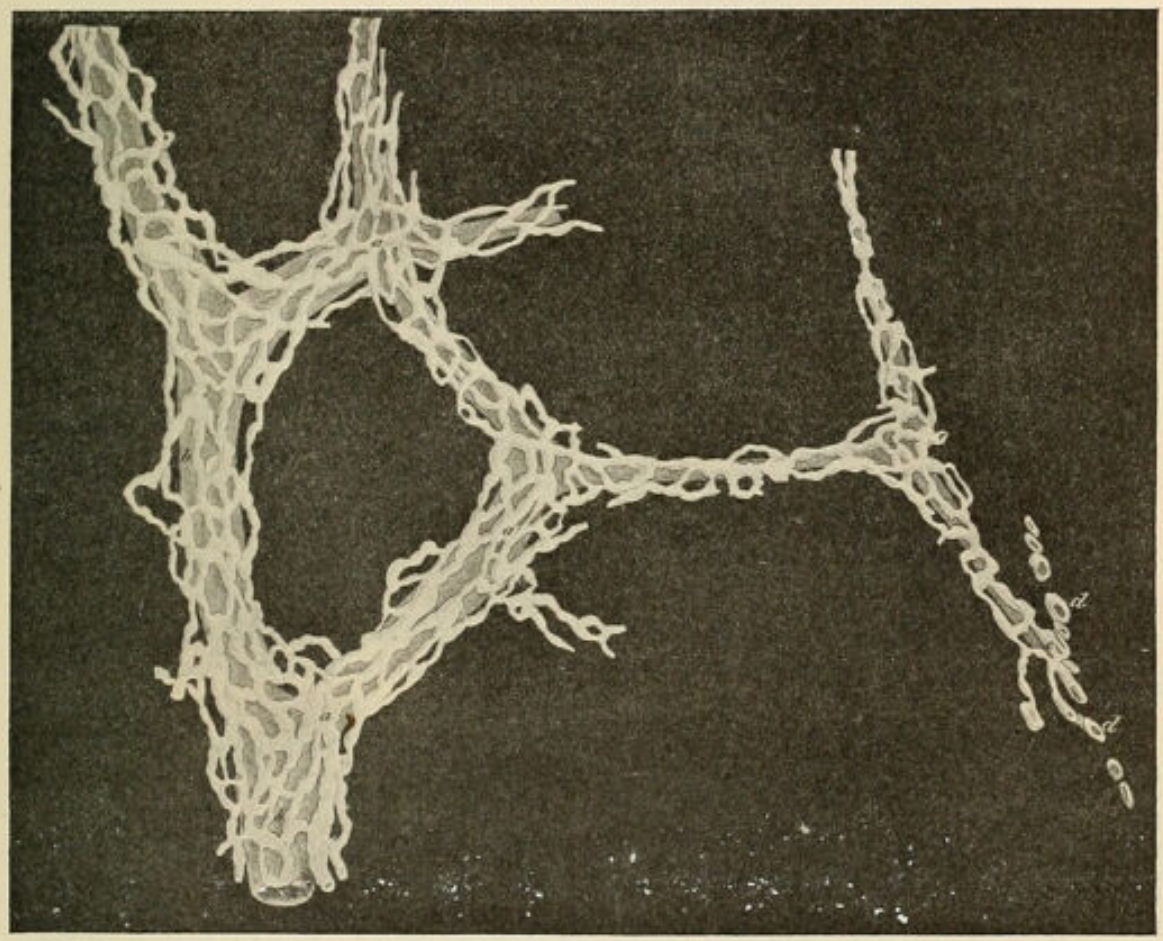

is in two layers, as in the kidney, the outer lying in the looser tissue around the adrenal and the inner lying within and just under the capsule. The latter is made up of a rich lymphatic plexus, which anastomoses with the capillaries of the parenchyma. The parenchymatous lymphatics are present in the form of plexuses which surround the groups of cells.

In spite of numerous investigations, endothelial-lined lymphatics have not been definitely found in the central nervous system, or in the peripheral nerves. The subarachnoid and similar spaces, including the perineural spaces, do not form parts of the lymphatic system.

Rich plexuses of lymphatic capillaries are present in the *tendons* of *muscles* (Schweigger-Seidel and Ludwig). In muscles, themselves, the question of the presence of lymphatics has long been disputed, sometimes answered in the affirmative, more often in the negative. A recent study by Aagaard, however, would seem to place beyond doubt the presence of lymphatic capillaries in *striated muscles*. By long continued injection, he was able to find lymphatics in the intramuscular portions of the tendons, which extended out among the muscle fibres themselves. He also found capillaries in the tongue musculature.

The *heart* is provided with a subpericardial plexus of lymphatic capillaries. A subendocardial plexus has also been described (Sappey, Rainer). Bock has recently found that there is an extremely rich lymphatic network throughout the substance of the heart. According to his description, the lymphatic capillaries are more numerous than the blood-capillaries.

The *periosteum of bones* is provided with a rich plexus of lymphatic capillaries. They are present in several layers, of which the outermost form the richest plexus. Lymphatic capillaries

have also been described accompanying the blood-vessels in the Haversian canals in bones (Rauber, Schwalbe, Budge). Nothing is known concerning the lymphatics of the bone marrow. *Cartilage* lacks both blood and lymphatic capillaries.

The capsular membranes of joints are richly provided with lymphatic capillaries (Tillmanns). They are arranged in two layers—an inner layer made up of a rich plexus of wide capillaries, lying just outside the subendothelial blood-capillaries, and an outer layer, consisting of a rich plexus in the subsynovial tissue. The lymphatic capillaries have no open connection with the joint cavity.

The membranes surrounding the *pleural*, *pericardial* and *peritoneal cavities* are richly supplied with lymphatic capillaries, which form here thick plexuses outside the endothelium. These plexuses are usually described with the underlying organ, as the subserous lymphatic capillaries of the intestine, etc. In the central tendon of the diaphragm the subperitoneal lymphatics are extremely rich. They widen out here to form very large endothelial-lined cavities which, in the spaces between the connective-tissue bundles, lie directly in contact with the peritoneal epithelium. The existence of open connections between these capillaries and the peritoneal and pleural surfaces (the "stomata" of von Recklinghausen) has recently been disproven. The capillaries on the two surfaces of the central tendon communicate freely with one another.

2. *THE LYMPHATIC VESSELS*

The lymph which enters the lymphatic capillaries passes over into collecting vessels (ducts), which carry it through the lymph-glands (nodes) to the large veins at the base of the neck. The lymph-vessels course in the loose subcutaneous tissues, in the connective tissues between muscles and organs, often accompanying the arteries and veins, sometimes forming networks around them. An idea of their arrangement can be best obtained by glancing at the illustrations of the lymphatics of special regions. In general they are made up of numerous long, narrow vessels, rarely more than half or three-fourths of a millimetre in diameter, which occasionally communicate with one another, and which radiate toward groups of lymph-glands placed in certain definite regions. In the lymph-glands the afferent lymph-vessels break up into capillaries, which again collect into efferent vessels. Several of these efferents from each lymph-gland may pass to a second lymph-gland, where they undergo a second widening into capillaries. In this way the lymph, passing through one, two, three or more lymph-nodes in succession, eventually reaches the thoracic duct, or one of the short ducts, all of which empty into the large veins at the base of the neck. The thoracic duct, which receives, at its lower end, the lymph from the lower half of the body, is the only lymphatic vessel which attains any considerable size (four to six millimetres in diameter) and is usually the only one large enough to be seen readily without injection.

In *structure* the lymphatic vessels much resemble the veins. They possess an intima, a media and an adventitia, although the line of demarcation between the different layers is not sharp. In the thoracic duct, the endothelium of the intima is succeeded by a delicate layer of fibres, mainly elastic; outside of this is the media, made up mainly of circular smooth muscle-cells, interspersed with elastic and connective-tissue fibres; then follows a layer of coarse elastic and connective-tissue fibres, which is succeeded by the adventitia, containing longitudinal and transverse bundles of smooth muscle-cells, as well as blood-vessels and nerves. The other lymphatic vessels possess the three layers, which, however, toward the capillaries, grow thinner, and eventually reach a stage in which, outside the endothelium, there are found only single muscle-cells, or muscle-cells in groups of two or three.

The lymphatic vessels are characterised by their great richness in valves, which are present throughout their entire course, from their beginnings in the capillary region to their openings into the veins of the neck. The valves are bi- or tri-cuspid, and are always arranged so as to prevent the flow of lymph back to the capillaries. They thus aid indirectly in the movement of the lymph, in that any external pressure on the vessels must always force the lymph onward.

Nerves of lymphatic vessels.—That the thoracic duct and the smaller lymphatic vessels are provided with nerves has been shown by several observers. According to Kytmanoff (in dogs) the nerves to the lymphatics are mainly non-medullated, and are both motor and sensory. They form four sets of plexuses—adventitial, supramuscular, intermuscular and subendothelial. Sensory nerve-endings (fig. 550) are found in adventitia and media, in the form of free-ending threads, and bush-like endings. Motor endings are present in connection with the smooth muscle cells of the media. In the intima there is a plexus of extremely fine varicose threads. The physiological action of the nerves supplying the receptaculum chyli has been tested by Camus and Gley who found in dogs a dilatation of the receptaculum as the result of electrical stimulation of the splanchnic nerve.

Movement of the lymph.—It has been estimated (Ludwig) that the amount of lymph which passes through the lymphatic ducts of a dog aggregates, during the twenty-four hours, one-third the body-weight. In the thoracic duct the lymph is under a sufficient pressure to burst the duct behind a ligature. In the absence of any especial propulsive organ, such as the heart for the blood-circulation, what are the forces which move the lymph? There must be recognised primary and accessory forces. As accessory forces there are the movement of the muscles and the

general pressure of the organs on the lymph-ducts. Since these are provided with valves, all preventing the lymph from flowing backward, any such pressure causes the lymph to move onward. As accessory agents must also be reckoned the smooth muscle and elastic tissue which is present in the walls of the lymph-vessels and in the lymph-gland. That these forces, however, are not primary is shown by numerous facts. There is an active circulation in the lymphatics of

FIG. 550.—A. THE ADVENTITIAL AND SUPRA-MUSCULAR NERVE PLEXUSES, TOGETHER WITH SENSORY ENDINGS IN THE THORACIC DUCT OF A DOG. (Methylene-blue method.) B. NERVE-FIBRES ON THE ENDOTHELIUM OF A LYMPHATIC CAPILLARY OF A DOG. (After Kytmanoff.)

A

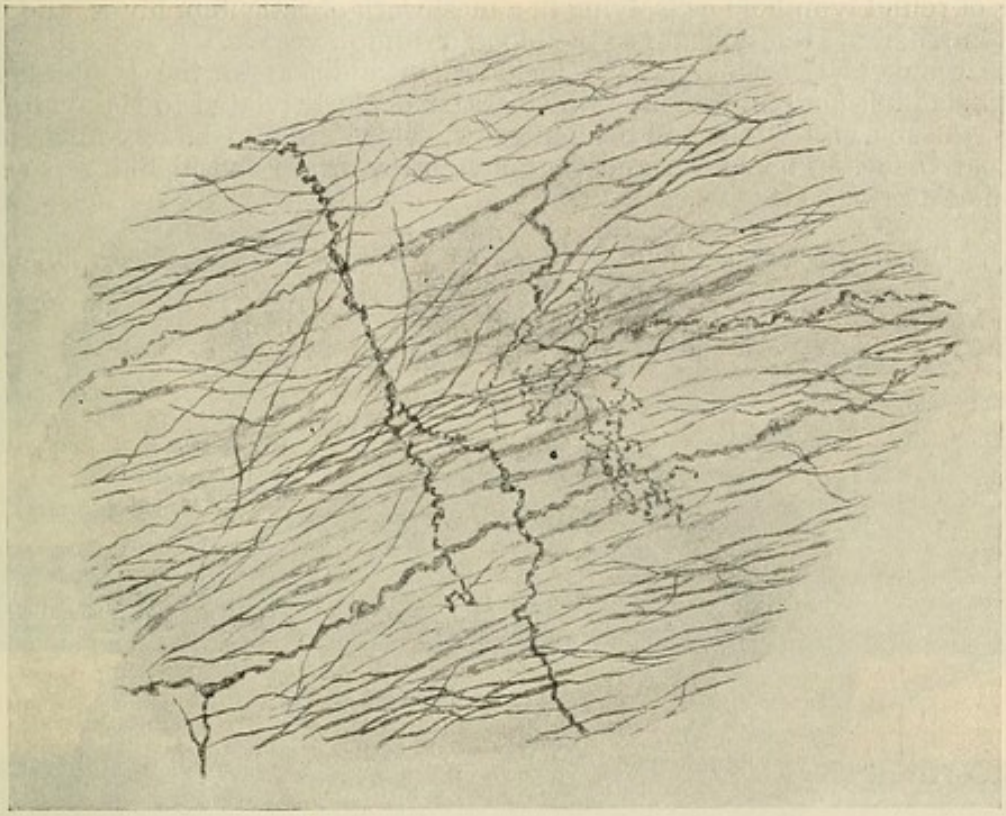

B

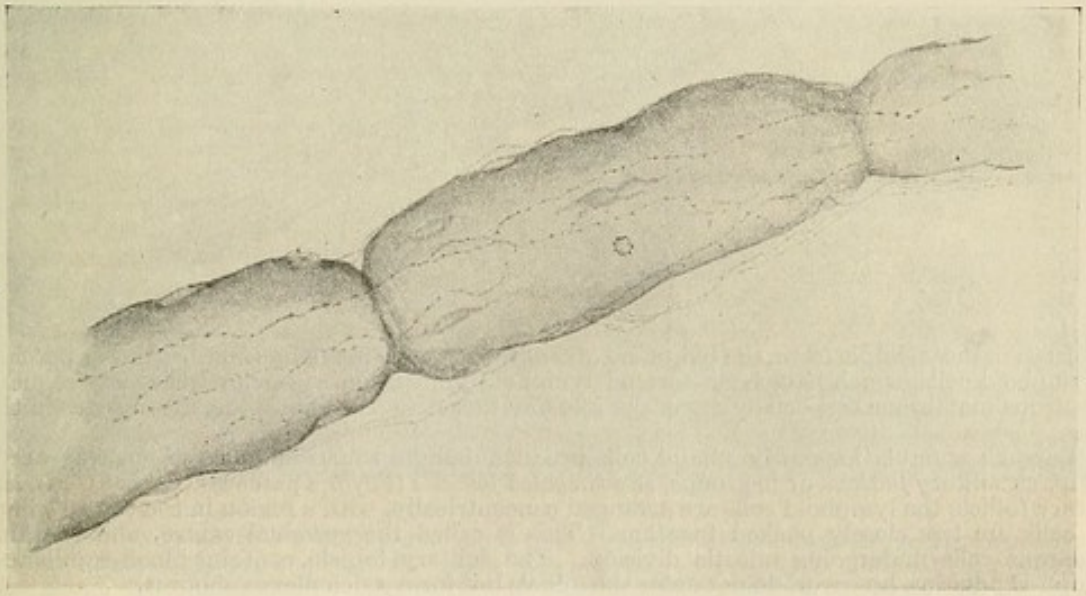

embryos long before valves develop. In many lower animals no valves develop save at the entrance of the lymphatics to the veins. That neither valves nor muscular movements are essential is shown by the fact that, in the tails of frog larvæ, where no valves are present and where the muscle movements have been completely paralysed by an anesthetic, the circulation of lymph continues unchecked.

The primary cause, therefore, for the movement of lymph is to be sought in the capillary region, in the force produced by the passage of lymph through the endothelial wall, whether this

process be a filtration and diffusion—in which case the causes would lie in the pressure and molecular condition of the tissue fluid outside the lymphatic—or whether it be an active secretion by the endothelium—in which case the driving force would be this secretory power of the endothelium.

3. THE LYMPHOID ORGANS

Closely associated with the lymphatic capillaries and vessels is a group of glandular structures known as lymphoid organs. They consist, essentially, of groups of round lymphoid cells, lying in a meshwork of reticulum fibres, and having often a definite relationship to the blood or lymph vessels.

The group of lymphoid organs includes, in addition to the lymph-glands [lymphoglandulæ] or lymph-nodes, which are particularly related to the lymphatic vessels, the spleen, thymus and bone-marrow, which are also largely made up of lymphoid tissue. The spleen and thymus, however, are considered separately with the DUCTLESS GLANDS.

FIG. 551.—DIAGRAM OF A LYMPH-NODE. (After Toldt, "Atlas of Human Anatomy, "Rebman, London and New York.)

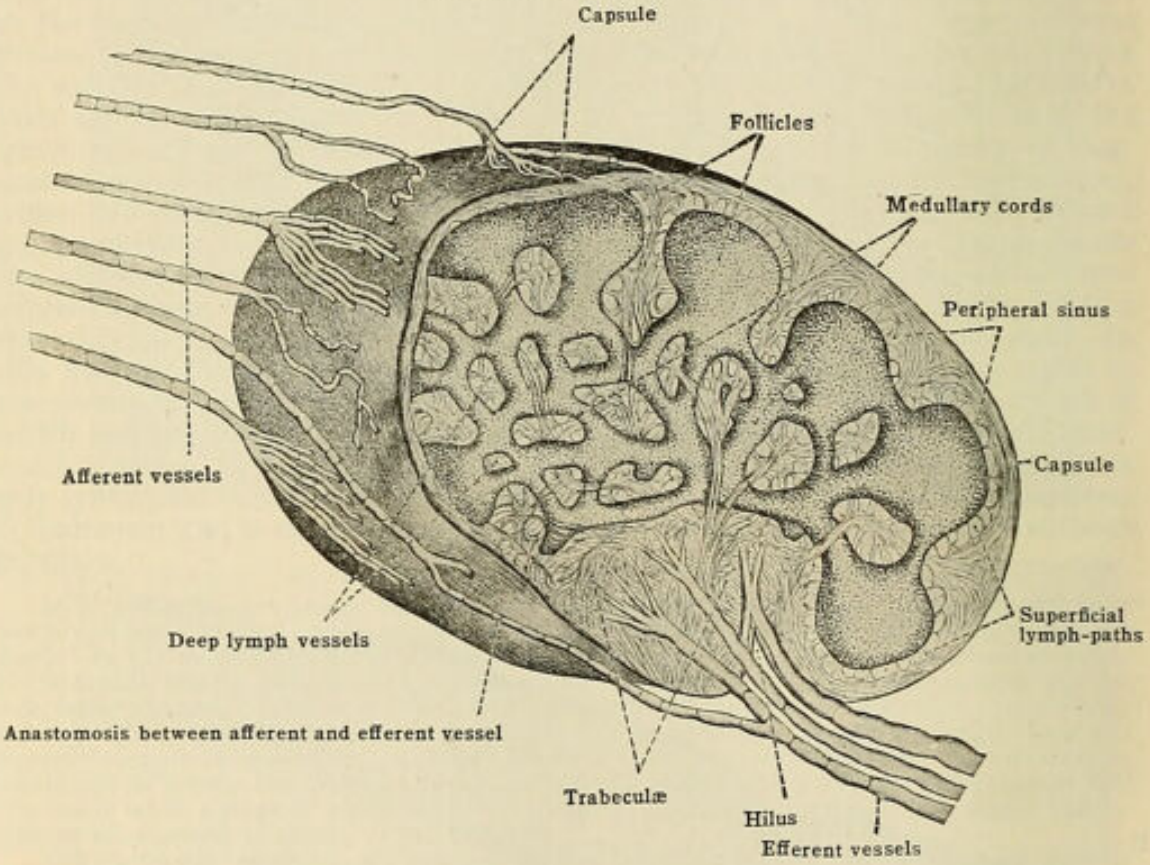

In their most simple form, the lymphoid organs form mere irregular accumulations or patches of lymphoid cells, which have been termed lymphoid infiltrations. Such patches are frequent in mucous membranes especially along the intestinal tract (fig. 549) and the air-passages in the lungs.

Larger accumulations of lymphoid cells produce definite round nodules, which may occur singly, as *solitary follicles* or in groups, as *aggregated follicles* (Peyer's patches) (fig. 548). In the solitary follicle the lymphoid cells are arranged concentrically, with a region in the centre where the cells are less closely packed together. This is called the germinal centre, and contains numerous cells undergoing mitotic division. The solitary follicle contains blood-capillaries. Lymph-capillaries, however, do not enter the follicle but form a rich plexus about it.

The **lymph-glands** or nodes (fig. 551) are larger lymphoid structures, which are developed along the course of the lymph-vessels. They vary much in size, shape, and colour, and may occur singly or in small or large groups. The *size* varies from the size of a pin-head to that of an olive, or larger. In *shape* they may be spherical, oval, or flattened on one or more sides, according to their relations to other organs. Each gland has an indentation or hilus, where the arteries enter, and where the veins and efferent ducts emerge. Their *colour* depends upon position and state of function. The glands along the respiratory tract are black, due to the presence of carbon granules. The mesenteric glands are milk-white during digestion, and other nodes are pale and translucent when their sinuses are filled with fluid, and pink or even red when red-blood

cells are present in the sinuses. The lymph-gland is made up of four distinct elements: lymphoid elements, lymphatic capillaries, supporting structures, and blood-vessels.

The *lymphoid elements* (fig. 551) are arranged as follicles and as cell-strings. The follicles lie around the circumference of the gland, and form the cortex [substantia corticalis]. The cell-strings or medullary cords are irregular cords of cells which extend from the follicles through the central or medullary portion [substantia medullaris] of the gland. The follicles and medullary cords are made up, as are the solitary follicles, of round lymphoid cells.

FIG. 552.—SURFACE VIEW AND SECTION OF A LYMPH-NODE SHOWING THE PERIPHERAL AND CENTRAL SINUSES. (After Teichmann.)

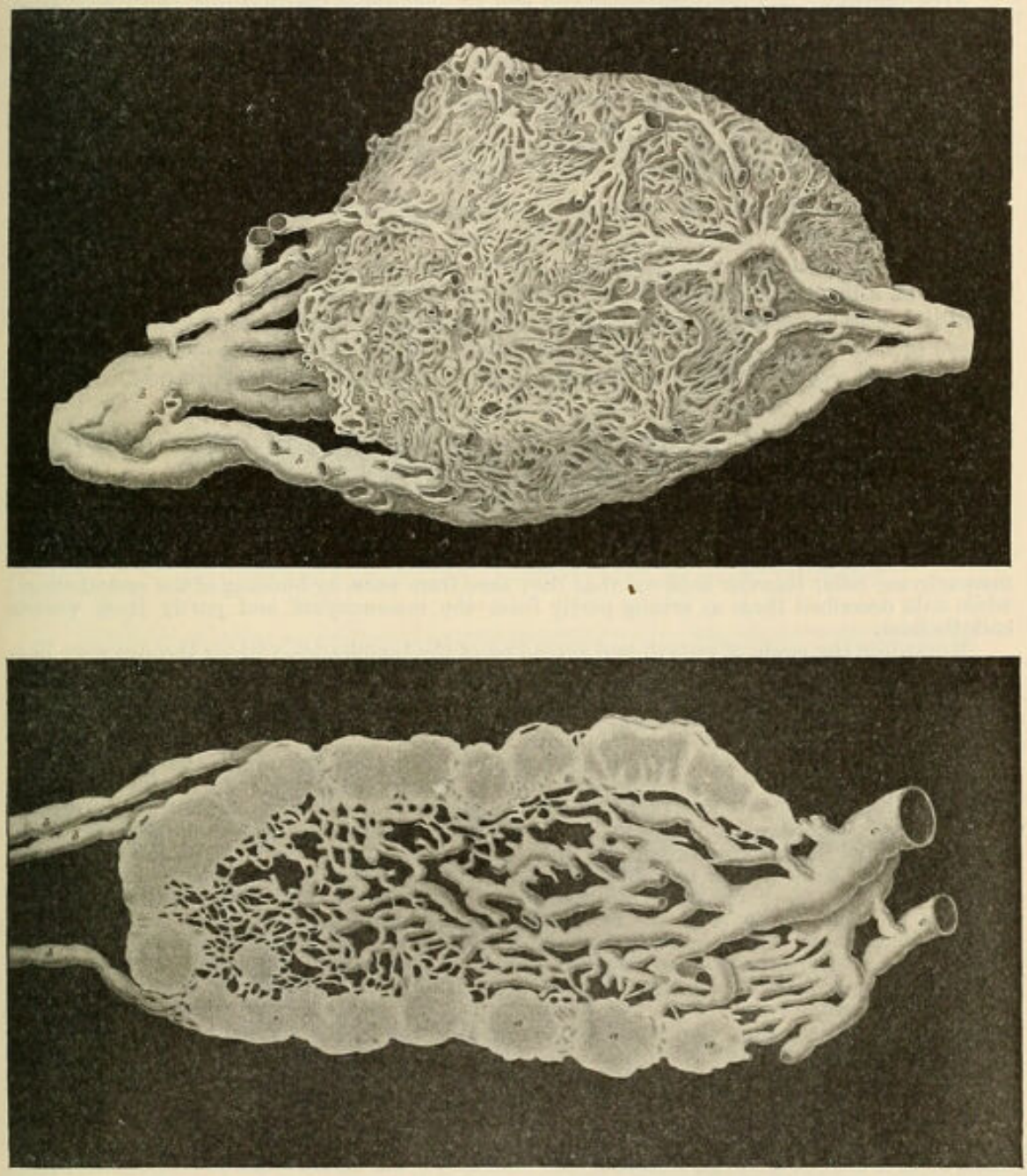

The *lymphatic vessels* (fig. 551) enter the lymph-gland as several vasa afferentia, and leave it, at the hilus, as the vasa efferentia. The vasa afferentia spread out in the cortical portion of the gland into an extremely rich plexus of wide capillaries which surround the follicles, forming the peripheral sinus. The capillaries do not enter the follicle. This plexus continues, around the follicles, into the medullary portion where it forms again a rich plexus, the medullary sinus, in the spaces around the medullary cords (fig. 552). At the hilus the medullary capillaries collect into larger vessels and emerge as the vasa efferentia.

The *supporting structures* consist of a fibrous capsule surrounding the gland, from which trabeculæ or septa pass in, around and between the follicles and cords. From the septa, a fine reticulum passes into the follicles and cords, where it forms a rich dense meshwork, in the interstices of which lie the lymphoid cells. The capsule and trabeculæ are made up of white fibres, elastic fibres and smooth muscle-fibres.

The *blood-vessels*, which enter and leave at the hilus, send branches into the follicles and into the medullary cords.

The enormous widening of the lymph-stream in the lymph-node from the vasa afferentia to the capillaries—like a brook widening out into a pond—causes a very great diminution in the rate of flow of the lymph. Thus there is present in the gland a very slowly moving stream of lymph, which is separated from the lymphoid tissue outside by a single layer of flattened endothelial cells. There is thus possible an easy interchange of substances, and an opportunity for the passage, through the endothelium, of wandering cells. While the entire mode of functioning of the lymph-gland is not clear, it is known that lymphocytes, formed here, enter the lymph-stream, and that substances such as, for instance, carbon granules, or leucocytes laden with bacteria, are checked in their course by the lymph-gland.

Arrangement.—The lymph-glands are so arranged throughout the body that all the lymph which enters the lymphatic capillaries must pass through one or more lymph-glands on its way to the veins.

It is possible that this rule may have exceptions, although none have yet been definitely proved. Thus, some of the small lymphatics which join the thoracic duct may enter it without having passed through a gland. Moreover, there is often found (fig. 551) a direct anastomosis between an afferent and an efferent lymphatic vessel.

Most of the glands are collected in certain regions, where they form centers toward which the lymphatic vessels radiate. Such groups are termed regional glands. The glands forming such a group are connected with one another by numerous anastomoses, which are termed lymphatic plexuses [plexus lymphatici]. In addition to the regional glands there are many isolated glands which lie along the course of the lymph-vessels, and through which pass the vessels draining a much more limited capillary area. Such glands are termed *intercalated* glands.

4. *THE DEVELOPMENT OF THE LYMPHATIC SYSTEM*

Our knowledge of the lymphatic system has been very greatly increased during the past ten years by studies on its mode of development. Previous to 1902 nothing definite was known about the primary development or the mode of growth of the lymphatic system. It was concluded by some (Budge, Gullard and Saxer) that the lymphatics arise from undifferentiated mesenchyme cells; Ranvier believed that they arise from veins by budding of the endothelium; while Sala described them as arising partly from the mesenchyme and partly from venous endothelium.

Regarding the mode of growth and spreading of the lymphatics, various theories were likewise held. Kölliker, His, Goethe and, later, Sala held that growth takes place by the successive addition of mesenchyme cells; Langer, Rouget, and Ranvier maintained that growth takes place by sprouting of the endothelium (fig. 553). S. Mayer thought that new lymphatics are derived from transformed blood-capillaries.

Miss Sabin in 1902 gave the first clear picture of the mode of origin and growth of the lymphatic system, and our present knowledge is largely based upon her discoveries. She showed by injections of embryo pigs that the lymphatics of the skin appear first in four regions of the body—two on each side at the base of the neck, and two in the inguinal region—in the form of sacs which are connected with the veins. From these four regions the lymphatics spread out step by step over the skin of the entire body, in the form of a richly anastomosing capillary plexus. Since the publication of Miss Sabin's paper, numerous studies have been made on the mode of development of lymphatics in many different animals, including man. The results of these studies indicate that the lymphatic endothelium first appears in the form of buddings-out from the veins in certain well-defined regions of the embryo. As to the exact manner of this primary origin views differ. Miss Sabin, in her first paper, held that it arises by budding from the veins. F. T. Lewis held that it is formed by the transformation of plexuses of blood-capillaries. This view was accepted by Miss Sabin, and verified by Huntington and McClure. Stromsten returned to Sala's view that the first lymphatic endothelium arises in part from venous endothelium, and in part from the mesenchyme cells. Hoyer and his pupils find that the first lymphatics arise as buds from the veins. This has also been found (1912) by E. R. and E. L. Clark in chick embryos.

Thus far six regions have been found, in which lymphatics develop from the veins—in the neck, on each side, at the angle formed by the internal jugular and subclavian veins; in the pelvis, on each side, along the iliac veins; and two unpaired sets in the region of the renal veins, one ventral to the aorta, the mesenteric, and one dorsal to the aorta, retroperitoneal. In these six regions the lymphatics soon coalesce to form large sacs, the jugular, iliac, mesenteric and retroperitoneal. The sacs are later broken up into the primary sets of lymph-nodes. The receptaculum chyli develops in the region of the retroperitoneal sac.

From these primary anlages derived from the veins the lymphatics spread out into the various organs and tissues of the body. The cutaneous lymphatics spread out from the two jugular and two iliac regions (Sabin), the lymphatics of the intestine from the mesenteric sac (Heuer).

The method by which this extension of the primary lymphatics occurs is still in dispute, but there seems to be conclusive evidence that it takes place by the sprouting of the endothelium (fig. 553); that the endothelium of the lymphatics, derived from the veins, is a specific, independent tissue, and that all new lymphatic endothelium is formed from lymphatic endothelium,

and not from blood-vessels or mesenchyme cells. This view is supported especially by the work of Sabin, MacCallum, Hoyer and his pupils and E. R. Clark.

On the other hand, F. T. Lewis has suggested that the spreading of lymphatics occurs by the transformation of blood-vessels into lymphatics; while Huntington and McClure and their pupils maintain that it occurs by the continued transformation of mesenchyme cells.

The lymphatics growing from the various primary centres meet and anastomose with one another, and gradually lose all connections with the veins save those at the base of the neck. Sylvester has found, however, that in South American monkeys the connections with the veins in the region of the renal veins are maintained in the adult. Valves do not appear in the lymphatic vessels until quite late, in human embryos about 5 or 6 cm. long. (Sabin.)

The *lymphatic nodes* do not make their appearance until the system of vessels is well established. They are at first represented by masses of lymphoid tissue in the meshes of a lymphatic network. Later the lymphoid mass breaks up into smaller portions, into which the blood-vessels and branches from the surrounding network penetrate; and each mass, together

FIG. 553.—THE SPROUTING OF LYMPHATIC CAPILLARIES IN THE PIG. (After MacCallum.)
The lymphatics are injected and the sprouts are both single cells and clumps of cells.

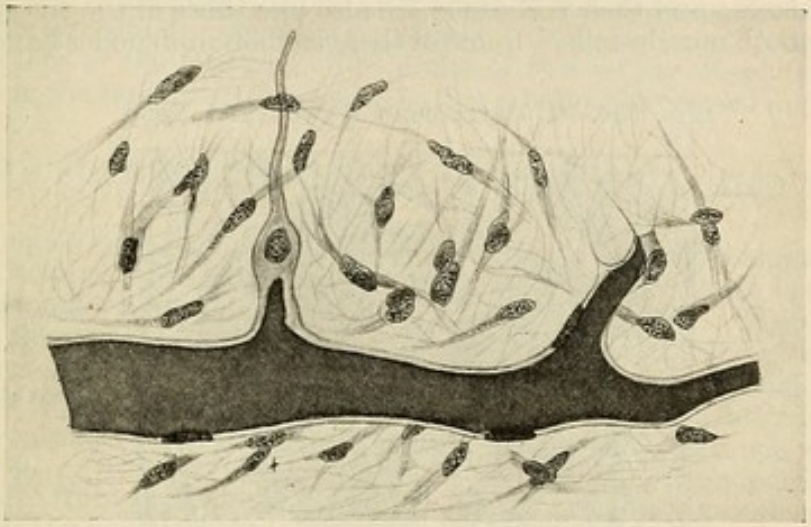

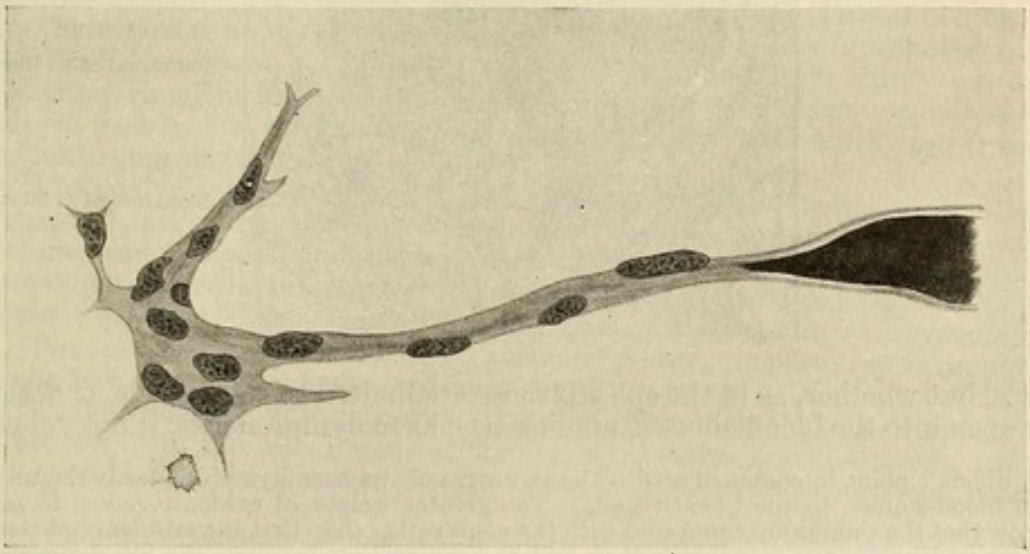

with the portions of the network surrounding it, becomes enclosed in a connective-tissue capsule. The original lymphoid tissue becomes transformed into the medullary cords and cortical nodules of the node, while the enclosing lymphatic capillaries form its peripheral lymph-sinus.

The earliest nodes appear in the places occupied by the primary lymphatic plexuses or sacs (Miss Sabin, F. T. Lewis, Jolly), and have been termed the "primary nodes" (Miss Sabin). Secondary and tertiary sets of nodes develop later at places of confluence of many lymphatics (cf. A. H. Clark.)

Regeneration and new growth of lymphatic vessels and glands.—While blood-vessels are known to possess throughout life the capacity for regeneration and new growth, this process in lymph-vessels has been very little studied. Yet enough has been learned from the work of Coffin and Evans to justify the statement that lymphatic vessels also possess the capacity for new growth. Evans made the interesting observation that lymphatic vessels grow into a tumor of connective-tissue origin (a round-celled sarcoma), while they fail to grow into a tumor of epithelial origin (an experimentally-produced peritoneal carcinoma in mice).

The question as to whether lymph-glands may form anew is not yet entirely settled. The study of the problem is extremely difficult, because very small lymph-nodes may be normally present in a certain region, yet they may escape observation until they become hypertrophied under certain conditions. A. W. Meyer in a careful experimental study found no evidence of new-formation of lymph glands. On the other hand, there is considerable evidence for the new-formation of lymph-glands under pathological conditions.

The hæmolymph nodes.—In addition to the ordinary lymph-nodes, there occur along the course of certain veins small nodes which are either red or brown in colour, according to their state of functional activity. These have been termed **hæmolymph nodes.** The red nodes closely resemble in structure an ordinary lymph-node, except that the sinuses are filled with blood, while the brown nodes show not blood, but blood pigment, both free in the sinuses and in the phagocytic cells of the sinuses. In certain respects these nodes resemble the spleen, there being a reduction of the medullary cords and an increase in the amount of the sinuses, which resemble those of the spleen-pulp rather than the more open lymphatic sinuses; and their trabeculæ are also like those of the spleen in having numerous smooth muscle-cells. Some of these hæmolymph nodes have lymphatic

Fig. 554.—A Developing Hæmolymph Node.

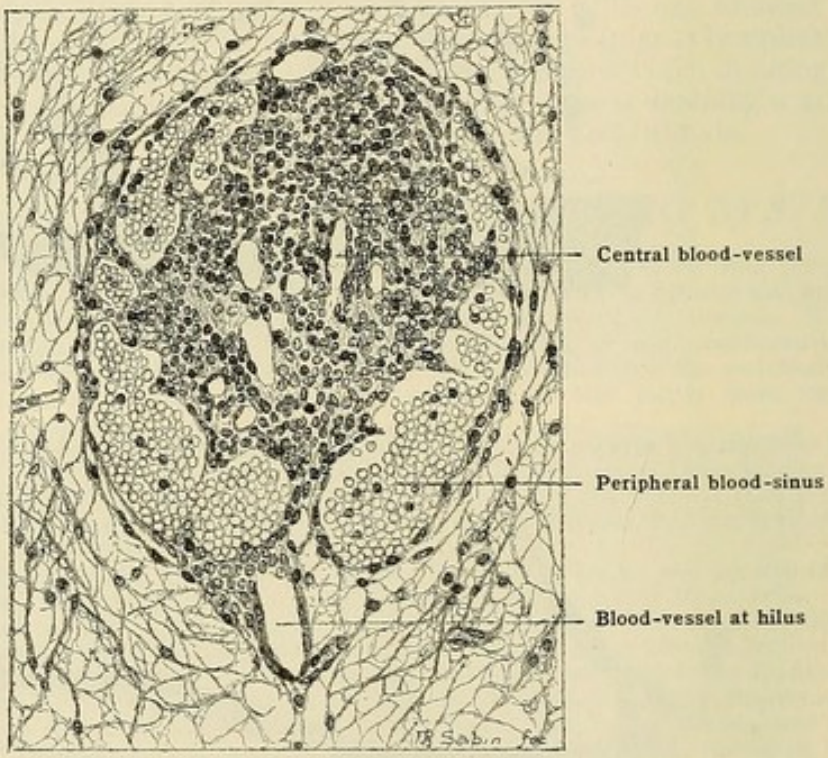

vessels, but whether, as in the spleen, these are limited to the capsule, or whether they open into the blood-sinuses, making true hæmolymph nodes, is not yet clear.

A difficult point in connection with the structure of the hæmolymph nodes is the relation of the blood-sinuses to the blood-vessels. The greater weight of evidence seems to favour the view that the sinuses are connected with the veins rather than that the arteries open directly into them, although one observer fails to find any connection between the blood-vessels and the central sinus (Schumacher). In fig. 554 is shown a hæmolymph node in the neck of a pig 24.5 cm. long. This stage marks the first appearance of the hæmal node in the neck, and shows the node in its simplest form, the follicle and its peripheral blood-sinus (Miss Sabin).

There are wide variations in the **distribution** and number of the hæmolymph nodes; indeed sufficient observations have not yet been made to determine their complete distribution. They have been divided into three groups, the prævertebral, the renal, and the splenic. In one subject, in which they were very numerous, they occurred at the root of the lung, near the bronchi and bronchial vessels, a few near the œsophagus, a continuous prævertebral chain in the abdomen extending from the diaphragm to the upper two or three sacral vertebræ, as well as a few along the cœliac axis and its branches, the superior mesenteric, renal, and iliac vessels (Lewis).

Schumacher, from a study of lymph-glands and hæmolymph glands of various stages, concludes that the hæmolymph glands are not to be considered as organs *sui generis*, but that they represent rudimentary forms of ordinary lymph-glands, which have lost their connections with the lymphatic vessels. Further investigations are needed to clear up this subject.

II. *SPECIAL ANATOMY OF THE LYMPHATIC SYSTEM*

The lymphatic system will be considered by regions as follows: A, head and neck; B, upper extremity; C, thorax; D, abdomen and pelvis; E, lower extremity.

A. THE LYMPHATICS OF THE HEAD AND NECK

The lymphatics of the head and neck may be divided into two sets. One set is superficial, draining the entire skin surface, and has its nodes, for the most part, in the neck, the principal group lying along the external jugular vein. The other set is deeper and drains the mucous membrane of the upper part of the digestive and respiratory tracts, together with the deep organs, such as the thyreoid gland and the tendons of the muscles. The nodes of this set are deeply placed, being situated along the carotid arteries, with outlying retro-pharyngeal nodes.

1. THE SUPERFICIAL NODES OF THE HEAD AND NECK

Lymph-nodes appear first in the neck in the process of development. In the pig the first node to appear develops from the lymph heart, which is in the supraclavicular triangle behind the sterno-cleido-mastoid muscle. From here ducts grow across the muscle and give rise to a chain of nodes along the external jugular vein. This chain is to be considered as the main chain of superficial nodes in the neck. From it lymphatic vessels grow over the back of the head, the side of the head, the face, and the front of the neck, and in their course groups of secondary nodes develop. The nodes of the main chain are known as the superficial cervical nodes, and are from four to six in number. The secondary groups are—(1) the occipital; (2) the posterior auricular; (3) the anterior auricular; (4) the parotid; (5) the submaxillary, with the facial as a tertiary set, and (6) the submental.

1. **The occipital nodes** [lymphoglandulæ occipitales].—The lymphatics of the skin of the back of the head collect into a few trunks that either empty into from one to three small nodes near the occipital insertion of the semispinalis capitis muscle, or pass by the secondary group and empty directly into the upper nodes of the main superficial cervical chain (fig. 555).

2. The **posterior auricular nodes** [lgl. auriculares posteriores].—A portion of the temporal part of the scalp, together with the posterior surface of the ear, except the lobule, and the posterior surface of the external auditory meatus, drain into two small nodes on the insertion of the sterno-cleido-mastoid muscle. The efferent vessels of these nodes pass to the upper part of the superficial cervical chain.

3. The **anterior auricular nodes** [lgl. auriculares anteriores] are few in number—from one to three—and are situated immediately in front of the tragus of the ear. They receive vessels from the anterior surface of the auricle and the external auditory meatus, from the integument of the temporal region and the lateral portion of the eyelids. Their efferents pass to the parotid and superior deep cervical nodes.

4. **The parotid nodes.**—The parotid group of nodes is considerably larger than the two preceding, containing from ten to sixteen nodes, and the group drains a more complex area. It receives vessels from the adjacent surface of the external ear, the external auditory meatus, the skin of the temporal and frontal regions, and the eyelids and nose. The deeper nodes of this set receive vessels from the parotid gland.

In the embryo these nodes lie in the pathway of the lymph-vessels that grow to the scalp; many of these vessels, however, pass the parotid group and empty into the superficial cervical chain. The nodes of the parotid group lie embedded in the substance of the parotid gland, and their efferents pass to the submaxillary and the superior superficial and deep cervical nodes.

As "inferior auricular nodes" Bartels designates one or two small glands of the parotid group which lie below the ear, and receive afferent vessels from the lower part of the ear.

5. **The submaxillary** [lgl. submaxillares] **and facial** [lgl. faciales profundæ] **nodes.**—The submaxillary (perhaps better "mandibular") group consists of a

chain of from three to six nodes, resting on the submaxillary (salivary) gland, along the inferior border of the mandible. They lie usually on the submaxillary gland, but may extend from the insertion of the anterior belly of the digastric to

FIG. 555.—THE LYMPHATICS OF THE HEAD AND NECK. (After Toldt, "Atlas of Human Anatomy," Rebman, London and New York.)

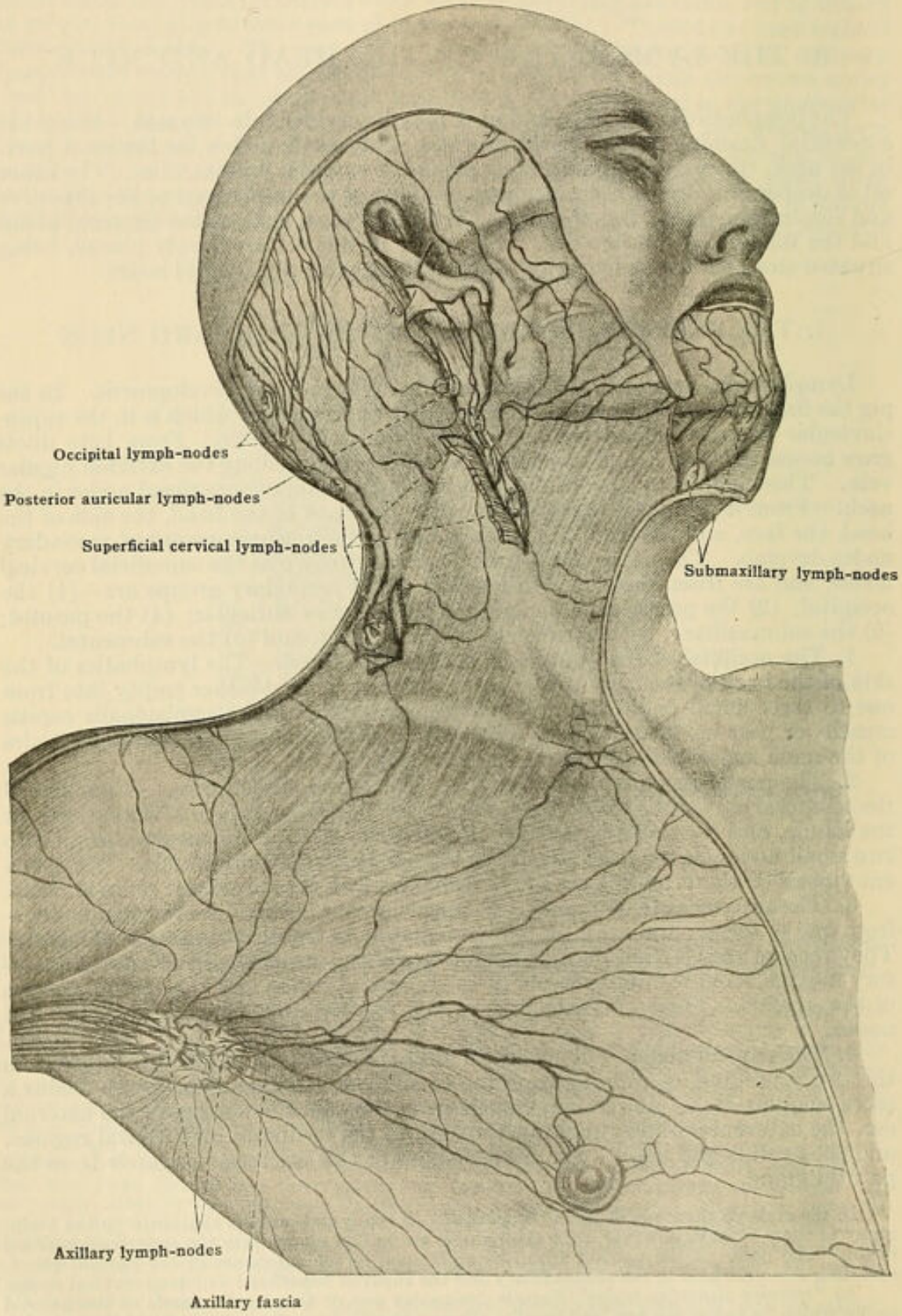

the angle of the jaw. They are about the size of a pea, and the largest is near the point where the external maxillary (facial) artery crosses the mandible. The submaxillary nodes, together with the next group, the facial, drain a complex area,

including not only skin, but mucous membrane. They receive lymph-vessels from the nose, cheek, upper lip, the external part of the lower lip, together with almost all those from the gums and teeth and from the anterior third of the lateral portions of the tongue. In agreement with the fact that these nodes, though lying superficially and draining the skin, drain also the mucous membrane, their vessels empty not only into the superficial cervical chain, but also into the deep carotid chain.

The **facial nodes** are evidently outlying nodes of the submaxillary group. They are in two main sets—(1) the **supra-maxillary set,** which consists of from one to thirteen nodes, resting on the mandible near the point where it is crossed by the external maxillary (facial) artery. (2) The **buccinator set,** lying on the

FIG. 556.—LYMPHATICS OF THE OUTER NOSE AND FACE. (After Küttner.)

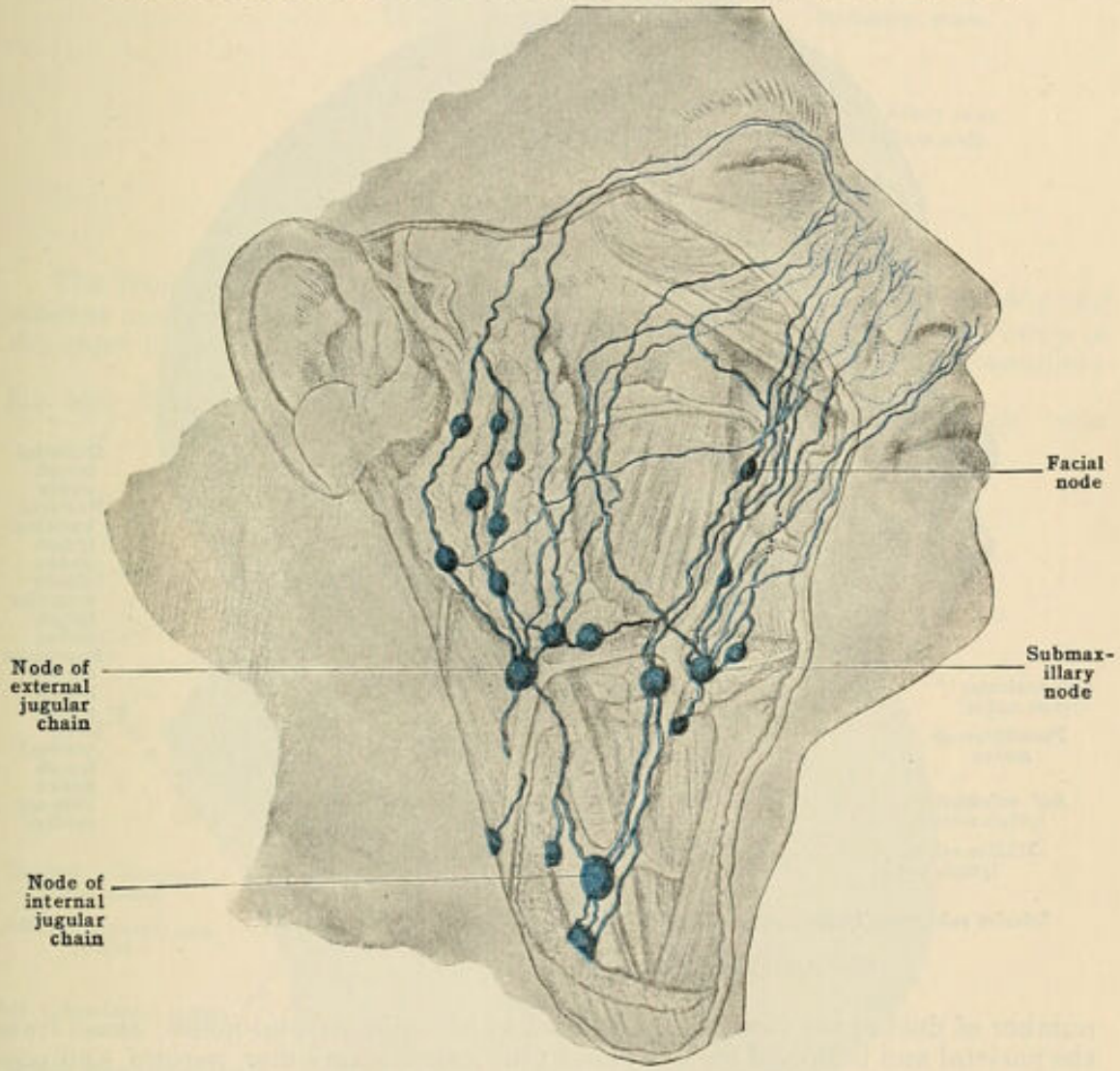

line connecting the lower margin of the ear and the angle of the jaw. Of these latter nodes, some lie near the point where the parotid duct perforates the buccinator muscle; the others are farther forward, between the external maxillary artery and the anterior facial vein. Additional nodes belonging to the group may occur near the nose and in the suborbital region. These facial nodes receive afferents from the outer surface of the nose, the lips, eyelids, cheek, temporal part of the face, the mucosa of the mouth, the teeth of the upper jaw, the gums, the tonsils, and the parotid gland. Their efferents pass to the submaxillary and parotid nodes.

6. The **submental nodes** [lgl. submentales], usually two in number, lie in the triangle bounded by the anterior bellies of the two digastric muscles and the hyoid bone (fig. 559). They are usually near the median line, and drain the skin of the chin, the skin and corresponding mucous membrane of the central part of the lower

lip and jaw, the floor of the mouth, and the tip of the tongue. The efferent vessels pass either to the submaxillary nodes or to the deep cervical chain.

2. THE LYMPHATIC VESSELS OF THE FACE

The different parts of the face and their lymphatic relation to these groups of superficial nodes will now be considered.

The **lymphatics of the scalp** form a rich network in the neighbourhood of the vertex, from which vessels pass in various directions. From the frontal region a

FIG 557.—LYMPHATIC NODES AND VESSELS OF THE EAR, EYELIDS, NOSE AND LIPS. Newborn child. P, parotid. M, submaxillary gland. B, buccal fat ("sucking pad"). Superolateral deep cervical lymph nodes are not labelled. (After Bartels.)

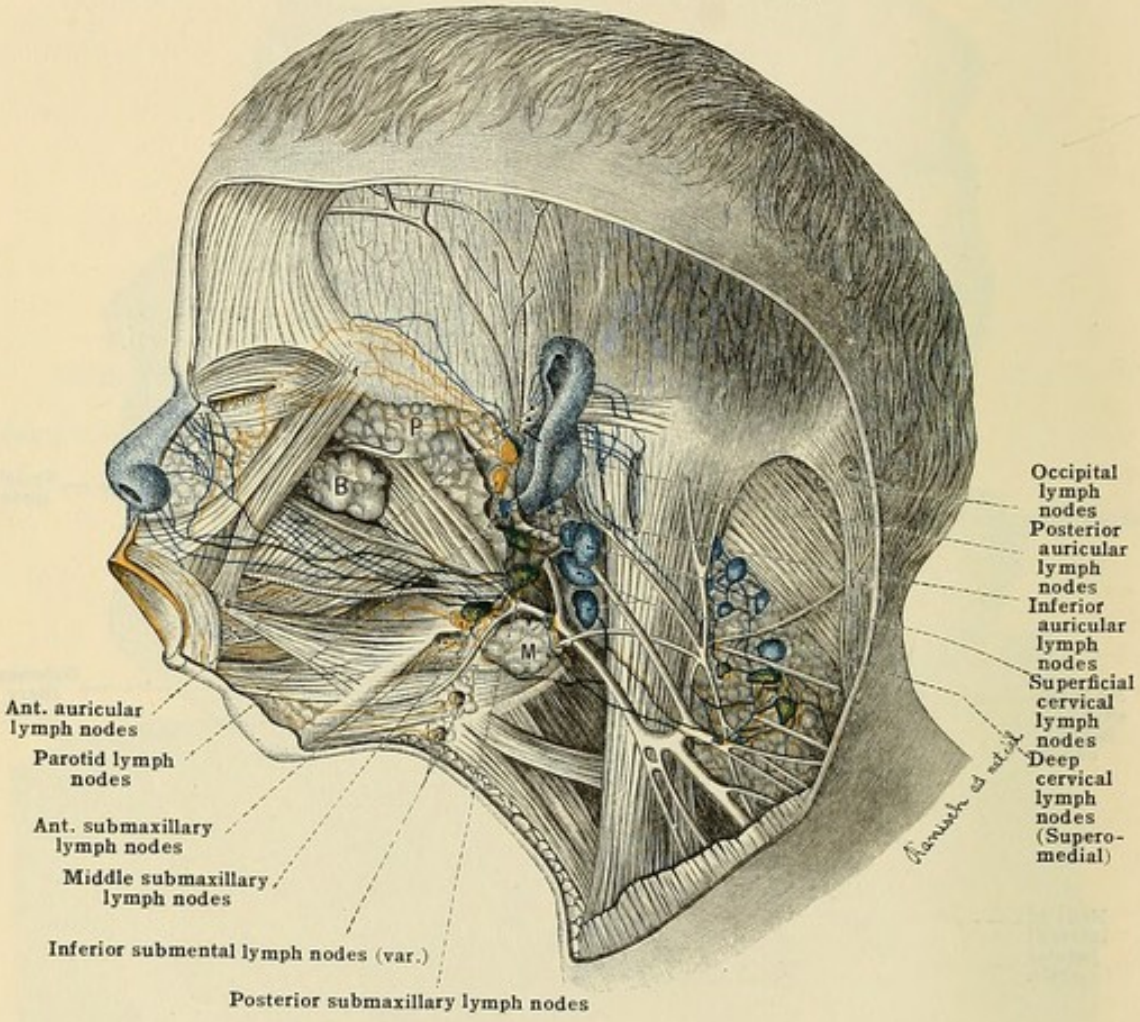

number of ducts pass downward and backward to the parotid nodes; those from the parietal and temporal regions pass to the anterior auricular, parotid, and posterior auricular nodes; and those from the occipital region pass partly to the occipital nodes and partly to the superior deep cervical group, while a single large vessel descends along the posterior border of the sterno-mastoid muscle to terminate in one of the inferior deep cervical nodes.

The lymphatics of the eyelids and conjunctiva.—The capillary plexus of the eyelids and the conjunctiva is an abundant one, and at the free border of the eyelids becomes extremely close. The lymphatics from the lateral three-fourths of the lids pass to the anterior auricular and parotid groups of nodes, while those from the medial one-fourth pass obliquely across the cheek with the facial vein to terminate in the facial and submaxillary nodes (figs. 556, 557, 561).

The lymphatics of the nose.—The lymphatics of the nose (fig. 556) form a network which is coarse at the root of the organ, but dense over the alar region. The vessels run in three sets—(1) one set passing over the eye to the parotid nodes; (2) a set passing under the eye to the same nodes; and (3) the most important

group, consisting of from six to ten trunks, passing to the facial and submaxillary nodes. There are some anastomoses between the capillaries of the skin and those of the mucous membrane of the nose.

FIG. 558.—THE FACIAL NODES. (After Buchbinder.)

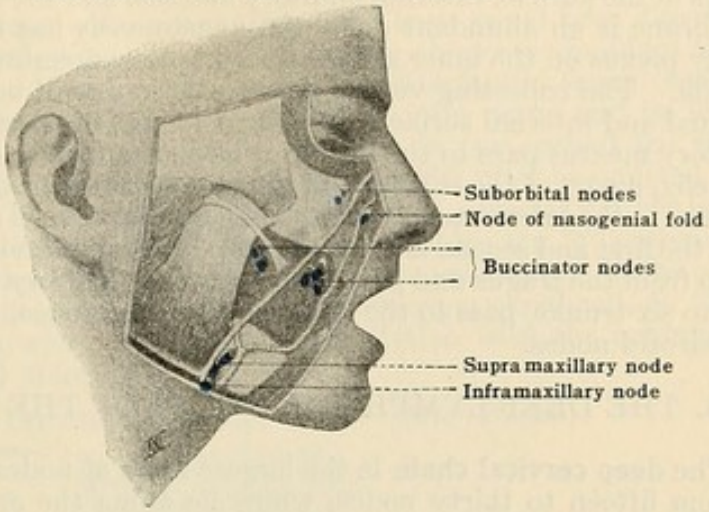

The lymphatics of the lips (fig. 559).—The capillary plexuses of the skin and mucous membrane are continuous at the free border of the lips. The vessels of the upper lip, of which there are about four on each side, pass to the submaxillary

FIG. 559.—THE LYMPHATICS OF THE LIPS. Newborn child. (From Bartels after Dorendorf.)

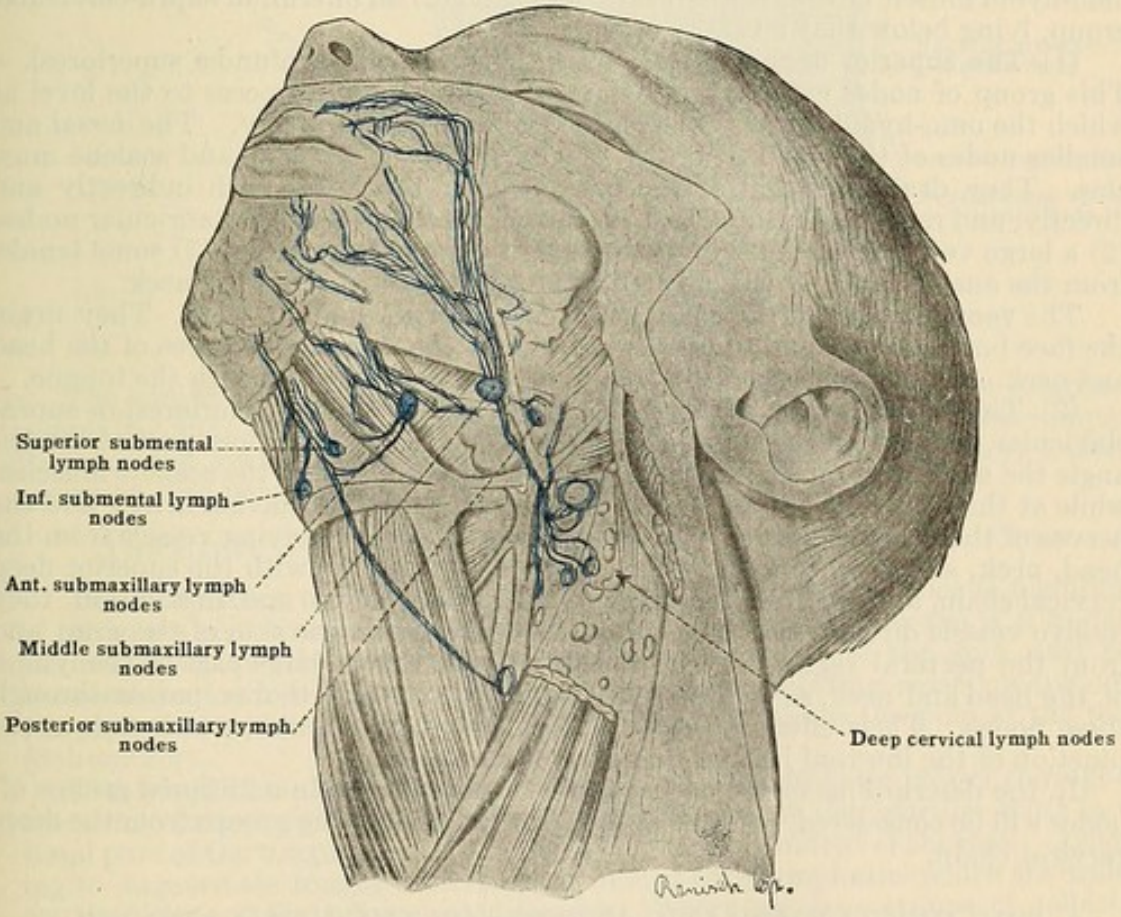

nodes. From the lower lip the trunks from near the angle of the mouth pass to the submaxillary nodes, while those from the centre of the lip pass to the submental nodes.

There are from two to four subcutaneous vessels and from two to three submucous vessels on either side. The collecting trunks passing to the submaxillary nodes do not anastomose, and

the same is true of the submucous vessels of the lower lip. The subcutaneous vessels, on the other hand, passing to the submental nodes, anastomose freely, an important fact in connection with the extension of cancer of the lower lip.

The lymphatics of the auricle and external auditory meatus.—The lymphatic plexus in the auricle, external auditory meatus, and the outer side of the tympanic membrane is an abundant one. An anastomosis has been described between a scanty plexus on the inner side of the tympanic membrane and the plexus on the outside. The collecting vessels pass to three sets of nodes:—(1) those from the external and internal surface of the auricle and the posterior part of the external auditory meatus pass to the posterior auricular nodes; (2) those from the lobule, the helix, a part of the concha and the outer portion of the external auditory meatus pass to the inferior auricular and superficial cervical chain; some of the vessels from the first and second areas also run to the deep cervical group; (3) an anterior group from the tragus and part of the external auditory meatus consisting of from four to six trunks, pass to the anterior auricular nodes, which are connected with the parotid nodes.

3. THE DEEP LYMPHATIC NODES OF THE HEAD AND NECK

The **deep cervical chain** is the largest mass of nodes in the neck. It consists of from fifteen to thirty nodes, which lie along the entire course of the carotid artery and internal jugular vein. This chain receives vessels from all the superficial nodes, also directly from the skin, as well as from the entire mucous membrane of the respiratory and alimentary tracts in the head and neck. Thus it drains both the superficial and the deep structures.

For convenience of description this long chain, though usually continuous, is divided into two groups—(1) a superior group, lying above the level at which the omo-hyoid muscle crosses the carotid artery, and (2) an inferior or supra-clavicular group, lying below that level.

(1) **The superior deep cervical nodes** [lgl. cervicales profundæ superiores].—This group of nodes extends from the tip of the mastoid process to the level at which the omo-hyoid muscle crosses the common carotid artery. The *dorsal* and smaller nodes of the chain lie on the splenius, levator scapulæ, and scalene muscles. They drain the skin of the back part of the head, both indirectly and directly, and receive (1) efferents from the occipital and posterior auricular nodes, (2) a large vessel from the skin of the occipital part of the scalp, (3) some trunks from the auricle, and (4) cutaneous and muscular vessels from the neck.

The **ventral nodes** of the chain lie on the internal jugular vein. They drain the face both directly and indirectly, as well as the deeper structures of the head and neck. They show especially well in fig. 563 in connection with the tongue.

(2) The **inferior deep cervical** [lgl. cervicales profundæ inferiores] or supra-clavicular nodes lie in the supra-clavicular triangle. In the upper part of the triangle the nodes rest on the splenius, the levator scapulæ, and the scalene muscles, while at the base of the triangle they are related to the subclavian artery and the nerves of the brachial plexus. They drain a wide area, receiving vessels from the head, neck, arm, and thoracic wall. They are connected with the superior deep cervical chain, and receive afferents from the axillary nodes, and, in addition, they receive vessels directly from the back of the scalp, from the skin of the arm, and from the pectoral region. Thus it will be seen that a large part of the lymph of the head and neck, as well as some from the arm and thorax, passes through these nodes. Their efferents unite to form the jugular trunk, which ends at the junction of the internal jugular and subclavian veins.

In the descriptions of the deep lymphatic vessels certain additional groups of nodes will be considered, which may be regarded as outlying groups from the deep cervical chain.

4. THE DEEP LYMPHATIC VESSELS OF THE HEAD AND NECK

The lymphatics of the brain.—It is now recognised that there are no lymphatics in the brain and cord, so that the function of absorption must be accomplished by means of the veins. There is an abundant exudation of lymph around the nervous system into the subdural space, which is connected with the central

canal of the nervous system, and which is to be considered as a zone in which the tissue-spaces are especially large. Along the arteries of the brain the adventitia is loose and open, possessing tissue-spaces which have received the confusing name of perivascular lymphatics. It would be better to name them perivascular tissue-spaces.

The lymphatics of the eye.—No lymphatic vessels have as yet been discovered either in the eyeball or in the orbit. In both, however, there are abundant tissue-spaces, the most noteworthy of the orbit being the **interfascial space (space of Tenon)**, which communicates by a space between the optic nerve and its sheath with the subarachnoid spaces of the cranial cavity. In the eyeball the tissue-spaces are abundant, even if the vitreous and aqueous chamber be omitted from the category. Numerous spaces exist in the chorioid coat, especially in the lamina supra-chorioidea, and in the sclerotic, both sets communicating by perivascular spaces surrounding the venæ vorticosæ with the interfascial space. In the cornea there are abundant lacunæ, united by their anastomosing canaliculi, to form a network of lymph-spaces which come into close relation with the conjunctival lymphatics at the corneal margin.

FIG. 560.—THE DEEP CERVICAL CHAIN. (After Poirier.)

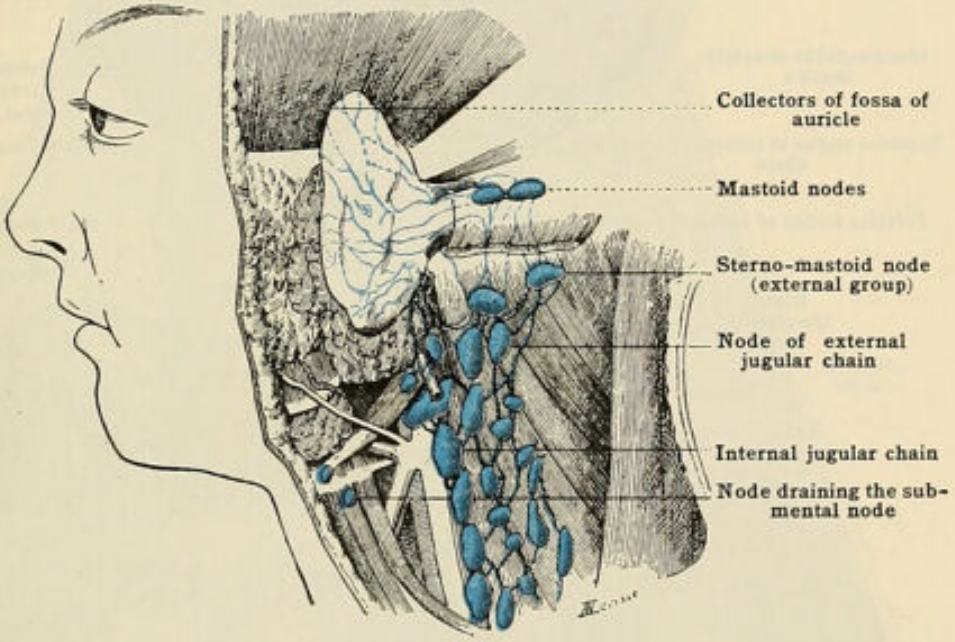

The conjunctiva, being a portion of the integument, does possess lymphatic vessels (fig. 562), arranged in a double network whose collecting vessels accompany those of the eyelids, and terminate with them in the submaxillary, anterior auricular, and parotid nodes.

THE LYMPHATICS OF THE DIGESTIVE TRACT IN THE HEAD AND NECK

The lymphatics of the gums.—The lymphatics from the mucous membrane of the gums pass to the submaxillary nodes. The capillary plexus is abundant; the collecting vessels arise from it on the inner surface of the gum, and pass between the teeth to reach a common semicircular collecting vessel on the outer surface. Lymphatics have recently been demonstrated in the pulp of the tooth (Schweitzer).

The lymphatics of the tongue.—There is a rich lymphatic plexus throughout the entire extent of the submucosa of the tongue, but that portion lying in the basal part of the tongue seems to be more or less independent of the rest. According to Aagaard the tongue muscles are provided with lymphatics which are drained by the ducts of the submucosal plexuses. There are four groups of collecting vessels—(1) apical; (2) marginal; (3) basal; and (4) central.

(1) The *apical vessels* are usually four in number, two on each side. One pair perforates the mylo-hyoid muscle and ends in a supra-hyoid median node, while the other pair pass to the deep cervical chain. The latter are long, slender vessels, which run along the frenum of the tongue to the surface of the mylo-hyoid muscle, cross the hyoid bone just behind the pulley of the digastric, and then run downward in the neck to a node of the deep cervical chain, just

above the omo-hyoid. It will be noted in fig. 563 that the most anterior vessels end in the lowest nodes, while those from the back of the tongue end in higher nodes.

(2) The *marginal vessels* are from eight to twelve in number. They all pass to the superior

FIG. 561.—LYMPHATICS OF THE HEAD, NECK, AND AXILLA. (After Toldt, "Atlas of Human Anatomy," Rebman, London and New York.)

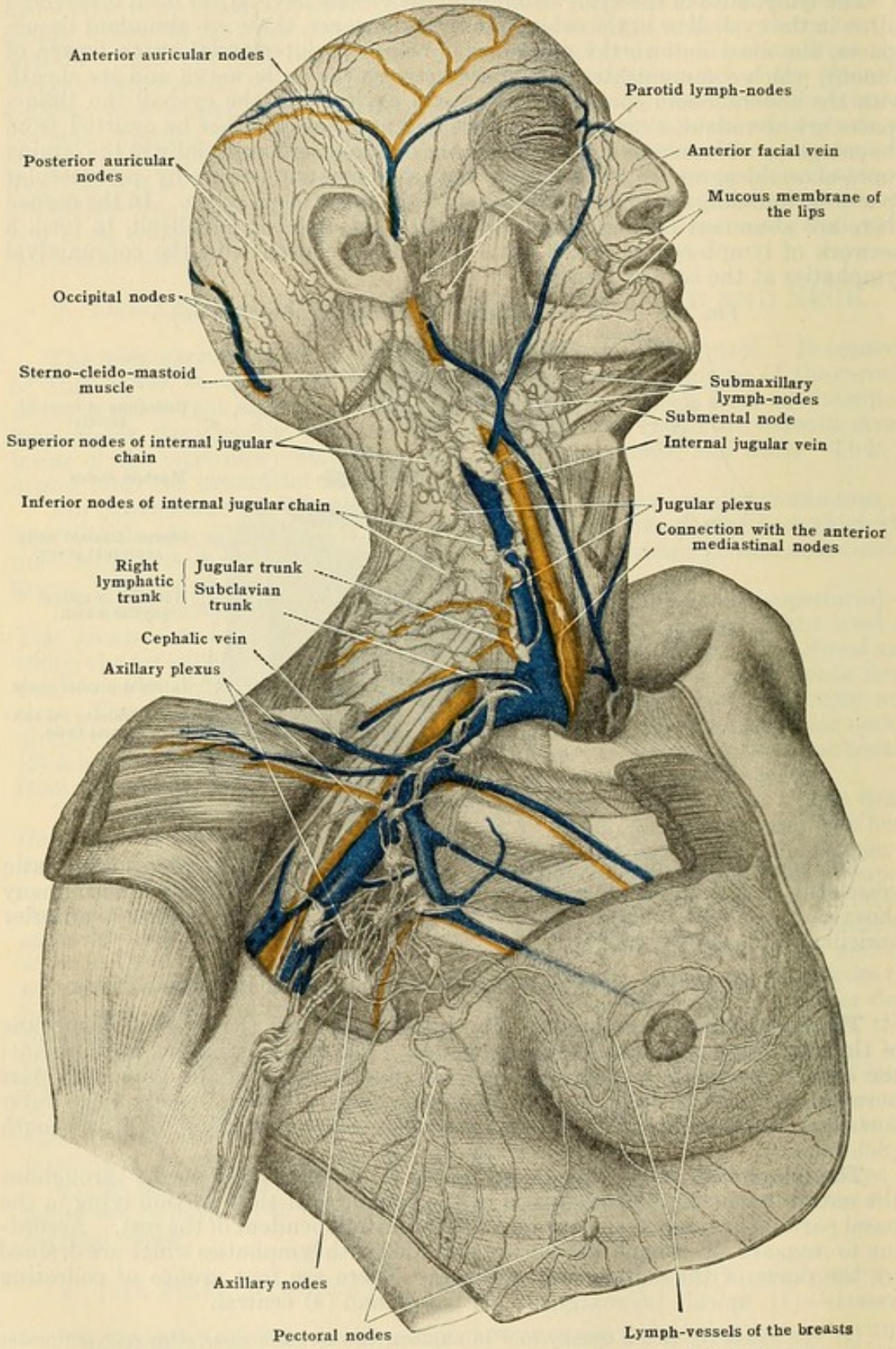

deep cervical nodes, a part of them passing external to the sublingual gland, while the larger number pass internal to it. There is one large and constant node at the point where the digastric muscle crosses the jugular vein, to which a large number of the vessels converge.

(3) The *basal vessels* are seven or eight in number, and drain the basal portion of the tongue. Some end in the large node just mentioned, while others run backward close to the median line, where they anastomose, as far as the glosso-epiglottidean fold, when they separate and join the tonsillar vessels to pass outward to the superior deep cervical nodes.

(4) The *central vessels*, arising from the central portion of the tongue, pass backward in the median line on the ventral surface of the tongue. They lie upon the mylo-hyoid muscle, cross the hyoid bone, and end in the superior deep cervical chain.

The lymphatics of the palate.—The lymphatics from the palate pass to the deep cervical chain. The trunks from the hard palate run in the submucosa as far as the last molar tooth, where they pass in front of the anterior pillars of the fauces and end in the superior deep cervical nodes beneath the digastric muscle. In the soft palate the capillary plexus is very rich, reaching a maximum in the uvula. From the inferior surface of the soft palate and the pillars of the fauces vessels pass directly to the superior deep cervical chain, but some of the vessels

FIG. 562.—THE LYMPHATICS OF THE CONJUNCTIVA. (After Teichmann.)

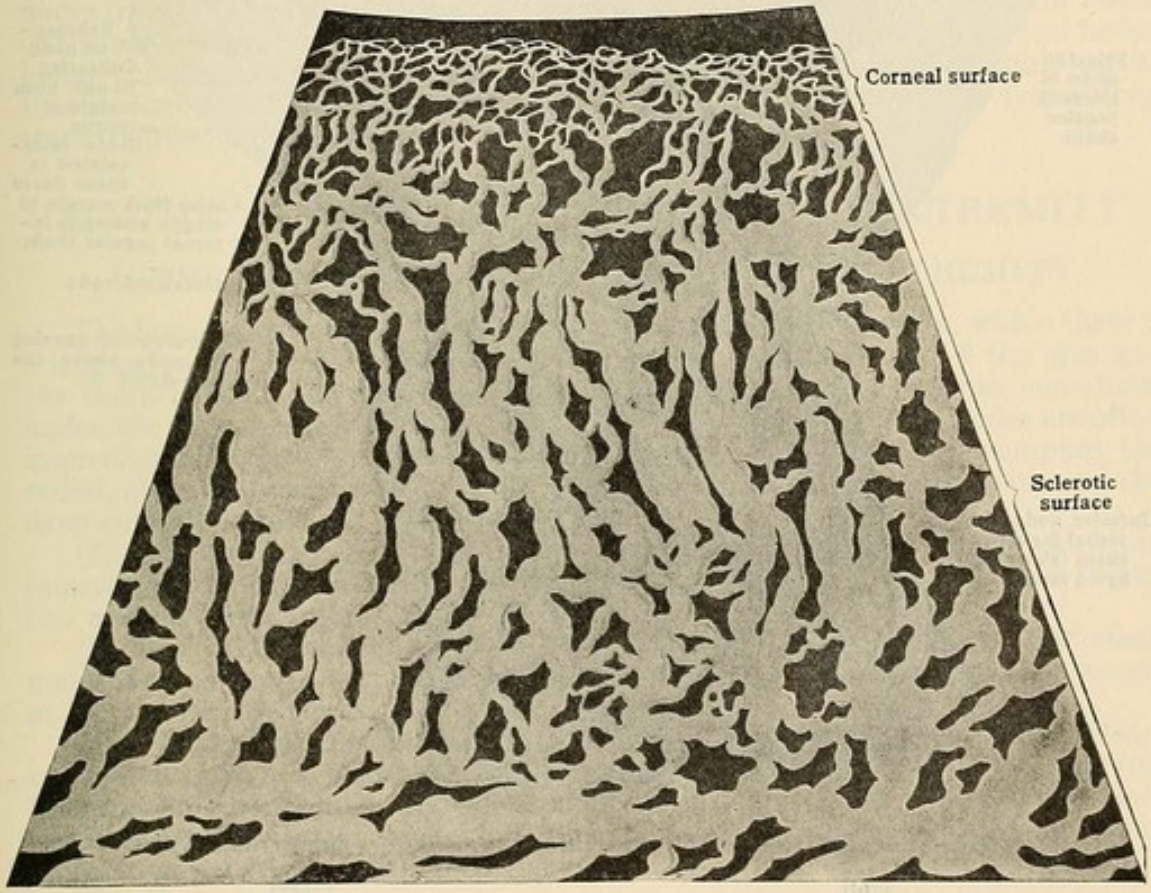

from the upper surface of the soft palate run forward with the pharyngeal vessels and end in the retro-pharyngeal nodes. It will be seen from fig. 564 that the retro-pharyngeal nodes are simply outlying nodes from the deep cervical chain.

The lymphatics of the pharynx.—As has just been stated, there are certain outlying nodes of the deep cervical chain which lie behind the pharynx. They receive some of the ducts from the submucosa of the roof of the pharynx, but many of the pharyngeal vessels pass by these nodes and end directly in the superior deep chain. The tonsil is especially rich in lymphatics, and its ducts, together with those from the middle and inferior portions of the pharynx, end in the superior deep cervical chain. The lymphatics of the Eustachian tube run to the lateral retro-pharyngeal lymph-nodes or, passing these, to the deep cervical nodes.

The lymphatics of the nasal cavities.—The mucous membrane of the nose contains a rich lymphatic plexus whose main ducts pass to the retro-pharyngeal nodes. An anterior set, however, anastomoses with the subcutaneous vessels, and through these their lymph is conveyed to the facial and submaxillary nodes. The posterior vessels run either to the deep cervical chain or to the retro-pharyngeal nodes. Key and Retzius have shown that an injection of the lymphatics of the nose may be made by injecting the subarachnoid spaces at the base of the

brain, although there is presumably no direct connection between the spaces and the lymphatic vessels. The lymphatics of the nasal sinuses end in the retro-pharyngeal nodes.

FIG. 563.—THE LYMPHATICS OF THE TONGUE. (Poirier and Charpy.)

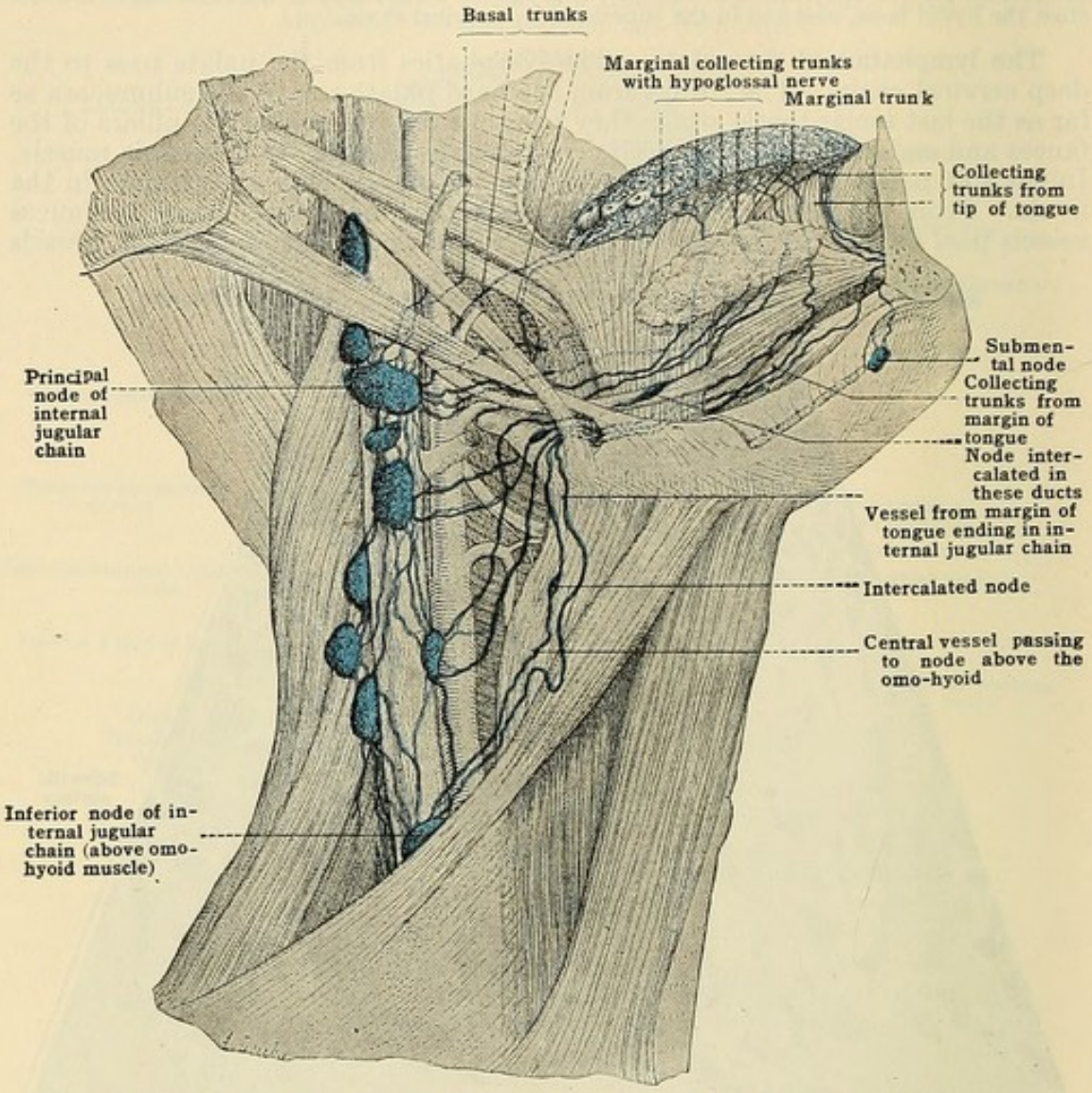

FIG. 564.—THE LYMPHATICS OF THE PHARYNX. (After Poirier and Cunéo.)

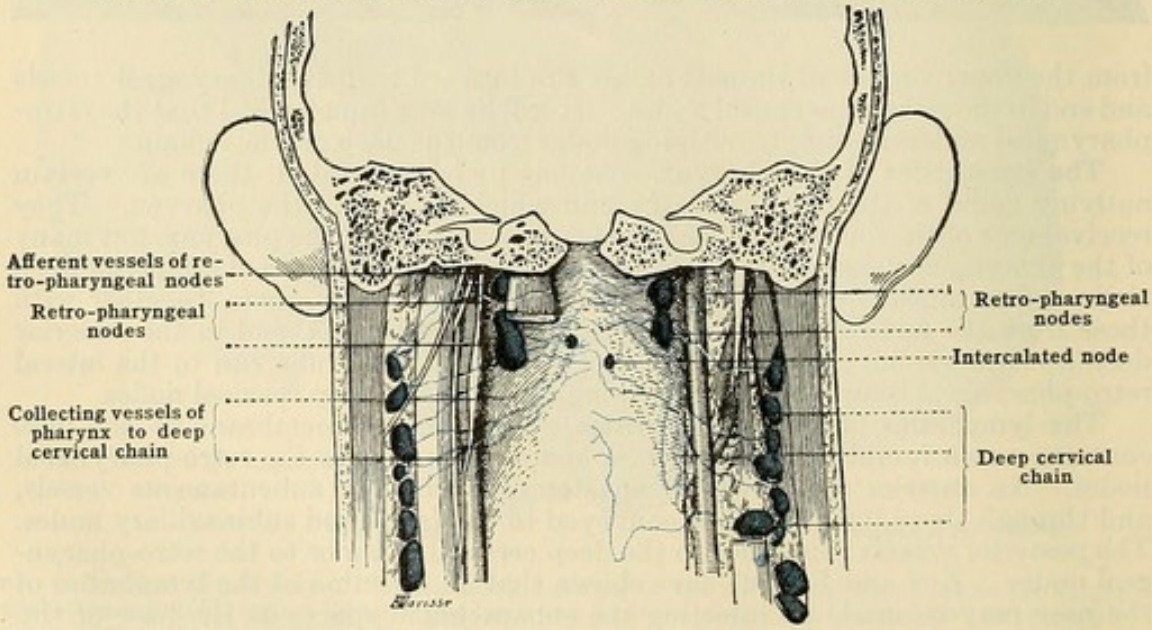

The lymphatics of the larynx.—The larynx is, for the most part, drained by the deep cervical nodes, although its lymph may also pass through certain outlying nodes situated upon its ventral surface. The mucous membrane is divided into two zones by the ventricular folds, the mucous membrane of these structures possessing but a scanty lymphatic plexus. The vessels from the upper part of the larynx, four or five in number, pass to the nodes of the superior deep cervical chain, situated near the digastric muscle; those from the lower part pass to the lower nodes of the same chain, some even descending as far as the supra-clavicular nodes. The lymphatics of the trachea pass, on each side, to the paratracheal and inferior deep cervical nodes.

The lymphatics of the thyreoid body.—The lymphatics of the thyreoid body pass either to the small nodes situated in front of the larynx and trachea, or to nodes of the deep cervical chain, a part of them ascending and a part descending.

It will thus have been seen that the lymphatics of the mucous membrane of the head and neck all end in the deep cervical chain of nodes or in the outlying nodes from it. Some of the vessels pass by the outlying nodes, but since the nodes of the chain are so closely connected, the lymph must pass through several nodes before entering the veins. The main tonsils, the numerous lingual and pharyngeal tonsils, together with small lymph-follicles in the submucosa of the respiratory tract, represent lymph-nodes in the capillary zone.

B. THE LYMPHATICS OF THE UPPER EXTREMITY

1. THE LYMPHATIC NODES OF THE UPPER EXTREMITY

The lymph-nodes of the arm lie, for the most part, in the axilla, where there is a large group of nodes which receive almost the entire drainage of the arm and the thoracic wall. In addition, there is in the arm a set of outlying superficial nodes, the superficial cubital (supra-trochlear), while small isolated nodes are often intercalated along the course of the deep lymphatic vessels which accompany the radial, ulnar, anterior interosseus and brachial arteries, the cephalic vein, and the deep cubital vessels.

(1) The antibrachial nodes are very small, pin-head sized nodes which are intercalated along the deep lymphatics which accompany the radial, ulnar, anterior and posterior interosseus arteries.

(2) The deep cubital nodes [lgl. cubitales profundæ] are also very small nodes, one or two in number, intercalated along the ducts, near the deep vessels at the bend of the elbow.

(3) The **superficial cubital node** [lgl. cubitales superficiales] (or supratrochlear) is situated three or four centimetres above the medial epicondyle of the humerus. It lies in the superficial fascia on the medial side of the basilic vein near the place where it passes through the deep fascia. It is usually single, but may be absent or represented by a chain of from two to five nodes. Its efferents follow the basilic vein.

(4) The **delto-pectoral nodes** are very small intercalated nodes from one to three in number, and are situated in the groove between the deltoid and pectoral muscles. Their vessels follow the cephalic vein.

(5) The **axillary nodes** [lgl. axillares], from twelve to thirty-six in number, may be divided into groups according to the areas which they drain (fig. 566). In addition to the upper extremity, they receive lymphatic drainage from the thoracic walls, including dorsal, lateral and ventral (mammary) regions.

(1) The *subclavian group* consists of four or five nodes, situated in the apex of the axillary fossa. They receive the efferent vessels of all the other groups, and their efferent vessels in turn unite to form a single trunk, the subclavian, which empties into the thoracic duct on the left side and on the right side either into the vein directly or else after uniting with the jugular trunk. (See pp. 726-728.)

(2) *The central group.* A little lower along the axillary artery is a group of three to five nodes, which makes a second centre for the vessels of the other groups, and sends its efferents to the subclavian group. It will be clear from the figure that the separation of groups 1 and 2 is arbitrary.

(3) *The brachial group.*—This consists of four or five nodes, and, as its position toward the junction of the axillary and brachial arteries indicates, is the main station for the lymphatics of the arm proper. It receives almost all the superficial and deep lymphatics of the arm, and its efferents pass to the central and subclavian groups, although a few pass directly to the

suprascapular group. Small, outlying nodes of this group may be intercalated along the vessels following the brachial artery throughout its course.

(4) *The subscapular group* [lgl. subscapulares].—In this group are six or seven nodes, which follow the subscapular artery and its branch, the circumflex (dorsal) scapular. Belonging

FIG. 565.—THE LYMPHATICS OF THE UPPER EXTREMITY. (After Toldt, "Atlas of Human Anatomy," Rebman, London and New York.)

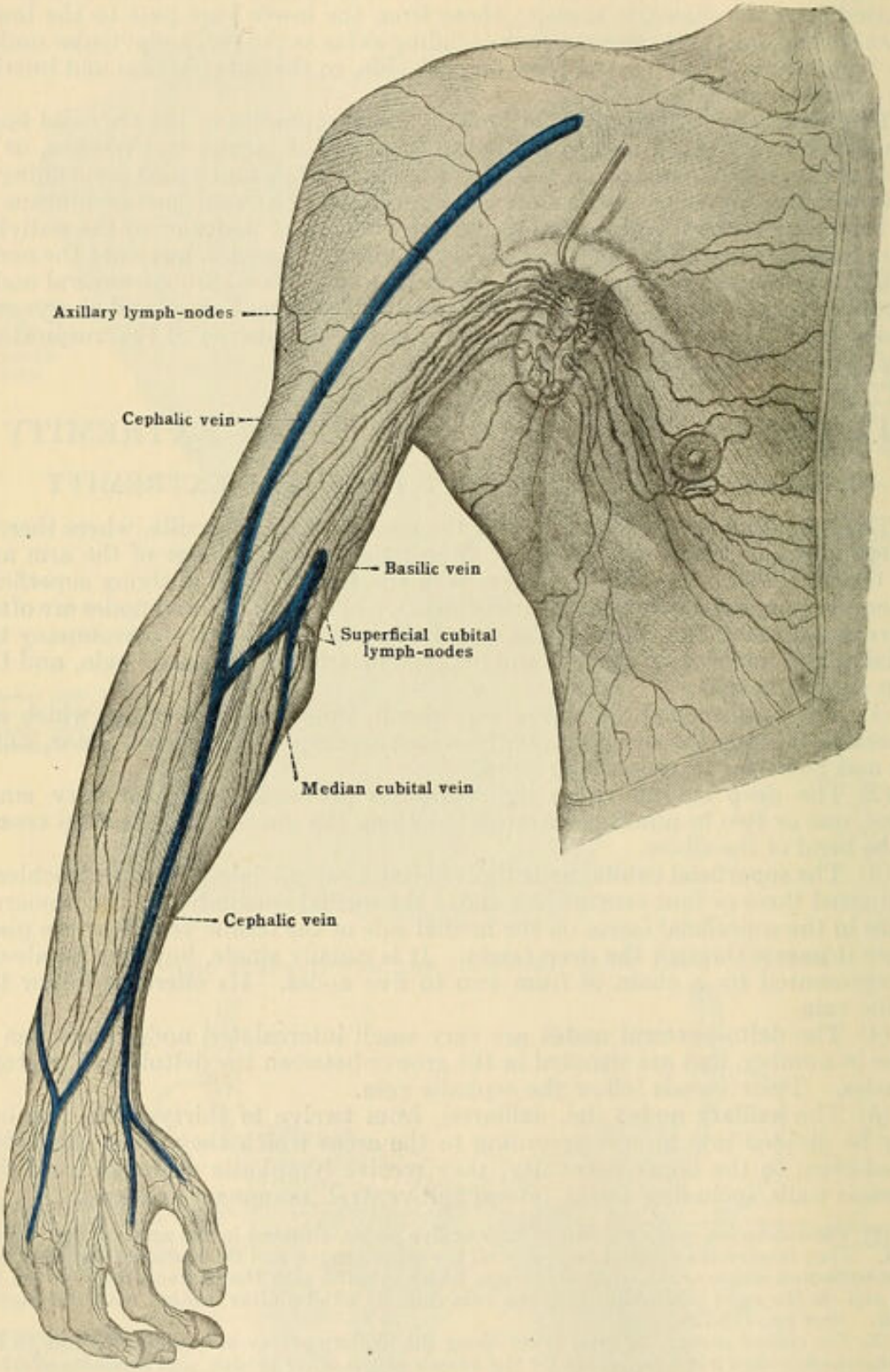

to it there are usually two or three small nodes on the dorsal surface of the scapula, in the groove which separates the teres major and minor. This group receives vessels from the dorsal surface of the thorax, as well as from the arm, and its efferents pass to the brachial group.

(5) *The anterior pectoral group* [lgl. pectorales].—This group consists of four or five nodes which lie along the lower border of the pectoralis major and drain the mammary gland and front of the chest. Their efferent vessels pass to the central and subclavian groups.

(6) The *posterior pectoral group* [lgl. pectorales] consists of small nodes situated on the inner wall of the axilla, along the course of the long thoracic artery. They receive afferents from the lateral integument of the thorax and drain into the nodes of the central group.

2. THE LYMPHATIC VESSELS OF THE UPPER EXTREMITY

The lymphatic vessels of the upper extremity are divided into two sets—a superficial and a deep set.

The superficial vessels.—The superficial lymphatic vessels of the arm course in two layers, the one quite subcutaneous, the other next the deep fascia, with frequent anastomoses between the two sets. The majority of these vessels remain superficial throughout the arm, but some of them pass through the deep fascia in the upper arm especially where the basilic vein pierces the deep fascia,

FIG. 566.—THE AXILLARY LYMPH-NODES. (After Poirier and Cunéo.)

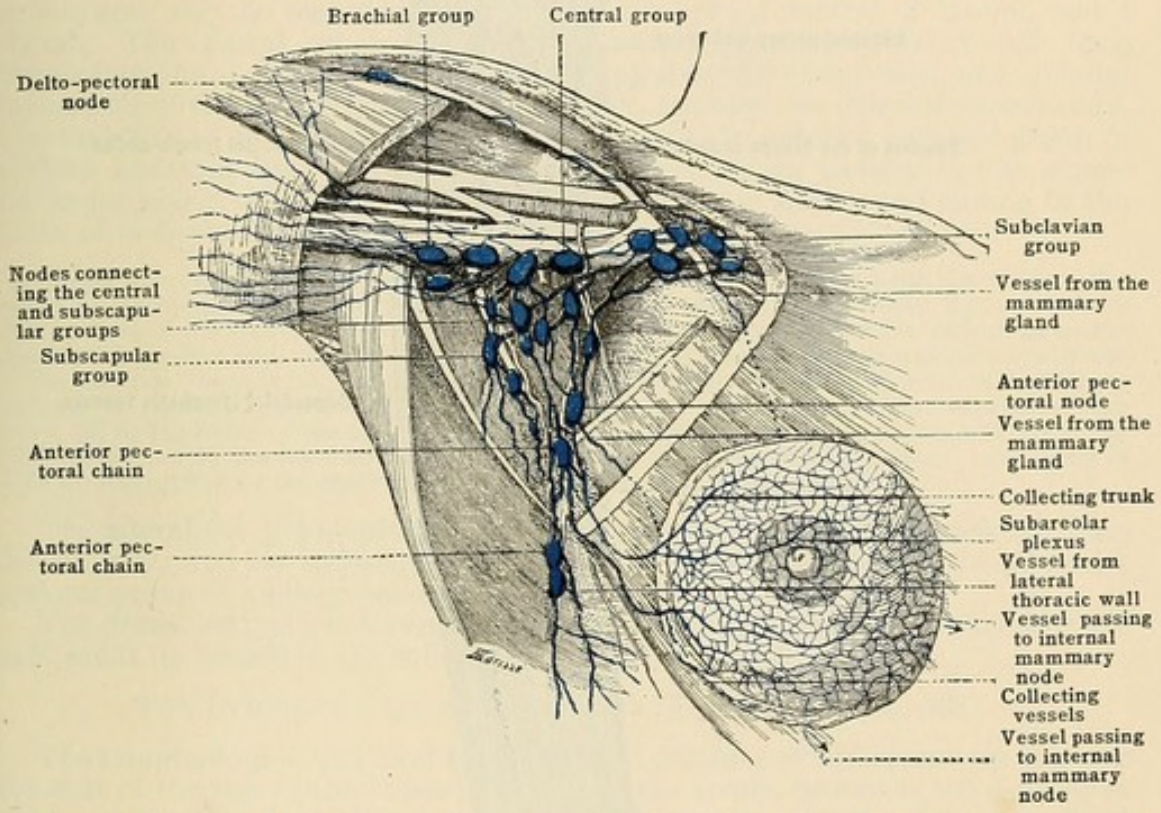

to join the deep lymphatics accompanying the brachial artery. The general distribution of the superficial lymphatics and their relations with the lymph-nodes are shown in figs. 565 and 567.

The capillary plexus is most dense in the palmar surfaces of the fingers, where the meshes are so fine that they can only be seen with a lens. On the dorsal surface of the fingers and hand the plexus is less dense. From the plexus on the palmar side of the fingers vessels come together at the base of the fingers where they pass dorsally to be joined by the dorsal vessels of the finger. They now follow two rather distinct curves: (1) those from the thumb and index finger and a part of the middle finger pass upward along the radial side of the forearm, course medially over the lower part of the biceps muscle, and empty into the axillary lymph-nodes. One or two vessels follow the cephalic vein and, after traversing the delto-pectoral node, pierce the costo-coracoid membrane to enter the subclavian nodes, or pass over the clavicle into the inferior deep cervical nodes. (2) Those from the rest of the fingers course for a short stretch on the dorsum of the forearm, when they turn toward the ulnar side, wind around to the volar side and either continue superficially along the upper arm to the axillary nodes, or pass into the superficial cubital node, or, joining the efferents from these nodes, pass through the deep fascia to unite with the deep lymphatics. (3) A set of vessels from the palm of the hand passes upward along the volar side of the forearm. Anastomoses are frequent between these groups of lymphatic vessels, particularly in the cubital region.

It will thus be seen that the superficial cubital nodes receive lymph from the ulnar digits and from the palm of the hand, but not from the thumb and forefinger.

The superficial lymphatics from the rest of the arm join these three main groups at various levels.

The deep vessels.—The deep lymphatic vessels of the upper extremity drain the joint capsules, periosteum, tendons, and (if the recent work of Aagaard is

correct) the muscles. They collect into vessels which, in general, accompany the arteries, in the forearm, the radial, ulnar, anterior and posterior interosseous, and in the arm the brachial. Above the elbow they are joined by numerous super-

FIG. 567.—THE LYMPHATICS OF THE FOREARM. (After Toldt, "Atlas of Human Anatomy," Rebman, London and New York.)

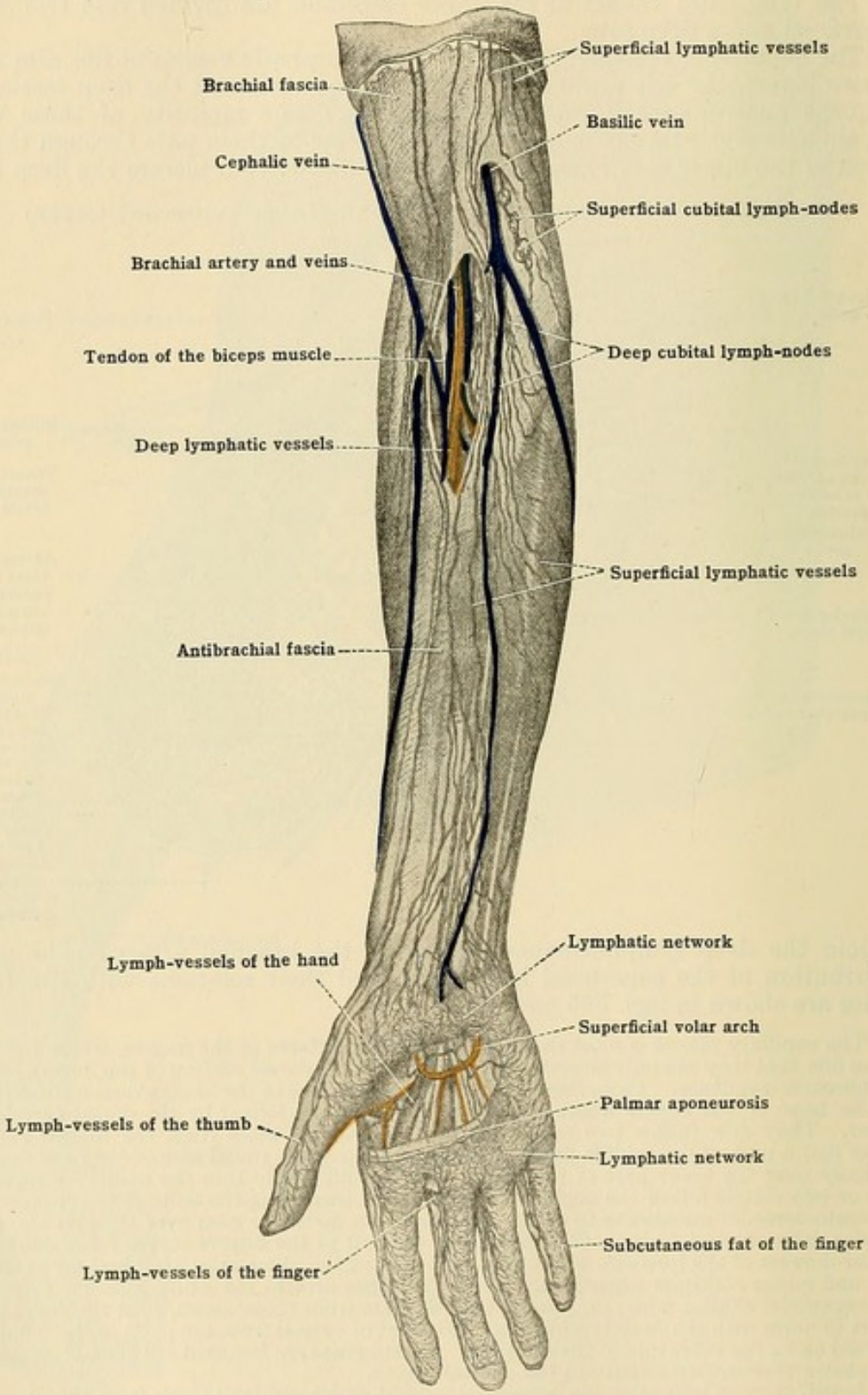

ficial lymphatic vessels including efferents from the superficial cubital nodes. Along their course in the forearm are intercalated small nodes (pin-head size), radial, ulnar, anterior and posterior interosseous (Mouchet) and deep cubital; and, in the arm, small brachial intercalated nodes. The deep vessels in the main enter the brachial group of axillary lymph-glands which lie behind the large vessels

and nerves, the efferents from which nodes pass either into the lower deep cervical lymph-nodes or directly into the subclavian trunk.

The lymphatics of the *shoulder-joint* have recently been described by Tananesco. He finds a ring of lymphatics in the joint capsule, whose efferents, in the main, following the arteries, run to the central and subclavian groups of axillary nodes.

C. THE LYMPHATICS OF THE THORAX

The lymphatics of the thorax will be considered under the following divisions: the superficial vessels, the deep nodes, and the deep vessels.

1. THE SUPERFICIAL LYMPHATIC VESSELS OF THE THORAX

The superficial lymphatics of the thorax pass almost exclusively to the axillary nodes, and may be regarded as forming three sets, a ventral, a lateral, and a dorsal. The **ventral set** drains the thoracic integument, which extends form the median line and the clavicle over to the lateral border of the chest, and includes the vessels of the mammary gland, which will, however, be described separately. The majority of the vessels from this area end in the anterior pectoral group of axillary nodes, a few, which arise beneath the clavicle, passing to the supraclavicular nodes, and a few perforating the intercostal spaces and ending in the chain of nodes along the internal mammary artery.

It has been shown that an injection into the subcutaneous plexus near the median line passes to the opposite side, and that, in addition to the anastomosis between the networks of the two sides of the thorax which this result manifests, there may also be a few collecting trunks crossing the median line, and, furthermore, anastomoses occur between the superficial networks of the anterior thoracic and abdominal walls. Thus while the main channel of lymphatic drainage is through the axilla, there are minor accessory channels to (1) the supraclavicular nodes, (2) to the axilla of the opposite side, (3) to the internal mammary chain, and (4) in isolated cases even to the inguinal nodes. These accessory channels may become more open in cases of obstruction to the main channel.

The **lateral set** of superficial thoracic lymphatics is much less extensive than the anterior, and its collecting vessels pass upward to open into the posterior pectoral group of axillary nodes.

The **dorsal set,** which occupies the subcutaneous tissue of the *dorsal* thoracic wall, sends its vessels to the subscapular group of axillary nodes.

The Lymphatics of the Mammary Gland (Figs 566, 568)

The lymphatic network over the peripheral portions of the mammary gland is like that of the rest of the thoracic wall. In the areola, however, the capillaries are far more abundant, forming a double subareolar plexus. The superficial plexus is so dense that its meshes can be seen only with a lens. The deeper plexus not only drains the superficial plexus, but receives the vessels from the mammary gland itself, and from it arise two large trunks, one from the inferior and one from the superior part of the plexus. These two vessels pass to one or two of the nodes belonging to the anterior pectoral group of axillary nodes. In addition there may be—(1) one or two vessels passing to the nodes along the axillary artery; (2) in rare cases a vessel passing directly to the subclavian nodes. There is also a definite channel from the medial margin of the gland to the internal mammary nodes, the ducts following the perforating branches of the internal mammary vessels, and it may be noted that the crossed anastomosis and that with the abdominal network, mentioned in connection with the superficial thoracic vessels, may, on occasions, serve as channels for the mammary drainage.

There is also clinical evidence indicating that lymphatic vessels from the lower and medial aspect of the mammary gland may pass through the abdominal wall in the angle between the xiphoid process and the costal cartilages, establishing a communication with the lymphatics of the abdomen in the diaphragmatic region.

Lymphatics of the thoracic muscles.—The recent studies of Aagaard make it probable that muscles are provided with lymphatics. Whether his findings will be substantiated or not, however, it is unquestioned that lymphatic vessels course through the pectoral muscles—some passing to the axillary, others to the subclavian, and still others to the internal mammary chain of nodes. This would suffice to explain the fact that cancer of the breast may extend into and through the pectoral muscles.

2. THE DEEP LYMPHATIC NODES OF THE THORAX

The lymphatic nodes of the thoracic cavity may be divided into the parietal and the visceral. The **parietal nodes** are arranged in two sets, the internal mammary chain and the intercostal nodes (fig. 570). Along the **internal mammary** artery are from four to six small nodes, [lgl. sternales] which receive ducts from the anterior thoracic and the upper part of the abdominal walls, from the anterior diaphragmatic nodes which drain the liver, and from the medial edge of the mammary gland. The efferent vessels usually unite with the vessels of the anterior mediastinal and bronchial nodes, to form the broncho-mediastinal trunk, which may join the thoracic duct on the left and the jugular or subclavian trunk on the right or may empty separately into the subclavian vein on both sides.

FIG. 568.—LYMPHATICS OF THE SUBAREOLAR PLEXUS OF THE BREAST. (After Sappey.)

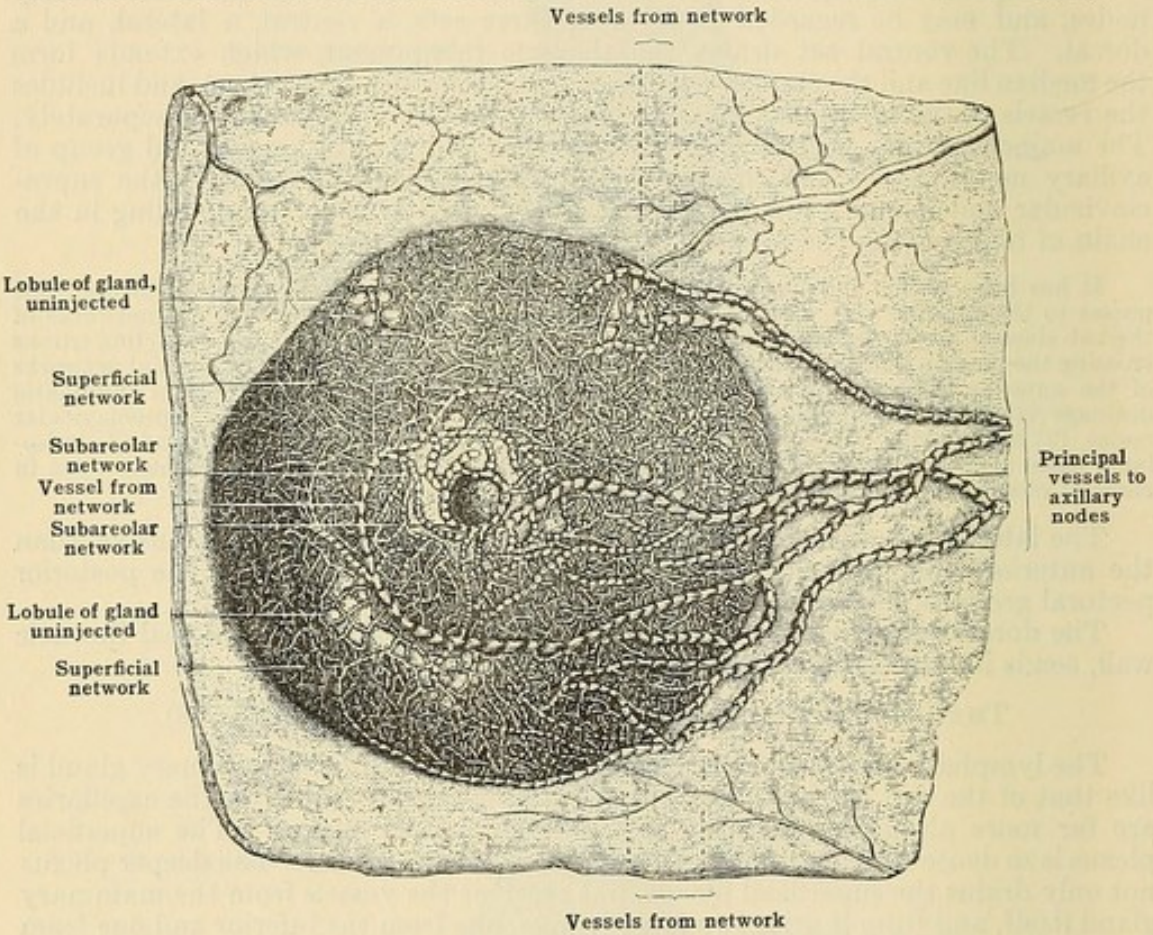

The **intercostal nodes** [lgl. intercostales] lie along the intercostal vessels, near the heads of the ribs. There are usually one or two in each space, and occasionally a node is placed where the perforating lateral artery is given off. They receive afferents from the deeper part of the thoracic wall and costal pleura. Their efferents enter the thoracic duct, those from the nodes of the lower four or five interspaces uniting usually to form a common duct on each side, but more marked on the left side, which descends to the receptaculum chyli.

The efferent lymph-vessels from the upper intercostal nodes often unite into common trunks which drain several interspaces, and which may pass through a large gland near the thoracic duct before emptying into it. Occasionally such collecting vessels from the right side cross the mid-line behind the aorta to reach a large gland to the left of the aorta.

The **visceral nodes** of the thorax are arranged in three groups:—

1. The **anterior mediastinal nodes** [lgl. mediastinales anteriores] are situated, as their name indicates, in the anterior mediastinum, and are arranged in an upper and a lower set. The upper set is situated upon the anterior surface of the arch of the aorta, and consists of eight or ten nodes, which receive afferents from the pericardium and the remains of the thymus gland. Their efferent vessels pass upward to join the broncho-mediastinal trunk. The lower set consists of from

three to six nodes, situated in the lower part of the mediastinum. They receive afferent ducts from the diaphragm, hence they are sometimes termed the **diaphragmatic nodes,** and also from the upper surface of the liver. Their efferents pass upward to open into the upper anterior mediastinal nodes.

2. The **posterior mediastinal nodes** [lgl. mediastinales posteriores] eight or ten in number, are situated along the thoracic aorta, and receive vessels from the mediastinal tissue and from the thoracic portion of the œsophagus. Their efferents open directly into the thoracic duct.

3. The **bronchial nodes** [lgl. bronchiales] form an extensive group lying along the sides of the lower part of the trachea, and along the bronchi as far as the hilus

FIG. 569.—THE TRACHEAL AND BRONCHIAL NODES. (Sukiennikow.)

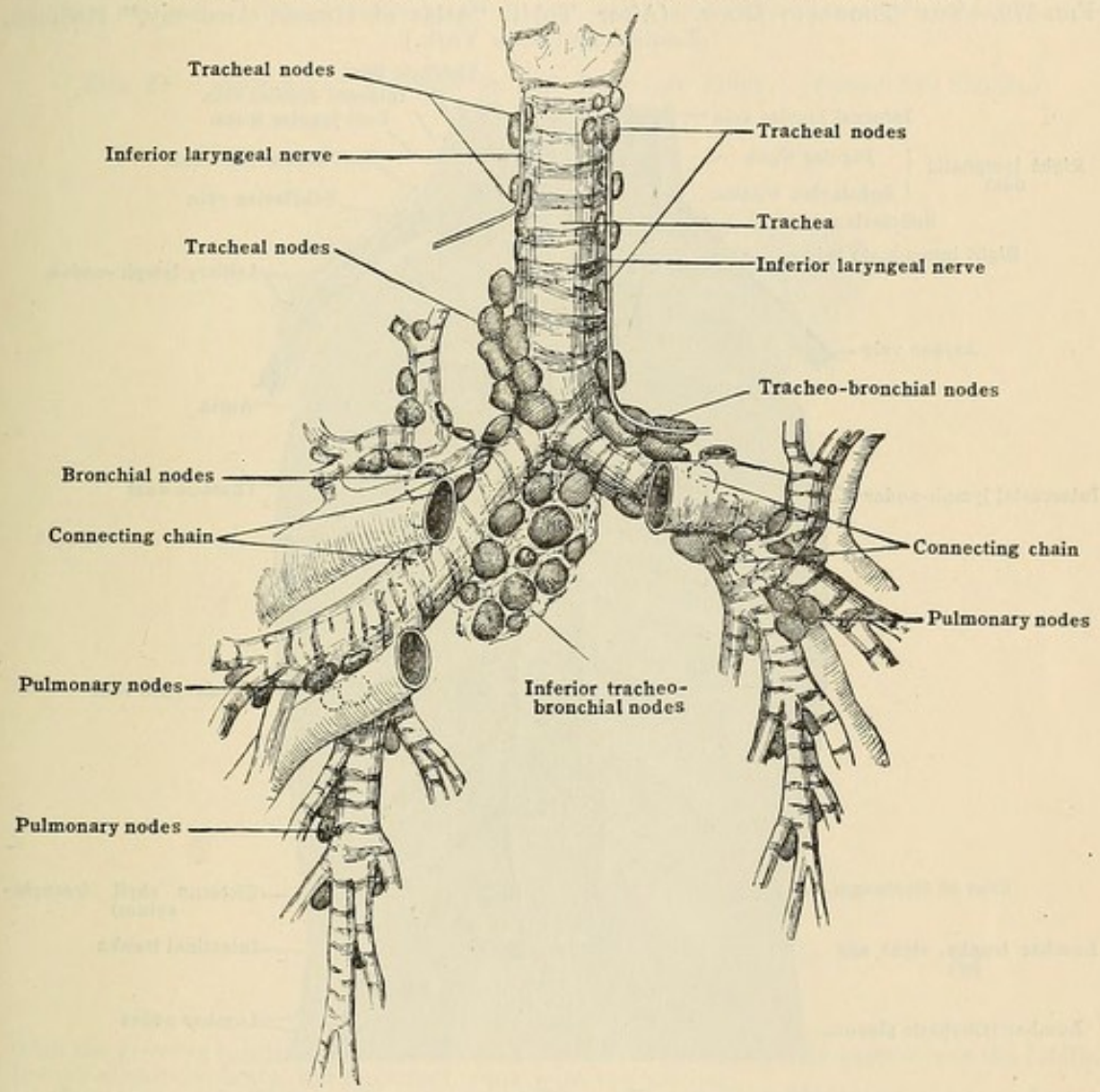

of each lung, those lying in the hilus being termed the **pulmonary nodes,** and others, according to their position, lateral tracheo-bronchial, inferior tracheo-bronchial (nodes of the bifurcation) and tracheal (paratracheal). They receive the drainage of the lower part of the trachea, the bronchi, the lungs, part of the œsophagus, and, to a small extent, the heart. Their efferent vessels unite with those from the upper anterior mediastinal and internal mammary nodes to form the broncho-mediastinal trunk.

3. THE DEEP LYMPHATIC VESSELS OF THE THORAX

In following the deep lymphatics of the thorax the course of development will be followed in describing first the thoracic duct and right lymphatic ducts, second the parietal vessels, and third the visceral vessels.

The Thoracic Duct

The **thoracic duct** [ductus thoracicus] (fig. 570), which is the main collecting duct of the lymphatic system, extends from the second lumbar vertebra along the spinal column and course of the aorta to the junction of the left internal jugular and subclavian veins. It receives all the lymphatics below the diaphragm, and the deep lymphatics from the dorsal half of the chest wall; and also, when joined, near its cephalic end, by the left broncho-mediastinal, subclavian and jugular trunks, from the remainder of the left half of the body, above the diaphragm. At the caudal end the duct is formed usually by the union of three collecting ducts, one from each of the lumbar groups of nodes, and an unpaired intestinal

Fig. 570.—The Thoracic Duct. (After Toldt, "Atlas of Human Anatomy," Rebman, London and New York.)

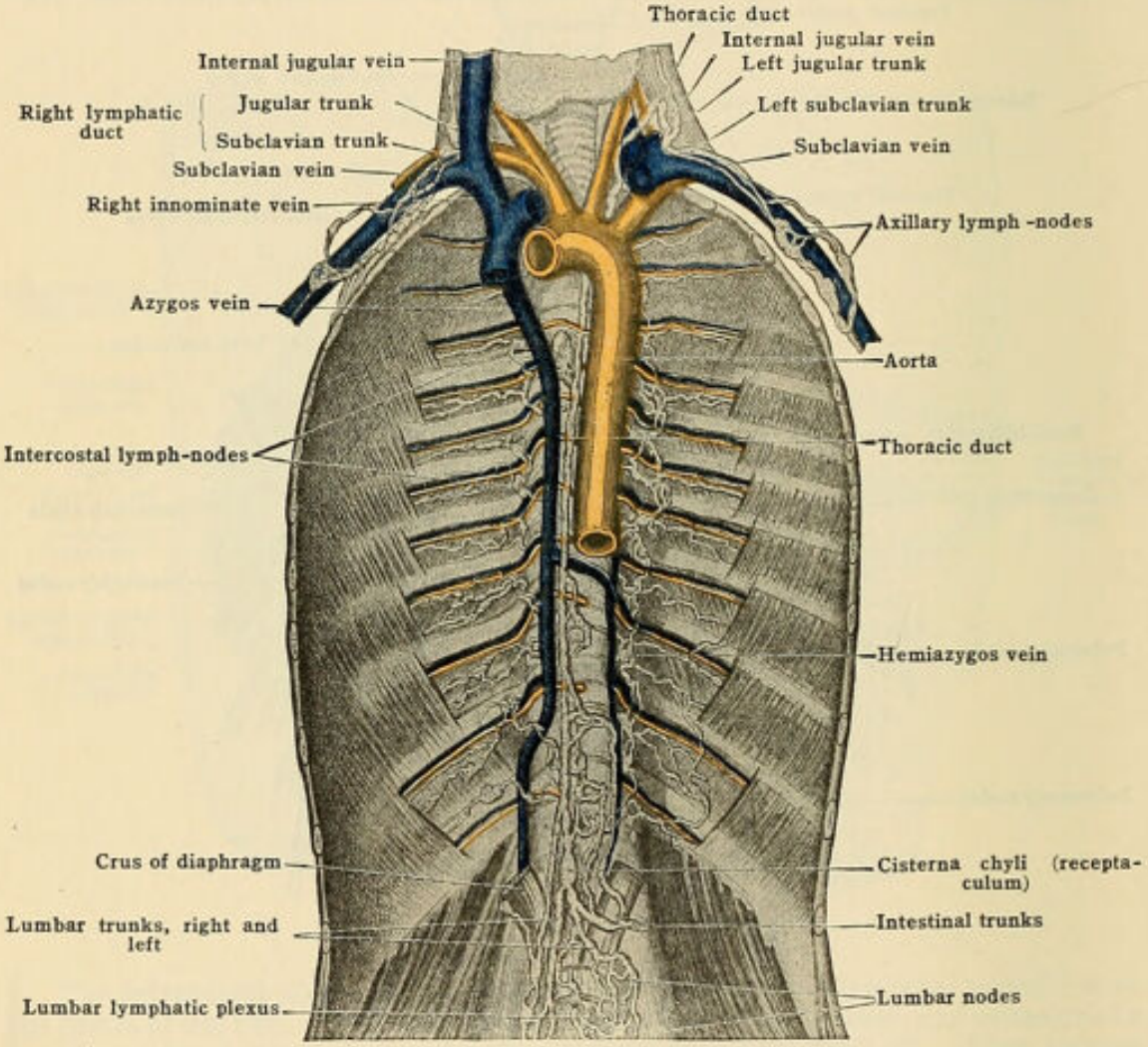

trunk. At its origin there is usually a dilated portion known as the **receptaculum [cisterna chyli]**. This usually ends opposite the body of the eleventh thoracic vertebra, and from here on the duct is from 4 to 6 mm. in diameter, until near its termination, where it is again wider.

In its cadual part, the duct lies dorsal to the aorta in the median line; it passes through the aortic opening in the diaphragm, and then inclines to the right and passes upward to about the fourth, fifth, or sixth thoracic vertebra, when it bends to the left and passes, continuing upward, over the apex of the left lung and the left subclavian artery, and in front of the root of the left vertebral artery and vein, and then curves downward to open into the left subclavian vein, close to its junction with the left internal jugular. The duct runs in the wall of the vein a short distance before ending.

Variations.—There is a wide range of variation from this usual course. The duct is frequently double throughout a part of its course, the two branches being connected by cross anastomoses, and finally uniting into a single trunk before joining the veins. It may be

multiple, or a single trunk may pass in front of the aorta instead of behind. In a few instances it has been found emptying into the right instead of the left subclavian vein. There is also a wide range of variation in the height to which the duct ascends in the neck before curving downward to the vein. As regards the termination of the thoracic duct, variations are also frequent; it may bifurcate and end as two ducts. It often connects with the lowermost part of the internal jugular, or the beginning of the innominate. According to Henle, there is one undoubted case reported of a thoracic duct ending in the azygos vein near the sixth thoracic vertebra, the duct being obliterated above this point. At the terminal bend the thoracic duct receives the jugular trunk from the neck; it may also receive the subclavian and the bronchomediastinal trunks, but it is more usual for these last two to open either separately or together into the subclavian.

Variations are extremely numerous in the region of the receptaculum. Severa lobservers state that, in the majority of cases in man, no definite receptaculum exists. Bartels found one in only 25 per cent. of the cases studied. Instead, there is present a widening of each of the two lumbar trunks, with several anastomoses between them (55 per cent., Bartels), or a widening of these two stems without anastomosis (5 per cent.), or a much elongated widening arising

FIG. 571.—ABDOMINAL PORTION OF THE THORACIC DUCT. (Poirier and Cunéo.)

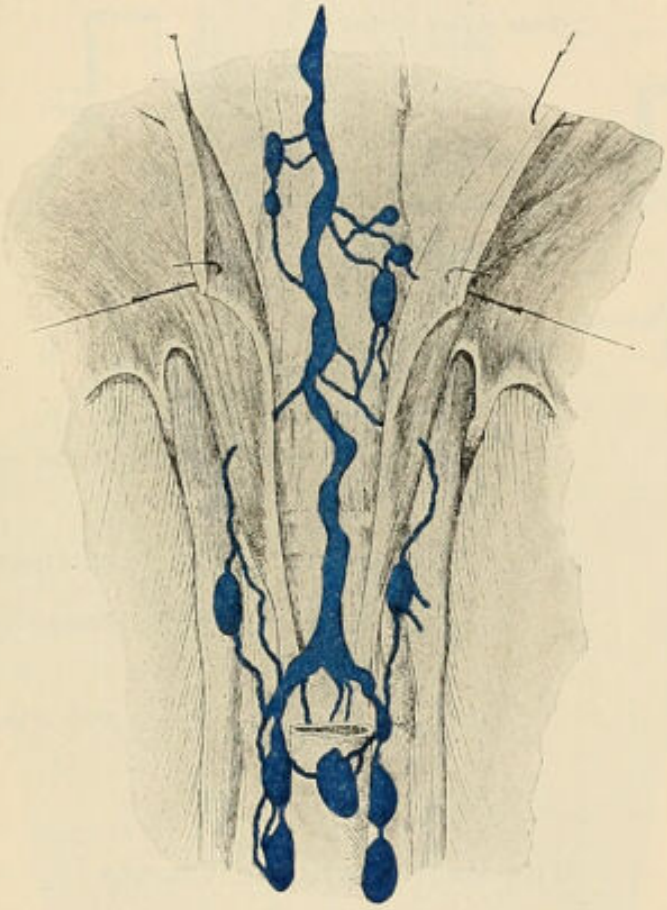

from the growing together of the two lumbar trunks (10 per cent.). In cases where the lumbar trunks remain separate, the intestinal trunk joins the left one.

Development.—While the exact mode of its development is still in dispute, enough is agreed upon by the various investigators to explain most of the variations in the thoracic duct. In brief, it is known that the lymphatics start in the neck as a variable number of outgrowths from the veins in the region of the junction between the later internal jugular and subclavian veins. A variable number of these connections disappear, while the various combinations of one, two, three or four which are retained furnish the numerous variations in number and position of the ducts which empty into the vein in the adult. Thus the thoracic duct may have one, two or even three openings into the veins, while the jugular, subclavian and bronchomediastinal trunks may join the thoracic duct or may enter the veins separately or in various combinations.

It is also known that the upper part of the thoracic duct is at first bilateral, being formed by outgrowths from the primary plexus, which meet in a common plexus around the aorta. Normally the right portion of these connections disappears, so that the thoracic duct empties into the left subclavian vein. In exceptional cases, where it opens into the right subclavian vein, there have also been present variations in the large right arterial trunk. These conditions in all probability at a certain stage in development produced a greater resistance to the lymph stream in the left than in the right vessel causing it to become obliterated so that the right instead of the left became the permanent ending of the duct.

Most of the other variations—the frequent presence of longer or shorter doublings of the duct with anastomoses between the two parts, the numerous variations in the region of the receptaculum chyli—are easily explained by the fact that the duct and receptaculum pass through a stage in development in which they form richly anastomosing plexuses around the aorta.

The Right Terminal Collecting Ducts

On the right side the jugular, subclavian, and broncho-mediastinal trunks usually open separately into the subclavian vein, the orifices of the first two being near together. When the jugular and subclavian trunks unite, the common duct is termed the right lymphatic duct; this is a rare form, and it is still more rare for the three ducts to unite to form a common stem (fig. 572). These variations have the same explanation, embryologically, as was given for the corresponding variations on the left side.

Fig. 572.—Terminal Collecting Ducts on the Right Side. (Poirier and Cunéo.)

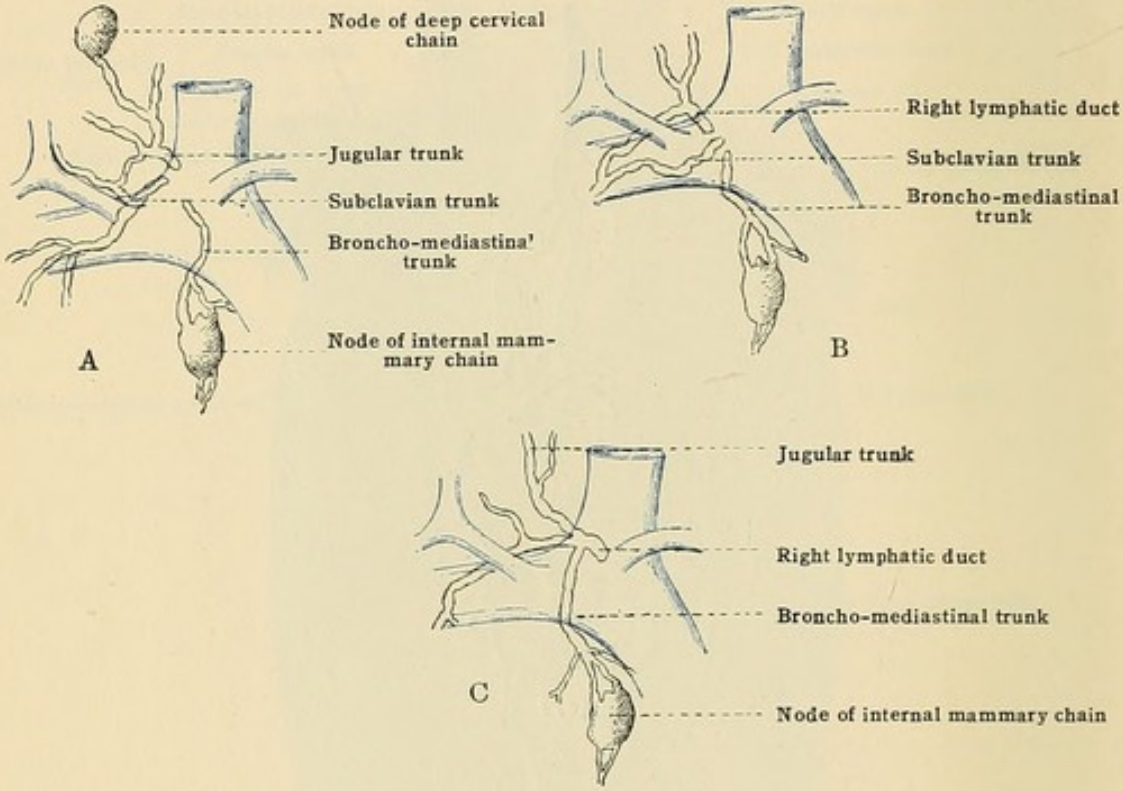

The Deep Lymphatic Vessels

As with the nodes, the deep lymphatic vessels of the thorax may be divided into a parietal and a visceral group. To the former group may be assigned the lymphatics of the intercostal spaces and those of the diaphragm.

The **intercostal lymphatics** form plexuses in each intercostal space, which receive lymph from the periosteum of the ribs and from the parietal pleura, and from which the drainage is either ventral or dorsal. From the dorsal half of each space the drainage is to the intercostal nodes, while from the ventral half it is toward the internal mammary nodes.

The lymphatics of the diaphragm.—There is an exceedingly rich plexus of capillaries both on the pleural and on the abdominal surface of the diaphragm, especially in the region of the central tendon, these plexuses lying in the subserous layers and being freely connected by vessels which perforate the muscle. There is, however, only slight communication between the plexuses of the right and left sides of the diaphragm. The vessels lie between the coarse muscle bundles, forming a very characteristic picture, in which the lymphatics stream outward radially, like the spokes of a wheel. The collecting vessels empty into three groups of small nodes on the convex surface. The *ventral group* lies ventral to the central tendon. Two or three nodes in the centre of this group receive

afferents from the liver and none from the diaphragm, but the rest receive vessels from the ventral surface of the diaphragm and the efferents of all pass to the lower set of anterior mediastinal nodes.

The *middle group* consists of from three to six nodes, which lie, on the left side, near the point where the phrenic nerve enters the diaphragm; on the right side, near the vena cava.

The *dorsal group* of four or five nodes is placed between the pillars of the diaphragm. The vessels from the lateral and dorsal groups pass to the posterior mediastinal nodes, and also to the upper cœliac nodes, which likewise receive the drainage from the dorsal part of the abdominal surface of the diaphragm.

FIG. 573.—THE LYMPHATICS OF THE ŒSOPHAGUS. (After Sakata.)

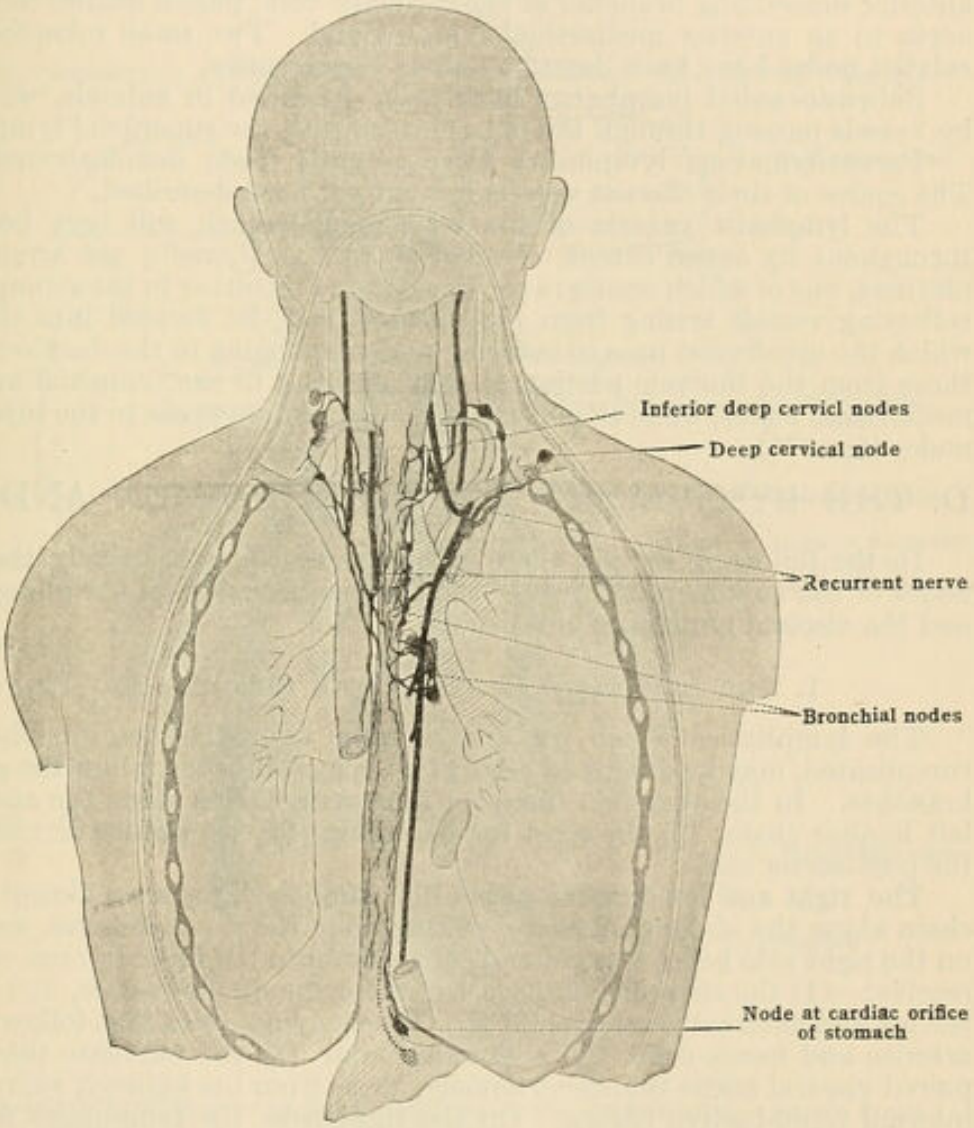

To the visceral group of thoracic lymphatics belong the vessels of the thymus, the lungs, the heart, and the œsophagus.

The **lymphatics of the thymus** drain, according to Severeanu, into three sets of glands, an anterior, a ventral and a dorsal group. The *anterior* set, one gland on each side, lies lateral to the cephalic end of the thymus, and drains into the jugular or subclavian trunk. The *ventral* set includes 4–6 of the anterior mediastinal lymph-glands. The *dorsal* set, 2 on each side, is made up of anterior mediastinal glands lying between the thymus and the pericardium.

The **lymphatics of the lungs** are arranged in two sets. A *deep set* takes its origin in plexuses which surround the terminal bronchi and follows the course of the bronchi, the pulmonary artery, and the pulmonary vein to the pulmonary nodes at the hilus, whence the stream passes to the main bronchial nodes (fig. 569), especially to those situated in the angle formed by the bifurcation of the trachea,

and thence to the broncho-mediastinal trunk. A *superficial set* arises in a network situated upon the surface of the lung beneath the visceral layer of the pleura.

According to Miller, who has studied the lymphatics of lung and pleura most carefully in dog and man, the only communications between the lymphatics of the pleura and the deep lymphatics occur around the veins which reach the pleural surface. These vessels are provided with valves so that the lymph stream passes, in them, toward the pleural surface. The collecting stems of the subpleural lymphatics pass independently to the pulmonary nodes.

Lymphatics of the heart.—The superficial (subepicardial) lymphatics of the heart collect to two main stems which accompany the main coronary vessels. The right stem accompanies the right coronary artery to its origin, passes on over the arch of the aorta and empties into one of the anterior mediastinal lymph-nodes. The left stem, formed by two stems accompanying the circumflex and anterior descending branches of the coronary vein, passes behind the arch of the aorta to an anterior mediastinal lymph-gland. Two small subepicardial intercalated nodes have been described along these trunks.

Subendocardial lymphatics have been described in animals, which connect by vessels passing through the musculature with the superficial lymphatics.

Parenchymatous lymphatics have recently been demonstrated by Bock. The course of their efferent vessels has not yet been described.

The **lymphatic vessels of the œsophagus,** which will here be considered throughout its entire extent, cervical as well as thoracic, are arranged in two plexuses, one of which occurs in the mucosa and the other in the submucosa. The collecting vessels arising from the plexuses may be divided into three sets, of which the uppermost pass to outlying nodes belonging to the deep cervical chain, those from the thoracic portion of the tube pass to the bronchial and posterior mediastinal nodes, while those from its lowermost part pass to the superior gastric nodes (fig. 573).

D. THE LYMPHATICS OF THE ABDOMEN AND PELVIS

In the following section there will be described successively the lymphatic nodes of the abdomen and pelvis, the lymphatic vessels of the abdominal walls, and the visceral lymphatic vessels.

1. The Lymphatic Nodes of the Abdomen and Pelvis

The lymphatics which connect directly with the thoracic duct, though complicated, may be described briefly by saying that they follow the aorta and its branches. In the abdomen there are four main chains along the aorta—(1) the left lumbar chain; (2) the right lumbar chain; (3) the pre-aortic chain; and (4) the post-aortic chain.

The right and left lumbar nodes [lgl. lumbales], form an almost continuous chain along the abdominal aorta, resting upon the psoas muscles, some of those on the right side being ventral and some dorsal to the inferior vena cava. They receive:—(1) the efferent lymphatics of the common iliac nodes, and hence drain the leg and external genitalia; (2) the efferent lymphatics that follow the lumbar arteries and hence drain the abdominal wall; (3) the efferents that follow the paired visceral aortic branches, namely, those from the kidneys, supra-renal, and internal reproductive organs. On the right side, the lymphatics from the reproductive organs pass to the nodes ventral to the vena cava—those of the abdominal walls pass to the dorsal set, while those from the kidney pass to both sets.

The efferent vessels of the lower lumbar nodes pass to higher ones and so on up the chain, the vessels from the uppermost nodes uniting to form a single **lumbar trunk** on each side. These trunks pass to the thoracic duct, forming two of the so-called trunks of origin of that vessel (fig. 571).

The **pre-aortic nodes** [lymphoglandulæ cœliacæ] are arranged in three groups at the root of each of the three unpaired visceral branches of the aorta—the cœliac, the superior mesenteric, and the inferior mesenteric arteries. The **cœliac nodes** are from one to three in number, and are in reality parts of chains of nodes extending along the branches of the artery and constituting the **hepatic, gastric,** and **splenic** nodes. They drain the stomach, duodenum, liver, pancreas, and spleen.

The **superior mesenteric** group is larger, and is continuous with the **mesenteric nodes** lying in the root of the mesentery. This group drains the remainder of the small intestine, the cæcum and appendix, the ascending and transverse colons, and the pancreas.

The **inferior mesenteric** group usually has two nodes, one on either side of the artery. It drains the rectum and descending and sigmoid colons. All the nodes in the mesentery and intestinal walls may be considered as outlying nodes of the pre-aortic group. They will be studied in connection with the visceral lymphatics.

The inferior mesenteric nodes drain into the neighbouring lumbar nodes, and also directly upward to the superior mesenteric nodes, and then again to the cœliac nodes. From the last a single stem, the **intestinal trunk,** arises and passes either to the right lumbar trunk or directly to the thoracic duct, forming the third of the so-called trunks of origin of the duct.

FIG. 574.—ABDOMINAL AORTIC NODES IN THE NEW-BORN. (Poirier and Charpy.)

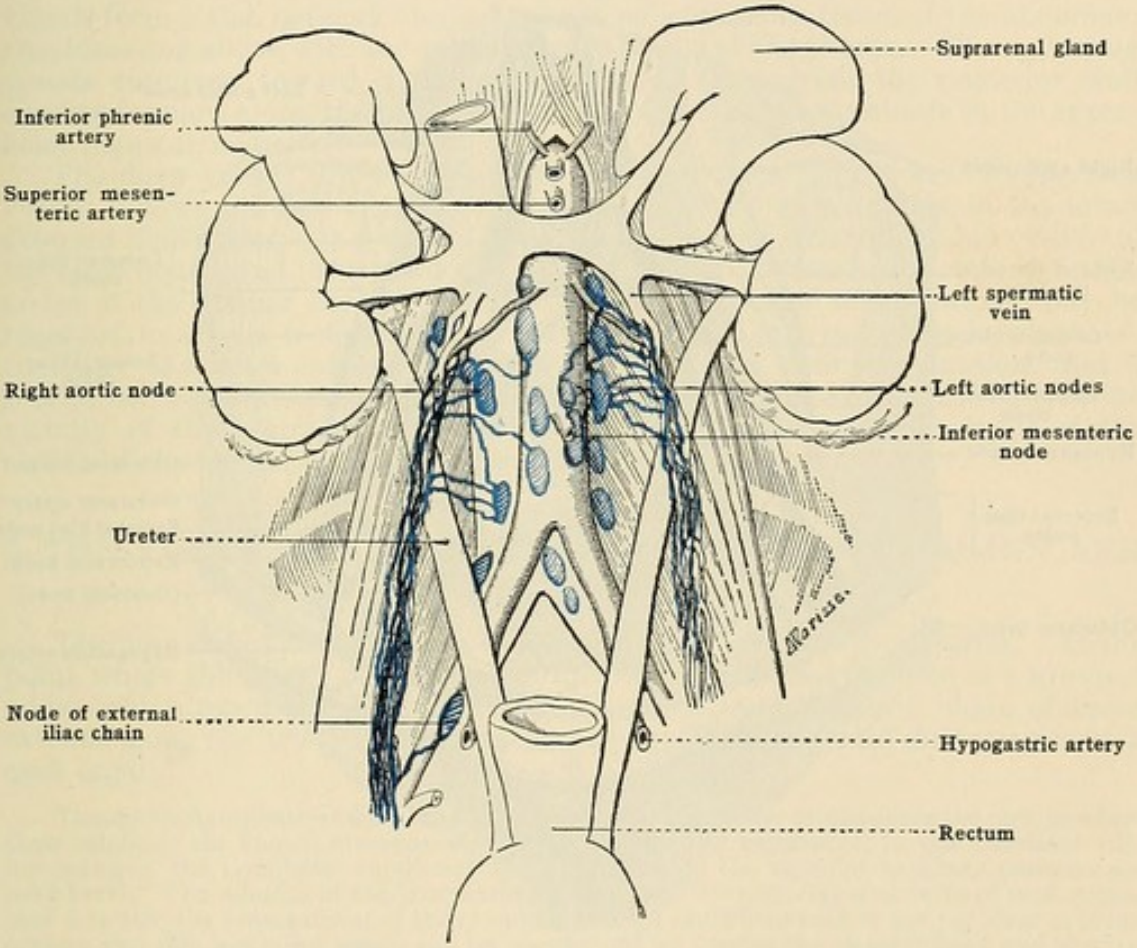

The **post-aortic nodes** are not true regional nodes, but receive vessels from the lumbar and pre-aortic chains.

Below the bifurcation of the aorta there are three large chains, the common iliac, the external iliac, and the hypogastric.

The **common iliac nodes** [lgl. iliacæ], are in three groups (fig. 575). The *external* set consists of about two nodes, which are in reality a part of a continuous chain extending along the side of the aorta, common iliac, and external iliac arteries. A second set of two to four *posterior nodes* lies behind the artery. These two groups receive the efferent vessels of the external iliac and hypogastric chains. The *internal* set usually consists of two nodes which rest upon the promontory of the sacrum. They receive vessels from the sacral nodes, together with most of those from the pelvic viscera, namely, from the prostate, neck of the bladder, neck of the uterus, the vagina, and part of the rectum. The efferent lymphatic vessels of the common iliac nodes pass to the lumbar chain.

External iliac nodes.—These are likewise in three sets—external, middle, and internal. The *external* chain consists of three or four nodes, the lowest one being behind the crural arch. They receive:—(1) some of the vessels of the superficial and deep inguinal nodes; (2) vessels from the glans or clitoris, which come through the inguinal canal; (3) vessels from the part of the abdominal wall supplied by the deep epigastric and deep circumflex arteries, along which there may be a few outlying nodes—the **epigastric nodes.**

The *middle* chain consists of two or three nodes behind the artery. When there are three, the lowest is likewise near the crural arch. It receives vessels from the bladder, prostate, neck of the uterus, and upper portion of the vagina. The *internal* chain consists of three or four nodes, and is the continuation of the deep inguinal nodes. Its lowest nodes are likewise near the femoral ring, while the next node is large and constant, and usually lies within the pelvis. This chain

FIG. 575.—ILIO-PELVIC NODES. (Cunéo and Marcille.)

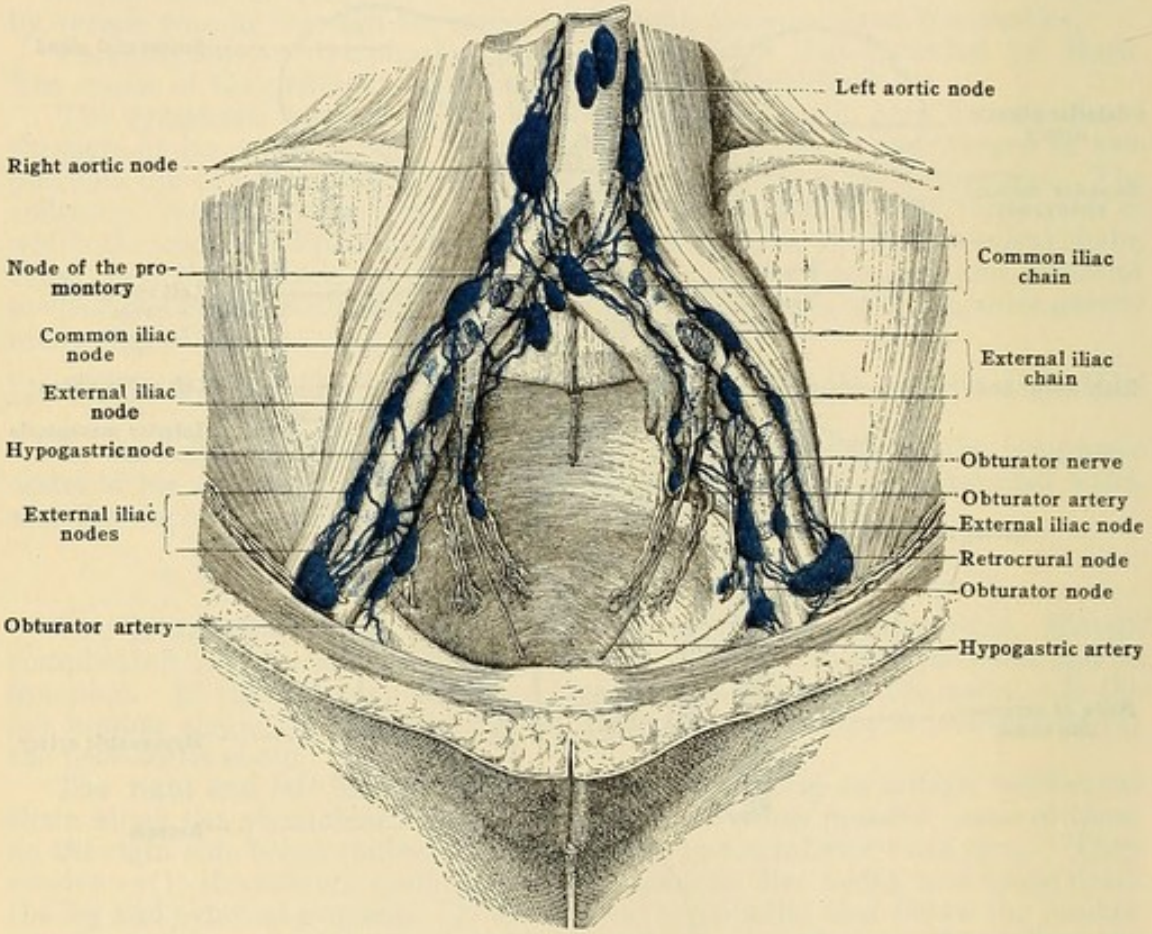

receives many vessels:—(1) from the superficial and deep inguinal nodes; (2) from the glans and clitoris through the femoral canal; (3) from the abdominal wall; (4) from the neighbourhood of the obturator vessels; (5) from the neck of the bladder, the prostate, and membranous part of the urethra; (6) from the hypogastric chain.

Thus, to sum up the nodes of the external iliac chains:—they are a part of a chain which includes the lumbar, common iliac, external iliac, and inguinal nodes. It will be noted that this extensive chain stops, for the most part, with the deep inguinal group. The external iliac nodes receive the efferents of the superficial and deep inguinal nodes; the middle and internal groups receive vessels from the pelvis. The efferent vessels of all the nodes in the chain pass to the higher nodes.

The **hypogastric nodes** [lgl. hypogastricæ].—These nodes are in groups near the origin of the branches of the hypogastric (internal iliac) artery. Thus they occur near the origin of the obturator, the uterine, or prostatic, the trunk of the

inferior gluteal (sciatic) and pudic, the middle hæmorrhoidal, and the lateral sacral arteries. All the nodes are beneath the pelvic fascia, and are connected by numerous anastomoses. They receive lymphatics from the structures supplied by the corresponding arteries, namely, from the pelvic viscera, the perineum, and the posterior surface of the thigh and gluteal region. Their efferent vessels pass partly to the middle group of the common iliac nodes, and partly to the posterior nodes of the same chain.

The **sacral nodes** [lgl. sacrales].—These nodes, 5 or 6 in number, lie in the hollow of the sacrum, in or near the mid-line. They receive afferent vessels from rectum and prostate, and their efferents pass to the hypogastric and lumbar nodes.

2. THE LYMPHATIC VESSELS OF THE ABDOMINAL WALLS

The lymphatic vessels of the abdominal walls are arranged in two sets, one of which is subcutaneous and the other deep or aponeurotic. The **subcutaneous** vessels form a rich network through all the subcutaneous tissue of the abdomen, anastomosing above with the subcutaneous plexus of the thorax. The collecting vessels converge toward the inguinal region, those from the posterior wall curving forward along the crest of the ilium, and they all terminate in the superficial inguinal nodes.

The **deep** vessels drain along three principal lines. (1) A set of collecting vessels follows the line of the deep epigastric artery to terminate in the lower external iliac nodes; (2) a second set follows the deep circumflex iliac vessels to the same nodes; and (3) a third set follows the lumbar vessels to terminate in the nodes of the lumbar chain. A group of small **epigastric nodes,** which may be regarded as offsets from the iliac chain, occur on the lymph-vessels which accompany the deep epigastric vessels, not far from their termination, and a second less constant group of usually three small **umbilical nodes** occurs in the vicinity of the umbilicus in the network covering the posterior layer of the sheath of the rectus abdominis muscle.

3. THE VISCERAL LYMPHATIC VESSELS OF THE ABDOMEN AND PELVIS

The lymphatics to the viscera follow along the course of the arteries. At the point where the artery of an organ branches from the aorta there is a group of nodes which represents the main regional group, and a second chain of nodes extends along the artery. The final arrangement of nodes and ducts varies with each organ.

Though the lymphatics follow the blood-vessels, the lymphatic capillaries in the regions where their relations are known are separated from the vascular capillaries; in the intestinal villi, for example, the lymphatic capillaries are central, while the vascular capillary plexuses are peripheral. The relation of the lymphatic capillaries to the essential structures of each organ, that is to say, the arrangement of the lymphatics in the absorbing area, is not yet clear in many organs, and this is a point which can be worked out by tracing the development and gradual invasion of each organ by the lymphatics. The old theory of the origin of the lymphatics from the tissue-spaces made this problem most difficult of attack.

In almost all organs there is a peripheral or capsular lymphatic plexus, which anastomoses with the parietal lymphatics, these anastomoses being particularly well developed in the case of the liver. In addition there are one or two deep plexuses in the great majority of the organs which drain partly directly to their regional nodes and partly by way of the peripheral plexus.

The Lymphatics of the Alimentary Tract

The lymphatics of the mouth, pharynx, and œsophagus have already been described (pp. 715, 730). In general, throughout the abdominal part of the alimentary canal, the distribution of nodes is as follows:—(1) There are primary regional nodes situated at the roots of the arteries as they leave the aorta, that is to say, around the cœliac and the superior and inferior mesenteric arteries; these

drain large segments of the intestine; (2) groups of definite and constant nodes placed along the branches of the arteries in the root of the mesentery; these drain a definite smaller segment of the intestine; (3) chains of nodes along the anastomotic loops of the arteries, close to the intestinal wall; these are of the type called 'intercalated nodes'; (4) solitary or compound follicles, situated within the submucosa or capillary zone of the lymphatics.

What may be taken as the typical arrangement of the lymphatic vessels in the intestine may be seen in fig. 576. There are three zones in which the capillary plexuses are spread out, namely, in the subserosa, the submucosa, and the mucosa. There is an abundant plexus of large capillaries just beneath the serosa; in the submucosa the plexus is also formed by large capillaries, while the mucosal plexus is finer. The lymph-follicles lie in the zone of the mucosal plexus, and it is from this that the central chyle vessels of the villi arise. The collecting vessels are formed by the union of vessels from the submucous and subserous plexuses. They traverse the three sets of nodes just described.

The lymphatics of the stomach (fig. 577).—The stomach differs from the rest of the alimentary canal in its blood-supply in having a ventral anastomotic loop, namely, that along the lesser curvature. Along this loop is the **superior gastric chain** [lgl. gastricæ superiores] of nodes, lying between the folds of the lesser omentum, some of them being on the posterior surface of the stomach. This is the most important group of nodes draining the stomach, and it has been shown that the lymph-vessels from the pylorus run obliquely across the stomach to the main mass of nodes near the cardia, an important point in the surgery of the pylorus. The efferent vessels of the chain pass to the cœliac nodes. The vessels of the greater curvature pass to a group of **inferior gastric nodes** [lgl. gastricæ inferiores], situated along the right gastro-epiploic artery, while those of the fundus follow the short gastric and left gastro-epiploic vessels to the nodes which lie along the splenic artery, both these sets of nodes also draining to the cœliac group. There is a zone half-way between the lesser and greater curvatures, in which the lymphatics are scanty. The lymphatics of the cardia connect with those of the œsophagus, and the mucosal plexus of the pylorus is continuous with that of the duodenum.

The lymphatics of the duodenum.—The lymphatics of the duodenum depart somewhat from the type, owing to its relations with the pancreas and the bile-ducts. The collecting vessels end:—(1) in nodes ventral to the pancreas, which follow the pancreatico-duodenal artery to the hepatic chain; (2) in nodes dorsal to the pancreas, which follow the superior mesenteric artery to the superior mesenteric nodes. There are anastomoses between the lymphatics of the duodenum and those of the pylorus, of the pancreas, and of the chain along the common bile-duct.

The **lymphatics of the jejuno-ileum** (fig. 578) have already served as the type of the arrangement of the intestinal lymphatics (see above). The mass of **mesenteric nodes** [lgl. mesentericæ] to which the lymphatics of the small intestine pass is the largest and one of the most important in the body, its individual nodes numbering anywhere from 130 to 150.

The lymphatics of the ileo-cæcal region.—The surgical importance of the lymph-nodes in connection with the appendix warrants a detailed description of them in which the observations of Brödel will be followed. The drainage of the cæcum and appendix is along the ileo-colic artery, and is carried on by three sets of collecting vessels—(1) an anterior cæcal set, which generally pass through one or more outlying nodes before reaching the ileo-cæcal mesenteric nodes; (2) a similar posterior set; and (3) an appendicular set, three to six in number, which usually pass directly to the ileo-cæcal nodes. The appendix thus has an independent drainage into one or two ileo-cæcal nodes, about 3 cm. above the ileum. The ileo-cæcal chain drains through the mesenteric nodes to the superior mesenteric group (figs. 579, 580).

The lymphatics of the large intestine.—Along the ascending colon there are but few nodes on the terminal vascular arches, but the number increases along the transverse colon, especially at its two angles. These nodes, together with those along the descending and sigmoid colons, are termed the **meso-colic nodes** [lgl. mesocolicæ], and they drain partly to the superior mesenteric and partly to the inferior mesenteric nodes, their efferents following the corresponding arteries.

The lymphatics of the transverse colon connect with those of the omentum; those of the descending colon are more scanty.

The lymphatics of the rectum and anus.—There are three lymphatic zones of the rectum and anus. (1) An **inferior zone,** corresponding to the anal integument, in which the capillary networks, both superficial and deep, are extremely abundant, and from which from three to five collecting vessels on either side pass to the inguinal region and end in the medial superficial inguinal nodes. (2) A

FIG. 576.—THE LYMPHATIC VESSELS OF THE INTESTINE. (After Mall.)

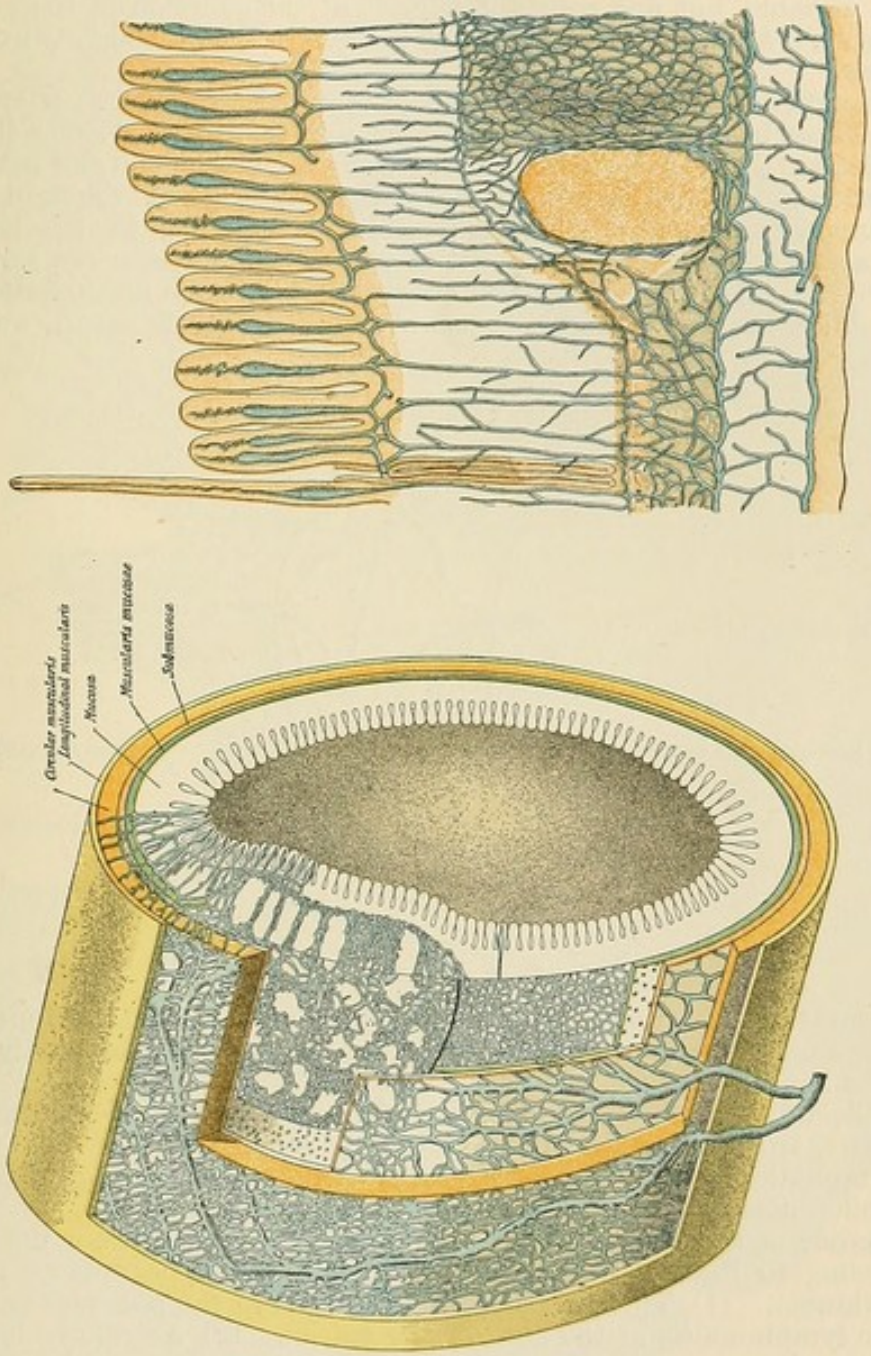

middle zone, corresponding with the transition zone of epithelium—that is, with the mucous membrane below the columns of Morgagni. Here the network is coarse, and has its meshes arranged vertically; its ducts drain partly into nodes situated along the inferior and middle hæmorrhoidal arteries, and partly pass to nodes in the meso-rectum, situated along the superior hæmorrhoidal artery and known as the **ano-rectal** nodes. (3) The **superior zone** corresponds to the remainder of the rectal mucous membrane, and contains a rich network whose collecting vessels pass to the ano-rectal glands, and thence along the superior hæmorrhoidal arteries to the inferior mesenteric nodes.

Lymphatics of the liver.—The lymphatic drainage of the liver is complicated and has great need of being entirely restudied from the standpoint of development. Its course is mainly to the cœliac nodes, but on the way it passes through a secondary group of three to six **hepatic nodes** [lgl. hepaticæ], situated along the hepatic artery. Some of these nodes are along the horizontal part of the artery, parallel to the superior border of the pancreas, while the rest follow the artery in its vertical course along with the portal vein, and become continuous at the portal fissure with two distinct chains of nodes, one of which follows the hepatic artery and portal vein, and the other the cystic and common bile-ducts. These nodes are variable, but one constant node is at the junction of the cystic and hepatic ducts. A part of the drainage of the liver is also through the **diaphragmatic nodes.**

The superficial collecting lymph-vessels of the liver have been studied by Sappey. Those from the superior surface include three sets. From the dorsal part vessels pass through the diaphragm with the vena cava, and end in the adjacent posterior mediastinal nodes. Some of these vessels from the right lobe pass in the coronary ligament to the cœliac nodes, and some from the left lobe to the superior gastric nodes. The second set of vessels from the superior surface runs over the ventral border to the hepatic nodes situated in the portal fissure. The third and most important set arises near the falciform ligament, and passes

FIG. 577.—THE LYMPHATIC ZONES OF THE STOMACH. (Cunéo.)

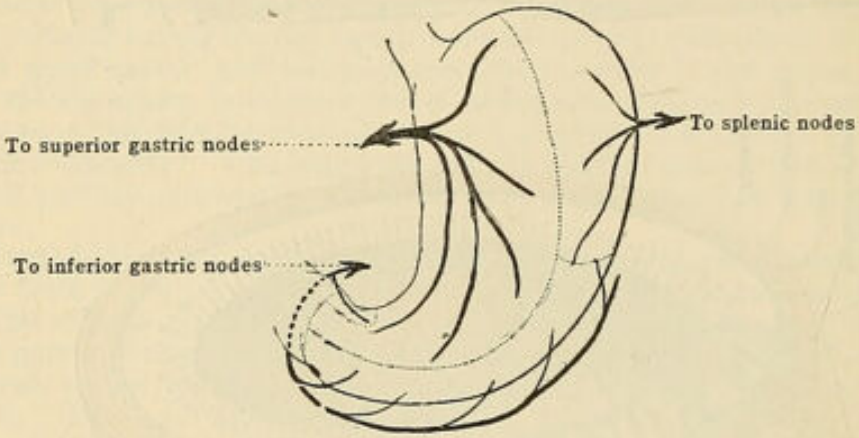

partly dorsalward to the anterior mediastinal group of nodes on the upper surface of the diaphragm, and to the nodes around the vena cava, and partly ventralward to the hepatic nodes of the portal fissure.

The collecting vessels of the inferior surface pass to the nodes situated in the portal fissure, either along the artery or the bile-ducts.

The lymphatics of the gall-bladder join the hepatic nodes along the cystic and common bile-ducts, and also the superior pancreatic nodes.

Lymphatics of the pancreas.—The lymph-vessels which drain the pancreas fall, according to Bartels, into four groups: left, anterior (upper), right and posterior (lower). (1) The left group drain the tail of the pancreas and pass to the splenic lymph-nodes, at the hilus of the spleen. (2) Anteriorly lymphatics pass to "superior pancreatic lymph-nodes," superior gastric and hepatic nodes. (3) To the right, lymphatics pass to "pancreatico-duodenal lymph-nodes." (4) Posteriorly lymphatics pass to the aortic, mesenteric, meso-colic, and inferior pancreatic nodes. The splenic, superior pancreatic, inferior pancreatic, and pancreatico-duodenal nodes are usually grouped together as "lymphoglandulæ pancreatico-lienales." Anastomoses exist between the lymphatics of the pancreas and those of the duodenum.

The **lymphatics of the spleen** (fig. 582) are found only in the form of a subcapsular plexus, there being no deep network (Mall). They pass to the **splenic nodes** [lgl. pancreatico-lienales], which are variable in number and are situated

along the course of the splenic vessels. In addition to the spleen they drain the fundus of the stomach and a part of the pancreas.

FIG. 578.—LYMPHATICS OF THE SMALL INTESTINE. (After Toldt, "Atlas of Human Anatomy," Rebman, London and New York.)

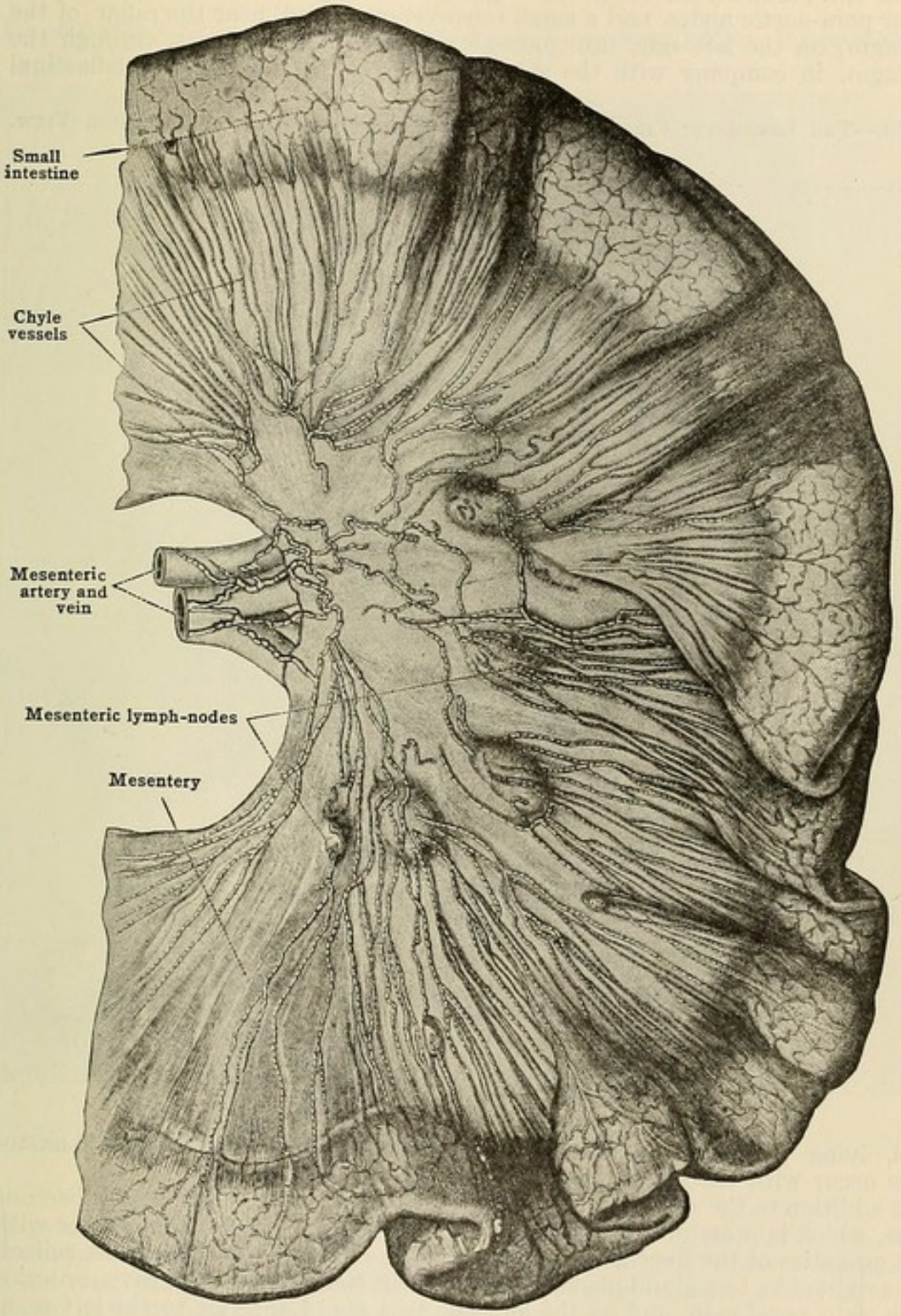

THE LYMPHATICS OF THE EXCRETORY ORGANS AND OF THE SUPRARENAL

The lymphatics of the kidney.—The lymphatic vessels from the deep capsular and parenchymatous lymphatics of the kidney run to the nodes of the lumbar chain (fig. 583). On the right side, part of the nodes concerned lie ventral and

part dorsal to the renal vein; one of the nodes lies as far caudalward as the bifurcation of the aorta; and one or two vessels may pass to pre-aortic nodes. On the left side the vessels end in four or five nodes of the lumbar group. The efferents of these nodes pass through the diaphragm and end in the thoracic duct.

The lymphatics of the Suprarenal.—The lymphatic vessels coming from the capsular and parenchymatous plexuses pass, on the right side, into two or three anterior para-aortic nodes, and a small retro-venous gland, near the pillar of the diaphragm; on the left side, into para-aortic nodes, and, in part, through the diaphragm, in company with the splanchnic nerve, to a posterior mediastinal

FIG. 579.—THE LYMPHATIC CIRCULATION OF THE ILEO-CÆCAL REGION, ANTERIOR VIEW. (After Kelly.)

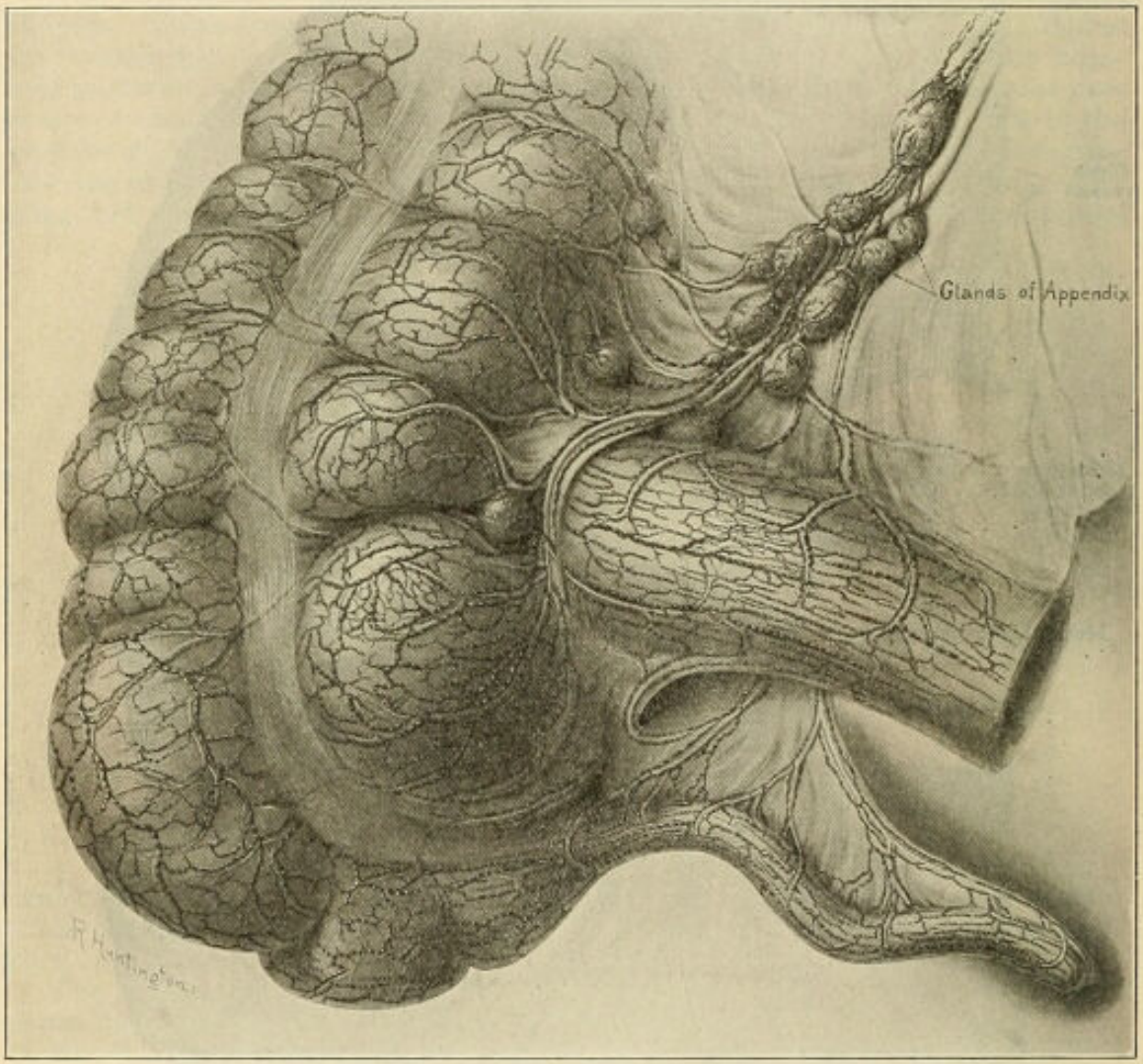

gland, lying between the ninth thoracic vertebra and the aorta. Anastomoses occur with the lymphatics of the kidney.

In addition to the capsular lymphatics proper, Kumita describes a subserous plexus, which is present over both kidney and adrenal, which anastomoses with the lymphatics of the liver and diaphragm. The efferents of this plexus collect, on the right side, to a gland placed to the right of the inferior vena cava, anterior to the right renal vein, and on the left side to a gland anterior to the left renal vein.

The lymphatics of the ureter.—Sakata has recently studied the lymphatics of the ureter. They fall into three groups: (1) An anterior (upper) group, which run to the anterior lumbar nodes, or join the renal lymphatics; (2) a middle group which pass to the posterior lumbar and interiliac nodes; (3) a posterior (lower) group which pass to hypogastric nodes and which anastomose with lymphatics of the bladder.

The lymphatics of the bladder.—The collecting vessels from the lower part of the ventral surface pass to a node of the external iliac group, situated near the femoral ring and the obturator nerve; those from the upper part of the ventral and dorsal surfaces pass to the middle node of the middle group of the external iliac chain, and from the rest of the dorsal surface they pass either to the hypogastric

FIG. 580.—THE LYMPHATIC CIRCULATION OF THE ILEO-CÆCAL REGION POSTERIOR VIEW. (After Kelly.)

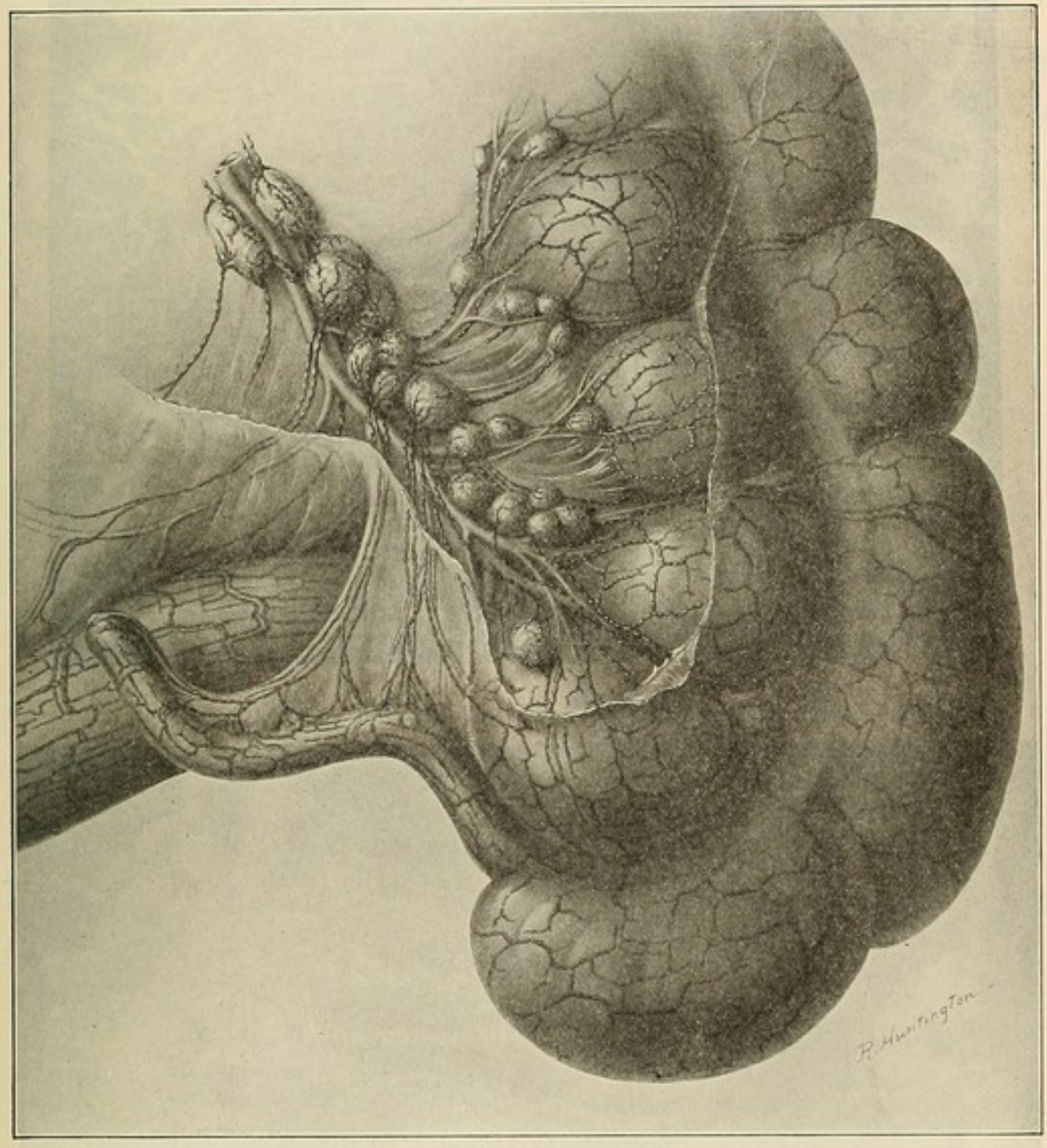

nodes or beyond these to the nodes at the bifurcation of the aorta (fig. 584). In this latter group end also the vessels from the neck of the bladder. Along some of the lymphatics of the bladder are intercalated lymph-nodes, which have been termed anterior and lateral vesical nodes.

The lymphatics of the prostate.—The lymphatics of the prostate have been studied in the dog by Walker and in man by Bruhns. The collecting vessels, six to eight on each side, pass along the prostatic artery to the nodes along the external border of the hypogastric artery. These nodes are connected with those along the external and common iliac arteries, and it is possible, from an injection of the prostate, to fill the entire chain of nodes as far as the renal artery. A trunk from the posterior surface runs up over the bladder and curves outward to

the middle node of the middle group of the external iliac chain, and still other vessels from the posterior surface run first downward, pass around the rectum, and then ascend to the lateral sacral nodes. From the anterior surface a descending duct may follow the deep artery of the penis, and the internal pudic to the hypogastric

FIG. 581.—THE SUPERFICIAL LYMPHATIC NETWORK OF THE LIVER. (After Teichmann).

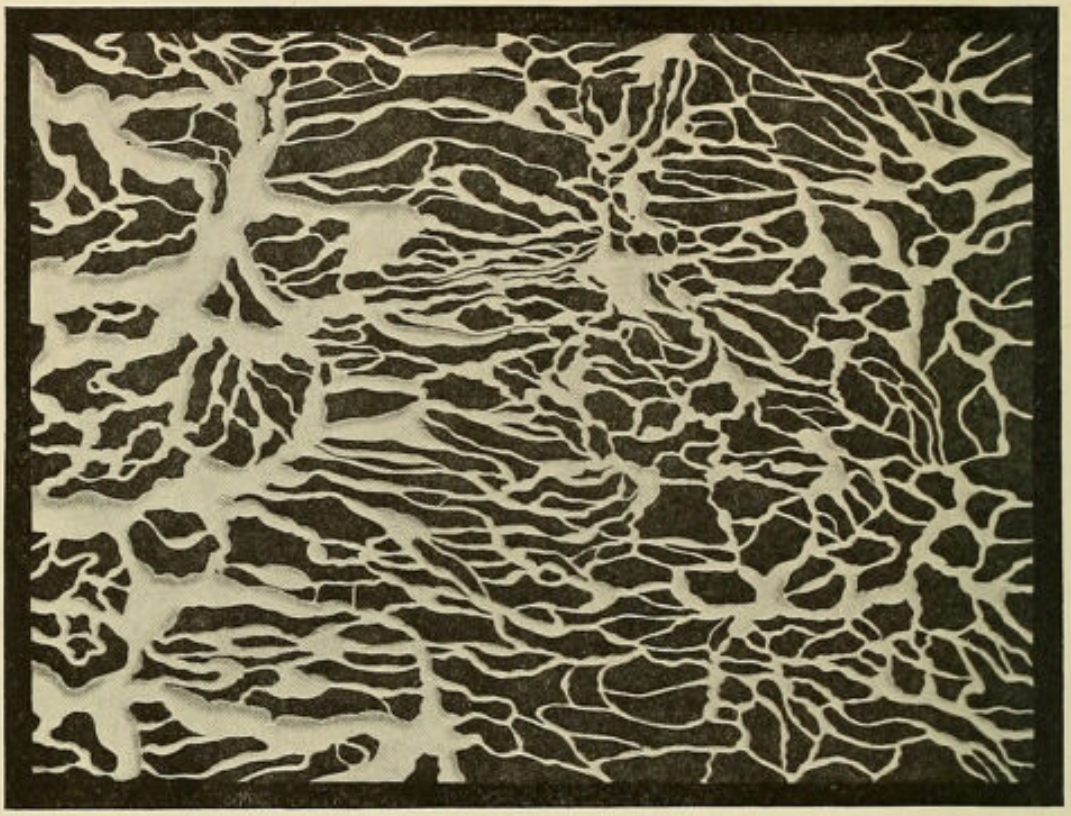

FIG. 582.—LYMPHATICS OF THE PERIPHERY OF A PIG'S SPLEEN. (After Teichmann.)

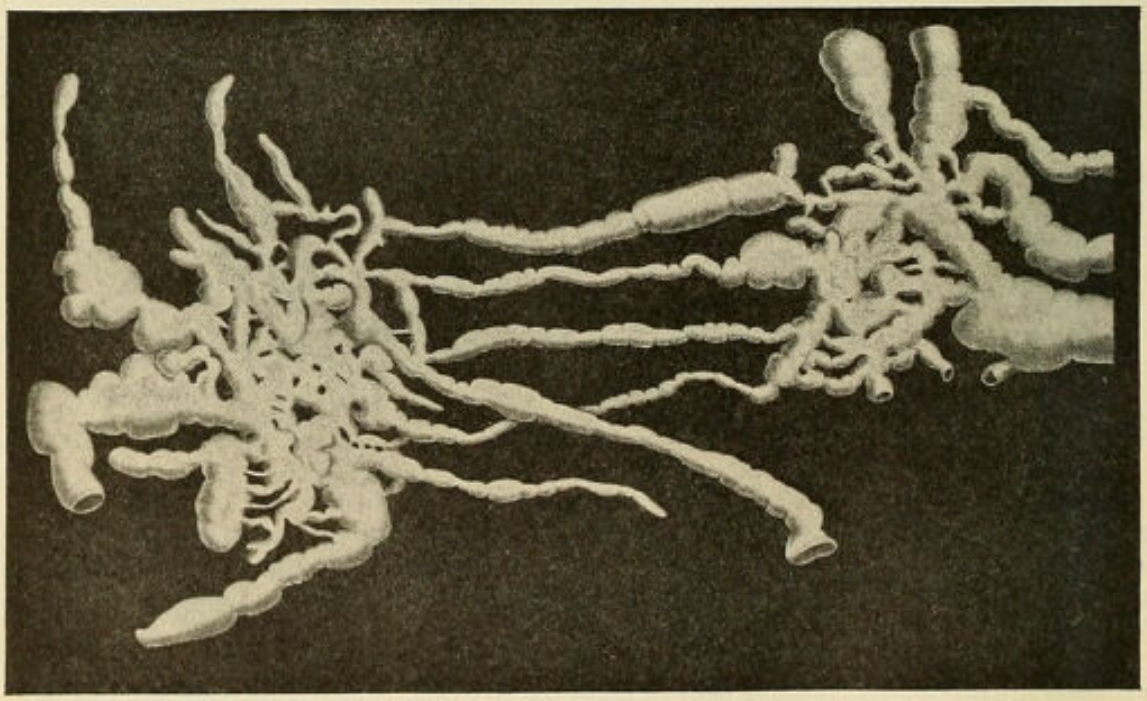

nodes (fig. 585). The lymphatics of the prostate anastomose with those of the bladder, ductus deferens and rectum.

The lymphatics of the urethra.—1. *In the Male.*—The capillary plexus of the urethra is in the mucous membrane. The collecting vessels from the mucous

FIG. 583.—LYMPHATICS OF THE KIDNEY. (After Poirier and Cunéo.)

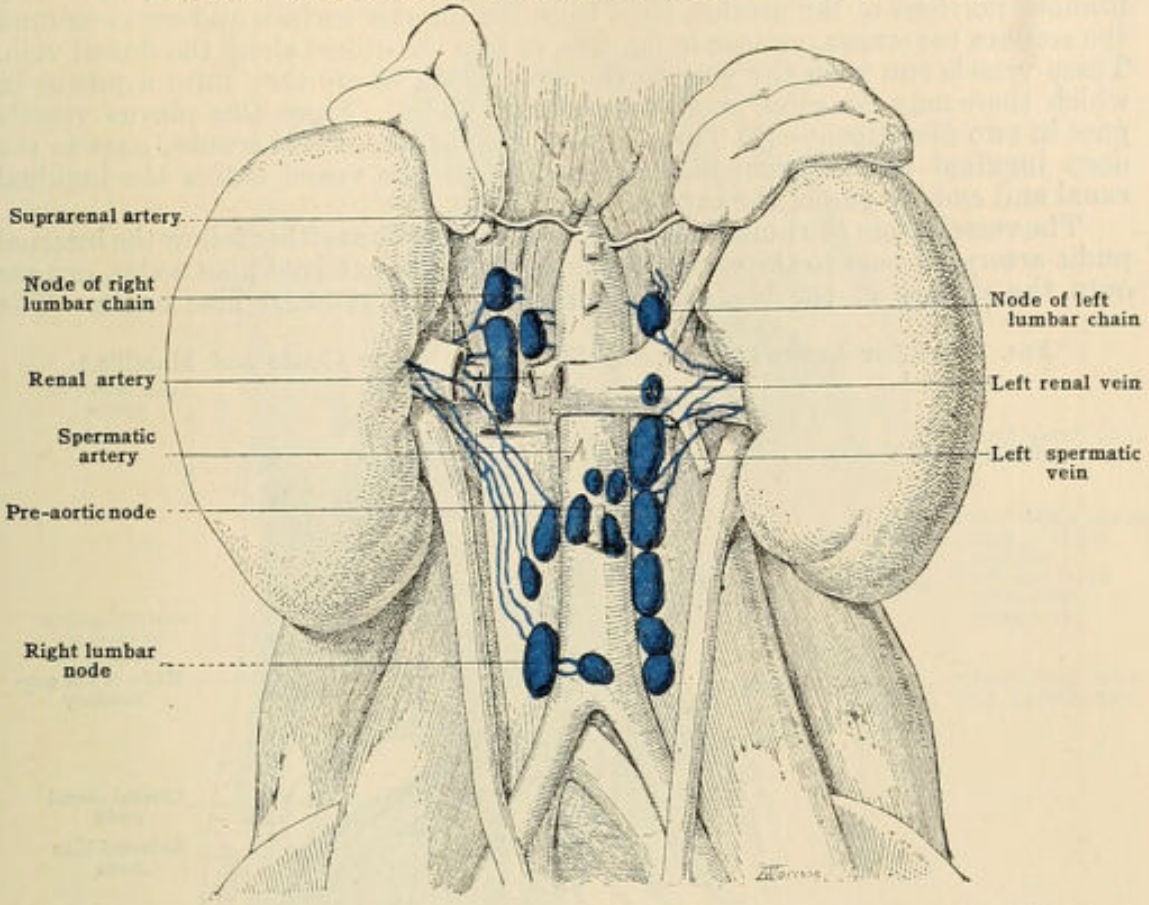

FIG. 584.—LYMPHATICS OF THE BLADDER. (After Cunéo and Marcille.)

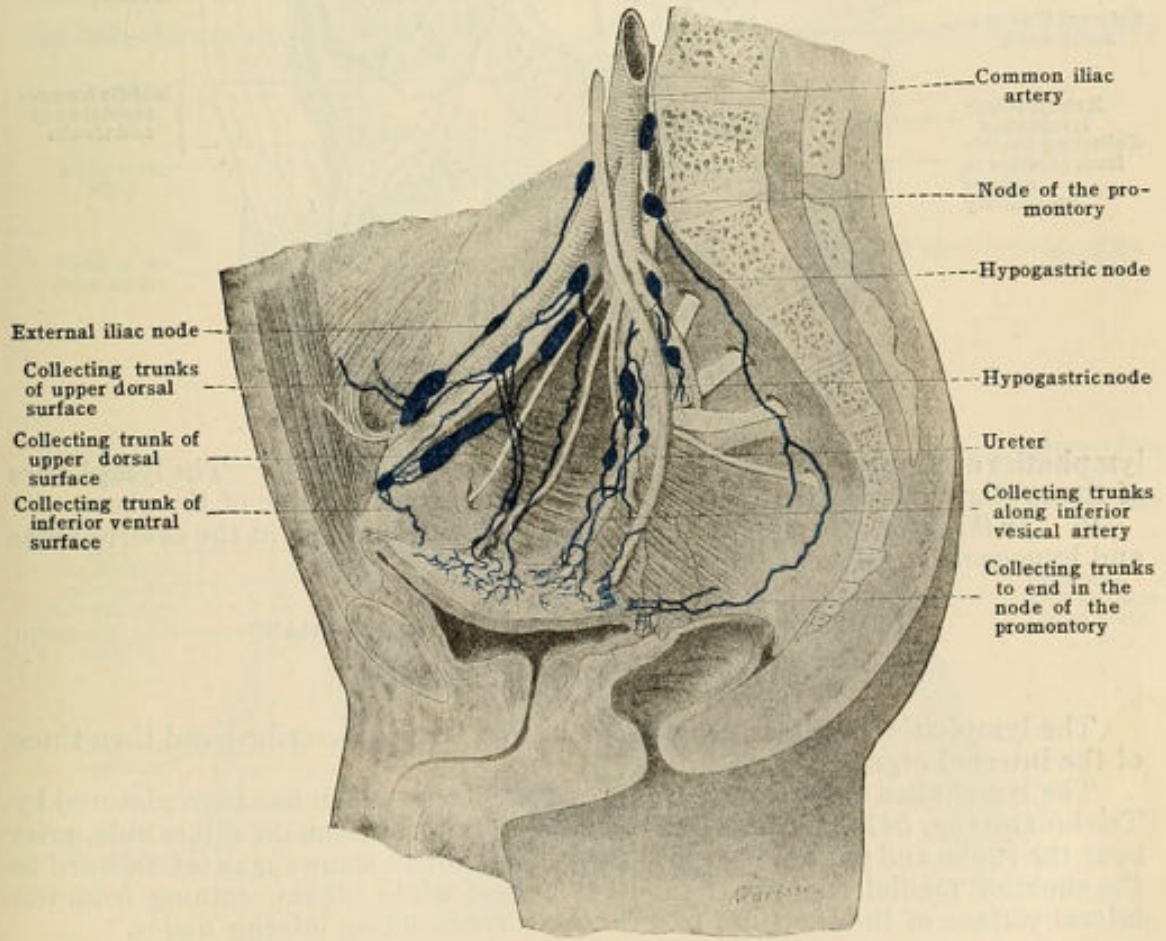

membrane of the glans follow the dorsal vein. Those from the penile and membranous portions of the urethra start from the inferior surface and curve around the corpora cavernosa, as seen in fig. 586, to join the others along the dorsal vein. These vessels run with the vein to the symphysis, where they form a plexus in which there may be some small intercalated nodes. From this plexus vessels pass in two directions:—(1) Three or four vessels, the crural trunks, pass to the deep inguinal and external iliac nodes, and (2) one vessel enters the inguinal canal and ends in one of the external iliac nodes.

The vessels from the bulbar and membranous portions either follow the internal pudic artery, or pass to the symphysis and end in the external iliac nodes, or pass onto the surface of the bladder and thence to the external iliac chain. The

FIG. 585.—THE LYMPHATICS OF THE PROSTATE. (After Cunéo and Marcille.)

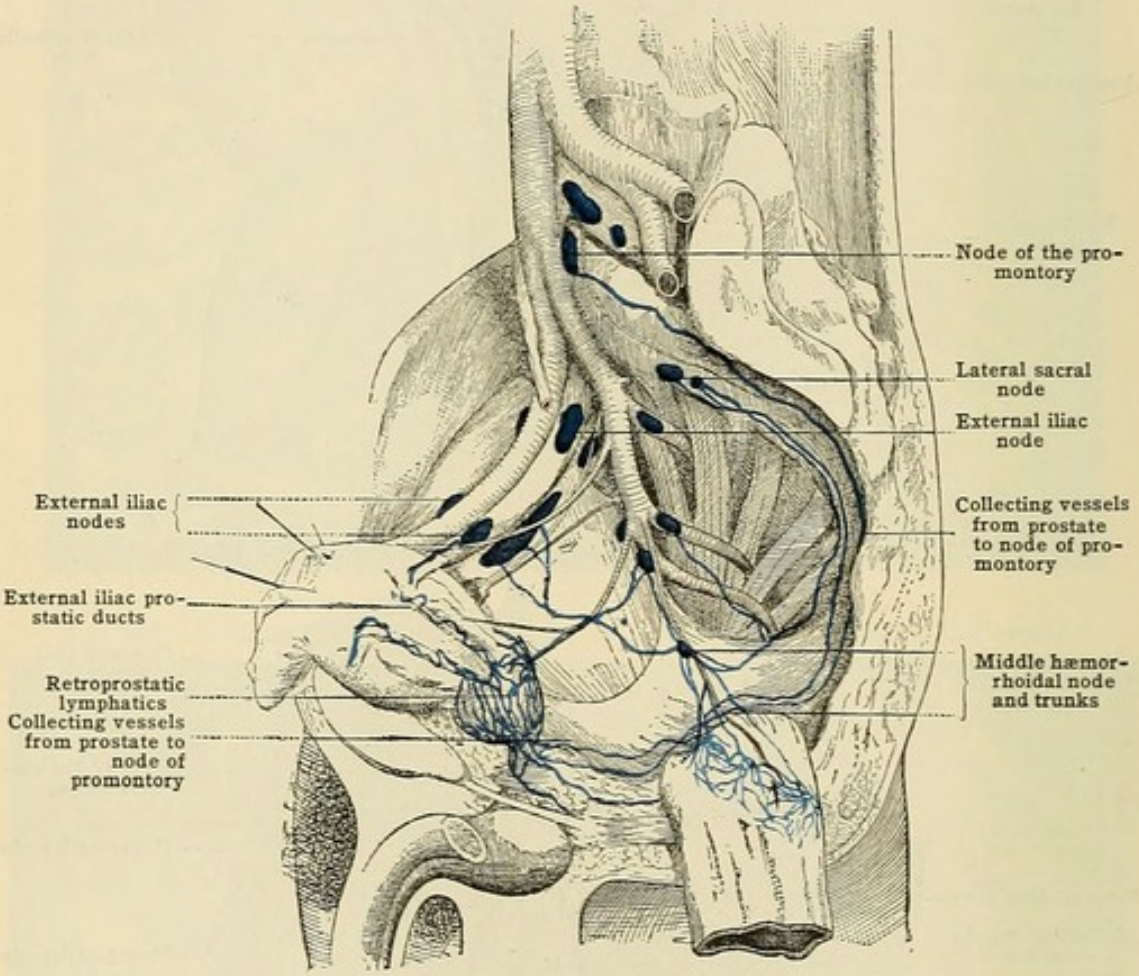

lymphatics of the prostatic portion run with the prostatic ducts. The lymphatics of the urethra anastomose with those of the bladder and those of the glans.

2. *In the female* the lymphatic vessels of the urethra end in the external iliac and hypogastric nodes.

LYMPHATICS OF THE REPRODUCTIVE ORGANS

In the Male (figs. 585, 586, 587)

The lymphatics of the external genitalia will be first described and then those of the internal organs (fig. 589).

The **lymphatics of the scrotum** form a rich plexus which has been pictured by Teichmann (fig. 547). The collecting vessels, ten to fifteen on either side, arise near the raphe and pass to the root of the penis, where some curve lateralward to the superior medial superficial inguinal nodes; while others, coming from the lateral surface of the scrotum, pass to the corresponding inferior nodes.

FIG. 586.—LYMPHATICS OF THE PENILE AND MEMBRANOUS PORTIONS OF THE URETHRA. (After Cunéo and Marcille.)

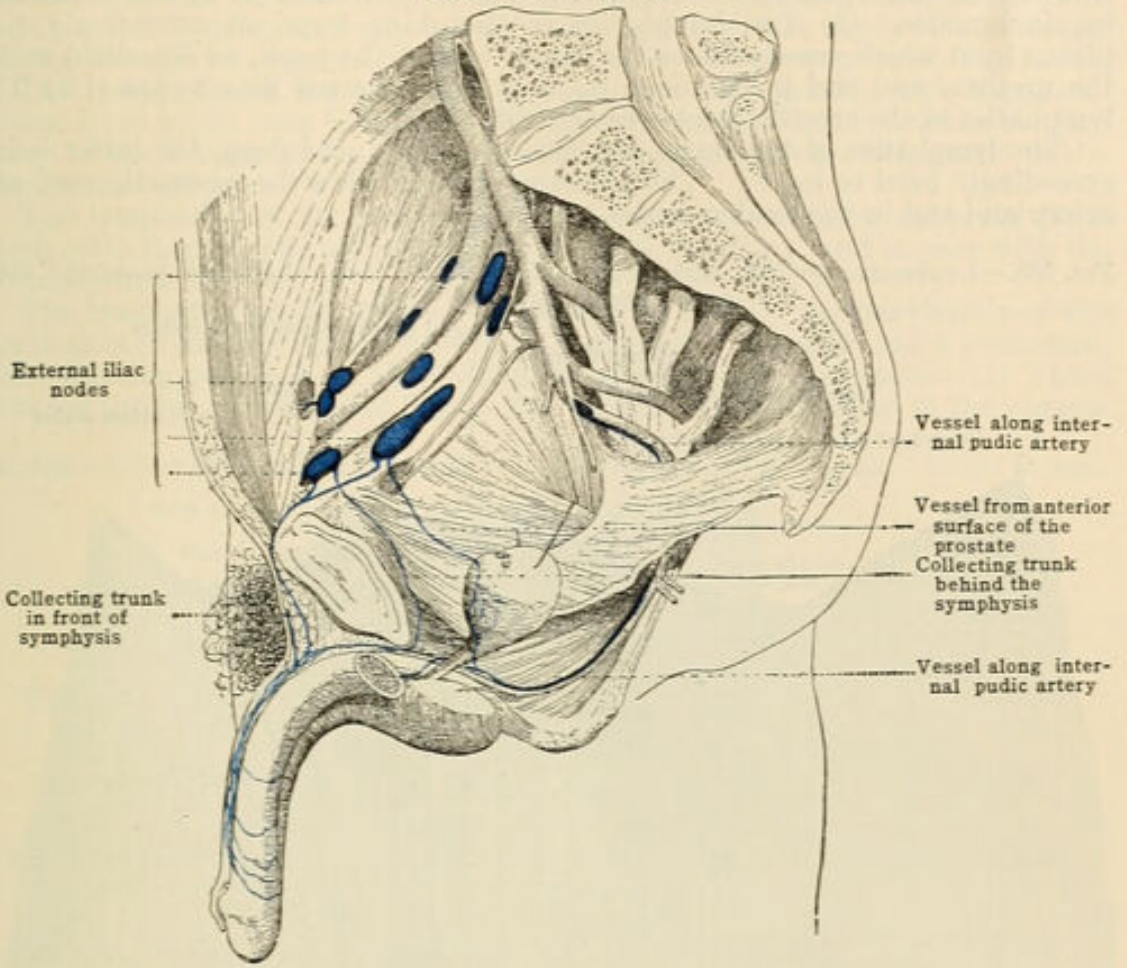

FIG. 587.—LYMPHATICS OF THE GLANS PENIS IN A NEW-BORN CHILD. (Cunéo and Marcille.)

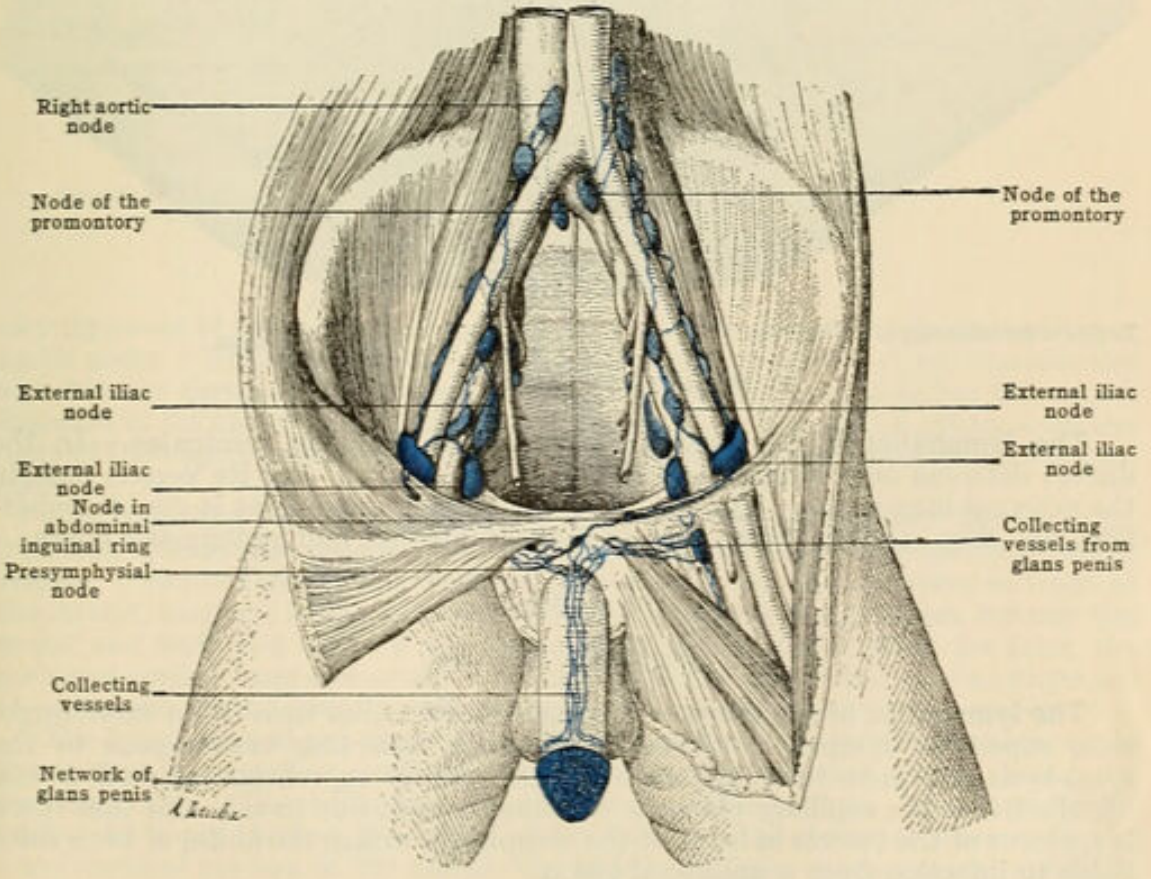

The lymphatics of the penis.—(1) The cutaneous lymphatics form a plexus from which collecting vessels follow the dorsal vein and end in the superficial inguinal nodes. (2) The lymphatics of the glans form an exceedingly rich plexus from which vessels follow the dorsal vein of the penis, as described under the urethra, and end in the deep inguinal and external iliac nodes. (3) The lymphatics of the erectile structures are little known.

The **lymphatics of the testis** are both superficial and deep, the latter being exceedingly hard to inject. The collecting vessels follow the spermatic cord and artery and end in the lumbar nodes.

FIG. 588.—LYMPHATICS OF THE PERINEUM. (After Toldt, "Atlas of Human Anatomy," Rebman, London and New York.)

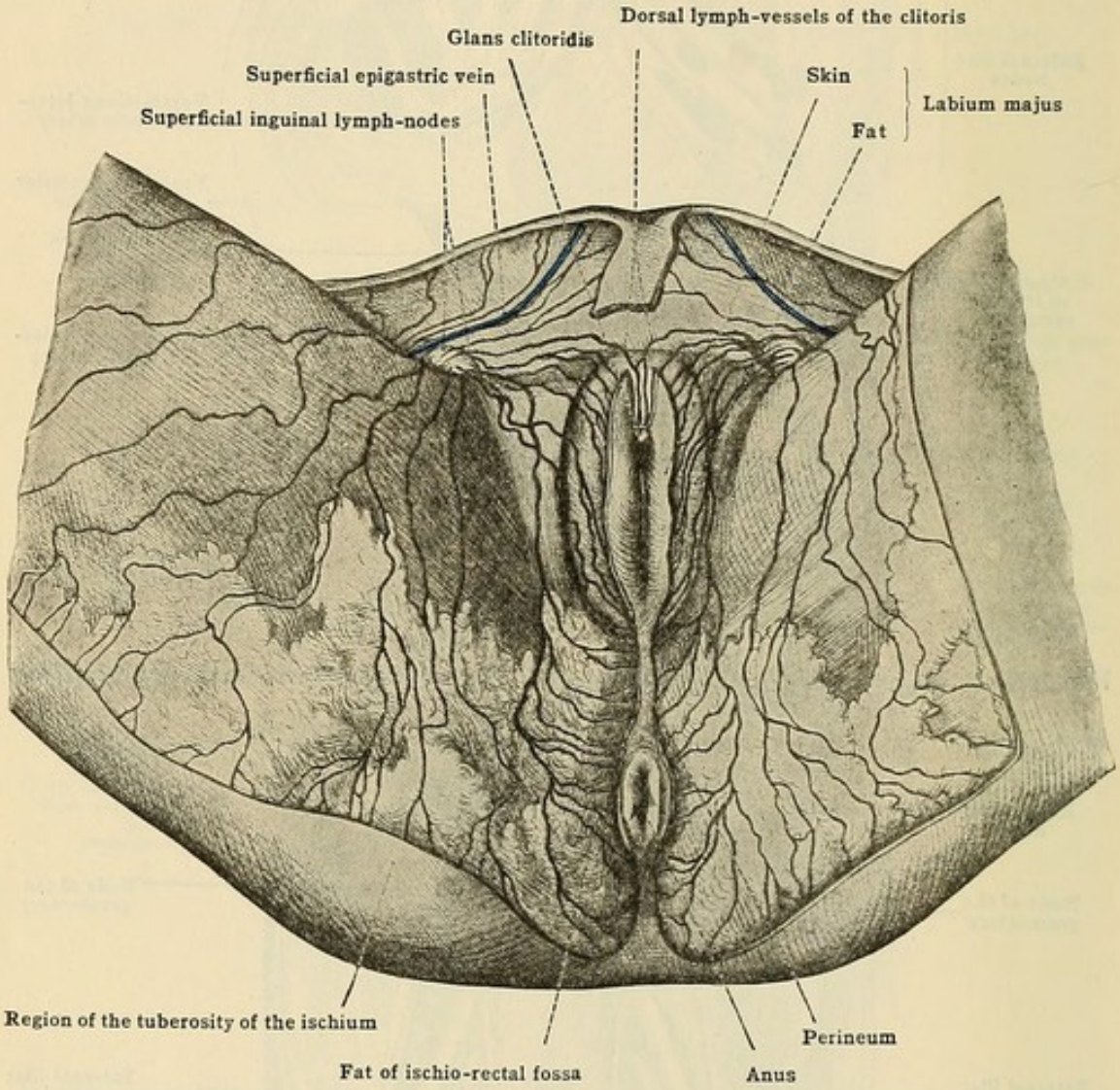

The lymphatics of the ductus deferens and vesiculæ seminales.—In the ductus deferens only a superficial set has been injected, and its vessels pass to the external iliac nodes. The plexus of the vesiculæ seminales is double, superficial and deep, and its vessels pass to the external iliac and hypogastric nodes.

In the Female

(Figs. 588, 589, 590)

The lymphatics of the vulva.—Throughout the vulva there is an exceedingly rich, superficial lymphatic plexus, from which collecting vessels pass to the symphysis and there turn lateralward to the medial superficial inguinal nodes. The fact that the capillary plexus is continuous from side to side and that there is a plexus of the vessels in front of the symphysis, makes the nodes of both sides liable to infection from a unilateral lesion.

The lymphatics of the clitoris.—The lymphatics of the glans of the clitoris form an abundant network from which collecting vessels pass toward the symphysis pubis, and thence principally to the deeper inguinal nodes, one or two, however, passing through the inguinal canal to terminate in the lower external iliac nodes.

The lymphatics of the ovary.—The ovary has a remarkably rich lymphatic plexus, from which from four to six vessels leave the hilus and follow the ovarian artery to the lumbar nodes. One vessel may run in the broad ligament to the internal iliac group.

The **lymphatics of the Fallopian tube** form three capillary networks from which collecting vessels run in part with those of the ovary, and in part with the uterine lymph-vessels.

The lymphatics of the uterus.—According to Poirier, the lymphatics of the uterus arise from three capillary plexuses, a mucous, a muscular, and a peritoneal. The collecting vessels from the *body of the uterus* are in three sets:—(1) Those from the fundus, consisting of four or five vessels, run lateralward in the suspen-

FIG. 589.—LYMPHATICS OF THE INTERNAL GENITAL ORGANS IN THE FEMALE. (After Poirier.

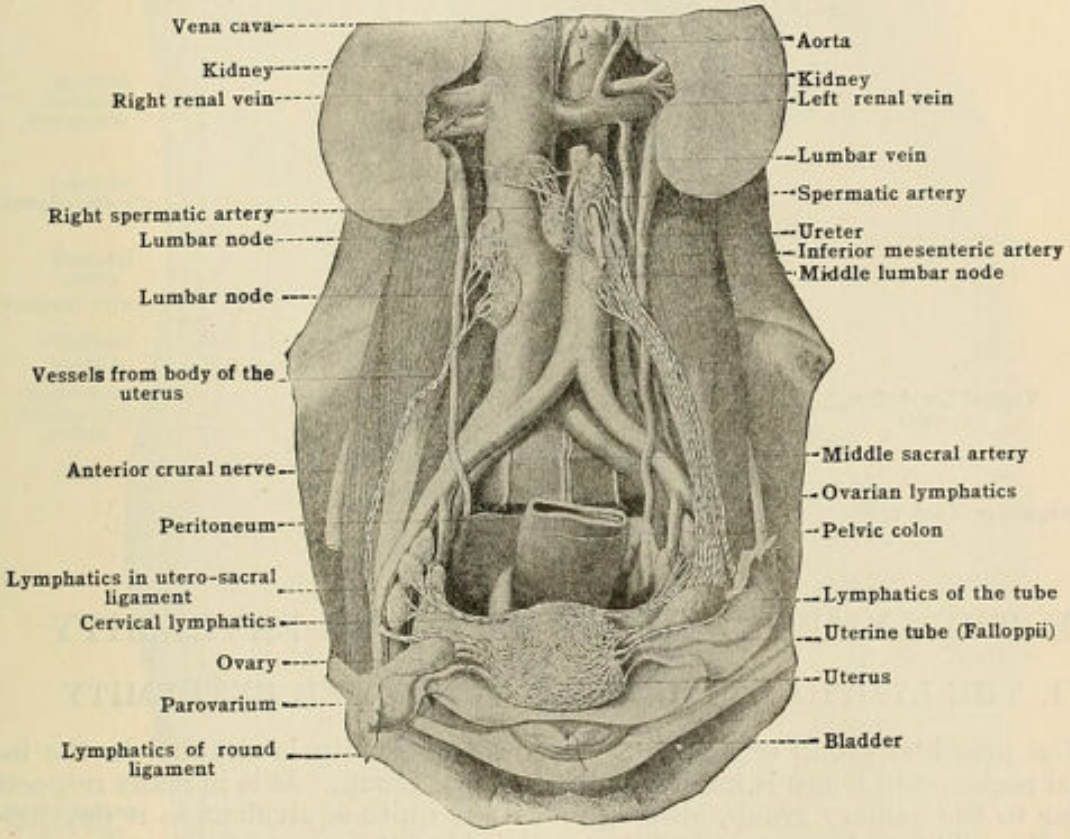

sory ligament of the ovary and follow the ovarian vessels to the lumbar and preaortic nodes. They anastomose with the lymphatics from the ovary opposite the fifth lumbar vertebra; (2) some small vessels from the fundus follow the round ligament of the uterus and terminate in the inguinal nodes; and (3) others from the body of the uterus pass laterally with the uterine vessels and terminate in the iliac nodes.

The collecting vessels from the *cervix*, five to eight in number, form a large lymphatic plexus just after leaving the cervix. From this plexus run three sets of vessels. Two or three vessels pass lateralward with the uterine artery in front of the ureter, and end in the external iliac nodes; a second set passes behind the ureter and ends in a node of the hypogastric group, and a third set from the posterior surface runs downward over the vagina and then backward and upward to end in the lateral sacral nodes and node of the promontory of the sacrum.

The lymphatics of the vagina (fig. 590).—There are two lymphatic plexuses in the vagina, a superficial and deep—the latter, the mucosal plexus, being exceedingly rich. The collecting vessels are in three groups. The superior set drains the upper third of the vagina and takes the same course as those from the lower cervical portion of the uterus; the middle set follows the vaginal artery to

the hypogastric nodes; and the inferior set runs to the lateral sacral nodes and to those of the promontory. The capillary network of the lower part of the vagina is continuous with the plexus of the vulva, which drains to the inguinal nodes.

FIG. 590.—LYMPHATICS OF THE VAGINA. (After Poirier.)

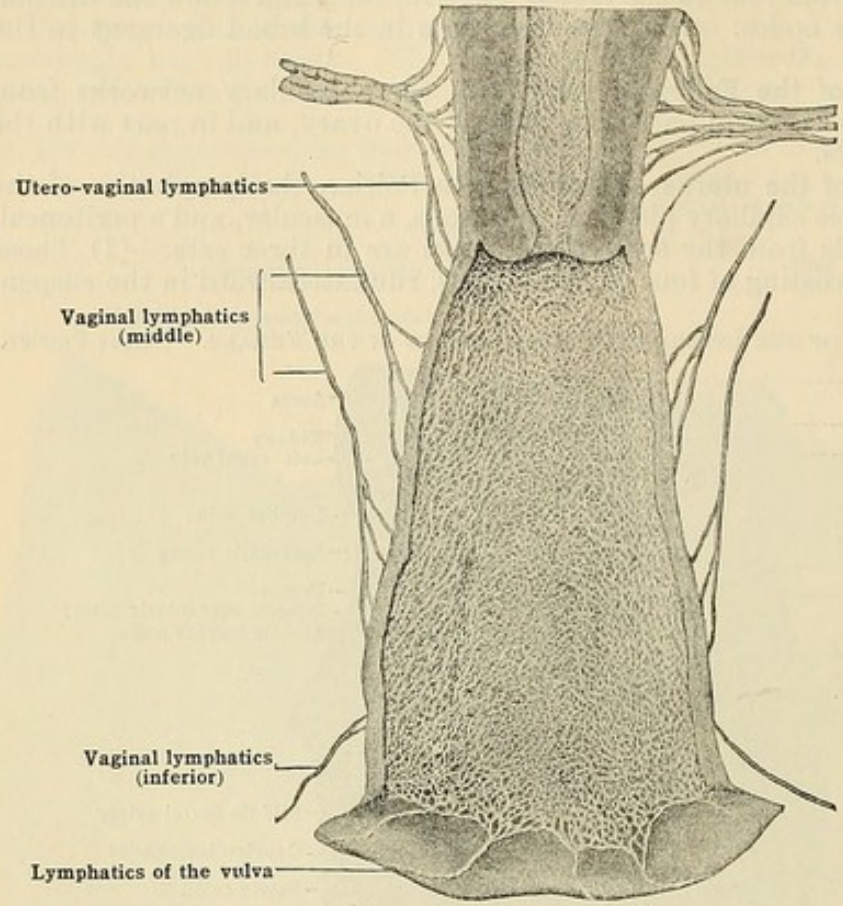

E. THE LYMPHATICS OF THE LOWER EXTREMITY

1. THE LYMPHATIC NODES OF THE LOWER EXTREMITY

The principal group of nodes of the lower extremity is situated in the inguinal region, and hence is known as the **inguinal group.** It is in many respects similar to the axillary group, although it is not quite equivalent to it developmentally. The nodes composing it are divisible into a superficial and a deep group, the former containing many more and larger nodes than the latter. Furthermore, it is convenient to divide each of these groups into an upper and a lower set, the dividing line being an arbitrary line drawn horizontally through the point where the saphenous vein pierces the fascia of the fossa ovalis. The nodes above this line are termed collectively the **inguinal nodes,** while those below it are known as the **subinguinal nodes.**

The superficial inguinal nodes [lgl. inguinales superficiales] (fig. 591), lie along the base of the femoral trigone immediately below Poupart's ligament, superficial to the fascia lata. Their number varies from ten to twenty. They receive the subcutaneous drainage of the abdominal walls, the gluteal region, and the perineal region, and their efferents descend to the fossa ovalis, which they perforate along with the saphenous vein and terminate in the lower external iliac nodes.

The **superficial subinguinal nodes** [lgl. subinguinales superficiales], occupy the lower part of the femoral trigone and receive the entire superficial drainage of the leg, as well as a few vessels from the gluteal region and from the perineum. Their efferents pierce the fossa ovalis and pass partly to the deep subinguinal nodes and partly directly to the lower external iliac nodes.

The deep nodes.—The deep nodes are small, and vary from one to three. They lie medial to the femoral vein, the highest one (node of Cloquet or of Rosenmüller) being placed in the femoral ring and being of especial surgical

FIG. 591.—THE SUPERFICIAL INGUINAL NODES. (After Toldt, "Atlas of Human Anatomy," Rebman, London and New York.)

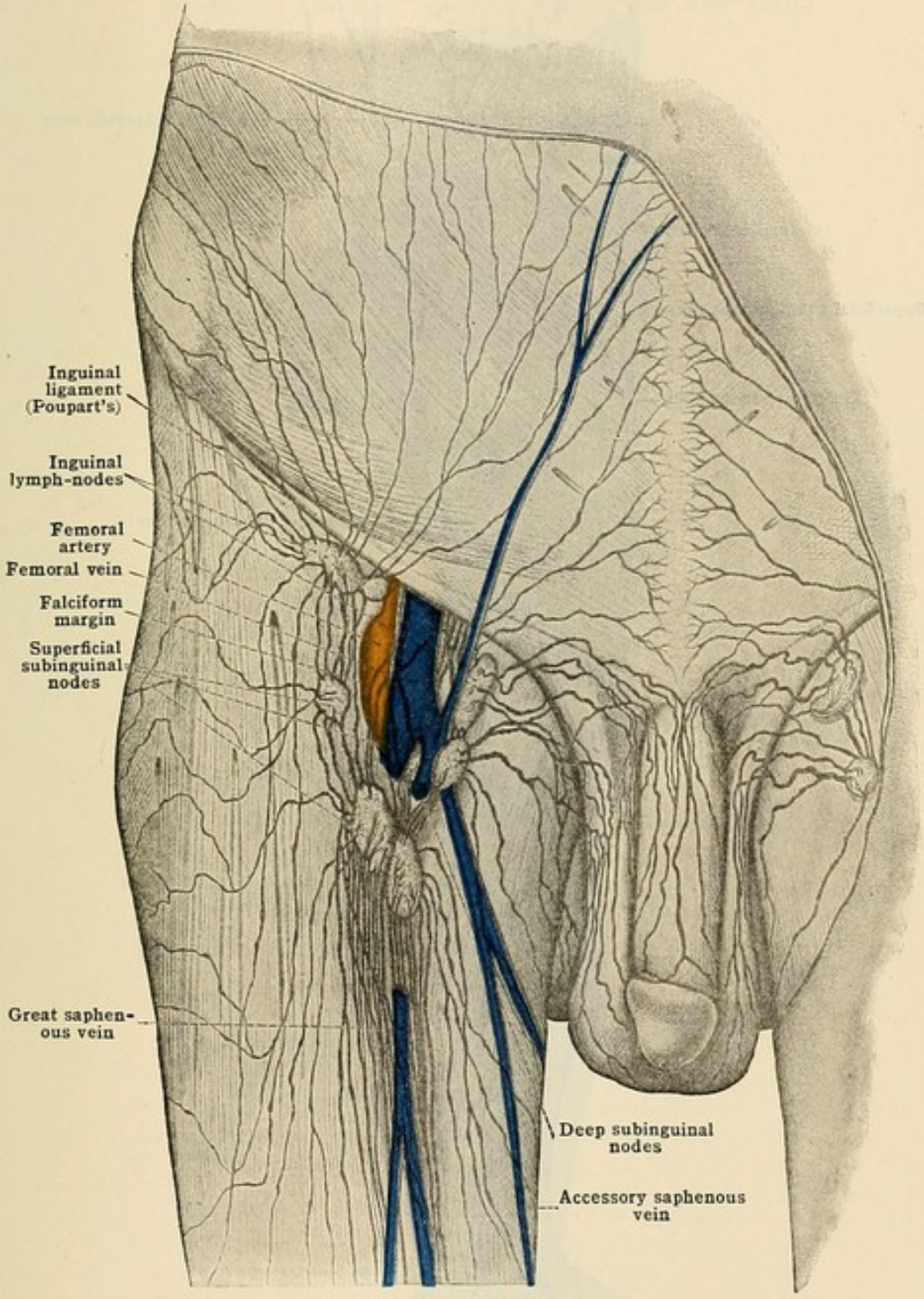

interest in that, when enlarged, it may simulate a strangulated hernia. The lowest node is below the point where the lesser saphenous joins the femoral vein. These deep nodes receive the deep lymphatics of the leg, the vessels from the glans penis in the male, and the clitoris in the female, and some of the vessels from the superficial subinguinal nodes. Their efferent vessels enter the external iliac nodes.

In addition to the inguinal group of nodes there are some other nodes in the lower limb situated along the course of the deep vessels. Thus there is a node in the course of the anterior tibial vessels below the knee, and there is a small

group of **popliteal nodes** [lgl. popliteæ], in the popliteal space, which are in the course of the lesser saphenous vessels, and receive the vessels which accompany the posterior tibial and peroneal vessels and those which drain the knee-joint.

FIG. 592.—THE SUPERFICIAL LYMPHATICS OF THE LOWER EXTREMITY. (After Toldt, "Atlas of Human Anatomy," Rebman, London and New York.)

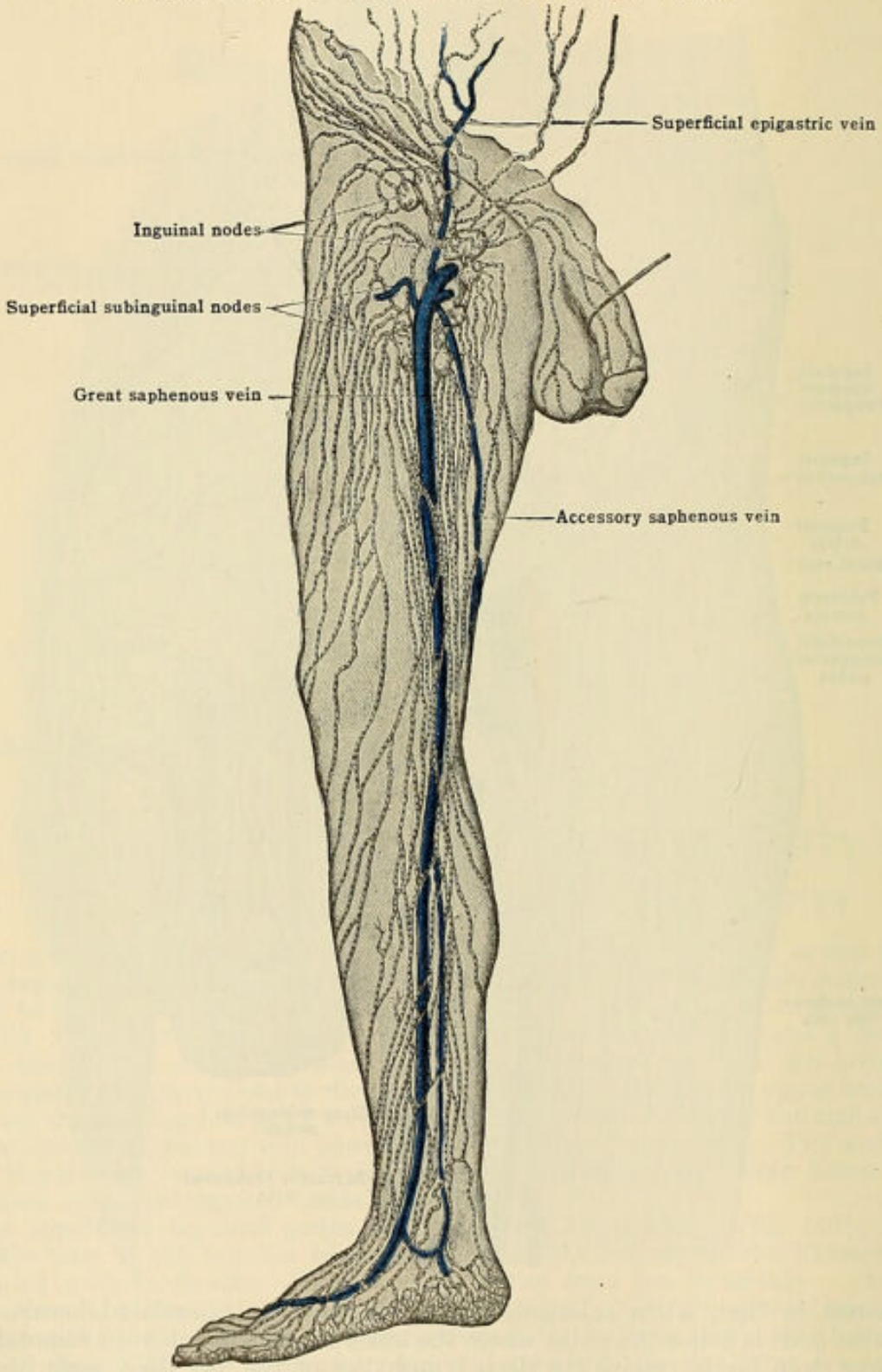

2. THE LYMPHATIC VESSELS OF THE LOWER EXTREMITY

As in the upper extremity, the subcutaneous capillary plexus of the lower varies greatly in complexity, being most abundant in the soles of the feet. The collecting vessels form two main groups. The medial, larger group follows the saphenous vein, and ends in the superficial subinguinal nodes, while the lateral

group curves around to join the medial, partly in the leg and partly in the thigh. Two or three vessels from the heel follow the lesser saphenous vein to the popliteal space. The vessels from the upper and dorsal part of the thigh curve around on both sides to reach the superficial inguinal nodes. The vessels of the anus and

FIG. 593.—THE LYMPHATICS OF THE BACK OF THE LOWER EXTREMITY. (After Toldt, "Atlas of Human Anatomy," Rebman, London and New York.)

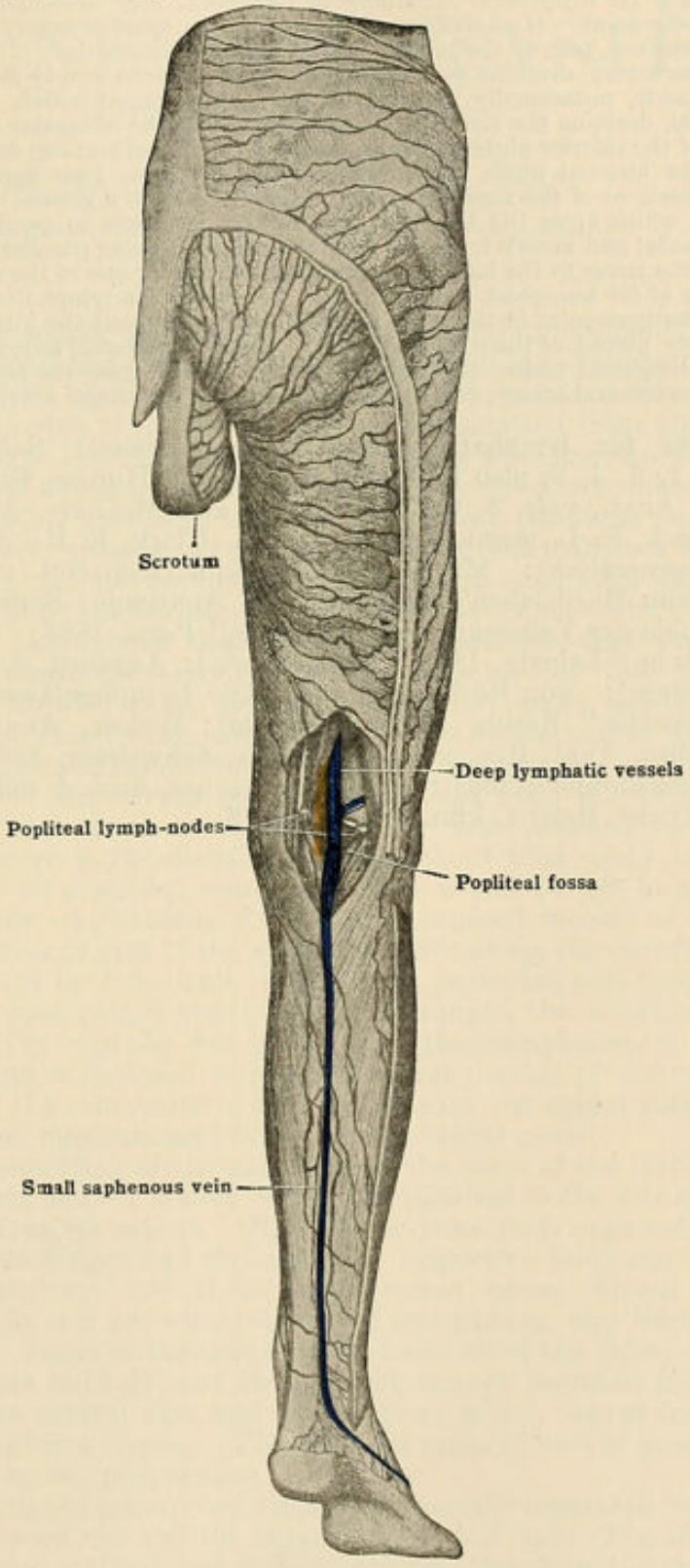

perineum, as well as those from the external genitalia, except from the glans penis or the clitoris, pass to the medial nodes of the superficial inguinal group.

The deep vessels follow the course of the arteries of the leg, those accompanying the dorsalis pedis and anterior tibial arteries coming into relation with the

anterior tibial node, when it is present, and then passing backward to join the vessels which accompany the posterior tibial and peroneal arteries. These terminate in the popliteal nodes, from which efferents follow the course of the femoral artery and terminate in the deep inguinal nodes. The deep lymphatic vessels accompanying the gluteal and obturator arteries pass to the hypogastric nodes.

Lymphatics of the hip-joint.—According to Clermont, they accompany, in the main, the arteries about the joint. (1) Satellites of the anterior circumflex artery, draining almost the entire ventral surface, pass to the lateral inferior external iliac node. (2) Satellites of the posterior circumflex artery, draining the dorsal and medial surfaces, empty into the medial inferior external iliac node, occasionally into one of the deep inguinal nodes. (3) Satellites of the obturator vessel, draining the round ligament, empty into the obturator or hypogastric nodes. (4) Satellites of the inferior gluteal vessels, draining the dorsal surface, empty into three small nodes along the internal pudic and inferior gluteal arteries. Less important ("accessory") vessels are: satellites of the superior gluteal artery leading to a gluteal node; vessels from the dorsal surface which cross the lateral border of the pectineus to reach the medial inferior external iliac node; and vessels from the ventral surface, crossing parallel to the cotyloid notch, passing under the psoas to the lateral inferior external iliac or one of the deep inguinal nodes.

Lymphatics of the knee-joint.—According to Tanasesco the lymphatics draining the structures around the knee-joint in the main follow the arteries about the joint and pass largely to the more deeply placed of the popliteal nodes. Some (superficial) follow the great saphenous vein to the subinguinal nodes, and sometimes deep vessels pass the popliteal nodes and, accompanying the femoral artery, run to the deep inguinal or inferior external iliac.

References for lymphatic system.—(*Development*): Sabin, Amer. Jour. Anat., vols. 1, 3, 4, 9, also in Keibel and Mall's Human Embryology; Lewis, Amer. Jour. Anat., vols. 5, 9; Huntington and McClure, Amer. Jour. Anat., vol. 10; Clark, E. L., Anat. Record, vol. 6; Clark, E. R., Amer. Jour. Anat., vol. 13. (*Regeneration*): Meyer, Johns Hopkins Hosp. Bul., vol. 17. (*General*): Bartels, in von Bardeleben's Handbuch d. Anatomie; Sappey, "Description et Iconographie des Vaisseaux Lymphatiques," Paris, 1885; Teichmann, "Das Saugadersystem," Leipzig, 1861. (*Muscle, etc.*): Aagaard, Anat. Hefte, Bd. 47. (*Connective tissue*): von Recklinghausen, "Die Lymphgefässe u. ihre Beziehung zum Bindegewebe," Berlin, 1862. (*Stomata*): Walter, Anat. Hefte, Bd. 46. (*Lung*): Miller, Anat. Rec., vol. 5. (*Teeth*): Schweitzer, Arch. f. mikr. Anat., Bd. 74. (*Hæmolymph glands*): von Schumacher, Arch. f. mikr. Anat., Bd. 81. *Tumors*): Evans, Beitr.z. klin. Chir., Bd. 78.

SECTION VII

THE NERVOUS SYSTEM

REVISED FOR THE FIFTH EDITION

BY IRVING HARDESTY, A.B., PH.D.

PROFESSOR OF ANATOMY, THE TULANE UNIVERSITY OF LOUISIANA

THE nervous system of man, both anatomically and functionally, is the most highly developed and definitely distributed of all the systems of the body. It consists of an aggregation of peculiarly differentiated tissue-elements, so arranged that through them stimuli may be transmitted from and to all the other tissue systems or functional apparatuses. It is a mechanism with parts so adjusted that stimuli affecting one tissue may be conveyed, controlled, modified, and distributed to other tissues so that the appropriate reactions result. While protoplasm will react without nerves, while muscle will contract without the mediation of nerves, yet the nervous system is of the most vital importance to the higher organisms in that the stimuli required for the functioning of the organs are so distributed throughout their component elements that the necessary harmonious and coordinate activities are produced. For this purpose the nervous system permeates every organ of the body; nerve cell-bodies, accumulated into groups, receive impulses and give rise to the nerves which ramify and divide into smaller and smaller branches till the division attains the individual nerve-fibres of which the nerves are composed, and even the fibres bifurcate repeatedly before their final termination upon their allotted elements. So intimate and extensive is the distribution throughout that could all the other tissues of the body be dissolved away, still there would be left in gossamer its form and proportions—a phantom of the body composed entirely of nerves.

The parent portion or **axis** of the system extends along the dorsal mid-line of the body, surrounded by bone and, in addition, protected and supported by a series of especially constructed membranes or meninges, the outermost of which is the strongest. The cephalic end of the axis, the **encephalon,** is remarkably enlarged in man, and is enclosed within the largest portion of the bony cavity, the cranium, while the remainder of the central axis, the **spinal cord,** continues through the foramen magnum and lies in the vertebral canal.

The intimate connection of the axis with all the parts of the body is attained by means of forty-six pairs of nerves, which are attached to the axis at somewhat regular intervals along its extent. They course from their segments of attachment through the meninges and through their respective foramina in the bony cavity to the periphery. Of these *cranio-spinal nerves*, fifteen pairs pass through the cranium and are attached to the encephalon, and thirty-one pairs to the spinal cord. Some of the cranial nerves and all of the thirty-one pairs of spinal nerves contain both *afferent fibres*, which convey impulses from the peripheral tissues to the central axis, and *efferent fibres*, which convey impulses from the axis to the peripheral tissues. The different pairs of nerves possess the two types of fibres in varying proportions.

Upon approaching the spinal cord, each spinal nerve is separated into two roots —its posterior or *dorsal root* and its anterior or *ventral root*. The afferent fibres enter the axis by way of the dorsal roots, which are, therefore, the sensory roots, and the efferent fibres leave the axis by way of the ventral or motor roots.

As usually studied, the nervous system is referred to in two main **divisions**:—

(1) The *central nervous system*, composed of—(*a*) The spinal cord, or medulla spinalis, and (*b*) the brain or encephalon.

FIG. 594.—SHOWING THE VENTRAL ASPECT OF THE CENTRAL NERVOUS SYSTEM, WITH THE PROXIMAL PORTIONS OF THE CRANIO-SPINAL NERVES ATTACHED AND THE RELATION OF THE PROXIMAL PORTION (GANGLIATED CORD) OF THE SYMPATHETIC NERVOUS SYSTEM. THE ENCEPHALON OR BRAIN IS STRAIGHTENED DORSALWARD FROM ITS MORE HORIZONTAL POSITION WITH REFERENCE TO THE SPINAL CORD. THE SPINAL GANGLIA AND THE DORSAL AND VENTRAL ROOTS OF THE SPINAL NERVES MAY BE NOTED.

(Composite drawing in part after Allen Thompson from Rauber—modified.)

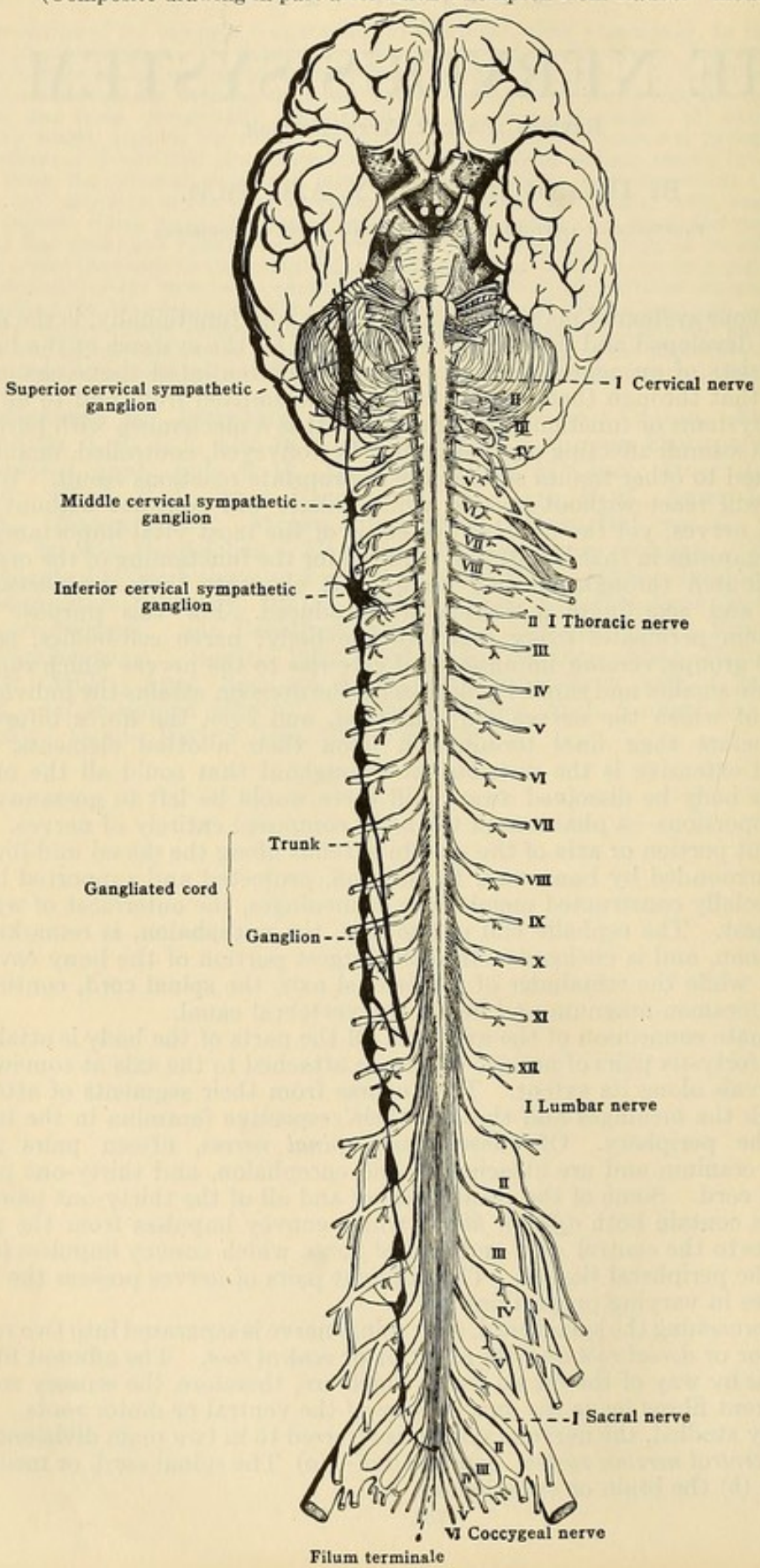

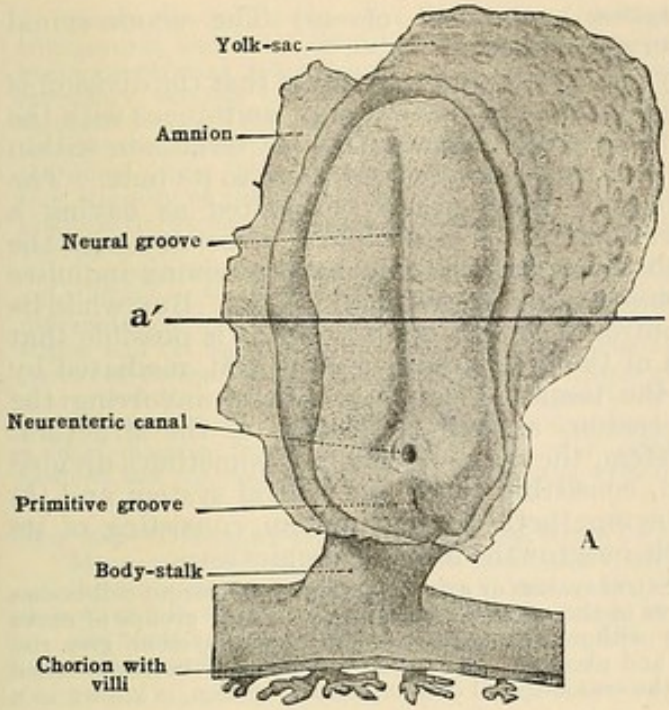
Yolk-sac
Amnion
Neural groove
a′
Neurenteric canal
Primitive groove
Body-stalk
Chorion with villi

A

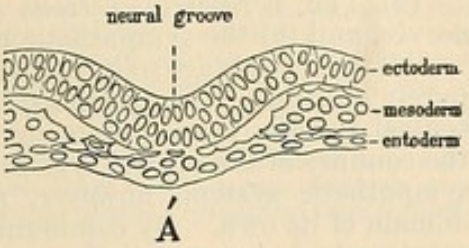
neural groove
ectoderm
mesoderm
entoderm

Á

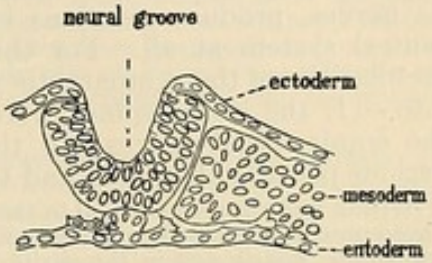
neural groove
ectoderm
mesoderm
entoderm

B′

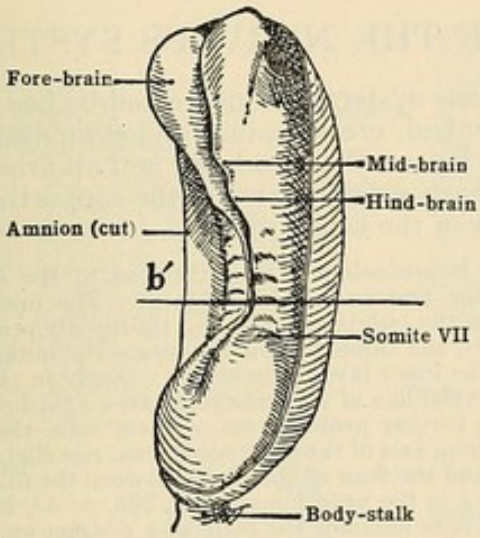
Fore-brain
Mid-brain
Hind-brain
Amnion (cut)
b′
Somite VII
Body-stalk

B

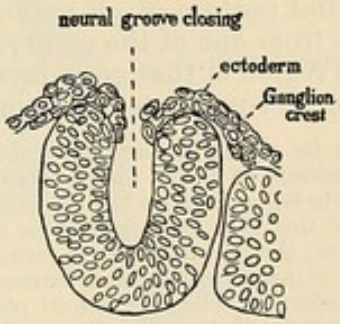
neural groove closing
ectoderm
Ganglion crest

C′

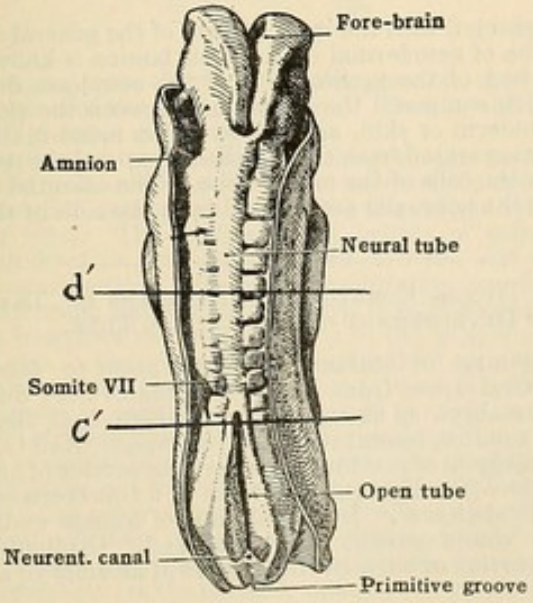
Fore-brain
Amnion
Neural tube
d′
Somite VII
c′
Open tube
Neurent. canal
Primitive groove

D

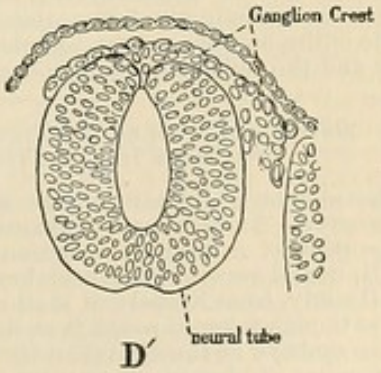
Ganglion Crest
neural tube

D′

(2) The *peripheral nervous system*, composed of—(*a*) The cranio-spinal nerves, and (*b*) the sympathetic nervous system.

All these parts are so intimately connected with each other that the division is purely arbitrary. The cranio-spinal nerves are anatomically continuous with the central system; their component fibres either arise within or terminate within the confines of the central system, and thus actually contribute to its bulk. The sympathetic system, however, may be more nearly considered as having a domain of its own. By communicating rami, it is intimately associated with the cranio-spinal nerves and thus with the central system, both receiving impulses from the central system and transmitting impulses which enter it. But, while its activities are largely under the control of the central system, it is possible that impulses may arise in the domain of the sympathetic system and, mediated by its nerves, produce reactions in the tissues it supplies without involving the central system at all. For this reason, as well as because of the structural peculiarities of the sympathetic system, the nervous system is sometimes divided into—(1) the cranio-spinal system, consisting of (*a*) the central system and (*b*) the cranio-spinal nerves; (2) the sympathetic nervous system, consisting of its various peripheral ganglia and their outgrowths forming its plexuses.

Within and closely proximal to the central system or axis are grouped the parent cell-bodies whose processes comprise the nerve fibres of the cranio-spinal nerves. Other groups of nerve cell-bodies, distributed in the periphery without the bounds of the central system, give rise to the fibres of the sympathetic nerves and plexuses. Any group of such cell-bodies situated in the periphery, whether belonging to the cranio-spinal or sympathetic system, is known as a *ganglion*.

THE DEVELOPMENT OF THE NERVOUS SYSTEM

The essential elements of the nervous system, the nerve cell-bodies and the essential portion of all nerve fibres, central, cranio-spinal and sympathetic, develop from one of the embryonic germ layers, the ectoderm, and all arise from a given region of that germ layer. Further a small portion of the supporting tissue of the nervous system, the neuroglia, is of the same origin.

In its development the nervous system is precocious. It is the first of the functional apparatuses to begin differentiation and is the first to acquire its form. The first trace of the embryo appears on the developing ovum as the *embryonic area*, and the rapidly proliferating cells of this area shortly become arranged into the three germinal layers:—the outer layer or *ectoderm*, the middle layer or *mesoderm*, and the inner layer or *entoderm*. Early in the process of this arrangement there is formed along the axial line of the embryonic area a thickened plate of ectodermal cells, the *neural plate*. In the further proliferation of these cells, the margins of the neural plate, which lie parallel with the long axis of the embryonic area, rise slightly above the general surface, forming the *neural folds*, and the floor of the plate between the folds undergoes a slight invagination, the process resulting in the *neural groove* (fig. 595, A, A^1, B and B^1). As development proceeds and the embryonic area assumes the form of a distinct embryo, the neural folds or lips of the groove gradually converge, and beginning at the oral end, finally unite. Thus the groove is converted into the *neural tube*, extending along the dorsal mid-line and enclosed within the body of the embryo by the now continuous ectoderm above (fig 595, C^1, D and D^1).

For a time the neural tube remains connected with the inner surface of the general ectoderm along the line of fusion by a residual lamina of ectodermal cells. This lamina is known as the *ganglion crest* (neural crest). It is a product of the proliferation of the ectoderm during the process of fusion, consists of the cells which composed the transition between the closing lips of the original groove and the general ectoderm or skin, and whose fusion aided in the closure of the tube. The ectoderm soon becomes separated from the ganglion crest and the cells of the crest become distinctly differentiated from the cells of the neural tube. The essential elements of the entire nervous system together with the neuroglia are derived from the cells of the neural tube and the cells of the ganglion crest.

FIG. 595.—DORSAL SURFACE VIEWS OF HUMAN EMBRYOS AND DIAGRAMS OF TRANSVERSE SECTIONS ILLUSTRATING THE DEVELOPMENT OF THE NEURAL TUBE.

A, dorsal view of human embryo at beginning of infolding of neural plate to form neural groove. Amnion partly removed. (Graf Spee, from Keibel and Mall.) A^1, diagram of portion of a transverse section of an embryo as though taken through A at the line a^1. B, dorsal view of human embryo of 7 somites, neural tube not yet closed, Mall Collection. (Dandy, from Keibel and Mall.) B^1, diagram of portion of a transverse section of an embryo as though taken through B at the line b^1. C^1, diagram of portion of a transverse section of an embryo as though taken through D at line c^1. D, dorsal view of human embryo of 8 somites, 2.11 m.m. long, neural tube closed except at caudal end. (Kollmann, from Keibel and Mall.) D^1, diagram of a portion of a transverse section of an embryo as though taken through D at line d^1.

Before the caudal extremity of the tube is entirely closed, its oral end undergoes marked enlargement and becomes distended into three vesicular dilations, the anterior, middle, and posterior primary *brain vesicles*. The anterior of these primary vesicles give off a series of secondary vesicles and by these, followed by further dilations, flexures of its axis, and by means of localized thickenings of its walls, the portion of the tube included in the three primary vesicles develops into the encephalon or brain of the adult. The remainder of the tube becomes the spinal cord. This latter portion retains the simpler form. By the proliferation and migration laterally of the cells lining this portion of the tube, there results a comparatively even bilateral thickening of its walls so that the mature spinal cord retains a cylindrical form throughout its length.

The proliferating and migrating cells of the wall of the neural tube are known as *germinal cells*. The products of their division are apparently indifferent at first, but later they become differentiated into two varieties: (1) *spongioblasts*, or those cells which will develop into neuroglia, and (2) *neuroblasts*, or those which will increase in size, develop processes and become nerve cell-bodies. As described below, the processes given off by a neuroblast are of two general characters: (1) a long process or axone which goes to form nerves, nerve roots, and nerve fasciculi, and (2) dendritic processes which are numerous, branch much more frequently and extend but a short distance from the cell-body. An adult cell-body with all its processes is known as a *neurone* and the neuroblasts of the developing system become transformed into the neurones

FIG. 596.—DIAGRAMS OF TRANSVERSE SECTIONS OF EMBRYONIC SPINAL CORDS SHOWING THE MIGRATION OF THE CELLS OF THE GANGLION CREST TO FORM THE SPINAL AND SYMPATHETIC GANGLIA AND THE ORIGIN OF THE DORSAL AND VENTRAL ROOTS OF THE SPINAL NERVES. A, a stage following D^1 of fig. 595. B, a later stage in which the ganglia and the components of the nerve are assuming their form resulting from the further migration and from processes being given off by the neuroblasts.

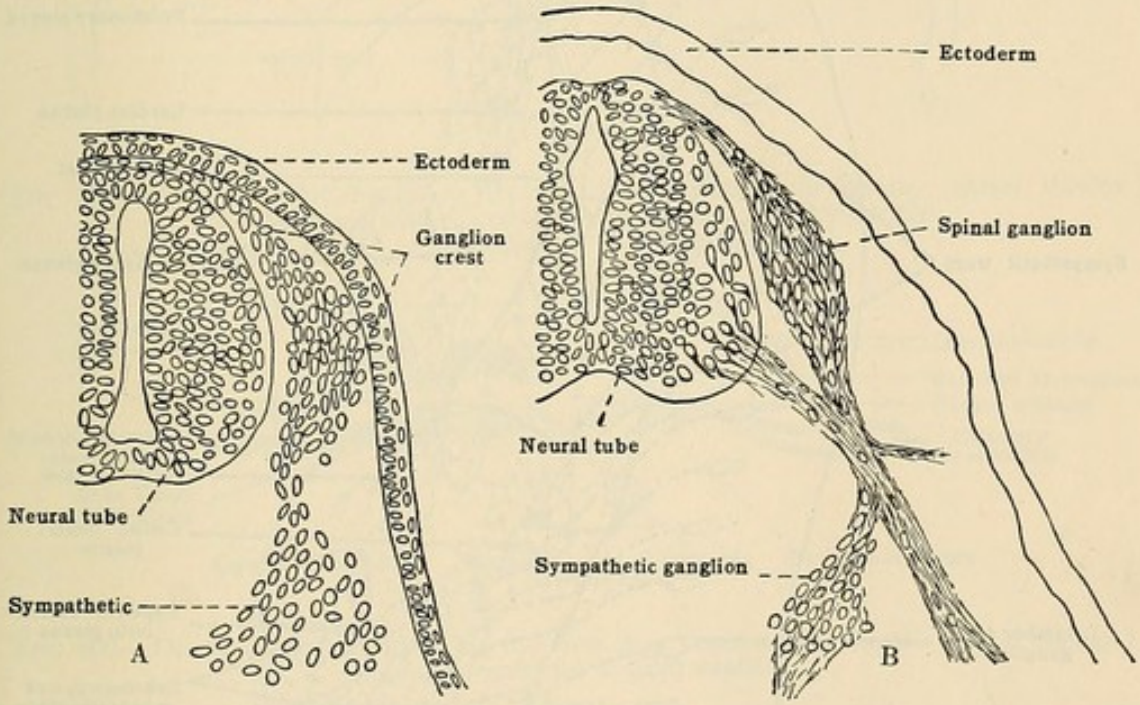

of the varying sizes, shapes, and arrangements of processes characteristic of different divisions and localities of the nervous system. Usually the first process to be noted is that which will become the axone or nerve fibre.

Neurones whose cell-bodies belong to the peripheral nervous system are not developed within the walls of the neural tube or central nervous system at all. These, comprising the spinal ganglion neurones and those of the sympathetic system, are derived from the cells of the ganglion crest. The wedge-shaped lamina of cells, comprising the ganglion crest, through rapid cell division, gradually extends outward and ventralward over the surface of the neural tube along either side. Soon the proliferation becomes most active in regions corresponding to the mesodermic somites or primitive body segments and this, together with the stress of the growing length of the body, results in the ganglion crest (originally a lamina) becoming segmented also. The segments or localised cell masses thus formed are the beginning not only of the spinal ganglia, but also of the ganglia of the entire sympathetic system. The cells of the crest migrate to assume a more lateral position, and then occurs a separation of their ranks. A portion of them remain in a dorsolateral position near the wall of the neural tube and develop into the neurones of the *spinal ganglia* (the sensory neurones of the spinal nerves), but others wander further out into the periphery and become the neurones of the sympathetic. Certain of those of this more nomadic group of cells settle within the vicinity of the vertebral column and by sending out their processes, form the *gangliated cord* or the proximal chain of sympathetic ganglia; others migrate further, but in more broken rank, and become the ganglia of the *prevertebral plexuses* (as the cardiac, cœliac and hypogastric plexuses), or the scattered intermediate chain of ganglia; while still others wander into the very walls of the peripheral organs and

FIG. 597.—DIAGRAM SHOWING THE CHIEF PATHS OF MIGRATION OF THE CELLS FROM THE GANGLIA OF THE SPINAL AND CRANIAL NERVES TO FORM THE ADULT SYMPATHETIC SYSTEM (AFTER SCHWALBE, MODIFIED.)

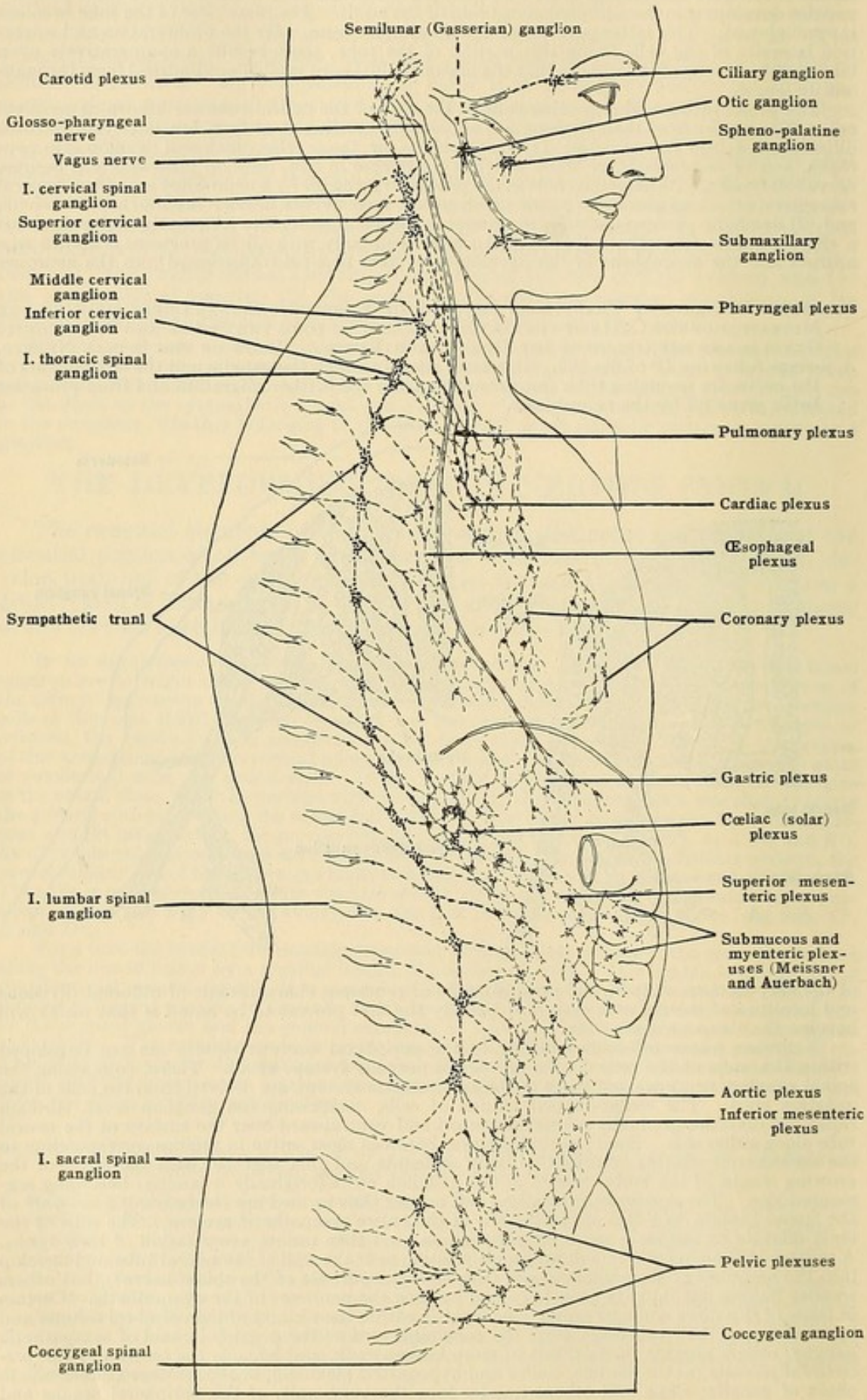

occur singly or in groups in such plexuses as those of Auerbach and Meissner, within the tunics of the walls of the alimentary canal. Scattered along between these proximal, intermediate, and distal groups there are to be found small straggling ganglia, many of which contain so few cell-bodies that they are indistinguishable with the unaided eye. All these sympathetic neurones, however, are always either directly or indirectly anatomically associated with and

FIG. 598.—DIAGRAMS OF ORAL PORTION OF HUMAN NEURAL TUBE SHOWING THE THREE PRIMARY BRAIN VESICLES AND SOME OF THE SECONDARY VESICLES DERIVED FROM THEM. A, diagram of dorsal view of early stage. B, lateral view at about the third week. C, lateral view at about the eighth week. After His, modified. m, mamillary vesicle; i, infundibular recess; o, olfactory vesicle.

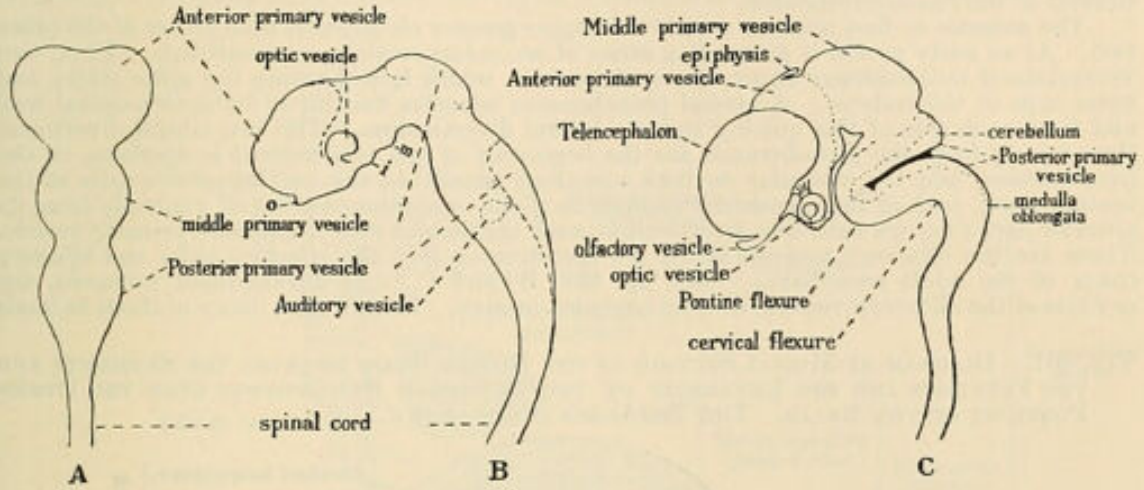

FIG. 599.—DIAGRAMMATIC SAGITTAL SECTION OF A VERTEBRATE BRAIN. (After Huxley.) 4, fourth ventricle; *s*, cerebral aqueduct; 3, third ventricle.

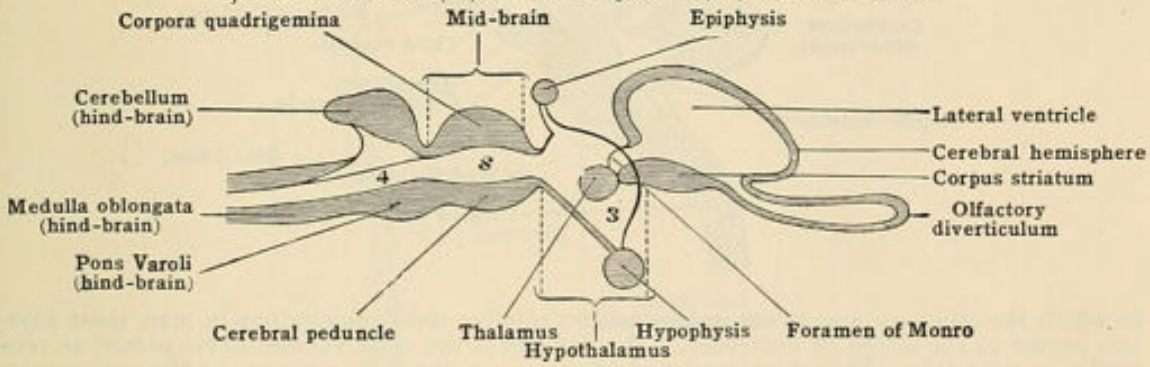

FIG. 600.—DIAGRAMMATIC HORIZONTAL SECTION OF A VERTEBRATE BRAIN. (Afte Huxley.) 4, fourth ventricle; 3, third ventricle.

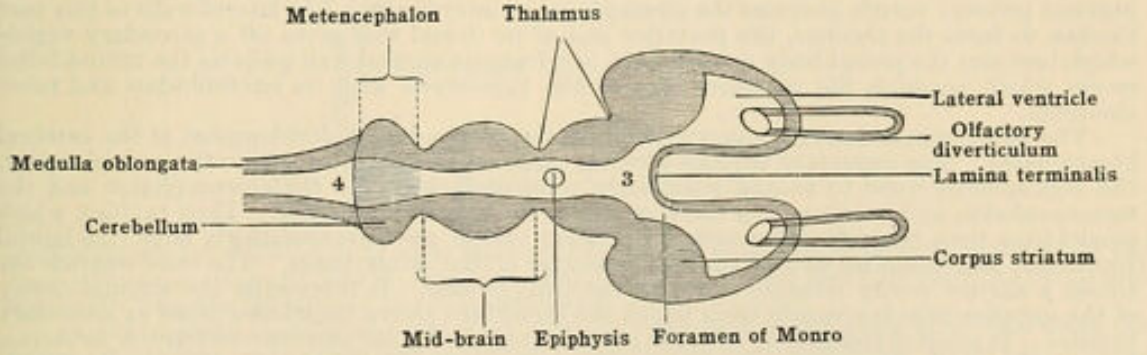

largely under the control of the neurones of the central system through central *visceral efferent fibres* passing to them by way of the rami communicantes or by way of the peripheral distribution of the spinal nerves.

The ganglia of the sensory portions of all those cranial nerves attached to the inferior of the main divisions of the brain and all the sympathetic ganglia of the head have an origin similar to that of the spinal and sympathetic ganglia in the remainder of the body.

The behavior of the walls of the three primary vesicles, into which the oral end of the neural tube is converted, is much more complex than in case of the spinal cord. Their walls do not

thicken uniformly and, to give rise to the form of the adult brain, the anterior and the posterior of the three vesicles give off secondary vesicles.

The walls of the posterior primary vesicle give rise to the posterior of the main divisions of the brain, the hind brain or *rhombencephalon*, the cerebellum developing from the anterior portion only of its dorsal wall, and the medulla oblongata and pons from its ventral wall. Its cavity persists and enlarges into the fourth ventricle of the adult, while the posterior portion of its dorsal wall does not develop functional nervous tissue at all but persists as a thin membrane known as the *chorioid tela of the fourth ventricle*. The cells which form the ganglia of the auditory and vestibular nerves arise from the dorsolateral regions of this vesicle.

From the middle primary vesicle comes the mid-brain or *mesencephalon*, the corprora quadrigemina [colliculi] developing from its entire dorsal wall and the cerebral peduncles occupying its ventral wall. The constriction between the middle and posterior vesicles becomes the *isthmus* of the rhombencephalon.

The anterior or first primary vesicle undergoes greater elaboration than either of the other two. At an early period it gives off a series of secondary vesicles or diverticula. First, two ventrolateral outpouchings occur, the *optic vesicles*, which later become the optic stalks and optic cups of the embryo. A medial protuberance becomes evident in its antero-dorsal wall and from each side of this quickly starts a lateral diverticulum. The two lateral diverticula thus arising from the protuberance are the beginning of the two *cerebral hemispheres* or the *telencephalon*, and the vesicular cavities contained persist as the two *lateral ventricles* of the brain. Soon, each of these vesicular rudiments of the hemispheres gives off ventrally from its anterior part a narrow tube-like diverticulum, each continuous into the parent primary vesicle. These are the olfactory vesicles which are transformed into the *olfactory bulbs* and *olfactory tracts* of the adult encephalon. (See fig. 598, B. and C.) As development proceeds, the cavities of the olfactory vesicles become occluded in man. However, in many of those animals

FIG. 601.—DIAGRAM OF MESIAL SECTION OF THE HUMAN BRAIN SHOWING THE SEGMENTS AND THE FLEXURES AND THE EXPANSION OF THE CEREBRAL HEMISPHERES OVER THE OTHER PORTIONS OF THE BRAIN. THE THALAMUS IS NOT SHOWN.

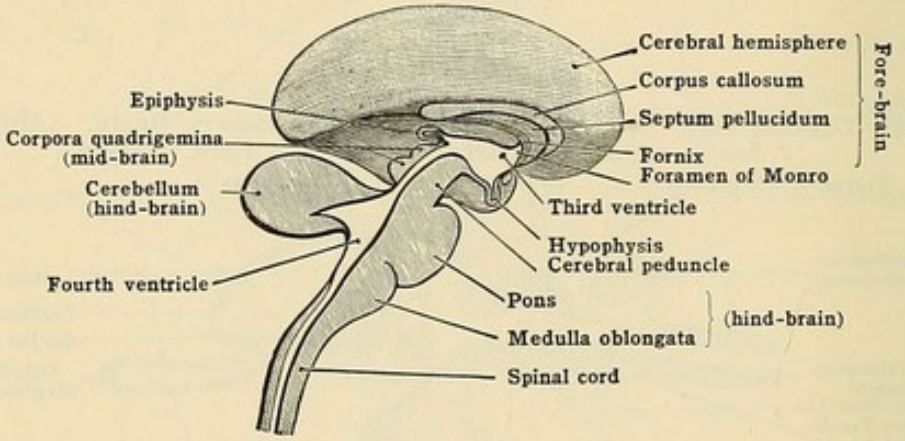

in which the olfactory apparatus attains greater relative development than in man, these cavities persist as the olfactory ventricles. The cavities of the optic vesicles never persist as ventricles in the adult. They form stalks which represent the future courses of the *optic nerves*, while from their extremities are developed the retinæ, portions of the ciliary bodies and portions of the iris of the ocular bulbs.

In addition to that which forms the cerebral hemispheres, the remaining portion of the anterior primary vesicle becomes the *diencephalon* or inter-brain. The lateral walls of this part thicken to form the *thalami*, the posterior end of its dorsal wall gives off a secondary vesicle which becomes the pineal body or *epiphysis*, and from its ventral wall projects the infundibular recess which becomes the posterior lobe of the *hypophysis* with its infundibulum and tuber cinereum.

The adult human brain is characterised by the preponderant development of the cerebral hemispheres. The secondary vesicles forming these expand till, held within the cranial cavity, the hemispheres come to extend posteriorly completely over the thalamencephalon and the mesencephalon and even overlap the cerebellum to its posterior border. Their cavities, which persist from their origin from the anterior primary vesicle, are correspondingly large (the lateral ventricles) and comprise two of the *four ventricles* of the adult brain. The *third ventricle* becomes a narrow cavity situated between the two thalami. It represents the original cavity of the anterior primary vesicle from which the structures above mentioned arose as secondary vesicles. It remains continuous with the lateral ventricles by the two *inter-ventricular foramina*, known also as the *foramina* of *monro*, one into each cerebral hemisphere. The *fourth ventricle* of the adult represents the cavity of the posterior primary vesicle and comes to lie between the cerebellum and medulla oblongata, since the cerebellum likewise extends posteriorly from its region of origin. The cavity of the middle primary vesicle becomes the *cerebral aqueduct*, or aqueduct of Sylvius, passing under the corpora quadrigemina and connecting the fourth or posterior ventricle with the third.

Development of the nerve fibres.—All axones begin as outgrowths or processes of the cytoplasm of neuroblasts. Most of such processes are sent out at a very early stage in the development of the nervous system and extend to the tissues they are to innervate when these tissues are as yet quite near the neural tube. Then, as the structures of the body elaborate and assume

their final forms and positions more remote from the central nervous system, the axones terminating in them must necessarily grow and be drawn out with the structures. At need, later axones are sent out by neurones developing later to supply the growth demands. Such axones follow the general paths made by those already extending to the tissues requiring them. Being processes of the cytoplasm of the cell-body, the growth and life of all axones (and dendrites) is under the control of the nucleus in the cell-body. They grow by absorbing nourishment, or having added to them substances, from the tissue stroma through which they pass, which stroma may be either ectodermal or mesodermal in origin.

The great majority of axones in the central nervous sytem and all in the peripheral system have sheaths about them. The sheath is an acquired structure and is not added till a relatively late period of development. These sheaths are of two general varieties, sheaths con-

FIG. 602.—DIAGRAM ILLUSTRATING THE GROSS DIVISIONS OF THE CENTRAL NERVOUS SYSTEM.

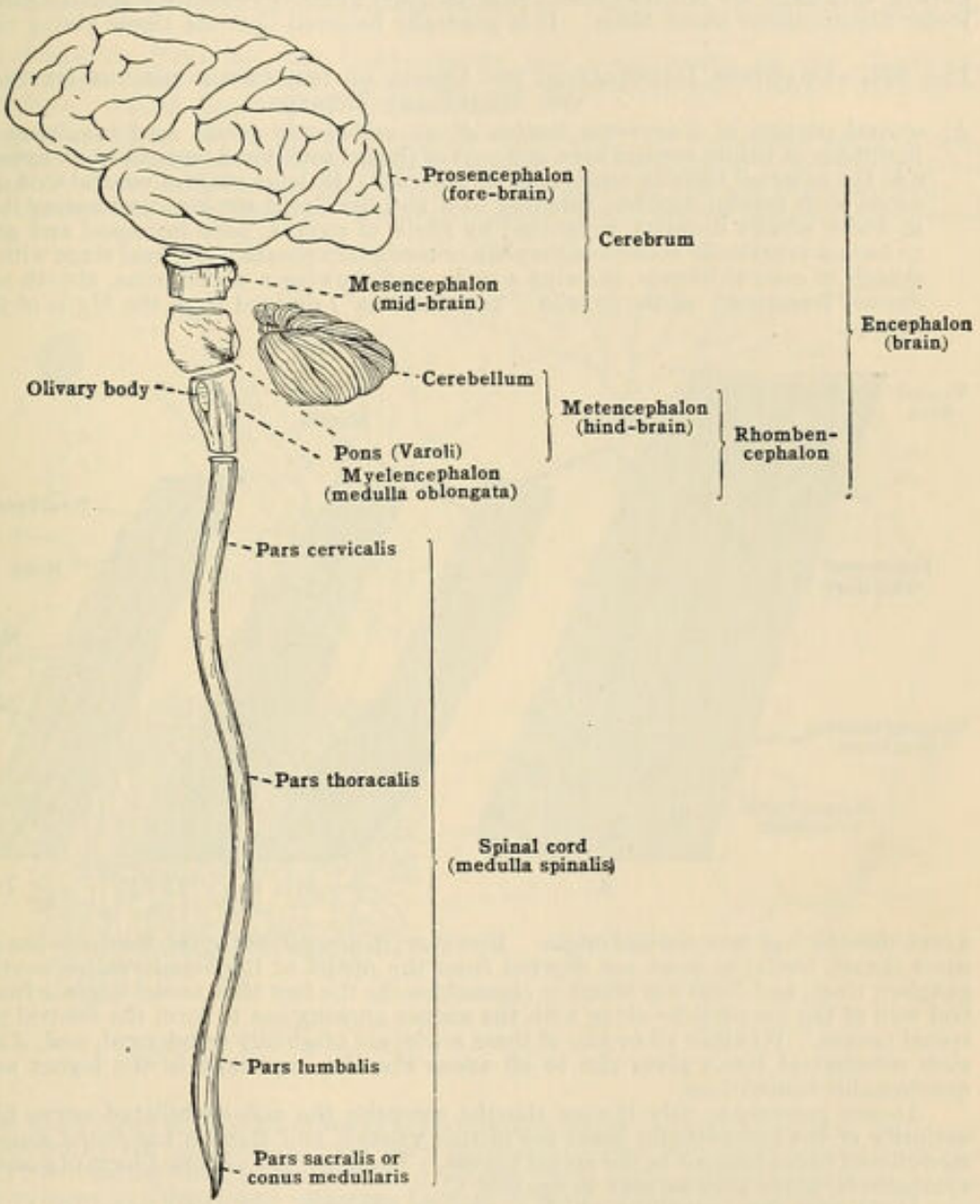

sisting merely of a fibrous coat with the nuclei belonging to it, and sheaths in which there has been added a coating of fat or myelin, *medullary sheaths*. A *nerve fibre* consists of an axone and its sheath whether medullated or non-medullated.

In the embryo, axones are given off from the developing neurones at a time when the entire ectodermic neural tube and embryonic ganglia and the mesodermic tissue surrounding them are each void of definite cell boundaries, each being a continuous mass of nucleated protoplasm, a *syncytium*. From these syncytia are developed the fibrous connective tissues of the later framework supporting the nervous system. Of this, the fibrous tissue, *neuroglia*, is derived from the ectodermal syncytium, while the white and elastic fibrous tissues are derived from the mesodermal or mesenchymal syncytium. Before any connective tissue fibrils are developed in either syncytium, before and at the time of the ingrowth of blood-vessels into the developing ganglia and the neural tube from the mesenchyme about them, there occurs an invasion of the mesenchymal syncytium into the ectodermal syncytium. This invasion occurs both as independent ingrowths and fusions at the periphery of the neural tube and by

the mesenchymal tissue being carried in by the ingrowing blood-vessels. After the mixture of the nuclei resulting from this fusion of the syncytia from the two sources, nuclei of mesodermal origin cannot be distinguished from those of ectodermal origin. Further, axones outgrowing from the embryonic ganglia and neural tube carry with them adhering portions of the ectodermal syncytium into the surrounding mesenchymal (fig. 603).

As development proceeds further, each syncytium becomes resolved into a reticulum of granular endoplasmic processes, containing the nuclei, with transparent exoplasm occupying its meshes. Fibrils soon form in the exoplasm and from these develop the connective-tissue fibres, whether neuroglia in the central nervous system or mesenchymal fibrous tissue both without and within it. Certain of these fibrils of course surround the axones imbedded among them and from condensations of such fibrils are derived the fibrous sheaths of the axones, the sheath nuclei being acquired from the adjacent nuclei of the original syncytium. These sheaths become more dense or pronounced as the axones extend and the fibrous tissue increases with growth, but there are always present fine marginal fibrils by which the sheaths grade into the looser fibrous tissue about them. It is generally believed that the tissue giving rise to these

FIG. 603.—DRAWINGS ILLUSTRATING THE ORIGIN OF THE AXONE AND THE DEVELOPMENT OF THE MEDULLARY SHEATHS.

A, ventral portion of transverse section of an embryonic spinal cord involving portion of periphery of future ventral horn and part of the mesenchymal (mesodermal) syncytium outside the external limiting membrane of the cord. B, later stage of ventral root (peripheral) axone with myelin droplets adhering to it and fibrillated stroma surrounding it. C, stage in which myelin droplets, supported by fibrils of stroma, have increased and accumulated to form a practically continuous myelin or medullary sheath. D, final stage with medullary sheath of even thickness, showing a node, and showing a neurilemma, sheath nucleus and fibrous framework of the myelin ("neurokeratin") derived from the fibrils of the original stroma.

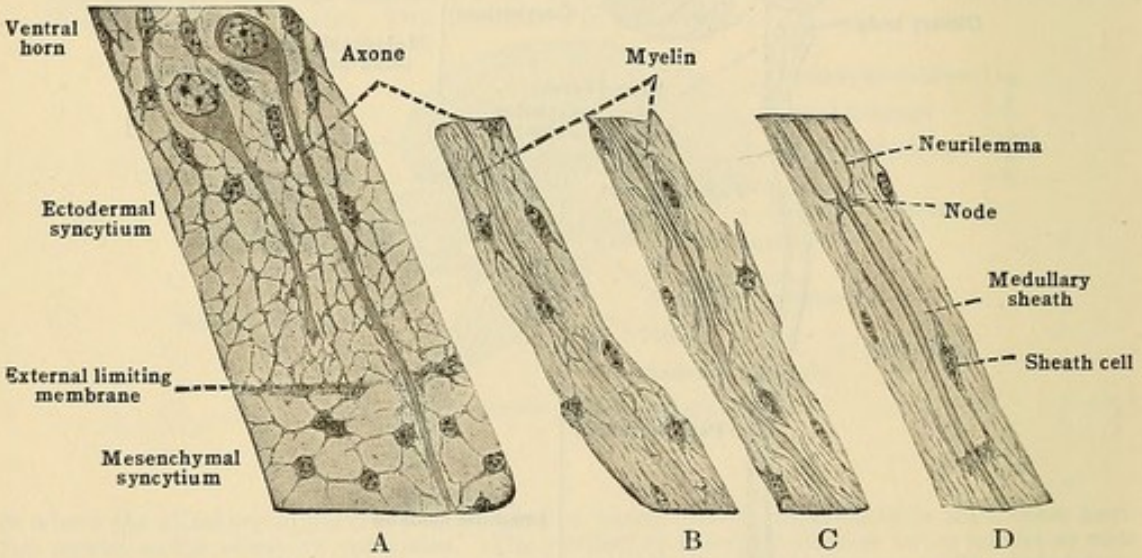

axone sheaths is of mesodermal origin. However, in amphibian larvæ, Harrison has shown that some sheath nuclei at least are derived from the nuclei of the ectodermal syncytium of the ganglion crest, and Neal has noted in elasmobranchs the fact that nuclei migrate from the ventral wall of the neural tube along with the axones growing out to form the ventral roots of the spinal nerves. Whether all or any of these nuclei are originally ectodermal, and, if so, whether such ectodermal tissue gives rise to all axone sheaths, especially in the higher animals, are questionable contentions.

Axones possessing only fibrous sheaths comprise the non-medullated nerve fibres. The majority of the sympathetic fibres are of this variety, and Ranson has found numerous non-medullated fibres present in the spinal nerves. The generally accepted form of non-medullated sympathetic fibres may be seen in fig. 609, C.

Medullated fibres are those which possess an investing coat of fat or myelin in addition to the fibrous sheath. Most of the fibres in the central nervous system and most of those belonging to the cranio-spinal nerves proper acquire myelin sheaths. Myelin begins to appear upon axones shortly after the beginning development in the syncytium of the fibrils of the fibrous connective tissue, and thus after the beginnings of what will become the fibrous sheaths. The fibrous portions of the sheaths in the central nervous system develop less rapidly and are far more scant than those of the medullated fibres of the peripheral nerves. Probably because of this, it has been claimed that myelin begins to appear on the axones of the central system before the appearance of the fibrous sheath. In man, the first appearance of myelin occurs at about the fourth month, but myelinisation is not completed till after birth. The cranio-spinal nerves contain completely medullated fibres before the central system does.

Myelin first appears as small droplets adhering to the axone at irregular intervals. These droplets increase in size and number and gradually accumulate to form a practically continuous sheath of fat immediately investing the axone. They probably result from the coalescence of finer droplets floating in the surrounding fibrillated stroma. However, collecting upon the axone,

the myelin retains the form of an emulsion, and as it increases in amount it incloses the adjacent fibrils which serve as a framework supporting the droplets of the emulsion in its meshes. Thus supported, the increasing myelin does not inclose the adjacent nuclei and endoplasm of the original syncytium. Probably because of the fibrous support of the myelin thus obtained, medullating fibres may be often seen presenting the beaded appearance shown in fig. 603, C, instead of an even distribution of the emulsion after it has become continuous along the axone. The "beads" probably represent the uneven beginning of the accumulation indicated in B of this figure. Increasing further, the myelin becomes a cylinder of even thickness, the adjacent nuclei being pressed away against its surface and the adjacent fibrils also condensed upon it.

There is good reason to believe that the fibrous portion of the sheath, the *primitive sheath* or *neurilemma*, of the medullated axone arises as a condensation of the fibrils of the surrounding stroma during development, that the sheath cells represent certain of the nearest nuclei incorporated from the original syncytium, and that the so-called *neuro-keratin* of the myelin represents the fibrous framework of the myelin inclosed by it during its accumulation upon the

FIG. 604.—SHOWING SOME OF THE VARIETIES OF THE CELL-BODIES OF THE NEURONES OF THE HUMAN NERVOUS SYSTEM, INCLUDING THE DENDRITES AND SMALL PORTIONS OF THE AXONES. AXONE SHEATHS NOT INCLUDED.

A. From spinal ganglion. *B*. From ventral horn of spinal cord. *C*. Pyramidal cell from cerebral cortex. *D*. Purkinje cell from cerebellar cortex. *E*. Golgi cell of type II from spinal cord. *F*. Fusiform cell from cerebral cortex. *G*. Sympathetic. *a*, axone; *d*, dendrites; *c*, collateral branches; *ad*, apical dendrites; *bd*, basal dendrites; *c*, central process; *p*, peripheral process.

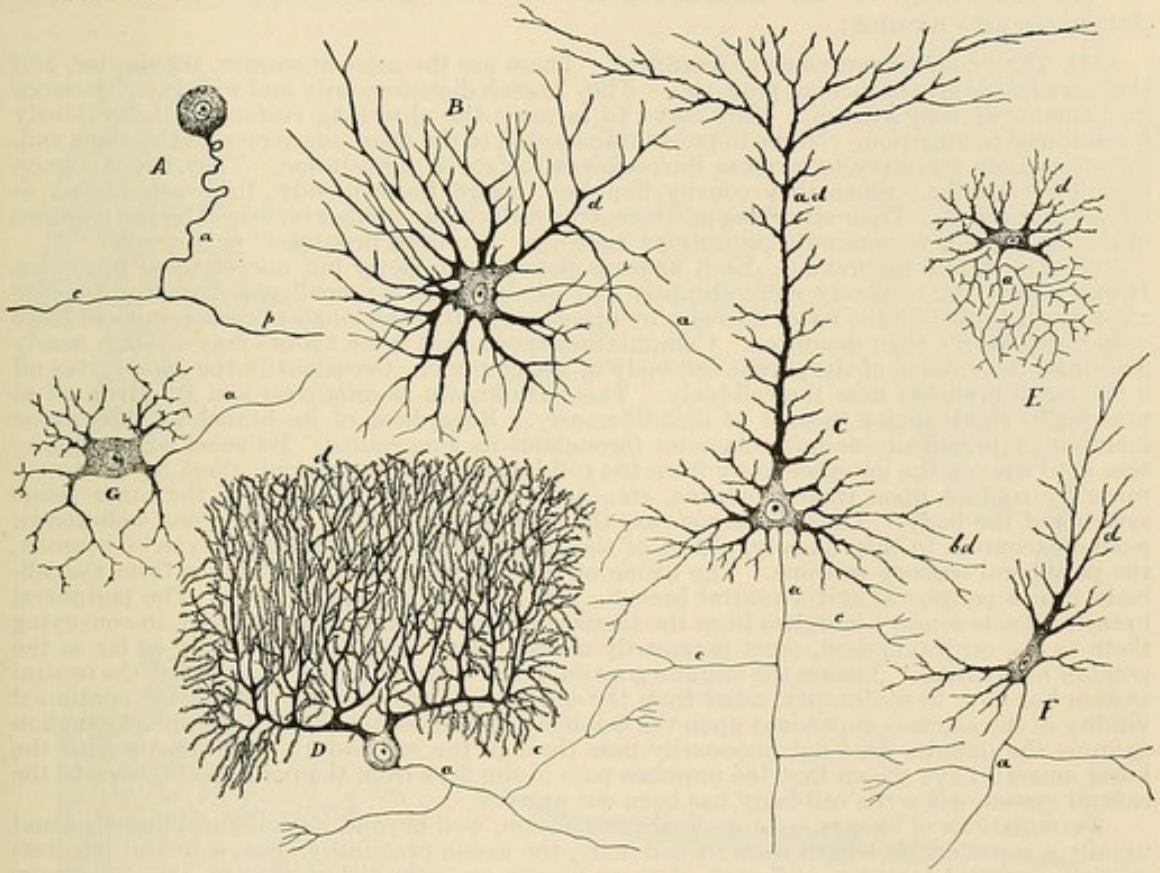

axone. The theory that the myelin arises as a differentiated portion of the axone and the theory that it is formed by the neurilemma have been advanced. That it is accumulated from the immediately surrounding fluid of the stroma and adheres to the axone, added droplets coalescing there, in preference to other tissue elements because of some physical or chemical peculiarity of the axone, is more probably correct.

As the medullary sheath approaches completeness, constrictions may be observed at more or less regular intervals at which the myelin emulsion is absent. There are the *nodes of Ranvier*. The process by which they arise is not clearly understood. While the fibre is growing in length, new myelin is added at the nodes. The internodal segments of the sheath increase in length with age, and each segment may possess from one to several sheath nuclei.

In adolescence, fibres whose medullary sheaths are in various stages of completeness may be found both in nerve bundles in the central system and in the cranio-spinal nerves, and in both, the sheaths of some axones certainly never acquire myelin. Also, in the adult, fibres whose medullary sheaths present the beaded appearance may be observed, probably representing cases of arrested accumulation of myelin. According to Westphal there is a slight increase in the thickness of the sheath with age. Larger axones acquire thicker sheaths of myelin than smaller ones. Some fibres of the sympathetic system are medullated but in such the myelin sheath is relatively thinner than in the cranio-spinal system. Beaded sheaths are frequent in sympathetic rami, though non-medullated fibres are most abundant.

FUNDAMENTALS OF CONSTRUCTION

The functionally mature nervous system consists of peculiarly differentiated essential cell elements held in place by two forms of supporting tissue and supplied with abundant blood-vessels.

The nervous element is distinguished from all other units of the structure of organs in that its cell-body gives off outgrowths or processes of peculiarly great length and characteristic form. Knowledge of the possible lengths and complexity of these processes is comparatively recent and, to include them together with their parent cell-body, which has long been known as the *nerve cell*, the term neurone is used. The **neurone,** therefore, may be defined as the nerve cell-body with all its processes, however numerous and far reaching they may be. As a class of tissue elements, all neurones possess characteristics distinguishing them from other tissue elements, but the varieties within this class vary greatly. They vary in form both according to function and according to their locality in the nervous system. They vary in different animals, those in the higher animals being more complex in form. Fig. 604 gives illustrations of the external form of the cell-body of a few of the types found in the human nervous system.

The cell-body of the neurone gives off two general types of processes, dendrites and axones:

(1) The dendritic processes or **dendrites.** These are the more numerous, the shorter, and the more frequently branching processes. They branch dichotomously and with rapid decrease in diameter as they branch. They serve to increase the absorbing surface of the cell-body for purposes of nutrition. Nerve impulses transmitted to the neurone are received by them and, therefore, they also serve to increase the recipient surface of the neurone. They never acquire medullary sheaths. Since they convey impulses toward the cell-body, they are known as *cellipital processes.* Their absorbing and receptive surfaces are further increased by the presence of thickly placed, very minute projections known as "pin-head processes" or *gemmules.*

(2) The **axone** (neuraxis). Each neurone possesses properly but one of these processes. It arises from the cell-body more abruptly and quickly becomes smaller in diameter than are most dendrites before the latter decrease by branching. It is the longest process, in most cases very much longer than dendrites. Computation shows that some axones may contain nearly 200 times the volume of the parent cell-body of the neurone. Occasionally the axone gives off a few small branches near the cell-body. These are known as *collaterals* and are given off at practically right angles instead of dichotomously. Regardless of its branching, the axone maintains a practically uniform diameter throughout its long course. Its usual nervous function is to convey the impulses away from the cell-body, either to transmit them to other neurones by contact upon their dendrites, etc., or to appropriate elements of the other tissue systems of the body. Thus the axones are the *cellifugal processes.* There is one well-known partial exception to this, namely, a part of the axone of the spinal ganglion type of neurone, the peripheral sensory neurone. The axone of this bifurcates a short distance from the cell-body into a peripheral and a central branch. See fig. 604, A, and fig. 610. The peripheral branch collects sensory impulses from the tissues of the body, the skin, etc., and, in conveying them to the central system, must necessarily convey them toward the cell-body as far as the point of bifurcation. Thence the impulse goes on in the central branch, still toward the central system but now, in conformity, away from the cell-body of the neurone. While the continued vitality of the axone is dependent upon the cell-body, in the peculiar case of the spinal ganglion neurone the impulse does not necessarily pass through the cell-body. Experiments with the lower animals have shown that the impulses pass in the fibre from the peripheral tissues to the central system when the cell-body has been cut away.

Terminations of axones.—At its final termination, well beyond its collateral branches and usually a considerable length from its cell-body, the axone practically always divides into two or more *terminal branches,* and each of these breaks up, now dichotomously, into numerous terminal twigs. These terminal twigs are known as *telodendria.* Telodendria vary in number and character of form according to the tissues in and upon which they terminate. Functionally, they are of three classes: Those terminating upon and in the other (peripheral) tissues of the body are either (1) *sensory* or (2) *motor.* In order to transmit impulses from one neurone to another, telodendria of the axone of one neurone are placed in contact with the dendrites or cell-body of another neurone forming (3) *synapses.* Upon approaching its termination, every axone loses its sheath, its telodendria being necessarily bare.

Sensory or afferent axones, receiving impulses from the skin or other epithelial surfaces, break up into very numerous telodendria each of which terminates directly upon the surface of the epithelial cell, such as the cells of the germinative (Malpigin) layer of the skin or those of its basal or columnar layer. Such telodendria are known as *free terminations.* Free terminations are also to be found in the connective tissues of the body. A second variety of peripheral termination of afferent axones is the *encapsulated form.* These are known as 'end organs' and 'corpuscles' and are named according to their complexity and position. Three of the different forms of them are shown in fig. 605, B, C, and D. These are always situated in fibrous connective tissue from which their capsules are derived. Their most elaborate form is the lamellated or Pacinian corpuscle. Besides the motor axones terminating upon the fibres of voluntary or skeletal muscle, sensory impulses are carried from this tissue and one of the forms of telodendria for this purpose terminates upon the muscle fibre. This is known as

FIG. 605.—SHOWING SOME VARIETIES OF PERIPHERAL TERMINATIONS OF AXONES.

A. 'Free termination' in epithelium (after Retzius). B. Krause's corpuscle from conjunctiva (after Dogiel). C. Meissner's corpuscle from skin (after Dogiel). D. Pacinian corpuscle (after Dogiel). E. Termination upon tendon sheath (Huber and DeWitt). F. Neuro-muscular spindle (after Ruffini). G. Motor termination upon smooth muscle-cell. H. Motor 'end-plate' on skeletal muscle fibre (after Böhm and von Davidoff). a, axone; t, telodendria.

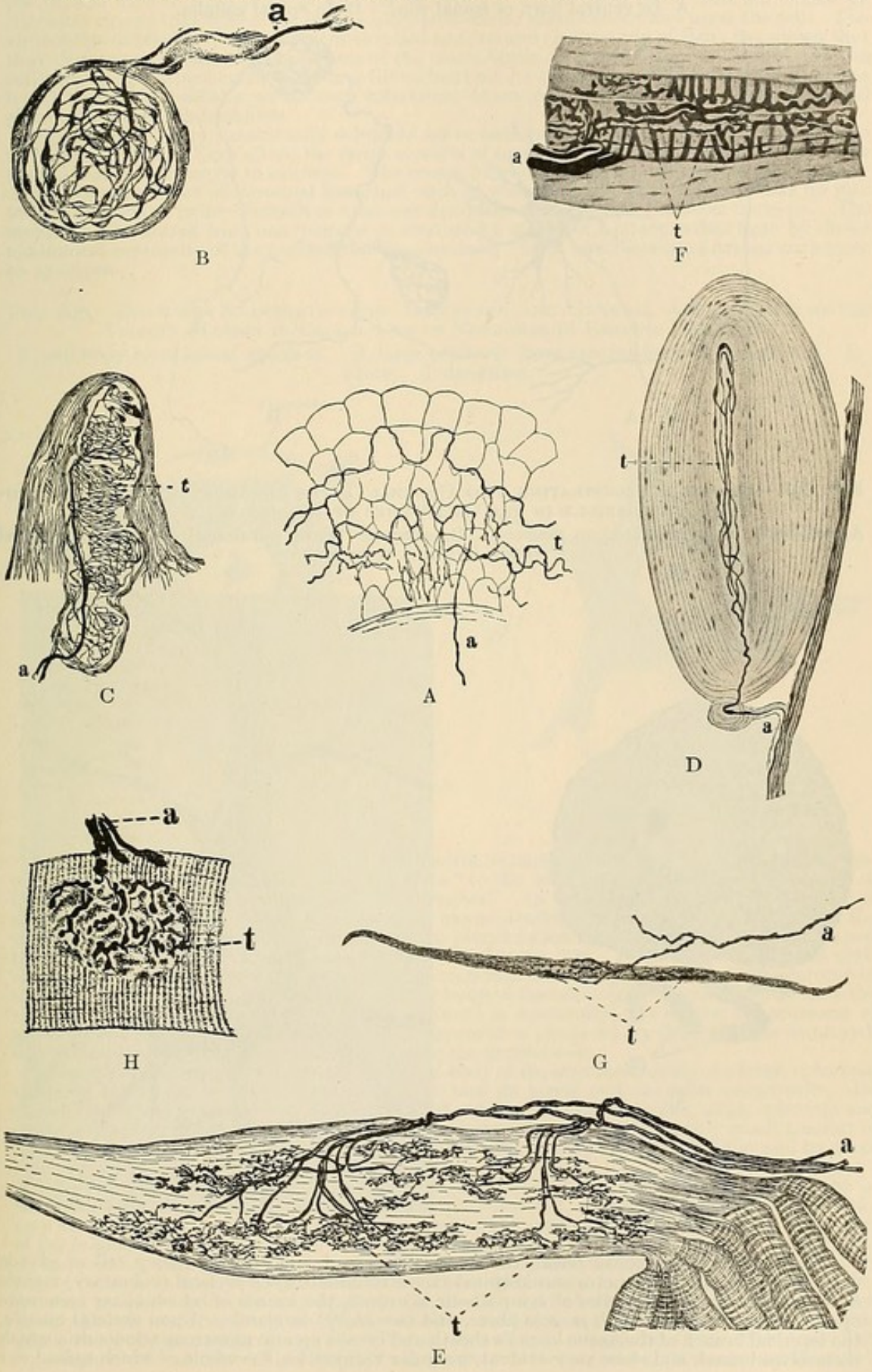

the 'neuromuscular spindle.' In it, the axone penetrates the sarcolemma and breaks into telodendria which coil spirally about the muscle fibre. The most extensive and elaborate form of sensory telodendria are those which spread out in plate-form upon tendons sheaths.

FIG. 606.—SCHEMES SHOWING TWO FORMS OF SYNAPSES OR THE TERMINATION OF AXONES UPON CELL-BODIES OF OTHER NEURONES.
A. In ventral horn of spinal cord. B. In spinal ganglia.

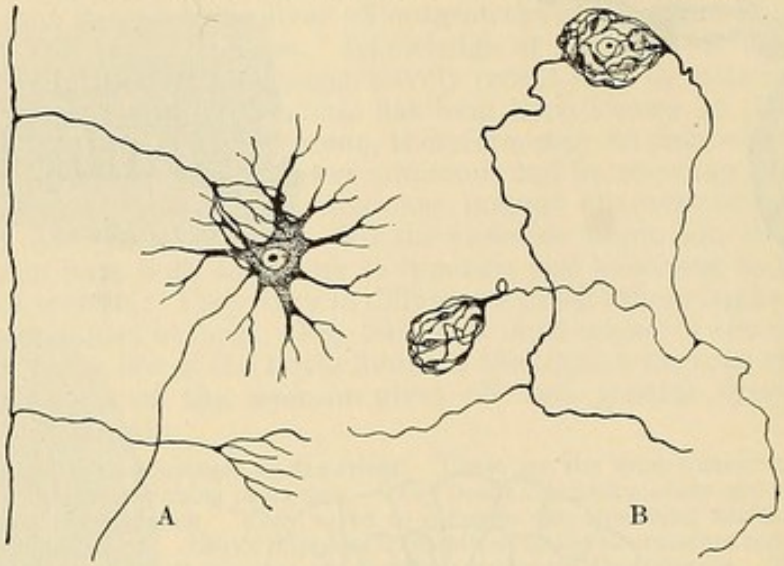

FIG. 607.—DRAWINGS ILLUSTRATING TWO GENERAL TYPES OF ARRANGEMENT OF NEUROFIBRILLÆ IN THE CELL-BODIES OF NEURONES.
A, cell-body of spinal-ganglion neurone. B, selected "giant pyramidal cell" from cerebral cortex, human. a, axone.

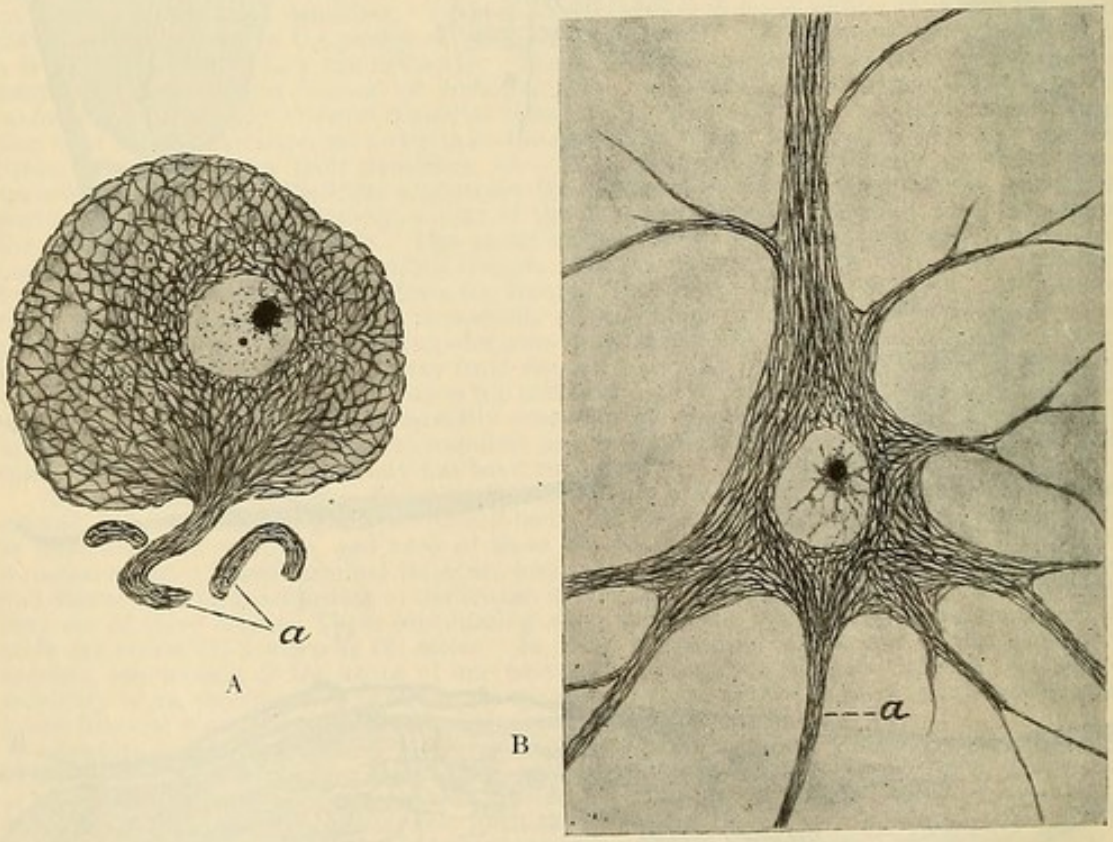

Motor peripheral axones terminate upon muscle and upon the secretory cell of glands (secretory axones). The motor cranio-spinal axones terminate upon skeletal (voluntary) muscle fibres and upon the cell-bodies of sympathetic neurones, the axones of which latter terminate upon cardiac muscle, smooth muscle fibres, and (secretory) in glands. Upon skeletal muscle, the terminal branch of the axone loses its sheath and breaks up into numerous telodendria which themselves branch and show very evident, irregular varicosities, the whole of which spread out

in plate-form, and lie in contact with the substance of the muscle fibre. In man and all mammals, the area covered is usually somewhat oval and is marked by a granular differentiation of the muscle substance. This with the telodendria is known as a *motor end-plate*. The telodendria of sympathetic axones ending upon cardiac and smooth muscle fibres are fewer and simpler than those of cranio-spinal axones upon skeletal muscle. They consist of a few fine fibrils, with very small varicosities along them and at their ultimate terminations, which run longitudinally along the muscle fibre in close relation with its substance. Those upon gland cells are similar in character except that they often form a loose pericellular plexus about and upon the cell. The varicosities of telodendria are sometimes called *end-feet* and closer study of them has shown that they themselves consist of fine plexuses of the neuro-fibrils described below as contained in the cell-body of the neurone and extending throughout all its processes. Quite recently Boek has found that a sympathetic axone may sometimes accompany a cranio-spinal axone to an end plate on a skeletal muscle fibre.

Synapses.—Every functionally complete nerve pathway consists of two or more neurones arranged in series. Very often, the series consists of many more than two, the impulses being transmitted from neurone to neurone. The axone, bearing the impulse away from the cell-body of one neurone, gives off terminal branches, each of which loses its sheath and breaks up into telodendria which twine themselves upon the dendrites or cell-body of another neurone. The mpulse is transferred from one neurone to another by means of contact rather than by direct anatomical continuity of the parts of the two neurones. Such terminations of axones are known as synapses.

FIG. 608.—DRAWINGS ILLUSTRATING THE ABUNDANCE AND GENERAL ARRANGEMENT OF THE TIGROID MASSES IN CELL-BODIES OF NEURONES IN RESTING CONDITION.

A, cell-body from spinal ganglion. B, large cell-body from ventral horn of spinal cord. a, axone. d, dendrites.

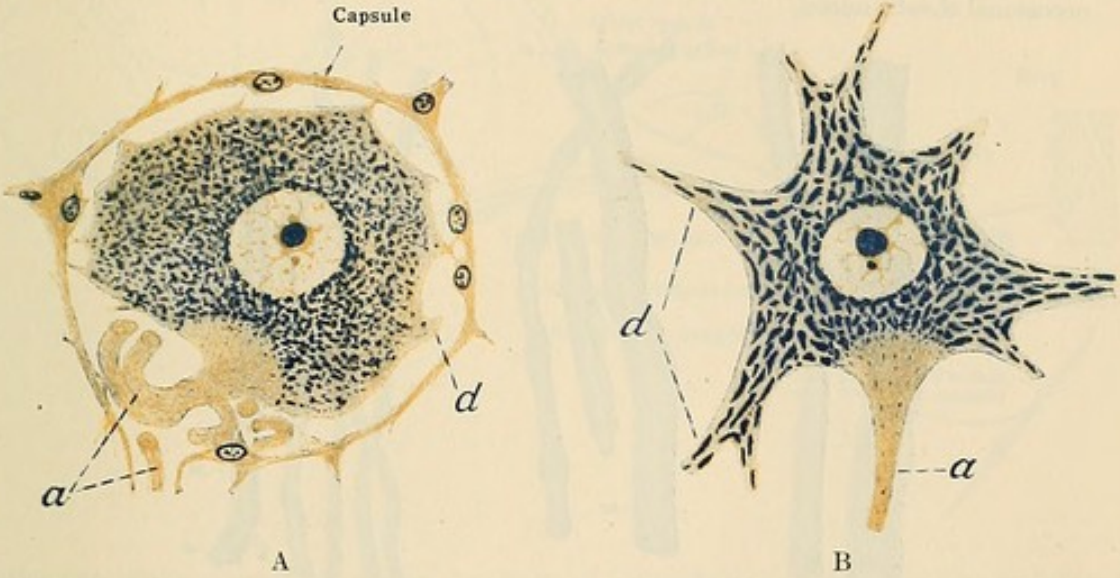

In the terminal arrangement of the telodendria, synapses assume forms varying from compact "*pericellular baskets*" and "*climbing fibres*" to the more open arborisations composed of fewer twigs in simpler arrangements, "*end-brushes.*" In case of the spinal ganglion type of neurone, the cell-body of the majority of which has no dendritic processes, the telodendria of the visiting axone form an anastomosing pericellular plexus inclosing the entire cell-body. This and the simple end-brush form of synapses are illustrated in fig. 606. It should be mentioned that, contrary to the general belief that impulses are transmitted by simple contact of the neurones in the series, it has been claimed that the ultimate twigs of the telodendria frequently penetrate the substance of the receiving cell-body and are fused in continuity. If during the processes of growth this becomes true, instead of being an appearance produced by the technique employed, it is better considered as merely an exception to the general rule.

Internal structure of the neurone.—The cell-body of the neurone consists of a large, spherical, vesicular nucleus and a cytoplasm continuous into its axone and dendritic outgrowths. Its nucleus is further characterized by having most usually but one nucleolus, large, spherical and densely staining, situated in a karyoplasm containing otherwise a remarkably small amount of chromatin. Of the cytoplasm, the two most interesting structures are its fibrillar and its granular components.

The **fibrillar structure,** known as the *neuro-fibrillæ*, represents a growth and elaboration of the spongioplasmic reticulum of the original, embryonal cell. The filaments increase in thickness during the development of the neurone, and, in the sending out of its processes, the meshes of the original reticulum become so drawn out in the processes as to give the appearance of a more or less parallel arrangement of threads. The reticular or net-like arrangement is usually more nearly retained in the cytoplasm immediately about the nucleus, since here the stress of the outgrowing processes is less directly applied. In the cell-body of the spinal ganglion type of neurone, when no dendrites are given off, the net-like arrangement is apparent throughout the cytoplasm except in that region giving rise to the axone. On the other hand, in the typical so-called "pyramidal cell" of the cerebral cortex, from which two chief processes, the axone and the apical

dendrite, are given off from opposite poles, the more reticular arrangement about the nucleus is often practically obliterated by the opposing growth stress.

So manifest does the parallel appearance of the neuro-fibrillæ in the processes often become that it has been interpreted as a series of individual and independent fibrils. In the application of gold chloride and similar methods to the neurones of lower forms, the reduced reagent is often precipitated upon the fibrils in parallel, seemingly independent lines. And, assuming the existence of independent fibrils, it has been contended that the neurone is not the functional unit of the nervous system but is itself composed of numerous functional units, individual fibrils, each for the conduction of nerve impulses. More recent and trustworthy methods, however, show that the neuro-fibrillæ retain their original reticular form, the threads anastomosing in all planes, and that the meshes of the net may, in the processes, be so drawn in one direction that a parallel appearance predominates. Further, it is now held that the neuroplasm, or the more fluid substance in which the fibrils lie throughout, is capable, and probably fully as capable, of conducting impulses as the fibrils.

Of the **granules** in the cytoplasm, the most interesting are those first described in detail by Nissl. These are the most abundant of those in the cell-body and are known as *tigroid masses* or *Nissl bodies*. They consist of numerous basophilic granules collected into clumps or masses of varying size. They are known to disappear during fatigue of the nervous system and they are more abundant in animals after a period of rest. They are distributed throughout the cytoplasm of the cell-body with the interesting exception that they are not found in the axone nor in the immediate vicinity of its place of origin from the cytoplasm, leaving a free region known as the *axone hillock*. As accumulated masses, they show characteristic shapes and arrangement

FIG. 609.—SHOWING PIECES OF AXONES.

A. From a cranio-spinal nerve. *B*. From the spinal cord. *C*. From the sympathetic. *a*, axones; *m*, medullary sheath; *n*, node of Ranvier; *s*, neurilemma or sheath of Schwann with occasional sheath-nuclei.

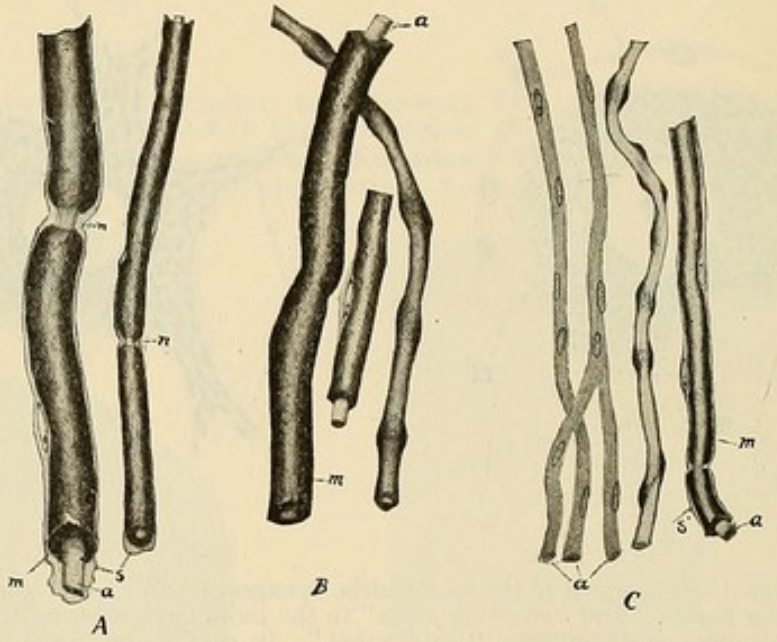

which are interpreted as signifying the shapes and arrangement of the spaces or meshes they occupy in the reticulum of the neuro-fibrillæ. In cell-bodies of the varieties found in the ventral horns of the spinal cord or in the cerebral and cerebellar cortex, for example, the masses situated immediately about the nucleus are smaller, more numerous and of irregular shape. Nearer and in the beginnings of the dendrites, they are larger and mostly of fusiform or diamond shape. Farther out in the dendrites, they become more and more thin and attenuated; and in the distant reaches of the dendrites they are invisible or absent. In the cell-body of the spinal ganglion they are of irregular shape, smaller and more numerous throughout the cytoplasm, being slightly smaller and more thickly placed in the immediate vicinity of the nucleus. In all neurones several hours post-mortem, they appear in fewer and larger masses and it was in this condition that Nissl originally described them in man. Closely examined, the masses of all sizes are found to be accumulations of finer granules. Functionally they are supposed to be of nutritive significance, substances in unstable chemical equiblibrium, energy stored in the cytoplasm, capable at need of being split into simpler forms usable in the activities of the neurone. The fact that tigroid masses are absent from the axone hillock, the axone, and the distant reaches of the dendrites may signify that the substance is chiefly present here only in the split and usable form. Also, in the axone especially, the neurofibrillæ are so closely arranged that the meshes of their net here are too small to contain masses of appreciable size. Close examination of the axone hillock and longitudinal sections of the axone in deeply stained preparations usually show a few very minute basophilic granules.

Sheaths of the axone.—The great majority of axones acquire sheaths about them which isolate and protect them in their course through other tissues or in company with other axones. A *nerve fibre* is an axone together with its sheath. In transverse sections, the axone comprises

the central portion of the nerve fibre or its so-called "axis-cylinder." It is of course the essential portion of the fibre. As noted above in describing their development, nerve fibres are classified according to the character of the sheaths. Those which possess sheaths of myelin, a peculiar form of fat, are known as *medullated fibres*, and those in which the sheaths are merely membranes of condensed fibrous tissue, void of myelin, are *non-medullated fibres*. A medullated fibre also possesses a fibrous membrane outside its myelin sheath, known as the *neurilemma* or sheath of Schwann. The neurilemma is of the same origin and general structure as the sheath of the non-medullated fibre, and both possess nuclei scattered along them. Medullated fibres, at more or less regular intervals, show constrictions at which the myelin sheath ceases, but over which the neurilemma continues. These constrictions are the *nodes of Ranvier*. The myelin is in the form of an emulsion, whose fat droplets are supported in a fine fibrous reticulum (neurokeratin), while the neurilemma without serves to hold it in place. The neurilemma possesses from one to three or four sheath nuclei between adjacent nodes of Ranvier.

There is no sharp line of separation between medullated and non-medullated fibres, for in any locality there may be found axones in all degrees of medullation. Most of the fibres

FIG. 610.—DIAGRAM OF TRANSVERSE SECTION OF SPINAL CORD WITH ROOTS OF SPINAL NERVE AND NEIGHBOURING GANGLIA ATTACHED, ILLUSTRATING SIMPLEST FORMS OF NEURONE CHAINS.

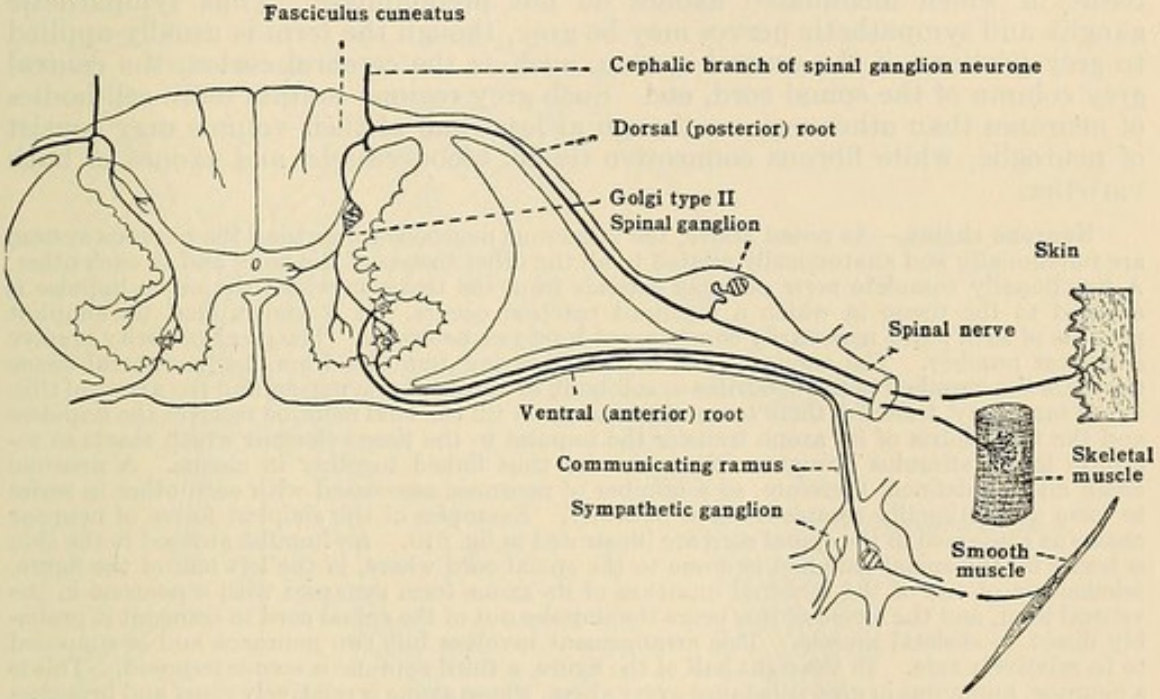

belonging to the sympathetic system (processes of sympathetic neurones) are non-medullated, but both partially medullated and completely medullated sympathetic fibres may be found. (See fig. 609.) The myelin sheaths of completely medullated sympathetic fibres are always thinner and less well developed than those of medullated cranio-spinal fibres. Most of the fibres belonging to the cranio-spinal nerves and to the central nervous system are medullated, but among the fibres belonging to either there are to be found numerous non-medullated fibres. As indicated in fig. 609, nodes of Ranvier are absent in the medullated fibres of the central system.

In all the higher vertebrates, the myelin sheath always begins on the axone a short distance from its parent cell-body. The neurilemma of the medullated and the fibrous membrane of the non-medullated fibre are each faintly continuous with the fibrous connective tissue surrounding it, and, in the cranio-spinal and sympathetic ganglia, in which each cell-body of the neurone has a fibrous capsule about it, the fibrous membrane or the neurilemma, as the case may be, is directly continuous into the capsule of the cell-body. Upon approaching its final termination, in other tissues or upon the dendrites or cell-body of other neurones, the nerve fibre always loses its sheath, the telodendria of the axone always being bare when placed in contact with the other element. In losing the sheath, the myelin sheath, if present, always ceases and the fibrous membrane becomes continuous with the tissue investing the receiving element, whether the capsule of the ganglion cell, the sarcolemma of the skeletal muscle fibre. the corium of the skin, or the connective-tissue capsule of the encapsulated terminal corpuscle,

The **connective tissue** of the nervous system is of two main varieties—*white fibrous connective tissue* and *neuroglia*. White fibrous tissue alone supports and binds together the peripheral system, and it is the chief supporting tissue of the central system. As connective tissues, these two varieties are quite similar in structure, each consisting of fine fibrillæ, either dispersed or in bundles, among which are distributed the nuclei of the parent syncytium. In both tissues nuclei are frequently found possessing varying amounts of cytoplasm which has not yet been transformed into the essential fibrils.

In addition to its enveloping membranes, the three meninges, which are of white fibrous tissue, the white fibrous tissue supporting the central system within is quite abundant. It is all

sent in from without, either as ingrowths of the developing pia mater, the most proximal of the membranes, or is carried in with the blood-vessels, of the walls of which it is an abundant component. Practically, the neuroglia as a connective tissue proper differs from white fibrous tissue only in origin and in its chemical or staining properties. Based upon the latter, there are methods of technique by which the two may be distinguished. White fibrous tissue is derived from the middle germ layer or the mesoderm, while neuroglia comes from the ectoderm. The epithelium lining the central canal of the spinal cord and the ventricles of the encephalon, with which the canal is continuous, is the remains of the mother tissue of the neuroglia, and in the adult is the only vestige representing its origin. The cells of this epithelium are known as *ependymal cells*, and they are usually classed as a variety of neuroglia.

Axones, with their medullated or non-medullated sheaths (nerve fibres) comprise all nerves in the periphery and all nerve tracts in the central system.

White substance [substantia alba] ("white matter") consists of a portion of nervous tissue in which medullated fibres predominate. The myelin sheaths, being in the form of a fat emulsion, reflect the entire spectrum and thus appear white.

Grey substance [substantia grisea] ("grey matter") is a portion of nervous tissue in which medullated axones do not predominate. Thus sympathetic ganglia and sympathetic nerves may be grey, though the term is usually applied to grey portions of the central system, such as the cerebral cortex, the central grey column of the spinal cord, etc. Such grey regions contain more cell-bodies of neurones than other regions, though at least half of their volume may consist of neuroglia, white fibrous connective tissue, blood-vessels, and axones of both varieties.

Neurone chains.—As noted above, the numerous neurones comprising the nervous system are functionally and anatomically related to all the other tissues of the body and to each other. A functionally complete *nerve pathway* extends from the tissue in which the nerve impulse is aroused to the tissue in which a resultant reaction occurs. It is known that the simplest possible of such paths necessarily comprises at least two neurones. The great majority involve a greater number. The axone of one neurone bearing impulses from the peripheral tissue transfers the impulses to the dendrites or cell-body of another by synapsis, and the axone of this, in the same way, transfers them to another and so on till the final neurone receives the impulses and the telodendria of its axone transfer the impulse to the tissue element which reacts in response to the stimulus brought. Neurones are thus linked together in chains. A neurone chain may be defined, therefore, as a number of neurones associated with each other in series to form a functionally complete nerve pathway. Examples of the simplest forms of neurone chains as contained in the spinal cord are illustrated in fig. 610. An impulse aroused in the skin is borne by the spinal ganglion neurone to the spinal cord where, in the left half of the figure, telodendria of one of the terminal branches of its axone form synapses with a neurone in the ventral horn, and the axone of this bears the impulse out of the spinal cord to transmit it probably direct to skeletal muscle. This arrangement involves but two neurones and is supposed to be relatively rare. In the right half of the figure, a third neurone is seen interposed. This is a neurone, numerous in grey substance everywhere, whose axone is relatively short and branches frequently, making possible several synapses in the near neighbourhood of its parent cell-body. Its type is referred to as the *Golgi neurone of type II*. This interposed, gives a chain of three neurones between the origin of the impulse in the periphery and the contraction of muscle in response. Simple chains like these can result only in reflex activities and such chains are often called *reflex arcs*. Another chain is indicated in the figure in which the reflex action involves involuntary or smooth muscle. This must involve at least one sympathetic neurone, and, should the Golgi neurone of type II form synapses with the ventral horn neurone involved, a chain composed of four neurones results. In the more extensive and complex neurone chains, such as those in which the impulse from the skin, as above, ascends to the cerebral cortex and the resultant muscular contraction is thrown under cerebral control, each of the several neurones or links in the series is not only referred to by name according to the position of its cell-body, but each is often called according to its order in the series, as "neurone of first order," "second order," "third order," etc.

A given axone may break into a considerable number of branches each of which forms synapses with a different second neurone, or, if peripheral, the telodendria of each branch may terminate upon a separate peripheral tissue element. Thus, a given impulse aroused in a peripheral tissue element may be transmitted to an ever increasing number of neurones, and the initial neurone may comprise the first link in a number of neurone chains. Such is quite general in the structural plan of the nervous system throughout. It is thought possible to consider each neurone interposed in a chain as a separate source of energy, a sort of relay in the nerve path; that the impulse passing through the axone is gradually weakened in overcoming resistance, but, when transferred to another neurone, it incites a splitting into usable form of the substance represented by the tigroid masses and thus a liberation of energy or a reinforcement of the impulse. Further, thus is made possible the economy of one neurone serving as a link in a number of neurone chains.

The axones (nerve fibres) taking part in the various neurone chains course in bundles of varying size, the larger of which have names. And there is a general tendency with axones of the same function and the same origin to course in company with each other. A fibre bearing impulses from the peripheral tissues to the central system is an *afferent fibre* or sensory fibre. A fibre bearing impulses out of the central system to peripheral tissues is an *efferent fibre* or motor

fibre. Efferent fibres which bear impulses to skeletal muscle are known as *somatic efferent fibres*, while those which terminate upon the cell-bodies of sympathetic neurones and thus bear impulses destined for smooth muscle, cardiac muscle and glands (secretory) are *visceral* or *splanchnic efferent fibres*.

A nerve is a closely associated aggregation of parallel nerve fibres coursing in the *periphery*. It may be spinal, cranial or sympathetic according to its attachment or according to the origin of the majority of its fibres. It may contain several functional and structural varieties of fibres. The spinal nerves contain all structural varieties. **Nerve roots** are those bundles of fibres which join to form a nerve. Most of the cranial nerves have but one root of origin. Nerve roots, in their turn, are formed by the junction of smaller *root-filaments*. *Nerve branches* result from the division of the nerve, the separation of its component fibres into separate bundles. Some branches are of sufficient size and significance to be called nerves and given separate names. The smaller branches are called *rami*, twigs, etc.

In the *central system*, a given bundle of fibres is called a **fasciculus,** while two or more adja-

FIG. 611.—DIAGRAM OF TRANSVERSE SECTION OF MEDULLA OBLONGATA, ILLUSTRATING NUCLEI OF TERMINATION AND NUCLEI OF ORIGIN.

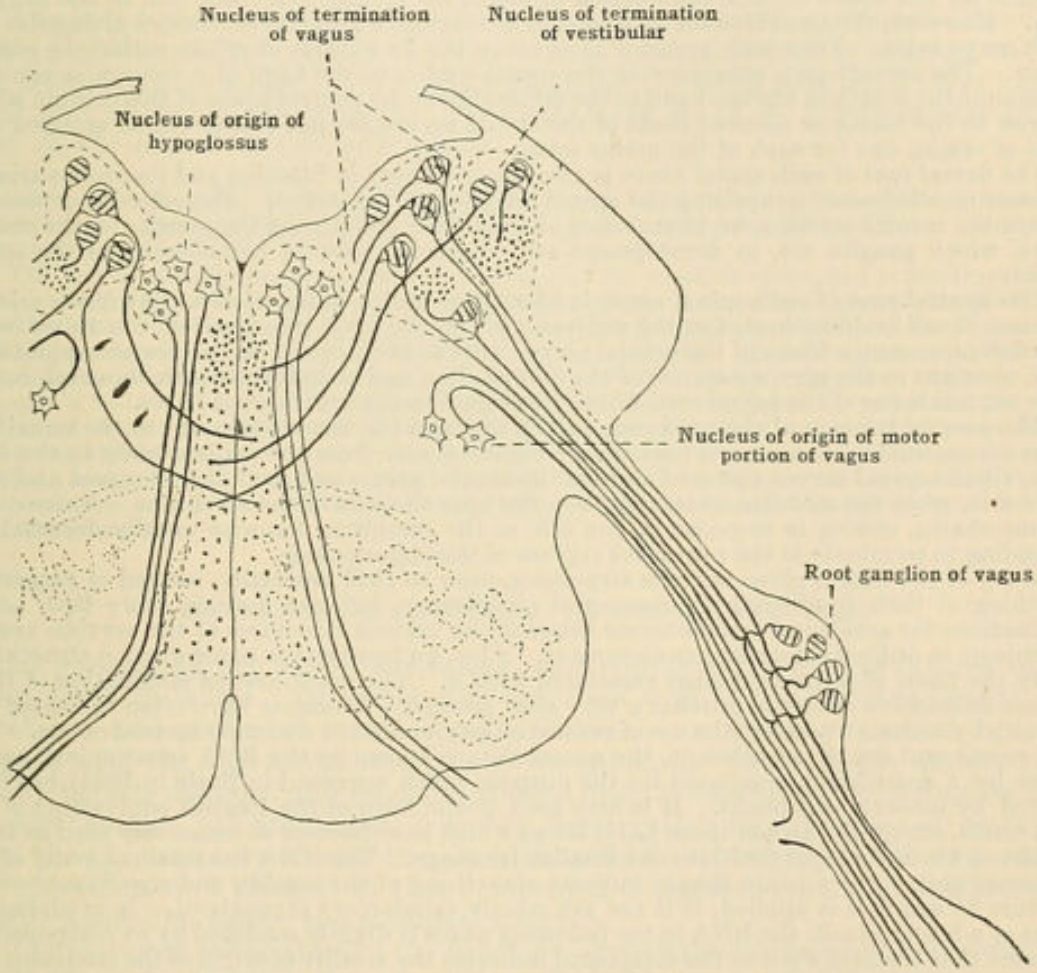

cent fasciculi coursing parallel to each other comprise a **funiculus,** a bundle of bundles. The central nervous system is bilaterally symmetrical throughout its length. A bundle of fibres arising from cell-bodies situated on one side and crossing the mid-line transversely to terminate in the opposite side is a **commissure.** The commissures vary greatly in size and contain fibres crossing in both directions. Scattered fibres which cross the mid-line are *commissural fibres.* Fibres of varying length, arising from cell-bodies situated in one locality of the central system, which do not cross the mid-line, but terminate in other localities of the same side, above and below the level of their origin or in a different region of the same level, form **association fasciculi.** The shortest association fasciculi, not extending beyond the bounds of a given division of the central system, are known as **fasciculi proprii.** When bundles of the same origin, functional direction and significance, running one on either side of the mid-line, cross the mid-line they are said to decussate and the crossing is known as a **decussation.** In the decussations, the direction of the crossing is oblique rather than transverse.

The cell-bodies of neurones whose axones go to form certain nerve roots, fasciculi and certain commissures show a tendency to accumulation in localized masses. In the *peripheral* system, such an accumulation of cell-bodies is known as a **ganglion;** in the *central system* such is distinguished as a **nucleus.** Thus, there are the *sympathetic ganglia* which give rise to sympathetic nerves and sympathetic roots of nerves; and on the beginning of each spinal nerve there is a *spinal ganglion* which gives rise to the afferent fibres of its dorsal root and in its nerve trunk. There are *ganglia on* the *cranial nerves* which give rise to the afferent or sensory axones in them and which are of the same significance as the spinal ganglia. Every ganglion, therefore, has

connected with it bundles of nerve fibres. Some of these fibres bear impulses from neighboring ganglia or from the tissues of the neighboring organs and transmit them to the cell-bodies of the ganglion; others arise from the cell-bodies in the ganglion and bear impulses to the central system or, in case of the sympathetic, to other ganglia or to the tissues of the peripheral organs. Necessarily, the larger the ganglion, the larger will be the bundles of fibres connected with it.

Nuclei may be considered in two general classes: (1) Recipient nuclei or nuclei of termination, and (2) Nuclei of origin.

A nucleus of termination is an accumulation of cell-bodies in which the axones of a given fasciculus or of a nerve root terminate, that is, cell-bodies which, by synapses, receive the impulses borne by the terminating axones. In most cases the impulses transferred to a nucleus so named are sensory in character. The nucleus may be considered as a defined region in which neurones of the next order are interpolated in a given nerve pathway or system of neurone chains. Fasciculi in the spinal cord which bear impulses to the cerebrum have their nuclei of termination in the medulla oblongata, and the sensory or afferent axones of the cranial nerves find their nuclei of termination upon entering the central system.

A nucleus of origin is an accumulation of cell-bodies of neurones which give origin to the axones going to form a given nerve root or a fasciculus. Strictly speaking, a nucleus of termination for one nerve tract is the nucleus of origin for another, the next link in the neurone chain. However, the term is commonly used to distinguish a group of cell-bodies giving rise to a motor nerve tract. Thus each motor cranial nerve has its nucleus of origin within the central system. The central grey substance of the spinal cord is in the form of a column continuous throughout the length of the cord and so the cell-bodies in the ventral horns of this column which give rise to the motor or afferent roots of the spinal nerves are not considered as grouped into nuclei of origin, one for each of the motor roots.

The **dorsal root** of each spinal nerve is afferent or sensory in function and its axones arise as processes of cell-bodies comprising the spinal ganglion of the nerve. The afferent or sensory fibres of the cranial nerves arise as processes of cell-bodies comprising the ganglia of the cranial nerves, which ganglia are, in development and character, exactly homologous to the spinal ganglia.

The **ventral root** of each spinal nerve is efferent or motor in function and its fibres arise as processes of cell-bodies situated in the ventral horn of the grey substance of the spinal cord. The efferent or motor fibres of the cranial nerves arise as processes of cell-bodies accumulated as nuclei of origin in the grey substance of the encephalon, and homologous with those cell-bodies of the ventral horns of the spinal cord which give origin to the ventral-root fibres.

The general relation of the cerebrum (which includes the mesencephalon) to the remainder of the nevous system is a *crossed relation*. Neurone chains from the general body to the cerebrum, via the spinal nerves and cord and via the cranial nerves and medulla oblongata and pons of one side, cross the mid-line to terminate in the opposite side of the cerebrum. Axones, and neurone chains, arising in response in one side of the cerebrum, likewise usually decussate in descending to terminate in the respective regions of the opposite side.

Many of the **names** given nervous structures, prior to 1850 especially, instead of suggesting something of their functional or anatomical significance, indicate nothing more than active imaginations for accidental resemblances between the various structures of the nervous system and objects in ordinary domestic environment. Also, quite often the name given a structure is merely the name of some anatomist associated with it. The much needed elimination of these old non-descriptive names is proving a very slow process. Attempts have often increased the difficulty by making necessary the use of several names for a given structure instead of one. The most recent and concerted attempt, the nomenclature known as the BNA (anatomical names chosen by a commission appointed for the purpose which convened in Basle in 1895), has been adopted by modern text-books. It is here used in the form of the English equivalents of the Latin terms, except in cases of those Latin terms which have become so commonly used as to be considered words incorporated into the English language. The BNA has retained many of the old names and, since a name should indicate something of the locality and significance of the structure to which it is applied, it is not yet wholly satisfactory throughout. In applying the names of a few fasciculi, the BNA in the following pages is slightly modified by so compounding the name that the first word in the compound indicates the locality of origin of the fasciculus and the second, the locality of its termination. Thus, "*Dorsal spino-cerebellar fasciculus*" indicates the more dorsally coursing of the fasciculi which arise from cell-bodies in the spinal cord and terminate in the cerebellum. This principle applies to many of the BNA names without change, as "*lateral cerebro-spinal fasciculus.*"

THE CENTRAL NERVOUS SYSTEM

The central nervous system [systema nervorum centrale] or organ is an aggregation of nuclei, fasciculi and commissures—a large axis of grey and white substance situated in the dorsal mid-line of the body—and the bundles of fibres connecting it with the tissues of other systems and with the peripheral ganglia are of necessity correspondingly large. So numerous are the axones connecting it and so intimately are its neurones associated that a disturbance affecting any one part of the system may extend to influence all other parts. The enlarged cephalic extremity of this central axis, the brain or **encephalon,** is a special aggregation of nuclei and masses of grey substance, many of which are much larger than any found in the periphery.

In the study of the central nervous system its enveloping membranes or meninges are met with first, and logically should be considered first, but since a comprehensive description of these membranes involves a foreknowledge of the various structures with which they are related, it is more expedient to consider them after making a closer study of the entire system they envelop.

For convenience of study, the central nervous system is separated into the gross divisions, spinal cord and brain (encephalon) as illustrated in fig. 602. Each of these divisions will be subdivided and considered with especial reference to its anatomical and functional relations to the other divisions and the interrelations of its component parts.

I. THE SPINAL CORD

The spinal cord [medulla spinalis] is the lower (caudal) and most attenuated portion of the central nervous system. It is approximately cylindrical in form and terminates conically. Its average length in the adult is 45 cm. (18 in.) in the male and 42 cm. in the female. It weighs from 26 to 28 grams or about 2 per cent. of the entire cerebro-spinal axis.

After birth it grows more rapidly and for a longer period than the encephalon, increasing in weight more than sevenfold, while the brain increases less than half that amount. Its specific gravity is given as 1.038.

The line of division between the spinal cord and the medulla oblongata is arbitrary. The outer border of the foramen magnum is commonly given, or, better, a transverse line just below the decussation of the pyramids. Lying in the vertebral canal, the adult cord usually extends to the upper border of the body of the second lumbar vertebra. However, cases may be found among taller individuals in which it extends no farther than the last thoracic vertebra. With increase in stature, its actual length increases, but the extent to which it may descend the vertebral canal decreases. Up to the third month of intra-uterine life it occupies the entire length of the vertebral canal, but owing to the fact that the vertebral column lengthens more rapidly and for a longer period than does the spinal cord, the latter, being attached to the brain above, soon ceases to occupy the entire canal. At birth its average extent is to the body of the third lumbar vertebra.

External Morphology of the Spinal Cord

In position in the body, the spinal cord conforms to the curvatures of the canal in which it lies. In addition to the bony wall of the vertebral canal, it is enveloped and protected by its three membranes or meninges, which are continuous with the like membranes of the encephalon: first, the **pia mater,** which closely invests the cord and sends ingrowths into its substance, contributing to its support; second, the **arachnoid,** a loosely constructed, thin membrane, separated from the pia mater by a considerable **subarachnoid space;** third, the **dura mater,** the outermost and thickest of the membranes, separated from the arachnoid by merely a slit-like space, the **subdural space.**

The intimate association of the central system with all the peripheral organs is attained chiefly through the spinal cord, and this is accomplished by means of thirty-one pairs of spinal nerves, which are attached along its lateral aspects. The nerves of each pair are attached opposite each other at more or less equal intervals along its entire length, and in passing to the periphery they penetrate the meninges, which contribute to and are continuous with the connective-tissue sheaths investing them. Each nerve is attached by two roots, an afferent or **dorsal root,** which enters the cord along its postero-lateral sulcus, and an efferent or **ventral root,** which makes its exit along the ventro-lateral aspect.

With its inequalities in thickness and its conical termination the spinal cord is subdivided into four parts or regions:—(1) The **cervical portion,** with eight pairs of cervical nerves; (2) the **thoracic portion,** with twelve pairs of thoracic nerves; (3) the **lumbar portion,** with five pairs of lumbar nerves; and (4) the **conus medullaris,** or sacral portion, with five pairs of sacral and one pair of coccygeal nerves. From the termination of the conus medullaris, the pia mater continues below in the subarachnoid space into the portion of the vertebral canal not occupied by the spinal cord, and forms the non-nervous, slender, thread-like terminus, the *filum terminale.* This becomes continuous with the dura mater at its lower extremity.

In the early fœtus the spinal nerves pass from their attachment to the spinal cord outward through the intervertebral foramina at right angles to the long axis of the cord, but, owing to the fact that the vertebral column increases considerably in length after the spinal cord has practically ceased growing, the nerve-roots become drawn caudad from their points of attachment, and, as is necessarily the case, their respective foramina are displaced progressively downward as the termination of the cord is approached, until finally the roots of the lumbar and sacral nerves extend downward as a brush of parallel bundles considerably below the levels at which they are attached. This brush of nerve-roots is the *cauda equina*. The dura mater, being more closely related to the bony wall of the canal than to the spinal cord, extends with the vertebral column and thus envelops the cauda equina, undergoing a slightly bulbous, conical dilation which decreases rapidly and terminates in the attenuated canal of the coccyx as the coccygeal ligament.

The enlargements.—Wherever there is a greater mass of tissue to be innervated, the region of the nervous system supplying such must of necessity possess a greater number of neurones. Therefore, the regions of the spinal cord associated with the skin and musculature of the regions of the superior and

FIG. 612.—DORSAL VIEW OF PORTION OF SPINAL CORD IN POSITION IN VERTEBRAL CANAL

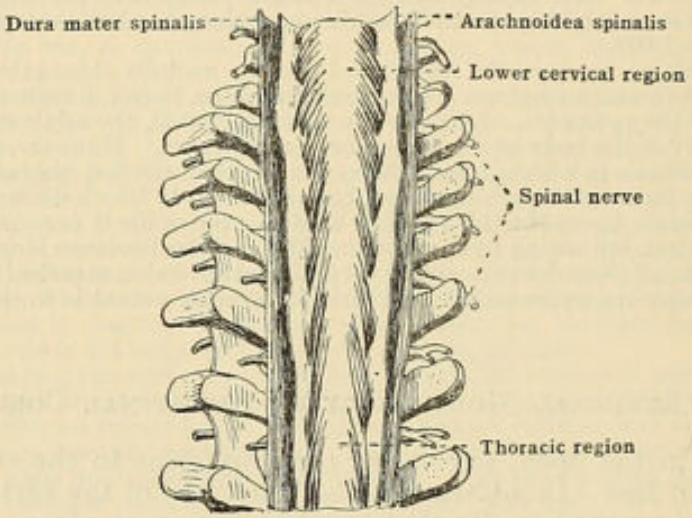

inferior limbs are thicker than the regions from which the neck or trunk alone are innervated. Thus in the lower cervical region the spinal cord becomes broadened into the *cervical enlargement*, and likewise in the lumbar region occurs the *lumbar enlargement*. The spinal nerves attached to these regions are of greater size than in other regions.

The **cervical enlargement** [intumescentia cervicalis] begins with the third cervical vertebra, acquires its greatest breadth (12 to 14 mm.) opposite the lower part of the fifth cervical vertebra (origin of the sixth cervical nerves), and extends to opposite the second thoracic vertebra. Unlike the lumbar enlargement, its lateral is noticeably greater than its dorso-ventral diameter.

The **lumbar enlargement** [intumescentia lumbalis] begins gradually with the ninth or tenth thoracic vertebra, is most marked at the twelfth thoracic vertebra (origin of the fourth lumbar nerves), and rapidly diminishes into the conus medullaris.

Both the lumbar and thoracic regions are practically circular in transverse section. Neither diameter of the lumbar is ever so great as the lateral diameter of the cervical enlargement. The thoracic part attains its smallest diameter opposite the fifth and sixth thoracic vertebræ (attachment of the seventh and eighth thoracic nerves.)

The enlargements occur with the development of the upper and lower limbs. In the embyro they are not evident until the limbs are formed. In the orang-utan and gorilla the cervical enlargement is greatly developed; the ostrich and emu have practically none at all.

Surface of the spinal cord.—The cord is separated into nearly symmetrical right and left halves by the broad **anterior median fissure** into which the pia mater is duplicated, and opposite this, on the dorsal surface, by the **posterior median sulcus.** Along the lower two-thirds of the cord this sulcus is shallowed to little

more than a line which marks the position of the posterior median septum; in the medulla oblongata it opens up and attains the character of a fissure. Each of the two lateral halves of the cord is marked off into a posterior, lateral, and anterior division by two other longitudinal sulci. Of these, the **postero-lateral sulcus** occurs as a slight groove 2 to 3½ mm. lateral from the posterior median sulcus, and is the groove in which the root filaments of the dorsal roots enter the cord in regular linear series. The ventral division is separated from the lateral

FIG. 613.—DRAWING FROM SPECIMEN SHOWING CAUDA EQUINA, THE ROOTS OF CERTAIN OF THE SPINAL NERVES WHICH FORM IT, AND ITS ACCOMPANYING DURA MATER. (Dorsal aspect.)

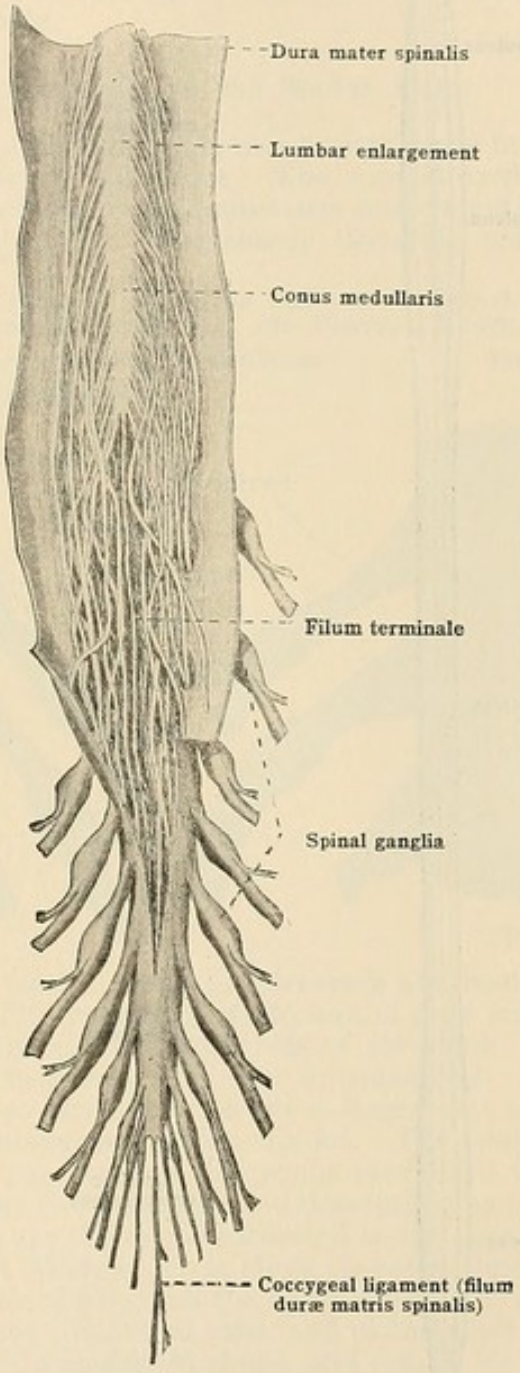

by the **antero-lateral sulcus.** This is rather an irregular, linear area than a sulcus. It is from 1 to 2 mm. broad, and represents the area along which the efferent fibres make their exit from the cord to be assembled into the respective ventral roots. This area varies in width according to the size of the nerve-roots, and, like the postero-lateral sulcus, its distance from the mid-line varies according to locality, being greatest on the enlargements of the cord. In the cervical region, and along a part of the thoracic, the posterior division is subdivided by a delicate longitudinal groove, the **postero-intermediate sulcus,** which becomes more evident

toward the medulla oblongata and represents the line of demarcation between the fasciculus gracilis and the fasciculus cuneatus. Occasionally in the upper cervical region a similar line may be seen along the ventral aspect close to the anterior

FIG. 614.—POSTERIOR AND ANTERIOR VIEWS OF THE SPINAL CORD. (Modified from Quain.)

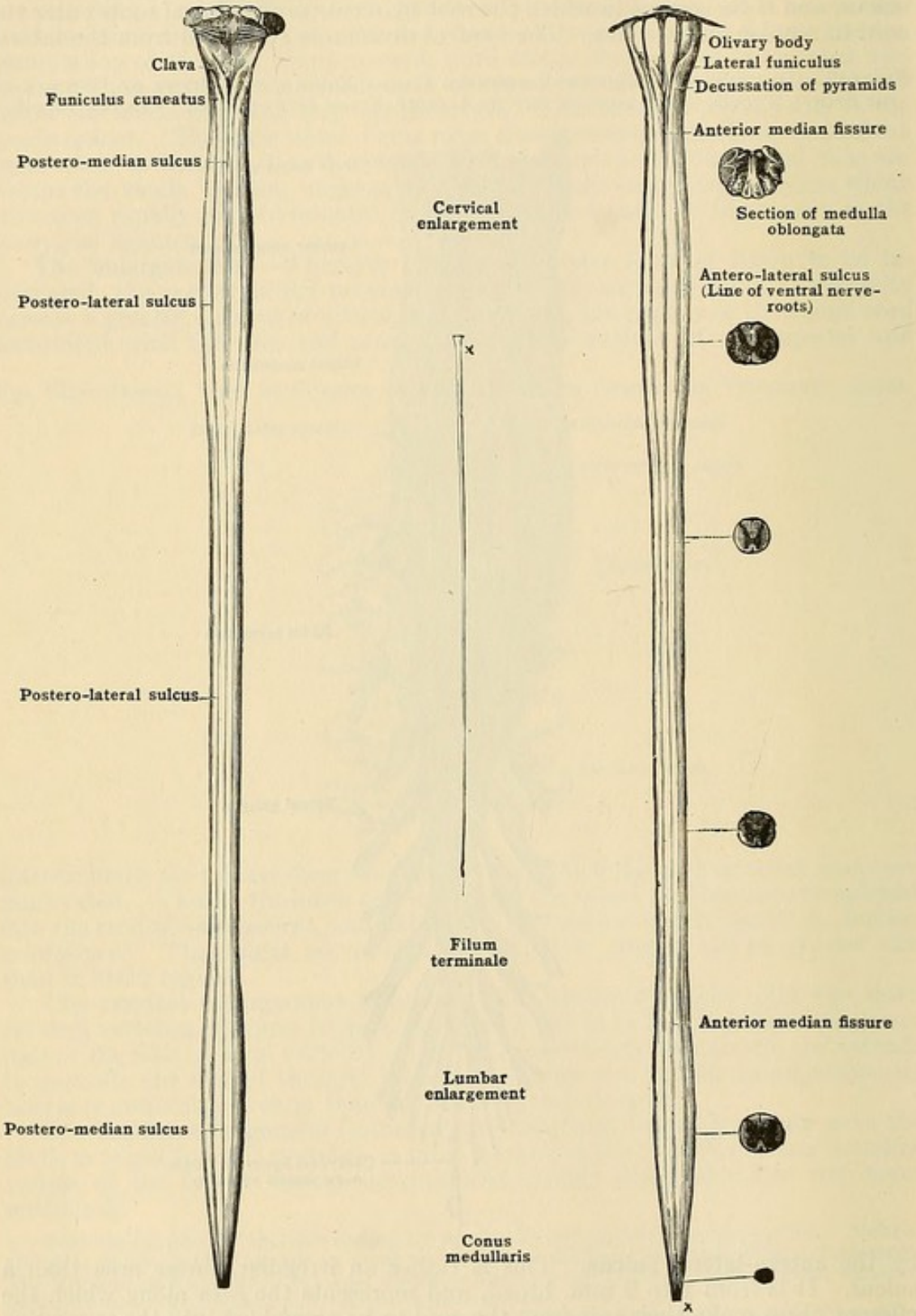

median fissure. This is the **antero-intermediate sulcus,** forming the lateral boundary of the ventral cerebro-spinal fasciculus.

Collectively, the entire space between the posterior median sulcus and the line of attachment of the dorsal roots is occupied by the **posterior funiculus;** the lateral space between the line of attachment of the dorsal and that of the ventral

roots, by the **lateral funiculus;** and the space between the ventral roots and the anterior median fissure, by the **anterior funiculus.** Each of these funiculi is subdivided within into its component fasciculi.

The dorsal and ventral nerve-roots are not attached to the cord as such, but are first frayed out into numerous thread-like bundles of axones which are distributed along their lines of entrance and exit. These bundles are the **root filaments** [fila radicularia] of the respective roots. The fila of the larger spinal nerves are fanned out to the extent of forming almost continuous lines of attachment, while in the thoracic nerves there are appreciable intervals between those of adjacent roots. Throughout, the intervals are less between the fila of the ventral than between those of the dorsal roots.

Internal Structure of the Spinal Cord

By reflected light masses of medullated axones appear white in the fresh, and such masses are known as **white substance.** The spinaal cord consists of a continuous, centrally placed column of grey substance surrounded by a variously thickened tunic of white substance. The closely investing pia mater sends

Fig. 615.—A, Ventral, and B, Dorsal, Views of Portion of Spinal Cord showing Modes of Attachment of Dorsal and Ventral Roots.

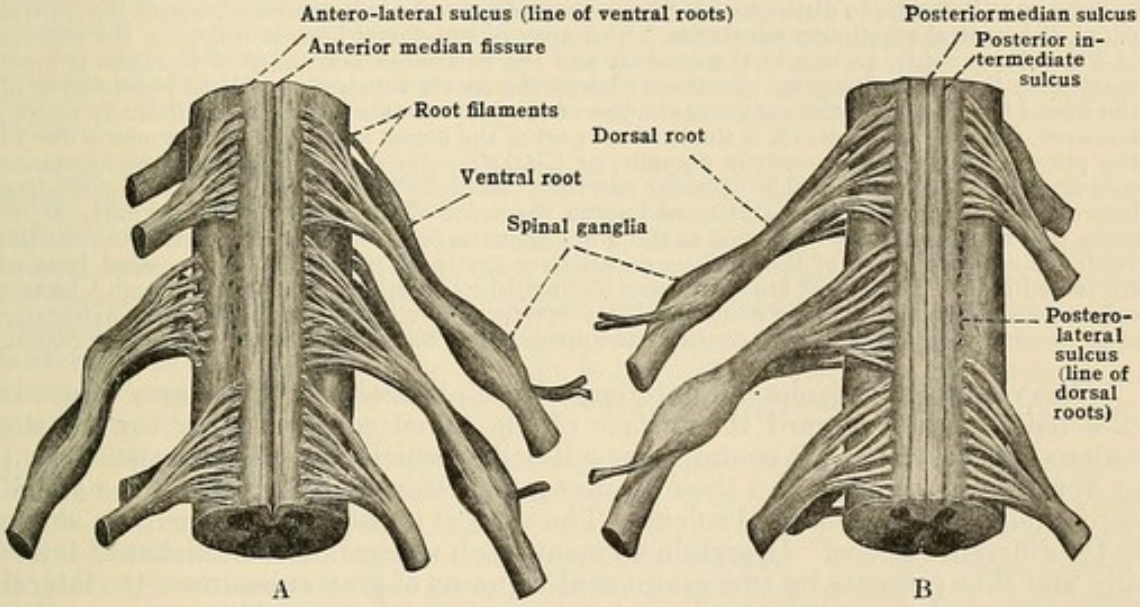

numerous ingrowths into the cord, bearing blood-vessels and contributing to its internal supporting tissue. The volume of white and of grey substance varies both absolutely and relatively at different levels of the cord. The absolute amount of grey substance increases with the enlargements. The absolute amount of white substance also increases with the enlargements coincident with the greater amount of grey substance in those regions. The relative amount of white substance increases in passing from the conus medullaris to the medulla oblongata, due to the fact that the ascending and descending axones associating the cord with the encephalon are the one contributed to the cord and the other gradually terminating in it at different levels along its entire descent.

The grey substance.—In the embryo all the nerve-cells of the grey substance are derived from the cells lining the neural tube, and in the adult the column of grey substance, though greatly modified in shape, still retains its position about the central canal. In transverse section the column appears as a grey figure of two laterally developed halves, connected across the mid-line by a more attenuated portion, the whole roughly resembling the letter H. The cross-bar of the H is known as the **grey commissure.** Naturally, it contains the **central canal,** which is quite small and is either rounded or laterally or ventrally oval in section, according to the level of the cord in which it is examined. The canal continues upward, and in the medulla oblongata opens out into the fourth ventricle. Downward, in the extremity of the conus medullaris, it widens slightly and forms the rhomboidal sinus or **terminal ventricle,** then is suddenly constricted into an extremely small

canal extending a short distance into the filum terminale, and there ends blindly. The grey commissure always lies somewhat nearer the ventral than the dorsal surface of the cord, and itself contains a few medullated axones which vary in amount in the different regions of the cord. The medullated axones crossing the mid-line on the ventral side of the central canal form the ventral or **anterior white commissure**; those, usually much fewer in number, crossing on the dorsal side of the central canal, form the dorsal or **posterior white commissure.** These two commissures comprise fibres crossing in the grey substance as distinguished from others which cross in the white substance dorsal and ventral to them. The axones of these commissures serve in functionally associating the two lateral halves of the grey column.

Each lateral half of the grey column presents a somewhat crescentic or comma-shaped appearance in transverse section, which also varies at the different levels of the cord. At all levels each half presents two vertical, well-defined horns, themselves spoken of as columns of grey substance. The **dorsal horn** [columna posterior] extends posteriorly and somewhat laterally toward the surface of the cord along the line of the postero-lateral sulcus. It is composed of an **apex** and a **neck** [cervix columnæ posterioris].

In structure the apex is peculiar. The greater portion of it consists of a mass of small nerve-cells and neuroglia tissue, among which a gelatinous substance of questionable origin predominates, giving the horn a semi-translucent appearance. This is termed the **gelatinous substance of Rolando,** to distinguish it from a similar appearance immediately about the central canal, **the central gelatinous substance.** The apex of the dorsal horn is widest in the regions of the enlargements, especially the lumbar, and the gelatinous substance of Rolando is most marked in the cervical region. In these regions the cervix consists of a slight constriction of the dorsal horn between the apex and the line of the grey commissure. In the thoracic region, however, the base of the cervix is the thickest part of the dorsal horn. This thickness is due to the presence there of the **nucleus dorsalis,** or Clarke's column—a column of grey substance containing numerous nerve-cells of larger size than elsewhere in the dorsal horn, and extending between the seventh cervical and third lumbar segments of the cord. Tapering finely at its ends, this nucleus attains its height in the lower thoracic or first lumbar segment. About the ventro-lateral periphery of the nucleus dorsalis are scattered nerve-cells of the same type as contained in it. These cells are sometimes distinguished as **Stilling's nucleus,** though Clarke's column was also described by Stilling. They are more numerous about the lower extremity of the nucleus dorsalis, and they continue to appear below its termination in the lumbar region.

The **ventral horn** [columna anterior] of each lateral half of the grey figure is directed ventrally toward the surface of the spinal cord, pointing toward the antero-lateral sulcus. It contains the cell-bodies which give origin to the efferent or ventral root axones, and these axones make their emergence from the spinal cord along the antero-lateral sulcus. The ventral horns vary markedly in shape in the different regions. In certain segments each ventral horn is thickened laterally and thus presents its two component columns of grey substance: the **lateral horn** [columna lateralis], a triangular projection of grey substance into the surrounding white substance, in line with or a little ventral to the line of the grey commissure; and the **ventral horn proper** [columna anterior], projecting ventrally. In the mid-thoracic region the lateral horn is relatively insignificant, and the anterior horn is quite slender; in the cervical and lumbar enlargements both horns are considerably enlarged.

The grey substance is not sharply demarcated from the white. In the blending of the two there are often small fasciculi of white substance embedded in the grey, and likewise the grey substance sends fine processes among the axones composing the white substance. Such processes or grey trabeculæ are most marked along the lateral aspects of the grey figure and present there the appearance known as the **reticular formation.** The reticular formation of the spinal cord is most evident in the cervical region (fig. 616).

Minute structure.—The large cell-bodies of the ventral horn as a whole are divisible into four groups, only three of which are to be distinguished in the mid-thoracic region of the spinal cord:—(1) A *ventral group* of cells, sometimes separated into a ventro-lateral and a ventro-medial portion (see figs. 616, 619), occupies the ventral horn proper, is constant throughout the entire length of the cord, and contributes axones to the ventral root, most of which probably supply the muscles adjacent to the vertebral column; (2) a *dorso-medial group* of cells, situated in the medial part of the ventral horn, just below the level of the central canal, gives origin to axones some of which go to the ventral root of the same side, but most of which cross the mid-line viâ the anterior white commissure, either to pass out in the ventral root of the opposite side or to enter the white substance of that side and course upward or downward, associating with other levels of the cord. Some of its axones terminate among the cells of the ventral horn

in the same level of the opposite side; (3) a *lateral group* of cells, sometimes separated into a dorso-lateral and a ventro-lateral portion, occupies the lateral column or horn, and is best differentiated in the cervical and lumbar enlargements. Most of the axones arising from its larger cells are contributed to the ventral root of the same side, and such axones probably supply the muscles of the extremities. Some of those from its ventral portion are distributed to the muscles of the body-wall; the dorso-lateral portion is that part of the lateral column which persists throughout the cord, and is considered as supplying the visceral efferent fibres in the ventral roots. (4) an *intermediate group*, occupying the mid-dorsal portion of the ventral horn. Axones arising from its cells are probably seldom contributed to the ventral root, but instead course wholly within the central nervous system. Some pass to the opposite side of the cord, chiefly viâ the anterior and possibly the posterior white commissure, to terminate either in the same or different levels of the grey column. Others of longer course pass to the periphery of the cord, join one of the spino-cerebellar fasciculi, and pass upward to the cerebellum.

Furthermore, there are scattered throughout the grey substance many smaller cell-bodies of neurones. These give rise to axones of shorter course, either **commissural** or **associational** proper. Of such axones many are quite short, coursing practically in the same level as that in which their cells of origin are located, and serve to associate the different parts of the grey substance of that level. Others course varying distances upward and downward for the association of different levels of the grey column.

It is evident from the above that in addition to the various nerve-cells it contains, there is also to be found a felt-work of axones in the grey substance. Many of these axones are medullated, though not in sufficient abundance to destroy the grey character of the substance. The felt-work is composed of three general varieties of fibres:—(1) The terminal branches of axones entering from the fasciculi of the white substance and forming end-brushes about the various cell-bodies in the grey substance (partly medullated); (2) axones given off from the cells of the grey substance and which pass into the surrounding white substance either to enter the ventral-roots or to join the ascending and descending fasciculi within the spinal cord (partly medullated); (3) axones of Golgi neurones of type II, which do not pass outside the confines of the grey substance (non-medullated). Some axones of any of these varieties may cross the mid-line and thus become commissural. In general all fibres of long course acquire medullary sheaths a short distance from their cells of origin, and lose them again just before termination.

The white substance of the spinal cord.—The great mass of the axones of the spinal cord course longitudinally and form the thick mantle surrounding the column of grey substance. This mantle is divided into right and left homolateral halves by the anterior median fissure along its ventral aspect, and along its dorsal aspect by the posterior median septum, which is for the most part a connective-tissue partition derived from the pia mater along the line of the posterior median sulcus. The mantle is supported internally by interwoven neuroglia and white fibrous connective tissue, the latter, derived chiefly from the pia mater, closely investing it without.

The axones of the white substance belong to three general neurone systems:—(1) The *spino-cerebral and cerebro-spinal system*, which consists of axones of long course, one set ascending and another descending, forming links in the neurone chains between the cerebrum and the peripheral organs. The ascending axones of this system collect the general bodily sensations which are conveyed to the cerebrum, the cells of which in response contribute axones which descend the cord, conveying efferent or motor impulses. (2) The *spino-cerebellar and cerebello-spinal* system consists of conduction paths, one set ascending and another descending, which are connections between cerebellar structures and the grey substance of the spinal cord. (3) The *spinal association* and *commissural system* of axones which serve to *associate* the different levels and the two sides of the spinal cord and which are proper to the spinal cord, i. e., they do not pass outside its confines.

Both the first and second systems increase in bulk as the cord is ascended. The ascending axones of each system are contributed to the white substance of the cord along its length, and therefore accumulate upward; the axones descending from the encephalon are distributed to the different levels of the cord along its length, and therefore diminish downward.

The mass of the third system of axones varies according to locality. Wherever there is a greater mass of neurones to be associated, as there is in the enlargements of the cord, a greater number of these axones is required. Their cells of origin, being in the grey substance of the cord, contribute to its bulk and thus both the cells and the axones of this system serve to make the enlargements more marked. In the lumbar and sacral regions the greater mass of the entire white substance consists of axones belonging to this system. It forms a dense felt-work about the grey column throughout the cord. Necessarily this system contains axones of various lengths. Some merely associate different levels within a single segment

FIG. 616.—TRANSVERSE SECTIONS FROM DIFFERENT SEGMENTS OF THE SPINAL CORD, SHOWING SHAPE AND RELATIVE PROPORTIONS OF GREY AND WHITE SUBSTANCE IN THE VARIOUS REGIONS.

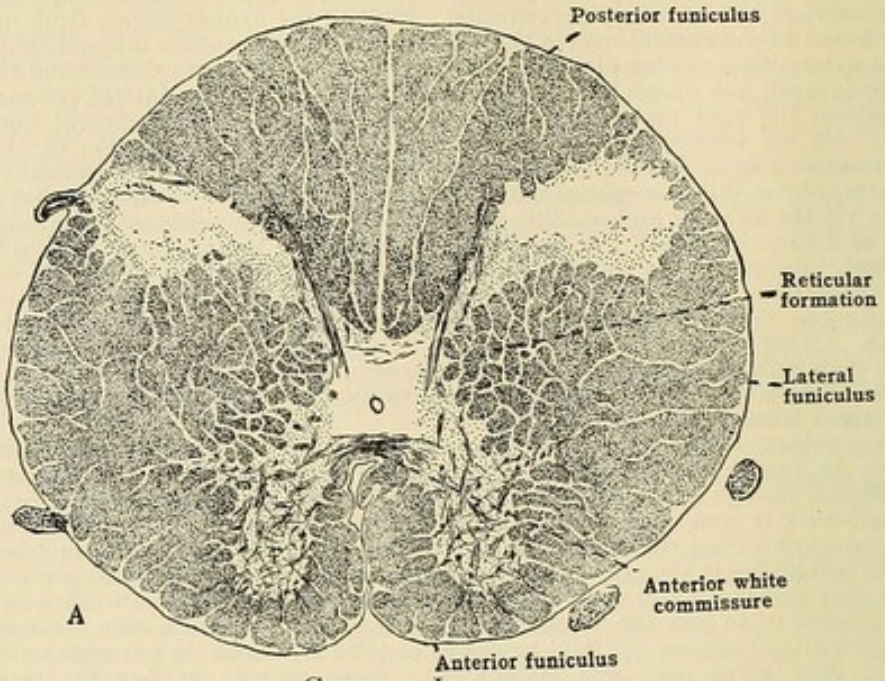

CERVICAL I

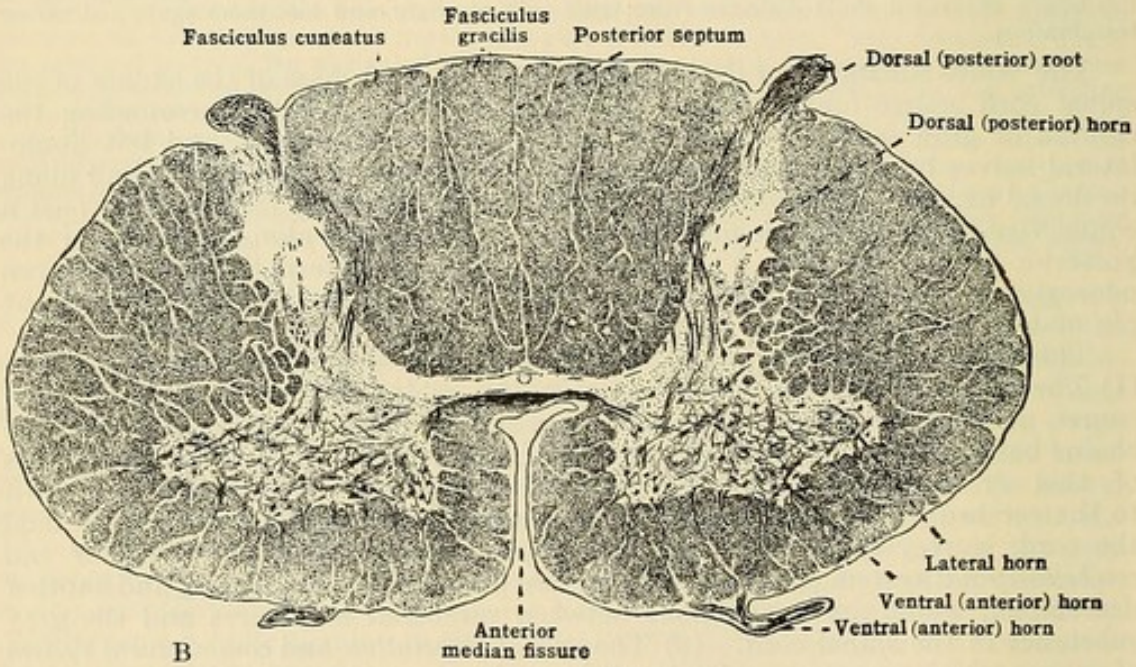

CERVICAL VI

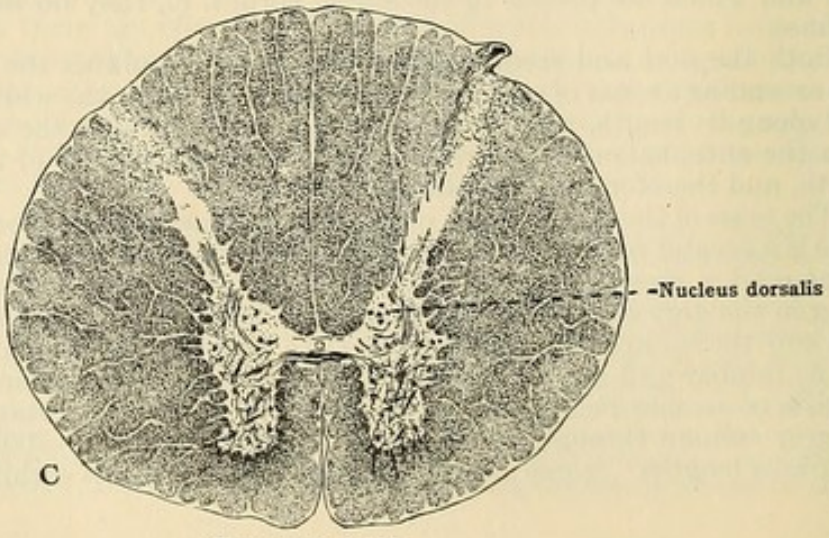

THORACIC VIII

of the cord; others associate the different segments with each other. Axones which associate the structures of the spinal cord with those of the medulla oblongata may be included in this system. Many of these axones cross the midline both in the grey and in the white substance to associate the neurones of the two sides of the grey column. For purposes of distinction, such as cross the midline are called **commissural fibres,** while those which course upward and down-

FIG. 616—*Continued.*



D

LUMBAR III

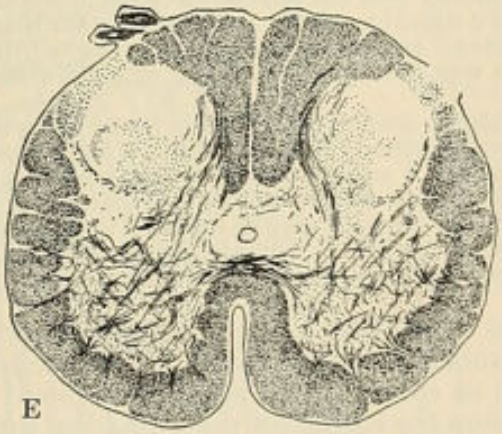

E

SACRAL IV



F

COCCYGEAL

ward on the same side are **association fibres.** Coursing in longitudinal bundles about the grey figure, the latter compose the **fasciculi proprii** or 'ground bundles' of the spinal cord.

METHODS BY WHICH THE CONDUCTION PATHS HAVE BEEN DETERMINED

A purely anatomical examination of a normal adult cord, prepared by whatever means, gives no indication of the fact that the mass of longitudinally coursing fibres of the white sub-

stance is composed of more or less definite bundles or fasciculi, each having a definite course, and whose axones form links (conduction paths) in a definite system of neurone chains.

Present information as to the size, position, and connections of the various fasciculi is based upon evidence obtained by three different lines of investigation:—

(1) **Physiological investigation.**—(*a*) Direct stimulation of definite bundles or areas in section and carefully noting the resulting reactions which indicate the function and course of the axones stimulated. (*b*) 'Wallerian degeneration' and the application of such methods as that of Marchi. When an axone is severed, that portion of it which is separated from its parent cell-body degenerates. Likewise a bundle of axones severed from their cells of origin, whether by accident or design, will degenerate from the point of the lesion on to the locality of their termination in whichever direction this may be. This phenomenon was noted by Waller in 1852 and is known as **Wallerian degeneration.** By the application of a staining technique which is differential for degenerated or degenerating axones and a study of serial sections containing the axones in question, their course and distribution may be determined. The locality of their cells of origin, if unknown, may be determined by repeated experiment till a point of lesion is found not followed by degeneration of the axones under investigation. (*c*) The axonic reaction or 'reaction from a distance.' Cell-bodies whose axones have been severed undergo chemical change and stain differently from those whose axones are intact. Thus cell-bodies giving origin to a bundle of severed axones may be located in correctly stained sections of the region containing them.

(2) **Embryological evidence.**—In the first stages of their development axones of the cerebro-spinal nervous system are non-medullated. They acquire their sheaths of myelin later. Axone pathways forming different chains become medullated at different periods. Based upon this fact a method of investigation originated by Flechsig is employed, by which the position and course of various pathways may be determined. A staining method differential for medullated axones alone is applied to the nervous systems of fœtuses of different ages, and pathways medullated at given stages may be followed from the locality of their origin to their termination. In the later stages, when most of the pathways are medullated and therefore stain alike, the less precocious pathways may be followed by their absence of medullation.

(3) **Direct anatomical evidence.**—(*a*) Stains differential for axones alone are applied to a given locality to determine the fact that the axones of a given bundle actually arise from the cell-bodies there, or that axones traced to a given locality actually terminate about the cell-bodies of that locality. For example, it may be proved anatomically that the axones of a dorsal root arise from the cells of the corresponding spinal ganglion, and then these axones may be traced into the spinal cord and their terminations noted either by collateral or terminal twigs, or the fasciculus they join in their cephalic course may be determined. (*b*) The staining properties and the size and distribution of the tigroid masses in the cell-bodies of sensory neurones differ from those in the motor neurones, and recently Malone has claimed that, in the central system, the cell-bodies in the nuclei of sensory neurone chains, those ascending toward the cerebral cortex, may be distinguished from the cell-bodies of the motor or descending chains by the arrangement and size of their tigroid masses. He claims further that in the same way, the cell-bodies of the somatic efferent neurones may be distinguished from those of the visceral efferent neurones. In this way the locality of origin of certain physiologically known paths may be determined.

(4) The so-called *pathologico-anatomical method* is based upon the same general principles as is the physiological (or experimental) method. A pathological lesion, a local infection or a tumor for example, may destroy a nucleus of cell-bodies or sever a bundle of axones, and the resulting degeneration of the axones may be followed through serial sections suitably prepared. The locality of the lesion known, the path may be followed to determine the locality of its termination; its locality of termination known from the symptoms resulting, the path may be followed to its cells of origin, or to determine whatever be the locality of the lesion.

Funiculi.—In order that the various fasciculi may be referred to with greater ease, the white substance of the spinal cord in section is divided into three areas known as funiculi or columns and which correspond to the funiculi already mentioned as evident upon the surface of the cord when intact. The funiculi are outlined wholly upon the basis of their position in the cord and with reference to the median line and the contour of the column of grey substance; their component fasciculi are defined upon the basis of function. (1) The *posterior funiculus* or column is bounded by the posterior median septum and the line of the dorsal horn; (2) the *lateral funiculus* or column is bounded by the lateral concavity of the grey column and the lines of entrance and exit of the dorsal and ventral roots; (3) the *ventral funiculus* or column is bounded by the line of exit of the ventral roots, and by the anterior median fissure.

The posterior funiculus or column [funiculus posterior].—This funiculus is composed of two general varieties of axones arranged in five fasciculi. First, and constituting the predominant type in all the higher segments of the cord, are the afferent or general sensory axones, which arise in the spinal ganglia, enter the cord by the dorsal roots, assume their distribution to the neurones of the cord, and then take their ascending course toward the encephalon. The axone of the spinal ganglion neurone undergoes a T-shaped division a short distance from the cell-body, one limb of this division terminating in the peripheral organs and the other going to form the dorsal root. Upon entering the cord the dorsal root axones

undergo a Y-shaped bifurcation in the neighbourhood of the dorsal horn, one branch ascending and the other descending. Their ascending branches form the **fasciculus gracilis** (Goll's column) and the **fasciculus cuneatus** (Burdach's column). These fasciculi are the chief ascending or sensory spino-cerebral connections, the direct sensory path to the brain. The neurones represented in them constitute the first link in the neurone chain between the periphery of the body and the cerebral cortex.

FIG. 617.—SHOWING DISPOSITION OF THE DORSAL ROOT FIBRES UPON ENTERING THE SPINAL CORD. (From Edinger, after Cajal.)

A, shows dorsal root axones DR, entering the spinal cord, bifurcating at B, and giving off collaterals C to the neurones of the cord. B shows the telodendria of these axones or of their collaterals displayed upon cell-bodies of the grey substance of the cord.

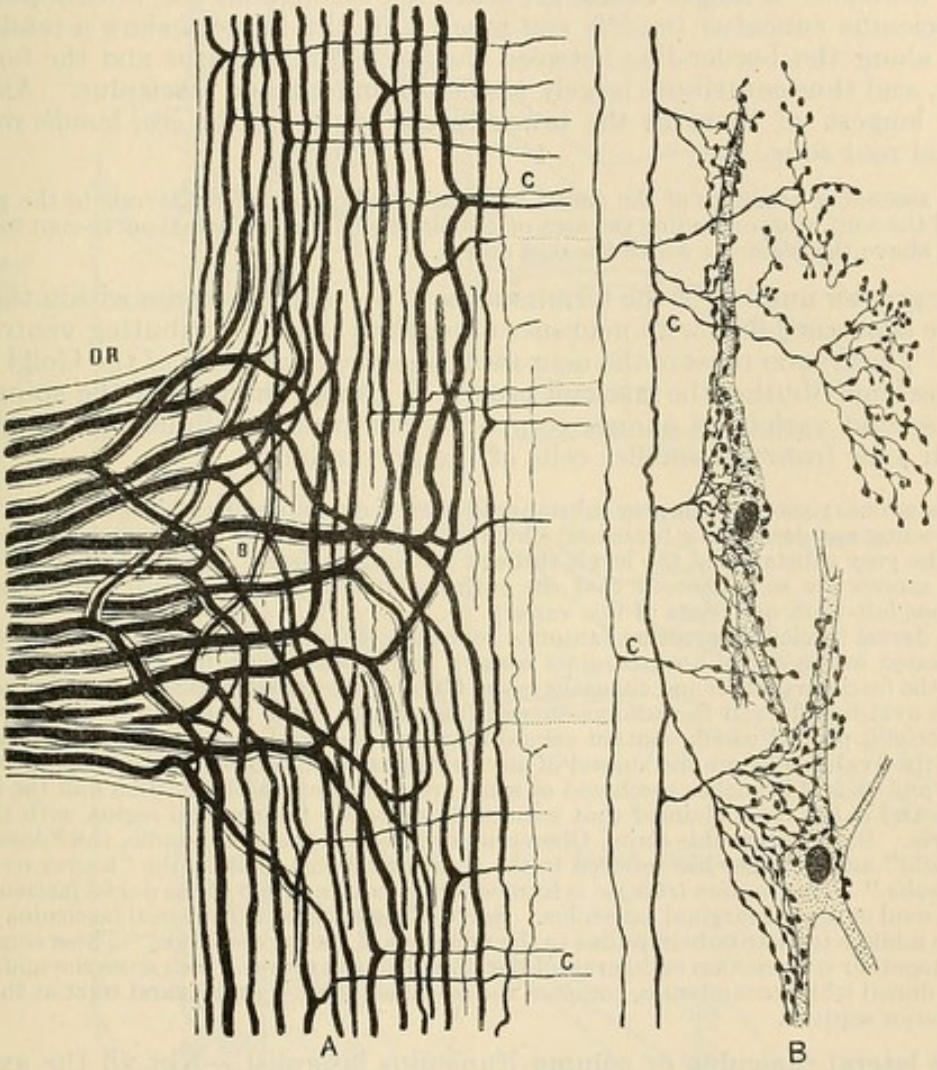

In threading their way toward the brain, these sensory axones tend to work toward the midline. Therefore those of longer course are to be found nearer the posterior septum, in the upper segments of the cord, than those axones which enter the cord by the dorsal roots of the upper segments. Thus it is that the fasciculus gracilis, the medial of the two fasciculi, contains the axones which arise in the spinal ganglia of the sacral and lumbar segments. In other words, it is the fasciculus bearing sensory impulses from the lower limbs to the brain, while the fasciculus cuneatus, the lateral of the two, is the corresponding pathway for the higher levels. Naturally, there is no fasciculus cuneatus as such in the lower segments of the spinal cord. The axones being much blended at first, it is only in the upper thoracic and cervical region that there is any anatomical demarcation between the two fasciculi. In this region the two become so distinct that there is in some cases an apparent connective-tissue septum between them, continuing inward from the postero-intermediate sulcus—the surface indication of the line of their junction (fig. 616).

Upon reaching the medulla oblongata the fibres of the fasciculus gracilis and the fasciculus cuneatus terminate about cells grouped to form the nuclei of these fasciculi. The nucleus of the fasciculus gracilis is situated medially and begins just below the point at which the central canal opens into the fourth ventricle; the nucleus of the fasciculus cuneatus is placed laterally and extends somewhat higher than the other nucleus. The neurones whose cell-bodies compose these

nuclei constitute the second links in the neurone chains conveying sensory impulses from the periphery to the cerebral cortex.

The descending or *caudal branches* of the dorsal root axones are concerned wholly with the neurones of the spinal cord. They descend varying distances, some of them as much as four segments of the cord, and give off numerous collaterals on their way to the cells of the grey column. Those terminating about cell-bodies of the ventral horn which give rise to the ventral or motor root-fibres, are responsible for certain of the so-called *'reflex activities'* and thus contribute to the simplest of the **reflex arcs.** In descending they serve to associate different levels of the grey substance of the cord with impulses entering by way of a single dorsal root. Some of their collaterals cross the mid-line in the posterior white commissure, and thus become connected with neurones of the opposite side. The caudal branches of longer course are scattered throughout the ventral portion of the fasciculus cuneatus (*middle root zone*), and the longest show a tendency to collect along the border-line between the fasciculus cuneatus and the fasciculus gracilis, and thus contribute largely to the **comma-shaped fasciculus.** Also some of the longest of them in the lower levels course in the *oval bundle* or septo-marginal root zone.

The ascending branches of the dorsal root axones also give off collaterals to the grey substance of the cord, thus extending the area of distribution of a given dorsal nerve-root to levels of the cord above the region at which the root enters.

The greater number of the terminations of dorsal root axones within the spinal cord are concerned first with neurones other than those contributing ventral root-fibres. The greater mass of the neurones concerned are those of the Golgi type II and those contributing the **fasciculi proprii** or **ground bundles** of the spinal cord, or the second variety of axones composing the posterior funiculus. The latter fasciculi arise from the smaller cells of the grey column.

These axones pass from the grey substance to enter the surrounding white substance, bifurcate into ascending and descending branches, which in their turn give off numerous collaterals to the cells of the grey substance of the levels through which they pass. The cell-bodies giving origin to such axones are so numerous that the entire column of grey substance is surrounded by a continuous felt-work of axones of this variety.

The **dorsal fasciculus proprius** (anterior root zone of posterior column) arises chiefly from cells situated in the dorsal horn (*stratum zonale*). Coincident with the ingrowth and arrangement of the fasciculi gracilis and cuneatus many fibres of the dorsal fasciculus proprius go to form both the oval bundle and the comma-shaped fasciculus. Thus these two bundles are mixed, being fasciculi proprii which contain caudal branches of dorsal root axones. The association fibres in the oval bundle are the longest of any belonging to the dorsal fasciculus proprius. The cephalic and caudal branches combined of some are said to extend more than half the length of the cord and it has been claimed that some even associate the cervical region with the conus medullaris. Based upon this claim, Obersteiner has called the oval bundle, the "dorso-medial sacral field" and Edinger has referred to the most dorsal part of it as the "*tractus cervico-lumbalis dorsalis.*" The '*median triangle*' is formed by the continuation of the dorsal fasciculi proprii with the oval or septo-marginal fasciculus. Some of the axones of the dorsal fasciculus proprius cross the midline to distribute impulses to the neurones of the opposite side. These commissural axones, together with certain collaterals of the dorsal root axones, which cross the mid-line outside the dorsal white commissure, compose the so-called **cornu-commissural tract** at the base of the posterior septum.

The lateral funiculus or column [funiculus lateralis].—Not all the axones of the posterior or dorsal nerve-roots extend to the encephalon. Estimation shows that the sum of all the dorsal roots is greatly in excess of the sum contained in the fasciculi cuneatus and gracilis just before these enter their nuclei of termination. Therefore many of the ascending dorsal root axones are concerned with spinal-cord relations wholly.

The **marginal zone of Lissauer,** situated along the lateral margin of the postero-lateral sulcus. is composed largely of dorsal root axones. Many of these finally work across the line of the sulcus into the posterior funiculus. Many of the dorsal root-fibres which do not reach the brain occur in Lissauer's zone. Many others of course occur throughout the posterior column. Lissauer's zone also contains some fibres arising from the small cells of the dorsal horn, and to this extent corresponds to a fasciculus proprius. Ranson has found that large numbers of the non-medullated dorsal root axones which enter the cord are contributed to Lissauer's zone.

The **lateral fasciculus proprius** (lateral ground bundle, lateral limiting layer) is situated in the lateral concavity of the grey column and is continuous with the other fasciculi proprii both dorsal and ventral. Beyond that it probably contains

fewer commissural axones, it is of the same general significance as the others. It is frequently divided into small bundles by the reticular formation (see fig. 616).

The lateral cerebro-spinal fasciculus (crossed pyramidal tract). In contrast to the sensory fibres passing through the spinal cord conveying impulses destined to reach the cerebral cortex, axones are given off from the pyramidal cells of the

FIG. 618.—DIAGRAM ILLUSTRATING THE FORMATION OF THE FASCICULI PROPRII (ASSOCIATION FASCICULI) AND THE COMMISSURAL FIBRES OF THE SPINAL CORD, AND THE GENERAL ARCHITECTURE OF THE CORD AS A MECHANISM FOR REFLEX ACTIVITIES.

The ventral fasciculus proprius is omitted and the lateral is shown on one side only. The lower spinal ganglion neurone shown illustrates the type whose ascending branch is of much longer extent than that of the upper one.

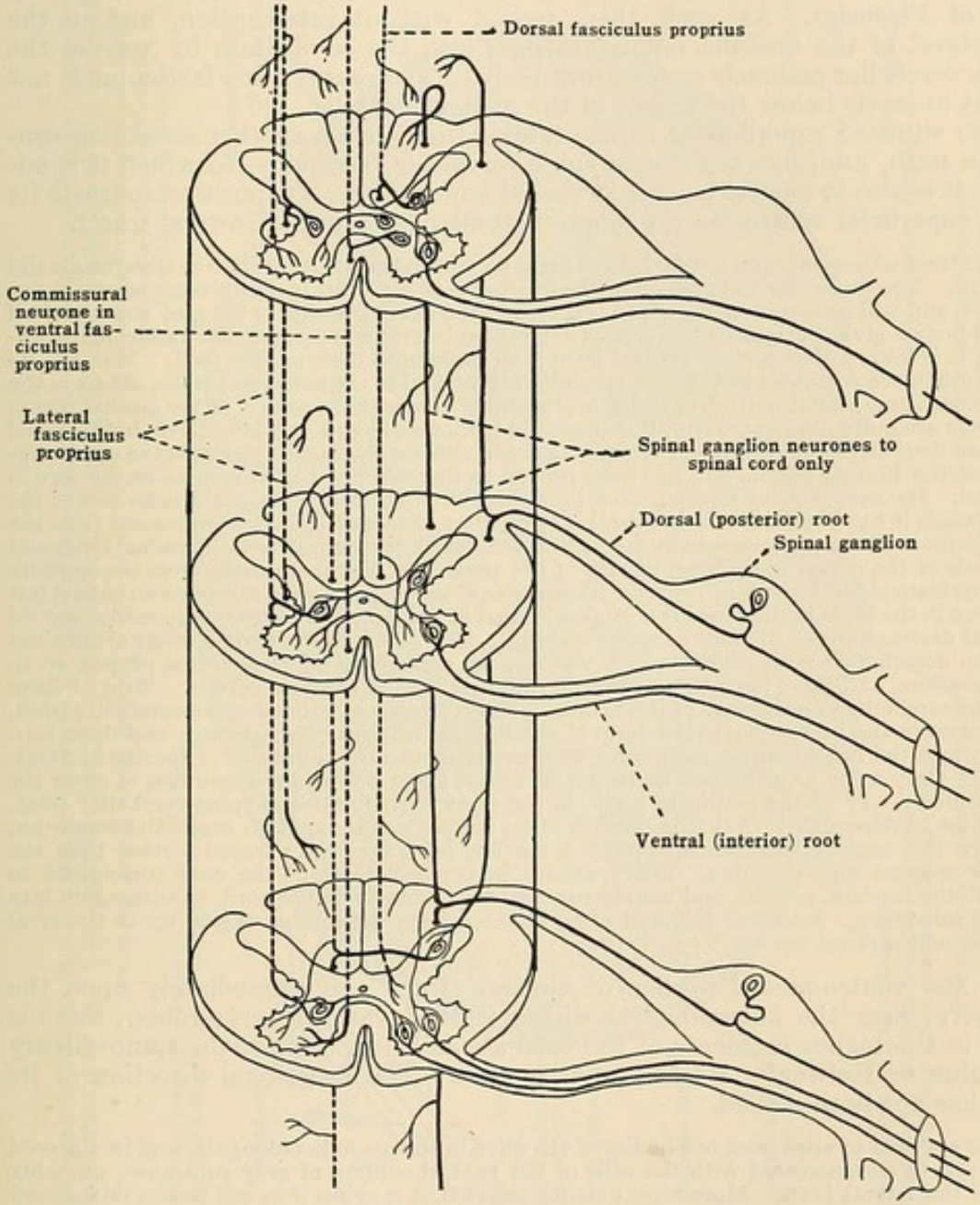

cortex, which descend to terminate about the cells of the grey substance of the spinal cord, chiefly the cells which give origin to the ventral root-fibers.

Upon reaching the medulla oblongata in their descent, these axones are accumulated into two well-defined, ventrally placed bundles, the **pyramids,** one from each cerebral hemisphere. In passing through the brain stem the pyramids contribute many fibres which cross the mid-line to terminate in the motor nuclei of the cranial nerves of the opposite side, and thus decrease appreciably in bulk. According to the estimate of Thompson, only about 160,000 of the pyramidal fibres are destined to enter the spinal cord.

Upon reaching the lower part of the medulla, the greater mass of the fibres of each pyramid, which are destined to enter the cord, suddenly cross the mid-line in the 'decussation of the

pyramids.' The remainder retain their ventral position in their descent decussating gradually in the cord itself. The pyramidal fibres which cross in the medulla course in the lateral column ventral to Lissauer's zone, and lateral to the lateral fasciculus proprius, and form the *lateral cerebro-spinal fasciculus* (crossed pyramidal tract). It is a large fasciculus, oval shaped in transection, and since its axones terminate in the grey column of the cord all along its length, it decreases in bulk as the cord is descended.

In addition to the three dispositions of the dorsal root axones given above, certain of them, either by collaterals or terminal twigs, form telodendria about the cells of the dorsal nucleus (Clarke's column), which nucleus extends from about the seventh cervical to the third lumbar segment of the cord. The axones given off by these cells pass to the dorso-lateral periphery of the lateral funiculus, and there collect to form the **dorsal spino-cerebellar fasciculus** (direct cerebellar tract of Flechsig). As such they ascend without interruption, and in the upper level of the medulla oblongata pass into the cerebellum by way of the inferior cerebellar peduncle or restiform body. Necessarily, this fasciculus is not evident in levels below the extent of the nucleus dorsalis.

Also situated superficially in the lateral funiculus is another ascending conduction path, and, like the dorsal spino-cerebellar fasciculus, to which it is adjacent, it is also in part at least a cerebellar connection. Its position suggests its name, **superficial ventro-lateral spino-cerebellar fasciculus (Gowers' tract).**

This tract at present does not include as great an area in transverse section as when originally described. The more internal portion of the original Gowers' tract is now given a separate significance, and will be considered separately. While the exact location in the grey column of all the cell-bodies giving origin to the superficial ventro-lateral spino-cerebellar fasciculus is uncertain, it is known that certain ventral horn cells contribute their axones to it. Many of its cells of origin are scattered in the area immediately ventral to the nucleus dorsalis, others in the intermediate and mesial portion of the lateral group of ventral horn cells. In the lumbar region these cells are quite numerous, and, therefore, the fasciculus begins at a lower level in the spinal cord than does the direct cerebellar tract. In degenerations it becomes visible in the upper segments of the lumbar region, and has been proved to increase notably in volume as the cord is ascended. Its axones arise for the most part directly from cell-bodies of the same side of the cord, though it has been shown by several investigators that many of its axones come from the grey substance of the opposite side by way of the ventral white commissure. Terminal twigs and collaterals of the dorsal root-fibres, mostly of the same side, but occasionally from the opposite side, terminate about its cells of origin. At one time Gowers' tract was considered an entity, but now, even in the more limited area it occupies, it must be considered a mixture of axones of several terminal destinations or distinct neurone systems. The destination of some of its axones has not been determined with certainty. A portion, the spino-cerebellar fasciculus proper, go to the cerebellum, and there have been traced to the cortex of the superior vermis. Most of these reach the cerebellum not by way of the restiform body, as does the dorsal spino-cerebellar tract, but pass on in the brain-stem to the level of the inferior corpora quadrigemina, and there turn back to join the brachium conjunctivum or superior cerebellar peduncle. (Auerbach, Mott, Hoche.) Only a few of its axones leave the fasciculus lower down in the medulla, to enter the cerebellum by way of the restiform body, in company with the dorsal spino-cerebellar tract. (Rossolimo, Tschermak.) Another portion of its axones are thought to reach the cerebrum, probably the nucleus lentiformis, though it has not been positively traced further than the superior corpora quadrigemina. Many axones in Gowers' tract of the cord correspond to those of the fasciculi proprii, and merely run varying distances in the cord, to turn again into its grey substance. Schaeffer followed some of these from the lumbar region up to the level of the second cervical nerve.

In the ventro-mesial border of Gowers' tract and immediately upon the periphery, near the antero-lateral sulcus (exit of ventral nerve-roots), there is found in the higher segments of the cord a small oval bundle, the **spino-olivary fasciculus** or **Helweg's** (Bechterew's) **bundle.** The functional direction of its fibres has not been settled.

It is asserted to arise from cell-bodies of the olive in the medulla oblongata, and in the cord is believed to be associated with the cells of the ventral column of grey substance, probably those of the lateral horn. More recent claims assert that it arises fron cell bodies in the cord and thus is spino-olivary. By some observers it has been traced as far down as the mid-thoracic region; by others, however, only as far as the third cervical segment. The olives being nuclei largely concerned with cerebellar connections, Helweg's fasciculus is probably an indirect cerebellar association with the spinal cord neurones. It is composed of axones of relatively very small diameter, and it is one of the last fasciculi of the spinal cord to become medullated.

Situated between the superficial ventro-lateral spino-cerebellar fasciculus and the lateral fasciculus proprius is an area which, in transverse sections, may be, by position, referred to collectively as the **intermediate fasciculus.** So intermingled are the axones comprising it that it has been called the **mixed lateral zone.** It contains fibres of at least five functional varieties:

FIG. 619.—SCHEMATIC REPRESENTATION OF THE SHAPE AND POSITION OF THE VARIOUS FASCICULI OR CONDUCTION PATHS OF THE SPINAL CORD AND THE GROUPING AND SIGNIFICANCE OF THE CELL-BODIES OF THE GREY SUBSTANCE. (Compiled from the schemes of von Lenhossèk and Held.)

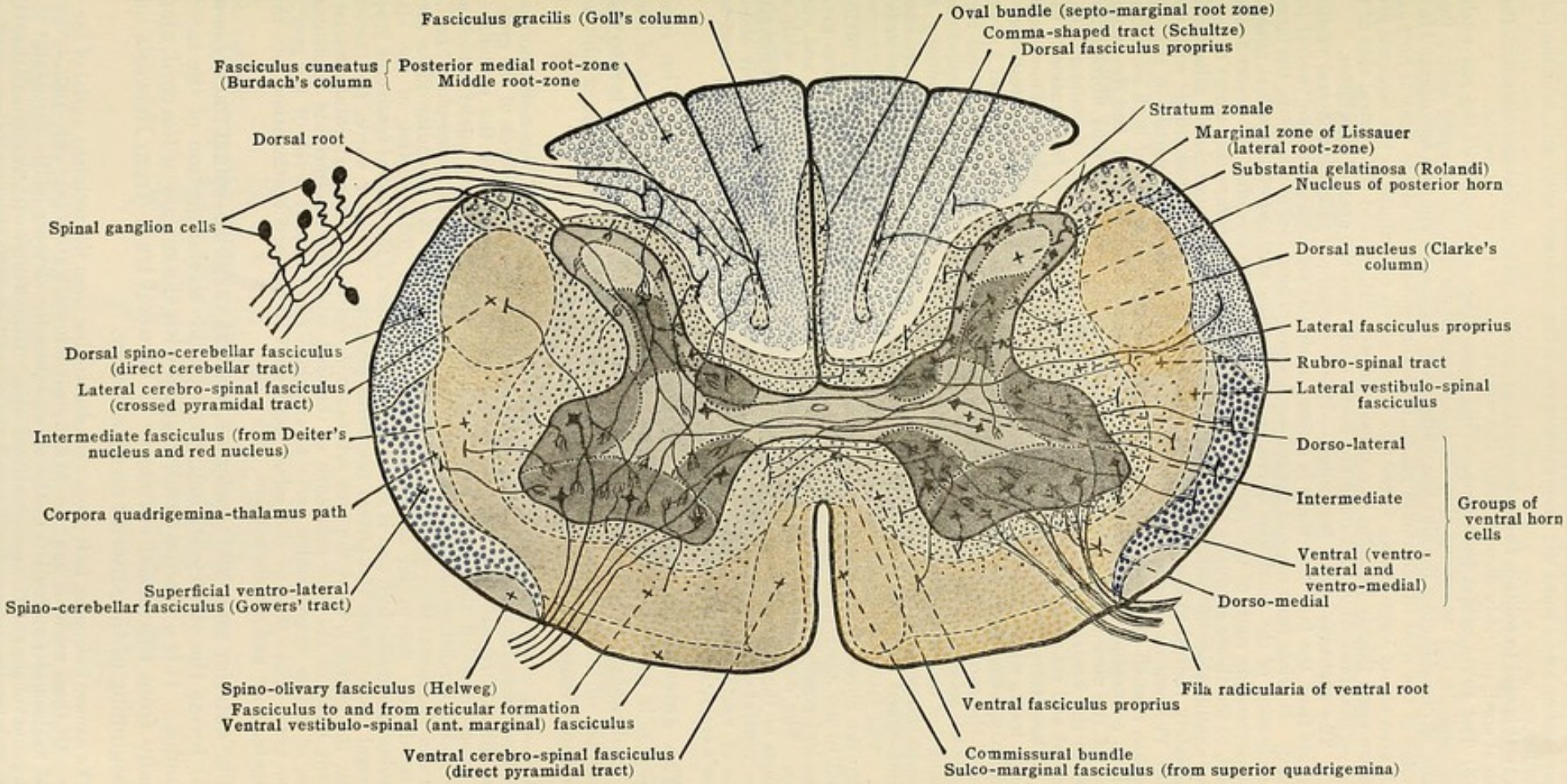

(1) Fibres belonging to the lateral fasciculus proprius which are of longer extent gradually course farther away from the grey substance of the cord and such mix into the intermediate fasciculus.

(2) It is said to contain fibres descending from the cerebellum to associate with the neurones of spinal cord, probably directly with the ventral root or motor neurones.

(3) **The rubro-spinal fasciculus.**—This arises from cell-bodies in the red nucleus of the tegmentum (in the mesencephalon) and is a crossed fasciculus. Axones arising from the red nucleus of one side cross the mid-line while yet in the mesencephalon and descend in the lateral funiculus of the cord to terminate gradually about cell-bodies of the ventral horn, both those which give rise of ventral root fibres and those which contribute to the fasciculi proprii. Its fibres are more thickly bundled in a crescentic area fitting onto the ventral side of the lateral cerebro-spinal fasciculus, and some are said to mix into the area of this latter.

(4) **The vestibulo-spinal fasciculus.**—This is sometimes called the lateral vestibulo-spinal fasciculus from the fact that there is a tract of similar significance in the ventral funiculus of the cord. It arises from some of the cell-bodies comprising Deiter's nucleus, the lateral nucleus of termination of the vestibular nerve, and from some of those of the spinal nucleus (nucleus of the descending root) of this nerve, all of which is in the medulla. It descends the cord, uncrossed, to terminate gradually about ventral horn cells, thus comprising a part of the apparatus for the equilibration of the body. Its fibres are thought to be more closely collected in the area immediately ventral to the rubro-spinal fasciculus, but of course commingle with the latter.

(5) The *corpora-quadrigemina-thalamus path*. The most lateral portion of the intermediate fasciculus, a small area once included in Gower's tract, contains fibres both ascending and descending, connecting the spinal cord with the thalamus (diencephalon) and the quadrigeminate bodies of the mesencephalon. These are crossed paths. The ascending fibres arise from cell-bodies in the ventral horn of one side, cross in the ventral white commissure (commissural neurones) and course upward in the intermediate fasciculus to their termination in the opposite side. Those terminating about cell-bodies in the thalamus form what is known as the **spino-thalamic tract,** while those terminating in the nuclei of the quadrigeminate bodies are called the **spino-mesencephalic** or **spino-tectal tract** (*tractus spino-tectalis*). It is not known in which region of the cord most of these fibres arise but it is quite probably the cervical region. The fibres which arise from cell-bodies of the thalamus and nuclei of the quadrigeminate bodies cross the mid-line *in the mesencephalon* and descend the cord to terminate gradually about cell-bodies in the ventral horn of the opposite side. Those from the thalamus are known as the **thalamo-spinal tract** and those from the quadrigemina, as the **mesencephalo-** or **tecto-spinal tract.** The latter is thought to be the larger.

By the fibres of the above tracts general sensory impulses from the body (skin, etc.) are carried to the central portion of the optic apparatus, and the descending fibres give a simple anatomical possibility for the movements of the body in response to visual and auditory impulses. The descending fibres are thought to terminate chiefly in contact with association neurones of the fasciculi proprii, these transferring the impulses to the neurones giving origin to the ventral or motor root fibres, but some are thought to terminate directly about the cell-bodies of ventral-root neurones. A portion of the intermediate fasciculus, most adjacent to Gower's tract, has been designated as *Loewenthal's tract.*

The anterior funiculus or column [funiculus anterior].—The *intermediate fasciculus* is continued ventrally and mesially across the line of exit of the ventral root axones, and thus into the anterior funiculus. This portion is also mixed, but its axones of long course associate somewhat different portions of the nerve axis from those connected by the more lateral portion.

According to the studies of Flechsig, von Bechterew, and Held, this mesial portion contains fibres, both ascending and descending, which associate the various levels of the grey substance of the spinal cord with the neurones in the reticular formation of the medulla oblongata. The levels to which they have been traced comprise the olivary nuclei, which are largely concerned in cerebellar connections, and the nuclei of the vagus, glosso-pharyngeal, auditory, facial and the spinal tract of the trigeminus. Also some of the ascending fibres are probably associated with the nuclei of the eye-moving nerves. This portion of the intermediate fasciculus also grades into and is mixed with the axones of the **ventral fasciculus proprius,** as is its lateral portion with the lateral fasciculus proprius. In other words, the fasciculi proprii proper, the axones nearest the grey substance, serve for the intersegmental association of the different levels of the grey substance of the cord, while the intermediate fasciculus contains axones of longer course which serve to associate more distant levels of the grey substance of the nerve axis—that of the spinal cord with its upward continuation into the medulla oblongata, pons and mesencephalon.

The **anterior marginal fasciculus, ventral vestibulo-spinal tract** (Loewenthal's tract) forms the superficial boundary of the mesial portion of the intermediate fasciculus. It is a narrow band, parallel with the surface of the cord, and extends mesially from the mesial extremity of Gowers' tract (from Helweg's bundle) to the beginning of the anterior median fissure.

The axones belonging to it proper are descending from the recipient nuclei of the vestibular nerve. Of these nuclei it has been held by some investigators that only Deiters' nucleus (the lateral nucleus of termination in the upper extremity of the medulla oblongata) gives origin to the axones of the anterior marginal fasciculus. Others agree with Tschermak that the superior and more laterally situated Bechterew's nucleus of the vestibular nerve also contributes axones

to it, and quite probably the nucleus of the spinal root of the vestibular adds further axones. Still other investigations have shown that a part at least of the fasciculus comes from the nucleus fastigius (roof nucleus) of the cerebellum. Since many axones from both Deiters' and Bechterew's nucleus terminate in the nucleus fastigius, the ventral vestibulo-spinal fasciculus

FIG. 620.—DIAGRAM OF SPINAL CORD ILLUSTRATING THE TWO CHIEF VARIETIES OF SPINO-CEREBRAL AND CEREBRO-SPINAL NEURONE CHAINS. The ventral tecto-spinal (sulco-marginal) fasciculus, fibres descending from the superior quadrigeminate bodies, is not filled in.

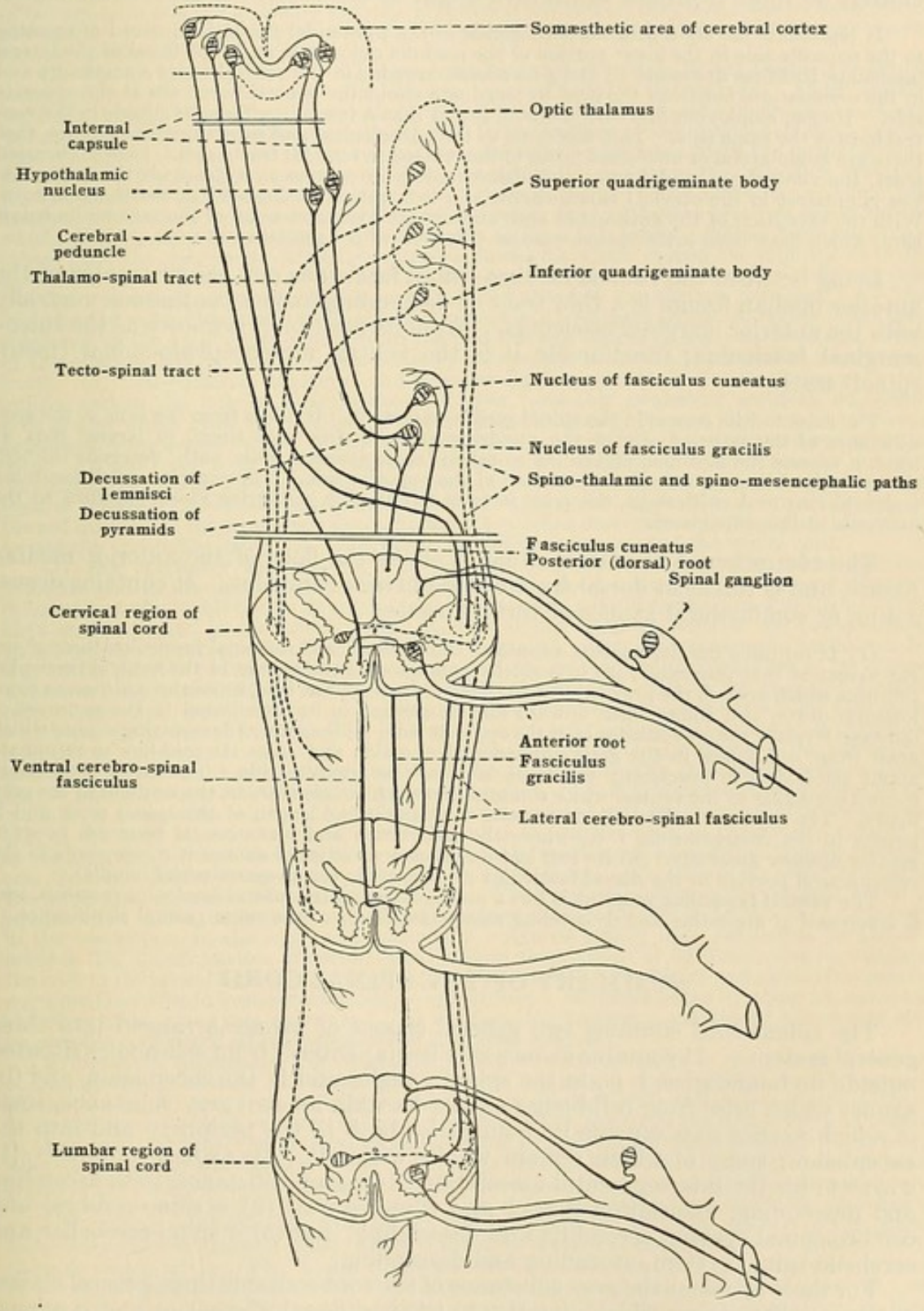

is, in any case, a conduction path from the nerve connections for equilibration to the grey substance of the spinal cord. The fasciculus is said to extend as far as the sacral region of the cord, its axones terminating about the cells of the ventral horns. The term "ventral" is added to its name to distinguish it from the vestibulo-spinal tract described above as coursing in the lateral funiculus. It is considered an uncrossed pathway.

The **ventral cerebro-spinal fasciculus** (anterior or direct pyramidal tract), as stated above, is the uncrossed portion of the descending cerebro-spinal system of neurones. It is a small, oblong bundle, situated mesially in the anterior funiculus, parallel with the anterior median fissure. Like the lateral cerebro-spinal fasciculus (crossed pyramidal tract), its axones arise from the large pyramidal cells of the motor area of the cerebral cortex, and transmit their impulses to the neurones of the ventral horns of the grey substance of the spinal cord, and almost entirely to those neurones which give origin to the ventral or motor root fibres.

It represents merely a delayed decussation of the pyramidal fibres, for instead of crossing to the opposite side in the lower portion of the medulla oblongata, as do the fibres of the lateral fasciculus, its fibres decussate all along its course, crossing in the ventral white commissure and in the *commissural bundle* of the cord to terminate about the ventral horn cells of the opposite side. Hoche, employing Marchi's method, found that a few of its fibres terminate in the ventral horn of the same side. This conforms to the pathological and experimental evidence that there are homolateral or uncrossed fibres in the crossed pyramidal tracts also. Like the crossed tract, the ventral pyramidal tract diminishes rapidly in volume as it descends the cord. Its loss is greatest in the cervical enlargement, and it is entirely exhausted in the thoracic cord. With the exception of the anthropoid apes and certain monkeys, none of the mammalia below man, which have been investigated, possess this ventral pyramidal tract

Lying between the ventral cerebro-spinal fasciculus and the pia mater of the anterior median fissure is a thin tract of descending axones continuous ventrally with the anterior marginal fasciculus. From its position it is known as the **sulco-marginal fasciculus;** functionally it is the ventral mesencephalo-spinal (tecto-spinal) tract.

The extent of its course in the spinal cord is uncertain. It arises from the cells of the grey substance of the superior pair of the quadrigeminate bodies, and there, in largest part at least, it crosses the mid-line, and in the so-called 'optic acoustic reflex path' descends through the medulla oblongata into the spinal cord of the opposite side. The superior quadrigeminate bodies having to do with sight, this tract forms a second path conveying visual impulses to the neurones of the spinal cord.

The **commissural bundle** is situated about the floor of the anterior median fissure, and is the most dorsal tract of the anterior funiculus. It contains decussating or commissural axones of three varieties.

(1) It contains the decussating axones of the ventral cerebro-spinal fasciculus throughout the extent of that fasciculus; (2) it is chiefly composed of the axones of the ventral fasciculus proprius which arise in the grey substance (ventral horn) of one side, cross the mid-line as commissural fibres, and course both upward and downward to be distributed to the neurones of different levels of the grey substance of the opposite side; (3) it contains decussating axones which arise from cell-bodies in the grey substance of one side and cross the mid-line to terminate about cell-bodies in practically the same level of the opposite side. The latter are merely axones belonging to the ventral white commissure which course without the confines of the grey figure. The commissural bundle is present throughout the length of the spinal cord, and is largest in the enlargements, i. e., where the association and commissural neurones occur in greater number generally. In its two last-mentioned varieties of axones it corresponds to the commissural portion of the dorsal fasciculus proprius (the cornu-commissural bundle).

The **ventral fasciculus proprius** is but a continuation of the lateral fasciculus proprius, and is composed of ascending and descending association fibres of the same general significance.

SUMMARY OF THE SPINAL CORD

The spinal cord contains two general classes of axones arranged into three general systems. It contains axones which—(a) enter it from cell-bodies situated outside its boundaries, i. e., in the spinal ganglia and in the encephalon, and (b) axones which arise from cell-bodies situated within its own grey substance, some of which axones pass outside its boundaries both to the periphery and into the encephalon; some of which remain wholly within it. Its axones comprise—(1) a system for the intersegmental association of its grey substance, both ascending and descending, association proper and commissural; (2) a spino-cerebral and cerebro-spinal system, ascending and descending; and (3) a spino-cerebellar and cerebello-spinal system, ascending and descending.

For these relations the grey substance of the cord contains three general classes of nerve-cells:—those which give rise to the peripheral efferent or motor axones of the ventral roots; those which give rise to central axones of long course, going to the encephalon; and those which supply its central axones of shorter course, the association and commissural systems.

The three systems: (1) **Association and commissural.**—Axones of spinal ganglion (afferent) neurones bifurcate within the cord into cephalic and caudal branches which extend varying distances upward and downward and terminate, (*a*) about cell-bodies whose axones are short and terminate within the grey substance of the same side and in the same level as their cell-bodies (*Golgi neurones of type II*); (*b*) about cell-bodies whose axones pass without the grey substance, bifurcate into cephalic and caudal branches to terminate in the grey substance of the same side but in various levels above and below (association fibres in the *dorsal*, *lateral* and *ventral fasciculi proprii*); (*c*) about cell-bodies whose axones cross the mid-line to terminate either in the same level of the grey substance of the opposite side, or bifurcate and the cephalic and caudal branches pass in the fasciculi proprii to terminate in various levels of the grey substance of the opposite side. The longer cephalic branches of (*b*) and (*c*) may terminate in the medulla oblongata. All, associated with ventral root (efferent) neurones, belong to the neurone chains for the so-called *reflex activities*.

(2) **The cerebral system.**—(*a*) The cephalic branches of certain spinal ganglion neurones *ascend* beyond the bounds of the spinal cord to terminate within the medulla. Those ascending from the spinal ganglia of lower thoracic and lumbo-sacral segments accumulate mesially to form the *fasciculus gracilis* which terminates in the nucleus of this fasciculus; those arising from the upper thoracic and cervical segments accumulate more laterally in the posterior funiculus to form the *fasciculus cuneatus* which terminates in the nucleus of the fasciculus cuneatus. (*b*) The impulses transferred to the neurones of these nuclei are borne across the mid-line and finally reach the sensory-motor area of the cerebral cortex, and cell-bodies here give rise to axones which *descend*, some decussating in the medulla to form the *lateral cerebro-spinal fasciculus*, others form the uncrossed *ventral cerebro-spinal fasciculus* which crosses the mid-line as it descends the cord. Both of these fasciculi transfer their impulses either directly to efferent ventral horn neurones, or to association neurones and these to the efferent neurones. (*c*) The cephalic and caudal branches of spinal ganglion neurones terminate about cell-bodies in the grey substance of the cord whose axones cross the mid-line and *ascend* laterally to terminate either in the quadrigeminate bodies (*spino-mesencephalic tract*), or in the thalamus (*spino-thalamic tract*). (*d*) Cell-bodies in thalamus and superior quadrigeminate bodies (receiving optic impulses) and in the inferior quadrigeminate bodies (probably mediating auditory impulses), give axones which cross the mid-line in the mesencephalon and *descend*, forming the *thalamo-spinal* and *mesencephalo-spinal tracts*, to terminate in contact with the efferent neurones of the cord. Axones from both sources descend in the lateral funiculus, while from the superior quadrigeminate body, a separate bundle descends in the ventral funiculus as the *sulco-marginal* (*ventral mesencephalo-spinal*) *fasciculus*. (*e*) The *rubro-spinal tract* arises from cell-bodies in the red nucleus (in the mesencephalon), crosses the mid-line and descends in the lateral funiculus to transfer (probably cerebellar) impulses to the efferent neurones of the spinal cord.

(3) **The cerebellar system.**—(*a*) The cephalic and caudal branches of spinal ganglion neurones give telodendria about the cell-bodies forming the *dorsal nucleus* of the cord (Clarke's column) and about cell-bodies situated in grey substances ventral to the dorsal nucleus ("Stilling's nucleus") and in the lateral horn. Axones arising from the cells of the dorsal nucleus pass laterally to form the *dorsal spino-cerebellar fasciculus* which *ascends* into the cerebellum by way of its inferior peduncle of the same side and terminates about cell-bodies of its cortex. Axones arising from Stilling's nucleus and the lateral horn cells, of both the *same* and *opposite sides* of the cord, accumulate to form the *superficial ventro-lateral spino-cerebellar fasciculus*, which *ascends* to enter the cerebellum by way of its superior peduncle and terminate about the cells of the cerebellar cortex. (*b*) A few axones arising in the roof nucleus of the cerebellum probably *descend* in the *anterior marginal fasciculus* in company with the *ventral vestibulo-spinal tract* to terminate upon the efferent neurones of the cord. (*c*) The inferior olivary nucleus, in the medulla, is a cerebellar relay and its cell-bodies are associated with the neurones of the upper portion of the same side of the spinal cord. Whether the axones arise in the olivary nucleus or in the grey substance of the cord is uncertain, but the more usual supposition favours the cord and thus the name, *spino-olivary fasciculus* is given them. (*d*) Among its other functions, the cerebellum is concerned with equilibration. The vestibular nerve is the afferent nerve of equilibration and a large mass of the axones arising from its nuclei of termination terminate in the cerebellum, in the roof nuclei especially. Axones arising from cell-bodies in Deiters' nucleus (its lateral nucleus of termination) and in the nucleus of its descending root *descend* the cord in the lateral funiculus to form the (lateral) *vestibulo-spinal tract*, and also in the *anterior marginal fasciculus* to form *ventral vestibulo-spinal tract*. Impulses borne by these axones reach the efferent or motor root neurones. The rubro-spinal fasciculus, mentioned above also may be possibly considered as belonging to the cerebellar system.

Sympathetic relations.—The cell-bodies of the efferent neurones in the ventral horns are of two general varieties: (*a*) those whose axones terminate upon skeletal muscle (somatic efferent), and (*b*) those whose axones terminate in contact with cell-bodies of sympathetic neurones, the *splanchnic* or *visceral efferent neurones*. The axones of the sympathetic neurones, in their turn, terminate upon cardiac and smooth muscle (motor) and in glands (secretory). Like the somatic, the visceral efferent neurones receive impulses within the ventral horns (*a*) from the cephalic and caudal branches of spinal ganglion neurones, (*b*) the descending cerebro-spinal fasciculi, and (*c*) from either, by way of the fasciculi proprii and Golgi neurones of type II. Their cell-bodies are situated for the most part in the dorsal portion of the lateral horn (dorso-lateral group of cells), which is the only portion of the lateral horn present in the thoracic region of the cord. Many of the visceral efferent fibres leave the spinal nerves distal to the spinal ganglia and make the white communicating rami, thus going to the nearest sympathetic ganglia; others pass on in the spinal nerve and its branches to terminate in more distal sympathetic ganglia. Dogiel has described axones which arise in sympathetic ganglia and terminate upon the cell-bodies of the spinal ganglia. Such convey sensory impulses which, however, enter the spinal cord by way of the dorsal root branch of the spinal ganglion neurone. Such afferent sympathetic neurones are relatively rare, the peripheral distribution of the ordinary

FIG. 621.—SCHEMATIC REPRESENTATION OF THE MORE IMPORTANT ARCHITECTURAL RELATIONS OF NEURONES IN THE SPINAL CORD, OMITTING THOSE INVOLVING THE MESENCEPHALON AND THALAMUS.

a, afferent (spinal ganglion) axone of spino-cerebral chain with bifurcation and caudal branch; b, afferent axone coursing in Lissauer's zone and distributed wholly within the cord; c, collaterals of a and b disposed in three ways; p, pyramidal axone in lateral (crossed) cerebro-spinal fasciculus distributed to levels of grey substance; pa, axone in ventral cerebro-spinal fasciculus decussating before termination; v, ventral root or motor neurones; n, nucleus dorsalis giving axone to dorsal spino-cerebellar fasciculus; g, ascending neurones of Gowers' tract; d, descending axone from cerebellum (probable); fp, neurones of fasciculi proprii, association proper; h, commissural neurones; e, Golgi cell of type II.

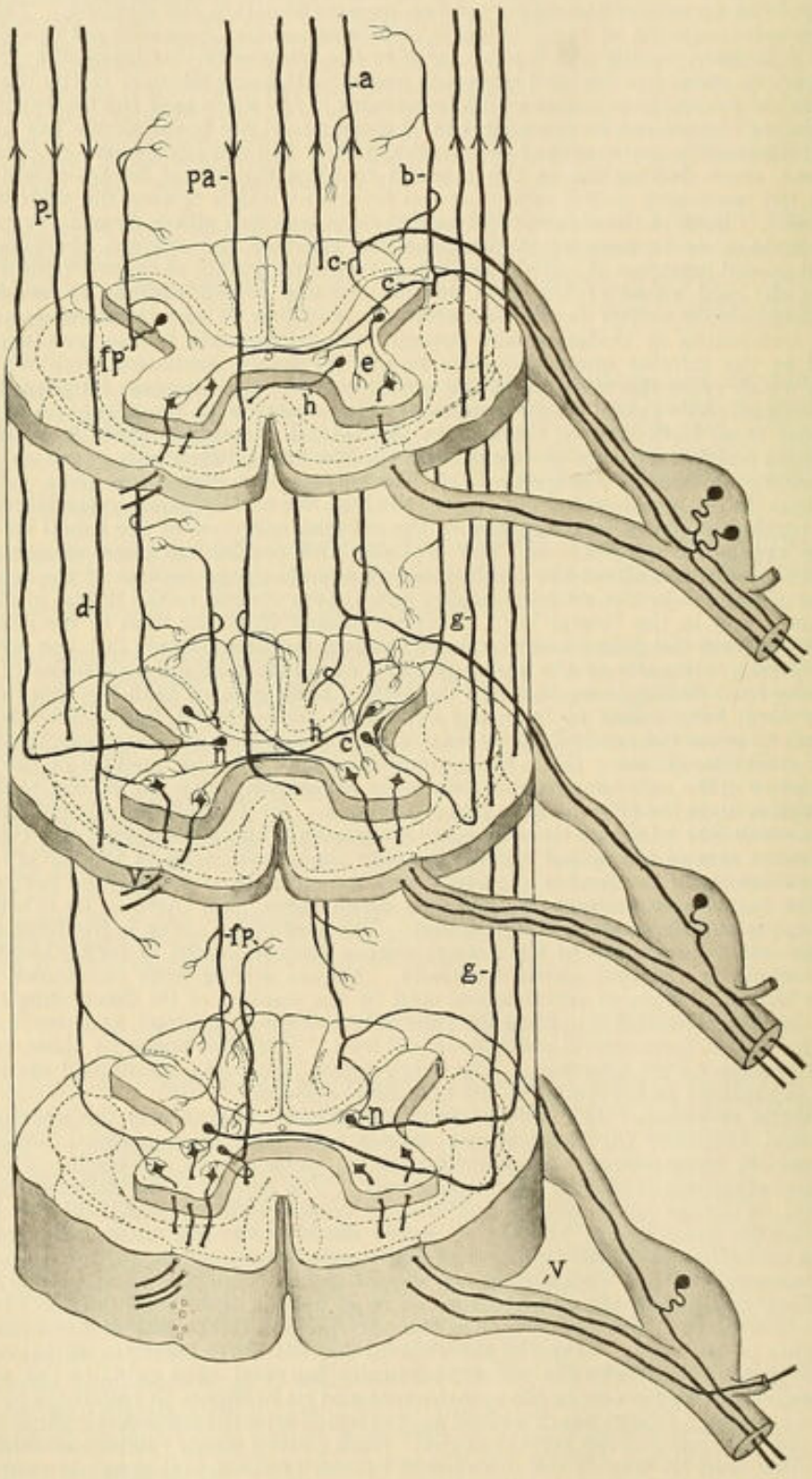

spinal ganglion neurone in the domain of the sympathetic supplying the needs for sensory axones.

In transverse sections of the spinal cord, the relative area of white substance as compared with that of grey increases as the cord is ascended. The absolute area of each varies with the locality, both being greatest in the enlargements. The grey substance predominates in the conus medullaris and lower lumbar segments. The white substance begins to predominate in the upper lumbar segments, not because of the increased presence of ascending and descending cerebral and cerebellar axones, but because of the increased volume of the fasciculi proprii coincident with the greater mass of grey substance to be intersegmentally associated in this region. In the thoracic region the greatly predominating white substance

FIG. 622.—GRAPHIC REPRESENTATION OF THE VARYING AMOUNTS OF GREY AND WHITE SUBSTANCE AND OF THE VARIATIONS IN AREA OF ENTIRE SECTIONS OF THE DIFFERENT SEGMENTS OF THE SPINAL CORD. (From Donaldson and Davis.)
(Based upon measurements from several adult human spinal cords.)

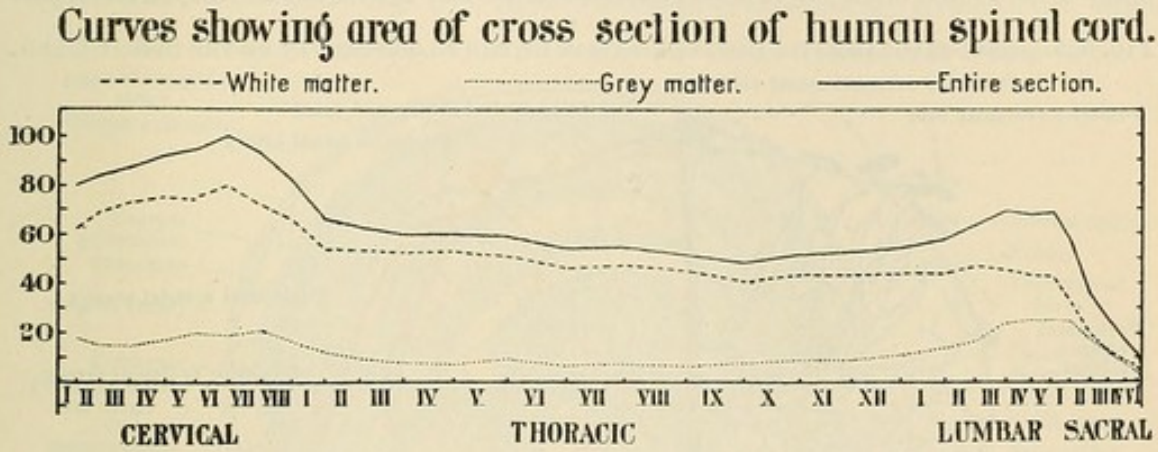

is composed mostly of the axones of long course. The greatly increased absolute amount of white substance in the cervical region is due both to the greater accumulation of cerebral and cerebellar axones in this region and to the increased volume of the fasciculi proprii of the cervical enlargement.

ORDER OF MEDULLATION OF THE FASCICULI OF THE CORD

The axones of the spinal cord begin to acquire their myelin sheaths during the fifth month of intra-uterine life and myelinization is not fully completed till between the fifteenth and twentieth years. In general, axones which have the same origin and the same locality of termination—the same function—acquire their sheaths at the same time. While it has been proved that the medullary sheath does not necessarily precede the functioning of an axone, it may be said that those fasciculi which first attain complete and definite functional ability are the first to become medullated. At birth all the fasciculi of the spinal cord are medullated except Helweg's fasciculus, and occasionally the lateral and ventral cerebro-spinal tracts. The latter tracts vary considerably and in general may be said to become medullated between the ninth month (before birth) and the second year. As indicated by their medullation, those axones by which the cord is enabled to function as an organ *per se*, that is, the axones making possible the simpler reflex activities, complete their development before those axones which involve the brain with the activities of the cord.

According to Flechsig and van Gehuchten, and investigators succeeding them, the following is the order in which the axones of the cord become medullated:—

(1) The afferent and efferent nerve-roots and commissural fibres of the grey substance.

(2) The fasciculi proprii, first the ventral, then the lateral, and last the dorsal, fasciculus proprius.

(3) The fasciculus cuneatus (Burdach's column) and Lissauer's zone—the area of those ascending spino-cerebral fibres which run the shorter course and which convey impulses from the upper limbs, thorax and neck.

(4) Fasciculus gracilis (Goll's column).

(5) The dorsal spino-cerebellar fasciculus (direct cerebellar tract).

(6) The superficial antero-lateral spino-cerebellar fasciculus (Gowers' tract).

(7) The lateral cerebro-spinal fasciculus (crossed pyramidal) and the ventral cerebro-spinal fasciculus (direct pyramidal tract).

(8) The spino-olivary or Helweg's (Bechterew's) fasciculus.

The axones descending from the cerebellum and the brain-stem are so mixed with other axones that it is difficult to determine the sequence of their medullation. The fasciculi containing them also contain axones of the variety in the fasciculi proprii and so show medullation early. It is probable that the ascending, spino-cerebellar, fibres acquire their myelin earlier than the descending, if descending exist.

Blood Supply of the Spinal Cord

The spinal rami of the sacral, lumbar, intercostal, or vertebral arteries, as the case may be, accompany the spinal nerves through the intervertebral foramina, traverse the dura mater and arachnoid, and each divides into a dorsal and a ventral radicular artery. These accompany the nerve-roots to the surface of the cord, and there break up into an anastomosing plexus in the pia mater. From this plexus are derived three tortuously coursing longitudinal arteries and numerous independent central branches, which latter penetrate the cord direct. Of the longitudinal arteries, the **anterior spinal artery** zigzags along the anterior median fissure and gives off the anterior central branches, which pass into the fissure and penetrate the cord. These branches give off a few twigs to the white substance in passing, but their most partial distribution is to the ventral portion of the grey substance. The two **posterior spinal arteries,** one on each side, course near the lines of entrance of the dorsal root-fibres. They each branch and anastomose, so that often two or more posterior arteries may appear in section upon either side

Fig. 623.—Semi-diagrammatic Representation of the Blood Supply of the Spinal Cord.

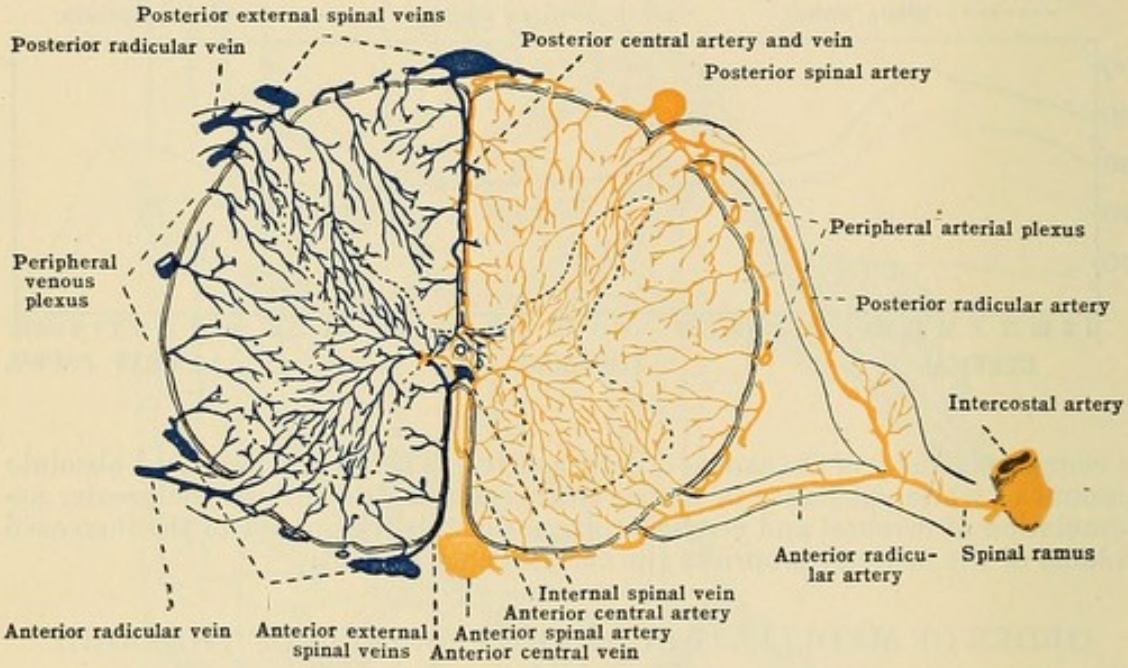

of the dorsal root. These give off transverse or central twigs to the white substance, but especially to the grey substance of the dorsal horns. Of the remaining central branches many enter the cord along the efferent fibres of the ventral roots, and are distributed chiefly to the grey substance; others from the peripheral plexus throughout penetrate the cord and break up into capillaries within the white substance. Some of the terminal twigs of these also enter the grey substance. The blood supply of the grey substance is so much more abundant than that of the white substance that in injected preparations the outline of the grey figure may be easily distinguished by its abundance of capillaries alone. The central branches are of the terminal variety. In the white substance the capillaries run for the most part longitudinally, or parallel with the axones.

The *venous system* is quite similar to the arterial. The blood of the central arteries is collected into corresponding central venous branches which converge into a superficial venous plexus in which are six main longitudinal channels, one along the posterior median sulcus, one along the anterior median fissure, and one along each of the four lines of the nerve-roots. These comprise the **posterior** and **anterior external spinal veins** (fig. 623).

The **internal spinal veins** course along the ventral surface of the grey commissure, and arise from the convergence of certain of the twigs of the *anterior central vein*. The *posterior central vein* courses along the posterior median septum in company with the posterior central artery, and empties into the *median dorsal vein*. The venous system communicates with the coarser extra-dural or internal vertebral plexus chiefly by way of the **radicular veins.**

II. THE BRAIN OR ENCEPHALON

The brain is that greatly modified and enlarged portion of the central nervous system which is enclosed within the cranial cavity. It is surrounded and supported by the same three membranes (meninges) that envelop the spinal cord.

While there is a considerable subarachnoid space, the brain more nearly fills its cavity than does the spinal cord.

The average length of the brain is about 165 mm. and its greatest transverse diameter about 140 mm. It averages longer in the male than in the female. Exclusive of its dura mater, the normal brain weighs from 1100 to 1700 gm. (40–60 oz.), varying in weight with the stature of the individual or with the bulk of the tissues to be innervated. Its average weight is 1360 gm. (48 oz.) in males and 1250 gm. (44 oz.) in females. It averages about fifty times heavier than the spinal cord, or about 98 per cent. of the entire cerebro-spinal axis. In its precocious growth it is at birth relatively much larger than at maturity. At birth it comprises about 13 per cent. of the total body-weight, while at maturity it averages only about 2 per cent of the weight of the body. Its specific gravity averages 1.036. In proportion to the body-weight the brain-weight averages somewhat higher in smaller men and women. Some very small dogs and monkeys and some mice have brains heavier in proportion to body-weight than man.

The minimal weight of the adult brain compatible with human intelligence may be placed at from 950 to 1000 grams. Above the minimal, there is only a general relation between the degree of intelligence and the weight of the brain, owing to the fact that several factors may be coincident with large brains. It may be said in general, however, that the average brain weight of eminent men is above the general average. Some men judged eminent have had brains weighing less than the general average. Of the records generally accepted, the greatest brain weight

FIG. 624.—MESIAL SECTION OF THE HEAD OF A FEMALE THIRTY-FIVE YEARS OLD.

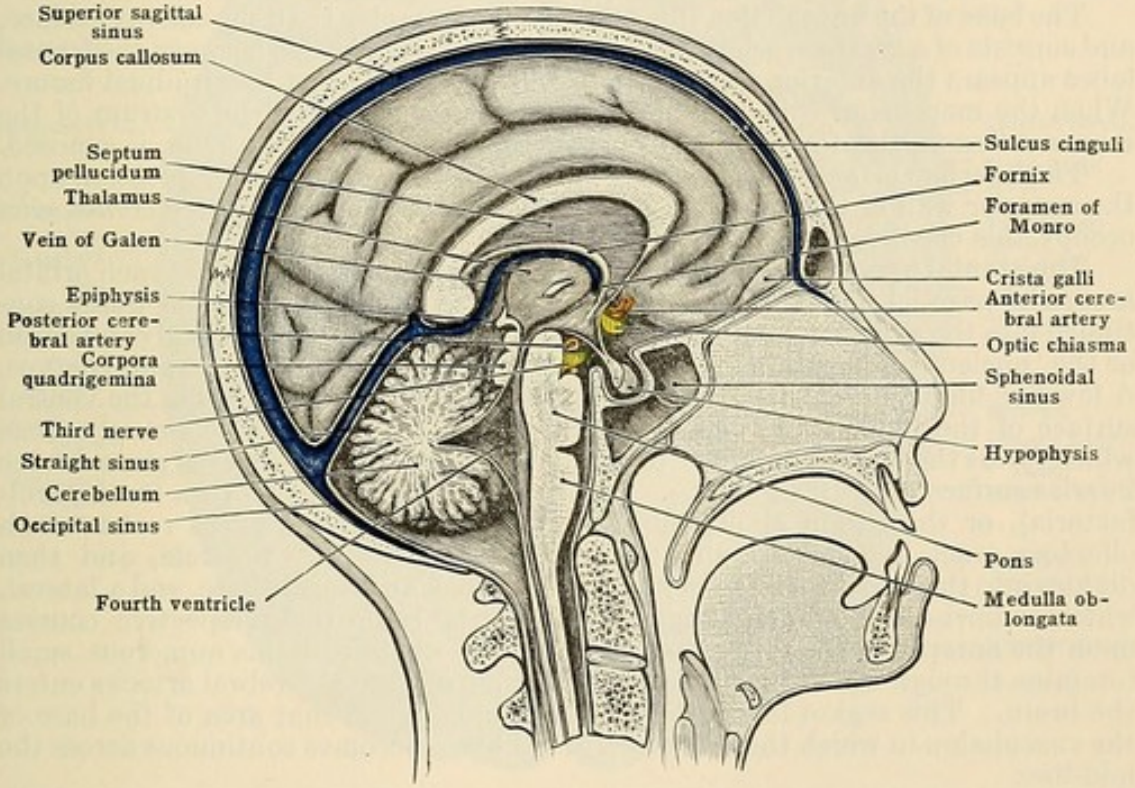

for eminent men is 2012 grams, recorded for the poet and novelist, Ivan Tourgenieff. The trustworthiness of this weighing is doubted by some authorities. From the undisputed records the following may be taken: Cuvier, 1830 grams; John Abercrombie, 1786 grams; Thackery, 1658 grams; Kant, 1600 grams; Spurzheim, 1559 grams; Daniel Webster, 1518 grams; Louis Agassiz, 1495 grams; Dante, 1420 grams; Helmholtz, 1440 grams; Goltz, 1395 grams; Liebig, 1352 grams; Walt Whitman, 1282 grams; Gall, 1198 grams. In the average brain weights for the races that for the Caucasian stands highest, the Chinese standing next, then the Malay, followed by the Negro, with the Australian lowest.

The differences between the meninges of the brain and those of the spinal cord occur chiefly in the dura mater. (1) The *dura mater* is about double the thickness of that of the spinal cord, and consists of two closely adhering layers, the outermost of which serves as the internal periosteum of the cranial bones, while that of the cord is entirely separate from the periosteum lining the vertebral canal. (2) The inner layer is duplicated in places into strong partitions which extend between the great natural divisions of the encephalon. Of these, the sickle-shaped *falx cerebri* extends between the hemispheres of the cerebrum, the crescentic *tentorium cerebelli* extends between the cerebellum and the overlapping posterior portion of the cerebrum, and the smaller *falx cerebelli* occupies the notch between the hemispheres of the cerebellum. Contained within these partitions of the dura mater are the great collecting venous sinuses of the brain. These will be considered in the more detailed description of the cranial meninges.

General topography.—In its superior aspect or **convex surface** the encephalon is oval in contour, with its **frontal pole** usually narrower than its **occipital pole.**

Viewed from above, the **cerebrum** comprises almost the entire dorsal aspect, the occipital lobes overlapping the **cerebellum** to such an extent that only the lateral and lower margins of the cerebellar hemispheres are visible. The **great longitudinal fissure** of the cerebrum separates the cerebral hemispheres.

Laterally the **temporal lobes,** with their rounded anterior extremities, the **temporal poles,** are each separated from the frontal and **parietal lobes** above by the **lateral cerebral fissure** (fissure of Sylvius). In the depths of this fissure and overlapped by the temporal lobe is situated the **insula,** or **island of Reil** (central lobe).

The surface of each cerebral hemisphere is thrown into numerous folds or curved elevations, the **gyri cerebri** or convolutions, which are separated from each other by slit-like fissures, the **sulci cerebri.** The gyri (and sulci) vary greatly in length, in depth, and in their degrees of curvature. The larger and deeper of them are similar in the two hemispheres; most of them are individually variable, but each gyrus of one hemisphere is homologous with that of the like region of the other hemisphere. By gently pressing open the great longitudinal fissure, the **corpus callosum,** the chief commissural pathway between the cerebral hemispheres, may be seen. The occipital margin of this large transverse band of white substance is rounded and thickened into the **splenium** of the corpus callosum, while its frontal margin is curved ventrally into its **genu** and rostrum.

The **base of the encephalon** (fig. 625) is more irregular than the convex surface, and consists of a greater variety of structures. In the mid-line between the frontal lobes appears the anterior and inferior extension of the great longitudinal fissure. When the margins of this are separated, the outer aspect of the **rostrum** of the *corpus callosum*, the downward continuation of the curve of the genu, is exposed.

The inferior surface of each frontal lobe is concave, due to its compression upon the superior wall of the orbit. The *orbital gyri* with their respective *orbital sulci* occupy this concave area.

The cranial nerves [nervi cerebrales].—Along the mesial border of each orbital area, and parallel with the great longitudinal fissure, lie the **olfactory bulbs** continued into the **olfactory tracts.** Each olfactory bulb is the first central connection or the 'nucleus of reception' of the **olfactory nerve,** the first of the cranial nerves. A few fine filaments of this nerve may often be discerned penetrating the ventral surface of the bulb. The olfactory bulb and tract lies in the *olfactory sulcus*, which forms the lateral boundary of the *gyrus rectus*, the most mesial gyrus of the inferior surface of the frontal lobe. Upon reaching the area of Broca (area parolfactoria), or the region about the medial extremity of the gyrus rectus, each olfactory tract undergoes a slight expansion, the **olfactory tubercle,** and then divides into three roots or **olfactory striæ**—a medial, an intermediate, and a lateral, which comprise the **olfactory trigone.** The striæ begin their respective courses upon the **anterior perforated substance,** an area which contains numerous small foramina through which the antero-lateral group of central cerebral arteries enters the brain. This region forms the anterior boundary of that area of the base of the encephalon in which the substance of the brain becomes continuous across the mid-line.

At the medial boundary of the anterior perforated substance the **optic nerves** come together and fuse to form the **optic chiasma.** Thence the **optic tracts** disappear under the poles of the temporal lobes in their backward course to the *thalami* and the geniculate bodies or metathalami.

Immediately behind the optic chiasma occurs that diverticulum from the floor of the third ventricle known as the **tuber cinereum.** It is connected by its tubular stalk, the **infundibulum,** with the **hypophysis** or pituitary body, which occupies its special depression (sella turcica) in the floor of the cranium and is usually torn from the encephalon in the process of its removal. Behind the tuber cinereum are the two **mammillary bodies** (corpora albicantia), each of which is connected with the fornix, one of the larger association fasciculi of the cerebrum. The **peduncles of the cerebrum** (crura cerebri) are the two great funiculi which associate the cerebral hemispheres with all the structures below them. They diverge from the anterior border of the **pons** (Varoli) and, one for each hemisphere, disappear under the poles of the temporal lobes. The pons (brachium pontis or middle cerebellar peduncle) is chiefly a bridge of white substance or a commissure between the cerebellar hemispheres.

The **oculomotor** or third pair of cranial nerves make their exit from the **posterior perforated substance** in the **interpeduncular fossa** just behind the corpora mammillaria.

The **trochlear nerves** emerge around the lateral aspects of the pedunculi cerebri along the anterior border of the pons. The trochlear is the smallest of the cranial nerves, and the only pair arising from the dorsal aspect of the brain.

The **trigeminus,** or fifth cranial nerve, is the largest. It penetrates the pons to find its recipient nuclei in the depths of the brain-stem. It is a purely sensory nerve, but it is accompanied by the much smaller **masticator nerve** which is motor and is usually referred to as the motor root of the trigeminus.

FIG. 625.—VIEW OF THE BASE OF THE BRAIN. (After Beaunis.)

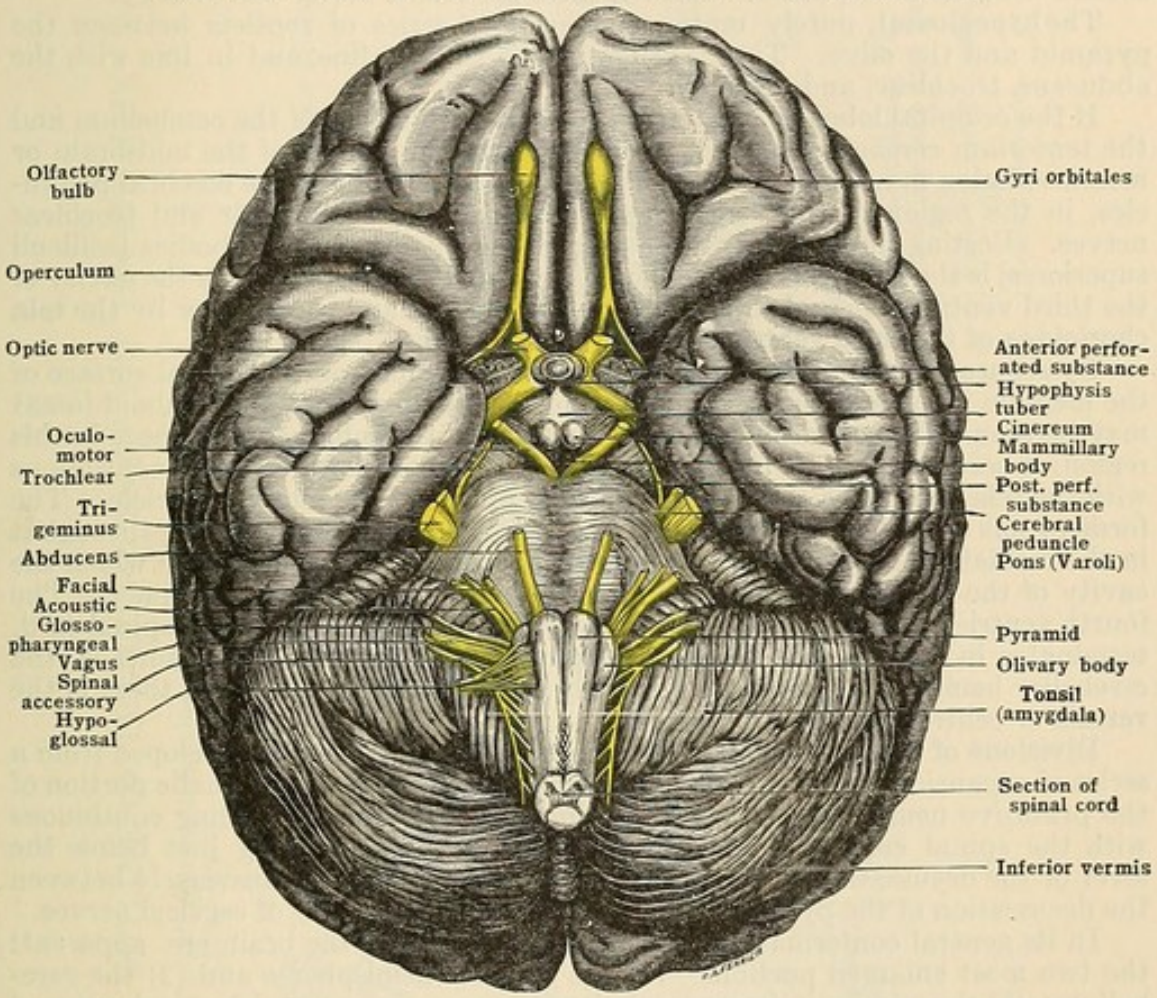

Five pairs of cranial nerves are attached to the brain-stem along the inferior border of the pons:—the **abducens** nerve, which is motor, emerges near the mid-line; the **facial,** motor, emerges from the more lateral aspect of the brain-stem; the **glosso-palatine** or the intermediate nerve of Wrisberg, largely sensory, is attached in company with the facial; and, entering the extreme lateral aspect of the stem are the **cochlear** and **vestibular** nerves. These latter two, when taken together as one, are known as the **acoustic** (auditory) or eighth cranial nerve. They are both purely sensory. The cochlear courses for the most part laterally and dorsally around the *inferior cerebellar peduncle,* giving it the appearance from which it derives its name, **'restiform body.'**

The remaining four pairs of the cranial nerves are attached directly to the **medulla oblongata.** This comprises that portion of the brain-stem beginning at the inferior border of the pons above, and continuous with the first segment of the spinal cord below. On its ventral surface the **pyramids** and the **olives** (olivary bodies) are the two most prominent structures. The pyramids, which are continuous below into the pyramidal (cerebro-spinal) tracts of the spinal cord, form the two tapering prominences along either side of the anterior median fissure; the olives are the oblong oval elevations situated between the pyramids and the resti-

form bodies, and each is the superficial indication of the inferior olivary nucleus.

The **glosso-pharyngeal,** the **vagus** (pneumogastric), and the **spinal accessory** cranial nerves are attached along the lateral aspect of the medulla oblongata in line with the facial nerve and between the olive and the restiform body. The spinal accessory, purely motor, is assembled from a series of rootlets which emerge from the lateral aspect of the first three or four cervical segments of the spinal cord, as well as from the medulla. It becomes fully formed before reaching the level of the olive, and passes lateralward in company with the vagus and further on joins the latter in part. The root filaments of the vagus and glossopharyngeal are arranged in a continuous series, and, if severed near the surface of the medulla, those belonging to the one nerve are difficult to distinguish from those belonging to the other. Both of these are mixed motor and sensory.

The **hypoglossal,** purely motor, emerges as a series of rootlets between the pyramid and the olive. Thus it arises nearer the mid-line, and in line with the abducens, trochlear, and oculomotor.

If the occipital lobes be lifted from the superior surface of the cerebellum and the tentorium cerebelli removed, the **quadrigeminate bodies** of the mid-brain or mesencephalon may be observed. These are situated above the cerebral peduncles, in the region of the ventral appearance of the oculomotor and trochlear nerves. Resting upon the superior pair of the quadrigeminate bodies [colliculi superiores] is the **epiphysis** or pineal body, and just anterior to this is the cavity of the third ventricle, bounded laterally by the thalami and roofed over by the **tela chorioidea of the third ventricle** (velum interpositum).

By separating the inferior margin of the cerebellum from the dorsal surface of the medulla oblongata the lower portion of the **fourth ventricle** (rhomboid fossa) may be seen. The **cisterna cerebello-medullaris,** the subarachnoid space in this region, is occupied in part by a thickening of the arachnoid. This is continuous with the tela chorioidea (ligula) and chorioid plexus of the fourth ventricle. The former roofs over the lower portion of the fourth ventricle, and, passing through it in the medial line, is the lymph passage, the **foramen** of **Magendie,** by which the cavity of the fourth ventricle communicates with the subarachnoid space. The fourth ventricle, as it becomes continuous with the central canal of the spinal cord, terminates in a point, the **calamus scriptorius.** From the inferior surface, the cerebellar hemispheres are more definitely demarcated, and between them is the **vermis** or central lobe of the cerebellum.

Divisions of the encephalon.—The encephalon as a whole is developed from a series of expansions, flexures, and thickenings of the wall of the cephalic portion of the primitive neural tube, the three primary brain vesicles. Being continuous with the spinal cord, it is arbitrarily considered as beginning just below the level of the decussation of the pyramids, or at a line drawn transversely between the decussation of the pyramids and the level of the first pair of cervical nerves.

In its general conformation four natural divisions of the brain are apparent: the two most enlarged portions—(1) the cerebral hemispheres and (2) the cerebellum; (3) the mid-brain (mesencephalon) between the cerebral hemispheres and the cerebellum, and (4) the medulla oblongata, the portion below the pons and above the spinal cord (fig. 602). However, the most logical and advantageous arrangement of the divisions and subdivisions of the encephalon is on the basis of their development from the walls of the embryonic brain vesicles. (See fig. 598.) On this basis, for example, both the medulla oblongata and the cerebellum with its pons are derived from the posterior of the primary vesicles, and are, therefore, included in a single gross division of the encephalon, viz., the *rhombencephalon.* In the following outline the anatomical components of the encephalon are arranged with reference to the three primary vesicles from the walls of which they are derived, and the primary flexures and thickenings of the walls of which they are elaborations.

During the early growth of the neural tube its basal or ventral portion and the lateral portions acquire a greater thickness than the roof of the tube, and thus the tube is longitudinally divided into a basal or **ventral zone** and an alar or **dorsal zone.** This is especially marked in the brain vesicles. Structures arising from the dorsal zone begin as localised thickenings of the roof. For example, in the rhombencephalon the greater part of the medulla oblongata and of the pons region is derived from the ventral zone, while the cerebellum is derived from the dorsal zone. The first of the flexures occurs in the region of the future mesencephalon, and is known as the **cephalic flexure;** next occurs the **cervical flexure,** at the junction with the spinal cord;

OUTLINE OF THE DIVISIONS OF THE ENCEPHALON

- **Encephalon (Brain)**
  - **Rhombencephalon**
    - Medulla oblongata—myelencephalon, I. (After-brain) — Posterior primary vesicle.
    - Metencephalon (Hind-brain)
      - Cerebellum, II_2,
      - Pons (Varolii), II_1,
      - *Middle part of fourth ventricle.*

      — Posterior primary vesicle.
    - Isthmus rhombencephali
      - Superior cerebellar peduncles,
      - Anterior medullary velum,
      - *Superior part of fourth ventricle.*

      — III. — Posterior primary vesicle.
  - **Cerebrum.**
    - Mesencephalon (Mid-brain)
      - Quadrigeminate bodies (colliculi), IV_2,
      - Cerebral peduncles (crura), IV_1,
      - Posterior perforated substance, IV,
      - *Aquæductus cerebri (Sylvii).*

      — Middle primary vesicle.
    - Prosencephalon (Fore-brain)
      - Diencephalon (Inter-brain)
        - Thalamencephalon
          - Thalamus, V_2,
          - Metathalamus, V_3 (Geniculate bodies),
          - Epithalamus, V_4 (Epiphysis, pineal body).
        - Mammillary portion of hypothalamus, V_1,
        - *Posterior portion of third ventricle.*
      - Telencephalon (End-brain)
        - Optic portion of hypothalamus, VI_1 (Hypophysis),
        - Optic nerves and retinæ, VI,
        - *Anterior portion of third ventricle.*
        - Cerebral hemispheres
          - Corpus striatum, VI_2,
          - Olfactory bulb and tract, VI_3,
          - Cerebral cortex (pallium), VI_4,
          - *Lateral ventricles.*

      — Anterior primary vesicle.

FIG. 626.—MEDIAN SAGITTAL SECTION THROUGH EMBRYONIC HUMAN BRAIN AT END OF FIRST MONTH. (After His.)

(Showing the localities of origin of the derivatives of the three primary vesicles named in outline on p. 797.)

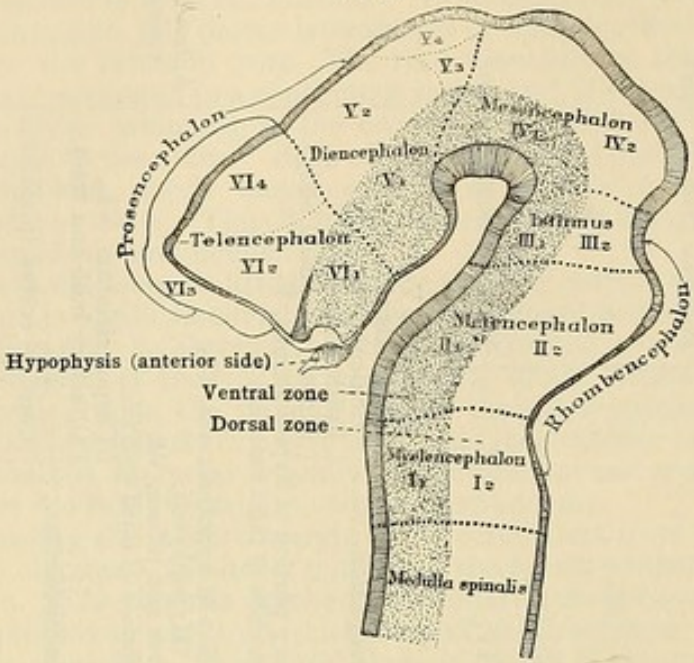

FIG. 627.—SAGITTAL SECTION OF BRAIN OF HUMAN EMBRYO OF THE THIRD MONTH. (After His)

(Reference numerals correspond with those of fig. 626 and those after names of parts in outline on p. 797.)

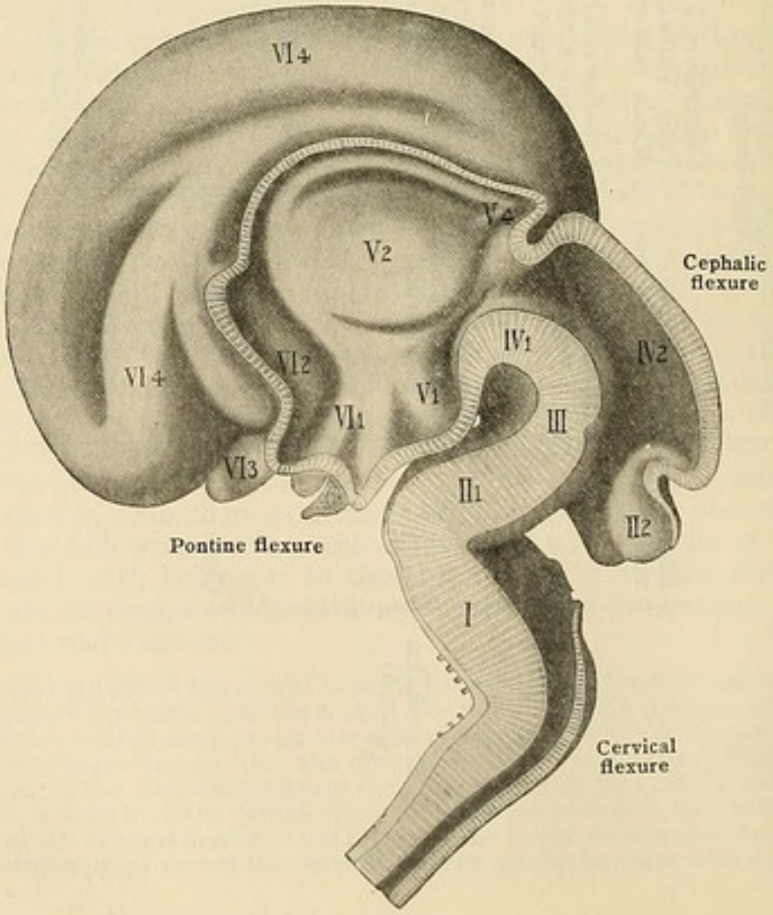

third, the **pontine flexure,** in the region of the future fourth ventricle. Both the cervical and pontine flexures, while having a significance in the growth processes, are almost entirely obliterated in the later growth of the encephalon.

The location of the development of the various parts of the encephalon may be determined, and their elaboration and changes in shape and position may be traced by comparing the accompanying figs. 626, 627, 628. The reference numbers in

FIG. 628.—MEDIAN SAGITTAL SECTION OF ADULT HUMAN BRAIN. (Drawing of model by His.) (Reference numerals same as in figs. 626 and 627.)

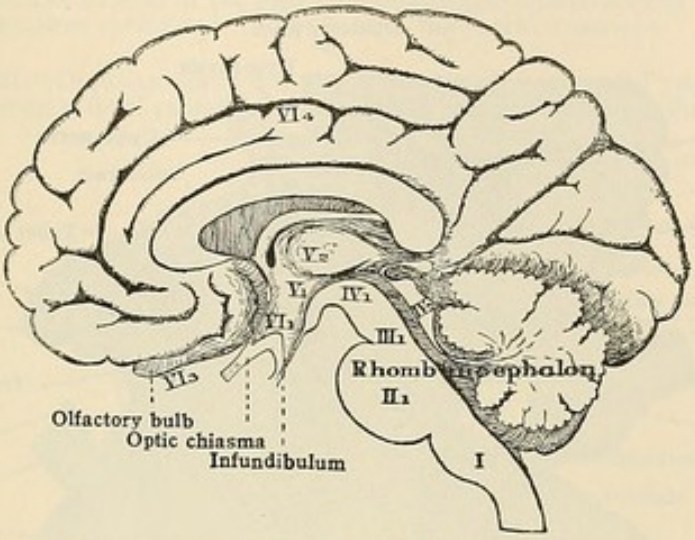

the last three figures correspond with the like numerals after the names of the parts on p. 797 in the outline of the divisions of the encephalon. The more detailed subdivisions of the parts will be met with in their individual descriptions.

THE RHOMBENCEPHALON

1. THE MEDULLA OBLONGATA

The **medulla oblongata** [myelencephalon] is the upward continuation of the spinal cord. It is only about 25 mm. long, extending from just above the first cervical nerve (beginning of the first cervical segment of the spinal cord) to the inferior border of the pons. It lies almost wholly within the cranial cavity, resting upon the superior surface of the basal portion of the occipital bone, with its lower extremity in the foramen magnum. Its weight is from 6 to 7 gm. or about one-half of one per cent of the whole cerebro-spinal axis. It is a continuation of the spinal cord, and more. It contains structures continuous with and homologous to the structures of the spinal cord, and in addition it contains structures which have no homologues in the spinal cord. Due in part to these additional structures, the medulla, as it approaches the pons, rapidly expands in both its dorso-ventral and especially in its lateral diameters. With it are associated nine of the pairs of cranial nerves.

On its anterior or **ventral aspect** the anterior median fissure of the spinal cord becomes broader and deeper because of the great height attained by the **pyramids.** At the level at which the pyramids emerge from the pons, the region in which they are largest, the fissure terminates in a triangular recess so deep as to merit the name **foramen cæcum.** The pyramids are the great descending cerebral or motor funiculi. In the medulla oblongata they decrease in bulk in passing toward the spinal cord, for the reason that many of the pyramidal axones are contributed to structures of the medulla, chiefly after crossing the mid-line. At the lower end of the medulla occurs the **decussation of the pyramids,** by which the anterior median fissure is almost obliterated for about 6 mm., and which, upon removal of the pia mater, may be easily observed as bundles of fibres interdigitating obliquely across the mid-line.

Not all the pyramidal fibres cross to the opposite side at this level in man, but a portion of those coursing in the lateral portion of the pyramid maintain their ventro-mesial position

and continue directly into the spinal cord, to form there the ventral cerebro-spinal fasciculus or direct pyramidal tract. However, most of such fibres finally cross the mid-line during their course in the spinal cord. The exact proportion of the direct fibres is variable, but always the greater mass of each pyramid crosses to the opposite side at the level of the decussation of the pyramids, and descends the cord as the lateral cerebro-spinal fasciculus or crossed pyramidal tract. Both of these pyramidal tracts are described in the discussion of the fasciculi of the cord.

FIG. 629.—SEMI-DIAGRAMMATIC REPRESENTATION OF THE VENTRAL ASPECT OF THE RHOMBENCEPHALON AND ADJACENT PORTIONS OF THE CEREBRUM. (Modified from Quain.)

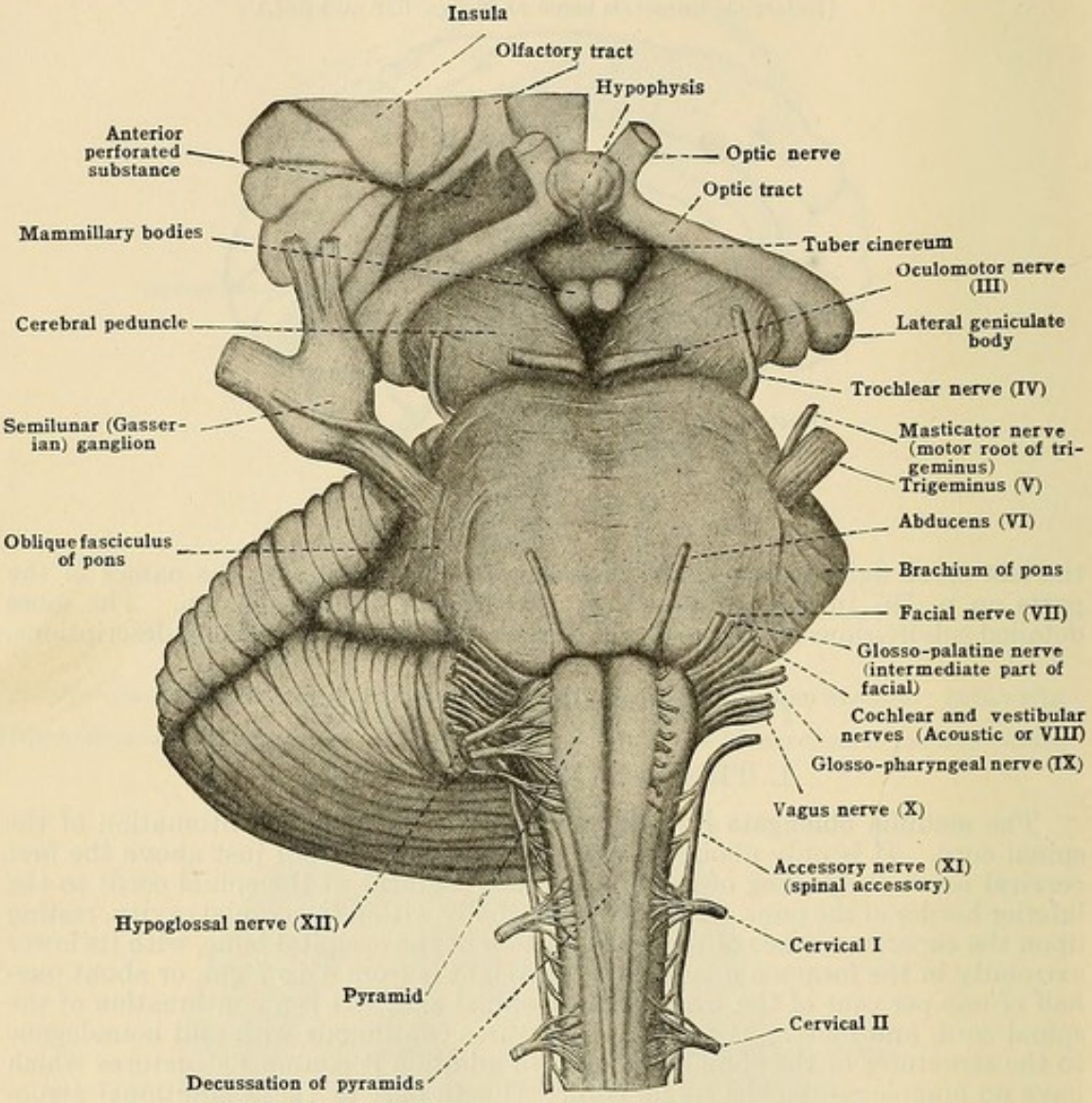

Each pyramid is bounded laterally by the **antero-lateral sulcus,** also continuous with that of the same name in the spinal cord. Toward the pons this sulcus separates the pyramid from the **olive** [oliva] (inferior olivary nucleus), and in the region of the olive there emerge along this sulcus the root filaments of the hypoglossal nerve. These are in line with the filaments of the ventral roots of the spinal nerves. The olives, as their name implies, are oblong oval eminences about 1.2 cm. in length. They extend to the border of the pons, and are somewhat thicker at their upper ends. Their surfaces are usually smooth, except at their lower ends, where they frequently appear ribbed, owing to bundles of the **external arcuate fibres** passing across them to and from the *restiform* body, which occupies the extreme lateral portion of the medulla. Along the line between the restiform body and the olive are attached the root filaments of the *vagus, glosso-pharyngeal,* and *spinal accessory nerves.* Both the *abducens* and the *facial* nerve emerge along the inferior border of the pons, the facial in line with the glosso-pharyngeal, but the abducens in line with the hypoglossus.

Dorsal aspect.—The increased lateral diameter of the medulla oblongata is contributed to a great extent by the **restiform bodies.** These are the inferior cere-

bellar peduncles (crura cerebelli ad medullam oblongatam) and contain the majority of the ascending fibres, which associate the cerebellum with the structures below it.

In toto, the restiform bodies are much larger than could be formed by the combined cerebellar fasciculi of the spinal cord, their great size being due to their receiving numerous axones coursing in both directions, which connect the cerebellum with structures contained in the medulla oblongata alone, so that in the medulla they increase as they approach the cerebellum. Their mesial borders form the lateral boundaries of the fourth ventricle. Their name (*restiform*, meaning rope-like) was suggested from the appearance frequently given them by the fibres of the cochlear (acoustic division of the eighth) nerve, which course around their lateral periphery to become the *striæ medullares* in the floor of the fourth ventricle.

FIG. 630.—DIAGRAM SHOWING THE DECUSSATION OF THE PYRAMIDS.
The uppermost level represented is near the inferior border of the pons.

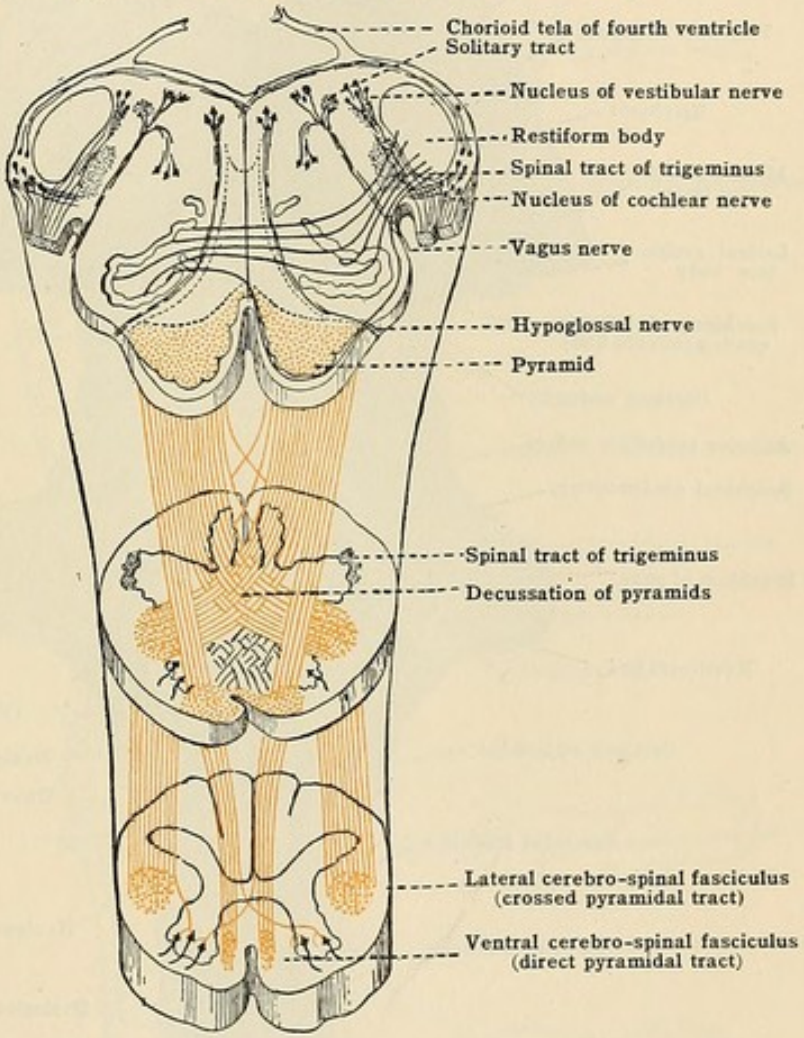

Upon removal of the cerebellum it may be seen that below the *calamus scriptorius* (inferior terminus of the fourth ventricle) the structures manifest in the dorsal surface of the medulla are directly continuous with those of the spinal cord. The fasciculus gracilis (Goll's column) of the spinal cord acquires a greater height and volume and becomes the **funiculus gracilis** of the medulla, and because of this increased height the posterior median sulcus of the cord becomes deepened into the **posterior median fissure.** The posterior intermediate sulcus is also accentuated by the fasciculus cuneatus (Burdach's column) likewise now enlarged into the **funiculus cuneatus** of the medulla. The lateral funiculus of the medulla, of course, does not contain the lateral or crossed pyramidal tract present in the spinal cord.

At the border of the calamus scriptorius the funiculus gracilis terminates in a slight elevation, the **clava,** which is the superficial indication of the **nucleus of the fasciculus gracilis.** Beginning somewhat more anteriorly, and having a somewhat greater length, is a similar enlargement of the funiculus cuneatus, the **tuberculum cuneatum** or **nucleus of the fasciculus cuneatus.**

These nuclei are the groups of nerve cell-bodies about which the ascending or sensory axones of the respective fasciculi terminate or where the sensory impulses are transferred to a second neurone in their course to the structures of the encephalon. These cell-bodies in their turn give off axones which immediately cross the mid-line and assume a more ventral position, contributing largely to the *lemniscus* or fillet of the opposite side, and thus such axones are the encephalic continuation of the central sensory pathway conveying impulses from the periphery of one side of the body to the opposite side of the cerebrum. The crossing of these axones is known as the *decussation of the lemnisci.*

FIG. 631.—DORSAL ASPECT OF MEDULLA OBLONGATA AND MESENCEPHALON, SHOWING THE FLOOR OF THE FOURTH VENTRICLE (RHOMBOID FOSSA). (Modified from Spalteholz.)

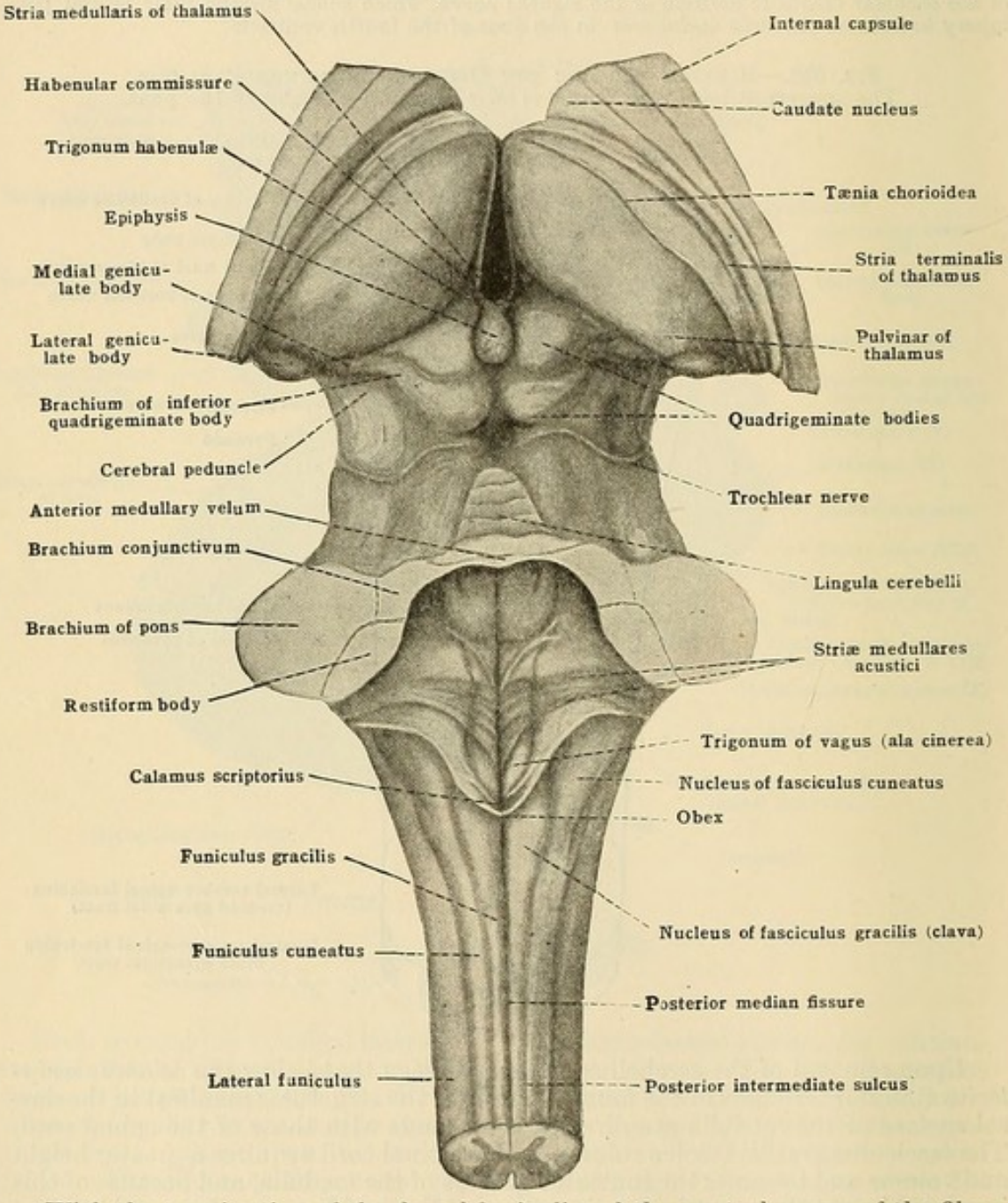

With the termination of the dorsal funiculi and the ventral course of the fibres of the lemnisci in their decussation, the central canal of the spinal cord loses its roof of nervous tissue in the medulla and comes to the surface as the fourth ventricle. The floor of the fourth ventricle, which corresponds to the floor of the central canal, is considerably widened into two **lateral recesses** opposite the junction of the inferior and middle cerebellar peduncles of either side, and, being pointed at both its superior and inferior extremities, it is rhomboidal in shape and thus is the **rhomboid fossa.** The pia mater of the spinal cord is maintained across the tip of the calamus scriptorius to form the **obex,** a small, semilunar lamina roofing over the immediate opening of the central canal. The obex carries a few medullated commissural fibres.

FIG. 632.—DIAGRAM OF THE SPINO-CEREBELLAR FASCICULI AND THE ORIGIN AND DECUSSATION OF THE LEMNISCI.

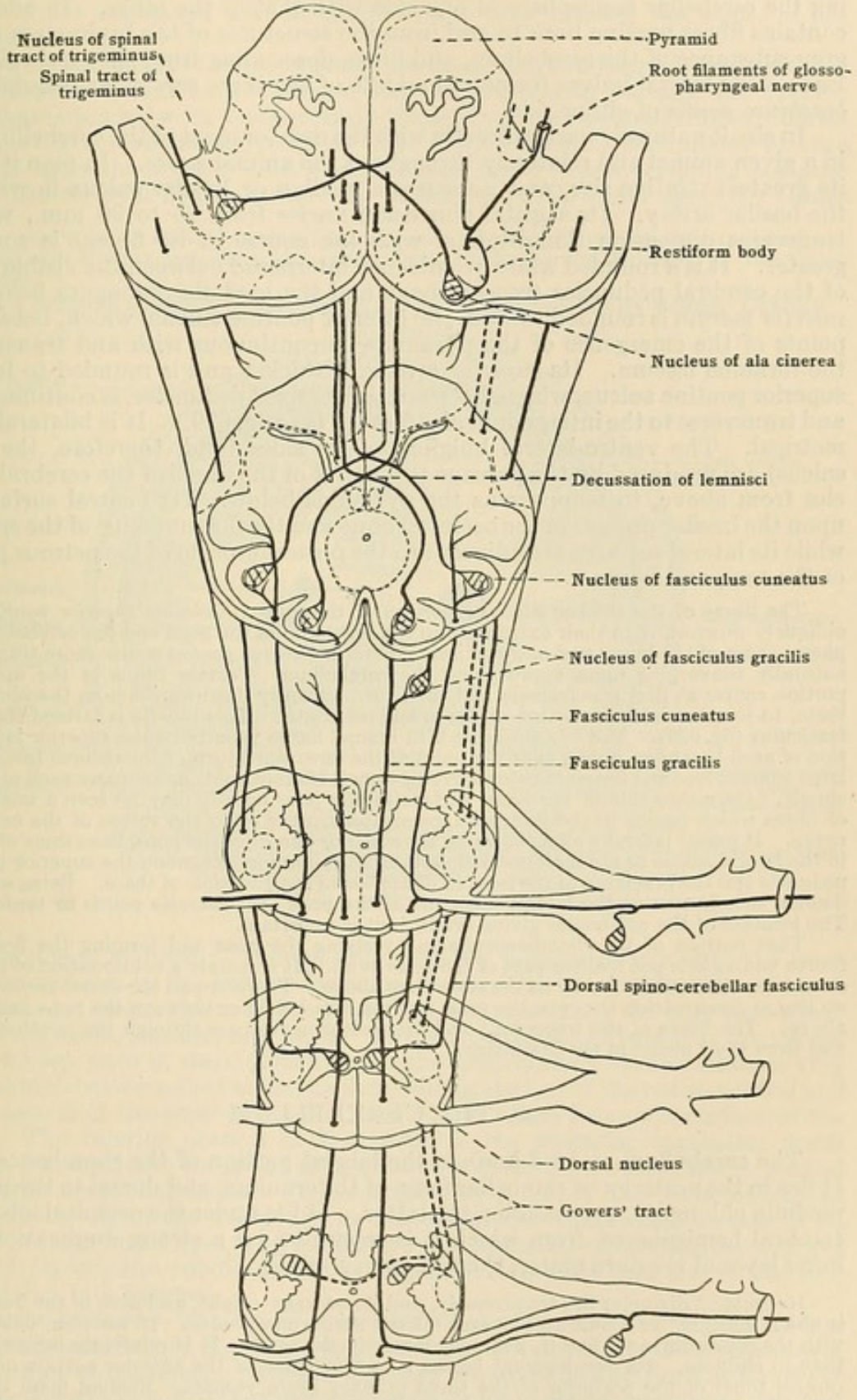

2. THE PONS

The **pons** (**Varoli**) is, for the most part, a great commissure or 'bridge' of white substance coursing about the ventral aspect of the brain-stem, and connecting the cerebellar hemisphere of one side with that of the other. In addition it contains fibres passing both to and from the structures of the brain-stem and the grey substance of the cerebellum, and fibres descending from the cerebral cortex. Each of its lateral halves forms the middle of the three cerebellar peduncles, the *brachium pontis* of either side.

In size it naturally varies directly with the development of the cerebellum, both in a given animal and relatively throughout the animal series. In man it attains its greatest relative size, and possesses a median or **basilar sulcus** in which lies the basilar artery. Its sagittal dimension varies from 25 to 30 mm., while its transverse dimension (longitudinal with the course of its fibres) is somewhat greater. It is a rounded white prominence interposed between the visible portion of the cerebral peduncles (crura) above and the medulla oblongata below. Its *inferior margin* is rounded to form the **inferior pontine sulcus,** which, between the points of the emergence of the pyramids, is continuous with and transverse to the foramen cæcum. Its *superior margin* is thicker and is rounded to form the **superior pontine sulcus,** which, between the cerebral peduncles, is continuous with and transverse to the interpeduncular fossa. (See fig. 629.) It is bilaterally symmetrical. The ventro-lateral bulgings of its sides (and, therefore, the basilar sulcus) are produced by the passage through it of the fibres of the cerebral peduncles from above, to reappear as the pyramids below. Its ventral surface rests upon the basilar process of the occipital bone and the dorsum sellæ of the sphenoid, while its lateral surfaces are adjacent to the posterior parts of the petrous portions of the temporal bones.

The fibres of the thicker superior portion of the pons (*fasciculus superior pontis*) course obliquely downward to their entrance into the brachium of the pons and the cerebellar hemisphere; those of the lower and mid-portions (*fasciculus medius pontis*) course more transversely, naturally converging upon approaching the cerebellum. Certain fibres of the upper mid-portion course at first transversely and then turn abruptly downward across the fibres above them, to join the inferior portion of the brachium pontis. This bundle is termed the **oblique fasciculus** (fig. 629). The *trigeminus* or fifth cranial nerve penetrates the superior lateral portion of each brachium pontis near the point of the downward turn of the oblique fasciculus; its large afferent root and the masticator nerve (its small efferent root) accompany each other quite closely. On either side of the basal surface of the pons usually may be seen a small bundle of fibres which begins in the interpeduncular fossa, near or in the sulcus of the oculomotor nerve. It passes laterally along or under the superior border of the pons, loses some of its fibres in the lateral sulcus of the mesencephalon, then runs inferiorly between the superior cerebellar peduncle and the brachium of the pons to disappear in the junction of these. Being sometimes double, it is known as the **lateral filaments of the pons** (*fila lateralia pontis* or *tænia pontis*). The location of the cell-bodies giving origin to it is uncertain.

That portion of the rhombencephalon overlying the pons and forming the floor of the fourth ventricle is not really a part of the pons at all. It is merely a continuation of the brain-stem from the medulla below to the structures above. Therefore on the *dorsal surface* there is no line of demarcation between the pons and medulla below or between the pons and isthmus above. The fibres of the trigeminus and masticator nerve pass through the pontine fibres to and from their nuclei in the brain-stem.

3. THE CEREBELLUM

The **cerebellum** or *hind brain* is the largest portion of the rhombencephalon. It lies in the posterior or cerebellar fossa of the cranium, and dorsal to the pons and medulla oblongata, overhanging the latter. It fits under the occipital lobes of the cerebral hemispheres, from which it is separated by a strong duplication of the inner layer of the dura mater, the *tentorium cerebelli*.

Its greatest diameter lies transversely, and its average weight, exclusive of the dura mater, is about 140 gm., or about 10 per cent. of the entire encephalon. It varies in development with the cerebrum, and, like it, averages larger in the male. It is relatively larger in adults than in children. Its development begins as a thickening of the anterior portion of the roof (dorsal zone) of the posterior of the three primary brain vesicles. Resting upon the brain-stem, it roofs over the fourth ventricle and is connected with the structures anterior, below, and posterior to it by its three pairs of peduncles.

The surface of the cerebellum is thrown into numerous narrow folia or **gyri,** which in the given localities run more or less parallel with each other. They are

separated by narrow but relatively deep **sulci.** Unlike the spinal cord and medulla, in which the grey substance is centrally placed and surrounded by a mantle of white substance, the surface of the cerebellum is itself a cortex of grey substance, the *cortical substance* [substantia corticalis], enclosing a core of white substance, the *medullary* body [corpus medullare]. However, within this central core of white substance are situated definite grey masses, the *nuclei* of the cre bellum.

The **gross divisions** of the cerebellum are three: the two larger lateral portions, the **hemispheres,** and between these the smaller central portion, the **vermis.** The demarcation between these gross divisions is not very evident from the dorsal surface, because the hemispheres in their extraordinary development in man encroach upon the vermis, and, being pressed under the overlapping occipital ends of the cerebral hemispheres, they become partially fused upon the vermis

FIG. 633.—SECTION OF HEAD PASSING THROUGH THE MASTOID PROCESSES OF THE TEMPORAL BONES AND BEHIND THE MEDULLA OBLONGATA. SHOWING THE POSITION OF THE CEREBELLUM.

(From a mounted specimen in the Anatomical Department of Trinity College, Dublin.)

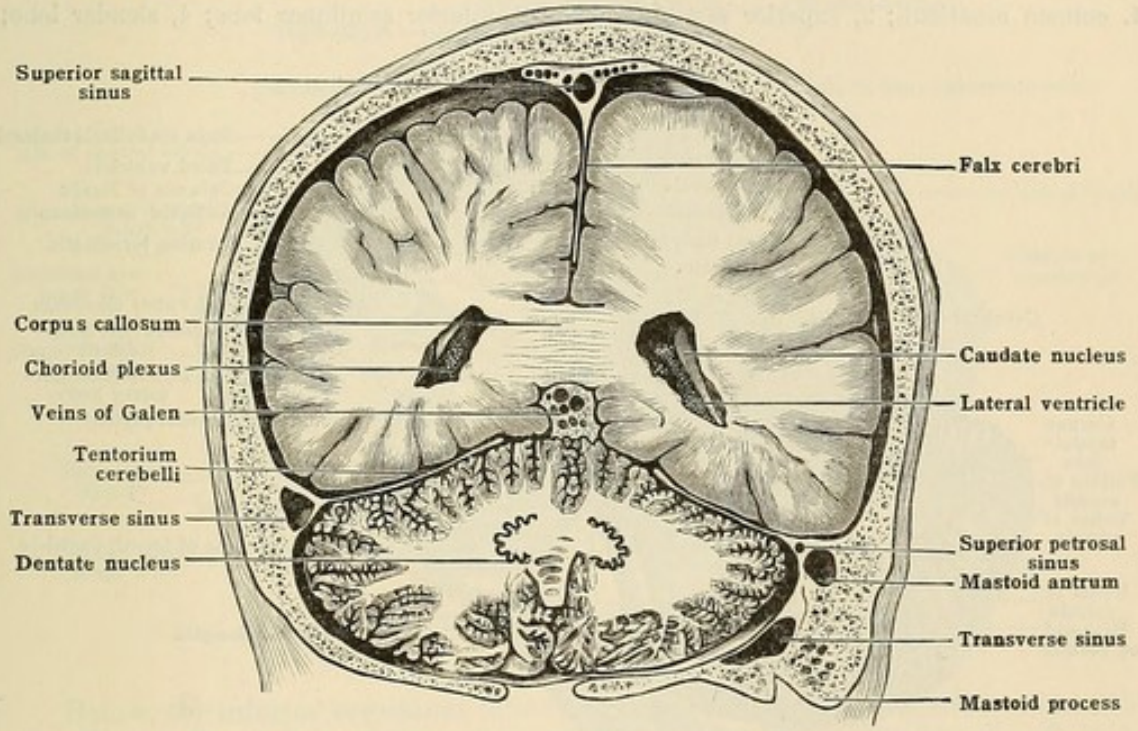

along the dorsal mid-line. Though differentiated simultaneously with the cerebellar hemispheres in the human fœtus, in most of the mammalia the vermis is the largest and most evident of the parts, and it is practically the only part which exists in the fishes, reptiles, and birds. In man, owing to the fact that the vermis does not keep pace in development with the hemispheres, there results a very decided notch between the two hemispheres along the line of the entire ventral and inferior aspect of the cerebellum, the floor of this notch being the surface of the vermis. The inferior portion of the notch is the **posterior cerebellar notch** (incisura marsupialis); its prolongation above is wider than below, and is termed the **superior cerebellar notch.** It is occupied by a fold of the dura mater, the falx cerebelli. With the variations in contour of the cerebellum, certain of its sulci are broader and deeper, and merit the name **fissures.** These are more or less definitely placed, and subdivide the hemispheres into **lobes** and the vermis (the median lobe) into **lobules.**

Superior surface.—The superior surface is bounded from the inferior surface by the **horizontal fissure** (fig. 635) which extends ventrolaterally, to the entrance of the brachium of the pons. Between this and the extreme anterior border of the dorsal surface are two other fissures, the **posterior** and **anterior semilunar fissures.** These, like the horizontal fissure, may be traced, with slight interruptions, across the mid-line, and consequently mark off not only the two hemispheres but also the vermis into corresponding divisions.

The **superior semilunar lobe** [lobulus semilunaris superior] (postero-superior lobe) of each hemisphere lies between the horizontal and the posterior semilunar fissures. It largely composes the outer border of the cerebellum, and, therefore, is the longest of the lobes.

The adjacent surface of the hemispheres, because of the frequently less complete development of the anterior semilunar fissure, is sometimes referred to as the **quadrangular lobe,** with its *posterior* and its *anterior portions.* On the other hand, especially when the anterior semilunar fissure is well marked, this area may be divided into—(1) the *posterior semilunar lobe,* between the posterior and anterior semilunar fissures, and (2) the *anterior semilunar lobe,* anterior to the anterior semilunar fissure (fig. 635).

Anterior to the quadrangular lobe on each hemisphere is the **ala of the central lobule,** bounded by the postcentral and the precentral sulcus. Anterior to this, on the anterior margin of the hemisphere, is the **vinculum lingulae,** a slender process continuous with the lingula of the vermis (fig. 658).

FIG. 634.—MEDIAN SECTION THROUGH CEREBELLUM AND BRAIN-STEM. (Allen Thompson, after Reichert.)
1. culmen monticuli; 2, superior semilunar lobe; 3, inferior semilunar lobe; 4, slender lobe; 5, biventral lobe; 6, tonsil.

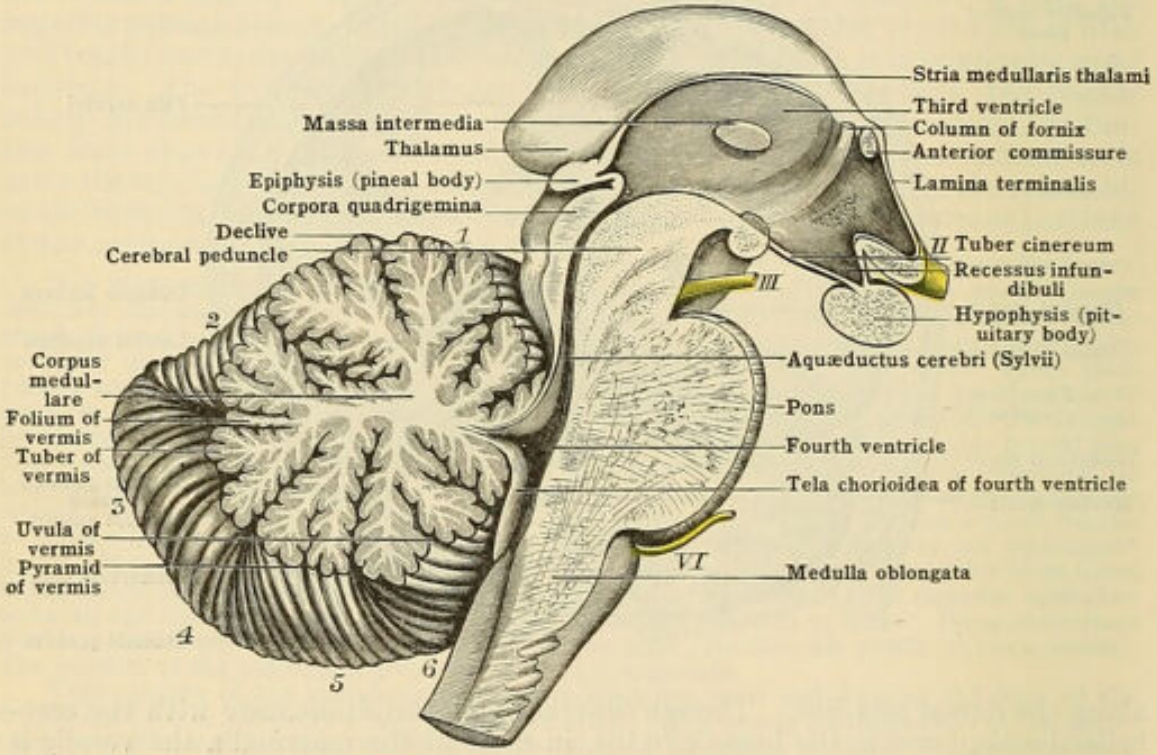

The superior aspect of the vermis, the **superior vermis,** because of the fusion of the hemispheres, is, for the most part, a slight ridge, the **monticulus** (fig. 635), instead of a depression. However, in the posterior portion of the dorsal surface the depression of the posterior notch begins, and here the horizontal and the posterior semilunar fissures approach each other so closely that the corresponding subdivision of the vermis is seldom more than a single folium, the **folium vermis** (*cacuminis*).

The monticulus proper is divided into an inferior lobule, the **declive,** and a superior lobule, the **culmen.** These appear as continuations across the midline of the posterior and anterior semilunar lobes of the hemispheres, and are separated by the corresponding fissures (fig. 635).

At the extreme anterior part of the superior surface and in the bottom of the anterior cerebellar notch lies a more definitely defined portion of the vermis. This is the **central lobule** (fig. 635). It is broadened laterally into two pointed wings, the *alæ* of the central lobule, the folia of which, if present, are parallel with those of the anterior semilunar lobes and separated from them by the **postcentral sulcus.**

If the anterior margin of the central lobule be lifted, the **lingula cerebelli**

(*lingula vermis*) will appear separated from the central lobule by the **pre-central sulcus.** It is a thin, tongue-like anterior projection of the cortical substance comprising four to eight folia adhering upon the *anterior medullary velum*, the roof of the superior portion of the fourth ventricle.

Inferior surface.—The three cerebellar peduncles of each side join to form a single mass of white substance, and enter the ventral aspect of each hemisphere at the medial and ventral extremity of the horizontal fissure. The inferior surface of the cerebellum is less convex than the superior surface. The hemispheres are decidedly separated by a continuation of the posterior cerebellar notch, which becomes broader, the **vallecula of the cerebellum,** which contains the inferior portion of the vermis, **vermis inferior,** and whose margins embrace the medulla oblongata. The inferior surfaces of the hemispheres are each divided by the intervening fissures into four lobes (fig. 636).

FIG. 635.—DIAGRAM OF THE SUPERIOR SURFACE OF THE CEREBELLUM.

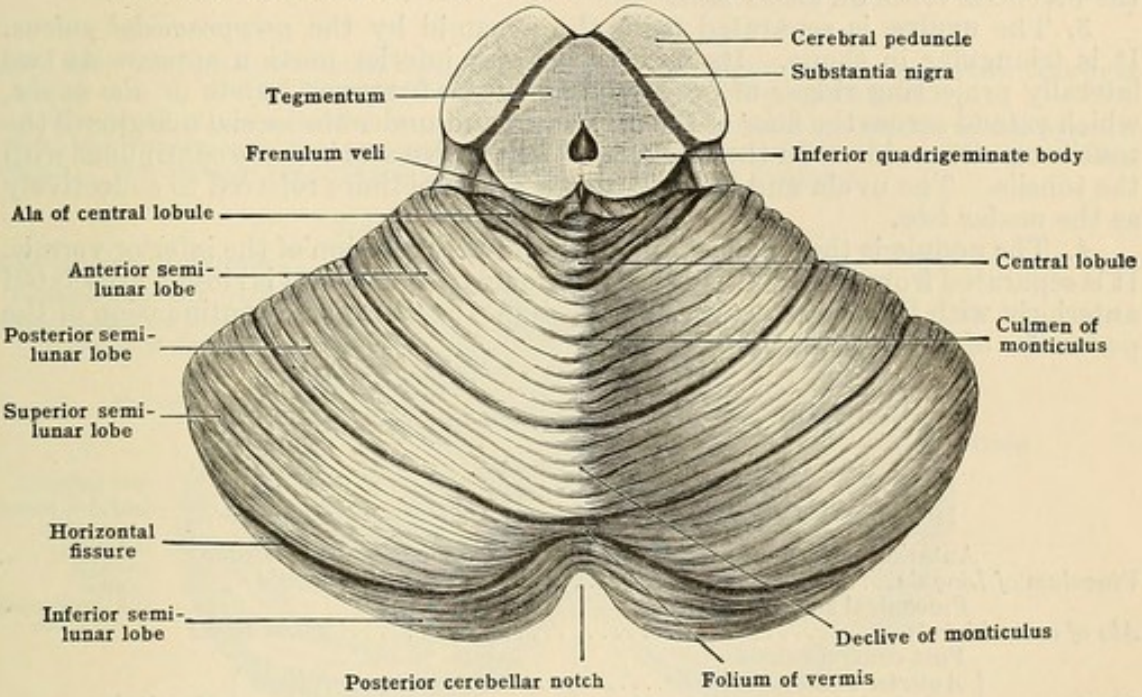

Below, the **inferior semilunar lobe** (postero-inferior lobe) is separated from the superior semilunar lobe of the superior surface by the horizontal fissure. It is the largest of the inferior lobes, and is broader at its medial extremity. Frequently two and sometimes three of its curved sulci appear deeper than others, and separate it into two or three **slender lobules** [lobuli graciles]. More commonly there are two of these, the *lobulus gracilis posterior* and *lobulus gracilis anterior*, separated by the *postero-inferior sulcus*.

The **biventral lobe** is smaller and more curved than the inferior semilunar lobe, from the anterior margin of which it is separated by the curved **antero-inferior sulcus.** Its medial extremity is pointed and does not extend to the vermis; its lateral extremity is broader and curves anteriorly to the ventral extremity of the horizontal fissure—the line of outer termination of the inferior semilunar lobe.

The **tonsil** [tonsilla cerebelli] (*amygdala*) is a rounded, triangular mass, placed mesially within the inner curvature of the biventral lobe, and separated from it by the **retrotonsillar fissure.** Its inferior mesial border slightly overlaps the vermis.

The smallest of the lobes is the **flocculus.** It lies adjacent to the inferior and lateral surface of the mass of white substance produced by the confluence of the three cerebellar peduncles, and extends into the mesial extremity of the horizontal fissure. It is so flattened that its short folia give it the appearance suggesting its name. Occasionally there is added a second, less perfectly formed portion, the *secondary flocculus*. From each floccular lobe there passes toward the midline a thin band of white substance, the **peduncle of the flocculus;** these extend

to meet each other at the most anterior portion of the inferior vermis, and thus form the narrow **posterior medullary velum.**

The **inferior vermis** (figs. 634, 636) is more definitely demarcated than the superior. Lying in the floor of the vallecula cerebelli, it is separated on each side from the adjacent lobes of the hemispheres by a well-marked sulcus about it, the *nidus avis*. By contour and by deeper transverse fissures (sulci) occurring at intervals across it, four divisions or lobules of the inferior vermis are recognised. These lobules, like those of the superior vermis, are each in intimate relation with the pair of lobes of the hemispheres adjacent to it on either side.

1. The **tuber vermis** is adjacent to the folium vermis of the superior aspect, and thus is the most inferior lobule of the inferior vermis. It is a short, somewhat pyramidal-shaped division, whose four or five transversely arranged folia are continuous with the folia of the inferior semilunar lobes on either side.

2. The **pyramid** is separated from the tuber vermis by the *post-pyramidal sulcus*. Its several folia cross the vallecula cerebelli and curve to connect with the biventral lobes on either side.

3. The **uvulva** is separated from the pyramid by the *prepyramidal sulcus*. It is triangular in shape. Its base or broader inferior portion appears as two laterally projecting ridges of grey substance, the **furrowed bands** or *alæ uvulæ*, which extend across the floor of the nidus avis and under the mesial margins of the tonsils on either side. In these bands its folia curve and become continuous with the tonsils. The uvula and the two tonsils are sometimes referred to collectively as the *uvular lobe*.

4. The **nodule** is the smallest and most anterior division of the inferior vermis. It is separated from the uvula by the **post-nodular sulcus,** and is closely associated anteriorly with the posterior medullary velum, the transverse continuation of the peduncles of the floccular lobes.

SUMMARY OF EXTERNAL FEATURES OF CEREBELLUM

Superior Surface.

HEMISPHERE		VERMIS	
Anterior border—Anterior medullary velum—Anterior border			
Vinculum of Lingula		*Lingula*	
Precentral sulcus			
Ala of central lobule		*Central lobule*	
Post-central sulcus			
Quadrangular lobe	*Anterior semilunar lobule*	*Culmen*	*Monticulus*
	Anterior semilunar fissure		
	Posterior semilunar lobule	*Declive*	
	Posterior semilunar fissure		
Superior semilunar lobe		*Folium.*	
Horizontal Fissure			

Inferior Surface

Horizontal Fissure			
Inferior semilunar lobe	*Posterior slender lobule*	*Tuber*	
	Posterior-inferior sulcus		
	Anterior slender lobule		
Anterior-inferior sulcus		Post-pyramidal sulcus	
Biventral lobe		*Pyramid*	
Retro-tonsillar fissure		Prepyramidal sulcus	
Tonsil		*Uvula*	
Horizontal Fissure		Post-nodular sulcus	
Flocculus		*Nodule*	
Posterior medullary velum			

Internal structure of the cerebellum (fig. 637).—The white substance of the cerebellum is continuous with its peduncles and forms a compact central mass. Over the surface of this the grey substance or cortex is spread in a thin but uniform and much folded layer. Upon section of the cerebellum certain of the sulci as well as the fissures are shown to be much deeper than is apparent from the surface. The deeper sulci separate the lobes into divisions, the **medullary laminæ,** each of which is composed of a number of folia and each of which has its own core of white substance. The folia of the laminæ line the sulci (and fissures), and also comprise their surface aspect, and are separated by the shallow, *secondary sulci*. The larger

laminæ are subdivided into from two to four secondary laminæ of varying size. Such subdivision is especially marked in the vermis. Here each lamina comprises a lobule and is, therefore, separated by a fissure, and each lobule is usually subdivided with the exception of the nodule, the folium, and the lingula. In sagittal sections, or sections transverse to the general direction of the sulci, this arrangement of the laminæ gives a foliate appearance, which, especially in sagittal sections of the vermis, is termed the **arbor vitæ** (see fig. 634).

The **cerebellar cortex** consists of three layers and contains four general types of cell-bodies of neurones, all of which possess features peculiar to the cerebellum.

The outermost or **molecular layer** contains small **stellate cells,** "basket cells," with relatively long dendrites. These serve to associate the different portions of a given folium. The axones of the largest of them give off branches which form pericellular baskets about the bodies of the *cells of Purkinje*, each axone contributing to several baskets. The **layer of Purkinje cells,** or the middle layer, is quite thin. The bodies of the cells of Purkinje are arranged in a single layer, and their elaborate systems of dendrites extend throughout and largely compose the molecular layer. The dendrites of these, the most essential cells of the cortex, are displayed in the form of arborescent fans (see fig. 604), arranged parallel with each other and transverse

FIG. 636.—DIAGRAM OF THE INFERIOR SURFACE OF THE CEREBELLUM AFTER THE REMOVAL OF THE MEDULLA OBLONGATA, PONS, AND MESENCEPHALON.

The tonsil of the right side is omitted in order to display the connection of the pyramid with the biventral lobe, the furrowed band of the uvula, and more fully the posterior medullary velum. The anterior notch is less evident than in the actual specimen.

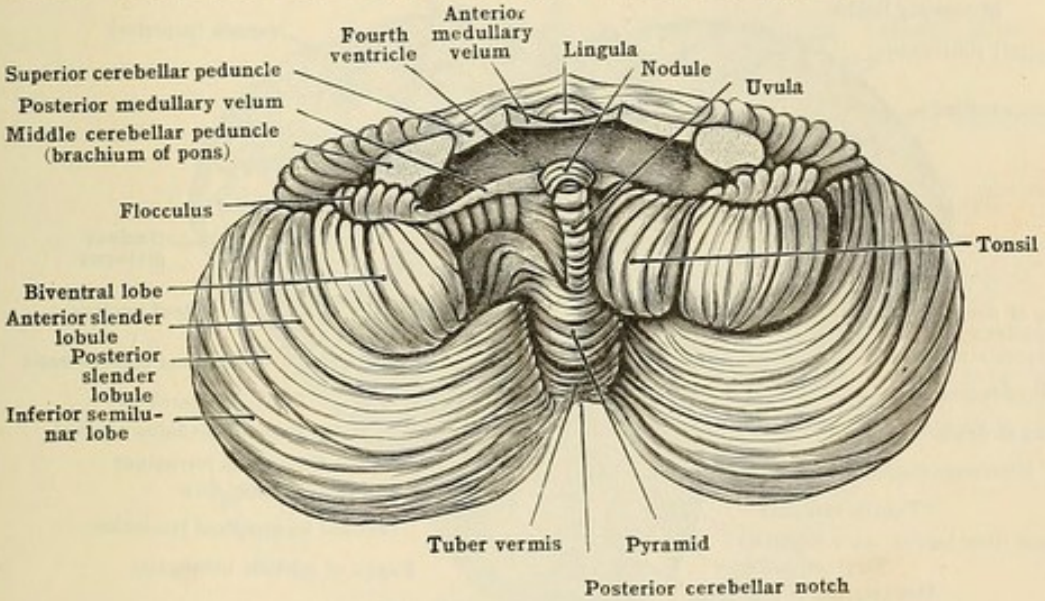

to the long axis of the folium containing them. Their axones are given off from the base of the cell-body and acquire their medullary sheaths quite close to the cell-body, and, after giving off several collaterals in the inner layer, pass into the general white substance and thence to other laminæ or lobes. Certain of them go to structures outside the cerebellum. The inner layer is the **granular layer.** It contains numerous small nerve-cells or "granule-cells" which possess from two to five radiating dendrites, unbranched except at their termination, which occurs suddenly in the form of three to six claw-like twigs. Their axones are given off either from the cell-body direct or more often from the base of one of the dendrites, and pass outward into the molecular layer, where they bifurcate and course in both directions parallel to the long axis of the folium, to become associated with the dendrites of the cells of Purkinje. In the layer of the cells of Purkinje there is situated at intervals a neurone of the Golgi type II (see fig. 604). The short, elaborately branched axone of this neurone is distributed among the cells of the granular layer. Axones conveying impulses to the cerebellar cortex terminate in the granular layer as '*moss fibres*,' or directly upon the cells of Purkinje as '*climbing fibres*,' and probably upon the cells of the Golgi type II.

Thus the neurones which receive impulses coming to the cortex are the cells of Purkinje, probably the Golgi cells of type II, and the granule-cells; those which distribute these impulses to other neurones of the folium are the Golgi cells of type II, the granule-cells, and the basket-cells (association neurones), and the collaterals of the cells of Purkinje. Impulses are conveyed from the cortex of a folium to that of other folia, lamina, lobules or lobes, or to the nuclei of the cerebellum, or to structures outside the cerebellum by the axones of the cells of Purkinje.

The **nuclei of the cerebellum** (fig. 637) are in its central core of white substance. They are four in number, and all are paired, those of each pair being situated opposite each other on either side of the mid-line.

1. The largest of them is the **dentate nucleus.** This is an isolated mass of grey substance situated in the core of white substance of each hemisphere. It is in the form of a folded or corrugated cup-shaped lamina, with the opening of the cup (*hilus*) directed anteriorly and obliquely toward the mid-line. It contains a mass of white substance and possesses a capsule. Its cell-bodies give rise to most of the fibres forming the superior cerebellar peduncles.

2. The **nucleus emboliformis** is an oblong and much smaller mass of grey substance, which lies immediately medial to the hilus of the dentate nucleus. It is probably of the same significance as the dentate nucleus, being merely a portion separated from it.

3. The **nucleus globosus,** the smallest of the cerebellar nuclei, is an irregular horizontal mass of grey substance with its larger end placed in front. It lies close to the medial side of the nucleus emboliformis, and often appears separated into two or more rounded or globular masses.

4. The **roof nucleus** [nucleus fastigii] is the second largest of the cerebellar nuclei, and is the most mesially placed. The pair is situated in the roof of the

FIG. 637.—SECTION OF CEREBELLUM AND BRAIN-STEM PASSING OBLIQUELY THROUGH INFERIOR PORTION OF CEREBELLUM TO SUPERIOR MARGIN OF PONS. (After Toldt, "Atlas of Human Anatomy," Rebman, London and New York.)

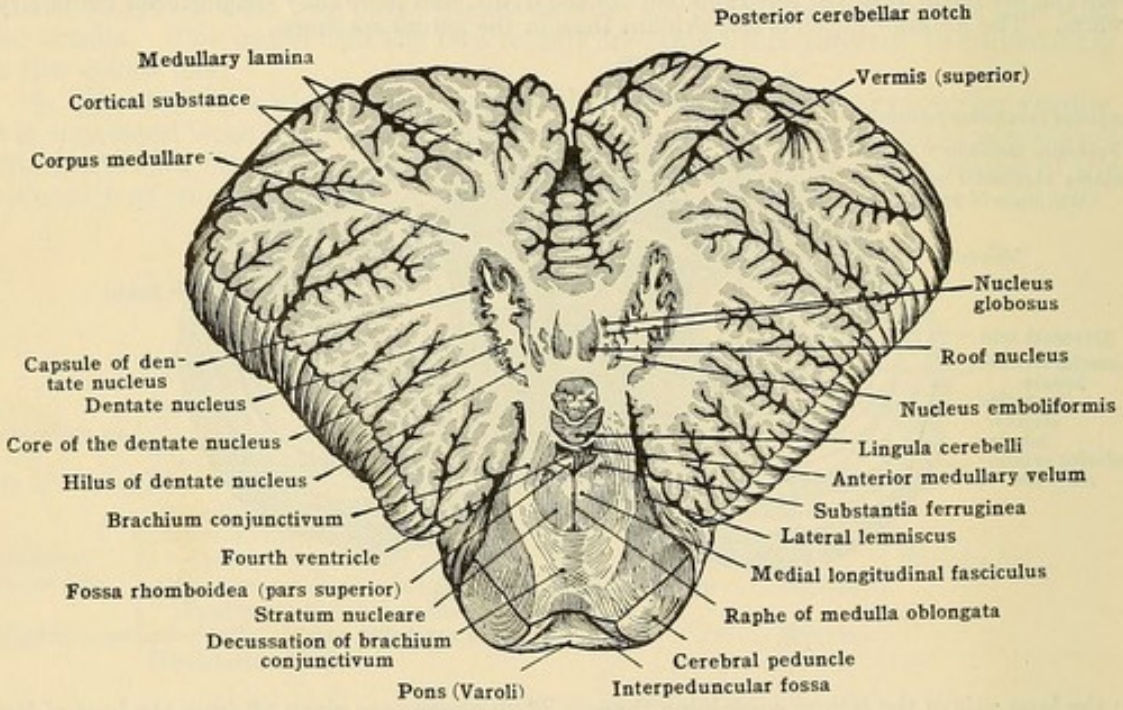

fourth ventricle, and so near the mid-line that both nuclei are in the white substance of the vermis. They are ovoid in shape, and the nucleus of one side receives axones from the nucleus of the vestibular nerve chiefly of the opposite side, the decussation of these axones taking place in the vermis. Its cells are larger than those of the two first-mentioned nuclei.

The peduncles of the cerebellum.—The peduncles consist of three pairs—the inferior, middle, and superior. The three peduncles of each side come together at the level of the lower border of the pons, and the entering and emerging fibres of which they are composed become continuous with the central core of white substance of the cerebellar hemispheres. (Fig. 631, 638, 639.)

The **restiform body** of the medulla oblongata is the inferior peduncle. It forms the lateral boundary of the inferior portion of the fourth ventricle, and upon reaching the level of the pons turns sharply backward into the cerebellum. In the region of the turn it is encircled externally by fibres of the cochlear nerve. It contains fibres, both ascending and descending, between the cerebellar cortex and the structures below the cerebellum.

Its fibres include: (1) fibres from the spinal cord including the dorsal spino-cerebellar fasciculus (direct cerebellar tract) and probably a small proportion of the ascending fibres of the superficial ventro-lateral spino-cerebellar fasciculus (Gowers' tract); (2) fibres from the

olive of the same and opposite side of the medulla oblongata; (3) fibres from the nuclei of the funiculus gracilis and cuneatus of the same and opposite sides; (4) fibres to and from the olive of the opposite side; (5) fibres to the nuclei of the motor cranial nerves; (6) fibres descending to the ventral horn cells of the spinal cord. The ascending or afferent fibres of the spino-cerebellar and cerebello-olivary fasciculi are the principal components of the inferior peduncle; the existence of fibres (5) and (6) is not well established. Of these, the fibres of the direct cerebellar tract terminate in the cortex of the superior vermis of both sides of the mid-line, but, for the most part, in that of the same side. The olivary fibres end in the cortex of both the superior vermis and the adjacent cortex of the hemispheres, and some of them terminate in the nucleus dentatus.

The **brachium pontis** or the middle peduncle is the largest of the three cerebellar peduncles. In it the pons fibres pass slightly downward and into the cerebellar hemisphere, between the lips of the anterior part of the horizontal fissure, entering lateral to the inferior peduncle.

FIG. 638.—TRANSPARENCY DRAWING SHOWING THE ORIGIN, COURSE, AND CONNECTIONS OF THE SUPERIOR CEREBELLAR PEDUNCLES (BRACHIA CONJUNCTIVA) IN THE FORMATION OF 'STILLING'S SCISSORS.'

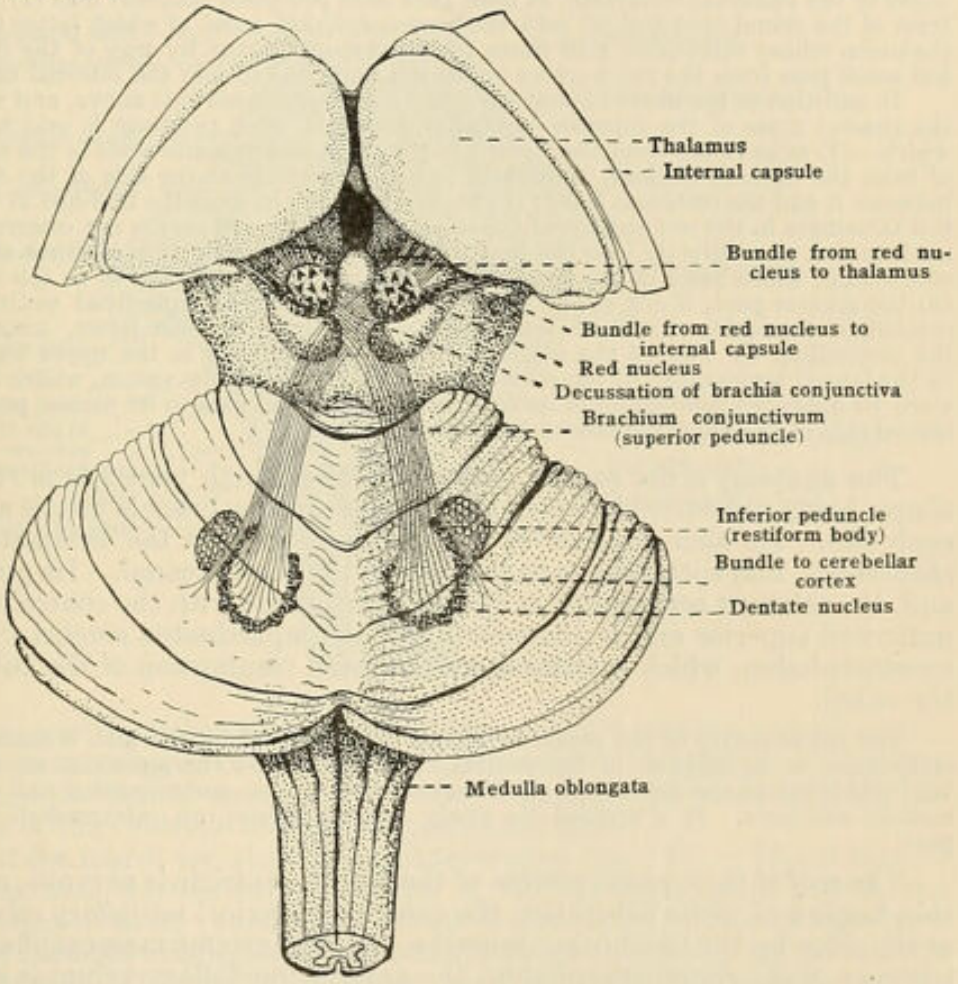

It consists of the transverse fibres of the pons, and within the cerebellum its fibres are distributed in two main groups—the upper transverse fibres of the pons apparently pass downward to radiate in the lower portion of the hemisphere, while the lower transverse fibres pass upward and medialward to radiate in the superior part of the hemisphere and vermis. For the most part the fibres of the middle peduncle may be considered as commissural fibres, passing from one side of the cerebellum to the other. Each peduncle contains fibres coursing in opposite directions. Many of these fibres are interrupted in their course to the opposite side by cells scattered throughout the pons, *nuclei of the pons*, and, therefore, in each brachium pontis some of the fibres are processes of the cells of the cerebellum and course toward the opposite side, while others are processes of the cells of the pontine nuclei and course to the cerebellar hemisphere of the same side. Many cell-bodies of the nuclei of the pons whose axones terminate in the cerebellum receive impulses from fibres descending from the *cerebral* cortex of the opposite side—*cortico-pontine fibres*. Furthermore, there are evidences after degeneration that the brachium pontis also contains a few fibres from the cerebellum to the structures of the brain-stem and spinal cord.

The **brachium conjunctivum** or superior cerebellar peduncle emerges from the cerebellum on the medial side of the brachium pontis and also on the superior and medial side of the course of the restiform body. It forms the lateral boundary of the superior portion of the fourth ventricle and is the cerebello-cerebral peduncle. Its transverse section appears semilunar in shape, with the concave side next to the cavity of the ventricle. The medial border, which inclines toward the mid-line, is connected with that of the corresponding peduncle of the opposite side by the *anterior medullary velum,* which thus roofs over the superior part of the fourth ventricle. The lateral border is distinguished from the pons by an open furrow or lateral sulcus.

The superior cerebellar peduncles are almost entirely efferent pathways as to the cerebellum and form the chief connections between the cerebellum and the cerebrum. They arise almost wholly from the dentate nuclei. As they course forward they slightly converge and disappear under the inferior quadrigeminate bodies. Here, in the tegmentum of the mesencephalon, they undergo an almost total **decussation,** and then the majority of the fibres of each peduncle, having thus crossed the mid-line, terminate in the *red nucleus* of the opposite side. The red, nucleus lies in the tegmentum of the mesencephalon, below the superior quadrigeminate bodies, and therefore quite close to the decussation. The cells of the red nucleus, about which the fibres of the peduncle terminate, in their turn send processes (axones) into (1) the rubro-spinal tract of the spinal cord and (2) into the prosencephalon, most of which latter terminate in the thalamus whose cell-bodies give fibres to the cerebral cortex by way of the internal capsule; but some pass from the red nucleus under the thalamus to join the internal capsule.

In addition to the fibres having the origin and course described above, and which constitute the greater mass of the superior cerebellar peduncle, each peduncle is said to contain fibres which—(1) arise in the cerebellar cortex of the same and opposite sides of the mid-line, instead of from the dentate nucleus, and which join the peduncle at the side of the dentate nucleus, between it and the restiform body; (2) fibres which do not cross the mid-line in the decussation, but terminate in the red nucleus of the same side; (3) some fibres are not interrupted in the red nucleus, but pass directly into the thalamus; (4) a small proportion of fibres afferent as to the cerebellum, which arise in the structures of the cerebrum and pass in to the cerebellum; and (5) the greater part, if not all, of the ascending fibres of the superficial ventro-lateral spino-cerebellar fasciculus (Gowers' tract) of the spinal cord. The latter, instead of entering the cerebellum by way of the restiform body, are deflected in the upper medulla and pass in the lateral tegmentum of the pons to the anterior medullary velum, where they turn backward to enter the cerebellum in its superior peduncle and pass to its cortex, probably from the lateral side of the dentate nucleus (see fig. 656).

The anatomy of the fourth ventricle.—The fourth ventricle is rhomboidal in shape, being considerably widened at the level of the brachia pontis and pointed at each end. Its floor consists of a slight depression in the brain-stem, the *fossa rhomboidea,* and corresponds to the floor of the central canal. Its pointed inferior end, the **calamus scriptorius,** is directly continuous with the central canal, and its narrowed superior end is continued into the aquæductus cerebri (Sylvii) of the mesencephalon, which is nothing more than a resumption of the tubular form of the canal.

The entire cavity of the ventricle is lined with an epithelium which is continuous with the epithelium, or ependyma, of the central canal below and the aqueduct above. The entire ventricle involves the *isthmus of the rhombencephalon,* the *metencephalon* and a portion of the *medulla oblongata.* It is divided for study into an inferior, an intermediate and a superior part.

The *roof of the superior portion* of the fourth ventricle is nervous, consisting of a thin lamina of white substance, the *anterior* (superior) *medullary velum,* thickened at the sides by the brachia conjunctiva. At its extreme mesencephalic end (in the isthmus of the rhombencephalon) the anterior medullary velum is slightly thickened by a continuation of the white substance of the inferior quadrigeminate bodies, forming the **frenulum veli.** The inferior portion of the velum is continuous with the white substance of the cerebellum, and is covered by the lingula cerebelli, an extension of the cortical substance of the superior vermis (fig. 631).

The *roof of the intermediate portion* of the fourth ventricle is formed by the cerebellum proper, the vermis and the mesial portions of the hemispheres. The nervous portion of the roof terminates with the *posterior* (inferior) *medullary velum,* a thin, narrow band of white substance which is the continuation of the peduncles of the floccular lobes, and which connects them at the mid-line with the nodule of the inferior vermis.

The *roof of the inferior portion* of the fourth ventricle is non-nervous. It is the **chorioid tela** of the fourth ventricle, a semilunar lamina consisting of the epithelial lining of the ventricle, reinforced by a continuation of the connective tissue of the pia mater and the adjacent portion of the arachnoid. Along the line of its

attachment to the surface of the medulla it is thickened, and in sections this portion bears the name **ligula** (*tænia ventriculi quarti*). The thickest portion spans the tip of the calamus scriptorius and is termed the **obex.** The width of the ventricular cavity is extended laterally from its widest part into the *lateral recesses*, narrow pockets on each side and around the upper parts of the restiform bodies. In the mid-line of the lower part of the chorioid tela there is a more or less well-marked opening, the *foramen of Magendie* (medial aperture of the fourth ventricle), which is a lymph-channel connecting the cavity of the ventricle with the subarachnoid space. There is a similar opening from each lateral recess (*lateral apertures of Key and Retzius*).

The *chorioid plexuses* of the fourth ventricle consist of highly vascular, lobular, villus-like processes of the ventricular lining (and pia-mater) of the chorioid tela. They are reddish in the fresh specimen, and the epithelial lining of the ventricle is closely adapted to the unevennesses of their surfaces. From below they run as

FIG. 639.—DIAGRAM OF THE ROOF AND LATERAL BOUNDARIES OF THE FOURTH VENTRICLE. The trochlear nerve should be shown emerging from the lateral boundary of the frenulum veli.

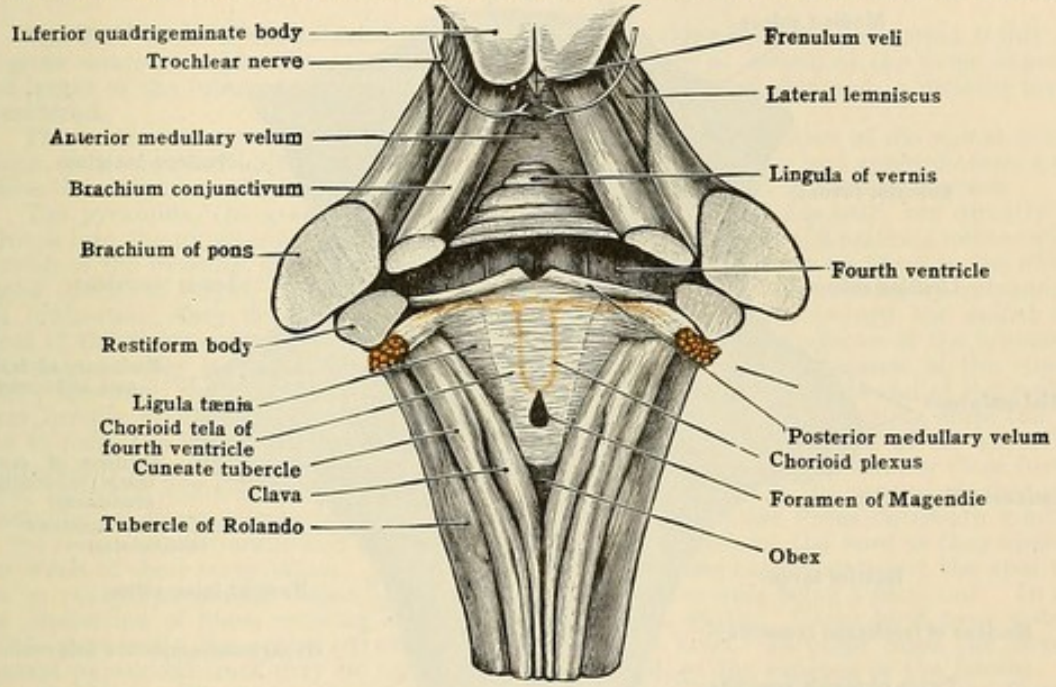

two parallel masses on either side of the mid-line, which become united above, and then are separated again into two lateral processes which bend at right angles and project into the lateral recesses. Portions frequently protrude through the three openings of the ventricle into the subarachnoid space.

The floor of the fourth ventricle [fossa rhomboidea] (fig. 640).—This is thrown into eminences and depressions indicative of the internal structures of the brain-stem subjacent to it. Its *inferior portion* is the dorsal surface of the upper portion of the medulla oblongata; its *intermediate portion* is the dorsal surface of the pons region, while its *superior portion* belongs to the isthmus of the rhombencephalon. Its triangular lower extremity terminates as the opening of the central canal of the spinal cord. This portion is deepened at the obex and shows furrows which point downward and converge medialward, giving the appearance known as the **calamus scriptorius.** The mid-line of the floor is sharply distinguished by the well-marked **median sulcus,** which becomes shallower above than below. In the tip of the calamus scriptorius, immediately anterior to the obex, the median sulcus deepens to become continuous into the central canal. This terminal depression is known as the **ventricle of Arantius.** Throughout the length of the floor on either side of the median sulcus is a continuous ridge, the **medial eminence,** which is bounded laterally by the **limiting sulcus.** Underlying the floor of the ventricle is a layer of grey substance of varying thickness, which is continuous with that surrounding the central canal of the cord. The medial eminence is subdivided into portions of unequal width and elevation, and the limiting sulcus accordingly shows foveæ of different depths.

Beginning at the calamus scriptorius, the following areas of the floor of the fourth ventricle are usually distinguished (fig. 640):—

The **area postrema** of Retzius is a superficial vascular structure bounded inferiorly by the tænia and overlying the terminal portion of the nucleus of the fasciculus gracilis (clava) and a portion of the nucleus of termination of the vagus nerve. The **funiculus separans,** a short oblique fold of the floor, composed chiefly of neuroglia, separates the area postrema from the **ala cinerea** (*trigonum vagi*), which is an oblique, grey-coloured, wing-shaped eminence indicating the middle third of the nucleus of termination (recipient nucleus) of the vagus and glossopharyngeal nerves. At the superior extremity of the ala cinerea is a well-marked triangular depression of the limiting sulcus known as the **inferior fovea.** Mesial to and extending above the ala cinerea is a narrow triangular eminence lying close to the median sulcus, which represents the nucleus of origin of the hypoglossal nerve, the **hypoglossal eminence** [trigonum n. hypoglossi]. The lateral field of this eminence shows small oblique rugæ, giving it a "feathery" appearance, the **area plumiformis** of Retzius. The **nucleus intercalatus** of Van Gehuchten is a wedge-shaped portion very slightly demarcated from the hypoglossal eminence, and intercalated between it and the inferior fovea. This nucleus is considered by some observers as an inferior

FIG. 640.—DORSAL SURFACE OF THE BRAIN-STEM SHOWING THE ANATOMY OF THE FLOOR OF THE FOURTH VENTRICLE. (Modified from Spalteholz.)

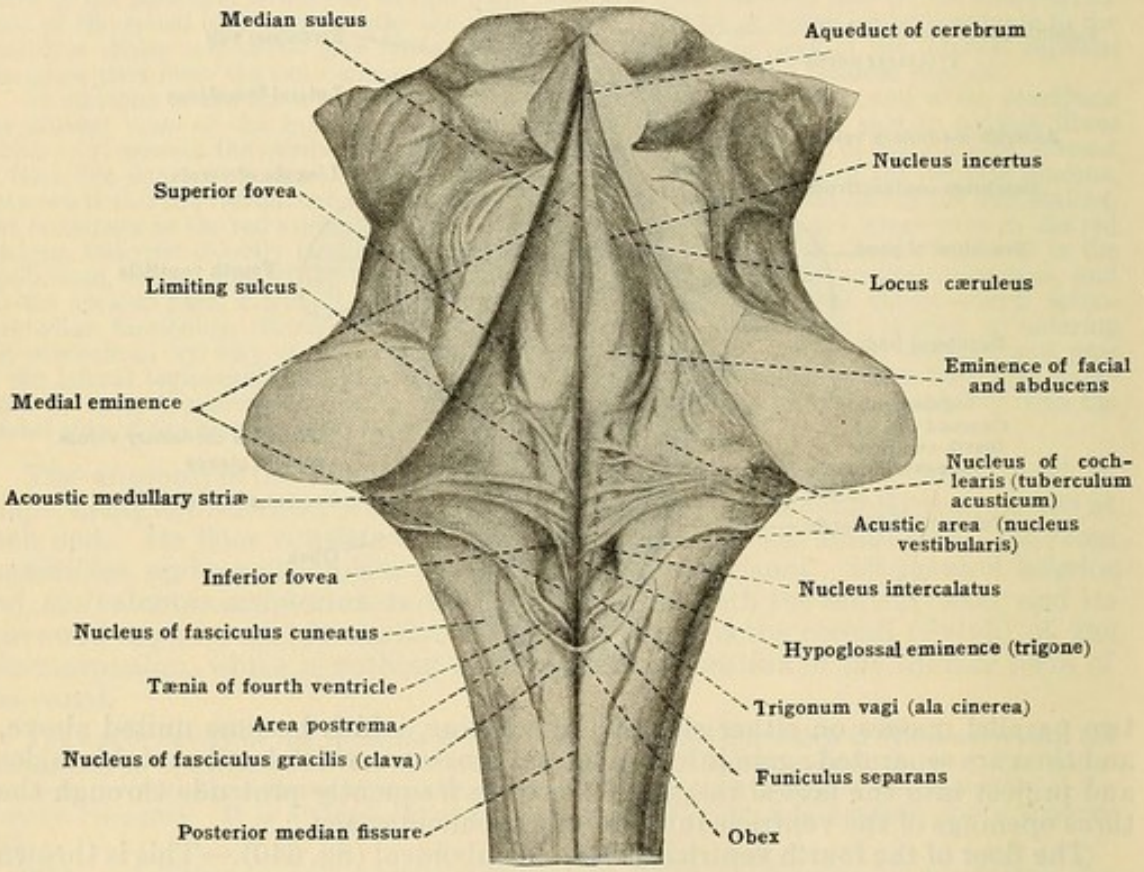

medial extension of the nucleus of termination of the vestibular nerve (area acustica), but Streeter, who has made a detailed study of the floor of the fourth ventricle by means of serial sections, doubts that it is a part of this nucleus. It is much more probable that it supplies visceral efferent fibres to the vagus and is thus a continuation of the dorsal efferent nucleus of the vagus.

Superior to the inferior fovea, and crossing each half of the floor of the fourth ventricle, are the **acoustic striæ.** These are bundles of axones arising in the dorsal nuclei of termination of the cochlear or auditory nerve, which are situated in the lateral periphery of each restiform body. The bundles course around the dorsal periphery of the upper portion of the restiform body, then across each half of the floor of the ventricle to the median sulcus, in which they suddenly turn ventrally into the substance of the medulla oblongata, and in doing so they cross the mid-line to enter the substance of the opposite side. The striæ vary greatly in different individuals, both in the degree of their prominence and their direction. Sometimes no striæ are visible from the surface. Frequently a bundle may be discerned which courses obliquely upward and lateralward from the median sulcus to disappear in the floor further away from the mid-line and again, a bundle may depart from the transverse course before reaching the median sulcus. Such a bundle ascending is sometimes called *conductor sonorus*. The acoustic striæ cross the **acoustic area.** This is the flattened elevation which occupies the whole lateral portion of the intermediate portion of the floor of the ventricle, lateral to the limiting sulcus, and extends into the inferior portion lateral to the inferior fovea. It represents the subjacent

nucleus of termination of the vestibular nerve. The dorsal and ventral nuclei of the cochlear nerve (*tuberculum acusticum*) are indicated by the ventro-lateral fullness in the contour of the restiform body. In many of the mammals they produce a well-marked protuberance.

In its superior portion the medial eminence occupies the greater part of the floor of the fourth ventricle, and in the upper part of the intermediate portion of the floor it presents a broader, well-marked, elongated elevation, the eminence of the facial and abducens or the **colliculus facialis.** This represents the mesially placed nucleus of origin of the abducens and the genu of the root of the facial nerve, which root courses around and above the nucleus of the abducens. The nucleus of the facial is too deeply situated to produce an eminence. Lateral to this eminence is a depression of the limiting sulcus, which overlies the mesial part of the region of the larger portion of the nucleus of termination of the trigeminus, and is the *fovea trigemini* or **superior fovea.** The strip of the floor above the superior fovea and lateral to the medial eminence often appears greyish blue or dark brown, owing to pigmented cells subjacent to it, and is known as the **locus cæruleus.** It also represents a portion of the nucleus of the trigeminus. The most superior portion of the medial eminence becomes narrow and lies close to the mid-line. The function of the underlying grey substance producing it is uncertain, and for this reason Streeter has named the elevation **nucleus incertus,** noting that by position it is closely related to the upper portion of the nucleus of the trigeminus.

Internal Structure of the Medulla Oblongata and Pons

The finer detail of the internal structure lies within the scope of microscopic rather than of gross anatomy. However, the significance and relations of certain of the more important and larger of the internal structures of the medulla and pons as observed in sections may be considered.

The entire brain-stem may be regarded as an upward continuation of the spinal cord, to which structures are added giving each part its peculiar character and conformation, and in which the structures characteristic of the spinal cord are modified in varying degrees.

The **pyramids,** the great descending or motor cerebro-spinal fasciculi, are directly continuous into the pyramidal fasciculi of the spinal cord. They form the extreme ventro-medial portion of the medulla, and from the fact that they contribute numerous fibres to the efferent nuclei (nuclei of origin) of the cranial nerves and to other portions of the grey substance of the brain-stem, they decrease appreciably in bulk in descending toward the spinal cord. Most of the fibres contributed to the medulla, as well as to other divisions of the brain-stem, decussate as they leave the pyramids, and terminate in the grey substance of the opposite side. However, the chief **decussation of the pyramids** occurs in the lower end of the medulla. Here usually about three-fourths of the fibres then comprising the pyramids cross the mid-line to form the lateral cerebro-spinal fasciculus (crossed pyramidal tract) of the spinal cord immediately below. The remaining fourth, comprising the more lateral fibres or those furthest away from the mid-line, continues uncrossed into the spinal cord as the ventral cerebro-spinal fasciculus or direct pyramidal tract. The majority of the latter fibres decussate gradually in the commissural bundle and in the ventral white commissure of the cord as they approach the levels of their termination. In practically all vertebrates except man and the apes there are no ventral pyramidal fasciculi, the decussation in the medulla being a total one. In man, the proportion of fibres crossing in the chief decussation varies. Cases have been noted in which apparently the entire pyramids decussate at this level. In other cases the direct or ventral pyramidal tract may be much larger than usual, at the expense of the lateral. The decussation usually appears to be symmetrical and it occurs so suddenly that the fibres, in coursing from the ventral to the lateral positions, detach the tips of the ventral horns of the spinal cord from the remainder of the grey figure, and these appear as isolated, irregularly shaped masses of grey substance in transverse sections of the medulla. From this level upward the outline of the grey figure of the cord is lost, and the cell-columns of the ventral horns occur in more or less detached groups as the motor nuclei of the cranial nerves.

The **origin and decussation of the lemnisci** (fillet) begins immediately above the decussation of the pyramids, and here the arrangements characteristic of the spinal cord are further modified. The dorsal portion of the grey figure of the cord is manifest up to this level, but here, after a considerable increase in its thickness, the grey commissure gives rise to two thick dorsal outgrowths on each side of the mid-line. These dorsal projections of grey substance comprise the nuclei of termination (relays) of the chief ascending or sensory spino-cerebral fasciculi of the spinal cord. The **nucleus of the fasciculus gracilis** (nucleus of Goll's column) arises a little before the **nucleus of the fasciculus cuneatus** (nucleus of Burdach's column). The former extends slightly downward from its point of origin, so that its inferior extremity is included in sections through the decussation of the pyramids (fig. 641). It produces a slight bulbous enlargement (the *clava*) of the end of the funiculus gracilis, while the nucleus of the fasciculus cuneatus corresponds to the *cuneate tubercle* of the external contour of the medulla (figs. 632, 640). From the cells of these nuclei arise the lemniscus—the cephalic continuation of the spino-cerebral pathway which conveys the general bodily sensations to the cerebrum. In passing out of the nuclei the fibres of the lemniscus course in a ventro-medial direction. Curving around the region of the central canal, they contribute largely to the **internal arcuate fibres,** then, sweeping across the mid-line, they convert it into the **raphe,** and immediately after crossing (decussating) they turn cephalad and collect to form the bundle known as the **lemniscus.**

In the medulla, the lemnisci are two thin bands of fibres spread vertically on each side of the raphe, with their lower or ventral edges thicker than their dorsal edges. In their course toward the cerebrum they increase in bulk, owing chiefly to fibres being added to them from the nuclei of termination of the afferent roots of the cranial nerves, which fibres likewise cross the mid-line as internal arcuate fibres to join the lemniscus of the opposite side. In passing

through the pons, the lemnisci gradually become spread horizontally, and beyond the pons their then more lateral portions are further displaced and come to course in the lateral borders of the isthmus rhombencephali and mesencephalon, while the medial portions remain nearer the mid-line. This lateral spreading of each lemniscus produces the **lateral lemniscus** and the **medial lemniscus,** distinguished in transverse sections of the superior pons and mesencephalic

FIG. 641.—TRANSVERSE SECTION OF MEDULLA OBLONGATA AT THE LEVEL OF THE DECUSSATION OF THE PYRAMIDS.

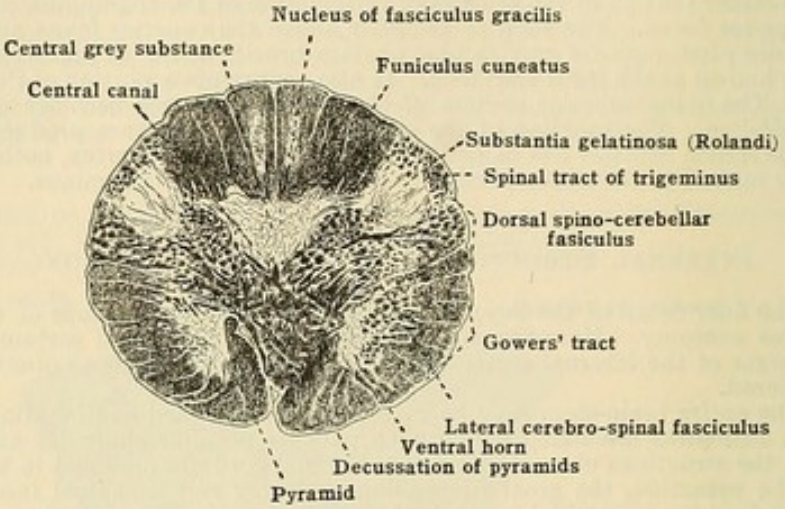

regions of the brain stem (fig. 660). The lateral lemniscus is contributed very largely by the cell-bodies of the nuclei of termination of the cochlear nerve of the opposite side.

The **reticular formation** of the medulla and pons region is considerably more abundant than in the spinal cord. As in the spinal cord, it consists of grey substance through which nerve-fibres, singly and in small bundles, course in all directions, and more sparsely than in other regions. In the medulla it is traversed by the internal arcuate fibres. It may be con-

FIG. 642.—TRANSVERSE SECTION OF MEDULLA OBLONGATA AT LEVEL OF THE DECUSSATION OF THE LEMNISCI.

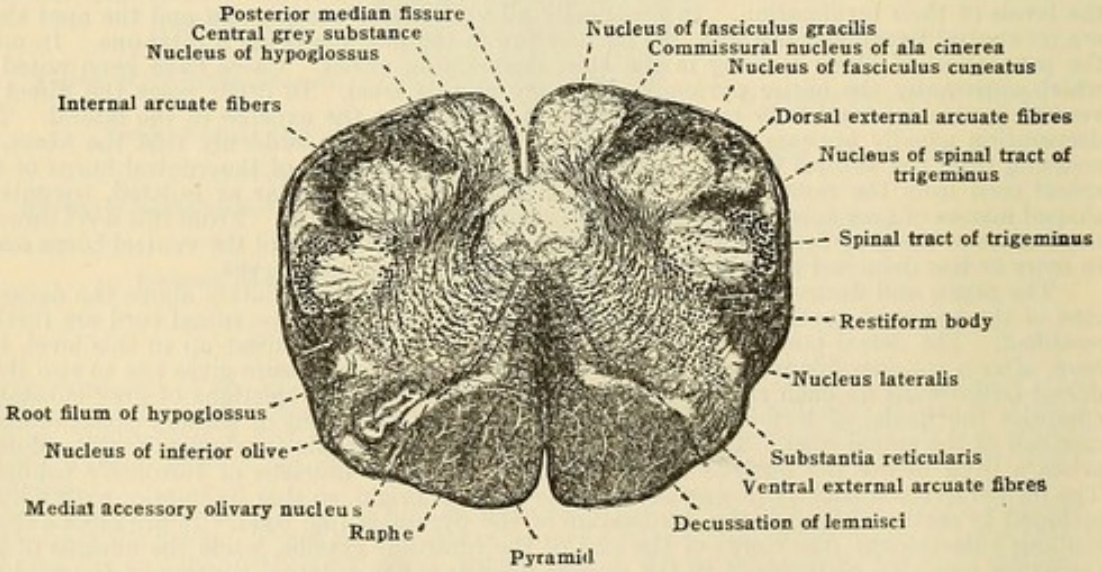

sidered an enlarged continuation of the middle portion of the grey column of the cord, dispersed by numerous fibres, giving it the reticulated appearance which suggests its name. Its numerous nerve-cells belong, for the most part, to the association and commissural systems of the brain stem, and, therefore, the fibres arising in it correspond largely to the fasciculi proprii of the spinal cord. As in the cord, most of the fibres are of short course, serving to associate different portions of the same level and adjacent levels with each other. Those of long course show a tendency to collect into a small, well-marked bundle which courses one on each side close to the mid-line, ventral to the central canal in the closed part of the medulla, and near the median sulcus of the floor of the fourth ventricle, in the open part. In the mesencephalon this bundle is again situated closely ventral to the aquæductus cerebri.

This bundle is known as the **medial longitudinal fasciculus** (posterior longitudinal bundle). It corresponds more nearly to the ventral fasciculus proprius of the spinal cord than to others of the fasciculi proprii. In the medulla it appears as the dorsal edge of the lemniscus, but in the shifting of the position of the lemniscus in the pons region, it retains its medial position and thus becomes isolated. By position it is especially adapted for the association of the nuclei of the cranial nerves. Evidence has been found that those fibres which arise in the corpora quadrigemina and descend the spinal cord in its sulco-marginal or ventral mesencephalo-spinal fasciculus, pass through the medulla in the medial longitudinal fasciculus. The nuclei of termination of the vestibular nerve are said also to contribute many fibres to it.

The **inferior olivary nucleus** is an added structure in the medulla oblongata, i. e., it has no homologue in the spinal cord. The two of them occupy the olivary prominences, *the olives* of the exterior, and constitute the most conspicuous and striking isolated masses of grey substance in sections of the medulla. They appear as crenated laminæ of grey substance folded so as to encup a dense mass of white substance, and in actual shape the entire nucleus has the form of an irregular corrugated cup with the opening or **hilus** on the side toward the midline. The mass is so crumpled that the diameter of the hilus is appreciably less than the length of the nucleus, and thus transverse sections of either extremity of it appear as closed capsules.

FIG. 643.—TRANSVERSE SECTION OF MEDULLA OBLONGATA THROUGH NUCLEI OF VAGUS AND HYPOGLOSSUS AND THROUGH THE MIDDLE OF THE OLIVES.

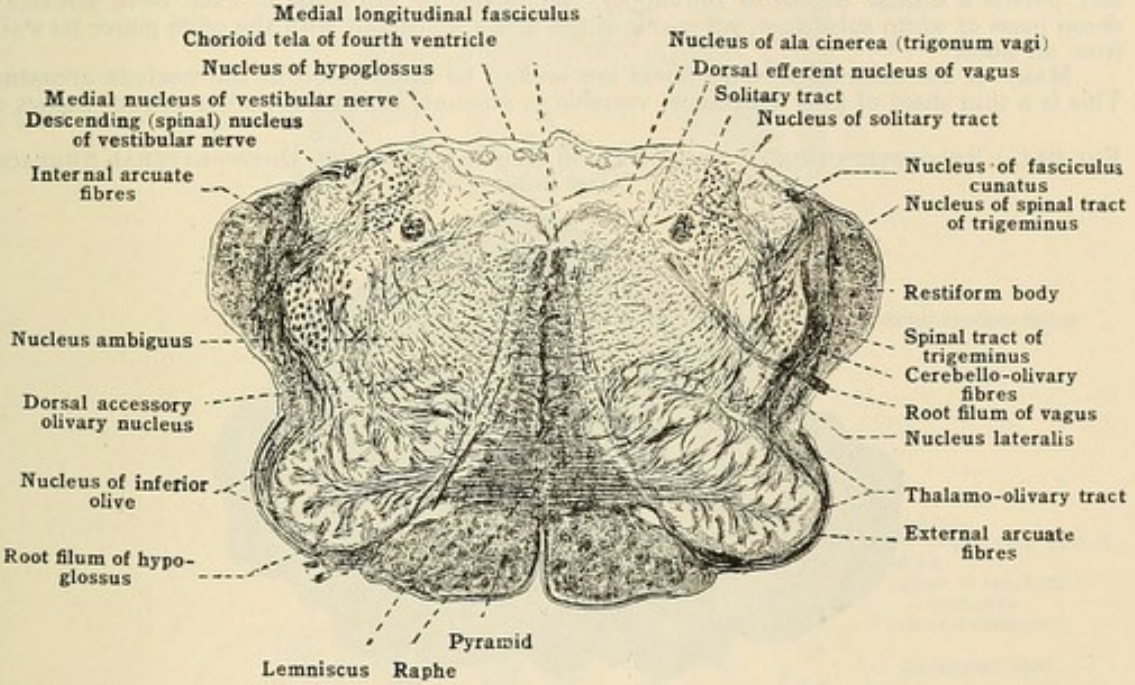

There are several small detached portions of the olivary nucleus known as the **accessory olivary nuclei.** These are named according to their position with reference to the chief portion or olive proper. They are plates less corrugated than the chief nucleus, and appear rod-like in sections. The largest is the *dorsal accessory olivary nucleus.* The *medial accessory olivary nucleus* is widest at its inferior end, which extends a little below the inferior extremity of the chief nucleus. The *lateral accessory olivary nucleus* is the smallest. In serial sections the accessory nuclei are found to be plates of grey substance usually continuous with one another.

The olivary nuclei are mainly cerebellar connections. By both ascending and descending fibres each cerebellar hemisphere is connected with the olivary nucleus of the same and opposite sides. Serial sections of a human brain with congenital absence of one cerebellar hemisphere, described by Strong, show that the chief connection of a hemisphere is with the olive of the opposite side. These fibres necessarily pass between the cerebellum and the olives by way of the restiform body, and, in so doing, form an obliquely coursing bundle in the lateral border of the medulla known as the **cerebello-olivary fibres** (fig. 643). The olivary nuclei also comprise a secondary relay between the spinal cord and the cerebellum by way of the spino-olivary fasciculus of the cervical cord, and it will be noted that they receive fibres from the thalami. The latter fibres, the **thalamo-olivary tract,** approach the olive at its lateral periphery, while upward through the brain-stem the tract courses in a more medial position. This tract comprises one of the cerebro-cerebellar paths. Arising in the thalamus and terminating in the olive, its impulses reach the opposite cerebellar hemisphere by way of the cerebello-olivary fibres.

The **arcuate fibres** are referred to as internal and external, according as they course dorsal or ventral to the inferior olivary nucleus.

The **internal arcuate fibres** comprise fibres destined for both the cerebellum and cerebrum, and also for the association of the tegmental grey substance of the two sides in which they course. Certain of the fibres passing between one restiform body (cerebellar hemisphere) and the olive of the opposite side course internal to the olive of the same side, and thus form the ventral portion of the internal arcuate fibres. As noted above, the internal arcuate fibres consist in

greatest part of fibres being contributed to the lemnisci, arising from the cells of the nucleus of the fasciculus gracilis and fasciculus cuneatus and sweeping downward and decussating to form the lemniscus of the opposite side. However, all the fibres arising in these nuclei do not enter the lemniscus. A few of them cross the mid-line with the internal arcuates, but pass on to enter the restiform body (cerebellar hemisphere) of the opposite side. Some of these course ventrally and, upon approaching the olive of the opposite side, are deflected around the ventral side of both the olive and the pyramid, and thus pass to the restiform body as external arcuate fibres also. Certain of the internal arcuate fibres arise from the cells of the nuclei of termination of the cranial nerves and from small cells situated in the grey substance of the reticular formation. These, in crossing the mid-line, correspond to the white commissures of the spinal cord. Some of them terminate in the medulla; others, especially those from the nuclei of termination of the cranial nerves, join the lemniscus and pass toward the cerebrum; others reach the cerebellar hemisphere of the opposite side.

The **external arcuate fibres,** in addition to those mentioned above, comprise certain fibres which arise in the nuclei of the fasciculus gracilis and cuneatus and pursue a dorso-lateral course to enter the restiform body (cerebellar hemisphere) of the same side. These form the dorsal segment of the external arcuates. The greater mass of the external arcuates are cerebello-olivary fibres. Certain of those passing from one olive to the restiform body of the opposite side are deflected at the raphe, and course on the ventral side of both the other olive and the pyramid in order to reach the opposite cerebello-olivary bundle. Likewise, those passing from the restiform body to the opposite olive are deflected by the olive of the same side and pursue a similar course to the raphe. While out of the hilus of each olive streams a dense mass of white substance, yet many of the fibres concerned with the olive pierce its walls from all sides.

Many of the external arcuate fibres are said to be interrupted in the **nucleus arcuatus.** This is a thin sheet of grey substance, variable in amount, which lies on the ventral aspect of

FIG. 644.—RECONSTRUCTION OF THE INFERIOR OLIVARY NUCLEUS, DORSO-LATERAL SURFACE. (After Sabin.)

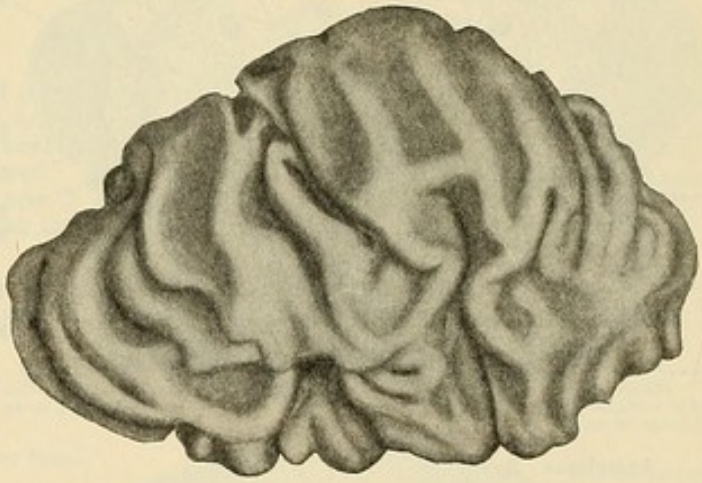

each pyramid, and, though it decreases inferiorly, it may be evident down to the decussation of the pyramids. The nucleus receives its name from the fact that its larger portion is interpolated in the course of the external arcuates. It is continuous anteriorly with the grey substance or nuclei of the pons.

The external arcuate fibres of longer course, like the olives with which they are largely concerned, have no homologues in the spinal cord.

The *central canal* of the closed portion of the medulla is surrounded by a greater amount of **central grey substance, substantia grisea centralis,** than is the canal in the spinal cord. This is largely gelatinous substance, *the central gelatinous substance,* and the nerve-fibres in coursing through the grey substance are partially deflected by it, leaving it as a cylindrical, more evident area of grey substance than in other regions. In the open portion of the medulla the central grey substance naturally forms a more transparent lamina just under the floor of the fourth ventricle. In the mesencephalon it again surrounds the reformed canal or aqueduct of the cerebrum.

The **central connections of the cranial nerves** are most easily homologised with spinal-cord structures. Functionally the cranial nerves are of three varieties:—(1) the motor or efferent nerves, comprising the oculomotor, the trochlear, masticator, the abducens, the facial, the spinal accessory, and the hypoglossus; (2) the sensory or afferent, comprising the olfactory, the optic, the trigeminus, the vestibular, and the cochlear and (3) the mixed, motor and sensory nerves, comprising the glosso-palatine, the glosso-pharyngeal, and the vagus. The **nuclei of origin** of the motor or efferent cranial nerves and the efferent portions of the mixed nerves are directly continuous with the cell columns of the ventral horns of the spinal cord, while the emerging root filaments and roots of these nerves correspond to the ventral roots of the spinal nerves. The **nuclei of ter-**

mination of the afferent or sensory cranial nerves and of the sensory portions of the mixed nerves correspond directly to the nuclei of the fasciculus gracilis and fasciculus cuneatus, and to the cell-bodies of association and commissural neurones of the medulla and cord and, functionally, are merely anterior continuations of these.

The nuclei of the efferent or motor cranial nerves lie in two parallel lines, one near the mid-line and the other more laterally placed. The nuclei giving origin to the oculomotor, the trochlear, the abducens, and the hypoglossus are near the mid-line, and correspond to the ventro-medial and dorso-medial cell groups of the ventral horns of the spinal cord; the nuclei of origin of the masticator (motor

FIGS. 645 AND 646.—DIAGRAMS SHOWING THE COMPOSITION OF THE CEREBELLAR PORTIONS OF THE INTERNAL AND EXTERNAL ARCUATE FIBRES.

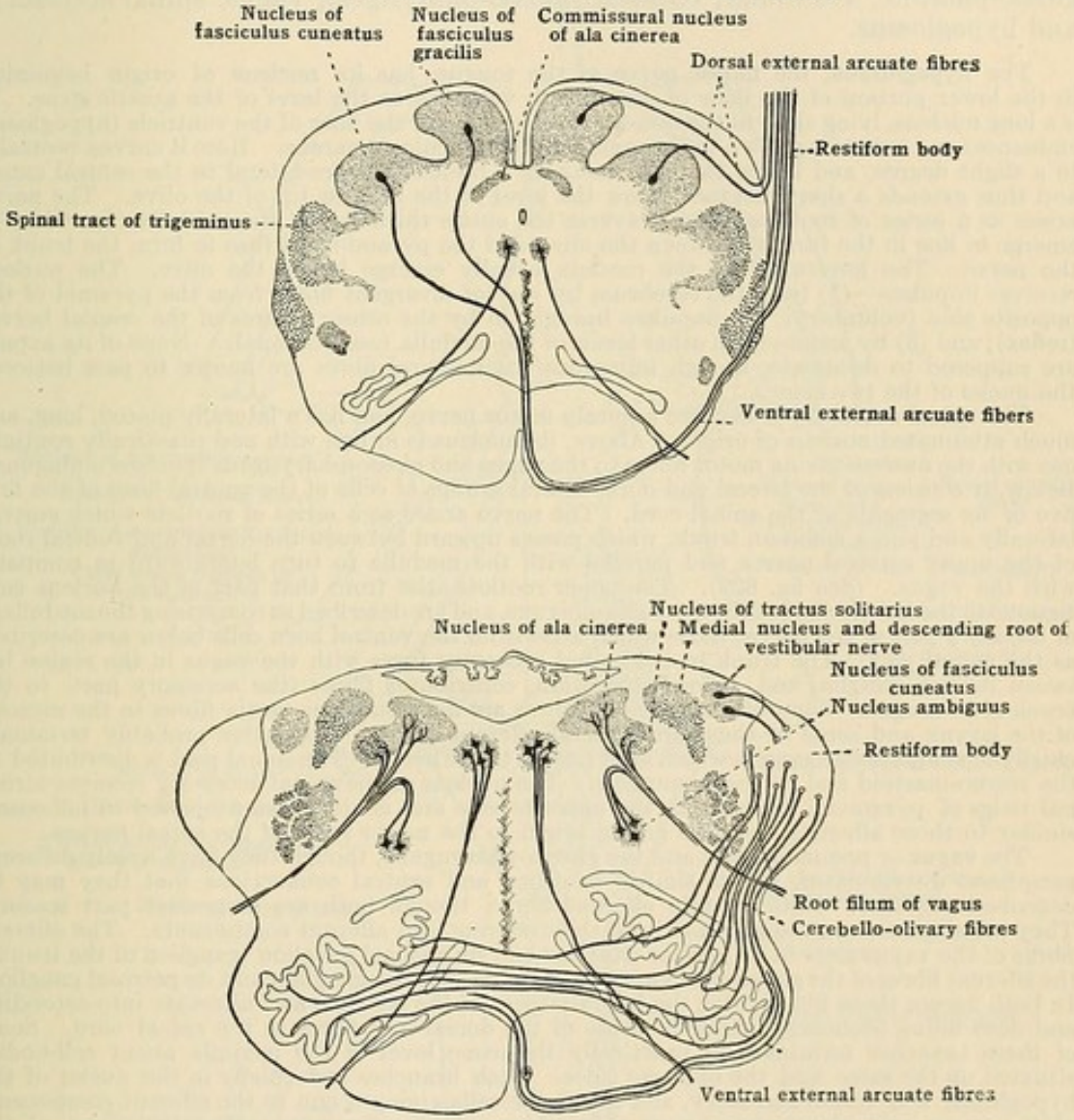

root of the trigeminus) of the facial, and the nucleus ambiguus giving origin to the motor portions of the glosso-pharyngeal and vagus nerves, together with the nucleus of the spinal accessory, correspond to the ventro-lateral and dorso-lateral cell-groups of the ventral horns of the spinal cord. The nerve-roots having medial nuclei of origin are those which make their exit from the brain-stem along the more medial superficial line, while those having the more lateral nuclei comprise the more lateral line of roots apparent on the surface of the stem. Some of the efferent fibres of the vagus, supposedly visceral efferent, arise from a small nucleus dorso-medial to the nucleus ambiguus, the *dorsal efferent nucleus of the vagus*. The first two pairs of cranial nerves, the olfactory and optic, are attached to the

prosencephalon. These are purely sensory, and make their entrance near the mid-line of the brain, both having superficially placed nuclei of termination. Of the other nerves, all having sensory or afferent functions enter the brain along the lateral or more dorsal line, and the ganglia giving origin to their afferent axones correspond directly to the spinal ganglia of the dorsal or afferent roots of the spinal nerves.

Commissural and associational neurones are much more numerous in the brain-stem than in the spinal cord. Their axones serve to connect the structures on the two sides of the mid-line and to associate the different levels of the same side. Just as in the spinal cord, those of longer course correspond to the fasciculi proprii. Many of their axones descend into the spinal cord.

Of the fifteen pairs of cranial nerves, eleven pairs are attached to the medulla oblongata and pons, viz., the trigeminus, the masticator, abducens, facial, glosso-palatine, vestibular, cochlear, glosso-pharyngeal, vagus, spinal accessory, and hypoglossus.

The **hypoglossus,** the motor nerve of the tongue, has its nucleus of origin beginning in the lower portion of the floor of the fourth ventricle at the level of the acustic striæ. It is a long nucleus, lying close to the mid-line and just under the floor of the ventricle (hypoglossal eminence) and extending down to the region of the funiculus separans. Here it curves ventrally to a slight degree, and below the obex assumes a position ventro-lateral to the central canal, and thus extends a short distance below the level of the inferior tip of the olive. The nerve arises as a series of rootlets which traverse the entire thickness of the medulla (fig. 643), to emerge in line in the furrow between the olive and the pyramid and fuse to form the trunk of the nerve. The lowermost of the rootlets usually emerge below the olive. The nucleus receives impulses—(1) from the cerebrum by way of divergent fibres from the pyramid of the opposite side (voluntary); (2) impulses brought in by the sensory fibres of the cranial nerves (reflex); and (3) by axones from other levels of the medulla (associational). None of its axones are supposed to decussate, though numerous commissural fibres are known to pass between the nuclei of the two sides.

The **spinal accessory** is likewise a purely motor nerve, and has a laterally placed, long, and much attenuated nucleus of origin. Above, its nucleus is in line with and practically continuous with the nucleus giving motor fibres to the vagus and glosso-pharyngeus (nucleus ambiguus). Below, it consists of the lateral and dorso-lateral groups of cells of the ventral horn of the first five or six segments of the spinal cord. The nerve arises as a series of rootlets which emerge laterally and join a common trunk, which passes upward between the dorsal and ventral roots of the upper cervical nerves and parallel with the medulla to turn lateralward in company with the vagus. (See fig. 629). The upper rootlets arise from that part of the nucleus contiguous to the inferior end of the nucleus ambiguus, and are described as comprising the medullary or *accessory part* of the nerve; those which arise from the ventral horn cells below are described as the *spinal part.* The trunk of the spinal accessory fuses with the vagus in the region between its two ganglia, and, before separation, contributes fibres (the accessory part) to the trunk of the vagus. Some of the accessory fibres are distributed as motor fibres to the muscles of the larynx and some of them are visceral efferent fibres. The latter probably terminate chiefly in sympathetic ganglia which send axones to the heart. The spinal part is distributed to the sterno-mastoid and trapezius muscles. The nucleus of the spinal accessory receives terminal twigs of pyramidal fibres from the opposite side and is otherwise subjected to influences similar to those affecting the cells giving origin to the motor roots of the spinal nerves.

The **vagus** or pneumogastric and the **glosso-pharyngeus,** though they have widely different peripheral distributions, are so similar in origin and central connections that they may be described together. Both contain efferent fibres, though both are in greater part sensory. They are similar as to the origin of both their efferent and afferent components. The afferent fibres of the vagus arise in its jugular ganglion and its nodosal ganglion (ganglion of the trunk); the afferent fibres of the glosso-pharyngeus arise in its superior ganglion and its petrosal ganglion. In both nerves these fibres enter the lateral aspect of the medulla and bifurcate into ascending and descending branches, similar to those of the dorsal root-fibres in the spinal cord. Some of these branches terminate in practically the same level of the medulla about cell-bodies situated on the same and the opposite sides. Such branches end chiefly in the nuclei of the hypoglossal and spinal accessory, and about the cells giving origin to the efferent components of the vagus and glosso-pharyngeus themselves—short reflex arcs. However, most of the afferent fibres terminate in the nucleus of termination of the vagus and glosso-pharyngeus:—(1) the **nucleus of the ala cinerea,** the middle portion of which is indicated in the floor of the fourth ventricle by the ala cinerea; (2) in the closed portion of the medulla, the lower end of the nucleus of the ala cinerea comes to lie in the dorso-lateral proximity of the central canal, and this portion is known as the *commissural nucleus of the ala cinera* (figs. 642 and 645) from the fact that fibres may be seen which pass directly from it across the mid-line; (3) the longer of the descending branches of the bifurcated fibres collect to form the **solitary tract,** a compact bundle situated dorsally just ventro-lateral to the nucleus of the ala cinerea and quite conspicuous in sections of the medulla. The fibres of this bundle terminate in the *nucleus of the solitary tract,* which is but a ventro-lateral and downward continuation of the nucleus of the ala cinerea enclosing the bundles forming the tract. It is most probable that the fibres of the solitary tract are chiefly from the vagus (pneumogastric), though Bruce has found evidence that the glosso-pharyngeal contributes to it appreciably. It decreases rapidly in descending the medulla, owing to the rapid termination of its fibres about the cells of its nucleus. It,

with the axones given by the cells of its nucleus, is believed to extend as far downward as the level of the fourth cervical segment of the spinal cord. This being in the level of origin of the phrenic nerve, the tract forms a link in the respiratory apparatus which aids in the co-ordinated respiratory movements. The axones given off by the cells of the nucleus of the ala cinerea (terminal nuclei of the vagus and glosso-pharyngeus) course on both sides of the

FIG. 647.—SCHEME SHOWING THE RELATIVE SIZE AND POSITION OF THE NUCLEI OF ORIGIN (RED) OF THE MOTOR AND THE NUCLEI OF TERMINATION (BLUE) OF THE SENSORY CRANIAL NERVES.

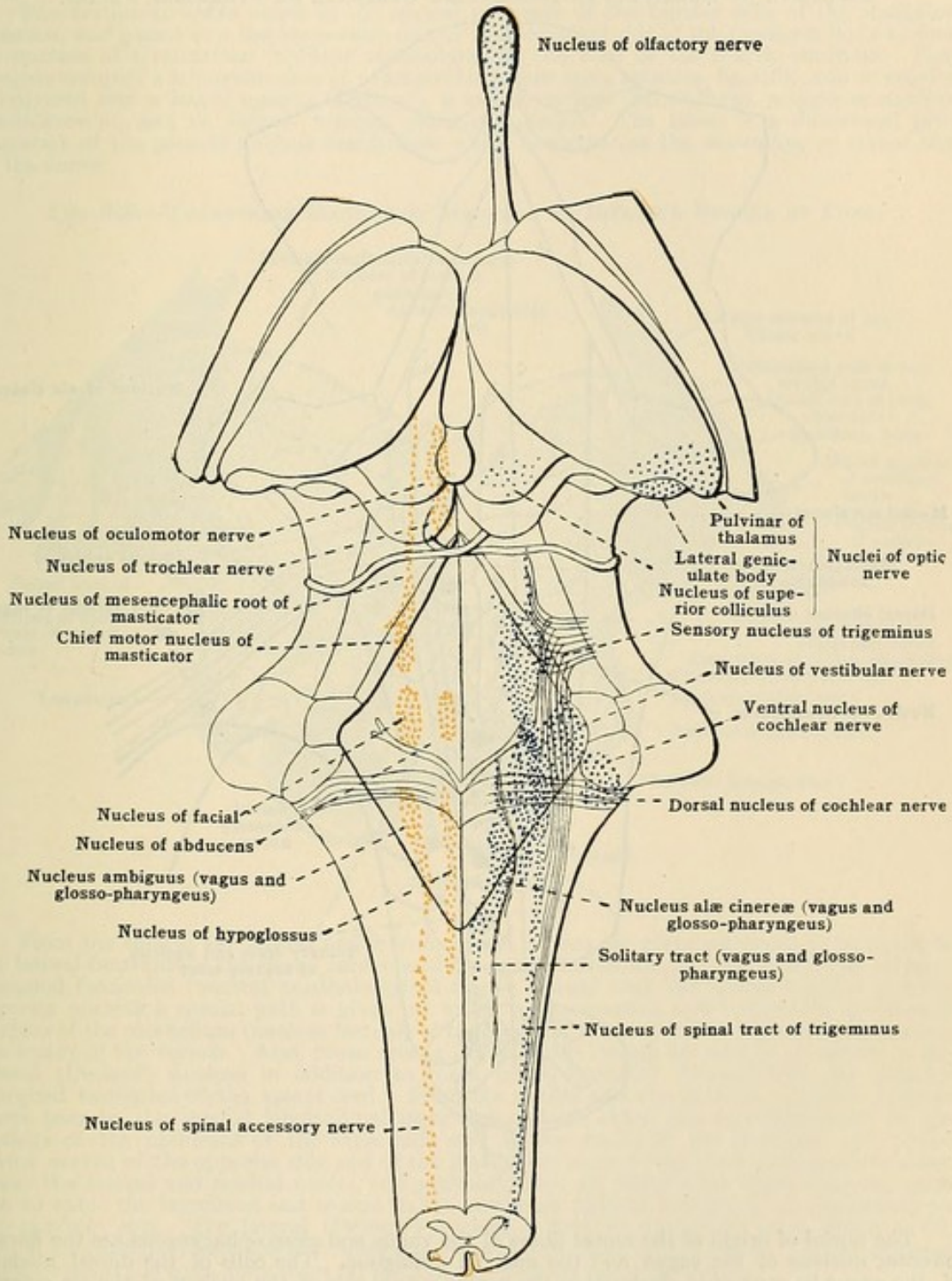

mid-line, associating nuclei of other cranial nerves with vagus and glosso-pharyngeal impulses, many decussating to be distributed to the structures of the opposite side. Many join the lemniscus of the opposite side and pass into the cerebrum; others are distributed to the motor neurones of the cervical cord of the same and opposite sides (reflex axones), and no doubt others form central connections with the cells of the reticular formation of the medulla, though their precise relations have not been determined."

Cell-bodies in the nucleus of the ala cinerea, the nucleus of the solitary tract and in the commissural nucleus of the ala cinerea comprise the so-called **respiratory** and **vaso-motor nuclei** ("**centres**") of the medulla. Some of the caudal branches of the axones given off by the cells of these nuclei descend the spinal cord, not only to the segments giving origin to the phrenic nerve, but also to those supplying the intercostal and levatores costarum muscles. Some of these augment the solitary tract; most of them descend in the reticular formation of the medulla and cord. Further, axones given off by these cells convey vaso-motor impulses which are distributed to visceral efferent neurones throughout the cord.

FIG. 648.—DIAGRAM ILLUSTRATING PRINCIPAL CENTRAL RELATIONS OF THE VAGUS NERVE, EXCLUSIVE OF RELATIONS TO DESCENDING CEREBRAL OR PYRAMIDAL FIBRES.

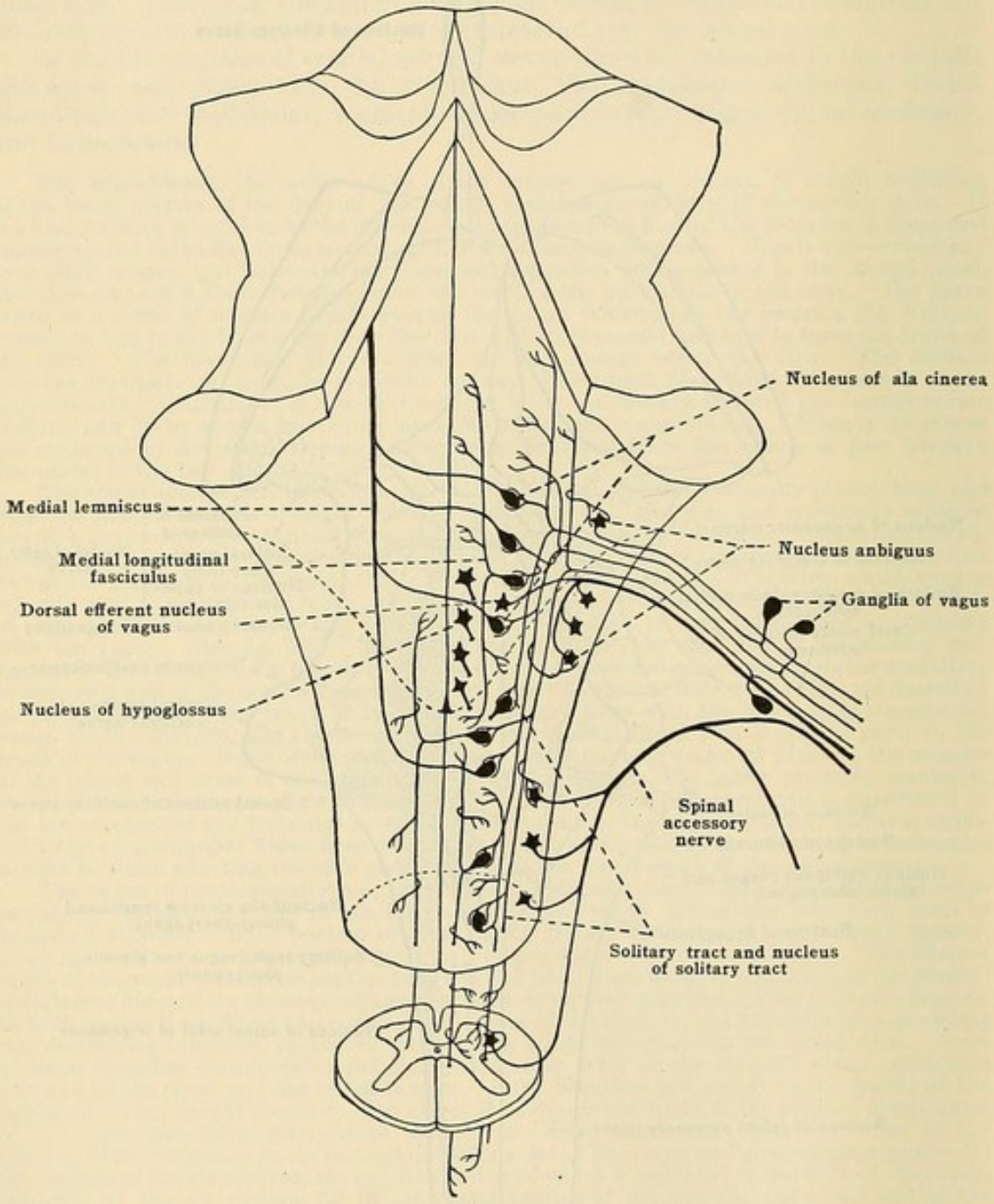

The nuclei of origin of the motor fibres of the vagus and glosso-pharyngeus are the **dorsal efferent nucleus of the vagus** and the **nucleus ambiguus.** The cells of the dorsal nucleus of the vagus lie somewhat clustered in the ventro-mesial side of the nucleus of the ala cinerea and lateral to the nucleus of the hypoglossus. Their axones pass outward among the entering or afferent vagus fibres, and it is suggested that most of them are visceral efferent fibres of the vagus, i. e., they terminate about sympathetic neurones. The *nucleus ambiguus* or ventral efferent nucleus of both nerves lies in the lateral half of the reticular formation, about mid-way between the olive and the line traversed by the rootlets of the two nerves. Its upper end is larger. Its cells are considerably dispersed by the fibres of the reticular formation. The axones arising from its cells course at first dorsalward and then turn abruptly outward to join

the rootlets of the vagus or glosso-pharyngeus, as the case may be. The vagus is thought to receive more efferent fibres from the nucleus ambiguus than does the glosso-pharyngeus, and Cunningham notes that it may be questioned whether the latter nerve contains any motor fibres at all, there being paths by which the fibres of its motor branch (to the stylo-pharyngeus muscle) might enter it other than direct from motor nuclei.

The *vestibular* and *cochlear* nerves are usually considered as one nerve and together are designated as the **acoustic** or eighth cranial nerve. While both are purely sensory, are similar in development and course together, they are distinct as to function and their nuclei of termination differ. They are here described as separate cranial nerves. The two nerves approach the brain stem together and enter it at the lateral aspect of the junction of medulla oblongata and pons.

The **vestibular nerve** arises as the central processes of the bipolar cells of the *vestibular ganglion*, and passes into the brain-stem on the ventro-mesial side of the restiform body to find its nucleus of termination (nucleus vestibularis) in the floor of the fourth ventricle. This nucleus occupies a triangular area of considerable extent (area acustica, fig. 640), and is usually subdivided into a *lateral nucleus* (Deiters'), a *medial nucleus* (Schwalbe's), a *superior nucleus* (Bechterew's), and an *inferior nucleus* (nucleus spinalis). The latter is a downward prolongation of the general nucleus vestibularis which accompanies the *descending or spinal root* of the nerve.

FIG. 649.—TRANSVERSE SECTION OF MEDULLA AT INFERIOR BORDER OF PONS.

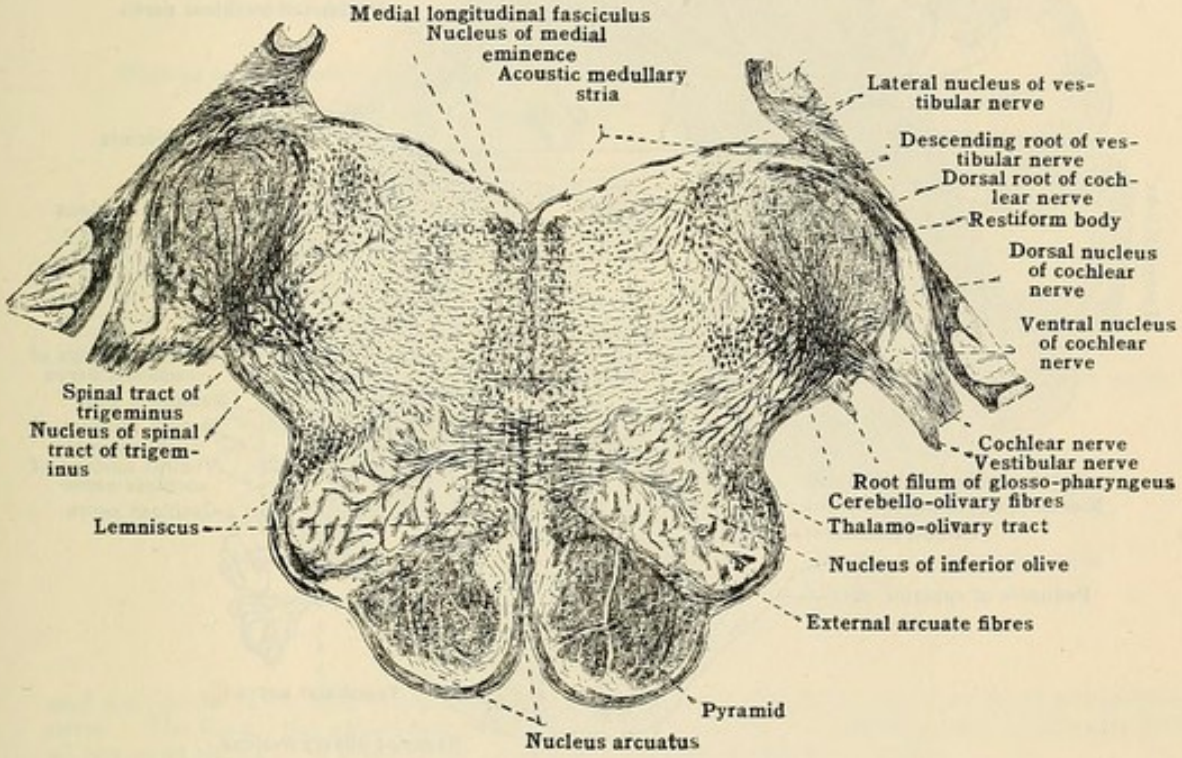

From the cells of the lateral and inferior nuclei axones are given off which form paths to the lateral funiculus of the spinal cord (vestibulo-spinal fasciculus, fig. 619) and to its anterior marginal fasciculus (ventral vestibulo-spinal tract). From both the lateral nucleus and the superior nucleus a special path is given off which passes upward and terminates in the roof nucleus of the cerebellum (nucleus fastigii) of the opposite side and in the nucleus dentatus and the cortex of the vermis. Also, fibres arising in the nuclei fastigii are said to terminate in the lateral (Deiters') nucleus in addition to those which probably descend into the anterior marginal fasciculus of the spinal cord. From the medial and also from the superior nucleus fibres pass to the medial longitudinal fasciculus of both sides, and are distributed to the nucleus of the abducens of the same side and to the nuclei of the trochlear and oculomotor nerves of the opposite side and of the masticator nerve of the same and opposite sides. From the lateral and medial nuclei, and probably from all, fibres arise which cross the midline to enter the lemniscus and ascend to the cerebrum (lateral portion of the thalamus) on the opposite side. The lateral (Deiters') nucleus is said to contribute more fibres to the medial longitudinal fasciculus than does a nucleus of any other cranial nerve. If any of these fibres descend the cord, they must do so in its anterior marginal fasciculus.

The *inferior nucleus* is accompanied by the *descending* or *spinal root* of the vestibular nerve, which begins to assemble in the nuclei above. This root is composed of both caudal branches of the entering fibres of the nerve and chiefly of fibres arising from the cells of its nuclei. Thus for the vestibular nerve it corresponds in every way to the solitary tract for the vagus, and to the spinal tract of the trigeminus. Such of its fibres as descend into the spinal cord most probably do so in the lateral vestibulo-spinal fasciculus.

Many of the anatomical details of the central connections of the vestibular nerve have not yet been determined with exactness. In addition to whatever other functions it may have,

it is considered to be the nerve of equilibration, and the connections noted above may be considered the pathways by which it exercises this function. The fibres of the apparatus which are represented in the spinal cord are supposed to convey impulses to the ventral horn (motor) cells of the cord as far down as the lumbar region.

The **cochlear nerve,** the auditory nerve proper, arises as the central processes of the bipolar cells of the *spiral ganglion* of the cochlea. In the lateral periphery of the restiform body, just before the latter enters the cerebellum, the nerve finds its two nuclei of termination, the *ventral nucleus* and the *dorsal nucleus* (tuberculum acusticum, fig. 640).

From the **dorsal nucleus** arise the *acoustic medullary striæ.* These bundles pass around the dorsal aspect of the restiform body and course just under the ependyma of the floor of the fourth ventricle to the mid-line, where they suddenly turn downward into the substance of the medulla and in doing so, cross to the opposite side and join the lemniscus. As the lemniscus becomes separated higher up into a medial and lateral portion, these fibres course in the lateral lemniscul and are distributed chiefly to the grey substance of the inferior quadrigeminate and media,

FIG. 650.—SCHEME SHOWING SOME OF THE CENTRAL CONNECTIONS OF THE ACOUSTIC NERVE. (In part after Edinger.)

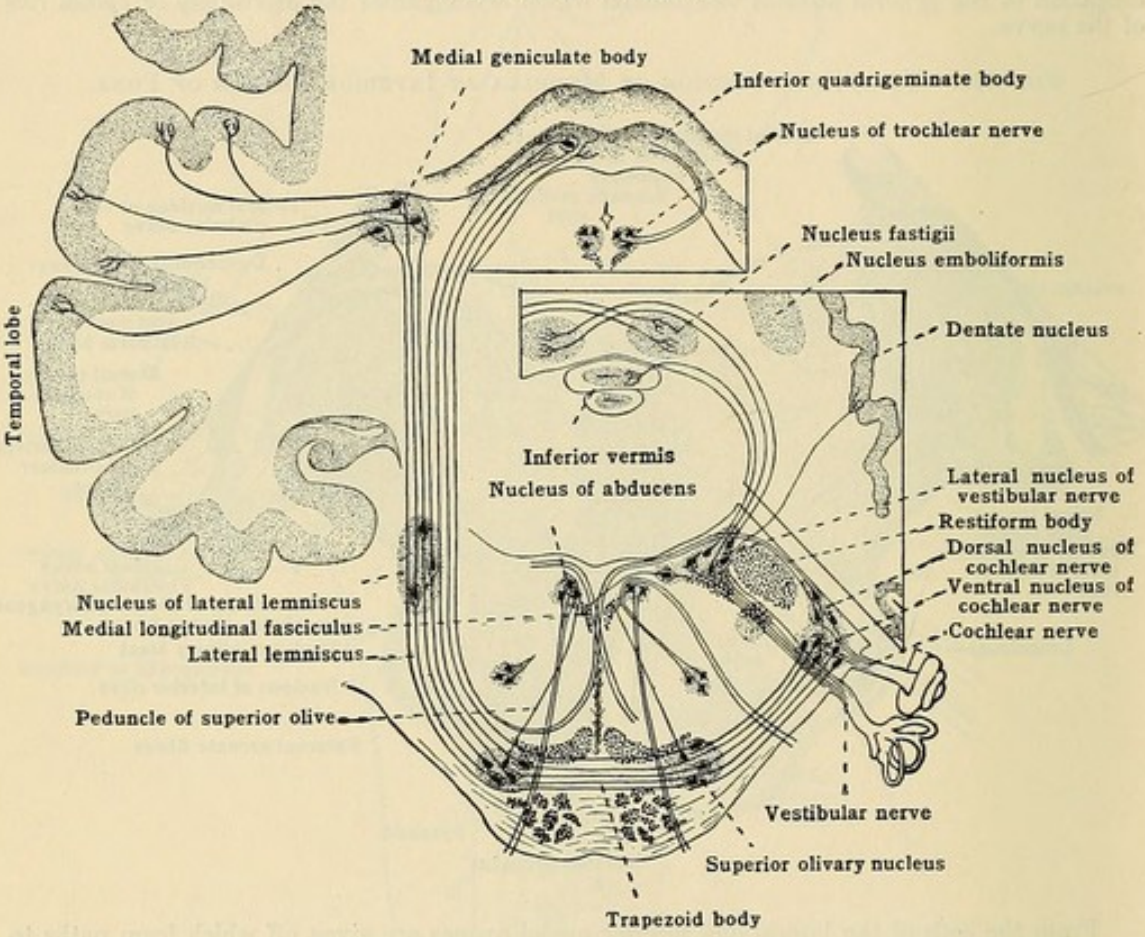

geniculate body of that side. At the mid-line some of their fibres join the median longitudinal fasciculus and by way of it are distributed to the nuclei of origin of other cranial nerves. In frequent cases, the acoustic striæ course so deeply beneath the ependyma as not to be superficially visible in the floor of the fourth ventricle.

From the **ventral nucleus** of termination fibres arise which terminate about the cells of the **superior olivary nucleus** of the same and opposite sides. The superior olive is a small accumulation of grey substance which lies in the level of the inferior portion of the pons, and in line with the much larger inferior olivary nucleus of the medulla. However, it is not analogous to the latter in any sense. The two superior olives form links in the central acoustic chain. From cells of the superior olivary nucleus of the same and opposite sides, fibres arise which pass by way of the lateral lemniscus and terminate in the grey substance of the inferior quadrigeminate body and in the medial geniculate body, thus associating these bodies with the ventral nucleus of cochlear termination of the opposite side. From the medial geniculate body fibres arise which pass to the cortex of the superior temporal gyrus. This path is supplemented by fibres arising in the inferior quadrigeminate body, which likewise go to the temporal lobe. In the lateral lemniscus some of the acoustic fibres are interrupted by cells of the *nucleus of the lateral lemniscus.* In crossing the mid-line, between the superior olives, the fibres from the two sources form a more or less compact bundle, the **corpus trapezoideum** (trapezium). To this are added fibres crossing between the **nuclei trapeozidei,** smaller masses of grey substance just ventral to the superior olives and probably of the same significance.

Also, some fibres arising in the nuclei of termination of the cochlear nerve pass to the inferior quadrigeminate body of the same side. On the other hand, the connection with the medial

geniculate body is thought to be wholly a crossed one. Further, some fibres are described as terminating in the *superior quadrigeminate body* of both the same and the opposite side. These, forming the *stratum lemnisci* of this body, are especially suggestive of associating auditory impulses with eye movements.

All the fibres arising in the superior olivary nucleus do not enter the corpus trapezoideum and the lateral lemniscus. A small bundle, the **peduncle of the superior olive,** arises in each nucleus and courses dorsally to the region of the nucleus of the abducens. Here certain of its fibres terminate about the cells of the nucleus of the abducens, while others enter the medial longitudinal fasciculus and pass to the nuclei of the trochlear and oculomotor nerves, thus further establishing connections between auditory impulses and eye movements.

The **facial nerve** is commonly described as consisting of the "facial proper" and its so-called sensory root or *pars intermedia*, the two together being designated as the seventh cranial nerve. However, the pars intermedia neither serves as a sensory root for the facial nor is it purely sensory. Many years ago Sapolini considered it a separate nerve and later it was called the *intermediate nerve of Wrisberg*. More recent investigations of its development and distribution, especially those of Streeter and Sheldon, further indicate that it merits a separate description

FIG. 651.—TRANSVERSE SECTION THROUGH INFERIOR BORDER OF PONS AND PORTION OF OVERLYING CEREBELLUM. (From Villiger.)

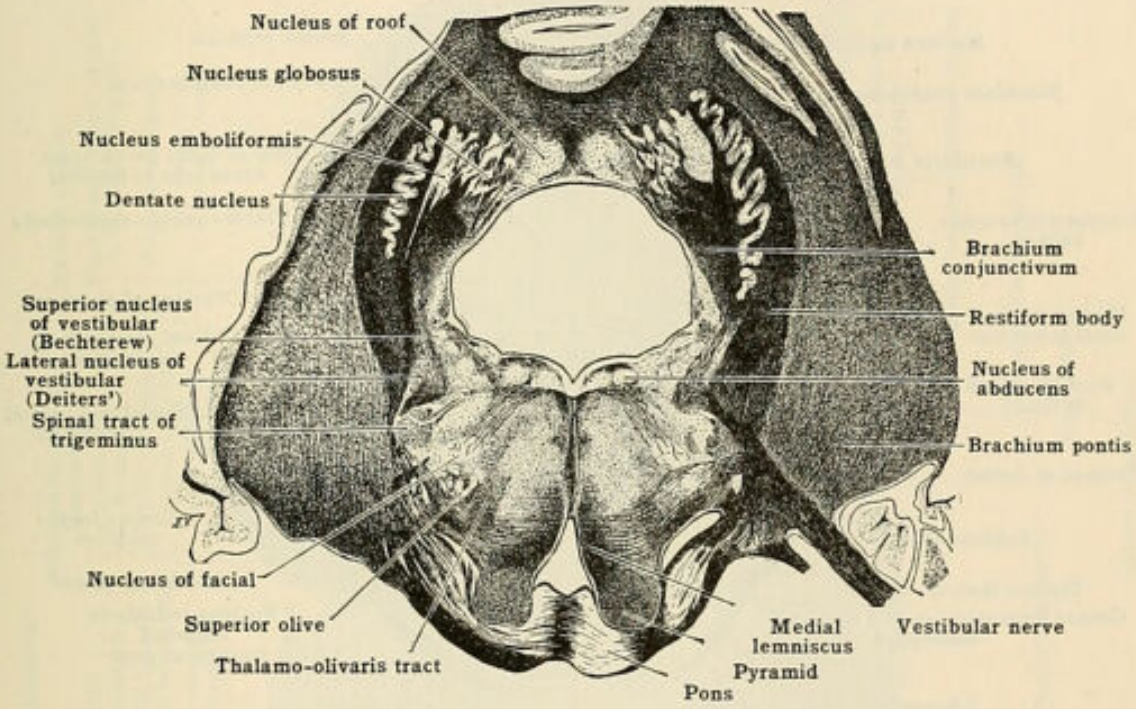

and a separate name, and, indicative of its distribution, it is here described as the *glosso-palatine nerve*. The facial, the glosso-palatine and the abducens all have their nuclei within the level of the pons though the roots of all appear from under its inferior border.

The **facial** [nervus facialis] has its nucleus (of origin) in the ventro-lateral region of the reticular formation, superior to and in line with the nucleus ambiguus. The axones given off by the cell-bodies of the nucleus collect into a bundle which, instead of passing ventrally and directly to the exterior of the pons, courses at first dorso-mesially to the mesial side of the nucleus of the abducens (ascending root of the facial); then it turns and courses superiorly for a few millimetres, parallel with the nucleus of the abducens and immediately beneath the floor of the fourth ventricle (*genu internum*); then it turns abruptly and pursues a ventro-lateral and inferior direction to its point of exit at the inferior border of the pons, just lateral to the olive and mesial to the entrance of the vestibular nerve. Its exit usually involves a few pons fibres. In transverse sections through the middle of the nucleus of the abducens the genu of the facial appears as a compact transversely cut bundle at the dorso-medial side of this nucleus.

The nucleus of the facial is described as consisting of two chief groups of cells, an anterior and a posterior group which give rise respectively to the axones of the superior and inferior branches of the facial nerve. It receives cortical impulses from the lower portion of the anterior central gyrus of the cerebral cortex, from the root fibres of the trigeminus of the same side, which serves as its sensory root, and (chiefly) fibres arising from the nuclei of termination of the trigeminus. The nuclei of termination of the optic and the auditory nerves of the same and opposite sides give rise to fibres which terminate about its cells. The fibres from the cerebral cortex descend in the pyramidal fasciculi and cross by way of the raphe and arcuate fibres to terminate in the nucleus of the opposite side. The anterior group of the cells of the facial nucleus must receive cortical fibres not only from the cerebral hemisphere of the opposite but also from that of the same side, evidenced by the fact that the superior branch of the nerve is but little affected in facial paralysis resulting from a lesion in the cerebral cortex of one side. A lesion destroying the root of the nerve or its nucleus of origin will of course give total facial paralysis in the side of the lesion.

The **glosso-palatine nerve** (*nervus intermedius*, sensory root of facial, etc.) is a mixed nerve but largely sensory. It accompanies the facial from a short distance beyond the geniculum (genu externum) of the facial to its attachment to the brain stem. Its *sensory fibres* arise as T-fibres of the cells of the *geniculate ganglion* (at the geniculum of the facial). The peripheral processes go as the *chorda tympani* to supply the epithelium of the anterior part of the tongue and that of the palate, especially of the palatine arches. The central processes enter the brain stem, bifurcate into caudal and cephalic branches, and find their nucleus of termination in a superior extension of the nucleus of the solitary tract (the ventral portion of the nucleus of the ala cinerea). The geniculate ganglion contains some cell-bodies of sympathetic neurones, left over in it during the period of migration form its homologue of the ganglion crest.

The *efferent fibres* of the glosso-palatine arise from cell-bodies lying dorso-medial to the nucleus of the facial and in the level between this and the nucleus of the masticator nerve superior to it. Its cells are usually scattered in the reticular formation in line with the dorsal efferent nucleus of the vagus. Since most of its fibres, at least, are concerned with sympathetic neurones (terminate in sympathetic ganglia) and convey secretory impulses destined for the salivary glands, it has been called the **nucleus salivatorius.**

FIG. 652.—TRANSVERSE SECTION THROUGH PONS AND PORTION OF CEREBELLUM AT LEVEL OF NUCLEI AND ROOT FILAMENTS OF ABDUCENS AND FACIAL NERVES. (From Villiger.)

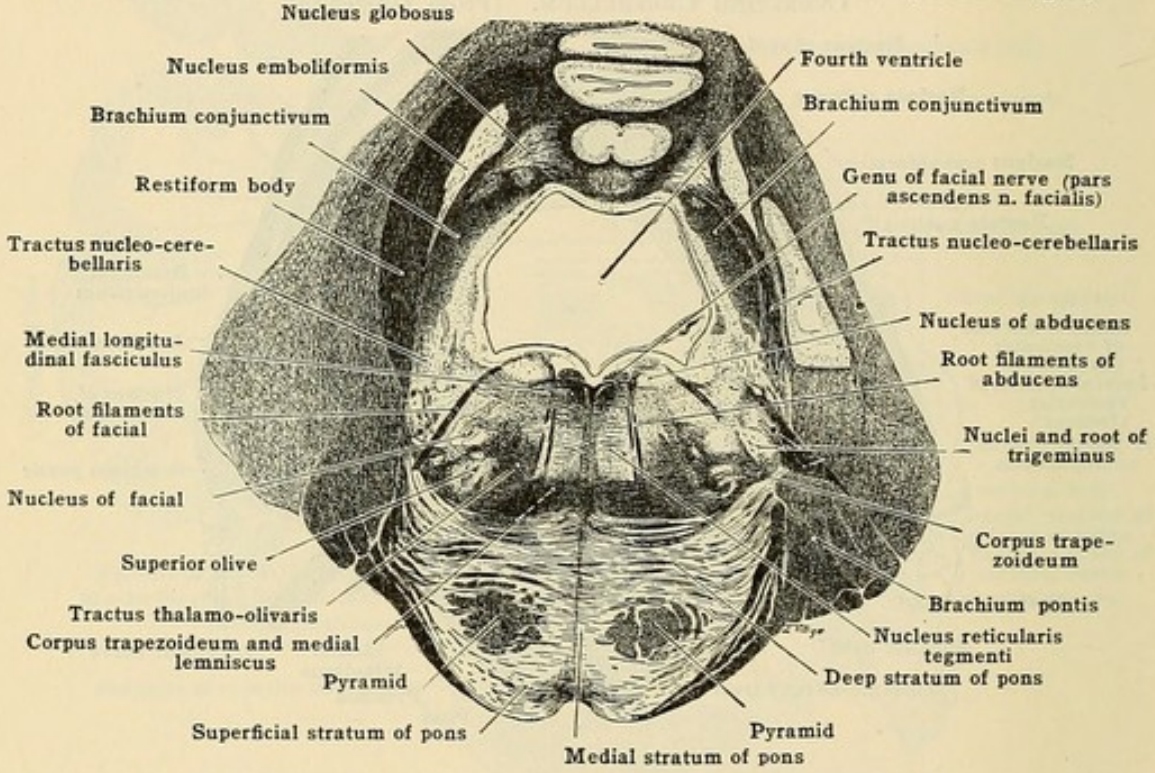

The **abducens** is a small, purely motor nerve, which supplies the lateral rectus muscle of the eye. Its *nucleus of origin* lies close to the mid-line in the medial eminence of the floor of the fourth ventricle, and in line with that of the hypoglossus. Its root-fibres, uncrossed, pursue a ventral course, inclining a little laterally and curving inferiorly to emerge from under the inferior border of the pons. They pass lateral to the pyramid, and often between some of its fasciculi. The nucleus receives cortical or voluntary impulses by way of the pyramidal fasciculi chiefly of the opposite side. Its connection with the auditory apparatus and the medial longitudinal fasciculus has already been noted. It probably receives afferent impulses through the fibres of the trigeminus as well as by fibres descending from the nuclei of termination of the optic nerve. It is also associated, by way of the medial longitudinal fasciculus, with the nucleus of the oculomotor nerve of the same and opposite sides.

The **trigeminus** is considerably larger than any of the nerves inferior to it, and has the most extensive central connections of any of the cranial nerves. It is a purely sensory nerve which enters through the brachium pontis in line with the facial nerve. It serves as the nerve of general sensibility for the face from the vertex of the scalp downward, and thus it corresponds to the afferent fibres (dorsal root) for all the nerves giving motor supply to structures underlying its domain. Its fibres arise from its large, trilobed, **semilunar** (Gasserian) **ganglion,** situated outside the brain. This corresponds to the dorsal root ganglion of a spinal nerve, and its cells give off the characteristic T-fibres with peripheral and central branches. The central or afferent branches upon entering the brain-stem bifurcate into ascending and descending divisions, just as the entering dorsal root-fibres of the spinal nerves, and find their *nucleus of termination* in a dorso-lateral column of grey substance, lying deeply and extending longitudinally through the brain stem, and consisting of the upward continuation of the gelatinous substance of Rolando of the spinal cord. Opposite the entrance of the nerve is a considerably thickened portion of this column of grey substance, known as the *sensory nucleus* of the trigeminus, and the remainder below is called the *nucleus of the spinal tract* (fig. 647). Both parts are equally "sensory." After bifurcation the branches of the entering fibres of the trigeminus terminate about the cells of these nuclei. The descending branches are much longer than the ascending,

FIG. 653.—DRAWING OF MODEL OF BRAIN-STEM SHOWING THE NUCLEI OF ORIGIN OF THE MOTOR CRANIAL NERVES. (After Sabin.)

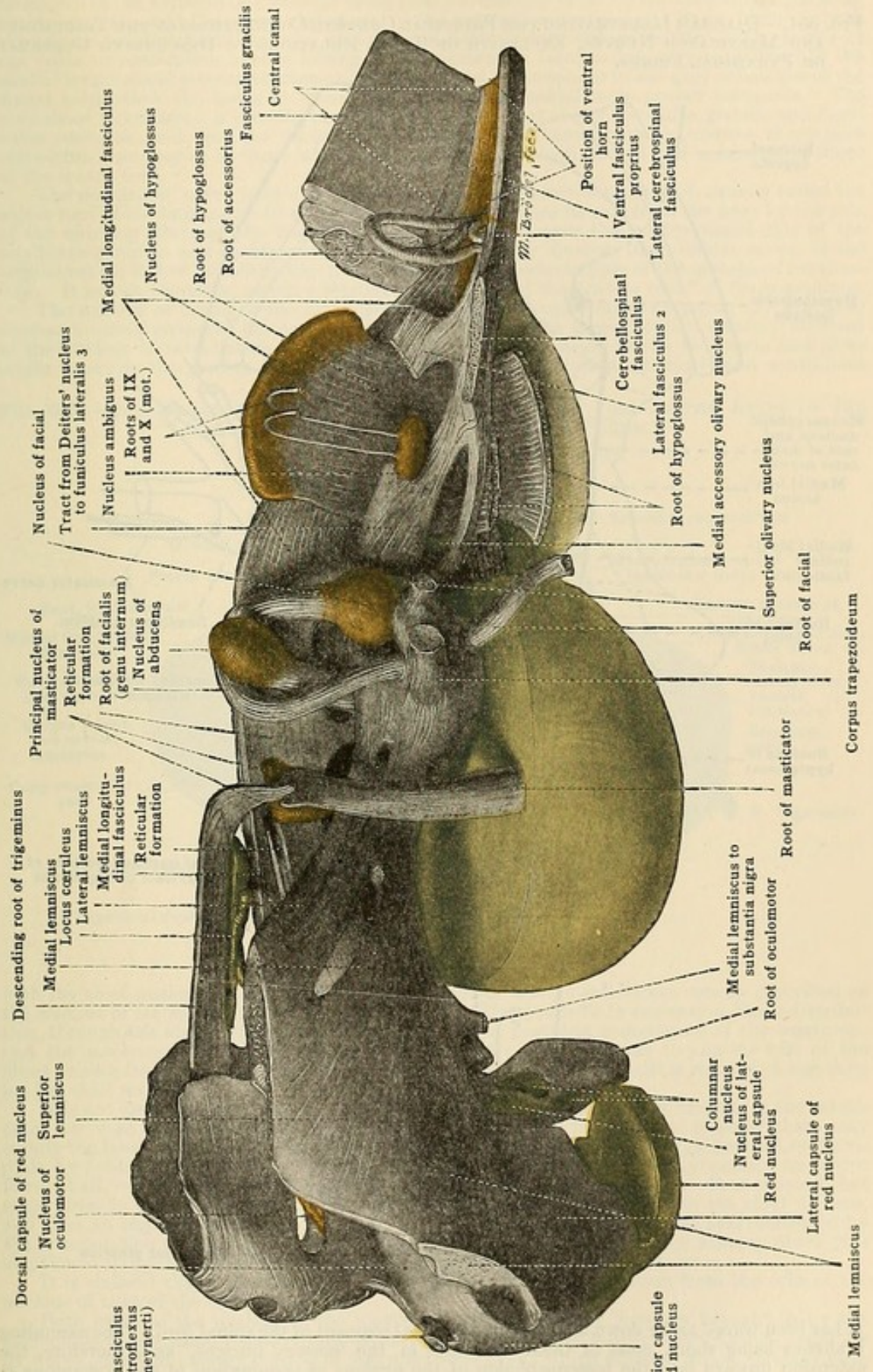

and in passing downward form the **spinal tract of the trigeminus,** well marked in all transverse sections of the medulla oblongata (figs. 641, 642, 643, 649). The spinal tract decreases rapidly in descending the medulla, owing to the rapid termination of its fibres in the nucleus of the tract.

FIG. 654.—DIAGRAM ILLUSTRATING THE PRINCIPAL CENTRAL CONNECTIONS OF THE TRIGEMINUS AND MASTICATOR NERVES, EXCLUSIVE OF THEIR RELATIONS TO DESCENDING CEREBRAL OR PYRAMIDAL FIBRES.

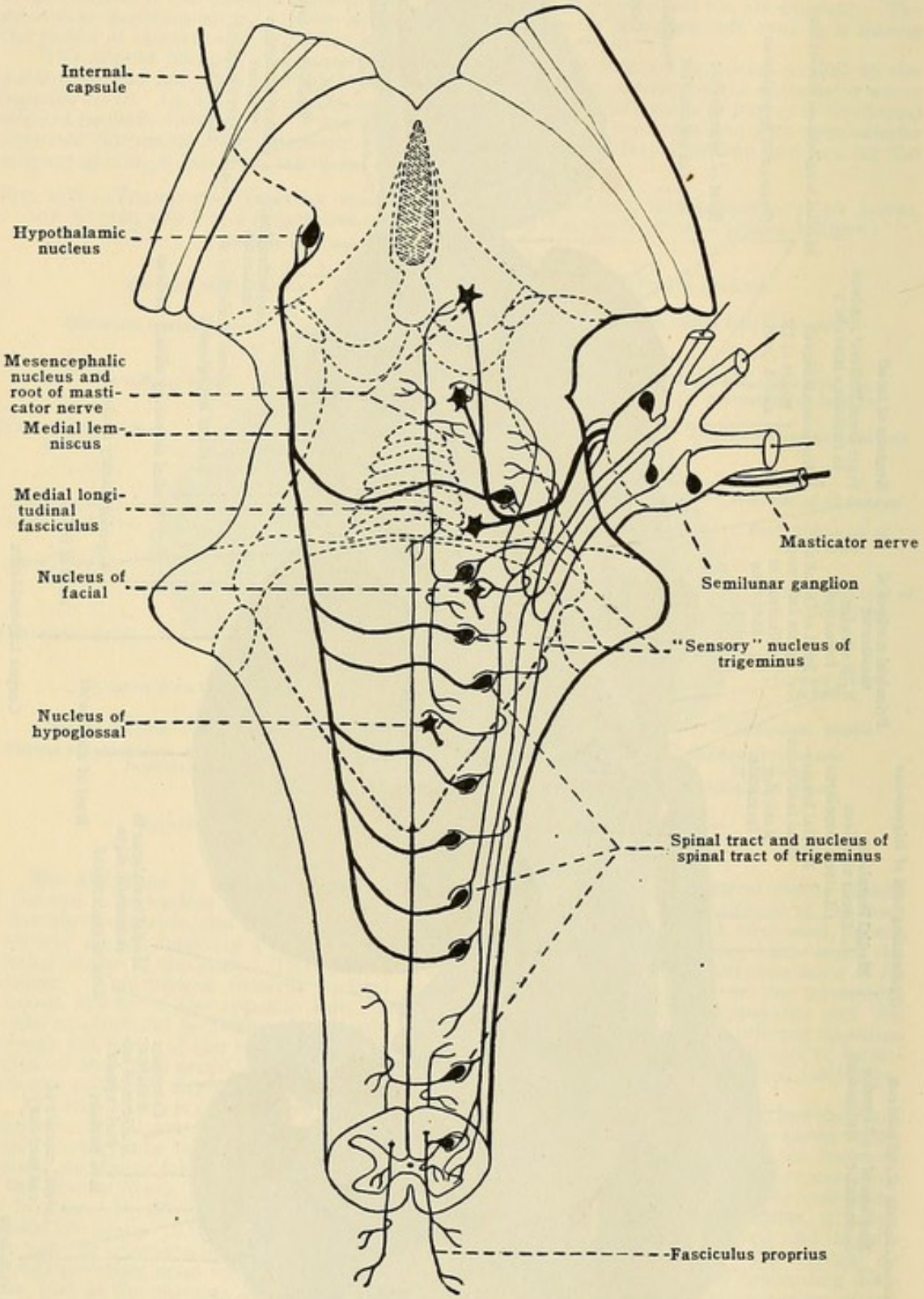

It has been traced as far down as the second cervical segment of the spinal cord. The ascending branches being short, most of them terminate in the 'sensory nucleus,' and, therefore, the extension upward into the mesencephalon of the nucleus of termination of the trigeminus is both shorter and more scant than the spinal extension.

Axones from the nucleus of termination of the trigeminus are distributed—(1) to the nuclei of masticator nerve of the same and opposite sides (short or simple reflex fibres); (2) to the

nuclei of the other motor cranial nerves, especially of the facial; (3) to the thalamus of the same and chiefly the opposite side, and thus, through interpolation of thalamic neurones, their impulses reach the somæsthetic area of the cerebral cortex. These fibres ascend in the recticular formation of the opposite side, most of them finally coursing strictly within the medial lemniscus. In crossing the mid-line they contribute to the internal arcuates. (4) Some fibres of both the trigeminus direct and from its nucleus pass laterally into the cerebellum. The longer of the reflex or association axones arising in the nucleus of termination may contribute to the medial longitudinal fasciculus; many of them descend to terminate in the grey substance of the spinal cord below the levels in which the fibres of the spinal tract proper terminate. The nucleus of termination is directly homologous to the nuclei of the fasciculus gracilis and fasciculus cuneatus, and, like the nuclei of termination of all sensory cranial nerves, it contains cell-bodies homologous to those which give rise to the fasciculi proprii and commissural fibres of the spinal cord.

The **masticator nerve** [*portio minor n. trigemini*] is a purely motor nerve, usually called the motor root of the trigeminus from the fact only that it makes its exit from the pons by the side of the entering fibres of the trigeminus, passes outward over the ventro-mesial side of the semilunar ganglion and accompanies the inferior maxillary division (mandibular nerve) of the trigeminus till it divides totally into its branches for the motor supply of the muscles of mastication. It serves, therefore, as but a relatively small part of the "motor root" of the trigeminus.

The nucleus of origin of the masticator nerve is attenuated into two parts: (1) The *chief nucleus* (*nucleus princeps*) lies on the dorso-medial side of the larger portion (sensory nucleus) of the nucleus of termination of the trigeminus. It is the larger of the two parts and gives origin to much the greater part of the masticator. (2) Scattered anteriorly and continuous

FIG. 655.—TRANSVERSE SECTION THROUGH UPPER PART OF PONS AT THE LEVEL OF THE ENTRANCE OF THE TRIGEMINUS. (From Villiger.)

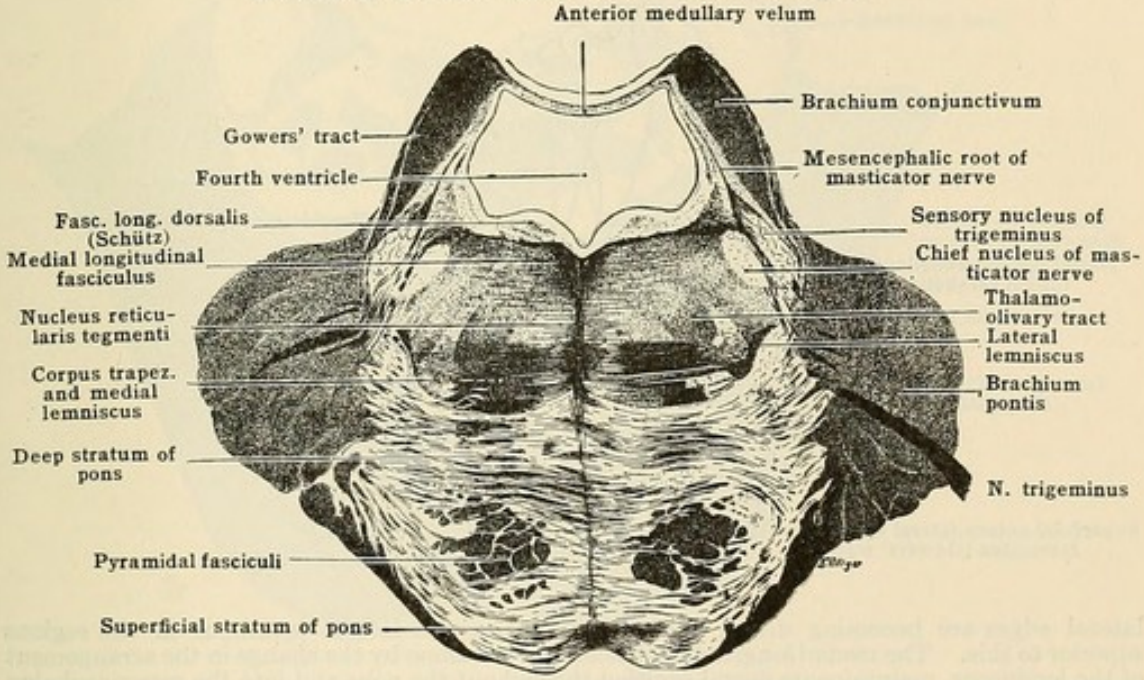

with the chief nucleus, in line with the *locus cæruleus*, are the cell-bodies usually described as the *nucleus of the mesencephalic* (descending) *root*. These cells lie in decreasing linear distribution, through the mesencephalon, as far anterior as the posterior commissure of the cerebrum, and the *mesencephalic root* of the nerve accumulates as it descends to join the exit of the fibres arising from the chief nucleus. The average diameter of its cells is somewhat less than for the chief nucleus.

It is not clearly settled that the fibres arising from the mesencephalic nucleus of the masticator nerve go to the muscles of mastication. As suggested by Kölliker, some of these may supply the tensor veli palatini and tensor tympani muscles. Recent investigations of lower animals by Johnston and Willems indicate that the mesencephalic root may contain no motor fibres at all, representing instead a portion of the sensory trigeminus fibres. It is claimed that some fibres in descending give off collaterals which terminate about cells in the chief nucleus, and thus an impulse descending by them is given a wider distribution and also reinforced by the interpolation of another neurone. Such fibres, however, may be the sensory fibres just mentioned terminating upon the cells of the nucleus to form simple reflex arcs.

It is claimed that each masticator nerve receives a few fibres arising from the cells of the nucleus of that of the opposite side.

Both parts of the nucleus of the masticator receive afferent impulses brought in by the trigeminus of the same (chiefly) and of the opposite side, and both receive cortical impulses by fibres from the inferior portion of the precentral gyrus which descend in the cerebral peduncles and cross to terminate in the nucleus of the opposite side.

The internal structure of the pons.—The nuclei and roots of the trigeminus, masticator, abducens, facial, glosso-palatine, cochlear and vestibular nerves are extended within the level

of the pons, and their position and course have been described above. The pons proper (the bridge) consists of a mass of transversely running fibres continuous on either side into the brachia pontis or middle cerebellar peduncles. In the animal series the relative amount of these fibres varies with the size of the cerebellum upon which they are dependent. They are relatively more abundant in man than in other animals.

In transverse sections the pons fibres are seen to course ventrally about the main axis of the brain-stem, making it possible to divide the section into a *basilar* or *ventral part* and a *dorsal part* (*tegmentum*). The fibres in their transverse and ventral course around the medulla oblongata involve the pyramids. At the inferior border of the pons the fibres little more than separate the pyramids as such from the main axis of the brain-stem, but more superiorly the pons fibres pass through the pyramids, splitting them into the **pyramidal fasciculi.** These pyramidal or chief *longitudinal fibres* of the pons are the continuation of the basal portion of the cerebral peduncles through the pons, to emerge as the pyramids proper at its inferior border. They occupy an intermediate or central area among the pons fibres of either side, leaving the periphery of the pons uninvaded. The *superficial pons fibres* form the solid bundle of its ventral and lateral periphery and the *deep pons fibres* form similar bundles dorsally enclosing the area of pyramidal fasciculi (fig. 655).

In transverse sections through the *inferior portion* of the pons, the *dorsal or tegmental part* consists of structures continuous with and analogous to the structures of the medulla oblongata immediately below, exclusive of the pyramids. In addition, this region contains the superior olivary nucleus and the corpus trapezoideum. The significance of these structures and their relation to the nucleus of termination of the cochlear nerve is shown in figs. 650, 651 and 652. In this region the *lemniscus* (fillet) changes from the sagittal to the coronal plane, and its

FIG. 656.—DIAGRAM SHOWING THE RHOMBENCEPHALIC COURSE OF GOWERS' TRACT AND THE DIRECT CEREBELLAR TRACT.

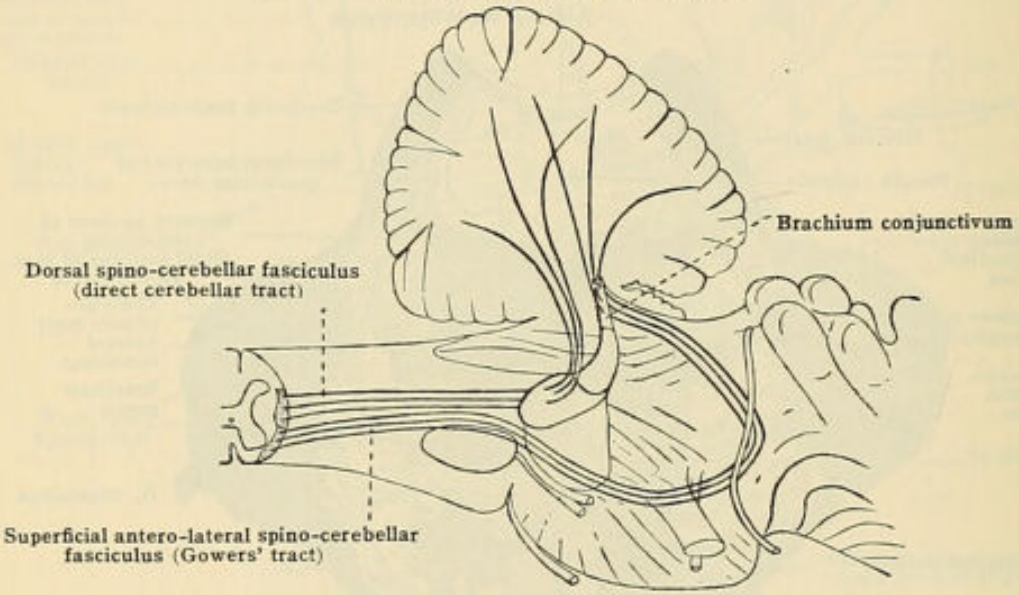

lateral edges are becoming drawn outward and carry the lateral lemniscus of the regions superior to this. The medial longitudinal fasciculus, left alone by the change in the arrangement of the leminscus, maintains its dorsal position throughout the pons and into the mesencephalon above. The **thalamo-olivary tract** appears loosely collected in the dorsal part of the pons, dorso-medial to the nucleus of the superior olive.

The **restiform body** acquires in this inferior region a more dorso-lateral position than in the medulla below. Its fibres are beginning to turn upward in their course to the cerebellum mesial to the brachium pontis. Here the restiform body is nearing completion, and the fibres now contained in it may be summarised as follows:—

(1) The fibres of the dorsal spino-cerebellar fasciculus (direct cerebellar tract) of the same side.

(2) Fibres from the nuclei of the fasciculus gracilis and fasciculus cuneatus of the same and opposite side (external arcuate fibres).

(3) Fibres to and from the inferior olives of the same and (chiefly) the opposite side (cerebello-olivary fibres).

(4) Sensory cerebellar fibres from the nuclei of termination of the vagus, glosso-pharyngeus, vestibular and trigeminus, vestibular especially, and from the cells of the reticular formation.

(5) Descending fibres to the motor nuclei of the vagus and glosso-pharyngeal, and fibres descending into the anterior marginal fasciculus of the spinal cord, the latter, however, being in large part interrupted by cells in the nuclei of the vestibular nerve.

(6) A few fibres arising from the arcuate nuclei. These nuclei are continuous superiorly with the nuclei of the pons and some of their fibres are described as entering the cerebellum by way of the restiform body instead of by way of the brachium of the pons as in the levels above.

The ascending fibres of the restiform body are distributed to the cortex of the vermis, the nucleus of the roof (*fastigii*), the nucleus dentatus, nucleus emboliformis, and nucleus globosus.

Very few if any of the fibres ascending the cord in *Gowers' tract* enter the cerebellum by way of the restiform body. This tract (the superficial antero-lateral spino-cerebellar fasciculus)

ascends the medulla, dispersed in the reticular formation, and therefore in a more ventral position than that of the direct cerebellar tract. In this position it becomes enclosed by the fibres of the pons, and so it passes upward, beyond the pons, around the lateral lemniscus to the brachium conjunctivum, and there turns back to enter the cerebellum by way of its superior peduncle. Certain clinical phenomena, probably purely psychological, have been alleged to indicate that some of the fibres of Gowers' tract pass on to the cerebrum instead of turning in the medullary velum to enter the cerebellum.

The dorsal part of a transverse section through the *upper part* of the pons contains the **superior cerebellar peduncles** [brachia conjunctiva] instead of the restiform bodies or inferior peduncles. Instead of the cerebellum forming the roof of the fourth ventricle, in this region the roof is formed by the anterior medullary velum bridging the space between the two brachia conjunctiva. Adhering upon the medullary velum is the **lingula cerebelli**—the superior and ventral extremity of the superior vermis. This is the only portion of the cerebellum attached to this region.

The lemniscus (fillet) is found more lateral than at the inferior border of the pons, and is divided into the *medial lemniscus* and *lateral lemniscus* proper. The lateral lemniscus has shifted dorsally until in this region it courses in the dorso-lateral margin of the section external to the brachium conjunctivum. The mesencephalic root of the masticator nerve occurs in the dorso-

FIG. 657.—DIAGRAM SHOWING CONNECTIONS OF THE FIBRES OF THE PONS.
The plane of the section is obliquely transverse or parallel with the direction of the brachia pontis

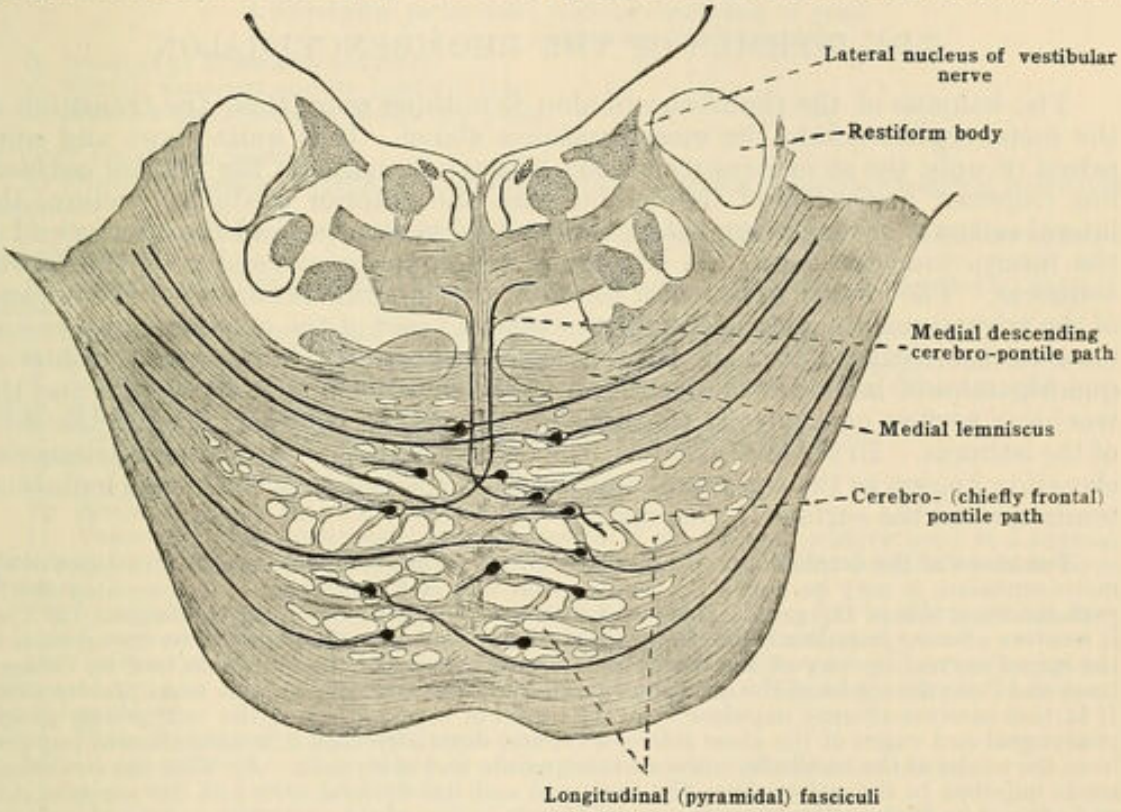

lateral margin of transverse sections through this region, and this and the trigeminus are the only cranial nerves represented here.

The transverse fibres of the ventral part of the section (pons proper), and therefore the brachia pontis, consist of fibres coursing in opposite directions. Many are fibres which are outgrowths of the Purkinje cells of the cortex of the cerebellar hemispheres, and pass either directly to the cerebellar hemisphere of the opposite side or turn dorsalward in the raphe to course longitudinally in the brain-stem both toward the spinal cord and toward the mesencephalon. Others terminate in the grey substance (nuclei) of the pons. Others are fibres which arise in the grey substance of the pons and pass to the cerebellar hemispheres, and still others are the cerebro-pontile fibres, from the temporal, occipital and frontal lobes.

The **grey substance of the pons** [**nuclei pontis**] occurs quite abundantly. At the inferior border of the pons it is found concentrated about the then more accumulated bundles of the emerging pyramids, and serial sections show it to be a direct upward continuation of the arcuate nuclei of the medulla oblongata below. Higher up it is dispersed throughout the central area in the interspaces between the transverse pontile and longitudinal pyramidal fasciculi. A large portion of the nerve-fibres passing through it are thought to be interrupted by its cells, which thus serve as links in some of the neurone chains represented by the fibres of the pons. Of the more important of such relations, the following are said to exist:—

(1) Fibres which arise in the cortex of one cerebellar hemisphere and terminate about cells of the nucleus pontis of the same and opposite side of the mid-line. These cells give off axones which pass to the other cerebellar hemisphere. In this relation the nuclei of the pons are analogous to the arcuate nuclei, save that the cerebellar fibres interrupted in the former are connected with the cerebellum by way of the brachia pontis instead of the restiform bodies.

(2) Certain of the descending cerebro-pontile fibres terminate about cells of the nuclei of the pons. Such cells give off fibres which probably, for the most part, pass to the cerebellar hemispheres, the impulses from the cerebral hemisphere of one side being conveyed to the opposite cerebellar hemisphere. Most of the descending cerebro-pontile fibres are thought to cross the mid-line to terminate about cells of the nuclei of the pons of the opposite side, a relation not sufficiently emphasised in the accompanying diagram (fig. 657).

Of the cerebro-pontile paths, the **frontal pontile path** (Arnold's bundle) is described as arising in the cortex of the frontal lobe (frontal operculum) passing in the anterior portion of the internal capsule down into the medial part of the base of the cerebral peduncle, and terminating in the grey substance of the pons. The descending **temporal pontile path,** sometimes called Türk's bundle, arises in the cortex of the temporal lobe, traverses the posterior portion of the internal capsule, lies lateral in the pyramidal portion of the cerebral peduncle, and terminates in the grey substance of the pons. In the posterior part of the internal capsule, the temporal pontile path is joined by a small bundle arising in the occipital lobe and going to the pons nuclei. This, supposedly smaller than the other two, adds an **occipito-pontile path.**

The total area in cross section of the pyramidal fasciculi as they enter the pons above is considerably greater than that which they possess as they emerge as the pyramids of the medulla below. The difference is considered very appreciably greater than can be explained as due to the loss of pyramidal fibres supplied to the nuclei of origin of the cranial nerves lying within the level of the pons, and the additional difference is explained as due to the termination within the pons of the cerebro-pontile paths.

THE ISTHMUS OF THE RHOMBENCEPHALON

The isthmus of the rhombencephalon is nothing more than the transition of the metencephalon into the mesencephalon above. It is quite short and comprised of only the structures which run through it, namely, the *brachia conjunctiva* (superior peduncles of the cerebellum), the anterior medullary velum, the lateral sulcus of the mesencephalon, the cerebral peduncles, and the inferior end of the interpeduncular fossa. It surrounds the superior extremity of the fourth ventricle. The lateral and medial lemnisci, the superior extension of the nucleus of the trigeminus, the mesencephalic nucleus and root of the masticator nerve and Gowers' tract extend through it. At the mid-line, just inferior to the inferior quadrigeminate bodies is the **frenulum** of the anterior medullary velum and the trochlear nerves, emerging at the sides of this, course ventrally around the sides of the isthmus. In the lateral sulcus, the isthmus shows usually a small triangular elevation known as the **trigonum lemnisci** from the fact that the lateral lemniscus tends toward the surface in this region.

Functions of the cerebellum.—From the above descriptions involving the structures of the metencephalon, it may be noted (1) that a given side of the cerebellum is associated chiefly with the same side of the general body and with the opposite side of the cerebrum. (2) That it receives afferent impulses from the spinal cord (brought into the cord by the dorsal roots of the spinal nerves) by way of the direct cerebellar fasciculus of the same side, and by Gowers' tract and from the nuclei of the fasciculus gracilis and cuneatus of the same and opposite sides. It further receives afferent impulses from the nuclei of termination of the trigeminus, glossopharyngeal and vagus of the same side chiefly, and especially does it receive afferent impulses from the nuclei of the vestibular nerve of the opposite and same side. (3) That the cerebellum sends impulses to the red nucleus, the thalamus and the cerebral cortex of the opposite side, and some of its fibres terminate in the nuclei of termination of the vestibular nerve and probably some fibres arising in its roof nuclei descend into the spinal cord direct. (4) That the cerebellum receives impulses from the thalamus of the opposite side by way of the thalamo-olivary tract and the inferior olive, and especially from the cerebral cortex of the opposite side by way of the frontal, temporal and occipital pontile paths and the nuclei of the pons. Further, fibres from the general pyramidal fasciculi are described as terminating about cells of the nuclei of the pons.

Taking into consideration these known associations of the cerebellum, the anatomically possible paths which in part may distribute cerebellar impulses to the grey substance sending efferent fibres to the peripheral tissues are (1) the general pyramidal fasciculi whose cortex of origin may receive impulses by *fibræ propriæ* from the cortical areas receiving impulses from the cerebellum. The pyramidal fasciculi, decussating, distribute impulses to the grey substance of the medulla and cord of the same side as that from which the cerebello-cerebral impulses passed to the cortex. (2) The lateral vestibulo-spinal and the anterior marginal fasciculi to the ventral horn of the spinal cord of the same side, probably carrying impulses descending from the cerebellum as well as impulses brought in by the vestibular nerve and descending direct from its nuclei of termination into the spinal cord. (3) The rubro-spinal tract of the cord and probably some of the thalamo-spinal fibres (corpora-quadrigemina-thalamus path), the red nuclei and thalami being associated abundantly with the cerebellum. These tracts likewise decussate in descending but likewise do the cerebellar impulses ascending to their cells of origin.

Whatever other functions it may possess, developmental defects and pathologic lesions show that the cerebellum has to do with the equilibration of the body and the finer coördinations, adjustive control of the contractions of functionally correlated groups of muscles. Making this

possible, in part at least, it is seen above that is it associated (1) directly with the special nerve of equilibration, the vestibular; (2) with the optic apparatus by way of the thalamus, and (3) with the afferent impulses from the general body, by way of the direct cerebellar and Gowers' tracts, by way of the nuclei of the fasciculus gracilis and cuneatus, and the nuclei of termination of the trigeminus, glosso-pharyngeal and vagus. It has been suggested that by way of these latter paths the cerebellum deals especially with those general afferent impulses which arise within the muscles of the body (neuro-muscular spindles, etc.) and which are grouped under the name "muscular sense." The cerebellum can be considered as an enlarged and modified portion of the grey substance of the spinal cord, receiving a greater number and variety of afferent impulses and with them mediating more comprehensive and complicated reflex activities than is possible with the less abundant grey substance of a given portion of the cord proper.

SUMMARY OF PRINCIPAL STRUCTURES IN RHOMBENCEPHALON

A. Gross Exterior.

1. Medulla Oblongata (Myelencephalon).
2. Metencephalon
   - Cerebellum
     - Hemispheres—lobes and lobules.
     - Vermis—lobules and lingula.
   - Pons
     - Dorsal part (preoblongata).
     - Ventral part (pons proper).
   - Cerebellar peduncles
     - superior—brachium conjunctivum.
     - middle—brachium of pons.
     - inferior—restiform body.
3. Isthmus of Rhombencephalon.
4. Fourth Ventricle and its Chorioid tela.
5. Anterior and Posterior Medullary Vela.

B. Grey and White Substance.

1. Funiculus gracilis, nucleus of fasciculus gracilis, funiculus cuneatus, nucleus of fasciculus cuneatus.
2. Internal and external arcuate fibres, decussation of lemnisci, lemniscus, medial lemniscus, lateral lemniscus.
3. Cerebral peduncles, pyramidal fasciculi, pyramids, decussation of pyramids, arcuate nuclei.
4. Superficial and deep strata of pons, nuclei of pons, branchia of pons.
5. Inferior olivary nuclei, cerebello-olivary fibres, thalamo-olivary tract, spino-olivary tract.
6. Nuclei emboliformis, globosus and fastigii (of the roof), and nucleus dentatus with brachium conjunctivum of cerebellum.
7. Central gelatinous substance and gelatinous substance of Rolando.
8. Reticular formation.
9. Hypoglossal nerve and nucleus of hypoglossal.
10. Spinal accessory nerve and lateral nucleus.
11. Vagus and glossopharyngeal nerves, nucleus of ala cinerea, solitary tract and nucleus of solitary tract, commissural nucleus of ala cinerea, nucleus ambiguus, dorsal efferent nucleus of vagus.
12. Vestibular nerve—its superior nucleus (Bechterew), its medial nucleus (Schwalbe), its lateral nucleus (Deiters), and the nucleus of its descending (spinal) root.
13. Cochlear nerve, dorsal nucleus and ventral nucleus of cochlear, acoustic medullary striæ, nucleus of superior olive, trapezoid body, nucleus trapezoidei, lateral lemniscus, nucleus of lateral lemniscus.
14. Facial nerve and nucleus of facial nerve.
15. Glosso-palatine nerve, nucleus of glosso-palatine and nucleus salivatorius.
16. Abducens and nucleus of abducens.
17. Trigeminus, "sensory nucleus" of trigeminus, spinal tract and nucleus of spinal tract of trigeminus.
18. Masticator nerve, chief nucleus and (so-called) mesencephalic nucleus and root of masticator.
19. Medial longitudinal fasciculus.
20. Nucleus intercalatus, nucleus of median eminence, nucleus incertus.

THE CEREBRUM

1. THE MESENCEPHALON

The mesencephalon or mid-brain is that small portion of the encephalon which is situated between and connects the rhombencephalon below with the prosencephalon above. It is continuous with the isthmus rhombencephali, and occupies the tentorial notch, the aperture of the dura mater which connects the meningeal cavity containing the cerebellum with that occupied by the prosencephalon. Its greatest length is about 18 mm., and it is broader ventrally than dorsally. Its dorsal surface is hidden by the overlapping occipital lobes of the cerebral hemispheres. It consists of—(1) the **lamina quadrigemina,** a plate of mixed grey and white substance which goes over lateralward and below into (2), the **cerebral**

peduncles (crura) and their tegmental structures, and it contains (3), the *nuclei of origin* of the *trochlear* and *oculomotor* nerves. It arises from thickenings of the walls of the middle cerebral vesicle of the embryo, the lamina quadrigemina arising from the dorsal or alar lamina of this portion of the neural tube, while the basal lamina thickens to form the nuclei of the nerves, the substantia nigra, etc., and by the ingrowing of the cerebral peduncles. By means of the lamina quadrigemina roofing it over, the neural canal throughout the mesencephalon retains its tubular form and is known as the **aquæductus cerebri** (Sylvii), connecting the cavity of the fourth ventricle below with that of the third ventricle above.

External features.—*Dorsal surface.*—The lamina quadrigemina shows four well-rounded elevations, the quadrigeminate bodies [**corpora quadrigemina**], divided by a flat median groove crossed at right angles by a transverse groove. The anterior pair of these, the *superior quadrigeminate bodies* [colliculi], are

FIG. 658.—DORSAL SURFACE OF MESENCEPHALON AND ADJACENT PARTS. (After Spalteholz.)

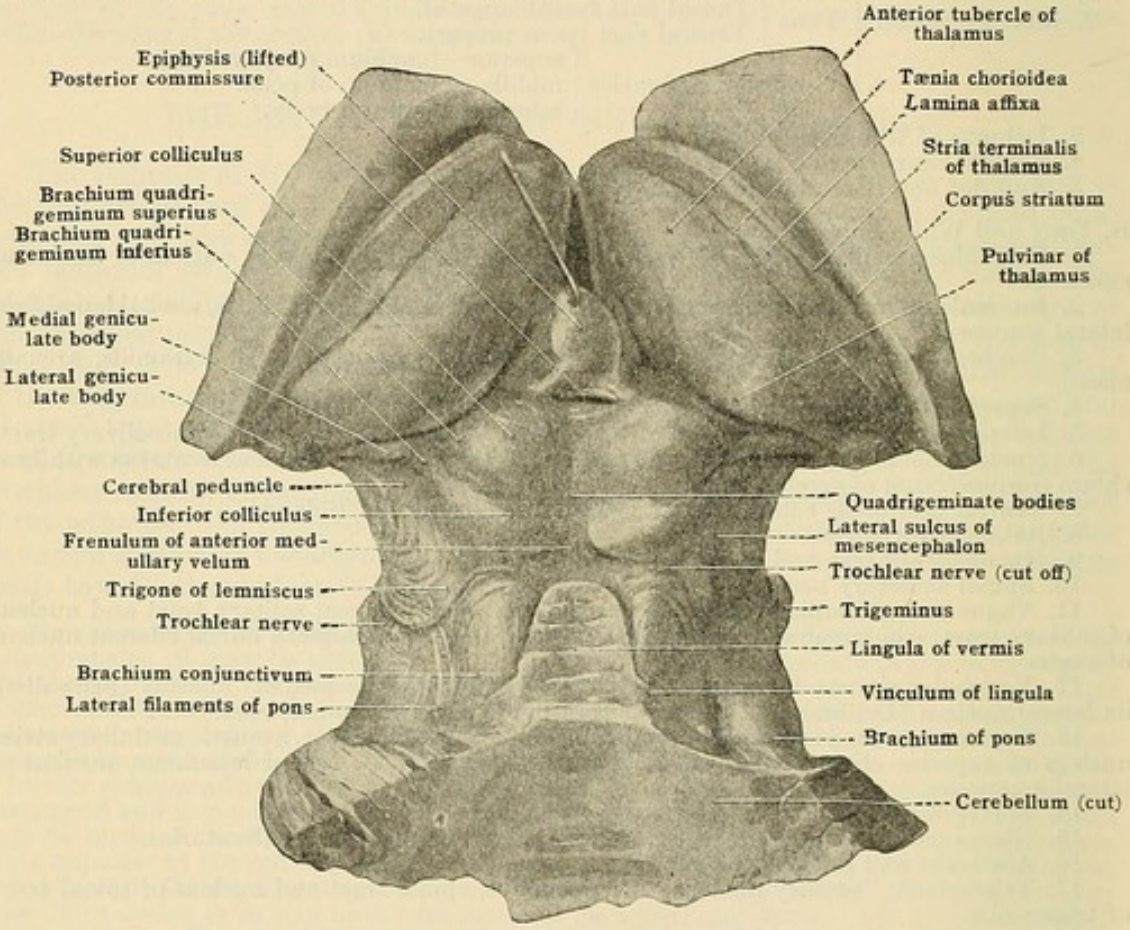

larger though less prominent than the inferior pair or *inferior colliculi*. Each colliculus is continued laterally and upward into its arm or brachium. The **inferior brachium** proceeds from the inferior colliculus, disappears beneath and is continuous into the **medial geniculate body,** and enters the thalamus. The **superior brachium** proceeds from the superior colliculus, disappears between the medial geniculate body and the overlapping pulvinar of the thalamus, and becomes continuous with the **lateral geniculate body** and thus with the lateral root of the optic tract.

The geniculate bodies are rounded elevations of grey substance which arise as detached portions of the thalami, and therefore belong to the thalamencephalon rather than to the mesencephalon. The superior quadrigeminate body or superior colliculus and the lateral geniculate body are a part of the *optic apparatus*, while the inferior colliculus and the medial geniculate body belong chiefly to the *auditory apparatus* (see CENTRAL CONNECTIONS OF COCHLEAR NERVE). Just as the terminal cochlear nuclei are connected by a few fibres with the superior colliculus, so do some fibres from the optic tract pass into the inferior colliculus. Also some fibres form the optic tract (mesial root) are said to terminate in the medial geniculate body. Resting in the broadened medial groove between the superior quadrigeminate bodies lies the non-nervous **epiphysis** or pineal body. This also belongs to the thalamencephalon. Under the stem of the epiphysis is a strong transverse band of white substance crossing the

mid-line as a bridge over the opening of the cerebral aqueduct into the third ventricle. This is the **posterior commissure** of the cerebrum, and contains commissural fibres arising in both the thalamencephalon and mesencephalon. The triangular area bounded by the stem of the epiphysis, the thalamus, and the superior colliculus with its brachium, is known as the **habenular trigone.**

Inferiorly, the lamina quadrigemina is continuous with the isthmus of the rhombencephalon by way of the brachia conjunctiva or superior cerebellar peduncles, and the anterior medullary velum which bridges between the mesial margins of these peduncles. The narrowed upper end of the velum, the part directly below the inferior quadrigeminate bodies, is thickened into a well-defined white band known as the **frenulum veli.** From the lateral margins of this band on each side and just below the inferior quadrigeminate bodies emerge the **trochlear nerves** (the fourth pair of cranial nerves), and the increased thickness of the band is largely due to the decussation of this pair of nerves taking place within it.

The brachium conjunctivum, together with the inferior and superior colliculi of each side, form a marked ridge which results in the *lateral sulcus* of the mesencephalon, a lateral depression between the base of this ridge and the cerebral peduncle below and continuous into the transverse sulcus at the superior border

FIG. 659.—DIAGRAM OF LATERAL VIEW OF MESENCEPHALON AND ADJACENT STRUCTURES. (After Gegenbaur, modified.)

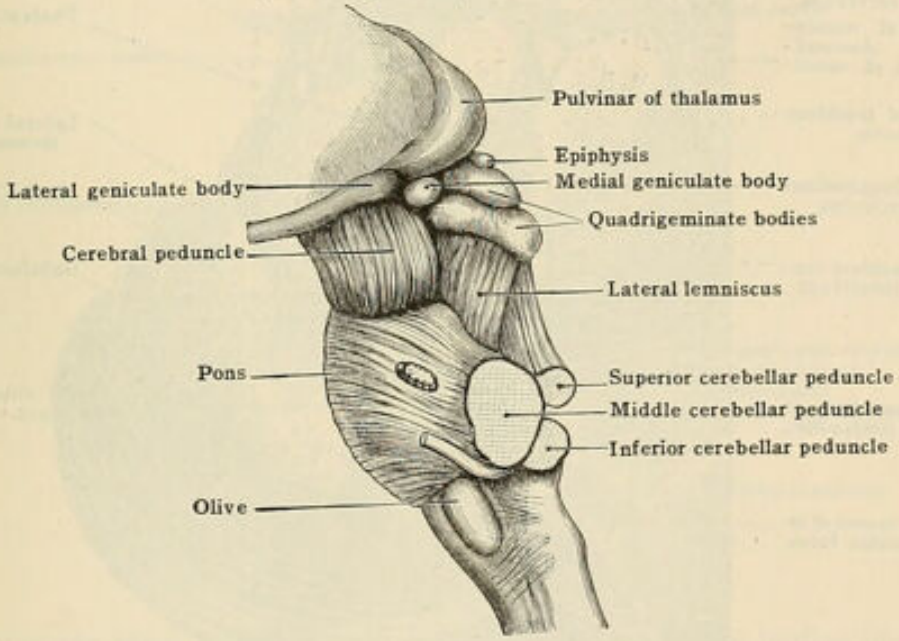

of the pons. The ridge is thickened laterally by the lateral lemniscus, which is disposed as a band of white substance passing obliquely upward from under the brachium pontis, applied to the lateral surface of the brachium conjunctivum and which enters the lateral margin of the mesencephalon. The region at which the lateral lemniscus approaches nearest the surface and in which the largest portion of its nucleus lies is the slightly elevated **trigone of the lemniscus.**

The **ventral surface** of the mesencephalon is formed by the **cerebral peduncles** (crura), two large bundles of white substance which are close to one another at the superior margin of the pons, but immediately diverge somewhat, producing the **interpeduncular fossa,** and in so doing pass upward and lateralward to disappear beneath the optic tracts (fig. 629). The *posterior recess* of the interpeduncular fossa extends slightly under the superior margin of the pons, while its *anterior recess* is occupied by the corpora mammillaria of the prosencephalon. The triangular floor of the fossa is the **posterior perforated substance,** a greyish area presenting numerous openings for the passage of blood-vessels. It is divided by a shallow median groove and is marked off from the medial surface of each peduncle by the *oculomotor sulcus,* out of which emerge the roots of the **oculomotor nerves.** The ventral surface of each peduncle is rounded and has a somewhat twisted appearance, indicating that its fibres curve from above medialward and downward. Sometimes two small, more or less transverse bands of fibres may be noted crossing the peduncle—an inferior, the *tænia pontis,* and a superior, the *transverse pedun-*

cular tract. The inferior represents detached fibres of the pons; the superior, running from the brachium of the inferior quadrigeminate body and disappearing in the oculomotor sulcus, appears to be derived from the quadrigeminate bodies. Since it is well developed in the cat, dog, sheep, and rabbit, but is absent or little marked in the mole, it is supposed to be concerned with the optic apparatus.

Internal structure.—Transverse sections of the mesencephalon throughout are composed of—(1) a *dorsal part*, consisting of the lamina quadrigemina or the grey substance of the corpora quadrigemina, with the strata and bundles of nerve-fibres connected with them, and the abundant central grey substance surrounding the aqueduct; (2) a *tegmental part*, consisting of the upward continuation of the reticular formation of the medulla oblongata and that of the

FIG. 660.—TRANSVERSE SECTION THROUGH THE INFERIOR QUADRIGEMINATE BODIES.

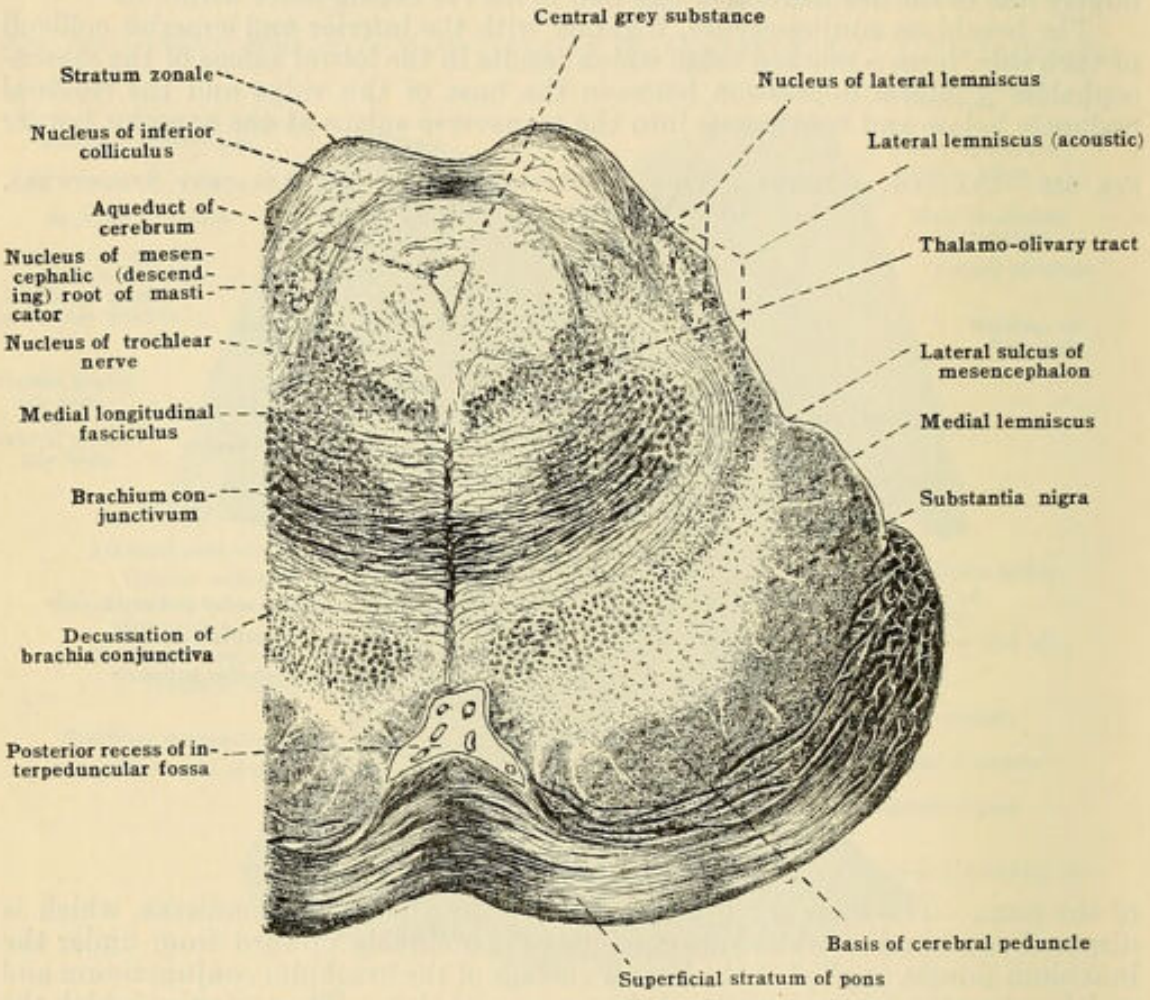

dorsal (tegmental) portion of the pons region, to which are added the superior cerebellar peduncles and the red nuclei of the tegmentum in which these peduncles terminate; (3) a paired *ventral part*, the cerebral peduncles, each of which consists of a thick, pigmented stratum of grey substance, the *substantia nigra*, spread upon the large, superficial, and somewhat crescentic tract of white substance known as the *basis* of the peduncle. The cerebral peduncles correspond to the longitudinal or pyramidal fasciculi of the pons and medulla. Likewise the lemniscus and the medial longitudinal fasciculus of the medulla and pons continue through all sections of the mesencephalon.

The **central grey substance** is a continuation of the central gelatinous substance of the spinal cord and the similar stratum of the medulla and that which immediately underlies the ependyma of the fourth ventricle. As in the spinal cord and medulla, it is largely composed of gelatinous substance. It is much more abundant in the mesencephalon, and in sections appears as a circumscribed area comparatively void of nerve-fibres.

The nucleus of the *mesencephalic root of the masticator nerve* may likewise be traced throughout the mesencephalon. It consists of a few small bundles of fibres surrounding a thin strand

of nerve-cells which give origin to its fibres. It courses caudalward close to the lateral margin of the central grey substance, and is quite small at its beginning in the extreme superior part of the mesencephalon, but as it descends toward the exit of its fibres from the pons, it increases slightly in size, due to the progressive addition of fibres. Its nucleus also increases slightly in bulk in approaching the region of the chief motor nucleus of the nerve. As mentioned above, the investigations of Johnston and Willems in lower animals suggest that the cells of the mesencephalic nucleus may be sensory instead of motor in character. The sensory nucleus (nucleus of termination) of the trigeminus tapers rapidly and probably does not extend throughout the mesencephalon.

The nuclei of the *trochlear* and *oculomotor* nerves form a practically continuous column of nerve-cells extending close to the mid-line and ventral to the aqueduct of the cerebrum. They are in line with the nuclei of origin of the abducens and hypoglossus, and, like them, may be regarded as an upward continuation of the ventral group of the cells of the ventral horn of the spinal cord. The portion of the column giving origin to the oculomotor nerve is considerably larger than that for the trochlear.

FIG. 661.—DIAGRAMS SHOWING THE COURSE OF ORIGIN OF THE TROCHLEAR NERVES. (Stilling. The upper figure shows roughly the entire central course of the trochlear nerves; the lower represents their region of exit in transverse section.

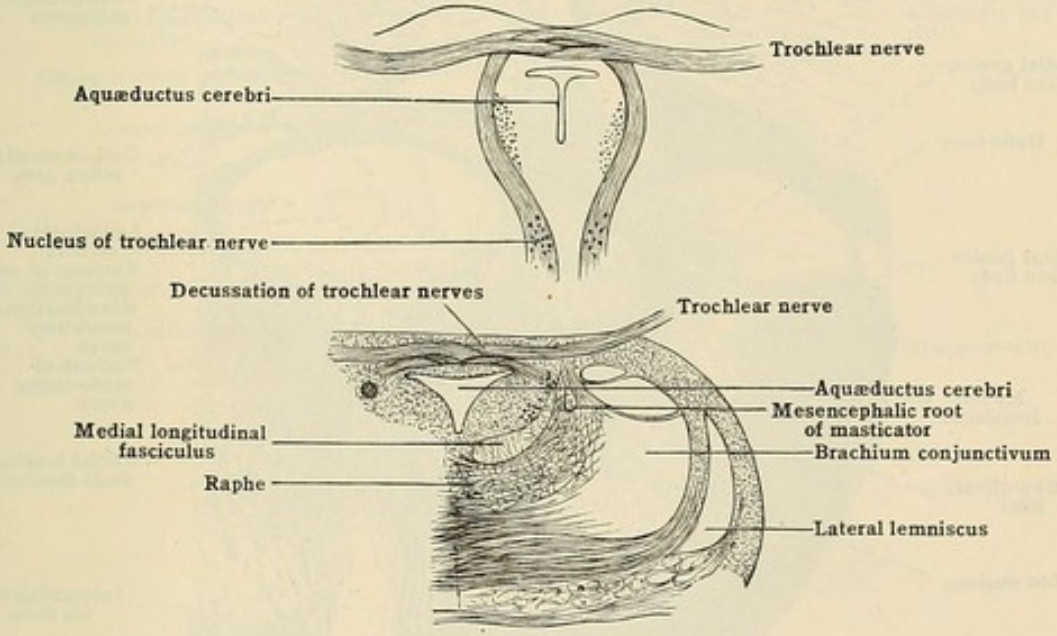

A transverse section through the inferior quadrigeminate bodies involves a portion of the decussation of the brachia conjunctiva and the nuclei of origin of the trochlear nerves, while a transverse section through the superior quadrigeminate bodies passes through the red nuclei of the tegmentum and the nuclei of origin of the oculomotor nerves. The latter section will also involve the brachia of the inferior quadrigeminate bodies and the medial geniculate bodies connected with them, and, if slanting slightly forward it will involve the pulvinars of the thalami and the lateral geniculate bodies.

The **trochlear or fourth nerve** is the smallest of the cranial nerves, and is the only one which makes its exit from the dorsal surface of the brain, as well as the only one whose fibres undergo a total decussation.

Its nucleus of origin is situated beneath the inferior quadrigeminate bodies in the ventral margin of the central grey substance, quite close to the mid-line and to its fellow nucleus of the opposite side, and it is closely associated with the dorso-mesial margin of the medial longitudinal fasciculus. Its root-fibres pass lateralward and dorsalward, curving around the margin of the central grey substance, mesial to the mesencephalic root of the masticator nerve. As the root curves toward the mid-line in the dorsal region just beneath the inferior quadrigeminate bodies, it turns sharply and courses inferiorly to approach the surface in the superior portion of the anterior medullary velum, the frenulum veli. In this it meets and undergoes a total decussation with the root of its fellow nerve, and then emerges at the medial margin of the superior cerebellar peduncle of the opposite side. Having emerged, it then passes ventrally around the cerebral peduncle, and thence pursues its course to the superior oblique muscle of the eye. It receives optic impulses from the superior quadrigeminate bodies and impulses from the cerebral cortex of chiefly the same side, and it is associated with the nuclei of other cranial nerves by way of the medial longitudinal fasciculus.

The **oculomotor or third nerve,** like the trochlear, is purely motor. It is the largest of the eye-muscle nerves. It supplies in all seven muscles of the optic apparatus:—two intrinsic, the sphincter iridis and the ciliary muscle, and five extrinsic. Of the latter, the levator palpebræ superioris is of the upper eyelid, while the remaining four, the superior, medial, and inferior recti and the obliquus inferior, are attached to the bulb of the eye. As is to be expected, its nucleus of origin is larger and much more complicated than that of the trochlear nerve.

Practically continuous with that of the trochlear below, the nucleus is 5 or 6 mm. in length and extends anteriorly a short distance beyond the bounds of the mesencephalon into the grey substance by the side of the third ventricle. It lies in the ventral part of the central grey substance, and is very intimately associated with the medial longitudinal fasciculus. Its thickest

FIG. 662.—TRANSVERSE SECTION THROUGH LEVEL OF SUPERIOR QUADRIGEMINATE BODIES.

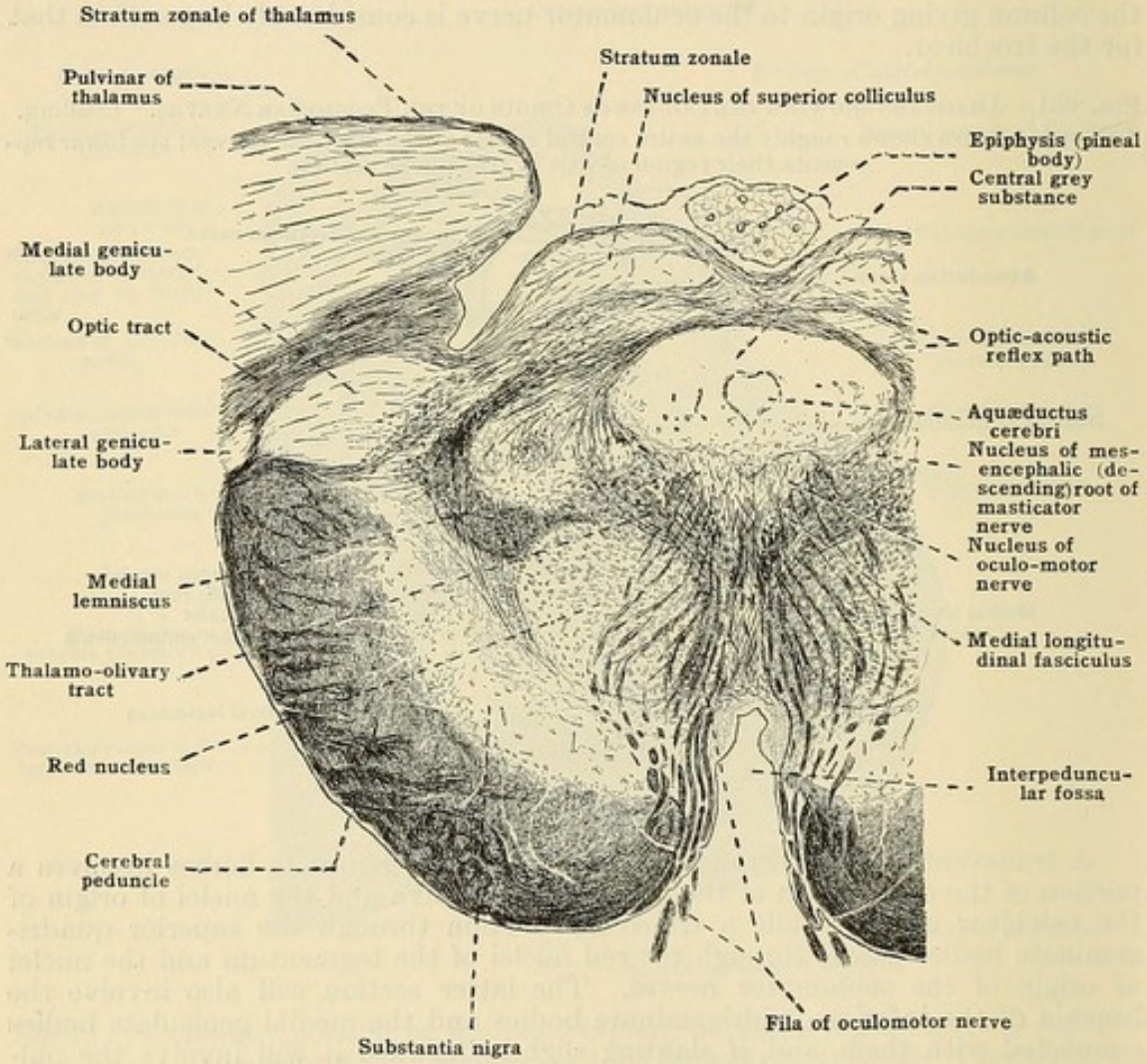

portion is beneath the summit of the superior quadrigeminate body. The root-fibres leave the nucleus from its ventral side and collect into bundles which pass through the medial longitudinal fasciculus and course ventrally to the mesial portion of the substantia nigra, where they emerge in from six to fifteen rootlets which blend to form the trunk of the nerve in the oculomotor sulcus of the cerebral peduncles. Those bundles which arise from the more lateral portion of the nucleus course in a series of curves through and around the substance of the red nucleus below and, in the substantia nigra, join those which pursue the more direct course. The trunk thus assembled passes lateralward around the mesial border of the cerebral peduncle.

A portion of the fibres of the oculomotor nerve upon leaving the nucleus decussate in the tegmentum immediately below and pass into the nerve of the opposite side, in which they are believed to be distributed to the opposite medial rectus muscle. The cells of the nucleus have been variously grouped and subdivided with reference to the different muscles supplied by the nerve. Perlia has divided them into eight cell-groups. The nucleus may be more easily considered as composed of an inferior and a superior medial group. The inferior group consists of a long lateral portion continuous with the nucleus of the trochlear nerve below, and a smaller medial portion, situated in the medial plane and continuous across the mid-line with its fellow of the opposite side. The superior medial group consists of cells of smaller size than the inferior, and is known as the *nucleus of Edinger and Westphal.* It is believed to give origin to

the fibres (visceral efferent fibres) which terminate in the ciliary ganglion, axones from which supply the two intrinsic muscles concerned, viz., the ciliary muscle and the sphincter iridis.

The nucleus of the oculomotor is associated with the remainder of the optic apparatus—(1) by way of the neurones of the superior quadrigeminate body with the optic tract (retina) and it receives impulses from the occipital part of the cerebral cortex of the same and the opposite sides, and probably from the motor cortex of the frontal lobe; (2) by way of the medial longitudinal fasciculus with the nuclei of the trochlear and abducens (the latter making possible the co-ordinate action of the lateral and medial recti for the conjugate eye movements produced by these muscles), and with the nucleus of the facial (associating the innervation of the levator palpebræ with that of the orbicularis oculi); (3) with the nuclei of termination of the sensory nerves, especially the auditory, by way of the lateral lemniscus and medial longitudinal fasciculus. It is probably connected with the cerebellum by way of the brachia conjunctiva and red nuclei.

FIG. 663.—DIAGRAM OF LONGITUDINAL SECTION OF NUCLEUS OF OCULOMOTOR NERVE. (After Edinger.)

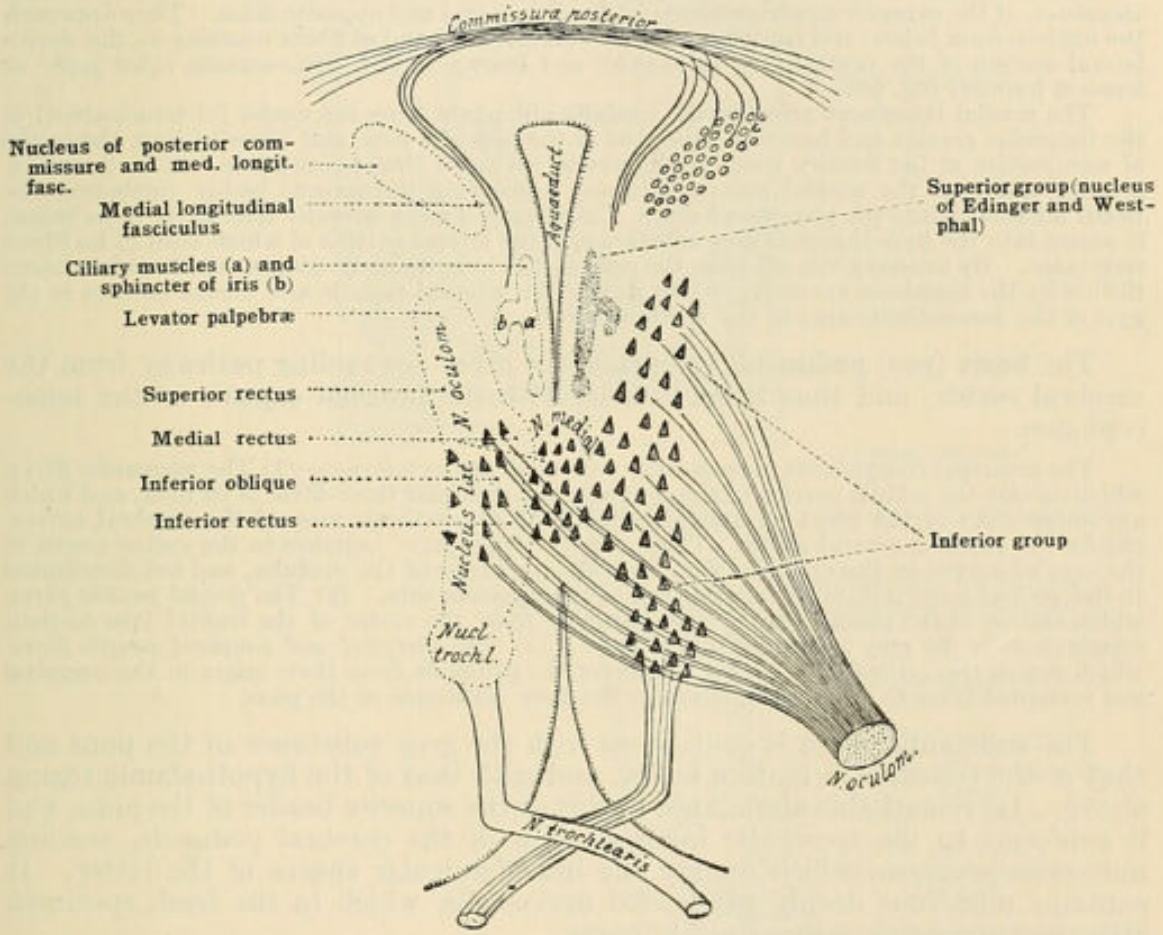

The eminence representing the **inferior quadrigeminate body** proper consists of an oval mass of grey substance, the *nucleus of the inferior colliculus*, containing numerous nerve-cells, most of which are of small size. A thin superficial lamina of white substance, the **stratum zonale,** forms its outermost boundary, and fibres from the lateral lemniscus enter it laterally and from below (*stratum lemnisci*). Near the lateral margin of the central grey substance occurs the beginning of the *inferior brachium*, a bundle containing fibres to and from the medial geniculate body and the inferior quadrigeminate body.

The **lemniscus** in the mesencephalon is considered in two parts. The more lateral portion of the lemniscal plate occuring in the pons has here spread dorso-laterally, and occupies a position in the lateral margin of the section, and is known as the **lateral lemniscus,** while the medial portion which remains practically unchanged in the tegmentum is distinguished as the **medial lemniscus.** (See fig. 660). In the upper portion of the lateral lemniscus occurs a small, scattered mass of grey substance, the *nucleus of the lateral lemniscus*, in which many of its fibres are interrupted.

The upper and greater portion of the **lateral lemniscus** with its nucleus belongs to the auditory apparatus, being connected with the nucleus of termination of the cochlear nerve, chiefly of the opposite side. (See fig. 650.) A large part of the fibres of this portion terminate in the inferior quadrigeminate bodies. Many of the latter enter at once the nucleus of the body

(nucleus of inferior colliculus) of the same side, and disappear among its cells; others cross the mid-line to the quadrigeminate body of the opposite side. In crossing, some pass superficially and thus contribute to the stratum zonale, while others pass either through the nucleus or below it and cross beneath the floor of the median groove between the stratum zonale and the dorsal surface of the central grey substance, forming there an evident decussation with similar fibres crossing from the opposite side. Most of the fibres arising from the cells of the nucleus of the inferior quadrigeminate body pass by way of the inferior brachium to the medial geniculate body and the thalamus; some pass ventrally to terminate in the nucleus of origin of the trochlear nerve and some pass forward and laterally to terminate in the cortex of the superior gyrus of the temporal lobe, the cortical area of hearing. Another portion of the lateral lemniscus passes obliquely forward in company with the inferior brachium, and terminates in the medial geniculate body. Thus a large portion of the lateral lemniscus, the inferior quadrigeminate bodies with their brachia and the medial geniculate bodies are concerned with the sense of hearing. The nucleus of the inferior quadrigeminate body receives fibres which arise in the cortex of the superior temporal gyrus of chiefly the same side.

Practically all the remainder of the lateral lemniscus terminates in the nucleus, or stratum cinereum, of the superior quadrigeminate body of the same and opposite sides. They approach the nucleus from below, and contribute to the well-marked band of fibres coursing on the dorso-lateral margin of the central grey substance, and known as the '*optic-acoustic reflex path*' or *stratum lemnisci* (fig. 662).

The **medial lemniscus** arises in the medulla oblongata from the nuclei (of termination) of the funiculus gracilis and funiculus cuneatus of the opposite side, and likewise from the nuclei of termination of the sensory roots of the cranial nerves of the opposite side. It is, therefore, a continuation of the central sensory pathway conveying the general bodily (including the head) sensations into the prosencephalon. Coursing still more laterally than in the pons below, it passes into the hypothalamic grey substance, in the lateral portion of which most of its fibres terminate. By axones given off from the cells of the hypothalamic nucleus the impulses borne thither by the lemniscus are conveyed by way of the internal capsule and corona radiata to the gyri of the somæsthetic area of the cerebral cortex.

The **basis** (pes) **pedunculi** comprises the great descending pathway from the cerebral cortex, and thus is continuous with the internal capsule of the telencephalon.

The principal components of each basis pedunculi are as follows:—(1) The *pyramidal fibres*, which occupy the middle portion of the peduncle and comprise three-fifths of its bulk, and which are outgrowths of the giant pyramidal cells of the somæsthetic area of the cerebral cortex, chiefly the anterior central gyrus. These supply 'voluntary' impulses to the motor nuclei of the cranial nerves on the opposite side, form the pyramids of the medulla, and are distributed to the ventral horn cells of the spinal cord of the opposite side. (2) The *frontal pontile fibres*, which course in the mesial part of the peduncle from the cortex of the frontal lobe to their termination in the grey substance of the pons. (3) The *occipital and temporal pontile fibres*, which run in the ventral and lateral portion of the peduncle from their origin in the occipital and temporal lobes to their termination in the grey substance of the pons.

The **substantia nigra** is continuous with the grey substance of the pons and that of the reticular formation below, and with that of the hypothalamic region above. Its remarkable abundance begins at the superior border of the pons, and it conforms to the crescentic inner contour of the cerebral peduncle, sending numerous processes which occupy the inter-fascicular spaces of the latter. It contains numerous deeply pigmented nerve-cells, which in the fresh specimen give the appearance suggesting its name.

Its anatomical significance is not well understood. It is known that some fibres of the medial lemniscus terminate about its cells instead of in the hypothalamus higher up, and Mellus has found in the monkey that a large portion of the pyramidal fibres arising in the thumb area of the cerebral cortex are interrupted in the substantia nigra. It is probable that other fibres of the peduncle also terminate here.

The **brachia conjunctiva** or superior cerebellar peduncles, in passing from their origin in the dentate nuclei, lose their flattened form and enter the mesencephalon as rounded bundles. In the tegmentum, under the inferior colliculi, the two brachia come together and undergo a sudden and complete decussation. Through this decussation the fibres of the brachium of one side pass forward to terminate, most of them, in the red nucleus [nucleus ruber] of the tegmentum of the opposite side (fig. 589). Some fibres are said to pass the red nucleus and terminate in the ventrolateral part of the thalamus.

The **red nuclei** are two large, globular masses of nerve-cells situated in the tegmentum under the superior quadrigeminate bodies. At all levels they are considerably mixed with the entering bundles of the brachia conjunctiva, and they contain a pigment which in the fresh condition gives them a reddish colour, suggesting their name.

They receive in addition descending fibres from the cerebral cortex (frontal operculum) and from the nuclei of the corpus striatum. From the cells of each red nucleus arise fibres

which pass—(1) into the thalamus and to the telencephalon (prosencephalic continuation of the cerebellar path), and (2) fibres which descend into the spinal cord, the 'rubro-spinal tract,' in the lateral funiculus (fig. 619). The latter cross from the red nucleus of the opposite side and descend in the tegmentum. The red nuclei are also in relation with the *fasciculus retroflexus* of Meynert, which belongs to the inter-brain.

FIG. 664.—SCHEME TO ILLUSTRATE THE PRINCIPAL OR CROSSED RELATIONS OF THE DESCENDING CORTICAL (PYRAMIDAL) FIBRES TO THE NUCLEI OF ORIGIN OF THE CRANIAL NERVES.

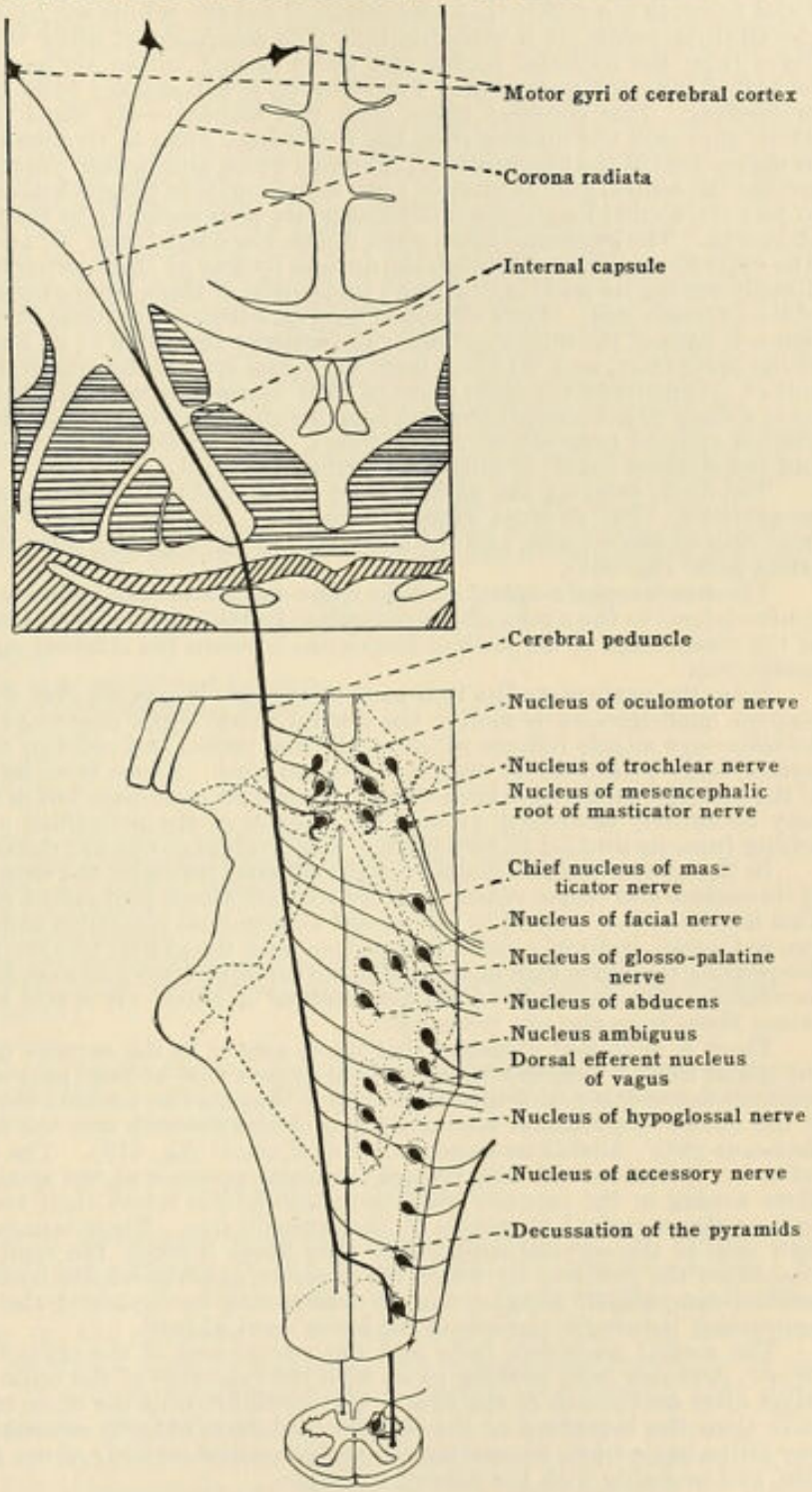

The **thalamo-olivary tract** courses in the mesencephalon more dorsally than in the pons region. It runs in the ventro-lateral boundary of central grey substance just lateral to the nuclei of the trochlear and oculomotor nerves.

A small *quadrigemino-pontile* strand of fibres has been described as arising in the quadrigemina, especially the inferior pair, and terminating in the nuclei of the pons. Impulses carried by these fibres are probably destined for the cerebellar hemisphere of the opposite side.

The **superior quadrigeminate bodies** (**superior colliculi**) are phylogenetically more important than the inferior. In certain of the lower vertebrates they are

enormously developed and in most of the mammals they are relatively larger and appear more complicated in structure than in man. They are concerned almost wholly with the visual apparatus, mediating most of the reflexes with which it is concerned.

The *nucleus* of the superior colliculus is of somewhat greater bulk than that of the inferior. It is capped by a strong *stratum zonale* (fig. 662), which has been described as composed chiefly of retinal fibres, passing to it from the optic tract by way of the superior brachium, but, since Cajal found in the rabbit that extirpation of the eye is followed by very slight degeneration of the stratum zonale, it is probable that it is composed of other than retinal fibres—possibly fibres from the occipital cortex and fibres arising within the nucleus itself. The nucleus is separated from the central grey substance by a well-marked band of fibres, the *stratum album profundum*. This contains fibres from two sources:—(1) fibres from the lateral lemniscus which approach the nucleus from the under side, some to terminate within it, others to cross to the nucleus of the opposite side; (2) fibres which arise within the nucleus and course ventrally around the central grey substance, both to terminate in the nucleus of the oculomotor nerve and to join the medial longitudinal fasciculus and pass probably to the nuclei of the trochlear and abducens. The lemniscus fibres often course less deeply than (2) and give the *stratum lemnisci*. The optic fibres proper approach the nucleus by way of the *superior brachium*, and are dispersed directly among its cells; only a small proportion of them cross over to terminate in the nucleus of the opposite side. They consist of two varieties:—(1) retinal fibres which arise in the ganglion-cell layer of the retina and enter the superior brachium at its junction with the lateral root of the optic tract, and (2) fibres from the visual area of the occipital lobe of the cerebral hemisphere. Sometimes the optic fibres in their course within the nucleus of the superior colliculus form a more or less evident stratum near the stratum album profundum. This is known as the *stratum opticum* (stratum album medium). The portion of the nucleus between this stratum and the stratum zonale is called the *stratum cinereum*.

The fibres entering the nucleus from the lateral lemniscus probably all represent auditory connections. The stratum album profundum, composed of the lemniscus fibres and fibres from cells of the nucleus, and the stratum opticum together, form the so-called **'optic-acoustic reflex path'** (fig. 662).

The **mesencephalo-spinal** amd the **spino-mesencephalic** (spino-tectal) paths course together ventro-lateral to the nuclei of the colliculi. In the superior quadrigeminate bodies they course in the dorsal edge of the median lemniscus, between the stratum opticum and stratum album profundum.

From the various studies that have been made it appears that the superior colliculus of the corpora quadrigemina is merely the central reflex organ concerned in the control of the eye muscles—eye muscle reflexes which result from retinal and cochlear stimulation, and from some general body sensations by way of the spinal cord. Fibres from its nucleus to the visual area of the occipital cortex have been claimed for certain mammals, but in man the superior colliculus may be entirely destroyed without disturbance of the perception of light or color and fibres arising from its nucleus to terminate in the cerebral cortex are denied.

In the level of the anterior part of the superior colliculus the fibres which arise from the cells of its nucleus and course ventrally in the stratum album profundum collect into a strong bundle. This bundle passes ventral to the medial longitudinal fasciculus and, in the space between the two red nuclei, it forms a dense decussation with the similar bundle from the opposite side. In decussating the fibres turn in spray-like curves downward and soon join the medial longitudinal fasciculus. This is the **'fountain decussation'** of Forel. It is said to be augmented by decussating fibres from the two red nuclei.

There is abundant evidence that fibres arising in the corpora quadrigemina descend into the spinal cord. Various studies make it appear that at least part of these are fibres from the fountain decussation, and that these course through the medulla oblongata in the ventral part of the medial longitudinal fasciculus, and thence descend into the cord in the 'quadrigemino-thalamus path' (lateral mesencephalo-spinal tract) (fig. 619). The medial longitudinal fasciculus is continuous with the ventral fasciculus proprius of the spinal cord and most of these fibres arising in the superior quadrigeminate bodies retain their ventral position in the cord as the sulco-marginal fasciculus of the opposite side. Their termination about those ventral horn cells of the cervical cord which send fibres through the rami communicantes probably establishes the pathway by which the superior quadrigeminate bodies are connected with the cervical sympathetic ganglia, and by which may be explained the disturbances in pupillary contraction induced by lesions of the lower cervical cord.

The medial geniculate body and the medial root of the optic tract, which runs into the former, probably have nothing to do with the functions of the optic apparatus. Both remain intact after extirpation of the eyes. The medial root of the optic tract is apparently nothing more than the beginning of the *inferior cerebral (Gudden's) commissure*, a bundle passing by way of the optic tract, connecting the medial geniculate body of one side with that of the other side, and probably with the inferior colliculus.

The **medial longitudinal fasciculus** (posterior longitudinal fasciculus), continuous into the ventral fasciculus proprius and the sulco-marginal fasciculus of the spinal cord, extends throughout the rhombencephalon and mesencephalon, and is represented in the hypothalamic region of the prosencephalon. Deserted by the lemniscus at the inferior border of the pons, it maintains its closely medial position and courses throughout in the immediate ventral margin of the central grey substance of the medulla and floor of the fourth ventricle, and likewise in the ventral margin of the central grey substance of the mesencephalon.

The two fasciculi constitute the principal association pathways of the brain-stem, and, true to their nature as such, they are among the first of its pathways to acquire medullation. In the mesencephalon they become two of its most conspicuous tracts, and their course, in most intimate association with the nuclei of origin of the nerves supplying the eye muscles, suggests what is probably one of their most important functions, viz., that of associating these nuclei with each other and of bearing to them fibres from the nuclei of the other cranial nerves necessary for the co-ordinate action of the muscles of the optic apparatus associated with the functions of these other nerves.

Fibres from each medial longitudinal fasciculus terminate either by collaterals or terminal arborisations about the cells of the motor nuclei of all the cranial nerves, and each nucleus probably contributes fibres to it. It also receives fibres from the nuclei of termination of the sensory nerves especially the vestibular. Thus it contains fibres coursing in both directions, and, while it is continually losing fibres by termination, it is being continually recruited and so maintains a practically uniform bulk. Thus, a given lesion never results in its total degeneration. Many of the fibres coursing in it arise from the opposite side of the mid-line. A special contribution of fibres of this kind is received by way of the fountain decussation from the nucleus of the superior colliculus of the opposite side. As noted above, it is in part continuous into the spinal cord as the ventral fasciculus proprius. It receives some fibres by way of the posterior commissure of the prosencephalon from a small nucleus common to it and the posterior commissure situated in the superior extension of the central grey substance of the mesencephalon. Van Gehuchten and Edinger describe for it a special *nucleus of the medial longitudinal fasciculus* situated beyond this commissure in the hypothalamic rsgion. This nucleus may be explained as an accumulation of the gray substance of the reticular formation below and as receiving impulses from the structures of the prosencephalon which are distributed by its axones to the structures below by way of the medial longitudinal fasciculus.

Scattered in the posterior part of the posterior perforated substance, near the superior border of the pons, is a small group of cell-bodies forming the **inter-peduncular nucleus** (interpeduncular ganglion of von Gudden). Fibres arising in the habenular nucleus of the diencephalon curve posteriorly, forming the *fasciculus retroflexus of Meynert*, and terminate about its cells. Fibres arising from its cells course dorsalward and terminate about association neurones in the ventral periphery of the central grey substance. It is concerned with olfactory impulses.

SUMMARY OF THE MESENCEPHALON

1. Quadrigeminate bodies:
   (*a*) Inferior colliculi, their nuclei and brachia.
   (*b*) Superior colliculi, their nuclei and brachia.
2. Peduncles of the cerebrum
3. Aqueduct of the cerebrum.
4. Central grey substance.
5. Substantia nigra.
6. Decussation of superior cerebellar peduncles and the red nuclei.
7. Medial lemniscus, lateral lemniscus and nucleus of lateral lemniscus.
8. Mesencephalic nucleus and root of masticator nerve.
9. Trochlear nerve and its nucleus.
10. Oculomotor nerve and its nucleus.
11. Mesencephalo-spinal and rubro-spinal tracts.
12. Medial longitudinal fasciculus, its nucleus, the nucleus of the posterior commissure.
13. The fountain decussation.
14. Interpeduncular nucleus.

As frequently realized in the above, the structures of the mesencephalon are both overlapped by, and are of necessity functionally continuous with, the structures of the next and most anterior division of the encephalon, the prosencephalon.

2. THE PROSENCEPHALON

The **prosencephalon** or **fore-brain** includes those portions of the encephalon derived from the walls of the anterior of the three embryonic brain-vesicles. In its adult architecture it consists of—(1) the **diencephalon** (**interbrain**), comprising the thalamencephalon or the thalami and the structures derived from and immediately adjacent to them, and, in addition, the mammillary portion of the hypothalamic region; (2) the **telencephalon** (**end-brain**), comprising the optic portion of the hypothalamic region and the cerebral hemispheres proper. The last mentioned consist of the entire cerebral cortex or superficial mantle of grey substance, including the rhinencephalon, and also the basal ganglia or buried nuclei (corpus striatum), together with the tracts of white substance connecting and associating the different regions of the hemispheres with each other and with the structures of the other divisions of the central nervous system.

EXTERNAL FEATURES OF THE PROSENCEPHALON

A. THE DIENCEPHALON.—The *basal surface* of this division of the brain consists of only the mammillary portion of the hypothalamic region (fig. 668).

This comprises—(1) the mammillary bodies [**corpora mammillaria**] (albicantia), the two rounded projections situated in the anterior part of the interpeduncular fossa, and (2) the anterior portion of the **posterior perforated substance** or the small triangle of grey substance forming the floor of the posterior part of the third ventricle, and which represents numerous openings for the passage of branches of the posterior cerebral arteries (fig. 668). The hypothalamic portions of the cerebral peduncles might be included. The structures of the optic or remaining portion of the hypothalamus belong to the telencephalon.

The upper or *dorsal surface* of the diencephalon is completely overlapped and hidden by the telencephalon, and covered by the intervening ingrowth of the

FIG. 665.—DORSAL SURFACE OF DIENCEPHALON WITH ADJACENT STRUCTURES. (After Obersteiner.)

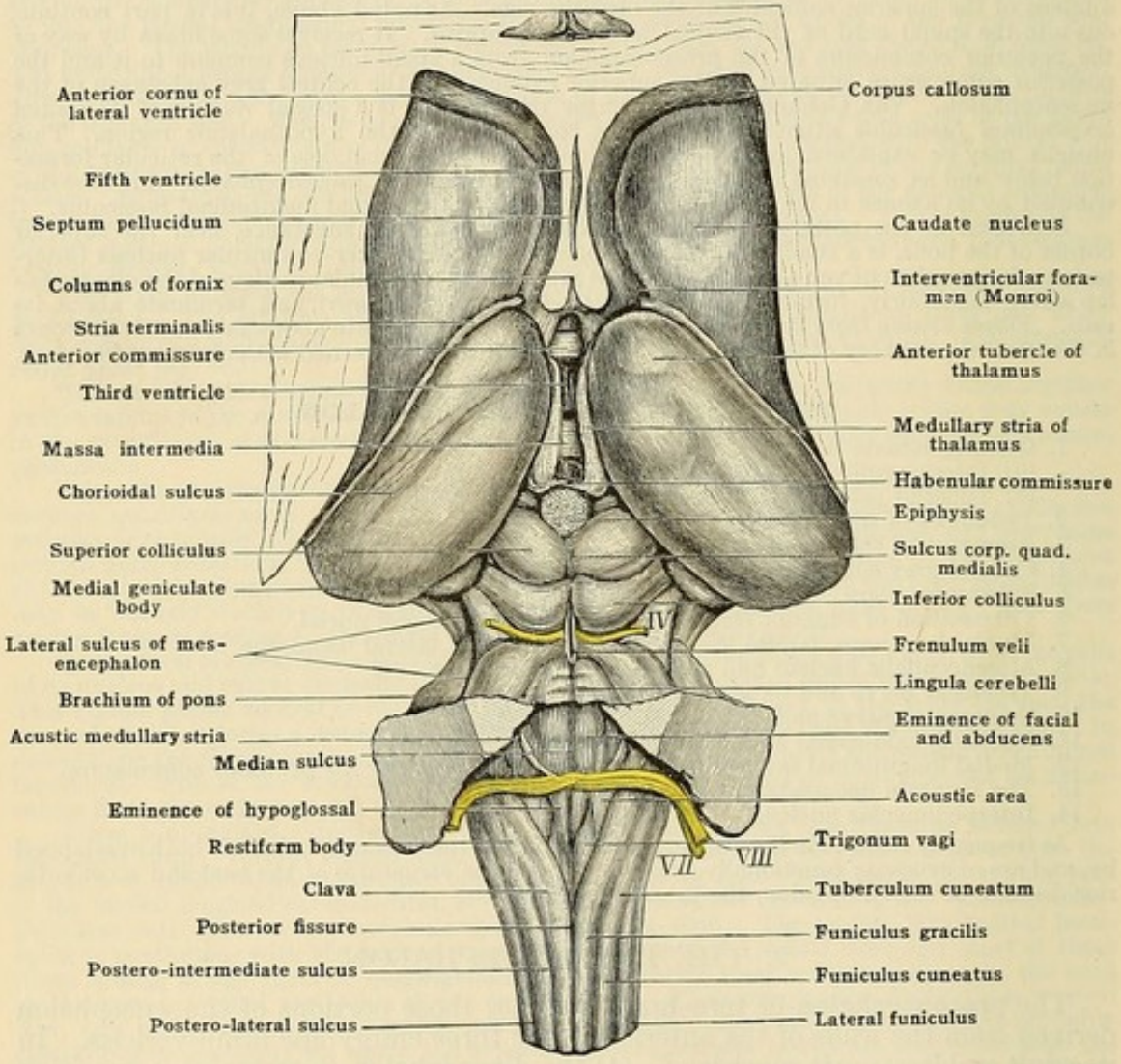

cerebral meninges, the tela chorioidea of the third ventricle (velum interpositum). These removed (fig. 665), it is seen that the thalami on either side are by far the most conspicuous objects of the diencephalon. They, together with the parts developed in connection with them, are distinguished as the **thalamencpehalon.** The thalamencephalon consists of—(1) the *thalami;* (2) the *metathalamus* or geniculate bodies; and (3) the *epithalamus,* comprising the *epiphysis* with the posterior commissure below it and the habenular trigone on either side.

The **thalami** are two ovoid, couch-like masses of grey substance which form the lateral walls of the third ventricle. The cavity of the ventricle is narrow, and quite frequently the thalami are continuous through it across the mid-line by a small but variable neck of grey substance, the **massa intermedia** ("middle commissure"). The upper surfaces of the thalami are free. The edges of the tela chorioidea of the third ventricle are attached to the lateral part of the surface of each thalamus, and, when removed, leave the *tænia chorioidea* lying in the chori-

oidal sulcus. Each thalamus is separated laterally from the caudate nucleus of the telencephalon, by a linear continuation of the white substance below, known as the **stria terminalis thalami** (tænia semicircularis). Like the quadrigemina, each thalamus is covered by a thin capsule of white substance, the **stratum zonale.** The average length of the thalamus is about 38 mm., and its width about 14 mm.; its inferior extremity is directed obliquely lateralward. The dorsal surface usually shows four eminences, indicating the position of the so-called nuclei of the thalamus within. These are the anterior nucleus or *anterior tubercle*, the *medial nucleus* or tubercle, the *lateral nucleus*, and the *pulvinar*, the tubercle of the posterior extremity. The pulvinar of the human brain is peculiar in the fact that it is so developed as to project inferiorly and slightly overhang the level of the quadrigeminate bodies. The projecting portion assumes relations with the optic tract and the metathalamus.

FIG. 666.—DISSECTION OF BRAIN SHOWING METATHALAMUS AND PULVINAR WITH ADJACENT STRUCTURES.

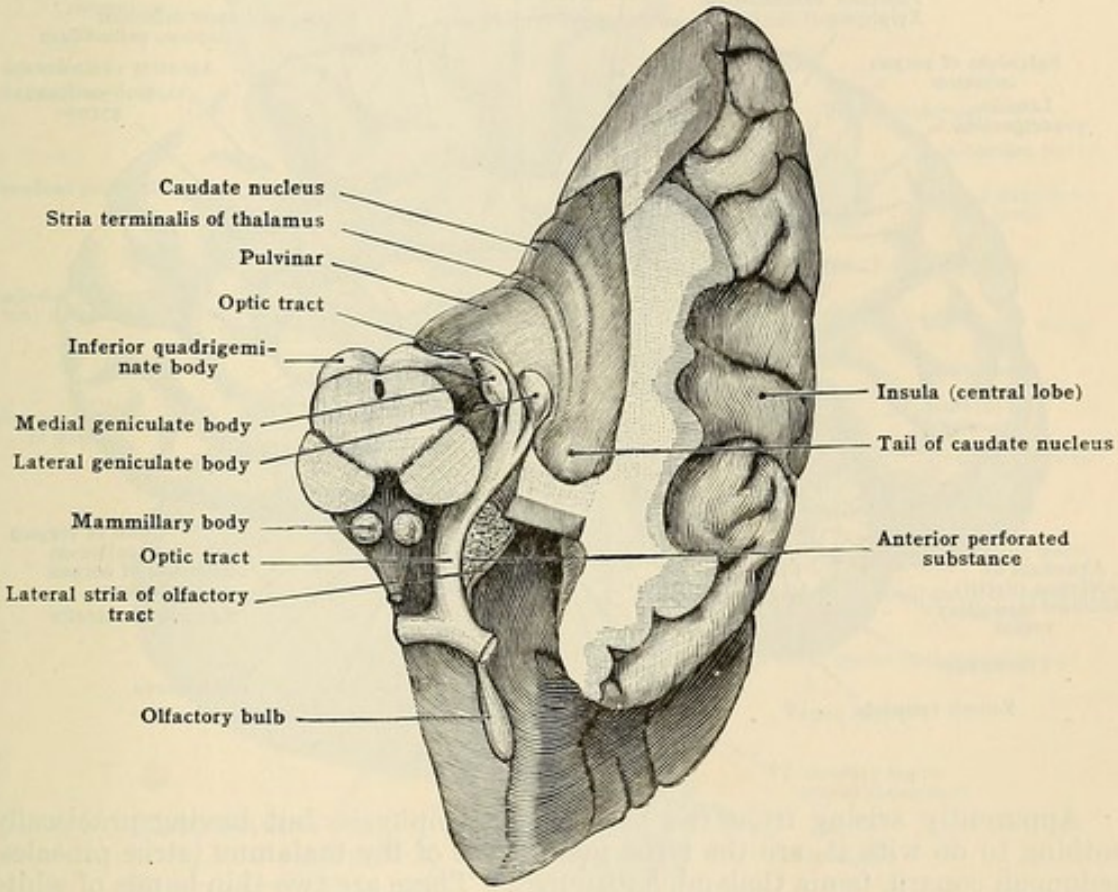

Both the structures of the **metathalamus,** the lateral and medial geniculate bodies, are connected with the optic tract, but it is thought that actual visual axones terminate only in the lateral genticulate body. As the optic tract curves around the cerebral peduncle it divides into two main roots. The *lateral geniculate body* receives a small portion of the fibres of the lateral root of the optic tract; the remainder pass under this body and enter the pulvinar of the thalamus. The *medial geniculate body* is connected with the medial root of the optic tract, which root consists largely, not of retinal fibres, as does the lateral root, but of the fibres forming Gudden's commissure (the inferior cerebral commissure). The retinal fibres contained in the medial root pass to terminate in the superior quadrigeminate bodies.

Of the **epithalamus,** the *epiphysis* (pineal body, conarium) is the most conspicuous external feature. This is an unpaired, cone-shaped structure, about 7 mm. long and 4 mm. broad, which also projects upon the mesencephalon so that its body rests in the groove between the superior quadrigeminate bodies. Its stem is attached in the mid-line at the posterior extremity of the third ventricle, and therefore just above the posterior commissure of the cerebrum (fig. 658). It is covered by pia mater, and is involved in a continuation of the tela chorioidea

of the third ventricle. Though it develops as a diverticulum of that portion of the anterior primary vesicle which gives origin to the thalamencephalon, it is wholly a non-nervous structure, other than the sympathetic fibres which enter it for the supply of its blood-vessels.

It consists of a dense capsule of fibrous tissue (pia mater) from which numerous septa pass inward, dividing the interior into a number of intercommunicating compartments filled with epithelial (ependymal) cells of the same origin as the ependyma lining the ventricles and aqueduct below. Among these cells are frequently found small accretions (brain-sand, acervulus cerebri), consisting of mixed phosphates of lime, magnesia, and ammonia and carbonates of lime. The compartments form a closed system. In function the epiphysis ranks as one of the glands of internal secretion of the body, and it is often referred to as the 'pineal gland.' However, it is perhaps functionless in man.

FIG. 667.—MESIAL SECTION OF ENTIRE BRAIN, SHOWING MESIAL SURFACE OF DIENCEPHALON AND TELENCEPHALON. (After Henle.)

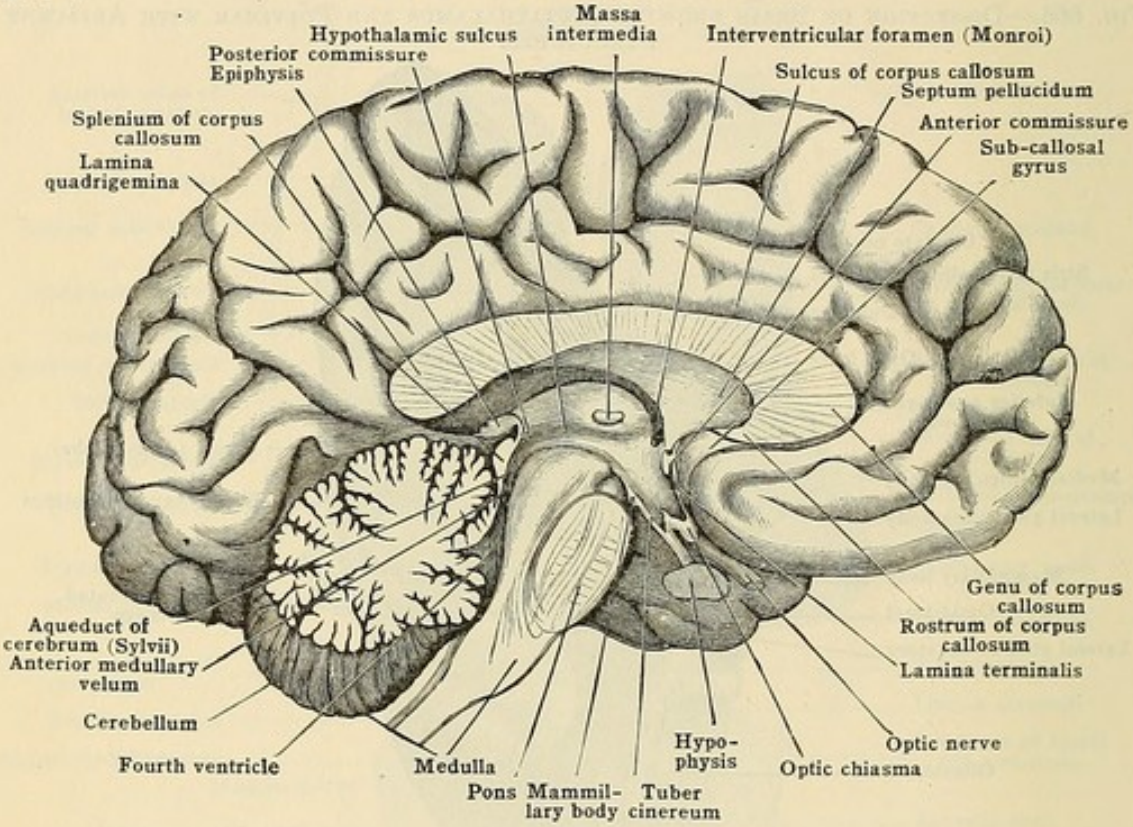

Apparently arising from the base of the epiphysis, but having practically nothing to do with it, are the **striæ medullares of the thalamus** (striæ pineales, pedunculi conarii, tænia thalami, habenulæ). These are two thin bands of white substance which extend from under the epiphysis anteriorly upon the thalamus, along the superior border of each lateral wall of the third ventricle, and thus form the boundaries between the superior and mesial surfaces of each thalamus.

They have been called the *habenulæ*, from their relation to the habenular nucleus, situated in the mesial grey substance at their inferior ends. They are continuous across the mid-line in the *habenular commissure*, just below the neck of the epiphysis, and between it and the posterior cerebral commissure, or, rather the superior part of the latter (figs. 631, 665). It will be seen below that each habenula contains olfactory fibers from the fornix, the anterior perforated substance and the septum pellucidum, as well as fibres out of the thalamus, and that most of its fibres terminate in the habenular nucleus.

The ventro-lateral surface of the thalamencephalon is continuous into the hypothalamic tegmental region, the upward continuation of the tegmental grey substance of the mesencephalon. It is also adjacent to a portion of the internal capsule. Both these relationships, as well as the fibre connections of the diencephalon with the structures above and below it, are deferred until the discussion of the internal structure of the prosencephalon.

The **mesial surface** of the diencephalon (fig. 667), allows a better view of the shape and relations of the **third ventricle.** Below the line of the massa intermedia the ventricle is usually somewhat wider than it is along the upper margins of

the thalami. This greater width is occasioned by a groove in the ventromesial surface of each thalamus, known as the **hypothalamic sulcus** (sulcus of Monro). It is along the line of this sulcus that the third ventricle is continuous with the aqueduct of the cerebrum, and thus with the fourth ventricle below, and, likewise, with the two lateral ventricles of the cerebral hemispheres at its anterior end. The latter junction occurs through a small oblique aperture, the **interventricular foramen** (foramen of Monro), one into each lateral ventricle. The dorsal or upper portion of the third ventricle extends posteriorly beneath its chorioid tela

FIG. 668.—VENTRAL ASPECT OF BRAIN-STEM INCLUDING MAMMILLARY AND OPTIC PORTIONS OF THE HYPOTHALAMUS.

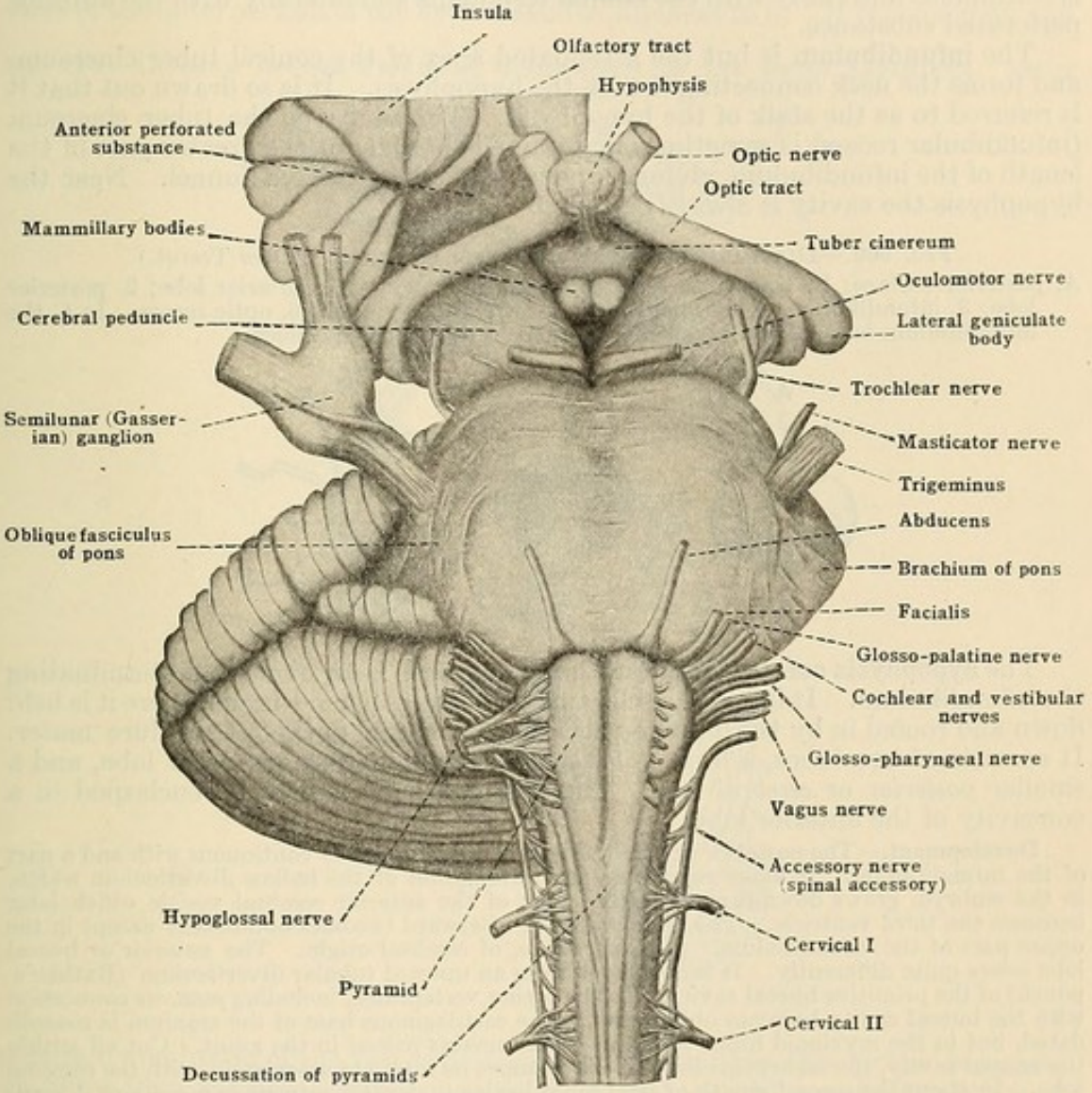

(velum interpositum) to form a small posterior recess about the epiphysis. This is known as the **supra-pineal recess.** The anterior and ventral extremity of the third ventricle involves the pars optica hypothalami, which belongs to the telencephalon.

B. THE TELENCEPHALON.—External features.—The **optic portion of the hypothalamus** consists of that small central area of the basal surface of the telencephalon which includes and surrounds the **optic chiasma,** and comprises the structures of the floor of the anterior and ventral portion of the third ventricle. The area extends anteriorly from the mammillary bodies in the interpeduncular fossa, and includes the **tuber cinereum** and **hypophysis** behind the optic chiasma, and some of the **anterior perforated substance** in front of it.

The most anterior portion of the third ventricle is in the form of a ventral extension. The wall of this portion is almost wholly non-nervous and quite thin, and thus the cavity of the ventricle is but thinly separated from the exterior of

the brain. The front portion of this wall is the **lamina terminalis** and in the ventricular side of the upper part of this lamina the **anterior commissure** of the cerebrum is apparent.

The **optic chiasma** lies across and presses into the lower portion of the lamina terminalis, and in so doing produces an anterior recess in the cavity of the ventricle known as the **optic recess.** Behind the optic chiasma the floor of the third ventricle bulges slightly, giving the outward appearance known as the **tuber cinereum,** and the cavity bounded by this terminates in the **infundibular recess.**

The **tuber cinereum** then is a hollow, conical projection of the floor of the third ventricle, between the corpora mammillaria and the optic chiasma. Its wall is continuous anteriorly with the lamina terminalis and laterally with the anterior perforated substance.

The **infundibulum** is but the attenuated apex of the conical tuber cinereum, and forms the neck connecting it with the hypophysis. It is so drawn out that it is referred to as the stalk of the hypophysis. The cavity of the tuber cinereum (infundibular recess) is sometimes maintained throughout the greater part of the length of the infundibulum, giving it the form of a long-necked funnel. Near the hypophysis the cavity is always occluded.

FIG. 669.—DIAGRAMS OF THE HYPOPHYSIS CEREBRI. (After Testut.)

A, posterior surface; B. transverse section; C, sagittal section; 1, anterior lobe; 2, posterior lobe; 3, infundibulum; 4, optic chiasma; 5, infundibular recess; 6, optic recess. In C the infundibulum is relatively much shorter than in the actual specimen.

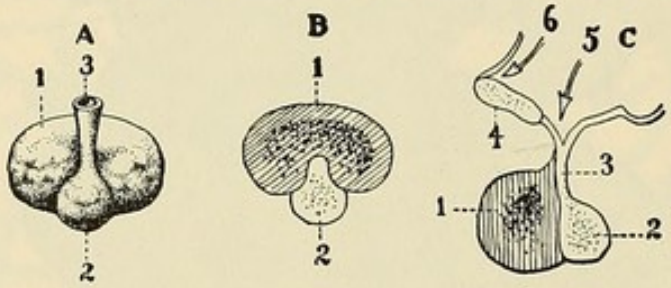

The **hypophysis cerebri** (pituitary body or gland) is an ovoid mass terminating the infundibulum. It lies in the sella turcica of the sphenoid bone, where it is held down and roofed in by the *diaphragma sellæ*, a spheroid pocket of the dura mater. It consists of two lobes, a large *anterior lobe*, the glandular or buccal lobe, and a smaller *posterior* or *cerebral lobe*. The posterior lobe is usually enclasped in a concavity of the anterior lobe.

Development.—The posterior or cerebral lobe alone is originally continuous with and a part of the infundibulum. It alone represents the termination of the hollow diverticulum which, in the embryo, grows downward from that part of the anterior cerebral vesicle which later becomes the third ventricle. The original cavity afterward becomes obliterated except in the upper part of the infundibulum. It is, therefore, of cerebral origin. The anterior or buccal lobe arises quite differently. It is developed from an upward tubular diverticulum (Rathke's pouch) of the primitive buccal cavity. In the higher vertebrates, including man, its connection with the buccal cavity becomes obliterated as the cartilaginous base of the cranium is consolidated, but in the myxinoid fishes the connection remains patent in the adult. Cut off within the cranial cavity, the embryonic buccal lobe assumes its intimate association with the cerebral lobe. In about the second month of fetal life it begins to develop numerous secondary diverticula which become the epithelial structures evident in the adult human subject.

Structure.—The posterior or cerebral lobe retains no organized structure. It may be said to consist of a mass of neuroglia and other fibrous connective tissue with the cells belonging to these and a moderate supply of blood-vessels, with some sympathetic cell-bodies and fibres for the blood-vessels. The anterior or glandular lobe is probably the functional part of the organ. In addition to its abundant supporting tissue, it consists of compartments lined with two kinds of cuboidal cells—cells of different size and different staining properties. The *principal* or more numerous cells are smaller, with thickly granular cytoplasm. In mixtures containing orange G and fuchsin these cells stain orange, while the *chromophile cells*, the larger and less numerous variety, take the fuchsin deeply. The compartments have an abundant blood supply. Near the interlobar septum, the cells frequently are arranged to form small vesicles which contain colloid substance, resembling the typical structure of the thyreoid body.

Like the epiphysis, the hypophysis must be regarded as glandular—a gland with internal secretion. In the case of giants and in acromegaly it is usually greatly enlarged. The principal cells increase greatly in number after removal of the thyreoid body.

The fundaments of the **optic nerve** are derived from this portion of the telencephalon, though the nuclei of termination of its fibres are located in the thalam-

encephalon and mesencephalon. The optic apparatus consists of the retinæ and optic nerves, the optic chiasma, the optic tracts, the superior quadrigeminate bodies with their relations with the nuclei of the eye-moving nerves, the metathalamus, the pulvinar of the thalamus, and the visual area of the cerebral cortex of the occipital lobe. The fibres of the optic nerves arise from the cells of the ganglion-cell layer of the retinæ. The fibres which arise in the mesial or nasal halves of each retina cross the mid-line to find their nuclei of termination in the central grey substance of the opposite side, while those from the outer or lateral halves terminate on the same side (fig. 670.)

The **optic chiasma** (optic commissure) is functionally independent of the structures of the optic portion of the hypothalamus adjacent to it. It is formed by the

FIG. 670.—DIAGRAM OF THE PRINCIPAL COMPONENTS OF THE OPTIC APPARATUS. (After Cunningham.)

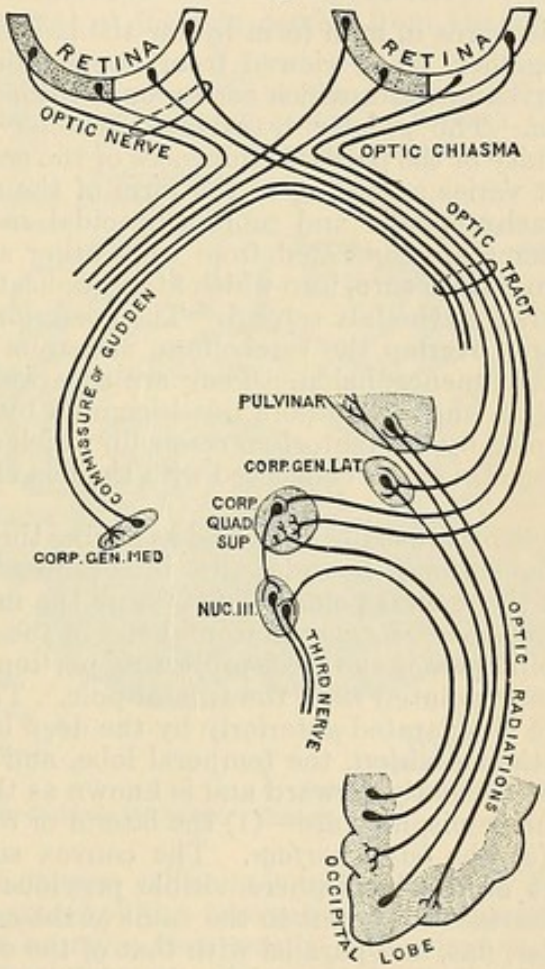

approach and fusion of the two optic nerves, and is knit together by the decussating fibres from the nasal halves of each retina, and, in addition, by the fibres of Gudden's commissure which is contained in it.

Beyond the chiasma the optic fibres continue as the **optic tracts** which course posteriorly around the cerebral peduncles to attain their entrance into the thalamenchephalon and mesencephalon. Upon reaching the pulvinar of the thalamus each optic tract divides into two roots, a lateral and mesial.

The *lateral root* contains practically all of the true visual fibres—fibres arising from the latera half of the retina of the same side and the nasal half of the retina of the opposite side. These fibres are distributed to three localities:—(1) part of them terminate in the lateral geniculate body; (2) the greater portion pass over and around the lateral geniculate body and enter the pulvinar; (3) a considerable portion enter the superior quadrigeminal brachium and course in it to terminate in the nucleus of the superior quadrigeminate body. The most evident function of this latter portion is to bear impulses which, by way of the neurones of the quadrigeminate body, are distributed to the nuclei of the oculomotor, trochlear, and abducent nerves, and thus mediate eye-moving reflexes. The cells of the lateral geniculate body and the pulvinar, about which the retinal fibres terminate, give off axones which terminate in the cortex of the visual area, chiefly the gyri about the calcarine fissure of the occipital lobe. In reaching this area they curve upward and backward, coursing in a compact band of white substance known as the optic

radiation (radiatio occipito-thalamica, fig. 699). Whether any fibres of the optic radiation arise in the superor quadrigeminate body is doubtful. It also is in large part composed of fibres arising from the cells of the visual area, which pass from the cortex to the pulvinar, superior quadrigeminate bodies, and possibly some to the medulla oblongata and spinal cord.

The *mesial root* of the optic tract contains few true visual fibres. It runs into the medial geniculate body, and neither it nor this body are appreciably affected after extirpation of both eyes. It may be considered as largely representing the fibres of **Gudden's commissure** (inferior cerebral commissure). This commissure consists of fibres which connect the medial geniculate bodies of the two sides with each other, and which, instead of crossing the mid-line through the mesencephalon, course in the optic tracts and cross by way of the posterior portion of the optic chiasma. It consists of fibres which both arise and terminate in each of the bodies, and, therefore, of fibres coursing in both directions. It is also claimed that the fibres of Gudden's commissure connect the medial geniculate body of each side with the inferior colliculus of the opposite side.

THE CEREBRAL HEMISPHERES

The cerebral hemispheres in man form by far the largest part of the central nervous system. Together, when viewed from above, they present an ovoid surface, markedly convex upward, which corresponds to the inner surface of the vault of the cranium. The greater transverse diameter of this surface lies posteriorly in the vicinity of the parietal eminences of the cranium. The outline of the superior aspect varies according to the form of the cranium, being more spheroidal in the brachycephalic and more ellipsoidal in the dolichocephalic forms. The hemispheres are separated from each other superiorly by a deep median slit, the **longitudinal fissure,** into which fits a duplication of the inner layer of the dura mater known as the falx cerebri. The posterior or occipital extremities of the hemispheres overlap the cerebellum, and thus entirely conceal the mesencephalon and thalamencephalon. They are separated from the superior surface of the cerebellum and the corpora quadrigemina by the deep **transverse fissure.** This is occupied by the tentorium cerebelli, which is similar to and continuous with the falx cerebri and is connected with the tela chorioidea of the third ventricle below.

Each of the hemispheres is usually described as having three poles or projecting extremities, and three surfaces bounded by intervening borders. The most anterior projection is the **frontal pole.** This is near the mid-line, and with its fellow of the other hemisphere, forms the frontal end of the ovoid contour of the cerebrum. The **occipital pole** is the most projecting portion of the posterior and inferior end, and is more pointed than the frontal pole. The infero-lateral portion of the hemisphere is separated anteriorly by the deep **lateral fissure** (fissure of Sylvius) into a distinct division, the temporal lobe, and the anterior portion of this lobe projects prominently forward and is known as the **temporal pole.**

The **surfaces** of the hemisphere are—(1) the lateral or *convex surface;* (2) the *medial surface;* and (3) the *basal surface.* The convex surface comprises the entire rounded aspect of the hemisphere visible previous to manipulation or dissection, and is the surface subjacent to the vault of the cranium. The mesial surface is perpendicular, flat, and parallel with that of the other hemisphere, the two bounding the longitudinal fissure and for the most part in contact with the falx cerebri. The **superomesial border** intervenes between the convex and medial surfaces, and is thus convex and extends from the frontal to the occipital pole.

The more complex *basal surface* fits into the anterior and middle cranial fossæ, and posteriorly rests upon the tentorium cerebelli. Thus it is subdivided into—(*a*) an *orbital area,* which is slightly concave, since it is adapted to the orbital plate of the frontal bone, and is separated from the convex surface by the necessarily arched **superciliary border** and from the mesial surface by the **medial orbital border,** the latter being straight and extending from the frontal pole mesial to the olfactory bulb and tract; (*b*) a *tentorial area* or surface, which is arched in conformity with the dorsal surface of the cerebellum. This is separated from the convex surface by the **infero-lateral border,** which runs from the occipital to the temporal pole; and from the mesial surface by the **medial occipital border,** which is a more or less rounded ridge extending from the occipital pole obliquely upward in the angle formed by the junction of the perpendicular falx cerebri and the horizontal tentorium cerebelli. This border is best seen in brains which have been hardened with the membranes *in situ.* The remainder of the basal surface includes the optic portion of the hypothalamus already considered, and the small

depressed and punctate area, the anterior perforated substance, which is penetrated by the antero-lateral group of the central branches of the anterior and middle cerebral arteries and into which the striæ of the olfactory trigone disappear. In addition to the orbital area the basal surface of the hemisphere shows signs of the impress of the petrous portion of the temporal bone and of the great wing of the sphenoid.

The corpus callosum.—In their early development as lateral dilations of the anterior primary brain-vesicles, the hemispheres are connected with each other only at the anterior end of the thalamencephalon, where they are both continuous with the lamina terminalis. As development proceeds and the hemispheres extend upward, backward, forward, and laterally to completely conceal the base, and as the pallium, or cortex, thickens and its folds begin to appear, the two hemispheres become united across the mid-line above the thalamencephalon and the third ventricle by the inter-growth of the great cerebral commissure, the **corpus callosum.** After removal of the falx cerebri from the longitudinal fissure, the

FIG. 671.—MESIAL AND TENTORIAL SURFACES OF RIGHT CEREBRAL HEMISPHERE, VIEWED FROM THE LEFT. (After Toldt, "Atlas of Human Anatomy," Rebman, London and New York.)

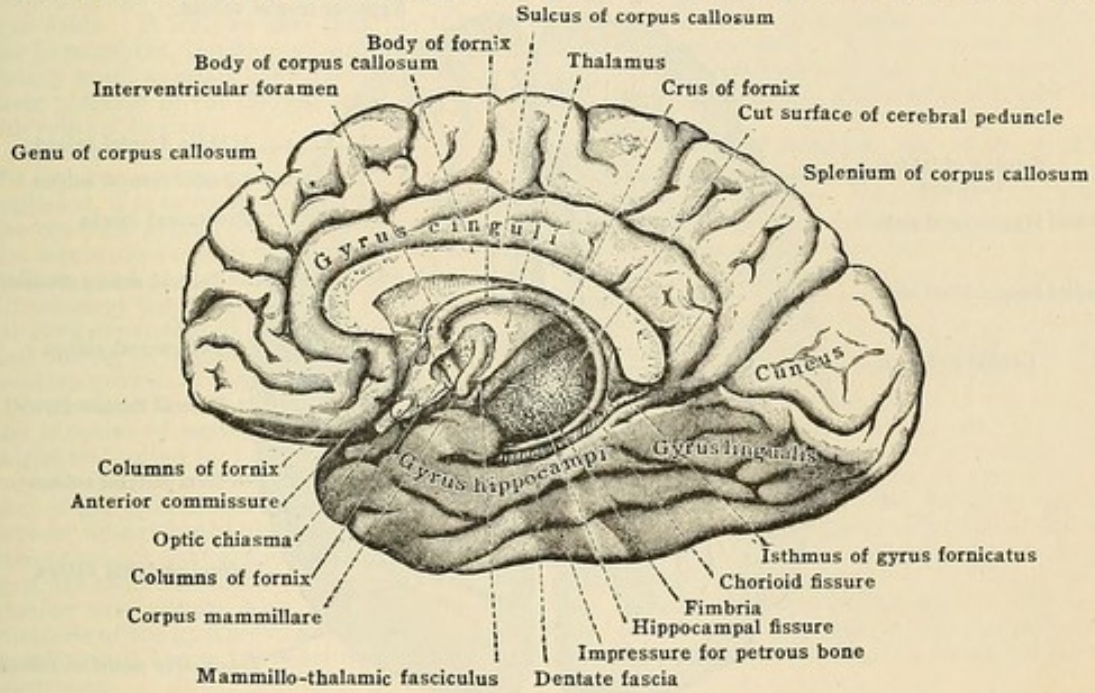

dorsal surface of the corpus callosum may be exposed by drawing apart the contiguous mesial surfaces of the hemispheres. It consists of a dense mass of pure white substance coursing transversely, and arises as out-growths from the cortical cells of both hemispheres. Thus it is the great pathway which associates the cortex of the two sides of the telencephalon. Only the smaller medial portion of the body lies free in the floor of the longitudinal fissure, by far the greater part being concealed in the substance of the hemispheres, where its fibres radiate to and from different localities of the pallium, forming the *radiation of the corpus callosum*. Its surface shows numerous transverse markings, the *transverse striæ*, which indicate the course of its component bundles of fibres. In addition there may be seen two delicate, variable longitudinal bands running over its surface on each side of the mid-line. The **medial longitudinal stria** (*stria Lancisii*) runs close to the median plane, around the anterior end from the gyrus subcallosus (fig. 672), and over the posterior end downward and lateralward to disappear in the hippocampal gyrus of the base of the telencephalon. The **lateral longitudinal stria** is more delicate than the mesial stria, courses lateral to the medial stria, and can be seen only within the sulcus of the corpus callosum (fig. 672). Both striæ are composed largely of axones having to do with the olfactory apparatus.

When severed along the median plane, it may be seen that the anterior margin of the corpus callosum is turned abruptly downward, forming the **genu,** and that this turn continues, so that the tapering edge of the body points posteriorly and

constitutes the **rostrum** (figs. 667, 671). The rostrum is in contact with the lamina terminalis of the third ventricle below by a short, thin, dorso-frontal continuation of this lamina, known as the **rostral lamina.** The rostral lamina may be considered as beginning at the anterior cerebral commissure with the anterior aspect of which it is in contact, and extending to the rostrum. Beginning with the rostrum and genu, the corpus callosum arches backward as the **body of the corpus callosum,** and ends over the quadrigeminate region in its rounded, thickened posterior margin, the **splenium.** It is bounded above by the sulcus of the corpus callosum, and, attached to its concave inferior surface, are the chorioid tela of the third ventricle, the fornix, the septum pellucidum, and the medial walls of the lateral ventricles.

Each cerebral hemisphere includes—(1) a superficial and much folded mantle or *pallium*, divided into lobes and gyri, and consisting of grey substance, the *cortex*, covering an abundant mass of white substance; (2) a modified portion, the

FIG. 672.—DIAGRAM OF CONVEX SURFACE OF RIGHT CEREBRAL HEMISPHERE AND PART OF UPPER SURFACE OF CORPUS CALLOSUM.

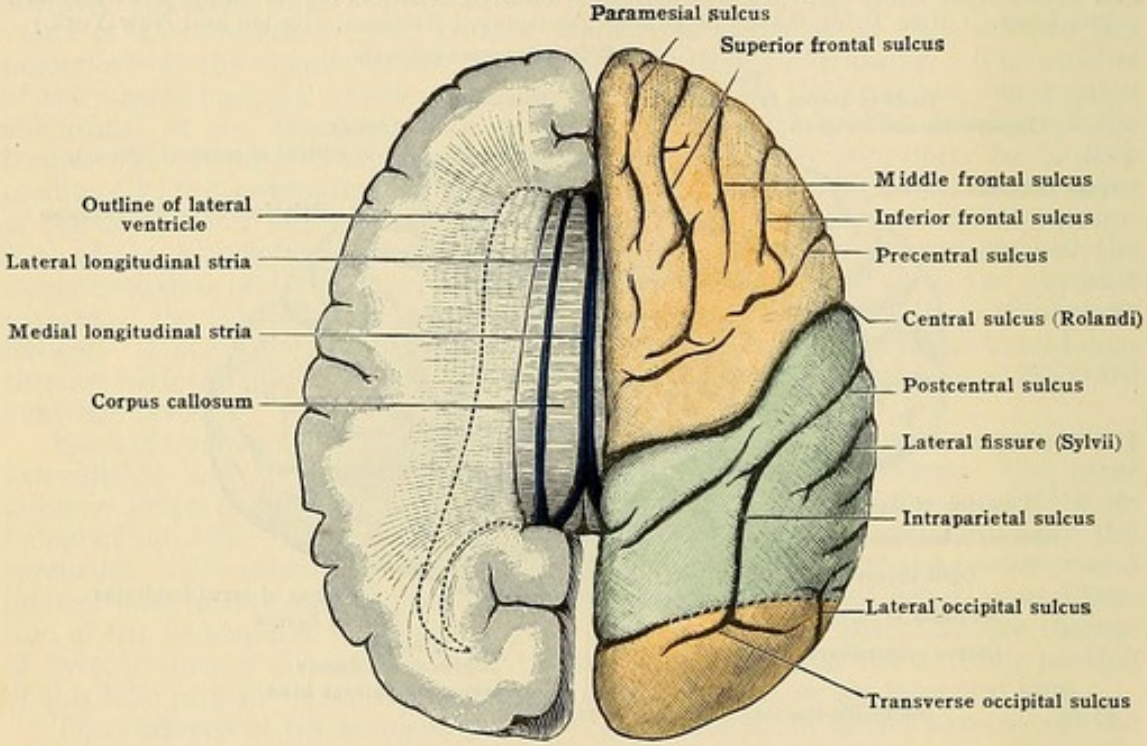

rhinencephalon, having especially to do with the impulses brought in by the olfactory nerve; (3) a cavity , the *lateral ventricle;* and (4) a buried mass of grey substance, the *caudate* and *lenticular nuclei*, which together with the *internal capsule* of white substance, are known as the *corpus striatum*.

Gyri, fissures, and sulci.—The cerebral pallium is thrown into numerous and variable folds or *gyri* (convolutions). These are separated from each other by corresponding furrows, the deeper and most constant of which are called *fissures;* the remainder, *sulci*. All the fissures and the main sulci are named. There are, however, numerous small and shallow sulci to which names are seldom given. These occur as short branches of main sulci or as short, isolated furrows bounding small gyri which connect adjacent gyri. These small gyri are likewise seldom given individual names. They are very variable both in different specimens and in the two hemispheres of the same specimen. Collectively, they are the so-called transitory gyri (gyri transitivi). Certain groups of them are named according to their locality, such as *orbital gyri* and *lateral occipital gyri*. Even the main gyri [gyri profundi] (and sulci) are very irregular in detail. Some of the main and deeper fissures are considerably deeper than others. Some are infoldings of the grey cortex so deep that a portion of their course may be indicated as slight bulgings in the walls of the lateral ventricles, e. g., the hippocampal and collateral fissures. While the general surface pattern is similar for all normal human brains, yet when a detailed comparison is made, the given gyri of different specimens are found to

vary greatly. The main gyri of the two hemispheres of the same brain, however, are nearly alike.

Origin of the gyri.—The gyri (and sulci) are the result of processes of unequal growth—folds necessarily resulting from the surface portion of the hemispheres increasing much more rapidly than the central core. In the early periods of fetal life the surfaces of the hemispheres are quite smooth. In many of the smaller mammals this condition is retained throughout life, but in the larger mammals, including man, as development proceeds the cerebral cortex becomes thrown into folds. The absolute amount of the grey substance of the hemispheres varies with the bulk of the animal, and apparently with its mental capabilities. This is especially true of the cortex, for in the larger brains, and that of man especially, by far the greater amount of the cerebral grey substance lies on the surface. Therefore, in either the growth or evolution of a small animal into a large one the amount of cerebral grey substance is increased, and in this increase the surface area of the brain is necessarily enlarged. It is a geometrical law that in the growth of a body the surface increases with the square, while the volume increases with the cube of the diameter. The cerebral hemisphere is a mass the increase of whose volume does not keep the required pace with the increase of its surface area or cortical layer. The white substance which forms the pallium arises in large measure as outgrowths from the cells of the cortical layer, and thus it can only increase in a certain proportion to the grey substance. Therefore, the surface mantle of grey substance of a hemisphere, enlarged in accordance with an increased bulk of body, is greater than is necessary to cover the surface of the geometrical figure formed by the combined white and grey substance. Consequently, in order to possess the preponderant amount of grey substance, the surface of the hemisphere is of necessity thrown into folds. It follows also that the thinner the cortical layer in proportion to the volume of the hemisphere, the greater and more folded will be the surface area. In accordance with this theory small animals have smooth or relatively smooth hemispheres, and that independently of their position in the animal scale or the amount of their intelligence, while large animals have convoluted brains.

The sulci in general begin to appear with the fifth month of fetal life, the larger of them, the fissures, appearing first and in a more or less regular order. Up to the fifth month the encephalon, due to its rapid growth, closely occupies the cranial capsule. During the fifth month the cranium begins to grow more rapidly than the encephalon, and a space is formed between the cerebrum and the inner surface of the cranium. This space allows further expansion of the pallium, and at the time the space is relatively greatest (during the sixth month) the form and direction of the principal gyri and sulci begin to be indicated. As growth proceeds the unrestricted expansion of the pallium results in the gyri again approaching the wall of the cranium, and during the eighth month of fetal life they again come in contact with it. Finally, the later relative growth of the cranium results in the space found between it and the cortex in the adult. It is obvious that the relation of the cranium may be a factor in the causation of the gyri, for the increase of surface area necessitated by the increased amount of cortical grey substance might be limited by a cranial cavity of small size. It is probable that the second contact of the cortex with the cranium (during the eighth month) may at least cause a deepening and accentuation of the gyri already begun. Evidently the form of the cranium modifies the gyri, and to a certain extent probably determines their direction, for in long, dolichocephalic crania the antero-posterior gyri are most accentuated, and in the wide, brachycephalic crania the transverse gyri are most marked. At birth all the main fissures and sulci are present, but some of the smaller sulci appear later. In the growing pallium both the bottoms of the sulci as well as the summits of the gyri move away from the geometrical center of the hemisphere, the summits more rapidly, and hence the sulci or fissures first formed grow gradually deeper as long as growth continues.

The mechanical factors in the growth processes which result in the more or less regular arrangement of the gyri of the hemispheres of a given group of animals have not been satisfactorily determined. It has been suggested that the differences in arrangement of the gyri in different groups of animals may be in part dependent upon the functional importance of the various regions—the amount of grey substance of a region varying with the functional importance, and the consequent local increases being accompanied by resultant local foldings. This idea is supported by the fact that while the somæsthetic (sensory-motor) area of the cortex varies with the bulk of the body, the frontal gyri, so much developed in man and which are one of the chief regions of the associational phenomena, are relatively independent of and do not vary with the weight of either the body or the brain.

Surface area.—The total surface area of the adult human telencephalon is about 2300 sq. cm. Of this area almost exactly one-third is contained on the outer or exposed surfaces of the gyri, while the other two-thirds is found in the walls of the sulci and fissures.

Lobes of the Telencephalon and the Gyri and Sulci

The folded pallium of each hemisphere is arbitrarily divided into lobes, partly by the use of certain of the main fissures and sulci as boundaries and partly by the use of imaginary lines (figs. 672, 673). These divisions are six in number, themselves subdivided into their component gyri:—

(1) Temporal lobe.
(2) Insula (Central lobe or Island of Reil).
(3) Frontal lobe.
(4) Parietal lobe.
(5) Occipital lobe.

(6) Olfactory brain or rhinencephalon (including structures comprised in the other lobes and often grouped under the two names *olfactory lobe* and *limbic lobe*).

This division of the cortex of the hemisphere is largely a merely topographical one. With the exception of the temporal lobe and the rhinencephalon, it has little of either morphological or functional value. The occipital lobe contains the recognised visual area of the cortex, but this area, as such, does not involve all of the lobe. In their functional significance, the frontal and parietal lobes, especially, overlap each other.

The temporal lobe.—This is the first lobe whose demarcation is indicated. During the second month of intra-uterine life there appears a slight depression on the lateral aspect of the then smooth hemisphere. As the pallium further grows, this depression deepens into a well-marked fossa with a relatively broad floor. This fossa marks the beginning of the lateral cerebral fissure or fissure of Sylvius, and is, therefore, known as the *Sylvian fossa*. As the pallium continues to project outward, the folds which form the margins of the Sylvian fossa increase in size and height and begin to overlap and conceal its broad floor, which is the beginning

FIG. 673.—DIAGRAM OF THE CONVEX SURFACE OF THE LEFT CEREBRAL HEMISPHERE SHOWING THE FIVE PRINCIPAL LOBES OF THE PALLIUM.

The opercular regions of the frontal, parietal, and temporal lobes are removed to show the central lobe or island of Reil.

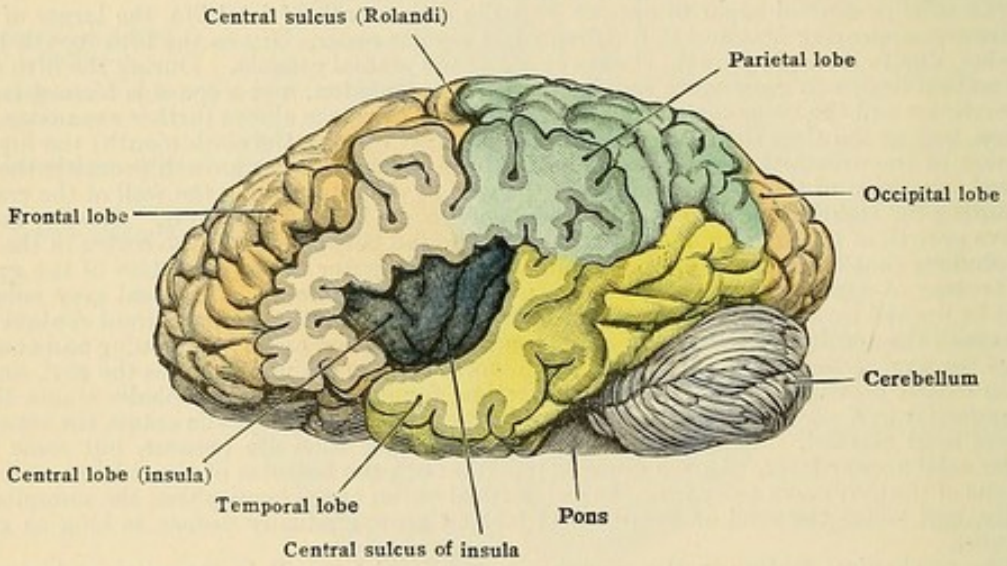

of the insula. The overlapping folds thus become the **opercula,** and as their lips approach each other, there results the deep fissure of Sylvius, which marks off anteriorly an infero-lateral limb of the pallium, termed by position the temporal lobe. As growth proceeds further, the temporal lobe thickens, the temporal pole extends further forward and becomes a free projection, thus lengthening the fissure of Sylvius and resulting in the inferior extension or stem of this fissure, which runs between the temporal pole and the frontal lobe and curves under so as to appear on the basal surface of the hemisphere. Finally the cortex of the lobe itself is thrown into folds or gyri. Its posterior end is never marked off from the lobes above and behind, except by arbitrary lines which will be mentioned in connection with those lobes.

The temporal lobe forms part of the lateral convex and tentorial surfaces of the hemisphere, and its anterior portion is adapted to the surface of the middle cranial fossa. It thus has a superior and lateral surface and a basal and tentorial surface. In these surfaces are the following gyri with their intervening and bounding sulci (fig. 674):—

The **superior temporal gyrus** is bounded by the posterior ramus of the lateral fissure, and extends from the temporal pole backward into the supra-marginal region of the parietal lobe above. The upper margin of this gyrus constitutes the **temporal operculum,** in that it aids in overlapping and enclosing the insula in the floor of the lateral fissure. This margin is for the most part smooth, being

occasionally interrupted by a few weak twigs of the lateral fissure. It is separated from the gyrus below by the **superior temporal sulcus,** which is parallel with the posterior ramus of the lateral fissure and is frequently called the *parallel sulcus.* The posterior extremity of this sulcus divides the angular gyrus of the parietal lobe, and its anterior end disappears in the temporal pole, sometimes as a continuous groove, sometimes in isolated pieces.

The **middle temporal gyrus** likewise begins in the temporal pole and is continuous backward into the angular gyrus of the parietal lobe.

The **inferior temporal gyrus** forms the infero-lateral border of the temporal lobe, and is usually more broken up than the two gyri above it. It begins continuous with them in the frontal pole, and extends horizontally backward into the lateral gyri of the occipital lobe. It is separated from the middle gyrus by the **middle temporal sulcus,** which likewise is never so continuous a furrow as the superior temporal sulcus. Frequently this sulcus occurs in detached portions and often terminates within the temporal lobe.

FIG. 674.—OUTLINE DRAWING OF CONVEX SURFACE OF LEFT CEREBRAL HEMISPHERE.
(After Toldt, "Atlas of Human Anatomy," Rebman, London and New York.)

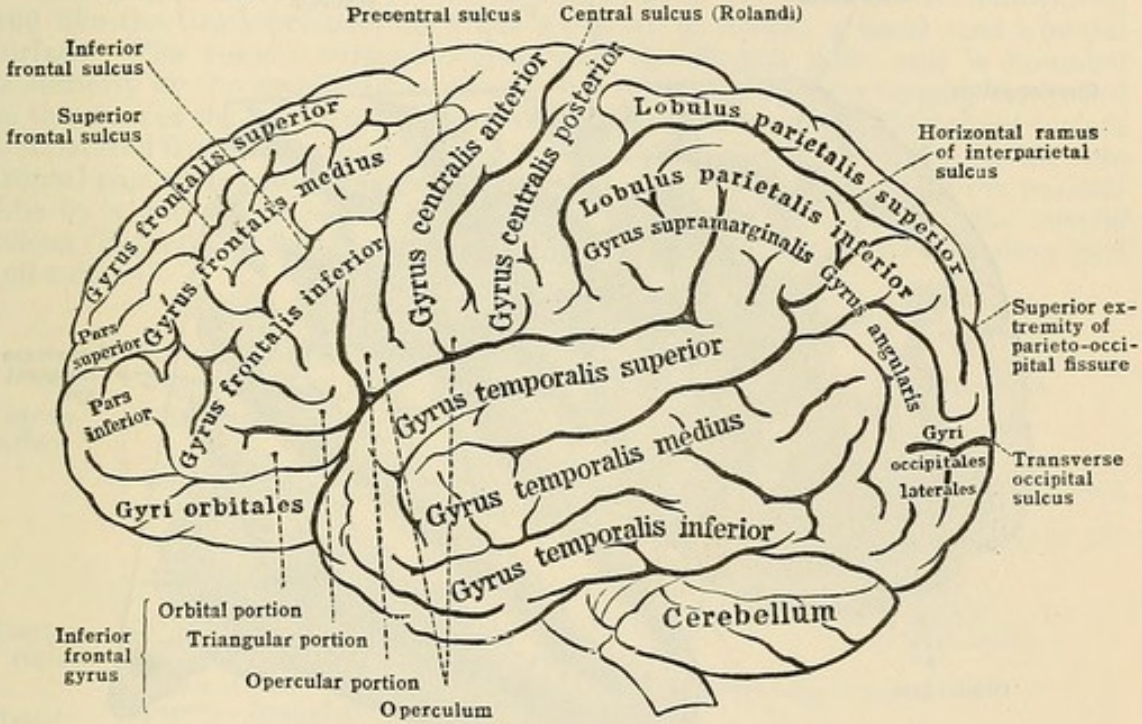

The **fusiform gyrus** is in the basal and tentorial surface of the temporal lobe (fig. 676). Its usual somewhat spindle shape suggests its name, and it is continuous backward into the occipital gyri, or its posterior end may be completely isolated by a union of the *inferior temporal sulcus* and the **collateral fissure,** which two furrows separate it from its neighbours on either side. Anteriorly the fusiform gyrus runs into the common substance of the other three gyri at the temporal pole.

The **lingual gyrus** is usually included in the tentorial surface of the temporal lobe, though in some texts it is regarded as a part of the occipital lobe. Its larger, posterior portion lies within the boundaries of the occipital lobe. Bounded laterally by the collateral fissure, it is continuous anteriorly into the hippocampal gyrus of the rhinencephalon (fig. 676).

All of the sulci give off occasional lateral twigs (*transverse temporal sulci*) which themselves may or may not branch, and which tend to divide the main gyri into **transverse temporal gyri.**

The lateral fissure (fissure of Sylvius).—As promised in its origin by the overlapping and enclosing of the broad floor of the Sylvian fossa by the adjacent folds of the pallium, the lateral fissure is the deepest and most conspicuous fissure of the cerebral hemisphere. Its main divisions are a short stem and three main branches. The **stem** lies in the basal surface of the hemisphere, where it begins

in a depression in the anterior perforated substance, the *vallecula Sylvii*, and passes forward and upward between and separating the temporal pole and the superciliary border of the frontal lobe. It corresponds in direction with the posterior border of the lesser wing of the sphenoid bone, which projects backward into it, and it contains the middle cerebral artery, the Sylvian vein, and the sinus alæ parvæ. It appears on the upper surface at a point known in cranial topography as the *Sylvian point*, where it divides into its three main branches:—

(1) The **posterior ramus** is the linear continuation of the fissure, and runs horizontally backward and upward to terminate in the supra-marginal gyrus of the parietal lobe.

(2) The **anterior ascending ramus** passes upward for about 10 mm., subdividing the inferior gyrus of the frontal lobe.

(3) The **anterior horizontal ramus** passes forward from the stem of the fissure about 10 mm., and likewise into the inferior frontal gyrus, but parallel with the superciliary border.

FIG. 675.—THE INSULA WITH ITS GYRI AND SULCI. (Shown by widely separating the opercula.)

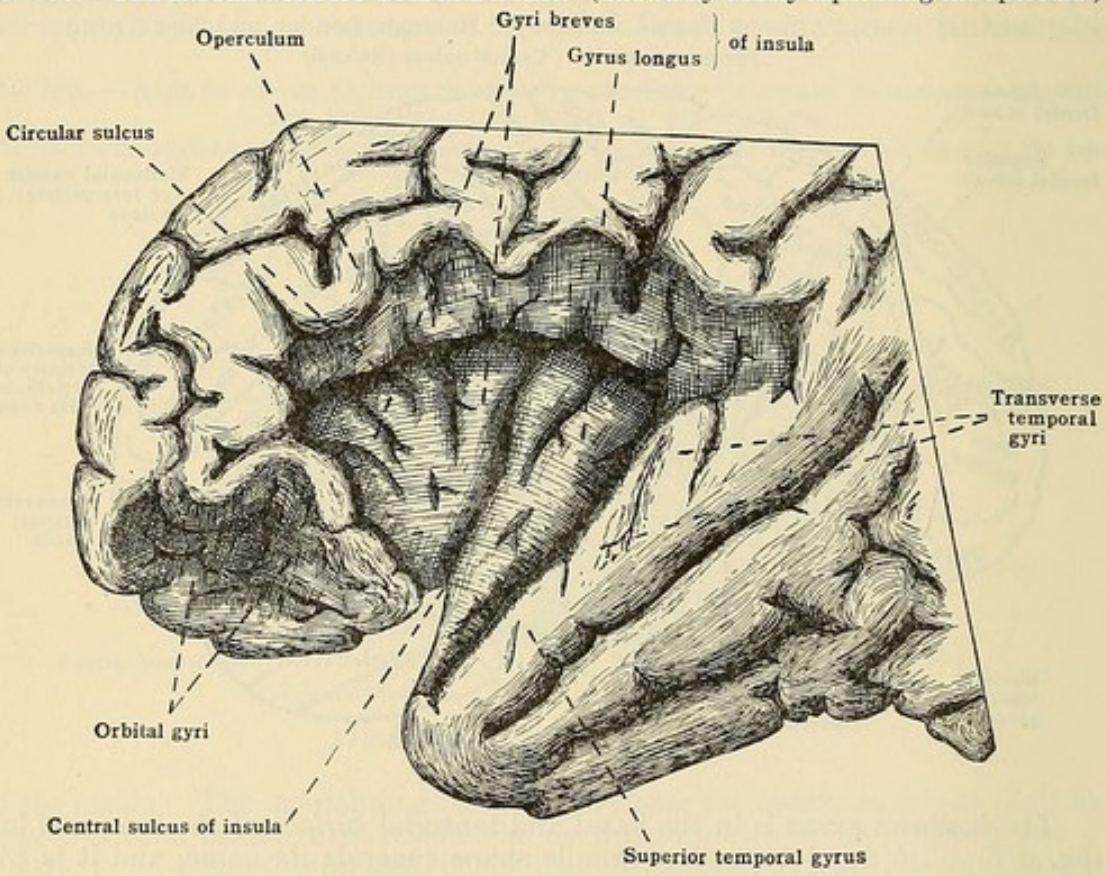

These branches, together with certain smaller collateral twigs, divide the overlapping or opercular portions of the adjacent pallium into (*a*) the *temporal operculum*, which lies below the posterior ramus; (*b*) the fronto-parietal operculum, or *operculum proper*, which lies above and behind the anterior ascending ramus; (*c*) the *frontal operculum*, between the latter and the anterior horizontal ramus; (*d*) and the *orbital operculum*, below the anterior horizontal ramus. Collectively the opercula are known as the *opercula of the insula*.

The insula (central lobe).—The insula or island of Reil is a triangular area of the cerebral cortex lying in the floor of the lateral fissure, and concealed by the opercula. Of these, the temporal operculum overlaps the insula to a greater extent than either the frontal or parietal. More than half of it may, therefore, be exposed, by gently pressing away the temporal lobe. The insula corresponds to the broad floor of the Sylvian fossa of the embryonic brain. In the developed condition its surface is convex lateralward and is itself folded into gyri. The apex of the triangle appears upon the basal surface of the hemisphere, and is the only portion which may be seen without disturbing the specimen. The apex appears as the end of a small gyrus under the temporal pole, and in close relation with the

anterior perforated substance and the vallecula Sylvii, and is known as the **limen of the insula.** In the folding process by which the opercula accomplish the overlapping and enclosing of the island, there results a deep sulcus which surrounds its entire area except at the limen insulæ. This is known as the **circular sulcus,** or limiting sulcus of Reil. The gyri (and sulci) of the insula radiate from the apex of the triangle. The **central sulcus** of the insula is the deepest. It runs from below backward and upward, parallel with the central sulcus of Rolando above and divides the insula into a larger anterior and a smaller posterior portion. The anterior portion consists of from three to five short irregular **gyri breves** or precentral gyri, separated by **sulci brevis;** the posterior portion consists of a single, slightly furrowed gyrus, which is long and arched and extends from the apex to the base of the triangle, the **gyrus longus.**

In a recent study of the insula of more than 200 human brains, including a few of idiots and paralytics and a series of young fœtuses, Nelidoff finds that the left island is more deeply marked by sulci and averages 11 mm. longer than the right; that, of the sulci in the island, the central sulcus is the first to appear, is the most persistent sulcus in defective brains, though occasionally absent in microcephalic idiots, and that in the average it is more pronounced in males than in females.

The frontal lobe.—This is the most anterior of the lobes of the hemisphere, and like the two lobes behind, it has a convex or lateral, a basal, and a mesial surface. The convex surface begins with the frontal pole, and is bounded posteriorly by the *central sulcus (Rolandi)*. The basal surface extends backward to the stem of the lateral fissure, covered by the frontal pole. The mesial surface is separated from the gyrus cinguli of the rhinencephalon (limbic lobe) by the subfrontal part of the **sulcus cinguli** (calloso-marginal fissure), and from the parietal lobe by a line drawn perpendicularly from the upper extremity of the central sulcus (Rolandi) to the sulcus cinguli. These surfaces include the following gyri and sulci:—

	Gyri.		Sulci.	
Convex surface	Anterior central gyrus.		Precentral sulcus	Superior.
	Superior frontal gyrus.			Inferior.
	Middle frontal gyrus	Superior portion.	Superior frontal sulcus.	
		Inferior portion.	Middle frontal sulcus.	
	Inferior frontal gyrus	Opercular portion.	Inferior frontal sulcus.	
		Triangular portion.	Anterior ascending ramus of lateral fissure.	
		Orbital portion.	Anterior horizontal ramus of lateral fissure.	
Basal surface	Orbital gyri	Lateral.	Orbital sulci	Lateral.
		Anterior.		Medial.
		Posterior.		Transverse.
		Medial.		
	Gyrus rectus.		Olfactory sulcus.	
Mesial surface	Superior frontal gyrus.			
	Marginal gyrus.			
	Paracentral lobule (anterior part).		Rostral sulci.	

Many of the sulci, especially the superior frontal and the rostral sulci, often give off twigs or are broken up into short furrows which give rise to small folds [gyri transitivi], too inconstant to be given special names.

The **anterior central gyrus** (ascending frontal convolution) is the only gyrus of the frontal lobe having a vertical direction. It lies parallel to the central sulcus (Rolandi), and thus extends obliquely across the convex surface from the posterior ramus of the lateral fissure (frontal operculum) to the supero-mesial border, and is continuous on the mesial surface with the anterior portion of the *para-central lobule.* It comprises the larger part of the motor portion of the somæsthetic (sensory-motor) area of the cerebral cortex. It is separated from the horizontal frontal gyri in front of it by the **precentral sulcus.**

This sulcus is developed in three parts, but the upper and middle parts in the fœtal brain usually fuse together, so that in the later condition it consists of a superior and an inferior segment. The superior cuts the supero-mesial border of the hemisphere and appears on the mesial surface in the paracentral lobule. On the convex surface it is usually connected with the posterior end of the superior frontal sulcus (fig. 674).

The **superior frontal gyrus** is a relatively broad, uneven convolution, comprising the anterior portion of the supero-mesial border of the hemisphere, and therefore extends horizontally from the precentral sulcus to the frontal pole. It is sometimes inperfectly divided into a superior and an inferior part by a series of

detached, irregular furrows, spoken of collectively as the *para-medial sulcus.* The resulting transitory gyri are of considerable interest in that they are peculiar to the human brain, and are said to be more marked in the higher than in the lower types.

The **middle frontal gyrus** is likewise a broad strip of pallium extending from the precentral sulcus to the temporal pole. It is separated from the superior frontal gyrus by the **superior frontal sulcus,** which is usually continuous into the superior section of the precentral sulcus and thence extends horizontally to the frontal pole. The middle frontal gyrus is in most cases subdivided anteriorly into a *superior* and an *inferior portion* by a **middle frontal sulcus.** This sulcus begins above and runs into the frontal pole, where, upon reaching the superciliary border, it frequently bifurcates into a transverse furrow, known as the *fronto-marginal sulcus.*

The **inferior frontal gyrus** forms the superior wall of the lateral fissure, and is separated from the middle frontal gyrus by the **inferior frontal sulcus.** This sulcus usually begins continuous with the inferior section of the precentral sulcus, and extends, very irregularly and frequently interrupted, toward the frontal pole. The gyrus abuts upon the anterior central gyrus, and its posterior portion is divided into three parts (the frontal opercula) by the anterior ascending and horizontal rami of the lateral fissure. The part behind the anterior ascending ramus is the **opercular portion** (a part of the fronto-parietal operculum or operculum proper), sometimes referred to as the *basilar portion.* In most brains this part is traversed by a short oblique furrow, the **diagonal sulcus.** The part between the two anterior rami of the lateral fissure is the cap-shaped **triangular portion.** This portion frequently involves one and sometimes two descending twigs of the inferior frontal sulcus. The part below the anterior horizontal ramus is by position the **orbital portion.**

It is seen that the inferior frontal gyrus gives rise to the whole of the frontal operculum and the anterior half of the fronto-parietal operculum. The opercular portion is of special interest in that in the left hemisphere it constitutes the celebrated **convolution of Broca,** the motor area for the function of speech. The area controlling speech, however, involves that part of the triangular portion bounding the anterior ascending ramus of the lateral fissure as well, and both these parts often appear more developed on the left hemisphere. The development of the opercula of the inferior frontal gyrus is a distinctive characteristic of the human brain. This gyrus does not develop opercula even in the highest varieties of apes. The development of the function of speech in man no doubt influences the development of the frontal opercula.

On the *basal surface* (fig. 676) of the frontal lobe is the orbital area and the gyrus rectus. The more pronounced of the **orbital sulci** are often so joined with each other as to form an H-shaped figure standing parallel to the mesial plane, and thus they comprise a *medial,* a *lateral* and a *transverse orbtial sulcus.* This figure naturally divides the orbital area into four gyri:—(1) The **lateral orbital gyrus** is the basal continuation of the inferior frontal gyrus, and is thus related to the orbital portion of the frontal operculum; (2) the **anterior orbital gyrus** is continuous at the pole with the middle frontal gyrus; (3) the **posterior orbital gyrus** is closely related to the limen insulæ and the stem of the lateral fissure, and its outer part is in relation with the orbital portion of the operculum; (4) the **medial orbital gyrus** is continuous over the superciliary border with the superior frontal gyrus. It frequently contains one or two short, isolated sulci. Its mesial boundary is the straight **olfactory sulcus,** in which lies the olfactory bulb and tract of the rhinencephalon. This sulcus marks off a narrow straight strip of cortex between it and the mesial border of the lobe known as the **gyrus rectus.** The posterior portion of the gyrus rectus comprises a part of the **parolfactory area** or Broca's area, which functionally belongs to the rhinencephalon. As an area or field, this appears mesially lying between the anterior and posterior parolfactory sulci.

On the *mesial surface* (fig. 679), of the frontal lobe the superior frontal gyrus is separated from the gyrus cinguli of the rhinencephalon (limbic lobe) by the well-marked **sulcus cinguli.** Anteriorly the superior frontal gyrus is subdivided by the main stem of the **rostral sulci** into a **marginal gyrus,** and what may be termed a **submarginal gyrus.** The marginal gyrus is usually broken into smaller parts by twigs of the rostral sulci, most of which are perpendicular to the main stem, while the submarginal gyrus is less frequently interrupted. Posteriorly the superior frontal gyrus constitutes the anterior portion of the *paracentral lobule,* a part of

the somæsthetic area of the mesial surface of the hemisphere. This lobule is usually marked off anteriorly by a vertical twig from the sulcus cinguli.

The **sulcus cinguli** (calloso-marginal fissure) is the longest and one of the most prominent sulci on the mesial surface of the hemisphere. It divides the anterior portion of the mesial surface into a marginal part above and a callosal part below —in other words, it separates the superior frontal gyrus from the gyrus cinguli. Its **subfrontal portion** begins below the rostrum of the corpus callosum and curves forward and upward around the genu, and then turns backward above the body of the corpus callosum. Before it reaches the level of the splenium, it turns upward and cuts and terminates in the supero-mesial border of the hemisphere, as the next sulcus behind the upper termination of the central sulcus. This upward

FIG. 676.—BASAL SURFACE OF THE CEREBRAL HEMISPHERES. (After Toldt, "Atlas of Human Anatomy," Rebman, London and New York.)

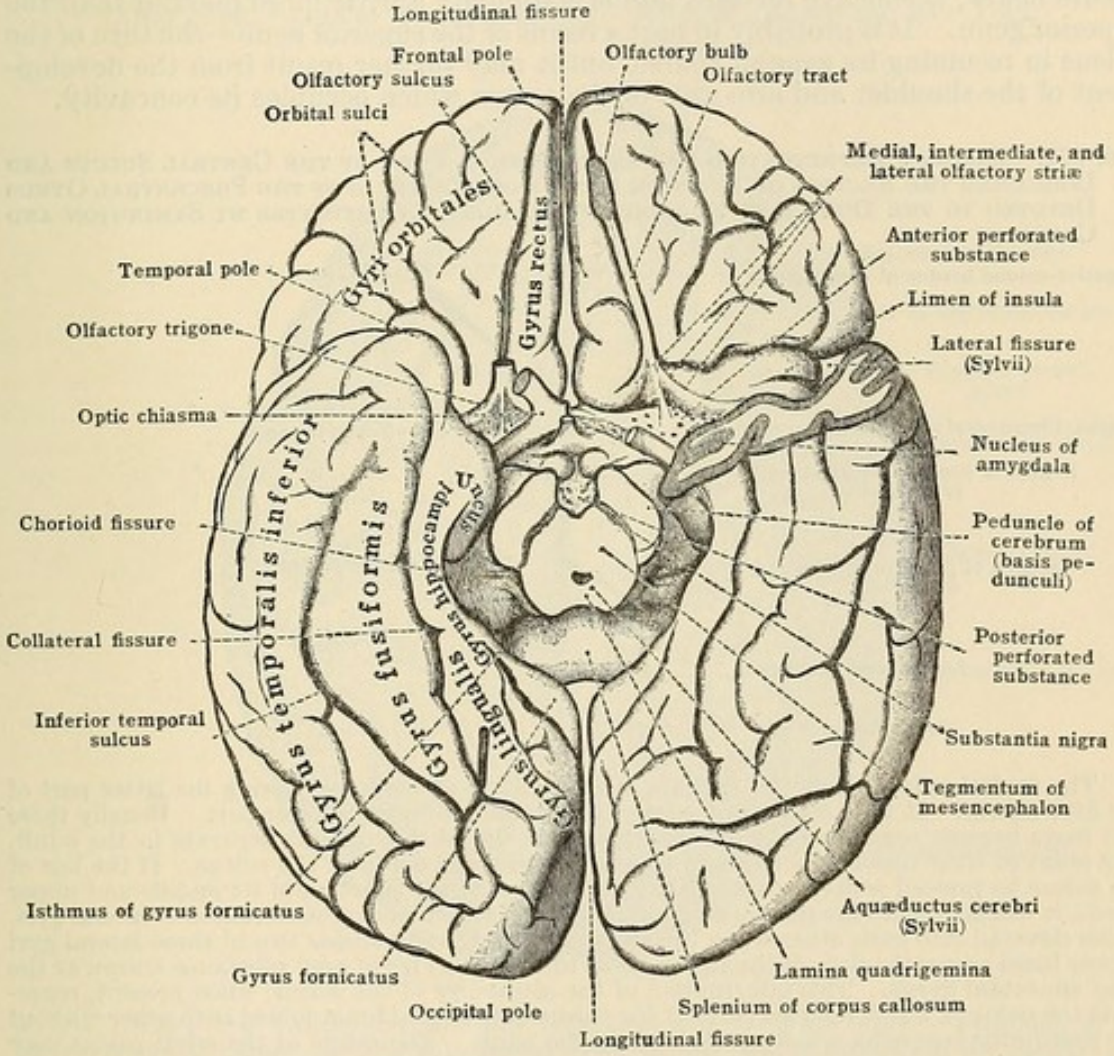

turn is the **marginal portion** of the sulcus cinguli. It is sometimes an abrupt curve and sometimes curves gradually, but its marginal relation to the upper end of the central sulcus is so constant that it serves as a means by which either of the sulci may be identified. The marginal portion separates the paracentral lobule from the precuneus (quadrate lobule), and is wholly within the parietal lobe. One of the most constant twigs of the sulcus cinguli is that which marks off the paracentral lobule from the superior frontal gyrus. Another sometimes divides the paracentral lobule into its frontal and parietal portions.

The sulcus cinguli is developed from two and sometimes three (anterior, middle, and posterior) separate furrows, which later extend and fuse into continuity. This method of its development may explain the irregularities frequently met with and the fact that sometimes in the adult the sulcus occurs in separate pieces.

The **central sulcus** (fissure of Rolando) (figs. 674, 678) is one of the principal landmarks of the convex surface of the hemisphere. It separates the frontal from the parietal lobe, and likewise divides the somæsthetic area of the pallium. Its

upper end terminates in and usually cuts the supero-mesial border of the hemisphere immediately in front of the termination of the marginal portion of the sulcus cinguli. Thence it pursues an oblique though sinuous course forward across the convex surface of the hemisphere, forming on the average an angle of about 72° with the supero-mesial border (**Rolandic angle**), and terminates in the fronto-parietal operculum immediately above the posterior ramus, and about 2.5 cm. behind the point of origin of the anterior rami of the lateral fissure. It rarely cuts through the fronto-parietal operculum. In its sinuous course, varying from the line of its supero-mesial end, two bends are marked (fig. 677):—(1) The **superior genu** occurs at about the junction of the upper and middle thirds of the sulcus and is concave forward. It accommodates the greater part of that portion of the cortex which is the motor area for the muscles of the leg and trunk, and the development of this area in man probably aids in producing it. (2) The **inferior genu** occurs below, is concave forward and is commonly a little more marked than the superior genu. It is probably in part a result of the superior genu—the turn of the sulcus in resuming its general course, but it may further result from the development of the shoulder and arm area of the cortex which occupies its concavity.

FIG. 677.—DIAGRAM REPRESENTING THE MOST COMMON FORM OF THE CENTRAL SULCUS AND INDICATING THE REGIONS OF JUNCTION UPON IT OF THE AREAS OF THE PRECENTRAL GYRUS DEVOTED TO THE DIFFERENT REGIONS OF THE BODY, AS ESTIMATED BY SYMINGTON AND CRYMBLE.

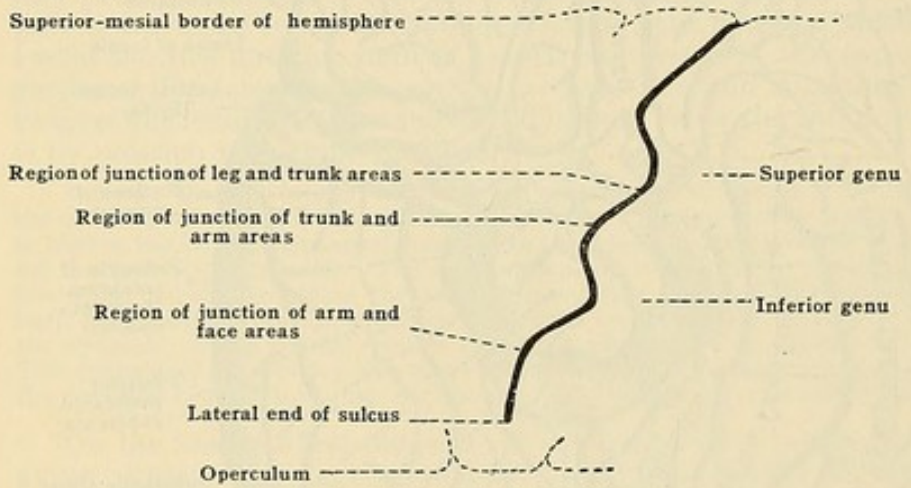

The **central sulcus** (**Rolandi**) appears in the pallium of the fœtus during the latter part of the fifth month. It then consists of a lower longer and an upper shorter part. Usually these two parts become continuous before birth; very rarely do they remain separate in the adult. The point of their fusion is sometimes manifest within the depth of the sulcus. If the lips of the sulcus be pressed widely apart at about the region of the junction of its middle and upper thirds, it will be found that the opposing walls give off a number of protuberances or lateral gyri, which dovetail into each other when the sulcus is closed. Sometimes two of these lateral gyri appear fused across the floor of the sulcus, so as to form a bridge of grey substance known as the **deep annectant gyrus.** This interruption of the continuity of the sulcus, when present, represents the point at which the two parts of the sulcus in the fœtal brain joined each other without the continuity becoming wholly completed in the adult. The genua of the adult sulcus may often be due to the precedent parts not being in line at the time of their fusion.

From a special study of the central sulcus of 237 normal adult hemispheres, Symington and Crymble (1913) give the following details: (1) that the most common course of the sulcus is that illustrated in fig. 677, above; (2) that it varies in depth both in a given specimen and in different specimens—the greatest variations in depth reported for a given sulcus being from 22 to 12 millimeters, the shallowest part being in the region of the deep annectant gyrus; (3) that the average length from the supero-mesial border of the hemisphere to the opercular end of the sulcus is about 9 cm. in direct line and 10.4 cm. following the curves of the sulcus. The average length of the curved floor is 7.9 cm. (4) From the supro-meisal end of the sulcus to the points of junction of the general areas of the precentral gyrus, direct line measurements give averages, (a) to the junction of leg and trunk areas, 3.5 cm.; (b) to junction of trunk and arm areas, 4.5 cm.; (c) to junction of arm and face areas, 7.5 cm.

The parietal lobe.—The parietal lobe occupies a somewhat smaller area of the human telencephalon than either the frontal or the temporal lobe. It has a convex and a mesial surface, but no basal surface. It is separated from the frontal lobe in front by the central sulcus; from the occipital lobe behind, on the mesial surface by the *parieto-occipital fissure* (fig. 650), and, on the convex surface,

by an arbitrary line drawn transversely around the convex surface of the hemisphere from the superior extremity of this fissure to the infero-lateral border; and it is separated from the temporal lobe below by the horizontal part of the posterior ramus of the lateral fissure, and by a line drawn in continuity with this horizontal part to intersect the transverse line drawn to limit it from the occipital lobe.

The preoccipital notch.—*In situ*, the infero-lateral border of the posterior portion of the hemisphere rests over a small portion of the parieto-mastoid suture of the cranium, and upon this structure occurs a fold or vertical thickening of the dura mater, which slightly indents the infero-lateral border. This indentation occurs about 4 cm. from the occipital pole, and is considered one of the points of limitation of the parietal from the occipital lobe, and is therefore called the preoccipital notch. While during late fœtal life and early childhood it is well marked, it is usually very slight in the adult brain, and is, as a rule, evident only in brains hardened

FIG. 678.—CONVEX SURFACE OF THE CEREBRAL HEMISPHERES AS VIEWED FROM ABOVE. (After Toldt, "Atlas of Human Anatomy," Rebman, London and New York.)

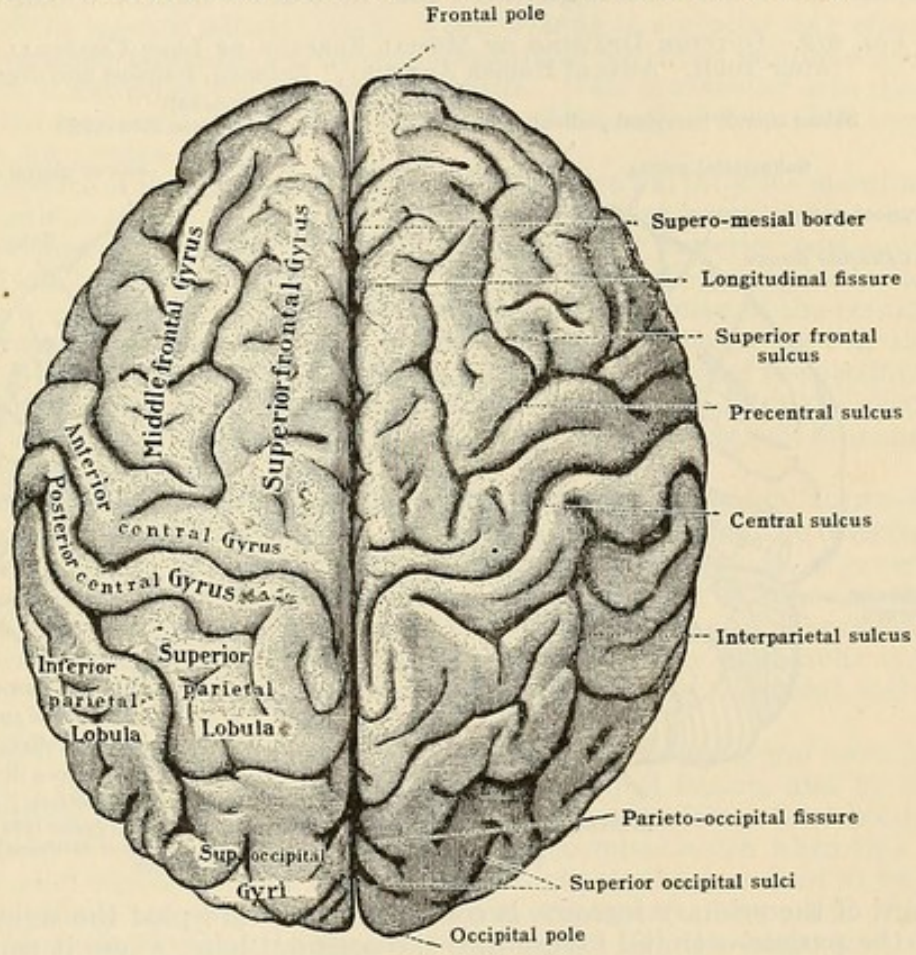

in situ. When it is visible, the arbitrary transverse line from the superior extremity of the parieto-occipital fissure, used as a boundary between the convex surfaces of the parietal and occipital lobes, should be so drawn as to bisect the preoccipital notch.

The *convex surface* of the parietal lobe comprises the following gyri and sulci:—

The **posterior central gyrus** (ascending parietal) extends obliquely across the hemisphere parallel with the anterior central gyrus of the frontal lobe, from which it is separated by the central sulcus. Its inferior end is bounded by the posterior ramus of the lateral fissure, and constitutes the posterior or parietal portion of the fronto-parietal operculum. Its upper end takes part in the supero-mesial border of the hemisphere, and is bounded posteriorly by the tip end of the marginal portion of the sulcus cinguli. Its postero-lateral boundary consists of the two more or less vertical rami or factors of the interparietal sulcus, viz., the inferior and superior portions of the *postcentral sulcus*, either continuous with each other or detached.

The **interparietal sulcus** (intraparietal) is often the most complicated sulcus of the pallium. Its development usually begins as four different furrows in the fœtal brain, and the difficulty with which it is traced in the adult brain depends

upon the extent to which these four factors become continuous in the later development. When continuity of the furrows is well established, the entire sulcus may be described as consisting of a convex *horizontal ramus*, which gives off a few short collateral twigs and whose either end is in the form of an irregular, reclining ⊣. The transverse bar of the anterior end arises from two of the four factors of the entire sulcus:—(1) an inferior furrow, the *inferior postcentral sulcus*, commencing above the posterior ramus of the lateral fissure and ascending as the boundary of the lower half of the posterior central gyrus, and (2) a superior furrow, the *superior postcentral sulcus*, lying behind the upper portion of the posterior central gyrus, and which, upon approaching the supero-mesial border, may turn backward a short distance parallel with the horizontal ramus, as in fig. 674. When confluent, these two factors form together a continuous **postcentral sulcus.** In the adult the inferior of the two is always continuous with the horizontal ramus; when confluent, the two figures join so as to form the transverse bar of the anterior end of this ramus. The horizontal ramus, which represents the

FIG. 679.—OUTLINE DRAWING OF MESIAL SURFACE OF LEFT CEREBRAL HEMISPHERE. (After Toldt, "Atlas of Human Anatomy," Rebman, London and New York.)

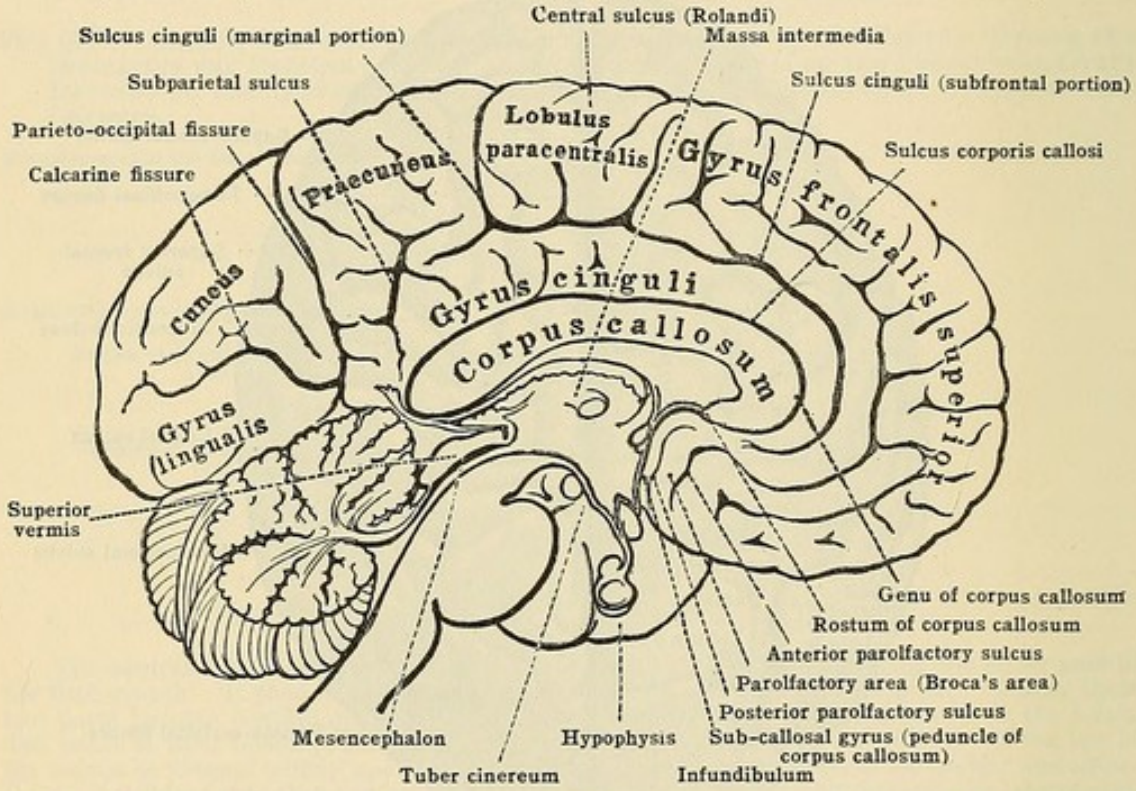

third of the primary furrows, is continued backward past the superior extremity of the parieto-occipital fissure into the occipital lobe, where it usually joins the *occipital ramus*, the fourth of the primary furrows. This ramus divides shortly into two branches which run at right angles to the stem, forming the *transverse occipital sulcus*, and thus arises the transverse bar of the posterior end of the interparietal sulcus. The occipital ramus may, however, consist of little more than the transverse bar, which may or may not be joined by the horizontal ramus. The occipital ramus is more frequently separate from the horizontal than is the postcentral sulcus. In their development the inferior postcentral sulcus appears first (during the latter part of the sixth month), the occipital ramus second, the horizontal ramus third, and last, the superior postcentral sulcus.

The **superior parietal lobule** (*gyrus*) is the area of the supero-mesial border of the parietal lobe. It is limited in front by the superior postcentral sulcus, below by the horizontal ramus of the interparietal sulcus, and posteriorly it is continuous around the superior end of the parieto-occipital fissure into the cortex of the occipital lobe. It is a relatively wide area (lobule), always invaded by collateral twigs of its limiting sulci, and usually contains a few short, isolated furrows. When the parieto-occipital fissure is considerably prolonged over the supero-mesial border (*external parieto-occipital fissure*), the continuation of the

lobule about the end of this fissure presents the appearance described as the **parieto-occipital arch.**

The **inferior parietal lobule** is limited in front by the inferior postcentral sulcus, and above by the horizontal ramus of the interparietal sulcus. It is continuous with the cortex of the temporal lobe below, and with that of the occipital lobe behind, and is therefore invaded by the ends of the sulci belonging to these lobes. Its anterior portion is separated from the temporal lobe by the horizontal portion of the posterior ramus of the lateral fissure. The upturned end of this ramus invades the anterior portion of the lobule and the broad fold, arched around this end and continuous behind it into the superior temporal gyrus, is known as the **supramarginal gryus**—the area to which auditory word- and tone-images are attributed. The **angular gyrus** is the portion which embraces the posterior end of the superior temporal sulcus, and is continuous behind this into the middle temporal gyrus and in front with the superior temporal gyrus. It is the area for visual word images. Its shape is usually such as to suggest its name. The most posterior part of the inferior parietal lobule, when arching in a similar way about the end of the middle temporal sulcus and continuous with the temporal gyri on its either side, is known as the **post-parietal gyrus.** This is a smaller area than either of the other two, and, owing to the variability of the end of the middle temporal sulcus, is not always evident.

The *mesial surface* of the parietal lobe is divided into two parts by the marginal portion of the sulcus cinguli. The anterior and smaller part is the mesial continuation of the posterior central gyrus, and comprises the posterior portion of the **paracentral lobule.** It is limited from the part of this lobule belonging to the frontal lobe by a vertical line drawn from the marginal extremity of the central sulcus. The **præcuneus** (*quadrate lobule*) is the posterior and larger part of the mesial surface of the parietal lobe. It is separatd from the cuneus of the occipital lobe by the parieto-occipital fissure, and is imperfectly separated from the gyrus cinguli (limbic lobe) below by the *subparietal sulcus* (postlimbic fissure), branches of which invade it extensively.

The occipital lobe.—This is a relatively small, trifacial, pyramidal segment, comprising the posterior extremity of the hemisphere, its apex being the occipital pole. Though one of the natural divisions of the cerebral hemisphere, it is very indefinitely marked off from the lobes anterior to it. Though it contains the cortical area of the visual apparatus, only in the brains of man and the apes does it occur as a well-defined posterior projection. In most of the mammalia it is not differentiated at all. Its three surfaces comprise a convex, a mesial, and a tentorial surface.

Its *convex surface* is separated from that of the parietal and temporal lobes by the superior and external extremity of the parieto-occipital fissure, and by an arbitrary line drawn transversely from this extremity to the infero-lateral border of the hemisphere, or so drawn as to bisect the pre-occipital notch when this is evident. The sulci which occur on the convex surface may be described as two, though both of these are very variable in their extent and shape, and their branches are inconstant both as to number and length. (1) the **transverse occipital sulcus** is the most constant in shape. It extends a variable distance transversely across the superior portion of the lobe, and, as noted above, it is frequently continuous with the interparietal sulcus through its occipital ramus, and when so, it appears as the posterior terminal bifurcation of this sulcus (fig. 674). When detached, it often occurs merely as a definite furrow with few rami, and sometimes the ramus by which it otherwise would join the interparietal sulcus is entirely absent. (2) The **lateral occipital sulcus** is always short, and has its deepest portion below the transverse sulcus. It usually has a somewhat oblique course toward the supero-mesial border. Sometimes it occurs in several detached pieces, then known collectively as the *lateral occipital sulci.*

Therefore, the gyri of the convex surface of the lobe are also variable. They are not sufficiently constant to merit individual names. The lateral occipital sulcus or sulci roughly divide them into an inferior and lateral area, known as the **lateral occipital gyri,** and into a uperior larea, the **superior occipital gyri.** The lateral area is continuous into the gyri of the temporal lobe, while the superior area is continuous into the gyri of the parietal lobe.

The *mesial surface* of the occipital lobe is separated from that of the parietal lobe (precuneus) and from the gyrus cinguli of the limbic lobe by the well-

marked parieto-occipital fissure. It comprises the constantly defined, wedge-shaped lobule known as the **cuneus,** and the posterior and mesial extremity of the **lingual gyrus.** Since the greater portion of the length of the lingual gyrus is involved in the basal surface of the temporal lobe, this gyrus as a whole has been considered as belonging to the temporal lobe (see figs. 671, 676). The cuneus is separated from the lingual gyrus by the posterior portion of the **calcarine fissure,** which always terminates in a bifurcation, one limb of which invades the cuneus near the superomesial border. In addition the cuneus may contain other twigs from both the fissures bounding it, and also, when wide, may contain one or more short, detached **sulci cunei.**

The **calcarine fissure** and the **parieto-occipital fissure** are almost invariably joined in the human brain, forming a **Y**-shaped figure, the prongs of which give the cuneus its shape. The calcarine fissure begins on the tentorial surface in the posterior portion of the hippocampal gyrus of the limbic lobe, below the splenium of the corpus callosum, and extends backward across the internal occipital border of the hemisphere. It then bends downward and proceeds to its terminal bifurcation in the polar portion of the occipital lobe. The stem or hippocampal portion of the fissure is deeper than the posterior or occipital portion. It produces a well-marked eminence in the medial wall of the posterior cornu of the lateral ventricle, known as the *calcar avis* or *hippocampus minor.* It is developed separately from the posterior portion, which itself first appears as two grooves. All three parts are usually continuous with each other before birth.

The **parieto-occipital fissure** usually appears from the first as a continuous groove. It begins in the supero-mesial border of the hemisphere, rarely extending into the convex surface more than 10 mm. (*external parieto-occipital fissure*), thence it extends vertically downward across the mesial surface (*internal parieto-occipital fissure*), and terminates by joining the calcarine fissure at the region of the downward bend of the latter, or at about the junction of its anterior and middle thirds. In certain of the lower apes and in the brain of the chimpanzee there is no junction between the two fissures, they being kept apart by a narrow neck of cortex, the **gyrus cunei.** Neither are they joined in the human fœtus. If in the adult human brain the region of their junction be opened widely, there will be found a submerged transitory *gyrus* (deep annectant gyrus), which is the gyrus cunei, superficial in the fœtus. In the higher apes and in micro-cephalic idiots this gyrus may be on the surface or partially submerged. Two other transitory gyri (annectant gyri) are to be found by pressing open the calcarine fissure, and they mark the points at which its three original grooves became continuous during its development into a boundary between the cuneus and the lingual gyrus. Of these, the **anterior cuneo-lingual gyrus** crosses the floor of the calcarine fissure on the posterior side of its junction with the parieto-occipital fissure, and therefore near the gyrus cunei. The **posterior cuneo-lingual gyrus** occurs near the region of the terminal bifurcation of the fissure.

The *tentorial surface* of the occipital lobe is blended intimately with that of the temporal lobe, from which it is separated only by an arbitrary line drawn to join the line of demarcation for the convex surface, at the region of the pre-occipital notch, and thence to the isthmus of the gyrus fornicatus—the narrow neck of cortex connecting the gyrus cinguli with the hippocampal gyrus, just below the splenium of the corpus callosum (see fig. 671). The gyri blending the occipital and temporal lobes across this line are the *lingual gyrus,* already mentioned, and the **fusiform gyrus** (occipito-temporal convolution). In fact, the tentorial surface of the lobe may be considered as nothing more than the posterior extremity of the fusiform gyrus, and the inferior portion of the same extremity of the lingual gyrus. The former is often somewhat broken up and is then continuous into the lateral occipital gyri. The two gyri are separated by the *collateral fissure* the posterior end of which extends into the occipital lobe. The fusiform gyrus is bounded laterally by the inferior temporal sulcus, which sometimes is continuous by a lateral twig, across the posterior end of this gyrus, with the collateral fissure.

The Rhinencephalon

The rhinencephalon or *olfactory brain* includes those portions of the cerebral hemisphere which are chiefly concerned as the central components of the olfactory apparatus. Owing to the preponderant development of the other divisions of the hemisphere, the parts comprising this division appear relatively but feebly developed in the human brain. In most of the mammals the sense of smell is relatively much more highly developed, and in many of the larger mammals the parts comprising the rhinencephalon are of greater absolute size than in man, though their cerebral hemispheres may be considerably smaller. In the human fœtus the parts of the rhinencephalon are relatively much more prominent than after the completed differentiations into the adult condition. In the broader

sense of the term the rhinencephalon includes those parts of the hemisphere usually classed as comprising two lobes, viz., the **olfactory lobe** and the **limbic lobe.** Neither of these is a 'lobe' in the sense of comprising a definite segment of the hemisphere, as do the other lobes, and therefore the rhinencephalon cannot be called a distinct lobe. It is so strung out that by one or the other of its parts it is either in contact or continuity with each of the other lobes of the hemisphere.

Morphologically, the rhinencephalon may be divided into an **anterior** and a **posterior division.**

The anterior division.—the *olfactory lobe* proper, belongs almost wholly to the base of the encephalon, and consists of the following parts:—

(1) The **olfactory bulb** is an elongated, oval enlargement of grey substance which lies upon the lamina cribrosa of the ethmoid bone, and, practically free, it presses under the anterior end of the olfactory sulcus in the basal surface of the frontal lobe. The numerous thin filaments of nonmedullated axones of the *olfactory nerve* enter the cranium through the foramina of the lamina cribrosa and pass into the ventral surface of the bulb.

FIG. 680.—BRAIN OF HUMAN FŒTUS OF 22.5 CM. (BEGINNING OF FIFTH MONTH), SHOWING THE PARTS OF THE DEVELOPING RHINENCEPHALON APPARENT ON THE BASAL SURFACE. (After Retzius.)

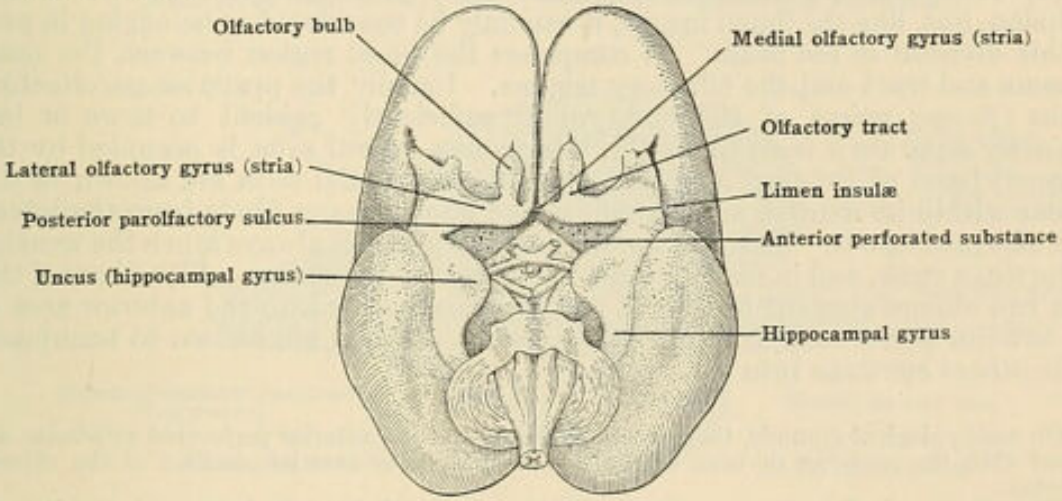

(2) The **olfactory tract** is a triangular band of white substance which arises in the olfactory bulb, and continues backward about 20 mm. to the region of the anterior perforated substance. It appears triangular in transverse section from the fact that its upper side fits into the olfactory sulcus. It becomes somewhat broader at its posterior end.

(3) The **olfactory trigone** (*olfactory tubercle*) is the small triangular ridge, the posterior continuation of the olfactory tract joining the anterior perforated substance. In it the olfactory tract breaks up into three roots, the *lateral, intermediate,* and *medial olfactory striæ* (*gyri*). The lateral olfactory stria emphasizes the lateral portion of the trigone into the **lateral olfactory gyrus,** a portion of which is directly continuous into the *limen insulæ* (figs. 676, 680).

While a few of the fibres of the lateral stria penetrate this region, the greater mass of them pass obliquely lateralward over it and gradually disappear in the antero-lateral portion of the anterior perforated substance, in which some of them terminate, but through which most of them pass to curve into the anterior end of the hippocampal gyrus and terminate there, chiefly in the uncus. In most of the mammals the lateral stria is so strong that it appears as a superficial white band passing directly into the uncus. In the early fœtus it is seen to enter the uncus in two branches, forming the medial **semilunar gyrus** and the lateral **gyrus ambiens** upon the uncus. A portion of the *limen insulæ* belongs to the rhinencephalon.

(4) The **parolfactory area** (Broca's area) involves the mesial extension of the olfactory trigone, and is concerned with the *medial olfactory* stria. On the basal surface of the hemisphere this area involves the posterior extremity of the gyrus rectus—a portion of which is sometimes separated from the remainder of the gyrus by a ventral prolongation of the *anterior parolfactory sulcus* of the medial surface (see figs. 679, 706). This prolongation when present has been called the **fissura serotina.** On the medial surface the parolfactory area appears as a

definite gyrus. In front this is separated from the superior frontal gyrus by the *anterior parolfactory sulcus*, and from the subcallosal gyrus behind by the deeper *posterior parolfactory sulcus* (fig. 679). It is continuous above into the gyrus cinguli of the limbic lobe, a portion of the posterior part of the rhinencephalon.

A large portion of the fibres of the medial stria are lost in the parolfactory area, and are known to terminate about the cells there. This stria or root of the olfactory tract forms a slight ridge on the ventral surface of the area, which is frequently prominent enough to retain the name **medial olfactory gyrus** applied to it in the fœtal brain (fig. 680).

(5) The **subcallosal gyrus** (peduncle of the corpus callosum) is the narrow fold of the pallium which lies between the posterior parolfactory sulcus and the rostral lamina and the ventral continuation of the latter into the lamina terminalis. It begins above, in part fused to the rostrum of the corpus callosum, and in part continuous with the gyrus cinguli, and ventrally it goes over lateralward and posteriorly into that portion of the anterior perforated substance known as the *diagonal band* of Broca, and in this way it extends into the uncus. Mesially, it approaches its fellow of the opposite side so closely that the groove separating the two is known as the *median subcallosal sulcus* of Retzius. Some fibres of the medial olfactory stria disappear in the substance of the subcallosal gyrus.

(6) The **anterior perforated substance** must be considered with the rhinencephalon, but, like the limen insulæ, it can only be considered as belonging in part to this division of the brain. It comprises the basal region between the optic chiasma and tract and the olfactory trigone. Usually the posterior parolfactory sulcus (*fissura prima* of the embryo) is sufficiently evident to more or less distinctly separate it from the latter. Its postero-lateral area is occupied by the diagonal band of Broca. A few fibres from the medial stria are known to disappear within its depths, and, as mentioned above, many fibres from the lateral stria also pass into it. The intermediate *olfactory stria* is always much the weakest of the three striæ, and in many specimens is apparently absent. The fibres of this stria run almost straight backward and plunge directly into the anterior area of the anterior perforated substance, where some of them are known to terminate, while others continue into the uncus.

On embryological grounds, the subcallosal gyrus and the anterior perforated substance are classed with the posterior division of the 'olfactory' lobe or anterior division of the rhinencephalon.

The olfactory bulb and tract arise as a hollow outgrowth from the lower and anterior part of the anterior of the three primary vesicles. It is a tubular structure at first, and in many of the mammals the cavity maintains throughout life as the *olfactory ventricle*. In man the cavity becomes occluded and the ependyma and gelatinous substance which surround it become the grey core of the bulb and tract of the adult.

The grey substance persists and develops chiefly in the bulb, and in fact produces it as such. It is much thicker on the inferior surface of the bulb than on the superior surface, and in section shows definite layers. From within outward, the principal of these layers are—(1) the layer of large cells whose shape suggests their name, *mitral cells;* (2) large dendrites of the mitral cells project toward the inferior surface of the bulb and there break up into numerous telodendria which copiously form synapses with like telodendria of the entering fibres of the olfactory nerve, thus forming rounded, much tangled glomeruli and the layer containing these, the *glomerular layer;* (3) the superficial layer, or *olfactory layer*, consists of the fibres of the olfactory nerve which form a dense interlacement with each other on the inferior surface of the bulb before they pass into its interior. The superior surface of the bulb becomes formed almost wholly of the fibres which arise as axones of the mitral cells and pass backward to form the olfactory tract, and thence to their localities of termination, chiefly by way of the three striæ. Along the dorsal, covered, aspect of the olfactory tract the gelatinous substance of the core may show through as a grey ridge.

The posterior division of the rhinencephalon or the so-called **limbic lobe** (a name introduced by Broca in 1878) takes part in both the medial and tentorial surfaces of the hemisphere (fig. 681). Seen from the medial surface, it forms an irregular elliptical figure which encloses the corpus callosum and the extremities of which approach each other at the anterior perforated substance, where they are continuous with the structures of the anterior division of the rhinencephalon. The figure is bounded externally by the sulcus cinguli above, by the subparietal sulcus (postlimbic sulcus) and the anterior limb of the calcarine fissure behind, and by the collateral fissure below. These respectively separate it from the frontal, parietal, occipital, and temporal lobes. It comprises the following

structures which are either wholly or in part devoted to the functions of the olfactory apparatus:—

1. Gyrus fornicatus
   - Part of gyrus cinguli and cingulum.
   - Isthmus of the gyrus fornicatus.
   - Hippocampus
     - hippocampal gyrus.
     - uncus.
     - dentate gyrus (fascia).
     - fimbria.
2. The medial and lateral longitudinal striæ upon the corpus callosum.
3. The fornix.
4. The mammillary body, the mammillo-thalamic fasciculus to the anterior nucleus of the thalamus and the mammillo-peduncular fasciculus.
5. Part of anterior cerebral commissure.
6. Part of septum pellucidum.
7. Most of medullary stria of thalamus.
8. Most of habenular nucleus.

The **gyrus fornicatus** comprises the greater mass of the limbic lobe. As seen above, it is a term used to collectively represent a number of conjoined structures.

FIG. 681.—DIAGRAM SHOWING POSITION OF STRUCTURES COMPRISING THE LIMBIC LOBE AS SEEN FROM THE MESIAL ASPECT OF THE CEREBRAL HEMISPHERE.

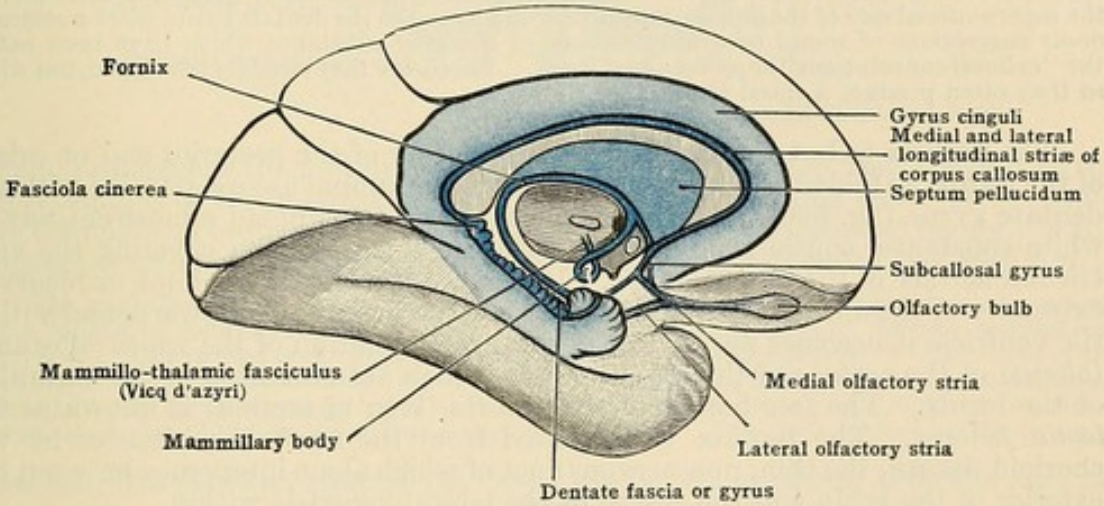

Being an incomplete ellipse in form, its two ends are united to form a closed ring by means of the connection of the parolfactory area with the gyrus cinguli and the connection of the anterior perforated substance with the uncus of the hippocampal gyrus. It is best described in terms of its three component parts indicated above:

The **gyrus cinguli** begins in junction with the area parolfactoria below the anterior end of the corpus callosum, and curves above so as to entirely embrace the upper surface of the latter. It is separated from the frontal lobe by the sulcus cinguli (calloso-marginal fissure), from the parietal lobe by the subparietal sulcus, and from the corpus callosum below by the **sulcus of the corpus callosum.** By the latter it is separated from the longitudinal striæ of the upper surface of the corpus callosum.

The gyrus cinguli covers over, and its cells are closely associated with, the **cingulum,** a well-marked arcuate band of white substance, which follows the gyrus in its bend around the rostrum and backward to turn around the splenium of the corpus callosum in the isthmus of the gyrus fornicatus, and then to course forward into the hippocampal gyrus and the uncus. The cingulum is largely an association fasciculus between the gyri of the temporal lobe and those gyri on the mesial surface of the cerebral hemisphere, its fibres for the most part running short courses, being continually added to it and continually leaving it. However, it contains olfactory axones running in two directions: (1) fibres from the medial olfactory stria and fibres arising in the parolfactory area, the gyrus subcallosus and the anterior perforated substance which course posteriorly for distribution in the cortex of the gyrus cinguli and hippocampal gyrus; (2)fibres arising in the hippocampal gyrus, especially the uncus, to course dorsalward through the isthmus and then forward as association fibres. Some fibres arising from the cortical cells of the gyrus cinguli pass inferiorly through the cingulum, through the corpus callosum and, anteriorly, through the septum pellucidum to join the fornix below (*perforating fibres of the fornix*).

The **isthmus of the gyrus fornicatus** is the constricted portion connecting the posterior end of the gyrus cinguli with that of the hippocampal gyrus (fig. 619

and 671). It is bounded externally by the anterior end of the calcarine fissure, and incloses the posterior turn of the cingulum.

The **hippocampus** is the name applied to the curved appearances produced in the floor of the lateral ventricle by the peculiar foldings of this part of the cerebral cortex. The *hippocampal gyrus* (gyrus of the hippocampus) is the main gyrus of the tentorial surface of the limbic lobe. Externally it is separated from the fusiform gyrus by the collateral fissure, and it is bounded internally by the **hippocampal** or, more inclusive, the **chorioid fissure.** Posteriorly it is partially divided by the calcarine fissure into the lingual gyrus (of the temporal lobe) and the isthmus of the gyrus fornicatus. Its anterior extremity is hooked backward and is known as the **uncus** (*gyrus uncinatus*). This is almost entirely separated from the temporal lobe by a groove, the **temporal notch.** If the hippocampal fissure be opened up, the **dentate gyrus** or fascia and the *fimbria* will be seen. These lie side by side, separated by the shallow **fimbrio-dentate sulcus** (fig. 690.)

The free edge of the dentate gyrus presents a peculiarly notched appearance, produced by numerous parallel grooves cutting it transversely. Its posterior end, sometimes called the *fasciola cinerea*, continues backward over the splenium of the corpus callosum, and upon the upper surface of the corpus callosum appears as a thin strip of grey substance which contains embedded in it the *medial* and *lateral longitudinal striæ*. This thin strip is sometimes called the **supracallosal gyrus** (*gyrus epicallosus, induseum griseum*), and is thought to represent a vestigial part of the hippocampal gyrus. Closely beneath the splenium of the corpus callosum, on the supero-mesial side of the hippocampal gyrus and mesial to the dentate gyrus, there sometimes occur suggestions of round or oval elevations of the grey substance which have been called the **"callosal convolutions"** or *gyri Andreæ Retzii*. Rarely are they strongly developed, but when so they often produce a spiral appearance.

The **fimbria** is but the fimbriated, free border of the posterior end or origin of the fornix, so folded as to project into the hippocampal fissure, parallel with the dentate gyrus (fig. 690). It is a conspicuous band composed almost entirely of white substance, continuous laterally with the thick stratum covering the ventricular surface of the hippocampus. It begins anteriorly in the hook or recurved extremity of the uncus. Traced backward, it is seen so curve upward, and within the ventricle it becomes part of the general accumulation of the white substance (*alveus*) of the surface of the hippocampus, which accumulation is the beginning of the fornix. The free border of the fimbria (seen in section) is known as the *tænia fimbriæ*. The fimbria is separated from the cerebral peduncles by the **chorioid fissure,** the thin, non-nervous floor of which alone intervenes between the exterior of the brain and the cavity of the lateral ventricle within.

The hippocampal fissure attains its greatest depth between the dentate gyrus and the hippocampal gyrus, and the resulting eminence produced in the floor of the lateral ventricle is known as the **hippocampus major,** as distinguished from the lesser eminence produced posteriorly by the end of the calcarine fissure and known as the *hippocampus minor* [calcar avis]. The collateral fissure may likewise produce a bulging in the wall of the ventricle, the *collateral eminence.* In transverse sections of the hippocampus major, the layers of grey and white substance present a coiled appearance known as the **cornu ammonis.** Externally the medial surface of the hippocampal gyrus adjoining the dentate gyrus has reflected over it a delicate reticular layer of white substance known as the *substantia reticularis alba* (*Arnoldi*).

The fornix is the great association pathway of the limbic lobe, and appears to be wholly concerned in the apparatus of the rhinencephalon. It is a bilateral structure arched beneath the corpus callosum, with which it is connected anteriorly by the septum pellucidum. Posteriorly it passes in contact with the splenium. It consists of two prominent strips of white substance, one for each hemisphere, the ends of which are separate from each other, while their intermediate parts are fused across the mid-line. These run above the chorioid tela of the third ventricle, and their lateral edges (*tæniæ fornicis*) rest, on each side, along the line of the tænia chorioidea. The posterior, separate ends are known as the posterior pillars or crura of the fornix; the fused, intermediate portion is the body, and the separate, anterior ends are the anterior pillars or columns of the fornix.

The posterior pillars [crura] of the fornix.—When seen from the medial aspect of the hemisphere, the fused portion of the fornix, in the separation of the hemispheres, is split along the mid-line (fig. 671). The half under examination

may be seen to course obliquely lateralward under the splenium of the corpus callosum, and then, continuous into the fimbria, to curve forward and ventralward toward the uncus. The greater mass of the fibres coursing in the fornix arise as outgrowths of the cells of the uncus, hippocampal gyrus, and dentate gyrus. They accumulate as a dense stratum on the ventricular surface of these gyri, termed the **alveus,** which crops outward as the fimbria and which passes backward and upward; upon reaching the region of the splenium it turns obliquely forward under

FIG. 682.—DIAGRAM SHOWING FORNIX AND ITS CONNECTIONS AS SEEN FROM ABOVE.

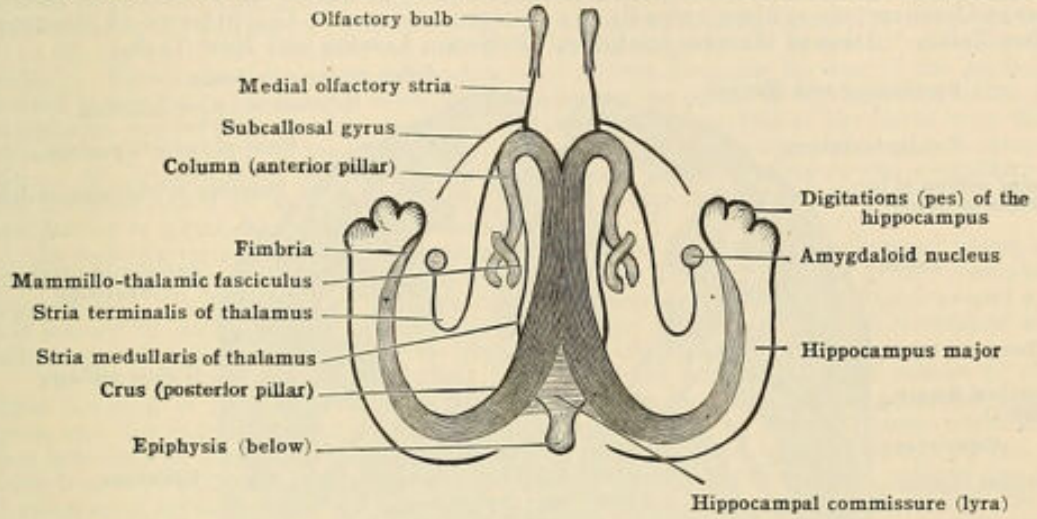

it and approaches the mid-line, to fuse with the like bundle from the gyri of the hippocampus of the opposite side. The bundles thus arising from the two sides are the pillars or crura of the fornix. They appear as two flattened bands of white substance which come in close contact with and even adhere to the splenium.

The angle formed by the mutual approach of the posterior pillars of the fornix is crossed by a lamina of commissural fibres connecting the hippocampal gyri of the two hemispheres (fig. 684). This lamina is the **hippocampal commissure** or *transverse fornix*. Like those of the fornix, its fibres arise from the cortex of the hippocampal gyri, but they serve as commissural fibres between the hippocampal gyri of the two hemispheres. Being of a different functional direction, it should not be considered a part of the fornix. The angle formed by the two pos-

FIG. 683.—DIAGRAM ILLUSTRATING THE ORIGIN AND COURSE OF FORNIX AS VIEWED FROM THE SIDE.

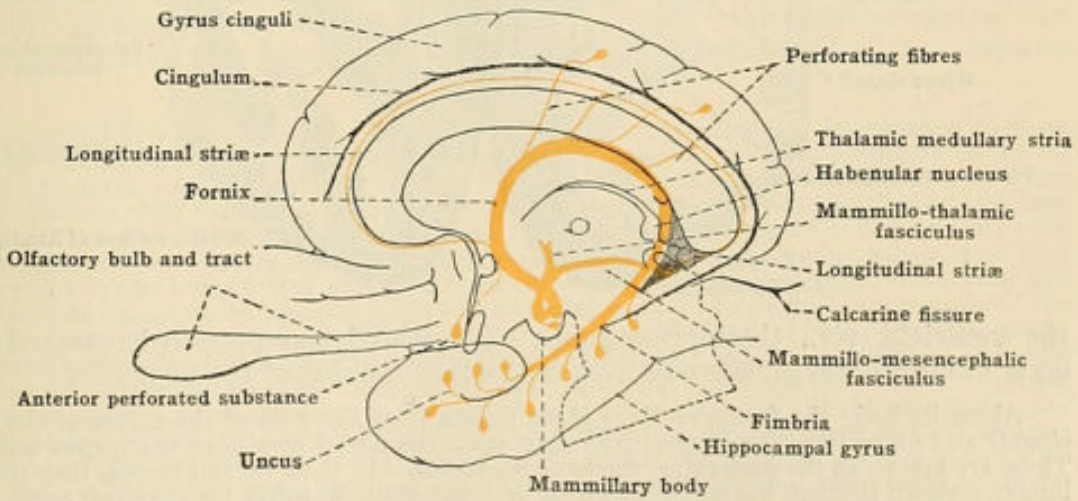

terior pillars of the fornix as traversed by the hippocampal commissure gives a picture named the **psalterium** or **lyra.** Usually the hippocampal commissure and the posterior pillars (crura) are in close contact with the under surface of the splenium. When occasionally they do not adhere, the space between is known as **Verga's ventricle.** According to recent studies of brains with degenerated corpus callosum, further commissural fibres between the limbic lobes course in the posterior angle of the septum pellucidum, and all along, transverse to the body of the fornix.

The body of the fornix appears as a triangular plate of white substance produced by the fusion of the pillars. Its base or widest portion is behind. It is not always bilaterally symmetrical. Its upper surface is attached by the septum

pellucidum to the lower surface of the corpus callosum. Below, it lies over the chorioid tela of the third ventricle, which separates it mesially from the cavity of the third ventricle and laterally from the upper surfaces of the thalami. Its sharp lateral edge or margin (tænia fornicis) projects into the lateral ventricle of either side in relation with the chorioid plexus of that ventricle, and thus the lateral portion of its upper surface forms part of the floor of the lateral ventricle—an arrangement to be expected, since the posterior pillars arise from the floor of

FIG. 684.—HORIZONTAL SECTION OF TELENCEPHALON SHOWING BODY OF FORNIX AND HIPPOCAMPAL COMMISSURE AS SEEN FROM BELOW AND THE ANTERIOR COMMISSURE IN SECTION. (After Toldt, "Atlas of Human Anatomy," Rebman, London and New York.)

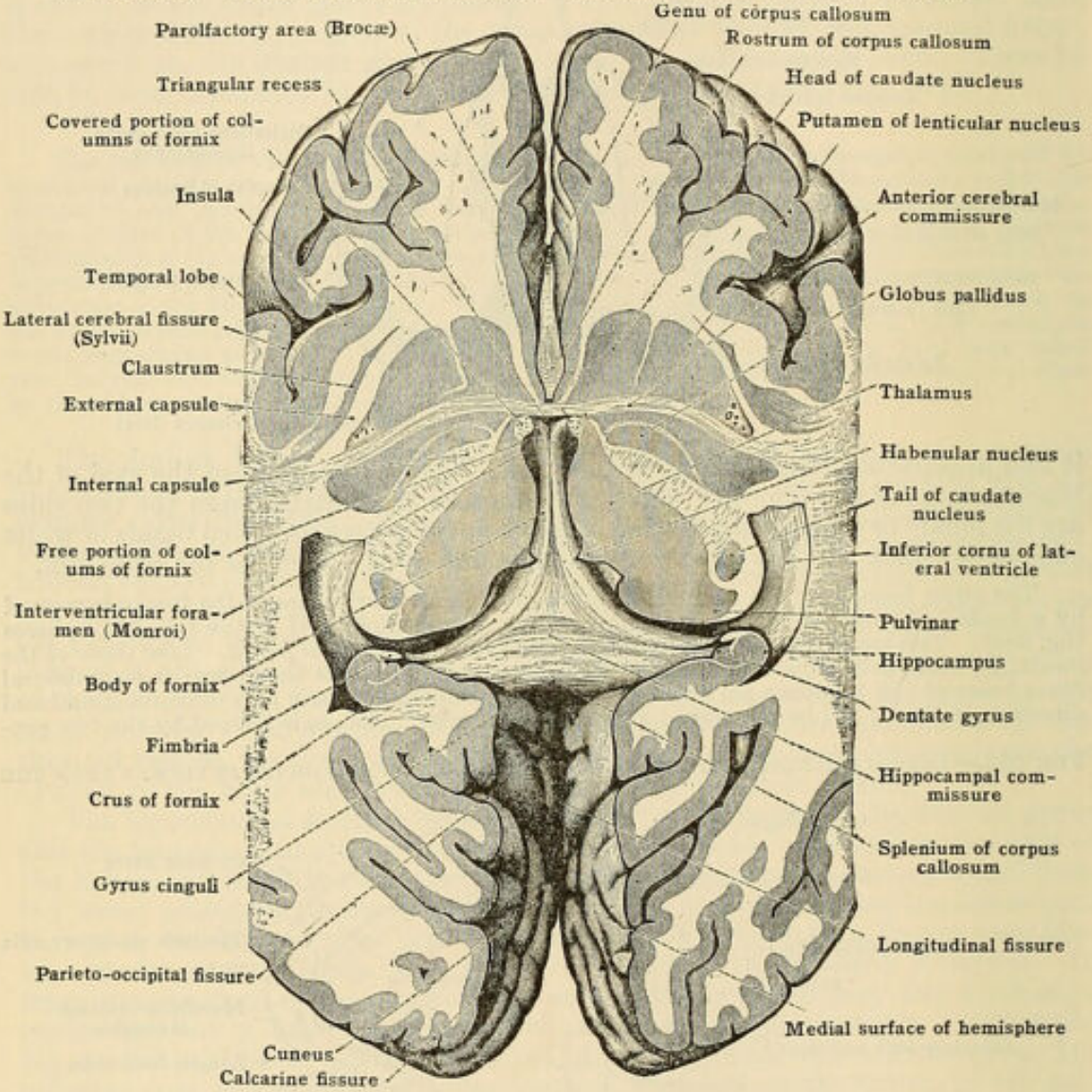

the ventricle, viz., the hippocampus. The ventricular portion is covered by a layer of ependyma in common with that lining the rest of the ventricle.

Along its body the fornix receives fibres arising from the cells of the cortex of the gyrus cinguli and fibres from the longitudinal striæ upon the dorsal surface of the corpus callosum. These are known as the **perforating fibres of the fornix.** In their ventral course, they pass obliquely forward through the corpus callosum and, anteriorly, through the posterior angle of the septum pellucidum to join the fornix and course in its functional direction. The fibres arising in the cortex of the gyrus cinguli may course short distances in the cingulum before perforating the corpus callosum.

The columns or anterior pillars of the fornix [columnæ fornicis], are two separate, cylindrical bundles which pass forward from the apex of the body of the fornix and then turn sharply downward along the anterior boundary of the third ventricle, just behind the anterior cerebral commissure. A part of each column, the *free portion* [pars libera], forms the anterior boundary of the interventricular foramen (Monroi). Thence the *covered portion* [pars tecta] sinks into the grey

substance of the lateral wall of the third ventricle, and passes downward to the base of the brain, where it appears on the exterior as the **mammillary body** [corpus mammillare] (fig. 671).

Some of its fibres are interrupted in the nuclei of the mammillary body, chiefly in its lateral nucleus; probably most of them merely double back, forming a genu. From the mammillary body the fibres are disposed in at least three ways:—(1) The greater part perhaps pass directly upward and are lost in the *anterior nucleus of the thalamus*, where they ramify freely and terminate about its cells. These fibres form the bundle known as the **mammillo-thalamic fasciculus**, or bundle of Vicq d'Azyr; (2) A portion of the fibres go to form a **mammillo-mesencephalic fasciculus** (**tegmento-mammillary fasciculus**, *mammillo-peduncular fasciculus*. This begins in the mammillary body and passes caudalward into the mesencephalon to terminate about cell-bodies in or in the region of, the so-called *nucleus of the medial longitudinal fasciculus and posterior commissure*. Fibres given by these cell-bodies may convey impulses by way of the medial longitudinal fasciculus or the general reticular formation to the nuclei in the mesencephalon, rhombencephalon and perhaps into the spinal cord. Some of this portion of the fibres from the mammillary body are said to pass caudalward through the mesencephalon without interruption there. (3) A portion of the fibres decussate in the superior parts of the mamillary bodies and are distributed to both the thalamus and the mesencephalon of the opposite side. This decussation is the **supramamillary commissure.**

As seen above, the fornix as a whole is composed of longitudinally directed fibres, some of which, however, cross the mid-line in the region of its body and course in the columns of the opposite side. For the greater part, its fibres rise from the cells of the hippocampal gyri, but it is known to contain some fibres which arise in the anterior perforated substance and subcallosal gyrus and course through the fornix to the hippocampal gyri.

The **medial** and **lateral longitudinal striæ** upon the corpus callosum consist of olfactory fibres coursing in both directions: (1) fibres arising in the parolfactory area, the subcallosal gyrus and the anterior perforated substance (diagonal band of Broca) course posteriorly and then inferiorly in them to the grey substance of the gryi of the hippocampus; (2) and chiefly, fibres from the hippocampal gyri course in them anteriorly and inferiorly around the rostrum of the corpus callosum, through the ventral part of the septum pellucidum, to join the fornix. It is suggested that the striæ, especially the medial, may be considered as a part of the fornix detached upon the dorsal surface of the corpus callosum during the projection of the latter between the cerebral hemispheres. The medial stria is often called the *stria Lancisii*.

The anterior cerebral commissure is only in part concerned in the rhinencephalon; it consists in greater part of commissural fibres connecting the two temporal lobes. It forms one of the four commissures of the telencephalon, the other three being the corpus callosum, the hippocampal commissure and the inferior cerebral commissure. It is a bundle of white substance with a slightly twisted appearance, which crosses the mid-line in the anterior boundary of the third ventricle between the lamina terminalis and the columns of the fornix (figs. 671 and 684), just below the interventricular foramen (foramen of Monro). In each hemisphere its main or temporal portion passes lateralward and slightly backward beneath the head of the caudate nucleus and through the anterior end of the lenticular nucleus, and thence is dispersed to the grey substance of the temporal lobe.

It contains fibres both to and from the temporal lobe of each side. In addition to these fibres the anterior commissure carries in its frontal side two sets of fibres belonging to the olfactory apparatus:—(1) fibres arising in the olfactory bulb of one side, which pass by way of the medial olfactory striæ through it to the olfactory bulb of the opposite side; (2) fibres which pass through it from the medial stria (olfactory bulb) of one side to the uncus of the opposite side.

The anterior commissure is a more primitive commissure than the corpus callosum, in that it is present in the lower forms when the latter is absent, and diminishes in relative size and importance as the corpus callosum appears and increases in size. In man the appearance of the anterior commissure precedes but little that of the corpus callosum. During the fifth month the lamina terminalis, which then alone unites the anterior ends of the two hemispheres, develops a thickening of its dorsal portion. In a part of this thickening, transverse fibres begin to appear and their increase in number results in the partial separation posteriorly of the part containing them from the rest of the lamina, and then follows the differentiation of this part into the anterior commissure. The remainder of the thickening of the lamina continues to increase in size with the increase of the hemispheres; its upper edge is directed posteriorly, and fibres begin to appear in it which arise in the cortex of one side and cross over to that of the other side. These fibres form the corpus callosum.

The corpus callosum, a development of fibres in the upper, expanded portion of the lamina terminalis, thus bridges over a portion of the longitudinal fissure between the hemispheres. In the mean time, the *fornix* arises as two bundles of fibres, one from the hippocampus of each side. In the complex mechanics of the development of the cerebrum these two bundles approach each other under the corpus callosum, fuse for a certain distance, and together arch the cavity of the third ventricle and come to acquire their adult position. There results from these processes of growth a completely enclosed space, a portion of the longitudinal fissure, the roof of which is the corpus callosum, its floor, the body of the fornix, and its lateral walls, portions of the mesial surfaces of the two cerebral hemispheres. The lateral walls of this space do not thicken

as do the other regions of the pallium, but remain thin and constitute the *septum pellucidum* of the adult, the space itself being the so-called *fifth ventricle* or cavity of the septum pellucidum.

The **septum pellucidum** is a thin, approximately triangular, vertically placed partition which separates the anterior portions of the two lateral ventricles from each other. Its widest portion lies in front, bounded by the genu and rostrum of the corpus callosum, the rostral lamina, and the anterior pillars of the fornix, to all of which it is attached. Prolonged backward under the body of the corpus callosum, it narrows rapidly and terminates at the line of adherence between the posterior portion of the fornix and the splenium of the corpus callosum. It consists of two thin layers, the **laminæ of the septum pellucidum,** arrested developments of portions of the pallium of the hemispheres. The laminæ enclose a narrow median cavity known as the **fifth ventricle** [cavum septi pellucidi]. This cavity is of very variable size, is completely closed, and does not merit the term 'ventricle,' as applied to the other cavities of the brain, in that it has no communication with the ventricular system and has a different lining from the other ventricles.

FIG. 685.—DIAGRAM SHOWING SOME OF THE PRINCIPAL TRACTS AND SYNAPSES OF THE OLFACTORY APPARATUS.

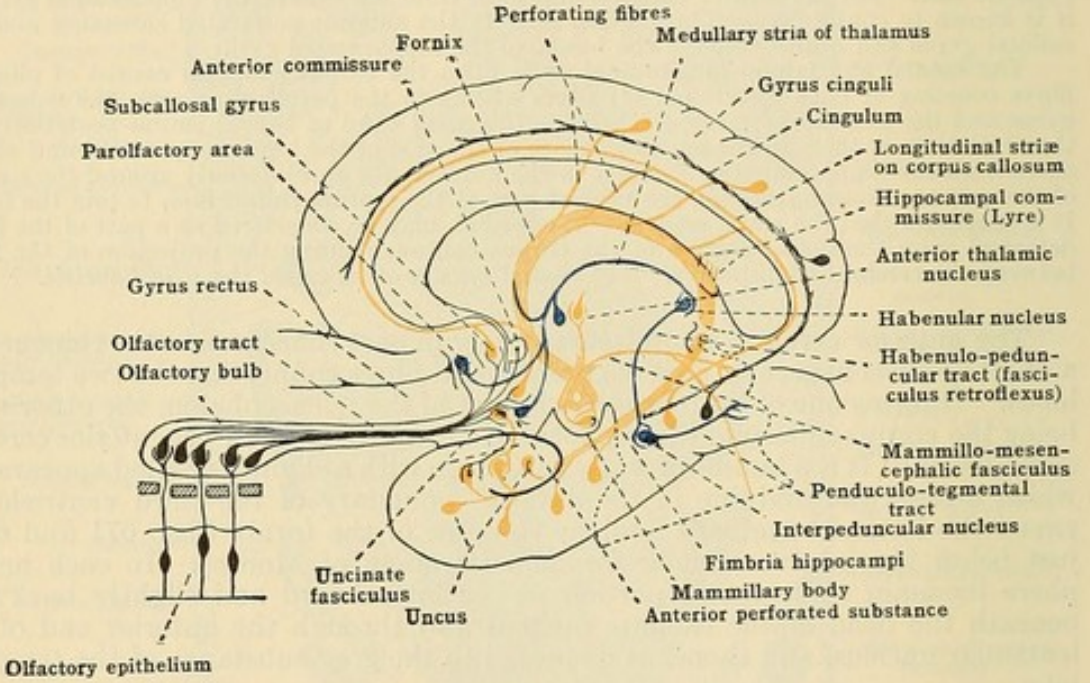

Each lamina of the septum pellucidum consists of a layer of degenerated grey substance next to the fifth ventricle and a layer of white substance next to the lateral ventricle, the latter covered by a layer of ependyma common to that ventricle. The white substance consists in part of fibres belonging to the general association systems of the hemispheres, and in part of four varieties of fibres concerned with the rhinencephalon:—(1) fibres from each medial olfactory stria are known to reach the septum pellucidum and thence go by way of the fornix to the hippocampus major; (2) fibres are thought to be contributed by the fornix to the septum pellucidum, and through it reach the subcallosal gyrus and perhaps the parolfactory area and even the olfactory bulb; (3) the posterior angle of the septum pellucidum is preforated by some commissural fibres passing from the body of the fornix and by some perforating fibres of the fornix, passing from above through it to the fornix below; (4) anteriorly, some fibres from the longitudinal striæ upon the corpus callosum pass through its inferior portion to join the fornix.

The medullary stria of the thalamus [stria medullaris thalami] (*striæ pinealis, tænia thalami*), already described as to position, receives fibres from three sources, the majority at least of which belong to the rhinencephalon: (1) fibres from the fornix near-by and thus from the cortex of hippocampal gyrus and gryus cinguli (a cortico-habenular tract); (2) fibres from the parolfactory area and the anterior perforated substance, through the septum pellucidum and lamina terminalis (a more direct olfacto-habenular tract); (3) fibres arising from the cell-bodies in the thalamus, supposedly chiefly from its anterior (olfactory) nucleus. These latter fibres make a thalamo-habenular tract.

The majority of the fibres of the medullary striæ terminate in the **habenular nuclei,** situated at the two sides of the stalk of the epiphysis. Most terminate in the habenular nucleus of the same side. Some cross in the *habenular commissure* (dorsal part of the posterior cerebral commissure) and terminate in the nucleus of the opposite side. A few are claimed to pass to the nuclei of the quadrigeminate bodies and a few others to join the association tracts of the mesencephalon. Axones given off by the cells of the habenular nucleus curve anteriorly, inferiorly, and then course posteriorly (fasciculus retroflexus) to terminate in the *interpeduncular nucleus*

(*a habenulo-peduncular tract*), and fibres arising in this latter nucleus pass to the cells about the central grey substance of the mesenecphalon (an inter-pedunculo-tegmental tract). The two mesencephalic paths here noted and the mammillo-mesencephalic fasciculus noted above give three anatomical possibilities for olfactory reflex activities, visceral (or sympathetic) and somatic, involving the motor cranial nerves and possibly the spinal nerves. Fibres arising in the cortex of the hippocampal gyrus, uncus especially, may pass by way of the cingulum and thence by any suitable association fasciculus of the cerebral hemisphere to the motor area of the cerebral cortex; also fibres may arise from the anterior nucleus of the thalamus and pass to the motor cortex by way of the internal capsule. From the motor cortex, the descending pyramidal fibres give the possibilities for any higher cortical activities induced by smell.

A more direct mesencephalic path has been suggested by Wallenberg, namely, that cells in the olfactory trigone and anterior perforated substance, about which terminates fibres of the olfactory tract, send axones directly posteriorly, around the tuber cinereum, to terminate in the mammillary body and thence the impulses may go to the mesencephalon. Such fibres, if they exist, would form an *olfacto-mammillary tract*. A path is described in the hedge-hog which arises from cells in the olfactory trigone and passes directly posteriorly to terminate in the grey substance of the mesencephalon—an *olfacto-mesencephalic tract*.

To the complicated central connections of the sense of smell, Dejerine adds yet another path, namely, a portion at least of the **terminal stria** [stria terminalis] of the thalamus (tænia semicircularis). This contains fibres arising from cells in the anterior perforated substance and in the septum pellucidum and fibres from the opposite side by way of the anterior commissure. It runs a crescentic course posteriorly, bounding the thalamus from the caudate nucleus, turning downward and then anteriorly in the wall of the inferior cornu of the lateral ventricle to terminate in the amygdaloid nucleus, which latter is a more or less detached bit of the cortex of the extreme anterior portion of the hippocampal gyrus (uncus). The stria is said also to contain fibres which arise in the amygdaloid nucleus and course in it forward to be given off to the thalamus and probably to the internal capsule and thence to the cerebral cortex above.

SUMMARY OF THE OLFACTORY APPARATUS

I. Peripheral part.

(1) Olfactory area of nasal epithelium containing the cell-bodies and peripheral processes of olfactory neurones (*olfactory ganglion*).

(2) Non-medullated central processes of olfactory neurones, the *olfactory nerve*, passing as numerous filaments through the cribriform plate of the ethmoid, to terminate in contact with the dendrites of the "mitral cells" (stratum glomerulosum) in the olfactory bulb.

II. The Rhinencephalon.

A. The anterior division.

(1) Olfactory bulb, olfactory tract, olfactory trigone (tubercle), lateral olfactory stria (gyrus), medial and intermediate olfactory striæ.

(2) The parolfactory area, subcallosal gyrus, anterior perforated substance including the diagonal band of Broca.

B. The posterior division.

(1) Part of anterior commissure, septum pellucidum, uncinate fasciculus, hippocampal gyrus (uncus especially), dentate gyrus, gyrus cinguli and cingulum.

(2) Fimbria, hippocampal commissure, fornix, longitudinal striæ upon corpus callosum, mammillary body, mammillo-thalamic fasciculus, mammillo-mesencephalic fasciculus.

(3) The anterior nucleus of the thalamus.

(4) The medullary stria of the thalamus, habenular nucleus, fasciculus retroflexus, interpeduncular nucleus, and interpedunculo-tegmental tract.

(5) Probably an olfacto-mammillary and an olfacto-mesencephalic tract, and a part of the terminal stria of the thalamus with the amygdaloid nucleus.

THE LATERAL VENTRICLES

Two of the four cavities of the ventricular system of the brain are in the telencephalon. From their position, one in each cerebral hemisphere, they are known as the **lateral ventricles.** They arise as lateral dilations of the cavity of the anterior of the primary vesicles, and, just as the fourth ventricle remains in communication with the third by way of the aqueduct of the cerebrum, so the lateral are connected with the third by the two interventricular foramina (Monroi). The whole ventricular system, including the central canal of the spinal cord, is lined by a continuous layer of ependyma and contains a small quantity of liquid known as the cerebro-spinal fluid.

Each lateral ventricle is of an irregular, horseshoe shape. It consists of a *central portion* or body and three cornua, which correspond to the three poles of the hemisphere. The portion projecting into the frontal lobe is known as the *anterior cornu*, that projecting into the occipital lobe is the *posterior cornu*, and the portion which sweeps anteriorly downward into the temporal lobe is the *inferior cornu*. The ventricles of different individuals vary considerably in capacity, and the cavity of a given ventricle is not uniform throughout. In some

localities the space may be quite appreciable, while in other places the walls may be approximate or even in apposition. Each lateral ventricle is a completely closed cavity except at the interventricular foramen. However, a strip of the floor of the inferior cornu is separated from the exterior of the brain by only the thin, non-nervous lamina forming the floor of the chorioid fissure.

The **interventricular foramen** (foramen of Monro), by which the lateral ventricle is continuous with the cavity of the third ventricle, is a small, roundish chan-

FIG. 686.—A CAST OF THE FOUR VENTRICLES OF THE ENCEPHALON. (After Welcker.)

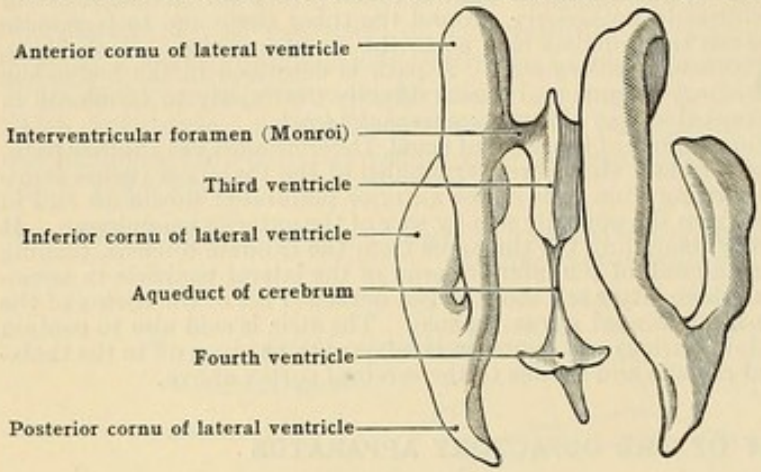

nel, 2 to 4 mm. wide, which opens into the mesial side of the posterior end of the anterior cornu. It is bounded in front by the free portion of the anterior pillars of the fornix, and behind by the anterior tubercle of the thalamus. That the greater part of the lateral ventricle is posterior to it is due to the backward extension of

FIG. 687.—DIAGRAM OF SAGITTAL SECTION THROUGH LATERAL PART OF RIGHT HEMISPHERE SHOWING LATERAL VENTRICLE FROM THE MESIAL SIDE OF THE SECTION.

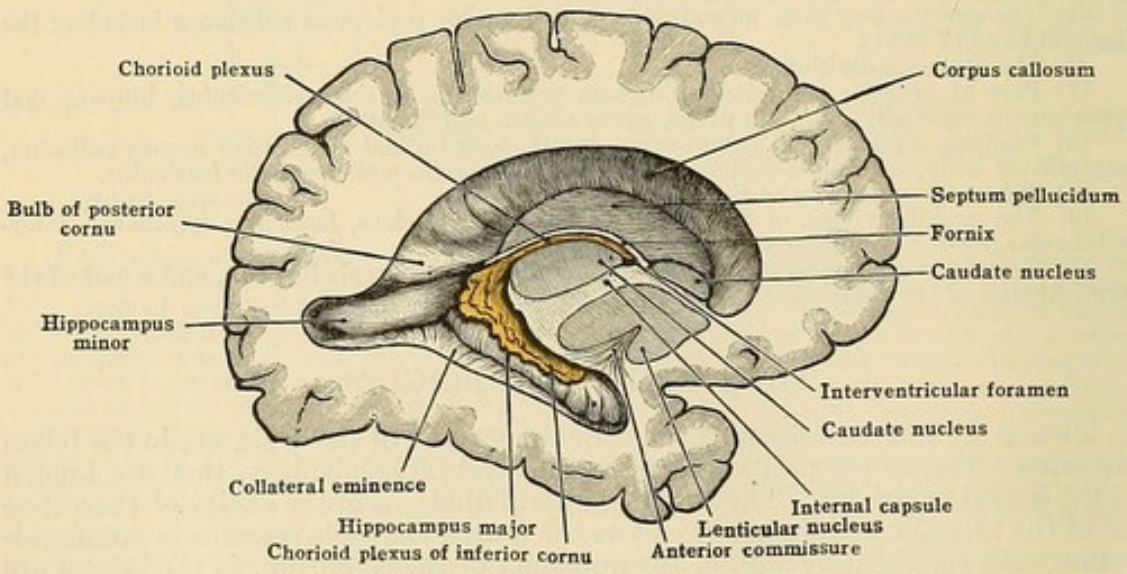

the hemispheres during their growth and elaboration. Through the two foramina indirectly, the cavities of the two lateral ventricles are in communication with each other.

The walls of the lateral ventricle.—The **anterior cornu** is a bowl-like cavity, convex forward and extending downward and medialward into the frontal lobe. Above and anteriorly it is bounded by the under surface of the corpus callosum and the radiations of its genu into the substance of the frontal lobe. Its median boundary is the septum pellucidum; the head of the caudate nucleus (part of the corpus striatum) gives it a bulging, infero-lateral wall, and the balance of its floor is formed by the white substance of the orbital part of the frontal lobe.

The **central portion** or body is more nearly horizontal. It lies within the parietal lobe and extends from the interventricular foramen to the level of the splenium of the corpus callosum. Its roof is formed by the inferior surface of the body of the corpus callosum, and its mesial wall consists of the posterior part of the septum pellucidum, attaching the fornix to the under surface of the corpus callosum. Like the anterior horn, it is given an oblique, infero-lateral wall by the narrower, middle part of the caudate nucleus. Several structures contribute to its floor:—(1) the stria terminalis of the thalamus, a line of white substance conforming to the genu of the internal capsule without, and constituting the

FIG. 688.—HORIZONTAL DISSECTION OF THE CEREBRAL HEMISPHERES.
The fornix has been removed to show the relation of the tela chorioidea of the third ventricle to the chorioid plexus of the lateral ventricles. (From a mounted specimen in the Anatomical Department of Trinity College, Dublin.)

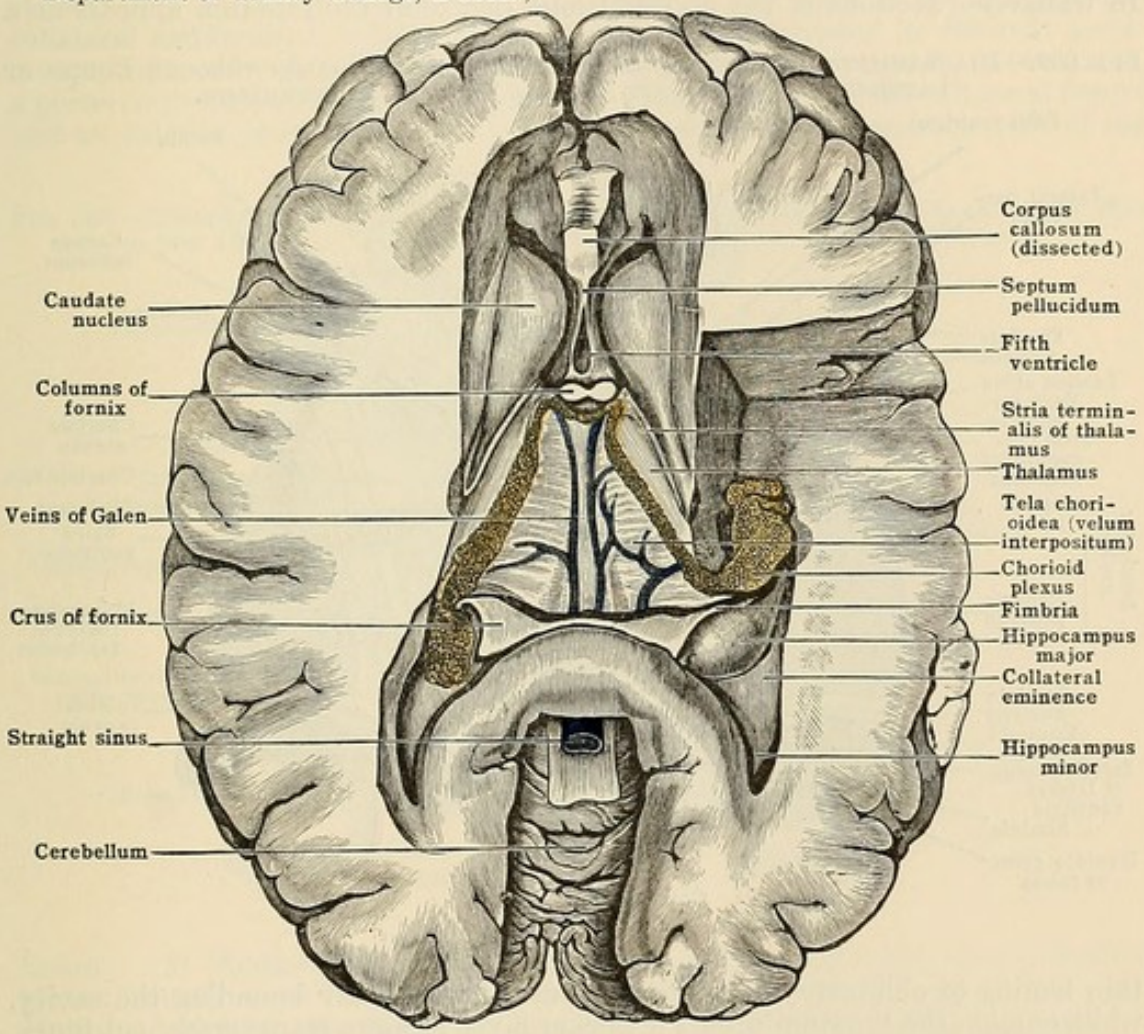

boundary between the caudate nucleus and the thalamus, and containing (2) the vena terminalis (vein of the corpus striatum); (3) the lamina affixa, a mesial continuation of the stria terminalis upon the surface of (4) the lateral part of the thalamus; (5) the medial edge of the lamina affixa, the tænia chorioidea, and the chorioid plexus continuing under (6) the edge (tænia) of the body and the beginning crura (posterior pillars) of the fornix (fig. 688).

The chorioid plexus of the lateral ventricle is continuous with that of the third ventricle. The chorioid tela of the third ventricle (velum interpositum) continues under the tænia of the fornix into the lateral ventricle, and there, along the line of the tænia chorioidea, becomes elaborated into a varicose, convoluted, villus-like fringe, rich in venous capillaries and lymphatics. This fringe is the chorioid plexus. It is continuous anteriorly, at the interventricular foramen, with the corresponding plexus of the opposite lateral ventricle and with the chorioid plexus of the third ventricle. The latter consists of two similar but smaller fringes, which project close together into the cavity of the third ventricle from the median portion of the ventral surface of the chorioid tela. Behind, the chorioid

plexus of the lateral ventricle curves posteriorly and inferiorly into the inferior cornu, being especially well developed at the region of its entrance into the latter, into what is called the **chorioid glomus.**

Though apparently lying free in the ventricle, the chorioid plexus is invested throughout by a layer of epithelium, the **epithelial chorioid lamina,** which is adapted to all its unevennesses of surface and which is a continuation of the ependymal lining of the remainder of the ventricle —continuous, on the one hand, with that of the lamina affixa and thalamus, and, on the other, with the epithelial covering upon the upper surface of the tænia of the fornix and fimbria.

The **posterior cornu** of the lateral ventricle is a crescentic cleft of variable length, convex lateralward, which is carried backward from the posterior end of the body of the ventricle and, curving medialward, comes to a point in the occipital lobe. Its *roof* and *lateral wall* are formed by a portion of the posterior radiation of the corpus callosum, which forms a layer, from its appearance known as the **tapetum.** In transverse sections of the occipital lobe (fig. 699) the tapetum appears as a

FIG. 689.—DIAGRAMMATIC TRANSVERSE SECTION OF PROSENCEPHALON THROUGH BODIES OF LATERAL VENTRICLES AND MIDDLE OF THALAMENCEPHALON.

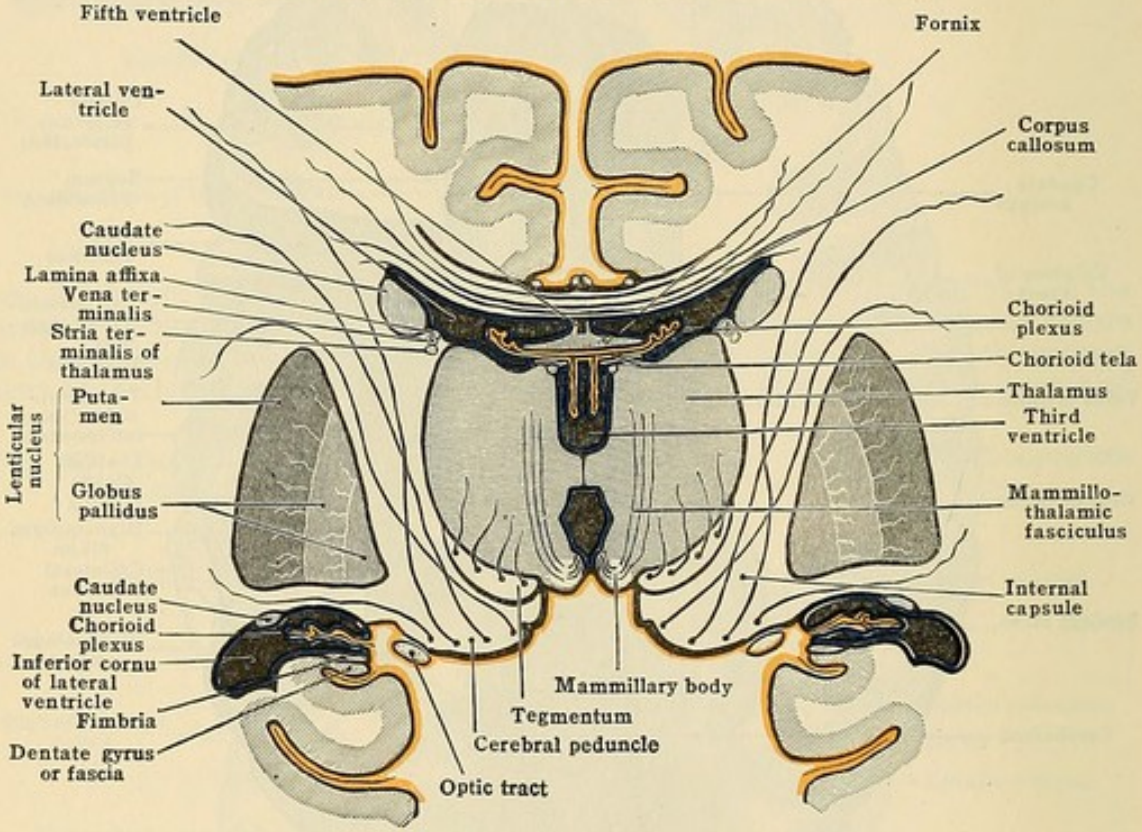

thin lamina of obliquely cut white substance immediately bounding the cavity, while outside the tapetum occurs a thicker layer of more transversely cut fibres, the occipito-thalamic radiation. In the medial or *inner wall* of the posterior horn run two variable longitudinal eminences:—(1) The superior of these is the **bulb of the posterior cornu,** and is formed by the occipital portion of the radiation of the corpus callosum (splenium), which bends around the impression of the deep parieto-occipital fissure, and, hook-like, sweeps into the occipital lobe. In horizontal sections these fibres, together with the splenium and the similar fibres into the opposite occipital lobe, form the figure known as the **forceps major.** (2) The inferior and thicker of the eminences is the **hippocampus minor [calcar avis]** (cock's spur), and is due to the anterior part of the calcarine fissure, by which the wall of the hemisphere is projected into the ventricle. The posterior horn, like the anterior, is not entered by the chorioid plexus.

The inferior cornu.—In its inferior and slightly lateral origin from the region of junction between the body of the ventricle and the posterior cornu, the inferior horn aids in producing a somewhat triangular dilation of the cavity known as the **collateral trigone.** Beginning as a part of the trigone, the cavity of this horn at first passes posteriorly and lateralward, but then suddenly curves anteriorly and

inferiorly into the medial part of the temporal lobe nearly parallel with the superior temporal sulcus. Above, it follows the curved crura (posterior pillars) of the fornix and fimbria; below, it does not extend to the temporal pole by from 2 to 3 cm. The *roof* and *lateral wall* are, for the most part, like those of the posterior horn, being formed by the tapetum, but medialward a strip of the roof is formed by the attenuated, inferior prolongation, or tail, of the caudate nucleus, together with the inferior extension of the stria terminalis of the thalamus. At the end of the inferior horn the roof shows a bulging, the **amygdaloid tubercle,** situated at the termination of the tail of the caudate nucleus. This bulging is produced by the *amygdaloid nucleus,* an accumulation of grey substance continuous with that of the cortex of the hippocampal gyrus, and which gives origin to part of the longitudinal fibres coursing in the stria terminalis of the thalamus.

In the *medial wall* and floor of the inferior horn the following structures are shown:—(1) In the posterior or trigonal part of the floor is the longitudinal **collateral eminence,** a bulging, very variable in development in different specimens, produced by the collateral fissure. This is often pronouncedly in two parts, a posterior prominence corresponding to the middle portion of the collateral fissure and an anterior prominence (less frequent) produced by the anterior part of the

FIG. 690.—DISSECTION OF RIGHT TEMPORAL LOBE SHOWING THE MEDIAL WALL OF THE END OF THE INFERIOR HORN OF THE LATERAL VENTRICLE. (From Spalteholz.)

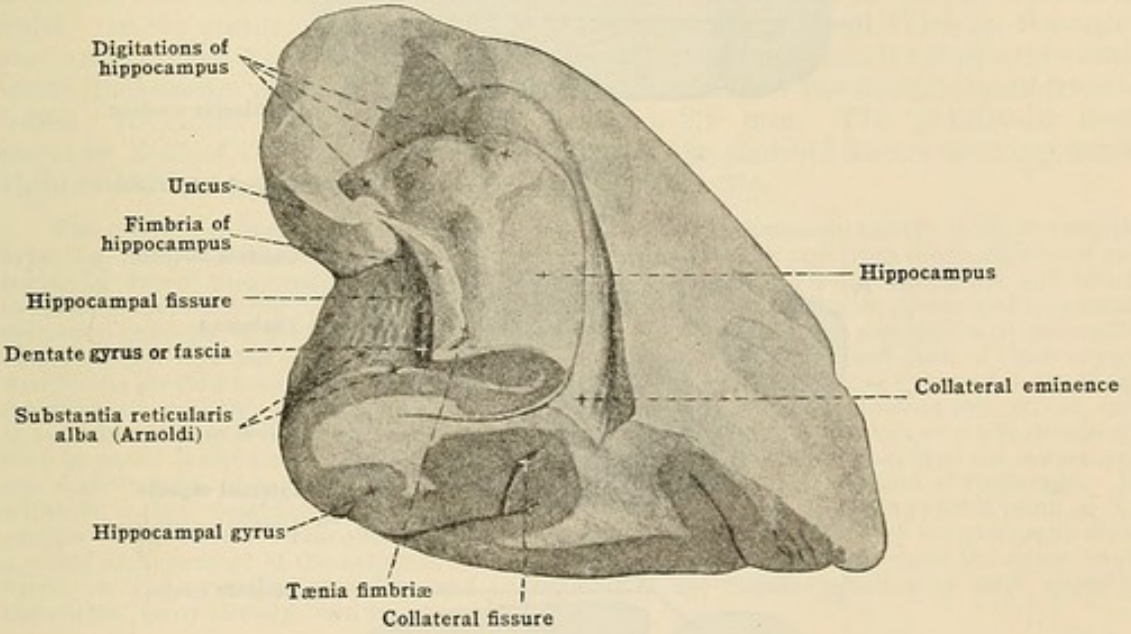

fissure. (2) Medial to this eminence lies the inferior extension of the **chorioid plexus,** usually more voluminous than the part in the body of the ventricle. (3) Partly covered by the chorioid plexus is the **hippocampus major,** a prominent, sickle-like ridge corresponding to the indentation of the hippocampal fissure. It begins as a narrow ridge posteriorly, at the end of the body of the ventricle, as the extension of the posterior pillar of the fornix, and expands anteriorly as the ventricular surface of the uncus. Its surface is not regular, but shows a concave medial margin as distinguished from a wider, convex, lateral surface. Its termination in front (*pes hippocampi*) is divided by two or three flat, radial grooves into a corresponding number of short elevations known as the *hippocampal digitations.* It is covered by a thick stratum of white substance, the *alveus,* arising from its depths and continued mesially into the fimbria. (4) The **fimbria** is so folded that its margin, *tænia fimbriæ,* lies in the cavity of the inferior horn attached to the chorioid plexus and the thin, non-nervous floor of the chorioid fissure.

The caudate nucleus (fig. 691).—As realised in the study of the lateral ventricle, the caudate nucleus is a comma-shaped mass of grey substance with a long, much-curved, and attenuated tail. Its *head* forms the bulging lateral wall of the anterior horn; thence it proceeds posteriorly in the lateral wall of the body of the ventricle and, at the collateral trigone, curves downward and its *tail* becomes

a medial portion of the roof of the inferior horn. It is separated from the thalamus adjacent to it by the stria terminalis of the thalamus (tænia semicircularis). The end of its tail extends anteriorly below to the level of the anterior horn of the ventricle above. Owing to its much curved shape, both horizontal and vertical sections of the hemisphere passing through the inferior horn may contain the nucleus cut at two places (see figs. 694 and 698.)

The caudate nucleus is the intraventricular of the two masses of grey substance which together are sometimes referred to as the **basal ganglia.** The extraventricular of these masses is the *lenticular nucleus*, which is buried in the substance of the hemisphere, laterally and inferior to the caudate nucleus. The two masses

FIG. 691.—DIAGRAMS OF LATERAL VIEW AND SECTIONS OF THE NUCLEI OF THE CORPUS STRIATUM WITH THE INTERNAL CAPSULE OMITTED.

A and B below represent horizontal sections along the lines A and B in the figure above. The figure also shows the relative position of the thalamus and the amygdaloid nucleus.

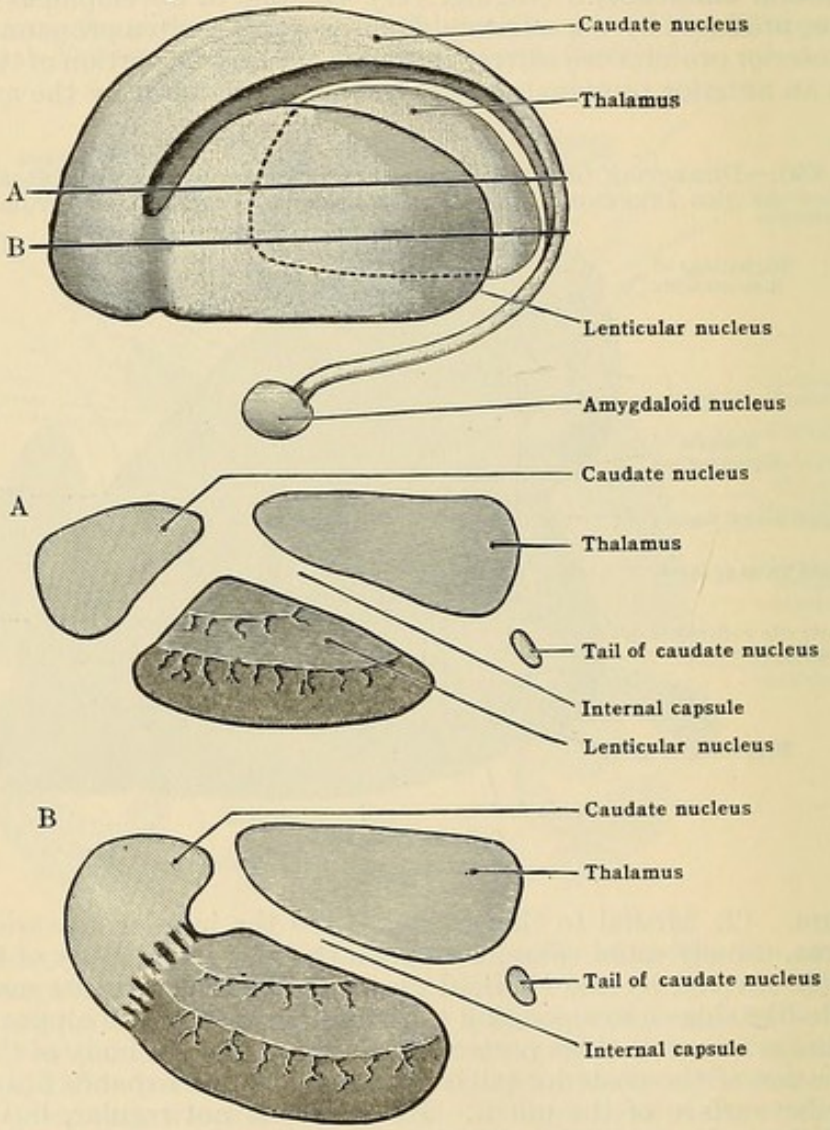

are separated by the *internal capsule*, a thick band of nerve-fibres continuous into the cerebral peduncles, and connecting the grey cortex of the hemisphere with the structures inferior to it. Anteriorly and below, the two nuclei become continuous and the white substance of the internal capsule, in separating them posteriorly, contributes to the striated appearance in sections, known collectively as the *corpus striatum* (figs. 692, 695). The corpus striatum as such is described below.

INTERNAL STRUCTURE OF THE PROSENCEPHALON

From the above examinations of their external and ventricular surfaces, it is apparent that the cerebral hemispheres consist of a folded, external mantle of grey substance, the cortex cerebri, spread more or less evenly over an internal mass

of white substance which contains embedded within it certain masses of grey substance, the chief of which are known as the caudate and lenticular nuclei of the corpus striatum. In addition, the hemispheres of the telencephalon overlie and are in functional connection with the structures of the diencephalon below, the chief of which are the thalamencephalon and the bases of the cerebral peduncles.

The grey substance of the telencephalon.—The grey substance is in intimate relation with the white substance, and in fact its cells give origin to the greater part of the fibres composing the white substance. The accumulations of grey substance to be considered are the cerebral cortex, with its variations in thickness and arrangement, the corpus striatum, the claustrum, and the amygdaloid nucleus.

The cerebral cortex [substantia corticalis] is distributed over the entire surface of each hemisphere except the peduncular region of the base and the region of the corpus callosum and fornix of the medial surface. Numerous measurements have been made to determine its average thickness. These have shown that the mantle is not uniformly distributed:—(1) that it is thicker on the convex surface than on the basal and medial surfaces; (2) that on the convex surface it is thicker on the central region of the hemisphere, somæsthetic area, than at the poles; (3) that in the average normal specimen it averages somewhat thicker on the left than on the right hemisphere; (4) that its average thickness varies greatly in different individuals, and that the thickness decreases with old age; (5) that it is probably somewhat thicker in males than in females, and (6) that in a given specimen it averages thicker on the summits of the gyri than in the floor of the corresponding sulci. In the normal adult conditions it averages about 4 mm. thick on the anterior and posterior central gyri, in the somæsthetic area, while it attains its mimimum thickness of about 2.5 mm. on the basal surface of the occipital and frontal lobes. Its total average thickness is about 2.9 mm. The practically non-nervous floor of the third ventricle and that of the chorioid fissure are very much thinner but are not considered in these measurements.

The cerebral cortex consists of layers of the cell-bodies of neurones, chiefly of the pyramidal type (fig. 604), which receive impulses from the structures below and from other regions of the cortex by way of fibres reaching them through the internal mass of white substance, and which in turn contribute fibres to the white substance. Certain fibres of shorter course and numerous collateral branches of fibres passing out of the cortex are devoted to the association of the region of their origin with the cortex of the immediate vicinity of their origin, and most of these course within the grey cortex itself. In certain gyri, such as the anterior central gyri and those of the medial surface of the occipital lobe, these short association fibres accumulate into strata, and in vertical sections give the cortex a stratified appearance. Two such strata of white substance may be noted in the above localities, one lying about midway in the thickness of the cortex and one slightly internal to this. They are known as the inner and outer **stripes of Baillarger.** In addition, a thin, superficial or *tangential layer* of fibres may often be distinguished lying in the surface of the cortex. Transverse sections through the anterior end of the hippocampus show a coiled arrangement of the layers of white substance, to which has been given the name *cornu ammonis.* The peculiar structure and appearance of the olfactory bulb and tract, parts of the cortex, have already been mentioned.

The corpus striatum is so called on account of the appearance in section of its component parts, the caudate and lenticular nuclei (basal ganglia) and the internal capsule between them. The two nuclei are directly continuous with each other at their anterior ends (fig. 691), and in addition they are connected by numerous small bands of grey substance which pass from one to the other through the internal capsule, especially its anterior part. Also each nucleus contributes numerous fibres to, and receives fibres from, the internal capsule. These bundles of fibres both arising and terminating within the nuclei, together with the grey substance among the fibres of the capsule, produce the ribbed and striped appearance suggesting the name, corpus striatum. The **caudate nucleus**—the intraventricular part of the corpus striatum—lies with its thicker anterior part (head) closely related to the internal capsule, but its tail passes posteriorly around the posterior border of the capsule and curves downward and anteriorly into the roof of the inferior cornu of the lateral ventricle.

The lenticular nucleus [nucleus lentiformis]—the extraventricular part of the corpus striatum—is embedded in the white substance of the cerebral hemisphere. It is somewhat pyriform in shape, not being so long as the caudate nucleus, and neither having a tail nor extending so far anteriorly. Its lower surface is separated from the inferior cornu of the lateral ventricle by the white substance of the roof of that cornu, and by the tail of the caudate nucleus, and, fur-

ther forward, the anterior commissure passes through its base. Its lateral surface is rounded and conforms both in extent and curvature with the surface of the insula, from which it is separated by the fibres of the external capsule and the intervening claustrum. Its oblique superior and mesial surface is adapted to the lateral surface of the internal capsule, and it comes to a rounded apex in the angle formed by the internal capsule and a plane parallel with the base of the hemisphere. In both horizontal and coronal (transverse) sections through its middle it resembles a compound biconvex lens. Internally this appearance is produced by two vertically curving laminæ of white substance, an **external** and an **internal medullary lamina,** which divide its substance into three zones:—the two medial zones together form an area, triangular in section, known as the **globus pallidus;** the lateral, larger and more grey, concavo-convex zone is the **putamen.** Radiating fibres from the medullary laminæ extend into the zones, especially those of the globus pallidus. These zones disappear in transverse sections of the anterior

FIG. 692.—CORONAL SECTION OF TELENCEPHALON PASSING THROUGH FRONTAL LOBES AND ANTERIOR PORTION OF CORPUS STRIATUM.

(From mounted specimen in the Anatomical Department of Trinity College, Dublin.)

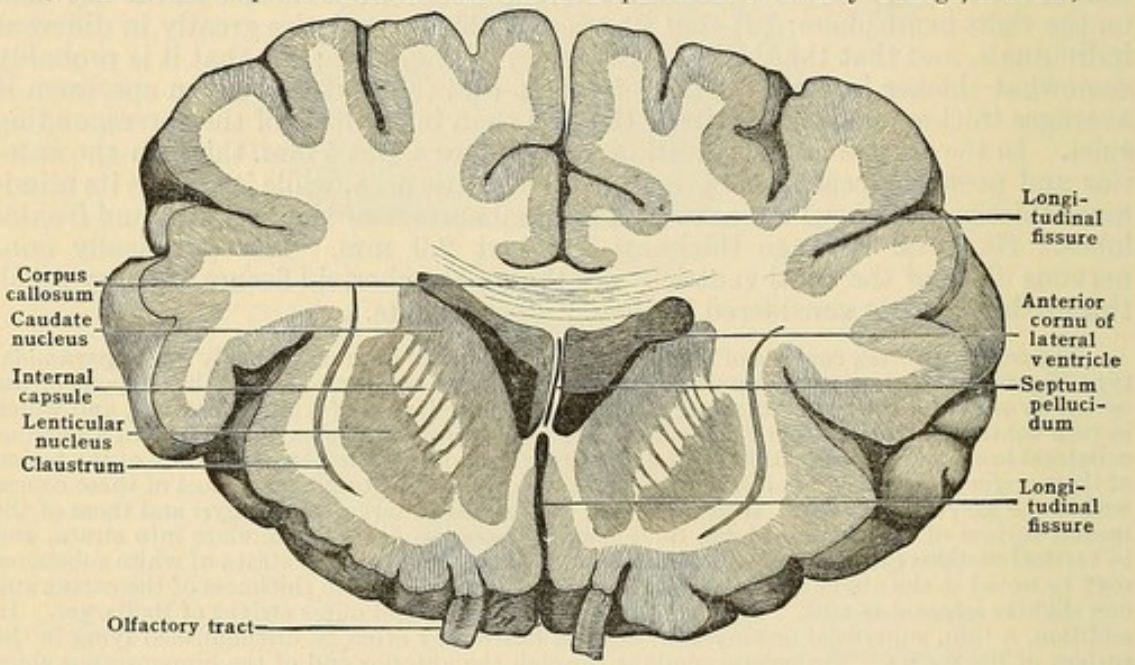

portion of the lenticular nucleus (fig. 692), due to the fact that the larger putamen alone comprises this portion and alone becomes continuous with the caudate nucleus. (See figs. 691, 696.)

Connections.—Both nuclei of the corpus striatum become continuous with the cortex in the region of the anterior perforated substance, and the putamen of the lenticular nucleus may blend with the anterior part of the base of the claustrum. The following are the principal fibre connections:—(1) Fibres arising in the nuclei which join the internal capsule to reach the cerebral cortex, and fibres arising in the cortex which descend by the same course to the cells of the nuclei. (2) Fibres which pass in both directions between the thalamus and the corpus striatum (caudate nucleus especially). These are more abundant anteriorly, and necessarily pass through the internal capsule. (3) The **ansa lenticularis,** or strio-subthalamic radiation, a usually distinct lamina, composed largely of fibres passing inferiorly between the thalamus and lenticular nucleus. It passes from the basal aspect of the anterior tubercle of the thalamus and curves below through the internal capsule to the basal surface of the lenticular nucleus, and there its fibres are distributed upward through its medullary lamina to the globus pallidus and putamen. Some enter the internal capsule and reach the cortex, chiefly that of the temporal lobe. The ansa lenticularis also contains fibres from the cortex of the temporal lobe to terminate in the inferior and mesial parts of the thalamus. The fibres associating the thalamus with the temporal lobe belong to the so-called *inferior peduncle of the thalamus.* (4) Fibres connecting both nuclei (chiefly the caudate) with the red nucleus and substantia nigra of the mesencephalon. These pass through the hypothalamic region and along the cerebral peduncle. No definitely localised functions have been with certainty ascribed to either nucleus. They serve as relays in the pathways associating the cortical grey substance with the structures below and in them the neurones concerned in these pathways are greatly increased.

The claustrum is a triangular plate of grey substance which is embedded in the white substance between the lenticular nucleus and the insula. Its medial

surface is concave, conforming to the convexity of the putamen. The sheet of white substance intervening between it and the putamen is known as the **external capsule.** Its lateral surface shows ridges or projections in section which conform to the neighbouring gyri of the insula, and it is spread through an area which quite closely coincides with that of the inusla. Below and anteriorly it becomes continuous with the cortex of the anterior perforated substance and with the lenticular nucleus at the region of the junction of these. Above and posteriorly it gradually becomes thinner, and finally disappears in the white substance about it. In origin it is thought to be a detached portion of the cortical grey substance of the insula.

The amygdaloid nucleus [nucleus amygdalæ] is represented by the amygdaloid tubercle, which has already been described in the extremity of the inferior cornu of the lateral ventricle (figs. 666 and 691). It is an almond-shaped mass of cells joined to the tail of the caudate nucleus, continuous above with the putamen and anteriorly continuous with the cortex of the hippocampal gyrus.

FIG. 693.—CORONAL SECTION OF TELENCEPHALON THROUGH THE ANTERIOR COMMISSURE, OPTIC CHIASMA, AND TRUNK OF CORPUS CALLOSUM. (After Toldt, "Atlas of Human Anatomy," Rebman, London and New York.)

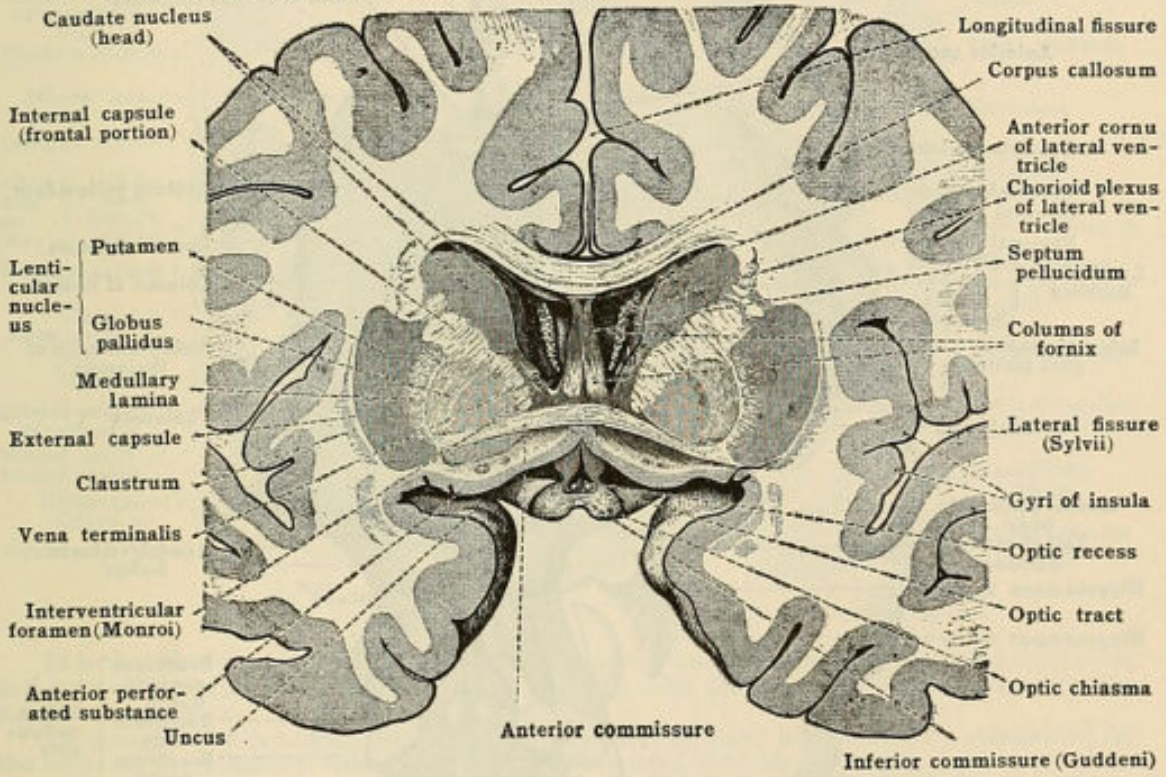

The chief connections of the amygdaloid nucleus by way of the *stria terminalis of the thalamus* are noted above under the description of the posterior division of the rhinencephalon. The amygdaloid nucleus, like the claustrum, is thought to represent a detached portion of the cortex, it being detached from the uncus. Considering this and its chief connections, it, with the stria terminalis of the thalamus, are concerned in the central portion of the olfactory apparatus.

The thalamus and hypothalamus.—The external features of these portions of the prosencephalon have been described in their natural place, but inasmuch as they contain the chief relays between the telencephalon and the divisions of the nervous system caudal to the prosencephalon, the consideration of their internal structure has been deferred till now. The principal grey masses to be considered are the thalamus and the hypothalamic nucleus. The structures comprising the metathalamus and epithalamus have already been mentioned in their relations with the mesencephalon and the optic and auditory apparatus.

The thalamus has upon its upper surface, under its ependyma, a thin **stratum zonale** of white substance, derived in part from the incoming fibres and in part from its own cells. Its oblique lateral surface conforms to the medial surface of the internal capsule; its vertical medial surface forms the lateral wall of the third ventricle, and below it is continuous into the hypothalamic (tegmental) region.

Its upper surface shows a middle, an anterior, and a posterior prominence or tubercle. The **anterior tubercle** (nucleus) forms the posterior boundary of the interventricular foramen; the posterior tubercle is the cushion-like **pulvinar** which projects backward over the lateral geniculate body and the brachium of the superior quadrigeminate body.

A horizontal section through the supero-medial edge, splitting the stria medullaris of the thalamus and thus passing above the massa intermedia, shows the grey mass of the thalamus divided into segments or nuclei by a more or less distinct **internal medullary lamina.** This extends the whole length of the thalamus, dividing its middle and posterior portion into the **medial** and the **lateral nucleus.**

FIG. 694.—HORIZONTAL DISSECTION SHOWING THE GREY AND WHITE SUBSTANCE OF THE TELENCEPHALON BELOW THE CORPUS CALLOSUM AND THE RELATIVE POSITION OF THE THALAMENCEPHALON. (After Landois and Stirling.)

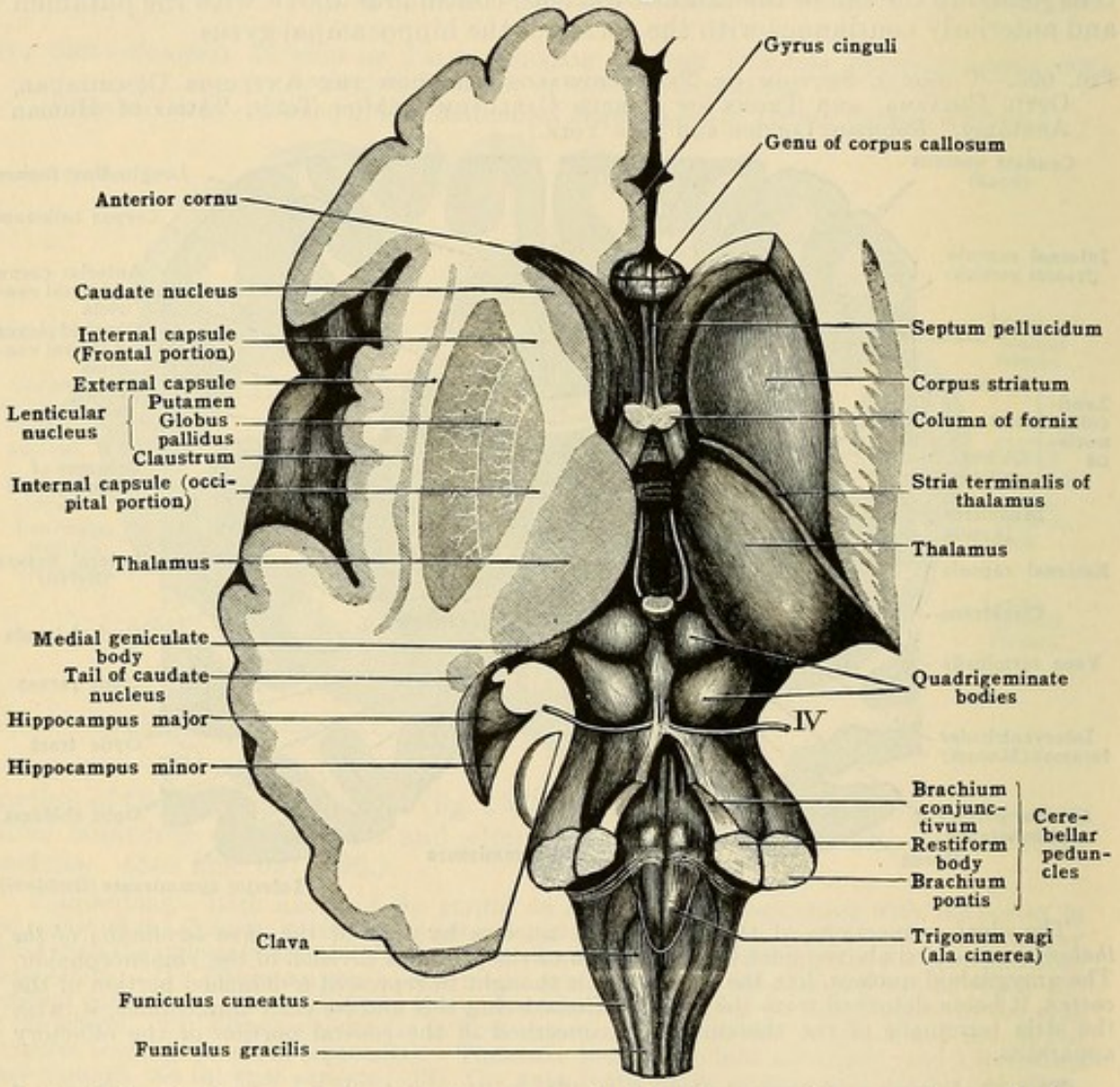

Anteriorly the lamina bifurcates into a medial limb, extending to the medial surface of the thalamus, and a lateral limb, extending forward to join the genu of the internal capsule (figs. 695, 700). This bifurcation results in a cup-like sheet of white substance which encloses the **anterior nucleus.** On the lateral surface of the section, next to the internal capsule, there may usually be distinguished an **external medullary lamina,** separated from the white substance of the capsule by a *reticular layer* of mixed white and grey substance.

The anterior nucleus, lying partially encapsulated in the bifurcation of the internal medullary lamina, is somewhat wedge-shaped and points backward between the anterior portions of the lateral and medial nuclei.

It is composed chiefly of large cells, and constitutes the anterior tubercle of the superior aspect. Its principal connection from below is with the nuclei of the mammillary body of the same and opposite sides, and with uninterrupted fibres derived from the columns of the fornix.

The fibres from both sources enter it by way of the *mammillo-thalamic fasciculus* (figs. 671 and 695). The significance of this connection is mentioned in the description of the limbic lobe.

The lateral nucleus, lying between the external and internal medullary laminæ, extends posteriorly to include the entire pulvinar.

The pulvinar, as already noted, together with the lateral geniculate body, constitutes the prosencephalic nucleus of termination of the optic tract, and the stratum zonale upon the surface of this nucleus might be called the stratum opticum. The anterior portion of the lateral nucleus receives fibres inferiorly from the red nucleus, from the brachium conjunctivum (cerebellum direct), and some fibres of the medial lemniscus terminate about its cells.

The medial nucleus lies medial to the internal medullary lamina and forms the posterior portion of the lateral wall of the third ventricle. It is shorter than the lateral nucleus, and is less extensively pervaded by fibres.

FIG. 695.—CORONAL SECTION OF PROSENCEPHALON THROUGH THALAMENCEPHALON AT REGION OF CORPORA MAMMILLARIA. (Seen from in front.) (After Toldt, "Atlas of Human Anatomy," Rebman, London and New York.)

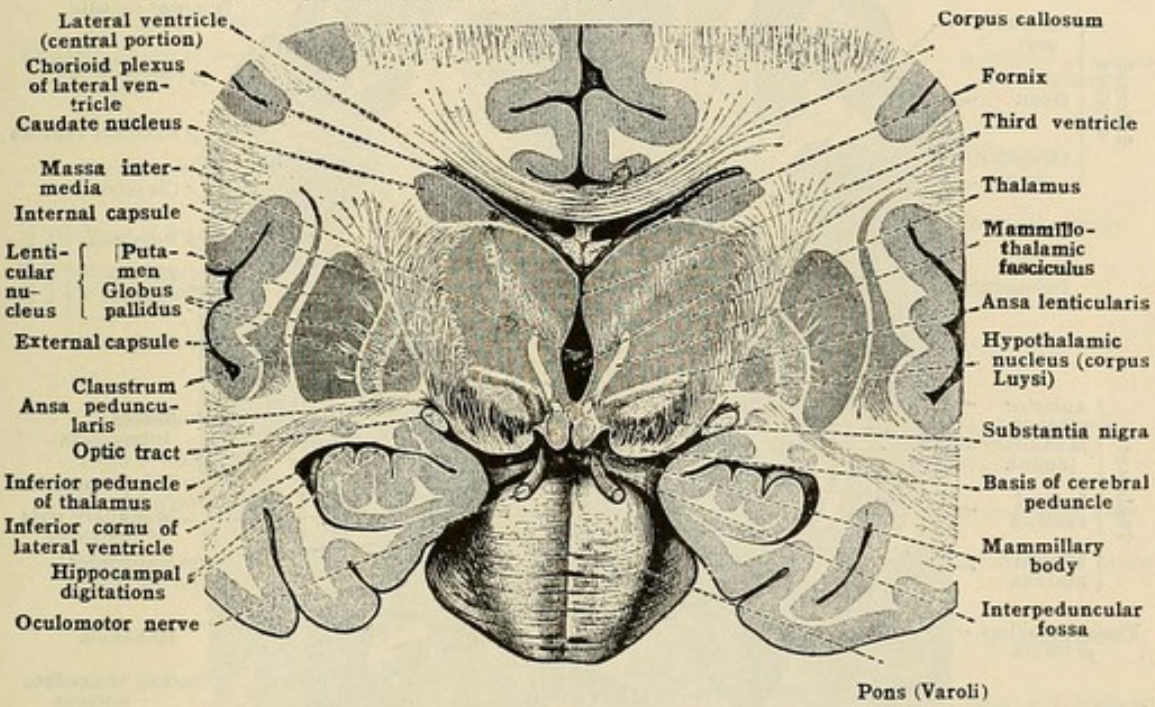

It is thought to receive fibres from the red nucleus, and perhaps some from the lemniscus, and is usually continuous across the third ventricle with the opposite medial nucleus by the massa intermedia.

In comparative anatomy, the nuclei of the thalamus have been variously subdivided by the different investigators. All the nuclei are connected with the lenticular nucleus by fibres passing between the two through the internal capsule directly, and by fibres curving from below, chiefly from the anterior, lateral and medial nuclei, and passing in the ansa lenticularis.

The cortical connections of the thalamus are abundant. They consist of fibres both to and from the cortex of the different lobes of the hemisphere, the greater part arising in the thalamus and terminating in the cortex. These fibres collect in the internal and external medullary laminæ and the stratum zonale; most of them enter the internal capsule and thence radiate to the different parts of the cortex.

They form the so-called peduncles of the thalamus, which have been distinguished both by the Flechsig method of investigation and by the degeneration method. The anterior or **frontal peduncle** passes from the lateral and anterior part of the thalamus through the frontal portion of the internal capsule, and radiates to the cortex of the frontal lobe. (See fig. 700.) The middle or **parietal peduncle** passes from the lateral surface of the thalamus through the intermediate part of the internal capsule, and upward to the cortex of the parietal lobe. The posterior or **occipital peduncle** passes chiefly from the pulvinar, through the occipital portion of the internal capsule, and radiates backward to the occipital lobe by way of the occipito-thalamic (optic) radiation (fig. 699). The **inferior peduncle** passes from the medial and basal surface of the thalamus (from the anterior and medial nuclei chiefly), turns outward to course beneath the lenticular nucleus, and radiates to the cortex of the temporal lobe and insula. The fibres of this peduncle course chiefly in the ansa lenticularis (fig. 695). Some turn upward in the external capsule to reach the cortex above the insula; others pass upward through the medullary laminæ of the lenticular nucleus.

The hypothalamic nuclues (fig. 698), or body of Luys, is the principal nucleus of termination of the medial lemniscus, the great sensory spino-cerebral pathwayl It is a biconvex plate of grey substance situated on the basal aspect of the latera. and anterior nuclei of the thalamus, and between these and the basis of the cerebral

FIG. 696.—HORIZONTAL SECTIONS OF THE PROSENCEPHALON THROUGH THE THALAMUS AND CORPUS STRIATUM.

The plane of the section of the left hemisphere splits the medullary stria of the thalamus and is about 15 millimeters superior to the plane through which the right hemisphere is cut. (After Toldt.)

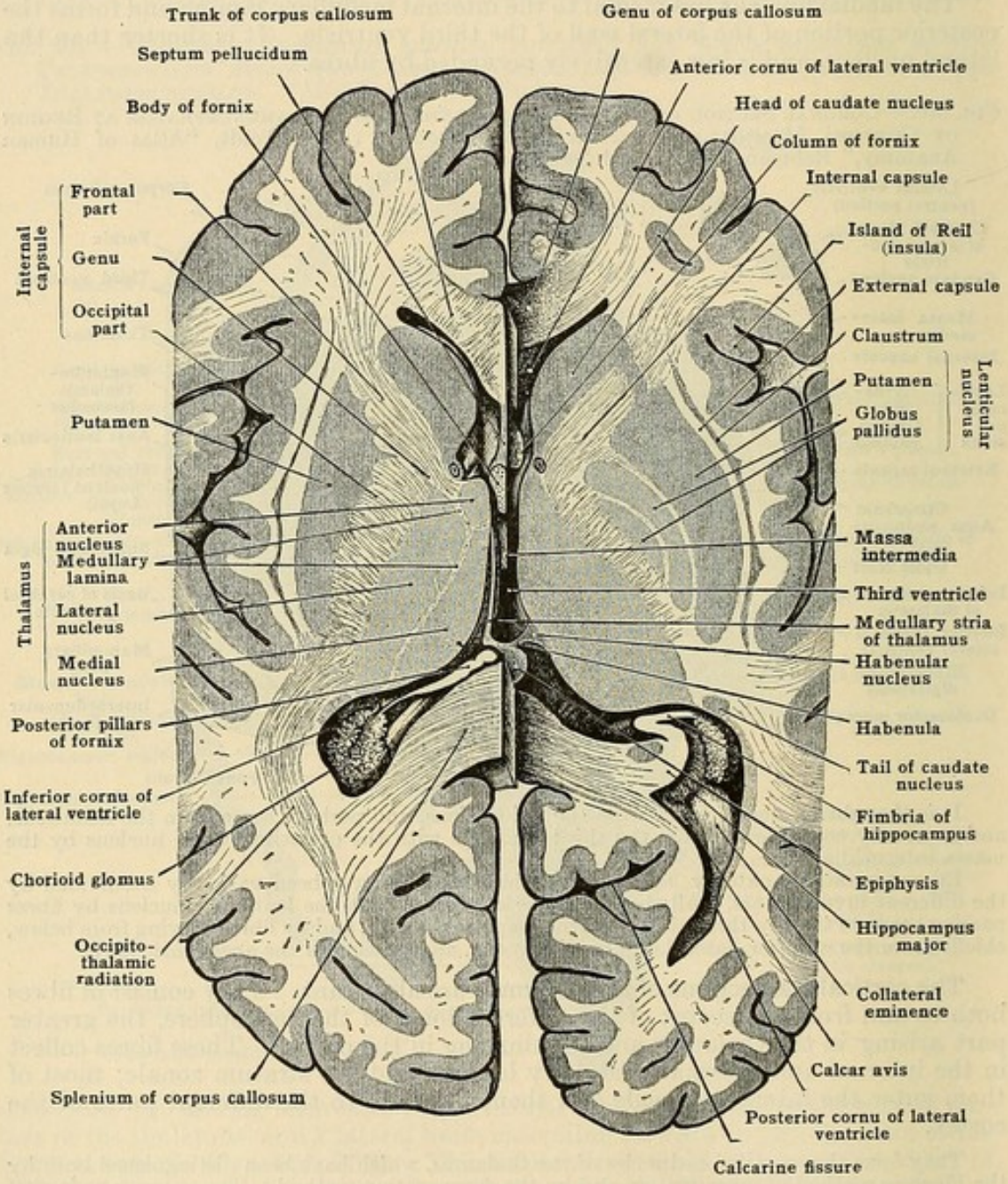

peduncle, or rather the substantia nigra, which is spread upon the dorsal surface of the peduncle, and which, though greatly diminished, extends into the hypothalamic region. The hypothalamic nucleus presents a brownish-pink colour in fresh material, due to pigment in its cells and to its abundant blood capillaries.

It contains the cell-bodies of the neurones of the third order in this pathway, those of the first order being situated in the spinal ganglia, and those of the second order in the nuclei of the fasciculus gracilis and fasciculus cuneatus. It is enclosed by a thin capsule of white substance, some of the fibres of which seem to decussate with those of the opposite side in the floor of the third ventricle, above and just behind the region of the corpora mammillaria. By far the greater part of the fibres arising from the nucleus join the internal capsule, and through it ascend to

radiate to the cortex of the pre- and post-central gyri, the sensory-motor or somæsthetic area of the hemisphere. The majority terminate in the post-central gyrus.

All the fibres connecting the cerebral cortex with both the thalamus and the hypothalamic nucleus belong to the so-called *projection fibres* of the cerebral hemisphere.

The *habenular nucleus* and the *fasciculus retroflexus* of Meynert have been noted in the description of the rhinencephalon. The **habenular nucleus,** a part of the epithalamus, is a small group of nerve cells situated in the habenular trigone just infero-lateral to the epiphysis. The fibres of the medullary stria of the thalamus (habenula) terminate about its cells. A small bundle of fibres crossing the mid-line under the epiphysis in the superior aspect of the posterior cerebral commissure is called the *commissure of the habenulæ*, from the fact that it connects the habenular nuclei of the two sides.

FIG. 697.—OBLIQUE FRONTAL SECTION THROUGH THE BRAIN IN THE DIRECTION OF THE CEREBRAL PEDUNCLES AND THE PYRAMIDS. (Seen from in front.) (After Toldt, "Atlas of Human Anatomy," Rebman, London and New York.)

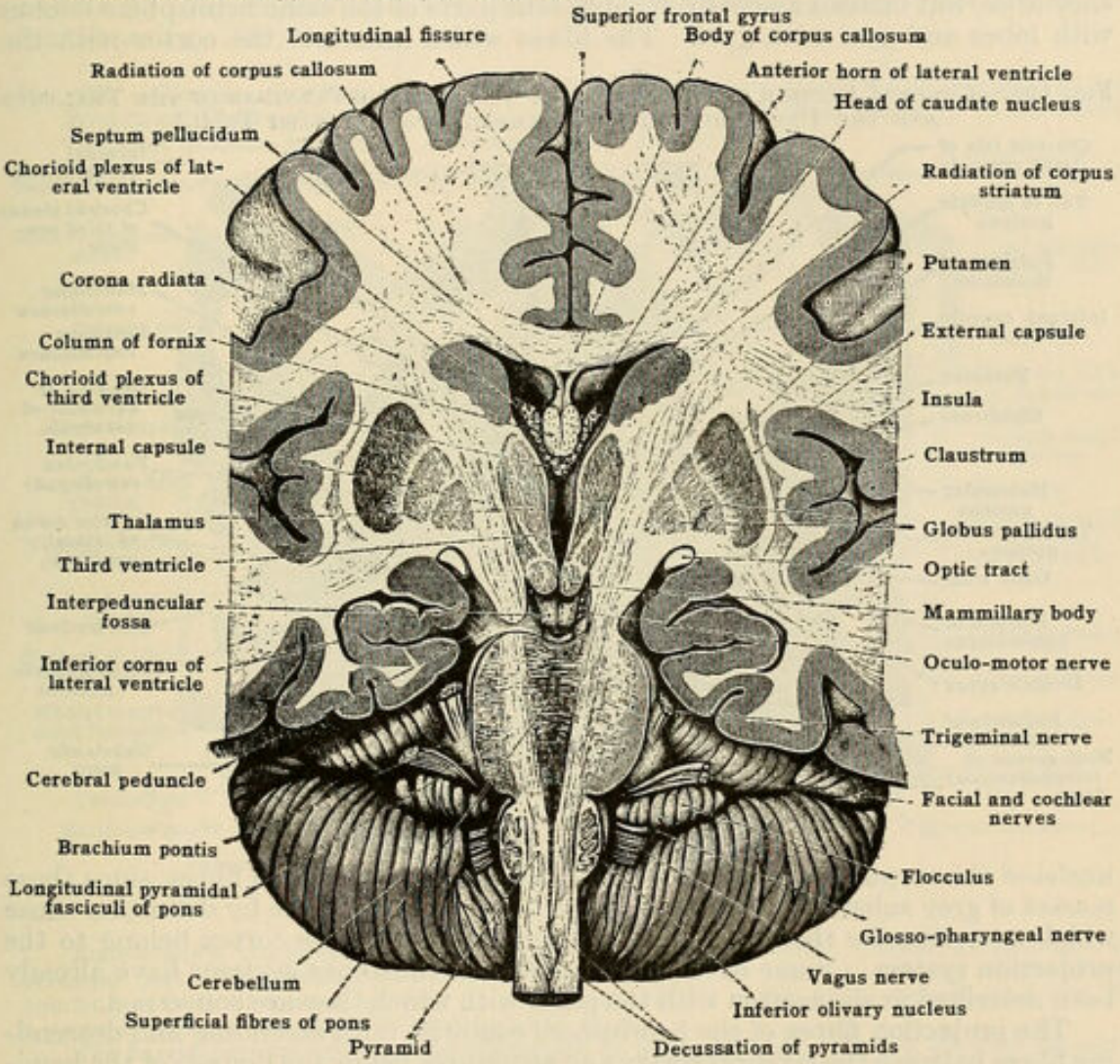

The **fasciculus retroflexus (Meynerti)** is a relatively strong bundle of medullated fibres which runs downward and then turns caudalward from the habenular nucleus toward the inferior portion of the interpeduncular fossa. It has been shown that many, at least, of the fibres of this bundle arise from the cells of the habenular nucleus. In its slightly caudad course, the bundle passes obliquely through the red nucleus, entering the medial superior aspect and making its exit from the ventro-mesial side of the inferior extremity of this nucleus. In the animals in which it has been studied, the bundle ends in the *interpeduncular nucleus* (ganglion), a group of nerve cells lying in the floor of the interpeduncular fossa at the level of the inferior quadrigemina. In man, the interpeduncular nucleus is not definitely assembled and the bundle seems to disappear in the posterior perforated substance. However, the microscope shows cells dispersed among the fibres of the bundle and these cells probably represent the nucleus.

The white substance of the telencephalon.—A horizontal section through the upper part of the trunk of the corpus callosum will pass above the basal grey substance of the corpus striatum, and, aided by the corpus callosum, each hemisphere in such a section will appear as if consisting of a solid, half-oval mass of white substance, bounded without by the grey layer of the cortex (fig. 672). As

seen at this level, the white substance of each hemisphere is known as the **centrum semiovale.** Horizontal sections passing below the body of the corpus callosum involve the corpus striatum and thalamus, and the appearance of the white substance is modified accordingly (fig. 694).

In the white substance of the cerebral hemispheres as a whole three main systems of fibres are recognised:—projection fibres, commissural fibres, and association fibres. The *projection fibres* are those of a more or less vertical course, which pass to and from the cortex of the hemisphere, associating it with the structures below the confines of the hemisphere. The *commissural fibres* are those of a transverse or horizontal course, which cross the mid-line and functionally connect the two hemispheres with each other. The *association fibres* are those which neither cross the mid-line nor pass beyond the bounds of the hemisphere in which they arise, but instead associate the different parts of the same hemisphere—lobes with lobes and gyri with gyri. The fibres which associate the cortex with the

FIG. 698.—CORONAL SECTION OF BRAIN PASSING THROUGH THE PULVINAR OF THE THALAMUS AND THE UNCUS OF THE HIPPOCAMPAL GYRUS. (After Toldt.)

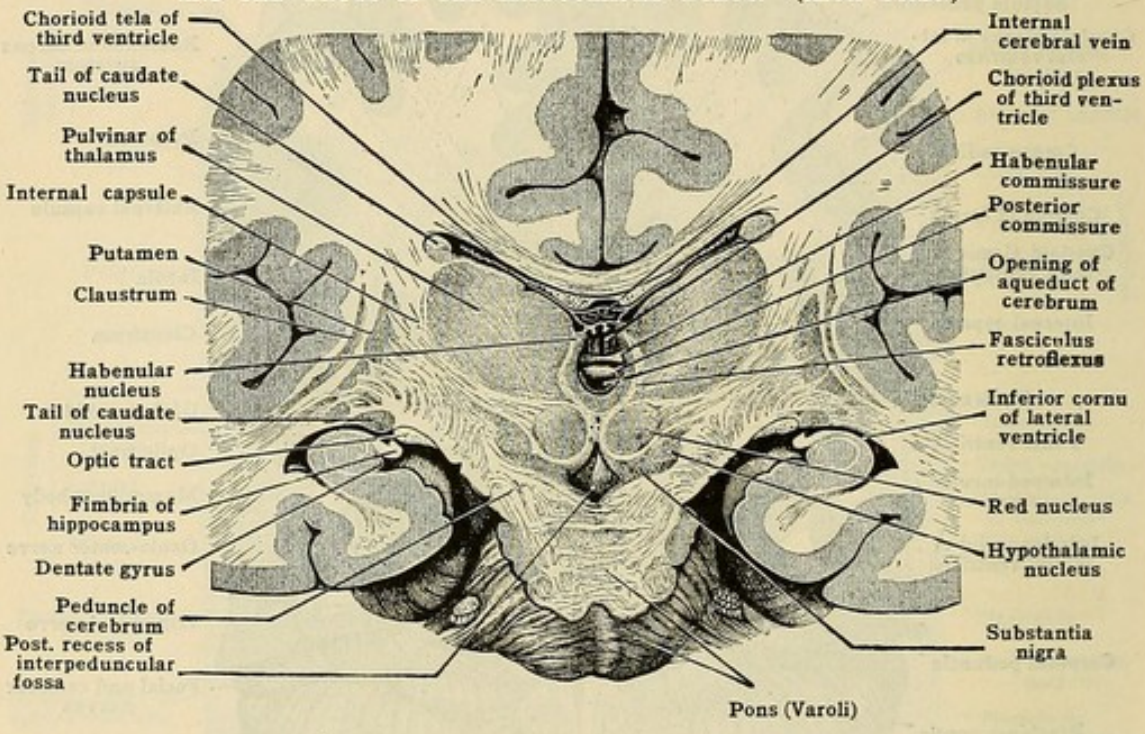

nuclei of the corpus striatum must also be classed as association fibres, since these masses of grey substance are a part of the telencephalon, while by definition those which associate the thalamus and hypothalamus with the cortex belong to the projection system. Some of the fibre bundles of the above systems have already been described in connection with the parts with which they are concerned.

The projection fibres of the hemisphere comprise both ascending and descending fibres between the cerebral cortex and structures below the bounds of the hemisphere, i.e., some arise in the structures below and terminate in the cortex; others arise from the cortical cells and terminate in the structures below, including the grey substance of the thalamencephalon, mesencephalon, rhombencephalon, and spinal cord. The projection fibres are given different names in the hemisphere according to their arrangement and the appearances to which they contribute in the dissections. Beginning with the pyramidal fasciculi and the basis of the peduncle, they contribute—(1) to the *internal capsule* and some to the *external capsule* and (2) to the *corona radiata.*

The internal capsule [capsula interna] is a band of white substance, consisting of the ascending fibres from the nuclei of the thalamus, hypothalamus, and corpus striatum, reinforced by the descending fibres from the cortex to these nuclei and by those descending in the cerebral peduncle to terminate in the mesencephalon, rhombencephalon and spinal cord. It is a broad, fan-like mass of fibres, which increases in width from the base of the hemisphere upward, and which is spread between the lenticular nucleus on its lateral aspect and the caudate nucleus and

thalamus on its medial side. To reach the cortex above, the course of its fibres necessarily intersects that of the radiations of the corpus callosum, and thus, together with the corpus callosum, the fan-like bands of the two hemispheres form a capsule containing the thalami, the third ventricle, the caudate nuclei, and the anterior and central portions of the lateral ventricles. In horizontal sections, each internal capsule appears bent at an angle, the **genu,** which approaches the cavity of the lateral ventricle along the line of the boundary between the thalamus and the caudate nucleus. Along the genu runs the stria terminalis of the thalamus, and through the genu the capsule receives fibres from the internal medullary lamina of the thalamus, from the stratum zonale of the thalamus and from that of the caudate nucleus. At the genu each capsule is separable into two parts:—(1) the **anterior (frontal) portion,** spreading between the caudate and lenticular nuclei; (2) the **posterior (occipital) portion,** between the lenticular nucleus and the thalamus (fig. 700.)

FIG. 699.—CORONAL SECTION THROUGH THE SPLENIUM OF THE CORPUS CALLOSUM AND THE POSTERIOR CORNUA OF THE LATERAL VENTRICLES. (Viewed from behind.) (After Toldt, "Atlas of Human Anatomy," Rebman, London and New York.)

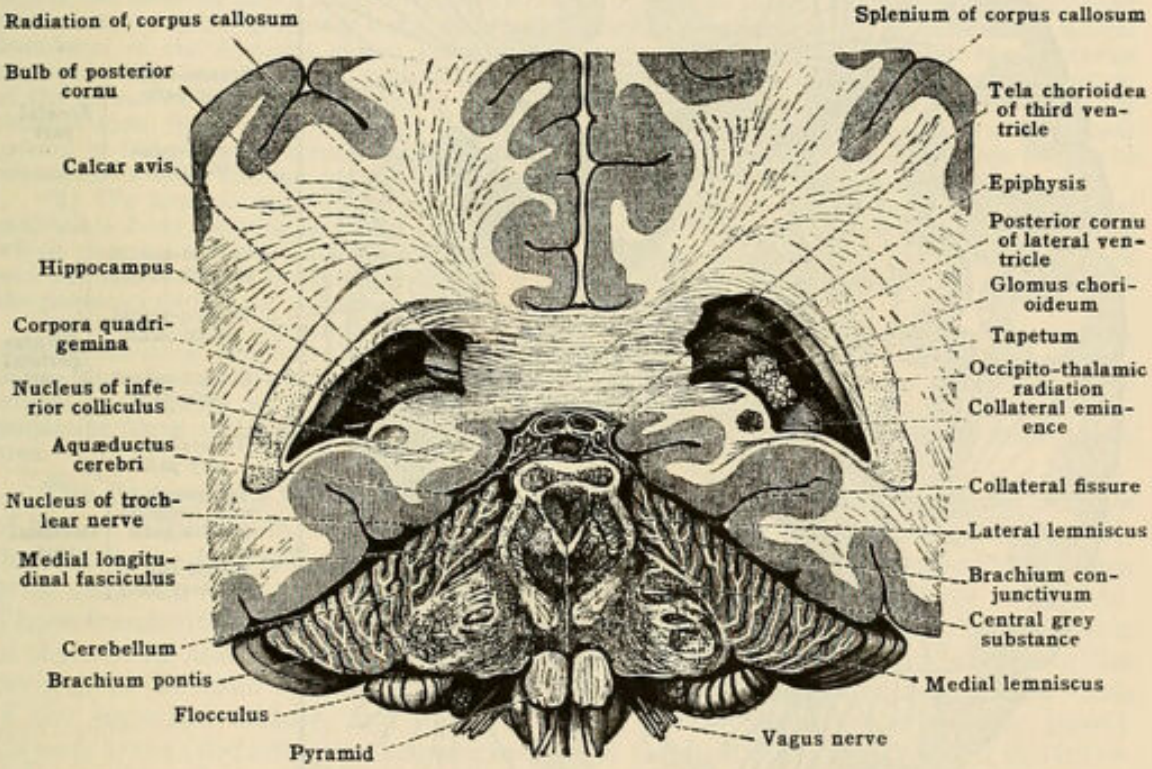

Functionally, the internal capsule may be divided into a frontal, a fronto-parietal and an occipital part. The **frontal part** consists of (1) an *anterior segment,* carrying chiefly fibres coursing in both directions between the thalamus and the cortex of the frontal lobe, and (2) a *posterior segment* carrying the frontol-pontile tract.

The **fronto-parietal part** may be considered in four segments:—(1) An anterior segment, the *genu,* carrying fibres from the cortex to the nuclei of the motor cranial nerves; (2) posterior to this is the *cortico-spinal segment for the arm and thorax,* descending cortical fibres to the regions of the spinal cord supplying these; (3) next is the *cortico-spinal segment for the lower extremity;* (4) a posterior segment carrying the *general sensory path* ascending from the hypothalamic nucleus, the infero-lateral part of the thalamus and the red nucleus to the cortex. All the segments of the fronto-parietal part carry in addition, fibres in both directions between the cortex above and the thalamus and the nuclei of the striate body.

The occipital part consists (1) of an anterior segment which carries the *temporal and occipital pontile paths,* and (2) a posterior segment carrying the *visual fibres* between the occipital cortex and the nuclei of termination of the optic nerve. This segment also carries the *auditory fibres* passing between the cortex of the superior temporal gyrus and the regions of termination of the lateral lemniscus. Thus it carries a visual and an auditory path.

The corona radiata.—Above the corpus callosum and laterally joining its radiations, the fibres of the internal capsule are dispersed in all directions. The appearance known in coronal sections of the hemispheres as the corona radiata is produced by the ascending and descending fibres of the internal capsule combined with the radiations of the corpus callosum. The radiations related to the internal

capsule may be divided into a frontal, a parietal and an occipital part, corresponding to the frontal, parietal and occipital peduncles of the thalamus, or to the parts of the internal capsule.

The radiation derived from the posterior segment of the occipital part of the internal capsule, the visual path, accumulates into a well-defined band of fibres which passes posteriorly into the occipital lobe, spreading in the lateral wall of the posterior cornu of the lateral ventricle immediately lateral to the tapetum. This band consists for the most part of fibres arising in the pulvinar of the thalamus and

FIG. 700.—DIAGRAM TO INDICATE THE RELATIVE POSITIONS OF THE PROJECTION FIBRES IN THE INTERNAL CAPSULE. (In part after Villiger.)

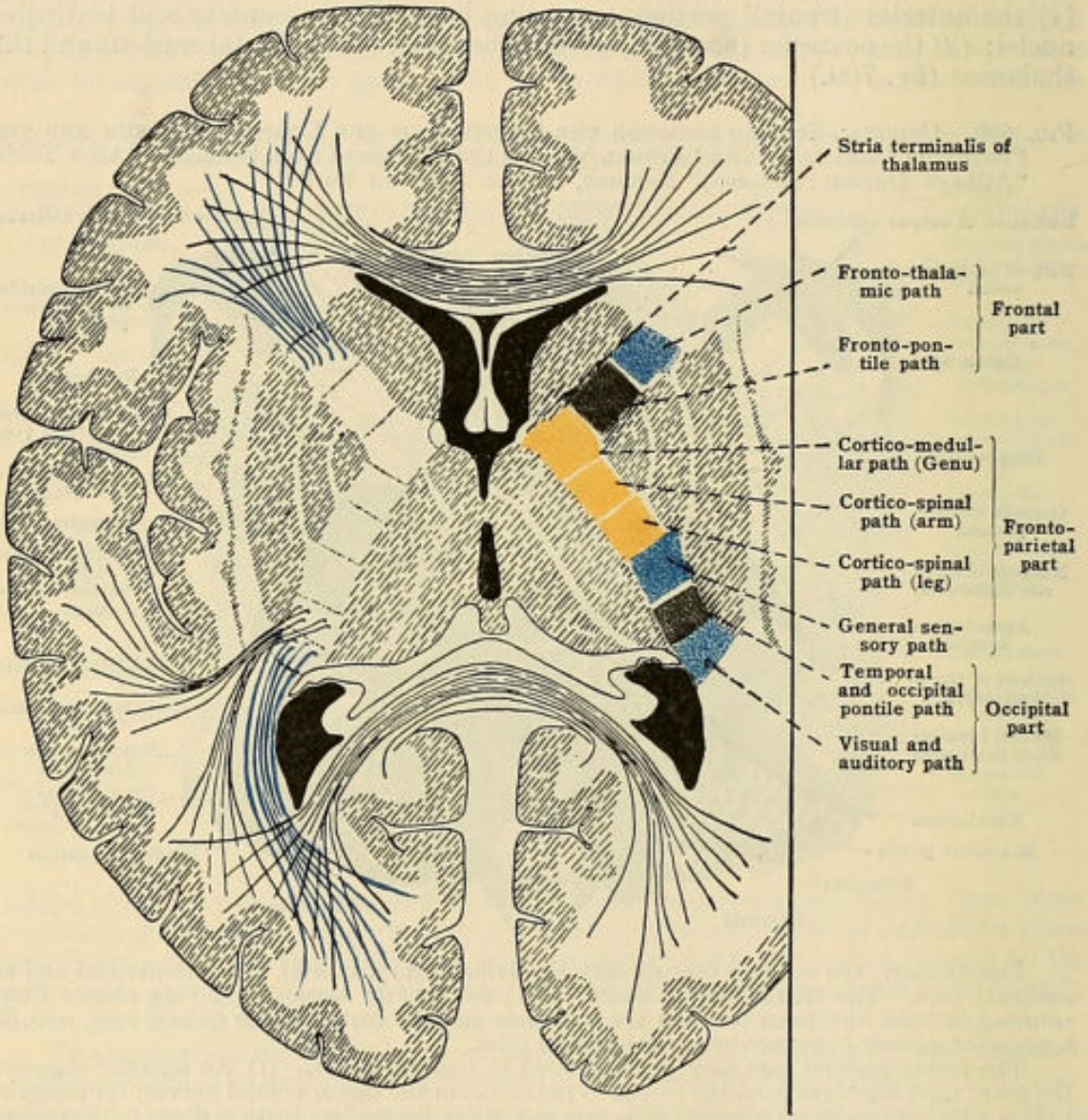

in the lateral geniculate body and going to the visual area of the occipital cortex, and of fibres arising in this cortex to terminate in the thalamus and mesencephalon. Being thus concerned with the optic apparatus, it is known as the **occipito-thalamic radiation** or **optic radiation** (fig. 699).

The external capsule is, as already noted, a thin sheet of white substance spread between the claustrum and the lenticular nucleus.

It owes its appearance as such to the presence of the claustrum. It joins the internal capsule at the upper, posterior, and anterior borders of the putamen, and below the claustrum it is continuous with the general white substance of the temporal lobe. Thus it contributes to an encapsulation of the lenticular nucleus by white substance. Most of the fibres contained in it belong to the association system. Its projection fibres consist of those of the inferior peduncle of the thalamus, which pass from the basal surface of the thalamus and, instead of continuing below to the cortex of the temporal lobe and insula, turn upward, around the lenticular nucleus to the cortex above the insula. Some of these thalamus fibres are known to pass upward through the laminæ of the lenticular nucleus instead of through the external capsule.

The ascending projection fibres arise mostly from the cells of the nuclei of the thalamus and hypothalamic nucleus; some arise from nuclei in the mesencephalon and from the red nucleus.

They may be summarised as follows:—

(1) *The terminal part of the general sensory pathway of the body.* The portion of the medial lemniscus which arises in the nuclei of the fasciculus gracilis and cuneatus, of the opposite side, terminates in the hypothalamic nucleus and the inferior portion of the lateral nucleus of the thalamus. The projection fibres given off by the latter nuclei pass chiefly through the posterior segment of the fronto-parietal part of the internal capsule and radiate to and terminate in the somæsthetic area of the cortex, chiefly in the posterior central gyrus. Some few pass outside around the lenticular nucleus, and ascend by way of the external capsule.

(2) *The terminal part of the general sensory pathway of the head and neck.* The nuclei of termination of the sensory portions of the cranial nerves of the rhombencephalon (except the nuclei of the cochlear nerve) give fibres which course upward in the medial lemniscus (fillet) and reticular substance of the opposite side and terminate in the infero-lateral portions of the thalamus and in the hypothalamic nucleus. Thence arise projection fibres which ascend to the somæsthetic area by practically the same route as those of the general sensory system for the body.

(3) *The terminal part of the auditory pathway.* The ventral and dorsal nuclei of termination of the cochlear nerve send impulses which, by way of the lateral lemniscus, are distributed to the inferior quadrigeminate body, the medial geniculate body, and the nucleus of the lateral lemniscus of the opposite side. These nuclei send projection fibres through the posterior segment of the fronto-parietal part of the internal capsule, and thence by the temporal portion of the corona radiata to the cortex of the superior temporal gyrus (auditory area). Probably some of these fibres pass by way of the inferior peduncle of the thalamus. Some of the fibres arising in the nuclei of termination of the vestibular nerve convey impulses which reach the somæsthetic area, but the origin of the terminal portion of this system is uncertain.

(4) *The terminal part of the visual pathway.* The cells of the pulvinar and the lateral geniculate body, serving as nuclei of termination of the optic tract, give off projection fibres which pass by way of the posterior segment of the occipital portion of the internal capsule and the occipito-thalamic radiation to the cortex of the occipital lobe, chiefly the region about the posterior end of the calcarine fissure—the visual area.

(5) *The terminal ascending cerebellar pathway.* The fibres of the brachium conjunctivum, after decussating, terminate both in the red nucleus and in the lateral nucleus of the thalamus. Some fibres from the red nucleus become projection fibres direct, others terminate in the medial and anterior portion of the lateral nucleus of the thalamus. From the thalamus the projection fibres of this system pass in the parietal peduncle of the thalamus to the somæsthetic area.

The descending projection fibres arise as outgrowths of the pyramidal cells of the cerebral cortex. Practically all of them cross to the opposite side in their descent to the structures of the brain stem and spinal cord. The majority of them arise near and within the gyri in which the respective ascending fibres terminate. Those transmitting cortical impulses to the cells giving origin to the motor fibres of the cranial and spinal nerves arise chiefly from the giant pyramidal cells of the precentral (anterior central) gyrus, the paracentral lobule and the posterior ends of the superior, middle, and inferior frontal gyri. These latter occupy nearly three-fourths (the anterior three segments) of the fronto-parietal part of the internal capsule and the middle three-fifths of the basis of the cerebral peduncle, and are usually called *pyramidal* fibres (fig. 700).

The principal descending projection fibres may be grouped as follows:

(1) **The pyramidal fibres to the spinal cord** (cortico-spinal or pyramidal fasciculi proper). These arise from the giant pyramidal cells of the upper two-thirds of the precentral gyrus, the anterior portion of the paracentral lobule and the posterior third of the superior frontal gyrus. Those for the lumbo-sacral region of the spinal cord arise nearest the supero-mesial border of the cerebral hemisphere. The tract descends through the two middle segments of the fronto-parietal part of the internal capsule. Those carrying cortical impulses for the muscles of the arm and shoulder course in the segment anterior to the course of those for the muscles of the leg. Both continue through the cerebral peduncles and the pons and through the pyramids of the medulla, and then decussate, passing down the spinal cord to terminate about the ventral horn cells (the origin of the motor nerve roots) of the opposite side.

(2) **The pyramidal fibres to the nuclei of origin of the motor cranial nerves** arise from the pyramidal cells in the inferior third of the precentral gyrus, the posterior end of the inferior frontal gyrus, the opercular margin of the posterior central gyrus, and probably some (for eye movements) in the posterior end of the middle frontal gyrus. The locality of the origin of the pyramidal fibres terminating in the nuclei of the facial and hypoglossal nerves only has been determined with certainty. The general tract passes in the genu of the internal capsule, through the cerebral peduncle, and, gradually decussating along the brain stem, terminates in the nuclei of the motor cranial nerves of the opposite side.

(3) **The frontal pontile path** (Arnold's bundle) arises in the cortex of the frontal lobe, anterior to the precentral gyrus, descends through the frontal part of the corona radiata and posterior segment of the frontal portion of the internal capsule into the fronto-mesial portion of the cerebral peduncle, and terminates in the nuclei of the pons.

(4) **The temporal pontile path** (Türk's bundle) arises in the cortex of the superior and middle temporal gyri, passes through the posterior segment of the occipital part of the internal capsule, enters the cerebral peduncle postero-lateral to its pyramidal portion, and terminates in the nuclei of the pons. An occipito-pontile path is described as arising in the occipital cortex and joining the temporal pontile path in the internal capsule to pass to the nuclei of the pons.

(5) **The occipito-mesencephalic path** (Flechsig's secondary optic radiation) arises in the cortex of the visual area of the occipital lobe (cuneus and about the calcarine fissure), passes forward through the occipito-thalamic radiation, downward in the posterior segment of the occipital portion of the internal capsule, and terminates in the nucleus of the superior quadrigeminate body and the lateral geniculate body. It is probable that some of its fibres terminate directly in the nuclei of the eye-moving nerves.

(6) Those **fibres of the fornix** which arise in the hippocampus and terminate in the corpus mammillare or pass through it to the anterior nucleus of the thalamus of the same and opposite side (mammillo-thalamic fasciculus) or pass into the mescencephalon and probably to structures lower down.

The commissural system of fibres.—The commissural fibres of the telencephalon serve to connect or associate the functional activities of one hemisphere with those of the other. They consist of three groups:—The corpus callosum, the anterior commissure and the hippocampal commissure.

(1) The **corpus callosum,** the great commissure of the brain. A general description of this with the medial and lateral striæ running over it has already been given. It is a thick band of white substance, about 10 cm. wide, which crosses between the two hemispheres at the bottom of the longitudinal fissure. Its shape is such that in its medial transverse section its parts are given the names *splenium*, *body*, *genu*, and *rostrum* (figs. 667 and 679). Its lower surface is medially joined to the fornix, in part by the septum pellucidum and in part directly. Laterally it is the tapetum of the roof of the lateral ventricle of either side. The majority of its fibres arise from the cortical cells of the two hemispheres, and terminate in the cortex of the side opposite that of their origin. In dissections, its fibres are seen to radiate toward all parts of the cortex—the radiation of the corpus callosum. These radiations may be divided into frontal, parietal, temporal and occipital parts. The occipital parts curve posteriorly in two strong bands from the splenium into the occipital lobes, producing the figure known as the **forceps major.** Anteriorly, the frontal parts are two similar but lesser bands which curve from the genu forward into the frontal lobe, producing the **forceps minor.**

(2) The **anterior commissure** has been described in connection with the rhinencephalon. In addition to the olfactory fibres coursing through it from the olfactory bulb and parolfactory area of one hemisphere to the uncus of the opposite hemisphere, its greater part consists of fibres which arise in the cortex of the temporal lobe, the uncus chiefly, of one side and terminate in that of the opposite side. It crosses in the substance of the anterior boundary of the third ventricle, and through the inferior portions of the lenticular nuclei, and can be seen only in dissections (figs. 684, 693). It is a relatively small, round bundle, and its mid-portion between its terminal radiations presents a somewhat twisted appearance.

(3) The **hippocampal commissure** (*transverse fornix*) belongs wholly to the limbic lobe (rhinencephalon), and has been described there. It connects the hippocampal gyri of the two sides, and crosses the mid-line under and usually adhering to the under surface of the splenium of the corpus callosum. Crossing the body of the fornix, it thins anteriorly and ceases in the posterior angle of the septum pellucidum.

With these three commissures of the telencephalon, the three other commissures of the prosencephalon should be called to mind. **The inferior cerebral commissure** (Gudden's commissure), while occurring in the optic chiasma and allotted by position to the telencephalon, really belongs to the diencephalon since it connects with each other the medial geniculate bodies of the two sides. **The supra-mammillary commissure,** connecting the nuclei of the mammillary bodies of the two sides, is allotted to the diencephalon. **The posterior cerebral commissure,** situated just below the stalk of the epiphysis, belongs to both the diencephalon and mesencephalon. Its superior part, the *habenular commissure*, connecting the two nuclei of the habenulæ, belongs wholly to the diencephalon. In its inferior part, the fibres arising in the thalamus of one side and terminating in that of the other side belong likewise to the diencephalon, but those passing between the superior quadrigeminate bodies of the two sides and between the so-called nuclei of the medial longitudinal fasciculi belong to the mesencephalon.

The association system of the hemisphere.—The possibilities for association bundles connecting the different parts of the same hemisphere with each other are innumerable, and a large number are recognised. They serve for the distribution or diffusion of impulses brought in from the exterior by the ascending projection system, and it is by means of them that the different areas of the cortex may function in harmony and coördination. Most of the association bundles are supposed to contain fibres coursing in both directions. Several of them have already been described in company with the grey masses with which they are concerned. They may be summarised as follows (see figs. 683, 701 and 702):—

(1) Those of short course, the **fibræ propriæ,** which associate contiguous gyri with each other. These arise from the cells of a gyrus and loop around the bottoms of the sulci, continually receiving and losing fibres in the cortex they associate. The stripes of Baillarger within the cortical layer might be included among the short association bundles.

(2) The **cingulum** (girdle) lies in the gyrus cinguli and is shaped correspondingly. It

extends from the anterior perforated substance and the subcallosal gyrus around the genu of the corpus callosum, then, under cover of the gyrus cinguli and around the splenium, and thence downward and forward in the hippocampal gyrus to the uncus. It is chiefly an aggregation of fibres of short course—fibres which associate neighbouring portions of the cortical substance

FIG. 701.—PHOTOGRAPH OF "TORN PREPARATION" OF CEREBRAL HEMISPHERE SHOWING SOME OF THE ASSOCIATION FASCICULI. (After R. B. Bean.)

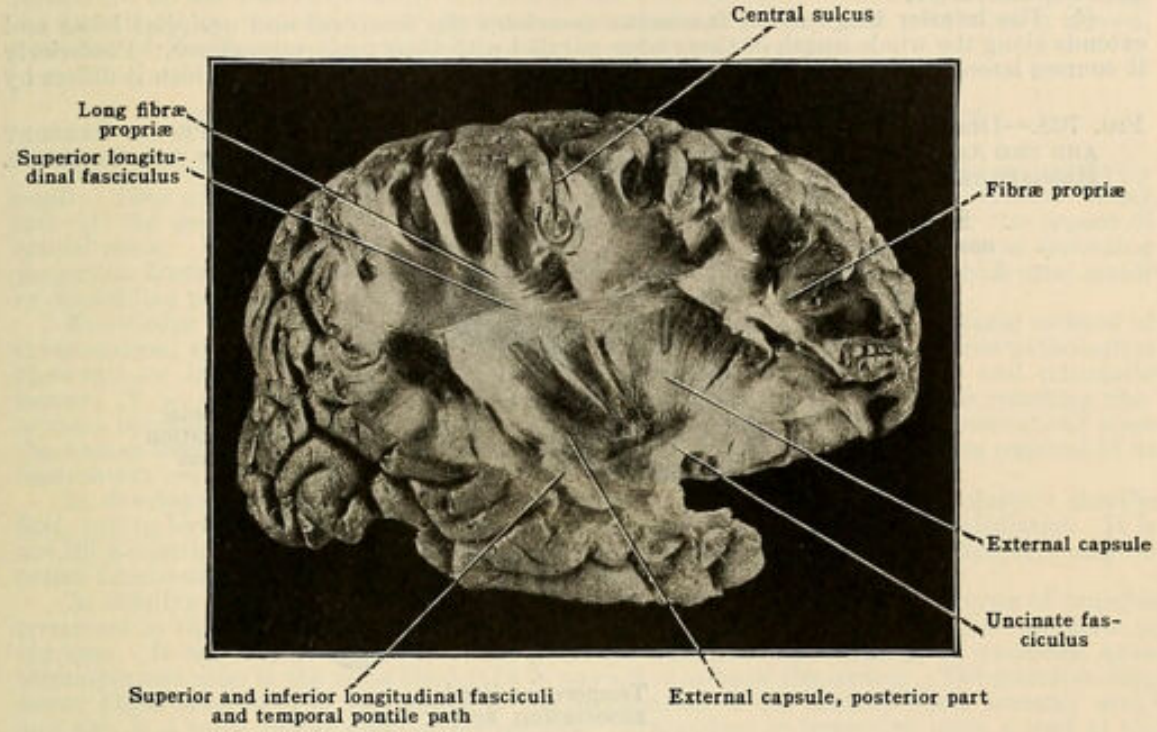

FIG. 702.—SCHEMATIC REPRESENTATION OF CERTAIN OF THE ASSOCIATION PATHWAYS OF THE CEREBRAL HEMISPHERE.

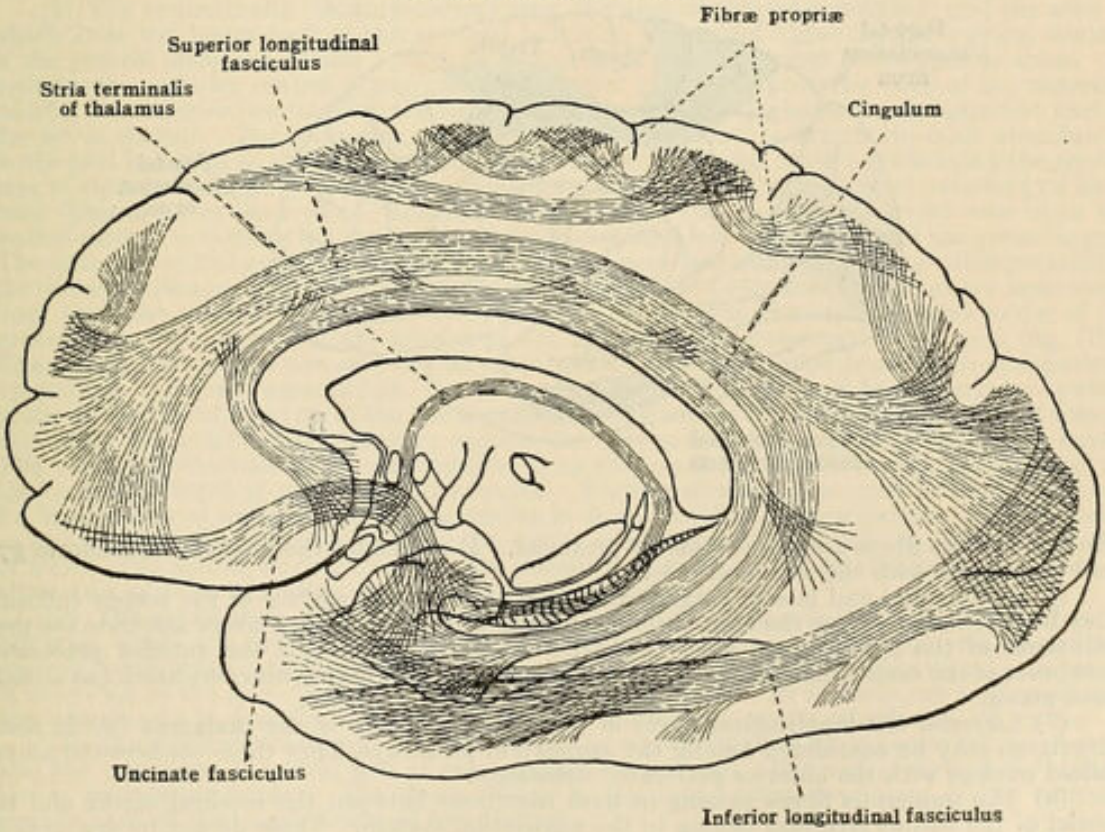

beneath which they course, and which, by continually overlapping each other, form the bundle.

(3) The **uncinate fasciculus** is a hook-shaped bundle which associates the uncus and anterior portion of the temporal lobe with the olfactory bulb, parolfactory area and anterior perforated substance and perhaps the frontal pole with the orbital gyri. Its shape is due to its having to curve medialward around the stem of the lateral cerebral fissure.

(4) The **superior longitudinal fasciculus** is the longest of the association paths, and associates the frontal, occipital, and temporal lobes. From the frontal lobe it passes laterally in the frontal and parietal operculum, transverse to the radiations of the corpus callosum and the lower part of the corona radiata, and above the insula to the region of the posterior end of the lateral fissure, and thence it curves downward and forward to the cortex of the temporal lobe. Some of its fibres extend to the cortex of the temporal pole. The occipital portion consists of a loose bundle given off from the region of the downward curve, which radiates thence to the occipital cortex.

(5) The **inferior longitudinal fasciculus** associates the temporal and occipital lobes and extends along the whole length of these lobes parallel with their tentorial surfaces. Posteriorly it courses lateral to the lower part of the occipito-thalamic radiation, from which it differs by

FIG. 703.—DIAGRAMS SUGGESTING THE GENERAL MOTOR, GENERAL AND SPECIAL SENSORY AND THE ASSOCIATION AREAS OF THE CONVEX AND MESIAL SURFACES OF THE CEREBRAL HEMISPHERE.

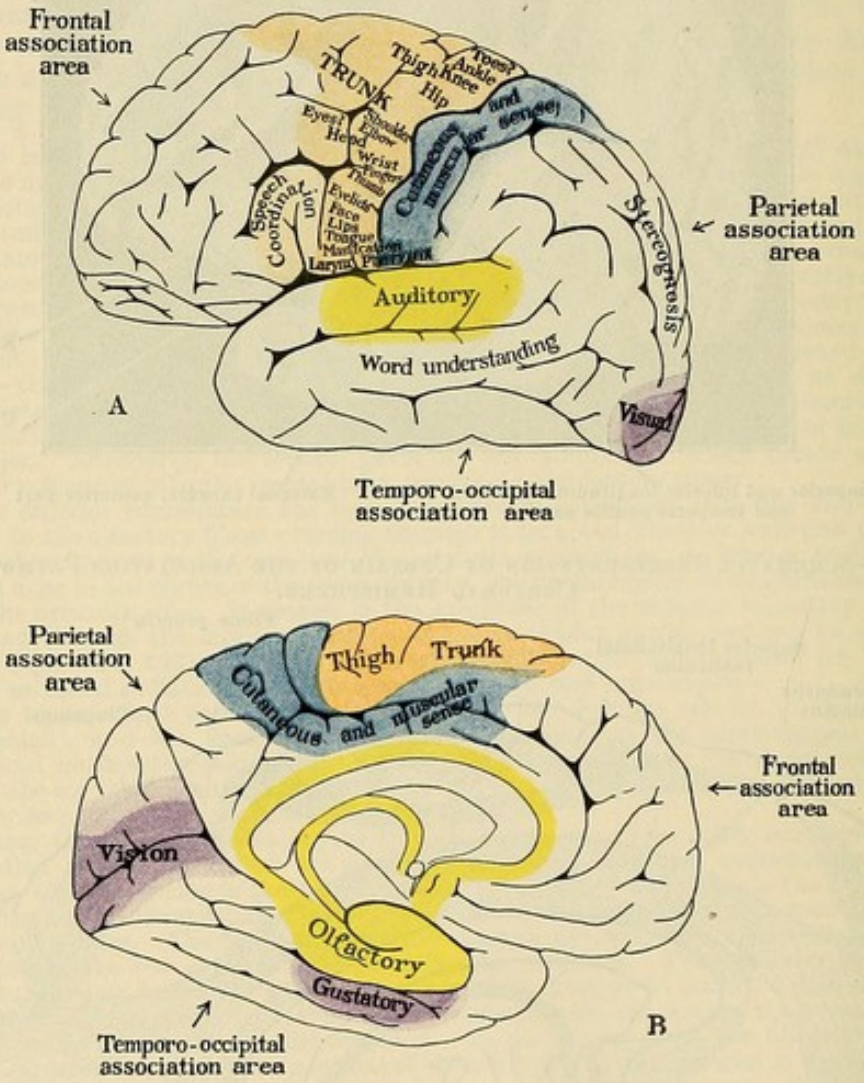

the fact that its fibres are less compactly arranged. It associates the lingual and fusiform gyri and the cuneus with the temporal pole.

(6) The medial and lateral **longitudinal striæ** of the upper surface of the corpus callosum may be considered among the association pathways, since most of their fibres associate the grey substance of the hippocampal gyrus with the subcallosal gyrus and the anterior perforated substance of the same hemisphere. Their significance as parts of the rhinencephalon has already been given.

(7) Likewise the longitudinal fibres in the **stria terminalis of the thalamus** (tænia semicircularis) may be considered among the association pathways, since these connect the amygdaloid nucleus with the anterior perforated substance.

(8) The numerous fibres passing in both directions between the cerebral cortex and the nuclei of the corpus striatum belong to the association system. These do not form a definite bundle, but, instead, contribute appreciably to the corona radiata. However, a pathway described as the **occipito-frontal fasciculus** probably consists largely of the more sagittally running fibres of this nature. The existence of this fasciculus has been noted in degenerations and in cases of arrested development of the corpus callosum. Its fibres are described as contributing greatly to the tapetum, and as coursing beneath the corpus callosum immediately

next to the ependyma of the lateral ventricle. As a mass, they appear in intimate connection with the caudate nucleus, and are spread toward both the frontal and the occipital lobes (chiefly the latter), in the mesial part of the corona radiata of those lobes. It is described as also containing fibres in both directions associating the occipital with the temporal lobe. *Vertical association fibres* pass through the caudate and lenticular nuclei between the cortex above and that of the temporal lobe below.

(9) Since the olfactory bulb is a part of the hemisphere proper, the *olfactory tract* may be considered an association pathway connecting the olfactory bulb with the parolfactory area, the subcallosal gyrus, the anterior perforated substance, and the uncus. As already shown, a portion of the fibres of the tract belongs to the commissural system.

THE FUNCTIONAL AREAS OF THE CEREBRAL CORTEX

The definitely known areas of specific function of the human cerebral cortex are relatively small. They comprise but little more than a third of the area of the entire hemisphere. They are—(1) the general sensory-motor or somæsthetic area, and (2) the areas for the organs of special sense. They represent portions of the cortex in which terminate sensory or ascending projection fibres bearing impulses from the given peripheral structures, and in which arise motor or descending projection fibres bearing impulses in response.

Knowledge of the location of the areas has been obtained—(1) by the Flechsig method of investigation, and to a considerable extent by Flechsig himself; (2) from clinico-pathological observations, largely studies of the phenomena resulting from brain tumors and traumatic lesions; (3) by experimental excitation of the cortex of monkeys and apes, the resulting phenomena being correlated with the anatomical findings and compared with the observations upon the human brain. The remaining larger and less known areas of the cortex are referred to as 'association centres' or areas of the 'higher psychic activities.'

In development, the sensory fibres to the specific areas acquire their medullary sheaths first, before birth, and then the respective motor fibres from each become medullated. It is not till a month after birth that the association centres show medullation and therefore acquire active functional connection with the specific areas.

In defining an area it is not claimed that all the fibres bearing a given type of impulse terminate in that area, nor that all the motor fibres leading to the given reaction originate in the area. It can only be said that of the fibres concerned in a given group of reactions, more terminate and arise in the areas cited than in any other areas of the cortex. The corresponding motor fibres arise both in the region of the termination of the sensory fibres (sensory area) and also in a zone (motor area) either partially surrounding or bordering upon a part of the region of termination.

The different areas are as follows:—

(1) **The somæsthetic (sensory-motor) area,** the area of general sensibility, and the area in which arise the larger part of the cerebral motor or pyramidal fibres for the cortical control of the general muscular system. As is to be expected, it is the largest of the specific areas. It includes the anterior central gyrus, posterior central gyrus, the posterior ends of the superior, middle, and inferior frontal gyri, the paracentral lobules, and the immediately adjacent part of the gyrus cinguli. The ascending or sensory fibres are found to terminate most abundantly in the part posterior to the central sulcus (Rolandi), the posterior central gyrus being the special area of cutaneous sensibility, and the adjacent anterior ends of the horizontal parietal gyri have been designated as the area of 'muscular sense.' Both these areas are carried over upon the medial surface to involve the lower part of the paracentral lobule and a part of the gyrus cinguli. The anterior central gyrus gives origin to relatively more motor fibres than the other portions of the somæsthetic area. In distribution, the muscles furthest away from the cortex are innervated from the most superior part of the area, the leg area being in the supero-mesial border of the hemisphere, while that from the head is in the anterior and inferior part of the area (fig. 703). The muscles of mastication and the laryngeal muscles are controlled from the fronto-parietal operculum. Broca's convolution, the opercular portion and part of the triangular portion of the inferior frontal gyrus, of the left hemisphere, constitutes the especial motor area of speech, and Mills has extended this area to include the supero-anterior portion of the insula below. The various authorities differ considerably as to the exact locations of many of the areas for the cortical control of given sets of muscles. Further observations must be skillfully made for localisation of areas of the human cortex in detail and further correlations must be determined between the experiments upon the cortex of anthropoid apes and the functions of that of man. The accompanying diagrams are compiled from several of the diagrams more usually given and must be considered as only approximately correct.

(2) **The visual area.**—The especial sensory portion of this area is that immediately bordering upon either side of the posterior part of the calcarine fissure. The entire area, motor and sensory overlapping each other, includes the whole of the cuneus. The motor visual area proper is described as the more peripheral portion of the entire area. In addition, an area producing eye movements is described as situated in the posterior end of the middle frontal gyrus.

(3) **The auditory (cochlear) area** comprises the middle third of the superior temporal gyrus and the transverse temporal gyri of the temporal operculum. The motor portion of this area lies in its inferior border. The fibres arising in the area course downward in the temporal pontile path to the motor nuclei of the medulla.

(4) **The olfactory area** consists of the olfactory trigone, the parolfactory area, the subcallosal gyrus, part of the anterior perforated substance, the hippocampal gyrus (especially the uncus), and the callosal half of the gyrus cinguli. Its motor or efferent area lies chiefly in the hippocampal gyrus, the fibres from which pass out from the telencephalon by way of the fornix and cingulum.

(5) **The gustatory area** is supposed to comprise the anterior portion of the fusiform gyrus and the zone (motor portion) about the anterior extremity of the inferior temporal sulcus.

(6) **The assocaition areas.**—The relatively large areas allotted at present to the so-called higher psychic activities are indicated in fig. 703. The great relative extent of these is one of the characteristics of the human brain. They probably merely represent the portions of the cortex of which little is known, and may eventually be subdivided into more specific areas. They are considered to be connected with the structures below by fewer projection fibres than are the recognised areas named above, while, on the other hand, they are rich in association fibres. By means of the latter they are in intimate connection with the specific areas and have abundant means of correlating and exercising a controlling influence upon the functions of these areas. According to Flechsig, they consist of—(1) a *parietal association area*, comprising that part of the parietal cortex between the somæsthetic area and the visual area; (2) an *occipito-temporal association area*, including the unspecified portions of the temporal lobe and the adjoining portion of the occipital lobe not included in the visual area; (3) a *frontal association area*, including all the frontal lobe anterior to the somesthetic and olfactory area. In the folds of the inferior parietal lobule of the parietal association area such intellectual activities as the optic discrimination of words, letters, numbers, and objects generally are supposed to

FIG. 704.—CONVEX SURFACE OF LEFT CEREBRAL HEMISPHERE WITH DIAGRAMMATIC PRESENTATION OF THE AREAS SUGGESTED AS CONCERNED WITH SPEECH.

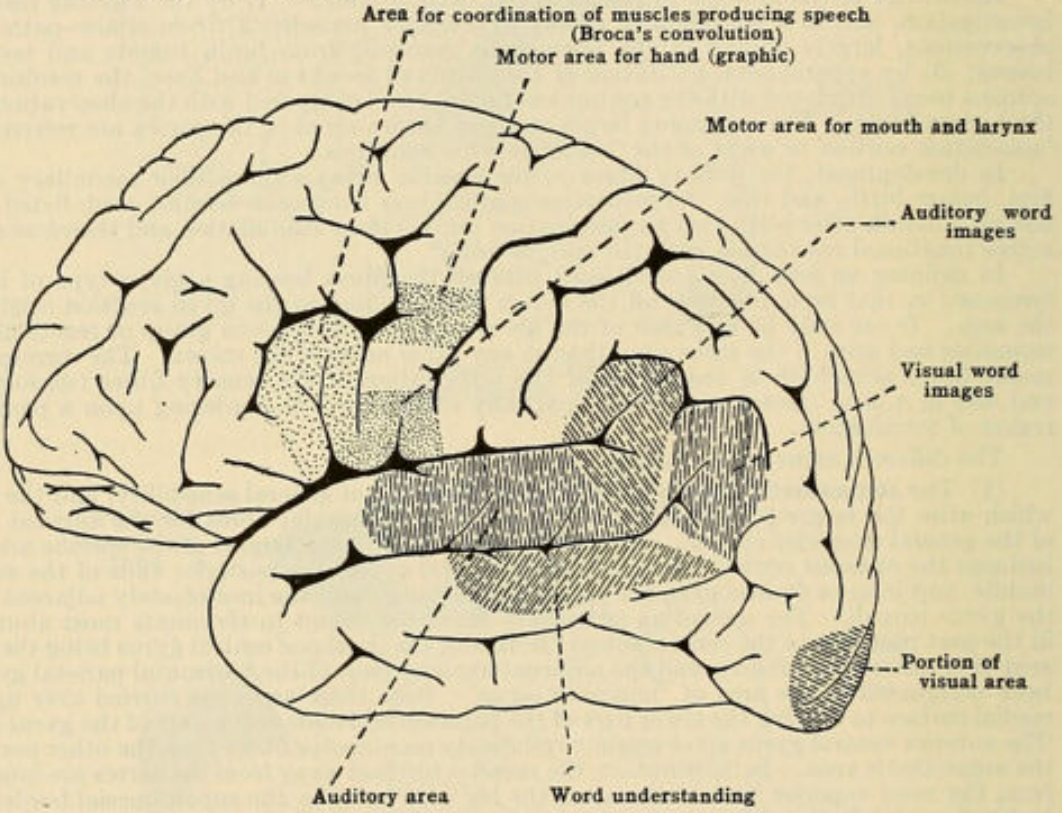

take place, while the superior parietal lobule continued into the posterior part of the præcuneus is the general region for the perception of form and solidity of objects—the stereognostic centre.

The *insula* is suggested as the area in which auditory, olfactory and gustatory impulses are associated with the motor areas beginning in the operculum dorso-laterally adjacent to it.

Observations of symptoms and the position of lesions accompanying them have made it possible to arrive at some trustworthy conclusions regarding the **cortical areas controlling speech.** Broca announced in 1861 that the inferior frontal gyrus of the *left* hemisphere was peculiarly concerned with speech. This area was later confined to the posterior end or opercular portion of this gyrus and the name "Broca's Convolution" was given it. It is now known that Broca's convolution and the adjacent portion of the triangular part of the inferior frontal gyrus as well comprise the *motor* area or *emissive speech area*—the area especially devoted to the control of that coordinated action of the muscles concerned which makes possible articulate speech. Patients in whom this area is impaired are unable to give utterance to words though they may understand them both written and spoken, and though they may give utterance to sound. This inability is known as *motor aphasia.* Results of observed lesions have further shown that the area in which the *auditory images* of words are retained (word memories) comprises the posterior end of the superior temporal gyrus and the adjoining portion of the supramarginal gyrus. Injury to this area is accompanied by inability to recognise spoken words although the patient hears them and may recognise and understand written words, a phenomenon known as "word-deafness" or *sensory aphasia.* This area may be considered as continuous with the superior portion of the posterior end of the middle temporal gyrus which has been suggested as the area of "word-understanding," or *"lalognosis."* On the other hand, the area in which visual images of words are retained is located as the angular gyrus. Injury to this results in an inability to recognise printed or written words although the patient

may hear, understand and speak them. This is called *"word-blindness."* This area is nearest the special area of vision on the one hand and on the other hand, is continuous into the area to which word-understanding is attributed. For purposes of writing, it must be associated with the motor area for the muscles of the hand in the precentral gyrus.

While the motor area for speech is most functional in the left hemisphere, the remaining areas concerned are probably equally developed in the two hemispheres.

III. GENERAL SUMMARY OF SOME OF THE PRINCIPAL CONDUCTION PATHS OF THE NERVOUS SYSTEM

In the following summary the arabic numerals indicate paragraphs in which are mentioned the nuclei or ganglia containing the cell-bodies of the neurones interposed in the chains; the small letters indicate the different names given to the different levels of the pathways through which their fibres run. For detailed descriptions of either nuclei or pathways see pages describing them. Only the more common neurone chains are followed here.

I. The Spino-cerebral and Cerebro-spinal Path

A. The ascending system of neurones. (fig. 705)

1. Spinal ganglion—neurone of first order.
   - (*a*) Terminal corpuscles and peripheral process of T-fibre.
   - (*b*) Dorsal or afferent root of spinal nerve.
   - (*c*) Ascending branch of bifurcation of dorsal root fibre in fasciculus gracilis, or fasciculus cuneatus of spinal cord.
2. Nucleus of fasciculus gracilis or nucleus of fasciculus cuneatus in medulla oblongata—neurone of second order.
   - (*a*) Internal arcuate fibres.
   - (*b*) Decussation of lemniscus.
   - (*c*) Interolivary stratum of lemniscus of opposite side.
   - (*d*) Medial lemniscus.
3. Hypothalamic nucleus and lateral nucleus of thalamus—neurone of third order.
   - (*a*) Internal capsule, posterior segment of fronto-parietal portion.
   - (*b*) Corona radiata, fronto-parietal part.
   - (*c*) Posterior central gyrus of somæsthetic area of cerebral cortex.

B. Descending system of neurones (fig. 706).

1. Giant pyramidal cells of precentral gyrus of somæsthetic area.
   - (*a*) Corona radiata, fronto-parietal part.
   - (*b*) Internal capsule, middle segments of fronto-parietal portion.
   - (*c*) Basis of the cerebral peduncle and the peduncle.
   - (*d*) Pyramid of medulla oblongata.
   - (e^1) Decussation of pyramids.
   - (f^1) Lateral cerebro-spinal fasciculus (crossed pyramidal tract).
   - (e^2) Ventral cerebro-spinal fasciculus (direct or uncrossed pyramidal tract).
   - (f^2) Gradual decussation of latter in cervical and upper thoracic regions of spinal cord.
2. Cells of ventral horn of spinal cord of opposite side.
   - (*a*) Ventral or efferent roots of spinal nerves.
   - (*b*) Peripheral nerve-trunks directly to skeletal muscles or indirectly to smooth muscle or glands by way of sympathetic neurones.

II. Short 'Reflex' Paths of Spinal Cord

1. Spinal ganglia.
   - (*a*) Terminal corpuscles and peripheral process of T-fibres.
   - (*b*) Dorsal root of spinal nerve.
   - (*c*) Collaterals and descending branches of bifurcation of dorsal root fibres in spinal cord
   - (*d*) Directly to ventral horn cells of same level of spinal cord.
   - (*e*) Or, more commonly, to same through intermediation of Golgi cell of type II.
   - (*f*) Or to neurones of fasciculi proprii to ventral horn cells of other levels of spinal cord.
2. Ventral horn cells of same (chiefly) and opposite side and thence by way of ventral roots and peripheral nerve trunks directly to muscles.
3. Dorso-lateral group of ventral horn cells of same (chiefly) and opposite sides and thence by ventral root fibres to cell-bodies in sympathetic ganglia.
4. Sympathetic axones to smooth muscle or glands.

III. Cerebral Path for the Cranial Nerves, Exclusive of Those of Special Sense

A. Ascending system of neurones.

1. Ganglia of origin of sensory components of vagus, glossopharyngeus, glosso-palatine and trigeminus.
   - (*a*) Peripheral arborisations and afferent peripheral branches of T-fibres of same.
   - (*b*) Central branches of T-fibres of same (sensory nerve roots).
2. Nuclei of termination of central branches (bifurcated and unbifurcated) in medulla oblongata.
   - (*a*) Reticular formation, internal arcuate fibres and medial lemniscus of the opposite side.

3. Hypothalamic nucleus and lateral nucleus of thalamus.
   (*a*) Internal capsule, posterior segment of fronto-parietal portion.
   (*b*) Corona radiata, fronto-parietal part.
   (*c*) Cerebral cortex—chiefly lower third of posterior central gyrus.

FIG. 705.—SCHEME OF ASCENDING OR SPINO-CEREBRAL CONDUCTION PATHWAYS.

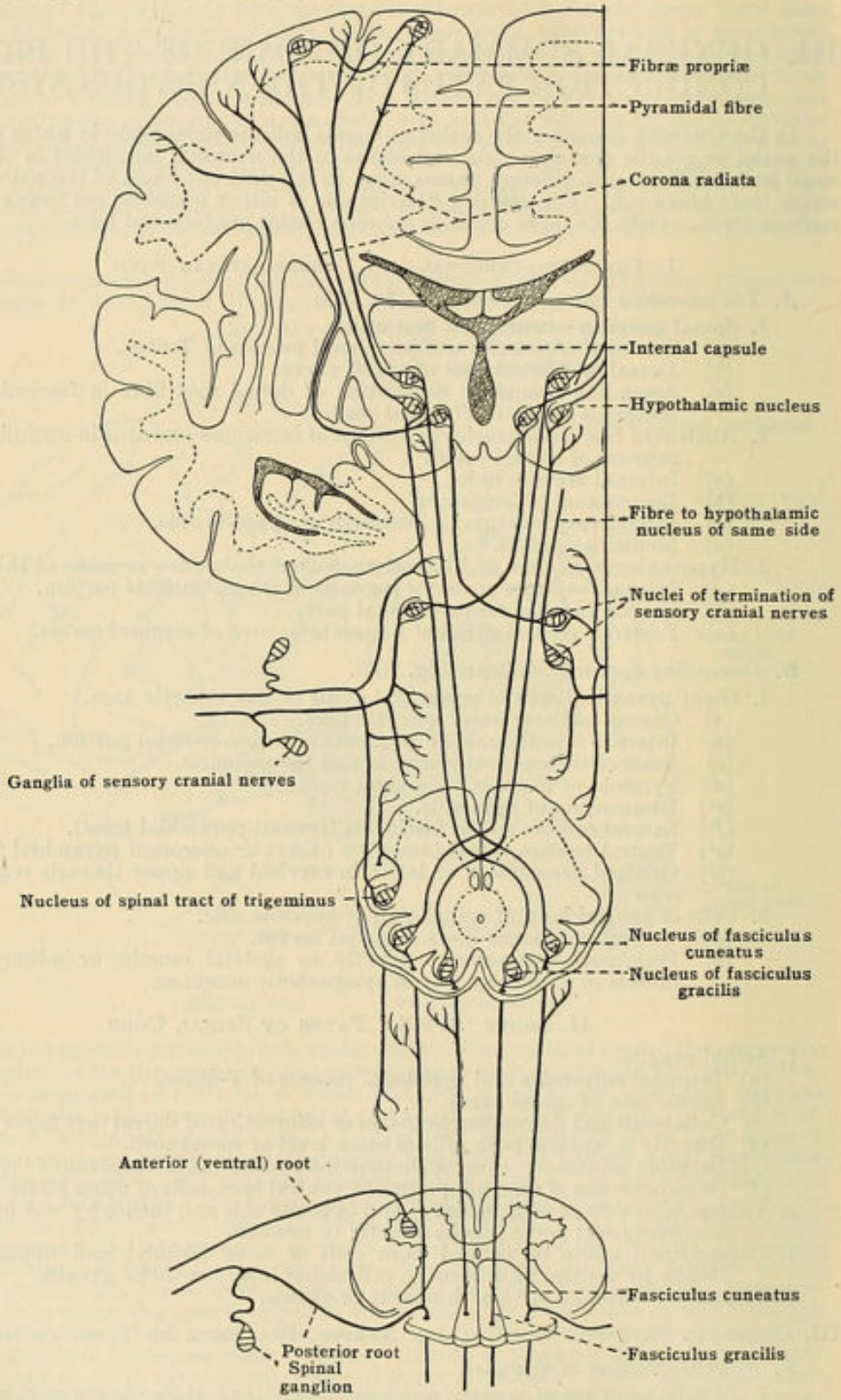

B. Descending system of neurones.

1. Pyramidal cells of opercular region of somæsthetic area.
   (*a*) Corona radiata, fronto-parietal.
   (*b*) Internal capsule, genu chiefly.
   (*c*) Basis of cerebral peduncle and peduncle.
   (*d*) Decussation in brain stem.

2. Nuclei of origin of motor cranial nerves and motor components of mixed cranial nerves, of opposite side chiefly and thence by way of these nerves to the respective muscles supplied.

Notes: (1) Most of the descending cortical fibres to the nucleus of origin of the trochlear

FIG. 706.—SCHEME OF DESCENDING CEREBRO-SPINAL CONDUCTION PATHWAYS.

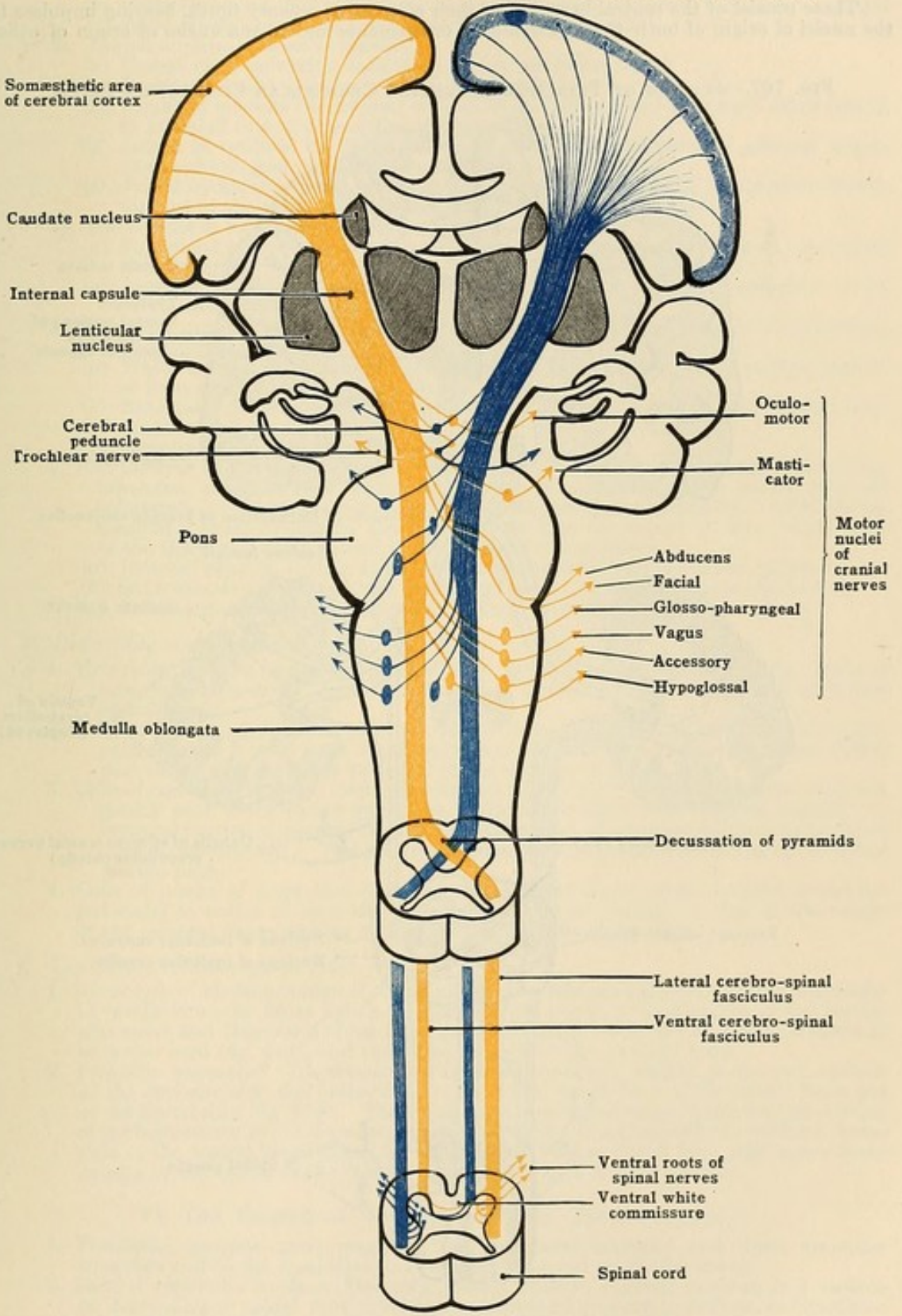

nerve and that portion of the nucleus of the oculomotor which supplies the internal rectus muscle apparently do not decussate but terminate in the nuclei of the same side.

(2) The efferent nucleus of the glosso-palatine (salivatory nucleus) and the dorsal efferent nucleus of the vagus give rise to visceral efferent fibres, i. e., carry impulses destined for smooth muscle and glands by way of sympathetic neurones. The same is true for the supero-median part of the nucleus of the oculomotor.

(3) The nuclei of termination of the cranial nerves, especially those of the vestibular and trigeminus, send fibres also into the cerebellum.

IV. The Short 'Reflex' Paths of the Cranial Nerves

These consist of the central branches of their afferent or sensory fibres, bearing impulses to the nuclei of origin of both their own motor components and to the nuclei of origin of other

Fig. 707.—Scheme of Principal Ascending Cerebellar Conduction Paths.

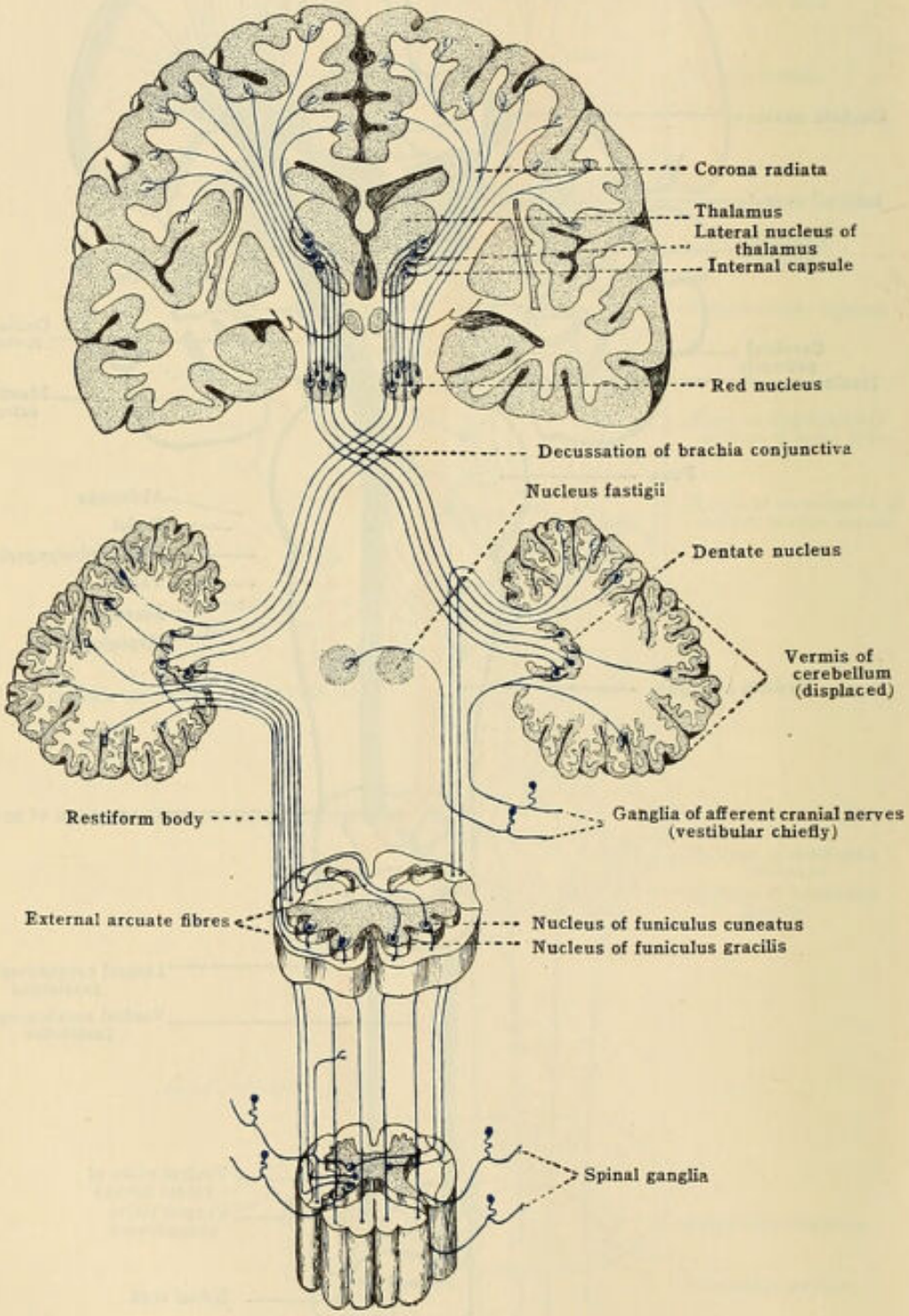

motor nerves. Fibres to the more distant nuclei pass to them by way of the medial longitudinal fasciculus. Instead of terminating in the motor nuclei directly, the sensory fibres are usually interrupted by a third or intermediate neurone interposed in the chain. The vagus and glosso-pharyngeus are connected by way of the solitary fasciculus and its nucleus with the structures below their level of entrance, even with the ventral horn cells of the upper segments of the cervical cord, and through these with the muscles of respiration.

V. Conduction Paths Involving the Cerebellum

A. Ascending cerebellar pathways.

1. Spinal ganglia.
   (*a*) Dorsal roots of spinal nerves.
   (*b*) Collaterals and descending branches of bifurcation of dorsal root fibres in spinal cord, chiefly those conveying impulses of *muscle-sense*.

2*x*. Dorsal nucleus (Clarke's column).
   (*a*) Dorsal spino-cerebellar fasciculus (direct cerebellar tract).
   (*b*) Restiform body (inferior cerebellar peduncle)—
   (*c*) Joined in medulla by external arcuate fibres (crossed and uncrossed fibres arising in nuclei of funiculus gracilis and cuneatus);
   (*d*) Joined in medulla by fibres arising in nuclei of termination of afferent vagus, glosso-pharyngeal, vestibular, and trigeminal nerves;
   (*e*) Joined by fibres both to and from (ascending and descending) the inferior olivary nucleus of the same and opposite sides (*cerebello-olivary fibres*).

2*y*. Nerve-cells in base of ventral horn of same and opposite side.
   (*a*) Superficial antero-lateral spino-cerebellar fasciculus (Gowers' tract), ascending through spinal cord and reticular formation of medulla and pons.
   (*b*) Anterior medullary velum and brachium conjunctivum to cerebellar cortex (vermis).

3. Cerebellar cortex (vermis), dentate nucleus, nucleus fastigii, nucleus emboliformis, and nucleus globosus.
   (*a*) White substance (corpus medullare) of cerebellum, associating various regions of its cortex and its nuclei with each other.
   (*b*) Brachium conjunctivum (superior cerebellar peduncle) arising chiefly from dentate nucleus.
   (*c*) Decussation of brachium conjunctivum.

4. Red nucleus and ventral portion of lateral nucleus of thalamus. Most fibres of the brachium conjunctivum terminate in the red nucleus; many merely give off collaterals to it in passing to their termination in the thalamus. Most of the ascending fibres arising in the red nucleus also terminate in the ventral part of the thalamus; some ascend to the cerebral cortex direct.
   (*a*) Internal capsule, middle third, and fronto-parietal part of corona radiata.
   (*b*) Somæsthetic area of cerebral cortex and cortex of frontal lobe anterior to it.
   (*c*) Inferior peduncle of thalamus to cortex of temporal lobe.

B. Descending cerebrocerebellar paths.

1. Pyramdial cells of somæsthetic area send fibres through corona radiata, internal capsule, and cerebral peduncle to nuclei of pons and arcuate nucleus of same and opposite side.
2. Cells of cortex of posterior part of frontal lobe give fibres to form frontal pontile path through frontal parts of corona radiata and internal capsule and through medial part of cerebral peduncle to nuclei of pons of opposite side.
3. Cells of cortex of temporal lobe (superior and middle gyri) give fibres to form temporal pontile path which passes under the lenticular nucleus into anterior segment of occipital portion of internal capsule and lateral part of cerebral peduncle to nuclei of pons of opposite side. This path is joined in the internal capsule by a small occipito-pontile path.
4. Cells of nuclei of pons send fibres by way of brachium pontis (middle cerebellar peduncle) to cortex of cerebellar hemisphere, of side opposite to that of the origin of the cerebral fibres making synapses with the cells of the pons.

C. Descending cerebello-spinal paths.

1. From cells of nucleus fastigii of same and opposite sides and probably from other nuclei of cerebellum arise fibres which terminate in the nuclei of termination of the vestibular nerve and these send fibres into the intermediate and anterior marginal fasciculi of spinal cord (fig. 619), and thence to the cells of the anterior horn.
2. Probably connected with the cerebellum is the pathway arising in the red nucleus of the opposite side and descending in the rubro-spinal tract of the lateral funiculus of the spinal cord (fig. 619). The rubro-spinal tract decussates in the ventral portion of the tegmentum of the mesencephalon and is said to pass through the medulla oblongata in the medial longitudinal fasciculus. It must be noted here that some fibres arising in the cortex of the frontal lobe terminate in the red nucleus.

VI. The Vestibular Conduction Paths (Equilibration)

1. Vestibular ganglion gives origin to the peripheral utricular and three ampullar branches and to the combined and centrally directed vestibular nerve.
2. Lateral vestibular nucleus (Deiters'), medial nucleus, superior nucleus, and nucleus of descending or spinal root (nuclei of termination) give origin to fibres as follows:—
   (*a*) From lateral and superior nuclei to nucleus fastigii of opposite side and to cortex of vermis and to dentate nucleus (cerebellar connection).
   (*b*) From medial and superior nuclei to nuclei of origin of eye-muscle nerves of same and opposite sides, by way of medial longitudinal fasciculi.
   (*c*) From lateral nucleus and nucleus of descending root through reticular formation into lateral and ventral vestibulo-spinal tracts of spinal cord.

(*d*) The nuclei receive fibres from the grey substance of the vermis. It is probable that all the nuclei of termination give off fibres bearing ascending impulses which ultimately reach the somæsthetic area, but the course pursued and neurones involved in such a chain are uncertain.

VII. The Auditory Conduction Path (Cochlear Nerve)

1. Spiral ganglion of the cochlea gives origin to short peripheral fibres to organ of Corti, and to the centrally directed cochlear nerve.
2. Dorsal and ventral nuclei of the cochlear nerve (nuclei of termination).
   (*a*) Striæ medullares arise from dorsal nucleus and pass around outer side of restiform body (acoustic tubercle), then medianward under ependyma of floor of fourth ventricle to mid-line, then ventralward into tegmentum, where they decussate and join trapezoid body and lateral lemniscus of opposite side.

Fig. 708.—Diagram Showing Some of the Connections of the Vestibular and Cochlear Nerves.

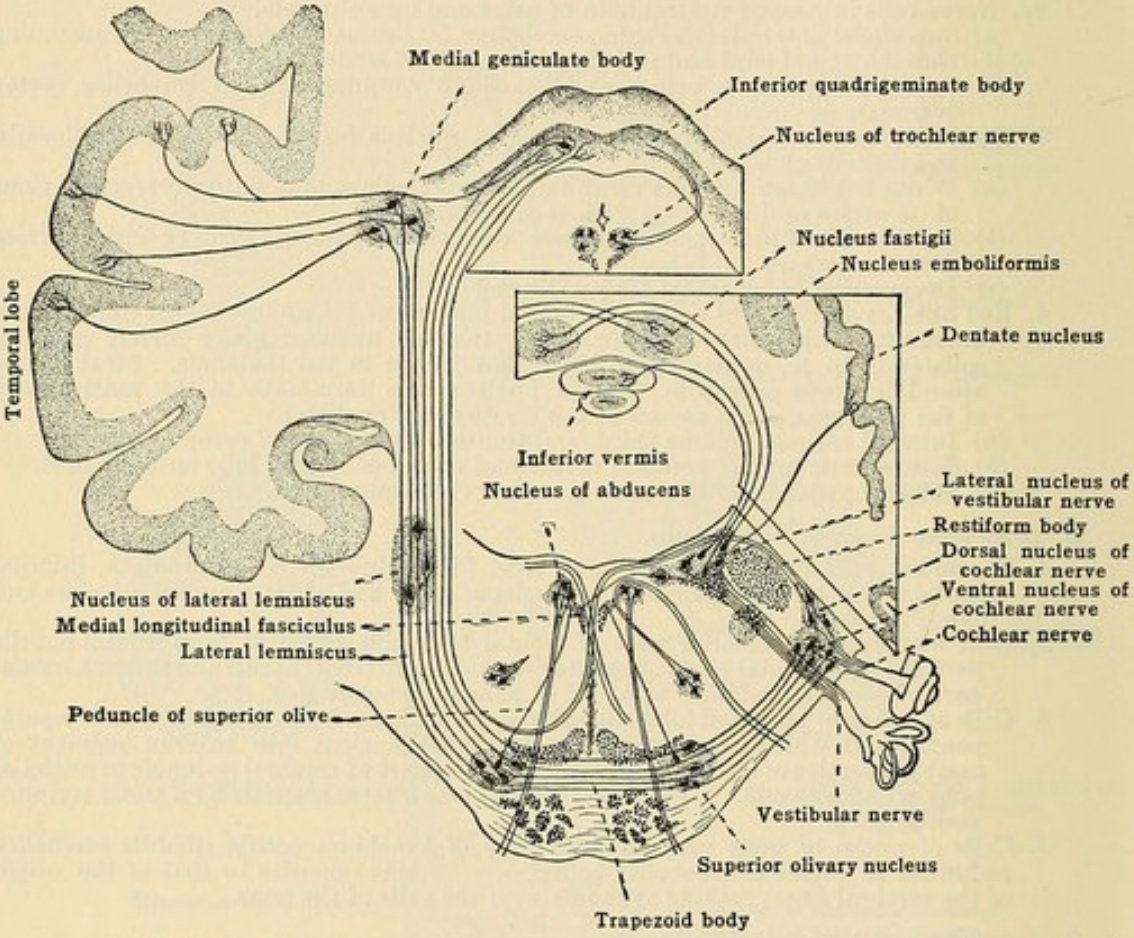

(*b*) Fibres arising in ventral nucleus pass ventrally medianward and some terminate in the superior olivary nucleus of same side; others pass by way of trapezoid body and lateral lemniscus to terminate in superior olivary nucleus, nucleus of lateral lemniscus, medial geniculate body and nucleus of inferior quadrigeminate body of the opposite side.

3. Nuclei of superior olives of both sides and nucleus of lateral lemniscus send fibres by way of lateral lemniscus to inferior quadrigeminate body and through inferior brachium to medial geniculate body, and some may pass uninterrupted to the cortex of the temporal lobe.
4. Fibres from medial geniculate body and probably from nucleus of inferior quadrigeminate body pass into internal capsule and through temporal part of corona radiata to middle third of superior temporal gyrus and adjacent portions (auditory area).
5. From striæ medullares and from superior olivary nucleus (peduncle of superior olive) arise fibres which terminate in nucleus of abducens or pass by way of the medial longitudinal fasciculus to other motor nuclei of cranial nerves. It is probable that fibres from the auditory area of the cerebral cortex are also distributed to nuclei of the cranial nerves.

VIII. Conduction Paths of the Optic Apparatus

A. Optic impulses.

1. 'Bipolar' cells of retina with short (peripheral) processes to layer of rods and cones (neuro-epithelium) and short centrally directed processes to ganglion-cell layer of retina (nucleus of termination).

2. Ganglion-cells of retina give origin to—
   (*a*) Optic stratum of retina.
   (*b*) Optic nerve.
   (*c*) Optic chiasma; fibres from nasal side of retina cross in chiasma to opposite side; fibres from lateral side of retina continue on same side in—
   (*d*) Optic tract to—
3. Pulvinar of thalamus, lateral geniculate body, and nucleus of superior quadrigeminate body.
   (*a*) Fibres from nucleus of superior quadrigeminate body pass ventrally, to nuclei of origin of oculomotor and trochlear nerves and to medial longitudinal fasciculus of same and opposite sides, and from it are distributed to nucleus of origin of abducens.
   (*b*) Fibres from lateral geniculate body and pulvinar pass through occipital portion of internal capsule and occipito-thalamic radiation (optic radiation) to cortex of occipital lobe (visual area).

FIG. 709.—DIAGRAM OF PRINCIPAL PATHWAYS OF OPTIC APPARATUS. (After Cunningham.)

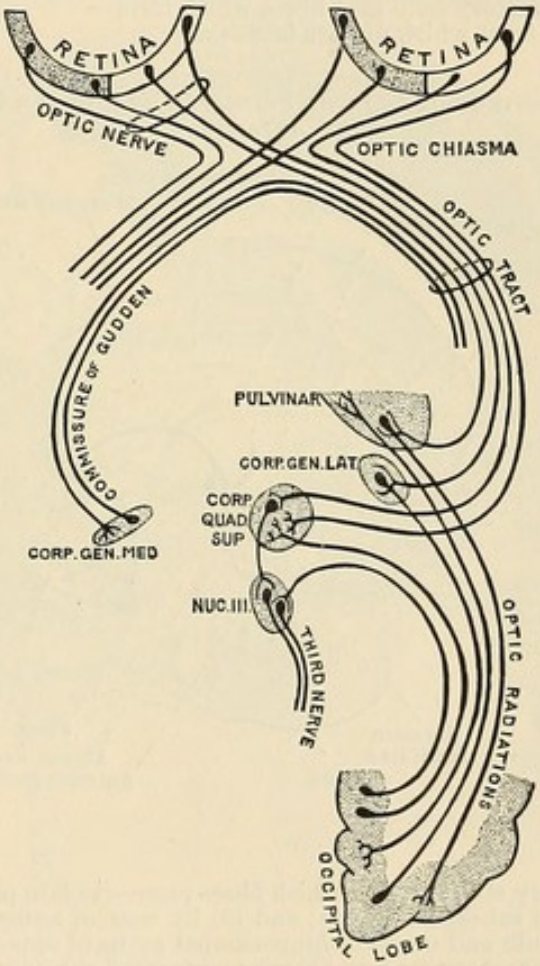

4. Cells of visual area of cortex send fibres through occipito-thalamic radiation and occipital portion of internal capsule to nucleus of superior quadrigeminate body (occipito-mesencephalic fasciculus), and thence, probably interrupted by cells of this nucleus, to nuclei of eye-muscle nerves.
5. Cells of nucleus of superior quadrigeminate body and pulvinar send fibres by way of medial longitudinal fasciculus into lateral and ventral funiculi of spinal cord (see fig. 619), chiefly of the opposite side. Fibres from the quadrigeminate body cross mid-line chiefly in decussation of 'optic-acoustic reflex path' (fig. 662).
6. The smaller cells of the supero-mesial group of the nucleus of the oculomotor nerve (nucleus of Edinger and Westphal) send axones, by way of the trunk of the nerve and the short root of the ciliary ganglion, which terminate about cells in—
7. The ciliary ganglion, whose cells send axones to enter the ocular bulb and terminate upon the smooth muscle fibres of the ciliary body and iris.

B. Skin-pupillary reflexes.

1. Peripheral processes of spinal ganglion cells terminating in the skin and central processes of same entering by way of dorsal roots of cervical nerves to bifurcate in spinal cord and give terminal twigs about—
2. Cells of the dorso-lateral group of the ventral horn of the same and opposite sides. These cells send (visceral efferent) axones to terminate about cells in—

3. The superior cervical sympathetic ganglion, which cells send axones chiefly by way of the carotid plexus and the sympathetic roots of the ciliary ganglion to terminat about cells in—
4. The ciliary ganglion. Such cells send axones into the ocular bulb to terminate in the ciliary body and radial muscle fibres of the iris, producing dilation of the pupil.

C. Auditory-eye reflexes.

1. Cells of the nuclei of termination of the cochlear nerve and superior olive send fibres by way of the medial longitudinal fasciculus (some to this by way of the peduncle of the superior olive) to the nuclei of origin of the eye-moving nerves.
2. The same nuclei of the cochlear nerve send axones by way of the lateral lemniscus to terminate in the superior quadrigeminate body and thence may be sent impulses which are distributed to the nuclei of the eye-moving nerves.

IX. Principal Conduction Paths of Olfactory Apparatus

1. Bipolar cells of olfactory region of nasal epithelium send short (peripheral) processes toward surface of nasal cavity and centrally directed processes, the olfactory nerve, through lamina cribrosa of ethmoid bone into olfactory bulb (glomerular layer).
2. 'Mitral cells' of olfactory bulb give fibres which form—
   (*a*) The olfactory tract which divides into—

Fig. 710.—Diagram Showing Some of the Principal Tracts and Synapses of the Olfactory Apparatus.

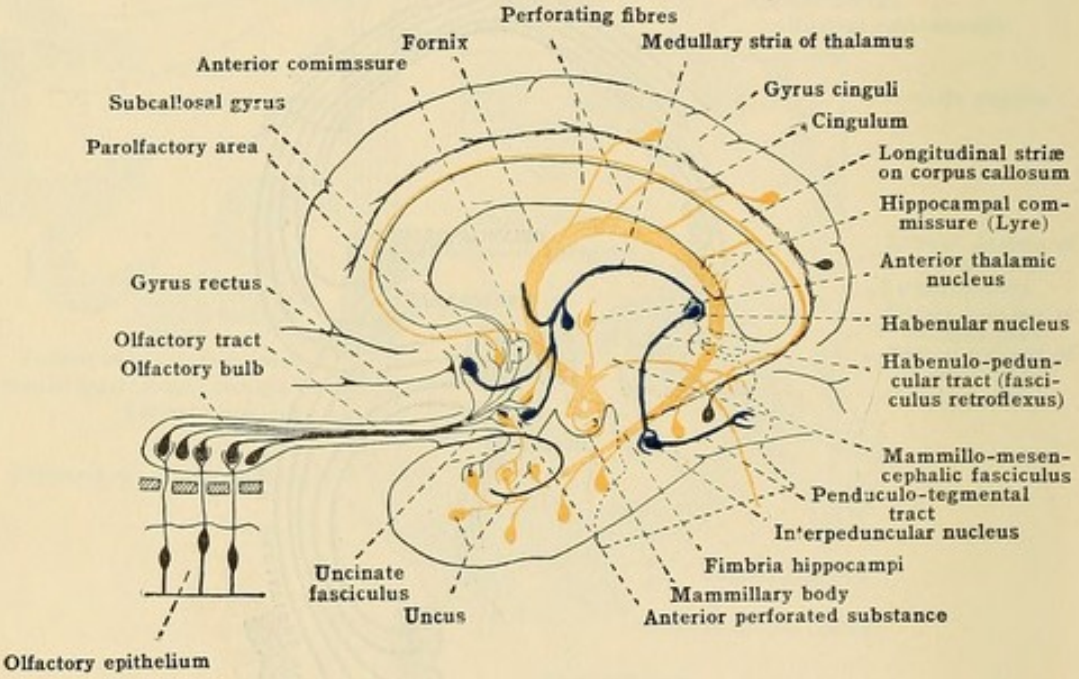

   (*b*) Medial olfactory stria through which fibres pass—(1) into parolfactory area (Broca's area); (2) into subcallosal gyrus; and (3) by way of anterior cerebral commissure to olfactory bulb and uncus of hippocampal gyrus of opposite side.
   (*c*) Intermediate olfactory stria to anterior perforated substance.
   (*d*) Lateral olfactory stria, which terminates to some extent in anterior perforated substance, but chiefly in uncus, hippocampal gyrus, and gyrus cinguli (olfactory area) of same side.
3. Cells of uncus and hippocampal gyrus give fibres which form—
   (*a*) The cingulum (in part), by which they are associated with the cortex of the gyrus cinguli and other areas of the cerebral cortex.
   (*b*) The hippocampal commissure (in part), by which they are connected with the grey substance of the opposite side.
   (*c*) The fornix, which, interrupted in part in the nuclei of the corpus mammillare, conveys impulses—(1) to the anterior nucleus of thalamus of the same (chiefly) and opposite sides (mammillo-thalamic fasciculus), and (2) into the mesencephalon and substantia nigra (mammillo-mesencephalic fasciculus), and by way of this tract probably to the nuclei of the mesencephalon and medulla oblongata.
4. The parolfactory area, anterior perforated substance, anterior portion of thalamus and fornix give fibres which form the medullary stria of the thalamus and which terminate in the habenular nucleus.
5. Habenular nucleus sends fibres in fasciculus retroflexus to terminate in interpeduncular nucleus.
6. Interpeduncular nucleus sends fibres to nuclei of mesencephalon and probably to structures below it.

The Relations of the Brain to the Walls of the Cranial Cavity

The precise methods by which the exact positions of the most important fissures, sulci, gyri, and areas can be ascertained and mapped out on the surface of the head in the living subject are fully described in Section XIII. Here, only a very general survey of the relations of the brain to the cranial bones is given and from a purely anatomical standpoint.

The parts of the brain which lie in closest relation with the walls of the cranial cavity are the olfactory bulb and tract, the basal and lateral surfaces of the cerebral hemispheres, the inferior surfaces of the lateral lobes of the cerebellum, the ventral surfaces of the medulla and pons, and the hypophysis.

Certain of these portions of the brain lie in relation with the basi-cranial axis, that is, with the basi-occipital, the basi-sphenoid, and the ethmoid bones, while others are associated with the sides and vault of the cranial cavity. Considering the former portions first, the ventral surface of the medulla oblongata, which is formed by the pyramids, lies upon the upper surface of the basi-occipital bone. More superiorly the ventral surface of the pons rests upon the basi-

Fig. 711.—Drawing of a Cast of the Head of an Adult Male.
(Prepared by Professor Cunningham to illustrate cranio-cerebral topography.)

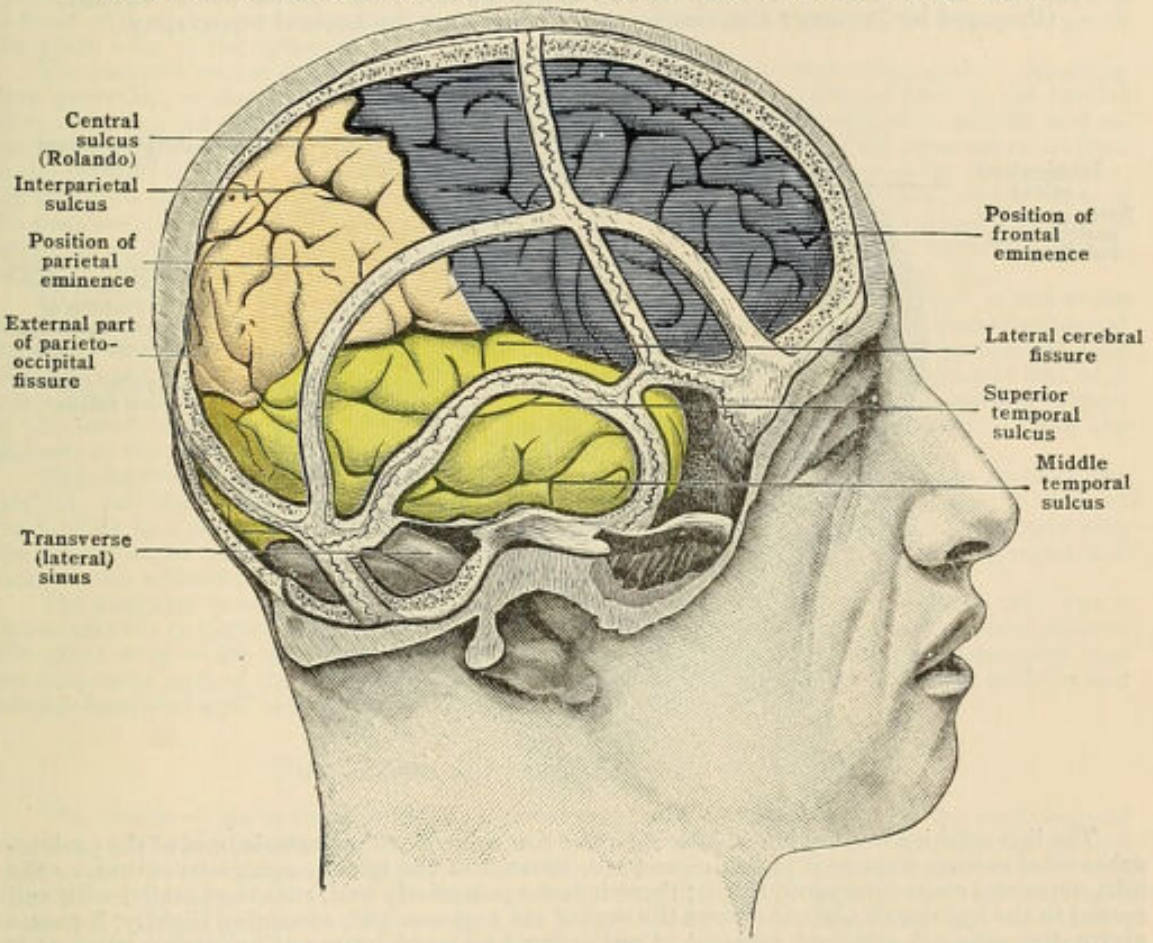

sphenoid, from which it is partly separated by the basilar artery and the pair of abducens nerves. In front of the dorsum sellæ the hypophysis (pituitary body) is lodged in the hypophyseal fossa. Still further forward the olfactory tracts lie in grooves on the upper surface of the presphenoid section of the sphenoid bone; and in front of the sphenoid the olfactory bulbs rest upon the cribriform plates of the ethmoid.

Posterior and lateral to the posterior part of the foramen magnum the lateral lobes of the cerebellum are in relation with the cranial wall, resting upon the lower parts of the supra-occipital and the posterior parts of the ex-occipital portions of the occipital bone, while anteriorly each lobe is in relation with the inner surface of the mastoid process and the posterior surface of the petrous portion of the temporal bone. The area of the skull wall which is in close relationship with the cerebellar hemispheres may be indicated, on the external surface of the skull, by a line which commences at the inferior part of the external occipital protuberance and thence runs upward and lateralward. It crosses the superior nuchal line a little beyond its centre, and, continuing in the same direction, crosses the inferior part of the lambdoid suture and reaches a point directly above the asterion (the meeting-point of the occipital, temporal, and parietal bones); thence it descends, just in front of the occipito-mastoid suture, to the tip of the mastoid process, and there turns medialward to its termination at the margin of the foramen magnum, immediately behind the posterior end of the occiptal condyle.

The basal surface of each cerebral hemisphere may be said to consist of two parts, an anterior and a posterior, separated by the stem of the lateral cerebral fissure. The anterior part, formed

by the orbital surface of the frontal lobe, rests upon the upper surfaces of the orbital plate of the frontal bone and the lesser wing of the sphenoid. It is, therefore, in close relation with the upper wall of the orbital cavity. The posterior part, behind the stem of the lateral fissure, begins with the anterior portion of the temporal lobe, including its pole. The pole itself projects against the orbital plate of the great wing of the sphenoid bone, and it is in relationship with the posterior part of the lateral wall of the orbit. The basal surface of the hemisphere, behind the pole of the temporal lobe is in contact with the upper surfaces of the great wing of the sphenoid and the petrous part of the temporal bone.

The convex surfaces of the cerebral hemispheres have the most extensive relationships with the cranial wall, and it is more especially to these surfaces that the surgeon turns his attention. The general area in which the convex surface of each cerebral hemisphere is in relation with the skull bones is readily indicated by a series of lines which correspond with the positions of its superciliary, infero-lateral, and supero-mesial borders.

The line marking the superciliary margin of the hemisphere commences at the nasion (the mid-point of the fronto-nasal suture); it passes lateralward above the superciliary ridge, crosses the temporal ridge, then, turning posteriorly in the temporal fossa, it reaches the parieto-sphenoidal suture, and continues backward along it to its posterior extremity.

FIG. 712.—DRAWING OF A CAST OF THE HEAD OF A NEWLY BORN MALE INFANT. (Prepared by Professor Cunningham to illustrate cranio-cerebral topography.)

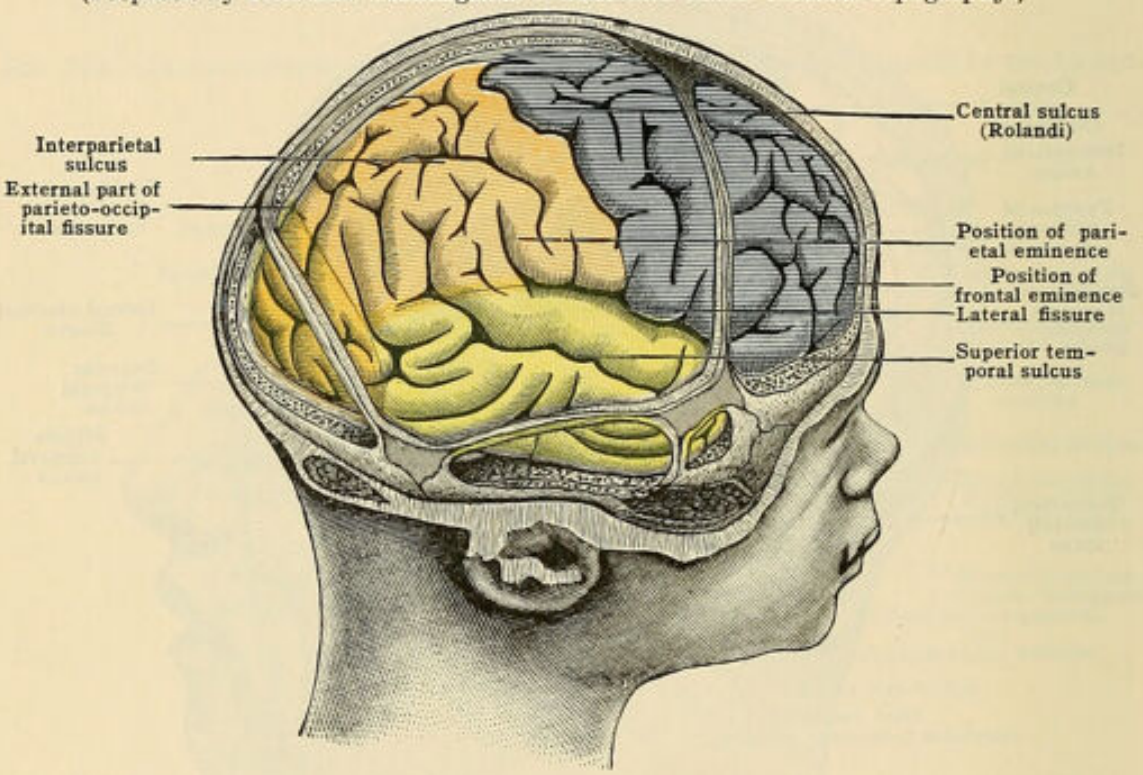

The line marking out the infero-lateral border commences at the posterior end of the parieto-sphenoidal suture, whence it passes downward, in front of the spheno-squamous suture, to the infra-temporal crest (pterygoid ridge); there it turns posteriorly and, running parallel with and mesial to the zygomatic arch, it crosses the root of the zygoma, and, ascending slightly, it passes above the external auditory meatus. Continuing backward with an inclination upward it reaches a point immediately above the asterion; thence it descends, and, crossing the inferior part of the lambdoid suture and the superior nuchal line, it passes medialward to the inferior part of the external occipital protuberance.

The supero-mesial border of the hemisphere is defined by a line which runs from the nasion to the inion. This line should be drawn about 5 mm. lateral to the sagittal suture, because the mesial area is occupied by the superior sagittal sinus, and it should be further away from the middle line on the right than on the left side, because the sinus tends to lie more to the right side.

The area of the skull wall enclosed by the three lines which mark the positions of the superciliary, infero-lateral, and the supero-mesial borders of the cerebral hemisphere is formed by the vertical plate of the frontal bone, the parietal bone, the great wing of the sphenoid, the squamous part of the temporal, and the upper section of the supra-occipital segment of the occipital bone. It covers the outer surfaces of the frontal, parietal, temporal, and occipital lobes of the cerebrum and the fissures and sulci which bound and mark them.

In every consideration of the topographical relations of the cerebral gyri to the walls of the cranial cavity it must be borne in mind that the conditions are not constant, and that, therefore, the relations are variable. The three main factors upon which this variability depends are age, sex, and the shape of the skull. As examples of the variations which occur it may be mentioned that the lateral cerebral fissure is relatively higher in the child than in the adult (compare figs. 711 and 712). The supero-mesial end of the central sulcus is further away from the coronal suture in the female and in the child than in the adult male, and in dolichocephalic than in

brachycephalic heads. The angle formed between the line of the central fissure and the mid-sagittal plane, which averages about 68° in the adult, is more acute in dolichocephalic heads, and the external part of the parieto-occipital fissure is further forward in the child, and possibly in the female, than it is in the adult male.

The position of the posterior horizontal limb of the lateral fissure varies even in the adult. Its posterior part is always under cover of the parietal bone, and it terminates either in front of or inferior to the parietal eminence, but the anterior part may be above, parallel with, or inferior to the squamo-parietal suture. In the adult the anterior part of the fissure runs upward and backward from the posterior end of the spheno-parietal suture along the anterior part of the squamo-parietal suture to its highest point; thence it continues in the same direction beneath the parietal bone toward the lambda, terminating either in front of or below the parietal eminence. In the child, however, the fissure is considerably above the line of the squamo-parietal suture (fig. 712), which it gradually approaches, attaining its adult position about the ninth year. This change of position, which occurs during the first nine years, is due partly to the ascent of the sutural line and partly to the descent of the fissure on the surface of the brain.

The frontal bone always covers the superior, middle, and inferior frontal gyri, except their posterior extremities, which are beneath the parietal bone (fig. 711). The ascending limb (ramus anterior ascendens) of the lateral fissure, which cuts into the posterior part of the inferior frontal gyrus, runs parallel with and under cover of the lower part of the coronal suture, or immediately in front of it, and the anterior horizontal limb is parallel with and beneath the upper margin of the great wing of the sphenoid.

The parietal bone is in relation with the convex surfaces of four lobes of the brain. Speaking very generally, it may be said that the anterior third covers the posterior part of the frontal lobe, including the anterior central gyrus, and the posterior ends of the superior, middle, and inferior frontal gyri and the precentral sulcus. The posterior two-thirds of the bone are superficial to the parietal lobe, the posterior part of the temporal lobe, the anterior part of the occipital lobe, the posterior part of the horizontal limb of the lateral fissure, the superior and inferior parts of the post-central sulcus, the interparietal sulcus, the posterior sections of the superior and middle temporal sulci, and the external part of the parieto-occipital fissure. The central sulcus is beneath the parietal bone at the junction of its middle and anterior thirds (fig. 711).

In the adult, the upper end of the central sulcus is situated at about 55 per cent. of the whole length of the naso-inionic line posterior to the nasion. It is about 4 or 5 cm. from the coronal suture. The inferior end of the sulcus, which extends to near the posterior horizontal limb of the lateral fissure, lies beneath the point of intersection of the auriculo-bregmatic line with a line drawn from the stephanion (the point where the temporal ridge cuts the coronal suture) to the asterion. This point is about 46 per cent. of the horizontal arc measured from the glabella to the inion.

The superior end of the parieto-occipital fissure usually lies about 5 mm. in front of the lambda, and the course of the fissure may be indicated by a line drawn from 5 mm. in front of the lambda to a point immediately above the asterion, and, as the latter point corresponds with the pre-occipital notch on the infero-lateral border of the hemisphere, the line in question will indicate the adjacent margins of the parietal, temporal, and occipital lobes.

The occipital bone is in close relation with the cerebellum, as already pointed out, but it also covers the posterior part of the lateral surface of the occipital lobe of the cerebral hemisphere. The great wing of the sphenoid covers the outer surface of the pole of the temporal lobe, and the squamous part of the temporal bone covers the anterior parts of the superior, middle, and inferior temporal gyri and the sulci which separate them.

The Blood Supply of the Encephalon

The double origin of the continuous arterial system of the brain given by the confluence of the two vertebral arteries and the two internal carotid arteries, together with the description of the general distribution of the different cerebral, mesencephalic, and cerebellar arteries into which the system is divided, and the origin and course of the corresponding veins, are fully dealt with in Section V. Here attention may be called briefly to the abundant and systematic internal distribution of the terminal branches of the system and their intimate arrangement for the actual nourishment of the nervous tissues within.

The general plan of the blood supply for the entire encephalon may be summarised as follows:—(1) At their origin the different arteries are so connected, directly or indirectly, on the base of the encephalon, that the blood approaching the brain by way of the vertebral and internal carotid arteries is practically a common supply for all the arteries of the encephalon, and a given part of it may possibly pass into any one of them. (2) In the pia mater of each gross division of the encephalon the different arteries again become connected with each other in a superficial, freely anastomosing plexus, continuous throughout. (3) From this plexus of the surface, naturally composed in part of the trunks of the different arteries themselves, arise branches which enter directly into the nervous substance and which break up into twigs that are *terminal;* i. e., twigs that *do not* anastomose with each other. (4) The arterial capillary system arising from the terminal twigs passes over into venous capillaries which converge to form corresponding venous twigs which in their turn pass to the surface and join in forming a peripheral, anastomosing venous plexus superimposed upon the similar arterial plexus. (5) From this venous plexus arise the different veins of the encephalon which may or may not accompany the arteries for a short distance, and which finally empty into the sinuses in the cranial dura mater. These, likewise confluent, empty into the internal jugular veins. The chorioid plexuses of the ventricles of the brain are modifications of the general anastomosing peripheral plexuses. The chorioid plexuses of the lateral and third ventricles are derived largely from branches of the chorioid arteries, which arises separately from the internal carotid artery.

The **blood supply of the cerebrum** may best be taken as an illustration of the general plan of the blood-vascular system of the encephalon. The terminal or internal branches of the surface plexus, derived from the posterior, middle, and anterior cerebral arteries, are arranged into two groups, a **central** or **ganglionic** and a **cortical group.** The central branches themselves form four groups in each hemisphere:—

(1) The *antero-mesial group* consists of terminal branches from the plexus of the domain of the anterior cerebral artery, which pass through the medial part of the anterior perforated substance and supply the head of the caudate nucleus, the septum pellucidum, the columns of the fornix, and the lamina terminalis.

(2) The *antero-lateral group* consists of terminal branches from the domain of the middle cerebral artery. These pierce the anterior perforated substance in two sub-groups—(*a*) the internal and (*b*) the external striate arteries (fig. 713). The **internal striate arteries** pass through the segments of the globus pallidus of the lenticular nucleus and through the internal capsule, to both of which they give branches, and they terminate in the caudate nucleus and thalamus. The **external striate arteries** are larger and more numerous. They pass upward between the external capsule and the putamen, and then through or around the upper part of the putamen into the internal capsule, where they form two groups, the *lenticulo-thalamic* and the *lenticulo-caudate groups.* The former terminate in the thalamus and the latter in the caudate nucleus. On account of its larger size at its origin and its direct linear continuation with the internal carotid, emboli (*thrombi*) pass more frequently into the middle cerebral artery

FIG. 713.—DIAGRAM SHOWING THE MANNER OF DISTRIBUTION OF THE CORTICAL AND CENTRAL BRANCHES OF THE CEREBRAL ARTERIES.

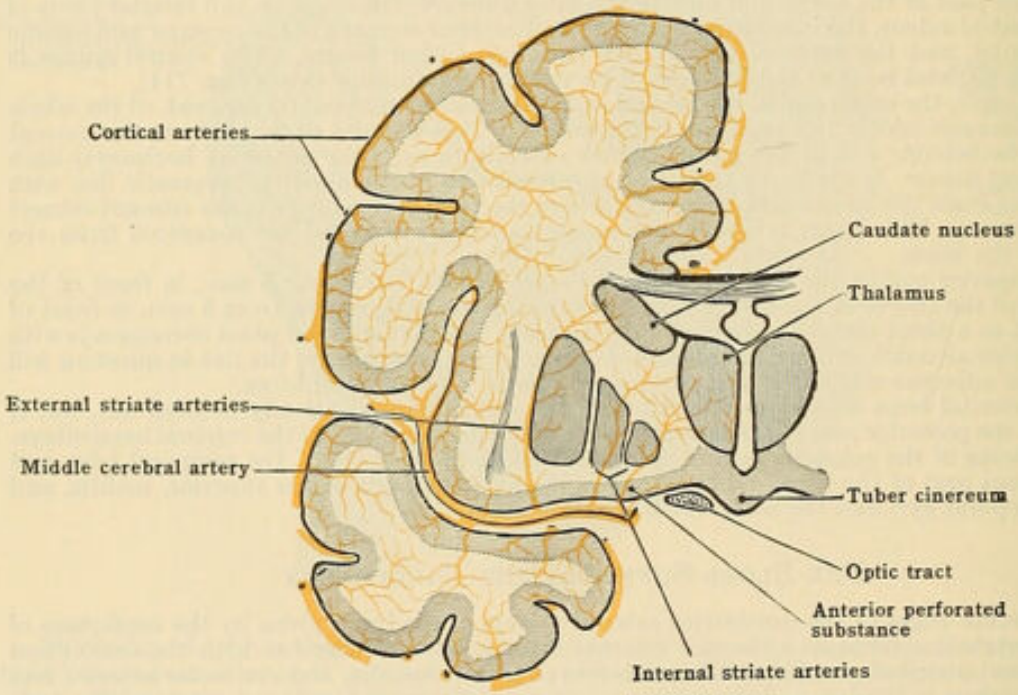

than into the anterior cerebral artery. One of the lenticulo-caudate arteries which is larger and longer than the others and which is a direct branch from the middle cerebral artery has been called the **'artery of cerebral hemorrhage'** (Charcot), on account of the greater frequency with which it is ruptured.

(3) The *postero-medial central* arteries are terminal branches of the posterior cerebral artery. They also enter the anterior perforated substance, but supply the floor of the third ventricle, the posterior part of the thalamus, and the hypothalamic region.

(4) The *postero-lateral group* are also terminal branches of the posterior cerebral artery. They supply the posterior part of the internal capsule, the pulvinar of the thalamus, the geniculate bodies, the corpora quadrigemina and their brachia, the epiphysis, and the cerebral peduncles.

The *cortical group* of the cerebral arteries arise from the anastomosing plexus in the pia mater of the cortical surfaces of the hemisphere. They pass into the cortical substance both from the summits of the gyri and from the walls of the sulci. They consist of short, medium, and long branches, and pass at right angles into the gyri. The short branches terminate in the cortical substance; the medium branches supply the more adjacent white substance, and the longer branches pass more deeply into the general medullary centre of the hemisphere.

All of both the central or ganglionic and the cortical arteries are terminal in the sense that they do not anastomose in the substance of the cerebrum.

The blood-vascular system of the other divisions of the encephalon is in accordance with the same general plan of that of the cerebrum. Slight individual modifications of the general plan are to be expected.

The **blood-vessels of the mesencephalon,** in addition to the supply derived from the postero-lateral group of central arteries, include the vessels of the quadrigeminate bodies and those of the cerebral peduncles. The **arteries** of the quadrigeminate bodies are usually six in number, three for each side—the **superior, middle,** and **inferior quadrigeminate arteries.** The superior and middle are branches of the posterior cerebral arteries, and the inferior are branches of the superior cerebellar arteries. The superior supply the superior quadrigeminate bodies and the epiphysis; the middle supply both the superior and inferior quadrigeminate bodies, and the inferior the inferior quadrigeminate bodies. They all anastomose in the pia on the surface of the stratum zonale, forming a fine-meshed plexus, and from this superficial plexus the terminal branches pass into the substance of the bodies. The **veins** terminate in the vein of Galen (v. cerebri magna.)

The **arteries of the cerebral peduncles** form two groups, mesial and lateral. The **mesial peduncular arteries** are branches of the basilar and the posterior cerebral arteries. They pass to the medial sides of the penduncles and supply the superior and medial part of the tegmentum. The vessels of this group which accompany the fibres of the oculomotor nerves are known as the radicular arteries; they supply the root-fibres and the nuclei of the nerves, which receive no other branches. The **lateral peduncular arteries** are branches of the posterior cerebral and

FIG. 714.—SHOWING THE CAPILLARY SUPPLY OF THE CEREBELLAR CORTEX. (After Aby, "Journal of Comparative Neurology," Vol. IX.)



superior cerebellar arteries. They supply the lateral portions of the peduncles and the lateral part of the tegmentum. The **veins** of the mid-brain terminate in the basilar veins and the vein of Galen.

The blood-vessels of the cerebellum.—Six arteries supply the cerebellum; two, the **posterior inferior cerebellar,** are derived from the vertebral arteries, and the remaining four, two **anterior inferior** and two **superior cerebellar,** from the basilar artery. The course and general distribution of the arteries are described in Section V, but here it must be noted that the branches of these six vessels form a rich network in the pia mater on the surfaces of the cerebellar lobes, and that extensions of the plexus pass with the folds of the pia mater into the sulci and fissures. From the superficial plexus terminal branches pass into the interior of the cerebellum and their collaterals form capillary plexuses in the white and grey substance. The extensions of the surface plexus are of three lengths:—(1) a longer set, which pass through the cortex of the cerebellum and supply the white substance of the corpus medullare; (2) a set of shorter arterioles which pass through the molecular layer of the cortex and break up in its granular layer; (3) the shortest set pass into the cortex and immediately break up in its molecular layer. The meshes of the capillary plexuses in the grey susbtance are ovoidal and their axes run radially. The meshes of the plexuses in the white substance are parallel with the nerve-fibres. In addition to the vessels mentioned, a distinct branch is distributed to each dentate nucleus. This springs either from the superior cerebellar or from the anterior inferior cerebellar artery of the corresponding side.

The **efferent veins** of the cerebellum do not accompany the arteries; they spring from a plexus in the pia mater which receives tributaries from the interior, and they form three groups on each cerebellar surface, the vermian veins and the lateral veins. The **superior vermian vein** runs forward on the superior surface of the vermis and terminates in the vein of Galen. The **inferior vermian vein** runs posteriorly and ends in one of the transverse sinuses. The **superior lateral veins** open into the superior petrosal or transverse sinuses, and the **inferior lateral veins** into the inferior petrosal and transverse sinuses. The vein from the dentate nucleus usually joins the inferior lateral veins.

The blood-vessels of the pons.—The arteries to the pons are branches of the basilar artery, and of its anterior inferior and superior cerebellar branches. The plexus in the pia mater is comparatively unimportant, and the branches which enter the substance of the pons form two main groups, the central and the peripheral. The **central arteries** spring directly from the basilar. They pass backward along the raphe, giving branches to the adjacent parts, and they terminate in the nuclei of the pons and those in the floor of the fourth ventricle. The **peripheral arteries** are radicular and intermediate. The *radicular branches* spring from the peripheral plexus and from the anterior inferior cerebellar arteries; they accompany the roots of the trigeminus, abducens, facial, vestibular, and cochlear nerves, supply their fibres and the adjacent parts, and they end in the grey nuclei with which the nerve-fibres are connected. The *intermediate arteries* enter the surfaces of the pons irregularly and break up into capillaries in its substance. **The veins** form a plexus on the surface. The dorsal and lateral part of this plexus is drained into the basilar vein on each side, and the inferior part is connected by efferent channels with the inferior petrosal sinus and the cerebellar veins.

The blood-vessels of the medulla oblongata.—The **arteries of the medulla** are derived directly from the vertebral arteries, from their anterior and posterior spinal and posterior inferior cerebellar branches, and from the basilar artery. The branches of these vessels form a plexus in the pia mater from which, and from the arteries themselves, three main groups of vessels pass into the medulla—the chorioidal, the central, and the peripheral. The **chorioidal arteries** are derived chiefly from the posterior inferior cerebellar arteries. They supply the chorioid plexus of the fourth ventricle. The **anterior central arteries** rise from the anterior spinal artery, from the basilar artery, and from the peripheral plexus; they pass caudalward along the raphe, supplying the adjacent parts of the ventral funiculi and the olivary bodies, and they break up into fine terminals in the **grey** substance of the floor of the fourth ventricle around the nuclei of the cranial nerves. The **posterior central arteries** spring from the posterior spinal arteries; they pass down the median septum of the inferior part of the medulla and supply the adjacent nervous substance. The **peripheral arteries,** like those of the spinal cord, are separable into radicular and intermediate groups. The *radicular arteries* pass from the anterior and posterior spinal branches and from the trunks of the vertebral arteries and accompany the fibres of the last six cranial nerves into the substance of the medulla. They supply the nerve-roots and adjacent white substance and they terminate in capillaries in the grey substance of the lateral part of the floor of the ventricle. The *intermediate peripheral arteries* spring from the arteries previously named and from the peripheral plexus, and they pass directly into the funiculi of the medulla, where they terminate in a capillary plexus which supplies the white substance and the grey nuclei; some of these arteries, more especially those derived from the posterior inferior cerebellar and the posterior spinal arteries, extend inward to the lateral part of the floor of the fourth ventricle.

The veins which issue from the medulla form a peripheral plexus in the pia mater in which there are two main longitudinal channels, an **anterior median** and a **posterior median vein.** The former communicates posteriorly with the anterior median vein of the cord, and anteriorly with the veins of the pons and with the veins which accompany the hypoglossal nerves. The latter veins empty into the internal jugular veins. The posterior median vein is continuous caudally with the corresponding vein of the cord, and anteriorly, in the region of the calamus scriptorius, it divides into branches which join the radicular veins. The blood is carried away from the peripheral plexus mainly by the **radicular veins,** which pass along the roots of the last six cranial nerves. Those which accompany the hypoglossal nerves have already been referred to. The others end in the terminal parts of the transverse sinuses, the inferior petrosal sinuses, or the inferior part of the occipital sinuses.

The **nerve supply of the blood-vessels** of the brain consists of a perivascular plexus of sympathetic nerve-fibres upon the walls of the vessels and medullated fibres which accompany the vessels and apparently terminate, for the most part, in the connective tissue about them. The former are thought to be vaso-motor in function; the latter probably sensory fibres of the cranio-spinal type. Nerves have been described only for the larger vessels.

IV. THE MENINGES

Three membranes, collectively called the **meninges,** envelope the entire central nervous system, separate it from the walls of the bony cavities in which it lies, and aid in its protection and support. They consist of feltworks in which white fibrous connective tissue predominates, and through them pass the blood-vessels which supply the central nerve-axis and the nerves by which the axis is connected with the periphery. Though there are definite spaces or cavities between them, the membranes are not wholly separated from each other, and they are both continuous with and contribute to the walls of the blood-vessels and the sheaths (epineurium) of the nerves passing through them. Beginning with the outermost, they are—(1) the *dura mater,* the thickest, most dense and resistant of the mem-

FIG. 715.—SHOWING THE SPINAL DURA MATER EXPOSED *in situ*. (Dorsal aspect.) (After Toldt, "Atlas of Human Anatomy," Rebman, London and New York.)

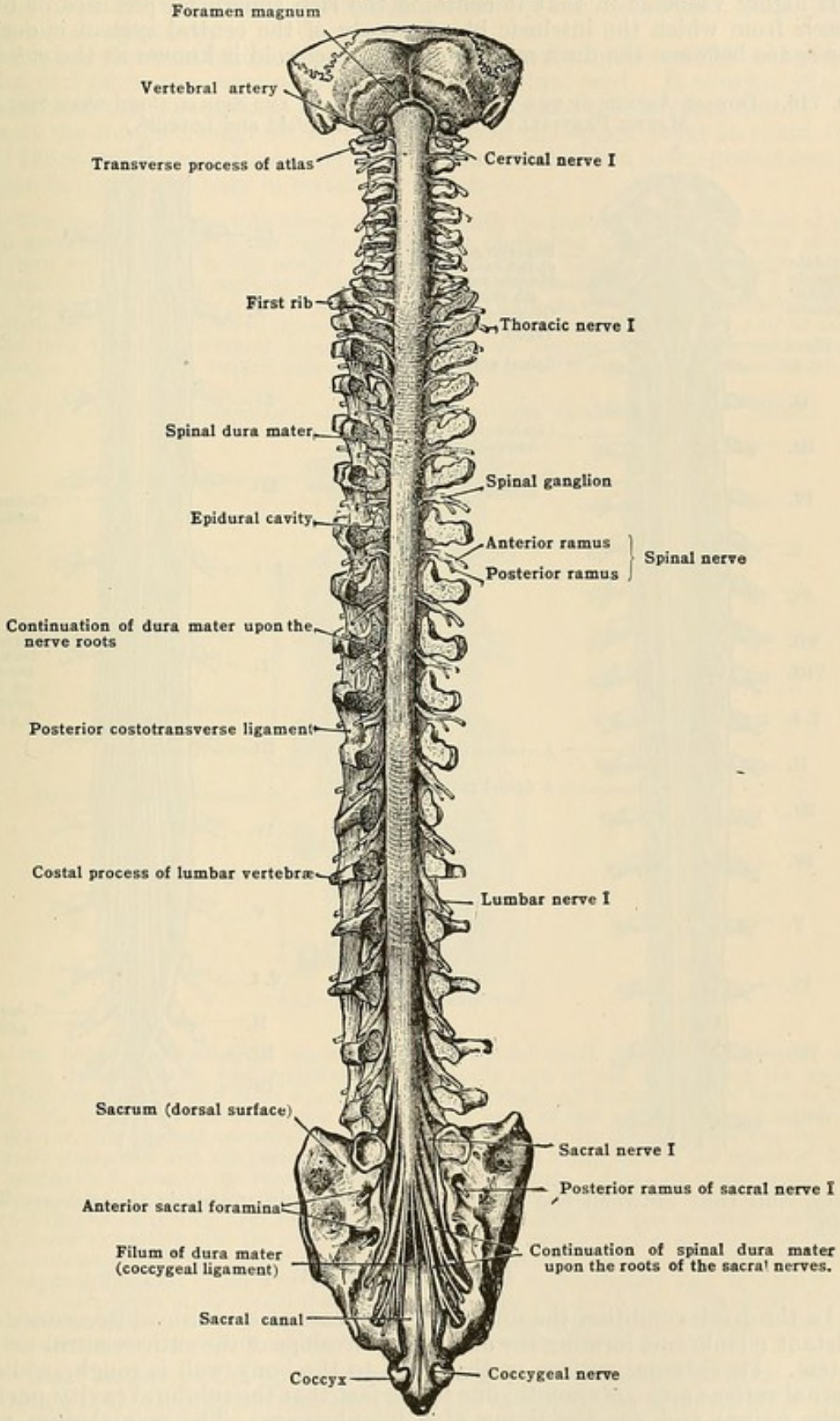

branes; (2) the *arachnoid*, the much less dense, web-like middle membrane; and (3) the *pia mater*, a thin, compact membrane, closely adapted to the surface of the central system, into which it sends numerous connective-tissue processes. It is highly vascular in that it contains the rich superficial plexuses of blood-vessels from which the intrinsic blood supply of the central system is derived. The space between the dura mater and the arachnoid is known as the *sub-dural*

FIG. 716.—DORSAL ASPECT OF THE MEDULLA OBLONGATA AND SPINAL CORD WITH THE DURA MATER PARTIALLY REMOVED. (Hirschfeld and Leveillé.)

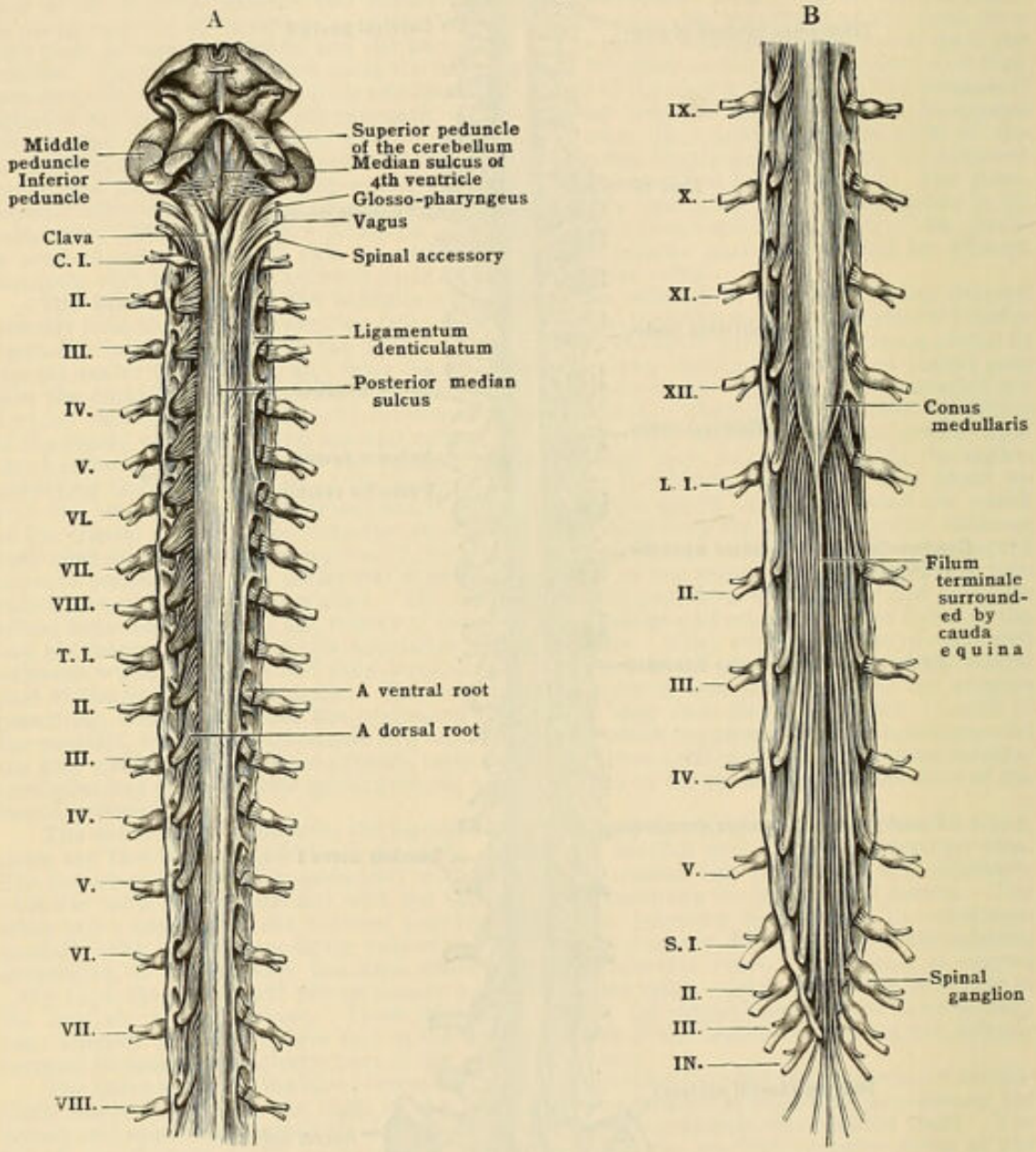

cavity, and that between the arachnoid and the pia mater is the *sub-arachnoid cavity*.

THE DURA MATER

In the fresh condition the dura mater appears as a bluish-white, exceedingly resistant membrane, forming the outermost envelope of the entire central nervous system. Its external surface or that next to the bony wall is rough, while its internal surface appears smooth, due to the fact that the subdural cavity partakes of the nature and has the lining of a lymph-space. The cranial dura mater consists of two distinct, closely associated layers, the outermost of which serves as the internal periosteum of the cranial bones. The spinal dura mater is described as consisting of but one layer. The internal periosteum of the spinal

canal, though continuous at the foramen magnum with the outer layer of the cranial dura mater, is not considered a part of the spinal dura mater, from the fact that it is so widely separated from the layer actually investing the spinal cord. Thus, since the cranial and spinal portions of the dura mater differ, they are described separately.

The spinal dura mater is a fibrous tube with funnel-shaped caudal end which encloses and forms the outermost support of the spinal cord. It consists of but one layer and this corresponds to the inner layer of the cranial dura mater. It begins at the foramen magnum and terminates in the spinal canal at about the level of the second piece of the os sacrum. It is firmly attached to the periosteum of the surrounding bones only in certain localities:—

(1) The upper end of the tube blends intimately with the periosteum of the margin of the foramen magnum, and thus in this locality it becomes continuous with the outer layer of the cranial dura mater. Also in this locality it is attached firmly, though less intimately, to the periosteum of the posterior surfaces of the second and third cervical vertebræ. This locality may be considered the upper fixation-point of the spinal dura mater. (2) It extends laterally and contributes to the connective tissue investments of each pair of spinal nerves, and as such it passes into the intervertebral foramina and becomes continuous with the periosteum lining each. (3) Along its ventral aspect the spinal dura mater is attached by numerous proc-

FIG. 717.—VIEW OF MEMBRANES OF SPINAL CORD FROM VENTRAL ASPECT. (Ellis.)

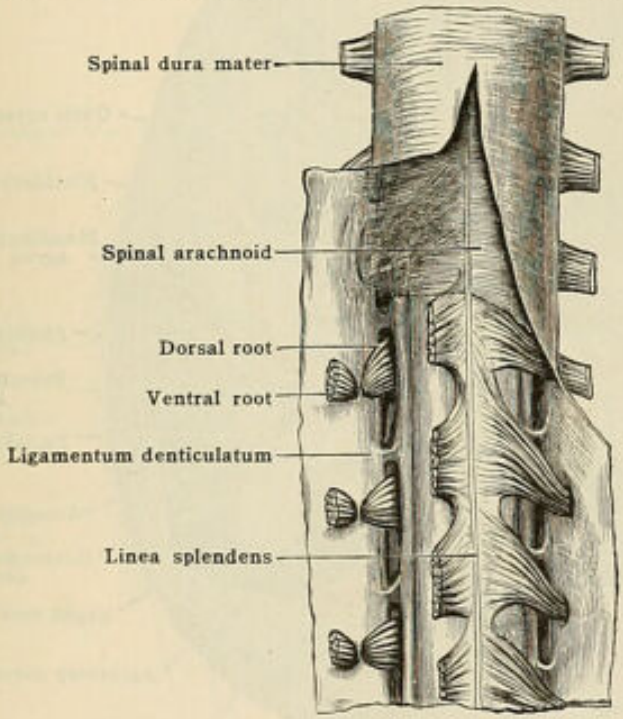

esses to the posterior longitudinal ligament of the vertebral canal. These attachments are more or less delicate, loose, and irregular, and are easily torn or cut in removing the specimen. They are stronger and more numerous in the cervical and lumbar regions than in the thoracic. (4) In the space between the dura and the walls of the vertebral canal (*epidural cavity*) lies the rich internal vertebral venous plexus, and along the lateral aspect the dura is occasionally connected with the periosteum through the tissue of the walls of the vessels of this plexus, especially in case of the vessels which penetrate the dura. Along its dorsal aspect the spinal dura mater is practically free from the wall of the vertebral canal. (5) At its lower and funnel-shaped extremity, opposite the second sacral vertebra, the tube suddenly contracts into a filament extending into the coccyx and breaking up into a number of processes which become continuous with the periosteum of the dorsal surface of the coccyx. This filament is the **coccygeal ligament** or *filum* of the dura mater, and its attachment may be considered the lower fixation-point of the spinal dura mater. (See figs. 613 and 715). The extent of the tube is maintained chiefly by means of the two fixation-points, for all the other attachments are sufficiently loose to permit of the movements of the vertebral column.

The *inner surface* of the spinal dura mater appears smooth, but upon closer examination it is found to be connected with the arachnoid by a few delicate subdural trabeculæ—occasional fine strands of connective tissue bridging the subdural space (fig. 725). Along its lateral aspects the inner surface is at intervals quite firmly attached to the pia mater by the dentations of the **ligamenta denticulata,** which are prolonged through the arachnoid.

Further, it is continuous at intervals with both the pia mater and arachnoid by way of the connective-tissue sheaths of the nerve-roots which are prolonged from the pia and blend with the dura mater in the passage of the nerve-roots through it. The dura is also pierced by the spinal rami of the vertebral arteries, and the connective tissue of the outer walls of these vessels blends with all three of the meninges. The filum terminale of the pia mater extends below the termination of the spinal cord into the point of the funnel-shaped end of the dura mater, and there blends with it in line with the coccygeal ligament of the outer surface.

The tube of the spinal dura mater varies in calibre with the variations in the diameter of the spinal cord. However, the termination of its cavity occurs about seven segments below the termination of the spinal cord. This extension contains the long intra-dural nerve-roots forming the cauda equina, and the calibre of this part, before its sudden contraction, is about as great as that found in any

FIG. 718.—THE DURA MATER ENCEPHALI OF THE BASE OF THE CRANIUM.
(After Toldt, "Atlas of Human Anatomy," Rebman, London and New York.)

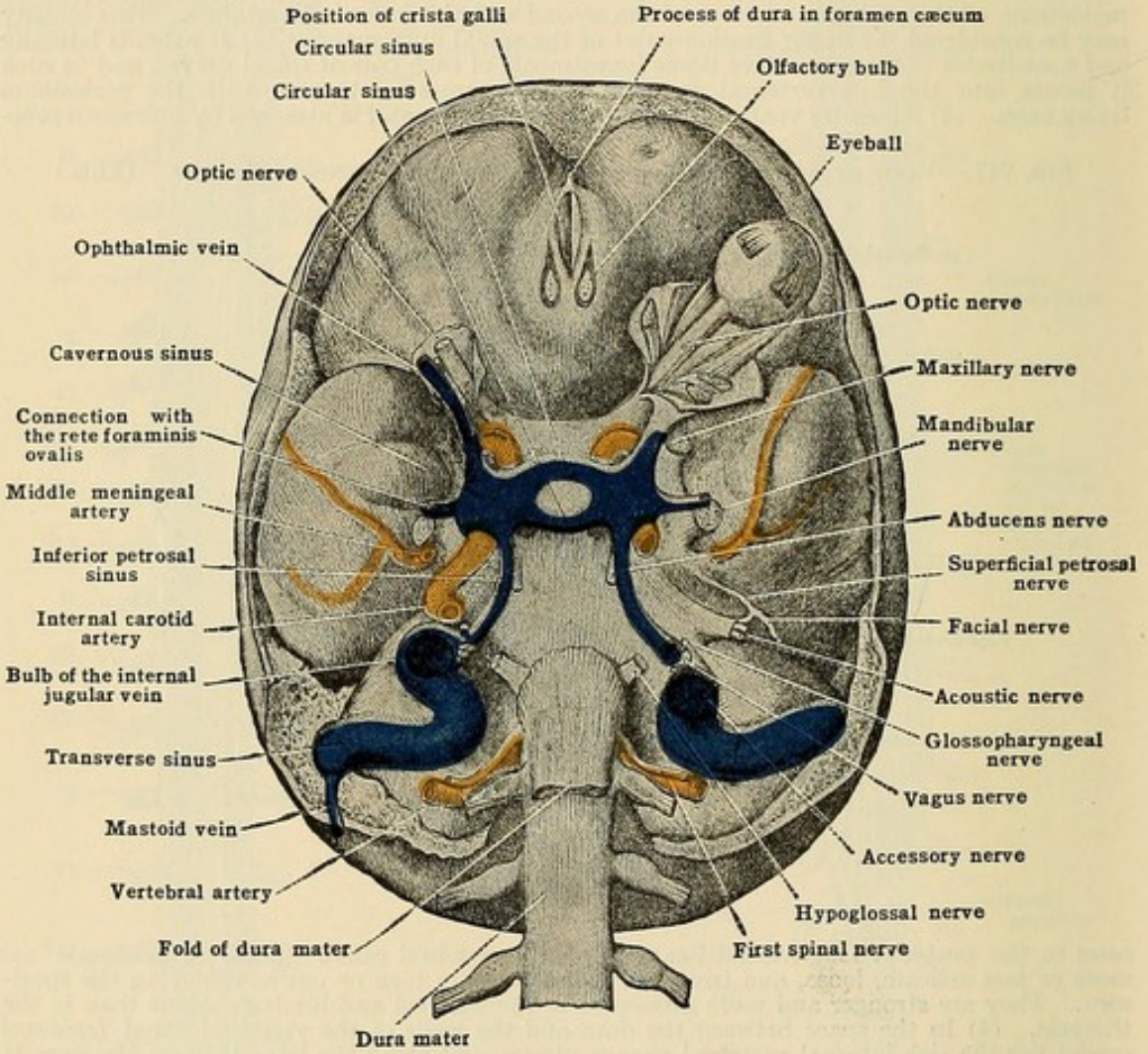

other region. As each pair of nerve-roots of the cauda equina passes outward, they lie free for a variable distance in a tubular extension of the dura before the latter blends with and contributes to the thickness of their sheath.

The **subdural cavity,** the space between the dura mater and the arachnoid, is the thinnest of the meningeal spaces. Along the ventral aspect especially, the spinal arachnoid is quite closely applied to the inner surface of the dura mater. It contains a small amount of cerebro-spinal fluid (lymph) which prevents friction between the opposing surfaces, and is continuous with the fluid in the like space of the cranial meninges.

The space communicates with the venous sinuses of the cranium in the region of the Pacchionian bodies, and its fluid is likewise in contact with the blood-vessels passing through it. It is probably continuous with the lymph-spaces of the nerve-roots passing through it, for colored fluids injected into it pass into the nerve-roots. The arachnoid is so thin and gauze-like that a ready interchange of fluids between this space and the subarachnoid space is possible by simple filtration.

The cranial dura mater [dura mater encephali].—The dura mater investing the brain performs a double function—it serves as an internal periosteum for the cranial bones and gives support and protection to the brain. In conformity with its double function it consists of two layers, easily separable in the child, but closely adhering to each other in the adult, except in occasional localities, where there exist small clefts lined with endothelium. The large blood sinuses and venous lacunæ, corresponding to the internal vertebral venous plexus of the vertebral canal, are placed between the two layers and the semilunar ganglia of the trigemini also lie between them. The cranial dura begins with the adhesion of the spinal dura mater to the periosteum at the foramen magnum, and it forms a sac-like envelope about the entire encephalon. Consisting of two layers, it is a much thicker membrane than that of the spinal cord.

The *outer surface* of the cranial dura mater when torn away from the cranial bones appears very uneven, and when placed in water presents a flocculent appearance.

FIG. 719.—CORONAL SECTION OF THE HEAD, PASSING THROUGH THE POSTERIOR HORNS OF THE LATERAL VENTRICLES.

From a mounted specimen in the Anatomical Department of Trinity College, Dublin.

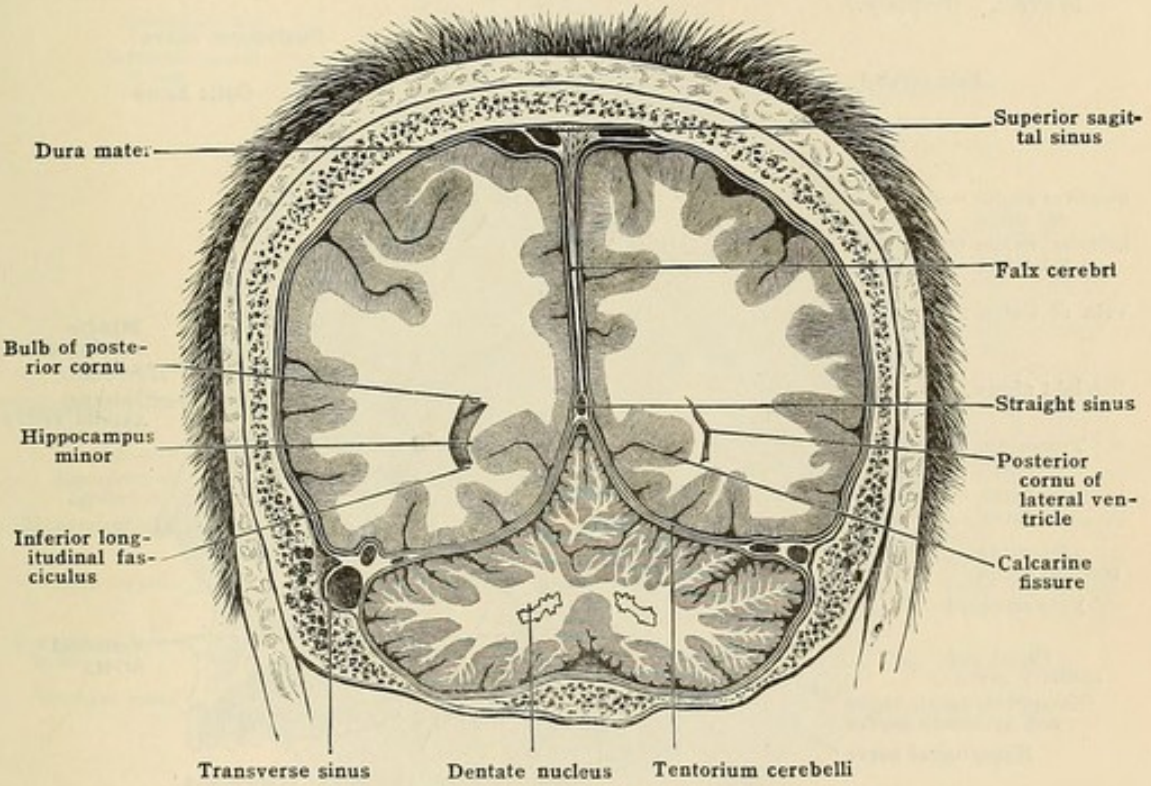

This is due to the many fine bundles of connective tissue and the blood-vessels which pass between the dura and the cranial bones and which are partially pulled out of their openings in the latter in the process of separation. The abundance of these connections, and, therefore, the degree of adhesion to the bones, varies in different localities. The separation is much less difficult from the inner table of the bones of the vault of the cranium than from the bones of the base of the cavity. The adhesions to the vault of the cranium are most firm along the lines of the sutures. This is due to the fact that during the period before the sutures are closed the outer layer of the dura mater is directly continuous with the external periosteum, and, in consequence of this condition during development, the connective-tissue connection is more abundant along these lines and some is even caught in the closure of the sutures. Along the vault there are occasionally noticed small lymph-spaces between the bone and the dura mater. The stronger adherence to the base of the cranial cavity is due to the numerous foramina in the floor, through which all the larger cranial blood-vessels and the cranial nerves pass, and the dura mater is continuous with the connective-tissue investments of these as well as with the periosteum lining the foramina. Also the floor of the cavity is more uneven than the vault, and the projections of the bones here tend to increase the firmness of attachment. The weight of the brain upon the floor probably contributes to the result.

The *inner surface* of the inner layer of the cranial dura mater forms the outer boundary of the subdural cavity. Except for the occasional delicate subdural trabeculæ and the passage of blood-vessels and nerve-roots, this surface appears

smooth and glistening, being lined by a layer of endothelium and containing a small amount of the cerebro-spinal lymph.

The subdural cavity of the base of the brain is prolonged a short distance outward along the roots of the various cranial nerves before it is obliterated by the blending of the dura mater with the sheaths of the nerves. This outward extension of the space is most marked about the optic and auditory nerves. In the optic especially, the dura mater remains separate from the nerve throughout its length, only fusing with its sheath upon the posterior surface of the ocular bulb (fig. 718).

One of the most striking differences between the cranial dura mater and that of the spinal cord is that the inner layer of the former undergoes striking septa-like duplications or folds, forming exceedingly strong partitions which project between the larger subdivisions of the encephalon. These are four in number, two large and two small—the falx cerebri and the tentorium cerebelli; the falx cerebelli and the diaphragma sellæ. The larger enclose within their folds the great venous sinuses, into which most of the spent blood of the encephalon collects to pass outward by way of the internal jugular veins (figs. 720, 721).

FIG. 720.—THE CRANIUM WITH ENCEPHALON REMOVED TO SHOW THE FALX CEREBRI, THE TENTORIUM CEREBELLI, AND THE PLACES WHERE THE CRANIAL NERVES PIERCE THE DURA MATER. (Sappey.)

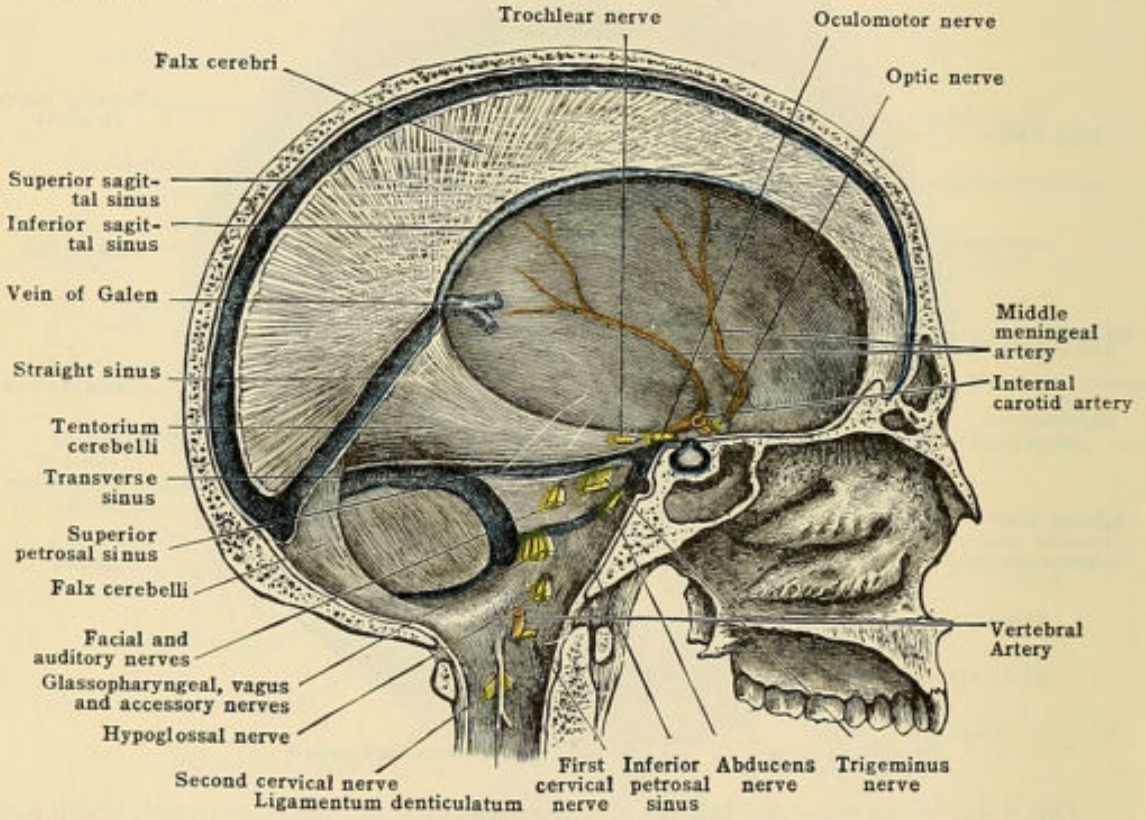

The **falx cerebri** is the most striking of these partitions. It is a sickle-shaped fold which projects vertically from the vault into the longitudinal fissure between the cerebral hemispheres. It begins attached to the crista galli in front, and arches to terminate by blending with the superior surface of the hirozontally placed tentorium cerebelli. Its convex, superior border joins the outer layer of the dura along the medial plane of the vault, and encloses the superior sagittal sinus. Its concave border is free and contains in its posterior two-thirds the smaller inferior sagittal sinus. The anterior and narrower end is often perforated and occasionally so much so as to appear as a coarse, fibrous reticulum. The posterior part of the concave border touches the upper surface of the corpus callosum, but the anterior part, which does not descend so low, is separated from the corpus callosum by a part of the subarachnoid space. The base of the fold which slopes downward and blends with the upper surface of the tentorium cerebelli, contains the straight sinus running along the line of junction.

The **tentorium cerebelli** is a large transverse, semilunar fold, concave forward. It descends from its central part which is elevated, and consequently it forms a

tent-shaped covering. Its superior surface is in relation with the tentorial surfaces of the hemispheres, and its inferior surface conforms accurately to the superior surface of the cerebellum. The outer or convex border of the fold is attached on each side to the posterior clinoid process, the superior border of the petrous portion of the temporal bone, the mastoid portion of the temporal bone, the posterior inferior angle of the parietal bone, and the horizontal ridge of the occipital bone. The transverse sinus lies in this border. From the internal occipital protuberance to the mastoid portion of the temporal bone and along the petrous part of the temporal bone it encloses the superior petrosal sinus.

The greater part of the inner or anterior border of the tentorium is free, and it forms the superior and lateral boundaries of an arched cavity, the **tentorial notch** or foramen ovale of Pacchioni, which encloses the mesencephalon, and through which ascend the cerebral peduncles and the posterior cerebral arteries. The anterior extremities of the inner border cross the outer border, and they are attached to the anterior clinoid processes. A depressed angle is formed between

FIG. 721.—SHOWING THE UPPER SURFACE OF THE TENTORIUM CEREBELLI AND THE TENTORIAL NOTCH THROUGH WHICH THE MID-BRAIN AND POSTERIOR CEREBRAL ARTERIES ENTER THE MIDDLE FOSSA OF THE CRANIUM.

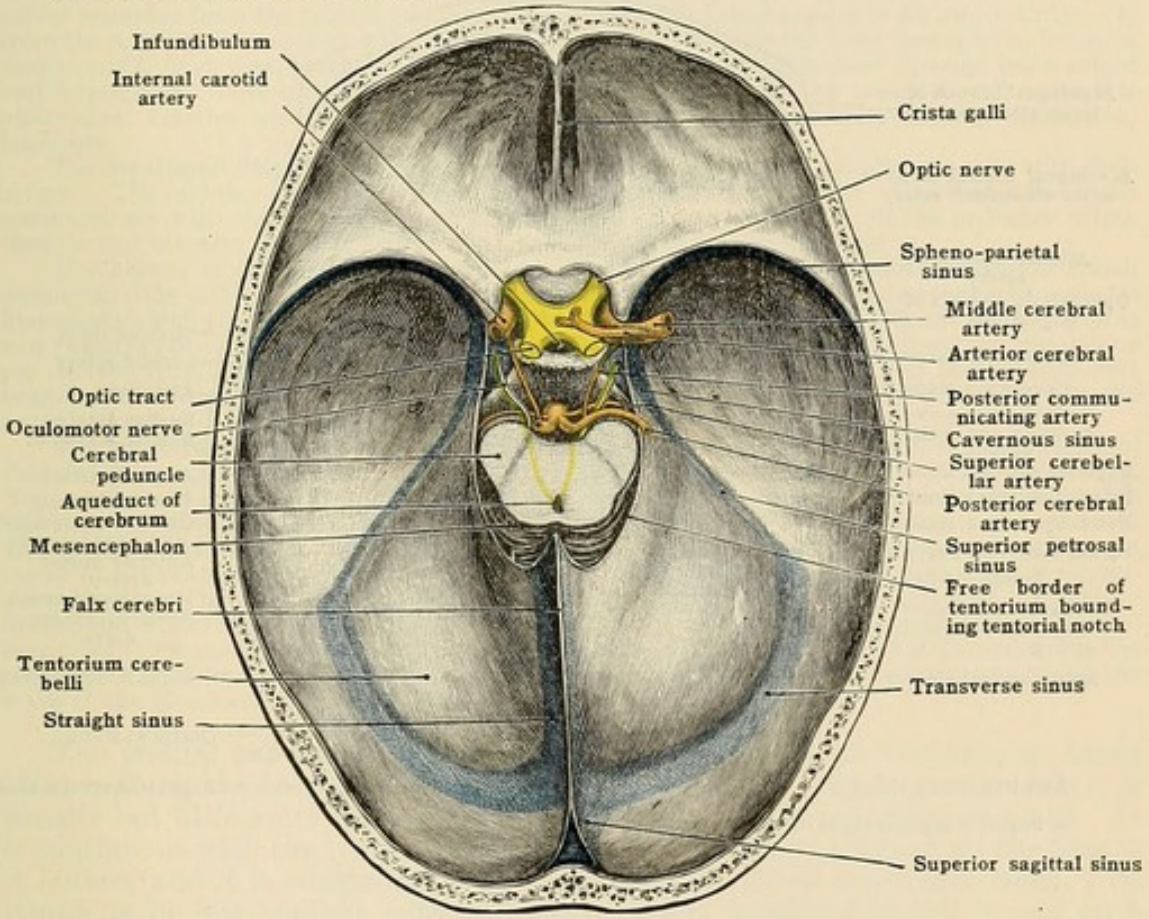

the inner and outer borders of the tentorium in the middle fossa of the skull at the lateral portion of the posterior clinoid process, and in this angle the root of the oculo-motor nerve pierces the inner layer of the dura mater.

The **falx cerebelli** is a small, sickle-shaped, triangular fold which projects forward into the small groove (*posterior cerebellar notch*), between the hemispheres of the cerebellum. Its base is attached to the tentorium; its postero-inferior border, along which runs the occipital sinus, is attached to the internal occipital crest. Its anterior border is free, and its apex, which lies immediately above the foramen magnum, usually bifurcates as it disappears anteriorly, grasping the foramen magnum from behind. Bifurcation is always the case when the internal occipital crest splits below to enclose a vermiform fossa.

The **diaphragma sellæ** is a small circular fold, deficient in the centre, which projects horizontally from the margins of the hypophyseal fossa or sella turcica. Its lateral border is attached to the clinoid processes and the limbus of the sphe-

noid, and its medial border forms the boundary of the *foramen of the diaphragma sellæ* and surrounds the infundibulum. Its superior surface is in relation with the base of the brain, and its inferior surface is in relation with the hypophysis, which it binds down in the hypophyseal fossa.

The spaces which lie between the layers of the cranial dura mater are Meckel's caves, the spaces which lodge the endolymphatic sacs, and the blood sinuses and lacunæ.

Meckel's caves are two cleft-like spaces or niches which lie, one on each side, in the trigeminal impression on the apex of the petrous portion of the temporal bone. Each space lodges the semilunar (Gasserian) ganglion and the trigeminus and masticator nerves of the corresponding side, and it communicates with the subdural space in the posterior fossa of the cranium by an oval opening, which lies above the superior border of the petrous portion of the temporal bone and inferior to the superior petrosal sinus.

FIG. 722.—SHOWING BLOOD-VESSELS OF CRANIAL DURA MATER AND CRANIAL NERVES IN THE BASE OF THE SKULL.

(On the left side the dura mater has been removed from the middle fossa.)

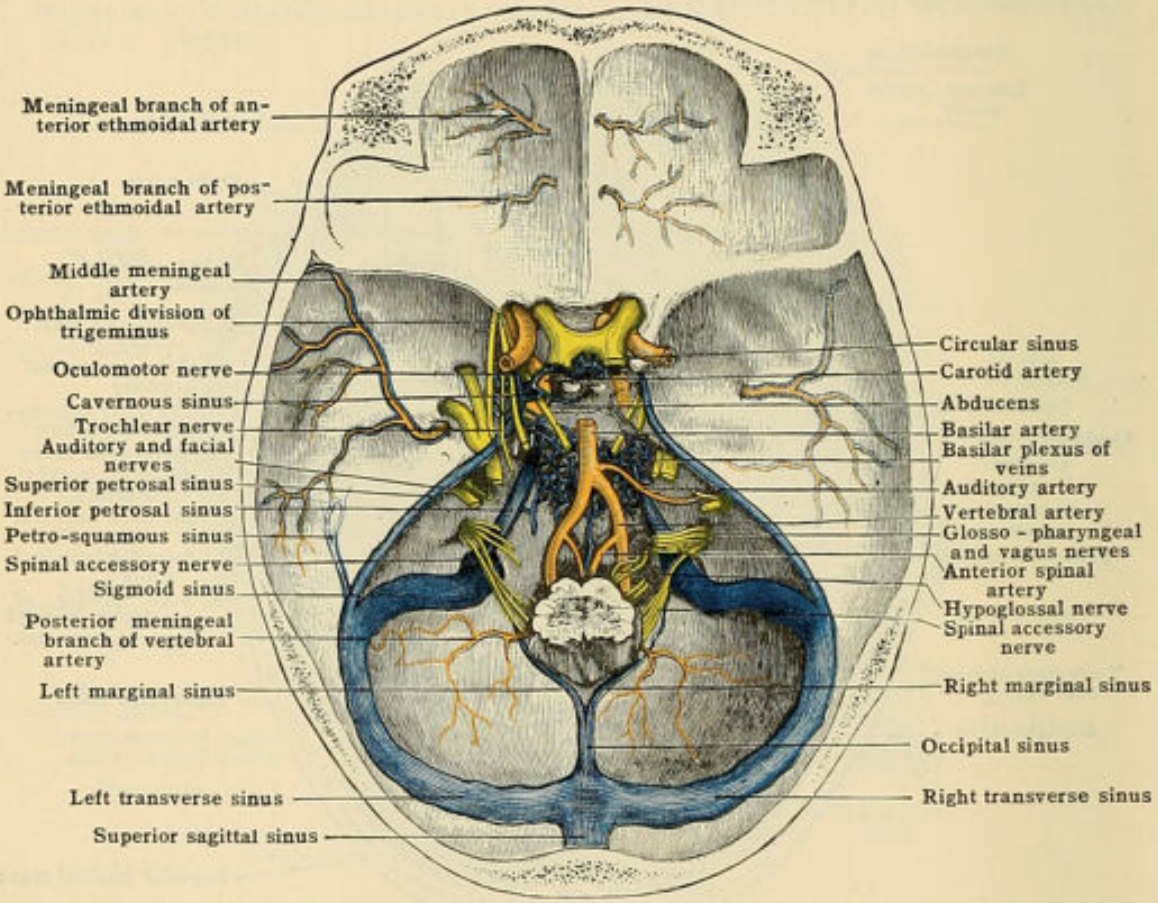

The space which contains the endolymphatic sac on each side lies behind the petrous portion of the temporal bone and communicates with the aquæductus vestibuli.

The venous sinuses and lacunæ.—The cranial blood sinuses have already been fully described in the account of the vascular system, and it is sufficient to note here that they are continuous, on the one hand, with the meningeal veins, and, on the other, with the veins outside the cranial walls. The vessels which establish communication between the blood sinuses and the extracranial veins are referred to collectively as **emissary veins.** They possibly help to maintain the regularity of the cranial circulation, and they have therefore a certain amount of practical importance.

The sinuses which are connected with the extracranial veins by emissary veins are the superior sagittal, the transverse (lateral), and the cavernous. Three or four emissary veins pass from the superior sagittal sinus:—one passes through the foramen cæcum and communicates with the veins of the roof of the nose, or, through the nasal bones, with the angular veins. Two pass through the parietal foramina and establish communications with the occipital veins, and a fourth, which is very inconstant, pierces the occipital protuberance and joins the tributaries of the occipital veins. Connecting each lateral sinus with the extracranial veins

there are, as a rule, two emissary veins:— one, the mastoid emissary vein, which passes through the mastoid foramen to the occipital or posterior auricular vein; and the other, the post-condyloid vein, which traverses the condyloid (posterior condyloid) foramen and joins the suboccipital plexus. The cavernous sinus is in communication anteriorly with the superior ophthalmic vein, and through the latter with the angular vein; it is connected with the pterygoid plexus by emissary veins which pass either through the foramen ovale or the foramen Vesalii, and with the pharyngeal plexus by small venous channels which accompany the internal carotid artery through the carotid canal.

The **venous lacunæ** or spaces are small clefts lined by endothelium which communicate with the meningeal veins and with the blood sinuses. They also have communications with the emissary veins and the diploic veins. They lie between the outer and inner layers of the dura mater, the majority of them at the sides of the superior sagittal sinus, but others are found in the tentorium associated with the transverse sinuses and the straight sinus.

Blood-vessels.—The blood supply of the cranial dura mater is derived from the **meningeal arteries,** which ramify in its outer layer. The more important of these arteries have already been described in the account of the vascular system, and it is only necessary here to recall the fact that the greater part of the dura mater above the tentorium cerebelli is supplied by branches of the middle meningeal arteries. These are reinforced—(1) at the vertex by branches of the occipital arteries which enter through the parietal foramina; (2) in the middle fossa by the small meningeal arteries and by meningeal branches of the internal carotid, lacrimal, and ascending pharyngeal arteries; and (3) in the anterior fossa by meningeal branches of the anterior and posterior ethmoidal arteries.

The dura mater in the posterior fossa of the skull, below the tentorium cerebelli, also receives branches from the middle meningeal arteries, but its blood supply is derived mainly—(1) from the meningeal branches of the vertebral arteries which enter the fossa through the foramen magnum, (2) from meningeal branches of the occipital arteries which enter through the mastoid and hypoglossal foramina, and (3) from meningeal branches of the occipital and ascending pharyngeal arteries which enter through the jugular and hypoglossal (anterior condyloid) foramina.

The **meningeal veins** accompany the arteries as *venæ comitantes,* usually one vein with each artery. The middle meningeal artery usually has two venæ comitantes. The meningeal veins communicate with the venous sinuses and with the diploic veins, and, unlike ordinary veins, they do not increase much in calibre as they approach their terminations.

The **nerves** of the dura mater are partly derived from the sympathetic filaments which accompany the arteries and partly from the cranial nerves. The nerves, other than sympathetic filaments, which supply the cranial dura mater are sensory fibres derived from the trigeminus and vagus nerves, and possibly from the first cervical nerves. The branches from the trigeminus are derived from the three divisions of that nerve on each side, and it has been stated that branches are given from the nasal branch of the ophthalmic division to the dura mater in the anterior fossa.

The meningeal branch of the ophthalmic division of the trigeminus supplies the tentorium; that from the maxillary division accompanies the branches of the middle meningeal artery. The meningeal branch of the mandibular division (nervus spinosus) passes into the skull through the foramen spinosum and is distributed to the dura mater over the great wing of the sphenoid and to the mastoid cells. The "*recurrent branch of the hypoglossal nerve*" passes to the dura mater of the posterior fossa of the cranium. This recurrent or meningeal branch of the hypoglossal nerve really consists of fibres derived from the superior cervical ganglion of the sympathetic, and contains sensory fibres from the first and second cervical nerves. The meningeal branch of the vagus springs from the ganglion of the root of that nerve, and is distributed in the posterior cranial fossa. The sympathetic filaments are distributed to the smooth muscle of the walls of the blood-vessels.

The cranial **subdural cavity** is not of uniform thickness throughout, being thinner along the basal aspect of the encephalon. The lymph contained in it is usually but little more than is sufficient to keep moist its bounding surfaces. It is continuous with the lymph capillaries of the nerves and those of all the tissues it bathes, and it is continuous with the similar cavity of the spinal canal. Its lymph is in free contact with the blood-vessels passing through it and with those in the tissues it bathes, and it is replenished by filtration through their walls. Though extensive, the subdural space is thin at best, for the dura mater is quite closely applied to the second of the three meninges.

The Arachnoid

The arachnoid or 'serous' membrane is the middle of the three meninges of the central nervous system. As in the case of the other two, an attempt is made to give this membrane a name descriptive of its texture. It is a gauzy reticulum of almost web-like delicacy, which in reality pervades the space it occupies.

Its *outer surface,* or that closely related to the dura mater and bounding the subdural cavity alone shows a sufficiently organized structure to merit the name of membrane. This surface is covered by a layer of endothelium which is identical with that lining the inner surface of the dura mater and is continuous with it by way of the endothelial cells covering the blood-vessels,

the nerve-roots, the ligamenta denticulata of the spinal cord, and the occasional delicate trabeculæ passing between the dura mater and the arachnoid. Immediately under the endothelium, the connective-tissue fibres of the arachnoid are woven into a very thin, more or less compact web. This, however, quickly grades into a loose, spongy reticulum which pervades the thick subarachnoid cavity throughout, and the strands of which are directly continuous into the more compact tissue of the pia mater. Thus an *inner surface* can hardly be claimed. This loose, sponge-like arachnoid tissue holds the cerebro-spinal fluid of the subarachnoid cavity, the meshes of the sponge constituting a reticular web of intercommunicating spaces lined by endothelioidal cells covering the strands of the web. The cranial subarachnoid cavity is larger, and the strands of the web are relatively more abundant than in that of the spinal canal. In addition, the cavity is traversed by the spinal and cranial nerves, by the blood-vessels passing to and from the pia, and, in the spinal canal distinctively, it is traversed by the ligamenta denticulata and the filum terminale. Through these the arachnoid is further continuous with the pia mater.

The cranial arachnoid is directly continuous into that of the spinal cord, and in the two localities does not differ as much as does the dura mater. Within the cranium, the arachnoid does not closely follow the surface of the encephalon. It is folded in between the cerebellum and cerebral hemispheres, following the contour of the tentorium cerebelli, but it does not dip into the fissures and sulci except the anterior part of the longitudinal fissure and slightly into the lateral (Sylvian) fissure. Otherwise it fills in the inequalities of surface of the encephalon, its outer surface forming a sheet enveloping the whole and bridging over the sulci and the deeper grooves between the gross divisions. Upon the summits of the gyri it is more closely applied to the pia mater, and there its reticulum becomes so dense

FIG. 723.—DIAGRAM SHOWING THE RELATIONS OF THE PIA MATER, THE ARACHNOID, AND THE SUBARACHNOID CAVITY TO THE BRAIN.

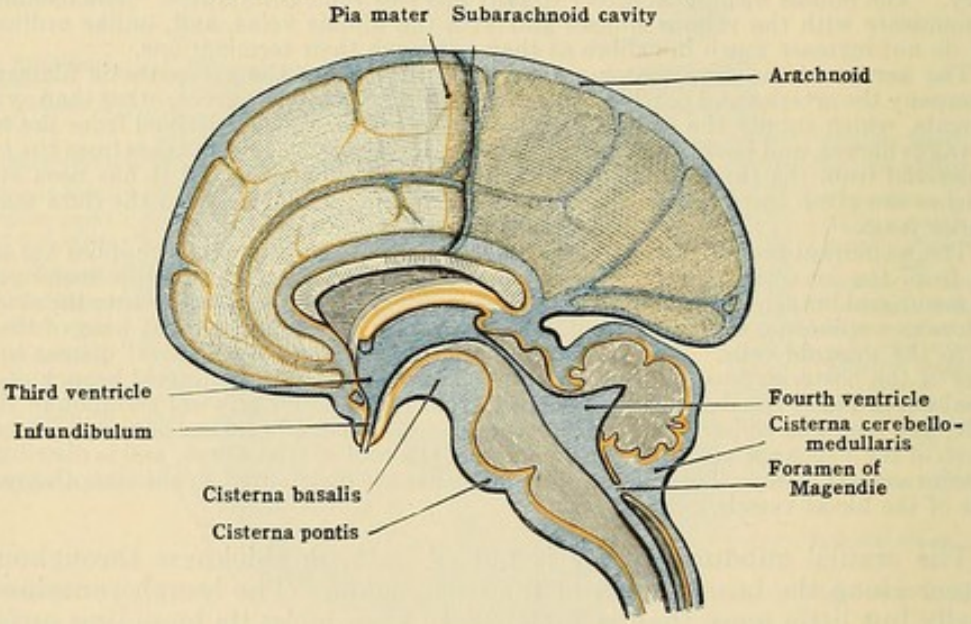

that the two membranes almost appear as one. The sulci, occupied by looser reticulum, form a continuous system of channels filled more abundantly by the cerebro-spinal fluid.

The arachnoid folds in between the cerebellum and medulla oblongata, and at the base of the brain it ensheathes the olfactory bulbs and tracts, and its outer surface forms a continuous sheet stretching from one temporal lobe to the other and bridging over the interpeduncular fossa and the inequalities of surface in the region of the optic chiasma and the stems of the lateral fissures. Obviously, therefore, the subarachnoid cavity between its outer surface and the pia mater is of considerable depth in certain localities. These localities comprise the *subarachnoid cisternæ*. These occur where the cavity at the base of the brain is especially large, and make possible a 'water-bed' which serves to protect the brain from injurious contact with the bones.

The following cisternæ are distinguished (fig. 723):—

(1) **The cisterna basalis** lies at the base of the cerebrum and is divided by the optic chiasma into two parts—(*a*) the *cisterna chiasmatis* and (*b*) the *cisterna interpeduncularis*.

(2) **The cisterna pontis** is situated about the pons, especially in its basilar sulcus and the

transverse fissures of either border, and is continuous anteriorly with the cisterna basalis and posteriorly with the subarachnoid cavity about the medulla.

(3) **The cisterna superior** lies in the angle between the splenium of the corpus callosum and the superior surfaces of the cerebellum and the mesencephalon, and is connected ventrally, around the cerebral peduncles, with the cisterna basalis.

(4) **The cisterna cerebello-medullaris** (cisterna magna) is the cavity between the inferior surface of the cerebellum and the dorsal surface of the medulla oblongata. It is continuous below into the spinal subarachnoid space. The fluid in this cavity is directly continuous with that in the fourth ventricle by way of the foramen of Magendie (median aperture of the fourth ventricle).

Pacchionian bodies [granulationes arachnoideales] (fig. 724.)—In certain situations, more particularly along the margins of the longitudinal fissure, particularly in the frontal region, and to a much less extent upon the superior surface of the vermis of the cerebellum, the subarachnoid tissue elaborates numerous small, ovoid or spherical nodules, the Pacchionian bodies. Each body or arachnoid villus consists of a retiform network of subarachnoid substance and its meshes are filled with cerebro-spinal fluid. The Pacchionian bodies on the vertex of the brain project through the inner layer of the dura mater, both into the superior sagittal sinus and into the venous spaces or **parasinoidal sinuses** which lie at the sides of that sinus, and, as they become larger, they press against the outer layer of the dura mater and produce ovoid depressions in the inner plate of the cranium.

FIG. 724.—CORONAL SECTION TRANSVERSE TO THE GREAT LONGITUDINAL FISSURE, SHOWING THE MENINGES. (Key and Retzius.)

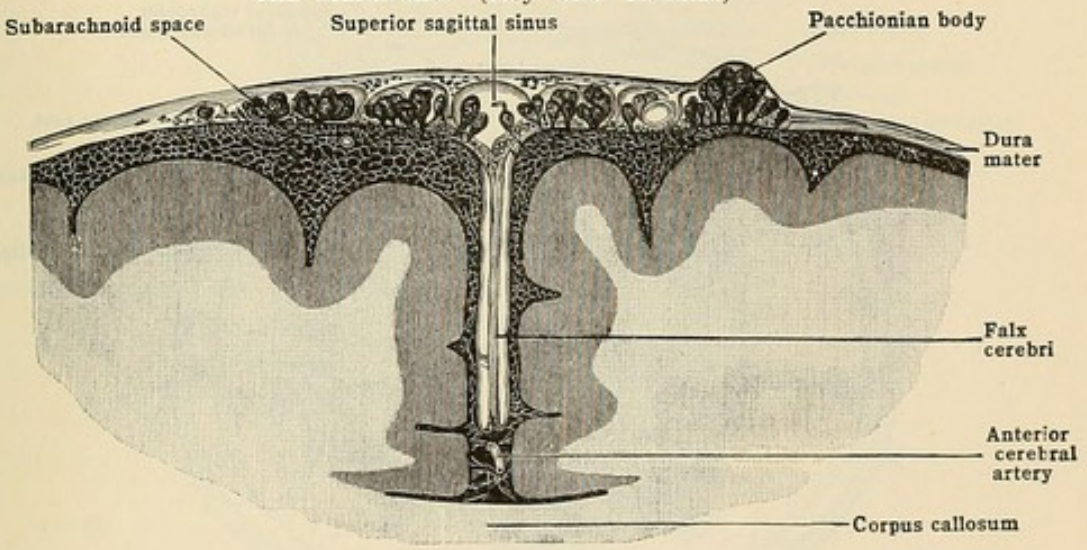

They probably facilitate the passage of lymph from the subarachnoid cavity into the blood sinuses, and thus may aid in relieving pressure within. On the other hand, through them the cerebro-spinal fluid is replenished at need from the blood plasma. They are not present at birth, but they appear at the tenth year and increase in number and size with advancing age. They are less marked in the female than in the male.

The spinal arachnoid (figs. 725, 726) is a loose, reticular sac which is most capacious about the lumbar enlargement of the spinal cord and about the cauda equina. Like that of the encephalon, the portion next to the dura mater alone resembles a membrane, being a loosely organized feltwork, covered on the side of the subdural cavity by a layer of endothelium common to that cavity. Throughout its length the spinal subarachnoid cavity is relatively wide, and, as in the cranium, contains a fine, spongy, web-like reticulum, numerous threads of which are continuous with the pia mater. This spongy tissue is the inner modification of the arachnoid, and its meshes are occupied by the cerebro-spinal fluid. It is not so abundant as in the cranial subarachnoid cavity.

In addition to the delicate threads, the arachnoid is more firmly attached to the pia mater by three incomplete partitions. The most continuous of these is arranged along the dorsal mid-line and is known as the **septum posticum** of Schwalbe (subarachnoid septum). This may be described as a linear accumulation of the spongy tissue which pervades the subarachnoid space. It is most incomplete in the upper cervical region, where it becomes merely a line of threads connecting with the pia. It is most complete as a septum in the lower cervical and in the thoracic region, but at best it maintains a spongy character. The other two partitions are

formed by the **denticulate ligaments,** which extend laterally from either side of the spinal cord, connecting the pia and dura mater and involving the arachnoid in passing through it. Within the subarachnoid cavity these form more or less complete septa, though outside the arachnoid they are attached to the dura only at the intervals of their pointed dentations. They belong to the pia mater and will be described with it. The arachnoid is further continuous with the pia by way of the connective-tissue sheaths of the roots of the spinal nerves and the blood-vessels passing through the subarachnoid cavity.

Vessels and nerves.—The arachnoid has no special blood supply and probably no special nerves other than those supplying the walls of the blood-vessels passing through it.

The cerebro-spinal fluid.—The subarachnoid cavity is the great lymph-space of the central nervous system. That of the spinal region is directly continuous into that of the cranium, and the fluid contained communicates freely with that in the ventricles of the brain and the central canal of the medulla and spinal cord by way of the foramen of Magendie or medial aperture into the fourth ventricle. In addition, there are the lateral apertures into the fourth ventricle and there is possible an interchange of fluid between the lateral ventricle and the subarachnoid cavity of the base of the brain by diffusion through the thin floor of the chorioid fissure. The arachnoid throughout is not a membrane sufficiently compact to seriously oppose diffusion between the fluid contained in its cavity and that contained in the subdural cavity, and the endothelium covering it probably even facilitates such activities. The cerebro-spinal fluid occupying the cavities is a transparent fluid of a slight yellow tinge, characteristic of the

FIG. 725.—DIAGRAM OF TRANSVERSE SECTION OF UPPER THORACIC REGION OF THE SPINAL CORD SHOWING THE RELATIONS OF THE SPINAL MENINGES AND THEIR CAVITIES.

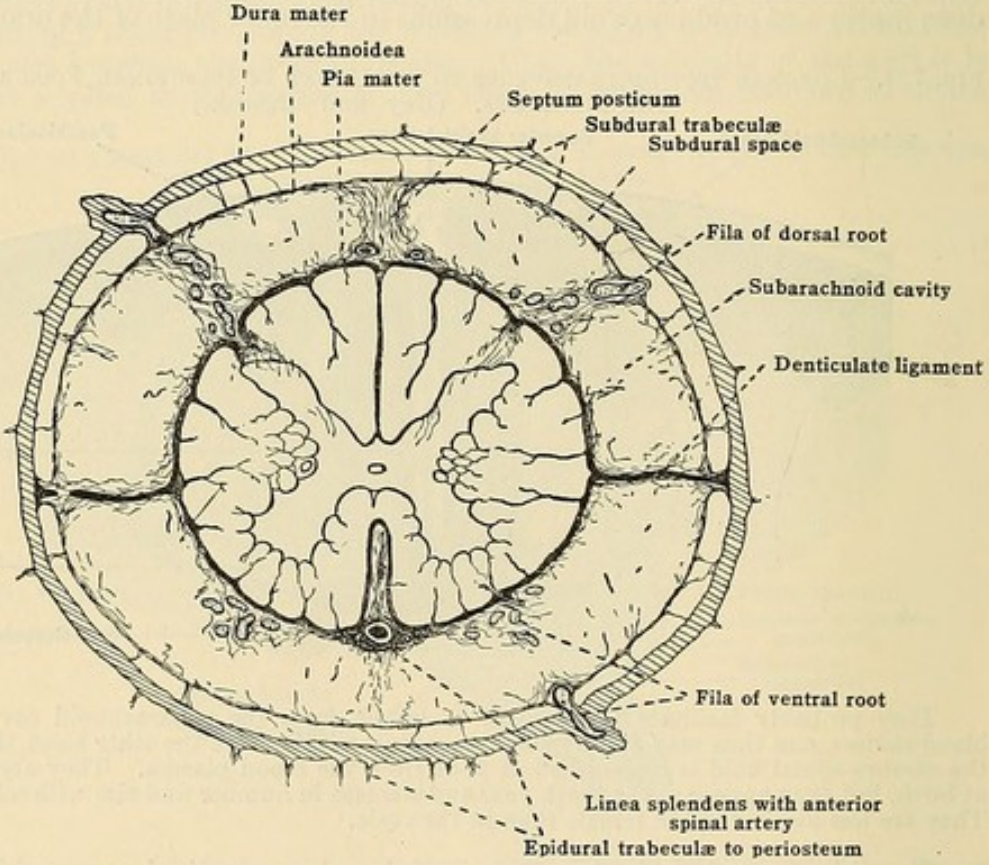

lymph in other lymph-spaces of the body. It is not very great in amount, probably never exceeding 200 c.c. in normal conditions. It is greatest in amount in old age, when the cavities are larger, due to atrophy and shrinkage of the nervous tissues. It collects from the lymph spaces in the meninges, and from exudation through the walls of the vascular chorioid plexuses and sinuses of the system it bathes. Its amount may be temporarily increased by a period of increased blood-pressure in the cranial vessels. Pressure due to its abundance may be relieved by diffusion through the membranes containing it, and especially through the villi of the Pacchionian bodies into the venous sinuses and lacunæ and thence into the venous system through the internal jugular veins.

THE PIA MATER

The **pia mater,** the third of the meninges, is a thin membrane which envelopes and closely adheres to the entire central nervous system and sends numerous processes into its substance. It likewise contributes the most proximal and compact portion of the sheaths worn by the nerve-roots in their passage through the meningeal spaces. It is very vascular in that the superficial plexuses of blood-vessels of

both the brain and spinal cord ramify in it as they give off the central branches into the nervous substance. The structure and arrangement of the membrane vary somewhat in the cranial and spinal regions.

The spinal pia mater consists of two layers, an inner and an outer. It is thicker and more compact than that of the encephalon, due to the extra development of its outer layer, which is in the form of a strong, fibrous layer with the fibres arranged for the most part longitudinally.

The spinal pia mater also appears less vascular than the cranial from the fact that the blood-vessels composing the plexus lying in it are obviously much smaller than those of the encephalon. Its inner layer is a thin feltwork of fibres which is closely adherent to the surface of the spinal cord throughout, sending numerous connective-tissue processes into it which contributes to the support of the nervous tissues. The larger of these processes carry with them the numerous intrinsic blood-vessels from the superficial plexus. The two layers are closely connected with each other, and are distinguished by the difference in the arrangement of their fibres.

The membrane dips into the anterior median fissure and bridges it over by forming an extra thickening along it. This thickening appears as a band along the mid-line of the ventral surface of the cord, the **linea splendens** (fig. 717). It carries, or ensheathes, the anterior spinal artery, the largest of the arterial trunks of the superficial plexus (fig. 725).

FIG. 726.—DIAGRAM SHOWING RELATIONS OF MENINGES TO SPINAL NERVE-ROOTS.

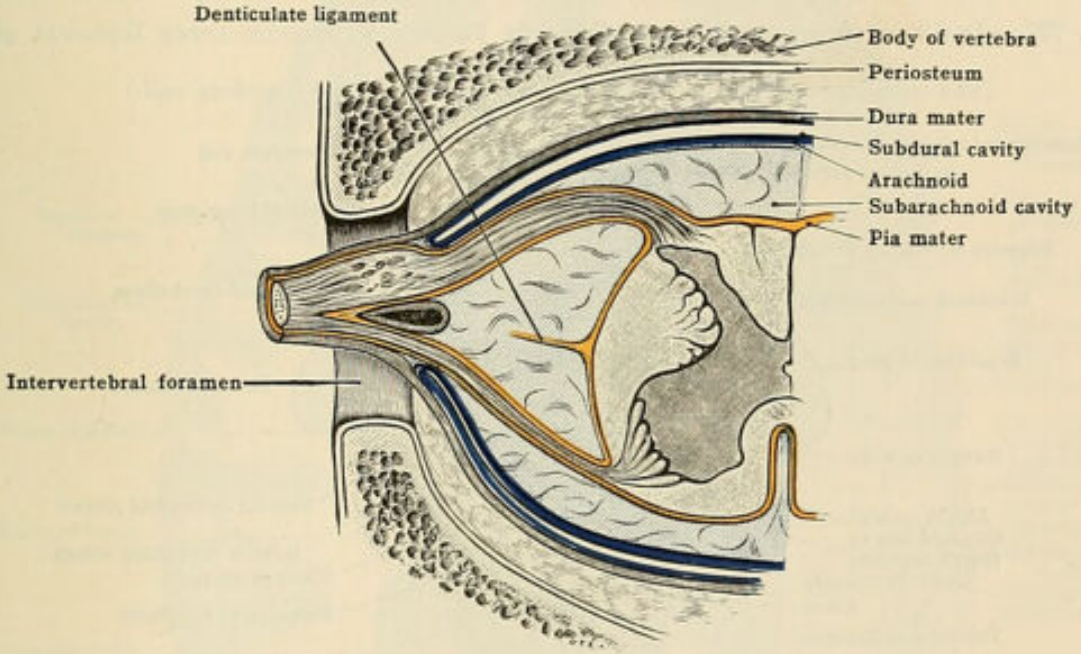

The pia mater contributes the innermost and most compact portion of the epineurium of each of the nerve-roots, and thus, upon the roots, it is prolonged laterally into the intervertebral foramina, where the dura mater blends with it in producing the increased thickness of the epineurium.

From each side of the cord the pia mater gives off a leaf-like fold, the **denticulate ligament,** which spreads laterally toward the dura mater midway between the lines of attachment of the dorsal and ventral nerve-roots. The outer border of this fold is dentate or scalloped into about twenty-one pointed processes, which extend through the arachnoid and are attached to the inner surface of the dura mater. The dentations are usually inserted between the levels of exit of the roots of the spinal nerves, the uppermost one a little cephalad to the first cervical nerve and the region where the vertebral artery perforates the dura mater; the most caudal one between the last thoracic and first lumbar nerves, or, between the last two thoracic nerves. The ligaments, aided slightly by the septum posticum, serve to hold the spinal cord more or less suspended in the subarachnoid cavity.

Below, at the sudden, conical termination of the spinal cord in the lumbar portion of the spinal canal, the pia mater is spun out into a thin, tubular filament, the **filum terminale,** which continues caudalward into the sac formed by the dura mater about the cauda equina, and at the end fuses with the dura mater in line with the filum of the spinal dura mater (coccygeal ligament) of the outside (figs. 613, 715).

The cranial pia mater is closely applied to the external surface of the brain, dipping into all the fissures, furrows, and sulci. It is connected with the arachnoid by numerous filaments of the spongy subarachnoid tissue and by the blood-vessels traversing the subarachnoid cavity. It is also pierced by the cranial nerves, and furnishes them their sheaths, which become continuous with the arachnoid and dura mater.

Its *outer surface* bounds the subarachnoid cavity. It is with difficulty separable into two layers of mixed white fibrous and elastic connective tissue, with slightly pigmented connective-tissue cells enmeshed between them. Its *inner surface* sends a large number of fibrous processes into the nervous substance, which blend with the neuroglia and aid in the support of the nervous elements. The larger of these processes accompany the central arterial and venous branches of the rich superficial plexuses of blood-vessels contained in the pia on the surface of the brain. Pieces of the pia when pulled off and placed in water present a flocculent appearance as to their inner surfaces, due to these processes having been pulled out.

The cranial pia mater sends strong, vascular duplications into two of the great fissures of the encephalon; viz., the *transverse cerebellar fissure*, between the cerebellum and the medulla oblongata, and the *transverse* cerebral fissure, between the cerebellum, mesencephalon, and thalamencephalon, and the overhanging cerebral hemispheres. These duplications are spread over the cavities of the fourth and third ventricles, and are known as the *chorioid telæ* of these ventricles respectively.

FIG. 727.—DIAGRAM SHOWING CHORIOID TELA OF FOURTH VENTRICLE AFTER REMOVAL OF CEREBELLUM.

(The trochlear nerve should be shown emerging from the frenulum veli.)

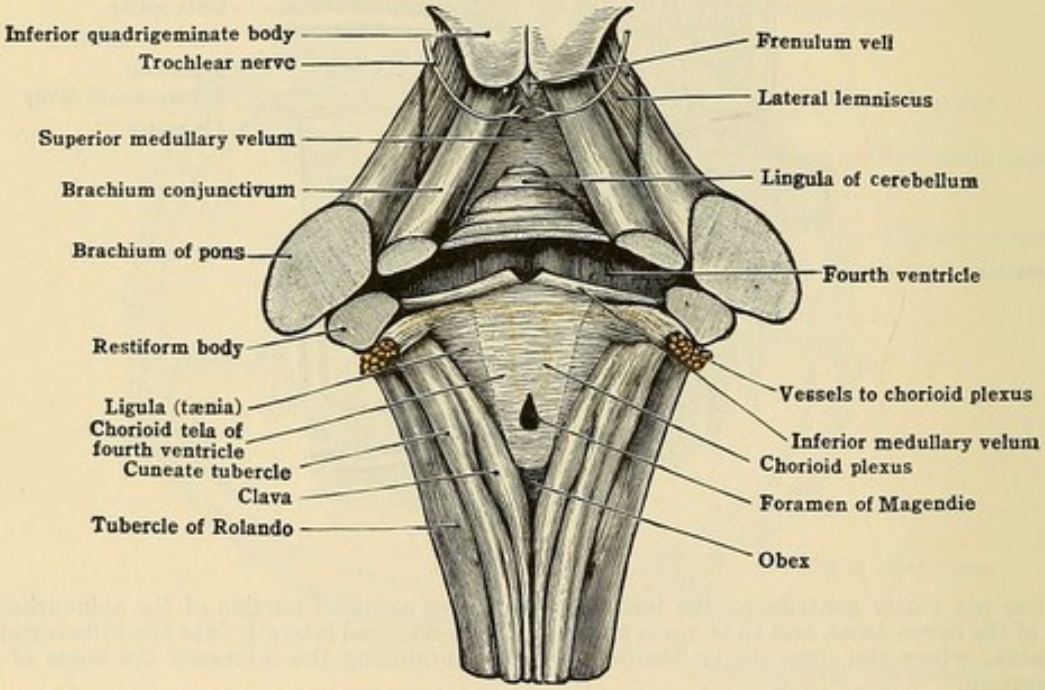

The tela chorioidea of the fourth ventricle lies in the transverse cerebellar fissure, between the inferior surface of the cerebellum (vermis chiefly) and the dorsal surface of the medulla (fourth ventricle). The two layers of this fold of the pia remain separate and a portion of the cisterna posterior of the subarachnoid cavity lies between them. The inferior of the layers is the tela chorioidea (fig. 727.) It is triangular in shape, with its base cephalad at the nodule of the vermis and its apex below at the level of the tuber vermis. The superior layer of the fold is the pia mater of the vermis. The tela chorioidea is strengthened by the epithelial roof (ependyma) of the fourth ventricle and is continuous with the pia mater of the medulla oblongata and spinal cord. In roofing over the fourth ventricle the tela chorioidea of the fourth ventricle constitutes the ligula and the obex. A little above the calamus scriptorius it is pierced by the foramen of Magendie and the two lateral apertures into the fourth ventricle.

In front of the foramen of Magendie the vessels of the chorioid tela, which are derived from the posterior inferior cerebellar arteries, form two longitudinal, lobulated strands which invaginate the epithelial roof of the ventricle, one on either side of the mid-line, and project into its cavity. These form the **chorioid**

plexus of the fourth ventricle. At the base of the tela the two chorioid plexuses join each other and then turn transversely lateralward into the lateral recesses of the ventricle, where they pass behind the restiform bodies and form the '*cornucopiæ*.'

The chorioid tela of the third ventricle, or **velum interpositum,** is a triangular duplication of the pia mater which extends between the fornix above and the thalami and third ventricle below, and in front fuses with the brain substance at the interventricular foramina.

In the transverse cerebral fissure the layers of pia forming this tela are separate, the upper being the pia of the under surface of the corpus callosum and continuous with that of the tentorial surfaces of the occipital lobes; the lower being continuous into the pia enfolding the epiphysis, and covering the mesencephalon, anterior medullary velum, and cerebellum. The

FIG. 728.—HORIZONTAL DISSECTION OF THE CEREBRUM SHOWING THE TELA CHORIOIDEA OF THE THIRD VENTRICLE.

(From a mounted specimen in the Anatomical Department of Trinity College, Dublin.)

The fornix has been removed to show the chorioid tela of the third ventricle.

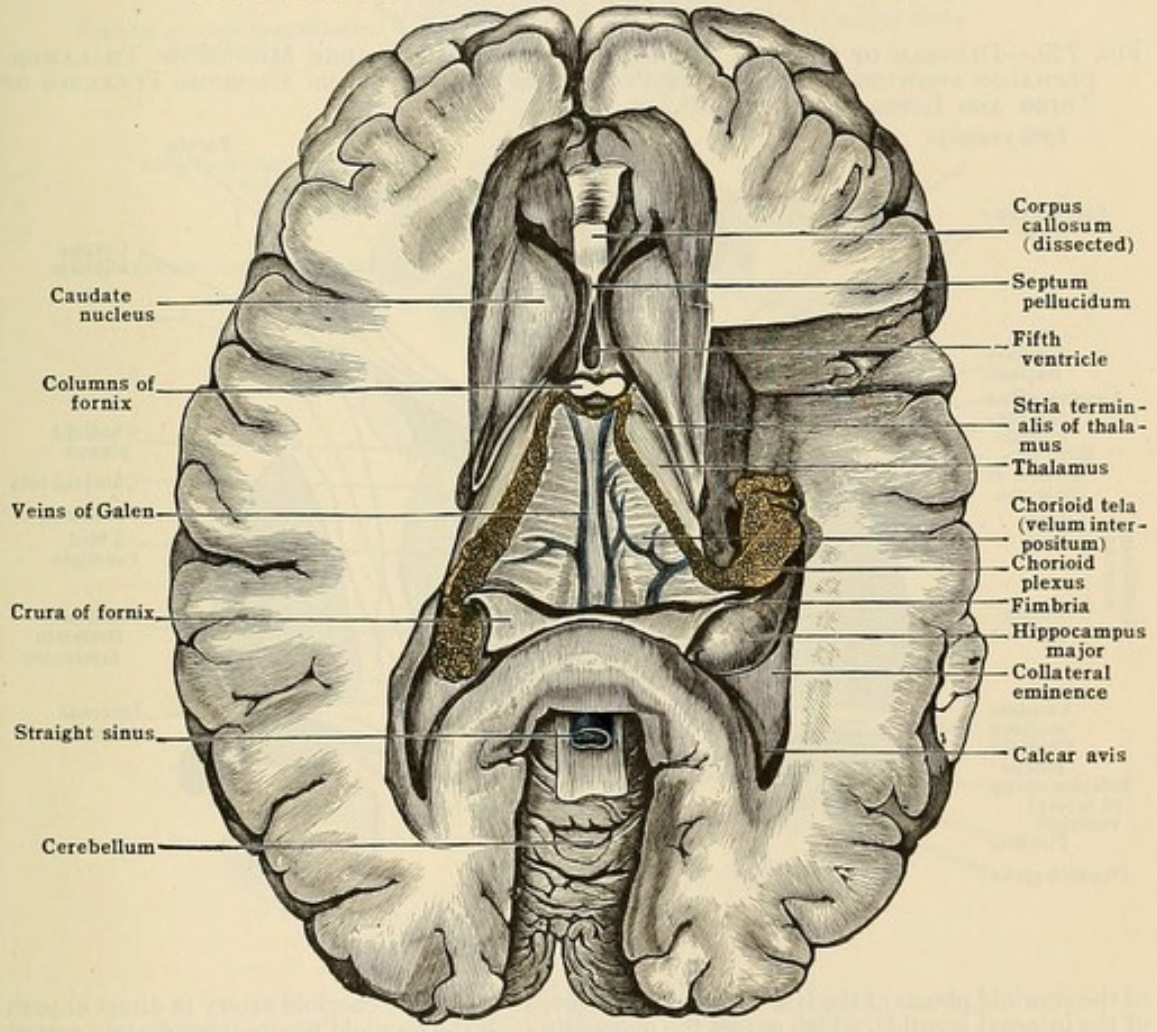

layers forming the portion of the duplication which roofs over the third ventricle are loosely adherent to each other and form the tela chorioidea proper of that ventricle. The upper surface of this portion is in relation with the fornix and its lower surface, covered by the epithelial chorioid lamina, lies laterally over the superior surfaces of both thalami, and mesially forms the roof of the third ventricle between them. The epithelium or ependyma is continuous with that covering the thalami and lining the ventricles. Between the two layers of this portion, and embedded in a small amount of the spongy subarachnoid tissue retained between them, are the two veins of Galen, the internal cerebral veins. Posteriorly these veins unite in the region of the epiphysis to form the single great cerebral vein (*vena cerebri magna*) which empties into the straight sinus. Anteriorly the veins of Galen receive the veins of the septum pellucidum from each lamina of the septum pellucidum above, and also the terminal vein (vein of corpus striatum), lying in the stria terminalis of the thalamus, empties into them from each side.

The chorioid tela of the third ventricle or velum interpositum extends laterally between the fornix and fimbria above and the stria terminalis of the thalamus be-

low into each lateral ventricle. The blood-vessels of the border projecting into the lateral ventricle are amplified into a plexus which appears as a strip of reddish, lobulated, villus-like processes known as the **chorioid plexus of the lateral ventricle.** The plexus, being in the border of the tela, begins at the interventricular foramen, extends through the body or central portion of the ventricle, and downward into its inferior cornu. It is most developed at the junction of the body with the inferior cornu, and is there known as the **glomus chorioideum.**

From the under surface of the chorioid tela of the third ventricle, hanging down on either side of the mid-line into the cavity of the ventricle, are two other longitudinal, lobulated strands of blood-vessels which are the **chorioid plexuses of the third ventricle.** At the anterior end of the third ventricle these two plexuses join with each other and also with the plexus of the lateral ventricle of each side through the interventricular foramina.

The chorioid plexuses of both the ventricles are covered by a layer of ependyma, *epithelial chorioid lamina*, which is but a reflexion of the ependyma lining the cavities throughout and represents the remains of the germinal layer of the embryonic brain vesicles. The blood-vessels

FIG. 729.—DIAGRAM OF CORONAL SECTION OF CEREBRUM THROUGH MIDDLE OF THALAMENCEPHALON SHOWING RELATIONS OF PIA MATER ENCEPHALI AND CHORIOID PLEXUSES OF THIRD AND LATERAL VENTRICLES.

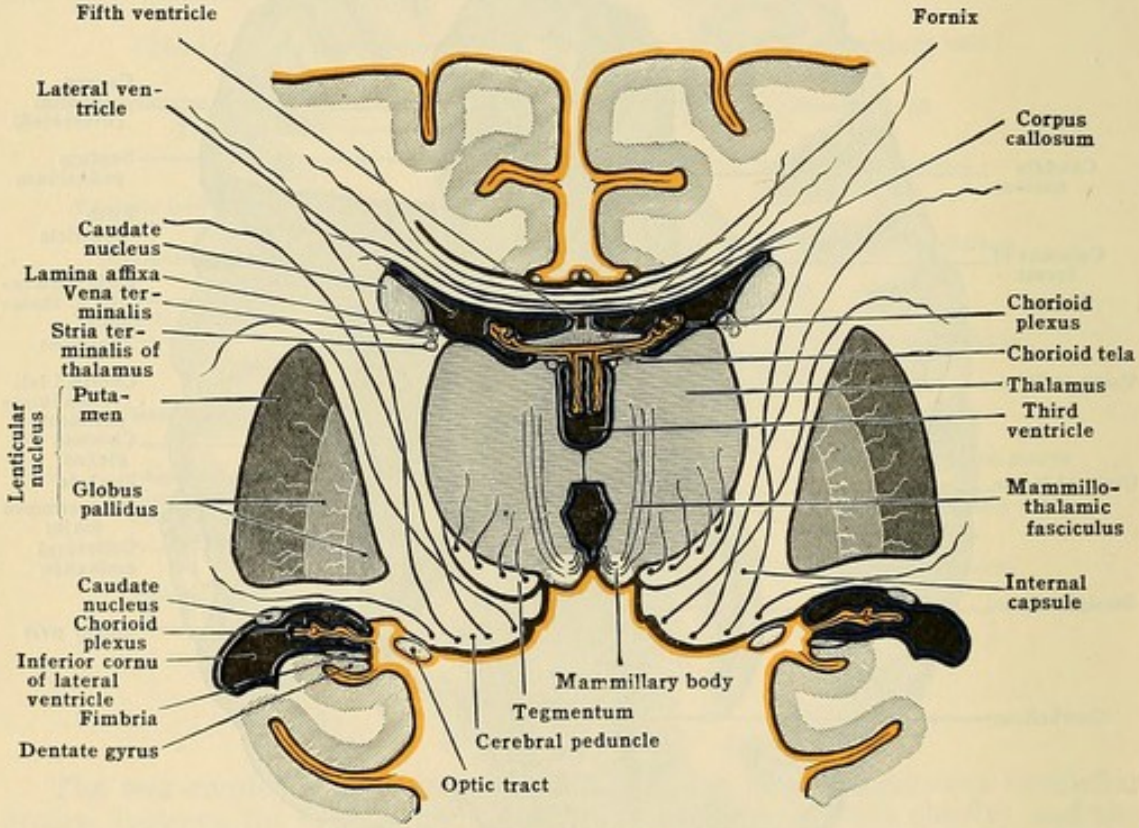

of the chorioid plexus of the lateral ventricle receive blood by the chorioid artery (a direct branch of the internal carotid), which enters the plexus through the chorioid fissure immediately mesial to the uncus, and also by the chorioidal branches of the posterior cerebral artery, which supply the plexus of the body of the ventricle. The chorioid plexuses of the third ventricle receive blood chiefly by branches from the superior cerebellar arteries. The greater part of the blood of both plexuses passes out by way of the tortuous chorioid veins, which, at the interventricular foramen, empty into the venæ terminales (veins of the corpus striatum), which, in their turn, go to form the greater part of the veins of Galen. Thence the blood passes by way of the vena cerebri magna into the straight sinus. It is probable that a large part of the cerebro-spinal fluid of the third and lateral ventricles is derived by diffusion through the walls of the vessels of the chorioid plexuses.

THE PERIPHERAL NERVOUS SYSTEM

The intimate connection and consequent control exercised by the central nervous system over all the tissues and organs of the body is attained through the

FIG. 730.—SHOWING THE RELATION BETWEEN THE CENTRAL AND THE PERIPHERAL NERVOUS SYSTEMS.

(Combination drawing, spinal part after Allen Thompson, from Rauber.)

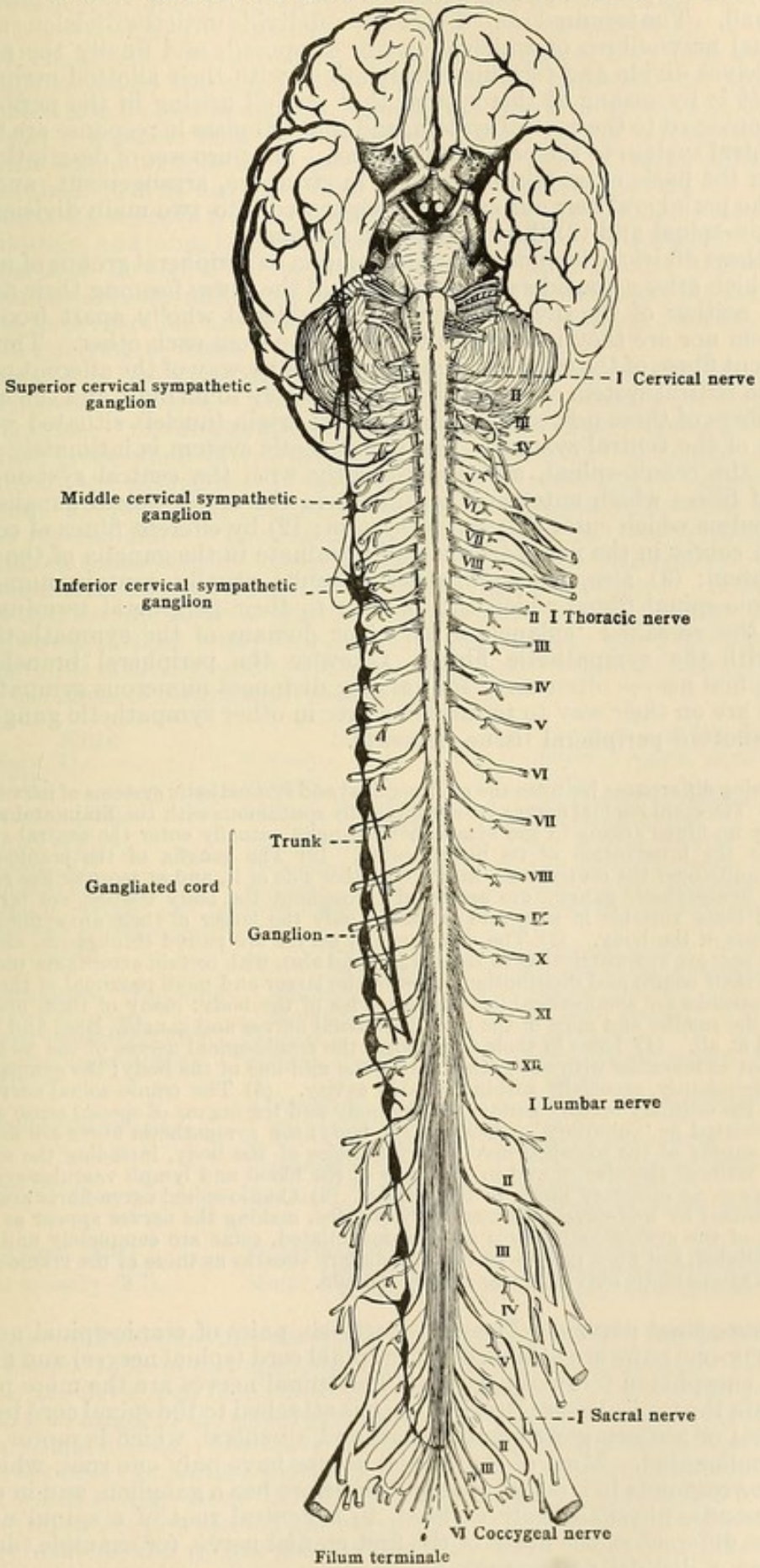

peripheral nervous system. This system, abundantly attached to the central system, consists of numerous bundles of nerve-fibres which divide and ramify throughout the body, anastomosing with each other and forming various plexuses, large and small. The terminal rami divide and subdivide until the divisions attain the individual nerve-fibres of which they are composed, and finally the nerve-fibres themselves divide and terminate in relations with their allotted peripheral elements. It is by means of this system that stimuli arising in the peripheral tissues are conveyed to the central system, and that impulses in response are borne from the central system to the peripheral organs. For purposes of description, as well as upon the basis of certain differences in structure, arrangement, and distribution, the peripheral nervous system is separated into two main divisions:—(1) **the cranio-spinal** and (2) **the sympathetic system.**

Both of these divisions include numerous ganglia or peripheral groups of nerve-cells from which arise a considerable proportion of the fibres forming their nerve-trunks, but neither of the divisions may be considered wholly apart from the central system nor are they independent or separate from each other. The sensory or afferent fibres of the cranio-spinal nerves pass by way of the afferent nerve-roots into the central system and contribute appreciably to its bulk, and the motor or efferent fibres of these nerves have their cells of origin (nuclei) situated within the confines of the central system. The sympathetic system is intimately associated with the cranio-spinal, and consequently with the central system—(1) by means of fibres which enter and terminate in the cranio-spinal ganglia and transfer impulses which enter the central system; (2) by efferent fibres of central origin which course in the nerve-trunks and terminate in the ganglia of the sympathetic system; (3) also, the sympathetic trunks usually contain numerous afferent cranio-spinal fibres which thus course to their peripheral termination, usually in the so-called 'splanchnic area,' or domain of the sympathetic, in company with the sympathetic fibres. Likewise the peripheral branches of the cranio-spinal nerves often carry for varying distances numerous sympathetic fibres which are on their way to terminate either in other sympathetic ganglia or upon their allotted peripheral tissue-elements.

The following **differences** between the cranio-spinal and sympathetic systems of nerves may be cited:—(1) The cranio-spinal nerves are anatomically continuous with the brain and spinal-cord; probably no fibres arising in the sympathetic ganglia actually enter the central system other than for the innervation of its blood-vessels. (2) The ganglia of the cranio-spinal nerves all lie quite near the central axis, in line on either side of it, and at more or less regular intervals; the sympathetic ganglia are scattered throughout the body tissues, are far more numerous and more variable in size, and probably only the larger of them are symmetrical for the two sides of the body. (3) The cranio-spinal nerves are paired throughout, and the nerves of each pair are symmetrical as to their origin and also, with certain exceptions (notably the vagus), in their course and distribution; most of the larger and more proximal of the sympathetic nerve-trunks are symmetrical for the two sides of the body; many of them are not, and many of the smaller and most of the more peripheral nerves and ganglia, large and small, are not paired at all. (4) Even in their finer twigs, the cranio-spinal nerves of the two sides probably do not anastomose with each other across the mid-line of the body; the sympathetic nerves do so abundantly, especially within the body cavity. (5) The cranio-spinal nerves are distributed to the ordinary sensory surfaces of the body and the organs of special sense and to the somatic, striated or 'voluntary' muscles of the body; the sympathetic fibres are devoted chiefly to the supply of the so-called involuntary muscles of the body, including the smooth muscle in the walls of the viscera and in the walls of the blood and lymph vascular-systems, while others serve as secretory fibres to the glands. (6) Cranio-spinal nerve-fibres are characterized in general by well-developed medullary sheaths, making the nerves appear as white strands; most of the sympathetic fibres are non-medullated, some are completely and some partially medullated, but none possess as thick medullary sheaths as those of the cranio-spinal nerves. Thus sympathetic nerves appear as grey strands.

The cranio-spinal nerves.—There are forty-six pairs of cranio-spinal nerves, of which thirty-one pairs are attached to the spinal cord (spinal nerves) and fifteen pairs to the encephalon (cranial nerves). The spinal nerves are the more primitive and retain the typical character, i. e., each is attached to the spinal cord by two roots, a dorsal or sensory ganglionated root, and a ventral, which is motor, and thus not ganglionated. Most of the cranial nerves have only one root, which in come cases corresponds to a dorsal root and therefore has a ganglion, and in other cases corresponds, physiologically at least, to a ventral root of a spinal nerve. Among other differences, the fibres of the first cranial nerve, for example, do not collect to form a distinct nerve-trunk.

I. THE CRANIAL NERVES

Customarily, the cranial nerves are described as comprising twelve pairs and each is referred to by number. However, present knowledge of their origin, central connections and peripheral distribution suggests that those enumerated as the fifth, seventh, and eighth pairs under the old nomenclature are better each separated into its two component nerves, each of which merits a separate description and a separate name. None of the cranial nerves corresponds closely to a typical spinal nerve with its motor and sensory root. The so-called motor portion of the fifth is no more its motor root than is the seventh nerve. The sensory portion of the seventh is not wholly sensory and rather resembles the ninth pair in distribution, and it has long been commonly referred to as a separate nerve. The two parts of the eighth nerve, both sensory, are known to be wholly different in functional character and are so named. Further, the names of the nerves, descriptive of their function, are pedagogically much more efficient than the use of numbers in referring to them.

Separating the three pairs mentioned, each into its two nerves, gives fifteen pairs instead of twelve. Their names and functional nature are given in the following table. The Roman numerals given in parentheses correspond to the serial numbers given when twelve pairs only are considered. It is also customary to enumerate the cranial nerves from in front backward and caudalward, and this custom is followed here, but again it would be pedagogically better to take them in the reverse order. Then each in its turn could be directly considered as in continuous series with the spinal nerves below and the similarities to and progressive modifications from the spinal type could be better realized. It will be remembered that *somatic motor* or *efferent* fibres are those which terminate directly upon the fibres of skeletal muscle while *visceral* motor fibres transfer their impulses to sympathetic neurones, and the axones of the latter terminate upon gland cells and upon the fibres of cardiac and smooth muscle.

Name	Nature	General Distribution
Olfactory (I)	Sensory	Olfactory region, nasal epithelium.
Optic (II)	Sensory	Retina.
Oculomotor (III)	Motor — Somatic	Eye-moving muscles.
	Motor — Visceral	Ciliary body, iris.
Trochlear (IV)	Motor-somatic	Eye-moving muscles.
Abducens (VI)	Motor-somatic	Eye-moving muscles.
Trigeminus (V)	Sensory	Face, mouth, and scalp.
Masticator (*minor part or motor root of trigeminus*).	Motor-somatic	Muscles of mastication.
Facial (VII)	Motor — Somatic	Facial muscles.
	Motor — Visceral (?)	Salivary glands, vessels(?).
Glossopalatine. (*Intermediate part of facial*).	Sensory	Tongue, palate.
	Motor-visceral	Salivary glands.
Cochlear (*auditory*) (VIII)..	Sensory	Internal ear.
Vestibular (*equilibrator*) (VIII).	Sensory	Semicircular canals, utriculus, sacculus.
Glossopharyngeal (IX).....	Sensory	Tongue, palate, pharynx.
	Motor — Somatic	Pharynx.
	Motor — Visceral	Glands and vessels.
Vagus (X).....	Sensory	Alimentary canal, lung, heart.
	Motor — Somatic	Larynx, pharynx.
	Motor — Visceral	Alimentary canal, heart, larynx, trachea, lung.
Hypoglossal (XII).....	Motor-somatic	Tongue-moving muscles.
Spinal acessory (XI).....	Motor — Somatic	Neck and shoulder muscles.
	Motor — Visceral	Pharynx, larynx, heart.

The cranial nerves, like the spinal nerves, are developed from cells of the primitive neural tube and, beginning with the fifth pair downward, all the sensory nerves are developed from the cells corresponding to those of the ganglion crest which give origin to the spinal ganglia with the sensory components or dorsal roots of the spinal nerves. Otherwise between the cranial nerves and the spinal nerves there are many important differences. Each spinal nerve has a dorsal or sensory root, which springs from the cells of a spinal ganglion; a ventral or motor root, whose fibres are processes of the nerve-cells which are situated in the walls of the central system, and at their attachment to the surface of the cord the two roots are some distance apart. Only one of the (usually considered) twelve pairs of cranial

nerves corresponds at all closely with typical spinal nerves. This one is the trigeminus which possesses a sensory ganglionated root and near its attachment is accompanied by a small motor nerve, the masticator, which serves in very small part as a corresponding motor root of the trigeminus. But even in this case where the similarity between the cranial and spinal nerves is greatest, there are still points of anatomical difference, which if not essential are very obvious, for the so-called motor root joins not the whole but only with one branch of the sensory portion. The two are only slightly separated from each other at their attachment to the surface of the brain. All the other cranial nerves differ in a still more marked manner from typical spinal nerves. The first nerve is an afferent nerve whose cells of origin (olfactory ganglion) are scattered in the mucous membrane

FIG. 731.—SURFACE ATTACHMENT OF THE CRANIAL NERVES.
(After Allen Thomson, modified.)

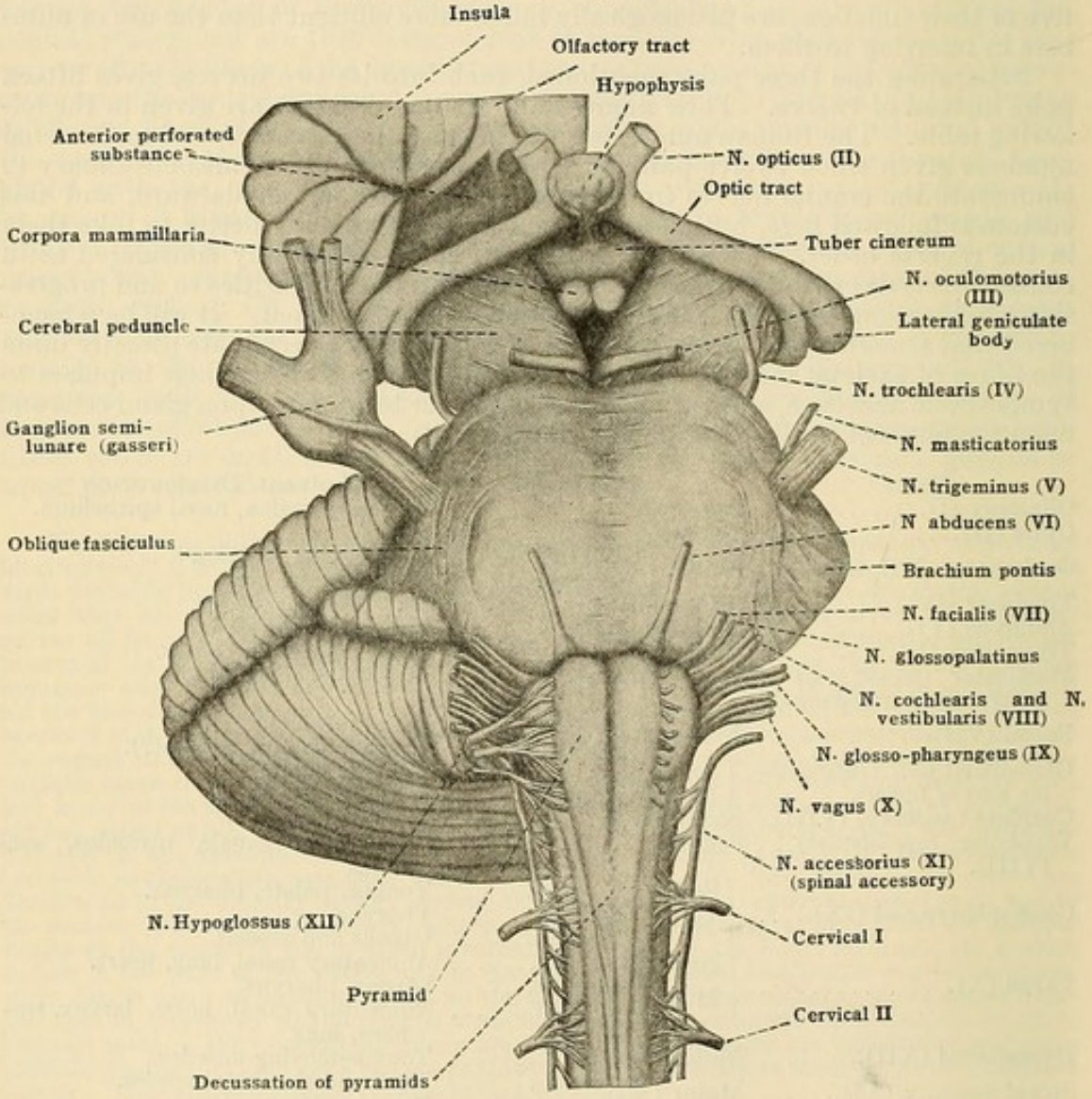

of the nose, an organ of special sense, and its fibres are not collected together into a nerve-trunk, but pass, as a number of small bundles, through the lamina cribrosa of the ethmoid bone directly into the olfactory bulb. The optic nerve is also a nerve of special sense. Its fibres form a very distinct bundle, similar in appearance to an ordinary nerve, from which, however, it differs essentially, both with regard to structure and development; for, unlike an ordinary nerve, its connective tissue consists to a large extent of neuroglia instead of ordinary connective tissue, and its component nerve-fibres are of much smaller calibre than those of an ordinary nerve. It represents the location of the original optic stalk, a diverticulum from the neural tube and it associates the retina (optic cup), a bit of modified cor-

tex, with the encephalon. The optic nerve, therefore, corresponds more closely with an association tract of the central system than with an ordinary nerve.

The oculomotor, trochlear, abducens and hypoglossal nerves are purely motor nerves, and thus correspond only with the ventral roots of spinal nerves. The spinal accessory is also purely motor. Its fibres arise from the cells of the anterior horn of the spinal cord and from a nucleus of the medulla which represents a displaced portion of that horn, but they do not leave the surface of the spinal cord and brain in the usual situation of ventral roots. On the contrary, they emerge in a series of rootlets from the lateral funiculus of the cord on the dorsal side of the ligamentum denticulatum, and from the upward prolongation of this funiculus.

The cochlear and vestibular are nerves of special sense, and in some respects both correspond closely with the dorsal root of a typical spinal nerve, and the ganglia of both represent spinal ganglia, but their distribution is limited to the membranous labyrinth.

The vagus and glosso-pharyngeal nerves contain both motor and sensory fibres, but they differ from typical spinal nerves in that the motor fibres, in company with the sensory, issue from the postero-lateral sulcus of the medulla, and they are intimately intermingled, from their origin, with the sensory fibres, which latter arise from ganglia interposed in the trunks of the nerves and otherwise correspond with the fibres of the dorsal root of a typical spinal nerve.

Superficial attachments and origins.—It is customary to speak of the area where the nerve-fibres leave or enter the brain substance as the superficial attachments of the cranial nerves, and the groups of cells from which the fibres spring, and about which they terminate, as their nuclei of origin or termination, respectively.

THE OLFACTORY NERVES

The **olfactory nerve-fibres** are the central processes of the bipolar olfactory nerve cell-bodies situated in the olfactory region of the nasal mucous membrane. In man, the olfactory region comprises the epithelium upon the superior third of the nasal septum and that upon practically the whole of the superior nasal concha. The area is relatively small as compared with that of other mammals and, as in other mammals, is characterized by an increased thickness of the epithelium and a yellowish brown colour in the fresh. The peripheral processes of the olfactory cell-bodies (the olfactory ganglion) are short and extend only to the surface of the olfactory epithelium. As the central processes pass upward from their cells of origin they form plexuses in the mucous membrane, and from the upper parts of these plexuses, immediately below the lamina cribrosa of the ethmoid, about twenty filaments issue on each side. These filaments comprise the **olfactory nerve.** They are non-medullated. They pass upward, through the foramina in the lamina cribrosa, into the anterior fossa of the cranium in two rows, and after piercing the dura mater, the arachnoid, and the pia mater, they enter the inferior surface of the olfactory bulb. They contribute to the superficial stratum of nerve-fibres on the inferior surface of the olfactory bulb and end in the **glomeruli,** which are formed by the terminal ramifications of the olfactory nerve-fibres intermingled with the similar ramifications of the main dendrites of the large mitral cells which lie in the deeper part of the grey substance of the olfactory bulb.

The olfactory nerve-fibres are grey fibres, since they do not possess medullary sheaths, and they are bound together into nerves by connective-tissue sheaths derived from the pia mater, from the subarachnoid tissue, and from the dura mater. Prolongations of the subarachnoid space pass outward along the nerves for a short distance.

Central connections.—The olfactory impulses are transmitted by way of the peripheral processes of the olfactory neurones through the cell-bodies and the olfactory nerve-fibres and through the glomeruli to the mitral cells. Thence they are carried by the central processes (axones) of the mitral cells, which pass backward along each olfactory tract and its three olfactory striæ (see Rhinencephalon, p. 864).

THE TERMINAL NERVE (*Nervus Terminalis*)

In lower vertebrates and recently in those mammals whose sense of smell is relatively much more developed than in man, three nerves have been found concerned with the olfactory apparatus:—(1) The olfactory nerve proper whose fibres, as noted above, are the central processes of

the nerve cell-bodies situated in the epithelium of the olfactory region of the nasal mucosa, and which terminate in the olfactory bulb; (2) The vomero-nasal nerve, whose fibres are the central processes of nerve cell-bodies situated in the epithelium of the vomero-nasal (Jacobson's) organ and which pass caudalward in the submucosa and upward to join the filaments of the olfactory nerve proper and which, in the dog, cat, rabbit, rat, etc., terminate in the accessory olfactory bulb—a small protuberance possessed by these animals on the postero-median aspect of the olfactory bulb proper; (3) The terminal nerve, a small plexiform nerve, which unlike the other two, is ganglionated.

In man, the vomero-nasal (Jacobson's) organ is rudimentary after birth and, therefore, the vomero-nasal nerve is not present, the only fibres for the vomero-nasal region being those of general sensibility from the trigeminus and sympathetic fibres common to the epithelium of the entire nasal fossa.

The terminal nerve has been recently described as present in the human fœtus and it is mentioned here because of the expressed belief that it is present in the adult. From the observations recorded for human and rabbit fœtuses and the adult dog and cat, the following description may be given: It is variably plexiform throughout its course. Its peripheral twigs are distributed to the mucosa of the nasal septum, some to the mucosa joining the olfactory region while other and larger twigs extend further forward and are distributed to mucosa of the vomero-nasal organ, accompanying and sharing in the distribution of the vomero-nasal nerve when this is present. Its central connections are in the form of two or three small roots which pass through the cribriform plate of the ethmoid bone in company with and mesial to the vomero-nasal nerve and then, still plexiform, extend caudalward over the infero-mesial aspect of the olfactory bulb and upon the olfactory peduncle or stalk (olfactory tract) beyond, a root often extending to near the lamina terminalis and optic chiasma. The roots disappear in the mesial and infero-mesial aspect of the frontal portion of the brain at different localities caudal to the olfactory bulb and usually near the olfactory peduncle, but often one may disappear in the region corresponding to the anterior perforated substance of the adult human brain.

Numerous small groups of ganglion cells are found interposed along both the peripheral and intracranial course of the terminal nerve. A group, larger in size than the others and situated in the intracranial course of the nerve, is called the *ganglion terminale*. The fibres of the nerve are non-medullated. Both the ganglion cells and the fibres of the nerve are described as having more the appearances characteristic of sympathetic neurones than of cranio-spinal. On the other hand, our conceptions of sympathetic neurones do not permit of their terminating within the central system except for the innervation of its blood vessels. It may result that, instead of being an independent nerve as now claimed, the nervus terminalis is a part of the forward extension of the cephalic sympathetic, the larger ganglia and plexuses of which latter are well known, and that its neurones receive and convey impulses to the gland cells of the nasal mucosa and to the muscle of the blood-vessels of the mucosa and those supplying the infero-mesial part of the frontal end of the cerebrum.

THE OPTIC NERVES

The **fibres of the optic nerve** are the central processes of the ganglion cells of the retina. Within the ocular bulb they converge to the optic papilla, where they are accumulated into a rounded bundle, the **optic nerve.** The nerve thus formed pierces the chorioid and the sclerotic coats, and, at the back of the bulb, enters the orbital fat, in which it passes backward and medialward to the optic foramen. After traversing the foramen it enters the middle fossa of the cranium, and anastomoses with its fellow from the opposite side, forming the optic chiasma. It may, therefore, for descriptive purposes, be divided into four portions—the intra-ocular, the intra-orbital, the intra-osseous, and the intra-cranial. The total length of the nerve varies from forty-five to fifty millimetres.

The **intra-ocular part** is rather less than one millimetre in length. It passes backward from the optic papilla through the chorioid and through the sclerotic coats of the bulb. As it passes through the latter coat of the bulb in many separate bundles, the area it traverses has a cribriform appearance when the nerve is removed, and consequently is known as the *lamina cribrosa scleræ.*

The **intra-orbital part** of the nerve emerges from the sclerotic about three millimetres below and to the median side of the posterior pole of the bulbus, and it is about thirty millimetres long. It passes backward and medialward, surrounded by the posterior part of the fascia bulbi (Tenon's capsule) and by the orbital fat, to the optic foramen.

As it runs backward in the orbit it is in relation above with the naso-ciliary (nasal) nerve and the ophthalmic artery which pass obliquely from behind and laterally, forward and medialward across the junction of its posterior and middle thirds, and also in relation with the superior ophthalmic vein, the superior rectus muscle, and the upper branch of the oculo-motor nerve. Below it are the inferior rectus muscle, and the inferior division of the oculo-motor nerve. To its lateral side, near the posterior part of the orbit, are the ophthalmic artery, the ciliary ganglion, the abducens nerve, and the external rectus muscle. The anterior two-thirds of this portion of the optic nerve are surrounded by the ciliary arteries and the ciliary nerves and it is penetrated on its

medial and lower aspect by the central artery of the retina. As it enters the optic foramen to become continuous with the intra-osseous part, it is in close relation with the ligaments of Lockwood and Zinn (annulus tendineus communis) and with the four recti muscles which arise from them.

The **intra-osseous portion** is from six to seven millimetres long. It lies between the roots of the small wing of the sphenoid and the body of that bone, and it is in relation below and laterally with the ophthalmic artery.

The **intra-cranial portion,** which is from ten to twelve millimetres long, runs backward and medialward, beneath the posterior end of the olfactory tract, and above the ophthalmic artery, the medial border of the internal carotid artery and the diaphragma sellæ to the chiasma. From the chiasma to the central connections of the nerve, the path is known as the optic tract.

Central connections.—The central connections of the fibres of the optic nerve have been considered with the optic chiasma and the optic tract (see p. 849).

FIG. 732.—NERVES OF THE NASAL CAVITY.

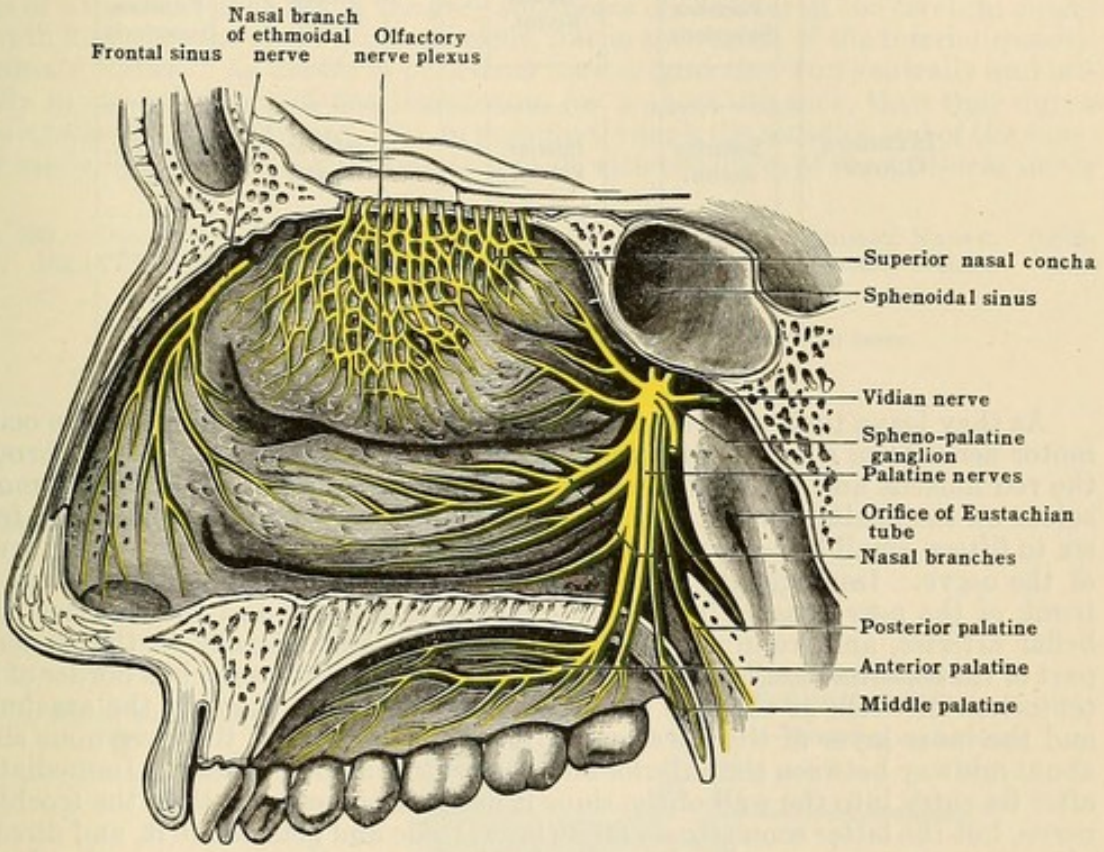

The sheaths of the optic nerve.—The optic nerve receives a sheath from each of the membranes of the brain, and prolongations of the subdural and subarachnoid cavities also pass outward along it to the posterior part of the sclera.

THE OCULO-MOTOR NERVES

The oculo-motor or third cranial nerve is a purely motor nerve. Each supplies seven muscles connected with the eye, two of which, the sphincter of the iris and ciliary muscle, are within the ocular bulb. The remaining five are in the orbital cavity, and four of them—the superior, inferior, and medial recti and the inferior oblique—are attached to the bulb, while the fifth, the levator palpebræ superioris, is inserted into the upper eyelid.

The fibres of the oculo-motor nerve spring from their nucleus of origin situated in the grey substance of the floor of the cerebral aquæduct in the region of the superior quadrigeminate body (fig. 662). The cells of this nucleus are divided into two main groups, a superior and an inferior (fig. 663). The **superior group** includes two nuclei, a medial and a lateral. The latter, besides being lateral, is also somewhat dorsal to the former. The **inferior group** has been divided into five secondary nuclei, according to the eye-muscles the cells of each group innervate. Three of the five lie lateral to the others and somewhat dorsally, and of the remaining two, which are placed more medially, one encroaches upon the mid-line (*nucleus medialis*) and is con-

tinuous with the corresponding group of the opposite side and is common to the oculo-motor nerves of both sides.

It has been found, by the study of diseased conditions and by experiments with animals, that the centres of innervation of the eye-muscles supplied by the nerve correspond to the above divisions of both the superior and inferior group of cells into a medial and lateral series. The relative position of the divisions of each group and the muscles they are thought to innervate are shown in the following diagram devised by Starr:—

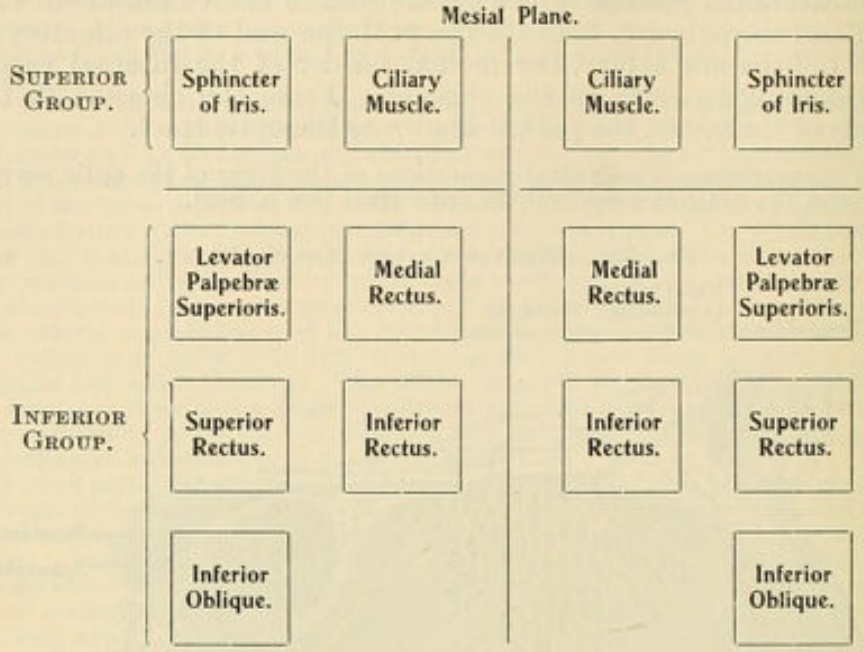

As they leave their nucleus of origin in the mid-brain, the fibres of the oculo-motor nerve form a series of fasciculi, which curve ventrally around and through the red nucleus and the medial part of the substantia nigra, to the oculo-motor sulcus on the medial surface of the cerebral peduncle, where they emerge in from six to fifteen small bundles which pierce the pia mater and collect into the trunk of the nerve. Immediately after its formation along the oculo-motor sulcus, the trunk of the nerve passes between the posterior cerebral and the superior cerebellar arteries, and, running downward, forward, and laterally in the posterior part of the cisterna basalis, it crosses the anterior part of the attached border of the tentorium cerebelli at the side of the dorsum sellæ, and, piercing the arachnoid and the inner layer of the dura mater, it enters the wall of the cavernous sinus about midway between the anterior and posterior clinoid processes. Immediately after its entry into the wall of the sinus it lies at a higher level than the trochlear nerve, but the latter soon crosses on its lateral side and gets above it, and directly afterward the oculo-motor nerve divides into a smaller superior and a larger inferior branch (fig. 734). Before its division **communications** join it from the cavernous plexus of the sympathetic about the internal carotid artery, and from the ophthalmic division of the trigeminus. Both branches proceed forward, and the nasal branch of the trigeminus, which has passed upward, on the lateral side of the inferior branch of the oculomotor lies between them. At the anterior end of the cavernous sinus the two branches pass through the superior orbital (sphenoidal) fissure, between the heads of the lateral rectus muscle, and enter the orbital cavity. In the orbit, the **superior branch** lies between the superior rectus and the optic nerve; it supplies the superior rectus and then turns round the medial border of that muscle and terminates in the levator palpebræ superioris. The **inferior branch** runs forward, beneath the optic nerve, and divides into three branches which supply the inferior and medial recti and the inferior oblique.

The branch to the inferior oblique muscle is connected with the ciliary ganglion by a short thick offset, the **short root of the ciliary ganglion,** by mediation of the sympathetic neurones of which the oculo-motor nerve sends impulses to the ciliary muscle and the sphincter muscle of the iris. The inferior branch also gives some small twigs to the inferior rectus. The branches of the oculo-motor nerve, which supply the recti muscles, enter the muscles on their ocular surfaces, but the branch to the inferior oblique muscle enters the posterior border of that muscle.

Some of the fibres which spring from the medial portion of the oculo-motor nucleus do not pass into the nerve of the same side, but into that of the opposite side, and it is believed that they are distributed to the opposite medial rectus muscle. Other fibres which arise from the nucleus descend in the medial longitudinal fasciculus and either terminate about the cells of the nucleus of the facial or join the facial nerve, in which they pass to the upper part of the orbicularis palpebrarum. The eye is opened by the oculo-motor and closed by the facial nerve.

Central connections.—The nucleus of the oculo-motor is associated with the middle portion of the anterior central gyrus, the posterior end of the middle frontal gyrus and with the cortex about the visual area of the occipital lobe of the opposite side of the brain by the pyramidal fibres. It is probably associated with the cerebellum by the fibres in the superior cerebellar peduncles, with the superior calliculus, and with the sensory nuclei of the other cranial nerves by the medial longitudinal fasciculus. To produce the coördinated activities of the eye-moving muscles, it must be associated with the nuclei of the trochlear and abducens.

THE TROCHLEAR NERVES

The fibres of each trochlear or fourth nerve (or patheticus) spring from the cells of a nucleus which lies in the grey substance of the floor of the cerebral aquæduct in line with the oculo-motor nucleus, but in the region of the inferior quadrigeminate bodies. As the fibres pass from their origins they run ventrally and laterally in the substance of the tegmentum for a short distance, then they curve medianward and dorsalward, and, in passing through the anterior end of the superior medullary velum they decussate totally with the fibres of the trochlear nerve

FIG. 733.—DIAGRAMS OF SECTIONS THROUGH THE ORIGIN OF THE TROCHLEAR NERVE. (Stilling.) (The upper figure is an oblique section, the lower is a coronal section.)

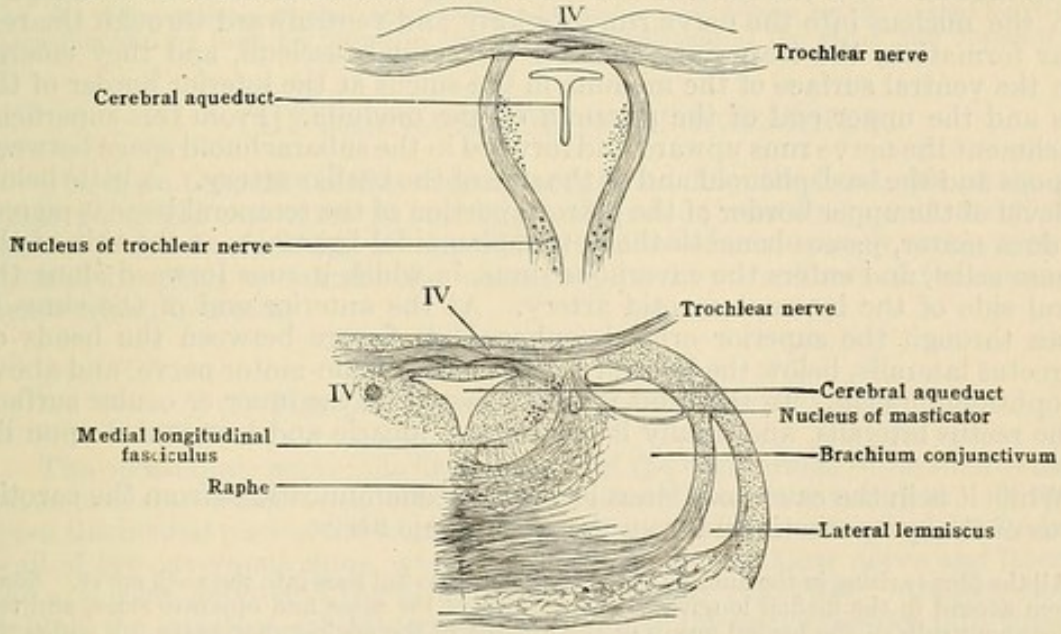

of the opposite side. After the decussation the fibres emerge from the surface of the superior medullary velum, at the side of the frenulum veli, usually in two small bundles, which pierce the pia mater and join together to form the slender trunk of the nerve. This trunk curves forward and ventralward to the base of the brain around the sides of the superior peduncle of the cerebellum and cerebral peduncle of the side opposite to that in which the nerve originates, running parallel with and between the superior cerebellar and posterior cerebral arteries. As it reaches the base of the brain behind the optic tract the nerve enters the cisterna basalis, in which it runs forward, immediately beneath or piercing the free border of the tentorium cerebelli, to the superior border of the petrous portion of the temporal bone, where it pierces the arachnoid and the dura mater and enters the posterior end of the lateral wall of the cavernous sinus. In the wall of the cavernous sinus it receives **communications** from the cavernous plexus of the sympathetic and by a small filament from the ophthalmic division of the trigeminus. It gradually ascends, as it passes forward in the lateral wall of the sinus, and, beyond the middle of the sinus, it crosses the lateral side of the trunk of the oculo-motor nerve and gains a higher position. At the anterior end of the sinus the nerve

enters the orbit above the lateral rectus and immediately turns medialward between the periosteum of the roof of the orbit and the levator palpebræ superioris. At the medial border of the roof it turns forward to its termination, and enters the orbital or superior surface of the superior oblique muscle to which its fibres are distributed.

The central connections of the nucleus of the trochlear nerve are similar to those of the oculo-motor save that its cells probably do not send fibres which connect with the facial nerve.

The trochlear is peculiar in that—(1) it is the smallest of the cranial nerves; (2) it is the only nerve having its superficial attachment upon the dorsal aspect of the encephalon; (3) it is the only cranial nerve whose fibres undergo a total decussation, and (4) in that it terminates in a muscle of the side of the body opposite that in which it has its origin. Gaskell has suggested that this latter condition has probably been brought about, phylogenetically, by the transference of the muscles which have carried their nerves with them. It should be remembered that most of the fibres arising from the medial group of the cells of the nucleus of the oculo-motor, cross the opposite side. This is thought to be especially true for those supplying the medial rectus muscle.

THE ABDUCENS

The abducens (or sixth nerve) on each side arises from the cells of a nucleus which lies in the grey substance of the floor of the fourth ventricle in the region of the inferior part of the pons. The nucleus is situated close to the middle line, ventral to the acoustic medullary striæ and beneath the colliculus facialis and it is in direct linear series with the nuclei of the oculo-motor, trochlear and hypoglossal nerves. It is the third of the eye-moving nerves. The fibres which pass from the nucleus into the nerve run inferiorly and ventralward through the reticular formation, the trapezium, and the pyramidal fasciculi, and they emerge from the ventral surface of the medulla in the sulcus at the inferior border of the pons and the upper end of the pyramid of the medulla. From this superficial attachment the nerve runs upward and forward in the subarachnoid space between the pons and the basisphenoid and at the side of the basilar artery. A little below the level of the upper border of the petrous portion of the temporal bone it pierces the dura mater, passes beneath the petro-sphenoidal ligament, at the side of the dorsum sellæ, and enters the cavernous sinus, in which it runs forward along the lateral side of the internal carotid artery. At the anterior end of the sinus it passes through the superior orbital (sphenoidal) fissure between the heads of the rectus lateralis, below the inferior branch of the oculo-motor nerve, and above the ophthalmic vein. In the orbit it runs forward on the inner or ocular surface of the rectus lateralis, and finally it pierces this muscle and terminates upon its fibres.

While it is in the cavernous sinus it receives communications from the carotid plexus of the sympathetic and from the ophthalmic nerve.

All the fibres arising in the nucleus of the sixth nerve do not pass into the sixth nerve. Some of them ascend in the medial longitudinal fasciculus of the same and opposite sides, and terminate about cells of the medial group of the nucleus of the oculo-motor nerve, by which the impulses are conveyed to the opposite medial rectus muscle. Thus impulses reaching the abducens nucleus can throw into simultaneous action the lateral rectus of the same side and the medial rectus of the opposite side, and thus turn both eyes in the same direction.

Central connections.—The nucleus of the abducens receives impulses from the anterior central gyrus of the opposite side by the pyramidal fibres, and it is associated with the sensory nuclei of other nerves by way of the medial longitudinal fasciculus, and that of the trigeminus especially through the reticular formation.

THE TRIGEMINUS

The trigeminus is the largest of the cranial nerves with the exception of the optic. It is usually described as the fifth cranial nerve and as possessing both a sensory and a motor root. For reasons already given, the "motor root" is here described separately and given the separate name, *masticator nerve*. The fibres of the trigeminus, which are all sensory, spring from the cells of the semilunar (Gasserian) ganglion, which corresponds with the ganglion of the dorsal root of a spinal nerve, and they enter the brain stem through the side of the anterior third of the pons.

The **semilunar (Gasserian) ganglion** is a semilunar mass which lies in Meckel's cave, a cleft in the dura mater above a depression in the medial part of the upper surface of the petrous portion of the temporal bone. The convexity of the ganglion is turned forward, and from it three large nerves, the *ophthalmic*, the *maxillary*, and the *mandibular*, are given off. From the concavity, which is directed backward, springs the root of the nerve. The medial end of the ganglion is in close relation with the cavernous sinus and the internal carotid artery at the foramen lacerum, and the lateral end lies to the medial side of the foramen ovale. The surfaces of the ganglion are striated, due to bundles of fibres traversing them. The upper surface is separated by the dura mater from the temporal lobe of the brain, and the lower rests upon the masticator nerve and the outer layer of dura mater upon the petrous portion of the temporal bone.

The fibres of the trigeminus root as they leave the semilunar (Gasserian) ganglion, form from thirty to forty fasciculi which are bound together into a flat band, from six to seven millimetres broad, which passes backward over the upper border of the petrous portion of the temporal bone and below the superior petrosal sinus into the posterior fossa of the cranium. In the posterior fossa it runs backward, medialward, and downward, and passes into the pons through its continuation into the middle peduncle of the cerebellum. In the tegmentum of the pons region, the fibres bifurcate into ascending and descending branches which terminate about the cells of the nucleus of termination of the trigeminus. This nucleus, large at the level of the entrance of the root, has tapering superior and inferior extremities. The inferior extremity of the nucleus, which is much the longer, descends as low as the upper portion of the spinal cord and the fibres of the root terminating about the cells of this extremity are known as the spinal tract of the trigeminus.

Central connections.—The nuclei of termination of the trigeminus send impulses to the somæsthetic area of the cortex of the opposite side by the fibres of the medial lemniscus (fillet) and, for reflex actions, to the motor nuclei of other cranial nerves by the medial longitudinal fasciculus and by fasciculi propri in the reticular formation of the same, and opposite sides.

THE BRANCHES OF THE TRIGEMINUS

The main branches of the trigeminus, given off by the front side of the semilunar ganglion, are three in number (ophthalmic, maxillary, and mandibular), each of which is referred to as a nerve and each of which is purely sensory, though the third branch, or mandibular nerve, is joined by the fibres of the masticator nerve which is motor.

(1) The Ophthalmic Nerve or First Division

The ophthalmic nerve, the first division of the trigeminus, is the smallest of the three branches which arise from the semilunar (Gasserian) ganglion. It springs from the medial part of the front of the ganglion and passes forward, in the lateral wall of the cavernous sinus, where it lies below the trochlear nerve and lateral to the abducens nerve and the internal carotid artery (fig. 734). A short distance behind the superior orbital (sphenoidal) fissure the nerve divides into three terminal branches—the frontal, lacrimal, and naso-ciliary (nasal) nerves. They pierce the dura mater, which closes the fissure, and pass forward into the orbit. Before its division the ophthalmic nerve receives filaments from the cavernous plexus of the sympathetic and it gives off, soon after its origin, a **tentorial (recurrent meningeal) branch** which runs backward, in close association with the trochlear nerve, and ramifies between the layers of the tentorium cerebelli. Further forward three branches spring from the ophthalmic nerve which contribute sensory fibres to the oculo-motor, trochlear, and abducens nerves.

The terminal branches.—(*a*) The **frontal nerve** is the largest terminal branch. It pierces the dura mater and passes into the orbit through the superior orbital (sphenoidal) fissure, above the rectus lateralis and a little below and to the lateral side of the trochlear nerve. In the orbit it runs forward, between the levator palpebræ superioris and the periosteum, and breaks up into three branches, the supra-orbital, frontal proper, and supratrochlear.

The **supra-orbital nerve**, the largest of the three branches, leaves the orbit at the supra-orbital notch (fig. 734). As it passes through the notch it gives off a small branch which enters the bone and supplies the diploë and the mucous membrane of the frontal sinus. Its terminal branches give twigs to the pericranium and to the skin of the scalp, the upper eyelid, the frontal

region, and the parietal region almost as far as the lambdoid suture (fig. 740). One branch running at the upper margin of the orbital cavity unites with a branch of the facial nerve.

The **frontal branch**, given off at a variable point, lies medial to the supra-orbital, passes through the frontal foramen, and is distributed to the skin of the forehead and upper eyelid (fig. 734).

The **supratrochlear branch** runs forward and medialward toward the upper and medial angle of the orbit, where it passes above the pulley of the superior oblique muscle, pierces the palpebral fascia, and ascends to the lower and middle part of the forehead, accompanied by the frontal artery (fig. 734). Before it leaves the orbit it sends a branch downward behind or in front of the pulley of the obliquus superior which joins with the infratrochlear nerve, and as it leaves the orbit it gives off filaments to supply the skin and conjunctiva of the medial third of the upper eyelid. Its terminal branches pierce the orbicularis and frontalis, and, as they pass to the skin of the forehead, they communicate with branches of the facial nerve.

(*b*) The **lacrimal nerve** [n. lacrimalis] is the smallest of the three branches of the ophthalmic division. It passes through the superior orbital (sphenoidal) fissure lateral to and slightly below the frontal nerve, and is directed forward and lateral-

FIG. 734.—NERVES OF THE ORBIT FROM ABOVE AND BEHIND. (Schematic.)

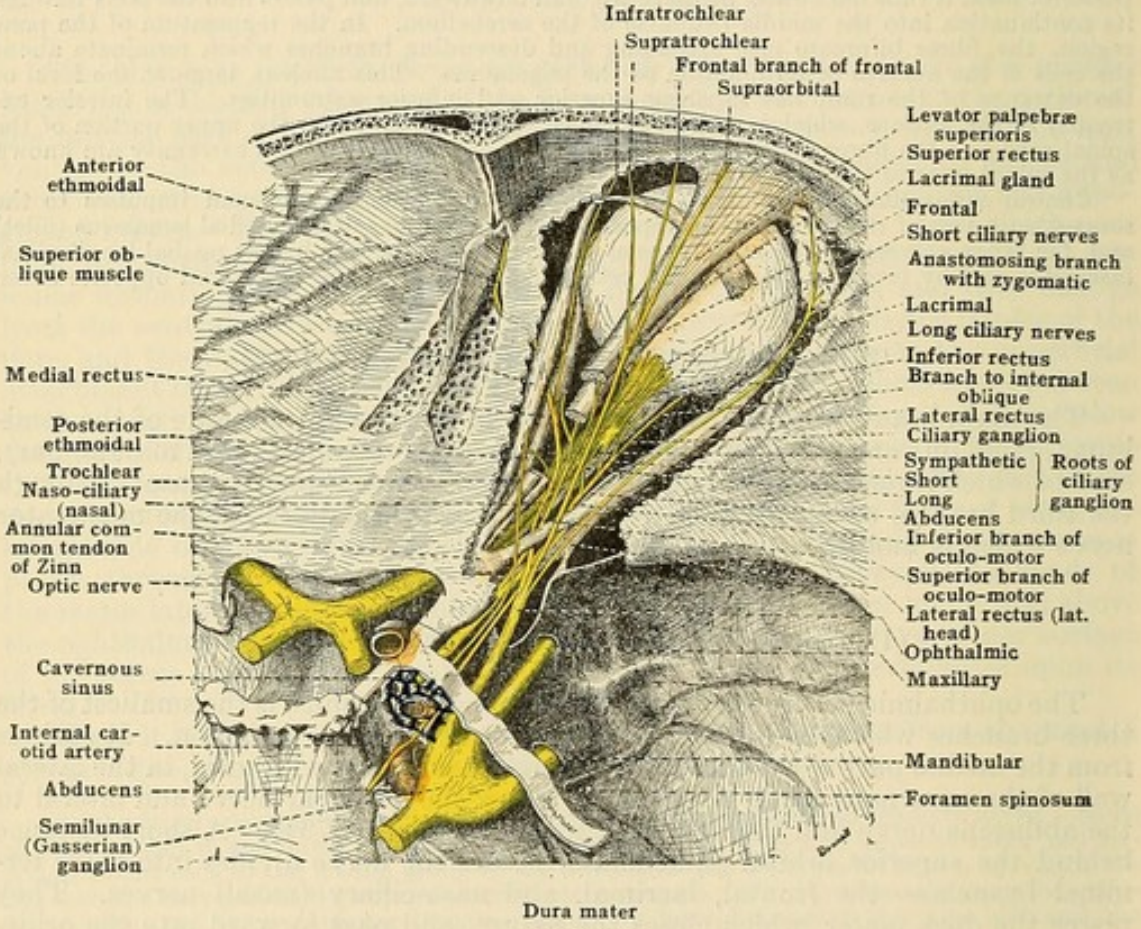

ward, along the upper border of the rectus lateralis to the lacrimal gland (fig. 734). On the lateral wall of the orbit it receives a small branch from the zygomatic nerve (the orbital branch of the maxillary nerve). This branch brings to the lacrimal nerve secretory fibres for the lacrimal gland. A small twig passes beyond the gland, pierces the palpebral fascia, supplies filaments to the conjunctiva, and is then distributed to the integument at the lateral angle of the eye and to the skin over the zygomatic process of the frontal bone.

(*c*) The **naso-ciliary (nasal) nerve** enters the orbit between the two heads of the rectus lateralis and between the superior and inferior branches of the oculo-motor nerve. In the orbit it lies at first lateral to the optic nerve, but, as it runs obliquely forward and medialward to the medial wall of the orbital cavity, it crosses above the optic nerve and between it and the rectus superior, and near the border of the rectus medialis it divides into its terminal branches, the chief of which are the *infratrochlear* and *anterior ethmoidal* nerves (fig. 734). In addition to those received from the cavernous plexus before the division of the ophthalmic nerve,

the naso-ciliary nerve itself receives numerous sympathetic (secretory and vaso-motor) fibres.

Its several **branches** are: (i) The **long root of the ciliary ganglion** which is given off at the superior orbital (sphenoidal) fissure. It is a slender filament which runs forward on the lateral side of the optic nerve to the superior and posterior part of the ciliary ganglion (fig. 734).

(ii) The **long ciliary nerves,** usually two in number, which arise from the naso-ciliary nerve as the latter is crossing above the optic nerve. They run forward, on the medial side of the optic nerve, pierce the sclerotic, and are distributed with the lower set of short ciliary nerves (fig. 734). The long root of the ciliary ganglion and the long ciliary nerves carry sensory fibres which belong to the naso-ciliary nerve proper, most of which merely pass through the ganglion, and it carries sympathetic fibres, added to it, most of which may terminate about the cell-bodies of the ganglion.

(iii) The **posterior ethmoidal (spheno-ethmoidal) branch** springs from the posterior border of the naso-ciliary nerve near the upper border of the rectus medialis. It passes through the posterior ethmoidal canal and is distributed to the mucous membrane of the posterior ethmoidal cells and the sphenoidal sinus.

(iv) The **infratrochlear nerve** passes forward between the obliquus superior and the rectus medialis, and under the pulley of the former muscle divides into two branches:—The **superior palpebral branch** helps to supply the eyelids with sensory fibres and usually anastomoses with the supratrochlear nerve. The **inferior palpebral branch** is distributed to the lacrimal sac, the conjunctiva and skin of the medial part of the upper eyelid, the caruncle, and the skin of the upper part of the side of the nose.

(v) The **anterior ethmoidal** (distal part of the nasal) **nerve,** passing forward and medialward between the obliquus superior and the rectus medialis, leaves the orbit through the anterior ethmoidal foramen, accompanied by the anterior ethmoidal vessels, and enters into the anterior fossa of the cranium (fig. 734). It then crosses the lamina cribrosa of the ethmoid, lying outside the dura mater, which separates it from the olfactory bulb, and descends into the nasal fossa through the ethmoidal fissure, a slit-like aperture at the side of the crista galli. In the submucosa of the nasal fossa it terminates by dividing into two sets of *anterior nasal branches*: the internal nasal branches and the external nasal branch (fig. 732).

The **internal nasal branches** divide into the **medial nasal branches** (the septal branches of the nasal nerve), which run downward and forward on the upper and front part of the septum, and the **lateral nasal branches** (the external terminal branch of the nasal nerve), which give twigs to the anterior extremities of the superior and middle nasal conchæ (turbinated bones), and to the mucous membrane of the lateral wall of the nose (fig. 732).

The **external nasal branch** (the anterior terminal branch of the nasal nerve) runs downward in a groove on the inner surface of the nasal bone. It pierces the wall of the nose between the nasal bone and the upper lateral cartilage, and supplies the integument of the lower part of the dorsum of the nose as far as the tip.

(2) The Maxillary Nerve or Second Division of the Trigeminus

The maxillary nerve is entirely sensory in function and it is intermediate in size between the ophthalmic and mandibular nerves.

It springs from the middle of the anterior border of the semilunar (Gasserian) ganglion and runs forward in the lower and outer part of the lateral wall of the cavernous sinus (fig. 735). Leaving the middle fossa of the cranium, by passing through the foramen rotundum, it enters the pterygo-palatine (spheno-maxillary) fossa (fig. 734), where it is joined by twigs with the spheno-palatine ganglion; then, changing its name, it passes forward, as the **infra-orbital nerve,** through the inferior orbital (spheno-maxillary) fissure into the infra-orbital sulcus in the floor of the orbit; continuing forward it traverses the infra-orbital canal accompanied by the infra-orbital artery, and appears in the face, beneath the levator labii superioris (quadratus) and above the levator anguli oris (caninus) where it divides into four sets of terminal branches which anastomose more or less freely with branches of the facial nerve to form the **infra-orbital plexus.**

Branches.—The branches of the maxillary nerve are—(*a*) branches given off in the middle fossa of the cranium; (*b*) branches given off in the pterygo-palatine (spheno-maxillary) fossa; (*c*) branches given off in the infra-orbital sulcus and canal; and (*d*) terminal branches.

(*a*) The **middle (recurrent) meningeal branch,** given off in the middle fossa of the cranium, breaks up into numerous branches which supply the dura mater with sensory fibres, reinforce the sympathetic plexus on the middle meningeal artery, and anastomose with the spinous nerve (the recurrent branch of the mandibular nerve).

(*b*) The branches given off in the pterygo-palatine (spheno-maxillary) fossa are the spheno-palatine nerves, the zygomatic branch of the maxillary nerve, and the posterior superior alveolar nerves.

The **spheno-palatine nerve** has two or three branches which descend in the pterygo-palatine fossa and give a small part of their fibres to the spheno-palatine (Meckel's) ganglion (fig. 735), the larger part of their fibres passing through the ganglion into its orbital, nasal, and palatine branches. (See SPHENO-PALATINE GANGLION, p. 962.)

The **zygomatic (orbital or temporo-malar) branch,** given off from the upper surface of the maxillary nerve, passes forward and lateralward, and, at the end of the inferior orbital (spheno-maxillary) fissure, passes through it into the orbit and divides into two branches, facial and temporal.

The **zygomatico-facial (malar) branch** runs forward, passes through a zygomatico-orbital foramen, then through the zygomatico-facial (malar) foramen, pierces the orbicularis palpebrarum, communicates with the zygomatic (malar) branch of the facial nerve, and supplies the skin of the prominence of the cheek. The **zygomatico-temporal (temporal) branch** runs upward in a groove in the lateral wall of the orbit, passes through a zygomatico-orbital foramen, then through the zygomatico-temporal (spheno-malar) foramen, and enters the temporal fossa. It turns around the anterior border of the temporal muscle, pierces the deep layer of the temporal fascia, and runs backward for a short distance in the fat between the superficial and deep lamellæ, then, turning lateralward, it pierces the superficial lamellæ about an inch above the zygoma, anastomoses with the temporal branch of the facial nerve, and supplies the skin of the anterior part of the temporal region.

The **infra-orbital nerve,** that part of the maxillary nerve lying distal to the spheno-palatine ganglion, enters the orbit through the inferior orbital (spheno-maxillary) fissure, accompanied by the infra-orbital artery, and with it passes through the infra-orbital canal (fig. 735) to the face, where it divides into four sets of terminal branches, some of which, by anastomoses with the branches of the facial nerve, form the **infra-orbital plexus.**

Three sets of **superior alveolar nerves** arise from the maxillary and the infra-orbital nerves, namely, the posterior superior alveolar branches, the middle superior alveolar branch, and the anterior superior alveolar branches.

FIG. 735.—LATERAL VIEW OF THE MAXILLARY NERVE.

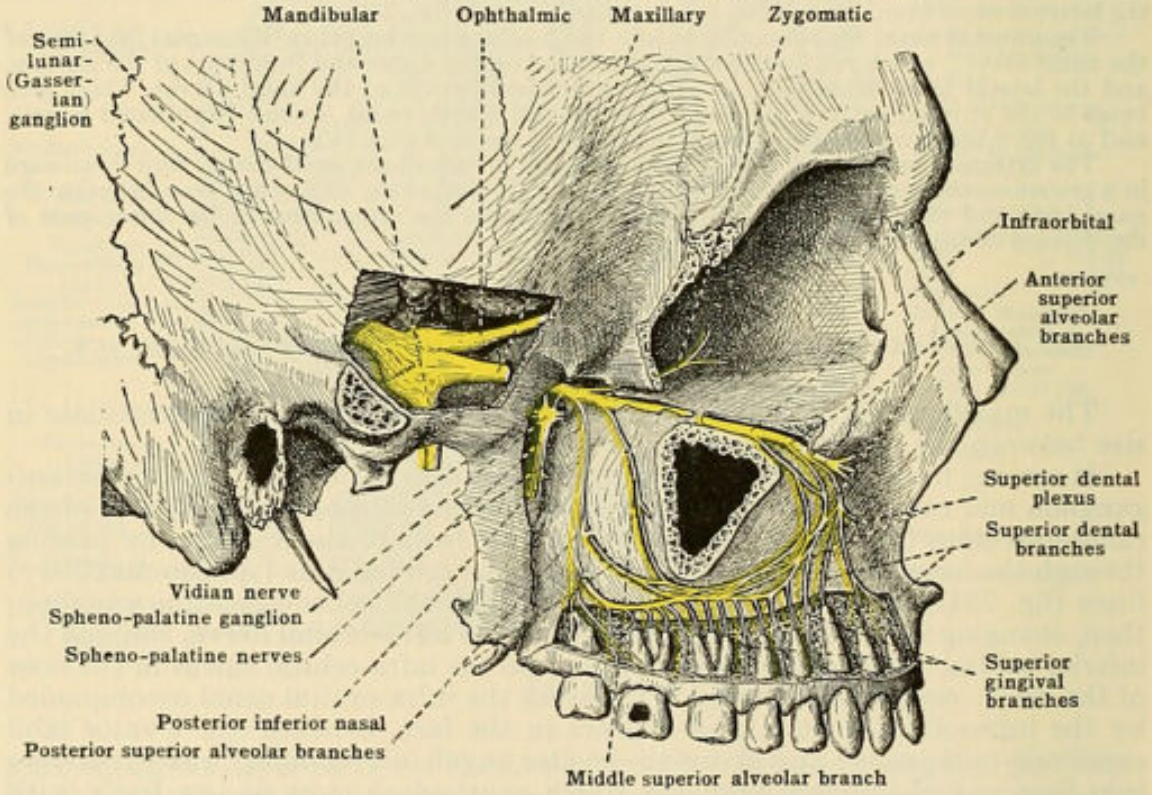

The **posterior superior alveolar (dental) nerves** are usually two in number, but sometimes arise by a single trunk. They pass downward and lateralward through the pterygo-maxillary fissure into the zygomatic fossa, where they give branches to the mucous membrane of the gums and the posterior part of the mouth; then they enter the posterior alveolar (dental) canals and unite with the other alveolar branches to form the **superior dental plexus,** through which they give branches to the roots and pulp cavities of the molar teeth and to the mucous membrane of the maxillary sinus (fig. 735).

(*c*) The branches given off in the infra-orbital sulcus and canal are the middle and anterior superior alveolar (dental) nerves.

(i) The **middle superior alveolar (dental) nerve** leaves the infra-orbital nerve in the posterior part of the infra-orbital sulcus, and, passing downward and forward in a canal in the maxilla, it divides into terminal branches that anastomose with the other alveolar branches to form the *superior dental plexus.* Through the plexus it supplies the bicuspid teeth and gives branches to the mucous membrane of the maxillary sinus and also to the gums (fig. 735).

(ii) The **anterior superior alveolar (dental) nerve** is the largest of the superior alveolar nerves. It is given off by the infra-orbital nerve in the anterior part of the infra-orbital canal, and passes downward in a bony canal in the anterior wall of the maxilla. After uniting with the other alveolar nerves to form the superior dental plexus, it supplies the canines and the incisors and gives branches to the mucous membrane of the maxillary sinus and the gums (fig. 735). It also gives off a **nasal branch** which enters the nasal fossa through a small foramen, and supplies the mucous membrane of the anterior part of the inferior meatus and the adjacent part of the floor of the nasal cavity.

(iii) The **superior dental plexus** is formed in the bony alveolar canals by the three superior alveolar nerves. It is convex downward and anastomoses across the mid-line with the corresponding plexus of the other side (fig. 735). From it arise the **superior dental branches** supplying the superior canines and incisors, **superior gingival branches** supplying the gums, and also branches to the mucous membrane of the maxillary sinus and to the bone. On the plexus are two gangliform enlargements, one, called the *ganglion of Valentine*, situated at the junction of the middle and the posterior branches, and the other, called the *ganglion of Bochdalek*, at the junction of the middle and anterior branches.

(*d*) The terminal branches of the maxillary nerve are the inferior palpebral, the external and internal nasal (nasal), and the superior labial.

The **inferior palpebral branches,** usually two, pass upward and supply sensory fibres to all the skin and conjunctiva of the lower eyelid (fig. 740).

The **external nasal branches** pass medialward under cover of the levator labii superioris (quadratus), and supply the skin of the posterior part of the lateral aspect of the nose.

The **internal nasal branches** pass downward and medialward under the lateral wall of the nose, and then turn upward to supply the skin of the vestibule of the nose.

The **superior labial branches,** three or four in number, as a rule are larger than the palpebral and nasal branches. They pass downward to supply the skin and mucous membrane of the upper lip and the neighbouring part of the cheek.

(3) The Mandibular Nerve or Third Division of the Trigeminus

The **mandibular division** is the largest of the three divisions of the trigeminus (figs. 736 and 740). As a nerve, it is usually described as formed by the union of two distinct nerves, namely, the entire masticator nerve and the large bundle of sensory fibres derived from the semilunar (Gasserian) ganglion which pass peripherally as the third division of the trigeminus. These two nerves remain separate until they pass through the foramen ovale and then unite immediately outside the skull to form a large trunk which almost directly after its formation divides into a small *anterior* and a larger *posterior portion*. The trunk is situated between the pterygoideus externus, laterally, and the otic ganglion and the tensor palati medially. In front of it is the posterior border of the pterygoideus internus, and behind it, the middle meningeal artery. Two branches arise from the trunk of the nerve before its division, namely, the spinous (recurrent) nerve and the nerve to the pterygoideus internus.

The **spinous (recurrent) nerve,** after receiving a vasomotor filament from the otic ganglion, enters the cranium through the foramen spinosum, accompanying the middle meningeal artery, and divides into an anterior and a posterior branch. The anterior branch communicates with the meningeal branch of the maxillary division of the trigeminus, furnishes filaments to the dura mater, and ends in the osseous substance of the great wing of the sphenoid. The posterior branch traverses the petrosquamous suture and ends in the lining membrane of the mastoid cells.

The fibres going to form the *nerve to the internal pterygoid muscle* are almost wholly motor fibres and therefore comprise a branch of the masticator nerve and are described as such under the description of the masticator (fig. 737).

The **anterior portion** of the mendibular nerve is smaller than the posterior and is chiefly composed of motor fibres which form branches of the masticator nerve and supply the muscles of mastication, the temporalis, masseter, and pterygoideus externus. Practically all of the sensory fibres of the anterior portion (fibres of the mandibular nerve proper) form the buccinator (long buccal) nerve. The latter is accompanied, in the first part of its course, by a small strand of motor or masticator fibres which leaves it to end in the anterior part of the temporal muscle.

The **buccinator (long buccal) nerve,** entirely sensory, passes between the two heads of the external pterygoid muscle and runs downward and forward under cover of or through the anterior fibres of the temporalis to the cheek (fig. 736). As it passes forward it emerges from under cover of the anterior border of the masseter and lies on the superficial surface of the buccinator, where it interlaces with the buccal branches of the facial nerve and gives off filaments to supply the superjacent skin; finally it pierces the buccinator and supplies the mucous membrane on its

inner surface as far forward as the angle of the mouth. The fibres of the anterior deep temporal nerve, a branch of the masticator, are frequently associated with the buccinator until the latter has passed between the heads of the external pterygoid; then the anterior deep temporal nerve separates from the buccinator and passes upward on the lateral surface of the upper head of the external pterygoid.

The **posterior portion** of the mandibular nerve divides into three large branches. Two of these, the lingual and the auriculo-temporal nerves, are exclusively sensory; the third, the inferior alveolar (dental) nerve, contains a strand of motor fibres, the mylo-hyoid nerve, which comprise a branch of the masticator nerve.

The **lingual nerve** is the most anterior branch of the mandibular nerve (figs. 736, 743). It lies in front and to the medial side of the inferior alveolar (dental) nerve and descends at first on the medial side of the pterygoideus externus, then between the pterygoideus internus and the ramus of the mandible to the posterior part of the mylohyoid ridge, where it passes off the anterior border of the pterygoideus internus; at this point it is situated a short distance behind the last

FIG. 736.—DISTRIBUTION OF THE MANDIBULAR DIVISION OF THE TRIGEMINUS COMBINED WITH BRANCHES OF THE MASTICATOR NERVE. (Henle.)

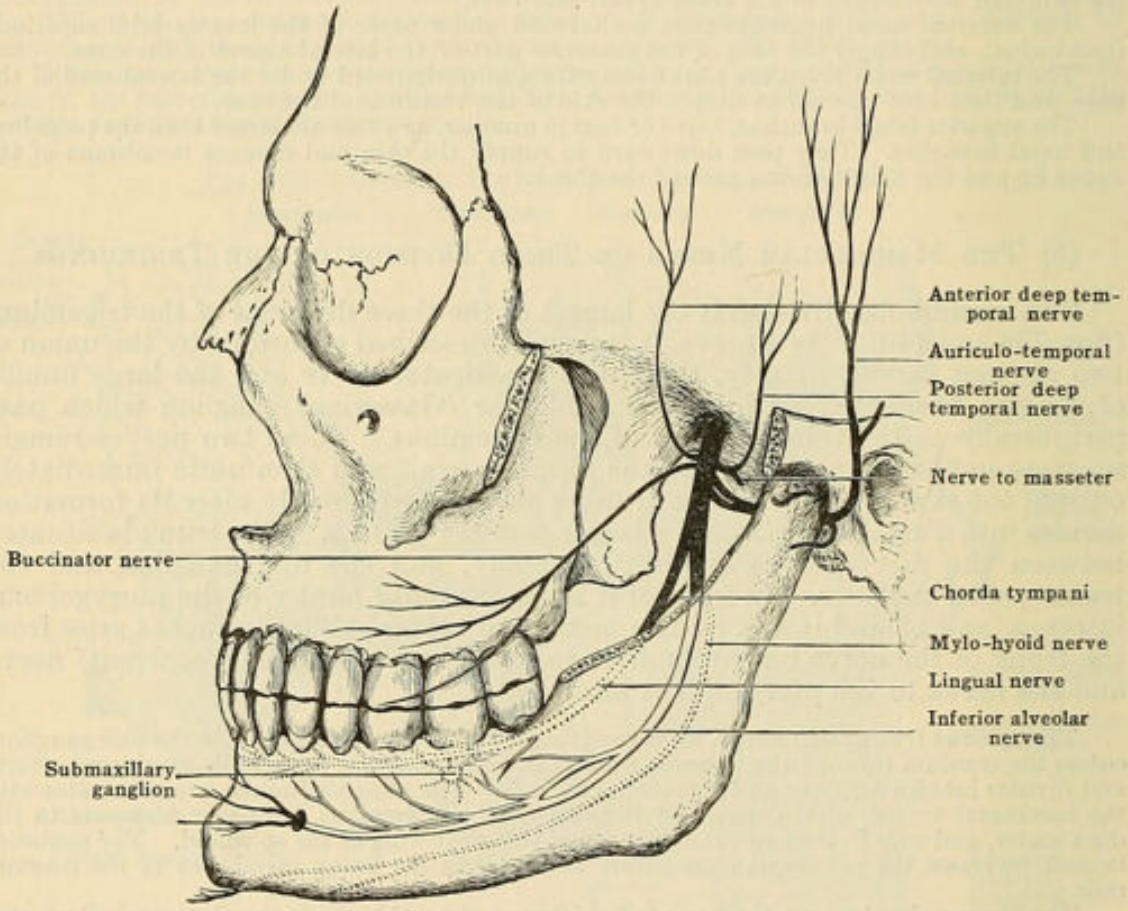

molar tooth and is covered in front by the mucous membrane of the posterior part of the mouth cavity. After leaving the pterygoideus internus it crosses the fibres of the superior constrictor, which are attached to the mandible, and turns forward toward the tip of the tongue, crossing the lateral surfaces of the styloglossus, hyoglossus, and genioglossus. In its course across the hyoglossus it lies first above, then to the lateral side of, and finally below Wharton's duct, and as it ascends on the genioglossus it lies on the medial side of the duct.

Communications and branches.—While it is on the medial side of the pterygoideus externus the lingual nerve is joined, at an acute angle, by the chorda tympani (figs. 736, 743), a branch of the glosso-palatine nerve, and as it lies between the ramus of the mandible and the pterygoideus internus it is connected by a branch with the inferior alveolar (dental) nerve, and gives off one or two small branches, the **rami isthmi faucium,** which are ditributed as sensory fibres to the tonsil and the mucous membrane of the posterior part of the mouth (fig. 743).

While it is above the duct it gives a branch, which contains many sensory and visceral motor chorda tympani fibres, to the submaxillary ganglion (see p. 963), and it receives branches, chiefly sympathetic, from that ganglion. A little further forward it is connected by one or two branches, which run along the anterior border of the hyoglossus, with the hypoglossal nerve

(fig. 743). It then gives off the **sublingual nerve,** which runs forward to supply the sublingual gland and the neighbouring mucous membrane (fig. 743). Its terminal (**lingual**) branches are derived chiefly from the glosso-palatine nerve. They pierce the muscular substance of the tongue and are distributed to the mucous membrane of its anterior two-thirds. They interlace with similar branches of the other side and with branches of the glosso-pharyngeal nerve.

The **inferior alveolar (dental) nerve** is the largest branch of the posterior portion of the mandibular nerve. It commences on the medial side of the external pterygoid muscle and descends to the interval between the spheno-mandibular ligament and the ramus of the mandible, where it receives one or two communicating branches from the lingual nerve. Opposite the middle of the medial surface of the ramus it enters the mandibular (inferior dental) canal, accompanied by the inferior alveolar (dental) artery, which lies in front of the nerve, and it runs downward and forward through the ramus and the body of the mandible (fig. 736). At the mental foramen it divides into two parts, one of which, the *mental nerve*, passes out through the mental foramen, the other, commonly called the *incisive branch*, continues forward in the canal, and supplies, through the inferior dental plexus, the inferior canine and incisor teeth and the corresponding regions of the gums.

Branches.—The branches of the inferior alveolar (dental) nerve are branches forming the inferior dental plexus, and the mental branch. A bundle of motor fibres, the *mylohyoid nerve*, a branch of the masticator nerve, is given off just before the inferior alevolar nerve enters the mandibular canal.

The **inferior dental plexus** is formed by a series of branches which communicate with one another within the bone, giving rise to a fine network. From this plexus two sets of branches are given off:—the **inferior dental branches,** corresponding in number to the roots of the teeth, enter the minute foramina of the apices of the roots and end in the pulp; the second set, the **inferior gingival branches,** supply the gums.

The **mental nerve** is a nerve of considerable size which emerges through the mental foramen (fig. 736). It communicates, near its exit from the bone, with branches of the facial nerve, and then divides into three branches. The smallest branch, turning downward, divides into several twigs, the *mental branches*, which supply the integument of the chin. The other two, *inferior labial branches*, pass upward, diverging as they ascend, and divide into a number of twigs. The stoutest twigs ramify to the mucous membrane which lines the lower lip. Other twigs are distributed to the integument and fascia of the lip and chin.

The **auriculo-temporal nerve** usually arises from the posterior portion of the mandibular nerve by two roots which embrace the middle meningeal artery and unite behind it to form the trunk of the nerve. The trunk passes backward on the medial aspect of the pterygoideus externus, and between the spheno-mandibular ligament and the temporo-mandibular articulation, lying in close relation with the capsule of the joint. Behind the joint it enters the upper part of the parotid gland, through which it turns upward and lateralward. It emerges from the upper end of the gland, crosses the root of the zygoma close to the posterior border of the superficial temporal artery, and divides into auricular and temporal terminal branches at the level of the tragus of the pinna (fig. 736).

Communications.—(*a*) Each of the two roots of the nerve receives a communication from the otic ganglion containing fibres derived from the glosso-pharyngeal nerve. These fibres have passed from the glosso-pharyngeal through the tympanic plexus and the small superficial petrosal nerve and through the otic ganglion.

(*b*) Sensory filaments pass from the auriculo-temporal nerve to the temporo-facial branch of the facial nerve.

(*c*) Filaments of connection with the sympathetic plexus on the internal maxillary artery.

(*d*) A communication to the inferior alveolar (dental) nerve.

Branches of the auriculo-temporal nerve.—(*a*) An **articular branch** to the temporo-mandibular joint, given off as the nerve lies on the medial side of the capsule.

(*b*) **Branches to the external auditory meatus.** Two branches, as a rule, are given off in the parotid gland. They enter the meatus by passing between the cartilage and the bone and supply the upper part of the meatus, the membrana tympani by a fine branch, and occasionally the lower branch gives twigs to the skin of the lobule of the pinna.

(*c*) **Parotid branches** are distributed to the substance of the parotid gland. Sensory or trigeminal fibres for the gland spring either directly from the nerve or from the communicating branches previously given by it to the glosso-palatine nerve. The parotid branches also contain fibres derived from the glosso-pharyngeal nerve which pass successively through its tympanic branch, the tympanic plexus, the small superficial petrosal nerve, the otic ganglion, and the communicating twigs from the otic ganglion to the roots of the auriculo-temporal nerve. The parotid branches are later again mentioned as concerned chiefly with the *gangliated cephalic plexus.*

(*d*) The **anterior auricular branches,** usually two in number, are distributed to the skin of the tragus and the upper and outer part of the pinna.

(*e*) The **superficial temporal branches** supply the integument of the greater part of the temporal region, and anastomose with the temporal branch of the facial nerve.

THE MASTICATOR NERVE (Fig. 737)

The masticator nerve (*motor root or portio minor of trigeminus*). The fibres of the masticator nerve spring from two nuclei, a slender upper or mesencephalic nucleus and a clustered lower or chief nucleus. The fibres arising in the mesencephalic nucleus descend along the lateral aspect of the nucleus to the pons as the *descending* or *mesencephalic root;** here they join the fibres from the chief motor nucleus and issue with them from the side of the pons in from six to ten root filaments. These blend to form the nerve, which is from one and a half to two millimetres broad. At the point where it emerges from the pons the nerve is in front of and ventral to the root of the trigeminus and it is separated from the latter by a few of the transverse fibres of the pons which constitute the *lingula of Wrisberg*. From its superficial exit from the pons, the masticator nerve passes upward, lateralward, and forward in the posterior fossa of the cranum, and along the medial and anterior aspect of the trigeminus, to the mouth of Meckel's cave. In this cavity it runs lateralward below the semilunar (Gasserian) ganglion to the foramen ovale, through which it passes to join the mandibular division of the

Fig. 737.—Schematic Representation of the Masticator Nerve and its Branches (in Black). Lateral view. Modified from Spalteholz.

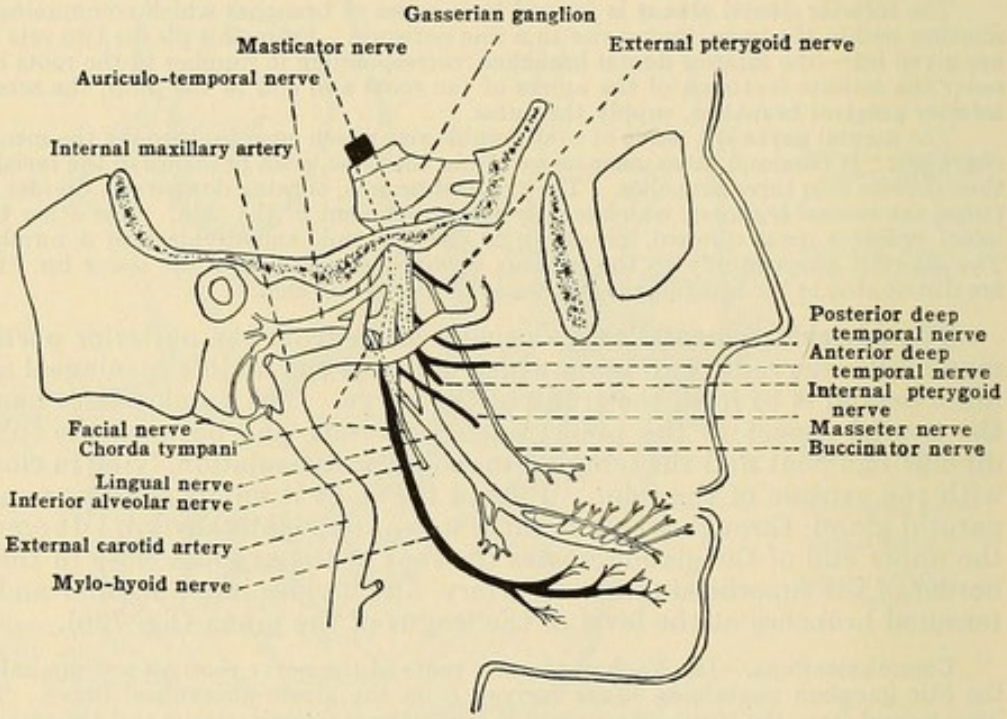

trigeminus immediately outside and below the base of the skull. The nerve is purely motor and its fibres are devoted almost wholly to the muscles having to do with mastication.

Central connections.—The nuclei of origin of the masticator nerve are connected with the lower part of the somæsthetic area of the cerebral cortex of the opposite side by the pyramidal fibres descending in the genu of the internal capsule, and they are associated with the sensory nuclei of other cranial nerves through the reticular formation and by the medial longitudinal fasciculus.

Branches.—Almost immediately after joining the trunk of the mandibular nerve, most of the fibres of the masticator leave it to form the greater part of the so-called anterior portion of the mandibular. However, one branch of masticator fibres, the nerve to the internal pterygoid muscle, is given off from the mandibular just before its division into anterior and posterior portions. The masticator

* Recent investigations indicate that the mesenephalic root is not wholly motor but at least in part sensory in character, and thus belongs partly to the trigeminal nerve. (See page 829.)

branches derived from the anterior portion are the *deep temporal* nerves, the *masseteric* nerve, and the nerve to the *external pterygoid*. One branch, the *mylo-hyoid* nerve, is carried in the posterior portion of the mandibular and is given off from its inferior alveolar branch.

The **nerve to the internal pterygoid** passes under cover of a dense layer of fascia derived from an expansion of the ligamentum pterygo-spinosum, and enters the deep surface of the muscle. Near its commencement this nerve furnishes a visceral motor root to the otic ganglion, and small twigs to the tensor tympani and tensor palati.

The **deep temporal nerves,** usually two in number, posterior and anterior, pass between the bone and the upper border of the external pterygoid muscle, and turn upward around the infra-temporal crest of the sphenoid bone to end in the deep surface of the temporalis (fig. 736). The posterior of the two often arises in common with the masseteric nerve. The anterior is frequently associated with the buccinator (long buccal) nerve till the latter has passed between the two heads of the pterygoideus externus. There is frequently a third branch, the **medius,** which passes lateralward above the pterygoideus externus, and turns upward close to the bone to enter the deep surface of that muscle. A small strand of masticator fibres accompanies the buccinator nerve to enter and end in the anterior part of the temporal muscle.

The **masseteric nerve,** which frequently arises in common with the posterior deep temporal nerve, passes between the bone and the pterygoideus externus, and accompanies the masseteric artery through the notch of the mandible to be distributed to the masseter (fig. 736). It is easily traced through the deeper fibres nearly to the anterior border of the masseter. As it emerges above the pterygoideus externus it gives off a twig to the temporo-mandibular articulation.

The **nerve to the external pterygoid,** after a course of about 3 mm. (an eighth of an inch), divides into twigs which enter the deep surface of the two heads of the muscle. It is usually adherent at its origin to the buccinator nerve.

The **mylo-hyoid branch,** carried in the posterior portion of the mandibular nerve, is given off immediately before the inferior alveolar (dental) nerve enters the mandibular (inferior dental) canal. It pierces the lower and back part of the spheno-mandibular ligament and runs downward and forward in the mylo-hyoid groove between the mandible on the lateral side, and the internal pterygoid muscle and the lateral surface of the submaxillary gland on the medial side. In the anterior part of the digastric triangle it is continued forward between the anterior part of the submaxillary gland and the mylo-hyoideus, and it breaks up into branches which supply the mylo-hyoideus and the anterior belly of the digastric (fig. 736).

THE FACIAL NERVE

The facial or seventh nerve is purely motor. It is accompanied a short distance by a bundle usually called its *sensory root* or the *intermediate nerve*. This latter, however, on the basis of its origin, distribution, and mixed instead of sensory character, is described separately below as the *glosso-palatine nerve*. It is smaller than the facial, is fused to the trunk of the facial and the ganglion giving rise to its sensory fibres is situated upon the external genu of the facial (figs. 738 and 741).

The fibres of the facial nerve (fig. 738) spring from a nucleus of cells situated laterally in the reticular formation at the level of the lower pons, dorsal to the superior olive, and between the root fibres of the abducens nerve and the laterally placed spinal tract of the trigeminus. From this nucleus the fibres of the nerve pass medially and dorsalward to the floor of the fourth ventricle and, just under the floor, they turn anteriorly, passing dorsal to the nucleus of the abducens (fig. 653, p. 827). At the anterior end of this nucleus they turn sharply ventralward and lateralward, and at this point it is claimed that fibres descending in the near-by medial longitudinal fasciculus from the nucleus of the oculo-motor nerve of the same side become intermingled with the fibres of the facial nerve and pass outward with them. This, however, is uncertain. Continuing ventralward through the reticular formation the fibres of the facial emerge from the brain-stem at the inferior border of the pons, lateral to the superficial attachment of the abducens. At the point of its emergence, the facial nerve pierces the pia mater, from which it receives a sheath, and then proceeds forward and lateralward in the posterior fossa of the cranium to the internal auditory meatus, which it enters in company with the glosso-palatine nerve and with the cochlear and vestibular nerves. As it lies in the meatus it is situated above and in front of the latter nerves, from which it is separated by the glosso-palatine, and it is surrounded, together with these three nerves, by sheaths of both the arachnoid and the dura mater and by prolongations of the subarachnoid and sub-dural spaces. While it is still in the meatus it blends with the glosso-palatine and thus the combined trunk is formed. At the outer end of the meatus the trunk pierces

the arachnoid and the dura mater and enters the facial canal (aqueduct of Fallopius), in which it runs forward and slightly lateralward to the hiatus Fallopii, where it makes an angular bend, the external genu [geniculum], around the anterior boundary of the vestibule of the inner ear; this bend is enlarged by the adhesion of the geniculate ganglion (of the glosso-palatine) upon its anterior border. From the geniculum the facial nerve runs backward in the facial canal along the lateral wall of the vestibule and the medial wall of the tympanum, above the fenestra vestibuli (ovalis), to the junction of the medial and posterior walls of the tympanic cavity; then, bending downward, it descends in the posterior wall to the stylo-mastoid foramen. As soon as it emerges from the stylo-mastoid foramen it turns forward around the lateral side of the base of the styloid process,

FIG. 738.—DIAGRAM OF THE FACIAL (YELLOW) AND GLOSSO-PALATINE NERVE (BLUE).

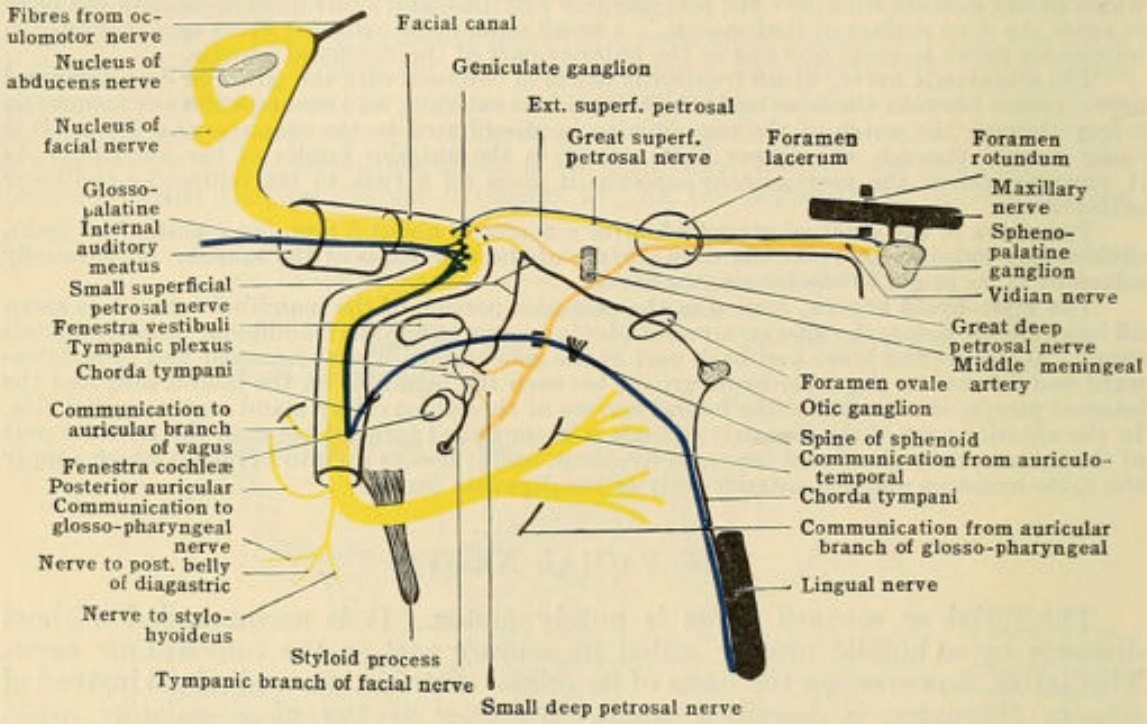

and plunges into the substance of the parotid gland, where it divides into its cervico-facial and temporo-facial terminal divisions. Before its terminal divisions, the nerve gives off three, and sometimes four, small branches: one, the nerve to the stapedius muscle, before it leaves the skull, the others after it leaves the skull.

The **nerve to the stapedius** is given off from the facial nerve as it descends in the posterior wall of the tympanum behind the pyramidal eminence. It is stated that filaments are also given off from the facial to the auditory artery (probably visceral motor from the glosso-palatine) while the nerve is passing through the internal auditory meatus.

After it leaves the skull the facial nerve gives off two or three coll teral branches and its two terminal divisions, the temporo-facial and cervico-facial. The collateral branches are the posterior auricular nerve, a branch to the posterior belly of the digastric, and sometimes a lingual branch.

(1) The **posterior auricular nerve** is the first branch of the extracranial portion of the facial nerve. It passes between the parotid gland and the anterior border of the sterno-mastoid muscle and runs upward in the deep interval between the external auditory meatus and the mastoid process. In this situation it communicates with the auricular branch of the vagus. It supplies the auricularis posterior, sends a slender twig upward to the auricularis superior, and ends in a long slender branch, **the occipital branch,** which passes backward to supply the occipitalis muscle. It also receives filaments from the small occipital and great auricular nerves, and supplies the intrinsic muscles of the auricle (pinna).

(2) The **nerve to the posterior belly of the digastric** arises from the facial nerve close to the stylo-mastoid foramen and enters the muscle near its centre, or sometimes near its origin. It usually gives off two branches: the **nerve to the stylo-hyoid,** which sometimes arises directly from the facial nerve and passes to the upper part of the muscle that it supplies, and the **anastomotic branch,** which joins the glosso-pharyngeal nerve below its petrous ganglion.

(3) The **lingual branch,** first described by Cruveilhier, is not commonly present. It arises a little below the nerve to the stylo-hyoideus and runs downward and medialward to the base of the tongue. In its course it passes to the medial sides of the stylo-glossus and stylo-pharyn-

geus, and runs downward along the anterior border of the latter muscle to the wall of the pharynx. It pierces the superior constrictor, insinuates itself between the tonsil and the anterior pillar of the fauces, and it is stated that it gives filaments to the base of the tongue and to the stylo-glossus and glosso-palatinus (palato-glossus) muscles.

The terminal divisions.—In the substance of the parotid gland the two terminal divisions of the facial nerve lie superficial to the external carotid artery and to the posterior facial (temporo-maxillary) vein. The way in which these terminal divisions give off their branches varies much in different subjects and often on the opposite sides of the same subject. One of the more common forms is here described.

The **temporo-facial** or upper division runs upward and forward, and, after receiving communicating twigs from the auriculo-temporal nerve, gives off temporal and zygomatic (malar) branches. The **cervico-facial** or lower division runs downward and forward, receives branches from the great auricular nerve, and

FIG. 739.—THE RIGHT FACIAL NERVE, WITHIN THE SKULL, AND THE RELATIONS OF THE GLOSSO-PALATINE AND GLOSSO-PHARYNGEAL NERVES WITH THE TYMPANIC AND INTERNAL CAROTID PLEXUSES. (From Sobotta's Atlas, modified.)

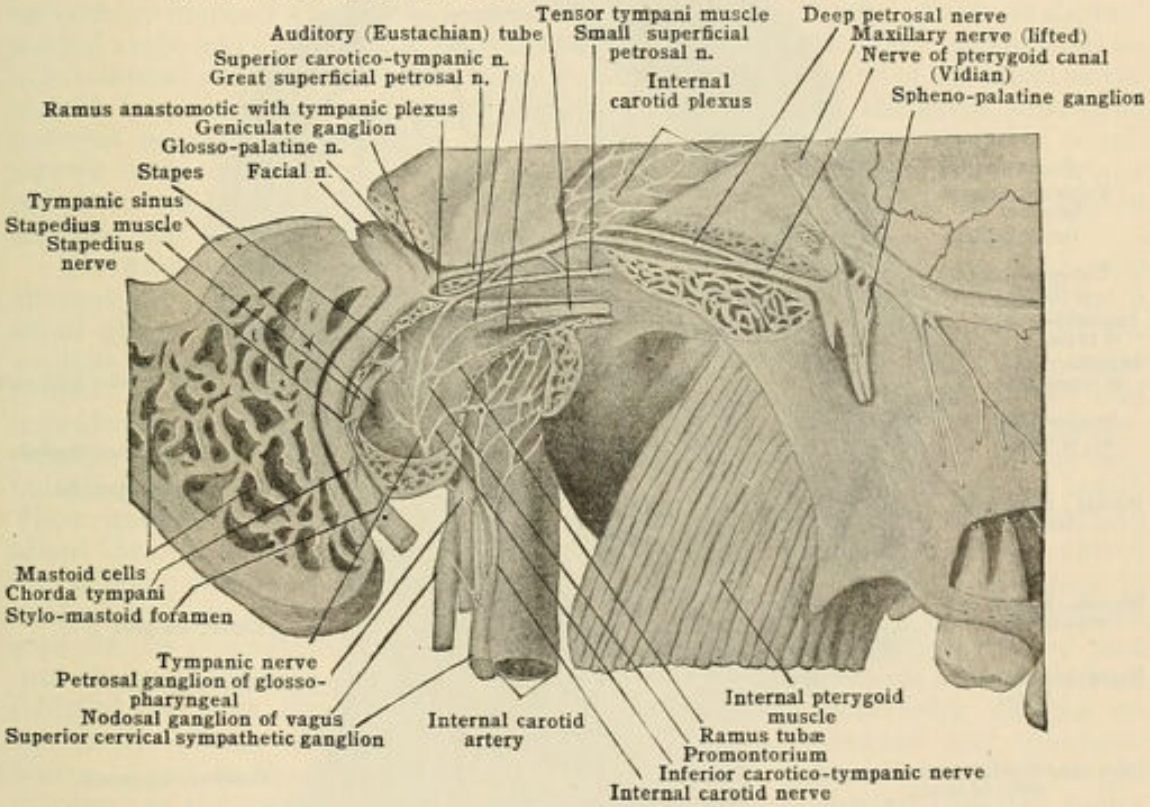

gives off—(1) *buccal branches*, comprising what have been called infraorbital and buccal branches; (2) the *marginal mandibular* (supra-mandibular) branch; and (3) the *ramus colli* (infra-mandibular branch). These branches from the two terminal divisions anastomose freely to form the **parotid plexus** (pes anserinus).

The **temporal branches** passing upward communicate freely with each other and with the zygomatic branches. They also communicate with the zygomatico-temporal branch of the zygomatic nerve (the orbital branch of the maxillary nerve) and with the supra-orbital nerve. They supply the frontalis, orbicularis oculi, corrugator supercilii, and auricularis anterior and superior (fig. 740).

The **zygomatic (malar) branches** passing upward and forward, communicate with the buccal branches of the facial nerve; with the zygomatico-facial branch of the zygomatic nerve (the orbital branch of the maxillary nerve); with the supraorbital and lacrimal branches of the ophthalmic nerve, and with the palpebral twigs of the maxillary. They supply both eyelids, the orbicularis oculi, and the zygomaticus (fig. 740).

The **buccal (infra-orbital and buccal) branches** arise sometimes from the lower terminal division and sometimes from both the upper and the lower terminal divisions. The buccal branches, passing forward upon the masseter and underneath the zygomaticus and quadratus labii superioris, interlace with the zygomatic and marginal mandibular (supra-mandibular) branches of the facial nerve, with the buccinator (long buccal) branch of the trigeminus, and with the terminal branches of the maxillary nerve, forming with the last-named nerve the **infra-orbital plexus.** They supply the zygomaticus, risorius, quadratus labii superioris, caninus,

buccinator, incisivi, orbicularis oris, triangularis, quadratus labii inferioris, and the muscles of the nose (fig. 740).

The **marginal mandibular (supra-mandibular) branch,** passing downward and forward under cover of the risorius and the depressors of the lower lip, communicates with the buccal branches and with the ramus colli of the facial nerve, and with the mental branch of the mandibular nerve. It supplies the quadratus labii inferioris and mentalis.

The ramus colli (infra-mandibular branch) runs downward and forward under cover of the platysma, which muscle it innervates (fig. 740). Beneath the platysma it forms one or more communicating loops, near its commencement, with the great auricular nerve, and longer loops, lower down, with the superficial cervical nerve.

Central connections.—The nucleus of origin of the facial in the rhombencephalon includes an anterior and a posterior group of cells which give rise respectively to its upper and lower terminal divisions. They are associated with the somæsthetic area (lower third of the anterior central gyrus) by way of the pyramidal fasciculi of the opposite and same sides, and with the nuclei of the other cranial nerves, including the nucleus of termination of the glosso-palatine, by way of the reticular formation and the medial longitudinal fasciculus.

FIG. 740.—SUPERFICIAL DISTRIBUTION OF THE FACIAL AND OTHER NERVES OF THE HEAD. (After Hirschfield and Leveillé.)

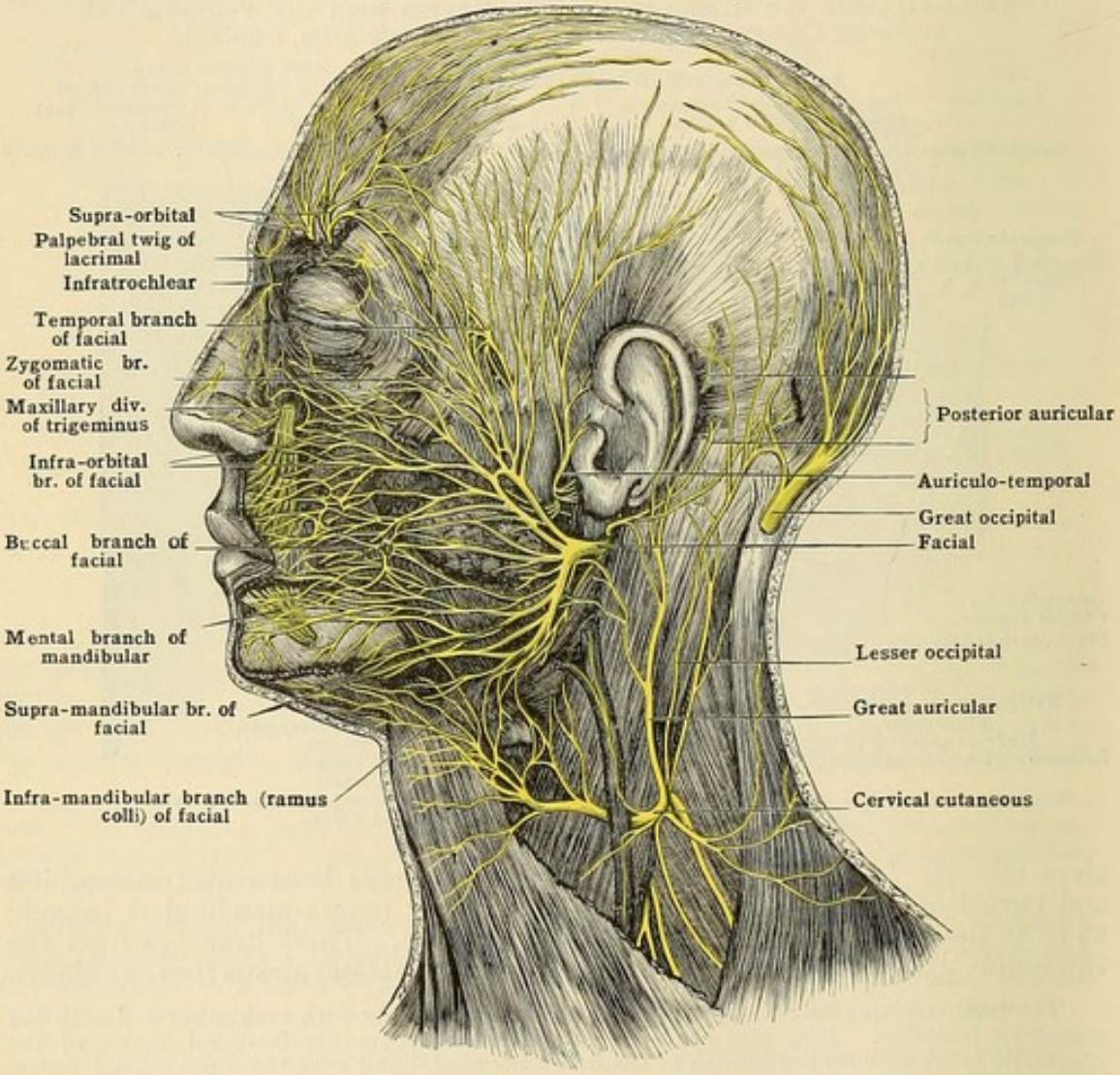

GLOSSO-PALATINE NERVE

The **glosso-palatine nerve** (*sensory root or pars intermedia of facial, nerve of Wrisberg*) contains both sensory and motor fibres. While it has a separate attachment to the medulla, it courses in close company with the facial and, in the internal auditory meatus, it is involved in the same sheath with the facial, which relation is maintained by its larger part thence through the facial canal till a short distance above the stylo-mastoid foramen. Here this larger part leaves the trunk of the facial as the *chorda tympani* nerve. The origin, central connections and peripheral distribution of the glosso-palatine are similar to those of the

glosso-pharyngeal nerve and suggest that it may be considered an aberrant portion of that nerve.

The **sensory portion** is much greater than the motor. Its fibres arise from cells situated in the geniculate ganglion which thus corresponds to a spinal ganglion. The *central processes* from these cells pass medialward in the facial canal (aqueduct of Fallopius) enclosed in the sheath of the facial nerve, which they leave in passing through the internal auditory meatus, to turn slightly downward in the posterior fossa of the cranium and enter the medulla at the inferior border of the pons, between the attachments of the facial and vestibular nerves. They course through the reticular formation of the medulla, medianward and dorsalward to terminate about cells which comprise a superior extension of the nucleus of termination of the glosso-pharyngeal nerve (nucleus of ala cinerea). The *peripheral processes* from the geniculate ganglion are distributed chiefly to the epithelium covering the soft palate, portions of the glosso-palatine arches, and the anterior two thirds of the tongue.

The **geniculate ganglion** is so named from the fact that it is embedded upon the anterior border of the external genu (*geniculum*, great bend) of the facial nerve, behind the hiatus Fallopii. It is somewhat triangular in form. From its supero-medial angle leave the central processes of its cells, the root of the nerve; from its infero-lateral angle leave the fibres which later leave the sheath of the facial as the chorda tympani, and its anterior angle is connected with the great superficial petrosal nerve (figs. 738 and 741). The geniculate ganglion contains a relatively large number of cell-bodies of sympathetic neurones many of whose processes run in this latter nerve, a relation mentioned below with the gangliated cephalic plexus.

The **motor portion** of the glosso-palatine consists for the most part of visceral efferent fibres, chiefly secretory. These arise in the medulla oblongata from a small group of cells scattered in the reticular formation dorso-medial to the nucleus of the facial and in line with the dorsal efferent nucleus of the vagus below. It is called the *salivatory nucleus*. The fibres course ventralward and lateralward to their exit, mingle with the entering sensory fibres of the glosso-palatine in the sheath of the facial and, through the branches of the glosso-palatine, pass to terminate in sympathetic ganglia of the head, large and small. These ganglia send axones which terminate in the smooth muscle of vessels and about the cells of the glands of the lingual and palatine mucous membrane and of the salivary glands proper. Some of the motor fibres of the nerve terminate in contact with the sympathetic cells remaining in the geniculate ganglion and which give rise to sympathetic fibres issuing from it. Most of the motor fibres pass into the great superficial petrosal nerve and the chorda tympani to terminate in (chiefly) or pass through the spheno-palatine and submaxillary ganglia respectively. Some may pass by the geniculo-tympanic branch and tympanic plexus to end in the otic ganglion. Many no doubt end in the smaller ganglia involved in the various sympathetic plexuses. It is suggested that the motor part carries secretory impulses destined chiefly for the sub-maxillary and sublingual glands. A small gangliated plexus on the capsule of the medial side of the parotid gland has been frequently dissected and found to communicate freely with twigs from the facial nerve and twigs concerned with the trigeminus. It is possible that some glosso-palatine visceral motor fibres terminate in these ganglia for secretory impulses to the parotid gland as well.

Central connections.—The nucleus of termination of the glosso-palatine nerve (superior extension of the nucleus of termination of the sensory portion of the glosso-pharyngeal) is associated with the somæsthetic area of the cerebral cortex of the opposite and same sides by way of the medial lemniscus, and with the salivatory nucleus and motor nuclei of other cranial nerves by way of the reticular formation and medial longitudinal fasciculus. The nucleus of origin of the motor portion (salivatory nucleus) may be associated not only with the nucleus of termination of the sensory part, but with the nuclei of termination of other cranial nerves, and perhaps with the motor area of the cortex of the opposite side by way of the pyramidal fasciculi.

Branches and communications.—Aside from its two or three small collateral twigs of communication, the fibres of the glosso-palatine course in two main branches or nerves: (1) the great superficial petrosal nerve, continued through the Vidian nerve, and extended through and beyond the spheno-palatine ganglion as the palatine portion of the glosso-palatine (palatine nerve); (2) the chorda tym-

pani, the larger branch, which extends to join and contribute its quota of fibres to the lingual nerve, a branch of the trigeminus.

In the internal auditory meatus, the glosso-palatine gives two delicate collaterals to the vestibular nerve, and some filaments (visceral motor probably) are described as given to the auditory artery and to the temporal bone.

A small **geniculo-tympanic branch** is given, in the facial canal, from the geniculate ganglion to the small superficial petrosal nerve. This is probably all visceral motor and sympathetic fibres (fig. 741).

There may occur a twig arising from or near the beginning of the chorda tympani and forming a *communication with the auricular branch of the vagus.*

A large part of the **great superficial petrosal nerve** is formed of glosso-palatine fibres. This nerve is further described below in its relation to the spheno-palatine ganglion. It arises from the anterior angle of the geniculate ganglion, enters the middle fossa of the cranium through

FIG. 741.—DIAGRAM OF THE GLOSSO-PALATINE NERVE (BLACK) AND THE RELATIONS OF THE GANGLIATED CEPHALIC PLEXUS TO OTHER CRANIAL NERVES. (After Bean.) Broken lines, motor; continuous lines, sympathetic; glosso-palatine in solid black. Medial view. Left side.

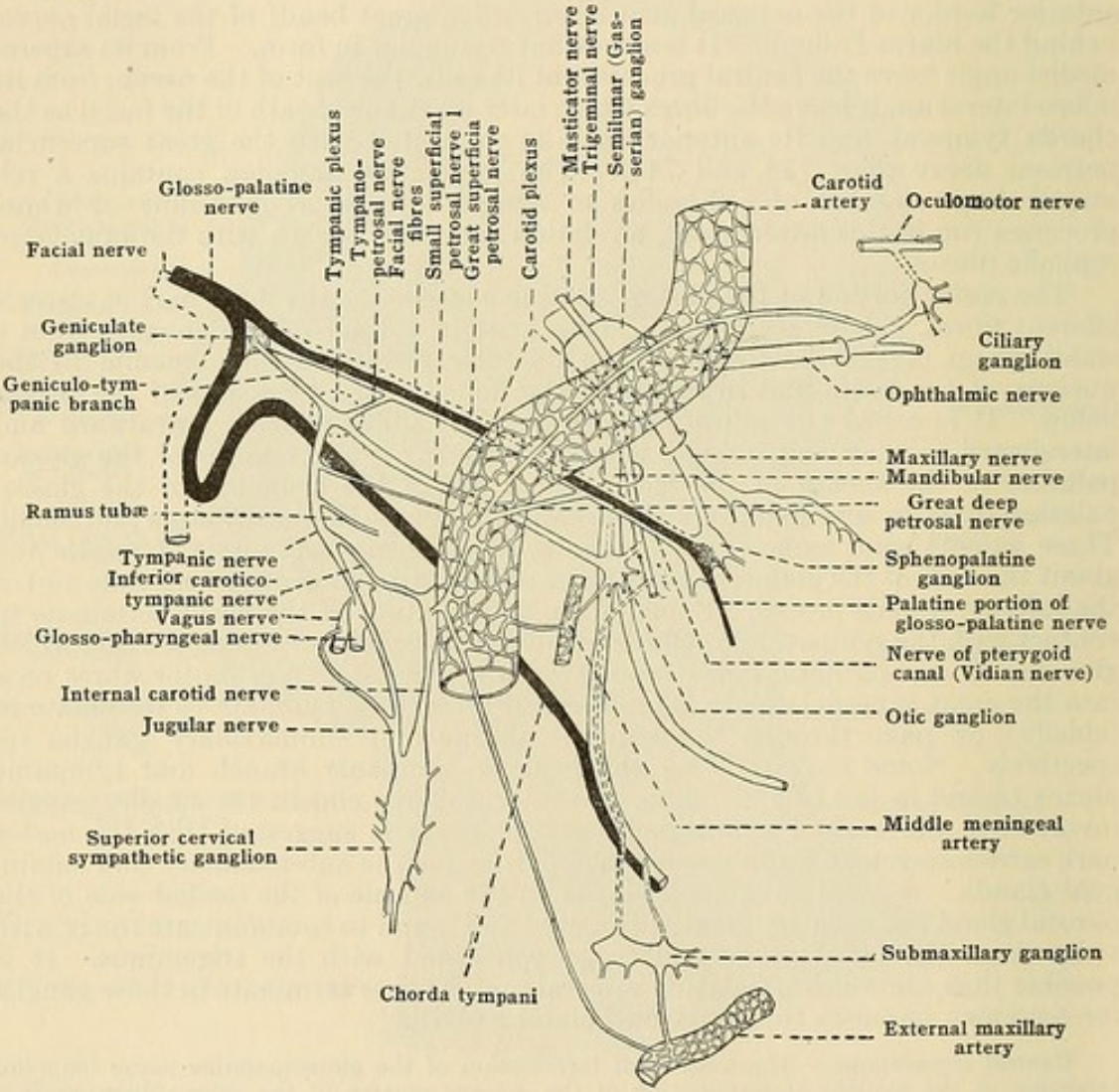

the hiatus Fallopii, and passes beneath the semilunar ganglion into the foramen lacerum, where it joins with the great deep petrosal nerve to form the Vidian nerve. Thence the glosso-palatine portion passes over or through the spheno-palatine ganglion to form the greater part of the **small** and **middle palatine nerves** which are distributed to the epithelium and glands of the soft palate, some of the sensory fibres probably terminating in the taste organs found there; the remainder serving as fibres of general sensibility. It is probable that most of the motor glosso-palatine fibres in the great superficial petrosal nerve terminate in the spheno-palatine ganglion; some may pass to the carotid plexus and to small ganglia elsewhere.

The chorda tympani consists to a very large extent of sensory fibres (peripheral processes of the cells of the geniculate ganglion), but it also contains motor fibres and is thus also a mixed nerve. It leaves the trunk of the facial nerve a short distance above the stylo-mastoid foramen, and pursues a slightly recurrent course upward and forward in the canaliculus chordæ tympani (iter chordæ posterius), a minute canal in the posterior wall of the tympanic cavity, and it

enters that cavity close to the posterior border of the membrana tympani. It crosses the cavity, running on the medial surface of the tympanic membrane at the junction of its upper and middle thirds, covered by the mucous membrane lining the tympanic cavity, and passes to the medial side of the manubrium of the malleus above the tendon of the tensor tympani. It leaves the tympanic cavity and passes to the base of the skull through a small foramen (the iter chordæ anterius) at the medial end of the petro-tympanic (Glaserian) fissure. At the base of the skull it inclines downward and forward on the medial side of the spine of the sphenoid, which it frequently grooves, and, on the medial side of the pterygoideus externus, it joins the posterior border of the lingual nerve at an acute angle. Some of its fibres (motor chiefly) leave the lingual nerve and pass to the sub-maxillary ganglion, and others (sensory) continue forward to the tongue, where, in company with fibres of the lingual nerve, they terminate in the epithelium covering the anterior two-thirds of the tongue. Some probably serve to convey sensations of taste, most of them are fibres of general sensibility. Before it joins the lingual nerve the chorda tympani receives a communicating twig from the otic ganglion (figs. 738, 741).

THE VESTIBULAR NERVE

The vestibular nerve is purely sensory. With the peripheral processes of its cells of origin terminating in the neuro-epithelium of the semicircular canals and

FIG. 742.—THE LEFT MEMBRANOUS LABYRINTH OF A HUMAN FŒTUS-OF 10 WEEKS (30 MM.), LATERAL ASPECT. Vestibular ganglion and nerve, red; cochlear nerve, yellow. (Streeter, American Journal of Anatomy.)

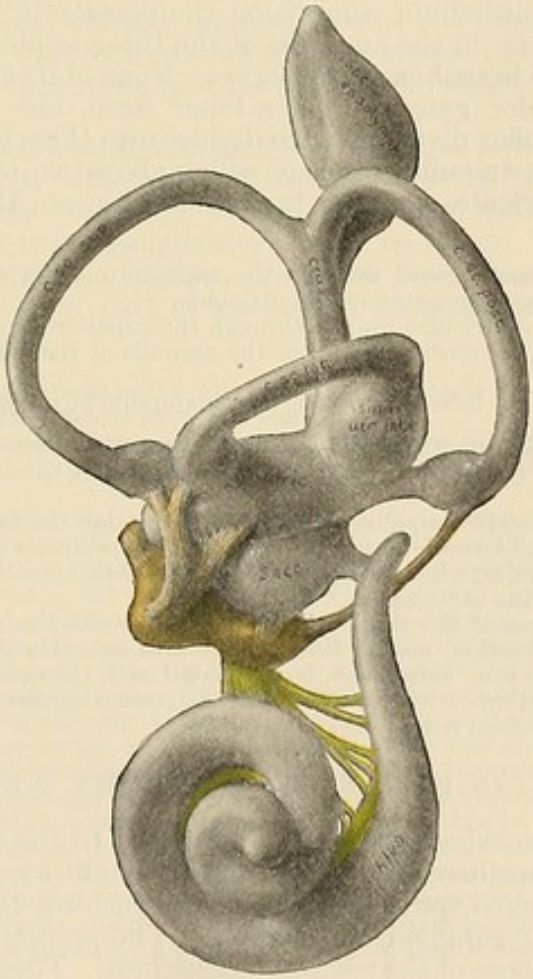

the vestibule, and their central processes conveying impulses which are distributed to the gray substance of the cerebellum and spinal cord, the nerve comprises a most important part of the apparatus for the equilibration of the body. It has been customary to describe the vestibular [radix vestibularis] and the cochlear [radix cochlearis] nerves combined as the **acoustic (auditory) or eighth cranial nerve.** While the two are blended in a common sheath from near the medulla to the bottom of the internal auditory meatus, they are likewise partly enclosed in the same sheath with the facial and glosso-palatine nerves and the internal auditory artery which accompany them in this meatus. At the bottom of the meatus

the vestibular and the cochlear are separate; they are separate at their entrance into the lateral aspect of the medulla oblongata; and their central connections, peripheral distributions and functions are different.

The vestibular nerve arises as processes of the cells of the **vestibular ganglion** (ganglion of Scarpa), situated upon and blended within the nerve at the bottom of the internal auditory meatus. Unlike the ordinary spinal ganglion, to which it corresponds, the cells of the vestibular ganglion retain an embryonal, "bipolar," form. The *central processes* course with the cochlear nerve in the internal auditory meatus medialward, caudad and slightly downward, inferior to the accompanying facial and glosso-palatine nerves, and, arching ventrally around the restiform body, they enter the medulla at the inferior border of the pons, lateral to the glosso-palatine and facial and medial to the entrance of the cochlear nerve. They find their nucleus of termination spread in the floor of the fourth ventricle and grouped as the median, the lateral (Deiters'), the superior, and the nucleus of the spinal root of the vestibular nerve. In the internal auditory meatus, the vestibular nerve is connected by two small filaments of fibres with the glosso-palatine nerve. These are either visceral motor fibres for the vessels of the domain of the vestibular or are aberrant fibres which course only temporarily with the vestibular and return to the glosso-palatine.

The *peripheral processes* of the cells of the vestibular ganglion terminate in the specialised or neuro-epithelium comprising the *maculæ* in the sacculus and the utriculus and the *cristæ* in the ampullæ of the three semicircular canals. Thus there are five **terminal branches** of the nerve. None of its fibres terminates in the cochlea. The vestibular ganglion has a lobar form, one lobe giving rise to a superior **utriculo-ampullar** division which divides into three terminal branches; the other giving a **sacculo-ampullar** division which gives two terminals.

The superior or **utriculo-ampullar branch** divides into the following terminal branches:—

(1) The **utricular branch** passes through the superior macula cribrosa of the vestibule and terminates in the macula acustica of the utriculus.

(2) Accompanying the utricular branch through the superior macula cribrosa is a branch, the **superior ampullar,** to the crista acustica of the ampulla of the superior semicircular canal, and—

(3) A similar branch, the **lateral ampullar,** to the ampulla of the lateral semicircular canal.

The inferior or **sacculo-ampullar branch** accompanies the cochlear nerve a short distance further than the superior, and divides into—

(4) A branch, the **posterior ampullar,** which passes through the foramen singulare and the inferior macula cribrosa and terminates in the ampulla of the posterior semicircular canal, and—

(5) A branch, the **saccular,** which passes through the middle macula cribrosa and terminates in the macula acustica of the sacculus.

The **central connections** of the vestibular nerve are described in detail on pages 823, 824. Its large nucleus of termination, spread through the area acustica in the floor of the fourth ventricle, and divided into four sub-nuclei, is associated with the nuclei fastigii, globosus, and emboliformis of the cerebellum, with the nuclei of the eye-moving nerves, with the spinal cord, and probably with the cerebral cortex.

THE COCHLEAR OR AUDITORY NERVE

The fibres of the cochlear nerve are distributed to the organ of Corti in the cochlea, and so are considered as comprising the auditory nerve proper. They arise from the long, coiled **spiral ganglion** of the cochlea, the cells of which, like those of the vestibular ganglion, are bipolar. The *peripheral processes* of these cells are shorter than those of the vestibular ganglion. They terminate about the auditory or hair-cells of the organ of Corti and thus collect impulses aroused by stimuli affecting these cells. The *central processes* of the ganglion cells continue through the modiolar canal and the tractus spiralis foraminosus of the cochlea, and thence, joining the vestibular nerve through the internal auditory meatus, accompanying the facial nerve and internal auditory artery, they course medialward and downward, approach and enclasp the restiform body (fig. 665) and enter the lateral aspect of brain-stem to terminate in their dorsal and ventral nuclei. A description of these nuclei and the further central connections of the cochlea with the superior olive, the nuclei of the eye-moving nerves, the inferior quadrigeminate bodies, the medial geniculate bodies, and with the cerebellum and temporal lobes of the cerebral hemispheres is given on pages 824, 839.

The cochlear nerve is separate from the vestibular at the bottom of the internal auditory meatus and at its entrance into the medulla.

THE GLOSSO-PHARYNGEAL NERVE

The glosso-pharyngeal or *ninth* cranial nerves are mixed nerves and each is attached to the medulla by several roots which enter the postero-lateral sulcus, dorsal to the anterior end of the olivary body and in direct line with the facial nerve.

The filaments, when traced lateralward, are seen to blend, in front of the flocculus, into a trunk which lies in front of the vagus nerve, but which passes through a separate opening through the arachnoid and the dura mater and through the jugular foramen. In the foramen this trunk lies in front, and lateral to the vagus nerve in a groove on the petrous portion of the temporal bone; and in this situation two ganglia are interposed in it, a superior or jugular, and an inferior or petrosal. After it emerges from the jugular foramen the glosso-pharyngeal nerve descends at first between the internal carotid artery and the internal jugular vein and to the lateral side of the vagus; then, bending forward and medialward, it descends medial to the styloid process and the muscles arising from it, and turning around the lower border of the stylo-pharyngeus it passes between the internal and the external carotid arteries, crosses the superficial surface of the stylo-pharyngeus, and runs forward and upward medial to the hyoglossus muscle and across the middle constrictor and the stylo-hyoid ligament, to the base of the tongue (fig. 743).

Ganglia.—The **superior** or **jugular ganglion** (ganglion of Ehrenritter), is a small, ovoid, reddish-grey body which lies on the back part of the nerve-trunk in the upper part of the jugular foramen. No branches arise from it. It is sometimes continuous with the petrosal ganglion or it may be absent.

The **inferior or petrosal ganglion,** (ganglion of Andersch), is an ovoid grey body which lies in the lower part of the jugular foramen, and appears to include all the fibres of the nerve.

Branches and communications.—(1) The petrosal ganglion is connected with the superior cervical ganglion of the sympathetic by a fine filament.

(2) It also has a filament of communication with the auricular branch of the vagus which varies inversely in size with the latter branch and sometimes entirely replaces it. This filament may be absent.

(3) An inconstant communication with the ganglion of the root of the vagus.

(4) A short distance below the petrous ganglion the trunk of the nerve is connected by a twig with that branch of the facial nerve which supplies the posterior belly of the digastric muscle. There is also a small twig (probably sensory) to the stylo-hyoid.

(5) **From the petrosal ganglion: The tympanic branch** (nerve of Jacobson) arises from the petrosal ganglion and passes through a foramen, which lies in the ridge of bone between the carotid canal and the jugular fossa, into the tympanic canaliculus (Jacobson's canal), where it is surrounded by a small, fusiform mass of vascular tissue, the *intumescentia tympanica*. After traversing the tympanic canaliculus it enters the tympanum at the junction of its lower and medial walls, and, ascending on the medial wall, breaks up into a number of branches which take part in the formation of the **tympanic plexus** on the surface of the promontory (fig. 739). The continuation of the nerve emerges from this plexus as the *small superficial petrosal nerve*, which runs through a small canal in the petrous portion of the temporal bone, beneath the canal for the tensor tympani, and appears in the middle fossa of the cranium through a foramen which lies in front of the hiatus Fallopii. From this foramen it runs forward and passes through the foramen ovale, the canaliculus innominatus, or the spheno-petrosal suture, and enters the zygomatic fossa, where it joins the otic ganglion. While it is in the canal in the temporal bone the small superficial petrosal nerve is joined by a **geniculo-tympanic branch** from the geniculate ganglion of the glosso-palatine nerve.

(6) **Branches from the tympanic plexus:**—(*a*) The **tubal branch** (ramus tubæ), a delicate branch, which runs forward to the mucous membrane of the tuba auditiva (Eustachian tube) and sends filaments backward to the region of the fenestra vestibuli (ovalis) and the fenestra cochleæ (rotunda).

(*b*) The **superior and inferior carotico-tympanic** (carotid) **branches** pass medianward to the internal carotid plexus (fig. 741).

The above communications carry fibres almost entirely concerned with the sympathetic plexuses of the head and they will be again mentioned below with the gangliated cephalic plexus.

Branches from the trunk of the nerve:—(1) **Pharyngeal branches,** which may be two or three in number, arise from the nerve a short distance below the petrosal ganglion. The principal and most constant of these passes on the lateral side of the internal carotid artery, and after a very short independent course joins with the pharyngeal branch of the vagus and with branches of the superior cervical ganglion to form the pharyngeal plexus (fig. 743).

(2) A **muscular branch** is distributed to the stylo-pharyngeus muscle. This branch receives a communication from the facial nerve (fig. 743).

(3) The **tonsillar branches** are a number of small twigs which arise under cover of the hyo-glossus muscle; they proceed to the tonsil, around which they form a plexus, the **circulus tonsillaris.** From this plexus fine twigs proceed to the glosso-palatine arches (pillars of the fauces) and to the soft palate.

(4) The **lingual branches** are the terminal branches of the nerve and supply the mucous membrane of the posterior half of the dorsum of the tongue, where, chiefly as taste-fibres, they are distributed to the vallate papillæ. Some small twigs pass backward to the follicular glands of the tongue, and to the anterior surface of the epiglottis. Other twigs are distributed around the foramen cæcum, where they communicate with the corresponding twigs of the opposite side.

The sensory fibres.—The sensory fibres of the glosso-pharyngeal nerve spring from the superior and petrosal ganglia and pass peripherally and centrally. The **peripheral** processes of the ganglion cells are those which are distributed to the mucous membrane (taste-buds) of the tongue and pharynx, and the **central** processes pass medialward to the medulla. In the medulla they pass dorsalward and medianward through the reticular formation and, bifurcating into ascending and descending branches, they end in the nucleus of termination of the glosso-pharyngeal nerve, that is, in the superior part of the nucleus alæ cinereæ and in the nucleus of the tractus solitarius.

The **motor fibres** arise from the nucleus ambiguus in the lateral funiculus of the medulla, in line with the nucleus of origin of the facial nerve. From this nucleus they pass at first dorsalward and then, turning lateralward, they emerge and join the sensory fibres and run with them in the trunk of the nerve (fig. 646).

Van Gehuchten's observations point to the conclusion that one motor nucleus of the glosso-pharyngeal nerve is separate from and lies above and to the medial side of the nucleus ambiguus, and that a portion of the nucleus of the ala cinerea is also a motor nucleus common to the glosso-pharyngeal and vagus nerves. It is quite probable that the former motor nucleus is that now considered as the dorsal motor nucleus of the vagus. An unknown proportion of the motor fibres are visceral motor and course in the various communications of the glosso-pharyngeal nerve with cephalic plexus.

Central connections.—The nuclei of termination of the glosso-pharyngeal nerve are associated with the motor nuclei of other cranial nerves by the medial longitudinal fasciculus, and with the somæsthetic area of the cortex cerebri of the opposite side by the medial lemniscus (fillet). The motor nucleus of the nerve is associated with the somæsthetic area by the pyramidal fibres.

THE HYPOGLOSSAL NERVE

The **hypoglossal nerves** are exclusively motor; they supply the genio-hyoidei and the extrinsic and intrinsic muscles of the tongue except the glosso-palatini. They are usually designated as the twelfth pair of cranial nerves. The fibres of each nerve issue from the cells of an elongated nucleus which lies in the floor of the central canal in the lower half of the medulla and in the floor of the fourth ventricle in the upper half beneath the trigonum hypoglossi. This nucleus is the upward continuation of the ventro-medial group of cells of the ventral horn of the spinal cord. From their origin the fibres run ventralward and somewhat lateralward, probably joined in the medulla by a few fibres from the nucleus ambiguus which is a segment of the upward prolongation of the lateral group of cells of the ventral horn. The conjoined fibres issue from the medulla in the sulcus between the pyramid and the olivary body, in a series of from ten to sixteen root filaments, which pierce the pia mater and unite with each other to form two bundles (fig. 731). These bundles pass forward and lateralward to the hypoglossal (anterior condyloid) foramen, where they pierce the arachnoid and dura mater. In the outer part of the foramen the two bundles unite to form the trunk of the nerve. At its commencement, at the base of the skull, the trunk of the hypoglossus lies on the medial side of the vagus, but as it descends in the neck it turns gradually around the dorsal and the lateral side of the latter nerve, lying between it and the internal jugular vein, and a little above the level of the hyoid bone it bends forward, and crosses lateral to the internal carotid artery, the root of origin of the occipital artery, the external carotid, and the loop formed by the first part of the lingual artery (fig. 743). After crossing the lingual artery it proceeds forward on the lateral surface of the hyo-glossus, crossing to the medial side of the posterior belly of the digastric, and the stylo-hyoid muscles. It disappears in the anterior part of the submaxillary region between the mylo-hyoid and the hyo-glossus, and divides into its terminal branches between the latter muscle and the genio-glossus.

As it descends in the neck the trunk lies deeply between the internal jugular vein and the internal carotid artery under cover of the parotid gland, the styloid muscles, and the posterior belly of the digastric, and it is crossed superficially by the posterior auricular and the occipital arteries. As it turns forward around the root of the occipital artery the sterno-mastoid branch of that vessel hooks downward across the nerve, and as it turns forward on the hyo-

glossus muscle it lies immediately above the ranine vein. It is crossed by the posterior belly of the digastric and the stylo-hyoid muscle, and it is covered superficially, behind the mylo-hyoid, by the lower part of the submaxillary gland.

Communications.—The hypoglossus is connected with the first cervical ganglion of the sympathetic, with the ganglion nodosum of the vagus, with the loop between the first and second cervical nerves, and with the lingual nerve; the latter communication is established along the anterior border of the hyo-glossus muscle (figs. 743 and 744).

Terminal branches.—These include (1) a meningeal branch; (2) branches from the cervical plexus; and (3) branches from the hypoglossus proper.

(1) A meningeal branch, frequently represented by two filaments, is given off in the hypoglossal (anterior condyloid) canal. It passes backward into the posterior fossa of the cranium and is distributed to the dura mater. It was believed at one time that the fibres of the meningeal branch were derived from the lingual nerve, but it is now deemed more probable that they are either sensory or visceral motor fibres from the cervical nerves, or from the vagus.

FIG. 743.—THE HYPOGLOSSAL, GLOSSO-PHARYNGEAL, AND LINGUAL NERVES. (Spalteholz.)

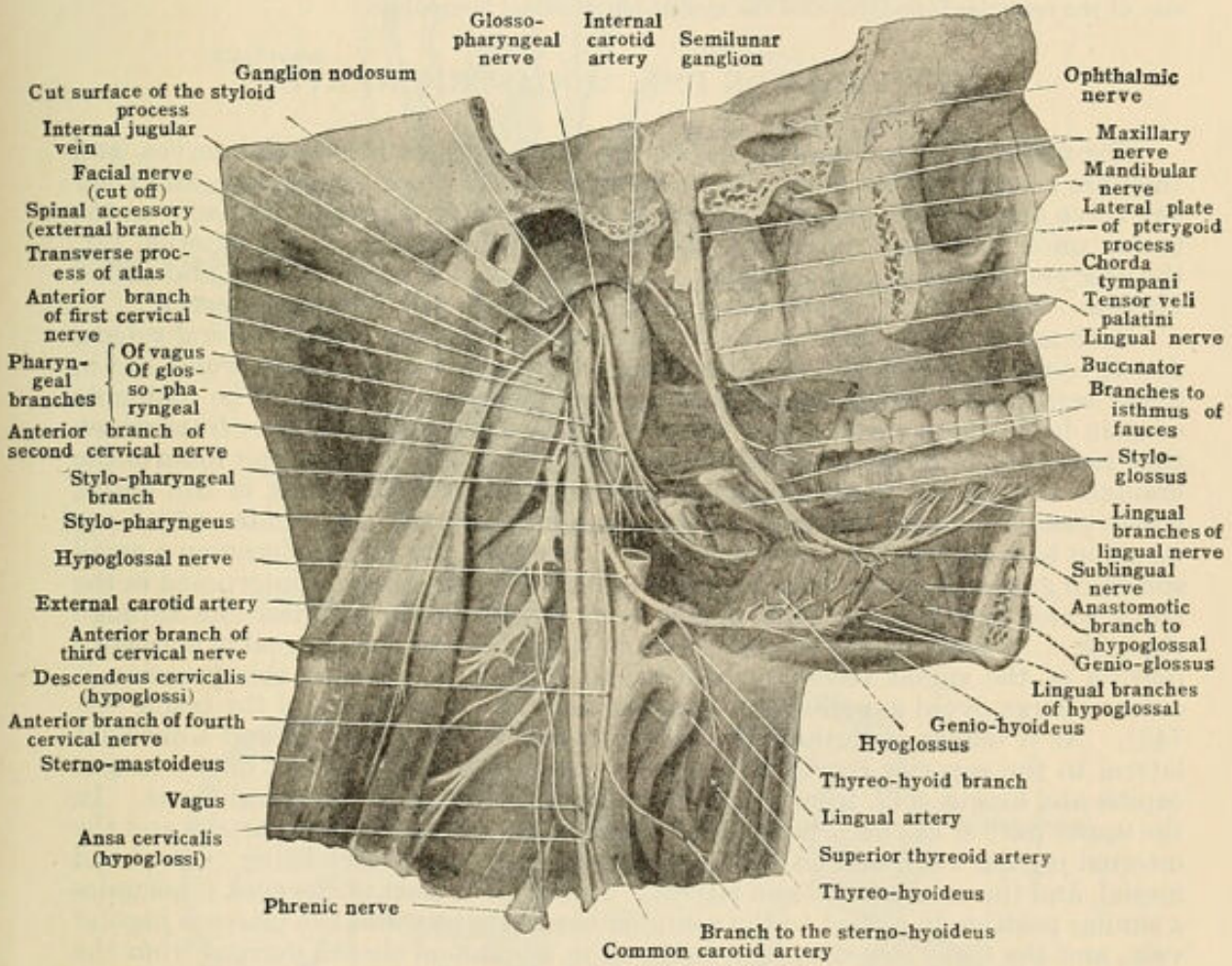

(2) **Branches which consist of fibres derived from the cervical plexus.**—The descendens cervicalis (hypoglossi) and the muscular twig to the thyreo-hyoid muscle, though apparently arising from the hypoglossal nerve, consists entirely of fibres which have passed into the hypoglossal nerve from the loop between the first two cervical nerves. Therefore, neither of them are branches of the hypoglossus proper. (See fig. 752.)

(a) The **descendens cervicalis (hypoglossi)** parts company with the hypoglossus at the point where the latter hooks around the occipital artery (fig. 743). It runs downward and slightly medialward on the sheath of the great vessels (occasionally within the sheath), and is joined at a variable level by branches from the second and third cervical nerves, forming with them a loop, the cervical loop [ansa hypoglossi] (fig. 743). The **cervical loop** may be placed at any level from a point immediately below the occipital artery to about four centimetres above the sternum. From this loop all the muscles attached to the hyoid bone are supplied. A twig to the **anterior belly of the omo-hyoid** arises from the descendens cervicalis in the upper part of its course. The nerves which supply the **sterno-hyoid, sterno-thyreoid,** and **posterior belly of the omo-hyoid** are given off by the cervical loop. Twigs from the first two nerves pass downward in the muscles behind the manubrium sterni and in rare cases communicate with the phrenic

nerve within the thorax. The nerve to the posterior belly of the omo-hyoid runs in a loop of the cervical fascia below the central tendon of the muscle.

(b) The **nerve to the thyreo-hyoid** leaves the hypoglossus near the tip of the great cornu of the hyoid bone, and runs obliquely downward and medialward to reach the muscle. All the fibres in (a) and (b) are derived from the first, second and third cervical nerves.

(c) The **nerve to the genio-hyoid** arises under cover of the mylo-hyoid, where loops are formed with the lingual nerve from which loops branches pass into the muscle. It probably contains some true hypoglossal fibres.

(3) The **branches of the hypoglossus proper,** the **rami linguales,** supply the stylo-glossus, hyo-glossus, genio-glossus, and the intrinsic muscular fibres of the tongue.

The **nerve to the stylo-glossus** is given off near the posterior border of the hyo-glossus. It pierces the stylo-glossus, and its fibres pursue a more or less recurrent course within the muscle.

The **nerves to the hyo-glossus** are several twigs which are supplied to the muscle as the hypoglossal nerve crosses it.

The **nerve to the genio-glossus** arises under cover of the mylo-hyoid in common with the terminal branches to the intrinsic muscles of the tongue. It communicates freely with branches of the lingual, forming long loops which lie on the genio-glossus. From these loops twigs pass into the genio-glossus and into the muscular substance of the tongue.

Central connections.—The nucleus of origin of the hypoglossus is associated with the somæsthetic area (operculum) of the cortex cerebri of the opposite side by the pyramidal fibres, and it is connected with the sensory nuclei (nuclei of termination) of other cranial nerves by way of the reticular formation and the medial longitudinal fasciculus.

THE VAGUS OR PNEUMOGASTRIC NERVE

The vagus or pneumogastric nerves are the longest of the cranial nerves, and they are remarkable for their almost vertical course, their asymmetry, and their extensive distribution, for, in addition to supplying the lung and stomach, as the name 'pneumo-gastric' indicates, each nerve gives branches to the external ear, the pharynx, the larynx, the trachea, the œsophagus, the heart, and the abdominal viscera. They are commonly referred to as the tenth pair of cranial nerves.

Each nerve is attached to the side of the medulla, in the postero-lateral sulcus, dorsal to the olivary body, by from twelve to fifteen root filaments which are in linear series with the filaments of the glosso-pharyngeal nerve. The filaments contain both sensory and motor fibres. They pierce the pia mater, from which they receive sheaths, and, traced outward, they pass into the posterior fossa of the cranium toward the jugular foramen and unite to form the trunk of the nerve, which passes through openings in the arachnoid and the dura mater which are common to it and to the spinal accessory nerve. In the jugular foramen a small spherical ganglion, the *jugular ganglion* (ganglion of the root), is interposed in the trunk which here turns at right angles to its former course and descends through the neck. As it leaves the jugular foramen it is joined by the internal or accessory portion of the spinal accessory nerve, and immediately below this junction it enters a large ovoid ganglion, the *ganglion nodosum* or ganglion of the trunk (fig. 743). As it descends through the neck the nerve passes ventral and somewhat lateral to the superior cervical sympathetic ganglion, and in front of the longus capitis and longus colli, from which it is separated by the prevertebral fascia. In the upper part of the neck it is placed between the internal carotid artery and the internal jugular vein, and on a plane dorsal to them, the artery being ventral and mesial, and the vein ventral and lateral. In the lower part of the neck it occupies a similar position in regard to the common carotid artery and the internal jugular vein, and the three structures are enclosed in a common sheath derived from the deep cervical fascia, but within the sheath each structure occupies a separate compartment (fig. 743). In the root of the neck and in the thorax the relations of the nerves of the two sides of the body differ somewhat, and they must, therefore, be considered separately.

The right vagus passes in front of the first part of the right subclavian artery in the root of the neck and then descends in the thorax, passing obliquely downward and backward on the right of the trachea, and behind the right innominate vein and the superior vena cava, to the back of the root of the right lung. Just before it reaches the right bronchus it lies close to the medial side of the vena azygos as the latter hooks forward over the root of the lung. At the back of the right bronchus the right vagus breaks up into a number of branches which join with the branches of the sympathetic to form the **right posterior pulmonary plexus,** and from this plexus it issues in the form of one or more cords, combined sensory, visceral motor and sympathetic, which descend on the œsophagus and break up into branches which join with branches of the left vagus, forming the **posterior œsophageal plexus.** At the lower part of the thorax fibres of this plexus become again associated in one trunk which passes through the diaphragm on the *posterior*

surface of the œsophagus, and is distributed to the *posterior* surface of the stomach and to the cœliac (solar) plexus and its offsets.

The **left vagus** descends through the root of the neck between the carotid and subclavian arteries and in front of the thoracic duct. In the upper part of the superior mediastinum it is crossed in front by the left phrenic nerve, and in the lower part of the same region it crosses in

FIG. 744.—DIAGRAM OF THE BRANCHES OF THE VAGUS NERVES.

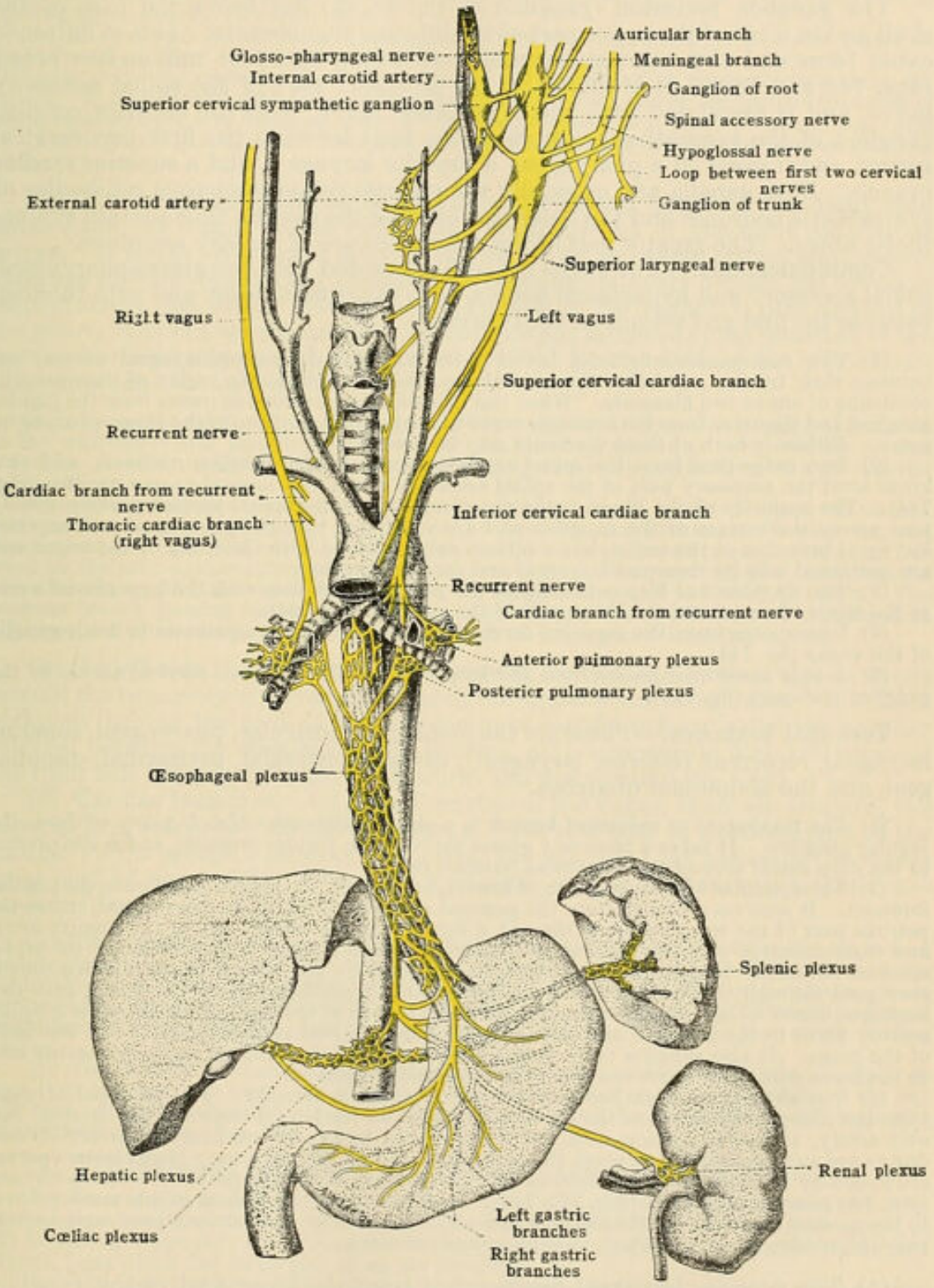

front of the root of the subclavian artery and the arch of the aorta and behind the left superior intercostal vein. Below the aortic arch it passes behind the left bronchus and divides into branches which unite with twigs of the sympathetic to form the **left posterior pulmonary plexus.** From this plexus the fibres of the left vagus issue as one or more cords that break up into anastomosing branches to form the anterior **œsophageal plexus.** At the lower part of the thorax this plexus becomes a single trunk, which passes through the diaphragm on the *anterior* surface of the œsophagus, and it is distributed to the *anterior* surface of the stomach and to the liver.

The **jugular ganglion** (ganglion of the root) is a spherical grey mass about five millimetres in diameter which lies in the jugular foramen (fig. 744). It is connected with the spinal accessory nerve and with the superior cervical sympathetic ganglion, and it gives off an auricular branch, by means of which it becomes associated with the facial and glosso-pharyngeal nerves, and a recurrent meningeal branch.

The **ganglion nodosum** (ganglion of the trunk) lies below the base of the skull and in front of the upper part of the internal jugular vein. It is of flattened ovoid form and about seventeen millimetres long and four millimetres broad (figs. 744 and 743). It is joined by the accessory part of the spinal accessory nerve, and is associated with the hypoglossal nerve, with the superior cervical ganglion of the sympathetic, and with the loop between the first two cervical nerves, and it gives off a pharyngeal, a superior laryngeal, and a superior cardiac branch. Both ganglia and especially the nodosal retain numerous cell-bodies of sympathetic neurones and the twigs issuing from the ganglia thus contain sympathetic fibres. The greater part of the cell-bodies are of sensory neurones.

Communications.—The vagus nerve is connected with the glosso-pharyngeal, spinal accessory and hypoglossal nerves, with the sympathetic, and with the loop between the first and second cervical nerves.

(1) Two communications exist between the vagus and glosso-pharyngeal nerves: one between their trunks, just below the base of the skull, and one, in the region of their ganglia, consisting of one or two filaments. When two filaments are present one passes from the jugular ganglion and the other from the auricular nerve to the petrosal ganglion of the glosso-pharyngeal nerve. Either or both of these filaments may be absent.

(2) Two twigs pass from the spinal accessory nerve to the ganglion nodosum, and at a lower level the accessory part of the spinal accessory nerve also joins the same ganglion (fig. 744). The majority of the fibres of the accessory part of the spinal accessory nerve merely pass across the surface of the ganglion and are continued into the pharyngeal and superior laryngeal branches of the vagus, but a certain number blend with the trunk of the vagus and are continued into its recurrent laryngeal and cardiac branches.

(3) Two or three fine filaments connect the ganglion nodosum with the hypoglossal nerve as the latter turns around the lower part of the ganglion (fig. 744).

(4) Fibres pass from the superior cervical ganglion of the sympathetic to both ganglia of the vagus (fig. 744).

(5) A twig sometimes passes from the loop between the first two cervical nerves to the ganglion nodosum (fig. 744).

Terminal branches.—These are the meningeal, auricular, pharyngeal, superior laryngeal, recurrent (inferior laryngeal), cardiac, bronchial, pericardial, œsophageal, and the abdominal branches.

(1) The **meningeal** or **recurrent branch** is a slender filament which is given off from the jugular ganglion. It takes a recurrent course through the jugular foramen, and is distributed to the dura mater around the transverse (lateral) sinus.

(2) The **auricular branch**, or **nerve of Arnold**, arises from the jugular ganglion in the jugular foramen. It receives a branch from the petrosal ganglion of the glosso-pharyngeal, enters the petrous part of the temporal bone through a foramen in the lateral wall of the jugular fossa, and communicates with the facial nerve or merely lies in contact with it as far as the stylo-mastoid foramen. It usually leaves the temporal bone by the stylo-mastoid foramen, but it may pass through the tympano-mastoid fissure, and it divides, behind the pinna, into two branches, one of which joins the posterior auricular branch of the facial while the other supplies sensory fibres to the posterior and inferior part of the external auditory meatus and the back of the pinna. It also supplies twigs to the osseous part of the external auditory meatus and to the lower part of the outer surface of the tympanic membrane.

(3) The **pharyngeal branches** may be two or three in number. The principal of these joins the pharyngeal branch of the glosso-pharyngeal on the lateral surface of the internal carotid artery, and after passing with the latter medial to the external carotid artery it turns downward and medialward to reach the posterior aspect of the pharynx. Here the two nerves are joined by branches from the superior cervical ganglion of the sympathetic, with which they form the **pharyngeal plexus** (figs. 743, 744). Branches from this plexus supply sensory fibres to the mucous membrane of the pharynx and motor fibres to the constrictores pharyngis, levator palatini, uvulæ, glosso-palatinus, and pharyngo-palatinus.

(4) The **superior laryngeal nerve** arises from the lower part of the ganglion nodosum, and passes obliquely downward and medialward behind and medial to both internal and external carotid arteries toward the larynx. In this course it describes a curve with the convexity downward and lateralward and divides into (i) a larger internal and (ii) a smaller external branch (fig. 744). Before its division it is joined by twigs with the sympathetic and with the pharyngeal plexus, and it gives a small branch to the internal carotid artery.

(a) The **internal branch** accompanies the superior laryngeal artery to the interval between the upper border of the thyreoid cartilage and the great cornu of the hyoid bone. It passes under cover of the thyreo-hyoid muscle and pierces the hyo-thyreoid membrane to gain the interior of the pharynx, where it lies in the lateral wall of the sinus piriformis and divides into a number of diverging branches. The ascending branches supply the mucous membrane on both surfaces of the epiglottis, and probably that of a small part of the root of the tongue. The descending branches ramify in the mucous membrane lining the larynx, and supply the mucous membrane which covers the back of the cricoid cartilage. One of the descending branches passes downward on the internal muscles of the larynx to anastomose with the terminal part of the inferior (recurrent) laryngeal nerve.

(b) The **external branch** runs downward on the inferior constrictor to the lower border of the thyreoid cartilage, where it ends, for the most part, in the crico-thyreoid muscle. A few filaments pierce the crico-thyreoid membrane and are distributed to the membrane lining the larynx. It occasionally gives off a cardiac branch which joins one of the cardiac branches of the sympathetic; it also furnishes twigs to the inferior constrictor, and communicating twigs to the pharyngeal plexus, and it receives a communication from the superior cervical ganglion of the sympathetic.

(5) The **recurrent** (**inferior** or **recurrent laryngeal**) **nerve** of the **right side** arises from the vagus at the root of the neck in front of the right subclavian artery. It hooks around the artery, passing below and then behind that vessel, and runs upward and slightly medialward, crossing obliquely behind the common carotid artery (fig. 744). Having gained the side of the trachea, it runs upward in the groove between the trachea and the œsophagus, accompanying branches of the inferior thyreoid artery, and, near the level of the lower border of the cricoid cartilage, becomes the inferior laryngeal nerve.

In its course the right recurrent nerve gives off branches to the trachea, œsophageal branches to the œsophagus and pharynx, and, near its commencement, one or more **inferior cardiac** branches. It communicates with the inferior cervical sympathetic ganglion and with the superior laryngeal nerve.

The **inferior laryngeal nerve,** the continuation of the recurrent, ascends between the trachea and œsophagus, enters the larynx under cover of the inferior constrictor of the pharynx, and divides into two branches, anterior and posterior. The *anterior branch* passes upward and forward on the crico-arytænoideus lateralis and thyreo-arytænoideus, and supplies these muscles and also the vocalis, arytænoideus obliquus, ary-epiglotticus, and thyreo-epiglotticus. The *posterior branch*, passing upward, supplies the crico-arytænoideus posterior and arytænoideus obliquus, and anastomoses with the medial branch of the superior laryngeal nerve.

On the **left side** the recurrent nerve arises in front of the aortic arch and winds around the concavity of the arch lateral to the ligamentum arteriosum. It crosses obliquely behind the root of the left common carotid artery, gains the angular interval between the œsophagus and trachea, and corresponds with the nerve of the right side in the remainder of its course and distribution (fig. 744).

(6) **Cardiac branches.**—Of these branches of the vagus, there are two sets, the superior and inferior. All the branches of both sets pass to the deep part of the cardiac plexus except a superior branch on the left side that passes to the superficial part of the cardiac plexus. All contain visceral motor, sympathetic and sensory fibres.

(a) The **superior** (**superior** and **inferior cervical**) **cardiac nerves** arise from the vagus and its branches in the neck (figs. 744, 786). Some of these branches on both sides join with the cardiac branches of the sympathetic in the neck and pass with them to the cardiac plexus. Some on the right side pass independently through the thorax to the deep part of the cardiac plexus, and a branch on the left side passes through the thorax to the superficial part of the cardiac plexus.

(b) The **inferior** (**thoracic**) **cardiac branches.**—These branches on the right side arise in part from the recurrent nerve and in part from the main trunk of the vagus, while on the left side they usually arise entirely from the recurrent. All these branches pass to the deep part of the cardiac plexus (figs. 744, 786).

(7) The **bronchial** (**pulmonary**) **branches** are anterior and posterior (fig. 744).

(a) The **anterior bronchial** (**pulmonary**) **branches** consist of a few small branches which arise at the upper border of the root of the lung. They pass forward to gain the anterior aspect of the bronchus, where they communicate with the sympathetic and form the **anterior pulmonary plexus,** from which fine twigs pass along the bronchus.

(b) The **posterior bronchial** (**pulmonary**) **branches.**—Almost the entire remaining trunk of the vagus usually divides into these branches, which join with branches from the second, third, and fourth thoracic ganglia of the sympathetic to form the **posterior pulmonary plexus** (fig. 744). The plexuses of the two sides join freely behind the bifurcation of the trachea, and branches from the plexus pass along each bronchus into the lung.

(8) The **pericardial branches** pass from the trunk of the vagus or from the bronchial or œsophageal plexuses to the anterior and posterior surfaces of the pericardium. They are chiefly sensory.

(9) **Œsophageal branches,** given off by the trunk of the nerve above the bronchial plexuses and from the œsophageal plexuses lower down, pass to the wall of the œsophagus.

(10) **Abdominal branches.**—The terminal part of the left vagus divides into many branches, some of which communicate freely along the lesser curvature of the stomach with filaments from the gastric plexus of the sympathetic, and to some extent with branches of the right vagus, to form the elongated **anterior gastric plexus** (fig. 744). From this plexus as well as from the nerve-trunk, **gastric branches** are given to the anterior surface of the stomach. **Hepatic branches** from the trunk or from this plexus pass in the lesser omentum to the hepatic plexus (fig. 744). The terminal part of the right vagus divides into many branches, and forms along the lesser curvature of the stomach an elongated **posterior gastric plexus** by communications with branches from the gastric plexus of the sympathetic and with branches from the right vagus. **Gastric branches** are given off by the trunk of the nerve and from this plexus. **Cœliac branches** are given by the trunk to the cœliac (solar) plexus, and **splenic** and **renal branches,** either directly or through the cœliac (solar) plexus, are given to the splenic and renal plexuses (fig. 744).

Central connections.—The **sensory fibres** of the vagus are processes of the cells of the jugular ganglion and the ganglion nodosum. The peripheral fibres from these cells bring in sensory impulses from the periphery, and their central fibres convey the impulses to the brain. The latter fibres enter the medulla in the filaments of attachment in the postero-lateral sulcus, and, in the reticular formation, they bifurcate into ascending and descending branches which end in the nuclei of termination of the vagus, namely, in the nucleus alæ cinereæ in the floor of the fourth ventricle and in the nucleus tractus solitarii. The tractus solitarius consists largely of the descending branches. These and the axones arising from the nuclei of termination of the vagus descend the spinal cord to terminate about ventral horn cells which give origin to the phrenic nerve and to motor fibres supplying other muscles of respiration, and they also convey impulses which are distributed to visceral motor neurones along the spinal cord.

The **motor fibres** spring from the nucleus ambiguus and from the dorsal efferent (motor) nucleus of the vagus, described on page 820. They join the sensory fibres in the reticular formation. Some of the motor fibres, especially those from the dorsal efferent nucleus, are visceral motor fibres.

The central connections of the vagus are similar to those of the glosso-pharyngeal nerve (fig. 647). Van Gehuchten's observations point to the conclusion that the chief nucleus of termination of the vagus nerve is that of the tractus solitarius.

THE SPINAL ACCESSORY NERVE

The spinal accessory nerve [n. accessorius] is exclusively motor. It consists of two parts, the accessory or superior, and the spinal or inferior part.

The fibres of the **accessory or superior portion** [ramus internus] ("accessory vagus") spring chiefly from the inferior continuation of the nucleus ambiguus, in common with the motor fibres of the vagus above, and they pass through the reticular formation to the postero-lateral sulcus of the medulla, where they emerge as a series of filaments, below those of the vagus. The filaments pierce the pia mater and unite, as they pass outward in the posterior fossa of the cranium, to form a part of the nerve which enters the aperture in the dura mater common to the vagus and spinal accessory nerves. In the aperture this trunk is joined by the spinal portion of the nerve.

The **spinal** or **inferior portion** [ramus externus] arises from the ventro-lateral cells of the ventral horn of the cord as low as the fifth, and rarely the seventh, cervical nerve. The fibres pass dorsalward and lateralward from their origins through the lateral part of the ventral horn and through the lateral funiculus of white substance, and they emerge from the lateral aspect of the cord behind the ligamentum denticulatum, along an oblique line, the lower fibres passing out immediately dorsal to the ligament, and the upper close to and sometimes in association with the dorsal roots of the upper two spinal nerves. As the spinal fibres pass out of the surface of the cord they unite to form an ascending strand which enters the posterior fossa of the cranium, through the foramen magnum, and, turning lateralward, blends more or less intimately with the accessory portion. Thus combined, the nerve enters the jugular foramen in company with the vagus, but here it is again separated into its two branches, which contain chiefly the same fibres as the original superior and inferior parts.

The **superior branch,** or accessory portion of the nerve, gives one or more filaments to the jugular ganglion (ganglion of the root of the vagus), and then joins either the trunk of the vagus directly or its ganglion nodosum, the fibres of the branch being contributed to the pharyngeal, laryngeal, and cardiac branches of the vagus. Fibres corresponding to the white rami communicantes, absent in the cervical nerves, probably enter the cervical sympathetic ganglion through this ramus of the spinal accessory nerve. The fibres from the accessory to the vagus therefore probably include visceral motor and cardio-inhibitory fibres.

The **inferior branch** or the spinal portion runs backward and downward under cover of the posterior belly of the digastric and the sterno-mastoid. It usually crosses in front of and to the lateral side of the internal jugular vein and between it and the occipital artery; then it

pierces the *sterno-mastoid*, supplies filaments to it, and interlaces in its substance with branches of the second cervical nerve. It emerges from the posterior border of the sterno-mastoid slightly above the level of the upper border of the thyreoid cartilage, passes obliquely downward and backward across the occipital portion of the posterior triangle, and disappears beneath the trapezius about the junction of the middle and lower thirds of the anterior border of that muscle (fig. 743). In the posterior triangle it receives communications from the third and fourth cervical nerves, and beneath the trapezius its fibres form a plexus with other branches of the same nerves. Its terminal filaments are distributed to the *trapezius* and they can be traced almost to the lower extremity of that muscle.

Central connections.—The nuclei of origin, like other motor nuclei, are connected with the somæsthetic area of the cerebral cortex of the opposite side by the pyramidal fibres, and they are associated with the sensory nuclei of other cranial nerves by the medial longitudinal fasciculus, and with sensations brought in by the spinal nerves by the fibres of the fasciculi proprii.

THE GANGLIATED CEPHALIC PLEXUS

The Sympathetic Ganglia of the Head and Their Associations with the Cranial Nerves

The sympathetic system of the head, like that of the remainder of the body described below, is arranged in the form of a continuous gangliated plexus subdivided into sub-plexuses. Unlike the great unpaired prevertebral plexuses in the thoracic and abdominal cavities, all the larger sympathetic ganglia of the head are paired, ganglia corresponding to each other being found on either side. Thus they may be considered as an upward extension of the series of paired lumbar, thoracic and cervical ganglia belonging to the sympathetic trunks lying along either side of the vertebral column. Numerous small ganglia, many of them microscopic, occur in the sub-plexuses throughout the head. These are irregular in size and position and those in the region of the median line are no doubt unpaired.

In **origin,** the ganglia of the cephalic plexus consist of cell-bodies which, in the early stages of development, migrated from the fundaments of the ganglia of the vagus, glosso-pharyngeal and glosso-palatine nerves, and most especially from that of the semilunar (Gasserian) ganglion of the trigeminus—a developmental relation identical with that of the remainder of the sympathetic system to the ganglia of the spinal nerves. Just as is known for the spinal ganglia, some cell-bodies destined to develop into sympathetic neurones, instead of migrating, remained within the confines of the ganglia of the above nerves, in company with the cell-bodies of their sensory neurones. This is thought to be especially true for the geniculate, the petrosal and the jugular ganglion. Therefore these ganglia must be considered as in small part sympathetic ganglia.

The gangliated cephalic plexus could properly be included as a division of the general sympathetic system described later. However, because its larger ganglia are so intimately associated with branches of the oculomotor, trigeminal, masticator, glosso-palatine, glosso-pharyngeal and vagus nerves, it is customary to describe it in connexion with the cranial nerves.

The larger **ganglia,** one on either side of the head, comprise the ciliary ganglion, the spheno-palatine (Meckel's) ganglion, the otic and the submaxillary ganglion. To these must be added portions of the geniculate, petrosal, jugular and the ganglion nodosum, and a part of the superior cervical sympathetic ganglion. The chief relations of the gangliated cephalic plexus to the cranial nerves are shown in fig. 741.

The so-called **roots and branches of the ganglia** carry three varieties of fibres: (1) Sensory, (2) Motor (visceral motor or preganglionic), and (3) Sympathetic. Most roots and branches are mixed, the name of a root being determined only by the variety of fibres predominating in it.

A bundle of sensory fibres going to a ganglion is called its **sensory root.** Such, however, cannot comprise a true root since none of its fibres arises in the ganglion and very few or none may terminate in it. The only sensory fibres terminating in a ganglion are the few which may approach it in any of the roots to terminate in its capsule or the capsules of its cells and convey impulses of general sensibility from the ganglion to the central nervous system. Almost all of the fibres of a "sensory root" merely pass around or through a ganglion and into its branches beyond, which they borrow as paths for reaching their allotted fields of distribution. In this relation it should be realized that while the ciliary, spheno-palatine, otic and submaxillary ganglia are customarily described under the discussion of the trigeminus, this nerve has functionally less to do with them than any of the other cranial nerves with which they are associated. Bundles of trigeminal (sensory) fibres, traceable in gross anatomy because medullated and of appreciable size, pass to the ganglia, but only to pass through them as continuations of the terminal branches of the trigeminus.

The so-called **motor root** of a ganglion may carry two kinds of fibres: (a) visceral motor (preganglionic) fibres, arising in the nuclei of origin in the central system and passing in the trunk

and branches of a cranial nerve (oculomotor, masticator, etc.) to enter and terminate in contact with the cell-bodies of the ganglion, which, in their turn, give fibres to the branches of the ganglion; (b) fibres of the same origin, name and course but which may pass through the ganglion to terminate in contact with the cells of a more distant ganglion. Any root, the motor especially, may contain somatic motor fibres, that is, fibres of central origin which pass through the ganglion uninterrupted and into its branches to terminate upon the fibres of skeletal (voluntary) muscle.

A **sympathetic root** likewise may carry two and perhaps three varieties of fibres conforming to the name: (a) fibres arising from the cells of other sympathetic ganglia and terminating in the ganglion in question; (b) fibres arising in other ganglia which pass through the ganglion in question to enter its branches and terminate either in other ganglia or upon their allotted muscular or glandular elements. A third is the fibre of the sensory sympathetic neurone, probably quite rare, which may arise from a cell-body in the ganglion and pass centralward in its root and in the appropriate cranial nerve to terminate about a cell-body of the dorsal-root or spinal ganglion type, the central process of which latter conveys this sensory impulse of sympathetic origin into the central system just as sensory cranio-spinal impulses are conveyed.

FIG. 745.—DIAGRAM TO ILLUSTRATE THE STRUCTURAL RELATIONS OF THE ROOTS AND BRANCHES OF A CEPHALIC SYMPATHETIC GANGLION. Sensory fibres, blue; motor, red; sympathetic, black.

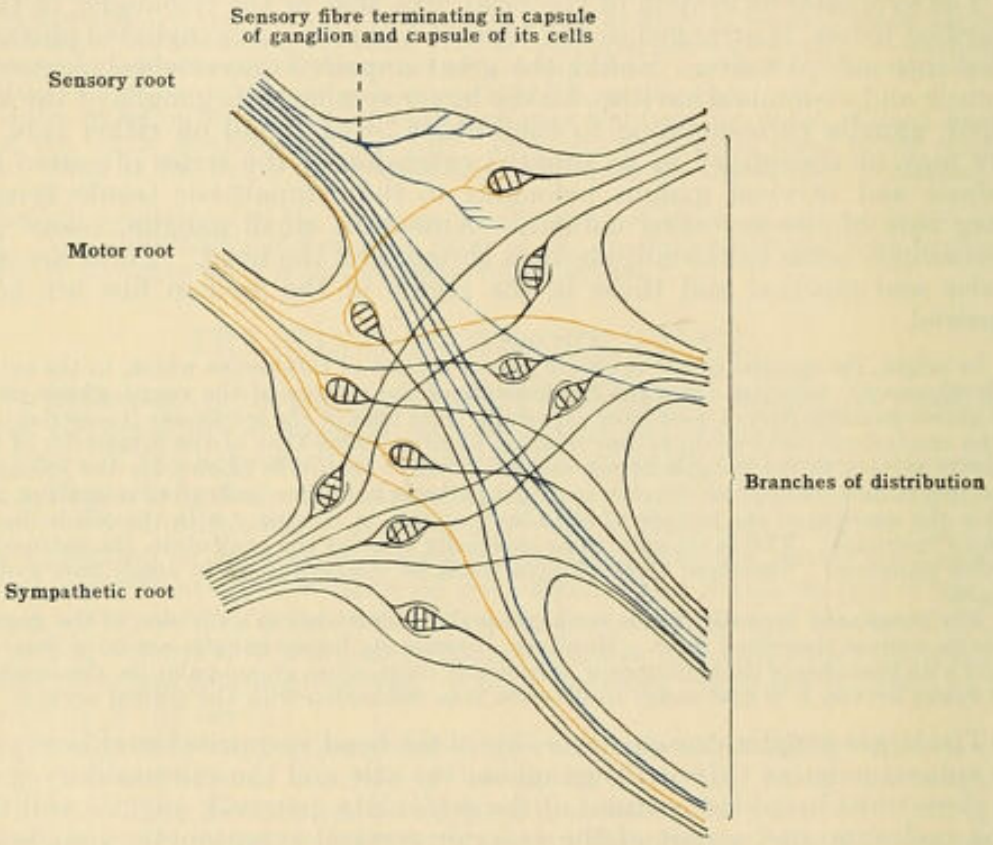

The **branches of distribution** of the ganglia, the larger of them often called nerves, are those bundles in which the fibres, both arising in or passing through the ganglia, course toward their terminations upon their allotted tissue elements of the head. The larger ganglia of the head are described as each possessing the three roots above mentioned. In the branches pass fibres motor to the vessels of the head, to the intrinsic muscles of the eye bulb, to the lacrimal glands, the mucous membranes (gland cells) of the nasal and oral cavities and the salivary glands, and sensory fibres conveying impulses from these structures.

The **plexuses** into which the gangliated cephalic plexus is divided and which connect the ganglia to form it, are numerous and vary greatly in size. They underlie the mucous membranes and they surround all the vessels and glands. They are named according to their locality. The largest of them are the tympanic plexus and the carotid and cavernous plexuses. They have been repeatedly referred to in their relations to the branches of the cranial nerves.

Of the numerous branches described from the **superior cervical sympathetic ganglion,** the two large ones which pass upward associate it especially with the gangliated cephalic plexus. That branch known as the *internal carotid nerve* may be considered as the direct continuation upward of the gangliated sympathetic trunk of the body. Through the branches of this, the carotico-tympanic and the deep petrosal nerves, and through the plexuses derived from it, the superior cervical ganglion may be associated with practically all the other sympathetic ganglia of the head (figs. 739 and 741). The other branch from the superior cervical ganglion, the *jugular nerve*, associates it with the ganglia of the glosso-pharyngeal and vagus nerves, with the petrosa ganglion by a direct branch and with the ganglia of the vagus through the nodosal plexus. These latter ganglia (and the nerves to which they belong) are connected, chiefly by

way of the tympanic nerve, which is from the petrosal ganglion, with the tympanic plexus (fig. 741).

The **tympanic plexus** serves as a common point of distribution of fibres from the superior cervical sympathetic ganglion, the ganglia of the vagus, the petrosal ganglion, and the geniculate ganglion, to the cavernous and carotid plexuses and to the spheno-palatine and otic ganglia. The superior cervical ganglion is associated with the cavernous and carotid plexuses direct by the internal carotid nerve and with the tympanic plexus by the inferior and superior carotico-tympanic nerves. The tympanic plexus receives fibres from the geniculate ganglion by a small *geniculo-tympanic branch* and it is connected with the spheno-palatine ganglion by a small anastomotic or *tympano-petrosal branch* to the great superficial petrosal nerve, and with the otic ganglion by the small superficial petrosal nerve. It is not directly connected with either the ciliary or the submaxillary ganglion. However, these ganglia, as well as the sphenopalatine and otic, are connected with the carotid plexus either directly by named branches or indirectly by way of plexuses derived from the carotid. The geniculo-tympanic branch, the tympanic nerve and twigs of the nodosal plexus may be considered as analogous to the rami communicantes of the spinal nerves.

The *parotid branches*, described above as branches of the auriculo-temporal nerve (from the trigeminus) and as containing fibres from the glossopharyngeal, should be mentioned here as belonging to the gangliated cephalic plexus. These branches are sympathetic fibres arising in the otic ganglion and passing as branches of the ganglion to the auriculo-temporal in which they remain till this nerve enters the parotid gland and then they are distributed to the gland. The visceral motor or preganglionic fibres which terminate about their cells of origin in the otic ganglion are derived from the glosso-pharyngeal nerve and pass successively through the tympanic nerve, the tympanic plexus, and the small superficial petrosal nerve to the otic ganglion.

The *tympanic nerve* (tympanic branch of the glosso-pharyngeal, or nerve of Jacobson), the branch to the Eustachian tube (*ramus tubæ*), and the superior and inferior *carotico-tympanic branches* are also described as branches of the glosso-pharyngeal nerve. These must likewise be considered as belonging to the gangliated cephalic plexus.

For purposes of dissection, it may be more expedient to consider separately, with its roots and branches, each of the larger ganglia of the gangliated cephalic plexus. Under this heading belong in part the *geniculate ganglion* of the glosso-palatine nerve, and the *ganglia of the glosso-pharyngeal and vagus*, especially the petrosal ganglion of the former and the jugular ganglion of the latter, from the fact that these ganglia contain numerous cell-bodies of sympathetic neurones as well as those of the sensory neurones of their nerves.

These ganglia, however, have been described with their corresponding cranial nerves. The sensory and motor roots of their sympathetic portions are contained in the roots of their nerves. The geniculate probably has no sympathetic root. The sympathetic roots of the petrosal and jugular ganglia are contained in the branches of the jugular nerve. The chief branches of distribution of the geniculate are the geniculo-tympanic branch, the great superficial petrosal nerve, and the external superficial petrosal nerve. The branches of the petrosal ganglion are the tympanic nerve and its branches of the tympanic plexus. The chief branch of distribution from the jugular ganglion is contained in the auricular branch of the vagus, or nerve of Arnold, supplemented by sympathetic fibres in the trunk of the vagus itself.

The principal cephalic sympathetic ganglia are the ciliary, the spheno-palatine (Meckel's), the otic and the submaxillary.

The Ciliary Ganglion

The ciliary, lenticular, or ophthalmic ganglion lies in the posterior part of the orbital cavity, about 6 mm. in front of the superior orbital (sphenoidal) fissure, to the lateral side of the optic nerve, and between the optic nerve and the external rectus muscle. It is a small, reddish, quadrangular body, compressed laterally, and it measures about two millimetres from before backward (fig. 734).

Roots.—(*a*) Its motor or short root enters its lower and posterior angle and is a visceral motor branch derived from the branch of the inferior division of the oculomotor nerve which supplies the inferior oblique muscle. The fibres of the motor root probably all terminate in the ciliary ganglion in connection with motor sympathetic neurones.

(*b*) The sensory or long root passes through the upper and back part of the ganglion. It is a branch of the naso-ciliary (nasal) nerve and is, therefore, composed of fibres from the trigeminus passing through the ganglion.

(*c*) The sympathetic root consists of fibres derived from the cavernous plexus of the sympathetic; it passes to the ganglion with the long root.

Branches.—From three to six **short ciliary nerves** emerge from the anterior border of the ganglion; they divide as they pass forward and eventually form about twenty nerves which are arranged in an upper and a lower group, and the latter group is joined by the long ciliary branches of the naso-ciliary (nasal) nerve, now sensory and sympathetic (fig. 734). When they reach the eyeball, the ciliary nerves pierce the sclerotic around the optic nerve, and pass forward in grooves on the inner surface of the sclera. The sympathetic fibres contained are distributed as motor fibres to the ciliary muscle, the sphincter of the iris, and to the vessels of these and of the cornea.

The Spheno-palatine or Meckel's Ganglion

This ganglion is associated with the maxillary nerve (fig. 743). It is a small reddish-grey body of triangular form, which is flattened at the sides, and measures about five millimetres from before backward. It lies deeply in the pterygo-palatine (spheno-maxillary) fossa at the lateral side of the spheno-palatine foramen and in front of the anterior end of the pterygoid (Vidian) canal. It is attached to the maxillary nerve, from which it receives its sensory root, and it is connected with the Vidian nerve, which furnishes it with motor and sympathetic filaments (fig. 739).

The exact position of the ganglion depends upon the size and shape of the sphenoidal air cells. When these are small, or high and narrow, the ganglion lies lateral to them; when they are large, or broad and flat, the ganglion lies inferior to them. Sometimes it may lie anterior to them if the cells are short from in front backward. The ganglion may be reached with ease by chipping away the bone around the sphenoidal air cells after the skull is divided sagitally.

Roots.—(*a*) Its **motor root,** consisting of visceral motor fibres of the glosso-palatine nerve, is contained in the great superficial petrosal nerve which is incorporated in the Vidian nerve. It springs from the anterior angle of the geniculate ganglion and passes through the hiatus of the facial canal (hiatus Fallopii) into the middle fossa of the cranium, where it runs forward and medialward, in a groove on the upper surface of the petrous part of the temporal bone, to the foramen lacerum, and in this part of its course it passes beneath the semilunar (Gasserian) ganglion and the masticator nerve. In the foramen lacerum it joins with the great deep petrosal nerve to form the Vidian nerve (nerve of the pterygoid canal), which passes forward through the pterygoid (Vidian) canal and its motor and sympathetic fibres terminate in the spheno-palatine ganglion in the pterygo-palatine (spheno-maxillary) fossa. The great superficial petrosal nerve contains sensory as well as sympathetic and motor fibres. The sensory fibres pass through the ganglion and, in the small palatine nerve, descend to the soft palate, where they terminate in the epithelium covering it and some are probably concerned with peripheral taste organs found there. They arise from the cells of the geniculate ganglion and therefore belong to the glosso-palatine nerve.

(*b*) The **sympathetic root** is the great deep petrosal portion of the Vidian nerve. This root, which is of reddish colour and of soft texture, springs from the carotid plexus which lies on the outer side of the internal carotid artery in the carotid canal. It enters the foramen lacerum through the apex of the petrous portion of the temporal bone, and unites with the great superficial petrosal branch of the facial nerve to form the Vidian nerve. The great superficial petrosal nerve also carries sympathetic fibres to the spheno-palatine ganglion, derived from the geniculate ganglion and from the tympanic plexus.

The **Vidian nerve [n. canalis pterygoidei]** commences by the union of the great superficial and deep petrosal nerves in the foramen lacerum, and runs forward through the pterygoid (Vidian) canal to the pterygo-palatine (spheno-maxillary) fossa to the spheno-palatine ganglion. The Vidian nerve often may be seen in a ridge of bone along the floor of the sphenoidal cells and its direction there depends upon the position of the spheno-palatine ganglion. While it is in the pterygoid canal the Vidian nerve is joined by a sphenoidal filament from the otic ganglion, and it gives branches to the upper and back part of the roof and septum of the nose, and to the lower end of the Eustachian tube.

(*c*) The **sensory roots** consist of the sensory fibres mentioned above in the great superficial petrosal nerve and of usually two spheno-palatine branches from the maxillary nerve. The majority of the fibres of these roots do not join the ganglion, but pass by its medial side and enter the palatine branches.

Branches.—The branches of the ganglion, containing sensory, vaso-motor and secretory fibres, are orbital or ascending, internal or nasal, descending or palatine, and posterior or pharyngeal.

Ascending branches.—The **orbital or ascending branches** are two or three small twigs which enter the orbit through the inferior orbital (spheno-maxillary) fissure and proceed, within the periosteum, to the inner wall of the orbit, where they pass through the posterior ethmoidal foramen and through the foramina in the suture behind that foramen to be distributed to the mucous membrane which lines the posterior ethmoidal cells and the sphenoidal sinus.

Internal branches.—The internal or nasal branches are derived in part from the medial side of the ganglion, but are also largely made up of fibres which pass from the spheno-palatine branches of the maxillary nerve without traversing the ganglionic substance. They are disposed in two sets, the lateral and the medial (septal) posterior superior nasal branches.

The **lateral posterior superior nasal branches** are six or seven small twigs which pass through the spheno-palatine foramen, and are distributed to the mucous membrane covering the posterior parts of the superior and middle nasal conchæ (turbinated bones) (fig. 732). They also furnish twigs to the lining membrane of the posterior ethmoidal cells.

The **medial posterior superior nasal (septal) branches,** two or three in number, pass medialward through the spheno-palatine foramen. They cross the roof of the nasal fossa to reach the back part of the nasal septum, where the smaller twigs terminate. The largest nerve of the set, the **naso-palatine nerve,** or **nerve of Cotunnius,** runs downward and forward in a groove in the vomer between the periosteum and the mucous membrane to the incisive (anterior palatine) canal, where it communicates with the nasal branch of the anterior superior alveolar nerve. The two naso-palatine nerves then pass through the foramina of Scarpa in the intermaxillary suture, the left nerve passing through the anterior of the two foramina. In the lower part of the incisive (anterior palatine) canal the two nerves form a plexiform communication (for-

merly described as Cloquet's ganglion) and they furnish twigs to the anterior or premaxillary part of the hard palate behind the incisor teeth. In this situation they communicate with the anterior palatine nerves.

Descending branches.—The descending branches are the great or anterior, the posterior, and the middle (external) palatine nerves. Like the internal set of branches, they are in part derived from the ganglion and in part are directly continuous with the spheno-palatine nerves (fig. 732).

The **great** or **anterior palatine** nerve, its sensory fibres derived from the maxillary nerve, arises from the inferior angle of Meckel's ganglion, and passes downward through the pterygo-palatine canal, accompanied by the descending palatine artery. Emerging from the canal at the greater (posterior) palatine foramen it divides into two or three branches, which pass forward in grooves in the hard palate and supply the glands and mucous membrane of the hard palate and the gums on the inner aspect of the alveolar border of the upper jaw. During its course through the pterygo-palatine canal the anterior palatine nerve gives off the **posterior inferior nasal nerves.** These nerves pass through small openings in the perpendicular plate of the palate bone to supply the mucous membrane covering the posterior part of the inferior nasal concha (turbinated bone) and the adjacent portions of the middle and inferior meatuses of the nose.

The **posterior** or **small palatine nerve** passes downward through a lesser palatine foramen (accessory palatine canal), and enters the soft palate, distributing branches to that organ, to the uvula, and to the tonsil. Its sensory fibres are derived from the glosso-palatine nerve, through the great superficial petrosal nerve and through the spheno-palatine ganglion. It was formerly believed to convey motor fibres from the facial nerve to the levator palati and azygos uvulæ, but it is now believed that these muscles are supplied by the spinal accessory nerve through the pharyngeal plexus (fig. 732).

The **middle** (**external**) **palatine nerve,** the smallest of the three, in part, likewise from the glosso-palatine nerve, traverses a lesser palatine foramen and supplies twigs to the tonsil and to the adjacent part of the soft palate (fig. 732).

Posterior branch.—The **pharyngeal branch,** which is of small size, passes backward and somewhat medialward through the pharyngeal canal accompanied by a pharyngeal branch of the spheno-palatine artery. It is distributed to the mucous membrane of the uppermost part of the pharynx, to the upper part of the posterior nares, to the opening of the Eustachian tube, and to the lining of the sphenoidal sinus. Its sensory fibres are derived from the maxillary nerve.

The Otic Ganglion

The otic or Arnold's ganglion is a small reddish-grey body which is associated with the mandibular nerve. It lies deeply in the zygomatic fossa, immediately below the foramen ovale, on the inner side of the trunk of the mandibular nerve. It is in relation internally with the tensor palati, which separates it from the Eustachian tube. In front of it is the posterior border of the pterygoideus internus, and behind it lie the middle and small meningeal arteries. It is compressed laterally, and its greatest diameter, which lies antero-posteriorly, is about three millimetres.

Roots.—The ganglion is closely connected with the nerve to the pterygoideus internus, through which it may receive a motor root from the masticator nerve. Through the small superficial petrosal nerve, which joins the upper and back part of the ganglion, it receives a motor root from the glosso-palatine nerve and sensory and motor fibres from the glosso-pharyngeal nerve. It receives also a slender *sphenoidal filament* from the Vidian nerve. The **sympathetic roots** are derived from the small superficial petrosal nerve and from the sympathetic plexus on the middle meningeal artery.

Branches.—The communicating branches which pass from the ganglion are:—(1) The filaments to the chorda tympani; some of whose fibres probably terminate in the submaxillary ganglion; (2) filaments to the auriculo-temporal nerve; (3) filaments to the spinous nerve (the recurrent branch of the mandibular nerve). The branches of distribution are sympathetic to the vessels and somatic motor branches to the tensor tympani, and tensor veli palatini.

The Submaxillary Ganglion

The submaxillary ganglion is suspended from the lingual division of the mandibular nerve by anterior and posterior branches. It is a small reddish body, of triangular or fusiform shape, which lies between the mylo-hyoideus and hyoglossus and above the duct of the submaxillary gland.

Roots.—The **sensory root** is received from the lingual nerve. The **motor root** is from both the masticator nerve by way of the lingual nerve, and from the glosso-palatine nerve by way of the chorda tympani. The motor fibres pass from the chorda tympani after it has joined the lingual, and the sensory fibres come directly from the lingual nerve. The **sympathetic root** is formed by filaments from the sympathetic plexus on the facial artery.

Branches.—(*a*) Five or six glandular branches are given to the submaxillary gland and to Wharton's duct.

(*b*) Branches to the lingual nerve and the sublingual gland.

(*c*) To the mucous membrane of the floor of the mouth.

II. THE SPINAL NERVES

The spinal nerves are arranged in pairs, the nerves of each pair being symmetrical in their attachment to either side of their respective segment of the spinal cord, and, in general, symmetrical in their course and distribution. There are usually thirty-one pairs of functional spinal nerves. For purposes of description these are topographically separated into *eight* pairs of *cervical* nerves, *twelve* pairs of *thoracic* nerves, *five* pairs of *lumbar*, *five* pairs of *sacral*, and *one* pair of *coccygeal* nerves. Occasionally the coccygeal or thirty-first pair is practically wanting, while, on the other hand, there may be frequently found small filaments representing one or even two additional pairs of coccygeal nerves below the thirty-first pair. These **rudimentary coccygeal nerves** are probably not functional. They never pass outside the vertebral canal, and often even remain within the tubular portion of the filum terminale. There sometimes occurs an increase in the number of vertebræ in the vertebral column and in such cases there is always a corresponding increase in the number of the spinal nerves.

Origin and attachment.—Each spinal nerve (unlike the cranial nerves) is attached to the spinal cord by two roots:—a sensory or afferent **dorsal root** [radix posterior] and a motor or efferent **ventral root** [radix anterior]. Each dorsal root has interposed in its course an ovoid mass of nerve-cells, the **spinal ganglion,** and the nerve-fibres forming the root arise from the cells of this ganglion and are thus of peripheral origin. The fibres composing the ventral root, on the other hand, are of central origin; they arise from the large motor cells of the ventral horn of the grey column within the spinal cord.

Each dorsal root-fibre upon leaving its cell of origin pursues a short tortuous course within the spinal ganglion and then undergoes a T-shaped bifurcation, one product of which passes toward the periphery, where it terminates for the collection of sensations and is known as the *peripheral branch*, or, since it conveys impulses toward the cell-body, the *dendrite* of the spinal

FIG. 746.—VENTRAL AND DORSAL VIEWS OF SPINAL CORD SHOWING MANNER OF ATTACHMENT OF DORSAL AND VENTRAL ROOTS.

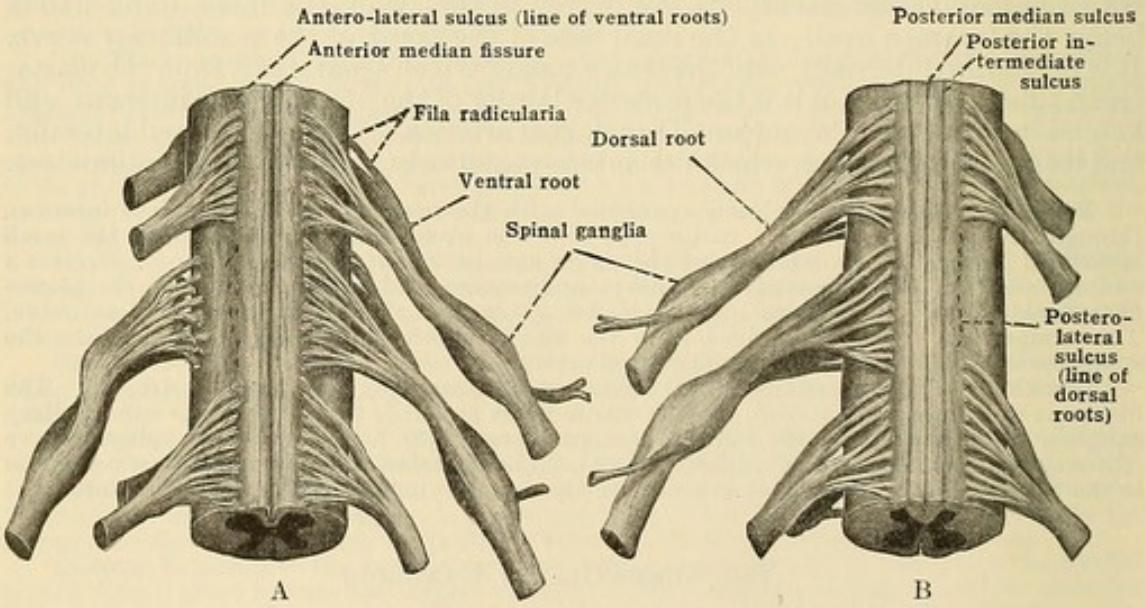

ganglion neurone. It is more correct, however, to consider the T-fibre as a bifurcated axone. The other product of the bifurcation, the *central branch*, passes into the spinal cord and in its course toward the cord contributes to form the dorsal root proper.

The central branches, upon emerging from the spinal ganglia, form a single compact bundle at first, which passes through the dura mater of the spinal cord and then breaks up into a series of **root-filaments** [fila radicularia]. These thread-like bundles of fibres spread out vertically in a fan-like manner and enter the cord in a direct linear series along its postero-lateral sulcus. The fibres of the ventral root emerge from the cord in a series of more finely divided root filaments, which, unlike the entering filaments of the dorsal root, are not arranged in direct linear series, but make their exit over a strip of the ventro-lateral aspect of the cord in some places as much as two millimetres wide.

As they enter the spinal cord the fibres of the dorsal roots undergo a Y-shaped division, both products of which course in the cord longitudinally, an ascending and a descending branch. The descending or caudal branches are shorter than the ascending, and soon enter and terminate

about the cells within the grey column of the cord, forming either associational, commissural, or reflex connections, or about cells whose fibres form cerebellar connections. The ascending or cephalic branches are either short, intermediate, or long. The short and intermediate branches are similar in function to the descending branches, save that they become associated with the grey substance of segments of the cord above rather than below the level of their entrance. The long branches convey impulses destined for the structures of the brain, and pass upward in the fasciculus gracilis or fasciculus cuneatus of the cord, and terminate in the nuclei of these fasciculi in the medulla oblongata (figs. 618 and 620).

Aberrant spinal ganglia.—In serial sections on either side of the spinal ganglion of a nerve there may often be found outlying cells either scattered or in groups of sufficient size to be called small ganglia. Such are more often found in the dorsal roots of the lumbar and sacral nerves. These cells are nothing more than spinal ganglion-cells displaced in the growth processes, and have the same nature and function as those in the ganglion. In some animals occasional cells very rarely have been found in the outer portion of the ventral root. These probably represent afferent fibres which enter the cord by way of the ventral root. Likewise, especially in the birds and amphibia, it has been shown that occasional efferent fibres may pass from the grey substance of the cord to the periphery by way of the dorsal instead of the ventral root.

Relative size of the roots.—The sensory or dorsal root is larger than the ventral root, indicating that the sensory area to be supplied is greater and perhaps more abundantly innervated than the area requiring motor fibres.

It has been shown that in the entire thirty-one spinal nerves of one side of the body of man the dorsal root-fibres number 653,627, while all the corresponding ventral roots contain but 233,700 fibres, a ratio of 3.2 : 1. (Ingbert.) In the increase in the size of the nerves for the supply of the limbs the gain of dorsal root or sensory fibres is far greater than the gain of ventral root-fibres. The first cervical or the sub-occipital nerve is always an exception to the rule; its dorsal root is always smaller than its ventral, and in rare cases may be rudimentary or entirely absent. The spinal ganglion and, therefore, the sensory root of the coccygeal nerve, is also quite frequently absent.

The dorsal and ventral root-fibres of each spinal nerve proceed outward from their segment of attachment to the spinal cord, pierce the pia mater and arachnoid, collect to form their respective roots, and pass into their respective intervertebral foramina. On the immediate peripheral side of the spinal ganglion the two roots blend, giving origin to the thus mixed **nerve-trunk.** As the trunk, the sensory and motor fibres make their exit from the vertebral canal through the intervertebral foramen.

Relation to the meninges.—The root filaments of each nerve receive connective-tissue support from the pia mater and arachnoid in passing through them. In the sub-arachnoid cavity they become assembled into their respective nerve-roots; and the roots, closely approaching each other, pass into the dura mater, from which they receive separate sheaths at first, but at the peripheral side of the ganglion these sheaths blend into one, which, with the subsequent blending of the roots, becomes the sheath or epineurium of the nerve trunk. By means of the sheaths derived from the meninges, especially the dura, the nerve-roots and the trunk are attached to the periosteum of the margins of the intervertebral foramina and thus are enabled to give some lateral support to the spinal cord in the upper portion of the canal.

The majority of the spinal ganglia lie in the intervertebral foramina, closely ensheathed, and thus outside the actual sac or cavity of the dura mater. The ganglia of the last lumbar and first four sacral nerves lie inside the vertebral canal, but since the sheath derived from the dura mater closely adheres to them, they are still outside the sac of the dura mater. The ganglia of the last sacral and of the coccygeal nerves (when present) lie in tubular extensions of the sub-dural cavity, and thus not only within the vertebral canal, but actually within the sac of the dura mater. The trunk of the first cervical nerve is assembled within the sac of the dura mater, and, therefore, the spinal ganglion of this nerve, when present, may lie within the sac.

Course and direction of emergence.—Invested with the connective-tissue sheath derived from the meninges, each thoracic, lumbar and sacral nerve emerges from the vertebral canal through the intervertebral foramen below the corresponding vertebra, and all the nerves are in relation with the spinal rami of the arteries and veins associated with the blood supply of the given localities of the spinal cord.

The first cervical nerve does not pass outward in an intervertebral foramen proper, but between the occipital bone and the posterior arch of the atlas and beneath the vertebral artery. Thus the eighth or last cervical nerve emerges between the seventh cervical and the first thoracic vertebra.

The first and second pairs of cervical nerves pass out of the vertebral canal almost at right angles to the levels of their attachment to the spinal cord. During the early periods of development the level of exit of each pair of spinal nerves is opposite the level of its attachment to the

cord, but, owing to the fact that in the later periods the vertebral column grows more rapidly than the cord and increases considerably in length after the cord has practically ceased growing, all the spinal nerves, with the exception of the first two, pass downward as well as outward. The obliquity of their course from the level of attachment to the level of exit increases progressively from above downward, and, as the cord ends at the level of the first or second lumbar vertebra, the roots of the lower lumbar and of the sacral nerves pass at first vertically downward within the dura mater, and form around the filum terminale a tapering sheaf of nerve-roots, the **cauda equina** (horse's tail) (fig. 613, p. 773).

Topography of attachment.—The relations between the levels of attachment of the spinal nerves to the cord and the spinous processes of the vertebræ situated opposite these levels have been investigated by Nuhn and by Reid. The following table compiled by Reid gives the extreme limits of attachment as observed in six subjects.

TABLE OF TOPOGRAPHY OF ATTACHMENT OF SPINAL NERVES TO THE SPINAL CORD. (Reid.)

(A) signifies the highest level at which the root filaments of a given nerve are attached to the cord, and (B) the lowest level observed. For example, the root filaments of the sixth thoracic nerve *may* be attached as high as the lower border of the spinous process of the second thoracic vertebra, or some may be attached as low as the upper border of the spinous process of the fifth thoracic vertebra, but in a given subject they do not necessarily extend either as high or as low as either of the levels indicated.

Nerves		
Second cervical	(A)	A little above the posterior arch of atlas.
	(B)	Midway between posterior arch of atlas and spine of epistropheus.
Third "	(A)	A little below posterior arch of atlas.
	(B)	Junction of upper two-thirds and lower third of spine of epistropheus.
Fourth "	(A)	Just below upper border of spine of epistropheus.
	(B)	Middle of spine of third cervical vertebra.
Fifth "	(A)	Just below lower border of spine of epistropheus.
	(B)	Just below lower border of spine of fourth cervical vertebra.
Sixth "	(A)	Lower border of spine of third cervical vertebra.
	(B)	Lower border of spine of fifth cervical vertebra.
Seventh "	(A)	Just below upper border of spine of fourth cervical vertebra.
	(B)	Just above lower border of spine of sixth cervical vertebra.
Eighth "	(A)	Upper border of spine of fifth cervical vertebra.
	(B)	Upper border of spine of seventh cervical vertebra.
First thoracic	(A)	Midway between spines of fifth cervical and sixth cervical vertebra.
	(B)	Junction of upper two-thirds and lower third of interval between seventh cervical and first thoracic vertebra.
Second "	(A)	Lower border of spine of sixth cervical vertebra.
	(B)	Just above lower border of spine of first thoracic vertebra.
Third thoracic	(A)	Just above middle of spine of seventh cervical vertebra.
	(B)	Lower border of spine of second thoracic vertebra.
Fourth "	(A)	Just below upper border of spine of first thoracic vertebra.
	(B)	Junction of upper third and lower two-thirds of spine of third thoracic vertebra.
Fifth "	(A)	Upper border of spine of second thoracic vertebra.
	(B)	Junction of upper quarter and lower three-quarters of spine of fourth thoracic vertebra.
Sixth "	(A)	Lower border of spine of second thoracic vertebra.
	(B)	Just below upper border of spine of fifth thoracic vertebra.
Seventh "	(A)	Junction of upper third and lower two-thirds of spine of fourth thoracic vertebra.
	(B)	Just above lower border of spine of fifth thoracic vertebra.
Eighth "	(A)	Junction of upper two-thirds and lower third of interval between spines of fourth thoracic and fifth thoracic vertebra.
	(B)	Junction of upper quarter and lower three-quarters of spine of sixth thoracic vertebra.
Ninth "	(A)	Midway between spines of fifth thoracic and sixth thoracic vertebra.
	(B)	Upper border of spine of seventh thoracic vertebra.
Tenth "	(A)	Midway between spines of sixth thoracic and seventh thoracic vertebra.
	(B)	Middle of the spine of eighth thoracic vertebra.
Eleventh "	(A)	Junction of upper quarter and lower three-quarters of spine of seventh thoracic vertebra.
	(B)	Just above spine of ninth thoracic vertebra.
Twelfth "	(A)	Junction of upper quarter and lower three-quarters of spine of eighth thoracic vertebra.
	(B)	Just below spine of ninth thoracic vertebra.
First lumbar	(A)	Midway between spines of eighth thoracic and ninth thoracic vertebræ.
	(B)	Lower border of spine of tenth thoracic vertebra.
Second "	(A)	Middle of spine of ninth thoracic vertebra.
	(B)	Junction of upper third and lower two-thirds of spine of eleventh thoracic vertebra.

Nerves		
Third	"	(A) Middle of spine of tenth thoracic vertebra. (B) Just below spine of eleventh thoracic vertebra.
Fourth	"	(A) Just below spine of tenth thoracic vertebra. (B) Junction of upper quarter and lower three-quarters of spine of twelfth thoracic vertebra.
Fifth	"	(A) Junction of upper third and lower two-thirds of spine of eleventh thoracic vertebra. (B) Middle of spine of twelfth thoracic vertebra.
First sacral		(A) Just above lower border of spine of eleventh thoracic vertebra.
Fifth	"	(B) Lower border of spine of first lumbar vertebra.
Coccygeal		(A) Lower border of spine of first lumbar vertebra. (B) Just below upper border of spine of second lumbar vertebra.

Relative size of the nerves.—The size of the different spinal nerves varies greatly. Just as the spinal cord shows marked enlargements in the cervical and lumbar regions necessitated by the greater amount of innervation required of these regions for the structures of the upper and lower limbs, so the nerves attached to these regions are considerably larger than elsewhere.

The smaller nerves are found at the two extremities of the cord and in the mid-thoracic region. The smallest nerve is the coccygeal, and the next in order of size are the lower sacral and the first two or three cervical nerves. The largest nerves are those which contribute most to the great nerve trunks for the innervation of the skin and muscles of the limbs:—the lower cervical and first thoracic for the upper limbs and the lower lumbar and first sacral for the lower limbs. The nerves gradually increase in the series in passing from the smaller toward the larger.

FIG. 747.—DIAGRAMS ILLUSTRATING THE ORIGIN AND DISTRIBUTION OF A TYPICAL SPINAL NERVE.

A, in thoracic region; B, in region of a limb (highly schematic).

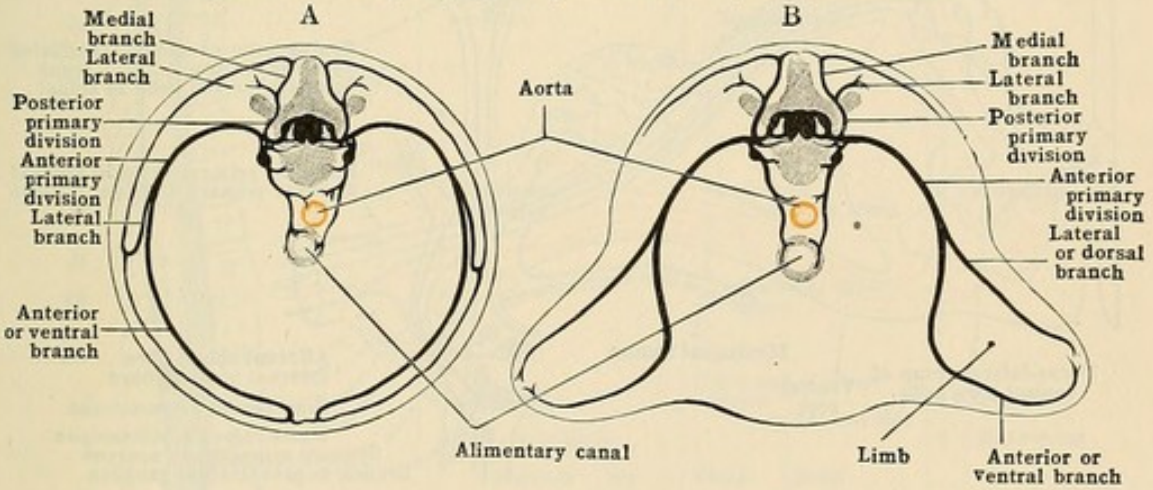

The primary divisions of the nerve-trunk.—A typical spinal nerve (middle thoracic, for example), just as it emerges from the intervertebral foramen, divides into four branches:—the two large primary divisions; viz., the **posterior primary division** [ramus posterior] and the **anterior primary division** [ramus anterior]; third, the small **ramus communicans,** by which it is connected with the sympathetic; and fourth, the smaller, **ramus meningeus** (*recurrent branch*), which immediately turns centralward for the innervation of the membranes and vessels of the spinal cord.

In general, the **posterior primary division** passes dorsalward between the arches or transverse processes of the two adjacent vertebræ in relation with the anterior costo-transverse ligament, and then divides (with the exception of the first cervical, the fourth and fifth thoracic, and the coccygeal nerves) into a **medial (internal) branch** and a **lateral (external) branch.** The medial branch turns toward the spinous processes of the vertebræ, and supplies the bones and joints and the muscles about them, and may or may not supply the skin overlying them. The lateral branch turns dorsalward and also supplies the adjacent muscles and bones, and, if the medial branch has not supplied the overlying skin, it also terminates in cutaneous twigs.

In the upper half of the spinal nerves the medial branches supply the skin; in the lower half, it is the lateral branches which do so. Both branches of almost all the posterior divisions, especially those of the lower nerves, show a tendency to run caudalward and thus are distributed to muscles and skin below the levels of their respective intervertebral foramina. They never supply the muscles of the limbs, though their cutaneous distribution extends upon the buttock, the shoulder, and the skin of the back of the head as far upward as the vertex. The posterior primary divisions, with the exception of those of the first three cervical nerves, are much smaller than the anterior primary divisions.

As their mixed function suggests, the posterior primary divisions contain both nerve-fibres from the ventral roots and peripheral processes of the spinal ganglion-cells. If the nerve-trunk on the immediate peripheral side of the spinal ganglion be teased, bundles of ventral root-fibres may be seen crossing the trunk obliquely to enter the posterior division, and fibres from the spinal ganglion may be also traced into it. Also a few sympathetic fibres, derived chiefly by way of the ramus communicans, are known to course in it for distribution in the walls of the blood-vessels, etc., of the area it supplies.

The anterior primary divisions run lateralward and ventralward. With the exception of the first two cervical nerves, which contribute the hypoglossal loop, they are larger than the posterior primary divisions, and appear as direct continuations of the nerve-trunks. Only in case of most of the thoracic nerves do they remain independent in their course. In these they run lateralward and ventralward in the body-wall. In general, these divisions supply the lateral and ventral

FIG. 748.—DIAGRAM ILLUSTRATING THE ORIGIN OF THE COMPONENT NERVE-FIBRES OF THE PRIMARY DIVISIONS OF A TYPICAL SPINAL NERVE.

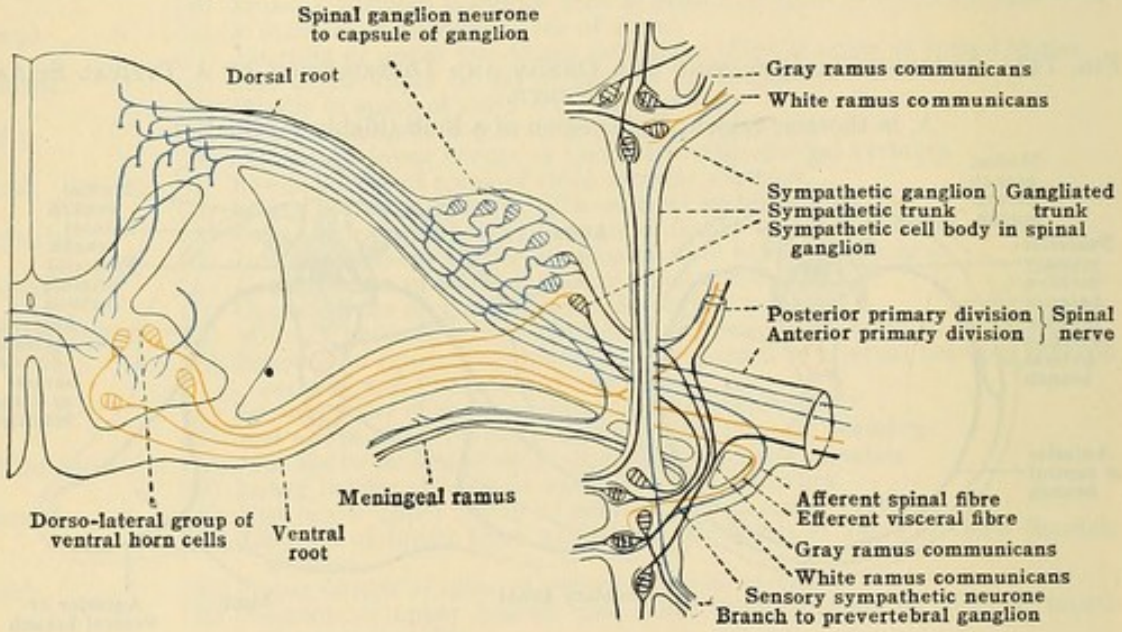

parts of the body, the limbs, and the perineum. In the cervical, lumbar, and sacral regions they lose their anatomical identity by dividing, subdividing, and anastomosing with each other so as to give rise to the three great spinal plexuses of the body—the **cervical,** the **brachial,** and the **lumbo-sacral plexuses.** The majority of the thoracic nerves retain the typical or primitive character in both their anterior and posterior primary divisions. In them the anterior division (intercostal nerve) divides into a **lateral** or dorsal and an **anterior** or ventral branch, both of which subdivide. The lateral branch is chiefly cutaneous; it pierces the superficial muscles and, in the subcutaneous connective tissue, divides into a smaller posterior and a larger anterior ramus, which respectively supply the skin of the sides and the lateral part of the ventral surface of the body. The anterior branch continues ventralward in the body-wall, giving off twigs along its course to the adjacent muscles and bones, and, as it approaches the ventral mid-line of the body, it turns sharply lateralward and sends rami medialward and lateralward to supply the skin of the ventral aspect of the body. In the region of the limbs the typical arrangement is interfered with in that what corresponds to the lateral and anterior branches of the division are carried out into the limbs for the skin and muscles there, instead of supplying the lateral and ventral parts of the body-wall.

Nerve-fibres arising in the spinal ganglion and fibres from the ventral root pass directly from the nerve-trunk into the anterior primary division of the spinal nerve. This division also receives sympathetic nerve-fibres by way of the ramus communicans. These latter accompany the division and are distributed to their allotted elements in the territory it supplies.

FIG. 749.—TABLE GIVING THE APPROXIMATE AREAS OF DISTRIBUTION OF THE DIFFERENT SPINAL NERVES WITH A DIAGRAM SHOWING THEIR RESPECTIVE LEVELS OF EXIT FROM THE VERTEBRAL COLUMN. (Arranged by Dr. Gowers.)

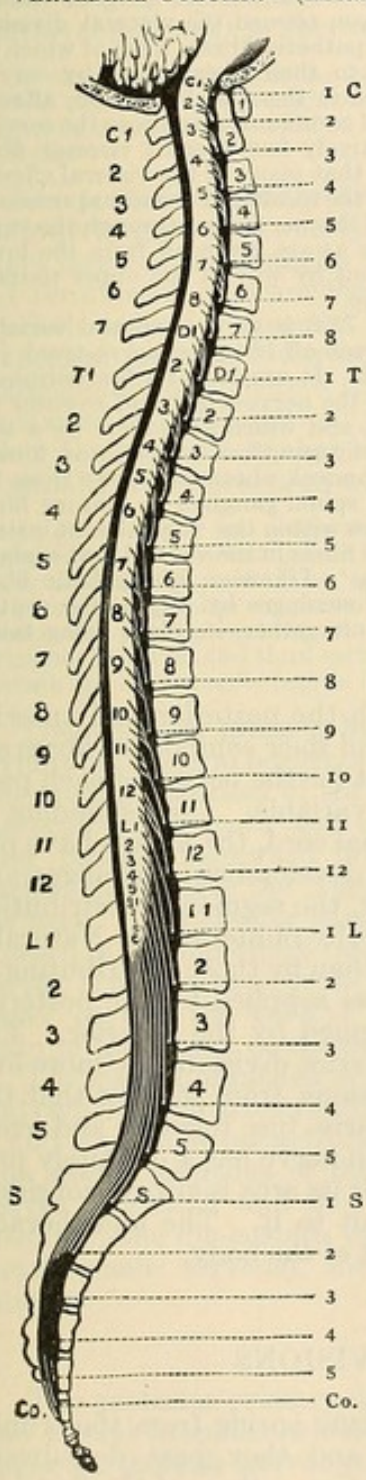

	MOTOR	SENSORY	REFLEX
1 C			
2		Neck and scalp	
3	Sterno-mastoid Trapezius	Neck and shoulder	
4	Diaphragm		
5	Serratus Shoulder	Shoulder	
6	Arm (musc.)	Arm	Scapular
7			
8	Hand (ulnar lowest)	Hand	
1 T			
2			
3			
4		Front of thorax	
5			Epigastric
6	Intercostal muscles	Xiphoid area	
7			
8			
9			
10	Abdominal Muscles	Abdomen (Umbilicus 10th)	Abdominal
11			
12		Buttock, upper part	
1 L			
2	Flexors, hip	Groin and scrotum (front)	Cremasteric
3	Extensors, knee	Thigh: Lateral side	Knee-joint
4	Adductors (hip)	Thigh: front	
5		Thigh: Medial side	
1 S	Abductors	Leg, medial side Buttock, lower	Gluteal
2	Extensors (?) Flexors, knee (?)	Back of thigh	Foot-clonus
3	Muscles of leg moving foot	Leg and foot (except medial part)	Plantar
4		Perineum and anus	
5	Perineal and anal muscles		
Co.		Skin from coccyx to anus	

The rami communicantes are small, short, thread-like branches by which the nerve-trunks are connected with the nearest ganglion of the vertically running gangliated cord of the sympathetic (sympathetic trunk). The trunk or anterior primary division of every spinal nerve has at least one of these; most of the nerves have two, and sometimes there are three. The nerves of the cervical region usually have but one, and this is composed largely of sympathetic fibres (grey

ramus). Where there are two, one usually contains medullated fibres, chiefly from the ventral root, sufficient to give it a whiter appearance (white ramus).

In the upper cervical and in the sacral regions one sympathetic ganglion may be connected with two or more spinal nerves, and sometimes one nerve is connected with two ganglia. The rami communicantes of the spinal nerves are equivalent to the communicating rami connecting certain of the cranial nerves with the sympathetic system (trigeminus, glosso-pharyngeus, vagus). The medullated fibres of the rami and, therefore, the white rami consist chiefly of fibres from the spinal nerves, viz., fibres from the spinal ganglion-cells which enter and course to their distribution through branches of the sympathetic nerves, **visceral afferent fibres,** and fibres from the ventral roots of the spinal nerves which terminate in the sympathetic ganglia, **visceral efferent**(preganglionic) **fibres.** Thus the white rami have been termed the **visceral divisions** of the spinal nerves. The grey rami consist chiefly of sympathetic fibres, most of which are non-medullated or partially medullated, and which course to their distribution by way of the spinal nerves. Some of the sympathetic fibres terminate in the spinal ganglion, **afferent sympathetic fibres** (fig. 748). The usual absence of white rami communicantes from the cervical nerves is explained on the grounds—(1) that probably relatively few efferent visceral fibres are given to the sympathetic from this region of the cord; (2) that many of the visceral efferent fibres which do arise from this region of the cord probably join the rootlets of the spinal accessory nerve and pass to the sympathetic system through the trunk of this nerve, and through the vagus with which it anastomoses; and (3) that such of these fibres as are given off from the lower segments of the cervical region, descend the cord and pass out by way of the upper thoracic nerves which give very evident white rami to the sympathetic.

The meningeal or **recurrent branch** (figs. 747, 748, and 762) is very small and variable, and is often difficult to find in ordinary dissections. It is given off from the nerve-trunk just before its anterior and posterior primary divisions are formed. It consists of a few peripheral branches of spinal ganglion-cells (sensory fibres) which leave the nerve-trunk and re-enter the vertebral canal for the sensory innervation of the meninges, and which are joined by a twig from the grey ramus or directly from the nearest sympathetic ganglion (vaso-motor fibres). There is considerable evidence, both physiological and anatomical, obtained chiefly from the animals, which shows that at times certain of the peripheral spinal ganglion or sensory fibres may turn backward in the nerve-trunk and pass to the meninges within the ventral root instead of contributing to a recurrent branch. The occurrence of such fibres in the ventral root explains the physiological phenomenon known as *'recurrent sensibility.'* Likewise, sympathetic fibres entering the trunk through the grey ramus may pass to the meninges by way of the ventral root, and at times the recurrent branch is probably absent altogether, its place being taken entirely by the meningeal fibres passing in the ventral root.

Areas of distribution of the spinal nerves.—Both the posterior and anterior primary divisions divide and subdivide repeatedly, and their component fibres are distributed to areas of the body more or less constant for the nerves of each pair, but the distribution of the different nerves is very variable. Corresponding to their attachment, each to a given segment of the spinal cord, the nerves have primarily a segmental distribution, but, owing to the developmental changes and displacement of parts during the growth of the body, the segmental distribution becomes greatly obscured and in some nerves practically obliterated. Naturally it is more retained by the nerves supplying the trunk than by those contributing to the innervation of the limbs and head, and the areas supplied by the posterior primary divisions are less disturbed than those supplied by the anterior. The segmental areas of cutaneous distribution of the posterior divisions are more evident than the areas of muscle supplied by these divisions, from the fact that the segmental myotomes from which the dorsal muscles arise fuse together and overlap each other considerably during development. No nerve has a definitely prescribed area of distribution, cutaneous or muscular, for its area is always considerably overlapped by the areas of the nerves adjacent to it. The mid-thoracic nerves more nearly supply a definitely prescribed belt of the body.

A. POSTERIOR PRIMARY DIVISIONS

The posterior primary divisions of the spinal nerves spring from the trunks immediately outside the intervertebral foramina, and they pass dorsalward between the adjacent transverse processes. With the exceptions of the first and second cervical nerves they are smaller than the corresponding anterior primary divisions, which in these nerves is smaller from the fact that a large portion of them go over into the hypoglossal or cervical loop. The posterior primary divisions, after passing between the transverse processes into the region of the back, divide into medial and lateral branches. This division, however, does not occur in the cases of the first cervical, the last two sacral, and the coccygeal nerves.

1. Cervical Nerves

The **posterior primary division of the first cervical** or **sub-occipital nerve** springs from the trunk, between the vertebral artery and the posterior arch of the atlas, passes dorsalward into the sub-occipital triangle, and breaks up into branches which supply the superior oblique, the inferior oblique, and the major rectus capitis posterior muscles, which form the lateral boundaries of the triangle. It also gives a branch across the posterior surface of the major rectus capitis posterior to the minor rectus capitis posterior, and a branch to the semispinalis capitis (complexus) in the roof of the triangle.

It communicates with the medial branch of the posterior primary division of the second cervical nerve, either through or over the inferior oblique muscle, and it occasionally gives a cutaneous branch to the skin of the upper part of the back of the neck and the lower part of the scalp.

The **posterior primary division of the second cervical nerve** is the largest posterior division of all the cervical nerves. It divides into a small lateral branch and a very large medial branch. The **lateral branch** gives a twig to the inferior oblique and terminates in branches which supply the splenius and longissimus capitis (trachelo-mastoid) muscles. The **medial branch** is the **greater occipital nerve.** It turns around the lower border of the inferior oblique, crosses the sub-occipital triangle obliquely, pierces the semispinalis capitis (complexus), the tendon of the trapezius, and the deep cervical fascia, passing through the latter immediately below the superior nuchal line of the occipital bone, and it divides into several terminal sensory branches which ramify in the superficial fascia of the scalp.

It gives one or two motor twigs to the semispinalis capitis (complexus), and its terminal branches which are accompanied by branches of the occipital artery supply the skin of the scalp, above the superior nuchal line, as far forward as the vertex. Occasionally one branch reaches the pinna and supplies the skin on the upper part of its medial aspect. As it turns around the inferior oblique it gives branches which join with the medial branches of the posterior primary divisions of the first and third cervical nerves, and in this manner a small looped plexus is formed beneath the semispinalis capitis (complexus) muscle, the *posterior cervical plexus of Cruveilhier.*

The **posterior primary branches of the third, fourth, and fifth cervical nerves** divide at the lateral border of the semispinalis colli into medial and lateral branches. The **medial branches** of the third, fourth, and fifth nerves run backward between the semispinalis colli and capitis (complexus), supplying both muscles. Then, after passing backward between the semispinalis capitis and the ligamentum nuchæ, they pierce the origin of the trapezius and supply the skin of the back of the neck. The greater part of the medial branch of the third nerve, which runs upward in the superficial fascia to the scalp, is called the **third** or **smallest occipital nerve**; it interlaces with the greater occipital nerve, and it supplies the skin of the upper part of the back of the neck, near the middle line, and the skin of the scalp in the region of the external occipital protuberance.

The **medial branches** of the posterior primary divisions of the sixth, seventh, and eighth cervical nerves pass to the median side of the semispinalis colli, between it and the subjacent multifidus spinæ, and they end in the neighbouring muscles. The **lateral branches of the posterior primary divisions of the last five cervical nerves** are small and they are distributed to the longissimus capitis (trachelo-mastoid), the ilio-costalis cervicis (cervicalis ascendens), the longissimus cervicis (transversalis cervicis), the semispinalis capitis (complexus), and the splenius muscles.

2. Thoracic Nerves

The **posterior primary divisions of all the thoracic nerves** divide into medial and lateral branches while in the vertebral groove. The **medial branches of the upper six thoracic nerves** pass dorsalward between the semispinalis dorsi and the multifidus spinæ; they supply the spinalis dorsi, the semispinalis dorsi, the multifidus spinæ, the rotatores spinæ, the intertransversales, and the interspinales muscles; and they end in cutaneous branches which, after piercing the trapezius, turn lateralward in the superficial fascia of the back, and supply the skin as far as the middle of the scapula. The cutaneous branch of the second nerve is the largest; it can be traced lateralward as far as the acromion process. The **medial branches of the lower six thoracic nerves** run dorsalward, between the longissi-

mus dorsi and the multifidus spinæ; they chiefly end in twigs to the adjacent muscles, but not uncommonly they give small cutaneous twigs which pierce the latissimus dorsi and the trapezius and end in the skin near the mid-line of the back.

The **lateral branches of the upper six thoracic nerves** pass between the longis-

FIG. 750.—DISTRIBUTION OF THE POSTERIOR PRIMARY DIVISIONS OF THE SPINAL NERVES. (Henle.)

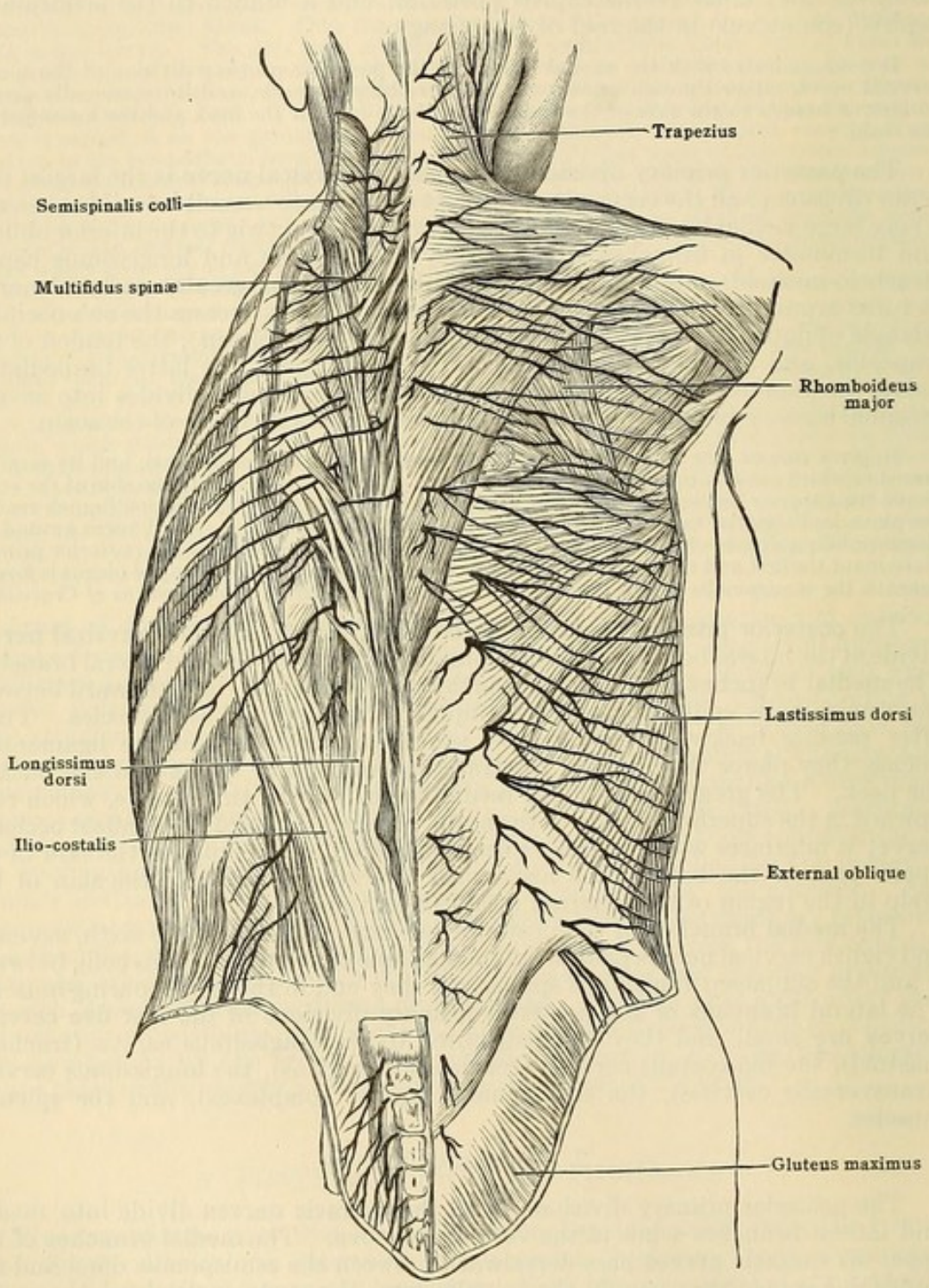

simus dorsi and the ilio-costalis dorsi (accessorius) and end in those muscles, but the **lateral branches of the six lower nerves** are longer; they pass into the interval between the longissimus dorsi and the ilio-costalis dorsi and give branches to them, and then they pierce the latissimus dorsi and are distributed to the skin of the lower and lateral part of the back.

3. Lumbar Nerves

The **medial branches** of the posterior primary divisions of all the lumbar nerves end in the multifidus spinæ and those of the three lower nerves send very small branches to the skin of the sacral region.

The **lateral branches of the upper three nerves** pass obliquely lateralward, supplying twigs to the adjacent muscles, pierce the posterior layer of the lumbar aponeurosis at the lateral border of the sacro-spinalis (erector spinæ) and enter the subcutaneous tissue. They are, for the most part, cutaneous, forming the **superior clunial nerves,** which cross the crest of the ilium and pass downward to occupy different planes in the thick superficial fascia which covers the upper part of the gluteus medius.

The branch from the first lumbar nerve is comparatively small, and occupies the most superficial plane. The second occupies an intermediate position. The lateral branch from the third nerve is the largest of the three, and occupies the lowest position; it distributes branches over the gluteus maximus as far as the great trochanter. The three nerves anastomose with one another and also with the cutaneous branches from the posterior primary divisions of the two upper sacral nerves.

The **lateral branch of the fourth lumbar nerve** is of small size and ends in the lower part of the sacro-spinalis (erector spinæ). That of the **fifth lumbar** is distributed to the sacro-spinalis and communicates with the first sacral nerve.

4. Sacral Nerves

The posterior primary divisions of the upper four sacral nerves escape from the vertebral canal by passing through the posterior sacral foramina; those of the fifth sacral nerve pass out through the hiatus sacralis between the posterior sacro-coccygeal ligaments. Those of the upper three sacral nerves divide in the ordinary manner into medial and lateral branches. Those of the lower two sacral nerves remain undivided.

The **medial branches** of the upper three sacral nerves are of small size, and are distributed to the multifidus spinæ. The **lateral branches** anastomose with one another and with the lateral branch of the last lumbar nerve, forming loops on the posterior surface of the sacrum from which branches proceed to the posterior surface of the sacro-tuberous (great sacro-sciatic) ligament, where they anastomose and form a second series of loops, from which loops two or three branches are given off. These branches pierce the gluteus maximus and come to the surface of that muscle in a line between the posterior superior spine of the ilium and the tip of the coccyx. Then, as the **middle clunial nerves,** they are distributed to the integument over the medial part of the gluteus maximus, and communicate, in their course through the superficial fascia, with the posterior branches of the lumbar nerves.

The posterior divisions of the **lower two sacral nerves** unite with one another, with the posterior branch of the third sacral, and with the coccygeal nerve, forming loops from which twigs pass to the integument over the lower end of the coccyx.

The **posterior primary division of the coccygeal nerve** is also undivided. It separates from the anterior division in the sacral canal and emerges through the hiatus sacralis, pierces the ligaments which close the lower part of that canal, receives a communication from the posterior division of the last sacral nerve, and ends in the skin over the dorsal aspect of the coccyx.

B. ANTERIOR PRIMARY DIVISIONS

The anterior primary divisions of the spinal nerves are larger than the posterior primary divisions, and each is joined near its origin by a grey ramus communicans from the sympathetic gangliated cord (figs. 751, 752, 762). Beginning with the first or second thoracic nerve and ending with the second or third lumber nerve, each anterior division sends to the gangliated cord a white ramus communicans. The same is true of the second and third or of the third and fourth sacral nerves. These white rami are appropriately designated the **visceral branches** of

the spinal nerves. The anterior primary divisions of the cervical, lumbar, sacral, and coccygeal nerves unite with one another to form **plexuses,** but the anterior primary divisions of the thoracic nerves, except the first and last, remain separate, pursue independent courses, and each divides, in a typical manner, into a lateral and an anterior or ventral branch. The separation of the anterior primary division into lateral and anterior branches is not confined to the thoracic nerves; it occurs also in the lower cervical, the lumbar, and the sacral nerves, but such a division cannot be clearly distinguished either in the upper cervical nerves, or in the coccygeal nerve.

1. *CERVICAL NERVES*

The anterior primary divisions of the **upper four cervical nerves** unite to form the **cervical plexus,** and each receives a communicating branch from the superior cervical sympathetic ganglion. The anterior divisions of the **lower four cervical nerves** are joined by the greater part of the first thoracic nerve and they unite to form the **brachial plexus** (figs. 751, 754, 755). The fifth and sixth cervical nerves receive communicating branches from the middle cervical sympathetic ganglion, and the seventh and eighth from the inferior cervical ganglion, while the first thoracic nerve is always connected with the first thoracic sympathetic ganglion by a grey ramus (figs. 751, 786) and in most cases also by a white ramus communicans.

THE CERVICAL PLEXUS

The cervical plexus (figs. 751, 752) is formed by the anterior primary divisions of the upper four cervical nerves which constitute the roots of the plexus. It lies in the upper part of the side of the neck, under cover of the sterno-mastoid, and upon the levator scapulæ and the scalenus medius. It is a looped plexus, consisting of three loops.

A large part of the anterior primary division of the **first cervical nerve** is given to the hypoglossal or cervical loop; the remainder passes to the cervical plexus and in doing so it runs lateralward on the posterior arch of the atlas beneath the vertebral artery, then it turns forward, between the vertebral artery and the outer side of the upper articular process of the atlas, and finally it descends, in front of the transverse process of the atlas, and unites with the upper branch of the second nerve, forming with it the first loop of the plexus. It gives branches to the rectus capitis lateralis, longus capitis (major rectus capitis anterior), and to the rectus capitis anterior (minor). The division communicates with the ganglion of the trunk of the vagus and with the superior cervical ganglion of the sympathetic system (fig. 752). From the first loop of the plexus, two branches of the division pass over into the sheath of the hypoglossal nerve and descend with it to contribute to the **hypoglossal loop** [ansa hypoglossi] or better, the *cervical loop*. The fibres entering the sheath of the hypoglossus, after giving a few twigs to the genio-hyoid and thyreo-hyoid muscles, leave the sheath as the **descendens cervicalis** (*hypoglossi*) and this latter joins the *communicans cervicalis*, (the portion of the loop from the second and third cervical nerves) and thus completes the cervical or hypoglossal loop.

This loop usually may be found between the sheaths of the sterno-mastoid muscle and the carotid artery, superficial to the internal jugular vein; sometimes it may lie in the carotid sheath between the carotid artery and the internal jugular vein; rarely it may lie dorsal to both the artery and vein. Sometimes it is relatively long, descending toward the sternum below the level of the thyreoid cartilage; again it is quite short and occurs near the level of the hyoid bone. The descendens cervicalis (hypoglossi) parts company with the hypoglossal nerve at the level at which the nerve curves around the occipital artery. It runs downward and slightly medialward on the sheaths of the great vessels and occasionally within the sheath of one of them.

The **second cervical nerve** (anterior primary division) passes behind the upper articular process of the axis and the vertebral artery, and between the intertransverse muscles extending from the first to the second cervical vertebræ, to the interval between the scalenus medius and the longus capitis (rectus capitis anterior major), where it divides into two parts. The upper part ascends and unites with the first nerve to form the first loop of the plexus, and the lower branch passes downward and dorsalward and joins the upper branch of the third nerve in

the second loop of the plexus (figs. 751, 752). This branch gives off the small occipital nerve and a filament to the sterno-mastoid, which communicates with the spinal accessory nerve in the substance of the muscle, and it gives branches which assist in forming the hypoglossal or cervical loop (ansa hypoglossi) the cervical cutaneous and the great auricular nerves (fig. 752).

FIG. 751.—ORIGIN OF THE CERVICAL AND BRACHIAL PLEXUS. (After Toldt, "Atlas of Human Anatomy," Rebman, London and New York.)

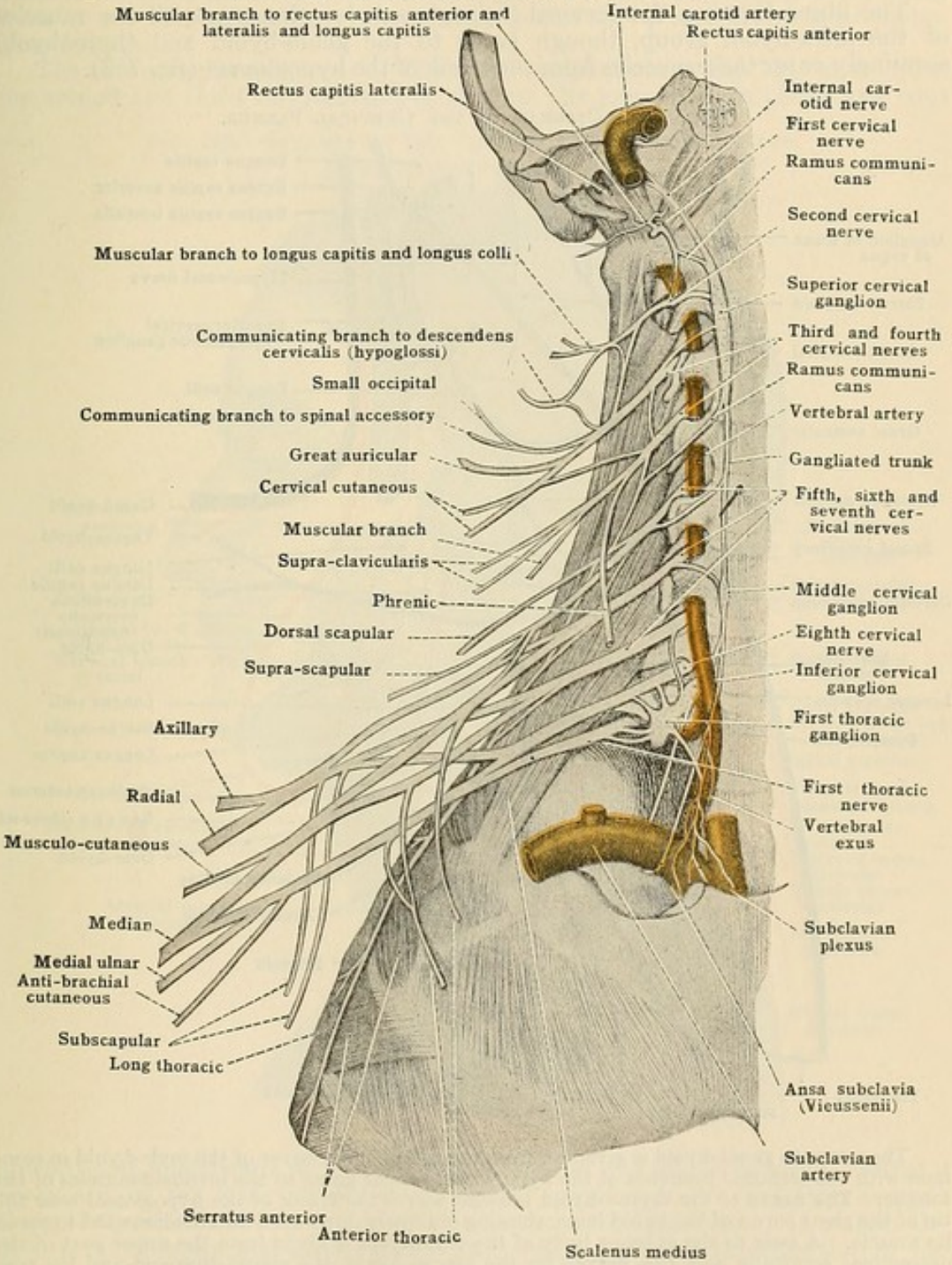

The **third** and **fourth cervical nerves** pass behind the vertebral artery (fig. 751) and between the intertransverse muscles to the interval between the scalenus medius and the longus capitis (rectus capitis anterior major), where the third unites with the second and fourth nerves and completes the lower two loops of the plexus. The anterior primary divisions of these nerves are about double the size of the preceding. The third gives off branches to the hypoglossal loop, to the

larger part of the great auricular and cervical cutaneous nerves, a branch to the phrenic, a branch to the supra-clavicular nerves, and muscular branches to the scalenus medius, levator scapulæ, longus capitis, and trapezius (fig. 752). The trapezius branch joins the spinal accessory nerve beneath the muscle. The fourth nerve gives a branch to the phrenic, a branch to the supra-clavicular nerves, and muscular branches to the scalenus medius, levator scapulæ, longus colli, and trapezius (fig. 752). The branch to the trapezius unites with the one from the third nerve and joins the spinal accessory nerve beneath the muscle.

The fibres forming the cervical (hypoglossal) loop innervate all the muscles of the infra-hyoid group, though twigs to the genio-hyoid and thyreohyoid seemingly enter these muscles from the trunk of the hypoglossus (fig. 752).

FIG. 752.—DIAGRAM OF THE CERVICAL PLEXUS.

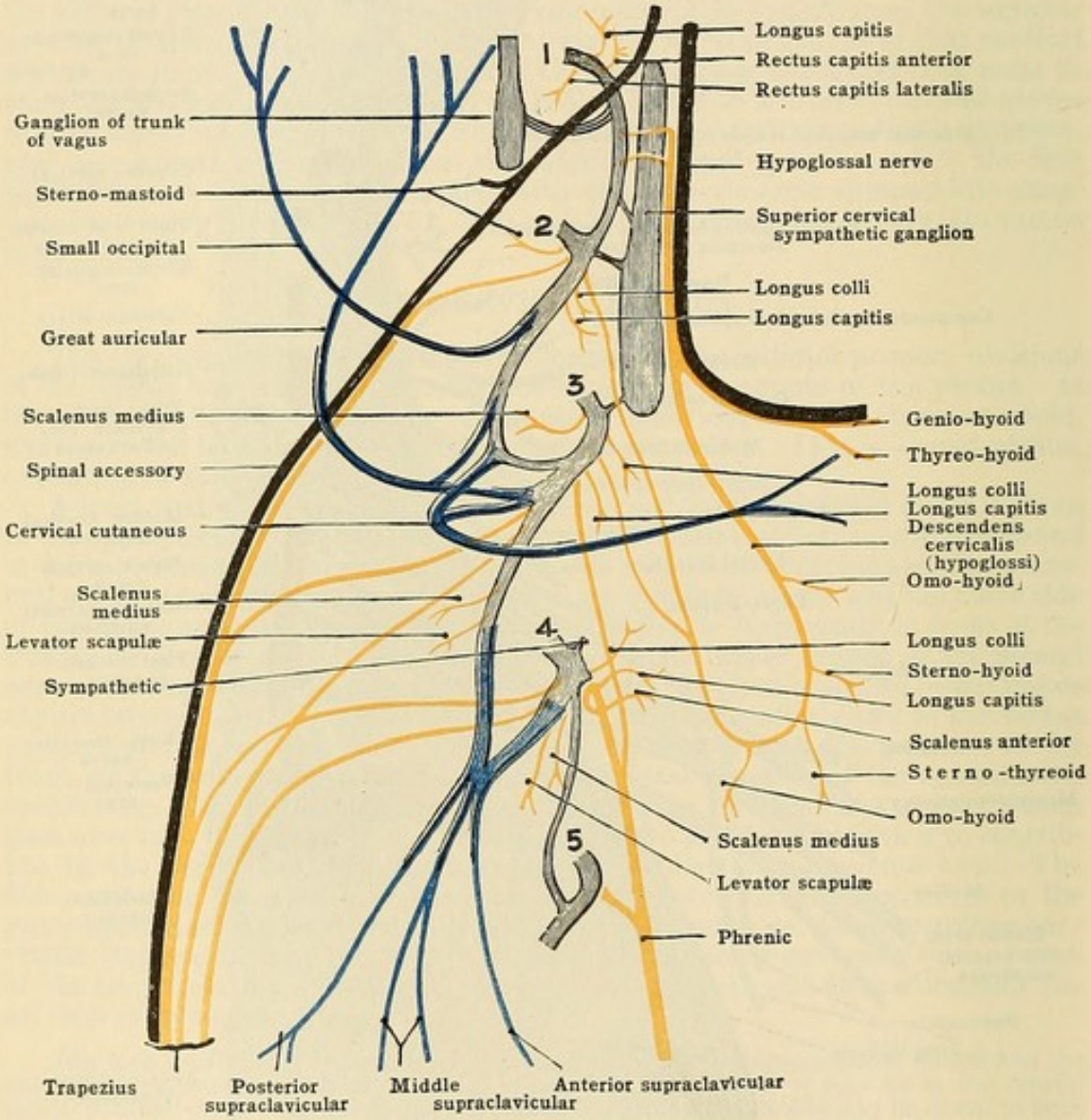

The **nerve to genio-hyoid** is given off from the trunk under cover of the mylo-hyoid in common with the terminal branches of the hypoglossal proper going to the intrinsic muscles of the tongue. **The nerve to the thyreo-hyoid** muscles leaves the trunk of the hypoglossal near the tip of the great cornu of the hyoid bone, running obliquely downward and medianward to reach its muscle. A twig to the anterior belly of the **omo-hyoid** is given from the upper part of the descendens cervicalis and the **nerves for the sterno-hyoid,** the **sterno-thyreoid** and the posterior belly of the **omo-hyoid** are supplied from the turn of the loop (fig. 752). The nerves to the sterno-hyoid and sterno-thyreoid send twigs downward in the muscles behind the manubrium sterni and fibres from these in rare cases join the phrenic nerve in the thorax. The nerve to the posterior belly of the **omo-hyoid** courses as a loop in the cervical fascia below the central tendon of its muscle.

Each root of the cervical plexus receives a communicating grey ramus from the superior cervical ganglion of the sympathetic, and from the roots and loops of

the plexus a number of branches arise which form two main groups, the superficial and the deep.

Superficial Branches of the Cervical Plexus

The superficial branches are described, according to the direction in which they run, as ascending, transverse, and descending branches. The *ascending branches* are the small occipital and the great auricular nerves. There is only one *transverse branch*, the cervical cutaneous (transverse cervical), and the *descending branches* are distinguished as the supraclavicular nerves and the cervical (hypoglossal) loop.

The ascending branches.—(1) The **small occipital nerve** (fig. 751) arises from the second and third cervical nerves, or from the loop between them, and runs

Fig. 753.—Superficial Branches of the Cervical Plexus.
(After Hirschfeld and Leveillé.)

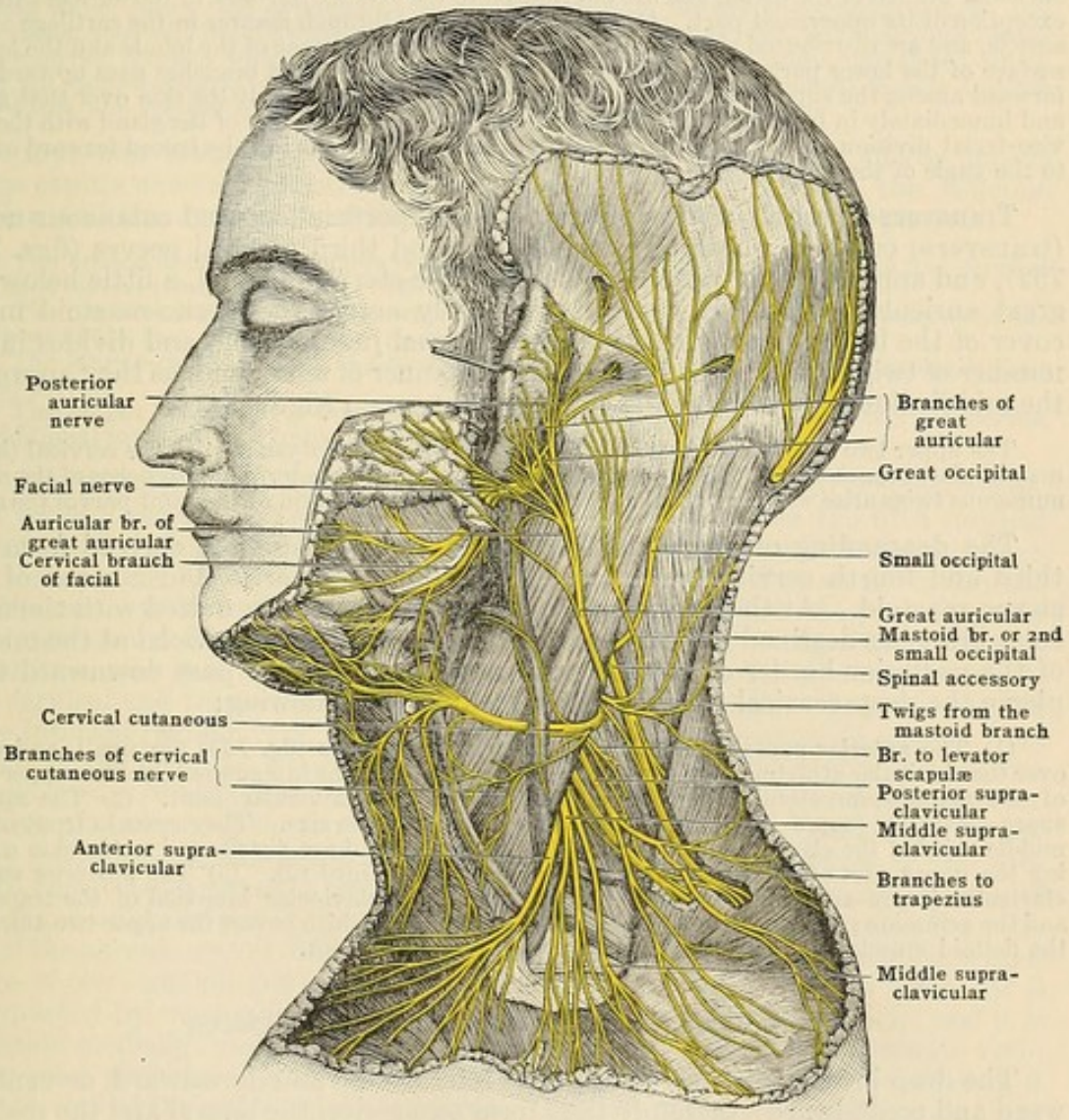

upward and dorsalward to the posterior border of the sterno-mastoid, where it hooks around the lower border of the spinal accessory nerve and then ascends along the posterior border of the muscle to the mastoid process. It pierces the deep cervical fascia and passes across the posterior part of the insertion of the sterno-mastoid into the superficial fascia of the scalp, in which it breaks up into auricular, mastoid, and occipital terminal branches.

(*a*) The **auricular branch** runs upward and slighly forward to reach the integument on the upper median part of the auricle (pinna), which it supplies. (*b*) The **mastoid branch** is distributed to the skin covering the base of the mastoid process. (*c*) The **occipital branches** ramify over the occipitalis muscle and are distributed to the skin of the scalp; they communicate with one another and with the great occipital nerve. The branches of the small occipital nerve

anastomose with twigs of the posterior auricular, great auricular, and great occipital nerves (fig. 753).

(2) The **great auricular nerve** arises from the second and third cervical nerves (figs. 751, 752). It accompanies the small occipital to the posterior border of the sterno-mastoid, but at that point it diverges from the small occipital (fig. 753) and runs upward and forward across the sterno-mastoid toward the angle of the mandible. When it is about half-way across the muscle it begins to break up into its terminal branches, which are named, according to the area of their distribution, mastoid, auricular, and facial.

As the nerve ascends obliquely across the sterno-mastoid it is embedded in the deep cervical fascia, is covered by superficial fascia and the platysma, and it lies parallel with and slightly dorsal to the external jugular vein. (*a*) The **mastoid branch** is small, and is distributed to the integument covering the mastoid process. It anastomoses with the posterior auricular and small occipital nerves. (*b*) The **auricular branches** are three or four stout twigs which interlace with the branches of the posterior auricular nerve; they cross the superficial surface of the posterior auricular branch of the facial, and are distributed to the skin on the back of the auricle with the exception of its uppermost part. One or two twigs pass through fissures in the cartilage of the auricle, and are distributed to the integument on the lateral surface of the lobule and the lateral surface of the lower part of the helix and anthelix. (*c*) The **facial** branches pass upward and forward among the superficial lobules of the parotid gland, and supply the skin over that gland and immediately in front of it, and they anastomose in the substance of the gland with the cervico-facial division of the facial nerve. In some cases fine twigs may be traced forward nearly to the angle of the mouth.

Transverse branch of the plexus.—The **superficial cervical cutaneous nerve** (transverse cervical) arises from the second and third cervical nerves (figs. 751, 752), and appears at the posterior border of the sterno-mastoid, a little below the great auricular nerve. It passes transversely across the sterno-mastoid under cover of the integument, platysma, and external jugular vein, and divides into a number of twigs which spread out after the manner of a fan, and, as they approach the middle line, extend from the chin to the sternum (fig. 753).

The upper two or three of these twigs unite, beneath the platysma, with the cervical (inframandibular) branch of the facial and thus form loops. From the terminal branches of the nerve numerous twigs arise which pierce the platysma and end in the skin of the front part of the neck.

The descending or **supra-clavicular branches.**—These are derived from the third and fourth cervical nerves (figs. 751, 752), and arise under cover of the sterno-mastoid. At their commencements they are usually united with the muscular branches destined for the trapezius. They become superficial at the middle of the posterior border of the sterno-mastoid, and as they pass downward they pierce the deep cervical fascia. They include the following:

(1) The **anterior supra-clavicular** (**suprasternal**) **branches** (fig. 753) are small, and cross over the clavicular attachment of the sterno-mastoid to reach the integument over the upper part of the manubrium sterni. They also supply the sterno-clavicular joint. (2) The **middle supra-clavicular** (**supra-clavicular**) **nerves** are of considerable size. They cross in front of the middle third of the clavicle under cover of the platysma, and are distributed to the skin covering the upper part of the pectoralis major as low as the third rib. (3) The **posterior supra-clavicular** (**supra-acromial**) **branches** (fig. 753) cross the clavicular insertion of the trapezius and the acromion process. They are distributed to the skin which covers the upper two-thirds of the deltoid muscle and they supply the acromio-clavicular joint.

Deep Branches of the Cervical Plexus

The deep branches of the plexus pass lateralward and dorsalward, or ventralward and medialward; therefore they form two series, the lateral and the medial.

The **lateral branches** of the deep series include communicating branches from the second, third, and fourth cervical nerves to the spinal accessory nerve, and muscular branches to the sterno-mastoid and the scalenus medius, levator scapulæ, and trapezius.

The **communicating branches.**—The communicating branch from the second cervical nerve is ultimately distributed to the sterno-mastoid, and those from the third and fourth nerves end in the trapezius.

1. The **nerve to the sterno-mastoid** arises from the second cervical nerve (fig. 753). It pierces the deep surface of the sterno-mastoid, and communicates within the muscle with the spinal accessory nerve.

2. The **nerves to the scalenus medius** (fig. 752) are derived from the third or fourth to the eighth cervical nerves close to their exit from the intervertebral foramina.

3. The **nerves to the levator scapulæ** (fig. 752) are derived from the third and fourth cervical nerves, and occasionally from the second or fifth. They pierce the superficial surface of the levator scapulæ, and supply the upper three divisions of that muscle.

4. The **branches to the trapezius** (fig. 752) are usually in the form of two stout twigs which are given off by the third and fourth cervical nerves. They emerge from under cover of the sterno-mastoid at its posterior border and cross the posterior superior triangle of the neck at a lower level than the spinal accessory nerve (fig. 753). They pass under cover of the trapezius in company with the last-named nerve, and communicate with it to form the **subtrapezial plexus,** from which the trapezius is supplied.

The **medial branches** of the deep series also comprise communicating and muscular branches.

The **communicating branches** (figs. 751, 752) include (1) branches which connect each of the first four cervical nerves with the superior cervical ganglion of the sympathetic; (2) a branch to the vagus; (3) a branch to the hypoglossal; and (4) branches which pass from the second and third cervical nerves to the *descendens cervicalis* (*hypoglossi*). The ultimate distribution of the twigs connected with the sympathetic and the vagus nerves is not known, but the fibres which pass to the hypoglossal nerve pass from it to the thyreo-hyoideus muscle, and to the descendens cervicalis and the latter joins with the branches from the second and third cervical nerves, forming with them the cervical or **hypoglossal loop** [ansa hypoglossi] which lies on the carotid sheath. From this loop the two bellies of the omo-hyoid muscle and the sterno-hyoid and sterno-thyreoid muscles are supplied as described above.

The **muscular branches** supply the rectus capitis lateralis, the longus capitis (rectus capitis anterior major), the rectus capitis anterior (minor), the scalenus anterior, and the diaphragm. The nerve to the latter muscle is the **phrenic.**

1. The **branch to the rectus capitis lateralis** is furnished to that muscle by the first cervical nerve as it crosses the deep surface of the muscle.

2. The **nerve to the rectus capitis anterior** (minor) is given off by the first nerve at the upper part of the loop in front of the transverse process of the atlas.

3. The **longus capitis** (rectus capitis anterior major) receives twigs from the upper four cervical nerves.

4. The **longus colli** receives branches from the second, third, and fourth cervical nerves, and additional branches also from the fifth and sixth nerves.

5. The **phrenic nerve** (fig. 752) springs chiefly from the fourth cervical nerve, but it usually receives a twig from the third and another from the fifth cervical nerve, a small communicating branch from the sympathetic, and, rarely, a branch from the vagus. The twig from the fifth cervical nerve is frequently connected with the nerve to the subclavius. After the union of its roots the phrenic nerve passes downward and medialward on the scalenus anterior (fig. 755). In this part of its course it is crossed by the tendon of the omo-hyoid and by the transverse cervical and transverse scapular (suprascapular) arteries. It is overlapped by the internal jugular vein, and it is covered by the sterno-mastoid muscle. At the root of the neck the left phrenic nerve lies behind the terminal portion of the thoracic duct, and each nerve passes off the anterior border of the scalenus anterior and descends in front of the first part of the subclavian artery and the pleura immediately below that artery; each nerve passes dorsal to the terminus of the subclavian vein, crosses either in front of or dorsal to the internal mammary artery and gains the medial surface of the pleural sac. From the root of the neck the relations of the phrenic nerves differ. The **right phrenic nerve** descends along the medial surface of the right pleural sac and crosses in front of the root of the lung. It is accompanied by the pericardiaco-phrenic artery (comes nervi phrenici), and it is in relation medially, and from above downward, with the right innominate vein, the superior vena cava, and the pericardium, the latter membrane separating it from the wall of the right atrium (auricle). The **left phrenic nerve** descends along the medial surface of the left pleural sac accompanied by the pericardiaco-phrenic (comes nervi phrenici) artery. In the superior mediastinum it lies between the left common carotid and the left subclavian arteries, and it crosses in front of the left vagus, the left superior intercostal vein, and the arch of the aorta. Below the arch of the aorta it crosses in front of the root of the left lung, and then lies along the left lateral surface of the pericardium, which separates it from the wall of the left ventricle.

Branches.—Both phrenic nerves distribute branches to the pericardium and to the pleura. The right nerve gives off a branch, **pericardiac,** which accompanies the superior vena cava and supplies the pericardium. Each phrenic nerve divides into numerous terminal **phrenico-abdominal** branches. As a rule, the right phrenic nerve divides into two main terminal branches, an anterior and a posterior. The *anterior* branch runs forward and one of its terminal filaments

anastomoses with the phrenic of the opposite side in front of the pericardium; others descend between the sternal and costal attachments of the diaphragm into the abdomen, where some of them supply the diaphragm and others descend in the falciform ligament to the peritoneum on the upper surface of the liver. The *posterior* branch passes through the vena caval opening and ramifies upon the lower surface of the diaphragm, anastomosing with the diaphragmatic plexus of the sympathetic, and its terminal branches supply the muscular fibres of the right half of the diaphragm, the inferior vena cava, and the right suprarenal gland.

The left phrenic nerve divides into several branches. One of the most anterior branches anastomoses with the right phrenic nerve; the others pierce the diaphragm and ramify on its under surface, where they anastomose with filaments of the left diaphragmatic plexus of the sympathetic and supply the left half of the diaphragm and the left suprarenal gland. The left phrenic nerve is considerably longer than the right nerve, partly on account of the lower level of the diaphragm on the left side, and partly on account of the greater convexity of the left side of the pericardium.

THE BRACHIAL PLEXUS

The **brachial plexus** (figs. 751, 754, 755) is formed by the anterior primary divisions of the **four lower cervical nerves** and the greater part of that of the

FIG. 754.—DIAGRAM OF A COMMON FORM OF BRACHIAL PLEXUS.
The posterior cord of the plexus is darkly shaded.

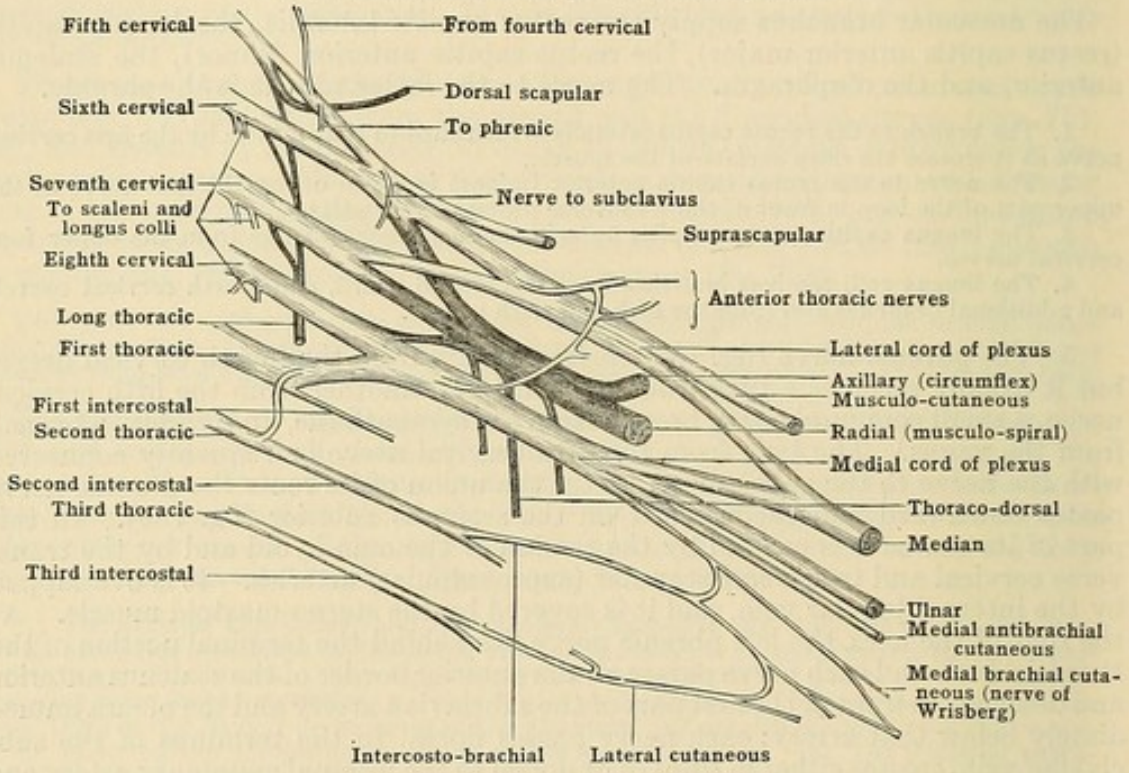

first thoracic nerve. It is usually joined by small twigs from the **fourth cervical** and **second thoracic nerves.**

The anterior primary divisions of the lower four cervical nerves, after passing dorsal to the vertebral artery and between the anterior and posterior parts of the intertransverse muscles, pass into the posterior triangle in the interval between the adjacent borders of the anterior and middle scalene muscles, where the fifth and sixth nerves receive a grey ramus communicans each from the middle cervical sympathetic ganglion, and the seventh and eighth nerves each receive a grey ramus from the inferior cervical sympathetic ganglion. The first thoracic is connected by two rami communicantes with the first thoracic sympathetic ganglion, and it divides into a smaller and a larger branch. The smaller branch passes along the intercostal space as the first intercostal nerve, and the larger branch, after being joined by a twig from the second thoracic nerve, passes upward and lateralward, in front of the neck of the first rib and behind the apex of the pleural sac, into the lower part of the posterior triangle of the neck, where it takes part in the formation of the plexus.

The anterior primary divisions of those cervical nerves that form the brachial plexus may be considered as typically giving off *anterior* and *posterior branches,*

except that the fifth and sixth nerves often unite before branching and give off their posterior branches as a common trunk, and the eighth nerve often receives its branch from the first thoracic nerve before giving off its posterior branch.

It is on account of this variation in the point of union of the fifth and sixth cervical nerves and of the eighth cervical and first thoracic nerves that so many different forms of the plexus have been pictured and described. But if the differences in primary branching be borne in mind, the formation of the plexus is always uniform and simple, notwithstanding its different appearances.

FIG. 755.—THE BRACHIAL PLEXUS AND ITS BRANCHES OF THE REGION OF THE NECK AND SHOULDER. (After Toldt, "Atlas of Human Anatomy," Rebman, London and New York.)

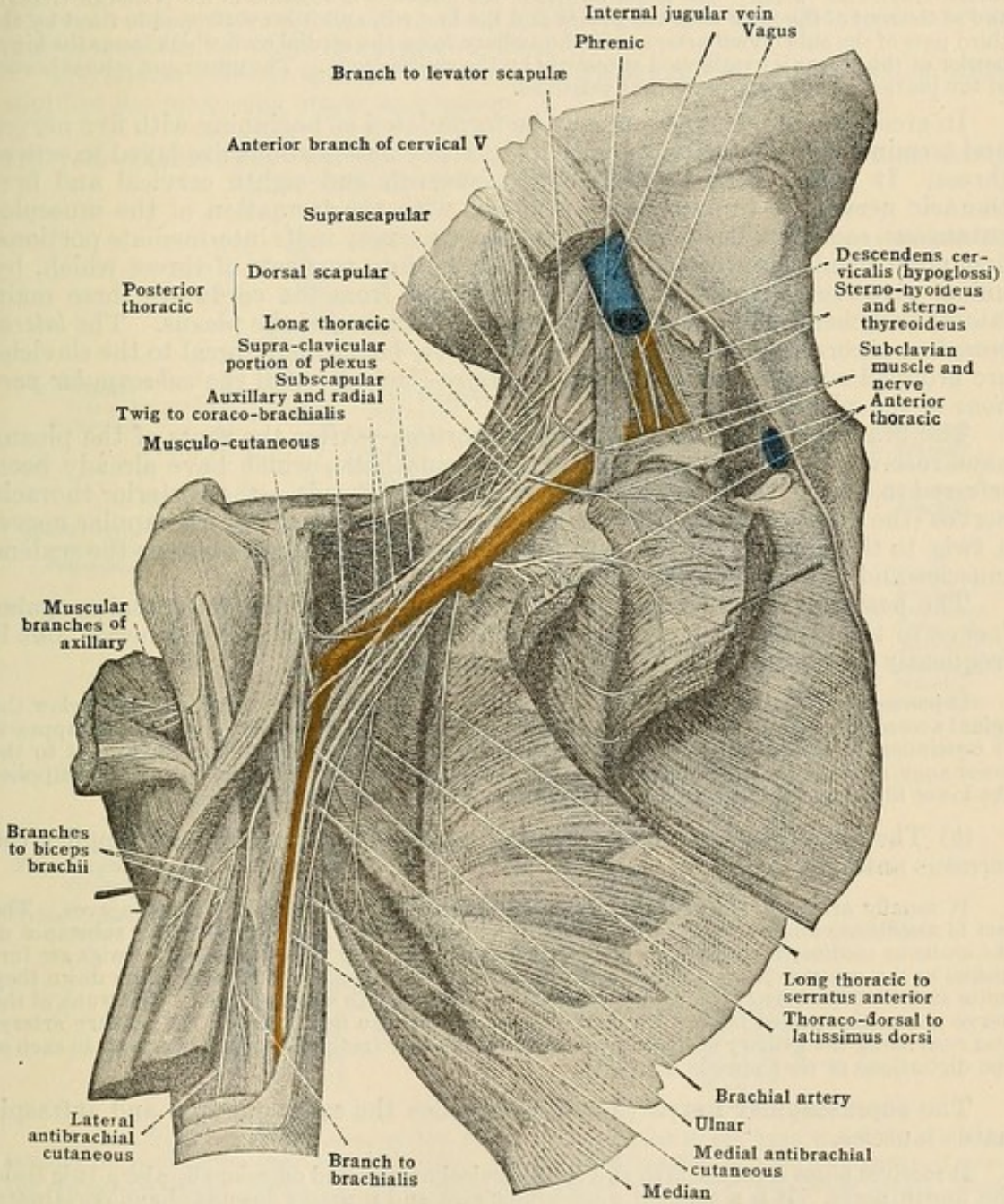

Three cords are formed from these branches in the following manner:—(1) The *lateral* (outer) cord [fasciculus lateralis] is formed by the anterior branches of the fifth, sixth, and seventh nerves; (2) the *medial* (inner) cord [fasciculus medialis], by the anterior branches of the eighth cervical and first thoracic nerves; and (3) the *posterior* cord [fasciculus posterior], by the posterior branches of all of these cervical nerves.

Relations.—The plexus extends from the lateral border of the scalenus anterior, where the roots of its constituent nerves appear, to the lower border of the pectoralis minor, where each

of its three cords divides into two terminal branches, and it lies in the posterior triangle, in the root of the neck, and in the axillary fossa. In the posterior triangle and in the root of the neck it is in relation behind with the scalenus medius (figs. 751, 755). In the posterior triangle it is covered superficially by the skin and superficial fascia, the platysma, the supra-clavicular branches of the cervical plexus, and the deep fascia, and it is crossed by the lower part of the external jugular vein, by the nerve to the subclavius, the transverse cervical vein and the transverse scapular (supra-scapular) vein, the posterior belly of the omo-hyoid muscle, and by the transverse cervical artery. At the root of the neck it lies behind the clavicle and the subclavius muscle, and the transverse scapular (suprascapular) artery crosses in front of it. In the axillary fossa the cords are arranged around the axillary artery, the lateral (outer) cord lying lateral to the artery, the medial (inner) cord medial to it, and the posterior cord dorsal to the artery. In this region the posterior relations of the plexus are the fat in the upper part of the fossa and the subscapularis muscle, and it is covered in front by the pectoral muscles and the coraco-clavicular fascia. The lower border of the plexus is in relation in the posterior triangle and at the root of the neck with the pleura and the first rib, and it is overlapped in front by the third part of the subclavian artery. In the axillary fossa the medial cord which forms the lower border of the plexus is overlapped anteriorly by the axillary vein. The upper and lateral border of the plexus has no very important relations.

In gross, the brachial plexus may be formulated as beginning with five nerves and terminating in five nerves, with its intermediate portions displayed in sets of threes. It begins with the fifth, sixth, seventh and eighth cervical and first thoracic nerves; it terminates as a plexus with the formation of the musculo-cutaneous, radial, axillary, median, and ulnar nerves; in its intermediate portions, first main trunks are formed and these divide into two sets of threes which, by union, give rise to three cords. The **branches from the cords** are three main lateral branches from each and the terminal branches of the plexus. The *lateral branches*, according as they are given off above, below, and dorsal to the clavicle, are grouped as the *supra-clavicular*, the *infra-clavicular* and the *subscapular portions* of the plexus.

The branches of the supra-clavicular portion.—After the roots of the plexus have received communications from the sympathetic, which have already been referred to, they give off a series of muscular branches, viz.—the posterior thoracic nerves (the dorsal scapular and the long thoracic nerve), the suprascapular nerve, a twig to the phrenic, the nerve to the subclavius, and small twigs to the scalene muscles and the longus colli muscle.

The **posterior thoracic nerves** are two in number:—(*a*) the **dorsal scapular** (nerve to the rhomboids) arises principally from the fifth cervical nerve, but it frequently receives a twig from the fourth nerve (fig. 751).

It passes downward and dorsalward, across the middle scalene, parallel with and below the spinal accessory nerve to the anterior border of the levator scapulæ, under which it disappears. It continues its descent under cover of the levator scapulæ and the rhomboids almost to the lower angle of the scapula, lying a little medial to the posterior border of the bone, and it supplies the lower fibres of the levator and the smaller and larger rhomboid muscles.

(*b*) The **long thoracic nerve** (external respiratory nerve of Bell) supplies the serratus anterior.

It usually arises, by three roots, from the fifth, sixth, and seventh cervical nerves. The last is sometimes absent (figs. 751 and 754). The upper two roots traverse the substance of the scalenus medius; the root from the seventh passes in front of that muscle. Twigs are furnished to the superior portion of the serratus anterior by the upper two roots; lower down they unite and are subsequently joined by the root from the seventh when present. The trunk of the nerve passes downward behind the brachial plexus and the first stage of the axillary artery, and runs along the axillary surface of the serratus anterior (magnus), supplying twigs to each of the digitations of that muscle (fig. 755).

The **suprascapular nerve** (fig. 751) supplies the supraspinatus and infraspinatus muscles.

It receives fibres from the fifth and sixth cervical nerves, and occasionally also a twig from the fourth nerve. It is a nerve of considerable size, and it passes downward and dorsalward parallel with the dorsal scapular nerve, at first along the upper border of the posterior belly of the omo-hyoid muscle, then internal to the latter muscle and under cover of the anterior border of the trapezius to the suprascapular notch (fig. 755), where it comes into relation with the transverse scapular (suprascapular) artery. It is separated from the artery at the notch by the superior transverse ligament, the nerve passing through the notch and the artery above the ligament. After entering the supraspinous fossa the nerve supplies branches to the supraspinatus and a branch to the shoulder-joint; then it descends through the great scapular notch between the bone and the inferior transverse ligament to the infraspinous fossa, where it terminates in the infraspinatus muscle.

The **twig to the phrenic** (fig. 751) arises from the fifth cervical nerve close to the point where the latter nerve receives its twig from the cervical plexus.

The **nerve to the subclavius** (fig. 755) is a small twig which arises from the fifth nerve or from the upper trunk of the plexus, but occasionally it receives additional fibres from the fourth and sixth nerves. It runs downward in front of the lower part of the plexus and the third stage of the subclavian artery and, after giving off sometimes a branch to the phrenic, pierces the posterior layer of the coraco-clavicular fascia, and enters the subclavius at its lower border.

Variety.—In rare cases the entire phrenic nerve may pass *viâ* the nerve to the subclavius in front of the third stage of the subclavian artery.

The *scaleni* and *longus colli* (figs. 751, 754) are supplied by twigs which arise from the lower three or four cervical nerves immediately after their exit from the intervertebral foramina.

The lateral branches of the infra-clavicular portion of the brachial plexus are the anterior thoracic nerves, from the lateral and medial cords respectively, the medial antibrachial (internal) cutaneous and the medial brachial (lesser internal) cutaneous nerves, from the medial cord, and the subscapular nerves and thoraco-dorsal from the posterior cord.

The **lateral anterior thoracic nerve** joins with the medial to form a loop which supplies the pectoralis major and minor.

FIG. 756.—DISTRIBUTION OF CUTANEOUS NERVES ON THE ANTERIOR AND POSTERIOR ASPECTS OF THE SUPERIOR EXTREMITY.

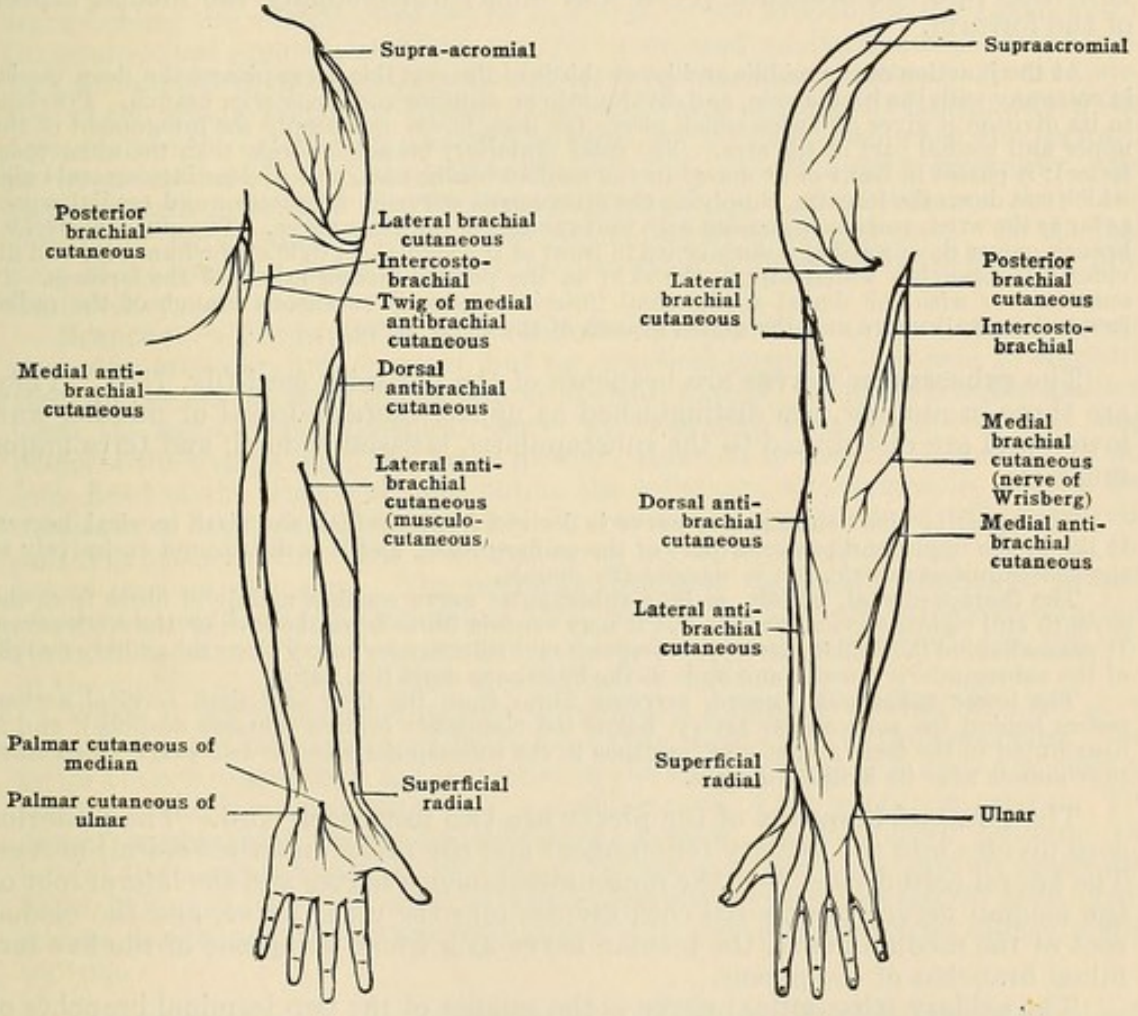

It arises from the lateral cord of the plexus and contains fibres from the fifth, sixth, and seventh cervical nerves (figs. 751, 754, 755). After joining the medial anterior thoracic it pierces the coraco-clavicular fascia and ends in branches that supply the pectoralis major muscle. The **medial anterior thoracic nerve** arises from the medial cord (figs. 751, 754, 755), contains fibres from the eighth cervical and first thoracic nerves, and passes forward between the first stage of the axillary artery and the axillary vein. It unites with a branch from the lateral anterior thoracic, to form a loop which is placed in front of the first stage of the axillary artery; it gives branches to the pectoralis minor, and branches which pass through the latter muscle and end in the pectoralis major. From the loop additional branches are furnished to the pectoralis major.

The **medial brachial (lesser internal) cutaneous nerve, or nerve of Wrisberg** (fig. 754), arises from the medial cord of the brachial plexus and sometimes contains fibres from the eighth cervical and first thoracic nerves, but usually fibres

from the first thoracic nerve alone. It runs downward on the medial side of the axillary vein, being separated by that vessel from the ulnar nerve, and it continues downward with a slight inclination dorsalward under cover of the deep fascia on the inner side of the arm. At the middle of the arm it pierces the deep fascia, and near the bend of the elbow it turns somewhat sharply dorsalward to supply the integument which covers the olecranon process (fig. 756).

As it traverses the axilla the nerve of Wrisberg communicates with the intercosto-brachial nerve, forming one, or sometimes two loops (fig. 754). In its course down the arm it gives a few fine twigs to the integument. This nerve may be absent, its place being taken by the intercosto-brachial or by part of the posterior brachial (internal) cutaneous branch of the radial (musculo-spiral) or, rarely, by a branch from the first intercostal nerve.

The **medial antibrachial (internal) cutaneous nerve** (figs. 751 and 754) arises from the medial cord in close relation with the ulnar nerve. It contains fibres from the eighth cervical and first thoracic nerves. At its origin it lies directly on the medial side of the axillary artery (fig. 755), but it soon becomes more superficial and then lies in the groove between the artery and the vein. In the upper two-thirds of the arm it lies in front and to the medial side of the brachial artery. It divides into two branches (volar and ulnar) which supply the medial aspect of the forearm.

At the junction of the middle and lower thirds of the arm this nerve pierces the deep fascia, in company with the basilic vein, and divides into an anterior and a posterior branch. Previous to its division it gives off twigs which pierce the deep fascia and supply the integument of the upper and medial part of the arm. The **volar (anterior) branch** is larger than the ulnar (posterior); it passes in front of or dorsal to the median basilic vein, and divides into several twigs which run down the forearm, supplying the integument covering its anterior and medial aspect as far as the wrist, and anastomosing with the branches of the ulnar nerve. The **ulnar (posterior) branch** passes downward and dorsalward in front of the medial condyle of the humerus, and divides into branches which supply the skin on the postero-medial aspect of the forearm. It anastomoses with the dorsal antibrachial (inferior external) cutaneous branch of the radial (musculo-spiral) nerve and the dorsal branch of the ulnar nerve).

The **subscapular nerves** are branches of the posterior cord (fig. 754). They are three in number, are distinguished as upper, thoraco-dorsal or middle, and lower, and are distributed to the subscapularis, latissimus dorsi, and teres major muscles.

The **upper** or **short subscapular nerve** is derived from the fifth and sixth cervical nerves. It lies in the upper and posterior part of the axillary fossa, and it is distributed exclusively to the subscapularis muscle. It is occasionally double.

The **thoraco-dorsal, middle,** or **long subscapular nerve** consists mainly of fibres from the seventh and eighth cervical nerves, but it may contain fibres from the fifth or the sixth nerve. It passes behind the axillary artery, accompanies the subscapular artery along the axillary margin of the subscapularis muscle, and ends in the latissimus dorsi (fig. 755).

The **lower subscapular nerve,** carrying fibres from the fifth and sixth cervical nerves, passes behind the subscapular artery, below the circumflex branch (dorsalis scapulæ), and is distributed to the teres major, and furnishes to the subscapularis one or two twigs which enter that muscle near its axillary margin.

The **terminal branches** of the plexus are two from each cord. The posterior cord divides into the axillary (circumflex) and the radial (musculo-spiral) nerves. The lateral cord divides into the musculo-cutaneous nerve, and the lateral root of the median nerve; the medial cord divides into the ulnar nerve, and the medial root of the median nerve, the median nerve as a whole being one of the five terminal branches of the plexus.

The **axillary (circumflex) nerve** is the smaller of the two terminal branches of the posterior cord, and contains fibres from the fifth and sixth cervical nerves (figs. 751 and 754). At the lower border of the subscapularis it passes dorsalward and accompanies the posterior circumflex artery through the quadrilateral space, which is bounded by the teres major, long head of triceps, and subscapularis muscles, and the surgical neck of the humerus, and it divides into a smaller superior and a larger inferior division. Previous to its division it furnishes an articular twig to the shoulder-joint. This twig pierces the inferior part of the articular capsule.

The **superior division** accompanies the posterior circumflex artery around the neck of the humerus, and gives off a number of stout twigs which enter the deltoid muscle (fig. 755). A few fine filaments pierce the deltoid and end in the integument which covers the middle third of that muscle.

The **inferior division** divides into cutaneous and muscular branches. The cutaneous branch (the **lateral brachial cutaneous nerve**) turns around the posterior border of the deltoid, pierces the deep fascia, and supplies the skin covering the lower third of the deltoid and a small area of integument below the insertion of the muscle (fig. 756). One muscular branch is distributed to the teres minor; it swells out into an ovoid or fusiform, reddish, gangliform enlargement before entering the muscle. Other branches supply the lower and posterior part of the deltoid.

The **radial (musculo-spiral) nerve** is the largest branch of the brachial plexus. It contains fibres from the sixth, seventh, and eighth cervical and sometimes from the fifth cervical and first thoracic nerves (figs. 751, 754). It commences at the lower border of the pectoralis minor, as the direct continuation of the posterior cord of the brachial plexus, and passes downward and lateralward in the axillary fossa behind the third part of the axillary artery (fig. 755) and in front of the subscapularis, latissimus dorsi, and teres major muscles. From the lower border of the axillary fossa it descends into the arm, where it lies, at first, on the medial side of the upper third of the humerus, behind the brachial artery and in front of the long head of the triceps; then it runs obliquely downward and lateralward behind the middle third of the humerus, in the groove for the radial nerve (musculo-spiral groove), and between the lateral and medial heads of the triceps. It is accompanied, in this part of its course, by the profunda artery. At the junction of the middle and lower thirds of the humerus it reaches the lateral side of the arm, pierces the external intermuscular septum, and runs downward and forward between the brachio-radialis and extensor carpi radialis longus externally, and the brachialis internally (fig. 758), and it terminates, a short distance above the capitulum, by dividing into deep and superficial terminal branches. In the last part of its course it is accompanied by the anterior terminal branch of the profunda artery.

Branches.—The branches of the radial or musculo-spiral nerve are *cutaneous*, *muscular*, *articular*, and *terminal*, but for practical purposes it is best to consider them in association with the situations of their origins. While it is **in the axillary fossa** the radial (musculo-spiral) nerve gives branches to the medial and long heads of the triceps (fig. 758), and a medial cutaneous branch. The branch to the long head of the triceps at once enters the substance of the muscle, that to the medial head breaks into branches which terminate in the muscle at different levels, and one of them, the *ulnar collateral nerve*, accompanies the ulnar nerve to the lower part of the arm. The **posterior brachial (internal) cutaneous branch** crosses the tendon of the latissimus dorsi, passes dorsal to the intercosto-brachial (intercosto-humeral) nerve, pierces the deep fascia, and is distributed to the skin of the middle of the back of the arm below the deltoid.

While it lies behind the middle third of the humerus, the radial nerve gives branches to the lateral and medial heads of the triceps and to the anconeus. The latter branch descends in the substance of the median head of the triceps, close to the bone, and it is accompanied by a small branch of the profunda artery. The **dorsal antibrachial (external) cutaneous branch,** passing down between the lateral and median heads of the triceps, divides near the elbow into its upper and lower branches (fig. 756), each of which perforates either the lateral head of the triceps muscle near its attachment to the humerus or the external intermuscular septum.

The **upper branch,** much the smaller, pierces the deep fascia in the line of the external intermuscular septum; it accompanies the lower part of the cephalic vein, and supplies the skin over the lower half of the lateral and anterior aspect of the arm. The **lower branch** is of considerable size. It pierces the deep fascia a little below the upper branch, runs behind the external condyle, and supplies the skin of the middle of the back of the forearm as far as the wrist, anastomosing with the medial antibrachial (internal) cutaneous and musculo-cutaneous nerves (fig. 759).

After the radial nerve has pierced the external intermuscular septum it gives branches to the brachio-radialis, extensor carpi radialis longus, and to the lateral portion of the brachialis (fig. 759). From one of these branches an articular filament is distributed to the elbow-joint.

The **terminal branches** of the radial nerve are:—a motor branch, the *deep radial*, to the supinator and extensor muscles of the forearm, and a sensory

branch, the *superficial radial*, which supplies the dorsal aspect of the radial half of the hand.

The **deep radial** [ramus profundus] (posterior interosseous) nerve runs downward in the interval between the brachialis and extensor carpi radialis longus. It passes in front of the lateral part of the elbow-joint, and after giving off branches to supply the extensor carpi radialis brevis and supinator, it is crossed in front by the radial recurrent artery (fig. 759). It then runs downward and dorsalward through the substance of the supinator, and enters the interval between the superficial and deep layers of muscles at the back of the forearm, where it comes into relation with the posterior interosseous artery, and accompanies it across

FIG. 757.—A DISSECTION OF THE CUTANEOUS NERVES ON THE DORSAL ASPECT OF THE HAND AND FINGERS. (H. St. J. B.)

The branches of the median nerve are shown in black.

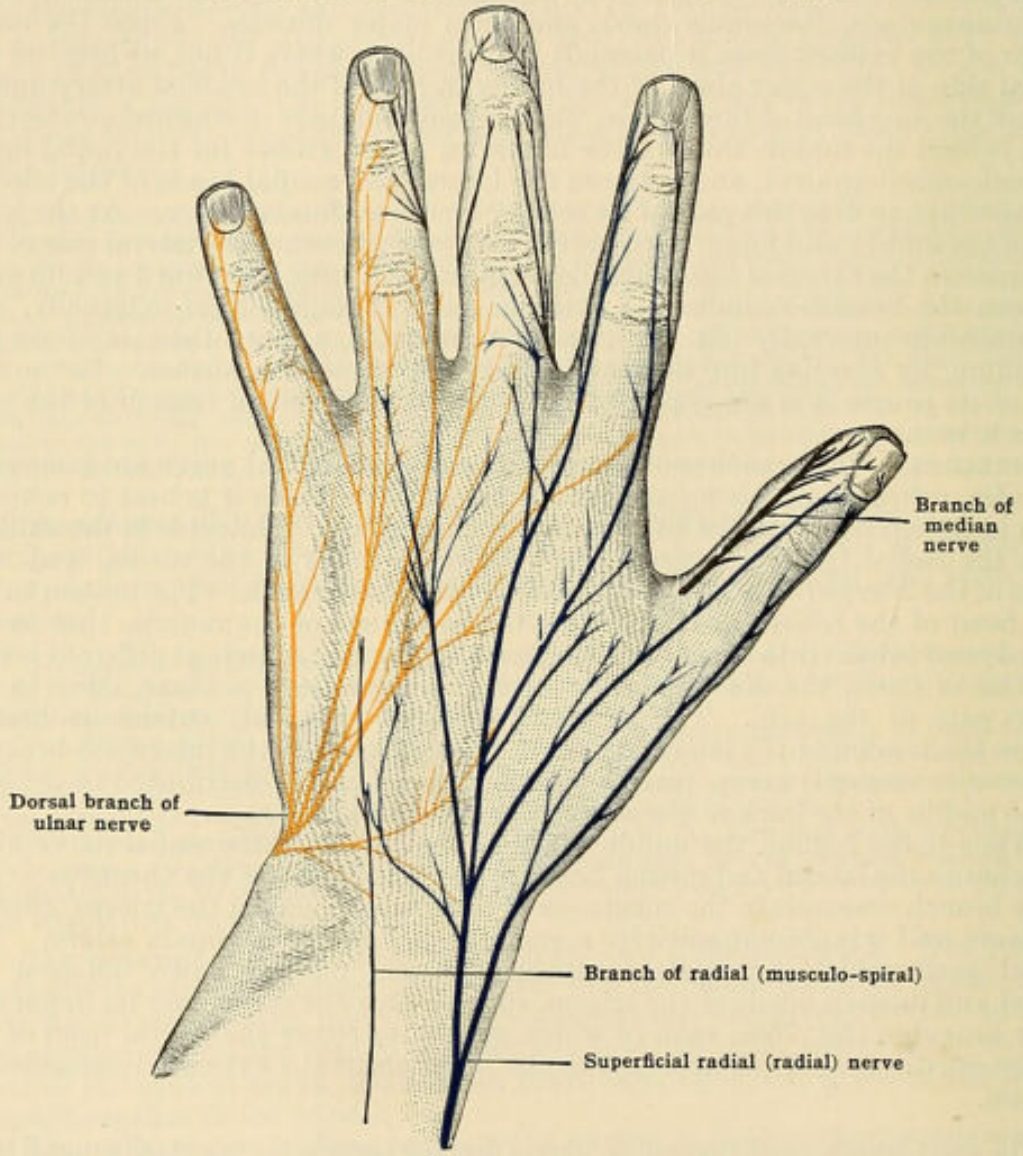

the abductor pollicis longus. At the lower border of the latter muscle it gives off a branch to the extensor pollicis longus, and another which crosses this muscle to the extensor indicis proprius.

Continuing distalward as the *dorsal antibrachial interosseous* nerve the deep radial leaves the posterior interosseous artery, dips beneath the extensor pollicis longus, and joins the volar interosseous artery. It accompanies this artery upon the interosseous membrane and upon the back of the radius, passes through the groove for the extensor digitorum communis and extensor indicis proprius to the dorsum of the wrist, and terminates in a gangliform enlargement which gives branches to the carpal articulations. The muscles supplied by the deep radial nerve are the extensor carpi radialis brevis, brachio-radialis (supinator longus), extensor digitorum communis, extensor digiti quinti proprius, extensor carpi ulnaris, extensor indicis proprius, and the extensor muscles of the thumb. The supinator (brevis) receives two twigs, one of which is given off before the nerve pierces the muscle and the other while it is passing through it.

The **superficial radial** (radial) nerve [ramus superficialis n. radialis] is somewhat smaller than the deep radial (posterior interosseous), and is a purely cutaneous nerve. It runs downward under cover of the brachio-radialis, passing in front of the elbow-joint, the radial recurrent artery, and the supinator (brevis). At the lower border of the supinator it approaches the radial artery at an acute angle, and runs parallel to the lateral side of that vessel in the middle third of the forearm, across the pronator teres. At the lower border of the pronator teres it bends dorsalward on the deep surface of the tendon of the brachio-radialis, and appears on the back of the forearm. It pierces the deep fascia and is directed across the dorsal carpal (posterior annular) ligament toward the dorsum of the wrist, where it divides into its terminal branches (fig. 759).

The most lateral of these branches supplies the skin on the radial part of the thenar eminence; the most medial, designated the **ulnar anastomotic branch,** communicates with the dorsal branch of the ulnar nerve. The other terminal branches, the **dorsal digital nerves,** supply to a variable extent the skin on the dorsum of the first digit, both sides of the second and the radial side of the third digit. These branches usually extend to the base of the nail of the first digit, to the distal interphalangeal joint of the second, not quite to the proximal interphalangeal joint of the third, and to the metacarpo-phalangeal joint of the fourth digit.

The **terminal branches of the lateral cord** of the brachial plexus are the musculo-cutaneous and the lateral component of the median nerve. The latter nerve will be described with the medial cord.

The **musculo-cutaneous nerve** is composed of fibres derived chiefly from the anterior divisions of the fifth and sixth cervical nerves, together usually with some fibres from that of the seventh (figs. 751 and 754). The nerve to the coraco-brachialis usually consists of two or three twigs given off from the nerve close to its origin before it enters the muscle (fig. 755). Sometimes, however, the fibres from the seventh cervical nerve pass directly to this muscle without joining the main trunk. The musculo-cutaneous nerve is placed at first close to the lateral side of the axillary artery (fig. 755), but soon it leaves that vessel and, piercing the coraco-brachialis muscle, it passes obliquely downward and lateralward between the biceps and brachialis muscles. Soon after piercing the coraco-brachialis it gives off **muscular branches** to each head of the *biceps* and to the *brachialis* (fig. 758). It also gives twigs to the *humerus*, to the *nutrient artery*, and gives the chief supply to the *elbow-joint*. Below the branch to the brachialis the cutaneous portion of the nerve forms the **lateral antibrachial cutaneous nerve** (figs. 756, 758). This portion continues downward between the biceps and brachialis, pierces the deep fascia at the lateral border of the former muscle a little above the bend of the elbow, receives a communication from the upper branch of the dorsal antibrachial (upper external) cutaneous branch of the radial (musculo-spiral) nerve, passes dorsal to the median cephalic vein, and divides into an anterior and a posterior branch.

The **anterior branch** runs downward on the lateral and anterior part of the forearm, supplying the integument of that region, and it terminates in the skin covering the middle part of the thenar eminence (fig. 759). A short distance above the wrist, after it has received a communicating twig from the superficial radial nerve, it gives off an articular branch to the carpal joints. This branch pierces the deep fascia and accompanies the radial artery to the dorsum of the wrist. The **posterior terminal branch** is small, and is directed downward and backward in front of the external condyle of the humerus, to be distributed to the skin on the lateral and posterior aspect of the forearm as low as the wrist (fig. 756). It anastomoses with the superficial radial and with the lower branch of the dorsal antibrachial (lower external) cutaneous branch of the radial nerve.

The **terminal branches of the medial cord** of the brachial plexus are the ulnar nerve and the medial component of the median nerve. Neither of these gives any branches in the upper arm, and thus they differ from the other terminal branches of the plexus. They both supply the muscles and joints of the forearm, and the muscles, joints, and integument of the hand.

The **ulnar nerve,** which is the largest branch of the medial cord of the brachial plexus, contains fibres from the anterior divisions of the eighth cervical and first thoracic nerves (figs. 752 and 762). It commences at the lower border of the pectoralis minor and runs downward in the axillary fossa in the posterior angle between the axillary artery and vein. In the upper half of the arm it lies on the medial side of the brachial artery (fig. 755), but at the level of the insertion of the

coraco-brachialis it passes backward at an acute angle, and, accompanied by the superior ulnar collateral (inferior profunda) artery, it pierces the internal intermuscular septum. After passing through the septum it runs downward, in a groove in the medial head of the triceps (fig. 758), to the interval between the olec-

FIG. 758.—NERVES OF THE RIGHT UPPER ARM VIEWED FROM IN FRONT. (Spalteholz.)

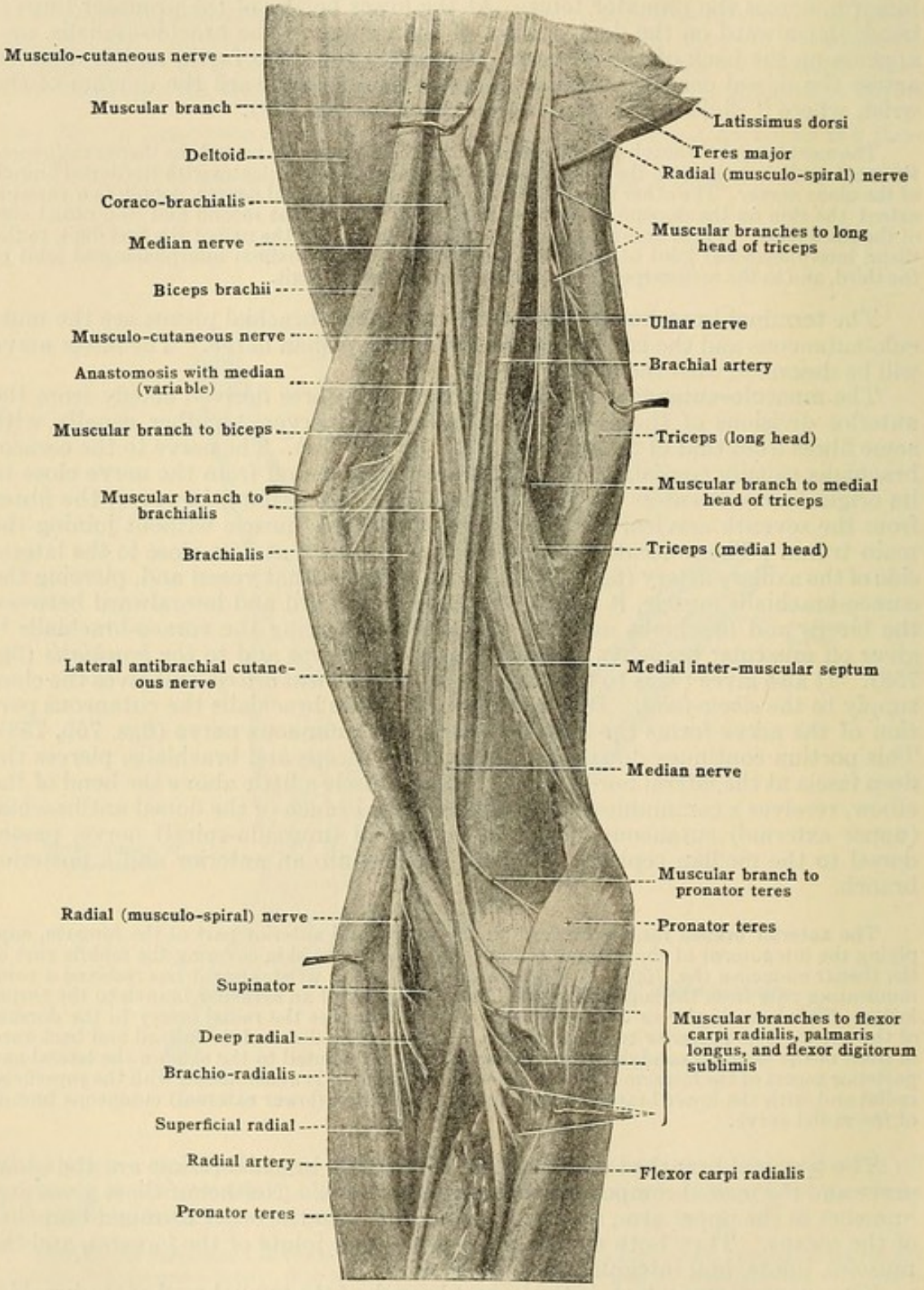

ranon process and the medial condyle of the humerus, and in this part of its course it is closely bound to the muscle by the deep fascia. Immediately below the medial condyle it passes between the two heads of the flexor carpi ulnaris, along the medial side of the medial collateral ligament of the elbow, and it comes into relation with the dorsal ulnar recurrent artery.

In the upper forearm the ulnar nerve lies on the flexor digitorum profundus, covered by the flexor carpi ulnaris. Near the junction of the upper and middle thirds of the forearm it is joined by the ulnar artery, which accompanies it to its termination, lying throughout on its radial side (fig. 759). In the lower part of the forearm it still rests on the flexor digitorum profundus, but

FIG. 759.—DEEP NERVES OF THE VOLAR SURFACE OF THE FOREARM. (After Toldt, "Atlas of Human Anatomy," Rebman, London and New York.)

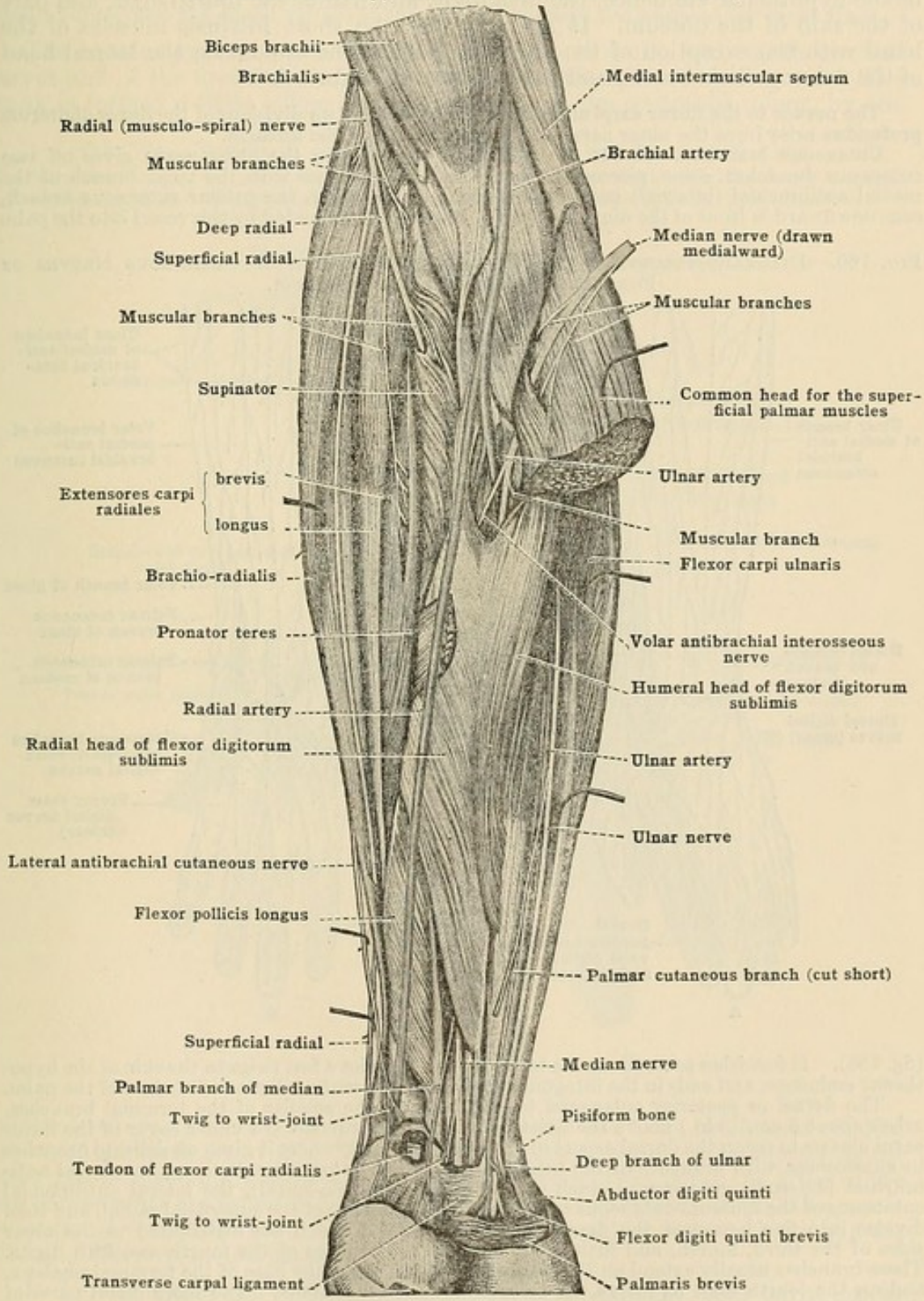

between the flexor carpi ulnaris and flexor digitorum sublimis, and is covered only by skin and fascia. At a variable point in this part of the forearm, usually about 5 to 8 cm. (2 to 3 in.) from the carpus, the nerve divides into its two terminal branches, a dorsal branch to the dorsal aspect of the hand, and a volar branch to the volar aspect.

Branches.—The ulnar resembles the median nerve in not furnishing any branches to the upper arm. As it passes between the olecranon process and the medial condyle it gives off two or three fine filaments to the elbow-joint. In the upper part of the forearm it supplies the flexor carpi ulnaris and the medial portion of the flexor digitorum profundus, and in the lower half it gives off the three cutaneous branches. In the palm of the hand it supplies the integument of the hypothenar eminence, the fifth digit, and half of the fourth digit, and part of the skin of the dorsum. It also supplies the short intrinsic muscles of the hand with the exception of the abductor pollicis, the opponens, the lateral head of the flexor pollicis brevis, and the two lateral lumbricales.

The **nerves to the flexor carpi ulnaris** and to the medial two divisions of the **flexor digitorum profundus** arise from the ulnar nerve in the upper third of the forearm.

Cutaneous branches.—About the middle of the forearm the ulnar nerve gives off two cutaneous branches:—one pierces the fascia and anastomoses with the volar branch of the medial antibrachial (internal) cutaneous nerve, and the other, the **palmar cutaneous branch,** runs downward in front of the ulnar artery (fig. 759) and is conducted by this vessel into the palm

FIG. 760.—DIAGRAMS ILLUSTRATING A COMMON DISTRIBUTION OF CUTANEOUS NERVES OF FOREARM. A, dorsum; B, volar aspect.

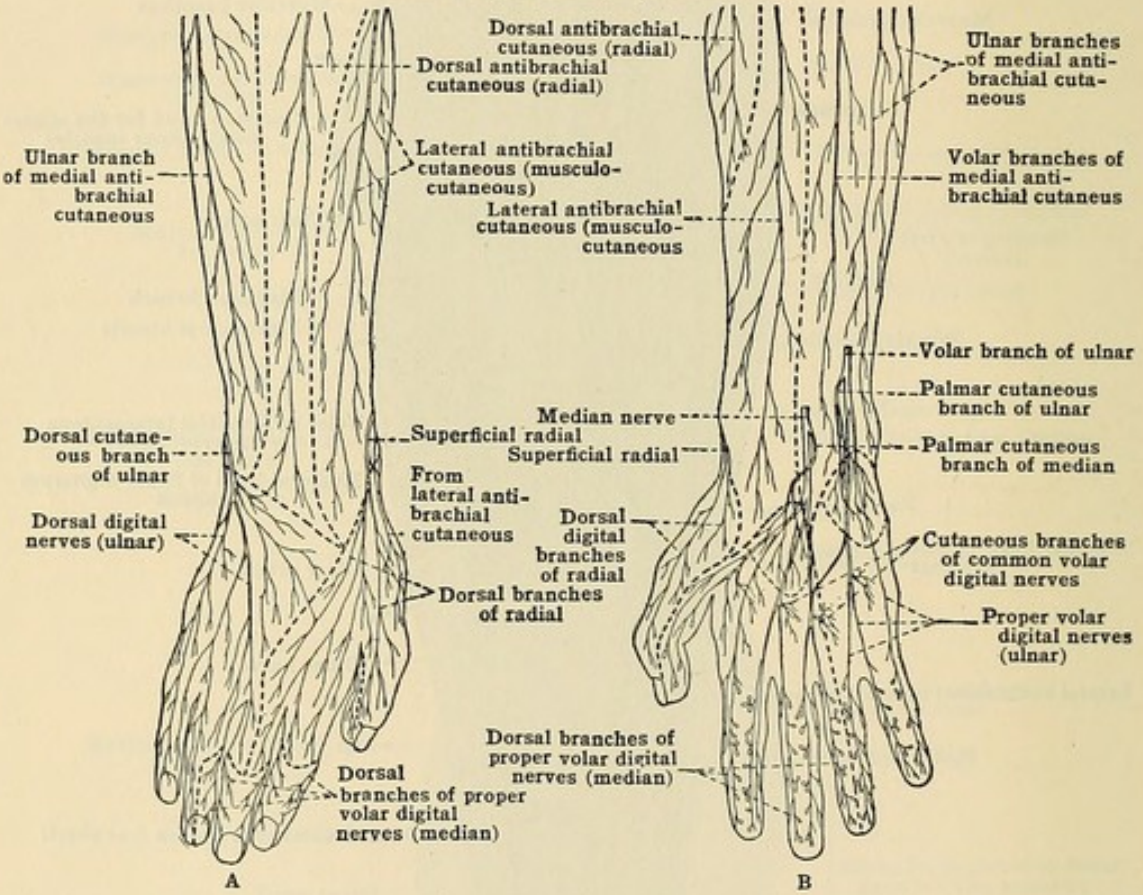

(fig. 756). It furnishes some filaments to the vessel, supplies a few twigs to the skin of the hypothenar eminence, and ends in the integument covering the central depressed surface of the palm.

The **dorsal** or **posterior cutaneous branch,** usually the smaller of the terminal branches, arises about 5 cm. (2 in.) above the wrist-joint, and passes backward under cover of the flexor carpi ulnaris to reach the dorsal aspect of the wrist (fig. 761), where it gives off delicate branches to anastomose with branches of the medial antibrachial (internal) cutaneous, the dorsal antibrachial (external) cutaneous branch of the radial (musculo-spiral), the lateral antibrachial cutaneous of the musculo-cutaneous nerve, and with branches of the superficial radial, and then divides into five branches, the **dorsal digitals** (fig. 757), which are distributed to the ulnar sides of the third, fourth, and fifth digits and the radial sides of the fourth and fifth digits. These branches usually extend on the fifth digit only as far as the base of the terminal phalanx, and on the fourth digit as far as the base of the second phalanx. The more distal parts of these digits are supplied by palmar digital branches of the ulnar nerve.

The **volar branch,** the other terminal branch of the ulnar nerve, continues its course between the flexor carpi ulnaris and flexor digitorum sublimis, on the medial side of the ulnar artery, to the wrist, where, on the lateral side of the pisiform bone, it divides into a **superficial** and a **deep branch** (figs. 759 and 761). The latter accompanies the deep branch of the ulnar artery into the interval between the abductor digiti quinti and flexor digiti quinti brevis, and then

passes through the fibres of the opponens digiti quinti to reach the deep surface of the flexor tendons and their synovial sheaths. It supplies the abductor and opponens digiti quinti, the flexor digiti quinti brevis, the third and fourth lumbricales, all the interossei, the adductors of the thumb, and the medial head, and occasionally the lateral head, of the flexor pollicis brevis. The **superficial branch** gives off a branch to supply the palmaris brevis muscle, an anastomosing branch to the median nerve, and then divides into two branches, the **proper volar digital branch,** which is distributed to the medial side of the fifth digit on its volar aspect, and the **common volar digital branch,** which passes underneath the palmar aponeurosis and divides into two branches, which supply the contiguous margins of the fourth and fifth digits. These branches usually supply also the dorsal surface of the second and third phalanges of the same digits.

The **median nerve** contains fibres of the sixth, seventh, and eighth cervical nerves and of the first thoracic, and sometimes of the fifth cervical nerve. The trunk is formed a little below the lower margin of the pectoralis minor, by the

FIG. 761.—NERVES OF THE PALMAR SURFACE OF THE HAND. (Testut.)
The transverse carpal (anterior annular) ligament, superficial palmar arch, the flexor tendons of the digits, and the proximal portions of the lumbrical muscles have been removed.

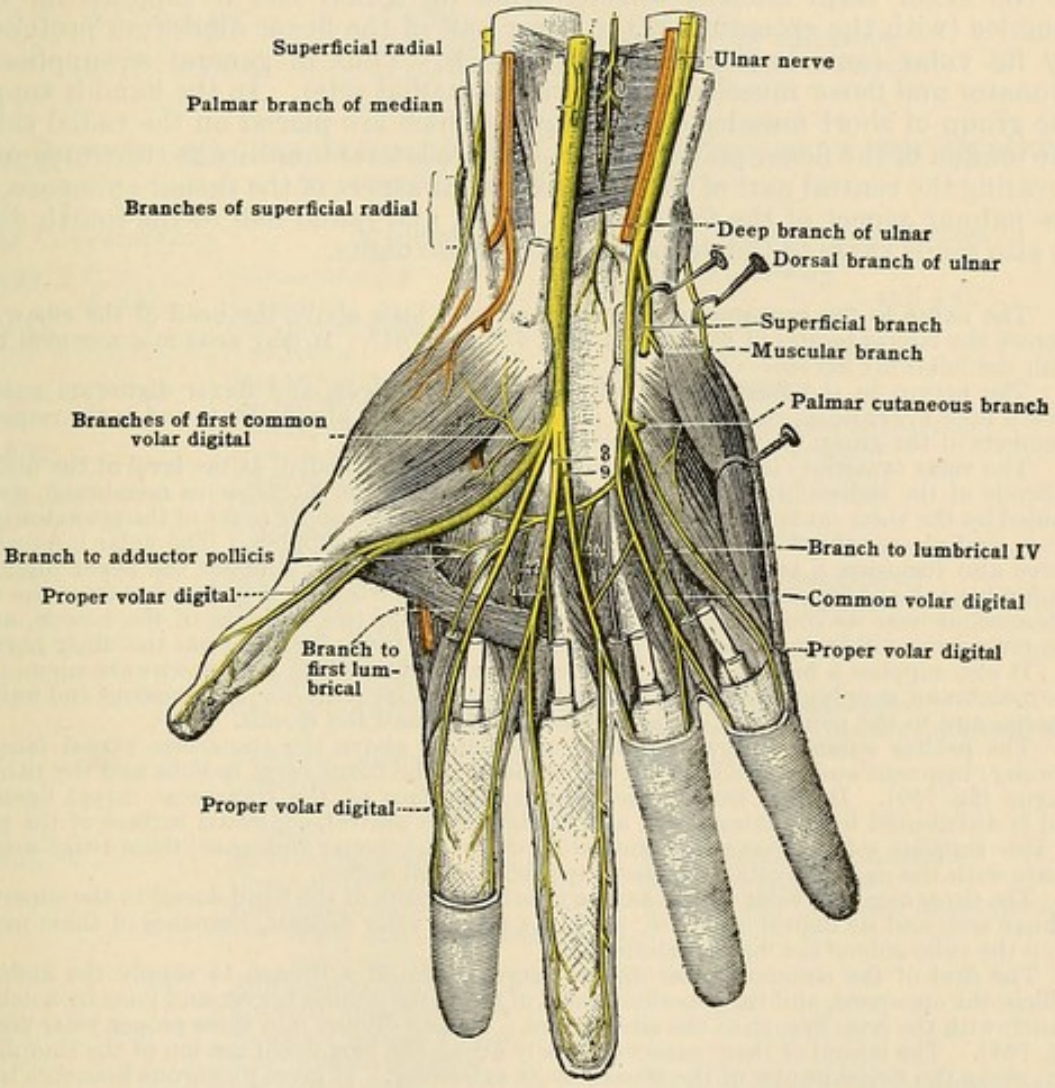

union of two components, one from the medial and one from the lateral cord of the brachial plexus (fig. 755). The medial component passes obliquely across the third part of the axillary artery, and in the upper part of the trunk the fibres of the two components are felted together. From its commencement the median nerve runs almost vertically through the lower part of the axillary fossa and through the arm and forearm to the hand.

In the fossa it lies lateral to the axillary artery and it is overlapped, on its lateral side, by the coraco-brachialis muscle. In the upper half of the arm it lies along the lateral side of the brachial artery, and it is overlapped by the medial border of the biceps. At the middle of the arm it passes in front of the brachial artery, and then it descends, on the medial side of the artery, to the elbow. In the upper part of the antecubital fossa it is still at the medial side of the brachial artery, but separated from it by a small interval, and in the lower part of the fossa it lies

along the medial side of the ulnar artery. In case of the high division of the brachial artery, when the radial and the ulnar arteries lie together in the upper arm, the median nerve may pass between them and then one or the other of the arteries will be superficial to the nerve. As it leaves the antecubital fossa it passes between the two heads of the pronator teres, and it crosses in front of the ulnar artery (fig. 759), from which it is separated by the deep head of the pronator. In the forearm it passes vertically downward, accompanied by the median (comes nervi mediani) artery. In the upper two-thirds of this region it lies deeply, between the flexor digitorum sublimis and the flexor digitorum profundus, but in the lower third it becomes more superficial, and is placed beneath the deep fascia, between the flexor carpi radialis on the radial side and the palmaris longus and flexor digitorum sublimis tendons on the ulnar side. It crosses beneath the transverse carpal (anterior annular) ligament, in front of the flexor tendons, and in the palm at the lower border of the ligament it enlarges and divides into three branches, the **common volar digital nerves** (fig. 760).

Branches.—The median nerve does not supply any part of the upper arm. In front of the elbow-joint it furnishes one or two filaments to that articulation. In the forearm it supplies all the superficial anterior muscles (with the exception of the flexor carpi ulnaris) directly from its trunk, and it supplies the deep muscles (with the exception of the ulnar half of the flexor digitorum profundus) by its volar (anterior) interosseous branch. Thus in general it supplies the pronator and flexor muscles of the forearm (radial side). In the hand it supplies the group of short muscles of the thumb, which are placed on the radial side of the tendon of the flexor pollicis longus, the two lateral lumbricales, the integument covering the central part of the palm and ulnar aspect of the thenar eminence, and the palmar aspect of the first, second, third, and radial half of the fourth digits. It also sends twigs to the dorsal aspect of these digits.

The **nerve to the pronator teres** usually arises a little above the bend of the elbow, and pierces the lateral border of the muscle (figs. 759 and 761). It may arise in a common trunk with the following nerves:—

The nerves to the **flexor carpi radialis, palmaris longus,** and **flexor digitorum sublimis** arise a little lower down, and pierce the pronator-flexor mass of muscles to end in the respective members of the group for which they are destined (fig. 758).

The **volar (anterior) interosseous nerve** arises from the median at the level of the bicipital tubercle of the radius (fig. 759), and runs downward, on the interosseous membrane, accompanied by the volar (anterior) interosseous artery. It passes under cover of the pronator quadratus, and pierces the deep surface of that muscle, which it supplies. The volar interosseous nerve also furnishes a twig to the front of the wrist-joint, and supplies the flexor digitorum profundus and the flexor pollicis longus. The nerve to the former muscle arises from the volar interosseous near its commencement; it supplies the outer two divisions of the muscle, and it communicates within the substance of the muscle with twigs derived from the ulnar nerve.

It also supplies a branch to the interosseous membrane which runs downward upon, or in, the membrane, supplying it and giving branches to the volar (anterior) interosseous and nutrient arteries and to the periosteum of the radius, the ulna, and the carpus.

The **palmar cutaneous branch** arises immediately above the transverse carpal (anterior annular) ligament and passes between the tendons of the flexor carpi radialis and the palmaris longus (fig. 759). It then crosses the superficial surface of the transverse carpal ligament, and is distributed to the integument and fascia on the central, depressed surface of the palm. It also supplies a few twigs to the medial border of the thenar eminence; these twigs communicate with the musculo-cutaneous and superficial radial nerves.

The three **common volar digital nerves** pass in the palm of the hand dorsal to the superficial palmar arch and its digital branches, while the **proper volar digitals,** branches of these nerves, lie on the volar side of the digital arteries.

The **first** of the common volar digital nerves gives off a branch to supply the abductor pollicis, the opponens, and the superficial head of the flexor pollicis brevis, and joins by a delicate branch with the deep branch of the ulnar nerve. It then divides into three **proper volar digitals** (fig. 761). The lateral of these passes obliquely across the long flexor tendon of the thumb and runs along the radial border of the thumb to its extremity. It gives numerous branches to the pulp of the thumb, and a strong twig which passes to the dorsum to supply the matrix of the nail. The second of these proper volar digitals supplies the medial side of the volar aspect of the thumb and gives off a twig to the matrix of the thumb nail. The third supplies the radial side of the second digit and gives a twig to the first lumbrical muscle.

The **second** common volar digital sends a twig to the second lumbrical muscle, and divides a little above the metacarpo-phalangeal articulation into two **proper volar digitals,** which respectively supply the adjacent sides of the second and third digits.

The **third** common volar digital communicates with the ulnar nerve, often gives a branch to the third lumbrical muscle, and divides into two **proper volar digitals** which supply the adjacent sides of the third and fourth digits.

As the proper volar digitals pass along the margins of the fingers they give off twigs for the innervation of the skin on the dorsum of the second and third phalanges and the matrix of their nails. Each of the nerves terminates in filaments to the pulp of the finger.

Table Showing Relation of Cervical and Thoracic Nerves to Branches of Brachial Plexus

Nerves Contributing.	Nerves, Branches of Plexus.
5 C.	Dorsal scapular (nerve to rhomboids)
	Nerve to subclavius
5 and 6 C.	Suprascapular
	Nerve to subclavius
	Upper subscapular
	Lower subscapular
	Axillary (circumflex)
5, 6, and 7 C.	Long (posterior) thoracic
	Lateral anterior thoracic
5, 6, and (7) C.	Musculo-cutaneous
(5), 6, 7, 8 C	Radial (musculo-spiral)
(5), 6, 7, 8 C., and 1 T	Median
7 and 8 C.	Thoraco-dorsal (middle or long subscapular)
8 C. and 1 T.	Medial anterior thoracic
	Ulnar
	Medial antibrachial (internal) cutaneous
1 T.	Medial brachial (lesser internal) cutaneous

Table Showing the Relations of the Cervical Nerves to the Muscles of the Upper Extremity

Nerves Contributing.	Muscles.	Nerves to Muscles.
Accessory, 2 C.	Sterno-mastoid	Spinal accessory
" 3, 4 C.	Trapezius	" " , 3 and 4 C.
3 and 4 C.	Levator scapulæ	3 and 4 C.
5 and 6 C.	Subclavius	Nerve to subclavius
	Supraspinatus	Suprascapular
	Infraspinatus	Suprascapular
	Subscapularis	Upper and lower subscapular
	Teres major	Lower subscapular
	Teres minor	Axillary (circumflex)
	Deltoid	Axillary (circumflex)
	Brachialis	Musculo-cutaneous
	Biceps	Musculo-cutaneous
	Brachioradialis	Radial (musculo-spiral)
	Supinator	Deep radial (posterior interosseous)
6 C.	Pronator teres	Median
	Flexor carpi radialis	"
	Palmaris longus	"
6 and 7 C.	Ext. carpi radialis longus	Radial (musculo-spiral)
	" " brevis	Deep radial (posterior interosseous)
	Abductor pollicis brevis	Median
	Opponens "	"
	Flexor pollicis brevis (superf. head)	"
5, 6, and 7 C.	Serratus anterior	Long (posterior) thoracic
7 C.	Coraco-brachialis	Musculo-cutaneous
	Ext. digitorum comm.	Deep radial (posterior interosseous)
	" digiti quinti proprius	" " " "
	" carpi ulnaris	" " " "
	Abductor pollicis longus	" " " "
	Extensor pollicis brevis	" " " "
	Extensor pollicis longus	" " " "
	Ext. indicus proprius	" " " "
7 and 8 C.	Latissimus dorsi	Thoraco-dorsal (long subscapular)
	Triceps	Radial (musculo-spiral)
	Anconeus	" " "
5, 6, 7, and 8 C.	Pectoralis major	Lat. and med. ant. thoracic
8 C.	Dorsal inteross.	Ulnar
	Palmar "	"
	Add. pollicis	"
	" pollicis trans.	"
	Flex. pollicis brev. (deep)	"
7, 8 C., and 1 T.	Pectoralis minor	Med. ant. thoracic
	Flex. digit. subl.	Median
	Lumbricalis	" and ulnar
8 C. and 1 T.	Flex. carpi ulnaris	Ulnar
	" digit. prof.	" and median
	" pollicis long.	Median
	Pronator quadratus	"

2. THE THORACIC NERVES

The **anterior primary divisions of the thoracic nerves,** with the exception of the first, retain, in the simplest form, the characters of anterior primary divisions of the typical spinal nerve. They do not form plexuses, but remain distinct from each other. Each divides into an easily recognisable lateral or dorsal and anterior or ventral branch (figs. 762 and 763), and they are not distributed to the limbs. The first, second, and last thoracic nerves, on account of their peculiarities, require separate description. The remainder are separable into two groups, an upper and a lower. The **upper group** consists of four nerves, the third to the sixth inclusive. which are distributed entirely to the thoracic wall. The **lower group** contains five nerves, the seventh to the eleventh inclusive, which are distributed partly

FIG. 762.—DIAGRAM OF THE DISTRIBUTION OF A TYPICAL THORACIC NERVE.

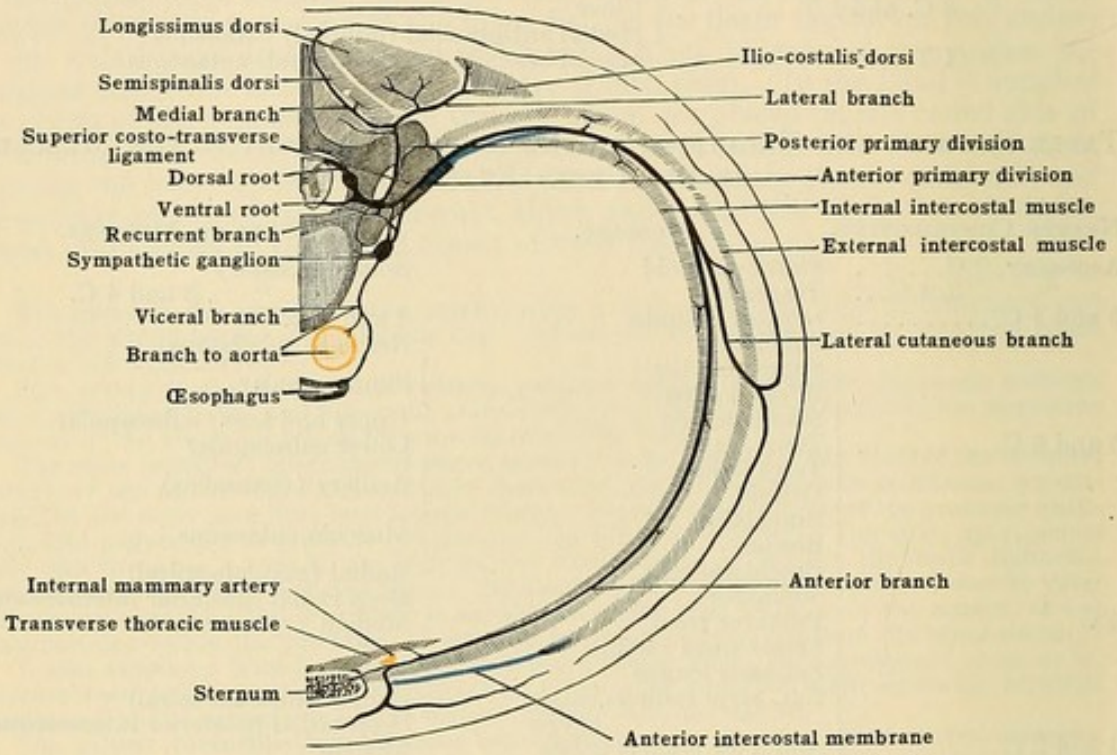

to the thoracic and partly to the abdominal wall. The upper group is therefore purely thoracic in distribution, and the lower thoraco-abdominal.

The **first thoracic nerve** is connected with the first thoracic sympathetic ganglion, and it frequently is joined by a small branch with the second nerve. It is distributed chiefly to the upper limb. Opposite the superior costo-transverse ligament of the second rib it divides into a larger and a smaller branch; the larger passes upward and lateralward, between the apex of the pleura and the neck of the first rib, and on the lateral side of the superior intercostal artery, to the root of the neck, where it joins the brachial plexus. The smaller branch continues along the intercostal space, below the first rib and between the intercostal muscles in which, as a rule, all its fibres terminate.

However, the smaller branch may give off a lateral cutaneous branch which connects with the medial brachial (lesser internal) cutaneous nerve and with the intercosto-brachial nerve in the axillary fossa; and occasionally it terminates in an anterior cutaneous branch at the anterior extremity of the first intercostal space.

The **second thoracic nerve,** as it lies between the pleura and the superior costo-transverse ligament of the third rib, gives a branch to the first nerve, then it pierces the posterior intercostal membrane and passes between the external and internal intercostal muscles in the second intercostal space. In the dorsal part of the space it sends branches backward, through the external intercostal muscle,

to supply the second levator costæ and the serratus posterior superior, and then it divides into a *lateral* and an *anterior* branch. The two branches run forward together to the mid-axillary line, where the lateral branch pierces the external intercostal muscle and passes between two digitations of the serratus anterior (magnus) into the axillary fossa; the anterior branch enters the substance of the internal intercostal muscle.

The **lateral branch,** the **intercosto-brachial** (*intercosto-humeral*), may divide into a small anterior and a large posterior division, or the anterior division may be absent. In either case the lateral branch anastomoses with the medial brachial (lesser internal) cutaneous nerve, and usually with the lateral branch of the third intercostal nerve; it also anastomoses with the lateral branch of the first nerve, if the latter is present. After forming these junctions it passes out of the axillary fossa, pierces the deep fascia, and supplies the integument in the upper and posterior half of the arm. It also gives off a few filaments which terminate in the skin over the axillary border of the scapula. The size of the intercosto-brachial nerve and the extent of its distribution are usually in inverse proportion to the size of the other cutaneous nerves of the upper arm, especially the middle brachial (lesser internal) cutaneous. When the latter nerve is absent, the intercosto-brachial usually takes its place.

The course and distribution of the **anterior branch,** when it is present, being similar to the course and distribution of the anterior branches of the next four nerves, do not require a separate description.

The **thoracic intercostal nerves** (upper group).—The third, fourth, fifth, and sixth thoracic nerves, in the posterior parts of the intercostal spaces, give **muscular branches** to the levatores costarum, the first to the fourth also giving branches to the serratus posterior superior. They pass forward a short distance between the external and internal intercostals, giving twigs to these muscles, and divide into two branches, lateral and anterior.

The **lateral cutaneous branches** continue forward between the intercostal muscles, and, near the mid-axillary line, pierce the external intercostals and serratus anterior (magnus) and divide into two branches, posterior and anterior. The *posterior branches* pass backward over the latissimus dorsi to supply the skin in the lower part of the scapular region. The *anterior branches*, in the four nerves, increase in size from above downward. They pass around the lateral border of the great pectoral muscle and are distributed to the integument over the front of the thorax and mamma, sending filaments, the *lateral mammary branches*, into the latter organ. The lowest two nerves also supply twigs to the upper digitations of the external oblique muscle.

The **anterior branches** run obliquely forward and medialward through the substance of the internal intercostal muscles, reaching the deep surface of these muscles at the extremity of the costal cartilages (fig. 762). They continue forward between these muscles and the pleura, pass in front of the internal mammary artery, turn abruptly ventralward a short distance from the sternum, pierce the internal intercostals, the anterior intercostal membrane, and the pectoralis major, and give off three sets of terminal branches. One set supplies the transverse thoracic muscle and the back of the sternum. A second set, cutaneous, runs mesially. The third set passes laterally over the pectoralis major, supplying the skin in that region, and, in the female, the mammary gland through the **medial mammary branches.** The anterior branches in their course supply the intercostal and subcostal muscles and give filaments that supply the ribs, the periosteum, and the pleura.

The thoraco-abdominal nerves (lower group).—The relations of the posterior portions of the seventh, eighth, ninth, tenth, and eleventh thoracic nerves to the thoracic wall are similar to those of the upper thoracic intercostal nerves. Each divides in a similar manner into a *lateral* and an *anterior* branch, but these branches are distributed partly to the abdominal and partly to the thoracic wall, and the smaller muscular branches have also different distributions.

The **lateral branches,** *lateral cutaneous nerves of the abdomen*, pierce the external intercostal muscles and pass through or between the digitations of the external oblique into the subcutaneous tissue, where they divide in the typical way into anterior and posterior branches. The *posterior branches* pass backward over the latissimus dorsi. The *anterior branches* give filaments to the digitations of the external oblique and extend forward, medialward and downward to the outer border of the sheath of the rectus.

The **anterior branches** pass forward between the external and internal intercostal muscles, to the ends of the intercostal spaces; there they insinuate

themselves between the interdigitating slips of the diaphragm and the transversus abdominis and enter the abdominal wall. The seventh, eighth, and ninth nerves, in their transit from the thoracic to the abdominal wall, pass behind the upturned ends of the eighth, ninth, and tenth rib-cartilages respectively. Having entered the abdominal wall the nerves run forward between the transversus abdominis and the internal oblique muscles to the outer border of the rectus abdominis, where they pierce the posterior lamella of the internal oblique aponeurosis and enter the sheath of the rectus. In the sheath they pass through the substance of the rectus. Finally they turn directly forward, pierce the anterior part of the sheath, and become **anterior cutaneous nerves of the abdomen.**

The muscular branches.—Muscular branches from all the thoraco-abdominal nerves are distributed to the levatores costarum, the intercostal muscles, the transversus abdominis, the internal oblique, and to the rectus abdominis, and the ninth, tenth, and eleventh nerves gives branches also to the serratus posterior inferior. Branches are also distributed from a variable number of the lower nerves to the costal portions of the diaphragm.

The last thoracic nerve.—The anterior primary division of the last thoracic nerve is distributed to the wall of the abdomen and to the skin of the upper and front part of the buttock. It appears in the thoracic wall immediately below the last rib, where it communicates with the sympathetic cord and gives off a communicating branch to the first lumbar nerve. It passes from the thorax into the abdomen beneath the lateral lumbo-costal arch (external arcuate ligament), accompanied by the subcostal artery, and it runs across the upper part of the quadratus lumborum dorsal to the kidney and to the ascending or the descending colon according to the side considered. At the lateral border of the quadratus lumborum it pierces the aponeurosis of attachment of the transversus abdominis muscle and divides, between the transversus and the internal oblique muscle, into a *lateral* and an *anterior* branch. It gives branches to the transversus abdominis, the quadratus lumborum, and the internal oblique muscles.

The **anterior branch** passes forward, between the internal oblique and the transversus abdominis, to which it supplies twigs. It enters the sheath of the rectus, turns forward through that muscle, and terminates in branches which become cutaneous midway between the umbilicus and the symphysis. Before it becomes cutaneous it supplies twigs to the transversus abdominis, the internal oblique, the rectus abdominis, and the pyramidalis muscles.

The **lateral branch** pierces the internal oblique; it supplies the lowest digitation of the external oblique, and then pierces the latter muscle from 2.5 to 8 cm. (1 to 3 in.) above the iliac crest, and descends in the superficial fascia of the anterior part of the gluteal region, crossing the iliac crest about 2.5 cm. (1 in.) behind its anterior extremity and reaching as far down as the level of the great trochanter. Occasionally this branch is absent and its place is taken by the iliac branch of the ilio-hypogastric. In such cases, however, the branch from the last thoracic to the first lumbar nerve is larger than usual.

THE LUMBO-SACRAL PLEXUS

The lumbo-sacral plexus is formed by the union of the anterior primary divisions of the lumbar, sacral, and coccygeal nerves. In about 50 per cent. of cases it receives a branch from the twelfth thoracic nerve. Its components are distributed to the lower extremity in a manner homologous and similar to the distribution of the parts of the brachial plexus to the upper extremity; the lumbar nerves are distributed similarly to the nerves formed from the anterior (medial and lateral) cords of the brachial plexus, and the sacral nerves are distributed in a manner similar to the distribution of the nerves from the posterior cord of the brachial plexus.

Partly for convenience of description and partly on account of the differences in position and course of some of the nerves arising from it, this plexus is subdivided into four parts—the lumbar, sacral, pudendal, and coccygeal plexuses. These plexuses overlap so that there is no definite line of demarcation between them. However, they will be considered separately.

3. *THE LUMBAR NERVES*

The anterior primary divisions of the five lumbar nerves increase in size from the first to the last. Each lumbar nerve is connected by one or two long, slender

rami with a lumbar sympathetic ganglion. The first three nerves and the greater part of the fourth enter into the formation of the lumbar plexus, and the smaller

FIG. 763.—CUTANEOUS NERVES OF THE THORAX AND ABDOMEN, VIEWED FROM THE SIDE. (After Henle.)

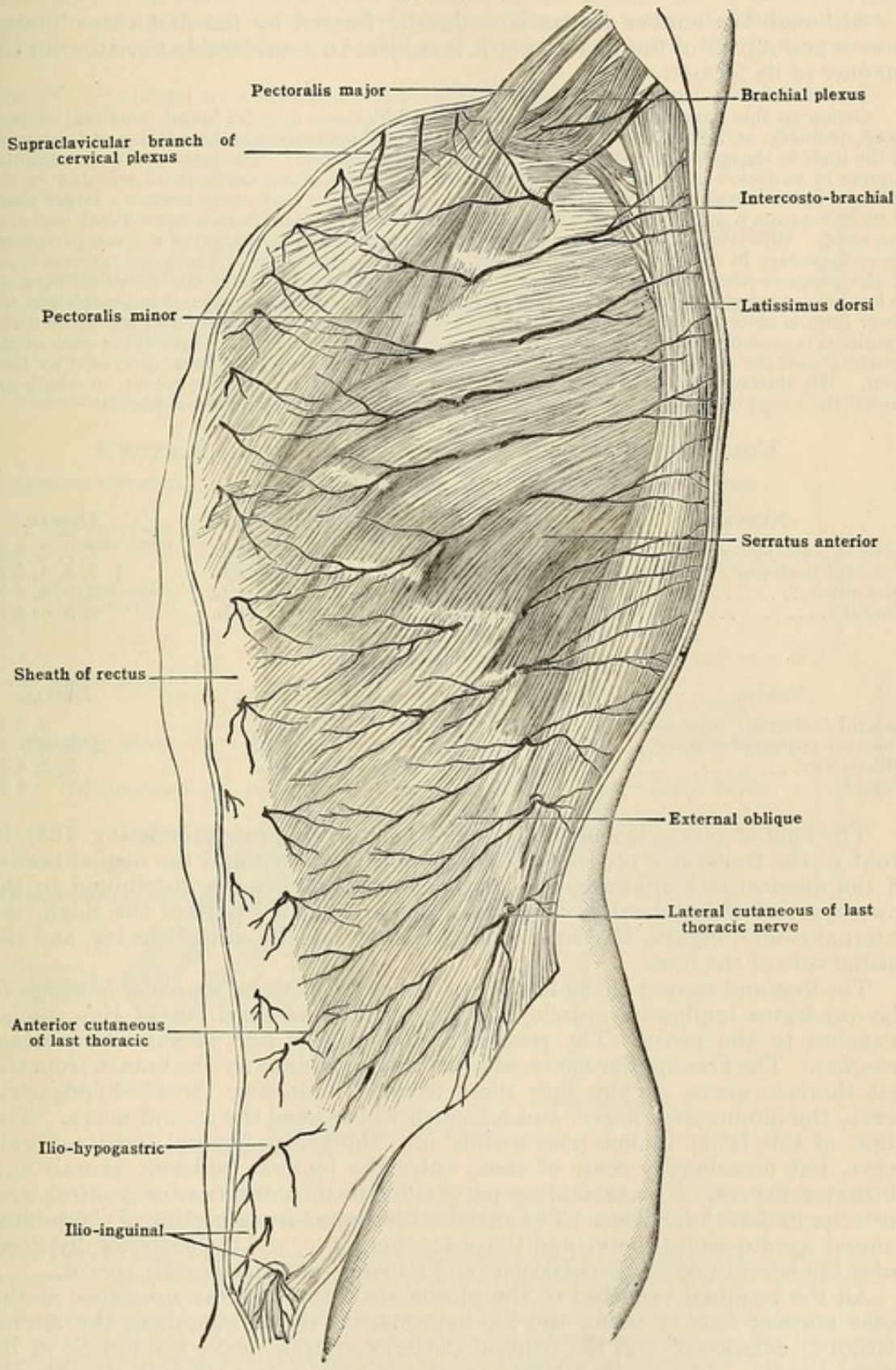

part of the fourth and the fifth nerve commonly unite to form the lumbo-sacral cord which takes part in the formation of the sacral plexus (figs. 764, 765). When the fourth nerve enters into the formation of both lumbar and sacral plexuses,

it may be called the *furcal nerve*, but this name is also applied to any of the nerves that enter into the formation of both plexuses, so there may be one or more furcal nerves.

THE LUMBAR PLEXUS

Although the **lumbar plexus** is ordinarily formed by the first three lumbar nerves and a part of the fourth, yet it is subject to considerable variation in the manner of its formation.

Owing to this variation three general classes of plexuses may be found, **proximal** or **prefixed, ordinary,** and **distal** or **post-fixed.** The basis of classification is the relation of the nerves of the limb to the spinal nerves which enter into their formation. The intermediate or slighter degrees of variation may consist only of changes in the size of the portions contributed by the different spinal nerves to a given peripheral nerve, for a given nerve may receive a larger share of its fibres from a more proximal spinal nerve, and a smaller share from a more distal nerve, or *vice versâ*. However, in the more marked degrees of variation the origin of a given peripheral nerve may vary in either direction to the extent of one spinal nerve. The more extreme types of the plexuses are sometimes associated with abnormal conditions of the vertebral column. It has been suggested that when the prefixed or proximal condition occurs, it indicates that the lower limb is placed a segment more proximal than in the ordinary cases, and when the distal condition is present, that the limb is arranged a segment more distal. Three types each of the proximal and the distal classes and one type of the ordinary class have been described by Bardeen. His statistics are made use of in the compilation of the following tables, in which are shown the range of variation and the common composition of each class of plexus:—

Composition of the Nerves of the Lumbar Plexus
Range of Variation

Nerve.	Proximal.	Ordinary.	Distal.
Lateral (external) cutaneous	12 T, 1, 2, 3 L.	1, 2, 3, 4 L.	1, 2, 3, 4 L.
Femoral (anterior crural) . . .	12 T, 1, 2, 3, 4 L.	1, 2, 3, 4 L.	1, 2, 3, 4, 5 L.
Obturator	1, 2, 3, 4 L.	1, 2, 3, 4 L.	2, 3, 4, 5 L.
Furcal	3 or 3, 4 L.	4 L.	4, 5 or 5 L.

Common Composition

Nerve.	Proximal.	Ordinary.	Distal.
Lateral (external) cutaneous	1, 2 L.	1, 2, 3 L.	2, 3 L.
Femoral (anterior crural) . .	1, 2, 3, 4 L.	2, 3, 4 L.	2, 3, 4, 5, L.
Obturator	1, 2, 3, 4 L.	2, 3, 4 L.	2, 3, 4 L.
Furcal	4 L.	4 L.	4 L.

The lumbar plexus lies in the posterior part of the psoas muscle (fig. 765), in front of the transverse processes of the lumbar vertebræ and the medial border of the quadratus lumborum, and its terminal branches are distributed to the lower part of the abdominal wall, the front and medial part of the thigh, the external genital organs, the front of the knee, the medial side of the leg, and the medial side of the foot.

The first and second of the lumbar nerves give collateral *muscular branches* to the quadratus lumborum muscle, and the second and third nerves give similar branches to the psoas. The remaining branches of the plexus are *terminal branches*. The first lumbar nerve, after it has been joined by the branch from the last thoracic nerve, divides into three terminal branches, the ilio-hypogastric nerve, the ilio-inguinal nerve, and a branch which joins the second nerve. The fibres of this latter branch pass mainly into the genito-femoral (genito-crural) nerve, but occasionally some of them enter the femoral (anterior crural) and obturator nerves. The remaining nerves divide into anterior or ventral and posterior or dorsal divisions. The **anterior divisions** form a portion of the genito-femoral (genito-crural) nerve and the obturator nerve, and the **posterior divisions** enter the lateral (external) cutaneous and femoral (anterior crural) nerves.

All the terminal branches of the plexus are formed in the substance of the psoas muscle; four of them, the ilio-hypogastric, the ilio-inguinal, the lateral (external) cutaneous, and the femoral (anterior crural), leave the muscle at its lateral border. The genito-femoral (genito-crural) passes through its anterior surface, and the obturator through its medial border.

Terminal branches.—The **ilio-hypogastric nerve** springs from the first lumbar nerve, after the latter has been joined by the communicating branch

from the last thoracic nerve, as it is in about 50 per cent. of the cases, and it thus contains fibres of both the last thoracic and the first lumbar nerves. It pierces the lateral border of the psoas and crosses in front of the quadratus lumborum (fig. 765), and behind the kidney and the colon. At the lateral border of the quadratus it pierces the aponeurosis of origin of the transversus abdominis and enters the areolar tissue between the transversus and the internal oblique, where it frequently communicates with the last thoracic and with the ilio-inguinal

FIG. 764.—DIAGRAM OF A COMMON FORM OF LUMBO-SACRAL PLEXUS. (Modified from Paterson.)

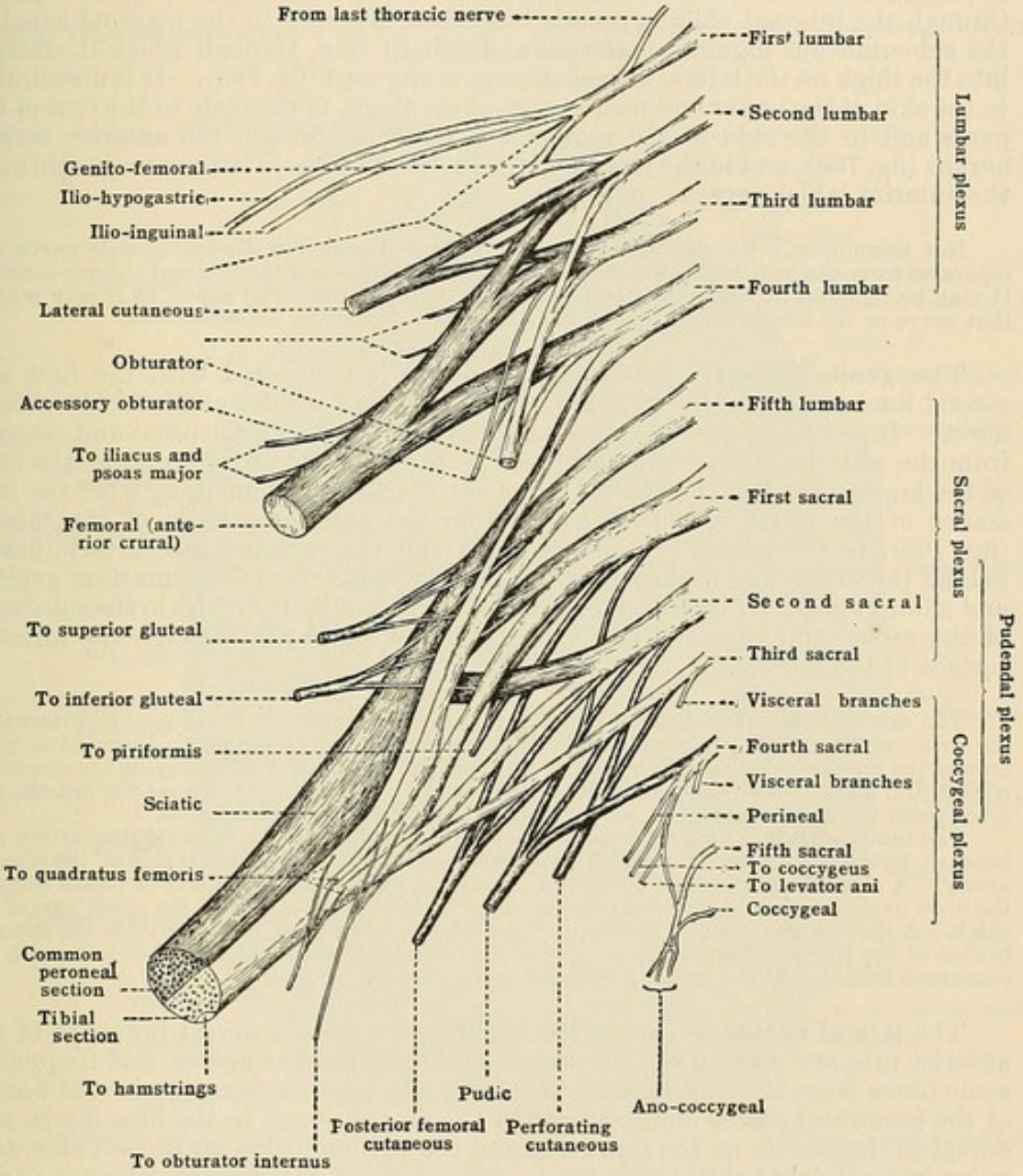

nerve, and it divides into an iliac and a hypogastric branch, which correspond, respectively, with the lateral and anterior branches of a typical spinal nerve.

The **anterior cutaneous (hypogastric) branch** passes forward and downward, between the transversus abdominis and the internal oblique muscles, giving branches to both; it communicates with the ilio-inguinal nerve, and, near the anterior superior spine of the ilium, it pierces the internal oblique muscle and continues forward beneath the external oblique aponeurosis toward the middle line. About 2.5 cm. (1 in.) above the subcutaneous inguinal ring it pierces the aponeurosis of the external oblique, becomes subcutaneous, and supplies the skin above the symphysis.

The **lateral cutaneous (iliac) branch** pierces the internal and external oblique muscles, emerging through the latter above the iliac crest at the junction of its anterior and middle thirds (fig. 769). It is distributed to the integument of the upper and lateral part of the thigh, in the neighborhood of the gluteus medius and tensor fasciæ latæ muscles (fig. 768).

The **ilio-inguinal nerve** arises principally from the first lumbar nerve, but it frequently contains fibres of the last thoracic nerve. It emerges from the lateral border of the psoas, at a lower level than the ilio-hypogastric nerve, and passes across the quadratus lumborum (figs. 765, 766). As a rule, it is below the level of the inferior end of the kidney, but it passes dorsal to the ascending or the descending colon according to the side considered, and crosses the posterior part of the inner lip of the iliac crest; it then runs forward on the upper part of the iliacus, pierces the transverus abdominis near the anterior part of the crest, and communicates with the anterior cutaneous (hypogastric) branch of the ilio-hypogastric nerve. A short distance below the anterior superior spine it passes through the internal oblique muscle, and then descends in the inguinal canal to the subcutaneous inguinal (external abdominal) ring, through which it emerges into the thigh on the lateral side of the spermatic cord (fig. 763). It is distributed to the skin of the upper and medial part of the thigh, in the male to the root of the penis and to the skin of the root of the scrotum through the **anterior scrotal nerves** (fig. 768), and in the female to the mons veneris and labium majus through the **anterior labial nerves.**

Not uncommonly the ilio-inguinal nerve is blended with the ilio-hypogastric nerve and separates from the latter between the transversus abdominis and the internal oblique muscles. It may be replaced by branches of the genito-femoral (genito-crural) nerve, or it may replace that nerve or the lateral cutaneous nerve.

The **genito-femoral (genito-crural) nerve** is connected with the first and second lumbar nerves, but the majority of its fibres are derived from the second nerve. It passes obliquely forward and downward through the psoas and emerges from the anterior surface of that muscle, close to its medial border, at the level of the lower border of the third lumbar vertebra. After emerging from the substance of the psoas it runs downward on the anterior surface of the muscle (fig. 765), to the lateral side of the aorta and the common iliac artery, passes behind the ureter and divides into two branches, an external spermatic or genital, and a lumbo-inguinal or crural (fig. 766). Occasionally it divides in the substance of the psoas, and then the two branches issue separately through the anterior surface of the muscle.

The **external spermatic (genital) branch** runs downward on the psoas muscle, external to the external iliac artery; it gives a branch to the psoas, and at Poupart's ligament it turns around the inferior epigastric artery and enters the inguinal canal, accompanying the spermatic cord in the male or the round ligament in the female. It supplies the cremaster muscle, and gives twigs to the integument of the scrotum (fig. 766) or the labium majus.

The **lumbo-inguinal (crural) branch** passes downward along the external iliac artery and beneath Poupart's ligament into the thigh, which it enters to the lateral side of the femoral artery. A short distance below Poupart's ligament it pierces the fascia lata or passes through the fossa ovalis (saphenous opening) and supplies the skin in the middle of the upper part of the thigh. A short distance below Poupart's ligament it sometimes sends branches to the anterior branch of the lateral cutaneous nerve, and about the middle of the thigh it often joins with the cutaneous branches of the femoral (anterior crural) nerve.

The **lateral cutaneous nerve** receives fibres from the dorsal branches of the anterior primary divisions of the second and third lumbar nerves, and frequently some fibres from the first lumbar (fig. 769). It emerges from the lateral border of the psoas and passes obliquely across the iliacus dorsal to the iliac fascia, and dorsal to the cæcum on the right side and the sigmoid colon on the left side, to a point immediately below the anterior superior spine of the ilium, where it passes below Poupart's ligament into the lateral angle of the femoral trigone (Scarpa's triangle). Leaving the trigone at once it passes through, behind, or in front of the sartorius and divides into two branches, anterior and posterior, which enter the deep fascia (fig. 766).

The **posterior branch** of the lateral cutaneous nerve breaks up into several secondary branches which become subcutaneous, and they supply the integument of the lateral part of the thigh, from the great trochanter to the level of the middle of the femur. The **anterior branch** runs downward in a canal in the deep fascia, for three or four inches, before it becomes subcutaneous. It usually divides into two branches, a lateral and a medial. The *lateral branch* supplies the skin of the lower half of the lateral side of the thigh, and the *medial branch* is distributed to the skin of the lateral side of the front of the thigh as far as the knee (fig. 766). Its lower filaments frequently unite with the cutaneous branches of the femoral (anterior

crural), and with the patellar branch of the saphenous nerve in front of the patella, forming with them the **patellar plexus.**

The **femoral (anterior crural) nerve** is the largest terminal branch of the lumbar plexus. It is formed chiefly by fibres of the dorsal branches of the anterior primary divisions of the second, third, and fourth lumbar nerves, but it sometimes receives fibres from the first nerve also (figs. 765 and 769). It emerges from the lateral border of the psoas a short distance above Poupart's ligament, and descends in the groove between the psoas and the iliacus, behindPoupart's ligment, into

FIG. 765.—LUMBO-SACRAL PLEXUS. (After Toldt, 'Atlas of Human Anatomy,' Rebman, London and New York.)

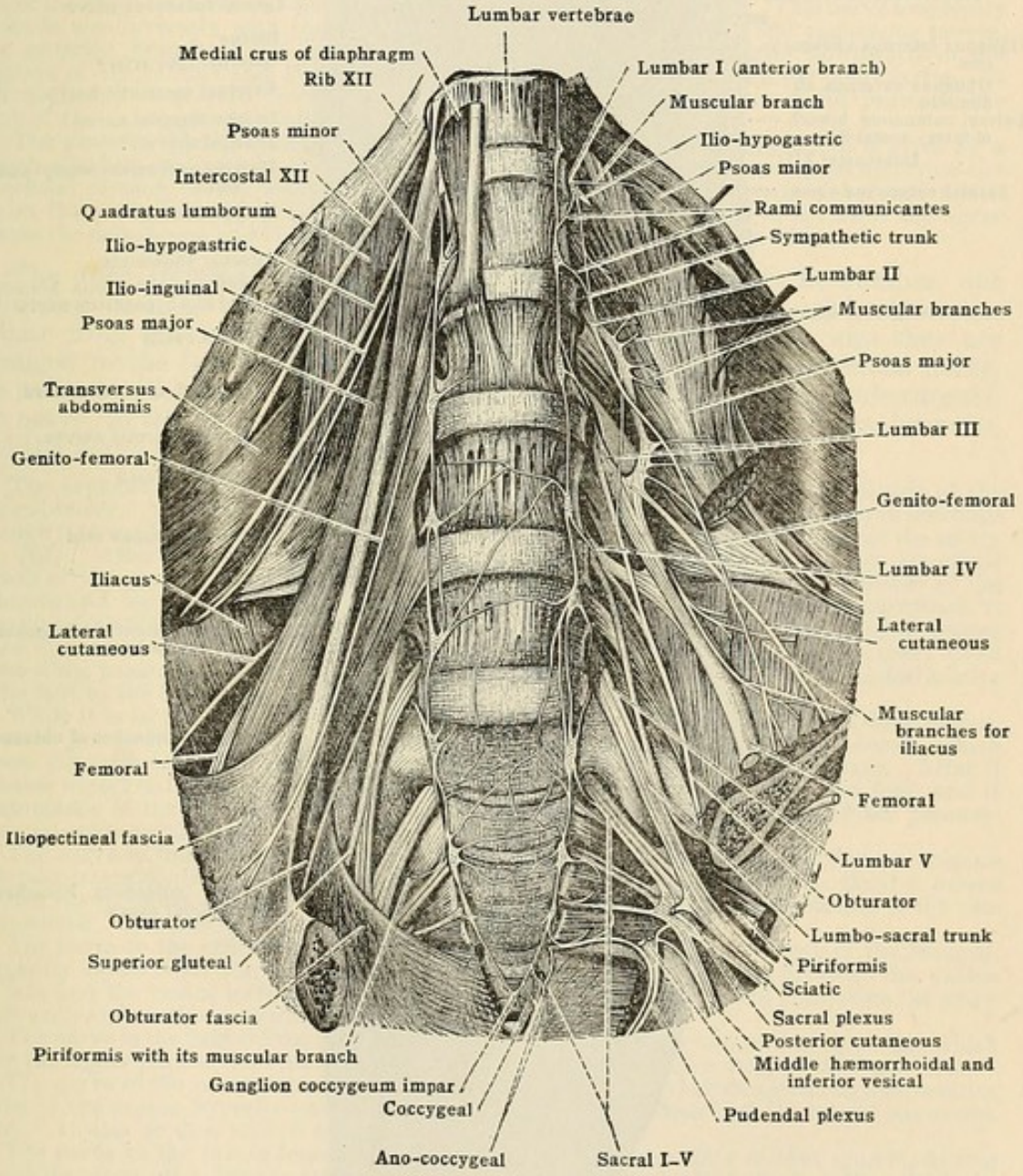

the femoral trigone (Scarpa's triangle), where it lies to the lateral side of the femoral artery (fig. 767), from which it is separated by some of the fibres of the psoas. In this situation it is flattened out and it divides into two series of terminal branches, the superficial and the deep. In general, they supply the muscles and skin on the anterior aspect of the thigh.

Branches.—The branches of the femoral nerve are collateral and terminal.

The **collateral branches** are twigs of supply to the iliacus, and a branch to the femoral artery; they are given off before the nerve enters the femoral trigone.

The **terminal branches** form two groups, the superficial and the deep.

The **superficial terminal branches** are two muscular branches, the nerve to the pectineus, and the nerve to the sartorius, and two anterior cutaneous branches.

FIG. 766.—CUTANEOUS NERVES OF THE RIGHT THIGH. (Spalteholz.)
(The iliac fascia has been removed, the fascia lata retained.)

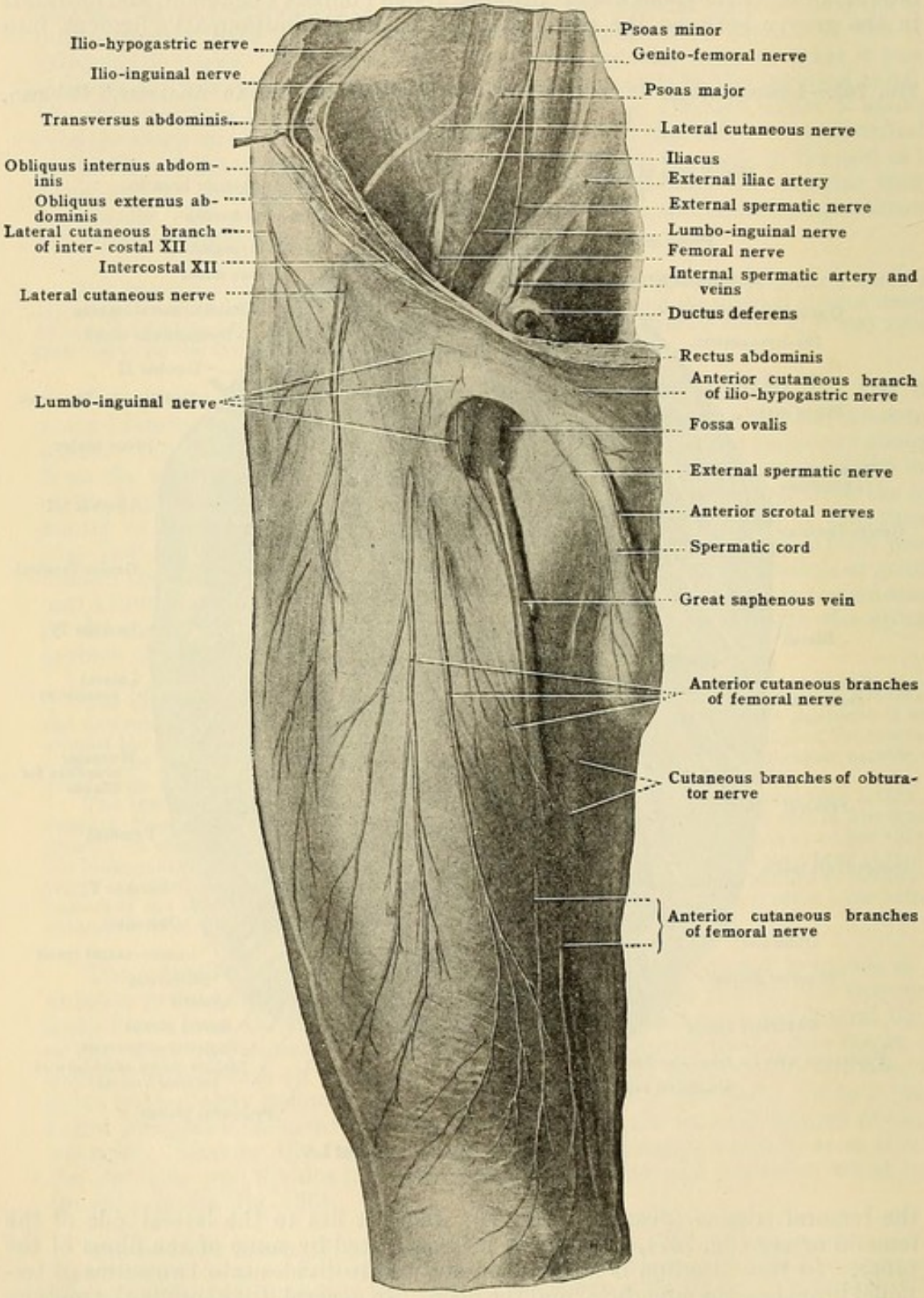

The **nerve to the pectineus** passes medially and downward behind the femoral sheath and in front of the psoas to the anterior surface of the pectineus, in which it terminates.

The **nerve to the sartorius** accompanies the middle cutaneous nerve; it leaves the latter nerve above the sartorius and ends in the upper part of the muscle.

The **anterior (middle and internal) cutaneous nerves** are best described separately. The **middle cutaneous nerve** soon divides into two branches, medial and lateral. The lateral branch pierces the sartorius and both branches become cutaneous about the junction of the upper and middle thirds of the thigh (figs. 766, 768). They descend along the medial part of the front of the thigh to the knee, supplying the skin in the lower two-thirds of the medial part of the front of the thigh, and their terminal filaments take part in the formation of the patellar plexus. About the middle of the thigh the middle cutaneous is often joined by a twig with the lumbo-inguinal nerve (crural branch of the genito-crural nerve). The **medial or internal cutaneous nerve** runs downward and medialward along the lateral side of the femoral artery, to the apex of the femoral trigone (Scarpa's triangle), where it crosses in front of the artery and divides into an anterior and a posterior terminal branch. Before this division takes place, however, two or three collateral branches are given off from the trunk. The highest of these passes through the fossa ovalis (saphenous opening), or it pierces the deep fascia immediately below the opening, and supplies the skin as low as the middle of the thigh. The lowest pierces the deep fascia at the middle of the thigh and it descends in the subcutaneous tissue, supplying the skin on the medial side of the thigh from the middle of the thigh to the knee (figs. 768, 769). This nerve frequently varies in size inversely with the cutaneous branches of the obturator and saphenous nerves. The **anterior branch** of the internal cutaneous nerve passes vertically downward to the junction of the middle and lower thirds of the thigh, where it pierces the deep fascia. It still continues downward for a short distance, then it turns lateralward and passes to the front of the knee, where it enters into the patellar plexus.

The **posterior branch** descends along the dorsal border of the sartorius, and it gives off a branch which passes beneath that muscle to unite with twigs from the saphenous and from the superficial division of the obturator nerve, forming with them the **subsartorial plexus** which lies on the roof of the adductor (Hunter's) canal. At the medial side of the knee the nerve pierces the deep fascia and it descends to the middle of the calf (figs. 766, 768).

The **deep terminal branches** of the femoral nerve are six in number, one cutaneous branch, the *saphenous*, and five *muscular branches*. The branches radiate from the termination of the trunk of the femoral nerve, and they are arranged in the following order from medial to lateral:—the saphenous nerve, the nerve to the vastus medialis, the nerve to the articularis genu (subcrureus), the nerve to the vastus intermedius (crureus), the nerve to the vastus lateralis, and the nerve to the rectus femoris.

The **saphenous nerve** passes down through Scarpa's triangle along the lateral side of the femoral artery. At the apex of the triangle it enters the adductor (Hunter's) canal and descends through it, lying first to the lateral side, then in front, and finally to the medial side of the artery (fig. 767). After emerging from the lower end of the canal, accompanied by the superficial branch of the genu suprema (anastomotic) artery, it passes between the dorsal border of the sartorius and the anterior border of the tendon of the gracilis, and, becoming superficial, it enters into relationship with the great saphenous vein and descends with it along the inner border of the upper two-thirds of the tibia (fig. 768). It crosses the medial surface of the lower third of the tibia, passes in front of the internal malleolus, and runs forward along the medial border of the foot to the ball of the great toe.

While it is in the adductor (Hunter's) canal it gives off a twig to the subsartorial plexus. Before it passes from under cover of the sartorius it gives off an infra-patellar branch, which pierces the sartorius just above the knee and passes outward to the patellar plexus. After it becomes superficial it supplies the integument on the medial side of the leg and foot, and it anastomoses, in the foot, with the medial dorsal cutaneous branch of the superficial peroneal (musculo-cutaneous) nerve.

The **nerve to the vastus medialis** accompanies the saphenous nerve in the femoral trigone (Scarpa's triangle), lying to its outer side. At the upper end of the adductor canal it passes beneath the sartorius, external to the roof of the canal, and enters the medial surface of the vastus medialis. It sends a twig down to the knee-joint.

The **nerve to the articularis genu (subcrureus)**, usually a terminal branch of the femoral, frequently arises from the nerve to the vastus intermedius. It passes between the vastus medialis and the vastus intermedius to the lower third of the thigh, where it supplies the articularis genu and sends a branch to the knee-joint.

The **nerve to the vastus intermedius (crureus)** is represented by two or three branches which enter the upper part of the muscle. One of them frequently sends a twig to the knee-joint.

The **nerve to the vastus lateralis** passes downward behind the rectus and along the anterior border of the vastus lateralis accompanied by the descending branch of the lateral circumflex artery. It also sends a branch to the knee-joint.

The **nerve to the rectus femoris** (fig. 767) enters the deep surface of that muscle, having previously given off a twig to the hip-joint which accompanies the ascending branch of the external circumflex artery.

The **obturator nerve** contains fibres from the anterior primary divisions of the second, third, and fourth lumbar nerves, but its largest root is derived from the third nerve (figs. 765, 769). It sometimes receives fibres from the first and third lumbar nerves. It emerges from the medial border of the psoas at the dorsal part of the brim of the pelvis, where it lies in close relation with the lumbo-sacral trunk of the plexus, from which it is separated by the ilio-lumbar artery. Immediately after its exit from the psoas it pierces the pelvic fascia, crosses the

lateral side of the internal iliac vessels and the ureter, and runs forward in the extraperitoneal fat, below the obliterated hypogastric artery and along the upper part of the medial surface of the obturator internus to the upper part of the obturator foramen, where it passes through the obturator canal below the so-called horizontal ramus of the pubis and above the obturator membrane, into the upper part of the thigh. It is accompanied in the pelvis and the obturator canal by the obturator artery, which lies at a lower level than the nerve, and it divides

FIG. 767.—FEMORAL AND OBTURATOR NERVES. (Ellis.)

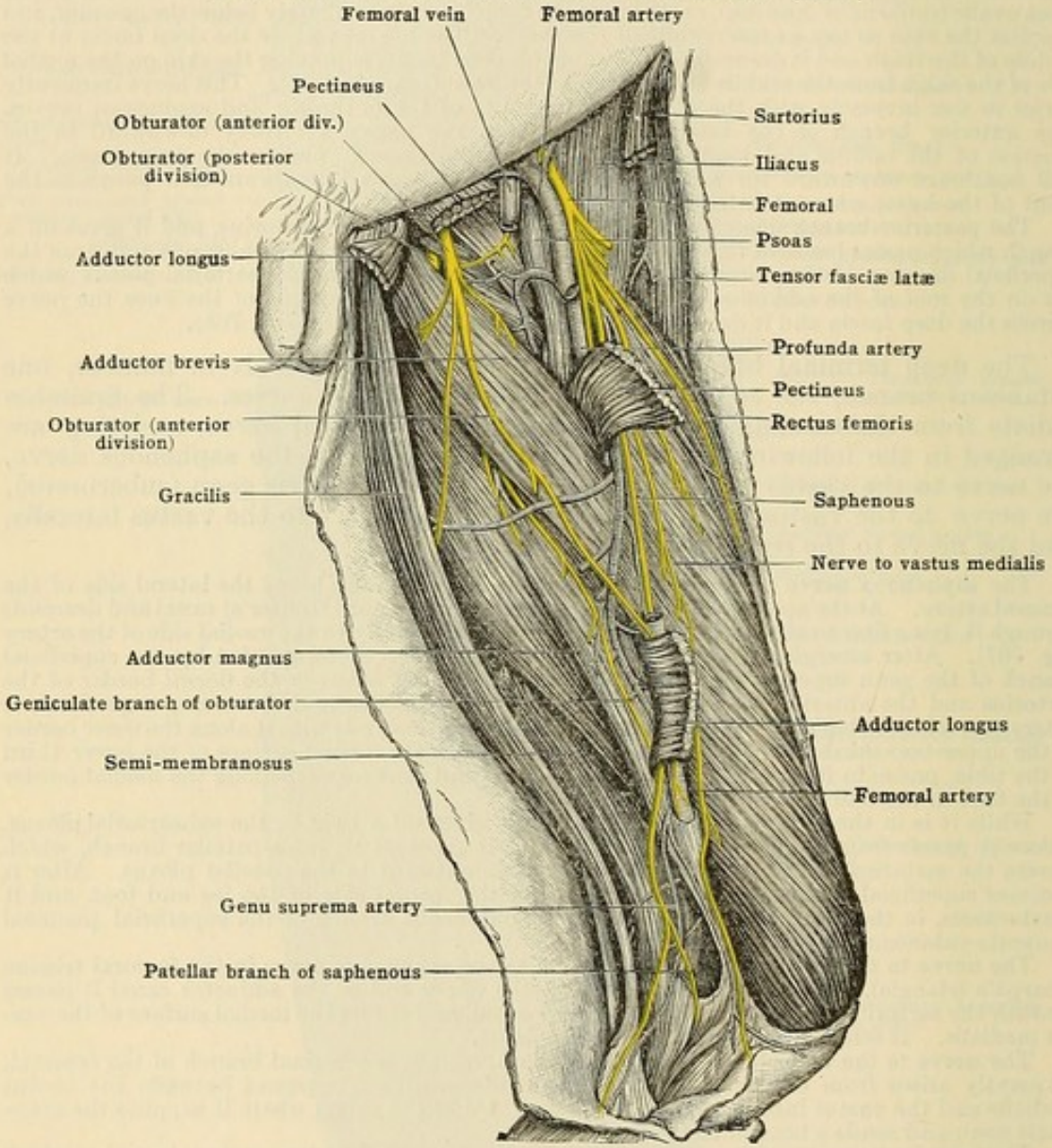

in the obturator canal into two branches, an anterior and a posterior, which supply the adductor group of muscles, the hip and knee-joints, and the skin on the medial aspect of the leg.

The **anterior branch** of the obturator has a twig joining it with the accessory obturator nerve, if that nerve is present, and then descends behind the pectineus and adductor longus and in front of the obturator externus and adductor magnus muscles (fig. 767). Its branches are:—

1. A **twig** to the accessory obturator nerve if the latter is present.
2. An **articular branch** to the hip-joint.
3. **Muscular branches** to the gracilis, adductor longus, and, usually, to the adductor brevis.
4. Two **terminal branches**, of which one is distributed to the femoral artery and the other communicates with the subsartorial plexus. The subsartorial branch is occasionally longer

than usual, and it then descends, along the dorsal border of the sartorius, to the medial side of the knee, where it enters the subcutaneous tissue, and, proceeding downward, supplies the skin on the medial side of the leg as far as the middle of the calf. Twigs join it with the saphenous.

The **posterior branch** of the obturator (fig. 767) pierces the upper part of the obturator externus and passes downward between the adductor brevis and adductor magnus. Its branches are:—

1. **Muscular branches** to the obturator externus, to the oblique fibres of the adductor magnus and to the adductor brevis when the latter is not entirely supplied by the anterior branch. The branch to the obturator externus is given off in the obturator canal.
2. An **articular branch** to the knee-joint which appears in some cases to be the continuation of the trunk of the posterior branch (fig. 767). It either pierces the lower part of the adductor

FIG. 768.—DISTRIBUTION OF CUTANEOUS NERVES ON THE POSTERIOR AND ANTERIOR ASPECTS OF THE INFERIOR EXTREMITY.

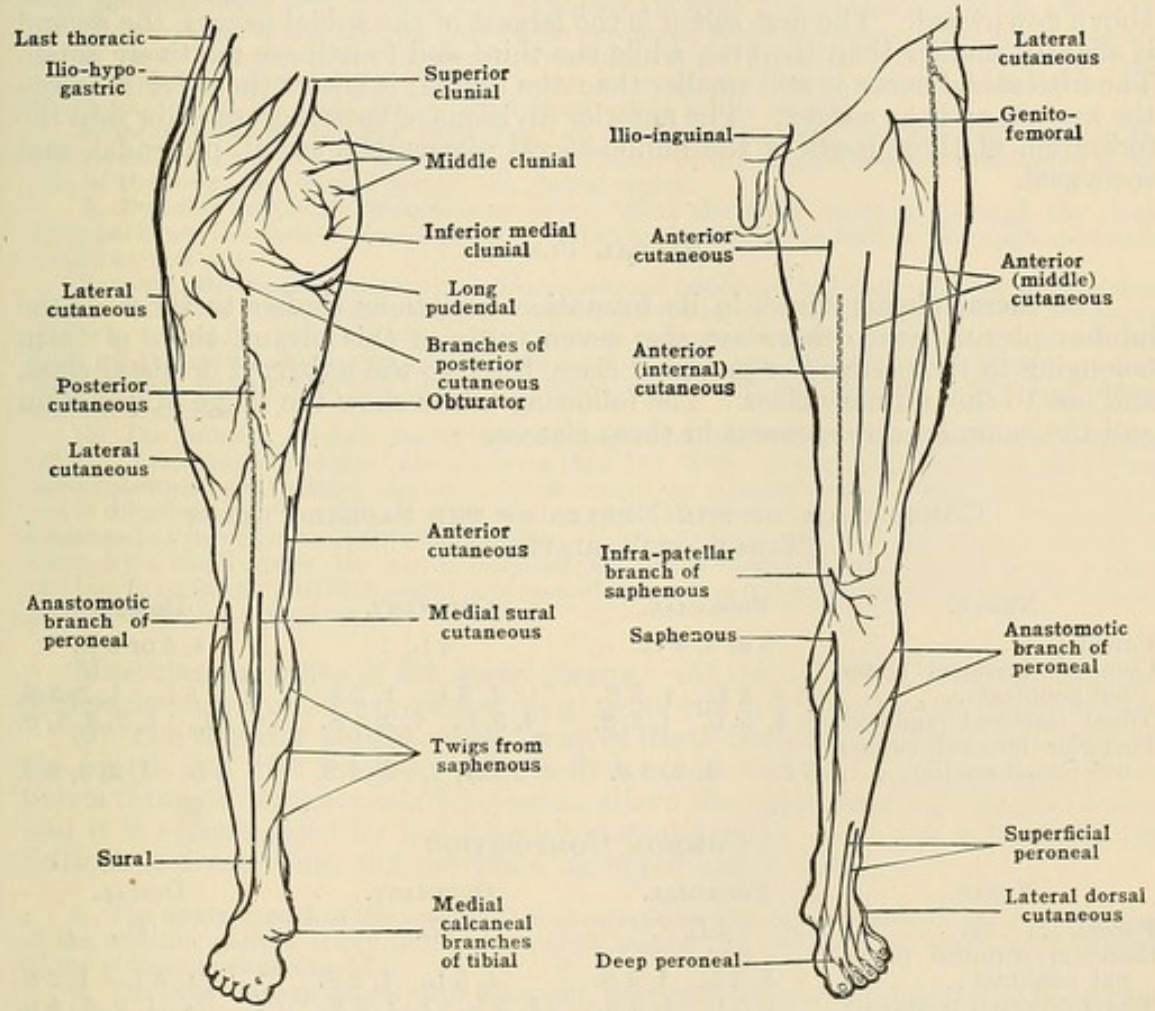

magnus, or it passes through the opening for the femoral artery. In the popliteal space it descends on the popliteal artery to the back of the joint, where it pierces the posterior ligament, and its terminal filaments are distributed to the crucial ligaments and the structures in their immediate neighbourhood. This branch is not uncommonly absent. Occasionally the posterior branch of the obturator nerve also supples a twig to the hip-joint.

The **accessory obturator nerve** arises from the third or fourth or from the third and fourth lumbar nerves, in the angles between the roots of the femoral (anterior crural) and obturator nerves. It is present in about twenty-nine per cent. of all cases (Eisler). It is often closely associated with the obturator nerve to the level of the brim of the pelvis, but instead of passing through the obturator foramen, it descends along the medial border of the psoas, crosses the anterior part of the brim of the pelvis, passes beneath the pectineus, and terminates in three main branches. One of these branches joins the anterior division of the obturator nerve, another supplies the pectineus, and the third is distributed to the hip-joint.

THE LUMBO-SACRAL TRUNK

The trunk of the plexus usually formed by the union of the smaller part of the fourth and the entire fifth lumbar nerves is called the **lumbo-sacral trunk**

(figs. 765, 769). Sometimes the larger part of the fourth nerve may help to form the trunk. It may receive fibres from the third lumbar nerve or be formed entirely from the fifth. At its formation it is situated on the ala of the sacrum under cover of the psoas. It descends into the pelvis, and, as it crosses the anterior border of the ala of the sacrum, it emerges from beneath the psoas at the medial side of the obturator nerve, from which it is separated by the ilio-lumbar artery. It passes behind the common iliac vessels and unites with the first and second sacral nerves, forming with them the upper trunk of the sacral plexus.

4. *SACRAL NERVES*

The anterior primary divisions of the upper four sacral nerves enter the pelvis through the anterior sacral foramina and they diminish in size progressively from above downward. The first sacral is the largest of the spinal nerves, the second is slightly smaller than the first, while the third and fourth are relatively small. The fifth sacral nerve is still smaller than the fourth; it enters the pelvis between the sacrum and the coccyx. The anterior divisions of these nerves enter into the formation of three parts of the lumbo-sacral plexus, the sacral, pudendal, and coccygeal.

Sacral Plexus

The **sacral plexus** shows in its formation variations similar to those of the lumbar plexus; hence there are also seven types of this plexus, three of them belonging to the prefixed or proximal class, three to the postfixed or distal class, and one to the ordinary class. The following tables show the range of variation and the common arrangement in these classes:—

Composition of the Nerves of the Sacral Plexus
Range of Variation

Nerve.	Proximal.	Ordinary.	Distal.
Furcal	3 or 3, 4 L.	4 L.	4, 5 or 5 L.
Common peroneal (external popliteal)	3, 4, 5 L. 1, 2 S.	4, 5 L. 1, 2 S.	4, 5 L. 1, 2, 3 S.
Tibial (internal popliteal)	3, 4, 5 L. 1, 2, S.	4, 5, L. 1, 2, 3 S.	4, 5 L. 1, 2, 3, 4, S.
Posterior femoral cutaneous (small sciatic)	5 L. 1, 2, 3 S.	5 L.1, 2, 3, 4 S.	5 L. 1, 2, 3, 4 S.

Common Composition

Nerve.	Proximal.	Ordinary.	Distal.
Furcal	4 L.	4L.	4L.
Common peroneal (external popliteal	4, 5 L. 1, 2 S.	4, 5 L. 1, 2 S.	4, 5 L. 1, 2 S.
Tibial (internal popliteal)	4, 5 L. 1, 2 S.	4, 5 L. 1, 2, 3 S.	4, L. 1, 2, 3, 4 S.
Posterior femoral cutaneous (small sciatic)	1, 2, 3 S.	1, 2, 3 S.	2, 3 S.

The ordinary type of sacral plexus is commonly formed by the smaller part of the anterior division of the fourth lumbar nerve and the entire anterior division of the fifth lumbar nerve, together with the first and parts of the second and third sacral nerves.

The plexus lies in the pelvis on the anterior surface of the piriformis (fig. 765) and behind the pelvic fascia and the branches of the hypogastric (internal iliac) artery. It is also dorsal to the coils of intestine, the lower part of the ilio-pelvic colon lying in front of the left plexus, and the lower part of the ileum in front of the right plexus.

The branches given off by this plexus are:—visceral, cutaneous, and muscular.

Visceral branches are given off from the second, third, and fourth sacral nerves to the pelvic viscera.

The visceral branches correspond to white rami communicantes, through not joining the sympathetic trunk. The branches from the second and fourth sacral nerves are inconstant.

Cutaneous branches.—(*a*) The **posterior femoral cutaneous (small sciatic) nerve** arises partly from the anterior and partly from the posterior branches of the anterior primary divisions of the first, second, and third sacral nerves. It lies on the back of the plexus (figs. 765, 769), leaves the pelvis at the lower border of the piriformis, and descends in the buttock between the gluteus maximus and the posterior surface of the sciatic nerve (fig. 770). At the lower border of the gluteus maximus it passes behind the long head of the biceps femoris, and descends, immediately beneath the deep fascia, through the thigh and the upper part of the popliteal space (fig. 740). At the lower part of the popliteal region it perforates the deep fascia, and it terminates in branches which are distributed to the skin of the calf.

Branches of the small sciatic.—1. **Perineal branches** are distributed in part to the skin of the upper and medial sides of the thigh on its dorsal aspect. One of the branches, known as the **long pudendal nerve,** runs forward and medialward in front of the tuberosity of the ischium to the lateral margin of the anterior part of the perineum, where it perforates the fascia lata and Colles' fascia and enters the anterior compartment of the perineum. In the perineum twigs join it with the superficial perineal nerves, and its terminal filaments are distributed to the skin of the scrotum in the male, and to the labium majus in the female.

2. **Inferior clunial** (gluteal) **branches,** two or three in number, are given off beneath the gluteus maximus; they turn around the lower border of this muscle and are distributed to the skin of the lower and lateral part of the gluteal region.

3. **Femoral cutaneous branches** are given off as the nerve descends through the thigh. They perforate the deep fascia and are distributed to the skin of the back of the thigh, especially on the medial side.

In case of the separate origin of the tibial (internal popliteal) and common peroneal (external popliteal) nerves, the posterior femoral cutaneous (small sciatic) also arises from the sacral plexus in two parts. The *ventral portion* descends with the tibial nerve below the piriformis and gives off the perineal branches and medial femoral branches, while the *dorsal portion* passes through that muscle with the common peroneal nerve, and furnishes the gluteal and lateral femoral branches.

(*b*) The **inferior medial clunial (perforating cutaneous) nerve** arises from the posterior portion of the second and third sacral nerves (figs. 765, 769). It perforates the lower part of the sacro-tuberous (great sciatic) ligament, turns around the inferior border of the gluteus maximus, and is distribtued to the skin over the lower and medial part of that muscle. It is sometimes associated at its origin with the pudic nerve. It is not always present. Its place is sometimes taken by a small nerve (the *greater coccygeal perforating nerve* of Eisler), arising from the third and fourth or fourth and fifth sacral nerves, and sometimes it is represented by a branch of the posterior femoral cutaneous.

Muscular branches of the sacral plexus.—(*a*) One or two small **nerves to the piriformis** pass from the posterior divisions of the first and second sacral nerves.

(*b*) The **superior gluteal nerve** receives fibres from the posterior branches of the fourth and fifth lumbar, and the first sacral nerves. It passes out of the pelvis through the great sciatic foramen, above the upper border of the piriformis, and it is accompanied by the superior gluteal artery. As soon as it enters the buttock it divides into two branches, an upper and a lower.

1. The **upper branch** is the smaller. It accompanies the upper branch of the deep division of the superior gluteal artery below the middle curved line of the ilium, and it ends entirely in the gluteus medius (fig. 770).

2. The **lower branch,** larger than the upper, passes forward across the middle of the gluteus minimus, with the lower branch of the gluteal artery; it supplies the gluteus medius and the gluteus minimus, and it ends in the medial and posterior part of the tensor fasciæ latæ.

(*c*) The **inferior gluteal nerve** is formed by fibres from the posterior branches of the fifth lumbar, and the first and second sacral nerves. It passes through the great sciatic foramen, below the piriformis, and divides into a number of branches which end in the gluteus maximus (figs. 765, 769).

(*d*) The **nerve of the quadratus femoris** is formed by the anterior branches of the fourth and fifth lumbar and the first and second sacral nerves. It lies on the front of the plexus and issues from the pelvis below the piriformis. In the buttock it lies at first between the sciatic nerve and the back of the ischium, and, at a lower level, between the obturator internus with the gemelli and the ischium. It terminates in the anterior surface of the quadratus femoris, having previously given off a branch to the hip-joint and another to the inferior gemellus.

(*e*) The **nerve of the obturator internus** is formed by the anterior branches of the fifth lumbar, and the first and second sacral nerves (figs. 765, 769). It leaves the pelvis below the piriformis, and crosses the spine of the ischium on the

lateral side of the internal pudic artery and on the medial side of the sciatic nerve. It gives a branch to the gemellus superior, and turns forward through the small sciatic foramen into the perineum, where it terminates in the inner surface of the obturator internus.

The **sciatic nerve** [n. ischiadicus].—The sciatic is not only the largest nerve of the sacral plexus, but it is also the largest nerve in the body. Its terminal branches are chiefly muscular, though some of its fibres are cutaneous. Although it is referred to as one trunk, it consists in reality of peroneal (lateral) and tibial (medial popliteal) portions, which are bound together by a sheath of fibrous tissue as far as the upper end of the popliteal space. In about 10 per cent. of the cases the two parts remain separate, and in such cases the peroneal (lateral popliteal)

FIG. 769.—A DISSECTION OF THE LUMBAR AND SACRAL PLEXUSES, FROM BEHIND.
(The anterior crural nerve is placed between the external cutaneous and obturator nerves.)

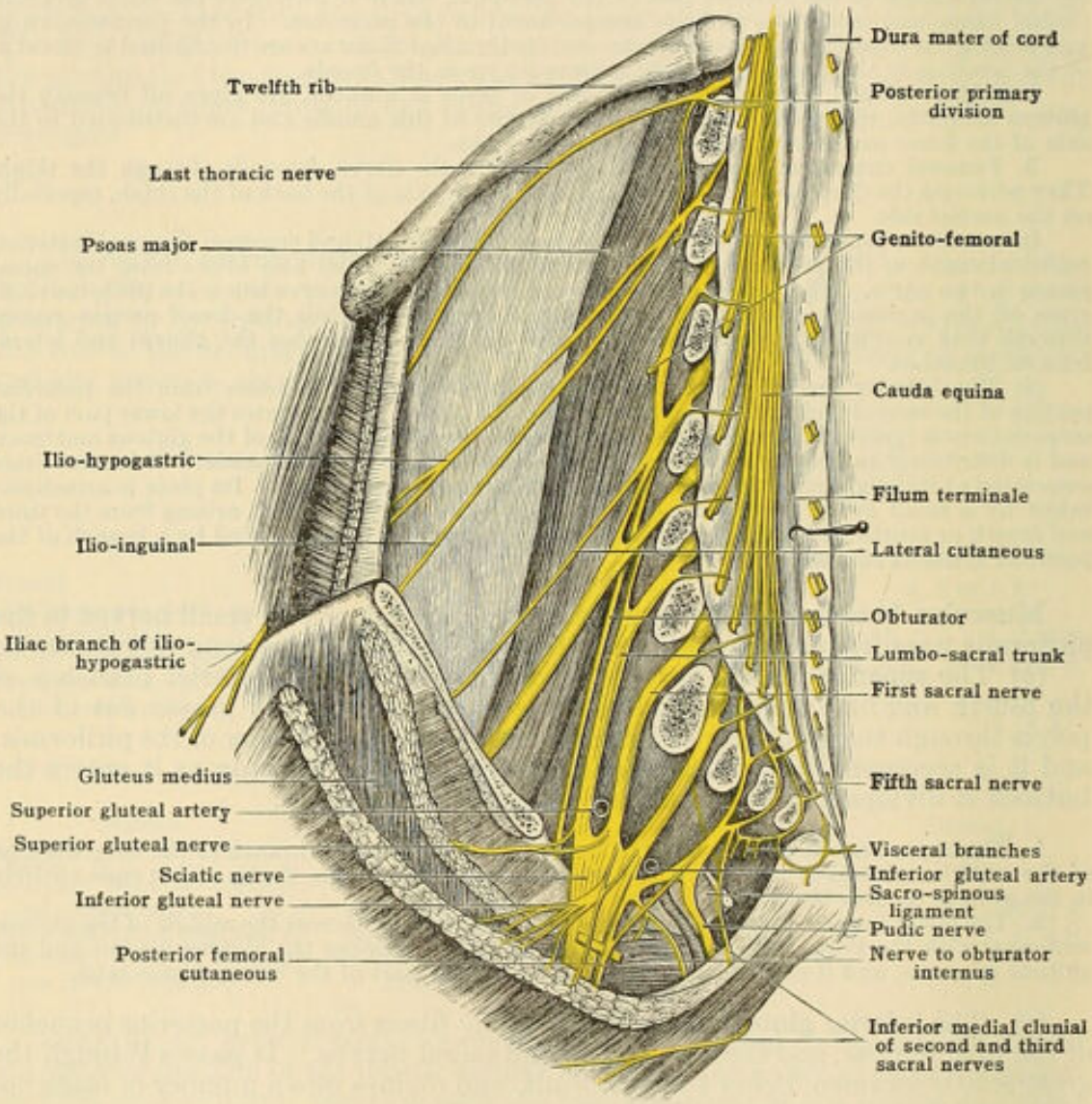

part usually pierces the piriformis. The peroneal portion of the nerve consists of fibres derived from the dorsal branches of the anterior primary divisions of the fourth and fifth lumbar and the first and second sacral nerves, while the tibial part is formed by the fibres from the anterior branches of the fourth and fifth lumbar, and the first, second, and third sacral nerves (figs. 765, 769). The common trunk leaves the pelvis by passing through the great sacro-sciatic foramen, usually below the piriformis, and descends through the buttock, running midway between the tuber ischii and the great trochanter (fig. 770). Passing down the thigh, the trunk terminates at the upper angle of the popliteal space by dividing

into the common peroneal (external politeal) and the tibial (internal popliteal) nerves (fig. 771).

The relation of the trunk to the piriformis muscle is more or less unique. It may pass either above or below the muscle, it may split and pass around the muscle, or the muscle may be split and surround the nerve. Again, there may be a splitting of both the muscle and the nerve, in which case any possible combination of the four parts may occur; a portion of the nerve may be above and a portion between the parts of the muscle, or a portion may be below and a portion between. The trunk of the nerve lies deeply in the thigh, and it is covered posteriorly by the skin and fascia, the gluteus maximus and the long head of the biceps femoris. Anteriorly it is in relation, from above downward, with the following structures:—the posterior surface of the ischium and the nerve to the quadratus femoris, the gemellus superior, obturator internus, gemellus inferior, quadratus femoris, and adductor magnus muscles.

Muscular branches of the sciatic are given off at the upper part of the thigh to the semitendinosus, to the long head of the biceps femoris, to the semimembranosus,

FIG. 770.—A DISSECTION OF THE NERVES IN THE GLUTEAL REGION.
(The gluteus maximus and gluteus medius have been divided near their insertions, and thrown upward.)

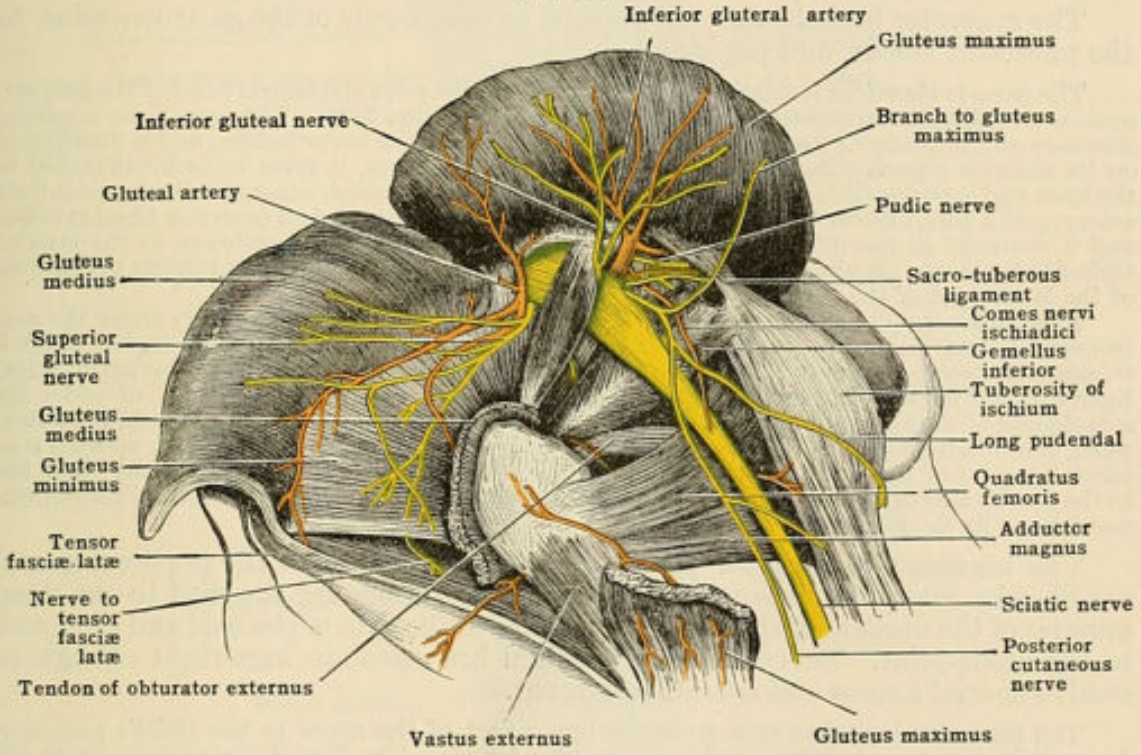

and to the adductor magnus, and, about the middle of the thigh, a branch is furnished to the short head of the biceps.

The branch to the **short head of the biceps femoris** is derived from the peroneal (lateral popliteal) portion of the nerve, while all the other muscular branches are given off by the tibial (medial popliteal) part. The **semitendinosus** receives two branches, one which enters it above and another which passes into it below its tendinous intersection. The nerve to the **long head of the biceps** descends along the sciatic trunk and enters the middle of the deep surface of the muscle. The nerves to the **semimembranosus** and **adductor magnus** arise by a common trunk which divides into three or four branches. One branch ends in the adductor, and the others are distributed to the semimembranosus. The branch to the adductor magnus supplies only those fibrés of the muscle which begin from the tuberosity of the ischium and descend vertically to the medial condyle of the femur.

At the apex of the popliteal space the two component parts of the common trunk of the sciatic become distinct. The **tibial nerve** (internal popliteal), formed by fibres from the anterior branches of the fourth and fifth lumbar and first, second, and third sacral nerves, passes vertically through the popliteal space, descends through the leg to a point midway between the medial malleolus and the most prominent part of the medial tubercle of the os calcis, where it divides into its terminal branches, the *lateral plantar* and the *medial plantar* nerves. The part of the nerve from the point of bifurcation to the lower border of the popliteus muscle is sometimes called the *internal popliteal;* the part of the nerve in the dorsum of the leg being then designated the *posterior tibial nerve.*

In the upper part of the popliteal space the tibial nerve lies relatively superficially, being covered dorsally by the skin and fascia, while in the lower part of the space it is overlapped by the heads of the gastrocnemius and is crossed by the plantaris. In the upper part of the space it lies in front of the posterior femoral cutaneous (small sciatic) nerve and to the lateral side of the vein and artery; at the middle of the space it is dorsal and in the lower part of the space it is medial to both of them.

The branches given off by the tibial nerve *in the popliteal space* are articular, cutaneous, and muscular.

The **articular branches** are usually three in number, a superior and an inferior internal articular and an azygos articular. They accompany the corresponding arteries, and, after piercing the ligaments, are distributed in the interior of the joint. The superior branch is often wanting.

The **cutaneous branch,** *the medial sural cutaneous* (tibial communicating) nerve, descends between the heads of the gastrocnemius, beneath the deep fascia, to the middle of the calf, where it pierces the fascia and unites with the peroneal anastomotic branch of the lateral sural cutaneous to form the sural (external saphenous) nerve, through which its fibres are distributed to the skin of the lower and dorsal part of the leg and the lateral side of the foot.

The **muscular branches** are distributed to both heads of the gastrocnemius, to the plantaris, soleus, and popliteus.

The *nerve to the soleus* is relatively large, and passes between the lateral head of the gastrocnemius and the plantaris before it reaches its termination (fig. 771). The *nerve to the popliteus* descends on the posterior surface of the muscle, turns around its lower border, and is distributed on its anterior aspect. In addition to supplying the popliteus, it gives articular branches to the knee and superior tibio-fibular joints, a branch to the tibia which accompanies the medullary artery, and a long, slender twig which gives filaments to the anterior and posterior tibial arteries, and it descends as the *interosseous crural nerve* on the interosseous membrane to the inferior tibio-fibular joint. It also gives branches to the interosseous membrane and to the periosteum of the lower part of the tibia.

Relations.—In the upper part of the leg the tibial nerve is placed deeply, under the gastrocnemius and soleus, but in the lower half it is merely covered by the deep fascia, which is thickened between the medial maleolus and the calcaneus to form the lacinate (internal annular) ligament, and the termination of the nerve lies either under cover of this ligament, or under the attachment of the abductor hallucis. The anterior relations of the nerve are, from above downward, the tibialis posterior, the flexor digitorum longus, the lower part of the tibia, and the posterior ligament of the ankle-joint. For a short distance after its commencement the nerve lies to the medial side of the posterior tibial artery; then it crosses behind the artery and runs downward along its lateral aspect.

The **branches** *of the lower part of the tibial nerve* (below the popliteal space) are likewise muscular, cutaneous, and articular. They are supplied to the deep muscles of the dorsum of the leg, to the fibula, to the skin of the heel and foot, and to the ankle-joint. Several of the terminal branches are important enough to receive special names and special treatment.

The **muscular branches** pass from the upper part of the nerve to the tibialis posterior, flexor digitorum longus, soleus, and flexor hallucis longus. The **fibular branch** arises with the nerve to the flexor hallucis longus, and accompanies the peroneal artery. It supplies the periosteum and gives filaments which accompany the medullary artery.

The **articular branches** arise from the lower part of the nerve, immediately above its terminal branches, and they pass into the ankle-joint through the deltoid ligament.

The **medial calcaneal (calcaneo-plantar cutaneous) nerves** arise from the trunk of the tibial nerve in the lower part of the leg. They pierce the laciniate (internal annular) ligament, and are distributed to the integument of the medial side and plantar surface of the heel and the adjoining part of the sole of the foot (fig. 771).

Terminal branches of tibial nerve.—The **medial plantar nerve** is the larger of the two terminal branches of the tibial nerve. It commences under cover of the lower border of the laciniate (internal annular) ligament, or under the posterior border of the abductor hallucis, and passes forward, accompanied by the small internal plantar artery, in the inter-muscular septum between the abductor hallucis and the flexor digitorum brevis. At the middle of the length of the foot it becomes superficial, in the interval between the two muscles, and divides into four sets of terminal branches (fig. 772):—

(*a*) **Muscular branches** pass from the trunk of the nerve to the abductor hallucis and the flexor digitorum brevis.

(*b*) **Articular branches** are distributed to the talo-navicular (astragalo-sacphoid) and the naviculari-cuneiform joint.

(*c*) **Plantar cutaneous branches** are supplied to the skin of the medial part of the sole.

(*d*) The **digital branches** are four in number, the first, a **proper plantar digital,** the second, third, and fourth, the **common plantar digitals.** Near the bases of the

FIG. 771.—MUSCLE NERVES OF THE RIGHT LEG, VIEWED FROM BEHIND. (Spalteholz.)
The semitendinosus, semimembranosus, biceps femoris, gastrocnemius, plantaris, soleus, and flexor hallucis longus have been wholly or in part removed.

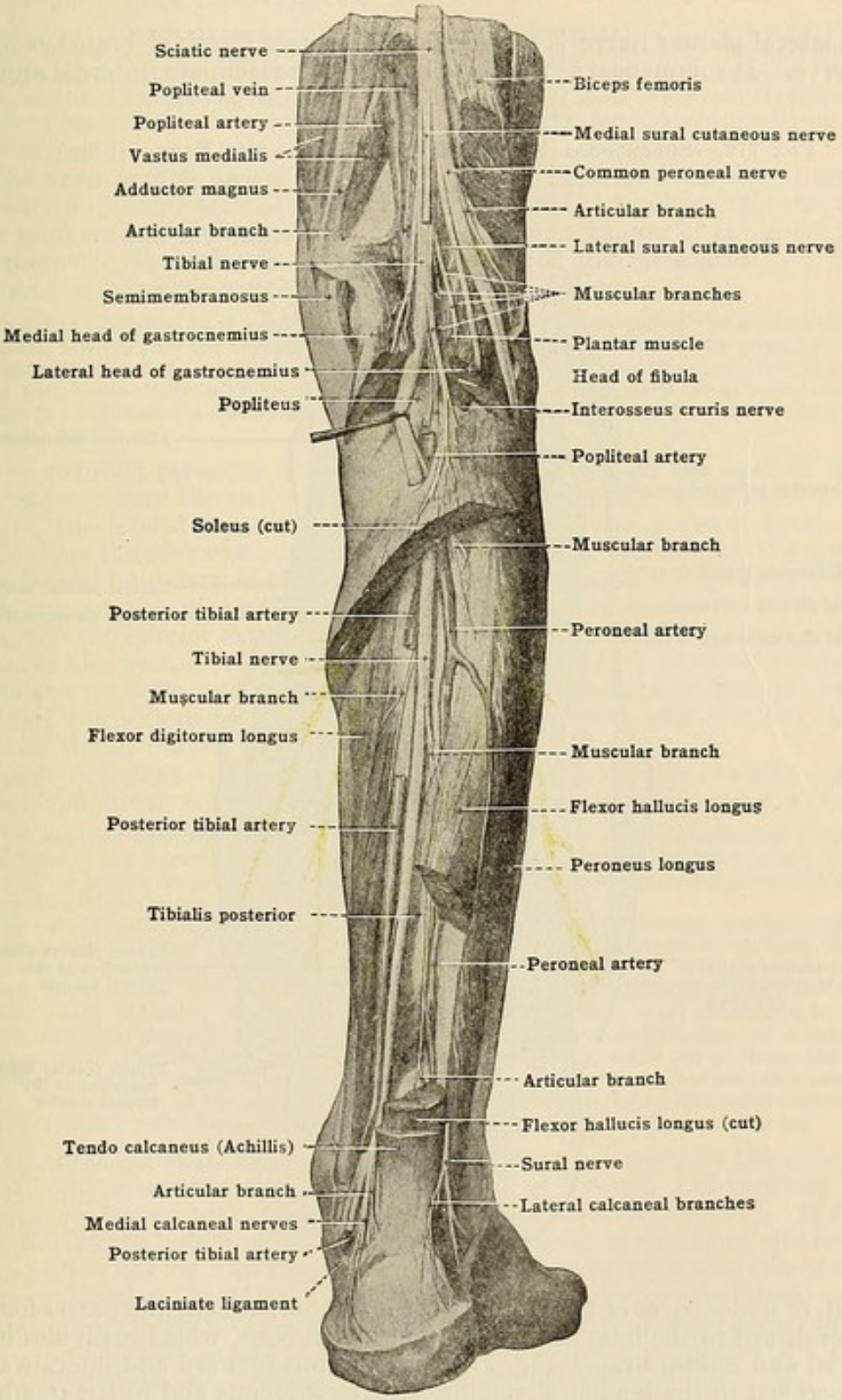

metatarsal bones, the second, third and fourth common plantar digital divide into **proper plantar digital nerves.**

The first proper plantar digital nerve becomes subcutaneous farther back than the others, and, after sending a branch to the flexor hallucis brevis, passes to the medial side of the great

toe. The second (common digital) nerve gives a twig to the first lumbrical and bifurcates to supply the adjacent sides of the first and second toes. The third supplies the adjacent sides of the second and third toes, and the fourth, after connecting with the superficial branch of the lateral plantar nerve, divides to supply the adjacent sides of the third and fourth toes. All the proper digital nerves run along the sides of the toes and lie below the corresponding arteries; they supply the joints of the toes, and each gives off a dorsal branch to the skin over the second and terminal phalanges and to the bed of the nail. All of them give fibres terminating in numerous Pacinian corpuscles.

The **lateral plantar nerve** is the smaller of the two terminal branches of the tibial nerve. It commences at the lower border of the laciniate (internal annular)

FIG. 772.—SUPERFICIAL NERVES IN THE SOLE OF THE FOOT. (Ellis.)

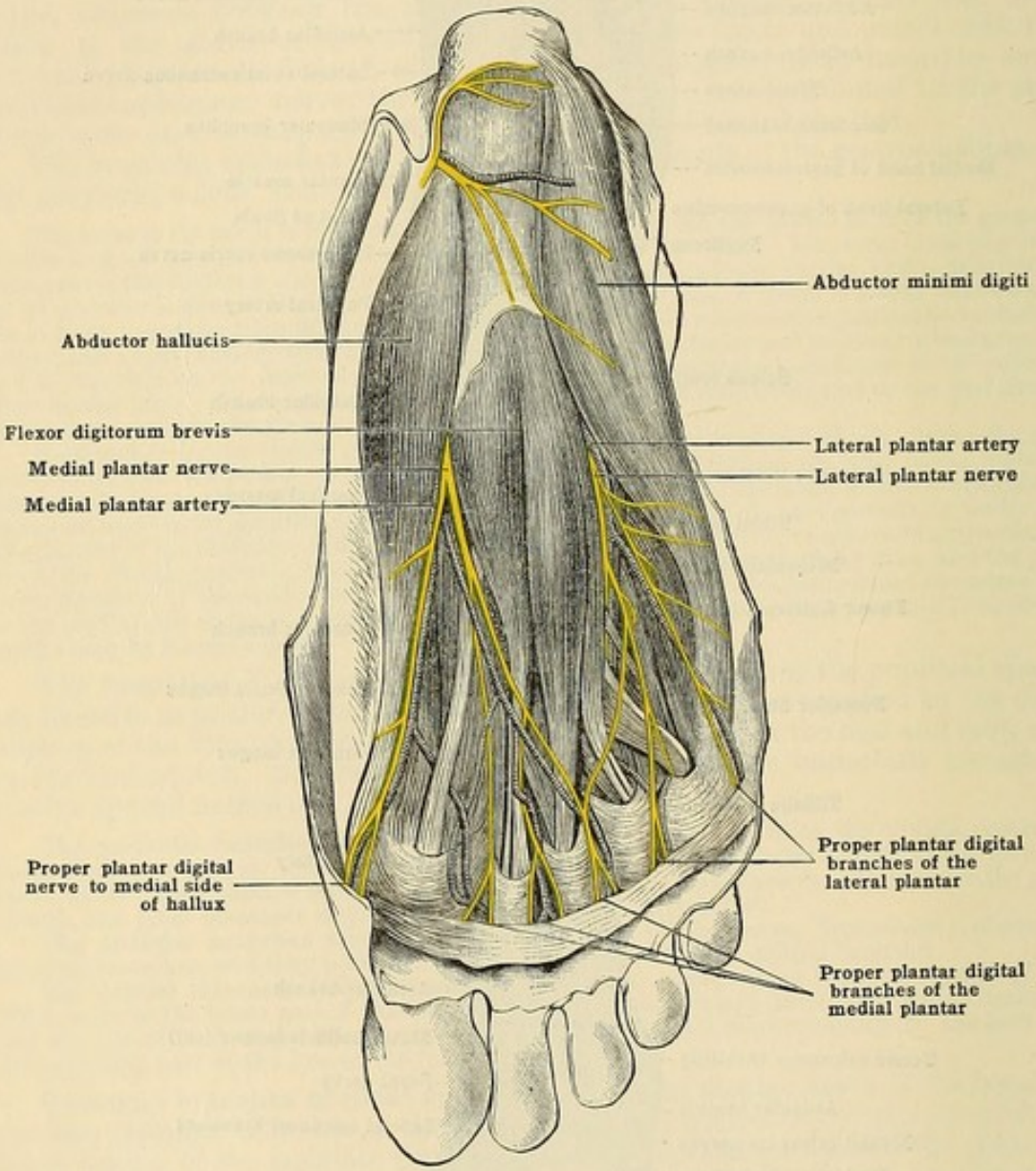

ligament, or under cover of the origin of the abductor hallucis, and passes forward and lateralward to the base of the fifth metatarsal bone, where it divides into a superficial and a deep branch (fig. 772). As it runs forward and lateralward it it is superficial to the tendon of the flexor hallucis longus and to the quadratus plantæ (flexor accessorius), and deep to the flexor digitorum brevis. At its termination it lies in the interval between the flexor digitorum brevis and abductor digiti quinti.

Branches.—From the trunk of the lateral plantar nerve muscular, superficial and deep, and articular branches are given off.

The **muscular branches** arise from the commencement of the nerve and are distributed to the abductor digiti quinti and quadratus plantæ.

The **articular branches** supply the calcaneo-cuboid joint.

The **superficial branch** supplies muscular filaments to the flexor digiti quinti brevis, the opponens, the third plantar and fourth dorsal interosseous muscles, and divides into two **common plantar digital nerves,** each of which subdivides to form **proper plantar digital nerves.**

The lateral of the two common branches supplies the lateral side of the fifth digit; the medial connects with the lateral digital branch of the medial plantar nerve (fig. 772) and divides into proper plantar digital nerves for the adjacent sides of the fourth and fifth digits. The digital branches of the superficial division of the lateral plantar, like those of the medial plantar, supply the skin of the toes and the beds of the nails, and their fibres terminate in numerouos Pacinian corpuscles.

The **deep branch** passes forward and medialward into the deep part of the sole with the plantar arterial arch. It runs deep to the quadratus plantæ, the long flexor tendons and the lumbricals, and the oblique adductor of the great toe. It lies, therefore, immediately beneath the bases of the metatarsal bones and it supplies the following muscular and articular branches:—

Muscular branches to the lateral three lumbricals, the interossei of the medial three intermetatarsal spaces, and the transverse and oblique adductor muscles of the great toe.

Articular branches to the intertarsal and to the tarso-metatarsal joints and not uncommonly to the metatarso-phalangeal joints also. Filaments from the deep branch frequently pass through the interosseous spaces and join with the interosseous branches of the deep peroneal (anterior tibial) nerve.

The **common peroneal (external popliteal) nerve.**—At the apex of the popliteal space, where the two component parts of the sciatic trunk usually become distinct, the lateral portion receives the name *common peroneal nerve.* It descends along the posterior border of the biceps femoris, which forms the upper part of the lateral boundary of the space (fig. 771). It leaves the space at the lateral angle, crosses the plantaris, the lateral head of the gastrocnemius, the popliteus, and the inferior external artery, and descends behind the upper part of the soleus, to the neck of the fibula, where it turns forward between the peroneus longus and the bone, and breaks up into its three terminal branches, the recurrent articular, the superficial peroneal (musculo-cutaneous), and the deep peroneal (anterior tibial) nerves (fig. 773).

Upper branches.—While it is in the popliteal space the common peroneal (external popliteal) nerve gives off two articular branches and a cutaneous branch.

The **superior articular branch** accompanies the superior external articular artery. The lateral head of the gastrocnemius, and it joins the inferior external articular artery behind the tendon of the biceps femoris. Both the upper and lower articular branches pierce the ligaments and are distributed in the interior of the knee joint.

The **cutaneous branch** (*communicans fibularis*), *lateral sural cutaneous,* is extremely variable both as to the number of its branches and as to the place of its anastomosis with the medial sural cutaneous. Leaving the common peroneal (external popliteal) in the popliteal space, it descends between the deep fascia and the lateral head of the gastrocnemius to the middle of the calf, where it pierces the fascia and unites with the medial sural cutaneous to form the sural (external saphenous) nerve. In its course it may give off no branches; or it may give off several, some of which supply the skin of the dorsum of the leg, while one of them, the peroneal anastomotic branch, unites with the medial sural cutaneous to form the sural (short saphenous) nerve. The junction of the peroneal anastomotic branch with the medial sural cutaneous may take place at any point between the popliteal space and the lower third of the leg.

The **sural (external or short saphenous) nerve** is formed by the union of the lateral sural cutaneous nerve either directly, or through a connecting branch, the peroneal anastomotic, with the medial sural cutaneous (fig. 771). It descends along the lateral border of the tendo Achillis, giving branches to the lower and lateral part of the leg, and **lateral calcaneal** branches to the lateral side of the heel. It passes dorsal to the lateral malleolus, turns forward across the lateral surface of the cruciate (external annular) ligament, and becomes the **lateral dorsal cutaneous nerve.** Continuing along the lateral side of the foot it divides into two branches, the **dorsal digitals,** one of which supplies the lateral side of the fifth digit, while the other anastomoses with or takes the place of a branch of the superficial peroneal (musculo-cutaneous) nerve, which is distributed to the adjacent sides of the fourth and fifth digits (fig. 773).

The terminal branches of the common peroneal.—(1) The **recurrent articular nerve** passes medialward, around the neck of the fibula, and through the upper

part of the attachment of the extensor digitorum longus. At the medial border of the fibula it becomes associated with the anterior tibial recurrent artery, with which it ascends through the upper part of the tibialis anterior to the head of the

FIG. 773.—DISTRIBUTION OF THE SUPERFICIAL AND DEEP PERONEAL NERVES ON THE ANTERIOR ASPECT OF THE LEG AND ON THE DORSUM OF THE FOOT. (Hirschfeld and Leveillé.)

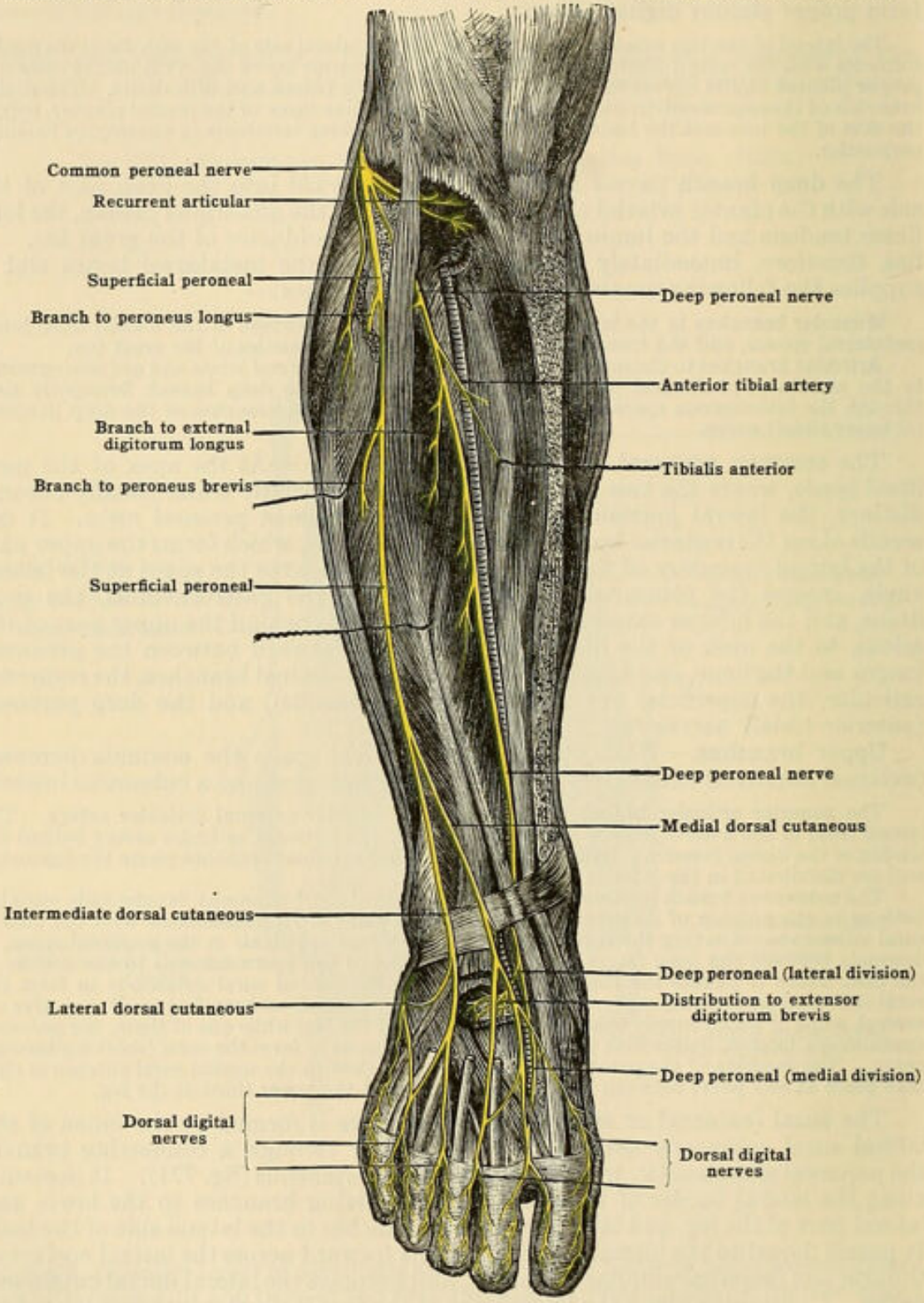

tibia and the knee-joint. It supplies the tibialis anterior, the superior tibiofibular joint, and the knee-joint.

(2) The **superficial peroneal** (**musculo-cutaneous**) **nerve** arises from the common peroneal between the peroneus longus and the neck of the fibula and descends in the intermuscular septum between the long and short peronei on the

lateral side, and the extensor digitorum longus on the medial side. It gives off muscular and cutaneous branches in its descent, and at the junction of the middle and lower thirds of the leg it pierces the deep fascia and divides into a *medial* and a *lateral branch* (fig. 773).

Muscular branches are given off from the superficial peroneal to the peroneus longus and peroneus brevis before the nerve pierces the deep fascia.

Cutaneous branches pass from the trunk of the superficial peroneal to the skin of the lower part of the front of the leg.

The **medial dorsal cutaneous** (internal cruciate branch of the superficial peroneal), passes downward and medialward across the transverse and the cruciate (anterior annular) ligament of the ankle and subdivides into two branches. The *medial branch* passes to the medial side of the great toe; it also supplies twigs to the skin of the medial side of the foot, and it anastomoses with the deep saphenous nerve and with the medial terminal branch of the deep peroneal (anterior tibial) nerve. The *lateral branch* passes to the base of the cleft between the second and third toes and divides into two dorsal digital branches which supply the adjacent sides of the cleft.

The **lateral branch** (**intermediate dorsal cutaneous**) of the superficial peroneal, in separating from the medial, crosses in front of the cruciate ligament and divides into two dorsal digital branches, which pass beneath the dorsal venous arch. The medial of these branches supplies the adjacent sides of the third and fourth toes (fig. 773). The lateral branch communicates with the sural (external saphenous) nerve and is distributed to the adjacent sides of the fourth and fifth toes. This latter branch is frequently replaced by the sural nerve.

(3) The **deep peroneal** (**anterior tibial**) **nerve** springs from the end of the common peroneal (external popliteal) nerve between the peroneus longus muscle and the neck of the fibula. It passes forward and medialward through the upper part of the origin of the extensor digitorum longus, to the interval between that muscle and the tibialis anterior; then it descends, in the anterior compartment of the leg, to the ankle, where it divides into a medial and a lateral terminal branch (fig. 773).

In the upper part of the leg the deep peroneal nerve lies between the extensor digitorum longus and tibialis anterior and lateral to the anterior tibial artery. In the middle of the leg it is in front of the artery and between the extensor hallucis longus and tibialis anterior; then it crosses beneath the extensor hallucis, and in the lower third of the leg it is again to the lateral side of the artery, but between the extensor hallucis longus and the extensor digitorum longus.

Branches furnished from the trunk of the deep peroneal are muscular, articular, and terminal.

The **muscular branches** supply the tibialis anterior, extensor digitorum longus, extensor hallucis longus, and peroneus tertius.

Articular filaments are given to the ankle-joint and the inferior tibio-fibular articulation.

Terminal branches.—The **medial terminal branch** passes downward along the side of the dorsalis pedis artery and divides into two dorsal digital branches which supply the adjacent sides of the first and second toes. It also gives filaments to the periosteum of the adjacent bones, to the metatarso-phalangeal and interphalangeal articulations, a twig to the dorsal interosseous muscle of the first space, and a perforating twig which connects with the lateral plantar nerve. The **lateral terminal branch** passes lateralward, beneath the extensor digitorum brevis, and it ends in a gangliform enlargement from which branches are distributed to the extensor digitorum brevis, the tarsal joints, and to the three lateral intermetatarsal spaces. The latter branches supply the neighbouring bones, periosteum, and joints. They give off perforating twigs, which pass through the spaces and anastomose with branches of the lateral plantar nerve, and the most medial also gives a twig to the second dorsal interosseous muscle.

TABLE SHOWING ORDINARY RELATIONS OF LUMBAR AND SACRAL NERVES TO BRANCHES OF THE LUMBAR AND SACRAL PLEXUSES AND TO THE PUDIC NERVE

NERVES CONTRIBUTING.	NERVES.
1 L.	Ilio-hypogastric
	Ilio-inguinal
1 and 2 L.	Genito-femoral
1, 2, and 3 L.	Lateral cutaneous
2, 3, and 4 L.	Femoral
	Obturator
4, 5 L., and 1 S.	Superior gluteal
	Nerve to quadratus femoris
4, 5 L., 1 and 2 S.	Sciatic (peroneal part)
4, 5 L., 1, 2, and 3 S.	Sciatic (tibial part)
5 L., 1 and 2 S.	Inferior gluteal
	Nerve to obturator internus
1 and 2 S.	Nerve to piriformis
2 and 3 S.	Medial inferior clunial
1, 2, and 3 S.	Posterior femoral cutaneous
2, 3, and 4 S.	Pudic

TABLE SHOWING RELATIONS OF MUSCLES OF LOWER EXTREMITY TO NERVES OF LUMBAR AND SACRAL PLEXUSES

NERVES CONTRIBUTING.	MUSCLES.	NERVES.
2 and 3 L.	Ilio-psoas	Femoral
	Sartorius	"
	Pectineus	"
	Adductor longus	Obturator
2, 3, and 4 L.	Gracilis	"
	Adductor brevis	"
3 and 4 L.	Quadriceps femoris	Femoral
	Obturator externus	Obturator
3, 4, and 5 L.	Adductor magnus	Obturator and sciatic
4, 5 L., and 1 S.	Gluteus medius	Superior gluteal
	" minimus	" "
	Tensor fasc. latæ	" "
	Semimembranosus	Sciatic
	Plantaris	Tibial
	Popliteus	"
	Quadratus femoris	Nerve to quad. fem.
	Inferior gemellus	" " "
5 L., and 1 S.	Flex. digit. long.	Tibial
	Tibialis posterior	Posterior medial
	Flexor digit. brev.	Plantar
	" hallucis brev.	"
	Abductor hallucis	"
	First lumbrical	"
5 L., 1 and 2 S.	Superior gemellus	Nerve to obt. int.
	Obturator internus	" "
	Gluteus maximus	Inferior gluteal
	Semitendinosus	Sciatic
	Soleus	Tibial
	Flex. hallucis long.	"
1 and 2 S.	Piriformis	
	Gastrocnemius	Tibial
	Flexor quadratus plantæ	Lateral plantar
	Abd. quinti digiti	" "
	Plantar interossei	" "
	Dorsal "	" "
	Add. hallucis trans.	" "
	" " obliq.	" "
1, 2, and 3 S.	Long head of biceps femoris	Sciatic
4, 5 L., and 1 S.	Ext. hall. long.	Deep peroneal
	" digit. "	" "
	" digit. brev.	" "
	Tibialis anterior	" "
	Peroneus tertius	" "
	" longus	Superficial peroneal
	" brevis	" peroneal

THE PUDENDAL PLEXUS

The **pudendal plexus**, like the parts of the lumbo-sacral plexus already described, varies in its formation. The accompanying tables show the extreme

range of variation and the common method of formation of the large nerve of this plexus in each of the three classes.

COMPOSITION OF THE NERVES OF THE PUDENDAL PLEXUS

Range of Variation

Nerve.	Proximal.	Ordinary.	Distal.
Pudic nerve	1, 2, 3, 4, 5 S.	1, 2, 3, 4 S.	2, 3, 4, 5 S.

Common Composition

Nerve.	Proximal.	Ordinary.	Distal.
Pudic nerve	2, 3 S.	2, 3, 4 S.	3, 4 S.

The pudendal plexus is commonly formed by parts of the anterior divisions of the second, third, and fourth sacral nerves. It lies in the lower part of the back of the pelvis, and gives off visceral, muscular, and terminal branches.

Visceral branches (pelvic splanchnics) arise from the third and fourth sacral nerves especially, and enter branches of the sympathetic plexus. They are distributed both directly (their afferent or sensory fibres terminating in the pelvic viscera) and by their visceral efferent fibres terminating in the ganglia of the sympathetic plexus to the pelvic viscera (figs. 765, 791). The **middle hæmorrhoidal nerves** pass to the rectum, the **inferior vesical nerves** to the bladder, and, in the female, the **vaginal nerves** to the vagina (see Sympathetic System).

Muscular branches are given by the fourth sacral nerve to the coccygeus, levator ani, and sphincter ani externus (fig. 765).

The nerves to the two former muscles pass into the pelvic surfaces of the muscles, but that to the last-named muscle, called the **perineal branch,** passes backward between the levator ani and the coccygeus, or through the posterior fibres of the latter muscle, into the posterior part of the ischio-rectal fossa, and, in addition to supplying the sphincter ani, it gives cutaneous filaments to the skin between the anus and the coccyx.

Terminal branches.—The **pudic nerve** [n. pudendus] rises usually from the anterior primary divisions of the second, third, and fourth sacral nerves (fig. 765). It emerges from the pelvis below the piriformis, crosses the spine of the ischium, lying to the medial side of the internal pudic artery (fig. 769), and accompanies the artery, through the small sciatic foramen, into Alcock's canal in the obturator fascia on the lateral wall of the ischio-rectal fossa, where it terminates by dividing into three branches, the inferior hæmorrhoidal, the perineal, and the dorsal nerve of the penis.

The **inferior hæmorrhoidal nerves** frequently arise independently from the third and fourth sacral nerves, pierce the medial wall of Alcock's canal, and pass forward and medialward through the ischio-rectal fat to supply the sphincter ani externus and adjacent skin. They anastomose with branches of the perineal nerve.

The **perineal nerve** runs forward for a short distance in Alcock's canal and divides into a deep and a superficial branch. The *deep branch* breaks up into filaments, one or two of which pierce the medial wall of the canal and pass medialward to the anterior fibres of the sphincter and levator ani. The remaining part of the nerve pierces the base of the uro-genital trigone (triangular ligament), and enters the superficial pouch of the urethral triangle, where it is distributed to the bulb of the urethra, and to the transversus perinei, bulbocavernosus, and ischiocavernosus. It also sends some sensory filaments to the mucous membrane of the urethra. The *superficial branch* almost at once divides into medial and lateral branches, the *posterior scrotal* (*labial*) nerves.

Both branches pass through the wall of Alcock's canal into the anterior part of the ischio-rectal fossa, then they pierce the base of the uro-genital trigone, and enter the superficial pouch of the urethral triangle. The lateral branch usually passes below the transversus perinei, and the medial branch above the muscle or through its fibres. The lateral branch connects with the long pudendal nerve, and with the inferior hæmorrhoidal nerve, and both branches end in terminal filaments which anastomose and which are distributed to the skin of the scrotum and the anterior part of the perineum in the male, and to the labium majus in the female.

The **dorsal nerve of the penis** runs forward in Alcock's canal above the internal pudic artery. It pierces the base of the uro-genital trigone, continues forward between the layers of the trigone, embedded in the fibres of the constrictor urethræ, and it gradually passes to the lateral side of the internal pudic artery. A short distance below the pudic arch it pierces the anterior layer of the uro-genital trigone, gives a branch to the corpus cavernosum penis, passes forward between that structure and the bone, and turns downward on the dorsum of the penis, passing between the layers of the fundiform (suspensory) ligament and along the outer side of the dorsal artery of the penis. It supplies the skin of the dorsum of the penis, and, having given branches to the prepuce, it breaks up into terminal filaments which are distributed to the glans penis.

The **dorsal nerve of the clitoris** is much smaller than the dorsal nerve of the penis to which it corresponds. Is is distributed to the clitories.

THE COCCYGEAL PLEXUS

This plexus is frequently, and with some reason, considered as a subdivision of the pudendal plexus, and sometimes it is described with the coccygeal nerves. It is formed chiefly by the anterior division of the fifth sacral nerve and the coccygeal nerve, but it receives a small filament from the anterior division of the fourth sacral nerve (figs. 765, 769). These constituents unite to form plexiform cords lying on either side of the coccyx. From these cords arise the **ano-coccygeal nerves,** which pierce the sacro-tuberous (great sacro-sciatic) ligament and supply the skin in the neighbourhood of the coccyx.

III. THE DISTRIBUTION OF THE CUTANEOUS BRANCHES OF THE SENSORY AND MIXED CRANIAL AND SPINAL NERVES

The cutaneous filaments of the sensory and mixed nerves are distributed to definite regions of the surface of the body which are known as 'cutaneous areas.' Each cutaneous area has one special nerve of supply and the central part of the area receives that nerve alone, but wherever the borders of two areas meet they reciprocally overlap, therefore each margin of every cutaneous area has two nerves of supply, its own nerve and that of an adjacent area, and of these, sometimes one and sometimes the other preponderates.

The Cutaneous Areas of the Scalp

The limits of the cutaneous areas in the scalp region are indicated in figs. 774, 776, but in general terms it may be said that the skin of the scalp in front of the pinna is supplied by four cutaneous nerves, viz., the mesial part by the supratrochlear and the supra-orbital branches of the ophthalmic division of the trigeminus, and the lateral part by the temporal branch of the maxillary division, and the auriculo-temporal branch of the mandibular division of the same nerve.

The portion of the scalp behind the pinna also receives four cutaneous nerves; laterally it is supplied by the great auricular and small occipital branches of the cervical plexus which contain filaments from the second and third cervical nerves, and medially it receives the great and smallest occipital nerves which are derived from the internal branches of the posterior primary divisions of the second and third cervical nerves respectively.

The Cutaneous Areas of the Face

With the exception of the skin over the posterior part of the masseter muscle, the whole of the skin of the face is supplied by the branches of the trigeminus. The nose is supplied medially by the supratrochlear, the infratrochlear, and the nasal branches of the ophthalmic division, and laterally by the infra-orbital branch of the maxillary division. The upper eyelid is supplied by the supratrochlear, the supra-orbital, and the lacrimal branches of the ophthalmic division; the lower eyelid by the infratrochlear branch of the ophthalmic division and by the infra-orbital and the zygomatico-facial (malar) branches of the maxillary division. The skin over the upper jaw and the zygomatic (malar) bone is supplied by the infra-orbital and zygomatico-facial branches of the maxillary division, that over the buccinator by the buccal branch of the mandibular division, and that over the lower jaw, from in front backward, by the mental, buccal, and auriculo-temporal branches of the mandibular division, except a small part near the posterior border which receives its supply from the great auricular nerve.

The Cutaneous Areas of the Auricle (Pinna)

The upper two-thirds of the outer surface of the pinna are supplied by the auriculo-temporal branch of the mandibular division of the trigeminus, and the lower third by twigs of the great

Fig. 774.—Diagram of the Cutaneous Nerve Areas of the Head and Neck.
Red—ophthalmic division of trigeminus. White—maxillary division of trigeminus.
Blue—mandibular division of trigeminus.
Dotted shading—Posterior primary divisions of cervical nerves.
Oblique shading—Ascending and transverse superficial branches of cervical plexus.
Transverse shading—Descending superficial branches of cervical plexus.
It must be remembered that the boundaries of each area are not distinct; wherever two areas meet they overlap.

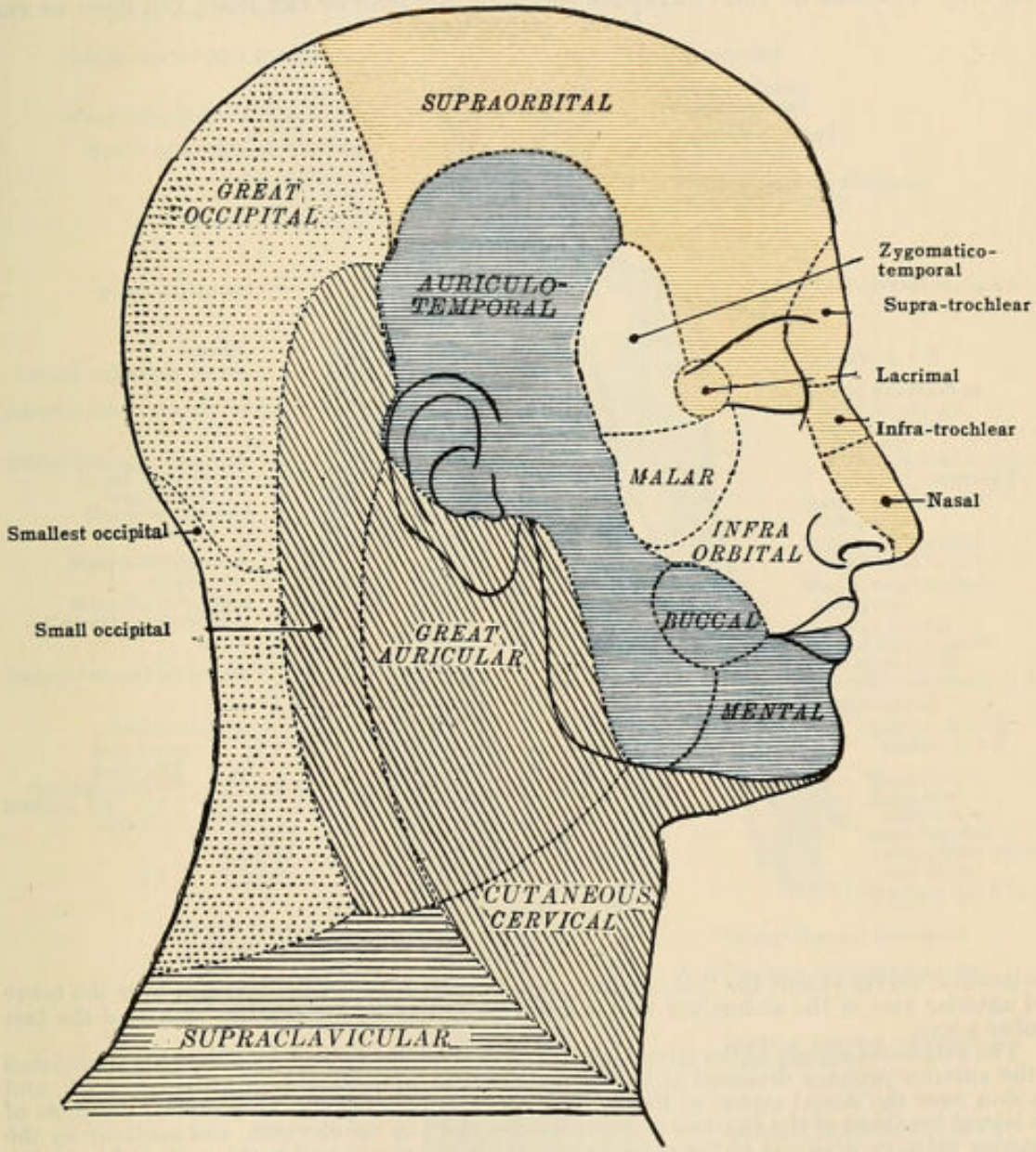

auricular nerve. The lower three-fourths of the cranial surface of the pinna are supplied by the great auricular nerve, and the upper fourth by the small occipital nerve. The posterior surface of the external auditory meatus receives filaments from the auricular branch of the vagus.

The Cutaneous Areas of the Neck

The skin over the anterior part of the neck is supplied by the superficial cervical branch of the cervical plexus, which contains fibres from the second and third cervical nerves, and in the lower part of its extent, by the anterior supra-clavicular nerves (suprasternal branches),

which convey twigs of the third and fourth cervical nerves (fig. 774). The lateral part of the neck receives filaments from the second, third, and fourth cervical nerves by way of the great auricular, small occipital, and middle supraclavicular (supra-clavicular) branches of the cervical plexus, and posteriorly the skin of the neck is supplied by the small occipital nerve and by the medial branches of the posterior primary divisions of the cervical nerves from the second to the sixth inclusive (fig. 776).

The Cutaneous Areas of the Trunk

The skin over the ventral aspect of the trunk as far down as the third rib is supplied by the anterior supra-clavicular (suprasternal) and middle supra-clavicular (supra-clavicular) branches of the cervical plexus, which contain filaments from the third and fourth cervical nerves (fig. 776). From the third rib to the lower part of the abdominal wall the skin receives the anterior cutaneous branches, and the anterior divisions of the lateral cutaneous branches of

Fig. 775.—Diagram of the Cutaneous Areas of the Side of the Body and Part of the Limb. (After Head.)

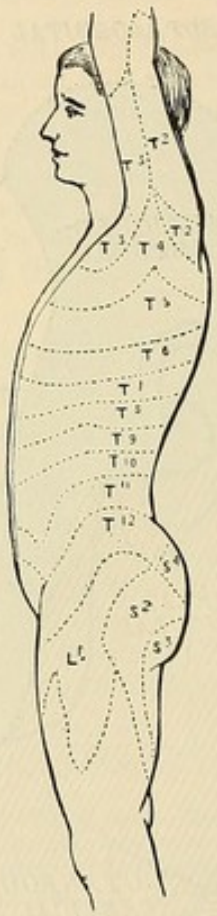

the thoracic nerves except the first, second, and twelfth (fig. 776). The skin over the lower and anterior part of the abdominal wall is supplied by the ilio-hypogastric branch of the first lumbar nerve.

The cutaneous supply of the lateral aspects of the body is derived from the lateral branches of the anterior primary divisions of the thoracic nerves from the second to the eleventh, and the skin over the dorsal aspect of the body is supplied laterally by the posterior divisions of the lateral branches of the thoracic nerves from the third to the eleventh, and medially by the posterior primary divisions of the thoracic nerves, in the upper half by their medial branches and in the lower half principally by their lateral branches.

THE CUTANEOUS AREAS OF THE LIMBS

The areas of skin of the upper and lower limbs which are supplied by the branches of the brachial, lumbar, and sacral plexuses are indicated in fig. 776, and the spinal nerves which contribute to each nerve area are noted. The question of the skin areas supplied by any given spinal nerve is one of great clinical importance, in connection with the diagnosis of injuries of nerves and of pathological conditions affecting them. Therefore, considerable attention has been directed to the matter and it has been found that the areas which become hypersensitive when certain spinal nerve-roots are irritated, or anæsthetic when the roots are destroyed, do

FIG. 776.—DIAGRAM SHOWING AREAS OF DISTRIUTION OF CUTANEOUS NERVES.

HEAD:—

RED—Ophthalmic division of trigeminus. White—maxillary division of trigeminus. Blue—mandibular division of trigeminus. Dotted area—Posterior primary divisions of cervical nerves. Oblique and transverse shading—Branches of cervical plexus.

BODY AND LIMBS:—

RED—Anterior branches of anterior primary divisions.. Blue—Posterior branches of anterior primary divisions. Two colours in one area indicate that the area is supplied by two sets of nerves, and it should be remembered that wherever two nerve areas approach each other they overlap. The dotted blue area of the posterior femoral cutaneous (small sciatic) indicates that the nerve comes from the posterior as well as from the anterior parts of the anterior primary divisions of the sacral nerves, but it supplies a flexor area. The area of the inferior medial cluneal nerve is left uncoloured, because its true nature is uncertain. Dotted shading—posterior primary divisions. The numbers and initial letters refer to the respective spinal nerves from which the nerves are derived.

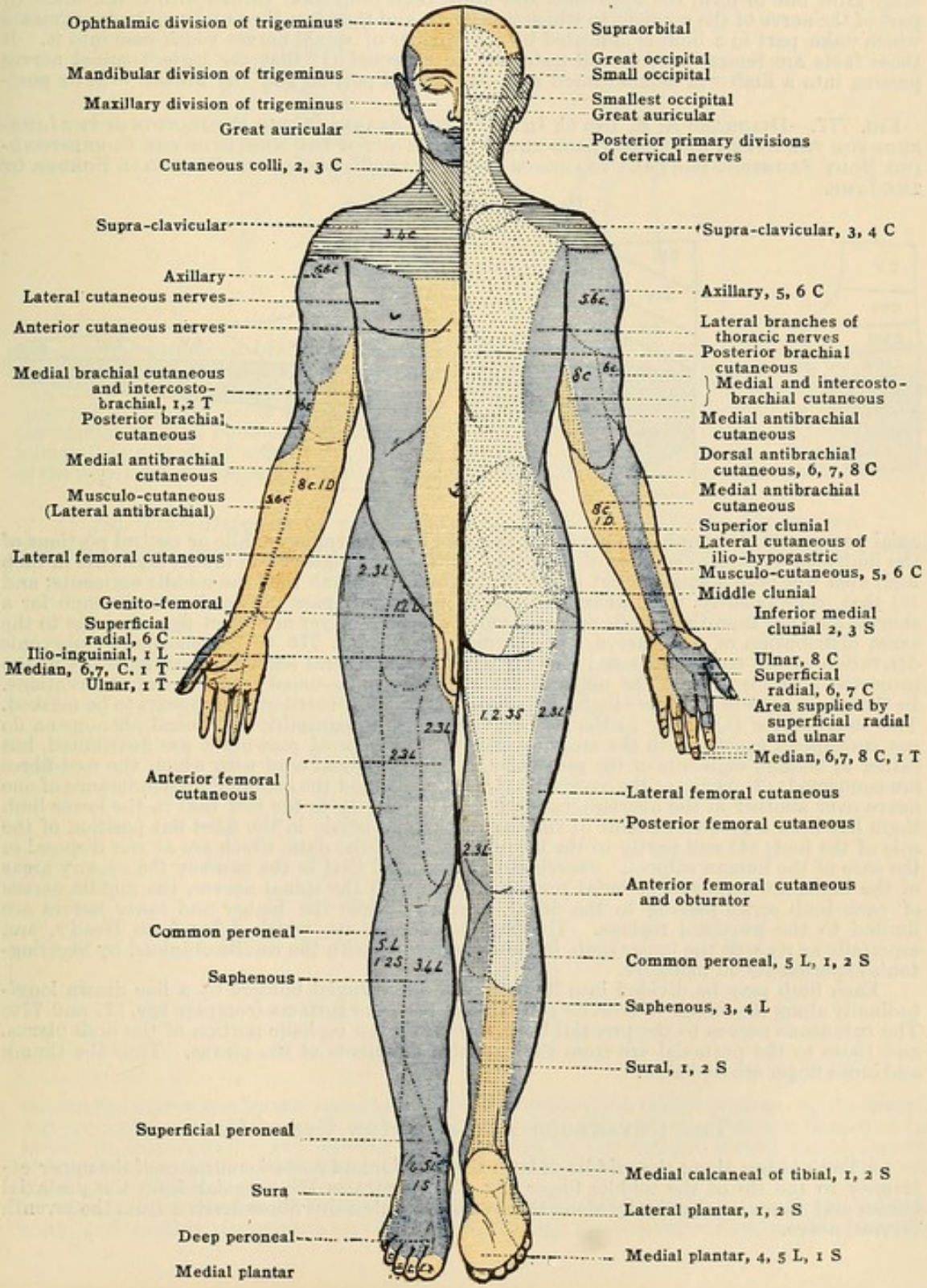

not correspond exactly with the regions to which the fibres of the roots can apparently be traced by dissection. Moreover, it has been discovered, partly by clinical observations on the human subject and partly by experiment on monkeys, that the nerves of the limbs have a more or less definite segmental distribution. To understand clearly this segmental arrangement the reader must remember that in the embryonic stage when no limbs are present the body is formed of a series of similar segments, each of which is provided with its own nerve. At a later stage when the limbs grow outward, each limb is formed by portions of a definite number of segments which fuse together into a common mass of somewhat wedge-like outline. Each rudimentary limb possesses a dorsal and a ventral surface. The dorsal surfaces of both the upper and the lower limbs are originally the extensor surfaces, and the ventral surfaces the flexor surfaces, but, as the upper limb rotates lateralward and the lower limb rotates medianward as development proceeds, in the adult, the extensor surface of the upper limb becomes the posterior surface, and the extensor surface of the lower limb, the anterior surface. The preaxial border of the upper limb is the radial or thumb border, and the postaxial border, the ulnar or little finger border. The preaxial border of the lower limb is the tibial or great toe border, and the postaxial border, the fibular or little toe border. As projections of the segments of the body grow out to form the limb-buds and limbs each projection carries with it the whole or part of the nerve of the segment to which it belongs, and therefore the number of body segments which take part in a limb is indicated by the number of spinal nerves which pass into it. If these facts are remembered it will naturally be expected (1) that the highest spinal nerves passing into a limb will be associated with its preaxial portion and the lowest with its post-

FIG. 777.—DIAGRAMS A, B, AND C, ILLUSTRATING STAGES IN THE PROJECTION OF THE LIMB-BUDS FOR THE UPPER EXTREMITY, AND THE DRAWING OUT OF THE NERVES OF THE CORRESPONDING BODY SEGMENTS FOR THE CUTANEOUS AREAS OF THE PREAXIAL AND POSTAXIAL BORDER OF THE LIMB.

Postaxial border shaded.

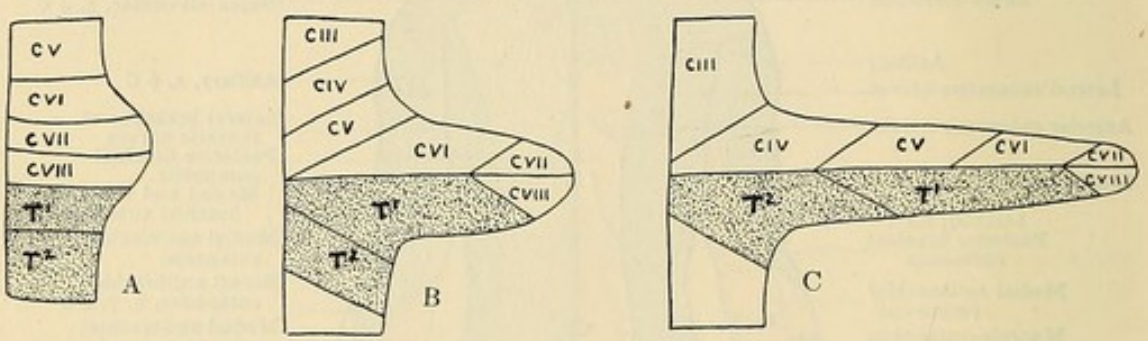

axial portion; (2) that only the nerves of those segments forming middle or central portions of the limbs will extend to the tips of the limbs; (3) that the highest and lowest segments in each limb area will take a smaller part in the formation of the limb that the middle segments; and (4) that, consequently, the highest and lowest nerves will pass outward into the limb for a shorter distance than the middle nerves. Observers are not yet in perfect agreement as to the exact distribution of each nerve, but the diagrams in figs. 775 to 781 show the embryonic derivation of the cutaneous areas and the adult dorso-ventral segmental arrangement in the projected portions of both the upper and lower limbs as assumed from clinical observations. In the upper parts of the lower limbs, the original segmental distributuion appears to be masked. This may be due (1) partly to the fact that the areas recognisable by clinical phenomena do not correspond exactly with the areas to which definite dorsal root-fibres are distributed, but rather to definite segments of the grey substance of the spinal cord with which the root-fibres are connected; (2) partly to the overlapping of segments and the acquired preponderance of one nerve over another in the overlapping areas, and (3) partly to the fact that in the lower limb there has been a greater amount of shifting of parts to result in the fixed flat position of the sole of the foot; (4) and partly to the incompleteness of the data which are at our disposal in the case of the human subject. Sherrington has proved that in the monkey the sensory areas of the limbs are arranged in serial correspondence with the spinal nerves, the middle nerves of each limb series passing to the distal extremity while the higher and lower nerves are limited to the proximal regions. Thorburn's observations, which differ from Head's, are, especially as regards the upper limb, in close conformity with the results obtained by Sherrington's experiments on monkeys.

Each limb may be divided into its preaxial and postaxial borders by a line drawn longitudinally along the middle of both its anterior and posterior surfaces (compare figs. 777 and 779) The cutaneous nerves to the preaxial border are from the cephalic portion of the limb plexus. and those to the postaxial are from the caudal components of the plexus. Thus the thumb and index finger are cephalad.

THE CUTANEOUS AREAS OF THE UPPER LIMB

A line passing along the middle of both the anterior and posterior surfaces of the upper extremity to the tip of the middle finger (fig. 779) separates the preaxial from the postaxial border and passes longitudinally along the area of the cutaneous fibres derived from the seventh cervical nerve.

The skin over the upper third of the deltoid muscle is supplied by the posterior supra-clavicular (supra-acromial) and middle supra-clavicular (supra-clavicular) nerves, which are branches of the cervical plexus containing fibres of the third and fourth cervical nerves, and that over the lower two-thirds by the axillary (circumflex) nerve which conveys fibres of the fifth and sixth cervical nerves (fig. 776).

The skin over the lateral surface of the upper arm is supplied externally by the axillary (circumflex) nerve above, and below by the superior branch of the dorsal antibrachial cutaneous,

FIG. 778.—DIAGRAM OF THE CUTANEOUS AREAS OF THE UPPER EXTREMITY.
(Modified from Head.)

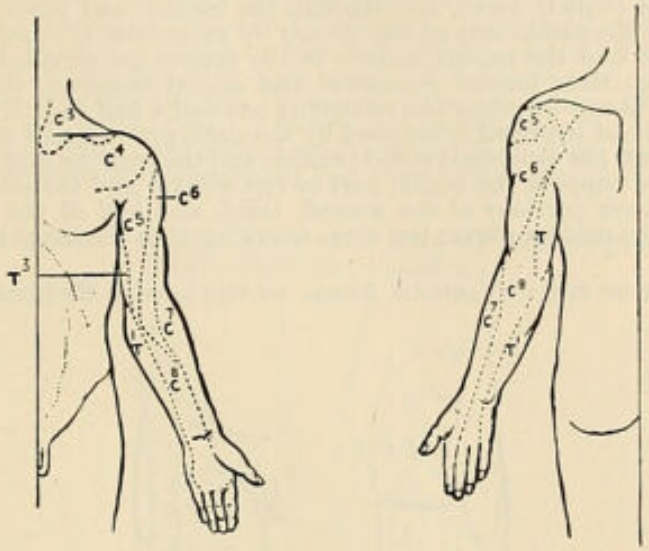

the external cutaneous branch of the radial (musculo-spiral) nerve. The former contains filaments of both the fifth and sixth cervical nerves, and the latter filaments of the sixth alone. The skin of the medial side of the upper arm is supplied by the medial antibrachial cutaneous (internal cutaneous) nerve with fibres of the eighth cervical and first thoracic nerves, and by the medial brachial cutaneous (lesser internal cutaneous) and intercosto-brachial (intercosto-humeral) nerves which are derived from the first and second thoracic nerves. The dorsal side of the upper arm is supplied, laterally, by the fifth and sixth cervical nerves through the axillary

FIG. 779.—DIAGRAM OF THE CUTANEOUS AREAS OF THE UPPER EXTREMITY.
The solid middle lines are drawn to separate preaxial (radial) borders from postaxial borders.
(After Thorburn, modified.)

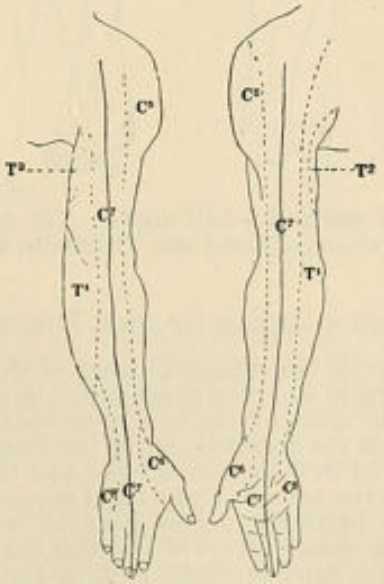

(circumflex) nerve and by the dorsal antibrachial cutaneous; the middle portion, by the seventh cervical nerve through the posterior brachial cutaneous, the internal cutaneous branch of the radial (musculo-spiral) nerve; and the medial portion by the first and second thoracic nerves through the medial brachial cutaneous (lesser internal cutaneous) nerve, and the intercosto-brachial (intercosto-humeral) nerve (fig. 776).

The front of the forearm is divided into three areas, a lateral which is supplied by the fifth, sixth, and possibly the seventh cervical nerves, through the musculo-cutaneous branch of the

brachial plexus; a middle which is supplied by the seventh cervical nerve as above, and a medial area supplied by the eighth cervical and first thoracic nerve through the medial antibrachial cutaneous (internal cutaneous) nerve. On the dorsal side of the forearm there are three areas: —(1) a lateral supplied by fibres of the fifth and sixth cervical nerves through the musculo-cutaneous nerve; (2) a middle, which receives fibres of the seventh, and probably some from the sixth and eighth cervical nerves through the lower branch of the dorsal antibrachial cutaneous of the radial (inferior external cutaneous branch of the musculo-spiral nerve), and (3) a medial which receives the eighth cervical and first thoracic nerves through the medial antibrachial cutaneous (figs. 776, 779).

The palm of the hand is supplied by the sixth, seventh, and eighth cervical nerves through the superficial radial (radial) nerve, and through the median and ulnar nerves. The superficial radial supplies the radial side of the thumb by its palmar cutaneous branch. The remainder of the palm and the palmar aspects of the fingers are supplied by the median and ulnar nerves through their palmar cutaneous and digital branches, the median supplying three and a half digits and the ulnar the remaining one and a half (figs. 776 and 779).

The dorsal aspect of the hand is supplied by the sixth, seventh, and eighth cervical nerves, which reach it through the superficial radial(radial) and through the median and ulnar nerves. The superficial radial supplies the lateral part of the dorsum and the lateral three and a half digits, except the lower portions of the second, third, and half of the fourth digits, which receive twigs from the median nerve; the ulnar nerve supplies the ulnar half of the dorsum of

FIG. 780.—DIAGRAM OF THE CUTANEOUS AREAS OF THE LOWER EXTREMITY. (After Head.)

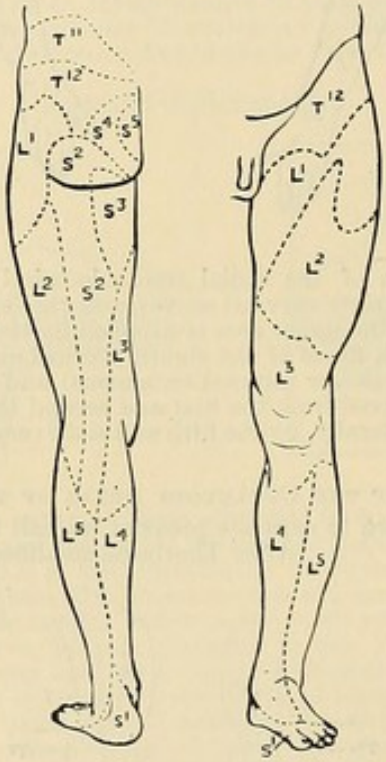

the hand, including the medial one and a half digits. The areas supplied by definite spinal nerves, according to the observations of Head and Thorburn, are shown in figures 778 and 779 respectively.

THE CUTANEOUS AREAS OF THE LOWER EXTREMITY

The segmental arrangement of the cutaneous areas of the lower extremity is not so well retained as in the upper, due largely to a greater amount of developmental shifting of the parts. Both of the lines separating the areas of the lumbar (cephalic) and the sacral (caudal) parts of the lumbo-sacral plexus lie on the dorsal aspect of the limb. The nerves from the lumbar part of the plexus are distributed to the entire anterior and the medial and lateral surfaces of the limb and to the muscles of the anterior and medial portions of the thigh and the anterior portion of the leg, whereas the cutaneous nerves from the sacral part of the plexus are confined to a narrow strip along the dorsal aspect of the limb (fig. 781). However, the muscular distribution of the sacral part is as much expanded as its cutaneous area is contracted; it supplies the muscles in the dorsal portions of the hip, thigh and knee, the whole of the dorsal part of the leg and ankle and the plantar muscles of the foot.

There are six cutaneous areas in the region of the buttock, three upper and three lower. Of the upper areas the lateral is supplied by the anterior primary divisions of the last thoracic and first lumbar nerves through the iliac branches of the last thoracic and the ilio-hypogastric nerves; the middle upper area receives the lateral divisions of the posterior primary branches of the upper three lumbar nerves, and the medial upper area is supplied by twigs from the lateral branches of the posterior primary divisions of the upper two or three sacral nerves (figs. 776, 780).

Of the lower three areas, the lateral receives filaments from the second and third lumbar nerves through the lateral femoral cutaneous (external cutaneous) branch of the lumbar plexus; the middle area is supplied by the first, second, and third sacral nerves through the posterior femoral cutaneous (small sciatic) nerve; and the medial area by the second and third sacral nerves through the medial inferior clunial (perforating cutaneous) branch of the sacral plexus (fig. 776).

On the back of the thigh there are three areas. According to Head, the medial and lateral areas are supplied by the second and third lumbar nerves, the former through the lateral femoral cutaneous (external cutaneous) branch of the lumbar plexus, and the latter through the anterior cutaneous branches of the femoral (internal cutaneous branch of the anterior crural) nerve. The middle area receives twigs from the first, second, and third sacral nerves through the posterior femoral cutaneous (small sciatic), a branch of the sacral plexus.

The front of the thigh is supplied by the first, second, and third lumbar nerves, and, according to Head, there are five cutaneous areas. The lateral area receives twigs of the second and third lumbar nerves through the lateral (external) cutaneous nerves. There are two medial areas, an upper and a lower. The former is supplied by the lumbo-inguinal (crural) branch of the genito-femoral (genito- crural), which conveys twigs of the first and second lumbar nerves; the latter receives fibres of the second and third lumbar nerves through one of the an-

FIG. 781.—DIAGRAM OF THE CUTANEOUS AREAS OF THE LOWER EXTREMITY
(After Thorburn, modified.)

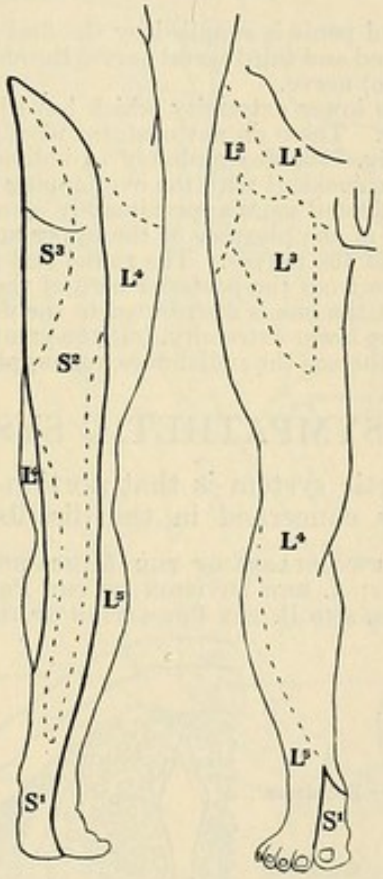

terior (middle) cutaneous branches of the femoral (anterior crural) nerve. The small upper and medial area is supplied by the first lumbar nerve through the ilio-inguinal, and the lower medial area receives twigs of the second and third lumbar nerves through one of the anterior cutaneous branches (internal cutaneous) of the femoral (anterior crural) nerve (fig. 776).

The front of the knee is supplied by the second, third, and fourth lumbar nerves through the anterior (middle and internal) cutaneous and saphenous (long saphenous) branches of the femoral (fig. 776).

Of the skin over the region of the popliteal space, the medial portion receives fibres from the second, third, and fourth lumbar nerves through the anterior (internal) cutaneous branch of the femoral (anterior crural) nerve and through the superficial division of the obturator nerve; the middle and lateral portion receives twigs of the first three sacral nerves through the posterior cutaneous (small sciatic) nerve (fig. 776).

The skin over the front and medial side of the leg is supplied by the fourth lumbar nerve through the saphenous nerve, and the skin of the front and lateral side receives nerve-fibres from the fifth lumbar nerves through the sural cutaneous (fibular communicating) branch of the common peroneal (external popliteal) nerve.

In the skin of the back of the leg four areas can be distinguished, a medial, two middle, upper and lower, and a lateral area. The medial area is supplied by the fourth lumbar nerves through an anterior cutaneous branch (internal cutaneous) of the femoral (anterior crural)

nerve and the superficial branch of the obturator nerve. The upper middle area is supplied by the second, and third sacral nerves through the posterior femoral cutaneous (small sciatic) nerve, and the lower middle area by the first sacral nerve through the sural (external saphenous) nerve. The lateral area is supplied by the fifth lumbar nerve through the lateral sural cutaneous (fibular communicating) branch of the common peroneal (external popliteal) nerve (fig. 776, 780, 781).

The skin of the dorsum of the foot is supplied principally by the fifth lumbar and by the first sacral nerves; the majority of the nerve-fibres travel by the superficial peroneal(musculocutaneous) nerve, but the adjacent sides of the first and second toes are supplied by the femoral (anterior crural) nerve and the side of the dorsum of the little toe is supplied through the sural (external saphenous).

The skin of the region of the heel is supplied by the first sacral nerve, the medial surface and medial part of the under surface by the medial calcaneal branches of the tibial (calcaneoplantar) nerve and the posterior, external, and lower aspects by the sural (external saphenous) nerve (fig. 776).

The sole of the foot in front of the heel receives cutaneous fibres from the fifth lumbar and the first sacral nerves; the medial area, which includes the medial three and a half digits, being supplied by the medial plantar nerve which conveys fibres of the fifth lumbar and the first sacral nerves; and the lateral area by the fifth lumbar nerve through the lateral plantar nerve.

The medial side of the foot is supplied by the first sacral and fourth lumbar nerves through the saphenous nerve and the lateral side by the fifth lumbar nerve through the sural (external saphenous) nerve.

The skin of the scrotum and penis is supplied by the first lumbar nerve through the ilioinguinal nerves, and by the second and third sacral nerves through the perineal and dorsal penile branches of the pudendal (pudic) nerve.

The cutaneous areas of the lower extremity which have been demarcated by Head and Thorburn are shown in fig. 780. These do not conform wholly with each other nor with the areas given in more detail in fig. 776, due probably to individual differences in subject and observer and to the difficulties coincident with the overlapping of the areas. Fig. 781 is more general in character and is considered more approximately correct.

The homology of the parts of the plexuses of the upper and lower extremities is not well carried out in the distribution of the nerves. The radial and great sciatic nerves are similar to the extent that the one arises from the posterior cord of the brachial plexus and the other from the sacral plexus, and that the one is distributed to the dorsal aspect of the arm and the other to the dorsal surface of the lower extremity, but the great sciatic supplies the sole of the foot, and the plantar muscles, whereas the radial does not supply the palm of the hand and the palmar muscles.

THE SYMPATHETIC SYSTEM

The so-called sympathetic system is that portion of the peripheral nervous system which is especially concerned in the distribution of impulses to the

FIG. 782.—DIAGRAM SHOWING TWO STAGES OF THE MIGRATION OF THE PRIMITIVE GANGLIA FROM THE GANGLION CREST; A. THE DIVISION OF THE PRIMITIVE GANGLIA INTO SPINAL AND SYMPATHETIC PORTIONS, AND B. THE FORMATION OF THE NERVES.

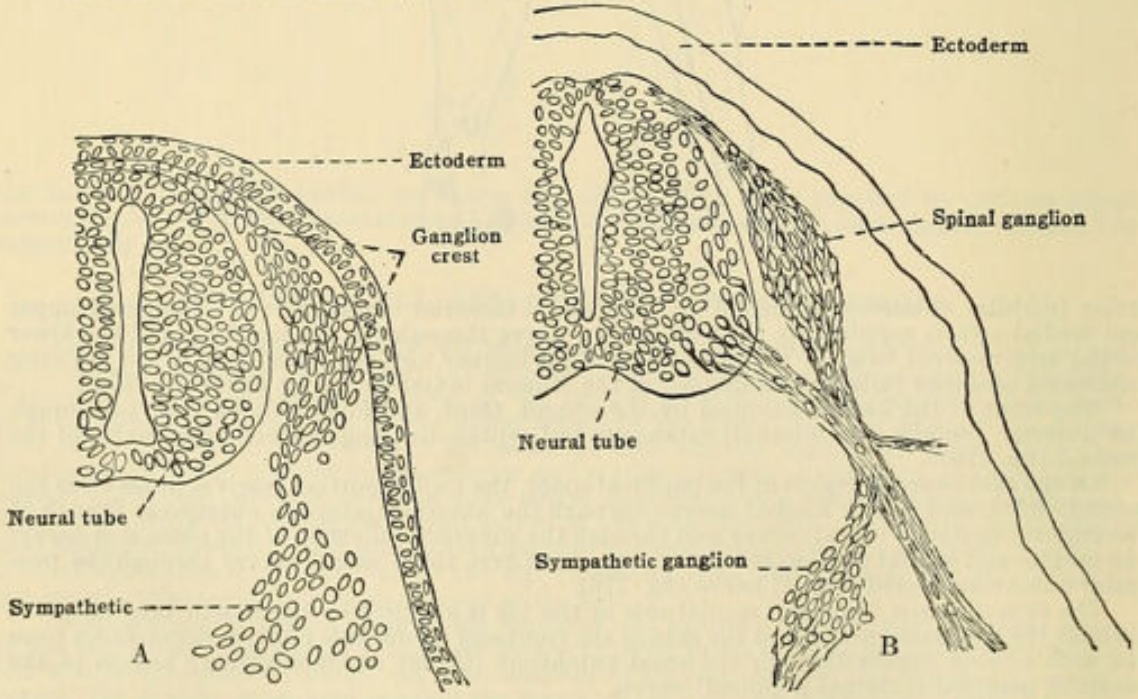

glandular tissues, to the muscle of the heart and blood-vessels, and to the non-striated muscular tissue of the body wherever found. Since these tissues are most

FIG. 783.—DIAGRAM SHOWING THE CHIEF PATHS OF MIGRATION OF THE CELLS FROM THE GANGLIA OF THE SPINAL AND CRANIAL NERVES TO FORM THE ADULT SYMPATHETIC SYSTEM (AFTER SCHWALBE, MODIFIED.)

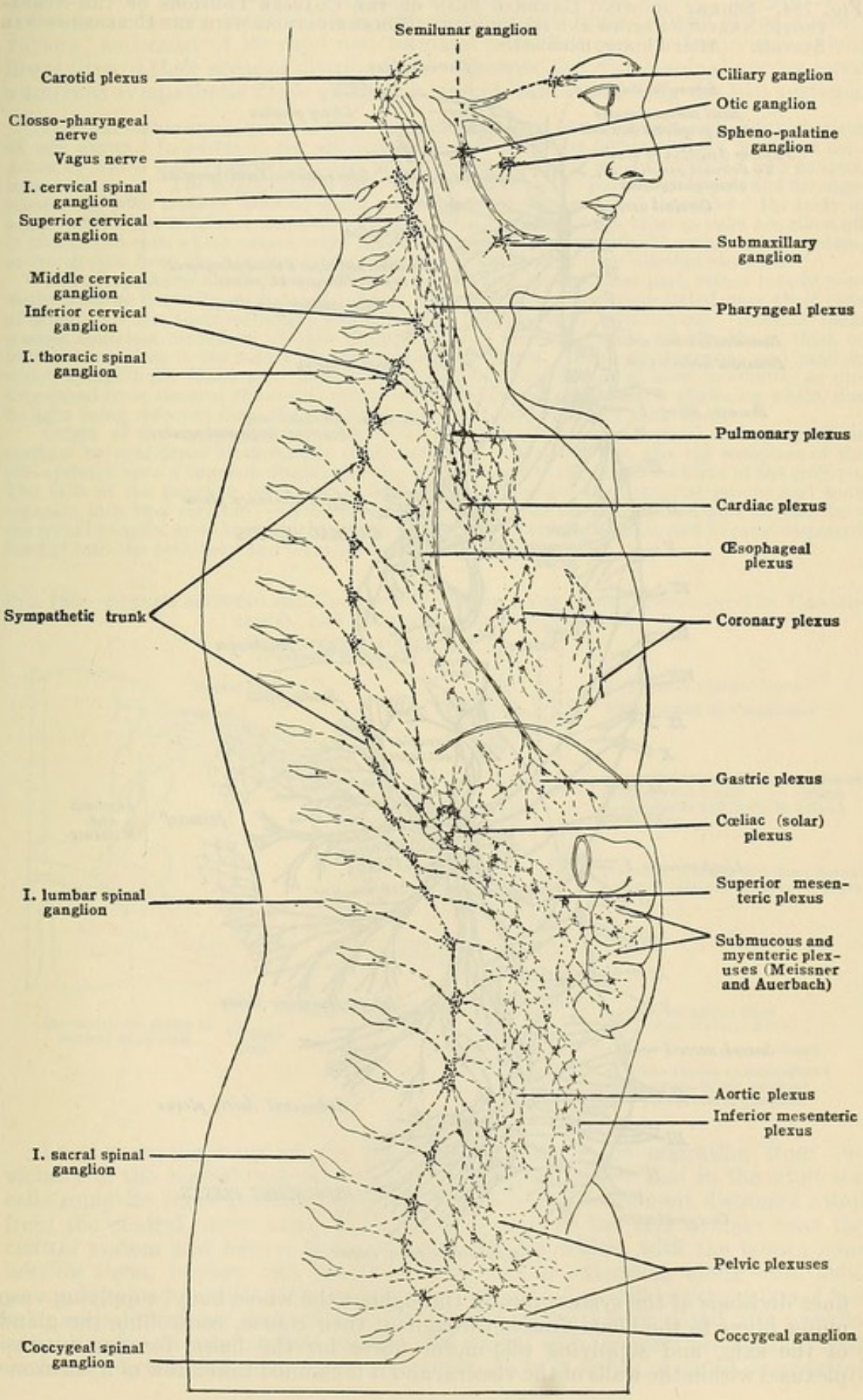

abundant in and largely comprise the viscera or splanchnic organs of the body, the largest and most evident of the structures comprising the sympathetic system are found either in or near the cavities containing the viscera. However, the

FIG. 784.—SCHEME SHOWING GENERAL PLAN OF THE COARSER PORTIONS OF THE SYMPATHETIC NERVOUS SYSTEM AND ITS PRINCIPAL COMMUNICATIONS WITH THE CEREBRO-SPINAL SYSTEM. (After Flower, modified.)

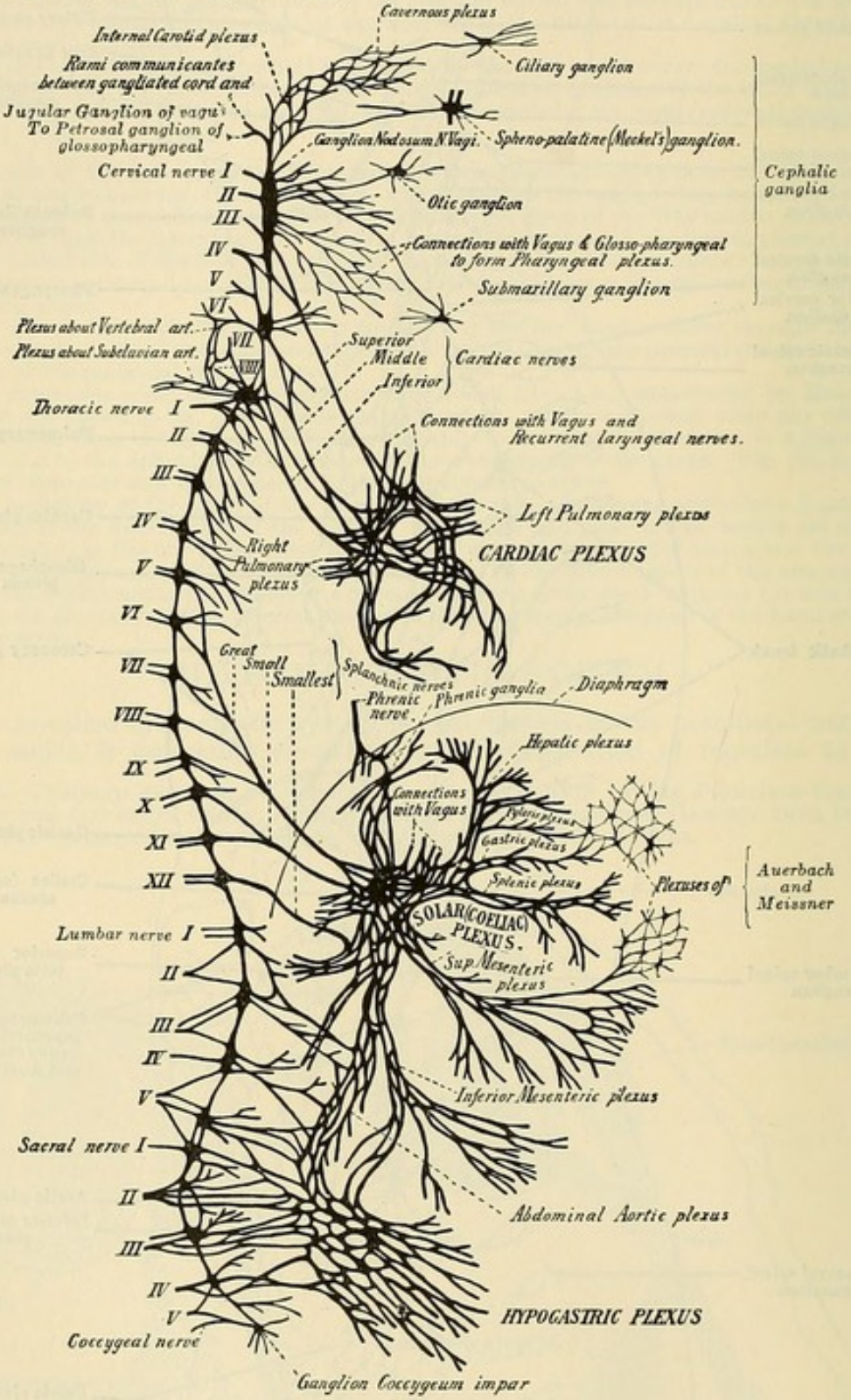

finer divisions of the system ramify throughout the whole body, supplying vaso-motor fibres to the blood-vessels throughout their course, controlling the glands of the skin, and supplying pilo-motor fibres for the hairs, forming intrinsic plexuses within the walls of the viscera, and it is claimed that a few of its neurones

convey inpulses toward the central system (sensory sympathetic neurones). While it is very probable that certain of the simpler reflexes of the splanchnic organs may be mediated by the sympathetic system alone, yet the sympathetic is by no means independent of the cranio-spinal system, but is rather, both anatomically and functionally merely a part of one continuous whole. Throughout, it shares its domain of termination with cranio-spinal fibres, chiefly of the sensory variety, and most of its rami and terminal branches carry a few cranio-spinal fibres toward their areas of distribution. Likewise the cranio-spinal nerves carry numerous sympathetic fibres gained by way of rami connecting the two systems.

Like the cranio-spinal system, the sympathetic consists of cell-bodies, each of which gives off one axone. In addition, the cell-bodies give off numerous dichotomously branched dendrites by which their receptive surfaces are increased, and they are accumulated into ganglia, large and small. The larger ganglia have more or less constant positions, shapes, and arrangements, while the smaller, some of which are microscopic, are scattered throughout the body in a seemingly more indefinite manner. The axones or fibres arising in these ganglia are given off in trunks and rami which associate the ganglia with each other or with the cranio-spinal system, or which pass from the ganglia to be distributed directly upon their allotted elements.

The **sympathetic fibres** arising from the ganglia are, for the most part, either totally non-medullated or partially medullated. Some fibres are completely medullated near their cells of origin, but lose their medullary sheaths before reaching their terminations. Some of them possess complete medullary sheaths throughout, but in no cases are the sheaths as thick or well developed as is the rule with the cranio-spinal fibres. Thus, nerve-trunks and rami in which sympathetic fibres predominate appear greyish in colour and more indefinite, as distinguished from those of the cranio-spinal nerves, which always appear a glistening white, due to light being reflected from the emulsified myelin of the sheaths of their fibres.

Origin of the sympathetic system.—Not only must the cranio-spinal and sympathetic systems be considered anatomically continuous and dependent, but also the neurones of the two systems have a common origin, namely, the ectoderm of the dorsal mid-line of the embryo. The cells of the ganglion crest (see p. 754) become arranged in segmental groups and soon separate into two varieties:—those which will remain near the spinal cord and develop into the spinal ganglia, and those which, during the growth processes, migrate and become displaced further into the periphery and form the sympathetic ganglia.

FIG. 785.—SCHEME SHOWING THE CONNECTION BETWEEN THE SYMPATHETIC AND THE CRANIO-SPINAL AND CENTRAL NERVOUS SYSTEMS.

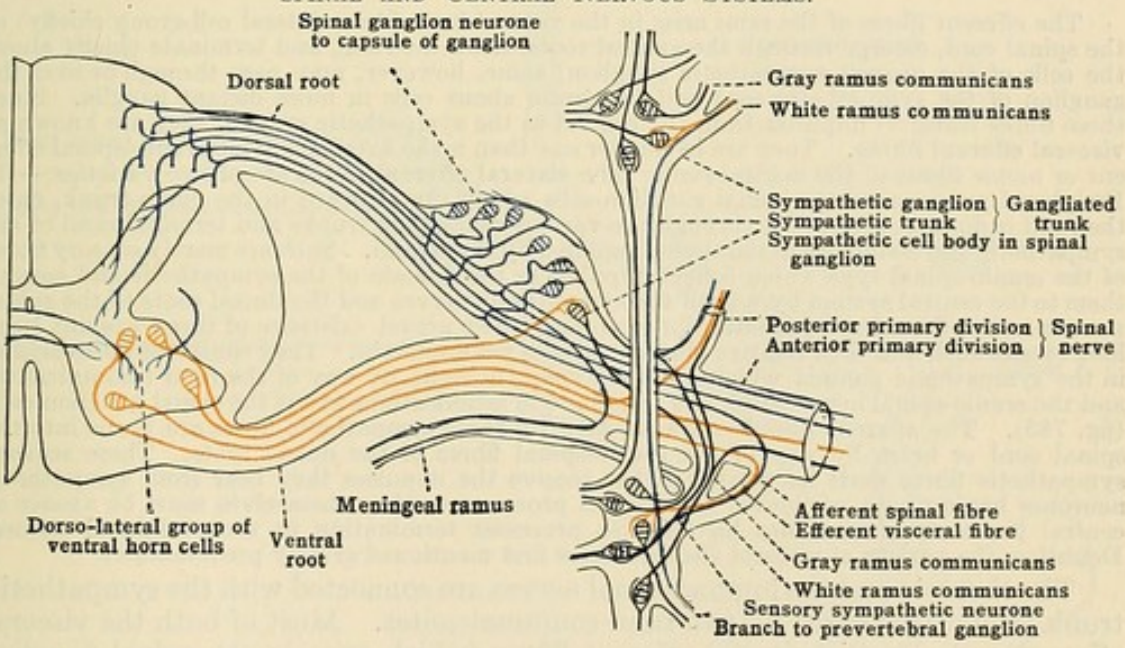

In the development of the sympathetic system the migration from the vicinity of the central system occurs to varying extents, so that in the adult the cells comprise three general groups of ganglia situated different distances away from the central nerve axis.—(1) A large portion of the cells remain near the central system and form a linear series of ganglia which, with the trunks connecting them, become two *gangliated nerve trunks* extending along each side, proximal to and parallel with the vertebral column; (2) a still larger portion of the cells migrate further toward the periphery and are accumulated into ganglia which assume an intermediate position and which, with the rami associating them with each other and with other structures, form a series of great *prevertebral*

plexuses; (3) still other cells wander even further away from the locality of their origin and invade the very walls of the organs innervated by the sympathetic system. The latter cells occur as numerous small terminal ganglia, most of which are microscopic and which, with the twigs connecting them, form the most peripheral of the sympathetic plexuses. Examples of these are the intrinsic ganglia of the heart and pancreas and the *plexuses of Auerbach* and *Meissner* in the walls of the digestive canal. Small, straggling ganglia may be found scattered between these three general groups. In the head, the gangliated trunks and great prevertebral plexuses are represented by the ciliary, sphenopalatine, otic and submaxillary ganglia and the plexuses associated with these. The supporting tissue of the sympathetic system accumulates early and is probably all of mesodermic origin.

Construction of the sympathetic system.—The sympathetic ganglia may be considered as relays in the pathways for the transmission of impulses from the region in which they arise to the tissues in which they are distributed; the cells composing the ganglia are the cell-bodies of the neurones interposed in the various neurone chains performing this function. A fibre arising from a cell-body in a given ganglion may pass out of the ganglion and proceed directly to its termination upon a smooth muscle-fibre or gland-cell, or it may pass through a connecting trunk to another ganglion and there terminate about and thus transmit the impulse to another cell, which, in its turn, may give off the fibre which bears the impulse to the appropriate tissue-element. Fibres arising in given ganglia may pass uninterrupted through other ganglia and proceed to their respective destinations. On the other hand, several neurones may be involved in the transmission of a given impulse when sent from a region distant from the tissue to which it is distributed.

Communication between the central nervous system and the sympathetic is established through both efferent and afferent fibres. In the region of the spinal cord both varieties of fibres pass from one system to the other by way of the **rami communicantes,** delicate bundles of fibres connecting the nearby sympathetic trunk with the respective spinal nerves (fig. 785).

The efferent fibres of the rami arise in the ventral horn (dorso-lateral cell-group chiefly) of the spinal cord, emerge through the ventral roots, enter the rami, and terminate chiefly about the cells of the nearest sympathetic ganglion; some, however, may pass through or over the ganglion of the sympathetic cord and terminate about cells in more distant ganglia. Since these fibres transmit impulses from the central to the sympathetic system, they are known as **visceral efferent fibres.** They are of smaller size than is the average for the cranio-spinal efferent or motor fibres of the ventral root. The **visceral afferent fibres** are of two varieties:—(1) Peripheral processes of the spinal ganglion-cells which run outward in the nerve-trunk, enter the rami communicantes, pass through the various connecting trunks and terminal rami of the sympathetic and terminate in the tissues supplied by these rami. Such are merely sensory fibres of the cranio-spinal type which collect impulses in the domain of the sympathetic and convey them to the central system by way of the sympathetic nerves and the dorsal roots of the spinal nerves. (2) Afferent sympathetic fibres proper. The actual existence of these has not been long established, and their relative abundance is as yet uncertain. They consist of fibres arising in the sympathetic ganglia which enter the spinal ganglia by way of the rami commnicantes and the cranio-spinal nerve-trunk and terminate in arborisations about the spinal ganglion-cells (fig. 785). The afferent impulses transmitted by these sympathetic fibres are borne into the spinal cord or brain by way of the cranio-spinal fibres of the dorsal roots. These sensory sympathetic fibres must necessarily either receive the impulses they bear from sympathetic neurones having both peripheral and central processes or they themselves must be axones or central processes of neurones having also processes terminating in the peripheral tissues. Doubtless the variety of visceral afferent fibres first mentioned greatly predominates.

The thoracic and the lumbar spinal nerves are connected with the sympathetic trunk (gangliated cord) by two rami communicantes. Most of both the visceral efferent and also the visceral afferent fibres (which arise in the spinal ganglia) pass by way of a separate ramus. Both these varieties being of the cranio-spinal type, and, therefore, medullated, they give the ramus a white appearance meriting the name **white ramus communicans.** Fibres of the sympathetic type predominate in the second ramus and thus it is the **grey ramus communicans.** The latter consists of:—(1) afferent sympathetic fibres and (2) of sympathetic fibres which join the primary divisions of the spinal nerves and course in them to their allotted tissues (fig. 785).

In the sacral region, most of the visceral efferent fibres pass over the ganglia of the sympathetic trunk and terminate in the more peripheral ganglia of the plexuses of this region. This is

especially true for the fibres passing from the second, third, and fourth sacral nerves. In the cervical region white rami are not in evidence, a fact probably explicable as due to an arrangement by which at least most of the visceral efferent fibres arising in the cervical segments of the spinal cord pass downward in these segments and join the sympathetic through the white rami of the upper thoracic nerves; others may enter the cervical portion of the gangliated cord through the spinal accessory or eleventh cranial nerve, rather than through individual white rami, while others pass into the nerves of the brachial plexus to terminate in the minute ganglia of the plexuses upon the blood-vessels of the limb. All the spinal nerves are joined by grey rami communicantes from the sympathetic trunk.

Vaso-motor fibres to the meninges and intrinsic blood-vessels of the spinal cord pass to the spinal nerves by way of the grey rami. Thence they may reach the meninges by one of three ways:—(1) through the delicate recurrent or meningeal branch of the spinal nerve (fig. 785); (2) through the trunk and ventral

FIG. 786.—DIAGRAM SUGGESTING THE ORIGIN, COURSE AND CONNECTIONS OF SYMPATHETIC NERVE-FIBRES.

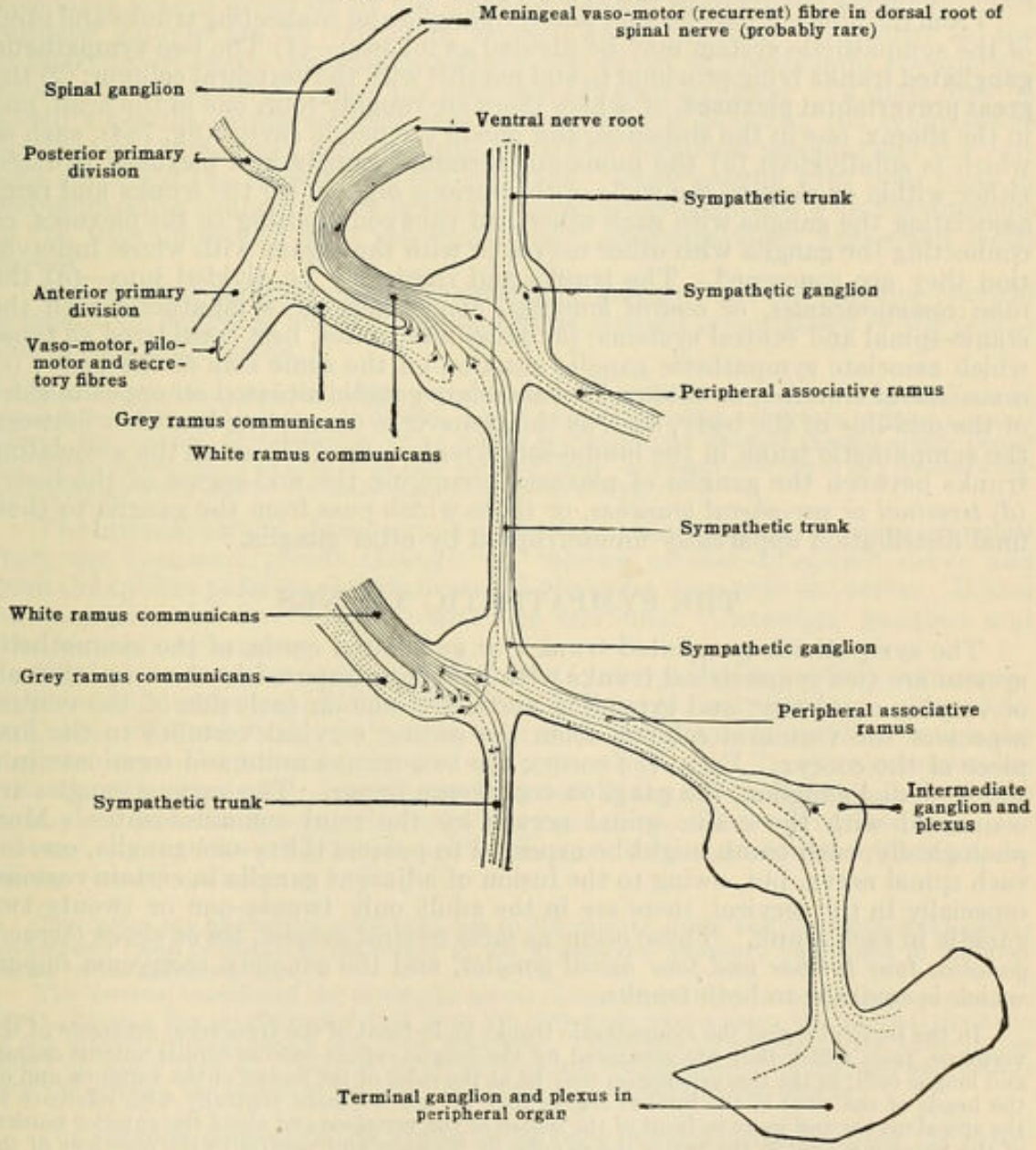

root of the spinal nerve; (3) probably more rarely, through the trunk and dorsal root of the spinal nerve (fig. 786).

Corresponding communications exist between the cranial nerves and the sympathetic, but the corresponding rami usually extend further toward the periphery and in not so regular a manner as the communications between the spinal nerves and the sympathetic system. The mesencephalon, for example, is chiefly connected with the ciliary ganglion of the sympathetic by fibres which are sent through the oculo-motor nerve and which enter this ganglion by way of its short root and terminate about its cells. Visceral efferent fibres from the rhombencephalon pass outward to the sympathetic in the roots of the facial, glosso-palatine, glosso-pharyngeal,

vagus, and spinal accessory nerves, all of which have more or less irregularly disposed communicating rami. The ganglia of origin of the vagus, more than perhaps any other nerve, both receive impulses from visceral efferent fibres and give origin to sympathetic fibres. Likewise twigs of other cranial nerves, especially of the trigeminus, connect with (pass through) the small sympathetic ganglia of the head. The meningeal branches given by certain of the cranial nerves contain vaso-motor fibres, and these correspond to the sympathetic fibres in the recurrent branches and in the roots of the spinal nerves.

It is known that spinal ganglia and certain of the ganglia of the cranial nerves contain cell-bodies of sympathetic neurones—cell-bodies which, during the period of the migration peripheralward, remained within the confines of these ganglia (fig. 785). These cell bodies receive efferent impulses from ventral root fibres and send their axones further into the periphery just as if in the sympathetic ganglion. Their relative abundance is not known. It is supposed that the ganglia of the vagus, glosso-pharyngeus, trigeminus and the geniculate ganglion contain a considerable proportion of such sympathetic cell-bodies.

From the above it may be seen that the ganglia and connecting trunks and rami of the sympathetic system may be divided as follows:—(1) The two **sympathetic gangliated trunks** lying proximal to and parallel with the vertebral column; (2) the **great prevertebral plexuses,** of which there are roughly four, one in the head, one in the thorax, one in the abdomen, and one in the pelvic cavity (fig. 784), each of which is subdivided; (3) the numerous **terminal ganglia and plexuses** situated either within or close to the walls of the various organs; (4) the **trunks** and **rami** associating the ganglia with each other and thus contributing to the plexuses, or connecting the ganglia with other nerves or with the organs with whose innervation they are concerned. The trunks and rami may be divided into—(*a*) the *rami communicantes,* or *central branches,* connecting the sympathetic with the cranio-spinal and central systems; (*b*) *associative trunks,* best considered as those which associate sympathetic ganglia situated on the same side of the body; (*c*) *commissural branches,* or those which associate ganglia situated on opposite sides of the mid-line of the body, such as the transverse connecting branches between the sympathetic trunk in the lumbo-sacral region (fig. 787), or all the associating trunks between the ganglia of plexuses occupying the mid-region of the body; (*d*) *terminal* or *peripheral branches,* or those which pass from the ganglia to their final distribution apparently uninterrupted by other ganglia.

THE SYMPATHETIC TRUNKS

The sympathetic gangliated trunks, or gangliated cords, of the sympathetic system are two symmetrical trunks with ganglia interposed in them at intervals of varying regularity, and extending vertically, one on each side of the ventral aspect of the vertebral column, from the second cervical vertebra to the first piece of the coccyx. Upon the coccyx the two trunks unite and terminate in a single medial ganglion, the **ganglion coccygeum impar.** The various ganglia are connected with the cranio-spinal nerves by the rami communicantes. Morphologically, each trunk might be expected to possess thirty-one ganglia, one for each spinal nerve, but, owing to the fusion of adjacent ganglia in certain regions, especially in the cervical, there are in the adult only twenty-one or twenty-two ganglia in each trunk. These occur as *three cervical ganglia, ten or eleven thoracic ganglia, four lumbar and four sacral ganglia,* and the *ganglion coccygeum impar,* which is common to both trunks.

In the cervical region the sympathetic trunks lie in front of the transverse processes of the vertebræ, from which they are separated by the longus capitis (rectus capitis anticus major) and longus colli; in the thoracic region they lie at the sides of the bodies of the vertebræ and on the heads of the ribs; in the lumbar region they are placed more ventrally with reference to the spinal nerves and more in front of the bodies of the vertebræ and along the anterior borders of the psoas muscles; in the pelvis the ganglia lie between and ventral to the openings of the sacral foramina. In the lower lumbar and sacral region one ganglion may send rami communicantes to two spinal nerves and one spinal nerve may be connected with two ganglia. The ganglia of the trunks throughout give off associative branches to the ganglia of the prevertebral plexuses and branches to the nearby viscera and blood-vessels. These branches may appear either white or grey according to the predominance of medullated or non-medullated fibres in them. In the lumbo-sacral region commissural or transverse branches between the ganglia of the two trunks are especially abundant. In trunks having a whiter appearance, the greater part of the medullated fibres producing it are sensory and visceral motor fibres from the spinal nerves which have passed through the sympathetic ganglia without termination. The nerve trunks connecting the ganglia of the sympathetic trunks all contain three varieties of fibres:—(1)

visceral motor fibres which have entered them in the white rami communicantes from the spinal nerves of higher or lower levels, and which are coursing in them to terminate in other ganglia, either in the trunks above or below or in ganglia not belonging to the trunks; (2) fibres arising in sympathetic ganglia of a higher or lower level and passing upward or downward to terminate in other ganglia of the trunk or to issue from the trunk and proceed to more peripheral ganglia or to ganglia of the opposite trunk (both associative and commissural fibres); (3) afferent fibres or sensory fibres arising either in the spinal ganglia, or sensory sympathetic fibres arising in sympathetic ganglia and coursing in the trunk to pass into spinal ganglia above or below by way of the grey rami communicantes.

THE CEPHALIC AND CERVICAL PORTIONS OF THE SYMPATHETIC TRUNK

The cephalic portion of the sympathetic system consists of numerous small ganglia and of numerous plexuses connected with the internal carotid nerve, the ascending branch given off by the superior cervical sympathetic ganglion. The cephalic ganglia are all relatively small. There are four considered in the ordinary macroscopic dissections, namely, the ciliary or ophthalmic, the spheno-palatine or Meckel's ganglion, the otic, and the submaxillary. To these may be added a portion of the superior cervical sympathetic ganglion, the sympathetic portions of the nodosal, petrous, geniculate and semilunar ganglia, and the various small ganglia dispersed in the plexuses. These ganglia with their roots or communicating branches have been described in their relations with the divisions of the trigeminus and with the oculo-motor, glosso-palatine, vagus and facial nerves.

The internal carotid nerve, the **ascending branch** from the superior cervical sympathetic ganglion, may be regarded as an upward prolongation of the primitive sympathetic trunk.

It arises from the upper end of the superior cervical ganglion and passes through the carotid canal into the cranial cavity. It divides into two branches which subdivide to form a coarse plexus, the *internal carotid plexus*, which partly surrounds the internal carotid artery before the latter enters the cavernous sinus (fig. 787 and 788). It passes with the artery to the cavernous sinus, where it forms the finer meshed *cavernous plexus.*

The **internal carotid plexus** supplies offsets to the artery and receives branches from the tympanic plexus through the inferior carotico-tympanic nerve and from the spheno-palatine ganglion through the great deep petrosal nerve. It also communicates by fine branches with the semilunar (Gasserian) ganglion and with the abducens nerve.

The **cavernous plexus** gives branches of communication to the oculo-motor and trochlear nerves and to the opthalmic division of the trigeminus. According to Toldt and Spalteholz, it communicates with the **tympanic plexus** through the superior carotico-tympanic (small deep petrosal) nerve. It also communicates with the ciliary ganglion through the **long root** *of the ciliary ganglion* and usually through a separate *sympathetic root* of this ganglion. These branches may pass through the superior orbital (sphenoidal) fissure either separately or with the naso-ciliary (nasal) nerve.

The cavernous plexus also gives branches to the carotid artery and filaments of the plexus accompany small branches of the artery to the hypophysis (pituitary body) and to the dura mater on the sphenoid bone.

The *terminal branches* of the cavernous plexus consist of delicate filaments that anastomose freely, forming fine plexuses, and pass from the cavernous plexus along the terminal divisions of the internal carotid artery and their branches. These fine plexuses take the name of the artery on which they lie. The four larger of them are the plexuses of the anterior and middle cerebral arteries, the plexus of the chorioid artery, and the ophthalmic plexus.

The **cervical portion of the sympathetic cord** extends upward along the great vessels of the neck. No white rami communicantes connect it directly with the spinal cord, but instead it receives visceral efferent fibres from the upper thoracic spinal nerves through the sympathetic trunk, and probably also from the cervical spinal cord through the spinal acessory nerve and the connections with the vagus. It sends **grey rami communicantes** to each of the cervical nerves. It extends from the subclavian artery to the base of the skull, lying dorsal to the sheath of the great vessels and in front of the longus capitis and longus colli, which separate is from the transverse processes of the cervical vertebræ (fig. 787). It usually

FIG. 787.—SHOWING THE SYMPATHETIC TRUNKS IN THEIR RELATION TO THE VERTEBRAL COLUMN, TO THE SPINAL NERVES, AND TO EACH OTHER. (Modified from Toldt, "Atlas of Human Anatomy," Rebman, London and New York.)

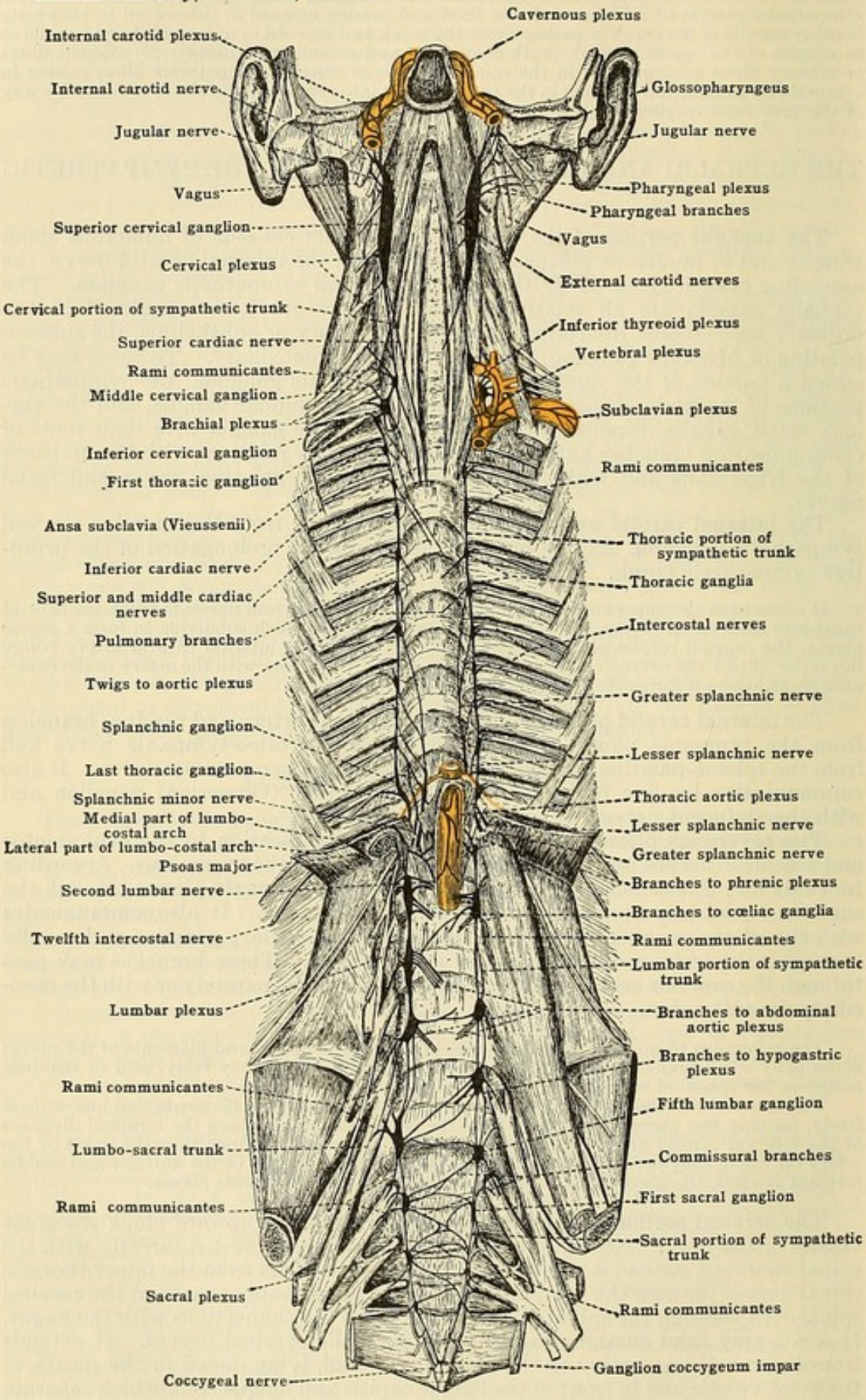

has but three **ganglia,** one at each end, the superior and inferior, and one between these two, called the middle ganglion. The latter varies somewhat in position and is sometimes absent.

1. Superior Cervical Ganglion

The **superior cervical ganglion** is usually fusiform in shape and is sometimes marked by one or more constrictions. There is ground for the belief that it is formed by the coalescence of four ganglia corresponding to the first four cervical nerves. It varies from an inch to one and one-half inches (2.5 to 3.7 cm.) in length, lying dorsal to the upper part of the sheath of the great vessels of the neck and in front of the transverse processes of the second and third cervical vertebræ.

Fig. 788.—Diagram of the Glosso-palatine Nerve and the Relations of the Ganglia-ted Cephalic Plexus to other Cranial Nerves. (After Bean.)

Broken lines, motor; continuous lines, sympathetic; glosso-palatine in solid black. Medial view. Left side.

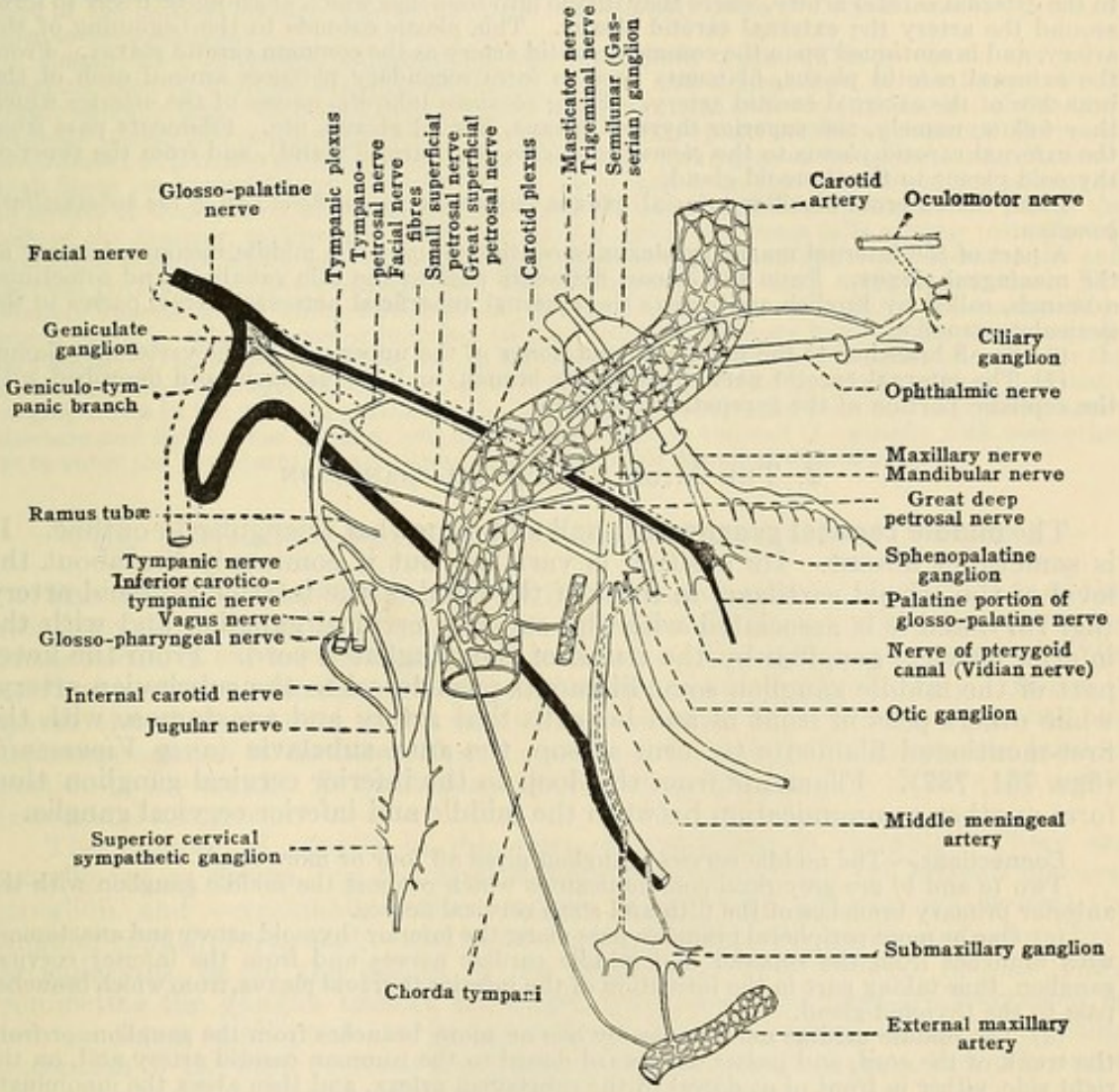

It occasionally extends upward as high as the transverse process of the first vertebra (fig. 787). It is connected with the middle cervical ganglion by the intervening trunk, and it gives off a large number of communicating branches.

Rarely, the ganglion may be double or split with a ventral portion lying superficial to the carotid sheath and a dorsal portion dorsal to the sheath, connected by sympathetic filaments near the superior and inferior extremities of the ganglion.

Communications:—(1) **Four grey rami communicantes** associate the ganglion with the anterior primary divisions of the first four cervical nerves.

(2) **Communicating branches to the cranial nerves.**—An irregular number of small twigs pass between the superior cervical ganglion and the hypoglossal nerve and to the ganglion nodosum of the vagus. A named branch, the *jugular nerve,* runs upward to the base of the skull and divides into two branches, one of which enters the jugular foramen and terminates in the jugular ganglion of the vagus, and the other ends in the petrous ganglion of the glossopharyngeus. (See fig. 788).

(3) **Four or five laryngo-pharyngeal branches** come from the superior ganglion and the plexus extending downward from it, and pass forward and medialward, lateral to the carotid vessels, to the wall of the pharynx, where they unite on the middle constrictor with the pharyngeal branches of the glosso-pharyngeus and vagus, forming with them the *pharyngeal plexus*, from which branches are distributed to the walls of the pharynx and to the superior and external laryngeal nerves (fig. 787).

(4) The **superior cervical cardiac nerve** springs from the lower part of the ganglion or from the trunk immediately below it. It passes downward behind the carotid sheath, either in front of or dorsal to the inferior thyreoid artery, and in front of the longus colli, and establishes communications with the upper cervical cardiac branch of the vagus, the middle cervical cardiac branch of the sympathetic, and with the inferior and external laryngeal nerves. At the root of the neck the nerve of the *right side* passes in front of or behind the first part of the right subclavian artery, and is continued along the innominate artery to the front of the bifurcation of the trachea, where it ends in the deep part of the cardiac plexus. The *left nerve* passes into the thorax along the front of the left common carotid artery, crosses the front of the arch of the aorta immediately anterior to the vagus, and terminates in the superficial part of the cardiac plexus (fig. 789). Filaments from both the right and left nerves pass to the inferior thyreoid plexus.

(5) The **external carotid nerves** (fig. 787) pass forward from the superior cervical ganglion to the external carotid artery, where they divide into branches which anastomose freely to form around the artery the **external carotid plexus.** This plexus extends to the beginning of the artery, and is continued upon the common carotid artery as the **common carotid plexus.** From the external carotid plexus, filaments pass to form secondary plexuses around each of the branches of the external carotid artery. These plexuses take the names of the arteries which they follow, namely, the **superior thyreoid plexus, lingual plexus,** etc. Filaments pass from the external carotid plexus to the *glomus caroticum* (the carotid gland), and from the superior thyreoid plexus to the thyreoid gland.

From the **external maxillary** (facial) **plexus** passes the *sympathetic root of the submaxillary ganglion*.

A part of the **internal maxillary plexus** is continued upon the middle meningeal artery as the **meningeal plexus.** From this plexus filaments pass to the otic ganglion, and sometimes a branch, called by English anatomists the **external superficial petrossal nerve,** passes to the geniculate ganglion.

(6) Small **branches to the ligaments and bones** of the upper part of the vertebral column.

(7) The **internal carotid nerve** (**ascending branch**) and plexus have been described with the cephalic portion of the sympathetic system.

2. The Middle Cervical Ganglion

The **middle cervical ganglion** is small and somewhat triangular in outline. It is sometimes absent. Its position is variable, but it commonly lies about the level of the cricoid cartilage, in front of the bend of the inferior thyreoid artery (fig. 787), and it is associated with the superior cervical ganglion and with the inferior cervical ganglion by the trunk of the gangliated cord. From the lower part of the middle ganglion some filaments pass dorsal to the subclavian artery, while others pass in front of and beneath that artery and anastomose with the first-mentioned filaments to form a loop, the **ansa subclavia** (*ansa Vieussenii*) (figs. 751, 787). Filaments from this loop to the inferior cervical ganglion thus form another communication between the middle and inferior cervical ganglia.

Connections.—The middle cervical ganglion gives off four or more rami.

Two (*a* and *b*) are grey rami communicantes which connect the middle ganglion with the anterior primary branches of the fifth and sixth cervical nerves.

(*c*) One or more peripheral branches pass along the inferior thyreoid artery and anastomose with branches from the superior and middle cardiac nerves and from the inferior cervical ganglion, thus taking part in the formation of the **inferior thyreoid plexus,** from which branches pass to the thyreoid gland.

(*d*) The **middle cardiac nerve** arises by one or more branches from the ganglion, or from the trunk of the cord, and passes downward dorsal to the common carotid artery and, on the right side, either in front of or dorsal to the subclavian artery, and then along the innominate artery to the deep part of the cardiac plexus (figs. 787 and 789). It is frequently larger than the superior cardiac nerve. On the left side the nerve runs between the subclavian and common carotid arteries. On both sides the nerve communicates with the inferior laryngeal nerve and external laryngeal nerve.

The middle cervical ganglion also gives branches to the common carotid plexus.

3. The Inferior Cervical Ganglion

The **inferior cervical ganglion** is irregular in form. It is larger than the middle cervical ganglion, and it lies deeply in the root of the neck dorsal to the vertebral artery or the first part of the subclavian artery, and ventral to the interval between the transverse processes of the last cervical and the first thoracic vertebræ (figs. 759, 761). It is connected with the middle cervical ganglion by

the sympathetic trunk, and by filaments passing to the ansa subclavia (Vieussenii), and it is either blended directly with the first thoracic ganglion or connected with it by a short stout portion of the trunk. It gives rami to the last two cervical nerves and peripheral branches to the vertebral and internal mammary arteries, to the heart, and to the inferior thyreoid plexus.

Connections.—(1) The rami to the seventh and eighth cervical nerves are **grey rami communicantes.**

(2) The **branches to the vertebral artery** are large and they unite with similar branches from the first thoracic ganglion to form a plexus, the **vertebral plexus** (fig. 787), which accompanies the artery into the posterior fossa of the cranium, where it is continued on the basilar artery. The plexus communicates in the neck by delicate threads with the cervical spinal nerves. These are probably meningeal rami.

(3) The branches to the internal mammary artery form the **internal mammary plexus.**

(4) The **inferior cardiac nerve** may arise from the inferior cervical ganglion, from the first thoracic ganglion, or by filaments from both these ganglia (figs. 787 and 789). It communicates with the recurrent laryngeal nerve and with the middle cardiac nerve, and passes to the deep part of the cardiac plexus. On the left side it frequently joins the middle cardiac nerve to form a common trunk.

Construction of the cervical portion of the sympathetic trunk.—This portion of the trunk contains both medullated and non-medullated fibres, and a large part of the former are of cranio-spinal origin. In the absence of white rami communicantes to this portion of the sympathetic trunk, it is evident that few if any of the cranio-spinal or **efferent visceral fibres** are contributed to it below the superior ganglion by the cervical region of the spinal cord. Instead, such fibres are known to enter by way of the white rami from the upper thoracic nerves, and to ascend to this portion of the sympathetic trunk. Most of these fibres terminate about the cells of the superior, middle, and inferior cervical ganglia, and these cells in their turn give off sympathetic fibres which pass by way of the branches mentioned above for the cephalic and cervical portions, to their distribution in the structures of the head, neck, and thorax. The efferent visceral fibres which terminate in the superior ganglion especially are among those which mediate—(1) vaso-motor impulses for the head; (2) secretory impulses for the submaxillary gland; (3) pilo-motor impulses for the hairs of the face and neck; (4) motor impulses for the smooth muscle of the eyelids and orbit, and (5) dilator impulses for the pupil. The sympathetic or grey fibres in the cervical portion of the sympathetic trunk arise from the cells of the upper thoracic and the cervical ganglia, and are passing either to connect the ganglia with each other or to enter the peripheral branches and proceed to their terminal distribution.

THE THORACIC PORTION OF THE SYMPATHETIC TRUNK

The thoracic part of the gangliated trunk runs downward on the heads of the ribs from the first to the tenth, and then passes a little ventralward on the sides of the bodies of the lower two thoracic vertebræ. Above it is continuous with the cervical portion at the root of the neck, dorsal to the vertebral artery. Below it leaves the thorax dorsal to the medial lumbo-costal arch (arcuate ligament), or sometimes dorsal to the lateral lumbo-costal arch, and continues into the lumbar portion of the trunk. It lies behind the costal pleura and crosses over the aortic intercostal arteries.

The number of ganglia in this part of the trunk is variable. There are usually ten or eleven, but the first is sometimes fused with the inferior cervical ganglion and occasionally other ganglia fuse. The ganglia are irregularly angular or fusiform in shape, and lie on the head of the ribs, on the costo-vertebral articulations, or on the bodies of the vertebræ. The portions of the trunk connecting the ganglia usually are single, but sometimes they are composed of two or three small cords in juxtaposition. Each ganglion, with the possible exception of the first, receives a *white ramus communicans* from a thoracic nerve and all give off *grey rami communicantes* to these nerves.

The **white rami communicantes,** as they approach the sympathetic trunk, quite often appear double, due to the separation of a large portion of their fibres into two main streams, one passing upward in the sympathetic trunk, and one passing downward. Of the white rami from the upper five thoracic nerves, the upward stream of fibres is much larger than the downward, due to the fact that a greater part of the efferent visceral fibers from these nerves are distributed through the cervical portion of the sympathetic trunk, as noted above in the construction of that portion. Usually the white rami from the spinal nerves pass directly to the corresponding ganglia of the trunk, and thus lie in company with the corresponding grey rami. Sometimes, however, they may join the intermediate portions of the trunk, and in the lower thoracic region especially, a ramus may pass from a nerve to the ganglion corresponding to the nerve above or below. The

fibres of the white rami from the lower thoracic nerves are in greater part directed downward in the sympathetic trunk, and also downward in its peripheral branches, to be distributed to the abdominal viscera. In all cases, however, some of the fibres of the thoracic white rami terminate in the ganglia nearest their junction with the trunk, while others pass into the nearest peripheral branches. In this way the white rami from all the thoracic spinal nerves, especially those of the mid-region, are directly concerned in the innervation of the thoracic viscera, lungs, œsophagus, aorta, etc.

The **first thoracic ganglion** is larger than the other ganglia of this region and is irregular in form. It may be narrowly ovoid or semilunar. It lies in front of the neck of the first rib, behind the pleura, and on the medial side of the costo-cervical trunk (superior intercostal artery), which vessel separates it from the prolongation of the portion of the first thoracic nerve which passes to the brachial plexus. It sometimes fuses with the inferior cervical ganglion, and, on the other hand, sometimes extends to the upper part of the second rib to fuse with the second thoracic ganglion. The result of the latter fusion resembles the stellate ganglion of the carnivora, and when it occurs, is sometimes referred to as the *ganglion stellatum*. When well developed, the first ganglion sends a branch to the cardiac plexus, forming the fourth cardiac nerve of Valentin.

The **second thoracic ganglion,** triangular in shape and almost as large as the preceding, is sometimes placed on the costo-vertebral articulation, and is sometimes partly concealed by the first rib.

The **third to the ninth thoracic ganglia** are usually placed opposite the heads of the corresponding ribs, but the **tenth** and **eleventh** may lie on the bodies of the vertebræ.

The fibres passing from the ganglia form two groups of branches, the *central* and the *peripheral*.

The **central** branches are the **grey rami communicantes,** which pass from the ganglia to the corresponding spinal nerves. After they have joined with the anterior primary divisions of the nerves, the fibres of these rami divide into four groups:—(1) Fibres which pass medialward along the roots of the nerves to supply vessels of the membranes of the spinal cord, or enter a meningeal or recurrent branch for the same purpose; (2) fibres which enter the spinal ganglion and terminate there (sensory sympathetic fibres); (3) fibres which pass dorsalward into the posterior primary divisions of the nerves; (4) fibres which pass lateralward in the anterior primary divisions of the nerves. The last two groups of fibres are distributed to the muscle of the blood-vessels of the body-walls, to the skin-glands, and to the muscles of the hairs of the body.

The **peripheral branches** of the ganglia form two series, an upper and a lower.

Those of the *upper series* pass from the upper four or five ganglia ventralward to be distributed as follows:—

(1) **Pulmonary branches** which accompany the intercostal arteries toward their aortic origin without forming plexuses around them, and pass to the posterior pulmonary plexus (fig. 789).

(2) **Aortic branches,** some of which arise directly from the ganglia and some from the pulmonary branches, and unite with branches from the cardiac plexus and from the splanchnic nerves to surround the aorta as the **thoracic aortic plexus** (fig. 789). This plexus accompanies the aorta into the abdomen and there joins with the cœliac (solar) plexus.

(3) **Œsophageal branches** join with the œsophageal plexus of the vagus.

(4) **Vertebral branches,** some of which pass with the nutrient arteries into the bodies of the vertebræ and some of which pass to the median line and there anastomose with similar branches from the opposite side (commissural branches).

The peripheral ganglionic branches forming the *lower series* consist largely of efferent and afferent fibres from the spinal nerves, which pass through the ganglia and reinforce the sympathetic filaments proper. Thus composed, these branches run ventralward and medialward on the sides of the bodies of the vertebræ and unite to form the splanchnic nerves which supply the abdominal organs, the afferent fibres serving to collect sensory impulses in this domain of the sympathetic.

(1) The **great splanchnic nerve** may be formed by branches from all the thoracic ganglia from the fifth to the tenth inclusive, or it may receive fibres from only two or three of these

ganglia (fig. 787). It is usually formed by branches from the fifth to the tenth. The superior branch, usually the largest, receives smaller inferior branches from the lower ganglia as it passes downward on the sides of the bodies of the vertebræ in the posterior mediastinum. The nerve enters the abdominal cavity by passing through the crus of the diaphragm, and joins the upper end of the cœliac (semilunar) ganglion of the cœliac (solar) plexus. Near the disk between the eleventh and the twelfth thoracic vertebra there is formed on the nerve the **splanchnic ganglion.** Filaments from the nerve and from this ganglion pass along the intercostal arteries to the aorta, œsophagus, and the thoracic duct, and some fibres from the right side pass to the vena azygos (major). Sometimes this nerve divides into two cords, giving off numerous branches which anastomose with each other and with the lesser splanchnic nerve to form a plexus, in the meshes of which are found some small ganglia.

(2) The **lesser splanchnic nerve** receives fibres from the ninth and tenth ganglia. Its course is similar to that of the great splanchnic nerve (fig. 787), but on a more dorsal plane, and it terminates in the cœliac (solar) and renal plexuses.

(3) The **least splanchnic nerve,** not always present, arises from the last thoracic ganglion or sometimes from the small splanchnic nerve. It passes through the crus of the diaphragm and ends in the renal plexus.

Construction of the thoracic portion of the cord.—The majority of the visceral efferent fibres which pass from the central nervous system enter the thoracic portion of the sympathetic trunk; some end there in ramifications around the cells of its ganglia, while others merely pass through on their way to more distant terminations. With regard to those which terminate in the ganglia, it has been shown that in the dog and cat many end in the ganglion stellatum which corresponds with the last cervical and the upper three or four thoracic ganglia in man. Among these are the fibres conveying secretory impulses to the sweat-glands of the upper limb, which emerge from the spinal cord in the thoracic nerves from the sixth to the ninth, and, in the dog, those which convey and transfer vaso-constrictor impulses to the sympathetic neurones supplying the pulmonary blood-vessels. These visceral efferent fibres leave the spinal cord in the second to the seventh thoracic nerves. Other fibres which terminate around the thoracic sympathetic ganglion-cells in the dog and cat are the vaso-constrictor fibres for the upper limbs and some of the vaso-constrictor fibres for the lower limbs.

Of the fibres which traverse the thoracic portion of the sympathetic trunk to gain more distant terminations, some ascend to the cervical region (p. 1033), others descend to the lumbar region, and many pass by the immediate peripheral branches to the splanchnic nerves.

Among those which descend to the lumbar region are pilo-motor fibres, vaso-motor fibres, and secretory fibres to the lower limb, some vaso-constrictor fibres to the abdominal blood-vessels, motor fibres to the circular, and inhibitory fibres to the longitudinal muscle of the rectum. The latter enter the sympathetic trunk by the lower thoracic nerves and pass in the lumbar peripheral branches to the aortic plexus, and terminate around the cells of the inferior mesenteric ganglion.

The visceral efferent fibres which pass through the thoracic ganglia to the splanchnic nerves are mainly vaso-motor fibres to the abdominal blood-vessels; the majority of them probably terminate around the cells of the ganglia in the cœlic (solar) plexus, but those for the renal blood-vessels no doubt end in the renal ganglia. In addition to all the above-mentioned fibres there are in the thoracic part of the sympathetic trunk afferent fibres of both sympathetic and cerebro-spinal type, passing toward the spinal ganglia and the latter, greatly predominating, pass into the dorsal roots of the thoracic spinal nerves.

THE LUMBAR PORTION OF THE SYMPATHETIC TRUNK

The lumbar portion of each trunk lies on the fronts of the bodies of the vertebræ along the anterior border of the psoas muscle, and nearer to the median line than the thoracic portion. It is connected with the thoracic portion of the sympathetic trunk by a slender intermediate portion of the trunk that may pass through the diaphragm or dorsal to it (fig. 787). The continuation of the lumbar into the sacral portion is also slender, and descends dorsal to the common iliac artery. The right trunk is partly covered by the vena cava inferior and the left by the aorta.

The **ganglia,** which are small and oval, vary in number from three to eight, but are usually four. Rarely they are so fused as to form one continuous ganglion.

White rami communicantes pass to the ganglia from the first two or three lumbar nerves only. This portion of the sympathetic trunk also receives visceral efferent and afferent fibres which are derived from the white rami communicantes of the lower thoracic nerves and continue downward in the trunk.

Branches.—As in the thoracic region, the branches from the ganglia are central and peripheral. The central are **grey rami communicantes.** There may be two branches to a nerve or one ramus may divide so as to join two adjacent spinal nerves. Sometimes a spinal nerve may receive as many as five grey rami from the sympathetic trunk.

The **peripheral branches** include:—(*a*) Branches passing to the aorta and taking part in the formation of the aortic plexus; (*b*) branches which descend in front of the common iliac artery to the hypogastric plexus; and (*c*) branches to the vertebræ and ligaments.

THE SACRAL PORTION OF THE SYMPATHETIC TRUNK

The sacral part of each trunk passes downward in front of the sacrum, immediately lateral to the medial borders of the anterior sacral foramina. It is continuous above with the lumbar portion of the trunk, and below it anastomoses freely in front of the coccyx with the trunk of the other side to form a plexus in the terminus of which is the **coccygeal ganglion** (*ganglion coccygeum impar*) (fig. 787). Like the cervical and lower lumbar portions of the sympathetic trunk, the sacral part receives no white rami communicantes from the spinal nerves.

The sacral **ganglia** are small in size, and usually four in number. The variation both in size and number is more marked in this portion of the trunk than in the two parts above.

Branches.—The branches of the sacral ganglia include:—

(1) Grey rami communicantes to the sacral nerves.

(2) Branches to the front of the sacrum which anastomose with their fellows of the opposite side (commissural branches).

(3) Branches which enter into the formation of the plexus on the middle sacral artery.

(4) Branches which join the pelvic plexuses.

(5) Branches given off by the ganglion coccygeum impar to the coccyx and its ligaments and to the *glomus coccygeum* (coccygeal gland).

Construction of the lumbar and sacral portions of the gangliated trunk.—The ganglia of both these portions of the trunk are very variable in shape, size, position, and number. There are usually four ganglia belonging to each portion, but sometimes as many as eight may be distinguished in the lumbar and at other times there may be as many as six in the sacral portion. In the majority of cases, especially in the sacral region, these masses of cells are so fused that their number is less than the number of the spinal nerves with which they are associated. As noted above, only the first two or three lumbar spinal nerves send white rami which enter these ganglia directly as such. However, visceral efferent fibres descend this entire stretch of the trunk, through both the lumbar and sacral portions, from the white rami of the lower thoracic and the upper lumbar nerves above. These fibres either terminate in the various ganglia or pass uninterrupted to the more distant sympathetic cell-bodies which are concerned in impulses that are vaso-motor to the genital organs, motor for the uterus, the vas deferens, and the muscular coats (circular coat especially) of the bladder. Also, some of them convey secretory, pilomotor, and vaso-motor impulses for the glands, skin, and vessels of the lower extremity in addition to the similar impulses conveyed in the peripheral branches from the lower part of the thoracic portion of the sympathetic trunk. The motor impulses for the uterus or vas deferens and for the bladder pass, in most part probably, by way of the peripheral branches from the lumbar portion of the cord, through the aortic plexus to the inferior mesenteric ganglion; others, the vaso-motor impulses to the genital organs especially, pass by way of the sacral ganglia and the peripheral branches from them to the hypogastric or pelvic plexus and the appropriate subplexuses of this region. Of the vaso-motor fibres for the penis, some of the constrictor fibres pass down the sacral portion of the sympathetic trunk and terminate about the cells of the sacral ganglia, and these cells send out sympathetic fibres which join and course in the pudic nerve (n. pudendus).

All of both the lumbar and sacral spinal nerves receive grey rami from the gangliated trunk. These, just as those from the other portions of the trunk, consist of—(1) vaso-motor fibres to vessels of the meninges and the vertebral canal; (2) sympathetic fibres which join the divisions of the spinal nerves and course in them to their distribution, and (3) afferent sympathetic fibres terminating in the spinal ganglia.

In addition to the visceral efferent fibres, the branches of the lumbo-sacral portion of the sympathetic trunk carry cerebro-spinal fibres of general sensibility—sensory fibres arising in the spinal ganglia of this and the lower thoracic region.

There are no white rami proper passing from the sacral spinal nerves to course or terminate in the sympathetic trunk. Visceral efferent fibres are given off by these nerves in abundance, but, instead of entering the trunk and its ganglia, they form bundles which pass over the trunk and directly into its peripheral branches and to the more distant ganglia. The bundles passing from the second, third, and fourth sacral nerves are large and especially definite. While homologous to white rami, such bundles are better known as the *visceral branches* of the sacral nerves or the **plevic splanchnics.** They contain some spinal sensory fibres, but consist for the most part of visceral efferent, conveying impulses, vaso-motor (vaso-dilator, chiefly) to the genital organs, both motor and inhibitory for the rectum, uterus, and bladder (longitudinal coat especially), and secretory for the prostate gland. These fibres contribute to the hypogastric plexus and are interrupted in the small ganglia of its sub-plexuses, named according to the various urino-genital organs concerned.

THE GREAT PREVERTEBRAL PLEXUSES

The great prevertebral plexuses, in the body cavities, are three in number—the cardiac, the cœliac (solar or epigastric), and the hypogastric or pelvic. The cardiac plexus lies behind and below the arch of the aorta, and the cœliac and

hypogastric plexuses are situated in front of the lumbar vertebræ. Each plexus receives not only sympathetic fibres which have passed from or through the ganglia of the sympathetic trunks of either side, but also both afferent and efferent cranio-spinal nerve-fibres derived directly from the cranio-spinal nerves. In addition the cardiac and cœliac plexuses receive both efferent visceral and cranio-spinal sensory or afferent visceral fibres from both vagus nerves. It should be clearly understood that the branches which run from the sympathetic gangliated trunks to the prevertebral plexuses contain medullated fibres which are passing, like the fibres from the sacral nerves, directly from the spinal cord to terminate about the cells of the plexuses.

1. The Cardiac Plexus

The cardiac plexus is formed by the cardiac branches from both vagus nerves and from both sympathetic trunks. It lies beneath and dorsal to the arch of the aorta, in front of the bifurcation of the trachea, and extends a short distance upward on the sides of the trachea. It is composed of a superficial and a deep part (fig. 789).

The **superficial part of the cardiac plexus** is much smaller than the deep part, and lies beneath the arch of the aorta in front of the right pulmonary artery. It is formed chiefly by the cardiac branches of the left vagus and by the left superior cardiac nerve, but sometimes receives filaments from the deep cardiac plexus. The **cardiac ganglion** (**ganglion of Wrisberg,**) usually found connected with this plexus, lies on the right side of the ligamentum arteriosum.

Branches.—From this plexus some branches pass to the left half of the deep cardiac plexus, and others accompany the left pulmonary artery to the *left anterior pulmonary plexus*. It also sends branches to the *right anterior coronary plexus*.

The **deep portion of the cardiac plexus** lies dorsal to the arch of the aorta at the sides of the lower part of the trachea and in front of its bifurcation. It consists of two lateral parts, more or less distinct, connected by numerous branches, which pass around the lower part of the trachea. It is formed by the superior, middle, and inferior cervical cardiac branches from the right sympathetic trunk, the middle and inferior cervical cardiac branches from the left trunk, and all the cervical and thoracic cardiac branches of the vagus except the superior cervical cardiac branch of the left vagus. It also receives branches from the superficial cardiac plexus.

The *left part of the deep cardiac plexus* gives branches to the left atrium (auricle) of the heart, to the left anterior pulmonary plexus, to the left coronary plexus, and sometimes to the superficial part of the cardiac plexus.

The *right part of the deep cardiac plexus* gives branches to the right atrium, to the right anterior pulmonary plexus, and to the right and the left coronary plexuses (fig. 789). The branches to the left coronary plexus pass behind the pulmonary artery. Some of those to the right coronary plexus pass anterior and some posterior to the right pulmonary artery.

The **coronary plexuses** are formed by branches given off by the cardiac plexus. They accompany the coronary arteries and are right and left.

The *right (anterior) coronary plexus* receives filaments from the superficial part of the cardiac plexus, but is formed chiefly by filaments from the right portion of the deep cardiac plexus (fig. 789). Its distribution to the heart follows that of the right coronary artery.

The *left (posterior) coronary plexus* is larger than the right plexus, and is formed for the most part by filaments from the left portion of the deep cardiac plexus, but it receives some filaments from the right portion of the deep cardiac plexus (fig. 789). Its distribution to the heart follows that of the left coronary artery.

The cardiac plexus and the network of nervous structures in the walls of the atria are the remains of the primitive plexuses found in the embryo, which are called the *bulbar*, the *intermediate*, and the *atrial* plexuses, terms which sufficiently indicate their relative positions. The bulbar plexus gives off the coronary nerves and is transformed into the superficial part of the deep cardiac plexus; the remainder of the deep cardiac plexus is formed by the intermediate plexus, and the atrial plexus becomes the network of the atrium.

The fibres which pass to the cardiac plexus are medullated and non-medullated; the former

FIG. 789. CARDIAC, PULMONARY, AND CORONARY PLEXUSES. (Schematic.)
(Modified from Cunningham.)

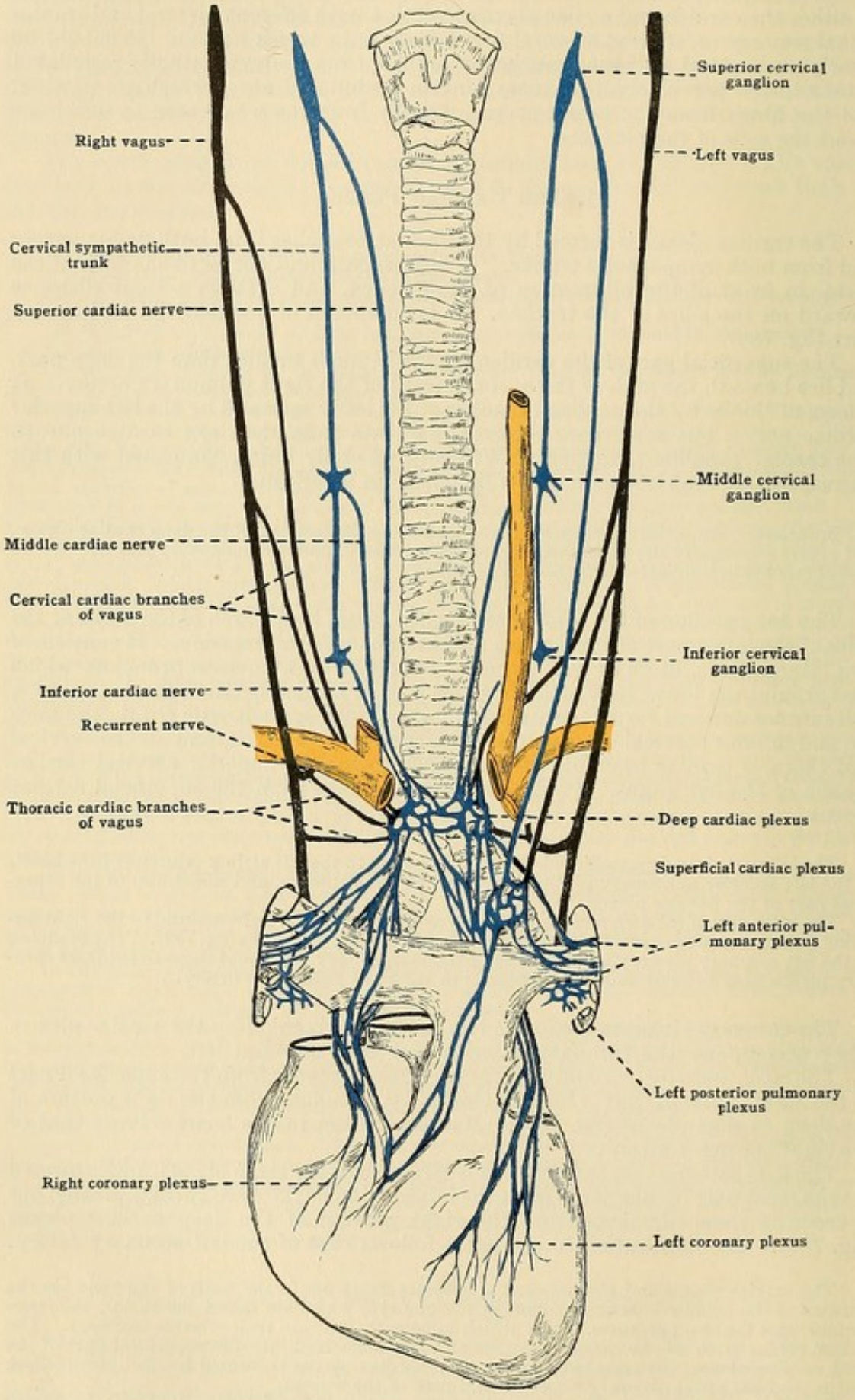

are the so-called inhibitory, the latter motor. The inhibitory impulses leave the central nervous system by the spinal accessory and vagus nerves. The motor fibres leave the spinal cord by the ventral roots and white rami communicantes of the thoracic nerves and terminate about the cells of the intervening sympathetic ganglia. From the cells of these ganglia arise the non-medullated (grey) fibres of the plexus. These fibres terminate directly upon the fibres of cardiac muscle or about the cells of the minute intrinsic cardiac ganglia which in their turn give axones to the muscle.

2. The Pulmonary Plexuses

The pulmonary plexuses are a continuation of the cardiac plexuses. The two are so intimately joined that it is difficult to distinguish them as separate plexuses. The pulmonary are formed by fibres from both the vagus and sympathetic nerves. The anterior and posterior pulmonary branches of the vagus unite, dorsal to the bifurcation of the trachea, with fibres from the second, third and fourth ganglia of the thoracic portion of the sympathetic trunk to form the anterior and posterior pulmonary plexuses that lie ventral and dorsal to the bifurcation of the trachea. Here the pulmonary plexuses of both sides connect with each other freely. Leaving the trachea, the plexuses pass into the lungs along the pulmonary arteries (figs. 744, 789). The parts of the plexus of each side are named according to their position anterior or posterior to the right and left pulmonary arteries; thus, there is a **right anterior** and a **right posterior,** a **left anterior** and a **left posterior pulmonary plexus.**

3. The Cœliac Plexus

The cœliac (solar or epigastric) plexus is the largest of the prevertebral plexuses. It is unpaired, and is continuous above with the aortic plexus of the thorax and below with the abdominal aortic and superior mesenteric plexuses. It lies in the epigastric region of the abdomen behind the bursa omentalis (lesser sac of the peritoneum) and the pancreas, upon the crura of the diaphragm and over the abdominal aorta, and around the origin of the cœliac and the superior mesenteric arteries. It occupies the interval between the suprarenal bodies and extends downward as far as the renal arteries. It is formed by the great and the lesser splanchnic nerves of both sides, by cœliac branches of the right vagus, and by filaments from the upper lumbar ganglia of the sympathetic trunk. It sometimes receives cœliac branches from the left vagus. It contains two large ganglia, the right and left cœliac (semilunar) ganglia (fig. 790).

The **cœliac (semilunar) ganglia** are two large, flat, irregularly shaped masses, separable into a varying number of ganglia. These two masses, or rather the smaller ganglia which compose them, are associated by a varying number of communicating branches. Each mass, right and left, lies upon the corresponding crus of the diaphragm, at the medial border of the corresponding suprarenal body, being sometimes overlapped by this body. The right mass lies behind the inferior vena cava. Each cœliac ganglion receives at its upper border the greater splanchnic nerve, and, near its lower border, lying over the origin of the renal artery, is a more or less detached part, known as the **aortico-renal ganglion.** This ganglion receives the lesser splanchnic nerve and may seemingly give origin to the greater part of the renal plexus. Another part of the cœliac ganglion, often found dorsal to the origin of the superior mesenteric artery, is known as the **superior mesenteric ganglion** (fig. 790).

From the cœliac plexus and its ganglia subordinate plexuses are continued upon the aorta and its branches. These comprise both paired and unpaired plexuses. The paired plexuses are the phrenic, suprarenal and renal, the spermatic in the male, and, in the female, the ovarian plexuses. The unpaired plexuses are the aortic, hepatic, splenic, superior gastric, inferior gastric, superior mesenteric, and inferior mesenteric.

That part of the cœliac plexus surrounding the cœliac artery was formerly described as the *cœliac plexus*. It is better considered as an unnamed part of the larger cœliac (solar) plexus. This part of the plexus receives fibres from both vagus nerves, and gives filaments that form plexuses around the branches of the cœliac artery and their ramifications.

The paired subordinate plexuses of the cœliac.—(1) The **phrenic (diaphragmatic) plexuses** consist of fibres from the upper part of the cœliac ganglia, which follow the inferior phrenic arteries and their branches on the under surface of the diaphragm (fig. 790). Filaments are given off by the roots of the plexuses to the suprarenal bodies, and others unite with the terminal branches of the phrenic nerves. The point of junction with the right phrenic nerve is marked by the **phrenic ganglion,** from which branches are distributed to the inferior vena cava, to the right suprarenal body, and to the hepatic plexus.

(2) The **suprarenal plexuses** are comparatively large plexuses, formed mainly by branches from the cœliac (semilunar) ganglia. However, fibres come to them from the cœliac plexus

FIG. 790.—ABDOMINAL PLEXUSES OF THE SYMPATHETIC. (After Toldt, "Atlas of Human Anatomy," Rebman, London and New York.)

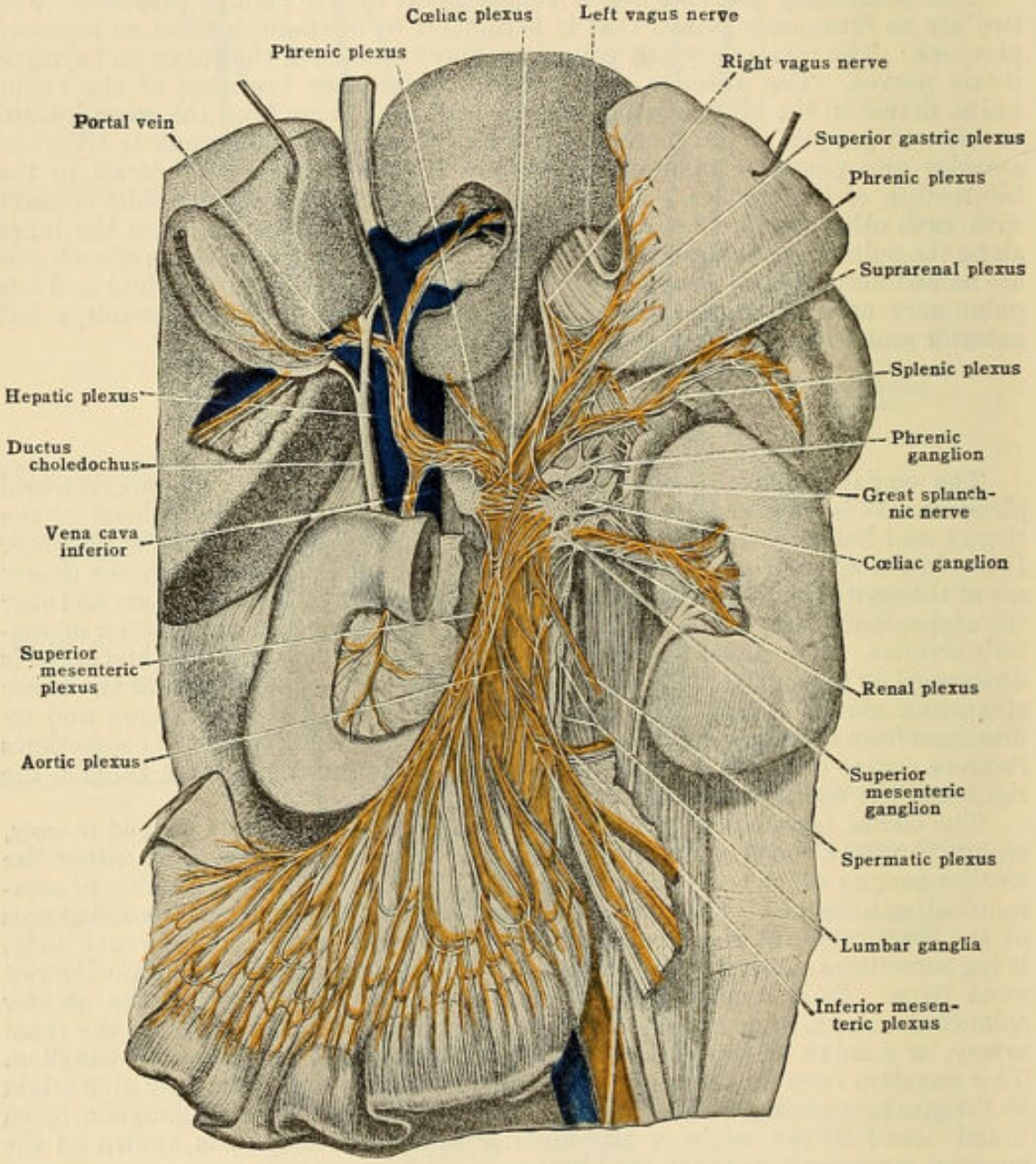

along the suprarenal arteries, from the phrenic plexus along the inferior phrenic arteries, and from the renal plexus along the inferior suprarenal arteries. They are distributed to the substance of the suprarenal bodies. Cell-bodies of sympathetic neurones are enclosed within the suprarenal bodies forming intrinsic ganglia. The medulla of the suprarenal is of ectodermal origin and considered as derived from undeveloped components of the sympathetic nervous system.

(3) The **renal plexuses** receive fibres from the lower part of the cœliac ganglia and from the cœliac and aortic plexuses. They also receive filaments from the least splanchnic nerves, when these nerves are present, and sometimes filaments from the small splanchnic nerves and from the first lumbar ganglion of the sympathetic trunk. These plexuses pass along the renal arteries into the substance of the kidneys. Most of the fibres of each renal plexus are grey fibres, and as they pass to the kidneys small *renal ganglia* are present upon them. Both renal plexuses give branches to the corresponding spermatic plexuses and to the ureter, and the right renal plexus gives filaments also to the inferior vena cava.

(4a) The **spermatic plexuses** (fig. 790) are formed by fibres from the renal and aortic plexuses. They accompany the spermatic arteries and are joined at the abdominal inguinal (internal abdominal) ring by fibres that have passed along the vas deferens from the pelvic plexuses. Their terminal filaments are distributed to the testis and the epididymis.

(4b) The **ovarian plexuses** are formed in the female like the spermatic plexuses in the male. They accompany the ovarian arteries and, in the broad ligament, receive fibres from the utero-vaginal plexus. They supply the ovaries, the broad ligaments, and the Fallopian tubes, and send some fibres to the fundus of the uterus, where they become continuous with the utero-vaginal plexus.

The unpaired subordinate plexuses:—(1) The **abdominal aortic plexus** is formed by two strands of fibres which descend along the sides of the aorta and communicate with each other across its ventral aspect. It is connected above with the renal plexuses, and it receives peripheral branches from some of the lumbar ganglia of the sympathetic trunk on each side. It often contains a number of ganglia, which are situated at the points where the peripheral branches join the plexus, and it terminates below, chiefly by anastomoses with the hypogastric plexus (figs. 790 and 791). Besides giving filaments to the inferior vena cava, it also gives fibres that form plexuses along each of the branches of the aorta. The fibres that pass from the lower end of the aortic plexus upon the common iliac artery form the **iliac plexus,** which is continued along the femoral artery as the **femoral plexus,** and still further along the popliteal artery as the **popliteal plexus.**

(2) The **superior gastric** (**coronary**) **plexus,** receiving filaments from the cœliac plexus, accompanies the left gastric (coronary) artery along the lesser curvature of the stomach. Its filaments anastomose with filaments of the vagus nerves and with the plexus that accompanies the right gastric (pyloric) artery (fig. 790), and it gives fibres to the walls of the stomach which terminate within the walls, about the cell bodies of the delicate gangliated plexus myentericus and plexus submucosus (plexuses of Auerbach and Meissner). The axones of these supply the smooth muscle of the stomach walls and its vessels.

(3) The **inferior gastric plexus** receives from the splenic plexus filaments that accompany the left gastro-epiploic artery. It gives filaments to the walls of the stomach, which terminate as in the superior gastric plexus, and it receives filaments from the vagus nerves and from the plexus that accompanies the right gastro-epiploic artery.

(4) The **hepatic plexus** receives filaments from the cœliac plexus and from the left vagus. It accompanies the hepatic artery and gives fibres that form plexuses on the branches of the artery and on their ramifications within the liver and gives secretory fibres to the liver cells. It also gives filaments to the portal vein (fig. 790).

The **splenic** or **lienal plexus** is formed by filaments from the cœliac plexus, the left cœliac (semilunar) ganglion, and from the right vagus. It accompanies the splenic artery and gives filaments which form plexuses on the branches of this artery, and which pass with the branches to supply fibres to the stomach and the pancreas (fig. 790).

(5) The **superior mesenteric plexus** is formed chiefly by filaments from the lower part of the cœliac plexus, but it also receives fibres from the right vagus and fibres direct from the cœliac (semilunar) ganglia. At the origin of this plexus, dorsal to the superior mesenteric artery, lies the *superior mesenteric ganglion* (fig. 790). The filaments of the plexus, which are white and firm, accompany the superior mesenteric artery and, following its branches and their ramifications, are distributed to the walls of the small intestine, the cæcum, and the ascending and transverse colon. From the *secondary plexuses* that accompany the branches of the artery fibres pass to form still other plexuses that lie near the wall of the intestine, between the branches of the artery and between the layers of the mesentery. Filaments pass with the branches of the arteries and from plexuses between them into the intestinal wall, and there form between the longitudinal and circular muscle layers of the intestine the fine gangliated **plexus myentericus** (plexus of Auerbach), and filaments from this plexus form in the submucosa the delicate **plexus submucosus** or plexus of Meissner. From these latter plexuses fibres arise which terminate upon the gland cells and smooth muscle fibres of the intestinal wall and its vessels. The white appearance of the filaments of the superior mesenteric plexus is due to the large number of cranio-spinal sensory and visceral motor fibres (vagus especially) in it.

(6) The **inferior mesenteric plexus** is derived chiefly from the left side of the aortic plexus. It descends upon the inferior mesenteric artery and gives off filaments which accompany the branches of the artery and are distributed to the descending colon and to the ilio-pelvic colon (figs. 790 and 791). The filaments which accompany the left colic branch of the inferior mesenteric artery anastomose with the filaments of the superior mesenteric plexus which accompany the middle colic artery. The filaments which accompany the superior hæmorrhoidal artery form the **superior hæmorrhoidal plexus.** This plexus gives off the *superior hæmorrhoidal nerves* (fig. 791) which supply the upper part of the rectum and anastomose with the *middle hæmorrhoidal plexus.*

4. The Hypogastric Plexus

The hypogastric plexus lies partly in the abdominal cavity and partly in the pelvic cavity. It is formed chiefly by filaments continued downward from the aortic plexus, and by the pelvic splanchnics and peripheral branches from the lumbo-sacral nerves and sympathetic trunk (fig. 784). The *abdominal part* of this plexus consists of plexiform bundles of fibres descending between the common iliac arteries and interlacing in front of the fifth lumbar vertebra to form a broad, flattened, plexiform mass. In its extent it receives branches from the lumbar ganglia of the sympathetic trunk. This plexiform mass then divides into two

parts, right and left, which descend into the pelvic cavity and which, by English authors, are frequently designated as the *pelvic plexuses*.

The *pelvic parts* of the hypogastric plexus (pelvic plexuses) lie at the sides of the rectum in the male, and at the sides of the rectum and the vagina in the female. They receive peripheral branches from the sacral ganglia of the sympathetic trunk and visceral efferent fibres by way of the *pelvic splanchnics* from the second and

FIG. 791.—THE HYPOGASTRIC AND SUB-PLEXUSES OF THE PELVIC CAVITY. (After Spalteholz.)

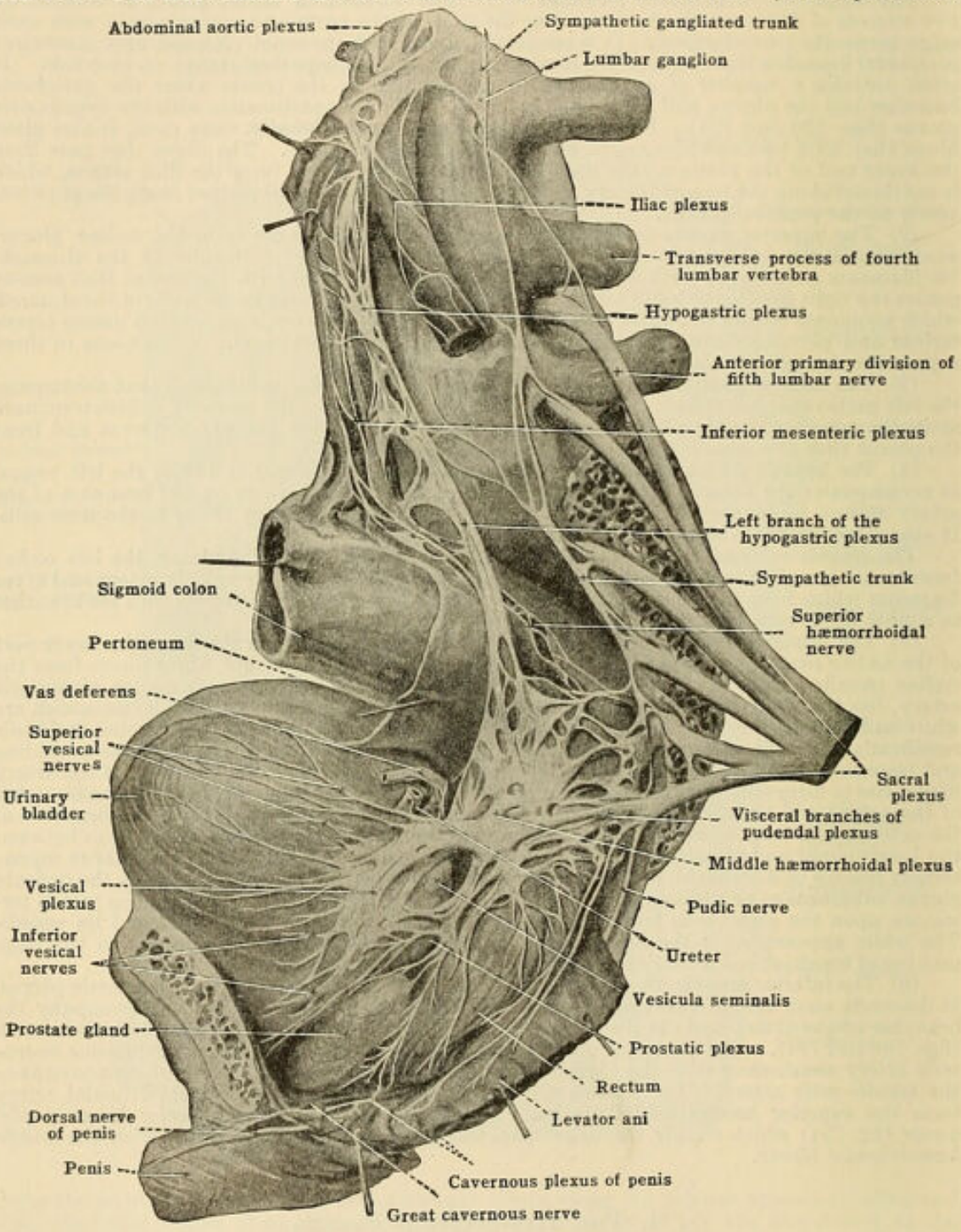

third or third and fourth sacral spinal nerves. Each pelvic part of the plexus accompanies the corresponding hypogastric (internal iliac) artery, and gives off secondary plexuses that continue on the branches of the artery to the pelvic viscera. Of these secondary plexuses, the middle hæmorrhoidal and the vesical plexus are common to both sexes and are paired.

The **middle hæmorrhoidal plexus** passes on each side along the middle hæmorrhoidal artery to the rectum, where it receives the superior hæmorrhoidal nerves and sends filaments into the wall of the rectum (fig. 791).

The **vesical plexus** receives some branches from the pelvic parts of the hypogastric plexus, but is largely reinforced by way of the pelvic splanchnics, from the third and fourth sacral nerves. Each part passes along the corresponding vesical arteries to the bladder, and gives off two sets of branches, namely, the *superior vesical nerves* (fig. 791), which supply the upper part of the bladder-wall and send some branches to the ureter, and the *inferior vesical nerves*, which supply the lower part of the bladder and, in the male, give secondary **deferential plexuses** to the vas deferens. These plexuses surround the vasa deferentia and the vesiculæ seminales and anastomose with the spermatic plexuses.

The **prostatic plexus,** found only in the male, is formed in two parts by nerves of considerable size, and lies chiefly on the sides of the prostate gland between it and the levator ani (fig. 791). Each of these parts supplies the gland and the prostatic part of the urethra, and sends offsets to the neck of the bladder and the vesiculæ seminales. This plexus is continued forward on either side to form the **cavernous plexus of the penis** (fig. 791), which anastomoses with branches of the dorsal nerve of the penis, gives off branches to the membranous part of the urethra, and also gives origin to two sets of nerves, namely, the large and the small cavernous nerves of the penis.

The **large cavernous nerve,** one on each side, runs forward to the middle of the dorsum of the penis, where it anastomoses with the dorsal nerve of the penis on the corresponding side, and ends in twigs which are distributed chiefly to the walls of the sinuses of the corpus cavernosum penis, but some of the terminal filaments supply the corpus cavernosum urethræ (corpus spongiosum) (fig. 791).

The **small cavernous** nerves are small filaments which pierce the uro-genital trigone (triangular ligament) and the compressor urethræ, and enter the posterior part of the corpus cavernosum.

The **utero-vaginal plexus,** found in the female, is formed in its *upper part* on each side largely by fibres derived from the pelvic part of the hypogastric plexus, but it receives some fibres from the pelvic splanchnics of the third and fourth sacral nerves. The nerves from this part of the plexus accompany the uterine arteries as they pass between the layers of the broad ligament. Some accompany each uterine artery and its branches to their termination, but a considerable number of fibres leave the artery and pass into the body of the uterus to supply its lower part and cervix. Between the layers of the broad ligament this plexus anastomoses with the ovarian plexus and sends some filaments to the uterine tube (Fallopian tube). The *lower part* of the plexus utero-vaginalis receives some fibres on each side from the pelvic part of the hypogastric plexus, but it is formed chiefly by efferent visceral fibres from the second, third, and fourth sacral nerves. These fibres terminate in contact with intrinsic cell-bodies whose axones supply the wall and mucous membrane of the vagina and urethra. From the plexus on the anterior surface of the vagina fibres pass to form the **cavernous plexus of the clitoris,** which gives off the great and lesser **cavernous nerves of the clitoris** for the supply of the clitoris. The utero-vaginal plexus of the female corresponds to the prostatic plexus of the male.

References for the Nervous System. A. **General.** Barker, Nervous System, 1899; Edinger, Vorlesungen, 1908; Johnston, Nervous System, 1906; (*phylogeny*) Parker, Anat. Rec., vol. 4; (*development*) Streeter, in Keibel and Mall's Human Embryology. B. **Brain and Spinal Cord.** Bechterew, Funktionen der Nervencentra, 3 vols., 1908; (*cell-structure*) Malone, Anat. Rec., vol. 7; (*axone-sheaths*) Hardesty, Amer. Jour. Anat., vol. 4; (*cortical localization*) Donaldson, Jour. Nerv. and Mental Dis., vol. 13; Smith, Jour. Anat. and Physiol., vol. 41; Israelsohn Arb. Wien. neurol. Inst., vol. 20; (*central fissure*) Symington and Crymble, Jour. Anat. and Physiol., vol. 47; (*brain-weight*) Pearl, Jour. Comp. Neurol., vol. 25; Spitzka, Phila. Med. Jour., 1903; (*ventricles* Harvey, Anat. Rec., vol. 4; (*mid-brain and medulla*) Sabin, Atlas, 1901; (*trigeminal nuclei*) Willems, Nevraxe, T. 12; (*spinal cord, comparative*) Bullard, Amer. Jour. Anat., vol. 14. C. **Peripheral.** (*Histogenesis*) Bardeen, Amer. Jour. Anat., vol. 2; (*experimental*) Harrison, Amer. Jour. Anat., vol. 5; Jour. Exper. Zool., vol. 9; (*phylogeny of facial*) Sheldon, Anat. Rec., vol. 3; (*trigeminus*) Symington, Jour. Anat. and Physiol., vol. 45; (*nervus termnialis*) Johnston, Anat. Rec., vol. 8. (*afferent spinal neurones*) Ranson, Jour. Comp. Neurol., vol. 18; (*structure*) Ranson, Anat. Rec., vol. 3; (*brachial plexus*) Todd, Anat. Anz., Bd. 42; (*abdominal, statistical*) Bardeen, Amer. Jour. Anat., vol. 1 (*sympathetic terminations*) Boeke, Anat. Anz., vol. 44.

SECTION VIII

SPECIAL SENSE ORGANS

Revised for the Fifth Edition

By DAVID WATERSTON, M.A.,M.D., F.R.C.S.E., King's College, London

Professor of Anatomy in the University of London

GENERAL CONSIDERATIONS

THE term "special sense organs" indicates those structures situated on or near the surface of the body which receive the impressions of sound, light taste and smell, and transmit them to the brain in the form of nerve impulses.

The essential difference between what is termed general sensibility and the special senses lies in the fact that the organs of special sense are each sensitive to a specific stimulus which does not affect the general sensory apparatus of the body surface to an appreciable degree.

Thus, the waves of light or of sound, flavoured substances which have a taste, and the minute particles which stimulate the sensory organ for smell—all these varied stimuli create no impression when they come into contact with the sensitive general surface of the body.

The vibration of sound waves present in an organ pipe may indeed be felt by the hand, but the sensation is that of vibration and not of sound.

This difference in function between the ordinary and the special senses as well as the difference between the individual organs of special sense, is associated with a difference in structure; for each special sense organ has a characteristic receptive mechanism of cells highly specialised in form and structure, which receive the stimuli coming from without, and transmit them to the brain in the form of a nerve-current. These cells may be derived by the specialisation of certain cells coming directly from the surface of the body, or they may be cells derived from the central nervous system—as in the case of the eye. In this case, the cells are placed in close relation to the terminals of a special cranial nerve.

Many of the sense organs, and especially the eye and ear, are highly complex in structure. The complexity is due largely to the elaborate mechanical arrangement for receiving the external stimulus, and for conveying it to, or focussing it upon, the sensory cells proper.

It must always be borne in mind that sensation itself is a function of the brain—it is the response in consciousness to the afferent impressions transmitted to the brain by the sensory nerves. Further, the *quality* of the sensation does not arise in the sense organ, but in the brain itself. Thus, stimulation of the trunk of the optic nerve by mechanical means produces sensations of light, apart from stimulation of the retina.

In the following account, the organs of smell, taste, vision and hearing will be successively considered.

I. THE OLFACTORY ORGAN

The olfactory apparatus [organon olfactus] in man does not reach the high development which is found in many of the lower animals. In them, not only is the sensory apparatus found distributed over a large area of the nasal mucous membrane, but the central connections of the olfactory nerves make up a considerable portion of the brain, including all those structures known under the name of rhinencephalon. In man, sensibility to smell is localised to a comparatively limited area in the upper part of the nasal cavity, known as the *olfactory area*.

The structure of the nose in all its parts has been fully dealt with in the

section on the RESPIRATORY SYSTEM—and hence it is not necessary to describe the whole nasal cavity.

The *olfactory area* of the nose includes the uppermost part of the nasal fossæ on the lateral wall above the superior concha, and a slightly larger area of the septum.

Fig. 792 shows the size of this area, and it will be noticed that the area on the lateral wall of the nose does not coincide with the area of the superior concha, but is rather smaller. It should be added that the olfactory nerves can be traced to a somewhat larger area of the mucous membrane, to the middle concha; it is, therefore, possible that the area indicated is too small.

The *mucous membrane* in the olfactory area has special characters, both naked eye and microscopic, which distinguish it from the rest of the nasal mucous

FIG. 792.—DIAGRAM OF THE DISTRIBUTION OF THE NERVES IN THE NASAL CAVITY. (Poirier and Charpy.) The olfactory area is represented by dots. A, septum. B, lateral wall.

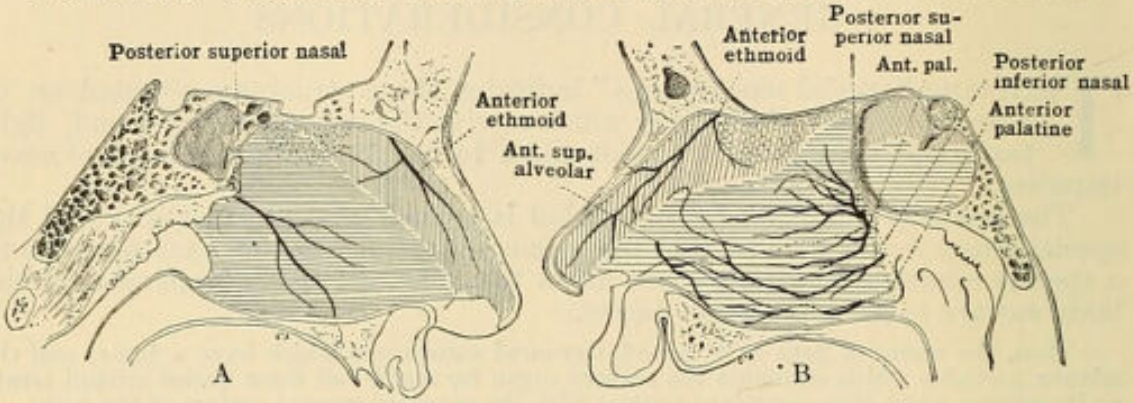

membrane. It is usually of a yellowish colour, and is soft and pulpy in consistence It is covered by a columnar ciliated epithelium and contains numerous glands (glands of Bowman).

The olfactory apparatus within it consists of the **olfactory cells.** These cells are elongated spindle-shaped structures, lying between the deeper parts of the investing columnar cells. From each a slender process passes to the surface of the mucosa, and terminates in a group of short hair-like processes, the *olfactory hairs* (v. Bumm), while from the deep portion of the cell a long slender process passes deeply into the mucosa. These processes resemble nerve filaments, with no medullary sheath, and they pass in the olfactory nerves to the *olfactory bulb*, in which they terminate in arborisation around the dendritic enlargements of the mitral cells of the olfactory bulb (see fig. 795; also Olfactory Nerve, p. 929).

FIG. 793.—SECTION SHOWING THE DEVELOPMENT OF THE OLFACTORY PIT.

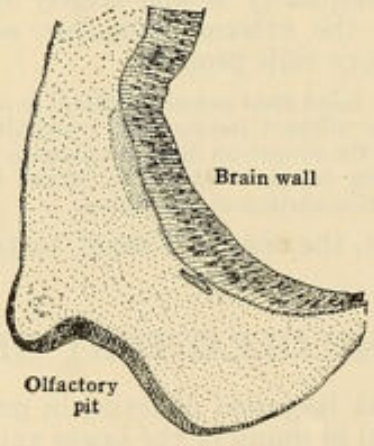

The connections of the olfactory bundle and tract with the brain are fully dealt with in the section on the NERVOUS SYSTEM.

The **development of the olfactory organ** is connected with the development of the nose, which represents at first only the olfactory portion. About the third week, a localised thickening of the surface epithelium occurs on the antero-ventral aspect of the head in the region of the fore-brain, forming on each side an *olfactory plate*. These plates become depressed from the surface by the growth of the margins, giving rise to the *olfactory pits*. The further changes are

associated with the formation of the face and nose (see MORPHOGENESIS). The cells of the surface epithelium on the olfactory pits in part form olfactory cells, and send processes inward which pass to the olfactory lobe of the brain, and form the olfactory nerve.

The **organ of Jacobson** is a small rudimentary structure in man. It is represented by a minute canal, 2 to 9 mm. long, placed on each side in the lower portion of the nasal septum, opening on the surface slightly above the orifice of the naso-palatine canal. Below it lies a small piece of cartilage, lying below the cartilage of the septum, and known as Jacobson's cartilage. The canal is lined by epithelium, but contains no olfactory cells. It is developed from a small portion of the olfactory plate which becomes separated from the area which gives rise to epithelium of the olfactory region.

II. ORGAN OF TASTE

The **taste organs** [organon gustus] consist of minute epithelial structures, the **taste buds** [calyculi gustatorii], situated mainly in the epithelial covering of the tongue and also in the epiglottis.

In the tongue, the taste buds are found mainly on the walls of the vallate papillæ (see p. 1106), but they are found to a slight extent scattered over the whole area of distribution of the glosso-pharyngeal nerve, on the surface of the foliate and fungiform papillæ, and on the plicæ fimbriatæ on the lower surface of the tongue.

FIGS. 794 AND 795.—DIAGRAMS ILLUSTRATING THE STRUCTURE OF THE TASTE BUDS AND THE OLFACTORY MUCOSA.

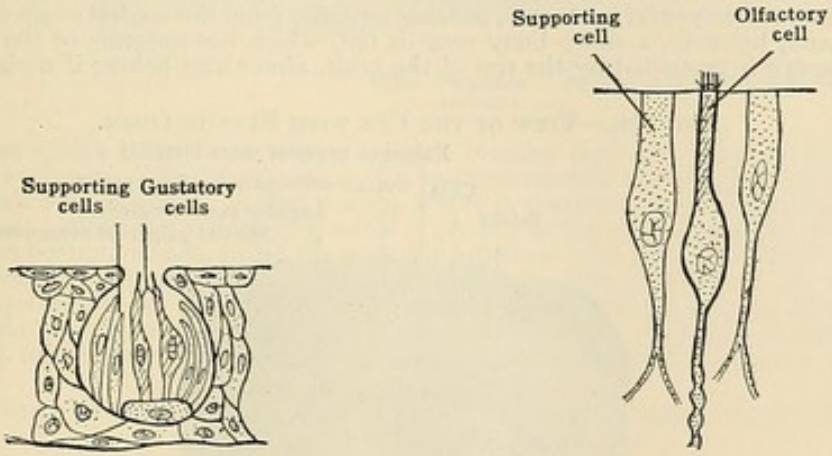

In the fœtus, the distribution is even wider, and they have been described as occurring on the soft palate, palatine arches, uvula, and in the mucous membrane covering the medial surfaces of the arytenoid cartilages. It is possible that such structures, though found in these regions in the fœtus, usually disappear in the adult.

Each **taste bud** is a hollow conical or oval structure, measuring .07–.08 mm. in length. At one end it opens by a small channel, termed the **pore canal,** which passes to the surface between adjacent epithelial cells. The surface opening is termed the *outer pore* and the opening at the taste bud the *inner taste pore.*

The taste bud consists of epithelial supporting, of gustatory and of basal cells, arranged as seen in figure 794. The **gustatory cells** are long slender fusiform cells. The free end of each passes to the inner taste pore, and terminates in stiff hair-like processes, which project toward the pore canal. The deep end of each is connected with a basal cell. Terminal branches of the glosso-pharyngeal nerve ramify around the gustatory cells, and convey to the brain the impulses generated by contact of the ends of these cells with sapid particles. The epithelial supporting cells line the taste buds, and also project into the interior between the olfactory cells.

Development.—The taste buds appear comparatively late in embryonic life—about the third month. They arise mainly from the entodermal portion of the tongue, by differentiation of the deeper cells of the epithelial covering over localised areas. Around these cells terminations of the glosso-pharyngeal nerve are found. These cells assume the characteristic shape and arrangement of the adult to form a taste bud. At first the opening of the bud lies upon the surface, but as the surrounding epithelial cells increase in size and thickness, the pore-canal is formed as a space between adjacent epithelial cells on the summit of the bud.

III. THE EYE

The sensory portion of the eye is the **retina,** a cup-shaped membrane, which lines the posterior half of the eyeball. It is formed of layers of nerve cells, from

which processes pass to the brain in the **optic nerve.** The **eyeball** is a hollow spherical structure, whose wall is formed externally by a fibrous tunic including the **sclera** (the white of the eye), and the **cornea** (the transparent area in the anterior aspect of the eyeball). Internal to the tunic formed by these membranes is a pigmented vascular membrane, the **chorioidal membrane,** of which the anterior part forms the **iris,** or the coloured part of the eye.

Within these tunics is formed a cavity, in which lies the **crystalline lens** of the eye. In front and behind the lens are two chambers; that in front of the lens contains the *aqueous humour* and that behind it the *vitreous.*

The study of the eye is best undertaken by examining the eye in the living, and subsequently by the dissection of specimens, and that order is followed in this account.

General Surface View

The two eyes are situated nearly in the line where the upper and middle thirds of the face meet; they lie right and left of the root of the nose, the most prominent part of the front of each globe being about 3 cm. (1¼ in.) from the mid-line of the face. Each eye is overshadowed by the corresponding eyebrow, and is capable of being concealed by its eyelids, upper and lower.

The orbital margin may be traced all round with the finger. At the junction of the medial and intermediate thirds of the upper margin the supraorbital notch (incisura supraorbitalis) can usually be felt, and the supraorbital nerve passing through it can sometimes be made to roll from side to side under the finger. The medial margin is the most difficult to trace in this way, partly because it is more rounded off than the others, partly because it is bridged over by a firm band (**medial palpebral ligament**), passing medially from the medial angle of the eyelids; below this band, however, a sharp bony crest is felt, which lies anterior to the lacrimal sac. Note how the eye is protected by the rim of the orbit, above and below; if we lay a hard flat

Fig. 796.—View of the Eye with Eyelids Open.

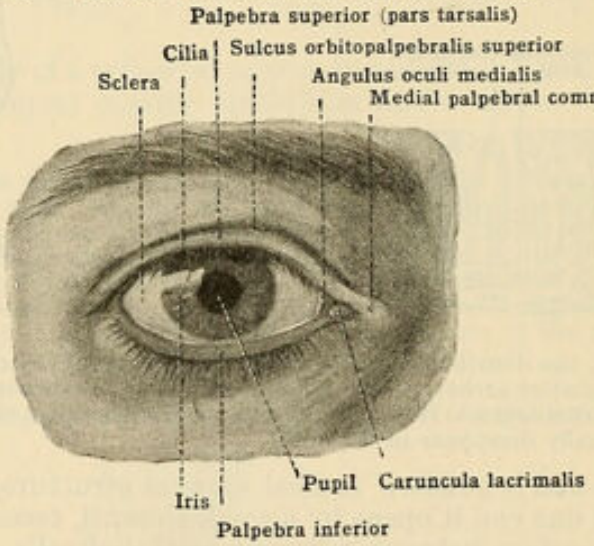

body over the orbital opening, it will rest upon the upper and lower bony prominences, and will not touch the surface of the globe. Medially, the eye is protected from injury mainly by the bridge of the nose; laterally it is most readily vulnerable, as here the orbital rim is comparatively low. With one finger placed over the closed upper lid, press the eyeball gently backward into the orbit, and observe the elastic resistance met with, due to the fact that the globe rests posteriorly on a pad of fat.

The space between the free edges of the upper and lower lids is known as the **palpebral aperture** [rima palpebrarum]: it is a mere slit when the lids are closed; but when they are open its shape is, roughly, that of an almond lying with its long axis horizontal, and about thirty millimetres in length.

When the eyes are directed to an object straight in front of them, this aperture is about twelve millimetres wide, but its width varies with upward and downward movements of the eyeball, being greatest on looking strongly upward, diminishing gradually as the eye looks progressively lower. The angles formed by the meeting of the lids at each end of the palpebral aperture are named respectively the lateral and medial angles (or canthi) [angulus oculi lateralis, medialis], of which the lateral is sharp, while the medial is rounded off. On a closer inspection, it will be found that, for the last five millimetres or so before reaching the medial angle the edges of the lids run an almost parallel course, and are here devoid of lashes. Through the open palpebral aperture the front of the eyeball comes into view, extending quite to the lateral, but not reaching as far as the medial, angle; just within the latter we find a small reddish prominence, the **lacrimal caruncle** [caruncula lacrimalis]; and between this and the eyeball a fold of

conjunctiva known as the **plica semilunaris.** While the eye is open, press one finger on the skin, a little beyond the lateral angle, and draw it firmly away from the middle line; observe that the upper lid then falls over the eyeball, and that the outline of a firm band already referred to (the medial palpebral ligament) becomes evident, passing between the medial angle and the nose. The falling of the lid is caused by our dragging upon a ligament (the lateral palpebral raphé) to which the lateral end of its tarsus is attached, and so putting the lid itself upon the stretch. If, while the eyeball is directed downward, we place one finger on the lateral end of the upper eyelid and draw it forcibly upward and laterally, we can usually cause the lower division of the lacrimal gland to present just above the lateral angle.

FIG. 797.—VIEW OF THE EYE WITH EYELIDS CLOSED.

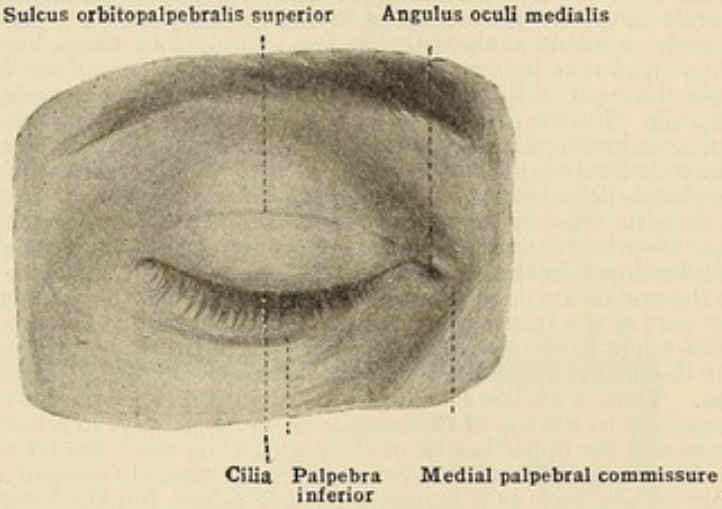

The **upper eyelid** [palpebra superior] is much broader than the lower, extending upward as far as the eyebrow. The skin covering it is loosely attached to the subjacent tissues above, but more firmly below, nearer the free margin, where it overlies a firm fibrous tissue called the **tarsus superior.** When the eye is open, a fold is present at the upper border of this lower more tightly applied portion of skin, called the **superior palpebral fold,** and by it the lid is marked off into an upper or orbital, and a lower or tarsal, division. The presence of the tarsus can be readily appreciated on our pinching horizontally the entire thickness of the eyelid below the palpebral fold. The **lower eyelid** [palpebra inferior] is similarly divided anatomically into a tarsal and an orbital part, but the demarcation is sometimes unrecognisable on the surface,

FIG. 798.—VIEW OF MEDIAL REGION OF THE EYE, WITH THE EYELIDS WIDELY SEPARATED AND THE EYEBALL TURNED LATERALLY.

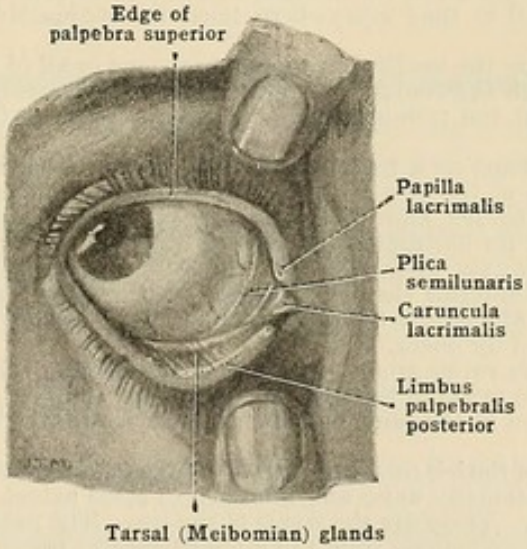

though a fold or groove (the **inferior palpebral**) is usually visible when the eye is widely opened. There is no precise limit of this lid below, but it may be regarded as extending to the level of the lower margin of the orbit. Numerous very fine short hairs are seen on the anterior surface of both eyelids. Each eyelid presents an anterior and a posterior surface, separated by a free margin with two edges:—(*a*) An anterior, rounded edge [limbus palpebralis anterior] along which the stiff cilia, or eyelashes, are closely placed in a triple row; and (*b*) a sharp posterior edge [limbus palpebralis posterior] which is applied to the surface of the globe (see fig. 813). The cilia of both eyelids have their points turned away from the palpebral aperture, so that the upper ones curve upward, and the lower downward; the cilia of the upper lid are the stronger,

and those in the middle of each row are longer than those at each end. Between the two edges just described, the lid-margin has a smooth surface, on which is a single row of minute apertures, the openings of large modified sebaceous glands, the **tarsal** or **Meibomian glands.** It is by these glistening, well-lubricated surfaces that the opposite lids come into apposition when they are closed. The secretion of these glands is known as the *sebum palpebrale.* The sharp posterior edge of the lid-margin marks the situation of the transition of skin into mucous membrane. Near the medial end of the margin of the lids we find a prominence, the **lacrimal papilla,** on the summit of which is a small hole [**punctum lacrimale**], the opening of the lacrimal duct (ductus lacrimalis) for the passage of tears into the lacrimal sac. The lower punctum is rather larger than the upper, and is placed further from the medial angle of the eye.

If we now examine the posterior surface of the eyelids—e. g., of the lower—we observe that it is lined by a soft mucous membrane, the **palpebral conjunctiva** [tunica conjunctiva palpebrarum]. Over the tarsal part of the lid the conjunctiva is closely adherent, but beyond this it is freely movable along with the loose submucous tissue here present. On tracing it backward, we find that it covers the whole posterior surface of the lids, and is then continued *forward* over the front of the eyeball, forming the conjunctival tunic of the globe [tunica conjunctiva bulbi]. The bend it makes as it changes its direction here is called the **conjunctival fornix** [fornix conjunctivæ superior or inferior]. Numerous underlying blood-vessels are visible through the palpebral conjunctiva, and under cover of its tarsal part we can see a series of nearly straight, parallel, light yellow lines, arranged perpendicularly to the free margin of the lid—the tarsal glands. The conjunctiva over the medial and lateral fourths of each lid is not quite so smooth as elsewhere, and is normally of a deeper red colour; we shall find later that there are glands well developed in these positions.

When the eyelids are opened naturally, we see through the palpebral aperture the following: the greater part of the transparent cornea, and behind it the coloured iris with the pupil in its centre; white sclera to the medial and lateral sides of the cornea; the semilunar fold and lacrimal caruncle at the medial angle. The extent of the eyeball visible in this way varies according to its position. Thus, with the eyes looking straight forward, the lower margin of the upper lid is nearly opposite to the top of the cornea, or, more strictly, to a line midway between the top of the cornea and the upper border of the pupil, while the lower lid corresponds with the lower margin of the cornea. When the eyes are directed strongly upward, the upper lid is relatively on a slightly higher level, as it is simultaneously raised, but the lower lid now leaves a strip of sclera exposed below the cornea. On looking downward the upper lid covers the upper part of the cornea as low down as the level of the top of the pupil, while the lower lid is about midway between the pupil and the lower margin of the cornea.

If we draw the eyelids forcibly apart, we expose the whole cornea, and a zone of sclera about eight and a half millimetres in breadth above and below, and ten millimetres in breadth to the lateral and medial sides—altogether about one-third of the globe; all the eyeball thus exposed is covered by the **ocular conjunctiva** [tunica conjunctiva bulbi]. Over the sclera the conjunctiva is freely movable, and through it we see superficial blood-vessels that can be made to slip from side to side along with it (episcleral vessels). Occasionally other deeper vessels may also be seen which do not move with the conjunctiva, but are attached to the sclera (anterior ciliary arteries and veins). Near the corneal border the conjunctiva ceases to be freely movable, and it is closely adherent to the whole anterior surface of the cornea, giving the latter its characteristic bright, reflecting appearance; no blood-vessels are visible through it here in health. When the lids are shut, the space enclosed between their posterior surfaces and the front of the eyeball is thus everywhere lined by conjunctiva, and is known as the **conjunctival sac.**

Not unfrequently the tendinous insertions of some or all of the recti muscles into the sclera may be seen through the conjunctiva, each insertion appearing as a series of whitish parallel lines running toward, but terminating about seven millimetres from, the corresponding corneal border.

The **cornea** appears as a transparent dome, having a curvature greater than that of the sclera; the junction of the two unequally curved surfaces is marked by a shallow depression running around the cornea, known as the **scleral sulcus** [sulcus scleræ]. In outline the cornea is nearly circular, but its horizontal diameter is slightly greater than its vertical. Between it and the iris a space exists, whose depth we can estimate roughly by looking at the eye from one side; this space, or anterior chamber [camera oculi anterior] is occupied by a clear fluid, the aqueous humour. Almost the whole anterior surface of the iris is visible, its extreme periphery only being concealed by sclera.

In colour the **iris** varies greatly in different individuals. Near its centre (really a little up and in) a round hole exists in the iris, the black *pupil* [pupilla], whose size varies considerably in different eyes, and in the same eye according to temporary conditions, such as exposure to light, etc.

On the surface of the iris we see a number of ridges [plicæ iridis] running more or less radially; adjoining ones occasionally unite and interlace to some extent, so as to leave large depressed meshes at intervals. These are the *crypts* of the iris. The radial ridges coming from the edge of the pupil, and those coming from the more peripheral part of the iris, meet in a zigzag elevated ridge concentric with the pupil, called the *corona iridis,* and by this ridge the iris is roughly marked off into two unequal zones—an outer, the **greater** [annulus iridis major] and an inner, the **lesser** [annulus iridis minor]. The border next the pupil [margo pupillaris] is edged with small, roundish, bead-like prominences of a dark brown colour, separated from one another by depressions, so that it presents a finely notched contour. Not infrequently, in a light-coloured iris, we may see the sphincter muscle through the anterior layers, in the form of a ring about one millimetre in breadth around the pupil. The annulus iridis major may be described as consisting of three parts:—(*a*) A comparatively smooth zone next the zigzag ridge; (*b*) a middle area, showing concentric but incompletely circular furrows; (*c*) a small peripheral darker part, presenting a sieve-like appearance. On the floor of the large depressed

meshes, or *crypts*, parallel radial vessels can be traced, belonging to the iris-stroma. The zig-zag line mentioned above corresponds to the position of the circulus arteriosus minor. Occasionally, especially in a light iris, superficial pigment spots of a rusty brown colour occur.

(In examining the living eye, the ophthalmoscope may now be used, so as to gain a view of the fundus, and to study the termination of the optic nerve, the distribution of the larger retinal vessels, etc.)

The general red reflex obtained from the fundus is due to the blood in a capillary network (**chorio-capillaris**) situated in the inner part of the chorioid. To the nasal side of the centre of the fundus is a paler area of a disc shape corresponding to the intraocular end of the optic nerve, and known as the **papilla of the optic nerve** [papilla n. optici]. This papilla (or 'optic disc') is nearly circular, but usually slightly oval vertically; it is of a light orange-pink colour, with a characteristic superficial translucency; its lateral third segment is paler than the rest as nerve-fibres and capillaries here are fewer in number. About its centre we often observe a well-marked whitish depression [excavatio papillæ n. optici], formed by the dispersion of the nerve-fibres as they spread out over the fundus; at the bottom of this depression a sieve-like appearance may be seen, due to the presence of the **lamina cribrosa scleræ,** which consists of a white fibrous tissue framework, with small, roundish, light-grey meshes in it, through which the nerve-fibre bundles pass. Also near the centre of the papilla, the retinal blood-vessels first come into view, the arteries narrower in size and lighter in colour than the veins; they divide dichotomously as they are distributed over the fundus. The retina proper is so transparent as to be ophthalmoscopically invisible, but its pigment-epithelium gives a very finely granular or darkly stippled appearance to the general red reflex. In the centre of the fundus, and therefore to the lateral side of the papilla, the ophthalmoscope often shows a shifting halo of light playing round a

FIG. 799.—THE NORMAL FUNDUS OF THE EYEBALL. (Parsons.)

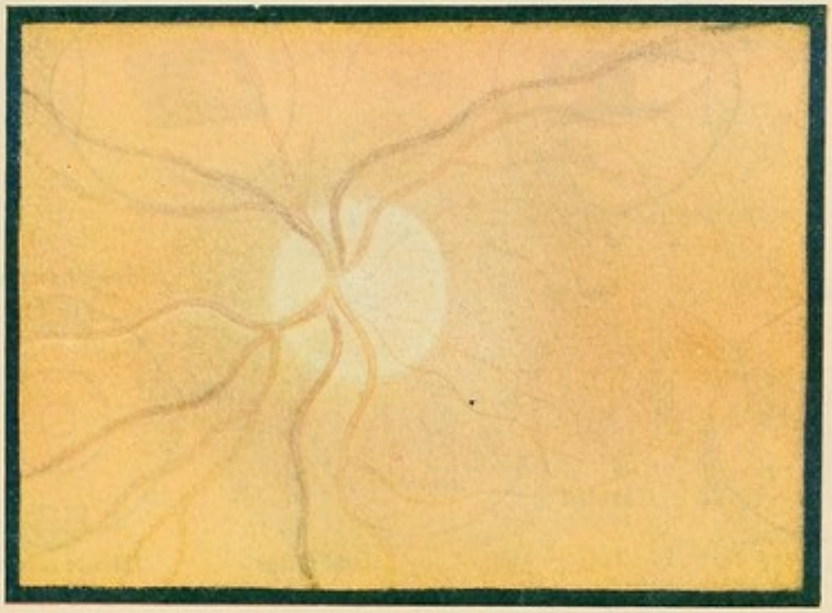

horizontally oval, comparatively dark enclosed area; this latter corresponds to the **yellow spot** [macula lutea] region, and about its centre a small pale spot usually marks the position of the **fovea centralis.**

Two structures visible at the nasal end of the palpebral aperture have been previously mentioned, and should now be examined more narrowly. The **lacrimal caruncle** is an island of modified skin, and fine hairs can commonly be detected on its surface, and it contains sebaceous and sweat glands. Lateral to it and separated from it by a narrow groove, is the **semilunar fold of conjunctiva**; it rests on the eyeball, and is a rudiment of the third eyelid or nictitating membrane, present in birds and well represented in many other vertebrates.

EXAMINATION OF THE EYEBALL

(In the following account, the structure of the eyeball is described as it would appear upon dissection.)

The **eyeball** [bulbus oculi] is almost spherical, but not perfectly so, mainly because its anterior, clear, or *corneal* segment has a greater curvature than the rest of the eye. Considering it as a globe, it has an **anterior pole** [polus anterior] and a **posterior pole** [polus posterior]; the former corresponding to the centre of the front of the cornea, the latter to the center of the posterior curvature. An imaginary straight line joining the two poles is called the **axis** of the eyeball. The **equator** of the eye is that part of its surface which lies midway between the two poles. The various **meridians** are circles which intersect the poles. The sagittal axis of the globe is the greatest (about 24.5 mm.), the vertical equatorial the least

(about 23.5 mm.), and the transverse equatorial axis is intermediate in length (about 23.9), so that the eyeball is in reality an ellipsoid, flattened slightly from above downward. These figures refer to the adult male; in the female the eyeball is .5 mm. smaller in all axes. Again, if the globe is divided in its mid-sagittal plane, the nasal division will be found to be slightly smaller than the temporal. The optic nerve joins the globe three or four millimetres to the nasal side of the posterior pole.

The shape of the eye depends on, and is preserved by, the outermost tunic, formed conjointly by the **cornea** and **sclera,** the entire outer surfaces of which are now in view. The anterior or corneal part has already been examined. All around the cornea there remains a little adherent conjunctiva; elsewhere, the sclera is directly exposed, except for some loose connective tissue which adheres to it, especially around the optic nerve entrance. In front of the equator we see the tendinous insertions of the four recti muscles. Behind the equator are the insertions of the two oblique muscles—that of the superior oblique tendinous, and further forward; that of the inferior more fleshy, and placed between the optic nerve and the *lateral* rectus.

FIG. 800.—DIAGRAMMATIC VIEW OF THE INSERTIONS OF THE OCULAR MUSCLES.

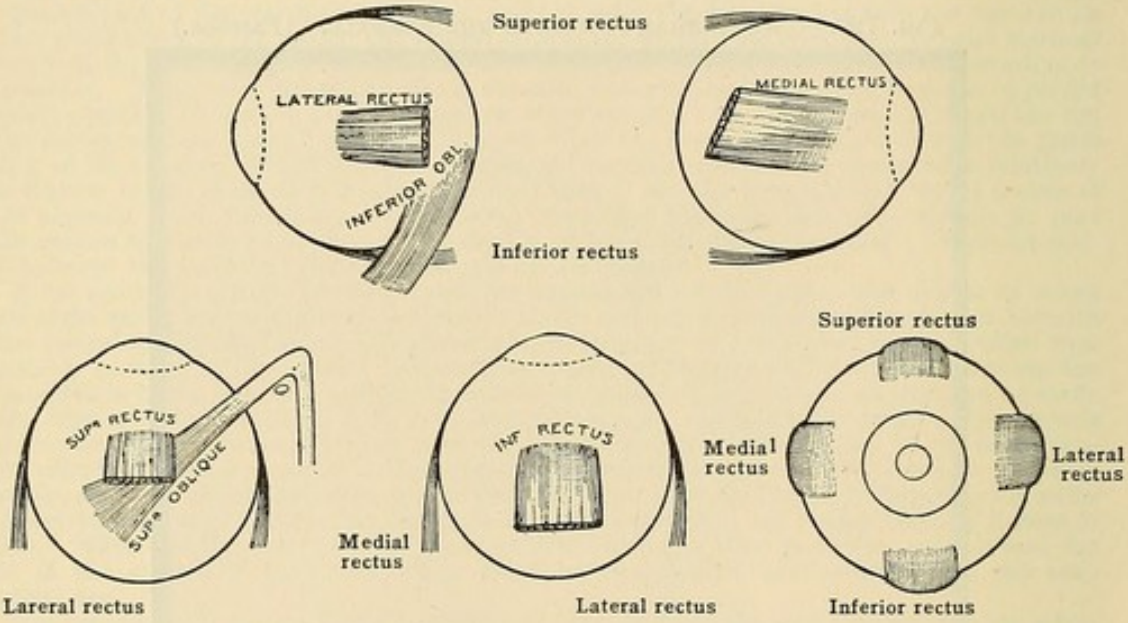

It is difficult to recognise the different recti muscles by their insertions if we do not know whether the eye examined is a right or a left one. To determine this we should hold the globe with the optic nerve toward us, and in the natural position with the superior oblique tendon uppermost. The inferior oblique tendon will now point to the side to which the eye belongs, and we can consequently determine the different recti muscles.

The medial [m. rectus medialis] rectus is inserted nearest (5.5 to 7 mm. from) the corneal border; the superior [m. rectus superior] rectus commonly, sometimes the lateral [m. rectus lateralis], is inserted furthest from it (7.7 to 8 mm.). All the recti tendons are broad and thin, but that of the medial is the broadest (8 to 10.3 mm.); those of the lateral and inferior the narrowest (6 to 9.2, or 9.8 mm., respectively). The greatest interval between two neighbouring tendons is that between the superior and medial recti (about 12 mm.); the least is between the superior and lateral (7 mm.). The form of the lines of insertion of the different tendons varies considerably, the inferior being almost straight, the superior and lateral convex forward, the medial further removed from the corneal border below than above.

The insertions of the oblique muscles [mm. obliqui] are at more than double the average distance of the insertions of the recti from the corneal border. That of the superior oblique is found on the superior surface of the sclera, about sixteen millimetres from the corneal edge, in the form of a line 10.7 mm. long sloping from before backward and medially. The inferior oblique has a long fleshy insertion lying between the lateral rectus and the optic nerve entrance; the posterior end of the insertion, which is also the higher, is only about five to six millimetres from the optic nerve, and from this point it slopes forward, laterally, and slightly downward.

Several small nerves and two arteries may be seen running forward and ultimately perforating the sclera not far from the entrance of the optic nerve. The two arteries are the long posterior ciliary [aa. ciliares posteriores longi]; they both perforate the globe in the horizontal meridian, 3.5 mm. from the optic nerve, one on the lateral, the other on the medial, side. The short ciliary arteries [aa. ciliares

posteriores breves] are too small to be seen in an ordinary examination. The nerves are the long and short ciliary [nn. ciliares longi, breves]. Nearer the equator large venous trunks emerge; they can be traced for some distance in front of their exit as dark lines, running antero-posteriorly internal to the sclera. The optic nerve is seen in section, surrounded loosely by a thick outer sheath; in the centre of the nerve-section a small red spot indicates the position of the central retinal blood-vessels [a. et v. centralis retinæ].

(The following structures appear in an eyeball divided into fore and hind halves by cutting through it in the equatorial plane.)

1. **Posterior hemisphere** seen from in front.—This is much the same view that the ophthalmoscope affords us. Unless the eye be very fresh, however, the **retina** will have lost its transparency, and will now present the appearance of a thin whitish membrane, detached in folds from the external coats, but still adherent at the optic papilla. The vitreous jelly lying within the retinal cup may be torn away. In the human eye the retina next the posterior pole is stained yellow [**macula lutea**]. On turning the retina over, a little pigment may be seen adhering to its outer surface here and there. Cut through the retina close to the optic disc all around and remove it: note how easily it is torn. We now see a dark brown surface, consisting of the **retinal pigment layer** [stratum pigmenti retinæ] adherent to the inner surface of the chorioid. Brush off the retinal pigment under water. The **chorioid** thus exposed can for the most part be fairly easily torn away from the thick sclera, as a lymph-space exists between them, but the attachment is firm around the optic nerve entrance, and also where the arteries and nerves join the chorioid after penetrating the sclera. The chorioid is darkly pigmented, of a brown colour, with markings on its surfaces corresponding to the distribution of its large veins. The inner

FIG. 801.—ANTERIOR HEMISPHERE OF EYEBALL, VIEWED FROM BEHIND.

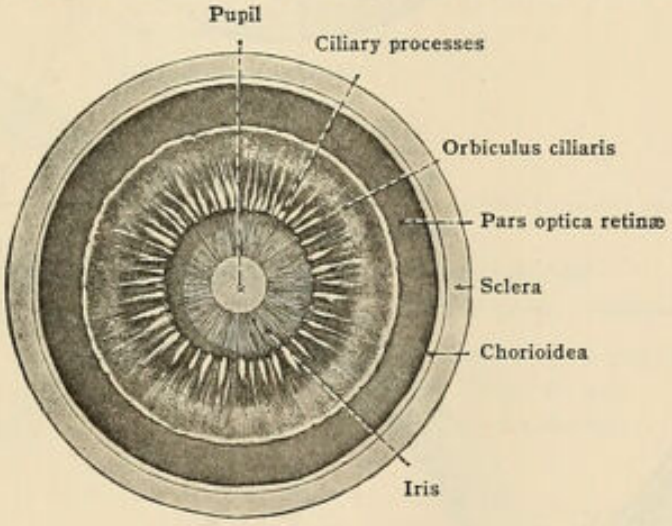

surface of the sclera is of a light brownish colour, mainly from the presence of a delicate pigmented layer, the **lamina suprachorioidea,** which adheres partly to it, partly to the chorioid, giving to their adjacent surfaces a flocculent appearance when examined under water.

2. **Anterior hemisphere** viewed from behind.—The round opening of the pupil is visible in the middle, in front of the large clear **crystalline lens.** The retina proper extends forward a little way from the line of section, and then ends abruptly in a wavy line called the **ora serrata,** beyond which it is only represented by a very thin membrane [**pars ciliaris retinæ**]. Outside the periphery of the lens are a number of **ciliary processes** arranged closely together in a circle concentric with the pupil, and each radially elongated; posteriorly they are continuous with n umerous fine folds, also radial, which soon get very indistinct as they pass backward, but reach almost to the ora serrata [**plicæ ciliares**]. Between the front of the ciliary processes and the edge of the pupil lies the **iris.** On removal of the retina the inner surface of all this region is seen to be darkly pigmented, but especially dark in front of the position of the ora serrata. Vitreous probably still adheres to the back of the lens, and by pulling upon it the lens can be removed along with its capsule and suspensory ligament; some pigment will now be found adhering to the front of the vitreous, torn from the ciliary processes, which are consequently now lighter in colour than before. The **lens-capsule** is transparent, and has a smooth glistening outer surface; through it a greyish, star-shaped figure may be observed on the anterior and posterior surfaces of the lens. The **suspensory ligament** is a transparent membrane attached to the capsule of the lens about its equator, and is best seen by floating the lens in water in a glass vessel placed on a dark ground. On opening the capsule we expose the lens itself, which is superficially soft and glutinous to the touch, but becomes firmer as we rub off its outer layers and approach its centre. Carefully tear the chorioid and iris from the sclerotic as far as possible; a firm adhesion exists just behind the corneal periphery. The outer surface of the chorioid thus exposed is found to be also rather darkly pigmented, but it shows a white ring corresponding to the adhesion just mentioned, and a pale area behind this ring indicates the position of the **ciliary muscle** [m. ciliaris]. On this surface numerous white nerve-cords are visible running

forward. Observe that the iris, the ciliary processes, etc., and the chorioid are all different parts of the same ocular tunic—mere local modifications of it. Similarly the sclera and cornea are seen to blend together to form one outer coat.

An eyeball should now be placed for half an hour in a freezing mixture of crushed ice and salt. It will thus become quite hard, and should at once be divided into two parts by cutting it antero-posteriorly through the centre of the cornea and the optic nerve. We thus gain another view of the relations of parts, the position of the lens between the aqueous and vitreous chambers, etc. On removing the lens, vitreous, and retina, and brushing off its pigment, the light markings corresponding to the chorioidal veins (**venæ vorticosæ**) should be noted, and their distribution studied. Usually four vortices or fountain-like markings are found in the whole chorioid,

FIG. 802.—HORIZONTAL SECTION OF THE EYEBALL. × 4.

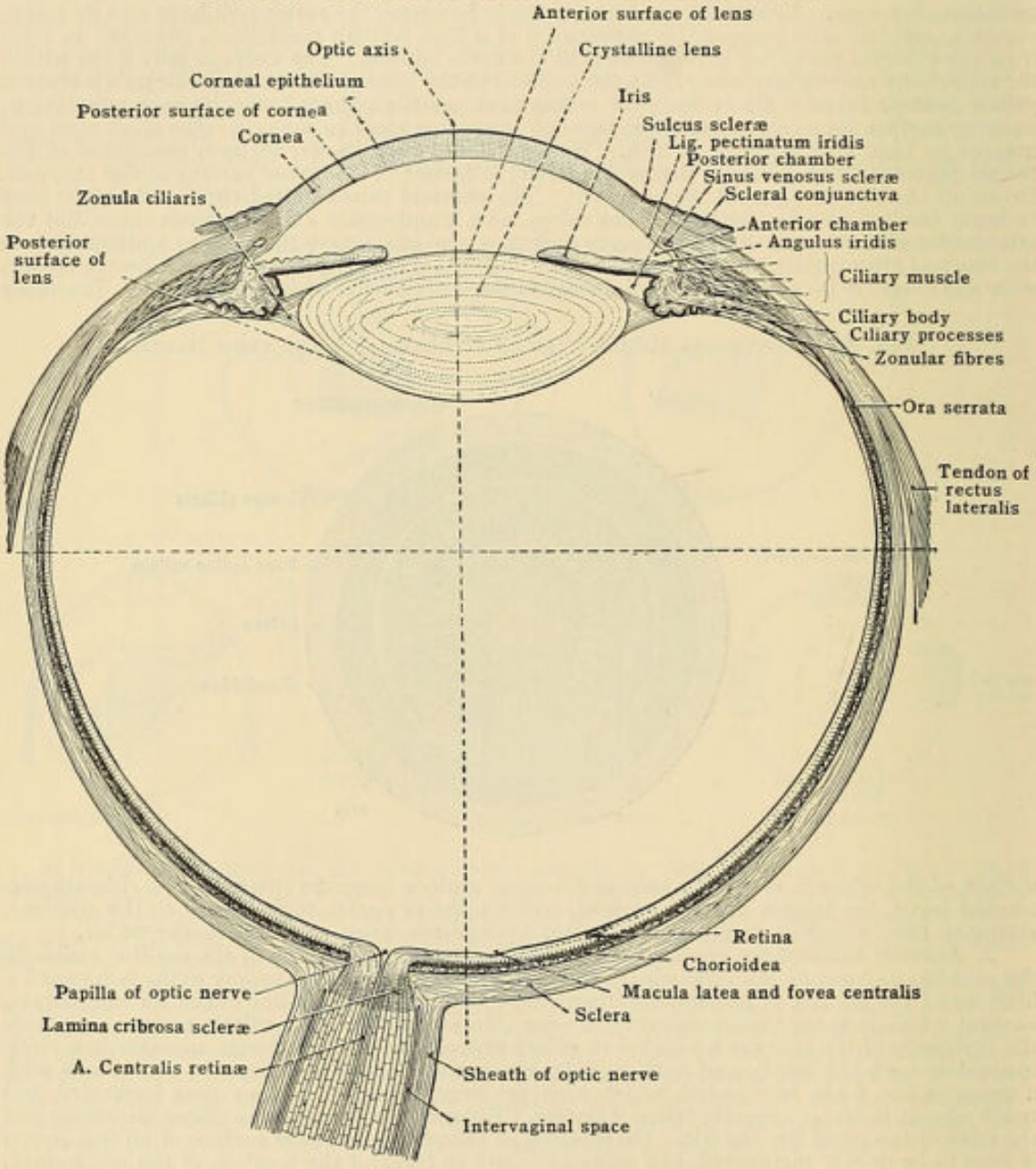

their points of junction situated at approximately equal distances from one another at about the line where the posterior and middle thirds of the globe meet. These sections should be kept for reference while following the further description of the ocular tunics.

The coats of the eyeball.—1. The **outer, fibrous coat of the eye** [tunica fibrosa oculi] is formed by the **sclera** and **cornea,** which pass into one another at the scleral sulcus. It consists throughout mainly of fine connective-tissue fibres, arranged in interlacing bundles, with small lymph-spaces at intervals between them. The naked-eye appearance of the two divisions of this fibrous coat is, however, quite different, the cornea being transparent, while the sclera is white and opaque.

The **sclera** encloses the posterior five-sixths or so of the eyeball. It is perfo-

rated by the entrance of the optic nerve, and the opening in the sclera, only partially bridged across by fibres from the inner layers, forms the **lamina cribrosa.**

The fibre-bundles composing the sclera are arranged more irregularly than in the cornea, and run mainly in two directions, viz., antero-posteriorly and circularly; the circular fibres are particularly well developed just behind the sulcus. It is thickest (about 1 mm.) posteriorly, where it is strengthened chiefly by the outer sheath of the optic nerve, and partly also by the tissue surrounding the ciliary vessels and nerves. It becomes gradually thinner as it passes forward, up to the line of insertion of the recti muscles, where it is .3 mm. thick. In front of that line it is again reinforced by their tendinous fibres becoming incorporated with it and its thickness increases to .6 mm. In children the sclera is often so thin as to allow the underlying chorioidal pigment to show through, its colour then appearing bluish white. In the aged, again, it is sometimes yellowish. It always contains a few pigment cells, but these are in the deep layer termed the *lamina fusca*, and only become visible externally where the sclera is pierced by vessels and nerves going to the chorioid. It is almost non-vascular, but quite at its anterior end a large **venous sinus** [sinus venosus scleræ; canalis Schlemmi (Lauthi)], (**canal of Schlemm**) runs in its deeper layers circularly around the cornea. Just in front of this sinus, at the corneal **limbus,** the sclera merges into the cornea, its inner layers changing first, and finally the outer ones.

FIG. 803.—PORTION OF FIG. 802, ENLARGED.

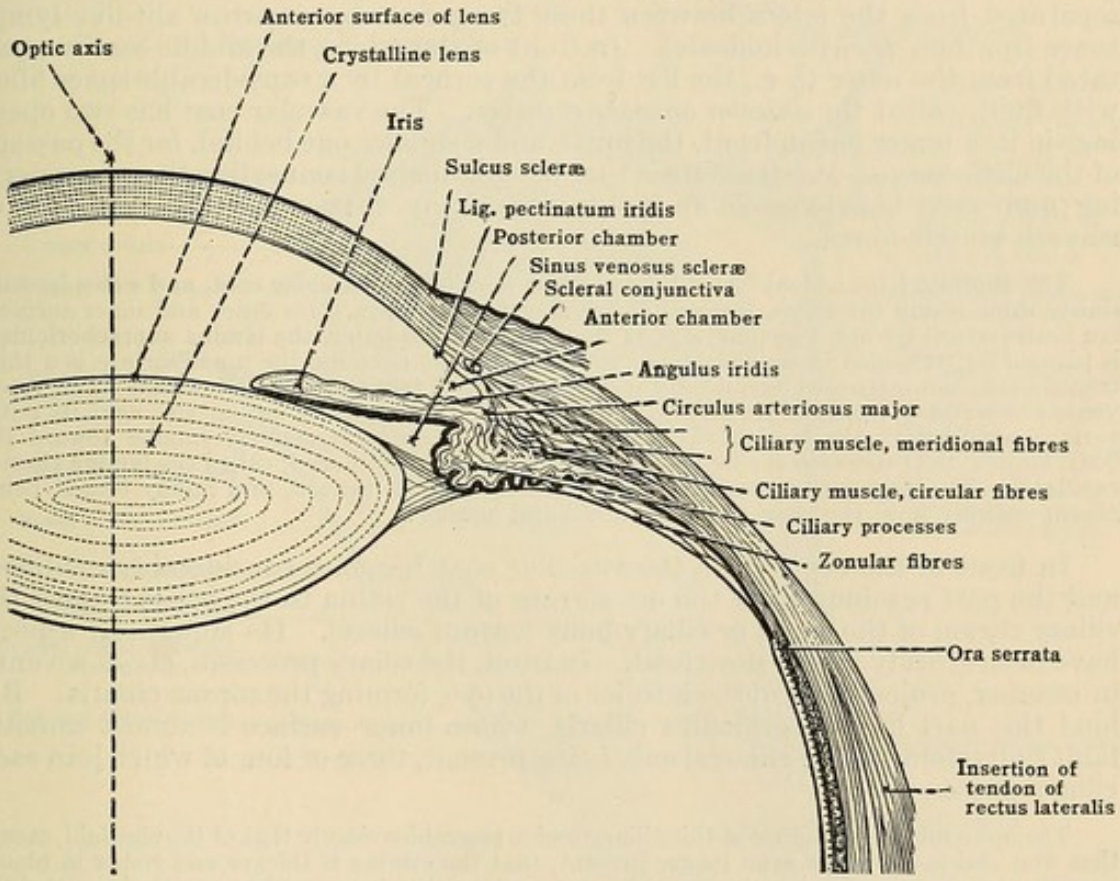

The **cornea** forms the anterior sixth of the eyeball. It is thickest at its periphery (1.1 mm.) and becomes gradually thinner toward its centre (0.8 mm.); the curvature of its posterior is consequently greater than that of its anterior surface, but even the latter is more curved than the surface of the sclera.

In the cornea proper, fibre-bundles are arranged so as to form a series of superposed lamellæ, each of which is connected here and there to the adjacent ones by fibres passing from one to the other, so that they can only be torn apart with difficulty. The corneal lymph-spaces communicate with one another by very fine canals, and thus not only is a thorough lymph-circulation provided for, but the protoplasm with which these spaces are partially occupied may be also regarded as continuous throughout. It contains no blood-vessels, with the exception of a rich plexus at its extreme periphery, on which its nutrition is ultimately dependent. The *sinus venosus of Schlemm* is an important channel for the return of blood and also of fluid which transudes into it from the anterior chamber. It consists of a network of venous spaces, formed of a principal vessel accompanied by several smaller ones, which unite with it and with one another in a plexiform manner. They commence indirectly with the spaces of the angle of the iris and they are in direct communication with the anterior ciliary veins.

The outer surface of the cornea is covered by an extension of the ocular conjunctiva, in the form of an epithelium several layers deep. The most external part of the true cornea appears homogeneous, even when highly magnified and constitutes the **anterior elastic lamina, Bowman's membrane,** though there is reason to believe that its structure only differs from that already described in the closeness of its fibrous texture; the two parts are certainly connected by fine fibres. Posteriorly, the cornea is lined by a firm, thin, glass-like layer (**posterior elastic lamina, membrane of Descemet**), distinct from the corneal tissue both anatomically and chemically. At the periphery this membrane breaks up into a number of fibres, which mainly arch over to join the base of the iris and form part of the **ligamentum pectinatum iridis.** The pectinate ligament is an open network of interlacing fibres, directly continuous with the circular and longitudinal bundles of sclera surrounding the venous sinus of Schlemm (Henderson). The interstices between these fibres constitute spaces (**spaces of Fontana**) [spatia anguli iridis (Fontanæ)] freely communicating with the aqueous chamber on the one hand, and indirectly with the venous sinus of the sclera on the other. The posterior elastic lamina is in turn lined by a single layer of flat cells, which are continuous peripherally with cells lining the spaces of the angle and the anterior surface of the iris which form the endothelium of the anterior chamber. The cornea is richly supplied with nerves, particularly in its most superficial layers.

2. The dark, **middle,** or **vascular coat of the eye** [tunica vasculosa oculi] is formed by the **iris, ciliary body,** and **chorioid.** It is closely applied to the sclera, but actually joins it only at the anterior and posterior limits of their course together, viz., at the scleral sulcus, and around the optic nerve entrance. It is separated from the sclera between these two points by a narrow slit-like lymp-space [spatium perichorioideale]. In front of the sulcus, the middle coat is separated from the outer (i. e., the iris from the cornea) by a considerable space filled with fluid, called the *anterior aqueous chamber*. The vascular coat has two openings in it; a larger one in front, the pupil, and a smaller one behind, for the passage of the optic nerve. Its structure is that of a pigmented connective tissue, supporting numerous blood-vessels and containing many nerves and three deposits of smooth muscle-fibres.

The **chorioid** [chorioidea] forms the posterior part of the vascular coat, and extends, with slowly diminishing thickness, forward as far as the ora serrata. Its outer and inner surfaces are both formed by non-vascular layers; that covering the outer, the **lamina suprachorioidea,** is pigmented, arranged in several fine loose lamellæ; that covering the inner surface is a thin, transparent, homogeneous membrane, called the **basal lamina** of the chorioid. The intervening chorioidal stroma is very rich in blood-vessels, which are of largest size next its outer surface constituting the **lamina vasculosa.** These become progressively smaller toward the basal lamina, next to which is a layer of closely placed wide capillaries, called the **lamina chorio-capillaris.** The pigment becomes less in amount as we pass inward, and finally ceases, being absent entirely from the choriocapillary and basal laminæ.

In front of the ora serrata the vascular coat becomes considerably modified, and the part reaching from the ora serrata of the retina to the iris is termed the ciliary region of the tract, or **ciliary body** [corpus ciliare]. Its superficial aspects have been already briefly described. In front, the ciliary processes, about seventy in number, project toward the interior of the eye, forming the **corona ciliaris.** Behind this part lies the **orbiculus ciliaris,** whose inner surface is almost smooth, faint radial folds [plicæ ciliares] only being present, three or four of which join each ciliary process.

The more minute structure of this ciliary region resembles closely that of the chorioid, except that the chorio-capillaris is no longer present, that the stroma is thicker and richer in blood-vessels, and that a muscular element (ciliary muscle) exists between the vascular layer and the lamina suprachorioidea. On antero-posterior section the ciliary body is triangular; the shortest side looks forward, and from about its middle the iris arises; the two long sides look respectively inward and outward, the inner having the ciliary processes upon it, while the outer is formed by the **ciliary muscle.** This muscle possesses smooth fibres and consists of an outer [fibræ meridionales (Brueckei)] and an inner division [fibræ circulares (Muelleri)]. The meridional fibres take origin from the outer fibrous coat of the eye at the sclero-corneal junction in front, and passing backward to join the outer layers of the orbiculus ciliaris and chorioid; the circular fibres are situated next to the ciliary processes. The entire muscle is destitute of pigment, and therefore is recognisable in the section by its light colour. The whole thickening of the vascular tunic in this region, muscle and folds and processes together, is named the **ciliary body.** It includes the corona ciliaris, formed of the ciliary processes and folds, and the orbicularis ciliaris containing the ciliary muscle.

The **iris** projects into the interior of the front half of the eye in the form of a circular disc perforated in the middle. The appearance of its anterior surface has already been described. The anterior surface is covered with a layer of endothelium except at the crypts near the ciliary border. Thus the lymph spaces between the stroma cells communicate directly with the anterior chamber. Its posterior

surface exhibits numerous radial folds running from the ciliary processes to near the pupillary margin; a thick layer of black pigment covers it and curls around this edge, so as to come into view all around the pupil as seen from in front. The *ciliary border* of the iris is continuous with the front of the ciliary body, and there it also receives fibres from the ligamentum pectinatum iridis; in other respects the iris is quite free, merely resting on the front of the lens-capsule near the pupil.

Its stroma [stroma iridis] is spongy in character, being made up of vessels covered by a thick adventitia, running from the periphery to the pupillary border, with interspaces filled by branching pigment cells, which are particularly abundant near the front surface. Deep in the stroma, running around near the pupillary border, we find a broad flat band of smooth muscle-fibres, constituting the **m. sphincter pupillæ.** Immediately behind the vascular tissue lies a thin membrane, consisting of fine, straight fibres running radially from the ciliary border to the stroma behind the sphincter. The nature of these fibres was long in dispute, but they are now accepted as being undoubtedly smooth muscular—and comprise the **m. dilatator pupillæ.**

FIG. 804.—DIAGRAMMATIC HORIZONTAL SECTION OF EYEBALL AND ORBIT.
(After Fuchs, much modified.)
Periorbita *green;* muscle-fascia *red;* Tenon's capsule *yellow.*

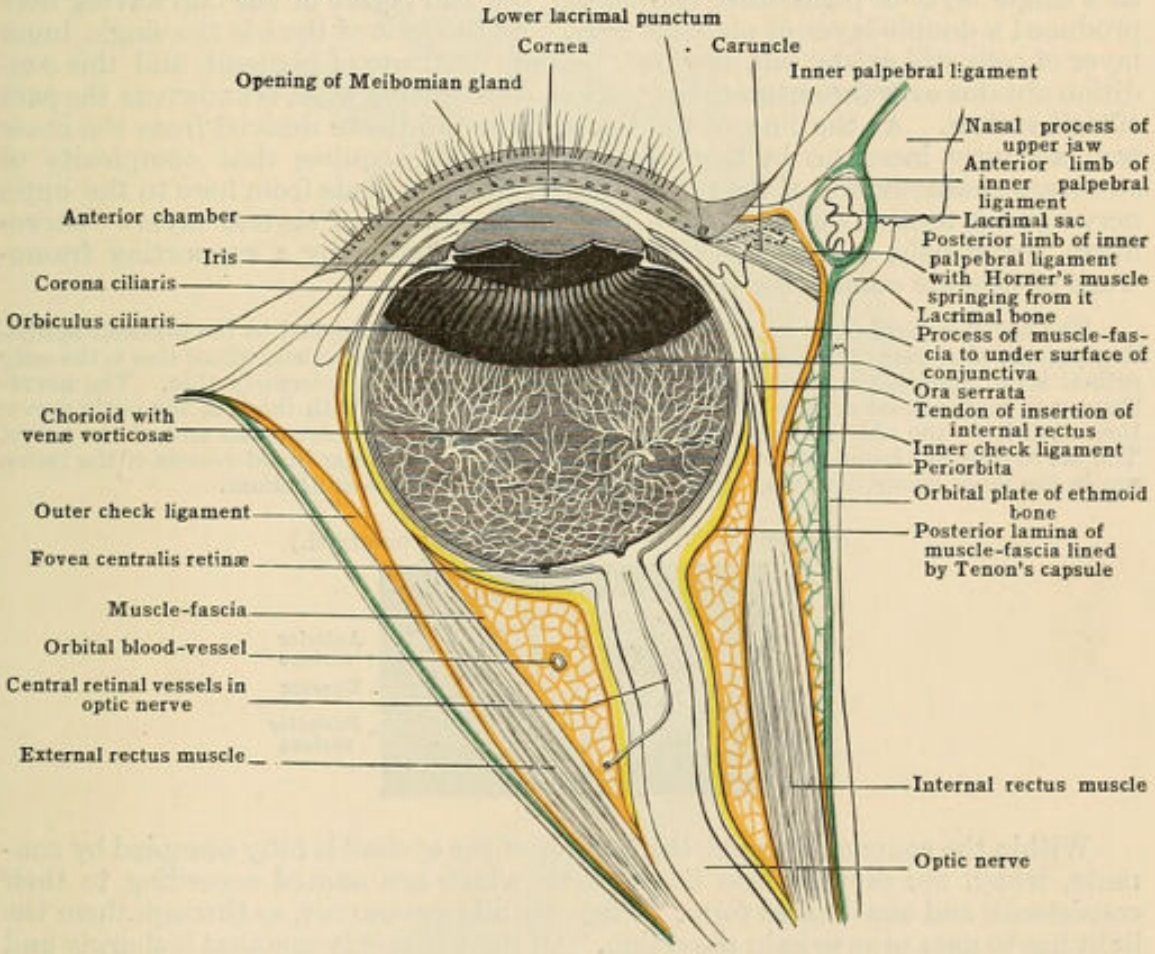

The *m. sphincter pupillæ* and the *ciliary muscle* are supplied indirectly by the oculomotor nerve through the ciliary ganglion. The dilatator pupillæ is supplied by *sympathetic fibres,* which have their origin from the cells of the superior cervical ganglion. Thence they ascend in the carotid and cavernous plexuses, and join the ophthalmic division of the trigeminal nerve, passing to the eyeball by way of the long ciliary nerves. The pre-ganglionic sympathetic fibres leave the spinal cord by the motor roots of the first two or three thoracic nerves, and ascend the sympathetic trunk to the superior cervical ganglion without interruption.

The posterior surface of the iris is lined by pigment already mentioned, consisting of two layers of pigmented cells, each layer representing the extension forward of one subdivision of the retina. The anterior surface of the iris is covered by a delicate epithelial layer, continuous with the cells of the posterior elastic lamina of the cornea. The colour of the iris in different individuals depends upon the amount of *stromal* pigment.

3. **The retina.**—The inner surface of the vascular coat is everywhere lined by a layer of pigment of corresponding extent, which usually adheres to it closely on dissection.

Developmentally this general pigment lining is quite distinct from the vascular coat, and represents the *outer wall* of the secondary optic vesicle or embryonic retina; it consists of a single layer of pigmented epithelial cells. It is known as the *stratum pigmenti*. The amount of pigment is greatest anteriorly, over the ciliary region and iris, and there is again a small local increase posteriorly, corresponding to the macula lutea and to the edge of the optic nerve entrance. In the ciliary region these cells have recently been described as lining numerous narrow tubular depressions in the inner part of the vascular tract, and they are said to have here a special function, viz., that of secreting the intraocular fluid.

From the manner in which the secondary optic vesicle, or *optic cup*, is formed, its two walls are necessarily continuous in front, at what may be termed the *lip* of the cup; we have just observed that the outer wall lines the vascular coat everywhere and corresponds in extent; consequently, the lip must be looked for at the edge of the pupil, i. e., at the termination of this coat anteriorly. The inner wall of the cup, consequently, reaches from the lip, or pupillary edge, in front to the optic stalk or nerve behind, and is in close apposition to the pigment-epithelium; unlike the outer, however, this wall is represented in the developed eye by tissues very dissimilar in structure in different parts of its extent. Tracing it backward from the pupillary edge, we find that over the whole posterior surface of the iris it exists as a single layer of pigmented epithelium, the two layers of the cup having here produced a double layer of pigment cells. At the root of the iris the single inner layer of cells still exists; but now they become destitute of pigment, and this condition obtains over the entire ciliary region, constituting what is known as the **pars ciliaris retinæ.** At the line of the ora serrata the tissue derived from the inner wall abruptly increases in thickness, and rapidly acquires that complexity of structure characteristic of the **retina proper,** which extends from here to the optic nerve and is termed the *pars optica retinæ*. It consists of several layers—nerve-fibres, nerve-cells, and nerve-epithelium—held together by a supporting framework of delicate connective tissue.

The nerve-epithelium is on the outer surface, immediately applied to the pigment-epithelium; at the posterior pole of the eye a small spot [**fovea centralis**] exists, where this is the only retinal layer represented, and where consequently the retina is extremely thin. The nerve-fibres run on the inner surface of the retina and are continuous with those of the optic nerve; they constitute the only retinal layer that is continued into the intraocular end of the nerve. The nerve-cells are found between these surface layers. The larger blood-vessels of the retina run in the inner layers, and none encroach on the layer of nerve-epithelium.

FIG. 805.—THE LENS. (Side view; enlarged.)

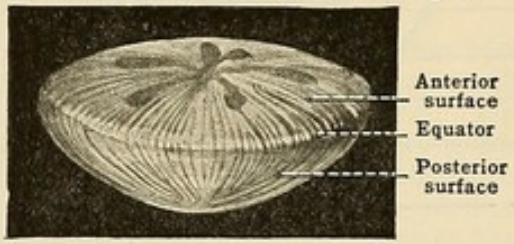

Within the coats mentioned, the interior of the eyeball is fully occupied by contents, which are divided into three parts, which are named according to their consistence and anatomical form. They are all transparent, as through them the light has to pass so as to gain the retina. Of these, the only one that is sharply and independently outlined is the lens, which is situated in the anterior half of the globe at the level of the ciliary processes, where it is suspended between the other contents, which fill respectively the space in front of it and the space behind it. The space in front of the lens called the aqueous chamber; that behind the lens is the vitreous chamber.

The **lens** [lens crystallina] is a biconvex disc, with its surfaces directed anteriorly and posteriorly; these surfaces meet at its rounded-off edge or **equator** [æquator lentis] which is near (but does not touch) the adjacent ciliary processes. The posterior is considerably more convex than the anterior surface; the central part of each surface is called its **pole** [polus anterior; polus posterior]. The lens is closely encased in a hyaline elastic capsule [capsula lentis] thicker over the anterior than over the posterior surface. Thus enclosed, it is held in position in the globe by a suspensory ligament, attached to the lens capsule near the equator of the eye, and swung from the ciliary region. Posteriorly, the lens rests in a cup

formed by the front part of the vitreous, while its anterior capsule is in contact with the aqueous fluid and lies close against the back of the pupillary margin of the iris. When in position the lens measures nine millimetres across, and about four millimetres between its poles.

On each surface a series of fine, sinuous, grey lines can be seen radiating from the pole toward the equator, called respectively the anterior and posterior **stellate figures.** The lines observable on the posterior are always so placed as to be intermediate with those on the anterior surface, so that on viewing them *through the lens* they occupy a position corresponding to the

FIG. 806.—DIAGRAMMATIC REPRESENTATION OF THE BLOOD-VESSELS OF THE EYEBALL. (Parsons, after Leber.)

Arteries *red*; veins *blue*.

s.p., Short posterior ciliary arteries. *l.p.c.*, Long posterior ciliary artery. *a.c.*, Anterior ciliary vessels. *C of S.*, Canal of Schlemm. *c.a.i.ma.*, Circulus arteriosus iridis major. *v.v.*, Venæ vorticosæ. *a. conj.*, Anterior conjunctival vessels. *p. conj.*, Posterior conjunctival vessels.

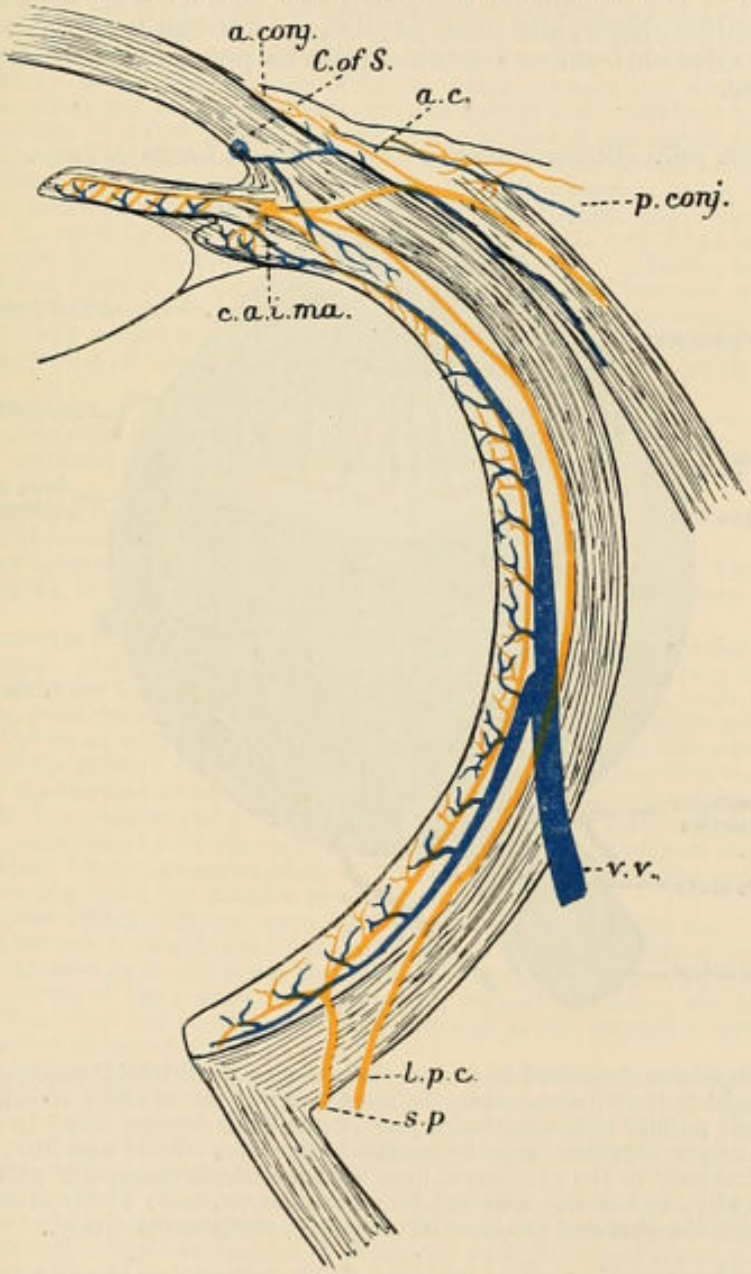

intervals between the lines on the anterior surface. The lens-capsule is comparatively brittle, and can be readily cut through when scraped with a sharp-pointed instrument; on doing so the divided edges curl outward, away from the lenticular substance. When removed from its capsule, the outer portion of the lens is found to be soft and glutinous, but its substance gets progressively firmer as we approach the centre. This harder central part is known as the **nucleus** [nucleus lentis], and the surrounding softer matter as **cortex** [substantia corticalis]. The cortical part shows a tendency to peel off in successive layers. It consists of long fibres, the ends of which meet in front and behind at the anterior and posterior stellate figures.

Histologically the capsule is not in immediate contact with the cortex over the front surface of the lens, a single layer of cells intervening, called the **epithelium lentis.**

The **zonula ciliaris** or **suspensory ligament of the lens** is formed by a number of fine zonular fibres [fibræ zonulares] passing from the ciliary body. They are attached to the lens-capsule a little in front of and behind the equator, and the spaces included between the fibres of the ligament are termed the *zonular spaces* [spatia zonularia]. A continuous space, which can be injected after death, round the margin of the lens is known as the canal of Petit. It is probably an artefact. This space is bridged across by fine intermediate suspensory fibres, and is occupied by fluid.

The **vitreous body** [corpus vitreum] is a transparent, colourless, jelly-like mass, the **vitreous humour,** enclosed in a delicate, clear, structureless membrane, called the *hyaloid membrane.* This latter is closely applied to the back of the posterior lens-capsule and of the suspensory ligament, and to the inner surface of the pars ciliaris retinæ, retina proper, and optic papilla. Although possessing some degree of firmness, the vitreous humour contains quite 98 per cent. of water, and has no definite structure.

FIG. 807.—BLOOD-VESSELS OF THE EYEBALL, LATERAL VIEW.

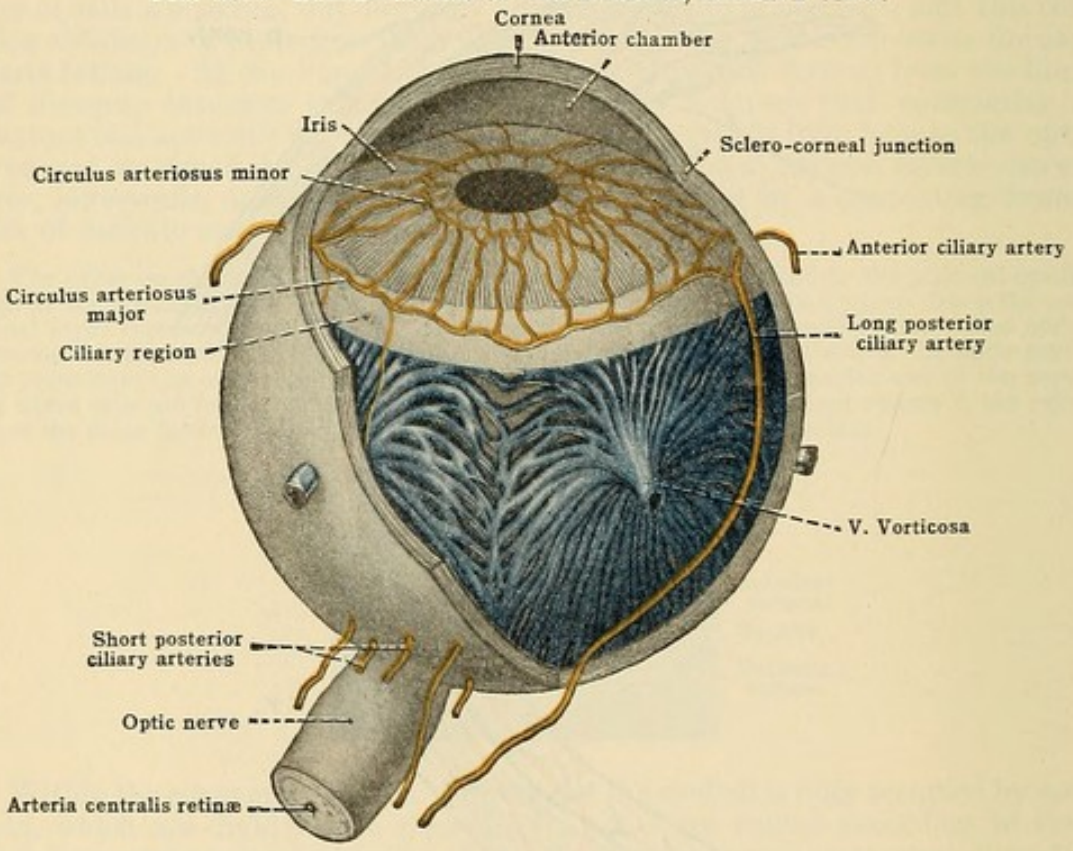

Membranes have been described in it, but these are really artificial products. In certain situations spaces exist in the vitreous mass, the most determinate of which runs in the form of a canal from the optic papilla to the posterior pole of the lens, corresponding to the position of the fœtal hyaloid artery (**hyaloid canal** or **canalis hyaloidea**). Other very fine spaces are described running circularly in the peripheral part of the vitreous concentric with its outer surface. Microscopically, wandering cells are found in the vitreous, which often here assume peculiar forms which the observer can, not infrequently, study subjectively.

The **aqueous humour** is a clear, watery fluid, occupying the space between the cornea on the one hand, and the ciliary body, zonula ciliaris, and lens on the other. The iris, projecting into this space, has both its surfaces bathed in the aqueous; but, as its inner part rests on the lens, it is regarded as dividing the space into two parts, an **anterior** larger, and a **posterior** smaller, **aqueous chamber** [camera oculi anterior; posterior], which communicate freely through the pupil.

Ciliary nerves of the eyeball.—The long and short ciliary nerves, after perforating the sclera run forward between it and the chorioid to the ciliary region,

where they form a plexus, from which proceed branches for the ciliary muscle, the iris, and the cornea.

The nerves of the iris enter it at its ciliary border, and run toward its pupillary edge, losing their medullary sheath sooner or later, and supplying especially the sphincter muscle. The corneal nerves form an annular plexus near the limbus, from which a few twigs proceed to the sclera and conjunctiva, while most of the offsets enter and run radially in the corneal stroma, branching and anastomosing so as to form a plexus. The nerves entering the cornea are about sixty in number, each containing from two to twelve non-medullated nerve-fibres.

Blood-vessels of the eyeball.—The eyeball receives blood from two sets of vessels, viz., the **retinal** and the **ciliary arteries,** as described in the section on the BLOOD-VASCULAR SYSTEM.

1. The **arteria centralis retinæ** either comes direct from the ophthalmic artery, or from one of its branches near the apex of the orbit. Entering the optic nerve twenty millimetres or less behind the globe, it runs forward in its axis to the end of the nerve-trunk, and then divides into branches which run in the inner layers of the retina, and divide dichotomously as they radiate toward the equator. The smaller branches lie more deeply in the retina, but none penetrate into the nerve-epithelium, so that the fovea centralis is non-vascular. In the retina, the branches of the central artery do not communicate with any other arteries, but while still in the optic nerve fine communications take place between this artery and neighbouring vessels. Thus (*a*) minute twigs from it, which help to nourish the axial part of the nerve, communicate with those running in the septa derived from the pial sheath. Again, as the nerve passes through the sclera, it is surrounded by a vascular ring [circulus vasculosus n. optici (Halleri)], formed of fine branches derived from the short posterior ciliary arteries; fine twigs passing inward from this ring to the optic nerve join the vessels of the pial sheath, and (*b*) an indirect communication is thus brought about between the retinal and ciliary vessels. Finally, as the nerve passes through the chorioid, there is (*c*) a direct connection between these two sets of vessels, the capillary network of the optic nerve being here continuous with the chorio-capillaris. Not infrequently, a branch from a short posterior ciliary artery pierces the optic papilla, and then courses over the adjoining retina (a cilio-retinal artery), supplying the latter in part in place of the central artery.

The **branches** of the a. centralis retinæ in the retina are: arteriola temporalis retinæ superior, arteriola temporalis retinæ inferior, arteriola nasalis retinæ superior, arteriola nasalis retinæ inferior, arteriola macularis superior, arteriola macularis inferior, arteriola retinæ medialis.

The **vena centralis retinæ** returns the blood of the corresponding artery and has branches corresponding to those of the artery.

2. **The ciliary system of blood-vessels** (see Blood-Vascular System).—There are three sets of arteries belonging to this system, all derived directly or indirectly from the ophthalmic artery.

(1) **Short posterior ciliary arteries** twelve to twenty in number, pierce the sclera round the optic nerve entrance, and are distributed in the chorioid. Before entering the eyeball, small twigs are given off to the adjoining sclera and to the dural sheath of the optic nerve.

(2) Two **long posterior ciliary arteries,** medial and lateral, piercing the sclera further from the nerve than the short ciliaries, run horizontally forward between the sclera and chorioid, one on each side of the globe. On arriving at the ciliary body, they join with the anterior ciliary arteries, forming the **circulus arteriosus major,** which sends off branches to the ciliary processes and the iris. The long ciliaries also give twigs to the ciliary muscle, and small recurrent branches run backward to anastomose with the short ciliary arteries. The arteries of the iris run radially toward the pupillary border, anastomosing with one another opposite the outer border of the sphincter and forming there the **circulus arteriosus minor.**

(3) The **anterior ciliary arteries** come from the arteries of the four recti muscles, one or two from each; they run forward, branching as they go, and finally pierce the sclera near the corneal border. Externally to the globe they send twigs to the adjoining sclera, to the conjunctiva, and to the border of the cornea. After passing through the sclera the arteries enter the ciliary muscle, where they end in twigs to the muscle and to the circulus arteriosus major, and in recurrent branches to the chorioid.

Veins.—The venous blood from almost the whole middle coat (chorioid, ciliary processes and iris, and part of the ciliary muscle) ultimately leaves the eyeball by—(1) the **venæ vorticosæ,** which have been already noticed in describing an antero-posterior section through the globe. One large vein passes backward from each vortex, piercing the sclera obliquely; it is joined by small episcleral veins when outside the globe.

(2) The **anterior ciliary veins** commence by the junction of a few small veins of the ciliary muscle; they pass outward through the sclera near the corneal border, receiving blood from the veins in connection with the sinus venosus of the sclera, and afterward from episcleral and conjunctival veins, and from the marginal corneal plexus. Finally they join the veins running in the recti muscles.

Lymphatic system of the eyeball.—Apart from those in the conjunctiva there are no lymphatic *vessels* in the eyeball, but the fluid is contained in *spaces* of various sizes. These are usually divided into an anterior and a posterior set.

1. **Anteriorly,** we have the anterior and posterior aqueous chambers (together composing the aqueous chamber of the eye), which communicate freely through the pupil. The aqueous humour is formed in the posterior of these chambers by

transudation from the vessels of the ciliary body and posterior surface of the iris (see also page 1076). The stream passes mainly forward through the pupil into the anterior aqueous chamber, whence it escapes slowly by passing through the spaces of the angle of the iris into the venous sinus of the sclera, and thence into the anterior ciliary veins. Part of the lymph-stream passes from the posterior aqueous chamber backward into the zonular spaces, out of which fluid can pass into the lens substance, or diffuse itself into the front of the vitreous body.

In the **cornea** the lymph travels in the spaces already mentioned as existing between the fibre-bundles, and in the nerve-channels and at the periphery of the cornea it flows off into the lymphatic vessels of the conjunctiva.

In the **iris** there is a system of lymphatic spaces opening anteriorly into the crypts of the surface, and communicating peripherally with the spaces of the angle of the iris.

FIG. 808.—LYMPHATIC SPACES OF THE EYEBALL (in green).

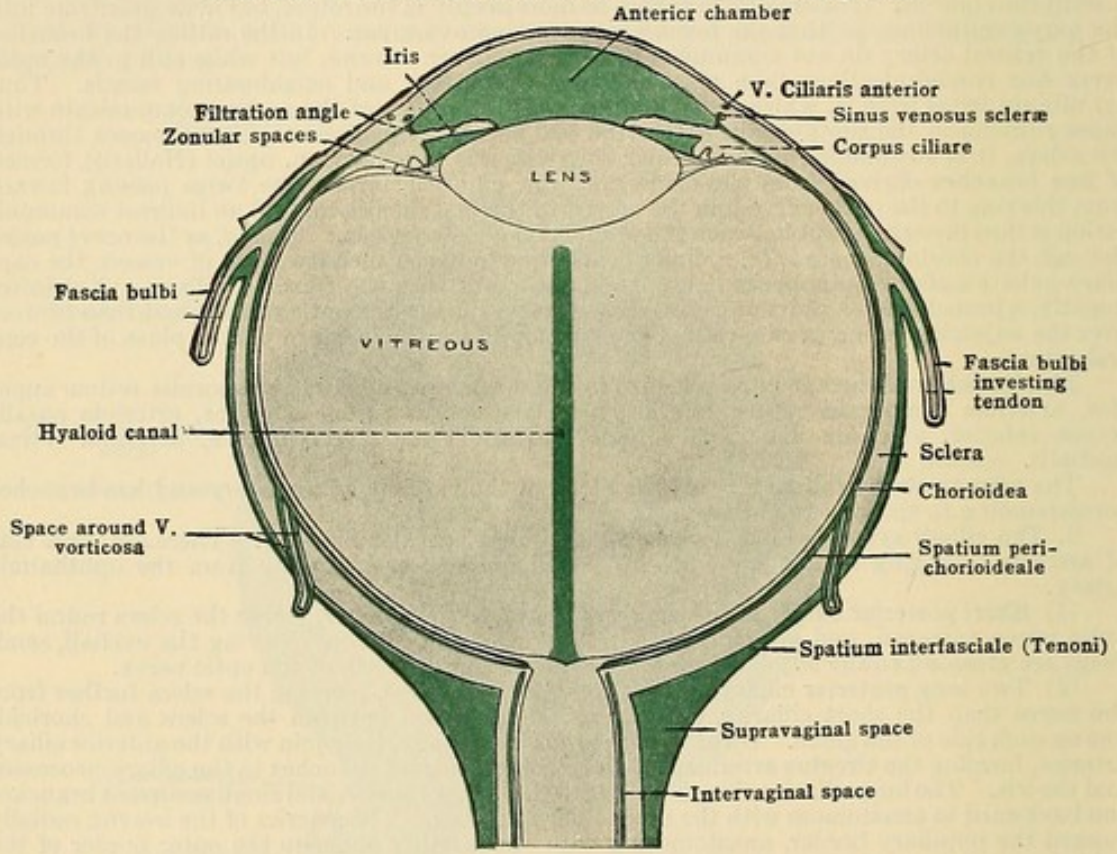

2. **Posteriorly,** we have (*a*) the hyaloid canal, between the posterior pole of the lens and the optic nerve entrance, and (*b*) the perivascular canals of the retina; the lymph from both of these situations flows into the spaces of the optic nerve, which communicate with the intervaginal spaces of the nerve, and thus with the great intracranial spaces. Further, between chorioid and sclera we have (*c*) the perichorioidal space, which gets the lymph from the chorioid, and communicates with the interfascial space (of Tenon) outside the sclera by perforations corresponding to the vasa vorticosa and posterior ciliary arteries, and with the intervaginal spaces around the optic nerve entrance. The interfascial space of Tenon, again, is continuous with the supravaginal space around the optic nerve, which communicates both with the intervaginal spaces, with the lymph-spaces of the orbit, and directly with the intracranial spaces at the apex of the orbit.

CAVITY OF THE ORBIT

GENERAL ARRANGEMENT OF ITS CONTENTS

The anterior wider half of the cavity is mainly occupied by the eyeball, which lies almost axially, but is rather nearer to the upper and lateral than it is to the other walls. The posterior two-thirds of the globe are in relation with soft parts,

chiefly muscles and fat, and its posterior pole is situated midway between the base (or opening) and the apex of the orbital cavity. The anterior third of the eyeball is naturally free, except for a thin covering of the conjunctiva, and projects slightly beyond the opening of the orbit, the degree of prominence varying with the amount of orbital fat, and also to some extent with the length of the globe. A straight line joining the medial and lateral orbital margins usually cuts the eye behind the cornea—laterally behind the ora serrata, medially further forward, at the junction of the ciliary body and iris. The globe is held in position by numerous bands of connective tissue. The lacrimal gland lies under the lateral part of the roof of the orbit anteriorly. The orbital fat occupies the spaces between the orbital muscles, and is in greatest amount immediately behind the eyeball; it also exists between the muscles and the orbital walls in the anterior half of the cavity. Six muscles, viz., the four recti, the superior oblique, and the levator palpebræ superioris, arise at the apex of the orbit, and diverge as they pass forward. The recti muscles—superior, inferior, lateral, and medial—run each near the corresponding orbital wall, but the superior is overlapped in part by the levator palpebræ. The superior oblique lies about midway between the superior and medial recti. A seventh muscle, the inferior oblique, has a short course entirely in the anterior part of the orbit, coming from its medial wall and passing below the globe between the termination of the inferior rectus and the orbital floor. The optic nerve with its sheaths passes from the optic foramen to the back of the eyeball, surrounded by the orbital fat, and more immediately by a loose connective tissue. Among the contents of the cavity are also to be enumerated many vessels and nerves and fibrous tissue septa, while its walls are clothed by periosteum (periorbita).

FIG. 809.—HORIZONTAL SECTION OF THE ORBITAL REGION, VIEWED FROM ABOVE.

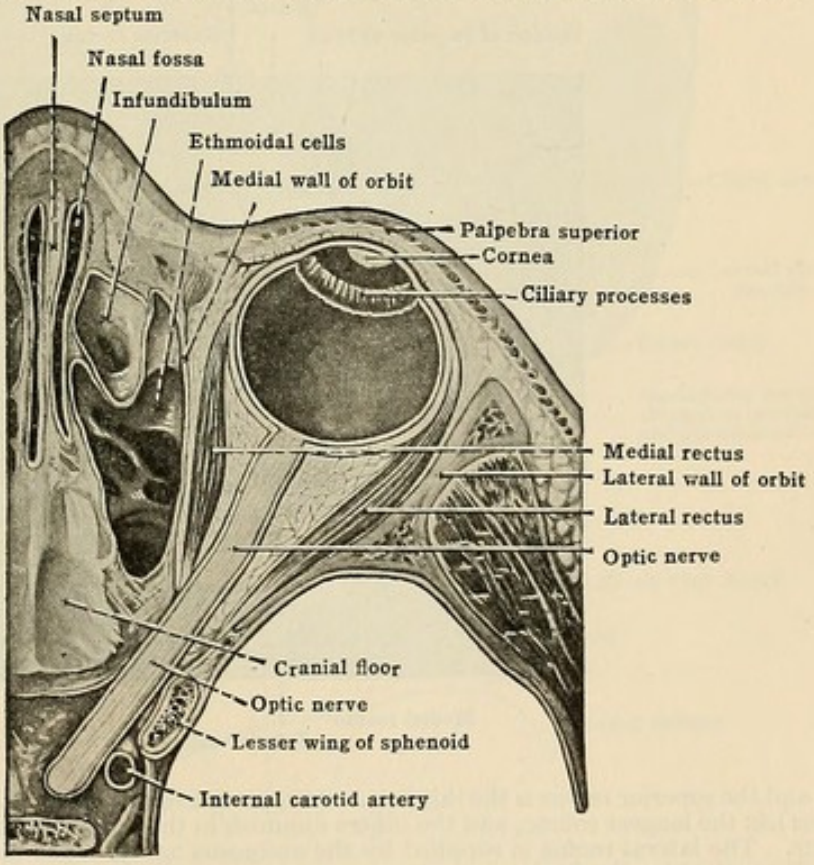

The **muscles of the orbit** are seven in number, of which six are *ocular*, i. e., are inserted into the eyeball and rotate it in different directions. These ocular muscles are arranged in opponent pairs, viz., **superior** and **inferior recti, superior** and **inferior obliques, lateral** and **medial recti.** With the exception of the short inferior oblique, they all arise from the back of the orbit along with the seventh orbital muscle, the **levator palpebræ superioris.** All these long muscles take their origin from the periosteum in the vicinity of the optic foramen. The four recti muscles arise from a fibrous ring, the **annulus tendineus communis,** which arches close over the upper

and medial edge of the foramen, and extends down and out so as to embrace part of the opening of the superior orbital fissure. Their origins may be said at first to form a short, common, tendinous tube, from which the individual muscles soon separate, taking the positions indicated by their respective names. The lateral rectus has two origins from bone, one on either side of the superior orbital fissure. But in the fresh state the fissure is here bridged across by fibrous tissue, from which this rectus also springs, so that its origin is in reality continuous. The part of this fibrous ring nearest the foramen (corresponding to the origins of the superior and medial recti) is closely connected with the outer sheath of the optic nerve. The remaining two long muscles arise just outside the upper and medial part of the above-mentioned ring, and are often partially united; the levator palpebræ tendon is in close relation to the origin of the superior rectus, while the superior oblique arises from the periosteum of the body of the sphenoid bone one or two millimetres in front of the origin of the medial rectus.

The **four recti muscles** lie rather close to the corresponding orbital walls for the first half of their course, the superior rectus, however, being overlapped in part by the levator palpebræ; they then turn toward the eyeball, running obliquely through the orbital fat, and are finally inserted by broad, thin tendons into the sclera in front of the equator. From their respective positions in the orbit, the axis of this cone of muscles is oblique to the antero-posterior axis of the eyeball. The thickest of these muscles is the medial rectus, next the lateral, then the infe-

FIG. 810.—DISSECTION OF THE LEFT ORBIT FROM IN FRONT.

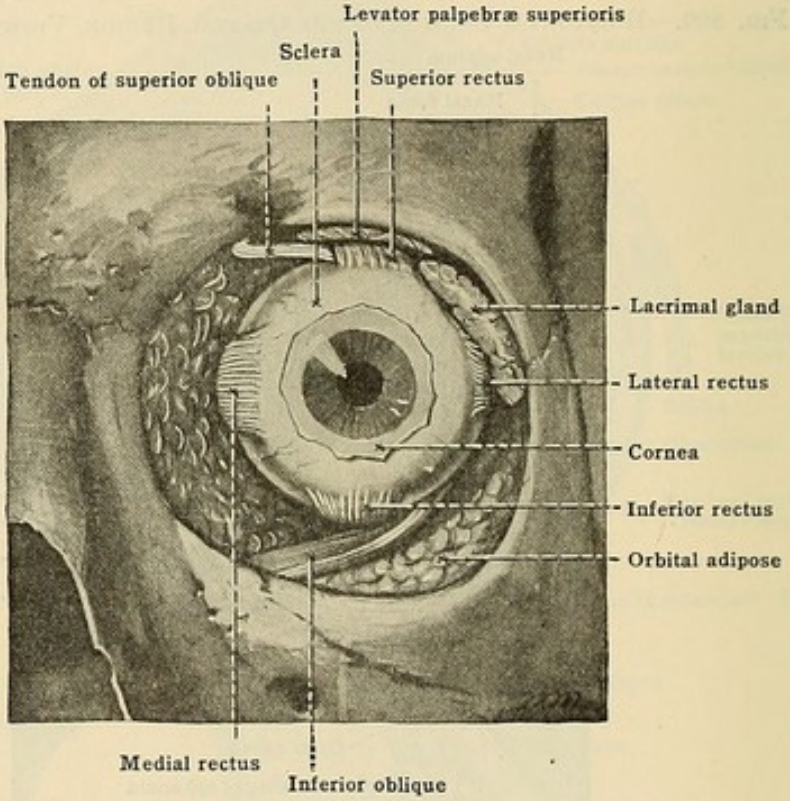

rior, and the superior rectus is the thinnest. As regards length, the muscular belly of the superior rectus has the longest course, and the others diminish in the order—medial, lateral, and inferior rectus. The lateral rectus is supplied by the abducens nerve. The other three recti muscles are all supplied by the oculomotor nerve.

The **levator palpebræ superioris** courses along the roof of the orbit close to the periosteum for the greater part of its course, partially overlapping the superior rectus; it finally descends through the orbital fat, and widens out to be inserted into the root of the upper lid. It may be briefly described as being inserted in two distinct layers separated by a horizontal interval. The upper or anterior layer of insertion is fibrous, and passes in front of the tarsus, where it comes into relation with fibres of the orbicularis. The lower layer consists of smooth muscle (Müller's **superior tarsal muscle**), and is inserted along the upper border of the tarsus. The levator has also connections with the sheath of the superior rectus. These different insertions of the muscle will be referred to later along with the description of the orbital fasciæ and of the upper eyelid. It gets its nerve supply from the oculomotor nerve, but the smooth muscle developed in its lower layer of insertion is supplied by the sympathetic nervous system. As its name expresses, its *action* is to raise the upper lid and to support it while the eye is open.

The **superior oblique** runs forward close to the medial part of the orbital roof until it reaches the fovea trochlearis near the medial angular process, where it becomes tendinous and passes through a fibro-cartilaginous pulley attached to the fovea just named. On passing through this pulley, or **trochlea**, the tendon bends at an angle of 50°, running posteriorly and laterally under the superior rectus to its insertion into the sclera. It is supplied by the trochlear nerve.

The **inferior oblique** arises from the front of the orbit, about the junction of its medial and inferior walls, just lateral to the lower end of the lacrimal groove. It runs, in a sloping direction, laterally and posteriorly, lying at first between the inferior rectus and the orbital floor, then between the lateral rectus and the globe; finally it ascends slightly, to be inserted by a short

tendon into the sclera at the back of the eye. Its nervous supply is derived from the oculomotor nerve. The precise manner of insertion of the different ocular muscles has been described above (p. 1056). For muscles of the eyelids and eyebrows, see pp. 1077 and 1078.

Action of the ocular muscles.—While rotating the globe so that the cornea is turned in different directions, the ocular muscles do not alter the position of the eyeball in the orbit either

FIG. 811.—SECTION THROUGH CONTENTS OF RIGHT ORBIT 8–11 MM. BEHIND THE EYEBALL, VIEWED FROM BEHIND. (After Lange.)

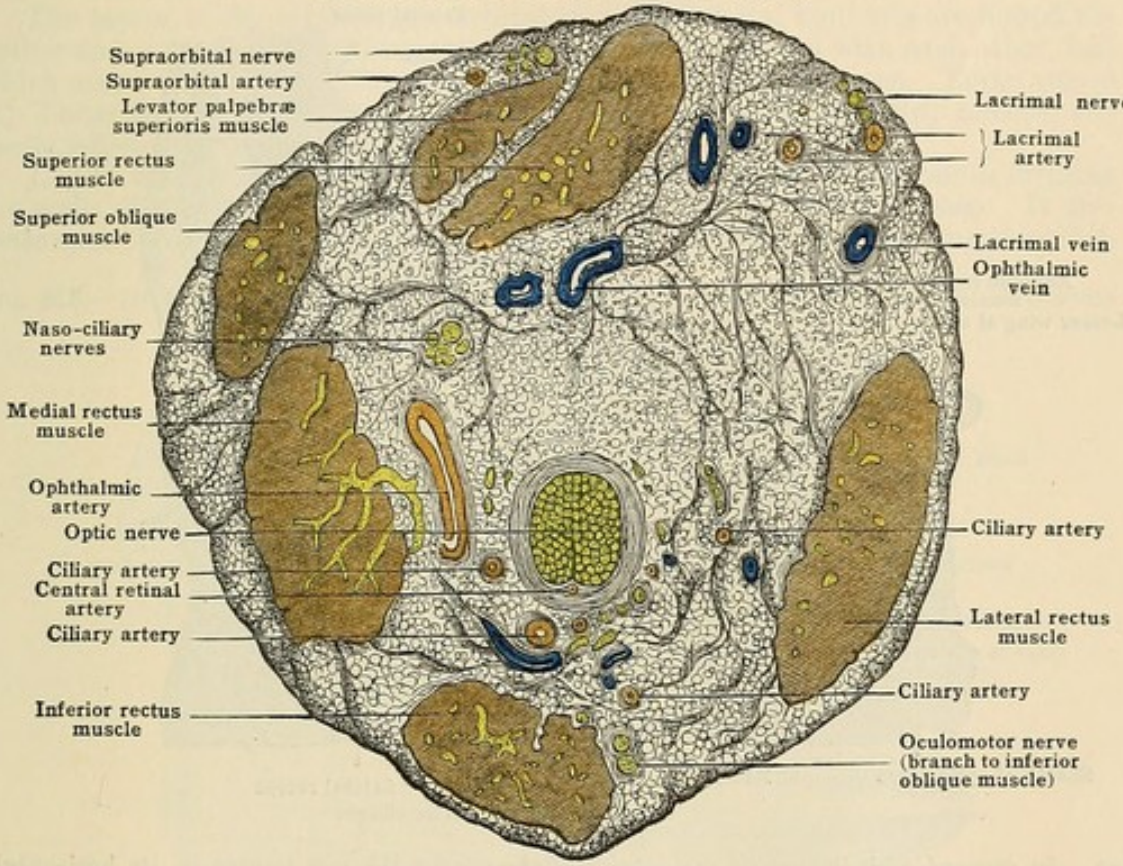

FIG. 812.—DIAGRAM REPRESENTING THE ORIGIN OF THE MUSCLES AT THE APEX OF THE RIGHT ORBIT.

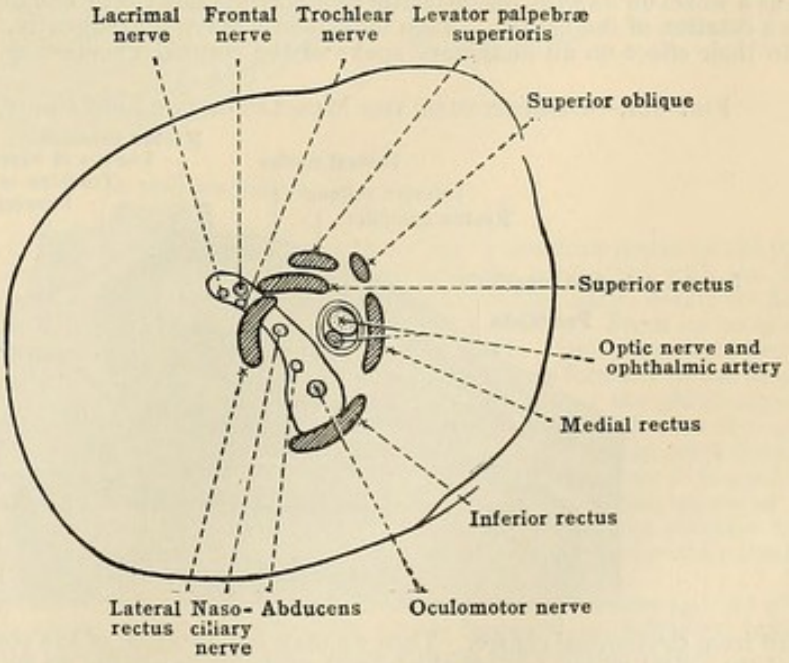

laterally, vertically, or antero-posteriorly. In speaking, therefore, of the eye being moved *upward* or *laterally*, etc., it is the altered position of the cornea or front of the eye that we mean to express; it is manifest that, if the cornea moves up, the back of the eyeball must simultaneously be depressed, and similarly with other movements. All the movements of the globe take

place by rotation, on axes passing through the centre. Though the possible axes are numerous in combined muscular action, there are three **principal axes** of rotation of the eyeball, and in reference to these the action of individual muscles must be described. Two of these axes are horizontal and one vertical; they all pass through the centre of rotation at right angles to one another. By rotation of the eye on its vertical axis the cornea is moved laterally (toward the temple) and medially (toward the nose): movements called respectively **abduction** and **adduction.** In upward and downward movements of the cornea the eye rotates on its horizontal equatorial axis. The other principal axis of rotation is the sagittal, which we have previously described as corresponding to the line joining the anterior and posterior poles of the globe (page 1055). In rotation of the eye on its sagittal axis, therefore, the cornea may be said to move as a wheel on its axle, for its centre now corresponds to one end of the axis; in other words, this is a **rotation of the cornea.** Such movements may, consequently, be expressed with reference to their effect on an imaginary spoke of the corneal wheel—e. g., one running vertically upward from the corneal centre. Thus we may say 'rotation of the cornea laterally' when this part of the wheel moves toward the lateral angle, or 'medially' when toward the nose.

FIG. 813.—DISSECTION OF THE MUSCLES OF THE RIGHT ORBIT, LATERAL VIEW.

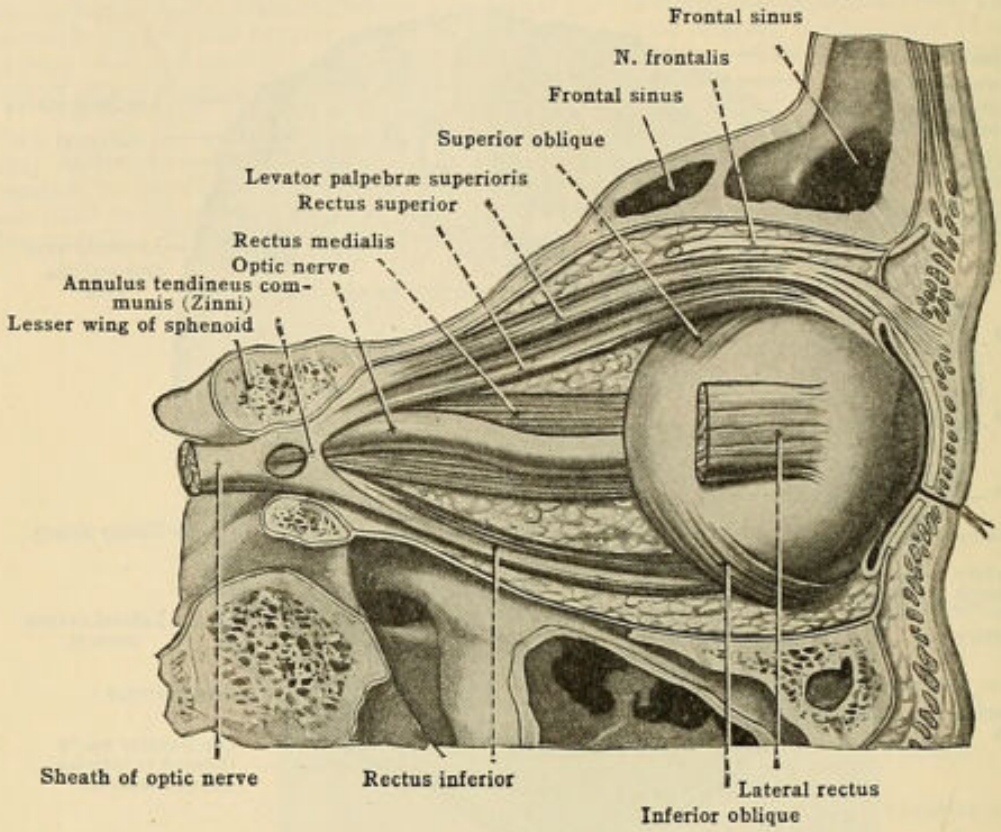

FIG. 814.—DISSECTION OF THE MUSCLES OF THE LEFT ORBIT, FROM ABOVE.

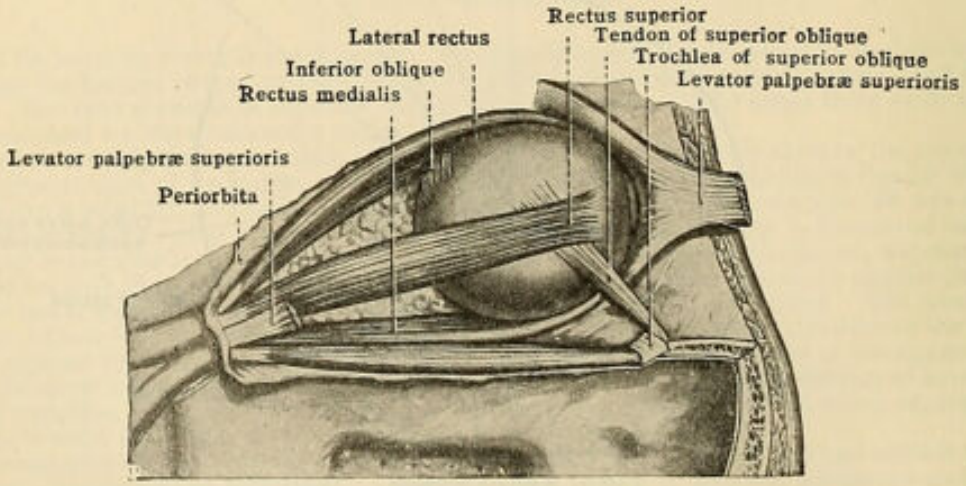

The only two muscles that rotate the eyeball merely on one axis are the **lateral rectus** and the **medial rectus**; the former abducting, and the latter adducting, the cornea. The action of the superior and inferior recti is complicated by the obliquity of the axes of muscles and globe previously mentioned.

The chief action of the **superior rectus** is to draw the cornea upward, but at the same time it adducts and rotates the cornea medially.

The **inferior rectus** mainly draws the cornea downward, also adducting it and rotating it laterally.

The chief action of the **superior oblique** is to rotate the cornea medially, also drawing it downward and slightly abducting it.

The **inferior oblique** mainly rotates the cornea laterally, also drawing it upward and slightly abducting it.

The fasciæ of the orbit [fasciæ orbitales].—The orbital contents are bound together and supported by fibrous tissues, which are connected with each other, but which may conveniently be regarded as belonging to three systems. These are:—(1) Those lining the bony walls; (2) those ensheathing the muscles; and (3) the tissue which partially encapsules the eyeball.

1. The **orbital periosteum** [periorbita], is closely applied to the bones forming the walls of the cavity, but may be stripped off with comparative ease. It presents openings for the passage of vessels and nerves entering and leaving the orbit.

FIG. 815.—DIAGRAM REPRESENTING THE ORBITAL FASCIÆ IN VERTICAL SECTION. Periorbita *black;* muscular sheaths *violet;* Tenon's capsule *green*.

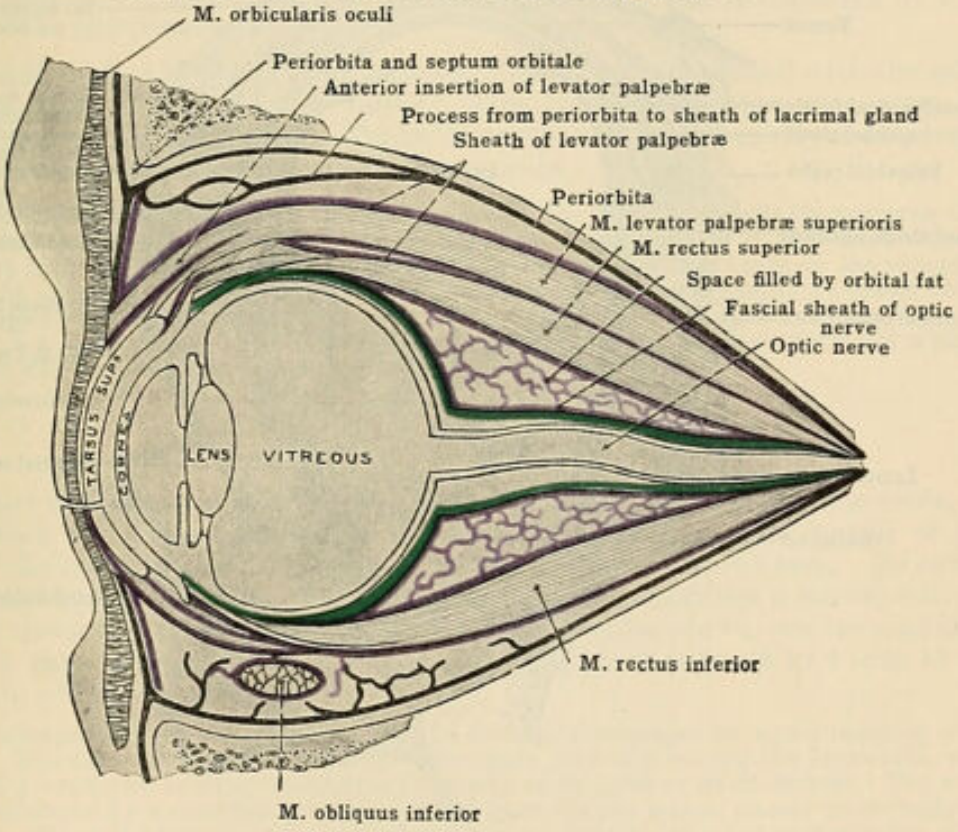

Posteriorly this tissue is very firm, being joined by processes of the dura mater at the optic foramen and superior orbital fissure; at the optic foramen it is also connected with the dura sheath of the optic nerve. As it covers the inferior orbital (spheno-maxillary) fissure its fibres are interwoven with smooth muscle, forming the **orbital muscle** of Müller. From its inner surface processes run into the orbital cavity, separating the fat lobules. One important process comes from the periorbita about midway along the roof of the orbit, runs forward to the back of the upper division of the lacrimal gland, and there splits, helping to form the gland-capsule: this capsule is joined at its medial border by other periorbital bands coming off near the upper orbital rim, and forming the suspensory ligament of the gland. On the side of the orbit the periorbita sends fibrous processes to the trochlea of the superior oblique, which keep it in position. On arriving at the lacrimal groove the periorbita divides into two layers, a thin posterior one continuing to line the bone forming the floor of the groove, whilst the thicker anterior layer bridges over the groove and the sac which lies in it, forming the limbs of the medial palpebral ligament (p. 1052).

Quite anteriorly, at the rim of the orbit, the periorbita sends off a membranous process which aids in forming the fibrous tissue of the eyelids (**orbito-tarsal ligament,** or **palpebral fascia**), and is itself continuous with the periosteum of the bones outside the orbital margin.

2. The orbital muscles are connected by a common fascia, which splits at their borders and furnishes a sheath to each. Processes of this fascia give membranous investments for the vessels and nerves (including the optic nerve), splitting simi-

larly to enclose them; these membranous processes also assist in separating the fat lobules.

Posteriorly, this fascia is thin and loose, and blends with the periorbita at the origin of the muscles. Anteriorly, it becomes thicker and firmer, accompanies the muscles to near the equator of the eyeball, and there divides into two laminæ, an anterior and a posterior; the former continues a forward course, forming a complete funnel-shaped investment all around, passing ultimately to the eyelids and orbital margin—whilst the latter turns backward, covering the hinder third of the globe.

The *anterior lamina* is a well-marked membrane everywhere, but in certain situations it presents special bands of thickening, corresponding to the direct continuation forward of the sheath of each rectus muscle. Above and below, this lamina spreads out in the form of two large membranes, which are finally applied to the deep surface of the palpebral fascia; the lower membrane constitutes what has been described as the suspensory ligament of the eyeball.' The upper membrane requires a fuller description, as its distribution is modified by the presence of the levator palpebræ muscle.

FIG. 816.—HORIZONTAL SECTION THROUGH LEFT ORBIT, VIEWED FROM ABOVE. (After von Gerlach. To show check ligaments, etc.)

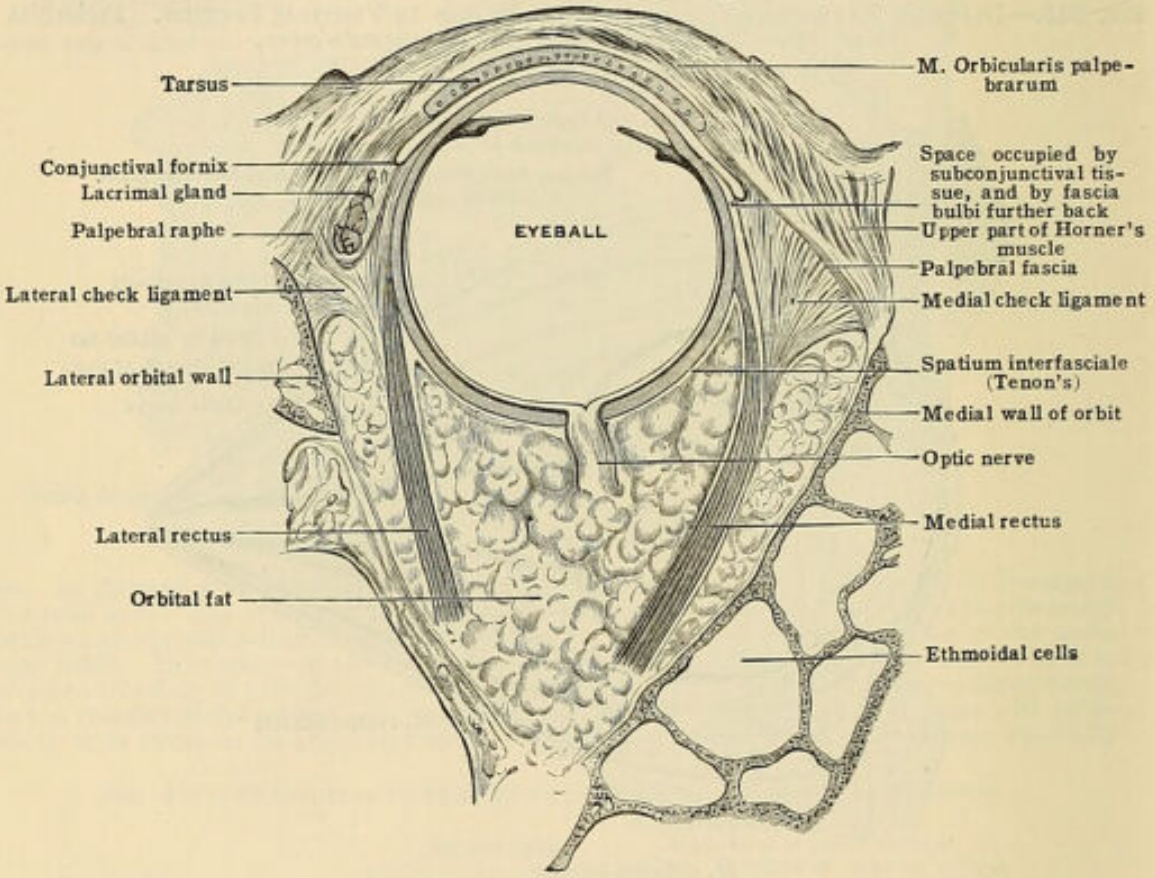

The upper part of the sheath of the superior rectus (along with the adjoining membrane on each side of it) passes to the deep surface of the levator, to which it closely adheres, and completely ensheaths this tendon by extending round its borders to its upper surface. The lower part of this levator sheath is applied to the inferior surface of the deeper of the two divisions of the levator muscle, *superior tarsal muscle*, and is attached to the upper border of the tarsus of the upper lid, reaching on each side to the lateral and medial angles of the orbit. The upper part of the sheath of the superior tarsal muscle reaches to the middle of the palpebral fascia, and is mainly continued forward between the muscle and the fascia to the anterior surface of the tarsus.

The lower membrane (suspensory ligament of the eyeball), joined by the sheath of the inferior rectus, reaches forward to the attached (posterior) border of the tarsus of the lower lid, where it is mainly attached, while a part of it extends to the lower palpebral fascia.

To understand the *special bands* of the anterior lamina mentioned above, we must follow the sheath of each rectus muscle forward, when we find that, while it is rather loosely applied to the muscular belly in its posterior two-thirds, it then suddenly becomes thicker, and is firmly attached to the muscle for some distance before finally leaving it, and is thereafter often accompanied by some muscle-fibres. The best developed of these bands, the *lateral check ligament*, passes anteriorly and laterally to the lateral angle of the orbit, helping to support the lacrimal gland on its way, and is inserted near the orbital edge immediately behind the lateral palpebral raphe. The medial band, or *medial check ligament*, is larger than the lateral, but not so thick; it passes forward and medially to be inserted into the upper part of the lacrimal crest and just behind it. These two bands, lateral and medial, come from the sheaths of the

corresponding recti muscles. From the sheath of the superior rectus come two thin bands, one from each border. The medial joins the sheath of the tendon of the superior oblique; the lateral goes to the lateral angle of the orbit, assisting in the support of part of the lacrimal gland. The sheath of the inferior rectus is thickened in front, and, on leaving the muscle, goes to the middle of the inferior oblique, splitting to enclose it; it then passes to be inserted into the lower medial angle of the orbit close behind its margin, about midway between the medial check ligament and the orbital attachment of the inferior oblique.

3. In addition to its partial investment by the muscle-fascia, the eyeball has a special membrane enclosing its hinder two-thirds, the **fascia bulbi** ("Tenon's capsule").

This is a thin, transparent tissue, situated immediately internal to the posterior lamina of the muscle-fascia. It follows the curve of the sclera from the insertion of the recti to about 3 mm. from the optic nerve entrance. There it leaves the eyeball and blends with the posterior lamina of the muscle-fascia; the combined membrane may be traced backward, enveloping the optic nerve-sheath loosely, approaching it as it nears the optic foramen, but never actually joining it. The interval between it and the nerve-sheath is called the *supravaginal lymph-space*. The fascia bulbi first comes into relation with the muscles at the point where they are left by their proper sheaths; it there invests their tendons, forms a small serous bursa on the anterior surface of each, and adheres to the sclera along a line running around the globe, just anterior to the insertions of the four recti muscles. Between this line and the corneal border, the conjunctiva is separated from the sclera by the subconjunctival tissue, strengthened by a fine expansion of the muscle-fascia.

The inner surface of the fascia is smooth, and is only connected with the sclera by a loose, wide-meshed areolar tissue. This interval between the sclera and fascia, known as the **interfascial (Tenon's) space,** is a lymph cavity, and permits free movements of the eyeball within the capsule.

Relation of the Fascia Bulbi to the Oblique Muscles.—The fascia surrounds the posterior third of the inferior oblique and its tendon, running along its ocular surface till it meets the fascial band coming from the inferior rectus (see above), and forming a serous bursa on the superficial surface of the oblique near its insertion. The tendon of the superior oblique for about its last five millimetres is invested solely by the fascia bulbi; in front of this, as far as the trochlea, the tendon lies in a membranous tube derived from the muscle fascia, the inner lining of which is smooth, and may be considered as a prolongation of the fascia bulbi.

The Optic Nerve

The part of this nerve with which we have here to do lies within the orbit, extending from the optic foramen to the eyeball (fig. 813). The length of this portion of the nerve is from 20 to 30 mm. and its diameter about 5 mm. Its course is somewhat S-shaped; thus, on entering the orbit, it describes a curve, with its convexity down and laterally, and then a second slighter curve, convex medially. Finally, it runs straight forward to the globe, which it enters 3 to 4 mm. to the medial side of its posterior pole.

In its passage through the optic foramen the nerve is surrounded by a prolongation of the meninges. The dura mater splits at the optic foramen, part of it joining the periorbita, while the remainder continues to surround the nerve loosely as its outer or **dural sheath.** The nerve is closely enveloped by a vascular covering derived from the pia mater, named accordingly the **pial sheath.** The space between these two sheaths is subdivided by a fine prolongation of the arachnoid (the **arachnoidal sheath**) into two parts, termed the intervaginal spaces [spatia intervaginalia], viz., an outer, narrow, *subdural*, and an inner, wider, *subarachnoid space*, communicating with the corresponding intracranial spaces. The arachnoidal sheath is connected with the sheath on each side of it by numerous fine processes which bridge across the intervening spaces. The pial sheath sends processes inward, which form a framework separating the bundles of nerve-fibres; between the enclosed nerve-fibres and each mesh of this framework there is a narrow interval occupied by lymph. The nerve-fibres are medullated, but have no primitive sheath. About fifteen or twenty millimetres behind the globe the central vessels enter, piercing obliquely the lower lateral quadrant of the nerve, and then run forward in its axis. They are accompanied throughout by a special process of the pial sheath, which forms a fibrous cord in the centre of the nerve.

On reaching the eyeball, the dural sheath is joined by the arachnoid, and turns away from the nerve to be continued into the outer two-thirds of the sclera. Similarly the pial sheath also here leaves the nerve, its greater part running into the inner third of the sclera, while a few of its fibres join the chorioid; the intervaginal spaces consequently end abruptly in the sclera around the nerve-entrance. In this locality the connective-tissue framework of the nerve becomes thicker and closer in its meshwork, and has been already alluded to as the **lamina cribrosa scleræ.** It is formed by processes passing out from the central fibrous cord at its termination and by processes passing inward from the pial sheath, sclera, and chorioid. It does not pass straight across the nerve, but follows the curve of the surrounding sclera, being therefore slightly convex backward. The nerve-trunk here quickly becomes reduced to one-half its former diam-

eter, the fibres losing their medullary sheath, and being continued henceforward as mere axis-cylinders. Apart from the consequent loss of bulk, this histological change may be readily recognised macroscopically in a longitudinal section of the nerve, its aspect here changing from opaque white to semi-translucent grey. The part of the nerve within the lamina cribrosa has already been noted in the ophthalmoscopic examination of the living eye (p. 1055).

The optic nerve is mainly nourished by fine vessels derived from those of the pial sheath, which run into the substance of the nerve in the processes above mentioned. In front of the entrance of the central retinal artery this vessel aids to some extent in the blood-supply of the axial part of the nerve.

FIG. 817.—TRANSVERSE SECTION THROUGH OPTIC NERVE, SHOWING THE RELATIONS OF ITS SHEATHS AND CONNECTIVE-TISSUE FRAMEWORK.

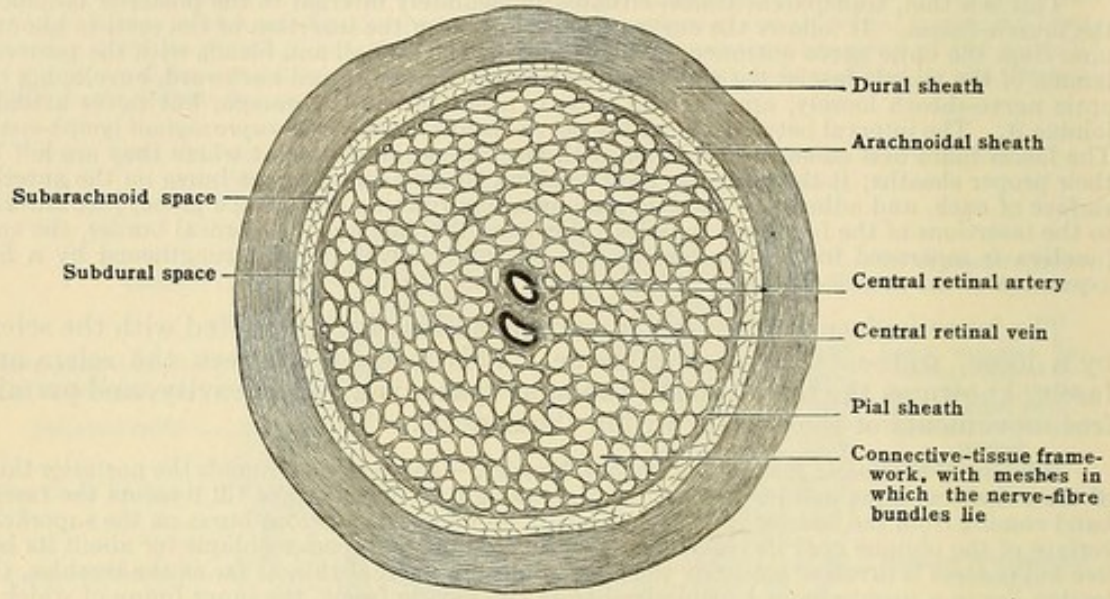

FIG. 818.—LONGITUDINAL SECTION THROUGH TERMINATION OF OPTIC NERVE.

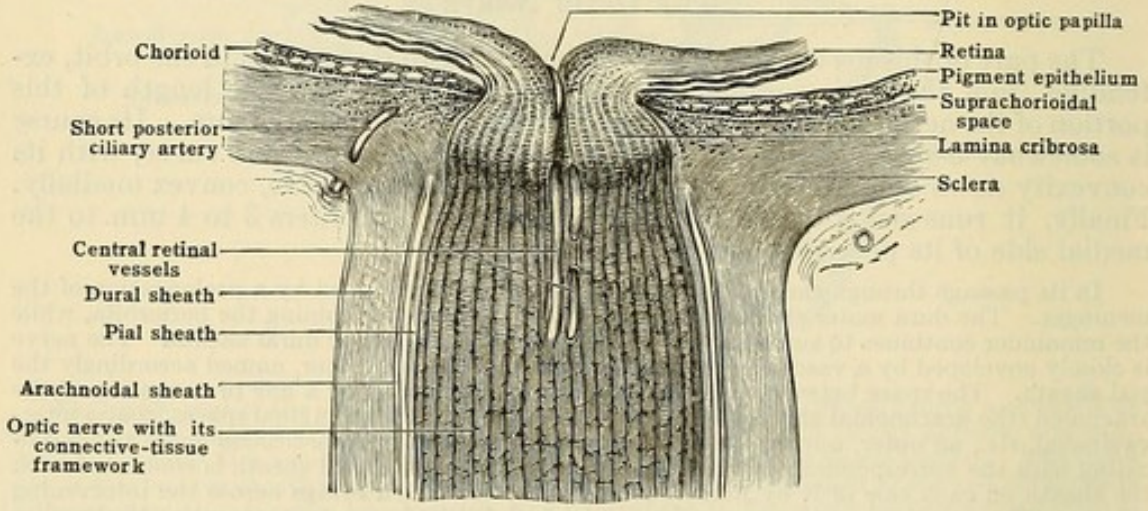

THE BLOOD-VESSELS AND NERVES OF THE ORBIT

As these structures will be more particularly described in other sections of this work, a very short general account will suffice here.

Arteries.—The main blood-supply is afforded by the **ophthalmic artery,** a branch of the internal carotid, which gains the orbit through the optic foramen, where it lies below and lateral to the nerve. On entering the orbit it ascends, and passes obliquely over the optic nerve to the medial wall of the orbit; in this early part of its course it gives off most of its branches, which vary much in their manner of origin and also in their course. The arteries of the orbit are remarkable for their tortuous course, for their delicate walls, and for their loose attachment to the surrounding tissues. The ophthalmic artery gives off special branches in the orbit to the lacrimal gland, the muscles, the retina (through the optic nerve), and the eyeball, as well as to the meninges, the ethmoidal cells, and the nasal mucous membrane. Twigs from all the different branches go to supply the fat, fasciæ, and ordinary nerves of the orbit. Branches which leave the orbit anteriorly ramify on the forehead and nose, and also go to the supply of

the eyelids and the tear-passages. The ophthalmic artery has many anastomoses with branches of the external carotid. The contents of the orbit are also supplied in part by the **infraorbital artery,** a branch of the internal maxillary; in particular this artery supplies part of the inferior rectus and inferior oblique muscles in the cavity, and also gives a branch to the lower eyelid.

Veins.—Branches, corresponding generally to those of the artery, unite to form the **superior** and **inferior ophthalmic veins,** which ultimately, either separately or united into one trunk, pass through the superior orbital fissure and empty into the cavernous sinus. The inferior vein is connected with the pterygoid plexus by a branch which leaves the orbit by the inferior orbital fissure.

Nerves of the orbit.—These are (A) **motor,** (B) **sensory,** and (C) **sympathetic,** and all enter the orbit by the superior orbital fissure, with the exception of one small sensory branch passing through the inferior orbital fissure. (The optic nerve has been already described, and is not included in this account.)

A. The **motor nerves** are the oculomotor, trochlear, and abducens.

1. The **oculomotor nerve** enters the orbit in two parts, an upper smaller, and a lower larger, division. The *upper division* [ramus superior] gives off two branches: one supplies the superior rectus, entering its lower surface far back; the other branch goes to the levator palpebræ, entering its lower surface in its posterior third. The *lower division* [ramus inferior] divides into three branches, of which one supplies the inferior rectus, entering its upper surface

FIG. 819.—THE BLOOD-VESSELS OF THE LEFT ORBIT, VIEWED FROM ABOVE.

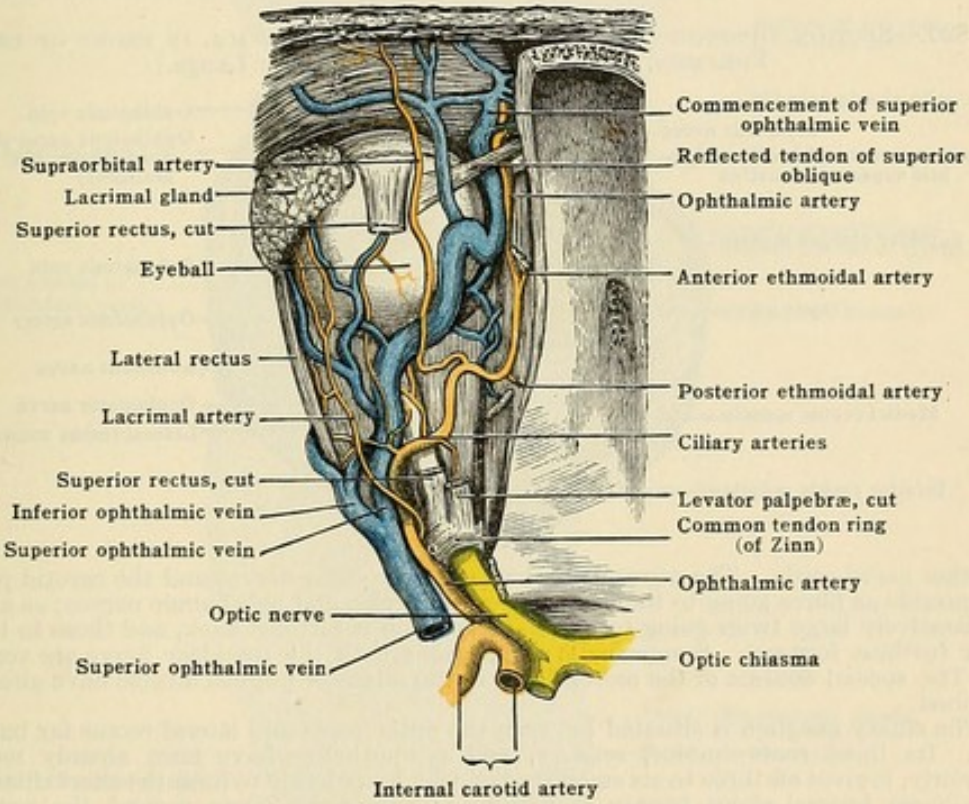

far back, and another supplies the medial rectus, entering its medial surface a little behind its middle. The third branch of the lower division gives (1) the short root to the ciliary ganglion, and (2) one or more twigs to the inferior rectus, and the remainder of this branch then enters the lower surface of the inferior oblique muscle about its middle.

2. The **trochlear nerve** supplies the superior oblique muscle, entering its upper surface about midway in its course.

3. The **abducens nerve** supplies the lateral rectus, entering its medial surface about the junction of the posterior and middle thirds of the muscle.

As regards the manner of termination of these motor nerves, it is found that in all the ocular muscles the nerve on its entrance breaks up into numerous bundles of fibres, which form first coarse and then fine plexuses, the latter ultimately sending off fine twigs supplying the muscle throughout with nerve-endings. The *posterior third* of these muscles is, however, comparatively poorly supplied with both kinds of plexuses and with nerve-endings.

B. The **sensory nerves** are supplied by the ophthalmic and maxillary divisions of the trigeminal cranial nerve. The ophthalmic division is chiefly orbital; while the maxillary sends only a small branch to the orbit.

1. The **ophthalmic division** of the trigeminal nerve enters the orbit in three divisions, namely:—

(1) **Frontal,** splitting subsequently into *supratrochlear* and *supraorbital*, both passing out of the orbit. It is distributed to the corresponding upper eyelid, and the skin over the root of the nose, the forehead, and the hairy scalp as far back as the coronal suture on the same side. It also gives branches to the periosteum in this region, and to the frontal sinus.

(2) **Lacrimal,** supplying the lacrimal gland, anastomosing with a branch of the maxillary

in the orbit, and finally piercing the upper eyelid. Outside the orbit it is distributed to the lateral part of the upper lid, the conjunctiva at the lateral angle, and the skin between this and the temporal region.

(3) **Naso-ciliary** [n. naso-ciliaris] giving off—(*a*) a branch to the ciliary ganglion, constituting its long root; (*b*) two or three *long ciliary nerves;* and (*c*) the *infratrochlear*, passing out of the orbit. The nerve then leaves the orbit as the anterior ethmoidal nerve [n. ethmoidalis anterior], re-entering the cranial cavity before being finally distributed to the nose. The infratrochlear branch [n. infratrochlearis], supplies the eyelids and skin of the side of the nose near the medial angle of the eye, the lacrimal sac, caruncle, and plica semilunaris. The anterior ethmoidal nerve, after its course in the cranial cavity, passes through an aperture in the front of the lamina cribrosa of the ethmoid bone, and is ultimately distributed to the nasal mucous membrane, and to the skin of the side and ridge of the nose near its tip.

2. The **maxillary division of the fifth nerve** gives a branch, called the **zygomatic nerve,** which passes into the orbit through the inferior orbital fissure, anastomoses with the lacrimal, and leaves the orbit in two divisions. These are distributed to the skin of the temple and of the prominent part of the cheek.

A few minute twigs from the spheno-palatine ganglion, and sometimes from the maxillary division of the fifth nerve, also pass through the inferior orbital fissure to supply the periorbita in this neighbourhood.

C. The **sympathetic nerves of the orbit** are mainly derived from the plexus on the internal carotid artery. With the exception of branches accompanying the ophthalmic artery, and of the distinct sympathetic root of the ciliary ganglion, they enter the orbit in the substance of

FIG. 820.—SECTION THROUGH CONTENTS OF RIGHT ORBIT, 1–2 MM. IN FRONT OF THE OPTIC FORAMEN, VIEWED FROM BEHIND. (After Lange.)

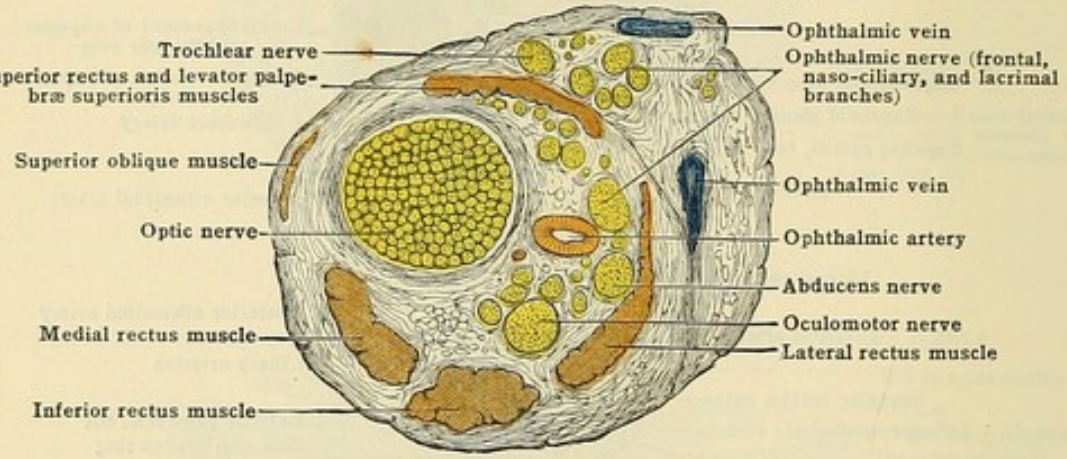

the other nerve-cords. The connections between the ocular nerves and the carotid plexus are recognisable as fibres going to the oculomotor, abducens, and ophthalmic nerves; as a rule, the comparatively large twigs going to the abducens join it furthest back, and those to the oculomotor furthest forward. Sympathetic connections with the trochlear nerve are very doubtful. The special courses of the motor fibres to the dilatator pupillæ muscle have already been described.

The **ciliary ganglion** is situated between the optic nerve and lateral rectus far back in the orbit. Its three roots—motor, sensory, and sympathetic—have been already mentioned. Anteriorly, it gives off three to six small trunks, which subdivide to form the **short ciliary nerves** [nn. ciliares breves] about twenty in number, piercing the sclera around the optic nerve entrance.

The lymphatic system of the orbit.—Although there are no lymphatic *vessels* or *glands* in the orbit, the passage of lymph is nevertheless well provided for. We have already observed the lymph channels within, between, and outside the sheaths of the optic nerve, and have seen how these communicate anteriorly with the lymph channels of the eyeball, and posteriorly with the intracranial meningeal spaces. In addition, there are lymph-spaces around the blood-vessels, situated between the outer coat and the loose investment furnished by the muscle fascia. The nerves of the orbit (apart from the optic) are probably similarly surrounded by lymph-spaces. In the absence of lymphatic vessels it is difficult to trace the circulation thoroughly; much of the lymph from the orbital cavity is said to pass into the parotid nodes.

THE EYELIDS

The cutaneous and conjunctival surfaces of the eyelids [palpebræ] have already been examined (p. 1053), and the position of the tarsus has been indicated. We have now to ascertain the nature and relations of the tarsus, and describe the other tissues entering into the formation of the eyelids (fig. 821).

The skin here is thin, bearing fine hairs, and having small sebaceous and numerous small sweat-glands. Immediately beneath it is a loose subcutaneous tissue, destitute of fat, separating the skin from the palpebral part of the **orbicularis muscle.** The lid-fibres of this muscle arise from the medial palpebral ligament, and course over the whole upper and lower eyelids in a succession of arches, so as to meet again beyond the lateral angle; there they in part join one another, in part are inserted into the lateral palpebral raphe. The muscular fibres are arranged in loose bundles, with spaces between them occupied by connective tissue; in the upper lid these connective-tissue fibres may be traced upward and backward into the fibrous expansion of the tendon of the levator palpebræ superioris. One strong bundle of orbicularis fibres, called the **musculus ciliaris Riolani,** is found near the edge of the lid, in front of and behind the efferent ducts of the tarsal glands (fig. 821).

FIG. 821.—SAGITTAL SECTION OF THE UPPER EYELID. (After Waldeyer and Fuchs.)

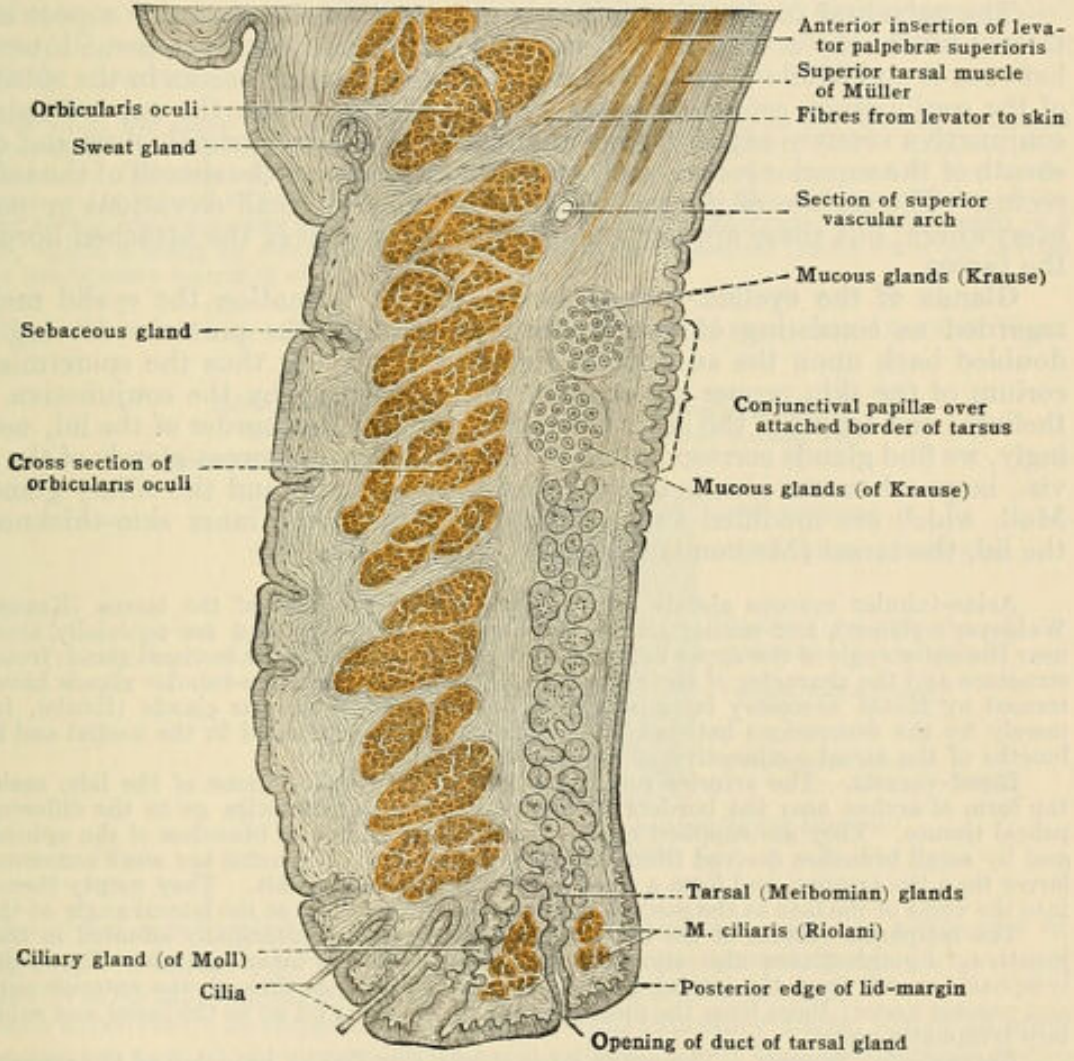

A **central connective tissue** separates the orbicularis muscle from the tarsus in the tarsal division of the lids. In the upper lid this is to be regarded as mainly the anterior or fibrous expansion of the tendon of the levator palpebræ, which sends connective-tissue septa between the bundles of the overlying orbicularis (as just mentioned) going to the skin. In the orbital part of this lid the central connective tissue includes also the palpebral fascia, lying here immediately beneath the orbicularis muscle; but this soon thins off and fades into the more deeply placed levator expansion. This latter is strengthened by an extension of the sheath of the superior rectus, by which this muscle is enabled to influence the elevation of the lid indirectly. In the lower lid the central connective tissue similarly consists of palpebral fascia, blended with a thin fibrous extension of the sheath of the inferior rectus. Immediately in front of each tarsus is a little loose connective tissue, which contains the large blood-vessels and nerves of the lids.

The **tarsus** of each lid is a stiff plate of close connective tissue, with its surfaces directed anteriorly and posteriorly; in its substance the tarsal glands are

embedded. One tarsal border is free, viz., toward the edge of the lid, the other is attached; the former is straight, while the latter is convex, especially in the upper lid.

The length of each tarsus is about twenty millimetres. Its breadth is greatest in the middle of the lid, and becomes gradually smaller toward each angle, where the tarsi are joined to the lateral raphe and medial palpebral ligament. The breadth of the upper tarsus (10 mm.) is about twice that of the lower. The thickness of each is greatest, and its texture closest, at the middle of its length, thinning off toward the angles of the eye and toward both borders. Into the superior anterior border of the upper tarsus the lower layer of the levator expansion is attached, consisting of smooth muscle-fibres constituting the **superior tarsal muscle** of Müller. In like manner, at the inferior border of the lower tarsus, bundles of smooth muscle-fibre are inserted (the **inferior tarsal muscle** of Müller), developed in what has been regarded as part of the extension of the sheath of the inferior rectus.

The **palpebral conjunctiva** is firmly adherent to the posterior aspect of the tarsus; but in the orbital part of the lid loose subconjunctival tissue intervenes between it and Müller's tarsal muscle. Lymphoid tissue occurs in the substance of the conjunctiva, especially in its orbital division. Near the upper fornix, the conjunctiva receives expansions of the tendon of the levator palpebræ and of the sheath of the superior rectus, and, at the lower fornix, of the sheath of the inferior rectus. The surface of the tarsal conjunctiva shows small elevations or papillæ everywhere; but these are particularly well marked over the attached border of the tarsus.

Glands of the eyelids.—From its manner of formation the eyelid may be regarded as consisting of two thicknesses of skin, the posterior having been doubled back upon the anterior at the edge of the lid; thus the epidermis and corium of the skin proper are represented respectively by the conjunctiva (epithelium) and tarsus of the inner thickness. At the free border of the lid, accordingly, we find glands corresponding to the sebaceous and sweat-glands of the skin, viz., large sebaceous glands of the cilia (Zeiss's glands) and the ciliary glands of Moll, which are modified sweat-glands. Again, in the inner skin-thickness of the lid, the tarsal (Meibomian) glands are sebaceous.

Acino-tubular mucous glands occur at the attached border of the tarsus (Krause's or Waldeyer's glands), and similar glands also occur at the fornix, and are especially abundant near the outer angle of the upper lid, close to the efferent ducts of the lacrimal gland; from their structure and the character of their secretion, these acinous or acino-tubular glands have been termed by Henle 'accessory lacrimal glands.' Other simple tubular glands (Henle), formed merely by the depressions between the papillæ, are best developed in the medial and lateral fourths of the tarsal conjunctiva of both lids.

Blood-vessels.—The arteries run in the central connective tissue of the lids, mainly in the form of arches near the borders of the tarsus, from which twigs go to the different palpebral tissues. They are supplied by the lacrimal and palpebral branches of the ophthalmic, and by small branches derived from the temporal artery. The veins are more numerous and larger than the arteries, and form a close plexus beneath each fornix. They empty themselves into the veins of the face at the medial, and into the orbital veins at the lateral angle of the eye.

The **lymphatic vessels of the lids** are numerous, and are principally situated in the conjunctiva. Lymph-spaces also surround the follicles of the tarsal glands. The palpebral lymphatic vessels from the lateral three-fourths of the lid pass through the anterior auricular and parotid nodes; those from the medial fourth of the lower lid go to the facial and submaxillary lymphatic nodes.

Nerves.—(*a*) **Sensory.** The upper lid is chiefly supplied by branches of the supraorbital and supratrochlear nerves, the lower lid by one or two branches of the infraorbital. At the medial angle the infratrochlear nerve also aids in the supply, and, at the lateral angle, the lacrimal. (*b*) **Motor.** The palpebral part of the orbicularis is supplied by branches of the facial nerve, which mainly enter it near the lateral angle. The tarsal muscles are supplied by the sympathetic nervous system.

The **medial palpebral ligament** has been referred to previously. Arising from the frontal process of the maxilla, it extends laterally over the front wall of the lacrimal sac, bends round the lateral wall of the sac, and then passes backward to the posterior crest on the lacrimal bone. It is thus U-shaped, having its limbs anterior and posterior, embracing the lacrimal sac; the anterior limb lies immediately beneath the skin, and is visible in the living. The palpebral fibres of the orbicularis are inserted into the anterior surface of both limbs, those attached to the posterior limb constituting the pars lacrimalis of the orbicularis palpebrarum (Horner's muscle). The **lateral palpebral raphe** is merely a stronger development of connective tissue in the orbicularis. Both ligaments are connected with the tarsi as already mentioned.

The Lacrimal Apparatus

The tears are secreted by an acinous gland, and flow through fine ducts to the upper lateral part of the conjunctival sac, whence they pass over the cornea and are drained off through the puncta, pass along the canaliculi into the lacrimal sac, and ultimately down the naso-lacrimal duct to the inferior meatus of the nose.

The **lacrimal gland** is situated near the front of the lateral part of the roof of the orbit, lying in a depression in the orbital plate of the frontal bone. It consists of two very unequal parts, one placed above and the other beneath the tendinous expansion of the levator palpebræ superioris, but small gaps in the expansion permit of connections between these two parts of the gland. The upper and larger subdivision (*superior lacrimal gland*) is a firm elongated body, about the size of a small almond; it has a greyish-red colour, and is made up of closely aggregated lobules. The upper surface (next the orbital roof) is convex, and its lower surface is slightly concave.

Anteriorly, the gland almost reaches the upper orbital margin, and it extends backward for approximately one-fourth the depth of the orbit, measuring about twelve millimetres in this direction. The lateral border of the gland descends to near the insertion of the fascial expansion of the lateral rectus, while its medial border almost reaches the lateral edge of the superior rectus; its transverse measurement is about twenty millimetres. It is enveloped in a capsule, which is slung by strong fibrous bands passing to its medial border from the orbital margin (suspensory ligament of the gland).

Fig. 822.—Dissection of the Eye to Show the Lacrimal Apparatus, Anterior View.

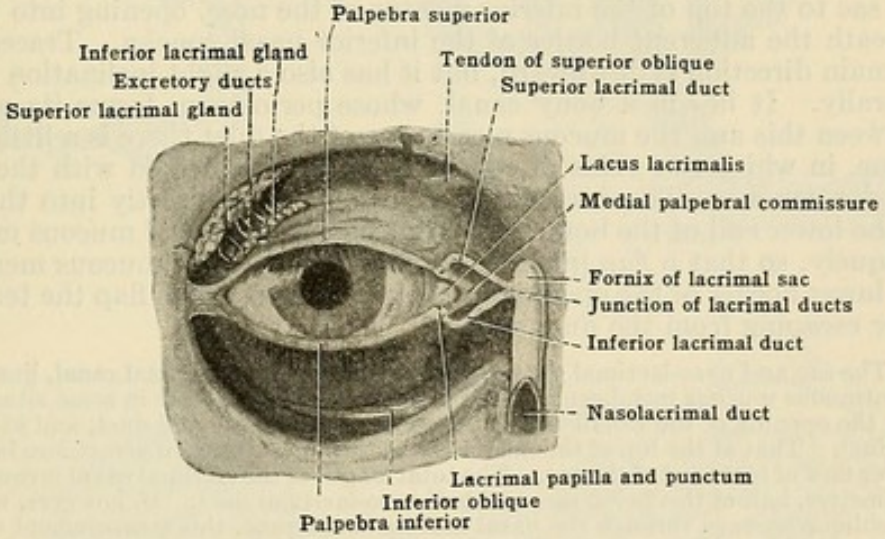

The lower subdivision of the gland (*inferior lacrimal gland*) is composed of loosely applied lobules, and lies immediately over the lateral third of the upper conjunctival fornix, reaching lateralward as far as the lateral angle.

Each subdivision of the gland possesses several **excretory ducts,** which all open on the lateral part of the upper fornix conjunctivæ, about four millimetres above the upper border of the tarsus. Those of the superior gland, three or four in number, pass between the lobules of the lower gland; the most lateral duct is the largest, and opens at the level of the lateral angle of the eye. The ducts of the inferior gland in part discharge themselves into those of the upper, but there are also several fine ducts from this subdivision that run an independent course.

Near the medial angle are the two **puncta lacrimalia,** upper and lower, each situated at the summit of its papilla. The top of each papilla curves backward toward the conjunctival sac, so that the puncta are well adapted for their function of draining off any fluid collecting there.

The **ductus (canaliculi) lacrimales** extend from the puncta to the lacrimal sac. The lumen at the punctum is horizontally oval, from its lips being slightly compressed antero-posteriorly; the lumen of the lower punctum is somewhat larger than that of the upper. As the lower papilla is a little further from the medial angle of the eye than the upper, the corresponding canaliculus is longer.

On tracing either ductus from its origin, we find that at first it runs nearly vertically for a short distance, then bends sharply toward the nose, and finally

courses more or less horizontally, converging slightly toward its fellow, and not infrequently joining it before opening into the sac. The calibre varies considerably in this course, being narrowest a short distance from the punctum, and widest at the bend, from which point it again narrows very gradually as it nears the sac.

The wall of the ductus consists mainly of elastic and white fibrous tissue, lined internally by epithelium, and covered externally by striated muscle (part of the orbicularis). The muscle-fibres run parallel to the ductus in the horizontal part of its course; but they are placed, some in front and some behind, around the vertical part, acting here as a kind of sphincter. Just before their termination, the ducts pierce the periosteal thickening that constitutes the posterior limb of the medial palpebral ligament.

The **lacrimal sac** [saccus lacrimalis] lies in a depression in the bone at the medial angle of the orbit (the lacrimal fossa). It is vertically elongated, and narrows at its upper and lower ends; the upper extremity or *fundus* is closed, while the lower is continuous with the naso-lacrimal duct. Laterally, the sac is somewhat compressed, so that its antero-posterior is greater than its transverse diameter. The ducts, either separately or by a short common tube, open into a bulging on the lateral surface of the sac near the fundus.

As has previously been mentioned, the sac is surrounded by periosteum, but between this and the mucous membrane forming the true sac-wall there is a loose connective tissue, so that the cavity is capable of considerable distention. The relations of the medial palpebral ligament have already been described; it is to be noted that the fundus of the sac extends above this ligament.

The **naso-lacrimal duct** [ductus naso-lacrimalis] reaches from the lower end of the sac to the top of the inferior meatus of the nose, opening into the latter just beneath the adherent border of the inferior nasal concha. Traced from above, its main direction is downward, but it has also a slight inclination backward and laterally. It lies in a bony canal, whose periosteum forms its outer covering. Between this and the mucous membrane of the duct there is a little intermediate tissue, in which run veins of considerable size connected with the plexus of the inferior concha. The duct does not usually open directly into the nasal cavity at the lower end of the bony canal, but pierces the nasal mucous membrane very obliquely, so that a *flap* [plica lacrimalis (Hasneri)] of mucous membrane covers the lower border of the opening in the bone, upon which flap the tears first trickle after escaping from the duct proper.

The sac and naso-lacrimal duct together constitute the **lacrimal canal,** lined throughout by a continuous mucous membrane. This membrane presents *folds* in some situations, especially near the opening of the canaliculi, at the junction of the sac and duct, and at the lower end of the duct. That at the top of the duct is the most important, as it sometimes interferes with the proper flow of tears out of the sac. The total length of the lacrimal canal is roughly twenty-four millimetres, half of this being sac, and half naso-lacrimal duct. If, however, we reckon as duct the oblique passage through the nasal mucous membrane, this measurement may occasionally be increased by eight or ten millimetres. The lacrimal sac, when distended, measures about six millimetres from before backward, by four millimetres transversely. The naso-lacrimal duct is practically circular, and has a diameter of about three millimetres, rather less at its junction with the sac, where we find the narrowest part of the whole lacrimal canal.

Development of the Eye

The eye is developed from the three sources involving two fundamental embryonic layers—the retina from a portion of the ectodermal wall of the forebrain on each side; the lens from the ectodermal surface epithelium; and the sclera, cornea (except epithelium) and chorioidal coat from the mesoderm which surrounds the former structures.

The process of development is, briefly, as follows:—The site of the eye is marked by a slight depression on the surface of the forebrain on either side. There later an outgrowth occurs from the ventro-lateral aspect on each side of the forebrain, in the form of a hollow vesicle, whose cavity is continuous with that of the forebrain. This outgrowth is termed the *primary optic vesicle* [vesicula ophthalmica]. The lateral surface of the vesicle comes into contact with the surface epithelium of the head and this epithelium becomes thickened at the area of contact. The superficial portion of the vesicle expands, while its connection with the brain remains slender; becoming depressed on the surface, it forms a cup-shaped hollow, the *secondary optic vesicle* or *optic cup* [caliculus ophthalmicus] whose wall is formed of two layers, an outer investing layer and an inner inverted one.

The *chorioidal fissure* is present almost from the first stages, as a cleft on the ventral aspect of both the distal portion of the vesicle, or cup, and of the stalk; and it is formed by an infolding of the surface into the cavity of the vesicle along a narrow linear area.

In this cleft are found vessels which pass to the hollow of the optic cup. The margins of the cleft meet and fuse, and enclose the vessels in the interior—hence the enclosure of the a. centralis retinæ within the optic nerve, and of the hyaloid artery in the interior of the vitreous. Should the margins of the cleft remain separate, the condition of coloboma results.

From the optic cup is formed the whole of the retinal or nervous tunic. It will be noticed that this tunic is composed of two layers, with a narrow slit-like interval between them, but that the layers are continuous with one another at the margin of the cup. This margin is afterward found, in the fully developed eye, at the pupillary margin of the iris. The outer investing layer forms the pigment layer, and the inner inverted layer gives rise to the other parts of the retina, viz., the pars optica, over the bottom of the cup, the pars ciliaris, in the ciliary region, and the pars iridica, near the margin of the original cup, including the dilatator and sphincter pupillæ muscles of the iris.

The *lens* is formed as a hollow invagination from the surface epithelium, which sinks into the hollow of the optic cup. The margins meet and fuse, enclosing a cavity, and the lens mass sinking more deeply in, loses its connection with the surface, and a layer of mesoderm passes in between them.

The anlages of the lens and the primitive retina are at first in contact with one another. They gradually draw apart, and the intervening space is filled by the *vitreous humour*. The origin of the vitreous humour is not yet fully understood, but it appears to be developed from the adjacent ectoderm of the optic cup, and in part from the surrounding mesoderm.

FIGS. 823, 824, 825 AND 826.—SECTIONS REPRESENTING FOUR SUCCESSIVE STAGES IN THE ORIGIN OF THE OPTIC VESICLE AND THE DEVELOPMENT OF THE EYEBALL.

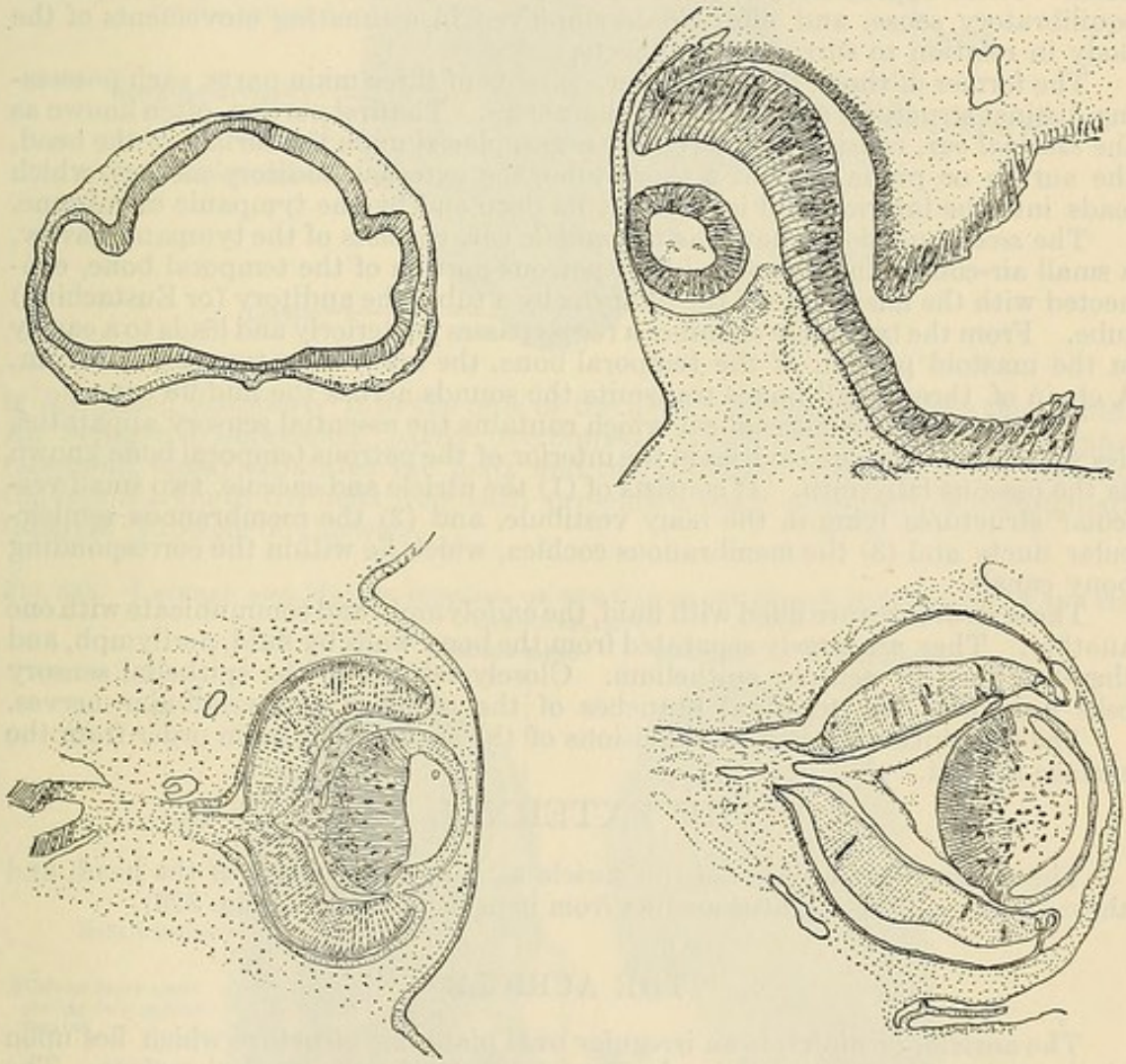

The optic cup and the lens are surrounded by mesoderm and from it are formed the structures of the tunica vasculosa (middle coat) in its different parts, viz., chorioid, ciliary body and iris, and also the sclera and cornea (fibrous portion).

The anterior chamber is formed by cleavage of the mesoderm, a space appearing in it, filled with fluid. The mesoderm surrounding this space forms the endothelium lining the anterior chamber. The mesoderm also forms a vascular covering for the front of the lens, termed the *capsula vasculosa lentis*, or pupillary membrane, which disappears from the surface of the lens in the later months of development.

The eyelids and conjunctiva are formed from the integumentary covering of the eye. The former are mostly skin folds, which, at first separate, meet and fuse with one another along their margin. Subsequently they become undermined by the ingrowth of epithelium from a central horizontal slit, the rima palpebrarum; the central part of the invading epithelium breaks down, and the free folds are formed.

The lacrimal gland is developed from a series of tubular outgrowths from the conjunctival sac.

The lacrimal canals and naso-lacrimal duct are formed by the growth of an epithelial band which passes through the mesoderm to the nasal cavity along the naso-lacrimal groove. This band loses its primitive connection with the groove, and is reunited to the lid margins by secondary epithelial bands which grow from the naso-lacrimal duct to the lid margin. Similarly a secondary connection is later made with the nasal cavity at the lower end of the duct. The position of the naso-lacrimal duct corresponds to the line of union of the nasal and maxillary processes; but the duct does not represent a portion of the cleft between these processes, and is formed secondarily between them.

IV. THE EAR

Under the name of the ear [organon auditus] there is included a number of structures of which some, the ear proper, constitute the auditory mechanism—that is, an apparatus for the collection, transmission and reception of the waves of sound; while others—the semicircular ducts and associated structures—are concerned in receiving and transmitting impressions produced by movements of the head. These impressions constitute the basis of what may be termed the static or equilibratory sense, and afford data employed in estimating movements of the body in relation to surrounding objects.

The former of these, the ear proper, consists of three main parts, each possessing distinct structural and functional characters. The first portion, often known as the *external* ear, consists of a receptive organ placed upon the surface of the head, the auricle or pinna, and of a short tube, the external auditory meatus, which leads into the interior, and is closed at its deep end by the tympanic membrane.

The *second* portion, known as the *middle* ear, consists of the tympanic cavity, a small air-containing chamber in the petrous portion of the temporal bone, connected with the nasal part of the pharynx by a tube, the auditory (or Eustachian) tube. From the tympanic chamber a recess passes posteriorly and leads to a cavity in the mastoid portion of the temporal bone, the mastoid or tympanic antrum. A chain of three small bones transmits the sounds across the middle ear.

The third part, or *internal* ear which contains the essential sensory apparatus, lies within the complex cavities in the interior of the petrous temporal bone known as the osseous labyrinth. It consists of (1) the utricle and saccule, two small vesicular structures lying in the bony vestibule, and (2) the membranous semicircular ducts and (3) the membranous cochlea, which lie within the corresponding bony canals.

These structures are filled with fluid, the endolymph, and communicate with one another. They are largely separated from the bony walls by fluid, perilymph, and they are lined by sensory epithelium. Closely related to the epithelial sensory cells are found the terminal branches of the cochlear and vestibular nerves.

The description of the three divisions of the ear is taken up in order from the surface inward.

1. THE EXTERNAL EAR

The **external ear** consists of the auricle attached to the side of the head, and the external auditory meatus leading from it to the middle ear (fig. 829).

THE AURICLE

The **auricle,** or pinna, is an irregular oval plate-like structure which lies upon the lateral surface of the head. It presents a lateral and a medial surface. The lateral surface is irregularly concave (fig. 827). The deepest part of its concavity situated near the centre, is termed the **concha,** and it is partially divided by a prominent oblique ridge, the **crus of the helix,** into a superior part, the **cymba conchæ,** and a large inferior part, the **cavum conchæ.** The cavum conchæ leads into the external auditory meatus, and is bounded ventrally by a prominent process, the **tragus,** which projects posteriorly over the entrance to the meatus. The tragus, is separated from the crus of the helix by a well-marked depression, the **anterior incisure** and has a small tubercle on it superiorly, the **supratragic tubercle.** Bounding the cavum conchæ posteriorly and inferiorly is a projection, the **antitragus,** lying opposite, but inferior, to the tragus, and between the two is a deep notch, the **intertragic notch** [incisura intertragica]. A prominent semicircular

ridge, the **anthelix,** bounds the concha posteriorly and superiorly. Inferiorly it is separated from the antitragus by a slight depression, the **posterior auricular sulcus.** Superiorly the anthelix divides into two ridges, the **crura of the anthelix,** and between these is a shallow depression, the **triangular fossa.** The superior and dorsal margin of the auricle is inverted and forms a prominent rim, the **helix,** which

FIG. 827—LATERAL SURFACE OF THE LEFT AURICLE.

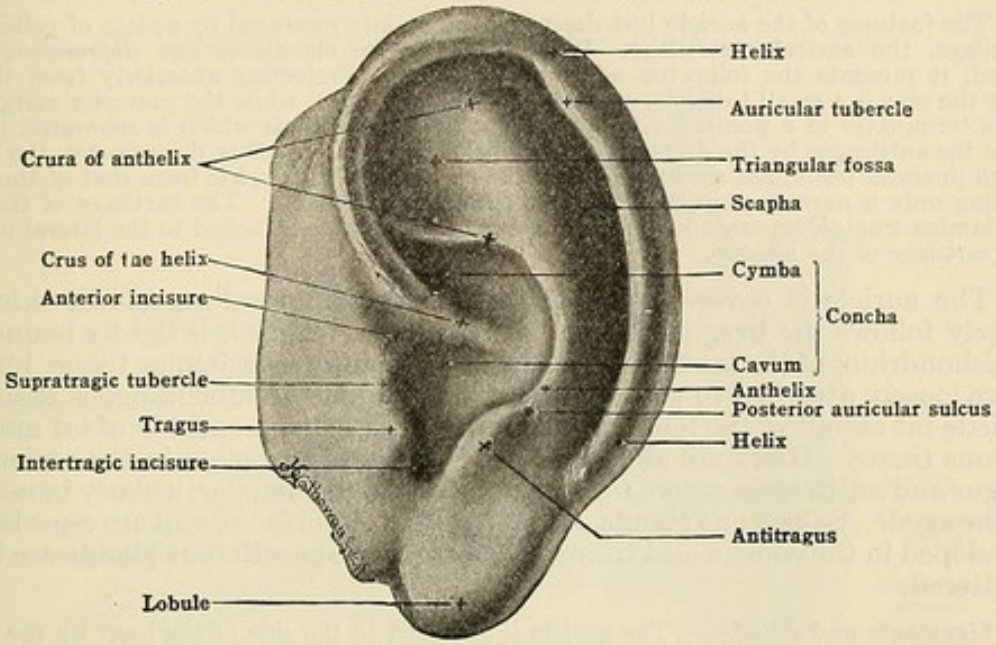

is continued anteriorly into the crus of the helix, and inferiorly into the **lobule.** An elongated depression, partly overlapped by the helix, termed the **scapha** (scaphoid fossa) separates the helix and the anthelix. Superiorly and dorsally the free margin of the helix frequently presents a slight projection, the **auricular tubercle** (tubercle of Darwin).

FIG. 828.—LATERAL AND MEDIAL SURFACE OF THE CARTILAGE OF THE RIGHT AURICLE AND ITS MUSCLES, ETC.

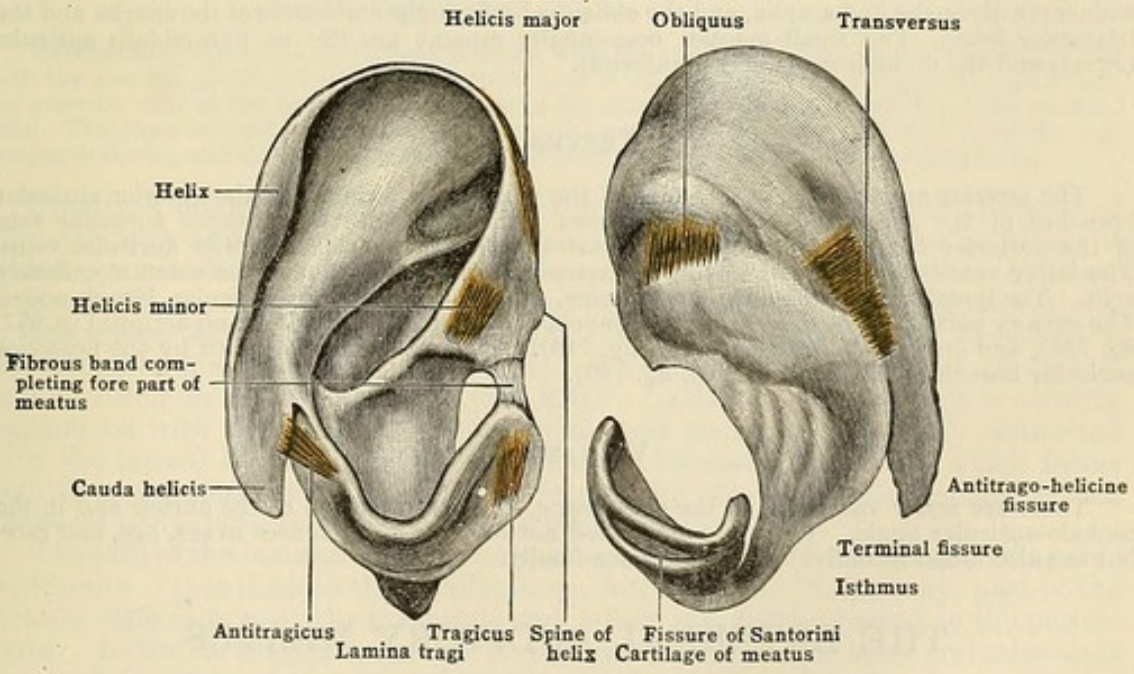

Upon the medial surface of the auricle the depressions of the lateral surface are represented by elevations, viz., the **eminence of the concha,** the **eminence of the scapha,** and the **eminence of the triangular fossa,** respectively; and the elevations by depressed areas, viz., the **fossa of the anthelix, transverse sulcus of the anthelix,**

and the **sulcus of the crus of the helix.** The attachment of approximately one-third of the medial surface covers up the two latter depressions. The **cephalo-auricular angle,** between the dorsal free part of the auricle and the side of the head, averages 20 to 30 degrees.

Structure of the Auricle

The features of the auricle just described are mainly produced by a plate of yellow elastic cartilage, the **auricular cartilage.** In addition to the elevations and depressions already noted, it presents the following additional features. Projecting anteriorly from the helix, near the crus is a small tubercle, **spine of the helix** (fig 828); while the posterior margin of the helix terminates in a pointed tail-like process, the **cauda helicis** which is separated inferiorly from the antitragus by the deep **antitrago-helicine fissure.** Another deep fissure, the **terminal notch** [incisura terminalis auris], separates the cartilage of the auricle from that of the meatus, leaving only a narrow strip, the **isthmus,** connecting the two. The cartilage of the tragus, the **lamina tragi,** is separated from that of the auricle and is attached to the lateral margin of the cartilage of the meatus.

The auricle is covered on both its medial and lateral aspects by skin which closely follows the irregularities of the cartilage. Thus it is tightly bound to the perichondrium of the lateral surface by the subcutaneous areolar tissue, but much more loosely attached to the medial surface, and in the subcutaneous tissue there is little fat except in the lobule, which is made up almost entirely of fat and tough fibrous tissue. **Hairs** are abundant but rudimentary, except in the region of the tragus and antitragus, where they may be large and long, particularly in males and in the aged. **Sebaceous glands** are found on both surfaces, and are especially well developed in the concha and triangular fossa, but **sudoriferous glands** are few and scattered.

Ligaments and muscles.—The auricle is attached to the side of the head by the skin, by the continuity of its cartilage with that of the acoustic meatus, and by certain extrinsic ligamente and muscles. Three ligaments may be distinguished in the connective tissue:—The **anterior ligament,** stretching from the zygoma to the helix and tragus; the **superior ligament,** from the superior margin of the bony external acoustic meatus to the spine of the helix; and the **posterior ligament,** from the mastoid process to the eminence of the concha. There are also three extrinsic muscles, the anterior, superior, and posterior auricular (see p. 337, fig. 341). Six intrinsic muscles are distinguished. These are poorly marked in man and vary much in development. Upon the lateral surface (fig. 828) the **helicis major** stretches from the spine of the helix to the ventral superior margin of the helix; the **helicis minor** overlies the crus helicis; the **tragicus** runs vertically upon the tragus; and the **antitragicus** stretches from the antitragus to the cauda helicis. Upon the medial surface (fig. 828) the **transversus auriculæ** stretches between the eminences of concha and scapha, and the **obliquus** between the eminences of the concha and the triangular fossa. Two small muscles occasionally present are the m. pyramidalis auriculæ (Jungi) and the m. incisuræ helicis (Santorini).

Vessels and Nerves of the Auricle

The **arteries** are the auricular branch of the posterior auricular and the anterior auricular branches of the superficial temporal arteries. The **veins** are the anterior auricular **vein** of the posterior facial (temporal) and the auricular branches of the posterior auricular veins. The latter vessels sometimes join the transverse (lateral) sinus through the mastoid emissary vein. The **lymphatics** empty into the anterior, posterior and inferior auricular lymph-nodes. The sensory **nerves** of the auricle are the branches of the great auricular, small occipital (p. 977, fig. 753), and auriculo-temporal (p. 941, fig. 740). The muscles are supplied by the posterior auricular branch of the facial (p. 944, fig. 740).

Variations

There are many variations in the size, shape, and conformation of the auricle and in the cephalo-auricular angle. These are associated not only with differences in sex, age, and race, but are also found in individuals of the same family.

THE EXTERNAL AUDITORY MEATUS

The **external auditory (acoustic) meatus** [meatus acusticus externus] extends medially and somewhat anteriorly and inferiorly from the concha to the tympanic membrane (fig. 829). It is about twenty-five mm. (1 in.) long, and, owing to the obliquity of the tympanic membrane, its anterior and inferior wall is 5–6 mm.

longer than the posterior and superior. It consists of a lateral **cartilaginous** and a medial **osseous portion.** The canal describes an S-shaped curve in both horizontal and vertical directions. Near the auricular end it is convex anteriorly and inferiorly, while at the tympanic end the curve is reversed, and is concave in the same direction. The lumen is irregularly elliptical in outline, the longer axis being vertical at the auricular, but nearly horizontal at its tympanic end. The meatus is constricted at about its centre, and also near the tympanum.

FIG. 829.—VERTICAL SECTION OF THE MIDDLE AND EXTERNAL EAR.

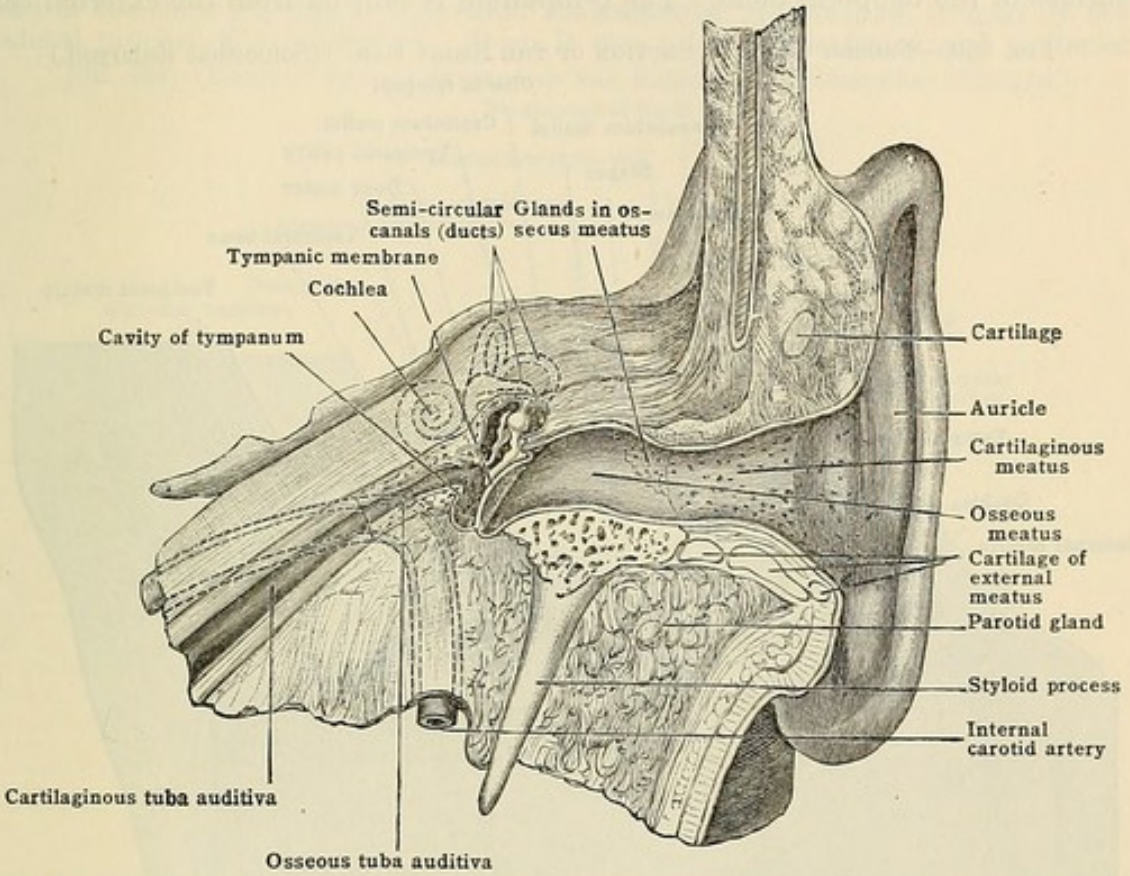

Relations.—The *anterior wall* is in relation with the condyle of the mandible medially, and with the parotid gland laterally; the *inferior wall* is closely bound to the parotid gland; and the *posterior wall* of the bony part is separated by only a thin plate of bone from the mastoid cells. The *superior wall* is separated at its medial end by a thin plate of bone from the epitympanic recess, and laterally a thicker layer of bone separates it from the cranial cavity.

Structure of the meatus.—The walls of the meatus are formed laterally of fibro-cartilage and medially of bone, lined internally by skin. The cartilage is folded upon itself to form a groove, deficient in its dorsal part, where the edges of the cartilage are united by dense connective tissue. The cartilaginous groove is thus converted into a canal. Medially, the cartilage forms about one-third of the circumference; laterally, two-thirds. Two fissures (*incisures of Santorini*) usually occur in its anterior wall (fig. 828). Laterally the cartilage is directly continuous with the cartilage of the auricle and medially it is firmly connected with the lateral lip of the osseous portion. The **osseous portion,** which forms slightly more than half the canal, is formed by the tympanic portion of the temporal bone; it is described in connection with that bone.

The **skin of the meatus** forms a continuous covering for the canal and tympanic membrane. It is thick in the cartilaginous, but very thin in the bony, part of the meatus, especially near the tympanic end, where it is tightly bound to the periosteum. In the cartilaginous meatus it contains numerous fine hairs and sebaceous glands, but neither hairs nor sebaceous glands are found in the bony meatus. Tubular **ceruminous glands,** which secrete the **cerumen** (ear wax), form a nearly continuous layer throughout the cartilaginous, but occur on only a small part of the posterior and superior wall of the bony, meatus. The openings of their ducts appear as dark points to the naked eye (fig. 829).

The **arteries** are branches from the posterior auricular, superficial temporal, and deep auricular arteries (q. v.). The **veins** and **lymphatics** connect with those of the auricle and empty similarly. The **nerves** are branches from the auriculo-temporal and the auricular ramus of the vagus.

2. THE MIDDLE EAR

Under the term middle ear there are included the tympanic cavity (tympanum), the tympanic antrum and the auditory (Eustachian) tube. These form a continuous irregular passage, filled with air, and located within and upon the surface of the temporal bone. The tympanum is shut off from the external ear

FIG. 830.—FROZEN CORONAL SECTION OF THE RIGHT EAR. (Somewhat Enlarged.)

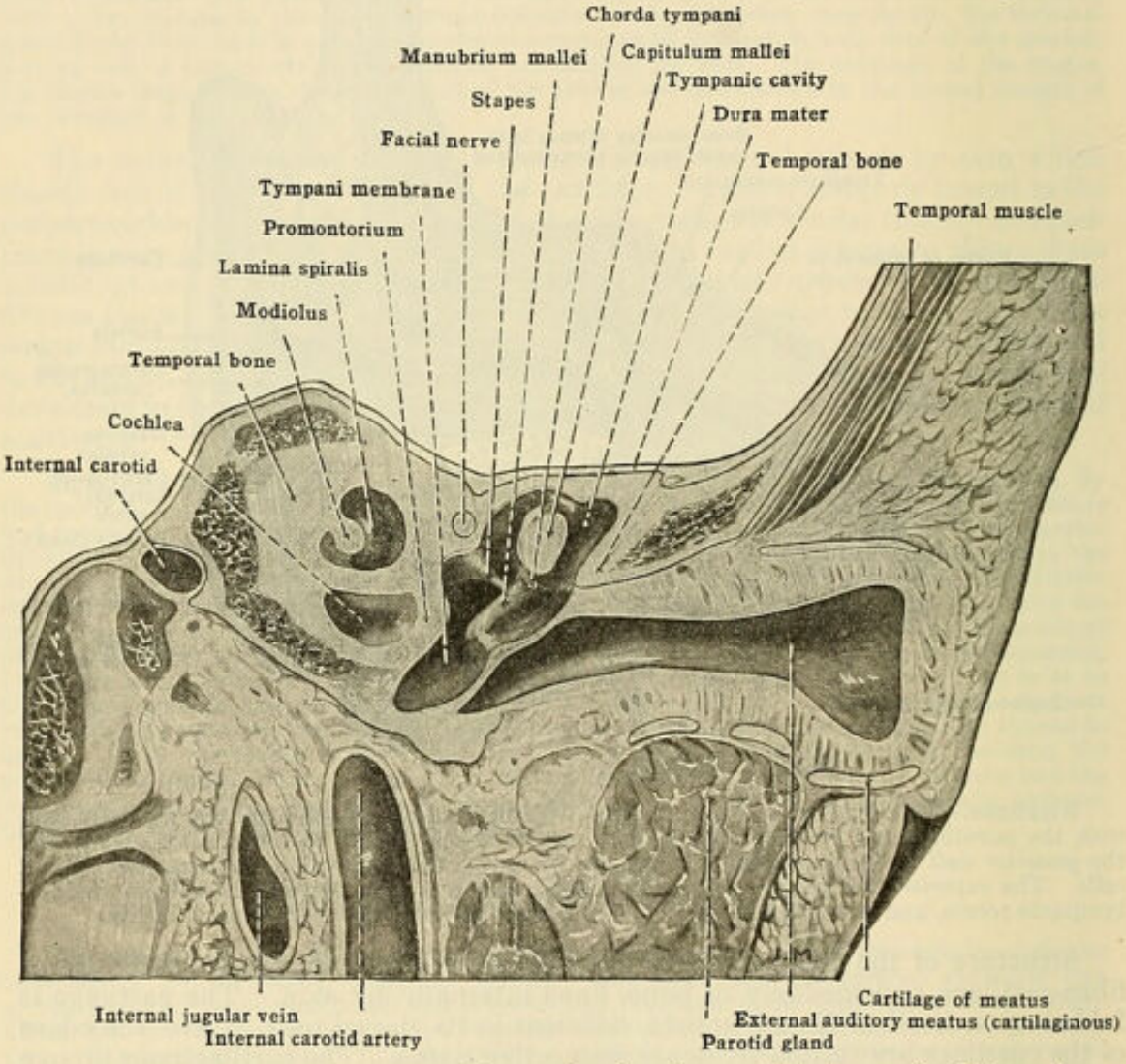

by the tympanic membrane; and from the chamber which forms the internal ear by the structures which fill in the cochlear and vestibular fenestræ. It communicates with the pharynx by the auditory (Eustachian) tube. The structures of the middle ear are of importance, and the study is somewhat difficult, on account of the small size of the structures, the depth at which they lie, and the hard character of the surrounding bone.

The illustrations (figs. 829, 830, 831, 833, 834) will help to explain the text and should be constantly referred to. Figs. 830 and 831 are taken from frozen sections traversing the right ear in the coronal planes; while figs. 833, 834 represent dissections.

The parts to be considered in order are the tympanic membrane, the tympanic cavity, the tympanic antrum and the auditory (Eustachian) tube.

THE TYMPANIC MEMBRANE

The **tympanic membrane** [membrana tympani] (fig. 835) is elliptical in shape, its long axis nearly vertical, measuring 9 to 10 mm., its short axis, 8 to 9 mm. It slopes medially from the superior and posterior to the inferior and anterior

wall of the meatus, forming, as a rule, with the superior wall, an angle of 140 degrees. It varies, however, greatly in form, size, and obliquity. Viewed from the meatus, it appears as a semitransparent membrane, which sometimes has a reddish tinge. It is drawn medially and made funnel-shape by the manubrium of the malleus, but the walls of the funnel bulge toward the meatus (fig. 834). The most depressed point at its centre, the **umbo,** is slightly inferior and posterior to the centre of the membrane, and corresponds to the tip of the manubrium (fig. 832). From it a whitish streak, the **malleolar stria,** caused by the manubrium shining through, passes superiorly toward the circumference. At the superior end of the stria is a slight projection, the **malleolar prominence,** formed by the lateral process of the malleus. From it two folds, the **anterior and posterior**

FIG. 831.—FROZEN CORONAL SECTION OF THE RIGHT EAR. (Somewhat Enlarged.)

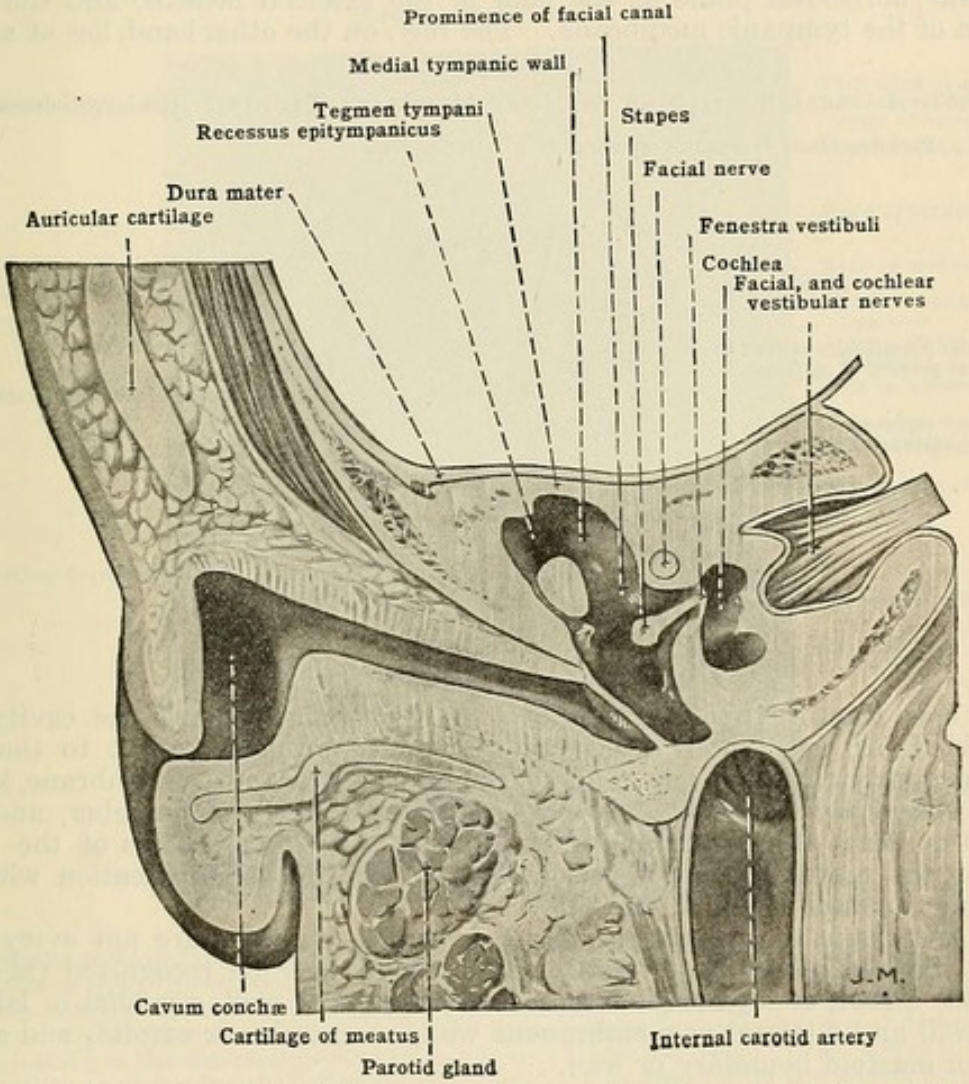

plicæ, stretch to the extremities of the tympanic sulcus (fig. 832). The small triangular area of the membrane bounded by the plicæ, is termed the **pars flaccida** (Shrapnell's membrane). It is thin and flaccid, and is attached directly to the petrous bone in the tympanic notch (notch of Rivinus). The larger part of the tympanic membrane, the **pars tensa,** is inferior to the plicæ and is tightly stretched. Its thickened margin, the **limbus,** is attached by a **fibro-cartilaginous annulus** to the tympanic sulcus, and at the spines of the tympanic ring is continuous with the plicæ.

Structure of the tympanic membrane.—The tympanic membrane is about .1 mm. thick, and consists of four layers. The lateral **cutaneous layer,** relatively thick, is a continuation of the skin lining the external auditory meatus. Next to it is a **radiate fibrous layer,** composed of connective tissue, the fibres of which are attached to the manubrium of the malleus and radiate from it. Medial to it is the **circular fibrous layer,** which has its fibres arranged concentrically and is especially thick at the circumference. It is closely bound to the radiate layer. The **mucous layer,** which is a continuation of the mucosa of the tympanic cavity, covers the medial surface of the membrane smoothly, except where the manubrium of the malleus causes a projection. The fibrous layers are attached to the fibro-cartilaginous ring and are not present in the pars flaccida.

The Tympanic Cavity

The **tympanic cavity** [cavum tympani], as has been stated, is an air-space, lined with mucous membrane, situated between the external and the internal ear. It is of irregular outline, but, roughly, it is a slit-like cavity, lying in an oblique antero-posterior plane. Its transverse diameter measures only from 2–4 mm., while the vertical and antero-posterior diameters measure about 15 mm. (fig. 834).

It is narrowest at the centre, and wider superiorly than inferiorly. The bony walls have already been partly described with the temporal bone, and hence the description given here will refer to the appearance found in the fresh, or unmacerated condition.

It will be noticed (see fig. 829) that the *floor* of the space is on very much the same horizontal plane as the floor of the external meatus, and the lower margin of the tympanic membrane. The *roof*, on the other hand, lies at a much

Fig. 832.—Lateral Surface of the Left Membrana Tympani. (Enlarged from life.)

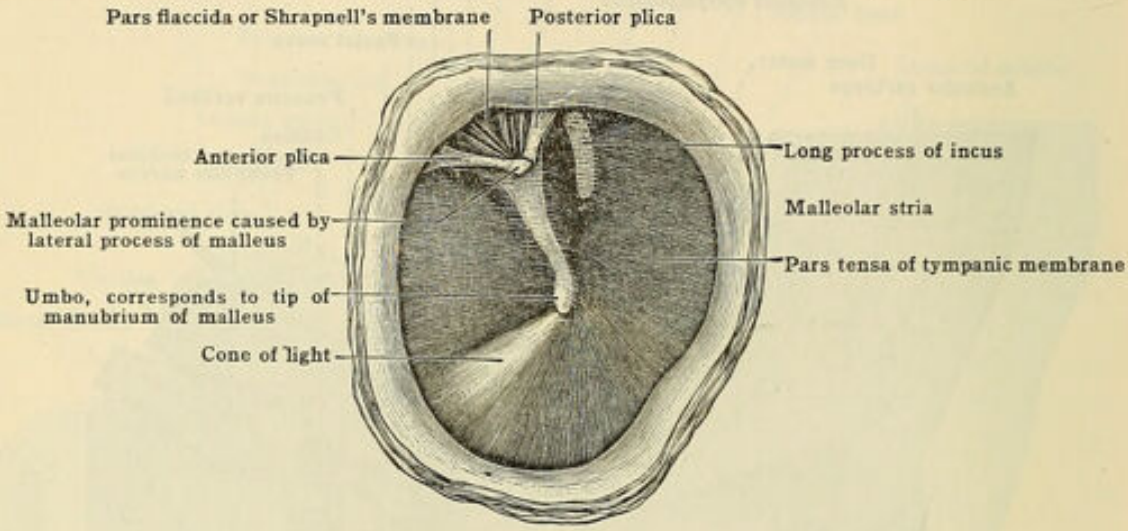

higher level than the upper margin of that membrane. Hence the cavity may be divided into two regions, a *lower* part, corresponding in extent to the tympanic membrane, and an *upper*, above the upper border of the membrane, known as the *epitympanic recess*. This division forms a definite chamber, and contains the head of the malleus and the body and short process of the incus. It is on the posterior part of this chamber that the communication with the tympanic antrum is found (fig. 835).

As the shape of the tympanum is irregular, its walls are not everywhere clearly marked off from one another, but there may be recognized (figs. 829 and 835) a **roof,** or **tegmental** wall, **a floor,** or **jugular** wall, a **medial** or **labyrinthine** wall and a **lateral** or **membranous** wall, an **anterior** or **carotid,** and a **posterior** or **mastoid** boundary or wall.

The roof, or **tegmental wall,** is formed by a portion of the tegmen tympani, a thin plate of bone which is continued backward to form the roof of the tympanic antrum. This plate is formed by the petrous part of the temporal bone, and at its lateral margin is the petro-squamous suture, where a slight deficiency in the roof may occur.

The floor, or **jugular wall** is very narrow transversely, and is in intimate relation to the internal jugular vein (fig. 831). As shown in fig. 833, the surface is frequently very irregular from stalactite-like projections between which are the tympanic cellulæ (air cells), while near the back there is occasionally a marked projection corresponding externally to the root of the styloid process.

The posterior or **mastoid wall** presents at its lower part, many additional tympanic cellulæ, and higher up, an elevation, the *pyramidal eminence*, on whose apex is an aperture transmitting the tendon of the stapedius muscle. The fleshy belly of that muscle is contained in a cavity in the interior of the bony pyramid of the posterior wall. Lateral to this is an aperture, the *apertura tympanica canaliculæ chordæ*, through which the chorda tympani nerve enters the tympanum, covered by a reflexion of the mucous membrane. Between this opening and the pyramid is a slight elevation; and above it is a fossa, termed the *sinus posterior*. Above this again is a recess, where the posterior ligament of the incus is attached, known as the *fossa incudis*. This portion of the posterior wall forms the boundary of the epitympanic recess. Here the cavity of the tympanum is continued with that of the antrum tympanicum, or mastoid antrum,

a large irregular space into which open the mastoid cells (see p. 1092). The boundaries of the orifice are formed above by the tegmen tympani, medially by the prominences of the lateral semicircular canal and facial nerve, and laterally by a plate of bone termed the *scutum*.

The **carotid (anterior) wall** presents superiorly the *tensor tympani muscle* in its canal, and at a lower level the opening of the *tuba auditiva* (Eustachian tube) (fig. 835). Inferiorly, a thin, bony wall, covered with tympanic cellulæ and pierced by the carotico-tympanic nerves, separates the tympanic cavity from the carotid canal.

The **membranous (lateral) wall** is formed mainly by the tympanic membrane, with the small rim of bone to which it is attached, but superiorly the lateral wall of the epitympanic recess is formed by a plate of bone termed the scutum.

The **labyrinth (medial) wall** (fig. 833) presents inferiorly the *promontory*, produced by the first turn of the cochlea with the *tympanic plexus* (Jacobson's nerve) lodged in grooves upon its surface. Inferior and posterior to the promontory is a depression or fossula at the bottom of

FIG. 833.—THE LABYRINTH (MEDIAL) WALL OF THE RIGHT TYMPANUM WITH THE TYMPANIC OSSICLES IN POSITION.

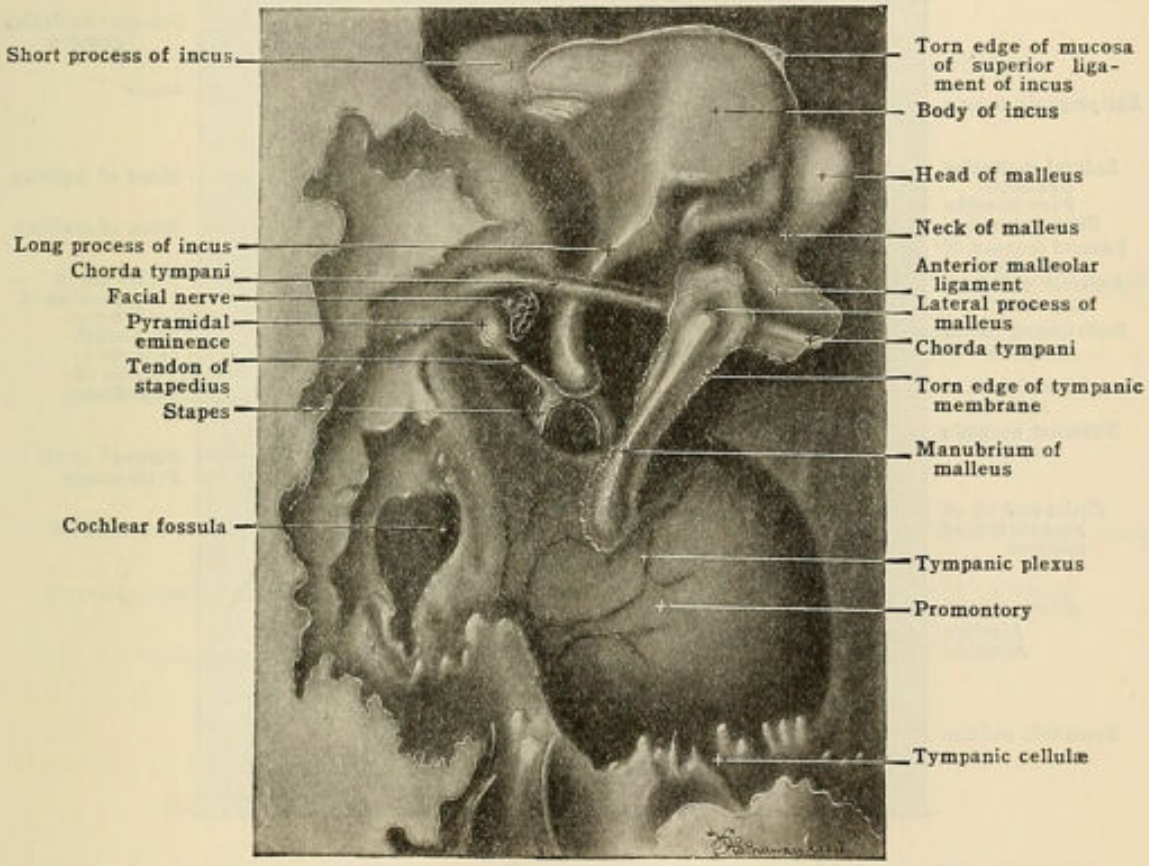

which is the *cochlear fenestra* (fenestra rotunda), closed by the *secondary tympanic membrane*, and posterior to the promontory is a smooth projection, the *subiculum of the promontory*, which forms the inferior border of a rather deep depression known as the *tympanic sinus*. Anteriorly and superiorly is the *cochleariform process*, and superiorly and posteriorly are a depression or fossula leading to the *vestibular fenestra* (*fenestra ovalis*), which is closed by the base of the stapes, the prominence of the facial (Fallopian) canal, and the prominence of the lateral semicircular canal, the two latter being formed in the medial wall of the entrance to the mastoid antrum.

The **tympanic mucous membrane** forms a complete covering for the walls and contents of the tympanic cavity. It is continuous anteriorly with the mucosa of the tuba auditiva (Eustachian tube) and posteriorly with that of the tympanic (mastoid) antrum and mastoid cells. It is a thin, transparent, vascular membrane intimately united to the periosteum. As it passes from the walls to the contents of the tympanic cavity, besides covering the ligaments of the malleus and the incus and the tendons of the tensor tympani and stapedius muscles, it forms a number of special folds and pouches.

The **anterior malleolar fold** is reflected from the tympanic membrane over the anterior process and ligament of the malleus and the adjacent part of the chorda tympani, and the **posterior malleolar fold** stretching between the manubrium and the posterior tympanic wall, surrounds the lateral ligament of the malleus and the posterior part of the chorda tympani. Each of these folds presents inferiorly a concave free border, and between them and the tympanic membrane are two blind pouches, the **anterior and posterior malleolar recesses** or pouches

of Tröltsch. Connected with the posterior recess is a third cul-de-sac, the **superior recess** of the tympanic membrane, or pouch of Prussak, situated between the pars flaccida of the tympanic membrane and the neck of the malleus. The floor of this recess is formed by the lateral process of the malleus, and is lower than its outlet; therefore, the recess may serve as a pocket in which pus or other fluid may accumulate. A somewhat variable fold of mucosa, the **plica incudis,** passes from the roof of the tympanic cavity to the body and short process of the incus. The body and short process of the incus, the head of the malleus, and this fold incompletely separate off a lateral **cupular portion** of the epitympanic recess, and a **stapedial fold** stretches from the posterior wall of the tympanic cavity and surrounds the stapes, including the oburator membrane, which stretches between its crura. Other inconstant folds have been described. The mucosa of the typanic cavity, except over the tympanic membrane, promontory, and ossicles, is covered by a columnar ciliated epithelium.

FIG. 834.—THE TYMPANIC CAVITY, ANTERIOR WALL REMOVED.

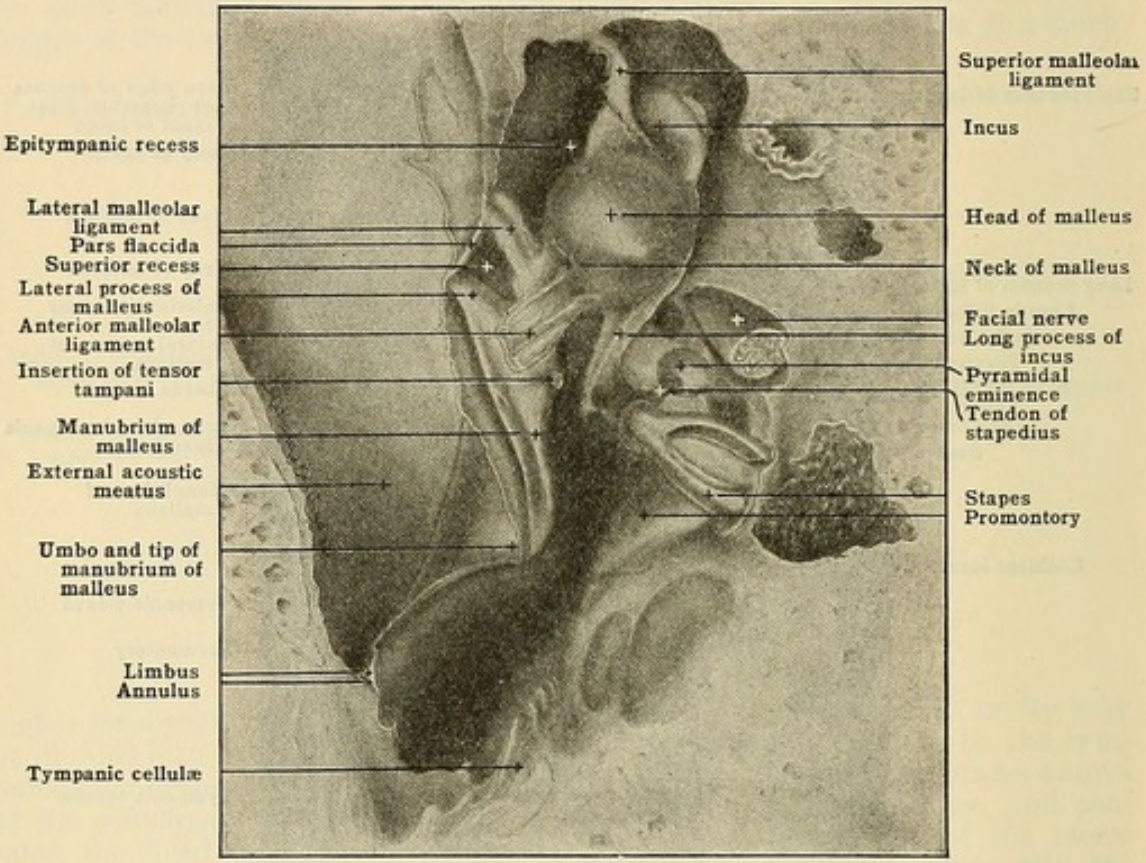

Bones.—The tympanic cavity contains three small movable bones, joined together and to the walls of the cavity, and having attached to them special muscles and ligaments. These auditory ossicles form a chain across the tympanic cavity connecting the tympanic membrane and the vestibular (oval) fenestra. They are the **malleus,** the **incus,** and the **stapes,** and are described in the section on OSTEOLOGY on p. 79.

Articulations of the ossicles.—The manubrium and lateral process of the malleus are imoedded in the tympanic membrane. The margin of the irregularly elliptical articular surface bn the posterior side of the head of the malleus is bound to the body of the incus by a thin capsular ligament, forming a diarthrodial joint, the **incudo-malleolar articulation.** From the inner surface of the capsular ligament, a wedge-shaped rim projects into the joint cavity and incompletely divides it. The long crus of the incus lies parallel to the manubrium of the malleus and on its superior and medial aspect (figs. 833 and 835). It ends in the lenticular process. The convex extremity of this fits into the concavity on the head of the stapes, to form a diarthrodial joint, the **incudo-stapedial articulation.** From its articulation with the incus, the stapes passes almost horizontally across the tympanic cavity to its junction with the medial wall. The cartilage-covered edge of the base is bound to the cartilage-covered rim of the vestibular (oval) fenestra by the annular ligament of the base of the stapes, thus forming the **tympano-stapedial syndesmosis.**

Ligaments of the ossicles.—In addition to the attachment of the manubrium of the malleus and the base of the stapes to the walls of the tympanic cavity, the bones have additional ligamentous attachments. The **superior malleolar liga-**

ment runs almost vertically from the superior wall of the epitympanic recess to the head of the malleus (fig. 834). The **anterior malleolar ligament** extends from the angular spine of the sphenoid bone through the petro-tympanic (Glaserian) fissure to the anterior or long process of the malleus, which it surrounds, and is inserted with it into the neck of the malleus. The **lateral malleolar ligament** is short and thick, and runs from the margins of the tympanic notch (notch of Rivinus) to the neck of the malleus (fig. 834). The **posterior ligament of the incus** passes from the fossa on the posterior tympanic wall to the crus brevis of the incus (fig. 835). The **superior ligament** of the incus is little more than mucous membrane; it runs from the tympanic roof to the body of the incus.

Muscles of the ossicles.—Each of the muscles of the ossicles is contained in a bony canal. The **tensor tympani** is a pinniform muscle about 2 cm. long. It arises from the cartilaginous part of the tuba auditiva (Eustachian tube), from the

FIG. 835.—MEDIAL SURFACE OF RIGHT MEMBRANA TYMPANI. (Enlarged.)

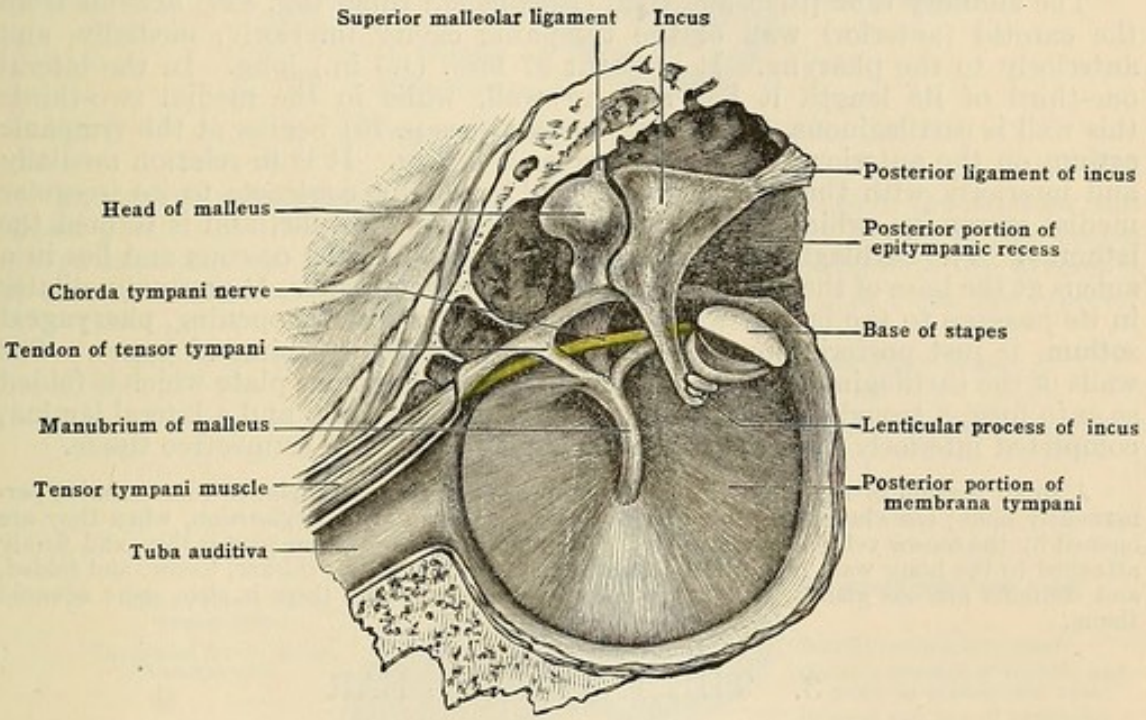

adjacent part of the great wing of the sphenoid, and from the bony walls of the semicanal which encloses it. It ends in a round tendon which turns almost at right angles over the cochleariform process and passes laterally across the tympanic cavity to be attached to the manubrium of the malleus near the neck. It draws the manubrium medially and tightens the tympanic membrane, and is supplied by the motor division of the trigeminal cranial nerve, through the tensor tympani branch from the otic ganglion. The **stapedius** arises in the interior of the hollow pyramidal eminence. The tendon escapes through the openings at the apex and then turns inferiorly and is inserted on the posterior surface of the neck of the stapes. It draws laterally the ventral border of the base of the stapes and is supplied by the facial nerve.

Vessels and nerves.—The **arteries of the tympanic cavity** are the anterior tympanic from the internal maxillary artery (fig. 451), the stylo-mastoid from the posterior auricular artery, the superficial petrosal from the middle meningeal artery, the inferior-tympanic from the ascending pharyngeal (fig. 446), and the carotio-tympanic branch from the internal carotid. The **veins** empty into the superior petrosal sinus and into the posterior facial (temporo-maxillary vein). The **nerves** are the tympanic plexus formed by the tympanic branch of the glosso-pharyngeal (p. 951), and the inferior and superior carotico-tympanic nerves which join the internal carotid plexus of the sympathetic (p. 960). The small superficial petrosal nerve takes its origin from the tympanic plexus, and the chorda tympani crosses the tympanic cavity from the posterior to the anterior wall (p. 948, figs. 738 and 835).

The Antrum Tympanicum

The aperture (*aditus*) in the upper part of the posterior wall of the tympanum leads into the chamber termed the **antrum tympanicum.** This is a comparatively large cavity, of irregular form, lying mainly behind but also somewhat above and lateral to the tympanum, and extends to the medial end of the external auditory meatus. It is lined by mucous membrane, continuous with that of the tympanic cavity, and into it open the **mastoid cells** (cellulæ mastoideæ). These cells are small, irregular cavities in the interior of the mastoid process and they communicate with one another freely. They vary exceedingly in their size and asrangement.

The *antrum tympanicum* has a roof, formed by the tegmen tympani, a posterior wall, separating it from the bend of the transverse sinus, a lateral wall, lying about 10 mm. from the surface of the head, a medial wall, and an anterior wall (see also p. 78).

The Auditory (Eustachian) Tube

The **auditory tube** [tuba auditiva] (Eustachian tube) (fig. 829) extends from the carotid (anterior) wall of the tympanic cavity inferiorly, medially, and anteriorly to the pharynx. It is about 37 mm. (1.5 in.) long. In the lateral one-third of its length it has a bony wall, while in the medial two-thirds this wall is cartilaginous. The **osseous part** (see p. 74) begins at the **tympanic ostium** on the anterior wall of the tympanic cavity. It is in relation medially and inferiorly with the carotid canal, and gradually contracts to its irregular medial extremity, which is the narrowest point in the tube, and is termed the **isthmus.** The **cartilaginous part** is firmly attached to the osseous and lies in a sulcus at the base of the angular spine of the sphenoid bone. It gradually dilates in its passage to the lateral wall of the pharynx, where its opening, **pharyngeal sotium,** is just posterior to the inferior nasal concha (turbinated bone). The walls of the cartilaginous part are formed by a cartilaginous plate which is folded so as to form a trough-like structure, consisting of a medial and a lateral **lamina,** completed inferiorly by a **membranous lamina** formed of connective tissue.

A small portion of the lumen in the superior part of the cartilaginous tube remains permanently open; elsewhere the walls are in contact, except during deglutition, when they are opened by the tensor veli palatini muscles. The mucosa of the osseous part is thin, and firmly attached to the bony wall, but in the cartilaginous part it becomes thicker, looser, and folded, and contains mucous glands, especially near the pharynx, where there is also some adenoid tissue.

3. THE INTERNAL EAR

The **internal ear** [auris interna] is the essential part of the organ of hearing. It consists of a cavity, the osseous labyrinth, contained within the petrous portion of the temporal bone, and enclosing a membranous labyrinth. The **osseous labyrinth** is divided into **cochlea, vestibule,** and **semicircular canals** (see p. 80), and the accompanying figures (338–838)show their position and relations.

It will be noticed that the vestibule forms a central chamber, from which the semicircular canals and the cochlea branch off; the former from the superior and dorsal portion, and the latter from the ventral and inferior.

It will further be noticed that the bony wall of this vestibule shows depressions and ridges on its interior, which are associated with parts of the membranous labyrinth, viz., an upper recess for the utricle (fovea hemielliptica) and a lower recess for the saccule (fovea hemispherica). There are openings in the bony wall for the entrance of nerves to the different parts of the membranous labyrinth, and for the transmission of the ductus endolymphaticus, as well as the small openings of the semicircular canals (ducts) and the opening of the cochlear canal (or duct).

The **membranous labyrinth,** in which the auditory (acoustic) nerves (cochlear and vestibular) end, lies within the osseous labyrinth, the form of which it more or less closely resembles. Thus the membranous semicircular ducts lie within the bony semicircular canals, the membranous cochlear duct within the bony cochlea; while the vestibule contains two small membranous sacs, the utricle and saccule, with their connections. The membranous structures are much smaller in diameter than the osseous, and are partially separated from the bone by an endothelial-lined space which is filled with a fluid, the **perilymph.** The

membranes are in contact, however, with the bony wall along their convex margin, and the utricle, saccule and cochlear canals are in contact with the bony walls over the areas where the nerves enter them. The fluid which fills the membranous labyrinth is termed the **endolymph.**

FIG. 836.—THE OSSEOUS LABYRINTH OF THE RIGHT SIDE.
(Modified from Soemmerring. Enlarged.)

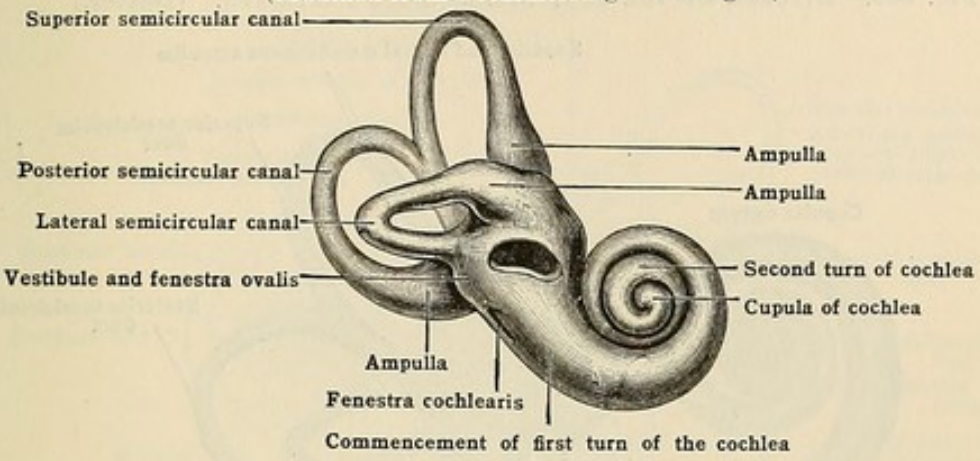

The **utricle** is an oval tubular sac, whose rounded end lies in the superior and dorsal portion of the vestibule. It is here tightly bound to the elliptic recess (fovea hemielliptica) by connective tissue and by the entrance of the filaments of the utricular division of the vestibular nerve as they pass from the superior

FIG. 837.—INTERIOR OF THE OSSEOUS LABYRINTH OF THE LEFT SIDE.
(Modified from Soemmerring. Enlarged.)

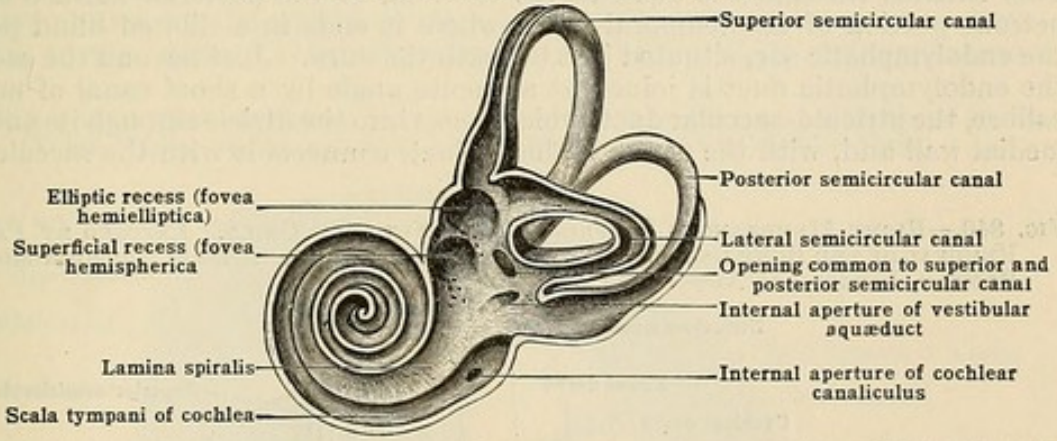

macula cribrosa to the wall of the utricle. In the anterior part of the interior of the utricle, an oval, whitish, thickened area, **macula acustica utriculi,** marks the terminal distribution of the nerve, and posteriorly the utricle is joined by the orifices of the semicircular ducts.

FIG. 838.—INTERIOR OF THE OSSEOUS COCHLEA. (Enlarged.)

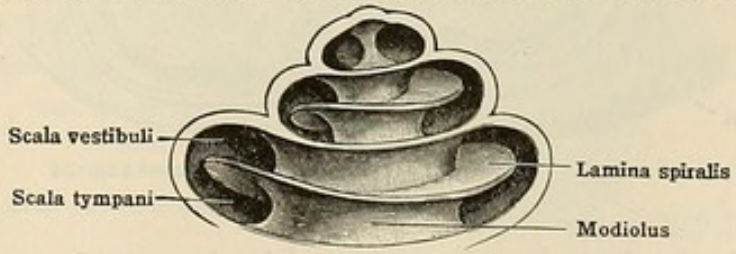

The **saccule** is a flattened, oval sac, smaller than the utricle, and situated in the anterior and inferior part of the vestibule. It is bound to the spherical recess (fovea hemisphærica) by connective tissue and by the saccular division of the

vestibular nerve, filaments of which extend from the middle macula cribrosa to the anterior and medial wall of the saccule, to be distributed over a thickened area, **macula acustica sacculi.** Anteriorly and inferiorly the saccule gradually passes into a short canal, the **ductus reuniens,** which connects it with the cochlear duct, and posteriorly the very small **endolymphatic duct** is attached (fig. 839).

FIG. 839.—DIAGRAM OF THE LEFT MEMBRANOUS LABYRINTH. (Deaver.)

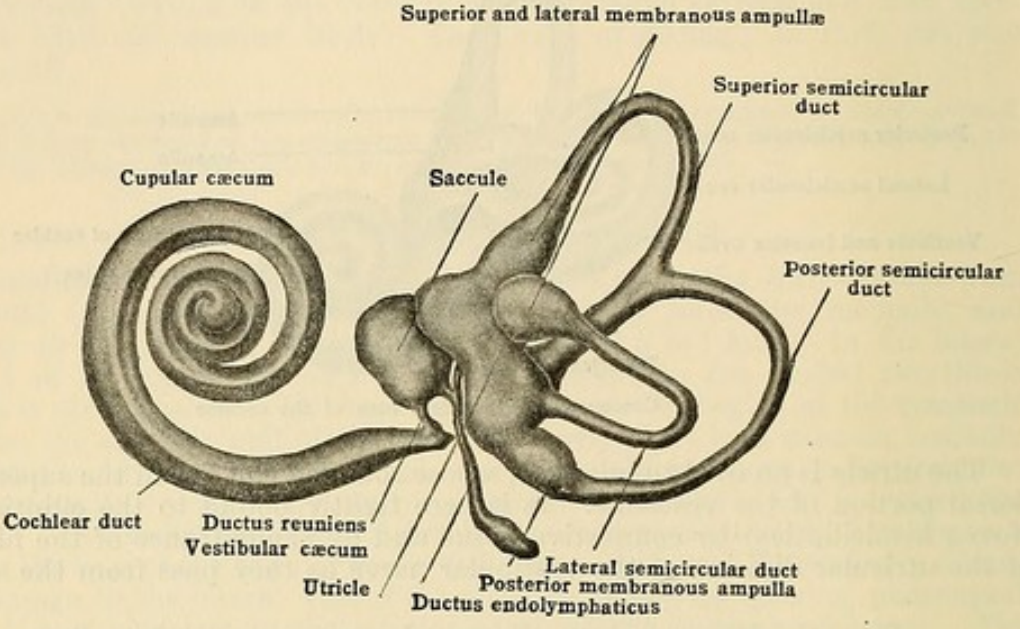

This extends through the aquæductus vestibuli to the posterior surface of the petrous portion of the temporal bone, where it ends in a dilated blind pouch, the **endolymphatic sac,** situated just beneath the dura. Just beyond the saccule, the endolymphatic duct is joined at an acute angle by a short canal of minute calibre, the **utriculo-saccular duct,** which opens into the utricle through its anterior medial wall and, with the endolymphatic duct, connects it with the saccule.

FIG. 840.—RIGHT MEMBRANOUS LABYRINTH OF A NEWBORN CHILD. EXPOSED BY PARTIAL REMOVAL OF THE BONY LABYRINTH. DORSAL view. (Toldt, "Atlas of Human Anatomy," Rebman, London and New York.)

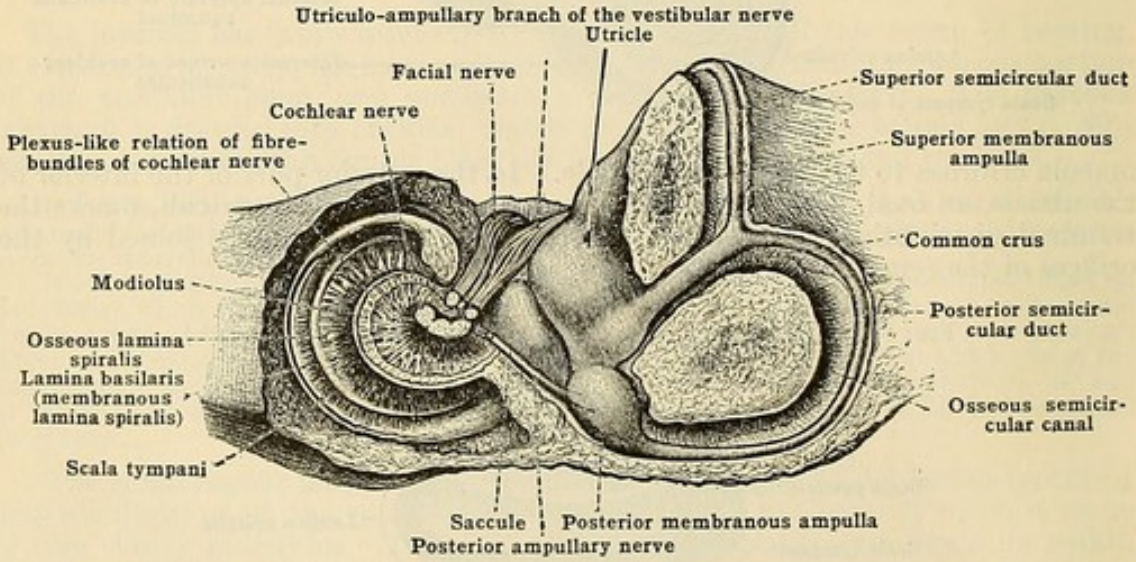

The **semicircular ducts** (membranous semicircular canals) are situated within the osseous semicircular canals and are, therefore, known as the lateral, superior, and posterior semicircular ducts. They connect with the utricle by five openings, the posterior and superior ducts uniting to form a common crus before their

termination. Each duct is less than a third of the diameter of the bony canal, from which it is separated by a large **perilymphatic space,** except along the greater curvature, where it is attached. The ducts are dilated in the bony

FIG. 841.—SCHEMATIC REPRESENTATION OF THE RIGHT MEMBRANOUS LABYRINTH AND THE DIVISIONS OF THE ACOUSTIC NERVE. Dorsal view. (Toldt, "Atlas of Human Anatomy," Rebman, London and New York.)

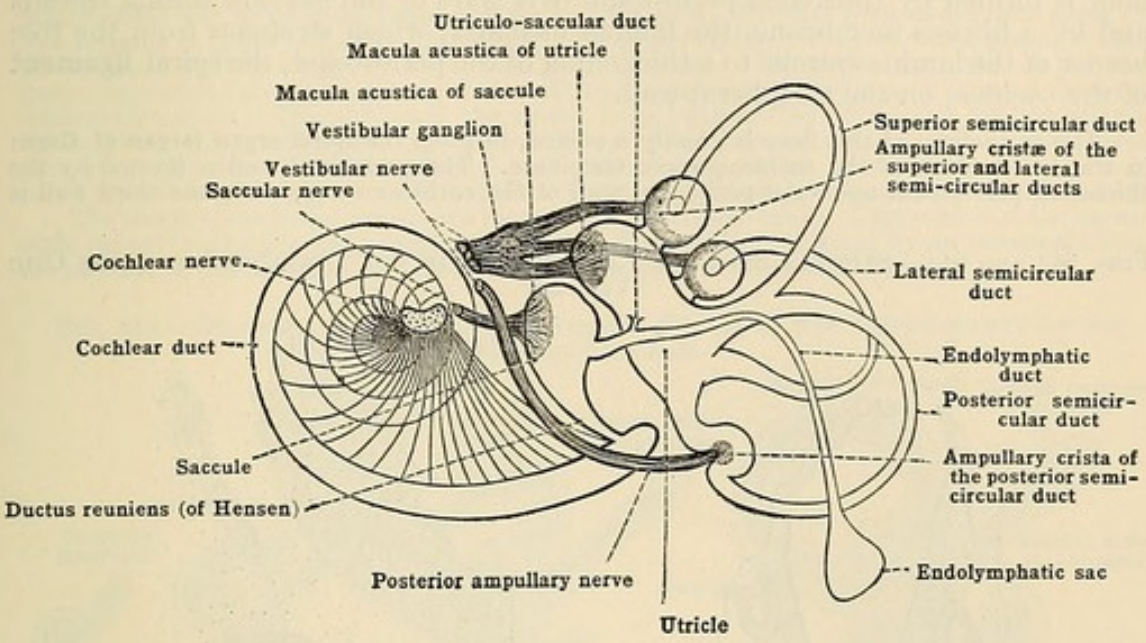

ampullæ, producing the **lateral, superior,** and **posterior membranous ampullæ,** and on the attached surface of each of these there is a transverse groove, the **ampullary sulcus,** for the ampullary division of the vestibular nerve, and corresponding to the sulcus a ridge, the **ampullary crista,** projects into the interior.

FIG. 842.—AXIAL SECTION THROUGH THE DECALCIFIED COCHLEA OF A NEWBORN CHILD (Toldt, "Atlas of Human Anatomy," Rebman, London and New York.)

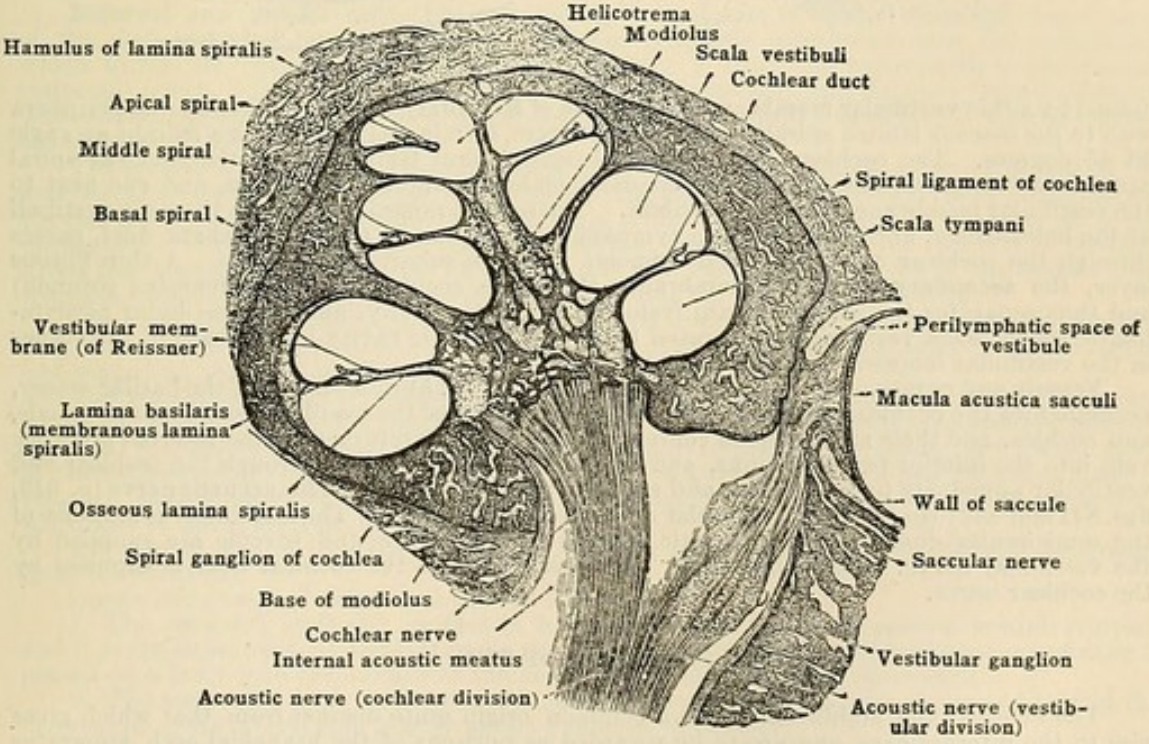

The cristæ in the ampullæ of the membranous semicircular ducts and the maculæ in the saccule and utricle are superficially covered with fine crystals of calcium carbonate, **otoconia** (otoliths).

The **cochlear duct** (membranous cochlea or scala media) begins within the cochlear recess of the vestibule in a blind pouch, the **vestibular cæcum,** and traversing the spiral canal of the cochlea, ends just beyond the hamulus of the lamina spiralis in a second blind pouch, the **cupular cæcum.** Close to the vestibular cæcum it is joined to the saccule by the **ductus reuniens.** It is lined throughout by epithelium and is somewhat triangular in cross-section. Its floor is formed by thickened periosteum over part of the osseous lamina spiralis and by a fibrous membrane, the **lamina basilaris,** which stretches from the free border of the lamina spiralis to a thickening of the periosteum, the **spiral ligament** of the cochlea, on the peripheral wall.

The epithelium of this floor is greatly modified, forming the **spiral organ** (**organ of Corti**) in which the fibres of the cochlear nerve terminate. The peripheral wall is formed by the thickened periosteum upon the peripheral wall of the cochlear canal, while the third wall is

FIGS. 843 AND 844.—SECTIONS SHOWING EARLY STAGES IN THE DEVELOPMENT OF THE OTIC VESICLE.

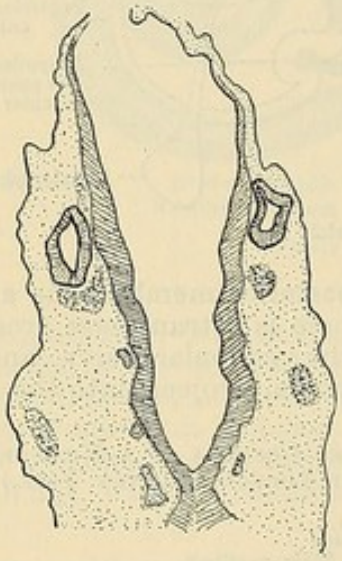

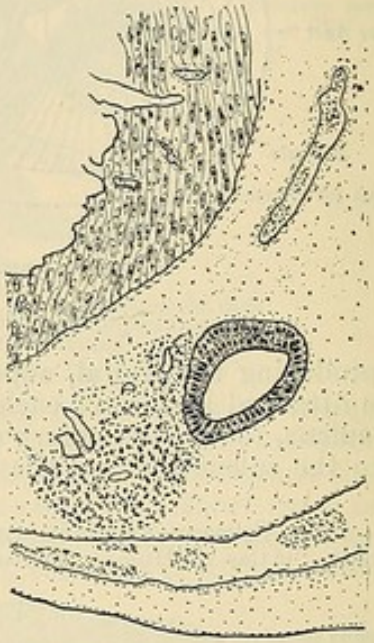

fomed by a thin **vestibular membrane** (**membrane of Reissner**) which passes from the periphera wall to the osseous lamina spiralis near its free margin, forming with the lamina spiralis an angle Ff 45 degrees. The cochlear duct and the osseous spiral lamina divide the cochlear spiral canal into two parts, one next to the basilar membrane, the **scala tympani,** and one next to the vestibular membrane, the **scala vestibuli.** The scala tympani unites with the scala vestibuli at the helicotrema, and from the scala tympani a minute canal, the **perilymphatic duct,** passes through the cochlear canaliculus and connects with the subarachnoid space. A thin fibrous layer, the **secondary tympanic membrane,** closes the cochlear fenestra (fenestra rotunda) and thus separates the scala tympani from the tympanic cavity, and the vestibular perilymphatic space (scala vestibuli) is separated from the tympanic cavity by the base of the stapes in the vestibular fenestra (fenestra ovalis).

Vessels and nerves.—The internal auditory artery , fig. 514), a branch of the basilar artery, accompanies the cochlear and vestibular nerve. It supplies the vestibule, semicircular canals, and cochlea, and their membranous contents. The blood is returned by the internal auditory vein into the inferior petrosal sinus, and by small veins which pass through the cochlear and vestibular aqueducts to the inferior and superior petrosal sinuses. **The acoustic nerve** (p. 949, figs. 841 and 842) consists of a vestibular and a cochlear division. The membranous ampullæ of the semicircular ducts and the acoustic maculæ of the utricle and saccule are supplied by the vestibular nerve. The spiral organ (organ of Corti) in the cochlear duct is supplied by the cochlear nerve.

DEVELOPMENT OF THE EAR

The external and middle ears have a common origin quite distinct from that which gives rise to the internal ears, and are to be regarded as portions of the branchial arch apparatus secondarily adapted to auditory purposes.

The sensory epithelium lining the internal ear is derived from the otic vesicle, a structure formed from the surface epithelium of the head, while the membrane and bones surrounding it are formed from the mesoderm which surrounds the vesicle.

Internal ear.—The process of development is as follows (fig. 843–845):—

By invagination from the surface, an epithelial-lined vesicle, termed the primitive otocyst or otic vesicle, is formed dorsal to the extremity of the second branchial cleft. It is at first merely a pit on the surface, but eventually it loses its connection with the surface epithelium and sinks into the interior. It then undergoes the alterations in shape and form shown in the accompanying fig. 845. The vesicle is at first somewhat oval, and a small hollow stalk arises from it, the *recess of the labyrinth*, which forms the ductus endolymphaticus in the adult. The ventral and dorsal portions of the cyst become enlarged. From the former two hollow plate-like projections arise, one placed vertically, the other horizontally, and along the free margins of these plates are formed the semicircular ducts, the superior and posterior from the vertical, and the lateral duct from the horizontal one. The central part of each plate becomes peforated, and the periphery is thus altered to the characteristic loop form of the adult semicircular ducts. The portion of the vesicle lying between the dorsal and ventral enlargements forms the primitive *atrium*. It becomes divided into two chambers, an upper dorsal connected with the semicircular ducts, forming the utricle, and an inferior ventral, the saccule, which is connected with that portion of the ventral expansion from which the cochlea is formed.

The recess of the labyrinth retains its connection with the cavity of the vesicle at the narrow stalk connecting utricle and saccule, (fig. 845). The cochlea is formed by an outgrowth from the saccule, at first straight, and later coiled in the fashion formed in the adult.

FIG. 845.—DIAGRAMS ILLUSTRATING SUCCESSIVE STAGES IN THE DEVELOPMENT OF THE MEMBRANOUS EAR.

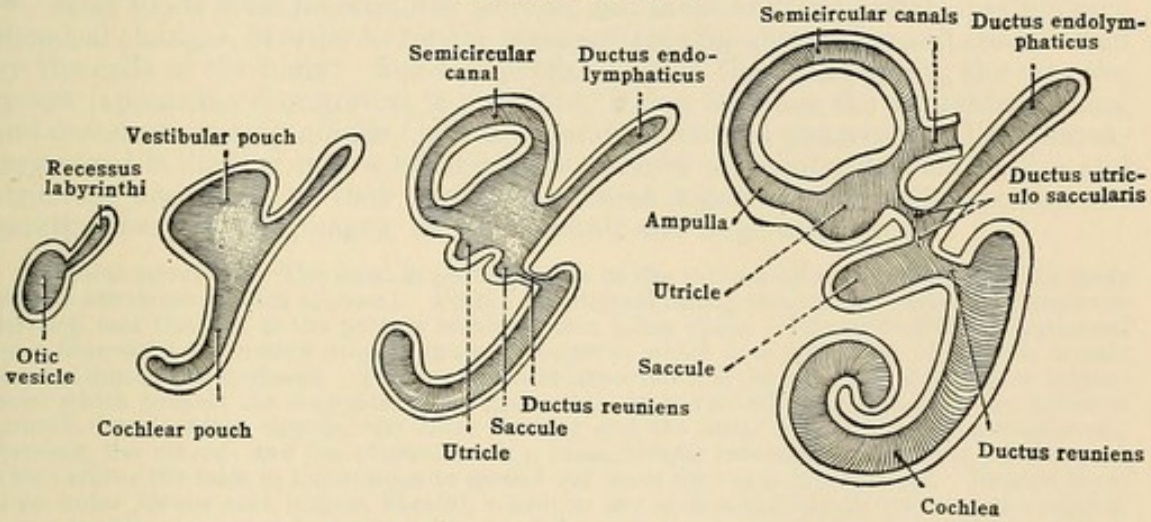

External and middle ear.—The *external auditory meatus* is formed from the dorsal part of the first (external branchial) pouch, and the tympanic membrane from the membrane which forms the floor of that pocket and separates it from the corresponding pharyngeal (internal) pouch. Its outer surface is thus formed from ectoderm and the inner from endoderm. The internal (pharyngeal) groove gives origin to the tympanic cavity and tuba auditiva, the margins of the groove uniting.

The *auricle* is formed from nodular thickening of the tissue bounding the outer end of the first branchial cleft. Three nodules are formed on the first (mandibular) and three on the second (hyoid) arch. Behind the latter, the free margin of the auricle is formed by a folding off of the integument. Later an additional tubercle is formed dorsally between the two sets of nodules. From the mandibular nodules are formed mainly the tragus and the crus of the helix—from the hyoid tubercles the scaphoid fossa, antitragus and the crus of the anthelix.

The *auditory ossicles*, and their muscles are formed from the neighbouring arches, the malleus and incus, together with the tensor tympani, being derived from the first arch, while the stapes and stapedius probably are derived from the second arch.

The tympanic cavity is at first quite small, but later increases greatly, partly by the condensation of the loose areolar tissue which underlies its mucous membrane, the auditory ossicles and their muscles being thus apparently brought within the cavity, and partly by the absorption of the neighbouring bone. By this latter process the antrum and the tympanic and mastoid cells are formed, all these depressions or cavities being lined by mucous membrane continuous with that of the tympanic cavity.

The Ear in the Child.—The ear in the newborn child shows several marked differences from the adult ear.

Among the principal differences are the following:—

1. The external auditory meatus is very short, since the bony portion is undeveloped, and is represented only by the tympanic ring. As a result of this, the tympanic membrane is placed on a level with the surface of the head, and looks very much downward.
2. The mastoid or tympanic antrum is relatively very large, and lies above and behind the tympanum. Its lateral wall is only about 1 mm. in thickness.
3. The mastoid process is not developed, and hence the stylomastoid foramen opens on the surface behind the lower part of the tympanic ring. The exit of the facial nerve is therefore much more upon the surface, and higher up than in the adult.
4. The auditory (Eustachian) tube is nearly horizontal in direction.
5. The ossicles are of nearly the same size as in the adult.

References for the Special Sense Organs.—For the *development* of the various sense organs, see article by Keibel in Keibel and Mall's Human Embryology, vol. 2. A. **Visual.** Graefe-Saemisch, Handbuch d. ges. Augenheilkunde; Salzmann, Anat. u. Histol. d. Augapfels, 1912; various papers in Archiv f. Ophthalmologie; (*Anterior chamber, etc.*) Henderson, Ophthalmic Review, 1910–11; (*Optic disc*) Johnson, Phil. Trans. Royal Soc. B. vol. 194; B. **Auditory.** Gray, Labyrinth of Mammals, 1910; (*Tectorial membrane, etc.*) Hardesty, Amer. Jour. Anat., vol. 8; (*Auditory nerve, comparative*) Holmes, Trans. Royal Irish Acad., vol. 32, ser. B; (*Experimental embryology*) Lewis, Amer. Jour. Anat., vols. 3, 7; C. **Olfactory.** Read, Amer. Jour. Anat., vol. 8. D. **Taste.** Von Ebner, in Koelliker's Handbuch d. Gewebelehre; Graberg, Anat. Hefte, Bd. 12.

SECTION IX

DIGESTIVE SYSTEM

REVISED FOR THE FIFTH EDITION

BY C. M. JACKSON, M.S., M.D.,

PROFESSOR OF ANATOMY IN THE UNIVERSITY OF MINNESOTA

IN order to furnish the living protoplasm with the materials necessary for energy, growth and repair, a constant supply of food must be provided. Most foods must be rendered soluble, and must undergo certain preliminary chemical changes, in order to render them suitable for absorption and assimilation by the cells of the body. For this preparation of the food-supply, the *digestive system* [apparatus digestorius] is provided, which includes the alimentary canal and certain accessory glands (salivary glands, liver and pancreas). The alimentary canal is divided into a number of successive segments, varying in size and structure according to their function. These segments (fig. 846) include the mouth, pharynx, œsophagus, stomach, small and large intestines.

Typical structure.—The most important layer of the tubular alimentary canal is the inner *mucous membrane* [tunica mucosa]. From its epithelial lining, the various digestive glands are derived, and through it the process of absorption takes place. The epithelium is supported by a fibrous tunic [lamina propria mucosæ] beneath which is a thin layer of smooth muscle [lamina muscularis mucosæ]. The layer next in importance is the *muscular* coat [tunica muscularis] which propels the contents along the canal. It is typically composed of two layers of smooth (involuntary) muscle, the inner circular and the outer longitudinal in arrangement. Between the mucosa and the muscularis is a loose, fibrous *submucous* layer [tela submucosa], which allows the folds in the mucosa to spread out when the canal is distended. Finally, there is an outer *fibrous* coat [tunica fibrosa], which in the abdominal cavity becomes the smooth *serous* coat [tunica serosa], or visceral layer of the peritoneum, which eliminates friction during movements. The variations in the structure of the alimentary canal in different regions are due chiefly to differences in the mucosa.

Glands.—Since the glands form an important part of the digestive system, the classification of glands in general will be discussed briefly. A gland may be somewhat loosely defined as an organ which elaborates a definite substance which is either a waste product to be eliminated (excreted), or a secretion to be further utilized by the organism. Glands may be divided into (a) *ductless glands* (e. g., spleen, thyreoid gland), which pour their secretions directly into the blood or lymph; and (b) *glands with ducts*, which open upon an epithelial surface. Some organs, however, belong in *both* classes (e. g., liver, pancreas).

The glands with ducts (the so-called 'true' glands) are always derived from an epithelial surface and may be further subdivided upon the basis of either (1) form or (2) cell-structure. According to **form,** glands are classified as either *tubular* or *saccular* (alveolar, acinous). Each of these may be either *simple* or *compound* (branched). The compound saccular form is often called *racemose*. Moreover, intermediate forms (tubulo-racemose) occur.

According to **cell-structure** and character of secretion, glands are divided into mucous and serous types. In the *mucous* type, the cells appear larger and lighter (fig. 867) when swollen with mucus which is secreted for purposes of lubrication. The goblet-cells of the intestine represent unicellular glands of this type. In the *serous* (or albuminous) type of glands, the cells usually appear somewhat smaller and more deeply stained, with numerous zymogen granules (fig. 867). The secretion is a watery, albuminous fluid, which contains the digestive enzymes. There occurs also a *mixed* type, with separate mucous and serous saccules, or both types of cells may occur in the same saccule (the serous cells as 'demilunes' or 'crescents' (fig. 867). In all cases, the epithelial gland cells are supported by a fibrous connective-tissue stroma, which provides a rich vascular and nerve-supply.

Morphology.—The alimentary canal in comparative anatomy is divided into the *head-gut* (mouth and pharynx), *fore-gut* (œsophagus and stomach), *mid-gut* (small intestine), and *hind-gut* (large intestine). Embryologically, the mid-gut corresponds roughly to the portion of the archenteron attached to the yolk-sac, the portions of the archenteron anterior and posterior to the yolk-sac being designated as fore-gut and hind-gut respectively. (See Section I, MORPHOGENESIS.) The lining epithelium of the alimentary tract is endodermal, excepting the anal canal and the mouth cavity, which are lined by invaginations of the ectoderm.

In the region of the mouth and pharynx, the digestive and respiratory systems are closely related in position, structure, function and origin. Morphologically, the head-gut represents a primitive alimentary-respiratory apparatus.

THE MOUTH

The **oral cavity** [cavum oris] represents the first segment of the alimentary canal. Its walls are exceedingly specialised in structure, corresponding to its manifold functions (mastication, insalivation, taste, speech, etc.).

Boundaries.—The oral cavity communicates anteriorly with the exterior through the transverse *oral fissure* [rima oris], and posteriorly with the pharynx through the *isthmus of the fauces* [isthmus faucium]. The *anterolateral walls* are formed by the flexible lips and cheeks. The *roof* is chiefly immovable and is

FIG. 846.—DIAGRAM OF THE ALIMENTARY CANAL.

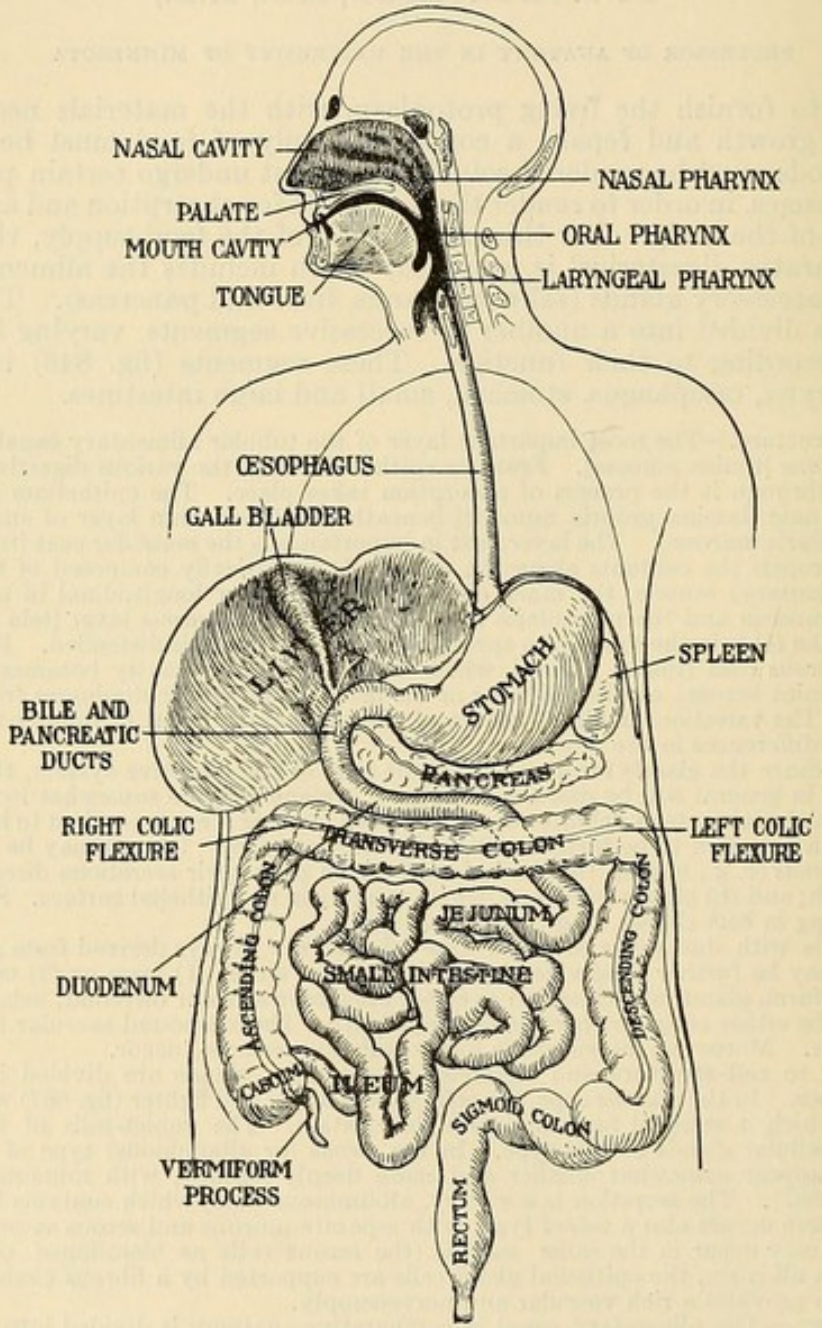

formed by the upper jaw with the hard and soft palate. The movable *floor* is formed by the lower jaw and the tongue.

Subdivisions.—The oral cavity is subdivided by the alveolar and dental arches into an inner cavity, the *oral cavity proper* [cavum oris proprium], and an outer *vestibule* [vestibulum oris] adjacent to the lips and cheeks (fig. 848). When the upper and the lower teeth are in apposition, the vestibule communicates

with the oral cavity proper (aside from the small interdental spaces) only through a space behind the last molar teeth on each side. Opening into the oral cavity are certain accessory glands, the salivary glands.

Fig. 847.—Coronal Section through Oral Region.

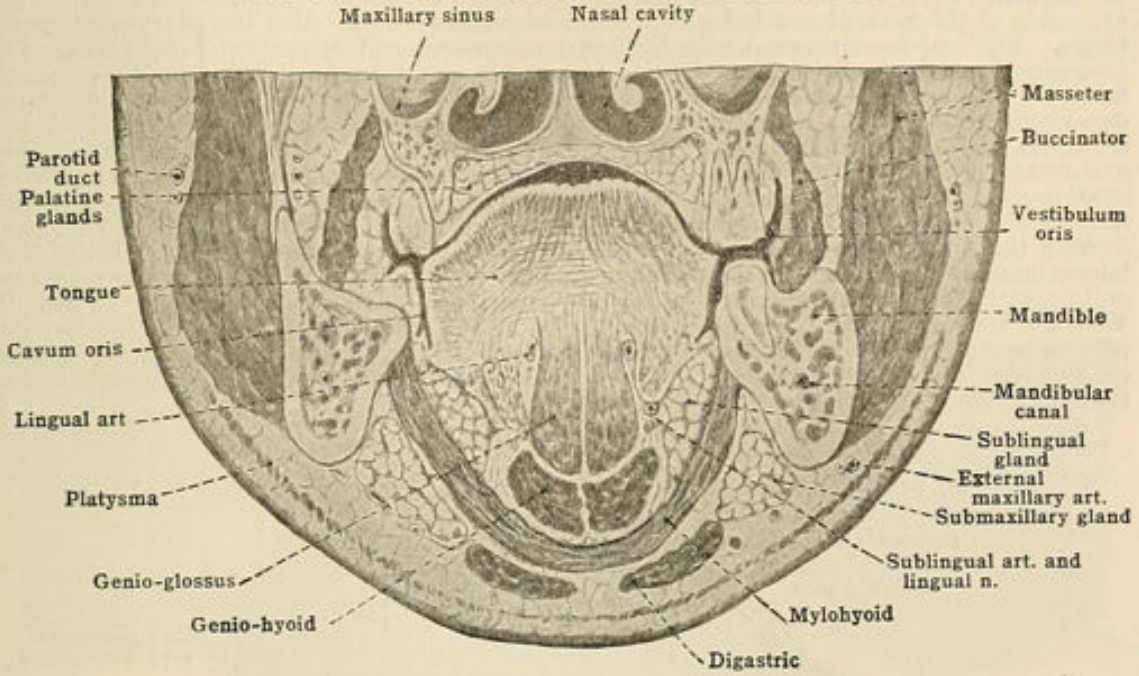

Structure.—Of the typical layers of the alimentary canal, only the mucous membrane can be recognised as a continuous layer in the mouth cavity. Even this is greatly modified and in structure somewhat resembles the skin, from which it is derived and with which it is continuous

Fig. 848.—Mid-sagittal Section of the Head, through Oral and Nasal Regions. (Rauber-Kopsch.)

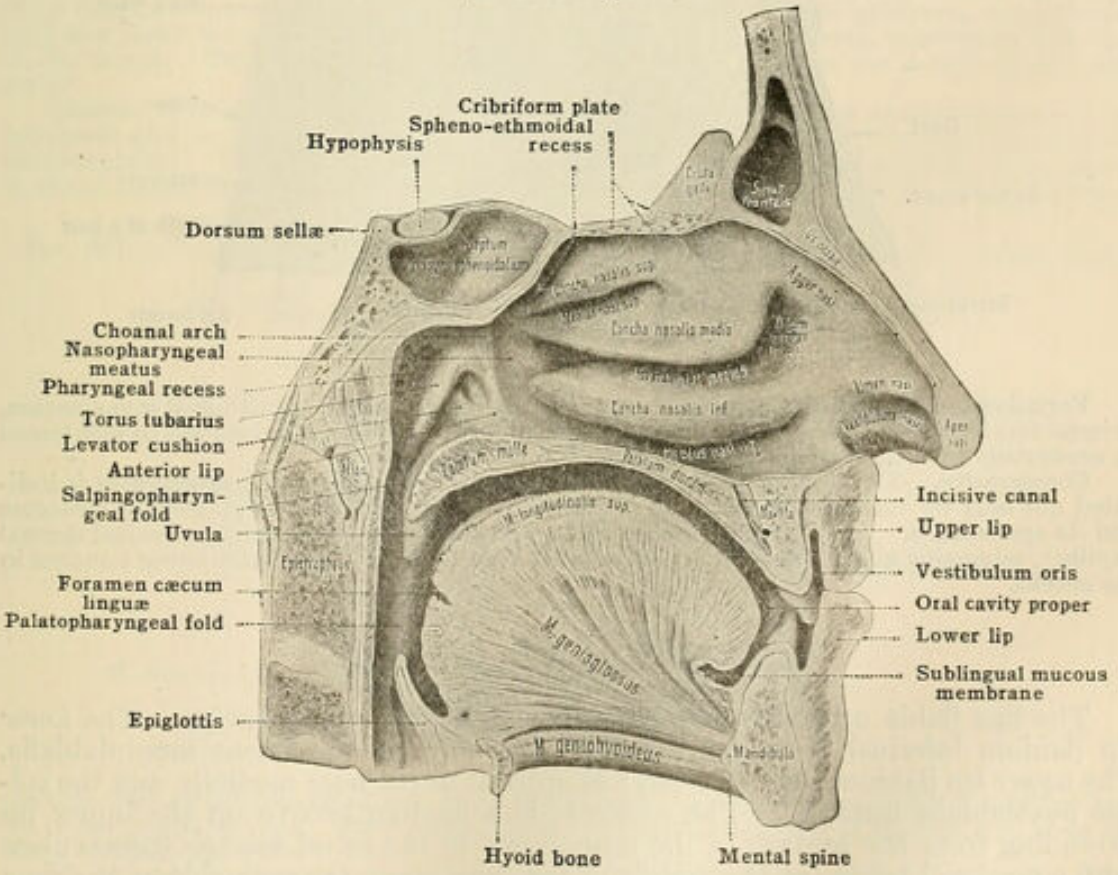

at the rima oris. The submucosa is a strong fibrous layer connecting the mucosa with adjacent structures, and lodging numerous racemose mucous glands. The muscles in the walls of the mouth cavity are not homologous with the typical muscularis of the alimentary canal. The outer fibrous tunic is also wanting.

The development of the oral cavity.—As stated in the section on MORPHOGENESIS, the oral cavity has its origin in a depression, the **oral fossa,** situated between the ventrally bent, developing head and the region occupied by the developing heart. This fossa is bounded anteriorly by the fronto-nasal process, and laterally by the maxillary and mandibular processes, portions of the first branchial arches. The fossa is lined by ectoderm. Its floor is in apposition with the cephalic end of the archenteron, lined by entoderm, the ectoderm of the oral fossa and the entoderm of the archenteron being in immediate contact and forming the **pharyngeal membrane.** The oral fossa deepens with further development, and becomes the oral sinus. The pharyngeal membrane becomes perforated in embryos about 2 mm. in length and disappears, leaving a free communication between the oral sinus and archenteron. On each side of the developing head and in a latero-ventral position there is early developed an area of thickened ectoderm, known as the nasal area. These areas soon develop into depressions, the nasal fossæ, and assume a position, one on either side of the fronto-nasal process; on each side of the fronto-nasal process there is developed a prominent protuberance, the globular process, each process forming the median wall of a nasal fossa. The lateral wall of each nasal fossa also thickens to form the lateral nasal process. With the further development, the ventral portion of each lateral nasal process fuses with the corresponding globular process, the maxillary processes also uniting with the globular processes, in this way separating the nasal fossæ from the oral sinus. With the further growth toward the median line of the maxillary processes the fronto-nasal process becomes narrower, ultimately forming the nasal septum and a small median portion of the upper jaw, the remainder of the upper jaw being formed by the maxillary processes, and the lower jaw having its origin in the mandibular processes.

FIG. 849.—SAGITTAL SECTION OF THE LOWER LIP. (Lewis and Stöhr.)

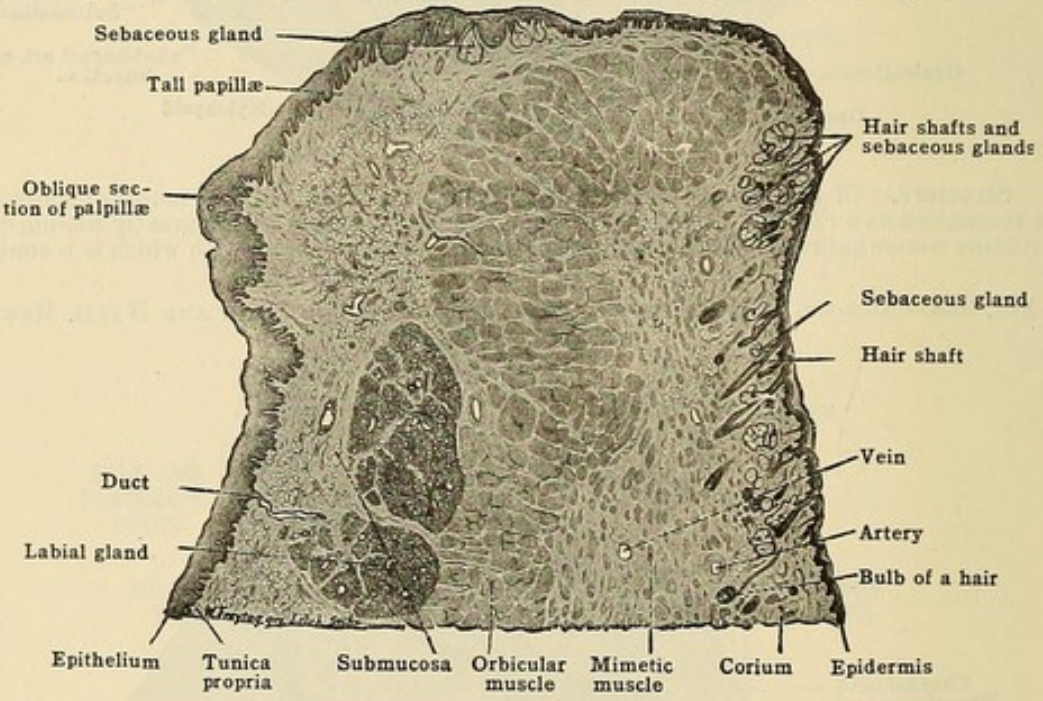

Variations.—The mouth is rarely absent, due to failure of the stomatodeal invagination, or imperforate, due to atresia of the pharyngeal membrane. Other variations will be mentioned in connection with the various mouth organs.

Comparative.—The phylogenetic origin of the mouth cavity from the integument is indicated not only by the ectodermal origin of its lining epithelium, but by its general structure and its appendages. Among the latter may be noted the teeth (representing modified dermal papillæ), sebaceous glands, and (in some rodents) even hairs in the mucosa lining pouches in the cheeks.

THE LIPS AND CHEEKS

The **lips** [labia oris] form the anterior wall of the mouth cavity. The *lower lip* [labium inferius] is marked off from the chin by the sulcus mentolabialis. The *upper lip* [labium superius] extends upward to the nose medially and the sulcus nasolabialis laterally. The *philtrum* is a median groove on the upper lip extending from the septum of the nose above to the *labial tubercle* [tuberculum labii superioris] below, at the middle of the rima oris. On each side of the rima oris the upper and the lower lips are continuous at the angle of the mouth [angulus oris], which is usually opposite the first premolar teeth. Laterally, the lips are

continuous with the *cheeks* [buccæ], which form the lateral walls of the mouth cavity.

In structure, the *lips* (fig. 849) consist essentially in a middle layer of cross-striated muscle (orbicularis oris) covered externally by skin which is continuous through the rima oris with the mucosa forming the inner layer of the lips. The mucosa lines the vestibulum oris and is reflected upon the gums above and below. In the median line above and below, there extends from the lip to the gum a small fold of the mucosa [frenulum labii superioris vel inferioris]. The structure of the *cheeks* (figs. 847, 864) is similar to that of the lips but somewhat more complicated.

FIG. 850.—LABIAL AND BUCCAL GLANDS EXPOSED BY DISSECTION OF THE SKIN FROM IN FRONT. (From Toldt's Atlas.)

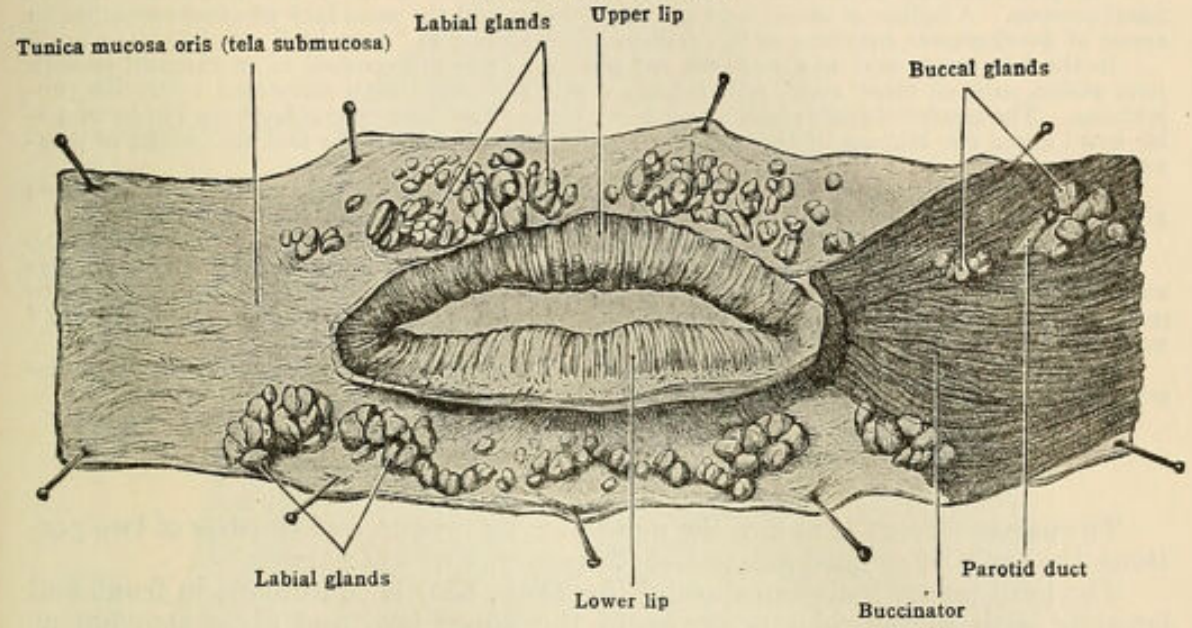

The muscular basis of the **cheek** is the buccinator muscle. External to this is a thick layer of fat [corpus adiposum buccæ] covered partly by the dermal muscles (platysma, zygomaticus, etc.) and lastly the skin. Internally the cheek is lined by the mucosa, continuous with that of the cheeks. The parotid duct opens into the vestibule opposite the second upper molar tooth.

Glands.—The *skin* of the lips and cheeks is well supplied with the usual sudoriparous and sebaceous glands. The mucosa likewise presents two kinds of glands, the sebaceous and the mucous glands. The *sebaceous* glands are relatively few in number and variable, being present in about 30 per cent. of cases in the adult (Stieda). They are similar in structure to those of

FIG. 851.—SECTION OF LABIAL MUCOSA, SHOWING GLANDS. × 16. (From Toldt's Atlas.)

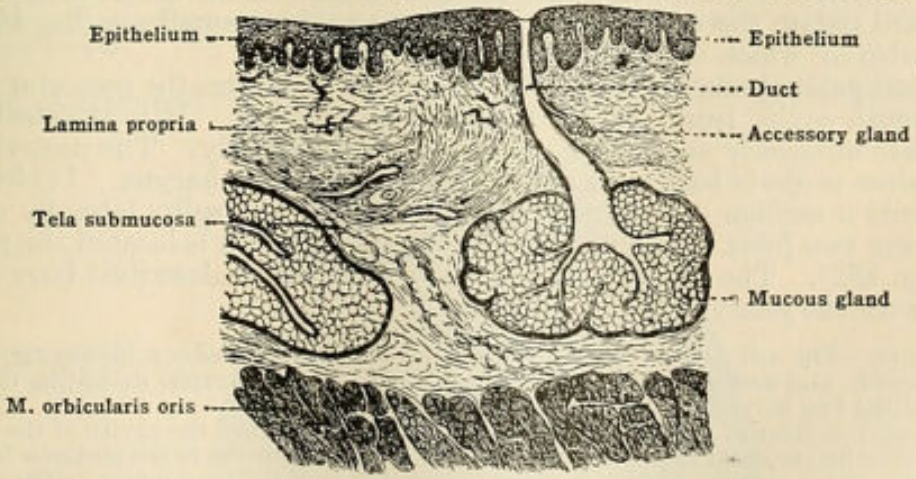

the skin (though not associated with hair follicles), and when present are visible as small yellowish bodies in the mucosa. They occur chiefly near the free margins of the lips and along the cheek opposite the teeth.

The *mucous glands* are much more numerous and constantly present (figs. 850, 851). They are all of the racemose type. They are variable but small in size, and closely packed together in the submucosa of the lips [glandulæ labiales], where they may easily be felt. Those of the cheeks [gl. buccales] are less numerous. A few of them especially in the region of the molar

teeth [gl. molares], are placed outside the buccinator. The ducts of the molar glands pierce this muscle near the parotid duct to open on the surface of the mucosa.

Vessels and nerves.—The mucosa of the lips and cheeks has a characteristic reddish hue, on account of the numerous blood-vessels which are visible through the thick but transparent stratified squamous epithelium (figs. 849, 851) The numerous papillæ of the lamina propria are highly vascular. The *blood-supply* of the lips and cheeks is derived chiefly from the labial (coronary) and buccal arteries. The rich *nerve-supply* (sensory) is from the infra-orbital, mental and buccal branches of the fifth. The lips are especially sensitive near the rima oris.

Development.—During the second month in the human embryo, ledges of epithelium grow into the substance of the mandibular and the fused fronto-nasal and maxillary processes. These ledges develop into grooves which separate the upper and the lower lips from the upper and the lower jaws, the grooves forming the oral vestibule.

The philtrum and labial tubercle are said to correspond to the lower part of the fronto-nasal process. A failure of union between the globular and the maxillary processes presents an arrest of development resulting in the malformation known as "hare-lip."

In the late fœtus and newborn, the red portion of the lips consists of an external smooth *pars glabra*, and an inner zone, *pars villosa*, which is covered with numerous villus-like projections. The largest of these reach a length of 1 mm. They also extend backward in an irregular band along the mucosa of the cheek. They disappear during the first few weeks of post-natal life.

In the infant, the corpus adiposum is especially well developed. On account of its supposed aid as a support for the buccinator in sucking, it has been called the "sucking pad."

The sebaceous glands of the mucosa are said not to appear until about the age of puberty.

Variations.—As is well known, the lips and cheeks are exceedingly variable in shape, size and structure in different individuals. There are also characteristic differences according to race and sex in the form and structure of the lips, rima oris, beard, etc. The "hare-lip" malformation was mentioned above.

Comparative.—Typical lips are found only in mammals, and are probably organs phylogenetically developed in connection with the process of suckling.

THE PALATE

The **palate** forms the roof of the mouth cavity proper, and consists of two portions, the anterior or hard palate and the posterior or soft palate.

The **hard palate** [palatum durum] (figs. 848, 852) is continuous in front and laterally with the alveolar processes of the upper jaw, and gives attachment posteriorly to the soft palate. It separates the mouth from the nasal cavity. It is supported by the palatine process of the maxilla and the horizontal part of the palate bone. The *oral surface* is concave from side to side, and also from before backward. It is covered by a thick, somewhat pale mucosa, which is firmly adherent to the periosteum through the submucosa. The submucosa contains numerous mucous *glands* [gl. palatinæ] (fig. 852), similar to those of the lips.

In the median line of the hard palate is a line or ridge, the *raphe* (fig. 852) terminating anteriorly in the small *incisive papilla*, which corresponds in position to the bony incisive foramen. Anteriorly there occur four to six more or less distinct *transverse ridges* [plicæ palatinæ transversæ]. Near the posterior margin of the hard palate there is on each side of the raphe a small pit (fig. 852), the *foveola palatina*, which is variable and inconstant.

The **soft palate** [palatum molle] (figs. 848, 892) separates the posterior portion of the mouth cavity from the nasal part of the pharynx. It is attached to the hard palate anteriorly and to the pharyngeal wall laterally. The posterior portion or *velum* projects backward and downward into the pharynx. Its free margin presents a median conical projection, the *uvula*, and splits laterally on each side to form two folds, the palatine arches, between which is located the palatine tonsil (fig. 852). The palatine arches and tonsil will be described later in connection with the pharynx.

Structure.—The soft palate is a fold of mucous membrane enclosing a fibrous aponeurosis, muscles, vessels, and nerves. It is marked in the middle line by a raphé indicating the line of junction of the two halves from which it was formed.

The posterior layer of the mucous fold which is directed toward the cavity of the pharynx is continuous with the nasal mucous membrane; the anterior layer lies in the posterior boundary of the mouth and is continuous with the mucous membrane of the hard palate. The structure of the mucosa is very similar to that of the lips (fig. 849). Mucous glands are numerous in both layers, but more especially in the anterior, and make up a large portion of the mucosa and submucosa (figs. 851, 852).

The aponeurosis is attached above to the posterior margin of the hard palate; laterally it is continuous with the aponeurotic layer of the pharyngeal wall; below, toward the lower margin of the velum, it gradually disappears. It gives attachment to fibres of the levator veli palatini and the pharyngo-palatinus (palato-pharyngeus) and to the tendon of the tensor veli palatini.

Muscles.—The muscles of the soft palate are described later (p. 1134) with those of the pharynx, with which they are closely associated.

Vessels and nerves.—The arterial supply of the *hard palate* is derived chiefly from the major palatine branches of the internal maxillary. The arteries of the *soft palate* include:

FIG. 852.—ROOF OF MOUTH, SHOWING HARD AND SOFT PALATE DISSECTED ON ONE SIDE. (Rauber-Kopsch.)

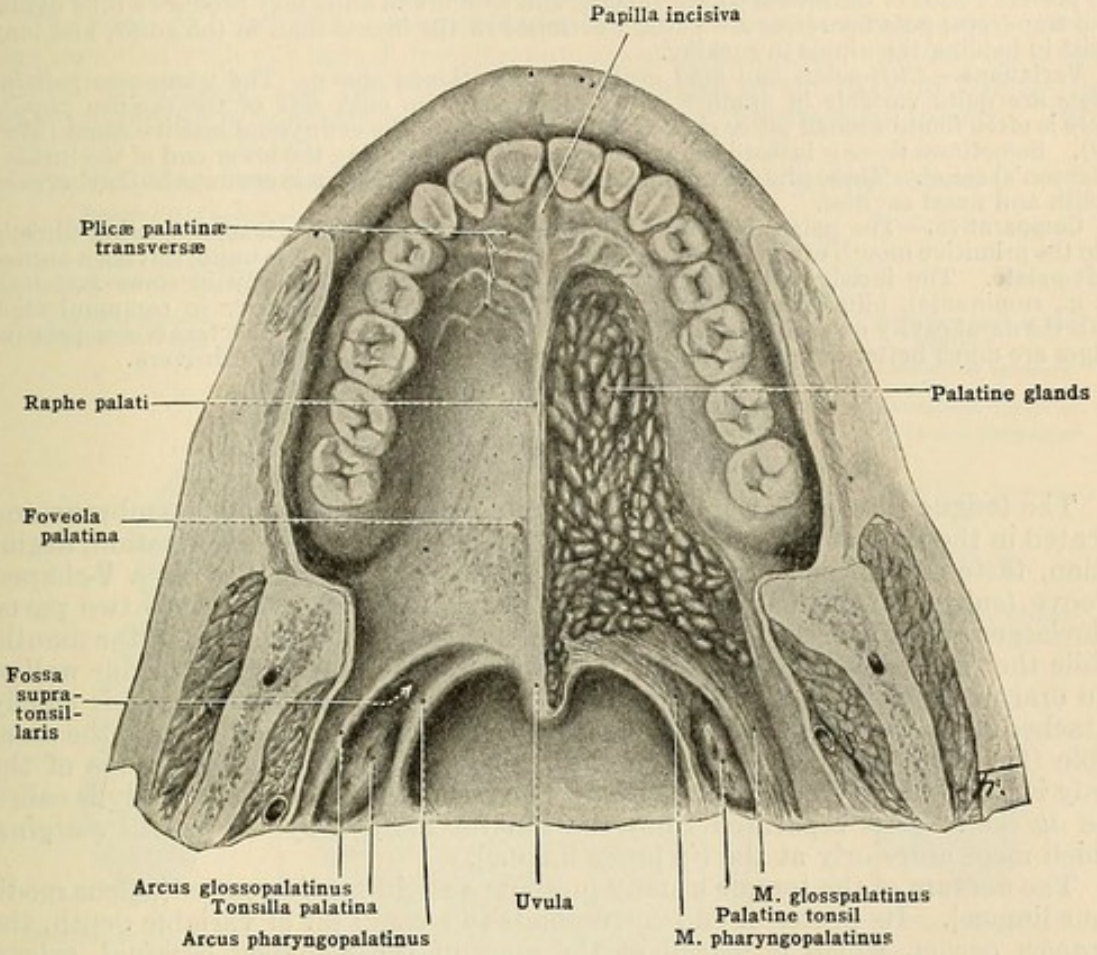

(1) Ascending palatine of external maxillary (facial); (2) pharyngeal branches of ascending pharyngeal; (3) twigs from descending palatine of internal maxillary, which enter the smaller palatine canals, are distributed to the soft palate and tonsils, and communicate with the ascending palatine of the external maxillary (facial) artery; (4) lingual artery, by twigs from the dorsal branch.

FIG. 853.—DEVELOPING PALATINE SHELVES, VIEWED FROM BELOW. (McMurrich, from His.)

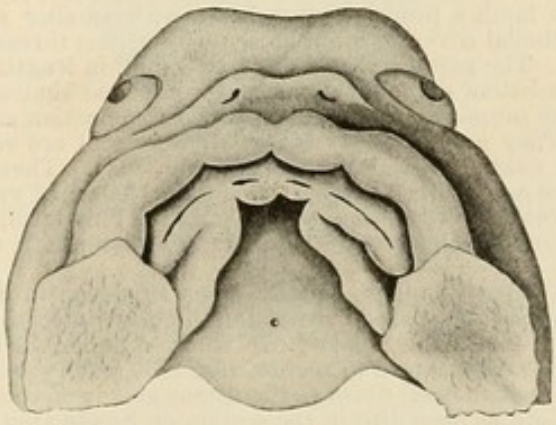

The *sensory nerves* to the palate are derived chiefly from the fifth through the sphenopalatine ganglion. The hard palate is supplied by the nasopalatine and anterior palatine branches; the soft palate chiefly by the median and posterior palatine branches. The *motor* nerves will be mentioned later in connection with the muscles.

The development of the palate.—The hard and soft palates arise (fig. 853) in two ridges of tissue, designated the **palate shelves,** which develop on the inner surfaces of the maxillary processes. These shelves grow toward the median line, and at the beginning of the third month of fœtal life meet beneath the nasal septum, uniting with each other and with the nasal septum, the union taking place from before backward. The incisive foramen indicates the place of meeting of the premaxillary and palate shelves, which closes the primitive communication between the oral and the nasal cavity. A want of union of the palate shelves presents an arrest of development known as cleft-palate. The *uvula* is similarly formed by the union of the posterior ends of the lateral palate anlages, and a failure to unite may produce a bifid uvula. The transverse *palatine ridges* are better developed in the infant than in the adult, and may assist in holding the nipple in sucking.

Variations.—*Cleft-palate* and *bifid uvula* were mentioned above. The transverse *palatine ridges* are quite variable in number and prominence. On each side of the *incisive papilla* there is often found a small pit or shallow tube, a vestige of the embryonal incisive canal (Merkel). Sometimes there is instead a single median pit, representing the lower end of the incisive (Stenson's) canal. These pits are remnants of the primitive embryonic communication between mouth and nasal cavities.

Comparative.—The palate is absent in fishes and amphibia, the choanæ opening directly into the primitive mouth cavity. In some birds, the palate shelves fail to unite, leaving a normal cleft-palate. The incisive (Stenson's) canal remains open permanently in some mammals (e. g., ruminants), bifurcating above and thus placing the mouth cavity in communication with the nasal cavity on each side in the vicinity of Jacobson's organ. The transverse palatine ridges are much better developed among many mammals, especially the carnivora.

THE TONGUE

The **tongue** [lingua] is a muscular organ covered with mucous membrane and located in the floor of the mouth. It is an important organ of mastication, deglutition, taste and speech. Upon its upper surface (figs. 854, 864) is a **V**-shaped groove (sulcus terminalis) indicating the division of the tongue into two parts. The larger anterior part, or *body* [corpus linguæ] belongs to the floor of the mouth, while the smaller posterior part, or *root* [radix linguæ], forms the anterior wall of the oral pharynx. The *inferior* surface (facies inferior) of the tongue is chiefly attached to the muscles of the floor of the mouth, from the hyoid bone to the mandible (fig. 858). Anteriorly and laterally, however, the inferior surface of the body is free and covered with mucosa. The superior surface of the body is called the *dorsum*. It is separated from the inferior surface by the *lateral margins*, which meet anteriorly at the *tip* [apex linguæ].

The **dorsum** of the tongue usually presents a slight *median groove* [sulcus medianus linguæ]. Its posterior end corresponds to a small pit of variable depth, the *foramen cæcum*, which is placed at the apex of the **V**-shaped *terminal sulcus*, The dorsum of the body has a characteristic rough appearance due to numerous small projections, the *lingual papillæ*.

Lingual papillæ.—Five or six varieties of papillæ are distinguished, between which intermediate forms occur. The *conical* [papillæ conices] and *thread-like* [papillæ filiformes] are most numerous, and are arranged more or less distinctly in rows parallel with the terminal sulcus (fig. 856). They are best developed toward the mid-line of the dorsum in its posterior part. As shown in vertical section (fig. 856), each papilla consists of an axial core of vascular fibrous tissue (from the lamina propria) often beset with smaller secondary papillæ. The stratified squamous epithelial covering often presents numerous thread-like prolongations from the apex of the papilla. The papillæ vary from 1 to 3 mm. in length.

The **fungiform** ("toad-stool shaped") papillæ are somewhat similar to the conical in structure, but larger and more prominent, with an expanded free portion and a slightly constricted stalk of attachment. They are relatively few in number and are scattered irregularly over the dorsum, being most numerous near the margins (fig. 864). They are easily distinguished in life by their larger size and reddish colour. A smaller, flattened variety of the fungiform is sometimes called the *lenticular* ('lens-shaped') papillæ. (This term, however, is applied by Toldt to certain small rounded elevations with underlying lymphatic nodules in the mucosa of the root of the tongue.)

The **vallate** (circumvallate) papillæ, usually seven to eleven in number, are conspicuous and arranged in a **V**-shaped line parallel with and slightly anterior to the sulcus terminalis, (figs. 854, 857). They are, as a rule, shaped like short cylinders, 1 to 2 mm. in width, and somewhat less in height. As is shown in section (fig. 857), each is surrounded by a trench or fossa, into the bottom of which open ducts of the serous glands of von Ebner. On the sides of the fossæ are the *taste-buds*, as described in the section on SENSE ORGANS.

The **foliate** papillæ are represented by a few (five to eight) parallel transverse or vertical folds of mucosa, along the margins of the tongue just anterior to the glosso-palatine arch on each side (fig. 864). They are variable in size and sometimes rudimentary. In structure they somewhat resemble the vallate papillæ (though of different form), their walls being studded with taste-buds.

The free **inferior surface** of the tongue (fig. 858) is covered by a thin smooth mucosa. In the median line is a prominent fold, the *frenulum*, which connects the tongue with the mandible and the floor of the mouth. On each side of the inferior surface, an irregular, variable, fringed fold, the *plica fimbriata*, extends from near the apex backward approximately parallel with the lateral margin of the tongue (fig. 858). Between the frenulum and the plicæ fimbriatæ, the lingual (ranine) veins are visible on each side beneath the mucosa.

The **root** (or base) of the tongue [radix linguæ] belongs to the pharynx, but is here included with the mouth for convenience of description. Its free surface is directed posteriorly, and represents the continuation of the dorsum linguæ (fig. 854). Laterally it is continuous with the region of the palatine tonsils. Infe-

FIG. 854.—DORSUM AND ROOT OF THE TONGUE. (Papillæ diagrammatic.)

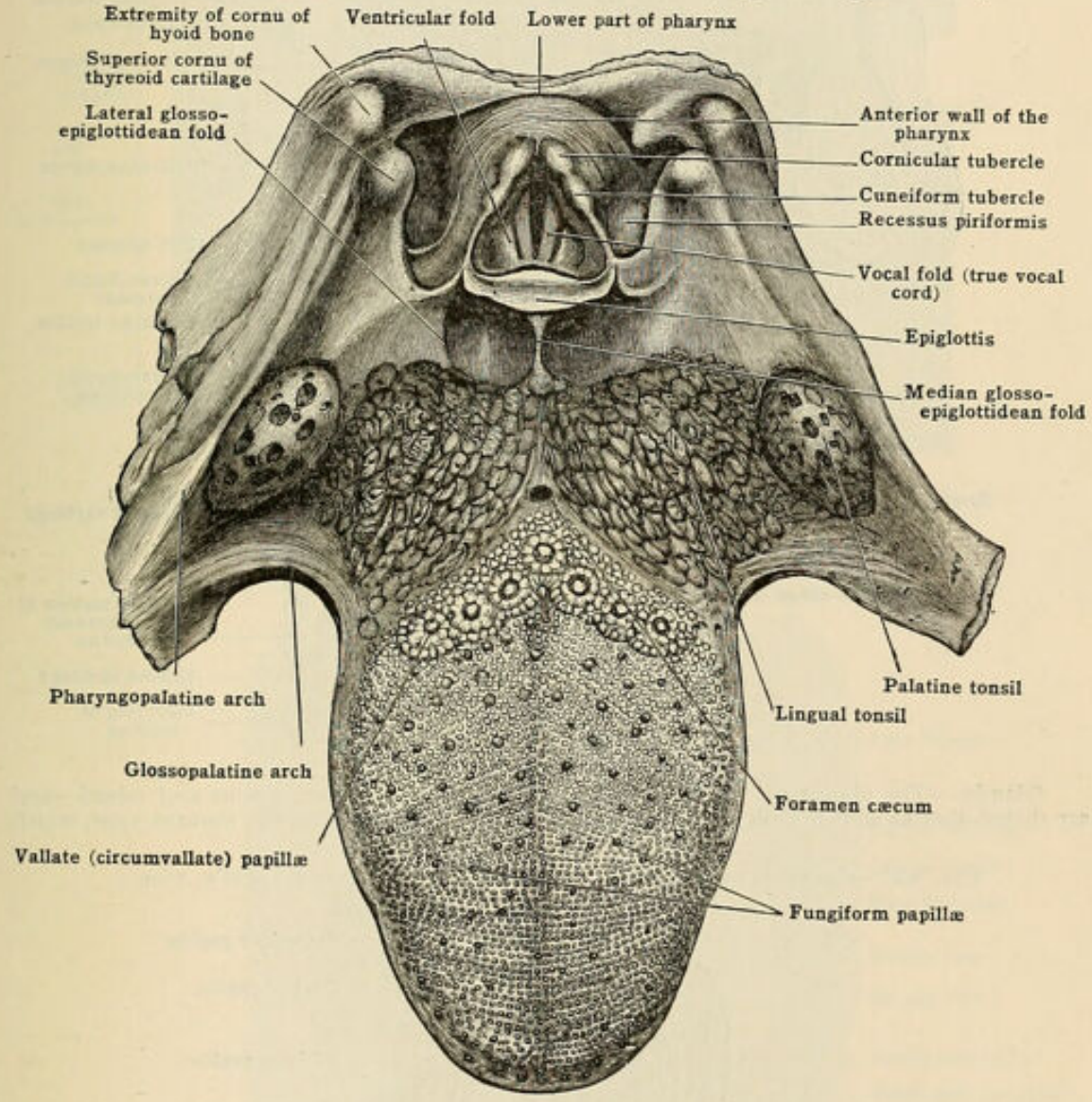

riorly it extends to the epiglottis, with which it is connected by a median and two lateral folds, between which are the depressions known as the *valleculæ*. The mucosa over the root of the tongue is irregular and warty in appearance due to the projections of the underlying nodular masses of lymphoid tissue, the *lingual follicles*. A *crypt* or tubular pocket of surface epithelium usually dips down into each of these follicles, as seen in surface view (fig. 854), and shown in section (fig. 859). The follicles vary from 34 to 102 in number, the average being 66 (Ostman), and are somewhat irregular in size and form. They are often arranged in more or less distinct longitudinal rows, with corresponding folds of the mucosa (Jurisch). The lingual follicles are collectively designated as the **lingual tonsil** [tonsilla linguæ]. Between the lingual follicles and around the periphery of the lingual tonsil there are found smaller ordinary nodules (without crypts) and indefinite

masses of lymphoid tissue. The sulcus terminalis forms a fairly sharp boundary between the lymphoid mucosa of the root and the papillated mucosa of the body of the tongue (fig. 854).

FIG. 855.—LEFT SIDE OF THE TONGUE, WITH ITS MUSCLES, ETC.

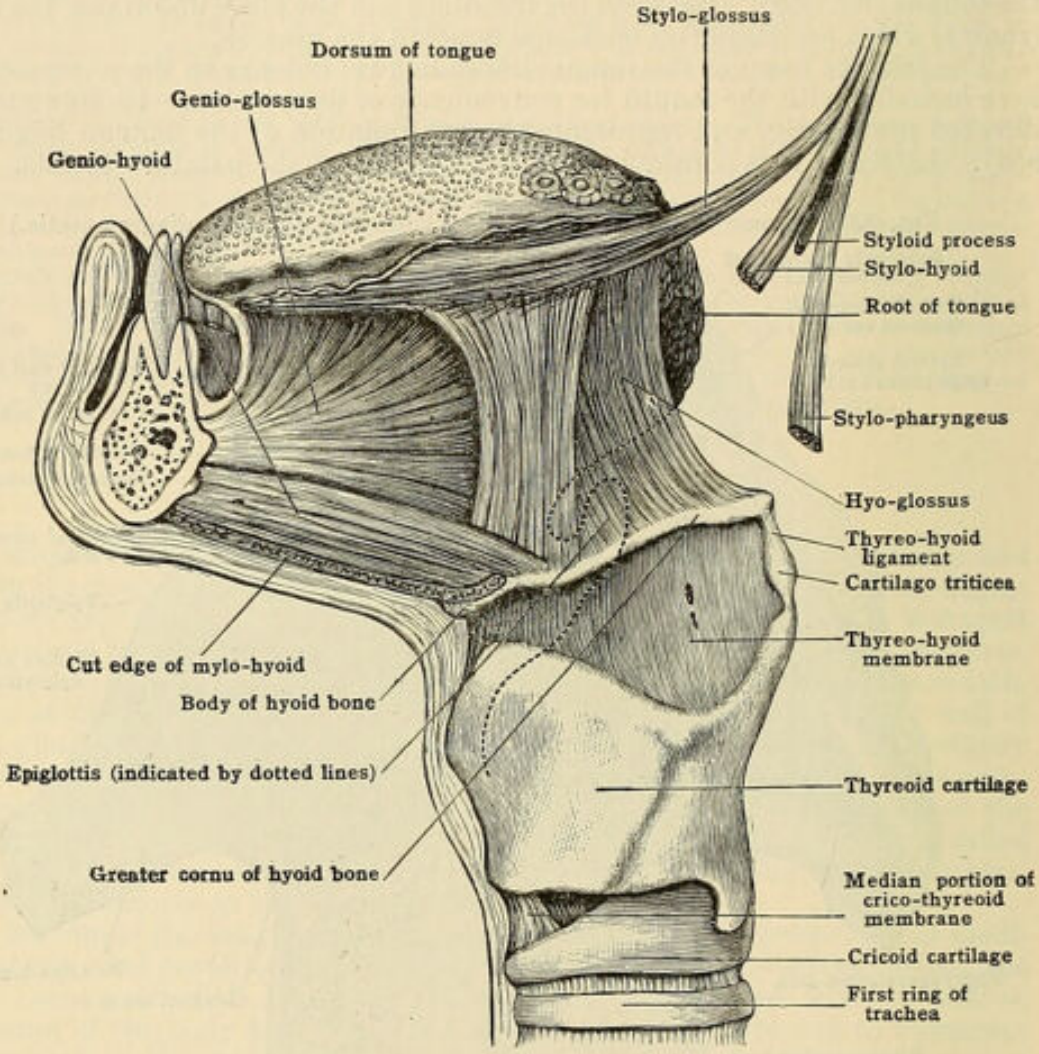

Glands.—The glands of the tongue are of three types—mucous, serous and mixed—and are distributed as shown in fig. 860. The most numerous are those of the **mucous** type, which

FIG. 856.—SECTION OF LINGUAL PAPILLÆ. × 20. (From Toldt's Atlas.)

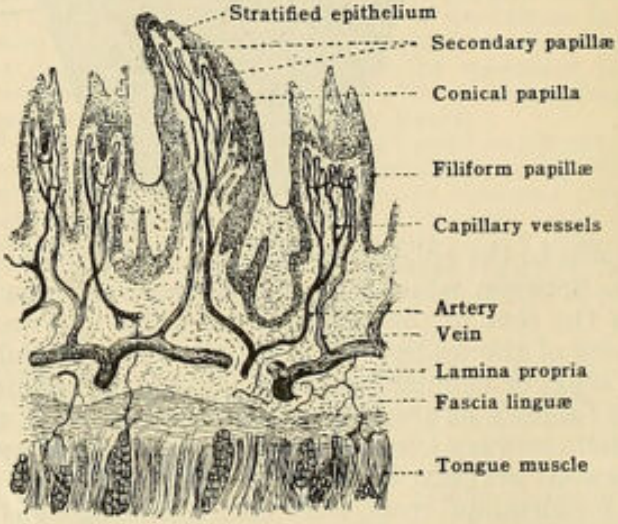

are typical for the mouth cavity in general and resemble those already described in the lips, cheeks and palate. They are spread over the entire surface of the root of the tongue, in the

spaces between the lingual follicles, usually opening upon the surface but in many cases into the crypts. Anteriorly, they extend a short distance along the posterior portion of the lateral

FIG. 857.—VERTICAL SECTION OF A HUMAN VALLATE PAPILLA WITH LINGUAL GLANDS. × 25. (Lewis and Stöhr.)

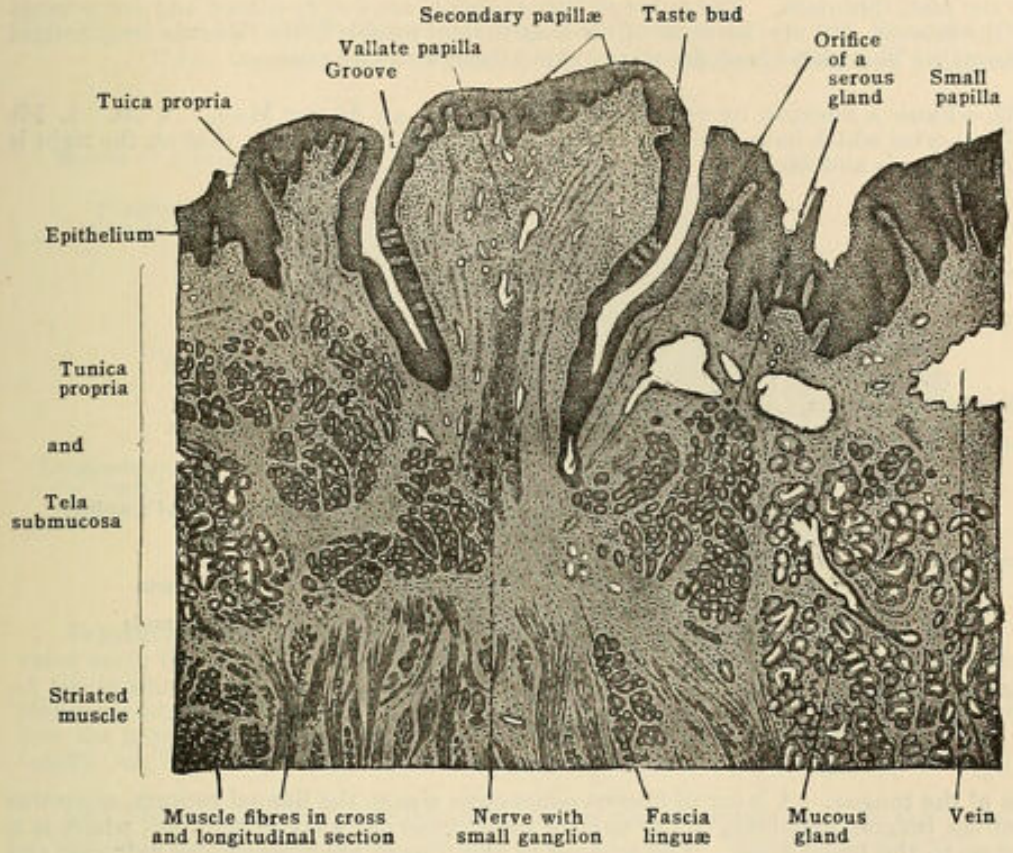

FIG. 858.—INFERIOR SURFACE OF THE TONGUE. (Modified from Spaltholz.)

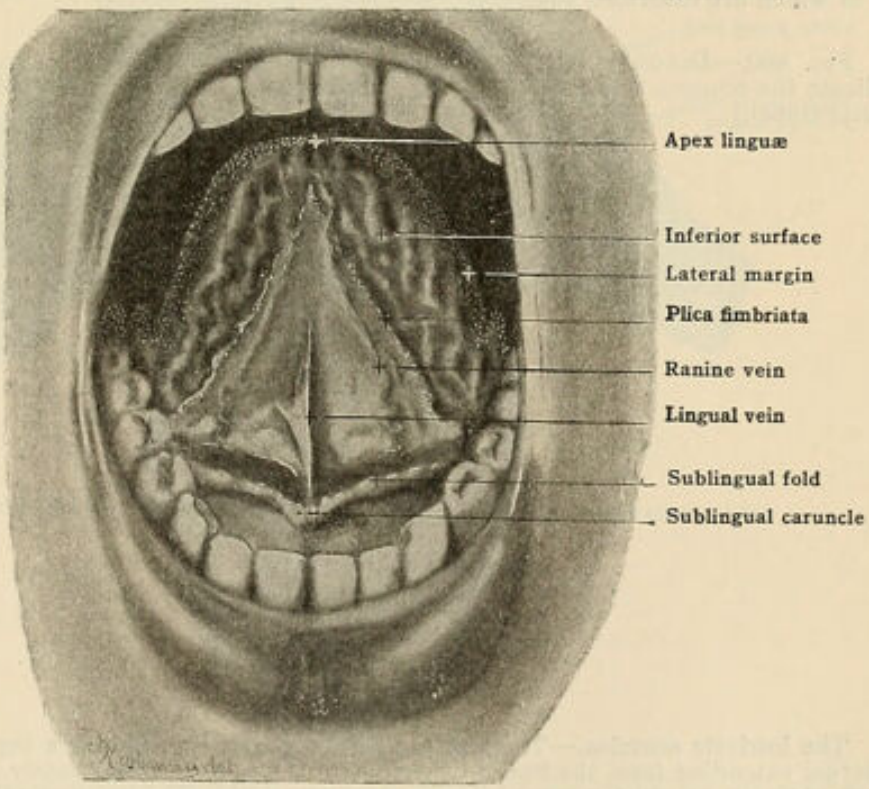

margin of the tongue, and also occupy small areas in and near the mid-line in front of the vallate papillæ.

In the immediate region of the vallate papillæ, and in the small lateral areas corresponding

to the foliate papillæ (i. e., in the regions of the taste-buds), the mucous glands are displaced by the **serous** glands (of von Ebner), which have a watery secretion (fig. 860). Finally, on the inferior surface of the tongue, on either side of the frenulum near the apex, are the **anterior lingual glands** (glands of Nuhn or Blandin). Each is about 15 mm. in length, and is composed of a group of racemose glands with three or four very small ducts opening on the surface of the tongue near the plica fimbriata. The anterior lingual glands are deeply placed and are covered not only by the mucosa, but also by some of the longitudinal muscle fibres (inferior longitudinal and styloglossus). This gland is of the mixed type, though chiefly mucous.

FIG. 859.—FROM A SECTION OF THE LINGUAL TONSIL OF AN ADULT MAN. × 20. 1. Pit containing leucocytes which have infiltrated its epithelium on the left side; that on the right is almost intact. (Lewis and Stöhr.)

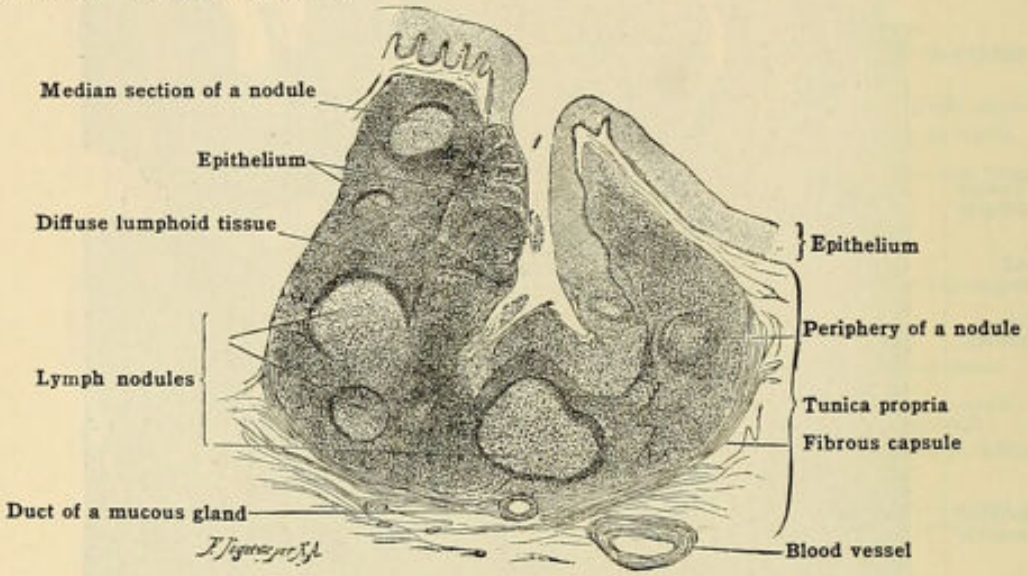

Muscles of the tongue.—A layer of fibrous connective tissue, the **lingual septum,** separates the halves of the tongue, extending in the median plane from the apex to the root, where it is attached below to the hyoid bone. The muscles of the tongue are classified as extrinsic and intrinsic. The **extrinsic muscles** (fig. 855) extend into the tongue from without. They are the hyoglossus, chondroglossus, genioglossus, styloglossus, and glossopalatinus (palatoglossus), all of which are described elsewhere (see Section IV.)

FIG. 860.—DIAGRAM OF THE DISTRIBUTION OF THE LINGUAL GLANDS. Horizontal lines indicate the mucous type; cross-hatched, the mixed type; and dotted areas, the serous type. (After Oppel.)

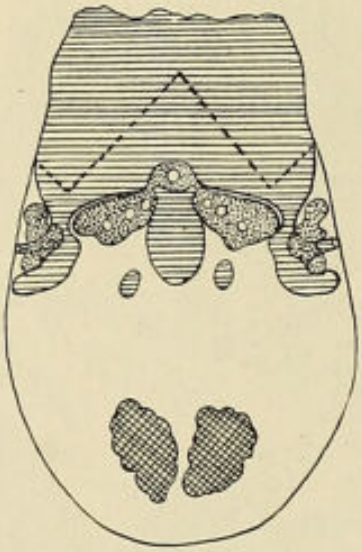

The intrinsic muscles.—The **longitudinalis superior** (fig. 861) is a superficial longitudinal stratum extending from the base to the apex of the tongue, immediately beneath the mucosa of the dorsum, to which many of its fibres are attached. The **longitudinalis inferior** (fig. 861) is composed of two muscle-bands extending from base to apex on the inferior surface of the tongue, and is situated between the hyoglossus and the genioglossus, some of its fibres near the apex mixing with the styloglossus, while dorsally some are attached to the hyoid bone. The **transversus linguæ** (fig. 861) consists of fibres which pass transversely, and is situated between

the superior and inferior longitudinal muscles. The fibres arise from, or pass through, the septum linguæ, and are attached to the mucosa of the dorsum and lateral margins of the tongue. The **verticalis linguæ** (fig. 861) is composed of fibres which pass from the mucosa of the dorsum to the mucosa of the inferior surface of the tongue, interlacing with those of the other intrinsic and extrinsic muscles.

FIG. 861.—TRANSVERSE SECTION THROUGH THE LEFT HALF OF THE TONGUE. (Magnified.) (From a preparation by Mr. J. Pollard, Middlesex Hospital Museum.)

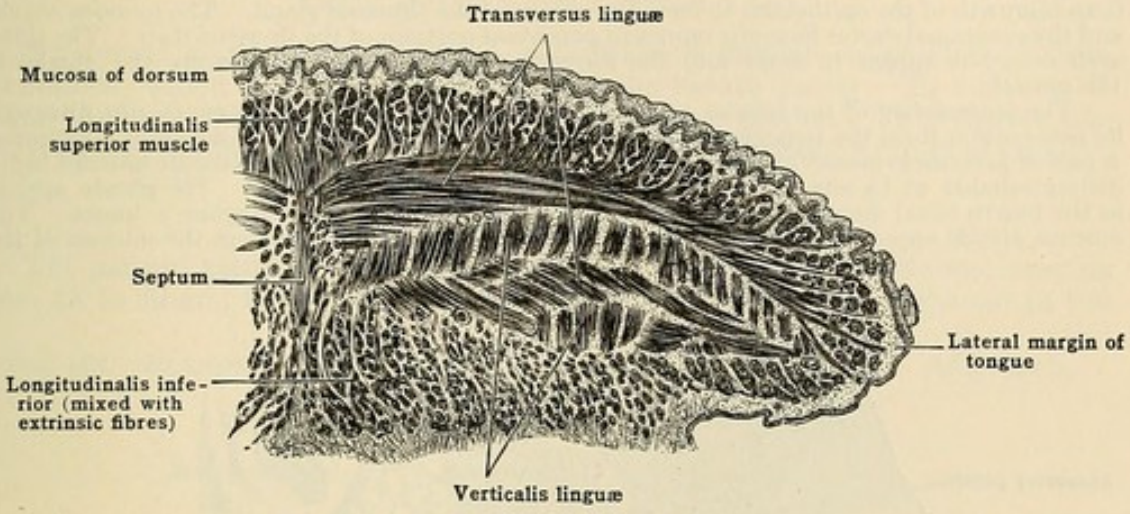

Vessels and nerves.—The **lingual arteries** furnish the principal blood-supply. The **lingual veins** carry the blood from the tongue to the internal jugular. The **lymphatics** form a network in the lamina propria, connected with a deeper network in the submucosa. The latter forms plexuses around the lingual follicles. The efferent lymph-vessels from the tongue empty chiefly into the superior deep cervical lymph-nodes. (For details concerning the blood- and lymph-vessels, see Sections V and VI.) **The nerves** are motor and sensory. The **hypoglossal nerve**

FIG. 862.—SCHEMATIC REPRESENTATION OF THE DISTRIBUTION OF TEE SENSORY NERVES IN THE MUCOUS MEMBRANE OF THE TONGUE. (Areas of distribution according to R. Zander. White dotted area indicates vagus; oblique lines, glosso-pharyngeal; horizontal lines lingual nerves.)

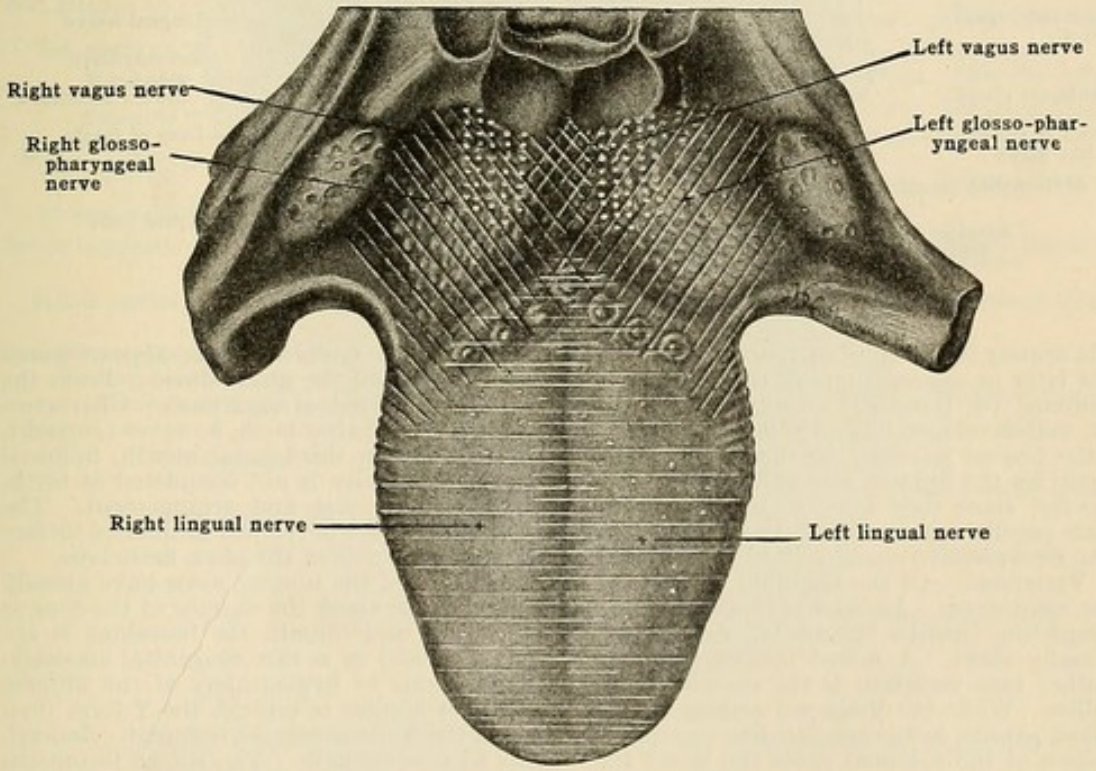

supplies the intrinsic and all the extrinsic muscles of the tongue except the glossopalatinus (palato-glossus), which is supplied from the pharyngeal plexus. The sensory nerves (fig. 862) are:—the **lingual nerve,** a branch of the mandibular division of the fifth, which, after joining with the chorda tympani from the seventh, is distributed to the anterior two-thirds of the tongue and represents the nerve of touch; the **lingual branches of the glossopharyngeal,** which are distrib-

uted to the root of the tongue, including also the vallate and foliate papillæ (nerve of taste); and **the superior laryngeal branch of the vagus,** which supplies a small area near the epiglottis.

Development.—The development of the tongue is quite complicated. In general, the *body* of the tongue is derived from the region corresponding to the ventral portion of the first arch, just behind the mandible. It does not develop from the tuberculum impar, however, which is a transitory structure (Hammar). The epithelium of the body of the tongue is probably of ectodermal origin. The *root* of the tongue develops from the corresponding lower portion of the second or hyoid arch, and its epithelium is endodermal in origin. The transverse groove between the two arches later becomes the *sulcus terminalis*. At the middle of this groove there is an ingrowth of the epithelium to form the anlage of the thyreoid gland. The *foramen cæcum* and the occasional *ductus lingualis* represent persistent portions of the thyreoid duct. The third arch does not appear to enter into the formation of the tongue, but forms the epiglottis (Hammar).

The *musculature* of the tongue appears to develop from the mesenchyme *in situ* although its innervation from the hypoglossal would indicate a derivation from the occipital myotomes. A pair of premuscle masses appears in the 9 mm. embryo, the individual extrinsic muscles being distinguishable at 14 mm., and the intrinsic at 20 mm. (W. H. Lewis). The *glands* appear in the fourth fœtal month as solid epithelial downgrowths which later acquire a lumen. The mucous glands appear first, the serous slightly later. Longitudinal folds in the mucosa of the

FIG. 863.—THE SALIVARY GLANDS.

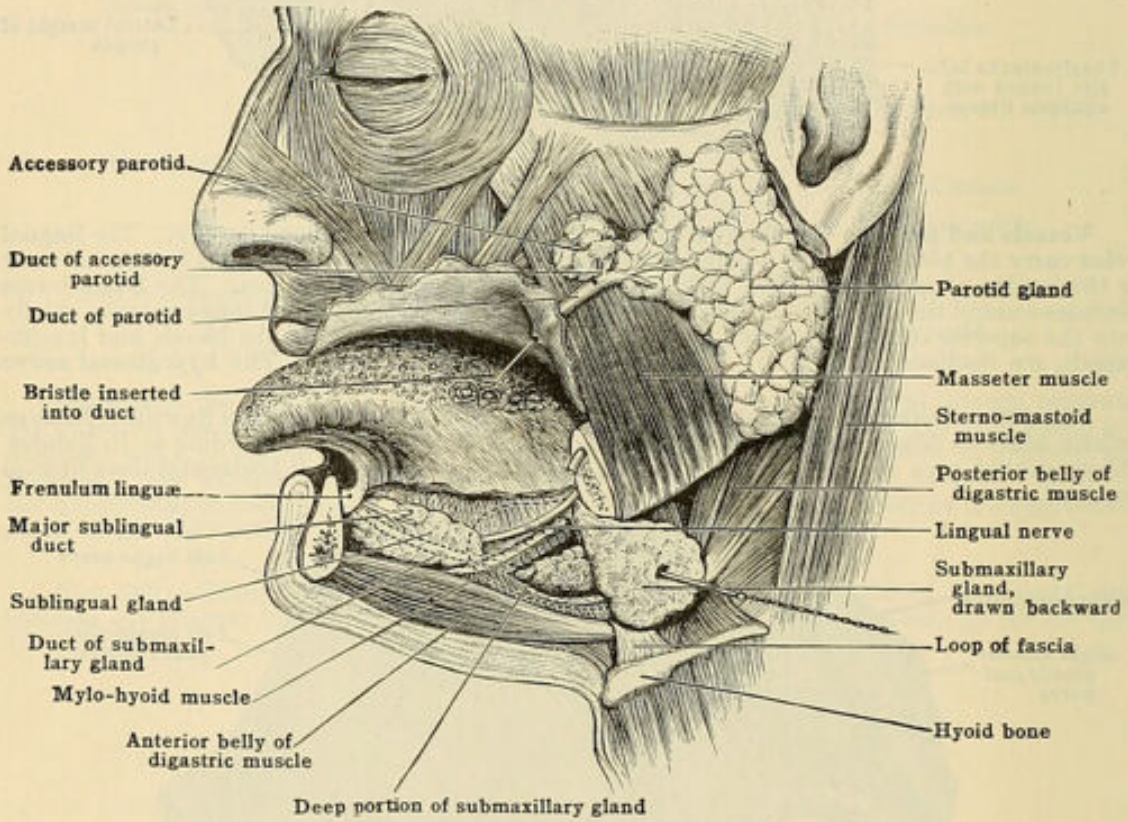

radix appear in the third or fourth fœtal month (Jurisch). The *lymphoid* tissue appears somewhat later as aggregations in the lamina propria, chiefly around the gland-ducts. From the beginning, the lymphoid structures are subject to marked individual variations. Characteristic, well-developed lingual follicles do not appear until some time after birth, however (Jurisch). Of the *lingual papillæ*, the fungiform appear at the end of the third fœtal month, followed shortly by the filiform and vallate. The formation of the papillæ is not completed at birth, however, since they later undergo changes in number, form, size and arrangement. The foliate papillæ appear about the fifth fœtal month. They are best developed in infants, undergoing retrogressive changes in the adult (Stahr). The same is true of the plicæ fimbriatæ.

Variations.—Of the manifold variations in the structure of the tongue, some have already been mentioned. Additional mucous glands sometimes occur along the margin of the tongue (completing Oppel's "glandular ring"). In "tongue-tied" individuals, the frenulum is abnormally short. A *forked* tongue (normal in some animals) is a rare congenital anomaly. Another rare variation is the so-called "*hairy*" tongue, due to hypertrophy of the filiform papillæ. While the **V**-shaped arrangement of the vallate papillæ is typical, the **Y**-form (two to four papillæ in the median line forming the stem of the **Y**) is nearly as frequent. Indeed, in some of the coloured races the latter type seems to predominate. The sulcus terminalis and foramen cæcum are often indistinct and sometimes absent.

Comparative.—The tongue of fishes and lower amphibia contains neither glands nor intrinsic musculature. Among higher vertebrates, the tongue varies exceedingly in form and structure, but always contains intrinsic musculature and mucous glands. The latter primitively form a ring around the margin and root of the tongue (Oppel). The serous glands occur only in mammals, and are associated closely with the papillæ bearing taste-buds.

The plica fimbriata in man is homologous with the 'sublingua' of lower mammals. According to Gegenbaur, the 'sublingua' represents the entire primitive vertebrate tongue, but this view is opposed by Oppel. Among various mammals, the number of vallate papillæ varies from one to thirty, but the V- or Y-arrangement is typical. The region of the foliate papillæ ('marginal organ') is typical for mammals, and is much better developed in some (e. g., rabbit) than in man. The mucosa of the root of the tongue is always different from that of the body. The lingual papillæ are especially developed in the tongue of carnivora.

THE SALIVARY GLANDS

Numerous glands—labial, buccal, palatine and lingual—have already been mentioned, which pour their secretions into the mouth cavity. In addition to these, there are three larger pairs, the salivary glands proper. They include the parotid, the submaxillary, and the sublingual (the latter really a group of glands).

THE PAROTID GLAND

The **parotid gland** [gl. parotis] is the largest of the salivary glands, varying from 15 to 30 gm. in weight. It is located below and in front of the ear in the

FIG. 864.—HORIZONTAL SECTION THROUGH HEAD AT LEVEL OF RIMA ORIS. (After Henle, modified.)

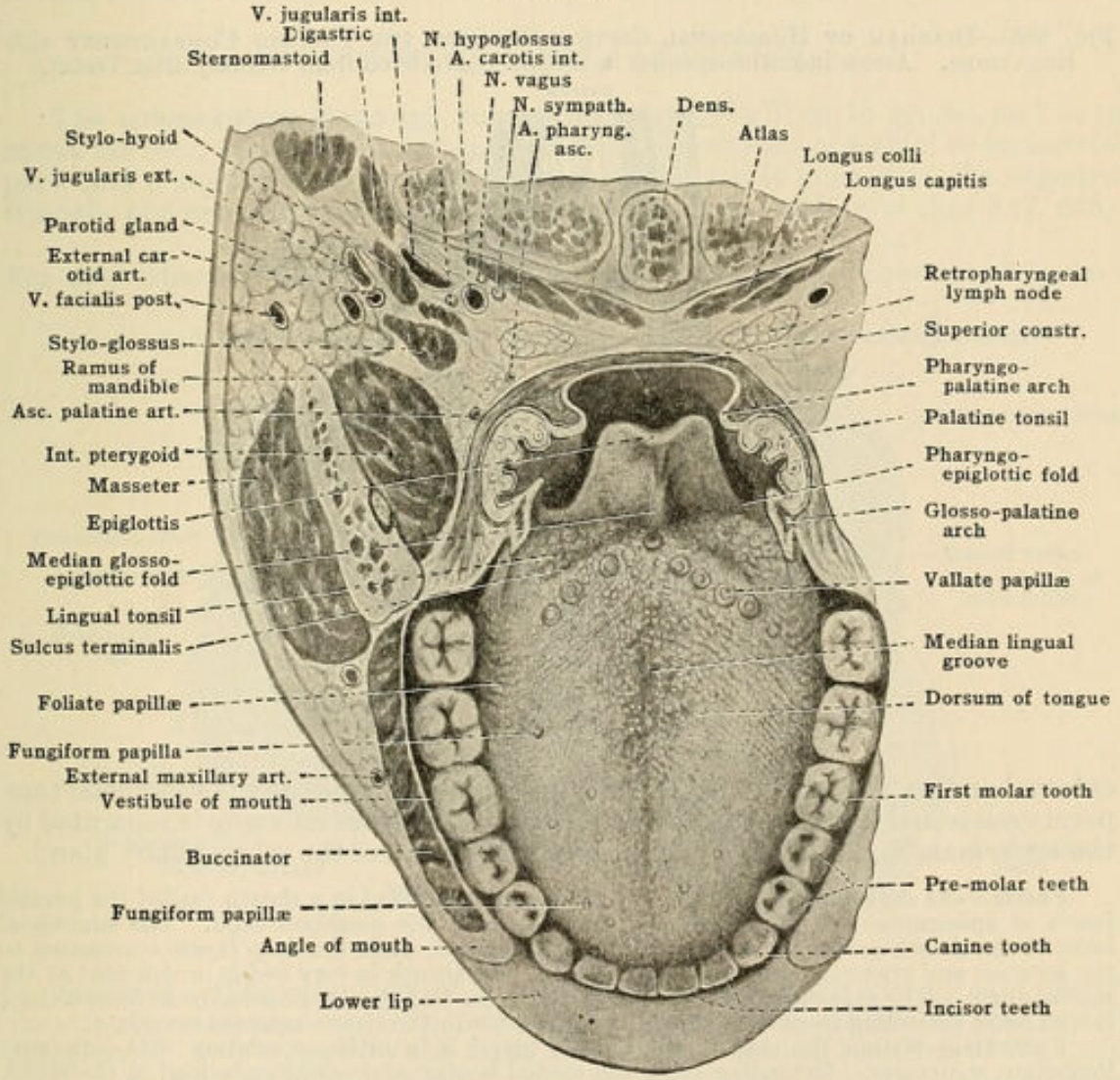

retromandibular fossa (fig. 863), extending from the zygomatic arch above to the angle of the mandible below.

Form and relations.—The parotid is somewhat prismatic or wedge-shaped (figs. 863, 864), with three surfaces and three borders or angles. The *lateral* surface is covered by skin and superficial fascia, and in its lower part by the platysma. The *anterior* surface overlaps the masseter and extends medialward in contact

with the posterior border of the mandibular ramus and with the posterior aspect of the internal pterygoid muscle. An irregular "pterygoid lobe" may extend between the internal and the external pterygoid muscles. The *posterior* surface is in contact with the sternomastoid muscle laterally, and with the styloid process and associated muscles medially. Between the sternomastoid and styloid process it touches the posterior belly of the digastric, and is in relation with the internal carotid and jugular vessels. The various structures in contact with the parotid gland often make more or less distinct grooves upon its posterior and anterior surfaces.

Borders.—The *anterior* border usually extends from below obliquely upward and forward so as to give the whole superficial surface a triangular appearance. Near the upper end of the anterior border, the parotid duct leaves the gland, and just above this there is usually a small separate *accessory lobe* [gl. parotis accessoria], of variable form and size. The branches of the facial nerve also emerge from the anterior border. The *posterior* border extends along the anterior aspect of the sterno-mastoid muscle up to the mastoid process. The *medial* border is deeply placed (at the junction of the anterior and posterior surfaces), and approaches the wall of the pharynx.

The *upper extremity* of the parotid sends a process into the posterior part of the manibular fossa, behind the condyle of the mandible, and is related with the

FIG. 865.—DIAGRAM OF HORIZONTAL SECTION SHOWING THE PAROTID COMPARTMENT AND RELATIONS. Arrow indicates opening in sheath. (Modified from Woolsey after Testut.)

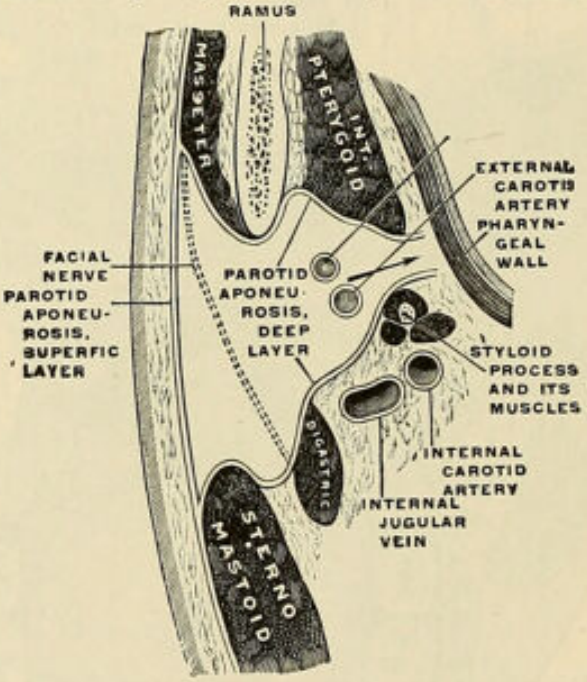

external auditory meatus. From the upper extremity emerge the superficial temporal vessels and the auriculo-temporal nerve. The *lower extremity* is separated by the stylo-mandibular ligament from the posterior end of the submaxillary gland.

Fascia.—As shown in fig. 865, the parotid gland is enclosed in a sheath (called the parotid fascia or aponeurosis) derived from the deep fascia of the neighbourhood. The superficial layer of the sheath covers the lateral surface of the gland, while the deep layers correspond to the anterior and posterior surfaces of the gland. The sheath is very feeble or deficient at the medial angle. The superficial and deep layers of the parotid sheath unite below to form a thick fascial band extending from the angle of the mandible to the sterno-mastoid muscle.

Contents.—Within the sheath, the parotid gland is in intimate relation with numerous important structures. Extending along the medial border, and partly embedded in the gland, is the external carotid artery, dividing above into the superficial temporal and internal maxillary (including the origins of the deep auricular and transverse facial); and the posterior facial (temporo-maxillary) vein and branches. The auriculo-temporal nerve passes through the upper part of the gland, while the facial nerve passes somewhat horizontally through it, dividing into its temporo-facial and cervico-facial divisions. Finally, there are embedded in the gland two or three deep lymphatic nodes, which receive lymphatic vessels from the external auditory meatus, the soft palate and the posterior part of the nasal fossa; and several superficial nodes, which receive lymphatic vessels from the temple, eyebrows and eyelids, cheek and auricle.

Structure.—The parotid is a racemose gland of the serous type.

Duct, vessels and nerves.—The **duct of the parotid** (Stenson's) issues from the anterior border of the gland, crosses the masseter a finger's breadth below the zygoma, and turns abruptly medialward round its anterior border. It penetrates the fat of the cheek and the fibres of the buccinator muscle, between which and the mucous membrane it runs for a short distance before it terminates, sometimes on the summit of a little papilla, by a minute orifice. This opening is placed opposite the crown of the second upper molar tooth. The duct commences by numerous branches, which converge toward the anterior border of the gland, and receives in its passage across the masseter the duct of the accessory parotid gland. The canal is about the size of a crow-quill, length about 35 to 40 mm., diameter 3 mm. Its mucous membrane is covered for a short distance, beginning with its oral termination, by stratified pavement epithelium, for the remainder of the distance by columnar epithelium. The coat of the duct is thick and tough, and consists of fibrous tissue intermixed with nonstriated muscle-fibres.

The **arteries** are derived from those lying in the gland substance and from the posterior auricular artery.

The **veins** terminate in the posterior facial (temporo-maxillary) trunk.

The **nerves.**—The parotid gland receives its secretory fibres from the otic ganglion, conveying impulses from the glosso-pharyngeal via the lesser petrosal and the auriculo-temporal; its sensory supply through branches of the fifth nerve; and its sympathetic supply from the carotid plexus. The **lymphatics** from the parotid gland terminate in the superficial and deep cervical glands, especially in the deeper group of parotid nodes embedded in the substance of the gland.

Variations.—The parotid is quite variable in size and in the form of its various processes, especially of the accessory lobe, as already mentioned. The lobulations are less distinct in infancy. Rarely the parotid is confined to the masseteric region, the retro-mandibular fossa being filled with a fatty tissue enclosing the vessels and nerves normally found with the gland.

THE SUBMAXILLARY GLAND

The **submaxillary gland** [gl. submaxillaris] weighs 7 to 10 grams, and is of about the form and size of a flattened walnut. It consists of a chief or superficial part, and a smaller deep process. The chief portion is located in the digastric triangle, and presents three surfaces—superficial, deep and lateral (figs. 847, 866).

FIG. 866.—MEDIAL VIEW OF THE SUBMAXILLARY AND SUBLINGUAL GLANDS. (Sobotta—McMurrich's Atlas.)

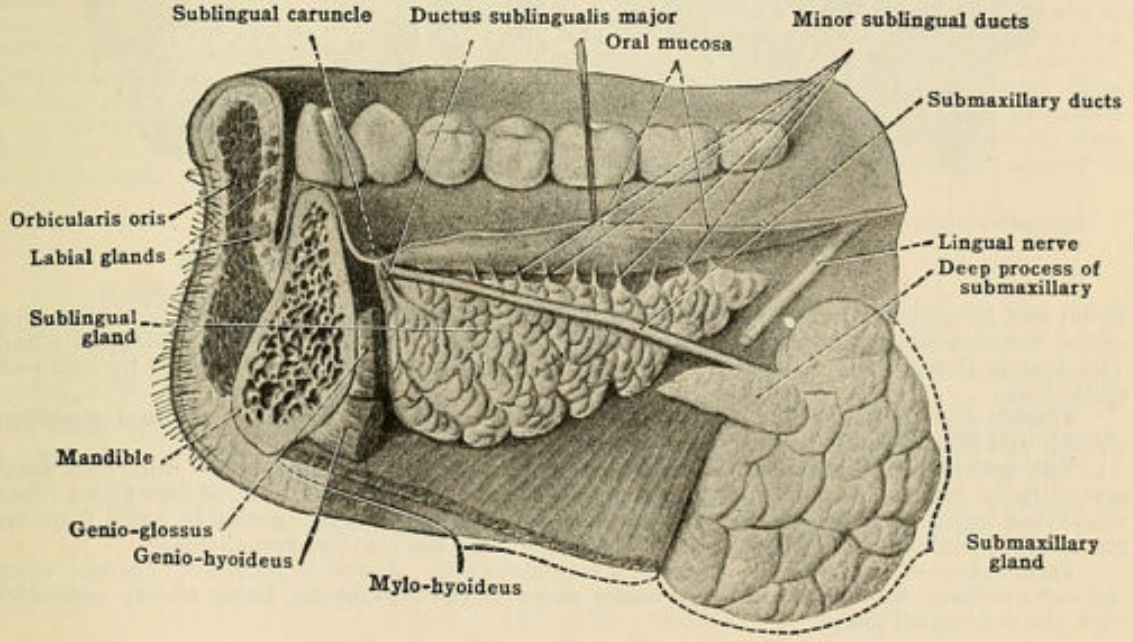

Surfaces.—The *superficial* or latero-inferior surface is covered by skin, superficial fascia, platysma and deep fascia (which forms an incomplete capsule around the gland). It is crossed by the facial vein and by cervical branches of the facial nerve. Several lymphatic glands, which receive vessels from the anterior facial region, lie upon or embedded in this surface.

The *lateral* surface is the smallest of the three. It is in contact with the submaxillary fossa of the medial surface of the mandible, and with the lower part of the internal pterygoid muscle. The posterior aspect of the gland is deeply grooved by the external maxillary (facial) artery and is separated from the parotid gland by the stylo-mandibular ligament. The *deep* or medio-superior surface is in contact with the lower surface of the mylohyoid, and behind this with the hyo-

glossus, stylohyoid and posterior belly of the digastric. Between this surface and the mylohyoid muscle are the mylohyoid nerve and artery and the submental artery.

The **deep portion** is a tongue-like process which passes from the deep surface of the submaxillary gland around the posterior border of the mylohyoid muscle, and extends forward in company with the duct, under cover of (above) the mylohyoid, and in relation with the hyoglossus and genioglossus muscles. At its commencement, the deep process lies just below the submaxillary ganglion and anteriorly it gives off the submaxillary duct as it approaches the sublingual gland.

Structure.—The submaxillary is a racemose gland belonging to the mixed type, some of the acini being serous, others mucous (fig. 867).

The **submaxillary (Wharton's) duct** springs from the deep surface of the superficial part of the gland; it passes forward and inward, along the medial surface of the deep lobe, and opens by a small orifice on the summit of a papilla [caruncula sublingualis] by the side of the frenulum of the tongue. It is crossed superficially by the lingual nerve. It lies at first between the mylo-

FIG. 867.—SECTION OF THE SUBMAXILLARY GLAND OF AN ADULT MAN. × 252. (Lewis and Stöhr.)

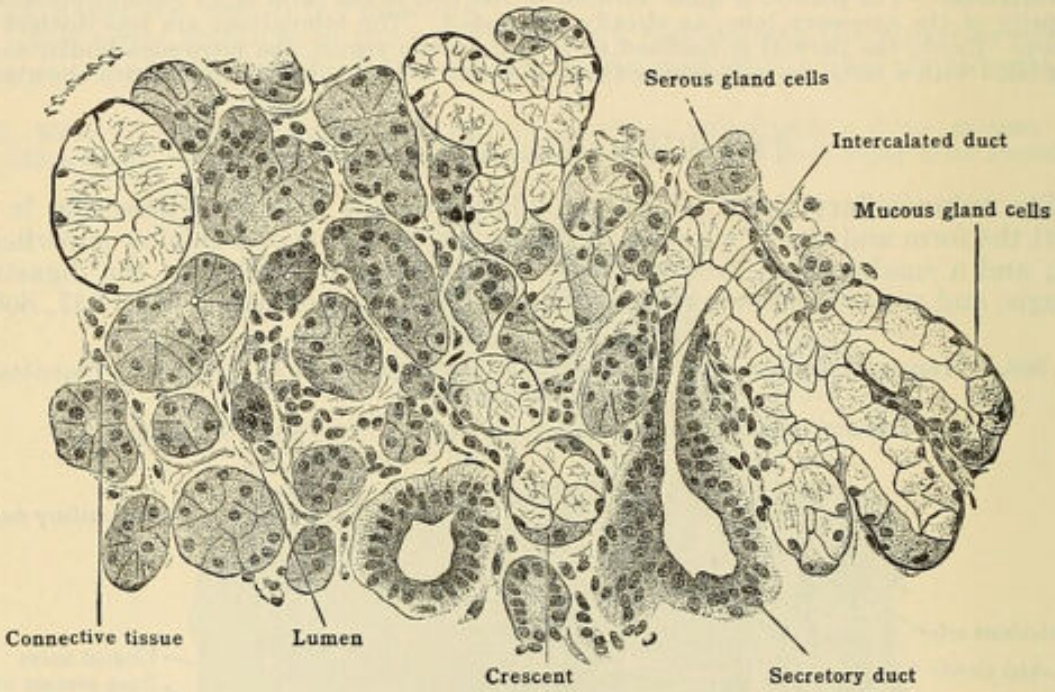

hyoid and hyoglossus; next, between the mylohyoid and genioglossus; and lastly, under cover of the mucous membrane of the mouth, between the genioglossus and the sublingual gland. The duct is about 5 cm. in length, and has comparatively thin walls. It is lined by columnar epithelium.

Vessels and nerves.—The **arteries** to the gland are derived from the external maxillary (facial) and lingual, and they are accompanied by corresponding *veins*.

The **nerves.**—The submaxillary gland receives its secretory fibres from numerous small sympathetic ganglia situated on the submaxillary duct and in the hilus of the gland, these conveying impulses from the chorda tympani; its sensory branches probably come from the geniculate ganglion, and its sympathetic branches from the cervical sympathetic.

Variations.—Absence of the gland is a rare anomaly. A case is recorded (Turner) where the submaxillary was placed entirely under cover of the mylohyoid, being closely associated with the sublingual gland.

THE SUBLINGUAL GLAND

The **sublingual gland** [gl. sublingualis]—the smallest of the salivary glands (2 to 3 gm.) is in reality a group of glands forming an elongated mass in the floor of the mouth under the tongue (fig. 847). *Above*, it forms a distinct ridge, covered by a fold of mucosa (plica sublingualis) upon which its ducts open (fig. 866). It is flattened from side to side, its *lower* border resting upon the upper surface of the mylohyoid, its *lateral* surface in contact with the sublingual fossa of the mandible, and its *medial* surface with the geniohyoid, geniohyoglossus, lingual nerve, deep lingual artery and submaxillary duct (fig. 863). *Anteriorly* it touches its fellow of the opposite side, while *posteriorly* it is often related with the deep process of the

submaxillary gland. It has no distinct capsule, thus differing from the submaxillary and parotid glands. In *structure*, it is a racemose mixed gland, but predominantly mucous.

Ducts.—The *minor sublingual ducts* [ductus sublinguales minores], ducts of Rivinus, vary from five to fifteen or more in number, and open on minute papillæ along the crest of the plica sublingualis (fig. 858). The anterior portion of the gland often forms a *larger (Bartholin's) duct* [ductus sublingualis major] which opens alongside the submaxillary duct on the *caruncula sublingualis* (figs. 858, 866).

Vessels and nerves.—The *arteries* are derived from the sublingual and submental, with corresponding *veins*. The *lymphatics* are tributaries of the superior deep cervical nodes.

Nerves.—The sublingual glands receive their secretory fibres from the submaxillary and associated sympathetic ganglia, conveying impulses from the chorda tympani; sympathetic branches come from the cervical sympathetic and sensory fibres probably from the geniculate ganglion, although this question needs further investigation.

Development of the salivary glands.—The salivary glands appear early as buds from the ectodermal epithelium extending into the adjacent mesenchyme of the mouth cavity. The *parotid* appears first on the side of the mouth cavity in an embryo of 8 mm., as a groove which becomes tubular and pushes back over the masseter to the ear region, developing branches (at first solid). Around the gland and between the branches is mesenchyme which becomes condensed to form the peripheral capsule. The *submaxillary* gland appears in the 13 mm. embryo as a ridge in the epithelium of the alveolo-lingual groove. The solid cord (lumen appearing later) grows forward to the region of its adult orifice. Its posterior end extends backward and gives off solid branches which later form the acini and duct system of the mature gland. The *sublingual* glands appear somewhat later (24 mm. embryo) as a series of separate anlages of variable number, budding off in the positions where the adult ducts empty. The major sublingual gland, if present, appears first. The histogenetic development of the salivary glands is not completed until some time after birth, probably about the time of weaning. However, mucin cells appear in the sublingual glands in the fœtus of four months and serous cells in the parotid of five months.

Variations.—The duct of Bartholin is present in about half of the cases, and the corresponding anterior part of the gland may be more or less separate [gl. sublingualis major]. The number of ducts may reach thirty (Tillaux). Rarely processes from the gland may penetrate the mylohyoid, appearing on its lower surface in one or more places (Moustin). Most of the variations in this and the other salivary glands are due to developmental irregularities.

Comparative.—Oral glands are not found in the lower aquatic vertebrates. Mucous glands occur in all terrestrial vertebrates, but true salivary (digestive) glands appear only in mammals. Although great variations occur in the different species of mammals, those in man (excepting the anterior lingual) are typical for the order. The sublingual gland, however, often occurs as two separate glands, corresponding to the sublingualis major and minor. The parotid gland apparently has no representative in forms below mammals. In some mammals (e. g., monkey) it has two main lobes—a larger superficial and a smaller deeper lobe between which lies the facial nerve (Gregoire). Other oral glands (e. g., orbital, zygomatic) appear in some mammals.

THE TEETH

The **teeth** [dentes] are highly specialized structures developed in the oral mucosa as organs of mastication and also (in man) of speech. The adult individual with perfect dentition has thirty-two teeth, arranged arch-like in the sockets (alveoli) of the maxilla and the mandible. Sixteen belong to the upper or maxillary arch; and sixteen to the lower or mandibular. The four central teeth in each dental arch are the *incisors;* the tooth next to these on each side is the *canine;* behind these are the two *premolars* (bicuspids); and lastly the three *molars*. This relation of teeth is expressed by the following dental formula:

$$\text{i}\,\frac{2}{2},\ \text{c}\,\frac{1}{1},\ \text{pm}\,\frac{2}{2},\ \text{m}\,\frac{3}{3} = 32.$$

Form.—Each tooth [dens] has a *crown* [corona dentis], the portion exposed beyond the gum, and covered with enamel (figs. 871, 872). The root [radix dentis] is the portion covered with cementum and embedded in the bony socket. At the line of union of crown and root is the slightly constricted *neck* [collum dentis]. The surface of the tooth directed toward the lip (or cheek) is termed the *labial* (or buccal) surface [facies labialis; f. buccalis]; while that toward the tongue is the *lingual* surface [f. lingualis]. The crowns of the opposite arches meet at the *masticating* surface [f. masticatoria]. The surfaces in contact with the adjacent teeth of the same arch [facies contactus] are, for the incisors and canines, termed *medial* and *lateral*, while those for the premolars and molars are termed *anterior* and *posterior*.

Structure.—As shown in longitudinal section (fig. 873), each tooth has a central *cavity* [cavum dentis] or pulp cavity, which is filled with *pulp* [pulpa dentis]. The pulp is a soft fibrous tissue richly supplied with vessels and sensory nerves which enter the *root canal* through the apical *foramen* [foramen apicis dentis]. The body of the tooth, both crown and root, is composed of a dense modified variety of bone called *dentine* [substantia eburnea]. It is yellowish in colour. The striated appearance of the dentine is due to numerous fine canals, the *dentinal*

FIG. 868.—TEETH OF AN ADULT, EXTERNAL VIEW.

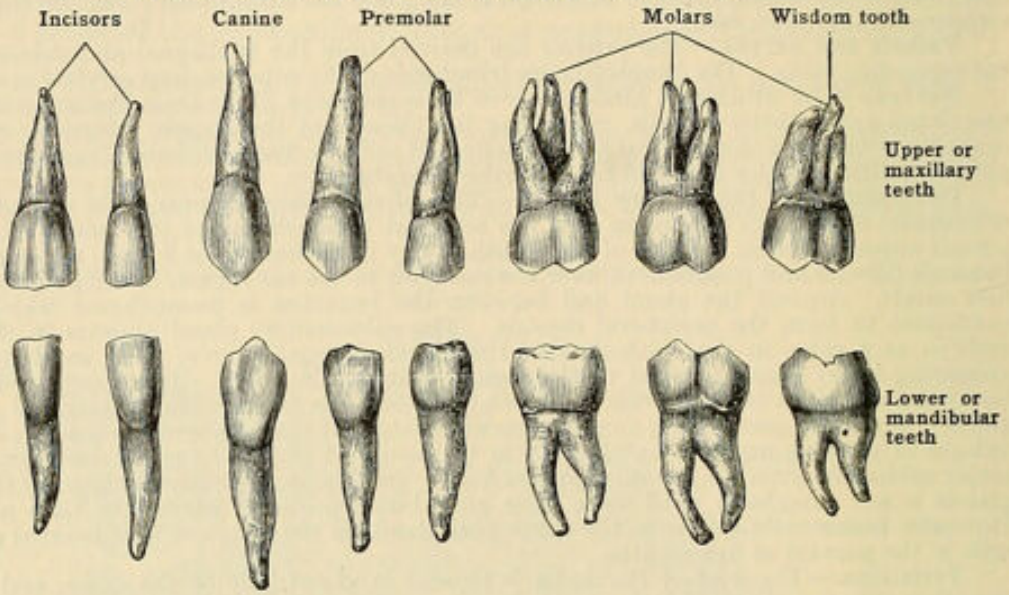

FIG. 869.—TEETH OF ADULT, LINGUAL SURFACES. (Broomell and Fischelis.)

FIG. 870.—TEETH OF ADULT, LABIAL AND BUCCAL SURFACES. (Broomell and Fischelis.)

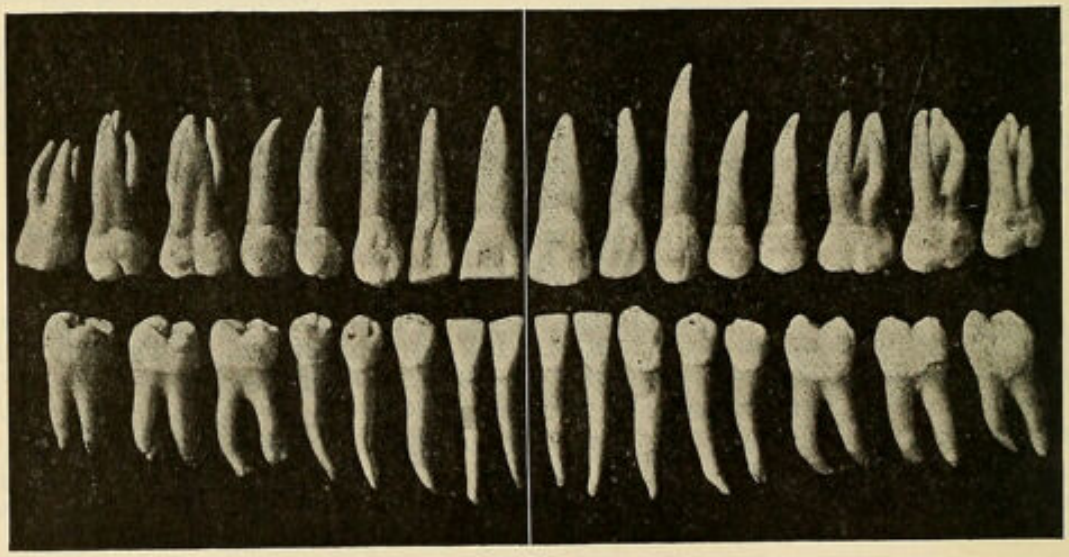

FIG. 871.—CANINE TOOTH, LINGUAL SURFACE.

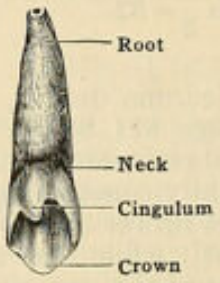

FIG. 872.—A MOLAR TOOTH IN SECTION.

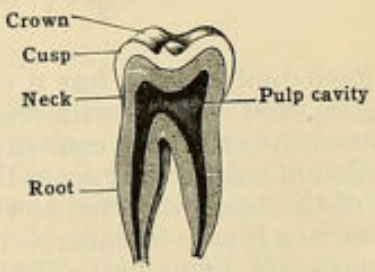

tubules. These contain 'Tomes' fibrils,' which are long protoplasmic branches of the *odontoblasts*, a layer of cells on the surface of the pulp. At the outer surface of the dentine are numerous small, irregular *interglobular spaces*, corresponding in the root to Tomes' 'granular sheath' (fig. 873). The dentine of the crown is covered with a layer of white *enamel* [substantia adamantina], which is the hardest substance in the body. It is composed of numerous minute

hexagonal *prisms* [prismata adamantina] which are arranged perpendicular to the surface and are of epithelial origin. In adult teeth, the enamel is often worn through in places, exposing the yellowish dentine. The dentine of the root is covered by a thin layer of *cementum* [substantia ossea], a layer of bone which is very thin at the neck, but becomes thicker toward the root apex (fig. 873). Surrounding the root is the *alveolar periosteum*, a fibrous membrane connecting the cementum firmly with the bony lining of the socket. For further details of the minute structure of teeth, works on histology may be consulted.

Gums.—Covering the alveolar portions of the maxilla and mandible are the **gums** [gingivæ]. They are continuous with the mucosa of the vestibule exter-

FIG. 873.—VERTICAL SECTION OF AN INFERIOR CANINE TOOTH, IN SITU. × 4. (From Toldt's Atlas.)

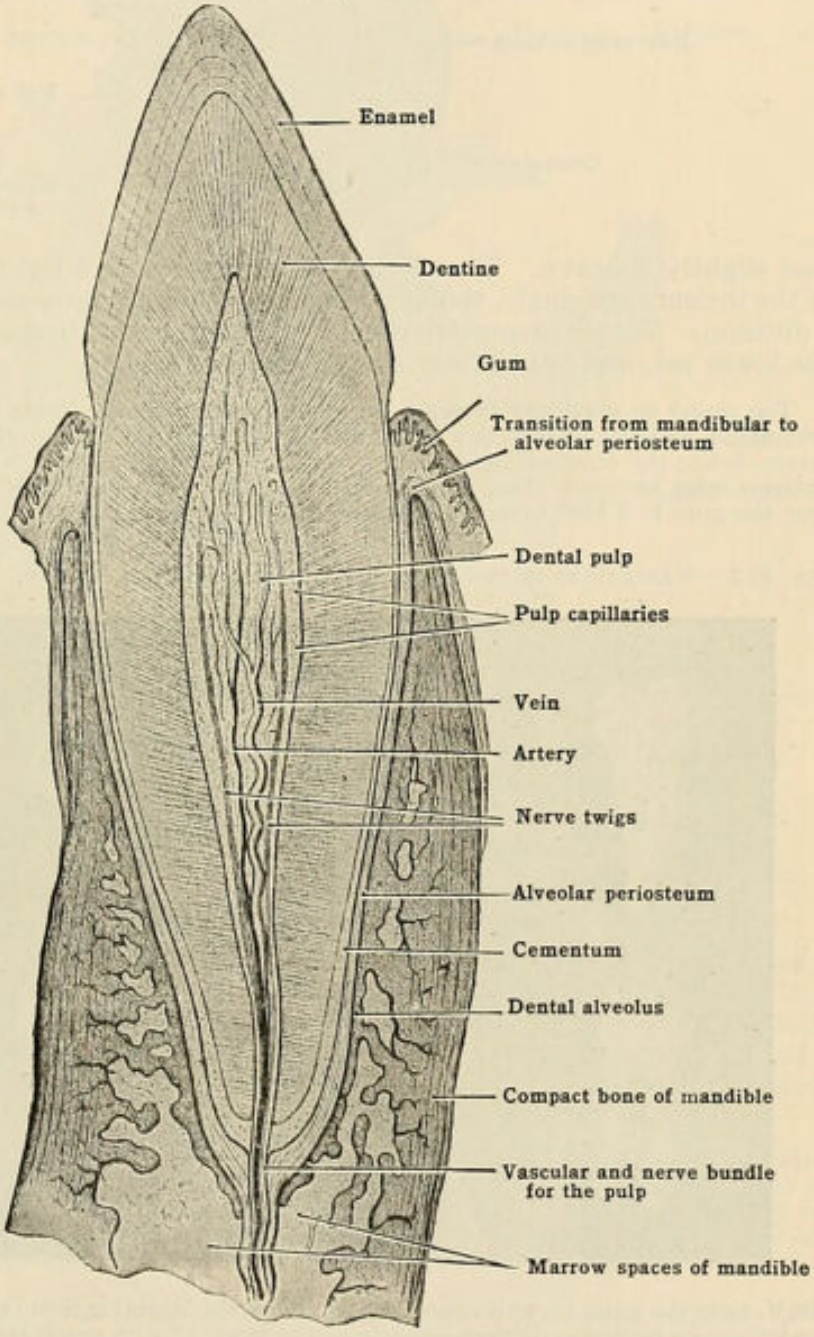

nally and of the palate or floor of the mouth internally. Like the mucosa of the mouth elsewhere, they are covered with stratified squamous epithelium. The lamina propria is especially thick and strong, and is firmly attached to the subjacent bone. Around the neck of each tooth, the epithelium of the gum forms an overlapping collar and the lamina propria is continuous with the alveolar periosteum (fig. 873).

The incisors.—(Figs. 868, 869, 870, 874.) The incisor teeth [dentes incisivi] are so named on account of their function in cutting the food. The *crown* has a

characteristic chisel shape. The *masticating* surface is narrow and chisel-edged. In recently erupted teeth, the cutting edge is elevated into three small cusps, which soon wear down, leaving a straight edge. These cusps correspond to three indistinct ridges on the labial surfaces. The lateral angle of the crown is usually more rounded than the medial. The *labial* surfaces are slightly convex, the *lingual* slightly concave. The *contact* surfaces are somewhat triangular. The *roots* of the incisors are single, though often longitudinally grooved, indicating traces of a division. They are somewhat conical, but flattened from side to side, expecially the lower set, and are slightly curved lateralward.

FIG. 874.—CROSS-SECTION OF THE MEDIAL UPPER INCISOR, IN SITU. × 4. (From Toldt's Atlas.)

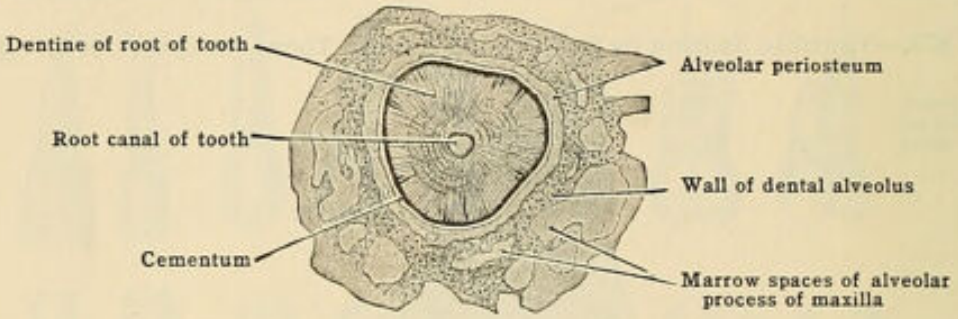

The upper or **maxillary incisors** are much larger than the lower. They are lodged in the premaxilla, and are inclined downward and forward. They overlap the lower incisors in mastication, hence the masticating surface is worn off and rounded at its posterior edge, while the anterior edge becomes sharp and chisel-like. The lingual surfaces of the crowns terminate near the gum in a low, inverted **V**-shaped ridge, the basal ridge or *cingulum*. At the apex of the **V**, near the gum, there is often (especially on the lateral incisor) a small *lingual cusp*. The medial upper incisor is distinguished from the lateral by its much larger size.

FIG. 875.—VARIATIONS IN THE FORM OF THE UPPER THIRD MOLAR. (Broomell and Fischelis.)

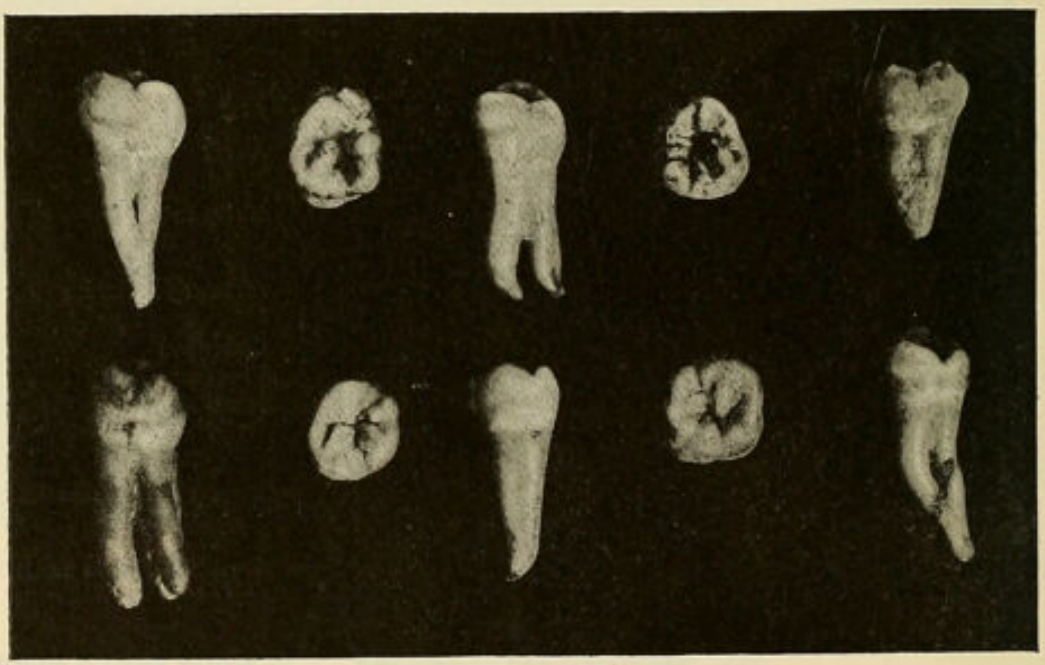

The lower or **mandibular incisors** are smaller than the upper, the cutting edges being only about half as wide. Being overlapped by the upper set, the lower incisors have the masticating surface worn off anteriorly, leaving a sharp cutting edge posteriorly. The lower incisors are vertically placed, and the crown becomes narrower toward the neck. A cingulum is rarely visible. The medial lower incisor, unlike the upper, is slightly smaller than the lateral.

The canines.—(Figs. 868, 869, 870, 871.) The canine teeth [dentes canini] so-called from their prominence in the dog-tribe, are the longest of all the teeth (fig. 868). The *crown* is thicker and more conical than in the incisors. The *masticating* surface forms a median angular point, on either side of which the cutting

edge slopes to the lateral angle. The medial limb of the cutting edge is usually somewhat shorter than the lateral, rendering the crown asymmetrical. The *labial* surface is convex, the *lingual* somewhat concave. The *root* is single, long, flattened from side to side and grooved on the sides as in the incisors. The canine root is usually slightly curved lateralward. The bony alveolar protuberances [juga alveolaria] are more prominent than those of any other teeth.

The **upper canine** slants forward and overlaps the lower, as in the incisors. The upper canine also presents a well-marked *cingulum*, and usually a distinct *lingual cusp* (fig. 871) below which a slight median ridge extends along the lingual surface. On the **lower canine,** these structures are poorly marked or absent. The lower canine is somewhat smaller than the upper, and its root is occasionally bifid.

The premolars.—(Figs. 868, 869, 870, 876, 877.) The premolars [dentes premolares] are so named on account of their position in front of the molars. The

FIG. 876.—DISSECTION SHOWING THE ROOTS OF THE TEETH. Teeth in Occlusion. × 1
(From Toldt's Atlas.)

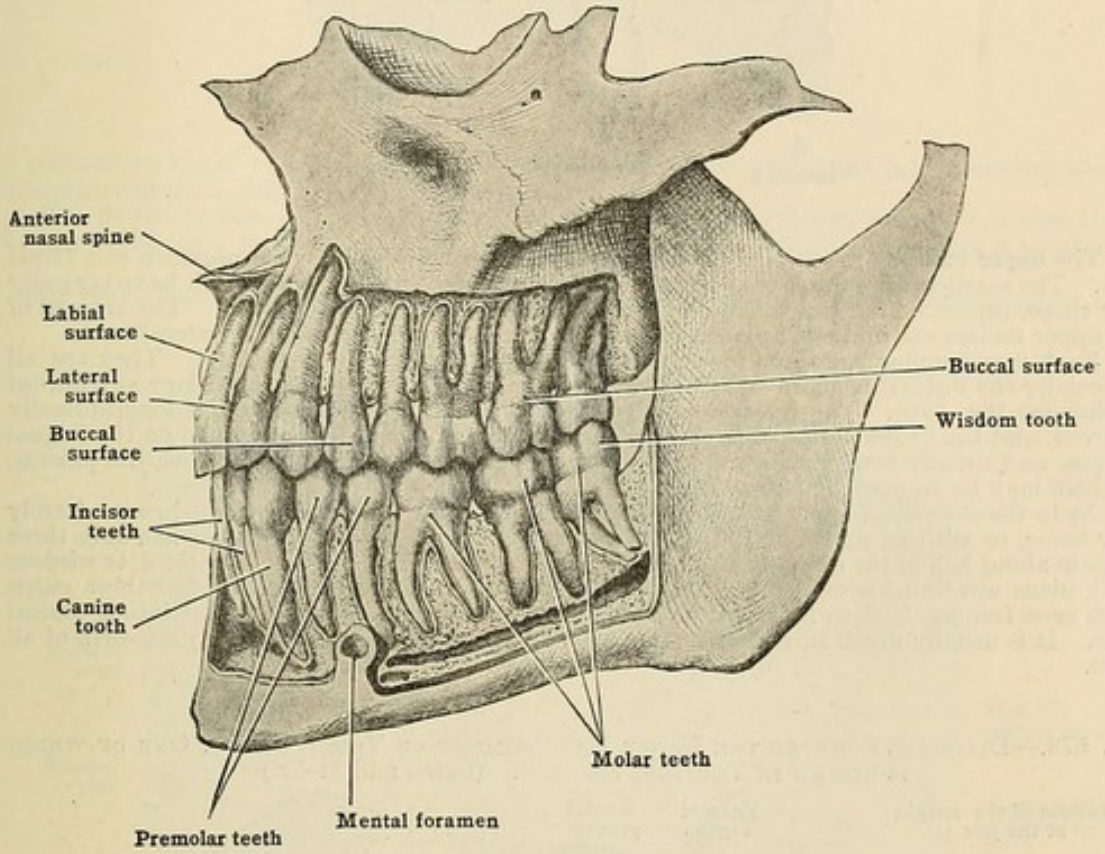

crown presents on the masticating surface two prominent cusps, on account of which the premolars are often called 'bicuspids.' The *buccal* and *lingual* surfaces are convex especially from side to side, so that the crown is somewhat cylindrical in form, with flattened, quadrilateral anterior and posterior *contact* surfaces. The *root* is (usually) single and more or less flattened antero-posteriorly, and usually somewhat curved backward.

The **upper premolars** are distinguished from the lower by a greater antero-posterior flattening of the crown and by a deep groove separating the cusps (excepting at their anterior and posterior margins) on the masticating surface. In the *first* upper premolar the lingual cusp and surface are decidedly smaller than the buccal; and the root is frequently bifid or double (occasionally even triple). In the *second* upper premolar the lingual cusp and surface are as large as the buccal; and the root, though deeply grooved, is rarely bifid.

In the **lower premolars,** the crowns are more cylindrical in form, and the cusps are united by a median ridge so that the masticating surface presents two small pits. The roots are more rounded and tapering, and rarely grooved. In the *first* lower premolar (like the corresponding upper) the lingual cusp and surface are much smaller than the buccal, the lingual cusp sometimes being rudimentary; while in the *second* they are more nearly equal. The second lower premolar is often slightly larger than the first, while in the upper premolars the converse is true. It should be noted, however, that the premolars are quite variable in all respects, and it is therefore often difficult to identify the individual isolated teeth.

The molars.—(Figs. 868, 869, 870, 872, 875, 876.) The molars [dentes molares] or 'grinders' are characterized by their large size, and by the presence of

three to five masticating cusps (hence sometimes called 'multicuspids'). The *crowns* are massive, somewhat resembling rounded cubes, and the lingual and buccal surfaces present vertical grooves continuous with the fissures separating the cusps. The *pulp cavity* (fig. 872) has slight extensions corresponding to the cusps, and also communicates with the canals of the *roots*, which are usually two or three in number, and more or less curved.

FIG. 877.—DIAGRAM SHOWING THE ARTICULATION OF THE TEETH. (Poirier-Charpy.)

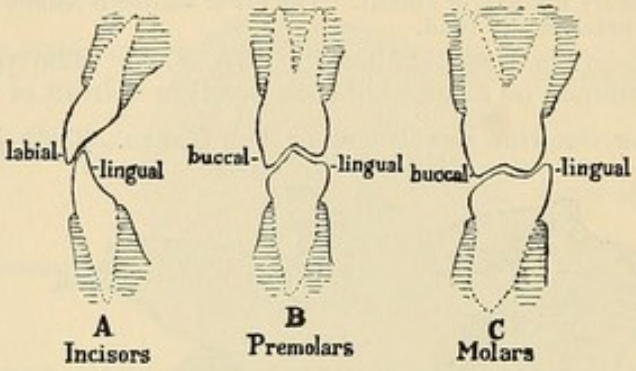

The **upper molars** are most easily distinguished from the lower by the presence of a triple root. The masticating surface is nearly square with rounded angles. They each have typically four cusps, separated by grooves resembling a diagonally placed H (fig. 852). The crowns of the upper molars are obliquely placed so as to slant downward and slightly lateralward.

Each upper molar has three roots, two buccal and one lingual or palatal. They are all (especially the buccal) in more or less close relation with the floor of the maxillary antrum (of Highmore) (fig. 876). The buccal roots are flattened antero-posteriorly, and longitudinally grooved, and bent backward. The palatal root is more rounded, with a groove on the lingual surface, and usually bent medialward. Either of the buccal roots may fuse with the palatal, or there may be an extra fourth root.

As to the *individual* upper molars, the *first* has almost invariably four typical cusps (rarely only three, or with an additional fifth rudimentary). The *second* upper molar has only three cusps in about half of the cases (in Europeans), and four in the remainder. The *third*, or wisdom tooth [dens serotinus] is exceedingly variable in size and form (fig. 875). It has three cusps much more frequently than four, and its three roots are often more or less fused into a conical mass. It is usually much smaller than the other molars, and is absent in nearly one-fifth of all cases.

FIG. 878.—DIAGRAMS SHOWING THE EARLY DEVELOPMENT OF THREE TEETH, ONE OF WHICH IS SHOWN IN VERTICAL SECTION. (Lewis and Stöhr.)

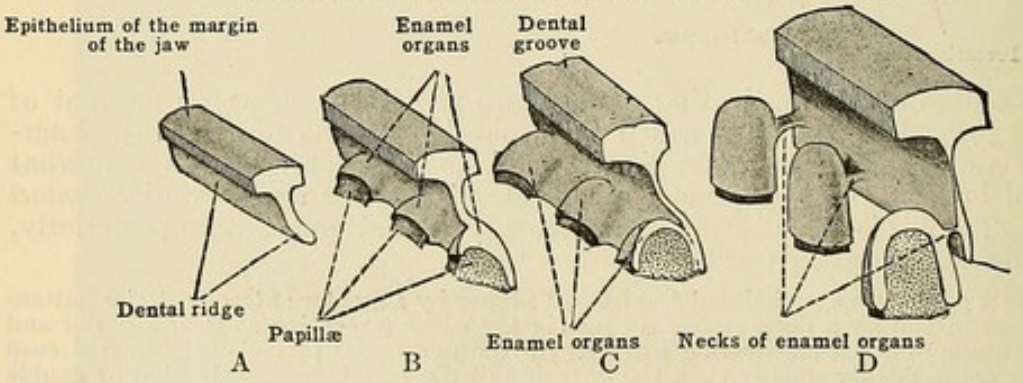

The **lower molars** have usually four or five cusps (two lingual, and two or three buccal) the fissures separating them being cross-shaped or stellate (fig. 864). The crowns incline upward and slightly medialward. They have each two roots, anterior and posterior, flattened antero-posteriorly, and usually somewhat curved backward. The roots, especially the anterior, may be longitudinally grooved. The anterior has two root-canals, the posterior usually only one. The apices of the roots of the lower molars, especially of the third, approach the mandibular (inferior dental) canal (fig. 876).

Of the *individual* lower molars, the *first* is usually slightly the largest, and has five cusps in the great majority of cases (variously estimated at from 60 to 95 per cent.), otherwise four. The four main cusps (two buccal and two lingual) are separated by a cruciform fissure, which bifurcates posteriorly to embrace the small fifth cusp (which is placed slightly to the buccal

side) when present. The *second* lower molar has usually four cusps (75 to 85 per cent. of cases), otherwise five, the fifth usually small or rudimentary. The roots are sometimes confluent. The lower *third* or wisdom tooth, like the upper, is usually small and exceedingly variable (fig. 875). It has usually four or five cusps; but the number may be increased to six or seven,

FIG. 879.—MODEL OF ECTODERM OF JAW OF HUMAN EMBRYO 40 MM. LONG, SHOWING DENTAL RIDGE WITH ENAMEL ORGANS FOR THE FIRST TEETH. (Kingsley, after Röse.)

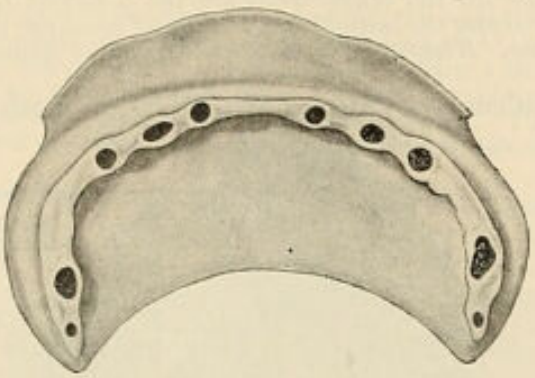

or reduced to three, two, or one. The roots are often short and fused into a conical mass in which sometimes only a single canal is present.

The **dental arches.**—On comparing the upper and the lower dental arches, it is seen that the upper (fig. 852) forms an elliptical curve, while the lower (fig. 864) resembles a parabola.

FIG. 880.—SECTION SHOWING LATER STAGES OF TOOTH DEVELOPMENT. (Szymonowicz.)

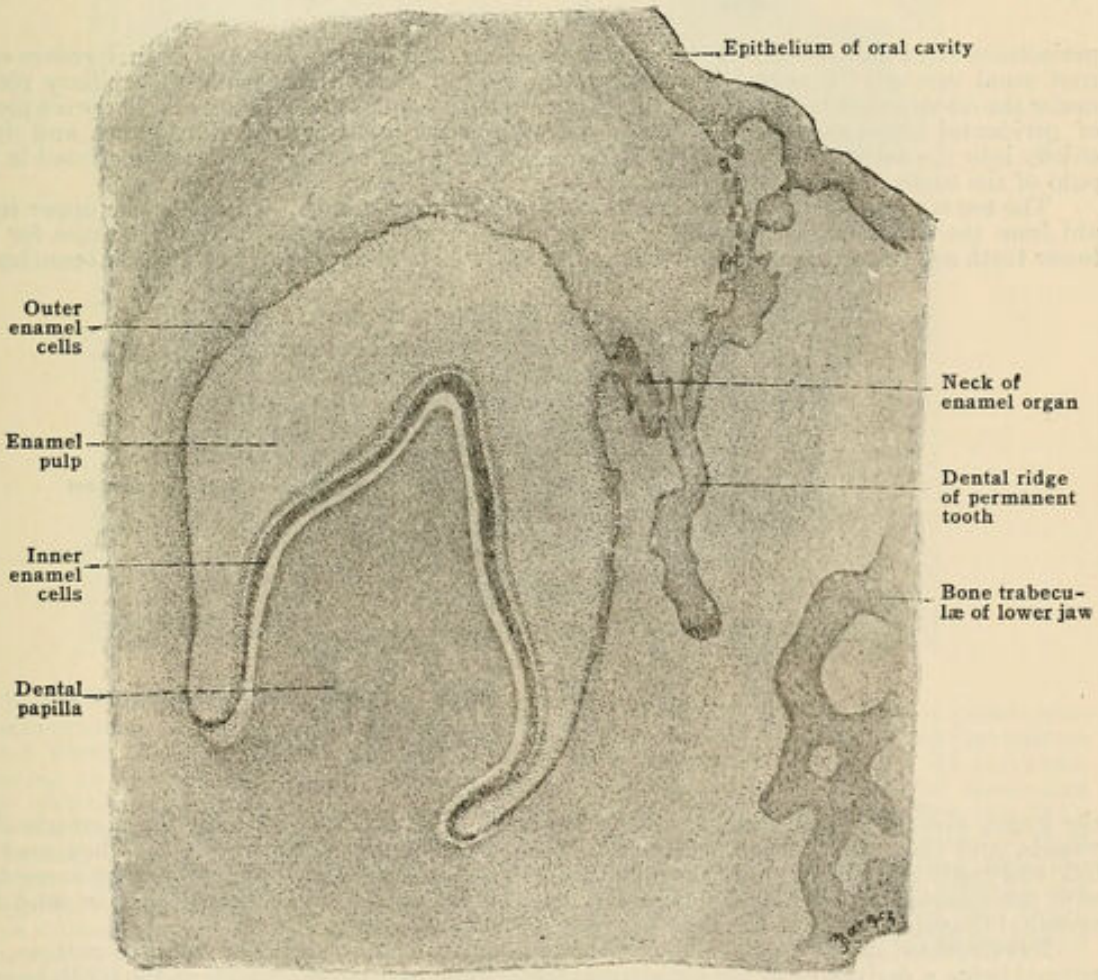

The upper arch is slightly larger (due chiefly to the slant of the teeth, as previously explained) so that it slightly overlaps the lower when the teeth are in occlusion. Thus, as shown in fig. 876, the upper incisors (and canines) overlap the lower. The buccal cusps of the lower premolars and molars fit into the groove between the upper buccal and lingual cusps; while the upper lingual cusps correspond to the groove between lower buccal and lingual cusps. This arrangement favors a more perfect mastication (see fig. 877).

Moreover, when viewed from the side (fig. 876), it is seen that in general, the corresponding teeth of the upper and the lower arches are not opposite, but alternate with each other. This is

due chiefly to the great width of the upper central incisor. The lower molars, however, especially the third, are wider (antero-posteriorly) than the upper, so that the two arches are nearly equal in length. The interdental line between the two arches is not straight, but slightly convex downward (fig. 876). In both arches, the crowns of the incisors and canines are taller than those of the premolars and molars.

Vessels and nerves.—The vessels and nerves of the teeth are distributed partly to the pulp and partly to the surrounding alveolar periosteum. The *arteries* are all derived from the internal maxillary. Those for the upper teeth are the posterior superior alveolar and the anterior superior alveolar (from the infraorbital). Similar branches to the lower jaw are given off by the inferior alveolar. They give off twigs to the gums (rami gingivales), the alveolar

Fig. 881.—Hard Palate of a Child of Five Years, Showing Deciduous Teeth.

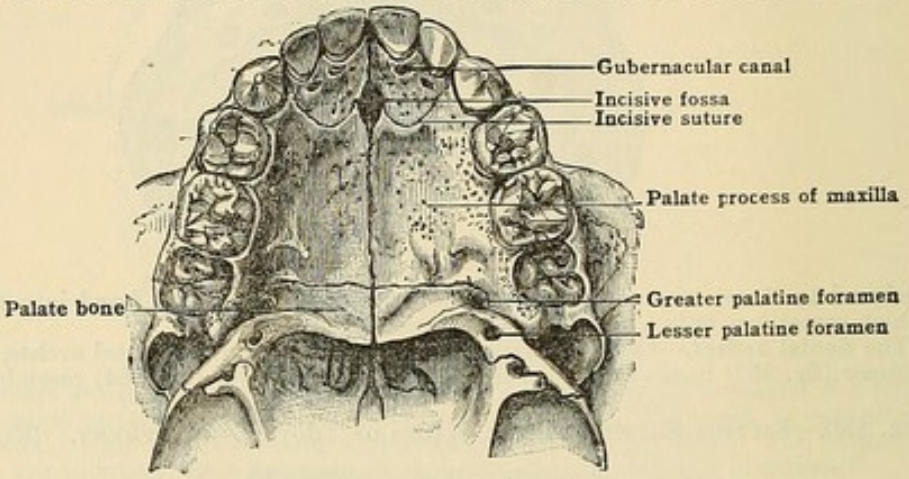

periosteum (rr. alveolares), and the pulp cavities (rr. dentales). A dental branch enters each root canal through the apical foramen, and breaks up into a rich peripheral capillary plexus under the odontoblast layer. From this plexus, the corresponding *veins* arise. There is a plexus of peridental *lymphatics*, which anastomose with those of the surrounding gums, and drain chiefly into the submaxillary nodes. Lymphatics have also recently been demonstrated in the pulp of the tooth (Schweitzer).

The **nerves** are sensory branches derived from the trigeminus. Those for the upper teeth are from the anterior, middle, and posterior superior alveolar (fig. 735); while those for the lower teeth are from the inferior alveolar (fig. 736). These nerves give numerous branches to

Fig. 882.—The Deciduous Teeth, External View.

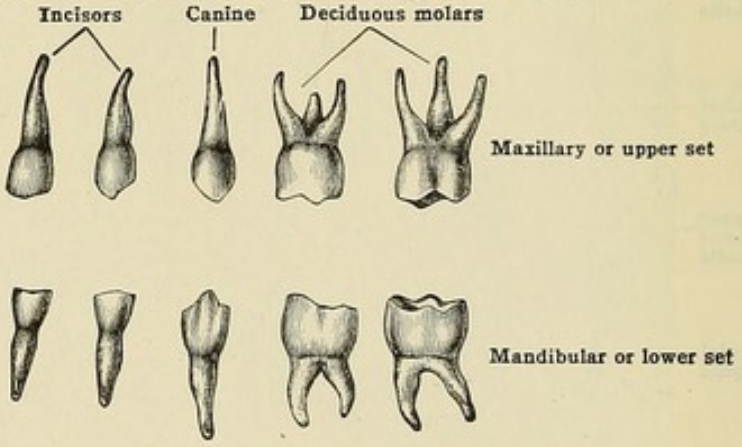

the gums, alveolar periosteum, and pulp cavities. The latter enter with the corresponding vessels, and their distribution within the tooth is a subject of controversy. They may be followed easily to a plexus under the odontoblasts; but whether they end freely, or in connection with the odontoblasts (which by some are considered as peripheral sensory cells), or send fine terminal branches out into the dentinal canals is still uncertain.

Development of the teeth.—The teeth represent calcified papillæ of the oral mucosa, the enamel being a derivative of the ectodermal epithelium, and the remainder of the tooth coming from the underlying mesenchyme. The first trace of the teeth appears in the human embryo of about 11 mm., in the form of an epithelial shelf, the *dental ridge*, extending into the mesenchyme corresponding to the future alveolar portions of the jaws (figs. 878, 879). From the dental ridge there is later produced a series of cup-shaped enlargements, the *enamel organs*, which become constricted off except for a slender neck attaching each to the common ridge. By the end of the third fœtal month, the twenty enamel organs of the temporary or deciduous teeth are formed. The concavity of each enamel organ is filled by the *dental papilla* of mesenchyme.

A somewhat later stage in the organogenesis of a tooth is shown in fig. 880. The mesenchymal cells on the surface of the dental papilla, next to the enamel organ, form a single layer of columnar cells, the *odontoblasts*. These cells form the dentine upon their outer surfaces, gradually retreating toward the center of the tooth as the dentine increases in thickness. The first dentine formed is irregular, enclosing the spatia interglobularia. The odontoblasts remain through life just beneath the dentine on the surface of the pulp, sending slender processes up into the dentinal tubules as previously noted in the structure of the adult tooth. The remainder of the dental papilla becomes the pulp, receiving its vascular and nerve supply at the point opposite the enamel organ, corresponding to the future root.

The *enamel organ* (fig. 880) is differentiated into three layers: a thin *outer* layer attached by the neck to the dental ridge; a thick *middle* layer (forming the spongy "enamel pulp"); and a single *inner* layer of cylindrical enamel cells, the *adamantoblasts*. The latter form the *enamel prisms*, which are deposited gradually upon the outer surface of the dentine.

FIG. 883.—DISSECTION SHOWING THE TEETH AT ABOUT SIX YEARS. (Broomell and Fischelis.)

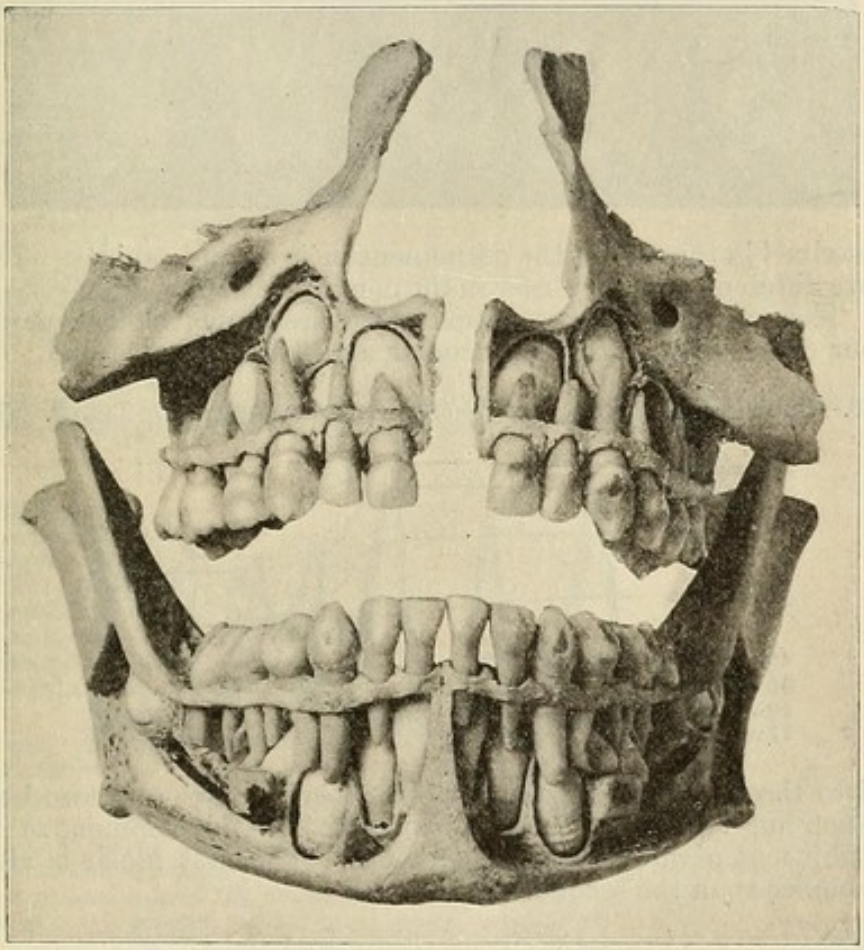

Surrounding the entire developing tooth there is formed a strong, fibrous connective-tissue membrane, the *tooth-sac*. The deeper part of this sac later becomes the *alveolar periosteum* around which the bony alveoli are formed. This bone may entirely surround the tooth-sac, excepting at the summit, where a foramen persists through which a process of connective tissue (*gubernaculum dentis*) connects the tooth-sac with the overlying gum (see figs. 114, 881). Upon the inner surface of the tooth-sac, next to the root, the bony *cementum* is deposited upon the dentine. The root gradually elongates, and is usually not completed until long after the eruption. The remaining superficial portion of the tooth-sac undergoes pressure atrophy and absorption. The remnants of the enamel organ, however, persist and form a thin tough cuticle [cuticula dentis], Nasmyth's membrane, which is soon worn off when the crown is exposed at the surface.

From the remainder of the dental ridge, which lies on the lingual side of the deciduous teeth (fig. 878), the *permanent teeth* are later derived in a very similar manner. (Rudimentary indications of a *prelacteal* dental ridge have also been described.) The anlages of the permanent teeth therefore lie to the lingual side of the deciduous (fig. 883). From the posterior end of the dental ridge a process extends into the jaw behind the deciduous teeth, and from this process the permanent molars (which have no deciduous predecessors) are formed. At birth, although no teeth have yet been cut, there are present in the gums the anlages of not only all of the deciduous teeth, but also all of the permanent teeth, with two exceptions. Those of the second molars do not appear until six weeks after birth, and of the third molars not until the fifth year. The remnants of the dental ridges become broken up into small masses of epithelial cells, which persist for a variable time.

The deciduous teeth.—The deciduous [dentes decidui], temporary or milk teeth are twenty in number, corresponding to the following formula:

$$\text{di}\ \frac{2}{2},\ \text{dc}\ \frac{1}{1},\ \text{dm}\ \frac{2}{2} = 20.$$

The deciduous teeth (figs. 882, 883) are much smaller in size than the permanent teeth, and their necks are more constricted. The enamel of the crown cap is thicker. In general, their form and structure otherwise is very similar to that

FIG. 884.—PULP-CAVITY OF THE UPPER FIRST MOLAR, FROM THE FIFTH TO THE NINTH YEAR (Broomell and Fischelis.)



already described in the case of the permanent incisors and canines. The molars, however, are different. Their cusps on the masticating surface are very sharp and irregular. There are usually three cusps on the first upper molar and four on the second; four cusps on the first lower molar and five on the second. The roots

FIG. 885.—SHOWING THE EXTENT OF CALCIFICATION OF DECIDUOUS TEETH. (Peirce.)

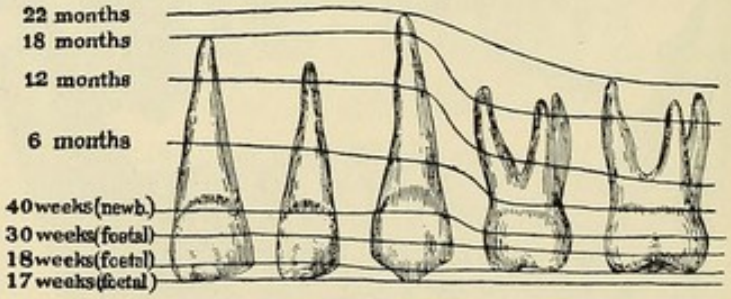

correspond to those of the permanent molars (three above and two below), but they are much more divergent, to allow room for the development of the corresponding subjacent permanent premolar teeth. The first molar is always considerably smaller than the second.

FIG. 886.—SHOWING THE EXTENT OF CALCIFICATION OF THE PERMANENT TEETH. (Peirce.)

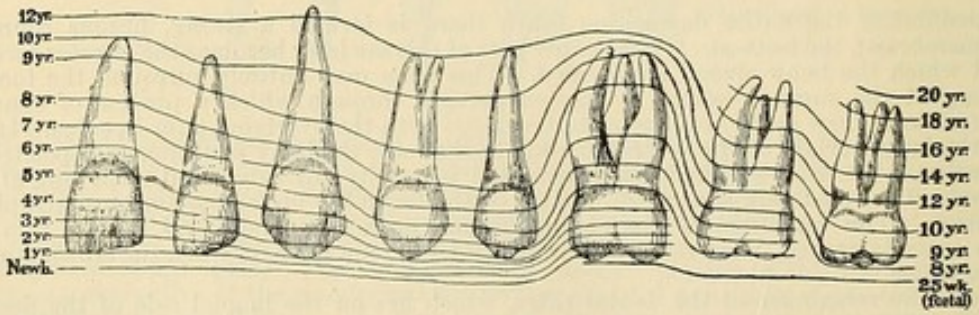

Calcification in the dentine and enamel of the teeth does not begin until the anlages of the crowns are well formed. The process of calcification follows that of the development of the tooth in general, beginning in the superficial portion of the crown and gradually spreading toward the root. Calcification in the *deciduous* teeth begins during the fifth fœtal month, and at birth the crowns are nearly completed (fig. 885). Of the *permanent* set of teeth, only the first molar has begun to calcify at birth (fig. 886). Calcification of the other permanent teeth begins during the second year; excepting the second molar, which begins during the fifth, and the third molar, which begins about the eighth year. There are, however, great variations

in the time at which the calcification of the various teeth begins. As a rule, the calcification of the roots is not completed at the apices until some time after the crowns are exposed in eruption.

Eruption of the teeth.—On account of pressure due to growth and expansion at the root of the tooth (and probably other obscure factors), the crowns are pushed toward the surface. The overlying portion of the tooth-sac, together with corresponding portions of the temporary alveolar bone, are absorbed, and the crown is "cut," i. e., breaks through the surface of the gum in eruption. In the case of the permanent teeth, this is normally preceded by a shedding of the deciduous teeth. The latter have been loosened by the absorption of their roots, which is perhaps due largely to the activity of certain *odontoclasts* (like the osteoclasts of bone) which are found in the region of absorption.

Time and order of eruption.—The *time* of the eruption of the various teeth is subject to great variation, so that no two investigators agree upon it. Aside from the wisdom teeth, the time of eruption is most variable in the canines and premolars, and least variable in the first permanent molars (Röse). The eruption averages four and one-half months earlier in the male, and is also earlier in well-to-do and city children (Röse). The *order* in which the teeth appear is less variable. The average time at which the various deciduous and permanent teeth appear is indicated approximately in the following table.

A. Deciduous Teeth

	Months after Birth (Average)
Lower central incisors	7 (6–8)
Upper central incisors	8–9
Upper lateral incisors	9–10
Lower lateral incisors	12–14
First molars	14
Canines	18
Second molars	22–24

B. Permanent Teeth

The average time at which the teeth in the lower jaw undergo eruption is shown in the table below. The corresponding teeth in the upper jaw appear a little later:—

	Years
First molars	6–7
Central incisors	7
Lateral incisors	8
First premolars	9–10
Second premolars	9–10
Canines	11
Second molars	12
Third molars (wisdom teeth)	17–25

Variations.—The great variability of the teeth has already been emphasized, and numerous variations described in connection with the various individual teeth and their development. In *number*, the teeth may be reduced, due to absence (oftenest of the third molar) or incomplete development with failure of eruption. An *increase* in the normal number is less common[1] It may be only apparent, due to the retention of a deciduous tooth. There may rarely, however, be a true extra third incisor or premolar, or a fourth molar. Aberrant teeth may occur either on the labial or palatal side of the dental arch. A third dentition appears rarely in old age. In *form*, there is much greater variation as before mentioned. All intermediate forms between rudimentary and fully developed teeth may occur. Fusion between neighbouring teeth is sometimes found, and deformities in the dental arches necessarily accompany palatal defects involving the alveolar arches.

Comparative.—As the oral mucosa represents an invagination of the integument, so the teeth are morphologically equivalent to dermal papillæ. The close relationship between the teeth and the dermal appendages is clearly shown among many of the lower vertebrates, but most clearly in the Selachians (which include sharks and allied forms). In fig. 887, which illustrates a sagittal section through the lower jaw of a young dogfish, it is clearly evident that the external placoid scales or 'dermal teeth' are continuous with the equivalent oral teeth at the oral margin of the jaw. Both the dermal teeth and the oral teeth are composed of dentine which presents an enlarged base and a somewhat conical apex. The base is embedded in the fibrous lamina propria (often in bony plates) while the apex projects through the epithelium and is covered with a thin cuticular layer the "enamel membrane." True enamel is usually rudimentary or absent in the primitive teeth of lower vertebrates, and represents a secondary acquisition. The dentine is in all cases derived from the connective tissue, and the enamel from the epithelium.

The process of development of the primitive oral teeth is also illustrated in fig. 887. Just within the oral margin there is a shelf-like downgrowth of the ectodermal epithelium, forming a primitive germinal ridge. Along this ridge may be seen the anlages of several rows of teeth in various stages of development. As fast as the mature teeth at the oral margin are worn off, new teeth pass up from below to replace them. Thus the primitive form of dentition is *polyphyodont*, with many sets of teeth developed successively throughout life. As we pass up the vertebrate scale there is a tendency to a reduction in the number of sets, although there is a

wide variation among the various forms. In most mammals, as in man, the number of sets of teeth has been reduced to two, or *diphyodont* dentition, with only traces of an earlier (prelacteal) and also a later (post-permanent) set. In some mammals (monotremes, cetacea) the dentition has been reduced to a single set, *monophyodont*, while in birds all except rudimentary traces of dentition have been lost.

As may be further observed in fig. 887, the primitive teeth are of a recurved conical form, and serve primarily for grasping and holding the food. The specialization of the teeth for purposes of mastication is in general a secondary acquisition amongst higher vertebrates.

It is also noteworthy that the primitive teeth, as found among nearly all forms below the mammals, are practically alike in form, i. e., *homodont*. Among mammals, however, there is a marked specialization of the teeth, or *heterodont* dentition. The mammalian teeth are usually differentiated into four distinct classes, incisors, canines, premolars and molars, similar to those found in man.

The typical or complete mammalian dentition, however, contains a larger number of teeth than found in man, and is represented by the formula

$$\text{i}\,\frac{3}{3},\ \text{c}\,\frac{1}{1},\ \text{pm}\,\frac{4}{4},\ \text{m}\,\frac{3}{3}=44.$$

Thus it is evident that there has been a reduction in the incisors and premolars in the human species, and there has been considerable discussion of the question as to which teeth of the

FIG. 887.—SECTION THROUGH LOWER JAW OF DOG-FISH, SHOWING THE DEVELOPMENT OF THE ORAL TEETH, AND THE TRANSITION TO DERMAL TEETH. M, mandible. (After Gegenbaur.)

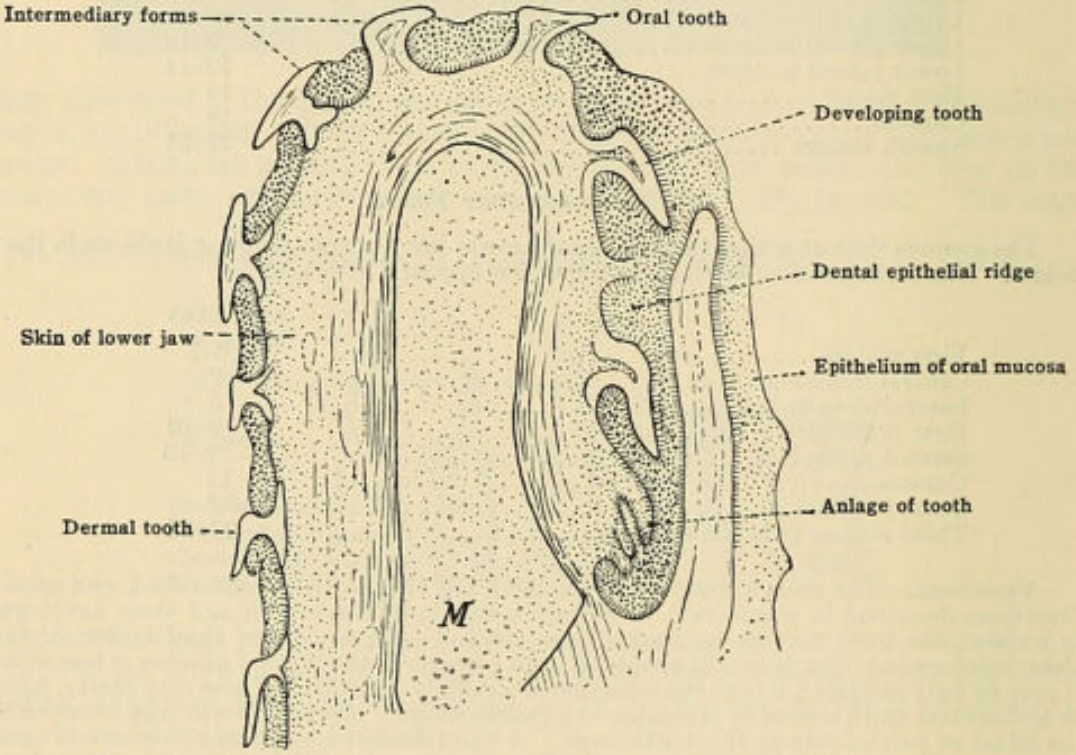

primitive series have been lost. This reduction in the number of teeth is probably correlated with the general reduction in the jaws, which are relatively much larger and stronger in the savage races and lower animals. The third molar, or wisdom tooth, is probably now on the road to extinction, due to a continuation of the same evolutionary process.

Another interesting problem, concerning which there has been much speculation, is the origin of the multicuspidate mammalian molar. It has clearly been derived from the primitive conical type of the homodont dentition, but as to the method of evolution there is a difference of opinion. According to one view (the 'concrescence' theory), the molar has been derived by a process of fusion, each cusp representing a primitive conical tooth. Another view (the 'differentiation' theory) is that the molar represents a single primitive tooth, upon the crown of which the various cusps have been differentiated. According to a third view, which is a compromise, the tritubercular (tricuspid) form of tooth, which is that found in the earliest fossil mammals, was derived by a process of concrescence of three primitive teeth, while from this tricuspid form the multicuspidate molar has been derived by a process of differentiation.

THE PHARYNX

The **pharynx** is a vertical, tubular passage, flattened antero-posteriorly, and extending from the base of the cranium *above* to the beginning of the œsophagus *below*. *Posteriorly*, it is in contact with the bodies of the upper six cervical vertebræ. *Laterally*, it is in relation with the internal and common carotid arteries,

the internal jugular vein, the sympathetic and the last four cranial nerves. *Anteriorly*, it communicates above with the nasal cavity, beneath this with the oral cavity, and below with the laryngeal cavity. The pharynx is correspondingly divided into three parts: the *nasal pharynx* [pars nasalis], which is exclusively respiratory in function; the *oral pharynx* [pars oralis], which is both respiratory and alimentary; and the *laryngeal pharynx* [pars laryngea], which is almost entirely alimentary.

Size and form.—The average length of the pharynx is about 12 cm. (5 inches). It is widest at the nasal pharynx, with a constriction (isthmus) connecting it with the widened oral pharynx, and is again somewhat narrowed at the junction of oral and laryngeal pharynx (fig. 888). It is narrowest at the point where it joins the œsophagus below. In sagittal section (fig. 848), it is evident that the anterior and posterior walls are closely approximated in the laryngeal pharynx, and have only a small space between them in the oral pharynx. The nasal pharynx, however, has a considerable antero-posterior depth, and by its bony walls is always kept open for respiratory purposes.

FIG. 888.—THE INTERIOR OF THE PHARYNX, VIEWED FROM BEHIND. (Sobotta-McMurrich.)

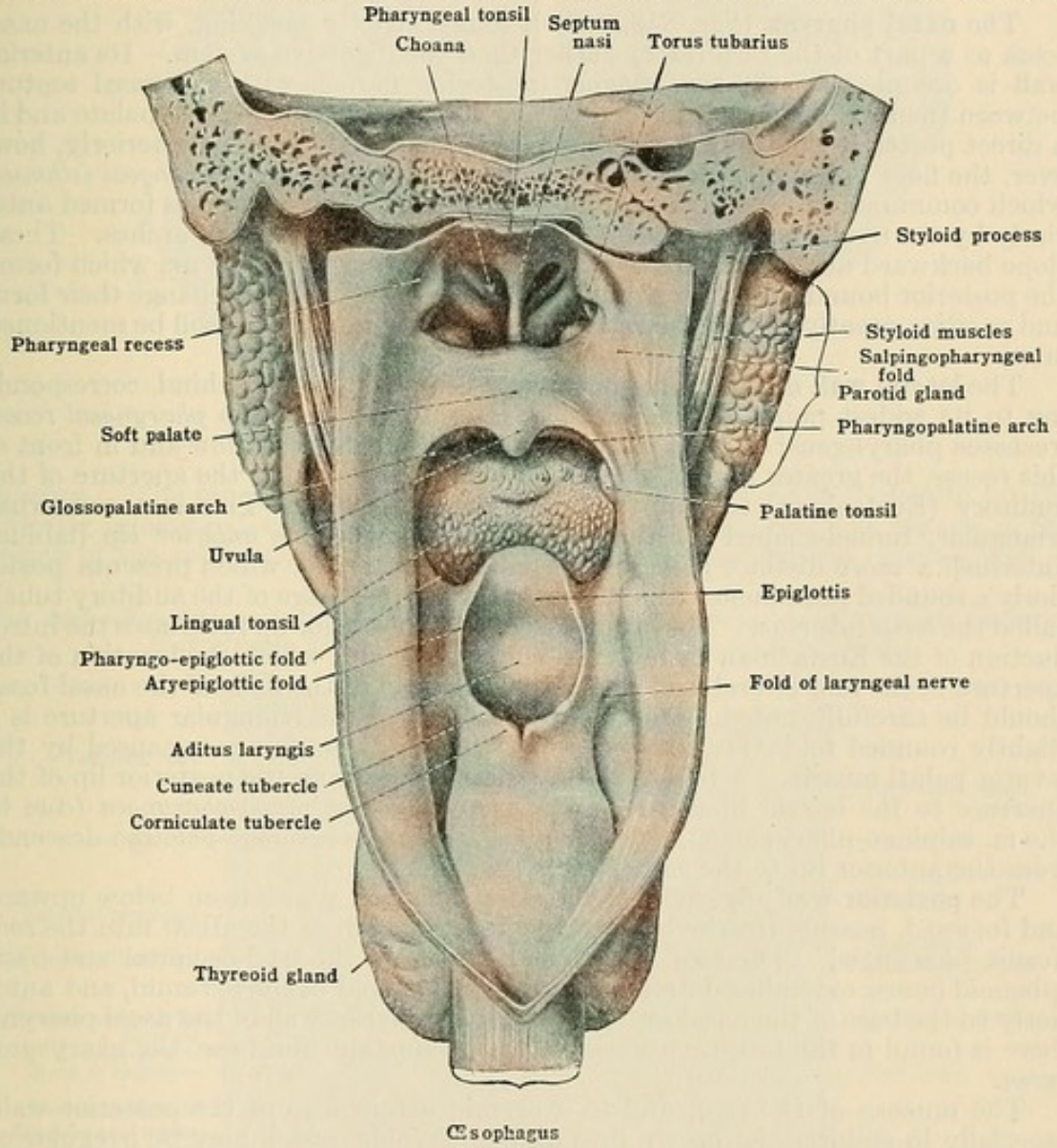

Structure.—The pharynx approaches the typical structure of the alimentary canal, yet differs from it in several important respects. The lining *mucosa* is continuous with that of the various cavities which open into the pharynx. Above, it is closely adherent to the base of the cranium, where it is thick and dark in colour. It becomes thinner where it approaches the openings of the auditory tubes and choanæ; and below it is paler and thrown into longitudinal folds. The epithelium of the greater part of the nasal pharynx (from the orifice of the auditory tube upward) is stratified ciliated columnar, while that of the remainder of the pharynx is stratified squamous.

External to the mucosa, there is a characteristic fibrous membrane, the *pharyngeal aponeurosis* [fascia pharyngobasilaris], which is well marked above, but below it loses its density and gradually disappears as a definite structure. Above, it is attached to the basilar portion of the occipital bone in front of the pharyngeal tubercle. Its attachment may be traced to the apex of the petrous portion of the temporal bone, and thence to the auditory (Eustachian) tube and medial lamina of the pterygoid process. It descends along the pterygo-mandibular ligament to the posterior end of the mylohyoid ridge of the lower jaw, and passes thence along the side of the tongue to the stylohyoid ligament, the hyoid bone, and thyreoid cartilage.

External to the pharyngeal aponeurosis is a thick *muscular* layer, made up of various cross-striated muscles, as will be described later. Outside of the muscular layer is a thin fibrous tunica adventitia, connected with the adjacent prevertebral fascia by a loose, areolar tissue. This loose tissue allows movement of the pharynx, and also favours the spreading of post-pharyngeal abscesses.

The **nasal pharynx** (figs. 848, 888) belongs, strictly speaking, with the nasal fossa as a part of the respiratory rather than the digestive system. Its **anterior wall** is occupied by the two *choanæ* (posterior nares), with the nasal septum between them. The *floor* is formed by the upper surface of the soft palate and in a direct posterior continuation of the floor of the nasal fossæ. Posteriorly, however, the floor presents a more or less narrowed opening, the *pharyngeal isthmus*, which communicates with the oral pharynx below. The isthmus is formed anteriorly by the uvula, laterally by the posterior (pharyngo-palatine) arches. These slope backward and downward to the posterior wall of the pharynx, which forms the posterior boundary of the isthmus. The floor and isthmus change their form and position greatly during the action of the palatal muscles, as will be mentioned later.

The **lateral wall** of the nasal pharynx presents above and behind, corresponding to its widest point, a wide, slit-like lateral extension, the *pharyngeal recess* [recessus pharyngeus] or fossa of Rosenmueller (fig. 888). Below and in front of this recess, the greater part of the lateral wall is occupied by the aperture of the auditory (Eustachian) tube [ostium pharyngeum tubæ]. This is a somewhat triangular, funnel-shaped opening, with an inconspicuous *anterior lip* [labium anterius], a more distinct *posterior lip* [labium posterius], which presents posteriorly a rounded prominence (due to the projecting cartilage of the auditory tube), called the *torus tubarius*. The prominence of the posterior lip facilitates the introduction of the Eustachian catheter, in connection with which the location of the aperture in the mid-lateral wall just above the level of the floor of the nasal fossa should be carefully noted. On the lower aspect of the triangular aperture is a slightly rounded fold, the *levator cushion*, which is a prominence caused by the levator palati muscle. A fold of mucosa descending from the posterior lip of the aperture to the lateral pharyngeal wall is the *plica salpingo-pharyngea* (due to the m. salpingo-pharyngeus). An inconspicuous *plica salpingo-palatina* descends from the anterior lip to the soft palate.

The **posterior wall** (fig. 848) of the nasal pharynx slopes from below upward and forward, passing (at the level of the anterior arch of the atlas) into the *roof* [fornix pharyngis]. The roof is attached chiefly to the basi-occipital and basi-sphenoid bones, extending laterally to the carotid canal of the pyramid, and anteriorly to the base of the nasal septum. In the posterior wall of the nasal pharynx there is found in the mucosa a variable and inconstant blind sac, the *pharyngeal bursa*.

The mucosa of the roof, and to a certain extent also of the posterior wall, especially in children, is thrown into numerous folds, which may be irregular or radiate from the neighbourhood of the bursa. There is often a median longitudinal groove (or sometimes ridge) at the posterior (inferior) end of which is the bursa. These folds of the mucosa contain much lymphoid tissue, both diffuse and in the form of numerous characteristic lymphoid nodules, with crypt-like invaginations of the surface epithelium. This area constitutes the **pharyngeal tonsil** [tonsilla pharyngea] (fig. 890), which is well-developed in children (often abnormally enlarged, producing 'adenoids'), but usually, though not always, atrophied in the adult. According to Symington, the involution of the pharyngeal tonsils begins at 6 or 7 years, and is usually completed at 10 years. In the region of the pharyngeal tonsil and elsewhere, the mucosa presents numerous small racemose mucous glands, especially thick in the palatal floor of the nasal pharynx and similar to those of the oral cavity.

The **oral pharynx** (figs. 848, 864, 888) is continuous *above* through the pharyn-

geal isthmus with the nasal pharynx and *below* with the laryngeal pharynx. Its *posterior* wall presents no special features. The *anterior* wall is deficient above, where there is a communication with the mouth cavity through the *isthmus*

FIG. 889.—VERTICAL SECTION OF A HUMAN PALATINE TONSIL. *a*, Stratified epithelium; *b*, basement membrane; *c*, tunica propria; *d*, trabeculæ; *e*, diffuse lymphoid tissue; *f*, nodules; *h*, capsule; *i*, mucous glands; *k*, striated muscle; *l*, blood vessel; *q*, pits. (From Radasch.)

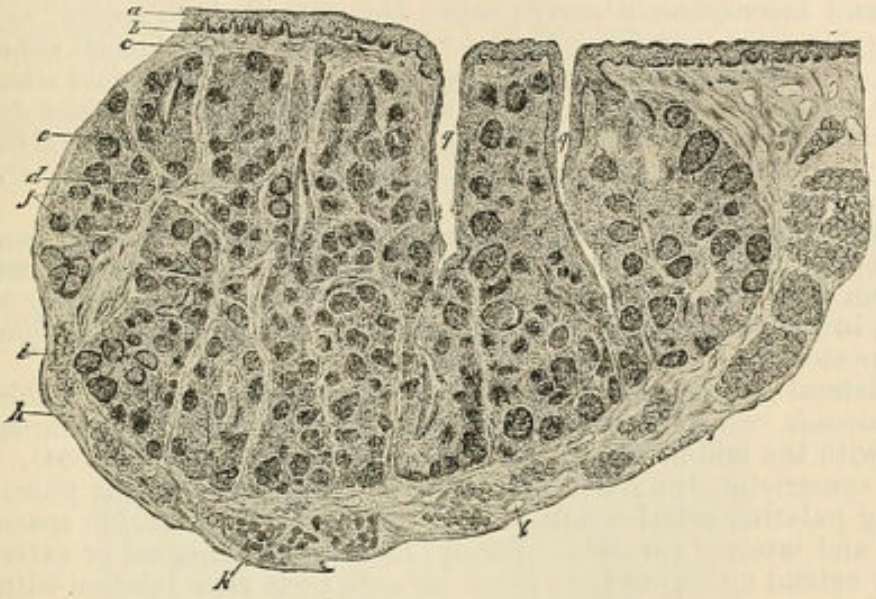

faucium. The faucial isthmus is bounded above by the uvula, laterally by the anterior (glosso-palatine) arches, and below by the dorsum of the tongue in the region of the sulcus terminalis. Below the faucial isthmus, the anterior wall of

FIG. 890.—PORTION OF A CORONAL SECTION THROUGH THE PHARYNGEAL REGION, SHOWING WALDEYER'S TONSILLAR RING. (Palatine tonsils hypertrophied.)

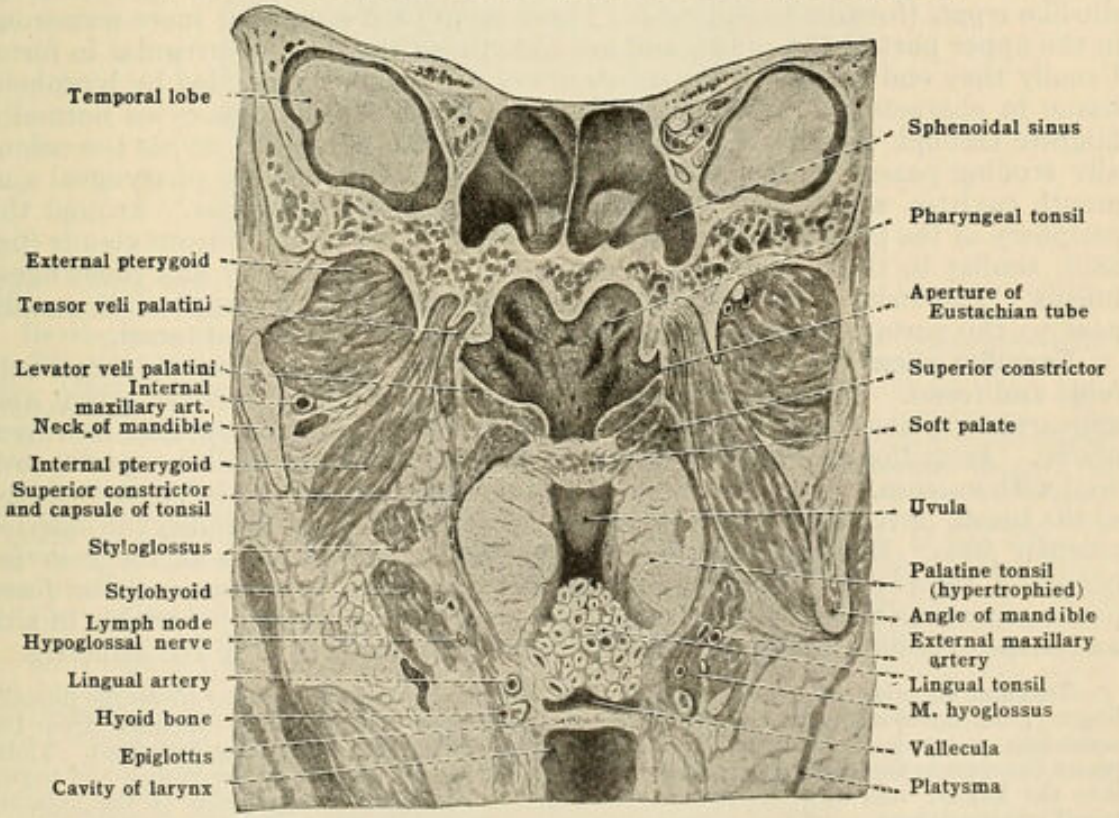

the oral pharynx is formed by the root of the tongue, which has been described previously. The *lateral* wall of the oral pharynx on each side presents the *palatine tonsil*, enclosed in a somewhat triangular *tonsillar fossa* [sinus tonsillaris]

limited anteriorly and posteriorly by the anterior and posterior palatine arches, and below by the root of the tongue.

The **palatine arches** are folds of the mucosa formed at the sides of the free posterior border of the soft palate, as already mentioned in connection with that organ. The *anterior arch* (or pillar) [arcus glossopalatinus] extends from the soft palate downward and forward to the lateral margin of the tongue, just behind the papillæ foliatæ. It is a fold of mucosa due to the underlying glosso-palatine muscle, and inconspicuous except when this muscle is in action, or when the tongue is depressed. It forms the lateral boundary of the faucial isthmus. The *posterior arch* [arcus pharyngopalatinus] is a more prominent fold which extends from the soft palate in the region of the uvula downward and backward to join the postero-lateral aspect of the pharyngeal wall. It forms the lateral boundary of the pharyngeal isthmus, and encloses the pharyngo-palatine muscle, whose actior will be explained later.

The **palatine tonsil** [tonsilla palatina] (figs. 864, 889, 890, 891) is a flattened ovoidal body, usually visible through the mouth cavity and faucial isthmus, and located on each side of the oral pharynx. The tonsil is extremely variable in size, but in the young adult averages about 20 mm. in height, 15 mm. in width (antero-posteriorly) and 12 mm. in thickness.

The **lateral** or attached **surface** of the tonsil is covered by a thin but firm fibrous *capsule*, which is continuous with the pharyngeal aponeurosis, and in contact with the middle constrictor muscle of the pharynx (fig. 864). Just outside the constrictor, the tonsil is in relation with the ascending pharyngeal and ascending palatine arteries, but is separated by a considerable space from the external and internal carotids. Rarely, however, the lingual or external maxillary may extend up higher than usual, so as to be in close relation with the lower aspect of the tonsil. Further lateralward, the palatine tonsil is in relation with the internal pterygoid muscle, and on the surface corresponds to a point somewhat above and in front of the angle of the mandible. The posterior border of the tonsil is thicker than the anterior, and forms a somewhat flattened surface in contact with the pharyngo-palatine muscle (fig. 891).

The **medial** or free **surface** of the tonsil is covered with mucosa and presents a variable number (12 to 30) small pits which are the openings into the tubular or slit-like *crypts* [fossulæ tonsillares]. These crypts are somewhat more numerous in the upper part of the tonsil, and are sometimes branched or irregular in form. Usually they end blindly in the substance of the tonsil, surrounded by lymphoid tissue in characteristic nodular masses (fig. 889). The lymphocytes normally migrate through the stratified squamous epithelium lining the crypts (occasionally eroding passages of considerable size), and escape into the pharyngeal and mouth cavities, where they form the so-called *salivary corpuscles*. Around the periphery of the palatine tonsil, within the capsule, are many mucous glands (fig. 889), similar to those described in connection with the lingual and pharyngeal tonsils. The ducts of the mucous glands sometimes enter the crypts, but usually pass to the surface chiefly around the margins of the palatine tonsil.

Tonsillar plicæ and fossæ.—Connected with the tonsil are certain important folds and fossæ. The *plica triangularis* (fig. 891) is a fold of variable extent and appearance, placed just behind the anterior arch, wider below and narrower above. According to Fetterolf, it is a prolongation of the tonsillar capsule, covered with mucosa. It may be adherent to the anterior part of the medial surface of the tonsil, or it may be free, in which case it covers a recess called the *anterior tonsillar fossa*. Occasionally there is a similar plica and fossa at the *posterior* border of the tonsil. Above the tonsil there is similarly a *supratonsillar fossa* [fossa supratonsillaris], which is also inconstant and exceedingly variable in size and shape. Killian found a supratonsillar fossa or canal in 41 of 105 cadavers.

Tonsillar vessels.—The *arteries* to the tonsil include the *anterior* tonsillar (from the dorsalis linguæ); the *inferior* tonsillar (from the external maxillary); the *posterior* tonsillar (from the ascending pharyngeal) and the *superior* tonsillar (from the descending palatine). These pierce the capsule and supply the gland. The *veins* form a plexus around the capsule and empty into the lingual vein and the pharyngeal plexus. The *lymphatic* relations of the palatine tonsil are important. *Afferent* vessels are received from adjacent areas of the mucosa in the pharynx, mouth and lower part of the nasal cavity (v. Lenart). These are connected with an extensive lymphatic plexus around the lymph follicles within the tonsil. *Efferent* lymphatic vessels pass chiefly to the upper deep cervical lymphatic nodes. One of these, located just behind the angle of the mandible, is so closely connected with the tonsil, and so constantly

enlarged following tonsillar infection, that it has been called the *tonsillar lymph gland* (Wood). There are also communications with the submaxillary and superficial cervical lymphatic nodes. The tonsillar lymphatic vessels connect also with those of the lingual tonsil in the root of the tongue.

The tonsillar ring.—The two palatine tonsils, together with the lingual tonsil below and the pharyngeal tonsil above, form an almost complete ring of characteristic tonsillar tissue surrounding the pharynx and known as Waldeyer's 'tonsillar ring' (fig. 890). It is a highly specialized development of the diffuse lymphoid tissue which is found everywhere in the mucosa of the alimentary and respiratory tracts. It may be noted that the 'tonsillar ring' corresponds to the anterior limit of the embryonic foregut, hence the epithelium is of endodermic origin. The arrangement of the tonsils, together with their lymphatic connections, has suggested the widely accepted view that they are to be considered as protective mechanisms whose function is to intercept infectious material which has entered the mouth or nasal cavities. This theory is supported by the experiments of v. Lenart, who found that substances injected into the nasal mucosa are intercepted partly in the tonsils, and partly in the cervical lymph

FIG. 891.—THE LEFT PALATINE TONSIL, SHOWING THE ARTERIAL SUPPLY.

1, Mesial aspect. 2, Postero-lateral aspect. E, lateral surface. B, posterior surface. T, medial surface. G, groove for pharyngo-palatine muscle. C, capsule. PT, plica triangularis. Arteries: AA, anterior tonsillar (from dorsal lingual); PA, posterior tonsillar (from ascending pharyngeal); SA, superior tonsillar (from descending palatine); IA, inferior tonsillar (anterior from dorsal lingual; posterior from tonsillar branch of internal maxillary). (Fetterolf: Amer. J. Med. Sc., 1912.)

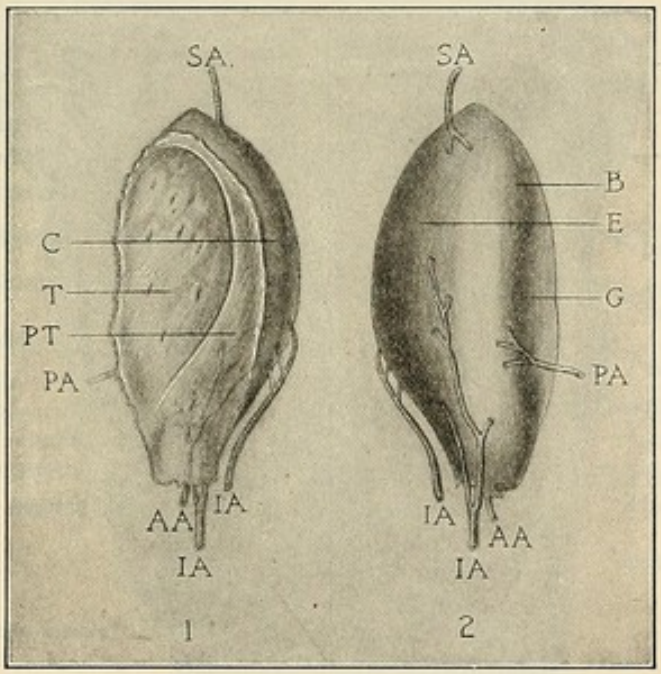

nodes. Oppel, however, opposes this view, holding that the function of the tonsils, as of lymphoid tissue elsewhere, is merely the production of lymphocytes.

Development of the tonsil.—According to Hammar, the palatine fossa (sinus tonsillaris) is a derivative of the second inner branchial groove and is visible in the human embryo of 17 mm. There appears in the floor of the fossa a tubercle (tuberculum tonsillare) which later becomes atrophied, excepting a portion which is converted into the plica triangularis. The primitive tonsil becomes divided into two lobes, upper and lower, by a fold (plica intratonsillaris) which later usually disappears. In the fœtus of about 100 mm. (crown-rump length) the epithelium of the floor grows into the subjacent mesenchyme in the form of somewhat irregular solid sprouts of epithelium. These later become hollow and form the crypts. Around them, in about the sixth fœtal month, the lymphoid tissue begins to accumulate, at first diffusely, later forming characteristic follicles. The lymphocytes arise *in situ* from the connective-tissue cells (Hammar) or by immigration from the blood-vessels (Stöhr). Retterer's claim that the tonsillar lymphoid cells are derived from the epithelial cells has not been confirmed.

The later fœtal development of the tonsil is subject to considerable individual variation. The supratonsillar fossa is a remnant of the upper part of the primitive sinus tonsillaris, which may be transformed into a canal by growth of adenoid tissue around it. It is inconstant and quite variable in size and extent. A portion of the sinus may likewise persist anteriorly (anterior tonsillar fossa) between the tonsil and the plica triangularis, but this portion is usually obliterated by fusion of the plica with the tonsil. The occasional retro-tonsillar fold and fossa are said to arise secondarily (Hammar).

Variations in the tonsil.—The palatine tonsil, like the lingual and pharyngeal tonsils, is an exceedingly variable organ. Many of the variations are developmental in origin, as above indicated, and are therefore *congenital*. Furthermore, the tonsils, like all lymphoid structures, are subject to marked *age* variations. Though fairly well formed at birth, they are yet somewhat undeveloped. They rapidly increase in relative size and complexity, however, being

best developed in childhood. After the age of puberty, they usually undergo certain retrogressive changes, become smaller in size, and in old age become almost entirely atrophied and lost. They are also markedly subject to inflammatory hypertrophy, especially in children. Variations in the relations of the *blood-vessels* were mentioned above.

The laryngeal pharynx (fig. 848) is the lower portion leading from the oral pharynx above into the œsophagus below (at the level of the lower border of the cricoid cartilage, usually opposite the sixth cervical centrum). It is wide above

FIG. 892.—THE MUSCLES OF THE SOFT PALATE AND THE PALATAL ARCHES AS SEEN FROM IN FRONT. (After Toldt, "Atlas of Human Anatomy," Rebman, London and New York.)

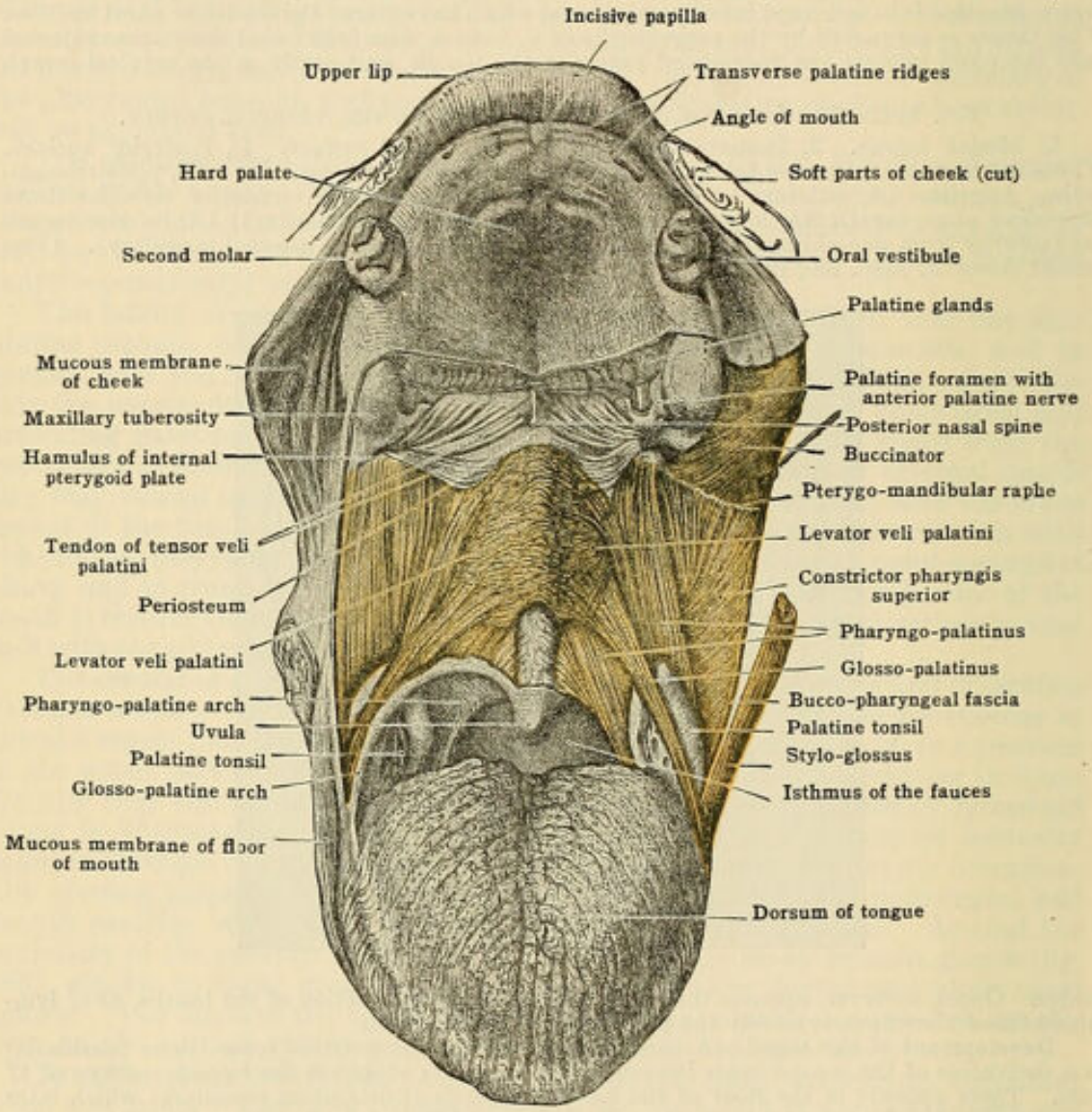

and narrow below (fig. 888). Its *posterior* walls are continuous with those of the oral pharynx and in relation with the vertebral centra. Its *lateral* walls are attached to the hyoid bone and the posterior part of the medial surface of the thyreoid cartilage. *Anteriorly* it is in relation with the larynx. In the median line above is the epiglottis, below which is the superior aperture of the larynx. Still lower is the posterior wall of the larynx, containing the arytænoid and lamina of the cricoid cartilage. Laterally, are the pharyngo-epiglottic folds, and below these on each side a deep, elongated fossa, the *recessus piriformis*, bounded laterally by the medial surface of the thyreoid cartilage. The *mucosa* of the laryngeal pharynx is similar to that of the oral pharynx, and contains racemose mucous glands, which are especially numerous in its anterior wall.

Muscles of the pharynx and soft palate.—These muscles (figs. 892, 893, 894), which are here grouped together for convenience of description, are chiefly sphincter-like constrictors in function. They include the constrictors of the faucial isthmus (mm. glossopalatini), the constrictors of the pharyngeal isthmus

(mm. pharyngopalatini), the three pharyngeal constrictors, and also the levator and the tensor veli palatini, the m. uvulæ and the stylo-pharyngeus. The stylo-pharyngeus and pharyngo-palatine muscles form an incomplete longitudinal layer within the more circularly arranged constrictors of the pharynx.

FIG. 893.—VIEW OF MUSCLES OF SOFT PALATE, AS SEEN FROM BEHIND, WITHIN THE PHARYNX. (Modified from Bourgery.)

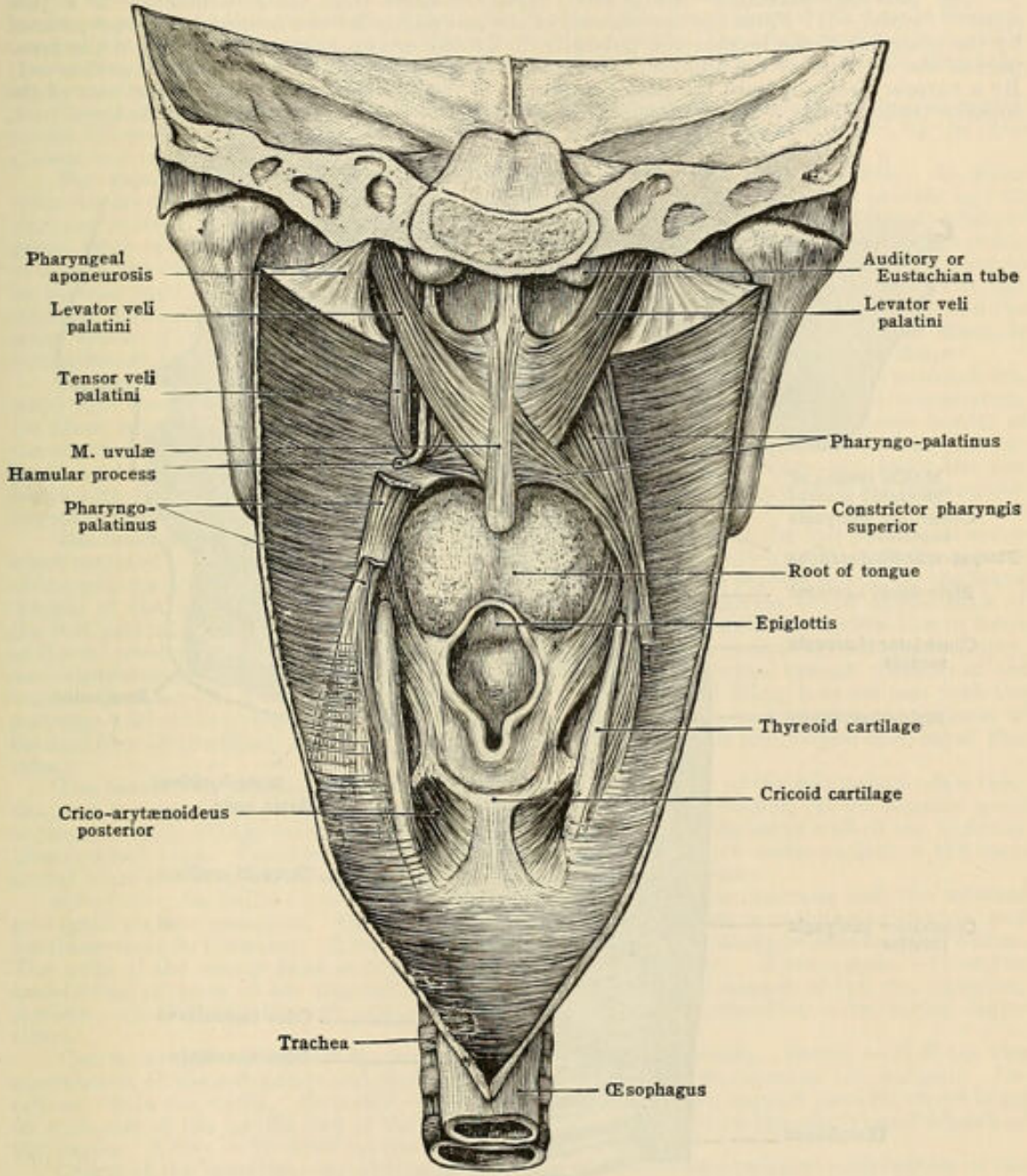

The muscles are arranged in layers either behind or in front of the aponeurosis, and in a horizontal section of the soft palate the following layers are met with from behind forward: (1) The mucous membrane on the pharyngeal surface; (2) the posterior layer of the pharyngo-palatinus (palato-pharyngeus); (3) the m. uvulæ; (4) the levator veli palatini; (5) the anterior layer of the pharyngo-palatinus; (6) the palatal aponeurosis with the tensor veli palatini; (7) the glosso-palatinus palato-glossus); and (8) the mucous membrane on the oral aspect.

The **glosso-palatinus** (palato-glossus) is a cylindrical muscle extending between the soft palate and the lateral border of the tongue. *Origin.*—From the oral surface of the palatal aponeurosis. *Insertion.*—(1) The superficial layer of muscles which covers the side and adjacent part of the under surface of the tongue; (2) the transversus linguæ. *Structure.*—At its origin the muscle forms a thin sheet, but the fibres, passing lateralward, quickly concentrate to form a cylindrical bundle, which passes downward beneath the mucous membrane of the pharynx

and in front of the tonsil, forming the glosso-palatine arch of the fauces. It reaches the side of the tongue at the junction of its middle and posterior thirds, and some of its fibres continue forward to join with those of the stylo-glossus and hyo-glossus, while the majority pass medially to become continuous with the transversus linguæ. *Nerve-supply.*—From the pharyngeal branches (plexus) of the vagus. *Action.*—(1) To draw the sides of the soft palate downward; (2) to draw the sides of the tongue upward and backward. The combination of these actions tends to constrict the faucial isthmus. (The origin and insertion of the glosso-palatinus as given above are often described as reversed.)

The **pharyngo-palatinus** (palato-pharyngeus)—named from its attachments—is a thin sheet. *Origin.*—(1) From the aponeurosis of the soft palate by two heads which are separated by the insertion of the levator veli palatini; (2) by one or two narrow bundles from the lower part of the cartilage of the auditory (Eustachian) tube (*salpingo-pharyngeus*). *Insertion.*—(1) By a narrow fasciculus into the posterior border of the thyreoid cartilage near the base of the superior cornu; (2) by a broad expansion into the fibrous layer of the pharynx at its lower part.

FIG. 894.—THE MUSCLES OF THE PHARYNX, LATERAL VIEW.

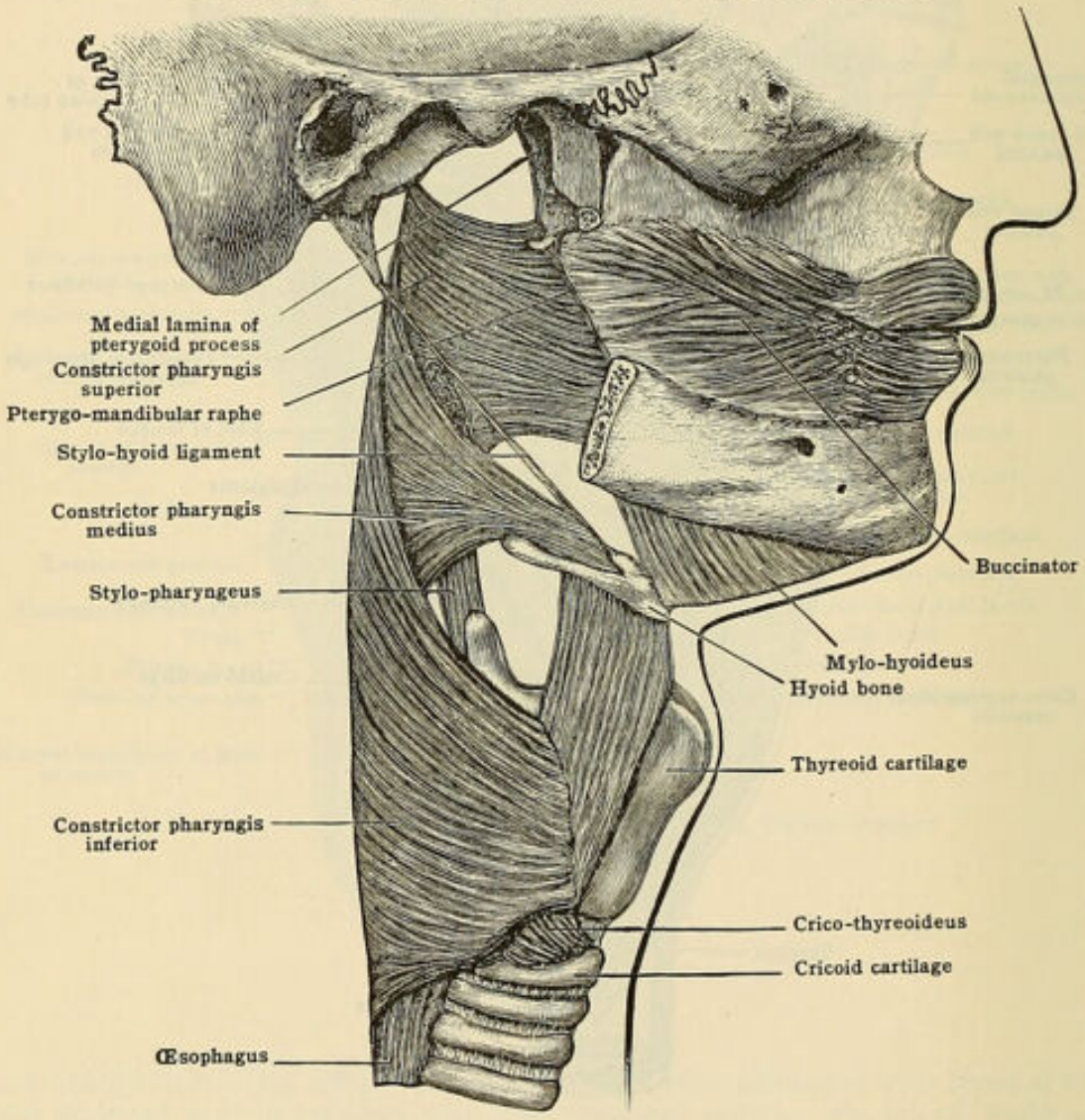

Structure.—The upper head of the muscle consists of scattered fibres which blend with the opposite muscle across the middle line; the lower head is thicker, and follows the curve of the posterior border of the palate. The two heads with the fasciculus from the auditory (Eustachian) tube form a compact muscular band in the posterior palatine arch; the fibres mingle with those of the stylo-pharyngeus, at the lower border of the superior constrictor, and then expand upon the lower part of the pharynx. *Nerve-supply.*—From the pharyngeal branch (plexus) of the vagus. *Action.*—(1) Approximates the posterior arches of the fauces; (2) depresses the soft palate; (3) elevates the pharynx and larynx. (The origin and insertion above given are often described as reversed.)

The **inferior constrictor** is thick and strong. It *arises* from the thyreoid cartilage immediately behind the oblique line and superior tubercle (thyreo-pharyngeus), and from a tendinous arch extending between the inferior tubercle of the thyreoid and the cricoid cartilage and also from the lateral surface of the cricoid cartilage (cricopharyngeus) (fig. 894). The fibres spread backward and medialward, the lowest horizontally, whilst those above ascend more and more obliquely, and are *inserted* into the fibrous raphé of the pharynx. Some of

the lowest fibres are continuous with the muscular fibres of the œsophagus, and the upper overlap the middle constrictor (fig. 894). The *nerve-supply* of all three constrictors is from the pharyngeal nerve.

Near the upper border the superior laryngeal nerve and artery pierce the thyreo-hyoid membrane to reach the larynx. The inferior laryngeal nerve ascends beneath the lower border immediately behind the crico-thyreoid articulation.

The **middle constrictor** is a fan-shaped muscle which *arises* from the lesser cornu of the hyoid bone and from the stylo-hyoid ligament (chondro-pharyngeus), and from the whole length of the greater cornu (cerato-pharyngeus). The diverging fibres are *inserted* into the median raphé, and blend with those of the opposite side. The lower fibres of the muscle descend, beneath the inferior constrictor, to the lower part of the pharynx; the upper overlap the superior constrictor, and reach the basilar process of the occipital bone, whilst the middle fibres run transversely (fig. 894).

The glosso-pharyngeal nerve passes downward above its upper border, the stylo-pharyngeus passes between it and the superior constrictor, and near its origin it is overlapped by the hyoglossus and crossed by the lingual artery.

The **superior constrictor** is quadrilateral in shape, pale, and thin (fig. 894). It *arises* from the lower third of the hinder edge of the median lamina of the pterygoid process and its hamular process (pterygo-pharyngeus), from the pterygo-mandibular ligament (bucco-pharyngeus), from the posterior fifth of the mylo-hyoid ridge of the mandible (mylo-pharyngeus), and from the side of the root of the tongue (glosso-pharyngeus). The fibres pass backward to be *inserted* into the median raphé, the highest reaching the pharyngeal tubercle. The Eustachian tube and the levator veli palatini are placed above the superior arched border, and the space (*sinus of Morgagni*) between this and the basilar process, devoid of muscular fibres, is strengthened by the pharyngeal aponeurosis, this portion of it being semilunar in shape.

The **stylo-pharyngeus** *arises* from the base of the styloid process internally. It passes downward and medialward to reach the pharynx between the superior and middle constrictors. Its fibres spread out as it descends beneath the mucous membrane. At the lower border of the superior constrictor some of its fibres join fibres of the pharyngo-palatinus (palato-pharyngeus), and are *inserted* into the posterior border of the thyreoid cartilage (fig. 894); the rest blend with the constrictors. The *nerve-supply* of the stylo-pharyngeus is from the glosso-pharyngeal nerve.

The **levator veli palatini**—named from its action on the velum of the soft palate—is somewhat rounded in its upper, but flattened in its lower, half. *Origin.*—(1) The inferior surface of the petrous portion of the temporal, anterior to the orifice of the carotid canal; (2) the lower margin of the cartilage of the auditory (Eustachian) tube. *Insertion.*—The aponeurosis of the soft palate; the terminal fibres of the muscles of each side meet in the middle line in front of the m. uvulæ. *Structure.*—Its origin is by a short tendon; the muscle then becomes fleshy, and continues so to its insertion. *Nerve-supply.*—From a pharyngeal branch (plexus) of the vagus. *Action.*—(1) To raise up the velum of the soft palate, and bring it in contact with the posterior wall of the pharynx; (2) to narrow the pharyngeal opening and to widen the isthmus of the auditory (Eustachian) tube. (According to Cleland, it closes the pharyngeal opening of this tube.)

The **tensor veli palatini**—named from its action on the velum of the soft palate—is a thin, flat, and narrow sheet. *Origin.*—(1) The scaphoid fossa of the sphenoid; (2) the angular spine of the sphenoid; (3) the lateral side of the membranous and cartilaginous wall of the auditory (Eustachian) tube. *Insertion.*—(1) Into the transverse ridge on the under surface of the horizontal plate of the palate bone; (2) the aponeurosis of the soft palate.

Structure.—Its belly as it descends between the pterygoideus internus and the internal pterygoid plate is muscular. On approaching the hamular process it becomes tendinous, and continues so to its insertion. A bursa is interposed between the hamular process and the tendon. The belly of the muscle is at nearly a right angle with its tendon. *Nerve-supply.*—From the mandibular division of the trigeminus through the tensor palati branch of the otic ganglion. *Actions.*—(1) Tightens the soft palate; (2) opens the auditory (Eustachian) tube during deglutition.

The **m. uvulæ.**—so named by reason of its position in the uvula. *Origin.*—(1) From the aponeurosis of the soft palate and tendinous expansions of the two tensores veli palatini. *Insertion.*—Into the uvula. *Structure.*—The muscle consists of two narrow parallel strips lying on each side of the middle line of the palate. *Nerve-supply.*—From the pharyngeal branch of the vagus. *Action.*—To draw up the uvula.

Origin of the muscles.—According to W. H. Lewis, the tensor palati is a derivative of the mandibular arch (probably split off from the pterygoid mass); the levator palati and m. uvulæ come with the facial musculature from the hyoid arch; the glosso-palatine, stylo-pharyngeus and pharyngeal constrictors probably from the third visceral arch, in a pre-muscle mass visible in a 9 mm. embryo. The adult innervation of the pharyngeal muscles does not agree entirely with this, however. The pharyngeal muscles (as above stated) are innervated chiefly from the vagus, whereas if derived from the third arch their innervation from the glosso-pharyngeus would be expected.

Process of swallowing.—In the act of swallowing, practically all of the muscles of the mouth, tongue, palate and pharynx are involved. By compression of the lips and cheeks, together with elevation of the tongue, the food is forced backward through the faucial isthmus into the oral pharynx. Constriction of the faucial isthmus by the glosso-palatine muscles assists in preventing a return to the mouth. By the action of the levator palati, tensor palati, and pharyngo-palatine muscles, the soft palate is retracted and tightened, with constriction of the pharyngeal isthmus, so as to prevent the passage of the food upward into the nasal pharynx. The pharynx is drawn upward by the stylo-pharyngeus, and the pressure produced by the pharyngeal constrictors (the contraction beginning above and extending downward) forces the food downward through the laryngeal pharynx and into the œsophagus. Passage of the food into the larynx is prevented by constriction of the superior aperture of the larynx.

Vessels and nerves.—The vessels of the tonsil and the motor nerves of the various muscles have already been mentioned. In general, the *arteries* to the pharynx are derived chiefly from the ascending pharyngeal, the ascending palatine branch of the external maxillary, and the descending palatine and pterygo-palatine branches of the internal maxillary. The *veins* form a venous plexus between the pharyngeal constrictors and the pharyngeal aponeurosis, and also an external plexus, communicating with the pterygoid plexus above and with the posterior facial or internal jugular vein below. The *lymphatic* vessels pass chiefly to the deep cervical nodes, those from the upper portion (including the pharyngeal tonsil) ending partly in the retro-pharyngeal glands. The *nerves* of the pharynx, both motor and sensory, are derived chiefly from the glosso-pharyngeal and vagus, by way of the pharyngeal plexus.

The development of the pharynx.—The pharynx is developed chiefly (if not entirely) from the anterior end of the archenteron. In this portion of the archenteron, with the development of the branchial arches, there are formed on each side four entodermal pouches or grooves (with a rudimentary fifth), the branchial clefts (see p. 17). With further development the first pair of branchial clefts form the tympanic cavities and the auditory or Eustachian tubes; the lower portion of each second branchial cleft persists as a fossa in which a palatine tonsil is developed; the remains of the third and fourth pairs are found on each side in the vallecula and piriform sinus of the larynx. The origin of the pharyngeal tonsil may be observed in the third month of fœtal life in the form of small folds of mucous membrane which, during the sixth month, become infiltrated with diffuse adenoid tissue, lymph-nodules differentiating in this toward the end of fœtal life. The pharyngeal bursa, which is not a constant structure (Killian), may be observed as a small diverticulum of the pharyngeal wall, closely connected with the anterior extremity of the notochord. The diverticulum develops independently of Rathke's pouch (which gives rise to the anterior portion of the hypophysis), and is also apparently distinct from Seesel's pocket.

The entire pharynx, like the associated facial region, is relatively small and undeveloped in the fœtus and newborn, but develops rapidly during infancy. The development of the muscles and of the palatine tonsils has already been considered.

Variations.—Variations in the palatine and pharyngeal tonsils and in the pharyngeal bursa have already been mentioned. Remnants of the visceral clefts may persist as aberrant diverticula or as 'branchial fistulæ' connected with the pharynx. Many additional *muscles* have been described, chiefly longitudinal muscles arising from the base of the cranium either by splitting of those normally present, or as separate slips. A detailed description of these may be found in Poirier-Charpy's work. Abnormally extensive fusion of the posterior arches of the palate with the walls of the pharynx may produce a congenital stenosis of the pharyngeal isthmus.

Comparative.—The pharynx is not distinctly separated from the mouth cavity in the lower vertebrates. It is the region containing the branchial or visceral clefts and is thus both respiratory and alimentary in function. The *nasal* pharynx, including the apertures of the auditory tubes, becomes distinct along with the nasal cavity when the palate is formed (from the reptiles upward). In the air-breathing vertebrates, the laryngeal aperture appears in the ventral wall of the pharynx just anterior to the beginning of the œsophagus. Of the *tonsils*, the *pharyngeal* are the most primitive, being present in the roof of the pharynx in amphibia, well-developed in reptiles, birds, and mammals (Killian). The *palatine* tonsils, on the other hand, are characteristic of mammals, being rarely absent, however (e. g., rat, guinea pig). From the embryological point of view, Hammar has classified the palatine tonsils in the various mammals under (1) the primary type (including rabbit, cat, and dog), in which the tonsil is formed from the embryonic tonsillar tubercle (described above under development of tonsil); and (2) the secondary type (including pig, ox, sheep and man), in which the tonsillar tubercle disappears and the tonsil is developed from the wall of the surrounding tonsillar sinus. Typical epithelial crypts (highly branched in the ox) are found only in the secondary type. The tonsil may form a single (lymphoid) lobe (cat, pig, rabbit) or may develop typically two lobes (ox, sheep, man), separated by the intratonsillar fold. There are great variations among different species as to relative size, number and character of folds, crypts, etc. The intimate relation of the epithelium with the underlying lymphoid tissue is characteristic and constant.

THE ŒSOPHAGUS

The **œsophagus** (figs. 895, 896) is that portion of the alimentary tract which extends between the pharynx and the stomach. It is more constricted than the rest of the canal, being narrowest at its commencement opposite the lower border of the cricoid cartilage. It is again somewhat contracted behind the left bronchus, and at its passage through the diaphragm, which is opposite the tenth or eleventh thoracic vertebra. It has an average length of 25 cm. (varying from 20 to 35 cm.). The average distance from the rima oris to the beginning of the œsophagus is about 15 cm. In its course downward the œsophagus follows the curves of the vertebral column until it finally passes forward in front of, and slightly to the left of, the aorta to gain the œsophageal opening in the diaphragm. In addition to these curves it presents two lateral curvatures, one convex toward the left side at the root of the neck and in the upper part of the thorax, and the other concave toward the left in the lower part of the thorax where it leaves the vertebral column. It lies in the middle line at its commencement (usually opposite the sixth cervical vertebra), and again, at a lower level, opposite the fifth thoracic vertebra.

After death the œsophagus is somewhat flattened from before backward, but it is more rounded during life. It is closed except during the passage of food, etc.

The *peristaltic movements* of the œsophagus can readily be observed by means of the Rœntgen-rays. Solids often lodge a short time at the level of the arch of the aorta, but pass quickly through the cardiac orifice. A swallow of liquid, on the other hand, is usually detained at the lower end of the œsophagus (probably by sphincteric action of the cardia) for about seven seconds before passing into the stomach (Pfahler).

FIG. 895.—THE ŒSOPHAGUS AND STOMACH. (Testut.)

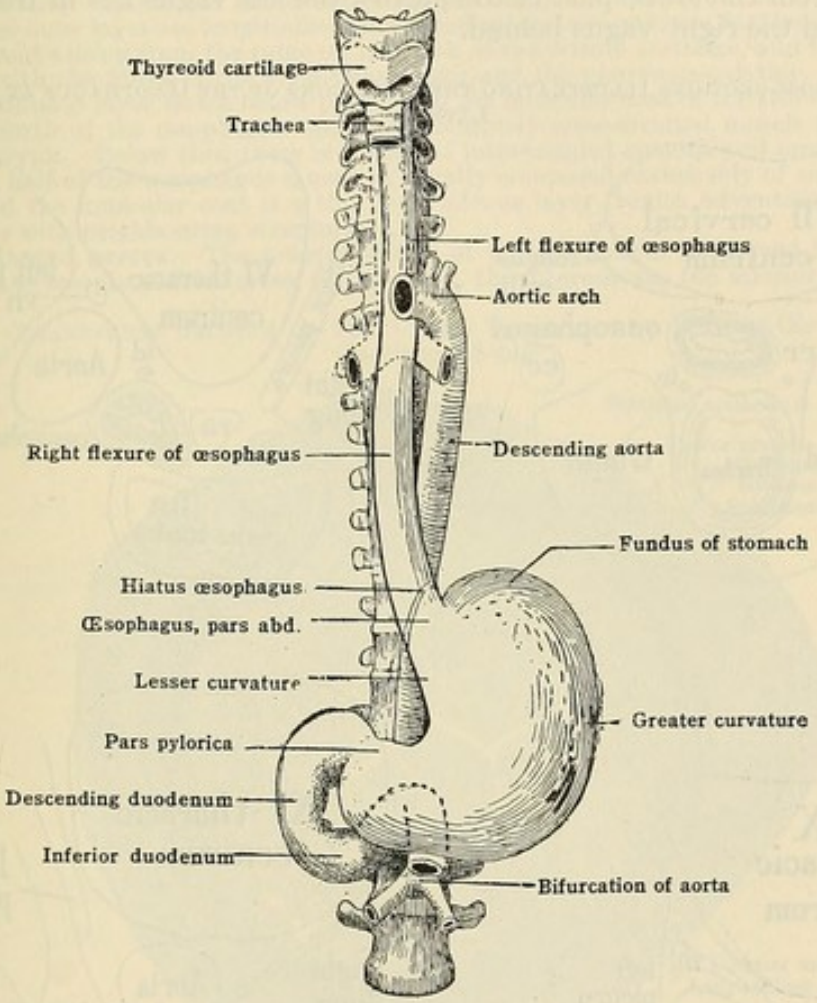

The œsophagus is divided into three parts: cervical, thoracic and abdominal.

Cervical portion.—The œsophagus has anteriorly the trachea, the posterior portion of the left lateral lobe of the thyreoid gland, and the left recurrent nerve, branches of the inferior thyreoid artery, and the carotid sheath. *Posteriorly*, it rests upon the vertebral column, the longus colli muscles, and prevertebral fascia. *On its right side* are placed the right carotid and right recurrent nerve; and *on the left side* the left inferior thyreoid vessels, left carotid artery, left subclavian, and the thoracic duct. The recurrent nerves pass upward on each side to gain the interval between the trachea and œsophagus. The left nerve, as already described, lies in front of the tube, and the right along its right border.

Thoracic portion.—The œsophagus descends in the thorax through the superior and the posterior mediastina. In the *superior mediastinum* its anterior relations are the trachea, with the deep cardiac plexus in front of its bifurcation, the left subclavian and carotid arteries crossing its left border obliquely, the left recurrent nerve, and the arch of the aorta. To the *left* are the left carotid and subclavian arteries, the end of the arch of the aorta, and the left pleural sac. To the *right* it is in relation with the right vagus nerve and the right pleural sac. *Posteriorly*, it rests upon the vertebral column, the left longus colli muscle, and it overlaps the thoracic duct. As it enters the *posterior mediastinum* it passes behind the left bronchus (or bifurcation of the trachea) and the right pulmonary artery, resting posteriorly on the vertebral column and thoracic duct. In the posterior

mediastinum it has *anteriorly* the pericardium, which separates it from the left atrium and a portion of the diaphragm; *posteriorly* it rests upon the vertebral column, accessory hemiazygos and hemiazygos veins, the right aortic intercostal arteries, the thoracic duct, and the descending aorta. To the *right* is the right pleural sac, the vena azygos, which it partly overlaps, and below, the thoracic duct. To the *left* in the upper part is the descending thoracic aorta, and, below, the left pleural sac is separated from it by a little loose areolar tissue. It is surrounded by the œsophageal plexus formed by the vagi nerves, and, as they emerge from the lower part of the plexus, the left vagus lies in front of the œsophagus and the right vagus behind.

FIG. 896.—CROSS-SECTIONS ILLUSTRATING THE RELATIONS OF THE ŒSOPHAGUS AT VARIOUS LEVELS.

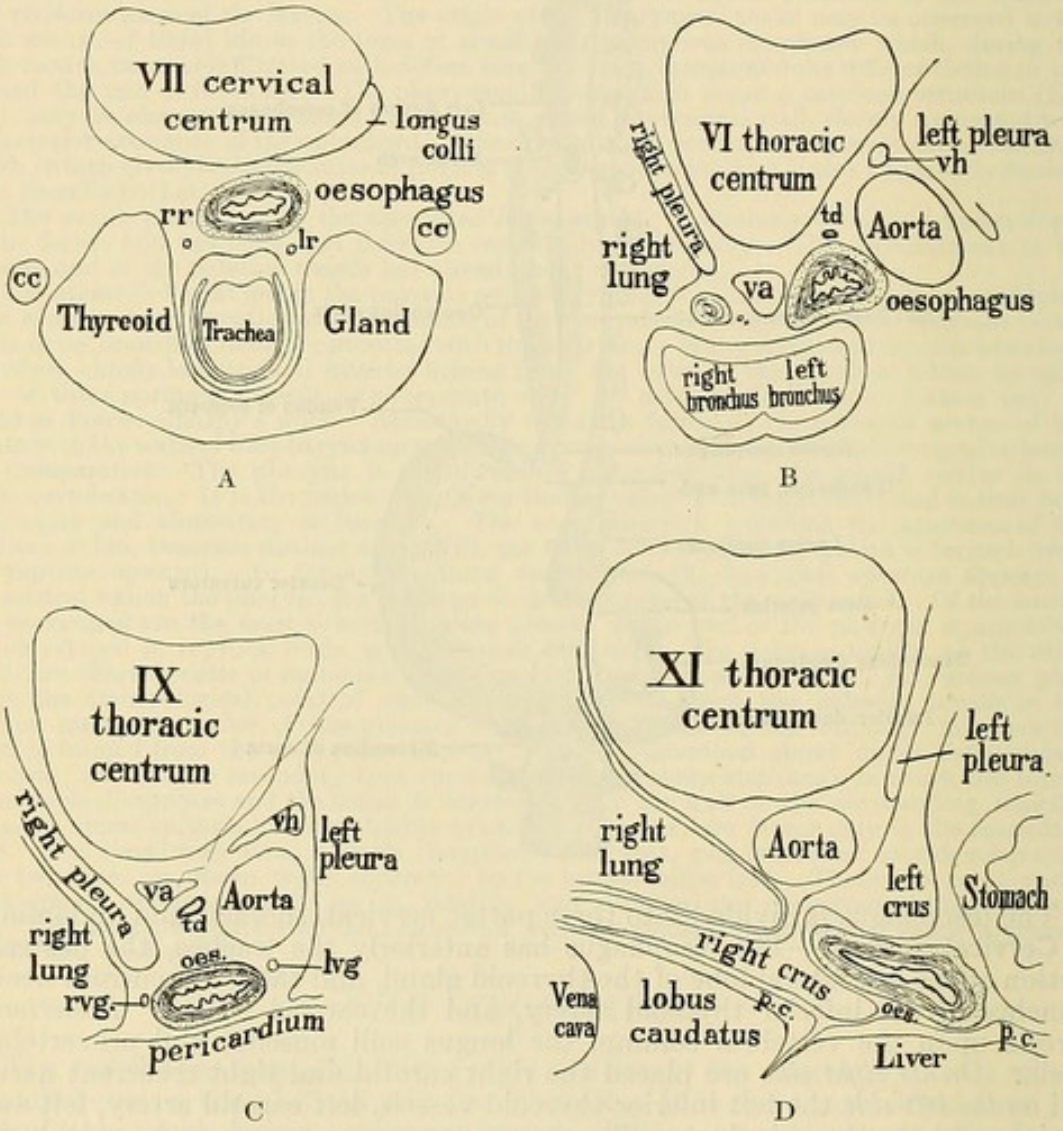

Abdominal portion.—The œsophagus lies in the epigastric region of the abdomen. *Anteriorly* is the left lobe of the liver. To the *left* the left lobe of the liver and the fundus of the stomach. To the *right* the caudate (Spigelian) lobe of the liver, and *posteriorly* the decussating fibres of the crura of the diaphragm and the left inferior phrenic artery. The abdominal portion is very short, usually not more than 2 cm. (4/5 inch) in length (see figs. 896 D, 907).

Structure.—The thick-walled œsophagus presents the four typical tunics of the alimentary canal (fig. 897). The mucosa and the muscularis are the most important, the submucosa and the external adventitia being accessory layers. The **mucosa** (fig. 897) is thick and strong, of reddish colour in its upper portion and more greyish below. It presents deep longitudinal folds to allow for distention, and when empty the lumen is therefore stellate in cross sections. The lining epithelium is stratified squamous. The lamina propria presents numerous papillæ, and is limited externally by a *muscularis mucosæ*. This is a comparatively thick layer (except at the upper end) and is composed of smooth muscle fibres, longitudinally arranged.

The submucosa (fig. 897) is a thick, very loose fibrous layer connecting the mucosa with the muscularis. It contains numerous vessels and nerves, and *mucous glands*. The latter [gl. œsophageæ] are of the racemose type, like those of the mouth, and are variable in number. There are also two sets of *superficial* glands, confined to the lamina propria, and resembling the fundus glands of the stomach. The upper set (Rüdinger-Schaffer glands) are found in 70 per cent. of cases, occurring above the level of the fifth tracheal ring. The lower set (œsophageal cardiac glands) form a ring around the œsophagus just above the cardiac aperture. A few small lymph nodes also occur in the submucosa, often around the ducts of the mucous glands.

The **muscularis** (fig. 897) is a thick reddish tunic with two distinct layers, approximately equal in thickness. The fibres of the *inner* layer are arranged circularly and are continuous with the inferior constrictor above and with the oblique fibres of the stomach below. The fibres of the *outer* layer are longitudinal and commence above as three flattened bands: a strong anterior band arising from the ridge on the back of the cricoid cartilage, and two lateral bands blending with the fibres of the stylo-pharyngeus and the pharyngo-palatine. These all unite into a continuous layer which below passes into the muscular coat of the stomach. The upper third or fourth of the œsophagus contains exclusively cross-striated muscle fibres, like those of the pharynx. Below this, there is a zone of intermingled smooth and cross-striated fibres. The lower half of the œsophagus muscle is usually composed exclusively of smooth fibres.

Around the muscular coat is a thin loose *fibrous* layer [tunica adventitia] connecting the œsophagus with neighbouring structures.

Vessels and nerves.—The *arterial* supply of the œsophagus is derived from the inferior thyreoid, the œsophageal branches of the aorta, the intercostals, the inferior phrenic and the

FIG. 897.—TRANSVERSE SECTION OF THE UPPER THIRD OF THE HUMAN ŒSOPHAGUS. × 5. (Lewis and Stöhr.)

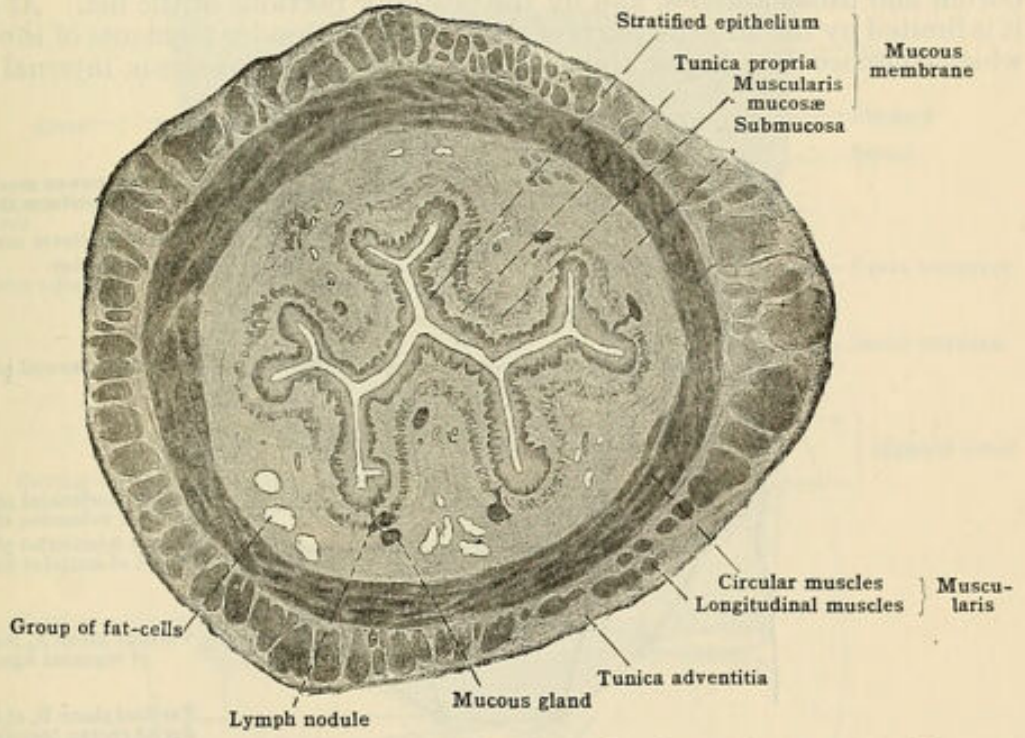

left gastric arteries. Branches pierce the wall and supply the various coats. The *veins* accompany the arteries. They form on the outer surface of the œsophagus a venous plexus opening into the gastric coronary vein below and the azygos and thyreoid veins above (thus establishing a communication between portal and systemic veins). There are also numerous *lymphatics* in the œsophagus arising chiefly in the mucosa and draining into the lower deep cervical, posterior mediastinal and superior gastric nodes. The *nerves* form two sympathetic plexuses, the submucous and the myenteric, from which the walls are supplied as will be described later for the stomach and intestine. Branches are received from the sympathetics, and from the vagus, including the recurrent nerve.

Development.—The embryonic œsophagus is at first relatively very short, but lengthens rapidly in connection with the descent of the stomach. The upper end is still high in children, corresponding to the higher vertebral level of the larynx. The lining epithelial cells are primitively cylindrical in form, and irregular ciliated areas are found from the third fœtal month up to birth (F. T. Lewis). In the embryo of about 20 mm., there is a proliferation of the epithelium, associated with the formation of vacuoles, but the lumen does not appear to be normally occluded. The primary longitudinal folds of the mucosa appear early (third month) and at the lower end seem to participate in the rotation of the stomach (F. P. Johnson). The superficial œsophageal glands appear about the fourth month (78 mm.), the deep glands at 240 mm. (Johnson). Of the muscular layers, the circular appears first (at about 10 mm.) the longitudinal slightly later (17 mm.).

Variations.—Usually a bundle of smooth *muscle* connects the œsophagus with the left bronchus [m. broncho-œsophageus], and another similarly with the left mediastinal pleura [m. pleuro-œsophageus]. More rarely there are similar bands connecting with the trachea, peri-

cardium, etc. Pouch-like *dilatations* of the œsophagus may occur, especially in the upper part of its posterior wall or at the lower end. According to C. R. Robinson, the latter include (1) *ampulla phrenica*, just above the diaphragm, and (2) *antrum cardiacum*, in the abdominal portion of the œsophagus. *Diverticula* also occur, some of which may be derived from the embryonic vacuolization of the epithelium previously described, as may likewise the occasional congenital *atresia*. Abnormal *strictures* of the œsophagus may occur, oftenest at the upper end, at the left bronchus, and near the lower end. Finally, the œsophagus may be in part either double or absent, and may communicate by fistula with the trachea.

Comparative.—The *length* of the œsophagus varies with the length of the neck, being shortest in fishes and amphibia where the œsophagus is not well marked off from the stomach. The *lining epithelium* is stratified squamous in mammals and birds, but often ciliated in lower forms. *Mucous glands* are absent in fishes, but occur typically in all higher forms. They are found best developed toward the lower end of the œsophagus, except in mammals, where they are usually more numerous at the upper end. *Dilatations* may occur normally, as in the crop of birds, which is richly supplied with glands. The *musculature* of the œsophagus is primitively entirely smooth (Oppel) as found in amphibia, reptiles and birds. A secondary replacement by cross-striated muscle is found to a variable extent in the majority of mammals and fishes.

THE ABDOMEN

The **abdomen** properly consists of that part of the body situated between the thorax and the pelvis. It is bounded *above* by the diaphragm; *below*, by the brim of the true pelvis; *behind*, by the vertebral column, diaphragm, quadratus lumborum and psoas muscles, and by the posterior portions of the ilia. *At the sides* it is limited by the anterior parts of the ilia and the hinder segments of the muscles which compose the anterior abdominal wall, viz., the transversus, internal oblique,

FIG. 898.—DIAGRAM OF THE ABDOMINAL REGIONS.

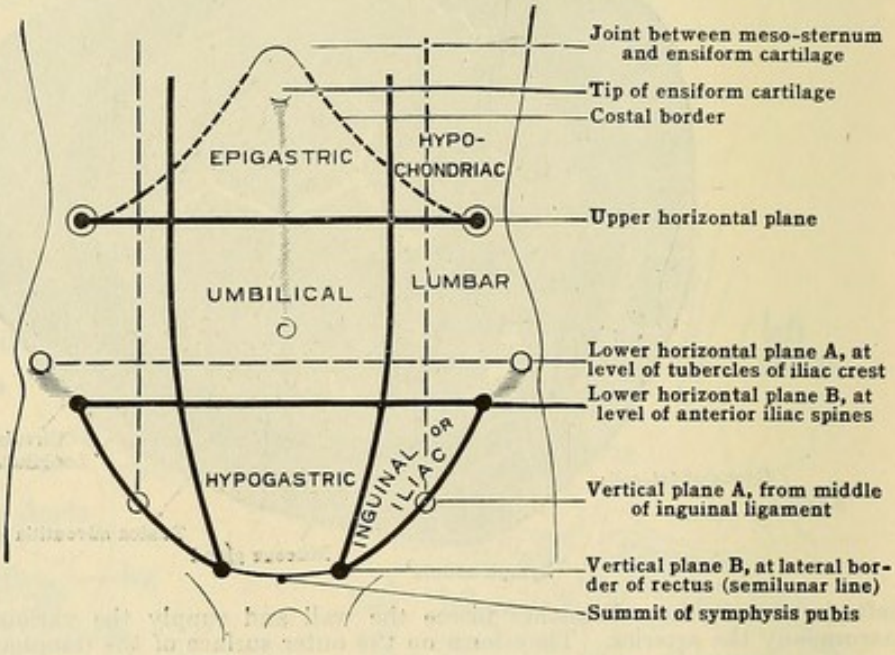

and external oblique. *In front*, besides these muscles, there are the two recti and pyramidales muscles. External to the peritoneum the abdomen is lined by a special layer of fascia.

It is customary for anatomists and physicians to divide, for purposes of description, the ventral surface of the abdomen, by means of two horizontal and two vertical lines, into nine regions (fig. 898). A complete uniformity in the use of the boundary lines marking these regional subdivisions has not as yet been attained, although the variations in the schemes used are not marked as concerns the main features. It should be borne in mind that it is necessary that the boundary lines used should be converted into planes carried through the whole depth of the abdomen and defined on the dorsal as well as the ventral surface, and that the relations defined can only be approximate, owing to the wide range of the physiological variation in the position of the abdominal contents. The nine regions or subdivisions may be outlined as follows:—The upper horizontal line or plane passes through the lowest point of the tenth costal cartilages, about 5 cm. above the umbilicus, and dorsally through the second or third lumbar vertebra. The lower

horizontal line and plane passes through the level of the anterior superior iliac spines, and dorsally about 2.5 cm. below the promontory of the sacrum. Cunningham has proposed that this line be passed through the tuberculum cristæ, therefore in a plane slightly higher than the interspinous plane. For the longitudinal lines and planes it has been customary to run vertical lines parallel with the mid-body line or mid-sagittal plane, and from the middle of the inguinal ligaments. The outer border of each rectus would seem, however, preferable as a guide for these longitudinal lines and planes, which may be easily localised above by the lateral infra-costal furrow and below by the pubic spines, leaving thus on each side an inguinal region which includes the whole of the inguinal canal. The boundary lines here indicated may be made intelligible by a reference to fig. 898. The regions thus outlined are known as the right and left hypochondriac and epigastric regions, found above the upper horizontal line; the right and left lumbar and the umbilical regions, found between the two horizontal lines; the right and left

FIG. 899.—THE ABDOMINAL VISCERA IN SITU, AFTER REMOVAL OF THE ANTERIOR ABDOMINAL WALL. (After Sarazin.)

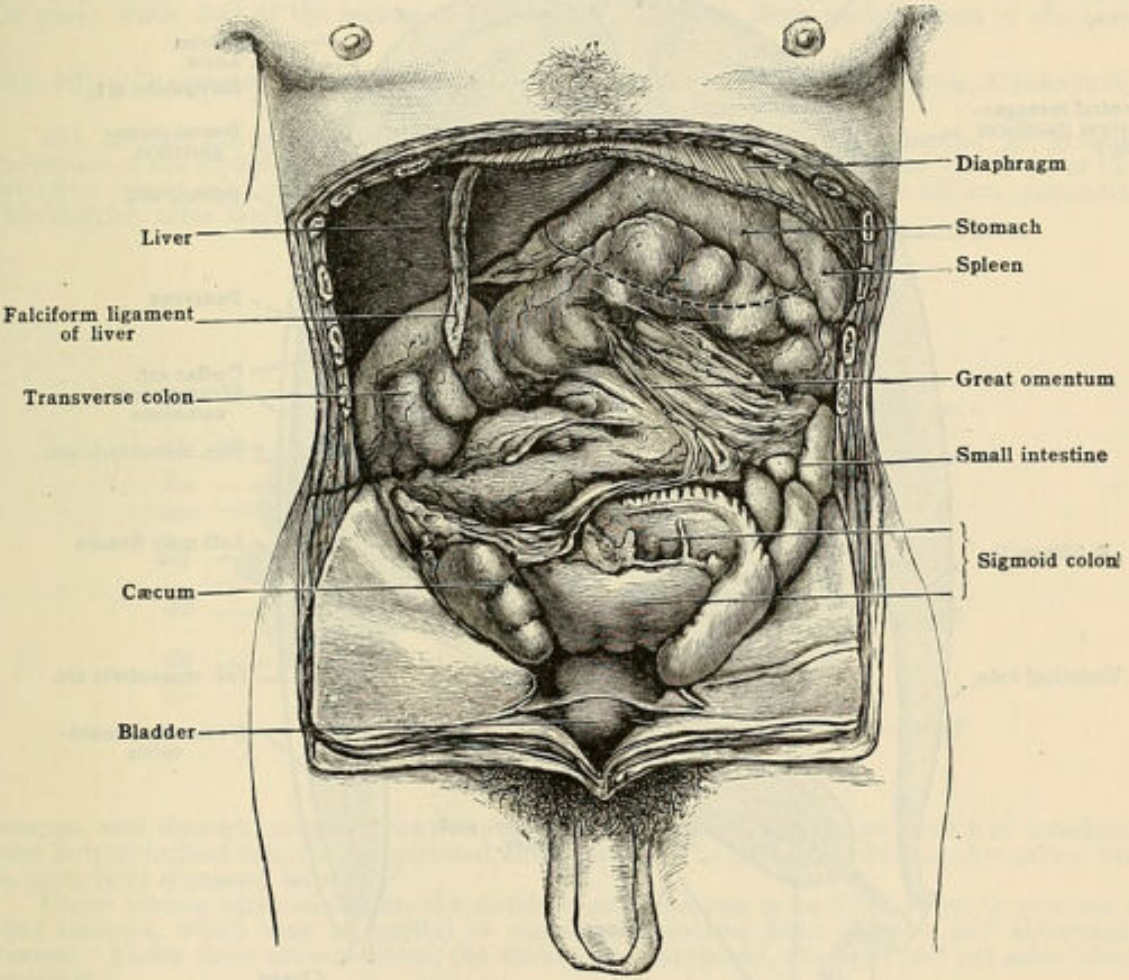

inguinal or iliac and the hypogastric regions, found below the lower horizontal lines. (According to the BNA, the lumbar regions are termed 'lateral abdominal'.)

On freely laying open an abdomen from the front, the general form of the space is seen to be an irregular hexagon, the sides of which are formed as follows:—The upper two by the margins of the costal cartilages with the ensiform cartilage between; the two lateral sides by the edges of the lateral boundary; and the two lower by the two inguinal ligaments which meet at the pubes.

In this irregular hexagon the following organs can be observed without disarranging their normal position (fig. 899). Above, on the right side, under the costal cartilages, can be seen the liver, which extends from the right across the median line to a point below the left costal cartilages. Below the liver, and lying to the left side, can be seen the anterior surface of the stomach; from the lower border of the stomach the omentum extends downward, and shining through it can be seen the middle part of the transverse colon. On each side and below the

irregularly folded omentum are exposed the coils of the small intestine; in the right iliac fossa a part of the cæcum appears; and in the left iliac fossa the lower (iliac) part of the descending colon and the beginning of the sigmoid colon.

To the left of the stomach and under cover of the lower ribs of the left side the edge of the spleen may possibly be observed; and just below the edge of the liver, and about the level of the tip of the ninth rib, the gall-bladder may be seen. The dome of the urinary bladder may be noticed just behind the symphysis pubis and in the median line. The disposition of the viscera in the fœtus is shown in fig. 953.

General morphology—Before taking up the various individual organs included in the abdominal and pelvic portions of the alimentary canal, a brief consideration of their general morphology is desirable. The primitive canal, as already described in the embryo (in the

FIG. 900.—DIGRAMMATIC REPRESENTATION OF AN EARLY STAGE IN THE DEVELOPMENT OF THE ALIMENTARY CANAL AND THE PERITONEUM. (After Sobotta-McMurrich.)

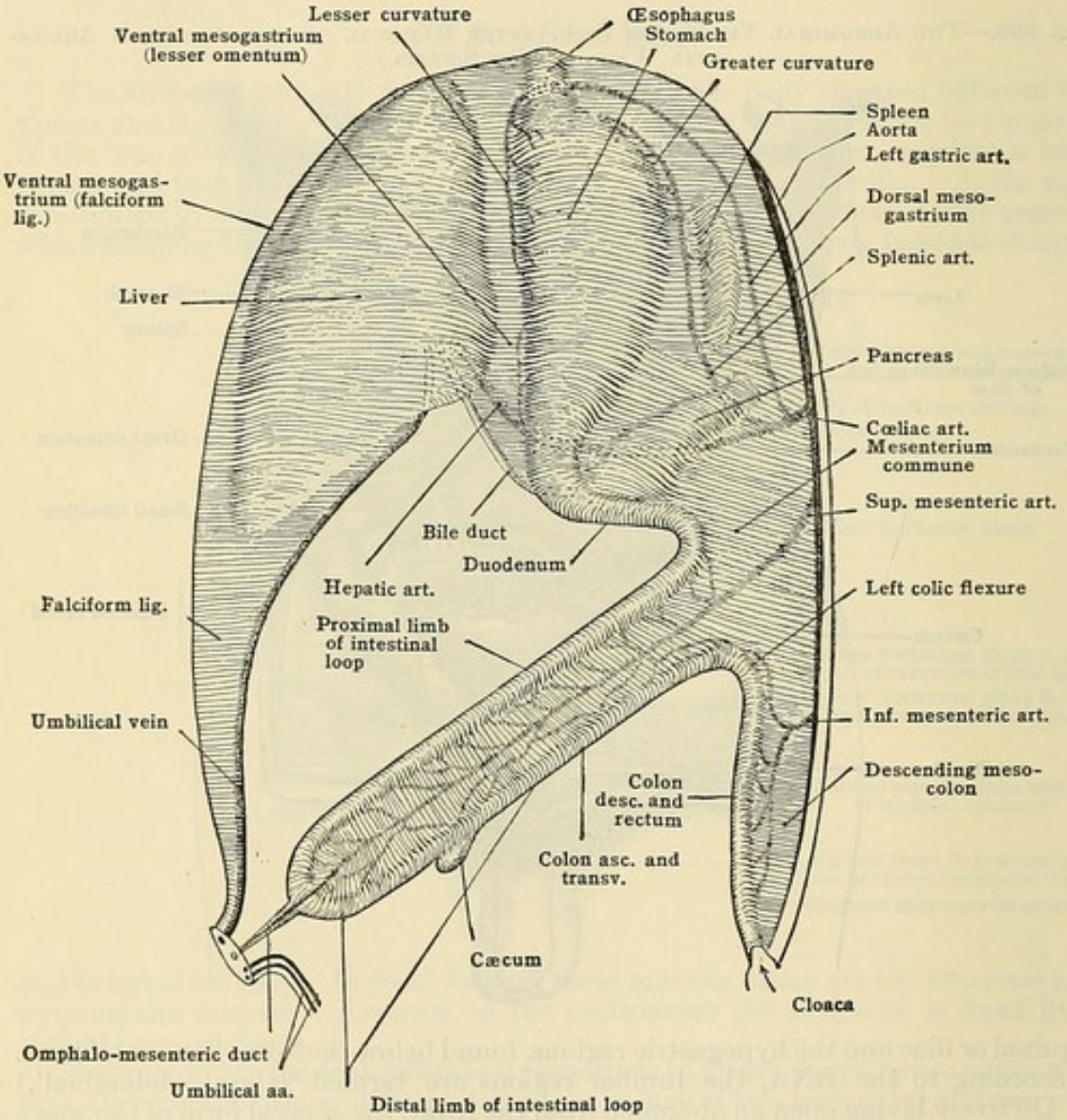

section on MORPHOGENESIS), and as found in the lower vertebrates is a comparatively straight, simple tube extending ventral to the body axis from mouth to anus. In the abdominal region (and primitively throughout the whole trunk), the canal lies within the body cavity, which is lined by parietal peritoneum. The visceral peritoneum is reflected from the mid-dorsal line as a double layer, the *primitive dorsal mesentery*, within which the vessels and nerves pass to the walls of the canal. Within the dorsal mesentery are also the spleen and pancreas. In the anterior (upper) region of the abdomen there is also a similar primitive *ventral* mesentery, which contains the liver.

The relations above mentioned are indicated diagrammatically in fig. 900, which represents a comparatively early stage in the development of the intestinal canal. The liver is already almost completely separated from the diaphragm (with which it was intimately associated in the earlier septum transversum). The ventral mesentery persists in the form of (1) the gastro-

hepatic or lesser omentum, connecting the stomach with the liver; and (2) the falciform ligament, connecting the liver with the ventral body wall.

The stomach undergoes a rotation on its longitudinal axis so that its anterior border (lesser curvature) is turned to the right, and its posterior border (greater curvature) to the left (fig. 901). Thus the posterior mesentery of the stomach [mesogastrium], bulges to the left and forward, carrying with it the spleen and pancreas. The portion of the mesentery corresponding to the pancreas, and that from the spleen to the root of the mesentery, become fused with the posterior body wall. The portion of the primitive mesogastrium between the stomach and spleen persists as the *gastro-splenic omentum* (or ligament), while the lower portion arches forward and downward as an extensive fold, the *great omentum*. The portion of the peritoneal cavity left behind the stomach is termed the *bursa omentalis*, or lesser sac, the remainder of the peritoneal cavity being the greater sac.

Along with the pancreas, the duodenum becomes adherent to the posterior wall. The remainder of the intestine forms a loop (fig. 901), the upper portion of which forms the jejuno-ileum, the lower portion the large intestine. The intestinal loop rotates counter-clockwise, so that the cæcum and ascending colon are carried over to the right side of the body cavity, where (with the corresponding portion of the primitive mesentery) they become adherent to the posterior body wall (fig. 901). The mesentery of the transverse colon persists (though fused partly with the great omentum, as explained later under development). The descending colon becomes displaced to the left side, and (together with its mesentery) becomes adherent to the posterior wall of the abdomen. The mesentery of the sigmoid colon usually persists (in part), while that of the rectum is obliterated. Through these modifications of the peri-

FIG. 901.—DIAGRAMS ILLUSTRATING THE DEVELOPMENT OF THE GREAT OMENTUM, MESENTERY, ETC. A, EARLIER STAGE; B, LATER STAGE.

bld, cæcum; dd, small intestine; dg, yolk-stalk; di, colon; du, duodenum; gc, greater curvature of the stomach; gg, bile duct; gn, mesogastrium; k, point where the loops of the intestine cross; mc, mesocolon; md, rectum; mes, mesentery; wf, vermiform appendix. (McMurrich after Hertwig.)

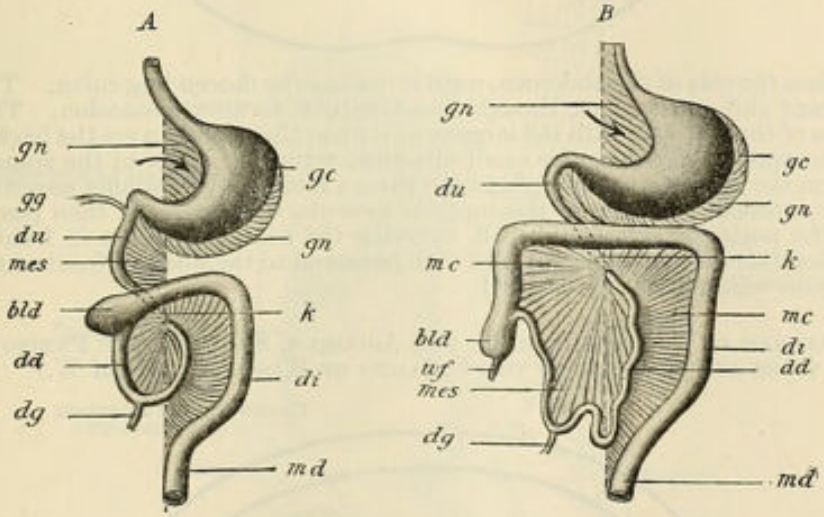

toneum, and through unequal growth in the different regions, the simple primitive intestinal tube is transformed into the complicated adult canal. The details of the transformation will be more fully discussed later.

Under certain rare conditions, the developmental process is modified so as to produce a *situs inversus*, which may be partial or complete, involving both thoracic and abdominal viscera. Under these circumstances, the viscera are transposed, the right and left sides being reversed.

THE PERITONEUM

The **peritoneum,** as has been shown, is a serous membrane which lines the cavity of the abdomen from the diaphragm to the pelvic floor, and invests or covers to a varying extent the viscera which that cavity contains. Viewed in its very simplest condition, it may be regarded as a closed sac, the inner surface of which is smooth, while the outer surface is rough and is attached to the tissues which surround it.

In the male subject the peritoneum forms actually a closed sac; but in the female its wall exhibits two minute punctures, which correspond to the openings of the Fallopian tubes. That part which lines the walls of the abdomen is termed the *parietal* peritoneum; that which is reflected on to the viscera is the *visceral* peritoneum. The disposition of the peritoneum may first be studied by noting

its arrangement as made evident in transverse sections of the abdomen at certain levels.

The first section to be described shows the peritoneum in its simplest condition. This is a transverse section through the body, at about the level of the upper surface of the fourth lumbar vertebra, and therefore about the site of the umbilicus (fig. 902).

Starting on the inner surface of the anterior abdominal wall, the peritoneum is seen to cover the transversalis fascia, and indirectly the anterior abdominal muscles; then, passing

FIG. 902.—DIAGRAM OF CROSS-SECTION OF THE ABDOMEN, SHOWING THE PERITONEAL RELATIONS AT THE LEVEL OF THE UMBILICUS. *AO*, Aorta. *AS. COL.*, Ascending colon. *DES. COL.*, Descending colon. *MES.*, Mesentery. *M. COL.*, Descending mesocolon. *SI*, Small intestine. *V.C.*, Vena cava inferior.

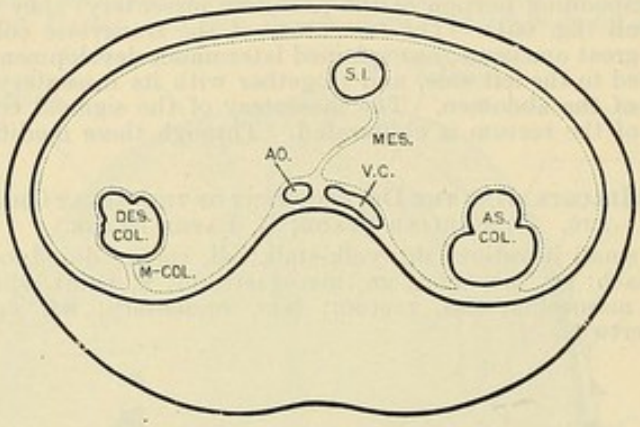

to the left, it lines the side of the abdomen, until it reaches the descending colon. This it covers, as a rule, in front and on the sides, though occasionally it forms a mesocolon. Then it passes over the bodies of the vertebræ with the large vessels upon them, and leaves the back of the abdomen to run forward and enclose the small intestine, returning again to the spine. The two layers thus form the mesentery, having between them a middle layer [lamina mesenterii propria] containing the terminal branches of the superior mesenteric vessels. It then passes over the right half of the posterior abdominal wall, covering the ascending colon in front and at the sides only (unless there be a mesocolon), and then passes on to the side and front of the abdomen to the point from which it was first traced.

FIG. 903.—DIAGRAM OF CROSS-SECTION OF THE ABDOMEN, SHOWING THE PERITONEAL RELATIONS AT THE LEVEL OF THE FORAMEN OF WINSLOW. (F. of W.)

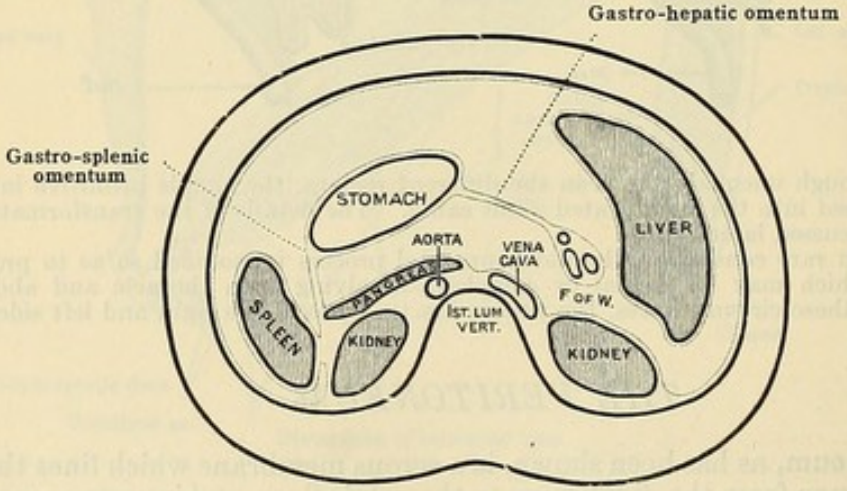

In tracing the peritoneum in a section of the body opposite the stomach (fig. 903), on a level with the first lumbar vertebra, its course becomes more complicated and difficult to follow.

In the section already given the peritoneum as a simple closed sac can be readily conceived; but at the level now exposed the serous membrane has been so introverted that there appear to be two sacs, one leading from the other, and known respectively as the greater and the lesser sac of the peritoneum. They communicate through the epiploic foramen (of Winslow). The lesser sac [bursa omentalis] is situated behind the stomach, so that on first opening the abdomen no trace of it is to be seen. It extends downward [recessus inferior] between the layers of the great omentum (though this part of the lesser sac is largely obliterated by adhesion

in the adult). It extends upward [recessus superior] behind the caudate lobe of the liver. The vestibule [vestibulum bursæ omentalis] is the portion which lies just behind the lesser omentum, and communicates with the greater sac through the epiploic foramen. In general, the lesser sac is limited *anteriorly* by the liver, stomach, and omenta; *posteriorly* by the posterior abdominal wall, and below, behind the great omentum, by the transverse meso-colon. Its disposition on vertical section is shown in fig. 904.

The **epiploic foramen** (**foramen of Winslow**) (figs. 903, 906) is situated just below the liver; it looks toward the right, and will readily admit one or two fingers. It is bounded *superiorly* by the caudate lobe of the liver; *inferiorly*, by the duodenum (pars superior); *posteriorly*, by the vena cava; and *anteriorly* by the right margin of the gastro-hepatic or lesser omentum, containing the structures passing to and from the liver. Starting at the epiploic foramen, the lesser sac will be found to turn to the left.

FIG. 904.—DIAGRAM OF A SAGITTAL SECTION OF THE TRUNK, SHOWING THE RELATIONS OF THE PERITONEUM. (Allen Thompson.)

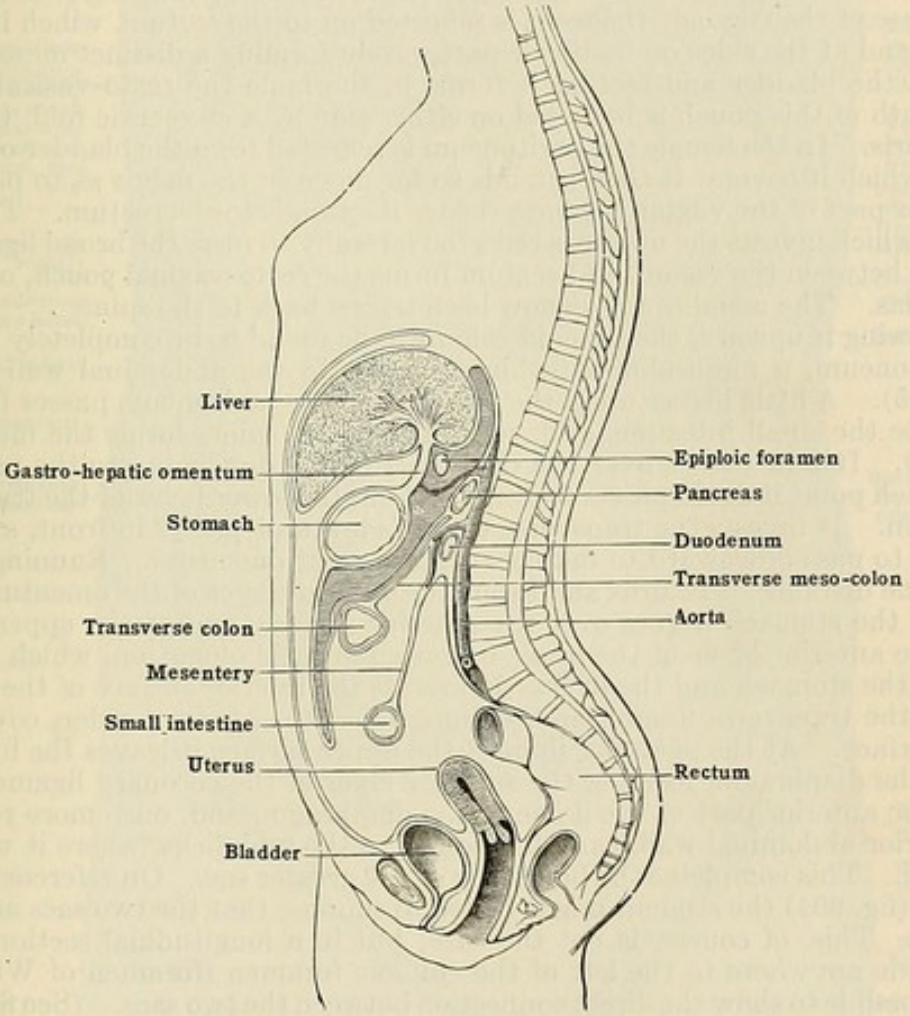

If, now, the peritoneum be viewed in a transverse section of the body at the level named, viz., through the first lumbar vertebra, it will be found that the section has probably passed through the epiploic foramen (fig. 903). Starting at the front of the abdomen and going to the right, the peritoneum is seen to line the anterior abdominal wall, to pass over the side of the abdomen, and to cover the front of the right kidney; it then extends on to the vena cava, when it becomes a part of the lesser sac; then along the back of the lesser sac, over the aorta and pancreas, which separate it from the vertebral column; next it reaches the anterior of the two internal surfaces of the spleen internal to the hilus. Here it meets with another layer of peritoneum, and helps to form the gastro-splenic ligament [lig. gastrolienale]. Leaving the spleen, it changes its direction forward and to the right, and runs to the stomach, forming the posterior, layer of the gastro-splenic ligament; it covers the posterior surface of the stomach, and leaves its mesial border (lesser curvature) to form the posterior layer of the lesser omentum, and then passes upward and to the right to the liver. In this transverse section it is only seen passing on the right margin of the lesser omentum, where it forms the anterior boundary of the epiploic foramen. Here it bends sharply around the omental margin enclosing the hepatic vessels continuing to the left as the anterior layer of the lesser omentum; and then passing to the left reaches the stomach, which it covers in front. It then forms the anterior layer of the gastro-

splenic ligament, and once more reaches the spleen. It passes right around the spleen to the back of the hilus, where it is reflected on to the left kidney as the lieno-renal ligament (fig. 903). Hence the peritoneum passes along the side and front of the abdomen to the point from which it started. In this section the liver is so divided as to appear separated from all connection with the other viscera and the abdominal wall, and to be surrounded by peritoneum.

The course of the peritoneum in a **longitudinal section of the body** will now be considered (fig. 904). Starting at the umbilicus and passing downward, the peritoneum is seen to line the anterior abdominal wall. Before reaching the pelvis it covers also the urachus, the deep epigastric arteries, and obliterated hypogastric arteries, which form ridges beneath it. For some little way above the os pubis the peritoneum is loosely connected with the abdominal wall, a circumstance which is made use of in supra-pubic cystotomy. Moreover, as the distended bladder rises from the pelvis it can detach the serous membrane to some extent from the anterior abdominal wall. In extreme distension of the bladder the peritoneum may be lifted up for some 5 cm. vertically above the symphysis. On reaching the os pubis it is reflected on to the upper part of the bladder, covering it as far back as the base of the trigone; thence it is reflected on to the rectum, wihch it covers in front and at the sides on its upper part, rarely forming a distinct mesorectum. Between the bladder and rectum it forms in the male the **recto-vesical pouch.** The mouth of this pouch is bounded on either side by a crescentic fold, the plica semilunaris. In the female the peritoneum is reflected from the bladder on to the uterus, which it covers; it then extends so far down in the pelvis as to pass over the upper part of the vagina behind; thence it extends to the rectum. The peritoneum which invests the uterus is reflected laterally to form the broad ligaments. The fold between the vagina and rectum forms the **recto-vaginal pouch,** or pouch of Douglas. The membrane has now been traced back to the spine.

Following it upward, the sigmoid colon will be found to be completely covered by peritoneum, a mesocolon attaching the gut to the abdominal wall (shown in fig. 905). A little higher up in the median line the peritoneum passes forward, to enclose the small intestine, and, returning to the spine, forms the mesentery (fig. 904). It now passes over the third part of the duodenum to the pancreas, from which point it again passes forward to form the lower layer of the transverse mesocolon. It invests the transverse colon below and partly in front, and then leaves it to pass downward to take part in the great omentum. Running downward some distance, it returns and forms the anterior layer of the omentum. On reaching the stomach it goes over the anterior surface, and at the upper border forms the anterior layer of the lesser or gastro-hepatic omentum, which extends between the stomach and the liver. It invests the inferior surface of the liver in front of the transverse fissure, and, turning over its anterior border, covers the upper surface. At the posterior limit of the upper surface it leaves the liver and goes to the diaphragm, forming the superior layer of the coronary ligament. It covers the anterior part of the dome of the diaphragm, and, once more reaching the anterior abdominal wall, can be followed to the umbilicus, where it was first described. This completes the boundary of the greater sac. On reference to the diagram (fig. 904) the student might be led to suppose that the two sacs are quite separate. This, of course, is not the case; but in a longitudinal section of the body made anywhere to the left of the epiploic foramen (foramen of Winslow), it is impossible to show the direct connection between the two sacs. (See fig. 905.)

The peritoneum has only been traced in this longitudinal section so far as it concerns the greater sac. It now remains to follow upon the same section (fig. 904) such part of the membrane as forms the **lesser sac.** The peritoneum here will be seen to cover the posterior surface of the stomach; thence from the lesser curvature it runs upward to the liver, forming the posterior layer of the lesser or gastro-hepatic omentum. It reaches the liver behind the transverse fissure. It covers only a part of its posterior surface (caudate lobe), and is reflected on to the diaphragm, forming the lower layer of the coronary ligament. It now goes downward over the posterior part of the dome of the diaphragm to the spine, separated from the latter by the great vessels. On reaching the anterior border of the pancreas it passes forward, and forms the upper layer of the transverse meso-colon. It then covers the upper half of the transverse colon, and, descending, forms the innermost layer of the great omentum. (The inner layers of the great omentum are usually fused in the adult, however, thus obliterating this portion of the lesser sac.) It now ascends, and, arriving at the greater curvature of the stomach,

passes on to its posterior wall. At this point its description was commenced. The general relations of the greater and the lesser sac are also evident in fig. 905 showing the lines along which the parietal peritoneum is reflected from the posterior abdominal wall as the visceral peritoneum, forming the various mesenteries and covering the various abdominal organs.

FIG. 905.—REFLECTIONS OF THE PERITONEUM ON THE POSTERIOR ABDOMINAL WALL. (From Rauber-Kopsch, modified.)

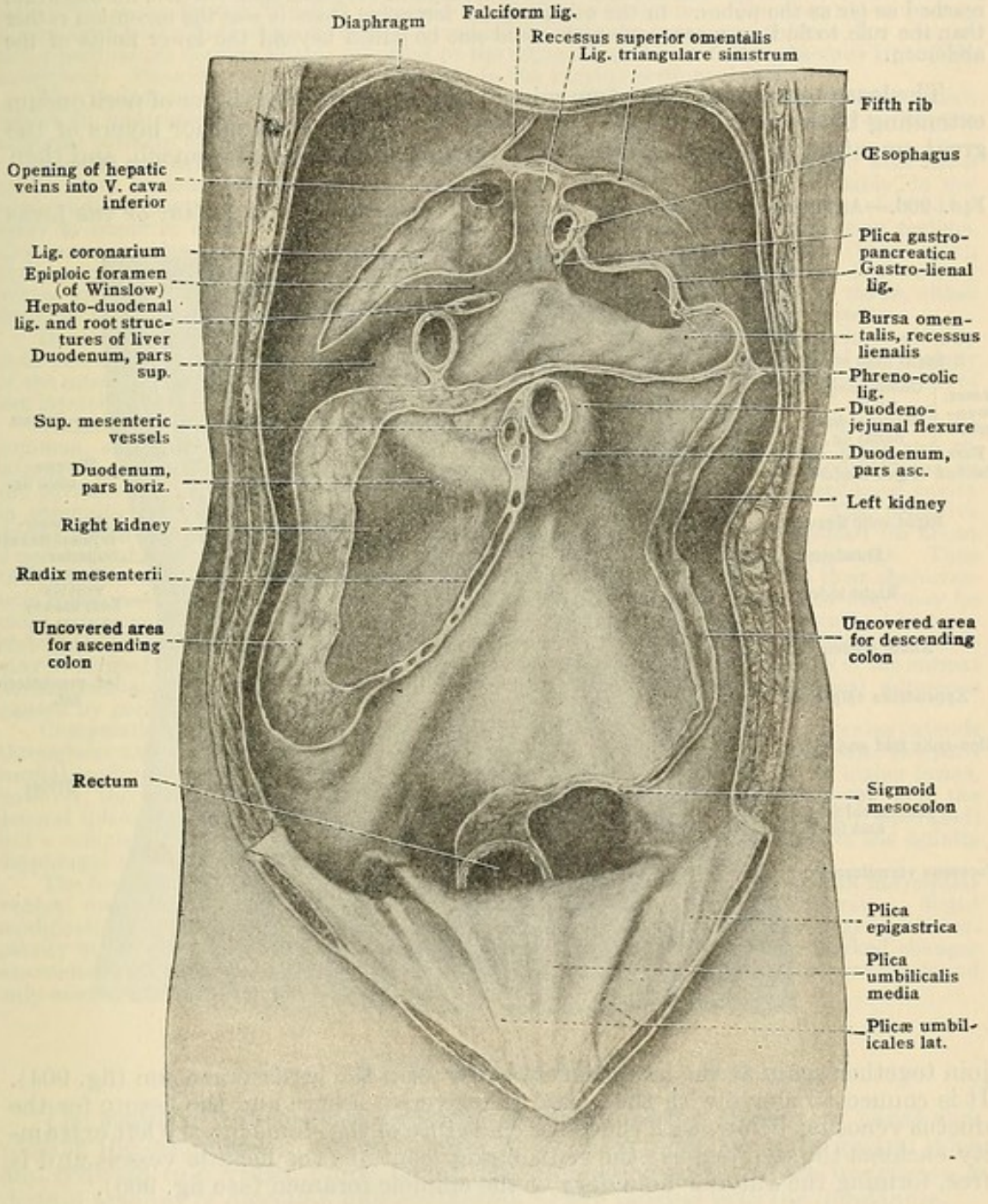

The precise manner in which certain organs—such as the liver, the cæcum, the duodenum, and the kidneys—are invested by peritoneum is described in the accounts of those viscera. To such accounts the reader is referred for a description of the many 'ligaments' (such as those of the bladder and liver) which are formed by the peritoneum.

The great omentum.—As is evident from its development, the great omentum [omentum majus] is formed of four layers of peritoneum, though this is quite impossible to demonstrate in an adult, the individual layers having become adherent.

The great omentum acts as an apron, protecting the intestines and providing

them with a heat-economising covering of fat. It is nearly quadrilateral in shape, and is variable in extent. In fig. 904 the great omentum is shown to be connected with the greater curvature of the stomach, on the one hand, and the transverse colon, on the other. Originally it extended backward above the transverse colon and mesocolon to the posterior abdominal wall. The line along which it fuses with the transverse colon and mesocolon during development is shown in fig. 904.

Mr. Lockwood has made some investigations on the lengths of the transverse meso-colon and great omentum in thirty-three cases. In twenty, under the age of forty-five, only one subject had a great omentum long enough to be drawn beyond the pubic spine; in five, the omentum reached as far as the pubes. In the cases beyond forty-five years it was the exception rather than the rule to find an omentum which could not be pulled beyond the lower limits of the abdomen.

The **lesser omentum** [omentum minus] consists of a double layer of peritoneum extending between the stomach and the liver. If the two anterior layers of the great omentum are traced upward, they are seen to enclose the stomach, and then

FIG. 906.—ABDOMINAL VISCERA, ANTERIOR VIEW, AFTER REMOVAL OF A PART OF THE LIVER AND INTESTINES. (Rauber-Kopsch.)

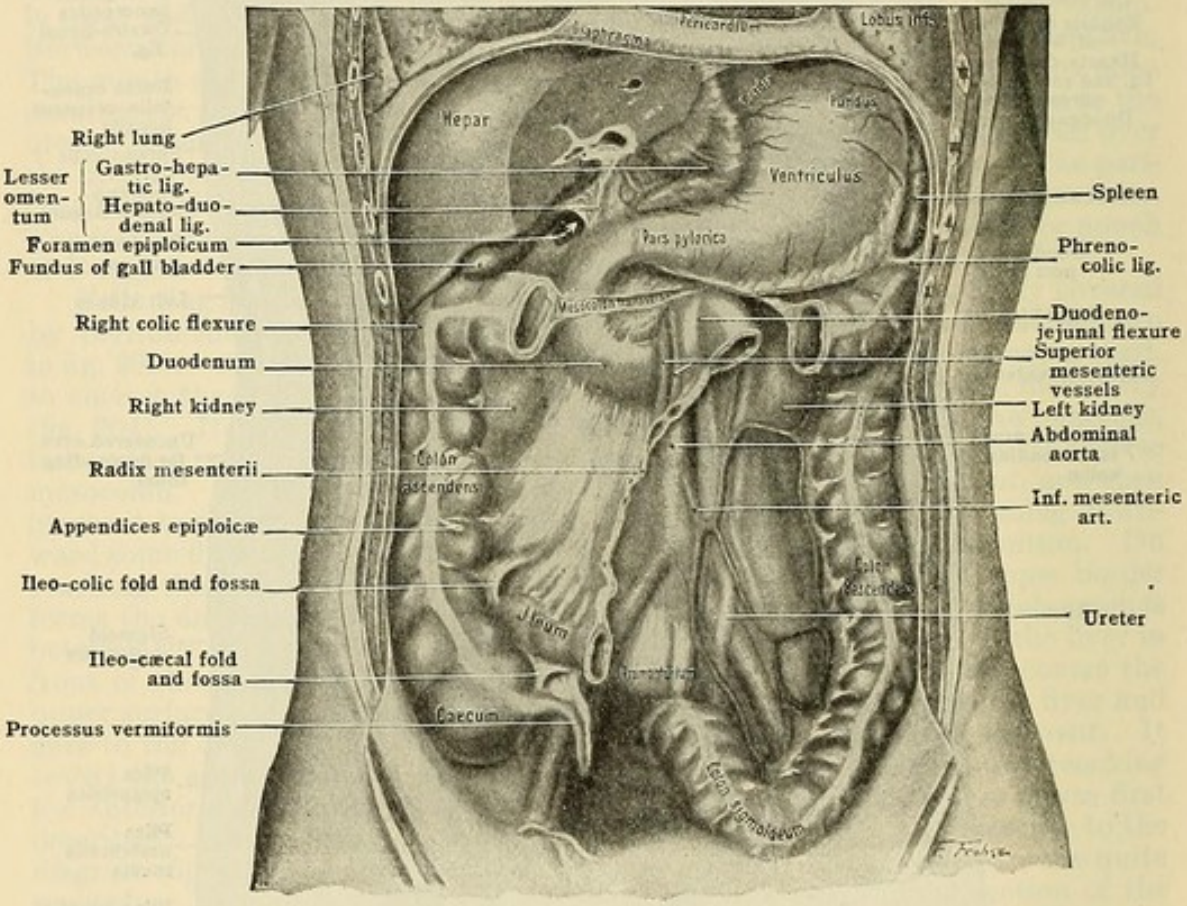

join together again at the lesser curvature to form the lesser omentum (fig. 904). It is connected above with the portal (transverse) fissure and the fissure for the ductus venosus; below, with the lesser curvature of the stomach; the left extremity encloses the œsophagus; the right border contains the hepatic vessels and is free, forming the anterior boundary of the epiploic foramen (see fig. 906).

The lesser omentum is divided into two parts. The portion connecting the portal fissure of the liver with the first part of the duodenum, and enclosing the root structures of the liver, is called the *hepato-duodenal ligament* [lig. hepatoduodenale]. The portion of the lesser omentum connecting the lesser curvature of the stomach with the fissure of the ductus venosus is the *gastro-hepatic* ligament [lig. hepatogastricum].

The **gastro-splenic ligament** [lig. gastrolienale] connects the left extremity of the stomach with the spleen, continuing the layers of peritoneum which enclose the stomach (fig. 903).

The gastro-phrenic and phreno-colic ligaments.—As the peritoneum passes from the diaphragm to the stomach it forms a small fold just to the left of the

œsophagus. This is the gastr o-phrenic ligament. A strong fold of the membrane also extends from the diaphragm (opposite the tenth and eleventh ribs) to the splenic flexure of the colon, and is known as the phreno-colic (costo-colic) ligament [lig. phrenicolienale]. (See figs. 905, 906.)

Minute anatomy.—The peritoneum, like all serous membranes, consists of two layers; a lining layer composed of simple squamous epithelium (mesothelium), and an underlying layer of fibrous connective tissue. The latter is highly elastic, and denser in the parietal than in the visceral layer. It often contains fat. In mesenteries and similar structures, the connective tissue is usually very scanty, except surrounding the vessels and nerves. Ruptures often occur in the omenta, which thus become fenestrated in structure. The visceral peritoneum is usually closely attached to the organs for which it forms the outer serous tunic, but the parietal peritoneum is often loosely attached to the adjacent wall by a fatty subserous layer [tela subserosa]. Smooth muscle occurs frequently in the various peritoneal folds.

The peritoneal cavity contains normally a very slight amount of watery fluid, which serves to lubricate the smooth peritoneal surface and thus to eliminate friction between adjacent surfaces during the movements of the alimentary canal.

Vessels and nerves.—The peritoneum is in general somewhat sparsely supplied with *blood-vessels* from various adjacent trunks. *Lymph-vessels* also occur, but they probably do not connect directly with the peritoneal cavity by stomata (as is found in the frog and as claimed by some to occur in man). They communicate with the lymphatics of neighbouring regions. The *nerves* are also comparatively scarce. They are partly of sympathetic origin (vasomotor), and partly sensory nerves from the intercostal (7th to 12th), and lumbar nerves. The sensory nerves are more frequent in the parietal peritoneum and end in the connective tissue, either freely or in special end-organs (varying from simple end-bulbs to Pacinian corpuscles).

Development.—The principal features in the development of the peritoneum have already been mentioned in the section on MORPHOGENESIS and in the remarks on the general morphology of the intestinal canal (p. 19). Further details will be included later under the development of the intestine, etc.

Variations.—Variations in the form and relations of the peritoneum are exceedingly common, and are most commonly of developmental origin. Variations in the form and relations of the various abdominal organs necessarily involve corresponding modifications in the peritoneum. The diaphragm may be incompletely formed, leaving the peritoneal cavity in communication with the pleural, or more rarely the pericardial cavity. The primitive dorsal mesentery of the intestine [mesenterium commune] may persist unmodified (in about 2 per cent. of adults), or the various secondary changes may be inhibited at any stage. Thus the stomach or the intestinal loop may fail, either wholly or partly, to undergo their characteristic rotations. The adhesions of the various mesenteries may be incomplete, or they may be more extensive than usual. For example, the sigmoid mesocolon may be more or less completely obliterated by adhesion, and numerous unusual peritoneal pockets or ligamentous bands may be formed in this way in various localities. Variations thus due to extensions of the normal developmental process are sometimes difficult to distinguish from pathological adhesions caused by peritonitis.

Comparative.—As previously mentioned, the primitive body cavity in vertebrates extends throughout the trunk region. In the cyclostomata, this primitive relation persists, the pericardial cavity remaining in communication with the general body cavity. In all higher forms, however, the pericardial cavity becomes entirely separated. In amphibia the lungs lie in the general (pleuroperitoneal) body cavity; in the reptiles and birds, they are partially separated; but a complete separation of the pleural cavities occurs only with the formation of the definite diaphragm in mammals.

The formation in the peritoneal cavity of a complete dorsal mesentery, and an incomplete ventral mesentery (in the hepatic region) is typical for all classes of vertebrates. Slight modifications in the form of the mesenteries depend chiefly upon the different degrees of complexity in the development of the various parts of the intestinal tract. The marked changes associated with extensive secondary adhesions of the primitive peritoneal structures are found only among the higher mammalia, especially in man.

THE STOMACH

The **stomach** [ventriculus; gaster] is a dilation of the alimentary canal succeeding the œsophagus. In the stomach the food is mixed with the gastric juice and reduced to a viscid, pulpy liquid, the chyme [chymus], which undergoes a certain amount of digestion and absorption before passing into the duodenum.

The stomach (figs. 906, 907) is a somewhat pear-shaped organ located in the upper, left side of the abdominal cavity. It presents a *body* [corpus ventriculi], with an enlarged upper end or *fundus*, on the right side of which is the *cardia*, the aperture communicating with the œsophagus. The body of the stomach is extremely variable in form, as will be explained later, but is in general divisible into a more expanded upper two-thirds, the *cardiac portion* [pars cardiaca], which is nearly vertical, and a more constricted lower third, the *pyloric portion* [pars pylorica], which turns horizontally toward the right. The pyloric portion often presents toward its lower end a slight, variable dilation, the *antrum pylori*,

succeeded by a short constricted *pyloric canal* (Jonnesco). At the lower end of this canal the *pylorus* forms the aperture leading into the duodenum, and contains a thick sphincter derived from the circular fibres of the muscular layer. The stomach has two borders and two surfaces. The medial (or upper) border forms the *lesser curvature* [curvatura ventriculi minor], which is concave (except near the pylorus) and gives attachment to the lesser omentum. The lateral (or lower) border forms the *greater curvature* [curvatura ventriculi major], which is convex, and gives attachment to the great omentum. The curvatures separate the *anterior surface* [paries anterior], which faces forward and upward, from the *posterior surface* [paries posterior], which is placed backward and downward.

Dimensions.—The dimensions of the stomach are subject to great variation and therefore only a gross approximation can be given. The *length* of the lesser curvature averages about 10 cm. (7.5 cm. to 15 cm.), and that of the greater

FIG. 907.—LONGITUDINAL SECTION OF STOMACH, SHOWING THE INTERIOR OF THE POSTERIOR HALF. (Rauber-Kopsch.)

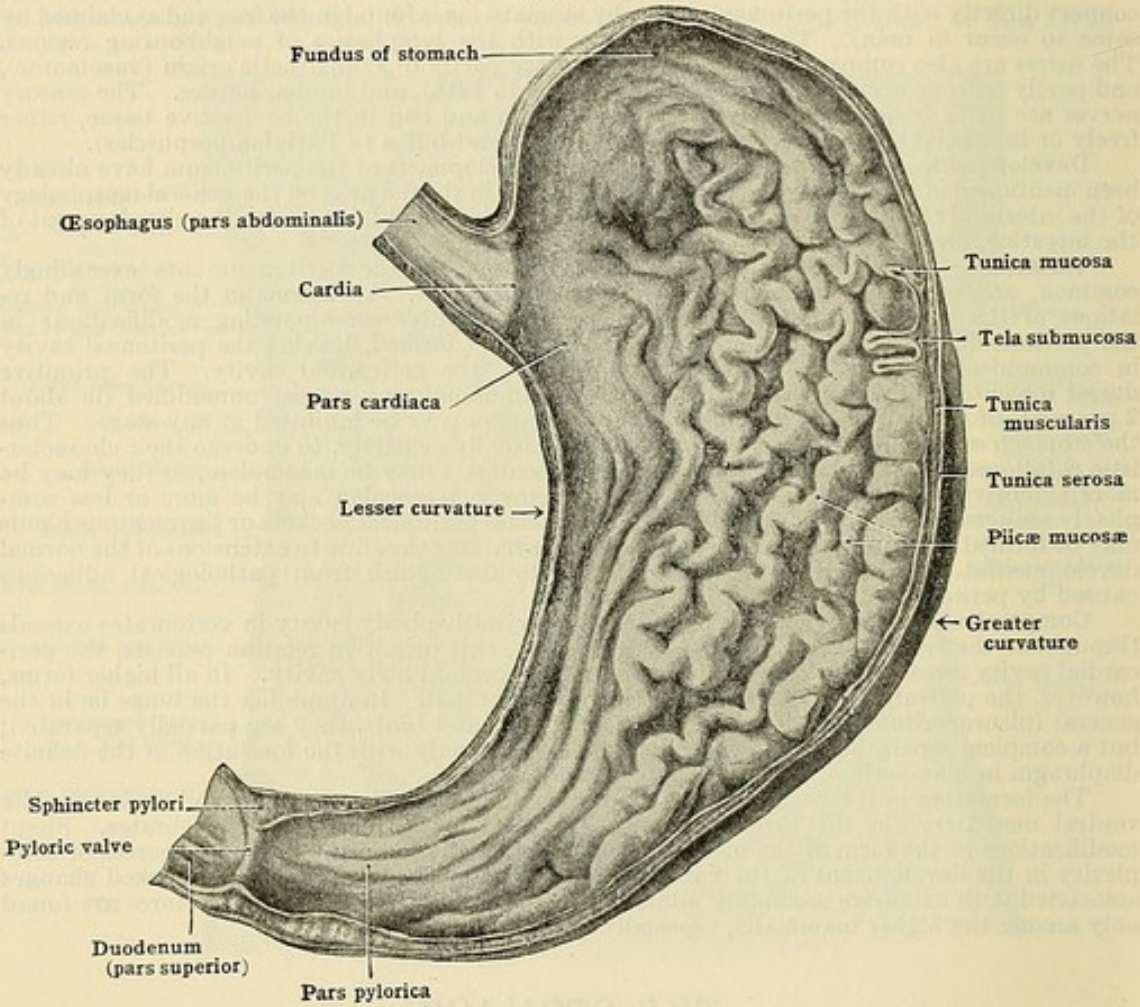

curvature is three or four times as great. The *diameter* varies exceedingly according to the amount of contents. When nearly empty, it presents, especially in the pyloric portion, a narrow tubular form, with a diameter of about 4 cm. or 5 cm. (fig. 1108, Section XIII). The diameter of the pylorus, which is the narrowest point in the alimentary canal when constricted is only about 1.5 cm. It is distensible, however, as hard bodies with diameters of 2 cm. or more may readily pass through.

The average *capacity* of the stomach is between one and two litres, being subject to extreme individual variations. In the newborn, it averages about 30 cc. (25 to 35 cc.), increasing very rapidly in the early postnatal months and reaching an average of 270 cc. at one year (Lissenko). The average *weight* of the adult stomach is about 135 gm.

Position and relations of the stomach.—The position and relations of the stomach, like its form and structure, are subject to many variations in different indi-

viduals, and in the same individual according to changes in physiological condition, posture, etc. It is therefore difficult to give a concise and accurate description.

The normal **position** of the stomach has long been disputed. It is generally recognised that the long axis is oblique, extending from above downward, forward and to the right. Some, however, especially among the older anatomists, have maintained that the gastric axis normally approaches more nearly to the *horizontal* type, with the pylorus but little below the cardia (approximately the position shown in figs. 915, 916). Others, especially among the more recent anatomists, have maintained that the axis of the stomach is normally more nearly *vertical* in position (see fig. 1125, Section XIII). The results of an extended and careful study, both in formalin-hardened bodies and by means of the Rœntgen-rays in the living body, demonstrate that there is much variability in the position of the stomach. Both the horizontal and the vertical types may occur as the extremes of normal variation, but the more usual type is the intermediate *oblique* position. The gastric axis, however, is not straight, but somewhat curved and bent in a reverse L-shape. The larger cardiac portion is approximately vertical (especially when the trunk is in the upright posture) the smaller pyloric portion more nearly horizontal (figs. 895, 906, 918, 919). In the empty stomach, the pylorus opens into the duodenum from left to right. In distention, however, the pylorus is carried in front of the duodenum. In extreme distention, it is carried to the right and downward so as to open upward and to the left.

FIG. 908.—LONGITUDINAL SECTION OF THE PYLORIC PORTION OF THE STOMACH. (Cunningham, Trans. Royal Soc. Edinb., vol. 45.)

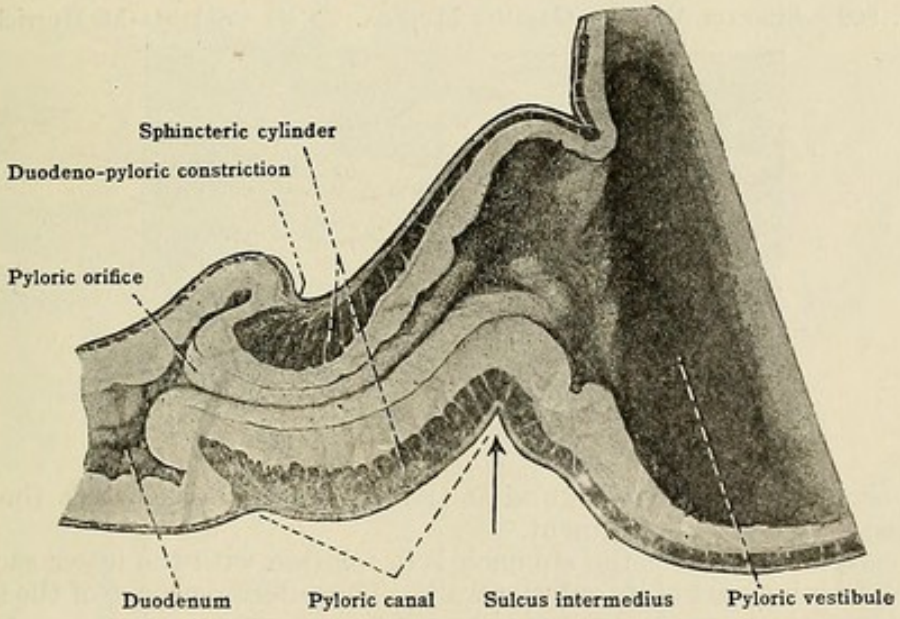

In **surface relation** (fig. 914), the stomach lies within the left hypochondriac and the epigastric regions. Often, however, especially when distended, it extends into the umbilical and even the right hypochondriac region. When empty, it usually lies almost entirely in the left half of the body, with the pylorus not more than 1 cm. or 2 cm. to the right of the mid-sagittal plane. When distended, the long axis of the stomach is lengthened and the pylorus is displaced 5 cm. or more to the right and downward. In distention, the stomach expands in all directions (except posteriorly), and does not appear to rotate as is sometimes stated. The position of the stomach, especially when distended, also varies appreciably according to the *posture* of the body. It sags downward when the body is in the upright position, and to the right or left when the body is placed on the corresponding side. The *cardia* lies on the left side of the 10th or 11th thoracic vertebra, and corresponds to a surface point behind the left 7th costal cartilage about 2.5 cm. from its sternal end. The *pylorus* usually lies opposite the right side of the 1st lumbar vertebra, about midway between ensiform cartilage and umbilicus, or in Addison's 'transpyloric line,' midway between the suprasternal notch and the symphysis pubis, when the body is recumbent; but descends to the 2d or lower in upright posture. The *fundus* corresponds to the left dome of the

diaphragm (which separates it from the lung and heart), opposite the sixth sterno-costal junction. The fundus of course rises and falls with respiratory movements of the diaphragm, the excursion being from 2 to 6 cm.

The relations of the stomach with *surrounding organs* are indicated diagrammatically in figs. 915 and 916. The *anterior surface* is in contact on the right with the left lobe of the liver, the pylorus reaching the quadrate lobe; on the left it is in contact with the diaphragm (separating it from the heart and left lung); and below with the anterior body wall by a triangular area of variable size. The *posterior surface* is in relation (separated by the lesser sac) with the pancreas, above which are areas of contact with the diaphragm, spleen, left kidney and suprarenal body; below the pancreas, the stomach is in contact with the transverse mesocolon, and through this with the transverse colon and coils of small intestine. The relation with the duodeno-jejunal angle is indicated in fig. 895. Further details concerning topography of the stomach are given in section XIII on CLINICAL AND TOPOGRAPHICAL ANATOMY.

Peritoneal relations.—The stomach is covered by peritoneum in its whole extent, except immediately along the curvatures and upon a small triangular space at the back of the cardiac orifice, where the viscus lies in direct contact with the diaphragm and possibly with the upper part of the left suprarenal gland. It is enclosed between two layers. These two layers at its lesser curvature come together to form the gastro-hepatic portion of the lesser omentum, and at the greater curvature extend downward to form the great omentum (figs. 903, 904). At the left of the œsophagus the two layers pass to the diaphragm, form-

FIG. 909.—SURFACE VIEW OF GASTRIC MUCOSA. × 4. (Sobotta-McMurrich.)



Gastric areas and foveolæ

ing the gastro-phrenic ligament; and at the fundus they pass on to the spleen, forming the gastro-splenic ligament.

The posterior surface of the stomach is in relation with the lesser sac (bursa omentalis), forming part of its anterior wall. The anterior surface of the stomach is in relation with the greater sac of the peritoneal cavity.

Minute anatomy.—The stomach is composed of the four typical layers of the alimentary canal—mucosa, submucosa, muscularis and serosa. The *mucosa* (figs. 907, 908, and 909) is thrown into a series of coarse *folds* (plicæ mucosæ), chiefly longitudinal, which disappear when the stomach is distended. Along the lesser curvature, the ridges are more regular (corresponding to Waldeyer's 'Magenstrasse') and form a longitudinal grooved channel from cardia to pylorus. Upon closer examination (fig. 909) the inner surface of the mucosa presents a somewhat warty ('mammilated') appearance, due to numerous small elevated areas [areæ gastricæ], varying from 1 to 6 mm. in diameter. When examined with a lens, it is seen that each area is beset with numerous small *pits* [foveolæ gastricæ], separated by partitions which sometimes (especially in the pyloric region) bear villus-like prolongations [plicæ villosæ]. The average number of foveolæ is estimated at 87 per sq. mm., or more than 6 millions for the entire stomach (Toldt). Into each pit or foveola open 3 to 5 gastric glands. The entire surface is covered with a simple columnar mucigenous epithelium.

The relations of the mucosa in section are shown in fig. 910. The thickness of the mucosa varies, being greatest (about 2 mm.) in the pyloric region, decreasing to less than .5 mm. in the cardiac region (Kölliker). The *lamina propria* is crowded with *glands*, of which three varieties are distinguished. The *cardiac* glands are tubulo-racemose (chiefly mucous) glands occupying a narrow zone a few millimeters in width adjacent to the cardiac orifice. The *fundic* glands [gl. gastricæ propriæ] occupy the greater part of the stomach, and are simple (partly branched) tubular glands (fig. 910). They contain three varieties of cells—mucous cells, peptic cells, and parietal cells. The parietal cells may secrete an organic chloride compound, but the HCl of the gastric juice is formed *not* in the gland tubules but at the surface of

the mucosa (Harvey and Bensley). The *pyloric* glands [gl. pyloricæ] are branched tubular glands occupying the pyloric region. Whether they are merely mucous or also secrete pepsin is still in dispute.

The interstitial tissue of the lamina propria contains diffuse lymphoid tissue and a few small *lymph nodules*, especially in the pyloric region. The *muscularis mucosæ* is a thin sheet of smooth muscle lying just below the fundus of the glands and is composed of an inner circular and an outer longitudinal layer.

The *tela submucosa* (fig. 910) is a very loose areolar, vascular layer which permits the wrinkling of the mucosa according to the degree of distention.

The *tunica muscularis* contains three layers of smooth muscle (figs. 911, 912, and 913). The outer or *longitudinal* layer [stratum longitudinale] is thickest along the lesser curvature, and is continuous with the longitudinal fibres of the œsophagus and the duodenum. On the anterior and posterior walls of the antrum pylori, the longitudinal fibres form thickened bands,

FIG. 910.—DIAGRAMMATIC SECTION OF THE STOMACH WALL SHOWING (*A*.) The Blood vessels, (*B*) the Tunics, and (*C*) the Lymphatics. *M*, Mucosa. M_1, Muscularis mucosæ. *S*, Submucosa. *I*, Circular, and *O*, longitudinal muscle layer. (Szymonowicz, after Mall.)

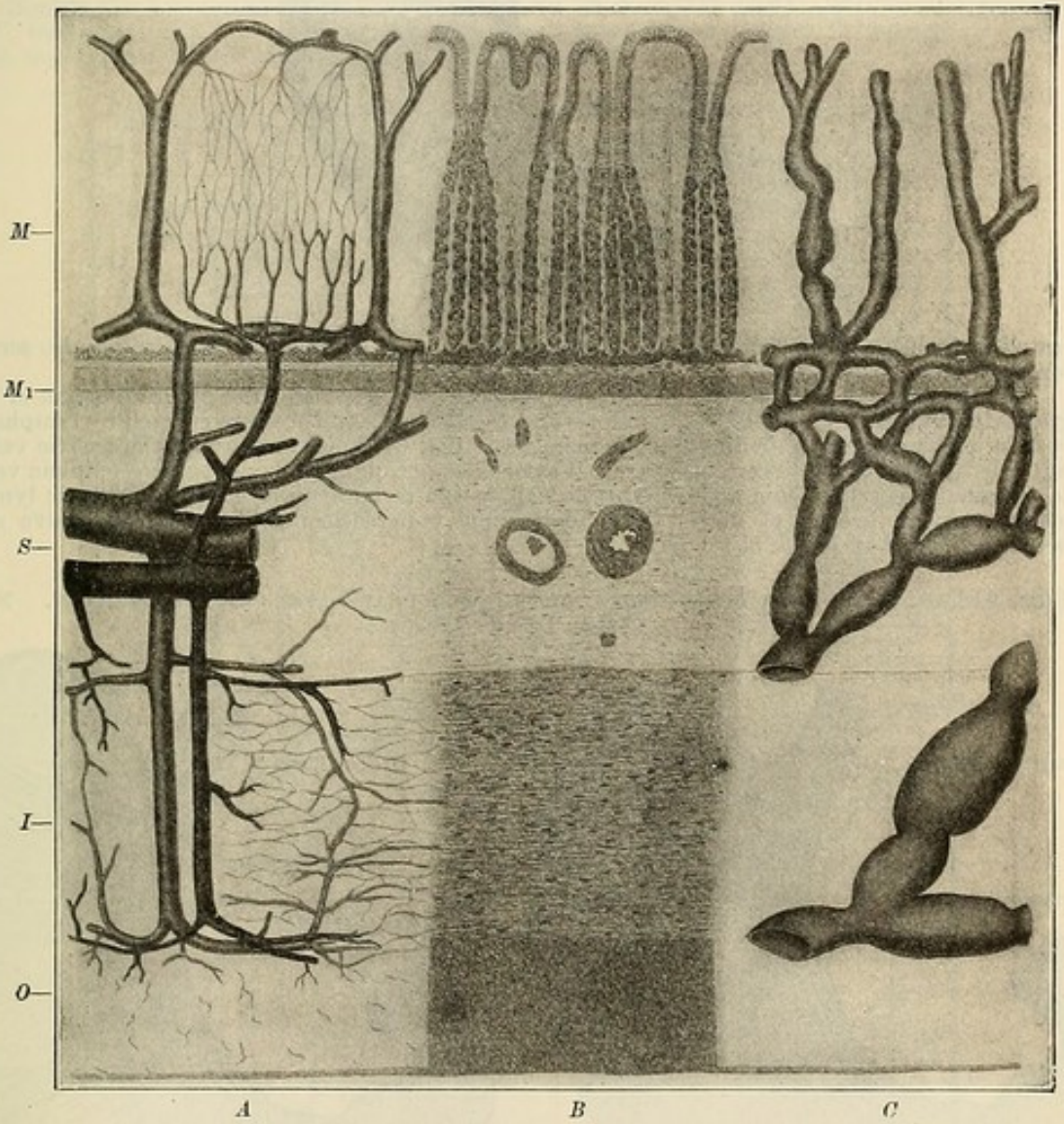

the *ligamenta pylori*. The middle or *circular* layer [stratum circulare] is continuous with the circular fibres of œsophagus and duodenum and surrounds the entire stomach. It is especially thickened in the region of the pyloric canal, at the lower end of which it forms a thickened ring-like band, the pyloric *sphincter* [m. sphincter pylori]. The inner or *oblique* layer [fibræ obliquæ] is composed of fibres continuous with the deepest circular fibres of the œsophagus. They form an incomplete layer which encircles the fundus and passes obliquely downward around the body of the stomach toward the greater curvature.

The external *tunica serosa* is formed by the peritoneum, and has the smooth shiny appearance and the structure typical for a serous membrane.

Blood-vessels.—The stomach receives its blood-supply from many branches. From the cœliac axis there is the left gastric artery, which runs along the lesser curve from left to right, anastomosing with the right gastric branch of the hepatic. Along the greater curve run the right and left gastro-epiploic arteries, anastomosing at the middle of the border, the left being

a branch of the splenic, the right a branch of the hepatic, through the gastro-duodenal artery. The stomach also receives branches from the splenic (vasa brevia) at the fundus. The vascular arches along the curvatures of the stomach are comparable to those in the intestinal mesentery (Mall).

The blood of the stomach is returned into the portal vein. The coronary vein and pyloric vein open separately into the portal vein; the right gastro-epiploic vein opens into the superior mesenteric, the left into the splenic.

The arrangement and distribution of the blood-vessels within the stomach wall are illus-

FIG. 911.—A DISSECTION OF THE MUSCULATURE OF THE STOMACH. (Lewis and Stöhr, after Spalteholz.) *a* and *e*, Longitudinal layer. *b* and *d*, Circular layer. *c*, Oblique layer. *Py*, Pylorus. *S.I.*, Sulcus intermedius.

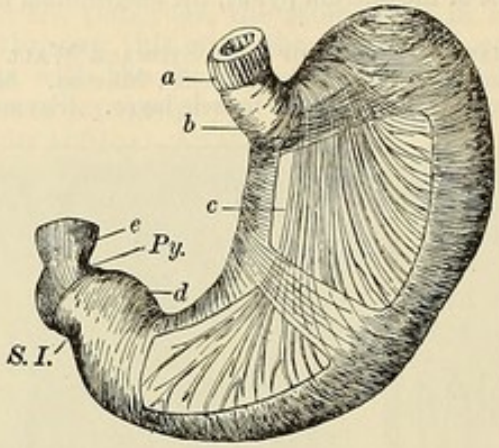

trated in fig. 910. The rich capillary plexus in the mucosa supplies the glands and also serves for absorption.

Lymphatics.—There is a set of nodes lying along the lesser and the pyloric portion of the greater curvature, and others at the pyloric and cardiac ends. These are entered by lymphatic vessels which, beginning in the mucous membrane (fig. 910), accompany all the gastric veins, but chiefly those of the lesser curvature. Vessels also accompany the left gastro-epiploic veins to terminate in the splenic nodes. On its way to the receptaculum chyli, the gastric lymph passes through groups of nodes [lymphoglandulæ pancreaticolienales] situated above and behind the head and neck of the pancreas.

FIGS. 912 AND 913.—DISSECTIONS SHOWING THE MUSCULAR LAYERS OF THE STOMACH. × 1. (From Toldt's Atlas.)

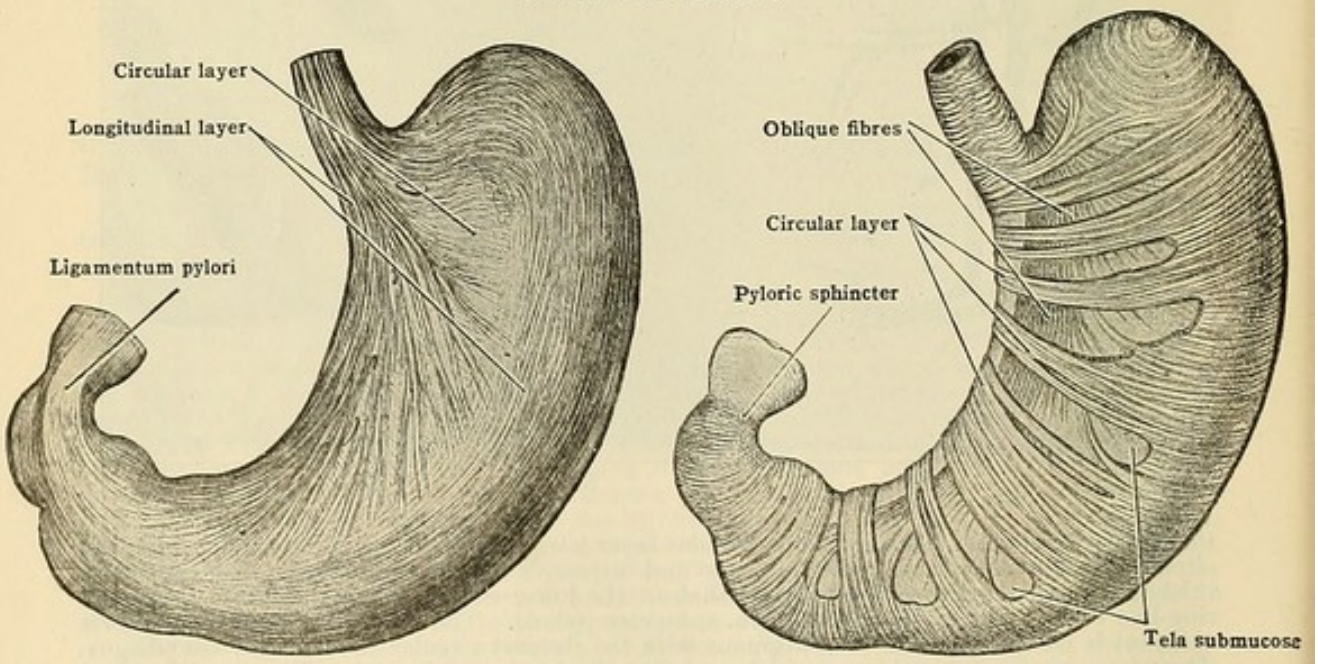

The arrangement of the lymphatic plexus within the stomach wall, beginning with blind rootlets in the mucosa, is shown in fig. 910.

Nerves.—The nerves of the stomach are derived in part from the vagi (which form the motor fibres of the stomach), the right vagus descending on the posterior wall, and the left on the anterior wall. The stomach also receives sympathetic branches from the cœliac plexus, following the arteries. Small ganglia occur along both vagus and sympathetic branches (Remak). The nerves join the gangliated plexuses, myenteric and submucous, in the wall of the stomach,

from which branches are distributed to the muscularis and the mucosa as for the intestine in general.

Development.—The stomach at first lies in the mid-sagittal plane in the cervical region. It participates in the general descent of the viscera (the œsophagus becoming correspondingly lengthened) and reaches its permanent vertebral level in the 17 mm. embryo (Jackson). In the meantime, beginning in the 7.5 mm. embryo (F. T. Lewis), a rotation of the stomach has occurred. The rotation is around the long axis, so that the anterior border (lesser curvature) is turned to the right, and the posterior border (greater curvature) to the left. The right surface therefore becomes posterior and the left anterior. During the process of descent, the pyloric end is the first to become fixed (at about 12 mm.). As the cardiac end continues to descend, it is displaced to the left, so the oblique position of the stomach is established early. The stomach is at first spindle-shaped, but the upper end begins to enlarge at about 10 mm. The fundus develops somewhat later as a localized outgrowth (Keith and Jones).

The fœtal stomach is somewhat crowded to the left by the relatively large liver (fig. 953).

FIG. 914.—OUTLINE SHOWING THE AVERAGE POSITION OF THE ABDOMINAL VISCERA IN 40 BODIES, ON A CENTIMETRE SCALE (REDUCED TO .36 NATURAL SIZE). *ML*, anterior mid-line *EF*, horizontal line half-way between pubes and suprasternal margin ("transpyloric" line), *CD*, line half way between pubes and line *EF*. (Addison.)

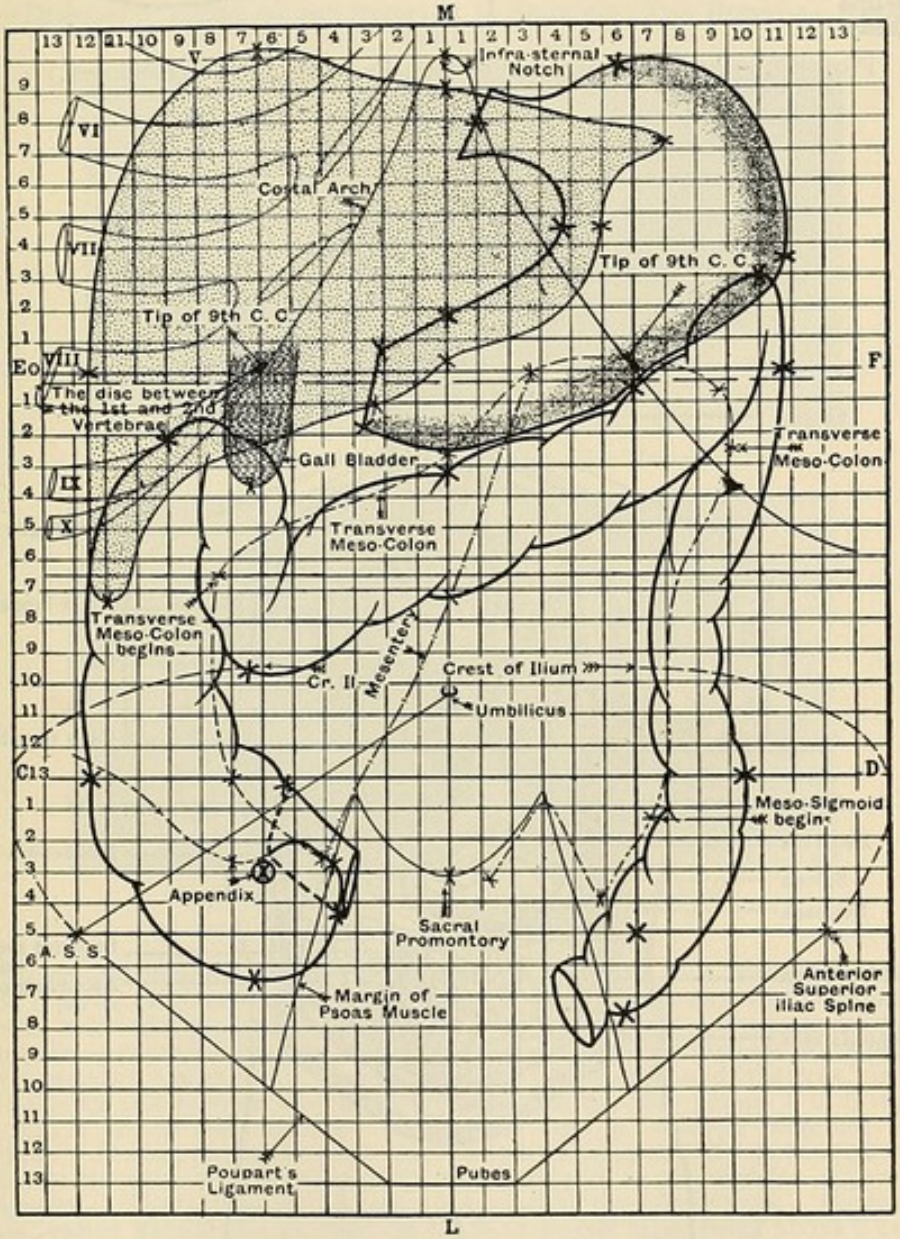

and its relations to surrounding organs undergo considerable change. Even in the fœtus it is quite variable, but its general form and position do not differ essentially from the adult condition.

Glands.—According to Johnson, in an embryo of 16 mm., the lining epithelium shows the primitive foveolæ as pit-like depressions which become elongated, forming irregular anastomosing grooves, separated by villus-like projections. The pits multiply and deepen, and from their bottoms the gastric glands bud off (at 120 mm.). The parietal cells appear very early in the gland fundus, but the differentiation of gland cells is still incomplete at birth.

FIGS. 915 AND 916.—DIAGRAMS OF THE CONTACT AREAS OF THE STOMACH, ANTERIOR AND POSTERIOR VIEWS.

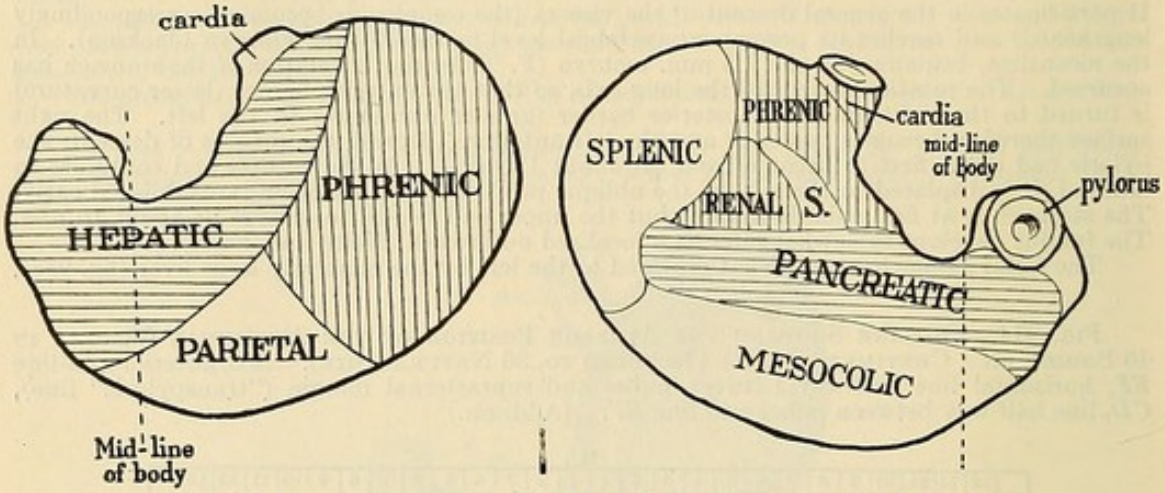

FIG. 917.—THE ABDOMINAL VISCERA, FROM BEHIND. (Rüdinger.)

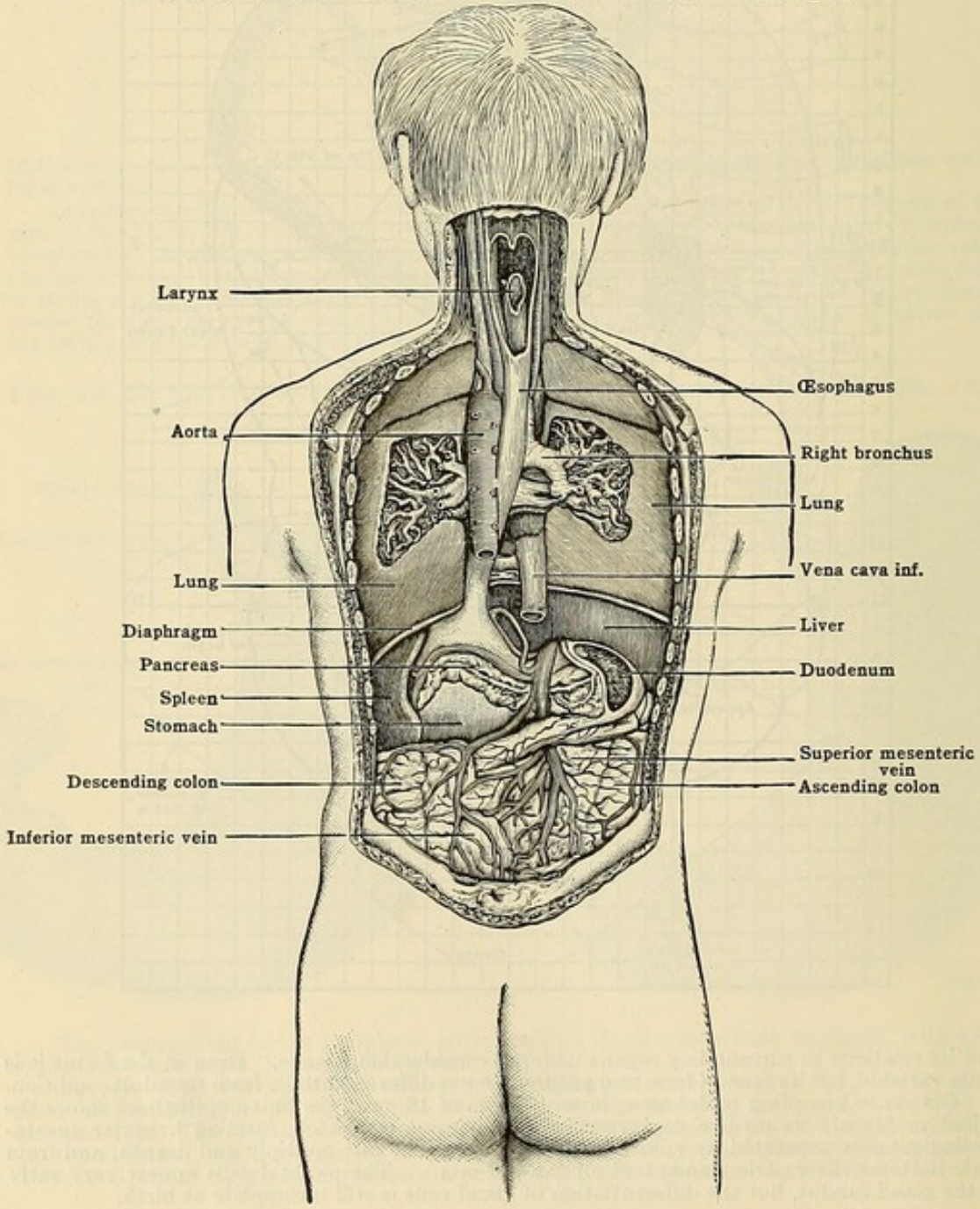

The circular layer of muscle is indicated at 16 mm.; the longitudinal much later, about 90 mm., and not completed before 240 mm. (F. T. Lewis).

Variations.—The great variability of the stomach in form, position and relations has already been repeatedly emphasized. These variations have been most carefully studied recently by various observers in the living body by means of the Rœntgen-rays. Some of the results of study by this method are shown in figs. 918, 919.

Peristalsis.—It would appear that most of the variations in the form of the stomach that have been described are merely various phases in the series of changes undergone by the stomach during the normal process of physiological digestion. The following account of these changes is based largely upon the radiographic observations of Cole. Earlier observations by various investigators upon the living stomach of man and lower animals (and especially the radiographic study of the cat by Cannon) have shown that the cardiac portion of the stomach is the first to become distended with food (and gas). Until a considerable degree of distention is reached, the pyloric portion usually remains a somewhat narrow contracted canal, along which distinct peristaltic contractions pass pylorusward.

Under favorable conditions, however, the peristaltic contractions may be observed to begin in the cardiac portion, although they are usually most distinct in the pyloric portion. Each individual contraction travels at the rate of about 2.5 cm. (1 inch) per second, so that it requires several seconds for a contraction to travel from fundus to pylorus. The number of simultaneous

FIG. 918.—DIFFERENT FORMS OF THE STOMACH AS SHOWN BY THE RŒNTGEN RAYS. Fundus not represented. (Cole.)

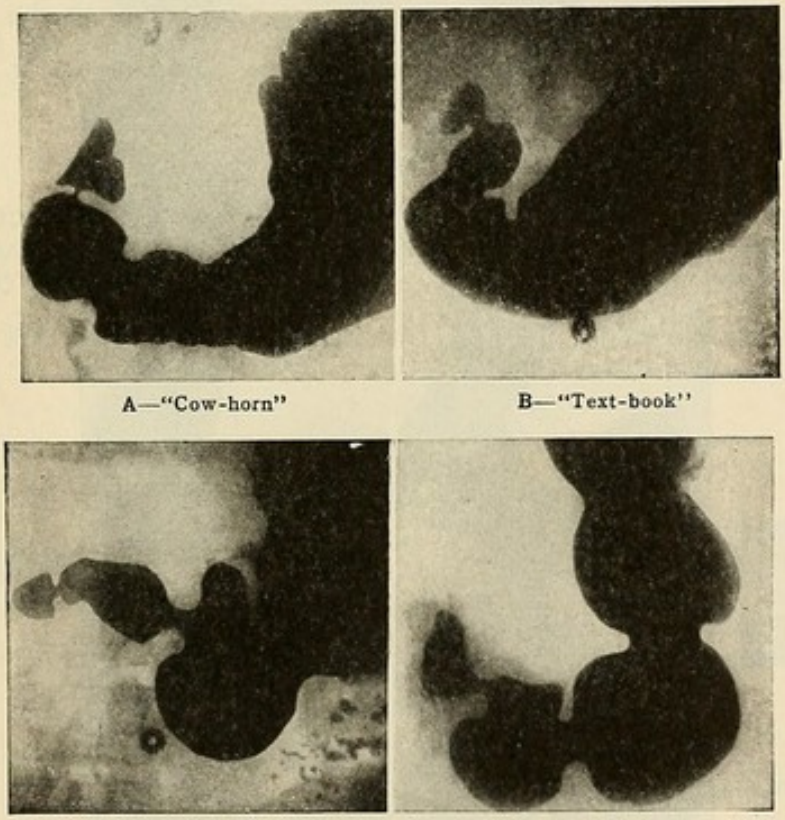

A—"Cow-horn" B—"Text-book"

C—"Drain-trap" D—"Fish-hook"

contractions present in the stomach varies from 1 to 6 or 7, 3 or 4 being the most common. In fig. 919, a series of 10 successive radiographs show the progression in a stomach with four simultaneous individual peristaltic contractions. The peristaltic movements are further complicated by the appearance (simultaneously in all) of successive periods of 'systole,' during which the peristaltic contractions become stronger and deeper, and 'diastole,' in which the contractions relax and become less distinct (Cole). In fig. 919, phases 1 to 6 represent the 'systole,' and 7 to 10 the 'diastole.' A 'systole' and a 'diastole' together make up a 'gastric cycle.' During the entire progress of an individual peristaltic contraction from fundus to pylorus, the number of 'cycles' appears to correspond to the number of peristaltic contractions present. Thus the figure represents a stomach of the 4-cycle type. The time required for a 'cycle' varies widely, the average (in the 3- or 4-cycle type) being about 2 or 3 seconds.

In the earlier stages of gastric digestion the pylorus usually remains closed, but after a variable time it relaxes slightly (lumen about 3 mm. in diameter) at intervals, allowing the chyme to be spurted into the duodenum.

Thus the various constrictions often found in the formalin-hardened stomachs, and the pyloric antrum, appear to be merely transient phases of the digestive process. The 'hour-glass' stomach is in many cases to be explained in this way; in others, however, the constriction is pathological and permanent. Various forms of abnormal lobulations and dilations also rarely occur.

Gastroptosis is a very common abnormality in which the body of the stomach extends vertically downward to the umbilicus, or lower, forming a sharp bend beyond which the pyloric portion turns upward to reach its termination. This form is especially common in women, due to tight lacing.

FIG. 919.—SERIAL RADIOGRAPHS TAKEN AT SHORT INTERVALS, SHOWING DIASTOLE (PHASES 7–10) AND SYSTOLE (PHASES 1–6), AND THE PROGRESSION TOWARD THE PYLORUS OF A FOUR-CYCLE TYPE OF GASTRIC PERISTALSIS. Fundus of the stomach not shown. (Cole.)

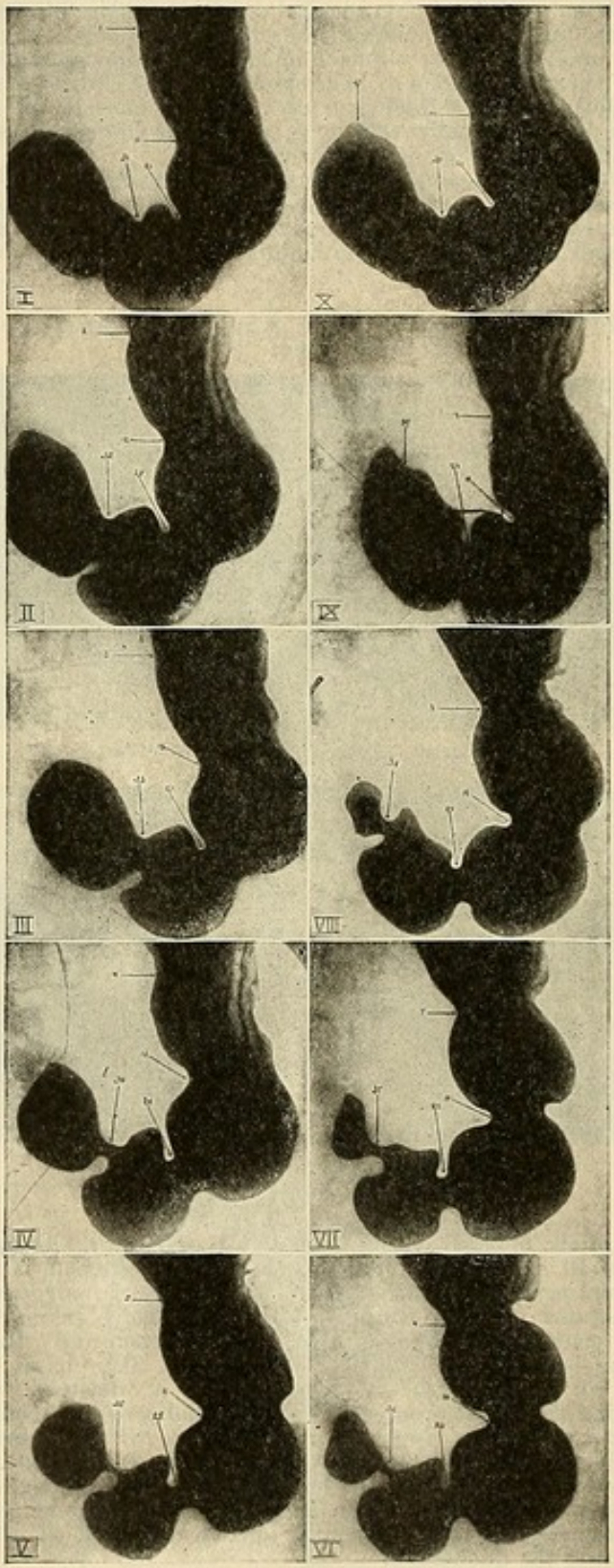

Comparative.—The primitive stomach is perhaps merely a receptacle for food, true digestive glands being absent in many of the fishes. The vertebrate stomach is a dilated sac of variable form, but is typically somewhat looped, with cardiac and pyloric segments. In *birds*, there is a peculiar arrangement, correlated with the absence of teeth. The stomach is divided into an

anterior glandular *proventriculus*, and a posterior muscular *gizzard* with a horny lining serving to grind the food. The *mammalian* stomach is the most variable in form and structure which are correlated with the method and character of alimentation. The cardiac end of the stomach is often lined to a variable extent with a prolongation of the œsophageal stratified squamous epithelium. The three kinds of glands, cardiac, fundic and pyloric, are typically present. In general, the stomach is larger and more complicated in herbivora than in carnivora. Instead of being a single sac, the stomach may be more or less divided into chambers. An incomplete division into cardiac and pyloric portions is so common that it may be considered typical. The most extreme specialization is found in the ruminants. In these the stomach has four chambers, the first two of which, however, are expansions of the œsophagus.

THE SMALL INTESTINE

The **small intestine** [intestinum tenue] extends from the pylorus to the ileo-cæcal orifice, and occupies most of the abdominal cavity below the liver and stomach. It is a cylindrical tube whose diameter decreases from about 4 cm. above to about 2.5 cm. at the lower end. Its *length*, when removed from the body and measured fresh, averages about 7 metres (23 ft.); but when formalin-hardened *in situ*, the length (which is probably nearer that during life) is only about 4 metres. The length does not seem to vary according to sex, height or weight in the adult, but it is said to be relatively longer in the child.

The small intestine includes two main divisions, the *duodenum* and the *mesenteric small intestine*, the latter being further subdivided into *jejunum* and *ileum*.

THE DUODENUM

The **duodenum** is the first part of the small intestine, and is very definite in position and extent. It is firmly attached to the posterior abdominal wall, being almost entirely retroperitoneal. It is the widest part of the small intestine, the

FIG. 920.—THE DUODENUM AND PANCREAS, ANTERIOR VIEW.

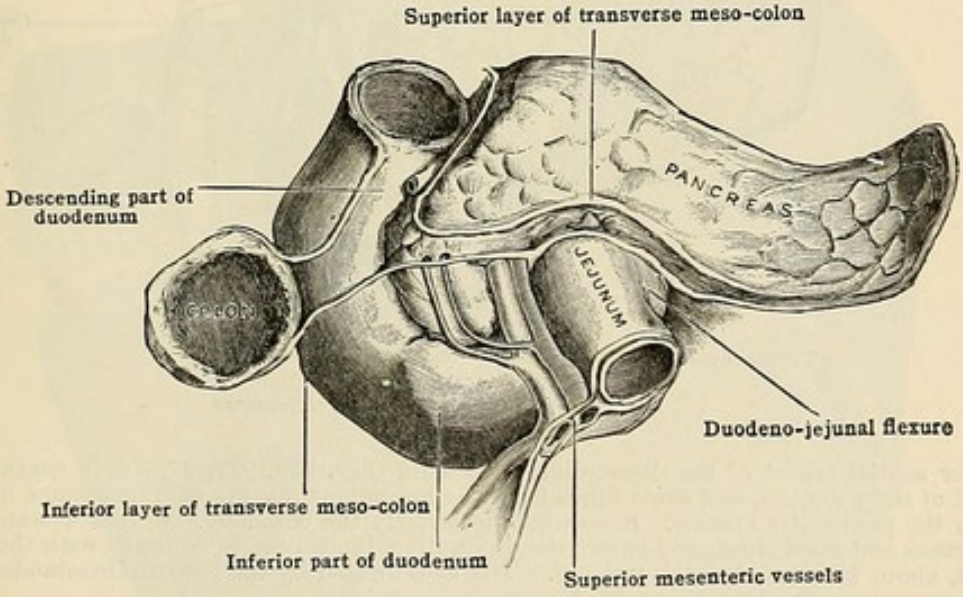

average width being 4 cm. or more, and is also the shortest segment, being only about 25 cm. in length. In general, it is somewhat C-shaped, the concavity enclosing the head of the pancreas (figs. 920, 921, 922).

Parts.—For convenience of description, the duodenum is divided into the following parts: (1) the first or *superior portion* [pars superior] which is short (5 cm. or less), leading from the pylorus and forming the *superior flexure* [flexura duodenalis superior]; (2) the *descending portion* [pars descendens], about 7 or 8 cm. in length, which receives the bile and pancreatic ducts and joins the inferior portion at the *inferior flexure* [flexura duodenalis inferior]; and (3) the *inferior portion* [pars inferior], which is again subdivided into (a) *transverse* portion [pars horizontalis], about 10 cm. long, which usually ascends slightly and passes gradually into (b) the *ascending* portion [pars ascendens], 2 or 3 cm. long, terminating in the *duodeno-jejunal flexure* [flexura duodenojejunalis].

Position and relations.—As shown in fig. 914, the duodenum usually lies chiefly in the lower part of the epigastric region, only the inferior (transverse) portion extending into the umbilical region. All but the terminal (ascending) portion of the duodenum lies to the right of the mid-line.

The *superior* portion usually lies at the level of the first lumbar vertebra (or the disk below). It is covered anteriorly, and to a variable extent posteriorly, by a prolongation of the peritoneum from the corresponding surfaces of the stomach. It is somewhat freely movable. When the stomach is empty, it extends from the pylorus almost horizontally to the right and backward. As the stomach becomes distended, however, the pylorus is carried to the right and downward for a variable distance, and the position of the superior part of the duodenum is correspondingly altered.

Superiorly it is in contact with the liver (quadrate lobe) and the neck of the gall-bladder and forms the lower boundary of the epiploic foramen; *anteriorly*, with the liver and (often) the transverse colon; *inferiorly* and *posteriorly*, with the head of the pancreas below, and with the common bile duct, hepatic vessels and portal vein above.

The second or *descending* portion of the duodenum extends along the right side of the first to the third lumbar vertebra. It is covered antero-laterally by peritoneum, excepting (usually) the area of contact with the transverse colon (figs. 906, 920).

Posteriorly (fig. 956) it is in contact with the right kidney, ureter and renal vessels, and below with the psoas muscle. *Anteriorly* (fig. 906) it is crossed by the transverse colon (the layers of the transverse mesocolon usually separated by an area of direct contact); above the colon, it may be in contact with the gall-bladder, and below the colon with coils of small intestine. The

FIG. 921.—THE DUODENUM AND PANCREAS, POSTERIOR VIEW.

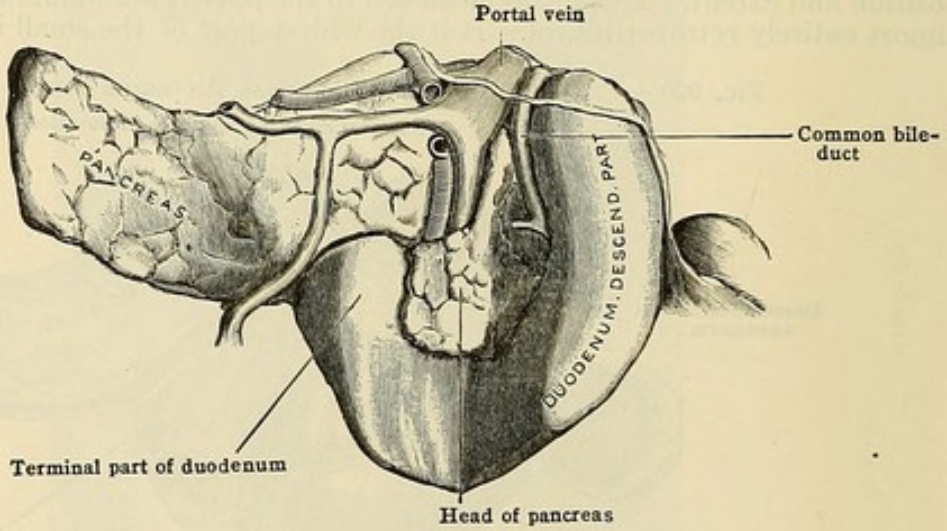

left or medial aspect of the descending duodenum (figs. 920, 921, 922) is in contact with the head of the pancreas, and some fibres from the muscular tunic are said to become intermingled with the pancreatic lobules. Somewhat posteriorly the common bile duct descends between pancreas and duodenum, and enters the descending duodenum, in common with the pancreatic duct, about 10 cm. below the pylorus. The loop formed by the pancreatico-duodenal arteries also runs along the descending duodenum.

The third or *transverse* portion of the duodenum usually crosses the body of the third lumbar vertebra, ascending slightly from the right to the left side (figs. 920, 921). It is covered anteriorly with peritoneum, excepting a small space where the superior mesenteric vessels enter the root of the mesentery.

Anteriorly it is further in contact with coils of small intestine; *superiorly*, with the head of the pancreas, and the inferior pancreatico-duodenal vessels; *posteriorly*, with the vena cava.

The terminal or *ascending* portion is covered anteriorly and laterally by peritoneum, and is in contact with coils of the ileum. To the *right* it is in relation with the head of the pancreas (processus uncinatus) and the superior mesenteric vessels; and *posteriorly* with the psoas muscle, aorta and left renal vessels. The *duodeno-jejunal flexure* usually lies opposite the second lumbar vertebra, and is in contact above with the inferior surface of the body of the pancreas, and the root of the transverse mesocolon.

FIG. 922.—DISSECTION OF THE DUODENUM AND PANCREAS, ANTERIOR VIEW.
(Rauber-Kopsch.)

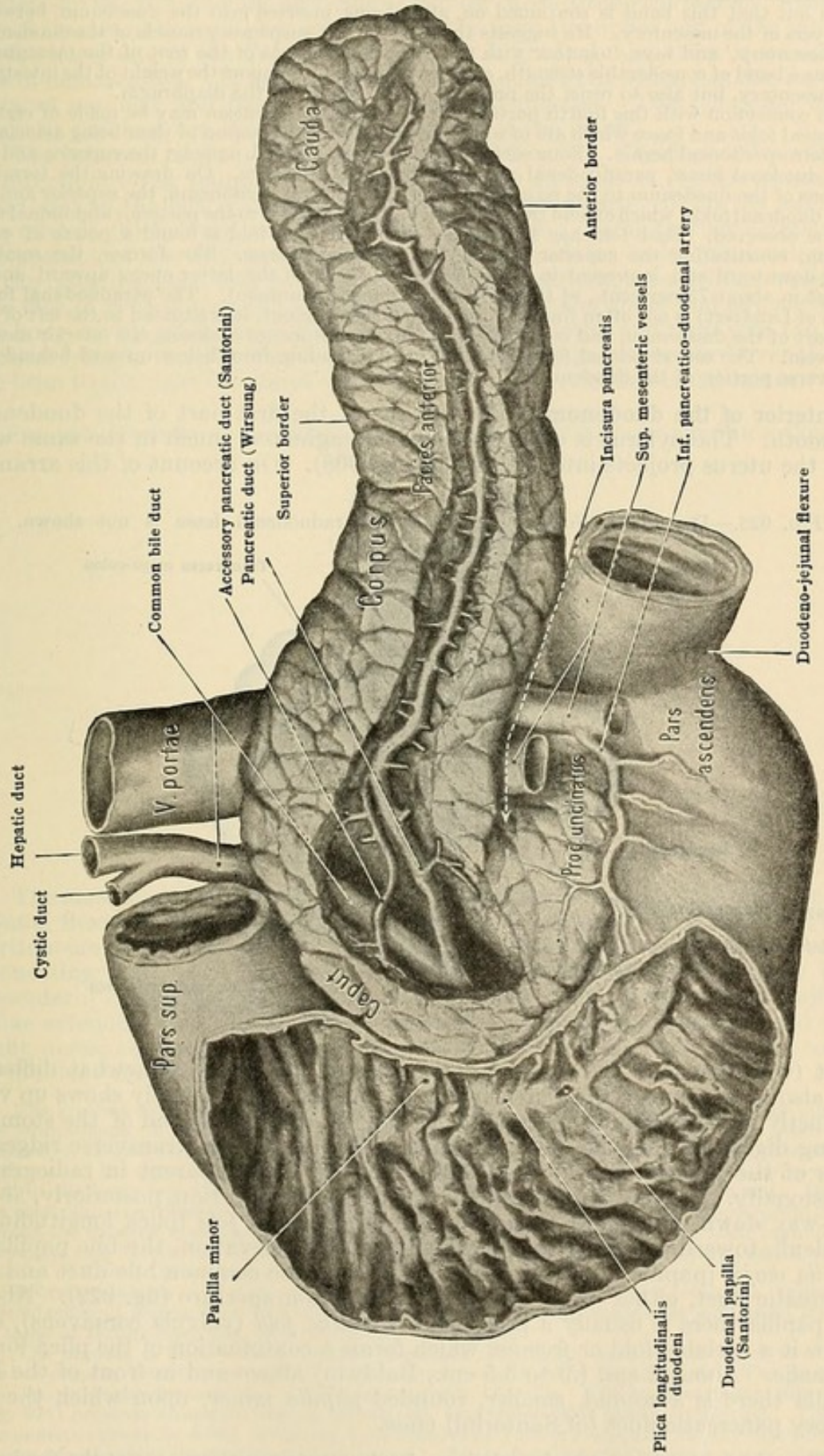

The end of the duodenum is firmly fixed in its place by the *suspensorius duodeni*. This name has been given to a fibro-muscular band that contains, according to Treitz, non-striated muscular fibres, and descends to the terminal part of the duodenum from the lumbar part of the diaphragm, passing to the left of the cœliac artery and behind the pancreas. Lockwood points out that this band is continued on, after being inserted into the duodenum, between the layers of the mesentery. He suggests the name of the 'suspensory muscle of the duodenum and mesentery,' and says, 'together with the other constituents of the root of the mesentery, it forms a band of considerable strength, sufficient not only to support the weight of the intestines and mesentery, but also to resist the pressure of the descent of the diaphragm.'

In connection with this fourth portion of the duodenum, mention may be made of certain peritoneal folds and fossæ which are of some surgical interest by reason of their being associated with retro-peritoneal hernia. Four such fossæ may be mentioned, namely, the superior and inferior duodenal fossæ, paraduodenal and the retroduodenal fossæ. On drawing the terminal portions of the duodenum to the right, two triangular folds of peritoneum, the superior and inferior duodenal folds, which extend from the wall of the duodenum to the posterior abdominal wall may be observed. Each fold has a free edge. Beneath each fold is found a pouch of peritoneum, constituting the **superior** and **inferior duodenal fossæ.** The former, the smaller, opens downward and is present in about 50 per cent., while the latter opens upward and is present in about 75 per cent., of the subjects examined (Jonnesco). The **paraduodenal fossa** (fossa of Landzert) is not often found in the adult; when present, it is situated to the left of the last part of the duodenum, and is formed by a fold of peritoneum enclosing the inferior mesenteric vein. The retroduodenal fossa is a rare form extending from below upward behind the transverse portion of the duodenum.

Interior of the duodenum.—The interior of the first part of the duodenum is smooth. The pylorus is often somewhat invaginated, much in the same way that the uterus projects into the vagina (fig. 908). On account of this arrange-

FIG. 923.—DUODENAL FOSSÆ AND FOLDS. Paraduodenal fossa is not shown. (After Cunningham.)

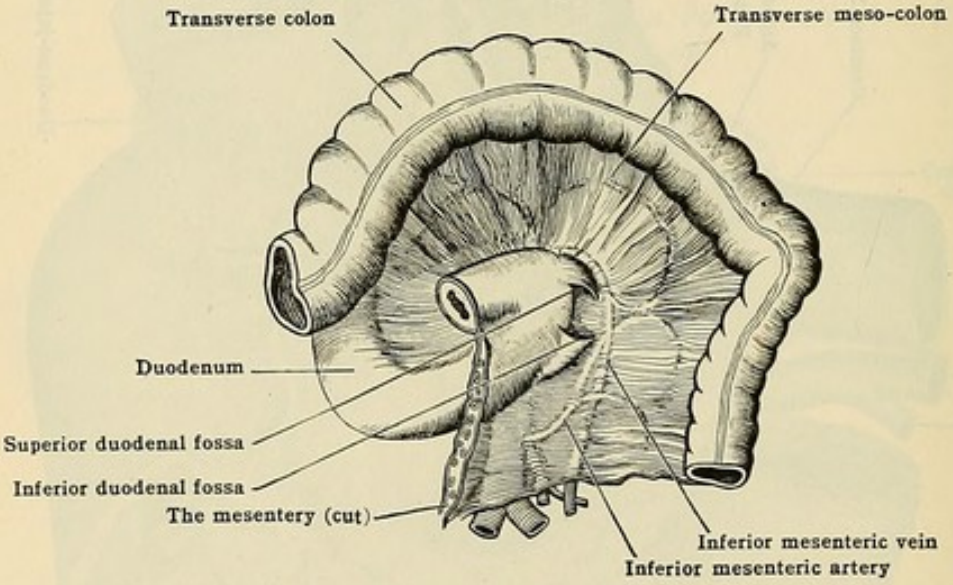

ment (which renders the complete emptying of the cavity somewhat difficult) and also on account of the distensibility of this portion, it usually shows up very distinctly in radiographic pictures as a 'cap' to the pyloric end of the stomach during digestion. In the lower portions of the duodenum, transverse ridges or folds of the mucosa appear (fig. 922) which are also apparent in radiographs occasionally. On the medial wall of the descending portion, posteriorly, about half-way down, is a more or less distinct *longitudinal fold* [plica longitudinalis duodeni], toward the lower end of which is a small elevation, the bile papilla, or *papilla major* [papilla duodeni], upon which open the common bile duct and the pancreatic duct, either separately or by a common aperture (fig. 922). Above the papilla there is usually a prominent *hood-like fold* (valvula connivens), and below it a variable fold or *frænum* which forms a continuation of the plica longitudinalis. About 2 cm. (.9 to 3.5 cm., Baldwin) above and in front of the bile papilla there is a second, smaller, rounded *papilla minor*, upon which the accessory pancreatic duct (of Santorini) ends.

The minute structure, vascular relations, development, variations, etc., of the duodenum will be considered later, with those of the small intestine as a whole.

THE JEJUNUM AND ILEUM

The mesenteric portion of the small intestine is divided into an upper half (or two-fifths), the *jejunum*, and a lower half (or three-fifths), the *ileum*. Although the character of the gut changes considerably from the upper end of the jejunum to the lower end of the ileum, the transition is gradual, and there is no definite line of demarcation. In general, the jejunum is somewhat wider, has thicker walls, is more vascular and has a more complicated mucosa. The lymphoid organs (Peyer's patches) are, however, characteristic of the ileum.

The **jejunum** begins at the duodeno-jejunal flexure. The first coil is variable in direction, being found (in order of frequency) as follows: (1) downward, forward and to the left; (2) directly forward and downward; (3) to the left, then downward; (4) forward and to the right (Harman). Some further details as to the position of the various succeeding coils are given later under the development of the intestine (figs. 930, 931). While there is considerable individual variation, it is true in general that the coils of *jejunum* occupy the upper and left portion of the body cavity, while those of the *ileum* occupy the lower and right side, the lower portion lying in the pelvic cavity. The ileum finally passes upward over the pelvic brim to the right iliac fossa where it terminates in the ileo-cæcal orifice.

FIG. 924.—PORTION OF THE SMALL INTESTINE, LAID OPEN TO SHOW THE PLICÆ CIRCULARES. (Brinton.)

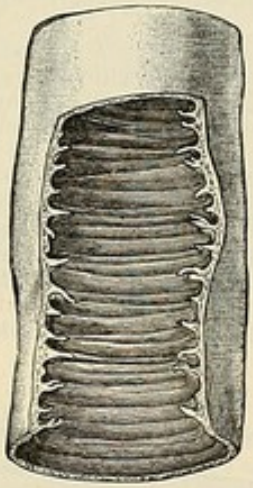

The **mesentery** [mesenterium] is a fan-shaped fold extending from the duodeno-jejunal flexure to the ileo-cæcal junction. It is composed of a double layer of peritoneum which encloses and supports the jejunum and ileum and their vessels, connecting them with the abdominal wall. The *root* of the mesentery [radix mesenterii] or parietal attachment, is only about 15 cm. long, corresponding to a line extending from the duodeno-jejunal flexure obliquely downward and to the right, across the transverse duodenum, the great vessels and the vertebral column to the ileo-cæcal junction (fig. 905).

The *visceral* attachment of the mesentery to the intestine, corresponding to the length of the jejuno-ileum, is nearly 7 metres long, and is thinner than at the root. The *width* of the mesentery, measured from parietal to visceral attachment, varies somewhat in different parts of the canal, the average being 18 or 20 cm. (ranging from 15 to 22.5 cm.). It is narrow above (also at the lower end), but reaches its full width about 30 cm. below its upper end. Between the two peritoneal layers of the mesentery is a third layer [lamina mesenterii propria] containing the superior mesenteric vessels (arteries, veins and lymphatics) with their branches and accompanying nerves, the small mesenteric lymph-nodes (50 to 100 in number), and a variable amount of fibro-adipose connective tissue.

Minute anatomy.—The small intestine has the four typical layers,—mucosa, submucosa, muscularis and serosa (figs. 927, 928). They are, in general, somewhat similar in structure to those of the stomach (fig. 910), excepting the mucosa.

The **mucosa** is lined with a simple cylindrical epithelium, underneath which is a fibrous *lamina propria*, limited externally by a *muscularis mucosæ*, as in the stomach. The muscularis mucosæ sends slender muscular bundles upward into the villi. The inner surface of the mucosa (fig. 924) presents numerous coarse, closely set, transverse folds [plicæ circulares]. These are permanent, crescentic folds, involving both mucosa and submucosa, and usually extending one-half to two-thirds of the way around the lumen. They often branch and anastomose, sometimes forming circles or spirals. The largest exceed 5 cm. in length and 3 mm. in width. The plicæ

circulares are absent from the first part of the duodenum, but become well-marked in the descending portion (fig. 922). They are largest and best developed in the lower duodenum and upper half of the jejunum, below which they gradually become smaller (fig. 924) and disappear at the lower end of the ileum.

The digestive and absorptive surface of the small intestine is further greatly increased by multitudes of small processes, the *villi* (figs. 925, 927), which give the mucosa a velvety appearance. They are largest (.5 to .7 mm. in height) and most numerous in the duodenum and jejunum, where they are typically leaf-shaped, and gradually become smaller, scattered and conical in the ileum. The villi are much reduced in distention of the intestine, and may even be temporarily obliterated. Between the bases of the villi there open short, simple tubular glands—the crypts of Lieberkuehn [gl. intestinales], whose fundus cells (of Paneth) probably secrete digestive enzymes. In the duodenum there are found, in addition, the larger tubulo-

FIG. 925.—*A*, SURFACE VIEW OF THE HARDENED MUCOSA OF THE SMALL INTESTINE. (After Kölliker.) *B*, SIDE VIEW OF A WAX RECONSTRUCTION OF THE EPITHELIUM IN THE HUMAN DUODENUM. (Huber.) *i.g.*, Intestinal gland. *v.*, Villus.

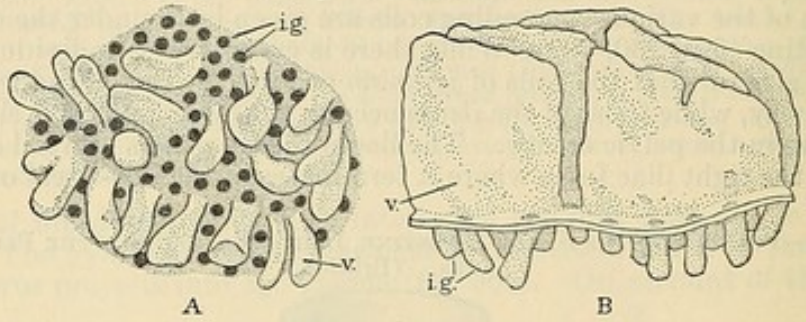

racemose glands of Brunner [gl. duodenales], which occupy the submucosa, and are especially numerous in the upper portion of the duodenum. They are purely mucous in character according to Bensley, although Oppel describes granular cells, similar to Paneth cells, which may secrete digestive enzymes.

Scattered over the whole of the mucous membrane of the small intestine are numerous small lymph-nodules, the larger of which extend into the submucosa; these are the so-called *solitary glands* [noduli lymphatici solitarii]. Aggregations of lymph-nodules, known as *Peyer's patches* [noduli lymphatici aggregati], situated in the mucosa and submucosa, are found in the ileum especially toward the lower end (fig. 926). They are oval, from 1.2 to 7.5 cm. in length and about 1 to 2.5 cm. in breadth, and are placed in the long axis of the bowel along a line most remote from the mesentery. They are variable in number, the average being about 20 to 30.

FIG. 926.—SURFACE VIEW OF THE MUCOSA OF THE ILEUM, SHOWING AGGREGATED LYMPH NODES (Peyer's Patch). (From Toldt's Atlas.)

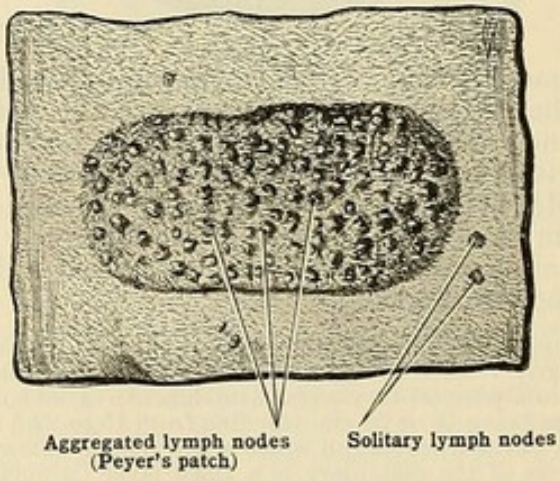

The **submucosa** is in general a loose areolar layer containing vascular and sympathetic plexuses (figs. 927, 928). The **muscularis** is composed of smooth muscle arranged in the two typical layers,—a thinner, outer longitudinal and a thicker, inner circular,—both of which become thinner toward the lower end of the ileum. The **serosa** is typical in structure, the squamous epithelial covering being absent in the retroperitoneal areas of the duodenum.

Blood-supply of the small intestine.—The small intestine receives its blood from the superior mesenteric artery and a branch coming indirectly from the hepatic, the superior pancreaticoduodenal. The superior mesenteric artery runs between the layers of the mesentery and gives off six or seven relatively large branches and a variable number of smaller branches. The first two or three of the larger branches divide into an ascending and a descending branch, which join above and below with the corresponding branches of the continguous arteries, forming thus a single row of arches. From about the beginning of the second quarter of the small

FIG. 927.—CROSS-SECTION OF ILEUM (contracted). *a*, *b*, *c*, Villi. *d*, Intestinal gland. *e*, Tunica propria. *f*, *f*., Muscularis mucosæ. *g*, Blood-vessel. *h*, Submucosa. *i*, Circular muscle. *k*, Longitudinal muscle. *l*, Serosa. *m*, Subserosa. *n*, Aggregated lymph nodules (Peyer's patch). (Radasch.)

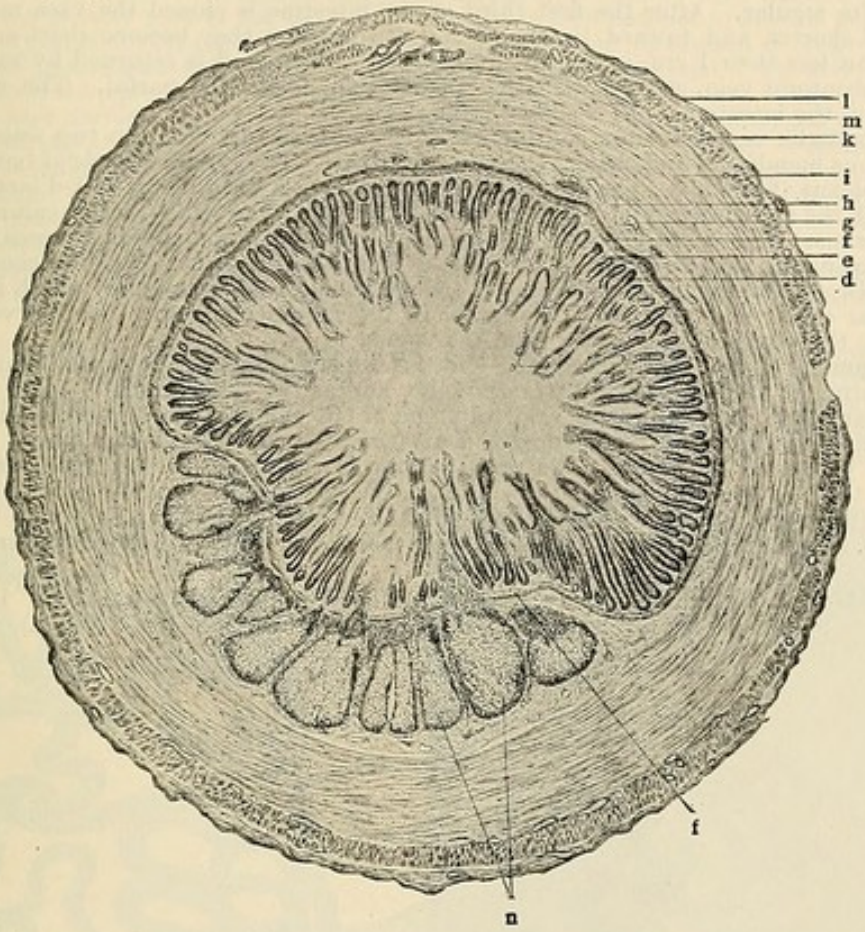

FIG. 928.—DIAGRAMS OF THE VASCULAR SUPPLY AND NERVES OF THE SMALL INTESTINE. *A*, Blood vessels; arteries as coarse black lines, capillaries as fine lines, veins shaded (after Mall). *B*, Lymphatics (after Mall). *C*, Nerves, based on Golgi preparations (after Cajal). *m*, Mucosa. *mm.*, Muscularis mucosæ. *s.m.*, Submucosa. *c.m.*, Circular muscle. *i.c.*, Intermuscular connective tissue. *l.m.*, Longitudinal muscle. *s*, Serosa. *c.l.*, Central lymphatic. *n.*, Nodule. *s.pl.* Submucous plexus. *m.pl.*, Myenteric plexus. (Lewis and Stöhr.)

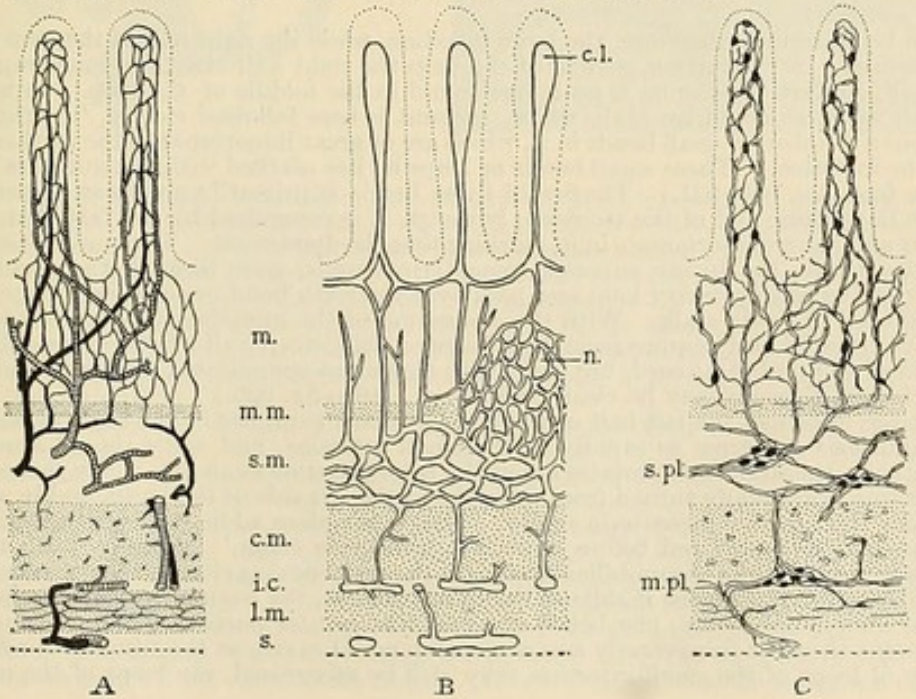

intestine a second tier of arches, formed in a similar manner, is often noted, and below the middle of the jejuno-ileum more than two tiers of arches may be present the complexity of the arches increasing, while the size of the vessels diminishes. From the convex border of the most distally placed arches there pass to the intestine straight branches, so-called vasa recta. Near the beginning of the jejunum these are numerous and large, and have a length of about 4 cm., and are quite regular. After the first third of the intestine is passed the vasa recta become smaller and shorter, and toward the lower end of the ileum they become short and irregular and are often less than 1 cm. in length. (Dwight.) The blood is returned by means of the superior mesenteric vein, which, with the splenic vein, forms the portal. The vascular arrangement in the intestinal wall is shown in fig. 928.

The **lymphatic** vessels form a continuous series, which is divided into two sets—viz., that of the mucous membrane and that of the muscular coat. The lymph-vessels of both sets form a copious plexus (fig. 928). The efferent lymphatic vessels form the so-called lacteals, which pass through the mesenteric lymph-nodes, finally reaching the cisterna (receptaculum) chyli.

The nerves.—The small intestine is supplied by means of the superior mesenteric plexus which is continuous with the lower part of the cœliac (solar) plexus. The branches follow the blood-vessels, and finally form two plexuses: one (Auerbach's or myenteric) which lies between the muscular coats; and another (Meissner's) in the submucous coat. The nerve fibres are chiefly from the sympathetic, partly from the vagus.

Development of the small intestine.—As the intestine is being separated from the yolk-vesicle it forms at first a relatively straight tube, and as the tube elongates there is formed a single primary loop, situated in the sagittal plane of the embryo, which loop extends into the cœlom of the umbilical cord; to its summit is attached the constricted attachment of the yolk-vesicle, the yolk-stalk (fig. 929). This primary loop of the intestine, as it elongates, turns on an axis, so that its caudal portion turns toward the left and its cephalic portion toward the right. We may then speak of a right and a left half of the loop. Near the top of the left half of the loop there is noted an enlargement which marks the cæcum, the greater part of the left

Fig. 929.—Model of Stomach and Intestine of Human Embryo 19 mm. Long. The figures on the intestine indicate the primary coils (× 16). (Mall.)

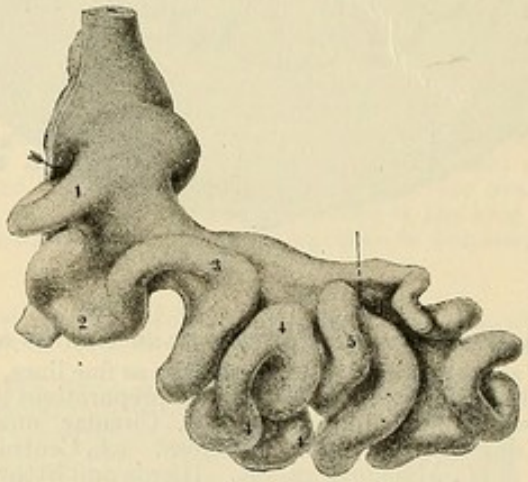

half of the loop forming, therefore, the large intestine, while the right half of the loop forms the small intestine. In the further growth of the loop the right half elongates more rapidly than the left half, so that the cæcum is no longer found in the middle of the loop. In an embryo of the fifth week, as noted by Mall, whose account is here followed closely, 'the right half of the loop has a number of small bends in it, which are of great importance in the further development of the intestine.' These small bends or loops he has marked with the numbers 1, 2, 3, 4, 5, 6. (See figs. 929, 930, 931.) The first of these bends is primarily not clear, appearing as a portion of the pyloric end of the stomach; however, it is recognised by the fact that the ducts of the liver and pancreas terminate in it, marking it as the duodenum. The omphalo-mesenteric veins and arteries, the future superior mesenteric vessels, pass through the middle of the mesentery of the large primary loop and pass over the sixth bend or secondary loop, to which is also attached the yolk-stalk. With the elongation of the intestine these six bends or loops become accentuated and acquire secondary loops or coils, nearly all of which are still found in the cœlom of the umbilical cord, but even with this more complicated coiling of the intestine the six primary divisions may be clearly made out. (See fig. 929.)

The large intestine, the left half of the large primary loop, lies in the sagittal plane of the embryo and does not grow as rapidly as the small intestine, and while this is acquiring the secondary coils, the whole mass rotates about the large intestine as an axis. 'By this process the small intestine is gradually turned from the right to the left side of the body, and in so doing is rolled under the superior mesenteric artery. This takes place while the large intestine has an antero-posterior direction and before there is a transverse colon.' (Mall.) With the return of the small intestine from the umbilical cœlom to the peritoneal cavity, which occurs apparently quite suddenly and during the middle of the fourth month, the cæcum comes to lie in the right half of the abdominal cavity, just below the liver; the greater portion of the remainder of the large intestine then lies transversely across the abdominal cavity as the transverse colon. The six groups of loops of the small intestine may still be recognised, the loops of the upper part

of the small intestine having rolled to the left of the superior mesenteric artery, while the loops which were formerly in the cord are found in the right side of the abdominal cavity. It is not difficult to trace these six groups of loops through the later stages of fœtal life to the newborn, and thence to the adult stage. In the adult, as also through the various stages of development, loop 1 forms the duodenum. From the primary groups of coils marked 2 and 3 are developed the greater part of the jejunum, arranged in two distinct groups of loops, situated in the left hypochondriac region. The part of the intestine developed from group 4 of the primary coils passes across the umbilical region to the right upper part of the abdomen. That part developed from group 5 of the primary coils recrosses the median line to the left iliac fossa, while that part derived from group 6 of the primary coils is found in the false pelvis and the lower part of the abdominal cavity between the psoas muscles. (Mall.) Figs. 900, 901, 930 may serve to make clear these statements. They present what may be regarded as the normal arrangement of the small intestine, having been found 21 times in 41 cadavers examined. Variations from this arrangement occur; the great majority of such variations are, however, not of sufficient importance to require special mention.

According to Johnson (upon whose descriptions the following account is based), there is in embryos of 13 mm. to 23 mm. a formation of vacuoles in the duodenal epithelium, which

Fig. 930.—Model Showing Course of Intestine, Made from Same Cadaver from which Fig. 931 was Drawn. (Mall.)

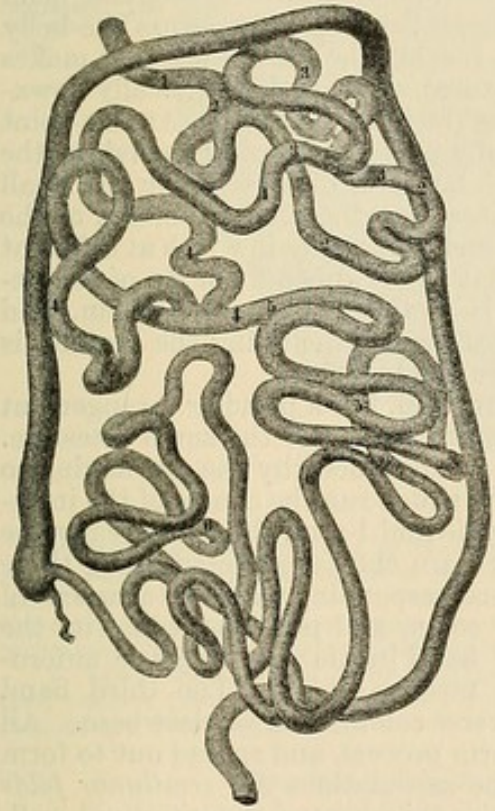

Fig. 931.—The Usual Position of the Intestine in the Abdominal Cavity. The numbers in the figure mark the parts which are homologous with the primary bends and groups of coils numbered from 1 to 6. (Mall.)

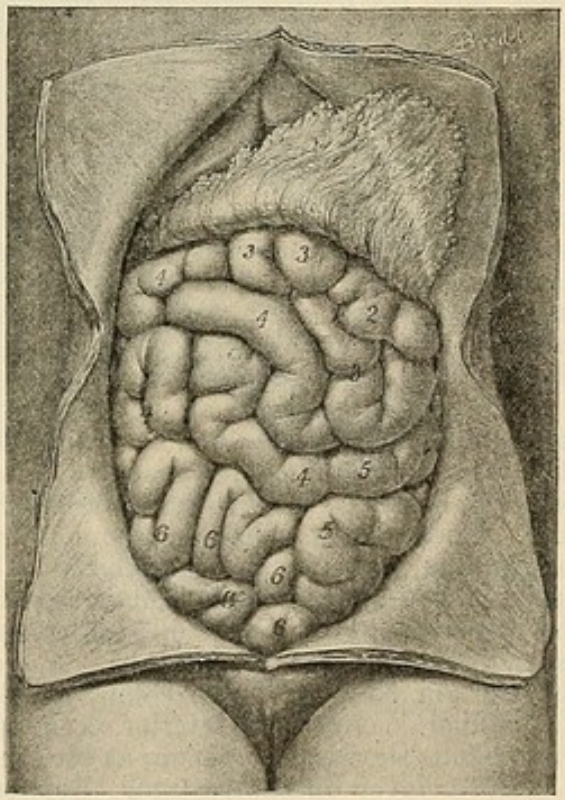

leads to complete temporary occlusion of the lumen. A persistence of this condition may cause permanent atresia. In the epithelium of the small intestine numerous pockets or cysts occur, which usually disappear, but may persist and form permanent diverticula or accessory pancreas. The *villi* begin to appear at 19 mm., first in the mucosa of the upper portion of the intestine, as localized outgrowths which become arranged in longitudinal rows. The crypts of Lieberkuehn bud off from the epithelium at 55 mm., and from those in the duodenum, the duodenal (Brunner's) glands begin to bud off at 78 mm. The plicæ circulares begin to appear at the mid-region of the small intestine at 73 mm. The circular muscle layer begins to appear at about 12 mm., the longitudinal at 75 mm.

Variations in the small intestine.—Although relatively fixed in position, the *duodenum* is quite variable in form. The **C**-shape previously described is the most common. When the pylorus and the duodeno-jejunal flexure are approximated, the form is nearly circular. When the two ends are more widely divergent, it approaches a **U**-form. Not infrequently, the inferior portion ascends abruptly from the inferior angle, giving a **V**-form. Finally, the terminal ascending portion may be very small or absent, in which case the duodenum approaches an **L**-form. Variations in the position of the various coils of the jejunum and ileum have already been discussed. The lymph-nodules, including Peyer's patches, like all lymphoid structures, are prominent during youth, but become atrophied in old age.

Meckel's diverticulum, which represents a derivation from the embryonic yolk stalk and sac, is found in about 2 per cent. of all adults. It is a blind tube or diverticulum of variable

size, usually approaching the intestine in width and averaging 5 cm. in length (ranging from 1 cm. to 13 cm.). Its attachment to the intestine varies from 15 cm. to 360 cm. (average 80 cm.) above the cæcum. It is usually attached opposite the mesentery. It may end freely, but is occasionally adherent to adjacent intestinal coils or connected with the anterior abdominal wall by a cord or band-like process.

Other diverticula of variable size and number may occur, usually along the mesenteric border of the intestine. They may be either congenital (probably from the embryonic pockets previously mentioned) or acquired. They occur most frequently in the duodenum (found by Baldwin in 15 of 105 cases) where they are usually associated with the openings of the bile and pancreatic ducts.

Comparative.—The comparative anatomy of the small intestine will be discussed later together with that of the large intestine.

THE LARGE INTESTINE

The **large intestine** [intestinum crassum] is that part of the alimentary canal which extends between the ileum and the anus. It is divided into the following parts: Cæcum, ascending, transverse, descending, and sigmoid colon, and rectum. It is so arranged as to surround the small intestine, making a circuit around the abdominal cavity from right to left (fig. 899). The *cæcum* lies in the right iliac fossa; thence the colon passes vertically upward on the right side (*ascending colon*) until the liver is reached. Here it forms a more or less rectangular bend (the right colic or hepatic flexure), and then passes transversely across the belly (*transverse colon*) below the stomach. It then reaches the spleen, where it makes a second sharp bend (the left colic or splenic flexure), and, passing vertically downward on the left side (*descending colon*), reaches the left iliac fossa. At this point it forms the loop of the sigmoid colon, and finally passes through the pelvis as the rectum (fig. 906). The large intestine is much larger in diameter than the small intestine, and is not so much convoluted. Excepting the dilated portion of the rectum, it is wider at the beginning than at the end. It varies in width at different parts from 3 to 8 cm. The length from the root of the appendix or tip of the cæcum to the point where the meso-colon ends is, in the male, about 140 cm., and in the female about 130 cm. The average total length, including the rectum, is about 150 cm. (5 ft.). The extremes found are 100 to 200 cm.

The large intestine, in all parts except the rectum, has a peculiar arrangement of its walls, which gives it a very different appearance from the small intestine. It is *sacculated*, and the sacculations [haustra] are produced by the gut having to adapt its length to three shorter muscular bands which run the course of the intestine. These bands, which are about 12 mm. wide and 1 mm. thick, are really the longitudinal fibres of the muscular wall, which are chiefly collected along three lines (fig. 935). One band [tænia mesocolica], corresponding to the attachment of the mesocolon, is posterior on the transverse colon, and postero-median on the ascending and descending colons. A second band [tænia omentalis] is antero-superior on the transverse colon, elsewhere postero-lateral. The third band [tænia libera] is free; it is inferior on the transverse colon, anterior elsewhere. All these bands start on the cæcum at the vermiform process, and spread out to form a uniform layer on the rectum. Between the sacculations are *semilunar folds* [plicæ semilunares coli], which involve the entire thickness of the intestinal wall, forming crescentic ridges of the mucosa which project into the lumen (figs. 932, 935). Along the free surface of the colon, especially near the tæniæ, are numerous small appendages [appendices epiploicæ], which are pouches of peritoneum containing fat (fig. 906).

The cæcum.—The cæcum [intestinum cæcum] is a *cul-de-sac* forming the first part of the large intestine. It is defined as that part of the colon which is situated below the entrance of the ileum. Its breadth is about 7.5 cm., and its length about 6 cm. (Fig. 932).

There is usually a more or less well-marked constriction opposite the ileo-cæcal orifice marking the boundary between cæcum and colon. The cæcum itself also frequently presents a constriction dividing it into two sacculations.

It lies in the right iliac fossa, and is usually situated upon the ilio-psoas muscle, and so placed that its apex or lowest point is just projecting beyond the medial border of that muscle (figs. 899, 906). It is usually entirely enveloped in peritoneum, and is free in the abdominal cavity, but more or less attached in about 10 per cent. of all cases. The apex of the cæcum usually corresponds to a point a

little to the medial side of the middle of the inguinal ligament. Less frequently the cæcum will be found to be in relation with the iliacus muscle only; or the bulk of it will lie upon that muscle, while the apex rests upon the psoas. In a number of cases the cæcum is entirely clear of both psoas and iliacus muscles, and hangs over the pelvic brim, or is lodged entirely within the pelvic cavity. Sometimes the cæcum may pass even to the left of the median line of the body.

This part of the colon is liable to considerable variation.

FIG. 932.—INTERIOR OF THE CÆCUM, ANTERIOR VIEW. (Rauber-Kopsch.)

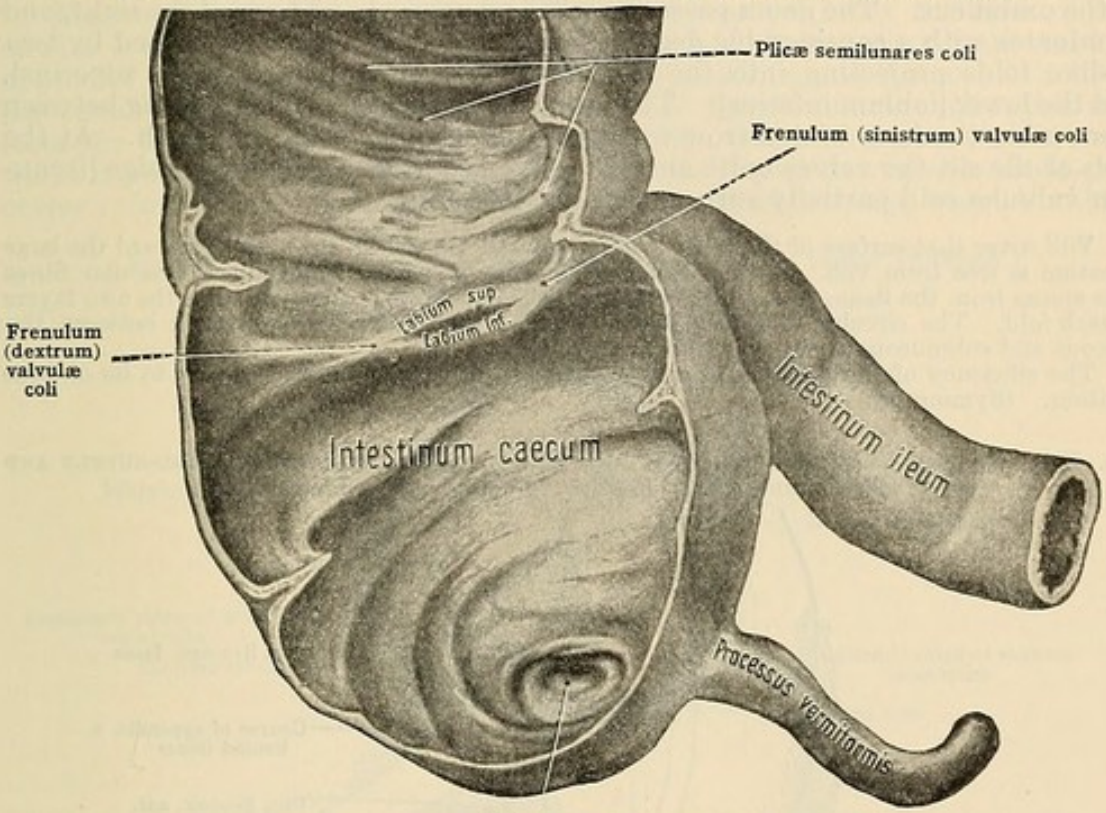

Its *variations* in form may be described under *four types:*

1. The fœtal type is conical in shape, the appendix arising from the apex, and forming a continuation of the long axis of the colon. The three muscular bands which meet at the appendix are nearly at equal distances apart (fig. 933, A). When the cæcum is empty and contracted it tends to approach this type.

2. The second form is more quadrilateral in shape than the last; the three bands retain their relative positions; the appendix appears between two bulging sacculi, instead of at the summit of a cone (fig. 933, B).

FIG. 933.—THE FOUR TYPES OF CÆCUM. (Treves.)

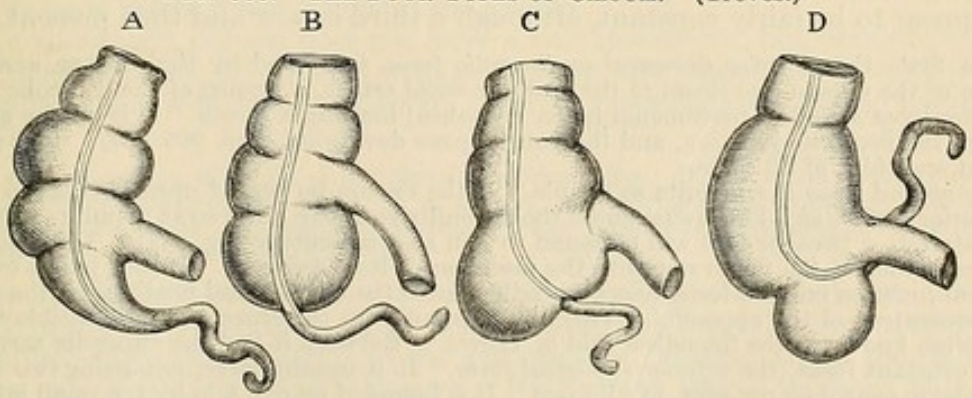

3. In the third type, that part of the cæcum lying to the right side of the anterior band grows out of proportion to that part to the left of the band. The anterior wall becomes more developed than the posterior, so that the apex is turned so much to the left and posteriorly that it nearly meets the ileo-cæcal junction. A false apex is formed by the highly developed part to the right of the anterior band. This is the usual cæcum found (fig. 933, C).

4. In the fourth type, the development of the part to the right of the anterior band is excessive, while the segment to the left of the band has atrophied. In this form the anterior band runs to the inferior angle of junction of the ileum with the cæcum. The root of the appendix is posterior to that angle. There is no trace of the original apex, and the appendix appears to spring almost from the ileo-cæcal junction (fig. 933, D.)

The ileo-cæcal valve.—The ileo-cæcal valve [valvula coli] is situated at the entrance of the ileum into the large intestine at the upper border of the cæcum, on the posterior aspect and toward the medial side (fig. 932). The valve usually lies nearly opposite the middle of a line from the anterior superior iliac spine (left) to the umbilicus. The ileum passes from below upward and toward the right, and terminates with a considerable degree of obliquity. The valve is formed by two lip-like folds projecting into the large intestine, the upper [labium superius], and the lower [labium inferius]. They are a little oblique. The opening between them takes the form of a narrow transverse slit about 1.2 cm. in length. At the ends of the slit the valves unite and are prolonged at either end as a ridge [frenulum valvulæ coli] partially surrounding the intestine.

Villi cover that surface of the folds looking toward the ileum; the surface toward the large intestine is free from villi. In the formation of this valve the longitudinal muscular fibres pass across from the ileum to the large intestine without dipping down between the two layers of each fold. The circular muscular fibres, on the other hand, are contained between the mucous and submucous layers which form these folds.

The efficiency of the valve in preventing the return of fæces is due largely to its oblique position. (Symington.)

FIG. 934.—CÆCUM, VERMIFORM PROCESS, AND END OF ILEUM, WITH THE BLOOD-SUPPLY AND THE NEIGHBOURING FOSSÆ. (Woolsey, after Merkel.)

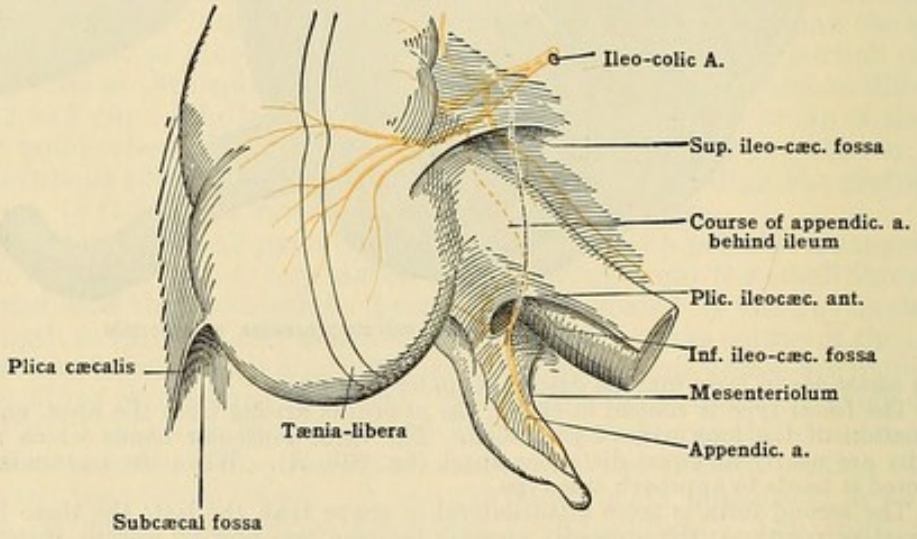

Ileo-cæcal fossæ.—About the cæcum, and especially in the vicinity of the ileo-cæcal junction, are certain fossæ collectively known as the ileo-cæcal fossæ. Two only appear to be fairly constant, although a third is now and then present.

The first, the *superior ileo-cæcal* or *ileo-colic fossa*, is formed by the passage across the junction of the cæcum and ileum of the anterior cæcal artery, a branch of the ileo-colic artery, which produces a fold of peritoneum [plica ileocolica] limiting a pouch. It is on the anterior aspect of the ileo-colic junction, and the pouch opens downward (figs. 906, 934). It is present in about one-third of all cases.

The second fossa is not quite so simple. If the cæcum be turned upward so as to expose its posterior surface as it lies *in situ*, and if the appendix be drawn down so as to put its mesentery on the stretch, a peculiar fold will be found to join that mesentery (fig. 934). This fold arises from the border of the ileum opposite the insertion of its mesentery. It then passes over the ileo-cæcal junction on its inferior aspect, is adherent to the cæcum, and finally joins the surface of the mesentery of the appendix. This fold is peculiar in the absence of any visible vessels, and is often known as the 'bloodless fold of Treves.' Between it and the appendix there is an almost constant fossa, the *inferior ileo-cæcal fossa*. It is usually large, admitting two fingers, and occurs in nearly 85 per cent. of all cases. It is bounded on one side by the small intestine, and on the other by the cæcum. The appendix is occasionally found in the fossa.

The *subcæcal* or *retrocolic* fossa is behind the cæcum and is found in about ten per cent. of all cases. It may extend for some distance behind the ascending colon. The appendix may be lodged in this fossa.

Paracæcal fossæ rarely occur, at the side of the cæcum.

Variations.—In addition to variations already mentioned the cæcum may vary in its general

development. It is sometimes small and insignificant; in other cases it reaches a large size. It may be so rotated that the ileum passes behind the colon and opens on the right side. The posterior part has been seen much more developed than the anterior, so that the ileum has entered from the front, and the appendix has come off from the anterior wall. The cæcum may remain undescended, and be found just under the liver or in the vicinity of the umbilicus. In case the rotation of the embryonic intestinal loop fails to occur (which rarely happens) the cæcum may remain permanently upon the right side. If the normal process of adhesion fails to occur, the cæcum and colon, along with the small intestine, may remain suspended from the mid-dorsal line by the primitive *mesenterium commune*. Or any of the intermediate stages of partial adhesion may persist.

The vermiform process.—Attached to what was originally the apex of the cæcum is a narrow, blind tube, the *vermiform process* [processus vermiformis] or *appendix*. It comes off at a variable distance (usually about 2.5 cm.) below the ileo-cæcal valve on the postero-medial aspect of the cæcum, though sometimes from the lower end of the cæcum, or elsewhere. On the interior, at the point where it joins the cæcum (fig. 932), there is a slight inconstant valve [valvula processus vermiformis]. The appendix joins the cæcum at the point where the three

FIG. 935.—CROSS-SECTION OF THE ASCENDING COLON. (Allen Thomson.)

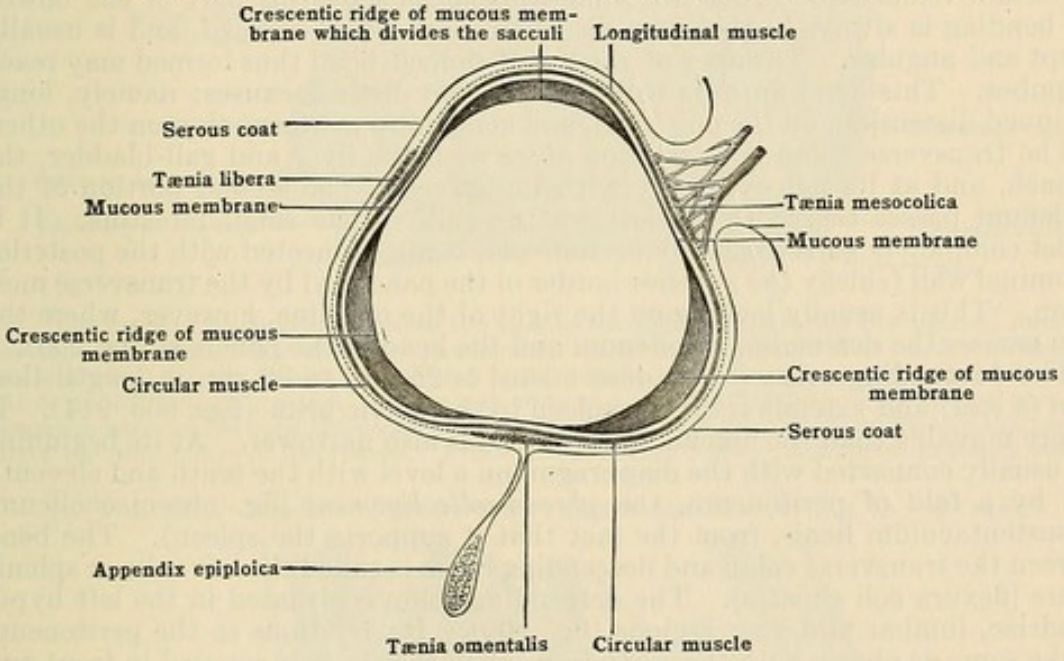

tæniæ meet, and the anterior tænia forms the best guide to this point. In the adult, the average length of the appendix is between 8 cm. and 10 cm., the extremes being 2 cm. to 25 cm. It is usually much twisted and coiled upon itself. Its direction is most frequently downward toward the pelvic cavity, or upward and medialward behind the ileum in the direction of the spleen. It occasionally turns lateralward, or more rarely upward behind the cæcum.

The vermiform process does not have a true mesentery, but usually (in about 90 per cent. of cases) is provided with a falciform fold [mesenteriolum] of peritoneum, continuous with the left (lower) layer of the mesentery of the ileum (figs. 906, 934).

In general outline this fold of peritoneum is triangular. In the adult it does not extend along the whole length of the tube. It is, in fact, too short for the appendix, and it is this that accounts for the twisted condition of this process. Along the free margin of the fold runs a branch of the ileo-colic artery (fig. 934).

The ascending colon.—The ascending colon [colon ascendens] (figs. 906, 914) extends in the right lumbar (lateral abdominal) region from the cæcum to the inferior surface of the liver, lateral to the gall-bladder, forming there the right colic [flexura coli dextra] or hepatic flexure. Its average length is about 20 cm. (or somewhat less when measured *in situ*). It is covered by peritoneum in front and on the side (fig. 902), but in a certain proportion of cases (26 per cent. according to Treves) this part of the large intestine is connected with the posterior wall of the abdomen by a meso-colon (usually very short) and is therefore surrounded by peritoneum. Connected with the ascending colon is sometimes found a fold of

peritoneum, extending from the right side of the gut to the abdominal wall at a little above the level of the highest part of the iliac crest. It forms a shelf upon which rests the extreme right margin of the liver. It might be called the *sustentaculum hepatis*.

The ascending colon is in relation *behind* with the right kidney, and the iliacus and quadratus lumborum. *In front* are some of the coils of the ileum (fig. 899), separating it from the anterior abdominal wall.

The transverse colon.—The transverse colon [colon transversum], smaller in diameter than the ascending, extends from the lower surface of the liver to the spleen. Its average length is from 40 to 50 cm. It describes an arch with its convexity forward and downward. It crosses through the umbilical region from the right hypochondrium to the left hypochondrium (figs. 899, 906, 914).

In the majority of cases the superficial part of the colic arch—as seen before the viscera are disturbed—is either in whole or in greater part above a straight line drawn transversely across the body between the highest points of the iliac crest. In about one-fourth of all cases it lies, in whole or in greater part, below this line.

Certain remarkable bends are sometimes formed by this part of the bowel. The bending is always in the same direction, namely, downward, and is usually abrupt and angular. The apex of the **V** or **U**-shaped bend thus formed may reach the pubes. This bend appears to be due to two distinct causes: namely, long-continued distention, on the one hand, and congenital malformation on the other.

The transverse colon is in relation *above* with the liver and gall-bladder, the stomach, and at its left extremity with the spleen. The second portion of the duodenum passes *behind* it. *Below* are the coils of the small intestine. It is almost completely surrounded by peritoneum, being connected with the posterior abdominal wall (chiefly the anterior border of the pancreas) by the transverse mesocolon. This is usually lacking on the right of the mid-line, however, where the colon crosses the descending duodenum and the head of the pancreas (fig. 905).

The **descending colon** [colon descendens] is 25 cm. to 30 cm. in length (less when *in situ*) and extends from the spleen to the pelvic brim (figs. 906, 914). It is more movable than the ascending colon and is also narrower. At its beginning it is usually connected with the diaphragm, on a level with the tenth and eleventh ribs, by a fold of peritoneum, the *phreno-colic ligament* [lig. phrenicocolicum] (or sustentaculum lienis, from the fact that it supports the spleen). The bend between the transverse colon and descending colon is called the left colic or splenic flexure [flexura coli sinistra]. The descending colon is situated in the left hypochondriac, lumbar and iliac regions (fig. 906). Its relations to the peritoneum are the same as obtain with the ascending colon, that is, it is covered in front and on the sides. A mesocolon is met with oftener on this side than on the right, occurring in 36 per cent. of all cases (Treves) (see fig. 902). It is found especially in the lower part of the descending colon, in the iliac fossa. This portion, extending from the iliac crest to the brim (superior aperture) of the pelvis, is sometimes described as a separate segment, the **iliac colon** (Jonnesco).

The descending colon is covered *anteriorly* by coils of small intestine; *posteriorly* it is in contact with the lower part of the left kidney, the quadratus lumborum, iliacus and psoas muscles. It terminates by crossing medialward over the psoas muscle and the external iliac vessels to join the sigmoid colon.

The **sigmoid colon** [colon sigmoideum] or pelvic colon, extends from the descending colon to the rectum (figs. 906, 914). It includes what was formerly described as the 'sigmoid flexure' and also the 'first portion' of the rectum. These together form a single loop which cannot conveniently be divided into parts.

The loop, the sigmoid colon, begins at the margin of the psoas, and ends where the sigmoid mesocolon ceases, opposite the second or third sacral vertebra.

The loop when unfolded describes a figure that may be compared to the capital omega. The average length of this sigmoid colon is about 40 cm. The normal position of the loop is not in the left iliac fossa, but wholly in the pelvis. The most common disposition of it may now be described. The sigmoid (pelvic) colon begins about midway between the lumbo-sacral eminence and the inguinal (Poupart's) ligament. It descends at first along the left pelvic wall, and may at once reach the pelvic floor. It then passes more or less horizontally and transversely across the pelvis from left to right, and commonly comes into contact with the right pelvic wall. At this point it is bent upon itself, and, passing once more

toward the left, reaches the middle line and joins the rectum. It will lie, therefore, in more or less direct contact with the bladder (and uterus in the female), and may possibly touch the cæcum. It is very closely related with the coils of small intestine that occupy the pelvis, and by these coils the loop is usually hidden. In about 90 per cent. of cases, the sigmoid colon lies entirely within the true pelvic cavity. In the remainder, it loops upward for a variable distance toward the umbilicus, a position normally found in infancy.

FIG. 936.—INTERIOR OF THE RECTUM. (× ⅔.) (From Toldt's Atlas.)

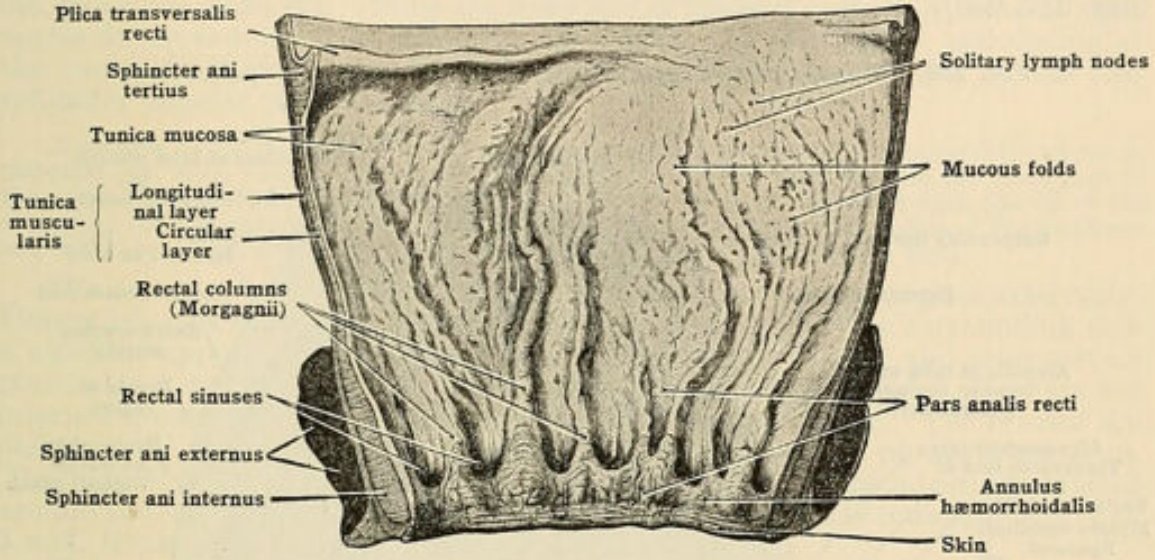

The sigmoid colon is attached to the abdominal and pelvic wall by the sigmoid mesocolon, so that it is quite surrounded by peritoneum. The line of attachment of this mesocolon is as follows: It usually crosses the psoas in a slight curve upward so as to pass over the iliac vessels at or about their bifurcation. The curve ends at a point either just to the medial side of the psoas muscle, or between the psoas and the middle line, or, as is most frequently the case, just over the bifurcation of the vessels. From this point the line of attachment proceeds vertically

FIG. 937.—MID-SAGITTAL SECTION OF THE MALE PELVIS. (× ⅓). (Braune.)

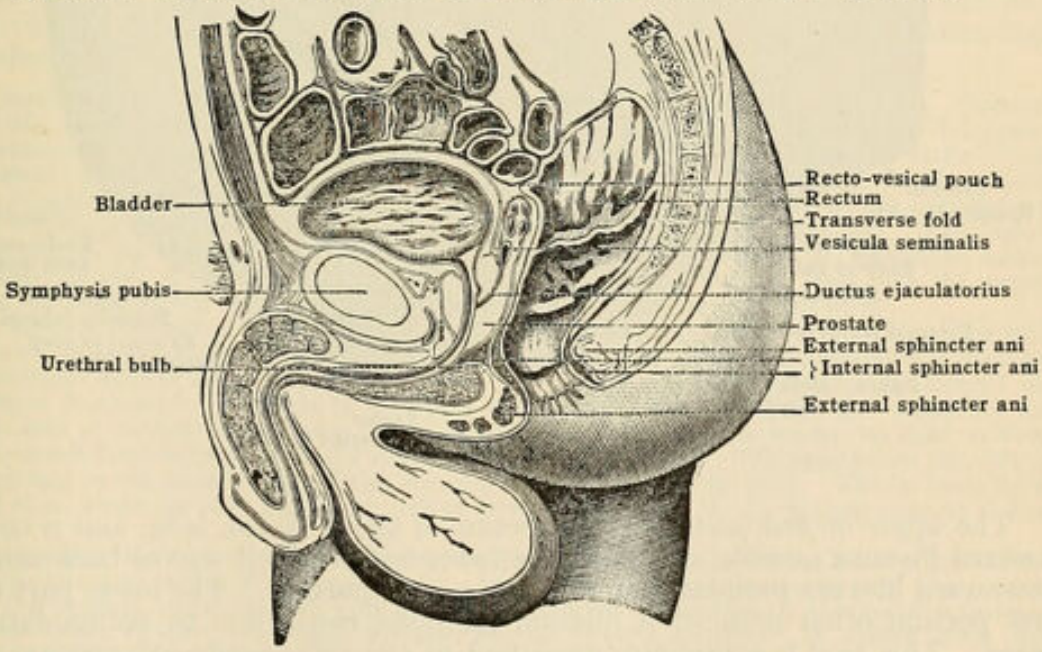

down, taking at first a slight curve to the right. Its course is to the left of the middle line, while its ending will be upon that line, about the second or third sacral vertebra. The sigmoid mesocolon measures from 3 to 8.7 cm. in width—i. e., from the parietes to the bowel,—at the widest point.

When a descending mesocolon exists, it joins that of the sigmoid colon. There is often no mesocolon over the psoas, the gut being adherent to that muscle. In connection with the sigmoid mesocolon is often found a fossa or pouch of peritoneum, known as the *intersigmoid fossa* [recessus intersigmoideus]. This pouch is formed by the incomplete adhesion of the

primitive mesocolon to the posterior abdominal wall. It is generally found over the bifurcation of the iliac vessels. The pouch is funnel-shaped, and the opening looks downward and to the left. It varies in depth from 2.5 to 3.7 cm., and is rarely the seat of the sigmoid hernia.

The rectum.—The rectum, according to the BNA nomenclature, is recognised as a division separate from the large intestine. The term rectum is now limited to that portion of the bowel below the mid-sacral region, where the mesocolon ceases. It is divided into two portions: the first extends downward and forward, in front of sacrum and coccyx, to the level of the pelvic floor; the second portion (the anal canal) extends from this point downward and backward to the anus (figs. 937, 938).

FIG. 938.—MID-SAGITTAL SECTION OF THE FEMALE PELVIS. (Spalteholz.)

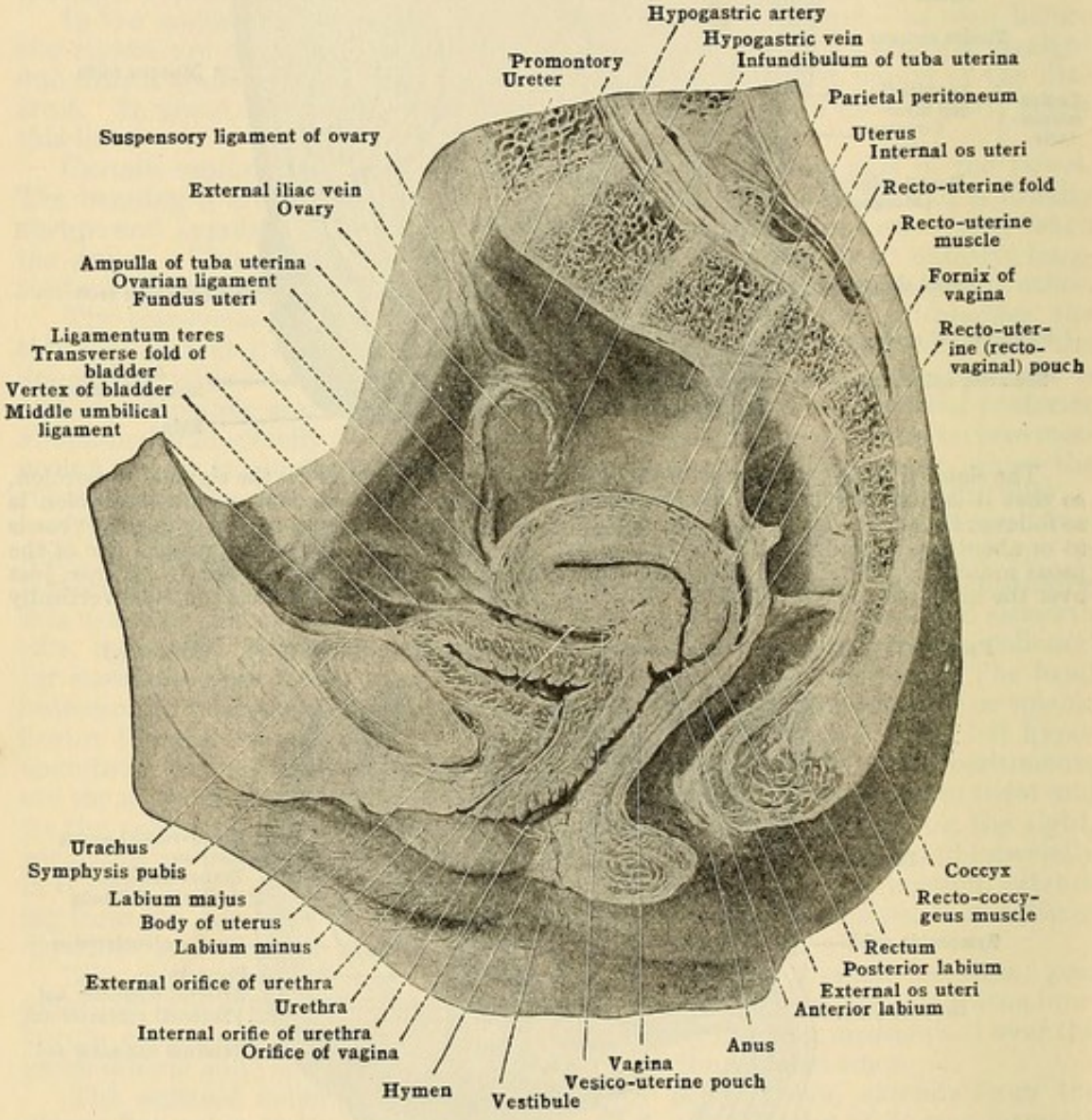

The *upper* or *first portion* of the rectum is about 10 cm. long, and is concave forward [flexura sacralis] except at the lower end where it curves backward and downward [flexura perinealis] to join the second portion. The lower part of the first portion often presents a dilation [ampulla recti], due to accumulation of fæces. This part is sometimes described as the *infra-peritoneal portion* of the rectum proper.

Anteriorly, the rectum is in contact with coils of ileum and, in the male, with the trigone of the bladder, the vesiculæ seminales, ductus deferentes, and posterior aspect of the prostate (fig. 937). In the female, it is in contact anteriorly with the vagina and the cervix uteri (fig. 938). *Posteriorly,* it is in contact with the sacrum, coccyx and ano-coccygeal body.

In the male, a small band of muscle fibres, the *recto-urethral* muscle, extends from the perineal flexure of the rectum to the membranous urethra.

The *peritoneum* is reflected anteriorly from the rectum to the bladder in the male (recto-vesical pouch) and to fornix of the vagina in the female (recto-vaginal pouch). In the newborn, the peritoneum reaches to the base of the prostate (Symington). On the posterior surface of the gut, there is no peritoneum below a point about 12.5 cm. from the anus. Thus the peritoneum at the upper end of the rectum entirely surrounds the gut. Lower down it covers only the sides and anterior wall, and lower still the anterior wall only, where it is reflected upon the bladder or vagina.

The second portion of the rectum, or **anal canal** [pars analis recti] is from 2.5 cm. to 3.5 cm. in length. From the lower end of the first portion, it turns at right angles downward and backward, passing through the pelvic floor, and ending at the anus. It is entirely below the peritoneum, and is surrounded by the two sphincter muscles (figs. 936, 937).

Anteriorly is the bulb of the urethra and the posterior margin of the urogenital trigone in the male (fig. 937), while in the female it is separated from the vestibule and the lower part of the vagina by the 'perineal body' (fig. 938). *Posteriorly* it is connected with the tip of the coccyx by the ano-coccygeal body. *Laterally* it is in contact with the margins of the levatores ani, which act as an accessory sphincter, and help to support the ampulla recti.

The anus.—The anus is the aperture by which the intestine opens externally. During life it is contracted by the sphincters, so as to give the surrounding skin a wrinkled appearance. Around the lower part of the rectum and anus certain muscles that are connected with its proper function are situated. They are the internal sphincter, the levator ani, and the external sphincter. The levator ani and external sphincter will be found described in the section on MUSCULATURE. The *internal sphincter* is a thickening of the circular fibres of the intestine, situated around the second portion or anal canal. It forms a complete muscular ring, 2 to 3 mm. thick, and is composed of non-striated muscle.

The rectum differs from the rest of the colon in having smoother walls and no appendices epiploicæ. At the upper end of the rectum, the tænia libera and tænia omentalis join to form a broad band which spreads out, covering the entire anterior aspect of the rectum. Similarly the tænia mesocolica spreads out upon the posterior aspect. Thus the rectum has a complete longitudinal muscle layer, which, however, is thicker anteriorly and posteriorly than laterally. It sends a bundle of fibres to the coccyx [m. recto-coccygeus]. Below, the longitudinal layer passes between the two sphincters and breaks up into numerous bundles which are interwoven with the external sphincter and levator ani, some of them terminating in the circumanal skin.

Its **mucous membrane** is thicker than that of the rest of the large intestine. Certain folds, chiefly longitudinal in direction, are seen in the lax state of the tube, which disappear when distended, but Houston had described three permanent oblique **transverse folds** [plicæ transversales recti] (fig. 936), containing bundles of non-striated muscle-cells, which project into the lumen of the tube: one is on the right at the level of the reflection of the peritoneum from the rectum; and two are on the left, one above and one below the right fold. That upon the right side is the largest and most constant, and its muscular bundle is sometimes called the *sphincter tertius*. It is located about 7.5 cm. above the anus. These folds, like the corresponding semilunar folds of the colon, when well marked involve the entire wall.

The mucous membrane of the upper portion of the anal canal presents a series of vertical folds known as **rectal columns** [columnæ rectales] (columns of Morgagni), containing bundles of non-striated muscle longitudinally arranged. These columns become more prominent as they extend downward. Just above the anus each two adjacent columns are united by an arch-like fold of mucous membrane, these folds forming what are known as the **anal valves,** while the small fossæ behind them are known as the **rectal sinuses.** The area below the valves and extending to the anus is termed the *annulus hæmorrhoidalis* (fig. 936). This is lined by a modified skin, while the area above the valves forms a transition to the typical mucosa of the rectum.

Minute structure of the large intestine.—In general, the large intestine has the four coats (fig. 939)—mucosa, submucosa, muscularis, and serosa—characteristic of the alimentary canal. The *mucosa* lacks the villi and plicæ circulares characteristic of the small intestine. It contains many solitary lymphatic nodules, but no Peyer's patches. It differs from the stomach in the absence of foveolæ, and in the presence of large numbers of mucous 'goblet cells' found both on the surface and along the numerous crypts of Lieberkuehn (which contain no cells of Paneth). The *submucosa* is much as in the small intestine. The *muscularis* has a continuous inner circular layer, the outer longitudinal fibres being chiefly gathered into the three bands, the teniæ coli, as above mentioned. The serosa is typical, excepting extraperitoneal areas where the epithelium is lacking. The appendices epiploicæ were also mentioned above.

The cæcum and colon present no special features worthy of mention, beyond the typical structure above outlined.

The *vermiform process*, however, differs in several important respects (fig. 940). The walls are relatively thick and the lumen small. The solitary lymph nodules are closely packed or confluent (especially in young people). They occupy the greater part of the submucosa, and somewhat resemble the Peyer's patches of the ileum. They, like all the lymphoid structures

FIG. 939.—CROSS-SECTION OF THE LARGE INTESTINE. *a*, Mucosa. *b*, Submucosa. *c*, Muscularis. *d*, Serosa. (Radasch.)

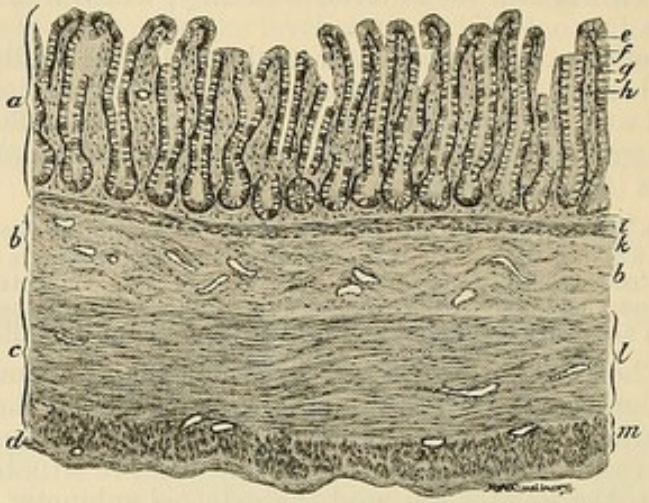

in general, tend to become atrophied in old age. Fat cells are usually abundant in the submucosa. The *muscularis* presents an inner circular layer and also a thin but complete outer longitudinal layer. The serosa is typical. The lumen shows a progressive tendency to obliteration as age advances (Ribbert). This condition is never found in infancy but occurs

FIG. 940.—TRANSVERSE SECTION OF THE HUMAN VERMIFORM PROCESS. (× 20). (Stöhr and Lewis, from Sobotta.) Note absence of villi and abundance of lymph nodules. *F*, Clusters of fat cells in submucosa. Only the inner part of the circular muscle is shown.

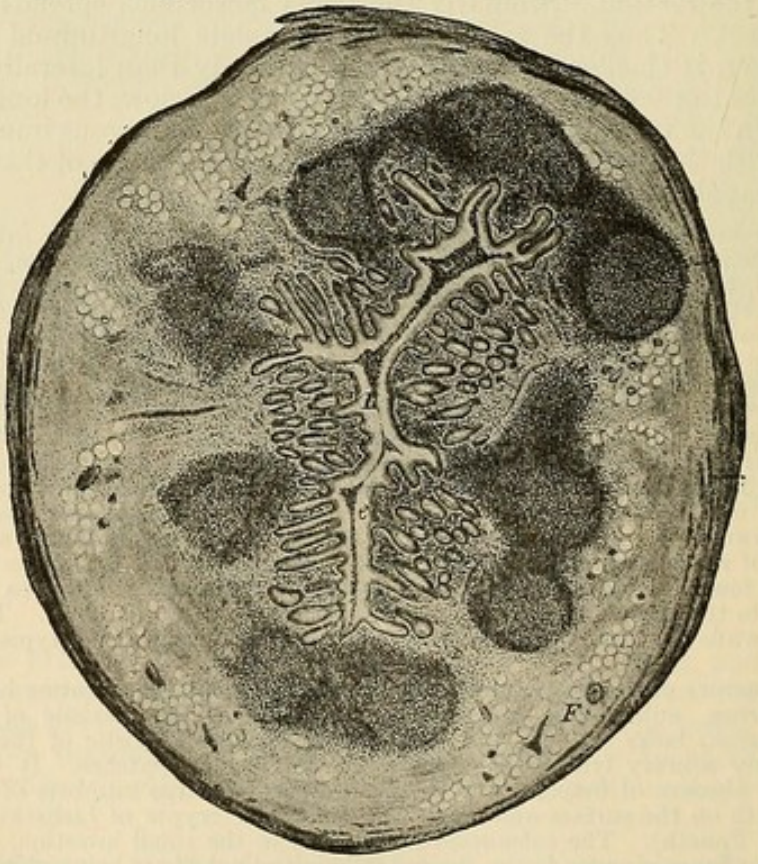

usually only partial) in over 25 per cent. of adults and in 50 per cent. of all cases over 50 years of age. It is, however, somewhat uncertain whether this represents a normal process. In obliteration, the glands and lymphoid nodules disappear, and the entire mucosa is transformed into an axial mass of fibrous connective tissue.

The *rectum* also presents several peculiarities of structure. Attention has already been

called to the transverse folds (of Houston) and the rectal columns, sinuses and valves. Just above the valves, the mucosa is transitional, the epithelium being partly stratified, and the crypts of Lieberkuehn few and scattering. Below the valves, the annulus hæmorrhoidalis is lined by a modified skin. Hairs and sebaceous and sweat glands do not appear until just outside the anal orifice. The thickening of the circular muscle to form the internal sphincter, and the somewhat uniform disposition of the longitudinal muscle have already been mentioned, as well as the absence of a serous coat in the lower portions.

Blood-vessels.—The large intestine is supplied with blood by the branches of the superior mesenteric and inferior mesenteric arteries, while it also receives a blood-supply from the internal iliac at the rectum. The vessels form a continuous series of arches from the cæcum, where the vasa intestini tenuis anastomose with the ileo-colic, the first branch of the superior mesenteric given to the large intestine.

The blood-supply of the rectum is from the inferior mesenteric by the superior hæmorrhoidal, from the hypogastric (internal iliac) by the middle hæmorrhoidal, and from the internal pudic by the inferior hæmorrhoidal. The vessels at the lower end of the rectum assume a longitudinal direction, communicating freely near the anus, and less freely above.

The blood of the large intestine is returned into the portal vein by means of the superior mesenteric and inferior mesenteric veins. At the rectum a communication is set up between the systemic and portal system of veins, since some of the blood of that part of the intestine is returned into the hypogastric (internal iliac) veins. In the lower end of the rectum the veins, like the arteries, are arranged longitudinally. This arrangement is called the hæmorrhoidal plexus.

The vermiform process is supplied by a special branch of the ileo-colic artery (fig. 934). This branch, the appendicular artery, crosses behind the terminal portion of the ileum (where pressure may obstruct the circulation) to enter the mesenteriolum. An accessory artery of small size also descends along the medial margin of the colon and cæcum, entering the base of the appendix.

The **nerves** and **lymphatics** of the large intestine differ in no important particular from those of the small intestine, so far as their relations within the intestinal wall are concerned.

The efferent lymphatic vessels in general follow the blood-vessels and pass through corresponding lymph nodes in the various regions (see p. 734). Those of the cæcum and vermiform process pass through the appendicular and ileo-cæcal nodes; those of the colon through mesocolic and mesenteric nodes. Those of the descending and sigmoid colons connect with the inferior mesenteric and lumbar nodes. The superior zone of the rectum is drained by lymphatics passing to the ano-rectal and inferior mesenteric nodes; the middle zone (region of rectal columns) to nodes along the three hæmorrhoidal arteries; the inferior zone (anal integument) chiefly to the superficial inguinal nodes.

Development of the large intestine.—At an early stage in the development of the intestinal canal, when this presents a single primary loop and soon after this loop has turned on its axis, there is observed on the left half of the loop, near its top, an enlargement which marks the beginning of the large intestine. With further growth this enlargement develops a lateral outgrowth on the side opposite to that to which the mesentery is attached, therefore free from the mesentery. A conical projection of the large intestine or colon beyond the place where this is joined to the small intestine is thus formed. This conical projection or pouch of the large intestine, which continues the colon somewhat beyond the insertion of the small intestine, develops into the cæcum and the vermiform process. It does not present, in its further growth, a uniform enlargement. The portion nearest the colon grows in size more rapidly than the terminal portion, this difference in size becoming more apparent as development proceeds, the smaller terminal portion forming the vermiform process. On the return of the intestine to the peritoneal cavity (in embryos of about 40 mm.) the cæcum lies on the right side, immediately below the liver. During the later fœtal months the cæcum gradually descends into the right iliac fossa, and there is thus established an ascending colon. The cæcum may, however, even in the adult, retain its embryonic position on the right side immediately beneath the liver, or may descend farther than usual.

The ascending and descending colons, the sigmoid meso-colon (in part), and the rectum with corresponding portions of the mesorectum, become adherent to the posterior body wall during the fourth and fifth fœtal months. At the same time, the posterior layer of the great omentum becomes fused with the upper (anterior) surface of the transverse meso-colon. The layer of retroperitoneal fascia corresponding to the obliterated mesocolon is shown in fig. 1005. Variations in the process of fusion give rise to numerous peritoneal variations in the adult.

The sigmoid colon is relatively long at birth. On account of the relatively small size of the true pelvic cavity, both sigmoid colon and coils of ileum are usually excluded from it in the fœtus and infant.

In fœtuses of four to six months (length 100 mm. to 240 mm.) transitory villi appear in the mucosa throughout the large intestine, including the vermiform process. They appear in rows, corresponding to longitudinal folds. Their early obliteration is possibly due to distention of the gut by the meconium. The glands bud off like those of the small intestine. Lymphoid nodules are present abundantly in the vermiform process at birth (Johnson). The circular muscular layer begins to appear in the lower part of the large intestine at 23 mm.; the teniæ at 75 to 99 mm. (F. T. Lewis).

Development of the rectum and anus.—The posterior end of the primitive intestine or archenteron, designated the hind-gut, presents a terminal portion which is somewhat dilated and known as the cloaca, into the lateral and ventral portions of which open the Wolffian ducts, and from the ventral portion of which arises the allantois. The ventral portion of the cloaca, which is an entodermal structure, comes in contact with the ectoderm to form the cloacal membrane, and this forms the floor of a slight depression. For a time the cloaca or hind-gut extends for some distance caudal to the cloacal membrane, forming what is known as the post anal gut; this, however, soon disappears. Early in the development of the human embryo

when this has attained a length of about 6.5 mm., the fold which separates the cloaca and hind, gut from the allantois deepens, and folds develop from the lateral walls of the cloaca which meet and gradually separate the cloaca into a dorsal portion, which forms the rectum, and a ventral portion which forms the uro-genital sinus. This uro-rectal septum extends in its further growth until the cloacal membrane is reached, separating it into a ventral portion known as the uro-genital membrane, and a dorsal portion known as the anal membrane. The anal membrane ruptures comparatively late in development, establishing thus a communication between the hind-gut (rectum) and the exterior. The mesoderm develops around the lower end of the rectum, so that the ectoderm becomes slightly invaginated and lines the portion of the anal canal below the valves. A want of rupture of the anal membrane constitutes an arrest of development known as atresia of the anus.

Folds of the mucosa representing the rectal columns, valves and sinuses appear in embryos during the third month, and are well developed during the latter half of the fœtal period (Johnson).

Variations.—The large intestine is exceedingly variable in its structure and relations, especially with reference to the peritoneum—so much so that it has been found more convenient to include a consideration of the variations along with the preceding description of the individual parts. The content of fæces (and gas) is as a rule relatively greatest in the cæcum, decreasing in ascending and transverse colons. The descending colon is usually empty, or nearly so, the sigmoid colon and rectum somewhat variable. The rectal ampulla is usually more dilated in women.

Comparative.—The morphology of both small and large intestines will be briefly considered here. As previously mentioned, the primitive form of intestine is a comparatively straight tube extending from stomach to anus, and connected by a primitive mesentery to the mid-dorsal line of the body cavity. There is in many of the lower forms no clear division into small and large intestine, though the rectal region is usually more dilated, and opens into a cloaca. *Diverticula* often occur in the region between large and small intestine. In many fishes, numerous "cæca" occur just below the pylorus, and in others an extensive *spiral valve* projects into the lumen of the intestine. The absorptive and digestive surface of the mucosa is further increased by the formation of various kinds of *folds*, and (beginning in amphibia) of *villi*. *Lymphoid tissue* is typically present in the mucosa, often localized in definite masses. Solitary nodules appear in amphibia, and Peyer's patches in birds. Tubular mucous glands occur in the lower forms, but Brunner's glands and crypts of Lieberkuehn with Paneth cells apparently only in mammals. A *cæcum* is usually present from the reptiles upward (double in birds), and often forms an important organ of digestion. The bile and pancreatic ducts open constantly a short distance below the pylorus. The small intestine is always longer than the large, but there is extreme variation in length among the various species. The four tunics—mucosa, submucosa, muscularis and serosa—are typical for vertebrates, the muscularis consisting of inner circular and outer longitudinal smooth muscle fibres.

Among *mammals*, the divisions of the intestine correspond in general to those found in the human species, but there is exceedingly great variation in the relative development of the various parts. In general, the length, size and complexity of structure is relatively greatest in the *herbivora* (whose food is more difficult of digestion), least in the *carnivora*, and intermediate in the *omnivora*. Even in the same species, the structure of the intestine may be appreciably modified according to habitual diet. The large intestine varies, but is always shorter and wider than the small intestine. In mammals the rectum only is said to be homologous with the large intestine of lower vertebrates. The *cæcum* is rarely absent and is enormously developed in herbivora. It often contains large amounts of lymphoid tissue, which, in pig and ox forms a so-called 'intestinal tonsil.' The *vermiform process* (found typically developed in man and higher anthropoids) apparently represents a retrogressive evolutionary change in the cæcal apex, although this interpretation is denied by some (Berry), who interpret the appendix as a progressive, functional lymphoid organ.

THE LIVER

The **liver** [hepar] is the largest gland in the body. Its secretion, the bile [bilis; fel], is poured into the duodenum through the common bile duct. In addition it has important functions as a 'ductless gland' in connection with the nitrogenous and carbohydrate metabolism. In form it is a variable somewhat irregular mass, roughly comparable to a modified hemisphere occupying the upper right portion of the abdominal cavity (figs. 899, 914). It presents a convex, rounded upper or *parietal* aspect, which is in contact with the diaphragm and adjacent body walls, and a lower, flattened *visceral* surface, in contact with the abdominal viscera. When viewed from the front, it is somewhat triangular in outline, occupying the right hypochondriac, the epigastric and (slightly) the left hypochondriac regions.

Physical characters.—In weight, the liver averages about 1500 gm. (3⅓ lbs.), but it is exceedingly variable, commonly ranging from 1000 gm. to 2000 gm. Its *relative* weight is also variable, averaging about 2.5 per cent. of the body in the adult male (somewhat higher in the female). Its *specific gravity* averages 1.056, so that the average weight of 1500 gm. would correspond to a *volume* of 1420 cc. Its *dimensions* are also quite variable. Its greatest *depth* (antero-posterior) averages about 15 cm., and its greatest *height* (vertical) is about the same. Its

width (horizontal) is about 20 cm., while its greatest *length* (measured obliquely from side to side) averages about 25 cm. The *colour* of the liver is a reddish-brown. It is firm in *consistency*, but friable, so that it is easily ruptured.

Surfaces and borders.—The most general division of the surface of the liver,

Fig. 941.—Superior Surface of the Liver.

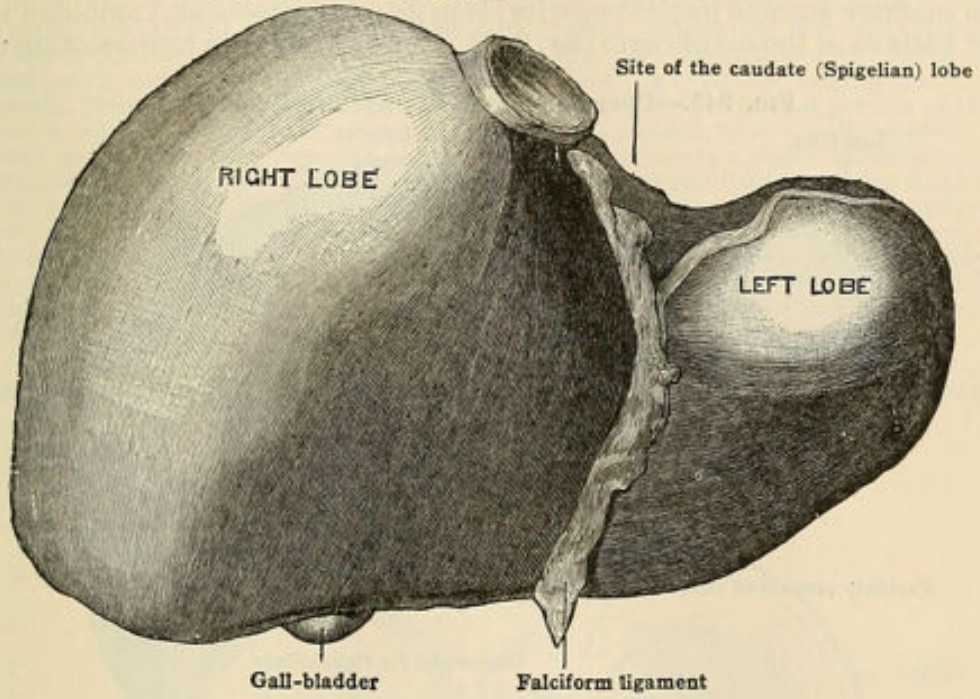

as above stated, is into two—the parietal and the visceral. The parietal surface is again subdivided, usually into two surfaces—posterior and superior.

The **posterior surface** [facies posterior] is triangular (fig. 943). It is wide on the right, where the right lobe is in contact with the diaphragm (corresponding

Fig. 942.—Inferior Surface of the Liver.

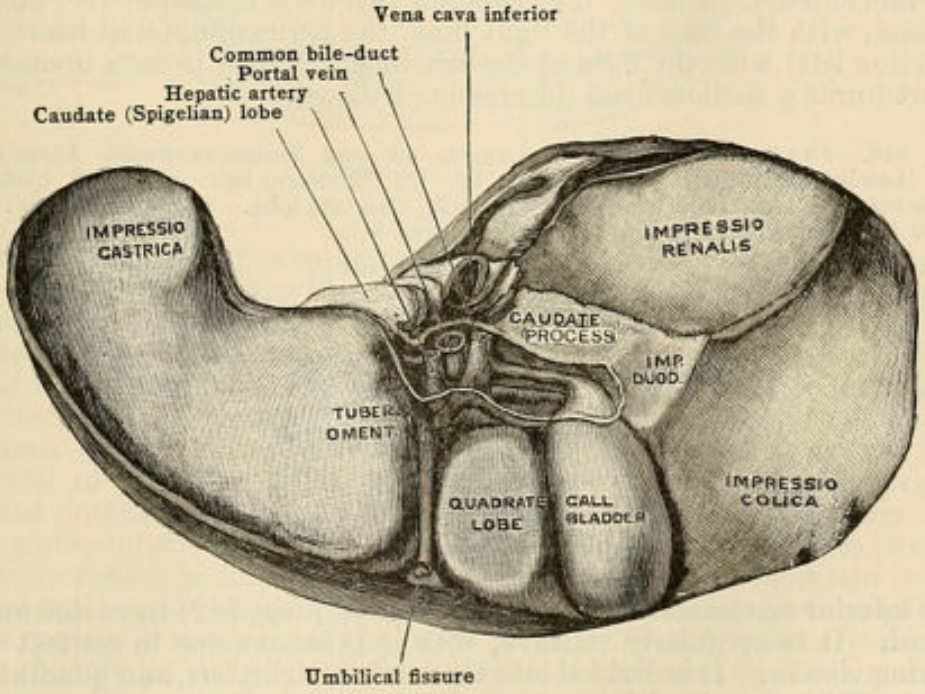

chiefly to the 'uncovered area' of the coronary ligament), and narrow on the left side, where the posterior margin of the left lobe is likewise attached to the diaphragm. At the lower, left hand corner of the right lobe is a small triangular area of contact with the suprarenal body [impressio suprarenalis]. Near the mid-line

is the caudate (Spigelian) lobe, opposite the tenth and eleventh thoracic vertebral bodies, from which it is separated by the diaphragm (chiefly the right crus). On the right of the caudate lobe is the fossa lodging the vena cava (sometimes bridged over), while to the left is the fissure of the ductus venosus, giving attachment to the upper portion of the lesser omentum (relations in cross-section shown in fig. 945).

The **superior surface** [facies superior] is in general convex and moulded to the inferior surface of the diaphragm (fig. 941). Tne relations in cross-section of the

FIG. 943.—POSTERIOR SURFACE OF THE LIVER.

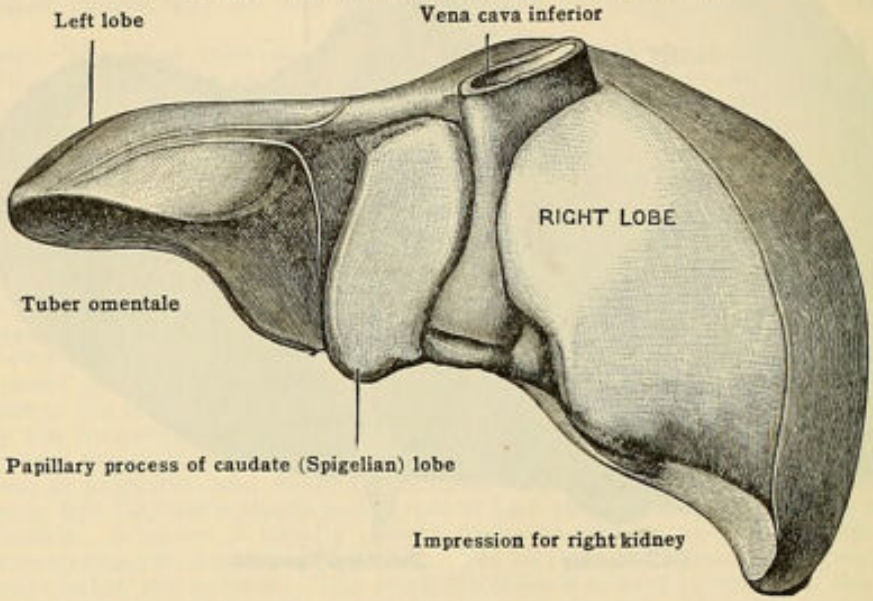

body are shown in fig. 945. It extends downward upon the anterior abdominal wall to a variable extent in the epigastric region, including the entire area of the liver visible from the front (fig. 941). It also presents a broad area extending downward on the right side. Symington accordingly distinguishes three surfaces corresponding to the superior surface above described, viz., right surface, anterior surface and superior surface. The superior surface is related above, through the diaphragm, with the base of the right lung, the pericardium and heart, and (on the extreme left) with the base of the left lung. Where it rests upon the liver, the heart forms a shallow fossa [impressio cardiaca].

FIG. 944.—DIAGRAM SHOWING LIGAMENTS ON THE DORSO-INFERIOR ASPECT OF THE LIVER. (Lewis and Stöhr.) *c.l.*, Coronary lig. *f.l.* Falciform lig. *g.b.*, Gall bladder. *l.o.*, Lesser omentum. *l.t.l.*, Left triangular lig. *o.b.*, Caudate lobe. *p.v.*, Portal vein. *r.l.*, Lig. teres. *r.t.l.*, Right triangular lig. *v.c.i.*, Vena cava inf.

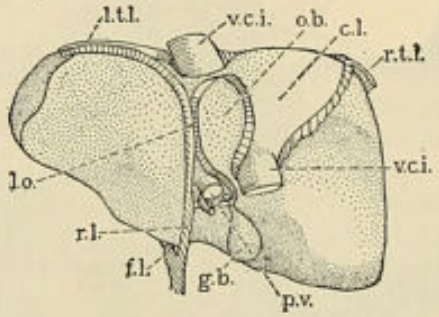

The **inferior** or **visceral surface** [facies inferior] (fig. 942) faces downward and backward. It is irregularly concave, with impressions due to contact with the underlying viscera. It is divided into three lobes, right, left, and quadrate, whose relations will be described later.

Of the **borders,** the *anterior* [margo anterior] is the best marked. It forms the inferior boundary of the triangular anterior view of the liver (figs. 899, 914, 941), and separates the superior from the inferior surface. Slightly to the left of the mid-line, it often presents a slight *umbilical* notch [incisura umbilicalis], where it

is crossed by the falciform ligament. The posterior surface is separated from the superior and inferior surfaces by ill-defined *postero-superior* and *postero-inferior* borders.

Surface outline.—The average position of the liver may be outlined upon the anterior surface of the body as follows (fig. 914): Locate one point on the right mid-clavicular (mid-Poupart) line opposite the fifth rib; a second point on the left mid-clavicular line about 2 cm. lower, in the fifth interspace; and a third point about 2 cm. below the costal arch (10th rib) on the right lateral wall. A line slightly concave upward, joining the first and second points defines the uppermost aspect of the lever. A line, strongly convex laterally, joining the first and third points, defines the right side of the liver. Finally, a third line, joining the second and third points, corresponds to the anterior border and defines the lowermost portion of the liver. This line is subject to many individual variations. In general, it is usually slightly convex downward as it crosses the epigastric region. It usually presents a slight umbilical notch, as before mentioned, and frequently a notch for the fundus of the gall-bladder, which is placed near the right mammary (mid-Poupart) line. The lower and right portion of the anterior border of the liver runs somewhat parallel with the infracostal margin. In the upright position, and in livers larger than usual, it extends about 2 cm. below the hypochondrium into the right lateral abdominal (lumbar) region (fig. 914). In the supine position, however, the liver recedes about 2 cm. toward the head. The liver of course participates also in the respiratory movements of the diaphragm.

FIG. 945.—CROSS-SECTION OF BODY AT LEVEL OF THE ELEVENTH THORACIC VERTEBRA. (Poirier-Charpy.)

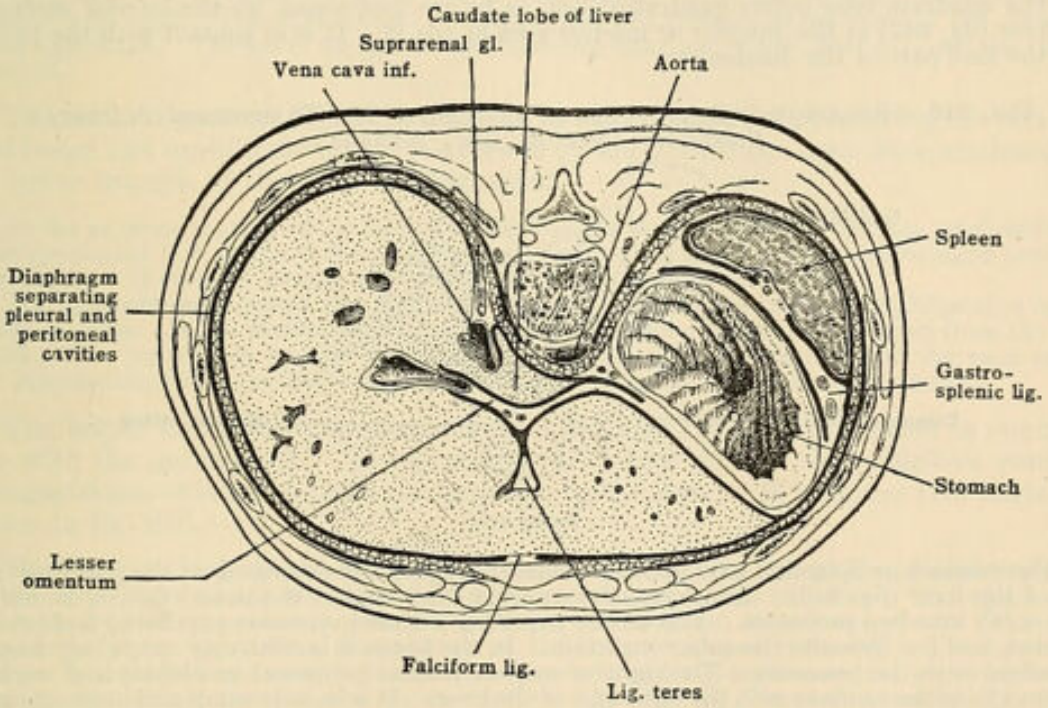

Lobes and fissures.—The superior surface is divided by the falciform ligament into two areas, corresponding to a larger right and a smaller left lobe (fig. 941). On the posterior and inferior surfaces of the liver (figs. 942, 943), an H-shaped arrangement of fossæ and fissures completes the demarcation of lobes. The left upright of the H [fossa sagittalis sinistra] corresponds to the prolongation of the line of attachment of the falciform ligament. It is made up of the umbilical fissure [fossa venæ umbilicalis], containing the round ligament, on the inferior surface; and of the *fossa ductus venosi*, containing the ligamentum venosum (obliterated ductus venosus) and the upper part of the lesser omentum, on the posterior surface of the liver. This left sagittal fossa separates the left lobe of the liver from the right lobe (in the wider sense of the term). The right lobe is further subdivided by the right upright and cross-bar of the H. The right upright [fossæ sagittales dextræ] is made up of the broad *fossa for the gall-bladder* [fossa vesicæ felleæ] on the inferior surface, and the broad *fossa venæ cavæ* on the posterior surface (fig. 943. These two fossæ are not continuous, but are separated by a narrow strip of liver, the caudate process of the caudate lobe (fig. 942). The cross-bar of the H is formed by the transverse or *portal fissure* [porta hepatis], which encloses the root structures of the liver, within the lower part of the lesser omentum (fig. 942). The area anterior to the cross-bar of the H corresponds to the quadrate

lobe of the inferior surface; that posterior to the cross-bar to the caudate lobe of the posterior surface; while the remainder of the liver, to the right of the H, is the right lobe (in the narrower sense).

The **right lobe** [lobus hepatis dexter] makes up the greater part of the liver. Its relations on the superior and posterior surfaces have already been mentioned. On the inferior or visceral surface (fig. 942), there appears posteriorly a large concavity [impressio renalis] for the right kidney; medially a faint impression [impressio duodenalis] for the descending duodenum; and antero-inferiorly a variable area [impressio colica] of contact with the right (hepatic) flexure of the colon. The caudate process joins the right with the caudate lobe.

The **left lobe** [lobus hepatis sinister] lies to the left of the left sagittal fissure and the falciform ligament. It is flattened but variable in form and size, and makes only about one-fifth of the entire liver. In children and especially in early fœtal life, it is relatively much larger. At the left extremity, there is usually found in the adult liver a variable fibrous band [appendix fibrosa hepatis] representing the atrophied remnant of the more extensive gland in earlier life. In this fibrous appendix (and in other parts of the liver) the bile ducts of the atrophied liver substance persist as *vasa aberrantia hepatis*.

The left lobe is related *superiorly*, through the diaphragm, with the heart and the base of the left lung. *Inferiorly* (fig. 942) it presents a large concavity [impressio gastrica] which is in contact with the anterior surface of the stomach. Above and behind the gastric impression is the rounded *tuber omentale* which is placed above the lesser curvature of the stomach and related, through the lesser omentum, with a corresponding tuberosity on the pancreas. To the left of the tuber omentale, and near the posterior aspect of the liver, is a small inconspicuous groove [impressio œsophagea] for the abdominal part of the œsophagus.

The **quadrate lobe** [lobus quadratus] lies, as before mentioned, on the inferior surface of the liver (fig. 942) in the anterior or inferior area of the H. It is in contact with the pylorus and the first part of the duodenum.

FIG. 946.—RELATION OF STRUCTURES AT AND BELOW THE TRANSVERSE OR PORTAL FISSURE. ANTEIOR VIEW. (Thane.)

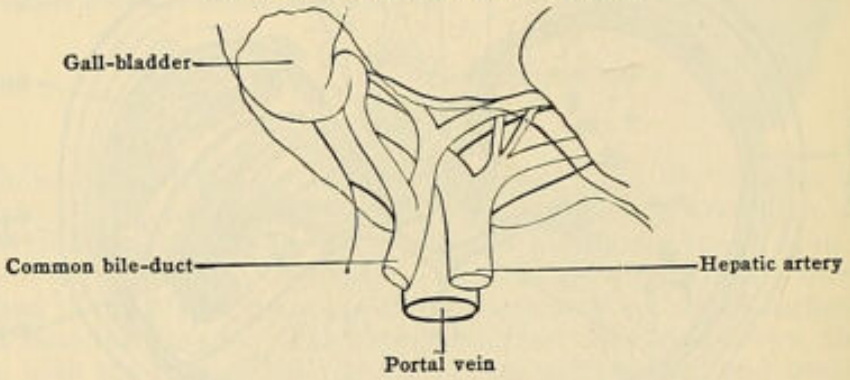

The **caudate** or **Spigelian lobe** [lobus caudatus; Spigeli] was described on the posterior surface of the liver (fig. 943). Inferiorly, the caudate lobe, behind the portal fissure, is divided by a notch into two processes. The left or *papillary process* [processus papillaris] is short and rounded, and lies opposite the tuber omentale. In the fœtus it is relatively much larger and is in contact with the pancreas. The right or *caudate process* [processus caudatus] is of variable size, and joins the caudate with the right lobe of the liver. It is usually small and inconspicuous. In the fœtus, however, it is relatively much larger, and extends downward to a variable extent behind the duodenum and head of the pancreas. In the adult, it forms the upper boundary of the epiploic foramen (of Winslow).

Peritoneal relations.—The liver in the adult is almost entirely surrounded by peritoneum. Although it develops together with the diaphragm in the common septum transversum (as explained previously, see figs. 951,952), the peritoneum soon extends in between liver and diaphragm, so that they remain in immediate contact only in the so-called 'uncovered area.' This is an irregular area on the posterior surface of the liver (chiefly on the right lobe), the margins of which correspond to the coronary ligament (figs. 905, 944). The posterior surface of the liver is therefore chiefly retroperitoneal, excepting the caudate (Spigelian) lobe, which is in contact with the recessus superior of the bursa omentalis (fig. 905). The superior and inferior surfaces of the liver are entirely covered with peritoneum, excepting the lines of attachment of the various peritoneal ligaments, and the fossa for the gall-bladder, which is usually directly in contact with the gall bladder with no intervening peritoneum.

Ligaments.—The liver is attached by five peritoneal ligaments—coronary, right and left triangular (lateral) and falciform ligaments and lesser omentum—and two accessory ligaments—teres and venosum.

The **coronary** ligament [lig. coronarium hepatis], as before mentioned, corre-

sponds to the reflections of peritoneum from the liver to the diaphragm at the margins of the 'uncovered area' (fig. 944) on the posterior surface of the liver.

Within this uncovered area the hepatic veins join the inferior vena cava. The coronary ligament, though somewhat irregular and variable in form, is elongated laterally and roughly quadrangular. At the four angles, the peritoneal layers come together and are prolonged into four ligaments—right and left triangular (lateral) and falciform ligaments and lesser omentum. There is often also a special prolongation of the coronary ligament downward upon the right kidney, forming the hepato-renal ligament [lig. hepatorenale]. This lies to the right of the foramen epiploicum.

The **right triangular** (or lateral) ligament [lig. triangulare dextrum] is a short but variable prolongation of the coronary ligament to the right and downward (figs. 905, 944). It connects the posterior surface of the right lobe of the liver with the corresponding portion of the diaphragm.

The **left triangular** (lateral) ligament [lig. triangulare sinistrum] is a longer, narrower prolongation of the coronary ligament to the left (figs. 905, 944). It connects the posterior aspect of the left lobe of the liver with the corresponding portion of the diaphragm.

The **falciform** ligament [lig. falciforme hepatis] is a double layer of peritoneum representing (as before mentioned) the ventral portion of the primitive ventral mesogastrium.

Its upper end is continuous posteriorly with the coronary ligament. It passes forward and downward over the superior surface of the liver. From its line of attachment to the liver (between right and left lobes) it passes forward and slightly to the left to the attachment on the anterior body wall. This attachment extends downward slightly to the right of the mid-line to the umbilicus. The lower margin of the falciform ligament is free, and encloses the round ligament.

The **round ligament** [lig. teres hepatis] is a fibrous cord representing the obliterated fœtal left umbilical vein. It extends upward from the umbilicus enclosed in the lower margin of the falciform ligament.

At the anterior margin of the liver it passes backward on the inferior surface, enclosed in a slight peritoneal fold at the bottom of the fossa venæ umbilicalis (sometimes bridged over by liver tissue). It ends by joining the left branch of the portal vein.

The **ligamentum venosum** [lig. venosum; Arantii] similarly represents the obliterated fœtal ductus venosus. It is a fibrous cord lying in the fossa ductus venosi, and extends from the left branch of the portal vein upward to the left hepatic vein near its opening into the vena cava. The ligamentum venosum lies within the hepatic attachment of the lesser omentum.

The **lesser omentum** [omentum minus] has already been discussed in connection with the peritoneum. It represents the dorsal part of the primitive ventral mesogastrium, extending from the stomach to the liver. It includes two parts, as shown in fig. 906.

The upper and larger part forms the *gastro-hepatic* ligament [lig. hepato-gastricum], connecting the liver (fossa ductus venosi) with the lesser curvature of the stomach. The upper part of this ligament is somewhat thicker, the lower part thinner and more transparent. The relations of the lesser omentum in cross-section of the body are shown in fig. 903. The lower and right portion of the lesser omentum extends beyond the pylorus and connects the portal fissure with the duodenum, forming the *hepato-duodenal* ligament [lig. hepatoduodenale] (fig. 905). Its right margin forms the anterior boundary of the epiploic foramen (of Winslow). Between its layers are located the root structures of the liver, as follows: hepatic artery to the left, common bile duct to the right, portal vein behind and between. A special prolongation of the hepato-duodenal ligament frequently extends downward to the transverse colon, forming the *hepato-colic* ligament [lig. hepatocolicum].

Fixation of the liver.—The liver is to a certain extent fixed in place by means of its various ligaments, and especially through the attachment of the hepatic veins to the inferior vena cava. On account of the close apposition of the liver to the diaphragm, the atmospheric pressure also helps in its support. Finally, the support of the liver, as well as of the abdominal viscera in general, is dependent to a considerable extent upon the tonic contraction of the abdominal muscles, which exerts a constant pressure upon the abdominal contents.

Blood-vessels.—The liver receives its *arterial* supply of blood from the hepatic artery, a branch of the cœliac, which passes up between the two layers of the lesser omentum, and dividing into two branches, one for each lobe, enters the liver at the portal fissure. The right branch gives off a branch to the gall-bladder. The liver receives a much larger supply of blood from the *portal vein*, which conveys to the liver blood from the stomach, intestines, pancreas, and spleen. It enters the portal fissure, and there divides into two branches. Below this fissure the hepatic artery lies to the left, the bile-duct to the right, and the portal vein behind and between the two (fig. 946). These three structures ascend to the liver between the layers of the lesser omentum in front of the epiploic foramen. At the actual fissure the order of the three structures from before backward is—duct, artery, vein.

The *hepatic veins*, by which the blood of the liver passes into the inferior vena cava, open usually by two large and several small openings into that vessel on the posterior surface of the gland at the bottom of the fossa venæ cavæ.

Lymphatics.—The lymphatics are divided into a deep and a superficial set. The *deep set* runs with the branches of the portal vein, artery, and duct through the liver, leaving at the portal fissure, where they join the vessels of the superficial set. The efferent deep vessels after leaving the portal fissure pass down in the lesser omentum in front of the portal vein, through the chain of hepatic lymphatic nodes, and ultimately end in a group of nodes at the upper border of the neck of the pancreas, in which the pyloric lymphatics also terminate.

The *superficial set* begins in the subperitoneal tissue. Those of the *upper surface* consist:—(1) Of vessels which pass up, principally, in the falciform ligament and right and left triangular ligaments, through the diaphragm, and so into the anterior mediastinal nodes, and finally into the right lymphatic duct. Some lymphatics of the right triangular ligament pass to the posterior mediastinal lymph-nodes and into the thoracic duct. (2) Of a set passing downward over the anterior border of the liver to the hepatic nodes in the portal fissure, and over the posterior surface to reach the superior gastric and cœliac nodes. On the lower surface, the lymphatics to the right of the gall-bladder enter the lumbar nodes. Those around the gall-bladder enter the hepatic nodes of the lesser omentum. Those to the left of the gall-bladder enter the superior gastric nodes.

Nerves.—The nerves of the liver are derived from the vagi (those from the left vagus entering from the stomach through the lesser omentum), and from the cœliac plexus of the sympathetic (including right vagus branches) through a plexus accompanying the hepatic artery. The terminations, so far as known, are chiefly to the walls of the vessels and of the bile ducts.

Structure of the liver.—The liver is, for the greater part, covered by peritoneum, beneath which is found the fibro-elastic layer known as Glisson's capsule. At the portal fissure, Glisson's capsule passes into the substance of the liver, accompanying the portal vessels, the branches of the hepatic artery, and the bile-ducts. The liver substance is composed of vascular units measuring from 1 to 2 mm., and known as liver lobules. These are in part (man) separated by

FIG. 947.—SECTION OF A PORTAL CANAL. (Quain.)

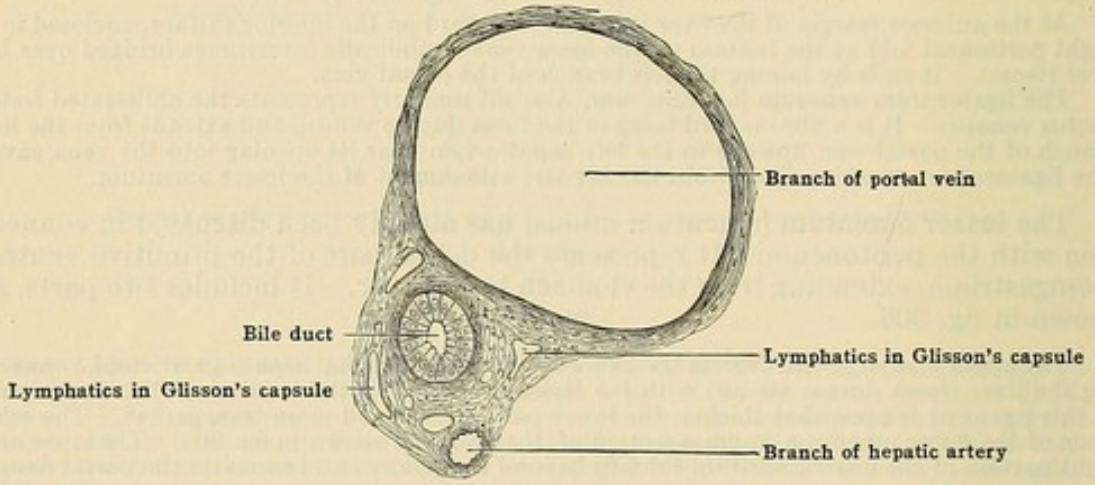

a small amount of interlobular connective tissue, which is a continuation of Glisson's capsule. In this interlobular connective tissue are found the terminal branches of the portal vessels; the hepatic artery, and the bile-ducts (figs. 947, 948). The branches of the portal vessels which encircle the liver lobules are known as the interlobular veins. From these are given off hepatic capillaries, which anastomose freely, but have in general a direction toward the centre of the lobule, and unite to form the central or intralobular veins, which in turn unite to form the sublobular veins, and these the hepatic veins. The intralobular branches of the hepatic arteries form capillaries which unite with the capillaries of the intralobular portal veins.

The liver is a modified compound tubular gland. The liver-cells are arranged in anastomosing cords and columns occupying the spaces formed by the hepatic capillaries. The bile-ducts have their origin in so-called bile-capillaries [ductus biliferi], situated in the columns of liver-cells; they anastomose freely and pass to the periphery of the lobules to form the primary divisions of the bile-ducts, and these unite to form the larger bile-ducts. The branches of the portal vessel are accompanied in their course through the liver by the branches of the hepatic artery and the bile-ducts, surrounded by extensions of Glisson's capsule forming the so-called 'portal canals' (fig. 947). The branches of the hepatic vein are solitary, their walls are thin and closely adherent to the liver substance, whence they remain wide open on sectioning the liver.

While it is customary to describe thus the liver lobules, it would be more logical to consider as the real lobules what Mall has described as the 'portal units.' Each portal unit includes the territory supplied by one interlobular branch of the portal vein, and drained by the accompanying bile-duct. The relations of the ordinary lobules and the portal units are evident in fig. 948. The portal unit corresponds more nearly to the lobule of other glands, where the duct is in the centre of the lobule.

Bile passages.—The bile passages, which transmit the bile from the liver to the duodenum, include the gall-bladder, the cystic duct, the hepatic ducts, and the common bile duct.

The **gall-bladder** [vesica fellea], which retains the bile, is situated between the right and quadrate lobes on the lower surface of the liver. It is pear-shaped, and when full, is usually seen projecting beyond the anterior border of the liver, coming in contact with the abdominal wall opposite the ninth costal cartilage at the lateral margin of the right rectus muscle (fig. 914). It extends back as far as the portal fissure.

It measures in length, from before backward, 7 to 10 cm. It is 2.5 to 3.5 cm. across at the widest part, and will hold about 35 cc. (1¼ oz.). The broad end of the sac is directed forward, downward, and to the right, and is called the *fundus*. The narrow end, or *neck* [collum vesicæ felleæ], which is curved first to the right, then to the left, lies within the gastro-duodenal ligament at the portal fissure. The intervening part is called the *body* [corpus vesicæ felleæ].

FIG. 948.—DIAGRAM OF THE PORTAL UNIT AND VASCULAR RELATIONS OF THE HEPATIC LOBULE. (After Szymonowicz.)

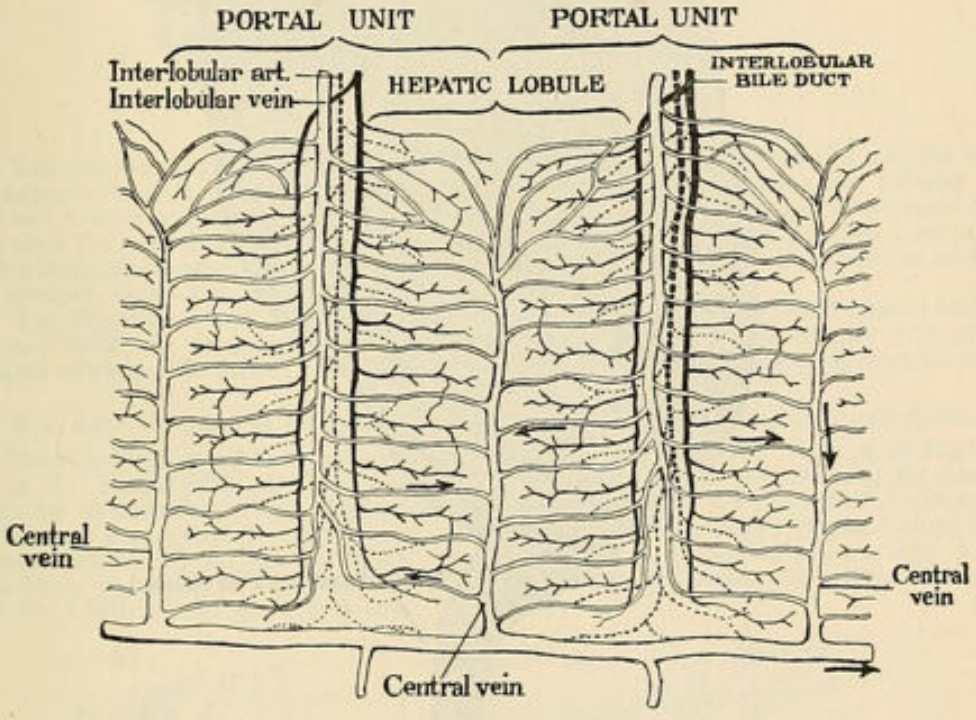

Its *upper surface* is in contact with the liver, lying in the fossa of the gall-bladder. It is attached to the liver by connective tissue. The lower surface is covered by peritoneum, which passes over its sides and inferior surface, though occasionally it entirely surrounds the gall-bladder, forming a sort of mesentery attaching to the liver. The *lower surface* comes into contact with the first part of the duodenum and the transverse colon, and occasionally with the pyloric end of the stomach or small intestine, which *post mortem* are often found stained with bile.

The neck of the gall-bladder opens into the *cystic duct* [ductus cysticus]. This is a tube about 3.5 cm. long and 3 mm. wide, which unites with the hepatic duct to form the ductus choledochus; it is directed backward and to the left as it runs in the gastro-hepatic ligament, the common hepatic artery being to the left and the right branch of the artery and portal vein behind. It joins the hepatic duct at an acute angle, and is kept patent by a spiral valve [valvula spiralis; Heisteri], formed by its mucous coat (fig. 949).

The *hepatic duct* [ductus hepaticus] begins with a branch from each lobe, right and left (that from the left receiving also the ducts from the caudate lobe), in the portal fissure, and is directed downward and to the right within the portal fissure and the hepato-duodenal ligament, the right branch of the hepatic artery being behind and the left branch to the left. It is from 3 to 5 cm. long; its diameter is about 4 mm. Uniting with the cystic duct, it forms the *common bile-duct* [ductus choledochus].

The **ductus choledochus** or **common bile-duct** is about 7.5 cm. in length and 6 mm. in width. It passes down between the layers of the lesser omentum, in front of the portal vein, and to the right of the hepatic artery (fig. 946); it then passes behind the first part of the duodenum, then between the second part and the head of the pancreas, being almost completely embedded in the substance of the pancreas, and ends a little below the middle of the descending duodenum by opening into that part of the intestine on its left side and somewhat behind (figs. 921, 922, 957). It pierces the intestinal wall very obliquely, running between the muscular layers for a distance of about 1 to 2 cm. There is a slight constriction at its termination. The pancreatic duct is generally united with the ductus choledochus just before its termination, and there is a slight papilla at their place of opening on the mucous surface of the duodenum. This papilla is about 8 or 10 cm. from the pylorus. After the pancreatic duct has entered the bile-duct there is (in about half the cases) a dilatation of the common tube called the **ampulla of Vater.**

FIG. 949.—INTERIOR OF THE GALL BLADDER AND DUCTS. (From Toldt's Atlas.)

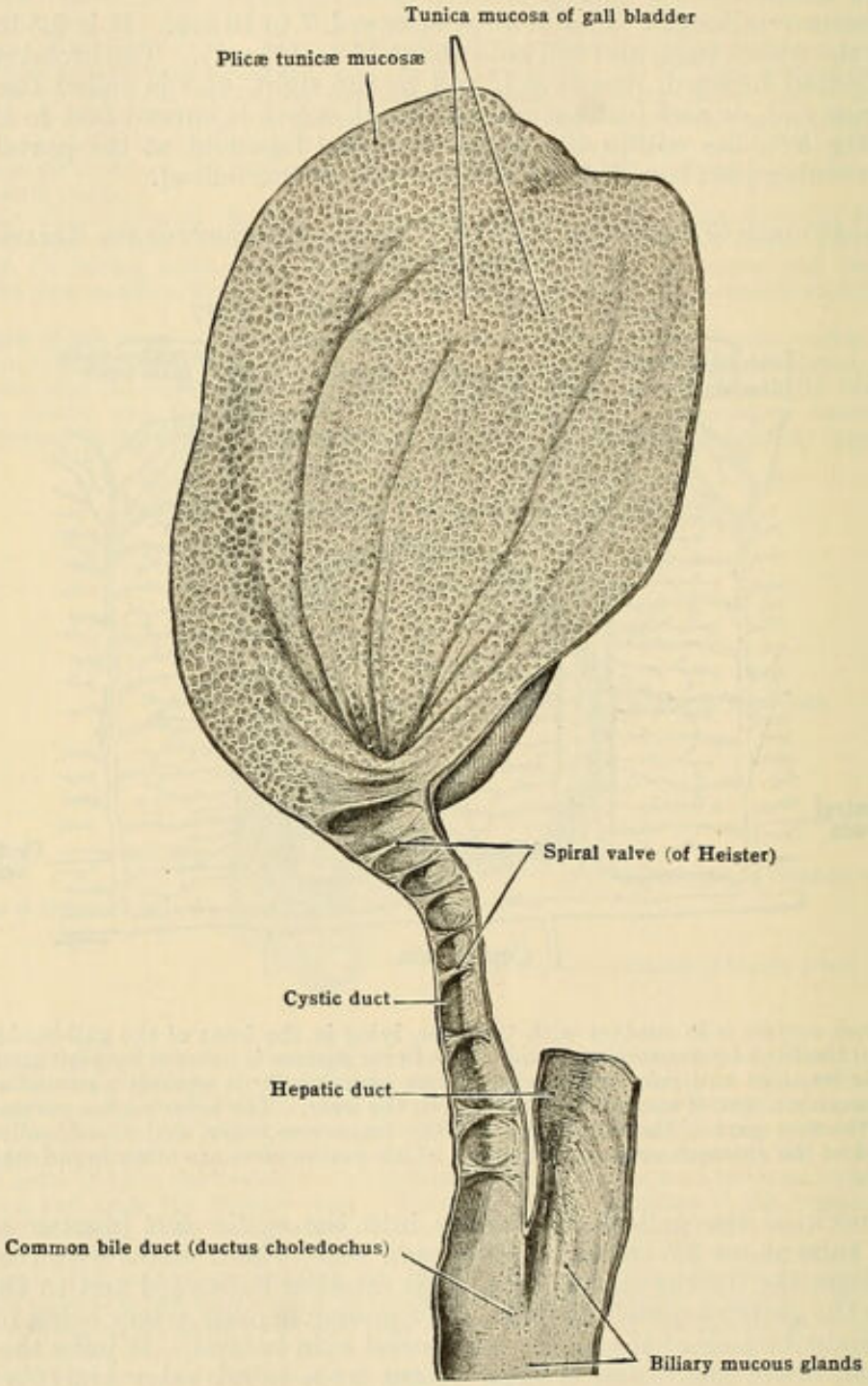

In its oblique course through the duodenal wall, the common bile duct is accompanied by the pancreatic duct, the two together usually causing the plica longitudinalis duodeni (fig. 922). Circular muscle fibres join with bundles of longitudinal fibres at the lower part of the ducts and form a sphincter around each (fig. 950). Contraction of the sphincter probably closes the orifice of the common bile duct, so that (except during digestion) the bile is backed up into the gall-bladder.

Structure of the gall-bladder.—The wall of the gall-bladder is made up of three coats—mucosa, fibro-muscular and serosa.

FIG. 950.—MACERATED DUODENAL PORTION OF THE COMMON BILE DUCT, SHOWING MUSCULATURE. *B*, Common bile duct. *W*, Pancreatic duct (of Wirsung). *S*, *IR*, Sphincter fibres of bile duct. *H*, Fibres of pancreatic duct. (Hendrickson.)

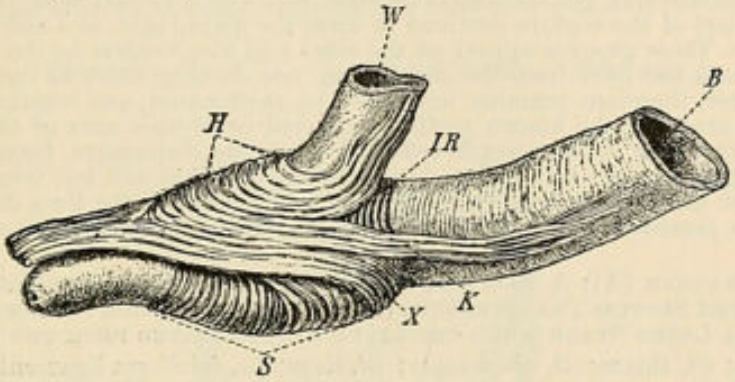

1. The *mucosa* is raised into folds bounding polygonal spaces, giving the interior a honeycomb appearance. It is lined with columnar epithelium, and contains a few tubular mucous glands and lymph-nodules, and is limited externally by a poorly developed muscularis mucosæ. At the neck the mucous membrane forms valve-like folds which project into the interior. This layer contains an anastomosis of blood-vessels, the capillaries being most numerous in the folds of the mucosa, and a fine plexus of lymphatics.

2. The *fibro-muscular coat* consists of interlacing bundles of non-striated muscle and fibrous tissue not definitely arranged, the muscular bundles running longitudinally and obliquely This layer contains the principal blood-vessels and lymphatics, and also a nerve plexus.

FIG. 951.—DIAGRAMS OF THE DEVELOPMENT OF THE LIVER. (Lewis and Stöhr.)

A, The condition in a 4.0 mm. human embryo. B, A 12 mm. pig. C, The arrangement of ducts in the human adult. *c. d.*, Cystic duct; *c. p.*, cavity of the peritoneum; *d.*, duodenum; *d.c.*, ductus choledochus; *dia.*, diaphragm; *div.*, diverticulum; *f. l.*, falciform ligament; *g. b.*, gall bladder; *g. o.*, greater omentum; *h. d.*, hepatic duct; *ht.*, heart; *int.*, intestine; *li.*, liver; *l. o.*, lesser omentum; *m.*, mediastinum; *oe.*, œsophagus; *p. c.*, pericardial cavity; *p. d.* pancreatic duct; *ph.*, pharynx; *p. v.*, portal vein; *st*, stomach; *tr.*, trabecula; *v. c. i.*, vena cava inferior; *v.v.* vitelline vein; *y. s.*, yolk sac.

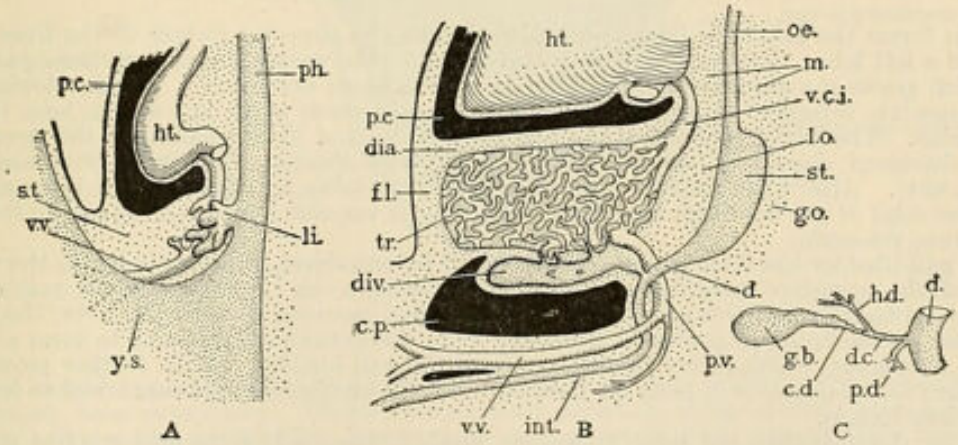

3. The *serosa* being formed by the peritoneum, is only found on the lower surface and part of the sides.

The *ducts* consist of a fibro-muscular and a mucous layer. In the fibro-muscular layer are non-striated muscle-cells which are chiefly circular, together with white fibrous tissue and elastic fibres. The mucous layer is lined with columnar epithelium, and has many mucous glands. In the cystic duct the mucous membrane is raised into folds, which are crescentic in form, and directed so obliquely as to seem to surround the lumen of the tube in a spiral manner.

The development of the liver.—The relations which the liver bears to the diaphragm, to its vessels and more especially the veins, and to its so-called ligaments, may be understood by a reference to its development (figs. 951, 952). In discussing the development of the peritoneum and the mesenteries it was shown that the liver has its origin in a bud of entoderm, which grows

into the transverse septum in the region where this is attached to the ventral mesoderm of the developing intestine; and that, with further development, the transverse septum differentiates into an upper thinner portion, inclosing the Cuvierian ducts, and destined to form the diaphragm, and a lower thicker portion in which the liver develops. Shortly after the formation of the entodermal bud which forms the liver this mass of epithelium becomes penetrated by outgrowths from the omphalo-mesenteric veins, reducing the epithelial mass to anastomosing trabeculæ separated by blood-spaces forming a sinusoidal circulation. The definite hepatic lobules are not differentiated until after birth. The process of the development of the lobules is very complicated, the vascular arrangement being shifted repeatedly (Mall).

The liver rapidly enlarges, filling the upper portion of the abdominal cavity, and extending along its ventral wall to the region of the umbilicus. During the enlargement it in a measure outgrows the transverse septum, and there are developed grooves which result in an infolding of the peritoneum covering the transverse septum, and which in part separate the developing liver from that part of the septum destined to form the diaphragm, and also from the ventral abdominal wall. These grooves appear at the sides and also ventral to the liver, but do not completely separate the liver from the diaphragm, nor do they meet in the median line. A portion of the liver, therefore, remains uncovered by peritoneum, and remains attached to the diaphragm; this area may be known as the uncovered or phrenic area of the liver. Around this area the peritoneum of the liver is reflected on to the diaphragm, forming the coronary ligament, with right and left extensions, designated as the right and left triangular ligaments. Owing to the fact that the grooves which develop on the sides of the liver do not meet in the median line, there persists a fold of peritoneum which attaches the liver to the ventral abdominal

FIG. 952.—DIAGRAM (A): A SAGITTAL SECTION OF AN EMBRYO SHOWING THE LIVER ENCLOSED WITHIN THE SEPTUM TRANSVERSUM; (B) A FRONTAL SECTION OF THE SAME; (C) FRONTAL SECTION OF A LATER STAGE WHEN THE LIVER HAS SEPARATED FROM THE DIAPHRAGM.

All, Allantois; *Cl*, cloaca; *D*, diaphragm; *Li*, liver; *Ls*, falciform ligament of the liver, *M*, mesentery; *Mg*, mesogastrium; *Pc*, pericardium; *S*, stomach; *ST*, septum transversum; *U*, umbilicus. (McMurrich.)

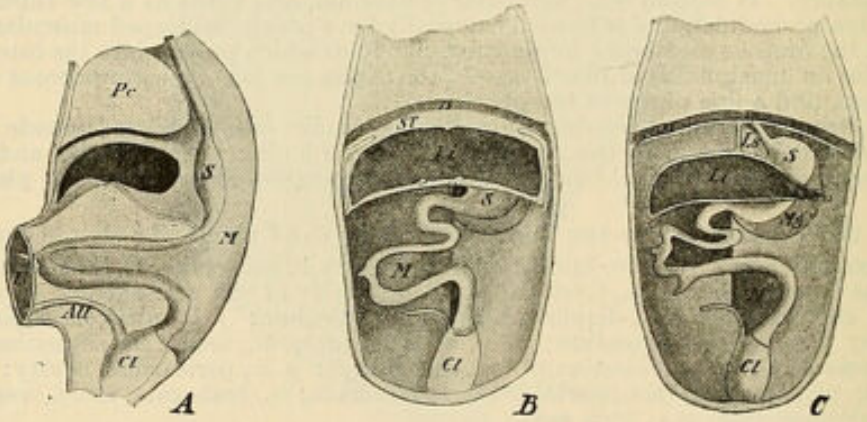

wall; this forms the falciform ligament, which divides the superior surface of the liver into a right and a left lobe. The region of the attachment of the ventral mesentery (mesogastrium) into which grows the entodermal liver bud, forms the lesser omentum. The developing liver early comes into intimate relation with the omphalo-mesenteric veins, and a little later the umbilical veins. The developmental history of these veins and their relation to the developing liver is discussed elsewhere (see DEVELOPMENT OF THE PORTAL VEIN AND INFERIOR VENA CAVA, p. 694). After birth the left umbilical vein forms the hepatic ligamentum teres, situated in the free edge of the falciform ligament. The ductus venosus likewise atrophies to form the ligamentum venosum.

The gall-bladder has its origin in a groove lined by entoderm, which appears on the ventral surface of the primitive intestine or archenteron, between the stomach and the yolk-vesicle. From the cephalic end of this groove grows out the bud destined to form the liver; the caudal end of the groove becomes gradually separated from the developing intestine to form a pouch, lined by entoderm, which forms the beginning of the gall-bladder. With further growth the attachment to the intestine of both the liver and the gall-bladder becomes narrowed to form the ductus choledochus.

During development, the liver undergoes marked changes in form and relative size. It grows with great rapidity in the embryo, its maximum relative size reaching 7 to 10 per cent. of the entire body about the third prenatal month. At this time, the liver is globular in form, the visceral surface very small, and the left lobe more nearly approaching the right in size. During the later fœtal months (fig. 953) and at birth, the liver forms about 5 per cent. of the whole body. It still remains relatively large in infancy, but decreases to about 2.5 per cent. in the adult. From the beginning, the relative weight of the liver averages slightly higher in the female.

Variations of the liver and bile passages.—Many variations of the liver have already been mentioned. In *size*, both relative and absolute, it is subject to marked individual variations, as well as according to age and sex (previously described). In *form*, the liver is also quite variable. There are two extreme types: (1) in which the liver is very wide, extending far over into the left hypochondrium, but relatively flattened from above downward; and (2) in which it

extends but slightly to the left, being somewhat flattened from side to side, and elongated vertically. This type may occur as a result of tight lacing, in which the liver is frequently deformed. The part projecting below the right costal margin may form the so-called 'Riedel's lobe.' All intermediate forms between these two types occur. Its *position and relations* will also vary necessarily according to differences in size and shape. For example, in the wide type and also in enlarged livers, the left lobe may extend over upon the spleen, a relation which is constant during prenatal life.

There may be *supernumerary fissures*, dividing the liver into additional lobes, as many as 16 having been described in an extreme case (Moser). These extra fissures often correspond to fissures which are normal in other mammals. There may also be *accessory lobes*, usually small, and connected with the main gland by stalks. Any one of the normal lobes may be *atrophied* or absent. There may also be *abnormal grooves* on the parietal surface of the liver. Of these, there are two varieties: (1) *costal* grooves, due to impressions of the overlying ribs and costal cartilages; and (2) *diaphragmatic* grooves, due to wrinkles in the diaphragm. These

FIG. 953.—THE VISCERA OF THE FŒTUS. (Rüdinger.)

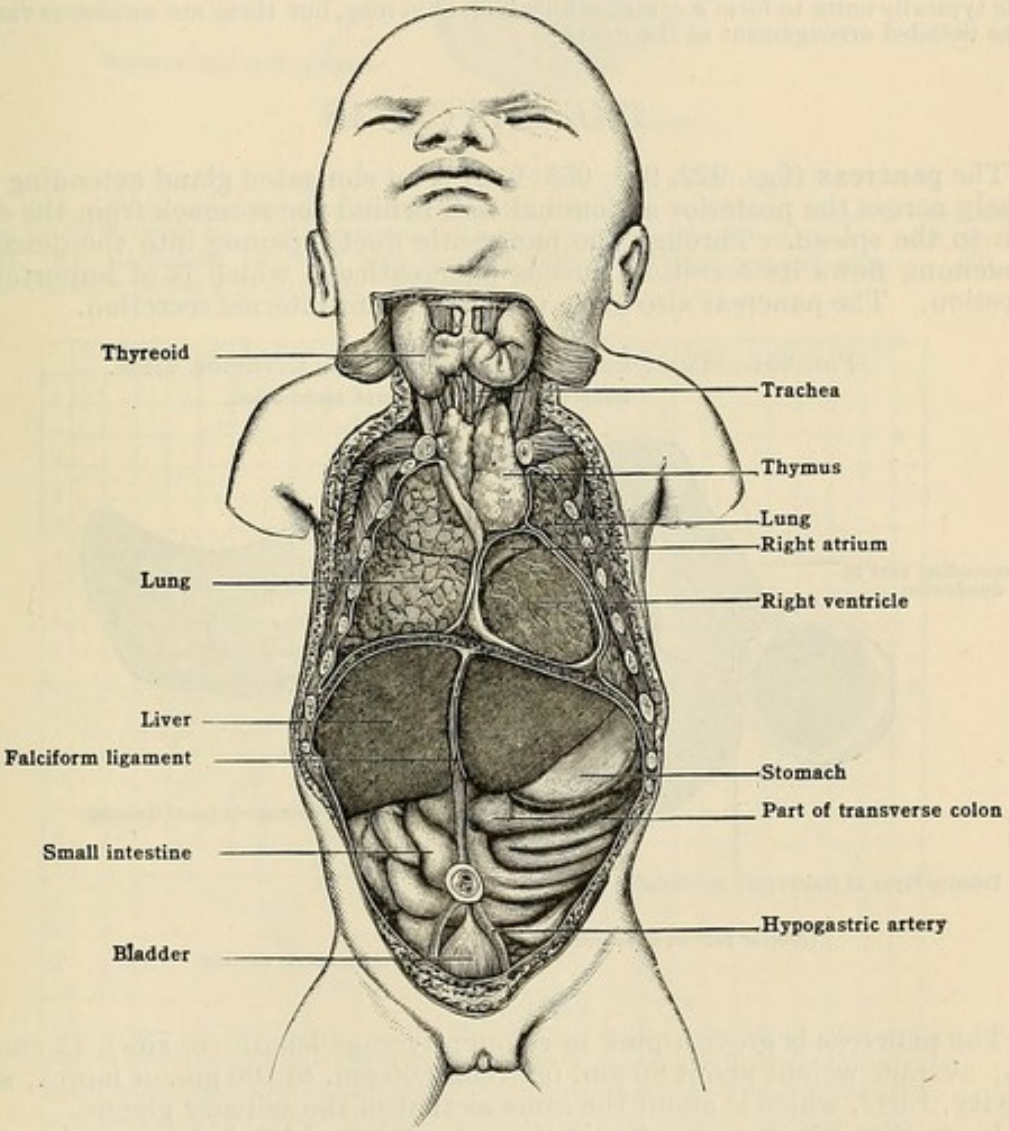

grooves most frequently occur in females, as a result of tight lacing. The *appendix fibrosa* has already been mentioned. There are numerous variation in the *vascular* arrangements, as well as in the *peritoneal* relations (particularly in connection with the coronary ligament).

The *bile passages* are even more variable than the liver proper. The *gall-bladder* is variable in *size* and capacity (25 cc. to 50 cc. or more), as well as in its *position* and *relations*. The fundus projects to a variable extent beyond the anterior margin of the liver so as to come into contact with the abdominal wall in a little more than half the cases, but is often retracted. The *fossa* of the gall-bladder is of variable depth, rarely so deep that it reaches the superior surface of the liver. The peritoneum usually covers only the sides and inferior surface of the gall-bladder, but occasionally surrounds it entirely, forming a short 'mesentery.' In rare cases the gall-bladder is *bifid* or *double*, and is occasionally *absent*. There are numerous variations in the *bile-ducts*. Rarely the hepatic ducts may communicate directly with the gall-bladder. The point at which hepatic and cystic ducts unite is variable, which affects the relative lengths of these and the ductus choledochus. The latter may open into the duodenum separately, instead of with the pancreatic duct.

Comparative.—The liver arises in all vertebrates as an outgrowth of the entodermic epithelium of the intestine just beyond the stomach. In amphioxus it remains a simple saccular diverticulum, but in all higher forms becomes a compound tubular gland. The tubular character becomes masked, however (in amniota, and especially in mammals), by the abundant anastomosis between the tubules, forming what is called a 'solid' gland. The relations with the portal venous system are constant. The liver frequently stores large quantities of fat, and may even undergo a complete fatty metamorphosis (lamprey). The colour of the liver is usually reddish-brown, but may be yellow, purple, green or even vermillion (due to bile pigments). In *size*, the liver is variable, but is usually relatively larger in anamniota. Among mammals, there is great variation according to diet, the liver being relatively larger in carnivora, smaller in herbivora, and intermediate in omnivora (including man). It is also relatively larger in *small* animals (including young and fœtal stages), probably on account of their more intense metabolism. There are typically two lobes, right and left, in the vertebrate liver. These are frequently subdivided, however, especially in mammals, which often present numerous lobes.

The **gall-bladder** is typically present, as in man, but varies in form, size and position. It may be completely buried in the liver. In some species it is absent, in which case the hepatic ducts open directly into the duodenum by one or more apertures. The hepatic and cystic ducts typically unite to form a common bile-duct, as in man, but there are numerous variations in the detailed arrangement of the ducts.

THE PANCREAS

The **pancreas** (figs. 922, 954, 955, 956) is an elongated gland extending transversely across the posterior abdominal wall behind the stomach from the duodenum to the spleen. Through the pancreatic duct, opening into the descending duodenum, flows its secretion [succus pancreaticus], which is of importance in digestion. The pancreas also has a very important internal secretion.

Fig. 954.—The Duodenum and Pancreas, Anterior View.

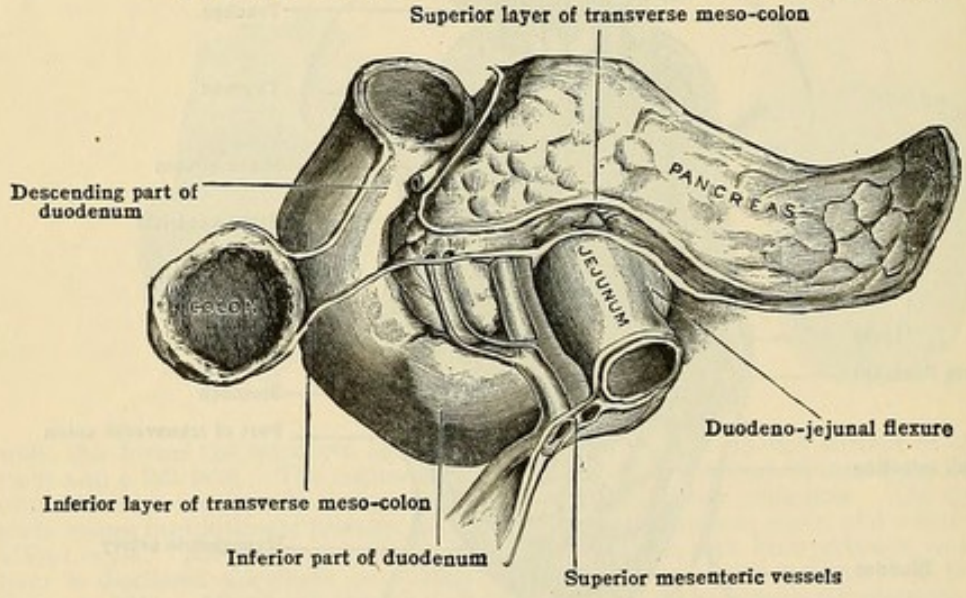

The pancreas is greyish-pink in colour; average length (*in situ*), 12 cm. to 15 cm.; average weight about 80 gm. (extremes 60 gm. to 100 gm. or more); specific gravity, 1.047, which is about the same as that of the salivary glands.

In *position*, the pancreas lies in the epigastric and left hypochondriac regions. In *form*, it somewhat resembles a pistol, with the handle placed to the right and the barrel to the left. The pancreas is accordingly divided into a *head*, lying within the duodenal loop; a *body*, extending to the left; and a *tail*, or splenic extremity.

The **head** [caput pancreatis] is a discoidal mass somewhat elongated vertically and flattened dorso-ventrally. It forms the enlarged right extremity of the pancreas and lies within the concavity of the duodenum (figs. 922, 954, 955). Its *relations* are as follows (figs. 954, 955, 956): Its *posterior* surface is placed opposite the second and third lumbar vertebræ, and is in contact with the aorta, the vena cava, the renal veins and right renal artery. The common bile-duct is also partly embedded in this surface. Its *anterior* surface is crossed by the transverse colon, above which is the pyloric extremity of the stomach, and below which are coils of

FIG. 955.—THE DUODENUM AND PANCREAS, POSTERIOR VIEW.

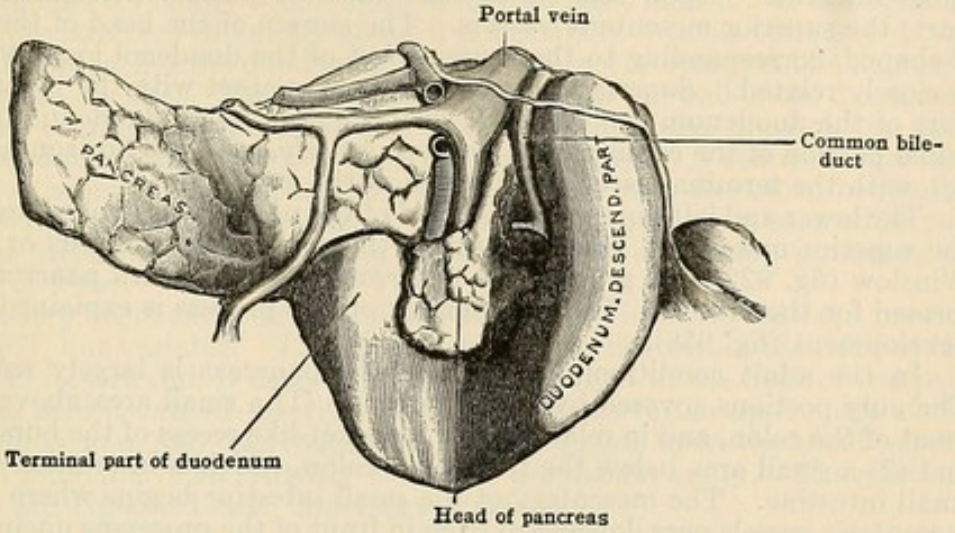

FIG. 956.—OUTLINE SHOWING THE AVERAGE POSITION OF THE DEEPER ABDOMINAL VISCERA IN 40 BODIES, ON A CENTIMETRE SCALE (reduced to .36 natural size). *AB*, anterior mid-line. *EF*, horizontal line half way between pubes and suprasternal margin. *CD*, line half way between pubes and line *EF*. (Addison.)

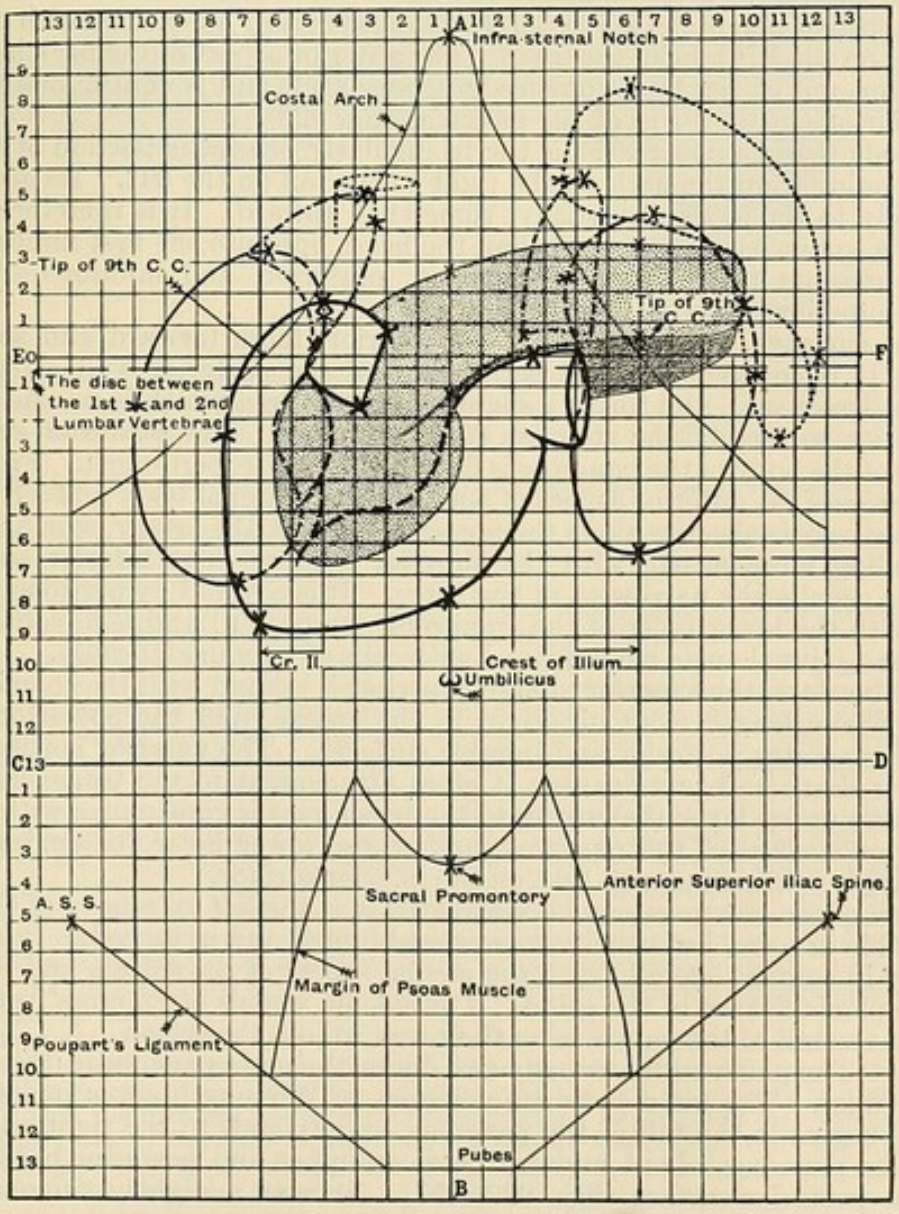

small intestine. Upon this surface are also the pancreatico-duodenal and (in part) the superior mesenteric vessels. The *margin* of the head of the pancreas is C-shaped, corresponding to the inner aspect of the duodenal loop, with which it is closely related. *Superiorly* the margin is in contact with the pylorus and first part of the duodenum; *on the right*, with the descending duodenum and the terminal portion of the common bile duct; *inferiorly*, with the horizontal, and *on the left*, with the terminal ascending portion of the duodenum.

The lower and left portion of the head of the pancreas is hooked around behind the superior mesenteric vessels, forming the **processus uncinatus** or pancreas of Winslow (fig. 922). A groove, the *pancreatic notch* [incisura pancreatis], is thus formed for the vessels. The morphology of this process is explained later under development (fig. 958).

In the adult condition, the head of the pancreas is largely *retroperitoneal.* The only portions covered by peritoneum are (1) a small area above the attachment of the colon, and in relation with a pocket-like recess of the bursa omentalis, and (2) a small area below the transverse colon, which is in relation with coils of small intestine. The mesentery of the small intestine begins where the superior mesenteric vessels pass downward from in front of the processus uncinatus.

The junction of the upper and left aspect of the head with the body of the pancreas is called the *neck.* This is a somewhat constricted portion grooved *posteriorly* by the superior mesenteric vessels, the vein here joining with the splenic to form the portal vein (fig. 955). *Anterior* to the neck is the pyloric portion of the stomach. The upper portion of the neck (together with a variable area on the left end of the body) projects above the lesser curvature of the stomach. This projection [tuber omentale] is related, through the lesser omentum, with a similar tuberosity on the left lobe of the liver. The anterior aspect of the neck is covered with peritoneum of the bursa omentalis (lesser sac), and is continuous with the anterior surface of the body of the pancreas (fig. 922).

The **body** [corpus pancreatis] is the triangularly prismatic portion of the pancreas extending from the neck on the right to the tail on the left. Its *direction* is transversely to the left and (usually) somewhat upward. It is therefore usually placed at a somewhat higher level than the head, opposite the first lumbar vertebra. It presents three surfaces—anterior, posterior, and inferior—and three borders—superior, anterior, and posterior.

Of the **surfaces,** the **anterior** [facies anterior] faces forward and somewhat upward. It is covered with the peritoneum of the posterior wall of the bursa omentalis (lesser sac), and forms a slightly concave area which is in contact with the posterior surface of the stomach (figs. 904, 906). The **posterior** surface [f. posterior] of the body of the pancreas is flattened and retroperitoneal. From right to left it crosses the anterior aspect of aorta, left suprarenal body and left kidney. The splenic vessels also run along the posterior surface, the artery, which is above, corresponding more nearly with the superior border. The **inferior** surface [f. inferior] is usually the narrowest of the three. It is covered by peritoneum (continuous with the lower layer of the transverse mesocolon) and is in contact with the duodeno-jejunal angle medially and with coils of jejunum laterally.

Of the **borders,** the **superior** [margo superior] is related with the splenic artery along its whole length from its origin in the cœliac, and the **posterior** [margo posterior] separates posterior and inferior surfaces. The **anterior** border [margo anterior] is sharp and prominent. It gives attachment to the transverse mesocolon, whose upper layer (belonging to the lesser sac) is continuous with that on the anterior surface of the pancreas, and whose lower layer (belonging to the greater sac) is continuous with that on the inferior surface.

The **tail** of the pancreas [cauda pancreatis] is at the left extremity of the body. It is variable in form, but usually somewhat blunted and upturned. It is almost invariably in contact *laterally* with the medial aspect of the spleen, and *inferiorly* with the splenic flexure of the colon. The splenic vessels often cross from above in front of the tail of the pancreas on their way to join the spleen.

Ducts.—The pancreas has usually two ducts, the main pancreatic duct and the accessory duct. The main *pancreatic* or duct of Wirsung [ductus pancreaticus; Wirsungi] begins in the tail of the pancreas, and extends to the right within the body of the pancreas, about midway between upper and posterior borders, but nearer the posterior surface (figs. 922, 957). It runs a slightly sinuous course

receiving branches all along, which enter nearly at right angles. It is largest in the head of the pancreas (diameter about 3 mm.) where it turns obliquely downward. As it approaches the duodenum, it is joined by the common bile duct, the two running side by side. They pass obliquely through the wall of the duodenum for a distance of about 15 mm. (usually causing a fold of the mucosa, the plica longitudinalis duodeni). They terminate finally, usually by a common aperture, but sometimes separately, on the duodenal *papilla major*, as described in connection with the interior of the duodenum. The common aperture is somewhat narrow, but just preceding this the duct is frequently dilated, forming what is called the *ampulla of Vater*.

The *accessory* pancreatic duct (duct of Santorini) is nearly always present (figs. 922, 957), but variable. This duct is small, and lies within the head of the pancreas. At its left end, it usually joins the main duct in the neck of the pancreas. From here it extends nearly horizontally across to the upper part of the descending duodenum and, piercing its wall, usually ends upon the small *papilla minor*, about 2 cm. above and slightly ventral to the papilla major. The relations of the ducts are explained later under development.

FIG. 957.—THE PANCREAS AND ITS DUCTS, DISSECTED FROM BEHIND.

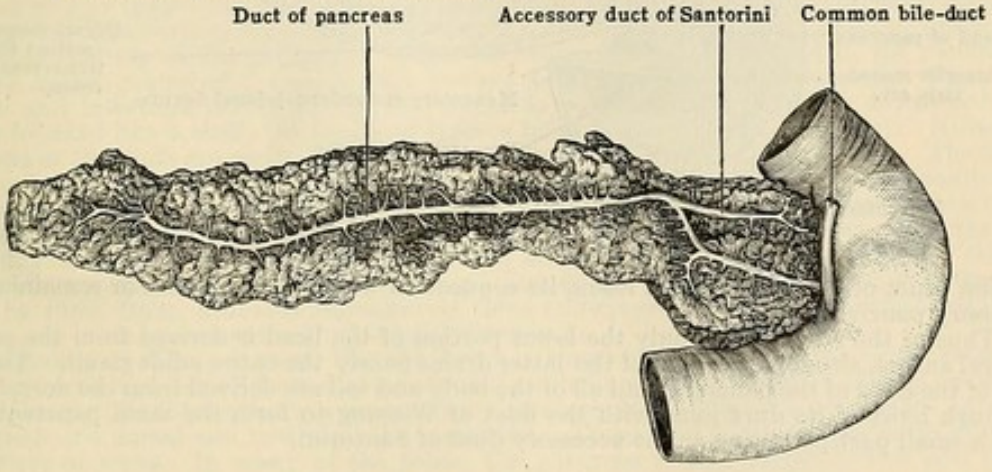

Blood-vessels.—The pancreas receives blood chiefly from the splenic artery through its pancreatic branches, and from the superior mesenteric and hepatic by the inferior and superior pancreatico-duodenal arteries, which form a loop running around, below, and to the right of its head.

The blood is returned into the portal vein by means of the splenic and superior mesenteric veins.

Lymphatics.—The lymphatics terminate in numerous glands which lie near the root of the superior mesenteric artery, above and below the neck of the pancreas. All the lymphatics drain ultimately into the cœliac glands.

Nerves.—These are branches of the cœliac plexus which accompany the arteries entering the gland. The main part of the cœliac plexus lies behind the gland.

Minute anatomy.—In many respects, the pancreas resembles the salivary glands in structure, hence its German name 'Bauchspeicheldrüse' ('abdominal salivary gland'). The gland proper is racemose (or tubulo-racemose) in structure, the secreting cells characteristically granular and 'serous' in type. The thin-walled 'intercalary ducts,' often invaginated to form 'centroacinar' cells, are characteristic. The lobules are very loosely joined by areolar tissue, and there is no distinct fibrous capsule around the gland. The most important of the distinctive characters of the pancreas is the presence throughout the gland of numerous small interlobular cell-masses of varied form and size—the *islets of Langerhans* (fig. 959). These have no ducts, but are richly supplied with blood-vessels. They are ductless glands of great importance in sugar metabolism, and their removal or disease produces diabetes. While derived embryologically from the same entodermal anlage which gives rise to the pancreas gland proper, they apparently have no direct connections with it in the adult. The question as to the possible metamorphosis of acini into islets, or *vice versa*, under certain conditions (e. g., hunger) in the adult has been much disputed. Bensley, however, has recently presented strong evidence against this view.

Development of the pancreas.—The pancreas has its origin in three entodermal buds, one of which (the dorsal anlage) grows from the dorsal portion of the duodenum, the other two (ventral anlages) from either side of the bile-duct. Of the two latter, only that growing from the right side of the bile-duct needs further consideration, as the other soon disappears. The dorsal anlage grows at first more rapidly than the ventral, which arises from the bile-duct. In their further growth both the dorsal and ventral anlages become lobed, these lobes dividing further to form the ducts and the alveoli of the gland. By about the end of the second month the distal end of the ventral portion comes in contact with the dorsal portion at a short distance

from the latter's connection with the duodenum. A fusion of the two portions thus takes place in this region, and at the same time there is established by anastomosis a connection between the terminal branches of the main duct of the dorsal portion—duct of Santorini—and the branches of the main duct of the ventral portion—the duct of Wirsung. With further development the duct of Wirsung develops into the main pancreatic duct, the duct of the dorsal

FIG. 958.—DIAGRAM SHOWING THE RELATIONS OF THE PANCREAS TO THE PRIMITIVE MESENTERY. (Poirier-Charpy.)

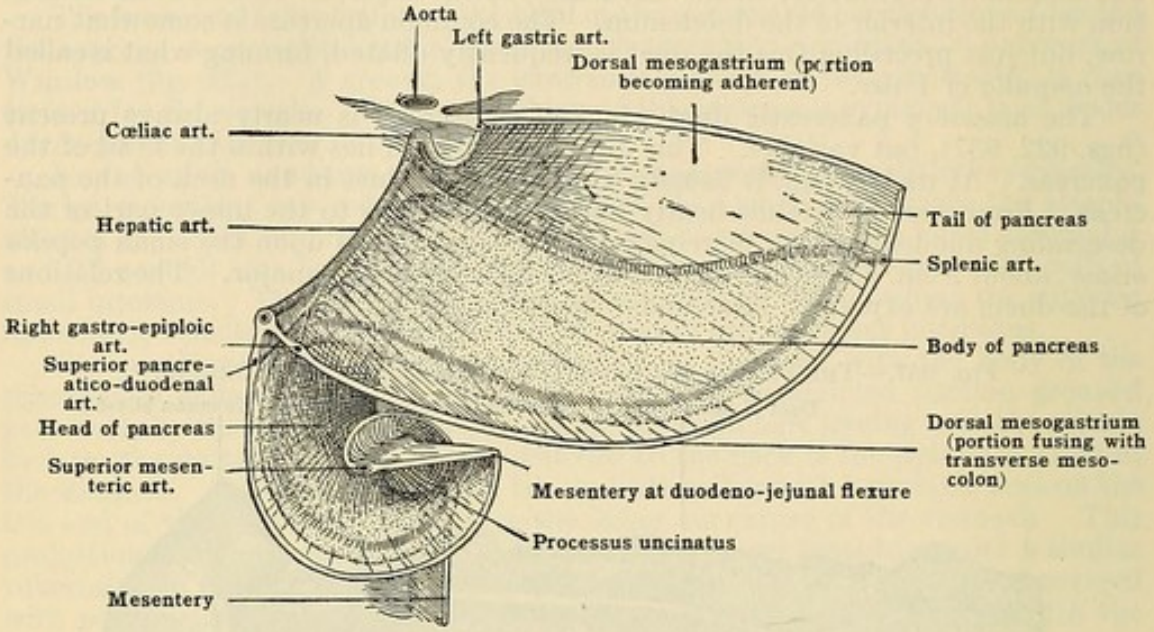

portion (duct of Santorini) either losing its connection with the duodenum or remaining as the accessory pancreatic duct.

Thus of the adult gland, only the lower portion of the head is derived from the primitive ventral anlage, although the duct of the latter drains nearly the entire adult gland. The upper part of the head of the pancreas, and all of the body and tail are derived from the dorsal anlage; although most of its duct joins with the duct of Wirsung to form the main pancreatic duct, only a small part persisting as the accessory duct of Santorini.

FIG. 959.—SECTION OF HUMAN PANCREAS, MAGNIFIED, SHOWING SEVERAL ISLETS OF LANGERHANS. (Radasch.) *a*, Interlobular connective tissue, containing an interlobular duct, *c*, *b*, Capillary. *d*, Interlobular duct. *e*, Alveoli. *f*, Islet of Langerhans.

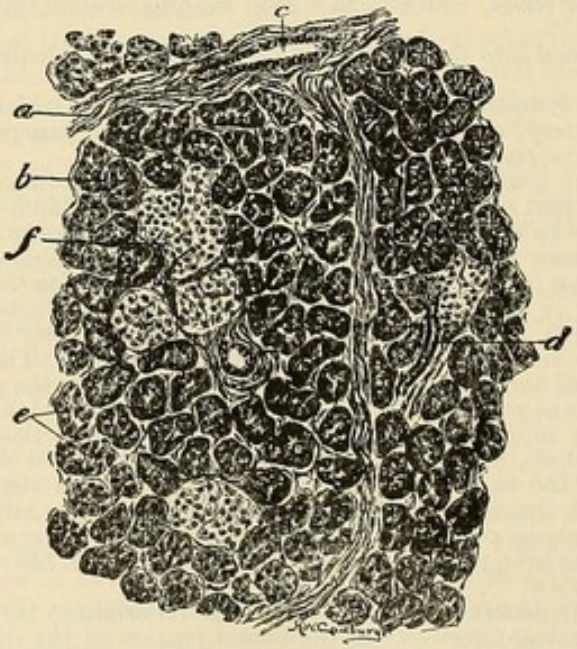

During the early stages in the development of the pancreas the entodermal buds from which it forms grow into the mesoduodenum, and later the dorsal mesogastrium. With the rotation of the stomach and the consequent change in the position of the mesogastrium and its partial fusion with the abdominal wall, the pancreas assumes a retroperitoneal position. This is illustrated by fig. 958. The head of the pancreas is involved in the rotation of the primitive

intestinal loop counter-clockwise around the superior mesenteric artery. This accounts for the position and the hook-like form of the processus uncinatus. Following this rotation, the duodenum and the head of the pancreas become pressed backward against the posterior abdominal wall, where they become adherent, with fusion and obliteration of the primitive peritoneum. The body of the pancreas, extending into the dorsal mesogastrium (fig. 900), is similarly caught in the pouch-like downgrowth of the latter to form the bursa omentalis (lesser sac), and is thereby carried over to the left side. When the posterior layer of the primitive bursa fold becomes fused with the posterior abdominal wall, the enclosed pancreas is likewise fixed and becomes retroperitoneal. Of these obliterated peritoneal layers of the embryo, only certain layers of fascia remain as their representatives in the adult. From the lower aspect of the pancreas downward, the posterior layer of the bursa fold becomes fused with the transverse mesocolon, so that in the adult the latter appears to arise from the anterior border of the pancreas (fig. 904).

Variations.—Aside from minor fluctuations in size and form, the variations of the pancreas are chiefly congenital and of embryonic origin. Cases of *accessory or supernumerary pancreas* are not rare. They are usually of small size and have separate ducts. They may occur along the wall of the duodenum, or even in the stomach or jejunum. They are perhaps in some way connected with the numerous intestinal diverticula which occur in the embryo. *Divided pancreas* differ from the accessory in that a mass of the pancreas becomes separated from the main gland, connected only by a duct. This occurs oftenest in the region of the tail (sometimes extending into the spleen) or of the processus uncinatus, forming what is termed a 'lesser pancreas.' Sometimes a ring of glandular tissue from the head of the pancreas surrounds the descending duodenum, forming an *annular pancreas*. Variations in the *direction* of the body are numerous; it may be horizontal, ascending or bent in various ways. These are doubtless congenital variations, as similar types have been described in the fœtus (Jackson). It has been experimentally demonstrated that varying degrees of distention of the stomach and intestines affect profoundly the *form of the body* of the pancreas. When the stomach alone is distended, the pancreas is flattened antero-posteriorly, the inferior surface being practically obliterated. When *both* stomach and intestines are distended, the pancreas is flattened from above downward, and extends forward like a shelf, the posterior surface being much reduced (Jackson). Numerous variations in the *ducts* are easily understood from their complicated development. The accessory duct (of Satorini) is in the fœtus as large as the main duct (of Wirsung), the preponderance of the latter being established later. The accessory duct in the adult may be larger than usual, and retain its primitive drainage, or even drain the entire gland in rare cases where the duct of Wirsung is absent. Or the accessory duct may be rudimentary or (rarely) absent. Similar variations occur in the main duct of Wirsung. Rarely the pancreas may open into the duodenum by three ducts, probably representing three embryonic anlages. Abnormalities of the pancreas are often associated with duodenal diverticula.

Comparative.—The pancreas, like the liver, is constant throughout the vertebrates. It always arises by budding off from the endodermal epithelium of the intestine, closely associated with the liver. There is typically a triple anlage (rarely multiple, which is perhaps the ancestral type), with one dorsal and two ventral outgrowths. These fuse and form the adult pancreas in a variety of ways. In many of the fishes, the pancreas is very small, diffuse and inconspicuous, sometimes embedded in the liver or intestinal wall. Of the three primitive ducts, usually only two persist (as in man), but often only one, or all three (in birds). All three types occur in mammals. The islets of Langerhans arise from the epithelial pancreas anlage, and appear to be constantly present, even in the lowest vertebrates. Laguesse even considers that phylogenetically they form the most primitive part of the pancreas, but this is doubtful.

References for digestive system.—*General and Comparative:* Quain's Anatomy, 11th ed.; Poirier-Charpy, Traité d'anatomie; Rauber-Kopsch, Lehrbuch der Anatomie, 9te Aufl.; Oppel, Mikroskopische Anatomie, Bd. 1–3; also 'Verdauungsapparat' in Merkel and Bonnet's 'Ergebnisse'; Wiedersheim, Bau des Menschen. *Topography:* (adult) Merkel, Topographische Anatomie; (developmental) Jackson, Anat. Rec., vol. 3. *Development:* Keibel and Mall's Manual. *Teeth:* Tomes, Dental Anatomy. *Tonsils:* (lingual) Jurisch, Anatomische, Hefte, Bd. 47; (pharyngeal) Symington, Brit. Med. Jour. (Oct., 1910); (palatine) Killian, Archiv f. Laryngol., Bd. 7. *Œsophagus:* Goetsch, Amer. Jour. Anat., vol. 10. *Stomach:* (structure), Bensley, Buck's Ref. Handb. Med. Sc., vol. 7 (1904); (form) Cunningham, Trans Royal Soc. Edinb., vol. 45; (radiography) Cole, Archives Roentgen Rays, 1911; also Journal Amer. Med. Assn., vol. 59. *Duodenum:* (diverticula), Baldwin, Anat. Rec., vol. 5. *Vermiform process:* Berry and Lack, Jour. Anat. and Phys., vol. 40. *Rectum:* Symington, Jour. Anat. and Phys., vol. 46. *Liver:* Mall, Amer. Jour. Anat., vol. 5. *Pancreas:* (islets) Bensley, Amer. Jour. Anat., vol. 12; (ducts) Baldwin, Anat. Rec., vol. 5.

SECTION X

THE RESPIRATORY SYSTEM

REVISED FOR THE FIFTH EDITION

BY R. J. TERRY, A.B., M.D.,

PROFESSOR OF ANATOMY IN WASHINGTON UNIVERSITY

RESPIRATION consists in the absorption by the organism of oxygen and the discharge of a waste-product, carbon dioxide.

Among unicellular animals the oxygen is taken up directly from the medium—water or air—in which they live, and the carbon dioxide given off into it. With the cells which make up the body of higher animals the principle is the same, but the interchange of gases is indirect. The blood stands as an intermediate element between the cells of the body and the medium inhabited

FIG. 960.—DISSECTION OF A MALE NEGRO, AGE 43 YEARS, TO SHOW THE ORGANS OF RESPIRATION IN SITU.

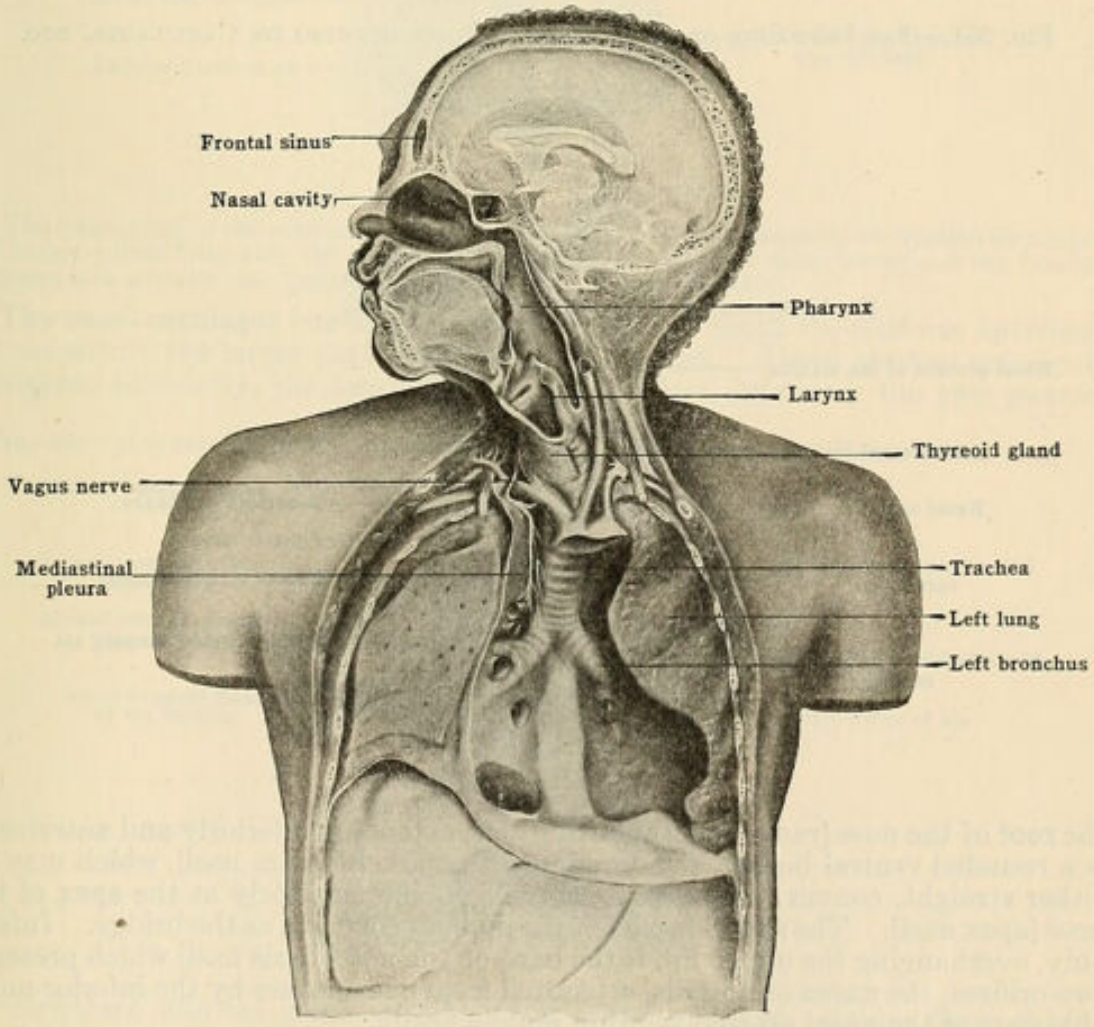

by the animals, and serves as a carrier of the gases between them. Moreover, special organs are provided for the rapid interchange between air and blood, which constitute the so-called **respiratory system.**

The respiratory system of air-breathing vertebrates consists of tubular and cavernous organs constructed so as to permit of the atmospheric air reaching the

blood circulating in the body. The essential organs in the system are the paired **lungs** located in the **thoracic cavity.** Air is carried to and from the lungs by the **trachea** and **bronchi,** and these simple transmitting tubes are in turn put into communication with the exterior by the mediation of other organs. The latter are, however, specially constructed in adaptation to other functions in addition to those relating to respiration: the **larynx** for the production of the voice, the **pharynx** and **mouth** in connection with alimentation, the **nasal cavity** and **external nose** functioning in the sense of smell. (For the description of the mouth and pharynx see Section IX; for the olfactory organ see Section VIII.)

The organs of circulation are always adapted to the form of the respiratory apparatus, and among all higher animals a connection is established between heart and lungs by the pulmonary artery, which carries venous blood to the latter, and by the pulmonary veins, which convey arterial blood from the lungs to the heart, whence the aorta takes it into the general circulation.

In their origin and development the respiratory organs are closely associated with or differentiated from the beginnings of the digestive apparatus. Thus the processes of the early development of the nasal cavity and mouth are interdependent; the origin of the greater part of the larynx, the trachea and lungs is by ventral outgrowth of the entodermal canal.

THE NOSE

The **external nose** [nasus externus] (fig. 961), shaped like a triangular pyramid, is formed of a bony and cartilaginous framework covered by muscles and the integument of the face externally and lined within by periosteal and perichondral layers overspread by mucous membrane. At the forehead, between the eyes, is

FIG. 961.—THE LEFT SIDE OF THE EXTERNAL NOSE, SHOWING ITS CARTILAGES, ETC.

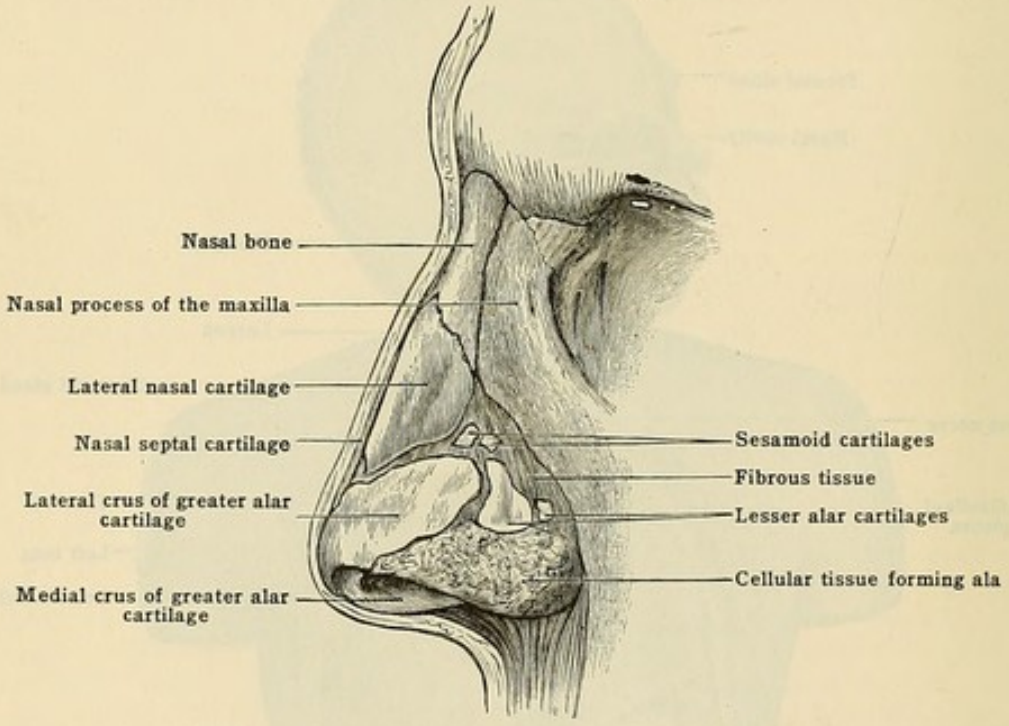

the **root** of the nose [radix nasi], and from this, extending inferiorly and anteriorly, is a rounded ventral border, the **dorsum** of the nose [dorsum nasi], which may be either straight, convex, or concave, and which ends inferiorly at the **apex** of the nose [apex nasi]. The superior part of the dorsum is known as the bridge. Inferiorly, overhanging the upper lip, is the **base** of the nose [basis nasi] which presents two orifices, the **nares** or nostrils, separated from one another by the inferior movable part of the nasal septum [septum mobile nasi].

The nostril of man is remarkable on account of its position, facing as it does almost directly downward. It is oval in form, with the long axis directed antero-posteriorly, or approximately so, in Europeans. The size of the nostril is under the control of muscles (see p. 334) and may be dilated or constricted by their action.

The sides of the nose slope from the dorsum laterally and posteriorly, and

below ferminate on each side in the **margin** of the nose [margo nasi]; posteriorly and inferiorly the sides are expanded and more convex, forming the **alæ nasi.** Each of these is separated from the rest of the lateral surface by a sulcus, and the inferior free margin of each bounds a naris laterally.

Three types of nose, distinguished by differences in the proportion of breadth and length are recognised by anthropologists: the leptorrhine or long, high nose; the platyrrhine or short, low nose; the mesorrhine, a form intermediate between the other two. The leptorrhine type prevails among white races, the platyrrhine in the black peoples and the mesorrhine in the red and yellow races.

FIG. 962.—ANTERIOR VIEW OF THE EXTERNAL NOSE, SHOWING ITS CARTILAGES, ETC.

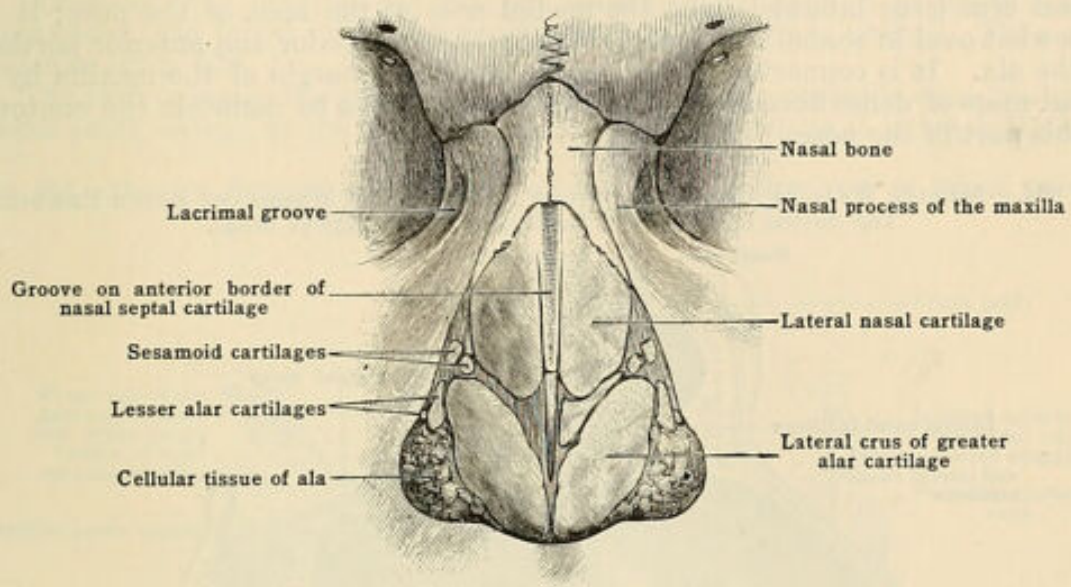

The framework of the external nose is formed partly of bone and partly of hyaline cartilage The bones, which form only the smaller superior part, are the two nasal bones and the fronta processes and anterior nasal spines of the two maxillæ (pp. 87, 108).

The nasal cartilages [cartilagines nasi] are located about the piriform aperture and constitute the larger part of the nasal framework. There are five principal cartilages: superiorly, the two *lateral nasal cartilages,* inferiorly the two *greater*

FIG. 963.—INFERIOR VIEW OF THE EXTERNAL NOSE, SHOWING ITS CARTILAGES, ETC.

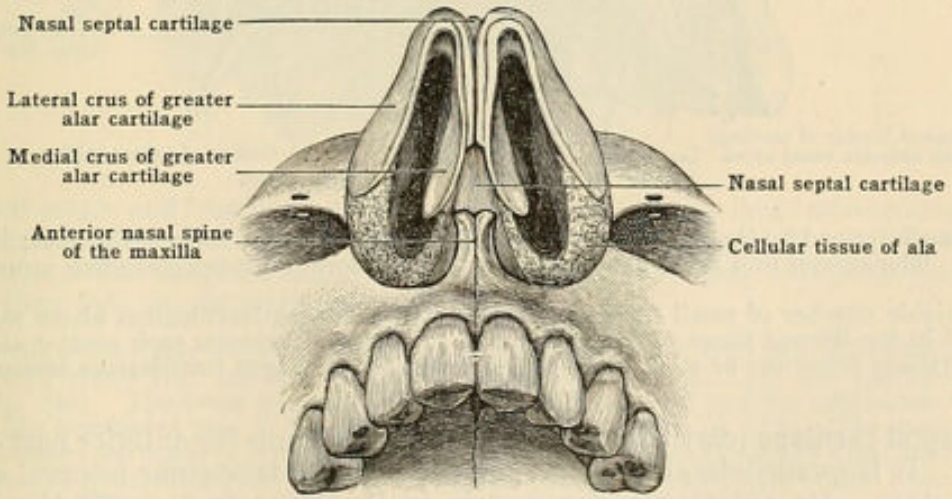

alar cartilages, and the single median *nasal septal cartilage.* Beides these there are the *lesser alar cartilages,* the *sesamoid cartilages,* and the *vomero-nasal cartilages* of Jacobson. The **lateral nasal cartilages** [cartilagines nasi laterales] are triangular and nearly flat lateral expansions of the septal cartilage, placed one on each side of the nose just inferior to the nasal bone. Each presents an inner and an outer surface and three margins. The medial margin is continuous in its superior third with the anterior margin of the septal cartilage, and through this with its

fellow of the opposite side, but it is separated inferiorly from the septal cartilage by a narrow cleft. The curved supero-lateral margin is firmly attached by strong fibrous tissue to the nasal bone and frontal process of the maxilla, and underlies these bones for a considerable distance, especially near the septum. The inferior margin is connected by fibrous tissue to the greater alar cartilage. The **greater alar cartilages** [cartilagines alares majores], variable in form, are situated one on each side of the apex of the nose (figs. 961, 963). Each is thin, pliant, curved, and so folded that it forms a medial and a lateral crus, which bound and tend to hold open each naris. The **medial crus** [crus mediale] is loosely attached to its fellow of the opposite side, the two being situated inferior to the septal cartilage and forming the tip of the nose and the inferior part of the mobile septum. The **lateral crus** [crus laterale] joins the medial crus at the apex of the nose; it is somewhat oval in shape, and curves dorsally in the superior and anterior portion of the ala. It is connected posteriorly to the nasal margin of the maxilla by a broad mass of dense fibrous and fatty tissue, and helps to maintain the contour of this part of the nose.

FIG. 964.—MEDIAL WALL OF THE NASAL CAVITY, THE MUCOUS MEMBRANE BEING REMOVED. The dotted line indicates the course of the incisive canal.

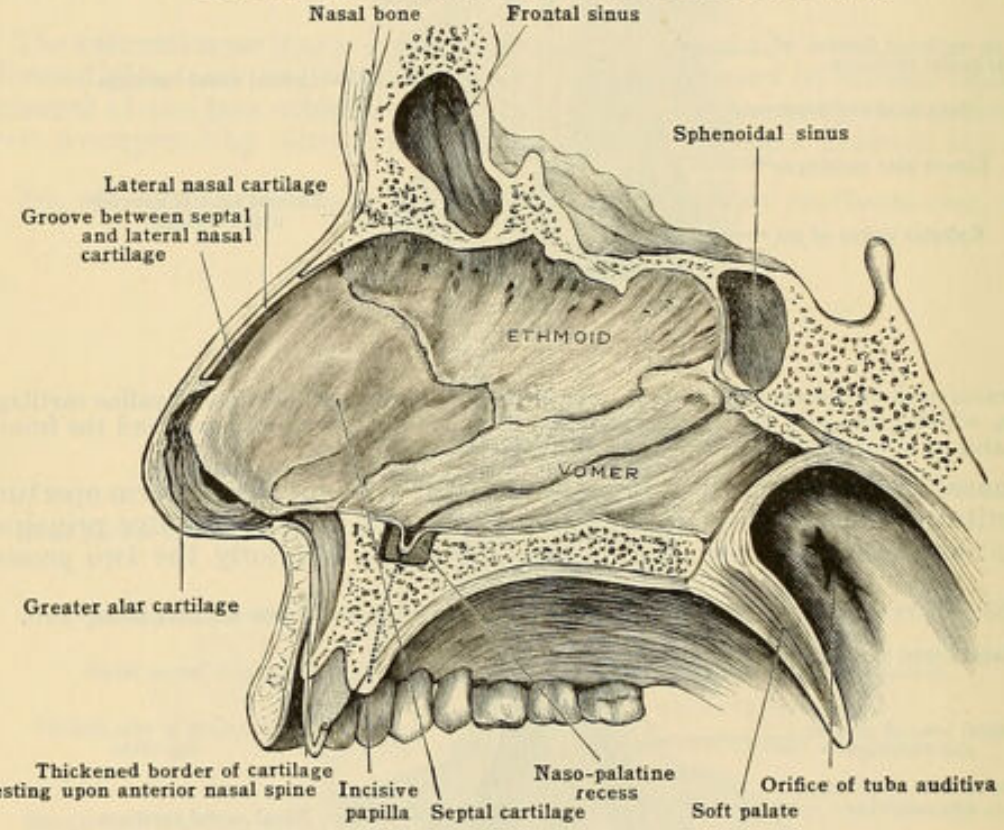

The angle formed by the crura (angulis pinnalis) varies with the shape of the nose; it averages 30°. The greater and lesser alar cartilages together form an incomplete ring around the naris.

A variable number of small cartilages, **lesser alar cartilages** [cartilagines alares minores] are found in the fibrous tissue of the ala, and in the interval between each greater alar and lateral cartilage occur one or more small plates, **sesamoid cartilages** [cartilagines sesamoideæ] (fig. 961).

The **septal cartilage** [cartilago septi nasi] (fig. 964) forms the anterior part of the septum. It is quadrilateral in shape and fits into the triangular interval of the bony septum. Its antero-superior margin in its upper part meets the internasal suture. Inferior to the nasal bone it presents a shallow groove which gradually narrows toward the tip of the nose, and whose borders are continuous superiorly with the lateral nasal cartilages, but are separated from their inferior two-thirds by a narrow slit. The most inferior part of this margin of the septal cartilage is placed between the greater alar cartilages. The antero-inferior margin extends backward from the rounded anterior angle to the anterior nasal spine. Inferiorly it is attached to the medial crus of the greater alar cartilage and to the

mobile nasal septum. The postero-superior margin is attached to the perpendicular plate of the ethmoid, and the postero-inferior margin joins the vomer and the ventral part of the nasal crest of the maxilla, the cartilage broadening out to obtain a wide though lax attachment to the nasal spine.

The shape of the septal cartilage varies with the extent of the ossification of the bony septum. Even in the adult a strip of cartilage may extend for a varying distance postero-superiorly between the vomer and perpendicular plate of the ethmoid, sometimes reaching the body of the sphenoid; it is known as the **sphenoidal process** of the septal cartilage [processus sphenoidalis septi cartilaginei]. The **vomero-nasal cartilage** [cartilago vomero-nasalis Jacobsoni*] is a narrow strip of cartilage firmly attached to each side of the septal cartilage, where this joins the anterior portion of the vomer.

Muscles.—The muscles are grouped according to function as dilators and contractors, the latter being comparatively feeble in their action. They are described on p. 334.

The **skin** covering the external nose is thin and freely movable upon the subjacent parts, except at the tip and over the cartilages, where it is much thicker,

FIG. 965.—OBLIQUE SECTION PASSING THROUGH THE NASAL CAVITY JUST IN FRONT OF THE CHOANÆ. (Seen from behind.)

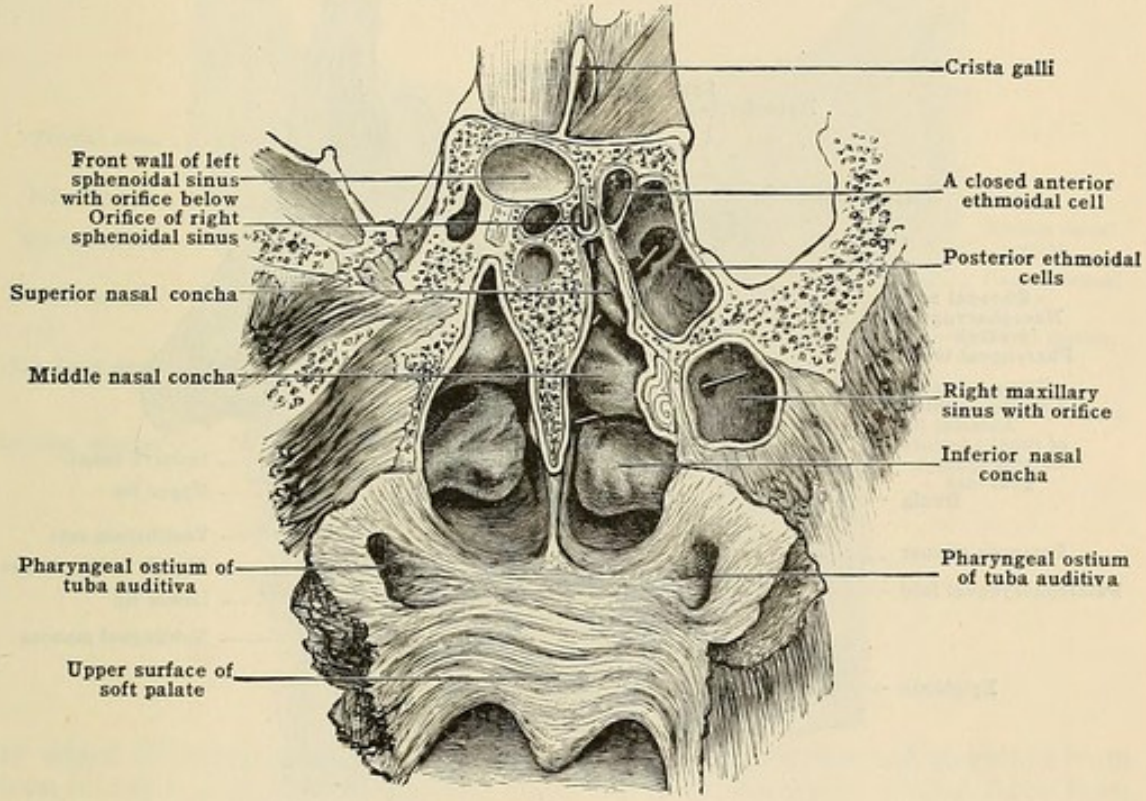

more adherent, and furnished with numerous exceptionally large sebaceous glands. At the nares it is reflected into the nasal cavity, where it passes into the mucous membrane. The hairs on the skin of the nose are very fine, except in the nares, where they may be strongly developed.

Vessels and nerves.—The **arteries** of the external nose are derived from the external maxillary (facial) artery (pp. 540 and 541), the ophthalmic artery (p. 554), and the infra-orbital artery (p. 549). The **veins** terminate in the anterior facial vein and the ophthalmic vein (p. 644). The **lymphatics** pass to the submaxillary lymphatic nodes (p. 712). The **motor nerves** are branches of the facial (p. 946). The **sensory nerves** are derived from the trigeminal through the frontal and naso-ciliary branches of the ophthalmic (p. 936) and infra-orbital branch of the maxillary (p. 939).

The **nasal cavity** [cavum nasi] is the ample space situated between the floor of the cranium and the roof of the mouth extending forward into the external nose and backward to the nasal part of the pharynx. With the exception of the inferior part of the nose its walls are of bone as already described (pp. 110, 112). The cartilages and membranes of the nose complete the boundaries anteriorly. Here the cavity opens to the exterior by the nares. At the back a free communi-

* Jacobson: Danish anatomist. B. 1783, D. 1843.

cation with the pharynx is established through the paired choanæ. Furthermore accessory nasal cavities, the paranasal sinuses, open into the cavum nasi. The walls of the nasal cavity are covered with periosteum and mucosa, the latter presenting important differences in the respiratory and olfactory regions. The organ of smell, included in the nasal cavity, is described on p. 1049.

The cavum nasi is divided into right and left symmetrical parts, called the nasal fossæ, by the **septum** of the nose [septum nasi]. The latter is supported by a framework composed of the *osseous septum* [septum nasi osseum] posteriorly, and the *cartilaginous septum* [septum cartilagineum] anteriorly. Antero-inferiorly, the small movable part of the septum is also called the *membranous septum* [septum membranaceum].

The nasal septum is almost always straight in primitive races and Caucasian children; but in a large proportion of Caucasian adults it is deflected to one side or the other.

FIG. 966.—SAGITTAL SECTION THROUGH THE FACIAL PART OF THE HEAD AND THE BODIES OF THE UPPER THREE CERVICAL VERTEBRAE. The section lies to the right of the median plane. The nasal septum has been removed. (Rauber-Kopsch.)

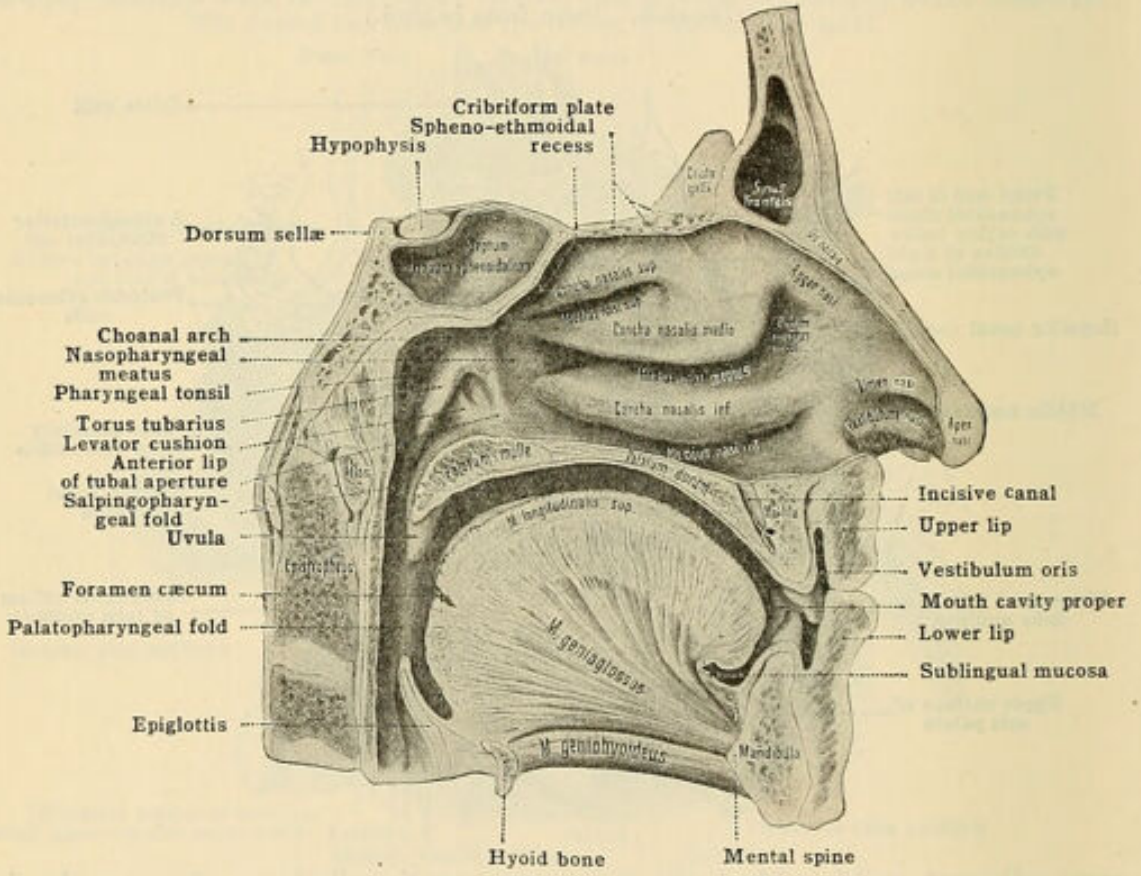

In the septum, upon each side, just superior to the nasal spines of the maxillæ, there is frequently a minute opening leading superiorly and posteriorly and ending blindly. This cavity is closely related to the vomero-nasal cartilage and is a rudimentary representative of the **vomero-nasal organ (of Jacobson)** [organon vomero-nasale], which in some animals is well developed and receives a branch of the olfactory nerve. On the floor of the nasal cavity about 2 cm. from the posterior margin of the naris and near the nasal septum a small depression, the nasopalatine recess, is often seen. This is the mouth of the incisive duct [ductus incisivus] which leads into the incisive canal for a greater or less distance and may even extend to the mouth, where its termination is marked by the incisive papilla. The incisive duct indicates the position of a foramen which in the embryo connected the mouth and nose.

The naris leads upward into the **vestibule** of the nose [vestibulum nasi], the small cavity within the compass of the greater alar cartilage. Its walls are lined with skin beset with the large hairs called **vibrissæ** and containing many sebaceous glands. The vibrissæ serve to protect the nasal cavity from the entrance of foreign matter. On the lateral wall, the vestibule is marked off from the rest of the nasal cavity by a distinct ridge, the **limen nasi,** corresponding to the superior margin of the greater alar cartilage. On the lateral wall of the cavity within the limen nasi are three antero-posterior ridges, the **superior, middle,** and **inferior**

conchæ (fig. 966). These have a bony framework (described on pp. 83, 110) and are covered by the mucous membrane of the nose. The conchæ are not parallel to one another but converge in a backward direction. The **superior nasal concha** [concha nasalis superior] is the smallest, projects only slightly medialward and downward from the upper, posterior part of the lateral wall, overhanging the groove called superior meatus of the nose. The **middle nasal concha** [concha nasalis media] is extensive, reaching from the fore part to the posterior confines of the lateral wall. Its free margin is nearly vertical in its anterior one-fourth, horizontal and laterally rolled in the rest of its extent. Under cover of this concha runs the middle meatus. The **inferior nasal concha** [concha nasalis inferior] is the longest, has a lateral attached and an inferior laterally rolled free margin running near the floor of the nasal cavity. Beneath it lies the inferior meatus.

Meatuses of the nose [meatus nasi] (figs. 966, 968). The name **common meatus** of the nose [meatus nasi communis] is given to that part of the nasal cav-

FIG. 967.—FRONTAL SECTION THROUGH THE FACIAL PORTION OF THE HEAD OF A WHITE MAN, AGE 28 YEARS.

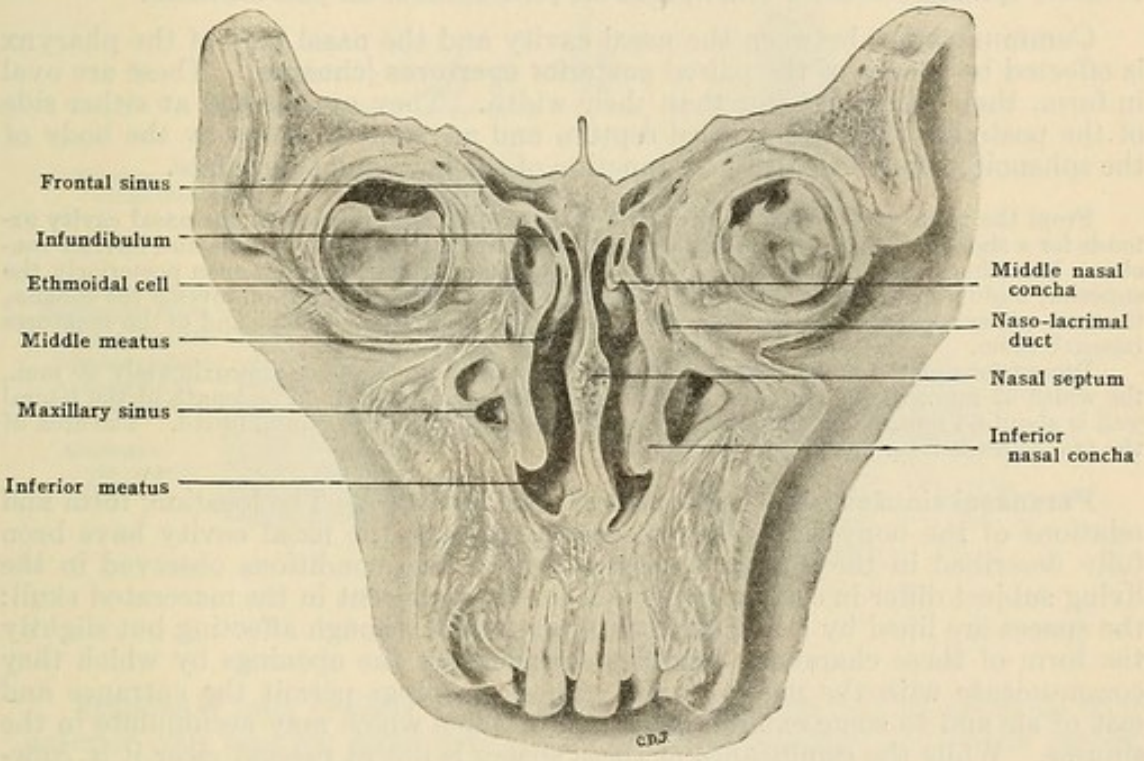

ity which lies between the septum nasi and the nasal conchæ and stretches from floor to roof. The three meatuses under cover of the nasal conchæ have been mentioned. These passages all communicate freely with the common meatus, extend antero-posteriorly and have a greater capacity in front than behind. The **superior meatus** [meatus nasi superior] is the smallest of the three. Into it open the posterior ethmoidal cells by one or two small foramina. The sphenopalatine foramen, which communicates with the meatus in the dry skull, is entirely covered up by mucous membrane. The **middle meatus** [meatus nasi medius] is a much larger passage. Upon its lateral wall is a rounded eminence, the **ethmoidal bulla,** caused by the middle ethmoidal cells and perforated by the opening into them. Inferior to this is a deep curved groove, the **hiatus semilunaris,** which is continued superiorly by the **ethmoidal infundibulum** [infundibulum ethmoidale] into the frontal sinus. It also receives the openings of the anterior ethmoidal cells and the **maxillary sinus.** The **inferior meatus** [meatus nasi inferior] is the longest of the three. Upon its lateral wall, just inferior to the attachment of the inferior concha, is the slit-like opening of the **naso-lacrimal duct** [ductus naso-lacrimalis], around the opening of which the mucous membrane forms a valve, the **plica lacrimalis** (Hasneri).

Recent investigation of the nasal conchæ indicates that two upper conchæ (concha nasalis superior and concha nasalis suprema [Santorini]) are more often present than one. Three upper conchæ are not rare.

The attached margins of the middle and inferior conchæ are both arched, the convexities being upward. The highest point of the convexity is near the middle of the attached margin in the inferior concha and lies about 17 mm. above the floor of the nose; the anterior end of this concha is approximately 25–35 mm. distant from the apex of the nose (Kallius).

From the anterior end of the middle concha a slight variable elevation of the mucous membrane of the nose extends forward and downward. This, the **agger nasi,** which is regarded as of constant occurrence in the new-born, appears to be a rudimentary representative of the naso-turbinale of mammals (Schwalbe).

Below the agger nasi a broad depression of the lateral wall, the **atrium meatus medii,** leads posteriorly beneath the anterior free margin of the middle concha to the middle meatus, while above the agger, between it and the roof of the nasal cavity, the slight **olfactory groove** [sulcus olfactorius] ascends upon the lateral wall to the olfactory region. In this region, above the superior concha, is a corner of the nasal cavity of interest on account of the sphenoidal sinus opening into it: this is the **spheno-ethmoidal recess** [recessus spheno-ethmoidalis].

Variation in the number and position of the openings into the meatuses is of practical interest. An accessory mouth of the maxillary sinus is rather frequently met with, especially in old people; it lies most commonly behind the hiatus semilunaris. The infundibulum ethmoidale may open independently of the hiatus semilunaris at a spot beneath the anterior end of the attached margin of the middle concha. In the inferior meatus the mouth of the naso-lacrimal duct, which is found 22–25 mm. behind the posterior margin of the nares, may have one or more accessory openings associated with it; these are perforations of the plica lacrimalis.

Communication between the nasal cavity and the nasal part of the pharynx is effected by means of the paired **posterior apertures [choanæ].** These are oval in form, their height greater than their width. They are located at either side of the posterior edge of the nasal septum and are limited above by the body of the sphenoid, below by the line of junction of the hard and soft palate.

From the plane of the choana forward a rather constricted portion of the nasal cavity extends for a short distance to reach the level of the posterior ends of the middle and inferior conchæ. Into this region, which is known as the **meatus naso-pharyngeus,** open posteriorly the superior, middle and inferior meatuses. Posterior rhinoscopic examination reveals the choanæ, the naso-pharyngeal meatus, the posterior extremities of the three conchæ and of the meatuses beneath them.

Dimensions of the nasal cavity.—The length of the floor averages approximately 40 mm., the width 32 mm., the height from floor to lamina cribrosa 47 mm. The length of the lateral wall is about 63 mm. The choana measures 29.8 mm. high and 15.5 mm. broad. The area of the two nares is 2 sq. cm.

Paranasal sinuses [sinus paranasales] (figs. 964-968).—The location, form and relations of the bony-walled spaces connected with the nasal cavity have been fully described in the section on OSTEOLOGY. The conditions observed in the living subject differ in certain respects from those present in the macerated skull; the spaces are lined by a mucous membrane which, though affecting but slightly the form of these chambers, modifies considerably the openings by which they communicate with the nasal cavity. These openings permit the entrance and exit of air and to some extent the escape of fluids which may accumulate in the sinuses. While the significance of these spaces is not at present clear it is, however, certain that they function in lightening the weight of the skull, and probable that indirectly they serve in connection with the sense of smell.

Maxillary sinus (of Highmore*) [sinus maxillaris Highmori] (figs. 965, 966, 967).

Entrance into the maxillary sinus is offered through the middle part of the hiatus semilunaris, that is, the deep, narrow notch between the ethmoidal bulla and uncinate process of the ethmoid. Viewed from within the sinus, the opening appears as an oval window in the upper part of the medial wall—a position unfavourable to the discharge of matter, when the body is in the upright posture. An accessory opening, situated behind the normal ostium, is present in about 10 per cent. of cases.

Measurements of 90 specimens of the adult sinus maxillaris gave as the average the following (Schaeffer):

Dorsosuperior diagonal	38 mm.
Ventrosuperior diagonal	38.5 mm.
Superoinferior	33 mm.
Ventrodorsal	34 mm.
Mediolateral	23 mm.

Increase in capacity of the maxillary sinus is sometimes observed as the result of more or less extensive excavation of the bony processes of the maxilla adjacent to it, viz.: the alveolar, palatal, frontal and zygomatic. On the other hand narrowing of the cavity is encountered,

* Highmore, Nathaniel: English physician. B. 1613, D. 1685.

caused by unusually thick walls of bone, bulging inward of the facial or nasal walls, and through retention of teeth. Incomplete division into two parts through the presence of a septum has several times been observed. Communication with ethmoidal cells and with the cavity of the orbital process of the palate bone sometimes exists.

Frontal sinus [sinus frontalis] (figs. 78, 964, 968).—The paired frontal sinuses, separated from each other by a bony septum, have in general the shape of a three-sided pyramid with the base below and the apex formed above in the frontal squama. In the base near the septum is located the superior aperture of the infundibulum which, it will be recalled, opens inferiorly at the anterior extremity of the hiatus semilunaris.

The form and size of the frontal sinuses are exceedingly variable. They may extend backward in the orbital part of the frontal bone as far as the suture between it and the small wing of the sphenoid; laterally into the zygomatic process; upward toward the coronal suture. The capacity of the sinus, as determined in a small number of cases, varied from 3 to 7.8 ccm. (Brühl). Asymmetry of the septum is frequently observed. Absence of one of the sinuses is not a rare condition; absence of both is occasionally encountered.

FIG. 968.—LEFT NASAL CAVITY. (Rauber-Kopsch.)

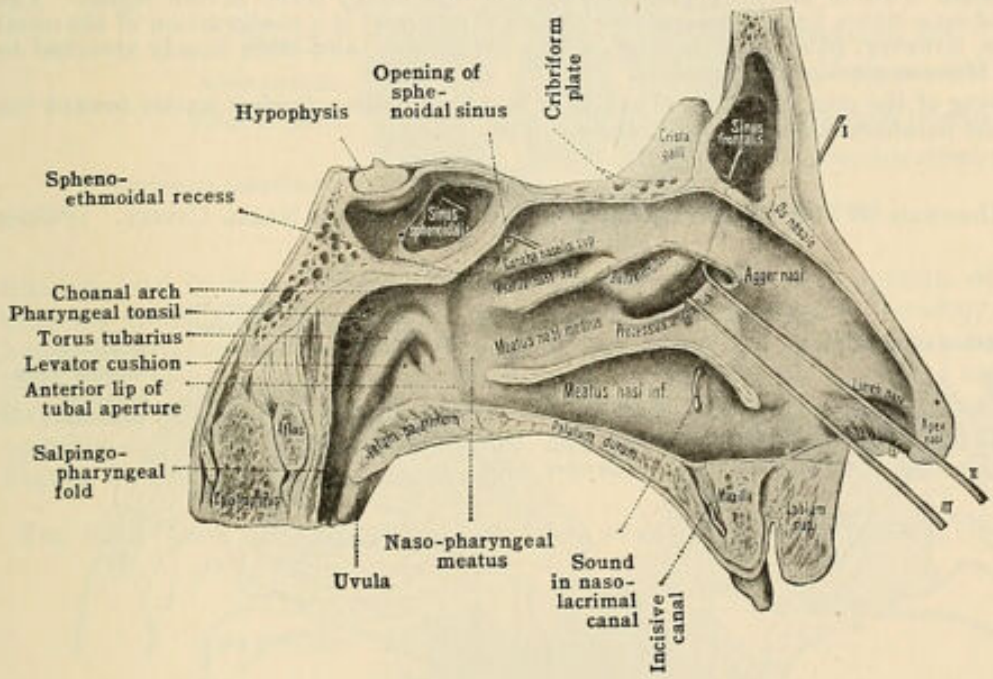

Ethmoidal cells [cellulæ ethmoidales] (figs. 965, 968).—The openings of the anterior cells into the semilunar hiatus and infundibulum, and of the posterior cells at the superior meatus have already been described.

Communications between the ethmoidal cells and the sphenoidal and maxillary sinuses are not rare; the cavity in the orbital process of the palate bone may open into the posterior cells. In old age, foramina through the lamina papyracea may appear, leading to the introduction of air into the orbit.

Sphenoidal sinus [sinus sphenoidalis] (figs. 964, 965, 966).—The apertures of the paired sphenoidal sinuses are, on account of the mucous membrane covering, much smaller than they are in the dried skull. They lie in the anterior wall near the septum, nearer the roof than the floor, and open into the spheno-ethmoidal recess.

Extension of the sphenoidal sinuses backward and also into neighbouring processes, and communication with ethmoidal cells and with the small cavity of the orbital process of the palate are not unusual. The capacity of the sinus varies between 1 and 4.2 ccm. (Brühl).

Functions of the paranasal sinuses.—Various functions have been attributed to the sinuses near the nose, none of which is entirely satisfying. Mediæval anatomists proposed that these cavities contributed to the resonance of the voice, or that they supplied the mucus by which the nasal cavity is kept moist. Lightening the skull, warming the inspired air and taking part, indirectly, in the sense of smell are functions assigned by anatomists of later times.

The **mucous membrane** of the nose [membrana mucosa nasi].—The nasal cavity is completely lined with mucous membrane, which inferiorly, at the limen nasi blends with the skin covering the walls of the vestibule (p. 1204). Posteriorly it joins the mucous membrane of the pharynx and palate. It covers some of the

openings which are seen in the bony walls; those apertures, however, which lead into the paranasal-sinuses and into the naso-lacrimal duct remain patent, although as already stated the bony openings are much reduced in size.

In the nasal cavity the bright rose-red vascular mucous membrane is tightly bound to the periosteum and perichondrium, and is covered with a ciliated columnar epithelium. Numerous large mucous **nasal glands** [glandulæ nasales] pour their more or less watery secretion over the entire surface. A very considerable venous plexus is found in many parts of the nasal mucosa. Over the inferior concha and to a less extent in the mucosa of the middle and superior conchæ, it forms the **cavernous plexuses** of the **conchæ** [plexus cavernosi concharum] contributing to build up about these bodies a true erectile tissue. The thickness which these glands and venous plexuses give to the mucous membrane of the conchæ causes the marked increase in size of these bodies over that of their bony supports. The region covered by the mucous membrane just described forms the greater part of the nasal cavity, and is known as the **respiratory region** [regio respiratoria]. The mucous membrane of a small area over the superior concha and the adjacent septal wall (fig. 969) has a somewhat different structure. In this area the olfactory nerves are distributed, whence it is known as the **olfactory region** [regio olfactoria] and its mucous membrane, compared with that of the respiratory region, is less vascular, yellow or yellowish-brown in colour, and covered by a non-ciliated epithelium. Its cells, specially modified, some of which are directly connected with the olfactory nerve, form the **olfactory organ** [organon olfactus]. Small mucous **olfactory glands** [glandulæ olfactoriæ] occur in the region. The mucous membrane which lines the paranasal sinuses throughout is a continuation of the nasal mucosa; it is, however, paler, less vascular, somewhat thinner, and more loosely attached to the bones. Mucous glands are numerous.

The waving of the cilia in the nasal cavity is such as to sweep foreign matter toward the choanæ; in the paranasal sinuses, toward the nasal cavity.

FIG. 969.—DIAGRAM OF THE DISTRIBUTION OF THE NERVES IN THE NASAL CAVITY. (Poirier and Charpy.)

The olfactory area is represented by dots.

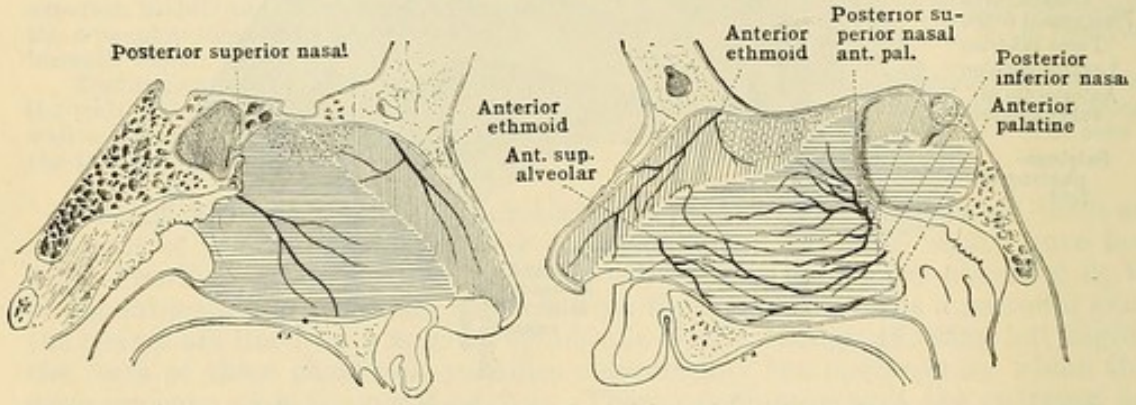

Vessels and nerves.—The **arteries** of the nasal cavity are the spheno-palatine artery from the internal maxillary which, through its posterior lateral nasal branches, supplies the middle and inferior conchæ (p. 549), the anterior and posterior ethmoidal arteries from the ophthalmic (p. 553), the descending palatine artery from the internal maxillary (p. 549), and the superior labial branch of the external maxillary to the vestibule. The **venous plexuses** of the mucous membrane are drained posteriorly by the spheno-palatine to join the pterygoid plexus, superiorly by the anterior and posterior ethmoidal veins to join the superior ophthalmic vein, and anteriorly by small branches to join the facial. The **lymphatics** form a well-developed plexus which is said to communicate indirectly, through the lymphatics surrounding the olfactory nerves, with the subdural and subarachnoid spaces. Posteriorly two or more well-developed trunks communicate with the pharyngeal lymphatics, and anteriorly the nasal lymphatics join with the lymphatics of the face. The **olfactory nerves** pass through the cribriform plate of the ethmoid bone and are distributed to the olfactory area (p. 929). The **trigeminal nerve** furnishes the following branches to the nasal cavity:—branches from the naso-ciliary branch of the ophthalmic nerve; the Vidian nerve; the posterior superior and posterior inferior nasal and the anterior palatine from the spheno-palatine ganglion (p. 962); the anterior superior alveolar from the infra-orbital division of the maxillary nerve (p. 938).

The development of the nose.—The nasal cavity makes its appearance as a depression of the ectoderm on either side of the median line, immediately in front of the oral fossa, with which the depressions are at first continuous. Later, by the union of the maxillary and globular processes (see p. 18), the depressions are separated from the anterior part of the oral fossa, and this separation is continued by the formation of the palatal processes of the maxillæ and palatine bones, so that finally the nasal cavities communicate posteriorly only with the pharynx.

The cartilage which forms the lateral walls of the nasal fossæ is at first quite smooth, but later it becomes eroded by absorption, whereby the nasal conchæ are formed. The erosion also extends into the ethmoid bone, forming the ethmoidal cells, and into the neighbouring bones to form the frontal, sphenoidal, and maxillary sinuses.

THE LARYNX

The **larynx** (figs. 960, 970, 971,), is a tubular organ, the framework of which is made of cartilages joined together and of elastic membranes. Its inner surface is covered by mucosa. From the membranes are formed a pair of **vocal folds** which, by the passage of air through the larynx, are thrown into vibration and so function in the generation of sound. These folds are affected in respect to their

FIG. 970.—VIEW OF INTERIOR OF LARYNX AS SEEN FROM ABOVE DURING INSPIRATION.

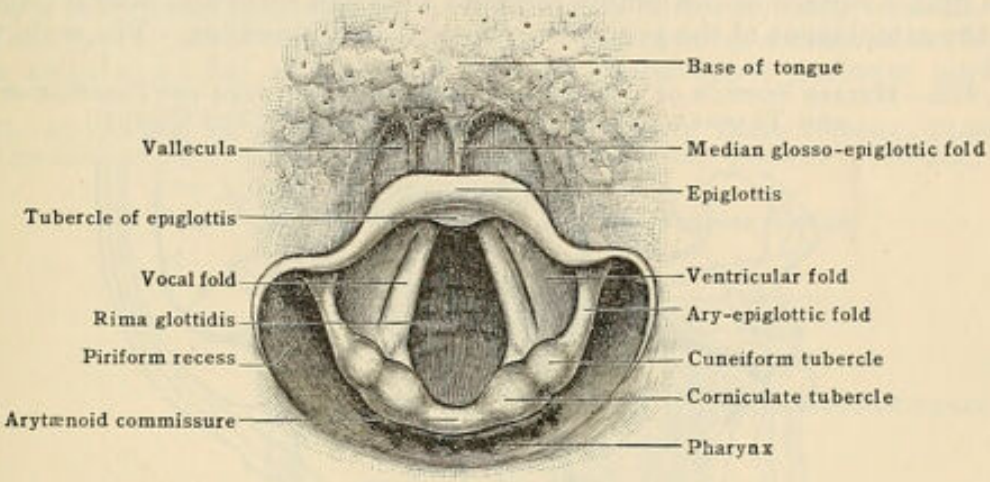

tension and in their mutual relation by the actions of a system of laryngeal muscles under the control of the vagus nerve and are made thereby, on the one hand, to produce those modifications of the sound involved in the voice and on the other hand to regulate the amount of air passing through the **cavity of the larynx.** The latter communicates above with the pharynx by means of the opening called the **laryngeal aperture,** and below with the cavity of the trachea. Figure 970 shows the laryngeal aperture with its boundaries, the **epiglottis** and

FIG. 971.—VIEW OF INTERIOR OF LARYNX AS SEEN FROM ABOVE DURING VOCALISATION.

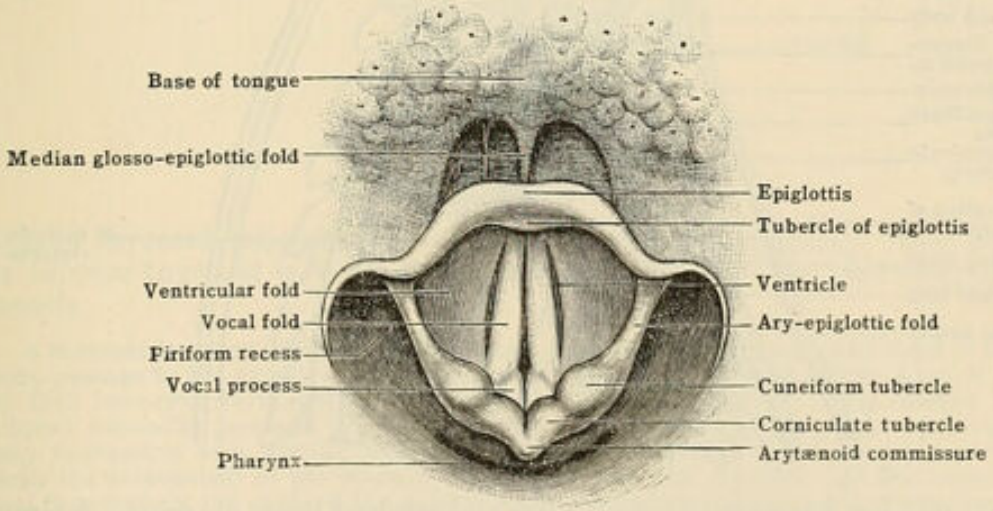

the **aryepiglottic folds;** also the cavity of the larynx where, on the walls right and left, appear the **ventricular** and vocal folds with the chink called rima glottidis separating them.

The position of the larynx and some of its important parts can be well seen in a median section (fig. 972).

THE CARTILAGES OF THE LARYNX

The number of cartilages entering into the framework of the larynx is nine, three of which are single and the rest in pairs. Their forms and positions are shown in fig. 973.

The **cricoid cartilage** [cartilago cricoidea] (figs. 973, 974, 975, 978), single, has been compared in its shape to a signet ring. Its position is at the lower end of the larynx, where it is connected with the first ring of the trachea. Posteriorly the cricoid cartilage expands into a broad **lamina** [lamina cartilaginis cricoideæ] which enters into the posterior boundary of the laryngeal cavity, while laterally and in front it forms a narrow **arch** [arcus cartilaginis cricoideæ]. On either side of the upper margin of the lamina is the elliptical **arytænoid articular surface** [facies articularis arytænoidea] its long axis parallel with the margin of the cricoid, its steeply sloping surface convex for articulation with the arytænoid cartilage. The hinder surface of the lamina presents a median ridge and lateral impressions for the attachment of the posterior crico-arytænoid muscles. The arch, weakest

FIG. 972.—MEDIAN SECTION OF A MAN 21 YEARS OF AGE, SHOWING THE POSITION OF LARYNX AND TRACHEA. (After W. Braune, from Poirier and Charpy.)

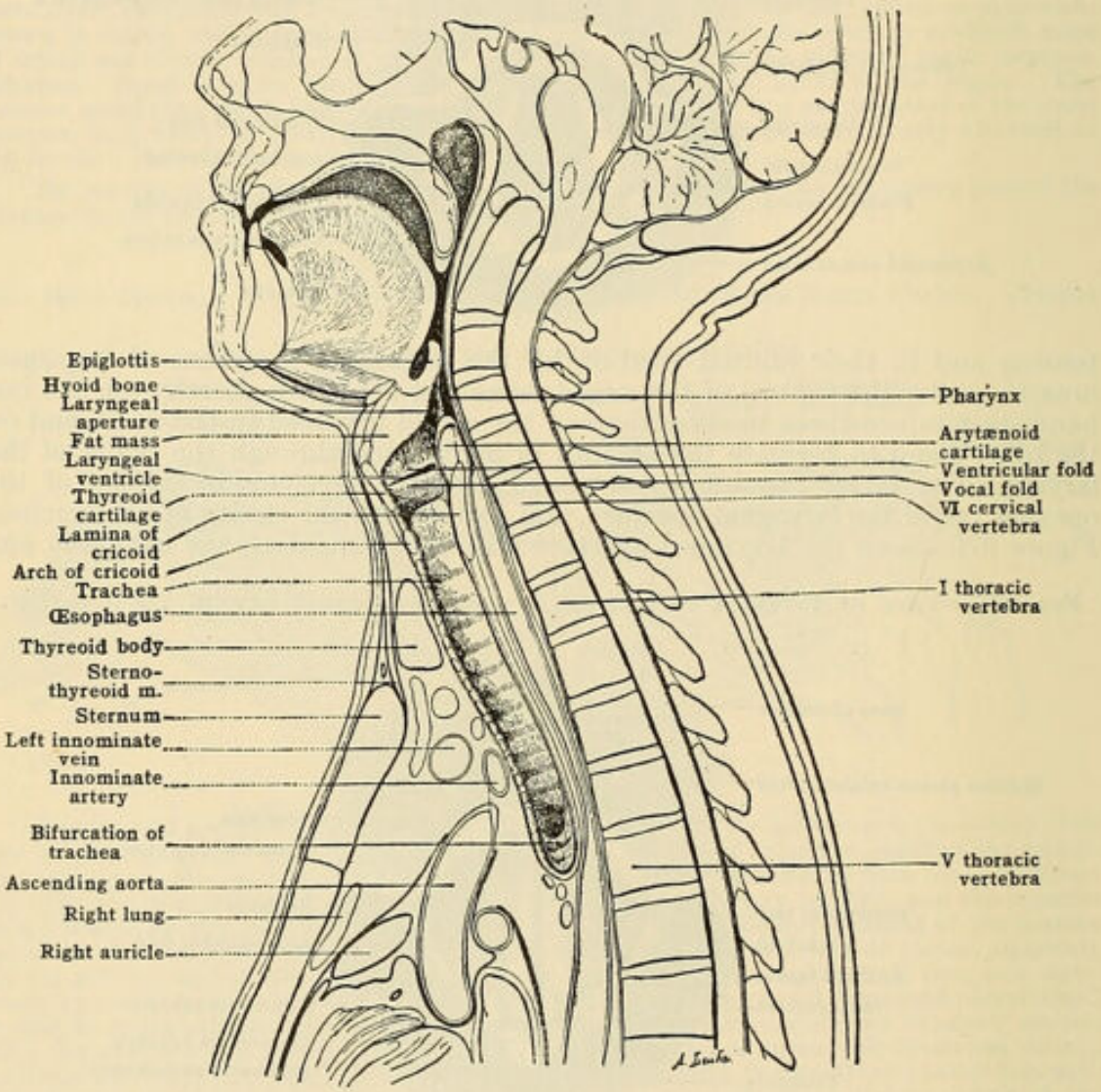

in its middle part, presents concave upper and straight lower margins. A circular, elevated **thyreoid articular surface** [facies articularis thyreoidea] for articulation with the inferior cornu of the thyreoid cartilage is situated upon the side of the cricoid where arch and lamina are continuous. The internal surface is covered by the laryngeal mucosa.

The **thyreoid cartilage** [cartilago thyreoidea] (figs. 973, 974, 975, 977), single and the largest in the laryngeal skeleton is composed of two broad **laminæ, right and left,** which meet and are fused anteriorly in the mid-line in a right angle, partly covering the other cartilages laterally and in front. The laminæ are stout, but their connection at the angle is through a weak strip of cartilage. The upper margin of each lamina is convex, and in front drops abruptly to form in the median line the **superior thyreoid notch** [incisura thyreoidea superior]. The anterior edges

meeting in the angle produce the **laryngeal prominence** [prominentia laryngea] ("Adam's apple"), which is seen on the front of the neck. The horizontal inferior margin presents near its middle the **inferior thyreoid tubercle** [tuberculum thyreoideum inferius], and in the median line the **inferior thyreoid notch** [incisura thyreoidea inferior]. The thick posterior margin of each lamina is continued above the superior edge in the long **superior cornu** [cornu superius], and below the inferior margin in the short **inferior cornu** [cornu inferius]. The former is directed slightly backward and medialward, and joins with the end of the greater cornu of the hyoid by ligament. The inferior cornu, curving medialward as it descends, articulates by a flat, circular facet upon the medial side of its extremity with the thyreoid articular surface of the cricoid cartilage. The external surface of the lamina affords attachment for muscles and presents in its upper posterior part the

FIG. 973.—CARTILAGES OF THE LARYNX SEEN FROM BEHIND IN THEIR NATURAL POSITIONS. THE CUNEIFORM CARTILAGE IS SOMEWHAT HIGHER THAN NORMAL. (Merkel.)

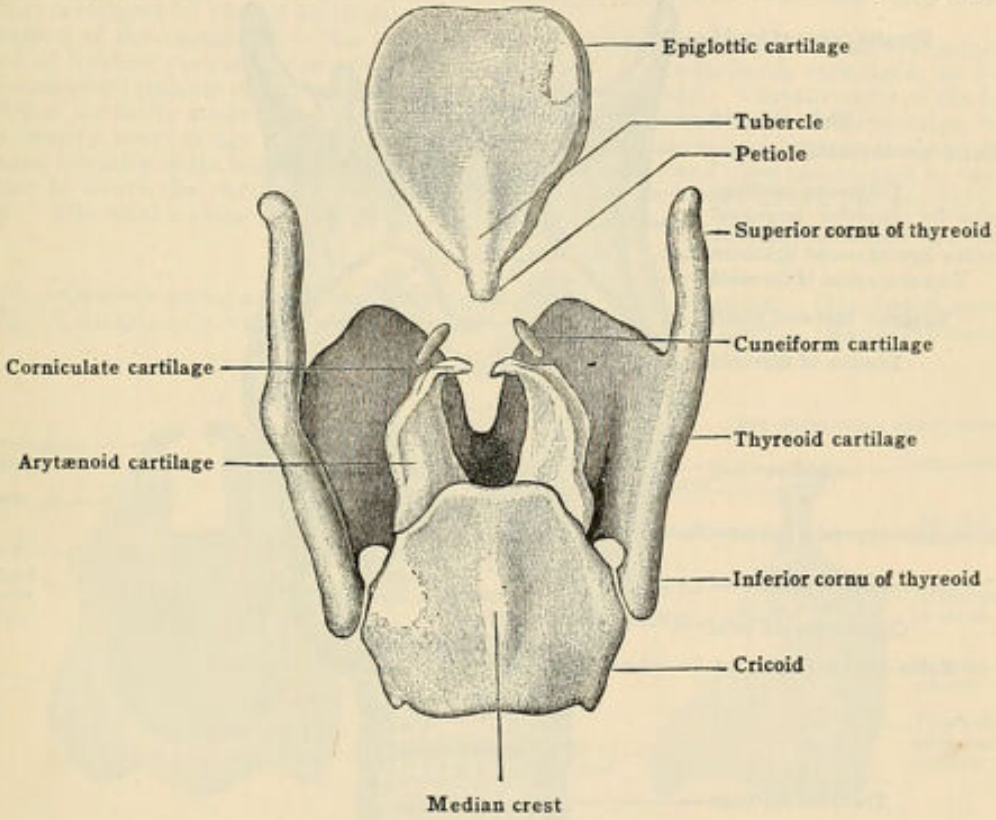

superior thyreoid tubercle [tuberculum thyreoideum superius]; in its lower part the inferior thyreoid tubercle. The internal surface of the thyreoid cartilage is smooth.

A **thyreoid foramen** [foramen thyreoideum], sometimes seen in the upper part of the lamina, giving passage to the superior laryngeal artery, results from the incomplete union of the fourth and fifth branchial cartilages from which the laminæ are derived. The **oblique line** [linea obliqua], extending between the thyreoid tubercles, is commonly present and is regarded by many anatomists as a normal feature of the external surface of the thyreoid cartilage. It marks the attachment of the sternohyoid and thyreohyoid muscles. At the insertion of the vocal ligaments in the angle of the laminæ a small perichondral process is often observed.

The **arytænoid cartilages** [cartilagines arytænoideæ] (figs. 973, 977, 978, 979), paired, surmount the lamina of the cricoid cartilage and give attachment to the vocal ligaments, whose relations and state of tension are altered by the changes in position which these cartilages are almost constantly undergoing.

Each cartilage is pyramidal in form, and moulded for the attachment of several muscles. The **apex,** which is above, is bent backward and medialward and is connected with a corniculate cartilage. The **base,** somewhat triangular in shape, presents at the lateral and posterior part an oval or circular concave **articular surface** [facies articularis], directed medialward and downward to meet the arytænoid articular surface of the cricoid cartilage. The lateral angle of the base is prolonged into a stout **muscular process** [processus muscularis] for the attach-

ment of the crico-arytænoid muscles, while the anterior angle is extended as a sharp projection, the **vocal process** [processus vocalis], which serves for the attachment of the vocal ligament. The surfaces of the arytænoid are named medial, posterior, and antero-lateral. The narrow **medial surface,** covered by the mucosa of the larynx, is nearly vertical, and faces the corresponding side of the opposite arytænoid, from which it is separated by a small space. The **posterior surface** is concave for muscular attachment. The **antero-lateral surface** is the largest, and presents an irregular contour.

On this surface a ridge, the **arcuate crest** [crista arcuata], extends horizontally between two hollows—the **triangular fovea** [fovea triangularis] above, which lodges some mucous glands, and a larger depression below, the **oblong fovea** [fovea oblonga] for the vocal muscle. The **colliculus** is a small eminence found upon the anterior margin and antero-lateral surface.

FIG. 974.—FRONT VIEW OF THE LARYNGEAL SKELETON. (Modified from Bourgery and Jacob.)

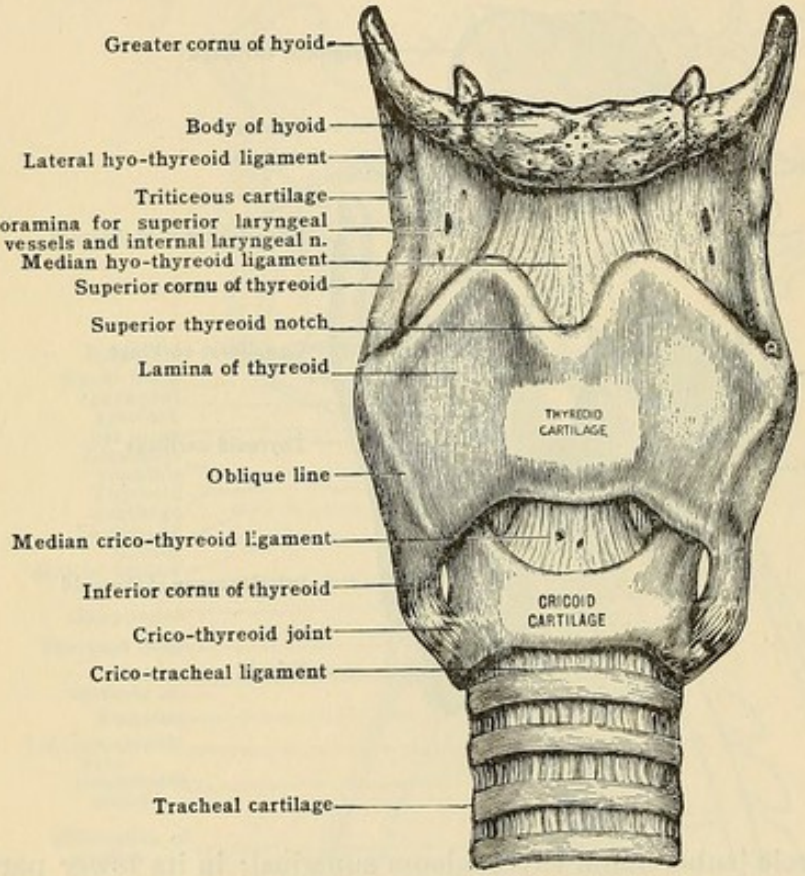

The corniculate cartilages (of Santorini) [cartilagines corniculatæ (Santorini*)] (figs. 973, 977).—This pair of small conical cartilages is set upon the bent apices of the arytænoids, continuing their curves backward and medialward.

The corniculate cartilage is not an independent structure in many lower animals, and its continuity with the arytænoid is sometimes met with in man where the two cartilages are normally developed in a continuous mass of tissue.

The **epiglottic cartilage** [cartilago epiglottica] (figs. 973, 977, 981, 987), unpaired, invested by mucosa behind and partly in front, thin and leaf-shaped, stands behind the root of the tongue and the body of the hyoid. It lies above the thyreoid cartilage, in front of the entrance of the larynx. The free upper margin is convex, or notched; the lower end tapers to a short stalk, the **petiole** of the epiglottis [petiolus epiglottidis], to which the thyreo-epiglottic ligament is attached.

The anterior surface is free above and covered by mucosa; in its lower part it is bound to the body of the hyoid, and is separated by a mass of fat from

* Santorini: Venetian anatomist. B. 1681, D. 1737.

the hyo-thyreoid ligament. Its posterior surface above is saddle-shaped; below, it is convex, presenting the **epiglottic tubercle** [tuberculum epiglotticum]. To the margins are attached the ary-epiglottic folds. The epiglottic cartilage presents numerous small holes and depressions for the accommodation of glands.

The **cuneiform cartilages (of Wrisberg)** [cartilagines cuneiformes (Wrisbergi*)] (fig. 973) lie as small, rod-like bodies in the ary-epiglottic folds anterior to the corniculate cartilages. They are variable in form and size and not rarely absent altogether.

These cartilages are parts of the epiglottic cartilage in some mammals where, as in man, they lie in the ary-epiglottic folds. Their relations to the arytænoids are regarded as secondary. Sutton has shown that in the ant-eater a continuous rim of yellow elastic cartilage extends from the sides of the epiglottic cartilage to the summits of the arytænoids. A minute unpaired *interarytænoid* or *procricoid cartilage* is rarely present imbedded in the cricopharyngeal ligament and covered by the pharyngeal mucosa. It is a constant structure in certain mammals. A pair of small *sesamoid cartilages*, also constantly present in some mammals, is occasionally found in man at the lateral margins of the arytænoids, connected with them and with the corniculate cartilages by elastic ligaments.

Structure of the cartilages.—The thyreoid, cricoid, and greater part of the arytænoid are composed of hyaline cartilage; the epiglottic, corniculate, and cuneiform cartilages, as well as the apex and vocal process of the arytænoid, are of elastic cartilage. Certain parts of the laryngeal skeleton normally undergo calcification and subsequent ossification. Calcification begins at about twenty years of age in the thyreoid and cricoid cartilages, and later in the arytænoid. The process begins a little later in the female than in the male, and does not extend so rapidly. The extent to which the cartilages are ossified and the time occupied in the process vary considerably. The elastic elements are not involved in the process.

FIG. 975.—CRICOID AND ARYTÆNOID CARTILAGES SEEN FROM BEFORE. (Rauber-Kopsch.)
FIG. 976.—CRICOID AND ARYTÆNOID CARTILAGES SEEN FROM THE LEFT. (Rauber-Kopsch.)

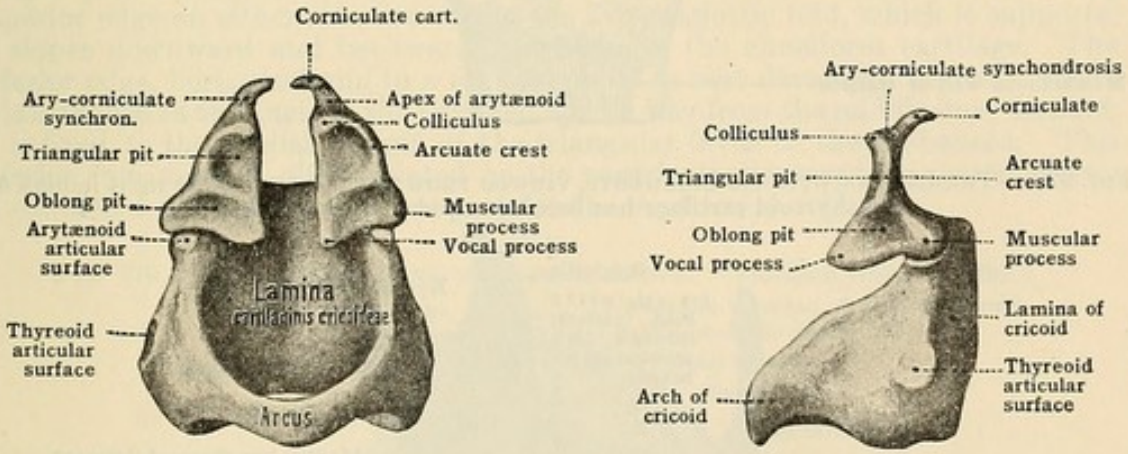

THE JOINTS AND FIBROUS MEMBRANES OF THE LARYNX

(1) CONNECTIONS BETWEEN THE LARYNGEAL CARTILAGES

The crico-thyreoid articulation (figs. 973, 974, 975).—The articular surfaces concerned are the thyreoid articular surface on the side of the cricoid and the articular surface on the inferior cornu of the thyreoid cartilage. The **crico-thyreoid articular capsule** [capsula articularis cricothyreoidea] attached around the margins of these surfaces and certain accessory bands serve to bind the cartilages together.

The accessory bands, **cerato-cricoid ligaments** fall into three groups radiating from the inferior cornu: the **ligamenta ceratocricoidea posteriora** upward and medialward to the superior margin of the cricoid; the **ligamenta ceratocricoidea lateralia** downward at the side and back of the capsule; the **ligamentum ceratocricoideum anterius** downward and forward. The capsule possesses a synovial layer.

A rotary movement about a transverse axis of the cricoid upon the thyreoid or *vice versa* and a slight backward and forward gliding are permitted at this joint.

* Wrisberg: German anatomist. B. 1737, D. 1808.

The crico-arytænoid articulation [articulatio cricoarytænoidea (figs. 973, 977, 978).—The articular surface of the cricoid cartilage and the articular surface of the arytænoid which enter into this articulation are so disposed that at no time do they meet in complete apposition. A loose capsule [capsula articularis crico-

FIG. 977.—THE LARYNGEAL SKELETON SEEN FROM BEHIND. (Poirier and Charpy.)

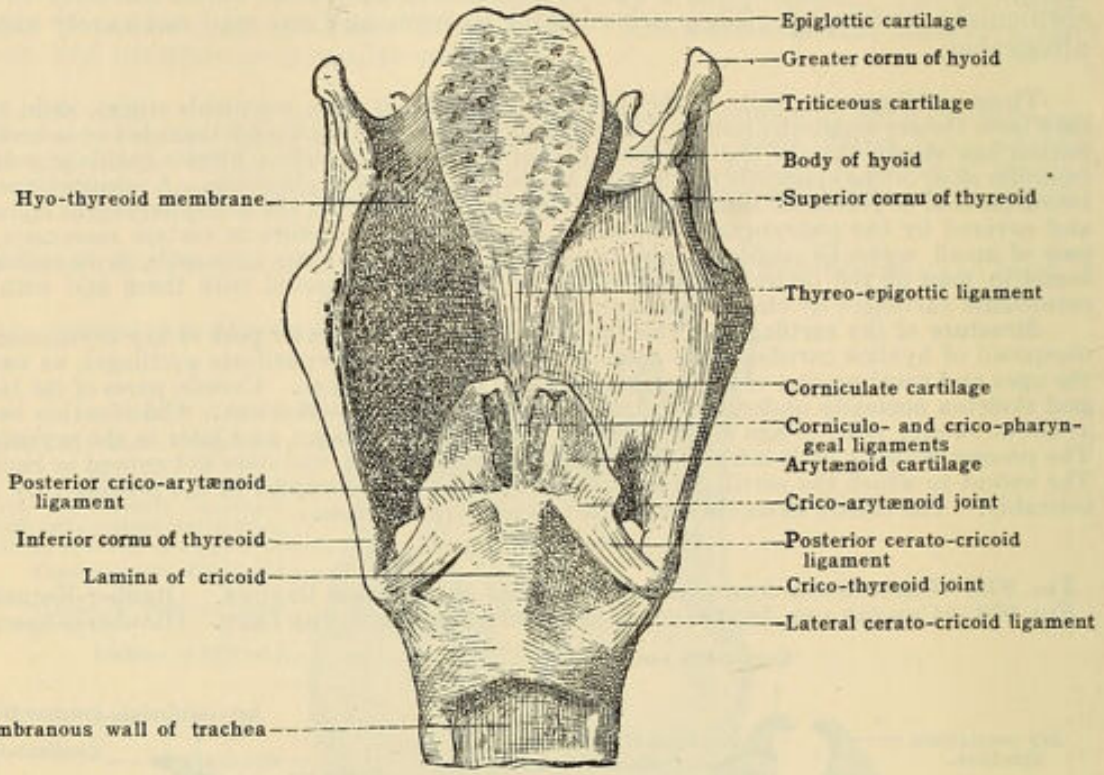

FIG. 978.—THE LARYNX WITH ITS LIGAMENTS, VIEWED FROM THE RIGHT. (The right lamina of the thyreoid cartilage has been removed.) (Spalteholz.)

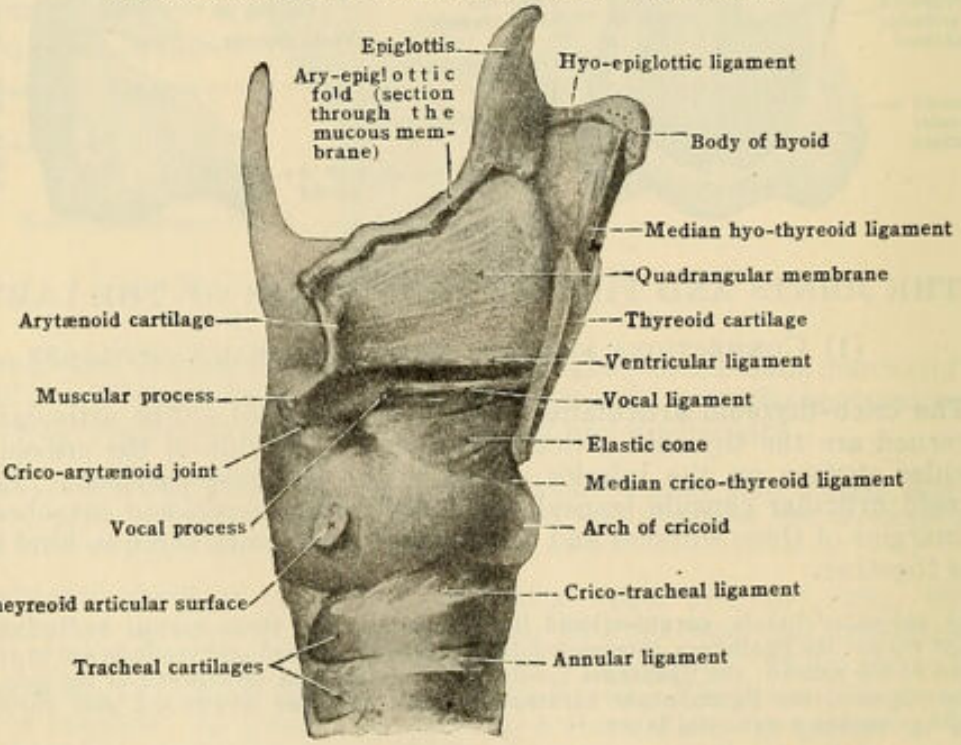

arytænoidea] of fibrous and synovial strata attached around the edges of the joint surfaces unites the cartilages.

Posterior crico-arytænoid ligament [lig. cricoarytænoideum posterius], attached above to the medial surface of the base and muscular process of the arytænoid, and below to the lamina

of the cricoid, is important in helping to fix the former cartilage in place upon the sloping arytænoid articular surface of the cricoid and in limiting its movements. Motion at this articulation is very free. The following simple movements of the arytænoid are best understood:—(1) gliding of the arytænoid toward or away from its fellow; (2) inclining forward and backward; (3) rotating on a vertical axis, so that the vocal process sweeps medialward or lateralward and also a little downward or upward.

The union of the corniculate cartilage with the apex of the arytænoid cartilage [synchondrosis arycorniculata] is usually by connective tissue; rarely is there a joint cavity.

The petiole of the epiglottic cartilage is connected with the thyreoid, below and behind the superior notch, by a strong, elastic **thyreo-epiglottic ligament** [lig. thyreoepiglotticum] (fig. 977).

(2) The Elastic Membrane of the Larynx

[Membrana elastica laryngis]

This name is given to a more or less continuous sheet of elastic fibres connected with the deeper parts of the laryngeal mucosa. Its upper part is known as the *quadrangular membrane*, the lower part as the *elastic cone*. A middle region of the elastic membrane lies opposite the ventricle of the larynx.

The **quadrangular membrane** (figs. 978, 981, 988) extends from the ary-epiglottic folds above to the level of the ventricular folds (false vocal cords) below. The lateral parts of this membrane are widely separated superiorly, but they converge toward the middle line as they descend. Anteriorly, the membrane is fixed in the angle of the thyreoid laminæ and to the sides of the epiglottic cartilage; posteriorly, to the corniculate cartilages and to the arytænoids. The superior edge on either side lies within the ary-epiglottic fold, which it supports; it slopes downward and backward and includes the cuneiform cartilage. The inferior edge, horizontal and in a sagittal plane, is best developed in front, where it is attached in the angle of the thyreoid a little way from the middle line; behind, it is fixed to the medial margin of the triangular fovea of the arytænoid. This inferior free margin, differentiated as the **ventricular ligament** [lig. ventriculare], is enclosed within, and is the support for the ventricular fold.

Fig. 979.—The Elastic Cone seen from Above. (Modified from Luschka.)

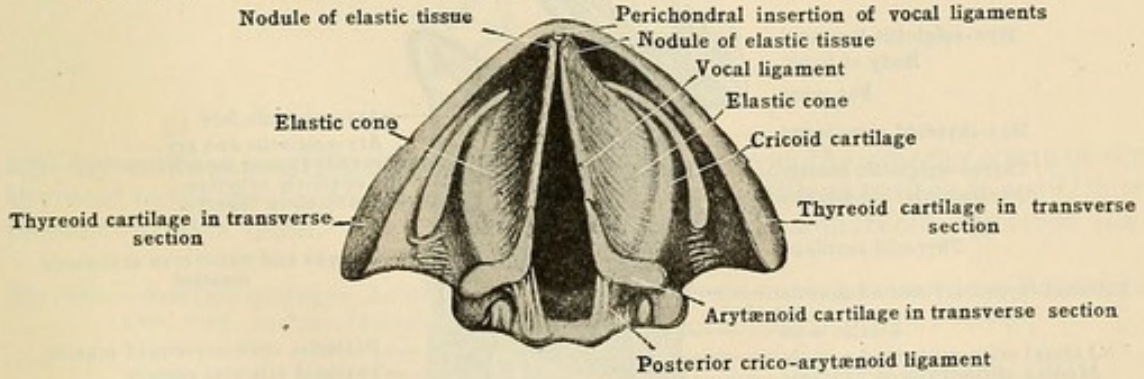

The elastic cone [conus elasticus] (figs. 978, 979).—This part of the elastic membrane extends from the level of the vocal folds to the superior margin of the cricoid cartilage. Its component fibres are attached in the re-entrant angle and adjacent lower margin of the thyreoid cartilage, whence they spread downward and backward to the upper edge of the cricoid arch and to the arytænoid cartilages. The strong anterior portion, perforated by vessels, is the **median crico-thyreoid ligament** [lig. cricothyreoideum (medium)] (figs. 974, 975). The lateral parts (lateral portions of the crico-thyreoid membrane) present superior free edges, somewhat thickened, which, running horizontally near the middle line from the thyreoid angle to the vocal processes, constitute the **vocal ligaments.** These are inserted anteriorly into a perichondral process in the thyreoid angle; posteriorly, they have a wide area of attachment to the upper and medial surfaces of the vocal processes of the arytænoids with the elastic fibres of which they are in part continuous. A yellowish, cellular nodule (sometimes cartilage) occurs in the

anterior end of each ligament. The vocal ligaments enter into the formation of the vocal folds (true vocal cords).

FIG. 980.—THE LARYNX SEEN FROM THE LEFT SIDE. (Modified from Luschka.)

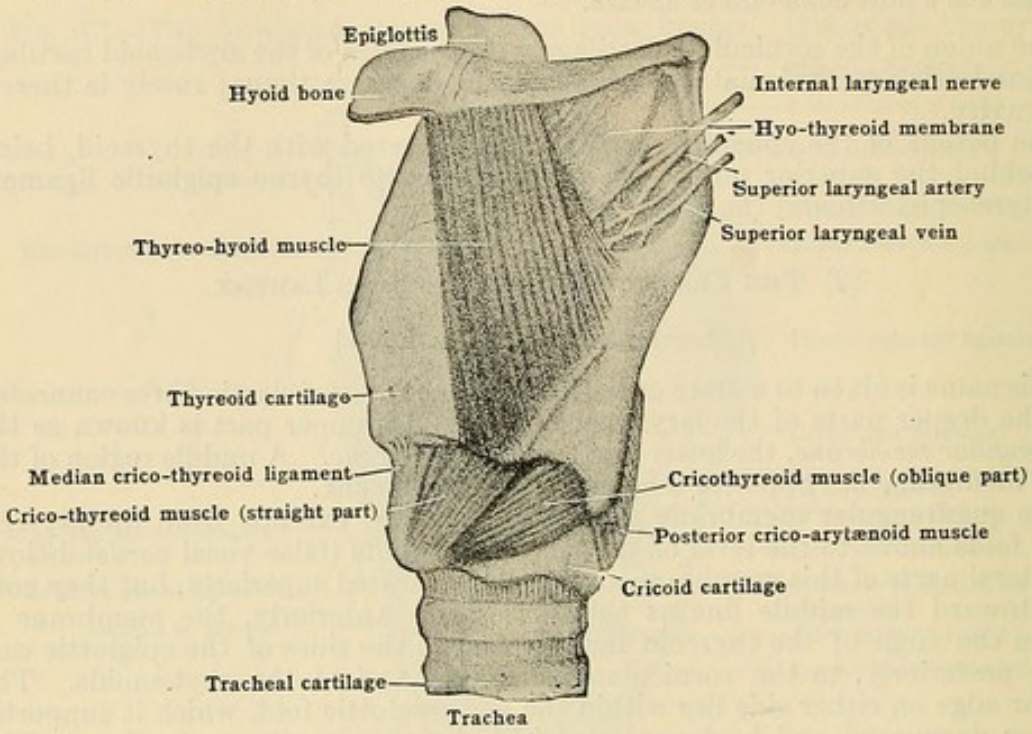

FIG. 981.—THE MUSCLES AND LIGAMENTS OF THE LARYNX SEEN FROM THE SIDE. (The left lamina of the thyreoid cartilage has been removed.)

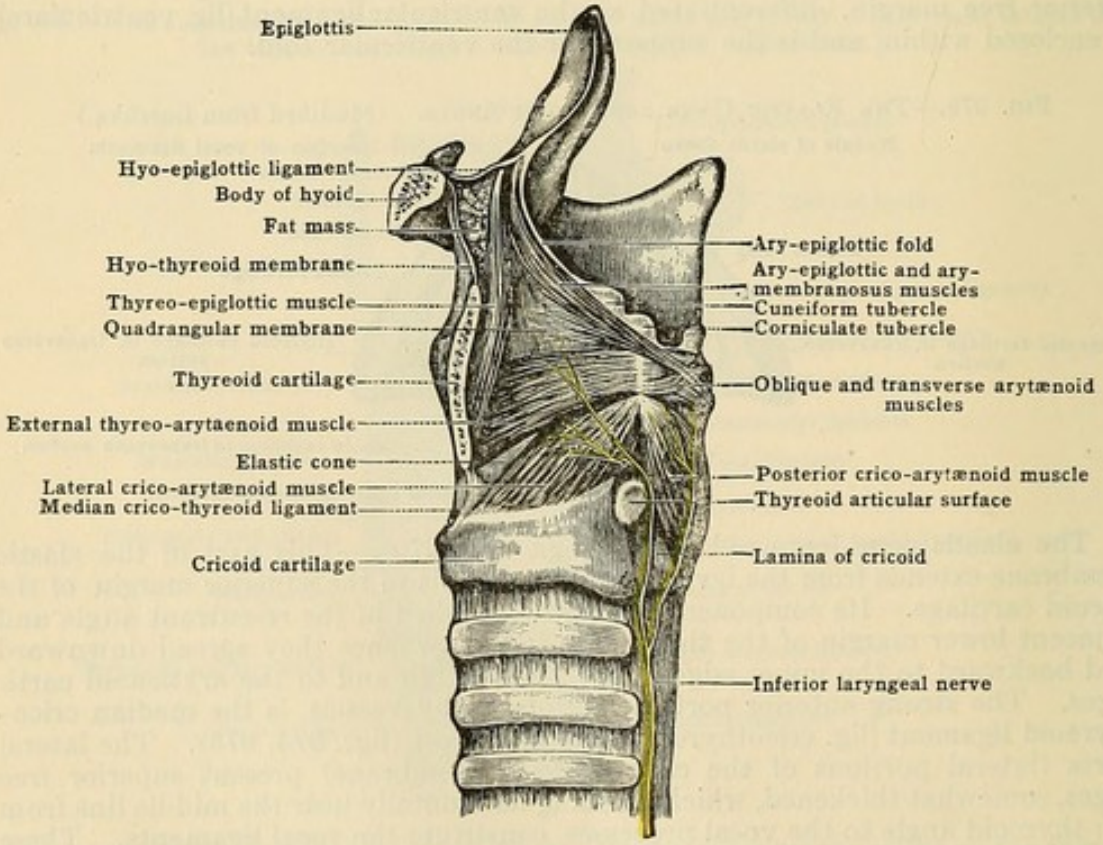

The median crico-thyreoid ligament is incised in the operation of laryngotomy. It is crossed by the anastomotic arch of the crico-thyreoid arteries, which, however, can be avoided in the operation by making a transverse cut through the ligament close to the superior margin of the arch of the cricoid cartilage.

(3) Connections between the Larynx and Neighbouring Structures

The **hyo-thyreoid membrane** [membrana hyothyreoidea] (figs. 977, 980, 981) is a loose, fibrous, elastic sheet, binding together the thyreoid cartilage and hyoid bone. It extends from the superior margin of the former to the greater cornua and

Fig. 982.—Scheme of Rima, showing Action of Posterior Crico-arytænoid Muscle, which draws the Arytænoid Cartilage from I to II. (Modified from Stirling.)

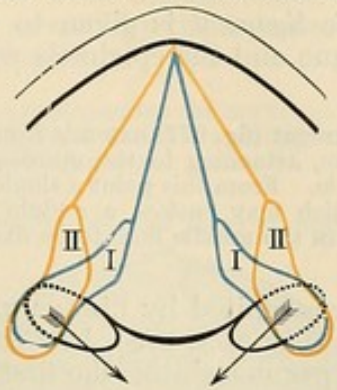

superior margin of the body of the latter. The superior laryngeal artery and vein and the internal laryngeal nerve pass through it from the side. Its posterior and lateral edge is cord-like, consisting of elastic fibres which stretch as the **lateral**

Fig. 983.—Scheme showing Action of the Transverse Arytænoid drawing Arytænoid Cartilage from Neutral Position I to II. (Modified from Stirling.)

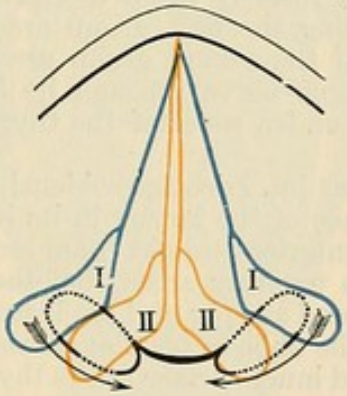

hyo-thyreoid ligament [lig. hyothyreoideum laterale] from the superior cornu of the thyreoid to the greater cornu of the hyoid. A small **cartilago triticea** is sometimes present in this band. The middle part, **median hyo-thyreoid ligament** [lig.

Fig. 984.—Scheme showing Action of Thyreo-artyænoid drawing the Vocal Processes and the Vocal Ligaments from II to I. (Modified from Stirling.)

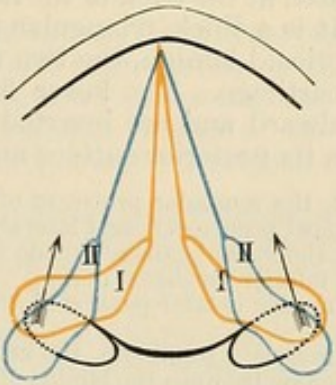

hyothyreoideum medium] thick and elastic, extends from the superior thyreoid notch upward behind the body of the hyoid to be attached to its superior margin, the *hyoid bursa* being interposed between the bone and the membrane.

The cartilago triticea is the remains of a connection between the thyreoid and hyoid present in the embryo. It persists in adult life in some lower animals.

The **hyo-epiglottic ligament** [lig. hyoepiglotticum] (figs. 978, 981) connects the anterior surface of the epiglottic cartilage with the superior margin of the body and the greater cornua of the hyoid. It is a broad sheet, lying above a mass of fat which stands between the median hyo-thyreoid membrane and the epiglottis and spreading laterally to join the pharyngeal aponeurosis in the region of the piriform recess.

The name *glosso-epiglottic ligament* is given to the elastic fibres extending between the root of the tongue and the epiglottis within the median glosso-epiglottic fold.

The **corniculo-pharyngeal ligament** (fig. 977) extends from the corniculate cartilage downward and toward the median line, attaching to the mucosa of the pharynx and joining its fellow behind the arytænoid muscle. From this point a single band, the **crico-pharyngeal ligament** [lig. cricopharyngeum], which may enclose a nodule of cartilage (**the interarytænoid or procricoid cartilage**), descends in the middle line, to be fixed to the cricoid lamina and into the pharyngeal mucosa.

The larynx and trachea are united by fibrous membrane, the **crico-tracheal ligament** [lig. cricotracheale] (figs. 974, 978), between the inferior margin of the cricoid cartilage and the upper margin of the first tracheal ring. Posteriorly the ligament is continued into the membranous wall of the trachea.

MUSCLES OF THE LARYNX

Of the many muscles connected with the larynx, two groups may be recognised, the members of one coming from neighbouring parts, fixing themselves to the larynx and acting upon the organ as a whole; the members of the other group confining themselves exclusively to the larynx and acting so as to affect its parts. The muscles composing the first group are described elsewhere. (See Section IV.) The muscles of the second group are composed of striated fibres and are supplied by the vagus nerve through its laryngeal branches. These muscles are all more or less under cover of the thyreoid cartilage, with one exception, the crico-thyreoid.

The **crico-thyreoid muscles** [m. cricothyreoideus] (fig. 980) are placed one on either side of the outer surface of the larynx in its lower part. Each muscle is partially separated into an anterior **straight** [pars recta] and a posterior **oblique portion** [pars obliqua], which together arise from the arch of the cricoid. The fibres of the straight part ascend steeply and are inserted into the inferior margin of the thyreoid cartilage. The oblique portion is inserted into the inferior cornu and into the lower margin and inner surface of the thyreoid cartilage.

The straight part elevates the arch of the cricoid, causing the lamina, and with it the arytænoid cartilages, to sink, while the oblique part draws forward the thyreoid; thus the vocal ligaments are made tense. The muscle is supplied by the external branch of the superior laryngeal nerve. A connexion between the posterior part of this muscle and the inferior constrictor of the pharynx and their common nerve-supply indicate their genetic relationship.

The **posterior crico-arytænoid** muscle [m. cricoarytænoideus posterior] (figs. 980, 981, 982), paired, is situated at the back of the larynx, covered by the submucous coat of the pharynx. It is a thick, triangular mass which takes origin from the posterior surface of the cricoid lamina, the two muscles being well separated by the median crest of the cartilage. The lower fibres ascend and the upper ones pass horizontally lateralward and are inserted into the muscular process of the arytænoid cartilage on its posterior surface and tip.

When these muscles contract, the muscular processes of the arytænoids are pulled backward and downward, while the vocal processes travel lateralward and a little upward, so that the rima glottidis is widened and the vocal ligaments made tense (fig. 982). The innervation is by the posterior branch of the inferior laryngeal nerve.

In ether narcosis the dilator muscle is later paralyzed and afterward earlier restored than the constrictors of the larynx.

At the lower margin of this muscle a small slip, the **cerato-cricoid muscle** [m. ceratocricoideus], is sometimes found, extending between the lamina of the cricoid and the inferior cornu of the thyreoid cartilage.

The constrictor laryngis.—Whereas the crico-arytænoideus posterior is a dilator of the larynx, the several muscles now to be considered are in the main con-

strictors. They form a ring, the constrictor laryngis, around the laryngeal cavity, interrupted, however, by the cartilages. In the larynx of amphibia and reptiles a complete sphincter guards the entrance to the air-passages.

The following muscles are included in the constrictor group:—

The **transverse arytænoid** muscle [m. arytænoideus transversus] (figs. 981) 983, 985) is a single muscle of quadrilateral form, extending across the middle line from the posterior concave surface of one arytænoid cartilage to that of the other. Its anterior surface, between the cartilages, is covered by the laryngeal mucosa; its posterior surface, crossed by the arytænoideus obliquus, is clothed by the submucous coat of the pharynx.

The arytænoideus transversus approximates the arytænoid cartilages and their vocal processes, which are at the same time elevated, and the vocal ligaments made tense. It is supplied by the posterior branch of the inferior laryngeal nerve.

FIG. 985.—THE NERVES OF THE LARYNX SEEN FROM BEHIND.

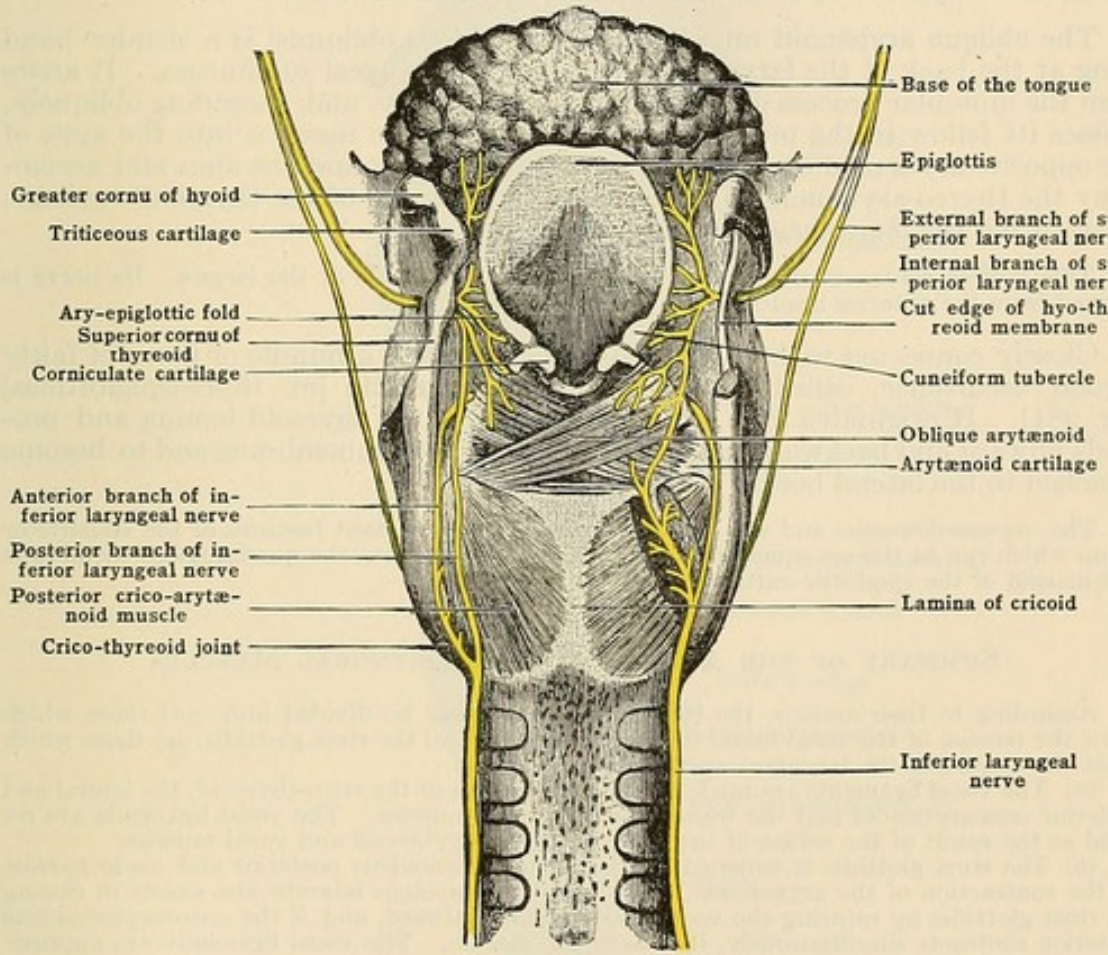

The **lateral crico-arytænoid** muscle [m. cricoarytænoideus lateralis] (fig. 981) arises from the upper margin and outer surface of the cricoid arch and from the elastic cone, whence the fibres extend backward and upward to an insertion on the anterior surface of the muscular process of the arytænoid cartilage. This muscle is inseparable from the thyreo-arytænoideus in about half the cases.

The lateral cricoarytænoids by their contraction cause the vocal processes to move toward the median line and a little downward, so that the vocal ligaments are approximated and slightly stretched. They antagonise the posterior crico-arytænoids. The anterior branch of the inferior laryngeal nerve supplies these muscles.

The **external thyreo-arytænoid** muscle [m. thyreoarytænoideus (externus)] (figs. 981, 984, 988), variable in form and in the disposition of its fibres, is closely connected with the preceding. It lies under cover of the thyreoid lamina lateral to the laryngeal saccule (ventricular appendix) and elastic cone. Arising within the angle of the thyreoid laminæ the muscle extends upward and backward to its insertion on the lateral margin of the arytænoid cartilage.

It draws forward the arytænoid cartilage (and also tilts the cricoid), and rotates it so that the vocal process passes medialward and downward, relaxing the vocal ligament. It is the antagonist of the crico-thyreoid (fig. 984). Its nerve-supply is the anterior branch of the inferior laryngeal.

The **vocal muscle** [m. vocalis], (fig. 988), prismatic in form, is the inner constant part of the thyreo-arytænoideus. It lies in the vocal lip lateral to the vocal ligament. Its fibres run from their origin in the angle of the thyreoid laminæ to their insertion in the vocal process and oblong fovea of the arytænoid cartilage.

It draws forward the vocal process, relaxing the vocal ligament. Its nerve comes from the anterior branch of the inferior laryngeal.

The insertion of certain fibres of this muscle into the elastic vocal ligament has been observed (ary-vocalis muscle of Ludwig). D. Lewis has shown that some of the elastic fibres in the vocal ligament are derived from the perimysium of the vocal muscle.

The **ventricular muscle** [m. ventricularis] consists of a few fibres derived from the thyreo-arytænoideus which reach the back of the laryngeal saccule and enter the ventricular fold. The small *thyreo-arytænoideus superior* extends from the angle of the thyreoid to the muscular process of the arytænoid upon the lateral surface of the main muscle.

The **oblique arytænoid** muscle [m. arytænoideus obliquus] is a slender band lying at the back of the larynx and under the pharyngeal submucosa. It arises from the muscular process of the arytænoid posteriorly, and, ascending obliquely, crosses its fellow in the median line. Some fibres are inserted into the apex of the opposite arytænoid cartilage; other fibres sweep around the apex and accompany the thyreo-arytænoid to an insertion in the angle of the thyreoid cartilage, constituting the *thyreo-arytænoideus obliquus.*

This muscle contracts the laryngeal aperture and vestibule of the larynx. Its nerve is derived from the anterior branch of the inferior laryngeal.

Closely connected with the thyreo-arytænoideus is a bundle of fibres of fairly regular occurrence, called the **thyreo-epiglottic muscle** [m. thyreoepiglotticus] (fig. 981). It originates from the inner surface of the thyreoid lamina and proceeds upward and backward to end in the quadrangular membrane and to become attached to the lateral border of the epiglottis.

The *ary-membranosus* and *ary-epiglottic muscles* are inconstant fascicles of the constrictor group which run in the ary-epiglottic fold and become fixed into the quadrangular membrane and margin of the epiglottic cartilage.

Summary of the Actions of the Laryngeal Muscles

According to their actions, the laryngeal muscles may be divided into—(*a*) those which effect the tension of the vocal folds; (*b*) those which control the rima glottidis; (*c*) those which effect the closure of the laryngeal aperture and vestibule.

(*a*) The vocal ligaments are made tense by the action of the crico-thyreoid, the lateral and posterior cricoarytænoid and the transverse arytænoid muscles. The vocal ligaments are relaxed as the result of the action of the external thyreo-arytænoid and vocal muscles.

(*b*) The rima glottidis is widened by the crico-arytænoideus posterior and made narrow by the contraction of the arytænoids. The crico-arytænoideus lateralis also assists in closing the rima glottidis by rotating the vocal processes medialward, and if the crico-arytænoideus posterior contracts simultaneously, it aids in the closure. The vocal ligaments are approximated also by the thyreo-arytænoideus [externus].

(*c*) The laryngeal aperture and vestibule are closed mainly by the arytænoideus transversus and thyreo-arytænoideus (externus), by which the arytænoid cartilages are brought into apposition and drawn toward the epiglottis. Other muscles derived from the constrictor group, arytænoideus obliquus and ary-epiglotticus assist in closing the laryngeal aperture.

CAVITY OF THE LARYNX AND LARYNGEAL MUCOSA

The **cavity of the larynx** [cavum laryngis] is relatively narrow and does not correspond in shape with the outer surface of the organ. Its form is shown in fig. 986 taken from a cast of the laryngeal cavity and the spaces continuous with it. Its walls are covered throughout by the **mucous membrane** of the larynx (figs. 987, 988).

The mucosa of the larynx is continuous above with the mucous membrane of the pharynx, below with that of the trachea (figs. 970, 971). At the root of the tongue the pharyngeal mucosa is reflected backward to the anterior surface of the epiglottis, presenting the **median** and **lateral glosso-epiglottic folds** [plica

glosso epiglottica medianaet lateralis]. From the sides of the pharynx it passes medialward, first sinking between the thyreoid cartilage laterally and the arytænoid and cricoid medially, entering into the walls of the piriform recess; then passing over the superior margin of the quadrangular membrane to form the ary-epiglottic fold.

At the medial side of the piriform recess a slight fold of the mucosa [plica nervi laryngei) corresponds to the superior laryngeal nerve. Between the root of the tongue and the epiglottis is a depression subdivided in the middle line and limited laterally by the median and lateral

FIG. 986.—CAST OF THE VESTIBULUM AND CAVUM ORIS, OF THE PHARYNX, LARYNX, OF THE UPPER PART OF THE TRACHEA AND ŒSOPHAGUS. Seen from in front and below. (Rauber-Kopsch.)

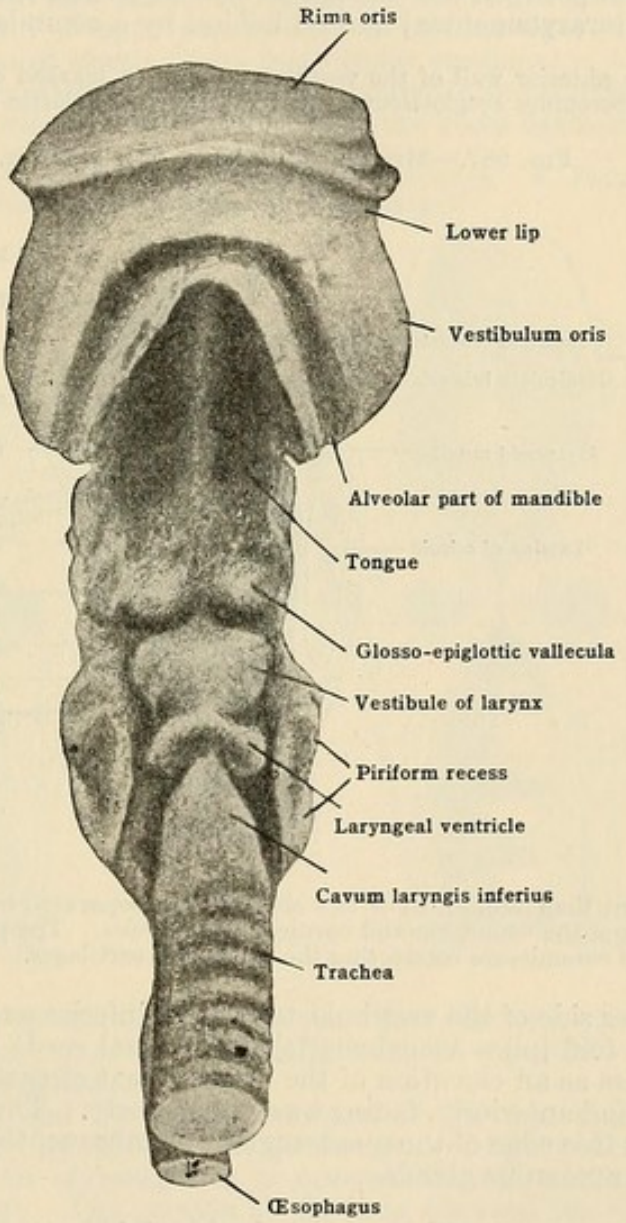

glosso-epiglottic folds; this is the **epiglottic vallecula** [vallecula epiglottica]. The piriform recess and the epiglottic vallecula are favorite sites for the lodgment of foreign bodies. The **ary-epiglottic fold** [plica aryepiglottica] extends from the side of the epiglottis to the apex of the arytænoid cartilage; within it are fibres of the ary-epiglottic and thyreo-epiglottic muscles and the cuneiform and corniculate cartilages. These cartilages correspond to two rounded eminences on each side of the laryngeal entrance, the **cuneiform** and **corniculate tubercles** [tuberculum cuneiforme (Wrisbergi); tuberculum corniculatum (Santorini)], respectively. Of these, the former is often small and inconspicuous, the latter usually well developed and prominent.

The cavity of the larynx above the level of the ventricular folds is known as the **vestibule** [vestibulum laryngis]. This is wide in its upper part, but the sides incline toward the median line in descending, and the cavity becomes narrow

transversely in approaching the region of the glottis. Here the cavity has received the special name, **superior entrance to the glottis** [aditus glottidis superior]. The parts of the framework of the larynx which enter into the walls of the vestibule are: in front, the epiglottic and thyreoid cartilages with the thyreo-epiglottic ligament; at the side, the quadrangular membrane, the cuneiform and corniculate cartilages, and the medial surface of the arytænoid cartilage; behind, the anterior surface of the transverse arytænoid muscle. The vestibule communicates with the pharynx by the **laryngeal aperture** [aditus laryngis] (figs. 970, 971, 972, 987), which looks upward and backward. The form of the aperture is oval or triangular, with the base in front; here it is bounded by the epiglottis; laterally by the ary-epiglottic fold of the mucosa. Posteriorly the laryngeal aperture is prolonged as a little notch between the corniculate cartilages and the apices of the arytænoids [**incisura interarytænoidea**] limited behind by a commissure of the mucosa.

The high anterior wall of the vestibule presents a marked convexity, the **tubercle of the epiglottis** [tuberculum epiglotticum], over the thyreo-epiglottic ligament. The lateral walls,

FIG. 987.—MEDIAN SECTION OF THE LARYNX. (Merkel.)

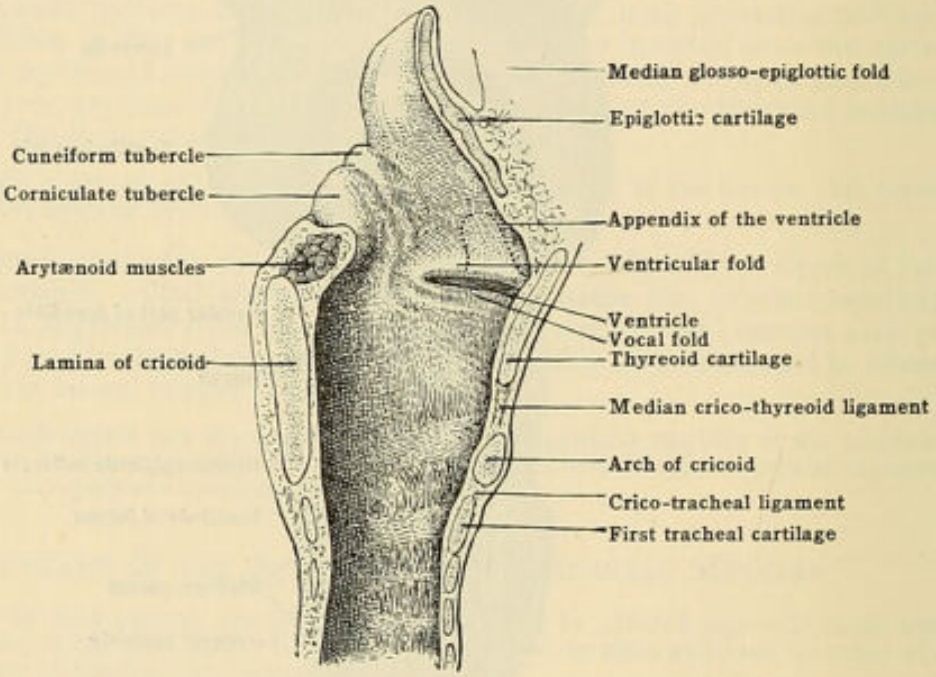

higher in front than behind, show two slight ridges, separated by a shallow groove, extending downward from the cuneiform and corniculate tubercles. The posterior wall, very low, corresponds to the commissure connecting the arytænoid cartilages.

On either side of the vestibule, toward its inferior end, is the sagittally running **ventricular fold** [plica ventricularis] (false vocal cord) (figs. 970, 971, 987, 988). This appears as an elevation of the mucous coat of the lateral wall, prominent in its middle and anteriorly, fading away posteriorly. The ventricular fold contains the inferior free edge of the quadrangular membrane, that is, the ventricular ligament, and numerous glands.

Wylie's experiments with the ventricular folds led him to conclude that the closure of the glottis in defæcation and vomiting is mainly effected by the apposition of these folds. (Quain.)

The interval between the right and left ventricular folds, the **vestibular slit** [rima vestibuli] leads downward to a space between the planes of the ventricular and vocal folds, which extends on each side into the **laryngeal ventricle** [ventriculus laryngis (Morgagni*)] (figs. 970, 971, 987, 988). The latter is a little antero-posterior pocket of the mucosa reaching from the level of the arytænoid nearly to the angle of the thyreoid cartilage, and undermining the ventricular fold; it opens into the cavity of the larynx by a narrow mouth limited above and below by the ventricular and vocal folds. From its anterior part a small diverticulum,

* Morgagni. Italian anatomist. B. 1682, D. 1771.

the **ventricular appendix** [appendix ventriculi laryngis] extends upward between the ventricular fold medially and the thyreo-arytænoid muscle and thyreoid cartilage laterally. Many mucous glands open into it.

The appendix is occasionally so large as to reach the level of the upper margin of the thyreoid cartilage or even the great cornu of the hyoid bone. The laryngeal pouches of some of the apes are remarkably developed and appear to serve in affecting the resonance of the voice. In man, their function, besides that of pouring out the secretion of the glands located within their walls, is not known.

The **vocal fold** [plica vocalis] (or true vocal cord) (figs. 970, 971, 987, 988) is the thin edge of a full, lip-like projection, the vocal lip. The vocal folds correspond in antero-posterior extent to the vocal ligament, and stand nearer the median line than the ventricular fold. In colour the vocal folds are pearly white, excepting the anterior end of each, where there is a **yellow spot** [macula flava] produced by a little mass of elastic tissue (sometimes cartilage) in the ligament, The **vocal lip** [labium vocale] forms the floor of the ventricle and contains the upper part of the elastic cone, whose thickened free edge, the vocal ligament, lies in the

FIG. 988.—FRONTAL SECTION OF A LARYNX HARDENED IN ALCOHOL. A. Posterior segment. B. Anterior segment. (Poirier and Charpy.)

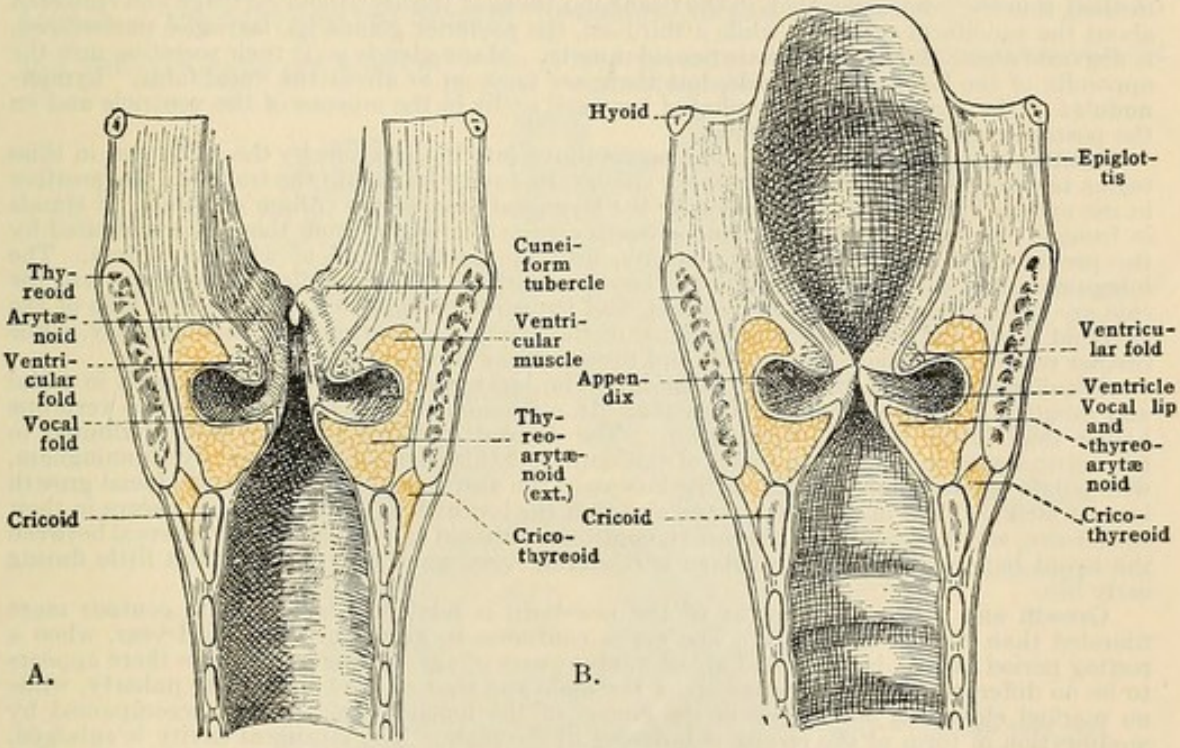

vocal fold and along the vocal muscle. The two vocal lips with the vocal folds and the intervening space, the rima glottidis, together constitute the sound-producing apparatus, the **glottis.**

Below the vocal folds and the medial surfaces of the arytænoid cartilages is a slit, the **rima glottidis** (figs. 970, 971, 988), the narrowest part of the laryngeal cavity, extending from the arytænoideus transversus muscle posteriorly to the thyreoid cartilage in front. The portion of the rima between the vocal folds is known as the **pars intermembranacea;** that between the arytænoids the **pars intercartilaginea.** The rima glottidis in easy respiration is narrow and has the form of a long triangle; in laboured breathing it is widely open and lozenge-shaped.

Below the level of the vocal folds is the space called the **inferior entrance to the glottis** [aditus glottidis inferior] (fig. 988), which is narrow from side to side above, wide and circular in section below—altogether somewhat funnel-shaped. Its walls are formed by the elastic cone and by the arch and lamina of the cricoid cartilage. The lining mucosa is separated from the elastic cone by numerous glands and loose connective tissue, a condition favorable to the development of œdema; below it is continuous with the mucosa of the trachea.

By means of the laryngoscope a more or less complete picture of the laryngeal aperture and the cavity of the larynx can be obtained (figs. 970, 971). There appear, highest up, the

root of the tongue with the epiglottic valleculæ and glosso-epiglottic folds leading backward to the epiglottis; behind the latter, the triangular aperture of the larynx, bounded at the sides by the ary-epiglottic folds. Further lateralward appear the piriform recesses, the laryngeal portions of which lie as transverse fissures behind the laryngeal aperture. Within the ary-epiglottic folds are seen the prominent corniculate tubercles on either side of the inter-arytænoid commissure and just anterior, the variable cuneiform tubercles. Within the vestibule the epiglottic tubercle rises upon the anterior wall, while at the sides appear the ventricular folds overhanging the slit-like openings of the laryngeal ventricles. Below this level the vocal folds stand out on either side approaching nearer the median plane than do the ventricular folds and conspicuous by their pearly whiteness. The form and extent of the rima glottidis and of its divisions, the intermembranous and intercartilaginous parts, can be inspected. Far down, the cricoid cartilage and anterior wall of the trachea may appear and under favourable conditions a glimpse of the bifurcation of the latter can be obtained.

The **mucous coat of the larynx** [tunica mucosa laryngis] in general is covered by a ciliated epithelium; the vocal lips, and, exceptionally, small areas of the mucosa of the laryngeal surface of the epiglottis and the ventricular folds possess a covering of flat, non-ciliated cells. The attachment of the mucosa to the underlying parts is very firm about the vocal folds and dorsal side of the epiglottis, and loose in the ary-epiglottic folds, where much areolar tissue is present. In general the mucosa is pink in colour, becoming bright red over the epiglottic tubercle and edges of the epiglottis and fading over the vocal folds, which appear almost white.

Numerous **mucous glands** [glandulæ laryngeæ] occur about the larynx and are aggregated into groups in certain places. One cluster of **anterior glands** [gl. laryngeæ anteriores] is found in front of and on the posterior side of the epiglottis; another, the **middle glands** [gl. laryngeæ mediæ], is in the ventricular fold, in the triangular fovea of the arytænoid cartilage and clustered about the cuneiform cartilage, while a third set, the **posterior glands** [gl. laryngeæ posteriores], is disposed about the transverse arytænoid muscle. Many glands pour their secretion into the appendix of the laryngeal ventricle, but there are none on or about the vocal folds. **Lymph-nodules** of the larynx [noduli lymphatici laryngei] occur in the mucosa of the ventricle and on the posterior surface of the epiglottis.

Position and relations.—The larynx opens above into the pharynx by the aditu and in thiss region is connected with the hyoid bone. Below, its cavity leads into the trachea. Its position in the neck is indicated on the surface by the laryngeal prominence (Adam's apple). It stands in front of the fourth, fifth, sixth, and seventh cervical vertebræ; from these it is separated by the prevertebral muscles and the pharynx, into the anterior wall of which it enters. The integument and cervical fascia cover the larynx anteriorly in the middle line, while toward the side are the sterno-hyoid, sterno-thryeoid, and thyreo-hyoid muscles. The lateral lobe of the thyreoid gland and the inferior constrictor of the pharynx are in relation to it laterally, while further removed are the great vessels and nerves of the neck.

Peculiarities of age and sex. Position.—The larynx is placed high in the neck in fœtal and infantile life and descends in later life. In a six-months fœtus the organ is two vertebræ higher than in the adult. (Symington.) The descent of the larynx has been attributed to the vertical growth of the facial part of the skull, but this cause is questioned by Cunningham, who points out the high position of the larynx in the anthropoid apes, where the facial growth is more striking than in man; it appears also that the larynx follows the thoracic viscera in their subsidence, which, according to Mehnert, continues until old age. At birth the interval between the hyoid bone and thyreoid cartilage is relatively very small and increases but little during early life.

Growth and form.—The larynx of the new-born is relatively large and in contour more rounded than that of the adult. The organ continues to grow until the third year, when a resting period begins, lasting until about twelve years of age, during which time there appears to be no difference between the larynx of the male and that of the female. At puberty, while no marked change is observable in the larynx of the female, rapid growth accompanied by modification of form of the larynx is initiated in the male. The laryngeal cavity is enlarged, the antero-posterior diameter markedly increased; the whole framework becomes stronger; the thyreoid cartilage especially increases greatly in its dimensions, giving rise to the laryngeal prominence; the vocal folds are lengthened and thickened, the voice changing in quality and pitch. These changes are, for the most part, effected in about two years, but complete development is not attained before twenty to twenty-five years of age. Castration is known to influence the development of the larynx, for in the eunuch it has been found to resemble that of a young woman. The changes in the structure of the cartilages have already been described.

Dimensions.—In the male the distance from the upper edge of the epiglottis to the lower margin of the cricoid is 70 mm.; in the female, 48 mm. The transverse diameter is 40 mm. in the male, 35 mm. in the female. The greatest sagittal diameter is 40 mm. in the male, 37 mm. in the female. The vocal folds in the male measure relaxed about 15 mm., in the female, but 11 mm.; when stretched, about 20 mm. and 15 mm. respectively.

The length of the rima glottidis in the quiescent state is on the average 23 mm. in the male; 17 mm. in the female. In the male the pars intermembranacea measures 15.5 mm., the pars intercartilaginea, 7.5 mm. In the female these are 11.5 mm. and 5.5 mm. respectively. The rima may be lengthened by stretching of the vocal folds to 27.5 mm. in the male and 20 mm. in the female. (Moura.) In the male the width of the rima glottidis is 6–8 mm. in its widest part, but may be increased nearly to 12 mm.

Vessels and nerves (figs. 980, 985).—The *arteries* supplying the larynx are the superior and inferior laryngeal, which accompany the internal and inferior laryngeal nerves respectively, and the crico-thyreoid arteries (see pp. 538, 564).

The superior and inferior laryngeal *veins* join the superior and inferior thyreoid veins respectively.

The *lymph* vascular system is well developed throughout the larynx generally, but in the

vocal folds where the mucosa is thin and tightly bound down the vessels are scarce and small in size (see p. 719).

The *nerves* of the larynx are the superior and inferior laryngeal branches of the vagus and also certain branches of the sympathetic. Taste-buds occur and are abundant in the mucosa of the posterjor surface of the epiglottis. The innervation of the muscles has already been indicated, and the description of the course and relations of these nerves will be found in the chapter on the PERIPHERAL NERVOUS SYSTEM. It should be mentioned here, however, that the idea of sharply limited territories of innervation, not only for the mucosa, but for the muscles as well, has been brought into question by the researches of Semon and Horsley, Exner, and others, which show that the distribution and functions of the laryngeal nerves are extremely complex.

The development of the larynx.—The larynx is developed partly from the lower portion of the embryonic pharynx and partly from the upper portion of the trachea. The cricoid cartilage represents the uppermost tracheal cartilage, while the thyreoid is formed by the fusion of four cartilages representing the ventral portions of the cartilages of the fourth and fifth branchial arches. The laryngeal muscles are derived from the musculature of these arches and consequently their nerve-supply is from the vagus. Whether or not the arytænoid and epiglottic cartilages are also derivatives of the branchial arches is uncertain, although it seems probable that they are.

THE TRACHEA AND BRONCHI

The tubular **trachea** (figs. 972, 989), or windpipe, extends from the larynx downward through the neck and into the thorax to end by dividing into two branches, the **right** and **left bronchi** [bronchus (dexter et sinister)], which lead to

FIG. 989—TRACHEA AND BRONCHI IN THEIR RELATIONS TO THE GREAT VESSELS AS SEEN FROM BEHIND. (After Gegenbaur.)

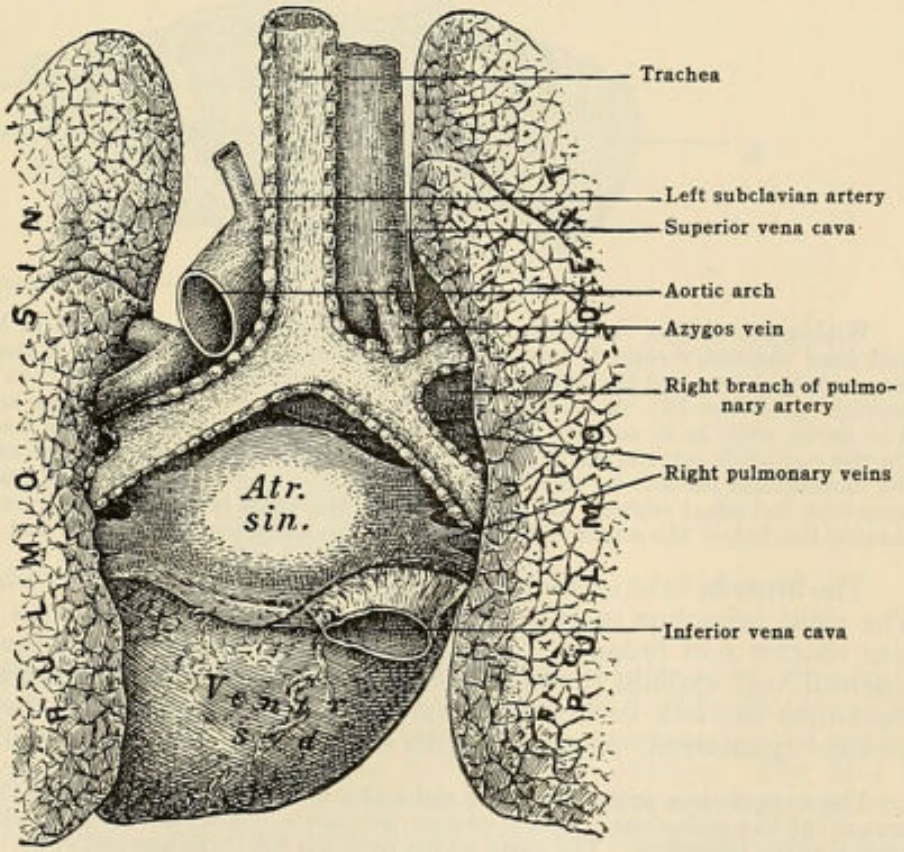

the lungs. These tubes are simple transmitters of the respiratory air. Their walls are, for the most part, stiff and elastic, consisting in large part of cartilage. While the general form of these tubes is cylindrical, a rounded contour is presented by their walls only in front and at the sides, the posterior surface being flat. The inner surface of the walls of the tubes presents a succession of slight annular projections caused by the cartilaginous rings which enter into their structure. The calibre of the trachea varies at different levels, a cast of the lumen being in general spindle-shaped. Its sectional area is less than the combined sectional areas of the two bronchi. When the **bifurcation** of the trachea [bifurcatio tracheæ] is viewed by looking down into its cavity, a sagitally directed keel, the carina tracheæ (fig. 990), is seen standing between the openings which lead into the bronchi. Its position is a little to the left of the mid-plane of the trachea in a slight majority of cases, or in the mid-plane in a large percentage.

Position and relations (figs. 972, 989, 1000).—The trachea lies in the median plane, extending from the level of the sixth cervical vertebra downward and backward, receding from the surface in following the curve of the vertebral column, and deviating a little to the right in approaching the level of the fourth thoracic vertebra, where it divides. Its lower end is fixed so that with elevation and descent of the larynx the tube is stretched and contracted, changes in length which also result from extension and flexion of the head and neck. The mobility of the trachea is favored by its loose investment of connective tissue.

About half of the trachea lies in the neck, but the extent varies with the length of the neck, the position of the head and with age; the trachea holds a lower position in adult life than in childhood and a still lower one in old age when the bifurcation may be as low as the sixth or seventh thoracic vertebra. In front and closely connected with it is the isthmus of the thyreoid gland, covering usually the second to fourth cartilages; anterior to this the cervical fascia and integuments. The cervical aponeurosis is attached to the upper margin of the sternum in two lamellæ, with an interspace containing the venous jugular arch, a lymph gland, and some fat. Between these aponeuroses and the trachea is another space containing the inferior thyreoid veins and some tracheal lymph-glands, and sometimes a thyreoidea ima artery. The innominate artery occasionally crosses the trachea obliquely in the root of the neck. Behind the trachea, in its whole length, lies the œsophagus, which in this part of its course inclines to the left. On either side are the great vessels and nerves of the neck, and the lobes of the thyreoid gland. The inferior laryngeal nerve lies in the angle between the œsophagus and trachea.

FIG. 990.—BIFURCATION OF THE TRACHEA SHOWING THE TRACHEAL KEEL. R. L. Right and left bronchi. (Heller and von Schroetter, from Poirier and Charpy.)

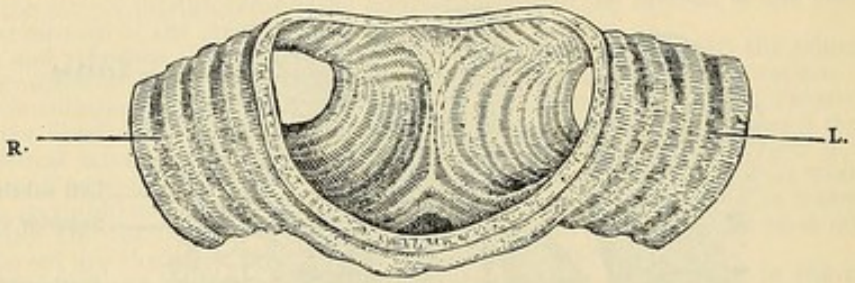

Within the thorax the trachea lies in the mediastinum, enveloped in loose areolar tissue and fixed through strong fibrous connections with the central tendon of the diaphragm. The innominate artery and the left common carotid are at first in front and then at its sides as they ascend, while the left innominate vein and the remains of the thymus are further forward. The aortic arch is in contact with the anterior surface of the trachea near the bifurcation. On the right side are the vagus nerve, the arch of the vena azygos, the superior vena cava, and the mediastinal pleura; on the left, the arch of the aorta, the left subclavian artery, and the recurrent laryngeal nerve. A large group of **bronchial lymph-glands** [lymphoglandulæ bronchiales] lies below the angle of bifurcation. The œsophagus is behind and to the left.

The **bronchi** take an oblique course to the hilus of the lung, where they branch. The right bronchus is nearer to the vertical in its course than is the left; it is also shorter and broader. These conditions, together with the position of the tracheal keel, explain the more frequent entrance of foreign bodies into the right than into the left bronchus. The asymmetrical course of the two bronchi is probably genetically associated with the position of the heart and aorta.

The azygos vein arches over the right bronchus, the vagus passes behind, and the right branch of the pulmonary artery crosses anteriorly below the level of the first (eparterial) branch of the bronchus. The aorta arches over the left bronchus and gains its posterior surface along with the œsophagus; the left branch of the pulmonary artery passes at first in front and then above the bronchus.

Dimensions.—On account of their elasticity considerable difficulty is met with in obtaining accurate measurements of the air-tubes. The length of the trachea is given at 95–122 mm.; its transverse diameter 20–27 mm.; the sagittal diameter 16–20 mm. The right bronchus has a length of 25–34 mm.; the left, 41–47 mm. The transverse diameter of the right is 18 mm.; of the left, 16 mm. The angle of bifurcation of the trachea varies from 56° to 90°, the mean being 70.4° a wide angle corresponding to the breadth of the thorax of man. The right bronchus makes an angle of 24.8° with the median plane; the left, 45.6°.

According to Tillaux the length of that portion of the trachea between the superior edge of the sternum and the cricoid cartilage varies with age and sex as follows:—

Adult male,	from 4.5 to 8.5 cm.	average,	6.5 cm.
Adult female,	" 5 to 7.5 cm.	"	6.4 cm.
Boys 2½ to 10 years,	" 2.7 to 6.5 cm.	"	4.4 cm.
Girls 3½ to 10½ "	" 4 to 6.5 cm.	"	5.1 cm.

The diameter of the lumen of the trachea when distended to a cylindrical form has been measured by Sée:—

New-born	4.12 to 5.6 mm.
Infant 2 years	7.5 to 8 mm.
Infant 4 to 7	8 to 10.5 mm.
Over 20 years, male	16 to 22.5 mm.
Over 20 years, female	13 to 16 mm.

Structure of the trachea and bronchi (figs. 978, 988, 989, 991).—The walls of the trachea and bronchi are composed of a series of cartilages having the form of incomplete rings, held together and enclosed by a strong and elastic fibrous membrane. Posteriorly, where the rings are deficient, this membrane remains as the **membranous wall** [paries membranacea]; between the cartilages it constitutes the **annular ligaments** [ligg. annularia (trachealia)].

FIG. 991.—SCHEMATIC LONGITUDINAL SECTION OF THE WALL OF THE TRACHEA. (Gegenbaur.)

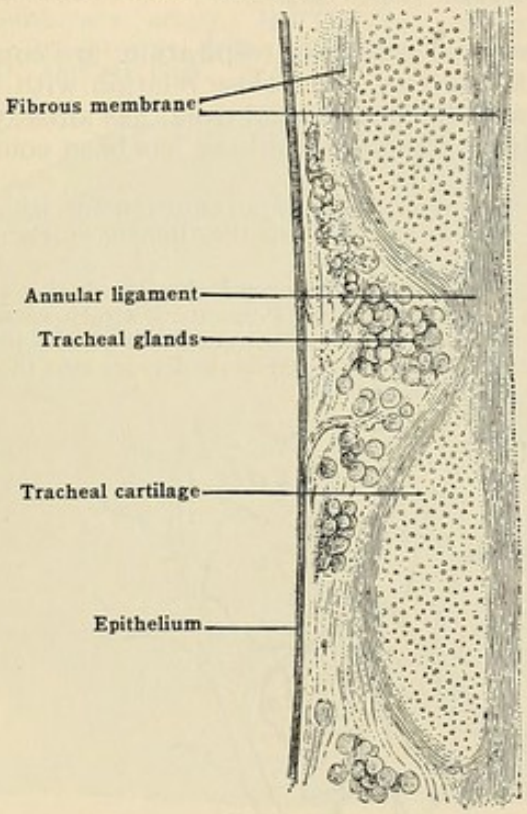

A **tracheal cartilage** [cartilago trachealis] comprises a little more than two-thirds of a circle. Its ends are rounded, its outer surface flat, while the inner surface is convex from above downward; the upper and lower margins are nearly parallel. The cartilages are from sixteen to twenty in number. The first is usually broader than the type, and is connected by the crico-tracheal ligament with the cricoid cartilage. Sometimes these two cartilages are in part continuous. The last cartilage is adapted to the bifurcation of the trachea and presents at the middle of its lower margin a hook-like process. This turns backward between the origins of the bronchi, and in the majority of cases gives a cartilaginous basis to the tracheal carina. Some of the tracheal cartilages vary from the type by bifurcating at one end. The cartilages keep the lumen of the trachea patent for the free passage of the air. Calcification occurs as with the laryngeal cartilages, but much later in life.

A **mucous coat** [tunica mucosa], soft and pinkish-white in colour, covers the inner surface of the trachea; posteriorly it is thrown into longitudinal folds. Mucous secreting **tracheal glands** [gl. tracheales] are present in the elastic **submucous coat** [tela submucosa] between the cartilages and at the back of the trachea. A thin layer of transversely disposed smooth muscle-fibres, stretching between the ends of the cartilages in the posterior wall, constitutes the **muscular**

coat [tunica muscularis]. Contraction of this trachealis muscle, as it is more properly named, causes the ends of the tracheal cartilages to be approximated and the lumen of the wind-pipe to be diminished.

The structure of the walls of the bronchi is similar to that of the trachea. The right bronchus possesses six to eight cartilages; the left, nine to twelve.

An inconstant *broncho-œsophageal* muscle may connect the back of the left bronchus with the gullet.

Vessels and nerves.—The *arteries* supplying these air-tubes come from the inferior thyreoid and from the internal mammary by its anterior mediastinal or bronchial branches. *Venous radicles* come together in the annular ligaments and join lateral veins on either side, which empty the blood into the plexuses of the neighbouring thyreoid veins.

Lymph-vessels are abundant, and are disposed in two sets, one in the mucosa, another in the submucosa. They drain into the tracheal, bronchial and œsophageal lymph-glands. *Nerves* are provided by the vagus direct, by the inferior laryngeal, and by the sympathetic.

THE LUNGS

The **lungs** [pulmones], the essential organs of respiration, are constructed in such a way as to permit the blood to come into close relation with the air (fig. 992). Their genetic connection with the entodermal canal has already been indicated (see also p. 1099). In plan of structure the lung has been compared with

FIG. 992.—SCHEMATIC SECTION OF A LOBULE OF THE LUNG SHOWING THE RELATION OF THE BLOOD-VESSELS TO THE AIR-SPACES. (After Miller, from the 'Reference Handbook of the Medical Sciences.')

b.r. Respiratory bronchiole. *d.al.* Alveolar duct; a second alveolar duct is shown cut off. *a,a.* Atria. *s.al.* Alveolar saccule. *a.p.* Alveolus. *art.* Pulmonary artery with its branches to the atria and saccules. *v.* Pulmonary vein with its tributaries from the pleura (1), the alveolar duct (2), and the place where the respiratory bronchiole divides into the two alveolar ducts (3).

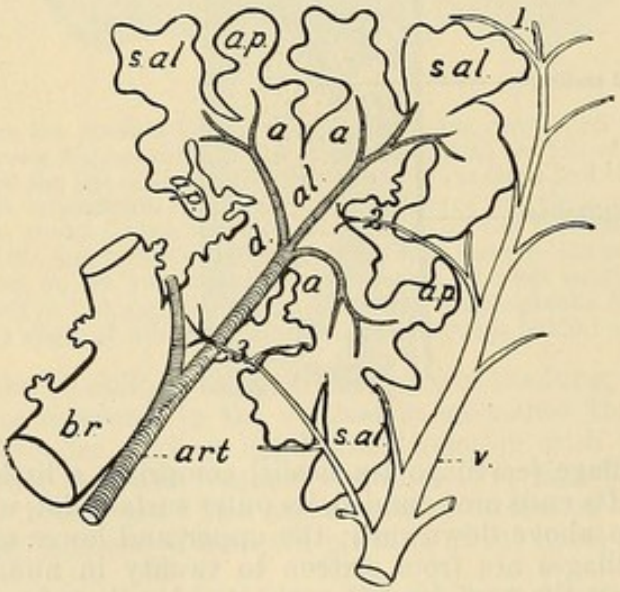

a gland, since it is composed of a tree-like system of tubes terminating in expanded spaces. Closely associated with the system of tubes are certain blood-vessels, some of which take part in nourishing the organ, others participate in its special mechanism.

The lungs are two in number, and lie one on either side of the thoracic cavity, separated by a partition known as the **mediastinum** (figs. 993, 997, 1000). Serous membranes covering the latter right and left are parts of two closed sacs, the **pleuræ,** each of which is reflected about a lung and the neighbouring chest-wall after the manner of serous membranes in general. The space enclosed within the sac-walls is the **pleural cavity,** genetically a subdivision of the cœlom.

Form (figs. 994, 998).—The lung is pyramidal or conical in form, with the **base** [basis pulmonis] below and resting on the diaphragm, and with **apex** [apex pulmonis] above, in the root of the neck. Two surfaces, costal and mediastinal, are described. The broad convex **costal surface** [facies costalis] is directed against

the thoracic wall in front, laterally and behind, and is marked by grooves corresponding to the ribs. The **mediastinal surface** [facies mediastinalis] is concave and presents a contour adapted to structures of the mediastinum (fig. 994). A special concavity on this surface, known as the *cardiac fossa*, corresponds to the prominence of the heart and is deeper in the left lung than in the right. Above and behind the cardiac fossa is a depression, the **hilus** of the lung [hilus pulmonis], where the bronchus and pulmonary vessels and nerves together constituting the **root** of the lung [radix pulmonis], enter and leave. Near the posterior edge of the mediastinal surface is a groove, which ascends and turns forward over the hilus; the groove of the left lung is adapted to the cylindrical surface of the aorta; that of the right, the vena azygos. A well-marked **subclavian sulcus** [sulcus subclavius] extends upward on this surface to the apex, corresponding on the right side to the lower part of the trachea and right subclavian artery, on the left to the left subclavian artery alone. Further forward is a groove adapted in the right lung to the superior cava; in the left to the left innominate vein. The lung is not in actual contact with these several structures, but is separated from them by the mediastinal pleura. The mediastinal surface passes gradually into the costal surface posteriorly, there being no proper posterior edge. Where the mediastinal and costal surfaces meet in front, a sharp **anterior margin** [margo anterior] exists (fig. 997). In the right lung this runs down in a gentle curve to turn lateralward in the inferior margin. In the left lung the anterior margin is cut into by a wide **cardiac notch** [incisura cardiaca], which is occupied by the heart in the pericardium as it is pressed toward the anterior thoracic wall. The cardiac notch is separated from the inferior margin by a little tongue of lung substance, the pulmonary **lingula** [lingula pulmonis].

FIG. 993.—HORIZONTAL SECTION OF THE THORAX OF A MAN, AGED FIFTY-SEVEN, AT THE LEVEL OF THE ROOTS OF THE LUNGS, SEEN FROM ABOVE. (J. S.) (Quain.) × 1.

A.A. Ascending aorta. A.M. Anterior mediastinum. A.V. Azygos vein. D.A. Descending aorta. E. Eparterial bronchus. I. Superior lobe of lung. L.B. Left bronchus. L.P. Left phrenic. L.P.V. Left pulmonary vein. L.V. Left vagus. Œs. Œsophagus. P.A. Pulmonary artery. P.C. Pericardial cavity. R.B. Right bronchus. R.P.A. Right branch of pulmonary artery. R.P.C. Right pleural cavity. R.P.N. Right phrenic. R.P.V. Right pulmonary vein. R.V. Right vagus. S. Inferior lobe of lung. Sc. Scapula. T.D. Thoracic duct. 3, 4, 5, 6, 7. Corresponding ribs.

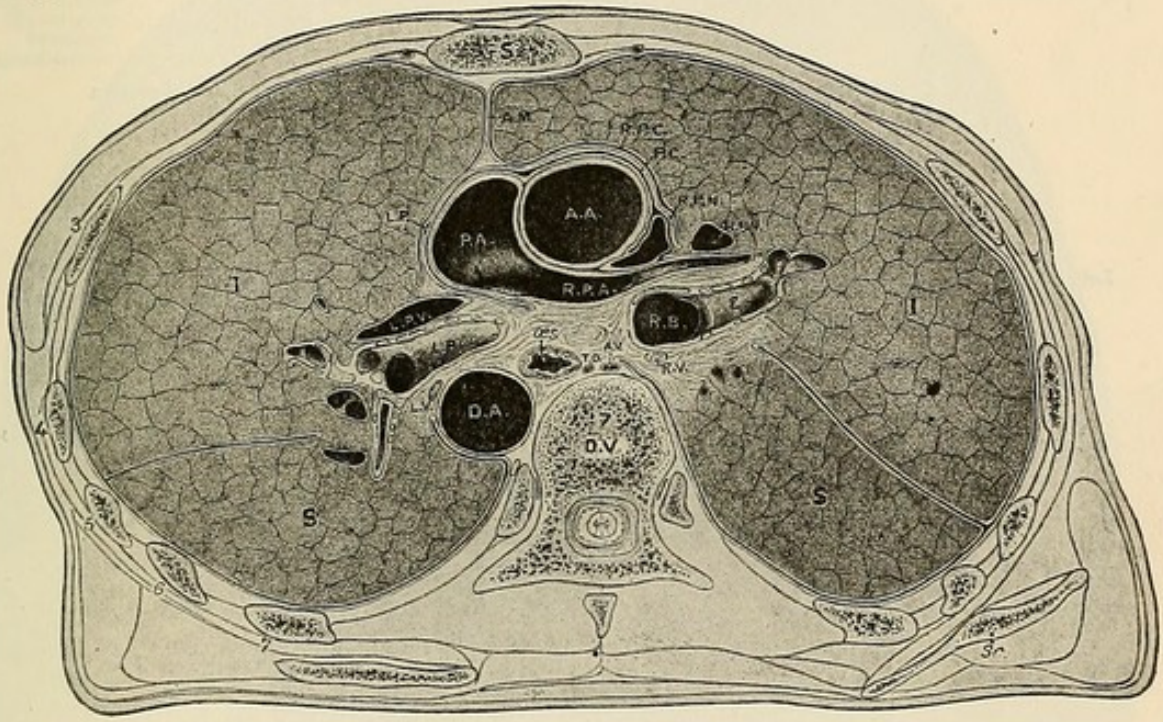

The **base** of the lung (fig. 994) presents the **diaphragmatic surface** [facies diaphragmatica] concave and oblique in adaptation to the dome of the diaphragm. It is limited by a sharp **inferior margin** [margo inferior], which follows the curves of the mediastinal and costal surfaces, and fits into the angle between the diaphragm and thoracic wall.

The **apex** (figs. 994, 997, 998) is rounded and points upward with an inclination forward and medially, accommodating itself to the structures within and about the superior aperture of the thorax.

A deep **interlobar fissure** [incisura interlobaris] (figs. 994, 998), reaching through the lung substance nearly to the hilus, divides each organ into a smaller **superior lobe** [lobus superior] and a larger **inferior lobe** [lobus inferior]. The interlobar fissure runs downward and forward beginning a short distance below the apex, and reaching the base near the anterior margin in the left lung, somewhat further back in the right lung. From the obliquity of the plane of the fissure it will be noticed that the inferior lobe reaches posteriorly to within a short distance of the apex, and includes the greater part of the back and base of the lung, while the superior lobe takes in the anterior margin and apex. The presence of a **middle lobe** [lobus medius] disturbs the symmetry of the right lung. This results from a deep, nearly horizontal incisure cutting through the lung somewhat below its middle, and extending between the anterior margin and the main interlobar fissure, which it reaches at about the level of the axillary line.

FIG. 994.—LEFT LUNG, VIEWED FROM THE MEDIASTINAL SURFACE. (Spalteholz.)

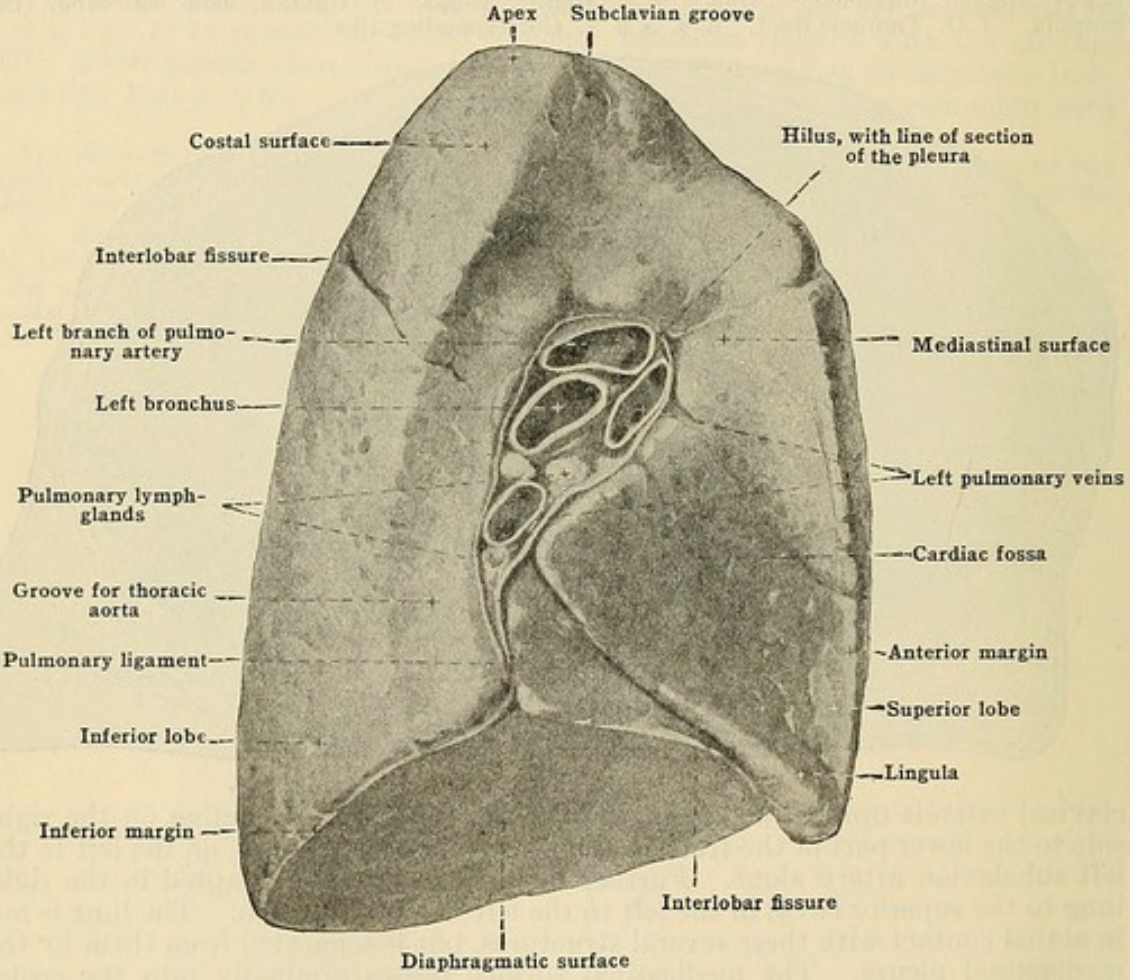

Besides possessing the individual peculiarities mentioned, the two lungs further differ from each other in general form and weight, the right lung being considerably broader and heavier than the left. The difference in length maintained by some anatomists, even if it prove constant, must be slight and of little practical importance. These differences seem to follow the asymmetry of the vault of the diaphragm and the position of the heart.

The **hilus** (fig. 994), already mentioned as situated on the mediastinal surface, presents in the left lung a raquette-shaped outline. Its average height is about 8.8 cm. (Luschka); it extends over both lobes. The hilu of the right lung, rather four-sided in outline and shorter than that of the left, is related to the three lobes. The entering structures, constituting the **root** of the lung (figs. 989, 993, 994), include the bronchus, pulmonary artery and veins, bronchial vessels, lymphatic vessels and glands, and pulmonary nerves. These are bound together by connective tissue and invested by the pleura. The bronchus is in the posterior and upper part of the root; the pulmonary vessels lie anteriorly, the veins below the arteries.

The surface of the lung is marked off in polygonal areas of different sizes (secondary lobules) by lines containing pigment. The pigmentation is especially deep on the lateral surface along the furrows corresponding to the ribs.

Branching of the bronchial tubes (fig. 995).—Each bronchus, from its origin at the bifurcation of the trachea, takes an oblique course to the hilus, and then continues in the lung as a main tube, extending toward the posterior part of the base. These stem-bronchi are curved, probably in adaptation to the heart, the right like the letter **C** and the left like an **S**. Throughout their course the stem-bronchi give off in monopodic fashion collateral branches, the **bronchial rami** [rami bronchiales], and these, branching in a similar way, reach all parts of the lung.

The first bronchial ramus of the right stem-bronchus arises above the place where the latter is crossed by the pulmonary artery and is named the **eparterial bronchial ramus** [ramus bronchialis eparterialis]; it supplies the superior lobe of the right lung, sending a special branch to the apex. All other bronchial rami, whether in the right or left lung, take origin from the

FIG. 995.—CAST OF THE AIR-TUBES AND THEIR BRANCHES, VIEWED FROM IN FRONT. (Spalteholz.)

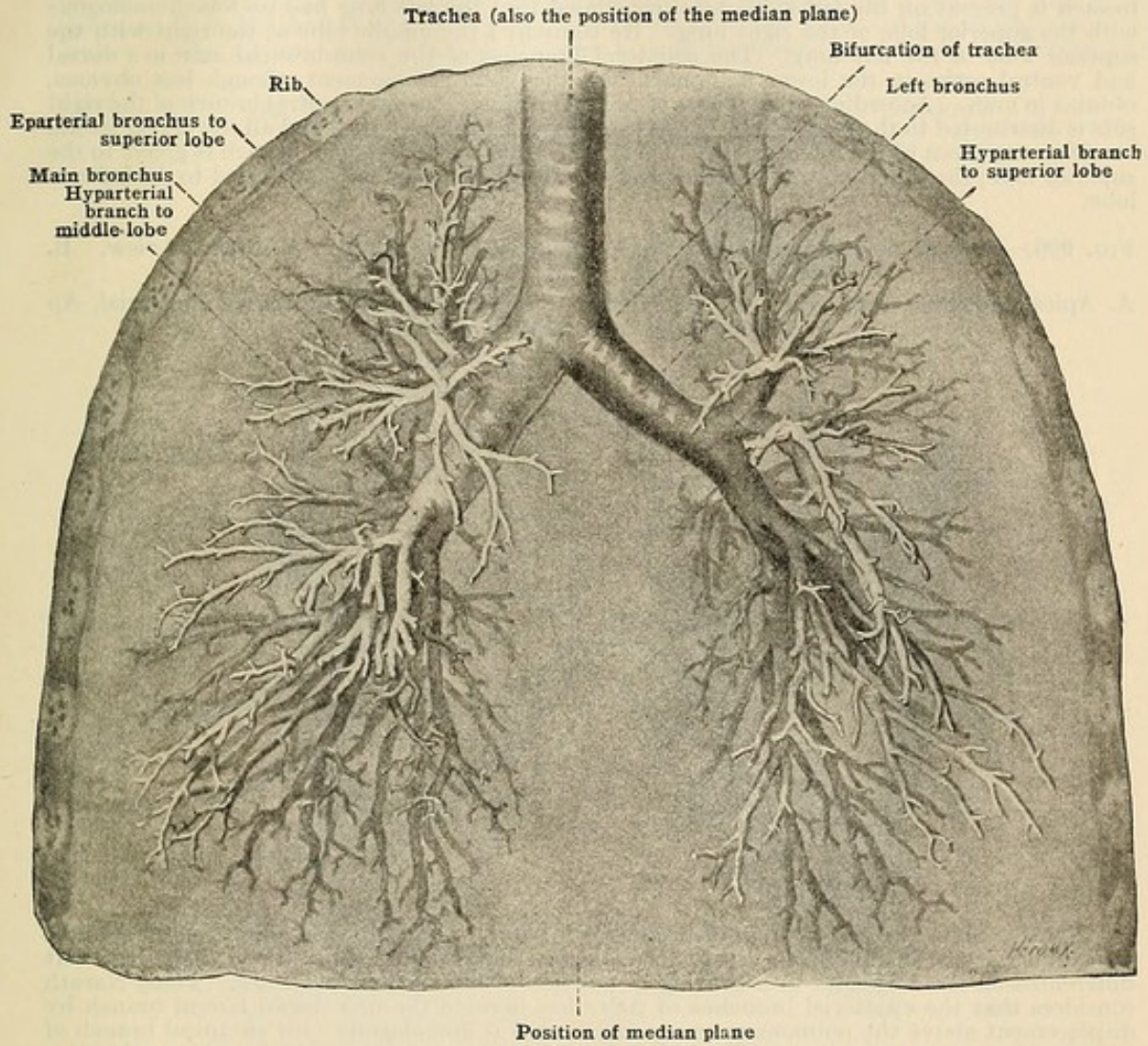

stem-bronchi below the level of the crossing of the pulmonary artery and are called **hyparterial bronchial rami** [rami bronchiales hyparteriales]. The second bronchial branch of the right lung goes to supply the middle lobe, while several bronchial branches enter the inferior lobe. On the left side, the first bronchial branch arises below the crossing of the pulmonary artery, and goes to supply the superior lobe, providing it with an apical ramus. The other branches are given to the inferior lobe.

Structure of the bronchial rami.—The larger bronchial rami contain in their walls both **C**-shaped and irregular plates of cartilage, the latter gradually replacing the former as the branches become smaller. The membranous wall is lost and plates of cartilage are disposed on all sides. The mucosa, with ciliated epithelium, is thrown into longitudinal folds covering bundles of elastic fibres of the membrana propria. Next to the latter is a continuous layer of smooth muscle-fibres circularly arranged. Mucous secreting **bronchial glands** [gl. bronchiales] are present as far as tubes of 1 mm. diameter; here the cartilages also disappear.

To W. S. Miller is due the credit of having greatly increased our knowledge of the finer structure of the lung and for having presented the conception of the primary lung lobule now generally accepted by anatomists. Some of the chief results of Miller's work are embodied in

the following descriptions pertaining to the termination of the air-tubes and to the blood and lymph vascular systems of the lungs and pleuræ.

Through further branching of the bronchial rami a great number of very fine **bronchioles** [bronchioli] are reached, whose walls possess a weak muscle layer and are lined by mucosa having an epithelium of flattened non-ciliated cells. These, subdividing, give rise to the **respiratory bronchioles** [bronchioli respiratorii], the walls of which are beset with alveoli (fig. 992). From the respiratory bronchioles arise the **alveolar ducts** [ductuli alveolares], or terminal bronchi, each of which leads to a group of air-spaces, called *atria*, each of which again communicates with a second series of air-spaces, the *air-sacs* (alveolar sacs or infundibula), whose walls are pouched out to form numerous **pulmonary alveoli** [alveoli pulmonum].

A terminal bronchus with its air-spaces and blood-vessels, lymphatics and nerves, together form a **pulmonary lobule** [lobulus pulmonum], the unit of lung structure.

Aeby divided the bronchial branches into two sets, according to their relation to the pulmonary artery. The branch arising above the place where the pulmonary artery crosses the stem-bronchus he named the **eparterial bronchus,** and those arising below the crossing he called **hyparterial.** An eparterial bronchus exists only on the right side; all other branches are hyparterial. Since the eparterial supplies the superior lobe of the right lung and no eparterial branch is present on the left side, Aeby concluded that the left lung had no lobe homologous with the superior lobe of the right lung. He compared the middle lobe of the right with the superior lobe of the left lung. The collateral branches of the stem-bronchi arise in a dorsal and ventral series in the lower mammals, and the same arrangement, though less obvious, obtains in man. According to the views of Aeby and Hasse, the first ventral branch of the right side is distributed to the middle lobe, while the remaining three ventral and all the dorsal lateral branches are given to the inferior lobe. On the left side, the first ventral branch is given to the superior lobe; the other ventral branches and the dorsal branches are distributed to the inferior lobe.

FIG. 996.—SCHEME OF THE BRONCHIAL TREE ACCORDING TO NARATH. A. Anterior view. B. Right lateral view. (Poirier and Charpy.)

A. Apical bronchus, collateral of the first ventral and susceptible of becoming eparterial, Ap in migrating to the bronchial trunk.

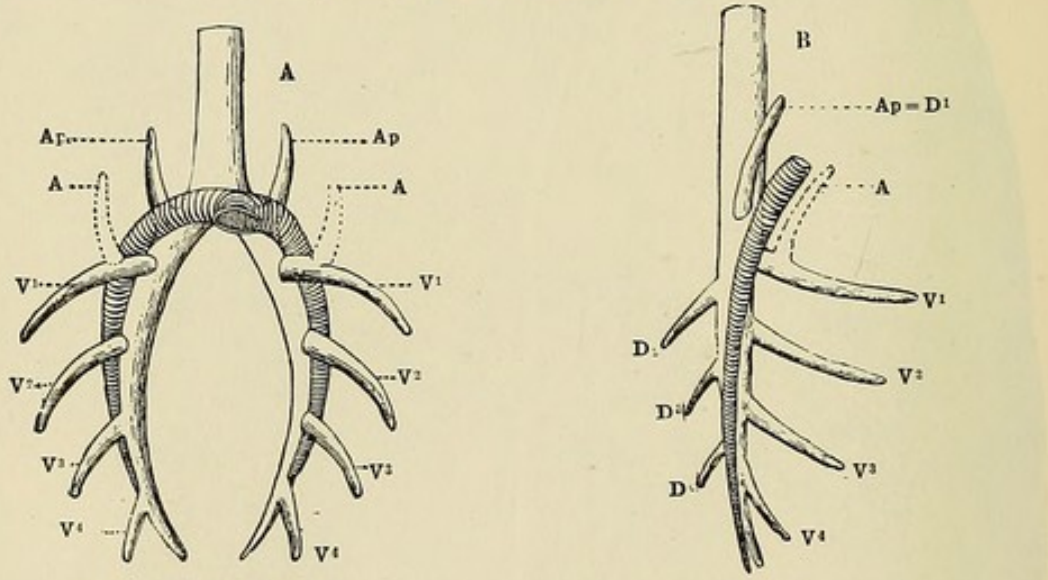

Narath considers the division of bronchial branches in accordance with their relation to the pulmonary artery as of no great morphological significance. He attributes the apparent differences on the two sides to a shifting in position of homologous branches. Thus, Narath considers that the eparterial bronchus of Aeby has become the first dorsal lateral branch by displacement above the pulmonary artery and that it is homologous with an apical branch of the left side, which retains its primitive origin from the first ventral branch (fig. 996). Narath's conception of the migration of the bronchial branches is supported by the results of Huntington's extensive studies of the bronchial tree in mammals.

The physical properties of the lungs.—The average *dimensions* in the adult male are as follows: Height of the lung is given at 25–27 cm., the greatest sagittal diameter at 16–17 cm., and the greatest transverse measurement as 10 cm. for the right and 7 cm. for the left. The *volume* of the lungs when well expanded is 6500 c.c. (Merkel.) The *weight* of the lungs can be found only approximately on account of the presence of blood and mucus. In the adult male the weight of both lungs is given as 1300 gm.; female, 1023 gm. The weight of the right lung compared with the left is as 11 is to 10. Ried and Hutchinson found the weight of the lungs compared with that of the body as 1 : 37 (male), 1 : 43 (female); in the fœtus at term, 1 : 70. After respiration has been established, the lung, if placed in water, will float. Its *specific gravity* is between 0.345 and 0.746. (Rauber.) The fœtal lung contains no air and is heavier than water. Its specific gravity is 1.045 to 1.056. (Krause.) Lung tissue, free of air, with vessels moderately filled, has likewise a specific gravity of 1.045 to 1.056. (Vierordt).

The colour of the lung result sfrom the presence of blood, pigment, and the air in the alveoli. It varies therefore as these constituents are all or in part present and with differences in their

proportions. Thus the general colour is red in the fœtus, pink, in the infant, and grey mottled with black in the adult. The dark colour is traceable to the carbonaceous matter carried into the lungs from the atmosphere.

In **consistence** the lung is soft and spongy, and when compressed between the fingers, emits a crackling sound. Among the physical properties the **elasticity** of the lung is quite remarkable: Under ordinary conditions the pressure of the air in the lung keeps the alveoli and the organ as a whole distended, but when the pleura has been opened and the air pressure equalised without and within, the lung collapses.

Topography.—The **apices** of the lungs extend upward as high as the first thoracic vertebra-a level considerably higher than the superior margin of the sternum (figs. 997, 998). The sub, clavian vein and artery and the brachial plexus, together with the anterior scalene muscle, control to a certain degree the height reached. There seems to be no constant difference between the levels attained by the apices of the two lungs. The extent to which the apex rises above the clavicle is rarely more than 3.5 cm. (Merkel), and will, of course, vary with individual differences in the position and form of this bone. The average is not over 2.5 cm. (1 in.).

The **base** of the lung, resting on the diaphragm, is separated by that thin partition from the underlying abdominal viscera: thus beneath the base of the right lung is the right lobe of the liver, while under the left lung are the left lobe of the liver, the fundus of the stomach, and the spleen. The position of the apex changes very little in respiration, and the same holds true for

FIG. 997.—POSITION OF THE LUNGS FROM BEFORE. (Merkel.)
The parietal pleura is shaded and outlined in black.

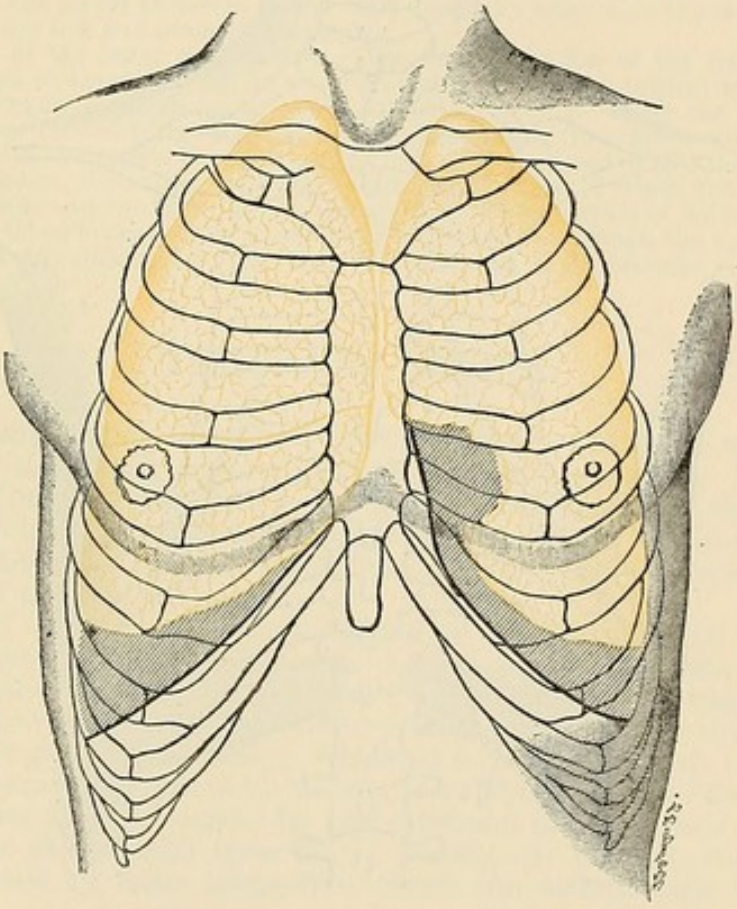

the hinder bulky part of the lung. The latter rests against the side of the vertebral column in the deep hollow of the angles of the ribs, and reaches below to the level of the eleventh costo-vertebral joint (fig. 998). The **anterior margins** (fig. 997) descend in curves from behind the sterno-clavicular joints, and run near together a little to the left of the median line. At the level of the sixth costo-sternal junction the anterior margin of the right lung turns lateralward to follow the sixth costal cartilage. The anterior margin of the left lung turns lateralward along the fourth costal cartilage as far as the para-sternal line, descending in a curve to the lingula and thus forming the cardiac incisure. The positions of the **inferior margins** (figs. 997, 998) of the two lungs are practically alike in their positions. Each extends in a curve covex downward, behind the sixth costal cartilage in its entire length, crosses the costo-chondral junction of the sixth rib to the superior margin of the eighth rib in the axillary line, and so to the ninth or tenth rib in the scapular line, whence they run horizontally medialward to the eleventh costo-vertebral joint.*

* These relations are the mean between the conditions observed in the cadaver and as found by physical examination of the living. In old age the inferior margins of the lungs reach a level one or two intercostal spaces lower than is the case in adult life (Mehnert).

The **interlobar fissure** (fig. 998) begins about 6 cm. below the apex of the lung at the level of the head of the third rib. With the arm hanging at the side, a line drawn across the back from the third thoracic spine to the root of the scapular spine would indicate the course of the upper part of this fissure. (Merkel.) Thence it passes downward and around the chest to the end of the sixth bony rib in the mammillary line. Merkel points out the use of the root of the scapular spine as a landmark for finding the limits of the lobes posteriorly: with the arm hanging at the side all above this spot is superior lobe; all below it the inferior. The short fissure of the right lung begins at the main interlobar fissure in the axillary line, about the level of the fourth rib or fourth interspace, and passes nearly horizontally to the anterior margin of the lung at the level of the fourth costal arch.

The **roots** of the lungs are placed opposite the fifth, sixth, and seventh thoracic vertebræ. The right root lies behind the inferior vena cava and under the arch of the azygos vein; the left root is beneath the aortic arch and in front of the thoracic aorta. The phrenic nerve passes in front of each root, the vagus behind. On the front and back are the pulmonary plexuses, anterior and posterior. The ligament of the pleura goes from the lower edge of the root.

Vessels and nerves of the lungs.—The **bronchial arteries** (see p. 588), belonging to the systemic system, carry blood for the nourishment of the lungs. They arise from the aorta or from an intercostal artery, two for the left lung and one for the right, and, entering at the hilus,

FIG. 998.—POSITION OF THE LUNGS FROM BEHIND. (Merkel.)
The pleura is represented as in Fig. 997.

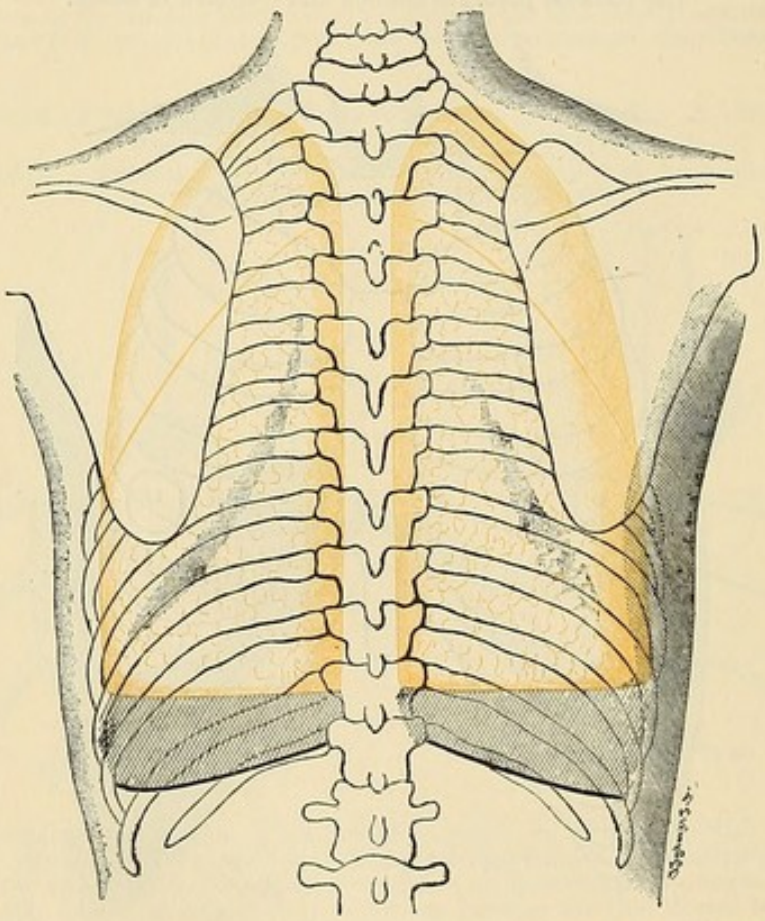

reach the hinder wall of the main bronchus. The bronchial arteries accompany the bronchi, whose walls they supply, as far as the distal ends of the alveolar ducts, beyond which they do not go. These vessels also supply the lymph glands of the hilus, the walls of the large pulmonary vessels, and the connective-tissue septa of the lung. **Bronchial veins** (see p. 664), anterior and posterior, arise from the walls of the first two or three divisions of the bronchi and end in the innominate and the azygos or in one of the intercostal veins; those arising from the walls of the smaller tubes, including the alveolar ducts, join the pulmonary veins. The **pulmonary artery** (see p. 528), entering the hilus in a plane anterior to the bronchus, turns to the posterior aspect of the main-stem, following its branches and their subdivisions to the lobules. Entering the lobule, the last branch of the vessel gives off as many twigs as there are atria (fig. 992), and these twigs end in dense capillary nets in the walls of the alveoli. Here the venous blood brought by the pulmonary artery, separated from the air in the alveolus only by a thin septum, is changed to arterial blood in the respiratory process. According to Miller, anastomosis between the branches of the pulmonary artery are exceptional. Anastomosis between the bronchial and pulmonary arteries has been claimed, but the connection apparently existing between these vessels is through the radicles of the bronchial veins which join the pulmonary veins. The pulmonary venous radicles begin at the capillary networks and drain the arterial blood into the pulmonary veins, which run between adjacent lobules and which receive also

blood coming from the capillary network of the pulmonary pleura and from the capillary network of the bronchi (fig. 992). Thus it will be seen that while the pulmonary vein carries mainly arterial blood, it carries also some venous blood. The **pulmonary veins** (see p. 529) follow the bronchial tree on the side opposite the arteries to the hilus, where, having converged to two large trunks located in the root of the lung below the plane of the artery, they pass to the left atrium. The pulmonary veins have no valves.

Lymphatics.—Miller has found the lymphatic vessels forming a closed tube system in the walls of the bronchi, in the pleura, and along the branches of the pulmonary artery and veins. Within the lung numerous **pulmonary lymph-glands** [lymphoglandulæ pulmonales] are found chiefly at the places of branching of the larger bronchi [lymphoglandulæ bronchiales]. Scattered along the latter, as well as associated with the branches of the pulmonary artery and vein, are found masses of lymphoid tissue. Deposits of carbonaceous matter in the lymphoid structures of the lung are present, except in early infancy; the amount increases with age.

Nerves.—The vagus and sympathetic contribute to form the pulmonary plexuses in front and behind the root of the lung, from which branches go to accompany bronchial arteries; a smaller number accompany the air-tubes (see p. 957).

Variations.—Congenital absence of one or both lungs has been observed. Variations in the lobes are not uncommon—four for the right and three for the left lung has been recorded. An *infracardiac lobe*, as found in certain mammals, sometimes occurs; an infracardiac bronchus is, however, constant in man. More or less complete fusion of the middle and upper lobes of the right lung is not rare. The lungs may be symmetrical, with two lobes each, the apical bronchus of the right springing from the first ventral bronchus, as is normal for the left lung (Waldeyer, Narath); or the lungs may have three lobes each, the apical bronchus of the left arising from the main bronchus. The apical bronchus of the right lung may arise from the trachea, an origin that is normal in the hog and other artiodactyls.

Development of the lungs and trachea.—The first indication of the trachea and lungs appears in embryos of about 32 mm. as a trough-like groove in the ventral wall of the upper part of the œsophagus, communicating above with the pharynx. Later the groove becomes constricted off from the œsophagus, the constriction extending from below upward, so that a tube is formed which opens into the pharynx above. The lower end of this tube soon becomes bilobed, and the lobes, elongating, give rise to additional lobes, of which there are primarily three in the right side and two in the left. The upper unpaired portion of the tube becomes the trachea, while the lobed lower portion gives rise to the bronchi and lungs, the complicated structure of the latter being produced by oft-repeated branchings of the bronchi.

THORACIC CAVITY

Thoracic cavity [cavum thoracis] is the term used to denote the space included by the walls of the thorax and occupied by the thoracic viscera. These are, on each side, the lung, surrounded by the pleural cavity, and in the middle the pericardium and heart, great vessels, trachea and œsophagus, all closely associated and forming a dividing wall, the mediastinal septum, standing between the right and left sides of the thoracic space.

The **limits** of the thoracic space are given by the skeletal parts of the thorax together with the ligaments involved in the articulations and the muscles and membranes interposed between the bones. The arched diaphragm forms the inferior limit; and the barrier presented by the scalene muscles and the cervical fascia makes the superior boundary, which, it is to be observed, lies above the plane of the superior aperture of the thorax and therefore in the base of the neck. These boundaries are approached by the extension of the pleural cavities; yet there intervenes the parietal layer of the pleural sac which is connected with the thoracic walls by loose connective tissue, the **endothoracic fascia** [fascia endothoracica].

The **form** of the thoracic space departs from the external contour of the thorax chiefly through the projection into it of the ridge made by the succession of centra of the thoracic spine, and by the presence on either side of the latter of the broad, deep pulmonary sulcus. On account of these features a transverse section of the thoracic space is somewhat heart-shaped, but, however, much compressed anteroposteriorly (fig. 993).

The arch of the diaphragm on the right side rises to the level of the spinous process of the seventh thoracic vertebra; on the left, to the level of the eighth thoracic spinous process. At its circumference the diaphragm is in contact to a variable extent above its origin with the inner surfaces of the costal arches. In the lower part of this zone a connection exists between the muscle and the thoracic wall through a continuation of the endothoracic fascia; in the upper part, the phrenico-costal sinus (see p. 1237) intervenes. The level reached by this deepest part of the pleural cavity is lower than the summit of the peritoneal cavity, so they overlap to a considerable extent.

THE PLEURA

The **pleura** (fig. 993) is a closed serous sac, which invests the lung (**pulmonary pleura**), and lines the inner surface of the thoracic walls (**parietal pleura**). The **pleural cavity** [cavum pleuræ] is the capillary space enclosed by the walls of the sac containing a little fluid which lubricates the apposed surfaces of the pulmonary and parietal membranes. There are two pleuræ, one in relation to each lung, completely separated by a sagittal partition, the **mediastinum.**

FIG. 999.—PLEURAL CAVITY OPENED FROM IN FRONT.

1, first rib; 2, manubrium sterni; 3, acromial extremity of clavicle; 4, xiphoid process, 5, linea alba; 6, m. transversus abdominis; 7, seventh rib; 8, sternocleidomastoid m.; 9, anterior scalene m.; 10, larynx; 11, thyreoid gland; 12, deep layer of cervical fascia in front of the trachea; 13, corresponds to upper part of anterior mediastinal cave; 14, pleural cupola; 15, mediastinal pleura; 16, lower margin of costal pleura; 17, pericardium; 18, superior lobe of lung; 19, middle lobe of right lung; 20, inferior lobe of lung; 21, diaphragm. (Rauber-Kopsch.)

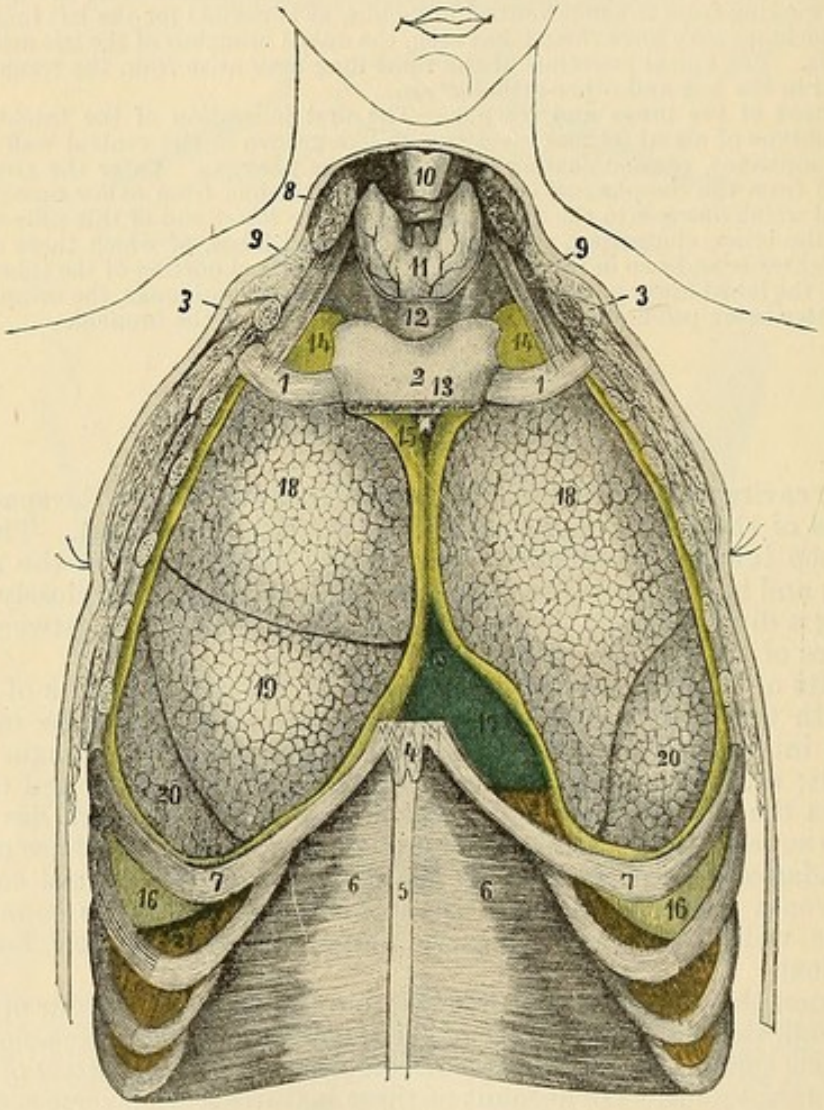

The **pulmonary pleura** [pleura pulmonalis] forms a smooth glistening coat over the outer surface of the lung, with the tissue of which it is inseparably connected. At the hilus the pulmonary pleura passes from the mediastinal surface of the lung to cover the root above, in front, and behind, and becomes continuous medialward with the parietal pleura of the mediastinum. Below the root of the lung the pleura is reflected medialward in a double layer as the **pulmonary ligament** [lig. pulmonale] (fig. 994).

This presents anterior and posterior surfaces and three margins; the base is mostly free, and directed toward the diaphragm, with which it is connected at its medial end; the apex is at the lung root, one margin is next to the lung, and the other joins the mediastinal pleura.

The **parietal pleura** [pleura parietalis] is divided, according to the regions of the chest with which it is associated, into the costal, diaphragmatic, and mediastinal pleura. The **costal pleura** [pleura costalis] lines the thoracic wall, to which it is bound not very firmly by the endothoracic fascia. It covers incompletely the back of the sternum and extends laterally upon the ribs and intercostal muscles. Posteriorly beyond the angles of the ribs it passes over the anterior rami of the thoracic nerves and intercostal vessels, the heads of the ribs, and the sympathetic trunk to the vertebral column; here it becomes continuous with the mediastinal pleura. Above, the pleura reaches beyond the superior margin of the sternum into the root of the neck, and in the form of a dome, the **cupola** of the pleura [cupola pleuræ], is adapted to the apex of the lung. It is supported by processes of the deep cervical fascia, and by a fibrous aponeurosis known as Sibson's fascia, coming from the scalenus minimus muscle and connected with the inner margin of the first rib. In relation to the pleural cupola are those structures already described as grouped about the lung apex: the brachial plexus, subclavian artery, anterior scalene muscle, and the subclavian vein, and, on the left side, in addition, the thoracic duct.

Below, the costal pleura is continuous with the **diaphragmatic pleura** [pleura diaphragmatica], which adheres closely to the thoracic surface of the diaphragm and covers it, excepting the pericardial area and where the diaphragm and thoracic wall are in contact.

The **mediastinal pleura** [pleura mediastinalis] is reflected from before backward at the right and left sides of the mediastinum as the **laminæ mediastinales,** covering the pericardium

FIG. 1000.—RIGHT LATERAL SURFACE OF THE MEDIASTINUM AFTER REMOVAL OF THE PLEURA. (Poirier and Charpy.)

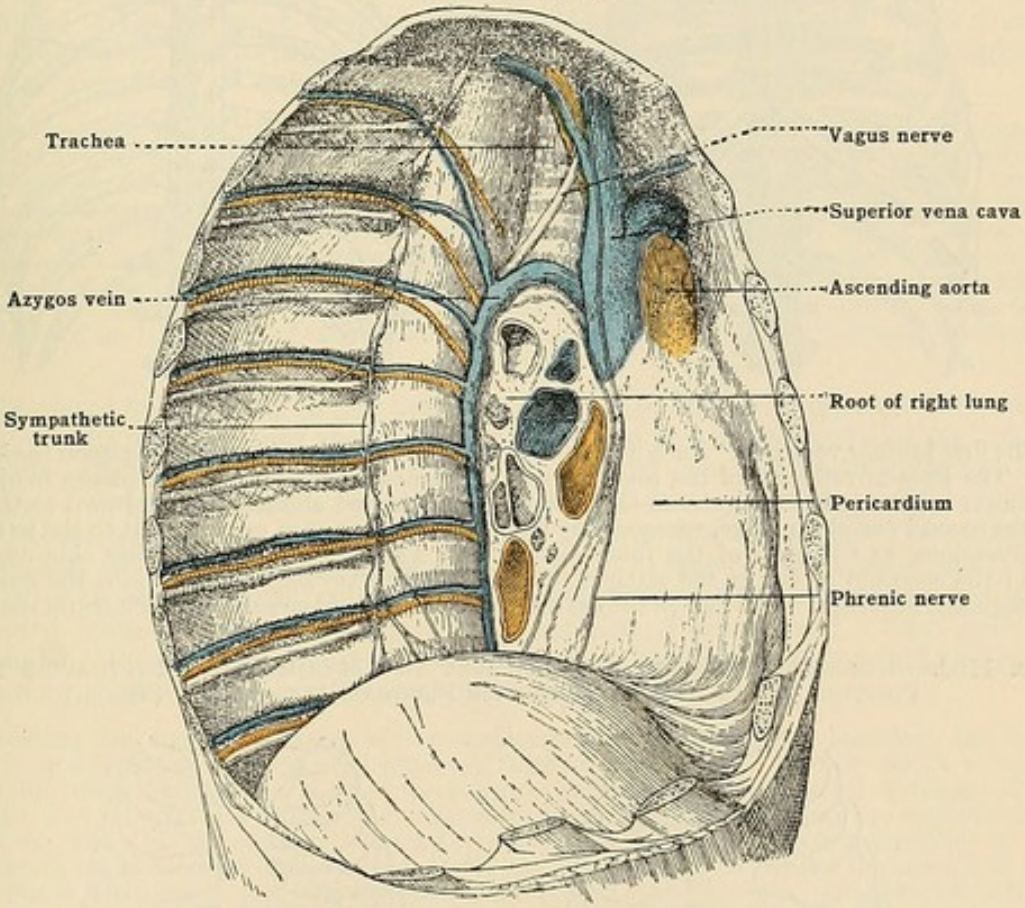

[pleura pericardiaca], to which it is closely adherent, and also the other structures of the mediastinum, with which the two layers are less firmly connected. Above the lung root the mediastinal pleura stretches directly from the spine to the sternum; but at the level of the root and below it, it is reflected laterally to the pulmonary pleura covering the root in front and behind and forming the pulmonary ligament.

The right mediastinal lamina covers (fig. 1000) the right innominate vein, the superior vena cava, the vena azygos, the trachea, the innominate artery, the right vagus and phrenic nerves, and the œsophagus. The left lamina lies against the left innominate vein, the arch of the aorta the left subclavian artery, the thoracic aorta, the left phrenic and vagus nerves, and the œsophagus. About the base of the heart-sac are a number of **adipose folds** [plicæ adiposæ] projecting from the pleura, the surfaces of which present some villous processes, the **pleural villi** [villi pleurales]; the latter also occur on the pulmonary pleura along the inferior margin of the lung.

The **lines of pleural reflexion** are of practical importance (figs. 997, 998, 1003). Posteriorly, the costal pleura simply turns forward in a gentle curve to become the mediastinal pleura, but anteriorly and inferiorly the membrane is folded upon itself, leaving intervening capillary spaces, the **sinuses** of the pleura [sinus pleuræ]. Such a space is present where the costal pleura is reflected upon the diaphragm, the **sinus phrenicocostalis,** the fold of the pleura occupying the upper part of the angle between the thoracic wall and diaphragm, the endothoracic fascia

filling the lower part. The inferior margin of the lung enters this sinus a variable distance in inspiration. The line of the costo-diaphragmatic reflexion begins in front on the sixth costal cartilage, which it follows, descending obliquely to cross the seventh interspace in the mammillary line. The greatest depth reached is at the tenth rib or interspace in the axillary line. The line of reflexion then continues around the thorax ascending slightly to the twelfth costo-vertebral joint.

The line of reflexion behind is sometimes found as low as the level of the transverse process

FIGS. 1001 AND 1002.—BOUNDARIES OF THE PLEURÆ AND LUNGS.

Lines of pleural reflection *red*, boundaries of the lungs and pulmonary lobes *black*.

1, sixth cervical vertebra; 2, first thoracic vetebra; 3, twelfth thoracic vertebra; 4, first lumbar vertebra; 5, manubrium sterni; 6, body of sternum; 7, xiphoid process; 8, first rib; 9, cartilage of seventh rib; 10, 11, 12, tenth, eleventh and twelfth ribs. (Rauber-Kopsch.)

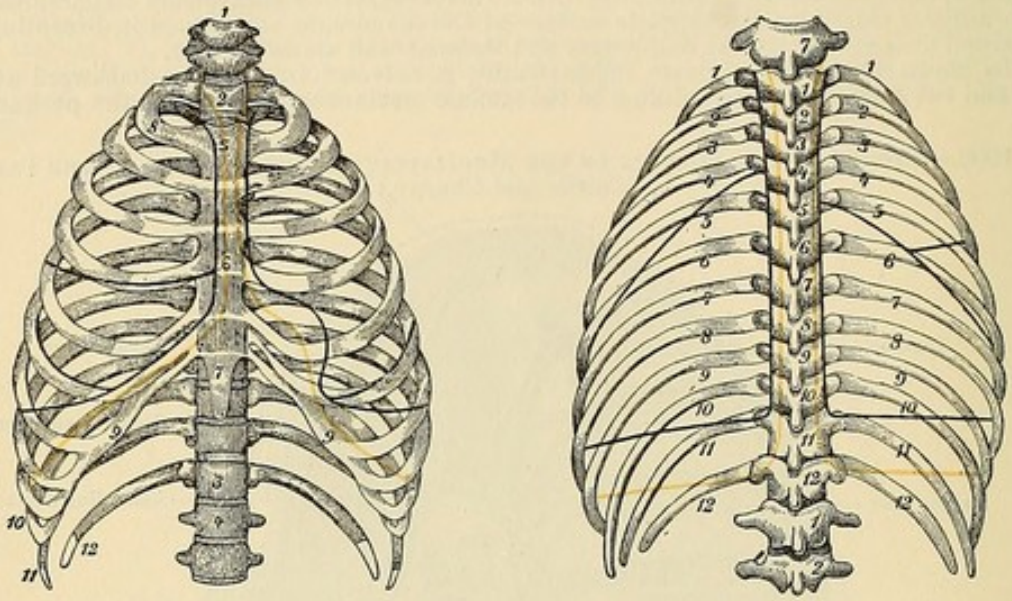

of the first lumbar vertebra. Such a possibility must be considered in operating upon the kidney.

The lines of reflexion of the costal pleura backward to the mediastinal pleura behind the sternum begin opposite the sterno-clavicular joints, descend obliquely medialward to the level of the second costal cartilage, whence they run near together or in contact, but to the left of the median line, to the level of the fourth cartilage. The reflexion on the *right* side continues from the sternum as far as the sixth rib cartilage, there turning laterally into the costo-diaphragmatic reflexion. The line on the *left* side, in the region of the cardiac notch (from the fourth

FIG. 1103.—SCHEMATIC DRAWING TO REPRESENT THE MAXIMUM OF FLUCTUATION IN THE POSITION OF THE ANTERIOR LINES OF PLEURAL REFLEXION. (Tanja.)

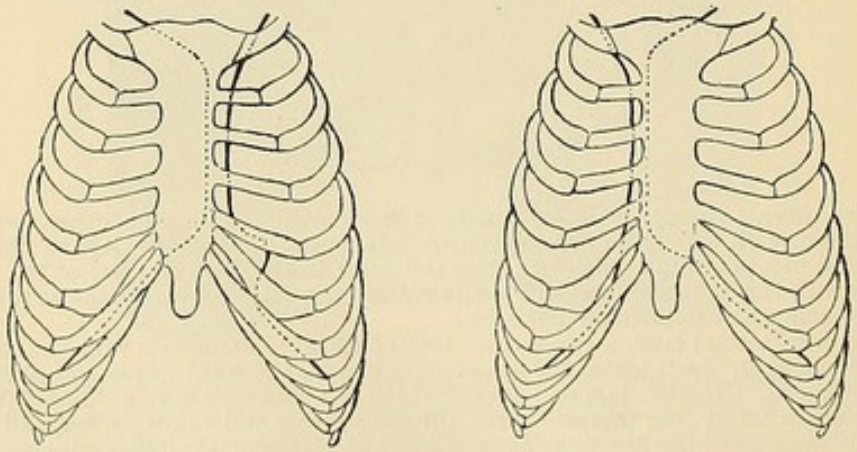

to the sixth cartilages), is a little to the left of the sternal margin. From this position of the line of reflexion it happens that there is left uncovered by pleura a small area of the pericardium which is in contact immediately with the chest-wall. A reduplication of the pleura takes place along the anterior line of reflexion, and into the **sinus costomediastinalis** so formed the thin anterior margin of the lung advances in inspiration. That part of the left costo-mediastinal sinus which is in front of the pericardium is not completely filled by the margin of the lung. Although the positions of the lines of reflexion of the mediastinal pleura here described are those

usually encountered, it should be noted that they are subject to variation. The extremes of variation of the anterior lines, as determined by Tanja, are indicated in fig. 1003.

Blood-vessels.—The vascular networks of the pulmonary pleura are derived from the bronchial artery and probably to some extent from the pulmonary artery which in the dog, is the only source of blood supply. The venous radicles arising from the network enter the lung. (See radicles of the pulmonary vein on page 1235.) The parietal pleura is supplied by **arteries** from several sources: internal mammary, intercostals, phrenics, mediastinal, and bronchial. The **veins** correspond to the arteries. The **lymphatics** of the pulmonary pleura form rich networks without definite relations to the lobules of the lung. They accompany the radicles of the pulmonary veins and drain into the bronchial lymph-glands. In the parietal pleura lymph-vessels are present most abundantly over the interspaces; they empty into the sternal and intercostal glands. (See p. 728.) The **nerves** supplied to the pulmonary pleura are branches from the pulmonary plexus; to the parietal pleura, from the intercostals, vagus, phrenic, and sympathetic.

MEDIASTINAL SEPTUM

The two pleural cavities are separated from each other by the **mediastinal septum** [septum mediastinale] (fig. 1000). This is a sagittal partition extending from the superior aperture of the thorax to the diaphragm between the thoracic vertebræ and the sternum, its free surfaces, right and left, formed by the mediastinal layers of the pleuræ. It is composed of the pericardium and heart and of structures which, for the most part, extend in a longitudinal direction through the thoracic cavity.

These include the œsophagus together with the vagus nerves, the thoracic duct, thoracic aorta and azygos vein; the trachea, the pulmonary vessels and the arch of the aorta with its great branches, the superior vena cava and its tributaries and the phrenic nerves; the thymus gland, internal mammary vessels and many lymph glands throughout the septum. These structures are packed together and supported by intervening connective tissue. Moreover, the connection of the sheaths of the great vessels with processes of the cervical fascia and the fixation of the pericardium to the diaphragm, give to the latter a strong support. Owing to the position of the heart, the two sides of the septum are not symmetrical, and it follows from the bulging of the left surface of the mediastinal septum that the left pleural cavity is encroached upon.

The name **mediastinal cavity** has been applied to the two regions of the mediastinal partition which find themselves located, the one in front, the other behind the plane of the heart. There is in reality no cavity, the term being used in this connection merely to donate space. Between the two spaces are interposed the pericardium and heart, the great vessels, trachea and bronchi. The **anterior mediastinal cavity** [cavum mediastinale anterius] is small. Its lateral limits are formed by the mediastinal layers of the pleuræ, right and left, which are reflected backward from the costal pleuræ of the anterior thoracic wall. The space is occupied by loose connective tissue, surrounding the thymus gland, the internal mammary vessels and a number of lymph-glands.

Recalling the lines of reflexion of the mediastinal pleuræ as above described, the form, position and extent of this space as observed from in front, will be understood; it is widest behind the inferior end of the body of the sternum and fifth and sixth costal cartilages of the left side (*area interpleurica inferior*); narrowest where the mediastinal layers are approximated behind the body of the sternum, broader again where the laminæ deviate posterior to the manubrium sterni (*area interpleurica superior*). In the latter space lies the thymus gland and the superior portions of the internal mammary vessels. In the area interpleurica inferior the pericardium comes into immediate contact with the anterior thoracic wall, and here the inferior portions of the left internal mammary vessels are found. The lymphatic vessels and glands of the anterior mediastinal space belong to the anterior mediastinal and sternal groups.

The **posterior mediastinal cavity** [cavum mediastinale posterius] (fig. 1000), limited behind by the thoracic vertebræ and laterally by the mediastinal layers of the pleuræ where they are reflected forward from the costal pleuræ of the posterior thoracic walls, is elongated and of more regular form than the anterior space. It includes the thoracic aorta, the œsophagus and vagi, the thoracic duct, azygos vein and lymph glands.

Within this space are also to be found the origins of the right intercostal arteries, the hemiazygos and, when present, the accessory hemiazygos veins, terminations of some of the left intercostal veins and the greater splanchnic nerves. The lymph glands belong to the posterior mediastinal group.

(Figs. 993, 994).—A subdivision of the mediastinal septum into anterior, middle, posterior, and superior mediastinal spaces has long been customary, and is useful for descriptive purposes.

The **superior mediastinum** is that part of the mediastinum which lies above the level of

the pericardium. It extends between the first four thoracic vertebræ behind and the manubrium sterni in front, and contains the arch of the aorta and the great vessels arising from it, the innominate veins, and the upper part of the superior vena cava, the thoracic duct, the lower portion of the trachea, and a portion of the œsophagus, the phrenics, vagi, left recurrent and cardiac nerves, and the thymus gland.

From the superior mediastinum the other three divisions of the space extend downward. The **anterior mediastinum** is identical with that part of the anterior mediastinal cavity which is below the level of manubrium sterni. The **middle mediastinum** lies between the layers of the mediastinal pleuræ in front of the root of the lungs; it contains the heart, enclosed in the pericardium, and the phrenic nerves. The **posterior mediastinum** corresponds to that portion of the posterior mediastinal cavity which extends below the plane of the fifth intervertebral fibro-cartilage.

References for Respiratory System. A. **External nose and nasal cavity.** Kallius, in von Bardeleben's Handbuch; Zuckerkandl, Normale u. path. Anatomie d. Nasenhöhle, Bd. 1, Wien, 1893; (*Development*) His, Archiv f. Anat. u. Phys., 1892; Killian, Arch. f. Laryngol., Bd. 4, 1896; Schaeffer, Jour. Morphol., vol. 21, 1910; (*Conchæ*) Peter, Arch. f. mikr. Anat., Bd. 60, 1902; (*Paranasal sinuses*) Bartels, Zeitschr. f. Morph. u. Anthrop., Bd. 8; Turner, Accessory Sinuses of the Nose, Edinburgh, 1901; (*Anthropology*) Hoyer, Morph. Arbeiten, vol. 4, 1894. B. **Larynx.** Gerlach, Anat. Hefte, H. 56; (*Development*) Lisser, Amer. Jour. Anat., vol. 12; (*Ossification*) Scheier, Arch. f. mikr. Anat., Bd. 59. C. **Lungs.** (*Structure; vascular supply*) Miller, Arch. f. Anat. u. Entw., 1900; Amer. Jour. Anat., vol. 7; Schultze, Sitzb. Akad Wiss., Berlin, 1906; (*Development*) Flint, Amer. Jour. Anat., vol. 6 (*Topographical*) Mehnert, Topogr. Altersveränderungen d. Atmungsapparatus, Jena, 1901. D. **Pleura.** Ruge Morph. Jahrb. Be. 41.

SECTION XI

UROGENITAL SYSTEM

REVISED FOR THE FIFTH EDITION

BY J. PLAYFAIR McMURRICH, A.M., PH.D., LL.D.

PROFESSOR OF ANATOMY IN THE UNIVERSITY OF TORONTO

The **urogenital system** [apparatus urogenitalis] includes (A) the **urinary organs** and (B) the **reproductive organs.**

A. THE URINARY ORGANS

THE organs forming the urinary apparatus [organa uropoëtica] are the **kidneys,** by which the secretion is produced; a duct, the **ureter,** proceeding from each kidney and conveying the secretion to the **bladder,** which serves as a reservoir for the urine and from which, by a single duct, the **urethra,** the secretion is carried to the exterior.

FIG. 1004.—POSTERO-MEDIAL ASPECT OF THE RIGHT KIDNEY.

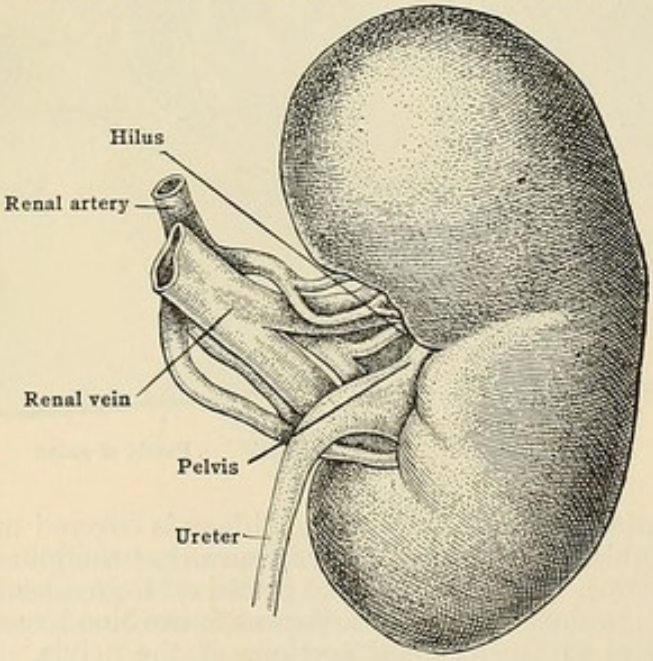

THE KIDNEYS

The **kidneys** [renes] are paired organs situated in the abdominal region and each is composed of a very great number of minute tubules, the renal tubules, enclosed within a definite and firm fibrous capsule. Each kidney is somewhat bean-shaped (fig. 1004) and is situated on the dorsal wall of the body, behind the parietal peritoneum, in such a way that the *ventral* or *visceral surface* [facies anterior] which is convex, looks obliquely ventrally and laterally, while the *dorsal* or *parietal surface* [facies posterior], usually less convex, looks dorsally and somewhat medially (fig. 1005). The *upper extremity* [extremitas superior] is usually larger

than the lower [extremitas inferior] and is about 1 cm. nearer the median sagittal plane of the body, owing to the long axis of the organ being directed obliquely downward and laterally. The *lateral border* [margo lateralis] is narrow and convex, and the medial border [margo medialis], which looks medially and ventrally, is concave, its middle third presenting a slit-like aperture, the **hilus.** This opens into a cavity, called the **sinus** (fig. 1006), which is about 2.5 cm. in depth and is occupied mainly by the dilated upper extremity of the ureter, known as the renal pelvis, the interval between this and the actual kidney substance containing adipose tissue in which are imbedded the renal vessels and nerves.

Size.—The length of the kidney in the male averages 10–12 cm., its breadth about 5.5 cm. and its thickness 3 cm.; it weighs 115–150 grams. The dimensions of the female kidney are nearly as great, but its weight is from one-seventh to one-fifth less. In the child the organ is relatively large, its weight compared with that of the entire body being about 1:133 at birth; but its permanent relation, which is about 1:217, is usually attained at the end of the tenth year.

FIG. 1005.—DIAGRAM SHOWING RELATION OF KIDNEY TO CAPSULE. (Gerota.)

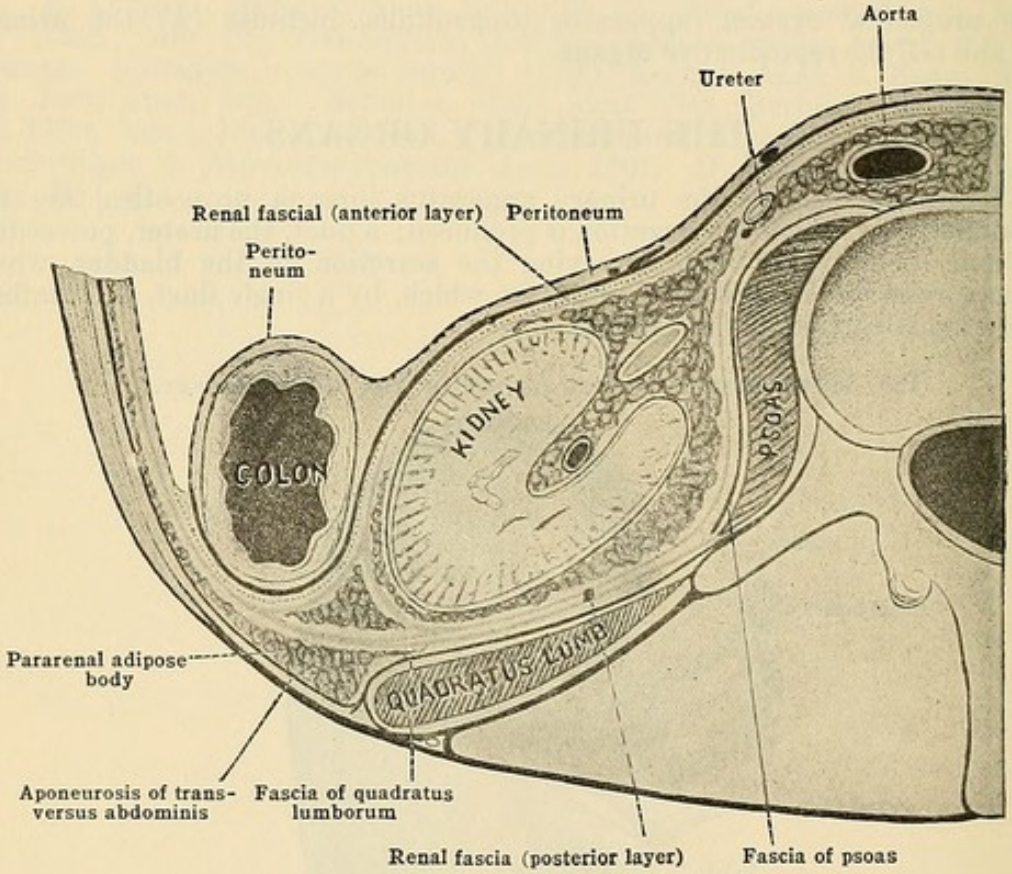

Investment and fixation.—The surface of the kidney is covered by a thin but strong *fibrous capsule* [tunica fibrosa], which turns inward at the hilus to line the walls of the sinus (fig. 1006). It may readily be peeled off from a healthy kidney, except at the bottom of the sinus, where it is adherent to the blood-vessels entering the kidney substance and to the terminal portions of the pelvis. External to the capsule is a quantity of fat tissue, the **adipose capsule** [capsula adiposa], which forms a complete investment for the organ and is prolonged through the hilus into the sinus.

The *peritoneum*, which covers the ventral surface of the adipose capsule, has usually been regarded as the principal means of fixation of the kidney, but in reality this is accomplished by means of a special **renal fascia** (fig. 1005), developed from the subperitoneal areolar tissue (Gerota).

Renal fascia.—Lateral to the kidney there occurs between the transversalis fascia and the peritoneum a subperitoneal fascia, which, as it approaches the convex border of the kidney, divides into two layers, one of which passes in front of and the other behind the kidney, enclosing the adipose capsule. Traced medially, the anterior layer of the renal fascia passes in front

of the renal vessels, and, over the aorta, becomes continuous with the corresponding layer of the opposite side; upward, it passes over the suprarenal gland and at the upper border of that organ becomes continuous with the posterior layer; and downward, it is lost in the adipose tissue intervening between the iliac fascia and muscle. The posterior layer, which is the thicker of the two, passes medially behind the renal vessels and is lost in the connective tissue in front of the vertebral column, and below it is lost, like the anterior layer, in the iliac region. Behind the posterior layer, between it and the quadratus lumborum, is a mass of adipose tissue, the **pararenal adipose body,** and both layers are united to the fibrous capsule of the kidney by trabeculæ of connective tissue which transverse the adipose capsule.

Each kidney is, accordingly, supported by these trabeculæ in a space bounded laterally and above by the layers of the renal fascia, and open medially and below. Should these trabeculæ become atrophied by wasting disease or ruptured by the pressure of the pregnant uterus, by the improper use of corsets, or by any other cause, the phenomenon of movable or wandering kidney may be set up by slight external violence, the organ tending to shift its place as far as the attachment of its vessels to the main trunks and the arrangement of the renal fascia will permit.

Position and relations.—The kidney is said to lie in the lumbar region. It is, however, intersected by the horizontal and vertical planes which separate the hypochondriac, lumbar, epigastric and umbilical regions from each other, and hence belongs to all these segments of the abdominal space. Its vertical level may be said to correspond to the last thoracic and upper two or three lumbar

FIG. 1006.—SECTION OF KIDNEY SHOWING THE SINUS. (After Henle.)

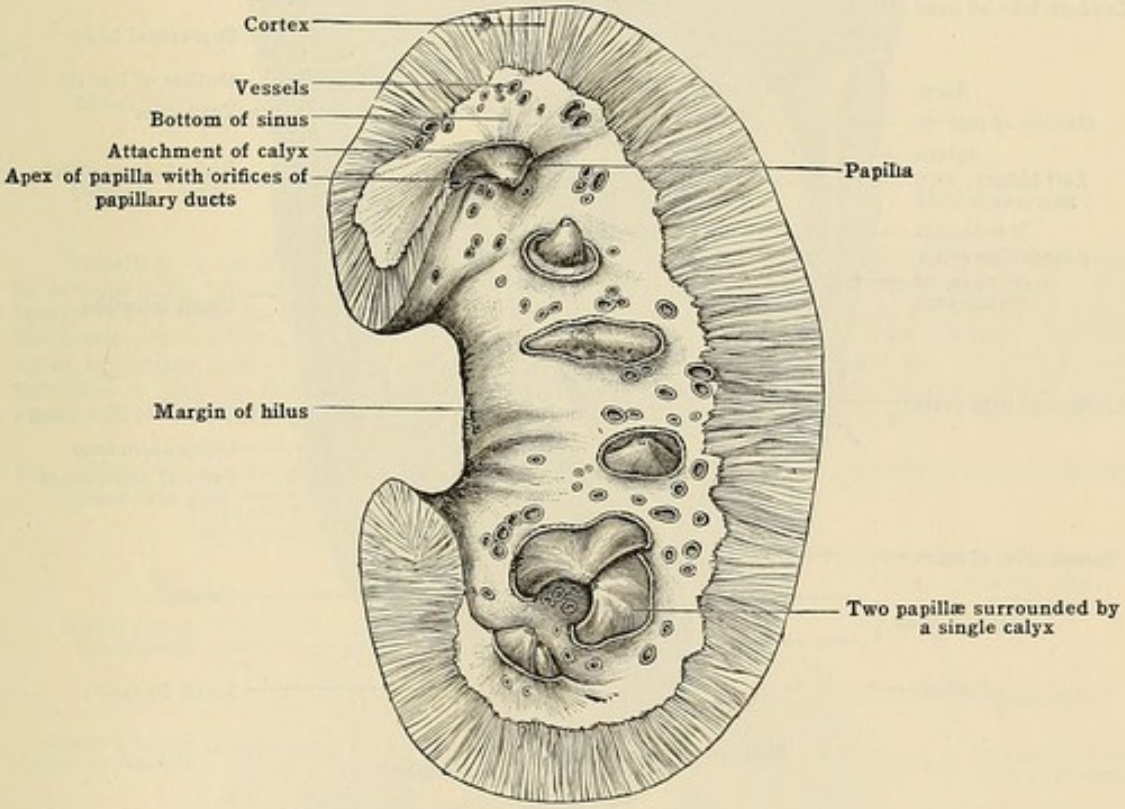

vertebræ, the right lying in most cases from 8 to 12 mm. ($\frac{1}{3}$ to $\frac{1}{2}$ in.) lower than the left; but exceptions to this rule are not infrequent.

The **posterior surface** (figs. 1007, 1008), with the corresponding portion of the fatty capsule and the pararenal adipose body, rests against the posterior abdominal wall extending upward in front of the eleventh and twelfth ribs, and medialward to overlap the tips of the transverse processes of the first and second lumbar vertebræ; the left kidney usually reaches as high as the upper border of the eleventh rib, the right only to its lower border. The only visceral relation posteriorly is on the left side, where the spleen slightly overlaps the kidney opposite the upper half of its lateral border, the adjacent surfaces of the two organs being, however, covered by peritoneum. The parietal relations (fig. 1008) on both sides are as follows: (1) the diaphragm, the left kidney, on account of its higher position, entering more extensively into this relation than the right; (2) the portion of the transversalis fascia covering the ventral surface of the quadratus lumborum; (3) the lateral border of the psoas; and (4) the last thoracic, ilio-

hypogastric and ilio-inguinal nerves and the anterior divisions of the subcostal and first lumbar vessels, all of which run obliquely downward and laterally in front of the quadratus lumborum.

The **upper extremity** of each kidney is crowned by the suprarenal gland (figs. 1007, 1009), which encroaches also upon its ventral surface and medial border and is fixed to it by fibres derived from the subperitoneal tissue.

The **anterior surface** of each kidney was primarily completely covered by peritoneum that separated it from neighboring viscera, but, owing to secondary changes whereby the ascending and descending colons, the duodenum and the pancreas become retro-peritoneal organs, these come into direct relation with one or the other of the kidneys and separate portions of them from actual contact with the peritoneum. Thus, in the case of the right kidney (fig. 1009), the

FIG. 1007.—THE ABDOMINAL VISCERA, SEEN FROM BEHIND.
(From the model of His.)
The kidneys are somewhat lower than usual in their relations to the ribs.

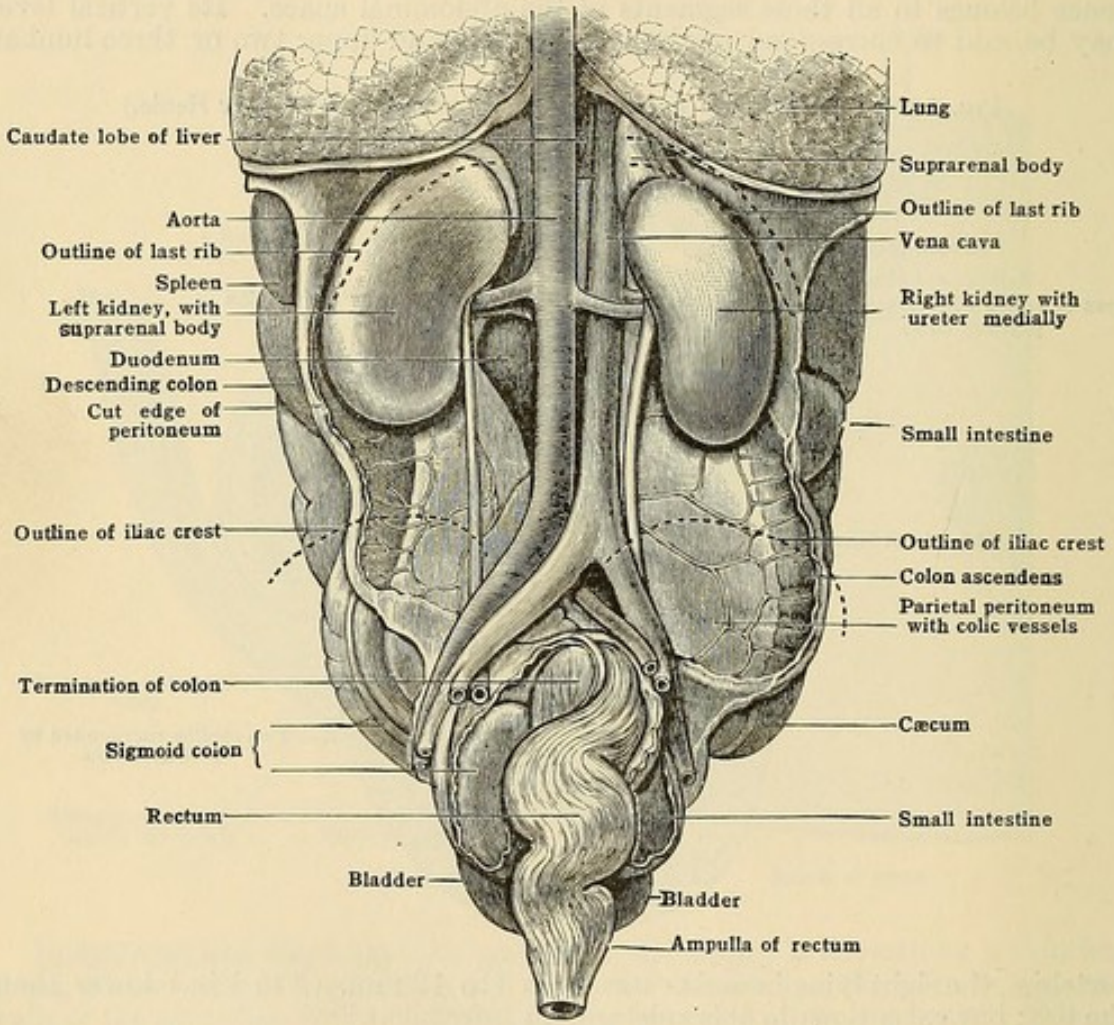

portion of the anterior surface immediately adjacent to the medial border has the descending portion of the duodenum in direct contact with it, and throughout a zone extending downward and laterally from the middle of the duodenal area to the lateral border the ascending colon and right colic flexure. Almost the entire upper half, however, and a small portion of the lower pole are covered directly by peritoneum, the upper peritoneal area having an indirect relation with the lower surface of the liver, upon which it produces the renal impression.

Similarly the anterior surface of the left kidney (fig. 1009) is in direct contact with the pancreas throughout a broad transverse band situated a little above the middle of the organ, and the splenic artery pursues its tortuous course along the upper border of this pancreatic area, while the corresponding vein is interposed between the pancreas and the surface of the kidney. The lateral portion of the lower extremity is in direct contact with the descending colon and its splenic

flexure, but the remainder of the lower extremity and the whole of the upper one-fourth of the organ is directly covered by peritoneum, the upper peritoneal area having, as an indirect relation, the posterior surface of the stomach medially, and the spleen laterally (figs. 956, 1009).

The **medial border** of the right kidney approaches the vena cava inferior very closely, especially above; that of the left is separated from the aorta by an interval of about 2.5 cm.

FIG. 1008.—DIAGRAM OF RELATIONS OF POSTERIOR SURFACE OF LEFT KIDNEY.

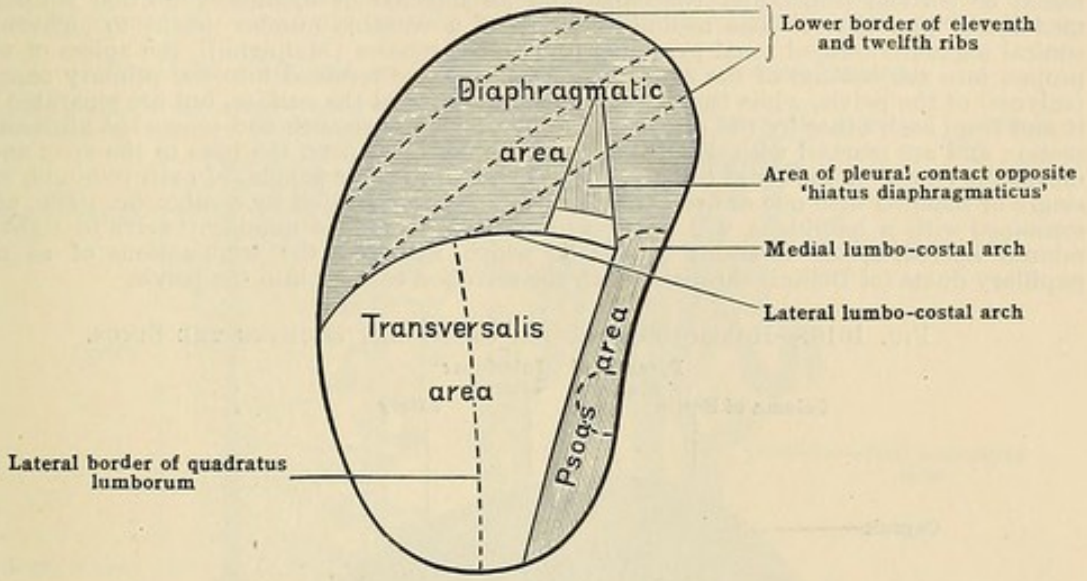

Variation in position.—The position of the kidneys in the abdominal cavity is subject to considerable variation. Thus while the upper pole of the right kidney may be said to lie typically opposite the lower half of the eleventh thoracic vertebra, it may be placed as high as the lower part of the tenth thoracic or as low as the upper half of the first lumbar. Similarly while the upper pole of the left kidney is as a rule opposite the middle of the eleventh thoracic vertebra it may lie half a vertebra higher or as low as the lower part of the second lumbar vertebra. The lower poles are distant from the crests of the ilia anywhere from 1.0 cm.–3.0

FIG. 1009.—DIAGRAM SHOWING ANTERIOR RELATIONS OF KIDNEYS AND SUPRARENAL BODIES.

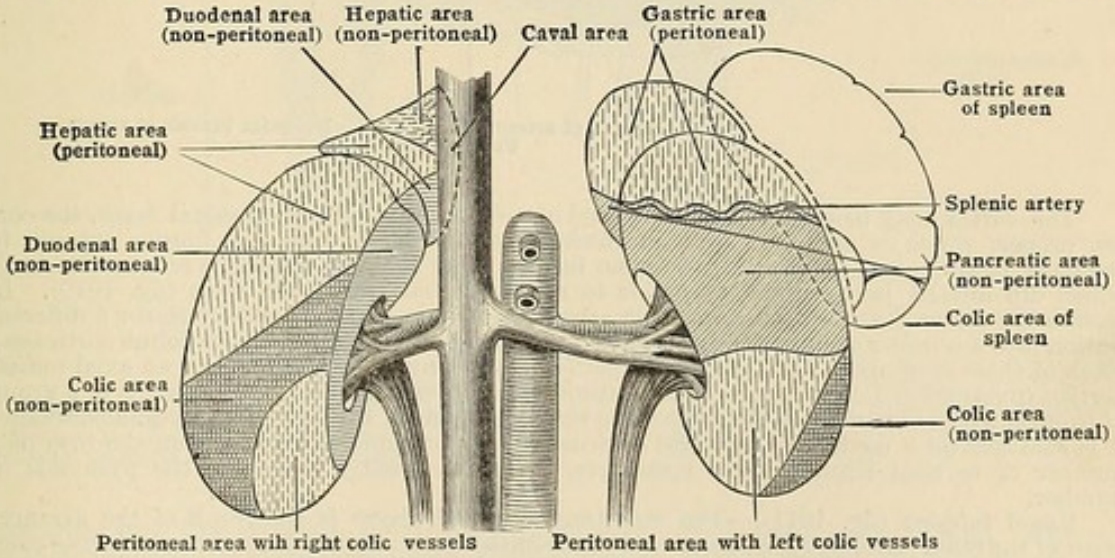

cm., the distance being, as a rule, somewhat less in females than in males. Occasionally the lower pole may even extend below the iliac crest, especially on the right side.

The lateral border of each kidney lies 8.5–10.0 cm. lateral to the spines of the lumbar vertebræ, a distance that brings them lateral to the lateral edge of the sacro-spinalis muscle and even to the lateral edge of the quadratus lumborum, so that this border may be readily approached through the posterior wall of the body. It must be remembered, however, that the upper part of the kidney rests upon the diaphragm, so that in the event of the twelfth rib being very short there may be danger of the incision being carried too far upward, resulting in injury to the diaphragm and pleura. It is also worthy of note that the diaphragmatic area of

the kidney corresponds with the region where a hiatus diaphragmaticus between the costal and lumbar portions of the muscle may occur and if this be pronounced the upper part of the posterior surface of the kidney may come into more or less direct relations to the pleura (fig. 1008).

Just as there may be variation in the position of the kidneys, so too there may be considerable variation in the extent to which they are in relation to the various structures mentioned above. And this is especially true as regards their relations to the colons; for if the kidneys were lower than usual they might lie entirely beneath the line of attachment of the transverse mesocolon and thus have no direct relations with either colon, or on the other hand either the ascending or descending colon, or both, may be provided with a mesentery, whereby they would be removed from direct contact with the kidney.

Structure.—A section through the kidney shows its substance to be composed of an external or cortical [substantia corticalis] and an internal or medullary portion [substantia medullaris] (fig. 1010). The medulla consists of a variable number (eight to eighteen) of conical segments termed **renal pyramids** [pyramides renales (Malpighii)], the apices of which project into the bottom of the sinus (fig. 1006) and are received into the primary segments (calyces) of the pelvis, while their bases are turned toward the surface, but are separated from it and from each other by the cortex. The pyramids are smooth and somewhat glistening in section and are marked with delicate striæ which converge from the base to the apex and indicate the course of the renal tubules. The blunted apex, or **papilla,** of each pyramid, either singly or blended with one or even two of its fellows, is embraced by a *calyx* (fig. 1006), and, if examined with a hand-lens, will be seen to present a variable number (twelve to eighty) of minute apertures, the **foramina papillaria,** which represent the terminations of as many papillary ducts (of Bellini) through which the secretion escapes into the pelvis.

FIG. 1010.—HORIZONTAL SECTION OF KIDNEY SHOWING THE SINUS.

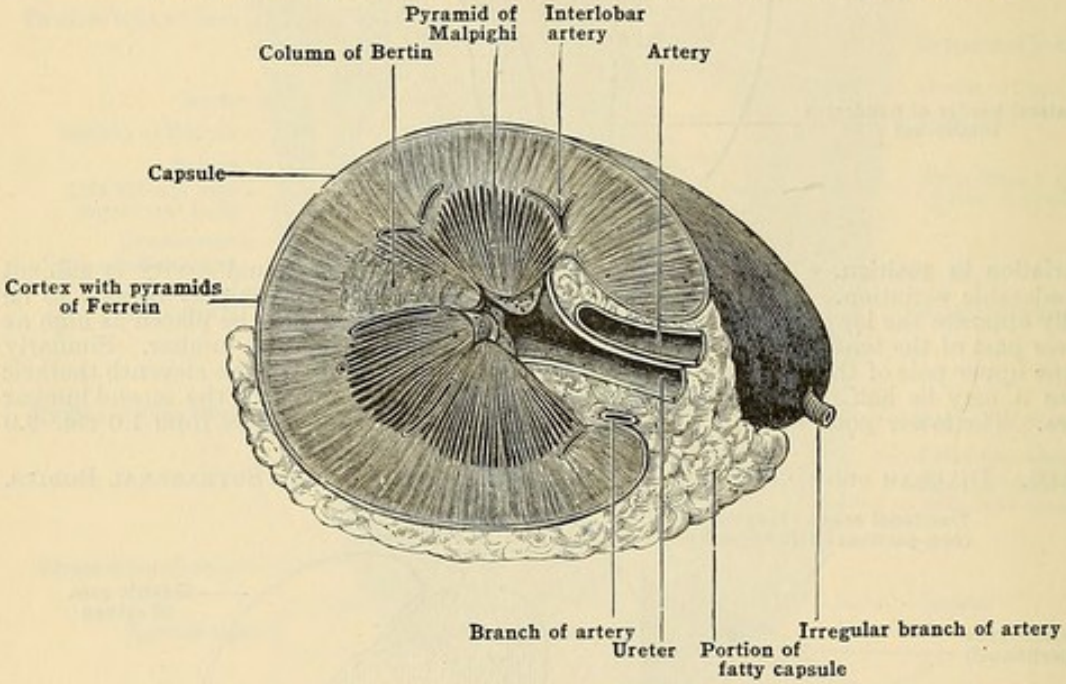

The **cortex** may be regarded as composed of two portions, (1) a peripheral layer, the cortex proper, which is about 12 mm. in thickness and extends from the fibrous capsule to the bases of the pyramids, and (2) processes termed **renal columns** [columnæ renales (Bertini)] which dip inward between the pyramids to reach the bottom of the sinus (fig. 1010). In section the cortex is somewhat granular in aspect, and when examined closely shows a differentiation into a number of imperfectly separated portions termed *cortical lobules* [lobuli corticales]. Each of these is composed of a *convoluted portion* [pars convoluta], surrounding an axial *radiate portion* (pyramid of Ferrein) [pars radiata (processus Ferreini)]. The latter consists of a group of tubules which extend from the cortex into the base of one of the medullary pyramids, whence it is also termed a medullary ray; and each medullary pyramid is formed from the rays of a number of cortical lobules, these structures, therefore, greatly exceeding the pyramids in number.

Renal tubules (fig. 1011).—The structure described above is the result of the arrangement of the renal tubules, which constitute the essential units of the kidney. Each of these commences in a spherical **glomerular capsule** (fig. 1011), one wall of which is invaginated by a small *glomerulus* of blood-vessels, the combination of glomerulus and capsule forming what is termed a **renal (Malpighian) corpuscle.** These corpuscles are situated in the convoluted portions of the cortical lobules, and from each of them there arises by a narrow neck a tubule, which quickly becomes wide and convoluted, this portion being termed the **first convoluted tubule.** This enters a medullary ray, where it narrows again and descends as a straight tubule, the **descending limb of Henle's loop,** into the subjacent medullary pyramid, and, turning upon itself, forming the **loop of Henle,** ascends to the cortex, where it again becomes wide and contorted, forming the **second convoluted tubule.** This again lies in the convoluted portion of the cortical lobule, and, becoming narrower, opens with other similar tubules into a straight or **collecting**

tubule, which occupies the axis of the medullary ray. Then, descending into the subjacent medullary pyramid, it unites with other collecting tubules, and finally opens into the renal pelvis at the summit of a papilla.

The tubules are lined with epithelium throughout, the cells being tesselated in the capsule, irregularly cubical in the convoluted tubules and ascending limbs, flattened on the descending limbs and loops of Henle, and columnar in the cortical collecting tubules and in the straight tubules of the medulla.

Vessels (fig. 1011).—The kidney is very vascular. The larger *arterial branches*, arranged in the sinus as has already been described, enter the substance of the kidney and pass up as the *interlobar arteries* in the renal columns. On reaching the bases of the pyramids they bend so as to run horizontally between these and the cortex, forming the *arcuate arteries* [arteriæ arciformes] from which interlobular branches pass up into the cortex and supply *afferent* branches to the Malpighian glomeruli. From the arcuate arteries numerous branches, the *arteriolæ rectæs*,

FIG. 1011.—SCHEME OF TUBULES AND VESSELS OF THE KIDNEY.

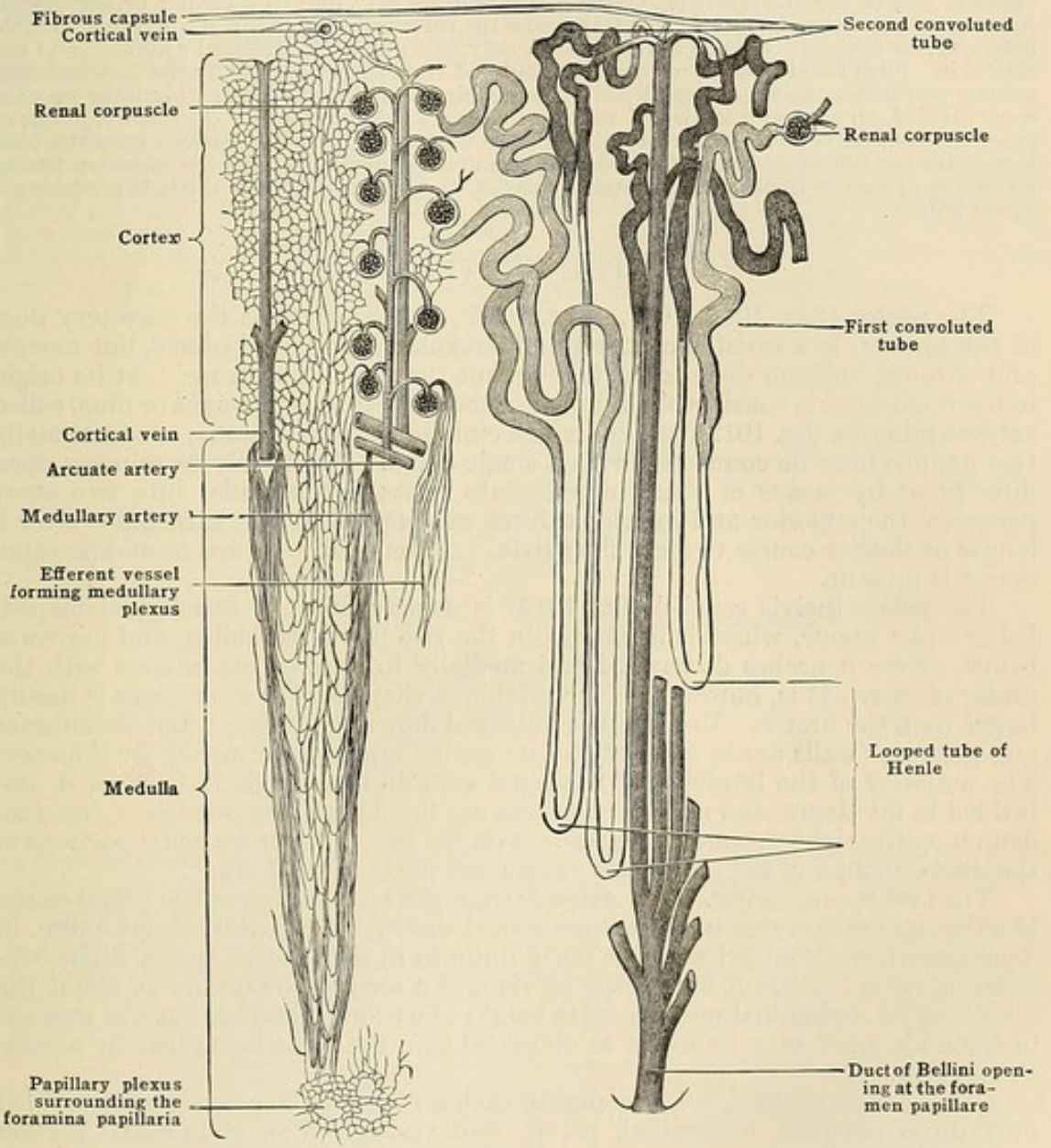

pass down into the pyramids, supplying the tubules of which these are composed. *Efferent* stems which issue from the Malpighian glomeruli break up into capillaries which supply the tubules contained in the cortex. *Veins* corresponding to the arteriolæ rectæ and to the interlobular, arcuate and interlobar arteries occur, opening into the renal veins, and, at the surface of the kidney, arranged in star-like groups, are the *stellate veins* [venæ stellatæ], which open into the interlobular veins and also communicate with the veins of the adipose capsule. The renal *lymphatics* may be divided into two sets, capsular and parenchymatous. They terminate in the upper lumbar nodes.

Nerves.—The nerves form a plexus accompanying the vessels, and are derived from the sympathetic and vagus through the renal plexuses.

Variations.—The kidney of a fœtus differs from that of the adult in being divided into a number of distinct **renal lobes,** each of which corresponds to the base of a renal pyramid and

is capped by a thin layer of cortex. Such a condition is permanent in some of the lower animals; but in man the superficial indications of morphological segmentation usually become obliterated during the progress of growth of the cortical tissue, and are seldom visible after the age of ten.

Development.—In the development of the embryo, representatives of three different sets of excretory organs occur, the permanent kidney (metanephros) being the last to form. The two earlier sets (pronephros and mesonephros) have a common duct, the **Wolffian duct,** and from the lower end of this an outgrowth develops, which extends upward on the posterior abdominal wall and comes into connection with a mass of embryonic tissue known as the **metanephric blastema.** The outgrowth gives rise to the ureter, pelvis and collecting tubules, while the remaining portions of the tubules are formed from the blastema.

Various *abnormalities* may result from modifications of the development of the kidneys. (1) Occasionally the ureteric outgrowth of one side fails to develop, the result being the occurrence of a single kidney. (2) The blastema may fail to attain its normal position, in which case the kidney may be situated in the iliac region or even in the pelvis; or the blastema may be drawn into an unusual position, the kidney resting on the vertebral column, or even on the opposite side of the abdomen; (3) or the two blastemas may fuse to a greater or less extent, forming a "horse-shoe kidney," extending across the vertebral column; or, if the fusion be more extensive, an apparently single kidney, which may rest upon the vertebral column, or to one side of it. Such fused kidneys may be distinguished from single kidneys by the fact that they possess two ureters opening normally into the bladder. (4) In rare cases, a blastema may become divided, an accessory kidney of varying size being thus produced. (5) Finally, in one or more of the tubules there may be a failure of the union of the portion derived from the blastema with the collecting tubule derived from the ureteric upgrowth, and the secretion having no means of escape from such malformed tubules, they become greatly dilated, producing a cystic kidney.

THE URETERS

The **ureter** (figs. 1004, 1007, 1012, 1015), which serves as the excretory duct of the kidney, is a canal, expanded and irregularly branched above, but narrow and of fairly uniform dimensions throughout the rest of its course. At its origin in the renal sinus it consists of a number of short tubes, usually eight or nine, called **calyces minores** (fig. 1012), each of which embraces a renal papilla, or occasionally two papillæ may be connected with a single calyx. These calyces minores open directly or by means of short intermediate tubes (**infundibula**) into two short passages, the superior and inferior **calyces majores,** which in turn unite after a longer or shorter course to form the **pelvis.** Occasionally a third or middle calyx major is present.

The **pelvis** [pelvis renalis] (fig. 1012) is usually more or less funnel-shaped, being wider above, where it lies between the two lips of the hilus, and narrower below, where it arches downward and medially to become continuous with the ureter proper. It is, however, very variable in shape and in some cases is hardly larger than the ureter. Usually it is flattened dorso-ventrally so that its anterior and posterior walls are in contact and its cavity represented merely by a fissure. The majority of the branches of the renal vein and artery lie in front of it, imbedded in fat tissue, and anterior to these are the descending portion of the duodenum on the right side and the pancreas on the left. The intra-renal portions of the ducts, including the pelvis, are considered parts of the kidney.

The **ureter** proper (fig. 1007) extends from the termination of the pelvis to the bladder, its course lying in the subperitoneal tissue. It is a tube about 5 mm. in diameter when distended and it is fairly uniform in size, except that a slight constriction occurs where it enters the pelvis and a second one occurs at about the middle of its abdominal portion. Its length is variously stated, but the average in the male adult may be taken as about 30 cm., the right being usually a little the shorter.

Course and relations.—The course of each ureter may be conveniently divided into three portions, abdominal, pelvic, and vesical. The **abdominal portion** [pars abdominalis] runs downward and slightly medially and is in relation *posteriorly* with the psoas muscle and its fascia; it crosses the genito-femoral nerve obliquely and in the lower part of its course passes in front of the common iliac artery near its bifurcation. *Anteriorly* it is covered by peritoneum and is crossed by the spermatic or ovarian vessels. *Medially* it is in relation on the right side with the inferior vena cava and on the left with the aorta, the vein being almost in contact with the right ureter, while the artery is separated from the left one by an interval that diminishes from 2.5 cm. above, to 1.5 cm. opposite the bifurcation of the vessel.

The **pelvic portion** [pars pelvina] passes in front of the sacro-iliac articulation

and then forward and downward upon the obturator internus and its fascia behind and below the psoas, crossing the obturator vessels and nerve and having anterior to it in the female the posterior border of the ovary. It thus reaches the level of the floor of the peritoneal cavity, whereupon, at about the level of the ischial spine, its course is directed forward and medially toward the bladder. In this part of its course *in the male*, it is crossed superiorly and medially by the ductus deferens, and then passes under cover of the free extremity of the vesicula seminalis, separated from its fellow by a distance of 37 mm. *In the female* it runs parallel with, and 8 to 12 mm. distant from, the cervix uteri, passes behind the uterine artery, through the uterine plexus of veins, and beneath the root of the broad ligament, and finally crosses the upper third of the lateral wall of the vagina to reach the vesico-vaginal interspace and enter the substance of the bladder at about the junction of its posterior, superior and lateral surfaces.

The **vesical portion,** about 12 mm. in length, runs obliquely downward and medialward through the coats of the bladder, and opens on its mucous surface about 20 to 25 mm. from both its fellow and the internal urethral orifice.

Structure.—The wall of the ureter is about 1 mm. ($\frac{1}{25}$ in.) in thickness, and consists of a mucous membrane, a muscular coat, and an external connective-tissue investment. The mucous membrane is longitudinally plicated, and is lined by transitional epithelium, continuous with that of the papillæ above and with that of the bladder below. Mucous follicles of simple form have been found in the upper part of the canal. The muscularis is about 0.5 mm. (1/50 in.) in thickness, and consists of two layers, an external, composed of annular fibres, and an internal,

FIG. 1012.—PELVIS AND UPPER PORTION OF URETER. (After Henle.)

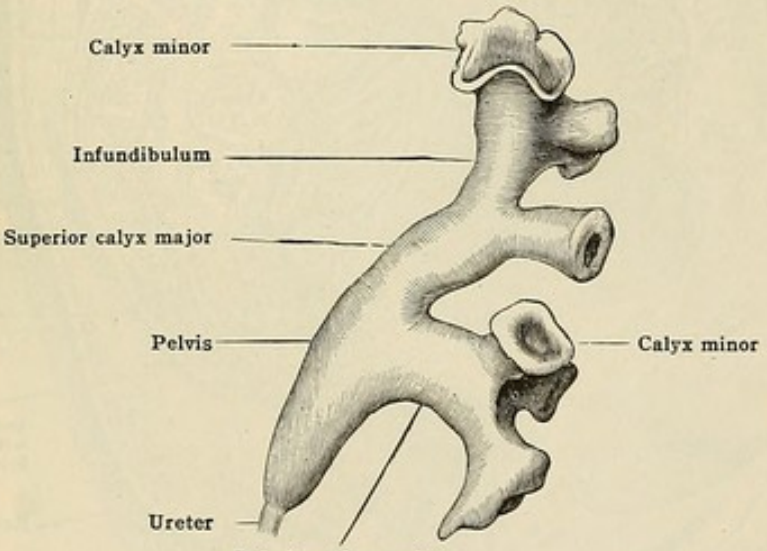

of fibres longitudinally disposed. After the tube has entered the bladder the circular fibres form a kind of sphincter around its vesical orifice; while the longitudinal fibres are continued onward through the wall of the bladder and terminate beneath its mucous membrane.

Vessels and nerves.—The *arteries* supplying the pelvis and upper part of the ureter come from the renal; the rest of the abdominal portion of the ureter is supplied by the spermatic (or ovarian), and its pelvic portion receives branches from the middle hæmorrhoidal and inferior vesical; the *veins* terminate in the corresponding trunks; and the *lymphatics* pass to the lumbar and hypogastric nodes. The *nerves* are supplied by the spermatic, renal, and hypogastric plexuses.

Variations.—Occasionally the depression which separates the two calyces majores extends through the pelvis, so that the calyces appear to open directly into the ureter. The fission may also affect the ureter to a greater or less extent, in extreme cases producing a duplication of the tube throughout its entire length.

THE URINARY BLADDER

The **urinary bladder** [vesica urinaria] is a receptacle, whose form, size, and position vary with the amount of its contents. The adult organ in its empty or moderately filled condition lies entirely below the level of the oblique plane of the pelvic inlet; but when considerably distended it rises into the abdomen and shows itself beneath the parietes as a characteristic mesial projection above the symphysis, a projection which in extreme distention of the bladder may extend nearly to the level of the umbilicus.

Form.—When distended it assumes in the male an ovoid shape with its longest diameter directed from above downward and backward; but in the female the transverse diameter is the greatest, in accordance with the greater breadth of the pelvic cavity. In the child it is somewhat pear-shaped, the stalk being represented by the urachus.

Parts.—For convenience in description five surfaces may be recognized, but they are but indistinctly separated from each other. One, the **anterior** or **pubic surface,** is directed forward and downward; second, the **superior** or **intestinal surface,** looks upward; the third, the **posterior surface,** looks backward; and the other two are the **lateral surfaces.** The anterior, superior, and lateral surfaces meet at the **vertex** of the bladder, from which the **middle umbilical ligament** (**urachus**) extends to the umbilicus; the posterior surface, sometimes flat and sometimes, especially in old age, convex, forms what is known as the base or **fundus** [fundus vesicæ]; and the portion of the viscus intervening between the vertex and

FIG. 1013.—MEDIAN SAGITTAL SECTION OF THE MALE PELVIS.
(From a preparation in the Museum of St. Thomas's Hospital.)

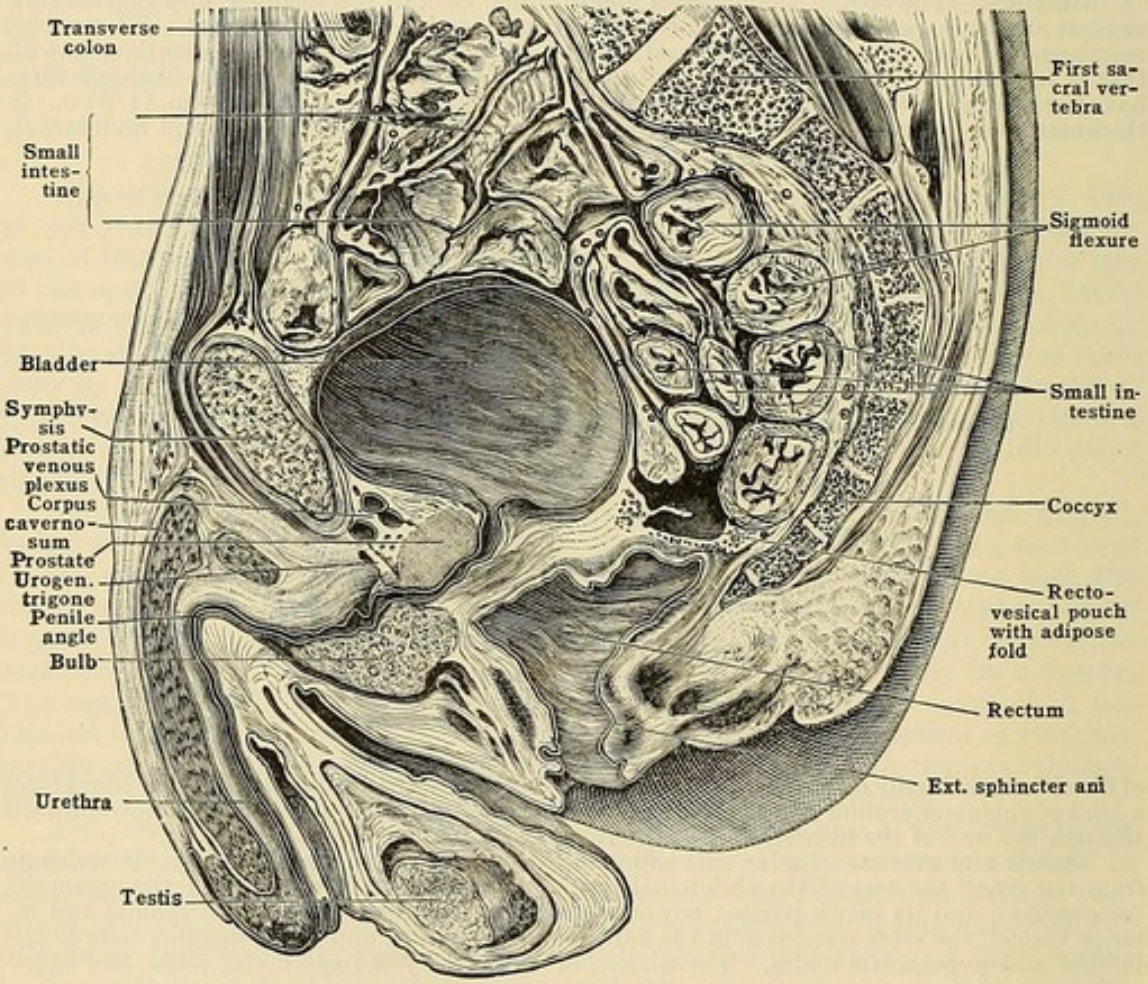

fundus is termed the **body** [corpus vesicæ]. In the centre of the line between the anterior and posterior surfaces is the *internal urethral orifice* [orificium urethræ internum], by which the bladder communicates with the urethra, and the portion of the organ immediately surrounding this is sometimes spoken of as the **neck.**

When the bladder is empty and relaxed, the superior surface sinks down upon the anterior and posterior surfaces, thus becoming concave, and the cavity of the organ is reduced to a **T**- or **Y**-shaped fissure. In the female, the cavity of the empty bladder in mid-sagittal section often more nearly resembles a figure 7 (see fig. 1014).

Relations.—The anterior surface looks downward and forward toward the symphysis pubis (figs. 1013, 1014). It is uncovered by peritoneum, but is separated from the pubic bones and anterior attachments of the obturatores interni and the levatores ani by a space known as the **prevesical space** (**cavum Retzii**),

which contains a variable quantity of loose fat continuous with the pelvic and abdominal subperitoneal tissue. Each lateral surface is covered by peritoneum down to the level at which it is crossed obliquely from behind forward and upward by the obliterated hypogastric artery. Below this level it is separated from the levator ani and obturator internus by subperitoneal tissue, which usually bears much fat in its meshes and ensheaths the vesical vessels and nerves. It is also crossed by the ductus deferens, which passes between the ureter and the wall of the bladder, a little above the level at which the former enters the wall of the bladder, at the junction of its lateral and posterior surfaces and about 3.5 cm. above the fundus. The posterior surface may be divided into two portions, an upper covered by the peritoneum of the recto-vesical or vesico-uterine pouch (fig. 1013), and a lower in direct contact *in the male* with the anterior wall of the

FIG. 1014.—MID-SAGITTAL SECTION OF THE FEMALE PELVIS. (Spalteholz.)

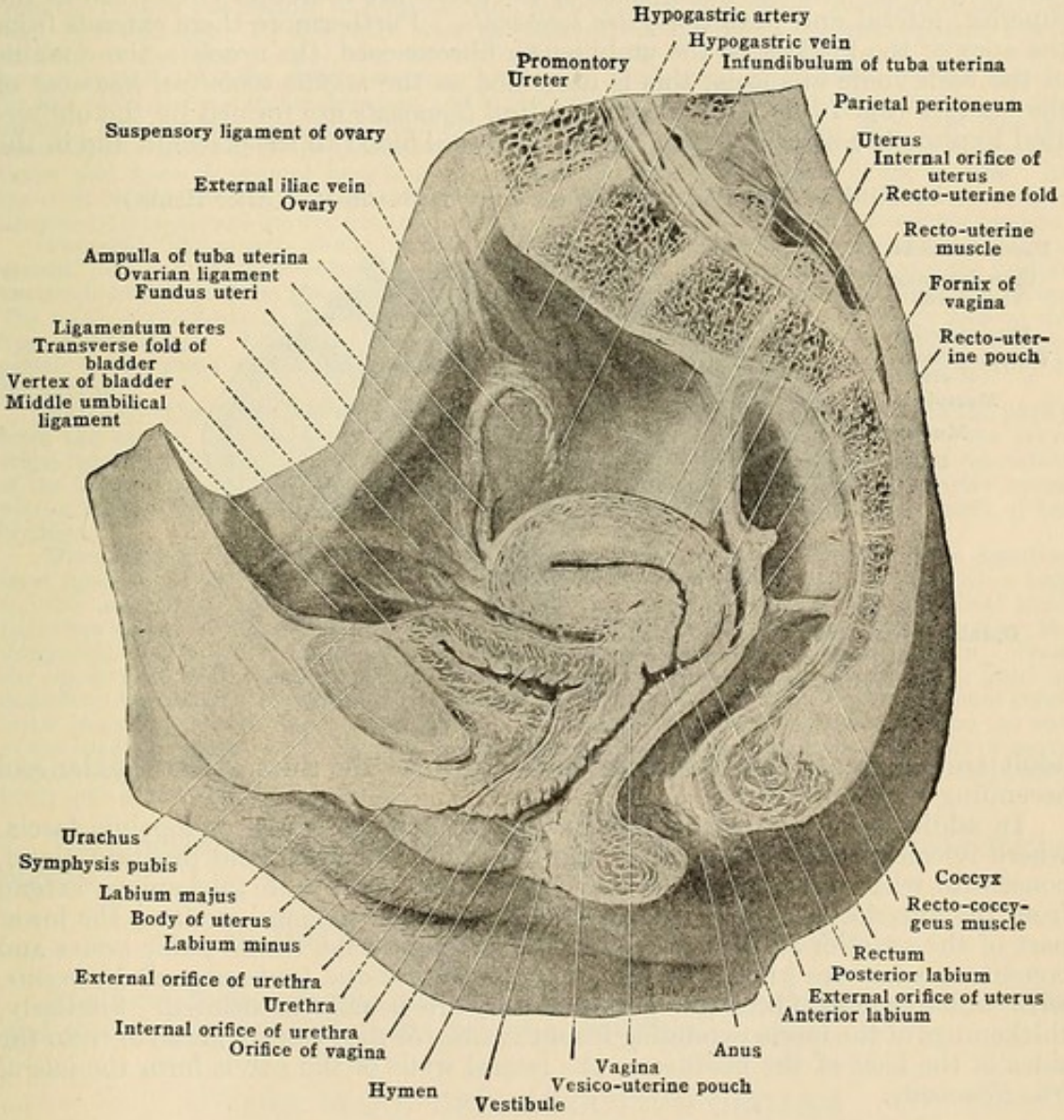

rectum and with the lower part of the ductus deferentes and the vesiculæ seminales. Between the diverging ductus deferentes there is a triangular space, whose base is formed by the line of reflexion of the recto-vesical pouch of peritoneum and the apex by the meeting of the ejaculatory ducts at the summit of the prostate. It represents the area of direct contact of the posterior wall of the bladder with the rectum. *In the female* the posterior surface is adherent in its lower part to the cervix of the uterus and the upper part of the anterior wall of the vagina (fig. 1014), but it is separated above from the body of the uterus by the shallow vesico-uterine pouch of peritoneum.

The superior surface is entirely covered by peritoneum. It looks almost

directly upward into the abdominal cavity and has resting upon it coils of the small intestines and sometimes a portion of the sigmoid colon behind these.

Variation in position.—In the normal condition the bladder of the adult lies below the upper border of the symphysis pubis, but if fully distended it may rise above this level, carrying with it the reflexion of peritoneum from its upper surface to the anterior abdominal wall. The anterior surface of the bladder is thus brought into relation with the anterior abdominal wall, being separated from it only by the enlarged prevesical space, and it is thus possible to enter the bladder above the symphysis pubis without penetrating the peritoneum.

In the infant, owing to the smaller extent of the pelvic cavity, the bladder lies at a somewhat higher level than in the adult and rises into the abdominal cavity. Indeed the entire bladder is above the horizontal level of the pubic crests, the urethral orifice being behind the upper margin of the symphysis pubis. As the child learns to walk, however, this position gradually alters and usually by the age of six years the adult relations have been acquired.

The fixation of the bladder.—The reflections of the peritoneum from the superior surface of the bladder to the anterior abdominal wall and from the sides and back to the corresponding walls of the pelvis are sometimes described as the superior, lateral and posterior *false ligaments*. Furthermore there extends from the apex of the bladder to the umbilicus a fibrous cord, the *urachus*, the remains of the embryonic allantois; this is described as the *middle umbilical ligament* of the bladder (fig. 1014), and *lateral umbilical ligaments* are formed by the obliterated hypogastric arteries which carried the fœtal blood to the placenta and in the

FIG. 1015.—THE POSTERIOR WALL OF THE BLADDER. (After Henle.)

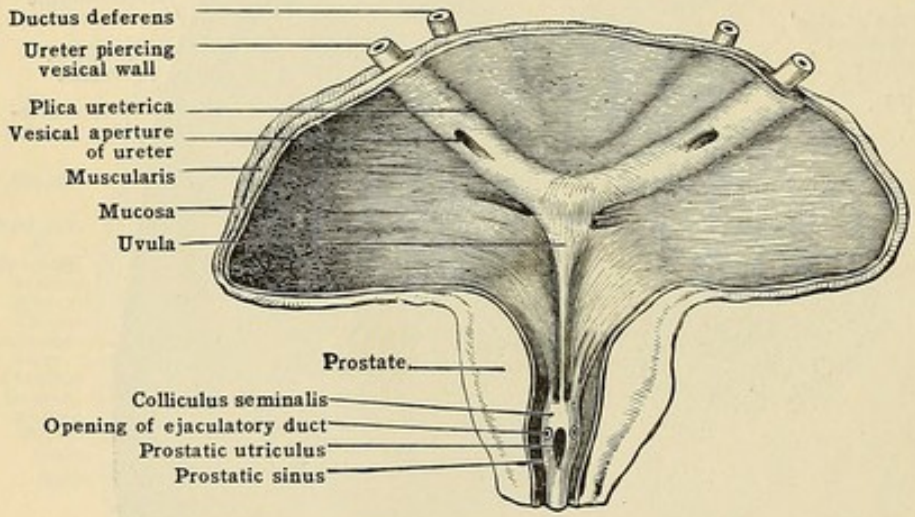

adult are represented by fibrous cords passing over the sides of the bladder and ascending to the umbilicus.

In addition to these structures certain thickenings of the endopelvic fascia, where it comes into relation with the base of the bladder and prostate gland, constitute what are termed the **true ligaments.** Two such thickenings extend from the anterior surface of the capsule of the prostate gland, or from the lower part of the anterior surface of the bladder in the female, to the pubic bones and constitute what are known as the *middle pubo-prostatic (pubo-vesical) ligaments*, with which muscle fibres [m. pubovesicalis] are usually associated. Similarly, thickenings of the fascia extending from the sides of the prostate gland or from the sides of the base of the bladder to the lateral walls of the pelvis form the *lateral true ligaments*.

Muscle fibres [m. rectovesicalis] also occur in the subperitoneal tissue contained within the peritoneal folds (posterior false ligaments) extending from the back of the bladder to the posterior wall of the pelvis and bounding the recto-vesical pouch of peritoneum in the male. They correspond to the *mm. rectouterini* of the female.

The internal surface.—The mucous membrane lining the internal surface of the bladder is soft and rose-coloured during life, and in the empty bladder is thrown into irregular folds which become effaced by distention. It is modified over a triangular area at the base of the bladder, termed the *trigone* [trigonum vesicæ (Lieutaudi)] (fig. 1015) whose three angles correspond with the orifices of the urethra and of the two ureters, and are separated from one another by a

distance of 20 to 25 mm. This area is paler in colour and free from the plication that characterizes the rest of the mucous membrane; it is bounded posteriorly by a transverse ridge, the *plica ureterica*, extending between the orifices of the ureters, and toward the urethral orifice presents a median longitudinal elevation, the *uvula vesicæ*, which is apt to be especially prominent in aged persons. The *internal urethral orifice* is normally situated at the lowest point of the bladder, at the junction of the anterior and posterior surfaces. It is surrounded by a more or less distinct circular elevation, the *urethral annulus*, and is usually on a level with about the center of the symphysis pubis and from 2.0 to 2.5 cm. behind it.

Structure.—The general characteristics of the *mucous membrane* of the bladder, which is lined by epithelium of the transitional variety, have already been described. It rests upon a loose *submucous tissue*, which contains numerous elastic fibres. The greater part of the thickness of the wall is formed, however, of the *muscular coat*, consisting of non-striped muscle tissue, the fibres of which are arranged in three more or less distinct layers. The *outer layer* is composed mainly of longitudinal fibres, some of which are continued forward to the pubis from the neck of the bladder to form the mm. pubovesicales and others backward to form the mm. rectovesicales. To this outer layer the term *m. detrusor urinæ* has been applied, but it should be noted that it does not contract independently of the circular layer. The *middle ayer* is thicker than the outer and more uniformly developed. It consists of fibres having for the most part a circular direction and is well developed over all the upper portion of the bladder, but becomes thinner in the region corresponding to the trigone. It is here that the *inner layer* is chiefly developed, consisting of fibres, which are situated partly in the submucous tissue and have a general longitudinal direction throughout the region of the trigone. At the neck of the bladder, however, they form a strong circular bundle, which is continued into the prostatic portion of the urethra and forms what is termed the *internal sphincter* of the bladder.

Vessels.—The *arteries* of the bladder are usually two in number, the superior and inferior vesical, branches of the hypogastric artery; the fundus also receives branches from the middle hæmorrhoidal and in the female twigs are also sent to it from the uterine and vaginal arteries. The *veins* form an extensive plexus at the sides of the bladder, from which stems pass to the hypogastric trunk. The *lymphatics* accompany the veins and communicate with the hypogastric nodes, some of those from the fundus passing to nodes situated at the promontory of the sacrum.

Nerves.—The *nerves* are derived partly from the hypogastric sympathetic plexus and partly from the second and third sacral nerves. The fibres from the latter constitute the nervi erigentes, stimulation of which produces contraction of the general musculature and relaxation of the internal sphincter. On each side of the bladder there is formed a sympathetic *vesical plexus*, from which *superior* and *inferior vesical* nerves pass to the corresponding parts of the bladder.

Development.—In the earlier stages of development the urogenital ducts and the digestive tract open below into a common cavity, the *cloaca*, from the ventral portion of which a long tubular outgrowth, the *allantois*, extends out to the placenta through the umbilical cord. Later the cloaca becomes divided in the frontal plane into a ventral portion which receives the urogenital ducts, and a dorsal portion, which becomes the lower end of the rectum. From the upper part of the ventral portion the bladder is developed. Since the cloaca is lined by endoderm the mucous membrane of the bladder is mainly derived from that embryonic layer, but it is worthy of note that portions of the lower ends of the ureters are taken up into the wall of the bladder, giving rise to the area of the trigone, whose mucous membrane is thus of mesodermal origin. The portion of the allantois within the body of the fœtus is transformed after birth into a fibrous cord, the *urachus*.

The **urethra** will be considered later in connection with the reproductive organs.

B. THE REPRODUCTIVE ORGANS

The reproductive organs include those of the male [organa genitalia virilia] and those of the female [organa genitalia muliebria].

THE MALE REPRODUCTIVE ORGANS

The reproductive organs of the male consist of (1) two **testes** in which the spermatozoa are formed, (2) their ducts, the **ductus deferentes;** enclosed throughout a portion of their course in the **spermatic cord;** and the **seminal vesicles,** reservoirs for the semen, connected with the ductus deferentes; (3) the **penis,** the organ of copulation, which is traversed by the urethra; (4) the **urethra,** a canal into which the ductus deferentes open and which also gives exit to the contents of the bladder; (5) the **prostate gland,** a musculoglandular structure surrounding the beginning of the urethra; (6) the **bulbo-urethral glands** which open into the urethra.

1. The Testes and Their Appendages

The scrotum.—The two testes, together with the beginning of the ductus deferentes, are contained within a pouch, the *scrotum*, which is divided into two compartments by a median sagittal septum, the edge of which is indicated on the surface by a ridge-like thickening of the integument, termed the *raphe*.

This double condition of the scrotum is explained by its origin from the fusion of two outpouchings of the lower portion of the abdominal wall, the inguinal canals forming, as it were, the necks of the outpouchings. The testes are primarily retroperitoneal abdominal organs, but later they descend through the inguinal canals into the scrotal outpouchings, where they lie between the peritoneal sac which each of these contains and the remaining layers of the wall, thus retaining their retroperitoneal position. The peritoneal sacs are at first in communication with the abdominal cavity, but after the descent of the testes each undergoes degeneration in its upper part, the cavity disappearing and the peritoneal tissue becoming converted into a portion of the connective tissue in which the ductus deferens and the vessels and nerves associated with it are imbedded in their course through the *spermatic cord*. The portion of the sac in relation with each testis persists, however, and wrapping itself around that structure forms for it a serous investment, the *tunica vaginalis propria* (fig. 1016).

The *integument* of the scrotum is more or less pigmented and presents numerous transverse ridges extending laterally on either side from the raphe. It is furnished in the adult with coarse, scattered hairs and its sebaceous and sudoriparous glands are well developed. The deeper layers of the dermis, have a pinkish colour, and form what is termed the *dartos* (fig. 1016), the colouration being due to the

Fig. 1016.—Horizontal Section of the Scrotum and Testis. (Diagrammatic.)

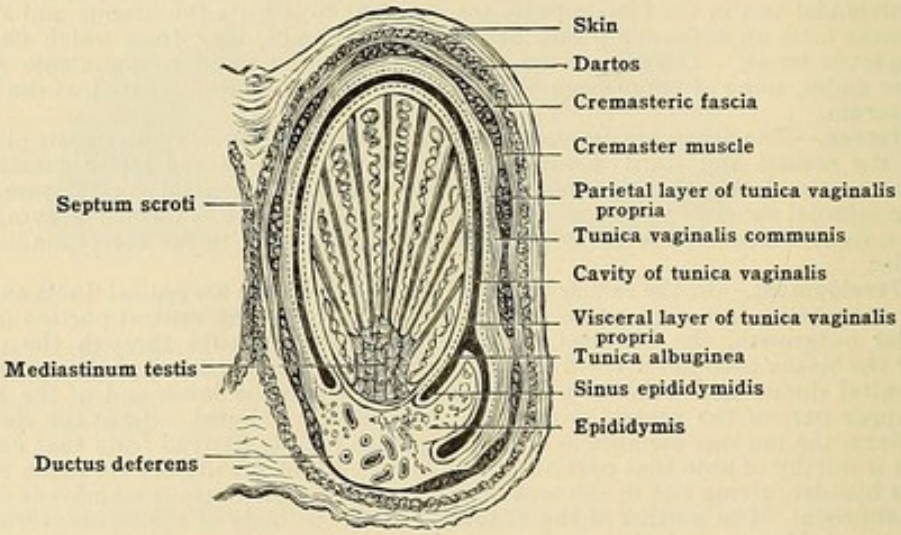

presence in it of numerous non-striated muscle fibres, which are for the most part arranged at right angles to the wrinkles of the surface and are the cause of these. The more superficial fibres of the dartos, like the rest of the integument, form a common investment for both testes, but the deeper ones of either side bend inward at the raphe and assist in the formation of the septum.

Internal to the dartos and closely related to it is a layer of laminated connective tissue, the *cremasteric fascia*. It is destitute of fat and is continuous at the subcutaneous inguinal ring with the intercrural fibres, being probably the scrotal representative of the external oblique muscle. It is succeeded by a strong sheet of fascia containing longitudinal bands of striated muscle tissue, forming what is termed the *cremaster muscle* (figs. 389, 1016) and being continuous above with the fibres of the internal oblique muscle of the abdomen. Internal to this is a thin layer of connective tissue, the *tunica vaginalis communis*, which is continuous with the transversalis fascia at the inguinal ring, and, finally, there is the *tunica vaginalis propria*, which forms the serous investment of the testis and, as has been stated, is of peritoneal origin. Like other similar serous investments it has the form of a double sac, the outer or parietal layer of which is closely adherent to the tunica vaginalis communis and contains numerous non-striped muscle fibres forming what has been termed the *internal cremaster muscle*. The inner or visceral layer is thinner and closely invests the testis and a

portion of the epididymis, being reflected from the inferior and posterior parts of the latter to be continuous with the parietal layer. Toward the upper part of the lateral surface of the testis it is folded in between that structure and the epididymis, forming a well-marked pocket, the *sinus epididymidis* (digital fossa) (fig. 1017), whose upper and lower lips form what are termed the *ligamenta epididymidis*.

Vessels and nerves.—The skin and dartos of the scrotum are supplied partly by the perineal branch of the internal pudendal *artery* and partly by the external pudendal branches of the femoral. The deeper layers are supplied by the spermatic branch of the inferior epigastric. The *veins* accompany the arteries, the external pudendals opening into the internal saphenous vein near its termination. The *lymphatics* terminate in the more medial inguinal nodes. Several *nerves* take part in the supply of the scrotum. The external spermatic branch of the genito-femoral gives sensory branches to the anterior and lateral surfaces and also supplies the external cremaster muscle; the posterior surface is supplied by the perineal branch of the pudendal nerve; and the inferior surface by the perineal branches of the posterior femoral

FIG. 1017.—THE LEFT TESTIS WITH VESSELS AND DUCT. (After Sappey.)

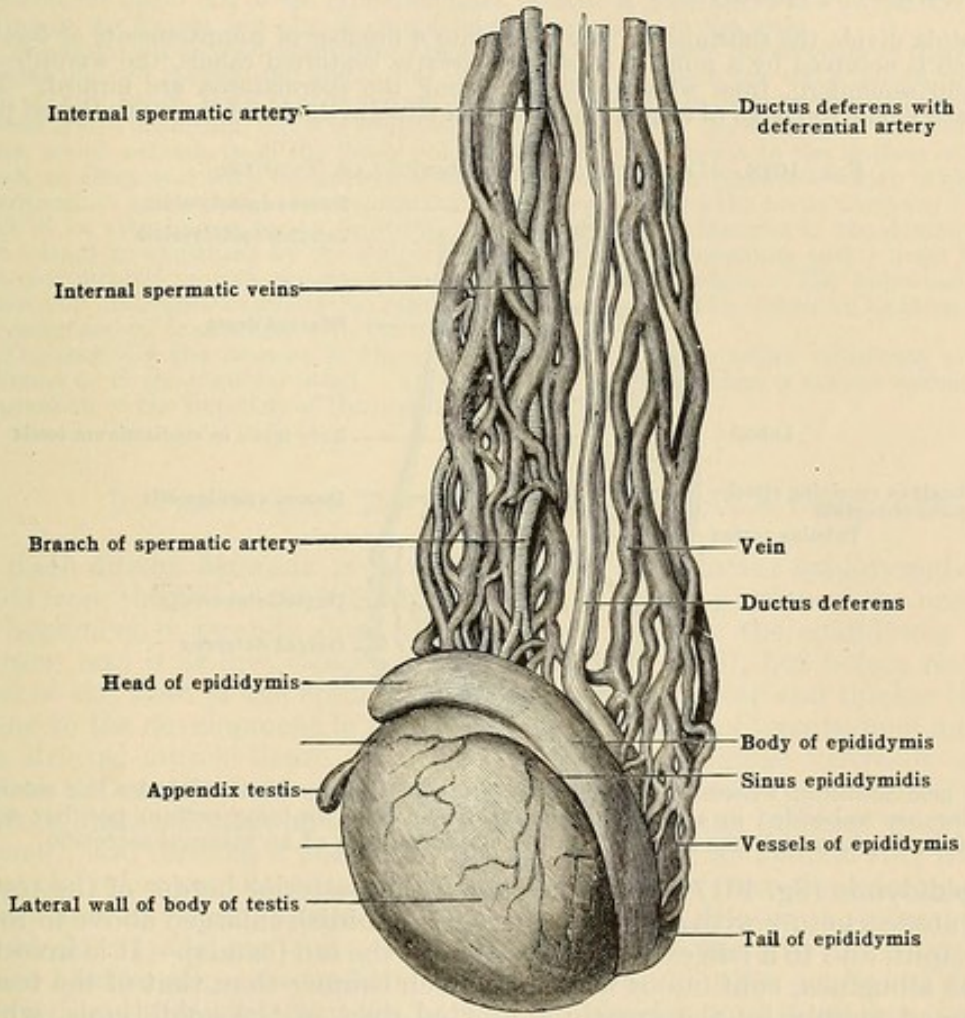

cutaneous. The anterior aspect of the scrotum is also supplied by anterior scrotal branches of the ilio-inguinal. The non-striped musculature is probably supplied by the internal spermatic nerve from the hypogastric plexus.

Hernia.—The communication of the tunica vaginalis propria with the abdominal peritoneum is usually obliterated within a few days after birth, but sometimes the process of obliteration is more or less incomplete. If the communication remains open there is a free passage for a loop of the intestine to enter the cavity of the tunica vaginalis, such a condition constituting what is known as the *congenital* variety of inguinal hernia. If the communication be interrupted only at the upper part of the original sac, so that the cavity of the tunica vaginalis propria extends a considerable distance up the spermatic cord a hernia, passing through the inguinal canal, may invaginate the upper part of the tunica vaginalis into the lower, producing what is termed the *encysted* variety of hernia. Or if, finally, the obliteration of the communication begins in the neighbourhood of the testis, a funnel-shaped prolongation of the peritoneal cavity may extend downward into the spermatic cord, and hernia into this constitutes the variety known as *hernia into the funicular process.*

The testis and epididymis.—The **testes** (fig. 1017) are the essential male organs of reproduction and are contained within the scrotum. They are two in number,

each being of a flattened oval form, with two *surfaces*, *medial* and *lateral*, two *borders*, *anterior* and *posterior*, and two *extremities*, *superior* and *inferior*. To the whole of the posterior border there is attached the *epididymis*, formed by the efferent ducts. The testis is obliquely placed, so that the medial surface also looks somewhat forward and downward.

The surface of the testis is covered by the visceral layer of the tunica vaginalis propria except where it is in contact with the epididymis, and is formed by a dense white inelastic capsule, the *tunica albuginea*, beneath which is a looser and more vascular layer known as the *tunica vasculosa*. From the inner surface of the albuginea, lamellæ of connective tissue, known as *septula*, converge toward the posterior border of the testis and toward its upper part unite together to form a network (fig. 1018), the *mediastinum testis* (or corpus Highmori), through which blood-vessels and lymphatics enter and leave the testis, while by the interspaces of the network, known as the *rete testis*, the tubules of the testis are placed in communication with the epididymis.

The septula divide the substance of the testis into a number of compartments or *lobules*, each of which is occupied by a number of slender, greatly contorted canals, the *seminiferous tubules* [tubuli seminiferi], from whose epithelial lining the spermatozoa are formed. The tubules of each lobule converge to form a single, almost straight duct and these *tubuli recti* pass

FIG. 1018.—DIAGRAM OF THE TESTICULAR TUBULES.

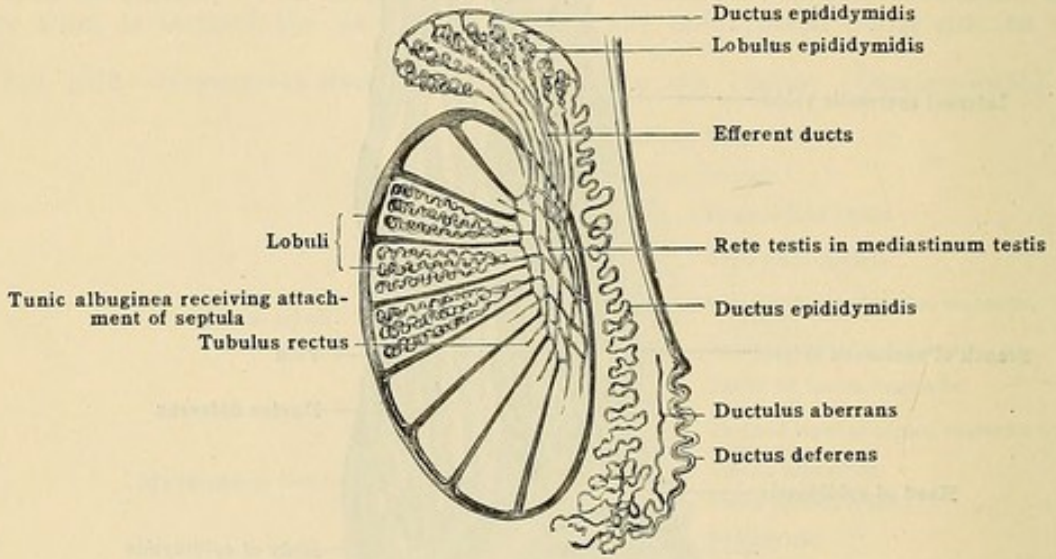

toward the mediastinum, where they open into the rete testis. In the lobules the seminiferous tubules are imbedded in a loose connective tissue that contains certain peculiar cells, the *interstitial cells*, to which has been attributed the formation of an internal secretion.

The **epididymis** (fig. 1017), which lies along the posterior border of the testis, is an elongated structure with a *body* [corpus epididymidis], enlarged above to form the *head* [caput] and to a less extent below to form the *tail* [cauda]. It is invested by a tunica albuginea, continuous with, but much thinner than that of the testis, and is formed mainly by the greatly contorted duct of the epididymis, which represents the beginning of the ductus deferens.

The head is formed by 12–14 tubules, the *efferent ducts* (fig. 1018), which take their origin from the rete testis as almost straight tubules, but gradually become greatly coiled, so that each duct has the form of an elongated cone, its coiled portion forming what is termed a *lobulus epididymidis*. At their coiled ends the various efferent ducts open into a single tube, the *ductus epididymidis*. Its diameter is only about 0.4 mm., but it measures 6.0–7.0 metres (18–21 feet) in its entire length, being coiled so extensively as to be contained within the body and tail of the epididymis. In this latter region it passes over into the ductus deferens.

Vessels.—The principal *artery* supplying the testis is the internal spermatic, from which branches are also sent to the epididymis. The deferential artery, a branch of the superior vesical, also sends branches to the epididymis and enters into extensive anastomoses with the testicular branches of the internal spermatic, and anastomoses also occur with the vessels supplying the scrotum. The *veins* correspond with the arteries. The *lymphatics* of the testis and epididymis unite to form four to six large stems which pass upward in the spermatic cord to terminate in the lower lumbar nodes.

Morphology.—The testis is primarily an abdominal organ and is developed in close relationship with the provisional kidney [mesonephros] whose duct, indeed, becomes the ductus deferens

and some of whose tubules, becoming the efferent ducts, place the seminiferous tubules in communication with the ductus deferens. The epididymis may therefore be said to be developed from the mesonephros. The portions of this structure that are not concerned in the formation of the efferent ducts disappear for the most part; a few of the tubules persist, however, as rudimentary organs associated with the epididymis. Among these may be mentioned one or more blindly ending, coiled tubules, varying from 5–30 cm. in length, which are connected with the ductus epididymidis usually in the tail of the epididymis. They are known as the *ductuli aberrantes* (fig. 1018) and may be regarded as persistent excretory mesonephric tubules. Another of the rudimentary organs is the *paradidymis* (*organ of Giraldès*), which is a whitish body, situated immediately above the head of the epididymis, and is composed of irregularly coiled tubules, which terminate blindly at both extremities. They may be regarded as efferent ducts that have failed to connect with the testis and are of interest in that they sometimes develop into cysts connected with the epididymis.

In addition there is frequently attached to the upper pole of the testis a solid oval body composed of connective tissue, known as the *appendix testis* (*hydatid of Morgagni*) (fig. 1017). It measures from 3 to 8 mm. in length and its significance is doubtful. A similar, though smaller structure, the *appendix epididymidis*, is attached less frequently to the head of the epididymis. It is usually provided with a distinct stalk and contains a cavity; it is believed to represent the upper end of the Müllerian duct, present in the embryo and giving rise to the tuba uterina in the female, but almost completely degenerating in the male.

The testis begins its descent from the abdominal cavity into the scrotum at the third month of fetal life and reaches the abdominal inguinal ring at about the sixth month, but it is not until shortly before birth that it arrives at its final location in the scrotum. The cause of the descent is still uncertain, but it is supposed to be partly due to the failure of a band of connective tissue, which extends from the lower pole of the embryonic testis to the bottom of the scrotal pouch, to keep pace with the growth of the body walls. This ligament, which is known as the *gubernaculum testis*, thus becomes relatively shorter and draws the testis downward toward the point of its attachment to the scrotum. There are various features in the descent, however, that cannot be explained by the simple traction of the gubernaculum and it must be regarded as a complicated growth process whose meaning is yet uncertain. The gubernaculum testis apparently undergoes degeneration after the testis has reached its definitive location and cannot be recognized in connection with the adult testis.

Occasionally the descent of the testis is interrupted, the organ remaining either in the abdomen or in the inguinal canal. This condition of **cryptorchism** is always associated with a suppression of the function of the organ.

2. The Ductus Deferentes and Vesiculæ Seminales

Each **ductus deferens** is the continuation of a ductus epididymidis and extends from the tail of the epididymis to the prostatic portion of the urethra. At its beginning it ascends along the posterior border of the epididymis (*testicular portion*) and is at first slender and tortuous (fig. 1018), but before reaching the level of the head of the epididymis it becomes straighter and thicker (fig. 1017), owing to the development in its walls of strong layers of longitudinal and circular non-striated muscle tissue. Thence it is continued almost vertically upward as one of the constituents of the spermatic cord (*funicular portion*) to the subcutaneous inguinal ring, and, entering this, traverses the inguinal canal (*inguinal portion*), still forming a portion of the cord. At the abdominal ring it separates from the other constituents of the cord and, looping over the inferior epigastric artery near its origin, passes downward and backward over the lateral surface of the bladder (*pelvic portion*). At the junction of the posterior and lateral surfaces of the bladder it passes medially to the ureter and is then continued downward, forward and medially upon the base of the bladder until it reaches the prostate gland (fig. 1019), whose substance it traverses, as the *ductus ejaculatorius*, to open into the prostatic portion of the urethra (see p. 1263).

Just before it reaches the prostate gland each ductus deferens presents an irregular spindle-shaped enlargement, the *ampulla* (figs. 1019, 1020), whose walls are somewhat sacculated. Just beyond this it is joined upon its lateral surface by a club-shaped lobulated structure, the **vesicula seminalis** (fig. 1019). Each vesicle measures 4.5–5.5 cm. in length and has a greatest diameter of about 2 cm. It rests upon the posterior surface of the bladder, lying parallel with and lateral to the corresponding ductus deferens, and in its upper one-third is in relation posteriorly with the peritoneum which forms the anterior wall of the recto-vesical pouch, while below it is in contact with the anterior wall of the lower part of the rectum, through which it may be palpated. Indeed, the two vesiculæ, together with the ductus deferentes, form the lateral boundaries of the triangular area at the base of the bladder, throughout which that organ is in relation to the rectum.

Each vesicle is enclosed within a fine capsule of connective tissue, which contains numerous non-striated muscle fibres and is continuous below with the capsule of the prostate gland. On removing this capsule the vesicle will be found to consist of a greatly coiled tube, 10–12 cm.

FIG. 1019.—DUCTUS DEFERENTES AND VESICULÆ SEMINALES. (After Sappey.)

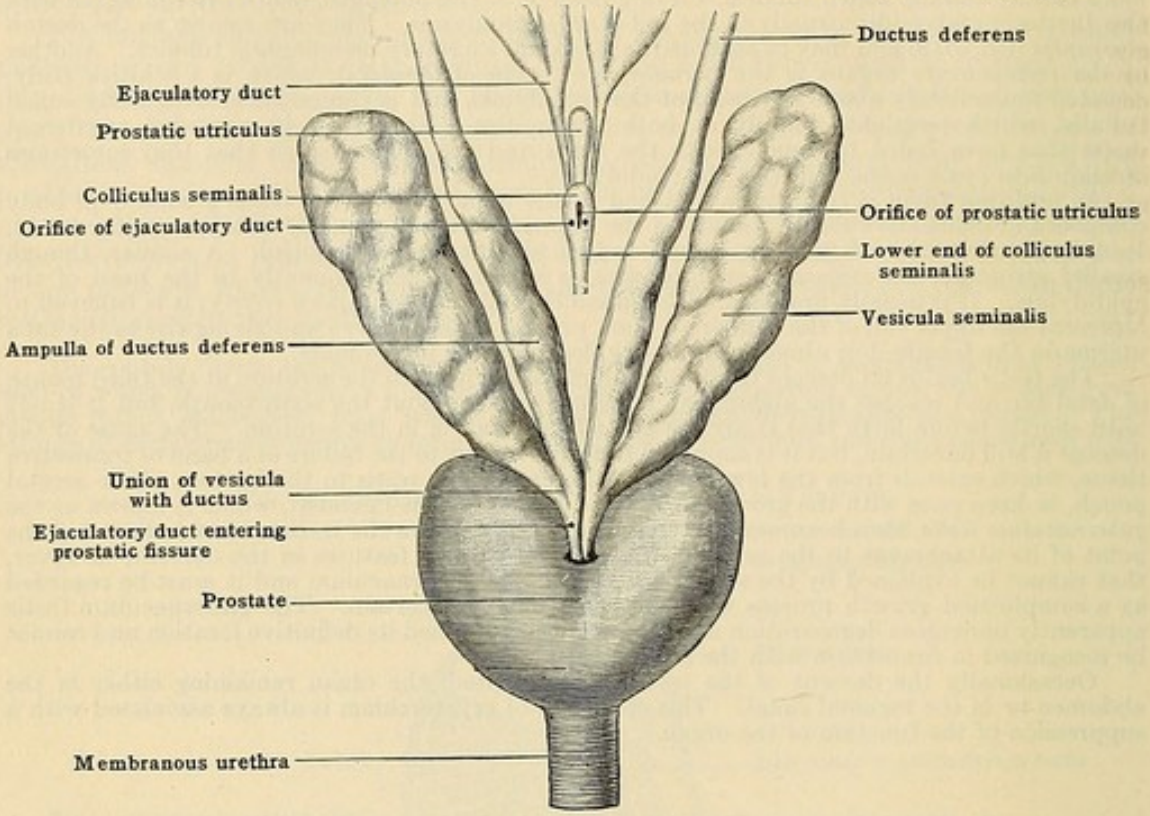

FIG. 1020.—DUCTUS DEFERENS AND VESICULA SEMINALIS DISSECTED. (After Sappey.)

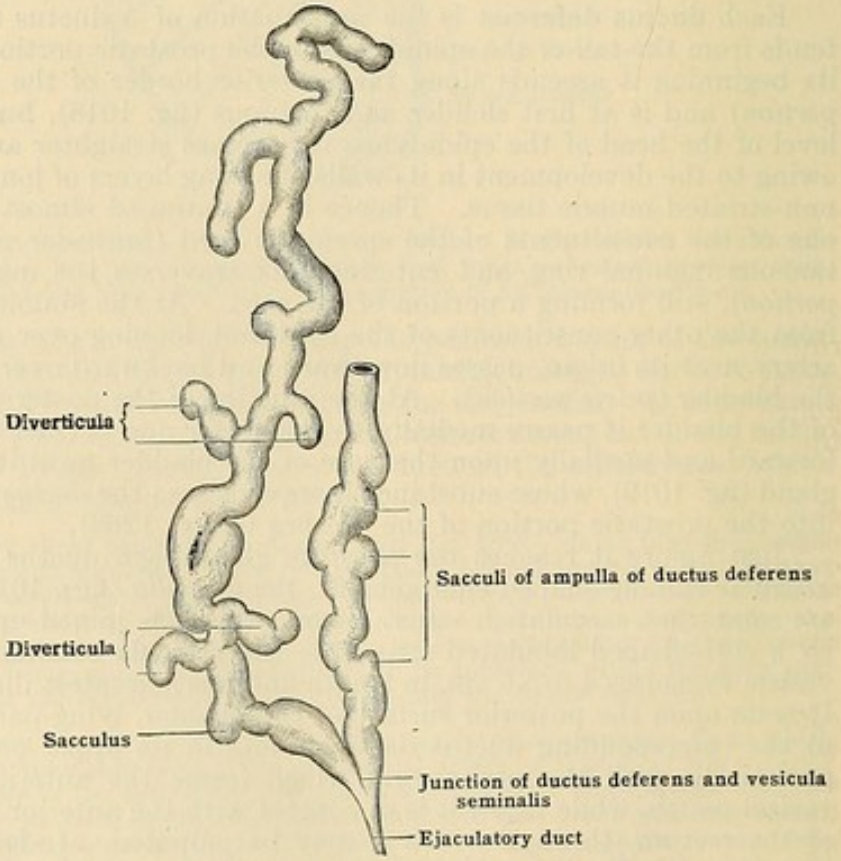

in length, which ends blindly and has attached to it on either side a number of short diverticula (fig. 1020). The walls of the tube and diverticula are formed of smooth muscle tissue, arranged in layers similar to those of the ductus deferentes, and are lined by a much folded mucous

membrane, whose cells contain considerable quantities of a yellowish-brown pigment, and also contribute a secretion to the seminal fluid. In addition to having this function the vesiculæ also serve as receptacles for the spermatozoa. They arise as diverticula from the embryonic ductus deferens, and it is worthy of note that a number (4 or 5) of similar but quite small diverticula arise from the upper part of each ductus ejaculatorius.

Vessels and nerves.—The *artery* supplying the ductus deferens is the a. deferentialis, a branch of the superior vesical. It accompanies the ductus to the tail of the epididymis and also gives a branch to the vesicula seminalis. The latter also receives branches from the middle hæmorrhoidal and inferior vesical arteries. The deferential *vein* accompanies the ductus deferens to the base of the bladder where it breaks up into a plexus that communicates with the seminal venous plexus formed by the veins from the seminal vesicles. This joins with the vesical and pudendal plexus and so communicates with the hypogastric vein. The *lymphatics* of the ductus deferentes and seminal vesicles pass to the external iliac and hypogastric nodes. The *nerves* of both structures are derived from the hypogastric plexus.

The spermatic cord.—In its descent through the inguinal canal into the scrotum the testis necessarily drags after it the ductus deferens and the testicular vessels and nerves, these structures coming together at the abdominal inguinal

FIG. 1021.—CROSS-SECTION OF THE SPERMATIC CORD.

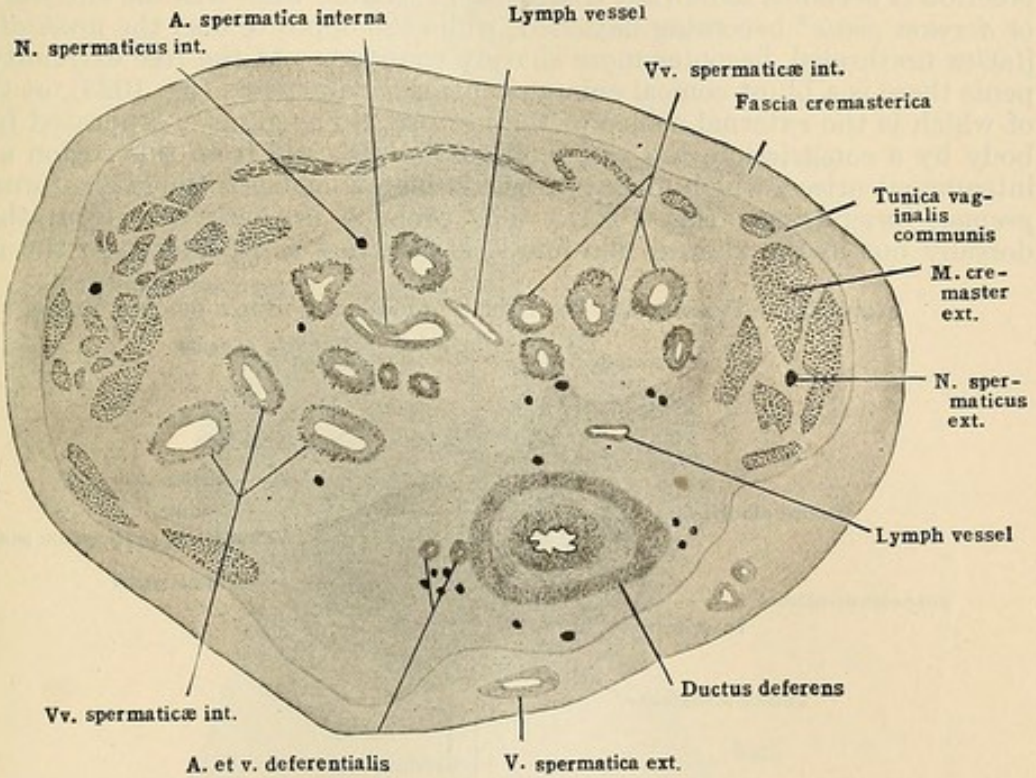

ring to form what is termed the *spermatic cord* [funiculus spermaticus]. This structure extends, therefore, from the abdominal inguinal ring, through the inguinal canal and the neck of the scrotal sack to the testis, and is enclosed within the same investing layers as the testis.

Thus as it emerges from the subcutaneous inguinal ring it receives an investment of connective tissue continuous with the intercrural fibres and the aponeurosis of the external oblique muscle. This cremasteric fascia has beneath it bands of striated muscle tissue, the *external cremaster muscle* (fig. 1021), especially developed on the posterior surface of the cord and continuous with the internal oblique muscle of the abdomen, and within these is an indistinct layer of connective tissue, the *tunica vaginalis communis*, which is received at the abdominal inguinal ring where it is continuous with the fascia transversalis.

Within the sheath thus formed there is a matrix of connective tissue, usually containing considerable amounts of fat and strands of non-striated muscle tissue, which form what is termed the *internal cremaster muscle (funicular portion)*, and imbedded in this connective tissue are the various essential constituents of the cord. These are as follows (figs. 1017, 1021): (1) the *ductus deferens*, occupying the posterior surface of the cord and having associated with it the deferential artery and veins and the deferential plexus of nerve fibres; (2) the *internal spermatic artery*, which occupies the axis of the cord and is surrounded by (3) the *internal spermatic veins*, which form a complicated network, known as the *pam-*

piniform plexus; (4) the *testicular lymphatics;* and (5) the *internal spermatic plexus* of nerves from the hypogastric plexus; and (6) branches of the *genito-femoral nerve* for the supply of the external cremaster muscles.

3. The Penis

The **penis** is composed of three rod-like bodies composed of erectile tissue (fig. 1023), firmly united together and invested by fascia and integument (fig. 1022). When this erectile tissue becomes engorged with blood the organ assumes an erect position, but otherwise it is pendulous, hanging downward in front of the scrotum from its attachment to the symphysis pubis. The erectile bodies are, however, prolonged backward beyond the symphysis pubis into the perineal region, and it is customary to speak of this perineal portion as the *root* of the penis [radix penis] or *pars fixa* in contrast to the *body* of the penis [corpus penis] or *pars libera.*

The **body of the penis** in its flaccid condition is almost cylindrical, but in erection it becomes somewhat triangular in section, what was the anterior surface or *dorsum penis** becoming flattened, while the opposite one, the *urethral surface* [facies urethralis], becomes more sharply rounded. At the free extremity of the penis there is a blunt conical enlargement, the **glans penis** (fig. 1023), at the apex of which is the external orifice of the urethra. The glans is separated from the body by a constriction, the *neck* [collum glandis], and from this region a fold of integument arises, which more or less completely encloses the glans, forming the *prepuce* [præputium] (fig. 1024). The prepuce is quite free from the glans dorsally but in the ventral mid-line it is attached to it, almost to the urethral

Fig. 1022.—Transverse Section through the Body of the Penis.

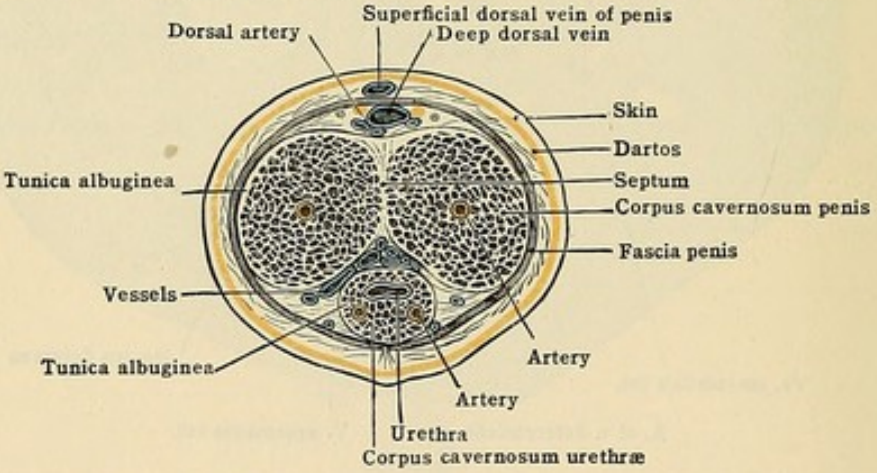

orifice, by a narrow line of adhesion, the *frenulum* [frenulum præputii], which contains blood-vessels of considerable size. The base of the glans has a well-marked rounded border, the *corona* [corona glandis], and is deeply concave for the reception of the distal ends of the corpora cavernosa penis.

The **integument** of the penis is continuous with that of the scrotum and like it is pigmented and contains no fat. Immediately below it there is a layer of non-striated muscular tissue, the *dartos,* and beneath this a layer of loose connective tissue, containing the superficial vessels and nerves of the penis; beneath this again is a denser, elastic sheet of connective tissue, the *fascia penis* (fig. 1022), which encloses the erectile bodies as far as the base of the glans and is continuous with the superficial fascia of the perineum and inguinal region. Where it passes beneath the symphysis pubis it receives from the anterior surface of the latter a strong band of fibrous tissue, which forms the *suspensory ligament* of the penis [lig. suspensorium penis].

Two of the erectile bodies of the penis, the **corpora cavernosa penis,** are paired (fig. 1023). They are attached at their proximal ends to the base of the tuberosity of the ischium, and in this part of their extent are termed the *crura penis,* being

* It should be noted that the terms "dorsum" and "dorsal" are used for the penis in a sense directly opposite their usual meaning.

composed of fibrous connective tissue, which has resting upon it the m. ischio-cavernosus (see Section IV). The two **crura** are situated in the lateral portions of the superficial perineal interspace and pass forward parallel with the rami of the ischia and pubis, gradually becoming transformed into cavernous erectile tissue. Shortly before they reach the level of the symphysis pubis the two corpora come into contact in the median line, their medial walls fusing to form a *septum*, and thus united they extend throughout the entire length of the body of the penis, occupying the dorsal portion of the space enclosed by the fascia penis (fig. 1022). They terminate at the posterior surface of the glans, where they taper

FIG. 1023.—DISSECTION OF THE PERINEUM SHOWING THE STRUCTURE AND RELATIONS OF THE PENIS.

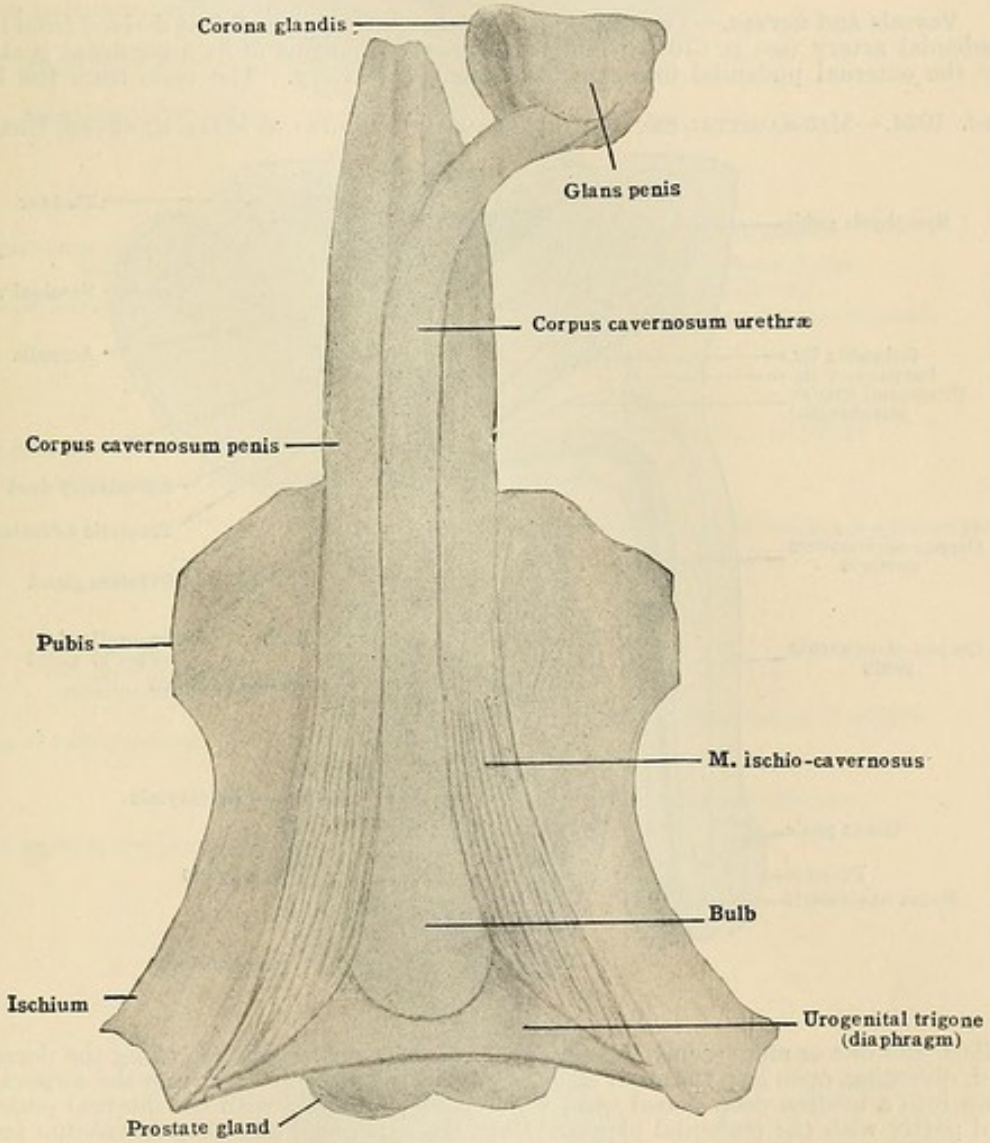

somewhat to be received into its basal concavity (fig. 1024). The septum in its proximal part forms a complete partition between the two bodies, but distally it is broken through by numerous clefts by which the blood lacunæ of the two bodies are placed in communication.

Each **corpus cavernosum penis** consists of a strong elastic fibrous sheath, the *tunica albuginea*, from which trabeculæ extend into the substance of the organ, dividing it into a network of communicating cavities, into which open terminal branches of the a. profunda penis, which traverses the axis of the corpus. These cavities consequently are to be regarded as vascular lacunæ, which, becoming engorged with blood, produce the enlargement and erection of the organ.

The third erectile organ is the **corpus cavernosum urethræ** (formerly "corpus spongiosum") (fig. 1023), so called because it is traversed throughout its entire length by the urethra (fig. 1024). It is an unpaired, median structure, having no

bony attachments and begins posteriorly in the superficial perineal interspace with an enlargement, the **bulb** [bulbus urethræ] (fig. 1023), whose posterior surface rests on the superficial fascia of the urogenital trigone and is enclosed by the m. bulbo-cavernosus. Anteriorly the bulb gradually tapers to a rather slender cylindrical portion, the *body*, very uniform in diameter, which extends throughout the entire length of the body of the penis, lying in the median line beneath the fused corpora cavernosa penis (figs. 1022, 1023). At the neck of the penis it undergoes a sudden enlargement to form the *glans*, the whole of that structure, which has already been described, being formed by the corpus cavernosum urethræ. The structure of the corpus cavernosum urethræ is essentially the same as that of the corpora cavernosa penis, the tunica albuginea, however, being much thinner.

Vessels and nerves.—The principal *arterial* supply of the penis is derived from the internal pudendal artery (see p. 610), although the proximal portion of its integument is also supplied by the external pudendal branches of the femoral artery. The *veins* from the integument

FIG. 1024.—MID-SAGITTAL SECTION (DIAGRAMMATIC) SHOWING MALE BLADDER, URETHRA, ETC.

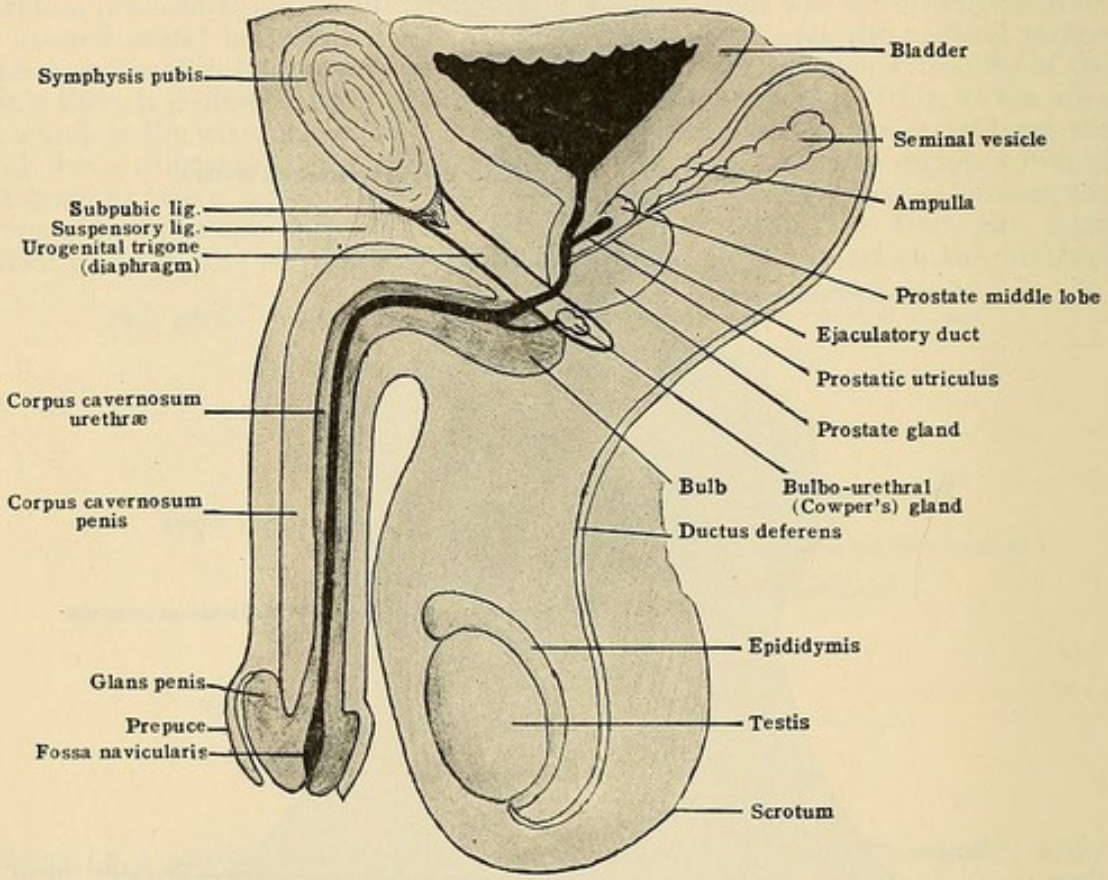

collect into one or more stems, the superficial dorsal veins, which run along the dorsal mid-line and, diverging, open into the great saphenous vein. The deep veins from the corpora cavernosa open into a median deep dorsal vein, which connects partly with the internal pudendal veins and partly with the pudendal plexus. Both the superficial and deep *lymphatics* terminate in the superficial inguinal nodes. The lymph-vessels from the glans are said to follow those of the urethra and end in the deep inguinal and external iliac nodes.

The *nerves* supplying the penis are the anterior scrotal branches of the ilio-inguinal and the perineal branches and dorsal nerve of the penis from the pudendal. Sympathetic fibres also pass to the penis from the hypogastric plexus and with these fibres from the third and fourth sacral nerves, which constitute what is termed the nervus erigens, since stimulation of it produces erection of the organ. An anatomical provision for the production of this phenomenon has been found in the occurrence of peculiar thickenings of the intima of the arteries of the penis, by which the lumina of the vessels are greatly diminished or even occluded when in a state of moderate contraction, as when the organ is flaccid. When the arteries are dilated the intimal thickenings become reduced in height and the blood is afforded a free passage into the lacunar spaces of the corpora cavernosa, which thus become engorged.

4. THE MALE URETHRA

The **urethra** is the canal which extends from the bladder to the extremity of the glans penis and serves for the passage of both the urine and the seminal fluid.

In its course (fig. 1024) it traverses first the prostate gland, then the urogenital diaphgram and then the entire length of the corpus cavernosum urethræ, and may thus be regarded as being composed of three portions.

The **prostatic portion** [pars prostatica] (fig. 1024) extends almost vertically downward from the neck of the bladder, traversing the substance of the prostate gland. In its proximal part there is on its posterior wall a median longitudinal ridge, the *crista urethralis*, which below dilates into an oval enlargement, the *colliculus seminalis* (figs. 1015, 1025), to accommodate which there is a marked

FIG. 1025.—THE MALE URETHRA, CLEFT ANTERIORLY TO SHOW THE MUCOUS COAT.

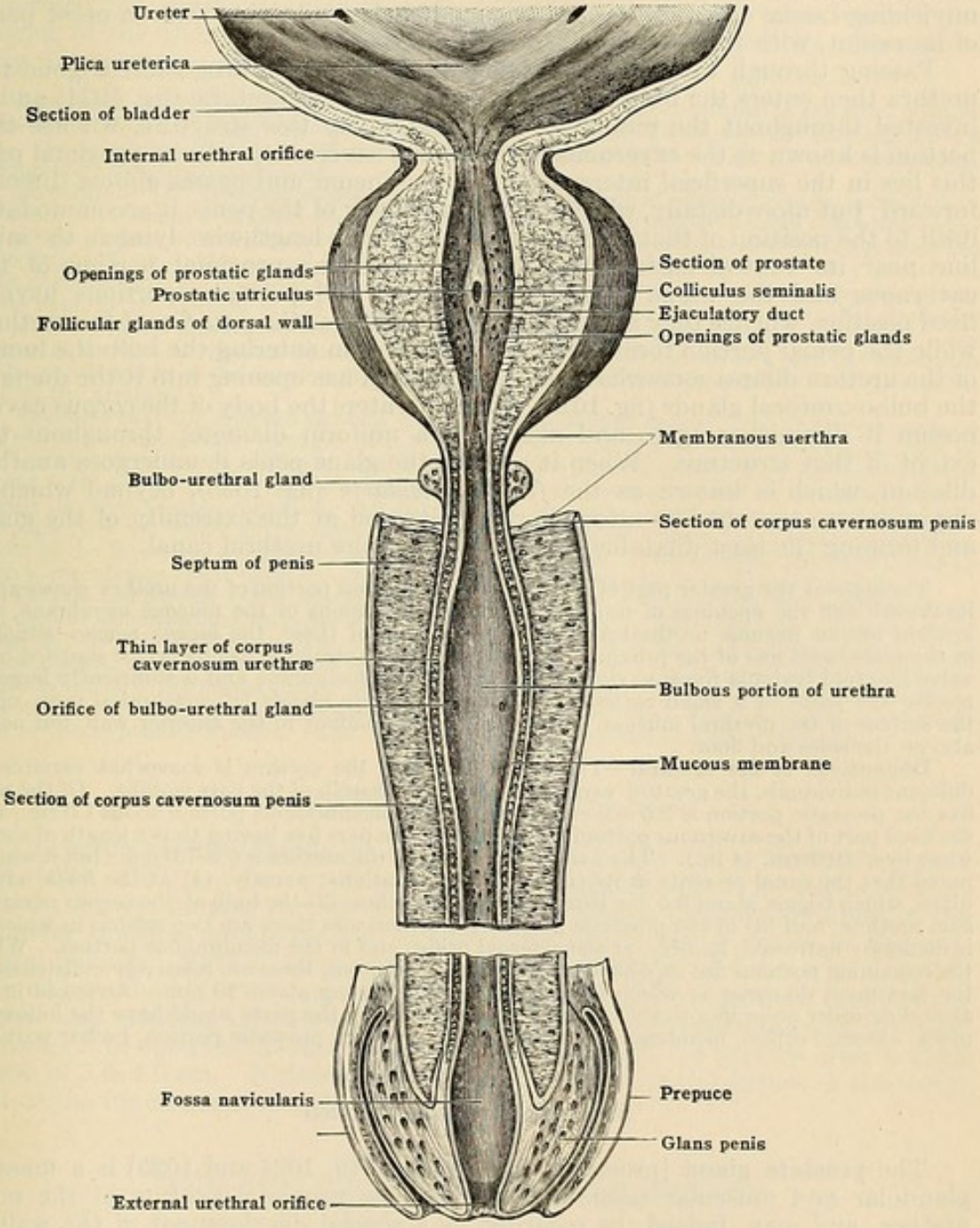

widening of the lumen of the urethra in this part of its course. At the centre of the colliculus there is an elongated opening of a pouch of varying depth, termed the *utriculus prostaticus* ("uterus masculinus"), which corresponds to the lower part of the vagina in the female (see p. 1279). Situated one on either side of this are the much smaller openings of the *ejaculatory ducts*. Owing to the prominence formed by the colliculus a section of the urethra in this region is somewhat ∩-shaped, and at the bottom of the furrows on either side of the median eleva-

tion are the minute openings of the numerous ducts of the prostate gland (fig. 1025).

On its emergence from the prostate gland the urethra at once penetrates the deep layer of fascia of the urogenital trigone and enters the deep perineal interspace, this portion of its course being known as the **membranous portion** [pars membranacea]. Its direction is now downward and slightly forward, curving beneath the subpubic ligament, from which it is separated by a plexus of veins and by the fibres of the sphincter urethræ membranaceæ, which form an almost complete investment for it. The lumen of this part of the urethra is much narrower than that of the prostatic portion, and since it traverses the rather unyielding fasciæ of the urogenital trigone it is less dilatable than in other parts of its extent, with the exception of the external orifice.

Passing through the superficial layer of fascia of the urogenital trigone the urethra then enters the bulb of the corpus cavernosum urethræ (fig. 1024) and is invested throughout the remainder of its extent by this structure, whence this portion is known as the **cavernous portion** [pars cavernosa]. In its proximal part this lies in the superficial interspace of the perineum and passes almost directly forward; but more distally, where it enters the body of the penis, it accommodates itself to the position of that organ, which it traverses lengthwise, lying in the midline near its ventral surface (fig. 1022). Thus the proximal portion of the cavernous and the whole of the membranous and prostatic portions have a fixed position, whence they are sometimes associated as the *pars fixa* of the urethra, while the penial portion forms the *pars mobilis*. On entering the bulb the lumen of the urethra dilates somewhat and in this region has opening into it the ducts of the bulbo-urethral glands (fig. 1025), but as it enters the body of the corpus cavernosum it diminishes again and maintains a uniform diameter throughout the extent of that structure. When it reaches the glans penis it undergoes another dilation, which is known as the *fossa navicularis* (fig. 1025), beyond which it diminishes to the slit-like *external orifice*, situated at the extremity of the glans and forming the least dilatable portion of the entire urethral canal.

Throughout the greater part of its extent the cavernous portion of the urethra shows upon its dorsal wall the openings of numerous tubular depressions of the mucous membrane, the *urethral lacunæ* [lacunæ urethrales (Morgagnii)]. One of these, the *lacuna magna*, situated in the mid-dorsal line of the proximal part of the fossa navicularis, has its orifice guarded by a valve-like fold [valvula fossæ navicularis] of the mucous membrane and is sufficiently large to receive the point of a small catheter. Numerous minute glands [gl. urethrales] open upon the surface of the urethral mucosa. They are most abundant in the anterior wall, but occur also on the sides and floor.

Dimensions of the urethra.—The entire length of the urethra is somewhat variable in different individuals, the greatest variation being in the length of the pars mobilis. Of the pars fixa the prostatic portion is 2.5–3.0 cm. in length, the membranous portion about 1.0 cm., and the fixed part of the cavernous portion 6.5 cm., the entire pars fixa having thus a length of somewhat over 10.0 cm. (4 in.). The average diameter of the urethra is 5.0–7.0 mm., but it will be noted that the canal presents in its course three dilatations; namely, (1) at the fossa navicularis, which begins about 0.5 cm. from the external orifice; (2) the bulb of the corpus cavernosum urethræ; and (3) in the prostatic portion. Furthermore there are two regions in which it is distinctly narrowed; namely, at the external orifice and in the membranous portion. While the remaining portions are capable of considerable distention, these are relatively indistensible, the maximum diameter to which they may be dilated being about 10 mm. Arranged in an ascending order according to their capability for distention the parts would have the following order: external orifice, membranous portion, penial portion, prostatic portion, bulbar portion.

5. The Prostate Gland

The **prostate gland** [prostata] (figs. 1013, 1019, 1024 and 1025) is a mass of glandular and muscular tissue surrounding the proximal portion of the male urethra, and may, indeed, be regarded as a special development of the wall of this portion of the canal. It is a more or less flattened conical structure whose *base* [basis prostatæ] is in contact with the lower surface of the bladder and the *apex* [apex prostatæ] with the deep fascia of the urogenital trigone. Its *anterior surface* [facies anterior] is in relation with the symphysis pubis, from which it is separated by the pudendal plexus of veins, and *posteriorly* [facies posterior] it is separated from the lower portion of the rectum only by some loose connective tissue; laterally it is in relation with the levatores ani, receiving an investment from the endopelvic fascia covering these.

The *urethra* enters the base of the gland near its anterior border and traverses it almost vertically, so that the greater portion of the gland is posterior to the canal. On the posterior surface of the gland is a more or less distinct median vertical groove, which serves to separate the lateral portion as the *lateral lobes* [lobus dexter et sinister], although the demarcation is merely a superficial one. The groove terminates above in a well-marked notch on the posterior border of the base, and immediately in front of this there is a deep funnel-shaped depression of the surface, which receives the ejaculatory ducts. Beginning at this depression two grooves pass forward and slightly lateralward across the surface of the base, marking off a more or less pronounced median elevation, which constitutes what is termed the *middle lobe* [lobus medius] (fig. 1024); since this lies beneath the trigone of the bladder behind the internal orifice of the urethra its enlargement may produce more or less occlusion of the latter.

Dimensions.—The longest *axis* of the prostate, which is almost vertical in the erect posture measures 2.5–3.0 cm., the *transverse* diameter at the base is 4.0–4.5 cm. and the *thickness* 2.0–2.5 cm. Its *weight* is normally 20–25 grms. but in old age it may be double that, its dimensions having correspondingly increased.

Structure.—The prostate consists of some 15–30 branched tubular glands imbedded in a matrix of connective tissue, containing a large amount of non-striped muscle tissue and forming at the surface of the gland a strong fibro-muscular capsule from which prolongations are contributed to the pubo-vesical ligaments and muscles. The glands, which vary greatly in their development, are outgrowths from the mucous membrane of the urethra, into which their ducts open at the bottom of the grooves that lie lateral to the colliculus seminalis; similarly, the matrix with its muscle tissue is evidently the modified muscular coat of the urethra. Consequently there is no distinct demarcation between the wall of the urethra and the substance of the gland, and from the developmental standpoint the gland is to be regarded as the modified wall of the urethra.

The facts that the prostate shows a special development at puberty and undergoes more or less extensive degenerative changes with the cessation of the reproductive function, as seen in old age and in castrates, indicate that it is associated physiologically with the reproductive organs. Its secretion is a thin alkaline fluid, which may contain round or elongate, concentrically layered bodies, measuring 0.3–0.5 mm. in diameter and known as *amyloid bodies*, although they are really albuminous in chemical composition. They are constantly found in adults in the lumina of the glands and may become calcified. The secretion has been found to have a stimulating effect upon the spermatozoa, and this may be its principal function.

Vessels and nerves.—The *arterial* supply of the prostate is derived from the inferior vesical and middle hæmorrhoidal branches of the hypogastric artery. The *veins* form a rich prostatic plexus in the immediate vicinity of the gland, this being part of the general plexus at the base of the bladder and communicating posteriorly with the seminal plexus and anteriorly with the pudendal plexus. It drains finally into the hypogastric vein. The *lymphatics* are very abundant and form a network on the posterior surface of the gland from which four principal vessels pass to the hypogastric nodes. The *nerves* are derived from the hypogastric plexus.

6. The Bulbo-urethral Glands

The **bulbo-urethral glands** [gl. bulbo-urethralis (Cowperi)] or **Cowper's glands** (figs. 1024, 1025) are two small tubulo-alveolar glands which lie one on either side of the membranous portion of the urethra, imbedded among the fibres of the sphincter urethræ membranaceæ, between the two layers of fascia of the urogenital trigone. Each is a rounded body with a diameter of 4.0–9.0 mm. and is drained by a duct [ductus excretorius] which perforates the superficial fascia of the trigone and, entering the substance of the bulb of the corpus cavernosum urethræ, traverses it to open on the floor of the bulbar portion of the urethra after a total course of 3.0–4.0 cm. Nothing is definitely known as to the nature of the secretion or the functions of the glands.

THE FEMALE REPRODUCTIVE ORGANS

The organs of reproduction in the female consist of (1) the *ovaries*, the essential organs of reproduction; (2) the *tubæ uterinæ* (Fallopian tubes), which serve as ducts for the conveyance of the ova to (3) the *uterus*, in which the embryo normally undergoes its development; (4) the *vagina*, a canal by which the uterus is placed in communication with the exterior; and (5) the *external genitalia*. In addition it will be necessary to consider here the female *urethra*, although it differs from that of the male in that it serves merely as a passage for the contents of the bladder and does not transmit the reproductive elements.

FIG. 1026.—THE FEMALE ORGANS OF GENERATION. (Modified from Sappey.)
(Vagina divided and laid open behind.)

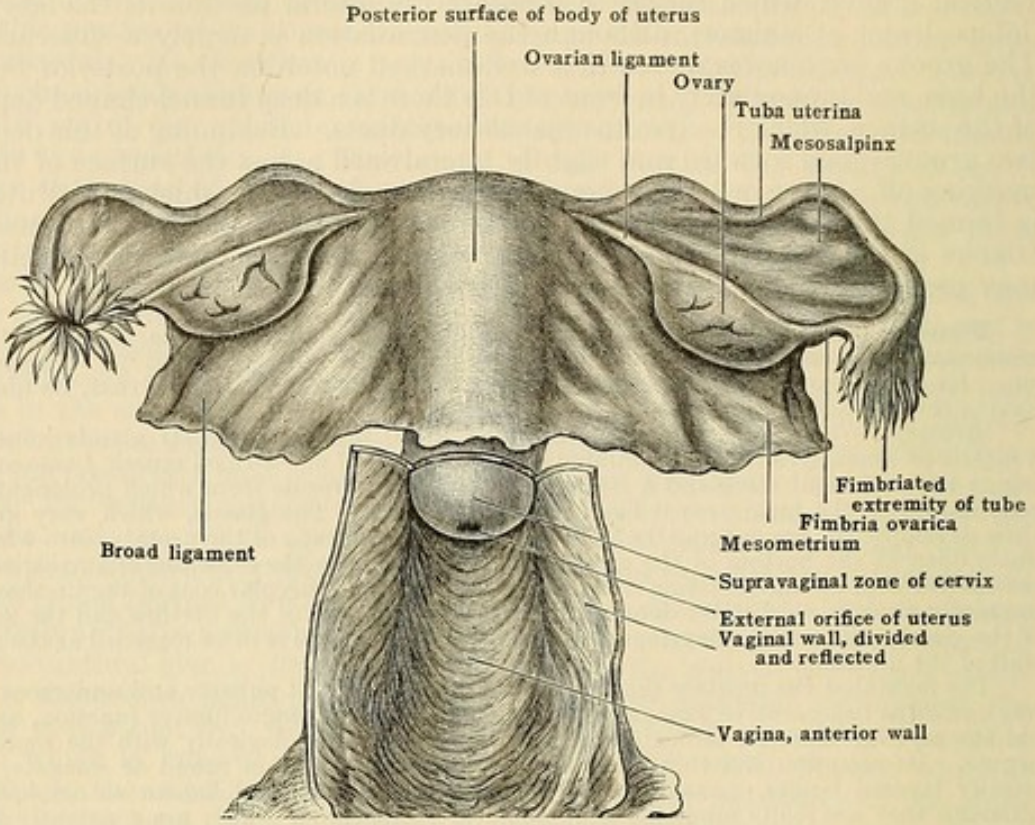

IG. 1027.—DIAGRAMMATIC SAGITTAL SECTION OF THE BROAD LIGAMENT.

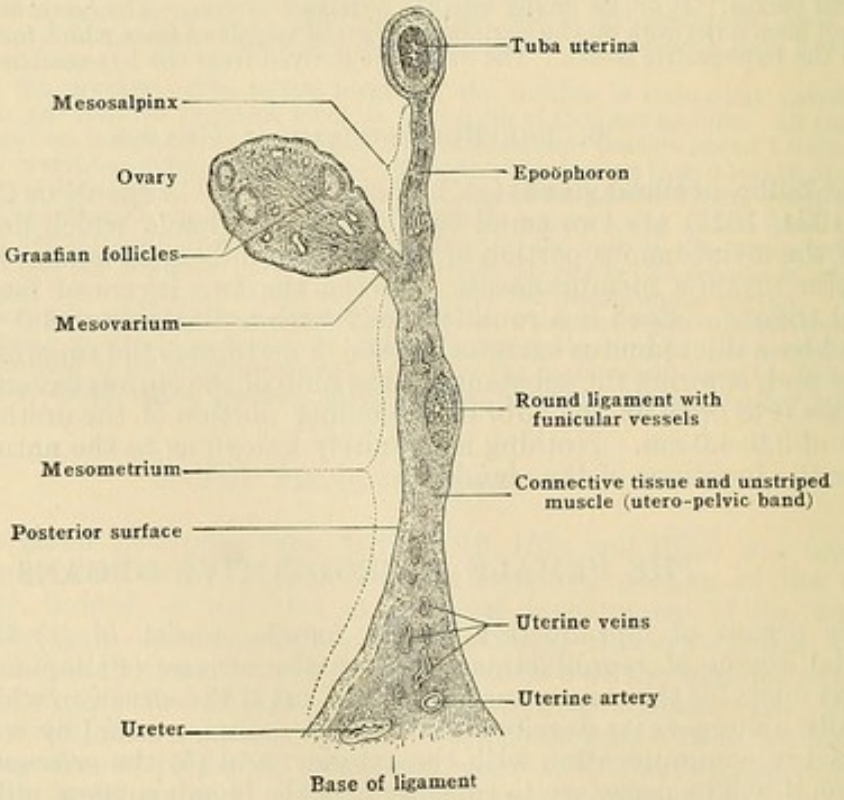

Broad ligament.—The first three of these structures are entirely contained within the true pelvis and are associated with a transverse fold of peritoneum which rises from the floor of the pelvic cavity between the bladder and the rectum, incompletely dividing the cavity into an anterior and a posterior compartment. It is known as the *broad ligament* of the uterus [lig. latum uteri] (fig. 1026). The broad ligament appears to extend laterally from the sides of the uterus to the lateral walls and floor of the pelvis, although in reality it extends across the pelvic cavity from side to side and encloses the uterus between the two layers of which it is composed. It is attached to the floor of the pelvis below, where the two layers are reflected, the one upon the anterior wall of the pelvis and the posterior and superior surfaces of the bladder, and the other posteriorly over the floor of the pelvis to the posterior pelvic wall and the rectum, forming the anterior wall of a deep depression between the rectum and uterus, known as the *recto-uterine pouch (of Douglas)* [excavatio rectouterina (cavum Douglasi)] (fig. 1035). Its lower border also passes upward upon the sides of the pelvis, resting upon the pelvic fascia, but its lateral borders are free, extending between the lateral wall of the pelvis and the extremity of the tuba uterina on each side and forming what are termed the *infundibulo-pelvic ligaments.* The upper border is also free and contains the tuba uterina on either side, and the fundus of the uterus in the midline (fig. 1027).

FIG. 1028.—CROSS-SECTIONS OF THE BODY ILLUSTRATING THE DEVELOPMENT OF THE FEMALE UROGENITAL SYSTEM. A, AT HIGHER LEVEL. B, AT LOWER LEVEL.

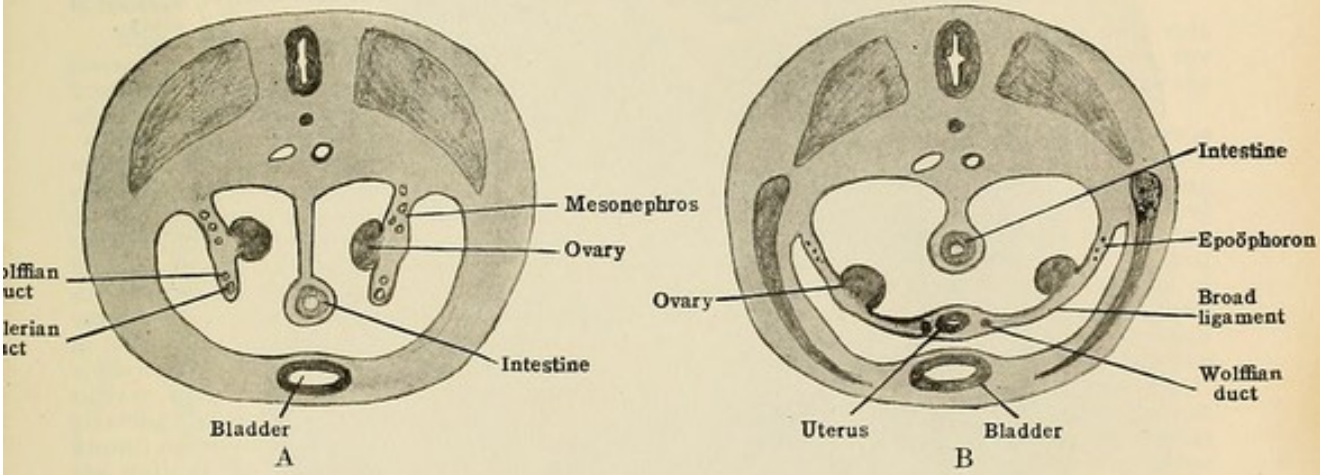

Attached to the posterior layer of the broad ligament a little below its upper border and therefore projecting into the posterior compartment of the pelvis, there is a horizontal shelf, termed the **mesovarium,** since it has the ovary attached to its free edge (fig. 1027). The portion of the broad ligament above this is known as the **mesosalpinx** (salpinx=tuba), while that below is termed the **mesometrium** (metra=uterus). The remaining structures that occur between the two layers of the broad ligament will be described with the organs with which they are associated, but it is to be noted that the ligament in its upper part is broader than the transverse diameter of the pelvic cavity and its sides are accordingly folded back upon the lateral walls of the cavity, following the course of the tuba uterina.

The broad ligament is the adult representative of the fold of peritoneum which encloses the embryonic excretory organ, the mesonephros. This is for a time a voluminous organ, projecting under cover of the peritoneum from the dorsal wall of the abdomen and bearing upon its medial wall a thickening, the **genital ridge** (fig. 1028 A), from which the reproductive gland develops. In the free edge of the peritoneum enclosing it two ducts occur, the **Wolffian duct,** which is the duct of the excretory organ and becomes the ductus deferens of the male, and the **Müllerian duct.** With the progress of development the two Müllerian ducts fuse in the lower portions of their course to form the uterus and vagina (prostatic utriculus of the male), while in their upper parts they remain separate and form the tubæ uterinæ. By this fusion the two peritoneal folds are brought into continuity at their edges, and (the mesonephros degenerating on the formation of the permanent kidney) constitute the broad ligament (fig. 1028 B). This structure therefore contains between its two layers the uterus and the remains of the mesonephros, and has the ovary attached to its posterior surface. In the male what corresponds to the broad ligament fuses with the peritoneum covering the posterior surface of the bladder.

1. The Ovaries

Form and position.—The *ovaries* [ovaria] are two whitish organs, situated one on either side of the pelvic cavity. Each has somewhat the shape of an almond (fig. 1026). It is attached by one of its edges [margo mesovaricus] to the border of the mesovarium, and since it is along this line of attachment that the vascular and nerve supply enters the substance of the organ, this border is spoken of as the *hilus* [hilus ovarii]. The opposite border is free [margo liber]. The larger rounded end is directed toward the free extremity of the tuba uterina and hence is known as the *tubal extremity* [extremitas tubaria], while the other, the *uterine extremity* [extremitas uterina], is directed toward the uterus; the two surfaces, owing to their topographic relations, are known as the *lateral* and *medial surfaces* [facies medialis et lateralis].

Fig. 1029.—The Female Pelvic Organs Viewed from Above. (Spalteholz.)

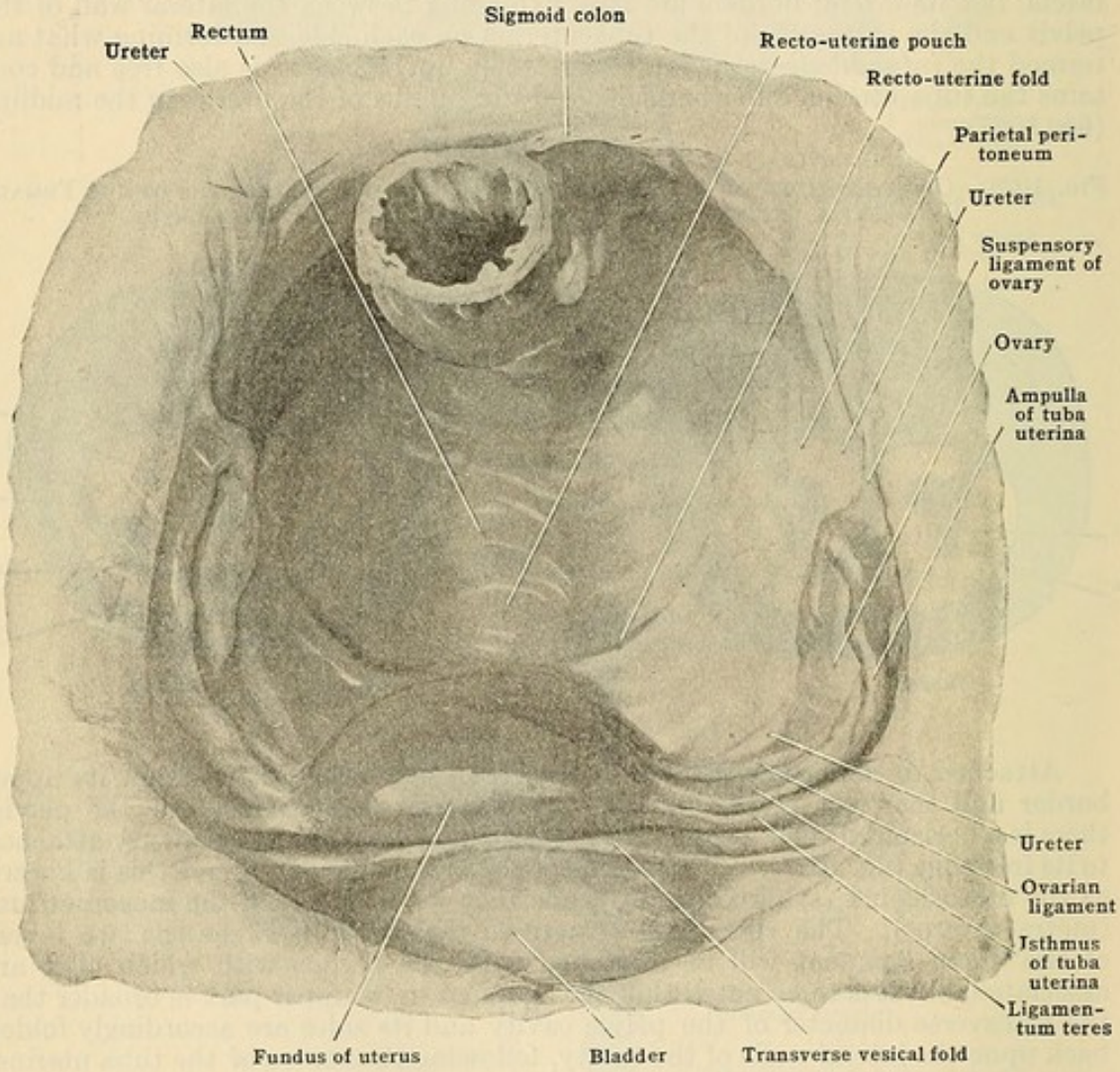

The exact position of the ovary in the pelvis is subject to some variation, but typically it lies almost in a sagittal plane (fig. 1029) against the lateral wall of the pelvis, resting in a distinct depression, the *fossa ovarica*, lined by peritoneum and bounded above by the external iliac vessels and behind by the ureter and uterine artery, while beneath its floor are the obturator vessels and nerve. The long axis of the ovary is almost vertical when the body is erect, the tubal pole being upward; the mesovarial border is directed forward and laterally, its free border dorsally and medially while its surfaces look almost laterally and medially.

Frequently, however, the uterus is displaced to one side, dragging the uterine extremity of the opposite ovary (by the attachment of the ovarian ligament) toward the mid-plane. The long axis of the ovary thus becomes oblique, approaching more or less the horizontal. The ascending portion of the tuba uterina rests upon its mesovarial border and the fimbriated mouth

of the tube is in contact with its medial surface. When enlarged the ovary may be felt through lateral wall of the vagina and, better, through that of the rectum; and its position with regard to the surface may be indicated by a point midway between the anterior superior spine of the ilium and the symphysis pubis or the opposite pubic tubercle.

The position assumed by the ovary is due to its attachment to the edge of the mesovarium and to the upper portion of the broad ligament being broader than the diameter of the pelvis, so that it is folded back upon the lateral walls of the cavity. In addition to its attachment to the broad ligament through the mesovarium, the ovary is also connected to the side of the uterus by the *ovarian ligament* [lig. ovarii proprium] (fig. 1026), a band of connective tissue with which numerous non-striped muscle fibres are intermingled. It lies between the two layers of the broad ligament, on the boundary line between the mesosalpinx and the mesometrium, and extends from the uterine pole of the ovary to the side of the uterus. Here it is attached just below the origin of the tuba uterina and above the point of attachment of the round ligament of the uterus, with which it is primarily continuous. Another ligament, termed the *suspensory ligament* of the ovary (figs. 1029, 1034), extends laterally between the two layers of the broad ligament from the tubal extremity of the ovary to the pelvic walls, forming the lateral portion of the lower boundary of the mesosalpinx. It is formed by the vessels and nerves (internal spermatic) passing to and from the ovary, and from the point where it meets the lateral pelvic wall it may be traced upward for some distance upon the posterior wall of the abdomen, behind the peritoneum, which it elevates into a more or less distinct fold, whose lateral wall on the right side becomes continuous above with the peritoneum lining the subcœcal fossa.

Size.—The *size* of the ovary varies considerably, that of the right side being as a rule somewhat larger than that of the left. The length may be anywhere from 2.5 cm. to 5.0 cm., the breadth about half the length and the thickness half the breadth. Its average weight in the adult is from 6.0 to 8.0 grms., but in old age it may fall to 2.0 grms.

Structure.—The ovary is covered by a layer of columnar epithelium which is continuous with the peritoneal epithelium along the line of the attachment of the mesovarium; the ovary consequently is not covered by peritoneum, but is rather to be regarded as a local thickening of the peritoneum. Its substance is a network of connective tissue, in which non-striped muscle fibres also occur, and is known as the *stroma*. The more central portions of this are largely occupied by blood-vessels but in the cortical portions are multitudes of immature ova, surrounded by their follicle cells [folliculi oophori primarii]; and also numbers of cavities of various sizes, lined with follicle cells and filled with fluid, each containing an ovum [ovulum] in a more or less advanced stage toward maturity. These are the *Graafian follicles* [folliculi oophori vesiculosi (Graafi)], and as they ripen they increase in diameter and approach the surface, upon which they may form marked prominences. When mature the follicles burst, allowing the escape of the ovum, scars being thus formed upon the surface of the ovary that are known as *corpora albicantia*. If, however, the ovum becomes fertilized and pregnancy results the walls of the follicle undergo a remarkable development, forming what is known as a *corpus luteum*.

Epoöphoron and paroöphoron.—Closely associated with the ovaries are two rudimentary organs situated between the layers of the mesosalpinx and representing remains of the mesonephros of the embryo. The larger of these is the *epoöphoron* (fig. 1030). It consists of a longitudinal duct [ductus epoöphori longitudinalis (Gartneri)], lying parallel with the tuba uterina and closed at either extremity, and 10–15 transverse ducts [ductuli transversi], which open into the longitudinal duct. It is the remains of the upper or reproductive portion of the mesonephros and therefore is the homologue of the epididymis of the male. In addition there is frequently to be found in the neighbourhood of the epoöphoron and close to the mouth of the tuba uterina one or more stalked, oval cysts, the *appendices vesiculosi* (*hydatids of Morgagni*), which may reach the size of a small pea.

The other organ is the *paroöphoron;* it is much smaller than the epoöphoron and usually disappears before adult life, but when present consists of a small group of coiled tubules, more or less distinct, representing a portion of the excretory portion of the mesonephros. Its equivalent in the male is therefore the paradidymis.

Vessels and nerves.—The chief *artery* is the ovarian, which together with the ovarian veins and lymphatics passes to the ovary in the suspensory ligament. An additional blood supply is furnished by the ovarian branch of the uterine artery. The *veins* follow the course of the arteries. As they emerge from the hilus they form a well-developed plexus (*pampiniform plexus*) between the layers of the mesovarium. Unstriped muscle fibres occur in the meshes of the plexus and the whole structure has much the appearance of erectile tissue. The *lymphatics* accompany the blood-vessels and terminate in the lumbar nodes. *Nerves* pass to the ovary with the ovarian artery from the renal and aortic sympathetic plexus.

2. The Tubæ Uterinæ

The **tubæ uterinæ** or **Fallopian tubes** (figs. 1026, 1030) serve to convey the ova to the uterus. They are two trumpet-shaped tubes, structurally continuous

with the superior angles of the uterus and running in the superior border of the broad ligament (mesosalpinx) to come into relation with the ovaries at their distal extremities. Each tube opens proximally into the uterine cavity and distally communicates with the pelvic portion of the peritoneal cavity by a funnel-shaped mouth, the **ostium abdominale,** which under normal conditions is closely applied to the surface of the ovary, so as to receive the ova as they are expelled from the Graafian follicles. Each tube is from 7 to 14 cm. in length and consists of a narrow straight portion, the **isthmus,** immediately adjoining the uterus, followed by a broader, more or less flexuous portion, the *ampulla,* which terminates in a funnel-like dilatation, the **infundibulum.** The margins of the infundibulum are fringed by numerous diverging processes, the **fimbria,** one of which, the **fimbria ovarica,** is much longer than the rest and extends along the free border of the mesosalpinx (the infundibulo-pelvic ligament) to reach the tubal pole of the ovary.

The course of each tube is at first almost horizontally laterally and backward from its attachment to the uterus, until it reaches the lateral wall of the pelvis and there comes into relation with the uterine extremity of the ovary (figs. 1029, 1034). It then bends at right angles and passes almost vertically upward

Fig. 1030.—The Broad Ligament and its Contents, seen from the Front. (After Sappey.)

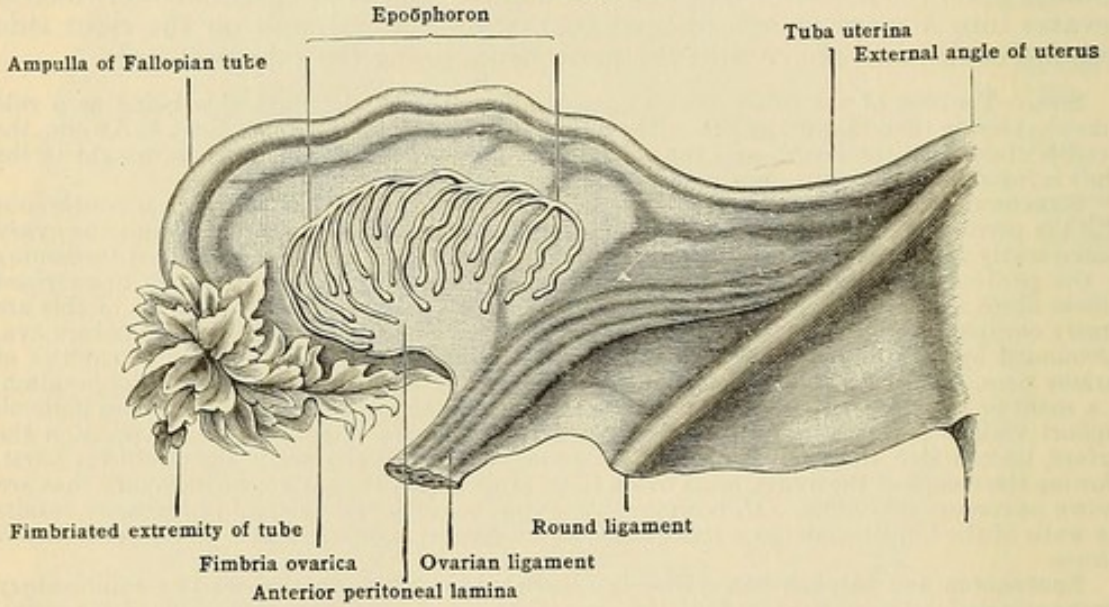

along the mesovarial border of the ovary until it reaches its tubal extremity, where it curves downward and backward so that the mouth of the infundibulum and the fimbriæ rest upon the medial surface of the ovary.

Structure.—The tubæ occupy the upper free edge of the mesosalpinx and are therefore enclosed within a *peritoneal covering* [tunica serosa] except a small strip along their lower surface (fig. 1027), and hence a rupture of one of them may lead to the escape of its contents either into the peritoneal cavity or into the subserous areolar tissue between the two layers of the broad ligament. At the margins of the infundibulum and the borders of its fimbriæ the peritoneal epithelium becomes directly continuous with the mucous membrane lining the interior of the tube. The *subserous areolar* tissue [tunica adventitia] in the immediate vicinity of the tube is lax and contains the blood-vessels and nerves by which the tube is supplied; it forms a loose connection between the peritoneum and the *muscular wall* [tunica muscularis] of the tube. This consists of two layers of non-striped muscle fibres, an outer longitudinal and an inner circular one, and reaches its greatest development toward the uterine end of the tube. The inner layer [tunica mucosa] of the tube is lined by a columnar ciliated epithelium which is raised into numerous folds, simple in the region of the isthmus, but becoming higher and more complex in the ampulla, where, in transverse sections, the lumen seems to have a labyrinthine form. The beat of the cilia is toward the uterus.

Vessels and nerves.—The *arteries* of the tubæ are derived from the ovarian and uterine, each of which gives off a tubal branch, which pass between the two layers of the mesosalpinx, the one medially and the other laterally, and anastomose to form a single stem. The *veins* accompany the arteries. The *lymphatics* accompany those from the ovary and fundus uteri and terminate chiefly in the lumbar nodes. The *nerves* of the ampulla are given off from the branches passing to the ovary, while those of the isthmus come from the uterine branches.

3. The Uterus

The **uterus** (fig. 1031) is an unpaired organ, situated between the two layers of the broad ligament and communicating above with the tubæ uterinæ and below with the vagina. It is pyriform in outline, although flattened antero-posteriorly (fig. 1032) and it is divided into two main portions, the **body** [corpus uteri] and the **cervix** by a transverse constriction, the **isthmus.**

The **body** is the portion above the isthmus and in adults, especially in women

Fig. 1031.—The Posterior Surface of the Uterus. (After Sappey.)

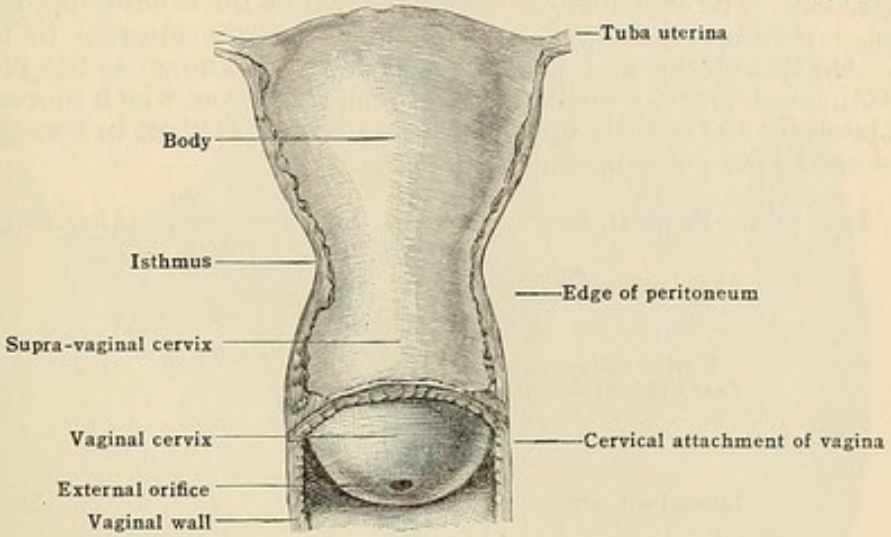

who have borne children, is much larger than the cervix, although the reverse is the case in children. In young girls the two parts are about equal in size. The **anterior** or *vesical surface* [facies vesicalis] is almost flat (fig. 1032), while the **posterior** or *intestinal surface* [facies intestinalis] is distinctly convex, the two surfaces meeting in well-marked rounded borders, at the upper extremities of which the tubæ uterinæ are attached. The superior border which extends between the points of attachment of the two tubæ is thick and rounded and forms

Fig. 1032.—Sagittal Section of the Virgin Uterus. (After Sappey.)

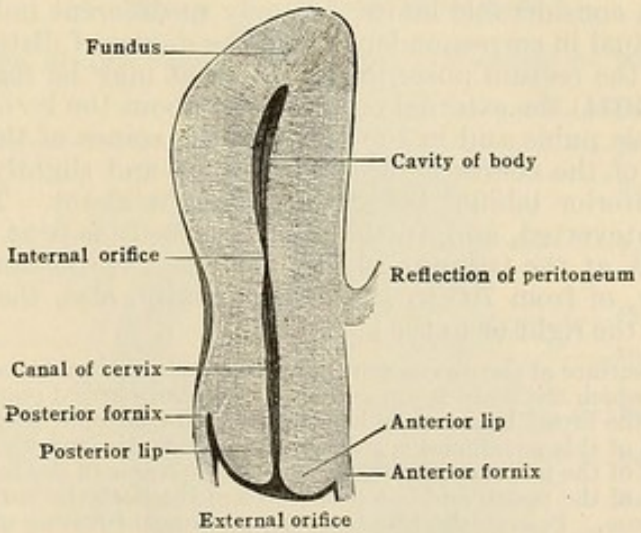

what is termed the *fundus uteri*. The *cavity* [cavum uteri] of the body is reduced to a fissure by the antero-posterior flattening of the walls and has a triangular form (fig. 1033), broad above where it communicates on either side with the cavity of a tuba uterina and narrow below where it communicates with the cavity of the cervix, this communication, which corresponds in position with the isthmus, forming what is known as the *internal orifice* [orificium internum] (internal os uteri).

The **cervix** is more cylindrical in form, though slightly expanded in the middle

of its length, and is divided into a *supravaginal* [portio supravaginalis] and a *vaginal portion* [portio vaginalis] by the attachment to it of the vagina (fig. 1031). The line of this attachment is oblique, about one-third of the anterior surface of the cervix and about one-half of the posterior surface belonging to the vaginal portion. At the lower extremity of the cervix is the *external orifice* [orificium externum] (external os uteri), which is round or oval before parturition has taken place and is bounded by two prominent *labia*, anterior and posterior, the anterior one [labium anterius] being shorter and thicker than the posterior [labium posterius] and reaching a lower level (fig. 1032). In women who have borne children the external orifice assumes a more slit-like form and the labia become notched and irregular. The cavity of the cervix, known as the *canal of the cervix* [canalis cervicis], is fusiform in shape, and extends from the internal to the external orifice. On its anterior and posterior walls are folds known as the *plicæ palmatæ* (fig. 1033), consisting of a median longitudinal ridge from which shorter elevations extend laterally and slightly upward; these are most distinct in young individuals and are apt to become obliterated by parturition.

FIG. 1033.—FRONTAL SECTION OF THE VIRGIN UTERUS. (After Sappey.)

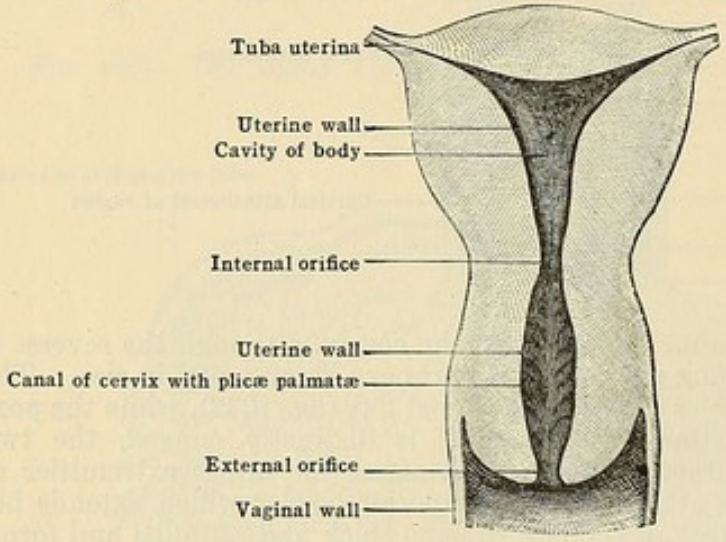

Position and relations.—The direction of the axis of the uterus is apparently variable within considerable limits, not only in different individuals, but also in any one individual in correspondence with the degree of distention of the bladder anteriorly and the rectum posteriorly. In what may be regarded as the typical condition (fig. 1034) the external orifice lies at about the level of the upper border of the symphysis pubis and in the plane of the spines of the ischia. From this point the axis of the cervix is directed upward and slightly forward, the lower level of the anterior labium being thus brought about. The entire uterus is, accordingly, anteverted, and, furthermore, the body is bent forward (anteflexed) upon the cervix at the isthmus, the axis of the two portions making an angle, open anteriorly, of from 70° to 100°. Frequently, also, the body is slightly inclined either to the right or to the left.

The anterior surface of the uterus rests upon the upper and posterior surfaces of the bladder (fig. 1029), from which the body is separated by the utero-vesical pouch of peritoneum. The anterior layer of the broad ligament as it passes over the anterior surface of the uterus forms the posterior wall of this pouch and is reflected forward to the superior surface of the bladder at about the level of the isthmus (fig. 1034), so that the whole of the anterior wall of the cervix is below the floor of the pouch and is separated from the posterior surface of the bladder only by connective tissue. Posteriorly, however, the peritoneal covering of the uterus, which here forms the anterior wall of the recto-uterine pouch, extends down as far as the uppermost portion of the vagina and consequently invests the entire surface of the uterus, whose convex posterior wall is thus separated from the rectum by the recto-uterine pouch (figs. 1029, 1035). Coils of the small intestine rest upon the posterior surface of the body and may also be interposed between the cervix and the rectum. An important relation is that of the ureters to the cervix, these ducts, as they pass to the bladder, running parallel with the cervix at a distance of from 8 to 12 mm. from it.

Ligaments.—The *broad ligament* between whose layers the uterus is situated has already been described (p. 1267). In addition there is attached to each border

FIG. 1034—MID-SAGITTAL SECTION OF THE FEMALE PELVIS (Spalteholz.)

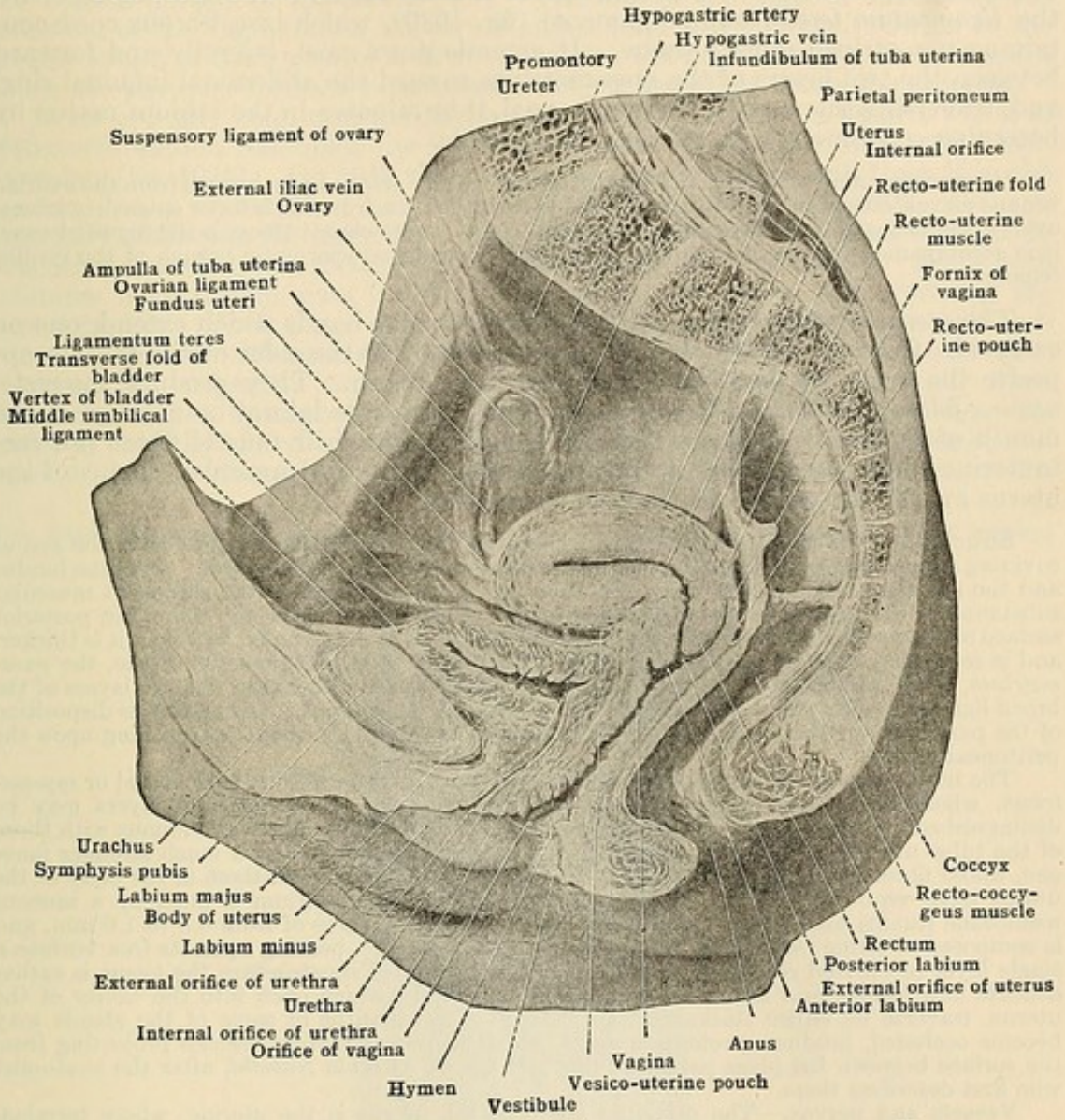

FIG. 1035.—SECTION OF THE PELVIS SHOWING THE LIGAMENTS OF THE UTERUS.

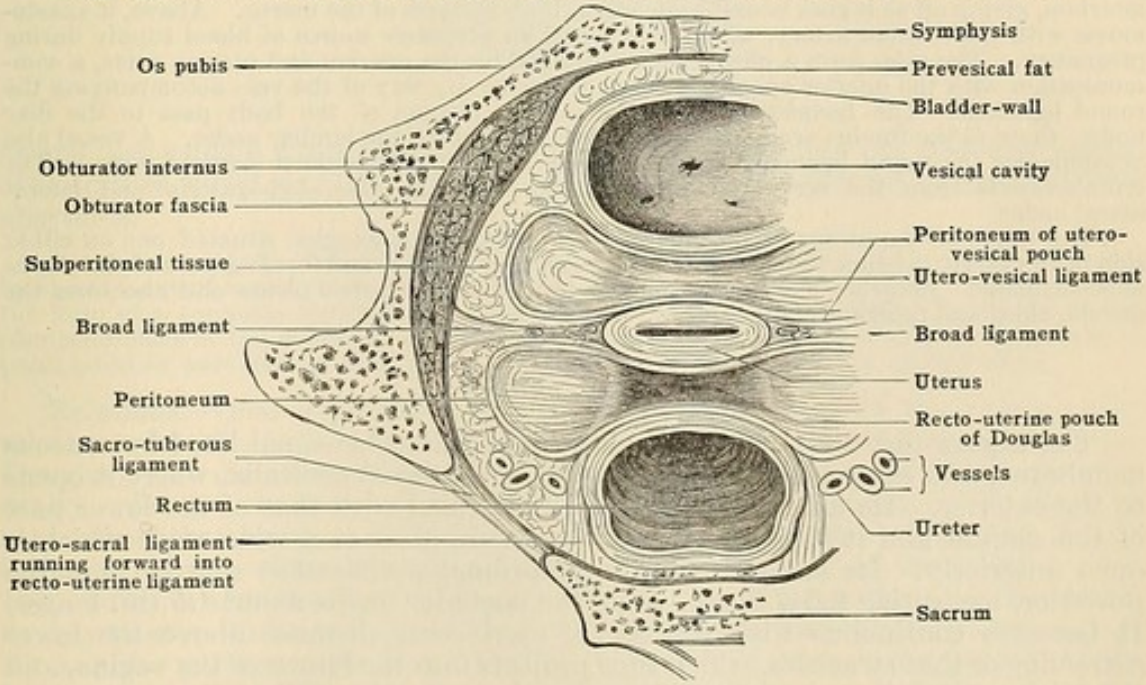

of the uterus, immediately below the point of attachment of the ovarian ligament, the *ligamentum teres* (round ligament) (fig. 1030), which is a fibrous cord containing non-striped muscle tissue. It extends downward, laterally and forward between the two layers of the mesometrium toward the abdominal inguinal ring, and, traversing this and the inguinal canal, it terminates in the labium majus by becoming continuous with its connective tissue.

It is accompanied by a funicular branch of the ovarian artery and a branch from the ovarian venous plexus, and in the lower part of its course by a branch from the inferior epigastric artery, over which it passes as it enters the abdominal ring. In its course through the inguinal canal it is accompanied by the ilio-inguinal nerve and the external spermatic branch of the genito-femoral.

The *utero-sacral ligaments* are flat fibro-muscular bands which extend, one on each side, from the upper part of the cervix uteri to the sides of the sacrum opposite the lower border of the sacro-iliac articulation. They produce the *recto-uterine folds* (fig. 1029) of peritoneum, which form the lateral boundaries of the mouth of the recto-uterine pouch (of Douglas) and their muscle fibres [m. rectouterinus] are continuous at one extremity with the muscular tissue of the uterus and at the other with that of the rectum.

Structure.—The portion of the broad ligament that invests the uterus forms the serous covering [tunica serosa] of the organ and is sometimes termed the *perimetrium*. Over the fundus and the greater portion of the body it is thin and firmly adherent to the subjacent muscular substance of the uterus, so that it cannot readily be separated from it. Over the posterior surface of the cervix and the lower part of the anterior surface of the body, however, it is thicker, and is separated from the muscular substance by a layer of loose connective tissue, the *parametrium*, which also extends upward along the sides of the uterus between the two layers of the broad ligament, with whose subserous areolar tissue it is continuous. Owing to this disposition of the parametrium the whole of the cervix may be amputated without encroaching upon the peritoneal cavity.

The main mass of the uterus is formed by the muscle tissue [tunica muscularis] or *myometrium*, whose fibres have a very complicated arrangement. Two principal layers may be distinguished, an outer, weak one, composed partly of longitudinal fibres continuous with those of the tubæ uterinæ, and of the round and utero-sacral ligaments, and a much stronger inner one, whose fibres run in various directions and have intermingled with them in the body of the uterus large venous plexuses. The inner surface of the myometrium is lined by a mucous membrane [tunica mucosa] or *endometrium*, which has a thickness of from 0.5 to 1.0 mm. and is composed of tissue resembling embryonic connective tissue, bearing upon its free surface a single layer of ciliated columnar epithelium. On account of its structure the tissue is rather delicate and friable, and numerous simple tubular glands, which open into the cavity of the uterus, traverse its entire thickness. In the cervix the mouths of some of the glands may become occluded, producing retention cysts, which appear as minute vesicles projecting from the surface between the plicæ palmatæ; they are known as *ovula Nabothi*, after the anatomist who first described them.

Vessels and nerves.—The principal *artery* of the uterus is the uterine, whose terminal portion ascends along the lateral border of the uterus in a tortuous course through the parametrium, giving off as it goes lateral branches to both surfaces of the uterus. Above, it anastomoses with the ovarian artery, which thus forms an accessory source of blood supply during pregnancy. The *veins* form a plexus that is drained by the ovarian and uterine veins, a communication with the inferior epigastric being also made by way of the vein accompanying the round ligament. The *lymphatics* from the greater portion of the body pass to the iliac nodes: those of the fundus accompany the ovarian vessels to the lumbar nodes. A vessel also accompanies the round ligament to terminate in one of the superficial inguinal nodes. The lymph-vessels from the cervix terminate in the external iliac, hypogastric and lateral sacral nodes.

The *nerves* of the uterus pass to it from two sympathetic ganglia, situated one on either side of the cervix, whence they are termed the cervical ganglia, and forming part of the *plexus utero-vaginalis*. Branches pass to the ganglia from the hypogastric plexus and also from the second, third and fourth sacral nerves.

4. The Vagina

The **vagina** (fig. 1034) is a muscular, highly dilatable canal lined by mucous membrane, and extends from the uterus to the external genitalia, where it opens to the exterior. Its long axis is practically parallel with that of the lower part of the sacrum and it therefore meets the cervix uteri at a wide angle which is open anteriorly. Its anterior wall is, accordingly, somewhat shorter than the posterior, measuring 6.0–7.0 cm., while the posterior one is about 1.5 cm. longer. It becomes continuous with the cervix uteri some distance above the lower extremity of that structure, which thus projects into the lumen of the vagina, and there is so formed a narrow circular space between the wall of the vagina and

the vaginal portion of the cervix uteri. The roof of the space is formed by the reflection of the vagina upon the cervix and is termed the *fornix*. Owing to the greater length of the posterior wall of the vagina the portion of the circular space below the posterior fornix is considerably deeper than that below the anterior.

In its ordinary condition the lumen of the vaginal canal is a fissure, which in transverse section resembles the form of the letter H with a rather long transverse bar (fig. 1036). On both the anterior and the posterior wall there is in the median line a well-marked longitudinal ridge, the *columna rugarum*, which is especially distinct in the lower part of the anterior wall, where it lies immediately beneath the urethra and forms what is known as the *urethral carina*. From both columnæ other ridges pass laterally and upward on either side, forming the *rugæ vaginales*. Both these and the columnæ diminish in distinctness with advance in age and with successive parturitions. Toward its lower end the vagina traverses the urogenital trigone, being much less dilatable in this region than elsewhere, and it opens below into the vestibule of the external genitalia. Its orifice is partially closed by a fold of connective tissue, rich in blood-vessels, and lined on both surfaces by mucous membrane. This membrane, known as the

FIG. 1036.—HORIZONTAL SECTION OF VAGINA AND ADJACENT STRUCTURES. (After Henle.)

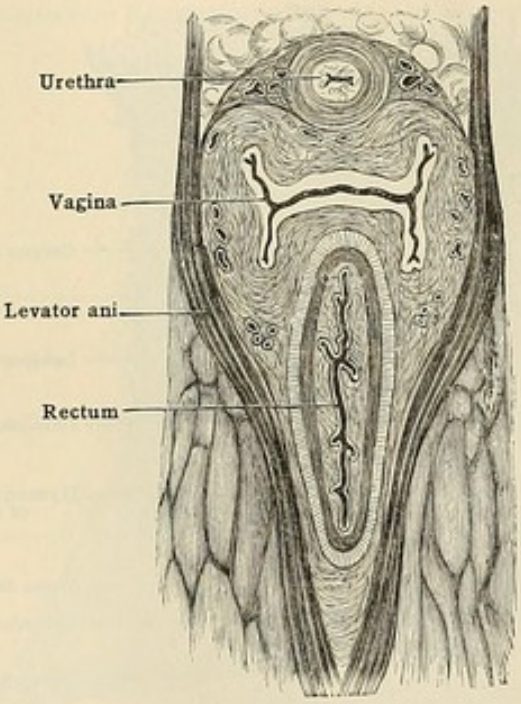

hymen, has usually a somewhat semilunar form, surrounding the posterior border of the orifice, but it may take the form of a circular curtain pierced by one or several apertures.

It varies greatly in strength and development and although it is nearly always ruptured by the first act of sexual congress, it may remain unbroken until parturition. Rarely it takes the form of a complete imperforate curtain and may necessitate a surgical operation at the commencement of the menstrual periods. After rupture the remains of the hymen persist as small lobed or wart-like structures, the *carunculæ hymenales*, around the vaginal orifice.

Relations.—The uppermost part of the posterior wall of the vagina is in relation with the peritoneum forming the floor of the recto-uterine pouch (of Douglas), but elsewhere the canal is entirely below the floor of the peritoneal cavity. Posteriorly it rests almost directly upon the rectum (fig. 1036), and the contents of that viscus may be readily felt through its walls. *Anteriorly* it is in intimate relation with the urethra and the posterior wall of the bladder (figs. 1034, 1036), while *laterally* it is crossed obliquely in its upper third by the ureters as they pass to the base of the bladder, and in its lower two-thirds by the edges of the anterior portion of the levatores ani. The *duct of Gärtner*, the remains of the lower portion of the Wolffian duct, may occasionally be found at the side of the

upper half of the vagina as a minute tube or fibrous cord. The external orifice is surrounded by the fibres of the bulbo-cavernosus muscle, which may be regarded as forming a sphincter (*sphincter vaginæ*).

Structure.—The wall of the vagina is formed mainly of non-striped muscle tissue, whose fibres are indistinctly arranged in two layers, an outer longitudinal and a less distinct inner circular one. Above, this tissue is continuous with that of the cervix uteri, as is also the mucous membrane which lines the lumen. This differs from that of the cervix in having a stratified squamous epithelium and in being destitute of glands.

Vessels and nerves.—The *arteries* of the upper part of the vagina are derived from the vaginal branch of the uterine; its middle portion is supplied by a vaginal branch from the inferior vesical and its lower part by the middle hæmorrhoidal and internal pudendal. The *veins* form a rich plexus on the surface and drain into the hypogastric vein. The *lymphatics* are very numerous and drain for the most part to the hypogastric and lateral sacral nodes; some of those from the lower portion of the canal joining with those from the external genitalia to pass to the inguinal nodes. The *nerves* passing to the vagina are derived from the utero-vaginal and vesical plexuses.

5. The Female External Genitalia and Urethra

The female **external genitalia** [pudendum muliebre] (vulva) present an elongated depression, occupying the entire perineal region and bounded laterally by

Fig. 1037.—The External Genitals of the Female.

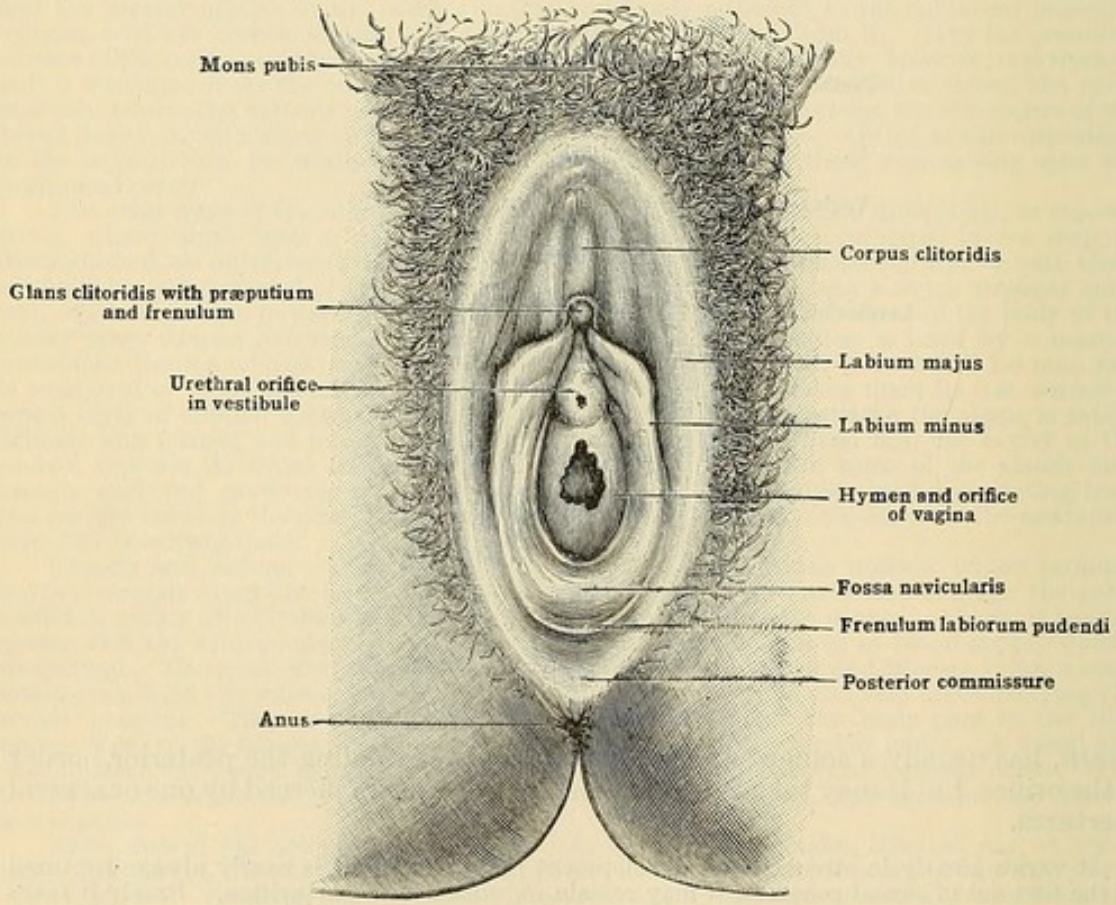

two folds of integument, the *labia majora* (fig. 1037). These anteriorly are continued into the *mons pubis*, an eminence of the integument over the symphysis pubis due to a development of adipose tissue. The medial surfaces of the two labia are normally in contact, the fissure between them being termed the *rima pudendi*, and where they meet anteriorly and posteriorly they form the *anterior* and *posterior commissures* [commissura labiorum anterior et posterior]. Just anterior to the latter is an inconstant transverse fold, the *frenulum labiorum pudendi* ("fourchette") (fig. 1037). The mons and the outer surfaces of the labia are covered by short crisp hairs, but the medial surfaces of the labia are smooth, possessing only rudimentary hairs, but beset with large sebaceous and sudoriparous glands. The interior of the labia is occupied by a mass of fat tissue in which the distal extremity of the round ligament of the uterus breaks up.

Within the depression bounded by the labia majora is a second pair of integumental folds, the *labia minora* (fig. 1037), which differ from the labia majora in being destitute of hairs and fat. They are usually concealed by the labia majora, but are sometimes largely developed and may then project through the rima pudendi, assuming a dried and pigmented appearance.

The labia minora divide and unite anteriorly over the distal extremity of the clitoris, forming the *præputium clitoridis* in front of the clitoris, and the *frenulum clitoridis* behind it. Posterior to this they diverge and reach their greatest height, gradually diminishing as they pass backward to terminate in a slight, inconstant, transverse fold, the *frenulum labiorum pudendi*, situated just anterior to the posterior commissure of the labia majora. Anterior to the frenulum is the *fossa navicularis* of the vestibule.

The vestibule.—The space between the two labia minora is termed the vestibule, and into its most anterior portion there projects the extremity of an erectile organ, the *clitoris* (fig. 1037), which is comparable to the penis of the male. It is, however, relatively small and is not perforated by the urethra, which lies below it. It is composed of two masses of erectile tissue, the *corpora cavernosa clitoridis*, which differ from the corresponding structures of the penis only in size. They are attached posteriorly to the rami of the pubis by the *crura clitoridis* (fig. 1038), and as they pass forward they converge and meet together to form the body of the organ, which, beneath the symphysis pubis, bends sharply upon itself

FIG. 1038.—DIAGRAMMATIC REPRESENTATION OF THE PERINÆAL STRUCTURES IN THE FEMALE.

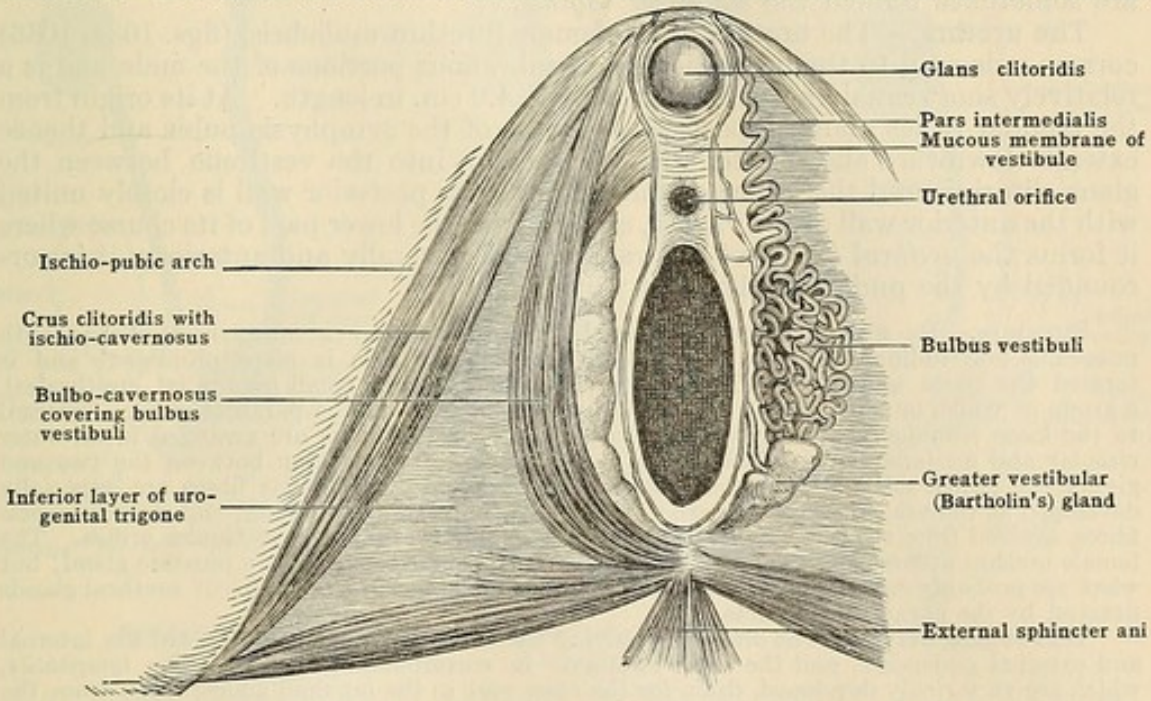

and passes posteriorly beneath the anterior commissure of the labia majora. Distally the corpora cavernosa abut upon another mass of erectile tissue, which fits like a cap over their extremities; it is formed by an anterior prolongation of the bulbi vestibuli and is termed the *glans clitoridis*, being comparable to the glans penis, from which it differs only in not being perforated by the urethra.

A short distance posterior to the glans clitoridis is the opening of the *urethra* [orificium urethræ externum], situated upon the summit of a slight papilla-like elevation. Lateral to this orifice are sometimes found the openings, one on either side, of two elongated slender ducts, the *paraurethral ducts* (ducts of Skene). Still more posteriorly is the external orifice of the *vagina* [orificium vaginæ], partially closed in the virgin by the *hymen*. Lateral to this, in the angles between the hymen and the labium minus on either side, is the opening of the greater vestibular gland, while the lesser glands open at various points on the floor of the vestibule, sometimes at the bottom of more or less distinct depressions.

Beneath the floor of the vestibule and resting upon the superficial layer of the urogenital trigone are two oval masses of erectile tissue, the *bulbi vestibuli* (fig. 1038), homologous with the corpus cavernosum urethræ of the male. They consist principally of a dense network of anastomosing blood-vessels, enclosed within

a thin investment of connective tissue. From the main mass of each bulbus a slender prolongation, the pars intermedia, extends anteriorly past the side of the urethra, to form the glans clitoridis.

The *greater vestibular glands* [gl. vestibularis major (Bartholini)] or glands of Bartholin (fig. 1038) represent the bulbo-urethral glands of the male. They are two small, compound tubular glands, situated one on either side immediately posterior to the bulbi vestibuli.

The single *duct* of each gland opens on the floor of the vestibule in the angle between the hymen and the orifice of the vagina and a little posterior to the mid-transverse line of the latter. Numerous small tubular glands occur in the integument forming the floor of the vestibule; they are termed the *lesser vestibular glands* and are especially developed in the interval between the urethral and vaginal orifices.

The **muscles** of the female external genitalia (fig. 1038) correspond to the perineal muscles of the male (see Section IV). There are two *transverse perineal* muscles, which have the same relations as in the male, and two *ischio-cavernosi*, which are related to the crura clitoridis just as those of the male are to the crura penis. The *bulbo-cavernosi*, however, present somewhat different relations, each being band-like in form, arising from the central point of the perineum and extending forward past the orifice of the vagina, over the greater vestibular gland and the bulbus, to form with its fellow of the other side a tendinous investment of the body of the clitoris. The two muscles act as a sphincter to the vagina and are sometimes termed the *sphincter vaginæ*.

The urethra.—The **urethra** of the female [urethra muliebris] (figs. 1034, 1036) corresponds only to the prostatic and membranous portions of the male and is a relatively short canal, measuring from 3.0 to 4.0 cm. in length. At its origin from the bladder it lies about opposite the middle of the symphysis pubis and thence extends downward and slightly forward to open into the vestibule between the glans clitoridis and the orifice of the vagina. Its posterior wall is closely united with the anterior wall of the vagina, especially in the lower part of its course where it forms the *urethral carina* of the vaginal wall; laterally and anteriorly it is surrounded by the pudendal plexus of veins.

Structure.—Its walls are very distensible, and are lined by a mucous membrane with numerous longitudinal folds, one of which on the posterior side is more prominent and is termed the *crista urethralis*. The mucosa contains numerous small glands [gl. urethrales], a group of which on each side is drained by the inconstant ductus paraurethralis. External to the loose submucosa is a sheet of smooth muscle, whose fibres are arranged in an outer circular and an inner longitudinal layer, a rich plexus of veins lying between the two and giving the entire sheet a somewhat spongy appearance. The circular fibres are especially developed at the vesical end of the canal, forming there a strong sphincter, and striped muscle fibres, derived from the bulbo-cavernosus, form a sphincter around its vestibular orifice. The female urethra differs from that of the male in not being enclosed within a prostate gland; but what are probably rudiments of this structure are to be found in the groups of urethral glands drained by the paraurethral ducts.

Vessels and nerves.—The *arteries* supplying the external female genitalia are the internal and external pudendals, and the *veins* terminate in corresponding trunks. The *lymphatics*, which are very richly developed, drain for the most part to the inguinal nodes; those from the urethra pass to the iliac nodes. The *nerves* are partly sympathetic and partly spinal; the former are derived from the hypogastric plexus, the latter principally from the pudendal, the anterior portions of the labia majora being supplied by the ilio-inguinal and the external spermatic branch of the genito-femoral.

DEVELOPMENT OF THE REPRODUCTIVE ORGANS

It has already been pointed out (p. 1267) that during development a transitory excretory organ, the **mesonephros** or **Wolffian body,** reaches a high degree of development, and its duct, the **Wolffian duct,** opens into a **cloaca** or common outlet for the intestinal and urinary passages. The mesonephros forms a strong projection from the posterior wall of the abdomen into the body cavity, and on the medial surface of the peritoneum which covers it a thickening appears which is termed the **genital ridge.** The upper part of this ridge becomes the ovary or testis, as the case may be, while the remainder of it becomes the ovarian and round ligaments in the female and the gubernaculum testis in the male.

As the ovary or testis develops the tubules of the upper part of the Wolffian body enter into relation with it, forming, indeed, in the case of the testis, a direct union with the seminferous tubules. The Wolffian body then becomes divisible into a reproductive and an excretory portion, and, when the metanephros or permanent kidney develops, the latter portion degenerates, leaving only a few rudiments, such as the paroöphoron in the female (p. 1269) and the vas aberrans and paradidymis (p. 1257) in the male. The reproductive portion also becomes much reduced in the female, persisting as the tubules of the epoöphoron (p. 1269), but in the male it

forms the lobules of the epididymis and serves to transmit the spermatozoa to the Wolffian duct.

In addition to the Wolffian duct, a second duct, the **Müllerian,** occurs in connection with the genito-urinary apparatus, and, like the Wolffian duct, it opens below into the cloaca. The history of the two ducts is very different in the two sexes. In the **male** the Wolffian duct persists to form the vas deferens, of which the seminal vesicle is an outgrowth and the ejaculatory duct the continuation, while the Müllerian duct degenerates, its lower end persisting as the prostatic utriculus and its upper end as the appendix of the epididymis. In the **female,** on the contrary, it is the Müllerian duct which persists, its lower portion fusing with the duct of the opposite side to form the vagina and uterus, while its upper portion forms the tuba uterina. Inhibition of the fusion of the lower ends of the two Müllerian ducts gives rise to the bihorned or divided uteri, or the bilocular uteri and vaginæ which occasionally occur. The Wolffian duct in the female almost completely disappears, persisting only as the longitudinal tube of the epoöphoron and as the rudimentary canal of Gärtner (p. 1275). With the degeneration of the mesonephros the peritoneum which covered it becomes a thin fold, having in its free edge the Müllerian duct and, on the fusion of the lower ends of the ducts, the two folds also fuse and so give rise to the broad ligament.

FIG. 1039.—DEVELOPMENT OF THE REPRODUCTIVE ORGANS.

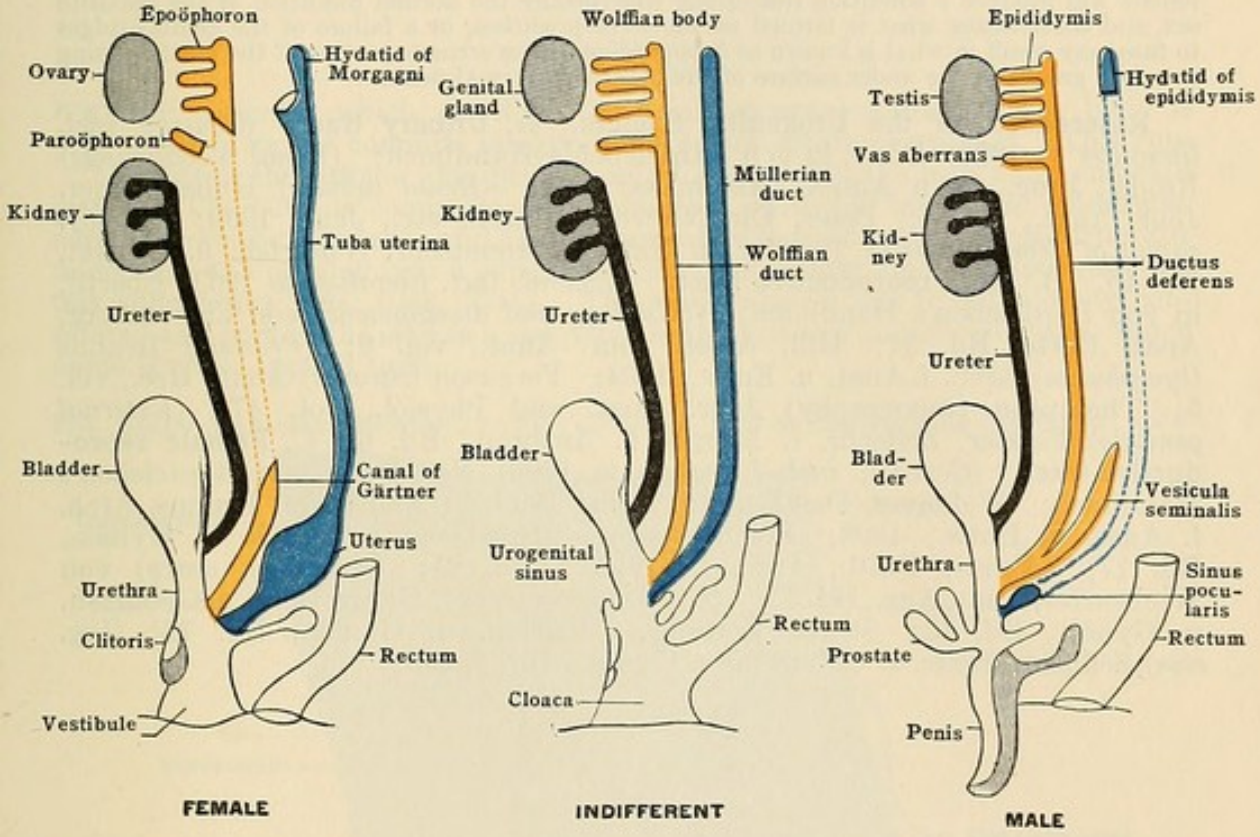

The developmental relations of the male and female organs may be seen from figure 1039 and also from the following table:—

	MALE	FEMALE
Genital ridge	Testis	Ovary
	Gubernaculum testis	Ovarian ligament Round ligament
Wolffian body	Head of epididymis	Epoöphoron
	Paradidymis Vas aberrans	Paroöphoron
Wolffian duct	Body and tail of epididymis	Longitudinal tubule of epoöphoron
	Ductus deferens	Canal of Gärtner
	Ejaculatory duct	
Müllerian duct	Appendix of epididymis (?)	Uterine (Fallopian) tube
		Uterus
	Prostatic utriculus	Vagina

The development of the external organs of generation in the two sexes presents a similar differentiation from a **common** condition. The division of the cloaca to form a **urogenital sinus** and the terminal part of the rectum has already been noted (p. 1253). In the floor of the sinus, to the sides of and above the urethral orifice, erectile tissue develops, forming a **genital tubercle.** An outpouching of that portion of the anterior abdominal wall to which the round ligament of the uterus or the gubernaculum was attached occurs to form the **genital swellings,**

lying one on either side of the sinus, and medial to these a pair of folds develop at the borders of the sinus, enclosing the genital tubercle above and forming the **genital folds.**

This condition practically represents the arrangement which persists to adult life in the **female.** The genital tubercle becomes the clitoris, the genital swellings the labia majora, the genital folds the labia minora, and the urogenital sinus, into which the urethra and Müllerian ducts (vagina) open, is the vestibule. In the **male** the development proceeds farther. The genital tubercle elongates to form the penis, and the free edges of the genital folds meet together and fuse, closing in the urogenital sinus and transforming it into the cavernous portion of the urethra, thus bringing it about that the male urethra subserves both reproductive and urinary functions. The genital swellings also meet and fuse together below the root of the penis, forming the scrotum.

The homologies of the parts in the two sexes may be seen from the following table:—

	Male	Female
Urogenital sinus	Cavernous portion of urethra	Vestibule
Genital tubercle	Penis	Clitoris
Genital folds	Integument and prepuce of penis	Prepuce of clitoris and labia minora
Genital swellings	Scrotum	Labia majora

Inhibition of the development of the parts in the male or their over-development in the female will produce a condition resembling superficially the normal condition of the opposite sex, and constituting what is termed *pseudo-hermaproditism;* or a failure of the genital ridges to fuse may result in what is known as *hypospadias,* the cavernous portion of the urethra being merely a groove in the under surface of the otherwise normal penis.

References for the Urogenital System. A. **Urinary tract.** (*General, incl. literature to* 1900) Disse, in von Bardeleben's Handbuch; (*Renal blood-vessels*) Brödel, Proc. Ass'n Amer. Anatomists, 1901; (*Renal tubules*) Huber, Amer. Jour. Anat., vol. 4; Peter, Die Nierenkanälchen, etc., Jena, 1909; (*Topography of female ureter*) Tandler u. Halban, Monatschr. Geburtsh. u. Gynäk., Bd. 15. B. **Male reproductive tract.** (*General, incl. literature to* 1903) Eberth, in von Bardeleben's Handbuch; (*Histology and development*) von Lichtenberg, Anat. Hefte, Bd. 31; Hill, Amer. Jour. Anat., vol. 9; (*Prostate*) Bruhns (*lymphatics*) Arch. f. Anat. u. Entw., 1904; Ferguson (*Stroma*) Anat. Rec., vol. 5; Thompson (topography) Jour. Anat. and Physiol., vol. 47; (*External genitals*) Forster, Zeitschr. f. Morph. u. Anthrop., Bd. 6. C. **Female reproductive tract.** (*General, incl. literature to* 1896) Nagel, in von Bardeleben's Handbuch; Waldeyer, Das Becken, Bonn, 1899; (*Lymphatics*) Bruhns, Arch. f. Anat. u. Entw., 1898; Polano (*ovary*) Monatschr. Geburtsh. u. Gynäk., Bd. 17; (*Nerves*) Roith, Arch. f. Gynäk., Bd. 81; (*Histology, ovary*) von Winiwarter, Anat. Anz., Bd. 33; (*Development, uterus*) Hegar, Beitr. z. Geburtsh. u. Gynäk., Bd. 13; Stratz, Zeitschr. Geburtsh. u. Gynäk., Bd. 72; (*Lig. eres*) Sellheim, Beitr. z. Geburtsh. u. Gynäk., Bd. 4, 1901.

SECTION XII

THE SKIN, MAMMARY GLANDS AND DUCTLESS GLANDS

REWRITTEN FOR THE FIFTH EDITION

BY ABRAM T. KERR, B.S., M.D.

PROFESSOR OF ANATOMY IN THE CORNELL UNIVERSITY MEDICAL COLLEGE

THE SKIN

THE covering which envelops the whole external surface of the body is known as the **common integument** [integumentum commune]. This consists of the **cutis** or skin proper and of *appendages*, the hair, nails, and skin glands. The cutis is composed of a superficial epithelial layer, the **epidermis,** derived from the ectoderm, and a deep connective tissue layer developed from the mesoderm and divided into a superficial part, the **corium,** and a deeper part the **tela subcutanea** (figs. 1040, 1041). The subcutaneous tela is not usually considered as a part of the skin in a restricted sense, but as a superficial fascia, which name is often applied to it.

FIG. 1040.—MAGNIFIED SECTION OF THE THICKENED SKIN OF THE PALM OF THE HAND. ×6

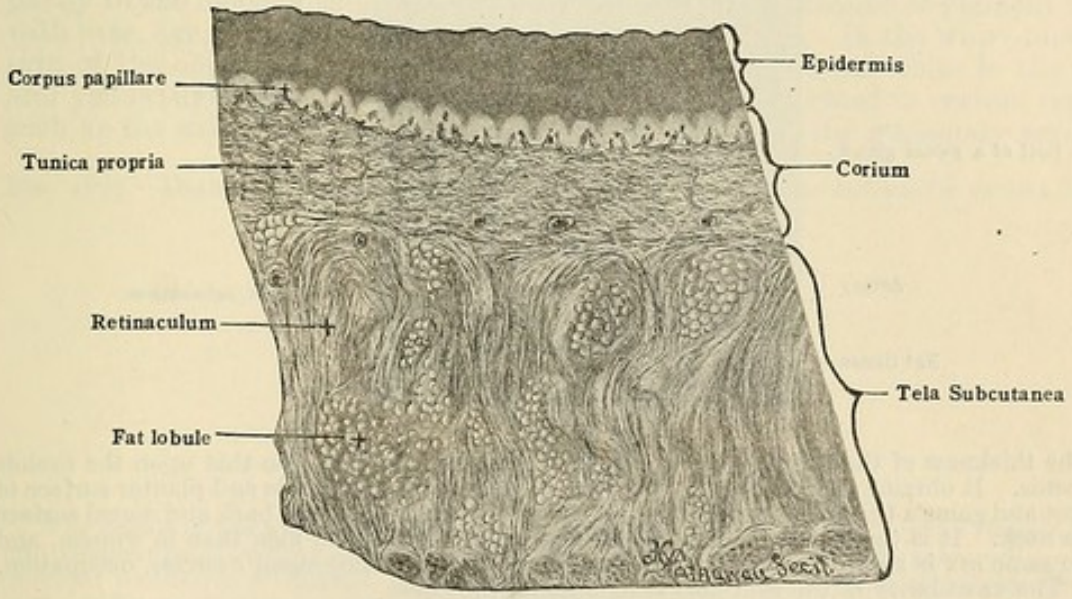

The skin forms an encasement for the entire body broken only in the regions where it merges with the mucous membranes. It serves not only as a direct physical protection to the underlying structures, but also, through its function as an organ of touch and of general sensibility, it indirectly protects the body by the action of the special end organs and peripheral terminations of the sensory nerves which thus bring the body into relations with its surroundings. Through the radiation and conduction of heat to and from the blood circulating in it, through the amount of secretion of its glands and the evaporation from its surface, the skin forms the principal organ for the regulation of the bodily heat. By means of the action of its sweat and sebaceous glands it possesses an important secretory function. It has also a minor rôle as an organ of respiration and absorption.

The **surface area** of the skin corresponds approximately to the surface of the body and naturally varies with the size of the individual. It has been variously estimated at from 10,500 to 18,700 sq. cm. for a medium-sized adult male.

The **aperturæ cutis** are holes through the skin where it joins with the mucous membrane, usually without sharp line of demarcation, at the nares, the rima oris, the anus, and the external urethra in the male, and at the vaginal vestibule in the female.

Owing to the fact that the skin extends beyond the surface at the aperaturæ cutis, and covers the major and minor pudendal labia, and the prepuce and extends into the external acoustic canal, the surface area is slightly greater than the surface of the body.

The **thickness** of the skin varies in different regions of the body and also in different individuals. The mean thickness is between 1 and 2 mm., the extremes ranging from .3 to 4.0 mm. or more. This is exclusive of the subcutaneous tela. The thickness appears to be in direct proportion to the amount of friction and pressure to which the part is subjected. Thus it is thicker on the dorsal than on the ventral surface of the trunk and neck, and on the flexor than on the extensor surfaces of the hands and feet. Otherwise it is thicker upon the extensor than on the flexor surface of the extremities.

FIG. 1041.—VERTICAL SECTION FROM THE SOLE OF THE FOOT OF AN ADULT. ×25. (Lewis and Stöhr.)

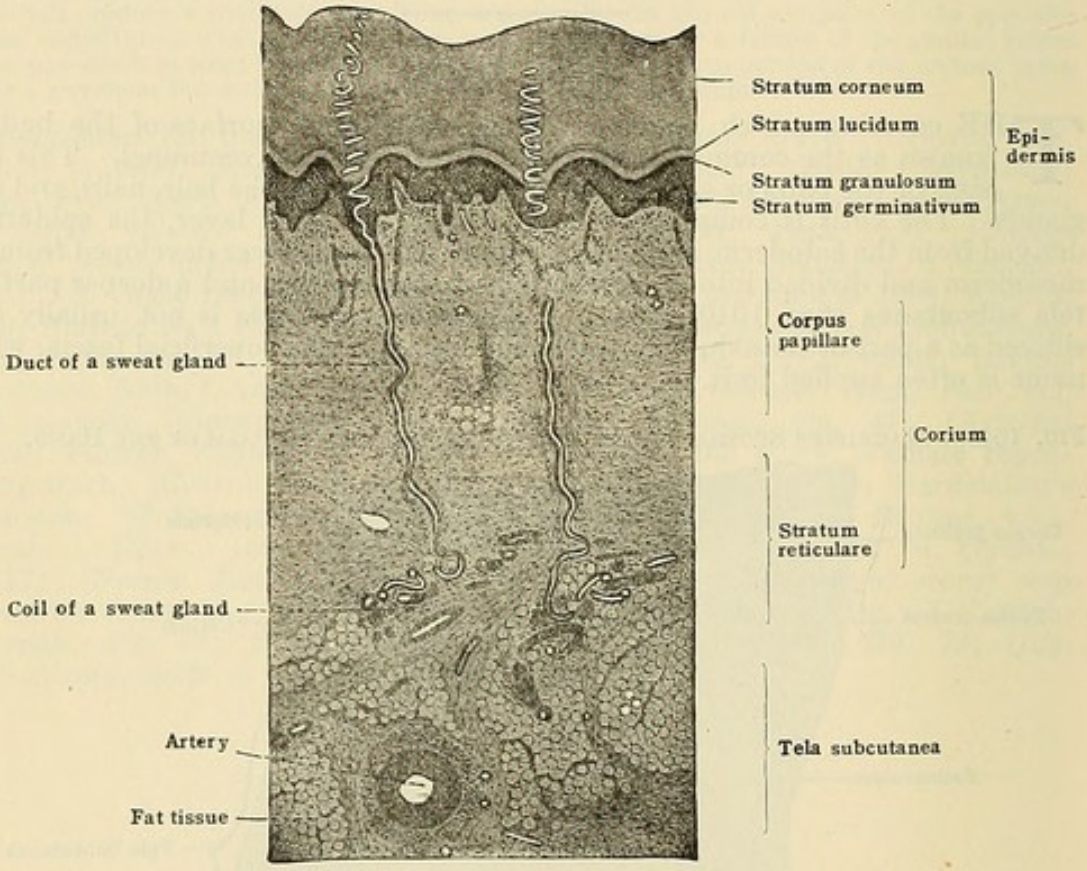

The thickness of the skin is least upon the tympanum and it is also thin upon the eyelids and penis. It obtains a thickness of 3 mm. on the volar surface of hands and plantar surface of the feet and gains a thickness of about 4 mm. on the cephalic part of the back and dorsal surface of the neck. It is thinner in the aged than in the adult, thicker in men than in women, and in the same sex is subject to much individual variation depending upon exercise, occupation, etc. The vascularity of the skin also influences its thickness.

Over most of the surface of the body the skin is **elastic** and so loosely attached that it may be stretched to a greater or less extent. The elasticity varies in different individuals. Closely associated with the elasticity is the manner of **attachment** of the skin to underlying structures. This varies somewhat according to the tissues which are covered but the great motility is due in the main to the very oblique arrangement of the connective tissue and elastic fibres of the deeper layers of the skin; the fixity to the more vertical arrangement of these fibres. An understanding of the looseness and elasticity of the skin is of much practical importance to the surgeon in certain operations.

When the traction is slow as over a slow-growing tumour, or over the abdomen and breasts in pregnancy, the skin may be stretched to a very considerable degree. In these cases there are often produced short parallel reddish streaks which when the stretching is relieved are re-

placed by whitish, silvery lines, **striæ** or **lineæ albicantes,** due to atrophy of the tissues. In spite of this the skin usually retains enough elasticity to contract gradually to its former extent as it does immediately after moderate stretching.

In most parts of the body the attachment is loose so that the skin is movable and may be pinched up into folds. In some places the attachment of the skin is firm and there is no slipping of the skin over underlying parts, as on the glans penis. In some other parts the motion is very limited as in the scalp and the volar surface of the hands and the plantar surface of the feet.

FIG. 1042.—FINGER PRINT (NATURAL SIZE) SHOWING CRISTÆ AND SULCI.

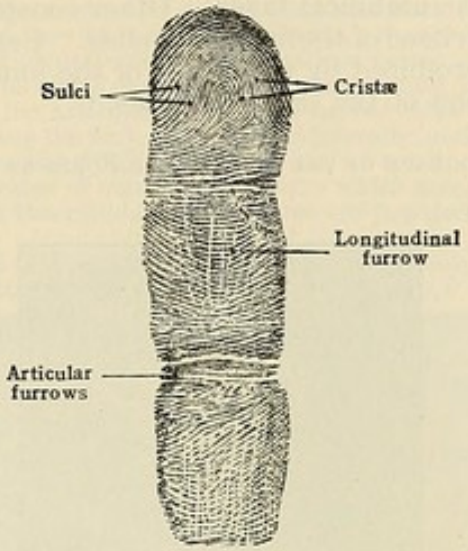

The **colour** of the skin varies greatly. It may be white, yellow, black, red, or any of the shades of these colours, and, according to the colour, the races of mankind have been roughly divided. The colouration is due partly to pigment and partly to the blood within the cutaneous vessels. The amount of pigment varies with race, age, sex, and with exposure to the sun and air. In the white races the skin of the child is a pinkish white, tending to become dead white in the adult and yellowish in the aged, and it is normally more pigmented in certain regions, such as the axillary region, the scrotum, the vulva, and the mammary areola.

FIG. 1043.—DIAGRAM SHOWING THE ARRANGEMENT OF THE PRINCIPAL CRISTÆ OF THE THUMB



The colour of the white, yellow, red, and black races is not produced by the climate, as we find different races existing under the same climatic conditions and the same coloured race under different conditions of climate. Each race presents several variations of colour; for example, in the white race we distinguish a blonde, a brunette, and an intermediate type. Anthropologists distinguish twenty to thirty different shades of colour in the skin. In blondes of the white race under the action of strong sun light the skin passes from a rose white to a brick red or becomes pigmented in spots, **freckles.** In the first case the pigment in the skin is not increased to any great extent but the skin is affected by a superficial inflammation, **erythema,** associated with exfoliation and often with the formation of blisters. In brunettes of the white race the sun burns the skin a dark yellowish or reddish brown, the degree of pigmentation here being increased and is spoken of as **tan.** The colouration is only temporary and diminishes on withdrawal from exposure. The sun darkens the skin in the yellow races also. In the newborn of the black races the skin is of a reddish colour, since the pigment although developed to some extent is at birth obscured by overlying opaque cells which later become transparent. The newborn of the yellow races are also lighter than their parents. In white races the shade of the skin is clearer on the ventral surface of the trunk and on the flexor surface of the extremities. In the black races the volar surface of the hands and the plantar surface of the feet as well as the sides of the digits are less deeply pigmented than the rest of the body. The colour of the skin is greatly influenced by the blood in its deeper layers which during life gives it a more or less distinctly reddish tinge, varying directly with the vascularity and inversely with the thickness of the epidermis. Absence

of the normal pigment is a not uncommon congenital anomaly producing albinism or leukoderma. It may affect all the skin structures or it may be partial.

The skin presents certain **elevations** and **depressions** due to the fact that it follows more or less closely the contour of the underlying structures, but in addition to this it possesses certain elevations and depressions peculiarly its own. They are found on the skin in various parts of the body. Some are permanent, others only temporary. Large permanent **folds** which include all the layers of the skin are seen, as the prepuce of the penis and the pudendal labia. The most marked depression is the **umbilical fovea.** Other conspicuous folds and furrows are seen in the neighbourhood of the lips and eyelids. Certain other less permanent folds and furrows are produced by the action of the joints, **joint-furrows,** and of the muscles of expression of the skin,**"wrinkles."**

FIG. 1044.—FROM A PHOTOGRAPH OF THE SUPERFICIAL FURROWS ON THE BACK OF THE HAND. (× 1.)



Other minute folds and furrows which affect only the epidermis and the superficial layer of the corium are seen in various places. These are represented by the numerous fine superficial creases, unassociated with elevations, forming rhomboidal and triangular figures over almost the whole of the surface of the skin (figs. 1042, 1043). They are especially numerous on the dorsal surface of the hands (fig. 1044). The fine curvilinear ridges [cristæ cutis] with intervening furrows [sulci cutis] arranged in parallel lines in groups on the flexor surface of the hands and feet are also of this type. They form patterns characteristic for each individual and permanent throughout life.

FIG. 1045.—FROM A PHOTOGRAPH OF THE SKIN RIDGES AND PAPILLÆ OF THE PALM OF THE HAND. EPITHELIUM COMPLETELY REMOVED ABOVE; PARTLY REMOVED BELOW. (× 5.)

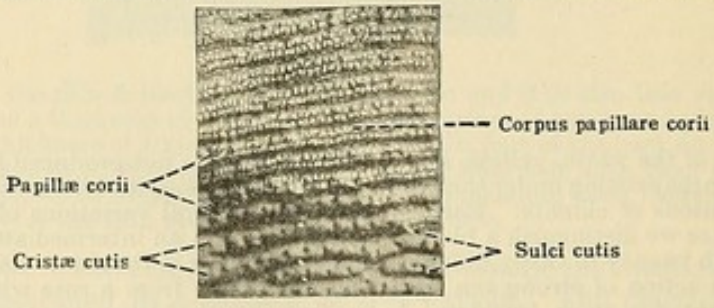

Among the projections are the large permanent folds of skin such as the **labia pudendi,** the **preputium penis,** the **frenula preputii, clitoridis,** and **labiorum pudendi,** and less marked ridges as the median **raphe** of the perineum, scrotum and penis, and the **tuberculum labii superioris.** Of a somewhat different sort are the **touch pads** [toruli tactiles] of the hands and feet. Among the larger depressions in addition to the **umbilical fovea,** is the **coccygeal foveola,** and a considerable number of well-marked permanent furrows found in various places, such as the **nasolabial** and **mentolabial sulci,** the **philtrum labii superioris,** the **infraorbital sulcus,** and the **infra-** and **supraorbitial palpebral sulci.** There are numerous **articular furrows** on both the flexor and extensor surfaces produced by the action of the joints, and associated with intervening folds of skin, particularly on the dorsal surface. They are especially noticeable on the hands. Variations of the palmar joint sulci are due to variations in opposition of the thumb and the use of the fingers and the relative arrangement of the thumb and fingers and joints. They are of

especial medical and surgical importance as indicating topographically the position of the joints, their relation to which has been recently made clearer by means of the X-ray.

The folds and furrows brought about through the action of the skin muscles run at right angles to the muscle fibres and are more or less transitory at first but become more permanent through repeated or long-continued action. They are represented by the **wrinkles** of the forehead, the lines of expression of the face, the transverse wrinkles of the scrotum and the radiating folds around the anus. The more superficial **cristæ cutis** and **sulci cutis** are arranged in groups within and around the touch pads, on the volar surface of the hands and the plantar surface of the feet (figs. 1042, 1043). The cristæ of each group are parallel. They correspond to the rows of papillæ of the corium.

Because the patterns of the cristæ and sulci are characteristic for the individual, and permanent from youth to old age, they have been classified in a number of types and are important medicolegally as a means of identification. The various systems of classification are based upon the arrangement over the distal phalanges of the fingers and make use of (1) a transverse ridge which is parallel with the articular plicæ (2) a curved ridge with its convexity distally and more or less closely meeting the first, medially and laterally, and (3) the curved and concentric ridges between these two (fig. 1043).

There are also a great number of minute depressions which mark the points where the hairs pierce the surface and where the glands open. These are popularly known as **pores.** Under

FIG. 1046.—PAPILLÆ OF THE CORIUM AFTER MACERATION. FROM RETOUCHED PHOTOGRAPH. EPITHELIUM REMOVED BY MACERATION. (× 25.)

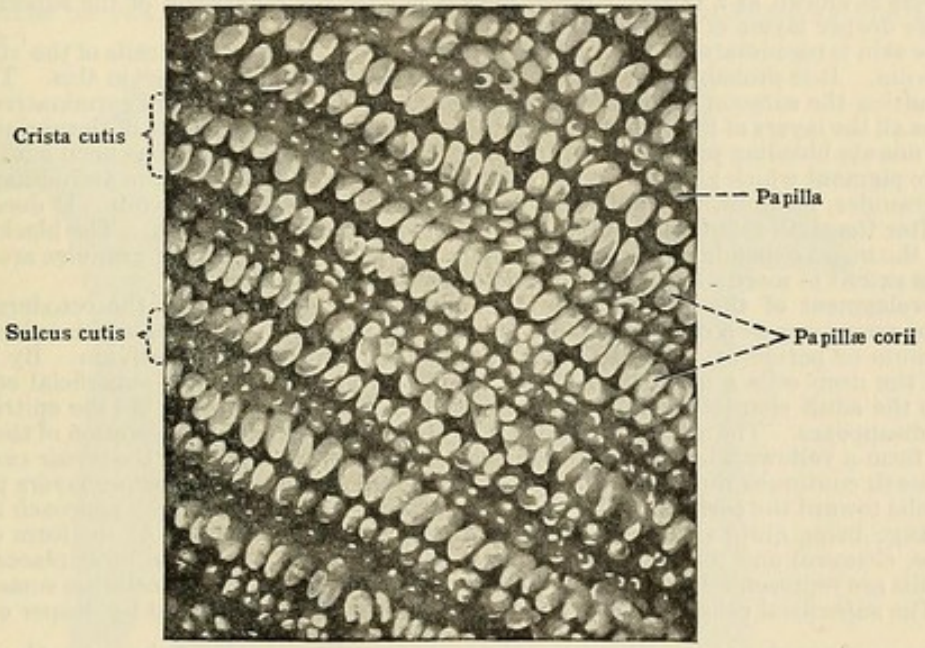

the influence of cold and emotion the hair muscles contract and cause a slight elevation of the skin at the point where the hair emerges. This roughened appearance of the skin is popularly known as "goose-flesh."

A complex wrinkling of the skin appears in old age, or in the course of exhausting diseases, as a result of loss of elasticity and from absorption of the cutaneous and subcutaneous fat. Rounded depressions called **dimples** are produced by the attachment of muscle-fibres to the deep surface of the skin, as on the chin and cheek, and are made more evident by the contraction of these fibres. Others are produced by the attachment of the skin by fibrous bands to bony eminences, as the elbow, shoulder, vertebræ, and posterior iliac spines. They are best seen when the subcutaneous adipose tissue is well developed.

The **cutis** is made up of two layers which are structurally and developmentally markedly different. The superficial ectodermic portion, **epidermis,** is made up almost entirely of closely packed epithelial cells, the deeper mesodermic part, **corium,** is formed largely of connective-tissue fibres.

The **epidermis** (cuticle, scarf-skin) is a cellular non-vascular membrane which forms the whole of the superficial layer of the skin and at the great openings through the skin, as the mouth and anus, blends gradually with the mucous membrane. It represents from one-tenth to over half the thickness of the skin, in different parts of the body, the usual thickness being .05 to .2 mm., ranging from .03 mm. to nearly 3 mm. The thickness varies also in different individuals. Its deep surface is molded exactly to the underlying corium but its superficial surface fails to reproduce all of the irregularities of the latter. In spite of this close association, blood-vessels never enter the epidermis.

Structure of the epidermis.—The cells of the epidermis are packed together in many irregular layers. The deepest cells are soft protoplasmic, somewhat elongated, perpendicular to

the surface of the corium and joined together by fine fibrils; more superficially they become round or polyhedral. These cells together with several more superficial layers form a stratum from which the other cells of the epidermis are developed and which therefore are known as the **stratum germinativum** (Malpighii). The cells in the superficial part of this stratum, in some situations, have a granular appearance forming a layer which is called the **stratum granulosum.** Superficial to this there is, also only in some places, a layer in which the cells are somewhat indistinct and transparent, and therefore known as the **stratum lucidum.** This is a transition between the softer and more opaque stratum germinativum and the firmer and more transparent superficial layer formed of large, flattened, dry, horny cells, known as **stratum corneum.**

In general the stratum germinativum is thicker than the stratum corneum. In certain parts as the face, the back, the back of the hands and feet, the two layers are equal in thickness. In other regions, as in the volar surface of the hands and plantar surface of the feet, the stratum corneum is much thicker than the stratum germinativum varying from two to three or even five times as thick. This increased thickness of the stratum corneum is not due to pressure alone as it is well marked in the fœtus, but it is not improbable that pressure may stimulate the further growth of the cells.

Where the papillæ of the corium are arranged in rows as on the volar surface of the hands and the plantar surface of the feet, the epidermis is molded to these so as to appear as ridges on the surface, already described as cristæ. In most other places the irregularities of the papillæ of the corium do not show on the surface. At short and regular intervals on the cristæ are notches and transverse furrows which mark the openings of the sweat glands.

The separation of the epidermis from the corium by the accumulation of serous fluid between the layers is known as a blister. Sometimes it is only the separation of the superficial layers from the deeper layers of the epidermis.

The skin is regenerated after a blister or a wound by growth of the cells of the stratum germinativum. It is probable that cells of the superficial layers take no part in this. Therefore in skin grafting the surgeon in order to transplant the cells of the stratum germinativum usually includes all the layers of the epidermis and the extreme tips of the papillæ of the corium as shown by the minute bleeding points left on the surface from which the graft has been cut.

The **pigment** which gives the main colour to the skin is caused by the accumulation of pigment granules, melanin, in the deepest cells of the stratum germinativum. It does not occur until after the sixth month of fœtal life and develops chiefly after birth. The blackness of the skin of the negro depends almost entirely upon this pigment. Pigment granules are also found to a less extent in more superficial cells and sometimes in the corium.

Development of the epidermis.—The epidermis is derived from the ectoderm, in early embryos appearing as a double stratum of cells, the superficial layer of which is known as the epitrichium or periderm, the deep layer becomes the stratum germinativum. By multiplication of the deep cells a number of layers are produced and the more superficial cells tend to assume the adult characteristics. At about the sixth month of fœtal life the epitrichial layer finally disappears. The surface layers are cast off and mixing with the secretion of the cutaneous glands form a yellowish layer over the surface of the skin of the fœtus, the *vernix caseosa.*

Growth continues throughout life. New cells are formed in the deeper layers pushing the older cells toward the surface. The character of the cells changes as they approach the surface, the change being quite abrupt at the level of the stratum lucidum. As the form of the cells changes, chemical and physical alterations of their contents occur. In most places the superficial cells are represented by thin scales but in the palms and soles the cells are somewhat swollen. The superficial cells are being constantly thrown off and replaced by deeper ones.

The **corium** (cutis, cutis vera, derma) is a fibrous vascular sheath composed of interwoven bundles of connective-tissue fibres intermixed with elastic fibres, connective-tissue cells, fat, and scattered unstriped muscle-fibres. It is traversed by rich plexuses of blood-vessels, lymph-vessels, and nerves, and encloses hair-bulbs and sebaceous and sudoriferous glands. It varies in thickness from .3 mm. to 3.0 mm. or more, usually ranging from .5 to 1.5 mm. It is to this layer that the strength and elasticity of the skin are due and it is also only this layer which when properly cured we know as leather.

The superficial layer of the corium is of finer, closer texture, free from fat, and forms a multitude of eminences called **papillæ corii** (figs. 1040, 1045, 1046) which project into corresponding depressions on the deep surface of the epidermis. For this reason this part of the corium although but indistinctly separated from the deeper layer is called the **corpus papillare.**

Some of the papillæ contain vessels, others nerves, hence they are known as vascular or tactile papillæ. They are very closely set, varying considerably in number in different parts of the body from 36 to 130 to a square millimetre, and it has been estimated that there are about 150 million papillæ on the whole surface. They also vary greatly in size not only in different regions but in the same region, being from .03 to .2 mm. or more in height.

The deeper layer of the corium, the **tunica propria** (stratum reticulare), is composed of coarser and less compact bands of fibrous tissue intermingled with small fat lobules. The fibrous and elastic tissue is arranged for the most part in intercrossing bundles nearly parallel to the surface of the skin.

The bundles running in some directions are usually more strongly developed and more numerous than those in others but the direction of the strongly developed bundles varies in

different parts of the body. In general those are best developed which have a direction parallel with the usual lines of tension of the skin, hence it results that wounds of the skin tend to gape most at right angles to these lines. The bundles take a direction nearly at right angles to the long axis of the limbs, and on the trunk run obliquely, caudally, and laterally from the spine (figs. 1047, 1048). On the scalp, forehead, chin, and epigastrium, equally strong bundles cross in all directions, and a round wound, instead of being linear as elsewhere, appears as a ragged or triangular hole. The arrangement of the connective-tissue bundles influences the arrangement of the blood-vessels of the skin.

The **tela subcutanea** or superficial fascia is also a fibrous vascular layer which passes as a gradual transition without definite line of demarcation from the deep surface of the tunica propria of the corium to connect it with the underlying structures.

Like the tunica propria it is composed of bundles of connective tissue containing elastic fibres and fat, but the bundles are larger and more loosely arranged, and form more distinct connective-tissue septa, which divide the fat, when present, into smaller and larger lobules. Where these connecting strands are especially large and well defined, they are known as **retinacula.** Over almost the whole surface of the body the connective-tissue strands of the tela

FIGS. 1047 AND 1048.—DIAGRAMS SHOWING THE ARRANGEMENT OF THE CONNECTIVE TISSUE BUNDLES OF THE SKIN ON THE ANTERIOR AND POSTERIOR SURFACES OF THE BODY. (After Langer.)

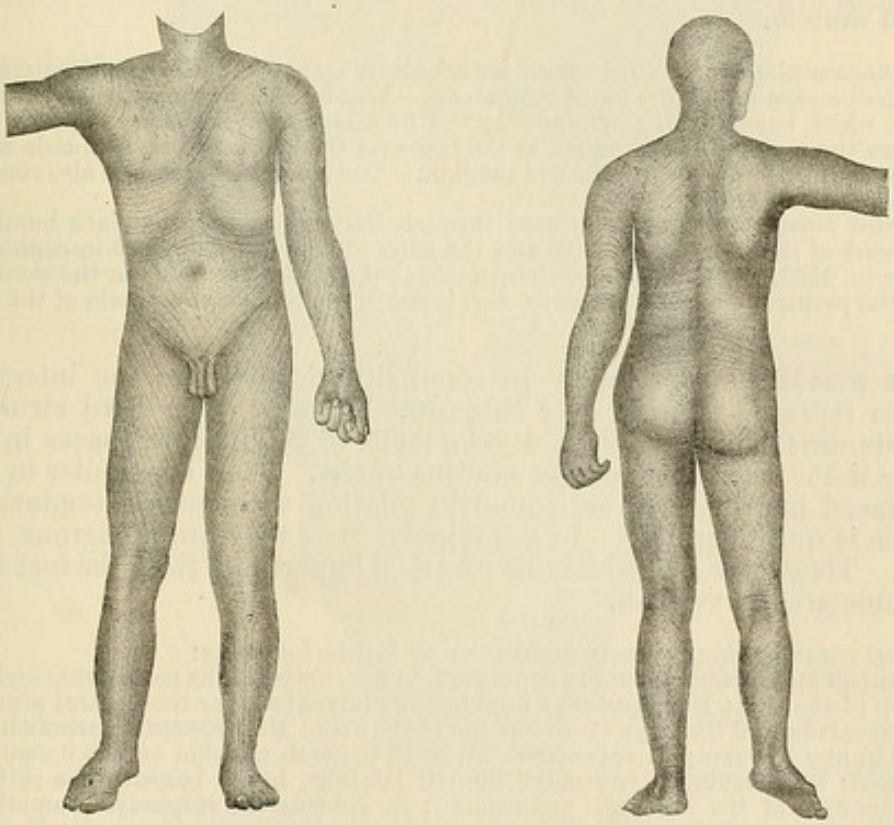

are arranged nearly parallel with the surface, and bind the skin so loosely to the parts beneath that it may stretch and move freely over the deeper parts. In some situations the connective-tissue bundles of the tela subcutanea run almost at right angles to the surface and bind the skin firmly to the deep fascia, as in the flexor surface of the hands and feet and in the scalp and face.

The quantity of subcutaneous fat varies considerably in different parts of the body. It is, for instance, entirely absent in the penis, scrotum, and eyelids. When it is abundant, the subcutaneous layer is known as the *panniculus adiposus.*

In some situations, as in the caudal portion of the abdomen and in the perineum, the connective tissue is so arranged that the panniculus may be divided into layers, so that a superficial and a deep layer of the superficial fascia may be recognised. The fat is well developed over the nates, volar surface of the hands and plantar surface of the feet, where it serves as pads or cushions; in the scalp it appears as a single uniform lobulated layer between the corium and the aponeurosis of the epicranial muscle; and on other parts of the surface it is somewhat unequally distributed and shows a tendency to accumulate in apparent disproportion in some localities, as on the abdomen, over the symphysis pubis, about the mammæ in females, etc. Everywhere except on the scalp it may undergo rapid and visible increase or decrease under the influence of change of nutrition.

The amount of *elastic tissue* mixed with the white fibrous connective tissue of which the corium and subcutaneous tela mainly consist varies in the different parts of the body. It is especially abundant in the deeper layer of the tela over the caudal part of the ventral abdominal wall where it forms almost a continuous sheet. Many elastic fibres also accompany the blood-vessels and are mingled with the connective-tissue sheaths around the hairs, the sweat glands, and their ducts.

The *papillæ corii* are usually simple cones but some are bulbous at their ends and others have duplicated apices. They may be perpendicular to the surface or oblique, in some places overlapping. Those on the flexor surfaces of the hands and feet are best developed and are arranged in rows so as to form long parallel curvilinear ridges, two of which are grouped together and correspond to one crista on the surface of the epidermis (figs. 1045, 1046). When there are no papillary ridges the papillæ are irregularly scattered, shorter, and may disappear in places or be replaced by ridges. The papillæ serve to give a greater surface area to the corium so as to bring a greater number of blood-vessels and nerves into closer relation with the epidermis and thus with the surface of the body. They are best developed where the epidermis is thickest. Thus they are the largest on the flexor surface of the hands and feet and beneath the nails and are smallest on the face, scrotum, and mammæ.

The skin, as removed in the dissecting room, usually includes the epidermis and more or less of the corium and subcutaneous tela. The cut surface is formed of connective tissue which has a shining bluish-white appearance with minute pits closely scattered over the surface. These pits are usually more or less completely filled with small yellow fat lobules.

Skin muscles.—In the subcutaneous tela and the corium muscle fibres are found in large and small groups. These are of two kinds, striated muscle and unstriated muscle.

Subcutaneous planes of *striated muscle* are relatively scanty in man when compared with the great panniculus carnosus of the lower mammalia. This is mainly represented by the platysma in the neck which has both its origin and part of its insertion in the skin. Closely associated with this are the muscles of expression of the face and the palmaris brevis muscle which have one end terminating in the deep surface of the skin. The epicranial muscle is also considered by some to belong to this group.

Unstriated muscle fibres are scattered through the corium collected into bundles in the neighbourhood of the sebaceous glands and the hairs. They are described in connection with these latter (p. 1293). In addition to these unstriated muscles are found in the scrotum as the dartos, in the perineum, around the anus, and beneath the papilla and areola of the mammary gland.

Bursæ mucosæ subcutanea.—In some situations where the integument is exposed to repeated friction over subjacent bones or other hard structures its movements are facilitated by the development of sac-like interspaces in the subcutaneous tissue, the **subcutaneous mucous bursæ.** They are similar to the more deeply placed bursæ which are found in relation with muscle tendons. Their occurrence is quite variable. In some individuals they are numerous, in others very few. They have a considerable practical importance from the fact that they may become greatly swollen.

The most constant subcutaneous mucous bursæ are the following:

Bursa anguli mandibulæ; B. subcutanea prementalis, between the periosteum and soft parts over the tip of the chin; **B. subcutanea prominentiæ laryngeæ** over the ventral prominence of the thyreoid cartilage of the larynx (often found in the male; **B. subcutanea acromialis,** between the acromion and the skin; **B. subcutanea olecrani,** beneath the skin on the dorsal surface of the olecranon; **B. subcutanea epicondyli humeri lateralis,** found beneath the skin over the lateral epicondyle of the humerus (occasional); **B. subcutanea epicondyli humeri medialis,** between the skin and the medial epicondyle of the humerus (more frequent); **B. subcutanea metacarpophalangea dorsalis,** between the skin and the dorsal side of the metacarpophalangeal joints (occasional, especially the fifth); **B. subcutanea digitorum dorsalis,** beneath the skin over the proximal finger-joints; and rarely over the distal finger-joints; **B. subcutanea trochanterica,** between the skin and the great trochanter of the femur; **B. subcutanea præpatellaris,** beneath the skin covering the caudal half of the patella; **B. subcutanea infrapatellaris,** between the skin and the cephalic end of the ligamentum patellæ; **B. subcutanea tuberositatis tibiæ** ventral to the tibial tuberosity, covered by skin or by skin and crural fascia; **B. subcutanea malleoli lateralis,** between the skin and the point of the lateral malleolus; **B. subcutanea malleoli medialis,** between the skin and medial malleolus; **B. subcutanea calcanea,** in the sole of the foot between the skin and the plantar surface of the calcaneum; **B. subcutanea sacralis,** beneath the skin which covers the lumbodorsal fascia and the region between the sacrum and coccyx.

Blood-vessels of the skin.—Both the corium and the subcutaneous tela are very vascular, but the size and number of vessels varies in different situations. Although the origin of the **cutaneous arteries** from the deep arteries and the positions where the subcutaneous arteries pierce the muscles vary greatly, the areas supplied by certain groups of arteries and the direction in which the arteries of the skin run show much regularity. Moreover the metameric arrangement of the arteries in the skin is clearly seen, especially upon the trunk. We can recognise two groups of skin arteries. One group is represented by a small number of rather large branches which are distributed throughout or principally in the subcutaneous tela and corium, as the inferior superficial epigastric artery, the arteries of the scalp, etc. These arteries tend to

disturb the metameric arrangement. In the other group the arteries are intrinsically for the supply of other organs but give off small end twigs to the skin, e. g., the arteries to the superficial muscles.

The arteries enter the corium from the subcutaneous tela, break up into smaller branches anastomose freely and in the deepest layer of the corium form a network, the **cutaneous rete** (subcutaneous plexus), **rete arteriosum cutaneum,** from which small branches are given off to supply the fat and sweat glands and also to the papillary layer of the corium. Here another network of arteries is formed, the **subpapillary rete, rete arteriosum subpapillare.** From the subpapillary plexus, minute twigs pass to the papillæ, to the hair follicles, and to the sebaceous and sudoriferous glands.

The **cutaneous veins** like the arteries may be divided into three groups: (1) small radicals which accompany the corresponding arteries and go to make up veins whose main function is to collect the blood from the muscles; (2) larger branches accompanying the arteries whose main course is in the subcutaneous tela as the inferior superficial epigastric vein; (3) large veins which run in the subcutaneous tela but have a course independent of the arteries such as those seen through the skin on the hands and arms. These large vessels will be found described in connection with the general description of the veins (Section V).

Minute venules arise from the capillaries of the papillæ, accompany the arteries and form parallel with the surface of the skin a series of closely connected plexuses. Four such plexuses,

FIG. 1049.—CUTANEOUS NERVES OF THE MIDDLE FINGER AND LAMELLOUS (PACINIAN) CORPUSCLES. (From Toldt's Atlas.)

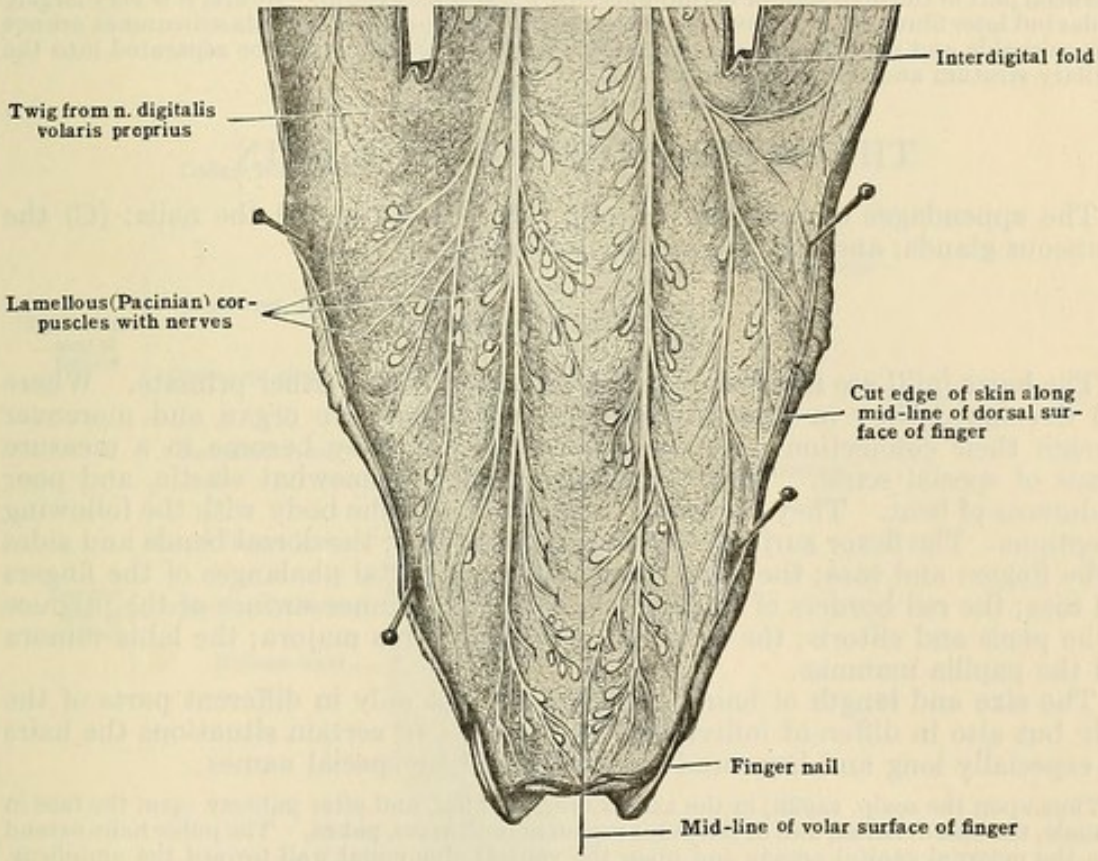

more distinct than the arterial, may be recognised in some situations. Of these **retia venosa** one is situated just beneath the papillæ, and another at the junction of the corium and subcutaneous tela. They receive branches from the fat, hair follicles, and glands, and empty into the large veins of the skin situated in the subcutaneous tissue.

Lymphatics of the skin.—The cutaneous lymphatic vessels are found in the skin of all parts of the body but are more abundant in certain places. The lymph-vessels of the skin are developmentally among the first lymph-vessels to appear. The larger vessels and glands of the subcutaneous tela will be found described in connection with the general lymphatic system Section VI). In the corium the lymphatics from the papillæ form a **subpapillary network** which opens into a **subcutaneous plexus** connected with the larger lymph-vessels of the subcutaneous tela. There are no lymph-vessels in the epidermis, but this is supposed to be nourished by the lymph in the tissue spaces between the cells and these spaces connect indirectly with the lymph-vessels.

The nerves.—The skin has one of the richest nerve supplies of the body. The nerves are in greater proportion in those parts which are most sensitive. The various skin areas are supplied by specific (segmental) nerves with much greater regularity than in the case of the arteries. The nerves supplying adjoining areas overlap so that there is an intermediate space supplied by both. The variations consist in an extension of one area and a corresponding contraction of an adjoining area. The distribution of the nerves in the skin shows, especially on the trunk and neck, a marked metameric arrangement. The arrangement of these nerves in the subcutaneous tela

and their areas of distribution will be found described in detail in the section on the Nervous System.

With the exception of the nerves to the sudoriferous and sebaceous glands, the skin-muscles and blood-vessels, all the cutaneous nerves are sensory. They have diverse modes of termination. Some end in the subcutaneous tela; others, the greater number, terminate in the corium; still others extend to the epidermis.

Toward their termination the nerves branch and rebranch, and just beneath the surface they form a great number of small twigs from which the terminal fibres arise. These may be divided into two groups, those that end freely and those whose termination is surrounded by a capsule. The free ends are slightly enlarged and terminate in the epidermis and in certain regions in the corium. The encapsulated terminations form special end organs and are found in the corium as the **bulbous corpuscles** (end-bulbs of Krause) [corpuscula bulboidea, Krauserii]; the **tactile corpuscles** (corpuscles of Meissner or Wagner) [corpuscula tactus, Meissneri]; and the **genital corpuscles** [corpuscula nervorum genitalia]. In the subcutaneous tela the end-bulbs are seen as the **lamellous corpuscles** (corpuscles of Vater: Pacinian corpuscles), [corpuscula lamellosa; Vateri, Pacini] shown in fig. 1049; the **Golgi-Mazzoni corpuscles** and the **Ruffini corpuscles.** All the terminations except the lamellous corpuscles are microscopic, not exceeding 0.2 mm. in length. The lamellous corpuscles, which are readily seen in reflecting the skin from the fingers and toes, may be as much as 2 mm. long and half as thick (fig. 1049). The exact function of each of the various endings is not known. They are undoubtedly sensory fibres except those to the glands, muscles, and blood-vessels.

Development of the corium and subcutaneous tela.—The corium is developed from the superficial part of the myotome or dermo-muscular plate of mesoderm. At first it is very largely cellular but later fibres are produced. In the earlier stages the corium and tela subcutanea are not distinguishable and only in the later embryonic period may the corium be separated into the papillary stratum and the tunica propria.

THE APPENDAGES OF THE SKIN

The appendages of the skin include: (A) the hairs; (B) the nails; (C) the cutaneous glands; and (D) the mammary glands.

A. THE HAIRS

The **hairs** [pili] are less developed in man than in any other primate. Where well developed they in themselves serve as a protective organ and moreover through their connection with the nervous system they become in a measure organs of special sense. They are strong, flexible, somewhat elastic, and poor conductors of heat. They cover the entire surface of the body with the following exceptions: The flexor surfaces of the hands and feet; the dorsal bends and sides of the fingers and toes; the dorsal surfaces of the distal phalanges of the fingers and toes; the red borders of the lips; the glands and inner surface of the prepuce of the penis and clitoris; the inner surface of the labia majora; the labia minora and the papilla mammæ.

The **size** and **length** of hairs varies greatly not only in different parts of the body but also in different individuals and races. In certain situations the hairs are especially long and large and are designated by special names.

Thus upon the scalp, **capilli,** in the axillary region, **hirci,** and after puberty upon the face in the male, the beard, **barba,** and in the pubic region in both sexes, **pubes.** The pubic hairs extend upon the external genital organs and upon the ventral abdominal wall toward the umbilicus. All of the hairs of these regions are not long and large but short and finer hairs are mixed with them in varying numbers. Strong, well-developed short hairs are found in connection with the organs of sense forming the eyebrows, **supercilia,** the eyelashes, **cilia,** at the entrance to the external acoustic meatus, **tragi,** and at the nares, **vibrissæ.** Upon the extensor surfaces of the extremities, upon the chest, and in other situations in some individuals, especially in adult males, the hairs are also longer and stronger than upon the rest of the body, where they are, as a rule, short, fine and downy. The first hairs appearing in the fœtus are very fine, and are called **lanugo.** The long hairs of the adult scalp may attain a length of 150 cm. or more; the short hairs average from .5 to 1.3 cm. in length, while the lanugo does not exceed 1.4 cm.

Excess of long hairs, **hypertrichosis,** may involve the whole hairy surface of the body. It is usually inherited and affects several individuals in the same family. Local areas of long hairs also occur as over nævi and upon the sacrum. Local congestion due to inflammation, irritation, or pressure may cause hypertrichosis. In women, hair upon the upper lip or other parts of the face may be an inherited peculiarity or due to some abnormality of the sexual organs. It is also not uncommon after the menopause.

In **diameter** the hairs vary from .005 mm. for the finest lanugo to .203 mm. for the coarsest hair of the beard; but they usually taper toward the tip and also are narrower toward the base. As a general rule, blonde hairs are the finest and black hairs the coarsest.

In **colour** the hairs may be either blonde, brown, black, red, or some gradation of these colours. The colour varies with the race, and also with the individual, and according to age. It is due to pigment in the cells of the hair but is also influenced by the amount of air between the cells.

Greying and whitening of the hair is due not only to a decrease of pigment but also to an increase in the amount of air between the cells. Sudden blanching of the hair is thought to be due almost entirely to an increase in the quantity of this contained air. Whitening of the hair is physiological in old age and not infrequent in younger persons. This may be an inherited peculiarity or may follow mental overwork, nervous shock, or prolonged disease. Local blanching is also seen as the result of disease.

The hair may be straight, waved, curled, or frizzled in varying degree. Here also there is not only an individual but also a racial variation, as instanced in the curled or crinkled hair of the African negro and the straight hair of the American Indian. The curliness is caused by the form and the manner of implantation in the skin. Straight hairs are round or oval in transection

FIG. 1050.—LONGITUDINAL SECTION OF A GROWING HAIR OF THE HEAD. (×30.) (From Toldt's Atlas.)

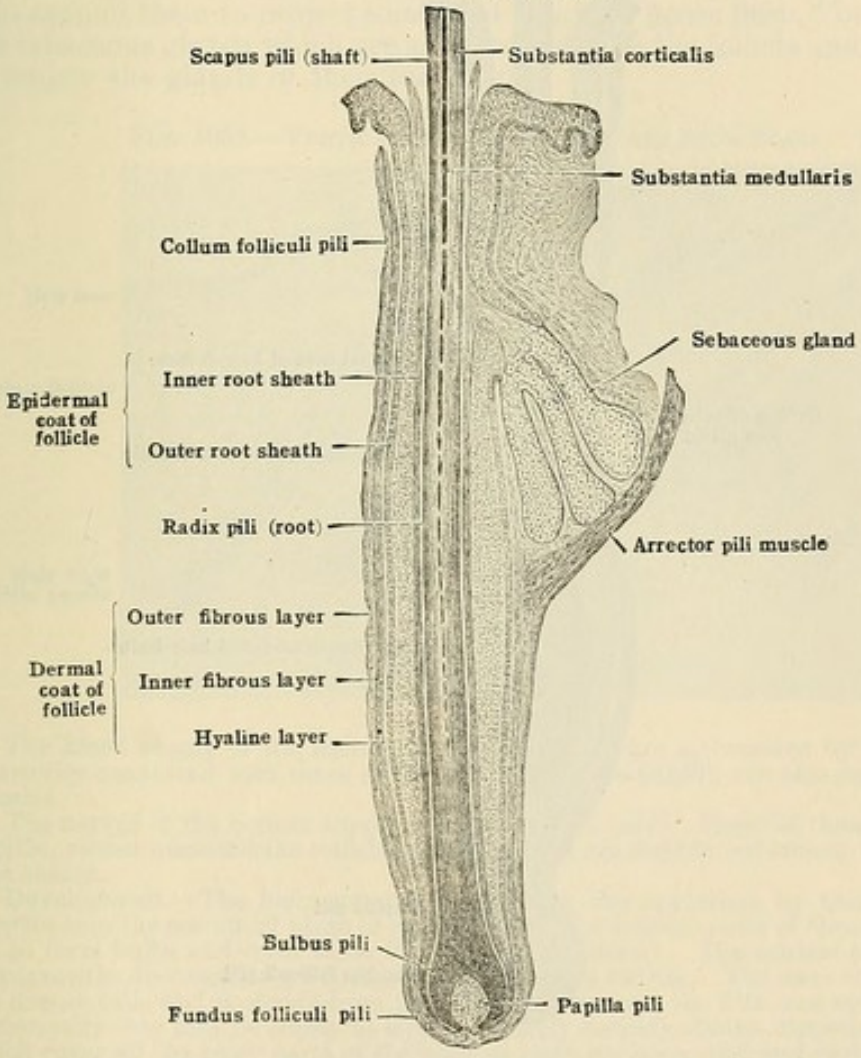

and curled hairs are more flattened. The root of curled hair has been observed in certain instances, as in the negro, to have a curved course in the skin which may account in a measure for its curliness.

The hairs are *arranged* singly or in groups of from two to five and, except those of the eyelashes, are implanted at oblique angles to the surface of the skin. The directions in which the hairs point are constant throughout life for the same individual. They are arranged in tracts in which the hairs diverge from a centre in whorls, the **vortices pilorum.**

These vortices are found constantly in certain definite regions and apportion the whole hairy surface. The centres of vortices are found at the vertex (sometimes double) upon the face, around the external auditory meatus, in the axilla, in the inguinal region, and sometimes on the lateral surface of the body. These are all paired except as a rule the first. Where adjoining vortices come together the hairs are arranged in lines along which they all point in nearly the same direction, only slightly diverging, forming the **hair streams, flumina pilorum.** In other lines and places the hairs point in converging directions such as at the umbilicus and over the tip of the coccyx.

The **number** of hairs to the square centimetre varies in different parts of the body and also in the same situation with the individual and with differences in race, colour and diameters.

The hairs are most numerous on the head, ranging from 170 to 300 to the square centimetre at the vertex. They are less numerous on other parts of the body, varying from 23 to 44 (per square centimetre) on the chin, and from 24 to 80 on the forearm. The greatest number is found with blonde hair, the next with brown, then black, and the least with red hair.

The structure of the hair.—Each hair consists of a **shaft** [scapus pili] (fig. 1050) projecting from the free surface of the skin to end (unless broken or cut) in a conical end [apex pili], and of a **root** [radix pili], imbedded in the case of the lanugo hair in the corium and of the larger hairs at various depths in the subcutaneous tela. Surrounding the root is a downgrowth of the skin known as the *follicle* [folliculus pili].

FIG. 1051.—LONGITUDINAL SECTION OF A HAIR READY TO FALL OUT, WITH FOLLICLE FOR NEW HAIR. (×30) (From Toldt's Atlas.)

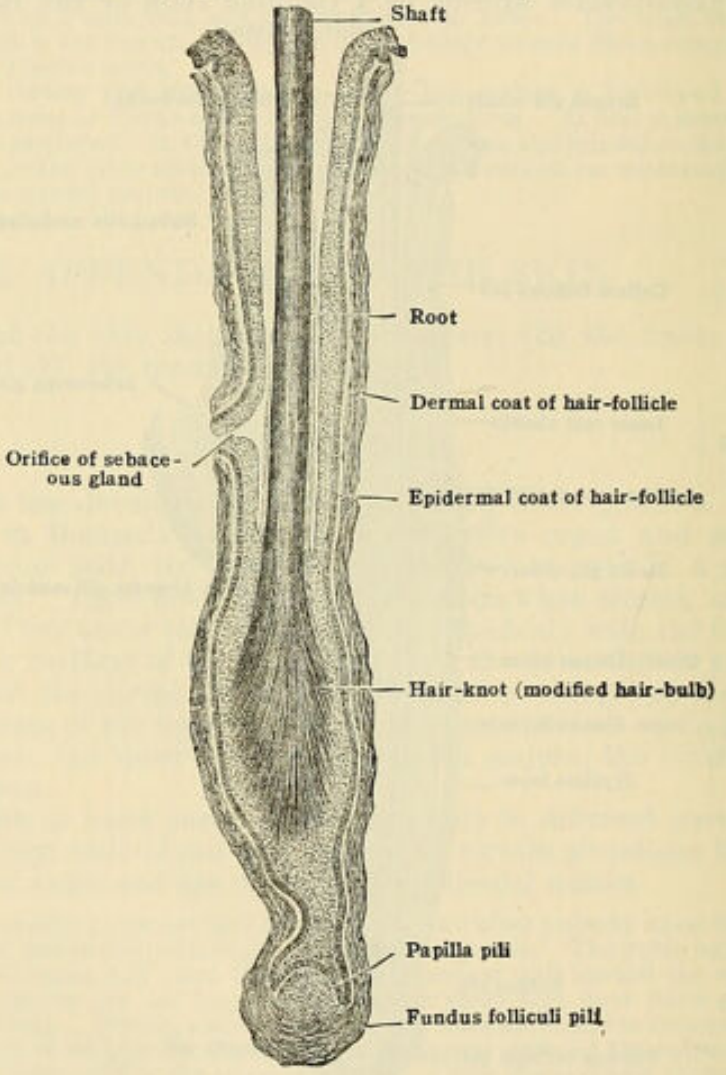

The root of the hair at its deepest parts swells to from one and one-half to three times the diameter of the shaft forming thus the **bulb** [bulbus pili] (fig. 1050). The bulb is hollow and a vascular connective-tissue process, the hair **papilla** [papilla pili] (figs. 1050, 1051) extends from the deepest part of the follicle into the cavity in its base. The follicle consists of an external connective-tissue portion formed by the corium, the **theca folliculi** and an internal epithelial portion belonging to the epidermis and divided into two portions, the **inner** and **outer root sheaths** (fig. 1050).

The theca of the follicle is composed of an outer loose longitudinal and a middle circular layer of connective tissue and an inner basement membrane. The outer root sheath is directly connected with the stratum germinativum of the epidermis. In its deeper part it consists of several layers of cells but of only one near the surface. The inner root sheath has been divided into three layers. At the junction of the outer and middle thirds of the follicle of most of the hairs, the ducts of usually two or more sebaceous glands connect with the space between the hair

and its follicle (figs. 1050, 1051). Immediately beneath this is the narrowest part of the follicle the **neck** [collum folliculi pili], especially important as the position of the nerve ending of the hair.

The hair is formed of epithelial cells arranged in two and sometimes three layers; an outer single-celled layer of transparent over-lapping cells, the **cuticle,** an intermediate layer several cells thick formed of irregular fusiform horny cells containing pigment and arranged in fibrous strands, the **substantia corticalis,** and in some of the larger hairs an internal two or three celled layer of angular cells occupying the center of the hair shaft for only part of its length, the **substantia medullaris.** Between both the cortical and medullary cells are spaces containing air. In the hair bulb, where the cells are larger and softer the layers are not distinguishable. The cells here being in process of division and being gradually transformed into the horny cells of the shaft.

Many of the hairs have in connection with their follicle round or flat bundles of unstriped muscle fibres, the **arrectores pilorum** (figs. 1050, 1052). These are situated on the side toward which the hairs point, their deep ends being attached to the hair follicle beneath the sebaceous glands which they more or less embrace and their superficial ends connected with the papillary layer of the skin. Contraction of the arrectores not only causes the hairs to become more erect and the skin around them to project somewhat causing "goose flesh," but also compresses the sebaceous glands which are situated between the follicle and muscle and helps to empty the glands of their secretion.

FIG. 1052.—VERTICAL SECTION OF THE SKIN FROM SCALP. (× 20.)

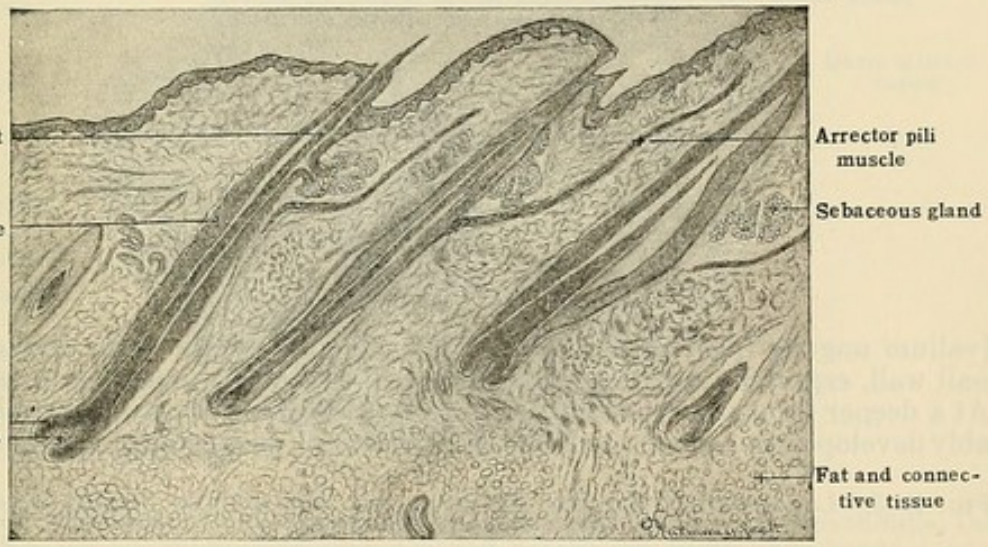

The blood supply of the hairs.—The hair follicles are surrounded by a capillary network of arteries connected with those of the corium and the papillæ are also supplied with loops of arteries.

The **nerves** of the corium supply branches to the hairs. Some of these branches enter the papillæ, others surround the follicle at its neck and are distributed among the cells of the outer root sheath.

Development.—The hairs are developed from the epidermis by thickenings and downgrowths into the corium of plugs of epithelium. The deepest parts of these plugs become swollen to form bulbs and from these the hairs are produced. The central cells of the epithelial downgrowths disintegrate producing the lumen of the follicle. The hairs continue to grow from the deeper cells and protrude from their follicles between the fifth and seventh fœtal months. Abnormally they may be scanty at birth and rarely entirely absent, **alopecia.** The lanugo hairs which cover all the hairy parts of the body at birth are soon shed and replaced by new hairs in the old follicles. Throughout life also the hairs are being constantly shed and replaced by new ones. This is accompanied by cornification of the bulb and fibrillation of the deep end of the hair (fig. 1051). Thinning of the hair and baldness occur when the shed hairs cease to be replaced. This is common in old age and a premature baldness appears to run in certain families. The rate of growth is normally from 1 to 1.5 cm. per month, but is subject to variation.

B. THE NAILS

The **nails** [ungues] are thin, semi-transparent, horny epidermic plates upon the dorsal surfaces of the distal phalanges of the fingers and toes. Through their hardness they serve as protective organs not only by covering the nerve endings and other delicate structures of the skin; but also by acting as natural weapons. On the fingers they form useful tools. They are four-sided plates presenting a dis-

tal free border [margo liber], which overhangs the tips of the fingers, an irregular, sharp proximal edge [margo occultus], and on each side a somewhat thinned border [margo lateralis] (fig. 1053).

FIG. 1053.—DORSAL SURFACE OF ISOLATED FINGER NAIL. (× 1.) (From Toldt's Atlas.)

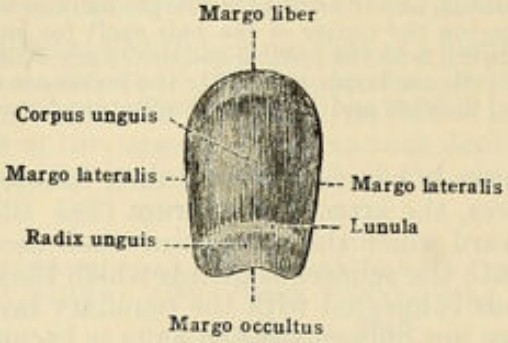

Each nail is composed of an exposed distal part, the **body** [corpus unguis], and a proximal covered part, the **root** [radix unguis], (fig. 1053), which ends in the margo occultus. The nail is at a slightly deeper level than the surrounding skin which overhangs the root and the lateral margins in a fold, the **nail wall**

FIG. 1054.—FINGER NAIL AND NAIL BED.

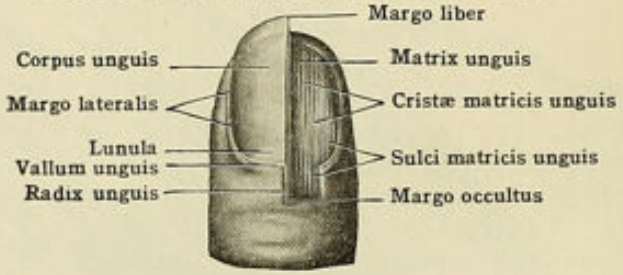

[vallum unguis] (figs. 1054, 1055, 1056). The epidermis of the free edge of the nail wall, especially proximally, is thickened and often appears as a ragged edge. At a deeper level than the above and extending somewhat more distally is a variably developed thin parchment-like membrane, the **eponychium,** closely attached to

FIG. 1055.—LONGITUDINAL SECTION THROUGH THE TIP OF THE MIDDLE FINGER. (× 2) (From Toldt's Atlas.)

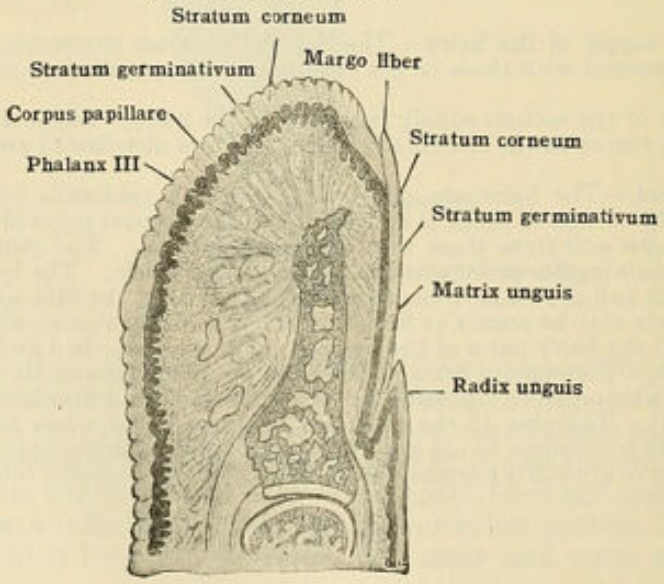

the superficial surface of the nail. It is the representative of the superficial layers of the embryonic epidermis which do not take part in the formation of the nail. The groove which is formed between the vallum and the underlying nail bed is known as the **sulcus matricis unguis.** This lodges the root and lateral margins

of the nail and is deepest in the centre of the root, becomes shallower toward the lateral margins, and finally disappears entirely toward the free border of the nail (figs. 1055, 1056).

The dorsal free exposed surface of the nail is formed by a hardened, thickened, horny layer of epithelium corresponding to the deeper parts of the stratum corneum (or the stratum lucidum) of the skin, the **stratum corneum unguis** (fig. 1056). It is convex from side to side (especially on the fifth finger), and also in some cases longitudinally. It presents a number of more or less well-marked fine longitudinal ridges. The stratum corneum forms the principal thickness of the nail. It is thicker and more solid on the toes than on the fingers. The portion of the nail which projects beyond the skin of the fingers and toes is greyish-white in colour. Unless broken or cut, it curves ventrally upon the ball of the finger or toe and tends to become long and claw-like. It may attain a length of 3 or more centimetres.

The concave volar or plantar surface of the nail is softer and is formed of a layer of epithelial cells which corresponds to the stratum germinativum (Malpgihii) of the skin and is known as the **stratum germinativum unguis** (fig. 1056). Because of the transparency of both layers of the nail the blood in the underlying matrix is seen through the body of the nail and gives to it a

FIG. 1056.—CROSS-SECTION THROUGH THE NAIL AND TIP OF THE RING FINGER. (× 4). (From Toldt's Atlas.)

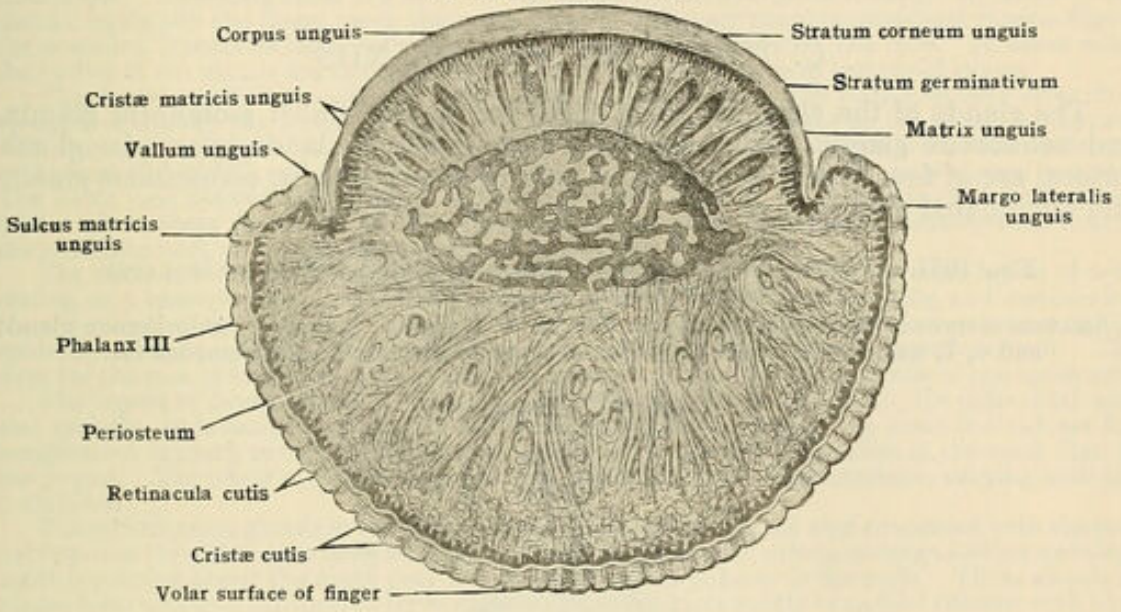

pinkish colour; but toward the root of the nail there is a semilunar area convex distally, the **lunula,** which is less transparent and opaque whitish in color (fig. 1053). The lunula is variously developed in different individuals. It is largest on the thumb and is often absent on the little finger. It is also smaller on the toes than on the fingers.

The stratum corneum unguis consist of thin, flattened, transparent, horny scales with shrunken nuclei. These cells are intimately joined together in thin layers. The stratum germinativum unguis is formed of cells continuous with and resembling those of the corresponding layer of the epidermis. Air may occur between the cells as with the hair. The cells of the root are not yet cornified or dried out.

The stratum germinativum unguis rests upon the corium, which here forms the so-called **nail bed** [matrix unguis].[1] This is made up of a dense feltwork of connective tissue fibres without fat. It is highly vascular and sensitive and the vertically arranged bundles bind the nails tightly to the periosteum of the terminal phalanges. The papillæ of the matrix beneath the body of the nail are arranged in strongly marked longitudinal ridges, the **cristæ matricis unguis.** The cristæ and papillæ of the matrix fit into corresponding depressions on the deep surface of the stratum germinativum unguis.

The cristæ of the matrix are small and low proximally and become larger and fewer distally. Those toward the lateral borders are somewhat oblique. The papillæ of the root are not in rows but are irregularly arranged and disappear entirely near the distal border of the lunula. Toward the free border of the nail the papillæ become large and change in character to that of the adjacent skin.

The best developed nails are those of the thumbs and great toes, the least developed, those of the fifth digits which on the toes are often represented only by a horny tubercle.

Blood-supply of the nails.—The **arteries** are numerous in the matrix beneath the body of the nail but fewer beneath the root. They pass from the deep parts of the nail bed toward the surface, running in the main longitudinally and sending anastomosing branches to the papillæ.

The nerves beneath the nail are abundant and terminate in free sensory endings and in special end organs of several sorts.

[1] The term nail bed is applied by some anatomists to that part of the corium beneath the body of the nail, the term matrix being reserved for the corium beneath the lunula and root.

Development of the nails.—The nails are developed from the epidermis. In early embryos over the dorsal surface of each distal phalanx there is seen a smoother and more adherent area of skin which becomes limited by folds distally as well as proximally and laterally. It is also distinguished by a greater number of cell layers which later become flatter than the surrounding cells. The number of cell layers still further increases and at about the fifth fœtal month the nail proper is formed by the deeper lying cells over an area extending from the proximal fold to the distal end of the lunula. The nail is pushed distally by constant formation of new cells in the same way as it continues to grow throughout life. The surface epithelial cells of the nail field cover the nail for some time as a thin layer, the **eponychium,** which later disappears except a small fringe near the root.

Growth of the Nails.—The nail grows in length and thickness by multiplication of those cells of the stratum germinativum which are situated between the margo occultus of the root and the distal border of the lunula. The older cells are pushed distally and toward the surface by the deeper cells. As a result the nail becomes gradually thicker from the occult border as far as the distal margin of the lunula. Over the rest of the nail bed no thickening appears to take place. The rate of growth is faster on the fingers than on the toes and varies with age, season, and the individual. When the nail is torn off, or detached through inflammation, it may be regenerated if the cells of the stratum germinativum have not been destroyed.

Congenital hypertrophy of the nails sometimes occurs, but absence or imperfect development is rarely seen. The white spots so frequently seen in the nail are caused by air between the cell layers due usually to injury or impaired development.

C. THE CUTANEOUS GLANDS

The **glands of the skin** [glandulæ cutis] are of two kinds: **glomiform glands,** and **sebaceous glands.** The *glomiform* ("skein-like") glands [glandulæ glomiformes] are of four types: sudoriferous glands, ciliary glands, ceruminous glands and circumanal glands.

FIG. 1057.—VERTICAL SECTION OF THE PALMAR SKIN SHOWING AN ISOLATED SUDORIFEROUS GLAND. (Testut.)

1, Stratum corneum; 2, Malpighian layer; 3. corium; 4, papilla; 5, body of sudoriferous gland; and 6, 7, its excretory duct; 8, orifice of duct on surface; 9, subcutaneous fat.

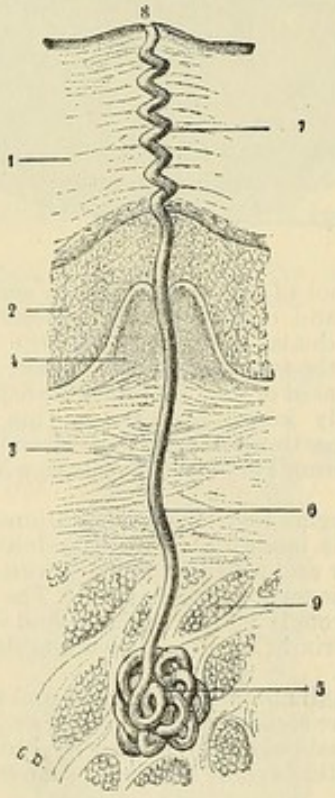

The **sudoriferous glands** [glandulæ sudoriferæ] or sweat glands are modified simple tubular glands which secrete the *sweat* [sudor]. They are found in the skin of all parts of the body except that part of the terminal phalanges covered by the nails, the concave surface of the concha of the ear, the labia minora, and the inferior part of the labia majora in the female and the surface of the prepuce and the glans penis in the male. The number found in different parts of the body varies greatly. They are very few on the convex surface of the concha and on

the eyelid. They are also rather scanty on the dorsal surface of the trunk and neck, more numerous on the ventral surface of these parts and on the extensor surfaces of the extremities, still more numerous on the flexor surfaces, and most numerous on the volar surface of the hands and plantar surface of the feet. They vary from less than 57 to more than 370 to the square centimetre. The total number has been variously estimated at from two to fifteen millions.

Each gland (fig. 1057) consists of a secretory portion or **body** [corpus gl. sudoriferæ], and an excretory **duct** [ductus sudoriferus], which opens on the surface of the skin by a mouth visible to the unaided eye, the so-called 'pore' [porus sudoriferus]. Occasionally the duct opens into a hair follicle.

The **bodies** of the glands are irregular or flattened spherical masses, yellowish or yellowish red in colour and somewhat transparent. They vary in size from .06 to 4 mm. or more with a mean diameter of .2 to .4 mm., the largest being found in the axilla. They are formed of the irregularly, many times coiled, terminal part of the gland tube. The bodies of the glands are situated in the deeper part of the corium or in the subcutaneous tela.

The wall of the rather wide-lumened gland tube is formed of a single layer of cubical or columnar epithelium containing fat and pigment granules and surrounded externally by a basement membrane. Enclosing these is a more or less dense connective-tissue sheath. In many of the glands, especially the larger ones, there is a layer of obliquely running unstriped muscle fibres, the so-called myoepithelium, between the basement membrane and the cells. In some cases the bodies of the glands are imbedded in a more or less dense mass of lymphoid tissue.

The **ducts,** beginning as several coils bound up with those of the bodies, extend often in a straight or slightly wavy course nearly at right angles to the surface as far as the epidermis. This they pierce as spiral canals of from two to sixteen turns, more marked where the epidermis is thickest (fig. 1041), and opened on the surface by somewhat widened funnel-shaped mouths. The ducts pass between the papillæ of the corium and open on the summits of the cutaneous cristæ where these are present. The diameter of the ducts is distinctly smaller than that of the secreting part of the glands, and this is true of the lumen also.

The ducts are lined by a stratified epithelium composed of two, three, or more layers of cells resting on a basement membrane without any intervening layers of muscle-cells, and surrounded by a connective-tissue sheath. This latter as well as the basement membrane ceases at the epidermis and the epithelial cells of the duct walls join those of the stratum germinativum. The duct for the rest of its course to the surface is merely a canal through the cells of the epidermis.

The degree of development of the sweat glands varies with the situation, the individual, and also racially, as instanced by their great development in the negro. In some individuals the perspiration is much more profuse than in others. The glands are smaller in the aged than in the young. The odour of the sweat is peculiar and more or less characteristic, varying with the individual.

The sudoriferous glands in the axillary region seem to be in some way connected with the sexual function for although a large number persist as small glands, others undergo further development beginning about the ninth year in the female and at puberty in the male. These glands in places form almost a continuous layer and are formed of large partly branched tubules with high secreting cells. The reddish colour of the sweat in the axillary and some other regions, especially in certain individuals, is probably derived from the pigment granules which are found in the glands here. The oil in the secretion lubricates the skin and keeps it soft and supple.

Blood-supply of the sudoriferous glands.—The sudoriferous glands are supplied from the deep cutaneous plexus by an abundant network of arteries which surround and penetrate between the coils of the gland tubules.

Nerves.—There is an enclosing network of nerve fibres some of which have been traced to the gland cells.

Development.—The sudoriferous glands are seen first in the fourth or fifth fœtal month. The anlages resemble closely those of the hair, but the cells are not so loosely packed. They project down as solid plugs which become long, slender, and tortuous rods. In the seventh fœtal month the rods begin to develop a lumen in the deeper parts, which also now begin to coil. A lumen soon develops also in the superficial parts and joins that in the deeper part of the gland. The outer of the two layers of epithelium in the ducts becomes transformed at its transition into the gland proper into the myoepithelial layer.

The **ciliary glands** [gl. ciliares; Molli] are modified sudoriferous glands of the branched tubo-alveolar type. They have simpler coils but are larger than ordinary sweat glands. They are situated in the eyelids near their free borders and open into the follicles of the cilia or close to them (see Section VIII).

The **circumanal glands** [gl. circumanales] are found in a circular area about 1.5 cm. wide which surrounds the anus, a short distance from it.

These glands are several times the size of the ordinary sweat glands and resemble the glands found in the axilla, their secretion likewise having a strong odour. They are branching tubular glands. The other kinds of glands which are found in this same area are ordinary sweat glands, glands with straight ducts, with saccules and secondary alveoli, and tubo-alveolar glands.

Cerumimous glands [gl. ceruminosæ] are glomiform glands somewhat modified from the sudoriferous type. They are branched tubo-alveolar glands

with relatively large lumina in the coils and narrow short ducts, and occur only in the external acoustic (auditory) meatus.

They are very abundant on the dorsal and superior part of the acoustic meatus in the region of the cartilaginous part, where in the adult most of them open on the surface of the skin close to hairs. Others open into the hair follicles as they all do in the fœtus and child. Their secretion, the **cerumen,** is, when freshly secreted, a fluid or semifluid oily material of a yellowish-brown colour, which on exposure to the air becomes solid like wax.

The **sebaceous glands** [gl. sebaceæ] are simple branched or unbranched alveolar glands distributed over nearly the whole surface of the body. Nine-tenths of them are closely associated with the hairs, into the follicles of which they empty (figs. 1050, 1051), and are therefore absent from certain of the non-hairy parts of the body, as the flexor surfaces of the hands and feet, the dorsal surfaces of the distal phalanges of the fingers and toes. On the other hand, a few are found, usually much modified, opening independent of the hair follicles, as at the angles of the red margins of the lips, around the nares, around the anus, and the *tarsal* (Meibomian) glands in the eyelids. Modified sebaceous glands are also found upon the mammary papilla and areola in the female, and in some cases upon the superficial surface of the glans and the surface of the prepuce of the penis, here known as **preputial glands;** also a few very small ones may be found upon the labia minora, the glans and prepuce of the clitoris.

The glands vary in *size* in different situations and also in individuals and races. They range from .2 to 2.2 mm. long and nearly as broad. Among the smallest are those of the scalp. The largest are found on the alæ of the nose and on the cheeks where their ducts are visible to the unaided eye. They are also large on the mons pubis, labia majora, scrotum, about the anus and on the mammary areola. Smaller glands are also found associated with these large ones. The size of the glands is independent of the size of the hairs with which they are associated but the number of glands depends upon the size of the hair. On small hairs one or more glands are always found and on large hairs there may be a whole wreath of from four to six separate glands opening into the hair follicle.

The *number* of sebaceous glands has never been exactly estimated, although, it is known that they are less numerous than the sudoriferous glands. This is very evident on the extremities, trunk, and neck, where they bear a relation of 1 to 6 or 8. On the scalp, concha of the ear, and skin of the face they are about equal in number while on the forehead, alæ of the nose, free borders of the eyelids and external genital organs in the female the number of sebaceous glands is greater than the number of sudoriferous glands.

Each sebaceous gland consists of a secretory portion, the **body,** connected with the hair follicle or the surface of the skin by a wide short **duct.** In the small glands, the body of the gland may consist of a single alveolus but in the larger glands there are from four to twenty of these connected by irregular ducts to a single excretory duct.

The **ducts** open into the hair follicles near their necks between the inner root sheath and the hair or upon the surface of the skin. They are always very short, cylindrical, or infundibuliform, and their epithelium is directly connected with that of the outer root sheath of the hair follicle or with the epidermis where the hair is wanting.

The glands lie in the superficial layers of the corium and where one or a few are connected to a single hair, they usually open into the hair follicles on the side toward which the hairs point. Where there are several glands for one hair they may completely surround the hairs like a rosette.

The cells of the body of the gland and of the duct are surrounded by a basement membrane outside of which is a connective-tissue sheath, both of which are continuous with corresponding coverings of the hair follicle.

The periphery of the alveolus is formed of small cubical epithelial cells, the central part of larger and more rounded cells. The cells of the alveolus show all stages of fatty degeneration, the peripheral cells contain small fatty particles, those nearest the centre larger and more numerous fat droplets, some of them being completely broken down. There is no distinct lumen to the alveolus but this is filled with degenerated cells, fatty particles and débris of broken-down and cast-off cells. The deeper cells continue to multiply and push the more superficial cells toward the lumen where they in turn are cast off. The secretion thus formed is known as the **sebum cutaneum.** It is a whitish or whitish-yellow mass composed of fat and broken-down cells of the consistency of thick oil which spreads over the surface of the skin and hair as a lubricant. Through the decomposition of its fat more or less odour is produced. When the gland duct is blocked the secretion is retained and becomes more solid and is known as a **comedo.** The active secretion of the sebaceous glands does not begin before the fifth or sixth year of life. It attains its maximum in the adult and decreases in the aged.

The relation of the arrectores pilorum to the sebaceous glands has been described in connection with the relation of these muscles to the hairs.

Vessels and nerves.—The sebaceous glands are surrounded by a fine capillary plexus of **blood-vessels** closely associated with those of the hairs and skin. Concerning their **lymph-vessels** little is known. The **nerves** of the sebaceous glands are connected with those of the skin and hair but the exact manner of distribution is not clearly understood.

Development.—The sebaceous glands appear first in the fifth fœtal month as single, rarely double, buds on the anlages of the hair follicles. The distal ends of these enlarge and become lobulated. In these solid masses of cells lumina for the alveoli and the ducts later are formed, through the fatty degeneration of the central cells. The oily contents of these cells together with the débris and the cast-off surface cells of the epidermis form the **vernix caseosa** on the surface of the fœtus.

D. THE MAMMARY GLANDS

The **mammary glands** [mammæ] or breasts are modified cutaneous glands. In the male they remain rudimentary and functionless throughout life, but in the female they are functionally closely associated with the reproductive organs since they secrete the milk for the nourishment of the newborn and are subjected to marked changes at puberty, throughout pregnancy, during and after lactation, and after the menopause.

FIG. 1058.—THE RIGHT MAMMA OF A GIRL 18 YEARS OLD. (Modified from Spalteholz.)

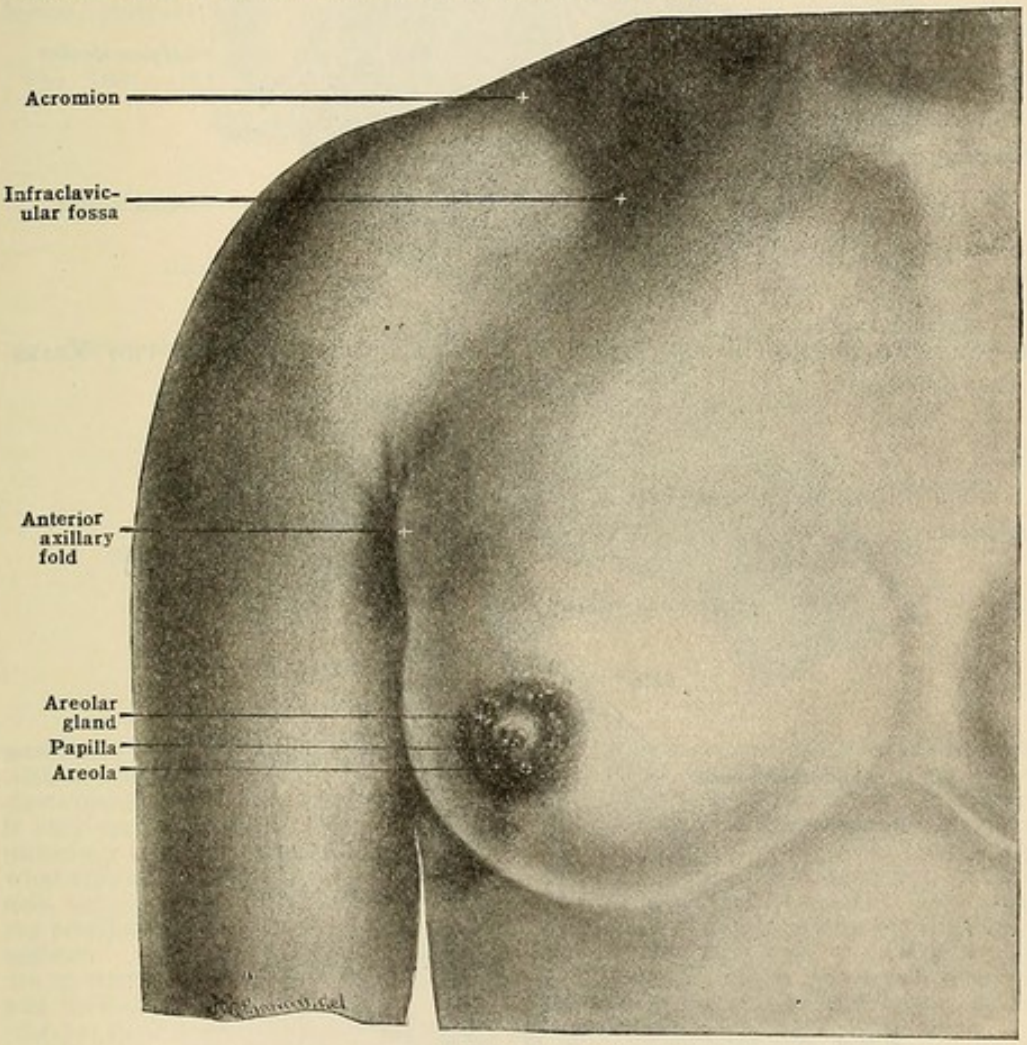

The two mammæ (fig. 1058) are situated on the ventral surface of the thorax one on each side of the sternum. As examined from the surface in a well-developed nulliparous female they appear to extend from the second or third rib to the sixth or seventh costal cartilage and from the lateral border of the sternum to beyond the ventral folds of the axillæ. Separating the two mammæ there is a median unraised area of variable size, the **sinus mammarum.**

In **shape** they are conical or hemispherical, and in consistency somewhat firm and elastic. The **size** of the two breasts is seldom equal, the left, as a rule being slightly the larger. Each measures from 10 to 13 cm. in diameter being slightly longer in the direction parallel to the lateral border of the pectoralis major muscle. The **weight** of each gland varies from 140 to 200 grams, or more.

Each mamma presents for examination a ventral surface and a dorsal surface. The **ventral surface** is free, covered by skin, smooth and convex. It is continuous

cephalically, without sharp demarcation, with the ventral surface of the thorax but laterally and caudally it is usually sharply defined (figs. 1058, 1060). It is

FIG. 1059.—THE FEMALE MAMMA DURING LACTATION. (After Luschka.)

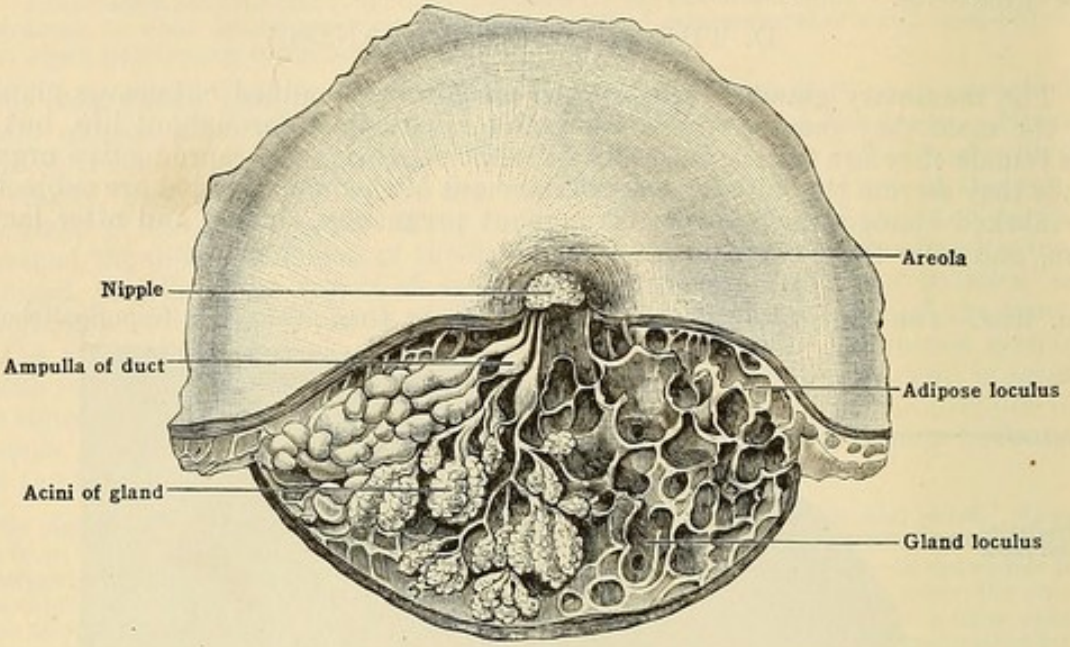

FIG. 1060.—SAGITTAL SECTION OF THE RIGHT MAMMA OF A WOMAN TWENTY-TWO YEARS OLD. (Testut.)

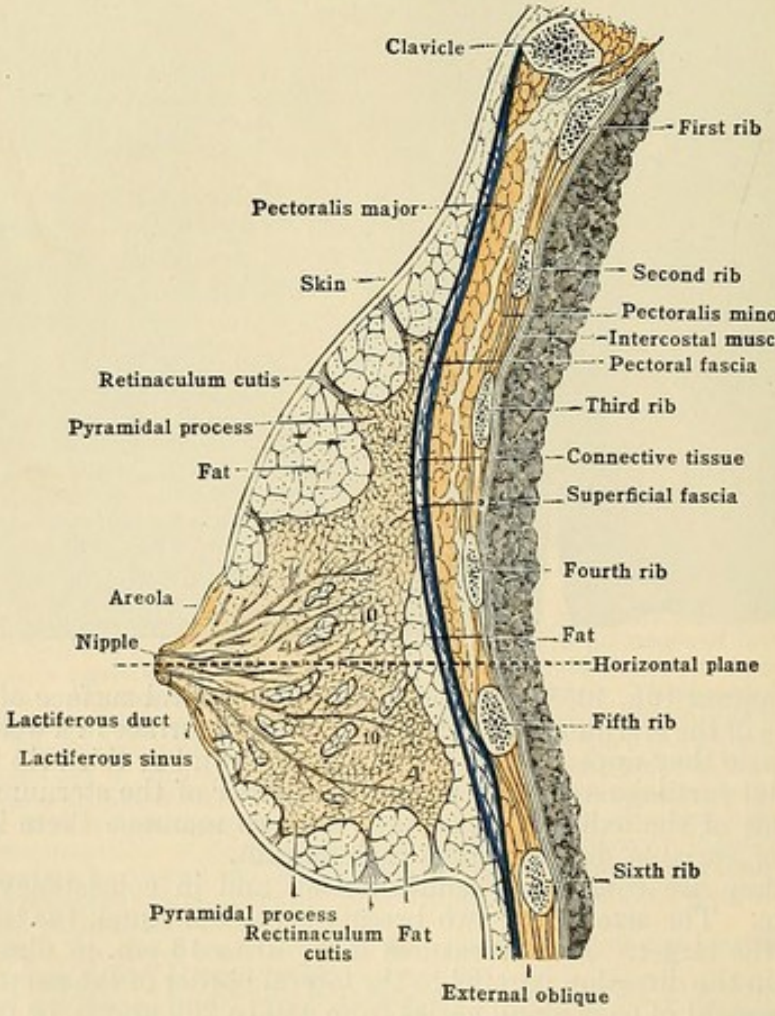

most prominent slightly meso-caudal to the centre and at this point there is a marked pigmented projection, the **nipple** [papilla mammæ] surrounded by a

slightly raised area, also pigmented, the **areola mammæ.** These two structures will be described separately later.

The **dorsal surface** of the mammary gland (figs. 1060, 1061) is attached and concave. It is in relation in its cephalo-medial two-thirds with the fsacia over the pectoralis major muscle. In its caudo-lateral third it extends over the base of the axillary fossa, where it is in relation with lymphatic glands and with the serratus anterior muscle, and at its most caudal part, sometimes with the external abdominal oblique muscle.

The usual **number** of breasts in the human species is two; rarely is the number reduced, much more often do we find an increase in this number. Each of these conditions is found in both sexes and may be complete or partial. Complete suppression of both breasts, **amastia,** is one of the rarest anomalies and is usually associated with other defects. Complete absence of one is less rare. A more frequent condition is arrest of development, **micromastia,** leading to rudimentary but functionless organs. Absence of the nipple, **athelia,** is much commoner and generally affects both breasts. All grades of the imperfection from complete absence to slightly imperfect nipple may be found. When there is an increase this may include the whole breast, **polymastia,** or just the nipple, **polythelia.** The supernumerary structures [mammæ

FIG. 1061.—HORIZONTAL SECTION OF THE RIGHT MAMMA OF A WOMAN 22 YEARS OLD. (Testut.)

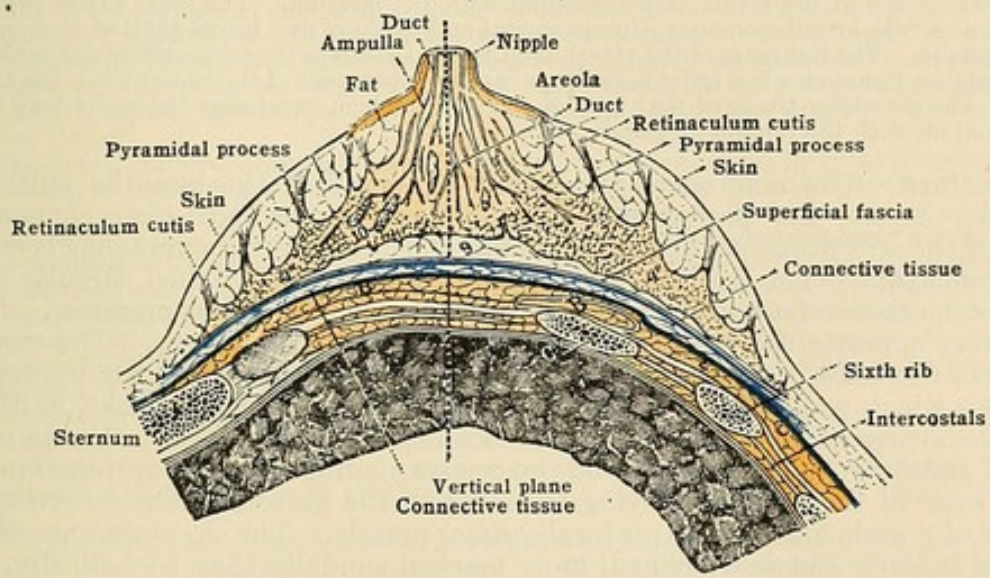

accessoriæ] may be represented only by a pigmented area representing an areola; or by a nipple with or without an areola; by a gland with a more or less perfect nipple and areola; or with ducts opening without a nipple; or there may be no opening on the surface. The extra mamma is very rarely perfectly developed and functional. Various observers have found the supernumerary breasts or nipples occurring in from 1 to 7 per cent. of the cases examined and somewhat oftener in males than in females. The extra organs are found more frequently on the left side, usually along a line extending from the axilla toward the genitalia. This corresponds to the position in which the mammæ occur in some other mammals and also to the milk line of the embryo. Although they are occasionally found in other situations, over 90 per cent. of them are encountered upon the ventral surface of the thorax along the above-mentioned line caudal and medial to the normal pair of breasts. They are frequently hereditary. It is doubtful whether their possessors are either more fertile or more liable to bear twins.

The **shape** of the breasts varies with the development and functional activity and the amount of fat. The smooth, somewhat conical breast of the nullipara becomes hemispherical with increase in the amount of fat, while in emaciation it may be reduced to a flattened disc with an irregular surface. After lactation the breasts tend to become more pendulous with marked sulci between them and the thoracic walls, and after repeated pregnancies they may become elongated so as to be almost conical or even have pedunculated bases.

The **size** of the mammary gland in girls remains relatively the same as in the infant up to puberty when it suddenly increases considerably and continues for a time to enlarge slightly at each menstrual period. There is also a temporary enlargement and soreness at each menstrual period, due perhaps to the increased vascular supply. Until the age of puberty the glands measure 8 to 10 mm. in diameter but when they have attained their complete adult development they have increased to 100 to 110 mm. in the cephalo-medial, 120 to 130 mm. in the cephalo-lateral (obliquely from above downward) direction, and 50 to 60 mm. in thickness. During pregnancy the breasts again increase in size, more especially

after the birth of the child. When their full functional activity is established, their volume may be two or three times as great as before pregnancy. After lactation they return again nearly to their former size, which they retain until another pregnancy. After the menopause the useless glands in some cases atrophy and are reduced to small discoidal masses. In others, especially in fat individuals, although the secreting tissue disappears, it is replaced by fat so that there is little or no reduction in size. In addition to the above-mentioned variations in size, the breasts are subject to great individual differences, the cause of which is little understood. Large robust women are sometimes seen with small mammary glands, and small women with large glands. In some individuals they are especially large.

The **weight** of each mamma varies, naturally, with the volume, increasing from 30 to 60 centigrams in the small gland of a young child to 140 to 200 grams after puberty and in nursing women reaching 400 to 500 and occasionally 800 to 900 grams.

The firm and elastic, well-developed breasts of young nulliparæ become during lactation even more firm and tense, but after lactation especially if there has been a long period of nursing they lose their consistency and after several pregnancies become soft and flabby.

The sulcus which defines the caudal border of the breast is but little marked in thin nulliparæ, more marked in fat women, and especially evident in some multiparæ. The relations of the dorsal surface of the gland vary somewhat with the position. The level varies with the stature; as a rule, in tall women it is more caudal and in short and broad-chested women it is more cephalic. The tightness of the attachment to the sheath of the pectoralis major muscle is quite variable, but even when quite loose there is some movement of the breast when the arm is raised. The glandular tissue of that part of the breast which overhangs the axilla may be in direct contact with the lymphatic glands.

Structure.—The mammary glands are composed of the essential epithelial glandular tissue, the **parenchyma,** the supporting and enclosing connective tissue of the subcutaneous tela, the **stroma,** and the covering cutaneous layer.

Parenchyma.—The essential part of each mamma is a flattened, circular mass of glandular tissue of a whitish or reddish-white colour, the **corpus mammæ.** This is thickest opposite the nipple and thinner toward the periphery. The ventral surface of this mass is convex and made uneven by numerous irregular pyramidal processes which project toward the skin. The dorsal surface, or base, is flat or slightly concave and much less irregular than the ventral surface. Minute processes of glandular tissue extend from the corpus mammæ into the retromammary tissue, some of them accompanying the septa of the pectoral fascia between the bundles of muscle fibres of the pectoralis major muscle. The circumference of the mamma is thick and well defined, more marked caudally than cephalically, but it presents numerous irregular processes which extend beyond the limits apparent from the surface. One of these especially large and well marked extends cephalolaterally into the axillary fossa, and there are frequently other large but less-marked projections.

The **corpus mammæ** is not a single structure but is composed of from fifteen to twenty separate **lobes** [lobi mammæ] (fig. 1059). These are larger and smaller irregular flattened pyramidal groups of glandular tissue, with their apices toward the nipple and their bases radiating toward the periphery of the gland.

Each lobe has a single excretory **duct** [ductus lactiferus] (figs. 1059, 1060, 1061), which opens by a contracted *orifice* [porus lactiferus] in a depression upon the tip of the nipple. When traced from the pore toward the circumference of the gland, the ducts are seen to run first directly dorsally through the nipple, parallel and close to one another. From the base of the nipple they diverge. Each duct is here visible to the unaided eye and measures from 1.5 to 2.5 mm. in diameter. Beneath the areola its diameter increases for a short distance to from 4 to 9 mm., forming thus a reservoir, the ampulla or **sinus lactiferus,** in which the secretion may accumulate for a time. Beyond this dilation the duct continues. gradually decreasing in size as it breaks up into smaller and smaller branches, There is no anastomosis between the ducts during their course, although at or beneath the pore two or more ducts may join to have a common opening. They possess no valves but when empty their inner surface is thrown into longitudinal plicæ.

The ducts have an external coat of white fibrous connective tissue mixed with circular and longitudinal elastic fibres. They are lined with a simple cuboidal or columnar epithelium, except near the orifice, where it is stratified squamous. External to the lining epithelium there

occurs in the smaller ducts a second layer of elongated cells resembling the myoepithelium of the sudoriparous glands.

Each of the terminal branches of a duct ends in a tubulosaccular, spherical or pyriform **alveolus.** A number of these alveoli which open into a common branch of the duct, when grouped together and bound up with connective tissue, constitute a **lobule** of the gland (lobulus mammæ). A lobe is made up of all the lobules whose ducts join one common excretory duct.

The alveoli are composed typically of a single layer of epithelial cells enclosed by a basement membrane. This layer is the true secretory epithelium. It consists in the more active gland of granular polyhedral or cuboidal cells which may be so closely placed as to leave almost no lumen to the alveoli. During lactation these cells may be found in different stages of secretory activity, their central ends being filled with minute oil globules and more or less flattened according to the degree of distention of the alveoli. The alveoli and ductules now possess considerable lumina which are filled with the above-mentioned milk globules liberated from the cells and suspended in a serous fluid also secreted by the cells. This constitutes the *milk* (lac femininum).

Stroma.—The lobes, lobules, and alveoli are completely covered by a connective-tissue sheath too delicate to constitute a distinct capsule. Outside of this the whole gland is embedded in the subcutaneous tela which forms for it a sheath, **capsula adiposa mammæ.** This is particularly well developed on the ventral surface where the fat fills in between the irregularities caused by the lobes and lobules and gives to the surface of the gland its smooth appearance. Within the corpus mammæ there is little fat between the lobules in nulliparæ but much more fat is found here in the stroma in multiparæ. When the fat is absorbed, as it is during lactation and in emaciation, the lobules stand out much more distinctly. There is however, no fat immediately beneath the areola and nipple. The connective tissue is here loosely arranged and allows free motility of the nipple and also permits the more easy distention of the ducts and sinuses during lactation. The connective-tissue strands, **retinacula mammæ,** which extend from the apices of the glandular processes on the ventral surface of the mamma are connected to the corium and correspond to the retinacula cutis found in other situations. These are sometimes particularly well developed over the cephalic part of the mamma and have been called the *suspensory ligament of Cooper.*

The dorsal surface of the mamma is bound to the pectoral fascia by loose connective tissue containing, as a rule, only a small amount of retromammary fat (figs. 1060, 1061). The attachment to the sheath of the pectoralis major muscle is at times so loose that the spaces between the connective tissue appear to form serous sinuses, the **sub-** or **retromammary bursæ.**

In addition to the axillary process or 'tail' of the gland, a projection is sometimes seen extending toward the sternum and another caudolaterally; also processes extending toward the clavicle and caudomedially have been described. Besides these large projections there are numerous branched interlacing processes which combine into larger and smaller masses on the ventral surface and exist as minute extensions on the dorsal surface. In thin women, the parenchyma at the apex of these triangular processes reaches nearly to the surface.

A mammary gland may be made up of a larger amount of stroma and a smaller amount of glandular tissue, or the reverse, and therefore a small breast may furnish more milk than a large one. There is also a variation in different parts of the same breast, one lobe or section may have well-developed lobules while in another they remain almost as at puberty, merely branching ducts.

The glandular tissue when sectioned is whitish with a greyish or pinkish cast and is firm and resistant, almost cartilaginous in consistency. It is thus easily distinguished from the adipose capsule.

Changes due to age and functional activity.—At birth the mamma consists mainly of fifteen to twenty slightly branched ducts lined with stratified squamous or columnar epithelium. In spite of the lack of true glandular tissue, within the first few days there may be such rapid cell proliferation that the ducts become distended with cells and detritus. By pressure upon the gland a few drops of this material may be expressed which constitutes the so-called 'witches milk.' From birth until puberty the mamma remains rudimentary, simply keeping pace with the general body growth, but in the female, at puberty, an abrupt change occurs. The tubules grow rapidly into the surrounding tissue and some acini (alveoli) appear; the stroma and fat are also greatly increased; and the breast becomes rounded and well formed but consists mainly of fatty stroma and ducts, with but a very small number (if any) of true secreting acini. At this time in both boys and girls the breast may become swollen and tender and a milk-like secretion may be produced similar to that at birth. The great increase in volume during pregnancy and lactation is due to the increase in the size and number of the lobules and acini, and is accompanied by a decrease in the interlobular and intralobular stroma and in the fat, so that the gland feels hard and uneven. The acini appear first in the periphery, thence along the larger ducts toward the centre of the corpus mammæ.

The secretion of the gland for the first two or three days after parturition until the free secretion of milk is established is termed the **colostrum.** It differs from normal milk not only in chemical composition but also in containing larger fat globules and special cells known as **colostrum corpuscles.**

The decrease of the gland nearly to its original size after lactation is due to an *involution* of the parenchyma, the acini being reduced to narrow tubules, most of them completely atrophying. With this is associated a development of fat and fibrous stroma. The gland does not, however, regain its virgin appearance but its main mass is looser and more irregular, less distinct, and the peripheral processes larger, while the stroma contains numerous fat-lobules. This causes the breast to be less smooth, firm, and elastic, and it tends to become pendulous and form a sulcus where it overhangs its base. With the end of sexual activity the secreting portions of the glands gradually atrophy, finally leaving little more than the ducts. Even these undergo senile atrophy, and the main mass of the gland is represented only by a flattened disc, in which the peripheral processes can scarcely be made out. In fat women there may be little reduction in size, but the breast is here transformed almost entirely into fat.

The **skin** covering the ventral surface of the breast is very white, covered with lanugo hairs associated with sebaceous glands, and contains many sweat glands of the ordinary type. It is so thin that the subjacent veins are readily seen through it. It is closely adherent to the subjacent fatty layer but its flexibility, elasticity, and motility over the deeper glandular tissue permit much stretching during the enlargement which occurs at the time of lactation. In spite of this, **linea albicantes** are often produced especially when the breasts have been unusually large. Aside from the above-mentioned particulars it does not differ from the skin of the adjacent part of the thorax, except over the centre of the breast where it forms the areola and nipple.

The **areola mammæ** (figs. 1058, 1059, 1060, 1061) is covered by a thin, delicate, pigmented skin. The *colour* in young nulliparæ is reddish, the shade varying with the complexion. During pregnancy the colour darkens, slightly in blondes, but so as to become almost black in marked brunettes.

This pigmentation serves as one of the signs of gestation. After lactation the colour fades, but little pigmentation remaining in blondes, considerable in brunettes. During pregnancy there is sometimes seen extending more or less beyond the areola a less deeply and less uniformly pigmented ring, the **secondary areola.** In size, the areola is subject to considerable individual variation and is increased in pregnancy.

The *surface* of the areola is roughened by a number of slight *elevations* irregularly arranged. These are due to underlying large sebaceous and rudimentary milk glands [gl. areolares; Montgomerii], tubercles of Montgomery. Projections caused by sebaceous glands are also found in the secondary areola. All of these tubercles enlarge greatly during pregnancy and the glands produce a slight secretion which is discharged through ducts that open on their summits. The sweat glands are few but large, and in addition to the lanugo hairs there are usually several well-developed hairs.

The *corium* of the areola is devoid of fat but contains a well-developed layer of smooth muscle fibres, the fascicles of which intercross in various directions but may be seen to be mainly of two orders, circular and radial. They are continuous with those of the nipple. The circular fibres are most numerous adjacent to the nipple, where they may form a layer nearly 2 mm. in thickness.

The areola varies greatly in size, measuring from 15 to 60 mm. in diameter. There is some confusion in regard to the areolar glands and the tubercles of Montgomery. Some consider the tubercles to be caused by the areolar glands, others consider them caused by the sebaceous glands. Sebaceous glands undoubtedly cause the projections in the secondary areola. The sudoriferous glands of the areola are large and compound tubular glands with a complicated glomerulus and are considered as transitions between sweat and mammary glands. The sebaceous glands are even more numerous than the sudoriferous and are composed of several lobes. They also have been considered by some as intermediate stages in the formation of mammary glands, but this is improbable. There are ten to fifteen very small areolar glands (though Pinard found an average of but four to each breast), whose structure is essentially identical with that of the principal mammary glands. They have dilations on their ducts and they open on the areola at times in common with a sebaceous gland.

The **nipple** [papilla mammæ] (figs. 1058, 1059, 1060, 1061) in well-developed nulliparæ is situated slightly meso-caudal to the centre of the breast and on a level with the fourth rib or fourth intercostal space about 12 cm. from the median line. But its position in reference to the thoracic wall varies greatly with age, individual, and the present and past activity of the gland. The nipple is usually somewhat conical or cylindrical with a rounded fissured tip marked by fifteen to twenty minute depressions into which the lactiferous ducts empty. The average length of the nipple is 10 mm. to 12 mm. The skin is thin, wrinkled, and pigmented like the areola, except over the tip of the nipple where there is no pigment.

The **corium** of the nipple has many large vascular and nervous papillæ and there is no fat in it. Hairs and sudoriferous glands are absent but sebaceous glands are present in great numbers. Their secretion here and over the areola serves to keep the skin soft and to protect it from the saliva of the nursing infant. In the deeper layers of the corium smooth muscle fibres form a loose stratum continuous with that of the areola. This is made up principally of an external circular layer and to a slight extent by an internal layer whose bundles of fibres are parallel with the milk ducts. Numerous interlacing muscle fibres connected with these layers and mixed with loose connective tissue, and elastic fibres, but no fat, surround the lactiferous ducts as they pass through the axis of the nipple.

The nipple usually does not project from the surface until the third year. It soon becomes conical but does not attain its full size until shortly after puberty. The size of the nipple is variable, ordinarily in proportion to the size of the gland, but large nipples are sometimes found on small breasts and small nipples on large breasts. During pregnancy the nipple increases in

size and becomes more sensitive and more easily erectile. The shape of the nipple in addition to conical or cylindrical may be hemispherical, flattened, discoidal, or slightly pedunculated. Its end may be invaginated or the entire nipple retracted beneath the surface of the gland and projecting only in response to stimuli.

The circular muscle fibres of the nipple act like those at its base in the areola. By intermittent, rhythmic contractions they tend to empty the lactiferous ducts; by continuous and tight contraction they act as a sphincter. When contracted they also narrow the nipple, make it harder, erect, and more projecting. When the vertical fibres contract they depress the tip of the nipple or they may retract the whole nipple beneath the surface. The muscle of the areola when stimulated puckers the skin toward the nipple causing circular concentric folds in the skin of the areola.

The **male mammary gland** [mamma virilis]. This develops exactly as with the female. From birth to puberty the glands in the two sexes have a parallel growth and development, but from this time on the glands in the male grow but slightly and reach their full development about the twentieth year.

The corpus mammæ in the adult male measures from 1.5 to 2.5 cm. in diameter and .3 to .5 cm. in thickness. It is whitish in colour, tough, and stringy. It is composed of the same number of lobes as in the female but these consist of little more than short ducts with no true acini and may be reduced to mere epithelial or connective-tissue strands. The areola and nipple are present and pigmented, but the nipple averages only 2 to 5 mm. in height. The areola has a diameter of 2 to 3 cm. and is covered with hairs. The areolar tubercles may be recognised and the areolar muscle is present. The position of the nipple in relation to the chest-wall is more constant than in the female as the breast is less movable. It is seldom beyond the limits of the fourth intercostal space or the two adjacent ribs, and averages 12 cm. from the median line. Occasionally the male breast may hypertrophy on one or both sides, **gynecomastia.**

Blood-supply.—The main arterial supply to the mammary gland is from mammary rami of perforating branches of the internal mammary artery (p. 567). Usually that from the second or third intercostal space is especially large. Small branches, external mammary rami, are also supplied to the caudal and lateral segments of the breast by the lateral thoracic artery (p. 571). Some rami from the thoracoacromial or supreme thoracic arteries (p. 571) may reach the cephalolateral segment of the breast and small twigs, lateral mammary rami, from the anterior branches of the lateral cutaneous rami of the aortic intercostal arteries (p. 589) supply its deep surface.

These vessels anastomose freely and form a wide-meshed network in the stroma of the ventral and dorsal surfaces from which branches proceed around the lobes and lobules and finally form a close network of capillaries around the alveoli. From these, venous capillaries arise and pass in two groups, one deep, accompanying the arteries, the others superficial. These latter extend to the ventral surface of the gland to form a loose network beneath the skin. During lactation these subcutaneous veins show through the skin as bluish lines, and frequently form a more or less complete circle around the nipple. They connect with the superficial veins of the neck superiorly, with those of the abdomen inferiorly, and with the thoracoepigastric vein laterally. The deep veins carry the blood to larger vessels, which empty into the subclavian, the intercostal, the internal mammary, and the axillary; and the superficial group may connect with the external jugular and femoral veins.

The lymphatics.—The lymphatics of the mammæ are extremely numerous, forming rich plexuses and free anastomoses. Their exact origin and distribution are not yet fully understood, but it is clear that there is a rich plexus in the skin of the areola and nipple which empties mainly into a subareolar plexus. Deep lymphatics arise in the spaces around the alveoli in all parts of the gland, and most of these converge toward the nipple where they join the subareolar plexuses. They anastomose freely with the cutaneous lymphatics and many of them empty into the subareolar plexus through large lymph-vessels which run parallel with the lacteal ducts. From the subareolar plexus usually two large lymph-vessels arise and pass toward the axilla to empty into the axillary lymph-glands (p. 719). Other lymphatic vessels of the mammary gland follow the course of the various blood-vessels.

There is usually a third trunk from the cephalic part of the breast and often a fourth from the caudal segment which join with the others to the axillary glands. The lymphatics of the mammary gland also communicate with the lymphatics of the skin, the ventral chest-wall and those of the deep fascia over the pectoral muscles, as well as the lymphatics of the opposite side. They also empty into the lymphatics which accompany the blood-vessels of this region, and thus communicate with the axillary, subclavicular, and supraclavicular lymphatic nodes (p. 722). Moreover, those from the medial portion of the gland accompany the branches of the internal mammary artery and empty into the sternal glands along the artery within the thorax. Since cancer of the breast extends and is disseminated through lymphatic channels, their distribution and connections are of great practical importance.

The nerves.—The gland proper receives its nerves laterally from the **lateral mammary rami of the anterior rami of the lateral cutaneous branches of the fourth to sixth intercostal nerves** and medially from the **medial mammary rami of the anterior cutaneous branches of the second to the fourth intercostal nerves.** The skin over the breast receives in addition to branches from the above nerves, branches from the **supraclavicular nerves** of the cervical plexus. It is altogether probable that sympathetic fibres reach the gland but by what course is not yet clear. The nerves are distributed in part to the skin, in part to the plain muscle of the areola and nipple, some to the blood-vessels, and others to the glandular tissue. The secretion is, however, not entirely controlled by nerves as it is influenced also by hormones from other organs brought to it by the blood.

Development.—In very early embryos the epithelium over an area on the side of the body extending from the fore to the hind limb (or beyond these limits) is seen to be deeper and more cubical, the mammary streak. In this area there is produced by multiplication of cells a ridge, the *mammry line or ridge*. In spots along this line, corresponding to the relative position of the mammary glands in some mammals and the supernumerary mammæ in man, the epithelium thickens. The intervening parts of the line disappear as the spots enlarge to form transient *mammary hillocks*. In man ordinarily development proceeds in but one of these hillocks on each side. The deep surface of the hillock projects into the corium as the superficial surface flattens out and the mesodermic cells of the corium condense around the ingrowth producing the *nipple zone*. Rapid proliferation of the deeper cells produces a *club-shaped stage* from the deeper surface of which small bud-like masses of epithelial cells sprout and extend as solid plugs into the corium. These are the anlages of the true secreting part of the gland and the number of buds corresponds to the number of lobes of the future gland. The sprouts extend beyond and beneath the nipple zone and are supported by closely packed connective-tissue cells forming the *stroma zone*. The epithelial buds continue to grow and branch and a lumen is finally produced in the originally solid plugs. The primary epithelial ingrowth degenerates and ultimately disappears. A cavity is produced in it which later connects with the lumina of the gland ducts. The depressed nipple zone becomes elevated above the surface soon after birth. Further development of the mammary gland has been discussed previously under changes due to age and functional activity (p. 1303).

THE DUCTLESS GLANDS

Under the term *ductless glands* are included not only certain glandular structures of epithelial origin with a more or less definitely known function and an internal secretion but also certain organs whose function is not definitely known or understood. Of the organs here considered, the function of the thyreoid gland, the parathyreoid glands, the chromaffin system, the medullary portion of the suprarenal glands, and the aortic paraganglia is somewhat definitely known. But the function of the thymus, the spleen, the cortical portion of the superenal glands, the glomus caroticum, and the glomus coccygeum is still in doubt; although probably some, if not all of them, have an internal secretion or at any rate are closely associated with the other glands of internal secretion. The hypophysis and the pineal body are not considered in this connection but will be found described with the brain (pp. 845, 848). The lymph-nodes, which may also be considered as ductless glands, are described in Section VI. Many of the true glands, such as the liver, pancreas and sexual glands, have also internal secretions which pass directly into the vascular system as in the ductless glands.

THE SPLEEN

The **spleen** [lien] is a large blood-vascular organ closely associated with the lymphatic system. Its exact function is still in doubt.

Position.—The spleen is situated in the dorsal part of the left cephalic segment of the abdominal cavity so deeply placed against the diaphragm and dorsal to the stomach and colon as to be invisible from the ventral surface of the body when the abdominal cavity is opened. It is mainly in the left hypochondriac region but its deepest and most cephalic part extends also into the epigastric region. It is obliquely placed with its long axis corresponding approximately to the line of the caudal ribs. It tends to become more vertical when the stomach is fully distended but when the stomach is empty and the colon distended it assumes a more horizontal position. Changes in the attitude of the body also cause slight alterations in the situation of the spleen. It moves with the excursions of the diaphragm in expiration and inspiration.

The **colour** of the spleen is, in life, a dark bluish-red or brownish-red, but after death it becomes darker with a more bluish or violet tint.

The **size** of the spleen is perhaps more variable than that of any other large

organ in the body. Not only does the size differ in different individuals but it changes greatly with the blood content in the same individual. There is a distinct expansion for a time after each meal and the spleen contracts and expands rythmically.

FIG. 1062.—WEDGE-SHAPED SPLEEN, VISCERAL SURFACE.

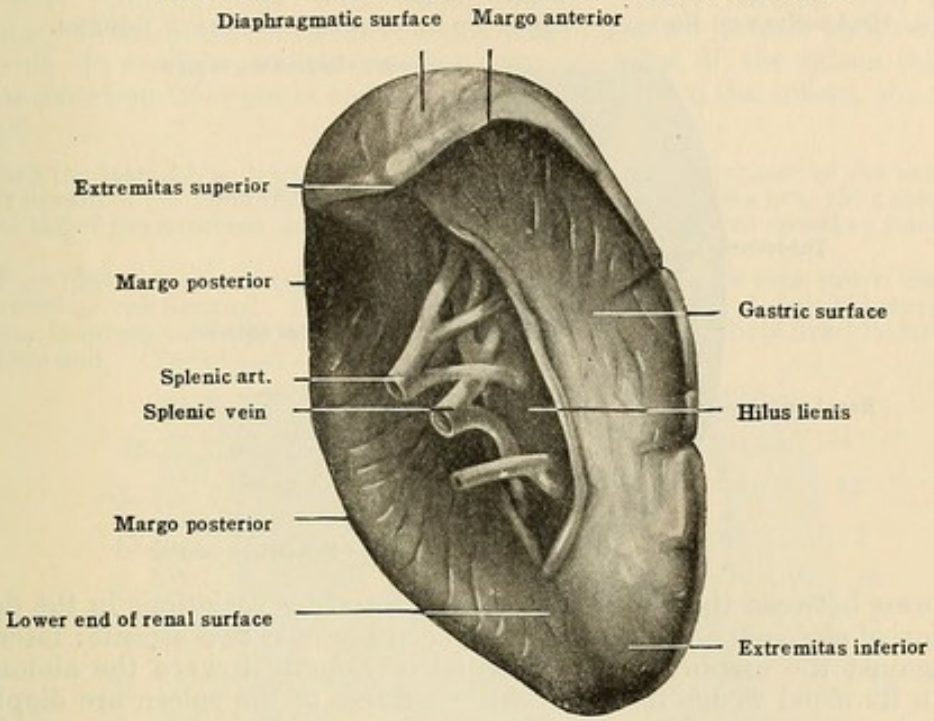

In the adult it usually measures 10 to 15 cm. in length, 7.5 to 10 cm. in breadth, and 2.5 to 4 cm. in thickness. The weight usually ranges from 150 to 225 gm. At birth it represents from $\frac{1}{326}$ to $\frac{1}{400}$ of the total body weight and this porportion is maintained without much variation until the age of fifty years, when (like the lymphoid organs in general) it begins to diminish

FIG. 1063.—TETRAHEDRAL-SHAPED SPLEEN, VISCERAL SURFACE.

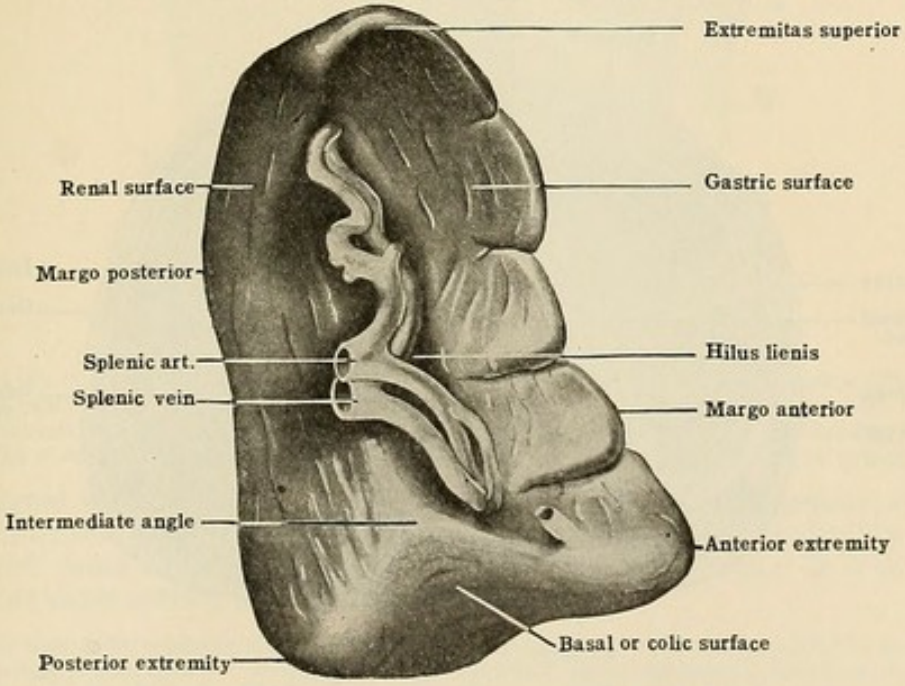

in size. This diminution continues until in the very old it represents but $\frac{1}{700}$ of the body weight. There is no great difference in relative size in the two sexes.

The spleen is somewhat soft and very friable. It is elastic, extensible, contractile, and extremely vascular.

Shape.—In form the spleen varies greatly. This is due largely to its softness which permits considerable modifications by the pressure of the distended or con-

tracted surrounding hollow viscera. When *in situ* with the stomach distended its shape may be compared to a blunt spherical wedge with a concave apex and rounded extremities, and possessing therefore three surfaces (fig. 1062); but when the stomach is contracted and the left flexure of the colon distended an additional surface is produced and its shape becomes tetrahedral (fig. 1063). Inter-

FIG. 1064.—SPLEEN SHOWING TUBERCLE ON THE INTERMEDIATE BORDER.

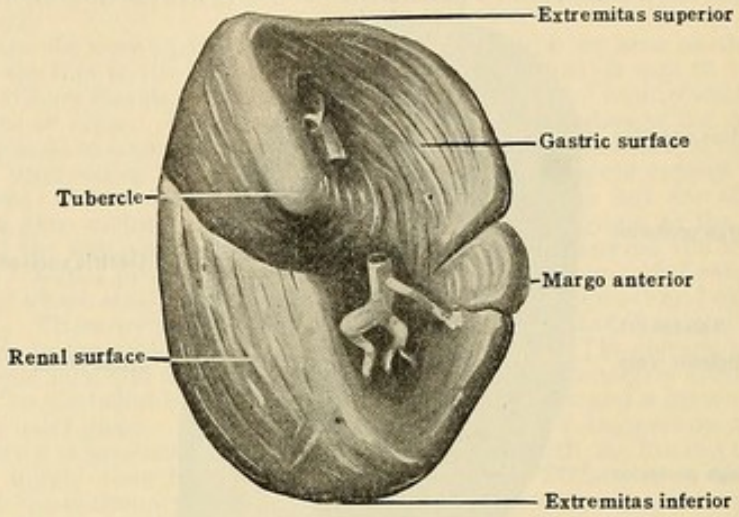

mediate forms between these extremes are produced by variations in the degree of distention of stomach and colon. The spleen presents two aspects: lateral or *parietal,* against the diaphragm; and medial or *visceral,* toward the abdominal cavity. In its usual wedge form the three surfaces of the spleen are diaphragmatic, gastric, and renal. There are three borders, anterior, posterior, and intermediate; and two extremities, superior and inferior.

FIG. 1065.—CROSS-SECTION OF THE BODY AT THE LOWER PART OF THE EPIGASTRIC REGION. (Rüdinger.)

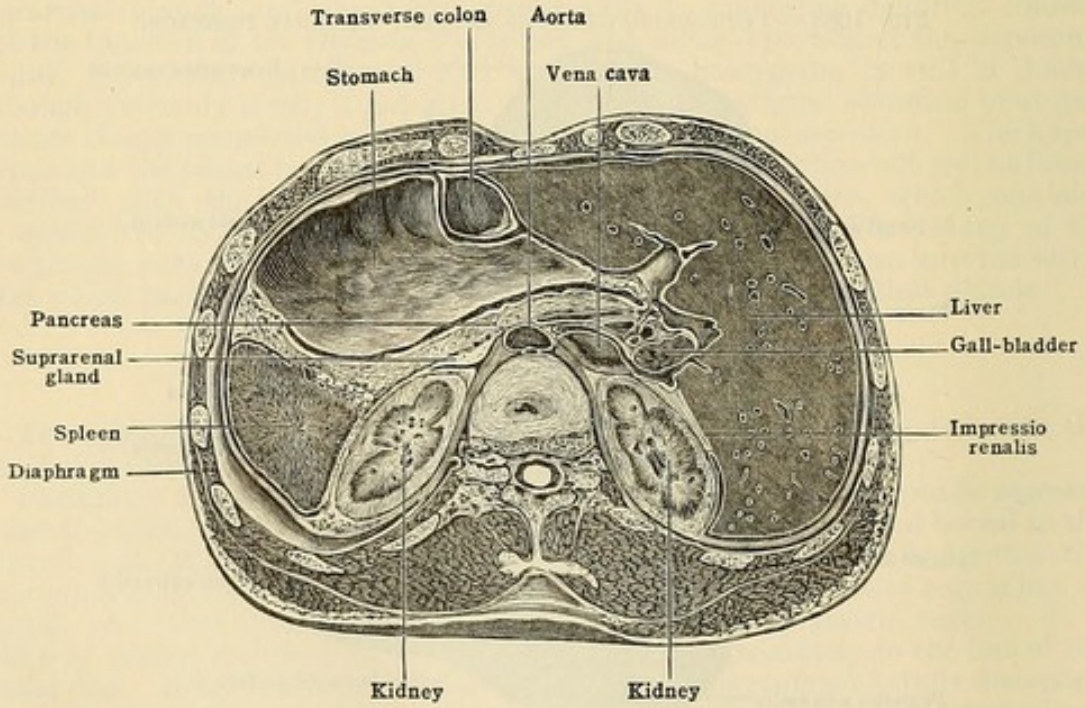

The **diaphragmatic surface** [facies diaphragmatica] is a smooth convex surface with an irregularly oval outline, in the wedge-shaped spleens wider cephalically, but in the tetrahedral-shaped spleens wider caudally. It looks dorsally toward the left and somewhat cephalically.

It lies against the diaphragm over an area opposite the ninth, tenth, and eleventh ribs and the intervening intercostal spaces, with its long axis corresponding in a general way to the course

of the ribs. Although it is separated from the ribs by the peritoneum, the diaphragm, and the left pleural cavity (cephalically also by the left lung) (figs. 1065, 1066), the ribs sometimes make impressions upon it.

The **gastric surface** [facies gastrica] is a semilunar-shaped surface, concave cephalo-caudally and from side to side, which looks ventrally to the right and somewhat caudally (figs. 1062, 1065, 1066). Nearly parallel with the dorsal boundary of this surface is a narrow depression usually formed by a series of pits, as a rule six or eight, which together form the **hilus** of the spleen [hilus lienis]. In this situation the vessels and nerves enter and leave the spleen, the vein being dorsal.

When the stomach is distended it is in contact with the major part of the gastric surface, the left flexure of the colon forming an impression upon a small area near the caudal extremity and the tail of the pancreas, as a rule, resting against a narrow area dorsal to the hilus or just

FIG. 1066.—SAGITTAL SECTION THROUGH THE LEFT SIDE OF THE BODY, SHOWING THE RELATIONS OF THE SPLEEN. IX, X, XI, XII, corresponding ribs. 1, Left kidney; 2, spleen; 3, pancreas; 4, splenic vessels; 5, transverse colon; 6, stomach; 7, left lobe of liver; 12, lung; 14, heart; 16, diaphragm. (Testut and Jacob.)

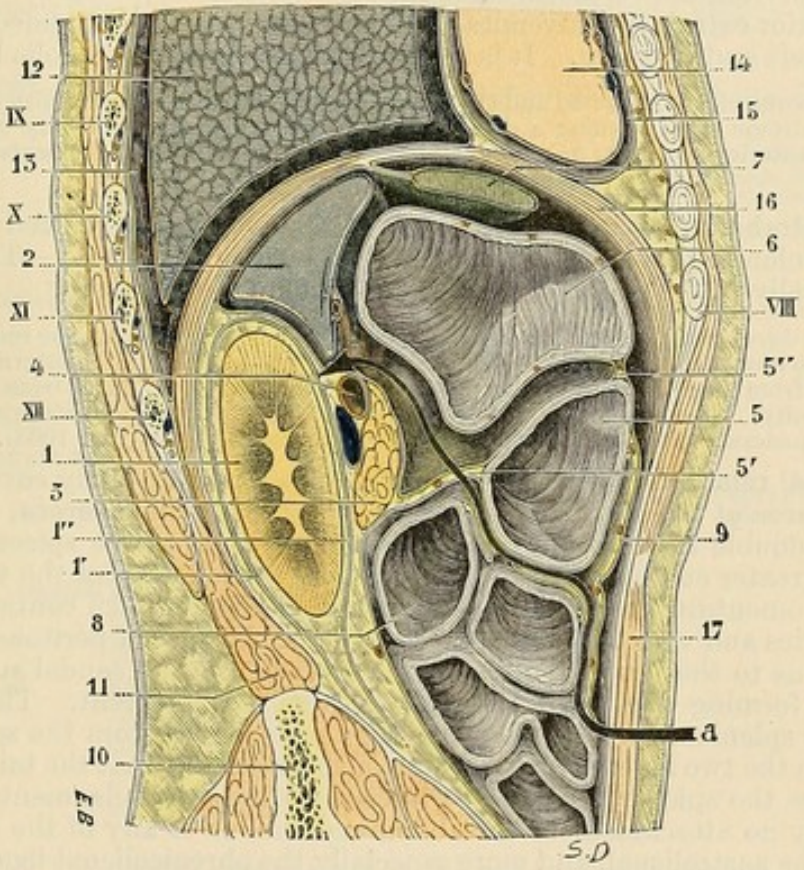

cephalic to the colon. When the stomach is empty and contracted and the colon distended the size of the gastric area is considerably decreased and the relative size of the colic impression greatly increased so as to form upon the spleen in this situation a colic or basal surface (fig. 1063). The stomach is, however, at all times in contact with some part of the spleen.

The **renal surface** [facies renalis] the smallest of the three surfaces, shorter as well as narrower than the gastric surface, is an oblong, flat or slightly concave area, which faces dorsally, to the right and slightly caudally. It is in relation with the anterior surface of the left kidney (fig. 1066).

In some cases the cephalic third of the renal surface is also in relation with the anterior surface of the suprarenal gland. It is separated from these latter structures, however, by the renal adipose capsule as well as by the peritoneum. The tail of the pancreas in some cases is in contact with a small area on the ventral part of this surface. In fat individuals these relations are not as intimate as the relations with other organs because of the large amount of suprarenal fat.

The **anterior border** [margo anterior] is clearly defined, thin, sharp, and more or less convex. It is marked in over 90 per cent. of the cases by one or more transverse or oblique notches, especially in its cephalic part. It is placed between the

diaphragm and the stomach and separates the diaphragmatic from the gastric surface (figs. 1062–1065).

The **posterior border** [margo posterior] is rounded, shorter, and straighter than the anterior border and is notched in less than a third of the cases. It separates the diaphragmatic from the renal surface and is lodged in the angle between the left kidney and the diaphragm (figs. 1062–1065).

The **intermediate border** is a blunt ridge dorsal to the hilus, separating the gastric from the renal surface.

It may be clearly defined or more or less obscure and often shows a marked tubercle (fig. 1064). When the stomach is contracted and the colon distended this border divides caudally into ventral and dorsal limbs both of which may be well marked or either may be deficient depending on the direction and degree of pressure of surrounding organs. When well marked there is produced at the point where the two limbs diverge a more or less marked projection, the intermediate extremity or angle (fig. 1063).

The **superior extremity** [extremitas superior], usually larger than the inferior extremity in the wedge-shaped spleens but smaller in the tetrahedral form, is rounded and bent medially. It extends as high as the tenth thoracic vertebra and lies 1 to 2 cm. from the vertebral column.

The **inferior extremity** [extremitas inferior], also somewhat rounded, is directed toward the left and caudally. It is in relation with the phrenicocolic ligament.

When the stomach is contracted and the colon distended the inferior extremity becomes much broader, in extreme cases forming a distinct **inferior border** ending ventrally in the anterior margin as an **anterior extremity** and dorsally in the posterior margin as the **posterior extremity** (fig. 1063).

In the **tetrahedral-shaped spleen** the additional surface produced by the pressure of the colon is known as the **basal** or **colic surface** (fig. 1063). This varies in size reciprocally with the degree of pressure of colon and stomach.

When well developed the colic surface is concave and is separated from the renal and gastric surfaces by the more or less sharply defined dorsal and ventral limbs of the intermediate border and separated from the diaphragmatic surface by an inferior margin produced from the broadened inferior extremity. The left flexure of the colon is in contact with the greater part of this surface, but the pancreas also usually lies against it in its cephalic part (fig. 1063).

Peritoneal relations.—The surface of the spleen is completely covered, except for a small area at the hilus, by a peritoneal coat, the **tunica serosa.** Ventral to the hilus a double layer of peritoneum is prolonged from the spleen to the left side of the greater curvature of the stomach and the left edge of the ventral layer of the great omentum, forming the **gastrolienal ligament** which contains the short gastric arteries and veins. Dorsally a second double layer of peritoneum extends from the hilus to the ventral surface of the kidney and the caudal surface of the diaphragm forming the **phrenicolienal** (lienorenal) **ligament.** This ligament encloses the splenic artery and veins as they pass to and from the spleen. It is also between the two layers of peritoneum of this ligament that the tail of the pancreas reaches the spleen (fig. 1065). Except by these two ligaments the spleen has normally no attachment to the abdominal wall or to any of the surrounding viscera. The gastrolienal, and more especially the phrenicolienal ligament, serve in a measure to anchor the spleen in its place in the abdominal cavity but in addition to these the spleen is supported by a fold of peritoneum which extends from the left colic flexure to the parietal peritoneum over the diaphragm, the **phrenicocolic ligament.** This serves as a sling in which the inferior extremity of the spleen rests. The spleen, however, is held in position in the abdominal cavity mainly by the intraabdominal pressure.

Topography.—The superior extremity of an average-sized spleen is located between the angle and tubercle of the tenth rib on the left side and about 3 to 4 cm. from the median line on a level with the spinous process of the ninth thoracic vertebra. In the majority of cases, it does not extend more than 2 cm. either cephalic or caudal to a transverse plane at the level of the infrasternal notch. The inferior extremity reaches nearly to the midaxillary line in the tenth intercostal space and 10 to 15 cm. from the superior extremity. The long axis therefore corresponds nearly to the shaft of the tenth rib. The posterior border lies beneath the cephalic border of the eleventh rib. The whole spleen (unless enlarged) lies dorsal to a plane passed through the midaxillary lines and is lateral to a line from the left sternoclavicular joint to the tip of the left eleventh rib. In deep inspiration the spleen is greatly depressed and if enlarged may be felt beneath the ribs.

Variations.—From the mean weight between 150 and 200 gm. there are wide variations. It is not rare to find spleens weighing 80 to 100 gm. and they are recorded as light as 10 and

20 gm. On the other hand, spleens weighing 3000 to 4000 gm. are sometimes found. These are usually, however, associated with an acute infectious disease, such as malaria or typhoid fever, or a progressive metamorphosis, such as leukemia.

Congenital *absence* of the spleen is one of the rarest anomalies. The presence of more than one spleen is the commonest anomaly of the spleen. Adami has found accessory spleens to occur in 11 per cent. of all autopsies. They are round or oblong and vary in size from a pea, or smaller, to a walnut. There are most often one or two but there may be twenty or more. They are found near the hilus on the dorsal side of the gastrolienal ligament, less often, in the great omentum, in the mesentery, on the wall of the intestine, or in the tail of the pancreas.

In certain cases the left lobe of the liver is very long and prolonged far to the left and separates the spleen from the diaphragm. This is the rule in the fœtus and is often found in the infant but is exceptional in the adult.

Exceptionally the spleen may be placed far caudal to the normal situation extending into the iliac region and even into the pelvis. This is due in part to congenital laxness of the supports, also to increase in weight. The spleen has been found in almost every part of the abdominal cavity and in transposition of the viscera it is upon the right side.

One or more **notches** on the anterior border are present according to Parsons in 93 per cent. of the cases, two or more in 66 per cent., but five, six, or seven much more rarely. On the posterior border notches are found in 32 per cent. of the cases, and on the inferior border in 8 per cent. In 20 per cent. of the cases a marked fissure, occasionally more than one, is found on the diaphragmatic surface. Most frequently it begins at one of the notches in the posterior border and passes for a distance across the surface, rarely reaching the anterior border. Occasionally such a fissure starts from the anterior border and rarely there is such a fissure connecting with neither border.

FIG. 1067.—PORTION OF SECTION OF THE SPLEEN OF AN ADULT MAN. ×15.
(Lewis and Stöhr.)

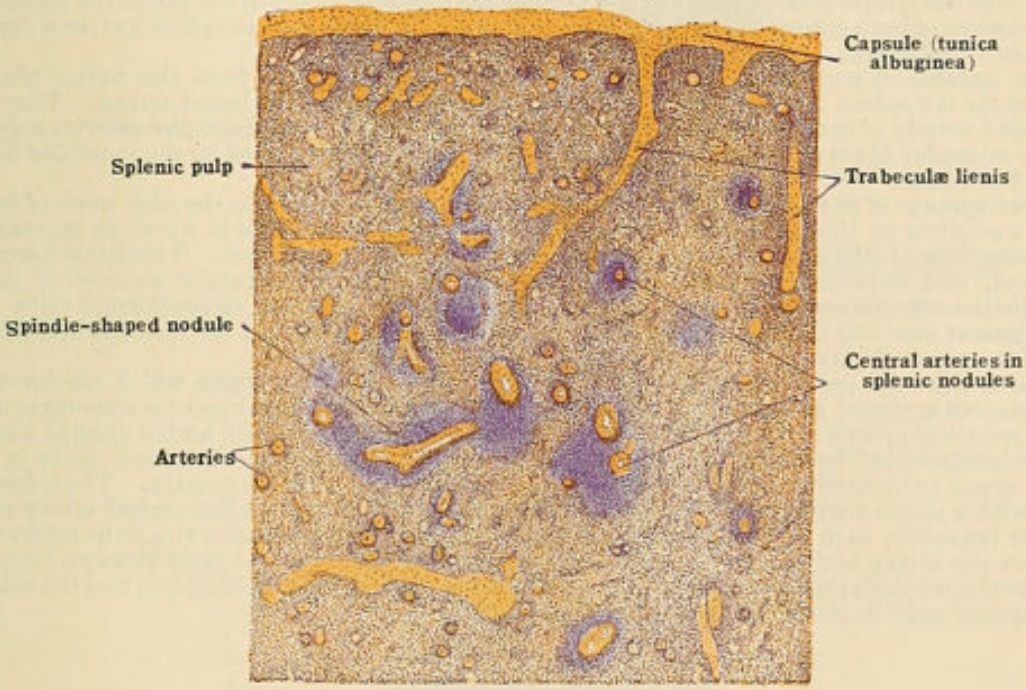

Structure.—The peritoneal covering of the spleen, **tunica serosa,** is intimately bound to the underlying, whitish, highly elastic fibrous capsule, the **tunica albuginea** (fig. 1067). This is composed mainly of white fibrous connective tissue but contains numerous fine elastic fibers, and a few smooth muscle fibres. It is much thicker than the serous covering and completely invests the spleen. From its deep surface the tunica albuginea gives off into the interior numerous trabeculæ, **trabeculæ lienis,** which join with one another and form a framework in which course the blood-vessels, more especially the veins. It is through the contraction of the smooth muscle fibres in the tunica albuginea and trabeculæ, that the regular periodic contraction and expansion of the spleen is produced.

In the meshes of the trabecular network, lymphoid tissue which forms the proper splenic tissue, the **pulpa lienis,** is located. This is soft, friable, and dark brownish or bluish-red in colour. In this, in a fresh spleen, are seen small round whitish or greyish masses from .25 to 1.5 mm. in diameter, the **Malpighian corpuscles** [noduli lymphatici lienales; Malpighii].

The trabeculæ are in connection with a reticular network which permeates the spleen substance or spleen-pulp. Mall has shown that the trabeculæ and vascular system together out-

line masses of spleen-pulp about 1 mm. in diameter, known as **splenic lobules.** Each lobule is bounded by three main trabeculæ, from each of which secondary trabeculæ pass into the substance of the lobule incompletely subdividing it into compartments, filled with splenic pulp, arranged in the form of anastomosing columns or cords and designated as pulp-cords. The branches of the splenic artery, after coursing for a short distance in the main trabeculæ, leave these, and, after further division, become surrounded with a layer of adenoid tissue, which layer presents here and there irregular thickenings forming the Malpighian corpuscles. An arterial branch, surrounded with adenoid tissue, enters the apex of a splenic lobule, constituting its intralobular vessel, which, soon after entering the lobule, loses its adenoid sheath and then sends a branch to each of the above-mentioned compartments. These branches do not anastomose. They give off terminal branches which course in the pulp-cords, form dilations, **ampullæ,** and terminate directly or indirectly in the large venous spaces found between the pulp-cords. From the latter the blood passes, by means of small intralobular veins, to interlobular veins situated in the trabeculæ bounding the lobules. Some of the ampullæ are connected with one another by capillary branches.

Blood-supply.—The spleen receives its blood from the splenic artery, which is very large in proportion to the size of the organ it supplies. It divides in the phrenicolienal ligament into from three to six or eight branches, **rami lienales** (fig. 1062), which enter the spleen at the hilus. After entering the spleen the arteries divide and subdivide and run to their termination in the ampullæ without anastomosing. They form what are known as terminal arteries. The main splenic artery is very tortuous. The vein, **vena lienalis,** leaves the spleen usually by the same number of branches as the entering artery. These unite in the phrenicolienal ligament to form a large trunk which is straighter than the splenic artery and lies caudal to it.

The lymphatics.—A superficial and a deep set of lymphatics have been described in the spleen. The former is said to form a plexus beneath the peritoneum and the latter to be derived from the fine perivascular spaces in the adenoid tissue around the vessels. From these several trunks arise and joining at the hilus pass between the layers of the phrenicolienal ligament to empty into the lymph-glands dorsal to and around the cephalic border of the tail of the pancreas. The presence of both superficial and deep sets of lymphatics in the human spleen has been denied by some investigators. According to Mall, there is no deep set.

The nerves.—The nerves are derived from the right vagus and from the cœliac plexus. They enter the spleen at the hilus, accompanying the branches of the lienal artery. They are composed mostly of non-medullated fibres which form a rich plexus around the arteries supplying the muscular fibres in the media while a second group has been traced to the muscular fibres of the trabeculæ.

Development of the spleen.—The first anlage of the spleen is seen in the fifth week of fœtal life as a swelling on the dorsal (left) surface of the mesogastrium. This is due to an increase in the mesenchymal cells as well as to a thickening of the cœlomic epithelium. This latter becomes stratified, and indistinctly differentiated from the underlying embryonic connective tissue through the transformation of the deepest of the epithelial cells into mesenchymal cells. As development proceeds the thickened mass becomes entirely isolated and the cœlomic epithelium covers it as a single layer.

The arteries are seen first as a capillary network throughout the organ which considerably later become arranged as tufts of widened capillaries, the anlage of the vascular structural unit. These spherical groups of arterial capillaries leading by wide openings into a wide meshed venous plexus are bounded by trabeculæ from the capsule. The number of structural units in the spleen seems to be fixed fairly early but the size and complexity changes greatly. The spherical mass with a single central artery changes to the adult condition where the central artery gives off side branches, each of which has a spherical mass of capillaries, and the pulp intervenes between the artery and the vein so that the capillary circulation of the early embryo becomes the cavernous circulation of the adult. The lienal lymphatic nodules of Malpighi and the splenic pulp appear only in the latter half of embryonic life.

THYREOID GLAND

The **thyreoid gland** [glandula thyreoidea] is an extremely vascular, ductless gland, whose internal secretion, acting as a stimulus to the tissues, has a profound influence on the nutrition of the body and on the nervous system. It is a single organ composed of two lateral, frequently unsymmetrical, masses, joined together by a transverse median band. The median transverse band or *isthmus* [isthmus gl. thyreoideæ] is thin and narrow, and often has a long slender process, the *pyramidal lobe* [lobus pyramidalis], extending from it cephalically. The lateral parts or *lobes* [lobi, dexter et sinister] form the principal mass of the gland.

It is **situated** in the ventral portion of the middle third of the neck on both sides of the larynx and the cephalic end of the trachea, dorsal to the infrahyoid group of muscles.

The **consistency** of the thyreoid gland is uniformly soft and compressible. The **colour** is reddish, with a brownish or yellowish cast, but becoming more bluish or reddish with changes in its blood content.

The **size** is subject to considerable individual variation and is slightly greater in women than in men. The normal thyreoid gland measures from 4 to 6 cm. in width at its widest part. The lateral lobes measure from 5 to 8 cm. in length,

about 2 cm. in width, and from 1.5 to 2.5 cm. in thickness. The right is usually a little longer than the left. The isthmus averages from .6 to .8 cm. in thickness and from .5 to 1.5 cm. in height.

The **weight** of the normal gland averages about 30 grams; but many specimens are found as light as 20 grams, and others weigh as much as 60 grams.

When hyperemic or congested the size of the gland may be markedly augumented. This occurs normally in most women at puberty and during menstruation and pregnancy. In various abnormal conditions of the gland there is an increase in size, sometimes to a marked degree. These enlargements are ordinarily grouped under the term struma or **goitre,** and may be associated with either a hyper- or hyposecretion of the gland. Decrease in size is common in old age and may appear prematurely in certain diseases.

The **shape** of the gland as viewed from the ventral surface is that of a capital **U** with the concavity directed cephalically (fig. 1068). The sides of the **U** are formed of the more or less elongated lobes connected slightly cephalic to their

FIG. 1068.—VENTRAL VIEW OF THE THYREOID GLAND.

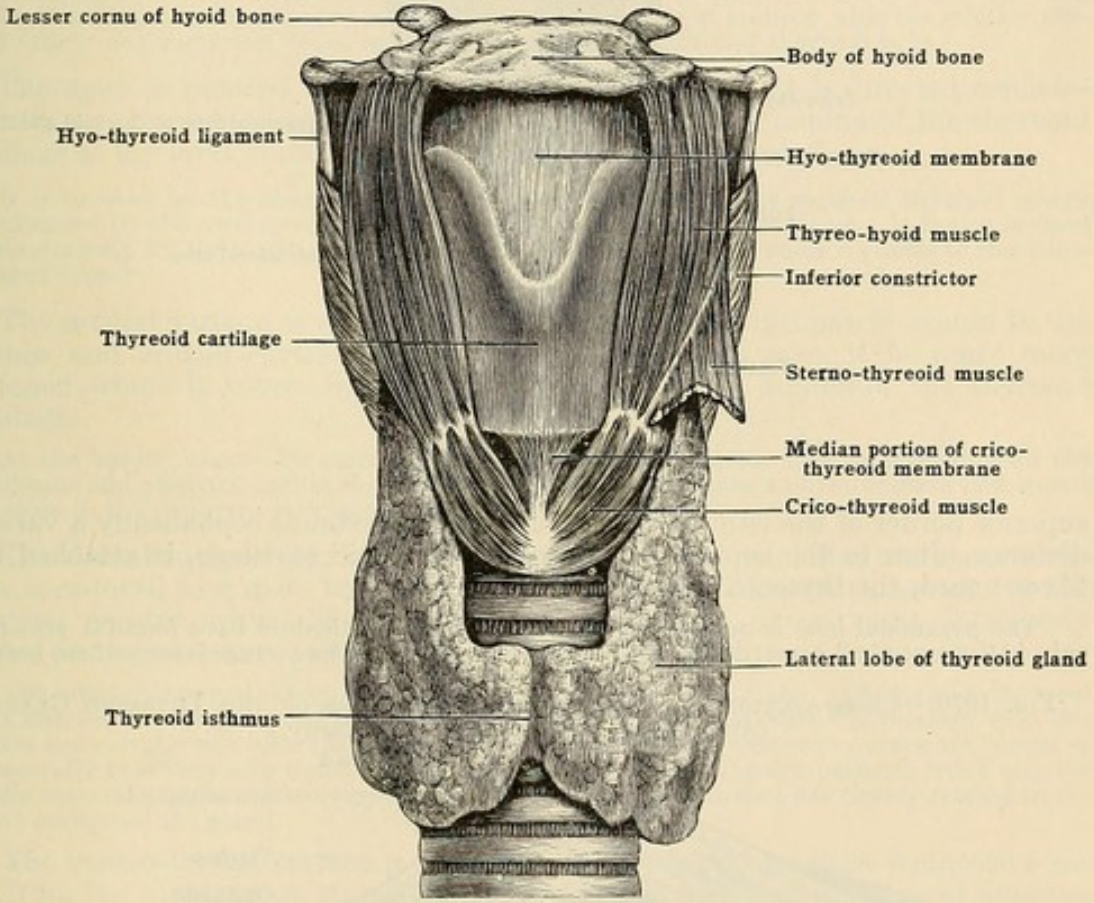

thickened caudal ends by the thin transverse isthmus. In transverse sections through the isthmus the gland is also **U**-shaped with the concavity directed dorsally, the lobes being on each side and the isthmus ventral to the trachea (fig. 1068). The surface of the gland is somewhat unevenly roughened.

The **isthmus glandulæ thyreoidæ** usually becomes wider laterally where it is attached by its two extremities to the lateral lobes (figs. 1068, 1069). Its ventral surface which is flat or somewhat convex is covered superficially by the subcutaneous tela and skin and beneath these by the superficial and middle layers of the cervical fascia. Between the layers of cervical fascia and close to the median line is the sterno-hyoid muscle and more laterally and deeper the sterno-thyreoid muscle. The dorsal surface is concave and is in relation with the first two to four rings of the trachea and sometimes with the cricoid cartilage.

The size and form of the isthmus is subject to considerable variation. It may be very short. Rarely it is wanting entirely or connects with but one lateral lobe. Its superior border is, as a rule, concave and is connected in many cases with the pyramidal lobe. The caudal border, although usually on the third ring of the trachea and 2.5 to 3 cm. from the jugular notch of the sternum, may be especially developed so that it extends caudally beyond the lateral lobes and produces a process which is known as the **medial lobe.**

The **pyramidal lobe** is usually a narrow elongated flattened somewhat conical process of thyreoid tissue representing the persistent portion of the median embryonic thyreoid (fig. 1069). Its base is attached ordinarily to the left side of the

FIG. 1069.—THYREOID GLAND, WITH PYRAMIDAL LOBE AND LEVATOR MUSCLE.

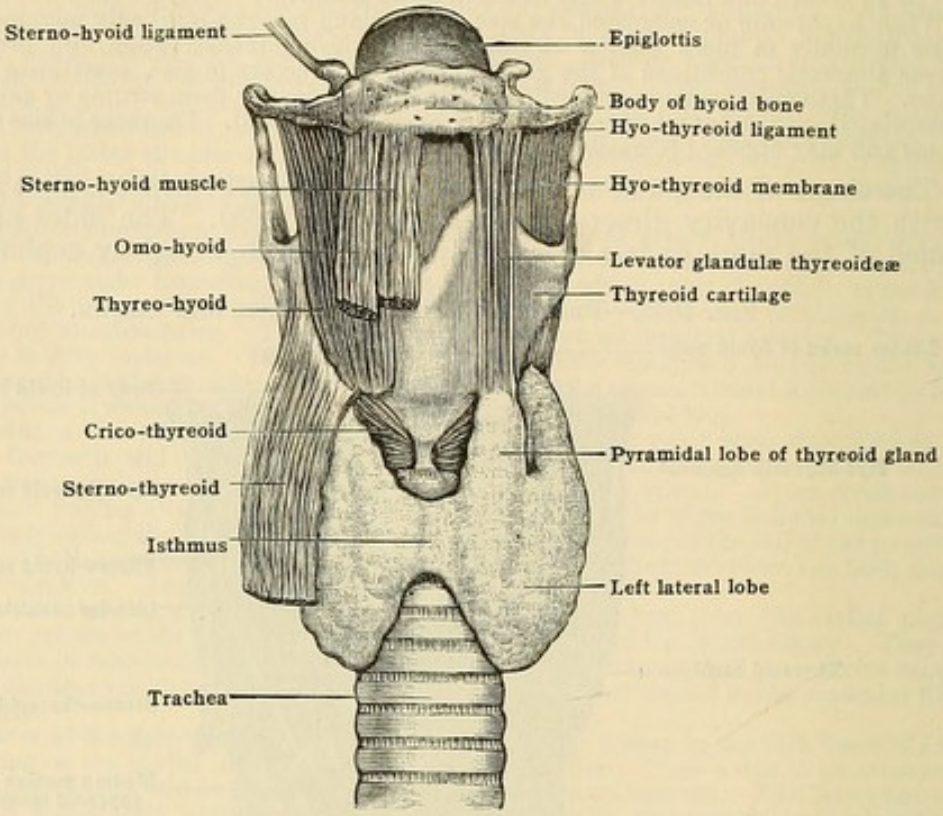

superior border of the isthmus and its apex which extends cephalically a variable distance, often to the superior border of the thyreoid cartilage, is attached by a fibrous cord, the **thyreoid ligament.**

The pyramidal lobe is not always present. Some investigators have found it present in only 40 per cent of all cases; others in as high as 90 per cent. The average is somewhere between

FIG. 1070.—CROSS-SECTION OF NECK SHOWING RELATIONS OF THE THYREOID GLAND. (After Braune, from Porier and Charpy.)

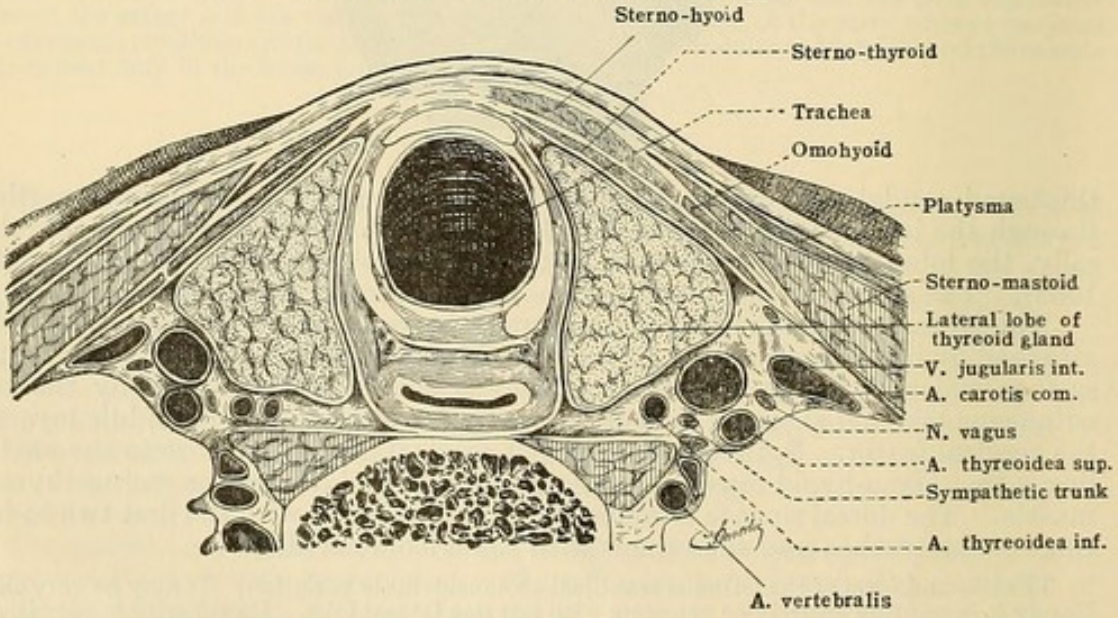

these extremes. It is closely adherent to the subjacent structures, usually at one side of the median line, more often the left. The superficial relations of the pyramidal lobe are similar to those of the isthmus. Its deep surface is in relation also with the cricoid and thyreoid cartilages, the crico-thyreoid muscle and the hyo-thyreoid ligament.

The pyramidal lobe, though usually single, may be double or bifid at its caudal end, one process joining each lateral lobe. It may be attached in the angle between the isthmus and one of the lateral lobes, or to the lateral lobe itself. It may be cylindrical, band-like, or swollen at its centre or cephalic end and is occasionally entirely separate from the rest of the thyreoid or divided into separate detached parts, thus forming accessory thyreoids. The apex in some cases extends to the middle of the thyreohyoid membrane or rarely to or beyond the hyoid bone or the process may be quite short. In the thyreoid ligament, attached to the apex, muscle fibres are sometimes found, aberrant parts of the infrahyoid muscles, the **levator of the thyreoid gland.**

The thyreoid **lobes,** right and left, are placed on each side of the trachea and larynx (figs. 1068, 1069, 1070). Each lobe is somewhat pyramidal in shape and presents for examination a base, an apex, a medial, a ventro-lateral, and a dorsal surface.

The **base** is roughly convex or pointed, rarely flattened, usually at the level of the fifth or sixth ring of the trachea (figs. 1068, 1069).

It is separated from the jugular notch of the sternum by a distance of 1.5 to 2 cm. but when the head is extended the distance is greatly increased. It is in relation with the inferior thyreoid artery and numerous veins, mostly tributaries of the inferior thyreoid vein.

The **apex** is pointed or rounded (figs. 1068, 1069). It is directed cephalodorsally and is situated at the dorsal border of the lateral lamina of the thyreoid cartilage at the level of its caudal, or rarely its middle, third.

It is covered by the sterno-thyreoid muscle beneath which the superior thyreoid artery accompanied by the corresponding vein crosses the apex to reach the gland. It is also crossed in this situation by the external ramus of the superior laryngeal nerve as it passes to the crico-thyreoid muscle.

The **medial surface** of the lateral lobe is concave and intimately bound to the trachea and cricoid cartilage (fig. 1070). Toward the apex it becomes more flattened where it comes into contact with the lateral lamina of the thyreoid cartilage.

At the border where this surface joins with the dorsal surface it is in relation with the œsophagus and pharynx, and in the angle between these structures and the trachea and larynx it is close to the recurrent laryngeal nerve.

The **dorsal surface** (fig. 1070) is broad and rounded caudally, but toward the apex is reduced to a mere border. It lies upon the fascial sheath containing the common carotid artery, the jugular vein, and vagus nerve, most intimately related to the common carotid artery which usually produces a groove in it.

The inferior thyreoid artery sends large branches over this surface. The inferior thyreoid veins also have large branches here. Imbedded in the connective tissue in relation with this surface the *parathyreoid bodies* are found, and in some cases the recurrent nerves are placed so far laterally that they also touch this surface. In many cases the sympathetic trunk and the middle cervical ganglia of the sympathetic with the cardiac branches are closely related to the dorsal surface of the gland.

The **ventro-lateral surface** is convex and is separated by loose connective tissue from the overlapping sterno-thyreoid, sterno-hyoid, and omo-hyoid muscles.

More superficial on its lateral aspect is the sterno-cleido-mastoid muscle. The above muscles are enclosed by the superficial and middle sheets of the cervical fascia. In the subcutaneous tela the platysma muscle spreads over the gland. This surface of the gland is covered by a plexus of veins and by branches of the superior thyreoid artery.

Accessory thyreoid glands are small masses of glandular tissue one or more of which may be found situated in the median line or at one side of it anywhere between the isthmus and the root of the tongue. They vary considerably in size and represent parts of the pyramidal lobe or isthmus which have become completely separated from the rest of the gland. In structure they are composed of the same tissue as the rest of the gland.

Fixation.—In addition to the connective tissue which binds the thyreoid gland to the trachea, it is attached by the connection of its capsule with the cervical fascia and by the fibrous prolongations from the capsule.

These prolongations are found medially attaching the isthmus and adjoining portions of the lateral lobes to the ventral surface of the cricoid cartilage, the caudal border of the thyreoid cartilage, and the sheath of the crico-thyreoid muscles, and laterally attaching the lateral lobes to the trachea and lateral surface of the cricoid cartilage. In addition to these the connection of the vessels and nerves to the gland helps to fix it in position.

Structure.—The thyreoid gland like other glands is composed of a connective-tissue **stroma** supporting an epithelial secreting **parenchyma.**

The connective tissue which covers the surface of the gland forming for it a **capsule,** may be divided into two layers, superficial and deep.

The *superficial layer* intimately connected with and derived from the fascia colli as pointed out above has an important function in supporting and fixing the gland. This layer is in some cases thin and transparent; in other cases it is very tough and thick. It is connected by loose areolar tissue with the thin deep layer of the capsule. Between these two layers the larger vessels run for a space before entering the gland and the veins, particularly, form here considerable plexuses.

From the deeper layer of the capsule numerous trabeculæ and septa carrying blood-vessels, lymphatics, and nerves pass into the gland and imperfectly separate its parenchyma into irregular masses of variable size, the **lobules** [lobuli]. Each lobule is composed of a number of closed, non-communicating, irregular, spherical, ovoid, or sometimes branched alveoli, acini or **vesicles,** varying in size from .045 to .22 mm. in diameter and separated and bound together by a vascular connective tissue continuous with that surrounding the lobules and with that of the cap-

FIG. 1071.—ARTERIES OF THE THYREOID GLAND, ANTERIOR VIEW. 1. Lateral lobe; 1′ pyramidal lobe; 2, trachea; 3, thyreoid cartilage; 4, crico-thyreoid membrane; 5, hyo-thyreoid membrane; 6, 7, 8, 9, inferior thyreoid artery and branches; 10, 11, 12, 13, 14, 15, superior; thyreoid artery and branches; 16, thyreoidea ima. (Testut and Jacob.)

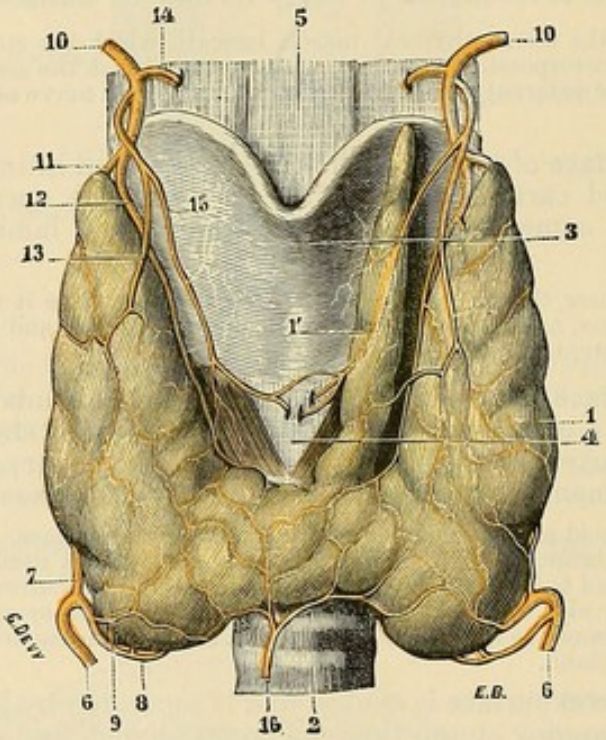

sule. The vesicles are filled with a yellowish viscous fluid, known as **colloid,** the secretion of the epithelial cells.

The vesicles are lined with a single layer of epithelial cells of a fairly uniform cuboidal or columnar shape, becoming flattened in distended vesicles and in old age. The cells are not supported by a basement membrane but are in close relation with connective tissue and capillary blood-vessels. An extremely rich lymphatic network surrounds the vesicles and the lymph-vessels come into intimate relation with the cells. Through these vessels the secretion is conveyed from the gland to the general circulation.

Blood-vessels.—The thyreoid gland has an extremely abundant blood-supply. The arteries are usually four in number but occasionally five (figs. 1071–1073).

The **superior thyreoid arteries** divide into two, three, or more main branches which reach the gland near the apex of the lateral lobes and supply mainly the ventral and medial surfaces of the cephalic portion of the lobes (fig. 1071). There is usually also a dorsal branch, which anastomoses with a branch from the inferior thyreoid. One of the ventral branches frequently connects along the cephalic border of the isthmus with its fellow of the opposite side. The **inferior thyreoid arteries** break up into two or three main branches, occasionally into many fine twigs, which reach the dorsal surface of the lateral lobes near the caudolateral borders and supply

mainly the dorsal and lateral surfaces of the caudal part of the gland (fig. 1071). There is usually a well-marked branch which passes cephalically to anastomose with a good-sized branch from the superior thyreoid. Small branches are distributed to the ventral surface of the caudal portion of the lobes and isthmus. The small fifth artery, the **thyreoid ima artery,** occasionally present, ascends on the ventral surface of the trachea and reaches the gland at the caudal border of the isthmus or of either lobe. It anastomoses with the other arteries which may be correspondingly reduced in size. The above-mentioned arteries branch freely and are distributed over the surface of the gland between the two layers of the capsule where they anastomose extensively with one another and with the arteries of the opposite side. From the surface plexus branches pass with the septa and trabeculæ through the gland to break up into the capillary plexuses around the vesicles.

The relation of the inferior thyreoid artery to the recurrent nerve is important from a surgical point of view but unfortunately is not constant. In some cases the nerve is ventral to the artery, more often on the right, in other cases it is dorsal and often the nerve passes between the branches of the artery. Their relation is most intimate close to the trachea Fig. 1073.

FIG. 1072.—VESSELS OF THE THYREOID GLAND, ANTERIOR VIEW. 1, 2, 3, Lateral lobes and isthmus; 4, pyramidal lobe; 5, hyoid bone; 6, thyreoid cartilage; 7, trachea; 8, common carotid; 9, internal jugular; 10, thyreo-linguo-facial vein; 11, superior thyreoid artery; 12, inferior laryngeal vessels; 13, middle thyreoid vein; 14, subclavian artery; 15, inferior thyreoid artery; 16, inferior lateral thyreoid veins; 17, inferior medial thyreoid veins; 18, left innominate vein; 19 aortic arch; 20, vagus nerve. (Testut.)



The **veins** (fig. 1072) issue from the substance of the gland along the septa which penetrate from its capsule. Between the two layers of the capsule they form a rich plexus of large vessels from which three large branches issue on each side.

The **superior thyreoid veins** leave the capsule of the ventral surfaces of the lateral lobes near their apices and pass cephalo-laterally to empty into the internal jugular veins, sometimes with the facial veins. The **middle thyreoid veins** are sometimes absent, when present they are often very small and pass from the lateral border of the lateral lobes laterally to empty into the internal jugular vein. The **inferior thyreoid veins** arise from the caudal and lateral part of the dorsal surfaces of the lateral lobes and pass caudolaterally to open into the innominate veins. Ventral to the trachea, caudal to the isthmus, the two inferior thyreoid veins are connected by numerous cross anastomoses and occasionally they open by a single trunk which joins the left innominate vein. A **thyreoidea ima vein** is sometimes present.

The **lymphatics** of the thyreoid gland begin as abundant plexuses around the vesicles of the gland lobules. These connect with the interlobular branches which empty into radicles accompanying the blood-vessels through the septa to the surface of the gland where they join a considerable plexus placed between the two layers of the capsule. From the cephalic portion of the isthmus and lobes efferent vessels extend cephalo-medially to one or two small

pre-laryngeal glands and cephalo-laterally along with the superior thyreoid artery to the deep cervical glands. From the caudal part of the lateral lobes and isthmus efferent vessels pass caudally to some small pre-tracheal glands and caudolaterally to the deep cervical glands.

The **nerves** of the thyreoid gland are probably all derived from the sympathetic and arise from the middle and inferior cervical ganglia and accompany the arteries to the gland.

Development.—The thyreoid gland is first seen in very young embryos as a prominence on the ventral wall of the pharynx. This becomes a stalked vesicle and divides into lateral lobes. The stalk elongates forming the **thyreoglossal duct** of His. Later the lumen is obliterated and the duct is then represented by an epithelial cord which soon loses its connection with the pharynx. It opens at first cephalic to the regular second branchial arch on the summit of the tuberculum impar but later shifts to its caudal boundary (Grosser). It is represented in the adult only by a short blind pouch, the **foramen cæcum** but very rarely a considerable duct may be present. The bilobed mass appears to shift caudally, increasing in size and spreading laterally and dorsally. The median cord of cells formed from the stalk becomes the isthmus and the pyramidal lobe, when this is present, the lateral portions form the lateral lobes. The gland is now composed of irregular, in general transversely disposed cords of cells. More rapid growth later occurs in the centres of the lateral lobes and the cell cords become closely packed with little connective tissue between. Lumina appear in different places in the cell cords and the cell cords are broken up into groups of cells; in these the lumina continue to appear even up into early childhood. On each side, diverticula from the more caudal pharyngeal pouches, the **ultimobranchial bodies,** come into contact with the dorsal and lateral parts of the anlage of the thyreoid gland and become partly enclosed in the neighbourhood of the transversely running cell cords. This core of cells becomes either a compact body or an irregular group of cells and is probably not transformed into thyreoid tissue.

THE PARATHYREOID GLANDS

The **parathyreoid glands** are small masses of epithelial cells found in the neighbourhood of the dorsal surface of the thyreoid gland but quite distinct from it and

FIG. 1073.—PARATHYREOID GLANDS, VIEWED FROM BEHIND (NATURAL SIZE).

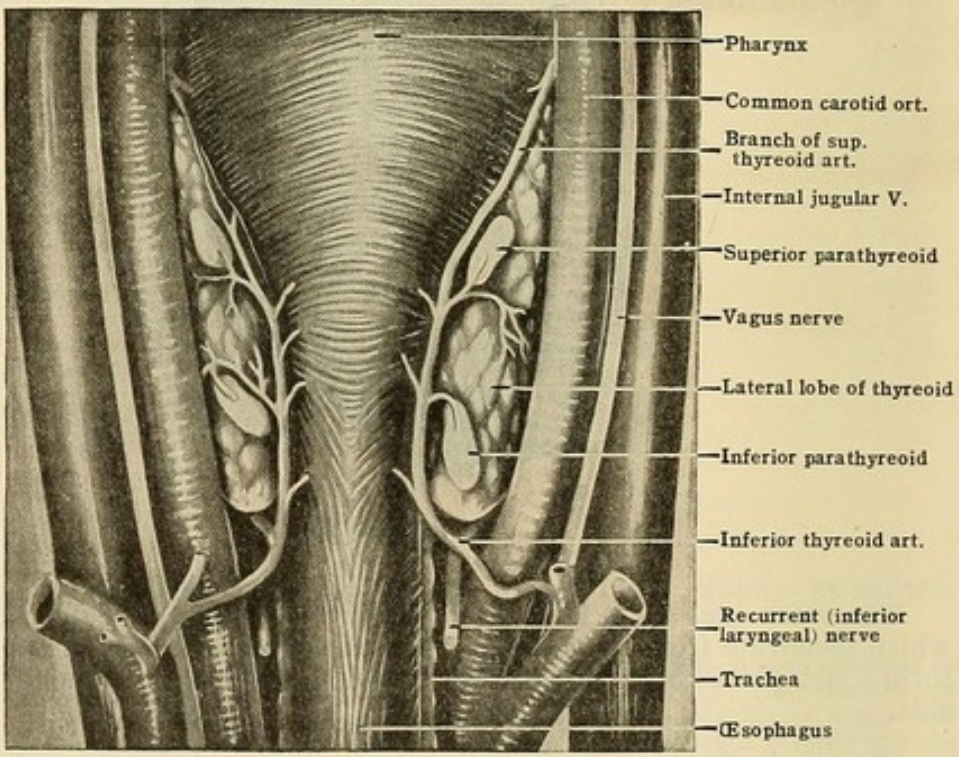

of different structure. They are ductless glands and although very small they are essential to life.

The usual **number** is four, two on each side, in relation with the lateral lobes of the thyreoid gland (fig. 1073). In **colour** they are yellowish with more or less of a reddish or brownish tint but lighter than the thyreoid gland. Their **consistency** varies somewhat but usually it is softer than that of the thyreoid gland. The **shape** of the majority of the glands is a flattened ovoid, sometimes tapering at one or both ends, rarely a flattened circular disc. At some place on the surface there is usually a depressed hilum where the artery enters and the vein leaves. The average **size** of the glands is 6 to 7 mm. in length; 3 to 4 mm. in width and 1 to 2 mm. in thickness. Occasionally they may be found 15 mm. in length. They

weigh from .01 to .1 gm. with an average of .035 gm. From their situation they have been divided into a *superior*, or internal, derived from the fourth branchial pouch, and an *inferior*, or external, derived from the third branchial pouch.

The **superior parathyreoid glands** (fig. 1073) are found, as a rule, on the dorsal surfaces of the lateral lobes of the thyreoid gland at about the junction of the cephalic and middle thirds Occasionally they may be situated in the areolar tissue at the level of the apex of the thyreoid gland or cephalic to it. They may be ventral to the prevertebral layer of the cervical fascia, on the dorsal wall of the œsophagus or pharynx and close to the dorsomedial margin of the thyreoid gland. They may also be placed at the level of the caudal border of the cricoid cartilagel rarely as high as the inferior cornu of the thyreoid cartilage or as low as the sixth trachea, ring. Sometimes they are imbedded completely in the thyreoid gland. As a rule, they are tightly attached to the capsule of the thyreoid gland or situated between its layers.

The **inferior parathyreoid glands** (fig. 1073) are less constant in their situation than the superior. They usually are found in relation with the dorsal surface of the lateral lobes of the thyreoid glands, not far from their bases. They may be quite outside the region of the thyreoid gland along the carotid arteries or the sides of the trachea, or they may be placed more cephalically than usual or extend caudal to the gland as far as the tenth tracheal ring, even into the thorax. They are imbedded, when caudally placed, in fatty areolar tissue in relation with the apex of the thymus gland and the inferior thyreoid veins or applied against the œsophagus.

The parathyreoids are intimately related to branches of the inferior thyreoid artery, a separate branch of which supplies each of them. When there is a large branch of the inferior thyreoid artery anastomosing with the superior they are more or less in line with this.

Each parathyreoid gland is surrounded by a fibrous *capsule* from which extremely vascular septa and trabeculæ penetrate into the gland separating and binding together the masses of polyhedral cells which are arranged in solid groups or intercommunicating cords of varying sizes and shapes.

The cell cords, as a rule, are not arranged like the thyreoid vesicles. At times the secretion may accumulate and produce a vesicular appearance and the secretion then closely resembles colloid. Two kinds of cells, oxyphile and principal cells, have been described; but the intermediate forms suggest that these are the same sort of cells in different stages of functional activity. The blood-vessels are distributed in the connective tissue of the trabeculæ and thus their sinusoids are brought into close connection with the cells of the gland. The nerves are also distributed along the septa. In the highly vascular connective tissue between the cell cords fat cells are found separate or in groups.

The *number* of parathyreoid glands found by different investigators varies. The average number in a series of cases is less than four. Whether this is due to a real absence of the glands or to failure to find them due to their aberrant location, their inclusion in the thyreoid gland, or the fusion of two glands, is not clear. In some cases it is the superior glands, in other cases the inferior glands, which appear to be missing. On the other hand various competent observers have reported finding more than four parathyreoid glands. Five or six are occasionally found; as many as eight have been recorded in one instance. In these cases the number on a side may not be symmetrical. The increased number may be due to the separation of buds in the course of development. The parathyreoid glands are liable to be associated with accessory thymus masses, with small lymphatic glands, and with fat lobules; and as they may somewhat resemble each of these, they may be mistaken unless a microscopic examination is made.

Blood-supply.—Each parathyreoid gland is supplied by a single separate artery derived, as a rule, from one of the glandular, muscular, or œsophageal branches of the inferior thyreoid artery or from the anastomosing branch between the superior and inferior thyreoid arteries. When the glands are in aberrant positions their arteries may be derived from the nearest source. The arteries are distributed along the trabeculæ and septa. The veins returning the blood either follow the arteries or they pass to the surface of the gland where they break up into a plexus of thin-walled vessels. Upon leaving the gland the veins empty into some one of the branches of the thyreoid veins.

Development.—The parathyreoids (epithelial bodies) begin as proliferations of the epithelium on the oral and lateral walls of the dorsal diverticulum of the third and fourth pharyngeal pouches. The cells show early a histological differentiation with vacuolated and reticulated plasma. The common pharyngo-branchial ducts diminish in size and become constricted off and separated from the pharynx. The parathyreoid glands later become independent and separated from the thymus anlages. The epithelial cells grow out in the form of cords separated by connective tissue and in intimate relation to the blood-vessels. Different kinds of cells are not distinguishable until postfœtal life when evidence of secretion begins.

THYMUS

The **thymus** is a transitory organ of epithelial origin, but in structure resembling the lymphoid tissue. Its function is not clearly understood but it seems to be intimately associated with the growth and nutrition of the individual, and it is classed with the ductless glands of internal secretion.

It is **situated** in the ventro-cephalic part of the thorax and extends into the caudal part of the neck (fig. 1074). It lies between the two pleural sacs ventral to the heart and great vessels, dorsal to the sternum and the sterno-thyreoid and sterno-cleido-mastoid muscles.

Although arising from the branchial clefts one on each side of the neck, the two portions become so closely associated that they are usually spoken of as one. Each of these parts is ordinarily regarded as a **lobe of the thymus** [lobus, dexter et sinister].

In **colour** the thymus is pinkish or reddish grey in the fœtus and newborn, becoming greyish white in the adult or yellowish as it undergoes involution. It is composed of soft, yielding tissue more friable than the thyreoid or spleen.

In **size** the thymus varies greatly. Under normal conditions it appears to attain its maximum size at about the age of puberty, and to continue large as long as the body continues to grow and then to undergo a gradual involution.

FIG. 1074.—THYMUS GLAND IN A CHILD AT BIRTH.

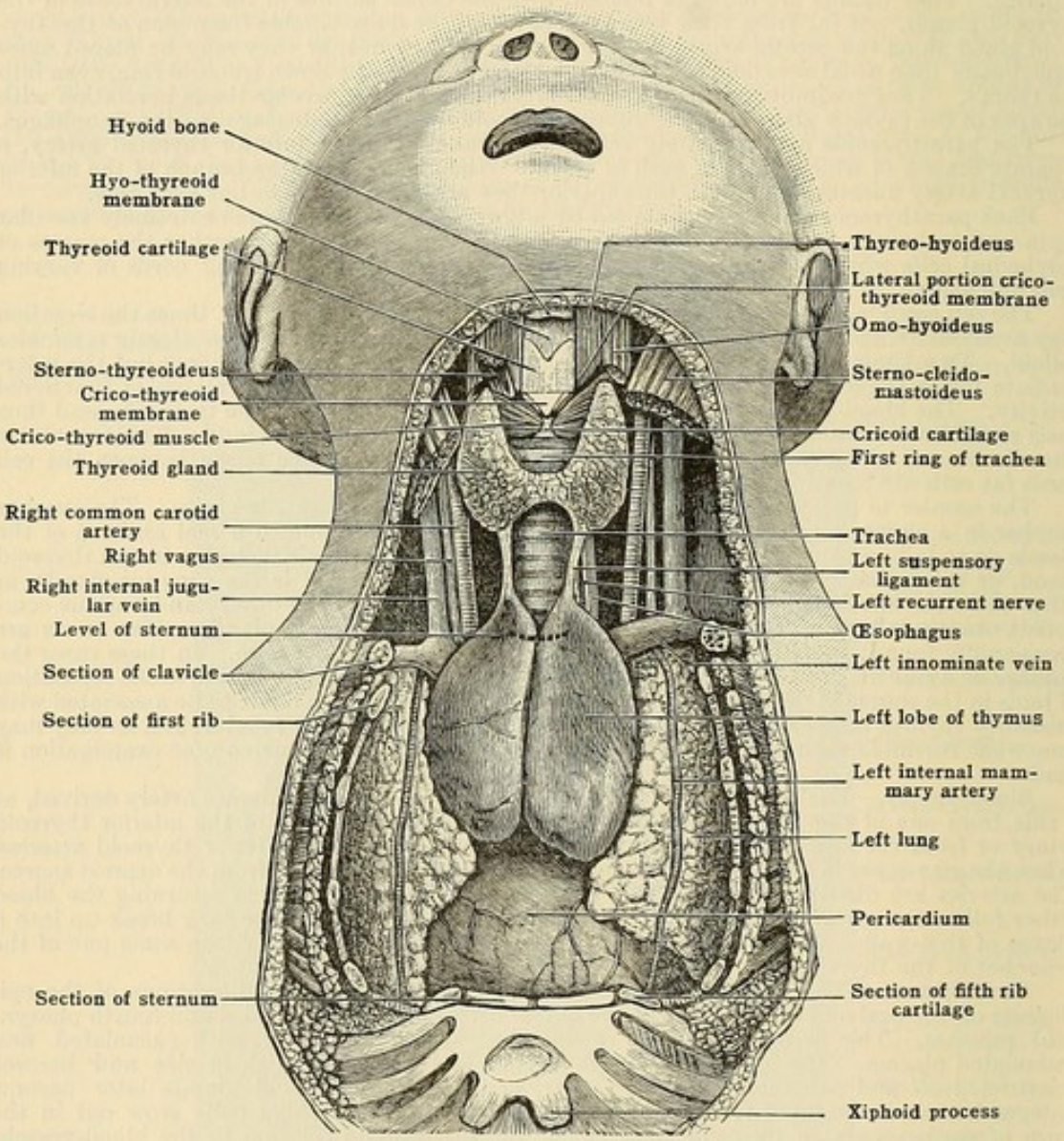

It is, however, very sensitive to any nutritive changes of the individual and becomes very small, even in the infant, under the influence of wasting diseases. It not infrequently exists in the adult only as a vestige but in some cases it may remain large until middle age or later. At birth it is usually from 50 to 60 mm. long cephalo-caudally and about half as broad.

The **weight** varies with the size. It is given by Hammar as over 13 gm. at birth, increasing to double this between the sixth and the tenth years and gaining its maximum of between 37 and 38 gm. between the eleventh and fifteenth years. From this time the weight decreases until between the ages of fifty-six and sixty-five it weighs between 25 and 26 gm. and at seventy-five years may be as light as 6 gm. The involution of the gland is not accompanied by a corresponding reduction in size and weight as the thymic tissue is gradually invaded by fatty tissue which maintains to some extent the form of the organ.

In **shape** the thymus is an elongated, spindle-shaped mass consisting of the central portion or body and two extremities (figs. 1074, 1075). The **body** is the

widest and largest part of the organ and has no distinct separation from the extremities. The **inferior extremity** is also broad and is known as the base. It rests on the pericardium, ordinarily extending as far caudal at birth as the atrio-ventricular furrow but rarely it may extend as far as the diaphragm. The **superior extremity** is much elongated and extends into the neck. It is represented by two horns nearly always unequal in size the left being usually the larger. It extends nearly to the thyreoid gland, in some cases reaching it.

Relations.—Topographically the thymus when well developed is divided into cervical and thoracic parts.

The **cervical portion** presents for examination an anterior surface and a posterior surface. The **anterior surface** is convex and is in relation with the sterno-thyreoid and sterno-cleido-mastoid muscle. The **posterior surface** is concave and rests medially upon the anterior surface of the trachea, laterally upon the common carotid artery and sometimes on the left side upon the œsophagus.

The **thoracic portion** of the thymus is much more important representing four-fifths of the organ (fig. 1075). It presents for examination an anterior, a posterior, and two lateral surfaces. The **anterior surface** is dorsal to the sternum from which it is separated cephalically by the origin of the sterno-thyreoid muscle. To a less extent it is in relation with the sterno-clavicular articulation and comes into contact laterally with three or four of the cephalic sterno-costal articulations and lateral to this with the internal mammary artery. The **posterior surface** is largely concave and is in relation caudally with the pericardium which separates it from the

FIG. 1075.—THYMUS IN AN ADULT. $\times\frac{1}{3}$. (From Toldt's Atlas.)

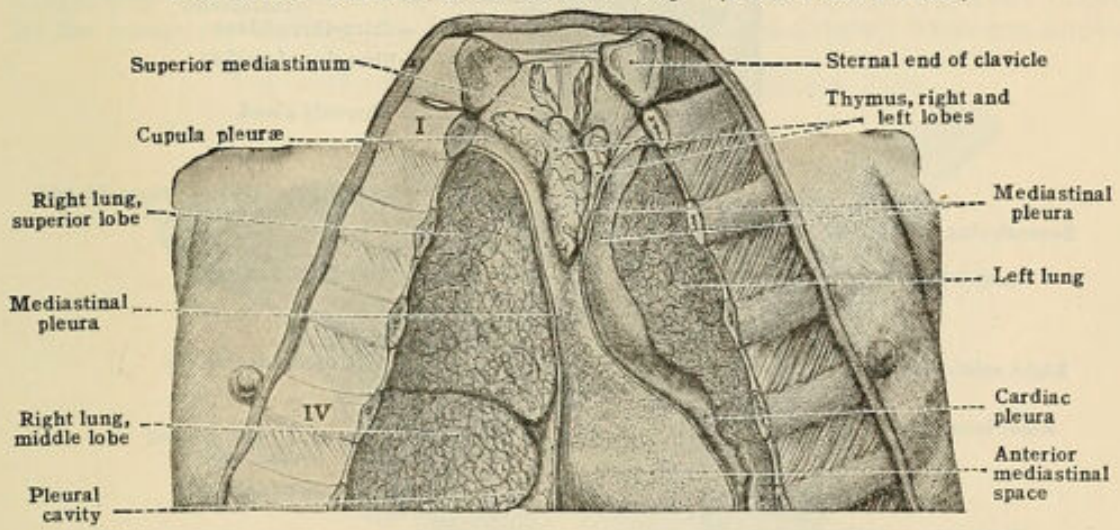

right atrium and ventricular portion of the aorta and pulmonary artery. The middle part is in relation with the aorta and to the right of this with the superior vena cava. The cephalic part is in relation with the branches of the aorta and superior vena cava. The **lateral surfaces** are somewhat flattened and are separated from the lungs by the mediastinal pleura. The phrenic nerve on the right side runs in the pleura near the dorsal border of this surface, on the left it is, as a rule, not in direct contact with the thymus.

Structure.—The two lateral lobes of which the thymus is composed are rarely of the same size; the right is usually the more strongly developed. They are joined at an oblique plane so that the ventral surface of the right is narrow and its dorsal surface broader and the reverse condition is found in the left lobe. The two lobes are separated from one another by connective tissue. Rarely the two are joined by a medial portion, **isthmus,** near the middle or toward the caudal end (fig. 1076).

Each lobe of the thymus is completely surrounded by a thin delicate connective-tissue capsule from which numerous septa extend through the gland accompanied by the blood-vessels and nerves. The capsule is composed mainly of white fibrous connective tissue with some elastic fibres. It rarely contains much fat in the newborn but the amount of fat increases as development and involution proceed. Fibrous prolongations from the capsule may extend from the apices of the lobes to be attached to the cervical fascia in the region of the lateral lobes of the thyreoid gland, acting as suspensory ligaments for the gland.

The lobes of thymus are divided into numerous small **lobules** [lobuli thymi] 4 to 11 mm. in diameter. These are of roundish or polyhedral shape with bases toward the surface where they show as polygonal areas. The lobules are separated and also bound together by the loose fibrous tissue septa which extend from the capsule.

Each of the primary lobules of the thymus is divided into a number of secondary lobules or follicles 1 to 2 mm. in diameter. These lymphoid-like masses of tissue are composed of a reticulum containing in its meshes lymphocytes or **thymus corpuscles.** The tissue is denser near the surface, forming a **cortex** and passes gradually into a tissue with looser meshed reticulum near the centre, **medulla.** In the medulla there are nests of concentrically arranged degenerated epithelial cells enclosing a central mass of granular cells containing colloid. These

nests are termed the **concentric corpuscles** of Hassall. The cortex is subdivided by secondary connective-tissue septa extending in from the septa between the lobules.

The **arteries** of the thymus are somewhat varied in their origin, usually derived from the internal mammary and inferior thyreoid of each side; branches are sometimes received from the innominate, subclavian, and superior thyreoid arteries. They reach the gland in various places and spreading out in the capsule pass with the trabeculæ through the gland to form a plexus around each small lobule. From this capillaries pass through the cortex to the medulla. The **veins** issue from the thymus in various places and are seen as numerous branches on its surface. The efferent vessels drain into various veins, mostly into the left innominate vein, also smaller branches into the internal mammary and inferior thyreoid veins.

The **lymphatics** arise around the small lobules and pass through the interlobular septa to the surface from which they are drained into small lymph nodes near the cephalic extremity, into glands ventrally between the thymus and the sternum, and into other glands dorsally between the thymus and the pericardium.

The **nerves** of the thymus are very minute. They are derived from the cervical sympathetic and from the vagus and reach the thymus for the most part along with the blood-vessels which they accompany through the septa.

FIG. 1076.—THYMUS IN A CHILD OF TWO YEARS.

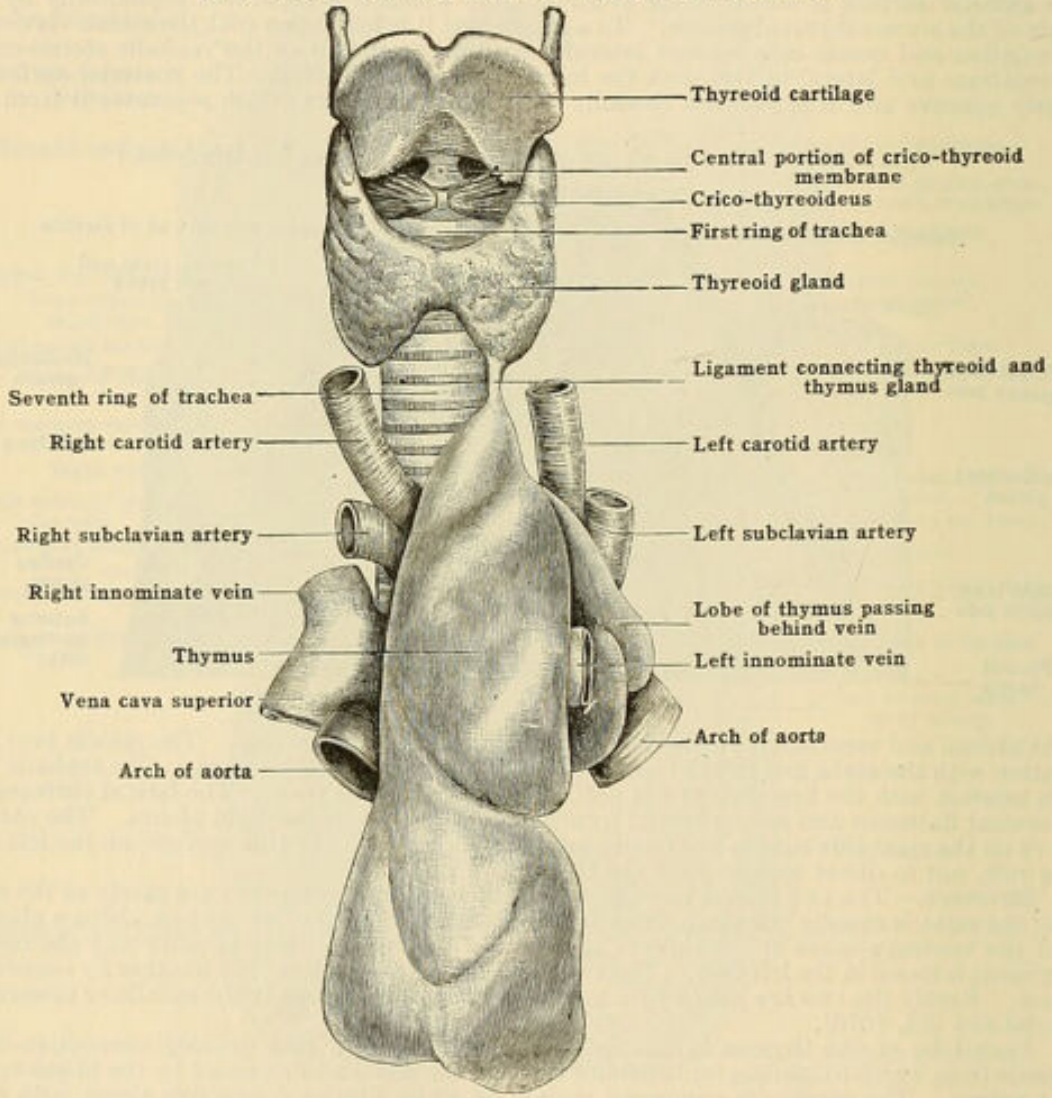

Development.—The thymus arises from the endodermal portion of the third pharyngeal pouch on each side, as a thickening due to an increase in the epithelial cells, followed by the production of a diverticulum. At about the sixth week the connections of the pouches with the branchial clefts are cut off but a strand of tissue may persist to represent the stalk. These thick-walled cylinders become solid cords, elongate so as to extend caudally into the thorax, and enlarge by a series of secondary buddings. The glands of the two sides come into contact and become intimately associated. The cephalic portion, as a rule, later atrophies and disappears. Occasionally a small part of it remains near the thyreoid cut off from the rest of the gland as an accessory thymus. From the fourth pharyngeal pouch rarely a thymus bud may be developed which produces in the adult also an accessory thymus. The epithelial character of the cells remains plainly evident for a time, then the characteristic differentiation into lymphoid structure, cortex and medulla appears. The reticulum and concentric corpuscles are undoubtedly of epithelial origin; but the thymus lymphocytes are considered by Hammar and others as leucocytes which have migrated to the thymus, while they are regarded by

Stöhr and his followers as modified epithelial elements, not true blood cells. Maurer, Bruant, and Bell regard them as modified epithelial cells which become true functional leucocytes.

THE CHROMAFFIN SYSTEM

It has recently been shown that in connection with the ganglia of the sympathetic nervous system, special cells, other than the nerve cells, are found. These differ from the nerve cells in that when subjected to the action of chromic acid salts there can be demonstrated in their protoplasm small granules which take on a darker stain. These cells are therefore known as **chromaffin cells.** They, with the cells of the sympathetic system, are derived from the ectoderm. They appear first as indifferent cells, the sympatho-chromaffin cells. Some of these later develop into sympathetic ganglion cells, others into chromaffin cells. Some of these latter cells remain, isolated or in groups, permanently associated with the sympathetic ganglia, the **paraganglia;** others become separated and form the medullary portion of the suprarenal glands, the aortic paraganglia, and the glomus caroticum.

THE SUPRARENAL GLANDS

The **suprarenal glands** [glandulæ suprarenales] or adrenal glands are small irregularly shaped glandular bodies composed of two quite different organs. In the lower vertebrates these two parts are entirely separated from one another

FIG. 1077.—THE SUPRARENAL GLANDS, VENTRAL VIEW.

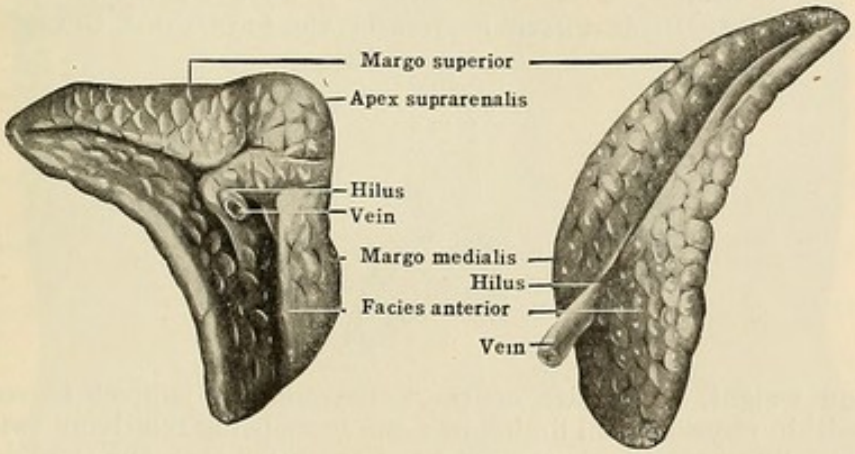

but in man and the mammals they have become joined together one within the other. The external cortical portion, of unknown function, is developed from the mesoderm. The internal medullary portion is derived from the sympatho-

FIG. 1078.—THE SUPRARENAL GLANDS, DORSAL VIEW.

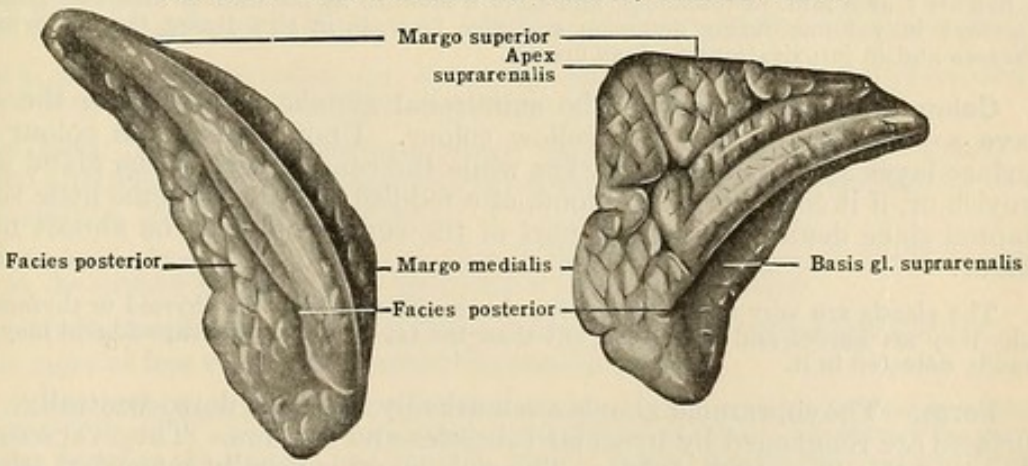

chromaffin tissues and thus from the ectoderm in common with the sympathetic nervous system. This part of the suprarenal glands is known to produce an internal secretion which reaches the general circulation through the veins and

whose principal function seems to be to aid in keeping up the tone and activity of the muscle and other tissues innervated by the sympathetic system.

Situation.—The glands are deeply placed in the epigastric region (fig. 1080) lying in the dorsal and cephalic part of the abdominal cavity, one on either side of the vertebral column in variable relation with the upper extremity of the kidney of the corresponding side.

Rarely they retain the fœtal relation, capping the superior extremity of the kidney and extending a little upon both medial and lateral borders. More frequently (especially on the left) they are placed more upon the medial borders of the kidneys, extending (on the left) as far caudal as the hilus, sometimes coming in contact with the renal vessels. An intermediate position is often found, especially on the right. In the high positions the suprarenals may be on a level with the tenth intercostal space or eleventh rib. In the low positions they may extend as far caudally as the first lumbar vertebra. The left is usually, but not always, a little higher than the right, corresponding to the position of the kidneys.

Fixation.—The suprarenals, enclosed in the renal adipose capsules, are attached to the renal fascia by connective-tissue strands and are loosely bound by connective tissue to the kidneys. The attachment to the kidneys is, however, so loose that the suprarenals are not dislocated when the kidneys are displaced. In addition to the attachments common to them and to the kidneys, they are joined by connective-tissue bands to the diaphragm, vena cava, and liver on the right side and to the diaphragm, aorta, pancreas and spleen on the left. They have also additional means of fixation through the arteries, veins, and nerve fibres which enter and leave them, and through the parietal peritoneum which in places covers their ventral surfaces.

FIG. 1079.—DIAGRAMMATIC SECTION OF THE SUPRARENAL GLAND.

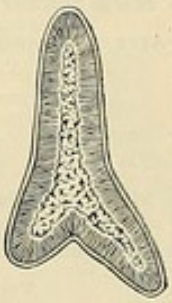

Size and weight.—The size of the suprarenals is subject to considerable variation within physiological limits, in some cases being relatively twice as large as in others. The two glands are rarely of the same size, the right being more often the smaller.

Proportionately they are much larger in the fœtus and embryo than in the adult, but they do not decrease in size in old age. They appear to be slightly lighter in women than in men. The average weight in the adult is from 4 to 5½ grams. As a rule, they measure about 30 mm. in height; 7 or 8 mm. in thickness; and have a breadth at the base of about 45 mm. They augment in volume during digestion and also increase in size during the acute infectious diseases and in intoxications such as uremia.

Colour and consistency.—The suprarenal glands as seen from the surface have a yellowish or brownish-yellow colour. Upon section the colour of the surface layer appears a little darker while the central part of the gland appears greyish or, if it contains much blood, of a reddish colour. If some little time has elapsed since death, the central part of the suprarenal may be almost black in colour.

The glands are very fragile and softer in consistency than the thyroid or thymus. As a rule, they are harder and more resistant than the fat of the adipose capsule and may be thus readily detected in it.

Form.—The suprarenal glands are markedly flattened dorso-ventrally. Their surfaces are roughened by irregular tubercles and furrows. They vary considerably in shape (figs. 1077, 1078). The *right* gland is usually somewhat triangular in outline while the *left* is, as a rule, semilunar. Each gland has an anterior and a posterior surface, a base and an apex, a medial and a superior margin.

The **anterior surface** [facies anterior] may be either convex or concave, and

look ventro-laterally. It is marked by a distinct transverse, oblique, or nearly vertical fissure, the **hilus suprarenalis.** At this point a small artery enters and the principal suprarenal vein takes exit from the gland. These surfaces are in relation with different organs on the right and left sides.

The anterior surface of the *right* gland is in the greatest part of its extent in contact with the posterior surface of the liver, upon which it produces the suprarenal impression. The medial edge of this surface is overlapped, cephalically by the inferior vena cava and caudally by the duodenum. The gland is situated between the two layers of the coronary ligament, in most cases, in direct contact with the liver to which it is bound by loose connective tissue; but, at times, the peritoneum which covers the ventral surface of the kidney extends for a greater or less distance between the suprarenal and the liver.

The anterior surface of the *left* gland, in some cases, may be in contact in its cephalic part with the left lobe of the liver and also, at times, with the spleen. The middle and major part lies against the fundus and cardiac end of the stomach, while caudally the suprarenal is often

FIG. 1080.—VENTRAL VIEW OF THE SUPRARENAL GLANDS, IN SITU. × ⅓. (From Toldt's Atlas.)

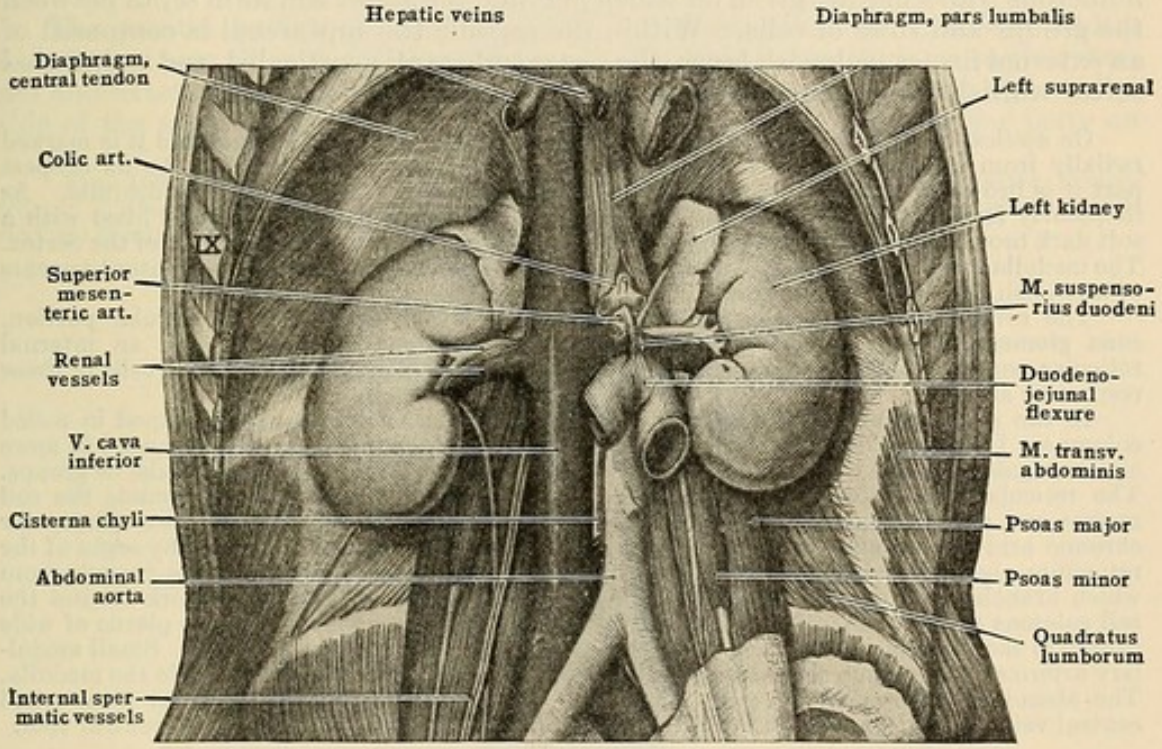

crossed by the tail of the pancreas and the splenic artery and vein. The whole or a large part of the anterior surface of the left suprarenal is covered by the parietal peritoneum of the omental bursa.

The **posterior surface** [facies posterior] of both the suprarenals is distinctly smaller than the anterior surface. It is flat or convex and looks dorso-medially.

It is in relation with the lumbar part of the diaphragm, to which it is bound by connective tissue, but from which it is separated by an extension of the renal adipose capsule.

The **base** [basis gl. suprarenalis] is a narrow elongated surface distinctly hollowed out, which lies in contact with the superior extremity of the kidney or its medial margin, cephalic to the hilus.

This surface looks dorsally, laterally, and somewhat caudally with the result that it extends farther on the anterior surface than on the posterior surface of the kidney.

The **medial border** [margo medialis] is sharp, thin, and irregularly convex. It extends more or less vertically to meet the superior border.

On the *right* it lies dorsal to the inferior vena cava cephalically and to the duodenum caudally and is close to, if not in contact with, the sympathetic cœliac ganglion. On the *left* the medial border lies dorsal to the stomach and caudally may be crossed by the pancreas and splenic vessels. It is in close proximity to the aorta and the cœliac sympathetic ganglion.

The **superior border** [margo superior] is sharp and thin and differs somewhat on the two sides.

On the *right* it is irregular, straight or convex, and extends, dorsal to the liver, obliquely cephalo-medially to meet the medial border in a more or less acute point, **apex suprarenalis,** which is directed cephalically and somewhat medially. On the *left* the superior border is irregularly convex in shape and nearly horizontal in direction. It passes gradually over into the medial border without the intervention of any distinct apex. It is dorsal to the stomach and in some cases comes into contact with the spleen.

Accessory suprarenal glands [gl. suprarenales accessoriæ] are often found in the connective tissue in the neighbourhood of the principal organs. They are also sometimes found in the kidney near the internal spermatic veins and in the region of the sexual glands. The structures recorded as accessory suprarenal glands may be complete suprarenal glands composed of the cortex and medulla or they may be composed of the cortex only. Masses of chromaffin tissue representing the medulla are sometimes spoken of as accessory suprarenals but these more properly belong with the chromaffin system.

Complete *absence* of the suprarenal glands has been recorded only in monsters with grave cranial and cephalic defects. Absence of one gland has been found and the fusion of the two has also been noted.

Structure.—The suprarenal glands are surrounded by a thin and tough fibrous *capsule* composed mainly of white fibrous connective tissue. From the capsule numerous trabeculæ are given off which pervade the gland and form septa between the groups and rows of cells. Within the capsule the suprarenal is composed of an external firmer yellowish layer, the *cortex* [substantia corticalis], and an internal softer whitish layer, the *medulla* [substantia medullaris] (fig. 1079).

On section the cortex is seen to form by far the greater part of the gland and it is marked radially from the centre toward the surface by darker and lighter streaks. In its deepest part it is brownish yellow or red and is usually slightly torn where it joins the medulla. As frequently found at autopsy the cortex is separated from the medulla by a slit filled with a soft dark brown or blackish mass caused by the breaking down of the deeper layer of the cortex. The medulla is a greyish, spongy, vascular mass which often because of its blood content appears of a reddish or reddish-brown colour.

The cortical portion of the gland is subdivided into a superficial, glomerular portion, **zona glomerulosa**; an intermediate, fascicular portion, **zona fasciculata**; and an internal reticular portion, **zona reticulata,** according to the peculiar grouping of the gland cells in these respective areas.

In the glomerular zone the cells are of irregular columnar shape, and grouped in coiled columns. In the fascicular zone the cells, which are of polyhedral shape, are arranged in more or less regular parallel columns, while in the reticular zone the cells form trabeculæ or groups. The reticular connective-tissue framework, continuous with the capsule, surrounds the cell masses and cell columns of the several zones. The cells of the medulla show an affinity for chromic acid—chromaffin cells—and are grouped in irregular masses separated by septa of the reticulum and venous spaces. The arteries form a close-meshed plexus in the capsule from which branches run more or less parallel toward the medulla forming a network around the cell columns of the glomerular and fascicular zones. This opens into a venous plexus of wide calibre in the reticular zone, which is connected with the vessels of the medulla. Small medullary arteries pass through the cortex without branching to end in a venous plexus in the medulla. The abundant wide-meshed venous sinuses in the medulla (sinusoids) join to form small central veins which converge toward the centre of the medulla to form the large central vein.

Vessels and nerves.—The suprarenal glands are richly supplied with vessels. The arteries are three—superior, middle and inferior.

From the inferior phrenic artery, the **superior suprarenal artery** arises and passes toward the superior border of the gland. From the aorta the **middle suprarenal artery** takes origin between the cœliac and superior mesenteric arteries and passes toward the medial border of the suprarenal. It is a branch of this artery which is usually found at the hilus along with the central vein. From the renal artery the **inferior suprarenal artery** arises and reaches the suprarenal near its base. These three arteries anastomose with one another and form a plexus in the capsule of the suprarenal from which the arteries for the interior of the gland are derived.

The large central vein from the medulla passes through the cortex to emerge at the hilus as the suprarenal vein, **vena suprarenalis.** The right vein opens usually into the inferior vena cava, where there is a valve, the left into the left renal vein. There may also be small branches connecting with the phrenic or the right renal vein.

The **lymphatics** of the suprarenals are very numerous and are represented by a superficial plexus in the capsule and a deep plexus in the medulla. These are connected by numerous anastomoses. They pass medially and converge into a number of trunks on each side which empty into lymph-glands situated along the aorta near the origin of the renal arteries. On the left side there is also the communication through the diaphragm with a posterior mediastinal gland.

The **nerves** are derived chiefly from the cœliac and renal plexuses but include filaments from the splanchnics, and according to some authors from the phrenic and vagus nerves also. These numerous fine twigs connect with the gland in many different places and form a rich plexus. Branches are distributed to the capsule, to the cortical substance, and to the medullary substance. Groups of sympathetic ganglion cells are found in the medullary part of the gland.

Development.—The suprarenal glands of mammals have their origin from two sources. The cortical mesodermic portion of the glands arises in early embryos as buds extending from

the mesothelium on both sides of the root of the mesentery into the mesoderm ventral to the aorta. A little later these become definite organs completely separated from the cœlomic epithelium and are soon vascularised, but the central vein does not become visible until considerably later. The suprarenal glands after their separation from the peritoneum form a ridge on either side of the posterior wall of the cœlom medial to the mesonephros. Some little time after the origin of the cortical portion of the gland has undergone cellular differentiation and has become surrounded by a delicate capsule, the medullary portion is formed by the migration of masses of sympatho-chromaffin cells from the medial side toward the centre of the organ so that they surround the central vein as the anlage of the medullary nucleus. They penetrate the cortical portion of the gland as development proceeds and become completely surrounded by it. These migrating masses are entirely or for the most part of chromaffin formative cells derived from the ectoderm. They are clearly differentiated from the cortical cells by their small size and darker colour, in stained sections. Migration of these cell masses into the gland seems to be continued even after birth. The differentiation of the cortex into three layers occurs late in development. The suprarenal glands are relatively large in fœtal life; and their relation to the kidneys is secondarily acquired.

THE GLOMUS CAROTICUM

The **carotid bodies** [glomera carotica] are small ovoid or spherical bodies found at or near the point where the common carotid arteries divide into the internal and external carotids (fig. 1081). They are usually on the dorsal and medial side of the angle of bifurcation of the arteries. There is ordinarily one body on

FIG. 1081.—THE GLOMUS CAROTICUM (CAROTID BODY). (From Testut, after Princeteau.) 1, Carotid body; 2, 3, 4, common, external and internal carotids; 5, int. jugular; 7, inf. cervical sympathetic ganglion; 8, vagus.

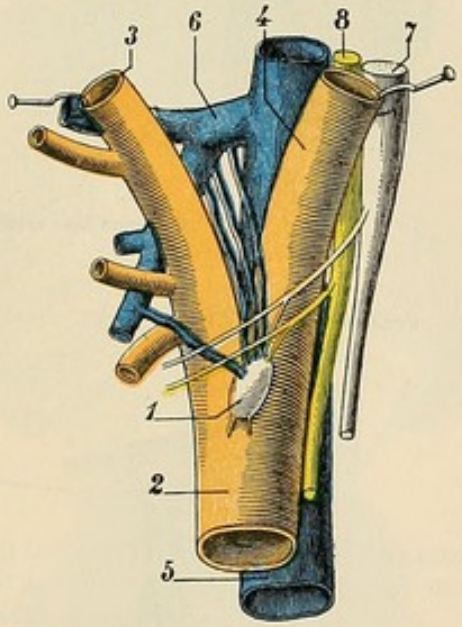

each side, 5 or 6 mm. in length and 2 or 3 mm. in thickness. It is reddish-yellow in colour and is attached to the carotid by fibrous tissue and by the vessels and nerves which enter it. A small special fibrous band may sometimes be recognised binding it to the common, external or internal carotid artery.

The carotid body or gland is composed of two essential parts: (1) round, oval, or polyhedral epithelial cells which contain chromaffin granules, and are bound together by a mass of fibrous connective tissue; and (2) a rich plexus of capillaries and sinusoids forming a mesh. Large lymph-vessels surround the outside of the gland. The carotid gland has a very abundant nerve supply, mostly from the sympathetic system, and ganglion cells are found in it. It may receive twigs from the superior laryngeal, hypoglossal, or glossopharyngeal nerves, as recorded by some observers.

The *size* of the carotid body varies considerably. At times the carotid bodies are absent; in other cases they are so small that they can be detected only in microscopic sections; occasionally they are 8 mm. in length by 4 or 5 mm. in thickness. Rarely the carotid bodies may be broken up into two or more smaller masses bound together by connective tissue. The carotid body may be larger in old individuals due to an increase in the connective tissue or vascular elements with a corresponding decrease in the epithelial cells. The origin is probably from sympathochromaffin cells but some investigators believe that they are derived from the endothelium of the blood-vessels and others that they arise from the endoderm of a branchial pouch.

FIGS. 1082 AND 1083.—AORTIC PARAGANGLIA. (Zuckerkandl.)

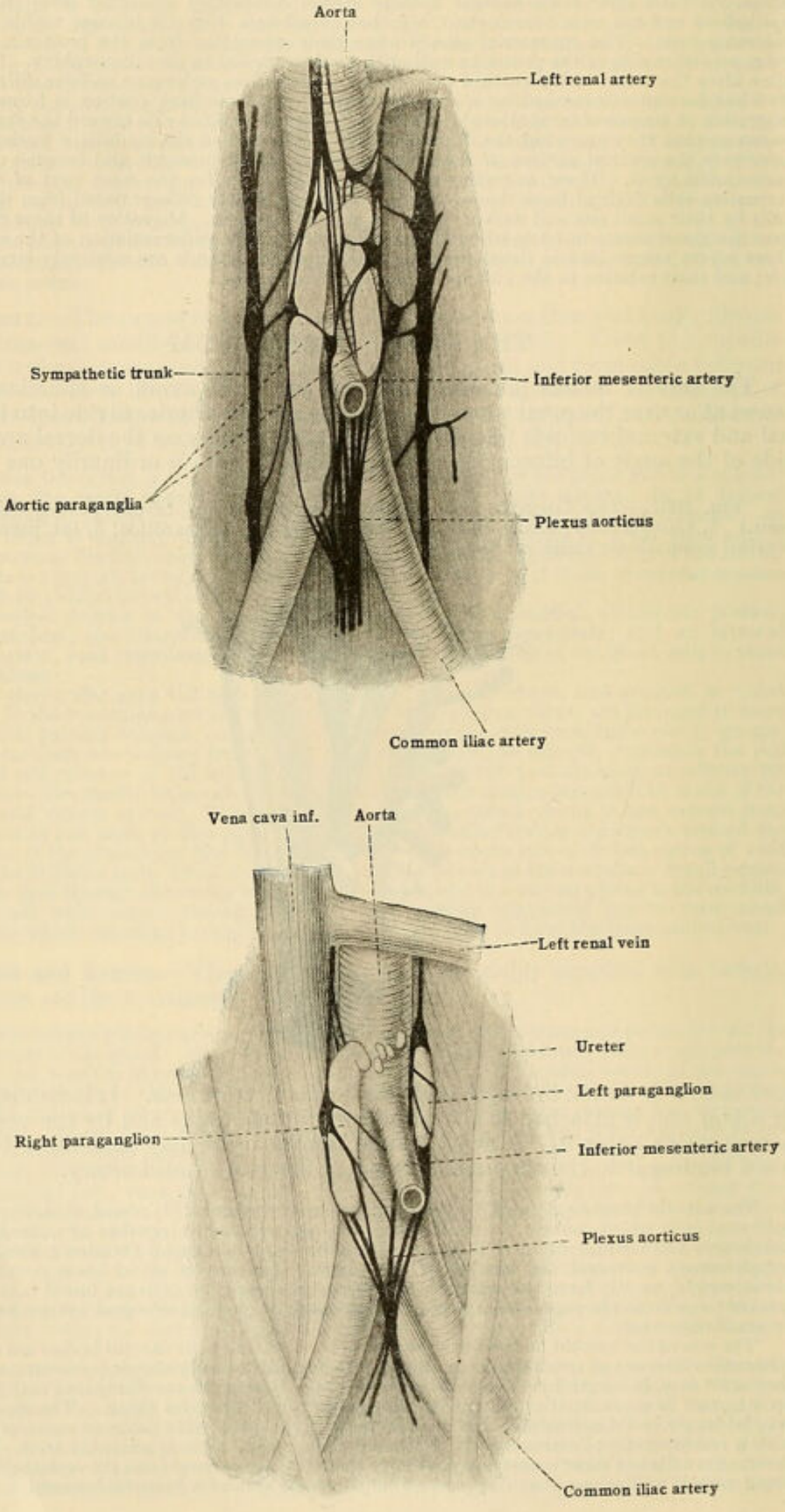

THE AORTIC PARAGANGLIA

The **abdominal chromaffin bodies,** the **paraganglia aortica,** or **paraganglia lumbalia,** are situated on each side of the abdominal aorta near the point of origin of the inferior mesenteric artery (figs. 1082, 1083). They are elongated, flattened, ovoid bodies, softer and greyer than the lymphatic glands and extremely variable in size.

They measure, as a rule, between 6 and 12 mm. in length, although occasionally as long as 30 mm. or as short as 1 mm. They may be connected by transverse bands in front of the aorta or occur as scattered nodules in this situation. They are intimately related to the aortic sympathetic plexus and at least one of them is uniformly found. They consist of a mass of chromaffin cells surrounded by a rich capillary plexus and contain many nerve fibres and nerve cells.

THE GLOMUS COCCYGEUM

The **coccygeal body** [glomus coccygeum] is a small, spherical greyish-red body consisting of a median unpaired mass 2 to 3 mm. in diameter, single or divided into three to six connected nodules. It is placed immediately ventral to the tip

FIG. 1084.—COCCYGEAL GLAND, IN SITU. 1, Sacrum; 2, coccyx; 3, coccygeal gland; 4, middle sacral artery; 5, 6, sacral sympathetic; 7, ganglion impar.; 8, last sacral; 9, coccygeal nerve; 10, gluteus maximus; 11, ischio-coccygeus; 12, levator ani; 13, ano-coccygeal raphe. (Testut.)

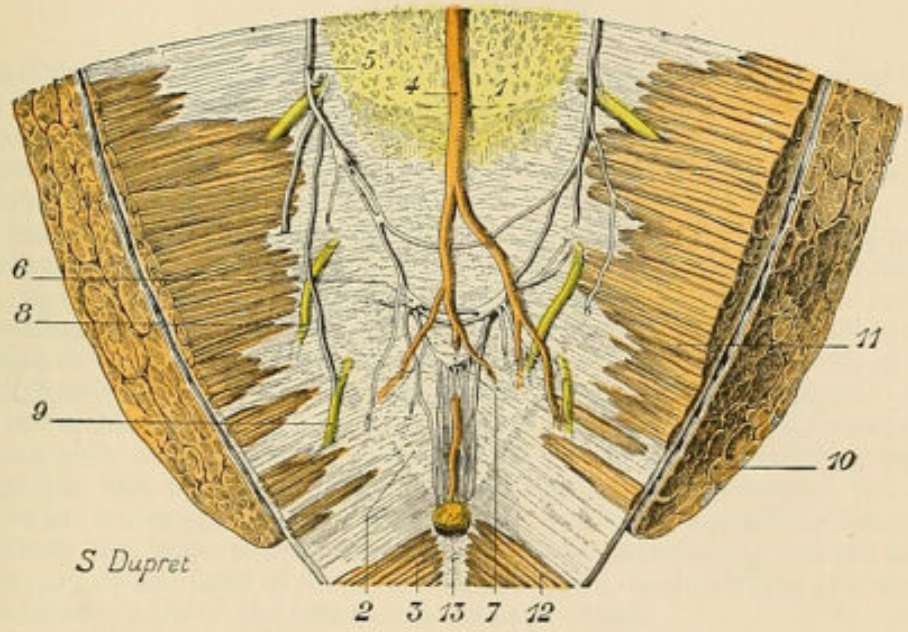

of the coccyx, imbedded in fat and in relation with the terminal branch or branches of the medial sacral artery, with the ischio-coccygeal muscles, and fibres of the sympathetic nervous system (fig. 1084).

It is composed of groups of epithelial cells bound together by a mass of fibrous tissue and containing a plexus of sinusoidal capillary vessels in intimate relation with the cells. Numerous nerve fibres also enter the gland. It is not certain that the cells are chromaffin in character or that the coccygeal body has an internal secretion.

A. References for the skin and mammary gland.—*General and topographic:* Quain's Anatomy, 11th ed., vol. ii, pt. 1; Testut, Traité d'Anatomie Humaine, 4th ed.; Poirier-Charpy, Traité d'Anatomie, vol. v; Rauber-Kopsch, Lehrbuch der Anatomie, 9th ed.; Bardeleben, Handbuch der Anatomie, vol. v, pt. 1; Merkel, Topographische Anatomie; Corning, Lehrbuch der topographischen Anatomie. *Development:* Keibel and Mall, Human Embryology. *Skin:* Heidenhain, Anat. Hefte., vol. xxx; Kean (finger prints), Jour. Amer. Med. Assoc., vol. xlvii; Unna (blood and lymph), Arch. f. mikr. Anat., vol. lxxii; Botezat (nerves) Anat. Anz., vol. xxxiii. *Nails:* Branca, Annales de Dermat. et Syphilis, 1910; *Mammary glands;* Kerr, Buck's Ref. Hand. Med. Sci. (Breast) vol. 4, 1914.

B. References for the ductless glands.—*General and topographic:* Quain's Anatomy, 11th ed.; Testut, Traité d'Anatomie Humaine, 4th ed., vol. iv; Poirier-Charpy, Traité d'Anatomie vol. iv.; Rauber-Kopsch, Lehrbuch der Anatomie, 9th ed.; Merkel, Topographische Anatomie; Corning, Lehrbuch der topographischen Anatomie, 3rd ed. *Development:* Keibel and Mall, Human Embryology. *Spleen:* Shepherd, Jour. Anat. and Physiol., vol. xxxvii; Mall, Amer. Jour. Anat., vol. ii. *Thyreoid:* Marshall, Jour. Anat. and Physiol., vol. xxix. *Parathyreoids:* Forsyth, Brit. Med. Jour., 1907; Rulison, Anat. Rec., vol. iii; Halsted and Evans, Annals of Surg., vol. xlvi. *Thymus:* Hammar, Erbge. d. Anat. u. Entwick., Bd., xix. *Suprarenal glands:* Gerard, Georges et Maurice, Bull. Mem. Soc. Anat. Paris, 1911, (6) T. 13; Ferguson, J. S., Amer. Jour. Anat., vol. v, 1905. *Carotid body:* Gomez, L. P., Am. Jour. Med. Sci., vol. cxxxvi; *Aortic paraganglia;* Zuckerkandl, Verhandl. d. Anat. Gesell., 15th Versamm., 1901.

SECTION XIII

CLINICAL AND TOPOGRAPHICAL ANATOMY

REVISED FOR THE FIFTH EDITION

BY JOHN MORLEY, CH.M., F.R.C.S.

HONORARY SURGEON, ANCOAT'S HOSPITAL, MANCHESTER; LECTURER IN CLINICAL ANATOMY, MANCHESTER UNIVERSITY

THE HEAD

IN describing the clinical and topographical relations, the divisions of the body will be successively considered in the following order: head, neck, thorax, abdomen, pelvis, back, upper and lower extremities.

The bony landmarks of the head will first be considered, followed by a separate description of the cranium and the face.

Bony landmarks.—These should be studied with the aid of a skull, as well as on the living subject. Beginning in front is the **nasion,** a depression at the root of the nose, and immediately above it, the **glabella,** a slight prominence joining the two supraciliary arches. These points mark the remains of the frontal suture, and the junction of the frontal, nasal, and superior maxillary bones and one of the sites of a meningocele. In the middle line, behind, is the external occipital protuberance, or **inion,** the thickest part of the vault, and corresponding internally with the meeting-point of six sinuses. A line joining the inion and glabella corresponds to the sagittal, and occasionally the frontal, suture, the falx cerebri, the superior sagittal sinus, widening as it runs backward, and the longitudinal fissure of the brain. From the inion the superior nuchal lines pass laterally toward the upper and back part of the base of the mastoid processes, and indicate the first or so-called horizontal part of the transverse (lateral) sinus.

This vessel usually presents a varying curve upward and runs in the tentorium. The second or sigmoid portion turns downward on the inner surface of the mastoid, then forward, and lastly downward again to the jugular foramen, thus describing the double curve from which this part takes its name. In the jugular foramen the vessel occupies the posterior compartment; its junction with the internal jugular is dilated and forms the bulb. A line curved downward and forward from the upper and back part of the base of the mastoid, reaching two-thirds of the way down toward the apex, will indicate the second part of the sinus. The spot where it finally curves inward to the bulb would be about 1.8 cm. (¾ in.) below and behind the meatus. The two portions of the transverse sinus meet at the asterion laterally; at the entry of the superior petrosal sinus medially. The right transverse sinus, the larger, is usually a continuation of the superior sagittal sinus, and, therefore, receives blood chiefly from the cortex of the brain; the left, arising in the straight sinus, drains the interior of the brain and the basal ganglia. Each transverse sinus receives blood from the temporal lobe, the cerebellum, diploë, tympanic antrum, internal ear, and two emissary veins, the mastoid and posterior condylar.

About 6.2 cm. (2½ in.) above the external occipital protuberance is the **lambda,** or meeting of the sagittal and lambdoidal sutures (posterior fontanelle, small and triradiate in shape). It is useful to remember, as guides on the scalp to the above two important points, that the lambda is on a level with the supraciliary ridges, and the external occipital protuberance on one with the zygomatic arches.

Below the external occipital protuberance, between it and the foramen magnum, an **occipital,** the commonest form of cranial **meningoceles,** makes its appearance. It comes through the median fissure in the cartilaginous part of the squamous portion of the bone.

The point of junction of the occipital, parietal, and mastoid bones, the **asterion,** is placed about 3.7 cm. (1½ in.) behind and 1.2 cm. (½ in.) above the centre of the auditory meatus (fig. 1085). It indicates the site of the posterior lateral fontanelle and just below it the superior nuchal line terminates. The **bregma,** or junction of the coronal, sagittal, and, in early life, the frontal suture (anterior fontanelle, large and lozenge-shaped), lies just in front of the centre of a line drawn transversely over the cranial vault from one pre-auricular point to the other (fig. 1090). The bregmatic fontanelle normally closes before the end of the second year. The lambdoid fontanelle is closed at birth. The **pterion,** or junction of the frontal and sphenoid in front, parietal and squamous bones behind, lies in the temporal fossa, 3.7 to 5 cm. (1½ to 2 in.) behind the zygomatic process of the frontal, and about the same distance above the zygoma (fig. 1085). This spot also gives the position of the trunk and the anterior and larger division of the middle meningeal artery (fig. 1090), the Sylvian point and divergence of the limbs of the lateral (Sylvian) fissure, the insula (island of Reil), and middle cerebral artery. It, further, corresponds to the anterior lateral fontanelle. On the side of the skull the **zygomatic arch,** the **temporal ridge,** and **external auditory meatus** need attention. That important landmark, the **zygomatic arch,** wide in front where it is formed by the zygomatic (malar), narrowing behind where it joins the temporal, gives off here three roots, the most anterior marked by the eminentia articularis, in front of the mandibular (glenoid) fossa, the middle behind this joint, while the posterior curves upward and backward to be continuous with the temporal ridge. Within the zygomatic arch lie **two fossæ** separated by the infra-temporal (pterygoid) ridge: above is the **temporal,** with the muscle and deep temporal vessels and nerves; below is the **infra-temporal** or **zygomatic** fossa, with the lower part of the temporal muscle, the two pterygoids, the internal maxillary vessels, and the mandibular division of the fifth. To the upper border of the zygomatic arch is attached the temporal fascia, to its lower, the masseter. Its upper border marks the level of the lower lateral margin of the cerebral hemisphere. A point corresponding to the middle root of the zygoma, immediately in front of the tragus, and on a level with the upper border of the bony meatus, is called the **pre-auricular point.** Here the superficial temporal vessels and the auriculo-temporal nerve cross the zygoma, and a patient's pulse may be taken by the anæsthetist. The lower end of the central (Rolandic) fissure lies 5 cm. (2 in.) vertically above this point. The **temporal ridge,** giving origin to the temporal fascia, starts from the zygomatic process of the frontal, and becoming less distinct, curves upward and backward over the lower part of that bone, crosses the coronal suture, traverses the parietal bone, curving downward and backward to its posterior inferior angle. Here it passes on to the temporal, and passing forward over the external auditory meatus, is continuous with the posterior root of the zygoma. Below the root of the zygoma will be felt the temporo-mandibular joint, and when the mouth is opened, the condyle will be felt to glide forward on the eminentia articularis, leaving a well-marked depression behind.

The **external auditory meatus,** measured from its opening on the concha to the membrane, is about 2.5 cm. (1 in.) in length; if from the tragus, 3.7 cm. (1½ in.). Its long axis is directed medially and a little forward with a slight convex curve upward, most marked in its centre. Between the summit of this curve and the membrane is a slight recess in which foreign bodies may lodge. The lumen is widest at its commencement, narrowest internally. To bring the cartilaginous portion in line with the bony, the pinna should be drawn well upward and backward. In the bony portion the skin and periosteum are intimately blended, thus accounting for the readiness with which necrosis occurs. The sensibility of the meatus is explained by the two branches sent by the auriculo-temporal nerve. The fact that the deeper part is supplied by the auricular branch of the vagus explains the vomiting and cough occasionally met with in affections of the meatus.

The **anterior inferior angle of the parietal bone,** and its great importance as a landmark, have already been noted. The **posterior inferior angle** of this bone (grooved by the transverse (lateral) sinus) lies a little above and behind the base of the mastoid, on a level with the roots of the zygoma (fig. 1085). Just below and in front of the tip of the mastoid the **transverse process of the atlas** can be made out in a spare subject.

In front, the circumference of the **bony orbit** can be traced in its whole extent. The *supraorbital notch* lies at the junction of the medial and intermediate thirds of the supraorbital arch. When this notch is a complete foramen, its detection is much less easy. To its medial side the *supratrochlear nerve* and *frontal arterd* cross the supraorbital margin; like the supraorbital, this nerve and vessel lie, at

first, in close relation with the periosteum. The frontal artery is one of the chief blood-supplies to flaps taken from the forehead. Owing to the paper-like thinness of the bones on the medial wall of the orbit, e. g., lacrimal, ethmoid, and body of sphenoid, and the mobility of the skin, injuries which are possibly penetrating ones, as from a slate-pencil, ferrule, etc., are always to be looked upon with suspicion. After a period of latency of symptoms, infection of the membranes and frontal abscess have often followed. Above the supraorbital margin is the supraciliary arch, and higher still the frontal eminence [tuber frontale].

FIG. 1085.—THE SKULL, SHOWING KRÖNLEIN'S METHOD OF CRANIOCEREBRAL TOPOGRAPHY.

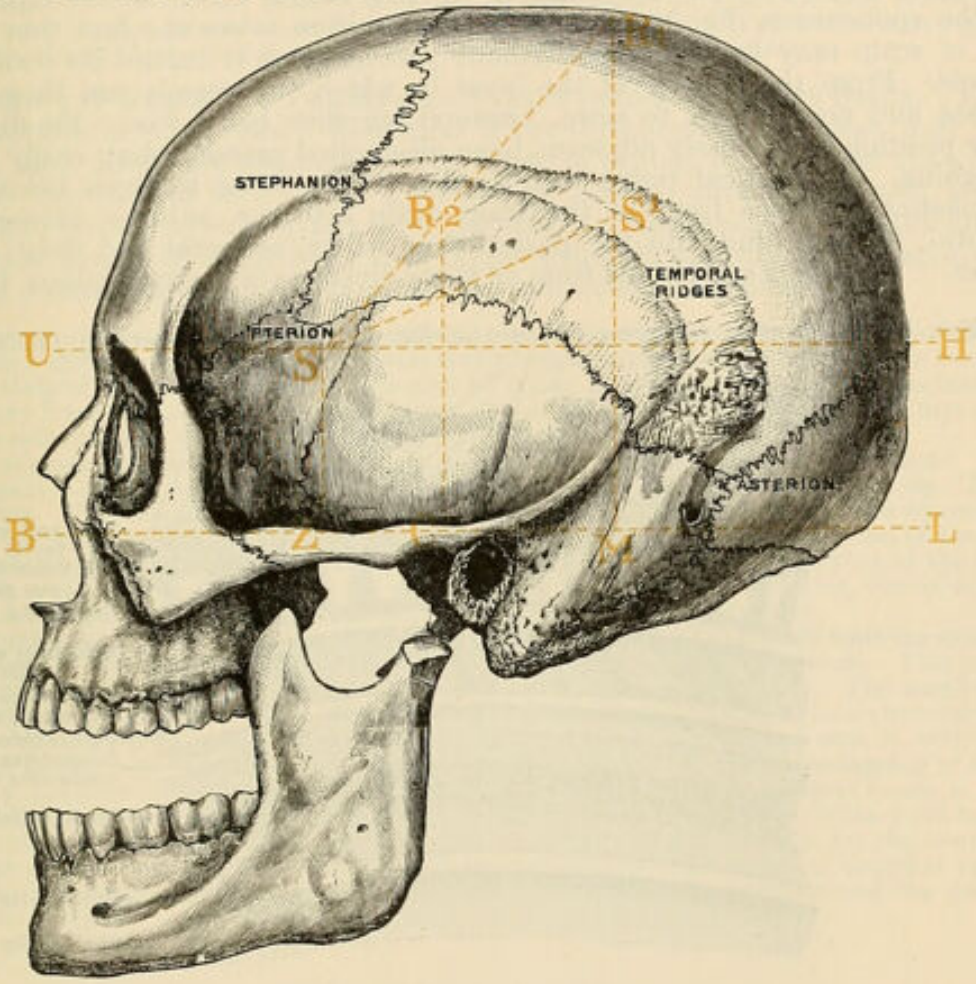

THE CRANIUM

Under this heading will be considered the scalp, the bony sinuses, craniocerebral topography and the hypophysis.

The scalp.—The importance of the **scalp** is best seen from an examination of its **layers** (fig. 1086). These are—(1) **skin**; (2) **subcutaneous fat** and **fibrous tissue**; (3) the **epicranius** (occipito-frontalis) and **aponeurosis**; (4) the **subaponeurotic layer** of connective tissue; (5) the **pericranium.**

The first three layers are connected and move together. The thick skin supported by the dense fibrous subcutaneous layer and epicranial aponeurosis, is well adapted to protect the underlying skull from the effects of trauma, and in this connection the mobility of the first three layers on the subaponeurotic areolar tissue is important. A scalp wound does not gape widely unless it involves the epicranial aponeurosis, in which case it involves the subjacent **"dangerous area"** of the scalp, so-called because pus in this layer may spread widely underneath the scalp and even give meningeal infection by spreading through the diploic or emissary veins. In the process of scalping (whether performed by the knife or by the hair being caught in machinery), separation takes place at this subaponeurotic layer which is loose, delicate and devoid of fat.

The numerous **sebaceous glands** frequently give rise to cysts in the scalp.

The **epicranius and aponeurosis** have been described elsewhere (p. 336).

The **pericranium** differs from periosteum elsewhere in that it gives little nourishment to the bone beneath, which derives most of its blood-supply from the meningeal vessels. After necrosis of the skull there is no tendency to the formation of an involucrum of new subperiosteal bone as in the long bones. The pericranium is firmly adherent to the sutures of the skull bones, so that any subpericranial effusion of blood or pus is limited by the sutures.

Of the **vessels of the scalp,** the *arteries*, arising in the anterior region from the internal, in the posterior from the external, carotid, are peculiar in their position. Thus they lie superficial to the deep fascia, which is here represented by the aponeurosis (fig. 1086). From this position arises the fact that a large flap of scalp may be separated without perishing, as it carries its own blood-vessels. From the density of the layer in which the vessels run they cannot retract and are difficult to seize, hæmorrhage thus being free. Finally, from their position over closely adjacent bone, ill-applied pressure may easily lead to sloughing. A practical point with regard to the veins is given below. The *lymphatics* from the front of the scalp drain into the anterior auricular and parotid, those behind into the posterior auricular, occipital and deep cervical nodes. The *nerves* are derived from all three divisions of the trigeminus, from the

FIG. 1086.—SECTION THROUGH THE SCALP, SKULL, AND DURA MATER. (Tillaux.)

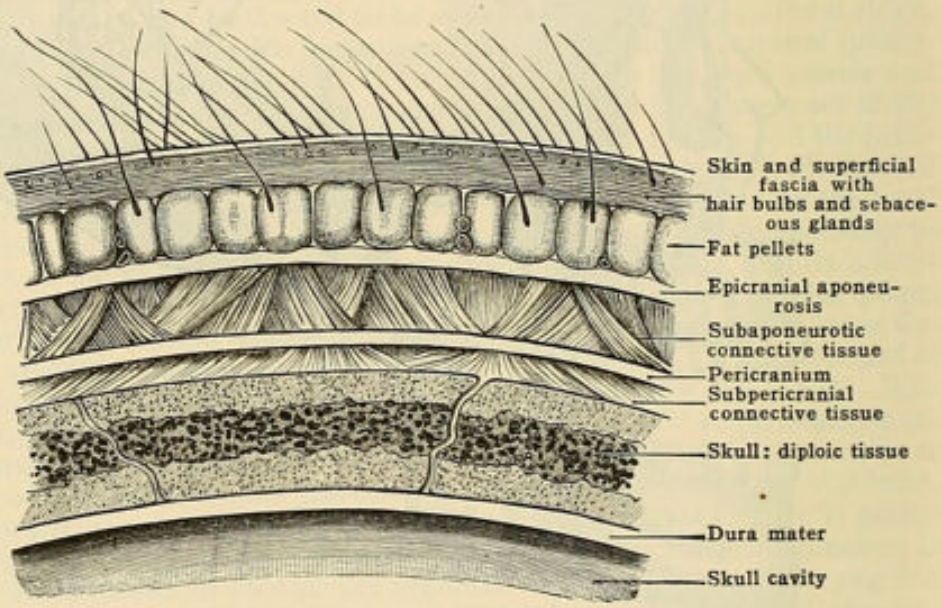

facial (motor) and also from three branches of the second and third cervical. The supply from the fifth explains the neuralgia in acute iritis, glaucoma, and herpes frontalis, and also the pains shooting up from the front of the ear in late cancer of the tongue.

The emissary veins.—These are communications between the sinuses within, and the veins outside, the cranium. Most of them are temporary, corresponding to the chief period of growth of the brain. Thus in early life, when the development of the brain has to be very rapid, owing to the approaching closure of its case, a free escape of blood is most essential, especially in children, with their sudden explosions of laughter and passionate crying.

The gravity of these emissary veins and their free communications with others are shown by the readiness with which they become the seat of thrombosis, and thus of blood-poisoning, in cranial injuries, erysipelas, infected wounds of the scalp, and necrosis of the skull. They include the following:

1. Vein through the foramen cæcum, between the anterior extremity of the superior sagittal sinus and the nasal mucous membrane. The value of this temporary outlet is well seen in the timely profuse epistaxis of children. Other more permanent communications between the skull cavity and nasal mucous membrane pass through the ethmoid foramina. The fact that the nasal mucous membrane is loose and ill-supported on the nasal conchæ (turbinate bones) allows its vessels to give way readily, and thus forms a salutary safeguard to the brain, warding off many an attack of apoplexy. 2. Vein through the mastoid foramen, between the transverse

(lateral) sinus and the posterior auricular and occipital veins. This is the largest, the most constant, and the most superficial of the emissary veins. Hence the old rule of applying blisters or leeches over it in cerebral congestion. 3. Vein through the posterior superior angle of the parietal between the superior sagittal sinus and the veins of the scalp. 4. Vein through the condyloid foramen between the transverse (lateral) sinus and the deep veins of the neck. 5. Vein through the hypoglossal canal between the occipital sinus and the deep veins of the neck. 6. Ophthalmic veins communicating with the cavernous sinus and the angular vein. These veins may be the source of fatal blood-poisoning, by conveying out of reach septic material, in acute periostitis of the orbit, or in osteitis, of dental origin, of the jaws. 7. Minute veins through the foramen ovale between the cavernous sinus and the pharyngeal and pterygoid veins. 8. Communications between the frontal diploic and supraorbital veins, between the anterior temporal diploic and deep temporal veins, and between the posterior temporal and occipital diploic veins and the transverse sinus. In addition to the veins specially mentioned, the scalp and sinuses communicate by numerous diploic veins, by those in the inter-sutural membrane, and through sutures before their obliteration, as already explained.

Structure of cranium.— Two layers and intervening **cancellous tissue.** Each layer has special properties. The **outer** gives thickness, smoothness, and uniformity, and, above all, elasticity. The **inner** is whiter, thinner, less regular— e. g. the depressions for vessels, Pacchionian bodies, dura mater, and brain. The **diploë,** formed by absorption after the skull has attained a certain thickness, reduces the weight of the skull without proportionately reducing its strength, and provides a material which will prevent the transmission of vibrations.

A blow on the head may fracture the internal layer only, the external one and diploë escaping. This is difficult to diagnose, and thus it is impossible to judge of the severity of a fracture from the state of the external layer. This may be whole, or merely cracked, while the internal shows many fragments, which may set up meningitis or other mischief. It is usual to find more extensive splintering of the inner than of the outer layer (table).

The average **thickness** of the adult skull-cap is about 5 mm. ($\frac{1}{5}$ in.). (Holden.) The thickest part is at the external occipital protuberance, where the bone is often 1.8 cm. ($\frac{3}{4}$ in.) in thickness. The thinnest part of the skull vault is over the temporal part of the squamous. The extreme fragility of the skull here is partly compensated for the by thickness of the soft parts; these two facts are always to be remembered in the diagnosis of a fracture of the skull here, after a slight injury. Other weak spots are the medial wall of the orbit, the cerebellar fossæ, and that part of the middle fossa corresponding to the glenoid cavity.

Anatomical conditions tending to minimise the effects of violence inflicted upon the skull.— (1) The **density** and **mobility of the scalp.** (2) The **dome-like shape of the skull.** This is calculated to bear relatively hard blows and also to allow them to glide off. (3) The **number of bones** tends to break up the force of a blow. (4) The **sutures** interrupt the transmission of violence. (5) The **inter-sutural membrane** (remains of fœtal periosteum) acts, in early life, as a linear buffer. (6) The **elasticity of the outer layer** (table). (7) The **overlapping of some bones,** e. g. the parietal by the squamous; and the alternate bevelling of adjacent bones, e. g. at the coronal suture. (8) The **presence of ribs,** or **groins,** e. g. (*a*) from the crista galli to the internal occipital protuberance; (*b*) from the root of the nose to the zygoma; (*c*) the temporal ridge from orbit to mastoid; (*d*) from mastoid to mastoid; (*e*) from external occipital protuberance to the foramen magnum. (9) **Buttresses,** e. g. zygomatic processes and the greater wing of the sphenoid. (10) The **mobility** of the head upon the spine.

THE BONY SINUSES

Frontal.—When well developed, the frontal sinuses may reach 5 cm. (2 in.) upward and 3.7 cm. ($1\frac{1}{2}$ in.) laterally, occupying the greater part of the vertical portion of the frontal bone. When very small, they scarcely extend above the nasal process. In any case, they are rarely symmetrical. The average dimensions of an adult frontal sinus are 3.7 cm. ($1\frac{1}{4}$ in.) in height, 2.5 cm. (1 in.) in breadth, and 1.8 cm. ($\frac{3}{4}$ in.) in depth. (Logan Turner.) The sinuses are separated by a septum. The posterior wall is very thin. Each sinus narrows downward into the infundibulum. This is 'deeply placed, at the back of the cavity, behind the frontal (nasal) process of the maxilla and near the medial wall of the orbit. Its termination in the middle meatus is about on a level with the palpebral fissure.' (Thane and Godlee.) Its direction is backward.

The communication of these sinuses with the nose accounts for the frontal headache, the persistence of polypi and ozæna, and the fact that a patient with a compound fracture opening up the sinuses can blow out a flame held close by.

To open the frontal sinus, while the incision which leaves the least scar is one along the shaved eyebrow, superficial laterally so to avoid the supraorbital nerve and vessels, running a little downward at the medial end, it is always to be remembered that, where the sinuses are little developed, this or a median incision may open the cranial cavity. To avoid this complication the sinus should always be opened at a spot vertically above the medial angle.

The development of these by the twentieth or twenty-fifth year may render a fracture

here much less grave in the adult than would otherwise be the case, the inner layer (table), if now separated from the outer, protecting the brain. Mr. Hilton showed that the absence of any external prominence here does not necessarily imply the absence of a sinus, as this may be formed by retrocession of the internal layer. In old people these sinuses may enlarge by the inner layer following the shrinking brain. Again, prominence of the supraciliary and frontal eminences does not necessarily point to the existence of a sinus at all, being due merely to a heaping up of bone.

The **mastoid** cells are arranged in two groups, of the utmost importance in that frequent and fatal disease, inflammation of the middle ear:—(A) The **upper,** or **'antrum,'** present both in early and late life, horizontal in direction, closely adjacent to and communicating with the tympanum. (B) The **lower, or vertical.** This group is not developed in early life.

A. **Tympanic antrum** (fig. 1088).—This is a small chamber lying behind the tympanum, into the upper and back part of which (epitympanic recess) it opens. Its size varies, especially with age. Almost as large at birth, it reaches its maximum (that of a pea) about the third or fourth year. After this its size usually diminishes somewhat, owing to the development of the encroaching bone around

FIG. 1087.—TEMPORAL BONE, SHOWING SUPRAMEATAL TRIANGLE. (Barr.)
The lower part of the transverse sinus is here placed too far back to be relied upon with constant accuracy.

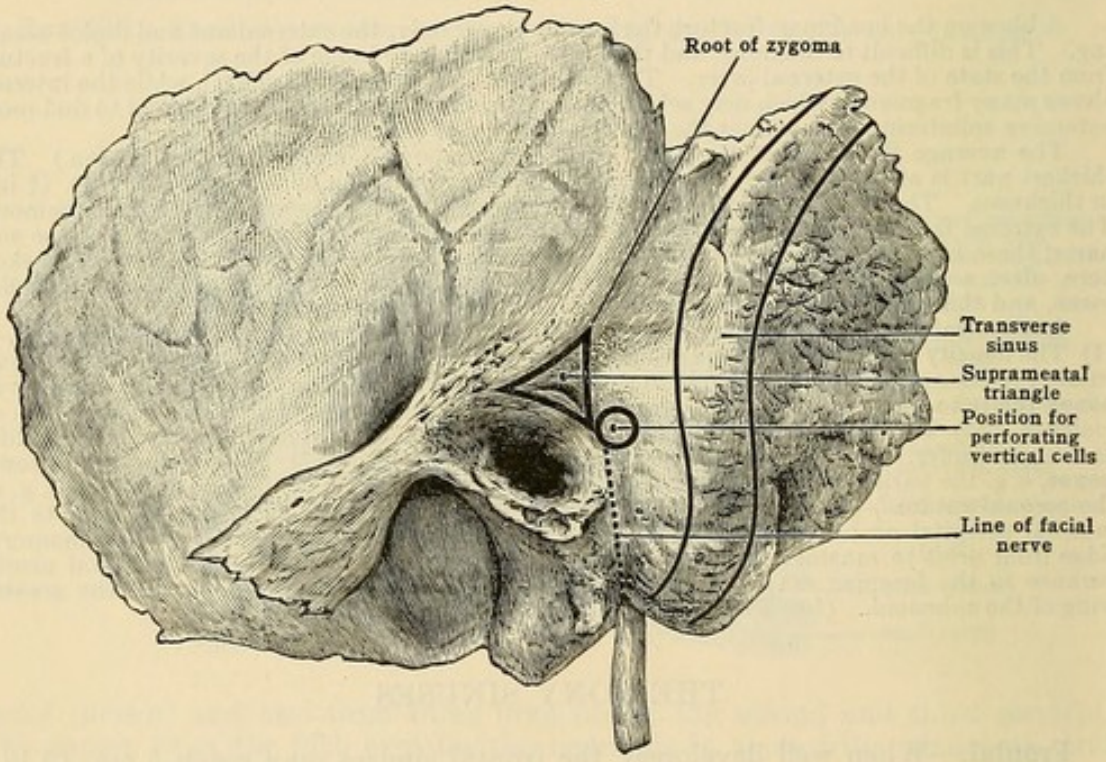

it. Its **roof,** or tegmen, is merely the backward continuation of the tegmen tympani. The level of this is indicated by the posterior root of the zygoma. 'The level of the floor of the adult skull at the tegmen antri is, on an average, less than one-fourth of an inch above the roof of the external osseous meatus; in children and adolescents, from one-sixteenth to one-eighth of an inch.' (Macewen.) In early life, when the bony landmarks, e. g. the suprameatal crest (fig. 1087), are little marked, the level of the upper margin of the bony meatus will be the safest guide to avoid opening the middle fossa.

The **lateral wall** of the antrum is formed by a plate descending from the squamous bone. This is very thin in early life, but as it develops by deposit under the periosteum, the depth of the antrum from the surface increases. Macewen gives the average of the depth as varying from one-eighth to three-fourths of an inch. The thinness of the outer wall in early life is of practical importance. It allows of suppuration making its way externally—subperiosteal mastoid abscess. This will be facilitated by any delay in the closure of the petro- and masto-squamosal sutures, by which this thin plate blends with the rest of the temporal bone. Further, by the path of veins running through these sutures or

their remnants, infection may reach such sinuses as the inferior petrosal. The sutures normally close in the second year after birth. Through the **floor,** the antrum communicates with the lower or vertical cells of the mastoid. This floor is on a lower level than the opening into the tympanum, and thus drainage of an infected antrum is difficult, fluid finding its way more readily into the lower cells. **Behind** the mastoid antrum and cells is the bend of the sigmoid part of the transverse (lateral) sinus, with its short descending portion (fig. 1087). The average distance of the sinus from the superior meatal triangle is 1 cm. ($\frac{2}{5}$ in.). It may be further back; on the other hand, it may come within 2 mm. ($\frac{1}{12}$ in.) from the meatus, and even overlap the outer wall of the antrum.

FIG. 1088.—THE MASTOID ANTRUM AND CELLS. (Jacobson and Steward.)

1. Posterior root of zygoma forming the supramastoid or suprameatal crest and upper part of Macewen's triangle. 2. Antrum, and in front of it, the epitympanic recess. 3. Vertical cells of the mastoid. 4. Ridge on the inner wall of the tympanum, caused by the facial canal. 5. Fenestræ on inner wall of tympanum, indicated in shadow. 6. A deficiency present in the tegmen tympani, enlarged with a small osteotrite to emphasise the thinness of the roof of the antrum and tympanum. 7. Cells extending, in this case, even into the root of the zygoma.

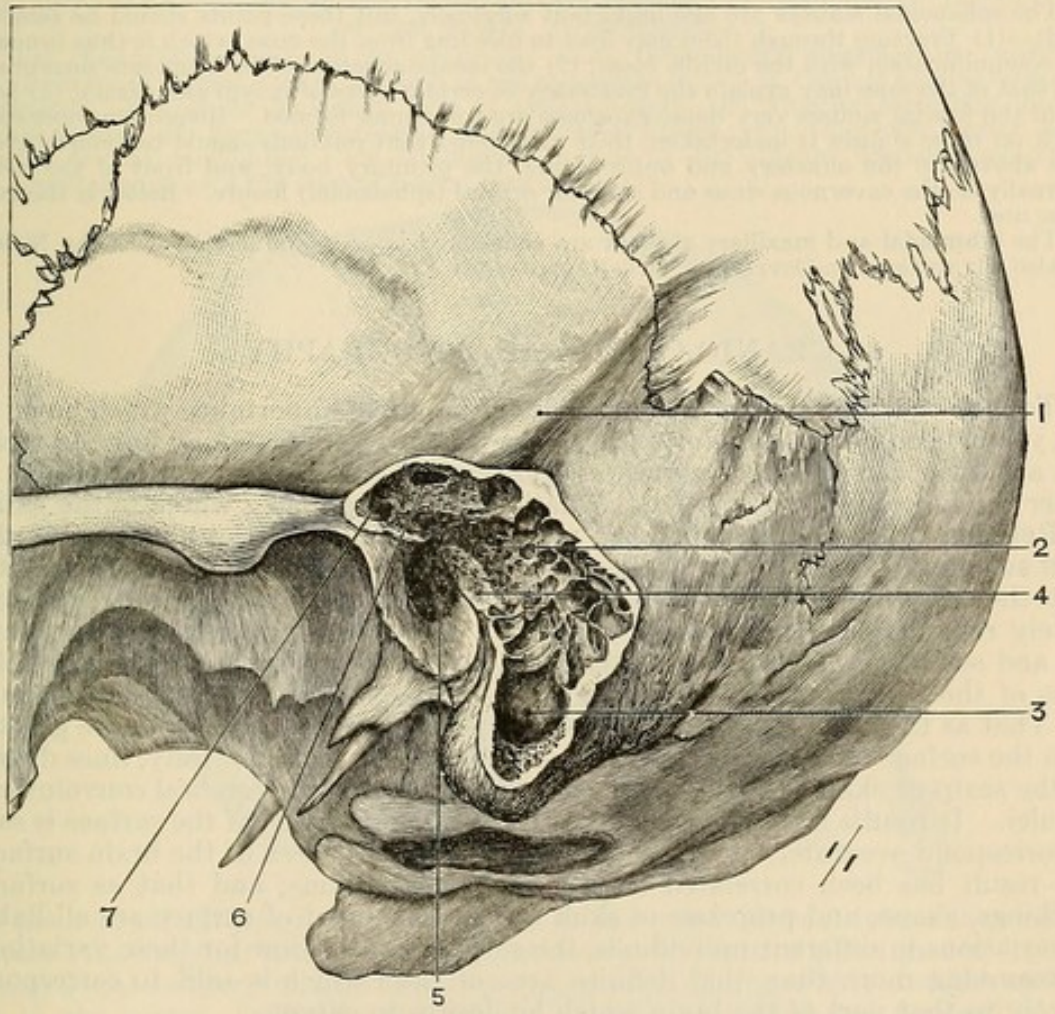

The exact position of the antrum, a little above and behind the external auditory meatus is represented by Macewen's 'suprameatal triangle.' This is a triangle bounded by the posterior root of the zygoma above, the upper and posterior segment of the bony external meatus below, and an imaginary line joining the above boundaries (fig. 1087). "Roughly speaking, if the orifice of the external osseous meatus be bisected horizontally, the upper half would be on the level of the mastoid antrum. If this segment be again bisected vertically, its posterior half would again correspond to the junction of the antrum and middle ear, and immediately behind this lies the suprameatal fossa.' (Macewen.) When opening the antrum through this triangle, the operator should work forward and medially, so as to avoid the transverse sinus (fig. 1087); while, to avoid the facial nerve (fig. 1087), he should hug the root of the zygoma and the upper part of the bony meatus as closely as possible. The level of the base of the brain will be a few lines above the posterior root of the zygoma (fig. 1089) and about 6 mm. ($\frac{1}{4}$ in.) above the roof of the bony meatus. (Macewen.)

B. **The lower or vertical cells of the mastoid** are developed later than is the antrum, and vary much in their contents. The condition of the mastoid cells varies very widely. They may be numerous (fig. 1088) or few. In the latter case they are replaced by diploë, or by bone which is unusually dense, without necessarily any pathological change. Hence mastoids have been classified as pneumatic, diploëtic, or sclerosed.

As part of the surgical anatomy of this most important region, the different paths by which infection of the tympanum and antrum may travel should be glanced at. The most important are:—(1) **Upward**: either by advancing caries or by infection of veins going to the superior petrosal sinus, or through the tegmina to the membranes; an abscess in the overlying temporal lobe, usually the middle and back part. (2) **Backward**: the transverse (lateral) sinus and cerebellum (abscess of the front and outer part of the lateral lobe) are reached in the same ways as those given above, the mastoid vein being the one chiefly affected here. Macewen has shown that the bony wall of the sinus, like those of the tegmina and the aqueduct of Fallopius, may be naturally imperfect. (3) **Downward**: where the vertical cells are well developed (fig. 929) mischief may reach the mastoid notch and cause deep-seated inflammation beneath the sterno-mastoid. (v. Bezold's abscess.) (4) **Lateralward**: the explanation of this, in early life, has been given above. (5) **Medialward**: the facial nerve, or by the fenestra ovalis; the labyrinth is now in danger. When the internal ear and auditory nerve are affected, infection finds another path to the cerebellar fossa.

The **sphenoidal sinuses** are less important surgically, but these points should be remembered:—(1) Fracture through them may lead to bleeding from the nose, which is thus brought into communication with the middle fossa; (2) the communication of their mucous membrane with that of the nose may explain the inveteracy of certain cases of polypi and ozæna; (3) here and in the frontal sinuses very dense exostoses are sometimes formed. Before any operative attack on these sinuses is undertaken, their most important relations should be remembered. Thus **above** are the olfactory and optic nerves, the pituitary body, and front of the pons. **Externally** lie the cavernous sinus and superior orbital (sphenoidal) fissure. **Below** is the roof of the nose.

The **ethmoidal** and **maxillary sinuses** are considered later in connection with the Nose. See also the sections on OSTEOLOGY AND RESPIRATORY SYSTEM.

CRANIO-CEREBRAL TOPOGRAPHY

To make as clear as possible the points of practical importance which have, of late years, been put on a definite basis, and which the surgeon may have to recall and act upon at very short notice, cranio-cerebral topography will be spoken of under the following headings: A. **Relation of the brain as a whole to the skull.** B. **Relation of the chief sulci and gyri to the skull.** C. **Localisation of the chief sulci and gyri.** Before alluding to the above, it is necessary to say distinctly that the following surface-markings and points of guidance are only approximately reliable, for the following reasons: (1) In two individuals of the same age and sex the sulci and convolutions are never precisely alike. (2) The relations of the convolutions and sulci to the surface vary in different individuals. (3) That as the surface area of the scalp and outer aspect of the skull are greater than the surface area of the brain, and as the convexities do not tally, lines drawn on the scalp or skull cannot always correspond precisely to cerebral convolutions or sulci. It results from the above that when a definite area of the surface is said to correspond accurately in any individual to a definite area of the brain surface, this result has been correlated from many examinations; and that as surface-markings, shape, and processes of skull and arrangement of surface are all liable to variations in different individuals, the surgeon must allow for these variations by removing more than that definite area of skull which is said to correspond exactly to that part of the brain which he desires to expose.

A. **Relation of the brain as a whole to the skull** (figs. 1089, 1091).—To trace *the lower level of each cerebral hemisphere* on the skull, the chalk would start from the lower part of the glabella; thence the line representing the lower borders of the frontal lobe pursues a course, slightly curved upward, about 0.8 cm. ($\frac{1}{3}$ in.) above the supraorbital margin; next, crossing the temporal crest about 1.2 cm. ($\frac{1}{2}$ in) above the zygomatic (external angular) process, it passes not quite horizontally but descending slightly to a point in the temporal fossa just below the tip of the great wing of the sphenoid (pterion), 2.5 cm. (1 in.) behind the zygomatic process. From this point the line of the level of the brain, now convex forward and corresponding to the anterior extremity of the temporal lobe, would dip down, still within the great wing of the sphenoid, to about the centre of the zygoma. Thence the line of the lower border of the temporal lobe would

travel along the upper border of this process about 6 mm. ($\frac{1}{4}$ in.) above the roof of the external auditory meatus (fig. 1089), and thence just above the base of the mastoid and the posterior inferior angle of the parietal, and so along the linea nuchæ suprema, and corresponding to the tentorium and horizontal part of the transverse (lateral) sinus, to the external occipital protuberance.

The **upper margin of each hemisphere** would be represented by a line drawn from just below the glabella, sufficiently to one side of the middle line to allow for the falx and superior sagittal sinus, to one immediately above the superior external occipital protuberance and inion.

B. **Relation of the chief fissures and convolutions to the skull.** C. **Localisation of the chief sulci and gyri.** These headings will be taken together.

It will be well first to indicate the position of the chief **sutures** which mark off the parietal bone, under which lies that part of the brain which is most important to the surgeon—the motor area. The upper limit of the bone will be indicated by the line already spoken of as giving the upper margin of the hemisphere—the **sagittal line,** or **Sagittal suture.** The anterior limit of the parietal bone, formed

FIG. 1089.—THE OUTLINE OF THE BRAIN AND ITS FISSURES IN RELATION TO THE SUTURES OF THE SKULL. (Cunningham.)

S.M. Supraciliary margin of the cerebrum. I.L.M. Infero-lateral margin of the cerebrum. L.S. Position of highest part of the arch of the transverse sinus. R. Central sulcus (Fissure of Rolando). s^1. Anterior horizontal limb of lateral fissure. s^2. Anterior ascending limb of lateral fissure. s^3. Posterior horizontal limb of lateral fissure. P.B. Opercular portion of the inferior frontal convolution. P.T. Triangular portion of the inferior frontal convolution. P.O. Orbital portion of the inferior frontal convolution.

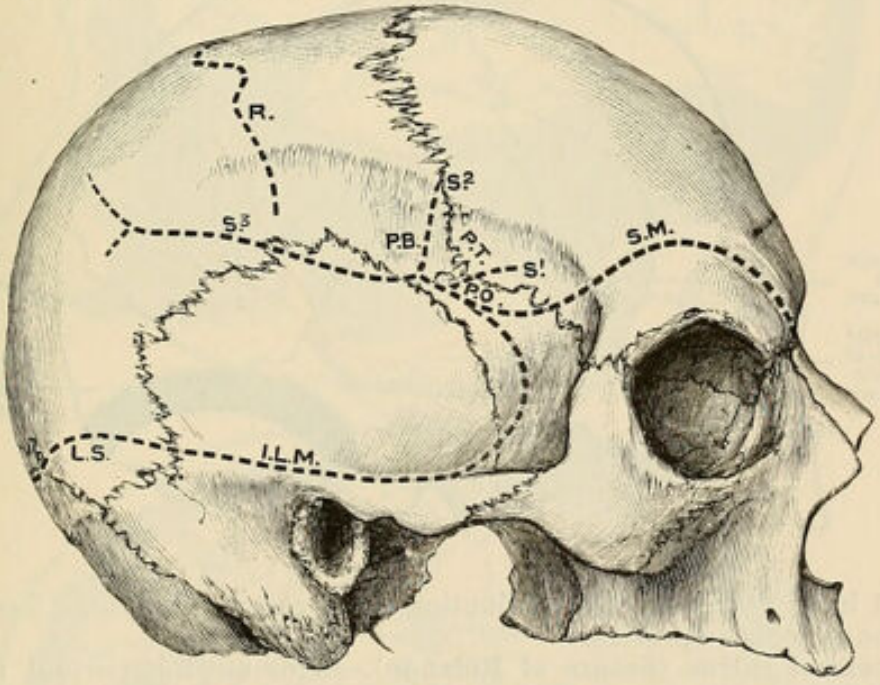

by the **coronal suture,** may be traced thus: The point where it leaves the sagittal suture (the bregma) will be found by drawing a line from a point just in front of the external auditory meatus (the pre-auricular point) (fig. 1085) straight upward on to the vertex; from this point a line drawn downward and forward to the middle of the zygomatic arch would indicate that of the coronal suture. Under this suture lie the posterior extremities of the three frontal convolutions; for the frontal lobe lies not only under the frontal bone, but extends backward under the anterior part of the parietal, the central sulcus (fissure of Rolando), which separates the frontal from the parietal lobe, lying from 3.7 to 5 cm. ($1\frac{1}{2}$ to 2 in.) behind the coronal suture at its upper extremity and about 2.5 cm. (1 in.) at its lower.

The squamoso-parietal suture, which marks the lower border of the anterior two-thirds of the parietal bone, is not so easy to define, owing to the irregularity and variations of its curve. Its highest point is usually 4.3 cm. ($1\frac{1}{4}$ in.) above the zygoma.

The lambdoid suture, which forms the posterior boundary of the parietal bone, will be marked out by a line which starts from a point (lambda) about 6.2 cm. ($2\frac{1}{2}$ in.) above the external occipital protuberance, and runs downward and forward to a point on a level with the zygoma, 3.7 cm. ($1\frac{1}{2}$ in.) behind and 1.2 cm. ($\frac{1}{2}$ in.) above the centre of the meatus.

The position of the chief sulci will now be given:—

Lateral (Sylvian) fissure (fig. 1089).—The point of appearance of this, on the outer side of the brain, practically corresponds to the pterion (p. 1332, fig. 1085)—a point which lies in the temporal fossa, about 3.7 cm. (1½ in.) behind the zygomatic process and about the same distance above the zygoma. From this point the lateral fissure, which here separates the frontal and parietal from the temporal lobe, runs backward and upward, ascending gently, at first in the line of the squamo-parietal suture, then crossing this suture about its centre and thence, ascending more rapidly, it climbs up to the temporal ridge, to end 1.8 cm. (¾ in.) below the parietal eminence. Its termination is surrounded by the supramarginal convolution, to which the parietal eminence corresponds with sufficient accuracy. Such being the surface-marking of the chief or posterior horizontal limb of the lateral fissure (s^3, fig. 1089), it remains to indicate briefly the two shorter limbs which bound the inferior frontal convolution, which, on the left side, contains the centre for speech (Broca's convolution), and corresponds to a point lying three fingers' breadth vertically above the centre of the zygomatic arch. (Stiles.) Of these, the anterior horizontal (s^1, fig. 1089) runs forward across the termination of the coronal, just above the line of the sphenoparietal suture. The ascending limb (s^2, fig. 1089) runs upward for about

FIG. 1090.—LATERAL VIEW OF THE SKULL, SHOWING THE TOPOGRAPHY OF THE MIDDLE MENINGEAL ARTERY AND THE TRANSVERSE SINUS.

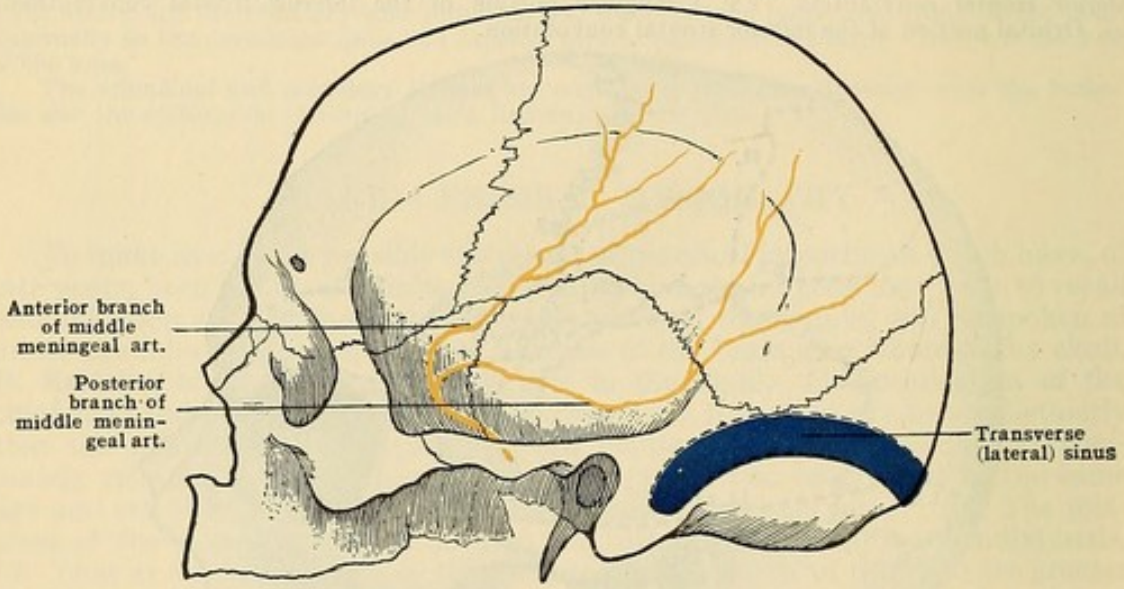

2.5 cm. (1 in.) just behind the termination of the coronal suture, or 5 cm. (2 in.) behind the zygomatic process.

The central sulcus (fissure of Rolando).—This most important fissure, in front of which, in the precentral convolution of the frontal lobe, lie the motor centres for the opposite side of the body, is situated under the parietal bone. It may be marked out with sufficient precision in the following way (Thane): The sagittal line, from glabella to external occipital protuberance, is bisected, and a point 1.2 cm. (½ in.) behind the centre represents the **superior Rolandic point.** From this point a line drawn downward and forward 9 cm. (3¾ in.) long, at an angle of 67½° with the sagittal line (i. e., ¾ of a right angle) will represent the central sulcus. The lower extremity of this line is known as the **inferior Rolandic point.**

This method is open to the objection that it only applies to the average adult skull, and not to skulls of all sizes. To obviate this difficulty the method of Krönlein may be employed in addition (fig. 1085). A base line BL is drawn through the lower border of the orbit and the upper border of the external acustic meatus. Parallel to this an upper horizontal line UH is marked out at the level of the upper margin of the orbit. Three lines vertical to the base line are now drawn, (1) at the posterior border of the mastoid process MR_1 (2) through the condyle of the lower jaw (CR_2), and (3) from the mid-point of the zygoma (ZS). The point R_1, where the first vertical joins the sagittal suture is the superior Rolandic point. The point S where the third vertical ZS cuts the line UH marks the junction of the three limbs of the lateral fissure. A line joining R_1 and S will cut the second vertical CR_2 at the inferior Rolandic point, R_2.

The posterior limb of the lateral fissure also may be represented by a line bisecting the angle R_1SH and ending behind at the point S^1 where it cuts the vertical MR_1.

Some further *points in the surgical anatomy of the cranium* must be referred to:—*The middle meningeal* artery. This vessel, entering the middle fossa by the foramen spinosum, grooves the great wing of the sphenoid and divides into two branches. The anterior grooves the anterior inferior angle of the parietal bone, and is then continued upward and slightly backward between the coronal suture and central sulcus (fig. 1090), almost to the vertex; the posterior branch takes a lower level, running backward under the squamous bone to supply the parietal and anterior part of the occipital bones. If a skull, bisected antero-posteriorly, be held up to the light, it will be seen how thin are the bones over the chief branches of this vessel, thus accounting for the slight violence sometimes sufficient to rupture it. The groove it occupies in the parietal is sometimes converted into a canal. A wounded artery retracting here may be very difficult to secure. The veins which accompany the artery and which lie lateral to it

FIG. 1091.—CEREBRAL TOPOGRAPHY AND LOCALIZATION. (CUSHING, FROM KEEN'S SURGERY.)

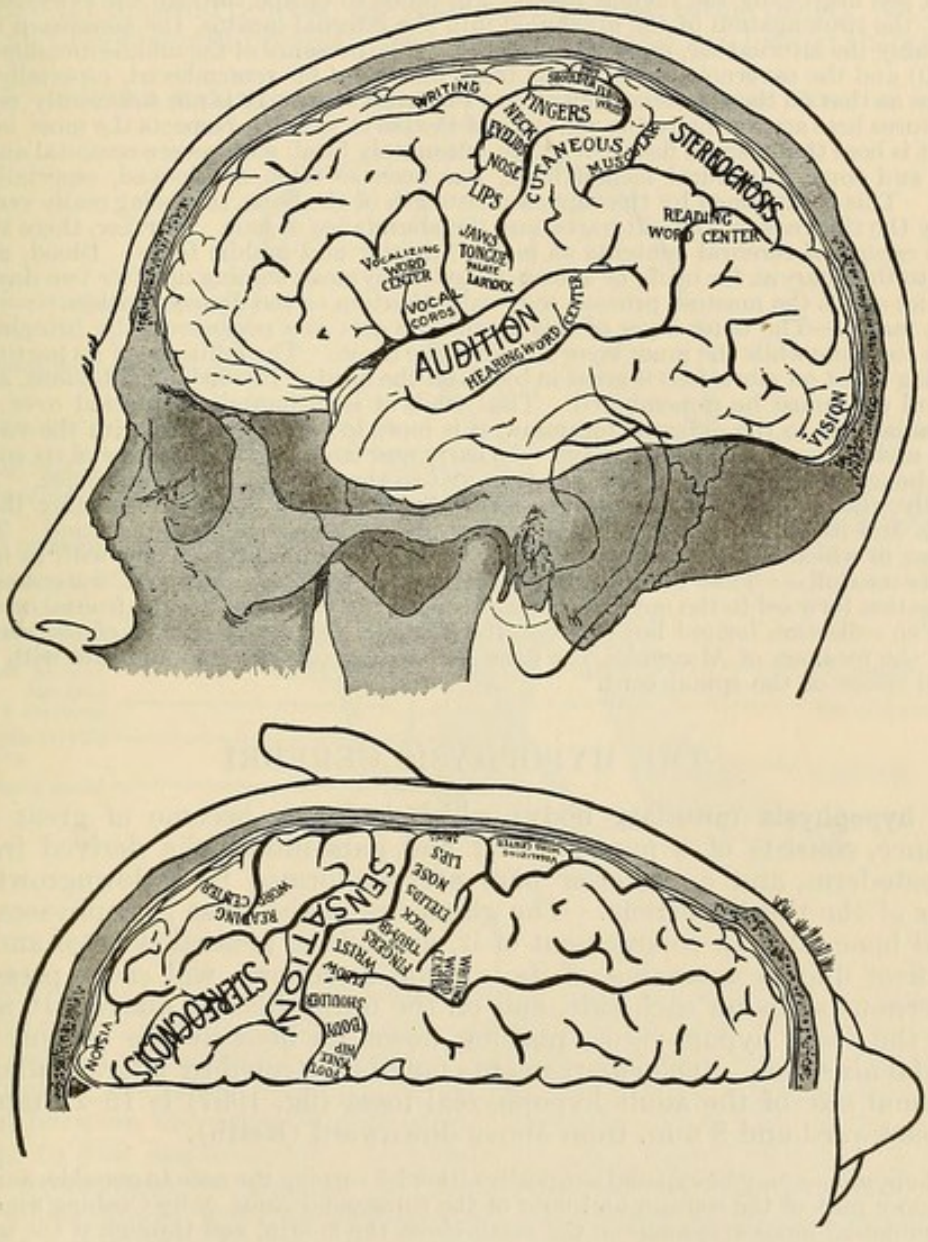

in the groove are thin-walled and sinus-like before they open into the spheno-parietal sinus, another explanation of the obstinacy of this hæmorrhage. According to the point of rupture, three hæmatomata should be remembered (Krönlein), anterior or fronto-temporal; middle, or temporo-parietal; and posterior, or parieto-occipital. The first two are much the most frequent, and exposure of the pterion, with free removal of the adjacent bone, will suffice for dealing with them.

Drainage of the lateral ventricle.—(1) Where the anterior fontanelle is closed, Poirier and Keen have opened the inferior cornu through the middle temporal convolution, the pin of the trephine being placed 3.1 cm. (1¼ in.) behind the external auditory meatus, and about the same distance above Reid's base-line which is drawn from the lower margin of the orbit through the mid-point of the external auditory meatus. The needle should here be directed to a point

about 5 cm. (2 in.) above the opposite ear. (2) Kocher's point for draining the lateral ventricle is taken over the frontal lobe 2.5 cm. from the median line and 3 cm. in front of the upper Rolandic point. The needle is passed downward and a little backward to a depth of 4 or 5 cm.

Up to this point the **outside** of the cranium has been mainly considered; it remains to draw attention to some of *the chief points in the surgical anatomy* of the **interior,** especially of the **base. The three fossæ** are of paramount importance in fracture. In the **anterior fossa** the delicacy of parts of the floor, the connection of this with the nose and orbit, and the exact adaptation of its irregular surface to that of the frontal lobes, no 'water-bed' intervening, are the chief points. Thus the slightness of a fatal fissure, the frequent presence of bruising after a blow perhaps on the occiput, which has been considered to have caused only concussion, the characteristic palpebral hæmorrhage, and the infection of a fracture here are all explained, together with the possibility and gravity of a fracture here from a severe blow on the nose. In the **middle fossa** the frequency of fractures is explained by the facts that while here, as in the other fossæ, a fracture often radiates down from the vertex, the overlying vault being a region often struck, the base is weakened by numerous foramina and fissures. Further, the resisting power of the petrous bone must be lessened by the cavities for the internal ear, the carotid, and, to a less degree, by the jugular fossa. For fluids to escape through the external meatus, the dura, the prolongation of the arachnoid into the internal meatus, the membrani tympani, and probably the internal ear, must all be injured. The presence of the middle meningeal artery (fig. 1090) and the cavernous sinus in this fossa must also be remembered, especially in such operations as that on the Gasserian ganglion. **Posterior fossa:** It is not sufficiently recognised that fractures here are, owing to the anatomy of the parts, in some respects the most important of all. It is here that a small fissure-fracture, ultimately fatal, with severe occipital and frontal bruising and some intradural hæmorrhage, has been so often overlooked, especially in the drunken. This is explained by the supposed strength of the bone, this being really very thin in places, by the thickness of the soft parts, and the abundance of hair. Further, there is no very apparent escape of cerebral contents as in the anterior and middle fossæ. Blood, etc., may trickle into the pharynx far back, or a deep-seated ecchymosis coming up after two days, under the muscles about the mastoid process, may call attention to the damage within.

Dura mater.—The outer layer of this membrane acts as a periosteum, by bringing blood-vessels to the bone while the inner layer supports the brain. The influence of its partitions and its damping effect on vibrations is great in blows on the head. Its varying adhesions, according to site and age, must be remembered. Thus while it is intimately connected over the base with its adhesions to the different foramina, it is more loosely connected with the vault, as is shown in middle meningeal hæmorrhage. In early and later life the closeness of its connection with the bones is also more marked. It is united to the inter-sutural membranes.

Finally, the existence of **the cerebro-spinal fluid** with its power of lessening the evil of vibrations and its aid in regulating intra-cranial pressure, must be borne in mind. The chief collections, in which the subarachnoid meshwork is almost absent, are met with in front and behind the medulla. That in front, also lying under the pons, Hilton's 'water-bed,' sends a prolongation forward to the optic chiasma, but does not extend under the frontal or temporal lobes. The collection behind lies between the medulla and under surface of the cerebellum. Here, by the foramen of Magendie, the intra-ventricular cavities communicate with the sub-arachnoid space of the spinal cord.

THE HYPOPHYSIS CEREBRI

The **hypophysis** (**pituitary body**) which has now become of great clinical importance, consists of a pars anterior and pars intermedia derived from the buccal ectoderm, and a posterior pars nervosa formed by a downgrowth from the floor of the third ventricle. The gland lies in the fossa hypophyseos of the sphenoid bone, and an enlargement of it, apart from general skeletal and nutritional effect due to anomalies of its internal secretions, will cause pressure on the cavernous sinus on each side, and on the optic chiasma above. It will also expand the fossa hypophyseos, pushing down its floor at the expense of the sphenoidal air sinus. Such enlargements may be detected by lateral radiograms. The normal size of the adult hypophyseal fossa (fig. 1097) is 10–12 mm. from before backward and 8 mm. from above downward (Keith).

The hypophysis may be exposed surgically either by turning the nose to one side, and removing the upper part of the septum and floor of the sphenoidal sinus, or by Cushing's method, in which a sublabial incision is made in the vestibule of the mouth, and through it the mucosa is then separated from each side of the nasal septum back to the sphenoidal sinus. A strip of septum is removed, and also the floor of the sphenoidal sinus, after which the hypophyseal fossa is opened and the gland exposed (fig. 1097).*

THE FACE

The topics included under this heading are the arteries, parotid region, nerves, mandible and maxilla, orbit, mouth, palate and nose.

The outline of the different bones—nasal, upper and lower jaws, zygomatic

* H. Cushing. The Pituitary Body and its Disorders, 1912.

and zygoma—can be readily traced. The last mentioned and the glabella are alluded to on pp. 1331 and 1332; and the canine fossa should be identified as one of the antral routes. The delicacy, laxity, and vascularity of the skin are of great importance in all operations, while the abundance of large gland orifices accounts for the frequency of lupus here.

Arteries.—The **supraorbital artery** can be felt beating just above its notch (junction of medial with lateral two-thirds of supraorbital margin); the little **frontal artery** is of importance, as it nourishes the flap when a new nose is taken from the forehead; the **superficial temporal,** accompanied by the auriculo-temporal nerve, can be felt where it crosses the root of the zygoma just in front of the tragus, its anterior branch about 3.1 cm. ($1\frac{1}{4}$ in.) above and behind the zygomatic process of the frontal; the **occipital,** accompanied by the great occipital nerve (fig. 450), pulsates to the medial side of the centre of a line drawn from the occipital protuberance to the mastoid process; the **posterior auricular,** rather deeply, between the auricle and the mastoid process. The **external carotid** lies behind the ascending

FIG. 1092.—SURFACE RELATIONS OF VESSELS AND NERVES IN LATERAL VIEW OF THE FACE AND NECK.

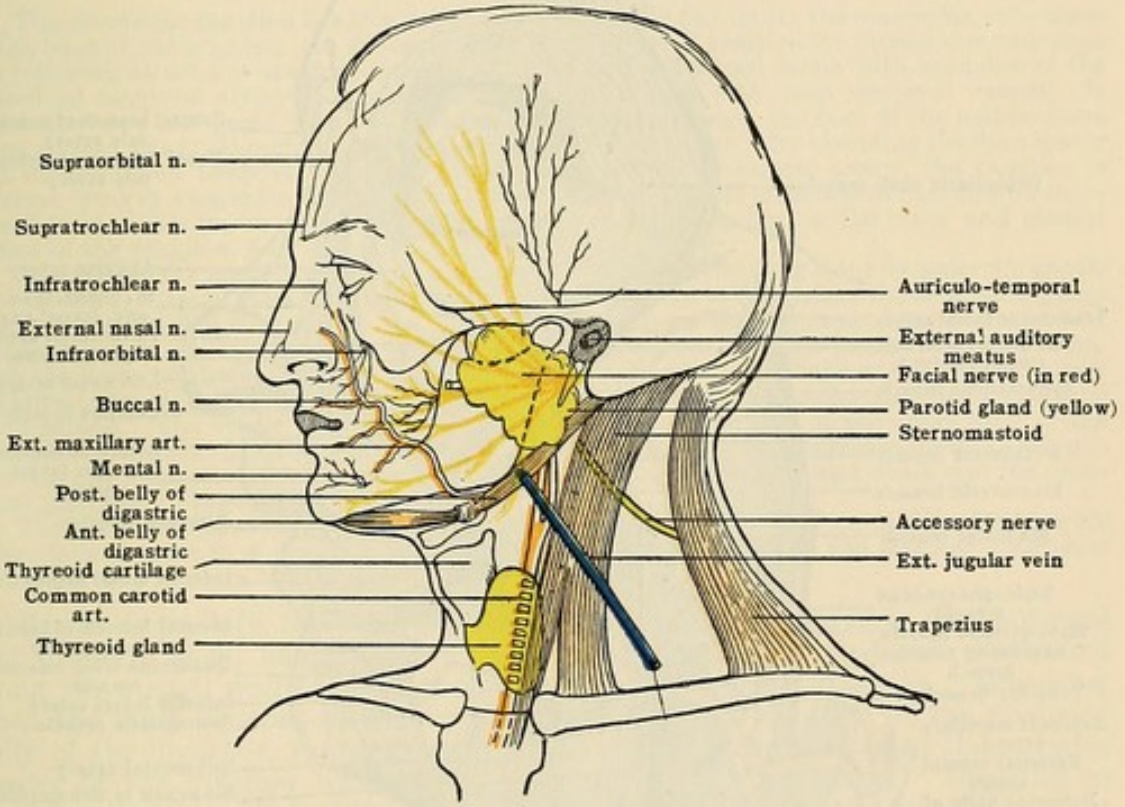

ramus of the jaw. The **external maxillary** (fig. 1093) crosses the jaw just in front of the masseter; if divided, both ends must be secured here. It can be felt again a little behind the angle of the mouth, just beneath the mucous membrane (it here gives off the labial branches, which can also be felt, lying deeply, if the lip is taken between the finger and thumb); and again by the side of the nose, as it runs up to the angulusoculi. The small angular branch is, from its position, always troublesome to secure. To trace the course of the **external maxillary** artery a line should be drawn from a point a little above and lateral to the tip of the great cornu of the hyoid to the lower part of the anterior border of the masseter, and thence to one lateral to and above the angle of the mouth, and so onward, lateral to the angle of the nose, up to the medial angle. The **anterior facial vein** takes a straight course behind the tortuous external maxillary artery. The absence of valves and its communication by the angular and ophthalmic veins with the cavernous sinus, and, by the deep facial, with the pterygoid plexus, are of grave importance in infective thrombosis. The external jugular vein will be mentioned later.

Parotid region.—A line drawn from the lower border of the meatus to a point midway between the nose and upper lip gives the level of the **parotid duct,** which

opens into the mouth opposite the second molar tooth. The level of the duct, somewhat inconstant, would be usually about a finger's breadth below the zygoma. It is accompanied by the transverse facial artery above, and the infraorbital branch of the facial nerve below.

The sheath of the parotid, continuous with those of the masseter and sterno-mastoid, is strong enough to cause most exquisitely painful tension when inflammation of the gland is present, and, together with the presence of deep processes of the gland in connection with the

FIG. 1093.—SCHEME OF THE EXTERNAL MAXILLARY (FACIAL) ARTERY. (Walsham.)

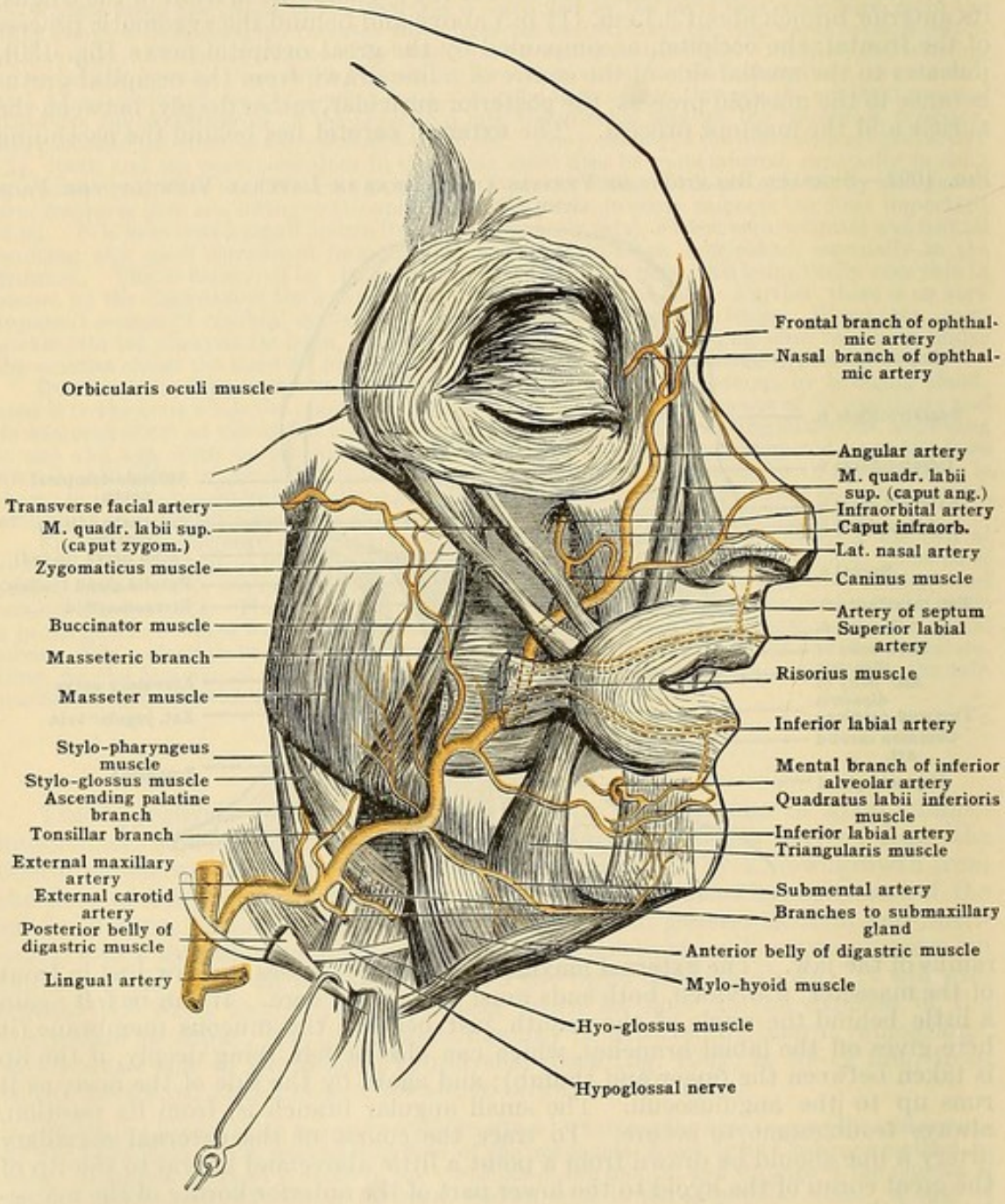

mandibular (glenoid) cavity and styloid process, to explain the deep burrowing of pus which may take place into the pharynx and pterygoid region. The relation of the capsule to growths, innocent or malignant, of the parotid is also important (See figs. 865, 1092).

The parotid region would be thus mapped out (fig. 1096). *Above* by the posterior two-thirds of the zygoma; *below*, by a line corresponding to the posterior belly of the digastric (fig. 1096); *behind*, are the external auditory meatus, mastoid, and sterno-mastoid. *In front* the gland and socia parotidis overlap the posterior part of the masseter, to a variable degree (fig. 1096).

Sensory nerves.—The cutaneous nerve areas of the face are shown in fig. 774. The **supraorbital** nerve, the main sensory branch of the ophthalmic, emerges from the orbit with its companion artery through the notch (occasionally a foramen) at the junction of the medial third and lateral two-thirds of the supraorbital margin. A line drawn from the supraorbital notch downward across the interval between the bicuspid teeth will cross the **infraorbital foramen** from which emerges the **infraorbital nerve,** the main terminal division of the maxillary, at a point 1 cm. below the orbital margin. The mental foramen, the point of exit of the *mental nerve*, a branch of the inferior alveolar, is found on a prolongation of the same line midway between the upper and lower margins of the mandible in the adult. In the infant in whom the alveolar element of the jaw is relatively large, the mental foramen is nearer the lower margin, while in the edentulous jaw of old age it is found much nearer the upper margin.

In trephining to expose the inferior alveolar (dental) nerve, one of the common seats of neuralgia and one in which a peripheral operation is justified from the results, the ascending ramus is opened midway between its anterior and posterior borders, on a level with the last molar.

The semilunar ganglion lies at a depth of 5.5–6 cm. (2¼ in.) under the eminentia articularis at the base of the zygoma. In exposing it for the purpose of excision for intractable neuralgia the following structures are encountered: (1) Skin and superficial fascia with branches of the superficial temporal artery; (2) temporal fascia and muscle with deep temporal vessels; (3) squamous bone and great wing of sphenoid, which are trephined, the floor of the middle fossa being gouged away; (4) middle meningeal vessels and dura mater. By elevating the dura mater and superimposed temporal lobe, and securing the middle meningeal artery, the ganglion is exposed, lying in a separate compartment [cavum Meckelii] of the dura, which contains cerebro-spinal fluid. The motor nerve of the muscles of mastication lies on the lower and medial aspect of the ganglion, and should not be divided.

Injection of the mandibular nerve with alcohol, by means of a long stout hypodermic needle is practised in cases of intractable neuralgia as an alternative to excision of the semilunar ganglion. A vertical line is drawn on the cheek downward from the junction of the posterior and middle thirds of the zygomatic arch, and the needle is entered on this line at a point 1.5 cm. from the lower border of the zygoma. It is directed upward and medially so as to pass through the lowest part of the mandibular notch. If the mouth is opened the notch is depressed and more room gained. The needle impinges first against the inferior surface of the great wing of the sphenoid bone, and when the point is lowered a little it engages in the foramen ovale at a depth of 4–4.5 cm. In most cases the needle can be passed through the foramen ovale into the semilunar ganglion. (Harris.)*

The **maxillary nerve** may be injected by passing a needle along the floor of the orbit from its infero-lateral angle in a direction backward and slightly medially to the foramen rotundum which lies 4.5 cm. from the surface.

Facial nerve.—In the petrous bone the course of this nerve is first outward and forward, then, having entered the facial canal, backward and downward along the medial wall of the tympanum, above the fenestra ovalis. Emerging from the stylo-mastoid foramen the nerve takes first the line of the posterior belly of the digastric, running forward and a little downward from the anterior border of the mastoid where this meets the auricle. (Godlee.) Entering at once the posterior part of the parotid, it crosses the neck of the mandible at the level of the lower border of the tragus.

The frequent paralysis of this nerve may thus depend upon—(1) cerebral causes; (2) disease of or injury to the petrous portion; (3) affections after its exit—Bell's paralysis. A diagnosis may be arrived at by attention to the following. In *cerebral disease* the lower part of the face is chiefly affected, the eyelids usually escaping. In all the other forms the whole side of the face is paralysed. Hemiplegia of the opposite side of the body and paralysis of the sixth nerve are usually present. In *petrous paralysis*, owing to involvement of the chorda tympani, there may be interference with the saliva and taste, affecting especially the anterior part of the tongue. The auditory nerve may also be affected. Here and in (3) there will be a history of disease or injury. In complete paralysis the smooth side of the face and forehead, the absence of power of expression, to frown, to blow, or whistle, the open eyelids and epiphora, and subsequent liability to mischief in the cornea, the dropping of the angle of the mouth and dribbling of saliva, the interference with mastication from paralysis of the buccinator, are the chief points.

Mandible.—Dislocation of the temporo-mandibular joint is referred to on p. 217. In the usual **dislocation,** from muscular action, the jaw is suddenly brought forward against the anterior part of the capsule, which tends, by the action of the depressors, to give way; the elevators then pull up the mandible, a sequence that must be remembered in reduction. In the commonest **fracture** of

* Lancet, Jan. 23, 1912.

the mandible—unilateral, near the mental foramen—the larger anterior fragment will be pulled by the depressors downward and medially, the smaller posterior one upward and usually lateral to the other fragment.

Maxilla.—The boundaries of the **maxillary sinus** (**antrum**) are of much importance. The base of this irregularly pyramidal cavity corresponds to the middle and inferior meatuses on the lateral wall of the nose; toward the upper and back part is the opening into the middle meatus. The apex runs laterally toward the zygomatic process. The roof is formed by the orbital plate with the infraorbital nerve and vessels anteriorly; the floor by the junction of the alveolar arch, carrying the first molars (and often the bicuspids), with the hard palate. It may be pierced by the roots of the second bicuspid or first and second molar teeth. Anteriorly, the antrum is bounded by the canine fossa; posteriorly it is in relation with the zygomatic fossa. The cavity, present at birth, increases gradually up to the twelfth year.

The chief paths of infection are through the teeth (especially the first and second molar), the nose, and frontal sinus. The obstinacy of inflammation here is explained by the site of the opening, high up on the medial wall, and thus inadequate drainage, by the imperfectly multilocular cavity of the interior and its rigid walls. The chief sites for *opening the antrum* are—(*a*) through the sockets of the first or second molars; (*b*) through the canine fossa, after the reflection of mucous membrane has been detached, midway between the roots of the teeth and the infraorbital foramen (this path gives more room); (*c*) through the inferior meatus of the nose.

THE ORBIT AND EYE

The **bony orbit** is a pyramidal fossa with its **base** at the orbital margin and its **apex** at the optic foramen. The medial walls of the two orbits are approximately parallel, but the lateral walls diverge as they are traced forward and lie at right angles to each other. The thin **floor** which is formed mainly by the maxilla and corresponds to the roof of the maxillary sinus, is readily destroyed by growths extending up from the sinus and in the process pressure on the infraorbital nerve is apt to cause pain referred to the cheek. The **roof** formed by the orbital plate of the frontal bone is also thin, and foreign bodies thrust into the orbit may perforate it and enter the frontal lobe of the cerebrum. The **medial wall** is chiefly constituted by the lacrimal and lamina papyracea of the ethmoid, both very thin bones. This wall is readily destroyed by malignant growths of the nose.

Injuries of the medial wall such as may be associated with fractures of the nose bring the ethmoidal air cells into communication with the cellular tissue of the orbit. The latter may thus be distended with air on attempting to blow the nose.

The **lateral wall** is formed in its anterior third by the zygomatic bone, which separates the orbit from the zygomatic fossa. The posterior two-thirds formed by the sphenoid bone separate the orbit from the temporal lobe of the brain in the middle cranial fossa. The orbit communicates with the cranium by the optic foramen, which transmits the optic nerve and ophthalmic artery and the superior orbital fissure through which pass all the other vessels and nerves of the orbit.

In cases of fracture of the base of the skull involving the anterior clinoid process, a traumatic communication (arterio-venous aneurysm) may be formed between the internal carotid artery and cavernous sinus, behind the apex of the orbit, giving rise to pulsating exophthalmos.

The **orbital margin** is larger in the transverse than in the vertical direction, and consequently there is more space on either side than above and below between it and the eyeball which is nearly spherical. The eyeball lies nearer to the medial than to the lateral margin and hence foreign bodies more commonly penetrate the orbit to the lateral side of the eye.

Behind the **fascia bulbi,** the eyeball rests on a mass of soft loose orbital fat in which foreign bodies may be hidden for a considerable time.

The structure of the eyelids.—The different layers are of much practical importance. (1) The **skin** is delicate and fatless, and contains pigment, the object of this being to protect the eye from bright light. It helps to explain the 'dark circles' of later life. (2) **Areolar tissue.** Owing to its looseness and delicacy, this is very liable to infiltration, as in œdema and erysipelas. (3)

Orbicularis. Paralysis of this, the palpebral portion, leads to epiphora, the puncta being no longer kept in their normal backward direction against the conjunctiva. (4) **Palpebral fascia,** reaching from the orbit to the tarsal cartilage. This is usually strong enough to prevent hæmorrhage, due to fractured base of skull, becoming subcutaneous. (5) **Levator palpebræ.** (6) **Tarsal plate;** in reality, densely felted fibrous tissue. (7) **Tarsal** (Meibomian) **glands, lashes, and sebaceous follicles.**

[Localised inflammation starting in any of these last three structures, especially the last, will cause a 'stye.' The frequency with which the lid-border is the seat of that most troublesome chronic inflammation, blepharitis, and its result, 'blear eye,' is explained by these anatomical points. Its circulation is terminal and slow; half skin and half mucous membrane, it is moister and more liable to local irritation than the skin; while its numerous glands readily participate in any inflammation.

FIG. 1094.—SAGITTAL SECTION THROUGH THE UPPER EYELID. (After Waldeyer and Fuchs.)

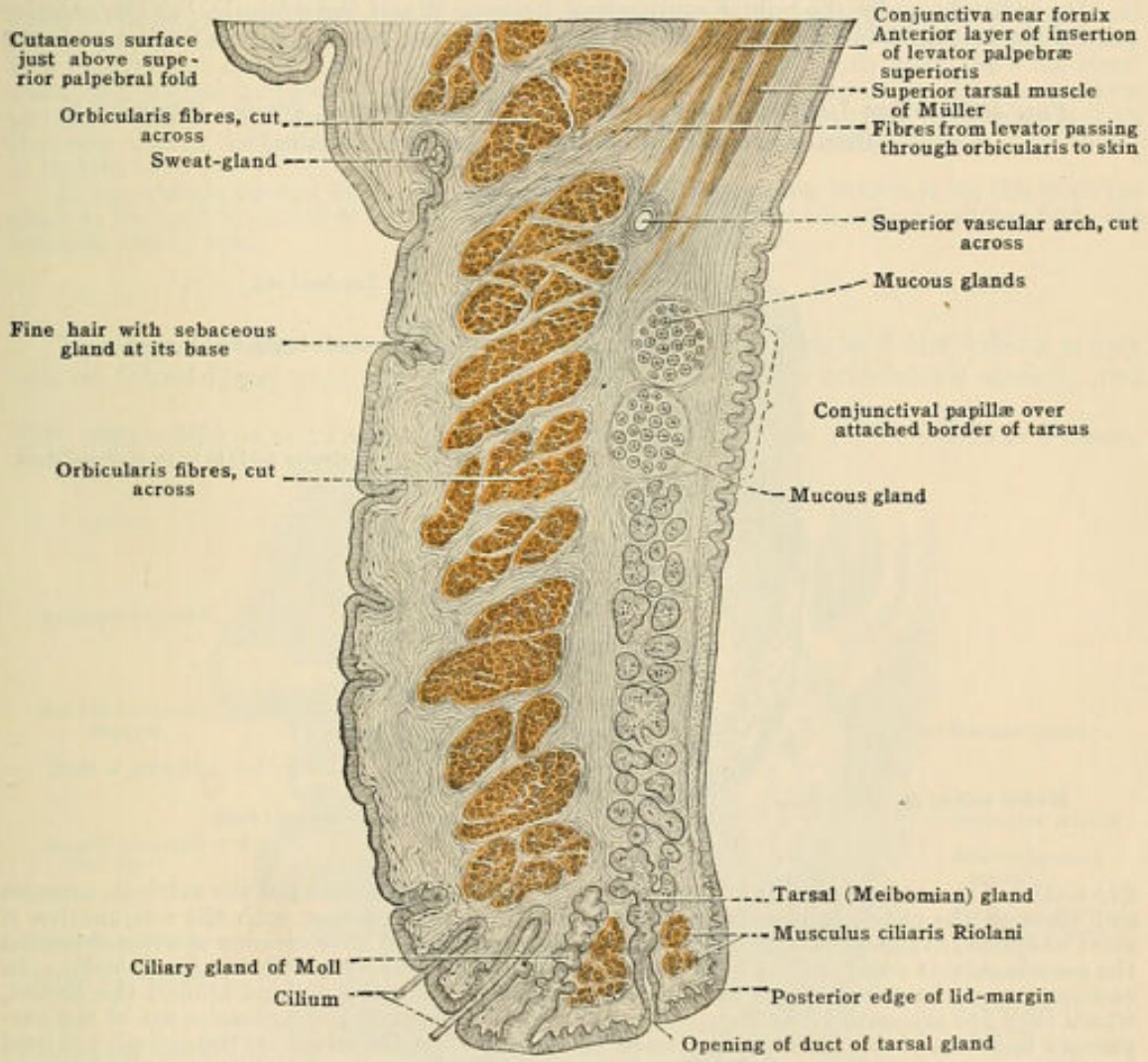

(8) **The conjunctiva.** To trace this important membrane, the lids should be everted, when the following will be noted. The conjunctiva over the tarsal part of the lid is closely adherent, and through it a series of nearly straight, parallel, light yellow lines and granules, the tarsal glands, can be seen. Owing to their position here (fig. 1094) and to avoid scarring, a tarsal cyst is always opened on its conjunctival surface.

Beyond the tarsi, the palpebral conjunctiva is thicker and freely movable owing to the abundant lax submucous tissue. Underlying vessels are visible here. Leaving the eyelid the conjunctiva is reflected onto the eyeball at the **fornix.** Into the lateral part of the upper fornix open the ducts of the lacrimal gland. The bulbar conjunctiva is continued over the front of the eyeball to the corneal margin. It is thin and contains fine vessels which are distinguished from subjacent episcleral vessels by the fact that they move with the conjunctiva.

These **conjunctival vessels,** derived from the lacrimal and palpebral arteries, become very visible in conjunctivitis. In deep inflammation affecting the iris and ciliary body, the episcleral branches of the anterior ciliary arteries (which are derived from the muscular and lacrimal arteries) become engorged and are visible as a pink circumcorneal zone of congestion, deeply situated under the conjunctiva. These branches take a large share in the nutrition of the cornea, and are responsible for the vascularity of *pannus* and the '*salmon patches*' of interstitial keratitis.

The **conjunctival nerves** for the upper lid and bulbar part of the membrane, and the nerves to the cornea, are supplied by the ophthalmic division of the trigeminal. The maxillary division of this nerve supplies the lower palpebral conjunctiva.

The differing structure of the palpebral and ocular portions has important bearings. Thus the palpebral conjunctiva is thick, highly vascular and sensitive. To this vascularity we owe the chemosis, or hot, red, tense swelling of purulent ophthalmia. The exquisite suffering of the same disease, or that caused by a foreign body, is explained by the numerous nerve-papillæ and end-bulbs. To the thickness and abundance of the connective tissue are due the contraction and permanent thickening which may occur in granular lids. The so-called granulations, met with in this disease on the palpebral conjunctiva, are really little nodules of hypertrophied lymphoid follicles, or mucous glands, which abound here.

Immediately under the bulbar conjunctiva, between it and the sclerotic, lies the anterior part of the **fascia bulbi** (of Tenon). This fibrous membrane forms a sheath for the posterior

FIG. 1095.—THE LACRIMAL APPARATUS AND NASO-LACRIMAL DUCT. (Bellamy.)
(Bristles are introduced into the puncta lacrimalia.)

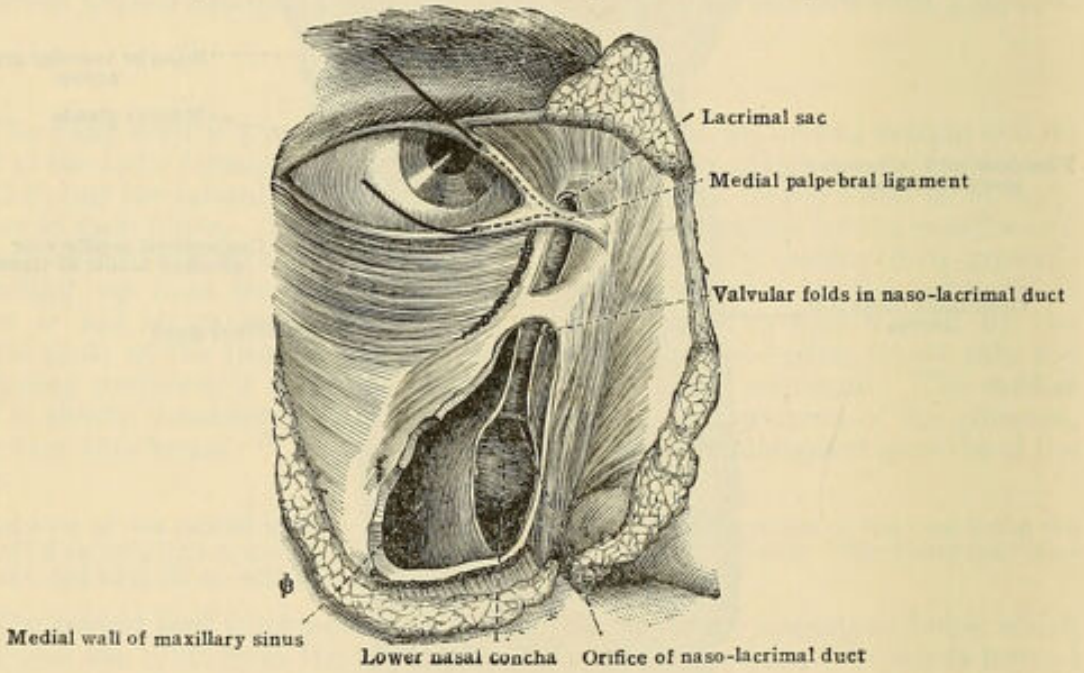

five-sixths of the eyeball, and is intimately connected with the sheaths of the extrinsic muscles and through the **check ligaments** with the orbital walls. Together with the conjunctiva it must be opened in the operation of tenotomy for strabismus, and after division of a rectus tendon the muscle retains some control over the eye through its connection with the fascia bulbi. In enucleation of the eyeball both conjunctiva and fascia bulbi are divided around the cornea, where they are intimately blended. In removal of the upper jaw the attachment of the suspensory ligament of this fascia must always be left if possible, for otherwise the eyeball will tend to fall forward and the cornea suffer from its exposure (Lockwood). Finally the cavity between the two layers of the capsule is continuous with the extensions of the cerebral membranes along the optic nerve, i. e., with the subarachnoid space.

For an account of the intrinsic and extrinsic muscles of the eye the reader is referred to the section on the EYE. Reference may be made here, however, to the part played by certain fibres of the **cervical sympathetic** system. Emerging from the cord at the first and second thoracic segments, the communicating fibres pass up the sympathetic chain in the neck to cell stations in the superior cervical ganglion. Thence continuing onward through the carotid canal and superior orbital fissure, they supply (1) the dilator muscle of the iris, (2) the unstriped muscle element in the eyelids, and (3) smooth muscle fibres, decribed by Sappey, in the check ligaments and fascia bulbi. Paralysis of the cervical sympathetic nerve in the neck, usually in its lowest part, by trauma or the pressure of a malignant growth, causes therefore (1) narrowing of the pupil, (2) narrowing of the palpebral fissure (pseudo-ptosis), and (3) enophthalmos.

The **lacrimal gland** lies in a hollow at the supero-lateral angle of the orbit, protected by the zygomatic process of the frontal bone. It is not palpable normally. Its lower or palpebral portion rests on the lateral third of the fornix

conjunctivæ, into which the numerous ducts open, and it may be seen through the conjunctiva on everting and raising the upper lid.

The position of the lacrimal puncta should be noted; owing to their backward direction, the lids must be previously everted. The puncta are kept open by a minute fibrous ring.

Each is situated on a minute papilla at the junction of the medial and straight third of the lid with the lateral curved two-thirds. Close to the medial angle, in addition to the puncta and papillæ, should be noted the caruncula lacrimalis, with its delicate hairs, and the plica semilunaris, which corresponds to the third eyelid of certain birds.

The **lacrimal sac** is a most important part of the lacrimal apparatus, from its disfiguring diseases; it lies in a bony groove, between the nasal process of the maxilla and the lacrimal bone. The medial palpebral ligament crosses it a little above its centre (fig. 1095). Thus two-thirds of the sac are below the ligament, and in suppuration the opening is made below it also. The angular artery ascends on the nasal side of the sac.

The manipulation of a probe along the lacrimal passages should thus be practised:—the lower lid being drawn laterally and downward by the thumb, the probe is passed vertically into the punctum, then turned horizontally and passed on till it reaches the medial wall of the sac. It is then rotated somewhat forward, raised vertically, and pushed gently along the duct downward, and a little lateralward and backward, till the floor of the nose is reached, the operator aiming, as it were, for the site of the first molar tooth. The *naso-lacrimal* duct extends from the lower end of the lacrimal sac to the inferior meatus of the nose and is about 1.2 cm (½ in.) in length.

If the eyes are opened naturally, the greatest part of the cornea, behind it the iris, with the pupil in the centre, on either side of the cornea some of the sclerotic, the semilunar fold, and caruncle can be seen.

THE MOUTH

The lips.—When the whole thickness of the lip is incised the labial artery will be found lying near the free margin, internal to the orbicularis muscle, and

FIG. 1096.—SIDE OF THE FACE AND MOUTH CAVITY, SHOWING THE THREE SALIVARY GLANSD.

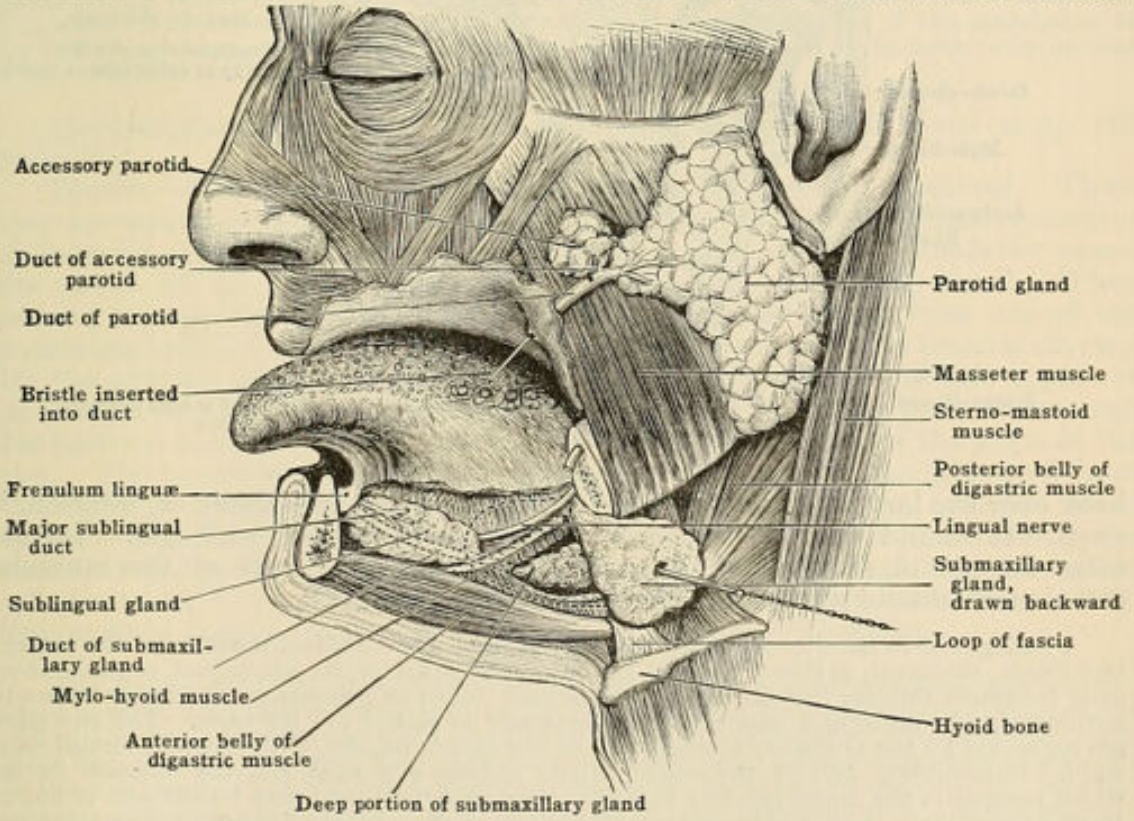

between it and the mucosa. There is a very free anastomosis between the arteries of the opposite sides.

If the tongue be raised, the under surface is seen to be smooth and devoid of papillæ. In the middle line is the **frenulum.** When division of this is really required in tongue-tie, the scissors should be kept close to the bone, in order to avoid the ranine vessels.

Of these, the veins can be seen just to one side; the arteries are close by, but deeper. Farther out are two more or less distinct fringed folds, the plicæ fimbriatæ, ruuning from behind forward and, like the frenulum, disappearing before the tip. Between these and the frenulum are the small apical mucous glands of Nuhn or Blandin. Farther back, at the junction of the mucous membrane and the alveoli, are two other projections of the mucosa, the sublingual; under these are the sublingual glands, the ranine veins, and, more deeply, Wharton's duct and the termination of the lingual nerve. The majority of the ducts of the sublingual gland (Rivinian) open on the sublingual ridges. A single larger one, Bartholin's, opens with that of Wharton, or close to it, on either side of the frenulum (fig. 1096). Dilatation of one of the Rivinian ducts, more frequently dilatation of a muciparous gland—and, much more rarely, dilatation of Wharton's duct —constitutes a 'ranula.'

The **submaxillary gland** can be felt nearer the angle of the jaw, lying between its fossa and the mucous membrane, especially if pressure is made from outside. The attachment of the **genio-glossi** can be felt behind the symphysis: the division of the muscles allows the **tongue** to come well out of the mouth; but when both have to be divided, the tongue loses much of its steadiness, and may easily fall

FIG. 1097.—SECTION OF THE SKULL AND BRAIN IN THE MEDIAN PLANE. (Braune.)

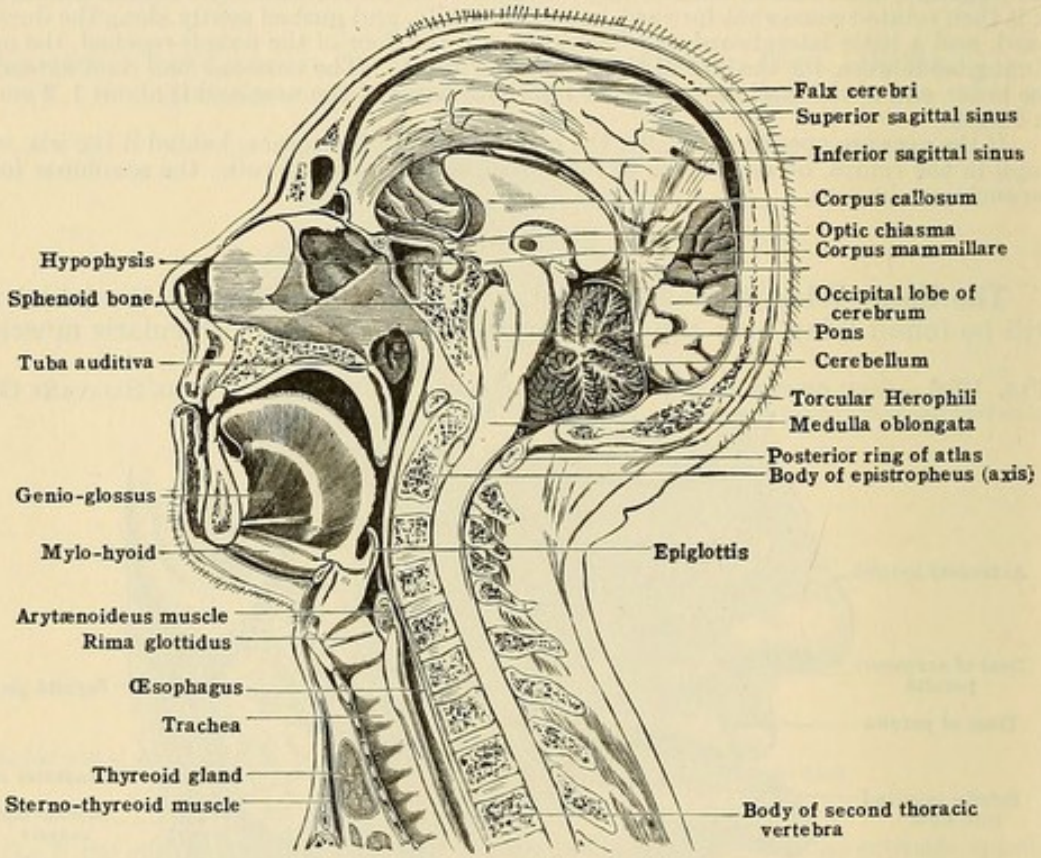

back over the larynx during the administration of the anæsthetic or, later on, in sleep. It should therefore be secured forward for a while with silk. For the same reason, in removal of one-half of the mandible, part of this muscular attachment should always be left, if possible.

Turning now to the dorsum of the tongue, this shows two distinct parts: one, the anterior two-thirds, *the buccal*, is rich in papillæ; the other, the posterior, *the pharyngeal*, contains abundant lymphoid follicles like the tonsil. This part possesses peculiar sensibility, as shown by movements of tongue and palate when a depressor is placed too far back. The two parts are separated by the ∨-shaped arrangement of the vallate papillæ, with the apex turned backward. Immediately behind the apical vallate papilla is a small pit, the foramen cæcum which represents the upper remains of the thyreoglossal tract, and may be the seat of lingual thyreoid growths. While the tongue is mainly a muscular organ, the fine fatty connective tissue in the septum and between the muscular bundles is the seat of that dangerous condition acute glossitis, and of gummatous infiltration. While the mouth is widely open, the pterygo-mandibular ligament can be seen and felt beneath the mucous membrane, behind the last molar tooth. Just below and in front of the lower attachment of this ligament the **lingual nerve** can be felt lying close to the bone below the last molar. The simplest and surest method of dividing the nerve here, to give relief from pain in incurable carcinoma of the tongue, is to draw the tongue out of the mouth and expose the nerve where it lies superficially under the mucous membrane thus made prominent between the side of the tongue and the gums, the centre of the incision

being opposite to the last molar tooth. (Roser, Létiévant.) In cancer of the tongue pain is often referred up the auriculo-temporal nerve to the ear and side of head.

Behind the last molar tooth can be felt the **coronoid process,** and higher up, just behind and medial to the tooth, the **pterygoid hamulus of the sphenoid.** This process is a landmark to the site of the greater palatine foramen, which lies just in front of it, and which transmits the greater palatine branch of the descending palatine artery, together with the anterior palatine nerve. The vessel and nerve run forward in grooves on the lower surface of the palatine process of the maxilla, giving off anastomosing branches toward the middle line, and join at the incisive foramen with the nasopalatine artery.

Their position must be remembered in raising the flaps during the operation for closure of a cleft in the hard palate. To ensure the vitality of the flaps the incisions must be made lateral to the vascular arch, close to and parallel with the upper alveolus, and should not extend beyond a point opposite to and just medial to the last molar tooth, for fear of encroaching upon the posterior palatine canal.

When the teeth are clenched, there is still a space, communicating between the mouth and pharynx behind the molar teeth, which admits a medium-sized catheter. When a patient breathes deeply through the mouth and the head is thrown back, the soft palate is raised, the pillars (arches) separated; the uvula and fauces, with the anterior and posterior pillars, with their attachments, the tonsils, and the back of the pharynx are exposed.

This portion of the pharyngeal mucous membrane would lie over the lower part of the second and the upper part of the third cervical vertebræ, the anterior arch of the atlas corresponding to the level of the posterior nares, and the body of the epistropheus (axis) to the level of the soft palate (fig. 1097). If a finger be introduced past the soft palate to this part of the spine and turned upward and downward, it is possible, with the aid of an anæsthetic, to examine the upper four or five and, in children, six vertebræ, as far as the anterior surfaces of their bodies. 'The part of the column which is accessible to a straight instrument introduced through the mouth is very limited, extending, in the adult, from the lower border of the axis to the middle or lower part of the fourth cervical vertebra; in the child, owing to the small size of the face, it comprises the bodies of the axis and of the third cervical vertebra.' (Thane and Godlee, from Chipault.) The distance from the incisor teeth to the commencement of the œsophagus at the cricoid cartilage is 15 cm. (6 in.) in the adult, and the distance from the teeth to the cardiac orifice of the stomach is 48 to 50 cm. (16 or 17 in.).

The lymphatic drainage of the face, mouth, and tongue is given on pp. 712 and 715.

Tonsils.—The **relations of the tonsils** should be carefully examined. Thus, they are separated externally by the superior constrictor and pharyngeal aponeurosis from the oscending pharyngeal and internal carotid arteries. The latter vessel lies about 2.5 cm. (1 in.) behind and to the lateral side of the tonsil. When serious hæmorrhage follows operations here, it usually comes from one of the numerous tonsillar branches (fig. 448). The extent to which the tonsil is covered by the anterior pillar, how far it projects upward beneath the soft palate or downward into the pharynx, have all important bearings on the mode of removal. Its position corresponds to a point a little above and in front of the angle of the jaw. The lateral surface, enclosed by an imperfect capsule and separated from the superior constrictor by connective tissue, explains how an enlarged tonsil can be dragged medialward by a vulsellum, and enucleated after an incision in the mucous membrane around. It is in this connective tissue that severe infective inflammation, e. g., after scarlet fever or an imbedded pipe-stem, may set up hæmorrhage or spreading cellulitis, retro-pharyngeal or otherwise.

The **finger introduced downward at the back of the mouth,** especially if the parts are rendered in sensitive by local anæsthetics, feels the vallate papillæ, the lingual and laryngeal surfaces of the epiglottis, the arytæno-epiglottidean folds, with the cuneiform and corniculate cartilages. **If the finger be moved upward** behind the soft palate and turned upward to the base of the skull, and then forward, it will feel the choanæ (posterior nares), separated by the vomer. The other boundaries of these are, laterally, the medial pterygoid plate and palate bones; above, the basisphenoid; and below, the horizontal plate of the palate bone and the inferior nasal spine. Within each nostril would be felt the posterior ends of the two lower nasal conchæ (turbinate bones); above and behind is felt the basilar process of the skull, the vault of the pharynx, and the bodies of the upper cervical vertebræ (fig. 1097).

The **size of the choanæ,** in the bony skull 2.5 cm. (1 in.) vertically by 1.2 cm. (½ in.), and the presence of any adenoids, are especially to be noted. The **richness of the naso-pharynx in glandular structures,** its proneness to inflammation, and of this inflammation to spread to other parts,—e. g., the tympanum,—are well known. The finger should be familiar with the feel of

adenoids—i. e., hypertrophied post-nasal lymphatic nodules—soft bodies of irregular shape blocking up the naso-pharynx. To make out how far this is the case, it is well to take the nasal septum as the starting-point.

Pharyngeal hypophyseal remnants.—In the naso-pharyngeal mucosa, a few millimetres behind the posterior border of the vomer, a group of glandular cells may be found on microscopical examination in all cases (Haberfeld), corresponding in histological appearance with the pars anterior of the hypophysis. These cells are a remnant of the primitive bud that grows toward the brain in front of the bucco-pharyngeal membrane to form the pars anterior of the hypophysis. In some cases of pituitary disorder they give rise to a palpable tumour in the naso-pharynx.

The palate.—Between the diverging pillars of the soft palate is the **isthmus faucium,** bounded above by the free margin of the palate, and below by the dorsum of the tongue. The space between the arches (pillars), glossopalatine and pharyngo-palatine, with attachments denoted by their names, shallow above, widens and deepens below. Of its lateral boundaries, the posterior pillars come nearer each other than the anterior. The coverings of the hard palate are chiefly mucous membrane, glands, and periosteum. These are intimately blended by fibrous septa, as in the superficial layers of scalp and palm of the hand. Hence the readiness with which necrosis takes place here.

Hare-lip and cleft palate.—Failure of union between the mesial nasal process and the maxillary process of the embryo gives rise to the deformity known as **hare-lip.**

The palate is developed from three primitive processes growing down from the basis cranii, viz., (1) the mesial nasal process forming the premaxilla which lies in front of the anterior palatine foramen and bears the four incisor teeth, (2) and (3) the maxillary process of either side. The slighter cases of failure to unite affect only the soft palate which is the last part to fuse. Complete alveolar cleft palate, which occurs combined with hare-lip and may be unilateral or bilateral, represents more serious non-union. In this condition the lateral incisor may be found either on the medial or on the lateral side of the cleft, which is explained by the fact that this tooth is developed in the groove between the two processes (Keith).

In paring the edges of a cleft soft palate, the following structures would be, successively, cut through:—(1) Oral mucous membrane; (2) submucous tissue, with vessels, nerves, and glands; (3) glosso-palatine muscle; (4) aponeurosis of tensor palati; (5) anterior fasciculus of pharyngo-palatine; (6) levator palati and uvular muscles; (7) posterior fasciculus of pharyngo-palatine; (8) submucous tissue, vessels, nerves, and glands; (9) posterior mucous membrane. The soft palate is thicker than it seems, the average in an adult being 6 mm. ($\frac{1}{4}$ in.). The muscles widening a cleft are the tensor and levator, while the superior constrictor closes it in swallowing. Of the *arteries* of the palate, from the external maxillary (facial), ascending pharyngeal, and internal maxillary, the largest is the descending palatine branch of the last. This emerges from the posterior palatine canal close to the inner side of the last molar tooth.

THE NOSE

On the face the outline of the nasal bones can be easily traced, and below them the lateral nasal cartilages, flat and also somewhat triangular. Below these are the greater alar cartilages, curved and so folded back that each forms a lateral and a medial plate. Of these, the medial meet below the septal cartilage to form the tip of the nose, while the lateral curve backward, and, together with dense masses of cellular tissue and fat and accessory cartilages, form the alæ.

With the speculum, especially if the head be thrown back and the tip of the nose drawn up, the lower part of the septum, floor of the nose, and greater portion of the inferior concha (turbinate bone) can be seen. On throwing the head further back, with a good light the lower margin of the middle concha can also be made out. This is much higher up and nearly on a level with the root of the nasal bone. The septum often deviates to one side. The mucous membrane over it is, in health, dull red in colour; that over the inferior concha is thicker. The anterior extremity of the latter bone is about 1.8 cm. ($\frac{3}{4}$ in.) behind the nasal orifice, while the opening of the naso-lacrimal duct is about 2.5 cm. (1 in.) behind and about 1.8 cm. ($\frac{3}{4}$ in.) above the floor, concealed by the anterior extremity of the inferior concha. The opening into the maxillary sinus (antrum) is situated in about the centre of the middle meatus and 2.5 cm. (1 in.) above the floor

The **olfactory area of the mucous membrane** extends over the highest concha (possibly also somewhat lower) and corresponding portions of the septum. The **respiratory portion** is more vascular and thicker, especially over the conchæ. It is firmly adherent to the periosteum and perichondrium. The veins, especially over the lower conchæ, form a dense plexus, closely resembling cavernous tissue.

This fact explains the severity of epistaxis, and, together with the drainage of blood into out-of-the-way veins, such as the spheno-palatine and ethmoidal,

FIG. 1098.—SECTION OF THE NOSE, SHOWING THE CONCHÆ (TURBINATE BONES) AND MEATUSES WITH THE OPENINGS IN DOTTED OUTLINE.

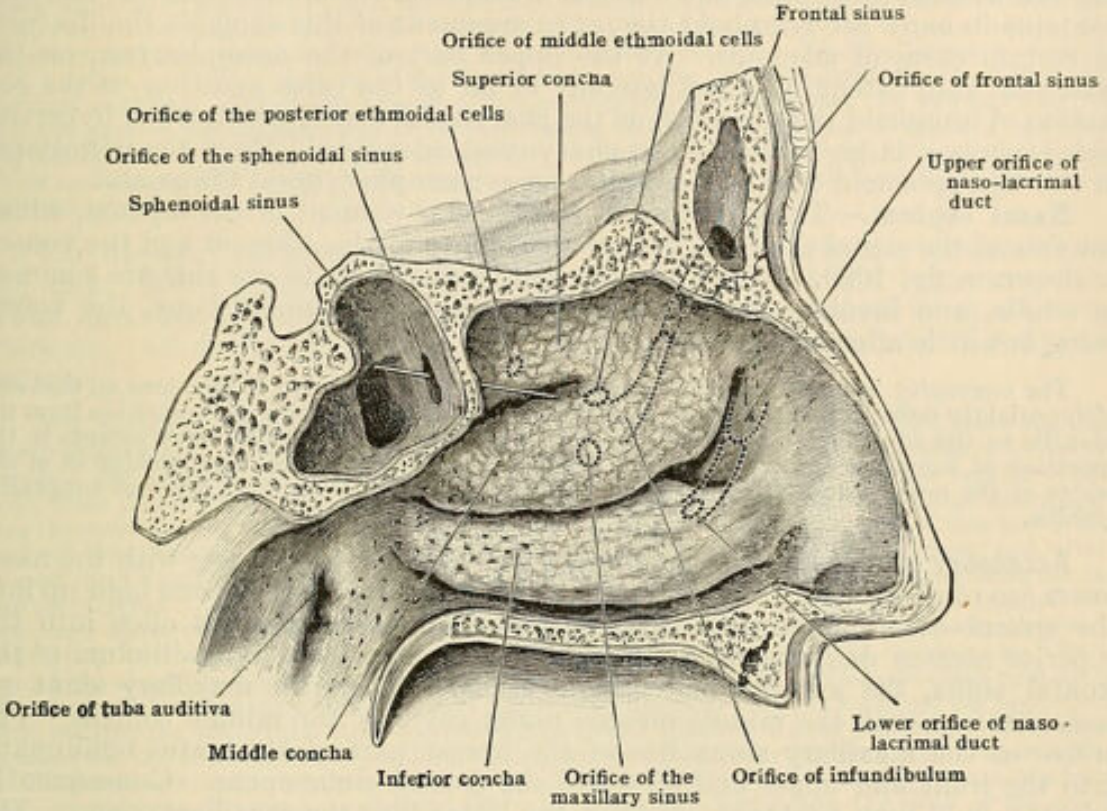

FIG. 1099.—SECTION SHOWING BONY AND CARTILAGINOUS SEPTUM.
The dotted line indicates the course of the incisive (anterior palatine) canal.

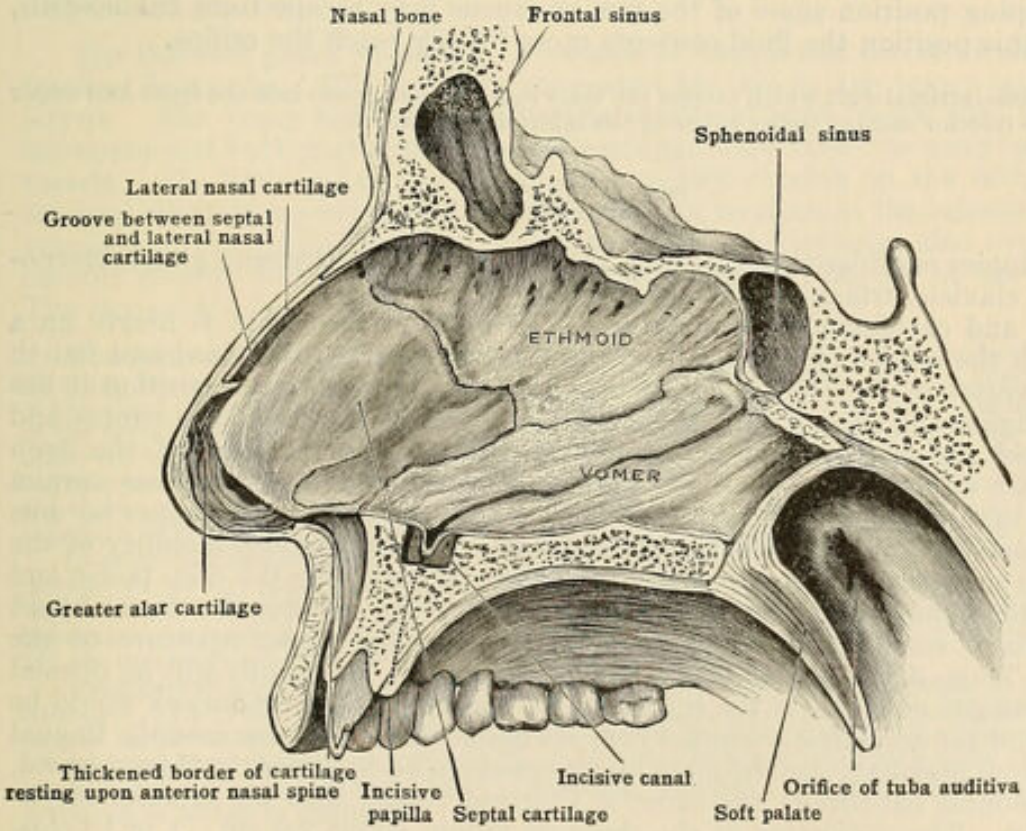

accounts for the serious results which may follow on a firmly impacted and infected plug. The boundaries of the posterior nares have been given above.

About 1.2 cm. (½ in.) behind the posterior extremities of the inferior conchæ, just above the level of the hard palate (fig. 1097), on the side of the naso-pharynx, are the openings of the *tubæ auditivæ* (**Eustachian tubes**). Oval in shape, these are bounded above and behind by the prominence of the cartilage, which is wanting below, thus facilitating the entry of a catheter. The lower part of the tube contains in early life lymphoid tissue; enlargement of this explains the deafness in certain cases of adenoids. At the upper part of the naso-pharynx, on the posterior wall, extending down laterally as far as the tubæ auditivæ, is the collection of lymphoid tissue known as the **pharyngeal tonsil,** which when hypertrophied, plays a large part in 'naso-pharyngeal adenoids.' From the periosteum of the basi-sphenoid and basi-occipital arise naso-pharyngeal fibromata.

Nasal septum.—The structure of the skeletal element of the septum, which consists of the septal cartilage, the vertical plate of the ethmoid and the vomer, is shown in fig. 1099. Slight deviations of the septum to one side are common in adults, and involve mainly the cartilage and the ethmoid bone, the vomer being but little affected as a rule.

The convexity is most commonly on the right side, and occlusion of the nares on that side with unsightly deflection of the whole nose, results in some cases during the transition from the nfantile to the adult facial conformation. Too extensive removal of the bony septum in the operation of submucous resection for the relief of this condition may cause sinking in of the bridge of the nose. More often, however, this is due to the destructive effect of congenital syphilis.

Accessory sinuses.—The communication of these air sinuses with the nasal fossæ are of great clinical importance. The **sphenoidal sinus** opens high up into the spheno-ethmoidal recess. **The posterior ethmoidal sinuses** open into the superior meatus under cover of the superior concha. The infundibulum of the **frontal sinus, the anterior** and **middle ethmoidal** and the **maxillary sinus** all communicate with the middle meatus under cover of the middle concha. The orifice of the **maxillary sinus** lies at the lowest part of the hiatus semilunaris into the front and upper end of which the frontal sinus opens. Consequently infected fluid may trickle down from the latter into the maxillary sinus. The orifice of this sinus is placed high up in its medial wall so that fluid does not drain away from it readily in case of infection. When the head is held forward in a stooping position some of the pus or mucus may escape from the nostrils, since in this position the fluid contents more readily reach the orifice.

The **naso-lacrimal duct** which carries the tears into the nose opens into the front and upper part of the inferior meatus under cover of the inferior concha.

THE NECK

The topics considered in the neck are the landmarks, thyreoid gland, sterno-mastoid, clavicle, triangles and cervical ribs.

Bony and cartilaginous landmarks.—The body of the hyoid is nearly on a level with the angles of the jaw, and the interval between the third and fourth cervical vertebræ (fig. 1097). With the head in the usual erect position it lies a little higher than the chin. It divides the front of the neck into supra- and infra-hyoid regions, convenient for remembering the distribution of the deep fascia. On either side of the body are the great cornua, with the lesser cornua attached to their upper borders at the junction with the body. The upper borders of these are the guides to the lingual arteries. The outline and mobility of the body and the great cornua are easily determined by relaxing the deep fascia and pushing the bone over to the opposite side. Below the hyoid is the thyreo-hyoid space, which corresponds with the epiglottis and the upper aperture of the larynx. Thus, if the throat be cut above the hyoid, the mouth will be opened and the tongue cut into; if the thyreo-hyoid space be cut, the pharynx would be opened and the epiglottis wounded near its base. In the former case the lingual and external maxillary are the most likely vessels to be wounded; in thyreo-hyoid, the commonest cut-throat, the superior thyreoid vessels, and the superior laryngeal nerve. The projection of the thyreoid notch, about 2.5 cm. (1 in.) below the hyoid, is much more distinct in men than in women or children. It does not appear before puberty, and thus flatness of the thyreoid must be expected

when the landmarks for tracheotomy are sought for in children with short fat necks.

The cricoid, on the other hand, is always to be made out. It corresponds in horizontal plane to the following:—(1) The sixth cervical vertebra. (2) The junction of pharynx and œsophagus: from the narrowing of the tube here, foreign bodies may lodge at this point and cause dyspnœa by pressing on the air-tube in front. The cricoid is taken as the centre of the incision in œsophagotomy, and also for ligature of the common carotid. (3) The junction of larynx and trachea. (4) The crossing of the omo-hyoid over the common carotid. (5) The middle cervical ganglion. Above the cricoid is the crico-thyreoid membrane. In laryngotomy, the deepest part of the incision should be kept to the middle line for fear of injuring the crico-thyreoids, and as near the cricoid as possible, so as to avoid the neighbourhood of the vocal cords and the small crico-thyreoid vessels. The space is always small, and, after middle life, increasingly rigid.

The distance between the cricoid and the manubrium is only about 3.7 cm. ($1\frac{1}{2}$ in.). When the neck is stretched, about 1.8 cm. ($\frac{3}{4}$ in.) more is gained. Thus, as a rule, there are not more than seven or eight tracheal rings above the sternum. Of these, the second, third, and fourth are covered by the thyreoid isthmus.

The parts met with in the middle line—(*a*) above, and (*b*) below, the isthmus—high and low tracheotomy—should be borne in mind: (*a*) Skin, superficial fascia, branches of transverse cervical and infra-mandibular nerves, lymphatics, cutaneous arteries, anterior jugular veins—with their transverse branches smaller above—deep fascia, sterno-hyoids, cellular tissue, superior thyreoid vessels, and pre-tracheal layer of deep fascia. The importance of this last is two-fold, as, first, the tube in tracheotomy may be passed between it and the trachea, and after a wound in this region this layer, continuous with the pericardium, may conduct discharges into the mediastina. (*b*) The surface structures are much the same, but the anterior jugular veins and their transverse branches are much larger. The inferior thyreoid veins are also larger. A thyreoidea ima may be present, and the innominate artery, especially in children, may be 1.2 cm. ($\frac{1}{2}$ in.) above the sternum. The trachea is also smaller, deeper, and less steadied by muscles. The thymus, too, in young children, may prove a difficulty. Thus, in children, the high operation, incising the cricoid and crico-tracheal membrane, if needful, is to be preferred. The cricoid is, however, not to be incised, if possible; the higher the tube is inserted, the greater the irritation.

The suprasternal notch, between the sternal heads of the sterno-mastoids in on a level with the disc between the second and third thoracic vertebræ. Just below the level of the cricoid cartilage, on deep pressure at the anterior border of the sterno-mastoid the transverse process of the sixth cervical vertebra may be felt. It is known as Chassaignac's carotid tubercle, and the common carotid may be compressed against it. Compression below it will command the vertebral artery as well.

The **thyreoid gland** enclosed in a capsule of deep fascia derived from the pre-tracheal layer (fig. 1070) is closely connected by this to the upper trachea and larynx. The upper somewhat pointed extremity of each lateral lobe reaches to the upper and back part of the thyreoid cartilage; here enter the superior thyreoid vessels. The lower layer and rounded extremity reaches to the fifth or sixth tracheal ring; its posterior and lower aspect is in relation to the inferior thyreoid vessels and the recurrent nerve; the lateral lobe, posteriorly, also overlaps the carotid sheath, which may be infiltrated in malignant disease of the thyreoid. The thyreoidea ima has been mentioned above.

The isthmus in the adult is opposite to the second, third, and fourth tracheal rings. At its upper border is an arterial arch formed by the superior thyreoids; over the anterior surface of the gland and isthmus the inferior thyreoid veins take origin in a plexus. The upper border of the thymus (fig. 1100) may be in relation with the lower border of the isthmus. From the upper border of the latter, the pyramidal lobe, especially on the left side, is often present, reaching by a pedicle to the hyoid. The pyramidal lobe, when present, is the persistent remnant of the thyreo-glossal duct, and occasionally cystic outgrowths persist obstinately as remnants of this duct, in the middle line, above, behind, and below (the commonest form) the hyoid bone.

In short-necked people the thyreoid is relatively lower in relation to the sternum, and enlargements of the gland are apt to become mainly intra-thoracic. An enlargement of the thyreoid is liable to give trouble by pressure on (1) the trachea, which is compressed laterally between the lateral lobes; (2) the œsophagus; (3) the internal jugular vein and carotid artery; (4) the recurrent laryngeal or cervical sympathetic nerves.

Parathyreoids.—These small glands, about the size of a pea, vary somewhat in number and situation. There are usually four—two behind each lateral lobe. The upper glands lie imbedded in the capsule of the thyreoid about the junction of the middle and upper thirds of the lateral lobes on the posterior aspect. The lower pair lie nearer the lower poles of the lateral lobes, sometimes separated from them by a distinct interval. Excision of all the parathyreoids gives rise to tetany in animals.

The **sterno-mastoid** is the landmark for several important operations. Its medial border, the thicker and better marked of the two, overlaps the carotids;

the common carotid corresponding, as far as the upper border of the thyreoid, with a line drawn from the sterno-clavicular joint to midway between the mastoid process and the angle of the jaw. The artery can be best compressed above the level of the cricoid, as here it is less deeply covered. The student should recall the deep relations of the sterno-mastoid, which he may classify as vessels, nerves, muscles, glands, and bones; or, according to their position, (1) those above the level of the angle of the jaw; (2) those between the angle of the jaw and the omo-hyoid; (3) those below the omo-hyoid.

Of the two heads of the sterno-mastoid, the sternal is the thicker and more prominent, the clavicular the wider. A stab through the interval which lies between the two heads might wound the bifurcation of the innominate on the right side, and the common carotid on the left, the internal jugular, vagus, and phrenic veins, according to the direction of the wound.

FIG. 1100.—THYMUS GLAND IN A CHILD AT BIRTH.

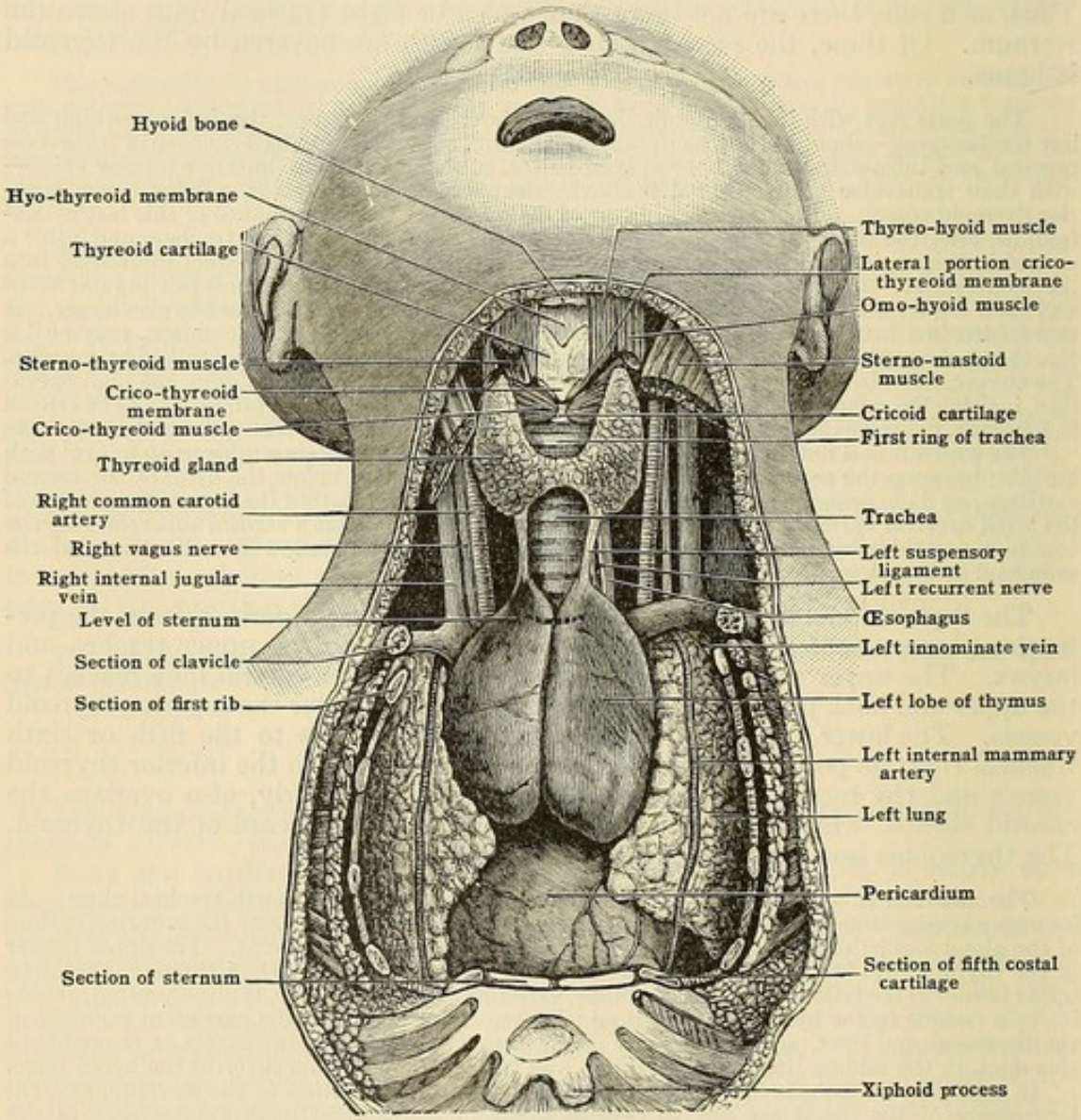

The **anterior jugular,** commencing in branches from the submaxillary and submental regions, descends at first in the superficial fascia between the middle line and anterior border of sterno-mastoid, perforates the deep fascia just above the clavicle, here entering Burns's space (p. 1361); it then curves laterally to pass beneath both origins of the sterno-mastoid a little above the clavicle, to end usually in the external jugular.

When distended, a large communicating branch between it and the common facial, which runs along the anterior border of the sterno-mastoid, must always be remembered in operations for removal of glands, etc. The varying level at which the external jugular crosses the lateral

border of the clavicular origin must be remembered in such operations as tenotomy here. These veins vary in size inversely to each other; the anterior jugulars are joined by numerous transvesre branches and become larger below. They have no valves.

Of the chief arteries to the sterno-mastoid, that from the superior thyreoid will be divided in gature of the common carotid; that from the occipital runs with the spinal accessory nerve.

Behind the sterno-clavicular joint lies the commencement of the innominate veins, the bifurcation of the innominate artery on the right, and the common carotid artery on the left; deeper still lie the pleura and lung.

The clavicle.—This bone can be felt beneath the skin in its whole length. It forms the only bony connection between the upper limbs and the trunk. As one traces it laterally toward the acromial end, it rises somewhat, particularly in children and in subjects of good muscular development. The skin over it is thin but very mobile, and consequently is not often wounded. The most important posterior relations of this bone are, passing from the medial end laterally, the subclavian vein, the subclavian artery, and the cords of the brachial plexus as they lie on the first rib.

FIG. 1101.—ANTERIOR AND LATERAL CERVICAL MUSCLES.

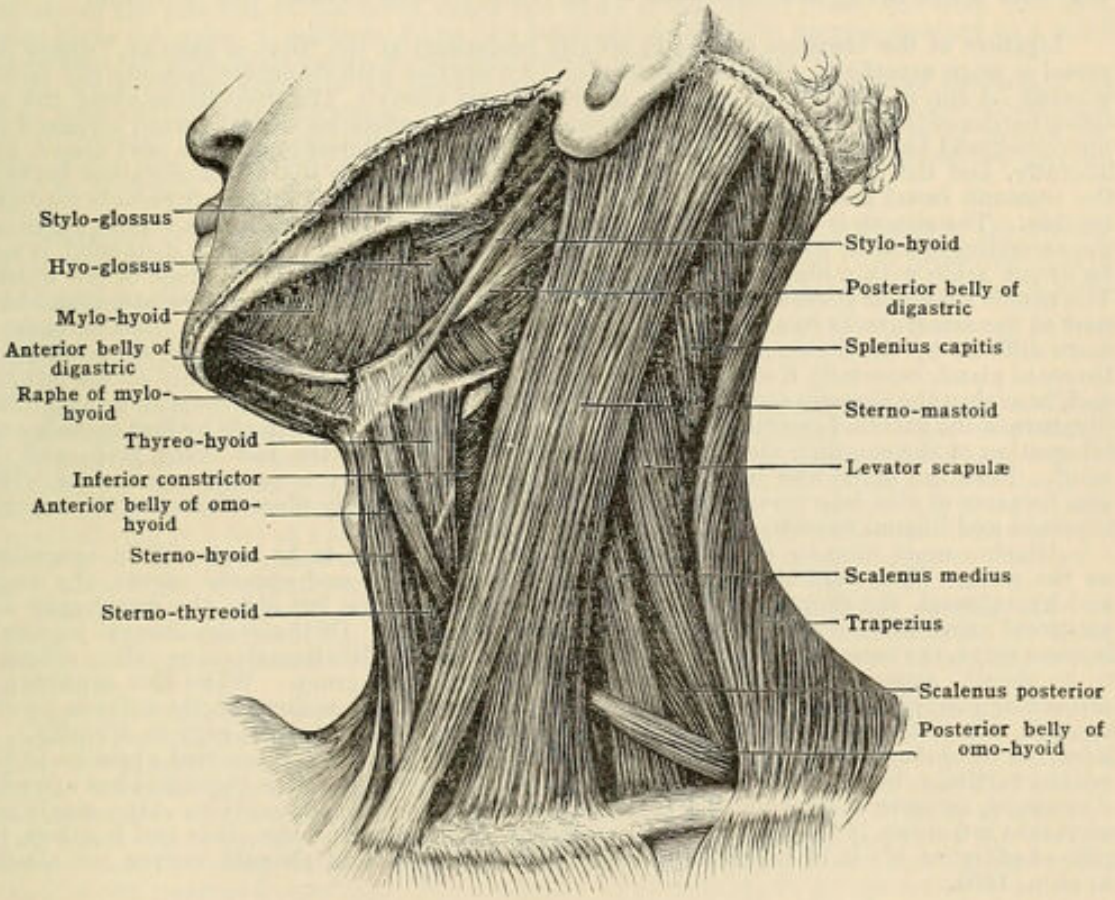

The vein occupies the angle between the first rib and the clavicle, and hence is, as a rule, the first structure compressed in growths of this bone. The artery lies on a deeper plane behind the mid-point of the clavicle, and the nerve cords extend a little further laterally. The subclavius muscle forms a protective cushion between the bone and these important structures, and this accounts for the rarity of injury to them in fracture of the clavicle. Behind the medial half of the clavicle the apex of the lung extends upward into the neck to a height of 2.5–3.7 cm. (1–1½ in.), and consequently is liable to be wounded by a stab in the root of the neck.

Cervical triangles.—In front of the sterno-mastoid is the **anterior triangle,** which is **subdivided into three smaller triangles** by the digastric muscle above, and the anterior belly of the omo-hyoid below (fig. 1101). These smaller triangles are called, from above, the submaxillary, the superior and inferior carotid triangles.

The **submaxillary** or **digastric triangle** is bounded above by the jaw, and a line drawn back to the mastoid process; below, by the digastric and stylo-hyoid muscles; and in front by the middle line of the neck.

This space contains the submaxillary gland, and embedded in the gland is the external maxillary artery, the facial vein lying superficial to the gland; deeper than the gland are the submental vessels and the mylo-hyoid vessels and nerve. Posteriorly, and separated from the above structures by the stylo-mandibular ligament, which subdivides the triangle into a submaxillary and parotid part, is the upper part of the external carotid artery running up into the parotid gland, where it gives off its two terminal and the posterior auricular branches. More deeply lie the internal jugular vein, internal carotid artery, and the vagus. The floor of the triangle is formed by the mylo-hyoid, hyo-glossus, and superior constrictor. The lingual artery may be tied here, or, better, in order to get behind the dorsalis linguæ, close to its origin, by an incision similar to that for exposing the external carotid.

The **hypoglossal** is a guide to the carotids and the occipital artery at the lower border of the digastric, and farther forward, to the subjacent lingual, from which it is separated by the hyo-glossus.

The **superior carotid triangle** is bounded above by the digastric, below by the omo-hyoid, and behind by the sterno-mastoid. It contains the upper part of the common carotid and its branches, the external being at first somewhat anterior to the internal. All the branches of the external carotid, save the three just given, are found in this space, together with their veins, the internal jugular vein, the vagus and sympathetic nerves, and, for a short distance, the accessory, together with those nerves which lie in front of and behind the carotids.

Ligature of the common carotid is usually performed at the 'seat of election,' where the vessel is more superficial, *above the omo-hyoid*. An incision with its centre opposite the cricoid is made 7.5 cm. (3 in.) long in the line of the carotid artery. The deep fascia along the anterior border of the sterno-mastoid having been divided, the cellular tissue beneath is opened up, the omo-hyoid identified and drawn down or divided. The sterno-mastoid is next drawn well laterally, and the artery felt for. At this stage, such veins as the communication between the common facial and the anterior jugular and the superior and middle thyreoids may give trouble. The sheath is next opened well to the medial side, opposite to the cricoid cartilage, the ascending cervical, when seen, being avoided. If the internal jugular be distended, it may be drawn aside with a blunt hook, or pressure made lightly in the upper angle of the wound. The needle should be passed from the lateral side in very close proximity to the lateral and back part of the artery, so as to avoid the vein and vagus. Ligature *below the omo-hyoid* is rendered more difficult by the presence of the anterior jugular, the pretracheal muscles, an overlapping thyreoid gland, especially if enlarged, the greater depth of the artery, especially on the left side and, here also, the closeness of the internal jugular. The *collateral circulation* is given at p. 1360. Ligature of the external carotid, otherwise difficult, is rendered very simple by first exposing the bifurcation of the common carotid artery, the incision similar to the last being prolonged upward. Here the facial and lingual veins and hypoglossal nerve cross the trunk, over which also lie some of the deep cervical glands. The ligature is usually placed between the superior thyreoid and lingual branches.

Allusion must here be made to **the chief structures liable to be met with in operations on the neck.** These are the **internal jugular,** the **accessory,** and **phrenic** nerves, the **vagus** and **hypoglossal,** the **thoracic duct,** low down and deep on the left side, the **œsophagus** and **recurrent nerve** in difficult operations on the thyreoid gland. Of these, the **internal jugular** is, in some ways, the most important. Glands, tuberculous or epitheliomatous, are often adherent to its sheath, especially those which drain the submaxillary group. When this condition is present or suspected, it is always well to begin the dissection low down in the inferior carotid triangle, where the structures are probably normal and the landmarks easy to identify. In infective thrombosis of the transverse sinus the internal jugular is often tied opposite to the cricoid cartilage, being either divided between two ligatures, or, if the thrombus has extended downward, as much of the vein as is possible is removed. This vein contains only a single pair of valves low down in the neck. In all operations here on it and the other two jugulars, the risk of entry of air is to be remembered. The **accessory** and **phrenic nerves** are alluded to on p. 1360.

The **inferior carotid** or **tracheal triangle** is bounded above by the omo-hyoid, behind by the sterno-mastoid, and in front by the middle line of the neck. It contains the lower part of the carotid sheath and its contents, with, behind it, the inferior laryngeal nerve and inferior thyreoid vessels, and to the medial side the trachea, thyreoid gland, and œsophagus. More deeply are the vertebral vessels; on the left side is the thoracic duct.

The position of the **branches of the external carotid** should be remembered. The great cornu of the hyoid and the ala of the thyreoid are landmarks for the origin of most of them.

The **superior thyreoid,** arising just below the level of the great cornu of the hyoid bone, passes downward and forward to the back part of the thyreoid cartilage and upper part of the thyreoid body. Many of its branches are important in surgery. The **superior laryngeal** perforates the thyreo-hyoid membrane. The **sterno-mastoid** passes laterally into the middle of the muscle, across the carotid sheath. The **crico-thyreoid** crosses the space of the same name just below the lower border of the thyreoid cartilage. The small **hyoid** branch runs to the lower

border of the hyoid bone. Anastomosing branches of the superior thyreoid form an arch along the upper border of the isthmus. The **lingual** artery arises from the parent trunk, opposite the tip of the great cornu of the hyoid, and passes forward just above the great cornu, crossed by the hypoglossal, and thence to the side of the tongue. In the first part of its course, before it reaches the hyo-glossus, it is curved, at first ascending, and then, having descended slightly, before it reaches the hyo-glossus, and while it lies under it, its curve is gentle, with the concavity upward; beyond the hyo-glossus, as it lies on the muscles of the tongue beneath the mucous membrane, it is tortuous. The **lingual vein,** it will be remembered, does not run with its artery, but lies superficial to the hyo-glossus. It receives the two small venæ comitantes which run with the lingual itself just before it crosses the common carotid. The line of the **external maxillary (facial) artery** (fig. 1093), which often arises with the lingual, has been given on p. 1343. The **occipital artery,** starting on the same level as the facial (i. e., at a point a little above and outside the tip of the great cornu of the hyoid bone), follows a line drawn upward and laterally, first to the interval between the transverse process of the atlas and the mastoid process, the former bone being felt just below and in front of the tip of the latter; thence, lying in the occipital groove of the mastoid, the artery ascends gradually, enters the scalp, together with the great occipital nerve, a little medial to a point midway between the external occipital protuberance and the mastoid process, to follow, tortuously and superficial to the aponeurosis, the line of the lambdoid suture.

The surface marking of the **digastric** and **omo-hyoid,** which subdivide the anterior triangle into the three smaller subtriangles above described, should be noted. The line of the **posterior belly of the digastric** corresponds to one drawn from the apex of the mastoid process to a point just above the junction of the great cornu and body of the hyoid bone; and from this spot, which gives the point of meeting of the two tendons, one slightly curving upward to a point just behind the symphysis menti, would give that of the **anterior belly.**

To trace the **omo-hyoid,** a line should be drawn from the lower margin of the side of the hyoid bone obliquely downward, so as to cross the common carotid opposite the cricoid cartilage and thence curving laterally under the sterno-mastoid at the junction of its middle and lower thirds, and then onward and still laterally parallel with and a little above the clavicle, as far as its centre.

Posterior triangle.—This shows in its lower part a wide depression, the supra-clavicular fossa. Here the brachial plexus may be felt, and, by pressure downward and backward immediately behind the clavicle, just lateral to and behind the lateral margin of the sterno-mastoid, the pulsation of the subclavian artery can be stopped against the first rib.

The supra-clavicular fossa should be opened out by depressing the arm, and parts relaxed by carrying the shoulder forward and turning the head to the same side. This vessel curves upward and laterally from behind the sterno-clavicular joint to disappear behind the centre of the clavicle, the highest point of the curve being 1.2 to 2.5 cm. (½ to 1 in.) above the bone. The artery on the left side lies more deeply than the right, and does not rise so high into the neck. The subclavian vein lies at a lower level, separated by the scalenus anterior, and under cover of the clavicle. Into the above curve rise the pleura and lung. The pleura must be expected to rise 2.5 cm. (1 in.) above the clavicle, behind the clavicular head of the sterno-mastoid.

The **transverse scapular** and **transverse cervical vessels** run laterally, parallel with the clavicle. The former lies behind the bone and subclavius; the latter also runs laterally in a transverse direction, across the root of the neck, but on a slightly higher plane, and thus a little above the clavicle.

Ligature of the third part of the subclavian is best performed by an angular incision, the horizontal portion along the centre of the clavicle, and the vertical one along the posterior border of the sterno-mastoid, with partial division of this and the trapezius when closely adjacent. The chief points to bear in mind are the venous plexus into which the external jugular, transverse cervical, transverse scapular, and cephalic veins enter; the omo-hyoid and division of the fascia which ties this to the clavicle; identification of the lateral margin of the scalenus anterior and the scalene tubercle; care of the transverse scapular artery and the descending branch of the transverse cervical. The needle is passed from above downward so as not to include the lowest cord of the brachial plexus, the vein, if distended, being depressed with a blunt hook. If the nerve to the subclavius be seen, it must be uninjured, as it occasionally forms an important part of the phrenic. The *collateral circulation* is given at p. 1360.

Crossing the sterno-mastoid, a little obliquely, in a line drawn from a point just below and behind the angle of the jaw which marks its origin in the union of the posterior part of the internal maxillary and the posterior auricular veins to the centre of the clavicle, runs the **external jugular vein.** Above, it lies between the platysma and deep fascia, and is accompanied by the group of superficial cervical nodes (p. 709). About 3.7 cm. (1½ in.) above the clavicle it perforates the deep cervical fascia, its coats being blended with the opening. Gentle pressure with a finger at this point renders the vein above clearly visible. The dilated part between this point and the subclavian vein is called the sinus, and is marked by two valves, neither of which is usually perfect.

Opening into the external jugular, in the middle or lower third of its course, is the **posterior external jugular,** a vessel which begins in the occipital region superficially and runs down in front of the anterior border of the trapezius, across the posterior triangle.

The **accessory** nerve, having crossed the transverse process of the atlas at a point lying a little below and in front of the apex of the mastoid, enters the anterior border of the sterno-mastoid at about the junction of the upper and middle thirds of the muscle. Having traversed the muscle obliquely, it leaves it usually at a point a little lower down, pursues a similar course across the posterior triangle and disappears under the anterior border of the trapezius, to enter into the subtrapezial plexus with the third and fourth cervical nerves.

Above it is accompanied by a branch from the occipital, below by the transverse cervical artery. It is always seen in thorough operations on the upper deep cervical glands. The nerve is resected in spasmodic torticollis, and in recent years inveterate facial paralysis has been treated by anastomosing the facial to this nerve or the hypoglossal. A line drawn from midway between the tip of the mastoid and the angle of the mandible along the above given course of the nerve would denote its position.

Just above the centre of the sterno-mastoid, the **small occipital, great auricular,** and **cutaneous cervical nerves** emerge, the first passing upward and backward to the scalp, the second upward and forward across the upper part of the sterno-mastoid to the ear, and the last turning straight forward to the front of the neck. The small occipital and great auricular are often in intimate association with the accessory at its exit from the muscle. At this point also care must be taken not to injure the nerve in removal of glands from the posterior triangle.

The **phrenic nerve,** taking its largest root from the fourth cervical, would begin deeply about the level of the hyoid bone; thence descending under the sterno-mastoid, and, passing obliquely medially across the scalenus anterior (the posterior borders of the above two muscles roughly correspond to each other in the lower part of the neck), it descends under the subclavian vein and clavicle to enter the thorax.

When the internal jugular is distended, its lateral border will be liable to overlap this nerve. The relations of the *scalenus anterior* should be noted here. In addition to the phrenic, which runs with a slight obliquity medially and is in close contact with the muscle, the following structures cross it medio-laterally: the subclavian vein and termination of the external jugular, the transverse scapular and transverse cervical vessels, and the omo-hyoid. At its medial margin are the thyreo-cervical trunk and vertebral arteries, and over them, the internal jugular. Behind it are the subclavian artery, the brachial plexus, and pleura.

The level of the **brachial plexus** (upper border) would be given by a line drawn from the cricoid cartilage to the centre of the clavicle. The lowest, medial cord (eighth cervical and first thoracic, giving off chiefly the ulnar, medial head of median, and medial antibrachial cutaneous) is just above and behind the subclavian artery. Its importance in ligature of the artery has been referred to (p. 1359).

In paralysis of the newly born, after some violent manipulation, it is usually the upper and lateral cord (fifth nerve, and axillary and median chiefly) which suffers, elevation and abduction at the shoulder and flexion at the elbow-joint being lost.

Collateral circulation after ligature of the common carotid (fig. 1102).—This takes place by means of (1) the free communication which exists between the opposite carotids, both without and within the cranium; and (2) by enlargement of the branches of the subclavian artery on the same side as that on which the carotid has been tied. Thus, outside the cranium, the superior and inferior thyreoids are the chief vessels employed (fig. 1102). Within the cranium the vertebral replaces the internal carotid.

Collateral circulation after ligature of the second and third parts of the subclavian (fig. 1102).—Here the following three sets of vessels are those chiefly employed:—

The transverse scapular, the transverse cervical,	with	The thoraco-acromial, infra- and subscapular, and circumflex scapular.
The superior intercostal, the aortic intercostals, and the internal mammary,	with	The lateral thoracic and subscapular arteries.
Numerous unnamed branches passing through the axilla from branches of the subclavian,	with	Branches of the axillary.

Deep cervical fascia.—The arrangement of this must be remembered—(*a*) above, and (*b*) below, the hyoid bone. The latter is far more important.

(*a*) **Arrangement above the hyoid bone.**—Here two chief processes can be made out:—(i) one, continuous with that in front of the sterno-mastoid, traced upward from the hyoid bone, encloses the submaxillary gland, passing over the mylo-hyoid, and, ascending, is connected with the lower border of the mandible, gives off the masseteric and parotid fasciæ, and is attached to the lower border of the zygoma, and, more posteriorly, to the mastoid and linea nuchæ suprema. (ii) A special process, which forms the stylo-mandibular ligament, is important in its power of checking over-action of the external pterygoid. By both these processes the anterior border of the sterno-mastoid is tied firmly forward to the mandible about its angle, and more deeply to the styloid process. This renders all operations under the upper part of the muscle, e. g., the removal of glands, extremely difficult.

(*b*) **Below the hyoid bone.**—The importance of the fascia here is infinitely greater. **Four layers** must be remembered; (i) **Superficial;** (ii) **pretracheal;** (iii) **prevertebral;** (iv) **carotid.** (i) **Superficial.** This starts from the ligamentum nuchæ, encases the trapezius, forms the roof of the posterior triangle where it is perforated by branches of the superficial cervical nerves and the external jugular

FIG. 1102.—THE COLLATERAL CIRCULATION AFTER LIGATURE OF THE COMMON CAROTID AND SUBCLAVIAN ARTERIES.

(A ligature is placed on the common carotid and on the third portion of the subclavian artery.)

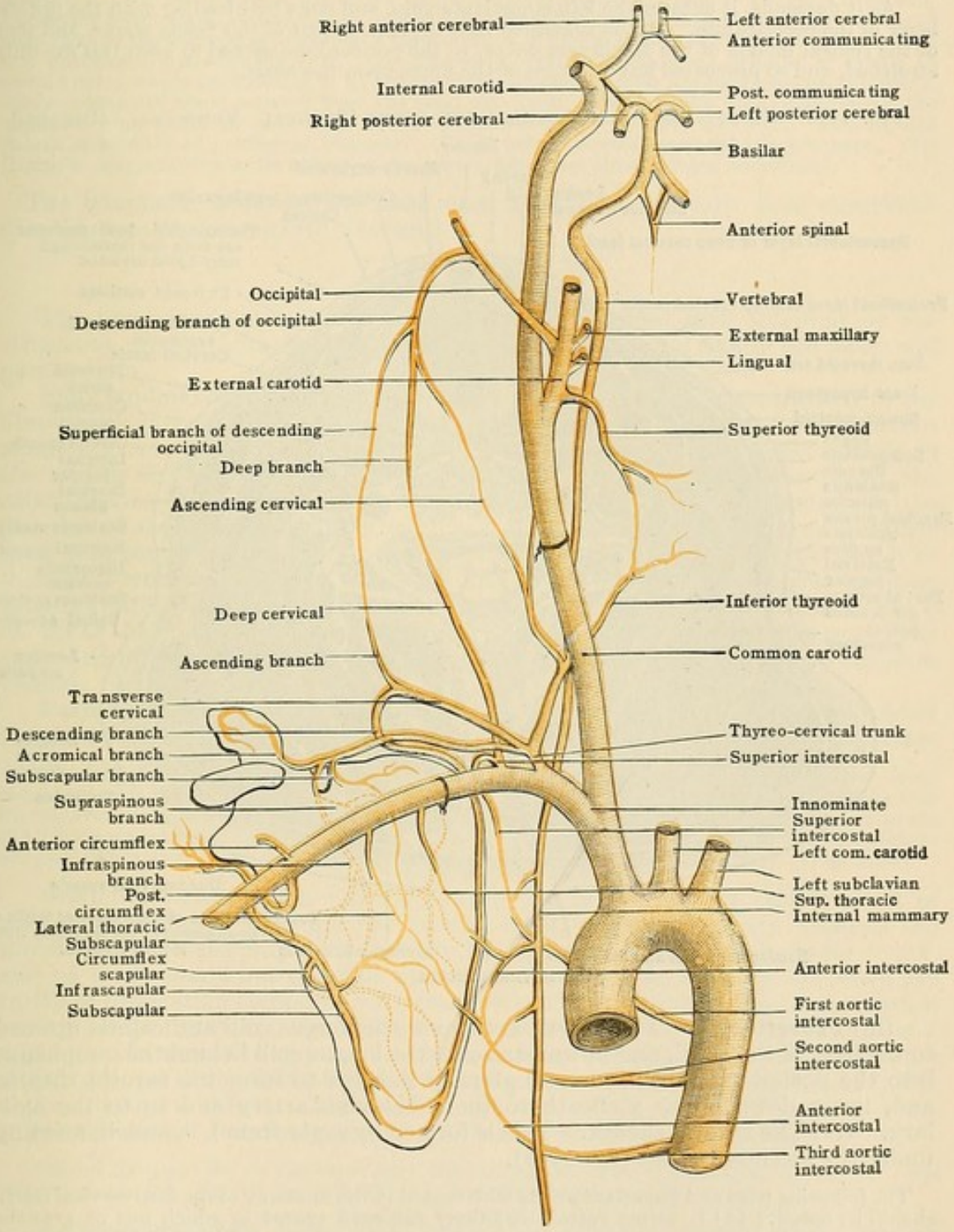

vein. Passing on it encloses the sterno-mastoid; and, passing over the anterior triangle, it meets its fellow in the middle line.

Thin behind, it is thickened anteriorly. Behind this thickened union lie the anterior jugular veins. Below, at a varying distance below the thyreoid cartilage, this layer divides into two, attached to the front and back of the manubrium. Between these (**Burns's space**)

lie some fat, a small gland, a communicating branch between the anterior jugulars and a small portion of the veins, and the sternal heads of the sterno-mastoids. The sheath to the depressors of the hyoid bone is partly derived from this layer, partly from the next. Laterally, this layer gives a sheath to the posterior belly of the omo-hyoid, is attached to the clavicle, and passing on, is continuous with the sheath to the subclavius and coraco-clavicular fascia.

(ii) **Pretracheal or middle.** This lies under the depressors of the hyoid, over the trachea, also encasing the thyreoid gland. Farther laterally it helps, together with the prevertebral, to form the carotid sheath. Traced downward, the pretracheal layer passes over the trachea into the thorax (middle mediastinum)

As it descends, it encases the left innominate vein, and ends by blending with the fibrous layer of the pericardium. Hilton suggested that the attachment of this fascia above, and that of the central tendon of the diaphragm below, to the pericardium served to keep this sac duly stretched, and so prevented any pressure of the lungs upon the heart.

FIG. 1103.—SECTION OF NECK THROUGH THE SIXTH CERVICAL VERTEBRA. (Braune.)

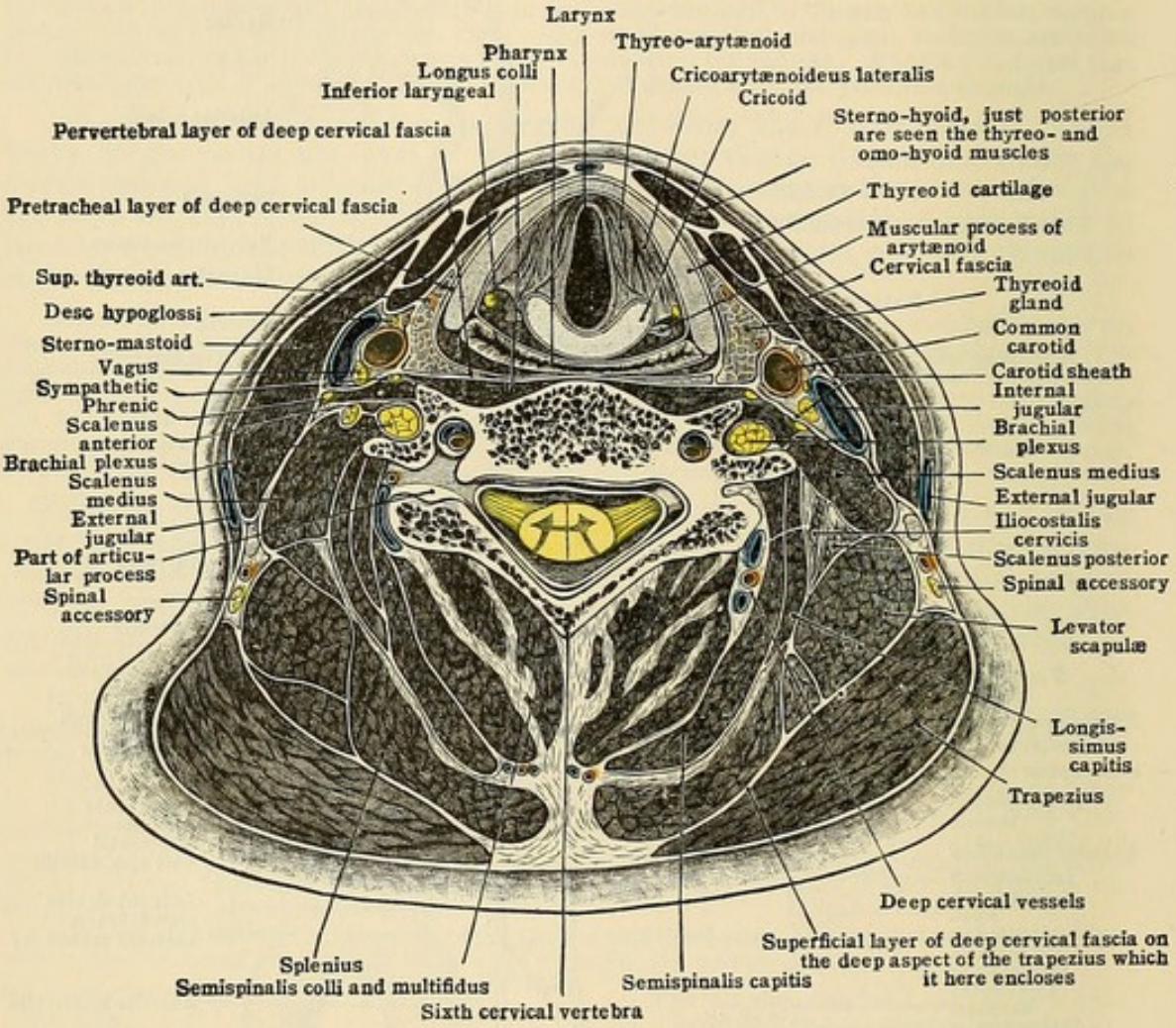

(iii) **Prevertebral.** This layer passes over the longus colli and capitis upward to the base of the skull, and downward over the longus colli behind the œsophagus into the posterior mediastinum. Laterally it helps to form the carotid sheath, and, lower down, gives a sheath to the subclavian artery and so to the axillary. (iv) **The carotid sheath.** This is formed by septa from i, ii, and iii, meeting under the sterno-mastoid (fig. 1103).

The following **uses** and **important points** with regard to the anatomy of the deep cervical fascia should be noted:—(A) It **forms certain definitely enclosed spaces** in which pus or growths may form, and by the walls of which these morbid structures may be tied down and thus rendered difficult of diagnosis, while their increasing pressure may embarrass the air-passages, etc. Thus: (1) In the first space, which lies between No. 1 and the skin, the structures met with, the platysma and superficial branches of the cervical plexus, are unimportant. Any abscess here is prone to extend, but superficially. (2) In the second space, between the superficial and middle layers, lies a narrow space containing loose cellular tissue and lymphatic glands. Suppuration here is very common, but usually comes forward. (3) This is the largest and most important of all. From its contents it has been called the **visceral compartment.** (Stiles.)

It is bounded in front by the middle, and behind by the prevertebral layer. Its contents are—larynx, trachea, œsophagus, thyreoid, carotid sheath, glands; and below, brachial plexus, subclavian artery, and abundant loose cellular tissue for the movements of the neck. Suppuration is somewhat rarer here; but either pus or growths, if confined in this space, may have baneful effects, from pressure, or from their tendency to travel behind the sternum. (4) This space between the prevertebral layer in front and muscles behind, is very limited. Retropharyngeal abscess forms here, and the dyspnœa it causes is thus explained. The origin of such abscesses is chiefly twofold, either in one of the highest deep cervical nodes, e. g., from infection of the naso-pharynx (p. 717), or from disease of the upper cervical vertebræ. In the former cases (Stiles, Chiene) the suppuration will be *in front* of the prevertebral fascia, pointing toward the pharynx; in the latter *behind* the above fascia, spreading laterally, behind the carotid sheath. In making his incision, now along the posterior border of the sterno-mastoid, the surgeon should keep close to the transverse processes of the vertebræ, to avoid opening the visceral compartment and infecting the structures in it. (B) The deep cervical fascia gives **sheaths** or **canals** to certain veins which perforate it, e. g., the external jugular. These are thus kept patent, and a ready passage of blood ensured from the head and neck. Further, this fact accounts for the readiness with which air may enter veins, in operations low down in the neck. The carotid sheath is another and different instance. (C) It **helps to resist atmospheric pressure.** (D) Hilton's suggestion as to **its action on the pericardium** has already been mentioned.

The lymphatic nodes of the head and neck have already been described. (See Section VI, LYMPHATIC SYSTEM.)

THE THORAX

The bony landmarks of the thorax will be discussed first, followed by the structures of the thoracic wall, the lungs and pleura, and finally the heart and pericardium.

Bony landmarks.—The top of the sternum corresponds (in inspiration) to the fibro-cartilage between the second and third thoracic vertebræ, and is distant about 6.2 cm. (2½ in.) from the spine. In the newborn child it corresponds to the middle of the first thoracic vertebra (Symington). If traced downward, the subcutaneous sternum presents a ridge (sternal angle of Louis) opposite to the junction of the manubrium and body, and the second costal cartilages on either side; this ridge usually corresponds to the disc between the fourth and fifth thoracic vertebræ. At the lower extremity of the sternum the xiphoid cartilage usually retires from the surface, presenting the depression of the epigastric angle or 'pit of the stomach.' This is opposite to the seventh costal cartilages and the expanded upper end of the recti, and corresponds to the tenth thoracic vertebra behind.

Parts behind manubrium.—There is little or no lung behind the first bone of the sternum, the space being occupied by the trachea and large vessels, as follows;

The left innominate vein crosses behind the sternum just below its upper border. Next come the great primary branches of the aortic arch. Deeper still is the trachea, dividing into its two bronchi opposite to the junction of the first and second bones of the sternum. Deepest of all is the œsophagus. About 2.5 cm. (1 in.) below the upper border of the sternum is the highest part of the aortic arch, lying on the bifurcation of the trachea. (Holden.) (Fig. 1104).

Sterno-clavicular joint.—The expanded end of the clavicle and the lack of proportion between this and the sternal facet, on which largely depends the mobility of this, the only joint that ties the upper extremity closely to the trunk, can be easily made out through the skin. Its strength, considerable when the rarity of dislocation compared with fracture of the clavicle is considered, depends mainly on its ligaments, the buffer-bond meniscus, the costo-clavicular ligament, which checks excessive upward and backward movements, and the fact that the elastic support of the first rib comes into play in strong depression of the shoulder as in carrying a weight. The relative weakness of the anterior ligament determines the greater frequency of anterior dislocation of the clavicle at this joint.

Behind the joint lie, on the right side, the innominate artery, right innominate vein, and pleura; on the left, the left innominate vein, the left carotid, and the pleura.

Acromio-clavicular joint.—On tracing the clavicle laterally, it is found to rise somewhat to its articulation with the acromion. This joint has very little mobility, and owes its protection to the strong conoid and trapezoid ligaments hard by. Owing to the way in which the joint-surfaces are bevelled, that of the clavicle looking obliquely downward, and resting upon the acromion, it is an upward displacement of the clavicle which usually takes place.

Ribs.—In counting these, the position of the second is denoted by the trans-

verse line at the junction of the manubrium and body of the sternum. It is well always to count ribs from this point and never from below, as the twelfth rib varies in size and may be obscured by the sacro-spinalis muscles. The *nipple* in the male, lies between the fourth and fifth, nearly an inch lateral to their cartilages. The lower border of the great pectoral corresponds to the fifth rib. The seventh, the longest of the ribs, is the last to articulate by its cartilage with the sternum. When the arm is raised, the first three digitations seen of the serratus anterior correspond to the fifth, sixth, and seventh ribs. The ninth rib

FIG. 1104.—THE ARCH OF THE AORTA, WITH THE PULMONARY ARTERY AND CHIEF BRANCHES OF THE AORTA.

(Modified from a dissection in St. Bartholomew's Hospital Museum.)

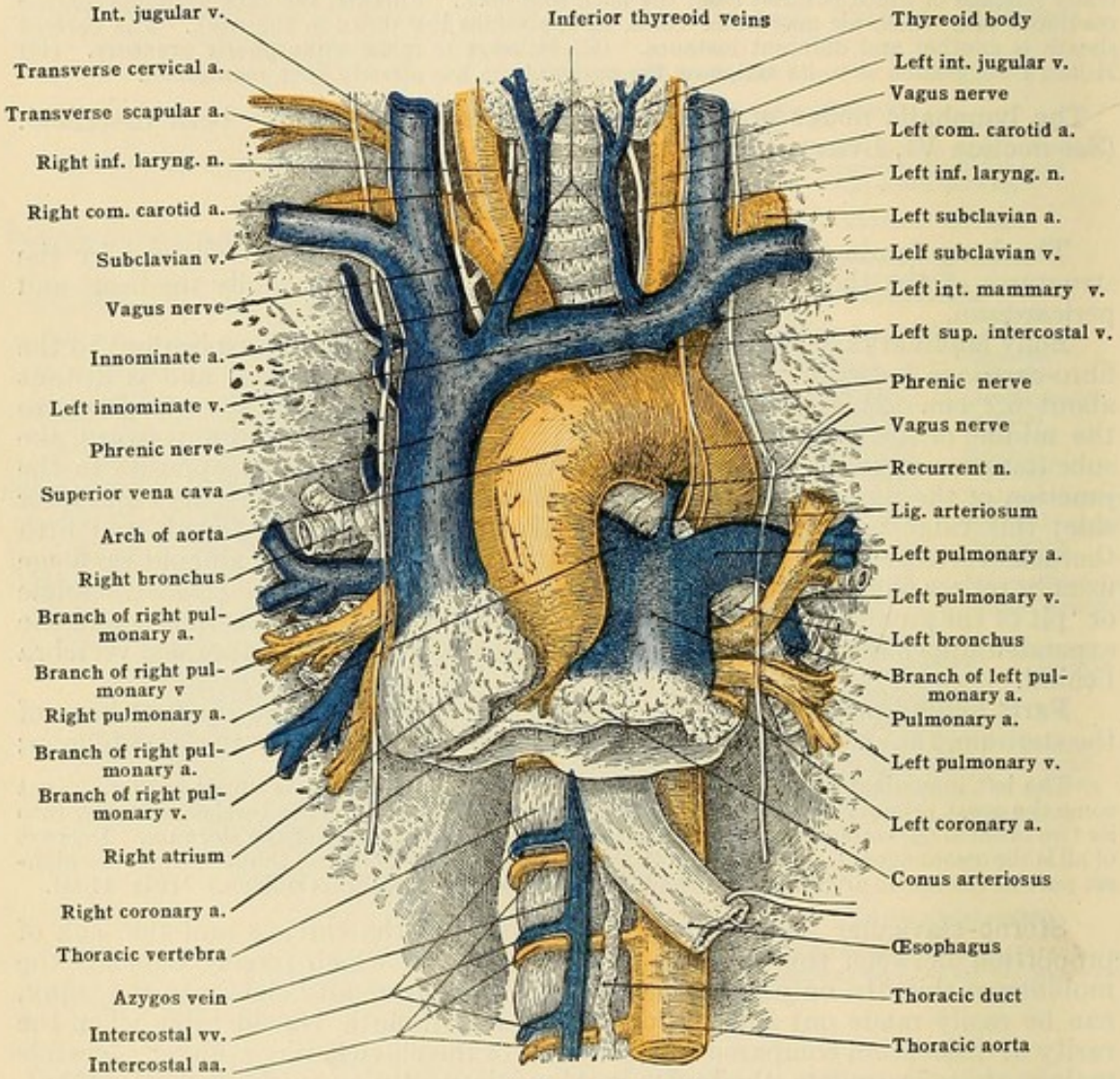

is the most oblique. The eleventh and twelfth can be felt lateral to the sacro-spinalis. Owing to the obliquity of the ribs, their sternal ends are on a much lower level than their vertebral extremities.

'Thus the first rib in front corresponds to the fourth rib behind, the second to the sixth, the third to the seventh, the fourth to the eighth, the fifth to the ninth, the sixth to the tenth, and the seventh to the eleventh. If a horizontal line be drawn round the body from before backward at the level of the inferior angle of the scapula, while the arms are at the sides, the line would cut the sternum in front between the fourth and fifth ribs, the fifth rib at the nipple line, and the ninth rib at the vertebral column.' (Treves.) The most frequently broken are the sixth, seventh, and eighth. The upper four and the two lowest ribs are best covered by soft parts, and, in the case of the former, the shoulder and arm take off some of the violence that would otherwise reach them. The way in which the ribs are embedded in the soft parts (fig. 1106), and the fact that the fragments are often held in place by the periosteum, account for the difficulty which is often met with in detecting crepitus. The intercostal spaces are wider in front than behind. The three upper are the widest of all.

Cervical ribs.—It occasionally happens that the rib element of the seventh cervical vertebra, normally fused with the true transverse process, is segmented off as a separate, though usually rudimentary, rib. This anomaly is generally bilateral. It occurred in 3 of 260 subjects (1.16 per cent.) examined by Wingate Todd.*

The anterior extremity of a cervical rib may, according to the degree of its development (1) lie free amongst the scalene muscles; (2) be connected with the sternum by a ligamentous prolongation; (3) articulate with the upper surface of the first thoracic at about its centre by a synchondrosis, or (4) form a complete rib, articulating by a costal cartilage with the sternum.

The lowest trunk of the brachial plexus formed by the eighth cervical and first thoracic roots, the subclavian artery and less commonly the subclavian vein, curve over the upper surface of these ribs. The abnormality owes its clinical importance to the pressure effects produced on the nerve trunk in a small proportion of the cases. This pressure is manifested by (1) pain, going on to anæsthesia down the medial side of arm, forearm and hand; (2) paralysis of the intrinsic muscles of the hand, producing the *main en griffe*, and to a less extent of the muscles of the forearm; (3) vascular effects (anæmia, gangrene, etc.), manifested chiefly in the hand. Todd has shown that these vascular effects are not due to mechanical pressure on the subclavian artery by the cervical rib as was formerly supposed, but are trophic lesions of the sympathetic (vasomotor) nerves. The vasomotor nerves to the arm mainly come from the second thoracic root by the communication it gives to the lowest cord of the brachial plexus, and so are exposed to pressure from the rib.

FIG. 1105.—CERVICAL RIBS, VIEWED FROM ABOVE. (× ½.) NN, IMPRESSION FOR LOWEST TRUNK OF BRACHIAL PLEXUS. AA, IMPRESSION FOR SUBCLAVIAN ARTERY. (T. WINGATE TODD.)

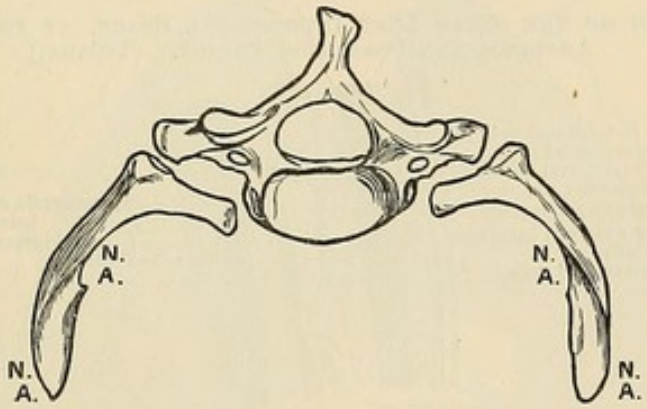

The same investigator has shown that similar symptoms may be produced occasionally by a first thoracic rib in cases where the brachial plexus has migrated caudad. In the living patient, unless a radiogram be taken showing all the vertebræ up to the base of the skull, it is not possible with precision to ascertain with which vertebra the highest rib present articulates.

Structures found in an intercostal space.—(1) Skin; (2) superficial fascia, with cutaneous vessels and nerves; (3) deep fascia; (4) external intercostal; (5) cellular interval between intercostals, containing trunks of intercostal vessels and nerves; (6) internal intercostals; (7) thin layer of fascia; (8) subpleural connective tissue; (9) pleura (fig. 1106).

The intercostal arteries are nine aortic and two from the superior intercostal. An aortic intercostal having given off its dorsal branch, lying beneath the pleura, crosses the space obliquely upward to gain the lower border of the rib above, enters the costal groove at the angle, and runs forward between the intercostal muscles to anastomose with the anterior intercostals from the internal mammary or musculo-phrenic. Hence the rule of making the incision in empyema above the upper margin of the lower rib and in front of the angle. Along the dorsal branch a vertebral abscess may track backward.

Internal mammary artery.—This descends behind the clavicle, the costal cartilages, and the first six spaces, about 1.2 cm. (½ in.) from the edge of the sternum. In the sixth intercostal space it divides into musculo-phrenic and superior epigastric acteries. Its venæ comitantes uniting join the innominate vein of the same side. A punctured wound of the artery is most easily secured in the second and third spaces; below, resection of part of a costal cartilage will be needed.

Structures passing through the upper aperture of the thorax.—If a section is made passing through the manubrium sterni, upper border of the first rib, and

* Journal of Anatomy and Physiology, Vol. 47, 1913.

upper part of the first thoracic vertebra, the following structures are met with:—(1) **In the middle line.** Sterno-hyoid and sterno-thyreoid muscles, with their sheaths of deep cervical fascia, cellular tissue in which are the remains of the thymus gland, the inferior thyreoid veins, the trachea and tracheal fascia, the œsophagus, and longus colli muscles. Between the trachea and œsophagus are the recurrent nerves. (2) **On each side.** The apex of the lung, covered by pleura, deep cervical fascia, and membranous cervical diaphragms ("Sibson's fascia") derived from the scalenes, rises about 3.7 cm. (1½ in.) above the first rib. Between it and the trachea and œsophagus lie the following: the internal mammary artery, the phrenic nerve; on the right side, the innominate vein and artery, with the vagus between the two, the cardiac nerves, and the right lymphatic duct. On the left side are the common carotid and subclavian arteries, with the left vagus between them, the cardiac nerves and the thoracic duct. Farthest back and on each side are the trunk of the sympathetic, the superior intercostal artery, and the first thoracic nerve.

The mamma.—This lies chiefly on the pectoralis major and slightly on the rectus abdominis and serratus anterior. It is usually described as reaching from the second to the sixth rib, and from the sternum to the anterior border of the axilla. It is most important to remember that the breast is often a much more extensive structure than would be included in the above very limited description. Thus—(1) the gland is not encapsuled at its periphery, its tissue branching and breaking up here to become continuous with the superficial fascia. (Stiles.) (2)

FIG. 1106.—SECTION OF THE SIXTH LEFT INTERCOSTAL SPACE, AT THE JUNCTION OF THE ANTERIOR AND POSTERIOR THIRDS. (Tillaux.)

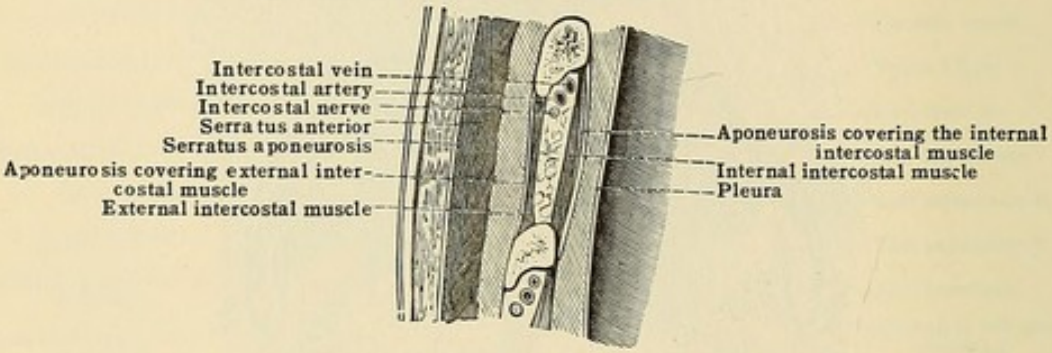

The retinacula cutis contain lymphatics and, sometimes, mammary tissue. (3) There is a lymphatic plexus, and, often, minute lobules of gland tissue, in the pectoral fascia. (Heidenhain.) Fully one-third of the whole mamma lies posterior and lateral to the axillary border of the pectoralis major so that it reaches almost to the mid-axillary line. That part of the upper and lateral quadrant known as the axillary lobe is of especial importance from its reaching into close vicinity with the anterior pectoral group of axillary nodes (p. 719). In the male the nipple is usually placed in the fourth space, nearly 2.5 cm. (1 in.) lateral to the cartilages of the fourth and fifth ribs. On the nipple itself open the fifteen or twenty ducts which dilate beneath it, and then diverge and break up for the supply of the lobules. The skin over the areola is very adherent, pigmented, and fatless. Here also are groups of little swellings corresponding to large sebaceous follicles and areolar glands. The skin over the breast is freely movable, and united to the fascia which encases the organ, and thus to the interlobular connective tissue, by bands of the same structure—the retinacula cutis. Under the breast, and giving it its mobility, is a cellulo-fatty layer, the seat of submammary abscess.

The **nerves** which supply the breast are the anterior cutaneous branches of the second, third, fourth, and fifth intercostal nerves, and the lateral branches of the last three. The connection of these trunks serves to explain the diffusion of the pain often observed in painful affections of the breast. Thus pain may be referred to the side of the chest and back (along the above intercostal trunks), over the scapula, along the medial side of the arm (along the intercosto-brachial nerve), or up into the neck. The gland is supplied by the following **arteries**: the aortic intercostals of the second, third, fourth, and fifth spaces, similar intercostal branches from the internal mammary, which runs outward, two small branches to each space, perforating branches from the same vessel, one or two given off opposite to each space, the long thoracic and external mammary (when present) from the axillary.

The lymphatics have already been described (p. 721, fig. 566).

In removal of the breast elliptical incisions will usually suffice if employed on wide lines, and if attention be paid to the following points:—(1) Those details in the surgical anatomy already referred to, especially those bearing on the extensiveness of this organ, and the proportionate difference between seen and unseen disease. (2) The importance of removing in one continuous piece the whole breast, all the skin over it, the costo-sternal part of the pectoralis major, the pectoralis minor, the axillary fat, and lymphatics.

Outline of the lungs. Their relation to the chest-wall.—To map out the lung, a line should be drawn from the apex, a point about 2.5 cm. (1 in.) above the clavicle, a little lateral to the sterno-mastoid muscle, at the junction of medial and middle thirds of clavicle, obliquely downward, behind the sterno-clavicular joint, to near the centre of the junction of the first and second bones of the sternum. Thence, on each side, a line should be drawn slightly convex as far as a similar point on the sternum lying opposite the articulation of the fourth chondro-sternal joint. On the right side the line may be dropped as low as the sixth chondro-sternal joint; on the left the incisura cardiaca may be shown by drawing a vertical line along the middle line of the sternum, from the level of the medial extremities of the fourth costal cartilages to the lower end of the gladiolus, and

FIG. 1107.—OUTLINE OF THE HEART, ITS VALVES, THE LUNGS (SHADED), AND THE PLEURA. (Holden.) (Cf. fig. 437.)

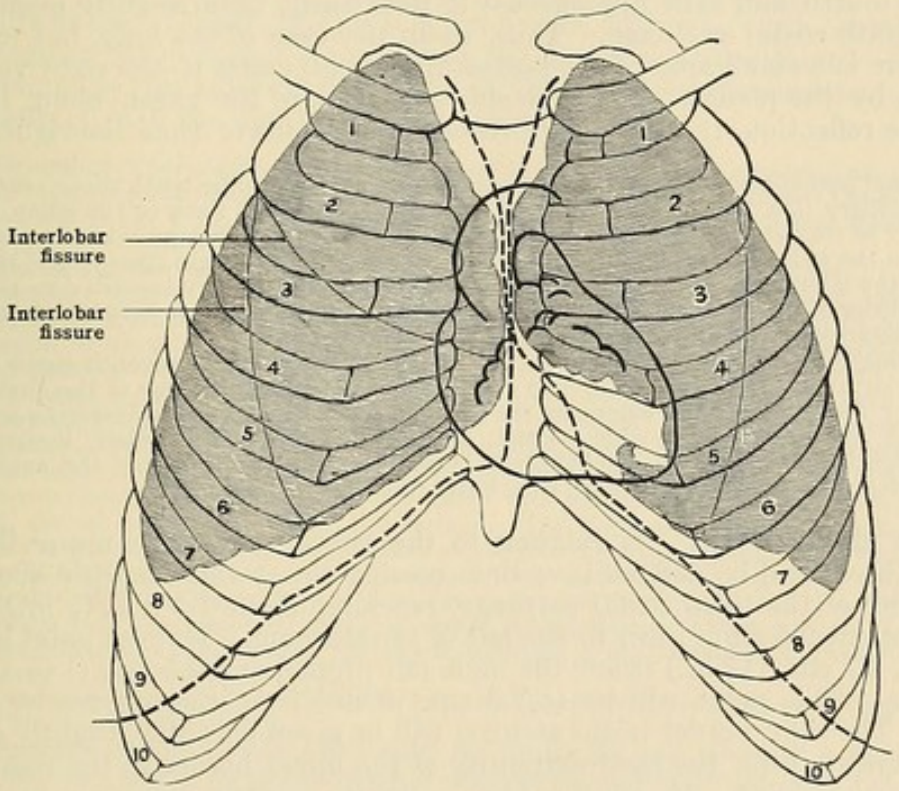

by carrying two other lines, from the extremities of the first line, outward so as to meet at a point over the heart's apex (Cunningham); to mark this gap, a line should be drawn sloping laterally and downward from the fourth chondro-sternal articulation across the fourth and fifth interspaces, to a point about 3.7 cm. ($1\frac{1}{2}$ in.) below the left nipple (male) and 2.5 cm. (1 in.) to its medial side. This point, lying in the fifth space, marks the apex of the heart. Thence the line curves medially to the sixth costal cartilage, a little medial to its chondro-sternal junction, and in the lateral vertical line. Thus the lower part of the anterior surface of the right ventricle is not covered by lung. The lower border of the lung will be marked on the right side by a line drawn from the sixth chondro-sternal articulation across the side of the chest down to the tenth thoracic spine. The lower border of the left lung will follow a similar line, starting on a level with a similar joint (sixth chondro-sternal joint), but much farther laterally than on the right side, i. e., in the fifth space, about 7.5 cm. (3 in.) to the left of the middle line, or a point corresponding to the heart's apex. In the nipple-line the lung crosses the sixth rib, in the mid-axillary line the eighth, and opposite

the angle of the scapula (the arms being close to the sides), the tenth rib. The position of the great fissure in each lung may be ascertained approximately by drawing a line curving downward and forward from the second thoracic spine to the lower border of the lung at the sixth costal cartilage; and the smaller fissure of the right lung extends from the middle of the foregoing to the junction of the fourth costal cartilage with the sternum. It will be seen from the above that there is little lung behind the manubrium. The connective tissue here between the lung margins contains the thymus, large up to the age of puberty, and, later, its remains. The hilus (root) of the lung is referred to on p. 1230.

The **pleura,** following much the same line as the lung above and in front, reaches lower down laterally and behind. Thus the two sacs starting from about 2.5 cm. (1 in.) above the medial third of the clavicle converge toward the angle of Louis (p. 1238); meeting here, they descend vertically, the left overlapping the right slightly, to the fourth chondro-sternal joint. Hence the *right* sac descends behind the sternum to the sterno-xiphoid junction and sixth chondro-sternal joint. Thence, as it curves to the back of the chest, it crosses the eighth rib close to the lateral vertical line (*vide supra*), the tenth in the mid-axillary, the eleventh in the line of the angle of the scapula, and thence toward the twelfth thoracic vertebra. On the *left* side the pleura parts company from the right at the level of the fourth chondro-sternal junction, deviating laterally and downward across the fourth and fifth interspaces; it then turns again slightly medially to meet the sixth costal cartilage. Thus, as in the case of the lung, but to a less extent, there is a small area of the pericardium, and, under it, the right ventricle uncovered by the pleura. Over the side and back of the chest, along its diaphragmatic reflection, the left pleura reaches a little lower than the right.

The *deepest part of the pleural sac* is where the reflection crosses the tenth rib or tenth space in the mid-axillary line. From this it ascends slightly as it curves back to the spine. (Cunningham.) *The relations of the pleura to the last rib* are of much importance to the surgeon in operations on the kidney. In the case of a twelth rib of ordinary length, the pleural reflection crosses it at the lateral border of the sacro-spinalis; when a rudimentary last rib does not reach the lateral border of this muscle, an incision carried upward into the angle between the eleventh rib and the sacro-spinalis will open the pleural sac. (Melsome.)

For **tapping the pleura** there are two chief **sites**:—(1) The sixth or seventh space in front of the posterior fold of the axilla. (2) The eighth space behind, in the line of the angle of the scapula. For **the incision of an empyema** the first is usually chosen. The overlying soft parts are not thick, the interspace is wide enough, drainage is sufficient (especially if part of the seventh or eighth rib be resected), and this site is free from the objection that the angle of the scapula overlaps the seventh and eighth ribs, unless the arm is raised.

Outline of the heart. Its relation to the chest-wall.—The upper limit of the heart (base) will be defined by a line crossing the sternum a little above the upper border of the third costal cartilage, reaching about 1.2 cm. ($\frac{1}{2}$ in.) to the right and about 2.5 cm. (1 in.) to the left of the sternum. Its apex point is in the fifth space, 3.7 cm. ($1\frac{1}{2}$ in.) below the male left nipple, and 2.5 cm. (1 in.) to the medial side. This point will be at 7.5 cm. (3 in.) from the left border of the sternum. The right border (right atrium) will be given by a line, slightly convex laterally, drawn from the right extremity of the upper border to the right sixth chondro-sternal joint. If another line, slightly convex upward, be drawn onward from this point across the last piece of the sternum, just above the xiphoid cartilage, to the apex, it will give the lower border (margo acutus of right ventricle), which rests on the central tendon of the diaphragm. The left border (margo obtusus of left ventricle) will be given by a line, convex to the left, passing from the left extremity of the upper border to the apex, medial to the nipple-line. This line should be 7.5 cm. (3 in.) from the middle of the sternum at the level of the fourth costal cartilage. The base of the heart is opposite four of the thoracic vertebræ, viz., the sixth, seventh, eighth, and ninth. The apex and anterior or costo-sternal surface have been mentioned. The inferior or diaphragmatic surface (chiefly left atrium and left ventricle) rests upon the diaphragm, mainly the central tendon, to which the intervening pericardium is connected, and is thus adjacent to the liver and a small portion of the stomach.

If a circle 5 cm. (2 in.) in diameter be described around a point midway between the left nipple and the lower end of the gladiolus, it will define with sufficient accuracy for practical purposes that part of the heart which lies immediately behind the chest wall, and which is uncovered by lung and (in part) by pleura. (Latham.)

The valves.—The **pulmonary valves** (the highest and most superficial) lie, in front of the aortic, behind the third left chondro-sternal joint, and opposite to the upper border of the third costal cartilage. The **aortic valves** lie behind and a little below these, opposite to the medial end of the third intercostal space, and on a level with the lower border of the third left costal cartilage. The **atrio-ventricular openings** lie at a somewhat lower level than that of the aortic and pulmonary. Thus the **tricuspid valves** lie behind the middle of the sternum at the level of the fourth intercostal space; and the **mitral valves,** the most deeply placed of all, lie a little to the left of these, behind the left edge of the sternum and the fourth left costal cartilage (fig. 1107; also cf. fig. 437).

'Thus these valves are so situated that the mouth of an ordinary-sized stethoscope will cover a portion of them all, if placed over the juncture of the third intercostal space, on the left side, with the sternum. All are covered by a thin layer of lung; therefore we hear their action better when the breathing is for a moment suspended.' (Holden.)

The pericardium.—This fibro-serous sac, occupying the middle mediastinum, is triangular in shape, with the apex upward. Here its fibrous layer gives investment to the large vessels, except the inferior cava. It is also continuous with the deep cervical fascia. The base, connected with the diaphragm, has been referred to above. In front an area of variable size (fig. 1107), owing to the divergence of the left pleura, is in contact with the left half of the lower part of the sternum, and more or less of the medial ends of the fourth, fifth, and sixth costal cartilages, here forming the posterior boundary of the anterior mediastinum. Behind, the pericardium is the anterior boundary of the posterior mediastinum, and is in close contact with the œsophagus and aorta.

Paracentesis of pericardium.—While the seat of election must here remain an open question, each case requiring a decision for itself, the one most suitable on the whole is the fifth left space, about 2.5 cm. (1 in.) from the sternum, so as to avoid injury to the internal mammary artery and the pleura, of which the line of reflection has been shown to vary.

In **incision of the pericardium** to establish free drainage, a portion of the fifth or sixth left costal cartilage should be carefully resected, the internal mammary artery tied, the transversus thoracis (triangularis sterni) scratched through, and the pleural reflexion pushed aside.

Relation of vessels to the wall of the thorax.—Aortic arch.—The ascending part of the aorta reaches from a spot behind the sternum, a little to the left of the centre, on a level with the third left costal cartilage, to the upper border of the second right cartilage; thus it passes upward, backward, and to the right, and is about 5 cm. (2 in.) long. The transverse part then crosses backward to the left behind the sternum (the highest part of the arch being about 2.5 cm. (1 in.) below the notch), reaching from the second right costal cartilage to the lower border of the fourth thoracic vertebra on the left side. This part recedes from the surface, and, with the next, cannot be marked out on the surface. The third, or descending part, the shortest of the three, reaches from the lower border of the fourth to that of the fifth thoracic vertebra.

Fig. 1104 will remind the reader of many of the pressure symptoms which may accompany an **aneurysm of the aortic arch**; e. g., pressure on the left innominate vein, the three large arteries, trachea, and left bronchus, recurrent nerve, œsophagus, and thoracic duct. In **aneurysm of the thoracic aorta,** pain, usually unilateral, referred to the corresponding intercostal nerves, is a common pressure symptom.

The pulmonary artery lies behind the left side of the sternum and its junction with the second and third costal cartilages.

Innominate artery.—A line drawn from the top of the arch, about 2.5 cm. (1 in.) below the sternal notch, and close to the centre, to the right sterno-clavicular joint, will give the line of this vessel.

Left common carotid.—This vessel will be denoted by a line somewhat similar to the above, passing from the level of the arch a little to the left of the last starting-point to the left sterno-clavicular joint.

Left subclavian artery.—A line from the end of the transverse arch, behind the left of the sternum, straight upward to the clavicle, delineates the vertical thoracic course of the long left subclavian artery; its thoracic portion lies behind the left carotid.

Innominate veins.—The **left,** 7.5 cm. (3 in.) long, extends very obliquely from the left sterno-clavicular joint, behind the upper part of the manubrium, to a point 1.2 cm. (½ in.) to the right of the sternum, on the lower border of the first right costal cartilage. The **right,** about 2.5 cm. (1 in.) long, descends almost vertically to the above point from the right sterno-clavicular joint.

Venæ cavæ.—The **superior** descends from the point above given for the meeting of the innominate veins in the first intercostal space, close to the sternum, and perforates the right atrium on a level with the third costal cartilage. The **inferior vena cava.**—The opening of this vein into the right atrium lies under the middle of the fifth right interspace and the adjacent part of the sternum.

The œsophagus.—The relations of this tube in its cervical and thoracic portions are most important, e.g., to the trachea and left bronchus; the vagi and left recurrent nerve; the pleuræ, left above and right below, aorta, and

pericardium. Its lymphatics go below into the posterior mediastinal and superior gastric nodes; above into the lower deep cervical nodes, a point sometimes diagnostic in malignant disease.

The lumen of the œsophagus is narrowed at three points:—(1) and best marked at the cricoid cartilage, (2) where it is crossed by the left bronchus, (3) as it passes through the diaphragm. The tube, 25 to 27 cm. (10 to 11 in.) long, extends from the sixth cervical to the lower border of the tenth thoracic vertebra. In an adult, the distance from the incisor teeth to the cricoid is about 15 cm. (6 in.); an additional 7.5 cm. (3 in.) gives the level of the crossing of the left bronchus, while from the teeth to the opening in the diaphragm would be from 41 to 43 cm. (16 to 17 in.). To expose the tube in the neck an incision is made on the left side, much as for the higher ligature of the common carotid, but carried lower down. The depressors of the hyoid being drawn medially or divided, the pretracheal fascia is opened, which allows of the overlapping thyreoid and trachea being displaced medially, while the carotid sheath is retracted laterally. The tracheal rings are the best guide to the œsophagus. The recurrent nerve must be avoided.

THE ABDOMEN

The regions and subdivisions will first be considered, the abdominal wall next, and finally the abdominal cavity, including the peritoneum and the various organs.

Subdivision of the abdominal cavity.—Certain arbitrary horizontal and vertical planes, represented by lines drawn on the ventral surface, are used to subdivide the abdomen for topographical purposes (fig. 898). A. **Horizontal planes.** (1) *Infracostal* through the lower margins of the tenth costal cartilages (the lowest part of the costal margin). This plane crosses the body of the third lumbar vertebra. (2) *Intertubercular*, passing through the tubercles, prominent points of the iliac crests, which are situated about 5 cm. (2 in.) behind the anterior superior spines. This plane crosses the body of the fifth lumbar vertebra. B. **Vertical planes.** (1) *Median vertical*, drawn upward in the middle line from the symphysis pubis. (2) *Lateral vertical*, drawn upward on each side parallel to the former, from a point midway between the anterior superior iliac spine and the symphysis pubis.

These lateral lines if prolonged upward into the thorax pass rather more than 2.5 cm. (1 in.) to the medial side of the male nipple and meet the clavicle a little medial to its mid-point.

According to the BNA system, the lateral vertical lines are slightly curved, extending upward from the pubic tubercle on each side along the lateral margin of the rectus muscle (corresponding to the linea semilunaris).

The infracostal and intertubercular planes, with the two lateral vertical planes that intersect them divide the abdomen into nine regions:—three **median,** viz., the **epigastric, umbilical,** and **hypogastric** and on each side three **lateral,** viz., **hypochondriac, lumbar,** and **iliac** (fig. 898).

Another transverse plane of practical importance, though we do not use it as a boundary of the abdominal subdivisions, is represented by Addison's **transpyloric line,** drawn horizontally through a point midway between the umbilicus and the sterno-xiphoid junction (or midway between the symphysis pubis and supra-sternal notch). It crosses the spine at the level of the first lumbar vertebra. It must be noted that the pylorus only lies in this plane during life when the subject is in the horizontal position. On assuming the upright position the pylorus falls at least one vertebra lower. **The sterno-xiphoid plane,** drawn horizontally through the junction of the body of the sternum with the xiphoid, cuts the spine at the disc between the ninth and tenth thoracic vertebræ, and the **umbilical plane,** passing through the umbilicus, crosses the disc between the third and fourth lumbar vertebræ (though in corpulent subjects it is somewhat lower).

The abdominal wall. Bony and muscular landmarks.—The **linea alba** forms a perceptible groove in the middle line from the xiphoid cartilage to below the umbilicus. It is a band of interlacing fibres, mostly crossing each other at right angles, that forms the main insertion of the transversus and oblique muscles, and stretches between the two recti muscles from xiphoid cartilage to symphysis. It is on the average 1.2 cm. ($\frac{1}{2}$ in.) wide above the umbilicus. Below the umbilicus it narrows rapidly and becomes merely a thin fibrous septum between the two recti, which in this position lie close together.

In its broad supra-umbilical portion, small hernial protrusions of subperitoneal fat often force their way through interstices in the linea alba, and true peritoneal sacs may be drawn through after them. The linea alba is not very vascular, and hence was at one time the favour-

ite site of incisions in opening the abdominal cavity. Since the resulting scar is weak and yielding, however, it is now more customary to make vertical incisions through the rectus sheath, to one side of the middle line, where the abdominal wall can be sutured in layers, and an incisional hernia prevented.

The umbilicus lies in the linea alba rather below its centre. It is somewhat prone to hernia formation (p. 1402) and is occasionally the site of congenital fistulæ, which may originate in a Meckel's diverticulum (p. 1376) or a patent urachus.

When the recti are thrown into contraction the **linea semilunaris** on each side is made evident as a groove, extending with a slight lateral convexity from the tip of the ninth costal cartilage, where the lateral vertical line meets the thoracic margin, to the pubic tubercle.

The contraction of the recti muscles also shows up the three lineæ transversæ, fibrous intersections adherent to the anterior layer of the sheath of the rectus, which cross the substance of the muscle (1) at the umbilicus, (2) at the tip of the xiphoid, and (3) midway between the former two. A tonic contraction of one or both recti localised to one of these segments occasionally gives rise to the "phantom" tumors which occur in some hysterical cases.

The linea semilunaris shares the disadvantages of the linea alba as a site for incisions, and there is the further danger of injury to the nerve supply of the rectus, which may involve a diffuse bulge of the atrophied muscle.

In tapping the bladder above the pubes, the trocar should be introduced immediately above the pubes and driven backward and a little downward. In this operation, and in suprapubic cystotomy, the retro-pubic space or **cavum Retzii** is opened. This is bounded in front by the pubes and superior fascia of the urogenital diaphragm, behind by the anterior surface of the bladder. Below are the true ligaments of this viscus. The space contains fatty tissue and veins, increasing in size with the advance of life. If about ten ounces of fluid are injected into the bladder, the peritoneum will be raised sufficiently to allow of a three-inch incision being made between the recti and pyramidales immediately above the pubes. The transversalis fascia is thicker below, and is often separated from the linea alba by fat, which must not be mistaken for the extra-peritoneal layer. The peritoneal reflexion is loosely connected to the bladder and can always be peeled upward.

A transverse line drawn from one anterior superior iliac spine to the other crosses at about the level of the top of the promontory of the sacrum. Such a line will always show whether the pelvis is horizontal or not. (Holden.)

The **inguinal (Poupart's) ligament** corresponds to a line drawn with a slight curve downward between the anterior superior iliac spine and the pubic tubercle. The first of these bony prominences corresponds to the starting-point of the above ligament, the attachment of the fascia lata to the ilium, the meeting of the fleshy and aponeurotic parts of the external oblique (denoted by a line drawn upward from this spine to the ninth costal cartilage, or often a little anteriorly to these points), the point of emergence of the lateral cutaneous nerve of the thigh, and part of the origins of the internal oblique, transversus, and tensor fasciæ latæ.

The pubic tubercle marks the lateral pillar (inferior crus) of the **subcutaneous inguinal (external abdominal) ring,** the mouth of which corresponds to the crest of the pubes lying between the tubercle and the symphysis. The neck of an inguinal hernia is above the tubercle and Poupart's ligament; that of a femoral hernia below and lateral to the tubercle, and below the same ligament. The ring, and especially its lateral pillar, can easily be felt by invaginating the scrotal skin with a finger, and pushing upward and laterally. In a female patient, if the thigh be abducted, the tense tendon of the adductor longus will lead up to the site of the ring. The **abdominal inguinal (internal abdominal) ring** is situated about 1.2 cm. ($\frac{1}{2}$ in.) above the centre of Poupart's ligament; oval in shape, and nearly vertical in direction, it has the arching fibres of the transversus above it, and to its medial side the inferior epigastric artery, lying behind the spermatic cord. The pulsations of this vessel here guide the finger in the insertion of the uppermost deep sutures in radical cure of hernia. The **canal** runs obliquely downward and forward between the two rings. In the adult it is about 3.7 cm. ($1\frac{1}{2}$ in.) long, but in early life, and in adults with a large hernia dragging upon the parts, the two rings are much nearer, and may be one behind the other. For the anatomy of inguinal hernia see p. 1304.

Vessels in the abdominal wall.—The three superficial branches of the common femoral, the external pudic, epigastric, and circumflex iliac, supply the lowest part of the abdominal wall and the adjacent groin and genitals. The others that have to be remembered are the inferior epigastrics and the epigastric branch

of the internal mammary, the deep circumflex iliacs, the last two intercostals, and the abdominal branches of the lumbar arteries.

Of these, the inferior epigastric is the most important; its course will be marked out by a line drawn from a point just medial to the centre of the inguinal ligament, upward and medially to the medial side of the abdominal ring, and thence to a point about midway between the pubes and umbilicus, forming the lateral boundary of Hesselbach's triangle (fig. 1121). Here the vessel, which at first lies between the peritoneum and fascia transversalis, perforates the latter and, passing over the semicircular line (fold of Douglas) enters the sheath of the rectus. It then runs upward, closely applied to the back of that muscle, and, a little above the level of the umbilicus, divides into branches which anastomose with the epigastric branch of the internal mammary.

One **superficial vein in the abdominal wall** needs especial mention, the thoraco-epigastric, joining the veins of the chest, e. g., the long thoracic above with, the superficial epigastric below. Its valves directing the blood downward below and upward above (Stiles) may be rendered incompetent when this vessel is enlarged, as in interference with the portal vein, with which it communicates by a vein in the round ligament, or in blocking of the inferior vena cava.

Lymphatics.—It is sufficiently correct to say here that those above the umbilical line go to the axillary, and those below that line to the inguinal nodes.

Nerves.—The lower seven intercostals and the ilio-hypogastric and ilio-inguinal supply the abdominal wall. The sixth and seventh intercostals supply the skin over the upper epigastrium; the eighth, the area of the middle linea transversa; the tenth, that of the umbilicus; the last thoracic, ilio-inguinal and ilio-hypogastric, the region above Poupart's ligament, and that of the pubes. The ilio-hypogastric supplies the skin over the subcutaneous inguinal (external abdominal) ring; the ilio-inguinal that over the cord and scrotum. The last thoracic and ilio-hypogastric cross the iliac crest to supply the skin of the buttock.

The diaphragm.—The upper limit of the diaphragm rises to the following levels in full expiration: Its central tendon to about the lower end of the body of the sternum, or the seventh chondro-sternal joint; the right half to the fifth rib, or about 1 cm. ($\frac{1}{2}$ in.) below the nipple; the left half not rising quite so high, i. e., to the fifth space, or 2.5 cm. (1 in.) below the nipple.

Topographical relations of abdominal viscera.—These will include the peritoneum, liver and bile passages, stomach, spleen, pancreas, intestines, kidneys and ureters, and large abdominal vessels.

The peritoneal spaces.—The peritoneum presents certain potential spaces, determined by its various reflections from the parietes and abdominal viscera. In these spaces collections of fluid such as abscesses or extravasations from hollow viscera or blood vessels may collect and become shut off by adhesions or overflow in various directions into neighbouring spaces. The transverse mesocolon and great omentum together form a shelf transversely placed, which divides the greater sac into two main divisions—supra-omental and infra-omental.

The **supra-omental region,** in which the various forms of subphrenic abscess are found, contains the following fossæ (Barnard).* (1) *Right subphrenic,* between the right lobe of the liver and right cupola of the diaphragm, bounded toward the median line by the falciform ligament, and behind by the coronary ligament. It communicates below with (2) the *subhepatic fossa* or right renal pouch (Morison), which is bounded above by the visceral surface of the liver, and below by the mesocolic shelf and right kidney. It extends from the right lateral abdominal wall, its most capacious part, across the median line under the left lobe of the liver, and on its posterior aspect lie the upper pole of the right kidney, epiploic foramen, and anterior surface of small omentum. (3) The **left subphrenic,** also known as the anterior perigastric fossa, lies between the left dome of the diaphragm above, and the left lobe of liver, stomach, spleen and omentum below. It is bounded on the right by the falciform ligament which lies somewhat to the right of the median line. (4) The **omental bursa** may be regarded as a diverticulum from the subhepatic fossa with which it communicates by the epiploic foramen. Abscesses in this sac are rare, but occasionally laceration of the pancreas which is closely related to it behind gives rise to a collection of pancreatic juice and blood in the lesser sac, known as a pancreatic pseudo-cyst (Jordan Lloyd).

The **infra-omental region** is subdivided in its abdominal part into (1) **right** and (2) **left compartments** by the attachment of the root of the mesentery to the spine, descending from the duodeno-jejunal flexure downward into the right iliac fossa. These fossæ communicate with the supra-omental regions in the neighbourhood of the hepatic and splenic flexures of the colon respectively, and below with (3) **the pelvis.** The deepest level of the peritoneum lining the pelvis constitutes in the male the recto-vesical, and in the female the recto-vaginal fossa (pouch of Douglas).

It should be noted that with a patient in the supine position, owing to the contour of the psoas muscles and the anterior convexity of the lumbar spine, any fluid above the pelvic brim will tend to gravitate into the subphrenic spaces across the flexures of the colon which lie far back in the loins. This is undesirable in view of the great absorbing power of the subphrenic lymphatics, and may be obviated by propping the patient in a half-sitting position.

*Barnard, H. L., Brit. Med. Journal, Feb. 15, 1908.

Viscera behind the linea alba.—From above downward there are the following:—(1) **Above the umbilicus**—the left lobe of the liver, the stomach, the transverse colon, part of the great omentum, the pancreas, and cœliac (solar) plexus. (2) **Below the umbilicus**—the rest of the great omentum, covering in the small intestines and their mesentery. In the child, the bladder occupies a partly abdominal position; and in the adult, the same viscus, if distended, will rise out of the pelvis and displace the above structures, raising the peritoneum until, if distended half way to the umbilicus, there is an area of nearly 5 cm. (2 in.) safe for operations above the symphysis. The gravid uterus also rises behind the linea alba.

The liver (figs. 914, 941, and 1125).—In the erect position, the anterior thin margin of the liver projects about 1 cm. ($\frac{1}{2}$ in.) below the costal cartilages, but can only be made out with difficulty in this position. It may also be displaced downward by pleuritic effusion or tight lacing. The liver is also, proportionately, much larger in small children.

Of the three more accessible surfaces, *the right lateral* is opposite the seventh to the eleventh intercostal arches, separated from them by the pleura, the thin base of the lung, and the diaphragm. The *superior* surface is accurately fitted with its right and left portions into the hollows of the diaphragm, a slightly depressed area intervening which corresponds to the central tendon. Its level corresponds to that of the diaphragm given above. On the left side, in the adult, the limit of the left lobe will be in the fifth interspace, about 7.5 cm. (3 in.) from the sternum. The *anterior* surface is in contact with the diaphragm, costal arches, and, between them, the xiphoid cartilage, and, below, with the abdominal wall. Both the superior and anterior surfaces are subdivided by the falciform ligament, an important point in subphrenic suppuration. In the right hypochondrium the anterior margin corresponds to the lower margin of the thorax; but in the epigastric region, running obliquely across from the ninth right to the eighth left costal cartilage, it crosses the middle line about a hand's breadth below the sterno-xiphoid articulation (Godlee), or half-way between the sterno-xiphoid junction and umbilicus, i.e., in the transpyloric line (fig. 914). Behind, the anterior margin, following the right lateral surface within the costal arches, crosses the last rib toward the level of the eleventh thoracic spine. In the anterior border, a little to the right of the median vertical plane, is the umbilical notch, where the falciform and round ligaments meet. Still further to the right, and just to the left of the mid-Poupart plane, is the fundus of the gall-bladder.

Gall-bladder and bile passages.—The fundus of the gall-bladder, situated in a fossa on the under surface of the right lobe of the liver, and having the quadrate lobe to its left, lies opposite to the right ninth costal cartilage, close to the lateral edge of the rectus. This point corresponds to the site of intersection of the lateral vertical and transpyloric lines. It is in contact with the hepatic flexure of the colon and the first piece of the duodenum, into either of which, but particularly the latter, large gall-stones impacted in the neck of the gall-bladder occasionally ulcerate. A distended gall-bladder as it enlarges tends to take a line obliquely from the above point where it emerges from under the costal margin toward the umbilicus.

The long axis of the gall-bladder is directed from the fundus backward and upward. The cystic duct runs from the neck downward and forward in the gastro-hepatic omentum, and so forms an acute angle with the gall-bladder. A spiral fold of mucous membrane at the junction of the two, which fulfils the function of keeping the lumen open for the flow of bile, adds to the difficulty of passing a bougie from the gall-bladder down into the common duct.

The hepatic and cystic ducts join in the right free margin of the gastro-hepatic omentum to form the **common bile-duct**, 7.5 cm. (3 in.) in length, which as it runs down to open into the duodenum presents four distinct stages. (1) It first lies in the free edge of lesser omentum in front of the epiploic foramen, with the hepatic artery to the medial side, and the portal vein behind them both. (2) Behind the first part of the duodenum with the gastro-duodenal artery accompanying it. (3) In a deep groove in the head of the pancreas, between that gland and the posterior aspect of the second part of the duodenum. The pancreatic tissue surrounds it completely in 75 per cent. of cases, (Bunger) hence the jaundice that occurs in chronic interstitial pancreatitis. (4) Piercing the muscular wall of the duodenum obliquely it ends by joining the main duct of the pancreas at the ampulla of Vater and opening into the second part of the duodenum by a common orifice. This orifice, situated on the postero-medial aspect of the gut, rather below the centre of the second portion, is raised on a small papilla and is narrower than the lumen of the common duct.

The stomach.—The study of this organ by rendering its contents opaque with bismuth salts and projecting its shadow by X-rays on a fluorescent screen, has greatly modified the conception of its shape and position formed from post-mortem and operative observations. Examined post-mortem, or at operations under general anæsthesia it forms a flaccid sac with its long axis directed from the fundus obliquely downward, forward, and to the right. Seen under X-rays,

with the patient standing upright, the cardiac portion (the fundus and body together) is vertical, and the smaller pyloric portion is directed backward and to the right and slightly upward (fig. 1125). The most fixed point is the cardiac orifice.

The **cardiac orifice** lies under the seventh left costal cartilage 2 cm. ($\frac{3}{4}$ in.) from the sterno-xiphoid junction at a depth of about 10 cm. (4 in.) from the surface. Behind, this point corresponds to the tenth thoracic vertebra.

The **pyloric orifice** lies in the transpyloric plane when the patient is recumbent, but when the patient is standing it falls to the level of the second or third lumbar vertebra, or lower still

FIG. 1108.—PHOTOGRAPH OF AN EMPTY STOMACH. (J. S. B. Stopford.)

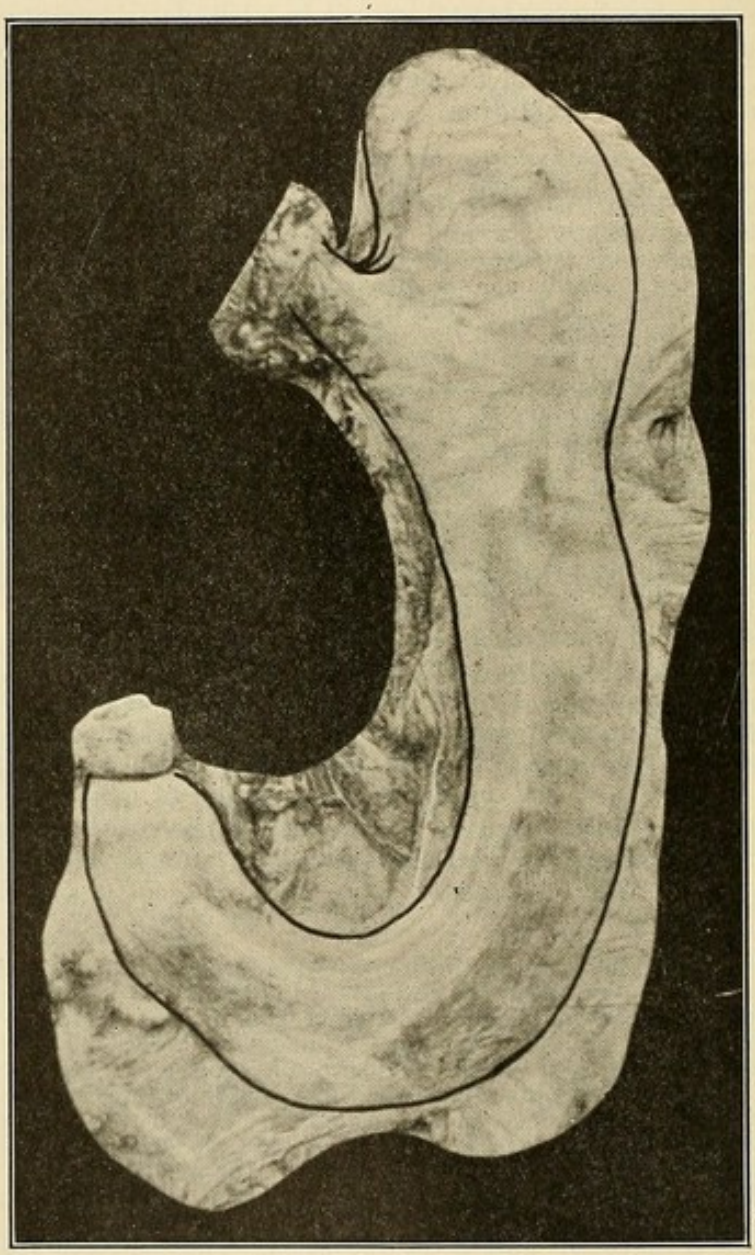

when any transient faintness or nausea causes loss of muscular tone (Barclay). The pylorus is slightly to the right of the middle line in the empty stomach. As the stomach fills it descends farther and moves a little farther to the right. The *lesser curvature* presents a definite notch at the junction of the cardiac and pyloric portions of the stomach—the *incisura angularis*. The *greater curvature* reaches the umbilical plane in the erect posture, even when the stomach is empty. When the viscus is full this curvature lies distinctly below this plane, being lower in women than in men (Hertz). The *pyloric portion* of the full stomach is directed backward and a little upward, as the distended pyloric vestibule moves further to the right than the pyloric orifice and lies on an anterior plane. In the recumbent posture the greater curvature lies above the umbilical plane, even when moderately distended, and the stomach is more obliquely placed. The *fundus* invariably contains gas, even when the stomach contains no food, in which case the organ forms a contracted J-shaped tube (fig. 1108). In extreme distention the left dome of the diaphragm is so pushed up by the fundus that it lies at a level as high as or even higher than the

right dome (Hertz). The pressure thus exerted on the heart accounts for the dyspnœa and cardiac pain so often associated with flatulence. The position of the pyloric sphincter is shown on the outer surface by a very constant venous ring running toward both lesser and greater curvatures in the subserous layer at right angles to the long axis of the pyloric canal (Moynihan).

In connection with the extravasation of contents that results from perforating ulcers of the stomach, a knowledge of the subphrenic peritoneal fossæ is important (p. 1372). Perforation is rare on the posterior surface since it is less mobile than the anterior, and protective adhesions form readily. When it does occur, extravasation into the omental bursa results, and such a perforation is exposed by turning up transverse colon and stomach and incising the transverse meso-colon. Perforation on the anterior surface usually gives rise to general peritonitis, but in the less serious cases an abscess may form localised to (1) the right subphrenic space, (2) the subhepatic fossa, or (3) the left subphrenic space, according to the situation of the ulcer on the stomach.

The spleen (fig. 1127; see also figures in Sections IX and XII).—This lies very obliquely in the left hypochondrium, its long axis corresponds closely with the line of the tenth rib. It is placed opposite the ninth, tenth, and eleventh ribs externally, being separated from these by the diaphragm; and medially it is connected with the great end of the stomach. Below, it overlaps slightly the lateral border of the left kidney (fig. 1127). Its highest point is on a level with the spine of the ninth thoracic, and its lowest with that of the eleventh thoracic vertebra. Its upper pole is distant about 3.7 (1½ in.) from the median plane of the body, and its lower pole about reaches the mid-axillary line on the same rib. (Godlee.) In the natural condition it cannot be felt; but if enlarged, its notched anterior margin extends downward toward the umbilicus, and is both characteristic and readily felt.

The pancreas.—The head of the pancreas lies in the hollow formed by the three parts of the duodenum, on the bodies of the second and third lumbar vertebræ. The inferior vena cava lies behind it. The neck, body, and tail of the pancreas pass obliquely to the left and slightly upward, crossing respectively the commencement of the portal vein, the aorta, and the left kidney. The root of the transverse mesocolon is attached to the anterior margin of the gland, so that its supero-anterior surface is related to the omental bursa, and its inferior surface to the greater sac. The importance of this relation in the formation of pancreatic pseudo-cysts has been referred to above.

Pancreatic ducts.—The main duct, the duct of Wirsung, opens into the common ampulla of Vater with the bile duct. This ampulla usually opens into the gut by a narrow orifice raised on a small papilla. A gall-stone impacted in the ampulla may cause a flow of bile backward along the duct of Wirsung, and so give rise to acute pancreatitis (Opie). The small accessory duct of Santorini opens into the duodenum independently about 2 cm. higher up. It often anastomoses with the larger duct in the substance of the gland.

Accessory nodules of pancreatic tissue are occasionally met with in the walls of the stomach or small intestine at different regions.

A cyst originating in the pancreas may "point" toward the anterior abdominal wall by three routes:—(1) Above the stomach through the lesser omentum; (2) between stomach and transverse colon through the great omentum; (3) below the transverse colon through the transverse mesocolon. The posterior aspect of the head of the gland, with the third part of the common bile duct may be exposed by incising the peritoneum on the lateral margin of the second part of the duodenum, and turning the gut medially toward the middle line.

Intestines. (A) **Small.**—The average length of the small intestine is about 6.85 m. (22½ ft.), though the length as measured *post mortem* varies considerably with the degree of contraction of the longitudinal muscular coat. The duodenum is about 25 cm. (10 in.) in length. Of the remaining portion the upper two-fifths constitute the jejunum and the lower three-fifths the ileum, though this division is quite arbitrary. Cases are recorded in which patients have survived the removal of over 5 m. (16 ft.) of small intestine.

The *first part* of the **duodenum** extends from the pylorus on the first or second lumbar vertebra, backward and to the right. It ends near the upper pole of the right kidney and on the medial side of the neck of the gall-bladder, by turning down to form the less mobile *second part*, which descends in front of the hilum of the right kidney to the level of the third lumbar vertebra. The *third part* of the duodenum crosses the body of the third lumbar vertebra horizontally in the infracostal plane, and then turns up obliquely to the left side of the spine and ends at the level of the upper border of the second lumbar vertebra in the duodeno-jejunal flexure. The first part is the most mobile, since it is covered back and front by peritoneum in the first half of its course. The second part has a peritoneal covering in front only and is devoid of it where it is crossed by the commencing transverse colon. The third part is covered by peritoneum in front except where the superior mesenteric vessels pass across it to join the commencement of the mesentery. It is probably the constricting effect of these vessels on the duodenum that gives rise to the acute dilatation of the stomach which occasionally follows abdominal operations.

The **duodeno-jejunal flexure**, which lies on the left side of the body of the second lumbar vertebra, immediately below the body of the pancreas, is held up to the right crus of the diaphragm by a band of fibro-muscular tissue known as the *suspensory ligament of Treitz*. Some of the fibres of this structure are continued onward into the root of the mesentery. It is not found in pronograde animals. The duodeno-jejunal flexure is the commonest site of traumatic rupture of the small intestine, since it is the point of union of a fixed and a freely movable portion of the gut.

In the operation of posterior gastro-enterostomy the duodeno-jejunal flexure is readily found by passing the hand along the under surface of the transverse meso-colon to the left side of the spine, the omentum and colon being turned upward. The first coil of the jejunum is anastomosed to the posterior wall of the stomach, which is exposed by making an opening in the transverse meso-colon.

In some cases the first few centimetres of the jejunum are found to be fused between the layers of the transverse meso-colon. Certain peritoneal fossæ are often found on the left side of the flexure. They may give rise to retro-peritoneal hernia and strangulation of intestine. The duodenal fossæ are described on p. 1164.

Jejunum and ileum.—The **mesentery** contains between its two peritoneal layers the superior mesenteric vessels and their intestinal branches, the superior mesenteric plexus, lacteals and many lymph nodes on their course. These nodes are frequently enlarged in abdominal tuberculosis in children (tabes mesenterica). The attached border of the mesentery may be marked out on the surface by a line drawn from just below the transpyloric plane and a little to the left of the middle line (the duodeno-jejunal flexure), which curves downward and to the right to end in the iliac fossa at the junction of the intertubercular and right lateral vertical lines (the ileo-cæcal valve).

Meckel's diverticulum which is present in about 2 per cent. of subjects (Treves) is found in the free border of the ileum 30 cm. to 1 m. (1 to 3 ft.) above the ileo-cæcal valve. It is a remains of the vitello-intestinal duct. It is usually a blind conical pouch some 6 to 9 cm. long with a free extremity, but may be attached to the umbilicus by a fibrous cord. This cord may cause acute intestinal obstruction by strangulating a coil of gut, or the diverticulum may be invaginated and form the starting-point of an intussusception.

The presence of **aggregated lymph nodules** (Peyer's patches) in the lower part of the ileum accounts for the fact that tuberculous ulcers and perforating typhoid ulcers are almost confined to this part of the gut.

Intestinal localisation.—It often happens that the surgeon wishes to ascertain roughly to what part of the small intestine a given coil presenting in a wound belongs. The variations in length of the small intestine and the considerable range of movement of the coils during peristalsis render the problem difficult, but it may be stated as a general rule that the upper third of the intestine lies in the left hypochondrium and is not usually encountered in a wound; the middle third occupies the middle part of the abdomen, and the lower third lies in the pelvis and right iliac fossa (Monks). The jejunum is thicker walled and more vascular than the ileum. The lumen steadily diminishes as we pass downward, hence foreign bodies such as gall-stones that pass through the jejunum are apt to become impacted in the lower ileum.

The most reliable indications of the level of a given coil are found, however, on inspection of the mesentery and its blood-vessels (see fig. 482 in Section V). Opposite the upper part of the bowel the mesenteric arteries are arranged in a series of large primary anastomosing loops. From these the vasa recta run to the gut 3 to 5 cm. long, straight and unbranched. Passing downward toward the lower end, the single large primary loops give place to smaller and more numerous secondary loops arranged in layers coming nearer and nearer to the bowel. Hence the vasa recta become shorter. They become also less regular and more branched, and in the lower third of the small intestine are less than 1 cm. in length. The mesenteric fat in the upper third never reaches quite to the free edge of the mensentery, so that clear transparent spaces are left near the bowel. In the lower third the fat usually occupies the whole of the mesentery right up to the intestine, and makes it thicker and more opaque.*

The average width of the mesentery, from its root at the posterior parietes to the bowel is 20 cm. (8 in.) and the longest part lies between 2 and 8 m. from the duodenum (Treves). The ileum is freely movable on a long mesentery down to the ileo-cæcal region. In some cases however a congenital fusion of the left half of the mesentery with the parietal peritoneum near the pelvic brim binds the bowel down a few inches above the ileo-cæcal valve, and has been said to give rise to symptoms of intestinal stasis. (Flint,† Gray, and Anderson.)

(B) **Large intestine. Ileo-cæcal region.**—The position of the ileo-cæcal valve may be marked on the surface by the junction of the intertubercular and right lateral vertical lines, though it is often found considerably lower. It is situated on the postero-medial aspect of the cæcum. The **cæcum,** which is the

* Monks: Trans. Amer. Surg. Assoc., 1913.

† Bulletin, Johns Hopkins Hospital, Oct., 1912.

blind extremity of the colon lying below the horizontal level of the ileo-cæcal valve, is approximately 6.2 cm. (2½ in.) in both vertical and transverse diameters, though its size varies much with the degree of distention. It lies usually in contact with the anterior abdominal wall above the lateral half of the inguinal ligament. The orifice of the appendix (vermiform process) lies some 2 cm. below the ileo-cæcal valve. The cæcum is completely covered by peritoneum as a rule, though exceptionally its posterior surface is bound down in the right iliac fossa.

The axial rotation of the midgut and descent of the cæcum that normally take place during intra-uterine life (p. 1168) are occasionally not completed, with the result that the cæcum and appendix may be found above and to the left of the umbilicus, or less uncommonly just below

FIG. 1109.—BLOOD-VESSELS OF THE ILEO-CÆAL REGION. (FROM KELLY).

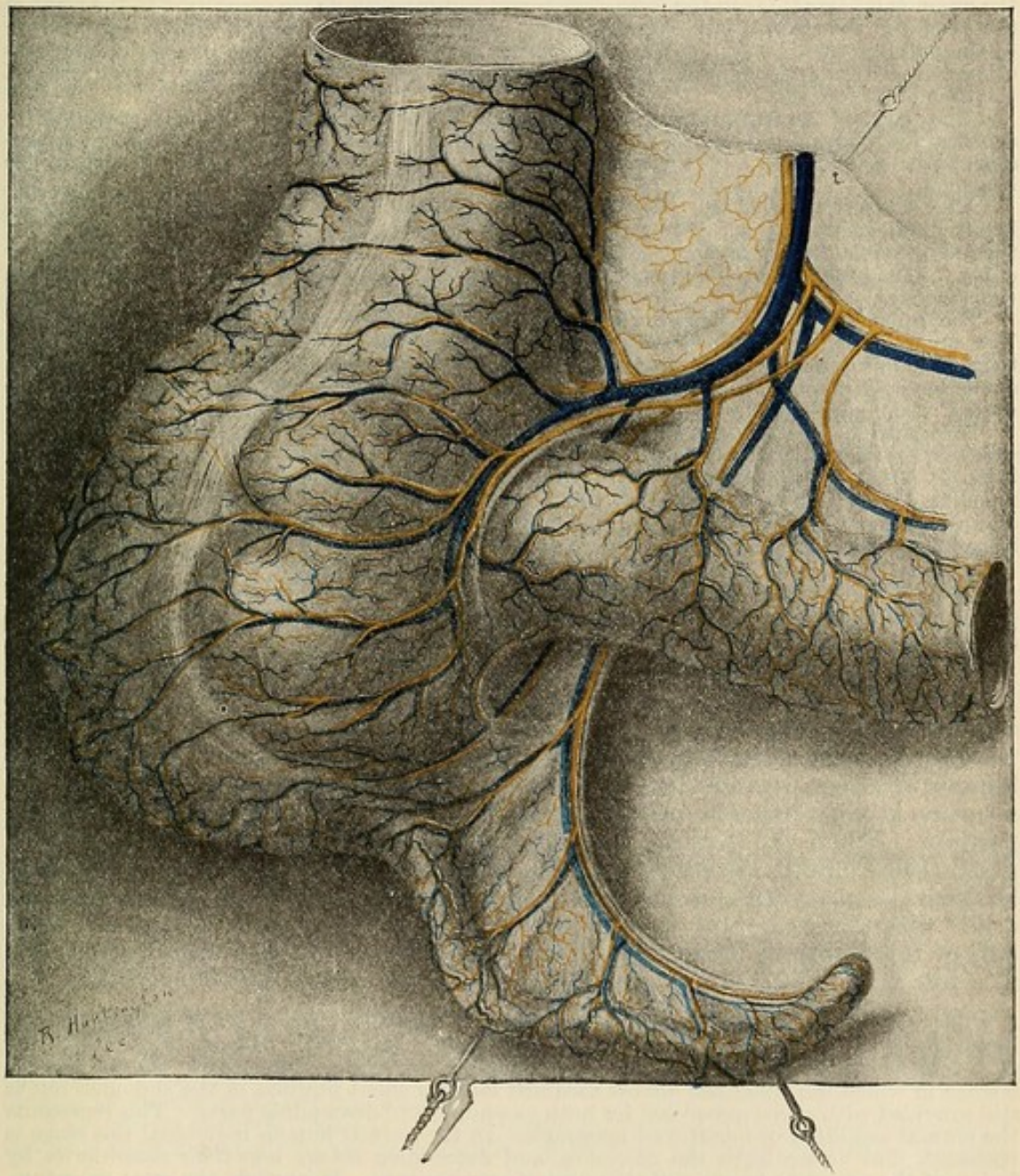

the right lobe of the liver (3 per cent., Alglave), when an attack of appendicitis may simulate inflammation of the gall-bladder. On the other hand certain cases occur in which the cæcum descends unusually far, proceeding downward and medially until it becomes a pelvic organ whenever the bladder and rectum are empty. This pelvic position of the cæcum is found in 10 per cent. of infants (G. M. Smith).*

In the commonest form of intussusception, the ileo-cæcal valve and lower ileum are prolapsed into the colon and carried down by the force of peristalsis toward the anus. The valve in these cases forms the apex of the intussusceptum, however far it travels.

* Anat. Record, vol. 5, 1911, p. 549.

The **vermiform process** (appendix) is developed at the apex of the cæcum, and persistence of the apical appendix of fœtal type, is not uncommon. The fact that all three tæniæ coli converge at the base of the appendix is an anatomical reminder of its primitive position. The anterior tænia is of great service in operations on the appendix, since by following it down from the colon the base of the appendix can always be found. The adult position of the base of the appendix on the postero-medial aspect of the cæcum is due to the disproportionate growth of the lateral saccule of the cæcum which comes to form the apparent cæcal apex.

The appendix averages 10 cm. (4 in.) in length in the adult. The position of its base only is at all constant. It lies distinctly below McBurney's point, which is midway between the umbilicus and the right anterior superior iliac spine. This point is often the seat of greatest tenderness in appendicitis. The appendix itself may be found (1) pointing upward and to the left toward the spleen, behind the terminal ileum and mesentery; (2) hanging over the pelvic brim, in which position tenderness on rectal examination or pain on micturition results when the organ is inflamed; (3) in the retro-colic fossa; and (4) with its tip projecting to the right of the cæcum in the right lateral paracolic fossa, where it causes tenderness when inflamed close to the anterior superior iliac spine. The course and to some extent the gravity of abscesses originating in the appendix will depend upon the position the inflamed organ is occupying at the time of perforation.

The **artery of the appendix** derived from the posterior branch of the ileo-colic reaches it by running down behind the end of the ileum. It raises a fold of peritoneum called the *mesenteriolum* or *mesoappendix*. Very rarely the artery comes from the anterior branch of the ileo-colic.

The *tæniæ coli* referred to above as converging on the base of the appendix contribute its longitudinal *muscular coat*. The inner circular coat is thicker, but along the attachment of the mesenteriole certain gaps for the passage of lymph and blood-vessels occur in the muscular coats. Through these gaps infection may easily spread from the mucosa to the peritoneum (Lockwood).

The appendix is essentially a *lymph gland* and has been called the "abdominal tonsil." The lymph follicles lie in the submucosa. They are poorly developed at birth but reach their full development within the first few weeks of extra-uterine life (Berry).* Obliteration of the lumen is common but is inflammatory in origin, and not, as was once thought, a change normal in advanced age.

Pericæcal fossæ.—In addition to the mesentery of the appendix certain other folds of peritoneum are usually present at the ileo-cæcal junction: (1) the **ileo-colic** or anterior vascular fold (fig. 1109) containing the anterior branch of the ileo-colic artery; (2) the **ileo-cæcal,** or bloodless fold of Treves, running from the lower border of ileum onto the cæcum. The appendix may be in a fossa behind either of these folds. It may also be found in the **retro-colic** fossa lying behind the cæcum and commencement of ascending colon.

The **colon** is readily distinguished from the small intestine by its three longitudinal tæniæ and saccules and by the appendices epiploicæ, which are developed before birth.

The **ascending colon** runs with a slight lateral convexity upward from its junction with the cæcum to the hepatic flexure which lies under the ninth right costal cartilage at the level of the second lumbar vertebra and in contact with the anterior surface of the right kidney and the lower surface of the right lobe of the liver. It lies lateral to the right lateral vertical plane. This description is only true of an ascending colon examined by X-rays in the recumbent position. When the patient stands up, the flexure sinks to the infracostal plane (third lumbar vertebra) or even lower. As the colon ascends in the angle between the quadratus lumborum and psoas, it also passes backward at an angle of 51° with the horizontal, as may be seen in a sagittal section through the right half of the abdomen (Coffey).† The cæcum and ascending colon are distended as a rule with fluid contents and gas, and form the widest part of the colon.

The variations in the **peritoneal attachments** of the colon, which are of growing clinical importance, are explained by its mode of development (p. 1179). During intra-uterine life after rotation of the midgut round an axis formed by the superior mesenteric vessels, there is a stage in which the colon has almost assumed its permanent position in the abdomen but is still provided with a free mesocolon for both ascending and descending parts. This represents the normal condition of quadruped mammals. In the normal human individual this stage is transient, and before birth the ascending and descending colons lose their mesenteries by fusion of the posterior layers with the parietal peritoneum. Meanwhile the great omentum, formed by a bulging out of the primitive dorsal mesogastrium, fuses with the transverse colon and its mesocolon. The extent of these processes of fusion varies, particularly as far as the ascending and descending colons are concerned. Thus only 52 per cent. of adults have neither ascending nor descending mesocolons (the normal condition). A mesocolon is found on the left side in 36 per cent. of all cases and on the right side in 26 per cent. (Treves). In only a

* Journ. Anat. and Phys., vol. 35, 1900, 83.

† Surgery, Gynecology and Obstetrics, vol. 15, 1912, p. 390.

small proportion (1.8 per cent., however, does the true primitive type of ascending mesocolon persist, continuous with the mesentery of the small intestine (G. M. Smith). Such an anomaly renders the patient liable to volvulus of the ileo-cæcal region. In the common types of incomplete fusion of its peritoneal attachments the colon is inadequately adapted to the upright position and is predisposed to ptosis. A layer of peritoneum sometimes found passing downward and medially from the parietes in the right flank onto the front of the ascending colon, known as Jackson's pericolic membrane, is probably due to persistence of an early stage in the development of the great omentum, which passes to the right across the ascending colon to join with the parietal peritoneum before the descent of the cæcum is complete, and so is the most primitive agent in fixing the proximal colon back in the right loin. This membrane is usually associated with a congenitally mobile ascending colon (Morley).*

At the **hepatic flexure** the colon bends forward and to the left, leaving the front of the kidney to which it is fixed, and crossing the second part of the duodenum. In the region of the flexure three inconstant peritoneal folds are met with giving it additional attachment to the neighbouring parts, viz., (1) the *phreno-colic* and less commonly (2) the *hepato-colic* and (3) *cysto-colic* ligaments (Testut). They must not be confused with pathological adhesions acquired after birth.

The **transverse colon** is freely mobile except at its extremities. It crosses the abdomen with a convexity downward and forward, being separated from the anterior abdominal wall in the middle region by the great omentum.

At the mid-line it usually lies near the umbilical plane in the recumbent posture, considerably lower in the erect, but may be found anywhere from the infra-costal plane to the pubes, depending on the tonicity of the stomach. Its main artery, the middle colic branch of the superior mesenteric, must be avoided carefully in the operations of gastro-enterostomy and gastrectomy, since ligature of it causes gangrene of the transverse colon.

The **splenic flexure** lies far back in the left hypochondrium and is considerably higher than the hepatic flexure. It is in contact with the lower end of the spleen, and is almost invariably held firmly in position by its *phreno-colic ligament*, derived from the left extremity of the great omentum.

The **descending colon** is of narrower calibre than the preceding parts and usually is found firmly contracted and empty. It passes downward and forward in the angle between the psoas and quadratus lumborum and obliquely across to the right the iliac fossa to end in the sigmoid or pelvic colon. The lower part of the descending colon, from the iliac crest to the pelvic brim, is often termed the *iliac* colon.

In its upper part it lies in front of the convex lateral margin of the left kidney. The variations in its peritoneal attachments have been referred to above (p. 1242). The operation of lumbar colostomy, common in pre-antiseptic days, was performed through an incision in the back parallel with the last rib. The colon lies 2.5 cm. (1 in.) to the lateral side of the edge of the sacro-spinalis, between the twelfth rib and iliac crest. The occurrence of a mesocolon here was a common source of difficulty in gaining access to the bowel without opening the peritoneum.

The **pelvic colon** (also known as the *sigmoid* or omega loop (Treves), is almost as long as the transverse colon, and forms a loop, the two ends of which, at the pelvic brim and at the front of the third sacral vertebra respectively, are placed somewhat closely together. The loop is thus anatomically predisposed to axial rotation, and is the commonest seat of volvulus in the whole intestinal tract.

On the left and inferior aspect of the pelvic mesocolon near its base, a small peritoneal fossa (*intersigmoid*) is usually found in the angle formed by the root of the mesocolon and the parietal peritoneum. It occasionally contains an internal hernia which may become strangulated.

The upper part of the pelvic colon is frequently brought out and opened through an incision in the left iliac region to form an artificial anus in cases of inoperable growth of the rectum.

In advanced life, and in the chronically constipated, certain **diverticula** of mucous membrane are occasionally met with which project through the vascular gaps of the muscular coat into the bases of the appendices epiploicæ in this region, and also between the layers of the pelvic mesocolon. They often contain fæcal concretions and may become inflamed or even perforate, forming an abscess in the left iliac fossa.†

The junction of pelvic colon and rectum opposite the third sacral vertebra forms a more or less acute angle and constitutes the narrowest part of the colon. It is a frequent site of stricture.

The kidneys.—These lie at the back of the abdominal cavity so deeply in the hypochondriac and epigastric region as to be beyond palpation in most individuals, unless enlarged or unduly mobile. The lower end of the right being slightly lower than its fellow, encroaches in health upon the lumbar and umbilical regions, and may be palpable on deep inspiration in spare subjects. These

* Lancet. Dec., 1913.

† McGrath: Surgery, Gynecology and Obstetrics, vol. 15, 1912, 429.

organs lie much higher and nearer to the vertebræ than is usually supposed to be the case, the upper two-thirds of the right and all the left kidney being behind the ribs. Relatively to the vertebræ, the kidneys lie along the sides of the last thoracic and the first three lumbar.

To mark them in from the front the following points should be noted: The upper extremity of the right should reach as high up as the seventh costal cartilage, the left up to the sixth, on either side close to the costo-chondral and inter-chondral junctions. This level will correspond to one half way between the sterno-xiphoid and transpyloric lines. The lower end,

Fig. 1110.—Renal Fascia, as seen in Cross-section.

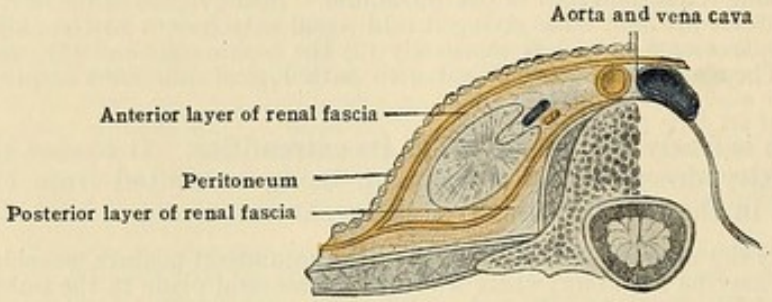

about 11 cm. (4½ in.) below this point, would be opposite to the subcostal line; that of the right kidney is usually lower, and may encroach upon the umbilical line. For practical purposes the hilus is opposite a point on the anterior abdominal wall, a finger's breadth medial to the tip of the ninth costal cartilage (Stiles), or the junction of the transpyloric and lateral vertical lines. The importance of the relation of the last rib has been mentioned at p. 1245. The lateral vertical line has one-third of the kidney to its lateral side, and two-thirds to its medial side. The shortest distance between the two kidneys, obliquely placed so as to be closer above, 'at the upper part of their medial borders' (Thane and Godlee), measures about 6.2 cm. (2½ in.).

On the posterior surface of the body the kidney's boundaries are indicated by the following:—(1) A line parallel with, and 2.5 cm. (1 in.) from, the mid-line, between the lower edge of the tip

Fig. 1111.—Renal Fascia, as seen in Sagittal Section.

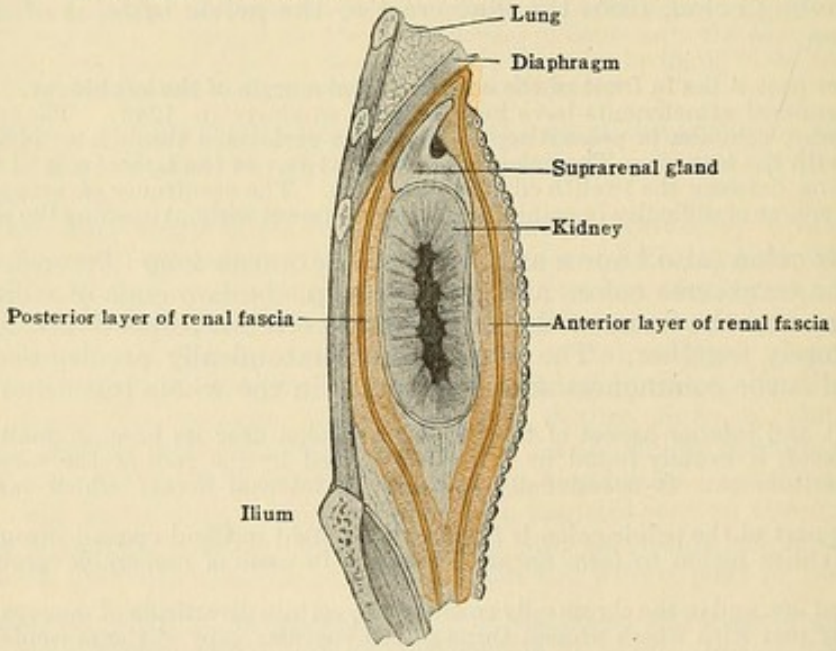

of the spinous process of the eleventh thoracic and the lower edge of the spinous process of the third lumbar vertebra; (2) and (3) lines drawn from the top and bottom of this line laterally, at right angles to it, for 7 cm. (2¾ in.); (4) a line parallel to the first, and connecting the extremities of (2) and (3). Within this parallelogram the kidney lies (Morris).

The **chief relations of the kidneys** are:—**posteriorly**—quadratus lumborum, psoas, diaphragm, last thoracic, ilio-hypogastric, and ilio-inguinal nerves. The twelfth rib lies behind both, the right, as a rule, not reaching above the upper border. The left often reaches the eleventh rib. The pleural reflection usually crosses the twelfth rib obliquely reaching below its neck. **Anteriorly**—The liver, right colic flexure and second part of the duodenum (figs. 956 and 1009), on

the right side. The liver, and stomach above, the body of the pancreas and spleen over the centre, and the descending colon over the lower part of the left kidney.

The attachments of the specialised fibrous sheets known as the **renal fascia** are shown in figs. 1110 and 1111.

The anterior and posterior layers are seen to be continuous above and laterally. Medially and below they remain separate and it is in this direction that the abnormally movable kidney travels. The fatty tissue between the kidney and the renal fascia is known as the perinephric fat; that outside the fascia is the paranephric fat.

The kidneys are maintained in position by (1) the vascular pedicle; (2) fatty capsule and fascia; (3) above all by the intra-abdominal pressure.

Failure to ascend during development from its original position near the pelvic brim to its normal level accounts for certain cases of *movable kidney* of congenital origin. In these cases

FIG. 1112.—THE ABDOMINAL AORTA AND VENA CAVA INFERIOR.

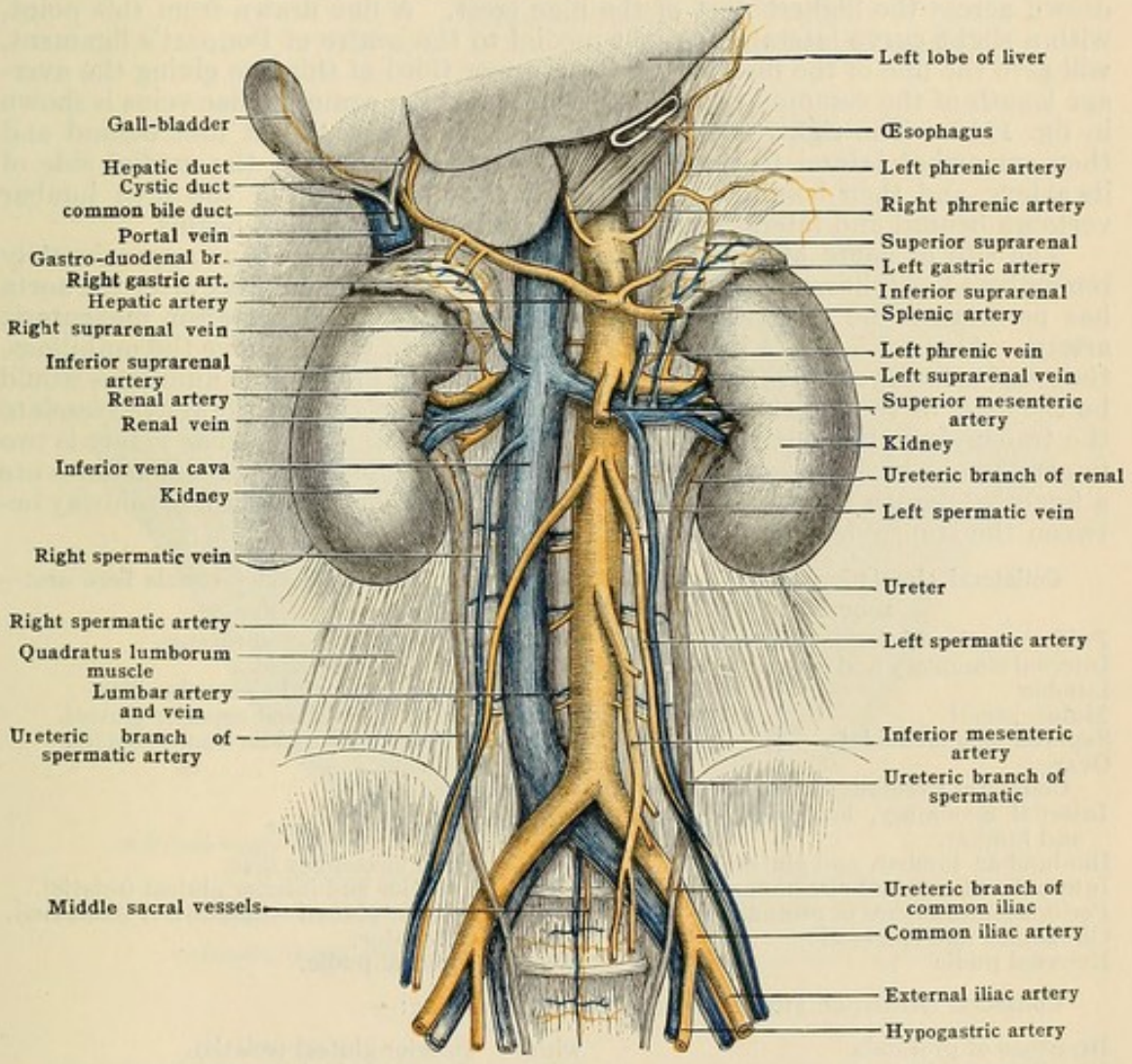

the renal artery may take origin from the common iliac artery. An *accessory renal artery* running into the lower end of the kidney from the aorta may cause kinking of the ureter and is a not uncommon cause of hydronephrosis.

The suprarenal glands are not so firmly attached to the kidneys as to the diaphragm; hence they are not encountered in operations for movable kidney and are not removed in nephrectomy.

Brödel has shown that incisions into the kidney should be made rather behind its convex border (Brödel's bloodless line). Occasionally fusion of the lower poles occurs during development across the middle line of the body, and a single *horseshoe kidney* results, with double ureter and vascular supply.

The ureter.—On an average 30 cm. (12 in). long, this tube descends almost vertically in its abdominal course on the psoas muscle. It is crossed obliquely

by the spermatic or ovarian vessels. It crosses the brim of the pelvis just in front of the bifurcation of the common iliac, and descends on the side wall of the pelvis in front of the hypogastric artery.

The abdominal part of the ureter may be exposed extraperitoneally by an extension forward of the usual lumbar renal incision. It is found lying between peritoneum and psoas 3.7 cm. (1½ in.) from the middle line and when the peritoneum is stripped from the posterior abdominal wall the ureter is invariably carried with it.

Aorta and iliac arteries.—The aorta enters the abdomen opposite the last thoracic vertebra, a point 12 to 15 cm. (5 to 6 in.) above the umbilicus, or rather above the mid-point between the infrasternal depression and the umbilicus (Thane and Godlee), and thence, lying to the left of the mid-line, divides into the two common iliacs opposite the disc between the third and fourth lumbar vertebræ, or opposite the body of the fourth lumbar vertebra. This point is about 2.5 cm. (1 in.) below and to the left of the umbilicus, and on a level with a line drawn across the highest part of the iliac crest. A line drawn from this point, with a slight curve laterally, to just medial to the centre of Poupart's ligament, will give the line of the iliac arteries; the upper third of this line giving the average length of the common iliac. The relation of the common iliac veins is shown in fig. 1112. The **right,** much shorter than its fellow, lies at first behind and then somewhat lateral to its artery. The **left** is at first to the medial side of its artery, and then behind the right. At the upper part of the fifth lumbar vertebra behind and lateral to the right artery, the vena cava begins.

The site of **some of the branches of the aorta** may be thus approximately remembered as follows: The **cœliac artery** is given off immediately after the aorta has perforated the diaphragm; directly below this is the **superior mesenteric artery.** About 2.5 cm. (1 in.) lower down, or 7.5 cm. (3 in.) above the umbilicus, the **renal arteries** are given off. About 2.5 cm. (1 in.) above the umbilicus would be the level of the **inferior mesenteric artery.** The relation of the above vessels to the transpyloric line (p. 1153) is as follows: (Stiles.) The cœliac artery is two fingers' breadth, the superior mesenteric one, above the line, the renal arteries are a finger's breadth below it. The origin of the inferior mesenteric is midway between the transpyloric and intertubercular lines.

Collateral circulation after ligature of the common iliac.—The chief vessels here are:—

ABOVE.		BELOW.
Pubic branch of inferior epigastric	with	Pubic branch of obturator.
Internal mammary and lower intercostals	with	Inferior epigastric.
Lumbar	with	Ilio-lumbar and circumflex iliac.
Middle sacral	with	Lateral sacral and superior gluteal.
Superior hæmorrhoidal	with	Inferior and middle hæmorrhoidal.
Ovarian	with	Uterine

Collateral circulation after ligature of the external iliac:—

Internal mammary, lower intercostals, and lumbar.	with	Inferior epigastric.
Ilio-lumbar, lumbar, and gluteal	with	Deep circumflex iliac.
Internal and external circumflex	with	Superior and inferior gluteal (sciatic).
Perforating branches of profunda	with	Inferior gluteal (comes nervi ischiadici).
Circumflex and epigastric	with	Obturator.
External pudic	with	Internal pudic.

Collateral circulation after ligature of the internal iliac:—

Branches of profunda	with	Inferior gluteal (sciatic).
Inferior mesenteric	with	Hæmorrhoidal arteries.
Vessel of opposite side	with	Pubic branch of obturator.
Branches of opposite side	with	Branches of pudic.
Superior and inferior gluteal (sciatic)	with	Circumflex and perforating of profunda.
Middle sacral	with	Lateral sacral.
Ilio-lumbar and superior gluteal	with	Circumflex iliac.

THE PELVIS

The male pelvis will be considered first, then the female pelvis, and finally a section on hernia.

The Male Pelvis

The topics under this heading will be considered in the following order: boundaries and subdivisions, scrotum and testis, ductus deferens and spermatic

cord, penis and urethra, prostate, bladder, ischio-rectal fossa, rectum and anal canal.

Bony boundaries.—These are the same in either sex. Above and in front is the symphysis pubis, rounded off by the subpubic ligament; diverging downward and laterally from this point on either side are the rami of the pubes and ischia, ending at the tuberosities of the latter. In the middle line behind is the apex of the coccyx, and reaching from this to the tuberosities are the sacro-tuberous (great sacro-sciatic) ligaments, to be felt by deep pressure, with the lower border of the gluteus maximus overlapping them.

The depth of the perineum varies greatly—from 5 to 7.5 cm. (2 to 3 in.) in the posterior and lateral part to 2.5 cm. (1 in.) or less in front. In the middle line, extending longitudinally through the perineum, is the raphe, the guide to the urethra, and 'the line of safety' (on account of the small size of the vessels here) for operations on it.

FIG. 1113.—THE MALE PERINEUM. (Modified from Hirschfeld and Leveillé.)

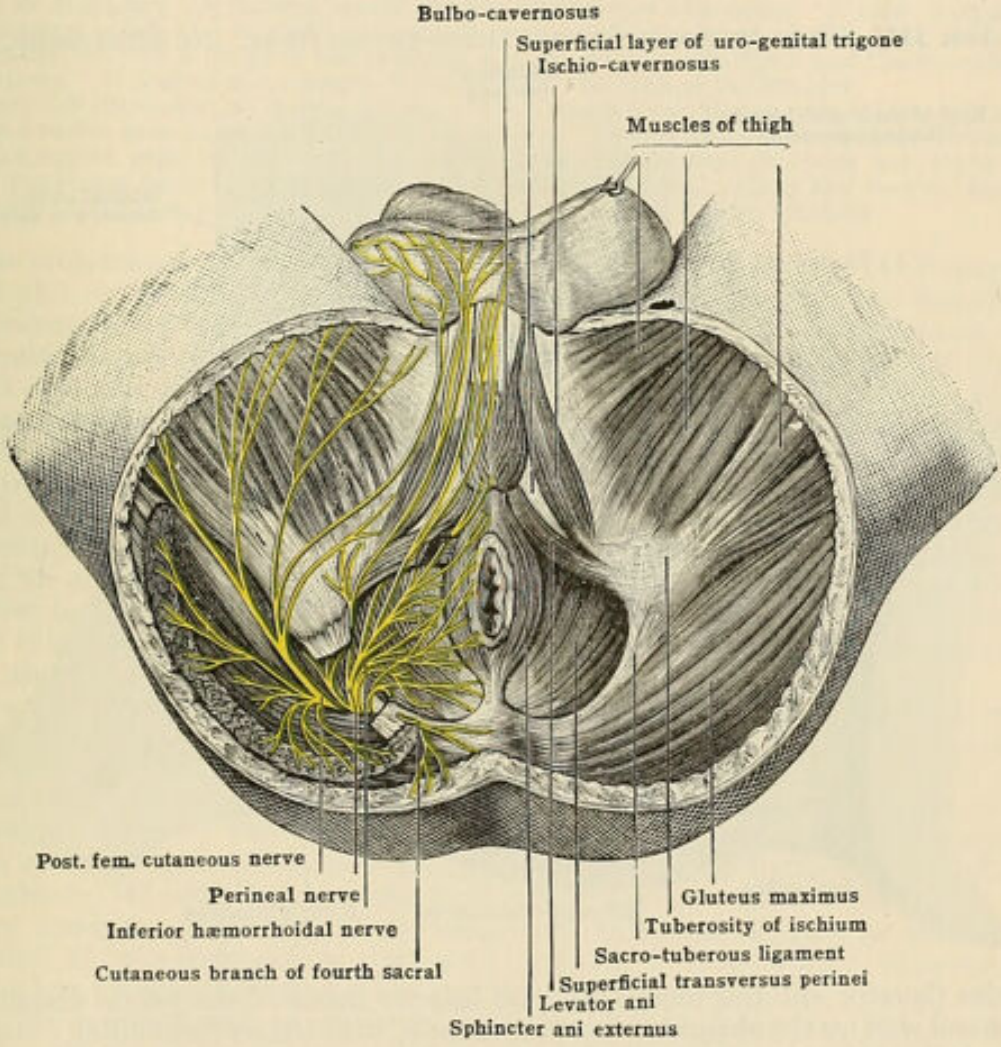

Subdivisions.—An imaginary line drawn transversely across the perineum from one tuber ischii to its fellow divides the lozenge-shaped space into **two triangles**—(1) An **anterior,** or **uro-genital;** and 2) a **posterior,** or **rectal.** The pelvic floor includes an upper or pelvic diaphragm (formed by the levator ani and coccygeus on each side) and a lower incomplete uro-genital diaphragm (or trigone).

The **pelvic diaphragm** (figs. 1113, 1114, 1115; see also figs. 397, 399, 400) is made up of the levator ani coccygeus muscles. It is somewhat funnel-shaped. When viewed from above or below (fig. 395), its fibres are seen to form horseshoe-like loops, arising on either side anteriorly, and passing posteriorly backward around the uro-genital apertures to be inserted chiefly in the mid-line posteriorly. The pelvic diaphragm serves primarily for the support of the abdominal viscera. For a detailed description of these muscles, as well as those of the uro-genital diaphragm, see section on the MUSCULAR SYSTEM.

The **uro-genital diaphragm** (or trigone) (fig. 400), the lower diaphragm of the pelvic floor, is both morphologically and functionally different from the upper. The uro-genital diaphragm is a sphincter muscular layer, derived (with the sphincter ani externus) from the primitive *sphincter cloacæ*. The uro-genital diaphragm is composed of superior and inferior fascial layers, enclosing the membranous urethra, the sphincter urethræ membranaceæ and the transversus perinei profundus. Superficial to the uro-genital diaphragm is the superficial perineal interspace (fig. 400). This is covered by the superficial perineal (Colles') fascia, and includes the crura and bulb of the corpora cavernosa, with associated muscles, vessels and nerves.

The space in the pelvic floor on each side below the pelvic diaphragm is the **ischio-rectal fossa** (figs. 399, 400, 1114). In the posterior or rectal triangle, where the urogenital diaphragm is absent, the ischio-rectal fossæ form large wedge-shaped spaces. The *lower* wall or base is formed chiefly by the corresponding skin and superficial fascia, and partly by the external sphincter ani; the *medial* wall by the

FIG. 1114.—CORONAL SECTION OF THE ISCHIO-RECTAL FOSSA. (G. Elliot Smith.)

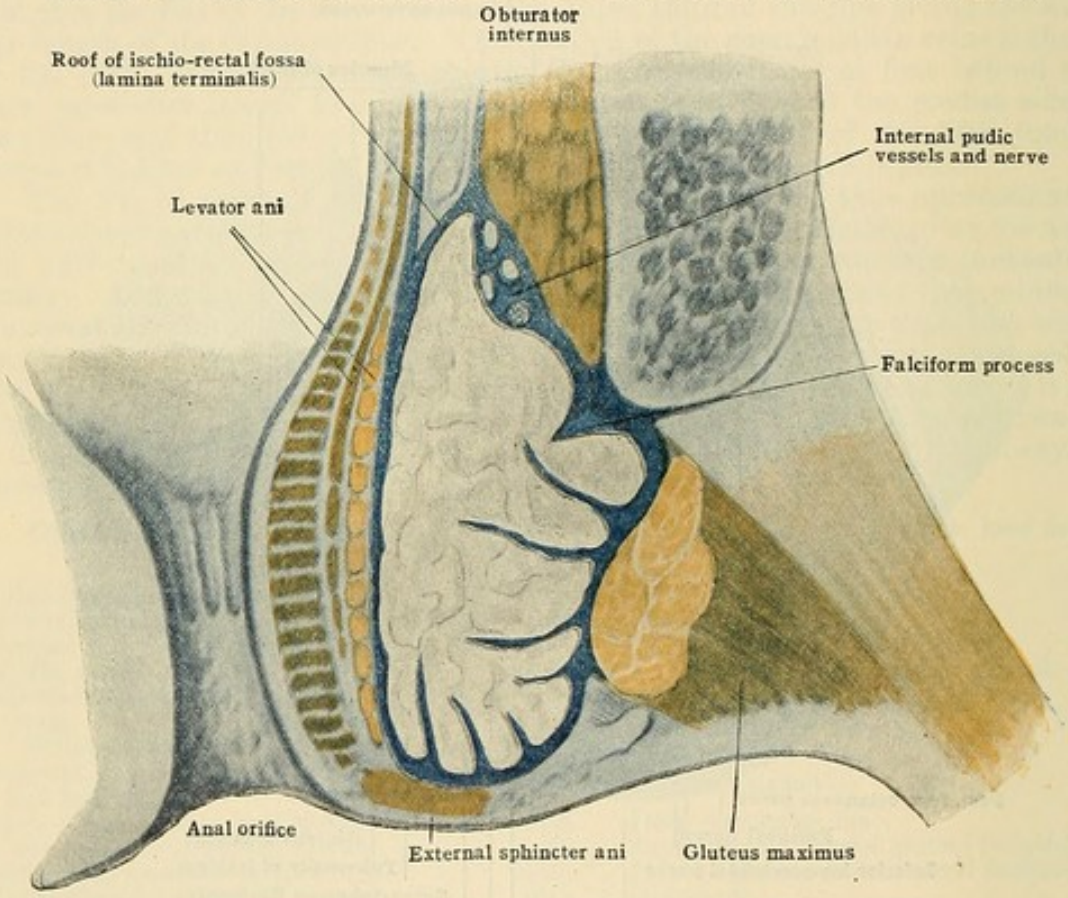

muscles (levator ani and coccygeus) and inferior fascia of the pelvic diaphragm; the *lateral* wall by the obturator internus muscle, with the corresponding obturator fascia (with Alcock's canal, including the pudic vessels and nerves). The *apex* of the fossa is above, where medial and lateral walls meet. The narrow fibrous roof strip joining the medial and lateral walls just above the level of the internal pudic vessels and nerves has been called the *lamina terminalis* (Elliot Smith, fig. 1114). Posteriorly the fossa is bounded by the gluteus maximus and lig. sacro-tuberosum. Anteriorly on each side the ischio-rectal fossæ extend as narrow spaces between the pelvic diaphragm above, the uro-genital diaphragm below, and the pelvic wall laterally (figs. 400, 401, 402).

Contents.—The ischio-rectal fossa is filled with loose adipose tissue continuous with the subcutaneous fat of the buttock. It is traversed by the inferior hæmorrhoidal branches of the internal pudic artery, with the associated veins and nerves, passing to the external anal sphincter, the skin and the adjacent mucosa. The superficial vessels and nerves, as they run forward to pierce the superficial perineal fascia, lie in this space, as well as the inferior clunial (perforating cutaneous) branches and branches of the fourth sacral nerve. The inferior

hæmorrhoidal veins traverse the fossa obliquely from the lateral wall downward and medially. They are usually somewhat dilated near the anal orifice, and when morbidly enlarged constitute the condition known as hæmorrhoids ("piles"). The inner opening of an anal fistula caused by the bursting of an ischio-rectal abscess into the gut is usually within 2 cm. of the anal margin, between the internal and external sphincters.

The **central point of the perineum** is in the adult nearly an inch (2.5 cm.) in front of the anus, or midway between the centre of the anus and root of the scrotum. Here the following structures meet, viz., the levatores ani, the two transverse perineal muscles, the bulbo-cavernosus, and the sphincter ani.

The comparative weakness of the attachment of the sphincter ani in front, i. e., not into a bony point, is important in the division of it, as in operation for fistula. The sphincter should never be cut through anteriorly, especially in women, where its attachment here, blending with the sphincter vaginæ, is a very weak one. This point also corresponds to the centre of the lower margin or base of the uro-genital diaphragm (triangular ligament). Its development varies much in different bodies. A little in front of this point is the bulb, with the corpus spongiosum passing forward from it. This would also be the level of the artery of the bulb, so that in lithotomy the incision should always begin below this point. A knife introduced at the central point, and carried backward and very slightly upward, should enter the membranous urethra just in front of the prostate, e. g., in median lithotomy and Cock's external urethrotomy. If pushed more deeply, it would enter the neck of the bladder.

In median lithotomy, an incision 3.7 cm. (1½ in.) long is made through the central tendinous point and raphe, so as to hit the membranous urethra. The following structures are divided:—Skin and fasciæ; some of the most anterior fibres of the external sphincter ani; raphe and central tendinous point; minute branches of transverse perineal vessels and nerves; base of uro-genital diaphragm in centre; membranous urethra and constrictor urethræ.

The attachments and arrangements of the **superficial fascia** (fig. 1115) must be traced and remembered. If the two layers of which it consists, the superficial alone extends over both urethral and rectal triangles alike, and is continuous with the similar structures in adjacent regions, the only difference being that, if traced foward into the scrotum and penis, it loses its fat, and contains dartos fibres. The deeper layer, found only over the urethral triangle, is called the fascia of Colles (fig. 1115). Attached at the sides to the rami of the pubes, behind to the base of the uro-genital trigone or diaphragm, and open in front, it forms the superficial wall of a somewhat triangular pouch, limited behind by the uro-genital trigone, and containing the superficial vessels, nerves, and muscles, the bulb, adjacent part of the urethra, and crura of the penis. Owing to this space being closed behind and open in front, and to its containing the above structures, fluids extravasated within this space will obviously tend to make their way forward into the scrotum, penis, and lower part of the abdominal wall.

The **uro-genital triangle** is subdivided into two planes by the inferior fascia of the uro-genital diaphragm and fascia of Colles. The structures *in the superficial plane*, between the uro-genital diaphragm and the fascia of Colles, have been given above. Those in the deeper, i. e., **between the two layers of fascia of the diaphragm,** are—(1) The membranous urethra; (2) deep transverse perineal muscle and sphincter of the membranous urethra; (3) the bulbo-urethral (Cowper's) glands; (4) and (5) part of the pudic artery and nerve, and branches.

The scrotum.—The skin of the scrotum is thin and delicate so that when distended, as by a hydrocele in the tunica vaginalis, it is remarkably translucent. Attached to its deep aspect is a layer of involuntary muscle, the dartos. When the dartos is contracted, as under the influence of cold, the scrotal skin becomes rugose.

To this tendency to wrinkling, with consequent irritation from retained dirt, and the presence of many sweat glands the frequency of epithelioma in this part is due. The dartos is apt to cause inversion of the skin in wounds of the scrotum, but this difficulty in suturing may be counteracted by the application of a hot sponge, which relaxes the muscle.

The **superficial fascia** of the scrotum is continuous with the fascia of Colles and the superficial fascia of the penis. Hence extravasation of urine under the fascia of Colles's balloons the scrotum and penis. The laxity of the areolar tissue under the dartos accounts for the great swelling that occurs in œdema of this part.

The lymphatics of the scrotum, important by reason of the extension of scrotal cancer, drain into the superficial inguinal nodes. Those from the anterior aspect nearest the median raphé run to the supero-lateral glands of this group, within a few cm. of the anterior superior spine.*

* Morley: Lancet, 1911 (ii), p. 1545.

The numerous large sebaceous glands that are found in the skin of the scrotum may give rise to cysts or adenomata. The deeper layers of the scrotum are derived from the abdominal wall, being brought down by the processus vaginalis in the descent of the testis.

Testis and epididymis.—The left **testis**, the first to descend, lies somewhat lower in the scrotum, and this fact is one reason of the frequency with which a

FIG. 1115.—THE ARTERIES OF THE PERINEUM.

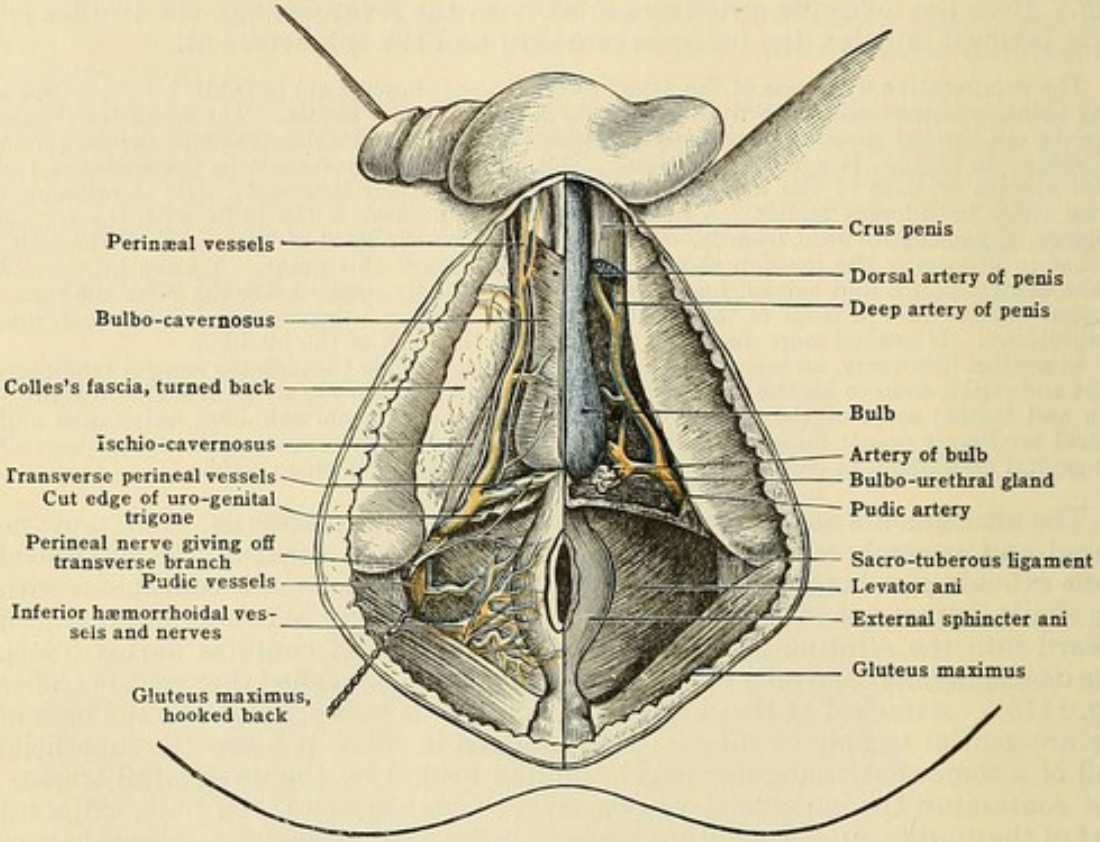

FIG. 1116.—SAGITTAL SECTION OF MALE PELVIS (×1/3). (Braune.)

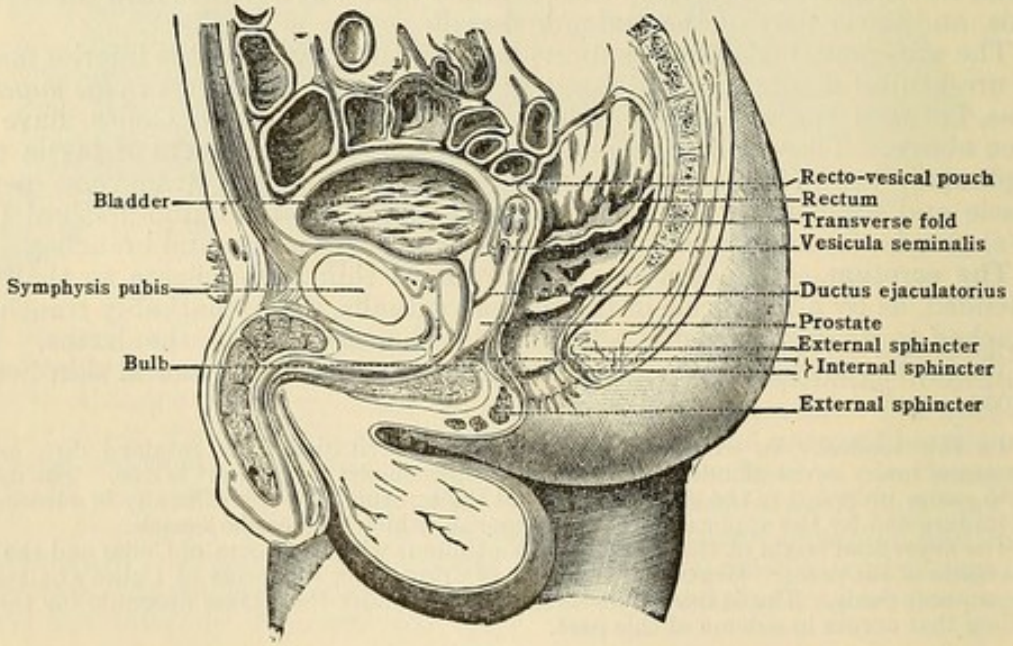

varicose condition of the spermatic veins occurs on the left side. On *palpation* the smooth firm body of the testis, pressure on which causes the characteristic "testicular sensation" can be felt to lie in front of and rather medially to the **epididymis.** The three parts of the latter, the *caput* above, the *body*, and the *cauda epididymidis* below, can also be distinguished. Running upward from the

back of the epididymis to the subcutaneous inguinal ring the **spermatic cord** can be felt. The bulk of the cord is made up of its coverings, of which the cremaster muscle is the most considerable, and of the pampiniform plexus of veins. On rolling the cord between the finger and thumb the **ductus deferens** can be felt like a piece of whipcord in the posterior part.

The *ductus* (*vas*) *deferens* is thickened and nodular in tuberculous epididymitis. In varicocele the dilated and elongated veins of the pampiniform plexus feel on palpation like a bag of worms in the scrotum. It is important that the student, before studying diseased conditions, should make himself familiar with the feel of the normal parts as mentioned above and be able to identify them.

Underneath the visceral layer of the tunica vaginalis, the body of the testis is covered by a dense fibrous layer, the *tunica albuginea*, which accounts for the small extent of swelling in orchitis as compared with epididymitis. The *lymphatics* of the testis run up in the spermatic cord through the inguinal canal, and accompanying the spermatic vessels end in the lumbar lymph nodes, below the level of the renal arteries. These nodes may be reached and removed along with the vessels by making an incision in the loin above the inguinal (Poupart's) ligament, and stripping the peritoneum off the posterior abdominal wall.

On the right side of the perineum (left side of this figure) Colles's fascia has been turned back to show the superficial vessels. On the left side the superficial vessels have been cut away with the anterior layer of the uro-genital trigone to show the deep vessels.

The **epididymis** is the convoluted first part of the duct of the testis, about 6 m. (20 feet) in length. Its three portions are in differing connection with the testis. Thus the *cauda* is held in place by connective tissue, the *body* by the same medium; the *caput* by the vasa efferentia. Thus, when tubercular disease begins here, the testis itself is more likely to be early involved.

Ductus deferens.—The two extremities and the course of this involve several practical points. About 45 cm. (18 in.) long, it begins, convoluted at first and with a distinct bend upward, in the cauda epididymidis. It thence passes almost vertically upward at the back of the testis and cord to the tubercle of the pubes. Entering the canal, it lies on the grooved upper aspect of the inguinal (Poupart's) ligament, and then under the arching fibres of the internal oblique and transversus, upon the transversalis fascia. Its position, characteristic feel, and yellowish aspect are well-known guides in operations for varicocele and hernia, while it is always to be isolated and palpated when tubercular disease below is suspected. Leaving the canal by the abdominal inguinal ring, it hooks round the inferior epigastric artery and then descends into the pelvis over the external iliac vessels. Continuing its course downward and backward over the side of the pelvis, it arches backward over the side of the bladder, superficial to the obliterated hypogastric artery, and then deep to the ureter. The two ducts now help to form the lateral boundaries of the external trigone, between the base of the bladder and the rectum. They here become dilated and sacculated and then contract again to empty into the ejaculatory ducts.

The **vesiculæ seminales** are diverticula growing out from the lower end of the deferential ducts at an acute angle, one on each side. They lie below and lateral to the deferential ducts and are related in front to the base of the bladder and posterior surface of the prostate, behind to the rectum, and above to the recto-vesical pouch of peritoneum, which also descends to cover the upper part of their posterior aspect. The normal vesiculæ seminales can scarcely be distinguished from the base of the bladder on rectal palpation, but when diseased, as in tuberculous or gonorrhœal vesiculitis, are enlarged and indurated and can be detected readily.

The **ejaculatory ducts,** formed by the union of the vesicular and deferential duct of each side, are 2–2.5 cm. in length. The first few millimeters of their course is extra-prostatic, and then entering the posterior surface of the prostate they run side by side downward and forward through the gland, close to the middle line, to open into the urethra on the colliculus seminalis at either side of the opening of the prostatic sinus. It is by these little ducts that infection travels from the urethra to the vesiculæ and epididymis in gonorrhœa.

Descent of the testis.—The testis is developed between the tenth and twelfth thoracic segments of the embryo, and subsequently moves downward. By the third month of intrauterine life it descends into the iliac fossa; from the fourth to the seventh month it lies at the abdominal inguinal ring; during the seventh month it passes obliquely through the abdominal wall by the inguinal canal; by the eighth month it lies at the subcutaneous inguinal ring, and it reaches the fundus of the scrotum about the time of birth. The left testis is slightly earlier than the right in all these stages. The descent referred to is due in part to the common descent of organs, associated with the descent of the diaphragm, but mainly to the **gubernaculum.** This is a mass of fibro-muscular tissue that forms under the *inguinal fold* (or *plica gubernatrix*) of peritoneum below the testis as it lies in the iliac fossa, and in the mesorchium. It grows down obliquely through the abdominal wall from a point lateral to the inferior epigastric artery, and tunnels out a passage for the testis. As it travels down into the scrotum it carries in front of it three layers of investing fascia derived from the abdominal wall, viz., external spermatic fascia from the external oblique, cremasteric from internal oblique and transversus muscles, and infundibuliform fascia from the transversalis fascia. The gubernaculum is attached above to the peritoneum and the posterior aspect of the testis, and by its subsequent contraction it draws down into the scrotum first a diverticulum of peritoneum, the **processus vaginalis,** and secondly the testis, which projects into the processus from behind just as it did into the cœlom.

Shortly after birth, obliteration of the processus vaginalis should occur, commencing at the deep abdominal ring and immediately above the testis. The part of the processus between these two points disappears completely. The lowest part, surrounding the testis, persists as the tunica vaginalis. Failure of obliteration, if complete, leaves a *congenital hernial sac;* if

only the upper part perists, and does not communicate with the tunica vaginalis, it is called a *funicular* sac. Cysts originating in the processus vaginalis between the upper and lower points of primary occlusion are known as *encysted hydrocele of the cord*.

Undescended testis.—It occasionally happens that descent of the testis fails on one or both sides, and in these cases the organ may remain, (1) in the iliac fossa, (2) in the inguinal canal, or (3) at the subcutaneous ring. Deprived of the protection normally afforded against injury by the scrotum and tunica vaginalis, the misplaced testis is subject to trauma, shows a tendency to torsion of its pedicle owing to its long mesorchium, and sometimes becomes the seat of malignant disease. A funicular hernial sac is generally present. Such testes are atrophic and functionally deficient, and it is probably owing to their small size at an early stage that the gubernaculum fails to gain a hold on them. It has been shown by Bevan* that in undescended testis the ductus deferens is usually long enough to allow the organ to be placed in the bottom of the scrotum by the surgeon without tension provided that the spermatic artery and pampiniform plexus of veins are divided. The blood-supply of the organ is then entirely derived from the deferential artery, a branch of the superior vesical. In rare cases the testis descends in a wrong direction (ectopia testis) and comes to lie in the perineum, over Scarpa's triangle, or on the pubes.

Penis.—The subcutaneous tissue of the penis, as on the scrotum, is devoid of fat and the delicate skin is very mobile and distensible, hence the ballooning of these parts in extravasation of urine or œdema. The fascia penis is continuous with Colles's fascia.

In radical amputation of the penis for malignant disease the whole organ, including the crura, is removed through an incision that splits the scrotum, and the stump of the corpus spongiosum (corpus cavernosum urethræ) is brought out into the perineum behind the scrotum.

The preputial orifice varies greatly in size. Normally large enough to allow easy retrac-

FIG. 1117.—CROSS-SECTION OF PENIS.

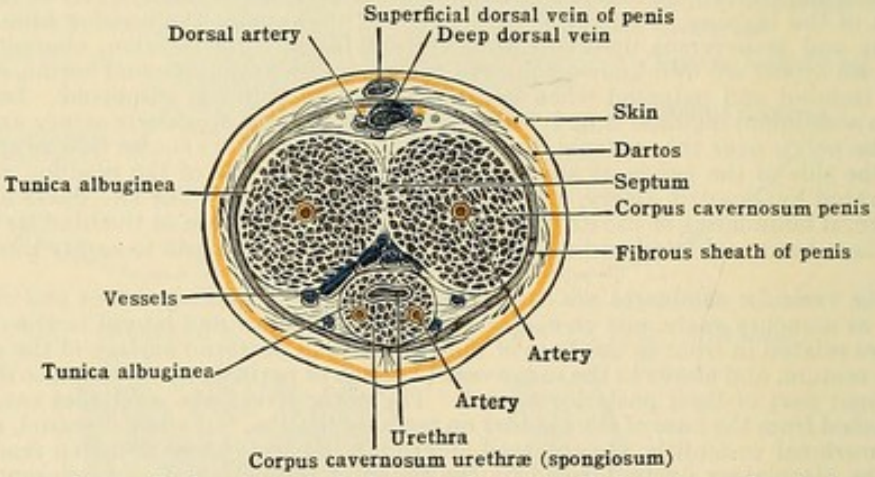

tion of the prepuce from off the glans, it is frequently so small that retraction is impossible and it may even cause difficulty in micturition. The mobility of the skin over the penis must be borne in mind in the operation of circumcision, and care taken lest too much of the prepuce be removed, leaving insufficient skin to cover the penis. In this operation the vessels from which bleeding occurs lie, (1) on the dorsum, (2) in the frenum.

Congenital malformations of penis.—At an early stage of development the urethra opens on the inferior aspect of the penis behind the glans. After the ingrowth of epithelium that forms the glandular urethra, this primitive meatus should close. Occasionally, however, it persists, and the glandular urethra is represented by a groove on the under aspect of the glans. In these cases of *hypospadias* the glans is flexed on the penis and the prepuce is deficient below and has a peculiar "hooded" appearance. In *epispadias* the upper wall of the urethra and corresponding part of the corpora cavernosa are absent. This condition is usually present in cases of ectopia vesicæ.

The **male urethra** is about 20 cm. (8 in.) in length, consisting of the **cavernous** portion, 16 cm. ($6\frac{1}{2}$ in.), **membranous** 1 cm. ($\frac{2}{5}$ in.) and **prostatic** 3 cm. ($1\frac{1}{4}$ in.). The narrowest part is the external orifice, and next to it the membranous urethra. The prostatic urethra is the widest and most dilatable. The bulbous urethra, just in front of the uro-genital diaphragm, is wider than the rest of the penile portion, but since it forms the most dependent spot in the fixed part of the urethra (from bladder to suspensory ligament of penis), it is specially prone to gonorrhœal stricture. Behind the bulb, the urethra narrows suddenly as it passes through the uro-genital diaphragm and contraction of the sphincters of

* Journ. Amer. Med. Assoc., vol. 41, 1903, p. 718.

the membranous urethra may here give additional difficulty in the passage of a catheter.

False passages most commonly occur through the floor of the bulb on account of this, difficulty in entering the membranous urethra. The point of a small catheter may also be caught in the following apertures: (1) The lacuna magna in the roof of the fossa navicularis of the glandular urethra; (2) other crypts or lacunæ in the penile part, mostly situated in the upper wall; (3) the prostatic sinus in the floor of the prostatic urethra about its centre. With the penis raised the urethra presents a simple curve under the symphysis with the proportions of an ordinary silver catheter.

It is in the region of the uro-genital diaphragm that the urethra is most liable to be damaged by a fall or blow, and the urine extravasated as a result will be beneath Colles's fascia. In rupture of the membranous urethra urine may find its way in front of the inferior fascia of the uro-genital diaphragm by coexisting injury to this, or through openings in the vessels, etc.; in a few such cases urine will make its way backward behind the fascia into the space of Retzius, ascending thence between the peritoneum and transversalis fascia. The attachment of the deep layer of superficial fascia to the base of the uro-genital diaphragm accounts for the fact that urine extravasated from a ruptured urethra or through an opening behind a stricture passes not backward into the anal triangle, but forward onto the scrotum and abdominal wall.

The **prostate** consists of a mass of racemose glandular tubules imbedded in a fibro-muscular stroma, that surrounds the first part of the urethra and lies below the neck of the bladder. Its **base** is intimately connected with the bladder by the continuation of vesical and urethral mucous membrane and by the insertion of the outer longitudinal muscular coat of the bladder into the gland. The inner circular muscle fibres of the bladder become specialised round the internal urethral orifice to form the *internal sphincter*.

Adenomatous enlargements of the gland usually grow upward through this sphincter which is thus dilated and pushed aside, so that the glandular growth is covered only by vesical mucous membrane.

The **apex** of the prostate lies at the level of the lower border of the pubic symphysis and 1.5 cm. behind it. It is firmly fixed to the superior fascia of the uro-genital diaphragm (deep layer of the uro-genital trigone) and here the urethra leaves it to become the membranous part. The **anterior surface** directed vertically lies 2 cm. behind the lower part of the pubic symphysis in relation to the prostatic plexus of veins; and from it the dense pubo-prostatic ligaments run forward on either side to the pubes. The **posterior surface** is in contact with the rectum, through the anterior wall of which it may be palpated 4 cm. ($1\frac{1}{2}$ in.) above the anal margin. It is separated from the rectum by the two layers of the recto-vesical septum (Elliot Smith).* The **lateral surfaces** are supported by the anterior fibres of the levator ani, from which, however, they are separated on each side by a dense mass of fibrous tissue in which the pudendal (prostatic) plexus of veins is imbedded.

The *prostatic urethra* traverses the gland nearer the anterior than the posterior surface, with a slight forward concavity. Its floor is placed posteriorly and presents an eminence, the *colliculus seminalis*, about the centre of which is the orifice of the prostatic sinus, on either side of which open the common ejaculatory ducts. The prostate is indefinitely divided into two lateral lobes. The fissure uniting them across the middle line in front of the urethra (the anterior commissure) is fibro-muscular and contains no glandular tissue. Behind the urethra the lateral lobes are continuous and the portion of gland lying between bladder, ejaculatory ducts and urethra has been erroneously termed the "middle lobe." Though not a separate lobe anatomically, adenomatous hypertrophy of this part is common, when it projects up into the bladder, and prevents the proper emptying of that organ.

Capsule and sheath of the prostate.—In senile enlargement of the prostate removal may be effected by the *suprapubic* or by the *perineal* route. In the former, the bladder is opened above the pubes, the mucous membrane lying over the gland as it projects into the bladder is scratched through behind, and with the finger the whole adenomatous mass is enucleated. This process usually involves tearing out the whole of the prostatic urethra, and the ejaculatory ducts. The parts left behind consist of (1) the "**capsule**" which is simply the outer part of the gland proper stretched over the adenomatous mass, and consists of fibro-muscular tissue with a few flattened glandular tubules (C. Wallace).† Outside this (2) the fibrous "sheath" is derived from the visceral layer of pelvic fascia, in which is imbedded, on the anterior and lateral aspects of the gland, the prostatic plexus. Since these veins are not torn there is com-

* Studies in Anatomy of the Pelvis. Journ. Anat. and Physiol., vol. 42, 1908.
† C. Wallace. Prostatic Enlargement, 1907.

paratively little hæmorrhage. In the *perineal* operation the posterior surface of the gland is exposed by cutting through the perineum between the bulb and external sphincter ani, and dividing the attachment of the recto-urethral muscle to the uro-genital diaphragm and its inferior fascia. This exposes the back of the recto-vesical septum (aponeurosis of Denonvilliers) which is split at its base, opening up the recto-prostatic space of Proust. By a longitudinal incision into the prostate on each side the adenomatous lateral lobes may be enucleated separately, and it is claimed without injury to the urethra or ejaculatory ducts (Hugh Young).*

The **bladder** lies above the pubic symphysis at birth and so is mainly an abdominal organ. The *anterior surface*, in contact with the abdominal wall, has no peritoneal covering, but posteriorly the peritoneal reflection descends to cover the posterior surface of the prostate, which is relatively lower than in the adult.

The adult bladder when empty forms a pyriform contracted organ behind the symphysis, and bounding the retro-pubic space of Retzius posteriorly. Into this space urine is extravasated in extra-peritoneal rupture of the bladder, and may mount up behind the abdominal wall in the extra-peritoneal tissue. The space is closed below by the pubo-prostatic ligaments and prostatic plexus of veins. In distention, the *neck* of the bladder and prostate being relatively fixed and immovable, the free *apex* rises up into the abdomen. As it does so it raises the peritoneum off the abdominal wall, so that in moderate distention 5 cm. (2 in.) of abdominal wall above the pubes are free of peritoneum, and the bladder may be tapped here safely. The *upper surface* and a little of the posterior are covered by peritoneum, which is also related to the upper halves of the vesiculæ seminales. Below the recto-vesical pouch the *base* of the bladder presents a small *triangular area* in contact with rectum, bounded by the peritoneal *cul-de-sac* above, the converging deferential ducts on each side and the prostate below. Through this triangle which is rather expanded in distention of the bladder, puncture *per rectum* was formerly practised. The *infero-lateral surfaces* are slung up by the levator ani as by a hammock. The *interior* of the bladder can be examined by the **cystoscope** in the living patient. The mucous membrane is loose and rugose in contraction, except over the trigone at the base, the angles of which are formed by the ureteric orifices and the internal meatus. The mucosa here is firmly adherent to the muscular coat and smooth. In hypertrophy of the bladder-muscle from obstruction, a fasciculated appearance of the mucosa is seen and possibly diverticula between the bands of muscle.

Rectum and anal canal.—The rectum proper extends from the end of the pelvic colon, opposite the third sacral vertebra, to the upper end of the narrow anal canal, which runs downward and backward almost at right angles to the rectum and is 3–4 cm. in length. The commencement of the rectum lies 13–14 cm. (5–5½ in.) above the anus in the adult. This point is marked internally by an infolding of the mucosa on the right and anterior wall and to some extent of the circular muscle fibres, due to the angle at which the free pelvic colon turns into the fixed rectum. This shelf of mucous membrane is known as the **upper transverse fold** (first valve of Houston).

Under normal conditions the rectum does not form a reservoir for fæcal material, which is stored in the lower end of the pelvic colon, above the upper transverse fold, leaving the rectum empty except in defæcation. The rectum proper is subdivided into two compartments by the **inferior transverse fold** on the anterior wall (third or great valve of Houston), situated 8–9 cm. (3–3½ in.) above the anus at the level of the anterior cul-de-sac of the peritoneum, and resulting from the adaptation of the rectum to the hollow of the sacrum. This can usually be made out on digital examination. The other transverse folds are inconstant and only present on great distention.

The rectum and anal canal may be divided into three regions: (1) **peritoneal** from the third sacral vertebra to the lower transverse fold and anterior reflexion of peritoneum onto bladder or vagina; (2) **infraperitoneal** (rectal ampulla) below this and above the levator ani; (3) **anal canal,** below the level of the levator ani, constriction by which marks it off from the ampulla and converts it into an antero-posterior slit.

The **mucous membrane** of the rectum proper is redundant and mobile and of a bright pink colour as seen by the sigmoidoscope. It is dotted over by **rectal pits,** visible to the naked eye, containing lymphoid follicles, and by the smaller and more numerous **Lieberkhün's glands.** In the peritoneal chamber the mucosa is transversely plicated. In the rectal ampulla it presents longitudinal folds in which lie branches of the superior hæmorrhoidal vessels. These longitudinal folds, known as the **rectal columns,** converge into the anal canal, and end at the level of the **anal valves** half way down the canal, each uniting two adjacent valves. The anal valves probably represent the original cloacal membrane, dividing the proctodæum (formed from the epiblast) from the hypoblastic hindgut, and persistence of this membrane gives one form of imperforate anus (Wood Jones†). The tearing down of a valve by hard fæces may be a cause of anal fissure, etc. (Ball). The mucous membrane of the anal canal is more firmly adherent

* Studies on Hypertrophy and Cancer of the Prostate. J. H. H. Reports, vol. 14, 1906.
† Brit. Med. Journal, Dec. 14, 1904.

to the underlying muscular coat than that of the rectum, hence in prolapse the mucosa of the rectal ampulla is the first to be extruded.

Peritoneal relations.—The peritoneal chamber of the rectum has no covering of peritoneum behind, and the peritoneum, at first covering its first aspect and sides, leaves the sides obliquely and finally is reflected onto the base of the bladder (or the vaginal fornix in the female), at the level of the inferior rectal fold, 8 cm. from the anus.

Blood-supply.—(1) The **superior hæmorrhoidal artery,** a continuation of the inferior mesenteric, reaches the rectum behind, via the pelvic meso-colon and bifurcates at once. The two branches run round on either side below the peritoneal reflection; giving off secondary branches that pierce the muscular coat about the level of the inferior transverse fold, or anterior peritoneal reflection. Joining the submucous layer, these arteries run down in the rectal columns to the anal canal, where they anastomose with (2) the **middle hæmorrhoidal arteries,** branches of the hypogastric (internal iliac) and (3) the **inferior hæmorrhoidal** branches of the internal pudendal. The veins correspond. Their free anastomosis in the **hæmorrhoidal plexus** under the rectal columns, the union afforded here between the portal and systemic veins, the absence of valves in the superior hæmorrhoidal veins, and the constriction they are subject to in passing through the muscular coat, are some of the anatomical causes of the frequency of hæmorrhoids.

The branches of the superior hæmorrhoidal artery to the rectum anastomose but little with one another, as compared with the sigmoid arteries to the pelvic colon. The main trunk of the superior hæmorrhoidal usually receives a large anastomotic branch from the lowest sigmoid artery 1–2 cm. below the sacral promontory, upon which the upper part of the rectum is dependent for its blood-supply after ligature of the superior hæmorrhoidal. Hence in high excision of the rectum it is important to place the ligature on the superior hæmorrhoidal above the sacral promontory if sloughing of the gut is to be avoided.*

For lymphatics of the rectum see p. 735.

Supports of the rectum.—The anal canal is fixed by its attachment to the levator ani and perineal body. After division of the perineal body and recto-urethral muscle in front, the rectum is readily separable from the back of the prostate and recto-vesical septum. When the levator ani has been divided on each side and the peritoneum opened, as in the perineal operation for excision of the rectum, the gut cannot be pulled down freely. The hand passed up behind it in the hollow of the sacrum meets on each side with a dense fibrous layer running from the sacrum opposite the third foramen onto the side of the rectum. This is the *rectal stalk* (Elliot Smith) and consists of dense fibrous tissue round the nervi erigentes from second, third and fourth sacral foramina and the middle hæmorrhoidal vessels. It lies about 2.5 cm. above the levator ani, and after division of it the bowel is easily freed, so that the whole of the rectum and part of the pelvic colon may be drawn out at the perineum without tension.

Rectal examination.—The following points can be made out by the finger introduced into rectum:—(1) The thickened, roll-like feel of a contracted external sphincter; (2) the narrower, more expanded, internal sphincter extending upward for 2.5 cm. (1 in.) from this; (3) the rectal insertion of the levatores ani, which here narrows somewhat the lumen of the gut; (4) above the anal canal, with its contrasting capaciousness, is the more or less dilated rectum proper; (5) the condition of the ischiorectal fossæ on either side; (6) the membranous urethra in front, especially if a staff has been introduced; the instrument now occupies the middle line, and has the normal amount of tissue between it and the finger, thus differing from one in a false passage (in a child an instrument is especially distinct); (7) just beyond the sphincters, or 3.7 cm. (1½ in.) within the anus, lies the prostate; (8) converging toward the base of the prostate, and forming the sides of the triangular space, are the vesiculæ seminales and ejaculatory ducts. These can rarely be felt unless diseased and enlarged; any enlargement of the sacculated ends of the deferential ducts is much more perceptible; (9) it is within this triangular space that the elasticity of a distended bladder can be felt. (10) Usually the lowest of the transverse folds (folds of Houston), semilunar in form and about 1.2 cm. (½ in.) in width, can be made out (fig. 1116). (11) Behind, the coccyx and its degree of pliability and the lower part of the sacrum. It may also be possible to feel enlarged sacral nodes and a growth from the other pelvic bones.

The above examination refers chiefly to the male. It remains to refer to **rectal examination in the female.** Anteriorly, the soft perinæal body and recto-vaginal septum will be met with, and, through the latter, the cervix and os uteri, and, higher up, the lower part of the cervix uteri. More laterally the ovaries may be felt, but the uterine or Fallopian tubes, unless enlarged and thickened, are not to be made out. The student should be familiar with the feel of a healthy recto-uterine or recto-vesical pouch, according to the sex, and the coils of intestine which it may contain, so as to be able to contrast this with any collection of inflammatory or other fluid or mischief descending from the upper pelvis, e. g., from the vermiform appendix. Posteriorly, certain structures are met with in either sex. After a very short interval (sphincter and ano-coccygeal body) the finger reaches the tip of the coccyx and explores the hollow of the sacrum. On each side are the ischial tuberosity and wall of the true pelvis. The finger hooked lateralward and upward, comes on the border of the falciform process of the sacro-tuberous (great sacro-sciatic) ligament, passing between the above-mentioned bones.

FEMALE GENITAL ORGANS

The external organs will be considered first, followed by the internal. Under the external organs are included, for convenience sake, the labia majora and minora at the sides; and, in the middle line, from above downward—(1) The glans clitoridis with its prepuce; (2) the vestibule; (3) the urethral orifice; (4) the

* H. Hartmann. Annals of Surgery, Dec., 1909.

vaginal orifice with the hymen or its remains; (5) the fossa navicularis; (6) the fourchette; (7) the skin over the base of the perineal body.

These parts have been described elsewhere, and only those points which are of importance in a clinical examination will be alluded to here.

The **labia majora** are two thick folds of skin, covered with hair on their outer surface, especially above, where they unite (*anterior commissure*) in the mons Veneris. They contain fat, vessels, and dartos, but become rapidly thinner below, where they are continuous at the front of the perineum (their *posterior commissure*).

When the above folds are drawn aside, the **labia minora,** or **nymphæ,** appear, not projecting, in a healthy adult, beyond the labia majora. They are small folds of skin, which meet above in the prepuce of the clitoris, and below blend with the labia majora about their centre. Sometimes, especially in nulliparæ, they unite posteriorly to form a slight fold, the fourchette.

The glans clitoridis, covered by its prepuce, occupies the middle line above.

Below it comes the **vestibule,** a triangular smooth surface of mucous membrane, bounded above by the clitoris, below by the upper margin of the vaginal orifice, and laterally by the labia minora. In the middle line of the vestibule and toward its lower part, about 12 mm. (½ in.) below the glans clitoridis, and 25 mm. (1 in.) above the fourchette, is the meatus or opening of the urethra (figs. 1034, 1037).

The **vaginal orifice** lies in the middle line between the base of the vestibule above, and the fossa navicularis below. Its orifice is partially closed in the virgin by a fold of mucous membrane, the **hymen** (fig. 1037). This is usually crescentic in shape attached below to the posterior margin of the vaginal orifice, and with a free edge towards the base of the vestibule. In some cases it is diaphragmatic i. e. attached all around, but perforated in the centre (fig. 1037).

The schrivelled remains of the hymen probably constitute the **carunculæ hymenales.** On either side of the vaginal orifice, at it lower part, lie the racemose, muciparous, **vestibular glands** (glands of Bartholin), situated beneath the superficial perineal fascia and sphincter vaginæ. Their ducts run slightly upward and open, external to the attachment of the hymen, within the labia minora. In relation to the upper two-thirds of the vaginal orifice, placed between the urogenital diaphragm behind and the sphincter vaginæ in front, are the vascular **bulbs** of the vestibule, rupture of which produces pudendal hæmatocele.

Fourchette and fossa navicularis.—The fourchette, as stated above, is the posterior commissure of the labia minora. Normally the inner aspect of this is in contact with the lower surface of the hymen. When the fourchette is pulled down by the finger, a shallow depression is seen, the **fossa navicularis,** with the fourchette for its posterior, and the hymen for its anterior, boundary.

Internal organs.—The examinations through the vagina and anus will be considered first, followed by uterus and appendages, ovary and ureter.

Examination per vaginam.—The finger, introduced past the gluteal cleft, perineum, and fourchette, comes upon the elliptical orifice of the vagina, and notes how far it is patulous or narrow; the presence or otherwise of any spasm from the adjacent muscles; then, passing into the canal itself, the presence or absence of rugæ, a naturally moist or a dry condition are observed. In the *anterior wall* the cord-like urethra can be rolled between the finger and the symphysis; and further up than this, if a sound be passed, the posterior wall of the bladder. The anterior wall of the vagina is about 6.7 cm. (2½ in.) long. The *posterior wall,* 7.5 cm. (3 in.) long, forms the recto-vaginal septum, and through it any fæces present in the bowel are easily felt. The cervix uteri is next felt for in the *roof* of the vagina, projecting downward and backward in a line drawn from the umbilicus to the coccyx. Besides its direction, its size, shape, mobility, and consistence should be noted. The os uteri should form a dimple or fissure in the centre of the cervix. Of its two lips, the posterior is the thicker and more fleshy feeling of the two. The vaginal *culs-de-sac* or fornices are next explored. These should be soft and elastic, giving an impression to the finger similar to that when it is introduced into the angles of the mouth. Any resistance felt here may be due to scars, swellings connected with the uterus (displacements or myomata), effusions of blood or inflammatory material, and, in the case of the lateral *culs-de-sac,* a displaced or enlarged ovary, or dilatations of the Fallopian tubes. The posterior cul-de-sac is much deeper than the anterior, and, owing to the peritoneum

descending upon the posterior wall of the vagina, when the finger is placed here it is only separated from the peritoneal sac by the vaginal wall and pelvic fascia. In examination of the pelvic organs the bimanual method, by which one hand on the hypogastric region, pushes them down and steadies them as well, is always to be employed to complete an examination.

The uterus and appendages.—The normal non-gravid uterus is usually anteflexed and anteverted so as to lie with its long axis approximately at right angles to that of the vagina. Its position varies considerably with the degree of distention of the bladder in front and of the rectum behind. The distance from external os to fundus, as estimated by the passage of a sound is in the adult virgin uterus 5.5 cm. of which 3 cm. belong to the cervix and 2.5 cm. to the body. In the empty multiparous uterus the total length of the cavity is 6 cm., 2.5 cm. comprising the neck and 3.5 cm. the body.

Peritoneal relations.—In front the peritoneum is reflected from the uterus to form the utero-vesical pouch at the level of the isthmus. Behind it covers not only the uterus but the posterior fornix of the vagina, before turning off onto the front of the rectum. Laterally the peritoneum leaves the uterus and passes on to the lateral pelvic wall as a large twofold partition fig. 1118), the broad ligament.

FIG. 1118.—SAGITTAL SECTION OF THE BROAD LIGAMENT.

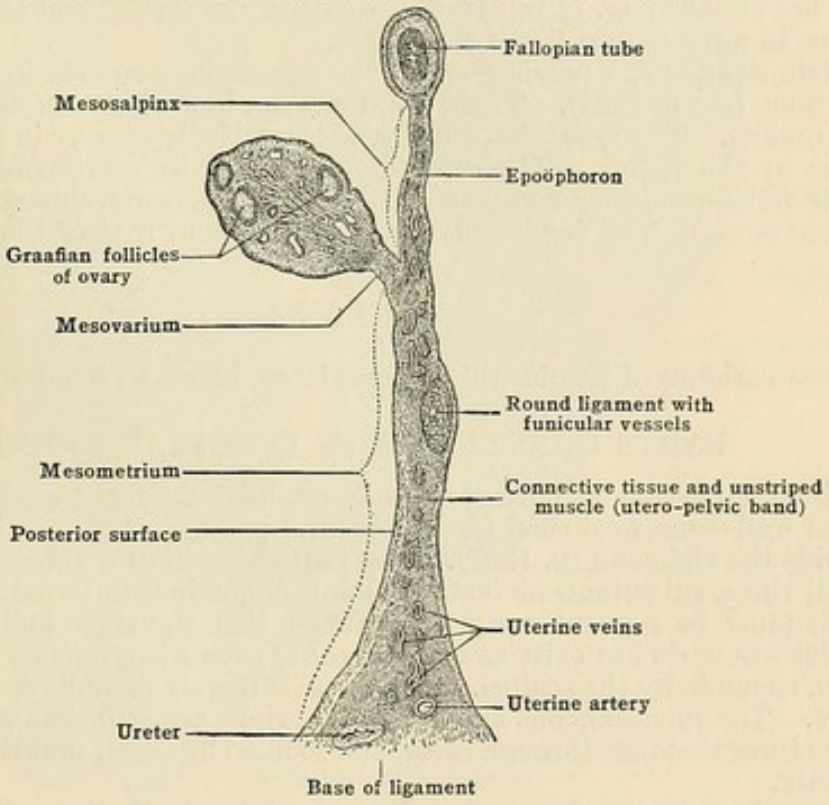

The **broad ligament,** bearing in its upper border the uterine tube, in front the round ligament and behind the ovary, consists of (1) an upper thin part, the mesosalpinx lying above the attachment of the mesovarium, and containing the ovarian vessels and the epoöphoron, and below this (2) the thicker mesometrium, between the layers of which is a dense mass of fibrous tissue surrounding the uterine artery.

The anterior aspect of the cervix below the utero-vesical pouch of peritoneum, is readily separable from the bladder with which it lies in contact, and the peritoneum may be raised off the uterus with ease in the lower part of its attachment both front and back. Over the upper part of the body and fundus, however, the peritoneal covering is firmly adherent, and cannot be dissected off.

The **ovary,** attached by its hilum to the mesovarium, lies in a fossa at the back of the lateral wall of the pelvis just between the diverging external iliac and hypogastric vessels. To feel it the finger should be pushed well up in the side of the vagina toward the lateral wall of the pelvis. On the abdominal surface its position corresponds to the middle of a line drawn from the anterior superior iliac spine of that side to the opposite pubic tubercle (Rawlings).

The *lymphatics* of the ovary follow the ovarian veins (see p. 745).

Supports of the uterus.—The great mobility of the body of the uterus has been referred to above. The organ derives its support almost entirely from the attachments of the cervix and vaginal fornices. These rest on the pelvic floor, formed by the levator ani and perineal body which support them the more efficiently since the long axis of the vagina is at right angles to that of the uterus. Above the pelvic diaphragm the cervix is held up to the pelvic walls by strong specialised bands of fibro-muscular tissue running in both antero-posterior and transverse directions. The chief of these, lying in the base of the broad ligaments is a fibrous sheath surrounding the uterine artery as it descends medially from the hypogastric. In the antero-posterior direction the utero-vesical ligaments hold up the cervix to the pubes in front and the sacro-uterine ligaments bind it to the anterior aspect of the sacrum behiind. While firmly supporting the uterus these bands are elastic, and so do not fix it rigidly, but allow of the cervix being drawn downward by traction with vulsellum forceps.

For *lymphatics* of uterus and vagina see p. 745.

The ureter.—The pelvic portion of this duct is of special importance in operations on the uterus and upper vagina. It crosses the brim of the pelvis on either side at the bifurcation of the common iliac artery, or just in front of it, and descends on the side wall in front of the hypogastric artery, crossing the obliterated umbilical and obturator arteries. Curving forward and medially it passes under the base of the broad ligament, where the uterine artery crosses above it, and so gains the lateral angle of the bladder by passing across in relation to the lateral fornix of the vagina. In the base of the broad ligament the ureter lies about 2 cm. ($\frac{5}{4}$ in.) from the side of the cervix, and this relation must be borne in mind in excision of the uterus.

Pelvic floor.—The pelvic floor of the female corresponds in general to that of the male (see p. 1383). There are, however, important differences, due to the sexual organs. The *urogenital diaphragm* is relatively smaller in area, due to perforation by the vagina. The *pelvic diaphragm* is also correspondingly modified, and the pubo-coccygeus component is more strongly developed (see section on MUSCULATURE.) The *ischio-rectal fossa* is similar to that of the male (p. 1384).

HERNIA

Three varieties of hernia will be considered, inguinal, femoral, and umbilical

PARTS CONCERNED IN INGUINAL HERNIA

In inguinal hernia, as in femoral and umbilical, there is a weak spot in the abdominal wall—one weakened for the needful passage of the testicle from within to outside the abdomen (p. 1387). The parts immediately concerned are the two inguinal rings, subcutaneous (external) and abdominal (internal), and the canal. Now, it must be remembered at the outset that the rings and canal are only potential—they do not exist as rings or canal save when opened up by a hernia, or when so made by the scalpel. The canal is merely an oblique slit or flat-sided passage. The subcutaneous and abdominal rings are so intimately blended with the structures that pass through them, and so filled by them, that they are potential rings only.

The subcutaneous inguinal (external abdominal) ring.—This is usually described as a ring: it is really only a separation or gap in the aponeurosis of the external oblique, by which in the male the testicle and cord, and in the female the round ligament by which the uterus is kept tilted a little foward, pass out from the abdomen. The size of this opening, the development and strength of its crura or pillars, the fascia closing the ring—all vary extremely. **Formation:** by divergence of two fasciculi of the external oblique aponeurosis. **Boundaries:** two crura—(1) Superior, the smaller, attached to the symphysis and blending with the suspensory ligament of the penis; (2) inferior, stronger, attached to the pubic tubercle and blending with the inguinal ligament, and so with the fascia lata. On this inferior, stronger crus rests the cord (and so the weight of the testicle) or round ligament. **Shape:** triangular or elliptical, with the base downward and medially toward the pubic crest.

Intercrural fibres (intercolumnar fascia) (external spermatic fascia).—This, derived from the lower part of the aponeurosis of the external oblique, ties the two crura together, and, being continued over the cord, prevents there being any ring here, unless made with a scalpel. This is the rule in the body: when any structure passes through an opening in a fibrous or muscular

layer, it carries with it a coating of tissue from that layer; e. g., the inferior cava passing through its foramen in the diaphragm, and the membranous urethra through the uro-genital diaphragm.

Effect of position of the thigh on the ring.—As the lower crus is blended with Poupart's ligament, and as the fascia lata is connected with this, movements of the thigh will affect the ring much, making it tighter or looser. Thus extension and abduction of the thigh stretch the crura and close the ring. In flexion and adduction of the thigh the crura are relaxed; and this is the position in which reduction of a hernia is attempted. In flexion and abduction of the thigh, the ring is open; and this is the position in which a patient should sit, with thighs widely apart, to try on a truss, and cough or strain downward, as in rowing. If the hernia is now kept up, the truss is satisfactory.

Helping to protect this most important spot, and preventing its being more than a potential ring, are not only the two crura and the intercrural fibres, but also a structure which has been called a third or posterior pillar, namely, the **reflected inguinal ligament.** This has its base above at the lower part of the linea alba, where it joins its fellow and the aponeurosis of the external oblique, and its apex downward and laterally, where, having passed behind the medial crus it blends with the lacunar (Gimbernat's) ligament. Again, the **falx inguinalis** (the con-

FIG. 1119.—THE PARTS CONCERNED IN INGUINAL HERNIA.
(From a dissection in the Hunterian Museum.)

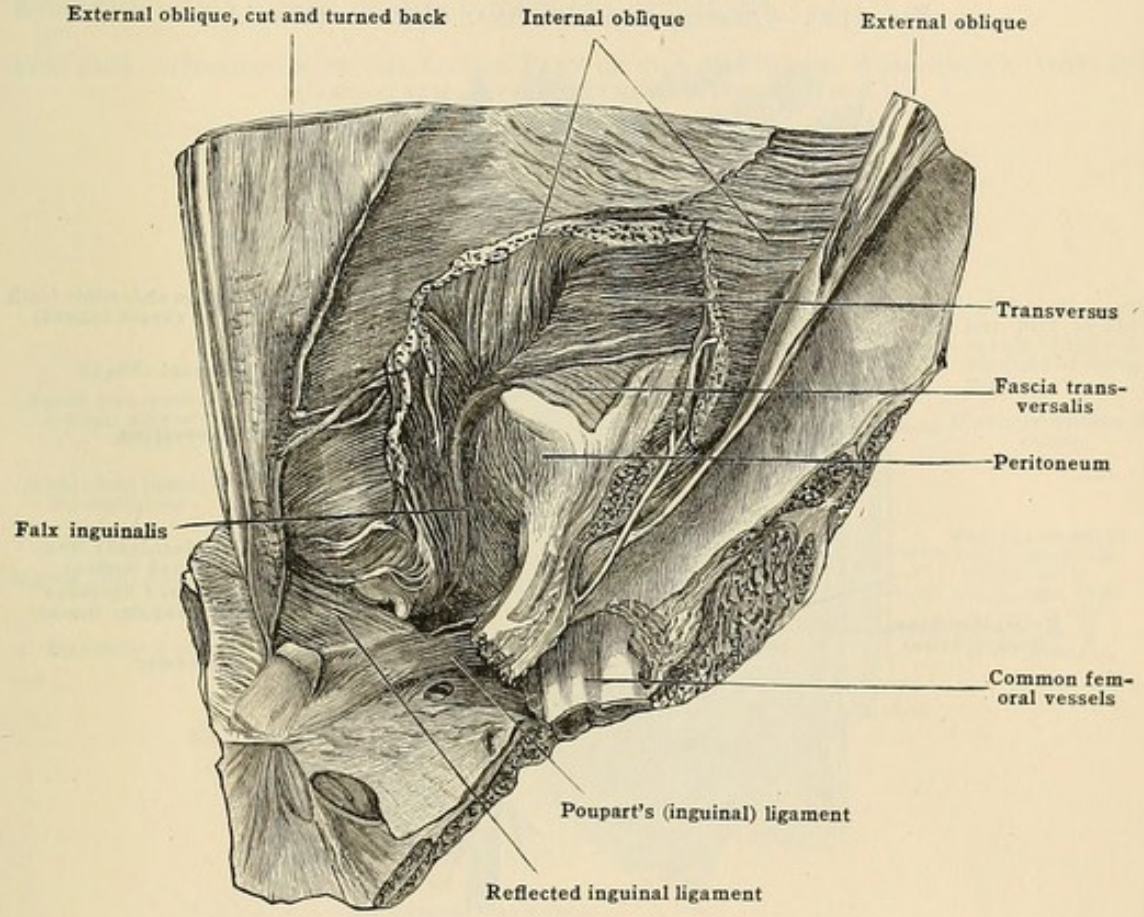

joined tendon of the internal oblique and transversalis), curving medially and downward to be attached to the ilio-pectineal line and spine, is a most powerful protection, behind, to what is otherwise a weak spot and a potential ring.

Inguinal canal.—This is not a canal in the usual sense, but a chink or flat-sided passage in the thickness of the abdominal wall. The descriptions of the canal usually given apply rather to the diseased than to the healthy state. It was a canal once, and for a time only, i. e., in the later months of fœtal life (p. 1387). It remains weak for a long time after, but only a vestige of it remains in the well-made adult.

Length.—In very early life there is no canal; one ring lies directly behind the other, so as to facilitate the easy passage of the testis. In the adult it measures about 37 mm. (1½ in.) in length, this lengthening being brought about by the growth and separation of the alæ of the pelvis. This increased obliquity gives additional safety. On the other hand, a large hernia has not only opened widely the canal and rings, but it has pulled them close together, and one behind the other thus not only rendering repair much more difficult, but also the path to the

peritoneal sac shorter and more direct. **Direction.**—From the abdominal to the subcutaneous ring, downward, forward, and medially.

Boundaries.—For convenience sake, certain limits (largely artificial) have been named:—

(1) *Floor.*—This is best marked near the outlet, where the cord rests on the grooved upper margin of the inguinal (Poupart's) and the lacunar (Gimbernat's) ligament. The meeting of the transversalis fascia with this ligament forms the floor. (2) *Roof.*—The apposition of the muscles and the arched border of the internal oblique and transversus. (3) *Anterior wall.*—Skin, superficial fascia, external oblique for all the way. Internal oblique, i. e., that part arising from Poupart's ligament, for the lateral third or so. To a slight extent, the transversus and the cremaster. (4) *Posterior wall.*—For the whole extent, transversalis fascia, extraperitoneal tissue, and peritoneum. For the medial two-thirds, conjoined tendon of internal oblique and transversus, and the lateral edge of the reflected inguinal ligament, when developed.

FIG. 1120.—DISSECTION OF INGUINAL CANAL. (Wood.)

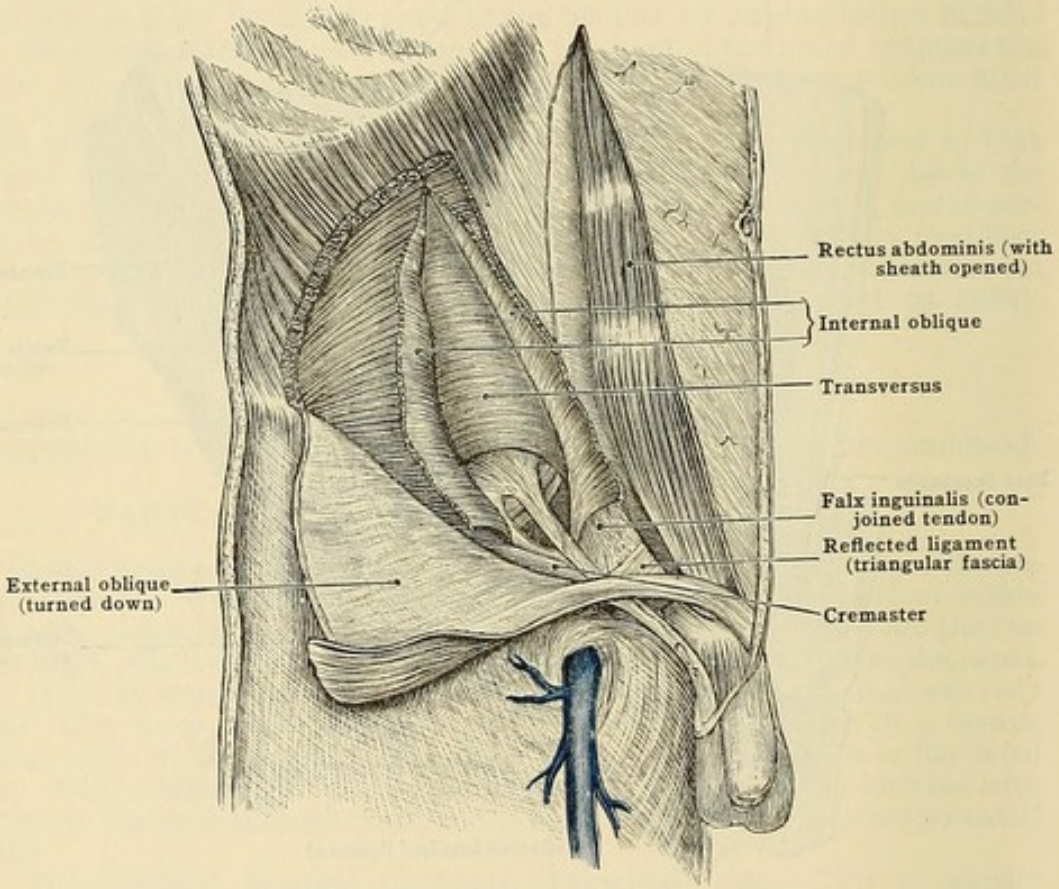

The transversalis fascia is thicker and better marked at its attachments below; these are—(*a*) laterally, to medial lip of iliac crest; (*b*) to the inguinal ligament between the anterior-superior spine and the femoral vessels, where it joins the fascia iliaca; (*c*) opposite the femoral vessels it also joins the fascia iliaca, and forms with it a funnel-shaped sheath; (*d*) medial to the femoral vessels the fascia transversalis is attached to the terminal (ilio-pectineal) line, behind the conjoined tendon, with which it blends. The *falx inguinalis* (*conjoined tendon*) needs special reference. It is formed by the lower fibres of the internal oblique and transversus (arciform fibres) arching downward over the cord to be inserted into the crest and spine and the terminal (ilio-pectineal) line. The fibres of the internal oblique become increasingly tendinous as they descend, and this, with the fact that below they give off the cremaster, may cause some difficulty in their identification when it is desired to unite them to the upper surface of Poupart's ligament in the operation of radical cure.

The abdominal inguinal (internal abdominal) ring.—It has already been said that the term 'ring' is here misapplied except in an artificial sense, as when an opening is made by a scalpel; or in abnormal conditions when a hernial sac is present. The abdominal ring is not a ring in the least, but merely a funnel-shaped expansion of the transversalis fascia, which the cord carries on with it as it escapes from the abdomen.

Site.—Midway between the anterior superior iliac spine and pubic tubercle. **Shape:** oval, with the long diameter vertical. **Boundaries:** centre of inguinal (Poupart's) ligament, about 12 mm. (½ in.) below. Medially, the inferior epigastric artery (fig. 1121); the position of this vessel, by its pulsation, is an important guide to the insertion of the highest sutures between the arciform fibres and the inguinal ligament. Owing to the artery lying to the medial side, the incision, in cutting to relieve the deep constriction of an inguinal hernia, should always be made directly upward, so as to avoid the above vessel. A large oblique hernia may so have altered the relations of the parts, including the artery, that it is difficult to decide whether the hernia is oblique or direct. The above incision will be safe, because, in either case, parallel to the vessel.

Coverings.—There are two chief forms of inguinal hernia:—

A. **The common form: lateral, or oblique.**—**Lateral,** because it appears (at the abdominal ring) lateral to the inferior epigastric artery. **Oblique,** because it traverses the whole of the inguinal canal, entering it at its inlet and leaving it at its outlet. This form is usually congenital in origin, and is due to non-obliteration of the processus vaginalis in infancy.

FIG. 1121.—DISSECTION OF THE LOWER PART OF THE ABDOMINAL WALL FROM WITHIN, THE PERITONEUM HAVING BEEN REMOVED. (Wood.)

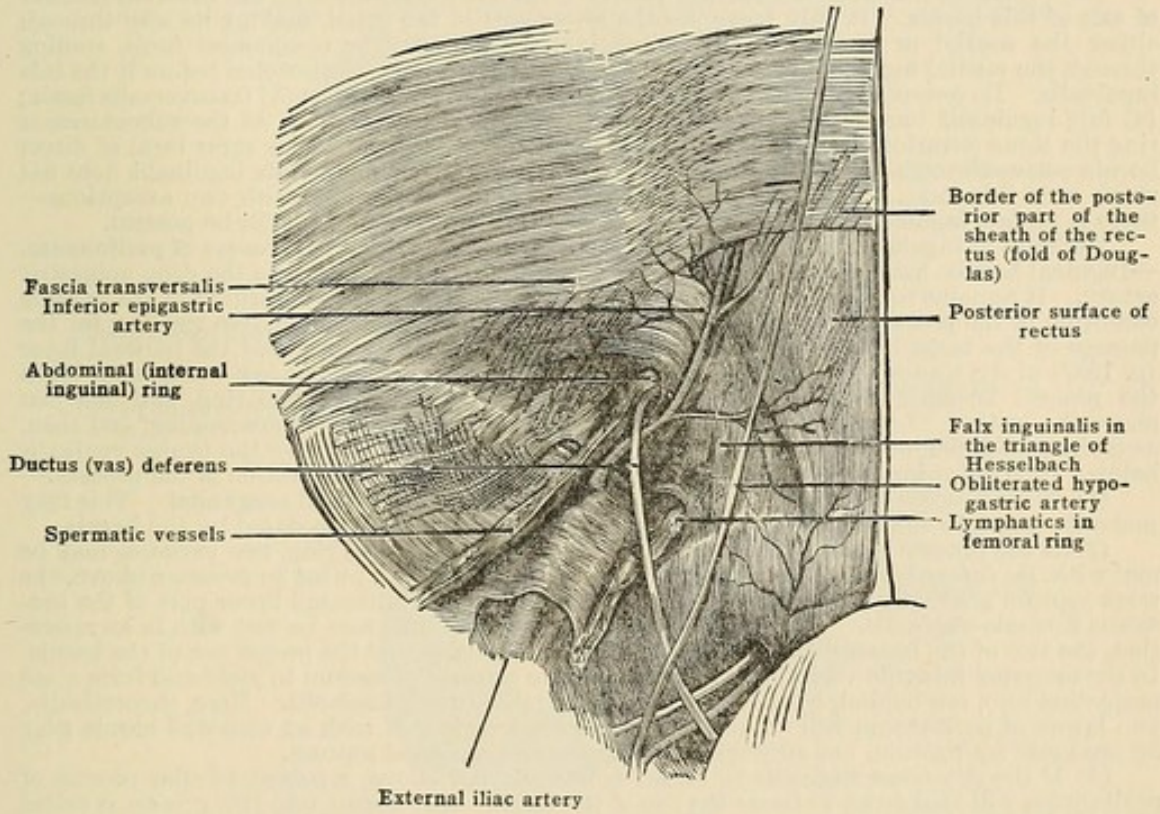

B. **Rarer form: medial, or direct.**—**Medial,** because it appears medial to the inferior epigastric artery. **Direct,** because, instead of making its way down the whole oblique canal, it comes by a short cut, as it were, only into the lower part of the canal, and then emerges by the same opening as the other.

A. **Oblique inguinal hernia.**—This possesses its **coverings** as follows:—

(1) **At the abdominal ring, or inlet,** it obtains three:—(*a*) Peritoneum; (*b*) extra-peritoneal fat; (*c*) infundibuliform fascia, or the vaginal process of transversalis fascia prolonged at this spot along the cord.

(2) **In the canal** it obtains one. As it emerges beneath the lower border of the internal oblique it gets some fibres from the cremaster.

(3) **At the subcutaneous ring, or outlet,** the hernia obtains three, viz.: (*a*) Intercrura fibres (intercolumnar fascia); (*b*) superficial fascia; and (*c*) skin.

B. **Direct inguinal hernia.**—This does not come through the abdominal ring, but, making its way through the posterior wall of the lower third of the canal, either through the medial or intermediate inguinal fossa. Its coverings, therefore, vary slightly with its mode of exit (*vide infra*).

Hitherto the two forms of inguinal hernia have been considered from the **superficial aspect,** that in which they are met with in practice. The inguinal region should also be studied as to

the **posterior aspect** of its so-called rings and canal, as these have to bear the early stress of a commencing hernia. It is against this aspect that a piece of omentum or intestine is constantly and insidiously pressing and endeavouring to make its way out. Furthermore, when either of the above constituents of hernia have made their way a little farther, and got out into the abdominal ring or into the canal, the patient is no longer sound.

On the posterior wall are certain cords and depressions, marking off regions which correspond to those on the surface. Thus, there are three prominent **cords** and three **fossæ** (fig. 1121).

Three cords—(1) Median, or **urachus**; (2) lateral, or the **obliterated hypogastric arteries.**

(1) Median, or urachus. This interesting fœtal relic, the intra-abdominal part of the allantois, passes up between the apex of the bladder and the umbilicus.

(2) The obliterated hypogastric arteries. These, the remains of vessels which during fœtal life carry the impure blood of the fœtus out to the mother through the umbilicus, run up and join the urachus at the umbilicus.

In relation to these cords are the following **fossæ**:—(*a*) A **medial** one, between the urachus and the obliterated hypogastric artery. This corresponds, on the anterior surface, to the subcutaneous inguinal (external abdominal) ring. Through this fossa comes the commonest form of direct inguinal hernia. (*b*) Between the obliterated hypogastric artery and the inferior epigastric artery, which runs upward and medially to form the lateral boundary of Hesselbach's triangle, is **an intermediate fossa.** This is the smallest of all. The rarer form of direct hernia comes through here. (*c*) The **lateral fossa** is lateral to the inferior epigastric artery. It is the most distinct of the three, from the way in which the cord or round ligament passes down within a glove-like vaginal process of the transversalis fascia. This fossa corresponds to the abdominal ring.

The coverings of a direct hernia may now be considered, together with **the two-fold manner of exit** of this hernia. It only traverses the lower part of the canal, making its way through either the medial or the intermediate inguinal pouch. (i) The commonest form, coming through the medial inguinal pouch, either pushes its way through or stretches before it the falx inguinalis. Its *coverings* are:—(1) Peritoneum; (2) extra-peritoneal fat; (3) transversalis fascia; (4) falx inguinalis (unless this is suddenly burst through); (5) (6) (7). At the subcutaneous ring the three coverings are the same as in the oblique variety. (ii) This rarer form of direct hernia comes through the intermediate inguinal pouch. As a rule, the falx inguinalis does not reach over this fossa. The coverings will be the same as in the last, with two exceptions—there is no falx inguinalis, and the cremasteric fascia, if well developed, will be present.

Varieties of inguinal hernia according to the condition of the vaginal process of peritoneum.—Inguinal herniæ have above been classified according to their relation to the deep epigastric artery. It remains to allude to the arrangement of these same herniæ according to the varying condition of the **processus vaginalis.** This pouch of peritoneum, which paves the way for the passage of the testis before this organ makes its start, eventually becomes the parietal layer (p. 1387) of the tunica vaginalis below, in this fashion: During the first few weeks after birth the process becomes obliterated at two spots—one near the abdominal ring, and one just above the testis. The obliterative process, commencing first above and descending, and then, ascending from below, the shrivelling continues until nothing is left save the tunica vaginalis below. The following are possible hernial results of an imperfect obliteration of the process:—

(1) If the process does not close at all, a descending **hernia** is called **congenital.** This may make its way into the scrotum. The testis is now enveloped and concealed by the hernia.

(2) If the process is closed only above, i. e., near the abdominal ring, two varieties may be met with, *the infantile* and the *infantile encysted.* In the *infantile*, owing to pressure above, the weak septum gradually yields and forms a sac behind the unobliterated lower part of the processus funiculo-vaginalis. Thus three layers of peritoneum may now be met with in an operation, the two of the incompletely obliterated tunica vaginalis, and the proper sac of the hernia. In the **encysted infantile** variety the hernial pressure causes the septum to yield and form a sac projecting into, not behind, the incompletely obliterated tunica vaginalis. Here, theoretically, two layers of peritoneum will be met with. Another variety of such an encysted hernia may be produced by rupture, not stretching, of the above-mentioned septum.

(3) If the processus vaginalis be closed below and not above, a patent tubular process of peritoneum will lead down as far as the top of the testis. Any hernia into this process is called **a hernia into the funicular process.** All these varieties save the congenital and hernia into the funicular process are rare in practice. Other practical points are that all herniæ in children and young adults are probably of congenital origin, and, therefore, the weakness is often bilateral, though it may not be so palpably. This applies to both sexes. Again in hernia of sudden origin into the funicular process with narrow surroundings, strangulation may be very acute.

Inguinal hernia in the female.—The inguinal canal in women is smaller and narrower than in men. Inguinal hernia is, therefore, less common in the female sex, and occurs in patients who happen to be the subjects of an unobliterated processus vaginalis, which extends for a varying distance along the round ligament, and is called the canal of Nuck. Inguinal hernia in the female is, therefore, always congenital. It is, practically, always of the oblique variety, and travels along the round ligament toward the labium majus. Its coverings will be the same as those of the oblique variety in the male, save that the cremaster, as a distinct muscle, is absent, and any fibres of the internal oblique which may be present are but little developed.

FEMORAL HERNIA

Parts concerned in femoral hernia.—(1) **Skin and superficial fascia of groin.**—The latter consists of two layers: (*a*) **Superficial layer of superficial fascia.**—Fatty, met with over the whole groin, and continuous with the superficial fascia

of the rest of the body. (*b*) **Deep layer of superficial fascia.**—Thin and membranous, only met with over the lower third of the abdominal wall and to the medial side of the groin.

It is continuous through the scrotum with the deep layer of the superficial fascia of the perineum. Just below the inguinal ligament it is joined to the fascia lata. From these two facts it results that in rupture or giving way of the urethra the extravasated urine may come forward by way of the genitals (p. 1385) and from the continuity of the fascia make its way on to the abdomen, but not down on to the thigh.

Between the two layers of superficial fascia lie the superficial nodes of the groin, the superficial branches of the common femoral artery, one or two cutaneous nerves, and some veins descending to the fossa ovalis to join the great saphenous vein.

(2) **Inguinal (Poupart's) ligament.**—This is also known as the crural arch, a misnomer, as 'crus' means leg. A description of its shape and attachments is given on p. 1371. Owing to the connection of the fascia lata to its lower border, the fossa ovalis (saphenous opening), which is situated in the fascia lata, and has its upper cornu blending with the inguinal ligament, will be affected by movements of the thigh, much as is the subcutaneous inguinal (external abdominal) ring, being tightened and stretched when the limb is extended and abducted, relaxed when it is adducted and flexed.

FIG. 1122.—THE LACUNÆ BENEATH THE INGUINAL LIGAMENT. (Lockwood.)

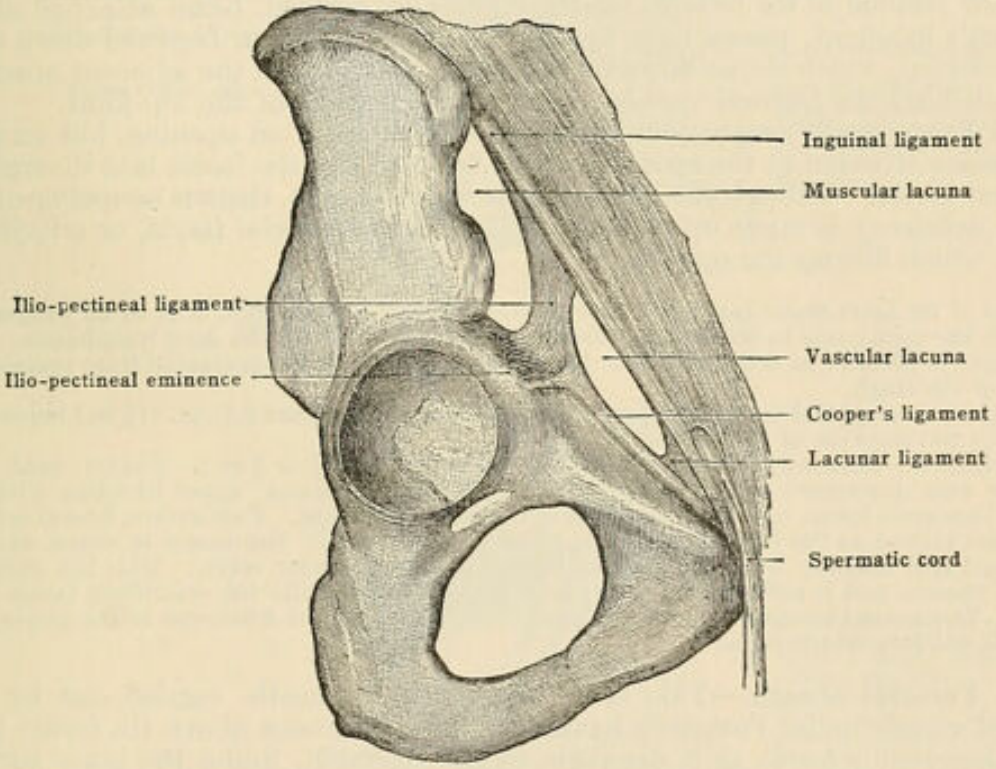

The **parts beneath the ligament** which block up the gap between it and the innominate bone are of the utmost importance in preventing the escape of a femoral hernia (fig. 1122).

The different structures are arranged in three compartments (fig. 1122), named latero-medially:—A. **lateral, iliac,** or **muscular;** B. **central,** or **vascular;** and C. **medial,** or **pectineal.** Of these, the first is the largest; the second or intermediate one lies slightly nearer to the inguinal ligament than the other two; while the medial compartment differs from the other two by not communicating with the pelvis, being closed above (*vide infra*).

(A) The **lateral, or iliac, compartment** is bounded in front by the inguinal ligament and the iliac fascia, which is here blending with it, behind by the ilium, laterally by this bone and the sartorius, and medially by the ilio-pectineal septum, which, descending from the blending of the iliac fascia and the inguinal ligament above, passes down to the ilio-pectineal eminence, and thence to the medial aspect of the front of the capsule of the hip-joint. This compartment transmits the ilio-psoas and femoral (anterior crural) and lateral cutaneous nerves. (B) The **vascular compartment** is bounded, in front, by the inguinal ligament and the transversalis fascia, which here blends with it, forming the so-called deep crural arch, and at the same time

descends on to the front of the femoral sheath. The posterior boundary, Cooper's ligament, is formed by the meeting of the ilio-pectineal septum laterally and the pectineal fascia or sheath—medially the lacunar (Gimbernat's) ligament, and laterally the ilio-pectineal septum. This intermediate compartment transmits the ex ernal iliac vessels and the lumbo-inguinal nerve. This lies to the lateral side of the artery, the vein medially. Between the vein and the base of the lacunar ligament is the femoral canal (*vide infra*). (C) The **medial** or **pectineal compartment** is bounded by the pectineal fascia, continuous with the pubic part of the fascia lata, and behind by the pubic ramus. It lodges the upper end of the pectineus muscle, and the handle of a scalpel passed upward along the muscle would be prevented from passing into the pelvis by the lacunar ligament and the blending of the pectineal fascia with the upper border of the pubic ramus.

(3) **Lacunar (Gimbernat's) ligament.**—This is merely the triangular medial attachment of Poupart's ligament. Its apex is attached to the pubic tubercle; of its three borders, the base is free toward the vein and the femoral canal. Its upper border is continuous with Poupart's ligament; its lower is attached to the terminal (ilio-pectineal) line.

(4) **Fascia lata.**—Two portions are described over the upper part of the thigh: —(*a*) An **iliac,** lateral and stronger, attached to the inguinal ligament in its whole extent and lying over the sartorius, ilio-psoas, and rectus. (*b*) A **pubic,** medial, weaker, and much less well defined, is attached above to the terminal line and the tubercle of the pubes. The upper cornu of the fossa ovalis is at the lacunar ligament, and at the lower cornu the two portions of the fascia blend.

Their relation to the femoral vessels.—The iliac portion, being attached along Poupart's ligament, passes over these. The pubic portion, fastened down over the pectineus, which slopes down on to a deeper plane than the adjacent muscles, passes behind the femoral vessels to end on the capsule of the hip-joint.

(5) **Fossa ovalis (saphenous opening).**—This is not an opening, but an oval depression, situated at the spot where the two parts of the fascia lata diverge on different levels. Though the fascia lata is wanting here, there is no real opening, as the deficiency is made up by the deep layer of superficial fascia, or cribriform fascia, which fills up the opening.

Uses of the fossa ovalis (saphenous opening).—Though a weak spot, it is so on purpose to transmit the saphenous to the femoral vein, and the superficial to the deep lymphatics. The depression is present in order to allow the saphenous vein to be protected from pressure in flexion of the thigh.

Site.—At the medial and upper part of the thigh, with its centre 3.7 cm. (1½ in.) below and lateral to the tubercle of the pubis.

Diameters.—Vertically, 2.5 cm. (1 in.), by 1.2 or 1.8 cm. (½ or ¾ in.). *Shape:* oval, with its long axis downward and laterally. *Two extremities* or *cornua:* upper blending with the lacunar ligament; lower, where the two parts of the fascia lata meet. *Two borders:* lateral or falciform, also known as the ligament of Hey, or femoral ligament. Semilunar in shape, arching downward and laterally from the lacunar ligament to the inferior cornu. This lies over the femoral vessels, and is adherent to them; to it is fixed superficially the cribriform fascia (*vide infra*). The medial border is much less prominent, owing to the weakness of the pubic part of the fascia lata which forms it.

(6) **Femoral sheath.**—This is a funnel-shaped sheath, carried out by the femoral vessels under Poupart's ligament, and continuous above (in front) with the transversalis fascia as it descends to the ligament, lining the inner surface of the abdominal wall; and (behind) with the iliac fascia, and below continuous with the proper sheath of the femoral vessels.

It is not only funnel-shaped, but large and loose, for two reasons:—(*a*) That there be plenty of room for the femoral vein and the slowly moving venous current in it to ascend without compression; (*b*) to allow all the movements of the thigh taking place—flexion and extension—without undue stretching of the vessels. By two connective-tissue septa the sheath is divided into three compartments—the lateral for the artery, the intermediate for the vein, and the medial one for the femoral canal (*vide infra*). Thus one septum lies between the artery and vein, and another between the vein and the femoral canal.

(7) **Femoral canal.**—Definition: the medial division of the femoral sheath. The fascia transversalis and fascia iliaca meet directly on the lateral side of the femoral artery, but not so closely on the medial side of the femoral vein. Hence a space exists here, perhaps to prevent the thin-walled vein, with its sluggish current, being pressed upon, but it is merely a slight gap—not a canal, unless so made by a knife or by the dilating influence of a hernia.

Length: about 1.9 cm. (¾ in.). *Limits:* below, fossa ovalis; above, femoral ring (*vide infra*).

Boundaries.—Laterally, a septum between it and the vein; medially, base of the lacunar ligament and meeting of fascia iliaca and transversalis; behind, fascia iliaca; in front, fascia transversalis.

Contents.—Cellular tissue and fat, continuous with extra-peritoneal fatty layer. A lymphatic node, which is inconstant. Lymphatics passing from inguinal nodes to those in the pelvis.

(8) **Femoral ring.**—This is mainly an artificial product. It is the upper or abdominal opening of the femoral canal. *Shape:* oval, with its long axis transverse. It is larger in women. *Boundaries:* medially, the lacunar ligament; laterally, the femoral vein; in front, the inguinal ligament and the thickening of the transversalis fascia attached to it, and called 'the deep crural arch'; behind the pectineus and Cooper's ligament, a thickened fascial bundle attached

FIG. 1123.—IRREGULARITIES OF THE OBTURATOR ARTERY. (After Gray.)

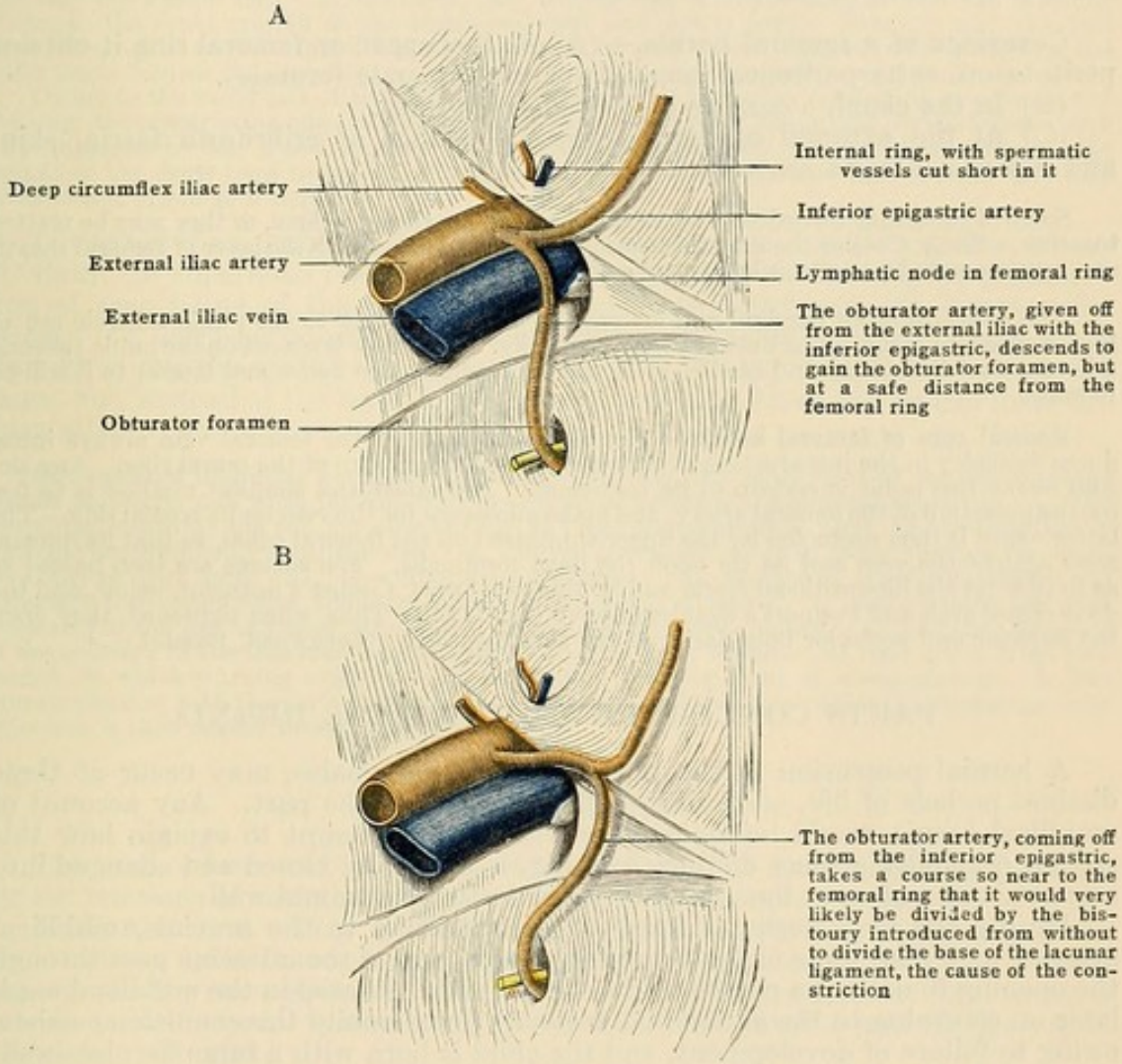

to the linea terminalis (fig. 1122). It is closed by the septum crurale, which is a barrier of fatty connective tissue, continuous with the extra-peritoneal fatty layer, perforated by lymphatics passing upward to the pelvic nodes.

Position of vessels around the ring.—Laterally the femoral vein; above, the epigastric vessels as they ascend from the external iliac vessels, pass close to the upper and lateral aspect of the ring; immediately in front are the cord and spermatic vessels always to be remembered in this hernia in the male; toward the medial side there may be an unimportant anastomosis between the epigastric artery above and the obturator below.

If from dilatation of the above anastomosis the obturator artery comes off abnormally from the inferior epigastric, it will descend, and usually does so, close to the junction of the external iliac and common femoral vein, and thus to the lateral and so the safe, side of the ring (fig. 1123, A). In a very few cases it curves more medially, close to the lacunar ligament, and thus to the medial side of the ring, and is then in great danger (fig. 1123, B). In two out of

every five cases the obturator arises from the inferior epigastric. In about thirty-seven per cent. of the cases with such an origin the artery either crosses or courses along the side of the ring. (Cunningham.)

Course of femoral hernia.—At first this is downward in the femoral canal. A pouch of peritoneum having been gradually, after repeated straining, coughing, etc., pushed through the weak spot, the femoral ring, further weakened perhaps, together with all the parts in the femoral arch, by child-bearing, some extra effort will force intestine or omentum into this pouch and thus form a hernia. Thus formed, femoral hernia passes at first downward in the femoral canal as far as the fossa ovalis, but, as a rule, does not go farther downward on the thigh, but mounts forward and upward, and somewhat laterally, even reaching the level of the inguinal ligament. The reasons for this change of position are:—(1) The narrowing of the femoral sheath, funnel-like, i. e., wide above, but narrowed below; (2) the unyielding nature of the lower margin of the fossa ovalis; (3) the fact that this margin and the lateral border are united to the femoral sheath; (4) the constant flexion of the thigh; (5) the fact that vessels (chiefly veins) and lymphatics descend to the fossa ovalis, the veins to join the saphenous vein and the lymphatics to join the deeper group; these descending vessels serve to loop upward or suspend a femoral hernia, and thus prevent its further course downward.

Coverings of a femoral hernia.—(A) **At the upper** or **femoral ring** it obtains peritoneum, extra-peritoneal fat, and septum femorale (crurale).

(B) **In the canal,** a coating of the femoral sheath.

(C) **At the external opening,** further coverings of cribriform fascia, skin, and superficial fascia are added.

Some of these may be deficient by the hernia bursting through them, or they may be matted together. Sir A. Cooper thought this especially likely to occur with the layer of femoral sheath and septum crurale, to which he gave the name of *fascia propria*.

The relations of an inguinal and femoral hernia respectively to the pubic tubercle are of importance in distinguishing between them clinically. If a finger is placed on the pubic tubercle a hernia that lies above and medial to it will be inguinal, one below and lateral to it will be femoral.

Radical cure of femoral hernia.—The close proximity of the femoral vein always introduces difficulty in the introduction of the deep sutures for closure of the crural ring. Any closure below this point is certain to be inefficient. The safest and simplest method is to feel for the pulsation of the femoral artery, and make allowance for the vein on its medial side. The latter vessel is then protected by the finger-tip passed up the femoral canal, so that its dorsum rests against the vein and its tip upon the linea terminalis. The sutures are then passed so as to pick up the ilio-pectineal fascia and its thickened part, Cooper's ligament, below, and the deep crural arch and Poupart's ligament above (fig. 1122). Thus, when tightened, they draw the anterior and posterior boundaries of the ring together. (Lockwood, Bassini.)

PARTS CONCERNED IN UMBILICAL HERNIA

A hernial protrusion at the umbilicus, or exomphalos, may occur at three distinct periods of life, according to the anatomy of the part. Any account of umbilical hernia would be incomplete without an attempt to explain how this region, originally a most distinct opening, is gradually closed and changed into a knotty mass of scar, the strongest point in the abdominal wall.

During the first weeks of fœtal life, in addition to the urachus, umbilical arteries, and vein, some of the mesentery and a loop of the intestine pass through the opening to occupy a portion of the body cavity situated in the umbilical cord, later on returning to the abdominal cavity. Occasionally this condition persists, owing to failure of development, and the child is born with a large hernial swelling outside the abdomen, imperfectly covered with skin and peritoneum. To this condition the term **congenital umbilical hernia** should be applied.

Later on in fœtal life it is the umbilical vessels alone which pass through this opening. At birth there is a distinct ring, which can be felt for some time after in the flaccid walls of an infant's belly. If this condition persist, a piece of intestine may find its way through, forming the condition which should be known as **infantile umbilical hernia.**

This condition is not uncommon. Why it is not more frequently met with is explained by the way in which this ring of infancy is closed and gradually converted into the dense mass of scar tissue so familiar in adult life. This is brought about—(1) by changes in the ring itself; (2) by changes in the vessels which pass through it.

(1) **Changes in the ring itself.**—The umbilical ring is surrounded by a sphincter-like arrangement of elastic fibres, best seen during the first few days of extra-uterine life, on the

posterior aspect of the belly wall. In older infants these fibres lose their elasticity, become more tendinous, and then shrink more and more. As they contract they divide, as by a ligature, the vessels passing through the ring, thus accounting for the fact that the cord, wherever divided, drops off at the same spot and without bleeding.

(2) **Changes in the vessels themselves.**—When blood ceases to traverse these, their lumen contains clots, their muscular tissue wastes, while the connective tissue of their outer coat hypertrophies and thickens. Thus, the umbilical vessels and the umbilical ring are, alike, converted into scar tissue, which blends together. This remains weak for some time, and may be distended by a hernia (infantile).

Finally, we have to consider the state of the umbilicus in adult life. The very dense, unyielding, fibrous knot shows two sets of fibres:—(1) Those decussating in the middle line; and (2) two sets of circular fibrous bundles which interlace at the lateral boundaries of the ring. The lower part of the ring is stronger than the upper. In other words, **umbilical hernia of adult life,** when it comes through the ring itself and not at the side, always comes through the upper part. In the lower three-fourths of the umbilicus the umbilical arteries and urachus are firmly closed by matting in a firm knot of scar tissue; in the upper there is only the umbilical vein and weaker scar. To the lower part run up the umbilical arteries and the urachus. Owing to the rapid growth of the abdominal wall and pelvis before puberty, and the fact that the urachus and the umbilical arteries, being of scar tissue, elongate with difficulty, the latter parts depress the umbilicus by reason of their intimate connection with its lower half.

Owing to the usual exit of an umbilical hernia of adult life being through the upper part of the ring, the constricting edge in strangulation should be sought below and divided downward. As pointed out by Mr. Wood, it is here that the dragging weight of the hernial contents and the weight of the dress tend to produce the chief results of strangulation. An incision here also gives better drainage if required.

Coverings of an umbilical hernia.—These, more or less matted together, are:—(1) Skin; (2) superficial fascia, which loses its fat over the hernia; (3) prolongation of scar tissue of the umbilicus gradually stretched out; (4) transversalis fascia; (5) extra-peritoneal fatty tissue; (6) peritoneum. If the hernia come through above the umbilicus, or just to one side, the coverings will be much the same; but, instead of the layer from the umbilical scar, there will be one from the linea alba.

Strangulated umbilical hernia of adult life.—In this, the most fatal of the strangulated herniæ ordinarily met with, the following are practical points in the surgical anatomy:—1. The coverings, including the sac, are always thin, at times so markedly so that the intra-peritoneal contents are practically subcutaneous. 2. The sac is multilocular, and one or more of its chambers may lie very deep. 3. The contents are numerous, viz., omentum, often voluminous and adherent, transverse colon, and later in the history, small intestine. 4. The contents are often adherent to the sac and each other, thus explaining the irreducibility. 5. The long duration of the presence of the transverse colon with its stouter walls accounts for the period, often prolonged, in which warning evidence of incarceration precedes that of strangulation. 6. The communication with the peritoneal sac is direct, short, and during a prolonged operation, free. Infection is thus readily brought about.

THE BACK

The surface form and landmarks of the back will be considered first, followed by the relations of skeleton, muscles, viscera and nervous system.

Median furrow.—This is more or less marked according to the muscular development, lying between the trapezii and semispinales capitis, in the cervical region, and the sacro-spinales lower down. The lower end of the furrow corresponds to the interval between the spines of the last lumbar and the first sacral vertebræ. (Holden.)

Vertebral spines.—Those of the upper cervical region are scarcely to be made out even by deep pressure. That of the axis may be detected in a thin subject. Over the spines of the middle three cervical vertebræ is normally a hollow, owing to these spines receding from the surface to allow of free extension of the neck. The seventh cervical is prominent, as its name denotes. Between the skull and atlas, or between the atlas and epistropheus, a pointed instrument might penetrate, especially in flexion of the neck.

Of the **thoracic spines,** the first is the most prominent, more marked than that of the last cervical; the third should be noted as on a level with the medial end of the scapular spine, and in some cases with the bifurcation of the trachea; that of the seventh with the lower angle of the scapula; that of the twelfth with the lowest part of the trapezius and the head of the twelfth rib. The obliquity and overlapping of the thoracic spines are to be remembered.

Of the **lumbar spines,** the most important are the second, which corresponds to the termination of the cord, and the fourth, which marks the highest part of the iliac crests and the bifurcation of the abdominal aorta. The lumbar spines project horizontally, and correspond with the vertebral bodies. The third is a little above the umbilicus.

Owing to the obliquity of the thoracic spines, most of them do not tally with the heads of the corresponding ribs. Thus, the spine of the second corresponds with the head of the third rib; the spine of the third with the head of the fourth rib; and so on till we come to the eleventh and twelfth vertebræ, which do tally with their corresponding ribs. (Holden.)

The lower ribs may be felt lateral to the sacro-spinalis but in counting them from below it must be remembered, as pointed out by Holl, that in quite a

FIG. 1124.—DIAGRAM AND TABLE SHOWING THE APPROXIMATE RELATION TO THE SPINAL NERVES OF THE VARIOUS MOTOR, SENSORY, AND REFLEX FUNCTIONS OF THE SPINAL CORD.
(Arranged by Dr. Gowers from anatomical and pathological data.)

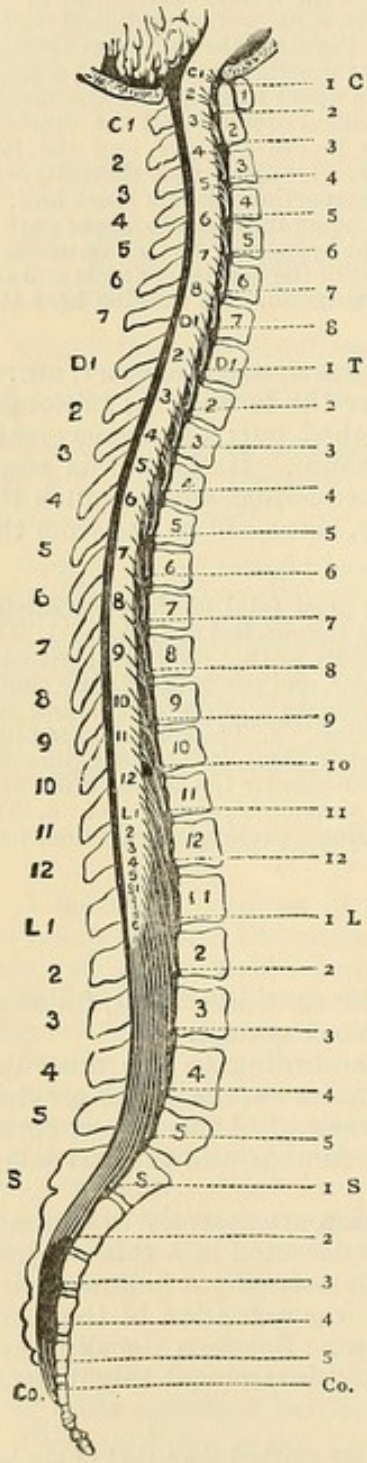

	MOTOR	SENSORY	REFLEX
1 C	Sterno-mastoid	Neck and scalp	
2	Trapezius	Neck and shoulder	
3	Diaphragm		
4	Serratus	Shoulder	Scapular
5	Shoulder	Arm	
6	Arm (musc.)	Hand	
7	Hand (ulnar lowest)		
8			
1 T			
2			
3			
4		Front of thorax	Epigastric
5			
6	Intercostal muscles	Xiphoid area	
7			
8			
9			
10	Abdominal Muscles	Abdomen (Umbilicus 10th)	Abdominal
11			
12		Buttock, upper part	
1 L			
2	Flexors, hip	Groin and scrotum (front)	Cremasteric
3	Extensors, knee	Thigh: Lateral side, front	Knee-joint
4	Adductors (h'p)	Medial side	
5		Leg, medial side	
1 S	Abductors	Buttock, lower	Gluteal
2	Extensors (?) Flexors, knee (?)	Back of thigh	Foot-clonus
3	Muscles of leg moving foot	Leg and foot (except medial part)	Plantar
4	Perineal and anal muscles	Perineum and anus	
5			
Co.		Skin from coccyx to anus	

considerable percentage the last rib is so abnormally short that it does not reach as far as the lateral border of the sacro-spinalis; or is so rudimentary as to resemble a transverse process (consequently the only safe method of counting ribs is from above). In these cases the lower end of the pleura may pass from the lower part of the twelfth thoracic vertebra, almost horizontally to the lower edge of the eleventh rib.

Muscles.—The student will remember the greater number and complexity and the numerous tendons of the muscles which run up on either side of the spines; the firmness and inextensibility of their sheaths; the large amount of cellular tissue between them; and the fact that toward the nape of the neck these muscles lie exposed instead of being protected in gutters, as is the case below: all these anatomical points explain the extreme painfulness and obstinacy of sprains here.

Trapezius.—To map out this muscle, the arm should be raised to a right angle with the trunk. The external occipital protuberance should be dotted in, and the superior nuchal line passing out from this; below, the twelfth thoracic spine should be marked; and laterally, the lateral third of the clavicle and the commencement of the scapular spine. Then a line should be drawn from the protuberance vertically downward to the twelfth thoracic spine; a second from about the middle of the superior nuchal line to the posterior and lateral third of the clavicle; and a third from the last thoracic spine upward and laterally to the root of the spine of the scapula.

FIG. 1125.—RELATIONS OF THE ABDOMINAL VISCERA TO THE ANTERIOR BODY WALL.

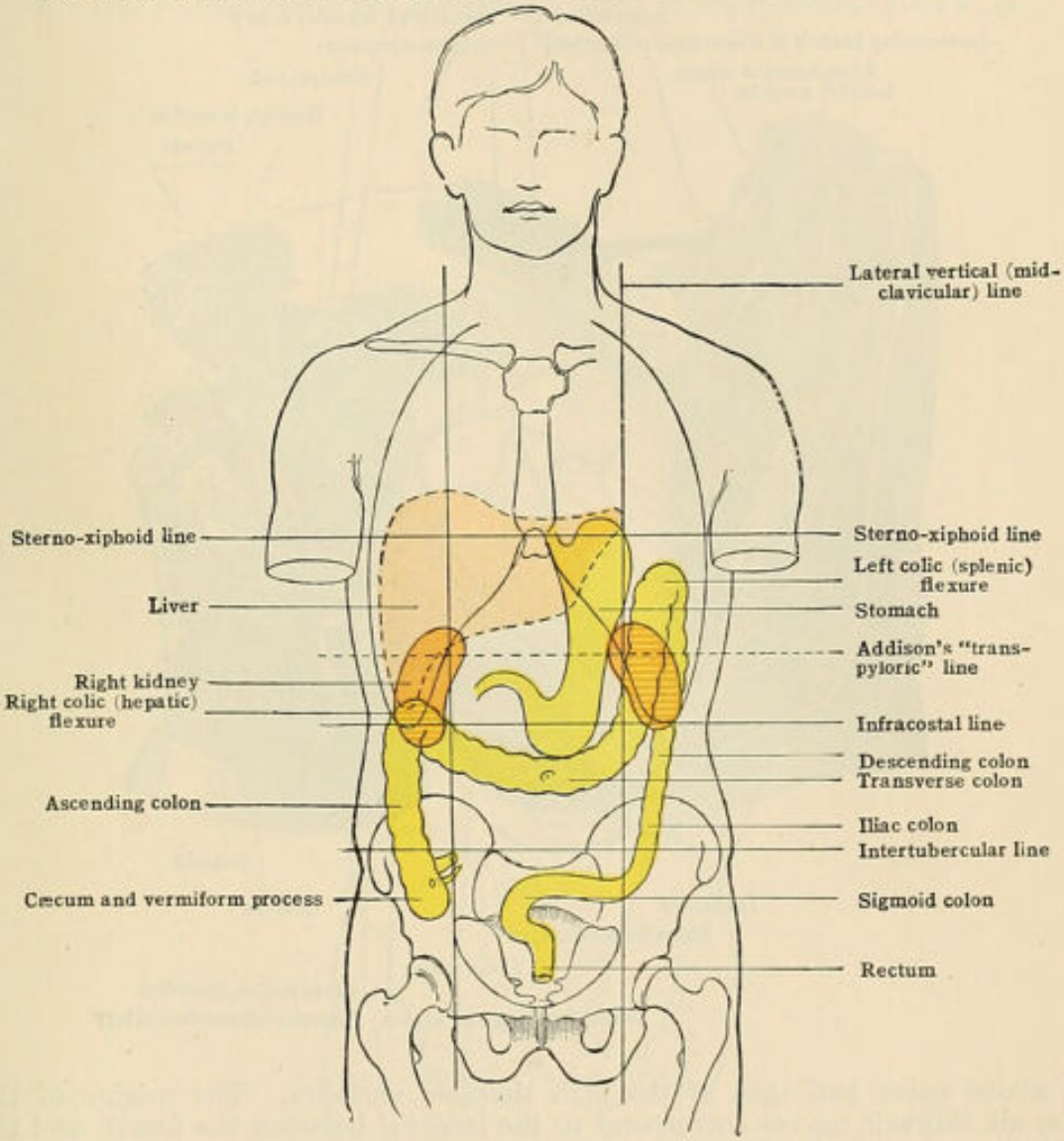

Latissimus dorsi.—The arm being raised above a right angle, the spines of the sixth thoracic and the third sacral vertebræ should be marked; then the outer lip of the crest of the ilium, the lower two or three ribs, the lower angle of the scapula, and the posterior fold of the axilla, and finally the intertubercular (bicipital) groove should all be marked.

A vertical line from the sixth thoracic to the third sacral spine will give the spinal origin of the muscle. Another from the third sacral spine to a point on the iliac crest, 2.5 cm. (1 in.) or more lateral to the edge of the sacro-spinalis, will give the origin of the muscle from the sheath of the sacro-spinalis and the ilium. A line from the sixth thoracic spine, almost transversely at first, with increasing slight obliquity over the inferior angle of the scapula to the axilla and intertubercular groove, will mark the upper border of the muscle. Another very oblique line from the point of the iliac crest upward and laterally to the axilla will give the lower border and the tapering triangular apex of the insertion. The muscle may be attached to the angle of the scapula, or separated from it by a bursa.

Triangle of Petit.—This small space lies above the crest of the ilium, at about its centre, bounded by the anterior edge of the latissimus behind and the posterior border of the external oblique, in front. Through this gap, when the muscles are weak, a lumbar abscess occasionally, and very rarely, a lumbar hernia, may appear.

Origin of spinal nerves.—It is very important to remember the relations of these to the vertebral spines, in determining the results of disease or injury of the cord and the parts thereby affected. The above relations may be given briefly as follows:—

The origins of the eight cervical nerves correspond to the cord between the occiput and the sixth cervical spine. The upper six thoracic come off between

FIG. 1126.—CHIEF ARTERIAL ANASTOMOSES ON THE SCAPULA.
(From a dissection in the Hunterian Museum.)

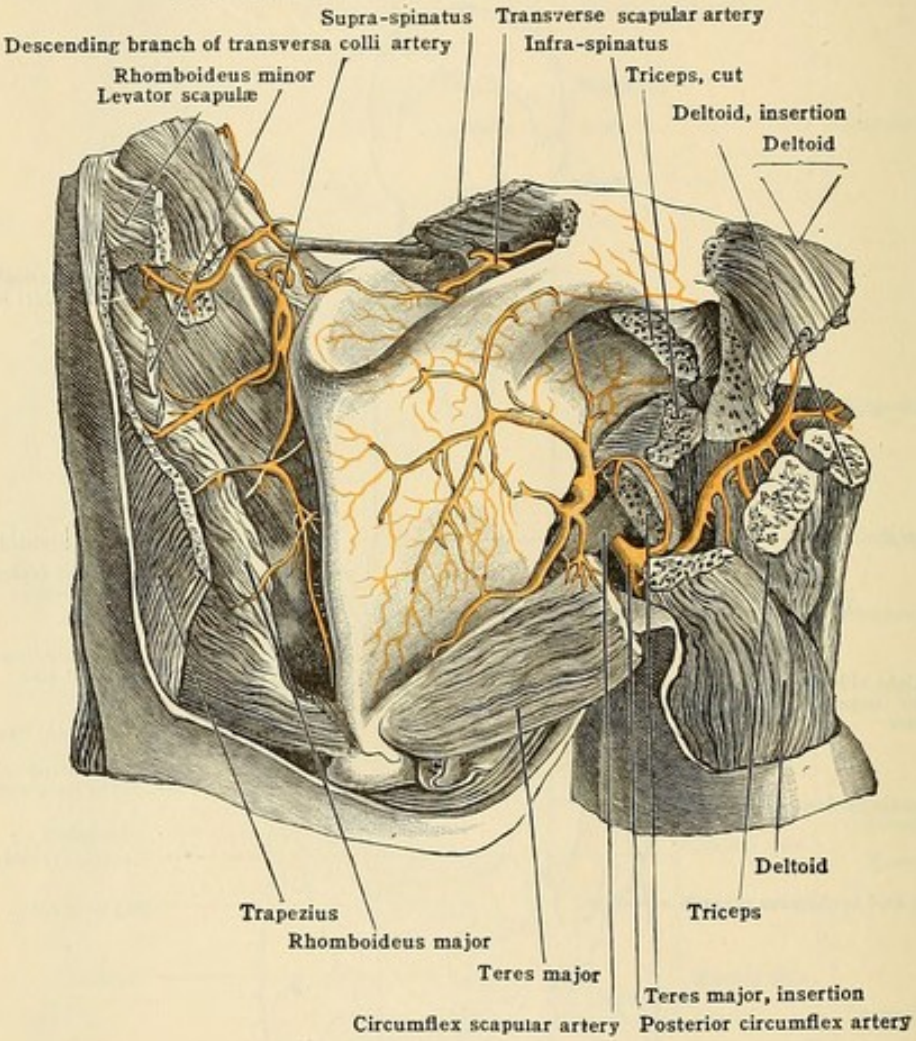

the above spine and that of the fifth thoracic vertebra. The origins of the lower six thoracic nerves correspond to the interval between the fourth and the tenth thoracic spines. The five lumbar arise opposite the eleventh and twelfth thoracic spines; and the origins of the five sacral correspond to the first lumbar spines. The diagram and table (fig. 1124), arranged by Dr. Gowers from anatomical and pathological data, show the relations of the origins of the nerves to their exits from the vertebral canal, and the regions supplied by each.

Scapula, its muscles and arterial anastomoses.—Amongst the landmarks in the back, the student should be careful to trace the angles and borders of the scapula as far as these are accessible. The upper border is the one most thickly covered. With the hands hanging down, the upper (medial) angle corresponds to the upper border of the second rib; the lower angle to the seventh intercostal space; and the root of the spine of the scapula to the interval between the third and fourth thoracic spines.

The axillary border of the scapula, covered by the latissimus dorsi and teres major, may best be palpated with the arm hanging to the side. The vertebral border is brought into prominence by placing the hand on the opposite shoulder. This border is held in apposition with the thorax by the serratus anterior; consequently in paralysis of that muscle, supplied by the long thoracic nerve (5, 6, and 7 C.), it becomes unduly prominent, giving rise to "winged scapula." Fig. 1126 shows the chief arteries around the scapula. The anastomoses on the acromial process between the transverse scapular (supra-scapular) thoraco-acromial, and circumflex humeral arteries are not shown. The numerous **points of ossification,** primary and secondary, by which this bone is developed explain, in part, the frequency of cartilaginous and other growths here.

The anatomy of the loin behind, the **ilio-costal region,** is of prime importance, owing to the numerous operations here. **The lateral border of the sacro-spinalis and quadratus lumborum** may be indicated on the surface thus. (Stiles.) That of the sacro-spinalis by drawing a line from a point on the iliac crest 8.2 cm. (3½ in.) (four fingers'-breadth) from the middle line upward and slightly laterally to the angles of the ribs. That of the quadratus passing upward and slightly medially lies a little lateral to that of the sacro-spinalis (erector) at the crest,

FIG. 1127.—RELATIONS OF THE ABDOMINAL VISCERA TO THE POSTERIOR BODY WALL.

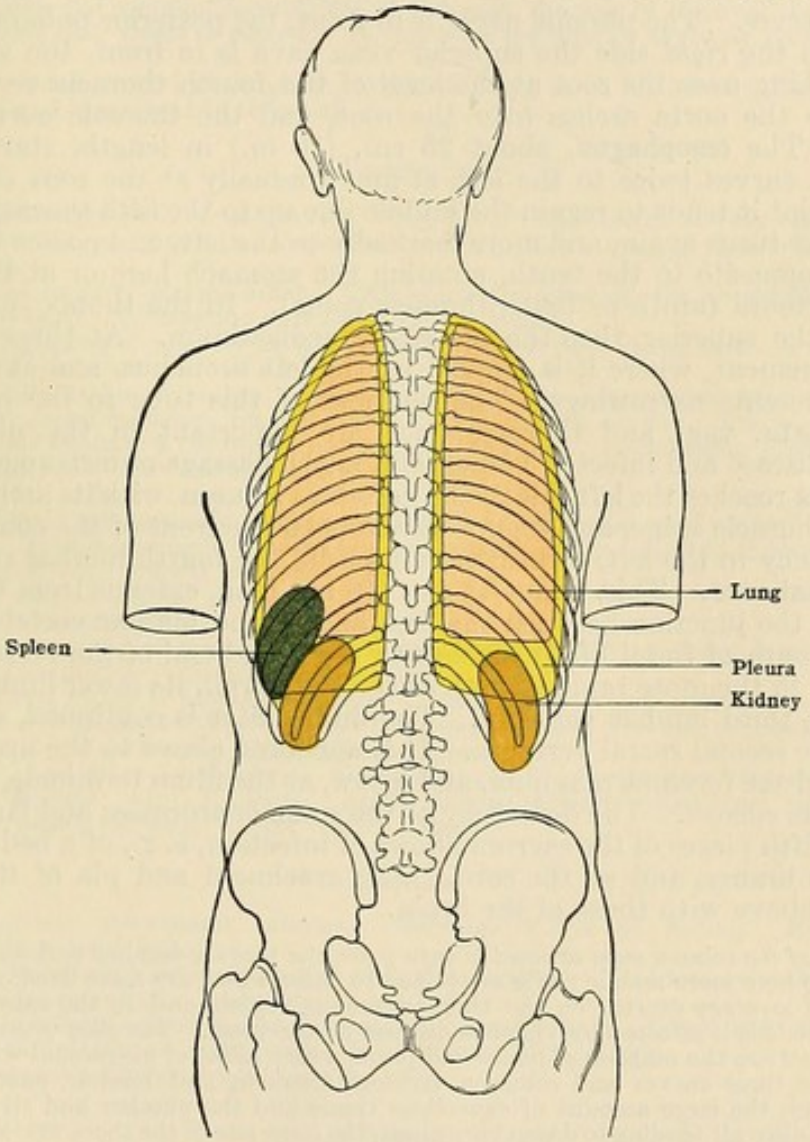

and a little medial to it at the twelfth rib. The ascending and descending colon lie in the slightly depressed angle between the two muscles. The ilio-costal region varies greatly in space according to the length of the lower ribs, shape of the chest, and development of the iliac crest. An incision here—that for exploration of the kidney may be taken as the type—would be an oblique one, about 10 cm. (4 in.) long, starting in the angle between the twelfth rib and the sacro-spinalis muscle and passing forward and downward toward the anterior extremity of the iliac crest. In its upper part the incision should lie 1.2 cm. (½ in.) below the tweltfh rib. The anterior fibres of the latissimus dorsi are divided behind, the posterior ones of the external oblique in front. The yellowish-white lumbar fascia now comes into view, and is the first important landmark. It and the fibres of the internal oblique and transversus which arise from it are next carefully divided. The last thoracic nerve and lowest intercostal artery may also require division. If the latter is cut close to the rib, the hæmorrhage is troublesome. The transversalis fascia remains to be divided. To avoid the peritoneum, the deeper part of the

incisions should always be made from behind forward. If more room is required, as in large growths or in exploration of the ureter, the incision must be prolonged beyond the iliac crest, the lumbo-ilio-inguinal incision of Morris.

Viscera.—Several of these, which can be mapped in behind—viz., the kidneys, spleen, etc.—have been already mentioned (pp. 1375, 1379).

The commencement of the **trachea** and **œsophagus** has been given in front as corresponding to the sixth cervical vertebra. If examined from behind, this point, owing to the obliquity of the spines, would be a little lower down. The **trachea,** about 12.5 cm. (5 in.) long, descending in the middle line, bifurcates opposite to the interval between the third and fourth thoracic spines (or fourth and fifth bodies). The **bronchi** enter the lungs at about the level of the fifth thoracic spine, the right being the shorter, wider, and more horizontal. The **root of the lung** is opposite to the fourth, fifth, and sixth dorsal spines, midway between these and the vertebral border of the scapula. The structures in it are the bronchus, pulmonary artery, two pulmonary veins, bronchial vessels, lymphatics, and nerves. The phrenic nerve is in front, the posterior pulmonary plexus behind. On the *right* side the superior vena cava is in front, the vena azygos (major) arching over the root at the level of the fourth thoracic vertebra. On the *left* side the aorta arches over the root, and the thoracic aorta descends behind it. The **œsophagus,** about 25 cm. (10 in.) in length, starting in the middle line, curves twice to the left, at first gradually at the root of the neck; from this point it tends to regain the middle line up to the fifth thoracic vertebra; thence finally turns again, and more markedly to the left, and passes through the diaphragm opposite to the tenth, entering the stomach here or at the eleventh thoracic vertebra (ninth or tenth thoracic spine). In the thorax this tube traverses first the superior, then the posterior, mediastinum. At three spots, i. e., its commencement, where it is crossed by the left bronchus, and at the cardiac orifice, it presents narrowings. The relations of this tube to the pleura, pericardium, aorta, vagi, and thoracic duct are important in the ulceration of malignant disease and infected bodies, and in the passage of instruments.

The **aorta** reaches the left side of the vertebral column, with its arch just above the fourth thoracic spine, and thence descends on the front of the column, with a slight tendency to the left, to bifurcate opposite the fourth lumbar spine.

The spinal cord.—This, about 45 cm. (18 in.) long, extends from the foramen magnum to the junction between the first and second lumbar vertebræ. Up to the third month of fœtal life it reaches to the sacral end of the vertebral canal; later, owing to the more rapid growth of the bony wall, its lower limit is at birth opposite the third lumbar vertebra. The dura mater is continued, as a sheath, as low as the second sacral vertebra. It is anchored above to the upper cervical vertebræ and the foramen magnum, and below, as the filum terminale, to the periosteum of the coccyx. The deficiency of the spinous processes and laminæ of the fourth and fifth pieces of the sacrum allows of infection, e. g., of a bed-sore reaching the membranes, and so the cord. The arachnoid and pia of the cord are continuous above with those of the brain.

The parts of the column most exposed to injury are the thoraco-lumbar and cervico-thoracic partly because here more mobile parts are joined to those which are more fixed, and also from the amount of leverage exerted on the thoraco-lumbar region, and, in the case of the upper region, because this is affected by violence exerted on the head. *The chief provisions for protection of the cord* are the number of bones and joints which allow of movement without serious weakening, the three curves and columns, cervical, thoracic, and lumbar, ensuring bending before breaking; the large amount of cancellous tissue and the number and structure of the intervertebral discs all tending to damp vibrations; the large size of the theca vertebralis and the way in which the cord, anchored and slung by the thirty-one pairs of nerves and the ligamenta denticulata, about twenty in number, occupies neutral ground in the centre of the canal as regards injury directly and indirectly applied.

In **lumbar puncture** (Quincke) as a means of diagnosis or of relieving pressure advantage is taken of the fact mentioned above that the theca extends below the cord.

A line drawn joining the highest points of the iliac crests crosses the fourth lumbar spine. The needle is inserted in the median line between the third and fourth or the fourth and fifth spines, and directed forward and slightly upward. The back must be flexed as fully as possible in order to widen the interspinous spaces. The needle is passed to a depth of about 5 cm. (2 in.) in an adult, or 1.8 cm. ($\frac{3}{4}$ in.) in an infant. In the supine position the lowest part of the subarachnoid space is in the mid-thoracic region, and an anæsthetic fluid, non-diffusible and of a

higher specific gravity than the cerebro-spinal fluid, will tend to gravitate there (Barker). The level of the anæsthesia can be varied by raising the pelvis or the shoulders to different levels.

The following table, from Holden and Windle, with additions, will be found very useful in determining the relation of numerous viscera and other structures to the bodies of the vertebræ.

VERTEBRAL LEVELS

Cervical

First. Level of hard palate.

Second. Level of free edge of upper teeth.

Second and third. Superior cervical ganglion of sympathetic.

Fourth. Hyoid bone. Upper aperture of larynx.

Fifth. Thyreoid cartilage and rima glottidis. Between this and the last would be the bifurcation of the common carotid.

Sixth. Cricoid cartilage. Ending of pharynx and larynx. Consisting of the fused fifth and sixth ganglia, the middle cervical ganglion is usually opposite this vertebra. Here the omo-hyoid crosses the common carotid, and at this spot, the seat of election, the centre of the incision for tying this vessel is placed. At this level the inferior thyreoid passes behind the carotid trunk.

Seventh. Inferior cervical ganglion. Apex of lung. Arch of thoracic duct over apex of lung, outward and downward to termination.

Thoracic

First. Summit of arch of subclavian. (Godlee.) The height of this varies. Usually it is from 1.2 to 2.5 cm. ($\frac{1}{2}$ to 1 in.) above the clavicle. It is always in close relation with the cervical pleura.

Second. Level of episternal notch. This is usually opposite the fibro-cartilage between the second and third. Bifurcation of innominate. (Godlee.)

Third. Beginning of superior cava, at junction of first right costal cartilage with sternum. Highest part of aortic arch, about 2.5 cm. (1 in.) below notch.

Fourth. Bifurcation of trachea. Second piece of aortic arch, extending from upper border of second right costal cartilage, reaches spine. Arch of vena azygos. The superior mediastinum is bounded behind by the upper four thoracic vertebræ. Louis' angle, junction of manubrium and gladiolus. Thoracic aorta begins.

Fifth to ninth. Base of heart.

Sixth. Pulmonary and aortic valves, opposite third left costal cartilage at its sternal junction, in front. Commencement of aorta and pulmonary artery. End of superior cava, third right chondro-sternal junction in front.

Seventh. Mitral orifice.

Eighth. Tricuspid orifice.

Ninth. Lower level of manubrium and sterno-xiphoid line (at lower border). Opening in diaphragm for inferior vena cava (lower border).

Tenth. Level of tip of xiphoid cartilage. Lower limit of lung posteriorly. Upper limit of liver comes to the surface posteriorly. Œsophagus passes through diaphragm. Cardiac orifice of stomach (sometimes). Upper limit of spleen.

Eleventh. Lower border of spleen. Suprarenal gland. Cardia (sometimes).

Twelfth. Lowest part of pleura. Aorta passes through diaphragm (lower border). Cœliac artery (lower border). Upper end of kidney.

Lumbar

First. Superior mesenteric arteries. Pancreas. Pelvis of kidney. Renal arteries. Transpyloric line. (Addison.)

Second. Spinal cord ends at junction of first and second. Duodeno-jejunal flexure. Receptaculum (cisterna) chyli. Lower end of left kidney.

Third. Umbilicus, opposite disc between third and fourth. Lower end of right kidney.

Fourth. Bifurcation of aortic arch. Highest part of iliac crest.

Fifth. Commencement of superior vena cava.

Sacral

Third. End of pelvic colon and beginning of first piece of rectum proper. Lower limit of spinal membranes.

Fifth. Reflexion of recto-vesical pouch of peritoneum 2.5 cm. (1 in.) above base of prostate.

Coccyx (tip). 2.5 cm. (1 in.) below this commencement of anal canal. Termination of filum terminale.

THE UPPER EXTREMITY

THE SHOULDER AND ARM

The surface form and landmarks of the upper extremity will first be considered followed by the various regions of the shoulder, arm, forearm and hand.

General surface form. Landmarks.—The following **surface-marks,** of the greatest importance in determining the nature of shoulder injuries, can be made out here:—The **clavicle** in its whole extent, the **acromion process,** the **great tuberosity,** and **upper part of the shaft of the humerus.** Much less distinctly, the position of the **coracoid process** in the infraclavicular fossa and the **head of the humerus** through the axilla can be made out. The anterior margin of the **clavicle,** convex medially and concave laterally, can be made out in its whole extent, the bone, if traced laterally, being found not to be horizontal, but rising somewhat to its junction with the acromion. The **sterno-** and **acromio-clavicular joints** have been referred to at p. 1363.

The *frequency of fracture of the clavicle* is explained chiefly by its exposure to shocks of varied kinds from the upper extremity, inseparable from the out-rigger-like action of the bone and its early ossification. On the other hand, *the main safeguards* are the elasticity and curves of the bone, the way in which it is embedded in muscles which will damp vibrations, and the buffer-bond fibro-cartilages at either extremity. The looseness and toughness of the overlying skin explain the rarity of compound fracture here. The junction of the two curves is the weakest spot and the usual site of fracture. The weight of the limb acting through the coraco-clavicular ligaments and overcoming the trapezius is the chief factor in the downward displacement; the pectoralis minor and serratus anterior acting on the scapula draw the acromial fragment forward. The tip of the *acromion*, when the arm hangs by the side with the hand supinated, is in the same line as the lateral condyle and the styloid process of the radius. On the medial side, the head and medial condyle of the humerus and the styloid process of the ulna are in the same line. Thus the *great tuberosity* looks laterally, the *head* medially, and the *lesser tuberosity* somewhat forward. Between the two tuberosities runs the **intertubercular (bicipital) groove,** which,

FIG. 1128.—TRANSVERSE SECTION THROUGH THE RIGHT SHOULDER-JOINT, SHOWING THE STRUCTURES IN CONTACT WITH IT. (Braune.)

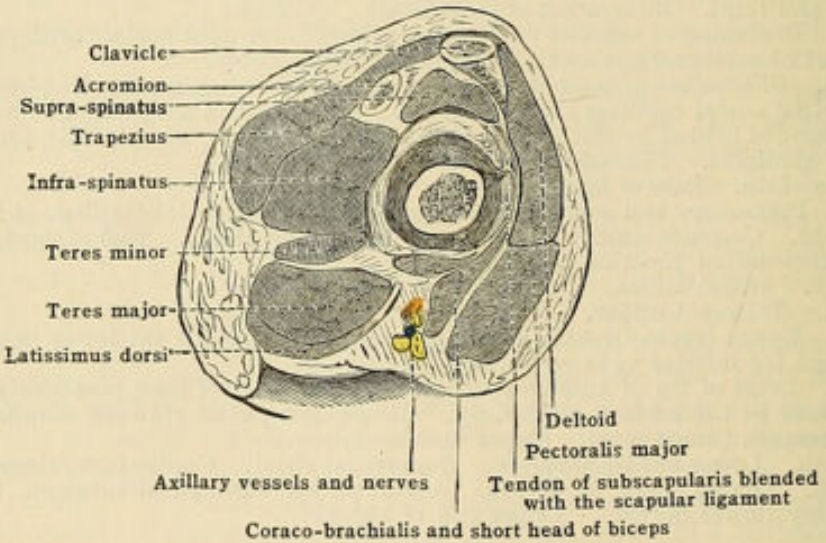

with the arm in the above position, looks directly forward. In thin subjects its lower part can be defined. Its position can be marked with sufficient accuracy by a line running downward from the acromion in the long axis of the humerus. Besides the tendon and its synovial sheath, the insertion of the latissimus dorsi, the humeral branch of the thoraco-acromial artery, and the anterior circumflex artery run in the groove. When the fingers are placed on the acromion and the thumb in the axilla, the lower edge of the glenoid cavity can be felt; and if the humerus be rotated (the elbow-joint being flexed), the head of the humerus can be felt also.

The **characteristic roundness of the shoulder** is due to the great tuberosity lying under the deltoid (fig. 1130). In dislocation the loss of this roundness is due to the absence of the head and tuberosity and consequent projection of the acromion.

This normal projection of the deltoid renders it impossible to place a flat straight body in contact with both the acromion and the lateral epicondyle at the same time (Hamilton's dislocation test). Below the junction of the lateral and middle thirds of the clavicle, between the contiguous origins of the pectoralis major and deltoid, is the infraclavicular fossa, in which lie the cephalic vein, the deltoid branch of the thoraco-acromial artery, and a lymphatic node which may be involved in obstinate tuberculosis of the cervical groups. On pressing deeply here, the coracoid process can be made out if the muscles are relaxed, and the axillary artery compressed against the second rib.

On raising the arm and abducting it, the different parts of the **deltoid** can often be made out —viz., fibres from the lower border of the spine of the scapula, the lateral edge of the acromion, and the lateral third or more of the front of the clavicle; the characteristic knitting of the surface

owing to the presence of fibrous septa continuous, alike, with the skin and the sheath of the muscle and the tendinous septa which separate the muscular bundles, will also be seen. The muscle will be marked out by a base-line reaching along the above bony points, and two sides converging from its extremities to the apex, a point on the lateral surface of the humerus, about its centre. In paralysis of the deltoid, the humerus being no longer braced up against the scapula, the finger-tips can be placed between it and the acromion.

To map out the **pectoralis major,** a line should be drawn down the lateral aspect of the sternum as far as the sixth costal cartilage, and then two others marking the borders of the muscle—the upper corresponding to the medial border of the deltoid, the lower starting from the sixth cartilage, and the two converging to the folded tendon, which is inserted as a double

FIG. 1129.—THE SHOULDER-JOINT, AS SHOWN BY THE RÖNTGEN-RAYS.

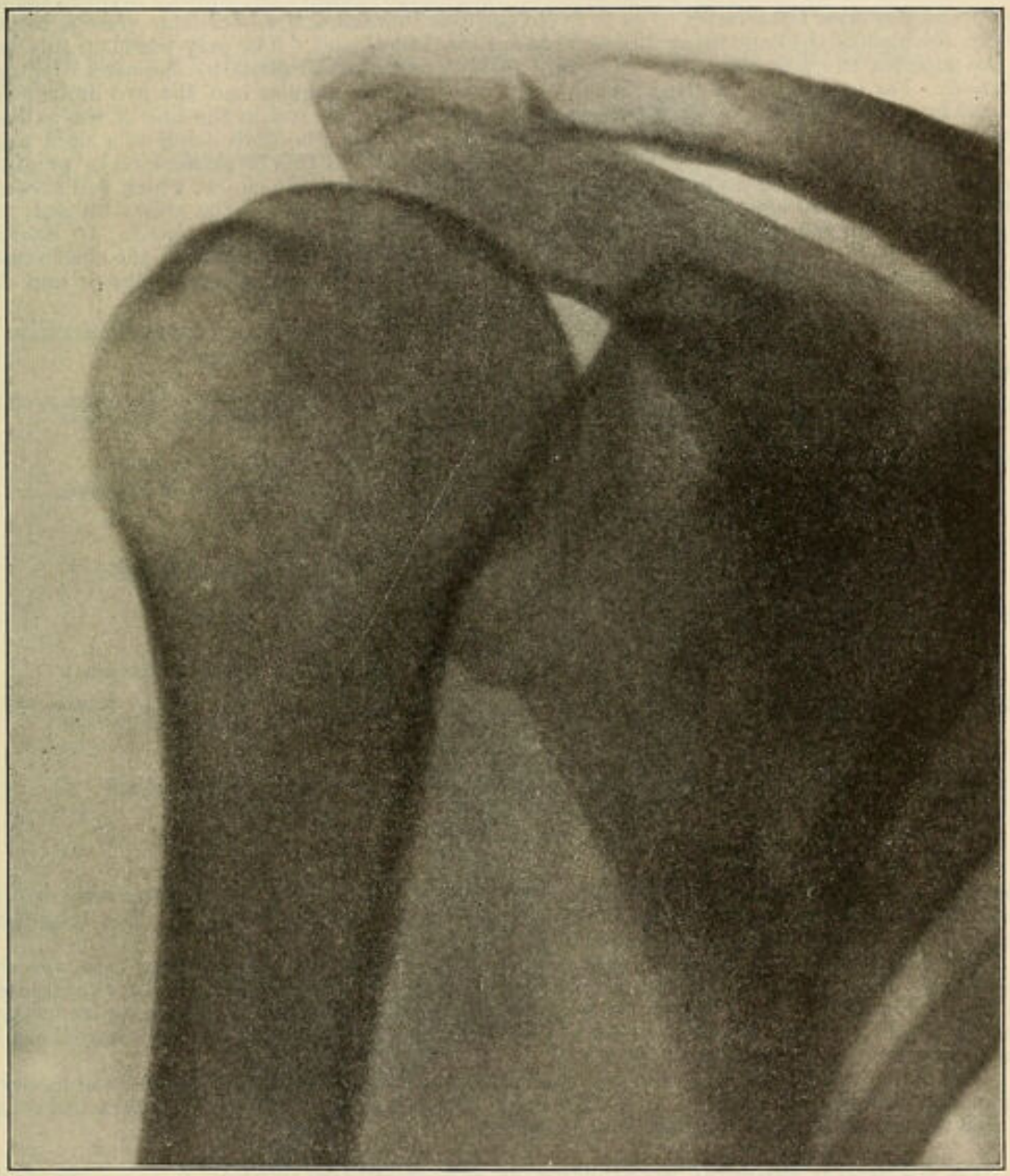

layer into the lateral tubercular (bicipital) ridge. The **pectoralis minor** will be marked out by two lines, from the upper border of the third and the lower border of the fifth rib, just lateral to their cartilages, and meeting at the coracoid process. The lower line gives the level of the long thoracic artery; the upper, where it meets the line of the axillary artery, that of the thoraco-acromial.

When the arm is abducted and the humerus rotated a little laterally, the prominence of a well-developed **coraco-brachialis** comes into view; a line drawn from the centre of the clavicle along the medial border of this muscle to its insertion into the humerus gives the line of the axillary artery.

Axillary fossa.—The boundaries of this space anterior, posterior, medial, or thoracic, lateral or humeral, apex and base, with the structures forming them and

the vessels and nerves in relation to them, must be remembered. The chief vessels are the axillary on the lateral wall, brought into prominence when the arm is abducted, as in removal of the mamma, and the subscapular on the posterior wall. The apex is felt, when the finger is pushed upward in an operation here, to be bounded by the clavicle in front, the first rib behind, and the coracoid somewhat laterally. The base is concave, owing to the coraco-clavicular (costo-coracoid) membrane as it descends to blend with the sheath of the pectoralis minor, giving also a process to the axillary fascia which unites the anterior and posterior boundaries. This process also sends septa to the skin.

An **axillary abscess,** always to be opened early to avoid subsequent interference with the movements of the shoulder, is reached by an incision on the medial wall, midway between the anterior and posterior boundaries, so as to avoid the long thoracic and subscapular vessels, respectively, the back of the knife being directed toward the lateral wall. The only vessel on this wall is the superior thoracic, which lies high up. Additional safety is given by the use of Hilton's method. For **exploration** of the axilla the best incision is an angular one, the two limbs being placed in a line with the anterior margin of the great pectoral, and in the line of the axillary vessels. This runs from a point on the centre of the clavicle (the limb being at a right angle to the trunk) to the medial margin of the coraco-brachialis. If this be obliterated by swelling, the above line should be prolonged to the middle of the bend of the elbow, which will give the guide to the brachial also. **Collateral circulation.** If the first part of the artery be tied, the channels are the same as in ligature of the third part of the subclavian (*q.v.*). In ligature of the third part of the axillary, if the ligature be *above* the circumflex arteries, the chief vessels concerned are the transverse scapular (suprascapular) and thoraco-acromial above and the

FIG. 1130.—DIAGRAMMATIC SECTION OF SHOULDER THROUGH THE INTERTUBERCULAR (BICIPITAL) GROOVE. (Anderson.)

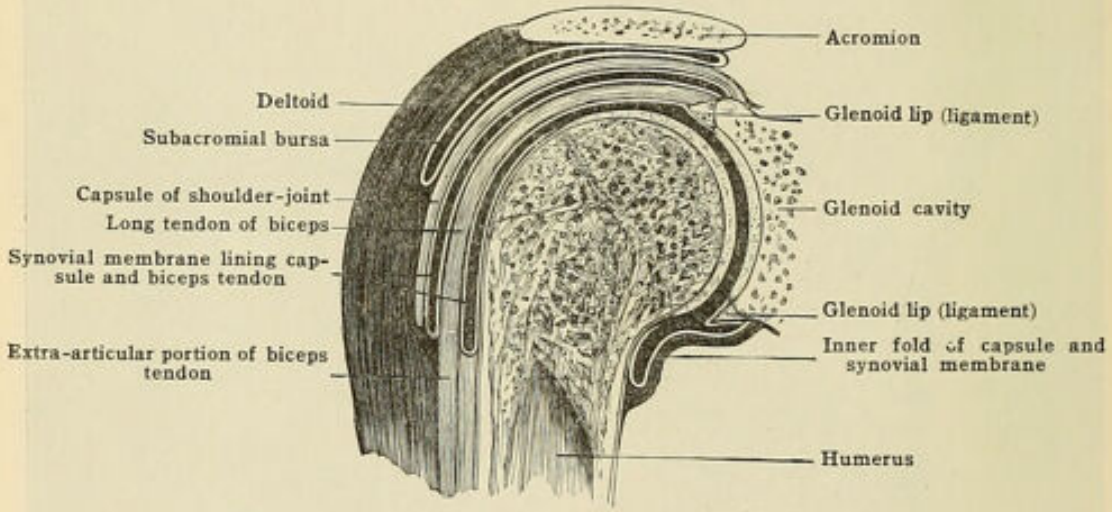

posterior circumflex below. If the ligature be *below* the circumflex, the anastomoses will be those concerned in ligature of the brachial above the profunda (p. 1414). The lymphatic nodes in the axilla have been mentioned at p. 719, (fig. 566).

The depression of the **axillary fossa** is best marked when the arm is raised from the side to an angle of about 45°, and when the muscles bounding it in front and behind are contracted. In proportion as the arm is raised, the hollow becomes less, the head of the humerus now projecting into it. When the folds are relaxed by bringing the arm to the side, the fingers can be pushed into the space so as to examine it.

The axillary (circumflex) nerve and posterior circumflex vessels wind around the humerus under the deltoid; a line drawn at a right angle to the humerus and a little above the centre of this muscle marks their position on the surface.

To trace the **synovial membrane of the shoulder-joint** is a comparatively simple matter (fig. 1130). Covering both aspects of the free edge of the glenoid ligament, it lines the inner aspect of the capsule, whereby it reaches the articular margin of the head of the humerus; there is a distinct reflection, below, from the capsule on to the humeral neck before the rim of the cartilage is reached.

An extensive protrusion of synovial membrane takes place in the form of a synovial bursa, at the medial and anterior part of the capsule, near the root of the coracoid process under the tendon of the subscapularis. Another protrusion takes place between the two tuberosities along the intertubercular groove, as low as the insertion of the pectoralis major. A third synovial protrusion may be seen, but not frequently, at the lateral or posterior aspect, in the form of a bursa, under the infra-spinatus tendon. Thus the continuity of the capsule is interrupted by **two** and **sometimes three synovial protrusions.**

Shoulder-joint.—The frequency of **dislocations** here, nearly equal to those of all the other joints put together, calls attention to the points contributing to make the joint alike insecure and safe. **Strength** is given by (1) the intimate blending of the short scapular muscles, especially the subscapularis with the capsule; (2) the coraco-acromial vault; (3) atmospheric pressure; (4) the long tendon of the biceps; (5) the elasticity of the clavicle; (6) the mobility of the scapula. The **weakness of the joint** is readily explained by its free mobility, the want of correspondence between the articular surfaces, its exposure to injury, and the length of the humeral lever. The rent in the capsule is usually anterior and below, and to this spot the head of the humerus must be made to return. While dislocations are usually primarily subglenoid, owing to the above part of the capsule being the thinnest and least protected, they take usually a secondarily forward direction,

FIG. 1131.—POSTERIOR VIEW OF THE SCAPULAR MUSCLES AND TRICEPS.

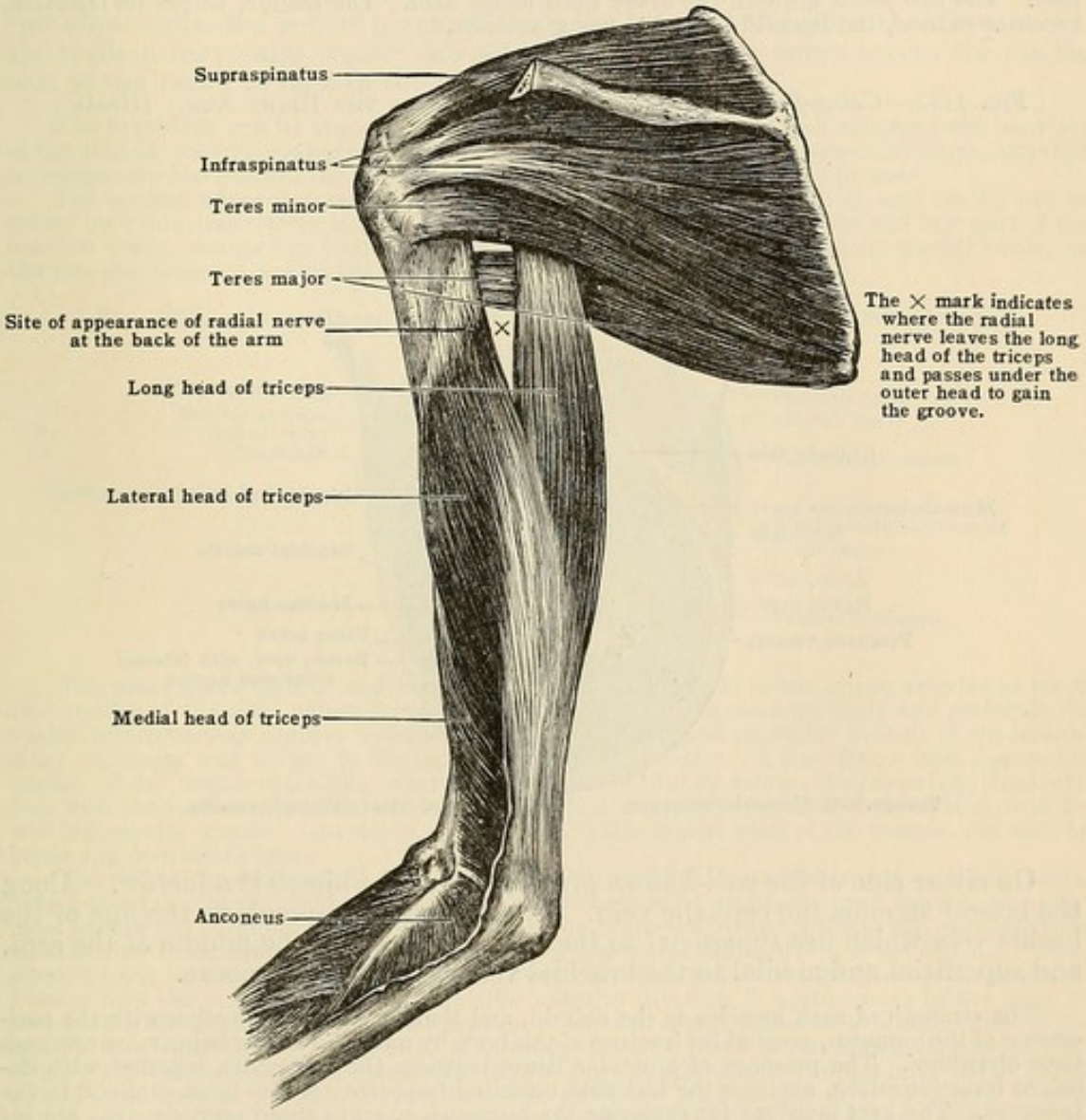

as the triceps prevents the head passing backward. In addition to the above features of the lower part of the capsule, laxity is here also a marked feature, to allow of free abduction and elevation. This movement will be accordingly much checked by any inflammatory matting of this part of the capsule.

The **best incision for exploring the joint** is one commencing midway between the coracoid and acromion processes and carried downward parallel with the anterior fibres of the deltoid. The cephalic vein and biceps tendon are to be avoided. If drainage is needed, it must be supplied by a counter-incision behind. This may be made along the posterior border of the deltoid, part of its humeral attachment being detached if necessary. The axillary (circumflex) nerve must be avoided in the upper part of the incision.

The **shaft of the humerus** is well covered by muscles in the greater part of its extent, especially above. Below the insertion of the deltoid, the lateral border of the bone can be traced downward into the lateral supracondyloid ridge. The medial border and ridge are less prominent.

Attached to these ridges and borders are the intermuscular septa, each lying between the triceps and brachialis (anterior), and the lateral one giving origin to the brachio-radialis (supinator longus) and extensor carpi radialis longus as well. The medial extends up to the insertion of the coraco-brachialis, the lateral to that of the deltoid. The lateral septum is perforated by the anterior part of the profunda vessels and the radial (musculo-spiral) nerve, the medial by the superior and posterior branch of the inferior ulnar collateral (anastomotica magna) artery and the ulnar nerve.

The **biceps** has a two-fold attachment above and below. The former is of much importance in steadying the various movements, especially the upward one, and in harmonising the simultaneous flexion and extension of the shoulder- and elbow-joints. (Cleland.) The lacertus fibrosus curving downward and medially with its semilunar edge upward, across the termination of the brachial artery, strengthens the deep fascia and the origin of the flexors of the forearm. The two heads unite in the lower third of the arm. The tendon, before its insertion, becomes twisted, the lateral border becoming anterior.

FIG. 1132.—CROSS-SECTION THROUGH THE MIDDLE OF THE RIGHT ARM. (Heath.)

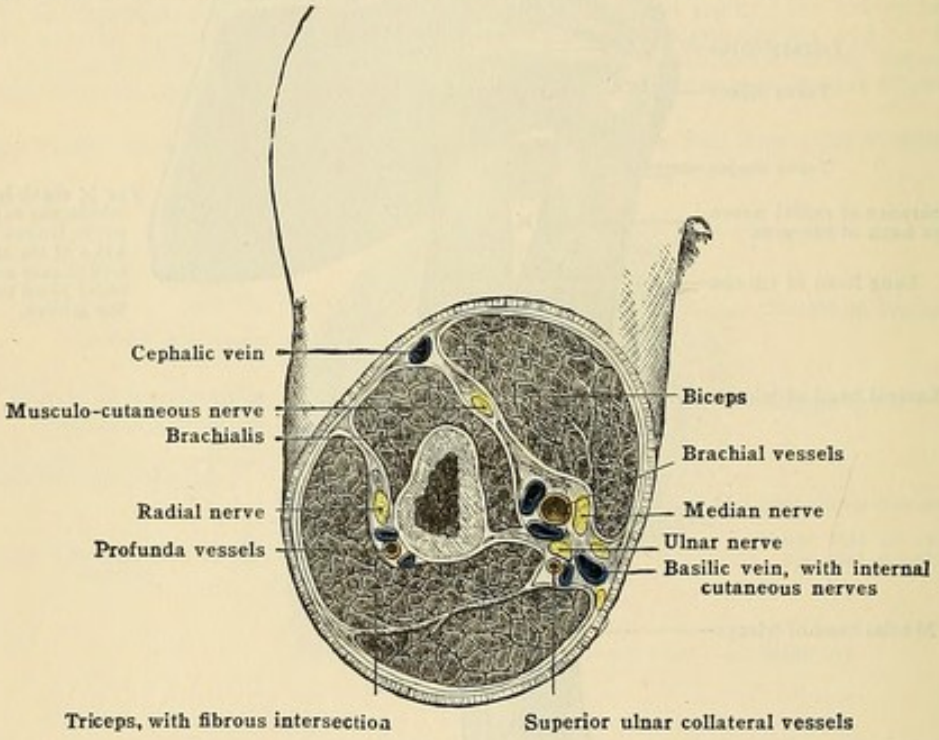

On either side of the well-known prominence of the biceps is a furrow. Along the lateral ascends the cephalic vein. The medial corresponds to the line of the basilic vein which lies superficial to the deep fascia below the middle of the arm, and superficial and medial to the brachial vessels and median nerve.

The strength of such muscles as the deltoid, and their intimate connection with the periosteum of the humerus, account for fracture of this bone by muscular action being more common than elsewhere. The presence of muscular tissue between the fragments, together with deficient immobilization, explains the fact that ununited fractures are also most common in the humerus. **The best incisions for exploring the humerus,** e. g., in acute necrosis, etc., are (*a*) for *the upper portion*, the two already mentioned along the anterior and posterior borders of the deltoid. In the latter case the presence of the radial (musculo-spiral) nerve in the deeper part of the wound must be remembered; (*b*) for *the lower end* one parallel with the lateral intermuscular septum, deepened between the brachialis and brachio-radialis.

A line drawn along the medial edge of the biceps from the insertion of the teres major to the middle of the bend of the elbow corresponds to the **brachial artery.** In the upper two-thirds, this artery can be compressed against the bone by pressure laterally; in its lower third the humerus is behind it, and pressure should be made backward. The presence of the median nerve will interfere with any prolonged digital pressure applied in the middle of the arm.

In ligature of the artery here the line extends from the mid-axillary region above, prolonged to the centre of the front of the elbow. The only structures seen should be the medial edge of the biceps, the basilic vein, and the median nerve. The profunda comes off 2.5 cm. (1 in.) below the teres major, having the same relation to the heads of the triceps; thus, it first lies on the long head, behind the axillary and brachial arteries, then between the long and medial heads, and next, in the groove, between the medial and lateral heads, and courses with the radial (musculo-spiral) nerve (fig. 1132); the nutrient artery arises opposite the middle of the humerus; in many cases it arises, on the back of the arm, from the profunda; the superior ulnar collateral (inferior profunda) below the middle, and courses with the ulnar nerve through the intermuscular septum to the back of the medial condyle. The inferior ulnar collateral (anastomotica magna) is given off from 2.5 to 5 cm. (1 to 2 in.) above the bend of the elbow. Fig. 1138 will show the **collateral circulation** after ligature of the brachial, according as the vessel is tied above or below the superior profunda, or below the superior ulnar collateral.

The **centre of the arm** is a landmark for many anatomical structures. On the lateral side is the insertion of the deltoid; on the medial, that of the coraco-brachialis. The basilic vein and the medial brachial cutaneous nerve (nerve of Wrisberg) here perforate the deep fascia, going in reverse directions. The superior ulnar collateral is here given off from the brachial and joins the ulnar nerve; the median nerve also crosses the artery, and the ulnar nerve leaves the medial side of the vessel to pass to the medial aspect of the limb.

The **brachialis** can be mapped out by two pointed processes which surround the insertion of the deltoid, pass downward into lines corresponding to the two intermuscular septa, and then converge over the front of the elbow to their insertion into the coronoid process.

The **median nerve** (lateral head, 5th. 6th, 7th C.; medial head, 8th C. and 1st T.) can be traced by a line drawn from the lateral side of the third part of the axillary and first part of the brachial artery, across this latter vessel about its centre, and then along its medial border to the forearm, where it passes between the two heads of the pronator teres.

FIG. 1133.—CROSS-SECTION THROUGH THE ELBOW. (× 1/2). (After Braune.)

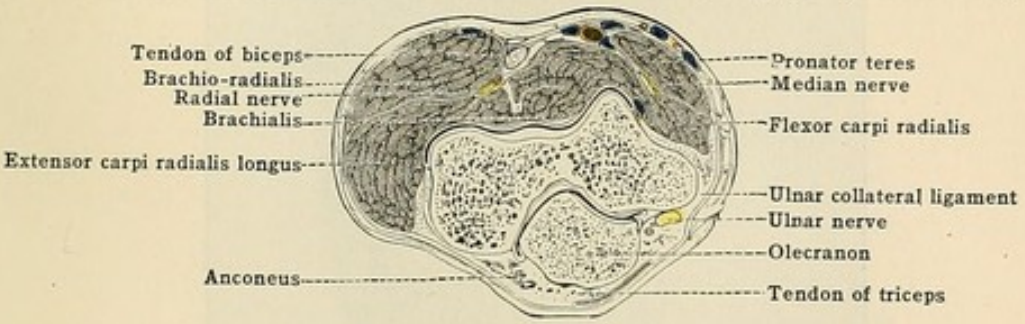

The **ulnar nerve** (8th C. and 1st T.) lies to the medial side of the above arteries as far as the middle of the arm, where it leaves the brachial to course more medially and perforate the medial intermuscular septum together with the superior and posterior branch of the inferior ulnar collateral and so get to the back of the medial condyle. A line drawn from the medial border of the coraco-brachialis, where, in the upper part of its course, the nerve is in close relation with the medial side of the axillary and brachial arteries, to the back of the medial condyle, will indicate its course. Low down, the nerve is in the medial head of the triceps, and may be injured in operations here.

The **radial (musculo-spiral) nerve** (5th, 6th, 7th, and 8th C.) can be traced by a line beginning behind the third part of the axillary artery, then carried vertically down behind the uppermost part of the brachial, and then, just below the posterior border of the axilla, curving backward behind the humerus and slightly downward just below the insertion of the deltoid. Thus, passing from laterally and from before backward in its groove, accompanied by the profunda vessels, first the trunk, and then the smaller anterior division, it again comes to the front by perforating the lateral intermuscular septum at a point about opposite to the junction of the middle and lower thirds of the arm, and passes down in front of the lateral supracondyloid ridge, lying here between the brachio-radialis and brachialis anterior, to the level of the lateral condyle, in front of which it divides into the superficial (radial) and deep (posterior interosseous) radials. The former of these accompanies the radial artery to the front of the arm, the latter travels backward to the back of the forearm. A line from the lateral condyle to the insertion of the deltoid indicates the lateral intermuscular septum.

In addition to injuries caused by fracture, the nerve may be injured in crutch pressure, the sleep of intoxication, use of an Esmarch's bandage, or the careless reduction of a dislocated shoulder with the foot in the axilla. To expose the nerve the incision begins below, over the lateral intermuscular septum, where it lies between the brachio-radialis and brachialis (anterior). Hence the incision is prolonged freely upward and backward toward the posterior border of the deltoid.

On the back of the arm is the **triceps muscle,** with its three heads and tendon of insertion, all brought into relief in a muscular subject when the forearm is strongly extended. Of the three heads, the medial is the least distinct, arising

below the groove (musculo-spiral) for the radial (musculo-spiral) nerve, reaching to each intermuscular septum, and tapering away above as high as the teres major. Most of the fibres of this head lie deeply. The lateral head, arising above the groove as high as the great tuberosity, appears in strong relief just below the deltoid; while the middle or long head, arising from the scapula just below the glenoid cavity, appears between the teres muscles. The tendon of insertion, passing into the upper and back part of the olecranon over a deep bursa, is shown by a somewhat depressed area. On the lateral side, an important expansion to the fascia over the anconeus is given off.

FIG. 1134.—THE ELBOW-JOINT, AS SHOWN BY THE RÖNTGEN-RAYS.

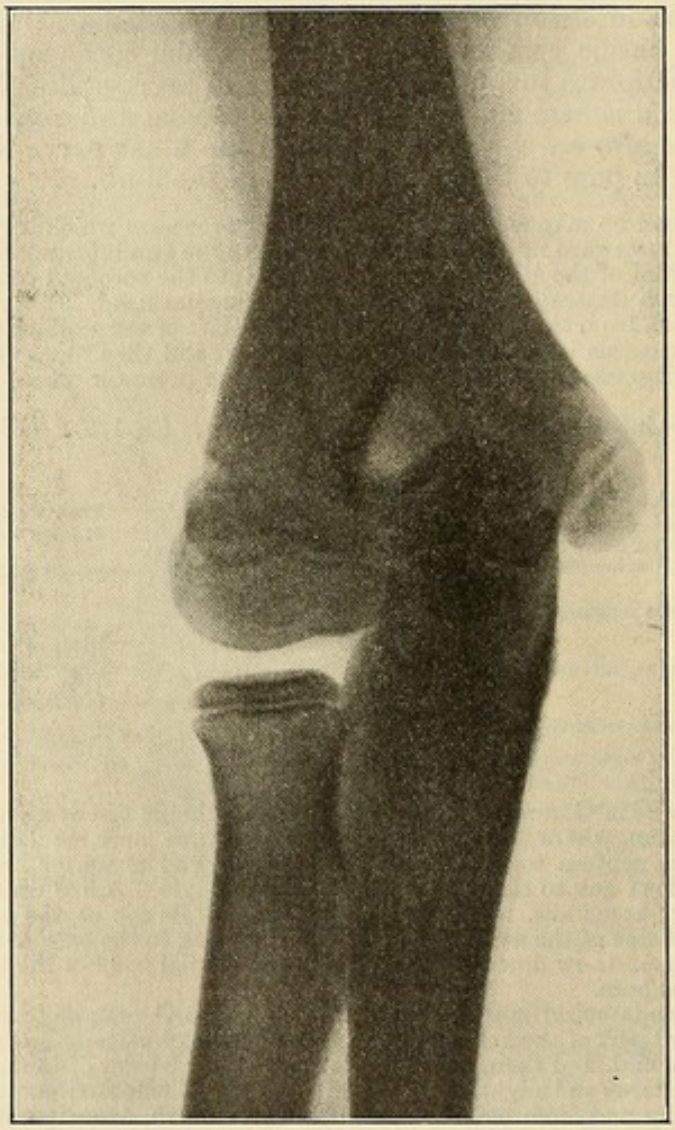

In the ossification of the humerus the epiphyses are of first importance. The **upper,** consisting of those for the head and two tuberosities, which form one about the seventh year, blends with the shaft between the twentieth and twenty-fifth years. Separation usually takes place at an earlier date, this being explained by the fact that the cone-like arrangement by which the diaphysis fits into the cap of the epiphysis becomes more marked toward the date of union, and thus tends to prevent displacement. (Thomson.) The **lower epiphysis.** The condition of this varies with the degree of coalescence of its four centres. The first and chief, that for the capitulum (second or third year), unites with those for the trochlea and lateral epicondyle soon after puberty, and forms an epiphysis which joins with the shaft at about sixteen. The epiphysis for the medial epicondyle appears at the fifth year and unites with the shaft at the eighteenth. Injury to this epiphysis may damage the ulnar nerve and open the elbow-joint. Thus, at and after puberty, there are two chief epiphyses to remember here:—(*a*) the larger, consisting of capitular, trochlear, and lateral epicondyle centres. This is almost entirely intra-articular; (*b*) the smaller, that for the medial epicondyle; the extent to which this is intra-articular varies. The structures that would be divided in **an amputation at the centre of the arm**

are shown in fig. 1132. The chief points needing attention are:—(1) To leave as much of the lever of the humerus as possible; (2) clean section of the large nerves, the radial (musculo-spiral) in its groove being especially liable to be frayed by the saw; (3) the difference between the amount of retraction of the free biceps in front, and the triceps behind, fixed to the bone and septa.

THE ELBOW

The **bony points,** epicondyles, olecranon, and head of radius, andtheir relation to one another, should be carefully studied. The *medial epicondyle* is the more prominent of the two, is directed backward as well as medially, and lies a little above its fellow. Above it can be traced upward the supracondyloid ridge and corresponding intermuscular septum. The *lateral epicondyle* is more rounded, and thus less prominent; below, and a little behind it, the *head of the radius* can be felt moving under the capitulum when the forearm is supinated and flexed. A depression marks this spot and corresponds to the interval between the anconeus and brachio-radialis and extensor carpi radialis longus; at the back, the upper part of the *olecranon* is covered by the triceps. The lower part is subcutaneous, and separated from the skin by a bursa. If the thumb and second finger be placed on the epicondyles and the index on the tip of the olecranon, and the forearm completely extended, the tip of the olecranon rises so as to be on the line joining the two epicondyles. In flexion at a right angle, the olecranon is below the line of the

FIG. 1135.—LONGITUDINAL SECTION OF THE ELBOW-JOINT. (One-half.) (Braune.)

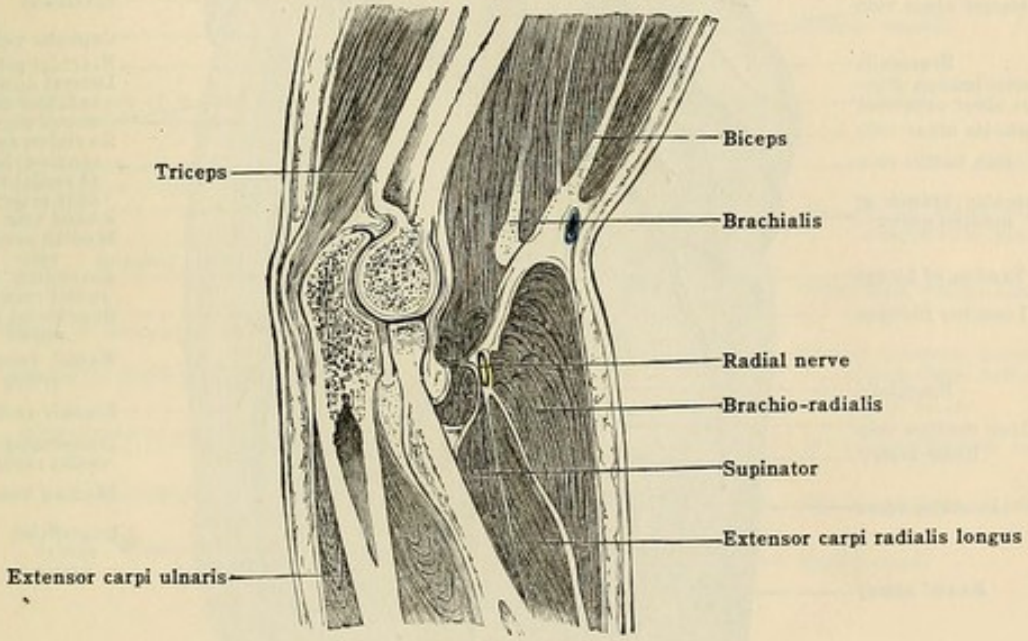

epicondyles, and in complete flexion quite in front of them. Between the medial epicondyle and olecranon is a pit, in which lie the ulnar nerve and the anastomosis between the inferior ulnar collateral and the posterior ulnar recurrent arteries. The coronoid process is so well covered by muscles, vessels, and nerves that its position cannot be distinctly made out.

The synovial membrane of the elbow-joint communicates with that of the superior radio-ulnar. Hence the facility with which tuberculous disease may be set up after neglected falls on the hand, in early life. At this time the weakness of the annular (orbicular) ligament leads to its being easily injured. Swelling, due to effusion into the joint, appears on either side of the triceps tendon, and soon obliterates the depression below the lateral epicondyle. The simplest incision for an infected elbow-joint is a vertical one, on the lateral side of the olecranon. A superficial swelling over the tip of the olecranon is due to effusion into the bursa between the soft parts and that bone. A deeper, less easily defined swelling in the same region is due to inflammation of the bursa between the olecranon and the triceps. A swelling on the medial side of the elbow-joint, if painful and accompanied by inflammation of the skin, may be due to mischief in the **epitrochlear lymphatic node** situated just above the medial epicondyle, and receiving lymphatics from the medial border of the forearm and the two medial fingers.

The hollow in front of the elbow.—The delicacy of the skin here must always be borne in mind in the application of splints. Owing to the insidious rapidity with which pressure may set up ischæmic paralysis, anterior angular splints are always to be used with caution. The **M-like**

arrangement of the superficial veins as usually described is by no means constant (fig. 1136). The median basilic is the vein usually chosen for venesection, owing to its larger size and its being firmly supported by the subjacent bicipital fascia which separates it from the brachial artery; but the median cephalic is the safer. The median basilic is crossed by branches of the medial antibrachial (internal) cutaneous nerve, while those of the musculo-cutaneous lie under the median cephalic. In the semiflexed position, the fold of the elbow is seen, a little above the level of the joint. This forms the base of the *triangular fossa* below the elbow, the lateral side corresponding to the brachio-radialis, the medial to the pronator teres, and the apex to the meeting of these muscles. The tendon of the biceps can be easily made out in the centre of the fossa, giving off above the lacertus fibrosus from its medial side to fasten down the flexors of the forearm. Under the tendon on its medial side lie the brachial artery and the median nerve, a little medial to it, for a short distance. The radial nerve (musculo-spiral) lies outside the fossa, between the brachio-radialis and the brachialis (anterior), and gives off its two

FIG. 1136.—THE BEND OF THE ELBOW WITH THE SUPERFICIAL VEINS.
(From a dissection by Dr. ALDER SMITH in the Museum of St. Bartholomew's Hospital.)

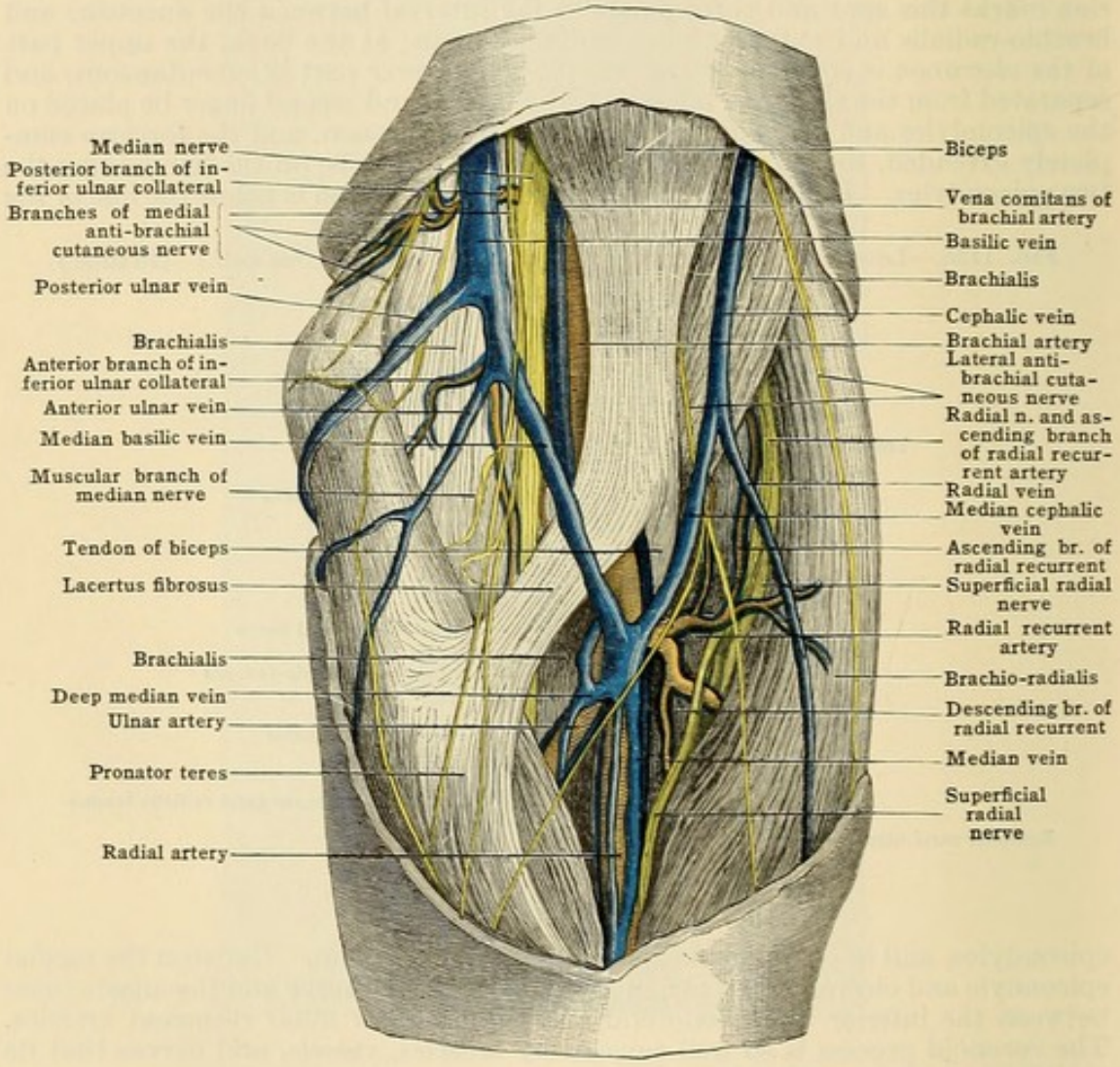

terminal branches in front of the lateral epicondyle. The brachial usually bifurcates opposite to the neck of the radius.

The **arterial anastomoses about the elbow-joint** are as follows: The radial recurrent runs up under cover of the brachio-radialis to anastomose with the anterior branch of the profunda **on the front of the lateral condyle.** The posterior interosseous recurrent ascends, between the supinator and the anconeus, to anastomose **on the back of the lateral condyle** with the posterior branch of the profunda. It further joins, by a large anastomotic arch across the back of the joint, with the inferior ulnar collateral (anastomotic magna) and posterior ulnar recurrent. The anterior ulnar recurrent passes upward on the brachialis to join the anterior part of the inferior ulnar collateral under the pronator teres, on the front of the medial epicondyle. The posterior ulnar recurrent makes for the interval between the **back of the medial epicondyle** and the olecranon, to join with the superior and the posterior branch of the inferior ulnar collateral.

It will be seen that the inferior ulnar collateral (anastomotica magna) is the artery most largely employed, distributing branches everywhere, save to the front of the lateral epicondyle.

THE FOREARM

Bony landmarks.—The *posterior border of the ulna* can be easily traced down from the olecranon to the back of the styloid process; the bone becomes somewhat rounded below, and lies between the flexor and extensor carpi ulnaris. The tip of the *styloid process* corresponds to the medial end of the line of the wrist-joint. The *radius* is covered above by the brachio-radialis and radial extensors of the carpus, and the outline of the bone is less easily followed. Its *styloid process* is readily made out below a finger's breadth above the thenar eminence. It is placed about 1.2 cm. ($\frac{1}{2}$ in.) lower than that of the styloid process of the ulna.

Thus, a line drawn straight between the two processes would fall a little below that of the wrist-joint, this being shown by a line drawn between the two processes forming a slight curve, with its concavity downward (corresponding to the concavity of the lower surface of the radius and fibro-cartilage) about 1.2 cm. ($\frac{1}{2}$ in.) above the straight line given above.

The radial styloid process is covered by the abductor longus and extensor brevis pollicis, while farther out lies the extensor pollicis longus. Between the styloid process of the ulna and

FIG. 1137.—THE BRACHIAL ARTERY AT THE BEND OF THE ELBOW.
(From a mounted specimen in the Anatomical Department of Trinity College, Dublin.)

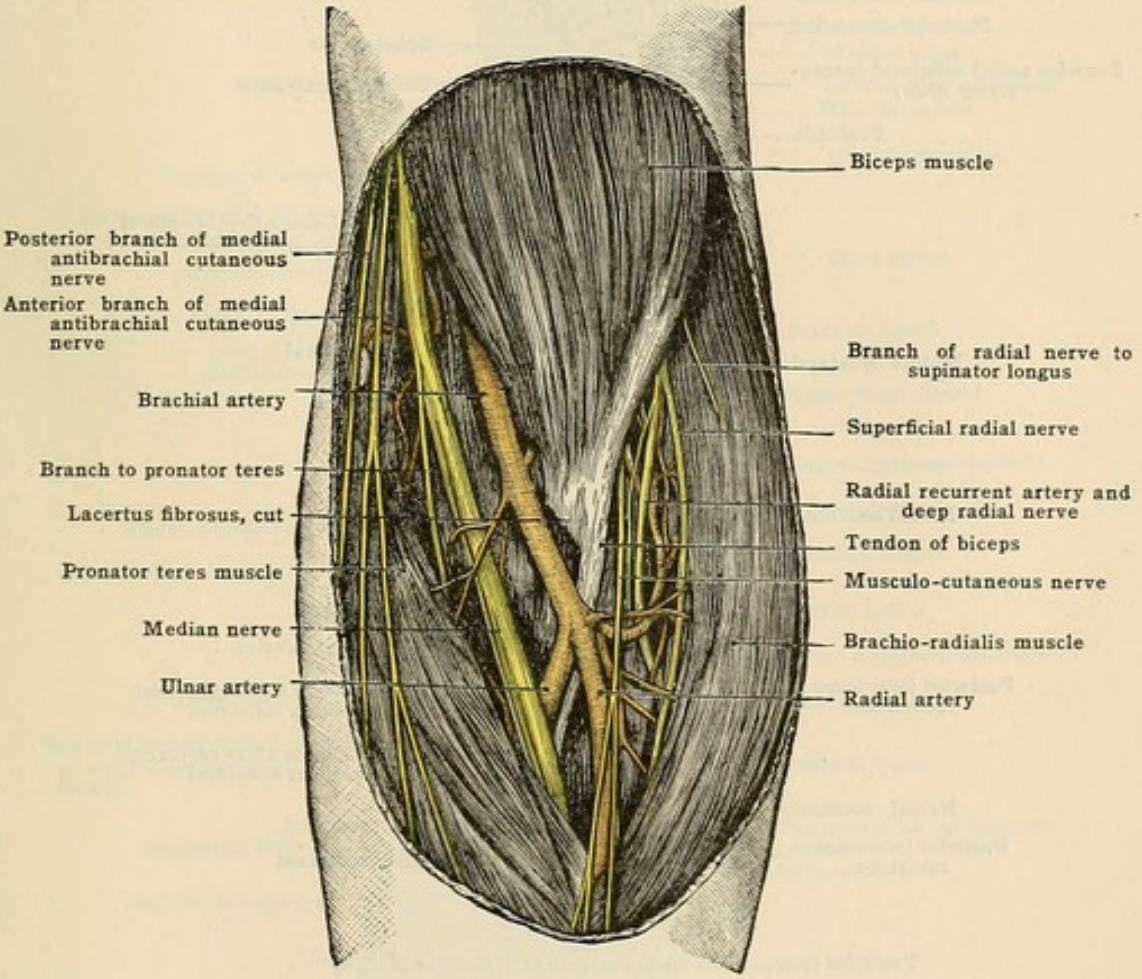

the rounded head is the groove for the extensor carpi ulnaris. The bones are nearest to each other in complete pronation, and farthest apart in complete supination. On section, the bones are found at every point nearer to the back than to the front of the limb, but increasingly so above. 'The lower the section proceeds down the limb, the less will the bones be covered at the sides, and the more equally will the soft parts be distributed about the anterior and posterior aspects of the limb. It will be noticed that where one bone is the more substantial, the other is the more slender, as near the elbow and wrist; and that it is about the centre of the limb that the two are most nearly of equal strength.' (Treves.) When the limb is pronated, the interosseous space is narrowed; in supination and the mid-position it is widened out. In pronation, both styloid processes can be distinctly made out; in supination, that of the radius is the more distinct, as now the skin and soft parts are stretched and raised over that of the ulna.

Joints.—The position of the **superior radio-ulnar joint** is marked by a dimple about 12 mm. ($\frac{1}{2}$ in.) below the lateral epicondyle. The **inferior** can just be felt,

when the forearm is pronated, between the head of the ulna and lower end of the radius. The recessus sacciformis here may be enlarged in rheumatic and other affections. The **interosseous membrane** not only ties the bones together and gives attachment to muscles, but in falls on the hand it enables the ulna to participate in the shock.

The following are important points with regard to **the bones.** *Common fractures. Olecranon.*—This usually takes place at the constricted centre of the semilunar (greater sigmoid) notch or the junction of the olecranon with the shaft. A fall is here the usual cause, and the heavier the fall, the more frequently is the fracture nearer the shaft, though displacement is now likely to be slight, owing to the abundance of fibrous and muscular structures on both sides

FIG 1138.—DIAGRAM OF THE ANASTOMOSES OF THE BRACHIAL ARTERY.
(MacCormac and Anderson.)

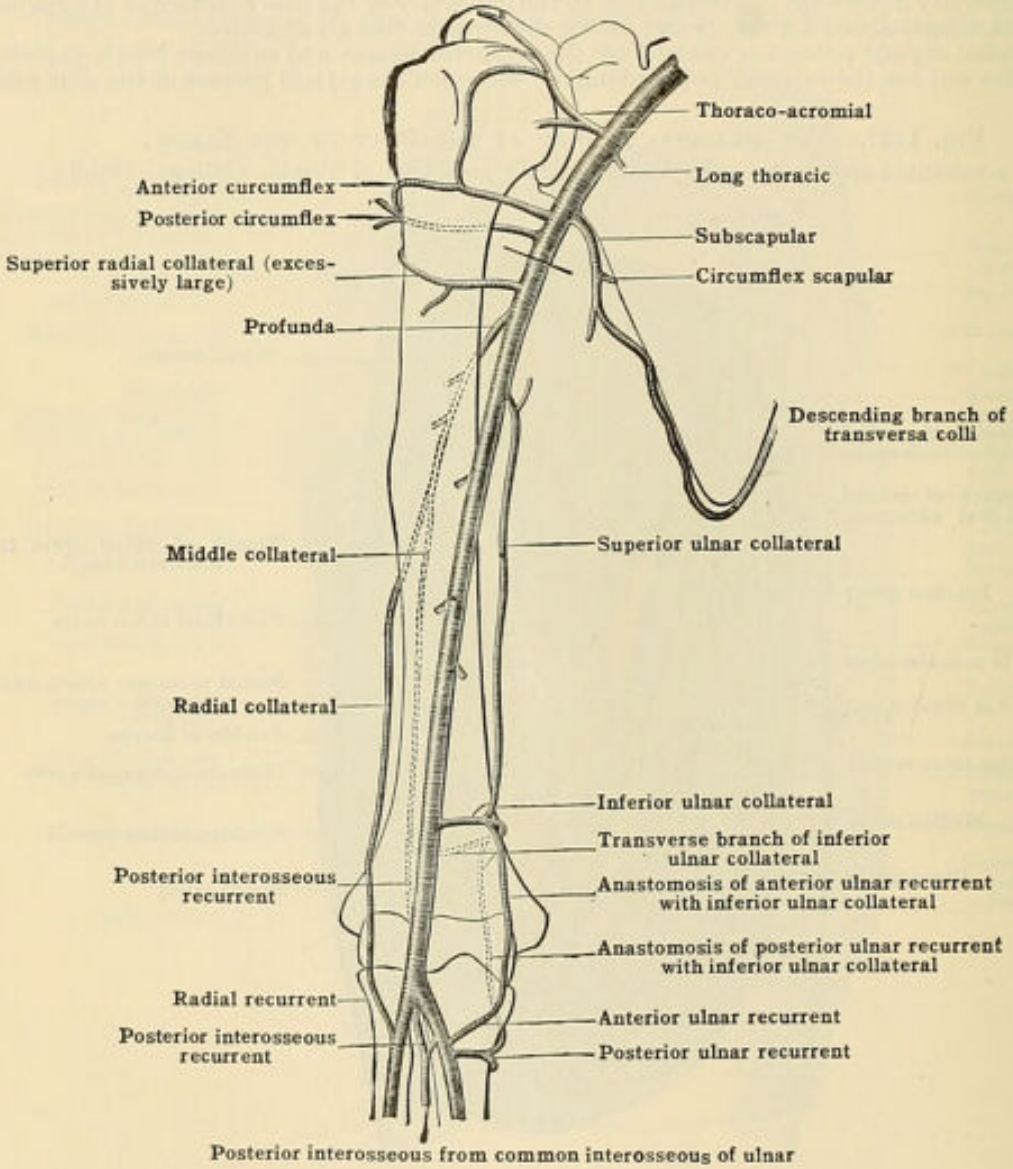

of the fracture. *The shaft of one or both bones.* Usual site, about the middle or a little below it, fracture of the radius being more frequent from its connection with the hand. In these fractures the chief muscular agencies are—(1) the extensors and flexors in drawing the lower fragment or fragments upward, forward, or backward, according to the direction of the fracture; (2) the biceps in drawing the upper fragment of the radius upward; (3) the influence of the pronator teres, if the fracture is, as usual, below it, and (4) that of the quadratus in drawing the lower fragments together. Thus the chief practical points are—(*a*) the reduction of displacement, whether antero-posterior or lateral; (*b*) the greater the number of fragments, the greater the tendency to union across the interosseous space, with its embarrassing results, and the greater the need of a supinated position in the setting; (*c*) the risk of gangrene here from the facility with which the vessels are compressed against the contiguous bones, especially in flexion of the forearm; and the consequent need of attention to the width of the splints and the bandaging; (*d*) the readiness with which ischæmic paralysis may rapidly and insidiously be caused. **Colles' fracture.** Here, after a fall on the hand, the radius gives way usually at its weakest part, about

FIG. 1139.—THE ARTERIES OF THE FOREARM WITH THE SUPERFICIAL VOLAR ARCH.

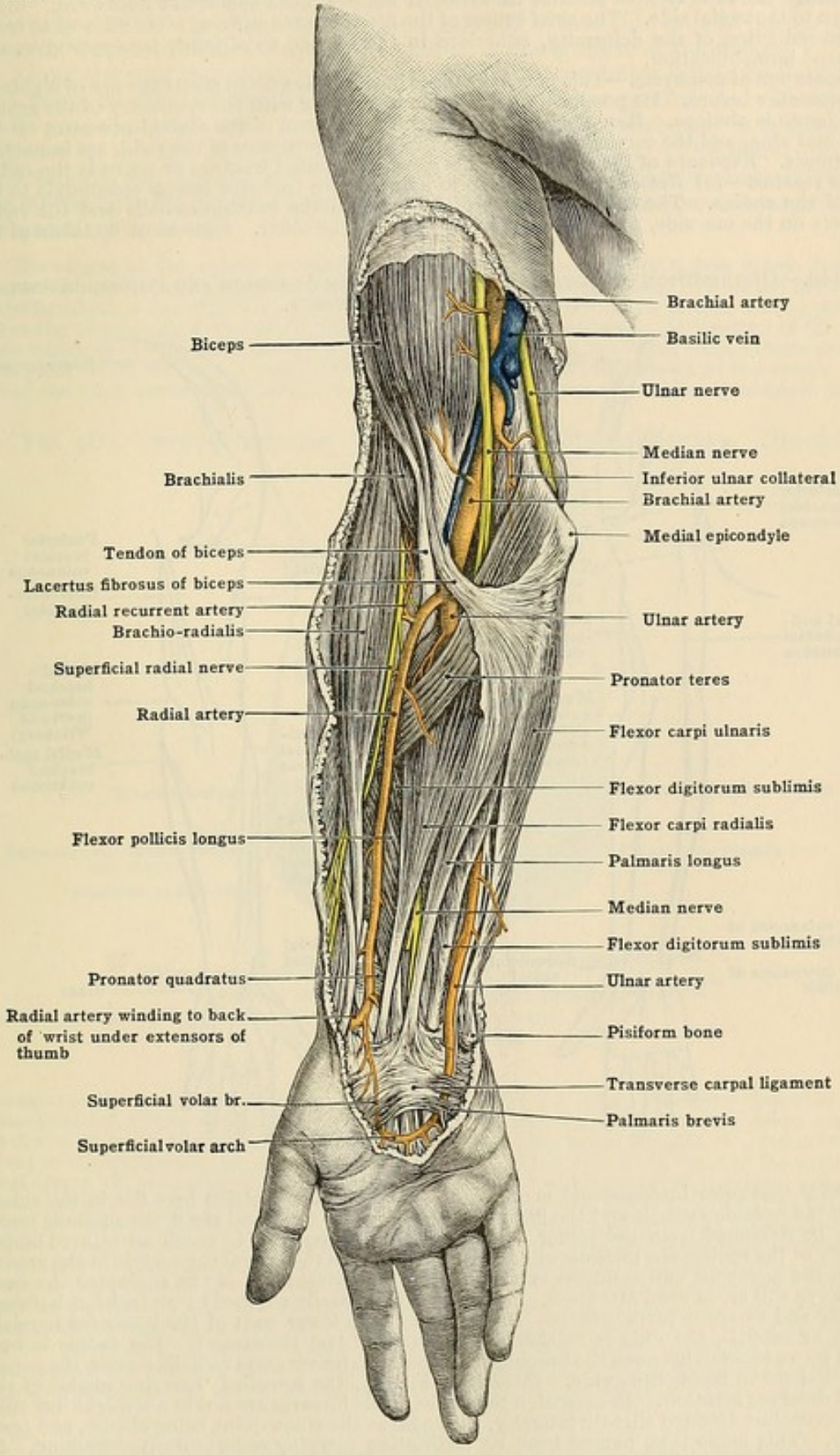

18 mm. (¾ in.) above its extremity, where the narrow compact tissue is suddenly expanding into cancellous. There is frequently impaction of the upper into the lower fragment. There is a three-fold displacement of the lower fragment:—(1) It is driven and drawn upward and backward. (2) It is rotated so that its articular surface looks somewhat backward. (3) It is drawn to the radial side. The chief causes of the discreditable stiffness often allowed to result are non-reduction of the deformity, adhesions in the opened wrist-joint, teno-synovitis, and prolonged immobilisation.

Separation of epiphysis.—This may take place in the **radius** up to about the age of eighteen: it is commoner before. Its possible importance in interfering with the symmetry of the growth of the bones is obvious. Here, as in Colles' fracture, the level of the styloid processes of the radius and ulna, and the correspondence of the two styloid processes of the radii, are important in diagnosis. **Exposure of the bones.** In the case of ununited fracture or necrosis the **radius** may be reached—(*a*) *Behind*, by an incision in a line drawn from the lateral epicondyle to the back of the radius. The field opened here lies between the brachio-radialis and the radial extensors on the one side, and the common extensor on the other. Care must be taken of the

FIG. 1140.—DISTRIBUTION OF CUTANEOUS NERVES ON THE ANTERIOR AND POSTERIOR ASPECTS OF THE SUPERIOR EXTREMITY.

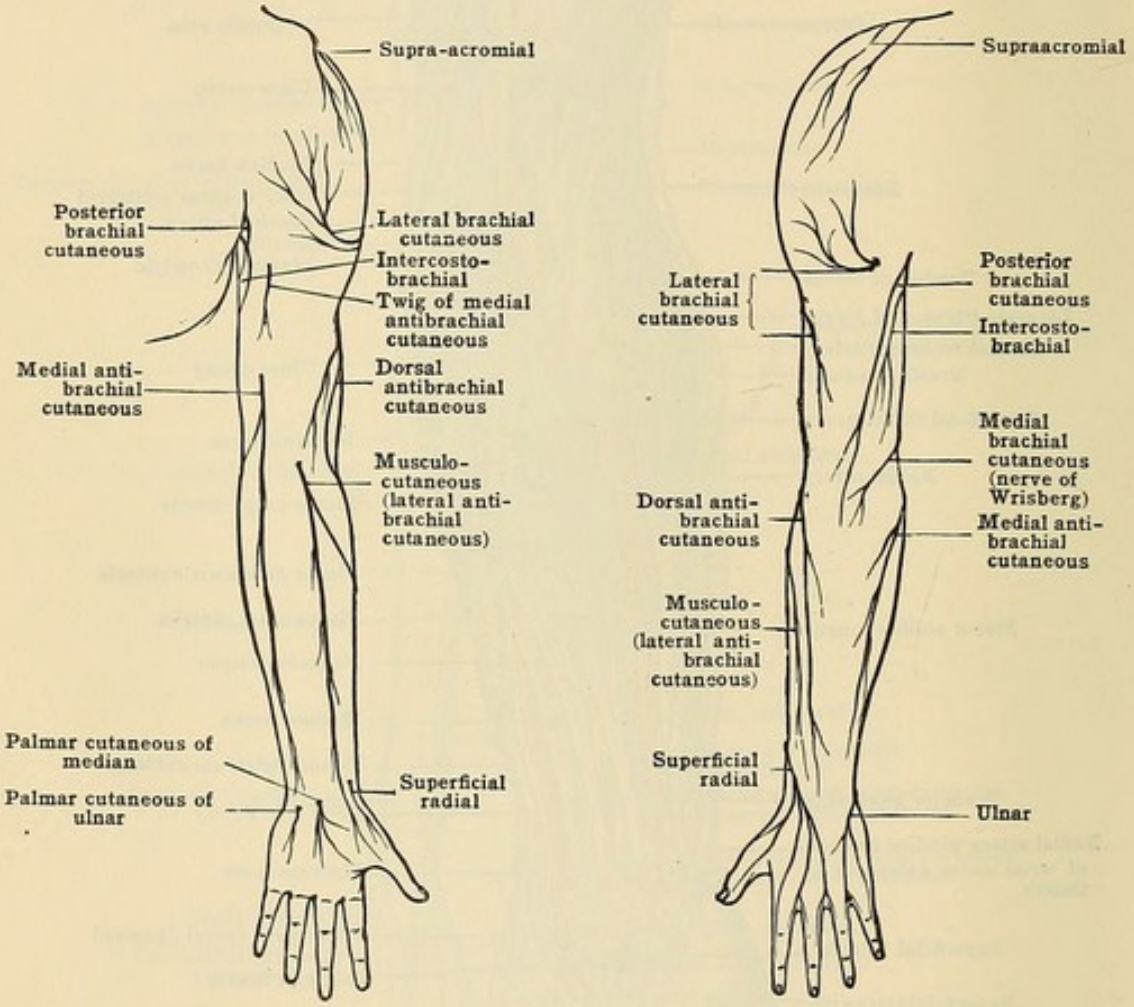

deep radial (posterior interosseous) nerve. (*b*) *In front.* The incision here lies in the sulcus between the brachio-radialis and the flexors. The pronator teres and the flexor sublimis must, in part, be detached from the radius. If more room is required to reach an injured upper extremity of the radius, the incision will descend from above the lateral epicondyle in the groove between the anconeus and common extensors. In the detachment of the supinator the deep radial nerve will again need attention. The **ulna** is more easily reached by an incision between the flexor and extensor carpi ulnaris. In removal of the lower part of the bones for myeloid sarcoma or osteitis, the ulna is reached in the interval last mentioned. The radius is best exposed by an incision between the brachio-radialis and extensor carpi radialis longus, the superficial radial nerve being the guide. (Morris.) Finally, the so-called 'carrying angle' of the forearm deserves mention. In extension the bones of the forearm are not in a straight line with the humerus, but directed slightly laterally, the angle at the elbow-joint being obtuse, and open laterally. This angle is so named from its facilitating carrying objects during walking. In flexion the forearm is deflected somewhat toward the middle line, mouth, etc. These properties are liable to be lost under many and widely different conditions, of which injuries to the epiphyses of the humerus, badly united fractures of the forearm, and osteoarthritis of the elbow-joint are instances.

Soft parts.—Along the lateral border, of the forearm descend the brachio-radialis and radial extensors of the carpus, fleshy above, tendinous below. About 3.7 cm. (1½ in.) above the styloid process of the radius, a fleshy swelling directed obliquely downward and forward from behind, across this lateral border of the forearm, denotes the extensors of the thumb crossing those of the carpus.

Along the medial border is the fleshy mass of the pronator teres and flexors, the ulna being covered by the flexor carpi ulnaris and flexor profundus. The tendon of the pronator is inserted into the radius a little below its centre—a point of importance in the treatment of fractures and in amputation. The flexor carpi ulnaris tendon can be felt just above the wrist making for the pisiform bone; and just lateral to it lies the **ulnar artery,** about to pass over the transverse carpal (anterior annular) ligament.

The course of the artery is denoted by the lower two-thirds of a line drawn from the front of the medial epicondyle to the lateral edge of the pisiform bone. From the bifurcation of the brachial, a line drawn to meet the former at the junction of its middle and upper third marks the upper part of the artery, here thickly covered by muscles. In **ligature of the artery** in *the middle* of the forearm, the white line and sulcus between the flexor carpi ulnaris and sublimis must be identified. A small muscular branch will often lead down to the artery. The line of the **ulnar nerve** is one drawn from the interval between the medial epicondyle and the

FIG. 1141.—SECTION THROUGH THE MIDDLE OF THE RIGHT FOREARM. (Heath.)

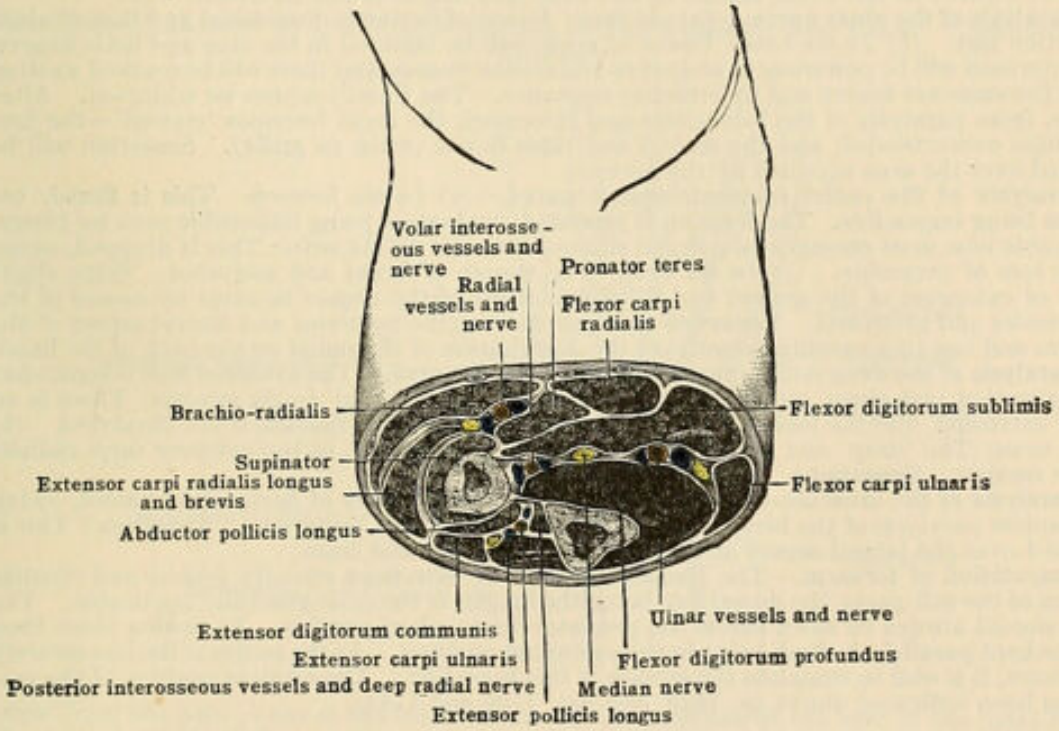

olecranon to the medial side of the ulnar artery just above the wrist. The nerve joins the artery at the junction of the upper and middle thirds of the forearm. The **median nerve** runs in a line drawn from the medial side of the brachial artery, in the elbow triangle, to a point beneath, or just to the medial side of, the palmaris longus at the mid-point of the front of the wrist. The **radial artery** will be marked by a line drawn from the centre of the bend of the elbow (where the brachial artery divides opposite to the neck of the radius) to a point just medial to the radial styloid process descending along the medial edge of the brachio-radialis. The muscular interval is that between the brachio-radialis and pronator teres above, and the flexor carpi radialis below. The **superficial radial nerve** will be marked by the same line (it lies just lateral to the artery) for its upper two-thirds; it then leaves the artery about 7.5 cm. (3 in.) above the wrist-joint, and passes to the back of the forearm under the tendon of the brachio-radialis. The **volar interosseous artery** runs down on the interosseous membrane and passes to the back of the forearm by perforating it below, having passed behind the pronator quadratus. The **dorsal interosseous** lies between the superficial and deep extensors. These small arteries reinforce the palmar through the carpal arches, and thus bring down blood after ligature of the trunks above.

The front of the forearm is supplied by the *musculo-cutaneous* on the lateral, and the *medial antibrachial* (internal) cutaneous on the medial, side; just above the wrist the palmar cutaneous branches of the median and ulnar perforate the deep fascia (fig. 1140). The back of the forearm is supplied by the *radial* (mus-

culo-spiral) and posterior branches of the musculo-cutaneous laterally, and the posterior branches of the medial antibrachial cutaneous medially (fig. 1140).

The **lymphatics of the upper extremity** are **superficial** and **deep**; the former run with the superficial veins, the latter with the deep vessels. Occasionally a few small **nodes** occur below the elbow. The epitrochlear nodes lie upon the basilic vein, a little above the medial epicondyle and draining the fourth and fifth digits. The majority of the lymphatics open into the axillary nodes, and terminate, on the left side in the thoracic duct, on the right in the lymphatic duct. A few, accompanying the cephalic vein, reach the subclavian or infraclavicular nodes, and thus communicate with the lymphatics of the neck.

It will be well briefly to consider here the chief *results of paralysis* of the main nerves of the upper extremity.

Paralysis of the median nerve.—(*a*) *In forearm:* Loss of pronation. (*b*) *At wrist:* Diminished flexion and tendency toward ulnar adduction. (*c*) *In the hand:* Power of grasp is lessened especially in the thumb and lateral two fingers. Owing to the loss of flexion in the phalanges of these fingers the phalanges are liable to become overextended by the action of the extensors and interossei. The thumb remains extended, adducted, and closely applied to the index, the human characteristic being thus lost, and the 'ape's hand' of Duchenne being produced. **Sensation** will be lost over the palmar aspect of the thumb and lateral two and one-half fingers and over the distal ends of the same fingers, to a varying degree, according to the sensory distribution of the median and other cutaneous nerves. The above applies to lesions of the trunk. If the nerve be injured at the wrist, flexion of the wrist and fingers is less interfered with.

Paralysis of the ulnar nerve.—(*a*) *At wrist:* Power of flexion is diminished and that of ulnar adduction lost. (*b*) *In the hand:* Power of grasp will be lessened in the ring and little fingers. The interossei will be powerless to abduct or adduct the fingers, and there will be marked wasting of the interosseous spaces and hypothenar eminence. The thumb cannot be adducted. After a time, from paralysis of the lumbricals and interossei, the hand becomes 'clawed'—the first phalanges overextended, and the second and third flexed (**main en griffe**). Sensation will be lessened over the area supplied by the nerve.

Paralysis of the radial (musculo-spiral) nerve.—(*a*) *In the forearm* This is flexed, extension being impossible. The forearm is pronated, supination being impossible save by biceps, which acts now most strongly on a flexed elbow-joint. (*b*) *In the wrist:* This is dropped, owing to the loss of extension. (*c*) *In the hand:* The thumb is flexed and adducted. Some slight power of extension of the second and third phalanges of the fingers remains by means of the lumbricales and interossei. **Sensation** is impaired over the posterior and lateral aspect of the forearm and lost to a varying extent over the distribution of the radial on the back of the hand.

Paralysis of the deep radial (posterior interosseous) nerve.—The evidence here is somewhat similar to that just given, but with the following differences. (*a*) *In the forearm:* There is no loss of extension, and the loss of supination is less as the brachio-radialis is not paralysed. (*b*) *At the wrist:* The 'drop' and loss of extension are not so marked, as the extensor carpi radialis longus escapes. **Sensation:** There is no loss.

Paralysis of the musculo-cutaneous nerve.—*Forearm:* Power of flexion is impaired, owing to complete paralysis of the biceps and partial of the brachialis (anterior). **Sensation:** This is impaired over the lateral aspect of the forearm, both back and front.

Amputation of forearm.—The 'mixed' method by skin-flaps roundly arched and circular division of the soft parts, the dorsal flap being the longer, is the most generally applicable. The bones should always be sawn below the pronator teres, when possible. In sawing them they must be kept parallel, the limb being in the supinated position. As the radius is the less securely held above, it is well to complete the section of this bone first. The relative position of the vessels has been indicated above (p. 1423, and figs. 1139 and 1141).

THE WRIST AND HAND

Bony points.—On the medial side the *styloid process* and, further laterally, the *head of the ulna* can be made out. On the lateral side, the *radial styloid process* descends about 1.2 cm. ($\frac{1}{2}$ in.) lower than that of the radius, and is somewhat anterior to it. Abduction of the hand is thus less free than adduction. Between the apex of the styloid process and the ball of the thumb a bony ridge can be felt, with some difficulty, formed by the *tubercle of the navicular* and the ridge of the *greater multangular* (trapezium). At the base of the hypothenar eminence the *pisiform* can be more readily distinguished. The *hook of the hamatum* (unciform) lies below and to the radial side of the pisiform. On the front of the metacarpo-phalangeal joint of the thumb, the *sesamoid bones* can be distinguished.

At the back of the wrist and hand the *triquetrum* (cuneiform) bone can be felt below the head of the ulna; and more toward the middle line the prominence of the *capitatum* (os magnum), which supports the third or longest digit.

A line drawn from the base of the fifth metacarpal bone to the radio-carpal joint, slightly curved downward, will give the line of the carpo-metacarpal joints. (Windle.) When the fingers are flexed, it will be seen that in each case it is the proximal bone which forms the prom-

inence; thus, the knuckle is formed by the head of the metacarpal, the interphalangeal prominence by the head of the first phalanx, and the distal one by the head of the second. Thus, the joint in each case lies below the prominence, the distal joint being 2 mm. ($\frac{1}{12}$ in.), the interphalangeal 4 mm. ($\frac{1}{6}$ in.), and the metacarpo-phalangeal 8 mm. ($\frac{1}{3}$ in.) below its prominence.

Skin and skin-folds.—The *skin* over the palm is thickened over the heads of the metacarpal bones and hypothenar eminence, thinner over the thenar. It is peculiar in its absence of sebaceous glands and hair-follicles; hence the absence of boils and sebaceous cysts. It is intimately connected with the palmar fascia, hence the chief difficulty in operations when this is contracted. Over the pulp of the digits the skin is closely connected with the periosteum of each ungual phalanx. The importance of this is alluded to under the heading of whitlow (*vide infra*).

Skin-folds: two or three of these are seen on the palmar surface of the wrist: two lower down, and usually close together, and one less well marked, a little higher up upon the forearm. None of these corresponds exactly to the wrist-joint (fig. 1142). The lowest 'precisely crosses the arch of the os magnum in the line of the third metacarpal bone' (Tillaux), and is not quite 1.8 cm. ($\frac{3}{4}$ in.) below the arch of the wrist-joint. It is about 1.2 cm. ($\frac{1}{2}$ in.) above the carpo-metacarpal joint line, and indicates very fairly the upper border of the transverse carpal (anterior annular) ligament.

'Of the many creases in the skin of the palm, three require especial notice. The first starts at the wrist, between the thenar and hypothenar eminences, and, marking off the former emi-

FIG. 1142.—RELATION OF THE VOLAR ARCHES TO THE FOLDS OF THE PALM. (Modified from Tillaux.)

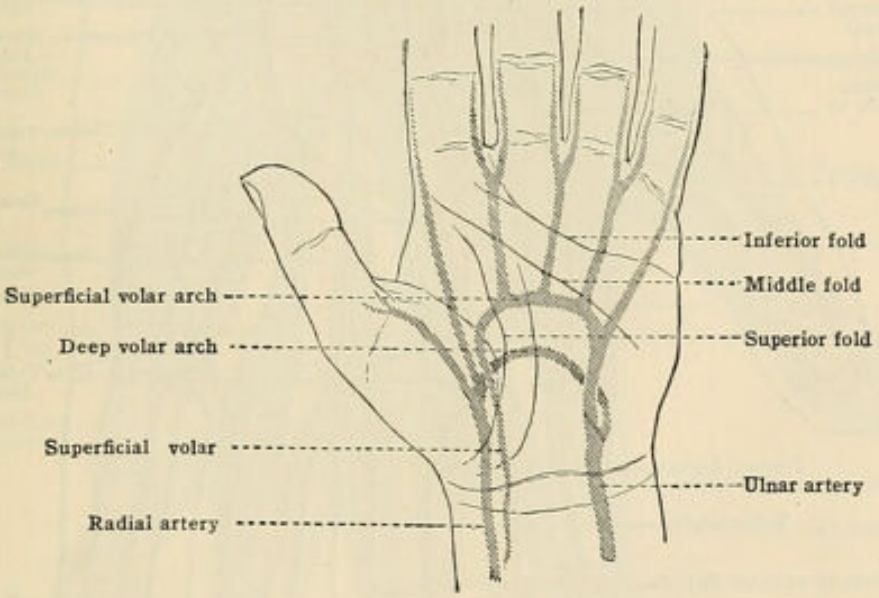

nence from the palm, ends at the lateral border of the hand and at the base of the index-finger. The second fold is slightly marked. It starts from the lateral border of the hand, where the first fold ends. It runs obliquely medially across the palm, with a marked inclination toward the wrist, and ends at the lateral limit of the hypothenar eminence. The third, lowest, and best marked of the folds starts from the little elevation opposite the cleft between the index and middle fingers, and runs nearly transversely to the ulnar border of the hand, crossing the hypothenar eminence at the upper end of its lower fourth. The first fold is produced by the adduction of the thumb; the second, mainly by the bending simultaneously of the metacarpo-phalangeal joints of the first and second fingers; and the third by the flexion of the three medial fingers. The second fold, as it crosses the third metacarpal bone, about corresponds to the lowest part of the superficial volar arch. The third fold crosses the necks of the metacarpal bones, and indicates pretty nearly the upper limits of the synovial sheaths for the flexor tendons of the three lateral fingers. A little way below this fold, the palmar aponeurosis breaks up into its four slips, and midway between the fold and the webs of the fingers lie the metacarpo-phalangeal joints. Of the transverse folds across the fronts of the fingers, corresponding to the metacarpo-phalangeal and interphalangeal joints, the highest is placed nearly 18 mm. ($\frac{3}{4}$ in.) below its corresponding joint. The middle folds are multiple for all the fingers, and are exactly opposite to the first interphalangeal joints. The distal creases are single, and are placed a little above the corresponding joints. There are two single creases on the thumb corresponding to the two joints, the higher crossing the metacarpo-phalangeal joint obliquely. The free edge of the web of the fingers, measured from the palmar surface, is about 1.8 cm. ($\frac{3}{4}$ in.) from the metacarpo-phalangeal joints. (Treves.)

The **superficial volar arch,** formed by the ulnar anastomosing with the superficial volar, or radialis indicis, will be shown by a line descending to the radial side

of the pisiform bone, and then, a little lower, curving across the palm on a line with the thumb when outstretched at right angles with the index-finger. The four common digital arteries, the main branches of the superficial arch, run downward along the interosseous spaces, and bifurcate 12 mm. ($\frac{1}{2}$ in.) above the webs of the fingers; the most medial digital does not bifurcate.

The digital arteries then descend along the sides of the fingers under the digital nerves, giving off twigs to the sheath of the tendons, which enter by apertures in it, and run in the vincula vasculosa. It is owing to the readiness with which these tiny twigs are strangled by inflammation that sloughing of the tendon takes place so readily and irreparably. Throughout its course the superficial volar arch deserves its name. It is only covered by the palmaris

FIG. 1143.—ANASTOMOSES AND DISTRIBUTION OF THE ARTERIES OF THE HAND.

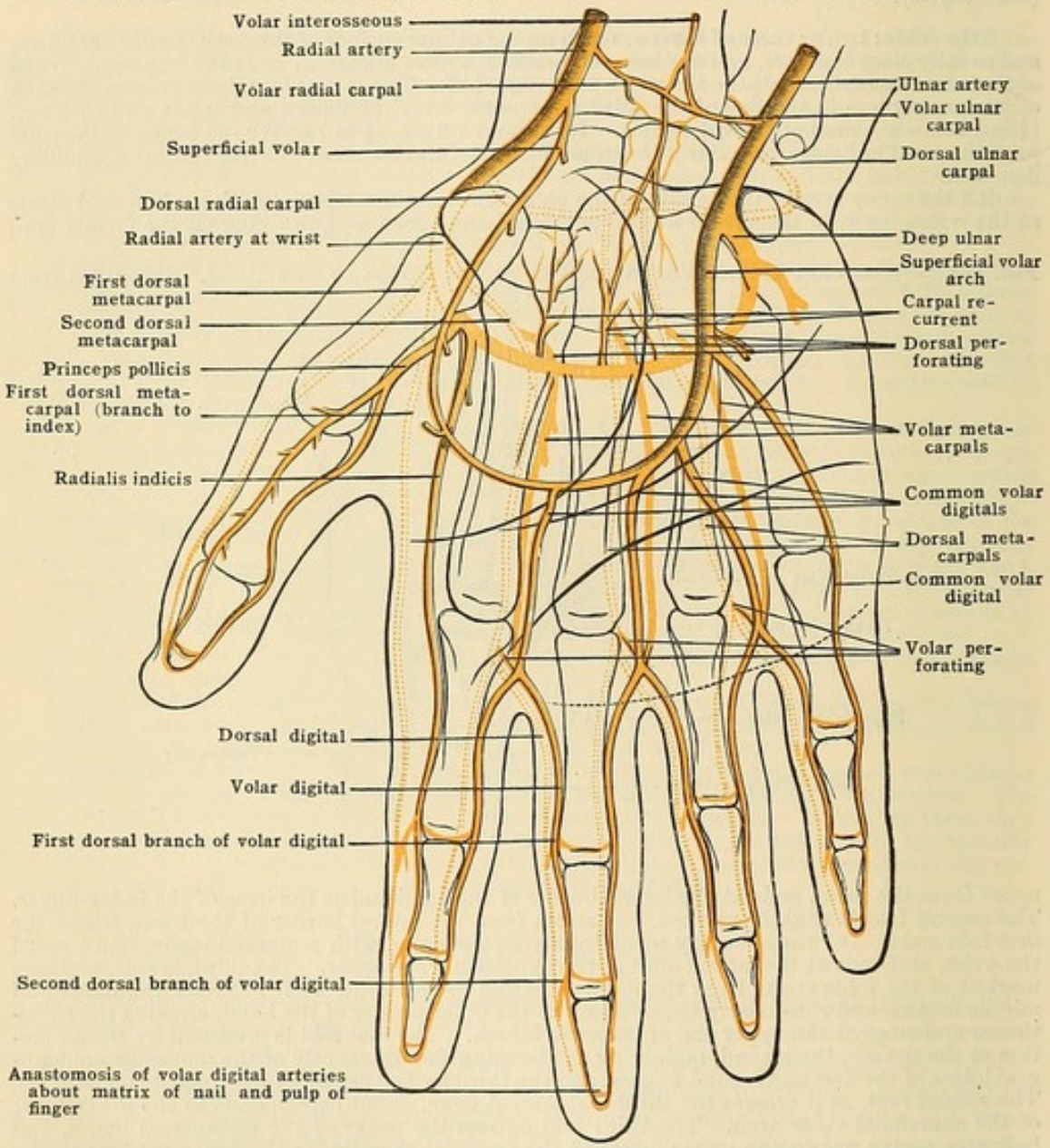

brevis and central part of the palmar fascia. Beneath it, medio-laterally are the flexor brevis and opponens digiti quinti, the digital branches of the ulnar and median nerves, and the flexor tendons and lumbricales.

The **deep volar arch,** formed by the radial and communicating branch of the ulnar, lies about 1.2 cm. ($\frac{1}{2}$ in.) nearer to the wrist than the superficial. It is not so curved as the superficial arch, and rests upon the interossei and metacarpal bones just below their bases. The structures separating it from the superficial arch have been already given.

Owing to the frequency of wounds here, the relation of *the structures in front of the wrist* is most important. The radial artery lies between the tendon of the

brachio-radialis and flexor carpi radialis. Next to this tendon is the palmaris longus, when present. At the mid-point of the front of the wrist and usually under the palmaris longus is the median nerve. To the medial side of the palmaris longus is the flexor sublimis, the tendons for the middle and ring-finger being in front. The tendon of the flexor carpi ulnaris is most medial and between this and the superficial flexor of the finger the ulnar nerve and vessels have come up into a superficial position.

FIG. 1144.—THE SUPERFICIAL MUSCLES OF THE PALM OF THE HAND.

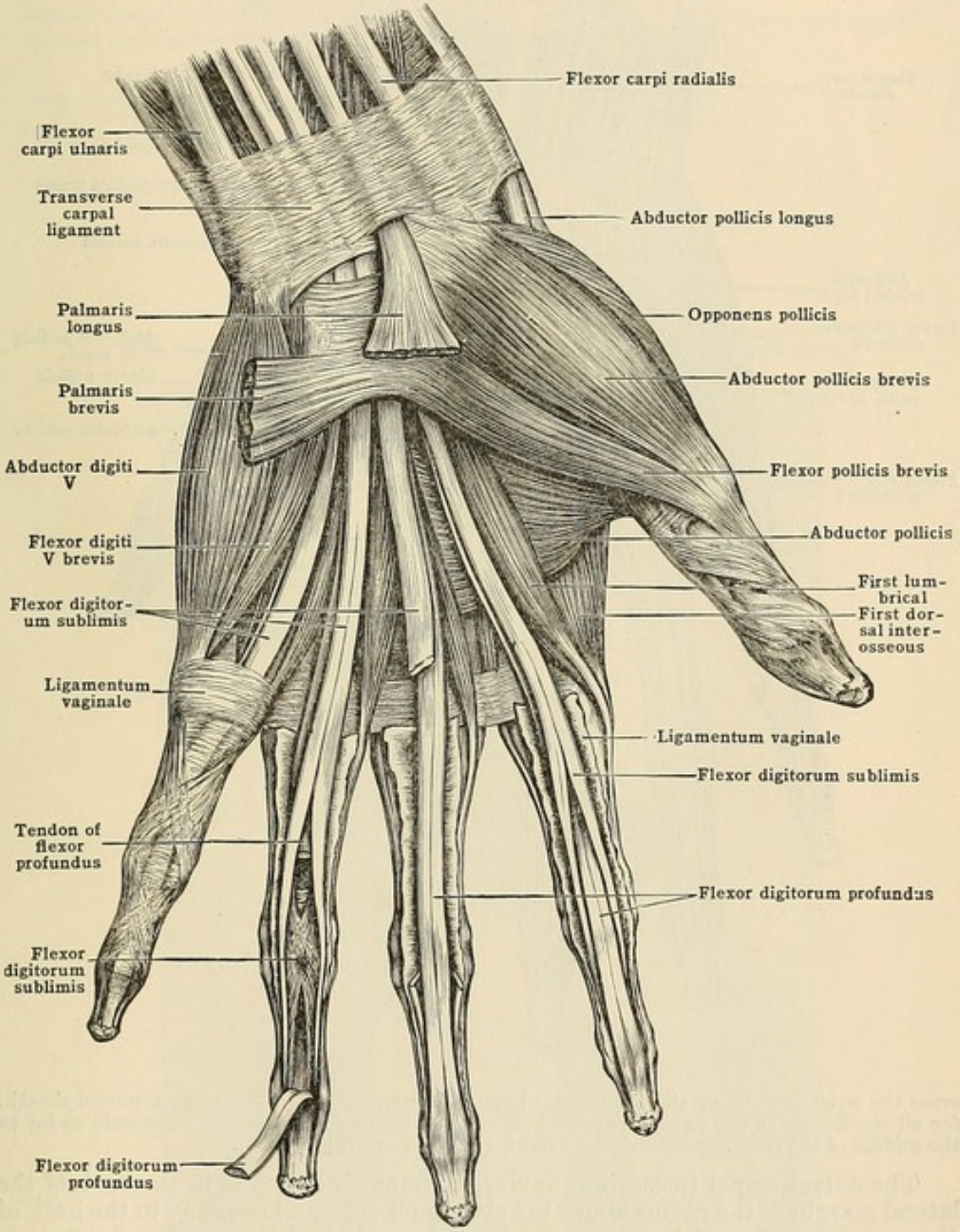

Fasciæ and sheaths.—The **transverse** and **dorsal carpal** (annular) **ligaments** bind down and hold in place the numerous tendons about the wrist. The **transverse carpal** (anterior annular), when healthy, cannot be detected. It is attached to the pisiform and triquetral (cuneiform) bones on the medial, and to the navicular and greater multangular (trapezium) on the lateral, side.

The ulnar nerve and vessels, the superficial volar, and palmar cutaneous branches of the median and ulnar pass over it. The ulnar artery and nerve are especially protected by their position between the pisiform and hook of the hamate (unciform), and also by a process of the flexor carpi ulnaris, which passes to the transverse ligament, thus forming a kind of tunnel. The flexor carpi radialis passes through a separate sheath formed by the ligaments and the groove in the greater multangular; while beneath the ligaments lie the flexor tendons, the median nerve, and accompanying artery. Attached to its upper border is the deep fascia of the forearm, and to its lower the palmar fascia and the palmaris longus tendon, while from the lateral and medial parts arise some of the thenar and hypothenar muscles. The upper border of the transverse carpal ligament corresponds to the lower of the two lines which

FIG. 1145.—THE DEEPER MUSCLES OF THE PALM OF THE HAND.

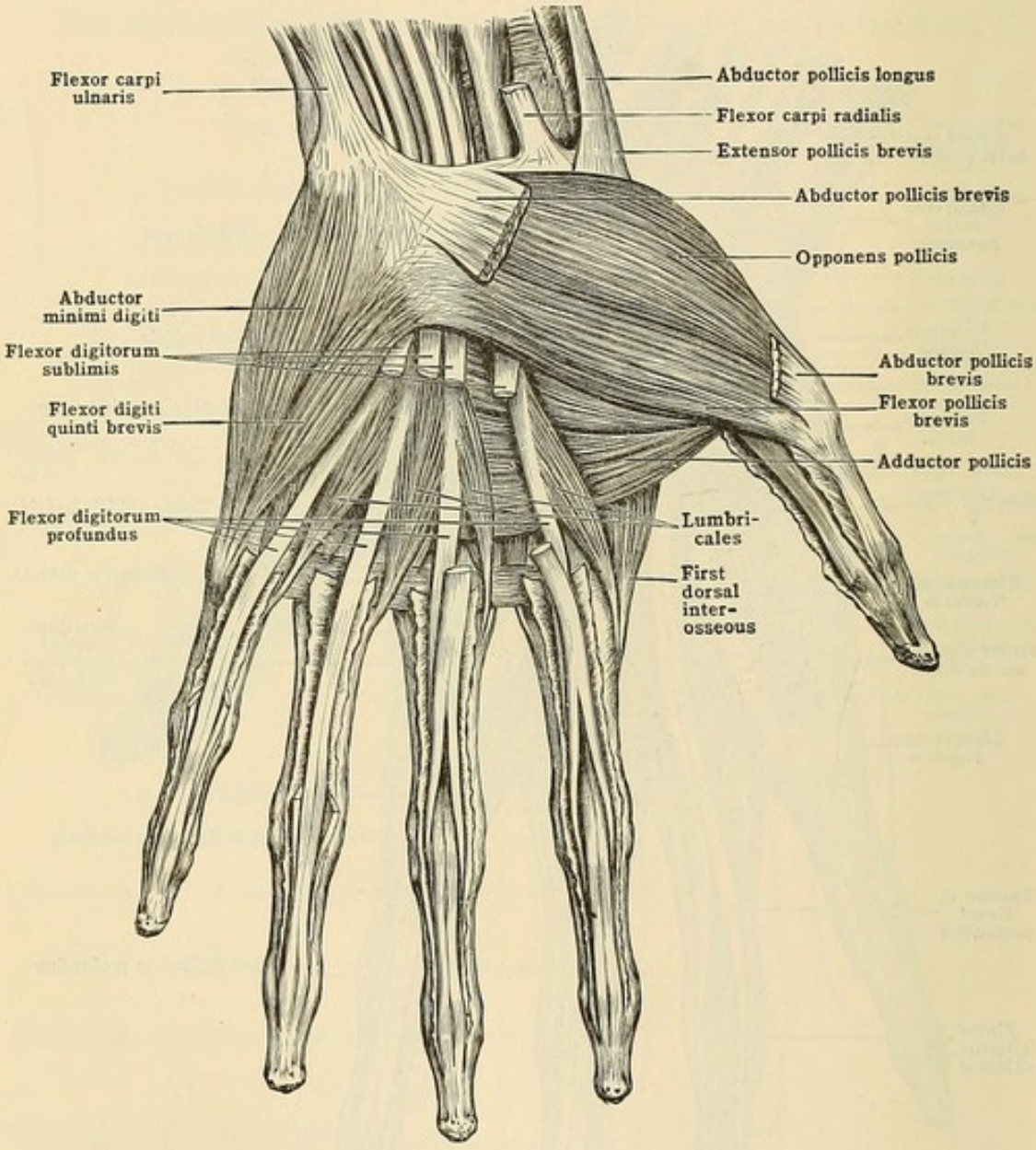

cross the wrist just above the thenar and hypothenar eminences. The large synovial sheath, for all the flexors of the fingers, reaches beneath and below the transverse ligaments as far as the middle of the palm, and above the wrist for 3.7 to 5 cm. (1½ to 2 in.).

The **dorsal carpal** (posterior annular) **ligament** is attached to the back of the lateral margin of the radius above the styloid process, and medially to the back of the styloid process of the ulna, the triquetrum and pisiform. Its direction is oblique, being higher on the radial side. It contains six tendon-compartments, of which four are on the radius.

The most lateral contains the long abductor and short extensor of the thumb; the second the two radial extensors of the carpus; the third, the extensor pollicis longus; this deep and narrow groove can be identified when the hand is extended, by its prominent lateral margin; the fourth transmits the extensor communis and extensor indicis proprius; the fifth, lying between the

FIG. 1146.—SECTION THROUGH REGION OF WRIST, A LITTLE ABOVE THE JOINT. RIGHT SIDE, UPPER HALF OF THE SECTION. (Tillaux.)

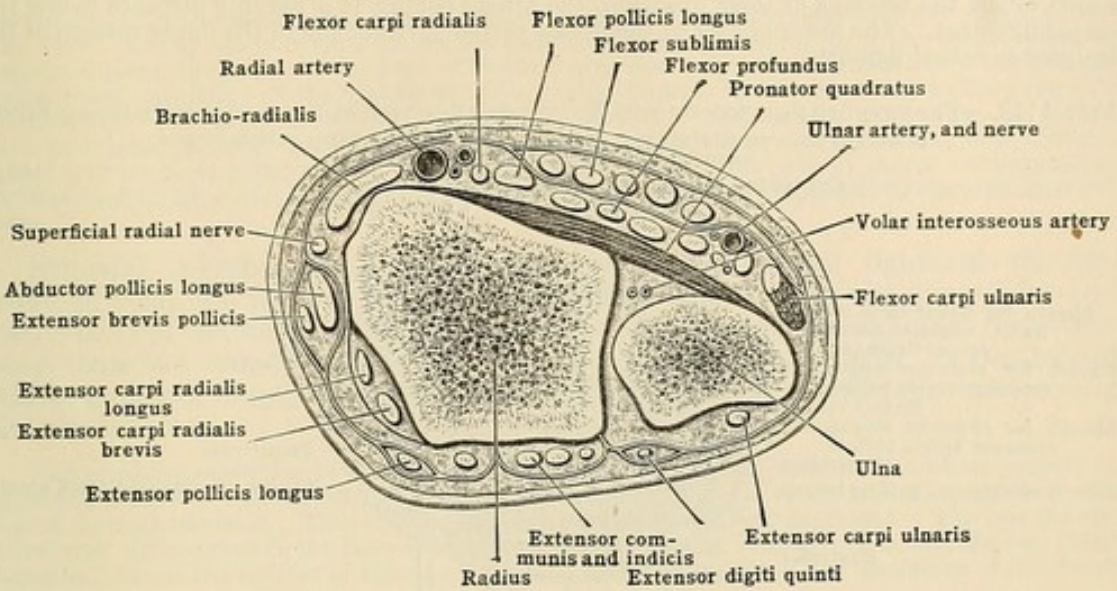

FIG. 1147.—REGION OF THE WRIST, AS SHOWN BY THE RÖNTGEN-RAYS.

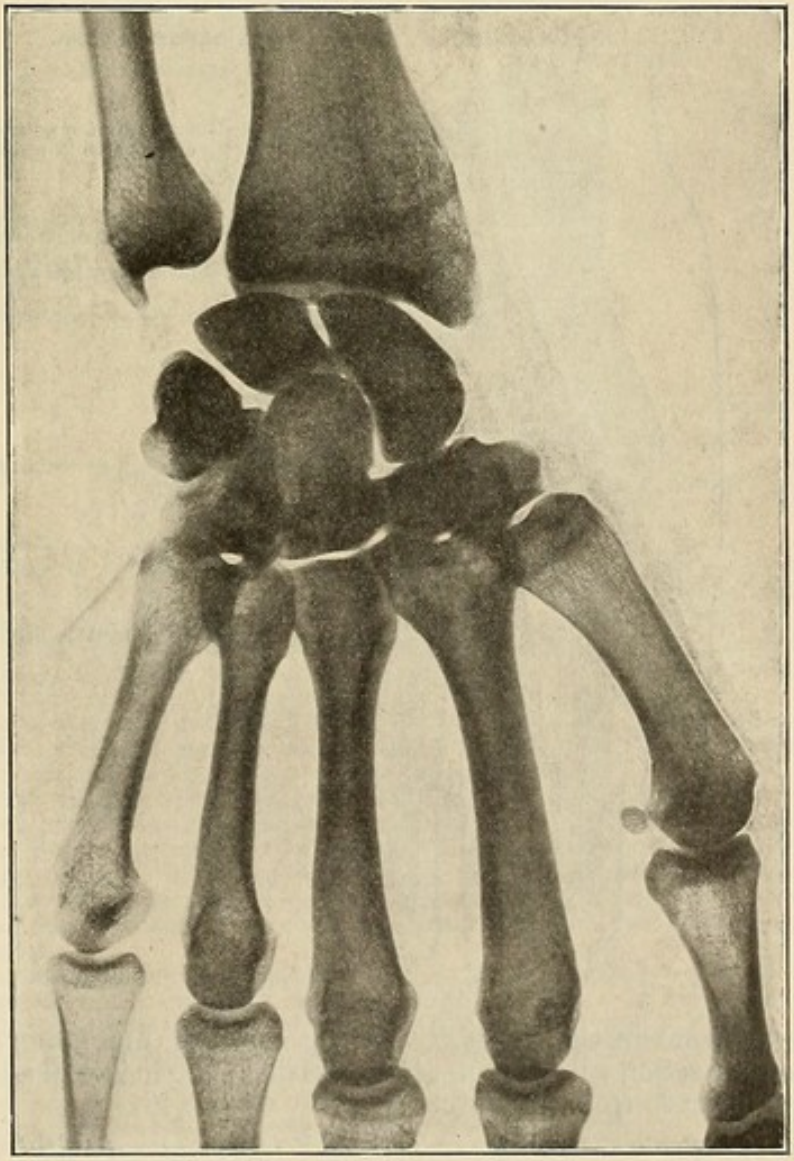

radius and ulna, the extensor digiti quinti; and the sixth, lying just lateral to the styloid process of the ulna, the extensor carpi ulnaris. The sheaths for the last two extensors are the only ones which follow the tendons of their insertion, the others ending at a varying distance below the carpal ligament. The lower border of the dorsal carpal corresponds to the upper margin of the transverse carpal ligament.

FIG. 1148.—TRANSVERSE SECTION OF THE WRIST THROUGH THE MIDDLE OF THE PISIFORM BONE.

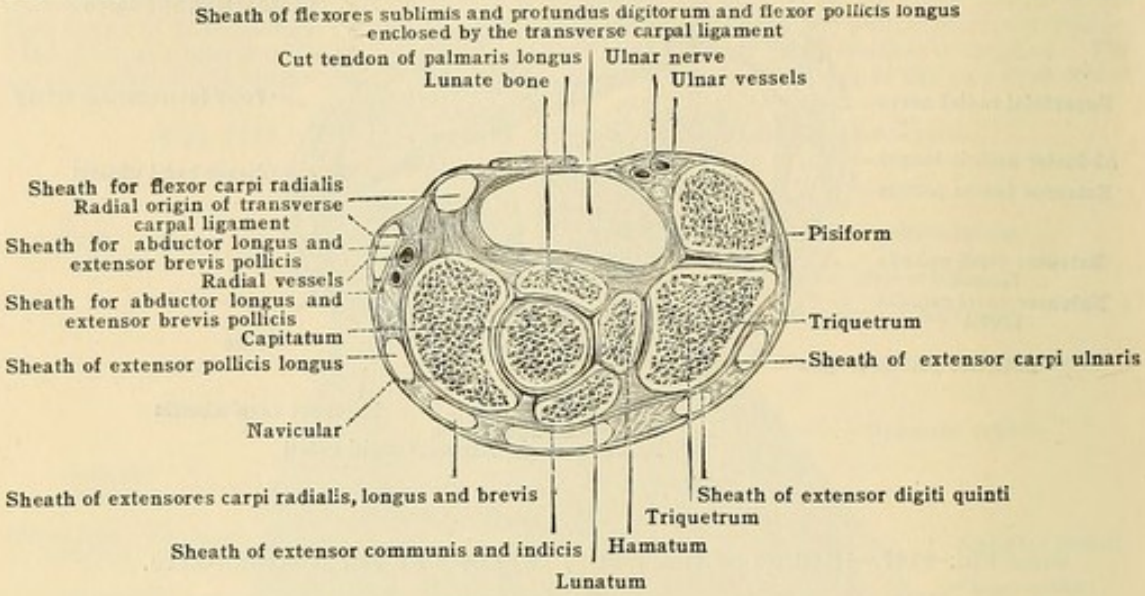

FIG. 1149.—DIAGRAM OF THE GREAT PALMAR BURSA.

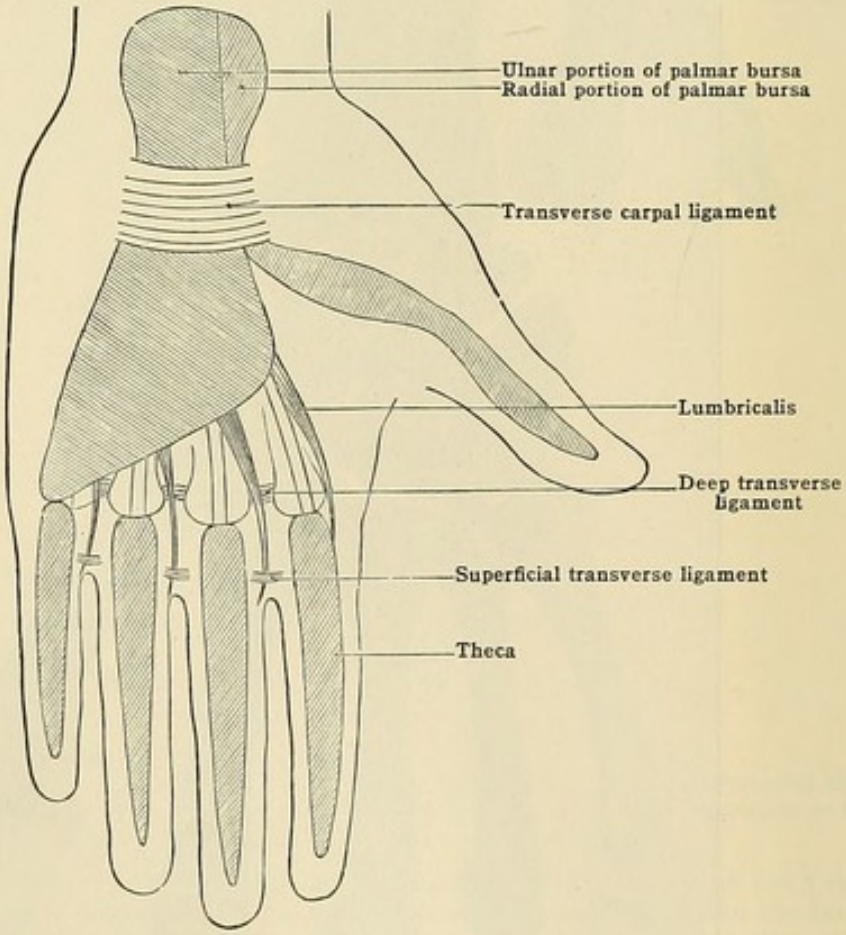

The **palmar aponeurosis,** by its strength, toughness, numerous attachments, and intimate connection with the superficial fascia and skin is well adapted to protect the parts beneath from pressure.

The thenar and hypothenar muscles are enclosed in two processes, which are thinner so as not to interfere with the contraction of the subjacent muscles. The central part, pointed above

at its attachment to the carpal ligament, spreads out fan-like below, and gives off four slips, each of which bifurcates into two processes, which are attached to the sides of the first phalanx of each finger and into the superficial transverse ligament of the web and the deeper one which ties the heads of the metacarpal bones together. Transverse fibres pass between the processes into which each of the four slips bifurcates, and thus form the beginning of the theca, which is continued down the finger to the base of the last phalanx. It is the contraction of the palmar aponeurosis, especially of the slip to the two medial fingers, which gives rise to Dupuytren's contraction. The **theca** is strong opposite the first two phalanges (ligamentum vaginale), weak and loose opposite the joints (ligamentum annulare). The density of this osseo-fibrous tunnel and its close proximity to the digital nerves explain the pain in thecal inflammation. Its tendency to gape widely after section is to be remembered in amputations through infected parts.

Synovial membranes.—Beneath the transverse carpal ligament lie two **synovial sacs,** one for the flexor pollicis longus, and one for the superficial and deep flexors of the fingers. They extend above the transverse ligament for rather more than 2.5 cm. (1 in.). The two sacs may communicate. A compound palmar ganglion has an hour-glass outline, the transverse carpal ligament forming the constriction.

The creaking sensation in teno-synovitis and that of 'melon-seed' bodies often present in tuberculosis here is well known. The sheath for the long flexor of the thumb reaches to the base of the last phalanx. That for the finger-flexors gives off four processes. The one for the little finger also reaches to the base of the last phalanx. Those for the index-, middle, and third fingers end about the middle of the metacarpal bones. Traced from the insertions of the flexor

FIG. 1150.—SECTION OF CARPUS THROUGH THE HAMATE BONE. (Two-thirds.) (Bellamy, after Henle.)

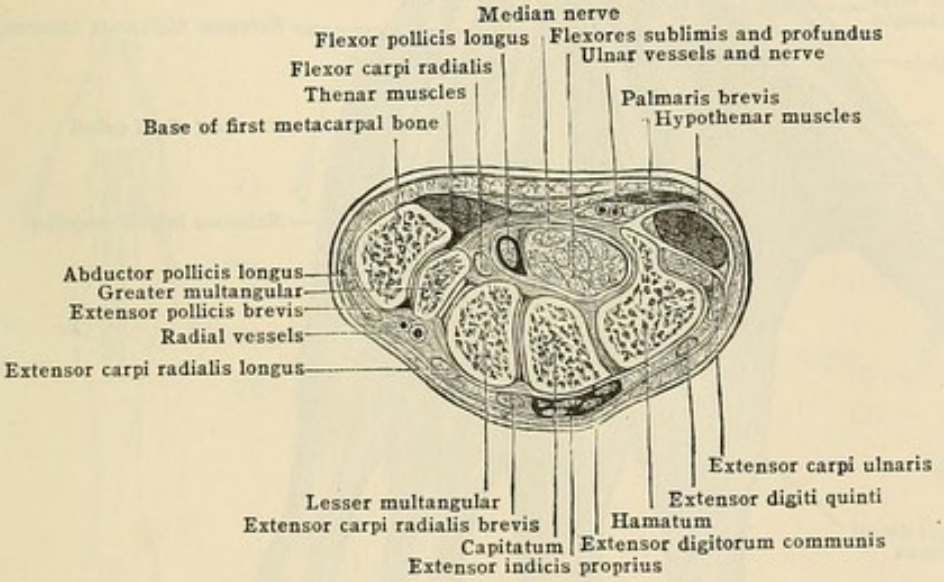

profundus, the digital synovial sheaths extend upward into the palm as far as the bifurcation of the palmar fascia (p. 1430), i. e., into a point about opposite to the necks of the metacarpal bones, denoted on the surface by the crease which corresponds to the flexion of the fingers. Thus, about 1.2 cm. (½in.) separates the sheaths of the lateral three fingers from the large synovial sac beneath the transverse carpal ligament. There is no synovial sheath beneath the pulp of the fingers or thumb, this part lying on the periosteum of the last phalanx.

This has an important bearing on **whitlow.** Infection here may be merely *subcuticular*, or deeper, in the latter case from the connection of the skin with the periosteum here existing the bone is soon affected, and necrosis keeps up a tedious ulcer. As the two centres of the phalanx do not unite till about the twentieth year, the distal one only requires removal; as the flexor sheath only reaches to the insertion of the flexor, i. e., into the proximal, part of the bone, both sheath and tendon may escape implication. Higher up along the fingers whitlow may be *cellulo-cutaneous* or *thecal*. While the continuity of the synovial sheath in the little finger and thumb (fig. 1149) renders infection here more dangerous, the short gap between the digital and the palmar sacs is readily traversed by acute infection, with all the grave results of thecal suppuration.

Suppuration in the hand owes much of its gravity to the possibility of infection of the synovial tendon sheaths and consequent sloughing of the tendons. At the same time it is now recognised that unless these sheaths are primarily infected pus collects at first in certain potential spaces, more or less well defined, in the looser connective tissue of the hand. One of these, known as the **middle palmar space** (Kanavel*) is situated on the front of the metacarpals of the middle and ring fingers, and lies deeply between the flexor tendons and the interosseous muscles. Continuations of this potential space extend downward along the lumbrical muscles

* Kanavel, A. B.: Infections of the Hand, 1912.

on the radial side of the three medial fingers, and may lead pus from the palm to the subcutaneous tissue of these fingers or *vice versa*. A second potential compartment, the **thenar space** (Kanavel) lies in front of the index metacarpal, between the flexors of the index-finger and the adductor transversus pollicis. As in the former space, the corresponding lumbrical muscle prolongs it down to the radial side of the index-finger.

Distention of the middle palmar space with pus leads to obliteration of the hollow of the palm and a variable extension of the swelling along the radial side of the three medial fingers. Distention of the thenar space follows the thenar eminence, obliterates the adduction crease of

FIG. 1151.—TENDONS UPON THE DORSUM OF THE HAND.

(The dorsal expansion or aponeurotic sheath has not been removed.)

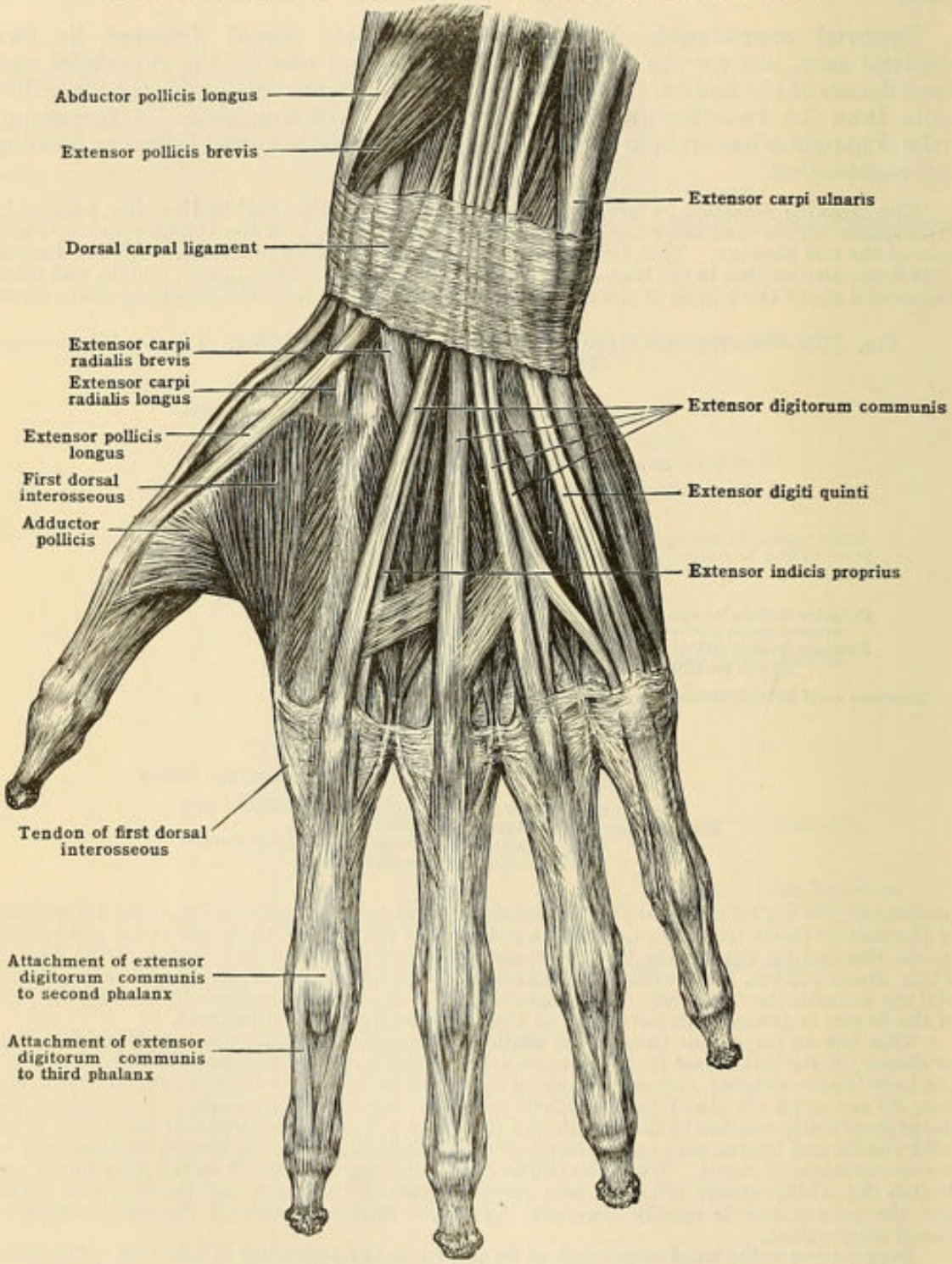

the thumb, and may extend down the radial side of the index-finger. There is not in either case the extreme tenderness and pain on passive extension of the fingers that is characteristic of infection of the synovial sheaths. The pus is best evacuated by an incision on the radial side of the finger most affected, a little behind the web, sinus forceps being passed along the lumbrical muscle into the palm, so as to avoid opening and infecting the synovial sheaths.

It must be remembered also that infection of the above fascial spaces may take place secondarily, by the bursting into them of pus from the synovial tendon sheaths.

Deeper are the **articular synovial sacs,** five in number:—(1) Between the interarticular cartilage and the head of the ulna; (2) between the radius and the interarticular cartilage above, and the navicular and lunate and triquetrum below; (3) between the greater multangular and first metacarpal bone; (4) between the pisiform and the triquetral bone; (5) between the two rows of carpal bones, sending two processes upward between the three bones of the upper row, and three downward between the four of the lower row; these three processes being also continued below into the medial four carpo-metacarpal and three intermetacarpal joints.

Beneath the palmar aponeurosis covering the *thenar eminence* are the following structures:—Superficial volar artery, abductor pollicis brevis, opponens pollicis, radial head of short flexor, tendon of long flexor, ulnar head of short flexor, first volar metacarpal arteries, metacarpal bone of the thumb, with the tendon of the flexor carpi radialis and greater multangular.

Beneath the *central part* of the palmar aponeurosis are the superficial arch and its digital branches; the ulnar and median nerves, with their branches; the flexors, superficial and deep, with their synovial sheath; and the lumbricales; then a layer of connective tissue (the only

FIG. 1152.—DIAGRAMS ILLUSTRATING THE INSERTIONS OF THE EXTENSOR, LUMBRICAL AND INTEROSSEOUS MUSCLES OF THE RIGHT HAND. A, Index finger. B, Middle finger. C, Ring finger. D, Little finger. 1L, 2L, 3L, 4L, Lumbricales. 1D9, 2D9, 3D9, 4D9, dorsal interossei. 1P9, 2P9, 3P9, palmar (volar) interossei. EC, Extensor communis digitorum. E9, Extensor indicis proprius. EMD, Extensor digiti quinti proprius. AMD, abductor digiti quinti (Willan: Anat. Anz. Bd. 42, 1912.)

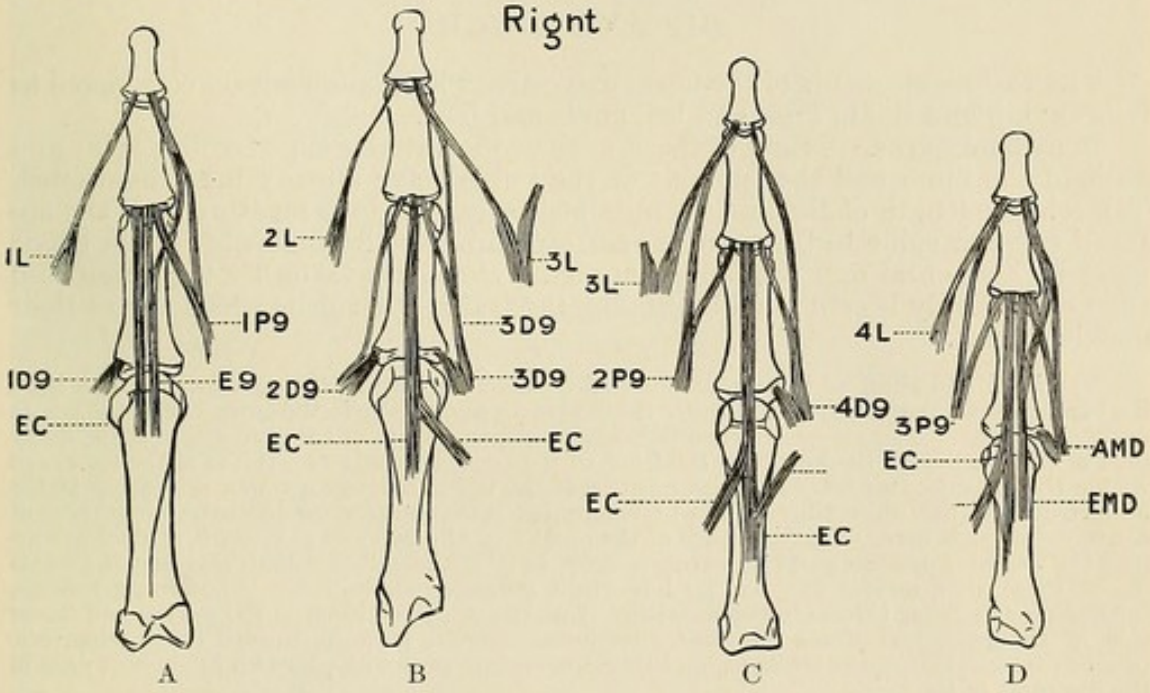

structure, together with the deep layer of fascia over the interossei, which prevents matter pent in by the palmar aponeurosis from making its way back out through the dorsum), the deep arch, the interossei, and the metacarpal bones.

In the *hypothenar eminence* under the fascia are part of the ulnar artery and nerve, the abductor and flexor brevis digiti quinti, the opponens, the deep branch of the ulnar artery and nerve, and the fifth metacarpal bone.

The back of the wrist and hand.—The dorsal carpal (posterior annular) ligament has already been described. On the lateral side is the so-called 'snuff-box space' (*tabatière anatomique* of Cloquet), a triangular hollow, bounded toward the radius by the long abductor and short extensor of the thumb, and toward the ulna by the long extensor. The navicular and greater multangular, with their dorsal ligaments, form the floor. In the roof lie the radial vein and branches of the radial nerve. More deeply is the artery, following a line from the apex of the styloid process to the back of the interosseous space.

The different tendons have already been given. Between the first two metacarpal bones is the first dorsal interosseous muscle, which forms a fleshy projection against the radial side of the index metacarpal, when the thumb and index are pressed together. On its palmar aspect is the adductor pollicis. Wasting of the former muscle is a ready indication of injury or disease of the ulnar nerve.

The skin on the dorsum, by its laxity, readily allows of œdema, this being sometimes evidence of pressure on the axillary vein by carcinomatous deposits. The dorsal venous arch receives the digital plexuses, and from it the radial and posterior ulnar veins ascend. The median vein begins in plexuses at the root of the thumb and the front of the wrist.

Ganglia are common on the dorsum, in connection with the extensors of the fingers and the thumb. While usually due to a weakening of the sheath and protrusion of this and the synovial membrane, such swellings may be due to a projection of the articular synovial membrane. Owing to the laxity of the skin, the slight vascularity, the size of the tendons, their connection with joint-capsules and with each other, which fixes them, the dorsum of the wrist is the 'seat of election,' for **tendon-anastomosis** and other operations. **Metacarpo-phalangeal dislocation.** This occurs in the thumb and the index-finger especially. The chief cause in the difficulty in reduction is the glenoid ligament. This, in reality a fibro-cartilaginous plate, is blended with the lateral ligaments on the palmar aspect of the joint, and is firmly attached to the phalanx, but more loosely to the metacarpal. Thus when dislocation occurs in violent hyperextension, the metacarpal attachment of the glenoid ligament gives way and it is carried by the phalanx over the head of the metacarpal bone. In the case of the thumb, the buttonhole-like slit with which the two heads of the flexor brevis, now displaced, embrace the head of the metacarpal, the contraction of the other short muscles, and, occasionally, a displaced long flexor, are additional causes. In the case both of the thumb and finger, tilting the phalanx well back on the dorsum of the metacarpal and then combined pressure with the thumbs forward against the base of the phalanx, when this is sharply flexed, will with an anæsthetic, be usually successful. The thumb should be, first, adducted into the palm.

THE LOWER EXTREMITY

HIP AND THIGH

The various segments of the lower extremity will be successively considered as follows: hip and thigh, knee and leg, ankle and foot.

Bony landmarks.—Many of these, such as the anterior superior iliac spine and crest of the ilium and the tubercle of the pubis, have already been mentioned. The relative length of the limbs is obtained by carrying the measure from the anterior superior spine to the tip of the corresponding medial malleolus. The pelvis must be horizontal and the limbs parallel. The share taken by the femur and tibia respectively is estimated by finding the transverse sulcus which marks their meeting-point.

The head and shaft of the **femur** are well covered in, save in the emaciated. The head lies just below Poupart's ligament, under the ilio-psoas, and a little to the outer side of the centre of that ligament. A line drawn horizontally laterally from the pubic tubercle will cross the lower part of the head. All the head and the front of the neck, but only two-thirds of the back, are within the capsule; this intra-capsular position of the upper epiphysis, which, appearing at the first year, does not unite till eighteen or twenty, accounts largely for the extreme gravity of acute epiphysitis here. The structure of the neck, i. e., the two sets of lamellæ, *vertical* to support the weight, *transverse* and *intersecting* in order to meet the pull of the muscles, and the wasting of these after middle life, has an important influence on injuries. The strong process, *femoral spur* or *calcar* (Merkel) which, arising from the compact tissue on the medial and under side of the neck, just above the lesser trochanter, spreads laterally toward the trochanteric (digital) fossa, also affords strength, and its degeneration probably plays an important part in the fractures of the neck.

Hip-joint.—The chief points of surgical importance are the following:—The capsule shows fibres chiefly longitudinal in front, circular behind. Of the former, the ilio-femoral or inverted Y-shaped ligament descends from the anterior inferior spine to the two extremities of the anterior intertrochanteric line. It not only checks extension and strengthens the front of the joint, but it keeps the pelvis and trunk propped forward on the heads of the femurs, thus preventing waste of muscular action. It is joined on the medial side by the pubo-capsular ligament, which checks abduction. Between the two is the medial part of the front capsule, and here the ilio-psoas bursa may communicate with the joint. This fact must be remembered in tuberculous disease of the psoas, and the presence of this bursa explains certain deep-seated swellings in the front of the joint in adults. Behind, the ischio-femoral is the strongest part of the capsule, its fibres blending with the circular and weaker part of the capsule here. Dislocation usually occurs at the posterior, lower and medial part of the joint. It is to be noted that in full extension and flexion the head of the femur is in contact with the weakest spot in the capsule, in front and behind, respectively. From the deep aspect of the capsule fibres pass up at the line of reflection of the synovial membrane on to the neck—the cervical ligaments of Stanley. In intracapsular fracture these

fibres keep the fragments together; hence one need of gentle handling; their softening may explain, a little later, an increase in the shortening.

Exploration of the joint.—This is usually effected by an oblique incision downward and slightly medially between the sartorius and rectus medially and the gluteus medius and minimus laterally. A branch of the ascending division of the lateral circumflex is the only artery met with. In tapping the joint the puncture is made in the same line, 2 or 3 inches below the anterior-superior spine. 'If the instrument is pushed upward, medially, and backward beneath the rectus, it will pass into the joint a little above the anterior intertrochanteric line. (Stiles.)

FIG. 1153.—REGION OF THE HIP-JOINT, AS SHOWN BY THE RÖNTGEN-RAYS.

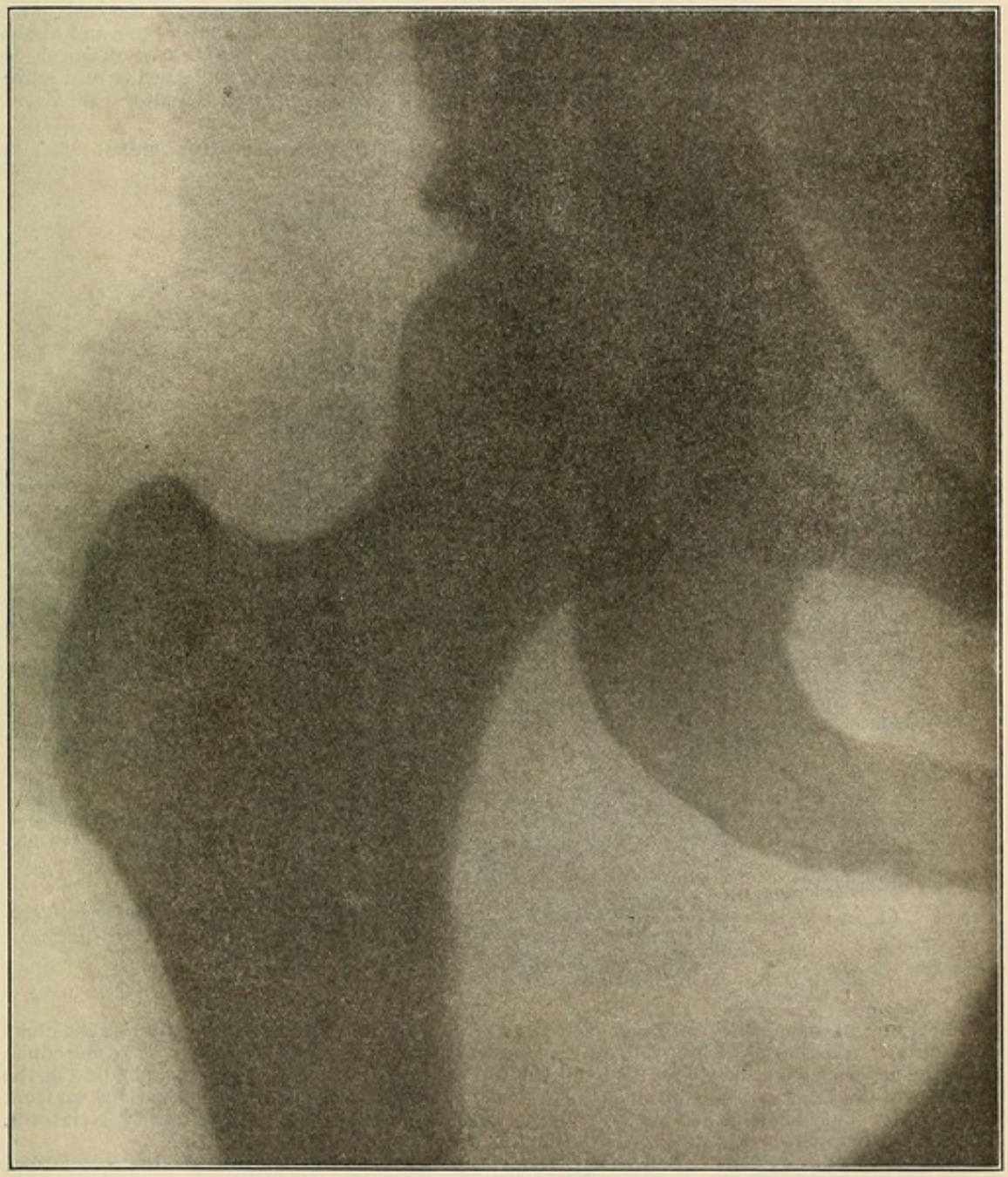

Trochanter major.—This valuable landmark is most prominent when the limb is rotated medially or adducted; it lies at the bottom of a depression when the femur is everted.

The chief structure of importance between it and the skin is the upper part of the insertion of the gluteus maximus, that going to the fascia lata, and the bursa beneath the muscle. This is often multilocular. It is, not very uncommonly, the seat of tubercular inflammation which readily invades the cancellous tissue of the trochanter. The top of the great trochanter is about 1.8 cm. ($\frac{3}{4}$ in.) below the level of the femoral head, and, when the femur is extended is a little below the centre of the hip-joint. This part of the bone is covered by the gluteus medius.

The slightness of the prominence of the great trochanter in the living subject compared with that in the skeleton is explained by fig. 1154, which shows how the descending gluteus medius and minimus fill up the space between the ilium and trochanter. To examine the great trochanter, the thigh should be abducted, so as to relax the strong fascia lata passing upward over the tensor and glutei to the iliac crest.

Nélaton's line.—This useful guide is a line drawn from the anterior superior spine of the ilium to the most prominent part of the tuberosity of the ischium. In normal limbs, the top of the great trochanter just touches this line. In dislocation, fractures of the neck, and in wasting of the neck, as in osteo-arthritis, the relation of the trochanter to Nélaton's line becomes altered.

The top of the great trochanter is a guide in Adams's operation for division of the neck of an ankylosed femur, the puncture being made and the saw entered 2.5 cm. (1 in.) above and about the same distance in front of this point. Owing to the fact that in many cases of ankylosis the neck is destroyed, the above operation has been largely replaced by the simpler and more widely applicable Gant's osteotomy just below the great trochanter, from the lateral side.

FIG. 1154.—TRANSVERSE SECTION OF THE HIP-JOINT AND ITS RELATIONS. (One-third.) (Braune.)

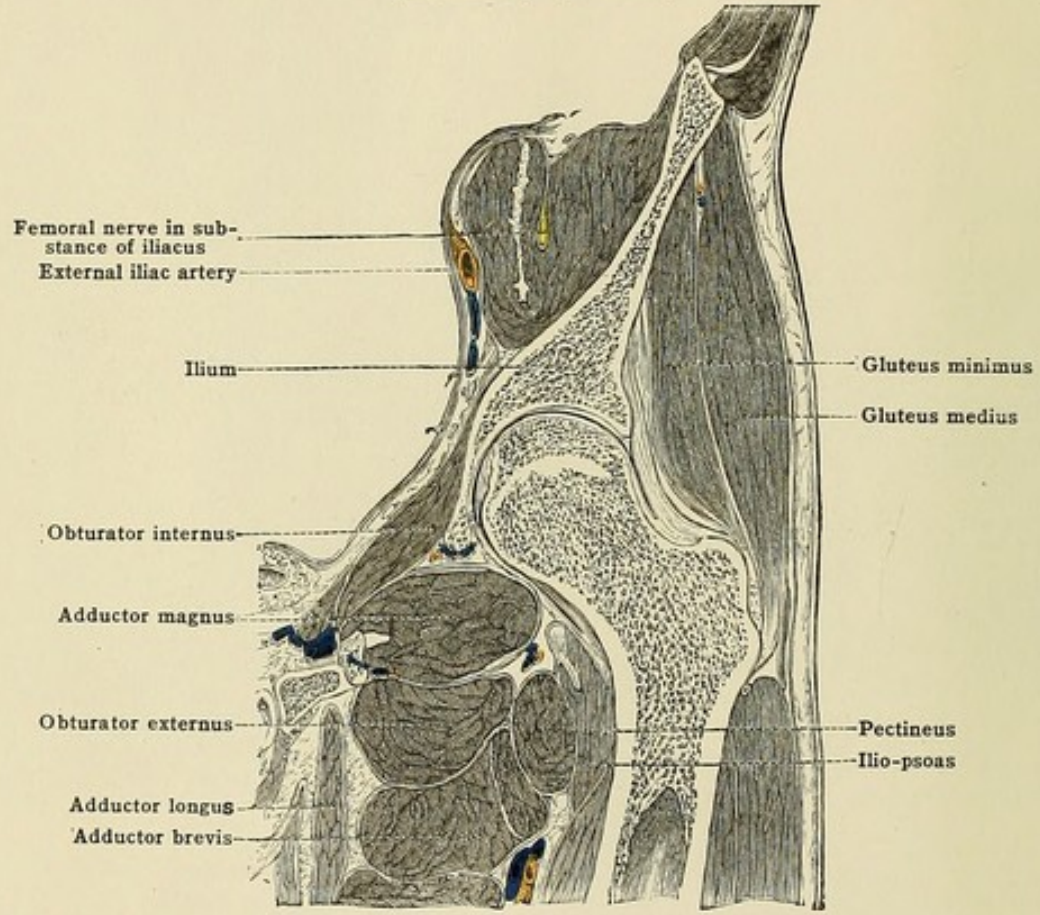

Bryant's triangle.—Bryant makes use of the following in deciding the position of the great trochanter. The patient being flat on his back (1) a line is dropped vertically on to the couch from the anterior superior spine; (2) from the top of the great trochanter a straight line in the long axis of the thigh is drawn to meet the first; (3) to complete the triangle, a line is drawn from the anterior superior spine to the top of the trochanter. This line is practically Nélaton's. The second line will be found diminished on the damaged or diseased side.

Muscular prominences.—The *tensor fasciæ latæ* forms a prominence beginning just lateral to the sartorius and reaching downward and somewhat backward to the strong fascia lata, 7.5 to 10 cm. (3 to 4 in.) below the great trochanter. Below this point, as far as the lateral condyle of the tibia, the strong *ilio-tibial band* can be felt. Like the inverted Y-shaped ligament, this band is a powerful saving of muscular action in maintaining the erect position. At the insertion of the tensor fasciæ latæ it bifurcates into two layers, which enclose the muscle. The superficial is attached to the iliac crest and the sheath of the gluteus medius; the deep blends with the capsule and the reflected head of the rectus. This deeper layer is perforated by the ascending branch of the lateral circumflex. The ilio-tibial band is a guide for reaching the femur (p. 1334). The *sartorius*, the chief landmark of the thigh, forming a boundary of the femoral trigone (Scarpa's triangle), the adductor (Hunter's) canal, and the popliteal space, can be readily brought into view by the patient's raising his limb slightly rotated laterally. In the middle line the *rectus* muscle stands out in bold relief, with its tendon of insertion and the patella, when the

leg is extended. On either side of this muscle is a furrow, and on either side, again, of this furrow the *vasti* become prominent. Between the vastus medialis and adductor muscles is a depression indicating the adductor canal. At the upper and medial third of the thigh, if the limb be abducted, the upper part of the *adductor longus* comes into strong relief. On the medial side below, above the knee-joint, the vertical fibres of the *adductor magnus* end in a powerful tendon coming down to the adductor tubercle (fig. 1159). This replaces here the medial intermuscular septum, and the insertion of the tendon marks the level of the lower epiphysial line of the femur. At the lateral and back part of the thigh the vastus lateralis is separated from the biceps by a groove which indicates the lateral intermuscular septum. Of these **septa,** prolongations inward from the fascia lata to the linea aspera, the lateral lies between the vastus lateralis and the biceps. It reaches from the lateral tuberosity of the femur to the insertion of the gluteus maximus. Just above the condyle it is perforated by the superior lateral articular vessel and nerve. The medial septum extends from the adductor tubercle to the trochanter. It is weak in

FIG. 1155.—THE MUSCLES ATTACHED TO THE PUBES.
(From a dissection in the Hunterian Museum.)

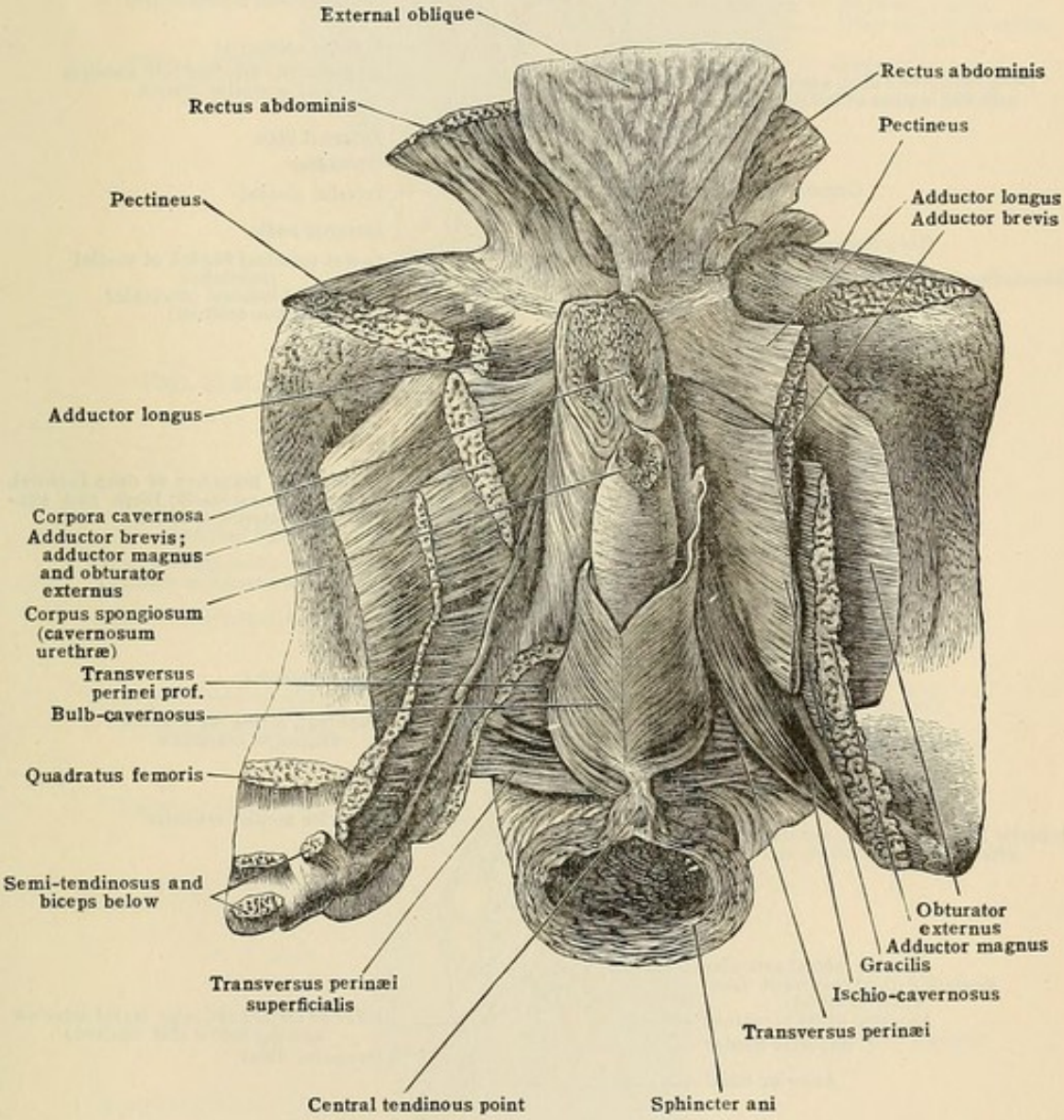

comparison, and separates the adductor from the vastus medialis. A **third,** the weakest of all, separates the adductor and the hamstrings. The **fascia lata** has the same effect as that in the neck in causing pus to burrow, especially downward, and in rendering the diagnosis of swellings beneath it difficult. Thickest above and on the lateral aspect, and again about the bony prominences at the knee-joint, at both of which sites it receives accessions from muscles, it is divided into **iliac** and **pubic portions.** The former is attached behind to sacrum and coccyx, iliac crest and the inguinal ligament, terminal line and pubic tubercle. Here it blends with the pubic portion, which is connected with the pubic arch. At the fossa ovalis (saphenous opening) the two may be said to separate, the iliac forming the upper cornu and lateral falciform margin, and descending over the femoral vessels and extensors. The pubic, much thinner, forms the medial margin of the fossa, and descends obliquely over the pectineus and adductor longus behind the vessels, to blend with the sheath of the ilio-psoas and capsule of the hip-joint.

The **inguinal (Poupart's) ligament.**—The abdomen is separated from the thigh by a fold, best marked in flexion—the inguinal furrow. In this, pressure detects the meeting of the aponeurosis of the external oblique and the fascia lata, i. e., Poupart's ligament, extending between the anterior superior spine of the ilium and the tubercle (spine) of the pubes. The line representing it should be drawn slightly convex downward, owing to the attachment of the deep fascia. It forms the base of the femoral trigone; its medial attachment blends with the triangular lacunar (Gimbernat's) ligament. The parts passing under the inguinal ligament and their arrangement have been given at p. 1399, fig. 1122.

FIG. 1156.—DIAGRAM OF ARTERIES OF THIGH.

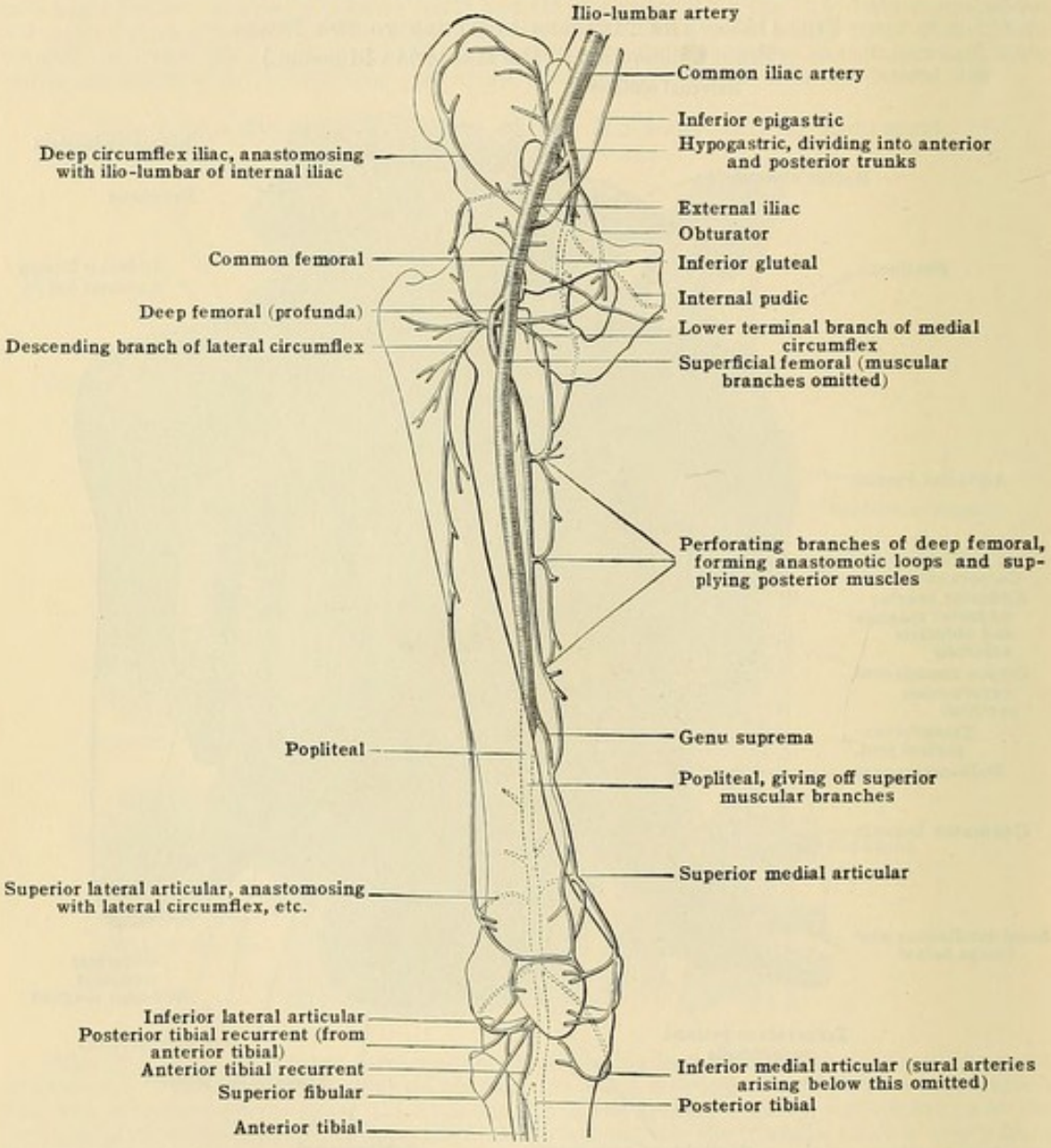

The **femoral trigone (Scarpa's triangle)** (fig. 1159).—Immediately below the inguinal ligament a hollow is seen corresponding to this region, the lateral and medial boundaries of which are brought into view when the limb is raised, the adductor longus especially when the limb is abducted, and the sartorius when the thigh is flexed and the limb extended and rotated laterally. The floor of the femoral trigone is not horizontal, the plane of the medial part being very oblique. It is formed latero-medially by the ilio-psoas, pectineus, adductor brevis (slightly), and adductor longus.

A **psoas abscess** descending below the inguinal ligament usually does so on the lateral aspect of the femoral vessels; if the sheath gives way, or if the abscess follows the profunda artery, it will pass beneath the adductor longus and point toward the medial side of the thigh. (Taylor.)

FIG. 1157.—SECTION OF THE RIGHT THIGH AT THE APEX OF THE FEMORAL TRIGONE. (Heath.)

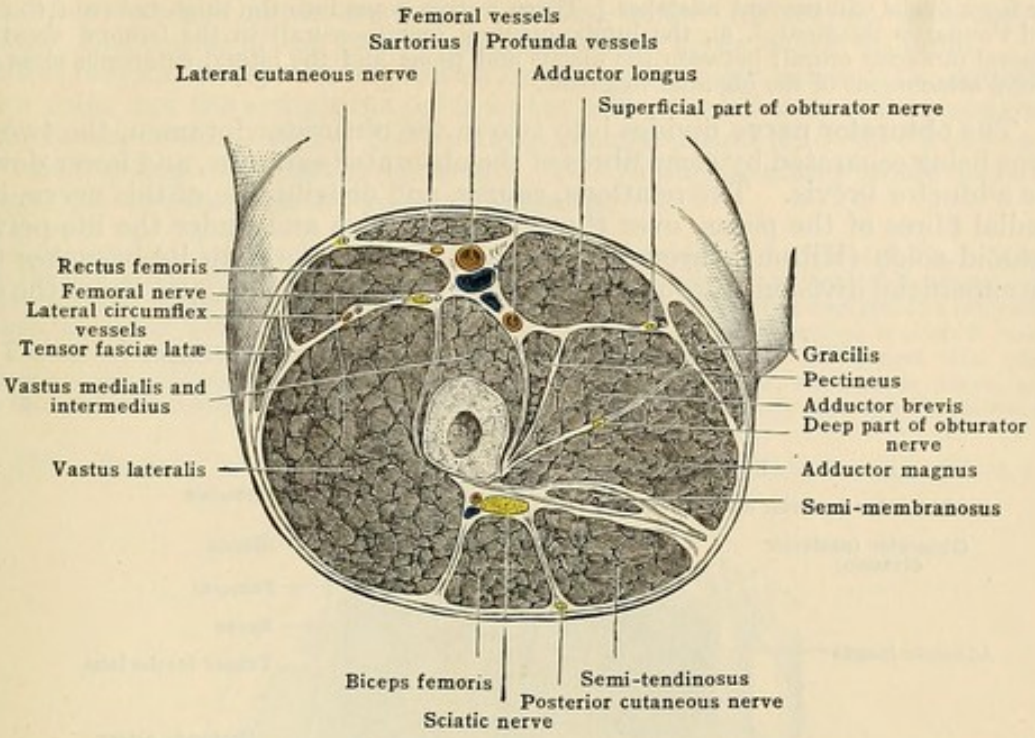

FIG. 1158.—SUPERFICIAL DISSECTION OF THE FRONT OF THE THIGH. (Hirschfeld and Leveillé.)

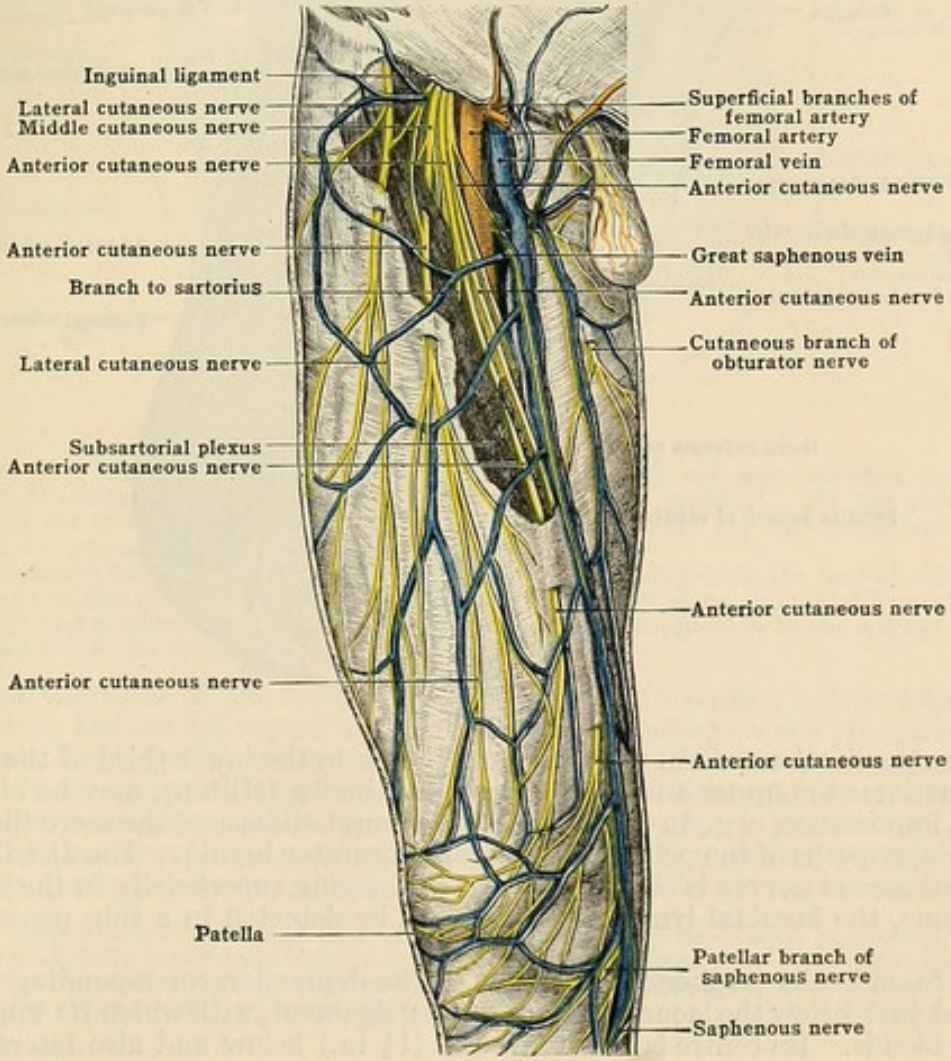

If it simulate a femoral hernia, examination of the back and the fact that the swelling is below the fossa ovalis will prevent mistakes. Three **nerves** come into the thigh between the pelvis and Poupart's ligament, i. e., the lumbo-inguinal (genito-crural) in the femoral sheath, the femoral (anterior crural) between the iliacus and psoas and the lateral cutaneous close to the lateral attachment of the inguinal ligament.

The **obturator nerve** divides into two in the obturator foramen, the two divisions being separated by some fibres of the obturator externus, and lower down by the adductor brevis. The relations, course, and distribution of this nerve, in the medial fibres of the psoas, over the sacro-iliac joint and under the ilio-pelvic or sigmoid colon (Hilton), through the obturator foramen with its branches (from the superficial division) through the cotyloid notch to the hip, and (from the deep)

FIG. 1159.—FEMORAL AND OBTURATOR NERVES. (Ellis.)

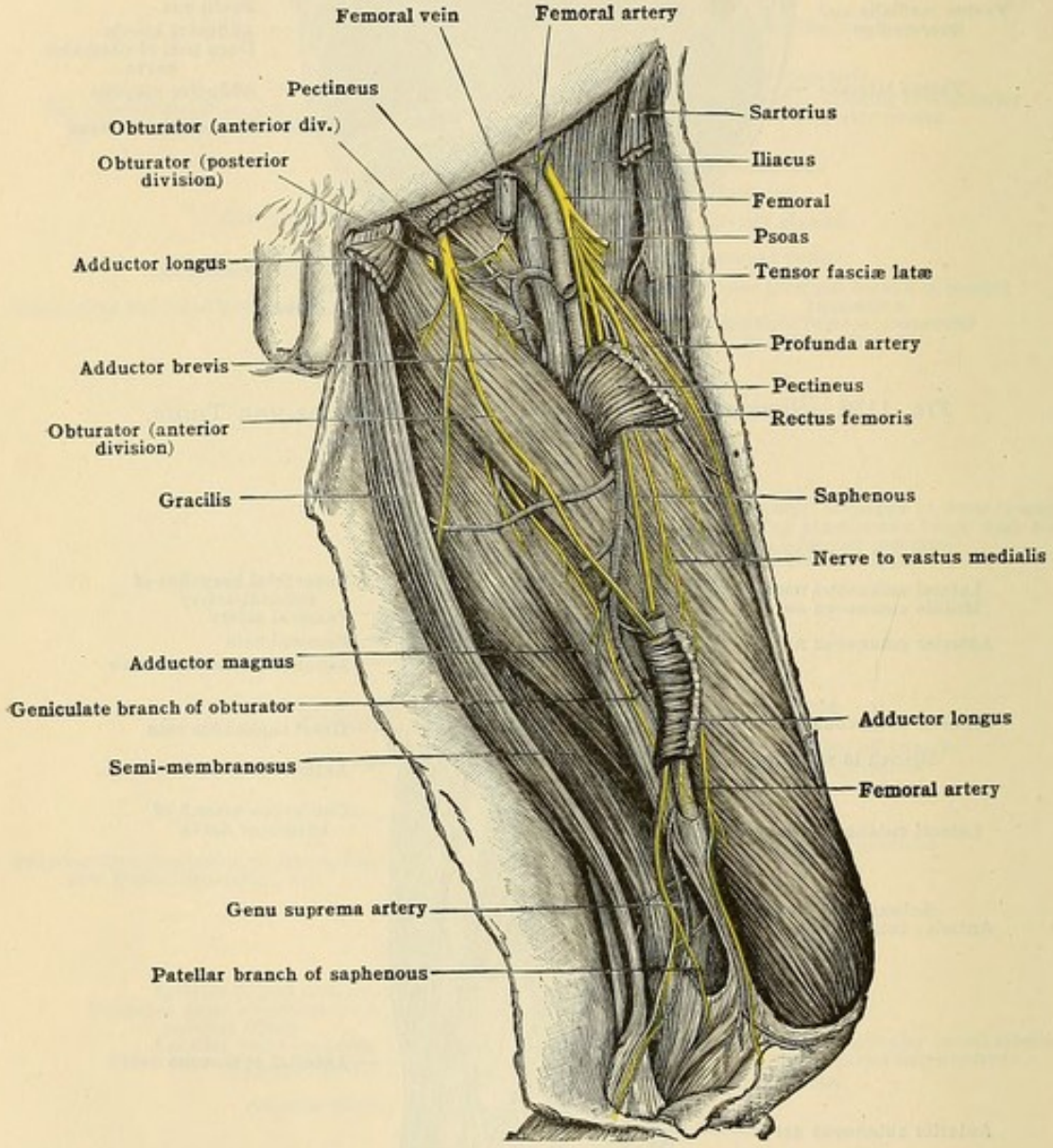

along the popliteal artery to the knee, and others to the lower third of the thigh, and sometimes the upper and medial aspect of the leg (Hilton), may be of much surgical importance, e. g., in carcinoma of the bowel, disease of the sacro-iliac and hip-joints, growths of the pelvis, and the rare obturator hernia. The distribution of the **cutaneous nerves** is shown in fig. 1158. Lying superficially in the base of the trigone, the **inguinal lymphatic nodes** can be detected in a thin person (fig. 1172).

The **fossa ovalis** (**saphenous opening**).—The depression corresponding to this is placed just below the lacunar (Gimbernat's) ligament, with which its upper extremity blends. Its centre is about 3.7 cm. (1½ in.) below and also lateral to a

line dropped vertically from the pubic tubercle. This and the other structures concerned in femoral hernia are fully described under this section (*vide supra*, p. 1398). The course of the great saphenous vein is given below, p. 1456.

Line of femoral artery.—A line drawn from the mid-point between the anterior superior spine and the symphysis pubis to the adductor tubercle will correspond with the course of this vessel. The sartorius usually crosses it 10 cm. (3 to 4 in.) below the inguinal (Poupart's) ligament. The profunda artery arises usually 3.7–5 cm. (1½ to 2 in.) below Poupart's ligament.

The incision for tying the femoral in the femoral trigone should be about 7.5 cm. (3 in.) long, in the line of the artery, and begins about 7.5 cm. (3 in.) below the inguinal ligament, and runs over the apex of the triangle. The femur is flexed slightly, abducted and rotated laterally. The fascia lata being divided, the sartorius, readily recognised by its direction, is drawn laterally. The closely subjacent sheath must be opened on its lateral side. Structures that may be seen are a vein joining the great saphenous, the anterior cutaneous, saphenous nerve, and that to the vastus medialis. The collateral *circulation* (fig. 1156) is mainly through the following

FIG. 1160.—SECTION OF THIGH THROUGH UPPER PART OF HUNTER'S CANAL. (W. A.)

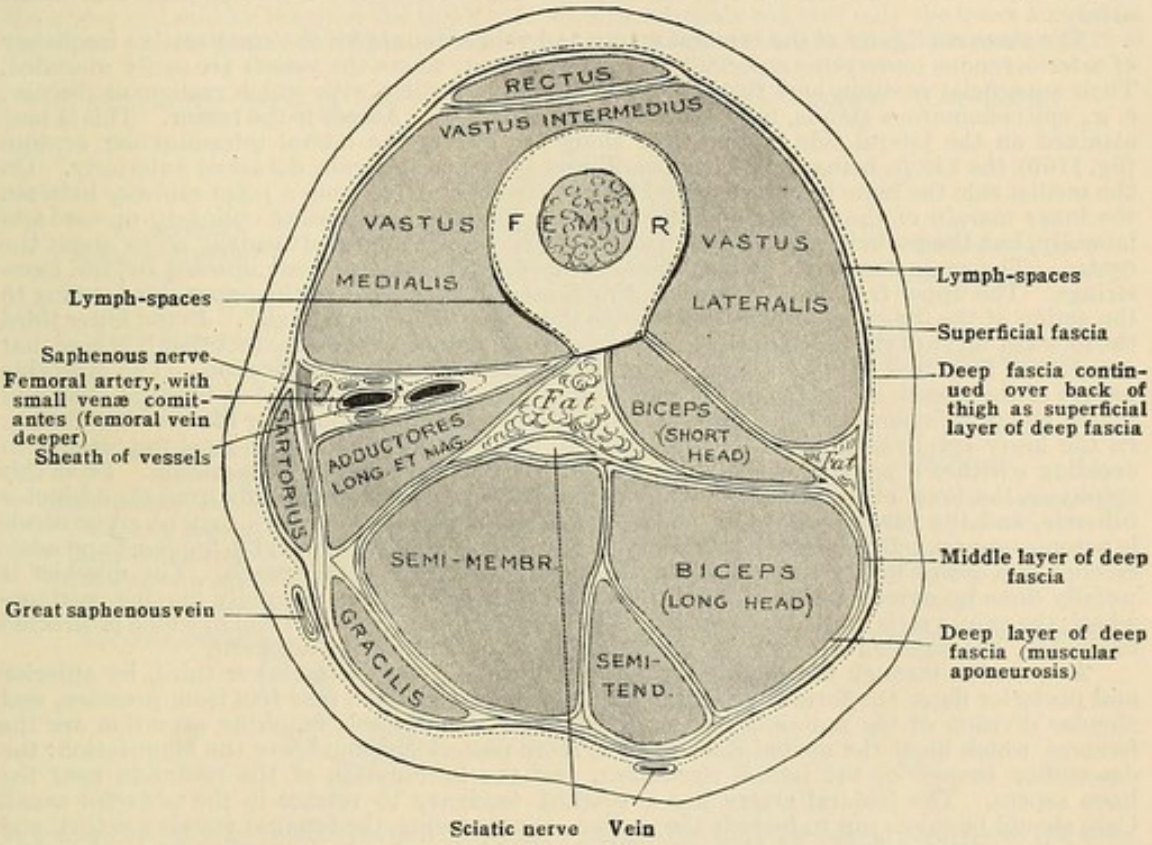

channels:—(1) The lateral and medial circumflex above, with the genu suprema and lower muscular branches of the femoral, and the articular of the popliteal. (2) The perforating branches of the profunda above, with the vessels below first given. (3) The comes nervi ischiadici with the articular of the popliteal.

The **femoral vein** lies, below the inguinal ligament, immediately to the medial side of the artery. From this point on the vein gets to a somewhat deeper plane, though still very close to the artery, and gradually inclining backward, lies behind its companion at the apex of the triangle, and below lies somewhat laterally to it.

From the apex of the femoral trigone (Scarpa's triangle) a depression runs down along the medial aspect of the thigh, corresponding to the groove already mentioned between the vastus medialis muscle and the adductors. Along this groove lies the sartorius, and beneath it the **adductor (Hunter's) canal,** a triangular inter-muscular gap with its apex toward the linea aspera, and its base or roof formed by the fibrous expansion which ties together its boundaries, viz., the adductor longus and magnus and the vastus medialis.

The vein, which in the upper part of the canal lies behind the artery, separating it from the three adductors, lower down inclines more and more to the lateral side. The saphenous nerve lies also in the canal, but not in the sheath. The above-mentioned space terminates at about the junction of the middle and lower thirds of the thigh, in the opening in the adductor magnus

by which the artery enters the upper and medial part of the popliteal space. The saphenous, the largest branch of the femoral nerve, having crossed the femoral vessels latero-medially, accompanies them as far as the opening in the adductor magnus. Here it perforates the aponeurotic roof, and is prolonged under the sartorius, accompanied by the superficial part of the genu suprema artery, to perforate the fascia lata between the sartorius and gracilis, and run with the great saphenous vein at the upper and medial part of the leg.

Pressure may be applied to the femoral artery—(1) Immediately below the inguinal ligament: it should here be directed backward so as to compress the vessel against the brim of the pelvis and the capsule of the hip-joint; (2) at the apex of the femoral trigone the pressure here being directed laterally and a little backward, so as to command the vessel against the bone; (3) in the adductor canal the pressure should be directed laterally with the same object. Care must be taken, especially above, to avoid the vein, which lies very close to the artery, and also the femoral nerve, which enters the thigh about 1.2 cm. (½ in.) outside the artery, and at once breaks up into its branches, superficial and deep.

In ligature of the femoral artery in Hunter's canal, the line of the incision, in the middle third of the thigh, must exactly follow that of the vessel. It is frequently made too lateral, exposing the vastus medialis. Branches of the saphenous vein being removed, the fascia lata is slit up and the sartorius identified by its fibres descending medially. Those of the vastus medialis are less oblique and are directed downward and laterally. The sartorius having been drawn to the medial side, usually, the aponeurotic roof of the canal is opened, and the femoral sheath identified. The vein, here posterior and to the lateral side, is closely connected to the artery.

The close contiguity of the femoral artery and vein accounts for the comparative frequency of arterio-venous aneurysms especially in the upper part, where the vessels are easily wounded. Their superficial position here further accounts for the facility with which malignant disease, e. g., epitheliomatous glands, may cause fatal hæmorrhage. **Access to the femur.** This is best attained on the lateral side of the shaft along the line of the lateral intermuscular septum (fig. 1160), the biceps being pulled backward, and the vastus lateralis detached anteriorly. On the medial side the bone may be exposed by an incision starting from a point midway between the inner margin of the patella and the adductor tubercle and passing obliquely upward and laterally, but the parts here are more vascular. **Fractures** of the shaft usually occur about the centre. The main tendency to displacement is of the lower fragment upward by the hamstrings. The upper fragment is anterior; this is especially marked in the upper third, owing to the action of the ilio-psoas, which also rotates the upper fragment laterally. In the lower third the forward curve of the femur and its more superficial position explain the fact that it is here that compound fractures of the femur may, occasionally, occur. **Ossification.** The unstable nature of the tissues about the upper epiphysis, which appears at the end of the first year and unites about eighteen, and the frequency of tuberculous disease in early life are well known. In the lower epiphysis ossification begins before birth, a point of medico-legal importance in deciding whether a newly born child has reached the full period of uterine gestation. From this epiphysis, the level of which is denoted by a line drawn horizontally laterally from the adductor tubercle, and the vascular growing tendon of the adductor magnus—the origin of an exostosis is not uncommon. **Displacement of this epiphysis** (it unites about twenty) in boyhood and adolescence is a grave injury from the immediate risk of the popliteal vessels. The mischief is usually done by overextension of the leg, as when this is caught in a rapidly moving carriage-wheel; the epiphysis is carried forward in front of the diaphysis, the lower end of which is directed backward, endangering the vessels which are posterior and closely adjacent.

Amputation through the thigh.—This is usually performed in the lower third, by anterior and posterior flaps, the former being the longer, so as to ensure a scar free from pressure, and circular division of the muscles, vessels, and nerves. The vessels requiring attention are the femoral, which lie at the medial side, and the more posteriorly, the lower the amputation; the descending branch of the lateral circumflex, and the termination of the profunda near the linea aspera. The femoral artery has a marked tendency to retract in the adductor canal. Care should be taken not to include the saphenous nerve when the femoral vessels are tied, and to cut the sciatic cleanly and high up. When amputation has to be performed in the upper third of the thigh, the tendency of the ilio-psoas to flex the shortened limb and thus bring the sawn femur against the end of the stump must be remembered, and met by keeping the patient propped up and the stump as horizontal as possible. Some of the structures now divided are shown in fig. 1160.

The buttocks. Bony landmarks.—The finger readily traces the whole outline of the iliac crest. Behind, it terminates in the posterior superior iliac spine, which corresponds in level to the second sacral spine and the centre of the sacro-iliac joint. (Holden.)

The third sacral spine marks the lowest limit of the spinal membranes and the cerebro-spinal fluid; it also corresponds to the upper border of the great sacro-sciatic notch. The first piece of the coccyx corresponds to the spine of the ischium. (Windle.) Its apex is in the furrow just behind the last piece of the rectum.

The tuberosities of the ischium are readily felt by deep pressure on either side of the anus. In the erect position they are covered by the lower margin of the gluteus maximus. In sitting they are protected by tough skin, fasciæ, with coarse fibrous fat, and often by a bursa known, according to the patients in whom it becomes enlarged, as weaver's, coachman's, lighterman's, drayman's bursa. The

skin of the buttock is coarse and difficult to cleanse satisfactorily. The abundance of sebaceous glands accounts for the frequency of boils here.

Gluteus maximus.—The 'fold of the buttock' neither corresponds accurately to, nor is caused by, the lower margin of this muscle. Thus, medially, it lies below the lower margin of the muscle, as it runs laterally it crosses it, and comes to lie on the muscle. The fold is really due to creasing of the skin adherent here to the coarsely fibro-fatty tissue over the tuber ischii during extension. But in early hip disease, in which flexion of the joint is, with wasting of the muscle, almost unvaryingly present, the fold disappears with well-known rapidity. The prominence of the buttock is mainly due to the gluteus maximus, especially behind and below, and in less degree to the other two glutei in front. Under the lower edge of the gluteus maximus the edge of the sacro-tuberous (great sacro-sciatic) ligament can be felt on deep pressure.

To mark out the upper border of the **gluteus maximus** a line is drawn from a point on the iliac crest 5 cm. (2 in.) in front of the posterior superior spine, downward and laterally to the back of the great trochanter. The lower border is marked out by a second line drawn from the side of the coccyx parallel with the former, and ending over the linea aspera at the junction of the upper and middle thirds of the thigh. It must be remembered that only the lower and internal fibres of the muscle are inserted into the gluteal ridge on the femur. The greater part of

FIG. 1161.—SECTION THROUGH THE HIP AND GLUTEAL REGION. (One-third.)

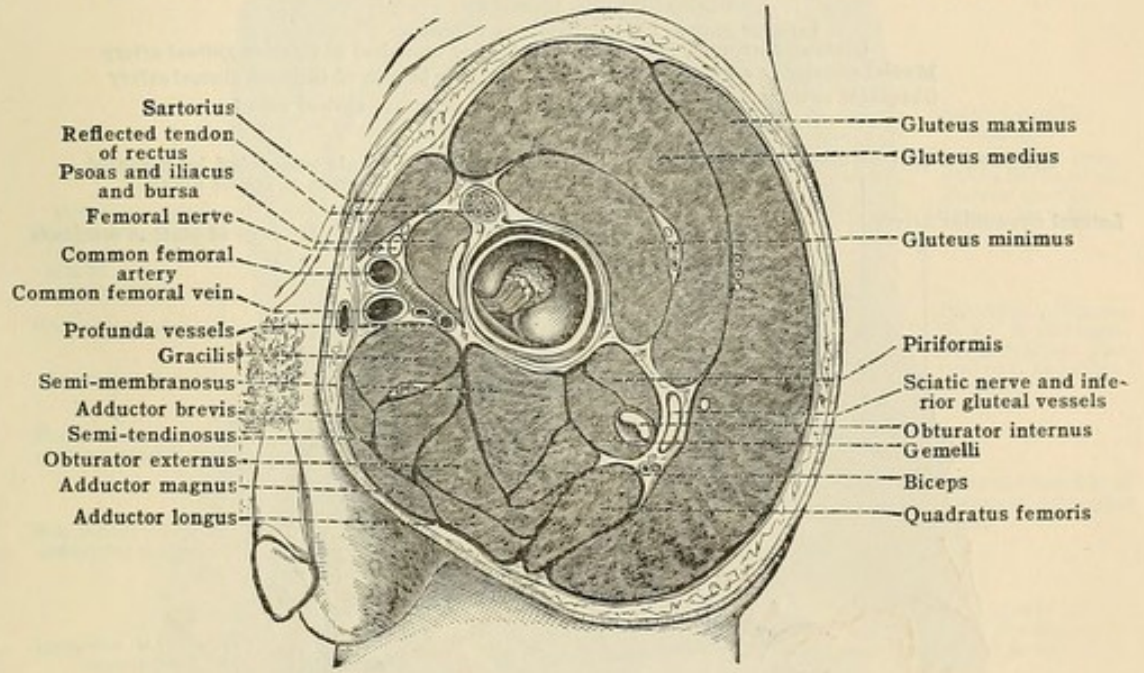

it is inserted into the fascia lata and ilio-tibial band and so into the lateral condyle of the tibia. Weakness of the gluteus maximus and tensor fasciæ latæ, with consequent laxity of the ilio-tibial band, gives rise to abnormal side-to-side passive mobility at the knee-joint in full extension.

Nerves and vessels.—The following **superficial nerves** can be marked in over the buttock (fig. 1182).

Behind the great trochanter, branches of the lateral cutaneous; coming down over the crest, the lateral cutaneous branch of the last thoracic (about in a line with the great trochanter), and behind this the lateral branch of the ilio-hypogastric. Two or three offsets of the posterior primary branches of the lumbar nerves cross the hinder part of the iliac crest at the lateral margin of the sacro-spinalis. Two or three twigs from the posterior divisions of the sacral nerves pierce the gluteus maximus close to the coccyx and sacrum, and ramify laterally. Finally, over the lower border of the gluteus maximus, turn upward branches of the posterior cutaneous (small sciatic) and its perineal branch (inferior pudendal), and the fourth sacral nerve.

Sciatic nerve (figs. 1162, 1163).—The point of emergence below the gluteus maximus and the track of this nerve (fourth and fifth lumbar and first three sacral nerves) will be given by a line drawn from a spot a little medial to the middle of the space between the great trochanter and the tuber ischii to the lower part of the back of the thigh, where it usually divides into the tibial and common peroneal (internal and external popliteal) nerves.

To stretch the nerve, an incision about three inches long is made in the line of the nerve, beginning about 3.7 cm. (1½ in.) below the gluteus maximus. The long head of the biceps which covers the nerve trunk and which is descending mediolaterally, is drawn medially. If the nerve is exposed lower down, the interval between the hamstrings is identified and these muscles drawn aside. The perineal branch of the posterior cutaneous (inferior pudenal) perforates the deep fascia about 2.5 cm. (1 in.) in front of the tuber ischii, and turns forward to supply the genitals.

Superior gluteal artery.—If a line be drawn from the posterior superior spine to the apex of the great trochanter, the limb being slightly flexed and rotated medially, the point of emergence of the artery from the upper part of the great sacro-sciatic notch will correspond with the junction of the upper and middle third of this line. (MacCormac.) The gluteal nerve emerges immediately below the artery, and sends branches into the deeper portion.

Inferior gluteal (sciatic) and pudic arteries.—The limb being rotated medially, a line is drawn from the posterior superior spine to the lateral part of the tuber ischii. The point of exit of the above arteries will correspond to the junction of the middle and lower thirds of this line. (MacCormac.)

THE KNEE

Bony landmarks.—The patella, the condyles of the femur, the condyles and tuberosity of the tibia, the head of the fibula, are all easily examined.

FIG. 1162.—THE GLUTEAL REGION, WITH THE SUPERIOR AND INFERIOR GLUTEAL AND PUDIC ARTERIES.

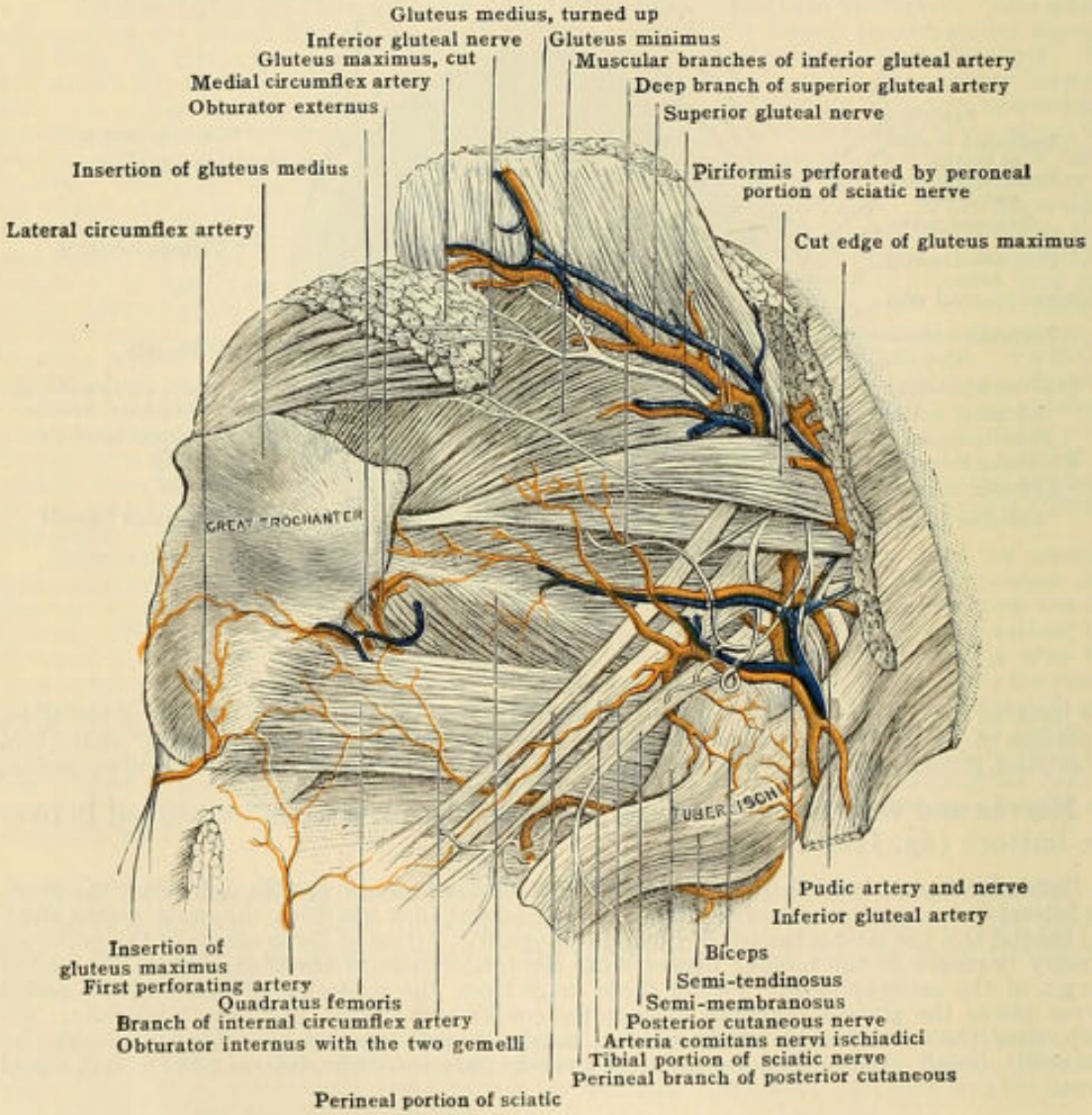

(From a dissection by W. J. Walsham in St. Bartholomew's Hospital Museum.)

The muscular branch of the inferior gluteal (sciatic) artery has been drawn inward over the tuber ischii with the reflected origin of the gluteus maximus muscle.

The patella.—The limb being supported in the straight position, and the extensor muscles relaxed, the natural range of mobility laterally of the patella can be estimated. This is interfered with by muscular action in inflammatory conditions,

or by early tuberculous ulceration of the contiguous cartilages. The numerous longitudinal striæ or sulci on the anterior surface of this bone can now also be detected. In these are embedded tendinous bundles of the rectus, so as to give firmer leverage. The fact that these fibres, thus tied down, are liable after stretching and tearing to fold in between the ends of the bone after fracture, is a ready explanation of the difficulty of ensuring bony union here. (Macewen.) The patella is separated from the tibia by a pad of fat and a deep bursa, save at its insertion. Owing to the lowest part of the patella being thus separated from the joint by fat, fracture here does not, necessarily, open the joint.

The bone has the following *relation to the femur* in different positions:—(1) In **extension,** the patella rises over the condyles, and in full extension only the lower third of its articular surface rests upon that of the condyles; its upper two-thirds lies upon the bed of fat which covers the

FIG. 1163.—DEEP DISSECTION OF THE GLUTEAL REGION. (From a preparation in the Hunterian Museum.)

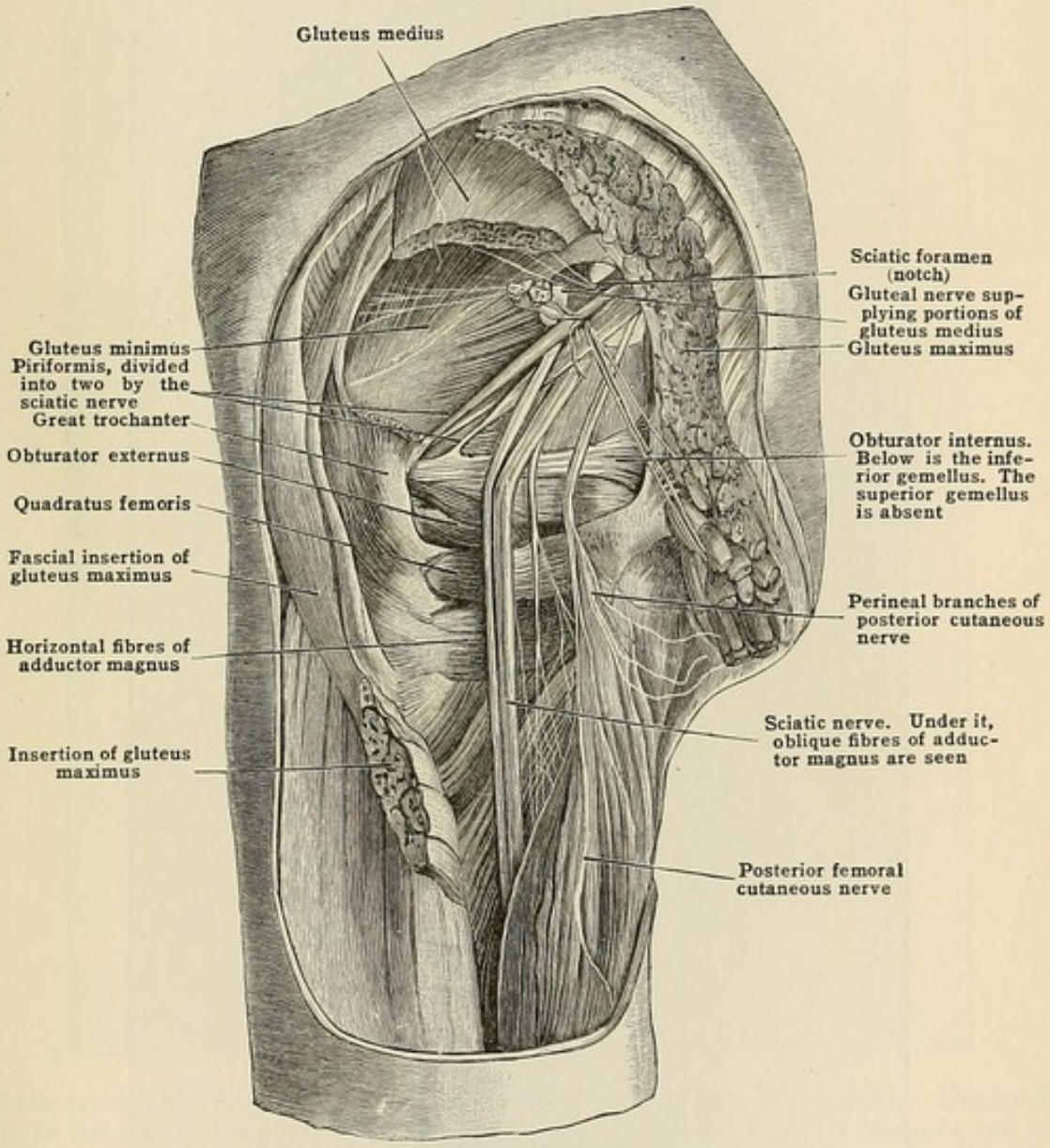

lower and front part of the femur. (2) In extreme **flexion,** as the prominent anterior surface of the condyles affords leverage to the quadriceps, the patella needs to project very little; thus, only its upper third is in contact with the femur, its lower two-thirds now resting on the pad of fat between it and the tibia. (3) In **semiflexion** the middle third of the patella rests upon the most prominent part of the condyles. (Humphry.) While the bone now affords the greatest amount of leverage to the quadriceps, it is also submitted to the greatest amount of strain from this muscle, which is acting almost at a right angle to the long axis of the patella. This position may therefore be called the 'area of danger,' as, in a sudden and violent contraction, the patella may be snapped across by muscular action, aided by the resistance given by the condyles, in the same way as a stick is snapped across the knee. The amount of separation of the fragments

in a fracture of the patella is due chiefly to the extent to which the lateral tendinous expansions of the vasti are torn; to a less degree to the hæmorrhage from the numerous articular vessels (p. 1452) and synovial effusion. The lower fragment is usually the smaller, and its fractured surface tilted forward; that of the upper one usually looks backward.

The patella, the largest of the sesamoid bones, **ossifies** by a centre which appears from the third to the fifth year. The process is completed about puberty. The rareness with which necrosis and caries occur here, when the exposed situation of the bone is remembered, is partly

FIG. 1164.—KNEE-JOINT AS SHOWN BY THE RÖNTGEN-RAYS, ANTERO-POSTERIOR VIEW.

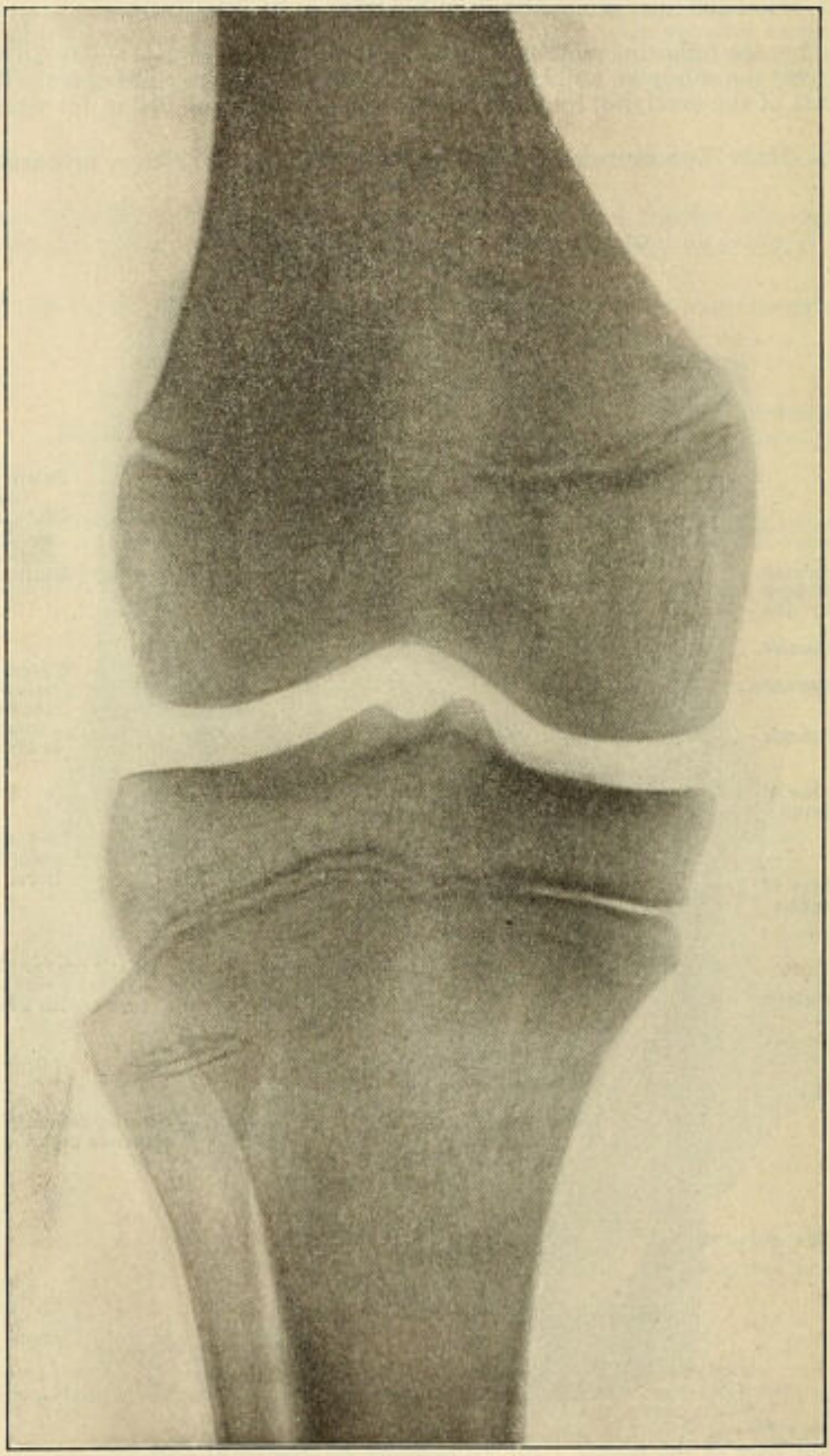

explained by the density of its tissue, especially in front, and the intimate blending of the rectus fibres with its periosteum. When the knee-joint is bent, the trochlear surface of the femur can be made out, with some difficulty, underneath the quadriceps expansion. The upper and lateral angle of this surface forms a useful landmark (Godlee) as a line drawn from it to the adductor tubercle marks the level of the lower epiphysis of the femur.

Dislocation of the patella.—The following anatomical facts account for this taking place much more frequently laterally:—(1) The medial edge of the patella is more prominent, and thus more exposed to injury; it is also well supported, as is seen when, the parts being relaxed, the

fingers are insinuated beneath each border. (2) The pull of the extensor upon the patella, ligamentum patellæ, and tibia is somewhat laterally, as the tibia is directed a little laterally to the femur, to meet the medial direction of this bone; the femora being directed medially here, to bring the knee-joints nearer the centre of gravity, and, so, counterbalance their wide separation above at the pelvis. The lateral pull of the quadriceps upon the patella is, in all normal action of the muscle, counteracted by the space taken in the trochlear surface by the lateral condyle, this being wider and creeping up higher, and having a more prominent and thus protective lip. In violent contraction, however, these counteracting points may be overcome.

The condyles of the femur and tibia.—It should be noted that on the medial side the prominence of the medial epicondyle of the femur is well marked, and that

FIG. 1165.—KNEE-JOINT AS SHOWN BY THE RÖNTGEN-RAYS, LATERAL VIEW.

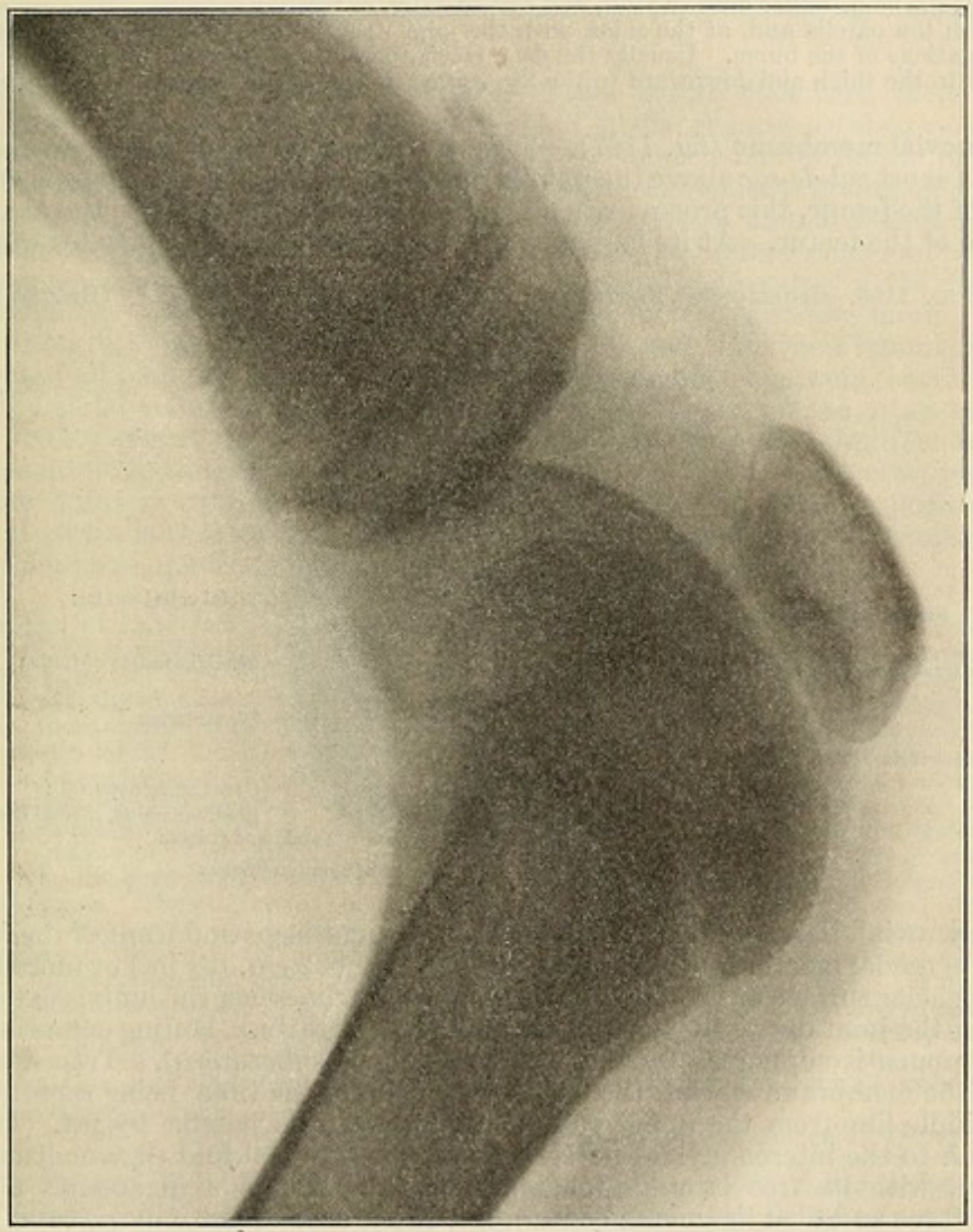

of the tibia is less so, while on the lateral side this condition is reversed. Descending to the lateral condyle of the tibia, the ilio-tibial band of the fascia lata can be traced. The more distinct lateral condyle is a good landmark for opening the joint in amputation and excision. It also indicates the lower level of the synovial membrane of the knee-joint.

Farther back are the biceps and fibular collateral (long external lateral) ligament. The gap on the medial side between the femoral and tibial condyles is the place for feeling for a displaced medial fibro-cartilage in 'internal derangement' of the knee, and also for 'lipping' in suspected osteoarthritis. On each femoral epicondyle, posteriorly, in a thin subject, can be felt its tubercle, which gives attachment to the collateral ligament. Owing to their being placed behind the centre of the bone, these ligaments become tight in extension. On the upper and posterior

part of the medial femoral epicondyle the adductor tubercle and the vertical tendon of the adductor magnus can be felt during flexion. This bony point is a guide to the lower epiphysis, the ossification of which and its occasional exostosis have been mentioned at p. 1442. The medial aspect of this epicondyle faces practically in the same direction as the head of the femur.

Ligamentum patellæ and tuberosity of tibia.—These, in a well-formed leg, should, with the centre of the ankle-joint, be all in the same straight line, a useful point in the adjustment of fractures. (Holden.) Behind the upper half of the ligament is the infrapatellar pad of fat; below, the lower half is separated from the tibia by a deep bursa. The tuberosity (tubercle) of the tibia is on a level with the head of the fibula.

Prepatellar bursa.—This usually protects the lower part of the patella and upper part of the ligamentum patellæ. It is liable to be enlarged in those who habitually kneel much, the enlargement being either fluid or solid, and occasionally, in tertiary syphilis. Its close connection with the patella and, at the sides, with the joint itself, is to be remembered in infective inflammations of the bursa. Usually the deep fascia, passing off from the sides of the patella upward to the thigh and downward to the leg, serves to conduct inflammation away from the joint.

Synovial membrane (fig. 1167).—This, the largest of the synovial membranes, forms a short *cul-de-sac* above the patella, between the quadriceps extensor and the front of the femur, this process reaching about 2.5 cm. (1 in.) above the trochlear surface of the femur. At its highest point this *cul-de-sac* communicates with an-

FIG. 1166.—HORIZONTAL SECTION OF THE KNEE-JOINT. (One-half.) (Braune.)

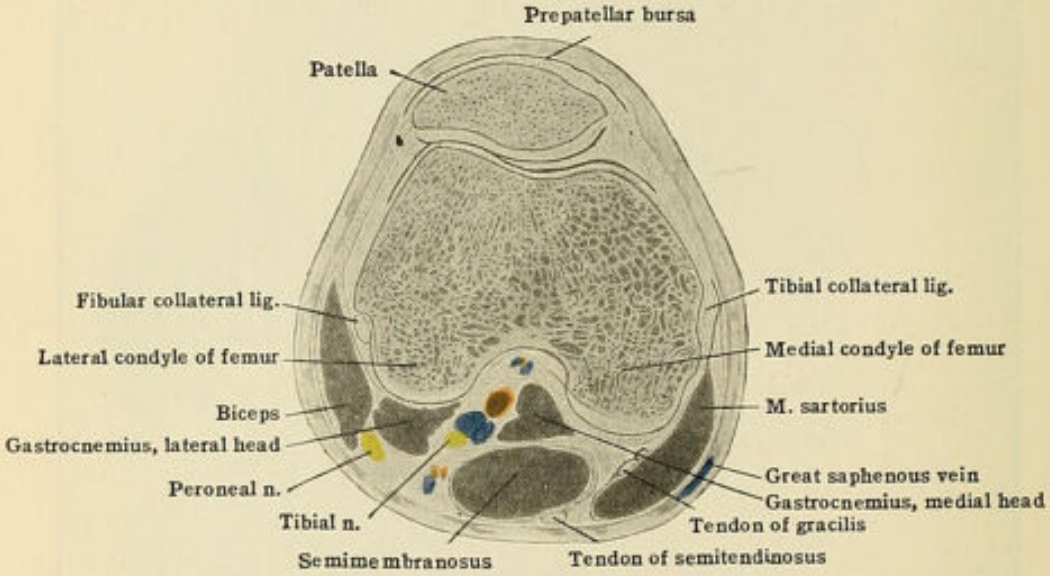

other synovial, bursa-like sac lying between the quadriceps and front of the femur. Thus, synovial membrane will usually be met with 6.2 cm. (2½ in.) or more above the trochlear surface or the upper border of the patella when the limb is extended. Flexing the joint draws the membrane down very slightly. During extension, the above pouch is supported by the articularis genu (subcrureus). Traced downward, the membrane reaches the level of the head of the tibia, being separated in the middle line from the upper part of the ligamentum patellæ by fat. It here gives off to the intercondyloid notch the patellar synovial fold (ligamentum mucosum), with its free lateral prolongations, the alar folds (ligamenta alaria). These three so-called ligaments contain fat, the processes not only padding gaps, but also meeting concussions.

The enlargement of these processes, under conditions not yet understood, may certainly be a cause of 'internal derangement,' and simulate a loosened meniscus. But the synovial membrane of this joint is not only the largest: it is also the most complicated, a fact accounting for the grave peril of infective arthritis, and the well-known difficulty of effective drainage and cleansing this joint. Thus 'it passes over the greater portion of the crucial ligaments, but the posterior surface of the posterior crucial, which is connected by means of fibro-areolar tissue to the front of the ligamentum posticum, and the lower portions of both crucial ligaments, where they are united together, of course cannot receive a complete covering from the membrane.,' (Morris.)

From the above ligaments the membrane is conducted, lining the lower part of the capsule and other ligaments, to the semilunar cartilages, first over their

upper surfaces to their free borders, and then along their under surfaces to the tibia. Between the lateral of these and the upper and back part of the tibia is a prolongation of the synovial membrane to facilitate the play of the popliteus tendon.

Finally, amid the complications of this synovial membrane, its communication with some of the bursæ mentioned below, and occasionally with the superior tibio-fibular joint, is to be borne in mind. In effusion the bony prominences are obliterated, and the patella 'floats.' The knee-joint is easily opened by free lateral incisions lying midway between the margins of the patella and the tuberosities of the condyles, drainage-tubes being passed so as to meet above the patella. The above-mentioned complications of the synovial membrane show that such drainage will be often inadequate. By passing a director to the back of the joint and cutting down upon it carefully from the popliteal space, better drainage will be given, but opening the joint by an anterior flap is needed where the above fail, and, even then, cleansing of the numerous deep recesses is obviously difficult.

Structures on the head of the tibia.—From before backward these are:—(1) Transverse ligament. (2) Anterior end of medial meniscus (fibro-cartilage). (3) Lower attachment of anterior crucial. (4) Anterior end of lateral meniscus blending with (3). (5) Posterior extremity of lateral meniscus giving off a strong process to posterior crucial. (6) Posterior extremity of medial meniscus. (7) Posterior crucial ligament. *Menisci.*—These serve as buffer-bonds and cushions between the contiguous bones. The more frequent displacement of the medial is explained by—(*a*) its greater fixity, and, therefore, its feeling strains more. Thus, in addition to weaker attachments to the coronary and transverse ligaments, it is connected all along its convex border with the inside of the capsule, and strongly with the tibial collateral ligament. The lateral meniscus, on the other hand, is more weakly attached to the capsule, especially opposite to the popliteus tendon, and has no tie to the fibular collateral ligament. (*b*) When, in the erect position, the knee-joint is rotated laterally and slightly flexed, a common position, an especial strain is thrown upon the very important tibial collateral ligament, and from the above-mentioned connection, on the medial meniscus also.

Position of knee-joint in disease.—In inflammatory effusion, the position which best accommodates the collection of fluid is one of moderate flexion, the ligaments being now mainly relaxed. Later on, when the ligaments are softened, the hamstrings obstinately displace the leg backward, the tibia being rotated laterally by the biceps. The antero-posterior displacement is always more marked than the lateral. In straightening an anchylosed joint, the resistance of the shortened lateral, crucial, and posterior ligaments, and the facility with which a softened upper epiphysial line of the tibia may give way, must never be forgotten. **Erasion and excision.**—The extent and complications of the synovial membrane render attention to the following points imperative:—(1) Free exposure of the joint usually by an anterior curved incision, the medial extremity of which must not damage the great saphenous vein. (2) The extent of the pouch under the quadriceps, it may be for 5 cm. (2 in.) above the patella, and the lateral recesses under the vasti. The pouches at the back of the joint are far more difficult to deal with, viz., the partial covering of the posterior crucial ligament, the proximity of the popliteal artery, the pouches in relation to the popliteus, gastrocnemii, and back of the femoral condyles. In **erasion,** the cartilage and bone, where diseased, are removed with a gouge. Owing to the removal, in addition to the synovial membrane, of the fibro-cartilages, and crucial ligaments, and the damage to lateral and patellar ligaments, there is a most obstinate tendency to flexion afterward. In **excision,** to avoid injury to the epiphysis, the section of the femur should not pass higher than through the upper third of the trochlear surface. Of the tibia, only 12 mm. (½ in.) should be removed.

Genu valgum.—Here the natural angle at which the femur inclines medially to the tibia is increased. As shown by the late v. Mikulicz, this is due to an abnormal growth downward of the medial part of the femoral diaphysis, the epiphysial line being gradually altered from one at right angles to the shaft to one which runs obliquely from without downward and medially. The femur is not only elongated on its medial side, but bent at its lower end, the concavity of the curve being lateral. Other changes have to be remembered. Pes valgus very commonly coexists, and in the tibia there may be a compensatory curve, the concavity being medial, in the lower third, or an analogous alteration in the line of the upper epiphysis may be present, its direction being no longer at a right angle with the shaft, but oblique. In Sir W. Macewen's supra-condyloid osteotomy, a longitudinal incision, about 3.7 cm. (1½ in.) long is made where the following lines meet, viz., one transverse, a finger's breadth above the upper margin of the lateral condyle, and one longitudinal, 1.2 cm. (½ in.) in front of the adductor magnus tendon. The bone is divided in front of the genu suprema and above the superior medial articular artery, above the epiphysial line and behind the upward extension of the synovial membrane under the quadriceps.

The following **bursæ about the knee-joint** must be remembered. Some, it will be seen, are much more constant than others:—

A. **In front.**—(1) One between the patella and skin, the bursa prepatellaris subcutanea (fig. 1167); (2) a deeper one between the ligamentum patellæ and the upper part of the tibia; (3) between the skin and the lower part of the tuberosity of the tibia. This is not constant.

B. **On the medial side.**—(1) One between the medial head of the gastrocnemius and medial condyle, often extending between the above muscle and the semi-membranosus. This is the largest of the bursæ about the knee-joint, and, after adult life, usually communicates with the knee-joint. But, owing to the narrow communication, it is rarely possible, when the parts are relaxed by flexion of the joint, to empty the cyst. For its removal a straight incision is made over the most prominent part of the swelling, its neck found by drawing aside the tendons. A ligature is then pushed high up around the neck, and the cyst cut away. (2) One superficial to the tibial (collateral) ligament, between it and the tendon of the sartorius, gracilis, and semi

FIG. 1167.—VERTICAL SECTION OF THE KNEE-JOINT IN THE ANTERO-POSTERIOR DIRECTION.
(The synovial bursa usually present above the upper synovial *cul-de-sac* is not shown.)
(The bones are somewhat drawn apart.) (After Braune.)

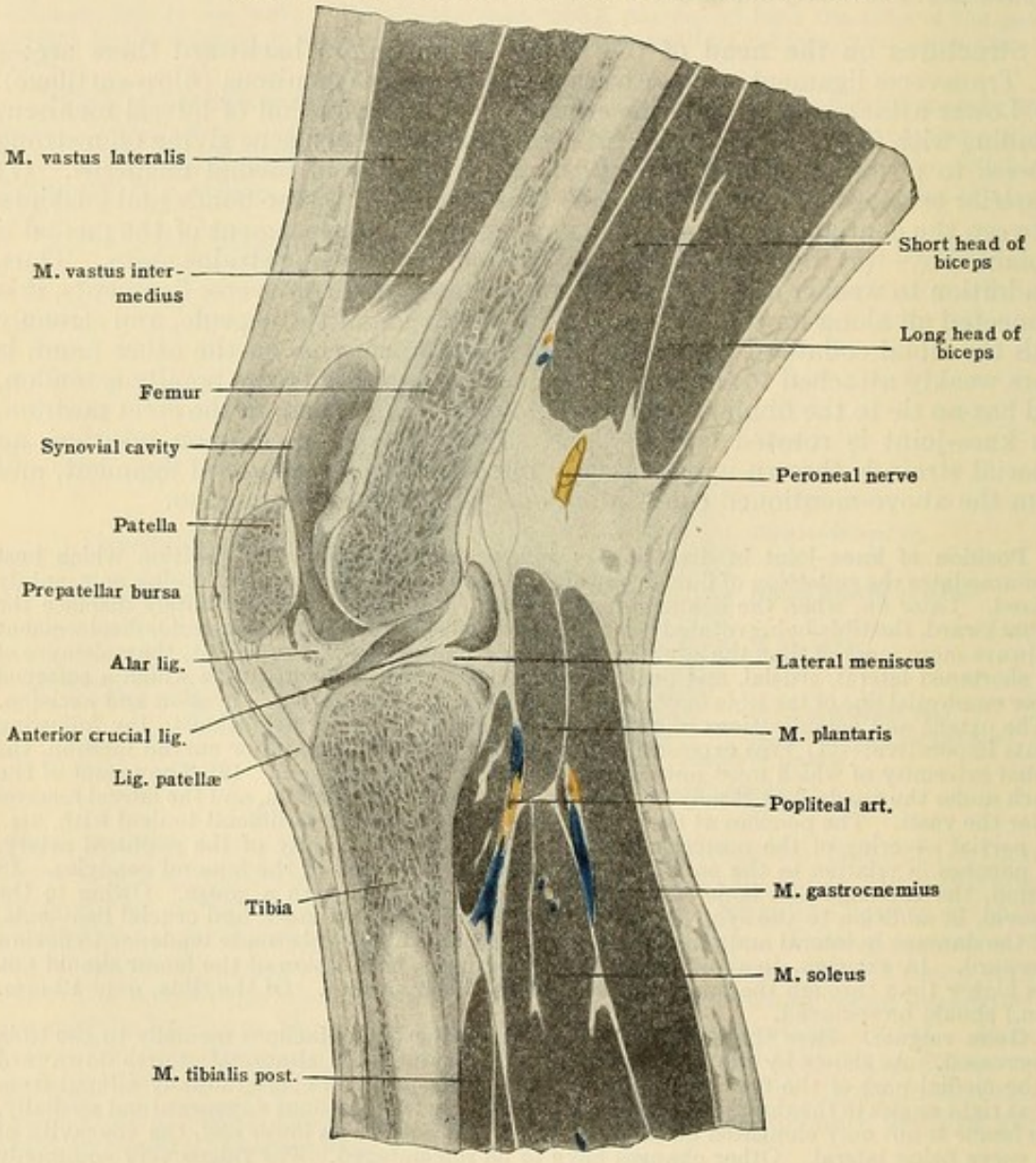

tendinosus. (3) One beneath the ligament, between it and the tendon of the semi-membranosus. (4) One between the medial condyle of the tibia and the semi-membranosus. (5) One between the semi-membranosus and semi-tendinosus. Of the above bursæ, the first two alone are constant. The second and third are often one bursa prolonged.

C. **On the lateral side.**—(1) One between the lateral head of the gastrocnemius and the condyle; (2) one superficial to the fibular collateral ligament between it and the biceps tendon; (3) one under the ligament between it and the popliteus tendon; (4) one between the popliteus tendon and the lateral condyle of the femur. This is usually a diverticulum from the synovial membrane.

The following explanations may be given of an inflamed knee-joint usually taking the flexed position:—(1) By experimental injections, Braune found that the capacity of the synovial sac reaches its maximum with a definite degree of flexion, i. e., at an angle of twenty-five degrees.

(2) As the same nerves supply the synovial membrane and the muscles which act upon the joint, reflex spasm of the flexors will help to explain the flexed position. (Hilton.)

Anastomoses around the front and sides of the knee-joint.—The most important of these take the form of **three transverse arches.** (1) The **highest** passes through the quadriceps fibres just above the upper edge of the patella. It is formed by a branch from the deep division of the genu suprema (anastomotica magna) and one from the lateral circumflex and superior lateral articular. The middle and lowest arches lie under the ligamentum patellæ. (2) The **middle arch,** formed by branches from the genu suprema and superior medial articular on the medial side, and the inferior lateral articular, on the lateral, runs in the fatty tissue

FIG. 1168.—SIDE VIEW OF THE POPLITEAL ARTERY.
(From a dissection in the Hunterian Museum.)

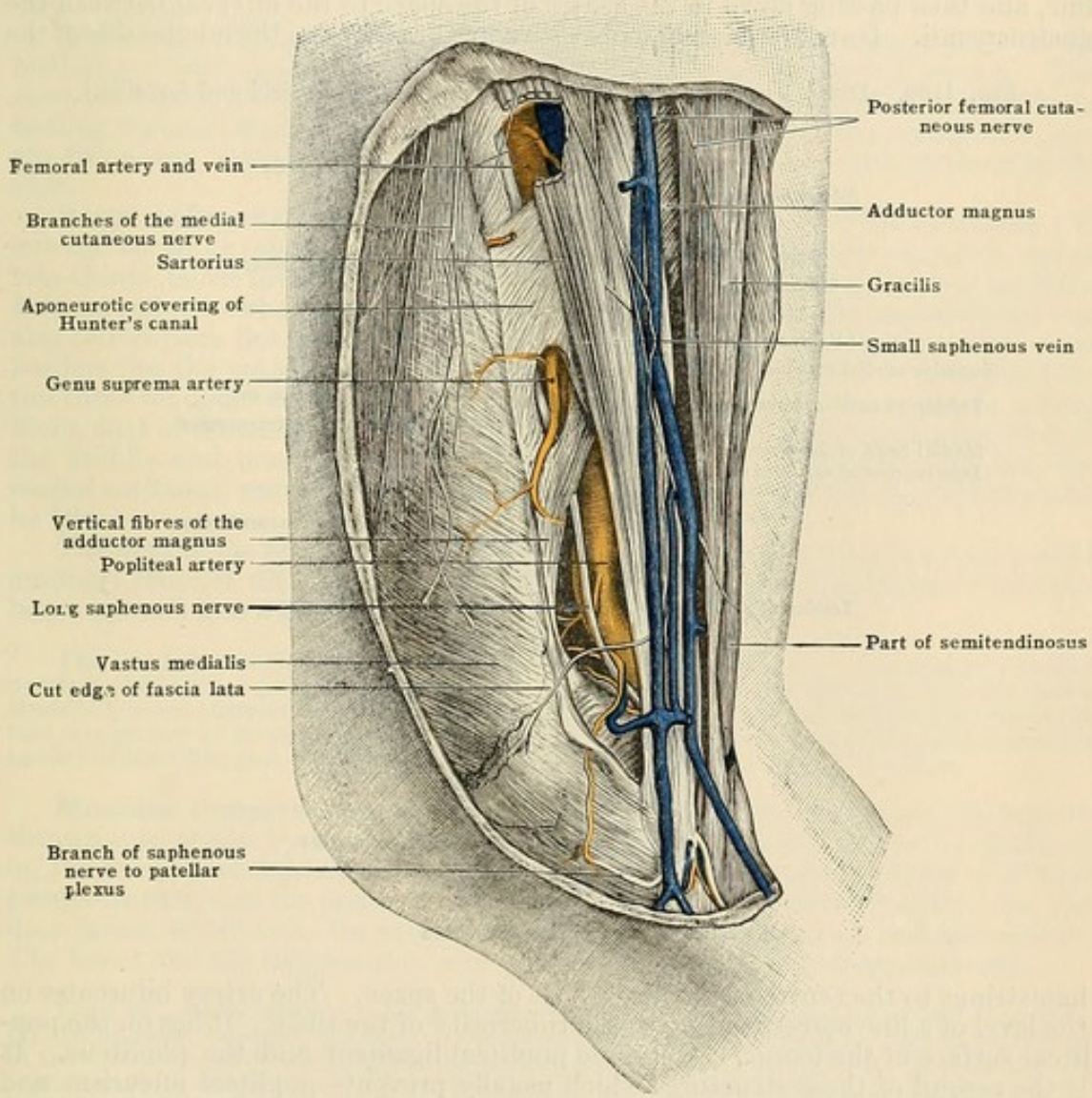

close to the apex of the patella. (3) The **lowest arch** lies on the tibia just above its tuberosity, and results from the anastomosis of the recurrent tibial and the inferior medial articular. Seven arteries thus take place in this series of anastomoses.

POPLITEAL SPACE

In flexion, the **hollow of this space** appears; in extension it is obliterated and its boundaries are ill-defined the only ones now to be made out being the semitendinosus and the biceps.

Popliteal tendons.—When the knee is a little bent and the foot rests on the ground, the following can be made out:—on the *lateral aspect*, behind the ilio-tibial band, and descending to the prominence on the lateral side of the head of the fibula, is the tendon of the biceps. This

prominence also gives attachment to the fibular collateral ligament, which splits the tendon into two parts. Behind is the apex (styloid process) from which the posterior part of the fibular collateral ligament arises. Parallel and close to the medial border of the tendon, the peroneal nerve descends, as a rounded cord, to cross the neck of the fibula and enter the peroneus longus. In tenotomy of the biceps an open incision should be employed to avoid injury to the nerve and insure the division of any contracted fascial bands. On the *medial side* the tendons are thus arranged: Nearest to the middle of the popliteal space is the long and more slender tendon of the semi-tendinosus; next, the thicker tendon of the semi-membranosus; this and the gracilis, which comes next, appear as one tendon, but by a little manipulation the finger can be made to sink into the interval between the semi-membranosus, with its thick rounded border laterally and the gracilis medially. The sartorius can easily be thrown into relief on the medial side of the joint by telling the patient to raise the leg extended, the limb being rotated laterally and one leg crosses over the other.

Popliteal vessels.—The **artery** traverses this space from above downward, appearing beneath the semi-membranosus, a little to the medial side of the middle line, and then passing down in the centre of the space to the interval between the gastrocnemii. Its course corresponds with a line drawn from the medial side of the

FIG. 1169.—DEEP VIEW OF THE POPLITEAL SPACE. (Hirschfeld and Leveillé.)

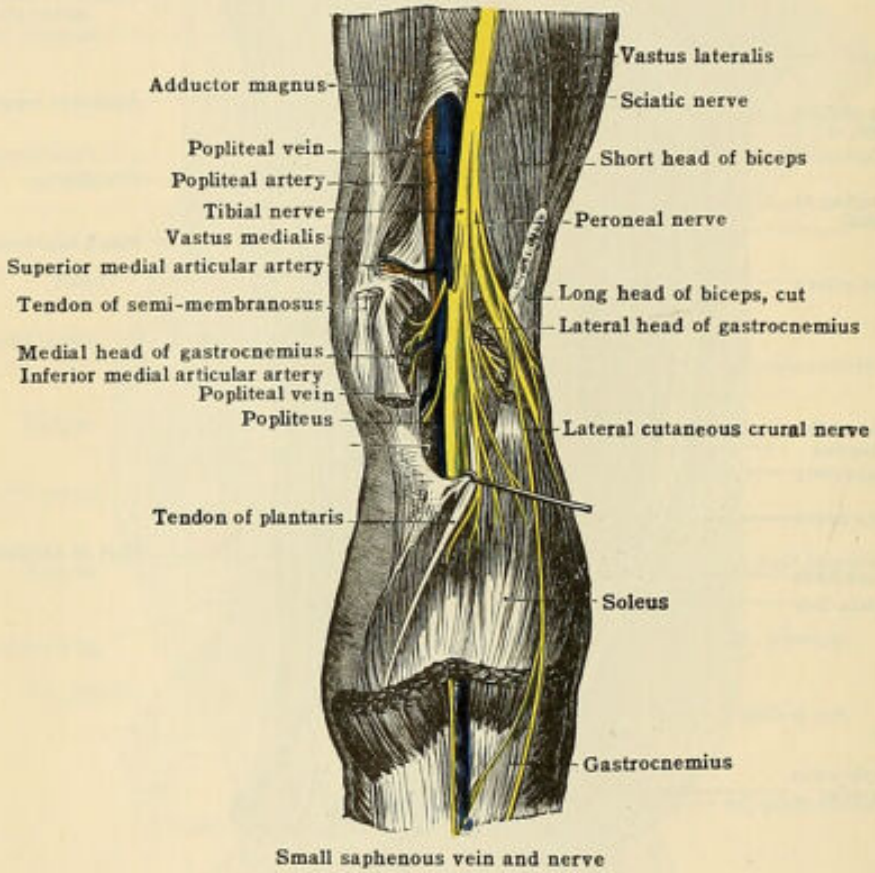

hamstrings to the centre of the lower part of the space. The artery bifurcates on the level of a line corresponding to the tuberosity of the tibia. It lies on the popliteal surface of the femur, the oblique popliteal ligament and the popliteus. It is the second of these structures which usually prevents popliteal aneurism and abscess from making their way into the joint.

The **popliteal vein,** intimately adherent to the artery, lies to the lateral side above, but crosses to its medial side below. The popliteal sheath is also unusually strong. The **tibial nerve** crosses the artery in the same direction as the vein, by which it is separated from the artery. This nerve is the direct continuation of the sciatic nerve (fig. 1169), and enters more into the space than its fellow branch. The close relation of the vein and nerve explains the early stiffness of the knee, the pains below, often called 'rheumatic,' and the œdema, in popliteal aneurism; also the pulsation of swellings not aneurismal.

The **superior articular arteries** (fig. 1169) course laterally and medially immediately above the femoral condyles; the way in which they cling closely to the bone here is one provision to prevent overstretching of the artery; the **inferior** ones lie just above the head of the fibula and below the medial condyle of the tibia (fig. 1169). The deep part of the genu suprema artery runs in front of the tendon of the adductor magnus; the superficial with the saphenous nerve.

The **popliteal artery may be ligatured**—(A) **Behind,** in the upper part of the popliteal space, just after its emergence from under the semi-membranosus. Here, for a short space

of about 2.5 cm. (1 in.), the vessel is comparatively superficial after division of the fasciæ. The nerve is generally seen first, and, with the vein, must be drawn laterally. The needle should be passed from the vein. (B) **From the front,** at the medial side. The thigh being flexed, abducted, and rotated laterally, a free incision is made parallel and just behind the adductor magnus tendon, commencing at the junction of the middle and lower third of the thigh. The sartorius and the hamstrings are drawn backward, and the adductor magnus forward. Care must be taken of the genu suprema (fig. 1168). The space between the hamstrings and the adductor magnus being carefully opened up, the artery will be found in fatty areolar tissue. The vein and tibial nerve are on the lateral side of the vessel. The needle is passed in laterо-medially. The collateral circulation (fig. 1156) depends chiefly on the genu suprema.

The **small saphenous vein** perforates the roof of the popliteal space in its lower part. As a rule, it is not visible, unless enlarged.

The **popliteal nodes** are not to be felt unless enlarged.

Bursæ in the popliteal space.—These have been already spoken of (p. 1449).

THE LEG

The skin.—The proneness of the skin to dermatitis in the lower third of the medial and front aspect of the leg as a result of varicose veins is well known. The close contiguity of the periosteum to the skin here accounts for the difficulty in healing chronic ulcers whose callous base has become fixed to the periosteum, and the frequency with which the upper fragment of a fractured tibia perforates the skin.

Bony landmarks.—From the *tuberosity* (tubercle) *of the tibia* descends the *anterior border* or 'shin.' This soon becomes sharp, and continues so for its upper two-thirds; in the lower third it disappears, to be overlaid by the extensor tendons. It is curved somewhat laterally above and medially below. The *medial border* can also be felt from the medial condyle to the medial malleolus. Between these two borders lies the *medial surface*, subcutaneous save above, where it is covered by the three tendons of insertion of the gracilis and semi-tendinosus, and, overlying them, that of the sartorius. The tibia is narrowest and weakest at the junction of the middle and lower thirds, the most common site of fracture. Behind the *medial malleolus*, part of the groove for and the tendon of the tibialis posterior can be felt.

The *head of the fibula* can be felt distinctly, but the shaft soon becomes buried amongst muscles till about 7.5 cm. (3 in.) above the *lateral malleolus*, where the bone expands into a large triangular subcutaneous surface.

This lies between the peroneus tertius and the other two peronei. The peroneus longus overlaps the brevis, especially in the upper two-thirds of the leg. In the lower third the brevis tends to become anterior (fig. 1173). Behind the lateral malleolus these tendons descend to the foot in a groove on its posterior border. The shaft of the fibula is placed on a plane posterior to that of the tibia, and curves backward in a direction reverse to that of the tibia.

Muscular compartments and prominences.—When the muscles of the leg are thrown into action by dorsi-flexion and plantar flexion of the foot or by standing on the toes, several groups of muscles stand out on the surface, owing to certain **compartments,** and the origin of certain muscles from, and their separation by, the deep fascia, which knits the surface into corresponding elevations and depressions. The bones and the two peroneal septa divide the leg into four **compartments.**

These are, medio-laterally:—(1) A **medial,** corresponding to the medial surface of the tibia. (2) An **anterior,** between the crest of the tibia and the anterior peroneal septum, attached to the antero-lateral border of the fibula, and separating the extensors from the peronei. Its surface-marking would be a line from the front of the head of the fibula to the front of the lateral malleolus. In this anterior compartment lie the extensor muscles and origin of the peroneus tertius, and the anterior tibial vessels and nerves. (3) A **lateral** or **peroneal** compartment, lying between the anterior and posterior peroneal septum, the latter being attached to the postero-lateral border of the fibula, and separating the peronei from the calf and deep flexors. This peroneal compartment, a narrow one, contains the two chief peronei and the peroneal (external popliteal) nerve and its three divisions. (4) Much the largest, this, the **posterior,** lies between the posterior peroneal septum and the medial border of the tibia, and contains the calf and deep flexor muscles, the posterior tibial vessels and nerves, and the peroneal artery and its posterior branch.

The space between the tibia and fibula in front is mainly occupied by the fleshy belly of the tibialis anterior; lateral to this, and much less prominent, is the narrower extensor digitorum longus; lateral to this, again, are the peronei longus and brevis. Lower down, in an interval between the tibialis and the extensor of the toes, the extensor hallucis, here almost entirely tendinous, comes to the surface. Behind, the prominence of the calf is mainly formed by the gastrocnemius. On the patient's rising on tip-toe, the tendo Achillis starts into relief

from about the middle of the leg. Of the two heads of the gastrocnemius, the medial is seen to be the larger. On either side of the tendon, but more distinctly on the lateral side, where it is less overlapped by the gastrocnemius, the soleus comes into view. Its muscular fibres are continued on the deep surface of the tendon to within a short distance of the heel. Between the tendon and the upper part of the os calcis is a bursa, occasionally the seat of effusion, as in gonorrhœa.

The bones.—Their relative position and curves have been mentioned (p. 1453). **Access.**—That to the **tibia** is easy along the medial aspect. The **fibula** is best explored by a free incision along the line of the posterior peroneal septum, which lies between the peronei and the muscles at the back (p. 1453). The presence of the superficial peroneal (musculo-cutaneous) nerve perforating the deep fascia in the lower third below and that of the common peroneal (external popliteal) in relation to the neck of the fibula above, must be remembered. **Fractures.**—When,

FIG. 1170.—ANASTOMOSES OF TIBIAL ARTERIES.

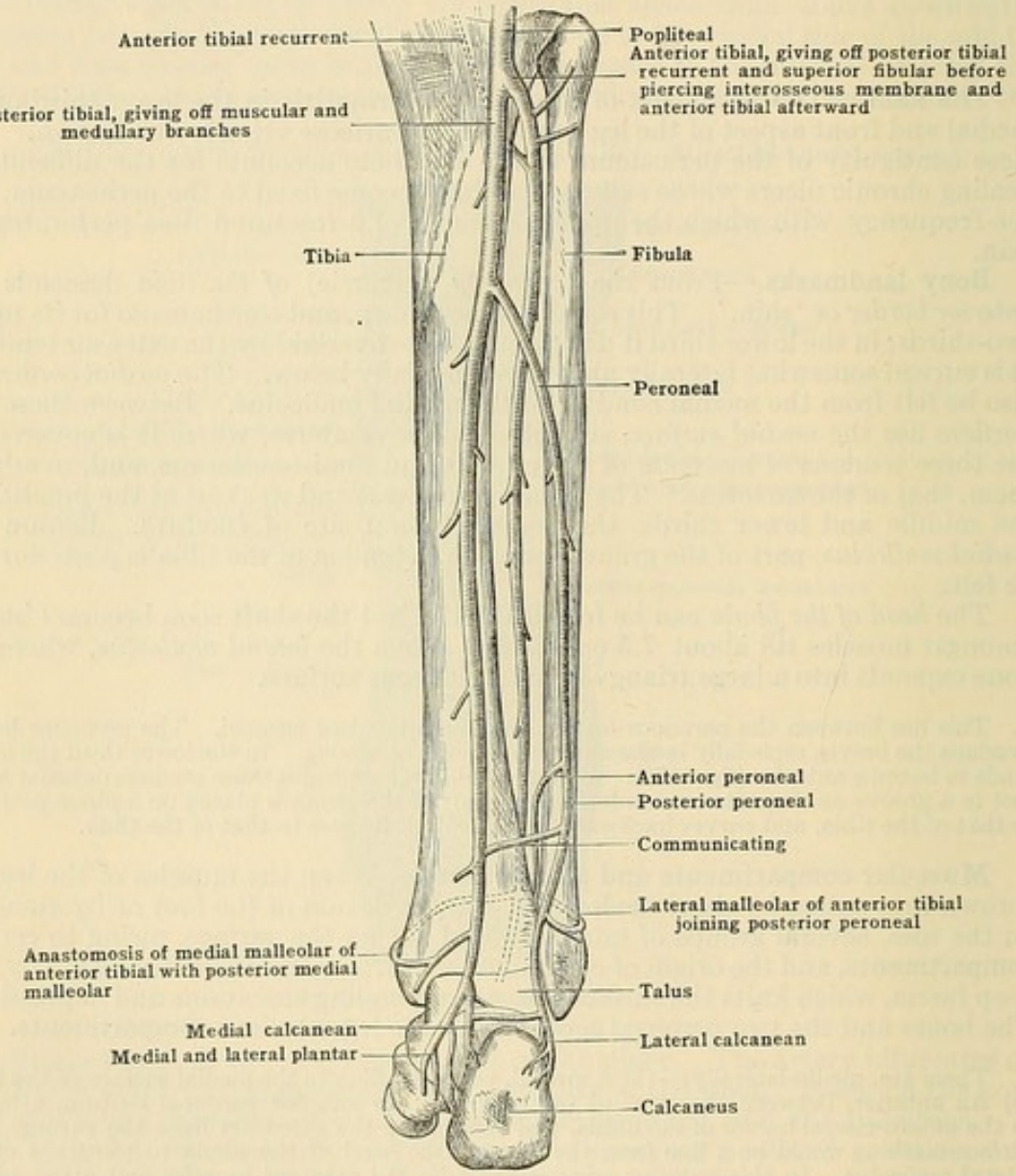

as is most frequent, the tibia gives way from indirect violence, the fracture is usually at the weakest spot, or the junction of the middle and lower thirds. The line of obliquity is generally marked, and from above downward and forward. The lower fragment, pulled upward by the powerful calf muscles, rides behind the upper, which projects forward under the skin. The fibula, bending more than the tibia, snaps at a higher level. Tenderness on pressure is the best guide here, as it is in suspected fractures of the upper tibia, transverse from direct violence. The most common variety of **fracture of the fibula** is that called after **Pott,** complicated with displacement of the foot. Here, from abduction of the foot, a severe strain is thrown upon the deltoid ligament, which gives way; the talus (astragalus) is pressed against the lateral malleolus, and the inferior tibio-fibular ligaments resisting, the fibula yields 5 to 7 cm. (2 to 3 in.) above the ankle, the upper end of the lower fragment being usually displaced toward the tibia. If the deltoid ligament is strong, the strain often tears off the medial malleolus. The medial margin of the foot is turned toward the ground, the lateral raised. The foot is also displaced backward. On the medial side of the ankle there is a marked projection of the lower end of the tibia; higher

up, on the lateral side, a depression where the fibula is broken. The need of replacing the foot and the weight-bearing talus (astragalus) accurately, the fact that the ankle-joint is opened and the numerous tendons likely to be matted are the chief points to bear in mind. In **Dupuytren's fracture** there is not only fracture of the lower end of the fibula, but the inferior tibio-fibular ligaments are now torn. The foot is displaced upward and laterally, together with the lower

FIG. 1171.—THE ANTERIOR TIBIAL ARTERY, DORSAL ARTERY OF THE FOOT, AND PERFORATING BRANCH OF THE PERONEAL ARTERY, AND THEIR BRANCHES.

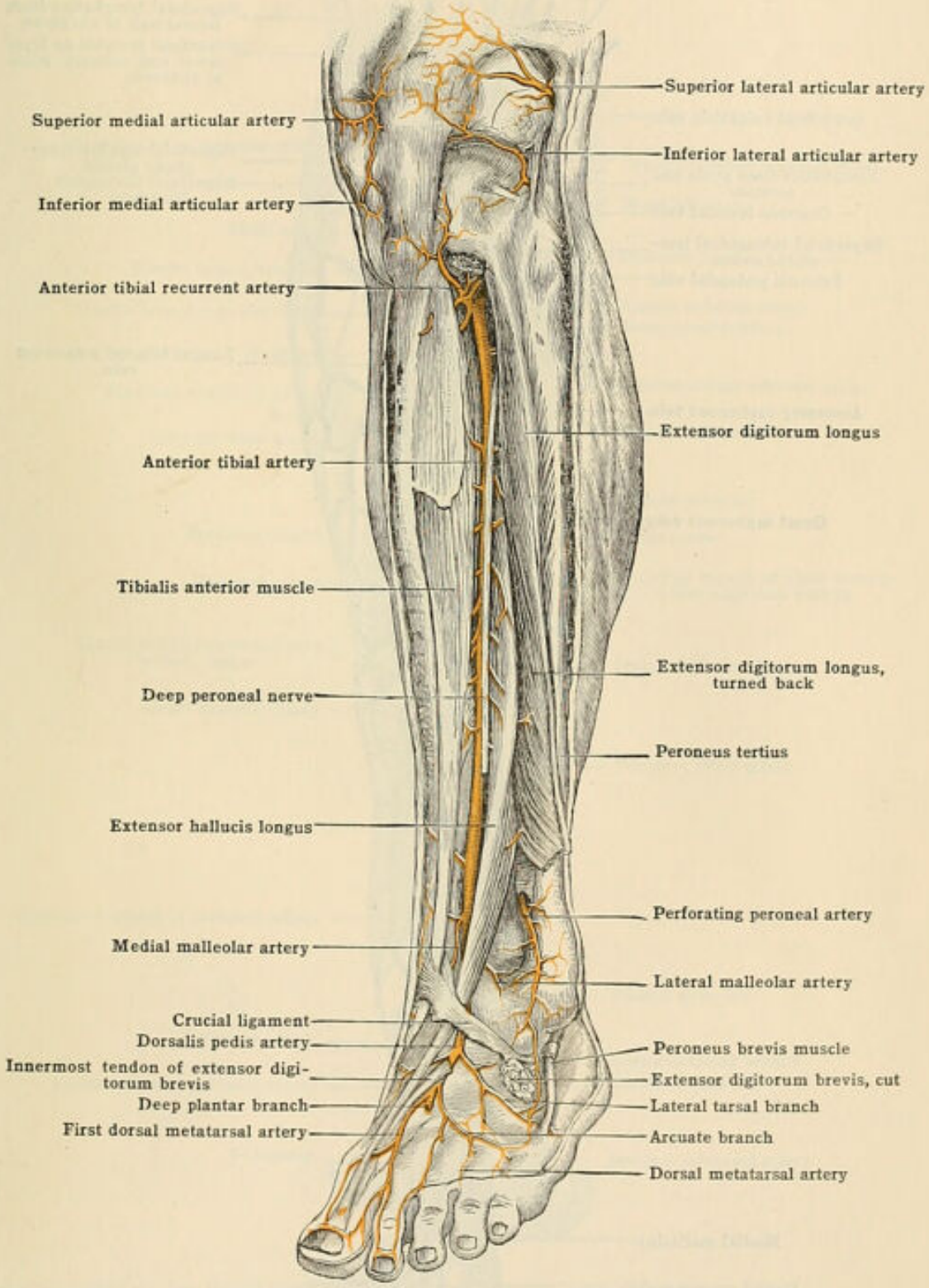

end of the fibula. **Epiphyses.**—The upper one of the tibia appears shortly before birth and includes the condyle and tuberosity. It does not fuse with the shaft till the age of twenty or later. This fact and the powerful strain of the rectus on this epiphysis explain the obscure pain sometimes complained of in young adults much given to athletics, over the tibial tuberosity. The lower epiphysis, including the medial malleolus, appears in the second and joins about the eighteenth year. Separation here is not very uncommon up to puberty. In **osteotomy** of the

tibia, simple or cuneiform, when the curve is antero-posterior as well as lateral, the close vicinity of the tibialis anterior tendon to the lateral border of the crest must be remembered, and when the fibula does not yield to careful force, it, also, must be divided, or damage may be done to the superior and inferior tibio-fibular ligaments, or to the epiphyses of the bones.

FIG. 1172.—THE SUPERFICIAL VEINS AND LYMPHATICS OF THE LEFT LOWER LIMB.

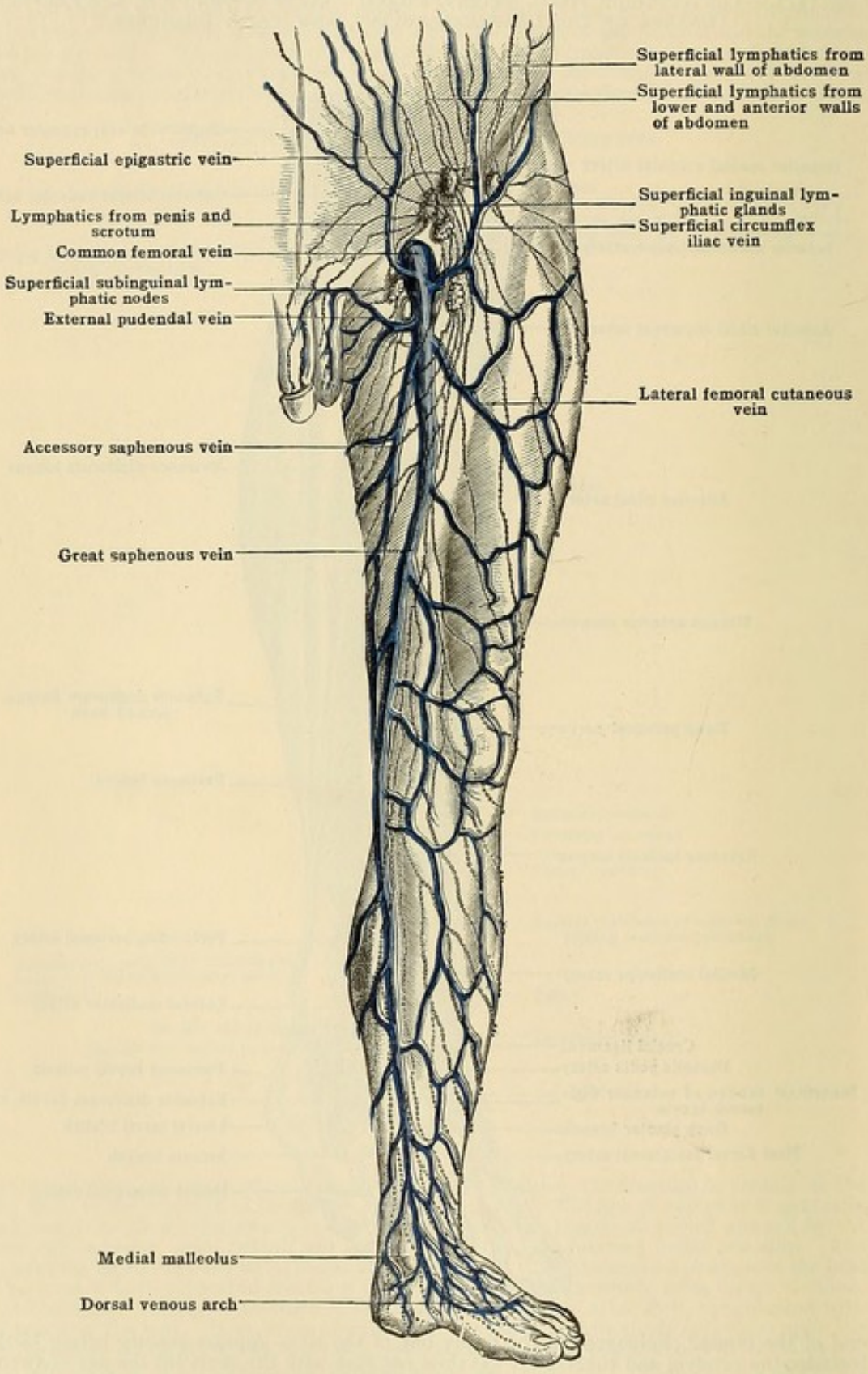

Vessels.—The **saphenous veins** should be carefully traced, owing to the tendency of these and their branches to become varicose. The **great saphenous**

(figs. 1158, 1172), having passed from the arch on the dorsum over the medial malleolus, runs up close to the medial border of the tibia, where it is to be avoided in ligature of the posterior tibial, to the back of the medial condyle; here this vessel is to be remembered in operations on the knee-joint; then upward along the thigh, over the roof of the adductor (Hunter's) canal, to the fossa ovalis (saphe-

FIG. 1173.—RELATIONS OF THE POPLITEAL ARTERY TO BONES AND MUSCLES.

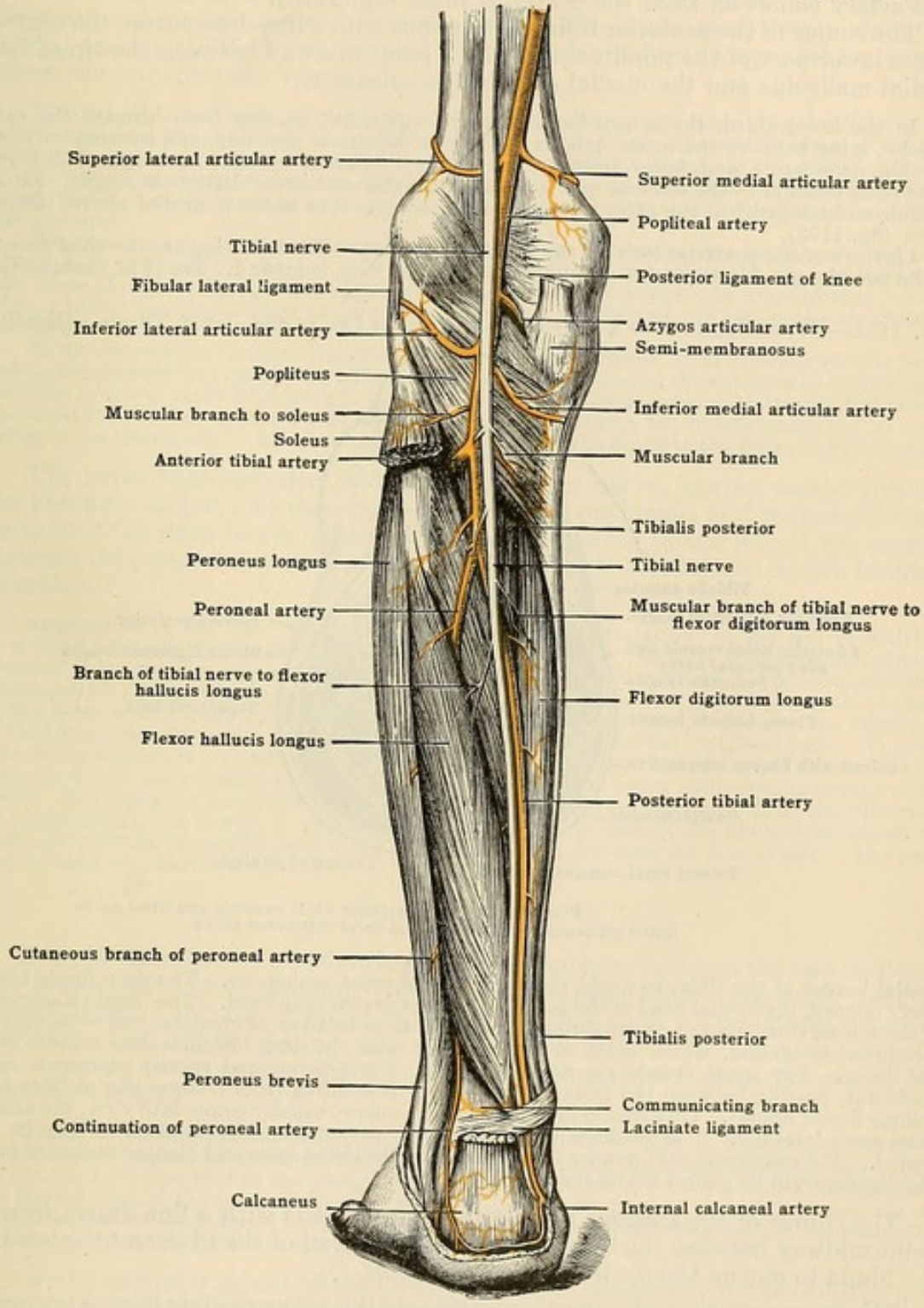

nous opening) (p. 1440 and fig. 1172), where it joins the femoral by perforating the cribriform fascia and the femoral sheath. Four to six valves are present, chiefly in the upper part.

The 'dangerous area,' or that in which thrombosis is most likely to occur, reaches from the centre of the thigh to the middle of the leg. (Bennett.) The saphenous nerve joins the vein below the knee, having been under the sartorius above this point (fig. 1159 and 1160). The

surface-marking of the upper part of the vein is a line drawn from the posterior border of the sartorius or the adductor tubercle to the lower part of the fossa ovalis. The **small saphenous** vein passes behind the lateral malleolus, runs upward over the middle of the calf, and joins the popliteal by perforating the deep fascia in the lower part of the popliteal space. This vein is accompained by the medial sural cutaneous (external saphenous) nerve throughout its course.

The **popliteal artery** bifurcates at the lower border of the popliteus, about on a level with the tuberosity of the tibia. About 5 cm. (2 in.) lower down the peroneal artery comes off from the posterior tibial (fig. 1173).

The course of the **posterior tibial** corresponds with a line drawn from the centre of the lower part of the popliteal space to a point midway between the tip of the medial malleolus and the medial edge of the calcaneus.

In the lower third, the artery becomes more superficial, passing from beneath the calf muscles, lying between the tendo Achillis and medial border of the tibia, and covered only by the skin, deep fascia, and, lower down, by the laciniate (internal annular) ligament. It is here, in its close relation to the tendons of the tibialis posterior and flexor digitorum longus, that it is liable to be injured in the older methods of tenotomy. The nerve is medial above, lateral below (fig. 1173).

Ligature of the posterior tibial in the middle of the leg.—The following are the chief points in the technique. An incision, 7.5 to 10 cm. (3 to 4 in.) long, is made 1.2 cm. (½ in.) behind the

FIG. 1174.—UPPER SEGMENT OF A SECTION OF THE RIGHT LEG IN THE UPPER THIRD. (Heath.)

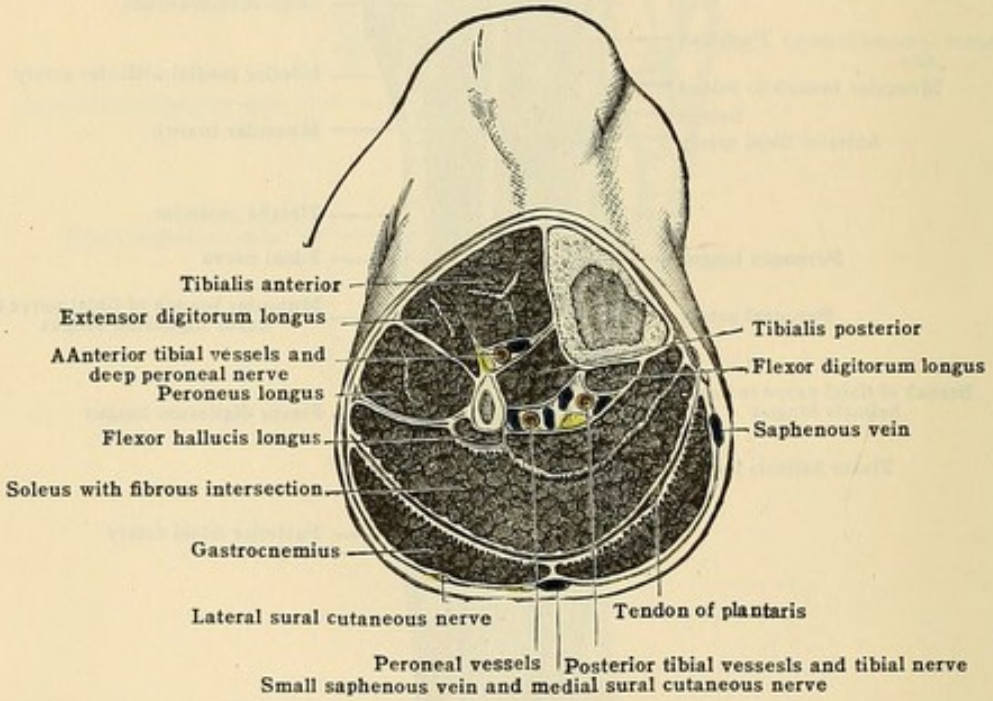

medial border of the tibia, to avoid the trunk of the great saphenous. The deep fascia being freely opened, the medial head of the gastrocnemius is drawn backward. The tibial attachment of the soleus, thus exposed, is cut through carefully, so as to allow of identification of its central membranous tendon, which must not be confused with the deep intermuscular septum over the flexor. Any sural vessels are now tied. The above-mentioned special septum is next made out, passing between the bones (vertical line descending from oblique line of tibia and oblique line of fibula). On division of this septum the nerve usually comes into view, the artery lying more laterally. The needle is passed from the nerve; the venæ comitantes may be included. The muscles should now be fully relaxed by flexion of knee and plantar flexion of foot. The ligature will be placed below the peroneal artery.

The course of the **anterior tibial artery** corresponds with a line drawn from a point midway between the lateral condyle of the head of the tibia and the head of the fibula to one on the centre of the ankle-joint.

This line corresponds to the lateral border of the tibialis anterior and the interval between it and the extensor digitorum longus (figs. 1170 and 1171). This is shown when the first of these muscles is thrown into action. The accompanying nerve is in front in the middle third of the leg, lateral above and below.

Ligature of the anterior tibial artery at the junction of the upper and middle thirds of the leg. The limb being flexed and rotated medially, an incision is made, 7.5 to 10 cm. (3 to 4 in.) long, in the line of the artery, distant 2.5 cm. (1 in.) or more (according to the size of the leg) from the crest, and beginning about 5 cm. (2 in.) below the head of the tibia. If, on exposure of the deep fascia, the intermuscular septum between the tibialis and long extensor of the toes

is not well defined, the fascia must be freely slit up in the line of the artery, and the sulcus felt for. A small muscular artery may lead down to the trunk. The foot is now dorsiflexed and the artery sought for deep on the interosseous membrane. The nerve should be drawn to the outer side. The venæ comitantes may be included in the ligature.

In senile gangrene the liability of the tibial arteries to disease and consequent thrombosis and interference with the collateral circulation accounts both for the extension of the disease and the difficulty in detecting pulsation.

The **peroneal artery,** given off from the posterior tibial about an inch below the popliteus, or two inches below the head of the fibula, runs deeply along the medial border of this bone, covered by the flexor hallucis longus, the nerve to which accompanies the vessel.

It gives off the *anterior peroneal*, through the interosseous membrane, to the front of the lateral malleolus about an inch above the level of the ankle-joint. Its continuation, as the posterior peroneal, runs behind the malleolus, to join the anastomosis about the ankle-joint.

The **nutrient artery** of the tibia arises from the posterior tibial near its commencement. It is the largest of all the nutrient arteries to the shafts of long bones; that for the fibula comes from the peroneal.

As a general rule, in **amputation** 2.5 cm. (1 in.) below the head of the fibula, only one main artery—the popliteal—is divided. In amputations 5 cm. (2 in.) below the head of the fibula, two main arteries—the anterior and posterior tibials—are divided. In amputations 7.5 cm. (3 in.) below the head, three main arteries—the two tibials and the peroneal—are divided. (Holden.)

In an amputation through the middle of the leg, the anterior tibial artery would be found cut on the interosseous membrane between the tibialis anterior and the extensor hallucis longus, the deep peroneal nerve here lying in front of the vessel. The posterior tibial would be between the superficial and deep muscles at the back of the leg lying on the tibialis posterior, its nerve being to the lateral side. The peroneal would be close to the fibula in the flexor hallucis longus.

The **superficial peroneal** (musculo-cutaneous) nerve, having passed through the peroneus longus and then between the peroneus longus and peroneus brevis, perforates the deep fascia in the lower third of the leg in the line of the septum between the peronei and extensors. Directly after, it divides into its two terminal branches.

Amputation of the leg.—To give one instance only, amputation 'at the seat of election, or a hand's-breadth below the knee-joint, will be alluded to. Lateral skin-flaps and circular division of the muscles give an excellent result in hospital practice where the various conditions which call for such a step are usually met with. The above name was given because the pressure of the body is well carried on the prominences about the knee-joint, especially the tuberosity of the tibia, when the patient walks with the knee flexed on a 'bucket' artificial limb. Thus the scar, being central, is here not of importance. Two broadly oval lateral flaps of skin and fasciæ are raised, and the remaining soft parts severed down to the bones with circular sweeps of the knife. In sawing the bone, the smaller size of the fibula and its position behind the tibia must be remembered. It is well, in order to ensure complete division of the fibula first, to roll the limb well over on its medial side, and place the saw well down on the lateral side. The parts cut through are shown in fig. 1174.

THE ANKLE

Bony landmarks.—The following are the differences between the two **malleoli**: The **medial** is the more prominent, shorter, and is placed more anteriorly than the lateral, being a little in front of the centre of the joint. The **lateral** descends lower by about 1.2 cm. ($\frac{1}{2}$ in.), and thus securely locks in the joint on this side; it is opposite to the centre of the ankle-joint, being placed about 1.2 cm. ($\frac{1}{2}$ in.) behind its fellow.

Owing to the lateral malleolus descending lower than the medial, in Syme's and Pirogoff's amputations the plantar incision should run between the tip of the lateral malleolus and a point 1.2 cm. ($\frac{1}{2}$ in.) below that of the medial one. When a fracture is set, or a dislocation adjusted, the medial edge of the patella, the medial malleolus, and the medial side of the great toe are useful landmarks and should be in the same vertical plane, regard being paid at the same time to the corresponding points in the opposite limb. (Holden.)

On the posterior aspect of the medial malleolus is a groove for the tibialis posterior and flexor digitorum longus, the first named being next the bone. The tip and borders of the process give attachment to the deltoid ligament. The anterior border and tip of the lateral malleolus give attachment to the anterior talo-fibular and calcaneo-fibular ligaments respectively, the posterior talo-fibular arising from a pit behind and below the articular facet. The posterior border is grooved for the two peronei. The line of the ankle-joint corresponds to one about 1.2 cm. ($\frac{1}{2}$ in.) below the tip of the medial malleolus drawn across the anterior aspect.

Effusion or tuberculous thickening shows itself first in front, between the medial malleolus and tibialis anterior and between the peroneus tertius and lateral malleolus and then behind, where it fills up the hollow between the tendo Achillis and the two malleoli. Owing to the thinness of the transverse crural (anterior) ligament, the extensor sheaths are easily affected in neglected tuberculous disease. Owing to the way in which the joint is locked in, it is not easy to open and drain an infected ankle-joint satisfactorily. Removal of a portion of the lateral

FIG. 1175.—BRANCHES OF THE COMMON PERONEAL NERVE.

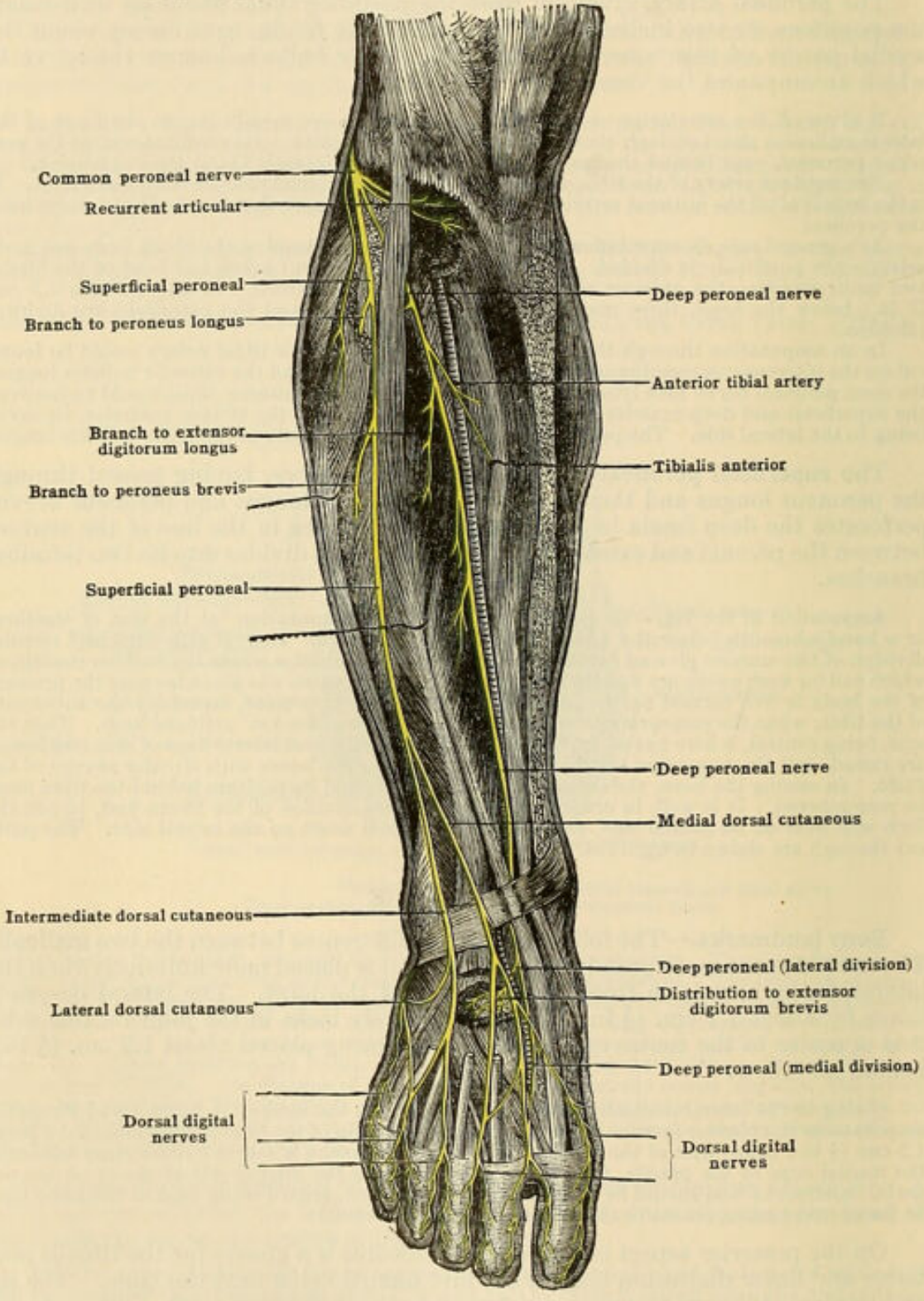

malleolus subperiosteally, leaving the tip and calcaneo-fibular, will admit of the insertion of a tube and good drainage if the foot is so slung as to keep its lateral aspect dependent.

Tendons.—(A) **In front of ankle.**—Latero-medially are—(1) The tibialis anterior, the largest and most medial. This tendon appears in the lower third of the leg, lying just under the deep fascia, close to the tibia; then, crossing over the

lower end of this and the ankle-joint, it passes over the medial side of the tarsus, to be inserted into the medial and lower part of the first cuneiform and the adjacent part of the first metatarsal. (2) The extensor hallucis longus. This tendon, concealed above, appears low down in a line just lateral to the last, and then, crossing over the termination of the anterior tibial vessels and nerves (to which its muscular part lies lateral), it descends along the medial part of the dorsum to be inserted into the base of the last phalanx of the great toe. (3) and (4) The extensor digitorum longus and peroneus tertius enter a common sheath in the transverse crural ligament. The former then divides into four tendons, which

FIG. 1176.—LATERAL VIEW OF THE ANKLE REGION, AS SHOWN BY THE RÖNTGEN-RAYS

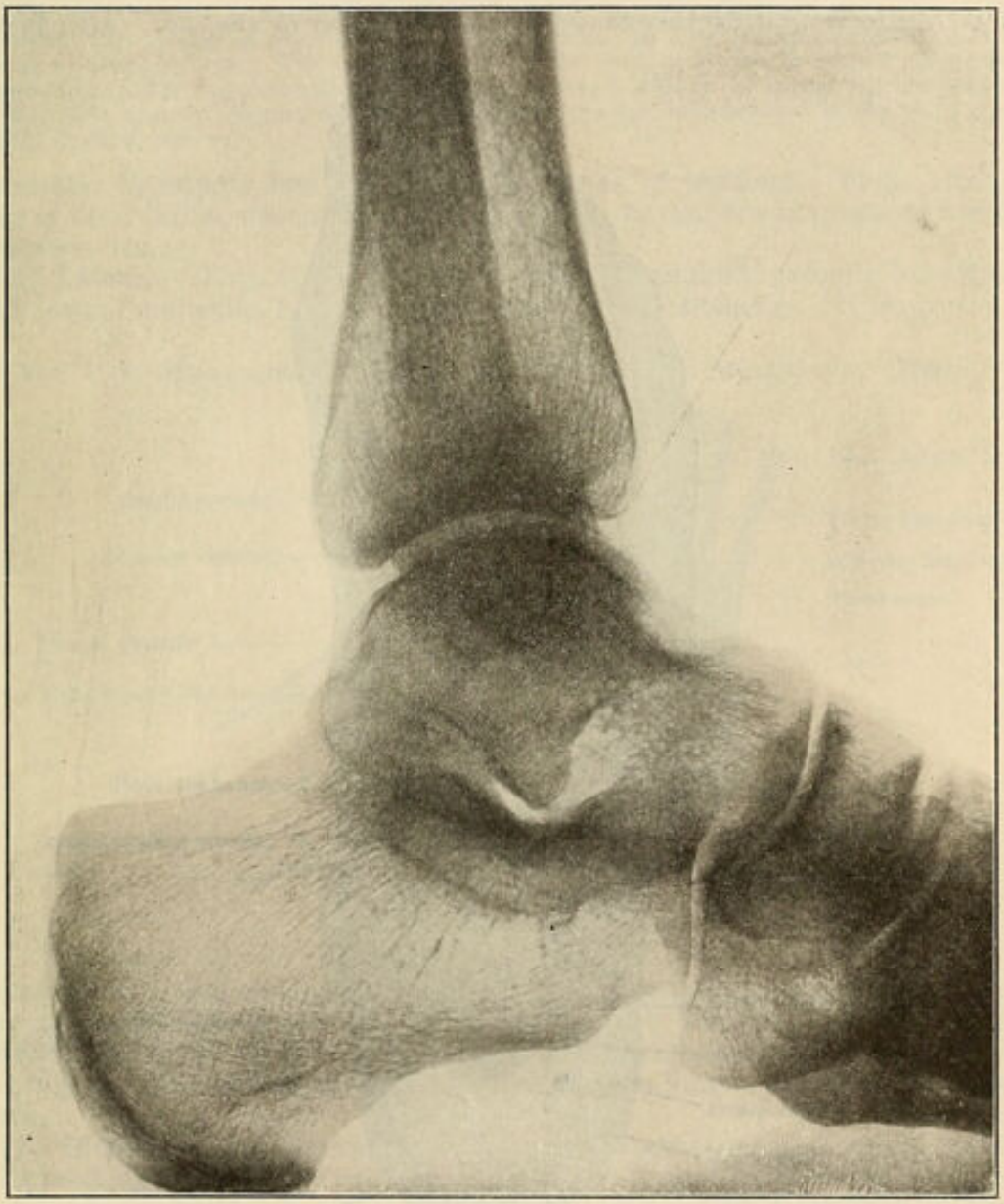

run to the four lateral toes. The peroneus tertius is inserted into the upper surface of the base of the fifth (often also the fourth) metatarsal bone.

(B) **Behind.**—The tendo Achillis, the thickest of all tendons, begins near the middle of the leg, in the junction of the tendons of the gastrocnemii and, a little lower, (p. 1453) the soleus. Very broad at its commencement, it gradually narrows and becomes very thick. About 3.7 cm. (1½ in.) from the heel, or about the level of the medial malleolus, is its narrowest point. After this it again expands slightly, to be inserted into the middle of the back part of the calcaneus. The long tendon of the plantaris runs along its medial side, to blend with it or to be attached to the calcaneus. On either side of the tendo Achillis are well-marked

furrows below. Along the medial, the tendon of the tibialis posterior and the posterior tibial vessels and nerve come nearer the surface. Along the lateral, the small saphenous vein (more superficially) ascends from behind the lateral malleolus.

(C) **On the medial side.**—The tendon of the tibialis posterior, which has previously crossed from the interspace between the bones of the leg to the medial side, lies behind the inner edge of the tibia above the medial malleolus, then behind this, being here under the flexor digitorum longus, the two tendons having become superficial on the medial side of the tendo Achillis. It then passes forward over the deltoid and under the laciniate (internal annular) ligament between the medial malleolus and the sustentaculum tali, and then below and close to the plantar cal-

FIG. 1177.—HORIZONTAL SECTION THROUGH THE LOWER PART OF THE LEG. (After Braune.)

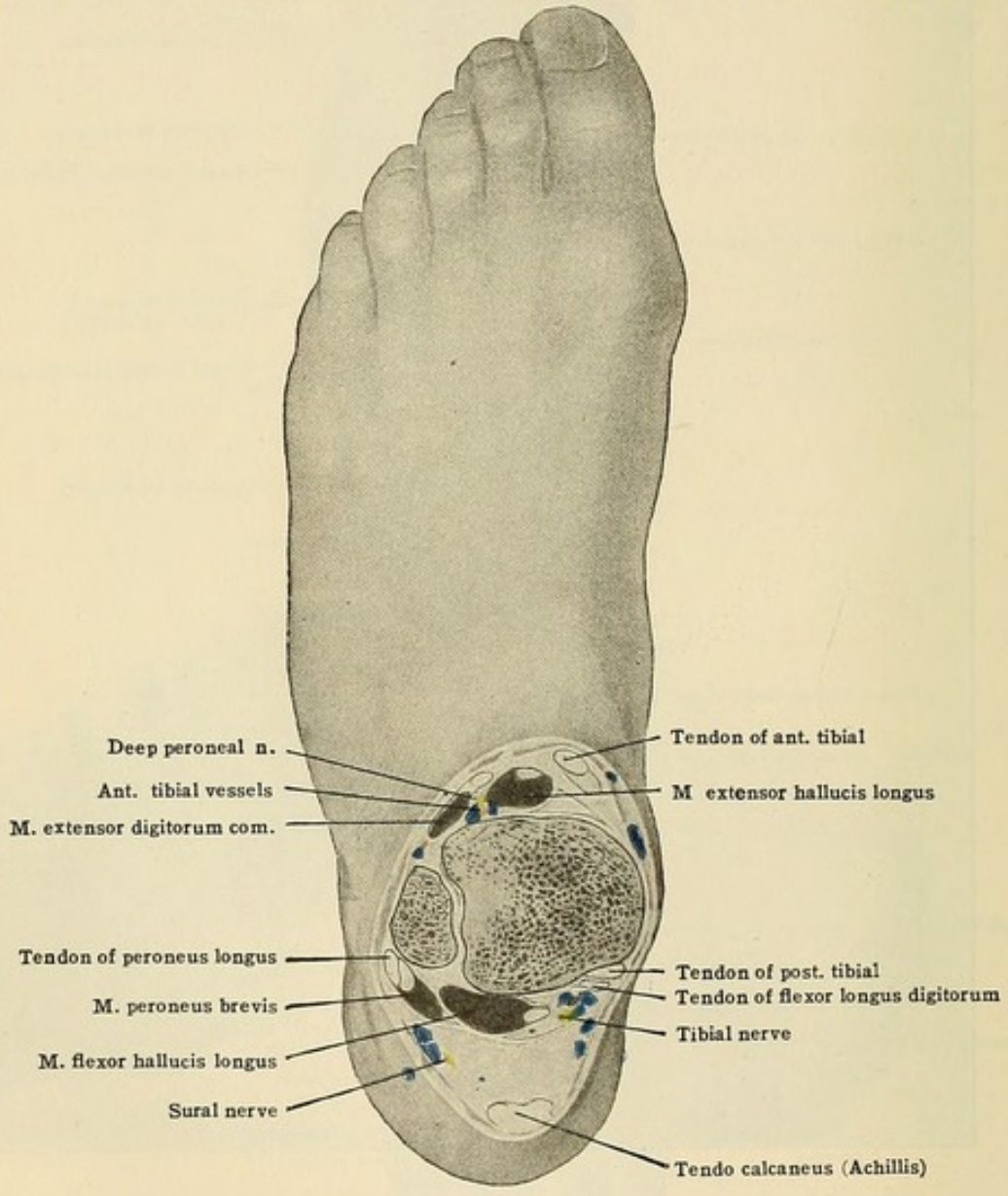

caneo-navicular ligament (*vide infra*), and so to its insertion, by numerous slips, into the tarsus and metatarsus, especially the tuberosity of the navicular. The tendon of the flexor hallucis longus cannot be felt. Having passed medially from the fibula, it crosses the lower end of the tibia in a separate furrow, then grooves the backof the talus, and passes under the sustentaculum tali on its way to its insertion.

The arrangement of the structures at the medial ankle from above downward, and mediolaterally, is as follows (fig. 1177):—tibialis posterior, flexor digitorum longus, companion vein, posterior tibial artery, companion vein, tibial nerve, flexor hallucis longus. The tibiales posterior and anterior turn the sole medially, antagonising the peronei. They also bear a large

share in maintaining the longitudinal arch of the foot. The flexors not only act upon the toes, but aid the calf muscles in straightening the foot upon the leg in walking or standing upon tip-toe; hence the value of educating them in cases of flat-foot.

(D) **Tendons on the lateral aspect.**—The tendons of the two peronei, which arise from the fibula between the extensor digitorum longus and flexor hallucis longus, pass behind the lateral malleolus, the brevis being nearer to the bone (fig. 1177). They then pass forward over the lateral surface of the calcaneus, separated by the peroneal tubercle when present, and diverge.

The brevis—the upper one—passes to the projection at the base of the fifth metatarsal; the longus, lying below the brevis on the calcaneus, winds round the lateral border of the foot, grooving the lateral border and under surface of the cuboid. Finally, crossing the sole obliquely forward and medially, it is inserted into the adjacent parts of the first cuneiform and the back part and under surface of the first metatarsal. While in connection with the under surface of the cuboid, this tendon is covered in by a sheath from the long plantar ligament, and often contains a sesamoid bone. The two peronei evert the foot, as is seen in talipes valgus and in fracture of the lower end of the fibula; the peroneus longus aids in the support of the arch of the foot (p. 1466), and, by keeping the great toe on the ground, is important in the third stage of walking, skating, etc.

Annular ligaments and synovial membranes of tendons.—These strap-like bands of deep fascia, which serve to keep the above tendons in position, are three in number, viz.:—

(A) **Lateral.**—This, the superior peroneal retinaculum, extends from the tip of the lateral malleolus to the lateral surface of the calcaneus. It keeps the two

FIG. 1178.—RELATIONS OF PARTS BEHIND THE MEDIAL MALLEOLUS. (Heath.)

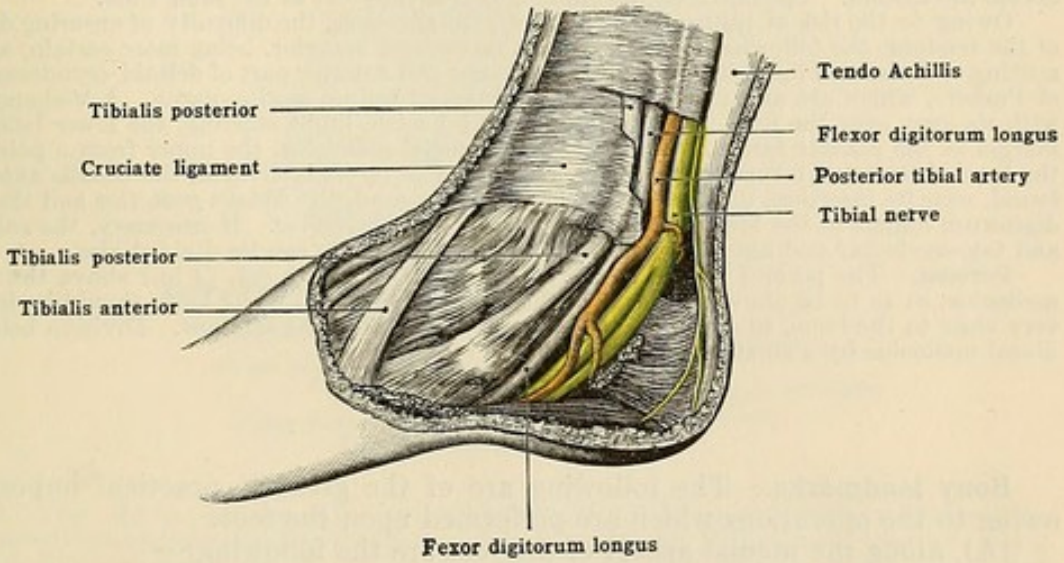

peronei in place, and surrounds them behind the fibula in one sheath with a single synovial sac, which extends upward into the leg for 3.7 cm. (1½ in.), and sends two processes into the two sheaths in which the tendons lie on the calcaneus. Farther on, while in relation with the cuboid, the peroneus longus has a second synovial sheath.

(B) **Medial.**—This, the laciniate ligament, crosses from the medial malleolus to the medial surface of the calcaneus. Beneath it are the following canals:—(1) For the tibialis posterior. This tendon-sheath is lined by a synovial membrane extending from a point 3.7 cm. (1½ in.) above the malleolus to the navicular. (2) For the flexor digitorum longus. The synovial sheath of this tendon is separate from that of the closely contiguous tibialis posterior. It extends upward into the leg about as high as the sheath just given. It reaches down into the sole of the foot; but where the tendon subdivides to enter the thecæ, each of these is lined by a separate synovial sheath. Next comes (3) a wide space for the posterior tibial vessels and nerve; and, lastly, (4) a canal, like the other two, with a separate synovial sheath, for the tendon of the flexor hallucis longus. The lower margin of this annular ligament gives an attachment to the abductor hallucis and blends with the plantar fascia. The medial calcaneal vessels and nerve perforate the ligament.

(C) **Anterior annular ligament.**—This is a double structure. (1) **Upper (transverse crural ligament), above the level of the ankle-joint,** and tying the tendons down to the lower third of the leg, passes transversely between the anterior crest of the tibia and fibula. Here is one sheath only, with a synovial membrane for the tibialis anterior. (2) **Lower, over the ankle-joint.** This band, the **cruciate ligament,** is arranged like the letter ≺, placed thus. It is attached by its root to the calcaneus, and by its bifurcations to the medial malleolus and plantar fascia.

This arrangement of the branches of this ligament is not constant. In this, the lower annular ligament, there are usually three sheaths with separate synovial membranes—the most medial (the strongest in each) for the tibialis anterior, the next for the extensor hallucis longus, and the third common to the extensor communis and peroneus tertius. The extensor digitorum brevis has a partial origin from this ligament.

Points in tenotomy and guides to the tendons.—The **tendo Achillis** should be divided about 3.7 cm. (1½ in.) above its insertion, its narrowest point, which is about on a level with the medial malleolus. The knife should be introduced on the medial side and close to the tendon, so as to avoid the posterior tibial artery (fig. 1178).

The **tibialis anterior** may be divided about 25 mm. (1 in.) above its insertion into the first cuneiform, a point which is below the level of its synovial sheath. The tendon has here the dorsalis pedis on its lateral side, but separated by the tendon of the extensor hallucis longus. The knife is introduced on this side.

The **tibialis posterior.**—The usual rule for dividing this tendon is to take a spot 5 cm. (2 in.) above the medial malleolus, and as accurately as possible midway between the anterior and medial borders of the leg. This point will give the medial margin of the tibia, in close apposition to which the tendon is lying, and is a point at which the tendon is rather farther from the artery than it is below, and is also above the commencement of its synovial sheath. A sharp-pointed knife is used first to open the sheath freely, and then a blunt-pointed one to divide the tendon. The flexor digitorum longus is usually cut at the same time.

Owing to the risk of injury to the posterior tibial vessels, the difficulty of ensuring division of the tendons, the following open method is, nowadays, superior, being more certain, and admitting of division of ligaments, e. g., talo-navicular and anterior part of deltoid (syndesmotomy of Parker), which are always contracted in advanced talipes equino-varus. A **V**-shaped flap with its apex over the first metatarsal bone and its two limbs starting, the lower below the margin of the plantar fascia on a line with the medial malleolus, the upper from a point over the head of the talus, is turned backward. The plantar fascia is divided, the tibialis anterior is found, near its insertion, under the upper lip of the wound, the tibialis posterior and the flexor digitorum longus in the lower, the former close to the navicular. If necessary, the calcaneo- and talo-navicular and anterior part of the deltoid ligaments can be divided also.

Peronei.—The peronei longus and brevis may be divided 5 cm. (2 in.) above the lateral malleolus, so as to be above the level of their synovial sheath. The knife should be inserted very close to the bone, so as to pass between the fibula and the tendons. Division below the ateral malleolus by a small flap is easier.

THE FOOT

Bony landmarks.—The following are of the greatest practical importance owing to the operations which are performed upon the foot.

(A) **Along the medial aspect of the foot** are the following:—

(1) Medial tuberosity of the calcaneus; (2) medial malleolus; (3) 2.5 cm. (1 in.) below the malleolus, the sustentaculum tali; (4) about 2.5 cm. (1 in.) in front of the medial malleolus, and a little lower, is the tuberosity of the navicular, the medial guide in Chopart's amputation, the gap between it and the sustentaculum being filled by the calcaneo-navicular ligament and the tendon of the tibialis posterior, in which there is often a sesamoid bone; (5) the first cuneiform; (6) the base of the first metatarsal; and (7) the head of the same bone, with its sesamoid bones below. (Holden).

(B) **Along the lateral aspect** are:—(1) The lateral tuberosity of the calcaneus; (2) the lateral malleolus; (3) the peroneal tubercle of the calcaneus (when present), 2.5 cm. (1 in.) below the malleolus, with the long peroneal tendon below it, and the short one above; (4) the projection of the anterior end of the calcaneus, and the calcaneo-cuboid joint, midway between the tip of the lateral malleolus and the base of the fifth metatarsal bone; (5) the base of the fifth metatarsal bone; (6) the head of this bone. The greater process of the calcaneus and the muscular origin of the short extensor lie between the peroneus brevis and tertius.

Levels of joints and lines of operations.—The line of the ankle-joint has been given at p. 1459. That of the talo-calcaneal joint—the limited lateral movements of the foot take place here and at the medio-tarsal joint—corresponds, on the lateral side, to a point a little in front of the lateral malleolus and midway between it and the peroneal tubercle; on the medial

side, to one just above the sustentaculum tali. In **Syme's amputation** through the ankle-joint, the incision starts from the tip of the lateral malleolus, and is then carried, pointing a little backward toward the heel, across the sole to a point 1.2 cm. (½ in.) below the medial malleolus. The chief supply to the heel-flap is from the medial calcaneal. Care should be taken to divide the posterior tibial below its bifurcation and not to prick this vessel afterward.

In **Pirogoff's amputation** the incision begins and ends at the same points, but is carried straight across the sole. In each amputation the extremities of the above incision are joined by one going directly across the ankle-joint, which lies about 1.2 cm. (½ in.) above the tip of the internal malleolus.

In **Chopart's medio-tarsal amputation,** which passes between the talus and the navicular on the medial side, and the calcaneus and the cuboid on the lateral, the line of the joints to be opened would be one drawn across the dorsum from a point just behind the tuberosity of the navicular to a point corresponding to the calcaneo-cuboid joint, just midway between the tip of the lateral malleolus and the base of the fifth metatarsal bone. The convexity of the plantar flap should reach to a point 2.5 cm. (1 in.) behind the heads of the metatarsal bones. Owing to the tendency of the unbalanced action of the calf muscles to tilt up the calcaneus and thus throw the scar down into the line of pressure, the powerful tibialis anterior tendon and those of the extensors should be carefully stitched into the tissues of the sole flap.

In **Lisfranc's,** or **Hey's,** or the **tarso-metatarsal amputation,** the bases of the fifth and first metatarsals must be defined. The first of these can always be detected, even in a stout or swollen foot; on the medial side the joint between the first cuneiform and the first metatarsal

FIG. 1179.—VERTICAL SECTION THROUGH THE CUNEIFORM AND CUBOID BONES. (One-half.)

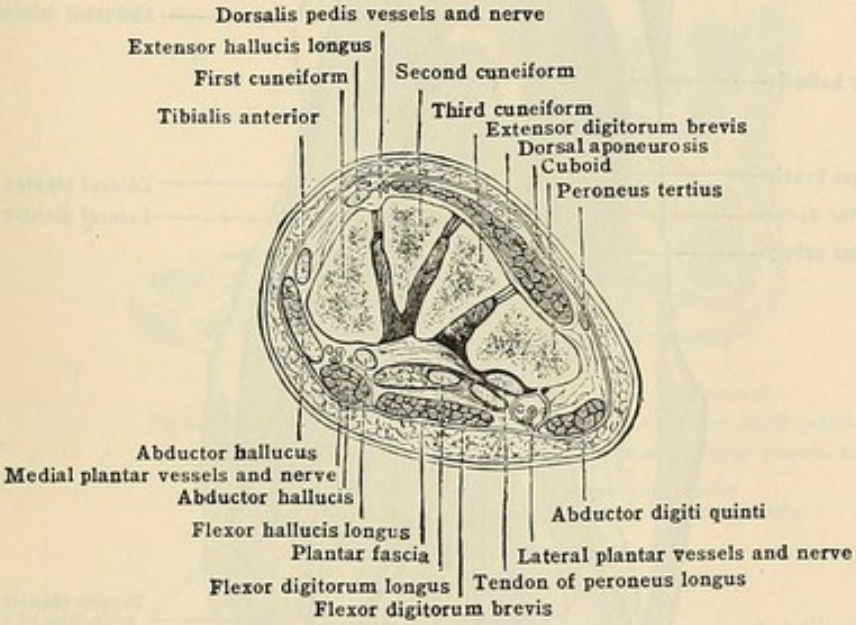

bone lies 3.7 cm. (1½ in.) in front of the navicular tuberosity. In opening the joint between the second metatarsal and the middle cuneiform, its position (the base of the former bone projecting upward on to a level 6 or 8 mm. (¼ or ⅓ in.) above the others), and the way in which it is locked in between its fellows and the cuneiform bones, must be remembered. The convexity of the plantar flap here reaches the heads of the metatarsal bones.

In marking out the flaps for the **amputation of the great toe,** the large size of the head of the first metatarsal, and the importance of leaving this so as not to diminish its supporting power and the treading width of the foot, and thus of marking out flaps sufficiently long and large, must be borne in mind. The dorsal incision should begin 3.7 cm. (1½ in.) above the web. The line of the joint is a little distal to the centre of the ball of the toe (fig. 1181). The sesamoid bones should be left, so as not to endanger the vitality of the flaps. In amputation of the other toes, the line of their metatarso-phalangeal joints lies a full inch above the web.

Bursæ and synovial membranes.—The synovial sheath of the extensor hallucis longus extends from the front of the ankle, over the instep, as far as the metatarsal bone of the great toe. There is generally a bursa over the instep, above, or it may be below, the tendon.

There is often an irregular bursa between the tendons of the extensor digitorum longus and the projecting end of the talus over which the tendons play. There is much friction here. It is well to be aware that this bursa sometimes communicates with the joint of the head of the talus. (Holden.) There is a deep synovial bursa between the tendo Achillis and the calcaneus. Numerous other bursæ may appear over any of the bony points in the foot, especially when they are rendered over-prominent by morbid conditions.

Synovial membranes.—In addition to that of the ankle-joint, there are **six** synovial membranes in the **tarsus,** viz.:—(1) Talo-calcaneal, peculiar to these

bones; (2) talo-calcaneo-navicular, common to these bones and the navicular; (3) between the calcaneus and the cuboid; (4) between the cuboid and the lateral two metatarsals; (5) between the first cuneiform and the first metatarsal; (6) a complicated and extensive one, which branches out between the navicular and cuneiform bones; between the cuneiforms; between the third cuneiform and the cuboid; between the second and third cuneiform and the second and third metatarsal bones; and between the second and third and the third and fourth metatarsal bones.

FIG. 1180.—SUPERFICIAL NERVES IN THE SOLE OF THE FOOT. (Ellis.)

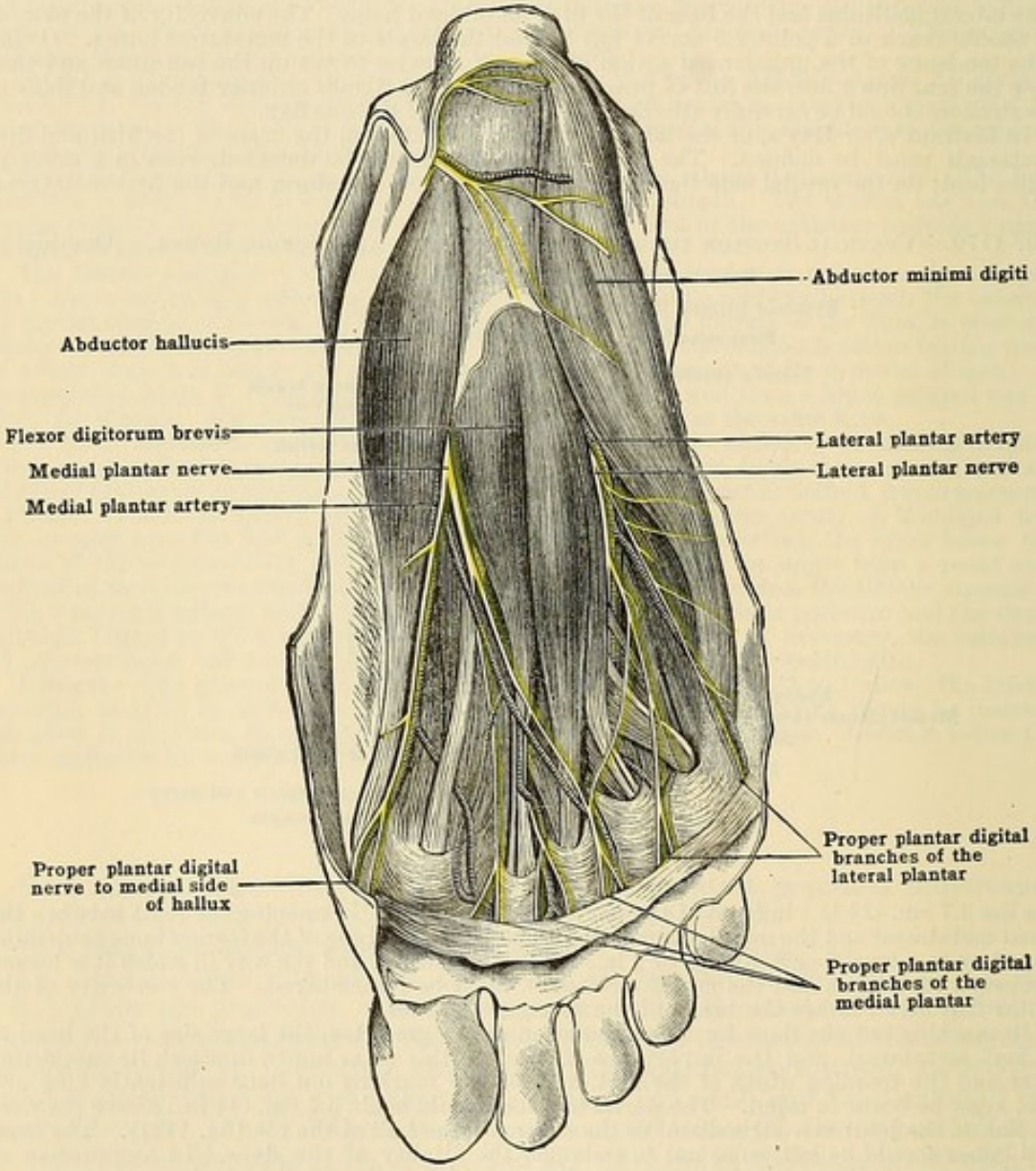

Dorsal artery.—The line of this is from the centre of the ankle-joint to the upper part of the first interosseous space.

On its medial side is the tendon of the extensor hallucis longus; on its lateral, the most medial tendon of the extensor digitorum longus. It is crossed by the most medial tendon of the extensor brevis. The origin of this muscle should be noted on the lateral and fore part of the calcaneus.

Cutaneous nerves (fig. 1182).—The sites of these, numerous on the dorsum of the foot, are as follows:—The **superficial peroneal** (**musculo-cutaneous**) **nerve,** having perforated the fascia in the lower third of the leg, divides into two chief branches, medial and lateral, which supply all the toes save the lateral part of the little, and the adjacent sides of the first and second. The **deep peroneal** becomes cutaneous in the first space, and is distributed to the contiguous sides of the above-

mentioned toes. The **sural nerve** runs with the small saphenous vein below the malleolus, and supplies all the lateral border of the foot and the lateral side of the little toe. The **saphenous nerve,** coursing with the great saphenous vein in front of the medial malleolus, supplies the medial border of the foot as far as the middle of the instep. The cutaneous nerves to the sole (from the medial calcaneal, medial, and lateral plantar) are shown in fig. 1180.

Plantar arteries.—The line of the medial would be one drawn from the bifurcation of the posterior tibial, or about midway between the tip of the medial malleolus and the medial border of the heel, to the middle of the plantar surface of the great toe. The course of the lateral plantar runs in a line drawn from the bifurcation, first obliquely across the foot to a point a little medial to the medial side of the base of the fifth metatarsal, and thence obliquely across the foot till it reaches the first space and joins with a communicating branch from the dorsal artery. It thus crosses the foot twice. In the first part, it is more superficial, in the second

FIG. 1181.—LONGITUDINAL SECTION OF FOOT. (One-third.) (Braune.)

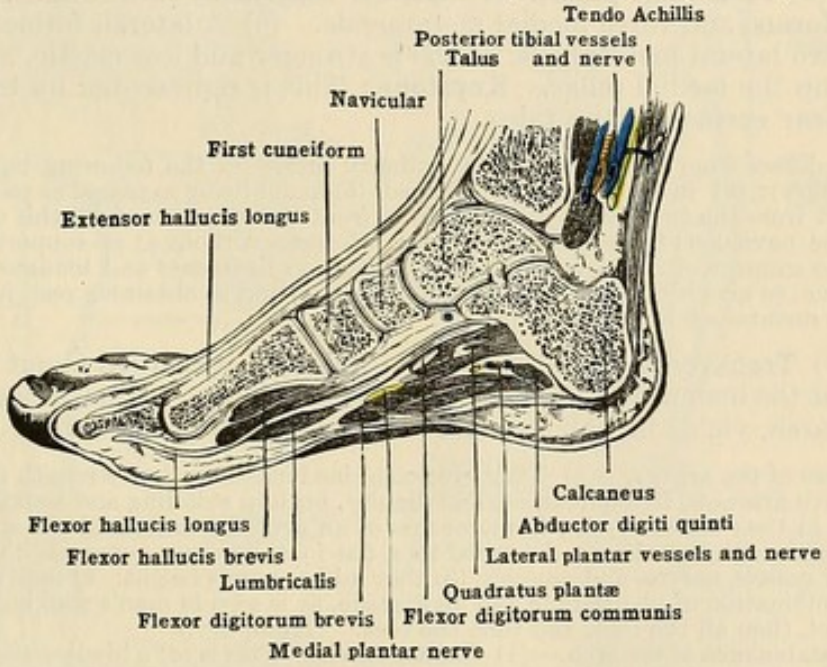

very deep; it here forms the plantar arch, and is only separated from the bases of the metatarsals by the interossei.

The anastomosing branches about the ankle-joint are shown in figs. 1170 and 1171.

Tarsal bones.—The chief surgical points about these is the frequency with which they are diseased and their changes in talipes. **Frequency of disease.**—This is explained, chiefly, by their delicate structure and the fact that on the aspect in which they are most exposed to injury the soft parts are scanty. Disease once started, often by slight injury, finds in the terminal circulation of the parts, and the frequent want of rest, other contributing causes. The numerous and complicated synovial membranes mentioned above explain the extension of the disease. The calcaneus is the only bone in which mischief is likely to remain limited. The presence of an epiphysis to this bone appearing about the age of ten and joining at puberty is to be remembered as a starting-point of disease here. **Talipes.**—To take one instance, a case of talipes equino-varus, of congenital origin and confirmed degree, the following are the chief structural changes which should have been obviated and now have to be met, given briefly. *Calcaneus.*—This is elevated posteriorly, and rotated so that its long axis is directed obliquely medially. *Talus.*—The inclination of the neck medially is much increased, and the whole bone protruded from the ankle-joint. According to some, the neck is increased in length. *Navicular.*—This is displaced medially so that it articulates with the medial side of the head of the talus, and its tuberosity may form a facet on the medial malleolus. *Cuboid.*—The dorsal surface of this is displaced downward, and bears much of the pressure in walking. *Tendons.*—Those chiefly shortened are the tendo Achillis and those of the tibials and flexor digitorum longus. The tendo Achillis is displaced medially. *Ligaments.*—Those on the lateral side are stretched, those on the medial, especially the anterior part of the deltoid, the dorsal talo-navicular and the plantar calcaneo-navicular ligaments are shortened. The plantar fascia is also shortened, together with the abductor hallucis, which arises from it.

ARCHES OF THE FOOT

These are two—the **longitudinal** and the **transverse.**

(A) **Longitudinal arch** (fig. 1181).—This is by far the most important. **Extent:** From the heel to the heads of the metatarsal bones. The toes do not add much to the strength and elasticity of the foot. (Humphry.) They enlarge its area and adapt it to inequalities of the ground, are useful in climbing, and in giving an impulse to the step before the foot is taken from the ground, in the third stage of walking. **Two pillars.**—The late Professor Humphry laid stress on the important differences between these two:—(1) **Posterior pillar:** This consists of the calcaneus and hinder part of the talus, viz., only two bones in order to secure solidity, and to enable the calf-muscles to act directly upon the heel, without any of that loss of power which would be brought about by many moving joint-surfaces. (2) **Anterior pillar:** Here there are many bones and joints to provide (*a*) elastic springiness, and (*b*) width. This anterior pillar may again be divided into two: (*a*) A **medial pillar,** very elastic, consisting of the talus, navicular, three cuneiforms, and three medial metatarsals. (*b*) A **lateral,** formed by the cuboids and two lateral metatarsals. This is stronger and less elastic, and tends to buttress up the medial pillar. **Keystone:** This is represented by the summit of the trochlear surface of the talus.

It differs from the keystones in ordinary arches in the following important particulars (Humphry): (*a*) in not being wedge-shaped; (*b*) in not being so placed as to support and receive support from the two halves of the arch: in front the talus does fulfil this condition by fitting into the navicular; behind, it overlaps the calcaneus without at all supporting it; (*c*) this arch and the support of its keystone largely depend on ligaments and tendons; (*d*) it is a mobile keystone: to give it chances of shifting its pressure, and so obtaining rest, its equilibrium is not always maintained in one position.

(B) **Transverse arch** (fig. 1179).—This is best marked about the centre of the foot, at the instep, along the tarso-metatarsal joints. This, as well as the longitudinal arch, yields in walking, and so gives elasticity and spring.

Uses of the arches.—(1) They give combined elasticity and strength to the tread. Thus they give firmness, free quickness, and dignity, both in standing and walking, instead of what we see in their absence, viz., the lameness of an artificial limb, and the shuffling or hobbling which goes with tight boots, deformed toes, flat-foot, bunions, corns, etc.; (2) they protect the plantar vessels, nerves, and muscles; (3) they add to man's height; (4) they make his gait a perfect combination of plantigrade and digitigrade, as is seen in man's walking, when he uses first the heel, then all the foot, and then the toes. (Humphry.)

Maintenance of the arch.—(1) **Plantar fascia.**—This is (*a*) a binding tie between the pillars of the longitudinal arch; (*b*) it protects the structures beneath; (*c*) it is a self-regulating ligament and protection. Thus, having a quantity of muscular tissue attached to its upper and back part, is constantly responds by the contraction of this, to the amount of any pressure made upon the foot. (2) **Plantar calcaneo-navicular ligament.**—This is a thick tie-plate of fibro-cartilaginous tissue, partly elastic, hence called the 'spring-ligament,' attached to the anterior margin of the sustentaculum tali and under surface of navicular. It is thickest at its medial side, where it blends with the anterior part of the deltoid ligament, and below, where the tibialis posterior, passing into the sole, is in contact with the ligament and gives much support to the head of the talus and the navicular, while it assists the power and spring of this ligament (*vide infra*). The dropping of the talus and navicular and their projection on the medial side in flat-foot are largely due to the giving way of the above ligament. (3) **Calcaneo-cuboid ligaments.** (*a*) **Long;** (*b*) **short.**—These ligaments are the main support of the lateral, firm, and less elastic part of the longitudinal arch. (4) **Tibialis posterior.**—The reason of this muscle having so many insertions below is to brace together the tarsal bones, and to prevent their separation when, in treading, the elastic anterior pillar tends to widen out. Of these numerous offsets, that to the navicular is the most important. Thus it strengthens the calcaneo-navicular ligament by blending with it, and thus supports the arch at a trying time. By coming into action when the heel is raised, this tendon helps the calcaneo-navicular ligament to support the head of the talus, and to maintain the arch of the foot when the weight of the body is thrown forward on to the instep. In other words, the tibialis posterior comes into play just when the heaviest of its duties is devolving upon this ligament, viz., when the heel is being raised, and the body-weight is being thrown over the instep on to the opposite foot. (5) **Peroneus longus.**—This raises the lateral pillar, and steadies the lateral side of the arch. Further, by its strong process attached to the first metatarsal bone, it keeps the great toe strapped down firmly against the ground; thus, keeping down the anterior pillar of the longitudinal arch, it aids the firmness of the tread. (Humphry.) (6) **Tibialis anterior.**—This braces up the keystone of the arch. Thus, by keeping up the first cuneiform, it maintains the navicular, and so indirectly the talus *in situ*.

Fig. 1172 will remind the reader of the arrangement of the **superficial lymphatics of the lower extremity.** These follow chiefly the saphenous veins, and enter the inguinal nodes, except those from the lateral aspect of the heel which

drain into the popliteal lymph-nodes. The superficial lymphatics of the buttock enter the lateral, and those over the adductor muscles the most medial group of the inguinal glands.

The deep lymphatics of the lower limb, comparatively few in number, follow the course of the deeper vessels. After passing through some four or five glands deeply placed about the popliteal vessels (these glands also receive the lymphatics along the small saphenous vein), the lymph is carried up by lymphatics along the femoral artery to the deep inguinal nodes; one very often occupies the femoral canal.

Fig. 1182 shows the distribution of the **superficial nerves** on both aspects of the limb.

FIG. 1182.—DISTRIBUTION OF CUTANEOUS NERVES ON THE POSTERIOR AND ANTERIOR ASPECTS OF THE INFERIOR EXTREMITY.

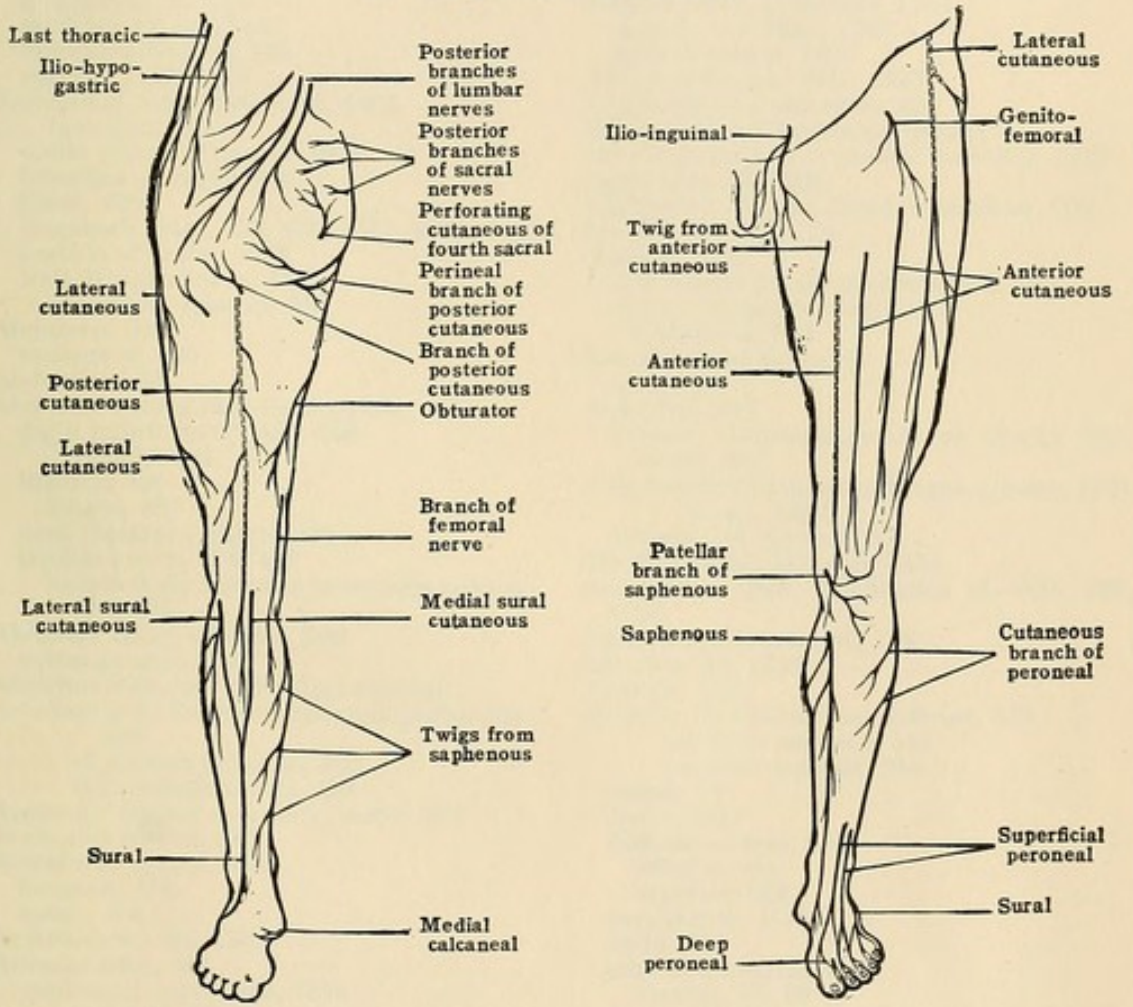

Paralysis of the nerves of the lower extremity.—The student should take this opportunity of considering from the surgical anatomy the results of paralysis of the nerve chiefly affected, viz., the great sciatic and its branches. *Sciatic:* The limb hangs flail-like, much in the position of one affected with advanced infantile paralysis. In addition to the results of paralysis of its two divisions, flexion at the knee will be lost, owing to paralysis of the hamstrings. *Peroneal (external popliteal) nerve:* The extensors and peronei being paralysed the foot drops, it cannot be dorsiflexed at the ankle nor abducted at the medio-tarsal joint. Adduction at the latter joint is impaired owing to paralysis of the tibialis anterior. The arch of the foot is largely lost owing to paralysis of the peroneus longus. Slight extension of the two distal phalanges of the four lateral toes is still possible by means of the interossei. Sensation is impaired over the distribution of the medial sural cutaneous deep, and superficial peroneal nerves. *Tibial (internal popliteal) nerve:* Here the calf muscles, the flexors, and the muscles of the sole of the foot are paralysed. The ankle cannot be plantar-flexed.



INDEX

Bold-face type indicates the more complete descriptions

A

Abdomen, 1142
  clinical anatomy of, 1370
  landmarks of, 1370
  lymphatic nodes of, 730
  lymphatics of, 730
  morphology of, 1144
  muscles acting on, 503
  regions, 1142, 1370
Abdominal aorta, **590,** 1382, 1408
    branches, 591
  aortic plexus of nerves, 1045
  branches of vagus, 958
  fossæ, 430
  (inguinal) rings, 429, 430, 1371, **1394, 1396**
  portion of ureter, 1248
  wall, lymphatics in, 733
    superficial veins in, 683
Abducens, 934
  nucleus of, 826
Abduction, 321
Abductor accessorius digiti quinti, 499
  digiti quinti (foot), 454, **498**
      (hand), 404
  hallucis, 496
    longus, 482
  ossis metatarsi quinti, 499
  pollicis brevis, 406, **407**
    longus (extensor ossis metacarpi pollicis), 392, **393**
Aberrant artery of aorta, 590
  spinal ganglia, 965
Abnormalities (see individual organs).
Accessorius ad flexorem digitorem profundum, 402
    of gluteus minimus, 462
    (ilio-costalis dorsi), 416
Accessory (spinal accessory) nerve, 958
Acervulus cerebri, 846
Acetabular artery, 608
  foramen, 174
  notch, 174
Acetabulum, 169, **173**
Acoustic area, 814
  (auditory) nerve, **949,** 1096
      nuclei of, 823
  meatus (see "Auditory Meatus").
  (medullary) striæ, 814, 824
Acromial branches of posterior circumflex humeral artery, 573
    of thoraco-acromial artery, 571
    of transverse scapular artery, 565
  (scapular) extremity of clavicle, 141
Acromio-clavicular joint, **251,** 1363
Acromion angle, 144
  process, 144
Acromio-thoracic axis, 571
Action of muscles (see corresponding muscle).
Adam's apple, 1211
Addison's transpyloric line, 1153, **1370**
Adduction, 321
Adductor brevis, 453, 471, **474**
  (Hunter's) canal, **468,** 618, 1441
  digiti secundi, 498
  hallucis, 454, 496, **498**
  longus, 453, 471, **472,** 1437
Adductor magnus, 453, 471, **474,** 1437
  (medial) group of thigh muscles, 453
  minimus, 474
  pollicis, 407, **408**
  tubercle of femur, 181
Adenoids, naso-pharyngeal, **1130,** 1354
Adipose body, pararenal, 1243
  capsule of kidney, 1242
  folds of pleura, 1237
Aditus of larynx, 1222, 1223
Adminiculum lineæ albæ, 427
Adrenals (see "Suprarenal glands").
Aeby's division of bronchial branches, 1232
Agger nasi, **88,** 1206
Aggregated follicles (Peyer's patches), 704
Air-cells, mastoid, 72
Air-sacs, 1232
Ala of central lobule of cerebellum, 806
  cinerea (trigonum vagi), 814
    nucleus of, 820
Alæ of frontal bone, 60
  nasi, 1201
Alar folds, 291
  (lateral occipito-odontoid or check) ligaments, 223
  (lower lateral) nasal cartilages, greater, 1201
      lesser, 1202
  processes of ethmoid, 81
Alcock's canal, 441, 445, 1384
Alimentary tract, lymphatics of, 699, **733,** 1168
Ali-sphenoid centre, 67, 119
Allantois, 13, 1253
Alopecia, 1293
Alveolar (dental) artery, inferior, 548
      posterior superior, 549
      anterior superior, 549
  canals, 87
  ducts, 1232
  (dental) nerves, 938
    inferior, 941
    superior, 938
  periosteum, 1119
  point, 109
  part of mandible, 96
    maxilla, 87, **90**
  saccules (air-sacs), 1153
  veins, 646
Alveoli (air-cells), 1232
Alveus, 877
  of limbic lobe, 868, 869
Amastia, 1301
Amnion, 9, 10
Ampulla, of ductus (vas) deferens, 1257
  lactiferous, 1302
  phrenica, 1142
  recti, 1176
  of semicircular canals, 80
  of tubæ uterinæ (Fallopian tubes), 1270
  of Vater, 1188
Ampullæ, membranous, 1095
  of splenic arterioles, 1312
Ampullar branches of vestibular ganglion, 950
Ampullary crista, 1095
  sulcus, 1095
Amputation at centre of the arm, 1416
  Chopart's medio-tarsal, 1465

Amputation of foot, 1465
of forearm, 1424
of great toe, 1465
of leg, 1459
Pirogoff's, 1465
Syme's, 1465
tarso-metatarsal (Hey's or Lisfranc's), 1465
through thigh, 1442
Amygdala (tonsil) of cerebellum, 807
Amygdaloid nucleus, 881
of lateral ventricle, 877
Amyloid tubercle of lateral ventricle, 877
Anal canal, 1177
surgical anatomy of, 1390
valves, **1177,** 1390
Anapophysis, 38
Anastomosis of arteries (see corresponding artery).
Anastomotic branch of facial nerve, 944
(perforating) of middle meningeal artery, 548
ulnar, of superficial radial nerve, 987
Anastomotica magna artery (genu suprema), 621
Anatomical neck of humerus, 147
Anatomy, definition of, 1
of fourth ventricle, 812
Anconeus, 374, 377, **379**
internus, 402
Andersch, ganglion of, 951
Angle(s), acromion, 144
cephalo-auricular, 1084
of fissure of Rolando, 860
infrasternal, 139
of Louis, 139
lumbo-sacral, 43
of mandible, 86
of maxilla, 88
of occipital bone, 53
of parietal bone, **57,** 1332
of rib, 127
sacro-vertebral, 39, 43
of scapula, 143
of sternum, **133,** 139
subscapular, 145
Angular artery, 540
gyrus, 863
motion of joints, 214
process, lateral (zygomatic), 60
medial, 60
vein, 643
Angulus Ludovici, 139
Ankle, annular ligaments, 1463
bony landmarks of, 1459
clinical anatomy of, 1459
synovial membranes of tendons at, 1463
tendons at, 1460
Ankle-joint, 297
arterial supply, 300
ligaments of, 298
movements, 300
muscles acting upon, 301
nerve-supply, 299
synovial membrane of, 299
Annular ligaments of ankle, 1463
of superior radio-ulnar joint, 262
of trachea and bronchi, 1227
of wrist, 387
Annulus(i) fibrosi of heart, 518
fibrosus, 318
inguinalis abdominalis, 430
subcutaneous, 430
iridis major, 1054
minor, 1054
tendineus communis, 1067
of tympanic membrane, 1087
urethral, 1253
Ano-coccygeal nerves, 1018
Anomalous (muscle of nose), 335
Ano-rectal lymphatic nodes, 735
Ansa hypoglossi, 953, **974,** 979
lenticularis, 880
subclavia (ansa Vieussenii), 1036
Antagonists (muscles), 322
Anthelix, 1082
Antibrachial cutaneous branch (external), dorsal, of radial nerve, 985
cutaneous nerve, lateral, 987
(internal) medial, 984
interosseous nerve, dorsal, 986
fascia, 384
vein, median, 667
Anti-tragicus, 1084
Antitrago-helicine fissure, 1084
Antitragus, 1082
Antrum cardiacum, 1142
of Highmore (maxillary), 87, 90, **111,** 1346
maxillary, 77, 79, 1274
pyloric, of stomach, 1151
tympanic (mastoid), 72, **73,** 78, 1092, **1336**
Anus, 1177
clinical anatomy of, 1390
development of, 1179
lymphatics of, 735
sphincters of, 448
Aorta, **529,** 586, 590
abdominal, **590,** 1382, 1408
branches, 591
arch of, 530
ascending, 529
descending, 586
development, 633
relations of, 1369, 1382
semilunar valves of, 517
thoracic, **586,** 1369
variations, 637, 638
Aortic arch, 530
intercostal arteries, 588
isthmus, 531
paraganglia, 1329
septum, 527
sinuses (of Valsalva), 518, 530
spindle, 531
Aortico-renal ganglion, 1043
Apertura pyriformis, 108, **112**
Aperturæ cutis, 1282
Apertures, anterior nasal (nares), 108, **1200**
of larynx, 1222
palpebral, 1052
of pelvis, 175, 176
posterior nasal (choanæ), 1206
superior thoracic, **138,** 1365
Apex of arytænoid cartilage, 124
of fibula, 190
of heart, 508
linguæ, 1106
of lung, **1230,** 1233
of nose, 1200
of patella, 185
of prostate, **1264,** 1389
of thyreoid lobes, 1315
of suprarenal gland, 1326
Apical dental (suspensory) ligament, 223
Aphasia, motor, 894
sensory, 894
Aponeuroses, 314, 317
Aponeurosis of epicranius (occipito-frontalis), 337
palmar, **387,** 1430
pharyngeal, 1130
plantar, 492
Apophysis of femur, 184
Apparatus, lacrimal, 1078
olfactory, 1049

Appendages of skin, 1290
cutaneous glands, 1296
hair (pili), 1290
mammary glands, 1299
nails (ungues), 1293
Appendices epiploicæ, 1170
vesiculosi (hydatids of Morgagni), 1269
Appendicular artery, **598,** 1378
skeleton, 139
Appendix epididymidis, 1257
testis (hydatid of Morgagni), 1257
ventricular, of larynx, 1223
vermiform, **1173,** 1378
Aquæductus cerebri (Sylvii), 834
vestibuli, **72,** 80, 117
Aqueduct of Fallopius (facial canal), 72
Aqueous chambers, 1064
humor, 1052
Arachnoid granulations (Pacchionian bodies), 649, **919**
membrane, 771, **917**
cranial, 918
spinal, 919
vessels and nerves of, 920
Arantius, ventricle of, 813
Arbor vitæ of cerebellum, 809
Arch of aorta, 530
branches of, 532
costal, 139
of cricoid cartilage, 1210
deep volar, **586,** 639, 1426
venous, 671
dental, 1123
digital venous, 667
dorsal venous (foot), 684
jugular venous, 648
lateral lumbo-costal, 437
medial lumbo-costal, 437
parieto-occipital, 863
plantar, 627
pubic, 176
superciliary, 59, 108
superficial volar, **582,** 639, 1425
venous, 671
tarsal, inferior, 554
superior, 554
venous, plantar, 687
of vertebræ, 30
zygomatic, 1332
Arches, of atlas, 32, 33
branchial, 17
of the foot, 1468
palatine, 1132
Architecture of heart, 518
Archoplasm, 5
Arciform process, 466
Arcs, reflex, 768
Arcuate (metatarsal) artery), 632
crest of arytænoid cartilage, 1212
fibres of medulla oblongata,
external, 800, **818**
internal, 815, **817**
ligament, external, 437
internal, 437
of symphysis pubis, 239
renal arteries, 1247
Arcus tendineus, 317, **440**
fasciæ pelvis (white line), 440
Area(s) acustica, 814
association, of cerebral cortex, 894
auditory (cochlear), of cerebral cortex, 893
of Broca (area parolfactoria), 858, **865**
cortical, of speech, 894
dangerous, of the leg, 1457
of scalp, 1333
gustatory, of cerebral cortex, 894
olfactory, of cerebral cortex, 893
Area(s), olfactory, of nasal cavity, 1049
plumiformis (of Retzius), 814
postrema of Retzius, 814
somæsthetic, of cerebral cortex, 893
surface, of telencephalon, 853
visual, of cerebral cortex, 893
Areas, cutaneous, of face, 1018
of lower extremity, 1024
of neck, 1019
of scalp, 1018
of trunk, 1020
of upper limb, 1022
of distribution of spinal nerves, 970
functional, of cerebral cortex, 893
Areola of mammary gland, 1300, **1304**
secondary, 1304
Areolar glands (of Montgomery), 1304
Arm, centre of, as a surgical landmark, 1414
fasciæ of, 377
musculature of, 362, 374
veins of, 667
Arnold's bundle, 832, **889**
ganglion, 963
nerve, 956
Arrectores pilorum, 1293
Arteria aberrans of aorta, 590
of superior intercostal, 568
centralis retinæ, 553, **1065**
princeps pollicis, 586
radialis indicis, 586
septi nasi, 541
Arterial supply of bones and joints (see corresponding bone or articulation).
system, morphogenesis and variations of, 633
Arteriolæ rectæ of kidney, 1247
Artery (see also "Blood-vessels").
Artery(ies), 527
aberrant, 568, 590
accessory (small) meningeal, 548
pudendal, **610,** 639
renal, 638
acetabular, 608
acromio-thoracic (thoraco-acromial), 571
angular, 540, **541**
anterior central of medulla, 908
cerebral, **554,** 562
ciliary, 553, **1065**
circumflex humeral, 572
communicating, 555, **562**
conjunctival, 553
deep temporal, 548
ethomidal, 554
inferior cerebellar, 561
intercostal, 588
interosseous, of forearm, 1423
mediastinal, 567
perforating, 620
peroneal, **626,** 640, 1459
scrotal (or labial), 620
spinal, 561, **792,** 638
superior alveolar (dental), 549
tibial, **629,** 640, 1458
recurrent, 632
tympanic, 547
aorta, **529,** 586, 637, 638
aortic intercostals, 588
appendicular, **598,** 1378
arcuate (metatarsal), 632
articular, of knee-joint, **622,** 1452
ascending cervical, 564
pharyngeal, 537
palatine, 540
of auricle (of ear), 1084
axillary, **569,** 1412
azygos, of vagina, 610
basilar, 561

Artery(ies), brachial, **573,** 640, 1414
of brain, 555, **905**
bronchial, **588,** 638, 1234
buccal, 548
of bulb of urethra, 613
caroticotympanic, 552
central or ganglionic, 906
of pons, 908
of cerebellum, 907
of cerebral hemorrhage (Charcot), 562, **906**
peduncles, 907
chorioid, **554,** 908
ciliary, 553, **1065**
circumflex (dorsal) scapular, 572
of the clitoris, 613
deep, 614
dorsal, 614
cœliac, **593,** 638
common carotid, 533
digital, 582
iliac, 603
interosseous, of forearm, 577
coronary, 519
cortical cerebral, 906
costo-cervical trunk, 568
cystic, 595
deep auricular, 547
cervical, 568
circumflex iliac, 616
lingual, 540
plantar (communicating), 633
deferential, 610
descending palatine, 549
dorsal of foot, line of, 1466
digital (foot), 633
(hand), 586
interosseous (metatarsal), 633
of forearm, 579
lingual, 539
metacarpal, 586
metatarsal (interosseous), 633
nasal, 554
perforating, of palm, 586
radial carpal, 585
thoracic (thoraco-dorsal), 572
ulnar carpal, 580
recurrent, 577
dorsalis hallucis, 633
pedis, 632
episcleral, 553
of external acoustic (auditory) meatus, 1086
carotid, **536,** 1343
iliac, 614
maxillary (facial), **540,** 638, 1343
pudendal (pudic), 619
spermatic, 615
striate, 906
femoral, **616,** 1441
common, 616
superficial, 616
fibular nutrient, 626
of the frænum, 540
frontal, **554,** 1343
gastro-duodenal, 594
genu suprema (anastomotica magna), **621,** 640
gluteal, 608
hepatic, 594
of humerus, nutrient, 576
hypogastric (internal iliac), **605,** 639
ilio-colic, 598
ilio-lumbar, 606
inferior alveolar (dental), 548
(deep) epigastric, **614,** 639
gluteal, **609,** 639, 1444
hæmorrhoidal, 613
labial (coronary), 541
Artery(ies), inferior laryngeal, 564
lateral articular, 623
medial articular, 622
mesenteric, **602,** 638
pancreatico-duodenal, 596
phrenic, **592,** 638
quadrigeminate, 907
suprarenal, 598
thyreoid, 564
tympanic, 537
ulnar collateral, 576
vesical, 609
infraorbital, **549,** 1075
innominate, **532,** 1369
internal auditory, 561
carotid, 549
mammary, 566
maxillary, **545,** 638
pudendal (pudic), **610,** 639
spermatic, **598,** 638, 1259
striate, 906
intercostals, **588,** 638
interosseous recurrent, 580
intestinal, 596
jejunal and iliac, 598
lacrimal, 552
lateral circumflex, **620,** 640
malleolar, 632
palpebral, 552
plantar, **627,** 640
posterior malleolar, 626
sacral, 607
tarsal, 632
thoracic, 571
left colic, 603
common carotid, 533
iliac, 605
coronary, 520
gastric, 593
gastro-epiploic, 595
pulmonary, 529
subclavian, 556
superior suprarenal, **592,** 1326
lenticulo-optic, 562
lenticulo-striate, 562
of lig. teres uteri, 615
lingual, 539
long posterior ciliary, 553, **1065**
lowest lumbar (ima), 603
lumbar, **593,** 638
major palatine, 549
masseteric, 548
medial circumflex, **620,** 640
malleolar, 632
palpebral, 554
plantar, 629
tarsal, 632
median, of forearm, **578,** 639
of medulla oblongata, 908
meningeal, 917
middle or azygos, 623
cerebral, **555,** 562
colic, 598
collateral, 576
hæmorrhoidal, 610
meningeal, **547,** 1341
quadrigeminate, 907
sacral, 603
suprarenal, **598,** 638
temporal, 545
vesical, 609
minor palatine, 549
musculo-phrenic, 567
nutrient of femur, 621
of humerus, 576
of radius and ulna, 579
of tibia, **626,** 1459

Artery(ies), obturator, **608,** 639
occipital, **542,** 638, 1343
œsophageal, 588
omphalo-mesenteric, 638
ophthalmic, **552,** 638, 1074
ovarian, 602
parietal, 543
peduncular, 907
of penis, 613
deep, 614
dorsal, 614
perforating, of the profunda, 620
pericardiac (of aorta), 588
pericardio-phrenic, 567
perineal, **613,** 639
peroneal, **626,** 640, 1459
plantar digital, 628
metatarsal, 628
popliteal, **621,** 640, 1452
posterior auricular, **543,** 1343
central of medulla, 908
cerebral, 561
circumflex humeral, 573
communicating, 554
conjunctival, 554
deep temporal, 548
ethmoidal, 553
inferior cerebellar, 561
meningeal, 537
peroneal, 626
scapular, 565
scrotal (labial), 613
spinal, 561, **792**
superior alveolar (dental), 549
tibial, **624,** 640,1458
recurrent, 632
princeps cervicis, 543
pollicis, 586
profunda or deep femoral, **620,** 640
(superior) profunda of arm, 576
axillaris, 640
proper digital, 582
heptaic, 595
of pterygoid canal (Vidian), 549
pulmonary, **528,** 1234
of quadrigeminate bodies, 907
radial, **582,** 1423
collateral, 576
recurrent, 583
at wrist, 584
radialis indicis, 586
renal, **598,** 638
of retina, central, 1065
right colic, 598
common iliac, 605
coronary, 519
gastric, 594
gastro-epiploic, 595
pulmonary, 529
subclavian, 557
superior suprarenal, 592
saphenous, 621
sciatic, 609, 640
short posterior ciliary, 553, **1065**
sigmoid, 603
spheno-palatine, 549
spinal, 590
splenic, 595
stapedial, 638
sternocleidomastoid, 542
stylo-mastoid, 544
subclavian, **556,** 638
subcostal, 588
sublingual, 540
submental, 541
subscapular, 571
superficial cervical, 566
Artery(ies), superficial circumflex iliac, 618
epigastric, 618
temporal, **545,** 1343
superior cerebellar, 561
epigastric, 567
gluteal, 608, 1444
hæmorrhoidal, 603
intercostal, 568
labial (coronary), 541
laryngeal, 538
lateral articular, 622
medial articular, 622
mesenteric, **596,** 638
pancreatico-duodenal, 595
phrenic, 590
quadrigeminate, 907
thoracic, 570
thyreoid, **538,** 638
tympanic, 548
ulnar collateral, 576
vesical, 609
supraorbital, **552,** 1343
suprarenal, 1326
suprascapular (transverse scapular), 564
sural, 622
systemic, 529
temporal, 545, 548, 1343
testicular, 601
thoraco-acromial, 571
of thymus, 567
thyroidea ima, 533
transverse cervical (transversa colli), **565,** 638
facial, 545
scapular, **564,** 638
of tympanic cavity, 1091
ulnar, **576,** 1423
umbilical, 609
urethral, 613
uterine, 610
vaginal, 610
variations of, 637, 639
vertebral, **559,** 638
of vertebral canal, 590
vesical, 609
Vidian, 549
volar interosseous of forearm, **577,** 639
metacarpal, 586
radial carpal, 584
ulnar carpal, 580
recurrent, 577
zygomatico-orbital, 545
Arthrodial diarthroses, 212
Articular arteries of knee-joint, **622,** 1452
branches of auriculo-temporal nerve, 941
of common peroneal (external popliteal) nerve, 1013
of deep peroneal (anterior tibial) nerve, 1015
of genu suprema artery, 621
of obturator nerve, 1004
of popliteal artery, 623
of posterior circumflex humeral artery, 573
of profunda artery, 621
of tibial (internal popliteal) nerve, 1010
of transverse scapular artery, 565
capsules of acromio-clavicular joint, 251
of articulation of atlas with occiput, 218
of atlanto-dental joint, 222
of capitular articulation, 241
of carpo-metacarpal joint of thumb, 273
of costo-transverse articulation, 243
of hip-joint, 277
of inferior radio-ulnar joint, 264
of knee-joint, 287
of lateral atlanto-epistrophic joint, 231

Articular capsules of mandibular articulation, 215
of medial tarso-metatarsal articulation, 308
of metacarpo-phalangeal joint of thumb, 275
of shoulder-joint, 254
of sterno-costo-clavicular joint, 248
of tibio-fibular union, 295
of vertebral joints, 228
cartilage, 211
of shoulder-joint, 255
disc of acromio-clavicular joint, 251
of inferior radio-ulnar joint, 264
of mandibular articulation, 216
of sterno-costo-clavicular joint, 249
furrows of skin, 1284
nerve, recurrent, of leg, 1013
process of vertebræ, 31
processes of vertebræ, ligaments connecting, 228
rete, of knee, 622
Articular tubercle of temporal bone, 71
veins of mandibular joint, 646
Articularis genu (subcrureus), 470
Articulation(s), 211
acromio-clavicular, 250
ankle, 297
of anterior parts of tarsus, 303
arycorniculate, 1215
atlanto-epistrophic, 220, 221
of atlas with occiput, 218
of auditory ossicles, 1090
of bodies of vertebræ, 225
calcaneo-cuboid, 306
carpal, 268
carpo-metacarpal, 272
classification of, 212
constituents of, 211
costo-capitular, 241
costo-chondral, 245
costo-transverse, 243
costo-vertebral, 241
crico-arytænoid, 1214
crico-thyreoid, 1213
cuboideo-navicular, 303
cubo-metatarsal, 308
cuneo-cuboid, 304
cuneo-navicular, 304
elbow, 258
front of thorax, 244
hip, **276,** 1434
incudo-malleolar, 1090
incudo-stapedial, 1090
interchondral, 246
intercoccygeal, 238
intercuneiform, 304
intermetacarpal, 273
intermetatarsal, 309
interphalangeal, of fingers, 276
of toes, 310
intersternal, 244
knee, 284
mandibular, 215
of lower limb, 276
medio-carpal, 270
medio-tarsal (transverse tarsal) 305
metacarpo-phalangeal, 274
of thumb, 275
metatarso-phalangeal, 310
movements of, 213
occipito-epistrophic, 223
of ossicles of ear, 1090
of pelvis, 234
radio-carpal (wrist-joint), 265
radio-ulnar, **261,** 1419
sacro-coccygeal, 237
Articulation(s), sacro-vertebral, 232
shoulder, **253,** 1413
of the skull, 215
between skull and vertebral column, 218
sterno-costal, 245
sterno-costo-clavicular, **248,** 1363
synarthrosis, 212
talo-navicular, 305
tarsal, 301
tarso-metatarsal, 307
tibio-fibular, 295
transverse tarsal, 305
of the trunk, 224
of upper extremity, 248
of vertebral column, 225
Ary-corniculate articulation (synchondrosis), 1215
Ary-epiglottic fold, 1221
muscle, 1220
Ary-membranosus muscle, 1220
Arytænoid cartilages, 1211
Arytænoideus obliquus, 1220
transversus, 1219
Ary-vocalis muscle of Ludwig, 1220
Ascending aorta, 529
cervical artery, 564
colon, **1173,** 1379
lumbar veins, 662, **663**
palatine artery, 541
pharyngeal artery, 537
Association areas of cerebral cortex, 894
frontal, 894
occipito-temporal, 894
parietal, 894
fibres of spinal cord, 789
system of cerebral hemisphere, 890
Asterion, 101, 1332
Asternal ribs, 127
Astragalus (talus), 192
Athelia, 1301
Atlanto-dental articular capsule, 222
articulation, 220
Atlanto-epistrophic articulation, 220
central, 221
lateral, 221
ligaments, anterior, 221
posterior, 221
Atlanto-mastoid muscle, 422
Atlanto-occipital articular capsule, 218
articulation, 218
ligaments, anterior, 218
posterior, 218
Atlas and epistropheus, joints between, 220
description, 32
development of, 46
with occiput, articulation of, 218
Atria of heart, 508, **511**
of lungs, 1232
Atrial musculature, 518
Atrial plexus, 1041
Atrio-vetnricular bundle (of His), 517, **519,** 527
orifice (ostium venosum) of left side, 514
of right side, 513
Atrium of heart, 512, 514
of middle nasal meatus, 1206
Attachments and origin of cranial nerves, 929
of spinal nerves, 964
topography of, 966
Attic of middle ear, 77
Attollens aurem, 337
Attrahens aurem, 337
Auditory (cochlear) area of cerebral cortex, 893
artery, internal, 561
conduction paths, 900

Auditory foramen, 125
meatus, external, 75, 108, **1084,** 1332
internal, **72,** 117
(cochlear) nerve, 949, **950**
(Eustachian) tube, 1092
pharyngeal aperture of, 1130
veins, internal, 652, **657**
Auerbach, plexus of, 1030, **1045,** 1168
Auricle (pinna) of ear, 1082
cutaneous areas of, 1019
lymphatics of, 714
vessels and nerves, 1084
of heart, 508
Auricular artery, deep, 547
posterior, **543,** 1343
branches, anterior, of auriculo-temporal nerve, 941
of great auricular nerve, 973
of occipital artery, 543
of posterior auricular artery, 544
of small occipital nerve, 977
of superficial temporal artery, 545
of vagus, 956
cartilage, 1084
fissure, 75, 108
lymph-nodes, anterior, 709
posterior, 709
muscles, 337
nerve, great, 978
posterior, 944
point, 101
sulcus, posterior, 1083
tubercle (tubercle of Darwin), 1083
veins, anterior, 646
posterior, 647
Auricularis anterior (attrahens aurem), 337
posterior (retrahens aurem), 337
superior (attollens aurem), 337
Auriculo-frontalis muscle, 337
Auriculo-temporal nerve, 941
Axial set of bones, 27
skeleton, 27, 29
Axillary arch, 374
artery, 569
collateral circulation, 1412
parts, 569, 570
fascia, 370, 371
fossa, clinical anatomy of, 1411
lymphatic nodes, 719
(circumflex) nerve, 984
vein, 671
Axis (epistropheus), **33,** 47
cœliac, 593
of eyeball, 1055
of heart, 509
of pelvis, 176
of scapula, 145
thyreoid (thyreocervical trunk), 564
Axones, 762
motor (efferent), 764
sensory (afferent), 762
sheaths of, 766
of spinal cord, 777
terminations of, 762
Azygos artery of vagina, 610
(major) vein, 662
minor (hemiazygos) vein, 662
tertia (accessory hemiazygos) vein, 663

B

Back of hand, 1433
clinical anatomy of, 1403
muscles (spinal), 410
Baillarger, stripes of, 879
Band, diagonal, of Broca, 866
ilio-tibial, 457, 458
Band, ilio-trochanteric, 280
moderator, of heart, 516
tendino-trochanteric, 280
Barba, 1290
Bars, hyoid, 119
mandibular, 119
metamorphosis of branchial or visceral, 119
thyreoid, 119
Bartholin, duct of, **1278,** 1392
glands of, **1278,** 1392
Basal ganglia, 878
vein, 657
Base of arytænoid cartilage, 1211
of cranium, 103, 113
of encephalon, 794
of heart, 508
line, Reid's, 1341
of lungs, **1229,** 1233
of nose, 1200
of prostate, **1264,** 1389
of skull, external, 103
of suprarenal gland, 1325
of thyreoid lobes, 1315
Basi-bregmatic axis, 112
Basi-cranial axis, 112
Basi-facial axis, 112
Basi-hyal, **100,** 119
Basilar artery, 561
groove, 54
plexus of veins, 651
sulcus of pons, 804
Basilic vein, 667
median (median cubital), 667
Basion, 108, 112
Basi-occipital, 119
Basi-pharyngeal canal, 63, **67**
Basis (pes) pedunculi, 840
cranii, interna, 113
Basi-sphenoid centre, **67,** 119
Basivertebral veins, 666
Bechterew's bundle, 784
nucleus of vestibular nerve, 823
Bell, external respiratory nerve of, 982
Belly of muscle, 314
Bertin, bones of, 67
columns of, 1246
Biceps brachii, 374, 379, **382**
relations, 1414
femoris, 453, **475**
Bicipital groove, 148
muscles, 314
Bicuspid teeth, 1121
(mitral) valve, 515, 516
Bifurcation of trachea, 1225
Bile-duct, common, **1188,** 1373
Bile-passages, 1186
Bipenniform muscles, 315
Birth, bones of skull at, 120
Biventer cervicis, 418
Biventral lobe of cerebellum, 807
Bladder (urinary), 1249
surgical anatomy of, 1390
Blandin, glands of, 1110
Blood-vascular system, 507
of small intestine, 1166
of spinal cord, 792
of stomach, 1155
Blood-vessels (see also "Arteries" and "Veins").
of abdominal wall, 1371
of brain, 905
of cerebellum, 907
ciliary, 1065
of conjunctiva, 1348
of ductus deferens, 1259
around elbow, 1418
of eyeball, 1065

Blood-vessels of eyelids, 1078
of face, 1343
of Fallopian tube, 1270
of female external genitals, 1278
of heart, 519
of kidney, 1247
of large intestine, 1179
of larynx, 1224
of lips and cheeks, 1104
of liver, 1185
of lungs, 1234
of lymph-glands, 706
of mammary glands, 1305
of nose, 1203, 1208
of œsophagus, 1141
of orbit 1074
of ovary, 1269
of palate, 1105
of parathyreoids, 1319
of parotid, 1115
of penis, 1262
of pericardium, 523
of pharynx, 1138
of pleura, 1239
of prostate 1265
of rectum, 1391
retinal, 1065
of scalp, 1334
of scrotum, 1255
of skin, 1288
of spleen, 1312
of sublingual gland, 1117
of submaxillary gland, 1116
of suprarenal glands, 1326
of teeth, 1124
of testis and appendages, 1256
of thymus, 1322
of thyreoid gland, 1316
of tongue, 1111
of trachea and bronchi, 1228
of ureter, 1249
of urinary bladder, 1253
of uterus, 1274
of vagina, 1276
of vulva, 1192
Bochdalek, ganglion of, 939
Body(ies) of axis (epistropheus), 33
carotid, 1327
ciliary, 1060
coccygeal, 1329
of corpus callosum, 852
of epididymis, 1256
of femur, 178
of fornix, 869
of gall-bladder, 1187
geniculate, **834,** 845
of hyoid bone, 99
inferior quadrigeminate, 839
of ischium, 171
(central portion) of lateral ventricles, 875
of Luys, 884
mammillary, 871
of nails, 1294
Nissl, 766
Pacchionian, 919
of pancreas, 1195
pararenal adipose, 1243
of penis, 1260
pineal, 845
pituitary, **848,** 1352
of pubis, 172
of radius, 153
restiform, 810
of medulla oblongata, 800
of rib, 127
of scapula, 141
of sphenoid, 62
Body(ies) of sternum, 133
of stomach, 1151
superior quadrigeminate, 825, 841
of sweat gland, 1297
of thymus, 1320
of tongue, 1106
of ulna, 157
of urinary bladder, 1250
of uterus, 1271
of vertebra, 30
vitreous, 1064
Wolffian, 1278
Bone(s), astragalus (talus), 191, 192
of Bertin (sphenoidal conchæ), 67
calcaneus, 191, **195**
capitate (os magnum), 159, **163**
carpal, 159
clavicle, 139
cotyloid, 173
coxal (os innominatum), 169
cuboid, 191, **199**
cuneiform, 161, 191, **197**
epipteric, **68,** 101
ethmoid, 81
of the face, 51
femur, 198
fibula, 189
fifth metacarpal, 167
fifth metatarsal, 203
first metacarpal, 165
first metatarsal, 201
of foot as a whole, 205
fourth metacarpal, 167
fourth metatarsal, 203
frontal, 59
greater multangular (trapezium), 159, **162**
hamate (unciform), 159, **163**
humerus, 146
hyoid, 99
incus, **79,** 119
innominate, 169
inferior nasal concha, 84
interparietal (inca bone), 57
lacrimal, 85
lesser multangular (trapezoid), 159, **162**
of limbs, homology of, 206
of the lower extremity, 169
lunate (semilunar), 159, **161**
malar, 93
malleus, **79,** 119
mandible, 95
maxilla, 87
metacarpal, 164
metatarsal, 200
of middle ear, 79
nasal, 86
navicular (scaphoid), 159, **160,** 191, **196**
occipital, 51
of orbit, 109
palate, 91
parietal, 57
patella, 184
phalanges, 167, 203
pisiform, 159, **162**
pre-maxilla, 89
radius, 152
ribs, 126
scapula, 141
second metacarpal, 166
second metatarsal, 202
sesamoid, 168, 204, 275, 317
of the skull, 51
at birth, 120
morphology of, 117
sphenoid, 62
stapes, **80,** 119
styloid, 168

Bone(s), suprasternal, 133
talus (astragalus), 191, **192**
tarsal, 191
temporal, 68
at birth, 122
mastoid portion, 68, **71**
petrous portion, 68, **72**
squamous portion, 68, **70**
tympanic portion, 69, 70, **75**
third metacarpal, 166
third metatarsal, 202
of thorax, 126
tibia, 185
triquetral (cuneiform), 159, **161**
turbinate, 67, 83, 84
of tympanum, 79
ulna, 155
of upper extremity, 139
vomer, 85
Wormian, 68
zygomatic, 93
Bony boundaries of perineum, 1383
landmarks of abdomen, 1370
of the ankle, 1459
of the buttocks, 1442
of elbow, 1417
of the foot, 1464
of forearm, 1419
of head, 1331
of the knee, 1447
of the leg, 1453
of the hip and thigh, 1434
of thorax, 1363
of wrist and hand, 1424
sinuses of skull, 1335
Borders (see individual organs).
Boundaries (see individual parts).
Bowman's membrane, 1060
Brachia conjunctiva (superior cerebellar peduncles), 831, 840
Brachial artery, **573,** 640, 1414
branches, 575
collateral circulation, 1414
(internal) cutaneous branch, posterior, of radial nerve, 985
cutaneous nerve, lateral, 985
medial, 983
fascia, 377
group of axillary lymphatic nodes, 719
plexus, 980
branches, 982
cords of, 981
relations of, **981,** 1360
terminal branches of, 985
venæ comitantes, 671
Brachialis, 374, 380, **382**
surface markings of, 1415
Brachio-cephalic (innominate) veins, 641
Brachio-radialis (supinator radii longus), 387, **388**
Brachium conjunctivum, 812
inferior, 834
superior, 834
pontis, 811
Brain (encephalon), 792
blood-supply of, 905
cerebral hemispheres, 850
cerebrum, 833
cerebellum, 804
diencephalon (inter-brain), 843
isthmus rhombencephali, 832
medulla oblongata, 799
meninges of, 908
mesencephalon (mid-brain), 833
pons (Varoli), 804
prosencephalon (fore-brain), 843
rhombencephalon, 799
Brain, telencephalon (end-brain), 847
topography of, 903, **1338**
Branches (see corresponding vessel or nerve).
Branchial arches, 17
bars, metamorphosis of, 119
grooves, 17
Branchiomerism, 16, 17
Breast, female (mammary gland), 1299
male, 1305
Bregma, **101,** 112, 1332
Brim of pelvis, 175
Broad (lateral) ligaments of uterus (alæ vespertilionis), **1267,** 1393
Broca's area, 858, 865
convolution, 858
diagonal band, 866
Bronchi, **1226,** 1231, 1408
Bronchial arteries, **588,** 638, 1234
branches, Aeby's division of, 1232
of internal mammary artery, 567
(pulmonary) branches of vagus, 957
glands, 1231
lymphatic nodes, **725,** 1225
tubes, branching of, 1231
veins, 664, 666, 1234
Bronchioles, 1232
Broncho-œsophageal muscle, 1141, 1228
Bronchus, eparterial, 1232
hyparterial, 1232
Brunner's glands, 1166
Bryant's triangle, 1436
Buccal branches of cervico-facial nerve, 945
artery, 548
nerve, long, 939
veins, 646
Buccinator, 334
(long buccal) nerve, 939
set of facial lymph-nodes, 711
Bulb(s), artery of, 613
of hair, 1292
of internal jugular vein, 659
olfactory, 758, **865**
of posterior cornu of lateral ventricle, 876
of urethra, 1262
Bulbar plexus, 1041
Bulbi vestibuli, 1277
Bulbo-cavernosus 443, **450**
in female (sphincter vaginæ), 451
Bulbo-urethral (Cowper's) glands, 1265
Bulbous corpuscles (end-bulbs of Krause), 1290
Bulbus aortæ, 530
Bulla, ethmoidal, **84.** 111, 1205
Bundle, Arnold's, 832, **889**
atrio-ventricular (of His), 517, **519,** 527
commissural, 788
Helweg's (Bechterew's), 784
posterior longitudinal, 817
Türk's, 832, **890**
of Vicq d'Azyr, 871
Burdach's column of spinal cord, 781
Bursa(æ) anguli mandibuli, 1288
anserina, 474
of anterior ilio-femoral musculature, 456
thigh muscles, 471
of the arm, subcutaneous, 377
muscular, 379, 383
of back of leg, 486, 491
bicipito-radialis, 383
cubitalis interossea, 383
of dorsal arm muscles, 379
epicondyli medialis dorsalis, 379
of facialis musculature, 330
of foot, **500,** 1465
of forearm and hand, 384, 395, 403
of front muscles of leg, 483
gluteofemorales, 462

Bursa(æ), hyoid, 1217
iliaca subtendinea, 457
iliopectinea, 456
of infra-hyoid muscles, 353
infrapatellaris profunda, 471
subcutanea, 466
intermetacarpophalangeæ, 395
intermetatarsophalangeæ, 500
intratendinea olecrani, 379
ischiadica musculi glutei maximi, 462
of ischio-pubo-femoral musculature, 464
of medial thigh muscles, 474
mucosæ, 313, 318
subcutaneous, 1288
subfascial, 318
submuscular, 318
subtendinous, 318
musculi abductoris pollicis longi, 395
anconei, 379
bicipitis femoris inferior, 476
superior, 476
gastrocnemialis, 476
coraco-brachialis, 383
extensoris carpi radialis brevis, 395
ulnaris, 395
pollicis longi, 395
flexoris carpi radialis, 403
ulnaris, 403
gastrocnemii lateralis, 486
medialis, 486
infraspinati, 370
latissimi dorsi, 370
obturatoris externi, 464
interni, 464
pectinei, 474
pectoralis majoris, 374
piriformis, 462
quadrati femoris, 464
recti femoris (inferior), 471
(superior), 471
sartorii propria, 471
semimembranosus, 476
sterno-hyoidei, 353
subscapularis, 370
supinatoris, 395
teretis majoris, 370
thyreo-hyoidei, 353
omentalis (lesser sac) **1146,** 1372
of pectoral muscles, 374
pharyngeal, 1130
of posterior ilio-femoral musculature, 476
præpatellaris subcutanea, 466
subfascialis, 466
subtendinea, 471
prepatellar, 1288, 1448
of shoulder musculature, 369
sinus tarsi, 483
subacromialis, 369
subcutanea acromialis, 365
calcanea, 477
digitorum dorsales, 384, 1288
epicondyli lateralis, 377
medialis, 377
infrapatellaris, 1288
malleoli medialis et lateralis, 477
metacarpo-phalangea dorsalis, 384, 1288
olecrani, 377, 384
prementalis, 330
prominentiæ laryngæ, 330
sacralis, 1288
trochanterica, 1288
tuberositatis tibiæ, 477
submammary (retromammary), 1303
subtendinea musculi extensoris hallucis longi, 483
olecrani, 379
supracoracoidea, 370
Bursa(æ), suprapatellaris, 471
synovial, 313, 318
tendinis calcanei, 486
musculi tibialis anterioris, 483
of ventral arm muscles, 383
Bursa tendinum musculi extensoris digitorum communis, 395
of trapezius, 350
trochanterica musculi glutei maximi, 462
medii anterior, 462
posterior, 462
minimi, 462
subcutanea, 457
Buttocks, bony landmarks of, 1442
clinical anatomy of, 1442
nerves of, 1443

C

Cæcum (caput coli), 1170
cupular, 1096
topography of, 1376
variations of, 1171
vestibular, 1096
Calamus scriptorius, 812
Calcaneal pillar, 205
Calcanean branches, lateral, of sural nerve, 1013
of peroneal artery, lateral, 626
of posterior tibial artery, medial, 626
nerves, medial, 1010
Calcaneo-cuboid articulation, 306
ligaments, 306, 307
Calcaneo-fibular ligament, 299
Calcaneo-metatarsal ligament 492,
Calcaneo-navicular ligament, lateral, 302, 305
plantar (spring), 305
Calcaneo-plantar cutaneous nerves, 1010
Calcaneus (os calcis), 191, **195**
Calcar avis (hippocampus minor), **864,** 868
femorale, 184
Calcarine fissure, 864
Calcification of bones, 27
of teeth, 1126
Callosal convolutions, 868
Calloso-marginal fissure, 857, **859**
Calyces of kidney, 1246
of ureter, 1248
Camper's fascia, 425
Canal(s), accessory palatine, 103
adductor (Hunter's), **468,** 618, 1441
Alcock's, 441, 445
alveolar, 87
anal, 1177
basi-pharyngeal, 63
carotid, 73, 108
central, of spinal cord, 775
of cervix, 1272
ethmoidal, 61, 83, 110, 113, **126**
facial (Fallopian), 72, 73, 77, **78**
femoral (crural), 468
gubernacular, 106
of Huguier, 75, 77, 108
hyaloid, 1064
hypoglossal, 117
inferior dental, 96
infra-orbital, 87, **126**
inguinal, 424, **430**
clinical anatomy of, 1395
lateral semicircular, 78
mandibular (inferior dental), 96, **126**
palatine, 92
of Petit, 1064
pharyngeal, 66, 92, 103
posterior palatine, 126
pterygoid (Vidian) canal, 103, 107, 108, **126**
pterygo-palatine, 88, **92,** 103

Canal(s), pyloric, 1152
sacral, 42
of Schlemm, 1059
semicircular, **80,** 1092
zygomatico-facial, 126
zygomatico-orbital, 94
Canaliculi, carotico-tympanic, 74
Canaliculus cochleæ (ductus perilymphaticus), 73, 81, 108
innominatus, 65
mastoid, 73
tympanic, 73, 108
Canalis musculo-tubarius, 73, **77,** 108
facialis, hiatus of, 116
Canine fossa, 87
teeth, 1120
Caninus (levator anguli oris), 332
Capillaries, lymphatic, 697
Capilli, 1290
Capitate (os magnum) bone, 159, **163**
Capitular (costo-central) articulation, 241
ligaments of tibio-fibular union, 295
Capitulum of humerus, 150
Capsular ligament of elbow-joint, 258
(perirenal) branches of renal arteries, 598
Capsule, articular, acromio-clavicular, 251
atlanto-dental, 222
atlanto-epistrophic, 221
atlanto-occipital, 218
of capitular articulation, 241
carpo-metacarpal of thumb, 273
costo-transverse, 243
crico-thyreoid, 1213
of hip-joint, 277
of knee-joint, 287
of mandibular articulation, 215
of medial tarso-metatarsal joint, 308
of metacarpo-phalangeal joint of thumb, 275
of shoulder-joint, 254
of sterno-costo-clavicular joint, 248
of tibio-fibular union, 295
of vertebral joints, 228
external (telencephalon), 881, **888**
Glisson's, 675, **1186**
glomerular, 1246
internal (telencephalon), 878, **886**
of kidney, 1242, 1303
of prostate, 1265, **1389**
of suprarenal gland, 1326
Tenon's, 1073
surgical importance of, 1348
of thyreoid gland, 1316
Caput angulare (levator labii superioris alæque nasi), 332
infraorbitale (levator labii superioris), 332
zygomaticum (zygomaticus minor), 332
Cardia of stomach, 1151
Cardiac branches of vagus, 957
fossa of lungs, 1229
ganglion (of Wrisberg), 1041
nerve, inferior, 1037
middle, 1036
superior cervical, 1036
notch of left lung, 1229
portion of stomach, 1151, 1374
plexus, 1041
vein, anterior, 521
great, 520
middle, 520
small cardiac, 521
smallest cardiac, 521
Carina tracheæ, 1225
urethral, **1275,** 1278
Carotico-clinoid foramen, 65
Carotico-tympanic artery, 552
canaliculi, 74
Carotico branches from tympanic plexus, 951, 961
Carotid arteries, common, 533
collateral circulation, **536,** 1360
external, 533, **536,** 1343
branches, 536
relations, 536
internal, 533, **549**
variations, 637
canal, 73, 108
gland (body), 550, **1327**
groove, 64
nerves, external, 1036
internal, 960, 1033
plexus of nerves, common, 1036
external, 1036
internal, 1033
ridge, 73
sheath, 1362
triangle, inferior (tracheal), 1358
superior, 1358
(anterior) wall of tympanic cavity, 1054
Carpal arch (rete), volar, 581
artery, dorsal radial, 585
dorsal ulnar, 580
volar radial, 584
volar ulnar, 581
bones, ossification of, 164
head of adductor pollicis, 408
joints, 268, 269
(annular) ligaments of wrist, 1427
rete, dorsal, 579, 585
Carpo-metacarpal joints, 272
of the thumb, 273
Carpus, description of, **159,** 270
ligaments, 384, 387
Cartilage (s), 211
alar, 1201, 1202
articular, of shoulder-joint, 255
arytænoid, 1211
auricular, 1084
corniculate (Santorini), 1212
costal, 130
cricoid, 1210
cuneiform (Wrisberg), 1213
epiglottic, 1212
interarytænoid (procricoid), **1213,** 1218
of larynx, 1209
lateral nasal, 1201
Meckel's, 98, **119**
nasal, 120
periotic, 117
septal nasal, 1202
sesamoid nasal, 1202
laryngeal, 1213
sphenotic, 117
thyreoid, 1210
tracheal, 1227
varieties, 211
vomero-nasal, 1203
Cartilaginous plate (pelvic joints), ear-shaped, 235
Cartilago triticea, 1217
Caruncle, lacrimal, **1052,** 1055
sublingual, 1117
Carunculæ hymenales (myrtiformes), 1275, 1392
Cauda equina, 772
helicis, 1084
Caudate branch of middle cerebral artery, 562
(Spigelian) lobe of liver, 1184
nucleus, **877,** 879
process of liver, 1184
Cavernous nerves of clitoris, 1047
of penis, 1047
plexus of nasal conchæ, 1208
of nerves, 1033

Cavernous (spongy) portion of male urethra, **1264,** 1388
sinus, **652,** 691
Caves, Meckel's, 916
Cavity, body, 14
epidural, 911
glenoid, of scapula, 143
of larynx, 1220
lesser sigmoid, of ulna, 157
mediastinal, 1239
nasal, 1203
oral, 1100
of orbit, 1066
pelvic, 175
pericardial, 522
pleural, 1236
of radius, sigmoid, 154
subarachnoid, 918
subdural, 912
thoracic, 1235
of tooth, 1118
tympanic, 77, **1088**
of ulna, greater sigmoid, 156
of uterus, 1271
Cavum conchæ, 1082
pelvis subperitoneale, 448
Retzii, 1250, **1371**
Cellifugal processes of neurone, 762
Cellipetal processes of neurone, 762
Cells, 4
chromaffin, 1323
ependymal, 768
ethmoidal, 83, **84,** 111, 1207
Golgi, in cerebellum, 809
gustatory, 1050
olfactory, 1051
mastoid, 1092, 1336
of Purkinje, 809
stellate, 809
Cementum of teeth, 1119
Central (ganglionic) arteries of cerebrum, 906
of medulla oblongata, 908
branches of cerebral arteries, 562, 563
canal of spinal cord, 775
connections of cranial nerves, 818
of abducens, 934
of cochlear, 824
of facial nerve, **825,** 946
of glosso-palatine, **825,** 947
of glosso-pharyngeal, **820,** 952
of hypoglossal, **820,** 954
of masticator, **829,** 942
of oculo-motor, **838,** 933
of olfactory, **873,** 929
of optic, **848,** 931
of spinal accessory, **820,** 959
of trigeminus, **826,** 935
of trochlear, **837,** 934
of vagus, **820,** 958
of vestibular, **823,** 950
gyrus, anterior (ascending frontal convolution), 857
posterior (ascending parietal), 861
lobe or insula, 856
lobule of cerebellum, 806
nervous system, 751
point of perineum, 1385
sulcus (fissure of Rolando), **859,** 1340
angle of, 860
inferior genu, 860
in foetus, 860
of insula, 857
superior genu, 860
tendon of perineum, 449
veins of retina, 659
Centres, association, of cerebral cortex, 894
Centrum semiovale, 886
Centrum (body) of vertebræ, 30
Cephalic index, 117
plexus, gangliated, 959
portion of sympathetic trunk, 1033
vein, **667,** 671
Cephalo-auricular angle, 1084
Cerato-cricoid ligaments, 1213
muscle, 1218
Cerato-hyal center, 100
segment, 119
Cerebellar artery, anterior inferior, **561,** 907
posterior inferior, **561,** 907
superior, **561,** 907
notches, 805, 915
peduncle, inferior, 810
superior, 812, **831**
tract, direct, of Flechsig, 784
veins, 657
Cerebello-olivary fibres, 817
Cerebellum (hind brain), 804
ala of central lobule, 806
anterior medullary velum of, 812
arbor vitæ of, 809
biventral lobe, 807
blood-vessels of, 907
brachium pontis, 811
conjunctivum, 812
central lobule of, 806
conduction paths of, 899
cortex of, 809
culmen of, 806
declive (clivus), 806
dentate nucleus of, 810
external features, 808
fissures, 805
flocculus, 807
peduncle of, 807
folium vermis (cacuminis), 806
fourth ventricle, anatomy of, 812
functions of, 832
gross divisions of, 805
hemispheres of, 805
inferior vermis, 808
internal structure of, 808
lingula of, 806
lobes and lobules, 805
monticulus, 806
nodule of inferior vermis, 808
notch of, 805
nuclei of, 809, 810
peduncles of, 810
posterior medullary velum, 808
pyramid of vermis, 808
sulci of, 805
superior vermis of, 806
tentorium of, 804
tonsil (amygdala) of, 807
tuber vermis, 808
uvula of vermis, 808
vallecula of, 807
veins of, 908
vermis of, 805, 807
Cerebral arteries, anterior, **554,** 562
branches, 562
middle, **555,** 562
posterior, **561,** 562
commissure, anterior, 871
inferior, 842, 890
cortex, 879
cornu ammonis, 879
functional areas of, 893
structure of, 879
hemispheres, 850
caudate nucleus, 877
corpus striatum, 868, **879**
cortex of, 852, **879,** 893
gyri of, 852

Cerebral hemispheres, lateral ventricle, 873
lobes of, 853
central (insula), 856
frontal, 857
occipital, 863
parietal, 860
temporal, 854
rhinencephalon, 864
sulci of, 852
path for cranial nerves, 895
peduncles (crura), 833, **835**
arteries of, 907
veins, 644, 657
central or deep (ganglionic), 655
great (of Galen), 657
inferior, 655
internal, 657
middle, 655
superior, 654
Cerebro-spinal fasciculus, lateral, 783
ventral, 788
fluid, **920,** 1342
path, 895
Cerebrum, 833
mesencephalon (mid-brain), 833
prosencephalon (fore-brain), 843
diencephalon (inter-brain), 843
telencephalon (end-brain), 847
Cerumen, 1085, **1298**
Ceruminous glands, 1085, **1297**
Cervical artery, ascending, 564
deep, 568
superficial, 566
transverse, 565
branches of uterine artery, 610
chains of lymphatic nodes, deep, 714
enlargement of spinal cord, 772
fascia, external, 347
middle, 350
ganglion of sympathetic, inferior, 1036
middle, 1036
superior, 960, **1035**
loop (ansa hypoglossi), 953, **974**
muscle, 330
nerves, 971, 974
anterior primary divisions, 974
posterior primary divisions, 971
plexus, 974
ascending branches of, 977
deep branches of, 978
descending branches of, 978
posterior, of Cruveilhier, 971
superficial branches of, 977
supra-clavicular branches of, 978
transverse branch, 978
portion of external maxillary artery, 540
of internal carotid artery, 550
of sympathetic trunk, 1033
construction of, 1037
of vertebral artery, 559
ribs, 131, **1365**
triangles, 1357
vein, deep, 661
veins, transverse, 672
vertebræ, description of, 31
development of, 47
Cervicalis ascendens, 416
Cervico-facial nerve, 945
Cervix of uterus, 1271
Chains of nerurones, 768
Chambers of the eye, 1064
Charcot's artery of cerebral hemorrhage, 562, **906**
Check (alar) ligaments, 223
of eyeball, 1072
Cheek, 1103
Chiasma, optic, 848, **849**
Choanæ (posterior nares), **107,** 112, 1130, 1206, 1351
Chondro-cranium, 117
Chondro-humeralis (epitrochlearis), 374
Chondro-glossus, 346
Chopart's medio-tarsal amputation, 1465
Chorda tympani nerve, 826, 946, **948**
Chordæ tendinæ, 515
Chords of Willis, 649
Chorio-capillaris, 1055
Chorioid, 1057, 1060
artery, **554,** 908
branches of posterior cerebral artery, 563
fissure, 868
glomus, 876
plexus of fourth ventricle, 922
of lateral ventricle, **875,** 877, 924
tela of fourth ventricle, 758, **812**
of third ventricle, 923
vein, 657
Chorioidal arteries of medulla oblongata, 908
fissure, 1080
lamina, epithelial, 876, 924
membrane, 1052
Chorion, 10
Chromaffin bodies, 1329
cells, 1323
system, 1323
Chromatin, 5
Cilia, 1290
Ciliary arteries, anterior, 1065
long posterior, 1065
short posterior, 1065
body, 1060
ganglion, **961,** 1076
branches, 961
roots, 932, 937, **961,** 1033
glands (glands of Moll), **1078,** 1297
muscle, 1057, **1060**
nerves of eyeball, **1064,** 1076
long, 937
short, **961,** 1076
processes, 1057
veins, 658
Cingulum, **867,** 890
of teeth, 1120, 1121
Circle of Willis (circulus arteriosus), 555
Circular sinus, 651
sulcus (limiting sulcus of Reil), 857
Circulation, collateral, of axillary artery, 1412
of brachial artery, 1414
of common carotid artery, 1360
iliac arteries, 1382
of external iliac artery, 1382
of femoral artery, 1441
of internal iliac artery, 1382
of popliteal artery, 1453
of subclavian artery, 1360
fœtal, 695
pulmonary, 507
systemic, 507
Circulus arteriosus major, 1065
minor, 1065
tonsillaris, 952
Circumanal glands, 1297
Circumduction, 215
Circumferential cartilage, 211
Circumflex artery, lateral, **620,** 640
medial, **620,** 640
femoral veins, 690
humeral artery, anterior, 572
posterior, 573
iliac artery, deep, 616
superficial, 618
vein, deep, 683
superficial, 684
nerve, 985

Circumflex (dorsal) scapular artery, 572
veins, 671
Circumvallate papillæ of tongue, 1106
Cisterna basalis, 918
cerebello-medullaris (cisterna magna), 919
chyli, 726
pontis, 918
subarachnoid, 918
superior, 919
Clarke's column of spinal cord, 776
Classification of articulations, 212
of muscles, 319
Claustrum, 880
Clava, 801
Clavicle, **139,** 1357, 1410
ossification of, 141
structure of, 141
Clavicular branch of thoraco-acromial artery, 571
Cleft, middle ear, 77
palate, **1106,** 1352
Clinical and topographical anatomy, 1331
of abdomen, 1370
of back, 1403
of head, 1331
of lower extremity, 1434
of neck, 1354
of pelvis, 1382
of thorax, 1363
of upper extremity, 1409
Clinoid process, anterior, 65, 116
middle, 65, 116
posterior, 63, 116
Clitoris, 1277
artery of, 613
cavernous nerves of, 1047
deep artery of, 614
dorsal artery of, 614
vein of, 1018
lymphatics of, 745
Clivus, 117
Cloaca, 1179, **1253,** 1278
Clunial (gluteal) branches, inferior, of posterior femoral cutaneous nerve, 1007
nerve, inferior medial (perforating cutaneous), 1007
middle, 973
superior, 973
Coats of the eyeball, 1058
Coccygeal body, 1329
cornua, 43
foveola, 1284
ganglion, 1040
ligament, 911
nerves, 973
posterior primary division of, 973
rudimentary, 964
plexus, 1018
vertebræ, 42
development of, 49
Coccygeus, 440, **448**
Coccyx, 30, **42**
muscles of, 448
Cochlea, **81,** 1092
Cochlear area of cerebral cortex, 893
duct (membranous cochlea, or scala media), 1090
fenestra, 1089
nerve, 824
nuclei of, 824
Cochleariform process, 1089
Cœliac artery (axis), **593,** 638
branches of vagus, 958
(semilunar) ganglia, 1043
lymphatic nodes, 730
plexus of nerves, 1043
Cœlom, 14
Colic, artery, left, 603
middle, 598
right, 598
flexures, **1173,** 1379
(basal) surface of spleen, 1310
veins, 677, 678
Collateral artery, inferior ulnar, 576
middle, 576
radial, 576
superior ulnar, 576
branch of intercostal arteries, 588
circulation of axillary artery, 1412
of brachial artery, 1414
of common carotid artery, **536,** 1360
iliac arteries, **605,** 1382
of external iliac artery, 1382
of femoral artery, 1441
of internal iliac artery, 1382
of popliteal artery, 1453
of subclavian artery, 1360
eminence, 868, **877**
fissure, 864
trigone of lateral ventricle, 876
Collecting renal tubule, 1246
Colles' fascia, 445
fracture, 1420
Colliculi, inferior, 834, **839**
superior, 841
Colliculus of arytænoid, 1212
facialis, 815
seminalis (verumontanum), **1263,** 1389
Colloid of thyreoid gland, 1316
Colon, ascending, **1173,** 1378
descending, **1174,** 1379
iliac, 1174
pelvic, **1174,** 1379
sigmoid, **1174,** 1379
transverse, **1174,** 1379
Colostrum, 1303
Column anterior of spinal cord, 786
Burdach's, 781
Clarke's, 776
Goll's, 781
lateral of spinal cord, 782
posterior of spinal cord, 780
vertebral, 29, **43**
Columna rugarum, 1275
Columns, anterior, of fornix, 870
rectal (of Morgagni), **1177,** 1390
renal (of Bertin), 1246
Comedo, 1298
Comma-shaped fasciculus, 782
Commissural branches of sympathetic, 1032
bundle, 788
fibres of white substance of spinal cord, 779
system of fibres, of telencephalon, 890
Commissure, 769
anterior cerebral, 848, **871,** 890
grey, of spinal cord, 775
habenular, **872,** 885, 890
hippocampal, 869, 890
inferior cerebral (Gudden's), 842, **850,** 890
middle cerebral, 844
optic, 849
posterior, of cerebrum, 835, 890
of vulva, 1276
supramammillary, **871,** 890
white, of spinal cord, 776
Common bile-duct (ductus choledochus), 1188
carotid artery, 533
branches, 536
collateral circulation, **536,** 1360
in the neck, 533
relations, 533, 534, 1369
thoracic portion of left, 533
digital arteries, 582
veins (foot), 684

Common digital veins, volar, 671
facial vein, 644, **646**
femoral artery, 616
iliac arteries, **603,** 605
collateral circulation, 605
veins, 679
interosseous artery of forearm, 570
Communicans cervicalis, 974
fibularis, 1013
Communicating artery, anterior, **555,** 562
posterior, 554
Comparative anatomy of large intestine, 1180
of lips and cheeks, 1104
of liver and gall-bladder, 1192
of palate, 1106
of pancreas, 1197
of peritoneum, 1151
of salivary glands, 1117
of stomach, 1160
of teeth, 1127
of tongue, 1112
of tonsils, 1138
Compartments under inguinal ligament, 1399
Complexus, 412, **417**
Compound bones, 27
Compressor bulbi proprius, 450
hemisphærium bulbi, 451
venæ dorsalis, 451
Conarium, 845
Concha, 1082
eminence of, 1083
Conchæ, nasal, 83, 84, 1205
sphenoidal, 64, **67**
Conchal (inferior turbinate) crest, 88, **92**
Conduction paths, auditory, 900
involving cerebellum, 899
of nervous system, summary of, 895
methods of determining, 779
of olfactory apparatus, 902
of optic apparatus, 900
vestibular, 899
Condylar foramen (canal), 54
fossa, **54,** 108
process of mandible, 96, 97
tubercle of mandible, 97
Condylarthroses, 213
Condyles, 29
of femur, 182
of femur and tibia, 1447
of mandible, 97
of occipital bone, **54,** 108
third occipital, 56
of tibia, 185
Condyloid emissary veins, 652
Cone, elastic, of larynx, 1215
Conical papillæ of tongue, 1106
Conjoined tendon of internal oblique and transversalis, 435
Conjugate diameter of pelvic inlet, 175
Conjunctiva, **1054,** 1347
lymphatics of, 698, **712**
ocular, 1054
palpebral, 1054
Conjunctival arteries, anterior, 553
posterior, 554
sac, 1054
semilunar fold of, 1055
veins, 658
Connecting fibro-cartilage, 211
Connections, central, of cranial nerves, 818
(for individual nerves, see "Central connections").
cortical, of thalamus, 883
of nuclei of corpus striatum, 880
Conoid ligament, 251
tubercle, 140
Constituents of articulations, 211
Constrictor laryngis, 1218
radicis penis, 450
vaginæ, 449
Constrictors of pharynx, 1137
Construction of nervous system, 762
Conus arteriosus, 516
medullaris, 771
Convoluted renal tubules, 1246
Convolutions, cerebral, 852
Cooper's ligament, 1400
Coraco-acromial ligament, 252
Coraco-brachialis, 374, 379, **381**
Coraco-clavicular union, 251
arterial supply, 251
ligaments, 251
movements, 252
nerve-supply, 251
(costo-coracoid) fascia, 371
Coraco-humeral ligament, 255
Coracoid (suprascapular or superior transverse) ligament, 253
process of scapula, 144
(conoid) tubercle, 140
Cord, oblique, 262
spermatic, **1259,** 1387
spinal, 751, **771**
clinical anatomy, 1408
external morphology of, 771
internal structure of, 775
Cords of brachial plexus, 917
gangliated, neurones of, 755
vocal (see "Vocal folds").
Corium, 1286
Cornea, 1052, 1054, 1056, **1059,** 1065
Corniculate cartilages (of Santorini), 1212
tubercle (of Santorini) of larynx, 1221
Corniculo-pharyngeal ligament, 1218
Cornu ammonis, **868,** 879
Cornua of fascia lata, 467
of fossa ovalis (saphenous opening), 467
of hyoid bone, 99, 100
of lateral ventricles, 873, 874, 876
of sacrum, 40
of thyreoid cartilage, 1211
Cornucopiæ, 923
Corona cilaris, 1060
glandis, 1260
iridis, 1054
radiata, 887
occipito-thalamic (optic) radiation of, 888
Coronal suture, **57,** 101, 1339
Coronary arteries, 519
ligaments of knee-joint, 290
of liver, 1184
plexuses of nerves, 1041
sinus, 521
valve (of Thebesius) of, 512
sulcus of heart, 510
(gastric) vein, 675
veins, 520
Coronoid fossa of humerus, 150
process of mandible, **97,** 1351
of ulna, 156
Corpora albicantia, 844, 1269
cavernosa of clitoris, 1277
penis, 1260
mammillaria (albicantia), 844
quadrigemina, 834
quadrigemina-thalamus path, 786
Corpus adiposum buccæ, 1103, 1104
callosum, 851
body of, 852
forceps major, 890
minor, 890
genu, 851
peduncle of, 866
radiation of, 851, **890**

Corpus callosum, rostral lamina of, 852
rostrum of, 852
splenium of, 852
striæ of, 851
sulcus of, 867
cavernosum urethræ (corpus spongiosum), 1261
Highmori, 1256
mammæ, 1302
papillare of skin, 1286
spongiosum (cavernosum urethræ), 1261
striatum, 879
caudate nucleus of, 879
connections of nuclei of, 880
internal capsule of, 886
lenticular nucleus of, 879
trapezoideum, 824
Corpuscles, bulbous (of Krause), 1290
genital, 1290
colostrum, 1303
concentric (Hassal's) of thymus, 1321, 1322
Golgi-Mazzoni, 1290
lamellous (Vater-Pacinian), 1290
renal (Malpighian), 1246
Ruffini, 1290
salivary, 1132
splenic (Malpighian), 1311
tactile (Meissner), 1290
Corrugator cutis ani, 445
muscle, 336
Cortex, cerebellar, 809
cerebral, 879
functional areas of, 893
of kidney, 1246
of lens of eye, 1062
of suprarenal gland, 1326
of thymus, 1321
Corti, organ of, 1096
Cortical branches of cerebral arteries, 562, 563
(superficial) cerebral veins, 654
connections of thalamus, 883
Cortico-pontine fibres, 811
Costal arch, 139
branch, lateral, of internal mammary artery, 567
cartilages, 130
Costal groove, 127
pleura, 1237
processes, 38
tuberosity of clavicle, 140
Costo-axillary veins, 671
Costo-central (capitular) articulation, 241
ligaments, 241
Costo-cervical arterial trunk, 568
Costo-chondral joints, 245
Costo-clavicular (rhomboid) ligament, 249
Costo-coracoid fascia, 371
ligament, 371
Costo-coracoideus, 374
Costo-mediastinal sinus, 1238
Costo-transverse articulations, 243
arterial supply, 244
ligaments of, 243
middle (neck), 243
posterior (tubercular), 243
superior, 243
movements, 244
nerve-supply, 244
foramen, 32, 127
of atlas, 33
Costo-xiphoid ligament, 244, 245
Costo-vertebral articulations, 241
groove, 138
Cotunnius, nerve of, 962
Cotyloid bone, 173
fibro-cartilage, 281
fossa, 169
Cowper's (cremasteric) fascia, 426, 434, 1254
glands, 1265
Coxal bone (os innominatum), 169
ossification of, 174
Cranial arachnoid, 918
cavity, floor of, 112
relations of brain to walls of, 903
dura mater, 913
fossa, anterior, 113
middle, 116
posterior, 116
surgical anatomy of, 1342
nerves, 927
abducens, 934
central connections of, 818
cochlear, 950
facial, 943
glosso-palatine, 946
glosso-pharyngeal, 951
hypoglossal, 952
masticator, 942
oculo-motor, 931
olfactory, 929
optic, 930
paths of, cerebral, 895
short reflex, 898
spinal accessory, 958
superficial attachments of, 929
terminal, 929
trigeminus, 934
trochlear, 933
vagus, 954
vestibular, 949
pia mater, 922
subdural cavity, 917
venous lacunæ, 649
sinuses, **649,** 692, 916
Cranio-cerebral topography, 903, 1338
Cranio-mandibular musculature, 325, 338, **341**
Cranium, 51
clinical anatomy of, 1333
measurements of, 117
remnants of cartilaginous, 124
Cremaster, 423, **434,** 1254
external, 1259
internal, 1254, 1259
Cremasteric branches of internal spermatic arteries, 501
fascia (external spermatic, or Cowper's fascia), 426, **434,** 1254
Crest(s), 29
arcuate, of arytænoid cartilage, 1212
conchal, 88, 92
ethmoidal, 92
external occipital, 52
of fibula, 190
frontal, 60
of greater tuberosity of humerus, 148
of ilium, 169
incisor, 90
inferior turbinate, 92
internal occipital, 53
interosseous, of radius, 153
of ulna, 157
intertrochanteric, 178
lacrimal, posterior, 85
nasal, 90
neural, 754
obturator, 173
of scapula, 144
sphenoidal, 63
superior turbinate, 92
of tibia, anterior, 188
transverse, 72
Cribriform lamina, 119
plate of ethmoid, 81

Crico-arytænoid articulation, 1214
ligament, 1214
Crico-arytænoideus lateralis, 1219
posterior, 1218
Cricoid cartilage, 1210
Crico-pharyngeal ligament, 1218
Crico-thyreoid articulation, 1213
ligament, 1215
muscles, 1218
Crico-tracheal ligament, 1218
Crista, ampullary, 950, 1095
galli, **81,** 113
supraventricularis, **516,** 527
terminalis, 513
urethralis, 1263
vestibuli, 80
Cristæ of matrix unguis, 1295
of skin, 1284
Crossed pyramidal tract, 783
Crown of tooth, 1117
Crucial anastomosis, 620
ligament of atlanto-epistrophic joint, 222
ligaments of knee-joint, 288
Cruciate ligament of leg (lower part of anterior annular ligament), 479
of fingers, 387
Crura of anthelix, 1083,
of cerebrum, 833, **835**
clitoridis, 1277
of diaphragm, 437
of fornix, 868
of greater alar nasal cartilages, 1202
of penis, 1261
of stapes, 80
Crural canal, 468
fascia, 477
nerve, anterior, 1001
interosseous 1010
Crureus, 468, **470**
Cruro-pedal muscles, 486
Crus of helix, **1082,** 1083
Cruveilhier, posterior cervical plexus of, 971
Cryptorchism, 1257
Crypts of iris, 1054
of Lieberkühn, 1166, 1177, 1390
of lingual tonsil, 1107
of palatine tonsil, 1132
Crystalline lens of eye, 1052, 1057, 1061
Cubital lymphatic node, superficial (supratrochlear), 719
Cuboid, 191, **199**
Cuboideo-navicular ligaments, 303
union, 303
Cubo-metatarsal joint, 309
ligaments, 309
Culmen of cerebellum, 806
Cuneiform bones, 159, 161, 191, **197**
first(medial, 197
third (lateral,) 198
second or middle, 197
cartilages (of Wrisberg), 1213
tubercle (of Wrisberg) of larynx, 1221
Cuneo-cuboid articulation 304
Cuneo-lingual gyrus, anterior, 864
posterior, 864
Cuneo-navicular articulation, 304
Cuneus, 864
Cupola of pleura, 1237
Cupular cæcum, 1096
portion of epitympanic recess, 1090
Curvatures of spinal column, 43
of stomach, **1152,** 1374
greater, 1152
lesser, 1152
Cusps of atrio-ventricular valves, 516
Cutaneous areas of face, 1018
of lower extremity, 1024
Cutaneous areas of neck, 1019
of pinna (auricle), 1019
of scalp, 1018
of trunk, 1020
of upper limb, 1022
branches of anterior ethmoidal artery, 554
of intercostal arteries, 589, 590
(communicans fibularis) of common peroneal nerve, 1013
of deep circumflex iliac artery, 616
dorsal antibrachial (external) of radial nerve, 987
of ilio-hypogastric nerve, 995
lateral, of thoracic nerves, 995
of median nerve, 992
plantar, of medial plantar nerve, 1010
posterior brachial (internal), of radial nerve, 985
femoral cutaneous nerve, 1007
of sacral plexus, 1007
of superficial peroneal (musculo-cutaneous) nerve, 1015
of superior epigastric artery, 567
(medial sural cutaneous or tibial communicating) of tibial nerve, 1010
of ulnar nerve, 990
glands, 1296
glomiform, 1296
sebaceous, 1298
nerves, anterior of abdomen, 996
of femoral nerve, 1003
calcaneo-plantar, 1010
of foot, lateral dorsal, 1013
surface markings, 1466
intermediate dorsal, of leg, 1015
lateral, 1000
of abdomen, 995
sural, 1013
medial antibrachial (internal), 934
brachial, 983
dorsal, of leg, 1015
sural, 1010
posterior femoral (small sciatic), 1007
superficial cervical, 978
rete arteriosum, 1289
veins, 1289
Cuticle (epidermis), 1285
Cutis, 1285, 1286
Cymba conchæ, 1082
Cystic artery, 595
duct, 1187
vein, 677
Cysto-colic ligament, 1379
Cytomorphosis, 7
Cytoplasm, 5

D

"Dangerous area" of leg, 1457
of scalp, 1333
Dartos, **1254,** 1260
Darwin, tubercle of, 1083
Deciduous (milk) teeth, 1126
times of eruption, 1127
Declive of cerebellum, 806
Decussation, fountain, 842
of lemnisci, 815
of pyramids, 799, **815**
of superior cerebellar peduncles (brachia conjunctiva), 840
Deferential artery, 610
plexus of nerves, 1047
Deiters' nucleus, 823
Deltoid branch of profunda artery, 576
of thoraco-acromial artery, 571
(internal lateral) ligament of ankle-joint, 298
surface markings, 1410

Deltoideus, 365
Delto-pectoral lymphatic nodes, 719
Dendrites, 762
Dens (odontoid process), 33
Dental arches, 1123
  branches, inferior, of inferior dental plexus, 941
    superior, of superior dental plexus, 938
  canal, inferior, 96, 126
  nerves, 938, 941
    inferior, 941
    superior, 938
Dentary centre, 98
Dentate fascia, 868
  gyrus, 868
  nucleus of cerebellum, 810
  sutures, 212
Dentine, 1118
Denticulate ligament, 920, 921
Depressor alæ nasi, 334
  anguli oris, 333
  labii inferioris, 332
  septi nasi, 334
Derma (corium), 1286
Descemet, membrane of, 1060
Descendens cervicalis (hypoglossi), 953, **974**, 979
Descending aorta, 586
  branches of cervical plexus, 978
    of lateral circumflex artery, 543
    (princeps cervicis) of occipital artery, 543
    of spheno-palatine (Meckel's) ganglion, 963
    of transverse cervical artery, 565
  colon, **1174**, 1379
  palatine artery, 549
Descent of the testis, 1257, **1387**
Development of anus, 1179
  of arteries, 633
  of articulations (joints), 213
  of bones, 27 (see also the individual bones)
  of brain, 754
  of central sulcus (fissure of Rolando), 860
  of corium, 1290
  of diaphragm, 120
  of ear, 1096
  of epidermis, 1286
  of eye, 1080
  of face, 18
  of hairs, 1293
  of heart, 523
  of hypophysis cerebri, 848
  of kidney, 1248
  of large intestine, 1179
  of larynx, 1225
  of limbs, 20
  of lips and cheeks, 1104
  of liver, 1189
  of lungs, 1235
  of lymphatic system, 706
  of lymph-nodes, 707
  of mammary gland, 1306
  of muscles, 316
  of nails, 1296
  of nerve fibres, 758
  of nervous system, 754
  of nose, 18, **1208**
  of œsophagus, 1141
  of oral cavity, 1102
  of palate, 1105
  of palato-pharyngeal muscles, 1137
  of pancreas, 1195
  of parathyreoid glands, 1319
  of pericardium, 527
  of peritoneum, 1144
  of pharynx, 1138
  of reproductive organs, 1278
Development of salivary glands, 1117
  of sebaceous glands, 1298
  of skull, 117
  of small intestine, 1168
  of spleen, 1312
  of stomach, 1157
  of suprarenal glands, 1326
  of sweat glands, 1297
  of teeth, 1124
  of thymus, 1322
  of thyreoid gland, 1318
  of tongue, 1112
  of tonsils, 1133
  of tympanum, 80
  of urinary bladder, 1253
  of veins, 690
  of ventricles of brain, 758
  of vermiform process, 1179
  of vertebræ, 45
  of viscera, 18
Diagonal sulcus, 858
  band of Broca, 866
Diameters of the pelvis, 175, **177**
Diaphragm, 425, **436**, 1372
  crura, 437
  and heart, recession of, 20
  lymphatics, 725, **728**
  pelvic, **440**, 1383
  urogenital, 440, 1383
Diaphragma pelvis (Meyer), 440
  sellæ, 848, **915**
Diaphragmatic pleura, 1237
  lymph nodes, 725, 736
  pelvic fascia, 442, 447
  plexuses of nerves, 1044
  surface of heart, 509
    of lung, 1229
    of spleen, 1308
Diaphysis, 28
Diapophyses, 51
Diarthroses, 212
  heteromorphic, 283
  homomorphic, 212
Diencephalon (interbrain), 758, **843**
Digastric fossa, 95
  muscles, 314
  triangle, 1357
Digastricus, 343, **344**
Digestive system, 1099
    abdomen, 1142
    intestines, 1161
    liver, 1180
    mouth, 1100
    œsophagus, 1138
    pancreas, 1192
    peritoneum, 1145
    pharynx, 1129
    stomach, 1151
Digital arteries, common (hand), 582
    dorsal (foot), 633
    plantar, 628
    proper (hand), 582
  branches, dorsal, of ulnar nerve, 990
    of medial plantar nerve, 1011
    volar, of ulnar nerve, 991
  fossa of epididymis, 1255
    of femur, 178
    of fibula, 191
  nerves, common plantar, 1011, 1013
    common volar, of hand, 991
    dorsal, of foot, 1013
      of hand, 987, 990
    proper plantar, 1011, 1013
    volar, of hand, 992
  veins (foot), dorsal, 684
    plantar, common, 684
    volar (hand), 671

Digital venous arch (hand), 667
Digitations, hippocampal, 877
Dilator naris anterior, 335
posterior, 335
pupillæ, 1061
Dimples of skin, 1285
Diploë, veins of, 648
Direct cerebellar tract of Flechsig, 784
pyramidal tract, 788
Disc, articular, of the acromio-clavicular joint, 251
of inferior radio-ulnar articulation, 264
of mandibular articulation, 216
of the sterno-costo-clavicular joint, 249
optic, 1055
Dislocation of mandible, 1345
metacarpo-phalangeal, 1434
of patella, 1446
Diverticula, intestinal, **1170,** 1379
Diverticulum, Meckel's, 1169
Dolichopellic pelvis, 177
Dorsalis hallucis artery, 633
pedis artery, 632
Dorso-epitrochlearis, 379
Dorsum of foot, muscles of, 492
of ilium, 165
of nose, 1200
of penis, 1260
sellæ (epihippi), **63,** 116
of tongue, 1106
Douglas' fold, 427
(recto-uterine or recto-vaginal) pouch, **1148,** 1267
Duct(s), alveolar, 1232
of Bartholin, 1117
cochlear, 1096
common bile, 1188
cystic, 1187
efferent of testis, 1256
ejaculatory, 1257, 1263, 1387
endolymphatic, 1094
of epididymis, 1256
of gall-bladder, **1188,** 1373
of Gärtner, 1275
hepatic, 1187
of lacrimal gland, excretory, 1047
lactiferous, 1302
of mammary glands, 1302
Müllerian, 1257, 1267, **1279**
naso-lacrimal, 1080, 1205, 1349
pancreatic (of Wirsung), **1194,** 1375
accessory (of Santorini), 1195
papillary (of Bellini), 1246
paraurethral (of Skene), **1277**
of parotid gland (Stenson's), **1115,** 1343
right lymphatic, 728
of Rivinus, 1117
semicircular, 1094
of sublingual gland, 1117
of submaxillary gland (Wharton's), 1116
of sweat glands, 1297
thoracic, 726
thyreo-glossal, 1318
utriculo-saccular, 1094
Wolffian, 1248, **1267,** 1278
Ductless glands, 1306
aortic paraganglia, 1329
chromaffin system, 1323
glomus caroticum, 1325
coccygeum, 1329
parathyreoid glands, 1318
spleen, 1306
suprarenal glands, 1323
thymus, 1319
thyreoid gland, 1312
Ductuli aberrantes (of epididymis), 1257
Ductus arteriosus (Botalli), 528
Ductus choledochus (common bile-duct), 1188
(vas) deferens, **1257,** 1259, 1387
(canaliculi) lacrimales, 1079
perilymphaticus, 81
reuniens of membranous labyrinth, 1094
venosus, 675, **694**
Duodenal fossæ, 1164
papillæ, **1164,** 1195
veins, 677
Duodeno-jejunal flexure, **1162,** 1376
Duodenum, **1161,** 1375
lymphatics of, 734
parts of, 1161
Dupuytren's fracture, 1455
Dura mater, 771, **910**
blood-vessels of, 917
cranial, 913
filum of, 911
nerves of, 917
spinal, 911
surgical anatomy of, 1342

E

Ear, 1082
development of, 1096
internal, 1092
middle, 1086
muscles of, **337,** 1084
ossicles of, 79, 1090
vessels and nerves, 1084, 1086, 1091, 1096
Ectoderm, 10
Ehrenritter, ganglion of, 951
Ejaculatory duct, 1257, 1263, **1387**
Elastic cone of larynx, 1215
membrane of larynx (Lauth), 1215
Elbow, clinical anatomy of, 1417
Elbow-joint, 258
arterial anastomoses around, 1418
supply of, 261
ligaments of, 258
movements of, 201
muscles acting upon, 261
nerve-supply of, 261
synovial membrane of, 261
Elevations of skin, 1284
Eleventh thoracic vertebra, 39
Elliptical recess (fovea hemielliptica), 80
Embryonic disc, 9, 10, 11
Eminence of auricle, 1083
collateral, 868, 877
frontal, 59, 108
hypoglossal, 814
ilio-pectineal, 169
medial, of floor of fourth ventricle, 813
parietal, 57
pyramidal, of temporal bone, 77
Eminentia arcuata, 78, 116
Emissary veins, 647, 649, 652, **916**
mastoid, 647
parietal, 649
of scalp, 1334
Enamel, 1118
Enarthrodial diarthroses, 213
Encephalon, 751, **792**
blood-supply of, 905
divisions of, 796
Endocardium, 508
Endoderm, 10
Endognathion centre, 91
Endolymph, 1093
Endolymphatic duct, 1094
sac, 1094
Endometrium, 1274
Endomysium, 315
Endo-pelvic fascia (recto-vesical), 442, 447

Endothoracic fascia, 1235
Enlargements of spinal cord, 772
Ensiform process (metasternum), 132, **134**
Eparterial bronchus, 1232
Ependymal cells, **768,** 846
Ephippial diarthroses, 212
Epicardium, 508
Epicondyles of femur, 183
of humerus, 151
Epicranial aponeurosis, 337
musculature, 336
Epicranio-temporalis, 337
Epicranius (occipito-frontalis), 336
Epidermis, (cuticle), 1285
Epididymal branches of int. spermatic arteries, 601
Epididymis, **1256,** 1386
Epidural cavity, 911
Epigastric artery, inferior (deep), **614,** 639
superficial, 618
superior, 567
lymphatic nodes, 732, 733
plexus, 1043
region, 1143
veins, inferior, 683
superficial, 684
superior, 666
Epiglottic cartilage, 1212
tubercle, **1212,** 1222
vallecula, 1221
Epihyal segment of styloid process, 119
Epimysium, 316
Epiphyseal cartilages, 28
lines, 28
Epiphyses, 28 (see also individual bones).
Epiphysis (pineal body), 758, 834, **845**
Epiploic foramen (of Winslow), 1147
or omental branches of epiploic arteries, 595
Epipteric bones, **68,** 101, 119
Episcleral arteries, 553
veins, 659
Epispadias, 1388
Epistropheus, description of, 33
Epithalamus, 845
Epithelial chorioid lamina, 924
Epithelium lentis, 1064
Epitrochleo-olecranonis (anconeus internus), 402
Epitympanic recess, 78
Eponychium, **1294,** 1296
Epoöphoron, 1269
Equator of eyeball, 1055
of lens of eye, 1062
Erector penis (or clitoridis), 451
spinæ, 412, **414**
Eruption of teeth, 1127
Ethmoid, 81
at birth, 124
cells, 83, **111,** 1207
Ethmoidal artery, anterior, 554
posterior, 553
branches of anterior ethmoidal artery, 554
of posterior ethmoidal artery, 553
bulla, **111,** 1205
canals, **61,** 83, 110, 113, 126
(superior turbinate) crest, 92
fissure, 113
infundibulum, 1205
nerve, anterior, 936, 937
posterior, 937
notch, 61
process, 85
spine, **63,** 113
veins, 659
Ethmo-turbinals, 119
Ethmo-vomerine region of skull, 117
Eustachian tube, 74, 1089, **1092**
Eustachian tube, openings of, **1130,** 1354
valve, 512
Excretory ducts of lacrimal gland, 1079
Exoccipital, 119
Exognathion centre, 91
Expiration, muscles which affect, 248
Extension (of muscles), 321
Extensor carpi radialis accessorius, 391
brevis, 388, **389**
intermedius, 391
longus, 387, **388**
ulnaris, 388, **391**
communis pollicis et indicis, 394
digiti annularis, 395
quinti proprius (extensor minimi digiti), 388, **391**
digitorum brevis (foot), 454, **492**
(hand), 395
communis, 388, **391**
longus, 453, 480, **481**
group of arm muscles, 377
hallucis brevis, 482, 492
longus, 453, 480, **482**
indicis proprius, 392, **394**
medii digiti, 395
ossis metacarpi pollicis (abductor pollicis longus), 393
pollicis brevis, 392, **394**
longus, 392, **394**
Extremity, lower, bones of, 169
clinical and topographical anatomy of, 1434
lymphatics of, 746
upper, bones of, 139
clinical and topographical anatomy of, 1409
lymphatics, **719,** 1424
Extrinsic muscles of tongue, 345
Eye, 1051
blood-vessels of, 1031
clinical anatomy of, 1346
crystalline lens, 1052
development of, 1080
eyelids, 1053, **1076**
general surface view, 1052
lymphatics of orbit, 715
nerves of, **1064,** 1348
Eyeball, (bulbus oculi), 1055
blood-vessels of, 1065
equator of, 1055
hemispheres of, 1057
insertions of muscles, 1056
muscles of, 501, **1067**
nerves of, 1064
poles of, 1055
Eyelashes (cilia), **1053,** 1347
Eyelids, 1053, **1076**
blood-vessels of, 1078
clinical anatomy, 1346
glands of, 1078
lymphatics of, **712,** 1078
nerves of, 1078
structure of, 1077

F

Face, bones of, 51
clinical anatomy, 1342
cutaneous areas of, 1018
development of, 18
lymphatic vessels of, 712
muscles of, 324, **329,** 501
veins of, 643
Facial (external maxillary) artery, **540,** 1343
branches of great auricular nerve, 978
(Fallopian) canal, 72, 77, **78**
lymph-nodes, 709, 711

Facial nerve, 943, **946,** 1345
nucleus of, 825
paralysis of, 1345
portion of external maxillary artery, 540
vein, anterior, **643,** 1343
common, 644, **646**
posterior (temporo-maxillary), 644
transverse, 646
Facialis, musculature, 324, **329,** 501
Falciform ligament of liver, 1185
margin of fascia lata, 467
process of great sacro-sciatic ligament, 236
Fallopian canal, 72, 77, **78**
tubes, 1269
Fallopius, aqueduct of (facial canal), 72
Falx cerebelli, 915
cerebri, 914
inguinalis (conjoined tendon of internal oblique and transversalis), **435,** 1396
Fascia(æ) antibrachial, 384
of arm, 377
axillary, 370, 371
brachial, 377
bulbi (Tenon's capsule), **1073,** 1348
Camper's, 425
Colles', 425
coraco-clavicular (costo-coracoid), 371
cranio-mandibular, 339
cremasteric (Cowper's), 426, **434,** 1254
cribrosa, 467
crural, 477
of deep musculature of shoulder girdle, 356
deep cervical, 1360
deep palmar, 387
dentate, 868
diaphragmatic pelvic, 442, 447
endo-pelvic (recto-vesical), 442, **447**
endothoracica, 1235
external cervical, 347
spermatic, 1387
of foot, 491
of forearm and hand, 384
of hand, 1427
of head and neck, 329
hypothenar, 387
iliac, 455, **466**
of ilio-femoral musculature, 455
ilio-pectineal, 455, **466**
of infrahyoid musculature, 350
intercolumnar (external spermatic), 1304
interpterygoid, 339
of ischio-pubo-femoral musculature, 463
lata, 454, 457, 466, 1400, 1436
lateral pharyngeal, 339
of leg, 477
lingual, 346
lumbar, 436
lumbo-dorsal, 414, 428
masseteric, 339
middle cervical, 350
muscle, 313
of musculature of shoulder, 365
nuchæ, 414
obturator, 439, 463
of orbit, 1071
palpebral, 1071
parietal (pelvic), 447
parotid, 339, 348, **1114**
of pectoral muscles, 371
of pelvis, muscular, 443, **446,** 447
subcutaneous, 445
penis, 1260
plantar, 1468
of posterior group of ilio-femoral muscles, 457
of prevertebral musculature, 355
prostatico-perineal, 447
Fascia(æ) psoas, 455
renal, 1242
of scalene musculature, 353
Scarpa's, **425,** 445
of scrotum, 1385
semilunar, 382
Sibson's, 129, **355,** 1237
of spinal musculature, 413
superficial, 313
perineal (Colles'), **445,** 1385
of shoulder girdle, 347
of supra-hyoid musculature, 344
temporal, 339
thenar, 387
of thigh, 466
thoraco-abdominal musculature, 425
subcutaneous, 425
transversalis, 426
triangular, 430
of upper limb musculature, 363
of urogenital diaphragm, 445
of wrist, 1427
transversi of palmar aponeurosis, 387
Fasciculus(i), 769
anterior marginal, 786
comma-shaped, 782
cuneatus (Burdach's column), 781
gracilis (Goll's column), 781
inferior longitudinal, 892
intermediate, 784
lateral cerebro-spinal, 783
mammillo-mesencephalic (tegmento-mammillary or mammillo-peduncular), 871
mammillo-thalamic, **871,** 883
medial longitudinal, 817, 842
oblique, 804
occipito-frontal, 892
pedunculo-mammillary, 849
proprii, 769
proprius, dorsal, 782
lateral, 782
ventral, 786
retroflexus of Meynert, 841, **843,** 872, 886
rubro-spinal, 786
spino-cerebellar, dorsal, 784
spino-olivary (Helweg's bundle), 784
sulco-marginal, 788
superficial ventro-lateral (spino-cerebellar), 784
superior longitudinal, 892
uncinate, 891
ventral cerebrospinal, 788
vestibulo-spinal, 786
Fasciola cinerea, 868
Fauces, isthmus of, 1100, 1130, 1131
Female, reproductive organs, 1265
clinical anatomy of, 1391
development of, 1278
external (vulva), 1276
lymphatics of, **744,** 1278
ovaries, 1238
tubæ uterinæ (Fallopian tubes), 1269
uterus, 1271
vagina, 1274
vessels and nerves of, 1278
urethra, 1278
Femoral artery, **616,** 1441
branches, 618
collateral circulation, 1441
common, 616
profunda or deep, 620, 640
superficial, 616
canal (crural canal), 468, 1400
cutaneous nerve, posterior (small sciatic), 1007
hernia, 1398
(anterior crural) nerve, 1001

Femoral plexus of nerves, 1045
ring, 466, **1401**
septum, 466
sheath, 1400
trigone (Scarpa's triangle), 467, **1438**
vein, **690,** 1441
tributaries, 690
Femoro-tibial muscle, 486
Femoro-popliteal vein, 685, 693
Femur, 178
clinical anatomy of, 1434, 1442
condyles of, 1447
ossification of, 184
trochanters of, 178
Fenestra cochleæ (rotunda), 73, **1089**
vestibuli (ovalis), 73, **1089**
Ferrein, pyramid of, 1246
Fibræ propriæ, 890
Fibres, arcuate, 817
association, of telencephalon, **890,** 893
of white substance of spinal cord, 779
of cerebellar cortex, 809
cerebello-olivary, 817
of cerebral cortex, 879
commissural system of, 890
external arcuate, of medulla oblongata, 800
intercrural (intercolumnar fascia), 430
internal arcuate, 815
muscles, 315
nerve, 767
development of, 758
projection, of telencephalon, 886
sympathetic, 970, **1029**
visceral afferent, 970
efferent, 970
Fibro-cartilages, cotyloid, 281
interosseous, 244
interpubic, 240
intervertebral, 225, 238
semilunar, 289
triangular (articular disc), 264
Fibula, description of, **189,** 1454
ossification of, 191
Fibular branch of posterior tibial artery, 626
collateral ligament, 286
nutrient branch of peroneal artery, 626
Fibulo-calcaneus medialis, 491
Fibulo-tibialis, 486
Fifth ventricle (cavity of septum pellucidum), 872
Fila radicularia, 775, 964
Filaments, root, of spinal nerves, 775
of pons, lateral, 804
Filiform, papillæ of tongue, 1106
Filum of dura mater, 911
terminale, **771,** 721
Fimbria, **868,** 877
ovarica, 127
Fimbriæ of tubæ uterinæ (Fallopian tube), 1270
Fimbriate folds of tongue, 1107
Fimbrio-dentate sulcus, 868
Fingers, 4
muscles acting on, 505
Fissura prima, 866
serotina, 865
Fissure(s), anterior median, 772
antitrago-helicine, 1084
auricular, 75, 108
calcarine, 864
calloso-marginal, 857, **859**
of cerebellum, 805
of cerebrum, 852
chorioid, 1080
collateral, **855,** 864
ethmoidal, 113
external parieto-occipital, 862
Fissure(s), Glaserian, 71, 77
hippocampal or (chorioid), 868
horizontal (of cerebellum), 805
inferior orbital (spheno-maxillary), 102, **109, 126**
lateral (Sylvian), 850, **855,** 1340
of liver, 1183
longitudinal, of cerebrum, 850
of lung, **1230,** 1234
oral, 1100
parieto-occipital, 860, **864**
petro-tympanic, 71, 77, 108, 126
portal, 1183
posterior median, of medulla oblongata, 801
postlimbic, 863
pterygo-maxillary, 102
pterygo-palatine, 102
retrotonsillar, of cerebellum, 807
of Rolando, **859,** 1340
semilunar (of cerebellum), 805
spheno-maxillary, **102,** 109
of spinal cord, 772
superior orbital (sphenoidal), **65,** 109, 116' 125
of Sylvius, 850, **855**
of telencephalon, 853
transverse, of cerebrum, 850
tympano-mastoid, 71, 75, 108
umbilical, of liver, 1183
Flechsig, direct cerebellar tract of, 784
secondary optic radiation of, 890
Flexion of muscles, 321
Flexor accessorius, 454, **495**
longus digitorum, 491
carpi radialis, 396, **398**
brevis (radio-carpeus), 403
ulnaris, 396, **398**
brevis (ulno-carpeus), 402
digiti quinti brevis (foot), 454, 498, **499**
(hand), 404
digitorum brevis, 454, **493**
longus, 454, 486, **489**
profundus, 401
Flexor digitorum profundus, 401
sublimis, 399
group of arm muscles, 379
hallucis brevis, 454, 496, **497**
longus, 454, 486, **490**
pollicis brevis, 407, **408**
longus, 402
Flexure(s) of duodeno-jejunal, 1376
of duodenum, 1161
left colic (splenic), 1174, **1379**
of rectum, 1176
right colic (hepatic), 1173, **1379**
Floating ribs, 127
Floccular fossa, 73
Flocculus of cerebellum, 807
peduncle of, 807
Floor of cranial cavity, 112
of fourth ventricle, 813
pelvic, 1384
in female, 1394
Fluid, cerebro-spinal, **920** 1342
Flumina pilorum, 1291
Fœtal circulation, 695
skull, general characters of, 120
Fold(s), adipose, of pleura, 1237
alar, 291
ary-epiglottic, 1221
of Douglas, 427
of duodenum, 1164
glosso-epiglottic, 1220
inferior palpebral, 1053
neural, 754
patellar, 290
recto-uterine, 1274

Fold(s), semilunar, of conjunctiva, 1055
of skin, 1284
sublingual, 1116
superior palpebral, 1053
transverse (Houston's), of rectum, **1177,** 1390
of tympanic mucous membrane, 1089
ventricular, of larynx, 1222
vocal, 1223
Foliate papillæ of tongue, 1106
Folium vermis (cacuminis) of cerebellum, 806
Follicles, Graafian, 1269
of hair, 1292
lingual, 1107
lymph, 704
Fontana, spaces of, 1060
Fontanelle(s), sagittal, 59
of skull, 120
Foot, amputations of, 1465
arches of, 1468
arteries of, 627, 631
bones of, 191, 205, 1467
bony landmarks of, 1464
bursæ of, 1465
clinical anatomy of, 1464
cutaneous nerves of, 1466
muscles acting on, at ankle-joint, 505
musculature of, 491
synovial membranes of, 1465
talipes, 1467
Foramen(ina), 29
acetabular, 174
apicis dentis, 1118
auditory, 125
cæcum, 61, 113, 1318
of ethmoid, 81
of medulla oblongata, 799
(Morgagni) of tongue, 1106
carotico-clinoid, 65
condylar, 54
costo-transverse, 127
of diaphragma sellæ, 916
epiploic (foramen of Winslow), 1147
greater palatine, 106
hypoglossal, **54,** 108, 125
incisive, 89
inferior dental, 96
infra-orbital, **87,** 1345
intervertebral, 30
intraventricular (Monroi), 847, **874**
jugular, **74,** 108, 117, 125
lacerum, **63,** 74, 108, 116
lesser palatine, 106
of Magendie, 813
magnum, 51, **56,** 108, 117, 125
mandibular (inferior dental), 96
mastoid, **72,** 108, 117
mental, 95
palatine, 106
of Monro, 847, **874**
of nerves of skull, 125
of norma facialis, 108
obturator (thyreoid), 174
optic, **63,** 64, 110, 116, 125
ovale, **65,** 116, 125
of Pacchioni, 116
papillaria, 1246
parietal, 57
petro-sphenoidal, 125
pharyngeal, 126
rotundum, **65,** 103, 116, 125
sacral, 40
scapular, 142
of Scarpa, **89,** 106, 126
spheno-palatine, **93,** 103, 111, 126
spinosum, **65,** 116
of Stenson, **89,** 106
Foramen(ina), sternal, 133
stylo-mastoid, **73,** 108, 126
supra-orbital, 60
supratrochlear, 150
thyreoid (thyreoid cartilage), 1211
trigeminal, 125
venæ cavæ, 438
venarum minimarum (Thebesii), 514
vertebral, 31
Vesalii, **65,** 116
zygomatico-temporal, 126
Forceps major, 876
Forearm, clinical anatomy of, 1419
common fractures of bones of, 1420
joints of, 1419
muscles of, 362
musculature of, 383
nerves of, 1423
synovial tendon sheaths of, 395, 403
vessels and nerves of, 1423
Fore-brain, 843
Formation, reticular, 816
Fornix, anterior pillars (columns) of, 870
body of, 869
conjunctival, **1054,** 1347
fibres of, 869, 870, **871,** 890
of limbic lobe, 868
pharyngeal, 1130
posterior pillars (crura), 868
transverse, 869, **890**
of vagina, 1275
Fossa(e), abdominal, 430
anterior cranial, 113
of anthelix, 1082
axillary, clinical anatomy of, 1411
canine, 87
cardiac, of lung, 1229
condylar, **54,** 108
coronoid, 150
cotyloid, 169
digastric, 95
digital, of femur, 178
of fibula, 191
ductus venosi, 1183
duodenal, 1164
of femur, intercondyloid, 182
floccular, 73
of gall-bladder, 1183
glenoid, 29
of humerus, coronoid, 150
olecranon, 150
radial, 151
hypophyseos, **63,** 116
iliac, 170
ileo-cæcal, 1172
ileo-colic, 1172
ilio-pectineal, 467
incisive, 87
incisor, 95
infraspinous, 142
infra-temporal (zygomatic), **101,** 1332
interpeduncular, 835
intersigmoid, 1175
ischio-rectal, 441, 445, **1384**
jugular, **73,** 108
lacrimal, **61,** 109
mandibular, 108
mastoid, 72
middle cranial, 116
nasal, 108, **110**
navicularis, 1264, 1277, **1392**
olecranon, 150
ovalis (of heart), 512
(saphenous opening), **467,** 1400, 1440
ovarica, 1268
paraduodenal (Landzert), 1164
pericardial, **1172,** 1378

Fossa(e), posterior cranial, 116
pterygoid, **66,** 107
pterygo-palatine (spheno-maxillary), 102
radial, 151
rhomboidea, 802
of Rosenmueller, 1130
scaphoid, 54, 55, 66, 95, 107
of skull, surgical anatomy of, 1342
spheno-maxillary (pterygo-palatine), 102
subarcuata, **73,** 117
subscapular, 141
supraspinous, 141
supratonsillar, 1132
Sylvian, 854
temporal, 101
triangular, of auricle, 1082
of elbow, 1418
trochanteric or digital, 178
trochlear, 61
venæ cavæ, 1183
vermiform, **53,** 108, 117
zygomatic, **101,** 1332
Fossula cochlearis, 72
petrosa, 73
vestibularis, 72
Fountain decussation (Forel), 842
Fourchette, **1276,** 1392
Fourth ventricle, 812
anatomy of, 812
chorioid plexus of, 922
floor of, 813
roof of, 812
tela chorioidea of, 922
Fovea of arytænoid cartilages, 1212
centralis, 1055
of femur, 178
hemielliptica, 80
hemisphærica, 80
inferior, of floor of fourth ventricle, 814
superior of, floor of fourth ventricle, 815
inguinalis, 430
pterygoidea, 97
sublingualis, 95
umbilical, 1284
Foveola palatina, 1104
Fracture or fractures of bones of the leg, 1454
Colles', 1420
common, of bones of forearm, 1420
Dupuytren's, 1455
of mandible, 1345
of olecranon, 1420
Pott's, 1454
Freckles, 1283
Frenulum of anterior medullary velum, 832
clitoridis, 1277
of ileo-cæcal valve, 1172
of penis, 1260
of tongue, **1107,** 1349
veli, **812,** 835
Frenum (duodenal), 1164
Frequency of disease of tarsal bones, 1396
Frontal artery, **554,** 1343
association area, 894
bone at birth, 123
description of, 59
branches of anterior ethmoidal artery, 554
of superficial temporal artery, 545
convolution, ascending, 851
crest, 60
eminences, 59, 108
gyrus, inferior, 858
middle, 858
superior, 857
lobe, 857
nerve, **935,** 1075
notch, 60
operculum, 856
Frontal pole, 850
pontile path (Arnold's bundle), 832, 840, **889**
process of maxilla, 87, 88
sinus, 59, 61, **1207,** 1335
spine, (nasal), 60
sulcus, inferior, 858
middle, 858
superior, 858
suture, 59
vein, 644
Frontal vein, 644
diploic, 648
Frontalis, 337
Fronto-ethmoidal cells, 84
Fronto-marginal sulcus, 858
Fronto-nasal plate, 117
process, 119
Fronto-sphenoidal process, 95
Functional areas of cerebral cortex, 893
Functions of cerebellum, 832
of muscle groups, 500
Fundiform ligament of penis, 427
Fundus of gall-bladder, 1187
of stomach, **1151,** 1374
uterus, 1271
Fungiform papillæ of tongue, 1106
Funiculi of nerves, 769
spinal cord, 774, **780**
Funiculus, anterior, 775, **786**
cuneatus of medulla oblongata, 801
gracilis of medulla oblongata, 801
lateral, 775, **782**
posterior, 774, **780**
separans, 814
Furcal nerve, 998
Furrow, 29
Furrows, articular, of skin, 1284
Fusiform gyrus (occipito-temporal convolution), **855,** 864
muscles, 315

G

Galea aponeurotica (epicranial aponeurosis), 337
Galen, veins of, 923
Gall-bladder, 1187
clinical anatomy of, 1372
ducts of, 1187, 1188, 1372
Ganglion(ia), aberrant spinal, 965
of Andersch, 951
aortico-renal, 1043
basal, 878
of Bochdalek, 939
cardiac (ganglion of Wrisberg), 1041
ciliary, **961,** 1033, 1076
coccygeum impar, 1032, 1040
cœliac (semilunar), 1043
(neural) crest, 754
first thoracic, 1038
geniculate, 826, **947**
inferior cervical, 1036
interpeduncular (von Gudden's), **843,** 872, 885
jugular (superior), of glosso-pharyngeus, 957
of vagus, 954, **956**
of glosso-pharyngeus, 951
middle cervical, 1036
nodosum (ganglion of trunk), 954, **956**
otic (Arnold's), 963
petrosal, 951
phrenic, 1044
renal, 1044
of root of vagus, 956
roots of, 959

Ganglion(ia), second thoracic, 1038
semilunar (Gasserian), 826, **938,** 1345
spheno-palatine (Meckel's), 962
spinal, 964
spiral, of cochlea, 950
splanchnic, 1039
submaxillary, 963
superior cervical, sympathetic, 960, **1035**
jugular, or Ehrenritter's, 951
mesenteric, 1043, 1045
sympathetic, 959, 1032
of head, 959
of synovial sheaths, 1434
terminal, 930
of trunk of vagus, 956
of Valentine, 939
vestibular, 823, **950**
of Wrisberg, cardiac, 498
Gangliated cephalic plexus, 959
nerve trunks (cords), 755, 1029, **1032**
Ganglionic branches of middle meningeal artery, 548
Gärtner, duct of, 1275
Gasserian (semilunar) ganglion, 826, **935,** 1345
Gastric artery, left, 593
right, 594
branches of epiploic arteries, 595
of vagus, 958
lymphatic nodes, 730, **734**
plexus of nerves, anterior, 958
inferior, 1045
posterior, 958
superior (coronary), 1045
surface of spleen, 1309
Gastrocnemius, 453, 484, **485**
Gastro-duodenal artery, 594
Gastro-epiploic artery, left, 595
right, 595
vein, left, 675
right, 675
Gastro-hepatic ligament, 1150
Gastro-phrenic ligament, 1150
Gastro-splenic (gastro-lienal) ligament (omentum), **1150,** 1310
Gastroptosis, 1160
Gemellus inferior, 464
superior, 464
Gemmules, 762
Genial tubercles, 95
Geniculate bodies, **834,** 845
ganglion, 826, **949**
Geniculo-tympanic branch of glosso-palatine, 951, 961
Genio-glossus, 346
Genio-hyoideus, 343, **344**
Genio-pharyngeus, 346
Genital corpuscles, 1290
ridge, 1267, 1278
swellings, 1279
tubercle, 1279
Genitalia, female, external, **1276**
clinical anatomy of, 1391
male, 1253
Genito-femoral (genito-crural) nerve, **1000,** 1260
Genu of corpus callosum, 851
of facial canal, 78
inferior, of central sulcus (fissure of Rolando), 860
of internal capsule (telencephalon), 887
superior, of central sulcus (fissure of Rolando), 860
suprema artery, **621,** 640
valgum, 1449
Germ layers, 9
Gimbernat's ligament, **424,** 429, 466, 1400
Gingival branches, inferior, of inferior dental plexus, 941
superior, of superior dental plexus, 939
Ginglymi diarthroses, 213
Girdle, pelvic, 207
shoulder, 207
Glabella, **60,** 101, 109, 1331
Gladiolus (mesosternum), 132
Gland(s), 1099
bronchial, 1231
Brunner's, 1166
bulbo-urethral (Cowper's) 1265
carotid, 550, **1327**
ceruminous, 1297
ciliary (of Moll), **1078,** 1297
circumanal, 1297
ductless, 1306
of eyelids, 1078
glomiform, 1296
greater vestibular (of Bartholin), **1278,** 1392
Henle's 1078
Krause's, 1078
lacrimal, **1079,** 1348
lingual, 1108
lesser vestibular, 1278
of Lieberkuehn, 1166, 1177, 1390
of lips and cheeks, 1103
lymphatic, 704
intercolated, 706
mammary, 1299
of Montgomery, 1304
mucous, of larynx, 1224
nasal,1208
of Nuhn or Blandin, 1110,
olfactory, 1208
para-thyreoid, **1318,** 1355
parotid, 348, 1113
accessory, 1114
preputial, 1298
prostate, 1264
salivary, 1113
sebaceous, 1298
of skin, 1296
of small intestine, 1166
of palate, 1104
sublingual, 1116
submaxillary, **1115,** 1350
sudoriferous (sweat),1296
suprarenal, 1323
accessory, 1326
tarsal (Meibomian), 1054, 1078
thymus, 1319
thyreoid, 1312
accessory, 1315
clinical anatomy of, 1355
tracheal, 1227
urethral (of Littré), 1264
Zeiss's, 1078
Glandular branches of external maxillary, 541
of inferior thyreoid artery, 564
Glans clitoridis, 1277
of penis, 1260
Glaserian fissure, 71, 77
Gleno-humeral bands, 254
ligament, 255
Glenoid cavity of scapula, 143
fossa, 29
ligament, (lip) 255
of metacarpo-phalangeal joints, 294
lip of shoulder-joint, 255
of hip-joint (cotyloid fibro-cartilage), 281
Gliding motion of joints, 214
Glisson's capsule, 675, **1186**
pallidus, 880
Glomerular capsule, 1246
layer of olfactory bulb, 866
Glomeruli of olfactory nerves, 929

Glomiform glands, 1296
Glomus caroticum (carotid gland), 1327
choroideum, 876
coccygeum, 1040, **1329**
Glosso-epiglottic folds, 1220
ligament **1218**
Glosso-hyal process, 99
Glosso-palatine arches, **1132**
nerve, 826, **946**
Glosso-palatinus (palato-glossus), 1135
Glosso-pharyngeal nerves, 820, **951**
Glottis, 1223
Gluteal arteries, **608,** 1444
branches, 609
superior, 608
inferior, **609,** 639
branches of internal pudendal artery, 613
of posterior femoral cutaneous nerve, 1007
line, anterior, 170
inferior, 166
posterior, 170
nerve, inferior, 1007
superior, 1007
tuberosity of femur, 178
veins, inferior 680
superior, 680
Gluteus maximus, 453, 457, **459**
surface marking, 1443
medius, 453, 457, **461**
minimus, 453, 457, **461**
Golgi cells in cerebellum, 809
Golgi-Mazzoni corpuscles, 1290
Goll's column, 781
Gomphosis sutures, 212
Gonion, 112, 113
Gower's tract, 784
Graafian follicles, 1269
Gracilis, 453, 471, **472**
Granular layer of cerebellar cortex, 809
Granulations, arachnoid, 649, **919**
Great auricular nerve, 978
cardiac vein, 520
omentum, 1149
(anterior) palatine nerve, 963
prevertebral plexuses of nerves, 1010
(internal) saphenous vein, **684,** 1456
splanchnic nerve, 1038
superficial petrosal nerve, 948
trochanter of femur, **178,** 1435
Greater alar (lower lateral) nasal cartilages, 1201
curvature of stomach, 1152
multangular (trapezium) bone, 162
occipital nerve, 971
palatine foramina, 106
canals, 92
tuberosity of humerus, 147
vestibular glands (glands of Bartholin), **1278,** 1392
Grey commissure of spinal cord, 775
rami communicantes of sympathetic system, 1030
substance, central, of mesencephalon, 836
of pons (nuclei pontis), 831
of nervous system, 768
of spinal cord, 775
Groove of atlas, 33
basilar, 54
bony, 29
carotid, 64
costal, 127
costo-vertebral, 138
of cuboid, peroneal, 199
infra-orbital, 87
intertubercular (bicipital), 148
lacrimal, 85, 87, 110
mylo-hyoid, 96
Groove, neural, 754
obturator, 172
occipital, 72
optic, 63, 113
for radial nerve (musculo-spiral), 149
sacral, 41
sigmoid, 72
Grouping of muscles according to function, 500
Growth, prenatal, 22
of the organs, 25
of the parts, 24
of the systems, 25
Gubernacular canals, 106
Gubernaculum testis, 1257, **1387**
Gudden's commissure (inferior cerebral commissure), 842, **850,** 890
Gums, 1119
lymphatics of, 715
Gustatory area of cerebral cortex, 894
cells, 1051
organ, 1051
Gynecomastia, 1305
Gyrus(i) Andreæ Retzii, 868
ambiens, 865
angular, 863
anterior central, 857
cuneo-lingual, 843
orbital, 858
breves (precentral gyri), 857
of cerebellum, 804
of cerebrum, 852
cinguli (cingulum), 867
cunei, 864
cuneo-lingual, 864
deep annectant, 860
dentate, 868
epicallosus, 868
external orbital, 838
fornicatus, 867
cinguli (cingulum), 867
hippocampus, 868
isthmus of, 867
fusiform (occipito-temporal convolution), **855,** 864
hippocampal, 868
inferior frontal, 858
temporal, 855
lateral occipital, 863
olfactory, 865
orbital, 859
lingual, **855,** 864
longus, 857
marginal, 858
medial olfactory, 866
orbital, 858
middle frontal, 858
temporal, 855
orbital, 858
origin of, 853
posterior central (ascending parietal), 861
orbital, 858
post-parietal, 863
profundi, 852
rectus, 858
semilunar, 865
subcallosal (peduncle of corpus callosum), 866
submarginal, 858
superior frontal, 857
occipital, 863
parietal, 862
temporal, 854
supracallosal, 868
supramarginal, 863
transitivus, 852
transverse temporal, 855
uncinatus, 868

H

Habenulæ, 846
Habenular commissure, 846, 872, 885, 890
  nucleus, 872, 885
  trigone, 835
Habenulo-peduncular tract, 873
Hæmolymph nodes, 708
Hæmorrhoidal artery, inferior, **613,** 1391
    middle, **610,** 1391
    superior, **603,** 1091
    of middle sacral artery, 603
  nerves, inferior, 1017
    middle, 1017
    superior, 1045
  plexus of nerves, middle, 1045, 1046
      superior, 1045
    of veins, **683,** 1391
Hairs (pili), 1290
    development of, 1293
    olfactory, 1050
Hamate (unciform) bone, 159, 163
Hamular process of sphenoid, **66,** 106, 1351
Hamulus, **81,** 163
Hand, bony points of, 1424
  clinical anatomy of, 1424
  fascia of, 1427
  muscles acting on, at wrist, 504
  musculature of, 363, 383, **403**
  skin-folds of, 1425
  synovial membranes of, 1431
Hard palate, 1104
Hare-lip, 1352
Harmonic sutures, 212
Hassal's corpuscles of thymus, 1322
Head of axis, 33
  of bone, 29
  bony landmarks of, 1331
  clinical and topographical anatomy of, 1331
  deep lymphatic nodes of, 714
      vessels of, 714
  of epididymis, 1256
  lymphatics of, 709
  of muscle, 314
  muscles acting on, 502
  musculature of, 323
  of pancreas, 1192
  process, 11
  sympathetic ganglia of, 959
Heart, 508
Heart, atria of, 511
  development of, **523**
  fœtal, 695
  ventricles of, 516
  lymphatics of, 701, **730,** 522
  muscle of, 518
  nerves of, 522
  relation to chest-wall, **523,** 1368
  vessels of, 519
Heister, valve of, 1187
Helicis major, 1084
  minor, 1084
Helicotrema, 81
Helix, 1083
Helweg's (Bechterew's) bundle, 784
Hemiazygos vein (azygos minor), 662
    accessory, 663
Hemispheres of cerebellum, 805
  cerebral, 850
Henle, loop of, 1246
Henle's glands, 1078
Hepatic artery, 594
  branches of superior epigastric artery, 567
  of vagus, 958
  duct, 1187
  (right colic) flexure, 1173, **1379**
  lymphatic nodes, 730, **736,** 1186
Hepatic lymphatics, 1186
    plexus of nerves, 1045
    veins, 675
Hepato-colic ligament, 1379
Hepato-duodenal ligament, **1150,** 1185
Hernia, congenital, 1255, 1387, **1398**
    femoral, 1394
    into the funicular process, 1255, **1398**
    infantile, 1398
    inguinal, 1255, **1394,** 1398
    scrotal, 1255
    surgical anatomy of, 1394
    umbilical, adult, 1402
Hesselbach, ligament of, 430
    triangle of, 1398
Hey's amputation, 1465
Hiatus, accessory, 116
    aorticus of diaphragm, 437
    canalis facialis, 73, 116
    œsophageus, 437
    sacralis, 40
    semilunaris of middle nasal meatus, 1205
Highest nuchal line, 52
Highmore, antrum of, 87, **90,** 111, **1206,** 1346
Hilus of kidney, 1242
    of lungs, 1229, 1230
    of ovary, 1268
    of spleen, 1309
    of suprarenal glands, 1325
Hind-brain, 804
Hip, musculature of, 453, **454**
Hip-joint, 276
    arterial supply, 282
    ligaments of, 277
    lymphatics of, 750
    movements of, 282
    muscles acting upon, 283
    nerve-supply, 282
    relations, 282
    surgical anatomy of, 1435
Hippocampal branch of posterior communi-
      cating artery, 554
    commissure (psalterium or lyra), **869,** 890
    digitations, 877
    (chorioid) fissure, 868
    gyrus, 868
Hippocampus, 868
    gyrus of, 868
    major, 868, **877**
    minor (calcar avis), 864, 868, **876**
Hirci, 1290
Homologies of parts in sexes, 1280
Homology of the bones of the limbs, 206
Horizontal fissure of cerebellum, 805
Horner's muscle, 336, **1078**
Horns of spinal cord, 776
Houston's folds of rectum, 1177, 1390
Huguier, canal of, 75, 77, 108
Humeral artery, anterior circumflex, 572
      posterior circumflex, 573
Humerus, description of, 146
    clinical anatomy of, 1410, 1414
    nutrient artery of, 576
    ossification of, **151,** 1416
    tuberosities of, 147
Humor, aqueous, 1052, **1064**
    vitreous, of eye, 1052, **1064**
Hunter's (adductor) canal, 468, 1441
Hyaloid canal (canal of Cloquet), 1064
    membrane, 1064
Hydatid of Morgagni, 1257, 1269
Hymen, **1275,** 1392
Hyo-epiglottic ligament, 1218
Hyo-glossal membrane, 346
Hyo-glossus, 346
Hyoid bars, 119
    bone, 99, 119

Hyoid bone at birth, 124
cornua of, 99, 100
muscles acting on, 501
branch of lingual artery, 540
of superior thyreoid artery, 538
bursa, 1217
Hyo-mandibular muscles, 325
Hyo-temporal muscles, 325
Hyo-thyreoid ligament, 1217
membrane, 1217
Hyparterial bronchus, 1232
Hypertrichosis, 1290
Hypertrophy of nails, 1296
Hypochondriac region, 1143
Hypochordal bar, 51
Hypogastric (internal iliac) artery, **605,** 638
branches, **606,** 639
lymphatic nodes, 732
plexuses of nerves, 1045
region, 1143
(internal iliac) vein, 679
tributaries, 680
Hypoglossal eminence (trigonum hypoglossi), 814
foramen (canal), **54,** 108, 117, 125
(cervical) loop, **974,** 979
nerve, 952
central connections, **820,** 954
nucleus of, 820
Hypomalar, 95
Hypophyseal fossa (sella turcica), 63
Hypophysis cerebri, 758, 847, **848,** 1342
development of, 848
Hypospadias, **1280,** 1388
Hypothalamic nucleus (body of Luys), 884
sulcus, (sulcus of Monro), 847
Hypothalamus, 881
optic portion of, 847
Hypothenar fascia, 387
Hypo-tympanic recess, 77

I

Ileo-cæcal fossa, 1172
(colic) valve, 1172
region, 1376
Ileo-colic artery, 598
fossa, 1172
vein, 677
Ileum, **1165,** 1376
Iliac arteries, collateral circulation, **605,** 1382
common, **603,** 605, 638
deep circumflex, 616
external, **614,** 638
superficial circumflex, 618
branch of ilio-lumbar artery, 607
(nutrient) branch of obturator artery, 608
colon, **1174,** 1379
fascia, 455, 466
fossa, 170
lymphatic nodes, common, 731
external, 732
plexus of nerves, 1045
spines, 169
vein, external, 683
internal (hypogastric), 679
veins, common, 679
Iliacus, 455
minor, 455
Ilio-coccygeus, 440, **448**
Ilio-costal region, 1407
Ilio-costalis cervicis (cervicalis ascendens), 416
dorsi (accessorius), 416
lumborum, 416
Ilio-femoral ligament, 278
musculature, 454
Ilio-hypogastric nerve, 998
Ilio-inguinal nerve, 1000
Ilio-lumbar artery, 606
ligament, 233
vein, 680
Ilio-pectineal eminence, 169
fascia, **455,** 466
fossa, 467
line, 173
Ilio-tibial band, **457,** 458, 1436
Ilio-trochanteric band, 280
Ilium, 169
crest of, 169
tuberosity of, 171
Inca bone, (interparietal), 57
Incisive branch of inferior alveolar (dental) artery, 548
foramen, 89
fossa, 87
papilla, 1104
sutures, 106
Incisivus labii inferioris, 332
superioris, 332
Incisor crest, 90
fossa, 95
teeth, 1120
Incisura, 29
apicis cordis, 510
interarytænoidea, 1222
Incisure, anterior, of auricle, 1082
antitragic, 1082
of Santorini, 1085
terminal (auricle), 1084
Incudo-malleolar articulation, 1090.
Incudo-stapedial articulation, 1090
Incus, 79, 119
ligaments of, 1091
Index, cephalic, 117
pelvic, 177
thoracic, 139
Induseum griseum, 868
Infra-clavicularis, 374
Infraglenoid tubercle of scapula, 143
Infrahyoid musculature, 327, **350**
portion of external cervical fascia, 347
Infra-omental region of peritoneum, 1372
Infra-orbital artery, **549,** 1075
branches of cervico-facial nerve, 945
canal, **87,** 103, 126
foramen, **87,** 1345
groove, 87
nerve, **937,** 939
plexus, **937,** 939, 945
process, 95
sulcus, 1284
vein, 646
Infraspinatus, 368
Infraspinous branches of posterior scapular artery, 566
of transverse scapular artery, 565
fossa, 142
Infra-temporal (zygomatic) fossa, **101,** 1332
ridge, 65
Infratrochlear nerve, 936, 937
Infra-vomerine center, 71
Infundibula (ureter), 1248
Infundibular recess, 848
Infundibulo-pelvic ligament, 1267
Infundibulum of cerebrum, 848
of ethmoid, 83
in middle nasal meatus, 111, **1205**
of tubæ uterinæ (Fallopian tubes), 1270
Inguinal abdominal (internal abdominal) ring, **430,** 1371, 1396
branches of femoral artery, 620
canal, 424, **430,** 1371, **1395**
hernia, 1255, **1394,** 1398

Inguinal (Poupart's) ligament, 424, **429,** 1371, 1399, 1438
reflected (triangular) fascia, **430,** 1395
lymphatic nodes, 746
ring, subcutaneous (external abdominal), **429,** 1371, 1394
(iliac) regions, 1143
Inion, **101,** 1331
Inlet or brim (superior aperture) of pelvis, 175
Innominate artery, **532,** 637, 1369
branches, 532
Innominate canal (canaliculus), 65
bone, 169
(brachio-cephalic) veins, **641,** 691, 692
relations to thoracic wall, 1369
Inscriptio tendinea, 317, 430
Insertion of muscles, 314 (see also individual muscles)
Inspiration, muscles which affect, 247
Insula (island of Reil), 856
Integument, 1281
Interarticular cartilage, 211
ligament (capitular articulation), 241
(sterno-costal joint), 245
menisci (semilunar fibro-cartilages), 289
Interarytænoid (procricoid) cartilage, 1213, 1218
Inter-brain, 843
Intercalated lymph-nodes, 706
Intercapitular veins (hand), 667
(foot), 684
Intercarpal ligaments, 269
Interchondral articulation, 246
arterial supply, 247
capsule of, 247
movements, 247
nerves, 247
Interclavicular ligament, 248
notch, 133
Intercoccygeal joints, 238
Intercondyloid fossa of femur, 182
eminence of tibia, 185
fossæ of tibia, 185
tubercles, 185
Intercostal branches of internal mammary artery, 567
arteries, 588
superior, 568
branches of musculo-phrenic artery, 567
ligaments, external, 423, 432
lymphatics, 724, 728
muscles, function of, 422
nerves, thoracic, 995
spaces, 139
veins, 664
Intercostales externi, 423, **432**
interni, 423, **433**
Intercosto-brachial (intercosto-humeral) nerve, 995
Intercrural (intercolumnar) fibres of external oblique, **430,** 1394
Intercuneiform articulation, 304
Interfascial (Tenon's) space, 715
Interfoveolar ligament, **430,** 435
Interior of skull, 112
Interlobar fissure of lungs, 1230
Intermediate cell mass, 15
crus of diaphragm, 437
fasciculus (mixed lateral zone), 784
plexus, 1041
Intermetacarpal articulations, 273
Intermetatarsal joints, 309
Intermuscular septa, 314
of foot, 492
of leg, 477
of thigh, 468
septum of arm, lateral, 377
Intermuscular septum of arm, medial, 377
Interossei dorsales (foot), 499
(hand), 410
plantares, 499
volares (hand), 409
Interosseous arteries of foot, 633
of forearm, **577,** 579, 1423
artery, of forearm, common, 577
dorsal, 579
volar, **577,** 639
crest of fibula, 190
of radius, 153
of tibia, 188
of ulna, 157
crural nerve, 1010
ligaments, anterior talo-calcaneal joint, 302
inferior, tibio-fibular articulation, 297
intercuneiform joints, 304
middle tarso-metatarsal joints, 308
of middle tibio-fibular union, 296
of pelvic, articulations, 235
of posterior talo-calcaneal joint, 301
superior, tibio-fibular joint, 295
membrane of forearm, 263, 264, 1420
muscles of foot, 454, **499**
of hand, 409
nerve, posterior, 986
volar (anterior), 992
recurrent artery, 580
Interparietal bone, 119
sulcus (intraparietal), 861
Interpeduncular fossa, 835
nucleus (ganglion), **843,** 885
Interphalangeal articulations of fingers, 276
of toes, 310
Interpterygoid fascia, 339
Interpubic fibro-cartilage, 240
Intersigmoid fossa, 1175
Interspinal muscles (interspinales), 412, **419**
Interspinous ligaments, 231
Intersternal joints, 244
Intertragic notch, 1082
Intertransversarii, 412, 417
Intertransverse ligaments, 231
muscles, anterior and lateral, 356
dorsal, 412
Intertrochanteric crest, 178
Intertubercular (bicipital), groove, 148
Intervaginal space of optic nerve, 1073
Interventricular foramen (foramen of Monro), 847, **874**
septum, 516
Intervertebral articulation, ligaments of, 225
fibro-cartilages, **225,** 238
veins, 666
Intestinal arteries, 596
veins, 677
lymphatic trunk, 731
Intestines, clinical anatomy of, 1375
large, **1170,** 1376
lymphatics of, 734
small, **1161,** 1375
Intracranial portion of internal carotid artery, 550
of vertebral artery, 560
Intralabial muscles, 331
Intraparietal sulcus, 861
Intrinsic muscles of great toe, 495
of larynx, 1218
of little toe, 498
of tongue, 1110
Introduction, 1
Intumescentia tympanica, 951
Involution of mammary gland, 1303
Iris, 1052, 1054, **1060,** 1065
Ischial spine, 172
Ischio-bulbosus muscle, 451

Ischio-capsular ligament, 278
Ischio-cavernosus (erector penis), 443, **451**
Ischio-femoralis, 461
Ischio-pubicus (Vlacovitch), 450
Ischio-pubo-femoral musculature, 463
Ischio-rectal fossæ, 441, **445,** 1384
Ischium, 171
Island of Reil (insula or central lobe), 865
Isthmus, aortic, 531
of Fallopian tubes, 1290
of fauces, **1100,** 1352
of gyrus fornicatus, 867
pharyngeal (faucium), **1100,** 1130, 1131, 1352
of rhombenecphalon, 758, **832**
of thymus, 1321
of thyreoid gland, 1313
of tuba auditiva (Eustachian tube), 1092
of uterus, 1271
Iter chordæ anterius, 126
posterius, **78,** 126

J

Jacobson, nerve of, **951,** 961
organ of, 1057, 1204
Jejunal and iliac branches of superior mesenteric artery, 598
Jejuno-ileum, lymphatics of, 734
Jejunum, **1165,** 1376
Joint-furrows, 1284
Joints (see "Articulations").
Jugular foramen, **74,** 108, 117, 125
fossa, 73, 108
ganglion (superior) of glosso-pharyngeal, 951
of vagus, 954, **956**
nerve, 960, **1035**
(interclavicular) notch, 133
process, **54,** 108
vein, anterior, 648
line of, 1356
external, **646,** 1359
internal, **659,** 691
posterior external, 648
venous arch, 648
Jugum sphenoidale, 67

K

Kidneys, **1241,** 1379
clinical anatomy of, 1379
development of, 1247
lymphatics of, 701, **737,** 1247
position and relations of, **1243,** 1380
structure, 1246
surfaces of, 1243
variations and comparative, 1247
vessels and nerves of, 1247
Knee-joint, 284
anastomoses around, 1457
arterial supply, 291
bursæ around, 1449
clinical anatomy of, 1449
ligaments of, 284
lymphatics of, 750
movements of, 292
muscles acting upon, 295
nerve-supply, 292
relations, 292
synovial membrane of, **290,** 1448
Krause, end-bulbs of, 1290
glands of, 1078
Krönlein's method for topography of brain, 1340

L

Labia (see also "Lips").
of cervix uteri, 1272
majora, **1276,** 1392
minora (nymphæ), **1277,** 1392
Labial arteries (of mouth), 541
(or scrotal) arteries, anterior, 620
posterior, 613
branches, inferior, of mental nerve, 941
superior, of maxillary nerve, 939
nerves, anterior, 1000
posterior, 1017
tubercle, 1102
veins (of mouth) 644
(of vulva), 683, 684
Labyrinth of ethmoid, 82
membranous, 1092
osseous, 80
Lacertus fibrosus (semilunar fascia), 382
Lacrimal apparatus, 1079
clinical anatomy of, 1346
artery, 552
bone, 85
at birth, 124
branch of dorsal nasal artery, 554
of middle meningeal artery, 548
canal, 1080
caruncle, 1052, 1055
crest, **85,** 110
ductus (canaliculi), 1079
fossa, **61,** 109
gland, **1079,** 1348
groove, 85, 87, 110
nerve, **936,** 1075
papilla, 1054
process, 85
puncta, **1079,** 1349
sac, **1080,** 1349
tubercle, 88
vein, 659
Lacrimo-ethmoidal cells, 84
Laciniate ligament (internal annular) of leg, 480
Lactiferous duct, 1254
sinus (ampulla), 1254
Lacuna(æ) laterales, 649
magna, 1264
of Morgagni (urethral), 1264
musculorum, 466
vasorum, 466
venous, of dura, 916
Lacunar (Gimbernat's) ligament, **424, 429,** 466, 1400
Lalognosis, 894
Lambda, **101,** 1331
Lambdoid suture, **57,** 101
Lamellous corpuscles of (Vater, or Pacinian), 1290
Lamina(æ), anterior elastic, of cornea, 1060
basal (vitreous), of chorioid, 1060
basilaris of membranous labyrinth, 1096
of cerebellum, medullary, 808
chorio-capillaris, 1060
cribriform, 119
cribrosa scleræ, 930, 1055, 1059, **1073**
of temporal bone, 92
of cricoid cartilage, 1210
epithelial chorioid, **876,** 924
fusca, 1059
mediastinales, 1237
medullary, of lenticular nucleus, 880
of thalamus, 882
papyracea (os planum), 83
posterior elastic, of cornea, 1060
quadrigemina, 833
rostal, of corpus callosum, 852

Lamina of septum pellucidum, 812
spiralis, 81
suprachoroidea, 1057, 1060
terminalis, (of brain), 848
(of ischio-rectal fossa), 1384
of thyreoid cartilage, 1210
tragi, 1084
of tuba auditiva, 1092
of vertebræ, 30
Landmarks of abdomen, 1370
bony of the ankle, 1459
of the buttocks, 1442
of cranium and scalp, 1333
of elbow, 1417
of the foot, 1464
of forearm, 1419
of the knee, 1447
of neck, 1354
of the leg, 1453
of thigh and hip, 1434
of wrist and hand, 1424
Langerhans, islets of, 1195
Lanugo, 1290
Large intestine, 1170
anus, 1177
blood-vessels of, 1179
cæcum or caput coli, **1170,** 1377
clinical anatomy of, 1376
colon, **1173,** 1378
development of, 1179
lymphatics of, 1179
nerves of, 1179
rectum, 1176
variations and comparative, 1130
vermiform process (appendix), **1173,** 1378
Laryngeal artery, superior, 538
inferior, 564
nerve, inferior, 957
superior, 956
pharynx, 1134
prominence, 1211
veins, inferior, 659
superior, 659
ventricle, 1222
Larynx, 1209
cartilages of, 1209
cavity of, 1220
development of, 1225
joints of, 1213
lymphatics of, **719,** 1224
muscles of, 326, 501, **1218**
vessels and nerves of, 1224
vocal folds (cords), 1223
Latissimo-condyloideus (dorso-epitrochlearis), 379
Latissimus dorsi, 368
clinical anatomy of, 1405
Law of developmental direction, 12
Laxator tympani muscle, 79
Left atrium of heart, 514
colic artery, 603
vein, 678
common carotid artery, 533
iliac artery, 605
coronary artery, 520
gastric artery, 593
gastro-epiploic artery, 595
vein, 677
innominate vein, 641
lower bronchial artery, 588
pulmonary artery, 529
veins, 529
subclavian artery, 556
upper bronchial artery, 588
ventricle of heart, 516, 517
Leg, bony landmarks of, 1453
clinical anatomy of, 1453
Leg, fasciæ of, 497
muscles acting on, 505
muscular compartments, 1453
musculature of, 453, **477**
vessels of, 1456
Lemnisci, decussation of, 815
of medulla oblongata, 815
Lemniscus, 831, **839**
lateral, 816, 831, **839**
medial, 816, 831, **839**
nucleus of, **824,** 839
Lens, crystalline, 1052, 1057, **1062**
Lens-capsule, 1057
Lenticular nucleus, 878, **879**
process of incus, 79
papillæ of tongue, 1106
Lenticulo-optic artery, 562
Lenticulo-striate artery, 562
Lesser alar (sesamoid) nasal cartilages, 1202
curvature of stomach, 1152
multangular (trapezoid) bone, 159, **162**
(gastro-hepatic) omentum, **1150,** 1185
palatine foramina, 106
sac of peritoneum, 1148
sigmoid cavity of ulna, 157
splanchnic nerve, 1039
tuberosity of humerus, 147
Levator ani, 440, **448**
claviculæ, 359
cushion, 1130
epiglottidis, 347
labii superioris, 322
alæque nasi, 332
menti, 334
palpebræ superioris, 1068
penis, 451
scapulæ 356, **359**
of thyreoid gland, 1315
veli palatini, 1137
Levatores costarum, 423, **432**
longi, 432
Levels, vertebral, 1409
Lieberkühn, (crypts) glands of, 1166, 1177, 1390
Lienal plexus of nerves, 1045
Lieno-renal ligament, 1310
Lieutaud, vesical trigone of, 1252
Ligament(s) (see also "Ligamentum"), 211
alar (occipito-dental or check), 223
of ankle-joint, **298,** 1463
annular, at ankle, 1463
of finger, 387
of superior radio-ulnar joint, 262
of trachea and bronchi, 1227
of wrist, 387
anterior, of ankle, 298
annular (wrist), 387
atlanto-epistrophic, 221
atlanto-occipital, 218
crucial, 288
longitudinal, 227
medio-carpal, 270
oblique (lateral occipito-atlantal), 219
sacro-coccygeal, 234
sacro-iliac, 234
of symphysis pubis, 239
talo-calcaneal, 302
talo-fibular, 299
apical dental (suspensory), 223
arcuate (subpubic), 239
connecting articular processes vertebræ, 228
Cooper's, 1400
of articulation of atlas with occiput, 218
of atlanto-epistrophic joint, 221
of auricle (of ear), 1084
uniting bodies of vertebræ, 225
broad (lateral), of uterus, **1267,** 1393

Ligament(s) of calcaneo-cuboid joint, 306
calcaneo-fibular, 299
calcaneo-metatarsal, 492
of capitular (costo-central) articulation, 241
capsular, of elbow-joint, 258
carpal (annular), 1427
of carpo-metacarpal joints, 272
of the carpus, dorsal, 384
transverse, 387
volar, 387
cerato-cricoid, 1213
check, of eyeball, 1072
coccygeal, 911
Colles', 430
conoid, 251
coraco-acromial, 252
coraco-clavicular, 251
coraco-humeral, 255
corniculo-pharyngeal, 1218
coronary, of knee-joint, 290
of liver, 1184
costo-clavicular, (rhomboid), 249
of costo-transverse articulation, 243
costo-xiphoid, 244,245
crico-arytænoid, 1214
crico-pharyngeal,1218
crico-tracheal, 1218
crucial, of central atlanto-dental joint, 222
of knee-joint, 288
cruciate, of leg, 479
of fingers, 387
of cuboideo-navicular union, 303
of cubo-metatarsal joint, 308
of cuneo-cuboid articulation, 304
of cuneo-navicular articulation, 304
cysto-colic, 1379
deltoid (of ankle-joint), 298
denticulate, 920, 921
dorsal intercarpal, 269
of elbow-joint, 258
external arcuate, 437
intercostal, 423, 432
lateral, of knee-joint, 286
falciform, of liver, 1185
fibular collateral, 286
of first row of carpal bones, 269
fundiform (superficial suspensory) of penis, 427
gastro-hepatic, **1150,** 1185
gastro-phrenic, 1150
gastro-splenic, (gastro-lienal), **1150,** 1310
Gimbernat's, 424, 429, 466
gleno-humeral, 255
glenoid (lip), 255
glosso-epiglottic, 1218
hepato-colic, 1379
hepato-duodenal, **1150,** 1185
Hesselbach's, 430
of hip-joint, 277
hyo-epiglottic, 1218
hyo-thyreoid, 1217
ilio-lumbar, 238
ilio-femoral, 278
immediate, 225
of incus, 1091
inferior interosseous, (tibio-fibular), 297
of inferior radio-ulnar joint, 264
inferior sacro-iliac, 235
transverse, (spino-glenoid), 253
infundibulo-pelvic, 1267
inguinal (Poupart's), 424, **429,** 1371, 1399, 1438
interarticular, 241, 245
interclavicular, 248
of intercuneiform joint, 304
interfoveolar, 430, 435
intermediate, 225
Ligament(s) of intermetacarpal joints, 273
of intermetatarsal joints, 309
internal arcuate, 437
lateral, of knee-joint, 286
of mandibular articulation, 215
interosseous, cubo-metatarsal joint, 309
anterior talo-calcaneal, 302
intercuneiform joints, 304
intermediate tarso-metatarsal joint, 308
metacarpal, 269
of pelvic articulations, 235
of posterior talo-calcaneal joint, 301
of interphalangeal joints, fingers, 276
of toes, 311
interspinous, 231
of intersternal joints, 244
intertransverse, 231, 238
of intervertebral articulation, 227
of knee-joint, 284
(internal annular) laciniate, of leg, 480
ischio-capsular, 278
lacunar (Gimbernat's) 424, 429, 466, 1400
of larynx, 1213
lateral, of ankle-joint, 299
calcaneo-navicular, 302, 305
hyo-thyreoid, 1217
malleolar, anterior, 296
posterior, 297
sacro-coccygeal (intertransverse), 238
of left vena cava, 521, **523**
of liver, 1184
malleolar (of tympanum), 1091
of mandibular articulation, 215
medial palpebral, 1052
median crico-thyreoid, 1215
hyo-thyreoid, 1217
of medio-carpal joint, 270
of metacarpo-phalangeal joints, 274, 275
of metatarso-phalangeal joints, 310
of mid radio-ulnar union, 262
middle costo-transverse, 243
tibio-fibular (interosseous), 296
morphology of, 213
neck, 243
oblique, of mid radio-ulnar union, 262
popliteal (ligament of Winslow), 287
occipito-cervical, 223
uniting occiput and epistropheus, 223
orbito-tarsal, 1071
of ossicles of ear, 1090
ovarian, 1269
patellar, 471
of pelvic articulations, 234
piso-hamate, 269
piso-metacarpal, 269
phreno-colic or costo-colic, 1150, 1174, 1310, 1379
phrenico-lienal (lieno-renal), 1310
plantar, 1468
calcaneo-cuboid, 307
calcaneo-navicular, 302, 305
accessory, 310
long, 307
pulmonary, 1236
posterior, of ankle-joint, 298
annular (wrist), 384
atlanto-epistrophic, 221
atlanto-occipital, 218
costo-transverse, 243
crucial (of knee), 288
longitudinal, 227
(dorsal) medio-carpal, 270
sacro-iliac, 234
of symphysis pubis, 239
of talo-calcaneal joint, 301
talo-fibular, 299
Poupart's, 424, **429,** 1371

Ligament(s), proper scapular, 252
pubo-prostatic (pubo-vesical), 1252
radial collateral, 261, 267
radiate of anterior costo-central or stellate, 242
of medio-carpal joint, 270
sterno-costal, 245
of radio-carpal joint, 266
of radio-ulnar joints, 261, **264**
reflected inguinal (triangular fascia), 430
rhomboid (costo-clavicular), 249
round, of uterus, 1274
of liver, 1185
of sacro-coccygeal articulation, 238
sacro-lumbar, 232
sacro-spinous or small sacro-sciatic, 236
sacro-tuberous, 235
of sacro-vertebral articulations, 232
of second row of carpal bones, 270
of shoulder-joint, 254
between skull and vertebral column, 218
spheno-mandibular, 217
spino-glenoid (inferior transverse), 253
connecting spinous processes of vertebræ, 229
spiral, of cochlea, 1096
spring, 305
sterno-clavicular, 248
of sterno-costal joints, 245
of sterno-costo-clavicular articulation, 248
sterno-pericardial, 522
stylo-hyoid, 99
stylo-mandibular (stylo-maxillary), 217
superficial transverse, 387
superior costo-transverse, 243
interosseous, tibio-fibular joint, 295
sacro-iliac, 234
sterno-costal, 245
transverse (coracoid or suprascapular), 253
supraspinous, 230, 238
suspensory, of Cooper, 1303
of the eyeball, 1072, 1348
of lens of eye, 1057, 1064
of ovary, 1269
of penis, 427, 1260
of Treitz, **1164**, 1376
of symphysis pubis, 238
talo-calcaneal, 302
of talo-navicular joint, 305
temporo-mandibular, 215
thyreo-epiglottic, 1215
thyreoid, 1314
tibial collateral, 286
tibio-fibular, 295
transverse, of central atlanto-epistrophic joint, 222
crural, 479
dorsal (medio-carpal joint), 270
of heads of metatarsal bones, 309
of hip-joint, 280
humeral, 256
of knee-joint, 289
of pubis, 446
connecting transverse processes of vertebræ, 231
trapezoid, 251
triangular, of liver, 1185
tubercular (posterior costo-transverse), 243
ulnar collateral, 259, **266**
umbilical, 1250, 1252
uniting laminæ of vertebræ, 229
of urinary bladder, 1252
utero-sacral, 1274
vaginal, 317
vaginal (fingers), 387
ventricular of larynx, 1215
Ligament(s), vocal, 1215
volar accessory (glenoid), 274
intercarpal, 269
radio-carpal, 266
Ligamenta denticulata, 911
flava, 229
Ligamentous branch of ovarian artery, 602
Ligamentum(a) alaria (knee-joint), 291
ano-coccygeum, 449
arteriosum, **528**, 531
breve, 399, 401
denticulatum, 920, 921
epididymis, 1255
interfoveolare, 430
longum, 399, 401
mucosum (knee-joint), 290
nuchæ, 231, 414
patellæ, **285**, 1448
pectinatum iridis, 1060
sacro-iliaca, anteriora, 177, **234**
teres, 280
of liver, 675, **1185**
(round ligament) of uterus, 1274
venosum of liver, **675**, 1185
Winslowii, 287
Ligature of anterior tibial artery, 1458
of brachial artery, 1414
of common carotid artery, 1358
of femoral artery, 1441
in Hunter's canal, 1442
of popliteal artery, 1452
of posterior tibial artery, 1458
of third part of subclavian artery, 1359
of ulnar artery, 1423
Ligula (tænia ventriculi quarti), 813
Limbic lobe, 865, 866
Limbous sutures, 212
Limbs, cutaneous areas of, 1020, 1022, 1024
development of, 20
Limbus of cornea, 1025
fossæ ovalis, 511
sphenoidalis, 63
of tympanic membrane, 1087
Limen of insula, 857, 865
nasi, 1204
Limiting sulcus of floor of fourth ventricle, 813
Line(s) (see also "Linea").
(striæ) albicantes, 1283, 1384
bony, 29
of femur, intertrochanteric, 178
spiral, 178
of fibula, oblique, 190
secondary oblique, 190
gluteal, 170
ilio-pectineal, 173
mylo-hyoid, 95
Nélaton's, 1436
oblique, of mandible, 95
of radius, 154
of thyreoid, 124
popliteal, 189
of scapula, oblique, 142
supra-condylar, of femur, 181
temporal (ridges), 57, 60, 1332
transpyloric (Addison's), 1153, **1370**
trapezoid (oblique), 140
of ulna, oblique, 157
Linea alba of abdomen, 427, **1370**
viscera behind, 1373
aspera, 178
pectinea of femur, 181
semicircularis, 427
semilunaris of abdomen, 1371
splendens, 921
suprema (highest nuchal line), 52
Lingual artery, 539
branches, 539

Lingual (gustatory) branch of inferior alveolar (dental) artery, 548
of glosso-pharyngeal nerve, 952
of facial nerve, 944
fascia, 346
follicles, 1107
gyrus, 864
nerve, **940**, 1350
papillæ, 1160
plexus of nerves, 1036
tonsil, 1107
veins, 660
Lingula cerebelli (lingula vermis), 806, 831
of left lung, 1229
of mandible, 96
of sphenoid, 64
of Wrisberg, 942
Lips, **1102**, 1349
of Eustachian aperture, 1130
glenoid, 255
of ileo-cæcal valve, 1172
lymphatics of, 713
variations and comparative, 1172
vocal, 1223
Lisfranc, amputation of, 1465
Lissauer, marginal zone of, 782
Little finger, muscles of, 404
Littré, glands of (urethral), 1264
Liver, 1180
blood-vessels of, 1185
clinical anatomy of, 1373
development of, 1189
ductus choledochus (common bile-duct), 1188
gall-bladder, 1187
ligaments of, 1184
lobes and fissures of, 1180
lymphatics of, 699, 736
topography of, 1373
Liver, surfaces and borders of, 1181
variations and comparative, 1190
Lobe(s), biventral, 807
central, 856
of cerebellum, 805
frontal, 857
inferior semilunar, of cerebellum, 807
limbic, 865, 866
of liver, 1183
of lungs, 1230
of mammary gland, 1302
occipital, 863
olfactory, 865
parietal, 860
of prostate, 1265
pyramidal, of thyreoid gland, 1314
quadrangular, 806
superior semilunar of cerebellum, 806
of telencephalon, 853
temporal, of cerebrum, 854
of thymus, 1320
of thyreoid gland, 1313
uvular, of cerebellum, 791
Lobule of auricle of ear, 1083
central, of cerebellum, 806
of cerebellum, 805
inferior parietal, 863
paracentral, 857, 863
quadrate, 863
splenic, 1312
superior parietal, 862
of testis, 1256
of thymus, 1321
of thyreoid gland, 1316
Lobulus epididymis (conus vasculosus), 1256
Locus cæruleus of floor of fourth ventricle, 815, 829
Loewenthal's tract, 786
Longissimus capitis (trachelo-mastoid), 416
cervicis (transversalis cervicis), 416
dorsi, 416
Longitudinal arch of foot, 1468
bundle, posterior, 817
fasciculus, inferior, 892
medial, 817, **842**
nucleus of, 871
superior, 892
fissure of cerebrum, 850
ligament of intervertebral articulation, 227
(sagittal) sinuses, 649, 650
striæ of corpus callosum, 851, 892
of hippocampus, 871
vertebral veins, 665
Longitudinalis linguæ inferior medius, 347
Longus capitis (rectus capitis anterior major), 355
colli, 355
Loop, cervical (hypoglossal), **953**, 979
Henle's, 1246
Louis, angle of, 139
Lower extremity, articulations of, 276
clinical anatomy of, 1434
cutaneous areas of, 1024
fasciæ of, 454
lymphatics of, 746, 748
musculature of, 452
Lowest lumbar (lumbalis ima) artery, 603
Lumbar arteries, 593, 638
lowest (ima), 603
branch of ilio-lumbar artery, 607
enlargement of spinal cord, 772
fascia, 436
lymphatic nodes, 730
trunks, 730
muscle, 436
nerves, 973, 996
posterior primary divisions, 973
plexus, 998
branches of, 998
composition of nerves of, 998
situation of, 998
portion of sympathetic system, 1039
puncture (Quincke), 1408
regions, 1143
ribs, 132
veins, 675
ascending, 662, **663**
vertebræ, 37
description, 37
development of, 48
Lumbo-costal arch, lateral, 437
medial, 437
Lumbo-dorsal fascia, 414, 428
Lumbo-inguinal (crural) branch of genito-femoral nerve, 1000
Lumbo-sacral angle, 43
plexus, 996
trunk, 1005
Lumbricales (foot), 454, **495**
(hand), 408, **409**
Lunate (semilunar) bone, 159, **161**
Lungs (pulmones), 1228
clinical anatomy of, 1367
development of, 1235
form of, 1228
lobes of, 1230
lymphatics of, **729**, 1235
surfaces of, 1229
topography of, **1233**, 1367
variations of, 1235
vessels and nerves of, 1234
Lunula of nails, 1295
of semilunar valves, 517
Luys, body of, 884
Lymph, movement of, 702

Lymphatic capillaries, 697, 698
duct, right (terminal collecting), 728
follicle, 704
nodes (glands) of abdomen and pelvis, 730
ano-rectal, 735
anterior auricular, 709
mediastinal, 724
axillary, 719
bronchial, **725,** 1226
buccinator, 711
cœliac, 730
common iliac, 731
deep cervical chain, 714
delto-pectoral, 719
development of, 707
diaphragmatic, 725, **736**
epigastric, 732, 733
external iliac, 732
facial, 709, 711
gastric, 730, **734**
of head and neck, 709, 714
hepatic, 730, **736**
hypogastric, 732
inferior deep cervical, 714
inguinal, 746
internal mammary, 724
intercostal, 724
of larynx, 1224
of lower extremity, 746
lumbar, 730
mesenteric, 731
meso-colic, 734
occipital, 709
parietal, of thorax, 724
parotid, 709
of pelvis, 730
popliteal, 748
post-aortic, 731
posterior mediastinal, 725
auricular, 709
pre-aortic, 730
pulmonary, 725
sacral, 733
splenic, 730, 736
structure of, 704
subinguinal, 746
submaxillary, 709
submental, 711
superficial cubital (supratrochlear), 719
superior deep cervical, 714
supramaxillary, 711
of thorax, deep, 724
visceral, 724
umbilical, 733
of upper extremity, 719
system, 697
general anatomy of, 697
special anatomy of, 709
development of, 706
of eyeball, 1065
of orbit, 1076
vessels, 702, 705
of abdomen and pelvis, 733
of eyelids, 1078
of face, 712
of head, 712, 714
of hip-joint, 750
of knee-joint, 750
of lower extremity, 748
of neck, 712, 714
of œsophagus, 730, 1141
regeneration of, 707
structure of, 702
of thorax, deep, 725
superficial, 723
Lymphatic vessels of upper extremity, deep, 721
superficial, 721
Lymphatics of abdomen and pelvis, 730
in abdominal wall, 1372
of alimentary tract, 699, **733**
of anus, 735
of auricle (of ear), **714,** 1084
of brain, 714
capillaries, 697
of clitoris, 745
of conjunctiva, 698, **712**
of diaphragm, 728
of digestive tract in head and neck, 715
of ductus deferens and seminal vesicles, 744
of duodenum, 734
of excretory organs, 737
of external auditory meatus, **714,** 1086
of the eye, **715,** 1065
of eyelids, 712
of Fallopian tube, **745,** 1270
of female external genitals, **744,** 1278
of gums, 715
of head and neck, 709
of heart, 522, 701, **730**
of ileocæcal region, 734
intercostal, 728
of jejuno-ileum, 734
of kidney, **737,** 1247
of large intestine, **734,** 1179
of larynx, **719,** 1224
of lips, 713
of liver, **736,** 1186
of lower extremity, **746,** 1468
of lungs, **729,** 1235
of mammary gland, **723,** 1305
of nasal cavities, **717,** 1208
of neck, 709
of nose, **712,** 1203, 1208
of ovary, **745,** 1269
of palate, 717
of pancreas, **736,** 1195
of parotid gland, 1115
of penis, **744,** 1262
of pharynx, **717,** 1138
of pleura, 1239
of prostate, **739,** 1265
of rectum and anus, 735
of reproductive organs, male, 742
of scalp, 712
of scrotum, **742,** 1255, 1385
of shoulder-joint, 723
of skin, 698, **1289**
of small intestine, 1168
of spleen, **736,** 1312
of stomach, **734,** 1156
of suprarenal glands, **738,** 1326
of teeth, 1124
of testis, **744,** 1256, 1387
of thoracic muscles, 723
of thorax, 723
of thyreoid gland, **719,** 1317
of thymus, **729,** 1322
of tongue, **715,** 1111
of tonsils, 1138
of trachea and bronchi, 699, **1228**
of tubæ (Fallopian tubes), 1270
of upper extremity, **719,** 1424
of ureter, **738,** 1249
of urethra, female, 742
male, 744
of urinary bladder, **739,** 1253
of uterus, **745,** 1274
of vagina, **745,** 1276
of vulva, **744,** 1278
Lymph-follicles, 704
Lymph-nodes, 704

Lymphoglandulæ, 704
Lymphoid organs, 704
Lyra, hippocampal, 869

M

Macewen's suprameatal triangle, 1337
Macula acustica sacculi, 950, **1094**
utriculi, 1093
lutea (yellow spot), 1055, 1057
Magendie, foramen of, 813
Major sublingual duct (of Bartholin), 1117
palatine artery, 549
Malar bone, 93
branches of maxillary nerve, 938
of temporo-facial nerve, 945
tubercle, 95
tuberosity, 93
Male mammary gland, 1305
pelvis, 1382
reproductive organs, **1253,** 1386
Malleolar artery, lateral, 632
medial, 632
posterior lateral artery, 626
folds of tympanic mucous membrane, 1089
ligaments, anterior lateral, 296
posterior lateral, 297
of ossicles of ear, 1091
prominence of tympanic membrane, 1087
recesses of tympanic mucous membrane, 1089
rete, lateral, 626, 632
medial, 626, 632
stria of tympanic membrane, 1087
Malleoli, clinical anatomy of, 1451
lateral, 191
medial, 189
Malleus, **79,** 119
Malpighi, pyramids of, 1246
Malpighian corpuscle (renal), 1246
(splenic), 1311
Mammary artery, external, 1305
internal, **566,** 1365
cutaneous branches of aortic intercostal arteries, 590
gland (mamma), 1299
clinical anatomy of, 1366
line (ridge), 1306
lymphatics of, **723,** 1305
in male, 1305
vessels and nerves of, 1305
plexus of nerves, internal, 1037
veins, internal, 666
venous plexus, 671
Mammillary bodies, 843, 871
process, 38
Mammillo-mesencephalic fasciculus, 871
Mammillo-thalamic fasciculus, 871, 883
Mandible (lower jaw), 95
age changes in, 99
at birth, 124
ossification of, 98
surgical anatomy of, 1345
Mandibular bars, 119
branches of cervico-facial nerve, 946
(inferior dental) canal, 96, 126
foramen, 96
fossa, 108
nerve (third division of trigeminus), 939, 1345
(sigmoid) notch, 96, 97
portion of internal maxillary artery, 546
spine, 96
Manubrium of malleus, 79
sterni (presternum), 132, 133
Margin, falciform, of fascia lata, 467
of lungs, 1229, 1233
Marginal gyrus, 858
sinuses, 650
zone of Lissauer, 782
Margo acutus of heart, 510
obtusus, 510
Marshall, oblique vein of, 521, **523**
Massa intermedia, 844
Masseter muscle, 338, **341**
Masseteric branch of external maxillary artery, 541
artery, 548
fascia, 339
nerve, 943
veins, 644, 646
Mastication, muscles of, 325
Masticator nerve, 829, **942**
Mastoid antrum (see "Tympanic antrum").
branch of great auricular nerve, 978
of occipital artery, 543
of small occipital nerve, 977
of stylo-mastoid artery, 544
canaliculus, 73
cells, **72,** 1092, 1336
foramen, **72,** 108, 117
(supra-meatal) fossa, 72
notch (digastric fossa), 72
process, 72, 108
development of, 76
Mater, dura, 771
pia, 771
Maxilla, **86,** 1346
at birth, 124
ossification of, 91
Maxillary artery, external, **540,** 638, 1343
internal, 545, 638
nerve (second division of trigeminus), 937
plexus of nerves, external, 1036
internal, 1036
process of inferior turbinate, 85
of palate bone, 92
sinus (antrum of Highmore), 87, **90,** 111, **1206,** 1346
vein, internal, 646
Maxillo-ethmoidal cells, 84
Maxillo-turbinates, 119
Meatal branch of stylomastoid artery, 544
Meatus, external auditory (acoustic), 75, 108, **1084,** 1332
internal auditory, 72, 117
naso-pharyngeus, 1206
of nose, 83, 111, **1205**
Meckel's cartilage, 98, 119
caves, 916
diverticulum, 1169
ganglion, 962
Median antibrachial vein, 667, 668
artery of forearm, **578,** 639
basilic (cubital) vein, 667, 669
cephalic vein, 668
crico-thyreoid ligament, 1215
cubital vein, 667
fissure of spinal cord, anterior, 772
hyo-thyreoid ligament, 1217
nerve, **991,** 1423
results of paralysis of, 1424
sulcus of floor of fourth ventricle, 813
Mediastinal artery, anterior, 567
branches of aorta, 590
lymphatic nodes, anterior, 724
posterior, 725
pleura, 1237
septum, 1239
surface of lungs, 1229
veins, 664, 667
Mediastinum, 20, 1228, **1239**
divisions, 1239
testis (corpus Highmori), 1256

Medio-carpal joint, 270
arterial supply, 270
ligaments, 270
movements of, 271
muscles acting upon, 270
nerve-supply of, 270
Medulla of kidney, 1246
oblongata, 799
blood-vessels of, 908
central connections of cranial nerves in, 818
ventral aspect of, 799
of suprarenal gland, 1321
of thymus, 1326
Medullary cavity, 28
lamina of lenticular nucleus, 880
of thalamus, 882
laminæ of cerebellum, 808
ray of kidney, 1246
sheaths, 759
striæ, acoustic, 824
velum, anterior (superior), 812
posterior, 808
Medullated fibres, 760, 767
Medullation of fasciculi of spinal cord, order of, 791
Meibomian glands, 1054, **1078**
Meissner, tactile corpuscles of, 1290
plexus of, 1030, 1045
Membrana sacciformis, 265
Membrane(s), Bowman's, 1060
choroidal, 1052
of Descemet, 1060
elastic, of larynx, 1215
hyaloid, 1064
hyo-glossal, 346
hyo-thyreoid, 1217
interosseous, of forearm, 1420
of mid-radio-ulnar union, 263, 264
of middle tibio-fibular union, 295
pharyngeal, 1102
quadrangular of larynx, 1215
secondary tympanic, 1089, **1096**
Shrapnell's, 1087
synovial, 211; (see also the individual articulations)
Membrane, tectorial, 223
tympanic, 1086
vestibular (membrane of Reissner), 1096
Membranous ampullæ, 1095
cochlea, 1095
cranium, 117
labyrinth, 1092
nasal septum, 511
semicircular canals, 1094
urethra, **1264,** 1388
Meningeal artery, accessory (small), 548
arteries, 917
middle, 547
surgical anatomy of, 1341
posterior, 537
branches of anterior ethmoidal artery, 554
of maxillary nerve, middle (recurrent) 937
of occipital artery, 543
of ophthalmic nerve, recurrent, 935
of posterior ethmoidal artery, 553
of spinal nerve-trunks (recurrent), 970
of vagus, 956
of vertebral artery, 560
plexus of nerves, 1036
veins, **646,** 917
Meninges, 908
arachnoid, 917
dura mater, 910
pia mater, 920
relation to spinal nerves, 965
Meningoceles, 1331
Menisci, interarticular, 289
Mental branch of inferior alveolar (dental) artery, 548
foramen, 95
muscle, 334
nerve, 941
protuberance, 95
spine, 95
tubercle, 95
Mentalis (levator menti), 334
Mento-labial sulci, 1284
Meridians of eyeball, 1055
Mesatipellic pelvis, 177
Mesencephalon, 758, **833**
blood-vessels of, 907
external features of, 834
internal structure of, **836,** 843
Mesencephalic root of masticator nerve, 836, **942**
nucleus of, 829
Mesencephalo- or tecto-spinal tract, 786, **842**
Mesenteric artery, inferior, **602,** 638
superior, **596,** 638
ganglion, superior, 1043, 1045
lymphatic nodes, 731
plexus of nerves, inferior, 1045
superior, 1045
vein, inferior, 678
superior, 677
Mesenteriolum, of appendix, 1173
Mesentery, **1165,** 1376
development of, 19
Mesethmoid, 119
Meso-colic lymphatic nodes, 734
Meso-colon, 1174, 1175
Mesoderm, 10, 14
Mesognathion centre, 91
Meso-metrium, 1267
Meso-nephros (Wolffian body), 16, 1256, **1278**
Meso-palatine suture, 89, 106
Meso-salpinx, 1267
Meso-scapula, 145
Meso-sternum, 132
Mesotendons, 318
Mesovarium, 1267
Metacarpal arteries, dorsal, 586
volar, 586
bones, 164
union of heads of, 274
head of adductor pollicis, 408
veins, dorsal, 667
volar, 671
Metacarpo-phalangeal joints, 274
of thumb, 275
Metacarpus, ossification of, 168
Metamerism, 15
of cranial musculature, 327
Metamorphosis of branchial (visceral) bars, 119
Metanephros, 1278
Metasternum, 132
Metatarsal artery, dorsal, 633
plantar, 628
bones, 200
union of heads of, 309
pillar, 205
veins, plantar, 687
Metatarso-phalangeal articulations, 310
Metatarsus, 200
Metathalamus (geniculate bodies), 845
Metopic suture, **59,** 101
Meynert, fasciculus retroflexus, 843, **885**
Micromastia, 1301
Mid-brain, 833
Middle alveolar canal, 87
(azygos) articular artery, 623

Middle cardiac nerve, 1036
vein, 520
cerebral artery, **555,** 562
vein, 655
clinoid process, 65
coat of eye, 1060
colic artery, 598
collateral (branch of profunda) artery, 576
constrictor of pharynx, 1137
costo-transverse (neck or interosseous) ligament, 243
cranial fossa, 116
Middle ear, 77, **1086**
ethmoidal cells, 111
hæmorrhoidal artery, 610
meatus of nose, 111
meningeal artery, **547,** 1341
veins, 646
nasal conchæ, 83
palatine foramina, 106
peduncle of cerebellum, 811
sacral artery, 603
vein, 679
suprarenal arteries, 598
temporal artery, 545
thalamic branch of posterior communicating artery, 554
thyreoid vein, 661
umbilical ligament, 1250
Mid-radio-ulnar union, 262
Milk, 1303
teeth, 1126
Minor palatine arteries, 549
sublingual ducts (of Rivini), 1117
Mitral cells of olfactory bulb, 866
(bicuspid) valve, 515, 516
Moderator band of heart, 516
Modiolus, 81
Molars, 1121
Molecular layer of cerebellar cortex, 809
Moll, glands of, 1078
Monro, foramen of, 847, **874**
sulcus of, 847
Mons pubis (veneris), 1276
Montgomery, glands of, 1304
Monticulus of cerebellum, 806
Morgagni, columns of, 1177
hydatid of, 1257, 1269
lacunæ of, 1264
sinus of, 1137
ventricle of, 1222
Morphogenesis, 7 (see also "Development")
Morphological axis of scapula, 145
Morphology (see also "Comparative Anatomy")
of alimentary canal, 1099
of joints, 213
of musculature of head and neck, 323
of pelvic outlet, 444
of skull, 117
of spinal cord, external, 771
of the testis, 1256
of the vertebræ, serial, 50
Morula, 9
Motor aphasia, 894
area of speech, 894
roots (see individual nerves)
Mouth, 1100
clinical anatomy of, 1349
muscles of, 332
Movements of joints, 214 (see also individual articulations)
Müllerian duct, 1257, 1267, **1279**
Multangular bone (trapezium) greater, 159, **162**
(trapezoid) lesser, 159, **162**
Multifidus, 412, **419**
Multipenniform muscle, 315
Muscle(s) (see also "Musculature")
abductor accessorius digiti quinti (foot), 499
digiti quinti (foot), 454, **498**
(hand), 404
hallucis, 454, **496**
longus, 482
ossis metatarsi quinti, 499
pollicis brevis, 406, 407
longus (extensor ossi metacarpi pollicis), 392, **393**
abnormal, of front of leg, 482
of back of leg, 491
of volar side of forearm and wrist, 392
accessorius ad flexorem digitorum profundum (forearm), 402
of gluteus minimus, 462
of spinal musculature, 416
accessory peroneal, 484
acting upon joints (see individual articulation)
adductor brevis, 453, 471, **474**
digiti secundi, 498
hallucis, 454, 496, **498**
longus, 453, 471, **472,** 1437
magnus, 453, 471, **474,** 1437
minimus, 474
pollicis, 407, **408**
anconeus, 374, 377, **379**
internus, 402
of the angle of the mouth, 332
anomalus, 335
antagonists, 322
anterior and lateral intertransverse, 356
antitragus, 1084
articularis genu, 470
atlanto-mastoid, 422
attached to the tendons of flexor digitorum, longus, 495
attachments of bones (see individual bones)
of auricle (of ear), **337,** 1084
auricularis anterior (attrahens aurem), 337
posterior (retrahens aurem), 337
superior (attollens aurem), 337
auriculo-frontalis, 337
ary-epiglottic, 1220
ary-membranosus, 1220
arytænoideus obliquus, 1220
transversus, 1218
ary-vocalis, of Ludwig, 1220
belly of, 314
biceps brachii, 374, 379, **382,** 1414
biceps femoris, 453, **475**
bicipital, 314
bipenniform, 315
biventer cervicis, 418
brachialis, 374, 380, **382**
brachio-radialis (supinator radii longus), 387, **388**
broncho-œsophageal, 1141, 1248
buccinator, 334
bulbo-cavernosus, 443, **450**
in female, (sphincter vaginæ), **450,** 1278
caninus, 332
caput angulare, 332
infraorbitale, 332
zygomaticum, 332
cerato-cricoid, 1218
cervical, 330
cervicalis ascendens, 416
chondro-humeralis (epitrochlearis), 374
chondro-glossus, 346
ciliaris Riolani, 1077
ciliary, 1057, 1060
classification of, 319
coccygeus, 440, **448**
complexus, 412, **417**

Muscle(s), compressor bulbi proprius, 450
hemisphærium bulbi, 451
venæ dorsalis, 451
constrictor laryngis, 1218
radicis clitoridis, 451
penis, 450
vaginæ, 449, 451
coraco-brachialis, 374, 379, **381**
corrugator, 336
cutis ani, 445
costo-coracoideus, 374
cremaster, 423, **434**, 1254, 1259
crico-arytænoideus lateralis, 1219
posterior, 1218
crico-thyreoid, 1218
crureus, 468, **470**
cruro-pedal, 486
deltoideus, 364, **365**, 1410
depressor alæ nasi, 334
anguli oris, 333
labii inferioris, 332
septi nasi, 334
diaphragm, 425, **436**
digastric variety of, 314
digastricus, 343, 344
dilator naris anterior, 335
posterior, 335
pupillæ, 1061
divisions of, 316
of dorsum of foot, 492
epicranio-temporalis, 337
epicranius, 336
epitrochleo-olecranonis (anconeus internus), 402
erector spinæ, 414
extensor carpi radialis accessorius, 391
brevis, 388, **399**
intermedius, 391
longus, 387, **388**
ulnaris, 388, **391**
communis pollicis et indicis, 394
digiti annularis, 395
quinti proprius, 388, **391**
digitorum brevis (foot), 454, **492**
(hand), 395
communis, 388, **391**
longus, 453, 480, **481**
hallucis brevis, 482, **492**
longus, 453, 480, **482**
indicis proprius, 392, **394**
medii digiti, 395
minimi digiti, 388, **391**
ossis metacarpi pollicis, 392, **393**
pollicis brevis, 392, **394**
longus, 392, **394**
erector penis (clitoridis), 443, 451
fasciæ, 313
femoro-tibial, 486
fibulo-calcaneus medialis, 491
fibulo-tibialis (peroneo-tibialis), 486
finer structure of, 315
flexor accessorius (digitorum longus), 491
(quadratus plantæ), 495
carpi radialis, 396, **398**
brevis (radio-carpeus), 403
ulnaris, 396, **398**
brevis (ulno-carpeus), 402
digiti quinti brevis (foot), 454, 498, **499**
(hand), 404
digitorum brevis (foot), 454, 493
longus (leg), 454, 486, **489**
profundus, 401
sublimis, 399
hallucis brevis, 454, 496, **497**
longus, 454, 486, **490**
pollicis brevis, 407, **408**
longus, 402
Muscle(s), of front of leg, 480
frontalis, 337
fusiform, 315
gastrocnemius, 453, 484, **485**
gemellus inferior, 464
superior, 464
genio-glossus, 346
genio-hyoideus, 343, **345**
genio-pharyngeus, 347
glosso-palatinus (palato-glossus), 1135
gluteus maximus, 443, 457, **459**
medius, 457, **461**
minimus, 457, **461**
gracilis, 453, 471, **472**
gross structure of, 314
grouped according to function, 500
head of, 314
helicis major, 1084
minor, 1084
Horner's, 336
hyo-glossus, 346
iliacus, 455
minor, 456
ilio-coccygeus, 440, **448**
ilio-costalis cervicis (cervicalis ascendens), 416
dorsi (accessorius), 416
lumborum, 416
incisivus labii inferioris, 332
superioris, 332
incisuræ helicis (Santorini), 1084
inferior constrictor of pharynx, 1136
oblique, 1068
infra-clavicularis, 374
infraspinatus, 364, **368**
insertion of, 314
intercostales externi, 423, **432**
interni, 423, **433**
internal cremaster, 1254, 1259
interossei dorsales (foot), 454, **499**
(hand), 410
plantares, 454, **499**
volares (hand), 409
interspinal, 412, **419**
intertransversarii, 417
intralabial, 331
ischio-bulbosus, 451
ischio-cavernosus (erector penis or clitoris) 443, 451
ischio-femoralis, 461
ischio-pubicus (Vlacovitch), 450
of larynx, 1218
latissimo-condyloideus (dorso-epitrochlearis), 379
laxator tympani, 79
latissimus dorsi, 364, **368**, 1405
levator anguli oris, 332
ani, 440, **448**
claviculæ, 359
epiglottidis, 347
labii superioris, 332
alæque nasi, 332
menti, 334
palpebræ superioris, 1068
scapulæ, 356, **359**
veli palatini, 1137
levatores costarum, 423, **432**
longi, 432
of little finger, 404
longissimus capitis (trachelo-mastoid), **416**
cervicis (transversalis cervicis), 416
dorsi, 416
longitudinalis superior and inferior, 1110
linguæ inferior medius, 347
longus capitis, 355
colli, 355
lumbar, 436

Muscle(s), lumbricales (foot), 454, **495**
(hand), 408
masseter, 341
mentalis, 334
middle constrictor of pharynx, 1137
multifidus, 412, **419**
multipenniform, 315
mylo-hyoideus, 343, **344**
nasalis, 334
pars alaris (depressor alæ nasi), 334
pars transversa (compressor naris), 334
nerves of, 318
nomenclature of, 319
number of, 315
obliquus abdominis externus, 423, **432**
internus, 423, **434**
auriculæ, 1084
capitis inferior, 412, **420**
superior, 412, **420**
obturator externus, 453, 463, **464**
internus, 453, **463**
occipitalis, 337
minor, 337
occipito-frontalis, 336
occipito-scapularis, 359
ocular, 1068
action, 1068
omo-hyoideus, 351
opponens digiti quinti (foot), 454, 498, **499**
(hand), 404, **405**
hallucis, 498
pollicis, 407, **408**
oral, 331
orbicularis oculi, **336,** 1077
oris, 331
of orbit, 324, 325, **1067**
orbital (of Mueller), 1071
origin of, 314
of ossicles of ear, 1091
palmaris brevis, 404
longus, 396, **398**
papillary, 515, **516,** 517
pectineus, 453, 471, **472**
pectoral group, 362, 370, **372**
abnormal, 374
pectoralis major, 370, **372,** 1411
minimus, 374
minor, 370, **373,** 1411
pectoro-dorsalis (axillary arch), 374
periorbital, 335
peroneo-calcaneus internus, 491
peroneo-tibialis, 486
peroneus brevis, 453, **483**
digiti quinti, 484
longus, 453, **483**
tertius, 453, 480, **482**
pharyngo-palatinus (palato-pharyngeus), 1136
of pharynx, 1134
physiology of, 320
piriformis, 457, **461**
plantaris, 454, 484, **485**
platysma, 330
pleuro-œsophageal, 1141
polygastric, 314
popliteus, 454, **486**
procerus, 336
pronator quadratus, 402
teres, 395, **396**
psoas major, 455
minor, 455, **456**
pterygoideus externus, 342
internus, 342
pubo-cavernosus (levator penis), 452
pubo-coccygeus, 440, **448**
pubo-peritonealis, 436
pubo-rectalis, 440, **448**
Muscle(s), pubo-transversalis, 436
pyramidalis, 424, **431**
auriculæ (Jungi), 1084
nasi, 336
quadrate, 332
quadratus femoris, 453, 463, **464**
labii inferioris, 332
superioris, 332
lumborum, 425, **436**
plantæ (flexor accessorius), 454, **495**
quadriceps femoris, 453, 468, **470**
radio-carpeus, 403
recti, of eye, 1068
recto-coccygeus, 449, 1177
recto-uterine, 1252
recto-vesical, 1252
rectus abdominis, 422, 424, **430**
acessorius, 471
capitis anterior (minor), 356
major, 355
lateralis, 356
posterior major, 417, **419**
minor, 412, **419**
femoris, 468, **470,** 1436
relation to the skin, 313
retrahens aurem, 337
rhomboideus major, 356, **358**
minor, 356, **358**
risorius, 333
rotatores, 412, **419**
sacro-coccygeus anterior, 448
posterior, 448
sacro-spinalis (erector spinæ), 412, **414**
sartorius, 453, **468,** 1436
scalenus anterior, 353
medius, 354
minimus, 355
posterius, 354
scansorius, 462
scapulo-clavicularis, 374
semimembranosus, 453, 475, **476**
semispinalis capitis (complexus), 412, **417**
cervicis, 419
dorsi, 419
semitendinosus, 453, 475, **476**
serratus anterior, 356, **359**
posterior inferior, 423, **431**
superior, 423, **431**
of shoulder musculature, 362, **365**
of soft palate, 1134
of sole of foot, 493
soleus, 454, 484, **485**
accessorius, 485, **491**
sphincter ani, externus, 441, **449**
internus, 1177
of bladder, 1253
pupillæ, 1061
urethræ (membranaceæ), 449
urogenitalis, 442, **449**
vaginæ, **451,** 1278
spinalis capitis (biventer cervicis), 418
cervicis, 412, **417**
dorsi, 412, **417**
splenius capitis, 414
cervicis, 414
accessorius, 414
stapedius, 1091
sternalis, 374
sterno-chondro-scapularis, 374
sterno-clavicularis, 374
sterno-cleido-mastoid, 347, **349**
sterno-hyoideus, 351
sterno-thyroideus, 351
stylo-glossus, 346
stylo-hyoideus, 343, **344**
stylo-pharyngeus, 1137
subanconeus, 378

Muscle(s), subclavius, 370, **373**
subcostales, 423, **434**
subcrureus, 470
subcutaneous, 313
suboccipital, 328, 412, **419**
subscapularis, 364, **369**
minor, 369
superior constrictor of pharynx, 1137
oblique, 1068
tarsal (Mueller's), 1068
supinator (brevis), 392
radii longus, 388
supracostales, 432, 433
supraspinatus, 364, **368**
synergists, 322
tail of, 314
tarsal, 1072, 1078
temporalis, 341
superficialis, 337
tensor capsularis articulationis metacarpo-phalangei digiti quinti, 406
fasciæ dorsalis pedis, 482
latæ 457, **459,** 1436
suralis, 476
laminæ posterioris vaginæ musculi recti abdominis, 436
laminæ posterioris vaginæ musculi recti et fasciæ transversalis abdominis, 436
ligamenti annularis anterior, 393
posterior, 393
tarsi (Horner's), 336
tympani, 1089, 1091
veli palatini, 1137
tenuissimus, 475
teres major, 364, **369**
minor, 364, **367**
of thigh, 453, **464**
of the thumb, 406
thyreo-arytænoideus (externus), 1219
internus (m. vocalis), 1220
obliquus, 1220
superior, 1220
thyreo-epiglottic, 1220
thyreo-hyoideus, 351
tibialis anterior, 453, **480,** 1468
posterior, 453, 486, **490,** 1468
secundus (tensor of capsule of ankle-joint), 491
tibio-astragalus anticus, 482
of tongue, 345, **346,** 1110
trachelo-mastoid, 416
tragicus, 1084
transversalis cervicis, 416
transverso-spinal, 412, **419**
transversus abdominis, 424, **435**
auriculæ, 1084
linguæ, 1110
menti, 333
nuchæ, 337
perinei profundus, 442, **449,** 1278
superficialis, 444, **452,** 1278
thoracis (triangularis sterni), 424, **434**
vaginæ (Führer), 449
trapezius, 347, **349,** 1405
triangularis, (depressor anguli oris), 333
sterni, 424, **434**
triceps brachii, 374, 377, **378,** 1416
suræ, 484
ulnaris digiti quinti, 392
ulno-carpeus, 402
unci-pisiformis, 403
unipenniform, 315
uvulæ, 1137
variation in, 320
vastus intermedius (crureus), 468, **470**
lateralis (vastus externus), 468, **470**
medialis (vastus internus), 468, **470**
Muscle(s), ventricular, of larynx, 1220
vertebro-occipital, 417
verticalis linguæ, 1111
vessels of, 319
vocalis, 1220
zygomaticus, 333
minor, 332
Muscular process of arytænoid, 1211
veins (of orbit), 658
Musculature (see also "Muscles"), 313
of the arm, 362, 374, 377, 379
cranio-mandibular, 338, **341**
epicranial, 336
of expiration, 248
external genital, 450
facialis, 324, 329, **380,** 501
of forearm and hand, 362, 383, 387
of foot, 454, **492**
functional groups, 500
of hand, 363, 403
of head, neck, and shoulder girdle, 323
of heart, 518
of the hip, 453, **454**
of inspiration, 247
of leg, 453, 477, **480**
of lower limb, 452
of mastication and swallowing, 325
of neck, 327
of pelvic outlet, 439, 448
prevertebral, 328, **355**
of respiration, 503
of shoulder girdle, 327, 347, **363**
spinal, 410, 412
of thigh, 453, **468**
thoracic-abdominal, 422, **430**
of the upper limb, 360
Musculi papillares, 515, **516,** 517
pectinati (heart), 513
Musculo-cutaneous nerve, 987, 1014, 1459
results of paralysis, 1424
Musculo-phrenic artery, 567
Musculo-spiral groove, 149
(radial) nerve, 985
results of paralysis of, 1424
Musculus ciliaris Riolani, 1077
interfoveolaris, 435
uvulæ, 1137
vocalis, 1220
Myelencephalon, 799
Mylo-hyoid branch of inferior alveolar (dental) artery, 548
nerve, 943
groove, 96
line, 95
Mylo-hyoideus, 343, **344**
Myocardium, 508, **518**
Myometrium, 1274

N

Nail-bed, 1295
Nails (ungues), 1293
Nail-wall, 1294
Nares, 1200
posterior (choanæ), 107, 112, **1206**
Nasal aperture, anterior, 108
bones at birth, 124
description of, 86
branches of anterior ethmoidal artery, 554
nerve, 937
of infra-orbital artery, 549
of maxillary nerve, 939
of posterior ethmoidal artery, 553
of spheno-palatine artery, 549
(Meckel's) ganglion, 962
cartilages, 1201
cavity, 1203

Nasal conchæ (turbinate bones), **83, 84,** 1205
crest, 90
fossæ, 108, **110**
glands, 1208
meatuses, 1205
muscles, 324, **334,** 501
notch, 60, 87
pharynx, 1130
septum, cartilaginous, **1204,** 1354
membranous, 1204
osseous, 111, 1354
sinuses, accessory, 1354
spine, anterior, 60, 87, 90, 112
posterior, 91
vein, external, 644
Nasalis, muscle, 334
pars transversa (compressor naris), 334
pars alaris (depressor alæ nasi), 334
Nasion, 109, 1331
Naso-ciliary (nasal) nerve, 936
Naso-frontal vein, 658
Naso-lacrimal duct, 111, **1080,** 1205, 1349
Naso-palatine nerve (of Cotunnius), 962
Naso-pharyngeal adenoids, **1130,** 1354
meatus, 1206
Navicular (scaphoid) bone, 159, 160, 191, **196**
Neck af axis, 33
cutaneous areas of, 1019
deep, lymphatic nodes of, 714
vessels of, 714
fasciæ of, **347,** 1360
of gall-bladder, 1187
landmarks, 1354
ligament, 243
lymphatics of, 709
musculature of, 323, **327**
of penis, 1260
superficial lymph-nodes of, 709
surgical anatomy of, 1354
of teeth, 1117
triangles of, 1357
Nélaton's line, 1436
Nephrotome, 16
Nerve(s), 769
in abdominal wall, 1372
accessory (spinal), 958, 1360
abducens, **934,** 1075
accessory obturator, 1005
acoustic (auditory), **949,** 1096
to adductor magnus, 1009
ano-coccygeal, 1018
anterior crural, 1001
cutaneous of abdomen, 995
of thigh, 1003
ethmoidal, 936, 937
interosseus, 992
labial, 1000
palatine, 963
scrotal, 1000
superior alveolar (dental), 938
tibial, 1015
of Arnold, 956
to articularis genu (subcrureus), 1003
of auricle of ear, 1084
auriculo-temporal, 941
axillary (circumflex), 984
to biceps femoris, 1009
bronchial (pulmonary), 957
buccinator (long buccal), 939
cardiac, 522
cavernous, of penis, 1047
of clitoris, 1047
cervical, 971, 974
cervico-facial, 945
chorda tympani, 826, 946, **948**
ciliary, of eyeball, 937, 1064, 1076
circumflex, 984
Nerve(s), coccygeal, 973
cochlear or auditory, 950
nucleus of, 624
common peroneal (external popliteal), 1013
plantar digital, 1011
communicans cervicalis, 974
fibularis, 1013
of conjunctiva, 1348
of Cotunnius, 962
cranial, 927
nuclei in medulla oblongata, 818
of cranial dura mater, 917
cranio-spinal, 926
cutaneous, of face, 1345
of foot, 1466
of forearm, 1423
of lower extremity, distribution of, **1024,** 1469
of thigh, 1025
perforating, 1007
deep peroneal (anterior tibial), **1015,** 1466
radial (posterior interosseous), 985, 986
temporal, 943
descendens cervicalis, 953, 974
dorsal antibrachial interosseus, 986
digital, of foot, 1013
of hand, 986, 990
of ductus deferens, 1259
of penis (or clitoris), 1018
scapular (nerve to rhomboids), 982
thoracic, 984
of external acoustic (auditory) meatus, 1086
carotid, 1036
popliteal, 1013
to external pterygoid muscle, 943
external respiratory, of Bell, 982
superficial petrosal, 1036
of eyeball, 1064
of eyelids, 1078
facial, **943,** 1345
nucleus of, 825
of female external genitalia, 1278
femoral (anterior crural), 1001
fibres, development of, 758
fifth cervical, 971
cranial (trigeminus), 934
first cervical, 971, **974**
thoracic, 994
to flexor carpi radialis, 992
ulnaris, 990
digitorum longus, 1010
profundus, 990
sublimis, 992
hallucis longus, 1010
foramina of skull, 125
fourth cervical, 971, 975
frontal, 935, 1075
furcal, 998
geniculo-tympanic, 948
to genio-glossus, 954
to genio-hyoid, 954, 976
genito-femoral (genito-crural), 1000
glosso-palatine, 946
nucleus of, 825
glosso-pharyngeal, 951
nucleus of, 820
great auricular, 978
(anterior) palatine, 963
splanchnic, 1038
superficial petrosal, 948
greater occipital, 971
of heart, 522
to hyo-glossus, 954
hypoglossal, **952,** 1111
nucleus of, 820
ilio-hypogastric, 998
ilio-inguinal, 1000

Nerve(s), inferior alveolar (dental), 941
cardiac, 957, 1037
clunial (gluteal), 1007
hæmorrhoidal, 1017
(or recurrent) laryngeal, 957
medial clunial (perforating cutaneous), 1007
vesical, 1017, 1047
infra-orbital, 937, **939,** 1345
infratrochlear, 936, **937**
intercosto-brachial (intercosto-humeral), 995
intermediate dorsal cutaneous, of leg, 1015
intermedius, 825
internal carotid, 960, **1033**
pterygoid muscle, 939, 943
interosseous crural, 1010
ischiadicus, 1008
of Jacobson, **951,** 961
jugular, **960,** 1035
of kidney, 1247
lacrimal, **936,** 1075
of large intestine, 1178
of larynx, 1225
last thoracic, 995
lateral anterior thoracic, 983
antibrachial cutaneous, 987
cutaneous, 1000
of abdomen, 995
brachial, 985
dorsal, 1013
sural, 1013
plantar, 1012
least splanchnic, 1039
lesser internal cutaneous, 983
splanchnic, 1039
to levator scapulæ, 979
lingual, **940,**, 1111, 1350
of lips and cheeks, 1104
of liver, 1186
long ciliary, 937
(middle) subscapular, 984
thoracic, 982
to longus capitis, 979
colli, 979
of lower extremity, paralysis of, 1469
lower subscapular, 984
lumbar, 973, 995
of lumbar plexus, composition of, 998
of lungs, 1235
of lymphatic vessels, 702
of mammary gland, 1305
mandibular (third division of trigeminus), **939,** 1345
masseteric, 943
masticator, 942
nucleus of, 829
maxillary, **937,** 1076, 1345
medial anterior thoracic, 983
antibrachial (internal) cutaneous nerve, 984
brachial cutaneous, 983
calcaneal (calcaneo-plantar cutaneous), 1010
dorsal cutaneous, of leg, 1015
plantar, 1010
sural cutaneous, 1010
median, **991,** 1415
mental, 941
middle cardiac, 1036
clunial, 973
hæmorrhoidal, 1017 a
(recurrent) meningel, 937
(external) palatine, 948, **963**
(long) subscapular, 984
superior alveolar (dental), 938
of muscles, 318
Nerve(s), musculo-cutaneous, **987,** 1459
results of paralysis, 1424
musculo-spiral, 985
to mylo-hyoid, 943
naso-ciliary (nasal), **936,** 1076
naso-palatine, 962
of nose, 1203, 1208
obturator, **1003,** 1440
accessory, 1005
to obturator internus, 1007
oculomotor, 835, 838, **931,** 1075
nucleus of, 837
of œsophagus, **958,** 1141
olfactory, 865, **929**
to omo-hyoid, 953, 976
ophthalmic, 1075
optic, 848, **930,** 1052, 1073
of orbit, 1075
of ovary, 1269
of palate, 1105
to palmaris longus, 992
of pancreas, 1195
of parotid gland, 1115
to pectineus, 1002
of penis, 1262
pericardiac, 957
perineal, 1017
peroneal, 1469
phrenic, 979
relations, 1360
to piriformis, 1007
of pleura, 1239
pneumogastric (vagus), 954
to popliteus, 1010
posterior auricular, 944
belly of digastric, 944
brachial cutaneous, 985
ethmoidal, 937
femoral cutaneous (small sciatic), 1007
inferior nasal, 963
interosseus, 986
(small) palatine, 963
scrotal (labial) nerves, 1017
superior alveolar (dental), 938
thoracic, 982
to pronator teres, 992
proper plantar digital, 1011
volar digital, 992
of prostate, 1265
pudic (pudendal), 1017
to quadratus femoris, 1007
radial (musculo-spiral), **985,** 1415
to rectus capitis anterior (minor), 979
lateralis, 979
femoris, 1003
recurrent articular, of leg, 1013
(inferior laryngeal), 957
to rhomboids, 982
roots, 769
rudimentary coccygeal, 964
sacral, 973, 1006
of sacral plexus, composition of, 1006
saphenous, **1003,** 1467
to sartorius, 1002
to scalene muscles, 978
sciatic (n. ischiadicus), **1008,** 1443, 1469
of scrotum, 1255
to semimembranosus, 1009
to semitendinosus, 1009
seventh cranial (facial), **943,** 1345
short subscapular, 984
of skin, 1289
of small intestine, 1168
occipital, 977
palatine, 948
sciatic, 1007
superficial petrosal, 951

Nerve(s), smallest occipital, 971
to soleus, 1010
spheno-palatine, 938
spinal, 964
accessory, 958
nucleus of, 820
origin of, 1406
spinous (recurrent), 939
of spleen, 1312
to stapedius muscle, 944
to sterno-mastoid, 978
to sterno-thyreoid, 953
of stomach, 1156
to stylo-glossus, 954
to stylo-hyoid, 944
to subclavius, 983
sublingual, 941
gland, 1116
of submaxillary gland, 1117
suboccipital, 971
subscapular, 984
superficial cervical cutaneous, 978
peroneal (musculo-cutaneous), **1014,** 1459, 1466
radial (radial), 986
superior alveolar, 938
cardiac, 957
cervical cardiac, 1036
clunial, 973
gluteal, 1007
hæmorrhoidal, 1045
laryngeal, 956
vesical, 1047
supra-acromial, 978
supraclavicular, 978
supra-orbital, **935,** 1345
of suprarenal glands, 1326
suprascapular, 982
supratrochlear, 936
sural (external or short saphenous), **1013,** 1467
of teeth, 1124
temporo-facial, 945
tenth cranial (vagus or pneumogastric), 954
terminalis, 929
thoracic, 971, 994
intercostal, 995
thoraco-abdominal, 995
thoraco-dorsal (middle or long) subscapular, 984
of thymus, 1322
to thyreo-hyoid, 953, 976
of thyreoid gland, 1318
tibial, **1009,** 1469
communicating, 1010
to tongue, 1111
of trachea and bronchi, 1228
to trapezius, 979
trigeminus, 934
nuclei of, 826
trochlear, 835, 837, **933,** 1075
nucleus of, 837
trunks, gangliated, 1029, 1032
of tubæ uterinæ (Fallopian tubes), 1270
tympanic, 961
of tympanic cavity, 1091
ulnar, **987,** 1415
anastomotic, 987
collateral, 985
upper (short) subscapular, 984
of ureter, 1249
of urinary bladder, 1253
of uterus, 1274
of vagina, **1017,** 1276
vagus or pneumogastric, 954
nucleus of, 820
Nerve(s), to vastus intermedius (crureus), 1003
lateralis, 1003
medialis, 1003
vestibular, 949
nuclei, 823
Vidian, 962
volar digital of hand, 992
(anterior) interosseous, 992
of Wrisberg, 946, 983
zygomatic, **938,** 1076
zygomatico-facial (malar), 938
zygomatico-temporal, 938
Nerve-foramina of the skull, 125
Nerve-supply of muscles (see "Nerves;" also corresponding muscles, articulations, etc.)
Nerve-trunks, gangliated, 1029, 1032
mixed, 965
spinal, primary divisions of, 944, 967, 970
Nervous system, 751
central, 751, 770
construction of, 762
development of, 754
general summary of some of principal paths of the nervous system, 895
peripheral, 754, 924
sympathetic, 1026
Nervus intermedius, 825
Neural branches of spinal arteries, 590
crest, 754
folds, 754
groove, 10, 11, 754
plate, 11, 754
tube, 14, 754
Neuraxis, 762
Neurenteric canal, 11
Neurilemma, 761
Neuroblasts, 755
Neuro-central suture, 45
Neuro-fibrillæ, 765
Neuroglia, 759, 767
Neuroglia, 759, 767
Neuro-muscular spindle, 764
Neurone, 755, 762
chains, 768
structure of, 765
systems of spinal cord, 777
Neurones of cerebral path for cranial nerves, 895
of cerebro-spinal path, 895
Nipple of mammary gland, 1300, **1304**
Nissl bodies, 766
Node(s), atrio-ventricular, 519
hæmolymph, 708
lymph(atic) (see "Lymphatic nodes")
Nodulus Arantii, 517
of cerebellum, 808
Nomenclature, anatomical, 1
of muscles, 319
Non-medullated fibres, 767
Norma basilaris, skull, 103
facialis of skull, 108
lateralis, skull, 101
occipitalis, skull, 101
verticalis, skull, 100
Nose, 1200
cartilages of, 1201
clinical anatomy of, 1352
development of, 1208
lymphatics of, 712
meatuses of, 1205
muscles of, 334
nostril (nares), 1200
olfactory area (region), 1050
sinuses connecting with, 1206
vessels and nerves, 1203, 1208
Notch, 29
acetabular, 174

Notch, cardiac, of left lung, 1229
of cerebellum, 805
ethmoidal, 61
frontal, 60
great scapular, 137
sciatic, 172
intertragic, 1082
jugular (interclavicular), 133
mandibular (sigmoid), 96, 97
mastoid, 72
nasal, 60, 87
pancreatic, 1194
posterior cerebellar, 915
preoccipital, 861
pterygoid, 66
radial (lesser sigmoid cavity) of ulna, 157
of Rivinus, 77
scapular, 142
semilunar (greater sigmoid cavity) of ulna, 156
small sciatic, 172
spheno-palatine, 91, 93
of spleen, 1311
supra-orbital, 60
temporal, 868
tentorial, 915
thyreoid, 1210, 1211
of tibia, popliteal, 185
tympanic, 77
ulnar (sigmoid cavity) of radius, 154
Notochord, 11
Notochordal region of skull, 117
Nuchal line, highest, 52
inferior, 52
superior, 52
Nuck, canal of, 1398
Nucleus(i), abducens nerve, 826
accessory olivary, 817
of the ala cinerea, 820
ambiguus, 822
amygdalæ, 881
amygdaloid, of lateral ventricle, 877
arcuatus, 818
Bechterew's, 823
caudate, 877, **879**
of cerebellum, 809
of cochlear nerve, 824
of cranial nerves in medulla oblongata, 818
Deiters's, 823
dentate, of cerebellum, 810
dorsal efferent, of cochlear nerve, 824
of vagus, 822
dorsalis (Clarke's column), 776
of Edinger and Westphal, 838
emboliformis of cerebellum, 810
of facial nerve, 825
fastigii (roof nucleus) of cerebellum, 810
funiculi cuneati (of Burdach's column), 801, **815**
gracilis (of Goll's column), 801, **815**
globosus of cerebellum, 810
of glosso-palatine nerve, 825
of glosso-pharyngeus, 820
habenular, 872, 885
of hypoglossal nerve, 820
hypothalmic, 884
incertus of floor of fourth ventricle, 815
of inferior colliculus, 839
inferior olivary, of medulla oblongata, 817
intercalatus, 814
interpeduncular (Von Gudden), 843, 872, 885
of lateral lemniscus, 824, **839**
of thalamus, 845
of lens of eye, 1062
lenticular, 878, 879
lentiformis, 857
Nucleus of masticator nerve, 829
of medial longitudinal fasciculus, **843,** 871
medial thalamic, 845
of mesencephalic root of trigeminus nerve, 829
of oculomotor (or third) nerve, 837
pontis, 831
pulpy, 226
red, 840
respiratory, 822
salivatorius, 826, 947
of scapula, 139
Schwalbe's, 823
of solitary-tract, 820
of spinal accessory nerve, 820
tract, 826
spinalis, 823
Stilling's, 776
of superior colliculus, 842
superior olivary, 824
of termination, 770
of thalamus, 871, 882
trapezoidei, 824
of trigeminus nerve, 826
of trochlear (or fourth) nerve, 837
of vagus or pneumogastric, 820
vasomotor, 822
ventral cochlear, 824
vestibularis, 823
Number of muscles, 315
Nutrient arteries of femur, 621
of fibula, 626
of humerus, 576
of radius and ulna, 579
tibial, **626,** 1459
branch of obturator artery, 608
of posterior circumflex humeral artery, 573
of transverse scapular artery, 565
Nymphæ (labia minora), **1277,** 1392

O

Obelion, 101
Obex, 802, 813
Oblique diameter of pelvic inlet, 175
fasciculus, 804
head of adductor hallucis, 498
of adductor pollicis, 408
ligament (mid-radio-ulnar union), 262
line of clavicle, 140
of fibula, 190
of mandible, 95
of radius, 154
posterior, 154
of scapula, 142
of thyreoid cartilage, 1211
of ulna, 157
muscle of eye, inferior, 1068
superior, 1068
popliteal ligament (ligamentum Winslowii), 287
sinus of pericardium, 523
vein of left atrium (of Marshall), 521, **523,** 691
Obliquus abdominis externus, 423, **432**
internus, 423, **434**
capitis inferior, 412, **420**
superior, 412, **420**
Oblong fovea of arytænoid, 1212
Obturator artery, **608,** 639
crest, 173
externus, 453, 463, **464**
fascia, 439, 463
(thyreoid) foramen, 174
groove, 172
internus, 453, **463**

Obturator nerve, **1003,** 1440
accessory, 1005
vein, 680
Occipital artery, **542,** 638, 1343
bone, 51
articulations of, 56
at birth, 121
ossification of, 56
branches of occipital artery, 543
of posterior auricular artery, 545
nerve, 944
of small occipital nerve, 977
condyle, third, 56
condyles, 108
crest, external, 52
internal, **53,** 117
groove, 72
gyri, 863
lobe, 863
lymph-nodes, 709
nerve, greater, 971
small, 977
smallest, 971
point, 101, 112
pole, 850
pontile fibres, 840
portion of vertebral artery, 560
protuberance, external, **52,** 101
internal, 53
sinus, 650
sulci, 862, 863
suture, 101
vein, 647
diploic, 648
Occipitalis, 337
minor, 337
Occipito-atlantal articulation, 218
ligaments, 219
Occipito-cervical ligament, 223
Occipito-epistrophic articulation, 223
Occipito-frontal fasciculus, 892
Occipito-frontalis, 336
Occipito-mastoid suture, 101
Occipito-mesencephalic path (Flechsig's secondary optic radiation), 890
Occipito-pontile path, 832
Occipito-scapularis, 359
Occipito-temporal association area, 894
convolution, 864
Occipito-thalamic (optic) radiation, 888
Occiput and atlas, ligaments uniting, 218
Ocular conjunctiva, 1054
muscles, 325, **1067**
Oculomotor nerves, 835, 838, **931**
nucleus of, 837
sulcus, 835
Odontoid process (dens) of axis, 33
Œsophageal arteries, 588
branches of inferior thyreoid artery, 564
of left gastric artery, 594
of vagus, 958
plexuses, 954, 955
veins, 661, 664
Œsophagus, 1138
clinical anatomy of, 1369, 1408
development of, 1141
lymphatic vessels of, **730,** 1141
variations and comparative, 1141
vessels and nerves of, 1141
Olecranon fossa of humerus, 150
process of ulna, 156
Olfacto-mammillary tract, 873
Olfacto-mesencephalic tract, 873
Olfactory apparatus, 1049
area of cerebral cortex, 893
(region) of nasal mucous membrane, 1049, 1352
Olfactory brain, 864
bulb, 758, **865,** 1050
cells, 1050
conduction path, 902
glands, 1208
groove, 1206
gyrus, lateral, 865
medial, 866
layer of olfactory bulb, 866
lobe, 865
nerve, 865, **929**
central connections, 929
organ, **1049,** 1208
region of nasal cavity, 1208
striæ (gyri), 865, 866
sulcus, 858
tract, 758, **865,** 893
development of, 758
trigone (tubercle), 865
ventricle, 866
Olivary, nuclei, accessory, 817
inferior, 817
superior, 824
Olives of medulla oblongata, 800
Omental branches of epiploic arteries, 595
bursa (lesser sac), **1146,** 1372
Omentum, great, 1149
lesser (gastro-hepatic), **1150,** 1185
Omo-hyoideus, 351
Omphalo-mesenteric artery, 638
Opercula of insula, 856
Operculum proper, 854, **856**
temporal, 854, **856**
Ophryon, 109, 112
Ophthalmic artery, **552,** 638, 1074
branches, 552
division of trigeminus (fifth nerve), **935,** 1075
veins, 658, 659, 1075
Ophthalmo-meningeal vein, 655
Opisthion, 107, 108
Opponens digiti quinti (foot), 454, 498, **499**
(hand), 404, **405**
hallucis, 498
pollicis, 407, **408**
Optic-acoustic reflex path, 840, 842
Optic apparatus, conduction paths of, 900
chiasma, 847, 848, 849
cup, 1080
disc, 1055
foramen, **63,** 64, 110, 116, 125
groove, **63,** 116
nerve, 848, **930,** 1052, 1073
sheaths of, 931, **1073**
papilla of, 1055
portion of hypothalamus, 847
radiation, 888
Flechsig's secondary, 890
recess, 848
tracts, 849
vesicle, 758, **1080**
Ora serrata, 1057
Oral cavity, 1100
development of, 1102
fissure, (rima oris), 1100
fossa, 1102
muscles, 331
orifice, muscles of, 501
pharynx, 1130
vestibule, 1100
Orbicular tubercle of incus, 79
Orbicularis ciliaris, 1060
oculi, **336,** 1097
oris, 331
Orbit, 108, **109,** 1332, 1346
fasciæ of, 1071
lymphatic system of, 1076
muscles of, 325, **1067**

Orbital branch of middle meningeal artery, 548
branches of maxillary nerve, 938
of spheno-palatine (Meckel's) ganglion, 963
fissure, inferior, **109,** 126
superior, 65, **109,** 116, 125
gyri, 858
muscle of Müller, 1071
periosteum, 1071
plates, 61
process of malar bone, 94
of palate bone, 91, 93
sulci, 858
wings of sphenoid, 64
Orbito-sphenoid centre, 67, 119
Organ(s), 4
of Giraldès, 1257
of Jacobson, 951, **961,** 1051, 1204
lymphoid, 704
olfactory, **1049,** 1208
reproductive, male, 1253
female, 1265
of special sense, 1049
spiral (organ of Corti), 1096
of taste, 1051
urinary, 1241
Orifice, atrio-ventricular, of heart, 513, 514
external urethral, 1264
of stomach, **1151,** 1374
(os) of uterus, 1271
Origin of muscles, 314 (see also individual muscles)
of spinal nerves, 964
Os calcis (calcaneus), 191, **195**
centrale, 164, 208
innominatum, 169
Japonicum, 95
linguæ, 99
planum, 83
trigonum, 194, 199
uteri, 1271
Vesalianum, 199
Osseous labyrinth, 80
part of tuba auditiva (Eustachian tube),1092
portion of external acoustic (auditory) meatus, 1085
Ossicles of ear, 79, 1090
articulations, 1090
ligaments, 1090
muscles, 1091
Ossification of bones, 27 (see also the individual bones")
Osteogenesis, 27
Osteology, 27
Ostium abdominale of tubæ uterinæ (Fallopian tubes), 1270
venosum (atrio-ventricular orifice), 513, 514
Otic (Arnold's) ganglion, 963
Otoconia (otoliths), 1095
Outlet (inferior aperture) of pelvis, 176
Ovarian arteries, 602
branches, 602
branches of uterine artery, 610
ligaments, 1269
plexuses of nerves, 1045
veins, 674
Ovaries, 1268
clinical anatomy of, 1393
lymphatics of, 701, **745,** 1269
vessels and nerves of, 1269
Ovula Nabothi, 1274
Ovum, segmentation of, 9

P

Pacchionian bodies (arachnoid granulations), 649, **919**
Pacchionius, foramen ovale of, 116
Pacinian corpuscles, 1290
Palate, 1104
bone, 91
at birth, 124
development of, 1106
hard, 1104
lymphatics of, 717
muscles acting on, 502
soft, 326, **1104**
surgical anatomy of, 1352
Palatine arches, 1132
branch of ascending pharyngeal artery, 537
artery, ascending, 541
descending, 549
major, 549
canals, 92, 103, 126
accessory, 103
foramina, 106
nerve, great (anterior), 963
middle (external), 948, **963**
posterior (small), 948, **963**
process of maxilla, 87, **88**
tonsil, 1132
variations and comparative, 1106
vein, 644
superior, 646
Palato-ethmoidal cells, 84
Palm, muscles acting on, 504
Palmar aponeurosis, **387,** 1430
arch, (see "Volar arch")
cutaneous branch of median nerve, 992
of ulnar nerve, 990
fascia, deep, 387
Palmaris brevis, 404
longus, 398
Palpebra, inferior, 1053
superior, 1053
Palpebral aperture, 1052
arteries, lateral, 552
branches of infratrochlear nerve, 937
of maxillary nerve, inferior, 939
of ophthalmic artery, palpebral, 552
of supra-orbital artery, 553
conjunctiva, 1054, **1078**
fascia, 1071
folds, 1053
ligament, medial, 1052, **1078**
raphe, lateral, 1078
veins, 644, 658
Pampiniform plexus, **674,** 1259
Pancreas, 1192
blood-supply of, 1195
development of, 1195
lymphatics of, 699, **736,** 1195
topographic, 1375
variations and comparative, 1197
Pancreatic branches of splenic artery, 595
duct (canal of Wirsung), **1194,** 1375
accessory (of Santorini), 1195
Pancreatico-duodenal artery, inferior, 596
superior, 595
vein, 675, 677
Panniculus adiposus, 313, 1287
carnosus, 313
Papilla, duodenal, 1164, 1195
hair, 1292
incisive, 1104
of kidney, 1246
lacrimal, 1054
(nipple) of mammary glands, 1300, **1304**
optic, 1055
Papillæ of skin, 1286
of tongue, 1106
Papillary ducts (of Bellini), 1246
muscles of heart, 515, **516,** 517
process of liver, 1184
Paracentral lobule, 857, 858, **863**

Paradidymis (organ of Giraldès), 1257
Paraduodenal fossa, 1164
Paraganglia, 1323
  aortic (lumbalia), 1329
Paralysis of deep radial (posterior interosseous) nerve, results of, 1424
  of facial nerve, 1345
  of median nerve, results of, 1424
  of musculo-cutaneous nerve, 1424
  of nerves of lower extremity, 1469
  of radial (musculo-spiral) nerve, 1424
  of ulnar nerve, results of, 1424
Paramedial sulcus, 858
Parametrium, 1274
Paranasal sinuses, 1206
Parapophysis, 51
Pararenal adipose body, 1243
Parasinoidal sinuses, 919
Para-thyreoid glands, 1318
Paraurethral ducts, 1277
Parietal association area, 894
  bones, 57
    at birth, 123
  branches of abdominal aorta, 592
    of hypogastric artery, 606
    (posterior temporal) of superficial temporal artery, 545
    of thoracic aorta, 588
  eminence, 57
  emissary vein, 649
  fascia of pelvis, 447
  foramen, 57
  lobe, 860
  lobule, inferior, 863
    (gyrus) superior, 862
  lymphatic nodes of thorax, 724
  peduncle of thalamus, 883
  pleura, 1237
Parieto-mastoid suture, 101
Parieto-occipital arch, 863
  fissure, 860, 864
Parolfactory area (Broca's area), 858, **865**
  sulci, 865, 866
Paroöphoron, 1269
Parotid branches of auriculo-temporal nerve, 941, 961
    of superficial temporal artery, 545
  fascia, 339, 348, 1114
  gland, 348, 1113
    accessory, 1114
    duct (Stenson's), **1115**, 1343
    lymph-nodes, 709
    veins, 644, 646
    vessels and nerves, 1115
  plexus (pes anserinus), 945
  region, 1343
Pars alaris (depressor alæ nasi), 334
  ciliaris retinæ, 1061
  fixa of penis, 1260, 1264
  flaccida (Shrapnell's membrane), 1087
  glabra of lips, 1104
  intercartilaginea, 1223
  intermedia of facial nerve, 946
    (of Köbelt), 1278
  intermembranacea, 1223
  libera of penis, 1260, 1264
  tensa, 1087
  transversa (compressor naris), 334
  villosa of lips, 1104
Parumbilical veins, 678
Patches, Peyer's, 704, 1166
Patella, 184
  clinical anatomy of, 1444
Patellar fold (ligamentum mucosum), 290
  ligament, 471
  plexus, 1001
  rete, 622
Paths, auditory conduction, 900
  cerebral, for cranial nerves, 895
  cerebro-spinal, 895
  conduction, involving cerebellum, 899
    of olfactory apparatus, 902
    of optic apparatus, 900
    summary of, 895
  frontal pontile (Arnold's bundle), 832, **889**
  occipito-mesencephalic, 890
  occipito-pontile, 832
  optic, 900
  optic-acoustic reflex, 840
  short reflex, of cranial nerves, 898
  spino-cerebral, 895
  of spinal cord, short reflex, 895
  temporal pontile (Türk's bundle), 832, 840, **890**
  vestibular, 899
Pecten of pubis, 173
Pectineo-femoral band, 278
Pectineus, 453, 471, **472**
Pectoral (descending) branch of anterior circumflex humeral artery, 573
  branch of thoraco-acromial artery, 571
  group, of muscles, 362, **370**
    of axillary lymphatic nodes, 720
Pectoralis major, 372
    surface markings, 1411
  minor, 373
    surface markings, 1410
  minimus, 374
Pectoro-dorsalis (axillary arch), 374
Pedicles of axis, 34
  of lumbar vertebræ, 37
  of vertebræ, 30
Peduncles of cerebellum, 810, 831
  of cerebrum, 833, 835
  of corpus callosum, 866
  of flocculus, 807
  of superior olive, 825
  of thalamus, 880, **883**
Peduncular tract, transverse, 835
Pedunculi conarii, 846
Pelvic articulations, 234
    ligaments of, 234
  diaphragm, 440, **448**, 1383
  fasciæ, 446
    clinical anatomy of, 1385
  floor in female, 1394
    in male, 1383
  girdle, 207
  index, 177
  inlet, diameters of, 175
  measurements, 177
  outlet, 176
    muscles of, 439
  colon, **1174**, 1379
  plexuses of nerves, 1046
  portion of ureter, 1248
  splanchnics, 1017, 1040, 1046
Pelvis, articulations of, 234
  axis of, 176
  description of, **175**, 1382
  differences according to sex, 177
  inlet (superior aperature) of, 175
  lymphatics of 730, 733
  major (false), 175
  measurements, 177
  minor (true), 175
  muscles acting on, 505
  outlet (inferior aperature), 176
  renal, 1248
  of ureter, 1247
  visceral lymphatic vessels of, 733
Penis, 1260
  artery of, 613
  cavernous plexus of, 1047

Penis, deep artery of, 614
dorsal artery of, 614
nerves of, 1018
lymphatics of, **744,** 1262
surgical anatomy of, 1388
vessels and nerves of, 1262
Perforated substance, anterior, 847, 866
posterior, 835, 844
Perforating branches of deep volar arch, 586
of lateral plantar artery, 628
of the profunda, 620
of internal mammary artery, 567
maxillary artery, 529
of peroneal artery, 626
veins, 690
Pericæcal fossæ, **1172,** 1378
Pericardiac branches of aorta, 588
of internal mammary artery, 567
of phrenic nerve, 979
Pericardial branches of vagus, 956
cavity, 522
development of, 527
lymph-capillaries of, 702
pleura, 1237
Pericardio-phrenic artery, 567
Pericardium, 522
development, 20, 525
surgical anatomy, 1369
vessels of, 523
Perichondrium, 28
Pericranium, 1334
Perilymph, 1092
Perilymphatic space of membranous labyrinth, 1095
Perimetrium, 1274
Perimysium internum (endomysium), 315
externum (epimysium,) 316
Perineal artery, **613,** 639
fascia, superficial, 445
nerve, 1017
Perineum, 1383
central tendon of, 449
muscles acting on, 503
surgical anatomy of, 1385
triangles of, 1383
Periorbita, 1071
Periorbital muscles, 335
Periosteal branches of supra-orbital artery, 553
Periosteum, 28
lymph-capillaries of, 701
Periotic capsule, 69, 117
cartilages, 117
Peripheral, nervous system, 754, 924
cranio-spinal system, 926
sympathetic system, 926, 1026
Peritoneal branches of superior epigastric artery, 567
cavity, lymphatic capillaries of, 702
Peritoneum, 1141
clinical and topographical anatomy of, 1372
development of, 1144, 1151
of rectum, 1177
spaces of, 1372
sections, 1146
variations and comparative, 1151
vessels and nerves, 1151
Permanent teeth, times of eruption of, 1127
Peroneal artery, **626,** 640, 1459
anterior (perforating), **626,** 1459
posterior, 626
groove of cuboid, 199
muscles, accessory, 484
nerve, common (external popliteal), 1013
results of paralysis of, 1469
deep, (anterior tibial), 1015, 1466
Peroneal nerve, superficial (musculo-cutaneous), **1014,** 1459, 1466
retinacula, 480
vein, 688
Peronei muscles, tenotomy of, 1464
accessory, 484
Peroneo-calcaneus internus (of Macalister), 491
Peroneo-tibialis, 486
Peroneus brevis, 453, **483**
digiti quinti, 484
longus, 453, **483,** 1468
tertius, 453, 480, **482**
Perpendicular plate (mesethmoid) of ethmoid, 82
Pes anserinus, 945
hippocampi, 877
pedunculi, 840
Petiole of epiglottic cartilage, 1212
Petit, canal of, 1064
triangle of, 434, 1406
Petrosal branch of middle meningeal artery, 548
ganglion, 951
nerve, external superficial, 1036
great superficial, 948
small superficial, 951
portion of internal carotid artery, 550
process, posterior, 63
sinuses, 1652
Petro-mastoid, 119
Petro-sphenoidal foramen, 125
Petro-squamous sinus, 653
(squamo-mastoid) suture, 71
Petro-tympanic (Glaserian), fissure 71, 77, 108, 126
Petrous portion of temporal bone, 68, **72**
Peyer's patches, 704, 1166
Phalanges of fingers, 167
ossification of, 168, 204
third, terminal, or ungual, 168, 204
of toes, 203
Pharyngeal aponeurosis, 1130
artery, ascending, **537,** 638
branches of ascending pharyngeal artery, 537
of inferior thyreoid artery, 564
of glosso-pharyngeal nerves, 951
of spheno-palatine (Meckel's) ganglion, 963
of vagus, 956
bursa, 1130
(pterygo-palatine) canal, 66, 92, 103
foramen, 126
hypophyseal remnants, 1352
sthmus (faucial), 1130, 1131
membrane, 1102
ostium of tuba auditiva, 1092
plexus of nerves, 956, 1036
of veins, 659
recess, 1130
tonsil, **1130,** 1354
tubercle, 54, 108
veins, 659
Pharyngo-palatine arches, 1132
Pharyngo-palatinus (palato-pharyngeus), 1136
Pharynx, 1128
development, 1138
laryngeal, 1134
lymphatics of, **717,** 1138
muscles of, 325, 502, **1134**
nasal, 1130
oral, 1130
variations and comparative, 1138
vessels and nerves, 1138
Philtrum, 1102, 1284
Phrenic arteries, inferior, **592,** 638

Phrenic arteries, superior, 590
branches of musculo-phrenic artery, 567
of superior epigastric artery, 567
ganglion, 1044
nerve, 979
relations of, 1360
(diaphragmatic) plexuses of nerves, 1044
veins, inferior, 675
superior, 667
Phrenico-costal sinus, 1237
Phreno-colic ligament, 1150, 1174, 1310, 1379
Phrenicolienal (lienorenal) ligament, 1310
Physiology of muscles, 320, 323
Pia mater, 771, **920**
cranial, 922
spinal, 921
Pigment of iris, 1061
retinal, 1062
of skin, 1286
Pillars of the foot, **205**, 1468
of fornix, anterior, 870
posterior, 868
Pineal body, 845
Pinna (see Auricle)
Piriformis, 453, 457, **461**
Pirogoff's amputation, 1465
Pisiform bone, 159, **162**
Pits, olfactory, 1050
rectal, 1390
Pituitary body, **848,** 1342
Plane or arthrodial diarthroses, 212
Plantar aponeurosis, 492
arch, 627
arteries, lines of, 1467
artery, deep (communicating), 633
lateral, **627,** 640
medial, 629
calcaneo-cuboid (short plantar) ligament, **307,** 1468
calcaneo-navicular ligament, 1468
digital (collateral) arteries, 628
branches, proper, of medial plantar nerve, 1011
nerves, common, 1011, 1013
proper, 1011, 1013
veins, 684
fascia, **492,** 1468
ligaments, 307, 1468
accessory, 310
metatarsal arteries, 628
veins, 687
nerve, lateral, 1009, **1012**
medial, 1009, **1010**
venous arch, 687
rete, 684
Plantaris, 454, 484, **485**
Planum popliteum, 181
Plate, cribriform, of ethmoid, 81
fronto-nasal, 117
neural, 754
olfactory, 1050
orbital, 61
perpendicular, of ethmoid, 82
pterygoid, 66
tympanic, 108
Platypellic pelvis, 177
Platysma, 330
Pleura, 1236
blood-vessels of, 1239
clinical anatomy of, 1368
development of, 20
lymphatics of, 701, 1239
nerves of, 1239
Pleural cavity, 1236
reflection, lines of, 1237
sinuses, 1237
villi, 1237
Pleurapophysis, 51
Plexuses of nerves, abdominal aortic, 1045
anterior pulmonary, 957
atrial, 1041
of Auerbach, 757, 1030
brachial, 980
line of, 1360
bulbar, 1041
cardiac, 1041
cavernous, 1033
of penis (or clitoris), 1047
of cephalic ganglia, 960
cervical, 974
coccygeal, 1018
cœliac, 1043
common carotid, 1036
coronary, 1041
deferential, 1047
external carotid, 1036
maxillary (facial), 1036
femoral, 1045
gangliated cephalic, 959
hepatic, 1045
hypogastric, 1045
iliac, 1045
inferior dental, 941
gastric, 1045
mesenteric, 1045
infra-orbital, **937,** 939, 945
internal carotid, 1033
mammary, 1037
maxillary 1036
intermediate, 1041
lingual, 1036
lumbar, 998
lumbo-sacral, 996
of Meissner, 757, 1030
meningeal, 1036
middle hæmorrhoidal, 1046
myentericus (plexus of Auerbach), 1045
œsophageal, 954, 955
ovarian, 1045
parotid, 945
patellar, 1001
pelvic, 1046
pharyngeal, 956, 1036
phrenic (diaphragmatic), 1044
popliteal, 1045
posterior cervical, of Cruveilhier, 971
œsophageal, 954
pulmonary, 954, 955, 957
pulmonary, 1043
prevertebral, 755, 1029, 1032, 1040
prostatic, 1047
pudendal, 1016
renal, 1044
sacral, 1006
spermatic, 1045, 1260
splenic (lienal), 1045
submucosus (plexus of Meissner), 1045
subsartorial, 1003
subtrapezial, 979
superior dental, 939
gastric (coronary), 1045
hæmorrhoidal, 1045
mesenteric, 1045
thyreoid, 1036
thoracic aortic, 1038
suprarenal, 1044
tympanic, 951, **961,** 1033, 1089
utero-vaginal, 1047
vertebral, 1037
vesical, 1047
of veins, anterior sacral, 679
basilar, 651
chorioid, of fourth ventricle, 922
of lateral ventricle, 924

Plexuses choroid of third ventricle, 924
chorioidea, 875, 877
hæmorrhoidal, 683
of internal carotid, 653
mammary, 671
pampiniform, **674,** 1259
pharyngeal, 659
pterygoid, 682
thyreoideus impar, 660
utero-vaginal, 683
vertebral, 664
vesical, 683
Plica(æ) ciliares, 1057
circulares, 1165
epigastrica, 430
fimbriata, 430
incudis, 1090
lacrimalis (Hasneri), 1080, 1205
longitudinalis duodeni, 1189
palatinæ transversæ, 1104, 1106
palmatæ, 1272
salpingo-pharyngea, 1130
salpingo-palatina, 1130
semilunaris, 1053, 1170
triangularis, 1132, 1133
of tympanic membrane, 1087
umbilicalis lateratis, 430
ureterica, 1252
Pneumogastric nerve, 954
Point(s), alveolar, 109
auricular, 101
central, of perineum, 1385
occipital, 101
pre-auricular, 1332
Rolandic, 1340
subnasal, 109
Poles, of cerebral hemispheres, 850
of eyeball, 1055
of lens of eye, 1062
Polygastric muscles, 314
Polymastia, 1301
Polythelia, 1301
Pons (Varoli), 804
basilar sulcus of, 804
blood-vessels of, 908
brachia conjunctiva (superior cerebellar peduncles), 831
grey substance of, 831
internal structure of, 815, 829
lemniscus (fillet) in, 831
Pontile path, frontal, 832, 840, **889**
temporal (Türk's bundle), 832, **890**
Pontine branches of basilar artery, 561
sulci, 804
Popliteal artery, **621,** 640, 1452
collateral circulation, 1453
ligament, oblique, 287
line, 189
lymphatic nodes, 748
nerve, external, 1013
internal, 1009
nerves, paralysis of, 1469
plexus of nerves, 1045
space, clinical anatomy of, 1451
vein, **688,** 1452
accessory, 689
Popliteus, 454, **486**
Pore, canal, 1051
of skin, 1285
sudoriferous, 1297
taste, 1051
Porta hepatis, 1183
Portal fissure of liver, 1183
vein, 528, **675**
development, 694
tributaries, 675
veins, accessory, 678
Position of organs (see corresponding Organ)
Post-aortic lymphatic nodes, 731
Post-auditory process, 122
Post-central branches of spinal arteries, 590
sulcus, inferior, 861, 862
superior, 861, 862
Post-glenoid process, 71
Post-limbic fissure, 863
Post-malar, 95
Post-nodular sulcus of cerebellum, 808
Post-parietal gyrus, 863
Post-scapula, 145
Post-sphenoid centre, 67
Pott's fracture, 1454
Pouch of Douglas, 1148, 1267, 1274
of Prussak, 1089
recto-uterine (recto-vaginal), 1148, 1267, 1274
recto-vesical, 1148
of Tröltsch, 1089
Poupart's ligament, 424, **429,** 1371, 1399, 1438
Præcuneus (quadrate lobe), 863
Præputium clitoridis, 1277
penis, 1260
Prævesical space (cavum Retzii), 1250
Pre-aortic lymphatic nodes, 730
Pre-auricular point, 1332
Precentral sulcus, **807,** 857
Preglenoid tubercle, 71
Pre-laminar branches of spinal arteries, 590
Premalar, 95
Premaxilla, 89, **91,** 119
Premolars, 1121
Preoccipital notch, 861
Pre-palatine centre, 91
Prepatellar bursa, 1448
Prepuce, 1260
Pre-scapula, 145
Pre-sphenoid centre, **67,** 119
Presternum, 132
Prevertebral musculature, 328, 355
plexuses, 755, 1029, 1032, **1040**
Primary curvatures of spinal column, 43
divisions of spinal nerve-trunk, 967
anterior, 968
posterior, 967
Primitive groove, 10
node, 11
pit, 10
streak, 10
Princeps cervicis artery, 543
pollicis artery, 586
Procerus (pyramidalis nasi), 336
Process(es), accessory (of vertebra), 38
acromion, 144
alar, of ethmoid, 81
alveolar, 87, **90**
anterior clinoid, **65,** 116
arciform, 466
caudate, of liver, 1184
ciliary, 1057
cochleariform, 1089
condylar, of mandible, 96
coracoid, of scapula, 144
coronoid of mandible, **96,** 1351
ensiform, 132, 134
ethmoidal, 85
external auditory, 75
frontal, of maxilla, 87, **88**
fronto-nasal, 119
fronto-sphenoidal, 95
glosso-hyal, 99
hamular, **66,** 106
infra-orbital, 95
jugular, **54,** 108
lacrimal, 85

Process(es), lenticular, of incus, 79
mastoid, **72,** 108
maxillary of inferior nasal concha, 84
of palate bone, 92
middle clinoid, **65,** 116
muscular, of arytænoid cartilage, 1211
orbital, of malar bone, 94
of palate bone, 91, 93
palatine, 87, **88**
posterior clinoid, **63,** 116
petrosal, 63
post-glenoid, 71
pterygoid, **62, 66**
pyramidal, of palate bone, 91, 92
sphenoidal, of palate bone, 91, 92
styloid, 70, **73, 75,** 108
of fibula, 190
of radius, 155
of third metacarpal bone, 166
of ulna, 158
supracondylar, 149
temporal, of malar bone, 95
trochlear, 195
unciform, 163
uncinate, of ethmoid, 83
vaginal of sphenoid, 63, 66
of temporal, 75
vermiform, 1378
vocal, of arytænoid cartilage, 1212
xiphoid, 132, 134
zygomatic, 70, 87, **88**
Processus cochleariformis, 77
Folii, 79
globulares, 119
gracilis, 79
marginalis, 95
tubarius, 66
uncinatus (of Winslow), 1194
vaginalis, 1387
Profunda (superior) artery, 576
axillaris artery, 640
(deep) femoral artery, **620,** 640
branches, 620
vein, 690
Projection fibres of white substance of telencephalon, 886, **889**
Prominence, laryngeal, 1211
Promontory in cochlea, 81, 1089
of temporal bone, 73
Pronation, 321
Pronator quadratus, 402
ridge of ulna, 157
teres, 395, **396**
Proper digital arteries, 582
plantar digital nerves, 1011
scapular ligaments, 252
volar digital nerves of hand, 992
veins, 671
Prosencephalon (fore-brain), 843
external features of 843
internal structure of, 878
Prostate, 1264
lymphatics of, **700,** 739
surgical anatomy of, 1389
vessels and nerves of, 1265
Prostatic branches of inferior vesical artery, 608
plexus of nerves, 1047
portion of urethra, **1263,** 1265, 1388
Prostatic utriculus (sinus pocularis, uterus masculinus), 1263
Prostatico-perineal fascia, 447
Protoplasm, 5
Protuberance, external occipital, 52
internal occipital, 52
mental, 95
Prussak, pouch of, 1089
Psalterium, hippocampal, 869
Psuedo-hermaphroditism, 1230
Psoas abscess, 1438
fascia, 455
major, 455
minor, 455
Pterion, **101,** 1332
Pterygoid, accessory, 342
branches of internal maxillary artery, 548
(Vidian) canal, 103, 107, 108, **126**
fossa, **66,** 107
hamulus (of sphenoid), **66,** 1351
muscles, 338, **342**
notch, 66
plate, lateral 66
medial, 66
plexus of veins, 646
portion of internal maxillary artery, 546
processes, 62, **66**
tubercle, 66
veins, 646
Pterygoideus externus, 338, **342**
internus, 338, **342**
Pterygo-maxillary fissure, 102
Pterygo-palatine (pharyngeal) canal, **88,** 92, 103
fissure, 102
(spheno-maxillary) fossa, 102
portion of internal maxillary artery, 546
Pubes, 1290
Pubic arch, 176
branch of inferior epigastric artery, 615
of obturator artery, 608
Pubis, 172
symphysis, 238
tubercle (spine) of, 172
Pubo-capsular (pectineo-femoral) band, 278
Pubo-cavernosus (levator penis), 451
Pubo-coccygeus, 440, **448**
Pubo-peritonealis, 436
Pubo-prostatic ligaments, middle, 1252
Pubo-rectalis, 440, **448**
Pubo-transversalis, 436
Pubo-vesical ligaments, 1252
Pudendal (pudic) artery, **610,** 639
accessory, 638
(superficial) external, 619
internal, **610,** 639
nerve, 1017
long, 1007
vein, external, 684
internal, 681
plexus of nerves, 1016
of veins, **682,** 683
Pulmonary artery, **528,** 1234
circulation, 507
left, 529
relations, 1369
right, 529
variations, 637
branches of vagus, 957
ligament, 1236
lymphatic nodes, 725
(visceral) pleura, 1236
plexus, anterior, 957, **1043**
posterior, 954, 955, 957, **1043**
(semilunar) valves, 517
veins, **529,** 1234
Pulp of tooth, 1118
Pulpa lienis, 1311
Pulpy nucleus of intervertebral fibro-cartilages, 226
Pulvinar of thalamus, 845, **889**
Puncta lacrimalia, 1054, **1079,** 1349
Pupil, 1054
Purkinje cells, 809
fibres of heart, 516

Putamen, 880
Pyloric antrum of stomach, 1151
canal, 1152
portion of stomach, 1151
vein, 675
Pylorus, **1152,** 1374
Pyramidal eminence of temporal bone, 77
fasciculi of pons, 830
fibres, 840, **889**
lobe of thyreoid gland, 1314
process of palate bone, 91, 92
tract, anterior or direct, 788
crossed, 783
Pyramidalis, 424, **431**
nasi, 336
Pyramids of Ferrein, 1246
of Malpighi (renal), 1246
of medulla oblongata, **783,** 799
decussation of, 815
structure of, 815
of vermis, 808
vertebral, 43

Q

Quadrangular lobe of cerebellum, 806
membrane of larynx, 1215
Quadrate lobe, of liver, 1184
muscles, 332
Quadratus femoris, 453, 463, **464**
labii inferioris (depressor labii inferioris), 332
superioris, 332
lumborum, 425, **436,** 1407
plantæ (flexor accessorius), 454, **495**
Quadriceps femoris, 453, 468, **470**
Quadrigeminate arteries, 907
body, inferior, **834,** 839
superior, 825, **834,** 841
Quadrigemino-pontile fibres, 841

R

Radial artery, 582
in palm (deep volar arch), 586
at the wrist, 584
carpal artery, dorsal, 585
volar, 584
collateral ligament, 261, 267
fossa of humerus, 151
(musculo-spiral) nerve, 985
line of, 1415, 1423
results of paralysis of, 1424
deep (posterior interosseous), 985
results of paralysis of, 1424
superficial (radial), 987
notch (lesser sigmoid cavity) of ulna, 157
recurrent artery, 583
venæ comitantes, 671
Radialis indicis artery, 586
Radiate (anterior costo-central or stellate) ligament, 242
sterno-costal ligament, anterior, 245
Radiation of corpus collosum, 851
Flechsig's secondary optic, 890
occipito-thalamic (optic), 888
Radicular veins, 792, 908
Radio-carpal or wrist-joint, 265
arterial supply of, 267
ligaments of, 266
movements of, 267
muscles acting upon, 268
nerve-supply, 267
relations of, 267
Radio-carpeus muscle, 403
Radio-ulnar joint, inferior, **263,** 419
mid, 262
superior, **262,** 1419
ligaments, 262, 264
Radius, 152
clinical anatomy of, 1419, 1422
Ramus(i) bronchial, 1231
colli (infra-mandibular branch), of cervico facial nerve, 946
communicantes, 969, **1030,** 1037
of fissure of Sylvius, 856
of ischium, 172
isthmi faucium, 940
linguales, 954
of mandible, 95
of pubis, 172
Ranvier, nodes of, 761, 767
Raphe of palate, 1104
lateral palpebral, 1078
scrotal, 1254
Receptaculum (cisterna) chyli, 726
Recess(es), elliptical, 80
epitympanic, 78
hypo-tympanic, 78
infundibular, 848
optic, 848
pharyngeal, 1130
spheno-ethmoidal, 1206
spherical, 80
supra-pineal, 847
of tumpanic mucous membrane, 1089
Recessus ellipticus (fovea hemielliptica), 80
sphæricus (fovea hemisphærica), 80
Rectal branches of lateral sacral arteries, 608
(hæmorrhoidal) of middle sacral arteries, 603
columns (of Morgagni), **1177,** 1390
examination, 1391
pits, 1390
sinuses, 1177
stalk, 1391
triangle, **440,** 1383
Recto-uterine folds, 1274
pouch (of Douglas), 1267, 1274
Recto-vaginal pouch of peritoneum, 1148
Recto-vesical pouch of peritoneum, 1148
Rectum, 1176
clinical anatomy of, 1390
lymphatics of, 735
supports of, 1391
Rectus abdominis, 422, 424, **430**
accessorius, 471
capitis anterior (minor), 356
lateralis, 356
major, 355
posterior major, 412, **419**
minor, 412, **419**
femoris, 468, **470,** 1436
Recurrent artery, anterior tibial, 632
dorsal ulnar, 577
interosseous, 580
posterior tibial, 632
radial, 583
volar ulnar, 577
articular nerve of leg, 1013
branches of deep volar arch, 586
of lacrimal, 552
of spinal nerve-trunks, 970
of vagus nerve, 956
meningeal branch of maxillary nerve, 937
of ophthalmic nerve, 935
(inferior laryngeal) nerve, 957
Red nuclei, 840
References for articulations, 311
blood-vascular system, 696
digestive system, 1197
ductless glands, 1329
lymphatic system, 750
morphogenesis, 25
musculature, 506
nervous system, 1047

References for osteology, 209
respiratory system, 1240
skin and mammary glands, 1329
special sense organs, 1098
urogenital system, 1280
Reflected inguinal ligament (Colles' ligament, triangular fascia), 1395
Reflex paths of cranial nerves, 898
of spinal cord, 895
optic acoustic, 840
Regeneration of lymphatics, 707
Region, ilio-costal, 1406
parotid, 1343
of skull, anterior, 108
inferior, 103
lateral, 101
posterior, 101
superior, 100
Regions of abdomen, **1142,** 1370
Reil, island of (insula), 856
Reissner, membrane of, 1096
Relations of organs (see corresponding organs)
Renal arteries, **598,** 638
accessory, 638
branches of lumbar arteries, 593
of vagus, 958
columns (of Bertin), 1246
(Malpighian) corpuscles, 1246
fascia, 1242
ganglia, 1044
pelvis, 1248
plexuses of nerves, 1044
pyramids (of Malpighi), 1246
surface of spleen, 1309
tubules, 1246
veins, 673
Reproductive organs, development of, 1278
female, 1265
male, 1253
lymphatics of, 742, 744
Respiration, 1199
musculature, 247, 248, 503
Respiratory nerve of Bell, external, 982
nucleus, 822
system, 1196
larynx, 1209
lungs, 1228
mediastinal septum, 1239
nose, 1200
pleuræ, 1236
thoracic cavity, 1235
trachea and bronchi, 1225
region of nose, **1208,** 1352
Restiform body, 800, 810
fibres of, 830
in pons, 830
Rete arteriosum, cutaneous, 1289
sub-papillary, 1289
articular of knee, 622
canalis hypoglossi, **650,** 665
dorsal carpal, 579, 585
venous (foot), 684
(hand), 667
foraminis ovalis, 646
lateral malleolar, 626, 632
medial malleolar, 626, 632
patellar, 622
plantar venous, 684
testis, 1256
volar carpal, 579, **581**
Retia venosa vertebrarum, 665
Reticular formation of medulla oblongata, 816
layer of thalamus, 882
of pons, 816
of spinal cord, 776
Retina, 1051, 1057, **1061**
Retinacula, 1287
mammæ, 1303
patellæ laterale, 471
mediale, 471
peroneal, 480
tendinum, 317
Retinal arteries, 1065
pigment layer, 1057
veins, 1065
Retractors of the lips, 332
Retrahens aurem, 337
Retro-pubic space (of Retzius), 1371
Retrotonsillar fissure of cerebellum, 807
Rhinencephalon, 864
Rhombencephalon, 758
isthmus of, 832
summary of principal structures in, 833
Rhomboid fossa, 802
ligament (costo-clavicular), 249
muscles, nerve to, 982
Rhomboideus major, 356, **358**
minor, 356, **358**
Ribs, 120
asternal or false, 127
bicipital, 132
cervical, 131, **1365**
clinical anatomy of, 1363, 1404
eleventh, 130
first, 128
floating, 127
lumbar, 132
ossification of, 130
peculiar, 128
second, 129
sternal (true), 127
tenth, 129
twelfth, 130
typical characters of, 127
variations of, 131
vertebral, 127
vertebro-chondral, 127
vertebro-sternal, 127
Ridge(s), carotid, 73
genital, 1267, 1278
nfra-temporal, 65
lateral supracondylar, 149
medial supracondylar, 149
pronator, of ulna, 157
transverse, of palate, 1104, 1106
temporal, 71
Right atrium (auricle) of heart, 512
branch of hepatic artery, 595
bronchial artery, 588
colic artery, 598
common iliac artery, 605
coronary artery, 519
branches, 519
gastric artery, 594
gastro-epiploic artery, 595
vein, 677
innominate vein, 641
lymphatic duct, 728
pulmonary artery, 529
veins, 529
superior intercostal vein, 664
terminal branch of hepatic artery, 589
collecting lymphatic duct, 728
ventricle of heart, 516
Rima glottidis, 1223
oris, 1100
palpebrarum, 1052
pudendi, 1276
vestibuli, 1222
Ring(s), abdominal inguinal (internal abdominal), **430,** 1371, 1396
femoral, 466, **1401**

Rings, subcutaneous inguinal (external abdominal), **429,** 1371, 1394
tonsillar (Waldeyer's), 1133
Risorius, 333
Rivinus, notch of, 77
Rolandic angle, 860
points, 1340
Rolando, fissure of, **859,** 1340
gelatinous substance of, 776
Root(s) of Arnold's or otic ganglion, 963
canal of tooth, 1118
of ciliary ganglion, long, 937
short, 932
filaments of spinal nerves, 775, 964
of hair, 1292
of lungs, 1229, **1230,** 1234, 1408
of nails, 1294
of nose, 1200
of optic tracts, 849
of penis, 1260
of spheno-palatine (Meckel's) ganglion, 962
of spinal nerves, 771, 964
of teeth, 1117
of tongue, 1107
Rosenmüller, fossa of, 1130
Rostral lamina of corpus calloum, 852
sulci, 858
Rostrum of corpus callosum, 852
of sphenoid, 63
Rotation, 215, 321
Rotatores, breves, 412, **419**
longi, 412, **419**
Round ligament liver, 1185
of uterus, 1274
Rubro-spinal fasciculus, 786
Ruffini, corpuscles of, 1290
Rugæ of vagina, 1275

S

Sac, conjunctival, 1054
endolymphatic, 1094
lacrimal, **1080,** 1349
lesser, 1148
synovial, 313
Saccular branch of vestibular ganglion, 950
Saccule of membranous labyrinth, 1093
Sacculo-ampullar division of vestibular nerve, 950
Sacral arteries, lateral, 607
middle, 603
branches, lateral of middle sacral artery, 603
canal, 42
cornua, 40
foramina, 40
groove, 41
hiatus, 40
lymphatic nodes, 733
nerves, 973, 1006
plexus, 1006
composition of nerves of, 1006
of veins, anterior, 679
portion of sympathetic system, 1040
veins, lateral, 680
middle, 679
vertebræ, development of, 48
Sacro-coccygeal articulation, 237
ligament, anterior, 238
deep posterior, 238
superficial posterior, 238
Sacro-coccygeus, anterior, 448
posterior, 448
Sacro-iliac articulation, 234
ligaments, anterior, 234
inferior, 235
posterior, 234
superior, 234
Sacro-lumbar ligament, 232
Sacro-spinalis (erector spinæ), 412, **414,** 1407
Sacro-spinous or small sacro-sciatic ligament, 236
Sacro-tuberous (great or posterior sacro-sciatic) ligament, 235
Sacro-vertebral angle, 39, 43
articulations, 232
Sacrum, description of, 30, **39**
sex and racial differences of, 42
Sagittal fontanelle, 59
sinus, inferior, 650
superior, 649
sulcus, 60
suture, **57,** 101
Salivary corpuscles, 1132
glands, 1113
development of, 1117
variations and comparative, 1117
Salivatory nucleus, 826, 947
Santorini, cartilages of, 1212
duct of, 1195
incisures of, 1085
Saphenous artery, 621
nerve, **1003,** 1467
external or short, 1010, 1013
opening (fossa ovalis), **467,** 1400, 1440
vein, accessory, 684
great (internal), **684,** 1456
small (external), **684,** 1458
Sarcolemma, 315
Sartorius, 453, **468,** 1436
Scala media, 1096
tympani, **81,** 1096
vestibuli, **81,** 1096
Scalene musculature, 328, **353**
tubercle, 129
Scalenus anterior, 353
medius, 354
minimus, 355
posterior, 354
Scalp, 1333
cutaneous areas of, 1018
lymphatics of, 712
Scansorius, 462
Scapha of auricle of ear, 1083
Scaphoid bone, 159, 160
fossa, 55, 66, 107
Scapula, 141
clinical anatomy of, 1406
Scapular artery, circumflex (dorsal), 572
posterior, 565
transverse (suprascapular), 564
foramen, 142
nerve, dorsal, 982
notch, 142
veins, transverse, 648
Scapulo-clavicular union, 250
Scapulo-clavicularis, 374
Scarf-skin (epidermis), 1285
Scarpa, fascia of, 425, 445
foramina of, **89,** 106, 126
triangle of, 467, **1438**
Schindylesis sutures, 212
Schlemm, canal of, 1059
Schwalbe, nucleus of, 823
Sciatic artery, **609,** 640
nerve (N. ischiadicus), **1008,** 1443
results of paralysis of, 1469
small, 1007
notch, great, 172
small, 172
Scleral sulcus, 1054
Sclera, 1052, 1056, **1058**
Sclerotome, 15
Scrotal (or labial) arteries, anterior, 620
posterior, 613

Scrotal nerves, anterior, 1000
posterior, 1017
veins, 684
Scrotum, 1254
lymphatics of, 698, **742,** 1255
surgical anatomy of, 1385
vessels and nerves of, 1255
Scutum, 1089
Sebaceous glands, 1298
Sebum cutaneum, 1298
palpebrale, 1054
Secondary tympanic membrane, 1089, 1096
Sections of peritoneum, 1146
Segmentation of the ovum, 9
Sella turcica, **63,** 113
Semicanalis m. tensoris tympani, 74
Semicircular canals, 78, 80
ducts (membranous semicircular canals), 1094
Semilunar bone, 159, **161**
fascia, 382
fibro-cartilages, 289
fissures of cerebellum, 805
fold of conjunctiva, 1055
of large intestine, 1170
ganglia, 1043
(Gasserian) ganglion, 826, **935,** 1345
gyrus, 865
lobe, inferior, of cerebellum, 807
superior, of cerebellum, 806
notch (greater sigmoid cavity), 156
valves, aortic, 517
pulmonary, 517
Semimembranosus, 453, 475, **476**
Seminal vesicles, 1257
Seminiferous tubules, 1256
Semispinalis capitis (complexus), 412, **417**
cervicis, 412, **419**
dorsi, 412, **419**
Semitendinosus, 453, 475, **476**
Sense, organs of special, 1049
Sensory aphasia, 894
axones, 762
Sensory-motor area of cerebral cortex, 893
Septa, intermuscular, 314
of thigh, 468
Septal branches of spheno-palatine artery, 549
nasal cartilage, 1202
Septulæ of mediastinum testis, 1256
Septum aortic, 527
of arm, intermuscular, 377
atriorum, 511
canalis musculotubarii, 73
femoral, 466
of foot, intermuscular, 492
of heart, membranous, **511,** 527
interventricular, 516
of leg, intermuscular, 477
linguæ, 346
mediastinal, 1239
nasal, 111, **1204,** 1354
Septum pellucidum, 872
cavity of, 872
laminæ of, 872
of penis, 1261
posticum of Schwalbe (subarachnoid septum), 919
sigmoid, 341
sphenoidal, 62
transversum, 20
Serial morphology of vertebræ, 50
Serrate sutures, 212
Serratus anterior (magnus), 356, **359**
posterior inferior, 423, **431**
superior, 423, **431**
Sesamoid bones, 68, 205, 275, 317
cartilages of larynx, 1213
Sesamoid nasal cartilages, 1202
plate, plantar, 310
tibial and fibular, 209
ulnar and radial, 209
Seventh cervical vertebræ, 34
cranial nerve (facial), **943,** 1345
Shaft of bones, 29 (see also the individual bones)
of hair, 1292
Sheath(s), carotid, 1362
femoral, 1400
medullary, 759
of optic nerve, 931
of parotid gland, 1344
primitive, 761
of prostate, 1389
of rectus muscle, 427
of hair roots, 1292
synovial tendon, 317, **318,** 403, 483, 484, 491
Shoulder, clinical anatomy of, 1409
musculature of, 323, 363, 503
Shoulder-blade (scapula), 141
Shoulder-girdle, 207
Shoulder-joint, 253
arterial supply, 257
clinical anatomy of, 1413
ligaments of, 254
lymphatics of, 723
movements of, 257
muscles acting upon, 258
nerve-supply of, 357
synovial membrane, 255, 1412
Shrapnell's membrane, 1087
Sibson's fascia, 129, **355,** 1237
Sigmoid artery, 603
cavity of radius, 154
of ulna, greater, 156
lesser, 157
colon, **1174,** 1379
groove, 72
notch, 96, 97
septum, 341
sinus, 652
vein, 678
Sinuses, accessory nasal, 1354
aortic (of Valsalva), 518
bony, of skull, 1335
cavernous, 652, 691
cervical, 17
circular, 651
connecting with nose, 1354
coronary, 521
costo-mediastinal, 1238
cranial venous, **649,** 692, 916
of dura mater, 649
epididymidis (digital fossa), 1255
frontal, 59, 61, **1207,** 1335
inferior petrosal, 652
sagittal (longitudinal), 650
intercavernosus, 651
of kidney, 1242
lactiferous, 1302
longitudinal vertebral, 665
mammarum, 1299
marginal, 650
maxillaris (antrum of Highmore), 87, 90, 111, **1206,** 1354
of Morgagni, 1137
oblique, of pericardium, 523
occipital, 650
paranasal, 1206
parasinoidal, 919
of pericardium, transverse, **523,** 527
petro-squamous, 653
phrenico-costal, 1237
pleural, 1237
of portal vein, 675

Sinuses, rectal, 1177
sigmoid, 652
sphenoidal, 62, **1207,** 1338
spheno-parietal, 653
straight, 650
superior petrosal, 652
sagittal (longitudinal), 649
tarsi, 195
transverse (lateral), 651
tympanic, 1089
uro-genital, 1279
of Valsalva, **518,** 530
venarum, 513
venosus, of heart, 525
of sclera (Schlemn), 1059
Sinusoids, 672, 675
Skeleton, 27
appendicular, 139
axial, 29
Skene, ducts of, 1277
Skin, 1281
appendages of, 129
corium, 1286
development of, 1286, 1290
epidermis, 1285
lymphatics of, 698, 1289
muscle-fibres of, 1288
tela subcutanea (superficial fascia), 1287
vessels and nerves, 1288
Skin-folds of wrist and hand, 1425
Skull, appendicular elements of, 117
articulations of, 215
at birth, 120
bones of, 51
bony landmarks, 1331
sinuses of, 1335
fœtal, general characters, 120
interior of, 112
morphology of, 117
nerve-foramina of, 125
regions of, anterior (norma facialis), 108
inferior (norma basalis), 103
lateral (norma lateralis), 101
posterior (norma occipitalis), 101
superior (norma verticalis), 100
topography of, 1338
as a whole, 160
Small cardiac vein, 521
intestine, **1161,** 1375
blood-supply, 1166
clinical anatomy of, 1375
development of, 1168
duodenum, 1161
ileum and jejunum, 1165
lymphatics of, 1168
nerves of, 1168
(accessory) meningeal artery, 548
occipital nerve, 977
palatine nerve, 948
(external) saphenous vein, **684,** 1458
sciatic nerve, 1007
superficial petrosal nerve, 951
Smaller palatine canals, 92
Smallest cardiac vein, 521
occipital nerve, 971
Snuff-box space (tabatiére anatomique), 1433
Soft palate, 1104
muscles of, 326
Solar plexus, 1043
Sole of foot, muscles of, 493
Soleus, 454, 484, **485**
accessorius, 491
Solitary follicles, 704
glands of small intestine, 1166
tract, 820
Somæsthetic (sensory-motor) area of cerebral cortex, 893
Somites, mesodermic, 14, 15
Space(s), Burns', 1356
of Fontana, 1060
intercostal, 139
interfascial (Tenon's), 715, 1073
popliteal, 1451
prævesical, 1250
snuff-box, 1433
subarachnoid, 771
subdural, 771
Special sense, organs of, 1049
Speech, cortical areas of, 894
Spermatic artery, external, 615
internal, **598,** 638, 1259
branch, external, of genito-femoral nerve, 1000
cord, 1254, **1259,** 1387
fascia, external, 1387
plexus of nerves, 1045
veins, **674,** 1259
Spermatozoa, 1256
Spheno-ethmoidal branch of naso-ciliary (nasal) nerve, 937
cells, 84
recess, 1206
Sphenoid, 62
at birth, 122
Sphenoidal conchæ (turbinate bones), 64, **67**
at birth, 124
development of, 119
crest, 63
(superior orbital) fissure, 65, 109, 116, **125**
process of palate bone, 91, 92
of septal cartilage, 1203
septum, 62
sinuses, **62,** 1207
Spheno-mandibular ligament, 217
Spheno-maxillary fissure, **102,** 109, 126
fossa, 102
Spheno-palatine artery, 549
nerve, 938
foramen, 93, 103, 111, **126**
(Meckel's) ganglion, 962
branches, 962
roots, 962
notch, 91, 93
vein, 646
Spheno-parietal sinus, 653
Sphenotic cartilage, 117
Spherical recess, 80
Sphincter ani externus, 441, **449**
internus, 1177
tertius, 1177
internal, of urinary bladder, 1253, 1389
pupillæ (iridis), 1061
urethræ (in female), 449
membranaceæ, 449
urogenitalis, 442, **449**
vaginæ, 1276, 1278
Spigelian lobe of liver, 1184
Spinal accessory nerve, 958
nucleus of, 820
arachnoid, 919
artery, anterior, 561, 638, **792**
posterior, 561, **792**
branches of aortic intercostal arteries, 590
of deep cervical artery, 568
of ilio-lumbar artery, 607
of lateral sacral arteries, 608
of superior intercostal arteries, 568
of vertebral artery, 560
cord, 751, **771**
blood supply of, 792
central canal of, 775
clinical anatomy of, 1408
external morphology of, 771
internal structure of, 775

Spinal cord, meninges of, 908
summary of, 788
surface of, 772
systems of neurones in, 777
terminal ventricle, 775
dura mater, 911
ganglia, 964
aberrant, 965
neurones of, 755
musculature, 410
nerves, 964
aberrant ganglia, 965
areas of distribution of, 970
attachment of, 964
cauda equina, 966
course of, 965
filia radicularia, 965
ganglion of, 964
origin of, 964
roots of, 964
topography of attachment of, 966, 1406
nerve-trunks, anterior primary divisions, 968
meningeal (recurrent) branch of, 970
posterior primary divisions, 967, 970
rami communicantes, 969
pia mater, 921
(inferior) portion of (spinal) accessory nerve, 958
tract, of trigeminus nerve, 828
veins, anterior, 665
posterior, 665
Spinalis capitis (biventer cervicis), 418
cervicis, 412, **417**
dorsi, 412, **417**
Spindle, aortic, 531
neuromuscular, 764
Spine(s), 29
anterior nasal, 87, 90, 112
ethmoidal, 63, 113
frontal (nasal), 60
of helix, 1084
of ilium, 169
ischial, 172
mandibular, 96
mental, 95
nasal (frontal), 60
posterior, 91
of pubis, 172
of scapula, 141, **144**
of sphenoid, **65,** 108
suprameatal, 72
of tibia (intercondyloid eminence), 185
vertebral, 1403
Spino-cerebellar fasciculi, 784
path, 985
Spino-mesencephalic (spino-tectal) tract, 786, 842
Spino-olivary fasciculus, 784
Spino-thalamic tract, 786
Spinous process of epistropheus, 34
of seventh cervical vertebra, 34
of vertebræ, 31
ligaments connecting, 229
Spiral canal of cochlea, 81
ganglion of cochlea, 950
ligament of cochlea, 1096
line of femur, 178
organ (organ of Corti), 1096
valve (of Heister), 1187
Splanchnic ganglion, 1039
nerve, great, 1038
least, 1039
lesser, 1039
pelvic, 1017, **1040,** 1046
Spleen (lien), 1306
development, 1312
lymphatics, **736,** 1312
Spleen, topography of, 1310, 1375
variations, 1310
vessels and nerves, 1312
Splenic artery, 595
branches of vagus, 958
(left colic) flexure, 1174, **1379**
lobules, 1312
lymphatic nodes, 730, 736
(lienal) plexus of nerves, 1045
pulp, 1311
vein, 677
Splenium of corpus callosum, 852
Splenius, 412, **414**
capitis, 414
cervicis, 414
accessorius, 414
Spongioblasts, 755
Spot, yellow, of fundus oculi, 1055
of larynx, 1223
Spring ligament, 305
Squamous portion of temporal bone, 68
sutures, 212
Stapedial fold, 1090
artery, 638
Stapedic branch of stylo-mastoid artery, 544
Stapedius, 1091
nerve to, 944
Stapes, **80,** 119
Stellate cells of cerebellar cortex, 809
figures of lens of eye, 1063
ligament, 242
Stem of fissure of Sylvius, 855
Stenson's duct, **1115,** 1343
foramina, **89,** 106
Stephanion, 101
Sternal branches of internal mammary artery, 567
foramen, 133
synchondrosis, 133
Sternalis, 374
Sternebræ, 132
Sterno-chondro-scapularis, 374
Sterno-clavicular joint, surgical anatomy of, 1363
ligaments, 248
Sterno-clavicularis, 374
Sterno-cleido-mastoid artery, 542
Sterno-cleido-mastoideus, 347, **349**
Sterno-costal articulations, 245
ligaments, 245
surface of heart, 510
Sterno-costo-clavicular articulation, 248
ligaments of, 248
movements of, 250
Sterno-hyoideus, 351
Sterno-mastoid branch of superior thyreoid artery, 538
as a landmark, 1355
vein, 660
Sterno-pericardial ligaments, 522
Sterno-thyreoideus, 351
Sterno-xiphoid plane, 1370
Sternum, 132
abnormalities of, 138
angle of, **133,** 139
body of, 133
development of, 135
Stilling's nucleus, 776
Stomach, 1151
blood-vessels of, 1151
clinical anatomy of, 1373
comparative, 1160
development of, 1157
lymphatics of, 734, 1156
nerves of, 1156
peristalsis of, 1159
position and relations, 1153

Straight (collecting), renal tubule, 1167
sinus, 450
Stratum album medium, 842
profundum, 842
cinereum, 842
corneum, 1286
unguis, 1295
germinativum (Malpighii), 1286, 1295
granulosum, 1286
lemnisci, 825, **839,** 842
lucidum, 1286
opticum (stratum album medium), 842
zonale, 839, 842, 845, 881
Streeter, nucleus incertus of, 815
Striæ acustica(æ), 814
(lineæ) albicantes, 1283, 1304
intermediate olfactory, 865
Lancisii, **851,** 871
lateral longitudinal, of corpus callosum, 851
longitudinal, of corpus callosum, **851,** 892
of hippocampus 871
medial longitudinal, of corpus callosum, 851
medullares acustici, 824
(pineales) of thalami, 846, 872
olfactory, 865, 866
terminalis thalami (tænia semicircularis), **845,** 892
of thalamus, **873,** 881, 892
transverse, of corpus callosum, 852
Striate arteries, external, 906
internal, 906
Stripes of Baillarger, 879
Structure of organs (see corresponding organ)
Stylo-glossus, 346
Stylo-hyal portion of styloid process, 75, 119
Stylo-hyoid ligaments, 99
Stylo-hyoideus, 343, **344**
Styloid bone, 168
process, 70, **73, 75,** 77, 108
of fibula, 190
of radius, 155
of third metacarpal bone, 166
of ulna, 158
Stylo-mandibular (stylo-maxillary) ligament, 217
Stylo-mastoid branch of posterior auricular artery, 544
foramen, **73,** 108, 126
vein, 646
Stylo-pharyngeus, 1137
Subanconeus, 378
Sub-arachnoid cavity or space, 771, 919
cisternæ, 918
Subcallosal gyrus (peduncle of corpus callosum), 866
sulcus, 866
Subclavian artery, 556
collateral circulation, 1360
left, 556
relations, 556, 558, 1369
right, 557
variations, 638
group of axillary lymphatic nodes, 719
sulcus, of lung, 1229
vein, 671
Subclavius, 373
Subcostal artery, 588
Subcostales, 423, **434**
Subcrureus, 470
Subcutaneous dorsal veins of penis, 684
inguinal (external abdominal) ring, **429,** 1371, 1394
muscles, 313
of hand, 404
Subdural cavity, 912, 917
space of spinal cord, 771
Subfascial bursæ mucosæ, 318
Subiculum of the promontory, 1089
Sublingual artery, 540
caruncle, 1116, 1117
fold, 1116
gland, 1116
ducts of, 1117
vessels and nerves, 1117
lymphatic nodes, 746
nerve, 941
vein, 660
Submammary (retromammary) bursæ, 1303
Submarginal gyrus, 858
Submaxillary ganglion, 963
roots, 963, 1036
gland, **1115,** 1350
duct of (Wharton's) 1116
vessels and nerves, 1116
lymph-nodes, 709
portion of external cervical fascia, 347
(digastric) triangle, 1357
Submental artery, 541
set of facial lymph-nodes, 711
vein, 644
Submuscular bursæ mucosæ, 318
Subnasal point, 109, 112
Suboccipital muscles, 412, **419**
nerve, 971
Subparietal sulcus (postlimbic fissure), 863
Subphrenic area of peritoneum, 1372
Subsartorial plexus, 1003
Subscapular angle, 145
artery, 571
branches of posterior scapular artery, 566
of transverse scapular artery, 565
fossa, 141
group of axillary lymphatic nodes, 720
nerves, 984
vein, 671
Subscapularis, 369
minor, 369
Substance, anterior perforated, 847, **866**
central grey, of mesencephalon, 836
of medulla, 818
gelatinous, central, of spinal cord, 776
of Rolando, 776
grey, of pons, 831
of nervous system, 768
of spinal cord, 775
of telencephalon, 879
posterior perforated, 835, **844**
white, nervous system, 768
of spinal cord, 775, 777
of telencephalon, 885
Substantia alba, 768
corticalis, 1293
grisea, 768, 818
medullaris, 1293
nigra, 836, **840**
reticularis alba (Arnoldi), 868
Subtendinous bursæ mucosæ, 318
Subtrapezial plexus, 979
Sudoriferous glands (sweat-glands), 1296
pore, 1297
Sulco-marginal fasciculus, 788
Sulcus(i), 29
ampullary, 1095
antero-inferior, 807
antero-intermediate, 774
antero-lateral, 773
auricular, 1082
basilar, of pons, 804
breves, 857
central (fissure of Rolando), **859,** 1340
of cerebellum, 805
of cerebrum, 852
cinguli (calloso-marginal fissure), 857, 858, **859**

Sulcus(i), circular, 857
coronarius, 510
of corpus callosum, 867
of crus of helix, 1084
cunei, 864
diagonal, 858
fimbrio-dentate, 868
of floor of fourth ventricle, 813
fronto-marginal, 858
of heart, 510, 511
hypothalamic, 847
inferior frontal, 858
postcentral, 861, 862
temporal, 855
infra-orbital, 1284
interparietal (intraparietal), 861
lateral occipital, 863
matricis unguis, 1294
median subcallosal, 866
mento-labial, 1284
middle frontal, 858
temporal, 855
of Monro, 847
oculomotor, 835
olfactory, 858
orbital, 858
parallel, 855
para-medial, 858
parolfactory, 865
pontine, 804
postcentral of cerebellum, 806, 861, **862**
posterior median, 772
postero-inferior, 807
postero-intermediate, 773
postero-lateral, 773
post-nodular, 808
pre-auricularis, 177
precentral, 807, **857**
rostral, 858
sagittal, 60
scleral, 1054
of skin, 1284
of spinal cord, 772
subclavian, of lung, 1229
subparietal, 863
superior frontal, 858
postcentral, 861, 862
temporal 855
supra-orbital, 1284
of telencephalon, 853
terminalis of tongue, 1106
of heart, 511
transverse occipital, 862, 863
temporal, 855
transversus, **59,** 108
of anthelix, 1083
tympanicus, 75
Supercilia, 1290
Superciliary arch, **59,** 108
Supination, 321
Supinator (brevis), 392
radii longus, 388
Supracallosal gyrus, 868
Supra-clavicular branches of cervical plexus, 978
nerves, 978
portion of brachial plexus, branches of, 982
Supra-condylar lines, 181
process, 149
ridge, lateral, 149
medial, 149
Supracostales, anterior, 433
posterior, 432
Supraglenoid tubercle of scapula, 144
Supra-hyoid musculature, 325, **344**
Supramammillary commissure, 871, 890
Supra-mandibular branch of cervico-facial nerve, 946
Supramarginal gyrus, 863
Supra-maxillary set of facial lymph-nodes, 711
Supra-meatal fossa, 72
spine, 72
triangle, Macewen's, 1337
Supra-occipital, 119
Supra-omental region of peritoneum, 1372
Supra-orbital artery, **552,** 1343
branches, 553
border, 60
nerve, 935
notch, 60
sulcus, 1284
vein, 644
Suprapineal recess, 847
Suprarenal artery, inferior, 598
middle, 598
superior, 592
glands, 1323, 1381
accessory (of Marchand), 1326
development, 1326
lymphatics, 701, **738**
vessels and nerves of, 1326
plexuses of nerves, 1044
veins, 673
Suprascapular (transverse cervical) artery, 564
(coracoid or superior transverse) ligament, 253
nerve, 982
Supraspinatus, 368
Supraspinous branches of posterior scapular artery, 566
of transverse scapular artery, 565
fossa, 141
ligament, 230, 238
Suprasternal bones, 133
Supratonsilar fossa, 1132
Supratragic tubercle, 1082
Supratrochlear branch of frontal nerve, 936
foramen, 150
lymphatic node, 719
Sural branches of popliteal artery, 622
(external or short saphenous) nerve, 1010, 1013, 1467
Surfaces of organs (see corresponding organ).
Surgical anatomy of organs (see corresponding organ).
Suspensorius duodeni, **1164,** 1376
Suspensory ligament of Cooper, 1303
of the eyeball, 1072, 1348
of lens of eye, 1057, 1064
(apical dental) of occipito-epistrophic articulation, 223
of ovary, 1269
of penis, **427,** 1260
of Treitz, 1164, 1376
Sustentaculum hepatis, 1174
lienis, 1174
tali, 195
Suture(s), 212
of anterior cranial fossa, 113
coronal, **57,** 101, 1339
frontal, 59
incisive, 106
lambdoid, **57,** 101, 1339
meso-palatine, **89,** 106
metopic, **59,** 101
neuro-central, 45
of norma facialis, 108
occipital, 101
occipito-mastoid, 101
parieto-mastoid, 101
petro-squamous, 71

Suture(s), sagittal, **57,** 101, 1339
squamoso-parietal, 1339
transverse, 108
palatine, 106
of vertex of skull, 101
Swallowing, muscles of, 325
process of, 1137
Sweat-glands, 1296
Swellings, genital, 1279
Sylvian fossa, 854
point, 856
Sylvius, aqueduct of, 834
fissure of, 850, **855,** 1340
Syme's amputation, 1465
Sympathetic fibres, 970, 1029
nerves of orbit, **1076,** 1348
relations of spinal cord, 789
system, 959, **1026**
construction of, 1030
ganglia of, 959
origin of, 1029
prevertebral plexuses of, 1029
trunks, 1032, 1033
Symphysis of mandible, 95
pubis, 238
ligaments of, 238
Synapses, 762, 765
Synarthroses, 212
Synchondroses, 212
sternal, 133
Syncytium, 759
Syndesmoses (synarthroses), 212
tympano-stapedial, 1090
Synergists, 322
Synovial bursæ, 313, 318
membrane, 211 (see also corresponding articulations)
sheaths (vaginæ mucosæ tendinum), 378
tendon-sheaths, 317
of forearm muscles, 395, 403
of leg muscles, 483, 484, 491
System, association, of hemisphere, 890
blood-vascular, 507
chromaffin, 1333
digestive, 1099
of fibres, commissural, 890
lymphatic, 697
nervous, 751
central, 751, 770
peripheral, 754, 924
sympathetic, 1026
neurone, 777, 895
respiratory, 1199
urogenital, 1241
Systemic arteries, 529
circulation, 507
veins, 640

T

Tabatière anatomique (of Cloquet), 1433
Table showing relations of cervical and thoracic nerves to branches of brachial plexus, 993
of lumbar and sacral nerves to branches of lumbar and sacral plexuses and to pudic nerve, 1016
of muscles of lower extremity to nerves of lumbar and sacral plexuses, 1016
of muscles of upper extremity to cervical nerves, 993
of vertebral levels, 1409
of distribution of spinal nerves (Gowers'), 969
Tactile corpuscles (Meissner), 1290
Tænia chorioidea, 844
fimbriæ, 868, 877
Tænia fornicis, 868
pontis, 855
semicircularis, 845, **873**
thalami, 846, 872
Tail of caudate nucleus, 877
of epididymis, 1256
of muscle, 314
of pancreas, 1194
Talipes, 1467
Talo-calcaneal union, 301
Talo-fibular ligament, anterior, 299
posterior, 299
Talo-navicular articulation, 305
ligament, 306
Talus or astragalus, 191, **192**
Tan, 1283
Tangential layer of fibres of cortex, 879
Tapetum of posterior cornu of lateral ventricle, 876
Tarsal arch, inferior, 554
superior, 554
arteries, medial, 632
bones, 191
clinical anatomy of, 1467
branches of dorsalis pedis artery, 632
elements, accessory, 199
(Meibomian) glands, **1054,** 1298
joints, 301
transverse, 305
muscles, 1072, 1078
Tarso-metatarsal articulation, 308
Tarsus, 191
anterior articulations of, 303
of eyelids, 1053, **1077**
Taste, organ of, 1051
Taste-buds, 1051
Taste-pores, 1051
Tectorial membrane, 223
Teeth, 1117
canine, 1120
deciduous or milk, 1126
incisor, 1119
molars, 1121
premolar or bicuspid, 1121
times of eruption, 1127
variations and comparative, 1127
vessels and nerves, 1124
Tegmen tympani, 77
Tegmento-mammillary fasciculus, 871
Tegmentum of pons, 830
Tela chorioidea, 758
of fourth ventricle, 922
subcutanea (superficial fascia), **313,** 1287
of the abdomen, 425
of the arm, 377
of the back, 413
of the forearm and hand, 384
of the foot, 491
of gluteal region, 457
of head and neck, 347
of leg, 477
of pectoral region, 371
of the perineum, 445
of shoulder, 365
of thigh, 466
of thoracic-abdominal musculature, 425
Telencephalon, 758, 847
gyri, fissures and sulci, 852
lobes, 853
central (insula), 856
frontal, 857
occipital, 863
parietal, 860
rhinencephalon, 864
temporal, 854
projection fibres of, 886
Telodendria of axones, 762

Temporal artery, anterior deep, 548
middle, 545
posterior deep, 548
superficial, **545,** 1343
bone, 68
at birth, 122
mastoid portion of, 68, **71**
petrous portion of, 68, **72**
squamous portion of, 68, **70**
tympanic portion of, 69, 70, **75**
branches, superficial, of auriculo-temporal nerve, 942
of maxillary nerve, 938
of temporo-facial nerve, 945
fascia, 339
fossa, 101
gyrus, inferior, 855
middle, 855
superior, 854
lines (ridges), 57, **60,** 71, 1332
lobe of cerebrum, 854
opercula of, 854
nerves, deep, 943
notch, 868
pole, 850
pontile path (Türk's path), 832, 840, **890**
process of malar bone, 95
sulcus, middle, 855
superior, 855
vein, deep, 646
diploic, 648
middle, 646
superficial, 646
wings of sphenoid, 65
Temporalis muscle, 338, **341**
superficialis, 337
Temporo-facial nerve, 945
Temporo-malar branch of maxillary nerve, 938
Temporo-maxillary (posterior facial) vein, 644
Tendino-trochanteric band, 280
Tendo Achillis, 485
Tendon(s), 314, 317
at the ankle, 1460
conjoined, 435
of the conus, 518
popliteal, 1451
of the quadriceps, 471
Tendon-sheaths, 317
of forearm muscles, 395, 403
of leg muscles, 483, 484, 491
Tenon's capsule, **1073,** 1348
space, 715
Tensor capsularis articulationis metacarpo-phalangei digiti quinti, 406
of the capsule of the ankle-joint, 491
fasciæ dorsalis pedis, 482
latæ, 457, **459** ,1436
suralis, 476
laminæ posterioris vaginæ musculi recti abdominis, 436
posterioris vaginæ musculi recti et fasciæ transversalis abdominis, 436
ligamenti annularis anterior, 393
posterior, 393
tarsi, (Horner's muscle), 336
tympani, 1089, 1091
vaginæ femoris (tensor fasciæ latæ), 457, **459,** 1436
veli palatini, 1137
Tentorial (recurrent meningeal) branch of ophthalmic nerve, 935
notch, 915
Tentorium cerebelli, 914
Tenuissimus, 475
Teres major, 369
minor, 369
Terminal branches (see corresponding artery or nerve)
incisure (auricle), 1084
nerve, 929
stria, of thalamus, 873
sulcus, 1106
vein (of corpus striatum), 657
ventricle of spinal cord, 775
Testes, **1255,** 1386
descent of, 1257, **1387**
lymphatics of, 700, **744,** 1256, 1387
Testicular arteries, 601
Tetrahedral-shaped spleen, 1310
Thalamencephalon, 844
Thalami, 758, **844**
Thalamo-olivary tract, **817,** 830
Thalamo-spinal tract, 786
Thalamus, 881
anterior tubercle (nucleus) of, 845, **882**
cortical connections of, 883
medullary lamina of, 882
nuclei of, 871, 882, 883
peduncles of, 880, 883
pulvinar of, 882
stratum zonale, 881
stria terminalis of, **845,** 881, 892
striæ medullares, 872
Thebesius foramina of, 514
valvula of, 512
Theca folliculi, 1292
Thenar fascia, 387
Thigh, bony landmarks of, 1434
fasciæ of, 466
muscles, 453, 464
acting on, 505
muscular prominences of, 1436
Third occipital condyle, 56
part of axillary artery, 570
of subclavian artery, 558
ventricle of brain, 846
chorioid plexuses of, 924
Thoracic aorta, **586,** 1369
aortic plexus, 1038
aperture, superior, 138
artery, dorsal, (thoraco-dorsal), 572
lateral, 571
superior, 570
cavity, 1235
duct, 726
ganglia, 1038
intercostal nerves, 995
muscles, lymphatics, 923
nerves, 971, **994**
lateral anterior, 983
medial anterior, 983
long, 982
posterior, 982
portion of left subclavian artery, 556
of sympathetic system, 1037
of thymus, 1321
vein, lateral, 671
vertebræ, description of, 30, 36
peculiar, 36
Thoracic-abdominal musculature, 422
fasciæ of, 425
muscles of, 430
nerves, 995
Thoraco-acromial (acromio-thoracic axis), artery, 571
vein, 671
Thoraco-dorsal (middle or long) subscapular nerve, 984
Thoraco-epigastric vein, **671,** 1372
Thorax, 126
articulations at front of, 244
bony landmarks, 1363
clinical anatomy of, 1363

Thorax, deep veins of, 665
lymphatics of, 723, 724, 725
movements of, 247
as a whole, 138
Thumb, muscles of, 406
acting on, 504
Thymic arteries, 567
veins, 661
Thymus, 1319
corpuscles of, 1321
cortex of, 1321
development of, 1322
lymphatics of, **729,** 1322
medulla of, 1321
vessels (and nerves) of, 1322
Thyreo-arytænoideus externus, 1219
internus (m. vocalis), 1220
obliquus, 1220
superior, 1220
Thyreocervical trunk (thyreoid axis), 564
Thyreo-epiglottic ligament, 1215
muscle, 1220
Thyreo-glossal duct, 1318
Thyreo-hyal centre, 100
segment, 119
Thyreo-hyoideus, 351
Thyreoid artery, inferior, 564
superior, **538,** 638
bars, 119
cartilage, 1210
gland, 1312
accessory, 1315
clinical anatomy of, 1355
development of, 1318
lymphatics of, 699, **719,** 1317
laminæ, 1210
ligament, 1314
vessels, 1316
notch, inferior, 1211
superior, 1210
plexus of nerves, inferior, 1036
superior, 1036
tubercle, inferior, 1211
superior, 1211
veins, 660, 661, 1317
Thyreoidea ima artery, 533
vein, 661
Tibia, **185,** 1454
condyles of femur and, 1447
epiphyses of, 1435
structures on head of, 1449
tuberosity of, and ligamentum patellæ, 1448
Tibial artery, anterior, **629,** 640, 1458
posterior, **624,** 640, 1458
collateral ligament, 286
communicating nerve, 1010
nerve (internal popliteal), 1009
paralysis of, 1469
anterior, 1015
posterior, 1009
nutrient artery, **626,** 1459
recurrent artery, anterior, 632
posterior, 632
veins, anterior, 688
posterior, 688
Tibialis anterior, 453, **480,** 1468
tenotomy, 1464
posterior, 454, 486, **490,** 1468
secundus (tensor of capsule of ankle-joint), 491
Tibio-astragalus anticus, 482
Tibio-fibular ligaments, 295
union, 295
Tigroid masses, 766
Tissues, 4
Toes, muscles acting on, 506
Tomes' fibrils and sheath, 1118
Tongue, 1106
development of, 1112
glands of, 1108
lymphatics of, 715
muscles of, 325, 345, **346,** 502, 1110
papillæ, 1106
surgical anatomy of, 1350
variations and comparative, 1112
vessels and nerves, 1111
Tonsil (amygdala) of cerebellum, 807
Tonsillar branch of external maxillary artery, 541
of ascending palatine, 541
of glosso-pharyngeal nerve, 952
fossæ, 1131, 1132
ring (Waldeyer's), 1133
Tonsils, lingual, 1107
lymphatics of, 1132
palatine, **1132,** 1351
pharyngeal, **1130,** 1354
variations and comparative, 1138
vessels of, 1132
Topography of attachment of spinal nerves, 966
of brain, general, 793, 1338
of organs (see corresponding organ)
Torcular Herophili, 650
Torus tubarius, 1130
Trabeculæ (carneæ) cordis, 516
lienis, 1311
Trabecular region of skull, 117
Trachea, **1225,** 1408
lymphatics of, **699,** 1228
vessels and nerves, of 1228
Tracheal branches of inferior thyreoid artery, 564
cartilages, 1227
glands, 1227
veins, 661
Trachelo-mastoid, 416
Tract, anterior or direct pyramidal, 788
crossed pyramidal, 783
direct cerebellar (Flechsig), 784
Gower's, 784
habenulo-peduncular, 873
Loewenthal's, 786
mesencephalo-(tecto-) spinal, 786, **842**
olfacto-mammillary, 873
olfacto-mesencephalic, 873
olfactory, 758, **865,** 893
optic, 849
solitary, 820
spinal, nucleus of, 826
of trigeminus nerve, 828
spino-mesencephalic (spino-tectal), 786, **842**
spino-thalamic, 786
thalamo-olivary, **817,** 830
thalamo-spinal, 786
transverse peduncular, 835
ventral vestibulo-spinal, 786
Tractus ilio-pubicus, 430
ilio-tibialis, 457, 458
spino-tectalis, 786
Tragi, 1290
Tragus, 1082
Trans-pyloric line (Addison), 1153, **1370**
Transversalis cervicis, 416
fascia, 426
Transverse arch of foot, 1468
carpal (anterior annular) ligaments, 1427
cervical (transversa colli) artery, **565,** 638
veins, 672
colon, 1174
crest, 72
crural ligament of leg (upper part of anterior annular ligament), 479

Transverse diameter of pelvic inlet, 175
facial artery, 545
vein, 646
fissure of cerebrum, 850
(Houston's) folds of rectum, **1177,** 1390
fornix, 869, **890**
humeral ligament, 256
ligament of central atlanto-epistrophic, 222
of heads of metatarsal bones, 309
hip-joint, 280
inferior (spino-glenoid), 253
of knee-joint, 289
of pubis, 446
superior (coracoid, or suprascapular), 253
nasal branch of dorsal nasal artery, 554
palatine suture, 106
processes of atlas, 33
of vertebræ, 31
ligaments connecting, 231
scapular (suprascapular) artery, **564,** 638
veins, 648
(lateral) sinus, **651,** 1331
of pericardium, **523,** 527
striæ of corpus callosum, 851
sulci, 108
suture, 108
Transverso-spinal muscles, 412, **419**
Transversus abdominis, 424, **435**
group of lateral division of thoraco-abdominal muscles, 434
menti, 333
nuchæ (occipitalis minor), 337
perinei profundus, 442, **449**
superficialis, 444, **452**
thoracis (triangularis sterni), 424, **434**
vaginæ (Führer), 449
Trapezium, 159, **162**
Trapezius, 347, **349**
clinical anatomy, 1405
Trapezoid bone, 159, **162**
ligament, 251
(oblique) line, 140
Treitz, suspensory ligament of, **1164,** 1376
Triangle, Bryant's, 1436
Hesselbach's, 1398
inferior carotid (tracheal), 1358
Macewen's suprameatal, 1337
of neck, posterior, 1359
of Petit, 434, 1406
rectal, 440, 1383
Scarpa's 467, **1438**
submaxillary (digastric), 1357
superior carotid, 1358
urogenital, **440,** 1383, 1385
Triangles, cervical, 1357
of perineum, 1383
Triangular fascia, 430
fibro-cartilage, 264
fossa of auricle, 1082
fovea of arytænoid, 1212
ligament, urogenital diaphragm, **442,** 1384
(lateral) ligaments of liver, 1185
Triangularis (depressor anguli oris), 333
sterni, 424, **434**
Tributaries of veins (see corresponding vein)
Triceps brachii, 374, 377, **378**
surface markings, 1416
suræ, 484
Tricuspid valve, 515, 516
Trigeminal foramen, 125
impression, 73
Trigeminus nerve, 934
nuclei of, 826
spinal tract of, 828
Trigona fibrosa, 518
Trigone, collateral, of lateral ventricle, 876
femoral, Scarpa's triangle, 467, **1438**
Trigone of lemniscus, 832, **835**
of Lieutaud, 1252
olfactory, 865
urogenital, **442,** 446, 1384
vesical (of Lieutaud), 1252
Trigonum lumbale (triangle of Petit), 434
Triquetral (cuneiform), bone, 159, **161**
Trochanter, great, 178
third, 181
Trochanteric of digital fossa, 178
Trochanters of femur, 178
clinical anatomy of, 1435
Trochlea, 318, 1068
of humerus, 150
of talus, 193
Trochlear branches of supra-orbital artery, 553
fossa, 61
nerve, 835, 837, **933**
process, 195
Tröltsch, pouches of, 1089
True ligaments of bladder and prostate, 1252
synchondroses, 212
Trunk, articulations of, 224
costo-cervical arterial, 568
cutaneous areas of, 1020
lumbo-sacral, 1005
lymphatic, intestinal, 731
lumbar, 730
sympathetic, gangliated, 1029, 1032
thyreocervical, 564
Tuba auditiva (Eustachian tube) 74, 1089, **1092,** 1354
Tubæ uterinæ (Fallopian tubes), 1269
lymphatics of, 700, **745,** 1270
vessels and nerves, 1270
Tubal branch of ovarian artery, 602
branches of uterine artery, 610
Tube, auditory, (Eustachian), 74, 1089, **1092,** 1354
neural, 754
Tuber calcanei, 196
cinereum, 847, 848
omentale, 1184
vermis, 808
Tubercle(s), 29
adductor, of femur, 181
amygdaloid, of lateral ventricle, 877
anterior of thalamus, 845, **882**
articular, of temporal bone, 71
of atlas, 32
auricular (tubercle of Darwin), 1083
of calcaneus, anterior, 195
condylar, of mandible, 97
coracoid (conoid) of clavicle, 140
corniculate, of larynx, 1221
cuneiform, of larynx, 1221
of epiglottis, 1212, 1222
of femur, cervical, 178
genial, 95
genital, 1279
inferior thyreoid, 1211
intervenosum (of Lower), 513
labial, 1102
lacrimal, 88
malar, 95
mental, 95
olfactory, 865
pharyngeal, 54, 108
preglenoid, 71
pterygoid, 66
(spine) of pubis, 172
for the quadratus, 178
of rib, 127
scalene, 129
of scapula, infraglenoid, 143

Tubercles, of scapula, supraglenoid, 144
superior thyreoid, 1211
supratragic, 1082
of thoracic vertebræ, 37
Tubercular (posterior costo-transverse) ligament, 243
Tuberculum acusticum, 815
cuneatum, 801
intervenosum (of Lower), 513
jugulare, 54
sellæ, **63,** 116
Tuberosity, 29
of calcaneus, 196
of clavicle, costal, 140
of cuboid, 199
of femur, gluteal, 178
of fifth metatarsal bone, 203
of first metatarsal bone, 201
of humerus, greater, 147
lesser, 147
of ilium, 171
of ischium, 172
malar, 93
of maxilla, **87,** 92, 106
of navicular (scaphoid), **161,** 196
of radius, 152
of tibia, 185
of ulna, 156
ungual (of third phalanx), 168
Tubes, Fallopian, 1269
Tubules, renal, 1246
seminiferous, 1256
Tubuli recti, 1256
Tunica albuginea of testis, 1256
of penis, 1260
of spleen, 1311
propria of corium, 1286
serosa of spleen, 1310
vaginalis communis (internal spermatic or infundibuliform fascia), 1254, 1259
propria, 1254
vasculosa (of testis), 1256
Turbinate bones (conchæ) 83, 84, 1205
sphenoidal, 64, 67
Türk's bundle, 832, **890**
Tympanic antrum, 72, 73, **78,** 1092, **1336**
artery, anterior, 547
inferior, 537
superior, 548
bone, at birth, 123
branch of petrosal ganglion, 951
of stylo-mastoid artery, 544
canaliculus, 73, 108
cavity, 77, 1088
vessels and nerves, 1091
walls of, 1088
membrane, 1086
secondary, 1089, **1096**
mucous membrane, 1089
nerve, 961
notch, 77
ostium of tuba auditiva, 1092
plate, 108
plexus, 951, **961,** 1033, 1089
portion of temporal bone, 69, **75**
sinus, 1089
sulcus, 75
veins, 696
Tympano-hyal portion of styloid process, 75, 119
Tympano-mastoid (auricular) fissure, 71, **75,**
Tympano-petrosal branch of tympanic plexus, 961
Tympano-stapedial syndosmosis, 1090
Tympanum, 77
bones of, 79
development of, 80

U

Ulna, 155
clinical anatomy of, 1419, 1422
Ulnar anastomotic branch of superficial radial nerve, 987
artery, **576,** 640, 1423
venæ comitantes, 671
collateral artery, inferior, 576
superior, 576
nerve, 985
collateral ligament, 259, 266
nerve, 987
line of, 1415, 1423
results of paralysis, 1424
notch (sigmoid cavity) of radius, 154
recurrent artery, volar, 577
Ulno-carpeus, 492
Ultimobranchial bodies, 1318
Umbilical artery, 609
fissure of liver, 1183
fovea, 1284
hernia, 1402
ligaments, 1250, 1252
lymphatic nodes, 733
notch, 1182
plane, 1370
recess, 675
region, 1143
vein, 675, **680**
Umbilicus, clinical anatomy of, 1371
Umbo of tympanic membrane, 1087
Unciform bone, 159
process, 163
Uncinate fasciculus, 891
process of ethmoid, 83
Unci-pisiformis, 403
Uncus, 868
Ungual phalanges, 168
process of third phalanx, 168
Ungues (nails), 1293
Union, coraco-clavicular, 251
cuboideo-navicular, 303
of heads of metacarpal bones, 274
of metatarsal bones, 309
of radius with ulna, 261
scapulo-clavicular, 250
talo-calcaneal, 301
tibio-fibular, 295
Unipenniform muscle, 315
Urachal branch of superior vesical artery, 609
Urachus, 1250, 1252, 1253, 1398
Ureter, 1248
clinical anatomy of, 1381, 1394
lymphatics of, **738,** 1249
portions of, 1248
vessels and nerves of, 1249
variations and development of, 1249
Ureteral branches of renal arteries, 598
of internal spermatic artery, 601
of ovarian arteries, 602
Ureteric branches of superior vesical artery, 609
Urethra, female, 1277, **1278**
lymphatics of, 742
male, **1262,** 1388
lymphatics of, 740
surgical anatomy of, 1389
Urethral annulus, 1253
artery, 613
bulb, artery of, 613
carina, **1275,** 1278
glands (of Littré), 1264
lacunæ (of Morgagni), 1264
orifice of bladder, 1253
Urinary bladder, 1249
development of, 1253

Urinary bladder, parts of, 1250
lymphatics of, 700, **739,** 1249
vessels and nerves of, 1253
organs, 1241
bladder, 1249
kidneys, 1241
ureters, 1249
Urogenital diaphragm, 440, 449
sinus, 1279
system, 1241
triangle, **440,** 1383, 1385
trigone (triangular ligament), 442, 1384
Uterine artery, 610
branch of ovarian artery, 602
veins, 683
Utero-sacral ligaments, 1274
Utero-vaginal plexus of nerves, 1047
of veins, 683
Uterus (womb), 1271
clinical anatomy of, 1393
lymphatics of, 700, **745,** 1274
masculinus, 1263
vessels and nerves of, 1274
Utricle, 1093
Utricular branch of vestibular ganglion, 950
Utriculo-ampullar division of vestibular nerve, 950
Utriculo-saccular duct, 1094
Utriculus, prostatic, 1263
Uvula of palate, **1104,** 1106, 1137
of urinary bladder, 1252
of vermis, 808

V

Vagina, **1274,** 1277
clinical anatomy of, 1392
lymphatics of, **745,** 1276
vessels and nerves of, 1276
Vagina fibrosa tendinis, 317
musculi flexoris hallucis longi, 491
flexorum digitorum longi, 491
tibialis posterior, 491
tendinis musculi extensoris carpi ulnaris, 395
digiti quinti, 395
hallucis longi, 483
pollicis longi, 395
flexoris carpi radialis, 403
pollicis longi, 403
peronæi longi plantaris, 484
tibialis anterioris, 483
tendinum musculorum abductoris pollicis longi et extensoris pollicis brevis, 395
extensoris digitorum communis et extensoris indicis, 395
longi, 483
extensorum carpi radialium, 395
flexorum communium, 403
peroneorum communis, 484
Vaginæ mucosæ tendinum, 318
tendinum digitales, 491
musculorum flexorum digitorum, 403
Vaginal artery, 610
ligaments, 317
of finger, 387
nerves, 1017
of sphenoid, 63, 66
of temporal bone, 75
Vagus (pneumogastric), 954
nucleus of, 820, 822
Valentine, ganglion of, 939
Vallate (circumvallate) papillæ of tongue, 1106
Vallecula cerebelli, 807
epiglottic, 1107, 1221
Sylvii, 856
Valsalva, sinus of, **518,** 530
Valve(s), anal, **1177,** 1390
of aorta, semilunar, 517
atrio-ventricular, 515
bicuspid (mitral), 515
of fossa navicularis, 512
of Heister, 1187
(folds) of Houston, 1390
ileo-cæcal (colic), 1172
mitral, 515
pulmonary semilunar, 517
sinus coronarii, 512
(of Thebesius), 512
tricuspid, 515
of veins, 528
venæ cavæ (Eustachian), 512
Valvula foraminis ovalis, 512
Variability, 25
Variations of blood-vessels, 508
arteries, 637, 639
veins, 69
of organs (see corresponding organ)
Vas aberrans, 640
(ductus) deferens, 1257
Vasa aberrantia hepatis, 1184
brevia, 595
vasorum, 528
Vascular coat of eye, 1060
Vaso-motor nuclei, 822
Vastus intermedius (crureus), 468, **470**
lateralis (vastus externus), 468, **470**
medialis (vastus internus), 468, **470**
Vater, ampulla of, 1188
corpuscles of, 1290
Vein(s) (see also "Vena"), 528
of abdominal wall, superficial, 683
accessory cephalic, 667
hemiazygos (azygos tertia), 663
popliteal, 689
portal, 678
saphenous, 684
angular, 643
anterior auricular, 646
bronchial, 666
cardiac, 521
external spinal, 792
facial, 643, 1343
jugular, **648,** 693
mediastinal, 667
parotid, 644
tibial, 688
articular of mandible, 646
ascending lumbar, 662, **663**
of auricle (of ear), 1084
axillary, 671
azygos (major), **662,** 693
basal, 657
basilic, 667
basivertebral, 666
brachial venæ comitantes, 671
of brain, 653
bronchial, 1234
buccal, 646
cardiac (coronary), 520
central (ganglionic), 655
of retina, 659
cephalic, **667,** 671
accessory, 667
cerebellar, 657, 908
cerebral, 654
chorioid, 657
ciliary, 658
circumflex, 671
of cochlear canaliculus, **652,** 658
common facial, 644, **646,** 693
iliac, 699
volar digital, 671

Vein(s), condyloid emissary, 652
conjunctival, 658
coronary (gastric), 675
of corpus striatum, 657
cortical or superficial cerebral, 654
costo-axillary, 671
cutaneous, 1289
cystic, 677
deep (ganglionic), 655
cervical, 661
circumflex iliac, 683
of clitoris, 683
temporal, 646
of the diploë, 648
dorsal digital (foot), 684
of clitoris, 683
lingual, 660
metacarpal, 667
metatarsal, 684
of penis, 681
duodenal, 677
of the ear, 667
emissary, 647, 649, 652, **916,** 1334
episcleral, 659
ethmoidal, 659
of external acoustic (auditory) meatus, 1086
iliac, 683
jugular, **646,** 693
nasal, 644
pudendal, 684
femoral, 690
venæ comitantes, 690
femoro-popliteal, 685, 693
frontal, 644
diploic, 648
great cerebral (of Galen), **657,** 923
cardiac, 520
(internal) saphenous, **684,** 693
hæmorrhoidal plexus of, 683
of head and neck, **642,** 693
superficial, 643
deep, 648
of heart, 520
hemiazygos (azygos minor), 662
accessory, 663
hepatic, 675
hypogastric (internal iliac), 679
ileo-colic, 677
ilio-lumbar, 680
inferior alveolar (dental), 646
cerebellar, 657
cerebral, 655
epigastric, 683
gluteal (sciatic), 680
hæmorrhoidal, 683
labial, 644
laryngeal, 659
mesenteric, 678
ophthalmic, 646, **659**
palpebral, 644
phrenic, 675
thyreoid, 661
infra-orbital, 646
innominate (brachio-cephalic), **641,** 691, 692
intercapitular (hand), 667
of foot, 684
intercostal, 664
internal auditory, 652, 657
cerebral, 657
jugular, **659,** 691, 693
mammary, 666
maxillary, 646
pudendal, 681
spinal, 792
intervertebral, 666
intestinal, 677
labial (of mouth), 644
Vein(s), labial (of vulva), 683, 684
lacrimal, 659
lateral circumflex, 690
sacral, 680
thoracic, 671
left colic, 678
gastro-epiploic, 677
superior intercostal, 664
lingual, 660
of lower extremity, **683,** 693
lumbar, 675
of Marshall, oblique, 521, **523**
masseteric, 644, 645
mastoid emissary, **647,** 652
medial perforating, 690
median antibrachial, 667, 668
basilic, 669
cephalic, 668
cubital, 667
of medulla, 908
of medulla oblongata, 657, 908
meningeal, 917
middle cardiac, 520
cerebral, 655
colic, 677
hæmorrhoidal, 683
meningeal, 646
sacral, 679
temporal, 646
morphogenesis and variations, 690
muscular (of orbit), 658
of nasal cavities, 657
naso-frontal, 658
oblique (of Marshall), of left atrium, 521, **523**
obturator, 680
occipital, 647
œsophageal, 661, 662
ophthalmic, 658, 659, 1075
ophthalmo-meningeal, 655
of orbit, 658
ovarian, 674
palatine, 644
palpebral, 658
pancreatic, 677
pancreatico-duodenal, 677
parietal emissary, 649
parumbilical, 678
pericardiac, 666
of pharynx, 659
plantar, digital, 684
metatarsal, 687
of pons, 657, 908
popliteal, 688
portal, 528, **675**
development of, 694
posterior auricular, 647
bronchial, 664
external jugular, 648
spinal, 792
facial (temporo-maxillary), 644
labial, 683
of left ventricle, 521
mediastinal, 664
parotid, 646
superior alveolar (dental), 646
tibial, 688
profunda or deep femoral, 690
proper volar digital (hand), 671
pterygoid plexus of, 646
pulmonary, **529,** 1235
pyloric, 675
radial venæ comitantes, 671
radicular, 792, 908
renal, **673,** 693
right colic, 677
gastro-epiploic, 677

Vein(s), right colic, superior intercostal, 664
sigmoid, 678
scrotal, 684
small cardiac, 521
(external) saphenous, **684,** 693
smallest cardiac, 521
spermatic, **674,** 1259
spheno-palatine, 646
spinal, 665
splenic, **677,** 1312
sterno-mastoid, 660
stylo-mastoid, 646
subclavian, 671
subcutaneous dorsal of penis, 684
sublingual, 660
submental, 644
subscapular, 671
superficial, in abdominal wall, 683
circumflex iliac, 684
epigastric, 684
of lower extremity, 683
temporal, 646
of upper extremity, 667
superior cerebellar, 657
cerebral, 654
epigastric, 666
gluteal, 680
hæmorrhoidal, 683
labial, 644
laryngeal, 659
mesenteric, 677
ophthalmic, 658
palatine, 646
palpebral, 644
phrenic, 667
thyreoid, 660
supra-orbital, 644
suprarenal, 673
systemic, 640
temporal (of diploë), 648
temporo-maxillary (posterior facial), 644
terminal (of corpus striatum), 657
thoraco-acromial, 671
thoraco-epigastric, **671,** 1372
of thorax, 662
thymic, 661
thyreoid, **660,** 1317
thyreoidea ima, 661
tracheal, 661
transverse cervical, 672
facial, 646
scapular (suprascapular), 648
tympanic, 646
cavity, 1091
ulnar venæ comitantes, 671
umbilical, 675, **680**
of upper extremity, 667
development of, 692
uterine, 683
vermian, 908
vertebral, 661, **664**
Vesalian, 646
volar metacarpal, 671
Velum, anterior (superior) medullary, 812
interpositum, 847, 923
of palate, 1104
posterior medullary, 808
Vena canaliculi cochleæ, 652, 658
cava, inferior, 672
development of, 693
superior, 641
development, 690
centralis retinæ, 1065
cerebri magna (Galeni), 657
comitans n. hypoglossi, 660
septi pellucidi, 657
Venæ cavæ, relation to thoracic wall, 1369
Venæ cavæ comitantes, 528
vorticosæ, 659, 1057, 1065
Venous arch, digital (hand), 667
lacunæ of dura, 916
plexuses, vertebral, 664
sinus of sclera, 1059
sinuses, cranial, 528, **649,** 916
Ventricle(s) of Arantius, 813
of brain, development of, 758
fifth, 872
fourth, 812
of heart, left, 516, 517
right, 516
of larynx (ventricle of Morgagni), 1222
lateral, of cerebral hemisphere, 873
drainage of, 1341
olfactory, 866
terminal, of spinal cord, 775
third, of brain, 846
Verga's, 869
Ventricular appendix (laryngeal saccule),1223
folds (false vocal cords), 1222
ligament of larynx, 1215
musculature, 518
muscle of larynx, 1220
Ventro-lateral fasciculus, superficial, 770
Verga's ventricle, 869
Vermiform process (appendix), **1173,** 1378
fossa, 53, 117
Vermis of cerebellum, 805
furrowed bands of uvula of, 808
inferior, 807, 808
pyramid of, 808
superior, 806
tubes, 808
uvula of, 808
Vernix caseosa, 1299
Vertebra prominens, 35
structure of, 45
Vertebra(æ), 29
articulations of bodies of, 225
cervical, 30, **31**
coccygeal, 30, **42**
lumbar, 30, **39**
ossification of, 45
thoracic (dorsal), 30, **36**
Vertebral artery, **559,** 638
articulations, 225
branches of lumbar arteries, 593
canal (spinal), 31
arteries of, 590
venous plexuses of, 664
column, 29
as a whole, 43
foramen, 31
groove, 43
levels, 1409
ligaments, 228
notches, 30
plexus of nerves, 1037
portion of vertebral artery, 560
spines, 1403
Vertebro-occipital muscle, 412, 417
Vertex of urinary bladder, 1250
Vesalian vein, 646
Vesalius, foramen of, **65,** 116
Vesical arteries, inferior, 609
middle, 609
superior, 609
branch of obturator artery, 608
nerves, inferior, 1017, 1047
superior, 1047
plexus of nerves, 1047
of veins, 683
portion of ureter, 1249
vein, 661
Vesicle(s), brain, 755

Vesicles, optic, 758
of thyreoid gland, 1316
Vesiculæ seminales, **1257,** 1387
lymphatics, 744
Vessels (see "Blood-vessels," "arteries," "veins," "lymphatic vessels").
Vestibular branch of stylo-mastoid artery, 544
cæcum, 1096
conduction paths, 899
fenestra, 73, 1089
ganglion (ganglion of Scarpa), 823, 950
glands, 1278
membrane (membrane of Reissner), 1096
nerve, 949
nuclei of, 823
slit, 1222
Vestibule (of temporal bone), 80
of larynx, 1221
of nose, 1204
oral, 1100
of vagina, **1277,** 1392
Vestibulo-spinal fasciculus, 786
Vibrissæ, **1204,** 1290
Vicq d'Azyr, bundle of, 871
Vidian artery, 549
canal, 103, 107, 108, 126
nerve (n. canalis pterygoidei), 962
Villi, pleural, 1237
of small intestine, 1166
Vincula tendinum, 399, 401
Visceral bars, metamorphosis of, 119
lymphatic nodes of thorax, 724
vessels of abdomen, and pelvis, 733
Visual area of cerebral cortex, 893
Vitreous body or humor of eye, 1052, **1064**
lamina of chorioid, 1026
Vocal folds (cords), false, 1222
true, 1223
ligaments, 1215
lip, 1223
muscle, 1220
process of arytænoid cartilage, 1212
Volar arch, deep, **586,** 639, 1426
venous, 671
superficial, **582,** 639, 1425
venous, 671
artery, superficial, 584
carpal rete (arch), 579, **581**
digital veins, 671
interosseous artery of forearm, 577
(anterior) interosseous nerve, 992
ligament, accessory (or glenoid), 274
metacarpal arteries, 586
veins, 671
musculature, 363
perforating branches of radial artery, 586
radial carpal artery, 584
(anterior) radio-carpal ligament, 266
ulnar carpal artery, 580
Vomer, 85
Vomero-nasal organ (of Jacobson), 1051, 1204
Vortices of hair, 1291
Vulva (external female genitalia), 1276

W

Waldeyer's tonsillar ring, 1133
Wallerian degeneration, 780
Wharton's duct, 1116
White commissures of spinal cord, 776
ramus communicans, 1030
substance of nervous system, 768
of spinal cord, 775, 777
of telencephalon, 885
Whitlow, 1431
Willis, circle of (circulus arteriosus), 555
chords of, 649
Wings of sphenoid, 62
great or temporal, 65
small or orbital, 64
Winslow, foramen of, 1147
Wirsung, duct of, 1194
Wisdom teeth, 1122
Wolffian body, 1278
duct, 1248, 1267, **1278**
Word-blindness, 895
Wormian bone, 68
Wrinkles of skin, 1284
Wrisberg, cardiac ganglion of, 1041
cartilages of, 1213
lingula of, 942
nerve of, 946, 983
Wrist, bony points of, 1424
clinical anatomy of, 1424
Wrist-joint, 265

X

Xiphoid branch of superior epigastric artery, 567
process, 132, 134

Y

Yellow spot (macula lutea), 1055
of larynx, 1223
Yolk-sac, 10, 13

Z

Zeiss's glands, 1078
Zinn, ligament of, 1067
Zona fasciculata, 1326
glomerulosa, 1326
reticulata, 1326
Zone(s), marginal, of Lissauer, 782
mixed lateral, 784
Zonula ciliaris, 1064
Zonular spaces, 1064
Zygapophysis, 57
Zygomatic arch, 1332
bone (malar), 93
at birth, 124
branches of lacrimal artery, 552
(orbital or temporo-malar) of maxillary nerve, 938
(malar) of temporo-facial nerve, 945
fossa, 101, 1332
process, 70, 87, **88**
Zygomatico-facial (malar) branch of maxillary nerve, 938
canals, 126
Zygomatico-orbital artery, 545
canals, 94
Zygomatico-temporal (temporal) branch of maxillary nerve, 938
foramen, 126
Zygomaticus (zygomaticus major), 333
minor, 332

COLUMBIA UNIVERSITY LIBRARIES

This book is due on the date indicated below, or at the expiration of a definite period after the date of borrowing, as provided by the library rules or by special arrangement with the Librarian in charge.

DATE BORROWED	DATE DUE	DATE BORROWED	DATE DUE
	MAR 20 1944		
	NOV 5 1946		

C28(842)M50

COLUMBIA UNIVERSITY LIBRARIES (hsl.stx)
QM 23 M83 1914 C.1
Morris's human anatomy.
2002191202

QM23 M83
1914
Morris
Human anatomy

MAR 20 1944

G. E. Falk
910 Riverside Dr.