

Duodenal ulcer / by B. G. A. Moynihan.

Contributors

Moynihan, Berkeley Moynihan, Baron, 1865-1936.
Augustus Long Health Sciences Library

Publication/Creation

Philadelphia and London : W. B. Saunders Company, 1910.

Persistent URL

<https://wellcomecollection.org/works/qdcje33t>

License and attribution

This material has been provided by This material has been provided by the Augustus C. Long Health Sciences Library at Columbia University and Columbia University Libraries/Information Services, through the Medical Heritage Library. The original may be consulted at the the Augustus C. Long Health Sciences Library at Columbia University and Columbia University. where the originals may be consulted.

This work has been identified as being free of known restrictions under copyright law, including all related and neighbouring rights and is being made available under the Creative Commons, Public Domain Mark.

You can copy, modify, distribute and perform the work, even for commercial purposes, without asking permission.

**wellcome
collection**

Wellcome Collection
183 Euston Road
London NW1 2BE UK
T +44 (0)20 7611 8722
E library@wellcomecollection.org
<https://wellcomecollection.org>

COLUMBIA LIBRARIES OFFSITE
HEALTH SCIENCES STANDARD



HX64138275

RC862 .M87

Duodenal ulcer, by B

RECAP

RC862


M87


Columbia University
in the City of New York

Copy 2





Department of Surgery
Gift of Dr. Joseph A. Blake





Digitized by the Internet Archive
in 2010 with funding from
Open Knowledge Commons





WORKS BY MR. B. G. A. MOYNIHAN

Retroperitoneal Hernia. London, 1899
Bailliere, Tindall & Cox

**The Surgical Treatment of Gastric and Duodenal
Ulcers.** W. B. Saunders & Co., 1903

Gall-Stones and their Surgical Treatment
Second Edition, 1905 W. B. Saunders & Co.

Abdominal Operations
Second Edition, 1906 W. B. Saunders Company

Duodenal Ulcer. W. B. Saunders Company, 1910

Pathology of the Living and other Essays. W. B.
Saunders Company, 1910

WITH MR. MAYO ROBSON

Diseases of the Stomach. Second Edition, 1905

Diseases of the Pancreas. W. B. Saunders & Co.
1902

DUODENAL ULCER

BY

B. G. A. MOYNIHAN, M.S. (LOND.), F.R.C.S.

LEEDS

ILLUSTRATED

PHILADELPHIA AND LONDON


W. B. SAUNDERS COMPANY

1910

Copyright, 1910, by W. B. Saunders Company

PRINTED IN AMERICA

TO
D. W. M.
S. B. M.
P. B. M.



PREFACE

AMONG the many and great developments of modern abdominal surgery, few of the problems which were to be unravelled have proved more interesting than that concerned with duodenal ulcer. Ten years ago ulceration of the duodenum was looked upon as a rare disease, and its confident recognition during life was believed to be hardly possible. To-day we know that this disease is common, and its discovery in the majority of cases presents no great difficulties to the trained clinician. In my own experience the diagnosis of duodenal ulcer is made with a degree of accuracy that is not exceeded in the case of any other abdominal disorder.

Perhaps the most remarkable feature in the history of this condition is the fact that its main symptoms have through generations of text-books been ascribed without reserve or hesitation to the existence not of an organic but of a purely functional disturbance. The varied and accumulating experience of a few surgeons soon led, however, to the conviction that the range of functional disorders of the stomach must for the future be greatly narrowed, that not a few of the so-called "neuroses" of the stomach were veritable examples of structural changes having their seat in the stomach, duodenum, gall-bladder or appendix. The term "dyspepsia" as used by the

older writers included every form of disorder in which the activity of the digestive processes seemed impaired. In this great group of conditions believed to be chiefly or entirely functional we now recognise that probably the majority of cases are due to organic diseases affecting not the stomach only, but also and more frequently the various organs I have named. The symptoms which the older physicians believed to be due to derangement of the functions of the stomach the surgeon has shewn to be caused by changes in the texture of one or other of these several organs.

Among all these forms of organic disease, duodenal ulcer stands out the clearest. We are now familiar with its symptoms, we have learnt of its dangers, we are well-equipped with the means of treating it with permanently satisfactory results.

One result of this surgical discovery must be that the physician now knowing well that which formerly was not suspected, namely, the attachment of the symptoms he recognises to an organic lesion, will insist upon a much stricter and a more prolonged medical treatment, and in this way it is probable, and is sincerely to be hoped, that some at least of the cases which now seek help at the hands of the surgeon, may be permanently relieved of their sufferings by this greater care, and escape the need of operative attentions.

In the appendix to this work all the cases of duodenal ulcer upon which I had operated up to the end of 1908 have been analysed by my colleague, Mr. Harold Collinson. A study of this record will, I think, support the claim that the surgical treatment of duodenal ulcer is becoming as

safe as can be expected of an abdominal operation of this magnitude, performed sometimes upon patients greatly enfeebled by loss of blood, or by the inability to eat sufficient for their needs. Up to the end of 1909 the mortality of the whole series of my cases was 1.6% per cent., and among the last 121 cases there was no death.


My very sincere thanks are due to my colleague, Mr. Harold Collinson, for his help, not only in the literary, but also in much of the operative work. He has helped me ungrudgingly at every opportunity.

The illustrations have been drawn for me by Miss Ethel M. Wright, to the excellence of whose work I am now, as in my earlier works, much indebted. The photographs have been taken from museum specimens by Mr. Henry George and by Messrs. Godart & Co. I am glad to be able to speak of the kindness and courtesy with which every curator placed his specimens at my disposal. The name of the museum, the number of the specimen, and the catalogue descriptions are given in every case.

My secretary, Miss J. Mackill, has given me constant help, for which I wish to express my thanks.

B. G. A. MOYNIHAN.

33 PARK SQUARE, LEEDS,
April, 1910.



CONTENTS

	PAGE
CHAPTER I	
HISTORY.....	17
CHAPTER II	
ULCERATION OF THE DUODENUM IN CASES OF BURNS OR SCALDS....	24
Position and Character of the Ulcer.....	38
Symptoms.....	41
CHAPTER III	
URÆMIC ULCER OF THE DUODENUM.....	44
CHAPTER IV	
TUBERCULOUS ULCERATION OF THE DUODENUM.....	68
CHAPTER V	
MELÆNA NEONATORUM AND DUODENAL ULCER.....	85
Symptoms and Diagnosis.....	89
CHAPTER VI	
CHRONIC DUODENAL ULCER—SYMPTOMS AND DIAGNOSIS.....	101
CHAPTER VII	
DIFFERENTIAL DIAGNOSIS.....	122
CHAPTER VIII	
TREATMENT OF CHRONIC DUODENAL ULCER.....	129
Surgical Treatment of Chronic Duodenal Ulcer.....	131
CHAPTER IX	
PERFORATION.....	162
Acute Ulcer.....	162
Chronic Ulcer.....	163

	PAGE
PERFORATION (Continued)	
Differential Diagnosis.....	171
Treatment.....	180
Subacute Perforation.....	188
Chronic Perforation.....	193

CHAPTER X

PATHOLOGY OF CHRONIC DUODENAL ULCER.....	210
--	-----

APPENDIX

A DETAILED STATEMENT OF ALL CASES OPERATED UPON TO THE END OF 1908; WITH AN ANALYSIS AND SUMMARY.....	251
Complete List of Cases of Chronic Duodenal Ulcer Treated by Operation.....	269

INDEX OF AUTHORS.....	363
INDEX.....	369

DUODENAL ULCER

CHAPTER I

HISTORY

THE earliest mention of duodenal ulcer in medical literature occurs in the London "Medico-chirurgical Transactions" of 1817 (viii, 232). Mr. Travers there reports the following cases:

CASE I.—Mr. —, aged thirty-five, of a strumous habit, but enjoying generally good health, was seized whilst dining in company with an excruciating pain in the abdomen, which he described as unlike any he had ever felt. The principal seat of his pain, which never remitted, was the region of the navel, and it was described as occasionally shooting from this part as from a centre over his whole body, and especially affecting his neck and shoulders. His abdomen was tense and hard; his respiration somewhat agitated; his pulse little, if at all, affected. Flatus rose in quantity from his stomach, but he had no disposition to vomit. At midnight the medicine, which he had taken soon after the attack, had not operated; he was exceedingly restless, unable to bear the slightest pressure of the hand upon the abdomen, and earnestly prayed to be relieved from his intolerable anguish by death. He often called for a spoonful of gruel, which in part returned, as if deglutition was interrupted by a spasm of the œsophagus. At 3 A. M. the pain was not mitigated; the pulse was quick, small, and fluttering. His intellect remained clear and perfect, but his strength was rapidly exhausting; his extremities became cold, and he

died in a warm bath at 6 A. M., about thirteen hours after the attack of pain.

I pass over the formalities of medical treatment; suffice it to say that all the obvious means of relief were perseveringly employed without any sensible effect.

Inspection of the Body.—The peritoneum was universally inflamed; recent adhesions attached the contiguous folds of the intestines to each other; a large quantity of fluid deeply tinged with bile was contained in the pelvis; and about a finger's breadth below the pylorus appeared a circular foramen, having a peritoneal margin, of the diameter of a writing-pen. It proved to be the centre of an irregular superficial ulcer of the mucous coat including in its extent two-thirds of the ring of the pylorus. There was no other appearance of ulceration in the intestinal canal.

CASE 2.—Mills, a hairdresser, had occasionally for the seven preceding years suffered sudden and very violent attacks of abdominal pain, from which he had always been speedily relieved by a wineglassful of brandy. On the day of the fatal attack he had endured without interruption, attending to his business, and in the evening went to the market to buy fish for his supper. On his return the pain became intolerable, and he took the usual dose of brandy, but did not obtain from it the expected relief; he sat in a bent posture, with a sunken countenance expressive of much agony. Now and then he vomited. He dreaded going upstairs, but at length, making a desperate effort, he ran up, and fell as he entered his room. It was evident that he was inflamed at this time, and the brandy appears to have aggravated the symptoms. He died in thirty-six hours from the commencement of acute pain; every part of the peritoneum was inflamed; a circular aperture of the peritoneum large enough to admit a crow's quill was found at the junction of the duodenum and stomach. It was the centre of an ulcer that had destroyed the villous and muscular coats of the bowel to the extent of half an inch. Coagulable lymph was effused about the pylorus, but not in quantity sufficient to produce an adhesion of the adjoining parts, so as to exclude the aperture from the cavity of the peritoneum. The margin

of the aperture was deeply tinged with bile, yet the contents of the peritoneum had only the appearance common to matters effused from inflamed serous membrane. Although the unhappy man had provided himself with food, it did not appear that he had taken any; but it is probable the peritoneal sac had been injected with brandy.

In the second edition of "Pathological and Practical Research on Diseases of the Stomach," etc., by Dr. John Abercrombie (Edinburgh, 1830, pp. 103 et seq.), five cases stored in the literature are collected together. One was recorded by Irvine, of Philadelphia, in 1824, a characteristic example of a chronic tuberculous ulcer; two by French physicians; and two were related in the "Midland Medical and Surgical Reporter" (May and November, 1829). In addition, a specimen in the Museum of the Royal College of Surgeons of Edinburgh is mentioned, in which perforation had occurred. Dr. Abercrombie remarks: "The leading peculiarity of disease of the duodenum, so far as we are at present acquainted with it, seems to be that the food is taken with relish, and the first stage of digestion is not impeded; but the pain begins about the time when the food is passing out of the stomach or from two to four hours after a meal." This observation seems to have attracted no attention, and never since to have been recalled. The first paper specially devoted to this subject appeared in 1861; it dealt solely with perforating ulcer, and notes were given of 3 cases observed by the author, and of 10 collected from the literature ("Klinger (Würzburg) Arch. f. phys. Heilk.," 1861, ii, 5). In 1863 two monographs appeared, one by Falken-

bach, "De ulcere duodenali chronico" (Berlin, 1861); the other and more important by Dr. F. Trier, "Ulcus corrosivum duodeni" (Copenhagen, 1863). Trier's paper was epitomised in the "British and For. Med.-Chi. Review" of January, 1864. It contained a report of all cases then on record, and in addition a series of 26 cases, mostly seen in the Frederick Hospital of Copenhagen, were given in detail. Professor Trier, of Copenhagen, has kindly translated this work for me, and I found the case records of great value. The work is certainly the most important of all the early monographs. In 1865 appeared Krauss' "Das perforirende Geschwur im Duodenum" (Berlin, Aug. Hirschwald). In this pamphlet there are 80 case records, for the most part in full detail. Between 1863 and 1882 a series of Paris theses appeared, in which a few additional cases were recorded, but nothing material was added to our knowledge. In 1883 Chvostec recorded ("Allg. Wien. med. Zeitg.," xxvii, 533) eight personal cases, and 135 extracted from published records. In 1887 Bucquoy ("Arch. Gén. de Méd.," i, 398 et seq.) published an article to which due credit has hardly yet been paid. For the first time he made a diagnosis of five cases from the symptoms alone, and verification in one was subsequently obtained by autopsy. He suggested that the symptoms observed in cases of duodenal ulcer were sufficiently precise and characteristic to enable a diagnosis to be made. Bucquoy was, I think, the first physician after the time of Abercrombie to suggest the possibility of a diagnosis being made during the life of the patient. In 1891 Oppenheimer's thesis

("Das Ulcus pepticum duodenale," Würzburg) appeared; it contained a summary of most of the recorded cases, and gave useful tables of them. A thesis ("Etude sur l'ulcere simple du duodenum," Paris, 1894) by Collin contained a summary of 257 cases recorded up to that time and notes of 5 cases observed by the author. Detailed records were also given of all the cases recorded in the preceding ten years. The work is valuable, and constant reference has since been made to it. In the "Guy's Hospital Reports" of 1893 there appeared a most exhaustive account of the "Diseases of the duodenum," written by Dr. Perry (now Sir Cooper Perry) and Dr. L. Shaw. The records of 17,652 autopsies performed at Guy's Hospital between 1826 and 1892 furnished the material from which the work was built. There is no better presentation of the subject from the pathological standpoint, and the whole work is a monument of industry. Up to this time the condition of duodenal ulcer had possessed no interest for the surgeon. It was not realised that the acute catastrophes of hæmorrhage or perforation fell within the province of the surgeon, nor had the symptoms of the chronic ulcer been recognized with sufficient certainty to enable a diagnosis to be offered. In 1894 Mr. H. P. Dean recorded the first successful case of perforating ulcer treated by operation ("Brit. Med. Jour.," 1894, i, 1014); he was followed by Mr. L. A. Dunn ("Brit. Med. Jour.," 1896, i, 846). The result of these two cases drew conspicuous attention to the subject, and other successes quickly followed. An excellent summary of the early cases, together with a critical review of the whole subject

of perforating duodenal ulcers, was given by Weir in his presidential address to the American Surgical Association ("Med. News," 1900, i, 690, 732). (For a complete early list see "Lancet," 1901, ii, 1656.) The surgical treatment of chronic duodenal ulcer was inaugurated by A. Codivilla ("Sei Casi Gastroenterost. Sperimentale." Mem.: Orig. Firenze, 1893, pp. 406-421, and "Contrib. alla Chirurg. gastrica," Bologna, 1898). The first case was operated upon on March 22, 1893, a stenosis of the duodenum two fingers' breadth beyond the pylorus being found. The patient, aged forty, was quite well five years later. The second case was operated upon by the same surgeon on May 5, 1898; the third by Pagenstecher in 1899 ("Deut. Zeit. f. klin. Chir.," 1899, lii, 569). My first case was operated upon in January, 1900 ("Lancet," 1905, i, 340), and the first paper dealing with the various features of this disease considered from the standpoint of the surgeons was written by myself in 1901 ("Lancet," 1901, ii, 1656). From this time the number of cases rapidly increased, as the benefits to be derived from operative treatment became realised; and to-day both W. J. Mayo and myself have operated upon over 250 cases. The various contributions of W. J. Mayo to this subject are of the highest merit (see especially "Brit. Med. Jour.," 1906, ii, 1299, and "Jour. Amer. Surg. Assoc.," 1908, ii, 556). Krauss states (p. 67) that the first occasion on which a diagnosis of duodenal ulcer was made and verified is related by Wunderlich ("Handbuch der Path. und Therap.," iii, 175). The following are the notes of the case:

Perforated duodenal ulcer. Abscess cavity between pancreas and duodenum.—Man, fifty-one, not strong, began in 1845 to have pain between right hypochondrium and epigastrium, which radiated over the whole abdomen. Pain came on in attacks three to four hours after meals and lasted a few hours until vomiting of undigested food occurred. Six months after this he vomited a large quantity of dark, foul-smelling blood; pains ceased then for a time, but returned after a year or so. Vomiting occurred from time to time and there was a tendency to constipation.

In 1852 pain and vomiting worse, rapid emaciation, death.

On section: Stomach enormously distended and displaced downwards; pylorus and duodenum were firmly adherent to the enlarged head of the pancreas by dense connective tissue. At the commencement of the duodenum was a circular perforation of the size of a groschen with callous margins. This led into a cavity of the size of half a walnut, whose base was formed by the pancreas.

CHAPTER II

ULCERATION OF THE DUODENUM IN CASES OF BURNS OR SCALDS

IN a paper which has since become classical Curling ("Med. Chir. Trans.," 1841-42, xxv, 260) called attention to the connexion between cases of burn or of scald



FIG. 1.—DUODENAL ULCER DUE TO BURNS.

Parts of a stomach and duodenum exhibiting an ulcer of the duodenum which presents the characters of the perforating ulcer of the stomach. It is of nearly circular form, has abrupt margins, and is an inch in diameter. It has extended through all the coats of the intestine and exposed the pancreas, the surface of which now

and acute ulceration of the duodenum. The term "*Curling's ulcer*" has now obtained universal currency, and no account of duodenal ulcer has been written in recent years without conspicuous mention being made of the association of this lesion with burns or scalds. Curling himself quotes Dupuytren ("*Leçons orales*," Brussels edition, 1836, i, 217-218) as having drawn attention to the congestion of various mucous membranes in the alimentary canal and to a similar condition of the blood-vessels in the brain and lungs in the early stages of burns; and to the occurrence of inflammation of the stomach and intestines after the patient had recovered from the immediate effects of the injury.

forms its base. The nearest margin of the ulcer is one-third of an inch from the pylorus. A bristle is placed in an artery in the pancreas, which was opened in the progress of the ulcer and permitted fatal hæmorrhage.

The patient, a girl aged fifteen, was admitted into the London Hospital, March 16, 1844, on account of a burn, which extended over the front of the chest, left upper extremity, neck, and upper part of the back, partially destroying the true skin. The injury was not followed by much collapse, but on the following day she had an attack of fever, which continued for four or five days. On the 21st she became very weak and complained of pain from the burn, for which opium, ammonia, and wine were administered. The following day she felt better, but from that period till her death she complained at intervals of pain in the epigastric region. On the 30th she vomited a large quantity of dark, tar-like fluid. From this time she sank rapidly, and expired about twelve hours afterwards, having passed in the course of the day dark matter by stool. On examination of the body (besides what is shewn in the preparation) the heart was found flabby, with only a small quantity of blood in its cavities. The stomach contained a quantity of dark fluid, resembling that vomited during life, and in the intestines there was dark, pitchy-looking matter. (See "*Lancet*," June 14, 1844, p. 387. Presented by T. Blizard Curling, Esq. Royal College of Surgeons Museum, No. 2429.)

“Si les sujets après avoir résisté à la première impression du feu, succombent, du troisième au huitième jour, à la

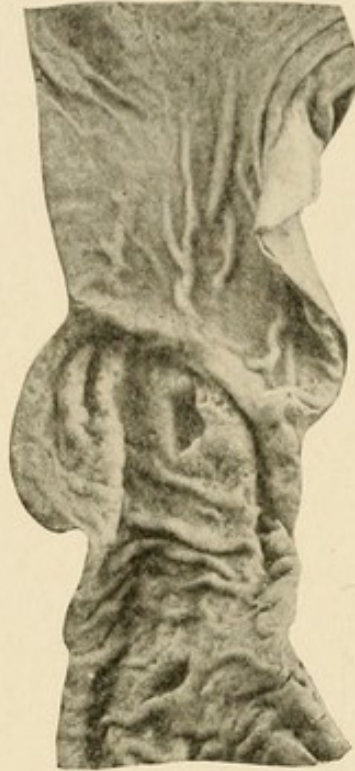

FIG. 2.—DUODENAL ULCER DUE TO BURNS.

The pyloric portion of a stomach and part of the duodenum. In the latter are two ulcers, the larger immediately beyond the valve, the other an inch and a half beyond it. The floor of the larger ulcer is deeply placed and very thin, being formed of peritoneum alone; but the edges are round, as if healing had commenced. In the lower ulcer this is even more marked.

From a boy aged seven, who was extensively burnt on the front and back of the body. In front the skin and subcutaneous tissue were destroyed from a little above the clavicles to within three inches of the pubes, so that when the slough separated the muscles were laid bare. The back was affected to a similar extent, though less deeply. He died four weeks after the injury. He had suffered during his life from no intestinal symptoms. (Royal College of Surgeons Museum, No. 2431. Presented by Thomas Blizard Curling.)

seconde période, a la violence de la réaction inflammatoire, après avoir présenté pendant la vie tous les phénomènes d'une vive irritation des viscères, on trouve à l'ouverture des

cadavres, tous les signs de la gastro-entérite la mieux caractérisée, et ordinairement accompagnée d'alterations inflammatoires de l'encéphale et des poumons. . . . Enfin si le sujet n'a succombé qu'à une époque beaucoup plus éloignée, pendant le cours de la période de suppuration et d'épuise-

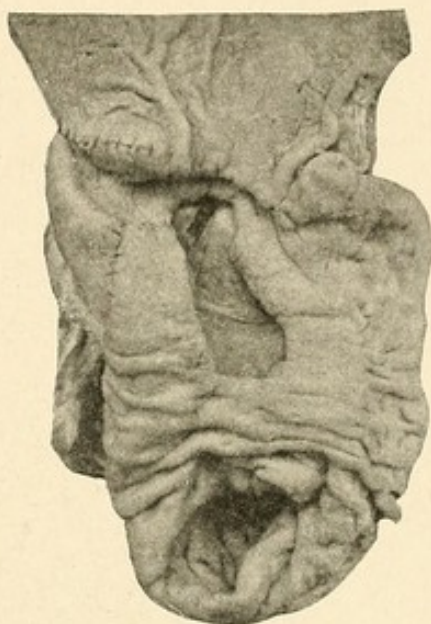

FIG. 3.—DUODENAL ULCER DUE TO BURNS.

A duodenum, showing an ulcer an inch and a half beyond the pylorus laying open the arteria pancreatico-duodenalis. It is of oblong shape with thick, rather undermined edges and smooth floor. The whole thickness of the bowel is destroyed and a rent has taken place into the peritoneal cavity close to the margin of the ulcer.

From a girl, aged seven, who was severely burnt over the greater part of the abdomen and the left thigh. Death took place eight days after, with hæmorrhage of the bowel. (See "Lancet," 1866, vol. i, p. 484. Royal College of Surgeons Museum, No. 2430. Presented by Thos. Blizard Curling, Esq.)

ment, on trouve dans les viscères, et surtout dans le canal digestif, des altérations profondes qui attestent la longue inflammation dont ils ont été affectés; la muqueuse est parsemée de plaques d'un rouge plus ou moins vif, ou plus ou moins foncé, d'ulcérations plus ou moins profondes; les ganglions mésentériques sont généralement engorgés," etc.

The first writer to note and to describe with full knowledge the occurrence of duodenal ulcer in cases of

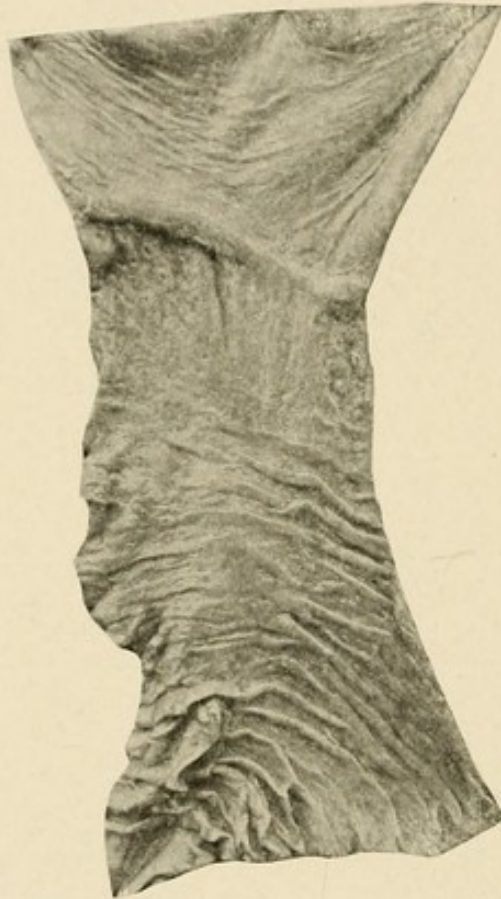

FIG. 4.—DUODENITIS FOLLOWING BURNS.

In the duodenum immediately beyond the pylorus are two clusters of enlarged Brunner's glands with evidently patulous orifices. The fresh appearances were those of recent inflammation and superficial ulceration of the mucous membranes covering the glands.

From a girl, aged six and a half years, who was admitted with extensive burns over the surface of the body and extremities, and who died on the ninth day from pneumonia; for the first three days vomiting was a prominent symptom. (St. Thomas's Hospital Museum, No. 1066.)

burn was neither Curling nor Dupuytren, but James Long, of Liverpool ("London Medical Gazette," 1840, new series i, 743). He relates the following two cases:

CASE 1.—Ann Jones, æt. twenty-eight, admitted into the Infirmary on the 2d of April, 1834, with an extensive and deep burn of the arms, chest, and nates. She states that she was in perfect health previous to the accident; she vomited more or less every day, sometimes excessively; had considerable pain on pressure in the epigastric region, with a red, glassy tongue and intense thirst; bowels constipated and relieved by enemata; the pulse for some days was small and weak, then full and strong; died on the eighth day after the accident.

Post-mortem examination: No peritoneal inflammation; stomach contracted; mucous membrane white, firm, not a vessel to be seen upon it; pylorus healthy; at the superior angle of the duodenum a perforation or ulceration existed of the size of a shilling; the margins of the perforation were adherent to the gall-bladder, but the slightest traction separated them; the surface of the gall-bladder filled up the area of the perforation, soft and, as it were, eroded, the softened surface being easily scraped off; the edges of the perforation and the corresponding surface of the gall-bladder were of a black color; two or three ulcers of the size of a pea and with dark edges were also found in the duodenum, and the remainder of the intestinal mucous membrane was quite healthy, excepting two small red patches in the sigmoid flexure of the colon, which corresponded to two masses of hardened fæces.

CASE 2.—Helena Birch, æt. fourteen, admitted May 24, 1834, with a burn of the second degree, of the nates, posterior part of the neck, and both arms; she was in perfect health prior to the accident. She complained of nothing except pain in the burned parts, until the tenth day after the accident. At this period pain in the epigastric region commenced; at the same time the hypogastric region became the seat of pain; the tongue was but slightly altered; she had no vomiting; and the pulse was small and quick. On the eleventh day the symptoms were more severe; on the morning of the twelfth the pain in the epigastric region became intense; very shortly afterwards she was seized with vomiting and profuse diarrhœa, sudden distension of the abdomen,

prostration of strength, and in eleven hours she died. There was no doubt that perforation had taken place in some parts of the gastro-intestinal tube; note, she always lay upon the abdomen.

Post-mortem examination: Peritoneal lining of abdominal muscles, and its reflections over the liver, uterus, and intestine, were coated with custard-like coagulated lymph; the omentum was in a similar state, and there was about two pints of whey-like fluid floating in the cavity of the abdomen; the peritoneal coat of the intestines was intensely red; the mucous lining of the stomach, jejunum, and ileum was quite healthy; a few red patches were visible in the colon; the duodenum at its superior angle presented a perforation the size of a shilling.

The state of the duodenum and of the perforation in this case differed from the preceding one only in the following particulars: the perforation was rather nearer to the pylorus, its margins were not black, it did not adhere to the gall-bladder, and there were no ulcerations.

Long adds: "I have been induced to give the two cases of perforation of the duodenum in detail, as I believe they are unique; indeed, I am not aware of any case being recorded of perforation of the gastro-intestinal tube occurring after a burn, except the one I quote from Liston, which approximates to my two cases by the perforation being near the pylorus, and by the change which had taken place in the duodenum."

He quotes the following case, recorded by Liston:

Female child, *æt.* three, on the 4th of May received a severe burn of the upper part of the abdomen, lower part of the chest, arms, and occiput; on the seventh day vomited blood, and died. Lymph in flakes, slightly gluing the intestines together; purulent yellowish fluid in the cavity of the abdomen; grumous blood with lymph lying at the lower border of the stomach; two ounces of grumous blood in the

stomach; perforation in stomach beyond the pylorus; the edges of the perforation elevated; some enlarged glands in the external coat of the stomach, near the perforation. The coats of the duodenum also, near the ulcer, were thickened and elevated, with spots of yellow hue.

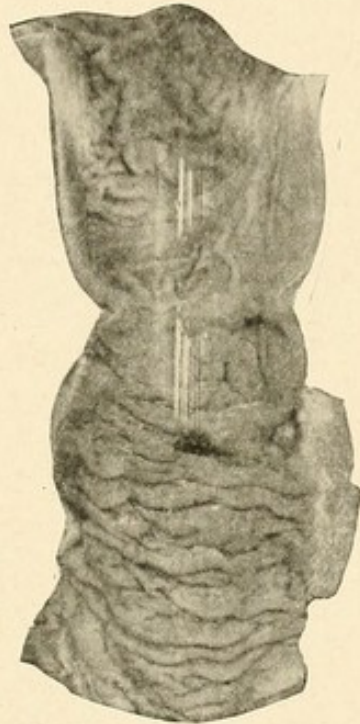


FIG. 5.—DUODENAL ULCER DUE TO BURNS.

There are two oval ulcers about half an inch in diameter, and many of smaller size. In the mucous membrane of the duodenum the two large ulcers have extended beyond the mucous membrane and penetrated all the coats of the intestine. One of them is closed by a continuous adherent surface of the pancreas; the other opened into the cavity of the abdomen.

From a child about two years of age, who died suddenly during the progress of recovery from a burn. (St. Barth. Hosp. Museum, No. 1969.)

This remarkable paper has been overlooked by every subsequent writer; its perusal leaves no doubt that the credit for priority in this matter is due entirely to Long.

Nearly all the large museums in London now contain

specimens showing "Curling's ulcers," and the impression seems to prevail that this morbid condition is one of some frequency, and that this type of ulcer includes a notable proportion of the whole number of ulcers which affect the duodenum. I believe, however, that the

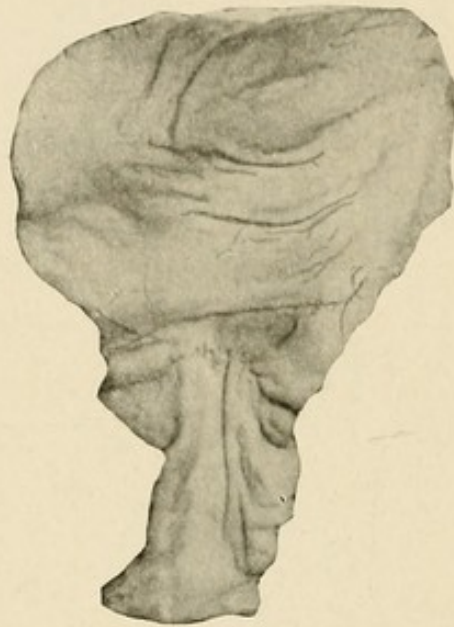

FIG. 6.—ULCER OF THE DUODENUM FOLLOWING A BURN.

The pyloric end of a stomach with the first part of the duodenum. Just beyond the pyloric ring there is a round, punched-out ulcer about a quarter of an inch in diameter, in the base of which is exposed the muscular coat of the intestine.

Marian C., æt. thirteen, was admitted under Mr. Durham for severe burns of the trunk. She died from tetanus about a fortnight after the accident. At the autopsy the skin over the injured parts was sloughing. (Guy's Hosp. Museum, No. 741.)

lesion is an extremely infrequent one, for in nearly twenty years not one single case has been observed in the post-mortem room of my own hospital wherein cases of burn are frequently admitted. In my own series of cases treated by operation it is the fact that no case has been met with in which a burn could be in

any degree held responsible for the appearance of the ulcer, nor indeed has any noteworthy scar of a burn or

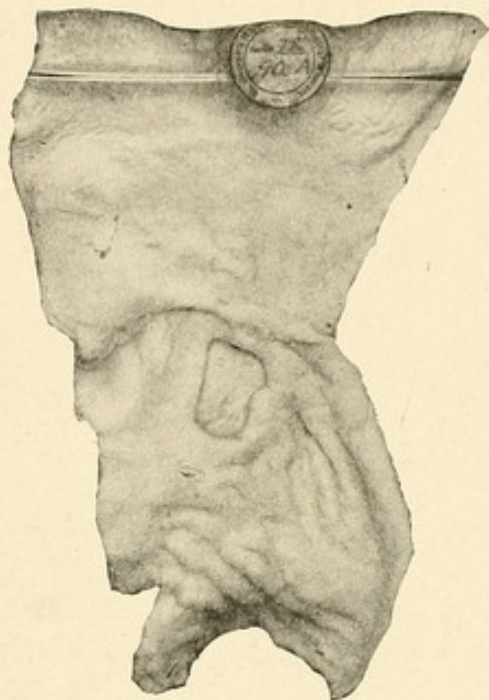

FIG. 7.—DUODENAL ULCER FOLLOWING BURNS.

Portion of the pyloric end of a stomach along with the duodenum showing an extensive ulcer in the first portion of the latter, following a burn. The inner aspect of the latter is very large, and of the size of a bean; and at its upper part is a small aperture through the muscular and peritoneal coats, which existed during life. The posterior part of the ulcer has been greatly strengthened by masses of fibrin which have been accumulated. The duodenum contained a large clot of blood, about six inches long, moulded upon its walls; no other part of the intestines was ulcerated, but they were highly congested.

The patient, Sarah T—, aged nineteen, was admitted April 9th, with extensive and painful burns about the thighs and shoulders. She died April 19th, ten days after admission, and before death the bowels, which had been confined for some days after the accident, became much relaxed and the *fæces* contained blood. On the day before her death she vomited much matter mixed with blood. (St. George's Hosp. Museum, No. 90 A.)

scald ever been found upon the surface of the bodies of patients who were treated for this disease. The cases

of chronic ulcer of the duodenum which have a clinical significance do not seem, therefore, to be in any way dependent upon these injuries.

It is perhaps owing to the interesting and obscure

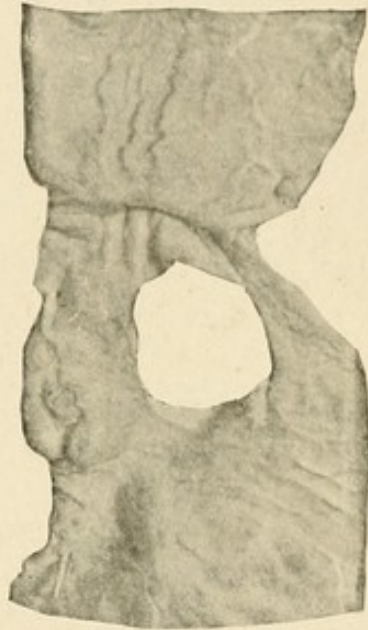


FIG. 8.—ULCER OF THE DUODENUM FOLLOWING A BURN.

The first part of the duodenum, shewing a clean-cut oval opening in its posterior wall, the upper limit of which is about half an inch from the pylorus. The ulcer is one and a half inches long, and in the recent state its base was formed by the pancreas, which was eroded. The ulcerative process had exposed and opened the superior pancreatico-duodenal artery.

Herbert E., *æt.* four, was admitted under Mr. Durham for several burns upon the lower extremities and buttocks. The child did well for sixteen days, after which he began to pass blood with his motions. The hæmorrhage proved fatal on the nineteenth day after the accident. At the autopsy the intestines were found to contain much black blood. (Guy's Hosp. Museum, No. 740.)

nature of these cases that unusual attention has been paid to them, and the impression as to their frequency has unconsciously become exaggerated. It is a fact, however, that acute ulceration of the duodenum does

occur in cases of burn or scald; and that the surface lesion does bear a definite causal relationship to the lesion of the mucosa of the alimentary canal, especially of the duodenum.

In his original paper Curling gave detailed notes of 12 cases, and subsequently recorded another case. Erichsen ("London Medical Gazette," 1843, xxxi, 544), in a study of the pathology of burns, cites 3 cases of ulcer of the first portion of the duodenum occurring on the fourth, seventh, and eighth days after the accident. Wilks ("Guy's Hosp. Rep.," 1856, 3d series, ii, 133), in a short paper, reviewed the 12 fatal cases surviving four days or over occurring within a period of eighteen months in Guy's Hospital. In every instance the duodenum was absolutely healthy. Confirmatory evidence of the accuracy of Curling's observations was given by Timothy Holmes ("System of Surgery," 1860, i, 738), Ponfick ("Berl. klin. Woch.," 1876, i, 225), W. Stokes ("Dublin Jour. Med. Sci.," 1876, lxii, 327), and others, and there is no longer any doubt as to the strict dependence of acute ulceration in the duodenum upon the destructive lesions of the skin produced by burns or scalds. On this point Perry and Shaw write:

"Although the investigation of all the cases of burn examined in the post-mortem room at Guy's shows a smaller percentage of duodenal ulcers than has been found in the less extended series of cases compiled at other institutions, we must, having regard to the extreme rarity of ulceration from all causes in this part of the alimentary canal, admit an undoubted relationship

between the cutaneous and intestinal lesion. Our own statistics indicate that whilst of persons dying from all causes 0.4 per cent. only are found with duodenal ulceration, no less than 3.3 per cent. of those dying from burns exhibit this condition."

The nature of the relationship between these two conditions has formed the subject of much interesting speculation. Curling in a foot-note (*loc cit.*, p. 277) states that he received from Bowman the hint that the glands of Brunner were the probable seat of ulceration. No evidence was then given, nor has any been since put forward to support this view; the supposed "sympathy" between these glands and the burnt skin, which has been suggested by Brown-Séguard and Handfield-Jones, is, as Perry and Shaw truthfully say, "entirely unsupported by any physiological or pathological evidence." W. Hunter ("*Path. Soc. Trans.*," 1890, xli, 105) suggested that the inflammation of the duodenum and the consecutive ulceration were due to the excretion of some irritant products through the bile. He found that after subcutaneous injections of toluylendiamine in dogs intense jaundice was produced; when the animals were killed three to seven days later certain changes were found in the duodenum. The duodenum, even before being opened, was obviously inflamed, its walls turgid, swollen, and feeling doughy to the touch. On being opened the most intense inflammatory congestion of the mucous and submucous coats was seen, and the lumen of the canal was filled with a large quantity of clear inflammatory mucus. In other cases ulcers were found. The changes were most marked in the

neighbourhood of the bile papilla. Occasionally other parts of the small intestine were affected, especially the terminal portion of the ileum. The appearances pointed to the action of a powerful irritant, the only channel of whose excretion was the bile. The close similarity between the duodenum and ulceration in cases of burns and that experimentally produced is evident. Hunter accordingly suggested that the factor common to both was the presence of a poison due to some destructive process occurring in the blood, and the discharge of this poison in the bile. Marked changes in the blood, occurring after burns, have been described by Lesser (quoted by Hunter, p. 111), and Ponfick and others have shewn that extensive scalds will produce, in animals, hæmolysis similar to that seen after the injection of toluylenediamine. Fenwick ("Jour. of Pathology," 1893, i, 417) found, however, that in dogs, after ligation of the common bile-duct, ulceration of the duodenum still followed the injection of this drug. It is therefore clear that for the present, and until clearer evidence is forthcoming, we must suspend our judgment in this matter.

This hypothesis, moreover, leaves untouched the undoubted fact that the ulceration is far more frequently met with above the biliary papilla than in the immediate vicinity of that point. Gandy in his thesis (Thèse de Paris, 1899) has shewn conclusively that, as many observers have individually recorded, congestion and hæmorrhagic erosion, the common precursors of toxic ulceration in mucous membranes, occur elsewhere in the alimentary canal. It is only necessary, therefore, to

detect some special feature, limited to the first part of the duodenum, which shall account for the disposition there shewn for the slightest lesion to be converted into an ulceration process. This special circumstance surely is the forcible injection of the acid chyme through the pylorus. The chyme impinges upon the duodenal wall at that part where ulceration is most commonly found; in addition to this mechanical assault or irritation, there is the possibly more potent action of the gastric juice as a chemical agent, digesting the already damaged portion of the intestinal wall.

Duodenal ulcer in connexion with burns is doubtless a toxic ulcer, and therefore analogous to the ulcer which occurs in septicæmia, uræmia, typhoid fever, erysipelas, and pemphigus. It is almost without exception the rule to find the ulcer only in cases where septic processes in the burnt skin have developed; and the frequency of duodenal ulcer in cases of burn or scald may well be due to the special liability to suppuration and to sloughing which these injuries display. A point which requires investigation in this connexion concerns the presence and possible influence of septic emboli, conveyed from the infected area to different regions in the body. In the alimentary canal they would produce hæmorrhagic infiltration, which, immediately beyond the pylorus, would readily be converted into ulcers by the action of the gastric juice.

POSITION AND CHARACTER OF THE ULCER

Both the ulcer, and the lesion which precedes it, whether congestion, ecchymosis, or hæmorrhagic erosion,

may be solitary or multiple. As they affect the duodenum they are only a part, though doubtless the most

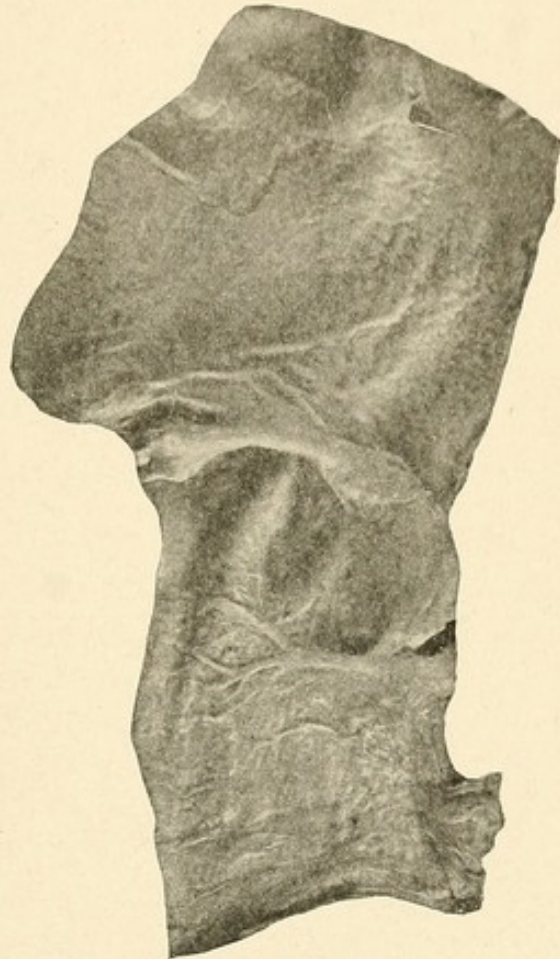

FIG. 9.—DUODENAL ULCER AND GASTRIC ULCER DUE TO BURNS.

The pyloric end of the stomach, the pylorus and part of the duodenum laid open, showing ulceration of the latter. About one-half inch beyond the pylorus there is an ulcer in the mucous membrane about the size of a sixpence, but somewhat irregular in shape. It looks as if a slough had recently separated, and the edges, which are broken off, appear to be already cicatrising. In the mucous membrane of the stomach about one and a half inches above the pylorus there is a small oval superficial ulcer, which is abruptly defined.

From a woman aged seventy, who died on the tenth day from burns. (London Hospital Museum, No. 1143.)

conspicuous part, of a process precisely similar which affects, or may affect, other parts of the alimentary

canal. Holmes ("System of Surgery," 1860, i, 738) and P. Laure ("Dict. encyclop. des Sciences Médicales," 1887, xxxiv, 603) record cases where ulceration in the jejunum and at the termination of the ileum was found. Ponfick ("Berl. klin. Woch.," 1877, xiv, 47) relates one case where hæmorrhagic erosion and superficial ulceration were present in the first part of the duodenum eighteen hours after the accident. In three-fourths of the cases the ulceration is found exclusively in the first part of the duodenum; in the remainder it is in the first and second, or the second parts. It is very rarely seen below the ampulla of Vater. In the 29 cases of Perry and Shaw the ulcer was single in 16 cases; in 12 there were two or more ulcers; in one information is lacking. The ulcer may be superficial, being a mere surface denudation of epithelium; more often it is deep, and appears as though a slough had separated from it. It may be circular, oval, or irregular; may be a mere loss of tissue or may, in rare cases, shew definite evidence of attempted repair. This form of ulcer is found in patients of all ages. The youngest patient whose history is recorded was a child of twelve months, who died on the twentieth day after being scalded extensively on the chest. Acute inflammation and ulceration were found in the duodenum (St. Bart.'s Hosp. Museum, 1969a). The oldest patient was a woman, seventy years of age, who died on the tenth day after being burnt. A small ulcer was found in the stomach, a larger one in the duodenum (London Hosp. Museum, 1143). A specimen from a woman of sixty-six, who

died on the seventeenth day, is in St. George's Hospital Museum (No. 90b).

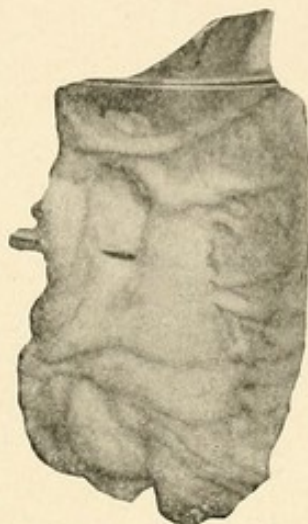

FIG. 10.—DUODENAL ULCER FOLLOWING BURNS.

Portion of the stomach and duodenum shewing a large oval ulcer in the latter, immediately below the pylorus. Removed from the body of a patient who was extensively burnt over the face, neck, and upper extremities. The ulcer is about one and one-half inches long and one-half inch in breadth and situated immediately beyond the pylorus. The muscular part of the walls is almost equally destroyed with the mucous part, and a branch of the pancreatico-duodenal artery is entirely laid open. The margins of the ulcers are rounded and swollen and are moderately muscular, its base being formed by the opposed pancreas. Below this larger patch of ulceration a smaller one also existed, and the neighbouring solitary glands are much enlarged. The entire intestinal tract, as low down as the lower part of the colon, contained a reddish and black fluid composed of faecal matter and coagulated blood.

The patient, Elizabeth J—, æt. five, was admitted on May 4, 1850. She suffered from pain in the abdomen, but not from vomiting and purging, and sank from collapse May 9th. (For details see Post-mortem and Case Books 1850, p. 82. St. George's Hosp. Museum, No. 90 C.)

SYMPTOMS

Clinically the ulcer, which occurs twice as frequently in females as in males, may assert itself with a great variety of manner. In no small proportion of the cases

the ulcer has been latent, producing no symptoms, and giving no hint of its presence, during the life of the patient. At the post-mortem examination one or two ulcers may be found, and the process of healing in some may be beginning, or may even be complete. In the majority of the cases either perforation or hæmorrhage or both are the first warnings given. In 20 of the 29 cases followed by Perry and Shaw one or both occurred. The case of earliest perforation is recorded by W. C. Hills ("Jour. of Mental Sci.," 1881, xxvi, 556); the patient was a girl of eighteen who was accidentally scalded to the second degree by hot water. Vomiting occurred the next day, and eighty-three hours later she died collapsed. At the autopsy an ulcer the size of a shilling was found on the posterior wall of the duodenum two inches from the pylorus. The ulcer involved all the coats of the duodenum, was in part adherent to the pancreas, and perforation into the general peritoneal cavity had occurred. A case of a death from hæmorrhage, the pancreatico-duodenal artery being opened, occurring four and one-half days after the injury is recorded by Caesar Hawkins ("Path. Soc. Trans.," 1851, ii, 290). Perforation may occur between the fifth and the twentieth days, and is most common on the tenth and eleventh. It is very rarely preceded by symptoms, and ends speedily in the death of the patient. There is no recorded case of surgical treatment being adopted, but there is no reason why it should not prove successful if the condition of the patient were not too exhausted by the extent or severity of the original injury. Hæmorrhage is more common than perforation;

in Perry and Shaw's twenty cases there were 7 of perforation and 13 of hæmorrhage. It is sometimes preceded by a sense of heat in the epigastrium or by collapse and great prostration. It has proved fatal as early as four and one-half days and as late as thirty-seven days after the accident; the day of maximum frequency is the fifteenth. In the ulcer from which the hæmorrhage comes no vessels may be seen laid open, the bleeding having occurred from several small points, or rarely a large artery, the pancreatico-duodenal, or a branch of it, may have its walls destroyed. In one case related by Keate ("Path. Soc. Trans.," 1850, i, 258) the patient, a girl of six, lived seventy-five days after being severely burnt; three ulcers were found in the duodenum. This is the longest period of survival mentioned in any of the records.

CHAPTER III

URÆMIC ULCER OF THE DUODENUM

It has long been a matter of common knowledge that superficial erosions, or ulcerations, are found in certain parts of the alimentary canal in fatal cases of Bright's disease. The regions most frequently affected are the lower portions of the small and the upper portions of the large intestines. The stomach also contains, not rarely, similar evidences of superficial ulcerations, more especially in its pyloric portion. The mouth has in some few instances shewn multiple points of inflammation, or of actual destruction of the mucous membrane, as Barié ("Arch. Gén. de Méd.," 1889, ii, 415), and later Renon ("Bull. Soc. Méd. des Hôpitaux," 1898, xv, 475) and Hirtz ("Sem. Méd.," 1902, xxii, 109), have shewn. An interesting case has been recorded by Dalché and Claude ("Bull. et Mem. de la Soc. Méd. des Hôpitaux de Paris," 1903, xx, 75), in which ulceration of the skin, of the mucous membranes of the mouth and anus, and of the umbilicus occurred in a case of Bright's disease. Hæmorrhages into the deeper layer of the skin and of the mucous membranes preceded the destruction of the upper layers; petechial hæmorrhages led rapidly to ulceration. Mathieu and Roux ("Arch. Gen. de Méd.," 1902, clxxxix, 14) record one case in which there was a continuous ulceration over a length of

30 centimetres in the ileum. The duodenum also, though more rarely, may be involved in a process of uræmic ulceration, as was pointed out by Treitz in 1859 and by Wilks and Moxon in the second (1875) edition (p. 405) of their "Lectures on Pathological Anatomy." Perry and Shaw point out that the remark that duodenal ulcers, like gastric ulcers, "are often associated with Bright's disease," occurs only in this edition, and it is not to be found in either the first or the third. As the second edition was revised by Moxon, the observation doubtless rests upon his authority alone. Most of our knowledge of this subject is due to the work of Perry and Shaw, who collected from the post-mortem records of Guy's Hospital, and from the literature, a series of cases which shewed the various forms of ulceration which might involve the duodenum in patients affected with Bright's disease. Since their work appeared, only a small number of cases have been recorded. The most noteworthy contribution, containing a record of 22 cases of "albuminuric ulcers" of the intestine, was published by W. H. Dickinson ("Med. Chir. Trans.," 1894, lxxvii, iii). G. Lecointe in 1903 devoted a Paris thesis to the consideration of the subject, and Barié and Delaunay ("Bull. et Mem. de la Soc. Méd. des Hôpit. de Paris," 1903, xx, 45) record in detail an exemplary instance of the condition and briefly review the reported cases.

An examination of all cases recorded shews that ulceration in the duodenum may be considered in some cases as dependent upon the change, usually an advanced change, which has occurred in the kidneys, and in other cases as being in all probability in no direct relationship

with, and possibly of older standing than, the renal lesion which is coexistent with it. One case in Perry and Shaw's series (No. 151) is, as they point out, distinguished at once from the rest inasmuch as the causal relation of the nephritis to the duodenal ulceration appears to be indisputable. "It is that of a man, aged thirty-six, who was admitted for albuminuria and

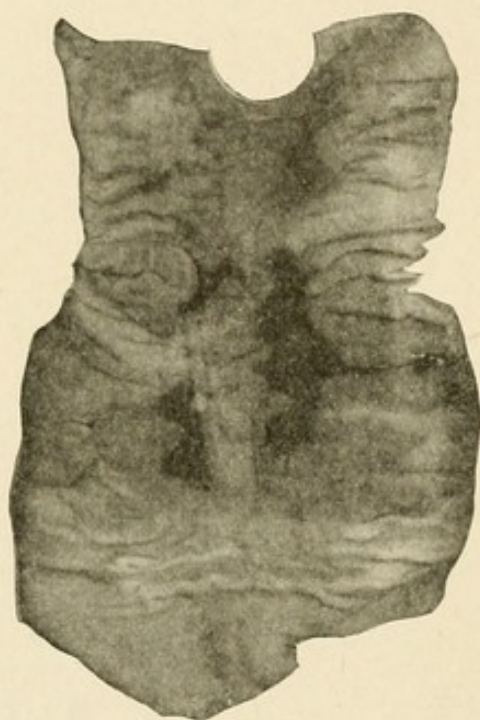


FIG. 11.—URÆMIC ULCERATION OF DUODENUM.

R. B., male, aged forty-eight, admitted November 7, 1904, under Dr. Penrose. A very muscular, tall man, admitted with marked œdema of both lower extremities. For sixteen years has passed small calculi in the urine. Died from failure of the right heart twelve days after admission. At the post-mortem the following conditions were found:

Kidneys: Right, 9 ounces; left, 3 ounces. The right is large. The left is small with adherent capsules, and the fat around is firmly adherent to both. On section, in the lower lobe of the right is a fairly large renal calculus in three pieces. The calculus is black in colour and surrounded by phosphates. In the left there are two minute similar calculi. The pelves of both kidneys are inflamed, but not particularly dilated. Both ureters are dilated from end to

diarrhœa, his illness dating from two months before his admission. He had passed blood in his motions. He died after he had been in hospital three days, and on post-mortem examination his kidneys were found to be extremely cirrhotic, and the left ventricle of the heart was hypertrophied. Ulcerated areas such as are common in Bright's disease were found scattered through the large and small intestines, and the lower half of the duodenum was similarly affected. This case seems to prove that the ulcerative enterocolitis of Bright's disease may, though rarely, extend as high as the duodenum. In all the other cases there is an absence of marked enteritis in the lower part of the intestine, and the conditions observed in the duodenum do not materially differ from those in cases where Bright's disease is not present."

end and firmly adherent to the surrounding fat. Their walls are thickened and their lining membranes are infected and inflamed. Half-way down the right two portions of calculus are impacted.

Ureters: The orifices of the ureters into the bladder are not noticeably dilated. The left opening is, however, larger than the right.

Bladder: The vesical lining membrane is generally infected and swollen from inflammation. This lesion, however, is not advanced.

Prostate: Normal.

Alimentary Canal: The stomach and intestines are much congested, the former shewing chronic gastritis as well.

In the duodenum from the pylorus to just above the bile papilla are nine ulcerated patches. These patches are scattered about, the largest being over one inch long; all are irregular in outline, with swollen, *not* undermined edges, and smooth floors; the floor in every case is a deep greyish-black in colour. No other ulcers are seen in the intestinal tract, the colon, in particular, being normal. The small gut as a whole, in addition to being congested, is œdematous and contains altered blood. (St. George's Hospital Museum, Specimen 90E.)

In the case reported by Barié and Delaunay the upper part of the small intestine was deeply congested, and the duodenum contained four recent ulcerations, from one of which a hæmorrhage had occurred so copious as to fill the large intestine and a part of the small intestine

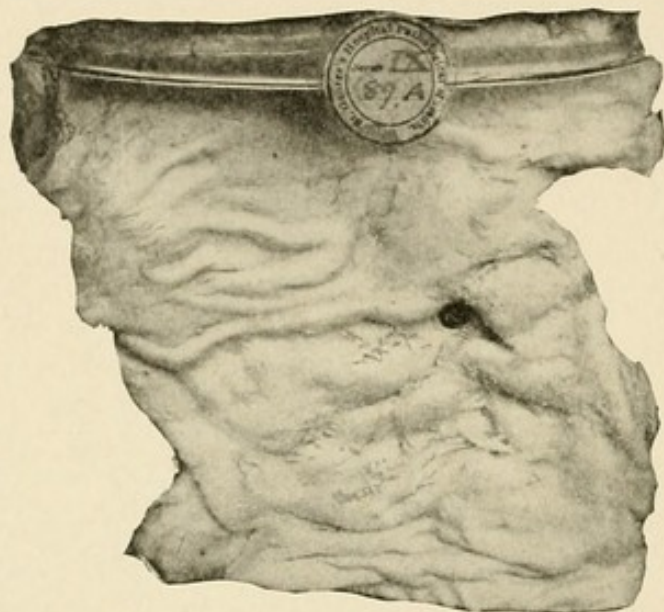


FIG. 12.—PERFORATING ULCER OF THE DUODENUM (POSSIBLY URÆMIC).

In the anterior wall of the duodenum just beyond the pylorus is a round, clean-cut perforation, of the calibre of a quill. The mucous and muscular coats of the gut are destroyed to a slightly greater extent than the peritoneal layer. The wall of the bowel is thickened, but not to a great extent around the perforation.

From the body of a painter, aged fifty-six, the subject of granular disease of the kidneys, who died in the hospital of peritonitis resulting from the perforation for which he was admitted. The origin is not apparent. (St. George's Hosp. Museum, No. 89A.)

with blood. There were no ulcerations or erosions in the colon. In two cases in Perry and Shaw's list (Nos. 58 and 59) hæmorrhagic erosions of the duodenum were found in association with morbid changes in the kidney. In one case—the only one observed in my series of

cases—an extensive ulcer of the duodenum seemed to be dependent upon an advanced pathological condition of the kidneys. In all these examples the ulceration involved chiefly the mucosa, it was extensive or seen in multiple

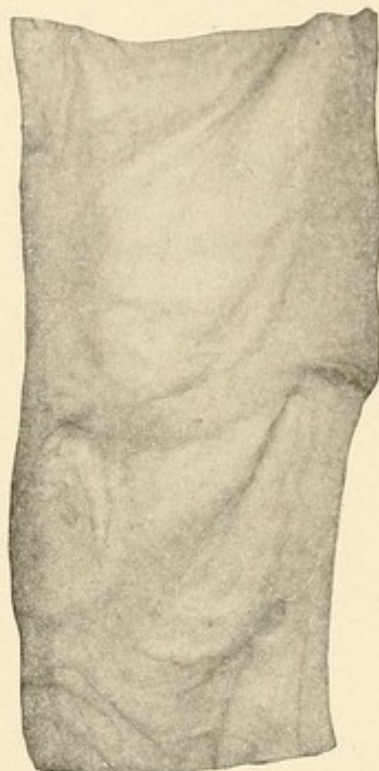


FIG. 13.—URÆMIC ULCERATION OF THE DUODENUM.

F. B., female, aged seventy-four. Admitted October 26, 1904, under the care of Dr. Ewart, for a failing heart. There was much œdema of the lower extremities and the abdomen contained a large quantity of fluid. Both kidneys were granular, and the duodenum contained in its first part nine irregularly shaped ulcers, with deep black bases. No other ulcers were present in the intestinal tract. (St. George's Hosp. Museum, No. 90F.)

points, associated with congestion or hæmorrhagic erosion in other parts of the inner surface of the bowel, and no evidence of attempted repair was anywhere displayed. The process was chiefly, if not wholly, one of destruction. In circumstances such as these the evidence

would, I think, support the view that the lesion in the bowel is secondary to the disease of the kidneys. The

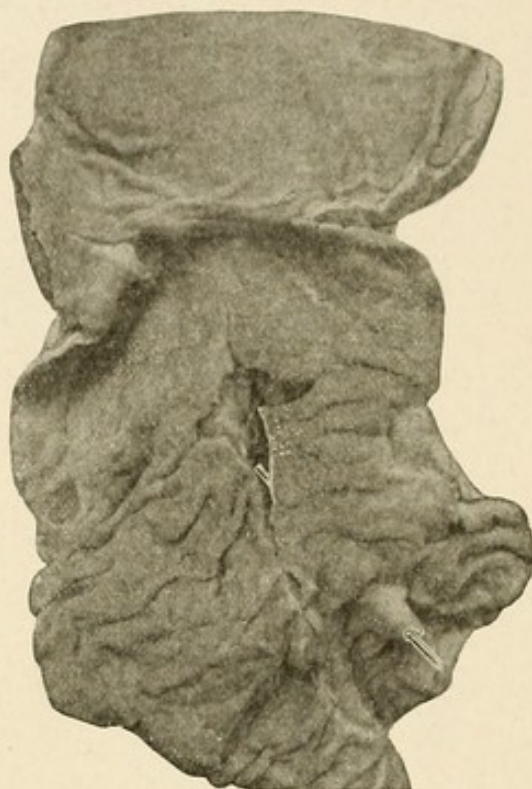

FIG. 14.—DUODENAL ULCER.

The first portion of a duodenum with the adjacent end of the stomach laid open to display an oblong ulcer in the former. It is situated an inch beyond the pylorus, and measures nearly an inch in its chief diameter, which is transverse. The margin of the ulcer is thickened and undermined, while its base is loosely attached to the subjacent head of the pancreas. A vertical section shows that the common bile-duct is in close relation with the floor of the ulcer. A blue rod marks the course of the duct. Close to the pyloric ring the depressed scars of two healed duodenal ulcers may be seen.

From a boy aged seventeen, who was admitted for nephritis and anasarca. He died of uræmia five months after the onset of his illness, having previously enjoyed very good health. (Royal College of Surgeons Museum, No. 2430A. Presented by Guy's Hospital, 1893.)

ulcer is almost always confined to the first portion of the duodenum, and (with only one exception) lies above the ampulla of Vater. The ulcer is, as a rule, solitary,

but two, three, four, and five separate ulcers have been noticed. The ulcers may be at the summit of the *valvulæ conniventes*, but more often are found as furrows or chaps on the under surface of these folds, at their points of attachment to the intestinal wall. The depth of the ulcer varies considerably; there may be only the slightest surface erosion, or the whole thickness of the intestinal wall may be destroyed, so that the pancreas is eaten into, an artery of large size eroded, the common bile-duct or the gall-bladder laid open, or the general cavity of the peritoneum invaded. Death may occur from hæmorrhage or from perforation. In order to ascertain if there is any causal relation between the condition of the kidneys and the ulceration of the duodenum Perry and Shaw estimated from the post-mortem records of Guy's Hospital the percentage of persons dying from nephritis; they found that some form of kidney disease was present in 7 per cent. of deaths. Their cases of duodenal ulcer numbered 70, and of these 7 per cent., or 5 cases, might have been expected to have coincident Bright's disease. As a matter of fact, 12 cases shewed this association, and "there appears therefore to be some reason for including Bright's disease as one of the predisposing causes of duodenal ulcer." The form of the kidney disease varies; there may be interstitial nephritis, tubal nephritis, or a combination of the two.

The direct causation of the ulcers has not been satisfactorily explained. Treitz, in his original description of the condition, ascribed the origin of the ulcers to the irritation of the mucosa set up by the excretion of ammonium carbonate. W. H. Dickinson ("Med. Chir.

Trans.," 1894, lxxvii, 111) suggested that the ulceration might be secondary to submucous hæmorrhages, the evidences of which are not seldom seen side by side with

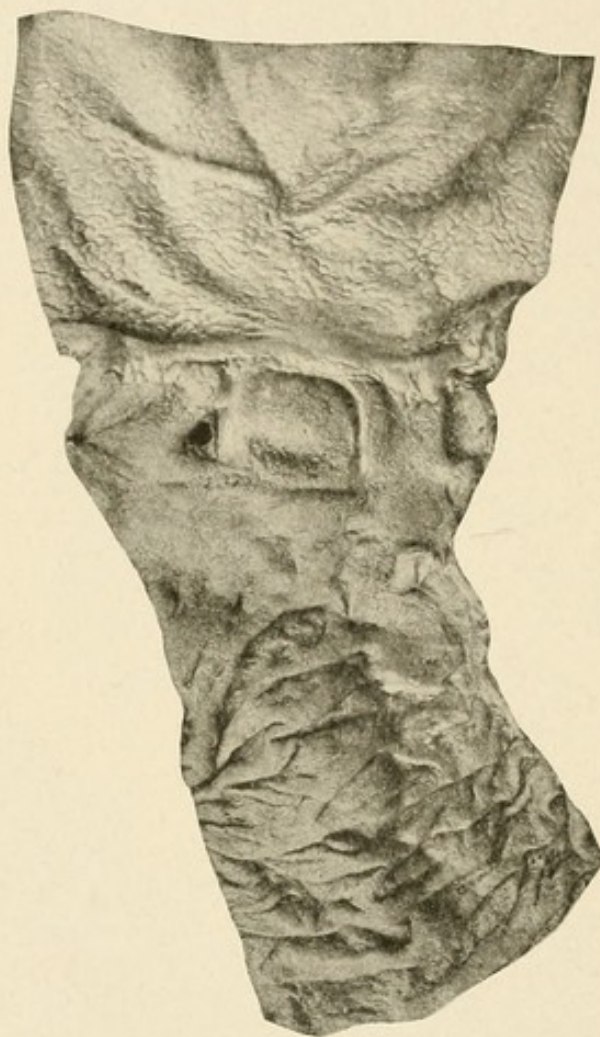


FIG. 15.—TYPHOID ULCER OF DUODENUM.

A small, somewhat triangular, typhoid ulcer (marked by a piece of blue glass rod) is situated almost immediately beyond the pyloric rings. The ulcer had perforated, causing general septic peritonitis. (Great Northern Central Hospital, No. 121.)

the ulcerated patches. Barié ("Arch. Gén. de Méd.," 1899, ii, 415) considers that "as a result of the renal insufficiency there are soon developed other, supple-

mentary paths for the elimination of the urinary poisons. These are established chiefly through the respiratory




FIG. 16.—ANTHRAX OF THE DUODENUM.

Three pieces of a duodenum mounted to illustrate the effects of anthrax. The topmost piece shows beneath the mucous membrane a flattened nodule measuring about half an inch in diameter and a sixteenth of an inch in thickness. It was situated at the lower end of the duodenum, and in the recent state the mucous membrane covering it presented a small central slough. The two lower pieces show brown dots and patches resulting from submucous hæmorrhage.

Walter B., æt. thirty-nine, was admitted under Mr. Durham for a "malignant pustule" upon the neck, which had been first noticed as a little pimple four days before admission. The pustule was immediately excised. Two days later the patient died. At the autopsy the cellular tissue of the neck was found to be œdematous, and there was considerable hæmorrhage beneath the arachnoid. No part of the alimentary canal appeared to be affected with anthrax except the duodenum. The peritoneal cavity contained about thirty ounces of yellowish fluid. (See *Insp.* 1884, No. 113.)

passages, by the skin, and perhaps by some of the serous membranes. But it is chiefly the alimentary canal which becomes the principal medium of excretion, and it is therein that the signs of irritation, stomatitis, dyspepsia, gastralgia, vomiting, and diarrhoea may arise." This hypothesis of the excretory activity of the intestinal tract in cases of uræmia is fully supported by the experimental work of Stassano ("Soc. de Biologie," 1902, ii, 24), which seems to shew the particular and special efficiency of the duodenum in the excretion of urinary toxines. Acute ulceration of the duodenum occurring in cases of anthrax, typhoid fever, and pemphigus, etc., may perhaps be thus explained.

The following is a complete list of all recorded cases of uræmic duodenal ulcer:

CASE 1.—Hæmorrhagic erosions of the duodenum: Sarah W——, æt. twenty-nine, was admitted under Dr. Rees for gout and dropsy. Some months later she died, and at the autopsy there was œdema of the lower extremities with tubal and interstitial nephritis, chronic peritonitis, and perihepatitis. There was also acute recent pericarditis, and much fluid in the right chest. In the duodenum were several eroded ulcers with edges sharply defined and bases occupied by adherent blood-clot. The ulceration was superficial, involving only the mucous membrane. (Perry and Shaw, Case 58, p. 230.)

CASE 2.—Hæmorrhagic erosions of the duodenum: Elizabeth G——, æt. thirty-six, was admitted under Dr. Pitt three days after the onset of a right hemiplegia. Albumen and casts were found in the urine. Four days after her admission she became comatose and died. At the autopsy there was chronic interstitial nephritis with some distension of the pelves of the kidneys. There were a few small hæmorrhagic erosions in the duodenum. The lungs were congested

and œdematous; the heart was normal. (Perry and Shaw, Case 59, p. 230.)

CASE 3.—Ulcer of the duodenum and stomach; cellulitis; nephritis: John B——, æt. fifty-six, was admitted under Mr. Cock for cellulitis of the leg. He lingered for many weeks, and at the autopsy the right leg was found to be in a sloughing state from the hip downwards. There was a chronic ulcer on the lesser curvature of the stomach. It was rather larger than a shilling, perfectly round, and with raised, smooth edges. The floor was composed solely of the peritoneal membrane, and this was so thin as to be quite diaphanous. There was a small, round, superficial ulcer at the commencement of the duodenum, and another in the ascending colon. The kidneys showed tubal and interstitial nephritis. (Perry and Shaw, Case 92, p. 237.)

CASE 4.—Suppurating knee-joint; tubal nephritis; ulcer of duodenum; hæmorrhage: A male with grey hair was admitted under Mr. Cooper Foster with a suppurating knee-joint. Amputation was performed. He rallied imperfectly, had signs of fever, and sank. He did not vomit until the day of his death and no blood was ever noticed in his motions. At the autopsy the stump presented a healthy granulating surface. There was recent pleurisy and pericarditis and a moderate degree of mitral stenosis. The kidneys weighed 13 ounces and were rather granular on the surface, but otherwise in the state of large white change with prominent stellate veins. On the hinder surface of the duodenum, half an inch beyond the pylorus, was a deep excavation of the size and form of half a chestnut; this exposed the pancreas, the duodenum being fastened at this point very firmly to the gland by a dense tissue. There was a small elevation in the ulcer, and a little artery here projected from the pancreatico-duodenal. On opening up the artery a weak thin patch was found in it, at which the rupture had taken place. The intestines were full of blood, little altered in character, and the stomach contained much half digested blood. (Perry and Shaw, Case 94, p. 238.)

CASE 5.—Burn; ulcer of the duodenum: A girl, æt. six, was admitted into St. George's Hospital under Mr. Keate

for severe burns, which two months later were sloughing. She died seventy-five days after the accident; and at the autopsy three ulcers were found in the first part of the duodenum; the largest, which was about the size of a four-penny piece, being within half an inch of the pylorus, the other two being close to the first. In the largest pair the base was formed by the muscular tissue; the smallest one was quite superficial. Both kidneys "presented well-marked specimens of the mottling degeneration." The duodenal glands were somewhat increased in size. (Perry and Shaw, Case 133, p. 247.)

CASE 6.—Granular kidneys; cirrhotic liver; ulcer of the duodenum; hæmorrhage: Harriet H—, æt. thirty-five, was admitted under Dr. Bright in 1834 for vomiting and albuminous urine. The vomit sometimes contained blood. She died twelve days after admission, and at the autopsy the mucous membrane of the stomach was much injected, and at several minute points apparently ulcerated. A simple ulcer of irregular figure, about the size of a sixpence, and resembling the complete and abrupt removal of so much mucous membrane, was found in the duodenum. The ulcer had slightly injected edges, and there were patches of congestion in the rest of the small intestine. The liver was cirrhotic and the kidneys were small and granular. (Perry and Shaw, Case 145, p. 250.)

CASE 7.—Contracted granular kidneys; ulcer of the duodenum and stomach: Elizabeth M—, æt. forty-one, was admitted under Dr. Babington in 1841 for Bright's disease. Symptoms of peritonitis supervened, and she died one month after her admission. At the autopsy the kidneys were found to be small and granular, and there was a contracted ulcer in the beginning of the duodenum, and a smaller and more recent one upon the pyloric ring. (Perry and Shaw, Case 146.)

CASE 8.—Granular kidneys; follicular ulceration of the duodenum: John P—, æt. fifty-seven, was admitted under Dr. Babington with malignant disease of the œsophagus, from which five weeks later he died. At the autopsy a stricture was found an inch and a half from its cardiac end. The stomach was contracted and its mucous membrane con-

gested. It contained an abundance of stringy mucus. The duodenum was intensely injected and presented numerous enlarged glands, many of which were ulcerated, the larger ulcers being close to the pylorus. The rest of the alimentary canal was normal, but exceedingly contracted and quite empty. The kidneys were small and the cortex was diminished in thickness. (Perry and Shaw, Case 147.)

CASE 9.—Interstitial nephritis; atheroma; perforating ulcer of the duodenum: Charles W——, æt. sixty-six, was admitted under Dr. Rees for œdema of the lower extremities and weakness. He had always been healthy till within a few weeks of his admission. His urine was found to be highly albuminous. He died a fortnight after his admission, but there is no clinical account of the symptoms immediately preceding his death. At the autopsy the kidneys were found to be granular and there was an old apoplectic cyst in the pons. The vessels were atheromatous and the heart hypertrophied. The abdominal cavity contained about three pints of turbid offensive fluid. The surface of the peritoneum was coated with lymph in some quantity, and reddened also by fine capillary injection. The cause of this peritonitis was perforation of the duodenum by an ulcer close to the pylorus on the upper aspect. The ulcer was of the size of a horse bean, and very clean-cut, having quite the "punched" appearance. The whole circumference of the proximal portion of the duodenum for a width of one and a half inches from the pyloric ring was curiously diseased, so that there appeared to be gland tissue in the submucous substance, and this formed a layer movable on the coats beneath, and of the thickness of a penny piece. At one spot this had yielded like an aneurysmal bulging, and at another spot, opposite to the hole above described, that is, on the lower border of the gut, there was a second small ulcer with abrupt margin and some soft blood-clot on its base, which was formed by the submucous tissue. (Perry and Shaw, Case 148.)

CASE 10.—Tubal nephritis; ulcers of the duodenum, one partly cicatrised: Eliz. W——, æt. fifty-five, was admitted under Dr. Moxon with vomiting, dropsy, and albuminuria,

of which she died. At the autopsy the pleural cavities contained a large quantity of serous fluid and the kidneys were affected by tubal nephritis. Just beyond the pyloric ring the duodenum contained two ulcers, one two inches in length, beginning just on the distal side of the pyloric ring, and the other, which was partly cicatrised, three-quarters of an inch from the valve. (Perry and Shaw, Case 149.)

CASE II.—Granular kidneys; ulcer of the duodenum opening the gastro-duodenal artery and common bile-duct: Thomas M—, æt. forty-eight, was admitted under Dr. Wilks for persistent abdominal pain of five months' duration. Eleven years previously he had had pain in the abdomen, which was severe and lasted several weeks, and he had had two or three attacks since that time. He was a plumber and painter, and there was a lead ring on his gums. There was slight jaundice. Twenty-eight days after his admission he was suddenly seized with great pain in the right hypochondrium. He became pale and collapsed, and subsequently passed black stools. He then sank into a drowsy condition, and died four days later. At the autopsy urate of soda was found in the joints, the kidneys were granular, and the left ventricle of the heart was hypertrophied. The cardiac muscle showed extensive fatty (Tabby) degeneration. Immediately below the pyloric ring the duodenum presented a somewhat quadrilateral shaped ulcer with thick indurated edges and a considerably depressed base. The floor of the ulcer was formed by the upper edge of the pancreas, and the portal fissure, which contained a considerable excess of fibrous tissue. Close to the pyloric ring was an aperture which opened into the gastro-duodenal artery, and to the right of this was a very similar elongated aperture, from which bile flowed freely on squeezing the gall-bladder. It led into the common duct about one inch from its termination. The hepatic duct in the portal fissure was considerably dilated and its walls were thick, but there was no obstruction to the exit of the bile then present. The duodenum contained bilious contents. Throughout the intestine was some jelly-like mucus, but only in the splenic flexure of the colon was there any blood. (Perry and Shaw, Case 150.)

CASE 12.—Ulceration of the duodenum; interstitial nephritis: George B——, æt. thirty-six, was admitted under Dr. Wilks with albuminuria and excessive diarrhœa. His illness was stated to have commenced two months before his admission. On the day after his admission he passed some blood, and became delirious, with a subnormal temperature. He died three days after admission, and at the autopsy his kidneys were found to show an extreme degree of interstitial nephritis and the left ventricle of the heart was hypertrophied. The stomach was practically healthy, as was also the upper half of the duodenum; below this there was extensive ragged ulceration all around the bowel, the mucous surface having entirely disappeared in parts, leaving a finely flocculated surface behind. The ulcers appeared to commence at the angle of reflection of the valvulæ conniventes, and in many places the larger valvulæ overlapped and hid them. There was a notable absence of any thickening of the edge of the ulcers, but much dark, slaty pigment in the submucous tissue, and also in the mucous membrane itself, where it remained. The ulcerated state extended a short way into the jejunum. Similar ulcerated areas were found in other parts of the small and large intestines, the affection of the latter being less severe than of the former. (Perry and Shaw, Case 151.)

CASE 13.—Acute upon chronic nephritis; ulcers of the duodenum: Arthur M——, æt. forty-two, was admitted under Dr. Moxon with vomiting, abdominal pain, and albuminuria. Fourteen days after admission he suffered from diarrhœa, and passed half a pint of blood by the rectum. He was found to have a fistula and a few hæmorrhoids; the former was operated upon, and no blood was passed in the motions afterwards. Anasarca supervened, the vomiting persisted, the urine contained blood-corpuscles and epithelial casts, he became delirious, and died comatose about two months after his admission. At the autopsy the lungs were œdematous, the left ventricle hypertrophied, and the kidneys were found in a condition of acute nephritis, weighing $17\frac{1}{2}$ ounces. In the abdomen about an inch beyond the pylorus was situated an ulcer of about a square inch in area, with an irregular, slightly raised edge and a base formed by the

pancreas. Towards the stomach the edge was much undermined, but there was no perforation into the peritoneal cavity. Opposite this ulcer was another round, punched-out ulcer, the size of a sixpenny-piece, which had perforated and reached the under surface of the gall-bladder, which formed the floor of the ulcer. The solitary follicles of the small intestine were enlarged. There was a small pedunculated polypus in the sigmoid flexure of the colon. (Perry and Shaw, Case 152.)

CASE 14.—Calculus vesicæ; tubal nephritis; chronic ulcer of the duodenum, practically healed: George K—, æt. sixty-two, was admitted under Mr. Bryant with symptoms of stone, from which he had suffered for eight years. Lithotomy was performed, and two large stones were removed from the bladder. He became delirious and died two days later. At the autopsy the kidneys showed tubal nephritis, and in the duodenum was a chronic ulcer just beyond the pylorus, with a linear cicatrix running from it. (Perry and Shaw, Case 153.)

CASE 15.—Tubal nephritis; recent and healed ulcers of the duodenum: John L—, æt. seventeen, was admitted under Dr. Pye-Smith for dropsy, from which he had suffered for nine weeks. On admission the urine was found to contain blood, albumen, and casts. The patient died three months after admission, and at the autopsy the kidneys were seen to be in a condition of chronic tubal nephritis. "One and a half inches beyond the pylorus in the first part of the duodenum there was an oval ulcer measuring one and a half inches by three-quarters of an inch, the longer diameter of which was directed across the bowel. The edges of the ulcer were irregular and undermined, and its base was ragged and sloughing. The duodenum was not unduly adherent to the neighbouring tissues. Close to the recent ulcer there were two healed ulcers." (Perry and Shaw, Case 154.)

CASE 16.—Granular kidneys; perforating ulcers of the duodenum: A male, whose age is not given, but who appears to have been about forty, entered a public-house at twelve o'clock, and was supplied with a glass of beer and porter mixed. He sat down and took up the newspaper, but soon

complained of feeling unwell, and placed his hand over the epigastric region, where he said he had pain. He sat there for some time, and at half past one was noticed asleep, as some thought; but as he continued so, and looked pale, an attempt was made to wake him, when he was found to be dead. It appeared that he had had slight abdominal pain the previous night, and severe pain at eight o'clock in the morning, for which he took a little brandy. At the autopsy the abdominal cavity was found to contain a quantity of darkish brown liquid devoid of any particular odour, but having a greasy appearance on its surface and an acid reaction. Half an inch from the pylorus on the upper and outer side of the first portion of the duodenum there was found a large, oval-shaped opening, half an inch long and of nearly the same width. There was reddening and injection of the peritoneum, but no lymph was effused. Seen from the inside of the duodenum, the ulcer was slightly funnel-shaped, and the edges were thickened and hard. The upper border of the ulcer was not more than a quarter of an inch from the pylorus, which was quite healthy. The mucous membrane lining the lower portion of the duodenum was of a deepish red colour. All the other intestines were healthy. The mucous membrane of the stomach was reddened, but free from ulceration. The liver was fatty and the kidneys were slightly granular. The heart appears to have been normal, except for slight atheroma of the mitral valve. The brain was healthy. The case is recorded by Mr. J. S. Fletcher in the "Association Medical Journal," 1854, p. 735. (Perry and Shaw, Case 155.)

CASE 17.—Granular kidneys; perforating ulcer of the duodenum: G. S.—, a large robust man, æt. sixty, was admitted into the Cholera Wards of the London Hospital in 1867 suffering with severe pain in the right side of the abdomen, vomiting, feeble pulse, and cold extremities. He had been at work as a carman till within an hour of his admission, and it was whilst at work that he was seized with the severe abdominal pain mentioned above. For the first twenty-four hours he was supposed to be suffering from colic, and he died with evident signs of peritonitis about

thirty-six hours after his admission. His wife was certain that he had made no complaint of ill health, except that for a few weeks he had experienced a sense of weight after taking food. At the autopsy the peritoneal cavity contained lymph and a large quantity of thick yellow fluid, on the surface of which was a fatty-looking matter. (The patient had taken castor oil in the hospital.) In the duodenum about three lines from the pylorus was an opening about the size of a fourpenny-piece, having a thin, well-defined margin and surrounded by a circle of thickened tissue. The gastrointestinal mucous membrane was otherwise healthy. Extensive granular degeneration of both kidneys was present, and the heart weighed 18 ounces. (Perry and Shaw, Case 156.)

CASE 18.—Granular kidneys; perforating ulcer of the duodenum: Henry H—, æt. fifty-six, a painter, was admitted into St. George's Hospital under Dr. Wadham suffering from severe abdominal pain. He had a hernia which had come down, and which he was unable to return. Reduction was easily effected, but as the pain continued he was ordered a dose of castor oil and laudanum and sent to bed. In the afternoon he was found to have a well-marked blue line on the gums, and as there was a history of three previous attacks of severe abdominal pain, lead colic was diagnosed. He died fourteen hours after his admission, and at the autopsy Dr. Whipham found evidence of recent peritonitis, the small intestines being matted together by soft lymph. On the anterior surface of the first portion of the duodenum just beyond the pylorus there was a small perforation, the size of a pea, with clearly cut edges. This was caused by a small ulcer, the edges of which were not thickened. The mucous and muscular coats were only slightly more destroyed than the serous. No other ulcer was found. The kidneys were granular, the cortex diminished, and the capsules adherent. (Perry and Shaw, Case 157.)

CASE 19.—Granular kidneys; contracting ulcer of duodenum; hæmorrhage: John H—, æt. sixty-three, was admitted to the Westminster Hospital under Dr. Sturges for collapse and severe epigastric pain. He slowly recovered from his collapse, but presently vomited a pint of blood,

became comatose, and died about an hour later. Two days before admission, whilst at work, he was seized with severe epigastric pain and faintness. He recovered so far as to resume his occupation as a blacksmith, but the pains and faintness thereupon recurring, he was sent into the hospital. At the autopsy the stomach was very large and distended with about two pints of black, clotted blood. The first part of the duodenum was dilated, resembling a small second stomach, and in it was a punched-out ulcer about the size of a florin, its base partly formed by the pancreas. In the floor was a longitudinal ulcerated slit about a quarter of an inch long which opened the pancreatico-duodenal artery. There was fluid blood in the œsophagus and intestines. The kidneys were granular, the heart hypertrophied, and there was urate of soda in the joints. There was also bronchitis and emphysema. The case is related by Dr. Hebb. (Perry and Shaw, Case 158.)

CASE 20.—Ulcer of the duodenum associated with disease of the kidneys. Man, aged fifty-six. Suffered for some time from slight hæmorrhage from the bowels, and vomited black blood on several occasions. While at work fainted, and was taken to hospital in a state of collapse. The following day he vomited 20 ounces of bright blood and complained of pain in the epigastrium; he died the same night. At the post-mortem the stomach contained a considerable quantity of fluid and clotted blood. A cicatrix about the size of half a crown was found in the duodenum, and was divided into two by a cut extending from the lesser curvature of the stomach. At about the centre was a clot of blood blocking the opening into a larger artery. The intestine contained blood. The kidneys were large and cystic and contained encapsulated masses of apparently new growth. (Haldane, "Edin. Med. Town.," 1861-62, Series 41.)

There are two specimens of uræmic ulceration of the duodenum in the Museum of St. George's Hospital. The medical registrar has kindly allowed me to take the following notes from the post-mortem records:

CASE 21.—F. B., female, aged seventy-four. Admitted October 26, 1904, under the care of Dr. Ewart, for a failing heart. There was much œdema of the lower extremities and the abdomen contained a large quantity of fluid. Both kidneys were granular, and the duodenum contained in its first part nine irregular shaped ulcers, with deep black bases. No other ulcers were present in the intestinal tract. (Specimen 90F.) (See Fig. 13.)

CASE 22.—R. B., male, æt. forty-eight, admitted November 7, 1904, under Dr. Penrose. A very muscular, tall man, admitted with marked œdema of both lower extremities. For sixteen years has passed small calculi in the urine. Died from failure of the right heart twelve days after admission. At the post-mortem the following conditions were found:

Kidneys: Right, 9 ounces; left, 3 ounces. The right is large. The left is small, with adherent capsules, and the fat around is firmly adherent to both. On section, in the lower pole of the right is a fairly large renal calculus in three pieces. The calculus is black in color and surrounded by phosphates. In the left there are two minute similar calculi. The pelves of both kidneys are inflamed, but not particularly dilated. Both ureters are dilated from end to end and firmly adherent to the surrounding fat. Their walls are thickened and their lining membranes are infected and inflamed. Half-way down the right two portions of calculus are impacted.

Ureters: The orifices of the ureters into the bladder are not noticeably dilated. The left opening is, however, larger than the right.

Bladder: The vesical lining membrane is generally infected and swollen from inflammation. This lesion, however, is not advanced.

Prostate: Normal.

Alimentary canal: The stomach and intestines are much congested, the former showing chronic gastritis as well. In the duodenum, from the pylorus to just above the bile papilla, are nine ulcerated patches. These patches are scattered about, the largest being over one inch long; all are irregular in outline, with swollen, *not* undermined

edges, and smooth floors; the floor in every case is a deep greyish-black in colour. No other ulcers are seen in the intestinal tract, the colon in particular being normal. The small gut as a whole, in addition to being congested, is œdematous and contains altered blood. (Specimen 90E.) (Fig. 11.)

CASE 23.—J. H., aged fifty-six, labourer, was admitted under Dr. Saintsbury on November 19, 1891, in a collapsed condition, he having fainted while at his work. He had fainted also the day previously, and for some time had been subject to slight attacks of hæmorrhage from the bowels and vomiting. There was some alcoholic history. On day of admission there was a hæmatemesis of 5 ounces, and recurrence of fainting attack. Two days after admission patient had severe epigastric pain, and a hæmatemesis of 20 ounces, after which he became very much collapsed, and notwithstanding treatment died two hours later (10.15 P. M., November 21, 1891). Post-mortem examination found a duodenal ulcer of the size of a florin, which on subsequent microscopic examination was found to be of a simple nature. And there was cystic disease of both kidneys. (From Royal Free Hospital, London. Notes kindly supplied by Dr. Adeline Roberts. Specimen xv, 6a, 581, in Royal Free Hospital Museum.)

CASE 24.—W. Y., aged seventy-four, cab driver, admitted under Mr. Roughton, November 26, 1907, with history of six months alternating constipation and diarrhœa. Abdominal pain two days. Vomited once. No fæces or flatus passed for about twenty-four hours. Pulse 120. Abdomen distended, very little movement. Signs of free fluid. Patient was operated on at once. Turbid fluid and gas found. Abdomen drained. Patient died two hours later. Post-mortem, a perforated duodenal ulcer found. General peritonitis. Kidneys cystic. (From notes kindly supplied by Dr. Adeline Roberts. Royal Free Hospital Museum.)

CASE 25.—P. S.—, aged twenty-five. Complained for two months of paroxysms of dyspnœa, occasional mistiness of vision, digestive troubles, and frequent vomiting. There was some emphysema of the lungs and the heart sounds were

muffled. The liver edge was slightly below the costal margin. There was no ascites, but some œdema of the legs. The urine contained albumen and no sugar. The patient has a bronchitic crisis, but recovered under treatment. Two days before death the patient developed diarrhœa, for which rectal examination revealed no cause; death from uræmic coma. At the autopsy there were cerebral softening, œdema and emphysema of the lungs, atheroma of the arteries, hypertrophy of the left ventricle. First part of the small intestine contained bile and blood, mucous membrane was congested and coated with viscid mucus. The colon was filled with black blood. In the first part of the duodenum 2 cm. from the pylorus was a punched-out ulcer, around which mucous membrane was inflamed. The size of the ulcer was about 1.5 cm. There was no thickening or exudation on the peritoneal surface of the duodenum. There was a second small ulcer, about $\frac{1}{2}$ cm. in diameter, quite shallow, in the second part of the duodenum. At a point about 8 cm. below the ampulla of Vater were two still smaller ulcerations, clean-cut, circular, and showing no hæmorrhage. Kidneys weighed, one 28 and one 30 grams, were granular on the surface, and cirrhotic. Histological examination of the large ulcer shewed normal peritoneum, epithelium thickened at the edge of the ulcer, with some necrosis. The floor of the ulcer was formed of fibrous tissue, more cellular near the intestinal surface. There was some interstitial hæmorrhage. No muscular tissue was seen at the level of the ulcer. Kidneys showed typical interstitial nephritis. (Barie and Delaunay, "Bull. Soc. Méd. des Hôpitaux," 1903, xx, 45.)

CASE 26.—A specimen in the Museum of the Royal College of Surgeons of England. No. 2430a. The first portion of the duodenum with the adjacent end of the stomach laid open to display an oblong ulcer in the former. It is situated an inch beyond the pylorus, and measures nearly an inch in its chief diameter, which is transverse. The margin of the ulcer is thickened and undermined, while its base is loosely attached to the subjacent head of the pancreas. A vertical section shows that the common bile-duct is in close relation with the floor of the ulcer. A blue rod marks the course of

the duct. Close to the pyloric ring the depressed scars of two healed duodenal ulcers may be seen. From a boy aged seventeen, who was admitted for nephritis and anasarca. He died of uræmia five months after the onset of his illness, having previously enjoyed very good health. (Presented by Guy's Hospital, 1893.)

CASE 27.—D——, December 3, 1903; female, aged thirty-eight. Has had symptoms on and off for ten years; worse of late. Vomiting, pain in left side, and nausea. The pain is always present, but worse after food. Vomiting makes the pain worse. The patient says she has vomited a little blood sometimes. Bowels constipated. Loss of weight. Now 5 st. 4¼ lbs. P. C.: Frequent vomiting. Tenderness over left hypochondrium. Free HCl in stomach contents after test meals. Urine acid, specific gravity 1018, albumen. No sugar. At the operation nothing abnormal found. No scars. Posterior gastro-enterostomy. The patient died December 8th. She was sent by Dr. Woodcock, Leeds. The patient developed hæmaturia and uræmic symptoms and died. Post-mortem report: "No peritonitis, union quite sound. Kidneys are small and present cysts on their surfaces. The capsule does not strip readily, being adherent in some places. On passing the finger over the surface of the kidney, a distinctly granular impression is imparted to it. The cortex is extremely narrow, almost all the kidney substance being made up of the pyramids. The pelves appear normal." There was ulceration without induration in the duodenum, probably uræmic in origin.

CHAPTER IV

TUBERCULOUS ULCERATION OF THE DUODENUM

IN cases of miliary tuberculosis scattered deposits may be found in the duodenum, as elsewhere in the body, and in some cases small superficial erosions of the mucous membrane, single or multiple, are present. They are of



FIG. 17.—TUBERCULOUS ULCERATION.

A portion of the duodenum showing tuberculous ulceration. The ulcer is irregularly oval, one inch long by one-fourth inch broad, with the long axis running transversely to the gut. The base is uneven and the peritoneal surface at that part is infiltrated with small nodules. (London Hospital Museum, Specimen No. 1154.)

no clinical significance, being merely a part of that universal deposit of tubercle which is found in the terminal stages of thoracic or abdominal phthisis. But there are cases, very few in number, in which the symp-

toms of chronic ulcer of the duodenum call for an operation, when the lesion disclosed in the intestine is plainly seen to be tuberculous in character. Two well-marked and indisputable cases have occurred in my own practice,

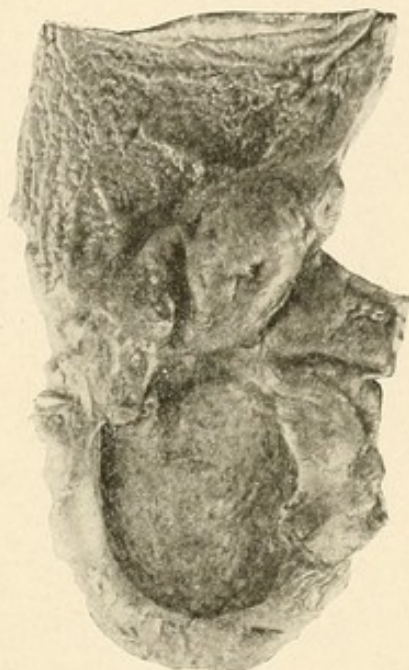

FIG. 18.—TUBERCULOUS ULCER OF THE DUODENUM.

Close to the pyloric valve is an irregular, circular ulcer, with raised, puckered edges, the size of a crown piece. All the coats of the bowel have been eaten away and the floor of the ulcer is formed by the pancreas. An artery of considerable size crosses it for a space of three-fourths of an inch; other smaller arteries with plugged orifices are seen to form little prominences.

From a man, aged forty-nine, who died in the hospital May 20, 1868. For two years previously he had been liable to repeated attacks of hæmatemesis and had suffered from constant pain below the right ribs. He died with rapid development of tubercle in his lungs. Reported by Dr. Murchison in "Pathological Societies Transactions," vol. xx, p. 174. (Middlesex Hospital Museum, No. 1428.)

and there are three others in which there was a probability that the ulcer was tuberculous. The two cases illustrate very different types. In the one type the patient is obviously the host of a tuberculous deposit;



FIG. 19.—TUBERCULOUS ULCERS OF THE DUODENUM.

Three circular ulcers are present in the specimen. Two of these have led to perforation, the peritoneum over one of them being considerably thickened. The base of the third ulcer is formed by the muscular coat. The edges of the ulcers are bevelled and shelving and appear as if punched-out. They are considerably indurated.

C. N., aged thirty-one, was admitted into the hospital under Dr. Sturges, on October 2, 1884. The patient was suffering from pulmonary phthisis, of which he died in a few days. At the post-mortem examination the abdominal cavity was found filled with a puriform fluid and there was acute patchy peritonitis. The stomach was in a condition of acute catarrh. There was a superficial ulcer of the mucous membrane of the cæcum. The abdominal glands were enlarged, especially near the duodenum. Both lungs were riddled with cavities and microscopic examination demonstrated the presence of the bacillus tuberculosis. (Westminster Hospital Museum, No. 454.)

he has the hectic flush, the lean and shrunken features, the pinched appearance of the phthisical patient. An examination of the chest reveals the evidences, acute or ancient, of consumption. The abdomen shews a dilated and perhaps hypertrophied stomach and waves of con-



FIG. 20.—TUBERCULOUS ULCERATION OF THE DUODENUM.

Pylorus and upper portion of the duodenum shewing two ulcers. About the centre of the specimen is a small, oval ulcer with thickened, indurated edges. Its long axis is directed across the gut. Hæmorrhage has taken place into its base. A similar smaller ulcer is seen between it and the pylorus. The large and small intestines were both the seat of extensive ulceration. From a man *æt.* twenty, who died of pulmonary phthisis. (Royal Free Hospital, No. 87.)

traction are seen on gentle inflation of the stomach. A swelling in or near the pylorus may be present, or a mass may be felt in the cæcum. An enquiry into the anamnesis elicits a history of long-standing "dyspepsia," and the symptoms of duodenal ulcer may be clearly

described. In such cases, especially if tuberculous deposits in the chest are absent or quiescent, the patient's wasted condition and ill health may seem to be largely dependent upon the mechanical obstruction at the

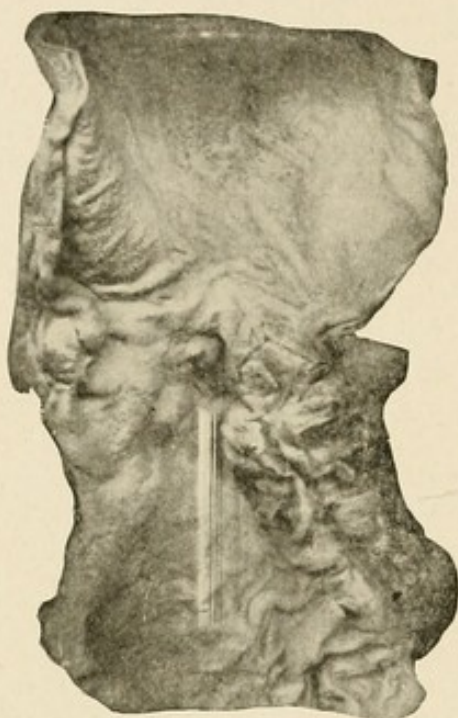

FIG. 21.—TUBERCULOUS ULCER OF THE DUODENUM.

Immediately beyond the pylorus are four irregularly shaped ulcers with raised, indurated margins and deeply excavated bases. One of them has perforated the intestine, with the exception of the peritoneal coat. The pancreas is firmly fixed to the gut by strong adhesions.

From a man aged forty-nine, who died of pulmonary mischief of long standing. No symptoms pointing to the condition of the duodenum were noticed during the time he was in the hospital.

(See account of case by Dr. Moore, in the "Pathological Societies Transactions," vol. xxxiv. St. Barth. Hosp. Museum, No. 1966a.)

outlet of the stomach, and surgical treatment may be considered necessary. In case 112 in my own series we knew of the existence of old and not very active tubercle in the chest, and it was probable that tuberculous peri-

tonitis beginning in the appendix, or possibly in a duodenal ulcer, was present. Yet because of the severe,




FIG. 22.—TUBERCULOUS ULCERATION OF THE DUODENUM.

A portion of the first part of a duodenum, showing a small, rounded ulcer with thickened edges, situated half an inch from the pylorus. The base of the ulcer is formed by the muscular coat of the bowel and miliary tubercles are visible beneath the peritoneum. Below is mounted a small piece of the ileum, exhibiting a well-marked tuberculous ulcer.

Stephen W., æt. twenty-six, was admitted under Dr. Bright in 1837 for chronic phthisis. At the autopsy there were numerous ulcers throughout the intestines and the mesenteric glands were caseous. (Guy's Hosp. Museum, No. 747.)

wearing pain of indigestion and the consequent malnutrition I thought it right to advise operation and to perform gastro-enterostomy for a large tuberculous

mass in the duodenum, which had started in a chronic ulcer, and had caused a high degree of stenosis.

In the second type, well illustrated by a case operated upon in May, 1909, and not included therefore in the series set forth in detail elsewhere, the patient gives a clear history of duodenal ulcer, and at the operation it is found that the ulcer is plainly tuberculous, and that scattered deposits of tubercle are found in all the parts around the ulcer. The following are the notes of my case:

G. B., male, aged forty-nine, sent by Dr. Blair, Helmsley. The patient has suffered for eight to ten years from indigestion. The attacks came on every few months, and were always worse between November and March. During the last winter has suffered more than ever. Pain usually comes two hours after a meal; but if heavy food is taken, pain comes in one to one and a half hours. It is felt in the epigastric and right hypogastric regions. The pain usually lasts until the next meal or until something is taken; brandy and water, rum, or tea and bread and butter give most relief. On April 3d last, two hours after tea, had a sudden very severe attack of pain, which prostrated him. He vomited several times. The pain lasted for a fortnight and all the upper part of the body was very tender. Since then has lost 7 lbs. in weight, and has been unable to take any food without pain coming on in a few minutes. Operation May 10, 1909. A large duodenal ulcer was found adherent to the under surface of the liver; it had evidently undergone a "subacute" perforation. Scattered all around it, more densely in the edges, were a number of typical miliary tubercles (one was excised and examined). The ulcer felt very hard and indurated and its margin was thick and raised and contained many tubercular nodules. The small intestine and appendix were examined and no other tuberculous deposit was found. The patient made a good recovery. A

week after operation he was thoroughly examined, but no evidence of tuberculosis could be discovered.

It is, of course, well known that tuberculous ulcers are found most commonly in the lower end of the ileum, and that they become less frequent higher in the intestine; in the duodenum they are certainly rare. In the vast majority of cases there can be no doubt that the tuberculous ulcer is secondary to an infection in the lungs. Sir Andrew Clark and Dr. Murchison, however, both consider that in cases reported by them the ulcer was primary, and had opened the portals of infection for a generalised tuberculosis. In one case in my series (No. 127), not recognized at the time as being tuberculous, phthisis developed subsequently.

The following is a complete list of all recorded cases of tuberculous ulcer of the duodenum:

DUODENAL ULCERS ASSOCIATED WITH TUBERCULOSIS

CASE 1.—Tuberculous ulcer of the duodenum: James N—— was admitted under Dr. Bright in 1827 for phthisis, from which he died. At the autopsy a small ulcer was found at the commencement of the duodenum, and there were many of larger size pretty thickly sprinkled throughout both the small and large intestines. Their edges were irregular and slightly elevated, and the ulceration “appeared to attend on the softening of tuberculous material.” (Perry and Shaw, Case 62.)

CASE 2.—Tuberculous ulcer of the duodenum: Stephen W——, æt. twenty-six, was admitted under Dr. Bright in 1837 for chronic phthisis. At the autopsy there were numerous ulcers throughout the intestine and the mesenteric glands were caseous. In the first part of the duodenum, half an inch from the pylorus, was a small rounded ulcer with thickened edges; the base of the ulcer was formed by the

muscular coat of the bowel, and miliary tubercles were visible beneath its serous investment. (Perry and Shaw, Case 63.)

CASE 3.—Tuberculous ulcer of stomach and duodenum. Duodenum contained a small ulcer near the pylorus, associated with similar ulcers in the jejunum and stomach, in a case of phthisis. (Perry and Shaw, Case 64.)

CASE 4.—Tuberculous ulceration of the duodenum; *ascaris lumbricoides*: Mary G—, æt. three, was admitted under Dr. Hughes for diarrhœa of three months' duration. Occasionally there was blood in the motions. Various remedies for the diarrhœa were tried, but the child became emaciated and died seven weeks after her admission. At the autopsy there were numerous tubercles in the lung and caseous abscesses in the liver. The duodenum contained a lumbricus teres, and the lower portion displayed some distinct ulceration. The cæcum and colon were ulcerated and the mesenteric glands caseous. (Perry and Shaw, Case 66.)

CASE 5.—Tuberculous ulcer of duodenum: Louisa C—, æt. thirty, was admitted under Dr. Pavy for phthisis, from which she died. Shortly after her admission she became maniacal and had epileptic seizures. At the autopsy an exostosis was found growing from the inner surface of the frontal bone on the right side, pressing upon and indenting the second frontal convolution. There were numerous tuberculous vomicæ in the lungs and a few ulcers in the duodenum. The jejunum, ileum, and cæcum were also affected by ulceration. The mesenteric glands were large and caseous. (Perry and Shaw, Case 67.)

CASE 6.—Tuberculous ulcer of the duodenum: John R—, æt. eleven, was admitted under Dr. Wilks with signs of phthisis. Fifteen weeks later he died, and at the autopsy a caseous mass was found in the brain and the lungs contained numerous vomicæ and tubercles. The duodenum as well as the small and large intestines presented numerous ulcers, varying in size from a quarter of an inch in diameter. There were caseous mesenteric glands. (Perry and Shaw, Case 68.)

CASE 7.—Tuberculous ulcer of duodenum: Peter S—, æt. thirty-six, was admitted under Dr. Wilks with signs of phthisis, from which he died. At the autopsy tuberculous

ulcers were found in the duodenum, jejunum, ileum, and cæcum, and a few in the colon. (Perry and Shaw, Case 69.)

CASE 8.—Phthisis; healed ulcer in duodenum: William J——, æt. forty-four, was admitted under Dr. Cholmeley in 1831 for phthisis, from which he died. At the autopsy numerous vomicæ were found in the lungs, and there were ulcers, probably tuberculous, in the small and large intestines. In the duodenum near the entrance of the ducts, which were healthy, there was a slight but decided contraction puckering the mucous membrane, and arising from hardening of the cellular membrane external to the gut, which very firmly united the pancreas to the same part. The pancreas was healthy. (Perry and Shaw, Case 73.)

CASE 9.—Phthisis; perforating ulcer of the duodenum: George E——, æt. thirty, was admitted into Guy's Hospital, having four months previously brought up blood. Just before admission, whilst apparently in good health, he was suddenly seized with abdominal pain and collapse. Subsequently symptoms of peritonitis supervened, and he died fifty-six hours from the onset of his illness. At the autopsy there was acute peritonitis, and castor oil was found floating in the abdominal cavity. In the first part of the duodenum, an inch from the pylorus, was an ulcer of the size of a shilling piece, having in its base a circular opening one-third of an inch in diameter. There were "aphthous ulcers" in the stomach, two small ones being covered with coagula. At the apex of the left lung was a small phthisical cavity. The case is quoted by Dr. Habershon in his work on "Diseases of the Abdomen." (Perry and Shaw, Case 74.)

CASE 10.—Ulcer of duodenum(?), tuberculous: James M——, æt. sixty-four, was admitted under Dr. Hughes in a prostrate and anæmic condition, and died about twelve weeks afterwards. For many years he had been exceedingly intemperate in his habits. For a short time before his death he suffered from cough, with dullness on the left side of the chest. Numerous vomicæ were found in the lungs. The stomach was large, and near the pylorus it contained a small excavated ulcer about the size and shape of a fourpenny-piece. There was no external thickening. There was a

similar ulcer in the duodenum near the pylorus. It was rather larger than that in the stomach. The stomach was submitted to microscopic examination in 1891, and showed a condition of acute gastritis with superficial ulceration. In the ileum the solitary and agminated glands were enlarged, and some were ulcerated. There were numerous ulcers in the cæcum and the colon. These were presumably tuberculous. (Perry and Shaw, Case 75.)

CASE 11.—Peptic ulcer in tuberculosis: John E——, æt. twenty-six, was admitted under Dr. Wilks with signs of tuberculous peritonitis and laryngitis. Two days later he died, and at the autopsy the left kidney and ureter, the prostate and testes, were tuberculous. There was much tubercle in the peritoneum and in the lungs, and the epiglottis was ulcerated. The duodenum contained a large quadrilateral ulcer, just beyond the pylorus, three-quarters of an inch across. The rest of the intestine was healthy. (Perry and Shaw, No. 76.)

CASE 12.—Phthisis; ulcer of duodenum; hæmorrhage: John K——, æt. forty-four, was admitted into St. Bartholomew's Hospital under Dr. Roupell, having for the last three months suffered from hæmorrhage from the bowels, and having vomited blood occasionally in small quantities. He died twelve days after admission, and at the autopsy the stomach and the rest of the alimentary canal were quite healthy, except that just beyond the pylorus was a large excavated ulcer an inch and a half in diameter, the base of which was formed by the pancreas. At the time of the inspection no blood was found in the intestines, nor was it ascertained from what vessel the hæmorrhage had proceeded. The patient had passed very little blood during his stay in the hospital. There was a cavity in the right apex and tubercle in both lungs. (Perry and Shaw, Case 77.)

CASE 13.—Tuberculous ulcer of duodenum; perforation: A lad, æt. eighteen, was admitted into the London Hospital under Sir Andrew Clark in a state of collapse, and was thought to be suffering from retention of urine. Two days before admission he had played in a cricket match, and on his return home felt sick, feverish, and otherwise uncomfortable.

Next day he was better, and after his supper took a short walk without fatigue. On the morning of admission he was seriously ill, vomited frequently, and was seen by a doctor, who found that he had passed no urine and sent him into the hospital. On admission the lad complained of nausea with occasional vomiting, pain in the right side of the abdomen, and shortness of breath. Pressure in the right hypochondrium increased the abdominal pain. The bladder was found to be empty. He was ordered some brandy mixture and placed in a warm bath. After fifteen minutes he was removed from the bath, and whilst being dried by the porter suddenly fainted and died. At the autopsy the peritoneal cavity was found to contain a small quantity of grumous fluid, and there was evidence of recent peritonitis. In the duodenum, about an inch and a half from the pylorus, was a small ulcer about the size of a sixpence, with thick, red, rounded margins, and a whitish granular base, in which there was a minute opening leading into the peritoneal cavity. The whole mucous membrane of the duodenum was greatly congested. Brunner's glands were enlarged, and a few of them, stuffed with a cheesy-looking compound, were ulcerated at their most projecting parts. No other disease was found in the abdominal organs. There was an ante-mortem thrombus in the pulmonary artery and yellow tubercle in the apex of the right lung. Sir Andrew Clark says: "To me the order of events seems to have been as follows: out of general ill-health there arose in the first place follicular disease, followed by ulceration of the duodenum; and in the second, the tubercular deposits, most probably of embolic origin, in the lungs." (See "Cases of Duodenal Perforation," by Sir Andrew Clark, in the "British Medical Journal," 1867, vol. i, p. 687.) (Perry and Shaw, Case 78.)

CASE 14.—Duodenal ulcer in phthisis: Thomas P——, æt. forty-nine, was admitted under Dr. Murchison into the Middlesex Hospital for pain in the right hypochondriac region, and occasional severe attacks of hæmatemesis, eight or nine of such attacks having occurred in the space of two years. After admission symptoms of phthisis supervened

and he died five weeks later. At the autopsy an ulcer was found in the duodenum, the size of a half-crown, situated immediately beyond the pylorus; the base was formed by the exposed pancreas and the edges were thickened and indurated. The lymphatic glands in the neighbourhood of this ulcer were enlarged, some of them to the size of a pigeon's egg, and there was tuberculous excavation of the apex of the right lung, and enlargement of the bronchial glands. Dr. Murchison thought that this was a case of the development of tubercle as the result of inoculation through a simple ulcer. (Perry and Shaw, Case 79.)

CASE 15.—Phthisis; perforating ulcer of the duodenum: George G—, æt. fifty-six, was admitted into St. George's Hospital under Dr. Barclay with intense abdominal pain, which was much increased on pressure, and was referred to the lower part of the abdomen, which was flat and very hard. He stated that with the exception of epigastric pain, worse after food, from which he had suffered for the last three weeks, he had always had good health. The pain had not been very severe, and had not incapacitated him from work. On the day of admission he had taken bread and cheese for dinner in the middle of the day. The meal was followed by the usual slight epigastric pain, and he thought nothing of it. But a little before six o'clock, whilst walking in the park, he was suddenly attacked by extreme violent pain in the belly, and was at once brought to the hospital. Perforation being suspected, he was treated with opium, and everything was administered by the rectum. He died about thirty-six hours from the onset of symptoms, and at the autopsy Dr. Whipham found miliary tubercle, and excess of fibrous tissue at the apex of the right lung. There was atheroma with dilatation of the arch of the aorta. Turbid yellow fluid and much recent lymph were found in the peritoneum. In the first portion of the duodenum a little beyond the pylorus, and on the anterior surface, was a rounded perforation with clean-cut edges, a little larger than a pea. On laying open the gut this was found to have been caused by a small, thin-edged ulcer, the diameter of which was a

little greater than that of the perforation. No other ulcer existed. (Perry and Shaw, Case 80.)

CASE 16.—Phthisis; perforating ulcer of the duodenum: Dr. Hebb, in his paper on "Two cases of perforating ulcer of the duodenum," in the "Westminster Hospital Reports," vol. vii, p. 84, refers to the case of a male, *æt.* thirty-one, who was admitted under Dr. Sturges, and died next day from peritonitis. At the post-mortem examination a large perforating ulcer of the duodenum was found, but there was also a very advanced phthisis, "to which, had he not been carried off by the perforating ulcer, he must have succumbed very shortly." (Perry and Shaw, Case 81.)

CASE 17.—(The following case is No. 8 in Trier's monograph.) M., *æt.* fifty-one. Seven years' history of pain after food, coming on within three or four hours. Pain was to the right of the umbilicus and a little above. Had hæmatemesis once, severely. Bowels constipated. Attacks of this type would come on at intervals. Wasting marked. Skin yellowish and dark. Atrophic and wrinkled. Sclerotics dirty yellow. Thought to be typically cancerous in appearance, probably secondary to ulcer. Abdomen prominent at and below umbilicus. Visible peristalsis from left to right. A visible tumour appeared in epigastrium, not adherent to abdominal wall, 1 to 2 inches in circumference. There was tenderness here also. In November he died following a severe attack of hæmatemesis, with violent abdominal pain lasting two days. Post-mortem: Obsolete tubercles in both lung apices. Stomach much dilated, pylorus and first part of duodenum firmly fixed to pancreas, which was twice the normal size and very hard. No changes in stomach. In the duodenum, close to the pylorus, was a circular opening leading into a cavity the size of half a walnut, the bottom of the cavity being formed by the pancreas. The lumen here was $\frac{1}{3}$ of an inch and was filled in by a thrombus.

CASE 18.—(The following is case 38 in Krauss's monograph.) Duodenal ulcer (perforating) in case of tuberculosis of lungs and intestine. Case related to the author by Dr. Elsasser, of Stuttgart: Mr. R., bookkeeper, *æt.* fifty,

had suffered for some time from pulmonary and intestinal tuberculosis. A few weeks preceding death he experienced an uncomfortable sensation in the abdomen after taking small quantities of food and drink. The pain commenced in the stomach and spread over the whole abdomen, terminating in a colicky exacerbation. Had several attacks of intestinal hæmorrhage; much reduced by his illness; signs of a diffuse peritonitis commencing in the right iliac region supervened, which proved fatal in a few days. On section both lungs showed extensive caseation; cavity as large as a hen's egg in the right upper lobe. In the intestine there were four perforations, one in the cæcum as large as a dollar, two others in the ileum, all due to tuberculous ulceration. The fourth perforation was quite different from the others. It appeared, newly formed, situated in the duodenum about 1 inch below the pylorus. There was no swelling of the mucous membrane. The remainder of the duodenum was normal. The jejunum was also free from ulceration.

CASE 19.—M., aged thirty-three. Double pulmonary tuberculosis; hypertrophic cirrhosis with ascites. Digestion good. No abdominal pain. Discomfort and painful respiration owing to ascites and œdema. Post-mortem: Tuberculous cavities at both apices; double pleural effusion. Stomach normal. Peritoneum showed whitish granulations, disseminated especially over intestines and gastro-hepatic omentum. Mesenteric glands very large and indurated. Less than 1 cm. from the pylorus a duodenal ulcer—a large ulcer elongated in the long axis of the bowel. Below this several smaller ulcers; in all, there were seven ulcers in the first part of the duodenum. Perforation in the largest ulcer seemed imminent; the base being formed of serosa only. Four ulcers were found in the jejuno-ileum. (Claude, "Bull. Soc. Anat. de Paris," 1896, lxxi, 230.)

CASE 20.—A. R., male, æt. thirty-six. For five years had suffered from pain and vomiting after eating. Pain came soon after taking food, and on three occasions there were very severe attacks of abdominal cramp, "as if the intestines were twisted or knotted." Death occurred in collapse and delirium. At the post-mortem many tuberculous

ulcers were found in the duodenum and throughout the entire length of the small intestine. The lungs were infiltrated with tubercles and the mesenteric glands were cheesy. (Satterthwaite, "Med. Record," New York, 1900, lvii, 485.)

CASE 21.—G. H., male, aged twenty, admitted with late phthisis; had hectic and night-sweats and chronic diarrhoea, and died of gradual exhaustion. The bowel was studded with ulcers from the duodenum to the cæcum. (Satterthwaite, "Med. Rec.," N. Y., 1900, lvii, 485.)

CASES 22 and 23.—Recorded by Francine ("Amer. Jour. Med. Sci.," 1905, cxxix, 429). The ulcers were discovered at autopsy; few details are given.

CASE 24.—S. West ("Diseases of the Organs of Respiration," second edition, 1909, ii, 437) relates one case of phthisis in which two small ulcers were found in the duodenum; perforation of one of them had caused death.

CASE 25.—J. S., aged twenty years, a stone-grinder, who had a slight family history of phthisis. In childhood patient had hip-joint disease and enlarged glands in the neck, which suppurated. Suffered for some years from cough, shortness of breath, night-sweats, emaciation and hæmoptysis. Both lungs were extensively affected. The glands round the trachea were enlarged and cheesy. There was extensive ulceration of the intestine and one small ulcer in the larynx at the base of the left vocal cord. (From notes supplied by the Registrar, Royal Free Hospital, London.)

There are two specimens of tuberculous ulcer in the Museum of the Westminster Hospital:

CASE 26.—(Specimen 454.) C—, aged thirty-one, was admitted into the hospital under Dr. Sturges, on October 2, 1884. The patient was suffering from pulmonary phthisis, of which he died in a few days. At the post-mortem examination the abdominal cavity was found filled with a puriform fluid and there was acute patchy peritonitis. The stomach was in a condition of acute catarrh. There was a superficial ulcer of the mucous membrane of the ileo-cæcal valve, and acute inflammation of the mucous membrane of the cæcum.

The abdominal glands were enlarged, especially near the duodenum. Both lungs were riddled with cavities, and microscopic examination demonstrated the presence of the tubercle bacillus. In the duodenum were three circular ulcers. Two of these had led to perforation, the peritoneum over one of them being considerably thickened. The base of the third ulcer was formed by the muscular coat. The edges of the ulcers are beveled and shelving and appear as if punched out. They are considerably indurated.

CASE 27.—(Specimen 454a.) E. H., æt. twenty-nine, had been well until six months before admission, when she began to suffer with pain on defæcation; she attended at St. George's Hospital and was there operated upon for fistula. She was discharged before the wound healed and was advised to go to a warmer climate. The family history was phthisical, and when admitted to the Western Hospital, on July 9, 1894, the patient was suffering from active phthisis, and was too ill for operation, dying on July 27th. Post-mortem examination: All lymphatic glands were large, caseous, and tubercular. The lungs were the seat of vomicae and fibro-caseous tubercles. The gastric and intestinal mucosæ displayed tuberculous ulceration, and tubercle was also present in the liver, spleen, and kidneys. The gastric and duodenal mucosa were studded with small, punched-out, tuberculous ulcers, which are especially numerous towards the fundus. They vary in size from that of a pin's head to that of a three-penny piece.

CASES 28, 29, 30, 31, 32, 33.—The specimens of these cases are in the museums of the various London hospitals. Photographs are here reproduced.

CASE 34.—Preparation 1594, in the museum of the Royal College of Surgeons of Edinburgh, shews tuberculous ulcers in the duodenum, jejunum, and ileum.

CHAPTER V

MELÆNA NEONATORUM AND DUODENAL ULCER

HÆMORRHAGE from the alimentary tract of the newborn occurring as hæmatemesis or melæna would appear to be not very infrequent, if we are to judge from the reports of maternity hospitals at home and abroad. In a very small proportion of the fatal cases an examination of the parts reveals the presence of one or more ulcers in the duodenum. This may be the only part of the alimentary canal in which a lesion is recognisable, or there may be hæmorrhagic infarcts or ulcers in the stomach, small or large intestine. With regard to the frequency of melæna neonatorum the following statistics are given by Shukowsky ("Archiv. f. Kinderheilk.," 1907, xlv, 321): Rilliet published one case only; Baillard, 15; Henoeh in thirty-eight years saw 14 cases; Kling in 12,000 births observed 17 cases; Hecker, 8 in 4000; Silbermann, 37 in 29,333; Lederer, 8 cases; Carans, 1 in 1911; Hergott, 2 in 3000; Genrich, 1 in 2900; Spiegelberg, 1 in 2500. Taking these and other smaller figures, and including his own, he considers that melæna occurs in not more than 1 in 1000 live-births. In a very small proportion only of these is the hæmorrhage due to an ulcer of the duodenum.

A reference to the cases recorded below will show that in some instances hæmorrhage comes within a few

hours of birth and rapidly proves fatal, whereas in others the onset of copious bleeding may occur only after a tedious and wasting illness characterised by a marked anæmia. Helmholz ("Deut. med. Woch.," 1909, i, 534), in an excellent article, states his belief that duodenal ulcer in late infancy is by no means so infrequent as has been supposed; and that its discovery is

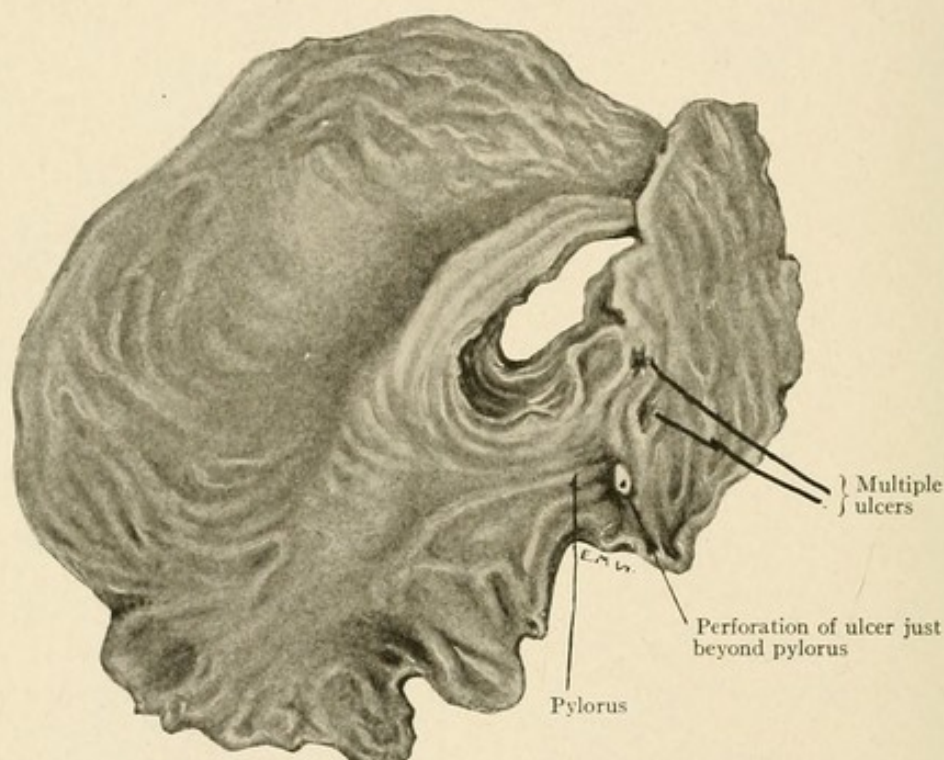


FIG. 23.—MULTIPLE ULCERS IN THE DUODENUM OF AN INFANT SIX WEEKS OLD. (Case 4 in Helmholz's list.)

so bound up with an antecedent wasting illness that some connexion must exist between them. In some of the earlier recorded cases there have been examples of extreme wasting, but this was held to be due to cicatricial changes in the ulcer causing duodenal obstruction and vomiting. Helmholz is of the opinion that the enfeebled wasting infant falls an easy victim to the disease; the

peptic ulcer of the duodenum being then developed more readily than in a healthy child. He then relates that in 16 cases of "Pädatrophie" coming to autopsy there were no less than 8 in which an ulcer was discovered. The cause of the onset of the lesion in early infancy has been much discussed. Landau ("Ueber melæna der Neugeborenen," etc., Breslau, 1874) believed that the incidence was due to thrombosis of the umbilical vein;

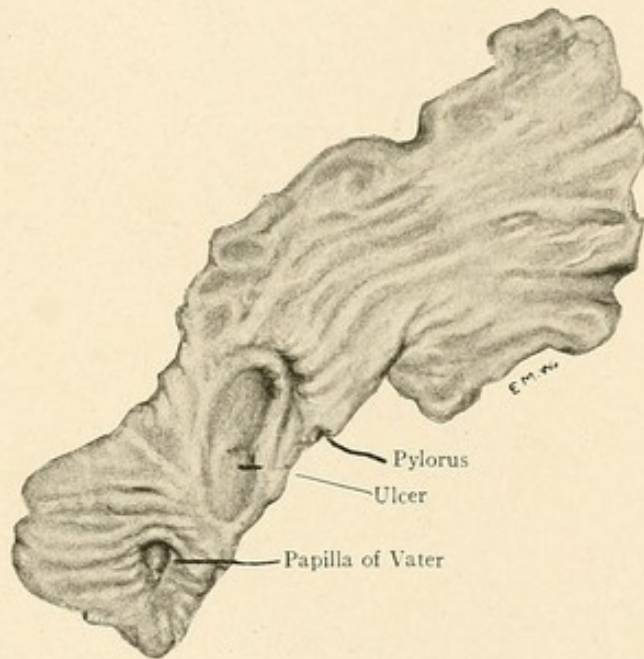


FIG. 24.—LARGE ULCER OF DUODENUM. (Case 7 in Helmholtz's list.)
The patient was four months old.

thrombi were carried thence into the general circulation, and were deposited in various organs. In the duodenum an infarct formed, and the removal of the dead area so resulting left an open ulcer in the bowel. With few exceptions this view has commended itself to later writers, and Helmholtz thus summarises the matter: "The typical duodenal ulcer came into being through a local necrosis of the intestinal wall which was caused

by a thrombosis of the vessels in the part affected. It was the digestive action of the gastric juice which caused the erosion of the dead area and the formation of the characteristic ulcer."

The ulcer is always found between the pylorus and the papilla of Vater, generally upon the upper and under wall of the first part. The ulcer may be single or there

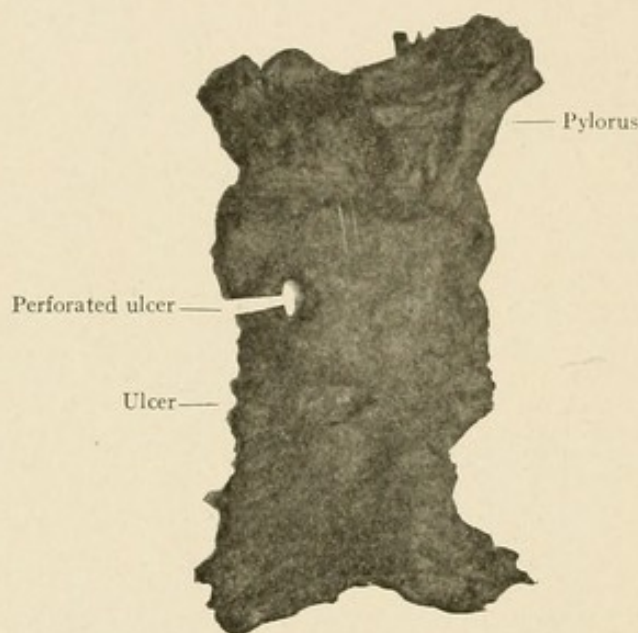


FIG. 25.—PERFORATION OF A DUODENAL ULCER IN A CHILD TWO AND A HALF MONTHS OLD.

Two ulcers are seen; the one nearer the pylorus has perforated (Dr. Cecil Finny's case).

may be two, three, or four ulcers. The edges are usually sharp and abrupt and have not the "terraced" appearances of the more chronic form of ulcer seen in the adult. In these ulcers there are evidences only of destruction; the evidences of repair are insignificant or absent. Erosion of the vessels encountered is the cause of hæmorrhage, and complete destruction of the bowel wall may result in perforation.

SYMPTOMS AND DIAGNOSIS

In the cases which prove fatal early, within the first seven days after birth, there are no earlier signs than hæmorrhage. The infant may seem normal and healthy at birth, but within a few hours melæna appears and continues without interruption. The child rapidly becomes pallid and loses weight speedily. A little blood may be vomited, but the chief discharge takes place by the bowel. In these cases the onset of symptoms is sudden, their development rapid, and the end is swift. No attempt has yet been made by operation to deal with the condition, but it is quite possible that success would attend such an effort if made early and by expert hands. In the latter cases there would seem to be good ground for the statements of Helmholtz that a period of weakness, wasting, and anæmia precedes or accompanies the development of an ulcer. His paper deserves careful attention, and will probably excite a keener interest in this subject.

The following list gives all the recorded cases of melæna neonatorum due to duodenal ulcer.

In the following cases death occurred within one week of the birth of the infant:

CASE I.—(Hecker (C.), "Klinik der Geburtskunde," ii, 1864, 244.) Case of duodenal ulcer in a child sixty-one hours old. Child born March 30, 1864, died after sixty-one hours, having lost $1\frac{3}{8}$ lbs. in weight.

At the post-mortem the stomach was found distended and contained blackish-brown mucous froth and air. The mucosa of the pyloric portion was stained red, and from there to the first curve of the duodenum there was a clot of blood filling the whole cavity. When this clot was removed, an ulcer was found on the anterior part of the duodenum adjoining the

pancreas 1 cm. in length and $1\frac{1}{2}$ cm. on its greatest breadth. On the base of the ulcer were scattered several black points which represented eroded blood-vessels. Throughout the whole intestinal canal there was found fresh red, somewhat frothy blood weighing about 3 ounces.

CASE 2.—(Spiegelberg, "Zwei Fälle von Magen-Darmblutung bei Neugeborenen in Folge von Duodenal-geschwüren," "Jahrb. f. Kinderheilkunde," 1869, 11,333.) Female, born November 4, 1866. No untoward symptoms on first three days. On the night of November 7th suddenly vomited large quantities of blood and passed blood per anum, and died some hours later in a condition of anæmia.

Post-mortem made by Prof. Waldeyer: Stomach somewhat distended by gas, mucosa swollen and covered with traces of blood. At the commencement of the duodenum was found a circular ulcer, somewhat larger than a lentil in size, to which a blood-clot was firmly adherent. The ulcer extended deeply into the muscularis. The mucosa further down was very pale and covered with an abundance of partially fluid and partially coagulated clot. The lymphatic follicles of the colon as far as the rectum were swollen to an extraordinary extent; otherwise the mucosa of the intestine was normal.

CASE 3.—(Spiegelberg, loc. cit.) Female, born naturally on March 5, 1868. Soon after birth blood-stained vomiting ensued and also melæna. Death occurred in fifty-five hours, showing symptoms of anæmia similar to those in the previous case.

Post-mortem performed by Prof. Waldeyer: Stomach contained about 30 c.c. of freshly coagulated blood. In the duodenum, exactly midway between the pylorus and the opening of the ductus choledochus, was a transversely situated ulcer, 1 cm. long and $\frac{1}{2}$ cm. wide, to the base of which a firm clot was adherent. Close beneath this ulcer were two others of the size of a lentil, the bases of which presented clots of fibrin and thrombosed vessels. The lower parts of the intestine contained meconium and coagulated masses of blood. All the solitary follicles were swollen as far down as the rectum.

In commenting on the above two cases the author

states that there could be no doubt that the fatal hæmorrhage had resulted from the duodenal ulceration, and the primary stages of the process leading to ulceration had commenced during the foetal life.

CASE 4.—(Landau (L.), "Ueber Melæna der Neugeborenen nebst Bemerkungen über die Obliteration der foetalen Wege," Breslau, 1874, p. 23.) Female, born naturally at full term on December 25, 1873. Had congenital spina bifida. Was quite well until the night of December 27th; then vomited chocolate-coloured matter and had profuse bloody diarrhœa. The child died on the evening of December 29th from acute anæmia.

Post-mortem December 30th: The stomach contained blood-stained masses with food remains. The duodenum was represented by a distended sausage-shaped body filled with blood-clot. After the removal of the clot an ulcer was found in the duodenum commencing 5 mm. from the pylorus and extending downwards for 8 mm. Its breadth was 6 mm. At certain points of the ulcer only the serous covering was left and the pancreas was visible through it. The intestinal canal contained masses of blood-clot.

CASE 5.—(Lorenz Kling, Inaugural Dissertation, München, 1875.) Male child, born May 31, 1861; mother a primipara; normal birth. On the second day the child vomited blood and passed bloody motions; continued on third day; death on the fourth day after birth.

On post-mortem examination: In the posterior wall of the duodenum adjacent to the pancreas was an ulcer 1 cm. long and 1½ cm. broad; only the mucous membrane destroyed. Further down, however, was another deeper ulcer, about the size of a lentil, penetrating to the serous coat. On the base of the ulcer were scattered hæmorrhagic spots. Liver pale, showing several yellowish islets.

CASE 6.—(Genrich, Inaug. Diss., Berlin, 1877, Case 1, p. 27.) A healthy child, which had taken nourishment sixteen hours after birth, began suddenly twenty hours after birth to have hæmatemesis; shortly afterwards melæna occurred and

was so abundant that the child "lay in blood." Death occurred twenty-one hours after birth. At the autopsy an ulcer was found in the duodenum $\frac{1}{2}$ cm. beyond the pylorus; it extended over three-fourths of the circumference of the bowel and was 2 cm. in breadth.

CASE 7.—(Kundrat, "Gerhardt. Handbuch d. Kinderkrankheiten," 1880, lv, 2, p. 398.) Female, seven days old, died April 13, 1877, from melæna. Had been a well developed child and otherwise healthy.

On post-mortem examination: In the anterior wall of the duodenum 2 mm. below the pylorus was an ulcer 4 mm. long and 2 mm. broad. On the posterior wall 1 cm. below the pylorus was another, 5 mm. long, 3 mm. broad, transversely placed. Both ulcers were covered with adhering clots. On removing the clot covering the second ulcer a bleeding vessel was exposed. The bleeding vessel proved to be a branch of the gastro-duodenal artery.

CASE 8.—(P. v. Zerschwitz, "Münch. med. Woch.," 1888, xxxv, 483.) K. M., male, born January 11, 1888, of a II-para. On the evening of the second day napkins were found blood-stained. Child passed at first dark and then red blood per anum. Continued until death occurred on the 13th (third day after birth).

On post-mortem examination the alimentary canal contained a large amount of blood. In the duodenum were several firm blood-clots. In the posterior wall, about 1 cm. above the opening of the ductus choledochus, was an oval ulcer, the length of which was 13 mm. and breadth 7.5 mm. The ulcer had a terraced appearance. The gastro-duodenal artery was empty and a sound passed into it came out at the base of the ulcer.

CASE 9.—(Munchmeyer, "Centralblatt f. Gynäk.," 1889, xiii, 286.) Child two days old, born partly asphyxiated after a prolonged labour. Melæna set in two days after birth and death occurred in a few hours.

On post-mortem examination two small superficial ulcers with irregular margins were found on the duodenum close to the pylorus.

CASE 10.—(T. D. Lister, "Trans. Path. Soc. Lond.," 1899,

i, 111.) This specimen shows a shallow ulcer in the duodenum about $\frac{1}{4}$ inch from the pylorus. Its edge is slightly raised and shelves gradually to the centre of the ulcer and into the surrounding duodenal wall. At the centre the ulcer deepens suddenly into the submucous tissue and its base is semi-transparent for an area of about 2 mm. by 1 mm. In the recent condition the ulcer was covered by an adherent clot, which apparently extended on to a rather large vessel at the base of the ulcer, and which seemed to be derived from the gastro-duodenal artery. The intestines were full of blood-clot, but there was nothing abnormal in their walls.

Abstract of case: Baby C., aged three days, was admitted to the East London Hospital for Children under Dr. Donkin on November 29 1897. The patient was passing blood per rectum. A saline enema was administered, and this was followed by a profuse hæmorrhage leaving the patient very anæmic and collapsed. Death occurred November 30th, the patient being then four days old.

CASE 11.—(de Noble (Paul), "Presse méd. Belge," 1892, xviv, p. 409; abstr. in "Schmidt's Jahrbucher," 1893, ccxxxviii, p. 167.) Author delivered child with forceps; it vomited blood twenty-four hours after birth, and evacuated blood with stools. This act was repeated three times within twenty-four hours and caused the child's death.

The autopsy showed that it had lost 900 gr. in weight. The umbilical cord was intact; the vena cava inferior was congested and filled with blood. The whole intestine was filled with masses of coagula. In the upper portion of the duodenum there was a superficial ulcer with irregular edges. The mucosa of the stomach and cæcum was injected. In the kidneys there were numerous uric acid infarcts.

CASE 12.—(Rheiner (G.), "Corr. Bl. für Schweizer Aerzte," 1898, xxviii, p. 524; abstr. in "Schmidt's Jahrbucher," 1901, cclxx, p. 260.) Child born of healthy parents, not asphyctic at birth; six hours after delivery had blood-stained stool. The hæmorrhages were repeated. Death occurred on the fifth day.

Post-mortem: Upon section an ulcer was found in the duodenum.

CASE 13.—Saxer ("Medizinische Gesellschaft zu Leipzig," "München. med. Woch.," 1902, xlix, 1362) demonstrated a case of fatal intestinal hæmorrhage from a small ulcer of the duodenum close beneath the pyloric ring in an infant three days old.

CASE 14.—(Kendall (H. W.), "Duodenal Ulcer in a Child Forty-four Hours Old," "Brit. Jour. Child. Dis.," 1906, iii, 501.) The child was born quite healthy and of good weight. Twenty-seven hours after birth it vomited a quantity of blood, and at the same time passed blood per anum. It passed a little more blood a few hours afterwards and was very weak. Thirty-six hours after the first vomiting it passed more blood, and died later from hæmorrhage. The mother was very healthy. The father's state of health was unknown. The child was illegitimate.

CASE 15.—(L. Kuttner, "Berlin. klin. Woch.," Nov. 9, 1908.) Infant, seven days old, developed vomiting and diarrhœa. Blood was observed in the stools when child was nine days old. On admission to hospital diarrhœa continued. When child was thirty days old a sudden profuse hæmorrhage from the bowel occurred. The blood was bright red in colour and suggested that the bleeding came from the lower bowel. Digital examination per rectum was negative. The child rapidly sank as a result of the bleeding and death occurred three hours later.

At the post-mortem the duodenum showed in the first part a circular ulcer 5 mm. in diameter. The edges of this ulcer were dark in colour and the base was undermined. The Peyer's patches and lymph-follicles were smaller. The intestines contained blood-stained fæces and dark, fluid blood.

CASE 16.—(Hench, "Vorlesungen über Kinderkrankheiten," 11th ed., 1903, pp. 59 et seq.) Two ulcers were found in the body of an infant who had died of melæna. No other details are given.

In the following cases death occurred over one week after the birth of the infant:

CASE 17.—(V. Torday, "Jahrb. für Kinderheilk.," 1906, lxiii,

563, and abstract in "Cent. f. Verdauungs-Krank.," 1907, ii, 191.) C. T., eight months old, admitted to the Budapest children's asylum March 4, 1905, with rickets and wasting. Constipation and vomiting, but no trace of blood in vomit or stools. Gradual wasting; death April 18th with pulmonary symptoms.

Post-mortem: Stomach very much contracted; tip of little finger with difficulty admitted through the pyloric opening. Five mm. below the pylorus along the lesser curvature was a round ulcer, 8 mm. long, extending over both anterior and posterior walls. Margins of the ulcer were soft, smooth, and white. In the centre was a small hæmorrhagic spot showing an erosion of a vessel. The contents of the small intestine were brownish-red in colour and in part tarry. Bronchopneumonia was present in the right upper lobe.

CASE 18.—(Borland (H. H.), "Lancet," 1903, ii, 1084.) Infantile acute eczema; hæmatemesis; duodenal ulcer; death: This unique condition of duodenal ulcer following acute eczema occurred in an infant of eight months. Eczema capitis began when the infant was two months old and persisted in moderate severity until about a week before death. Then there was an exacerbation of the eczema which was intense, affecting the head, neck, and part of the trunk. There was much œdema of the face and a great number of vesicles and pustules formed. On the fourth day after the exacerbation began the infant vomited blood, and from this time on the stools were tarry. During the next two days there was severe retching and some vomiting of blood, together with evidences of acute abdominal pain; and the baby died after vomiting a single mouthful of bright red blood.

The necropsy revealed a few ounces of bloody serum in the peritoneum, but no evidence of peritonitis. The lesser sac of the peritoneum contained a clot filling practically the entire space. On the posterior wall of the duodenum just below the pylorus was found a round ulcer with punched-out edges; the perforation was about the size of a split pea and directed towards the lesser sac. The stomach contained altered blood and its mucous membrane was merely congested.

In commenting upon the case the author calls attention to the analogous occurrence of such duodenal ulcers in cases of burns on the skin, particularly in young subjects.

CASE 19.—(Kuttner, "Berlin. klin. Woch.," Nov. 9, 1908.) Child aged four, quite well all its life. On the day before admission began to have diarrhoea, which continued during its stay in the hospital. Six days after admission a profuse attack of hæmatemesis occurred, and the child died shortly afterwards.

Post-mortem examination: The abdominal cavity contained about 100 c.c. of turbid yellow fluid. In the duodenum just below the pylorus were three ulcers varying in size from a pea to a penny piece. These ulcers involved all the coats of the intestine except the peritoneal coat. The mucous membrane of the large intestine was red and swollen and showed sloughing areas. The cortex of the kidneys was swollen.

Pathological report: Pseudo-membranous colitis. Duodenal ulcers. Parenchymatous nephritis.

CASE 20.—(Adriance (Vanderpoel), "Archives of Pediatrics," 1901, xviii, 277.) Duodenal ulcer in an infant of ten months; chronic ulcerative follicular colitis: E. R., male, born December 6, 1899. Admitted to the Nursery and Child's Hospital on August 23, 1900, with vomiting and distended abdomen. In spite of careful dieting the child became worse, and before death there was almost constant vomiting. Blood was vomited three times and a considerable amount of blood was passed in the stools. Death occurred October 6, 1900, the child being then ten months old.

On post-mortem examination the stomach was found to contain bright, not partially digested blood. In the posterior wall of the duodenum just below the pylorus was a small oval ulcer measuring 1 by 2 cm. The margins of the ulcer were sharply cut out, showing no induration. Its base was formed by the head of the pancreas, to which it was firmly adherent. The remaining portion of the small intestine was normal. The large intestine showed numerous ulcerated solitary

follicles. The liver was fatty. The mesenteric lymph-glands were moderately enlarged.

CASE 21.—(Finny, "Proceedings of the Royal Soc. of Med.," Dec., 1908.) Male child, born April 12, 1908, of a primipara; healthy at birth, but began to vomit a few days afterwards, which continued until death, on June 27th, when ten weeks old. There was visible peristalsis in the stomach. The stools were at times dark and tarry. Death occurred suddenly from an internal perforation.

On post-mortem examination the stomach was found much distended. The duodenum was found inflamed and thickened 2 inches from the pylorus. On its posterior aspect near the liver was a perforation from which bile-stained material was oozing. The pyloric opening was very narrow, just admitting a silver director. On opening the duodenum two ulcers were found on its posterior wall. Both had a punched-out appearance. The floor of one had given way, but that of the other, though very thin, still remained. There were no other ulcers anywhere and all the other organs were healthy.

CASE 22.—(Veit, "Zeitschrift. f. klin. Med.," 1881, iv, 471, and "Deut. med. Woch.," 1881, vii, 681.) Case of melæna neonatorum associated with a duodenal ulcer: Child seven weeks old, well developed, died in convulsions. No actual melæna, but motions were greenish-yellow; blood-stained froth and coffee-ground material came from mouth.

On post-mortem examination stomach and intestines appeared dark brown. In the interior of the duodenum was a large clot. When this was removed, two ulcers were seen in the upper horizontal portion. They penetrated as far as the serosa, but did not perforate it. The mesenteric glands were swollen. The intestines contained a large quantity of blood and clots.

The following cases are recorded by Helmholtz in his paper ("Deut. med. Woch.," 1909, i, 534):

CASE 23.—Child, two months, admitted July 3d; wasting and diarrhœa; stools thin and watery; no history of lues; collapse. Death August 19th.

Post-mortem, five hours after death: right ventricle dilated; hyperæmia of lungs; spleen enlarged; stomach covered with thick mucus. In the duodenum, about $\frac{1}{2}$ cm. above the papilla of Vater, were two large ulcers, triradiate, punched-out, and having smooth bases; immediately below the pylorus was another small, sharply defined ulcer, 2 mm. in diameter.

Microscopic examination of ulcer: Section through the middle of the ulcer showed degeneration of the mucous coat, hyaline necrosis of the superficial coats, increase of connective tissue, small-celled infiltration of the muscularis.

CASE 24.—Hildegard O., six weeks old, born July 4, 1908; admitted July 13; died August 20, 1908. On admission, child pale; intertrigo, aphthæ, and vulvitis present. Dyspepsia—fed on buttermilk. Rapid emaciation; stools green and slimy. Temperature subnormal. Death from collapse.

Post-mortem: Duodenum showed small hæmorrhages in the mucosa. On a line with the papilla of Vater was a small ulcer, about 2 mm. in diameter, filled with yellowish-brown matter. No hæmorrhage to be seen on margins of the ulcer. Contents of the upper part of the small intestine were blood-stained. Peyer's patches and the solitary follicles were swollen. No ulceration. Lungs showed hypostatic congestion. Heart normal. Stomach contained much mucus.

CASE 25.—Martin H., six weeks old, born July 8, 1908; admitted July 27; died August 21, 1908. History of maternal syphilis. On admission, snuffles and depressed nose. Dyspepsia, relieved at first by buttermilk. On August 14th stools became thin and slimy. Rapid emaciation in spite of all measures. Obstinate constipation, then passage of black, tarry stools. Died suddenly in collapse.

Post-mortem: Duodenum contained blood-stained masses; whole of the mucosa reddened. About 1 cm. below the pylorus was a sharply circumscribed, punched-out ulcer about 3 by 4 mm. in size. The base of the ulcer was flat and greyish-yellow in colour, showing several hæmorrhagic spots. Margins partly overhanging and partly flattened. Serosa intact. Immediately below this ulcer was a second one, more super-

ficial, 2 mm. in diameter. Base greyish-red, also showing a few small hæmorrhages. Heart and lungs normal.

CASE 26.—Willie R., six weeks old, born July 16, 1908; admitted July 30; died August 26, 1908. On admission, well-nourished child. Dyspepsia. Rapid emaciation; temporary improvement with centrifugised breast-milk. Stools became offensive. Died suddenly in collapse.

Post-mortem: Suppurative peritonitis commencing around pylorus, localised to right hypochondrium. A small perforation was present in the duodenum just below the pylorus, and this was the cause of the peritonitis. On opening the stomach and duodenum an ulcer was seen in the latter immediately below the pylorus, about 3 mm. in diameter. The ulcer was punched-out, but the terraced appearance was not evident. There were two very small ulcers close by, and another, about $1\frac{1}{2}$ cm., lower down. All these three presented a similar punched-out appearance. The stomach and intestines contained blood-stained masses. Hypostatic congestion of lungs. Spleen soft. Other organs normal.

CASE 27.—Kurt. K., seven weeks old, born July 8, 1908; admitted July 20; died August 29, 1908. On admission, emaciation, offensive stools. One blood-stained motion shortly before death.

Post-mortem: Perforating ulcer of duodenum just below the pylorus; fibrinous adhesions around the perforation preventing peritonitis. On opening the stomach and duodenum a large ulcer was seen, 5 by 1 cm. in size. The perforation was 2 mm. in diameter and situated at the upper end of the ulcer. The duodenal wall appeared almost wholly destroyed, and at the base of the ulcer a large, eroded artery was seen. There was a large quantity of blood in the upper part of the small intestine.

CASE 28.—Alfred K., fourteen weeks old, born May 27, 1908; admitted June 2; died September 2, 1908. On admission, a well-nourished child. Dyspepsia; wasting; offensive stools; died suddenly.

Post-mortem: Midway between pylorus and papilla of Vater were two small, punched-out ulcers, 2 to 3 mm. in diameter. Edges uneven and partly overhanging, base greyish

in colour. Numerous hæmorrhagic foci seen on the margins. Intestine otherwise normal. Thymus atrophied. Other organs normal.

CASE 29.—Erich S., four months old, admitted September 1, 1908; died September 25, 1908. On admission, poorly nourished child; diffuse bronchitis. Black, tarry motions continued for two days. Child became very anæmic—527,000 reds per cubic millimeter. Hæmoglobin 15 per cent. Saline infusions and gelatin subcutaneously. Death from anæmia.

Post-mortem: In the duodenum, 4 mm. below the pylorus, was an ulcer 6 by 1.8 cm. in measurement. Base of the ulcer was thickly covered with mucus. On removal of this it was seen that the upper part of the ulcer was deeper than the lower. Another ulcer present, $\frac{1}{2}$ cm. below the pylorus, 2 mm. in diameter. The solitary follicles were enlarged; otherwise intestine normal. After suitable preparation the specimen showed the terraced appearance of a typical peptic ulcer.

CASE 30.—William T., ten weeks old, born August 10, 1908; admitted September 28, 1908; died October 28, 1908. On admission, slight jaundice, dyspepsia, offensive stools, wasting. Death from pulmonary complications.

Post-mortem: In the duodenum, $\frac{1}{2}$ cm. below the pylorus, was an oval, punched-out ulcer, measuring 2 by 4 mm. The margins were smooth and the base was clean. Midway between the pylorus and the papilla were two ulcers, one very superficial, about 2 mm. in diameter; the second was deeper, more irregular, about the same size as the one near the pylorus. The upper portion of the intestine contained much blood. The lungs showed pneumonic consolidation, posteriorly more marked on the right side. Other organs normal.

CHAPTER VI

CHRONIC DUODENAL ULCER—SYMPTOMS AND DIAGNOSIS

THERE are few diseases whose symptoms appear in such a definite and well ordered sequence as is observed in duodenal ulcer. It is true that there are cases, of which fuller details must presently be given, in which the regular appearance of the symptoms is absent, or in which one symptom is so exaggerated as to dwarf, or even to destroy, the value of others. But these exceptions are few, and they do not belittle the value of the general statement that the symptoms of duodenal ulcer are definite, and not easily to be mistaken, and that they appear in an order and with a precision which are indeed remarkable.

The patient may date his complaint from an early period in his life. It is not very uncommon for a man, in answer to the question as to how long he has suffered, to reply, "All my life." A man of sixty-one, upon whom I operated, had first experienced symptoms at the age of nineteen; others had symptoms "as long as they could remember." This goes to shew that the ulceration or its antecedent may begin at an early period in life, and the symptoms may, with periods of repose, continue up to middle age, or even to advanced years. As a rule, the patient is in middle age, from twenty-five to forty-five; and males are more frequently affected

than females. If the earlier history is well remembered, the patient will say that insidiously, almost imperceptibly, he began to suffer from a sense of weight, oppression, or distension in the epigastrium after meals. At the first the discomfort may apparently be capricious, but it is not long before notice is taken of the fact that it comes usually two hours or a little more after food has been taken. Immediately after a meal there is ease; if pain or discomfort were present before, the meal relieves them, and soon banishes them completely for a time. Then again the pain is felt in two hours, three hours, four hours, or sometimes even six hours later. When the pain comes three or four hours after food, I have found that the ulcer is "tucked back"; it is, that is to say, adherent posteriorly in such manner as to prevent its delivery into the abdominal wound. One feels that if much traction is made on the duodenum, the ulcer would be pulled away from the upper part of the kidney pouch. The position of the pyloric vein shows that the ulcer is in the first, and not, as might be supposed, in the second, part of the bowel. When the pain consistently comes at an earlier time than two hours after food, two conditions may be found: either an active ulcer has contracted recent adhesions to the abdominal wall or the liver; or stenosis is beginning to develop. As a rule, the pain comes gradually, and gradually increases, becoming more severe and being accompanied by a sense of fullness, distention, a "blown out" feeling; and there is an eructation of bitter fluid or of gas, which affords relief. The interval between the taking of food and the onset

of the pain is very remarkable; it is constant from day to day if the character and quantity of the food remain the same. If the food is entirely liquid, the pain comes rather earlier; if it is heavy, solid, "indigestible," the pain comes later; with an ordinary meal, of liquid and solid, the pain very rarely appears in less than two hours. Many patients will volunteer the statement that the pain begins to appear "when they are beginning to feel hungry," and I therefore suggested in one of my early papers the term "hunger pain" as descriptive of this particular symptom. The pain, as a rule, is noticed, at first, only or chiefly after the heaviest meal of the day. If dinner is taken between 1 P. M. and 2 P. M., the pain will come with unvarying regularity at, or near, 4 P. M. For a long period this may be the only time of day when discomfort is felt, but later in the attack, or in subsequent attacks, it is noticed that after every meal the pain comes at its characteristic interval, and that by every meal the pain is relieved, only to return in due time. When inquiry is made from a patient as to whether food causes the pain, he will not seldom answer, "Oh, no; food always makes the pain better; the pain comes when I am beginning to feel hungry." It is a very characteristic feature of the pain that it wakes the patient in the night, and constantly the time of waking is said to be 2 o'clock. The relief of the pain by food, quickly realised by patients themselves, leads to the practice of keeping near at hand a biscuit or some other food, or drink which can be taken at once. Many patients carry a biscuit in the pocket, or have a glass of milk and a piece of bread and butter ready at certain times, to be

taken at the moment of the onset of pain. It is a common experience to find that patients place by their bedsides some food to be taken in the early hours of the morning when the pain awakens them. The regular appearance of the pain after definite intervals from the taking of food is remarkable, and is consistent. The pain is often preceded or accompanied by a sensation of weight or of fullness and distension in the epigastrium; it is described as "boring," "gnawing," "burning." It may be relieved by belching, and constant efforts are often made to bring about the eructation of gas, which is followed by momentary relief. Sometimes there may be a slight regurgitation of food, and the patient complains that the taste of this is bitter, or acid; the throat then feels hot or as if scalded, and the teeth are said to feel as if made of chalk. A few patients complain that a free gush of saliva may occur. The swallowing of this may give temporary relief to the pain. In some cases the flow of saliva may be copious and distressing. For long periods, sometimes throughout the history of the case, the pain remains confined to the epigastrium, but it may strike through to the back or pass round the right side. When the pain is severe, relief is often gained by pressure, and I have known patients wakened in the night to hug a pillow to the abdomen to obtain relief in this way. On some occasions, though this is infrequent, the pain is said to be "cramp-like" in character; a sort of spasm is felt, with exacerbations and remissions, as in all forms of "colic." It is very probable that a spasm of the pylorus, protective, no doubt, in its character, is actually present; for such a condition, as I pointed out several

years ago, may be witnessed during the conduct of an operation. The pyloric muscle hardens by degrees until a state of firm contraction is reached, when a solid, cylindrical, whitish mass forms, which imparts a feeling similar to that experienced when the normal uterus is handled. The spasm slowly passes away and the stomach assumes its normal appearance. This sensation of cramp is often accompanied by a feeling of great epigastric distension. I have twice seen this cramp well marked in patients who were operated upon under local anæsthesia only: they both described their sensations at the moment as one of "bursting" and "distension."* Throughout the whole period during which the pain is felt the appetite remains good. In many cases the patient volunteers the statement that he feels a keen relish for his food, takes it with good appetite, and enjoys it. Frequently he eats less than he feels he could enjoy, because experience has taught him that excess, or even satisfaction, is apt to be followed by an increase of pain, or pain of a more enduring character. Fluid food, when taken to the exclusion of all solids, often causes the pain to come earlier after food and to last longer than when the ordinary meals are taken. A patient will often say that he feels worse when he is strictly dieted in this way; but, as a rule, persistence in liquid diet, especially during the earliest stages of the disease, will bring relief after a

*I have often wondered, since this, whether the "colic" described by patients (hepatic colic, renal colic, intestinal colic) is due, as we have always supposed, to the contraction of unstriped muscular tissue; it is possible that it is rather the result of the distension which is present behind the segment in which the muscular spasm is occurring.

time. Vomiting is very infrequent; it is rarely present until stenosis develops; and stenosis appears only in the later periods when the ulcer or ulcers are healed. A severe pyloric cramp, which may be caused by an active ulcer, produces, of course, an evanescent stenosis. The majority of the patients upon whom I have operated have never vomited.

These are the characteristic symptoms described by the patient in the anamnesis. Upon them alone a confident diagnosis of duodenal ulcer may be made. Certainly the most characteristic feature enabling a diagnosis of chronic duodenal ulcer to be made is the periodicity of the symptoms and their recurrence from time to time in "attacks," their complete abeyance in the intervals. A single probably brief attack of these symptoms may mean that a superficial lesion is present in the duodenum; but as to this I cannot say, as I have never yet operated in or after a first attack. After a second attack I have operated in one case and excised a small, quite well-defined ulcer. In subsequent attacks the ulcer is always visible. A patient who has suffered for years will say that an "attack" comes on as a result of exposure to cold, or getting the feet wet, or a hasty or "indigestible" meal, or worry or overwork. A cause can almost always be assigned for the onset of symptoms; a recurrence of the cause is always followed by a reappearance of the symptoms. The most common of all these causes is "getting cold"; in consequence the great majority of the patients will say that the attacks are especially prone to come in the winter months—December, January, or February. In the summer the symptoms are almost

always absent. One patient of mine was perfectly well for three years when in India. He returned to England in November, and within a fortnight had "caught a chill" and all the symptoms returned. In several cases I have known an attack to follow close upon an illness diagnosed as influenza, and in a few cases the initial attack has so occurred. The "attacks" vary in length from two to three weeks up to several months. It is remarkable that an attack may frequently be cut short by a few days' rest in the country or at the seaside. Two of my patients, medical men, told me that a long "week-end" at the sea, with plenty of open-air exercise, free from the anxieties of practice, would always cut short an attack in the earlier years of their trouble. Both the onset and the termination of an attack may be quite sudden. A chill may bring on an attack in a few minutes, and the symptoms may continue for months. In more than one instance I have known the symptoms to cease abruptly, when the patient has been riding or has been in the middle of a game of golf, or taking a walk. In the end the pain may become a matter of daily experience, but it still retains its characters as I have described them. In the intervals between the attacks there is complete immunity from suffering, food is taken with full enjoyment and with keen zest; there is no discomfort of any kind; weight is gained, and mental and bodily vigour are at their highest. So complete may the recovery be, that the very suggestion that the former attacks have been due to organic disease may be scouted or received with the tolerant smile of disbelief. The explanation is given that there has been "hyperchlorhydria" or that

the case is one of "acid dyspepsia" or possibly of "neurosis." The idea is deep rooted that the symptoms are always due to an excessive acidity in the gastric juice, but, as I shall presently show, there is no foundation in fact for this venerable fallacy.

The cause of "hunger pain" has never been satisfactorily explained. I had long accepted complacently the statement that the pain began at the time when the pylorus relaxed to allow of the food passing into the duodenum; that the pain was due, that is to say, to contact, the surface of the ulcer being chafed or fretted by the food as it passed onwards. The relief from pain which followed the taking of food, or an alkali, was held to be due to the closure of the pylorus which this was supposed necessarily to entail. But Dr. Hertz has recently shewn me that this explanation cannot be true; for if to a patient suffering from duodenal ulcer (as subsequently demonstrated by operation) a meal be given in which bismuth has been mixed, an examination with the *x*-ray screen will shew that food begins to leave the stomach, and to pass over the ulcer into the duodenum within the first few minutes. The pain seems to come when more than half the meal has left the stomach; it cannot therefore be due to any movement or disturbance of the stomach, due to its full or empty state, in accordance with one suggestion which has been made, for the pain is absent if the stomach is kept quite empty for several hours. It would seem that the only possible explanation is that the contents of the stomach towards the end of digestion possess, for some reason, a greater acrimony than at any other time. It may be

that the acid content is then greater, or that some other change, of which at present we know nothing, has taken place.

These symptoms, so perfectly characteristic of duodenal ulcer, may be present for years, without producing any physical signs. It is therefore not necessary to the attaining of an accurate diagnosis that any examination of the patient be made. The anamnesis is everything; the physical examination is relatively nothing. There is, in the stage when the presence of the ulcer should be recognised, no single physical sign indicating the presence of organic disease. Signs which confirm the accuracy of the diagnosis may appear later, but there is no need to await their arrival before making, as we can make with the utmost confidence, an exact diagnosis.

In a large number of cases an examination of the abdomen reveals no abnormal condition. There is perhaps some epigastric tenderness in the middle line, or to the right, but even in the stages of active ulceration this is by no means constant. If a patient be examined during the time that he is suffering pain, say between two and three hours after a meal, when the pain is probably at its height, there is usually some tenderness, which may, rarely, be exquisite. It is commonly in the middle line, over an area two or three inches in diameter. In a very few cases I have found that the patient complains of pain and of tenderness on the left side; and no explanation of this anomaly appeared at the time of operation. When pain is present and acute, the right epigastric reflex may be strongly accentuated; in the same patient examined when no

pain is present the reflex of the two sides will be found equal. Local tenderness is generally combined with local rigidity, and the upper part of the right rectus muscle may be firmly contracted and tense. The contrast between the muscles of the two sides is then striking.

These signs, tenderness in the mid-line and to the right, firm contraction with rigidity of the upper part of the right rectus, and a briskness of the right epigastric reflex are the only signs present in cases of duodenal ulcer. They are relatively of little importance, for they are found in a well-marked degree only in a small proportion of the cases, and in these only, as a rule, when pain is present. They afford perhaps some slender confirmation of the diagnosis; but in themselves, apart from the clinical history, are of no substantial value. In the later stages of duodenal ulcer when stenosis has occurred, the usual signs of a dilated and obstructed stomach are present.

It is therefore chiefly, indeed as a rule quite exclusively, upon the anamnesis, that the diagnosis of duodenal ulcer is made.

In a rather later stage dilatation of the stomach, with motor incompetence, may appear. The stomach, that is to say, is unable to empty itself completely within the normal period of time. What should be considered a "normal period" is not agreed upon by all writers. I have arbitrarily adopted the period of twelve hours. If a stomach is not able to empty its contents into the duodenum within twelve hours, it is very probable that there is organic disease which prevents it doing so.

Gastric stasis then may be found in cases of duodenal ulcer; it is due always to the narrowing which occurs by reason of the healing, partial, as a rule, but sometimes complete, of the ulcer or ulcers. I have never found that stasis of this degree was present as a result of pyloric spasm. It is possible that a spasm of the pylorus prevents the stomach from emptying as quickly as it otherwise would do; for the spasm no doubt exists because of the need for protection of the ulcer of the duodenum from the harm which contact with the acid chyme would inflict. The spasm is reflex and is protective, as was so beautifully shewn by Cannon and Murphy ("Annals of Surgery," 1906, vol. xliii, 512). But a spasmodic contraction of the muscle which guards the outlet does not prevent the stomach from emptying within the period of twelve hours. Its occurrence is probably protective also in the fact that it arouses symptoms the mere presence of which makes the patient less eager to take food in full quantities. Gastric stasis denotes, therefore, the existence of a narrowing in the duodenum due to organic disease. When this narrowing attains even a very moderate degree, an hypertrophy of the musculature of the stomach develops, as always happens in the alimentary canal; and the evidence of this may be found in the peristaltic waves seen when the stomach is examined. If the stomach is empty or only partially filled, these muscular contractions may not be seen, but the administration of the two halves of a Seidlitz powder separately will soon excite them.

In all cases of duodenal ulcer, indeed, in all cases of intractable stomach disorder, a test meal should be given.

There are a number, by no means inconsiderable, of patients who have been referred to me as cases of "hyperacidity," "acid gastritis," upon whom I have operated and have demonstrated the existence of a duodenal ulcer. Recurrent severe "hyperchlorhydria" is duodenal ulcer. The symptoms of which the patient makes complaint are ascribed to hyperacidity; but it is extremely interesting to know that it is usual for the gastric juice in such cases to contain less free HCl than the normal.

It is undoubtedly the rule in intractable cases of so-called "acid dyspepsia," as I have seen them, for there to be no hyperacidity; and it is in my experience invariable to find duodenal ulcer in such cases. No one is more sceptical than myself in interpreting the appearance of the stomach and duodenum during the course of an operation. I do not believe in the duodenal ulcer which I cannot demonstrate to the most sceptical assistant or onlooker. No "anæmic spots" or trivial, often imaginary thickenings do I accept as being enough to account for protracted symptoms. The ulcer is always a visible, tangible, demonstrable lesion. And in a large experience I have never operated upon a case of protracted or recurrent "hyperchlorhydria" without finding a duodenal ulcer. In such cases it is very rare to find any excess of acidity when a test meal has been given.

A sign which sometimes appears early in the course of this disease, but which is more often a late symptom, is hæmorrhage. It is, of course, an evidence that the process of ulceration has extended to such a depth as to open up a large vessel, and so deep an invasion of the coats of the bowel is usually accomplished only after the

lapse of months or of years. When bleeding occurs, in a quantity sufficient for it to be recognised as hæmatemesis or melæna, it is with few exceptions an evidence of the deep penetration of the walls of the duodenum by an ulcer whose existence should have been recognised long ago. Neither hæmatemesis nor melæna should be considered as among the usual signs of duodenal ulcer; they are both complications whose onset should have been forestalled; they are a witness to neglected opportunities.

The frequency with which bleeding occurs from a duodenal ulcer has been variously estimated by different authorities. Thus Krauss in the 70 cases collected by him found that in 20 free hæmorrhage had been observed. Oppenheimer in "over 100" cases found bleeding recorded in 34. In Perry and Shaw's series of 60 cases presenting symptoms in a total of 151 cases, hæmatemesis or melæna was present in 23. Nine patients had hæmatemesis, nine had melæna, and five had both hæmatemesis and melæna. In Nothnagel's Encyclopedia (p. 245) it is said that "severe hæmorrhage occurs in about one-third of cases." Fenwick estimates the frequency of hæmorrhage in acute cases at 26 per cent., or in chronic cases at 40 per cent.

All these figures seem to me to be valueless. They are compiled from statistics every item in which is open to disproof or doubt. The symptoms which characterise duodenal ulcer so unmistakably were unknown to every one of these authorities; the frequency of the disease was therefore quite unappreciated. Only patients who suffer from such complications as stenosis, perforation, or

hæmorrhage were known to suffer from an ulcer in the duodenum, and the verification of the diagnosis could only then be made upon the post-mortem table. In my own series of cases hæmorrhage has been noticed in 37.6 per cent. But with the new light which has now been shed upon this important subject by the work of the surgeon, we have come to recognise that hæmorrhage is not a symptom, but a late complication; that its onset is not to be awaited in order that a doubtful diagnosis may receive confirmation, but that its appearance is to be prevented by a timely recognition of the significance of the early symptoms. Hæmorrhage, when it does occur, may be manifest either as hæmatemesis or as melæna; the blood may be discharged in the vomit, or in the fæces. Melæna may, and indeed usually does, exist without hæmatemesis, but when blood is vomited there is almost without exception some blood also in the stools. I believe hæmorrhage from a duodenal ulcer to be a sign of grave significance, of far more serious import than bleeding from a gastric ulcer. In the latter death very rarely occurs; in the former it is more frequent than is generally supposed. I have thrice had the experience of advising operation for duodenal ulcer in cases where hæmorrhage subsequently occurred and proved fatal before surgical help could be given. Hæmorrhage from a gastric ulcer is sometimes very copious and gives rise to great alarm, but when the bleeding ceases spontaneously the patient recovers quickly. In duodenal ulcer the bleeding causes faintness and anæmia the exact origin of which may not be obvious till the bowels are moved. Then faintness and prostration come

again and again; an abundance of blood, at first black, but later of a brighter hue, is passed, and the patient may rapidly become exsanguine and die. The manner in which hæmorrhage appears varies much in different cases. As a rule, there is a considerable exacerbation in the symptoms before the bleeding comes; the "indigestion" is more acute, the feeling of distension or oppression after food is greater, and the patient himself does not feel so well. Then suddenly he becomes faint and weak and breathless, the head feels light and "swimming," and the sight seems quickly to grow dim. The patient looks white, his lips are bloodless, and sweat covers the brow; he asks constantly for air and is breathless; he displays, in brief, all the classical signs of an internal hæmorrhage. That this has occurred is presently made certain by the voiding of blood in the characteristic "tarry" motions or by the ejection of brighter blood in the vomit.

In other cases the hæmorrhage may occur insidiously, without the patient having noticed it: he is aware only of a continuing weakness and frailty which he can hardly understand. A case in my own series was an exemplary instance of this. The man was sent to me because of a right inguinal hernia. As he entered my room I was struck with his blanched appearance, and my diagnosis of duodenal ulcer was made before he reached a chair. When I asked him to tell me his symptoms, he had nothing to say but that he had a hernia. I asked if he had noticed any loss of blood; he replied in the negative. I enquired whether "indigestion" had been observed, and he said at once that he had "suffered from that for

years," and that recently it had been very severe. I took the man into hospital and found that he had melæna. I elicited then a perfectly clear history of duodenal ulcer, for which I performed gastro-enterostomy. The case has been very successful (No. 46).

It is probable that a certain degree of hæmorrhage occurs in many cases of duodenal ulcer without being recognised. The surface of the ulcer, when fretted, probably bleeds a little, and if the stools were carefully and regularly examined, traces of occult blood would surely be found. I have in a few cases found this to be the case, but since I have realised how accurately the existence of an ulcer can be recognised from a study of the clinical symptoms alone, I have not pursued this line of investigation closely. Occult blood, blood that is in quantities too small to be seen by the naked eye, but capable of recognition by other tests, is therefore probably very frequent.

The vessels which are opened by the deep invasion of the walls of the bowel by the ulcer vary considerably in size; in proportion to their size the hæmorrhage is slight or abundant. The following are some of the larger vessels which have been eroded, with the result that fatal hæmorrhage has occurred: the aorta; the hepatic, gastroduodenal, superior pancreatic-duodenal, right gastro-epiploic, and pyloric arteries; the portal and superior mesenteric veins. In a few cases hæmorrhage has been so sudden in onset and so profuse as to cause death, which was almost instantaneous. When the base of an ulcer from which fatal hæmorrhage has occurred comes to be examined, the vessel involved is usually found to have

thick and rigid walls. The opening from which the blood has come is at the side of the artery, which remains wide open. There is neither closure nor retraction of the vessel, whose walls, stiff as the stem of a clay pipe, seem incapable of contraction.

Such is a brief description of the characteristic symptoms of chronic duodenal ulcer. If a patient presents these symptoms, the diagnosis of duodenal ulcer may confidently be entertained. There is no need for further evidence than that which is so afforded. I constantly operate upon the strength of the history alone, and as often do I demonstrate the existence of a chronic ulcer, a tangible and visible lesion, as the cause of the symptoms. Of nothing concerned with the relationship between altered structure and altered function am I so convinced as that symptoms such as I have portrayed owe their origin to, and are dependent for their perpetuation and their periodic repetition upon, a chronic duodenal ulcer. A description of these symptoms is to be met with in most of the text-books of medicine, under the caption "hyperchlorhydria" or "acid gastritis," and the belief that these words are a sufficient diagnosis is very general. After giving a diagnosis of duodenal ulcer, I am not infrequently met with the objection that the patient's symptoms are indicative of nothing more than "persistent hyperchlorhydria." This is the medical term for the surgical condition duodenal ulcer. The symptoms of "acid dyspepsia," if they are intractable and recurrent, are due to the demonstrable lesion, duodenal ulcer. Of that there can no longer be any doubt. The most interesting feature, however, in such cases is that an excess

of free hydrochloric acid is not present, as a rule; indeed, it is most exceptional to find any greatly increased acidity. This is well shewn in the reference given elsewhere to a series of examinations of the gastric juice made upon consecutive cases submitted to operation, many of which had borne the clinical label "hyperacidity" for months or years. It is true that in such cases an "acid rising" occurs; chyme brought up into the mouth burns the œsophagus and the pharynx, makes the mouth hot, and the teeth to feel "chalky." But chyme is naturally acid; it is the regurgitation which is abnormal. The acidity of the stomach contents when brought back in the act of vomiting some time after a meal is well known, and the effect on the teeth and the buccal mucous membrane is similar to that found in "acid dyspepsia." In cases of "hyperchlorhydria" this constant regurgitation of acid chyme is probably due to the fact that a protective spasm of the pylorus is present, and that the stomach contents, hindered or retarded in their onward progression, are eager to find the only other means of escape from the stomach.

The terms "acid dyspepsia," "hyperacidity," "hyperchlorhydria," are then not only dangerous as concealing the fact that the condition which causes them is not functional, as is implied, but organic; but they are misnomers also, for the presence of an excess of acid is most infrequent.

The description I have given applies to the great majority of the cases of chronic duodenal ulcer, but there are certain variations of type, which, though exceptional, are important, and should be recognised. For

example, there are cases in which a chronic duodenal ulcer is afterwards found in which all symptoms and signs are quite insignificant in comparison with hæmorrhage. A patient of my own (case 114) had suffered in only the slightest degree from a little flatulence and indigestion about a year before I saw him. For several months he was free from all pain or discomfort. Suddenly one evening, while at his club, he fainted, and hæmatemesis occurred, to be followed by melæna, which persisted without interruption, though in varying quantity, for ten weeks. Even during this period the fluid food he took caused no distress. I feared, and so also did Dr. Malim, who referred the patient to me, that unless the bleeding was checked the severe and unceasing anæmia would end in death. I operated and found a small duodenal ulcer which I excised; at its base a small artery was eroded. Similar cases, though none so striking, have occurred, to the number of five. In all hæmorrhage overshadowed all other symptoms, and added to them a significance which was unmistakable. In a case operated upon in 1909 almost fatal hæmorrhage had occurred twice during a period when other symptoms were very slight. The patient had, however, had almost no solid food for two and one-half years. Three small ulcers were found on the anterior wall of the duodenum.

In several cases the hæmorrhage which has produced profound anæmia, lassitude, weakness, and breathlessness may have escaped notice. One of my very early cases had repeated sudden attacks of faintness, pallor, and enduring anæmia, with only very trivial indigestion. Until he was by chance confined to bed it was not recog-

nised that the stools were black and tarry. A close enquiry was then made into the history, a diagnosis of duodenal ulcer made by Dr. G. P. Anning, and an operation undertaken. In a certain group of cases, then, hæmorrhage may be predominant over all other signs or symptoms.

There is a small group of cases in which the symptoms of active ulceration are almost completely latent, and the patient first consults his medical man because of repeated and copious vomiting, which is found to be due to an obstruction near the pylorus. The first pronounced symptoms are due not to the ulcer, but to the stenosis which has insidiously developed in the scar. On enquiring closely into the history of all these cases I have found that symptoms of "indigestion" have been present in the earlier years, but that they have been kept in subjection either by the most sedulous attention to the diet, by constant draughts of a bismuth and morphine mixture, or by repeated doses of carbonate of soda, or by lavage of the stomach. So easily are the symptoms kept in check by one means or another that the remembrance of their existence, or even of their occurrence, may have faded from the patient's mind. The stricture which at last results may be as thin as whipcord, or may be caused by a hard fibrous mass the size of a golf ball. In all the cases within this group the symptoms of the ulcer are overshadowed by the signs due to the scar which results from its healing.

There is a type less frequent than the above and more baffling to the diagnostician in which little can be elicited except a complaint of "acidity." Many of the patients

complain of "heartburn," "waterbrash," or "acidity," but, as a rule, these symptoms are trivial in comparison with the real pain which the patients suffer. But in very rare cases the intensity of the acid regurgitation may be such that all other troubles seem by comparison insignificant. The most exemplary instance of this, within my own experience, occurred in the case of a medical man, who had suffered for twenty years. His chief complaint was of incessant and intolerable acidity, and it required a close investigation of his very early history to extract a clear account of "hunger pain." For years he had washed the stomach out often two or three hours after a meal, not because of pain or distress, but solely because the acid waterbrash was so unpleasant. The stomach contents after test meals shewed only a little more than half the normal acidity, and at the operation the cheloid scar of a chronic ulcer was found in the duodenum. (No. 175.)

CHAPTER VII

DIFFERENTIAL DIAGNOSIS

THE only difficulty likely to be encountered in making an accurate diagnosis of duodenal ulcer is concerned with the discrimination of this condition from cholelithiasis. In a consecutive series of 100 operations wherein I had made a diagnosis of duodenal ulcer, an error was committed in three cases. In two of them gall-stone disease was present, and in the third gall-stones and appendicitis. In earlier cases I had made the diagnosis incorrectly more often than this, but in nearly all cases an organic lesion was found to be present. The earlier errors were made in cases of gastric ulcer, cholelithiasis, and appendicitis, either simple or tuberculous.

In the differentiation from gastric ulcer there is, as a rule, no great difficulty. If pain after food does not appear for two hours or more, it may be said with reasonable confidence that the ulcer is in the duodenum. I am convinced of the importance of the time-element in cases of gastric and duodenal ulcer. If pain appears early, within an hour or so, the ulcer is certainly in the stomach, probably on the lesser curvature, and to the cardiac side of that sphincter in the stomach which Cunningham has described. If pain comes between one and two hours after food, the ulcer is probably in the pyloric antrum; the long interval of relief is then possibly due

to the firm contraction of the muscle at the junction of the storage and grinder portions of the stomach. This tonic action of the sphincter is perhaps more marked in cases of ulcer than in the normal conditions, and it may be that it is protective in character. The period of relief from pain conferred by the taking of a meal is then the first and a chief point to be considered in the differential diagnosis.

The striking recurrence of a duodenal ulcer at various seasons of the year is not shared by gastric ulcer. One of the most authentic features in duodenal ulcer is this recurrence of attacks in the cold and wet seasons. One patient after another will tell of the influence of the cold weather, or of a chill, upon the natural history of his disorder; some of these patients complain constantly of cold hands and cold feet; but the blood pressure in many of the cases is certainly high. In gastric ulcer there does not seem to be the same dependence of the attacks upon the climate or the seasons.

In gastric ulcer pain is always referred to the middle line, and it usually is so in duodenal cases, though not always. There is not seldom a chief complaint of pain on the right side, radiating over the right costal margin up towards the breast, or round to the back. Tenderness on deep pressure, if present, is always to the right. If the ulcer has attached itself to the liver or to the anterior abdominal wall, these radiating pains, and the area of tenderness, are undoubtedly more marked.

In gastric ulcer the radiation is often to the left costal margin and to the left breast, and even at times may be felt down the arm. Tenderness on deep pressure be-

neath the left costal margin when a deep inspiration is taken is often found when an ulcer is present on the lesser curvature towards the cardia.

So far as the preventable complications of ulcer are concerned, it is undoubtedly the case that hæmatemesis in the absence of, or in marked excess of, melæna is found only in gastric ulcer. Both hæmatemesis and melæna may be present in cases of duodenal ulcer, but the latter is more frequent and is in excess of the former.

The chief difficulty in diagnosis is met with in cholelithiasis; but here also a close scrutiny and analysis of the symptoms should enable a correct forecast to be made in almost every instance. Above all in importance is the orderly sequence of events. There is method in the natural history of duodenal ulcer; there are the definite attacks, attributable to well-recognised causes, appearing at certain seasons, eased by diet, instantly relieved by alkalis or by lavage, to be followed presently by the complete abeyance of all symptoms. Such a definite periodicity is never seen in gall-stone disease. The character of the pain in the two differs essentially. In the very great majority of cases of duodenal ulcer the pain, though it may be severe, is tolerable; in cholelithiasis it often is almost unendurable. I have known medical men who suffered from gall-stones to carry with them a small bottle of chloroform, so that if an attack of pain came they could inhale the vapour and get relief. Though I have operated upon many medical men with duodenal ulcers, I have never known one to look upon the pain as so terrifying a thing as to call for this. Moreover, in hepatic colic the onset of pain is usually within

an hour of the taking of food. The pain begins suddenly, as a feeling of acute distension, and it is only after a while that the feeling of cramp develops. In an attack of hepatic colic there is often a "catch in the breath," a most characteristic symptom, and a feeling of great depression and nausea is accompanied by sweating. Acidity, or heartburn, is not infrequently present in cholelithiasis. The pain, as I have said, begins suddenly, and almost instantly it may pass away. It is abrupt, in both onset and relief, and in both it differs from the pain of duodenal ulcer. Food or an alkali has no influence in relieving the pain of gall-stones, and the idea of even the smallest quantity of nourishment is repugnant. I believe a frequent and important feature of cholelithiasis to be the experiencing of chills and sweats; a feeling of "gooseflesh," shivering, and subsequent heat are often mentioned in the anamnesis. The sensation of pain felt in the shoulder-blade is very suggestive of gall-stone impaction in the cystic duct. As Dr. J. B. Murphy has shewn, the introduction of a probe into the cystic duct through a cholecystotomy opening is at once recognised by the patient, who refers the pain to the right shoulder-blade. So definite a localisation is not known in duodenal ulcer.

In cholelithiasis, in its more advanced form, the pain is capricious in onset, comes upon the patient unawares, and grips him instantly in such manner as to compel him to cease from all other things than the means of getting relief. The pain is cramp-like, and a feeling of insufferable distension in the epigastrium is present. The pain extends across the abdomen in its upper part, and passes

through, or round, the side to the shoulder-blade. There is a sharp catch in the breath and a feeling of chilliness and fever. The attack may be of such severity that chloroform or morphine is needed to obtain relief. Nausea, retching, and vomiting prostrate the patient, and then ease may come. Freedom from pain is often instant, only a feeling of stiffness or soreness remains for some hours. There is no approach to the regular, orderly sequence of events that is so strongly suggestive of ulcer of the duodenum. The complications of duodenal ulcer, hæmatemesis, and melæna are not seen in cases of cholelithiasis in which a difficulty of diagnosis is likely to arise.

There are cases, extremely few in number, I believe, wherein a mimicry of the symptoms of duodenal ulcer is found, in the absence, upon exploration, of any definite organic lesion. It is true that one hears of such cases not very infrequently, but, in almost all, no adequate examination of other parts has been made. I have, for example, known gastro-enterostomy to be performed after a diagnosis of duodenal ulcer had been made. The symptoms were of a kind to make such a diagnosis reasonably probable. The patient died; at the autopsy a gall-bladder full of stones was discovered and no other lesion of any kind. I believe it to be true that in most cases where, at the time of operation, a duodenal (or gastric) ulcer cannot be found, some other lesion, in the gall-bladder, small intestine, or appendix, is present, and is overlooked. In a very small number, however, an organic lesion may in fact be absent. Such cases require further investigation. All that I am prepared to say with regard to them now is that as my experience

has increased the number of those cases has decreased to the vanishing point. Too strong emphasis cannot be laid, however, upon this; that in the absence of a demonstrable lesion the operation of gastro-enterostomy is not justifiable. It will give no relief and disaster will often follow fast upon it.

It is in cases of severe hæmorrhage disclosed either by hæmatemesis or by melæna that the greatest difficulty of diagnosis may arise. I have twice been asked to see, with a view to immediate operation, patients who voided blood by the stomach or by the bowel in such large and repeated quantities as to lead to the belief that life was imperilled. In both the diagnosis of duodenal ulcer has been made, partly because the greater part of the blood has been passed by the rectum, and partly because some vague history of ill-health and "dyspepsia" had preceded the onset of the hæmorrhage. In both cases I was saved from an error in diagnosis by a careful enquiry into the anamnesis, and by examination of the abdomen; for in both I discovered an enlarged spleen, and in both the "dyspepsia" was not of the kind I have been led to associate with ulceration of the stomach or duodenum. Both cases proved to be examples of Banti's disease, and in one case I eventually removed the spleen and demonstrated the integrity of the duodenum. Splenic anæmia is therefore the one condition it is supremely important to bear in mind in cases of severe hæmatemesis or melæna, especially in those instances in which the characteristic disturbances of digestion are absent or inconspicuous. In Banti's disease the examination of the blood dis-

closes a persisting anæmia of the secondary type. In the hæmorrhages which result from a simple or organic lesion in the stomach or duodenum the blood changes are transient.

I have once made the serious mistake of operating upon a patient who had had repeated attacks of hæmatemesis and melæna, the cause of which I believed to be an ulcer near the pylorus in the stomach or duodenum. The patient's life had more than once been in jeopardy. I could discover no cause for the hæmorrhage, and the bleeding continued from the intestine, and from the wound till death occurred. The patient's mother then informed us of the fact, which she acknowledged to have concealed deliberately at the patient's request, that her son was a "bleeder." The genealogical chart was characteristic; three men in two generations had died of hæmorrhage, which submitted to no control.

There are cases of cirrhosis of the liver in which some slender doubt may possibly exist as to the presence of a gastric or duodenal ulcer. More especially is this the case if the patient has been a hard drinker and has bled freely from the stomach or bowel. The alcoholic gastritis gives rise to protracted dyspepsia, and it is from dilated veins in the œsophagus or stomach that the hæmorrhage comes. A strict enquiry into the anamnesis will quickly dispel the doubts which may at first be entertained.

CHAPTER VIII

THE TREATMENT OF CHRONIC DUODENAL ULCER

IN my opinion the treatment of a chronic duodenal ulcer should always be surgical. Chronicity in an ulcer is attested by the recurrence of "attacks" of a well-defined character. When a series of these attacks have occurred, the ulcer is always to be plainly seen and demonstrated; and my experience in a long series of operations is that the conditions in the ulcer are such that nothing but surgical treatment could possibly avail. The ulcer is so large, or so indurated, or the ulcers are so numerous that even if the lesions were to cicatrise completely one of two things would result: either a hard, fibrous surface, readily breaking down under provocation, would remain, or a stenosis of the bowel would inevitably follow.

But the question at once arises as to when the case is first to be recognised as surgical, as to when we are entitled to say that medical treatment will probably prove to be of little or no permanent value. What are the conditions present in the duodenum in the first of all the "attacks"? I have at present no means of knowing. I have never yet operated in or after a first attack, and so have no evidence upon the point. I have once operated at the close of a second attack; the patient being referred to me by my colleague, Dr. T. Wardrop Griffith. An ulcer about $\frac{1}{4}$ inch in diameter on the anterior surface

of the duodenum was excised. The ulcer was clean, with terraced margins, it was indurated, and it had destroyed the whole of the muscular coat of the bowel. Though the attack had passed away completely, the ulcer was still open and unhealed. In subsequent attacks the ulcer is always to be seen or felt and possesses the characteristic appearance. An ulcer which has caused recurrent attacks has always involved the serous coat, and is accordingly easily to be seen from without. It is only when attacks recur that a diagnosis of chronic duodenal ulcer can confidently be made; it is only when this diagnosis can be made that surgical treatment is necessary. In a first attack, or even in a second, medical treatment may be tried. But I believe it to be true to say that the significance of the symptoms in these attacks has never yet been fully recognised by the physician. It has not been realised that these symptoms are due to a structural lesion, and consequently (after a diagnosis of "acid gastritis" or "neurosis") treatment has been perfunctory and brief. Up to the present time it is, with the exception of the single case I have mentioned, only after repeated attacks, sustained often over a period of years, that the surgical needs of the case have been recognised. If the first of the attacks be due to a duodenal ulcer, then medical treatment of a sufficiently protracted and careful character should be tried. But when attacks recur in the typical manner I have described, the lesion found is of such a nature that anything other than surgical treatment is not worth considering. It is safer, speedier, and more certain than any other mode of treatment.

I do not desire to say that at the very commencement of this disease medical treatment is futile. Of the exact conditions present in the duodenum in the earlier attacks we possess no information. It may be that a condition of congestion, or of superficial mucous ulceration visible only from the interior, is present. If so, surgical treatment is not to be considered. But a better opinion upon the most suitable method of treatment of such cases may be expressed when we possess some more accurate information of the pathological conditions which are present at this stage of the disorder.

THE SURGICAL TREATMENT OF CHRONIC DUODENAL ULCER

The procedure to be adopted by the surgeon in the operative treatment of a chronic duodenal ulcer will depend upon the conditions disclosed at the time the examination of the lesion is made. If the ulcer is small, placed on the anterior surface of the duodenum, and free from adhesions, it may safely be excised, and the wound in the duodenum closed. If the ulcer is large and indurated, occupying perhaps more than half of the circumference of the gut, or if multiple ulcers are found, or two ulcers of the "kissing" variety, then gastroenterostomy will be necessary. If the ulcer is associated with a chronic gastric ulcer near the pylorus, and perhaps in other circumstances, the resection of the affected area may be necessary. In two cases when the ulcer was small and did not affect the first half inch of the duodenum I resected the ulcer and a cylinder of the gut, closed the distal end, and attached the proximal end to the side of the second portion of the duodenum; making, that is,

an end-to-side anastomosis. In certain cases the excision of the ulcer, followed by the performance of Finney's operation, may be necessary.

In the very great majority of cases the operation of gastro-enterostomy is the most applicable, and, in its results, the most satisfactory. But in order that it should give not only immediate but also permanent relief, the ulcer must be so large as, either in its present form, or by the time healing is complete in it, to offer obstruction, or means must be taken to secure the infolding of the ulcer. Cases have been recorded by Kocher, Quènu, and others in which, after gastro-enterostomy has been performed, apparently with success, the symptoms returned, and death occurred from hæmorrhage or from perforation. (See also Eve, "Lancet," 1908, i, 1822.) We know by clinical observation and by experiment that a gastro-enterostomy opening is a free outlet from the stomach only when some obstruction to the onward passage of the food exists (see "Brit. Med. Journal," 1908, i, 1092). A duodenal ulcer causes such impediment either because it lessens, by reason of the cicatricial processes engaged in it, the lumen of the intestine, and prevents the intestine from distending when food is ready to pass; or because, like other lesions, gall-stones, appendicitis, tuberculous disease of the intestine, etc., it excites a spasm of the pylorus. The former of these is permanent, and probably tends slowly to increase; the latter is transient and disappears as soon as the exciting cause is removed. In such cases a gastro-enterostomy opening which has acted well as an outlet from the stomach, and has in

this way allowed the ulcer beyond the natural pylorus to heal, may cease to act when the ulcer is soundly healed. If that ulcer is small, its scar may be inconspicuous and offer little or no obstacle to the easy escape of food. The pylorus then again transmits all the food, the ulcer subjected to renewed irritation breaks down, and the symptoms are repeated. The last state of the patient is the same as the first. That this is not mere hypothesis, one case at least upon which I have myself operated (Case 173) shews, I believe, quite clearly. It is in my judgment, therefore, always desirable to infold such an ulcer. A. B. Mitchell, of Belfast, has shewn that this produces very much the same effect as excision. The ulcer is soon removed and an intact mucosa remains. Perforation and hæmorrhage are prevented, and recurrence of the ulcer need not be feared. The lumen of the gut, moreover, is permanently narrowed, and the gastro-enterostomy opening becomes the constant outlet from the stomach.

Excision of a duodenal ulcer can be safely performed only when the wound which remains after removal of the ulcer can be sutured without any present, or the risk of future, narrowing. It is rare for a case to be submitted to the surgeon in an early stage; the lack of acquaintance with the clear and characteristic symptoms of the disease, the widespread but erroneous belief that persistent hyperchlorhydria is a "functional" rather than an "organic" disease, result in a delay which is both unnecessary and dangerous. By the time an operation is performed the ulcer is usually large, puckered, indurated, or adherent; and excision is no longer possible.

The following are the methods of treatment open to the surgeon:

1. Excision of the ulcer. Simple excision. Finney's operation.
2. Gastro-enterostomy.

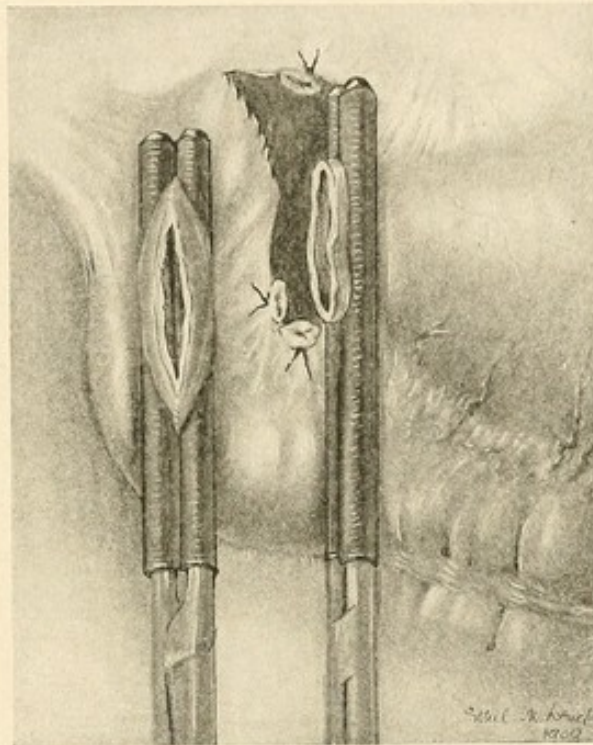


FIG. 27.—EXCISION OF A DUODENAL ULCER.

The distal cut end of the duodenum is closed, and an end-to-side anastomosis performed.

3. Resection of the duodenum, with or without the pyloric portion of the stomach.
4. Resection and end-to-side anastomosis, the pylorus being left intact.

1. **Excision of the Ulcer.**—The abdomen being opened and the parts inspected, the duodenum is brought well up into the wound. In most cases, since the ulcer

is small and free from adhesion, the first part of the gut can be brought easily within reach, and can be held securely by the fingers of an assistant during the sub-

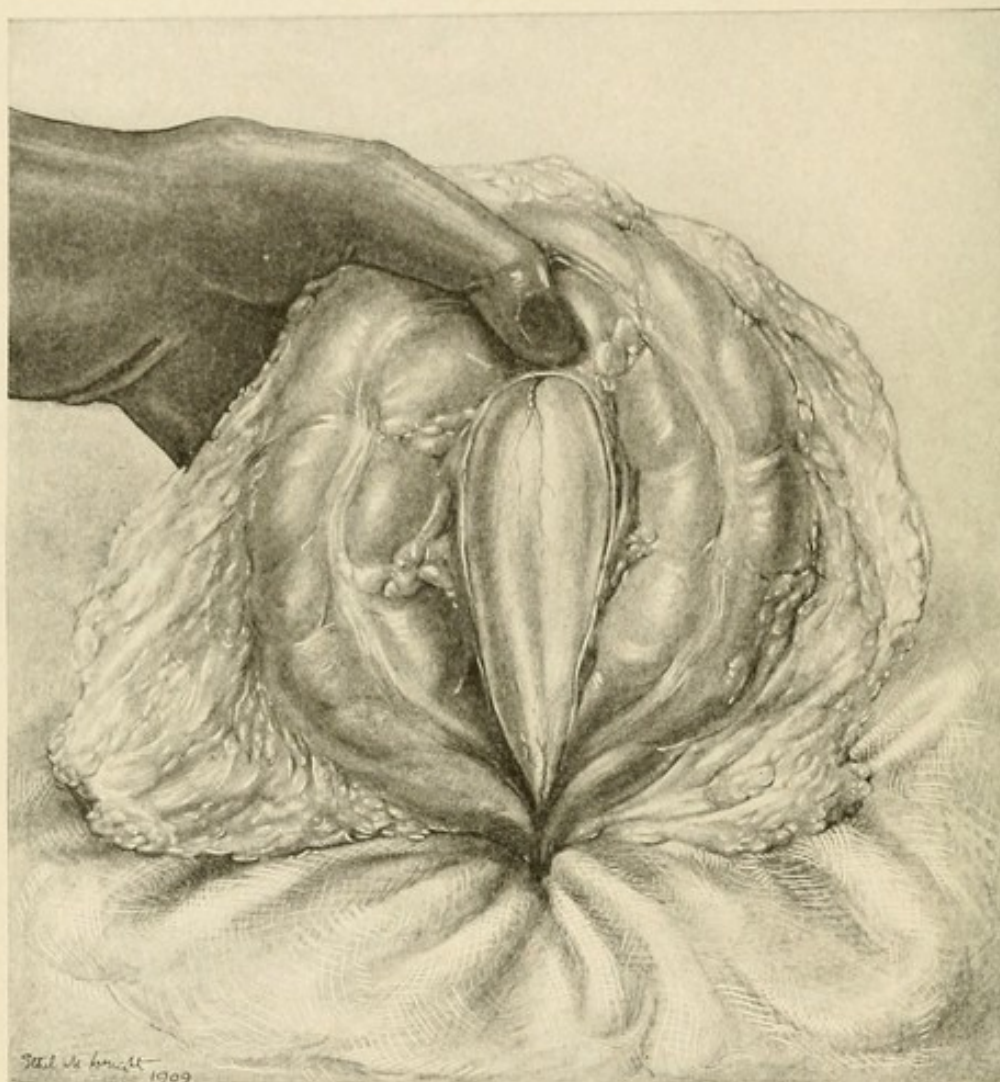


FIG. 28.—GASTRO-ENTEROSTOMY.

The transverse mesocolon has been incised and the posterior surface of the stomach is made to project through the opening. The vessels of the greater curvature are seen immediately beneath the thumb.

sequent manœuvres. As soon as the gut is well placed, hot moist swabs are packed around it, so that any fluid which may escape from the duodenum is caught at once

by them and prevented from soiling any part of the wound edges or of the viscera. This packing cannot be too carefully done. The pyloric part of the stomach is then drawn out of the abdomen and held by an assist-

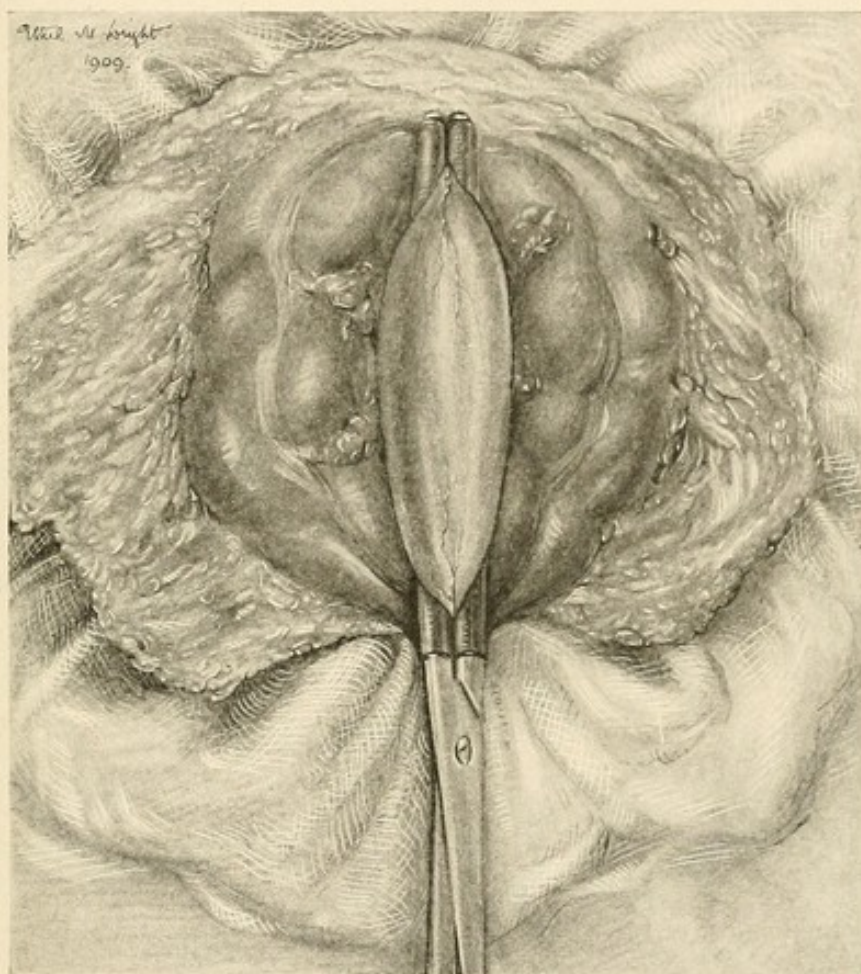


FIG. 29.—GASTRO-ENTEROSTOMY.

The clamp is applied vertically to the stomach.

ant against the left margin of the wound, in such manner as to prevent any fluid contents from escaping freely. The ulcer is then surrounded by two horizontal incisions enclosing an ellipse between them. The incisions are carried through all the coats of the gut and the ulcer is

removed. At the middle of the upper and lower margins of the incisions a fine vulsellum forceps is placed; on drawing these two apart, the incision, which before was horizontal, now becomes vertical, and in this direction it is sutured. I prefer to use fine catgut for the inner stitch, which is introduced in the "loop on the mucosa" method. A fine edge of all the coats is thus inverted. The catgut suture is drawn tight so as to secure all cut vessels in the edge. This line of sutures is then infolded by a continuous stitch of fine Pagenstecher thread. It is important to secure a good apposition of serous surfaces, and yet it is equally important to avoid the turning in of too broad a surface, lest subsequent stenosis result. The operation is then complete, and the swabs are removed, the viscera returned, and the abdominal wound closed. This procedure may be varied by performing a wider excision of the ulcer, and by continuing the ends of the horizontal incisions well to each end, into the stomach and on to the second part of the duodenum. The large wound which results is then sutured after the manner adopted in Finney's operation.

2. **Gastro-enterostomy.**—In all cases of simple duodenal ulcer the posterior operation (von Hacker's method) can be performed. In my judgment the posterior no loop operation with a vertical application of the jejunum to the stomach is by far the most satisfactory procedure. Various hypothetical objections have been brought against it, but they have not been substantiated by clinical experience. The operation is performed in this manner: An incision about 4 or 5 inches in length is made 1 inch to the right of the middle line above the

umbilicus, and is carried at once down to the anterior sheath of the rectus, which is divided. The rectus fibres are then split vertically, or the inner part of the sheath is dissected up from the front of the muscle-belly and the whole muscle displaced outwards from the middle line. The posterior sheath is then incised and the abdomen is opened. The skin is covered by "tetra cloth" attached by special forceps to the wound edges and ends. The stomach, duodenum, and gall-bladder are then examined with great care. The immediate discovery of a single lesion whose existence has been anticipated should never satisfy the surgeon. There may be more lesions than one, and a knowledge of their presence and whereabouts may be necessary to the complete relief of the patient. When this examination is complete and the need for gastro-enterostomy assured, the stomach, transverse colon, and omentum are withdrawn from the abdomen and turned upwards to expose the under surface of the transverse mesocolon. The origin of the jejunum is then sought. There are times when the first few inches of the jejunum are attached to the under surface of the mesocolon, by adhesions, possibly physiological, possibly pathological. The mesocolic band, a short ligament springing from the under surface of the mesocolon and attached to the jejunum below, may extend on to the gut for 3 inches or more. If so, it should be divided, until the jejunum is free up to its origin. An opening is then made through the under surface of the mesocolon at a bloodless spot close to the jejunal origin, and the opening is enlarged towards the transverse colon until three fingers can easily be passed

through into the lesser sac. Through this opening the posterior wall of the stomach is pushed, by the left hand of the surgeon pressed against the anterior wall. It is essential to see that the part needed for the anastomosis is brought through the opening. This part consists of a vertical fold in line with the vertical part of the

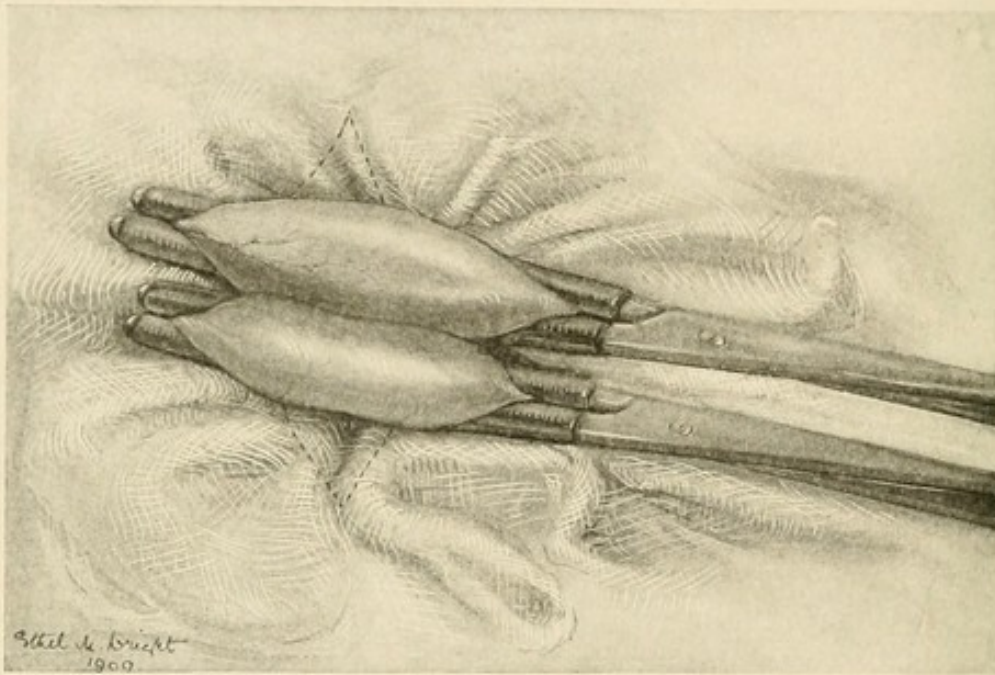


FIG. 30.—GASTRO-ENTEROSTOMY.

The two clamps, the upper on the stomach, the lower on the jejunum, lie side by side. All other viscera are replaced within the abdomen and gauze and rubber pads surround the clamps closely.

lesser curvature (and therefore in line with the right margin of the oesophagus), and it ends below at the lowest point of the greater curvature. A fold of the posterior surface along this line is then seized by the fingers of the surgeon and drawn well out of the abdomen. This is quite easily done in most patients, but duodenal ulcer is sometimes found in fat, sleek patients whose abdominal

wall may be 3 or 4 inches in thickness. In them it may be difficult, or even impossible, and the anterior operation may alone be possible. As the fold lies in the grip of the fingers it is embraced by a clamp applied vertically; the handle of the clamp points to the pubes, the tip of the blades to the chin. A good fold, 3 or 4 inches in length, is held. The clamp is then gently turned until it is almost transverse, the handle being towards the

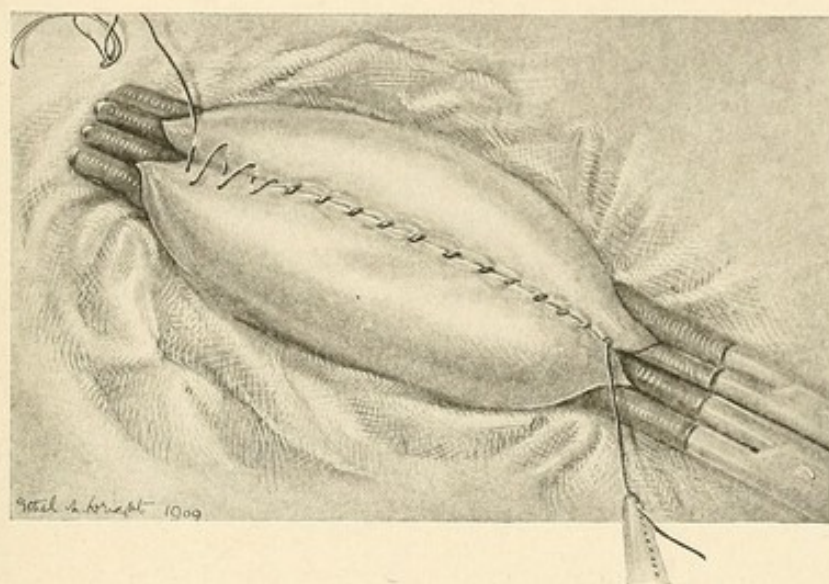


FIG. 31.—GASTRO-ENTEROSTOMY.
The first layer of sutures introduced.

assistant. Meanwhile the uppermost part of the jejunum, which has been given into the assistant's hands, is now drawn well out of the abdomen and clamped. The clamp is applied by the assistant while the length of the gut is held up by the surgeon; when the clamp is in position, and before it is locked, the jejunum at the proximal end is pulled forwards as taut as possible, while the clamp is depressed by the assistant as forcibly as can be; this secures that the gut as close as possible to

the flexure is included in the grip of the clamp. All viscera are now returned within the abdomen, the stomach, transverse colon, and omentum being passed into the peritoneal cavity through the part of the incision above the clamp. The clamps alone are now outside the abdomen, and they embrace folds, about 3 or 4 inches in length, of the stomach and jejunum, and they lie horizontally. They are surrounded by hot moist swabs;

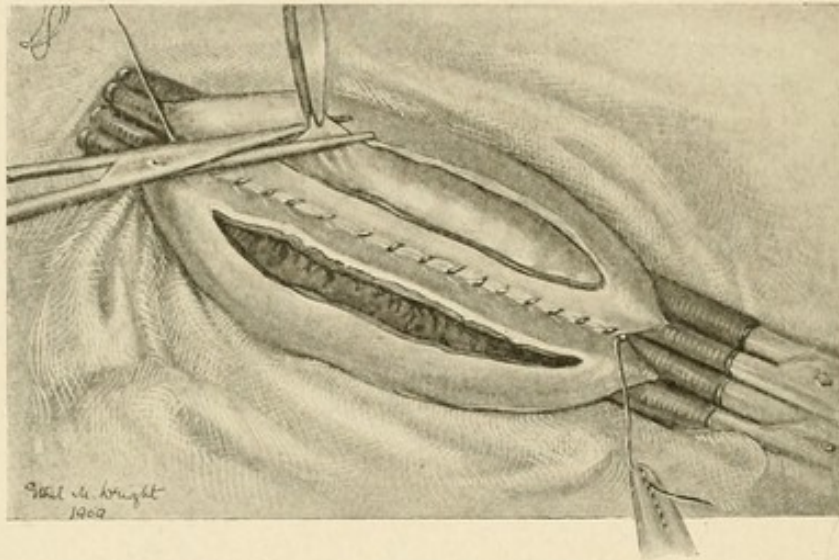


FIG. 32.—GASTRO-ENTEROSTOMY.

The viscera are now incised through their serous and muscular coats. The mucous membrane pouts into the wound and is then excised.

and a gauze strip is placed between them. Swabs made of a sheet of dental rubber with three or four thicknesses of gauze on each side are the best. There is accordingly absolutely no exposure of viscera, and any leakage of blood or contents from the stomach or jejunum has no possible chance of reaching the wound edges or the peritoneal cavity. The union of the two viscera is now begun. Two sutures only are used; both are continuous.

The outer suture is sero-muscular; the inner includes all the coats. The needle I prefer is a curved needle of my own pattern; it is slender, five-eighths of a circle in its curve, has a slot eye, and is of such a diameter that it is the slightest degree thicker than the finest Pagenstecher thread when doubled. (These needles are made by Downs Bros., of London.) This needle picks up almost automatically the exact amount of the viscera

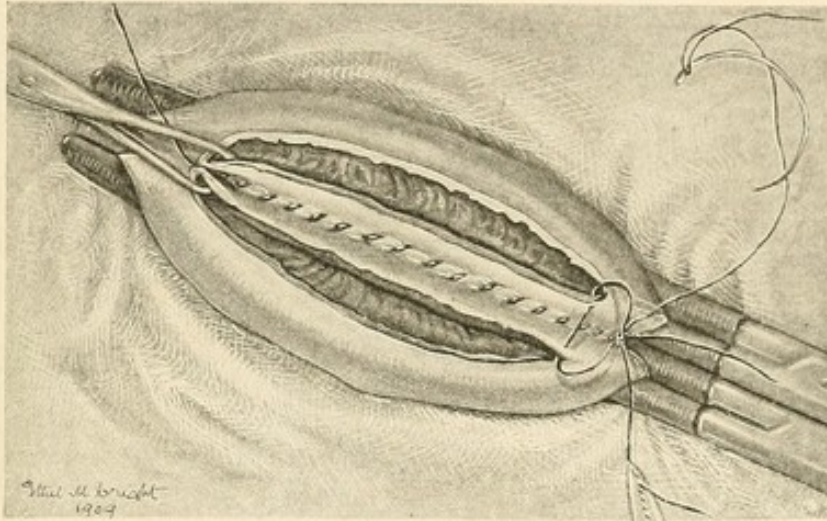


FIG. 33.—GASTRO-ENTEROSTOMY.

The inner, through and through, continuous stitch is here begun.

that is necessary, and because of the relationship between its thickness and that of the thread which it carries there is no "pull" necessary when the thread is to be drawn through the punctures which the needle has already made.

I greatly prefer a curved needle. If a surgeon practises with it a few times, he will find it easier to use than a straight one, and he will find it quicker also. But it

is necessary to hold the needle in the right way (see illustrative figure).

The first suture is now introduced. It engages the sero-muscular tunics of the viscera and begins at the most distant end from the surgeon, and is brought towards him. After the first stitch the suture is knotted; afterwards the suture runs without interruption or alteration until the whole length of the clamped portions is united.

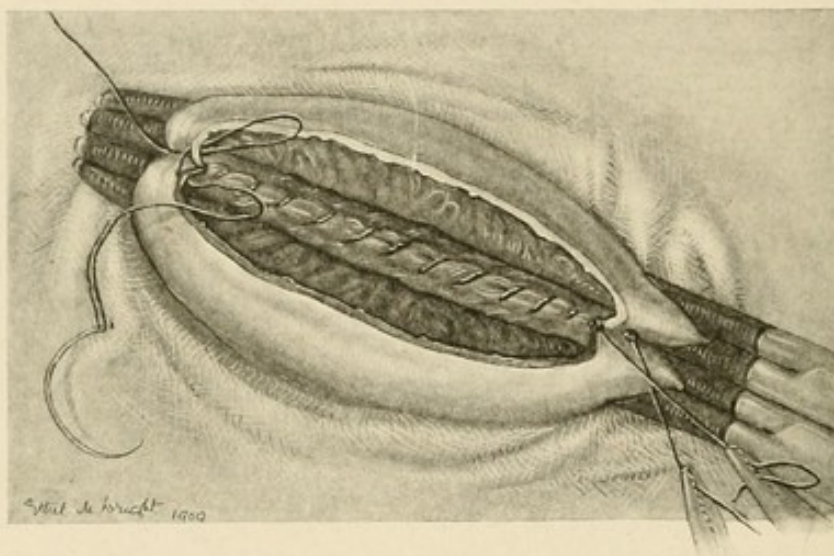


FIG. 34.—GASTRO-ENTEROSTOMY.

The inner stitch is half completed; turning the corner.

It is at the tip of the clamp that the greater curvature of the stomach lies, and care is necessary to see that the lowest part of the curvature is engaged in the suture. The large vessels which are seen at this point should be avoided, or included in the needle so as to secure them and prevent hæmorrhage from their cut ends. As the suture is introduced it is pulled fairly tight, so as to bring the opposing surfaces snugly together. The part of the thread between the last stitch and the needle,

when drawn upon, raises up a little hillock on each viscus, shewing where the next insertion of the needle is to be made, and making that insertion easier. The number of introductions of the needle is usually about eight or ten to the inch, and at least $2\frac{1}{2}$ inches should be included in this suture. When this first line is completed, the needle is laid aside for a time. The next step consists in opening the viscera by an incision parallel to the line

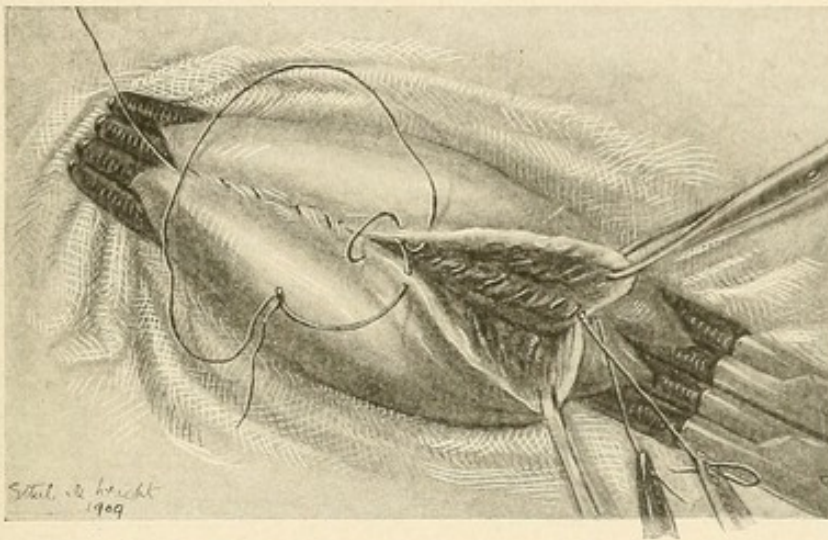


FIG. 35.—GASTRO-ENTEROSTOMY.

The anterior stitch, continued. This shews the method of introducing the loop in the mucosa stitch.

of suture just completed. Before the opening is made, a few loose pieces of moist gauze are packed round to catch any blood or discharge which escapes. The incision is made about $\frac{1}{4}$ inch from the suture line; at first only the serous and muscular coats are divided; as they retract the mucosa pouts into the wound, broadly in the centre, narrowly at each extremity. The whole of this strip of the mucous membrane is excised; that from the stomach comes away readily in one piece, that from the

jejunum generally in several pieces. At each end of the jejunal opening an additional triangular piece has always to be taken. After the openings have been made and the cavities wiped clean with gauze, an Allis's forceps is placed at the end near the surgeon; it embraces all the coats of each organ and forms a sort of "basting stitch." The inner suture is now introduced. It is a

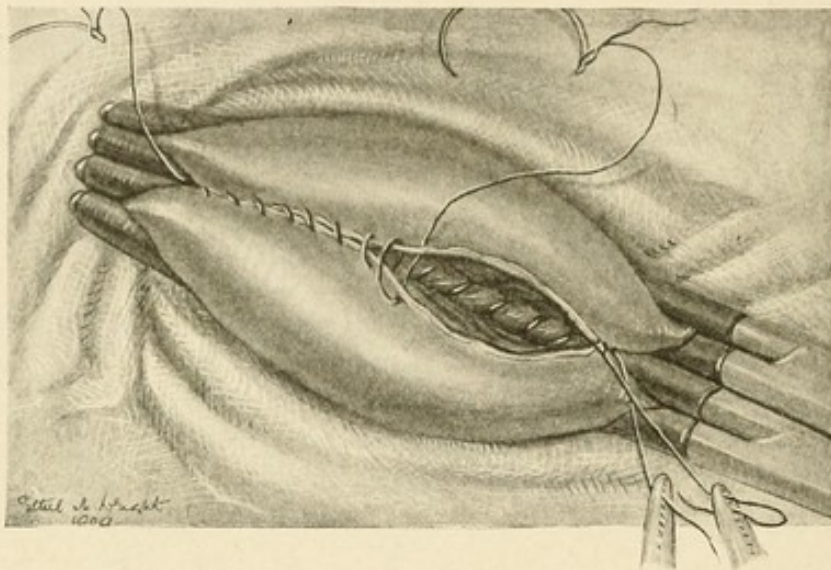


FIG. 36.—GASTRO-ENTEROSTOMY.

The anterior stitch applied in the ordinary manner. This results in a slight eversion of the mucosa, which is an advantage. This is the stitch I prefer.

running stitch which picks up all the coats on both sides; it is drawn rather tight, so as to act as an hæmostatic suture; the separate parts of it are placed close together in order to ensure that no considerable vessel escapes. At its first introduction the needle passes from the mucous to the serous surface of the jejunum in the angle at the left extremity, then from the serous to the mucous surfaces of the stomach; when the knot is tied it lies, there-

fore, upon the mucous surface. When the right extremity of the openings is reached, the corner is turned and the suture continued along the anterior edges. I have

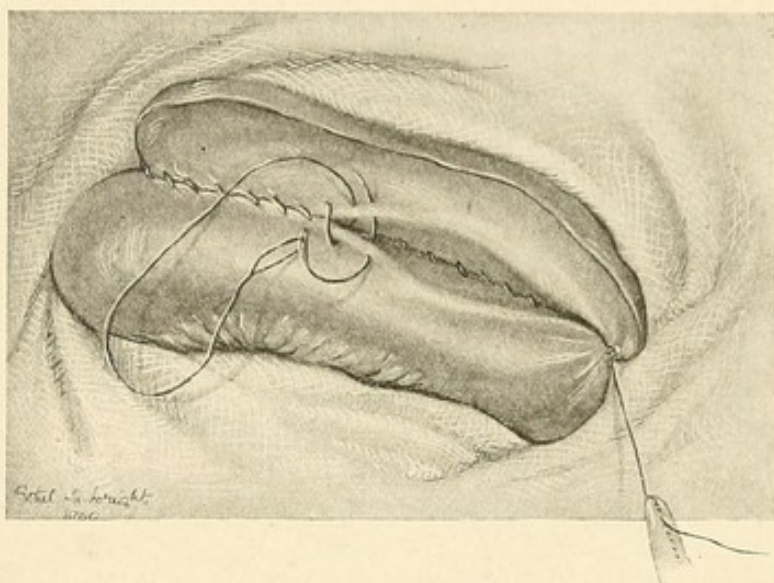


FIG. 37.—GASTRO-ENTEROSTOMY.
The inner stitch completed. The outer suture continued.

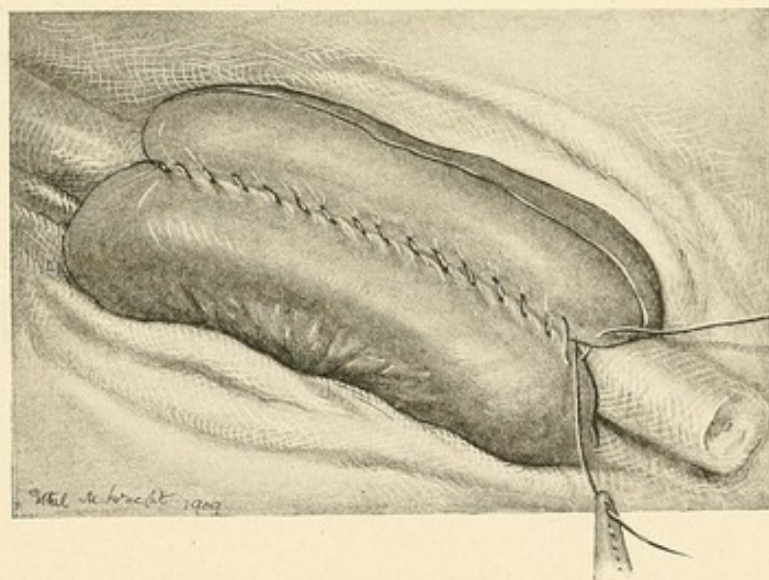


FIG. 38.—GASTRO-ENTEROSTOMY.
The outer stitch in the act of completion. The last introduction of the needle is made beyond the first stitch.

used two types of suture for the return half—the “loop on the mucosa” stitch, or the ordinary running suture which passes from serosa to mucosa of the jejunum, and

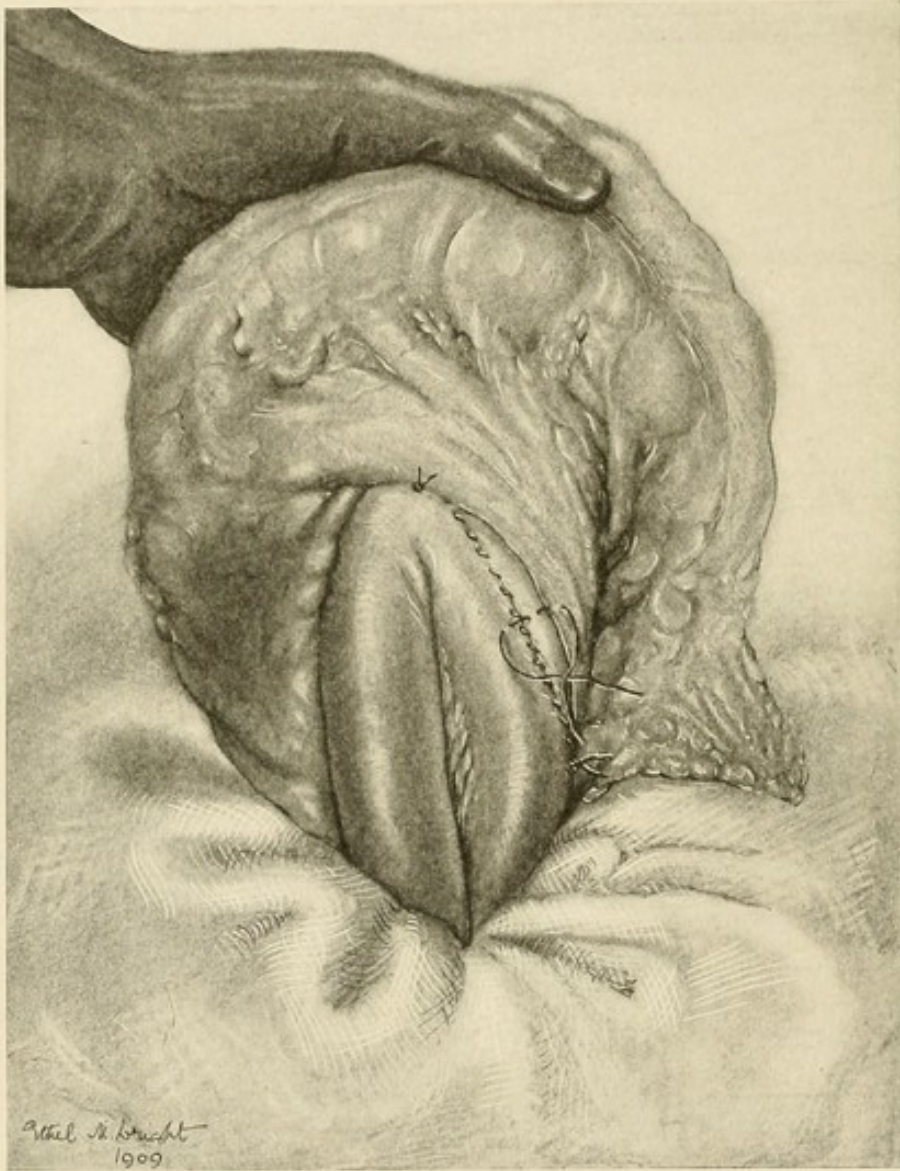


FIG. 39.—GASTRO-ENTEROSTOMY.

The suture line completed. The viscera are lifted out from the abdomen and the mesocolon is sutured to the stomach and jejunum. Note that the stitch is taken a little distance away from the cut edge of the mesocolon, so that the frayed edge of the latter is turned inwards to the lesser sac when the stitch is tied.

then from mucosa to serosa of the stomach. I prefer the latter, for when drawn tight it slightly everts the

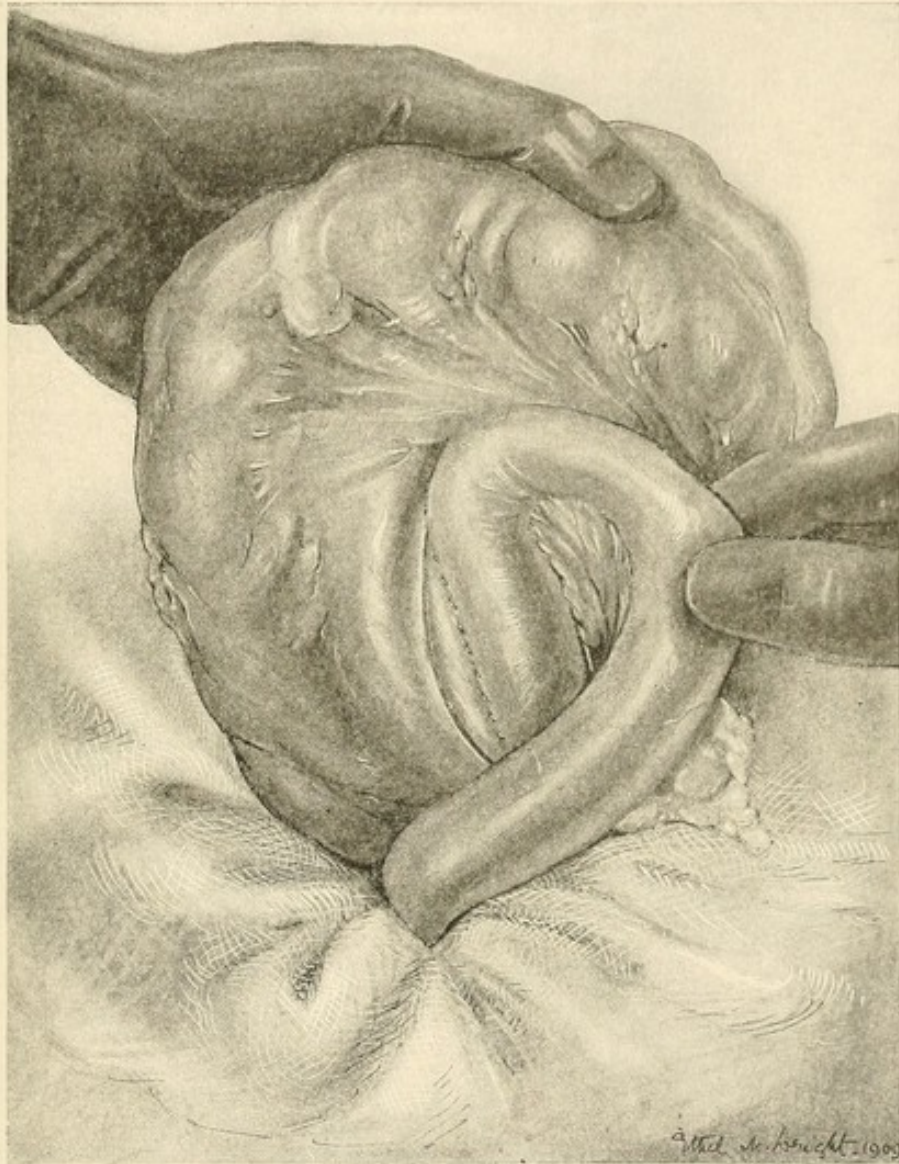


FIG. 40.—GASTRO-ENTEROSTOMY.

The opposite side of the anastomosis. A similar mesocolic suture is taken here.

mucosa; so that when the clamps are removed any small bleeding vessel is seen at once and secured by a separate suture or by a ligature. When the "loop on the mucosa"

stitch is used, some vessel may escape sufficient constriction, and hæmatemesis may be the result. A few of my patients have vomited blood after I had used this suture; it was never serious in any of them, but such an event should be avoided if possible. When the suture has been continued completely round the margins of

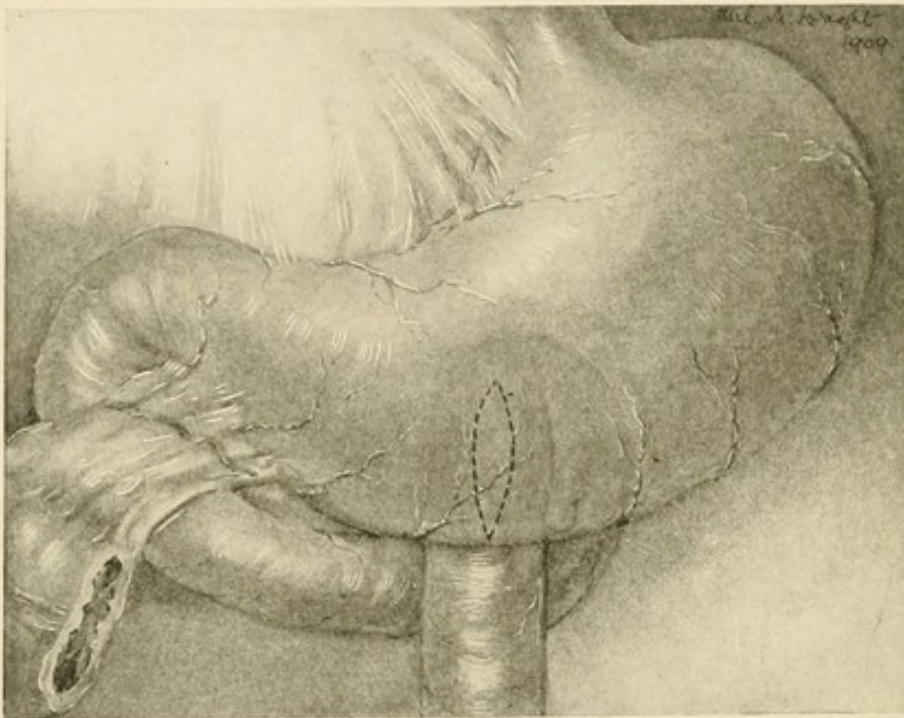


FIG. 41.—GASTRO-ENTEROSTOMY.

Diagram of the operation complete. There is no jejunal "loop," and the opening in the stomach is vertical.

the opening to the starting-point, it is knotted and cut short. The clamps are now loosened, but are left in position, so as to prevent the viscera from slipping back into the abdomen. If any bleeding vessel is seen, it is caught and ligatured. The parts are then wiped a few times with hot moist gauze, to remove all blood or gastric discharge that may perhaps have escaped; the gloved

hands of the surgeon and assistant are thoroughly rinsed and all instruments used up to this point are covered over with a clean sterile towel, and are used no more. The outer sero-muscular suture is now resumed. The needle temporarily laid aside is taken up and the suture continued from the greater curvature up towards its original starting-point near the lesser curvature. After each turn of the needle the thread is drawn tight and a ridge raised up on both sides. It is into these ridges that the needle is next passed. When the suture has returned to the starting-point, a single introduction of the needle is made beyond the first stitch, so as to overlap it. Before the last two or three turns of the needle it is well to remove the clamps, to relieve the little tension of the jejunum especially. A greater security is in this way given to the visceral opposition at the end. The suture lines are now complete and the anastomosis is made. The parts are wiped once again, and the gauze strip which lay behind the viscera removed. The whole suture line is finally inspected.

It now remains to close the opening through the mesocolon with the lesser sac. This is done by passing three or four sutures, which pick up, on the one hand, the under surface of the mesocolon about $\frac{3}{4}$ inch from the edge, and, on the other, the stomach and jejunum exactly at the suture line. When each stitch is tightened, the free rough edge of the mesocolic opening is rolled inwards to the lesser sac, so that only a smooth intact surface presents below. The opening into the lesser sac is thus securely closed, all rough surfaces are avoided, and

the suture line, though it does not need it, is materially strengthened and supported.

The last step is to replace the viscera and to infold the duodenal ulcer. This secure closure of the ulcer I hold to be most necessary; it adds nothing to the risks of the operation, takes only two or three minutes to perform,

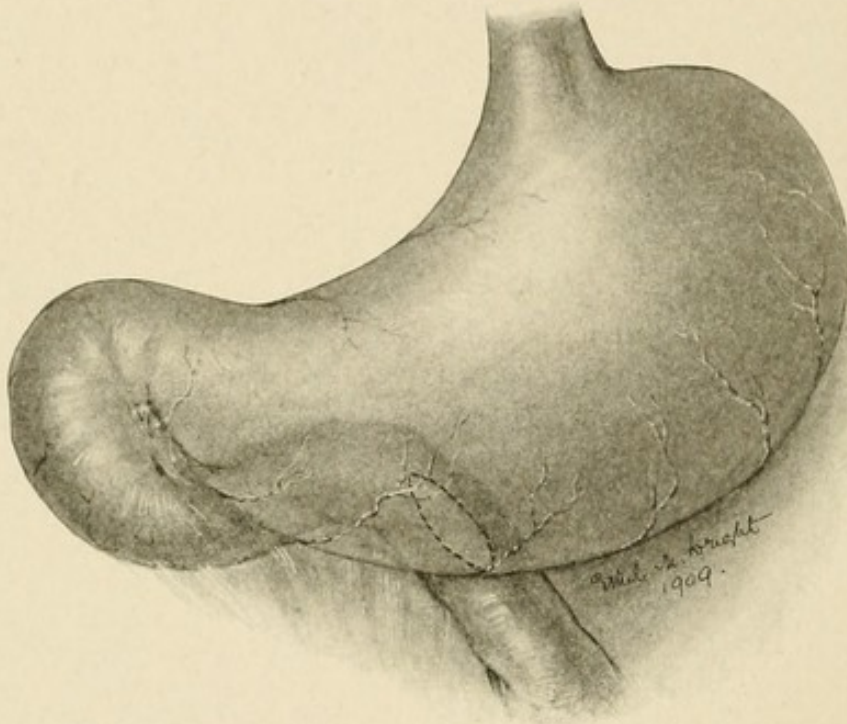


FIG. 42.—GASTRO-ENTEROSTOMY.

The anastomosis may be made "antiperistaltic," the jejunum being directed to the left (after W. J. Mayo).

and removes the contingency of a later disaster. A few interrupted Lembert's sutures are passed from one side of the ulcer to the other, and as they are tightened the ulcer is pushed inwards and infolded (Fig. 43). In some cases anterior gastro-enterostomy, or Roux's operation, may be necessary.

After-treatment.—As soon as the operation is completed the patient is placed in a warm bed, lying on the back with one pillow. After an hour or two—as soon, that is, as the effect of the anæsthetic is passing off—the patient is propped up in bed with a bed-rest or five or six pillows. The position is one of great comfort to the patient, but

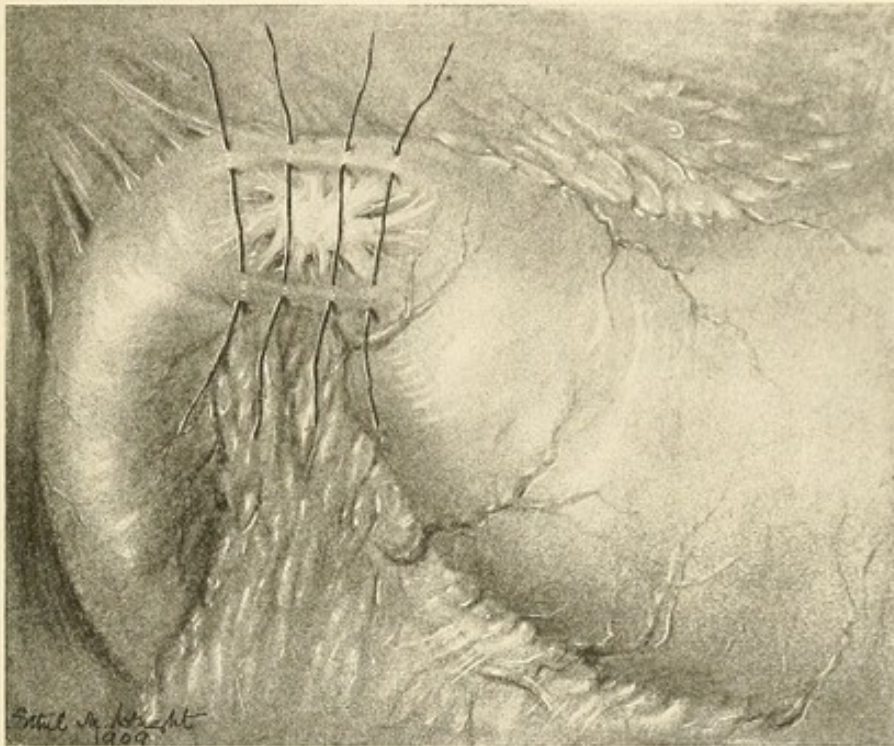


FIG. 43.—INFOLDING OF A DUODENAL ULCER.

Performed as a matter of routine after the gastro-enterostomy is completed.

it is difficult to maintain. There is a very marked tendency, for a heavy man particularly, to slide down in the bed. A most useful device for keeping the patient in the sitting position is that suggested by Dr. Cairns Forsyth. A hard, round pillow, covered with mackintosh and a pillow slip, is placed beneath the patient's thighs, immediately below the buttocks. To each end

of this pillow a stout strap is attached, terminating in a buckle. A second strap is fixed to the upright end of the bed, and its lower end engages with the buckle attached to the pillow; by pulling this strap tight and fixing it, the position of the pillow is made secure. The patient is supported by this pillow quite comfortably, and is prevented from slipping down in the bed. About five



FIG. 44.—ANTERIOR GASTRO-ENTEROSTOMY.

or six hours after the operation the feeling of nausea caused by the ether will have passed off, and the patient begins to ask for fluid. At once water is given, an ounce or more at a time to begin with, and in two or three hours a cup of tea. Most patients like tea better than any other drink; during the first twenty-four hours three or four cups, made to the patient's liking, may be given.

I do not restrict the quantity of water allowed to patients. They rarely drink more than 20 or 30 ounces in the first twenty-four hours, but it is their own desire which

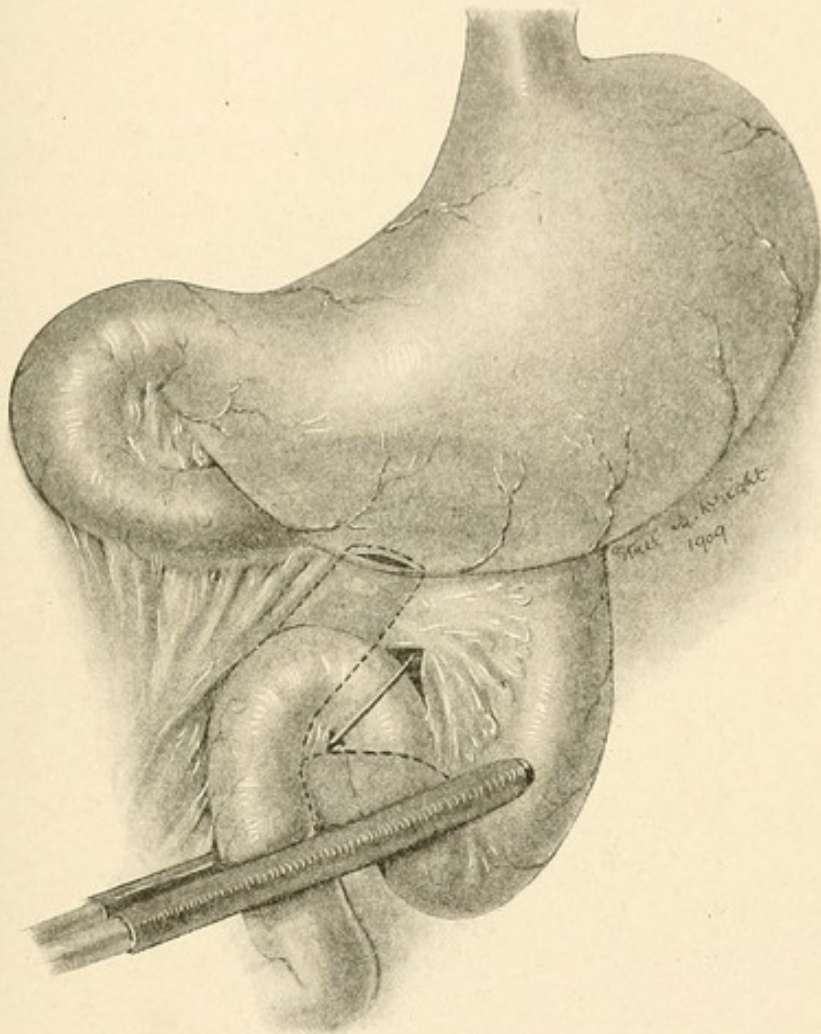


FIG. 45.—GASTRO-ENTEROSTOMY, ROUX'S OPERATION.
The distal end of the jejunum is here united to the stomach: an end-to-side anastomosis.

regulates the quantity given, not any order of mine. There is no harm done by giving fluids freely. If a patient can vomit without injury to the suture line, it is quite certain that the passage of fluids through the

anastomotic opening will do no hurt. For the last three or four years I have put no restraint upon patients in this matter, even from the first. Thirst is the most intolerable of all sufferings after abdominal section, and there is no justification for allowing a patient to suffer from it. Fluid taken by the mouth has to pass to the large intestine to be absorbed. The intestines are kept

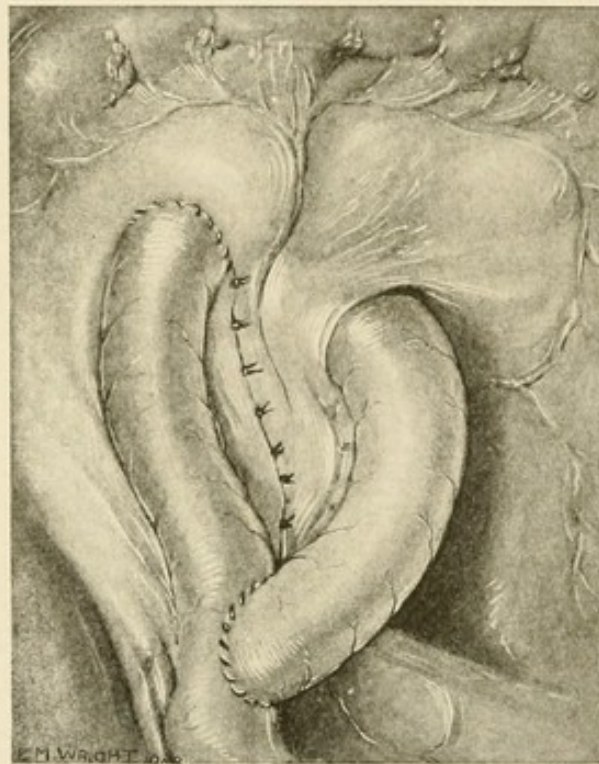


FIG. 46.—ROUX'S OPERATION (COMPLETE).

active therefore, and this is entirely an advantage. I do not order solid food, until a patient himself asks for it. In the early days milk, soups, tea, and cocoa are given freely, but solid food is not desired by a patient until eight or ten days have passed. As soon as the request is made I grant it, ordering sweetbread, fish, bread and butter, mince, and so on, and the quantities

taken are not restricted. In eighteen or twenty days ordinary food can be taken and enjoyed. I discourage

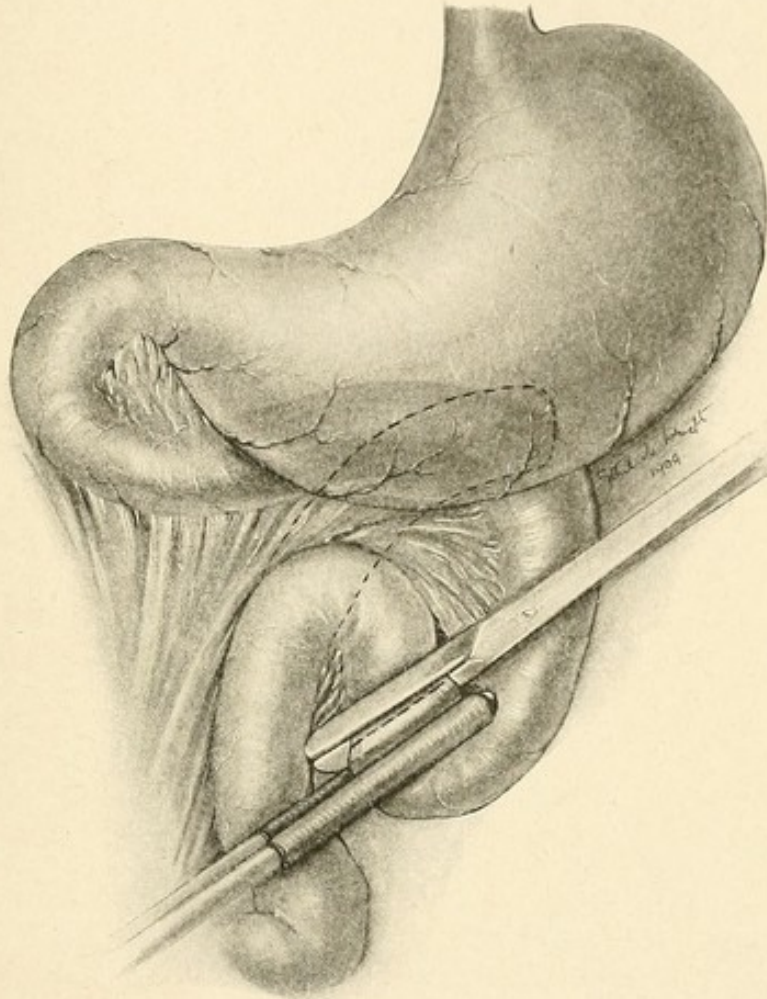


FIG. 47.—MODIFICATION OF ROUX'S OPERATION AS PERFORMED BY THE AUTHOR.

The jejunum is divided between a rubber-covered clamp and a Parker-Kerr clamp. It is cut across with the knife passed as close as possible to the latter. The division is carried on into the mesentery.

pastry, fresh fruits, and green vegetables in all cases for some time, for these things are without value as foods.

On the night of the operation the patient may be allowed $\frac{1}{6}$ gr. of morphine hypodermically. There is

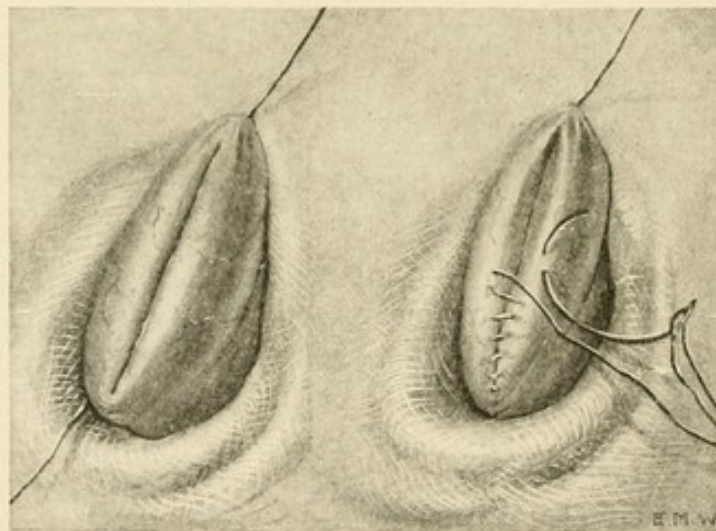
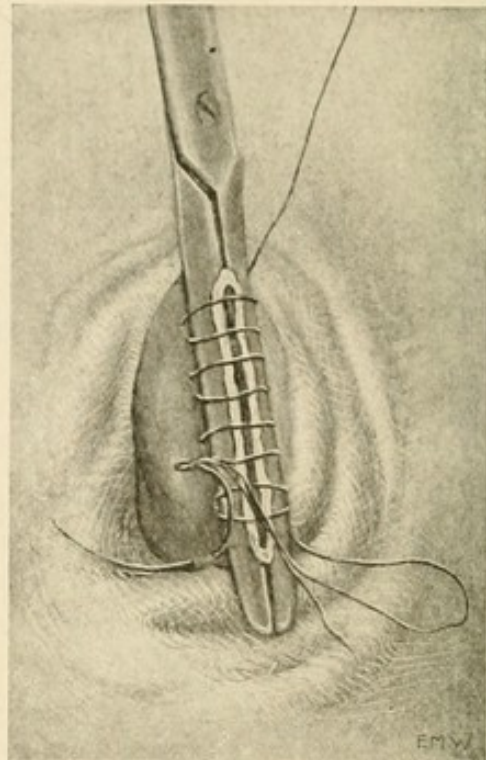
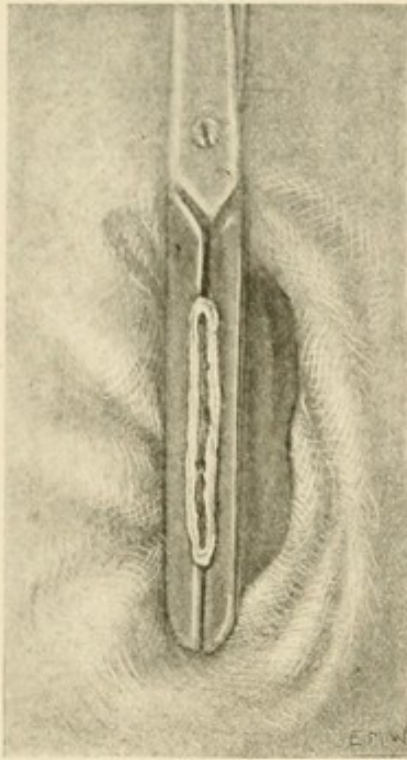


FIG. 48.—MODIFICATION OF ROUX'S OPERATION.

Closure of the distal end of the jejunum. In the figures the bowel should not be seen protruding between the blades of the clamp. The stitch is taken parallel to the blade, first on one side, and then on the other. On reaching the tip of the clamp, the clamp is loosened and removed and the stitch quickly drawn tight; the edges of the gut are rolled inwards and the stitch now returns to the starting-point, where it is tied and cut short. (After Parker and Kerr's method.)

usually not much pain after an operation involving the stomach; but if the patient complains of pain, I do not

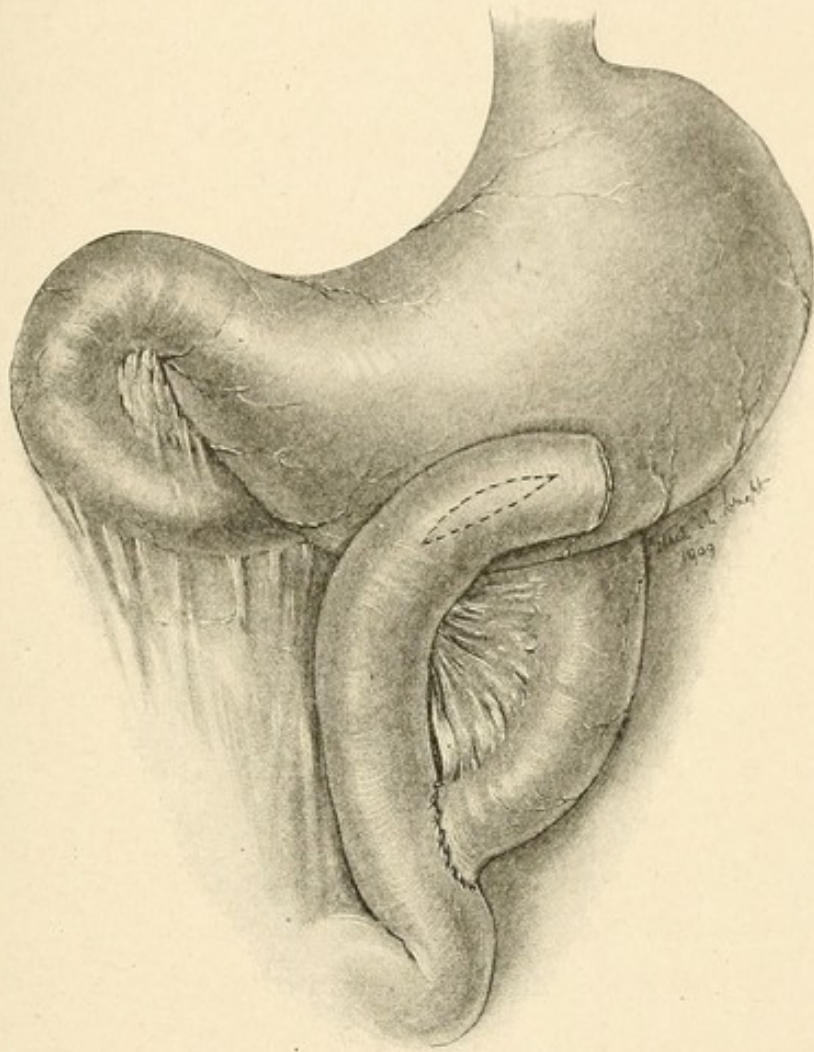


FIG. 49.—MODIFICATION OF ROUX'S OPERATION.

After closure of the distal end of the jejunum, gastro-enterostomy is performed. The proximal cut end of the jejunum is then united to the side of the distal end, about 4 inches below the anastomosis with the stomach.

hesitate to give one hypodermic injection of morphine. It is extremely rare for a second dose to be asked for or to be given. In all cases a simple enema, with or without

turpentine, is given twenty-four hours after operation. Flatus is brought away, and the patient is more comfortable. An aperient, castor oil or calomel, is given about the fifth day. Several times daily the teeth are brushed and the mouth rinsed with some fragrant wash, such as glycothymoline or listerine or odol. The patient is allowed up some time during the second week, usually on the ninth or tenth day.

3. **Resection of the Duodenum, with or without a Portion of the Stomach.**—In some few cases—cases of hour-glass duodenum or of duodenal ulcer associated with a gastric ulcer as to whose condition (whether simple or malignant) some doubt exists—removal of a part of the duodenum may be necessary. If the portion to be removed is small, an end-to-end anastomosis may be practised after the duodenum has been “mobilised” according to the method of Kocher and Finney. In most cases, however, a closure of the divided ends of the stomach and duodenum, followed by gastro-enterostomy, will be necessary. The technical details are in all respects those to be observed in cases of partial gastrectomy, and no special discussion of them here is necessary.

4. **Resection of the Duodenum Alone, the Pylorus Being Left Intact.**—I have only twice practised this operation, which I think in certain cases may prove to be useful. The excision of a cylinder of the duodenum is preceded by the separation of the omenta on the upper and lower borders after ligation. Each end of the segment to be removed is then seized with a clamp, the intervening ulcer-bearing portion excised,

and the distal end closed by suture. The second portion of the duodenum is then lifted away from the hinder wall of the abdomen, and a clamp applied vertically to it. Then the proximal cut end of the duodenum is united by suture to an incision in the clamped second part of the bowels. In the first case in which I performed this operation I made the anastomotic opening too small, and I therefore performed gastro-enterostomy immediately. The second case has been done very well. It is possibly an advantage to leave intact the pyloric valve, whose exquisite mechanism has been described by Pawlow.

CHAPTER IX

PERFORATION

PERFORATION is the most serious of the complications which can affect a duodenal ulcer. When it occurs, the patient's life is in great jeopardy, and recourse to early surgical treatment can alone offer any hope of recovery. It is true that in some cases life may be prolonged for some weeks or even months; but such cases are so infrequent as to form a negligible proportion of the total number, and they are not to be looked upon as offering any support to the view that by medical treatment alone the life of any patient can be saved. Perforation may occur in an acute ulcer, or in a chronic ulcer, and at the extremes of life. The youngest example is recorded by Cecil Finny ("Lancet," 1908, ii, 1748); it occurred in a child two months old. The oldest patient I have seen was a woman aged seventy-seven, who died without operation. The ulcer in the former case was "acute"; in the latter, symptoms had been present for forty years.

ACUTE ULCER

The perforation of an acute ulcer, the type of ulcer occurring in cases of burns, in septicæmia, typhoid fever, etc., is of little clinical importance. In the great majority of the recorded cases, as a reference to the literature will show, the perforation has produced, in patients

already enfeebled by a serious disease, so great a prostration or collapse that a diagnosis does not seem to have been made, and accordingly no attempt to deal surgically with the condition has been suggested. The rarity of the acute duodenal ulcer, its occurrence in people who are already gravely ill from other causes, and the consequent lack of any abrupt transition from health to desperate illness, account for the absence of timely recognition of the catastrophe. There is no reason why, given such recognition, an operation should not be adopted, with a fair chance of success.

CHRONIC ULCER

It is commonly the chronic form of duodenal ulcer which perforates. Though the perforation is "acute," the ulcer in which the perforation occurs is "chronic." In my own series of 11 cases there has not been a single instance of an acute ulcer perforating; in all cases the evidence that the ulcer had long been present was undeniable. Moreover, the ulcer would seem to have been recently the seat of more active pathological changes than were customary: for in almost every instance it had given not only sustained evidence of its presence, but had been responsible for a very distinct exacerbation in the severity of the symptoms for days or weeks before. The perforation occurs, then, as a rule, with few exceptions, in a chronic ulcer, whose symptoms have repeatedly excited attention, and whose increased activity has been announced by the more marked intensity of those symptoms in the recent days. The warning is given, but is consistently unheeded. This fact, to which I have repeat-

edly drawn attention, is of the greatest importance, for it means that with care and timely help the perforation of an ulcer can be prevented, or at least rendered less likely. In a few cases, including two of my own, the catastrophe occurred when the patients were in bed awaiting the performance of gastro-enterostomy which had been arranged for the same day. It is possible that the straining caused by the use of the stomach-tube has a harmful effect. I am well aware of the fact that cases are recorded by various observers in which it is said that no previous symptoms have been present, the patients having taken ordinary diet, without pain or discomfort, up to the moment when symptoms abruptly appeared. Cases are also recorded by Miles ("Edin. Med. Journ.," 1906, ii, 109) and others in which patients who had previously suffered from indigestion had been free from symptoms for a "considerable period" prior to the occurrence of perforation. Before such evidence is accepted, however, we must have fuller details of the history, for patients who at first deny the existence of symptoms will generally acknowledge that they have had "indigestion" so long as to have ceased to remark upon it; it has been a part of their daily condition, to which they submit uncomplaining. The best authenticated case of perforation without antecedent symptoms is given by A. B. Mitchell, who writes:

"A publican, aged forty-three, steadfastly maintained, in face of the strictest cross-examination, that up to the moment of perforation, on 21st July, 1907, he never had any discomfort whatsoever. He was shown by me at a meeting of the Ulster Medical Society on 5th March, 1908, when he stated that he

had remained in excellent health since the operation, seven and a half months previously. Four days later, however, he again perforated without any premonitory symptom. He had been drinking freely, and after operation developed some incipient sign of delirium tremens. On this occasion gastro-jejunosomy was combined with closure of the perforation, with successful result."

This man had been a "steady drinker"—a fact which may account for the latency of his symptoms.

The immediate cause of the perforation is not easy to discover. In not a few cases some definite disturbance is held responsible, such as, a blow on the side, over-reaching, a sudden twist, or coughing or sneezing. In one of my own cases the patient was crushed by a heavy barrel which ran across the abdomen (Case 8). In another case the distension of the upper part of the jejunum and of the duodenum, by reason of the obstruction of the jejunum in a right duodenal hernia, seemed to have burst what was doubtless already a weak spot in the bowel wall (Case 10). In some cases a heavy meal an hour or two before is held culpable. In most of the cases, however, no definite causative factor can be ascertained.

In describing the symptoms attendant upon the perforation of a duodenal ulcer I wish to draw a very necessary distinction between those which are due to the perforation itself, and those which are due to the conditions which are aroused, secondarily, by the perforation. The descriptions which are usually given of the symptoms following upon the perforation are, in fact, complications which early treatment could prevent.

When perforation occurs, there is a sudden onset of

the most intolerable, agonising pain. The pain is hardly exceeded in severity by any that a human being can suffer; the extremity of agony is reached. So profound may the instant impression be, that death results. Some of the so-called "sudden deaths" are due to this form of perforation. I recorded such a case myself ("Lancet," 1901, ii, 1656), and specimen 806 in St. Mary's Hospital Museum, which shews a perforation of a chronic ulcer in the first part of the duodenum, was taken from the body of an Oxford professor, who fell down and died in the street in London. The patient is always prostrate with agony; he looks pale and faint, his face wears a deeply anxious expression, the eyes are wide and watchful, beads of sweat stand out upon the brow, and lines are quickly graven on the cheeks. The patient breathes shortly and quickly; he cannot take a deep inspiration, the attempt to do so ends in a groan or shout of agony and a spasm of pain. The answers to one's questions are given in snatches, and every expiratory phase ends abruptly in a catch. Collapse is certainly not present, however, when the patient is seen within an hour or two, if it is to be measured by the ordinary signs. For the pulse is not rapid, it is usually not more than 80, and its quality is not much impaired. The surface of the body is perhaps a little cold, though not generally so, at first. Any examination of the abdomen is resented. It will be found that the abdominal wall is tight; it is held with a rigidity that never for one instant slackens. The abdomen is retracted, never at this stage distended; that comes later. The extreme tenseness of all the abdominal muscles cannot be induced to relax by any

change of posture; the protective muscular splint is never removed; the muscles are never off their guard. When it is remembered that the diaphragm is also an abdominal muscle, the shallow respiration is at once understood. A careful examination of the abdomen will, I believe, always (though I cannot assert it positively) reveal an area of more exquisite tenderness, and if possible of even more obdurate resistance than the rest. This area will be found to the right of the mid-line and above the umbilicus. In cases of gastric perforation the area varies, in my experience, according to the position of the ulcer. Vomiting may occur at the first, but usually does not; doubtless its presence depends upon the state of repletion of the stomach. I find that it was observed in about 25 per cent. of the recorded cases; it is accordingly of no value as a diagnostic sign. The liver dullness is not impaired, but percussion of the liver, or indeed of any part of the abdomen, is deeply resented by the patient. The symptoms I have described are those due to the perforation, to the sudden onset of the rupture in the ulcer; they are ample to permit of an assured diagnosis of some perforation, and of a probable diagnosis of duodenal perforation, being made. By degrees, however, and as a rule speedily, the symptoms alter, as pathological changes are set going by the escape of fluid through the opening at the base of the ulcer. The chief of these, and the most significant, is the steady, uninterrupted rise in the pulse-rate. As the frequency increases, the quality becomes poorer. If observed from hour to hour, the change is always for the worse, unless morphine be given, when a temporary betterment

is noticed. The abdomen, though it never, or only at the last, when there is profound toxæmia, loses its rigidity, becomes fuller until a uniform and tight distension is found. Tenderness becomes more marked on the right side in almost every instance, and the right iliac fossa may come to be the most exquisitely tender, and on palpation the fullest, region of the belly. The temperature, which at first had been normal or even subnormal, rises a little, and may attain a height of 101° or even more. The breathless condition persists, and increases as the abdomen fills. A livid color comes over the face; the face and the limbs become cold and damp, and capillary cyanosis develops at the last. The duration from perforation to the death of the patient in this condition may vary from two to five days. From the first there is intestinal stasis, as a rule, absolute; neither flatus nor fæces are passed except in response to repeated enemata, and then only in meagre quantity.

Such is the course followed in the majority of cases, unless surgical treatment is adopted. It is modified only by the administration of morphine, which may work wonders in the apparent improvement of the patient's condition. It brings back a look of comfort to the face, warmth to the limbs, and ease from suffering; but its effect is brief, and large and repeated doses have to be given to produce a response. As soon as the effect begins to wear away the pain returns. The constant repetition of the drug will do much to blind the medical man to the true condition of the patient; the symptoms are masked. It is owing to the effect of the constantly repeated doses of morphine, in these and in similar cases,

which improve the patient's condition while they blind the surgeon, that the use of the drug has been entirely suspended in the practice of many. Many of us have become frightened of the drug, quite needlessly, for properly used its value is beyond question.

It is remarkable how constantly the right side of the abdomen is chiefly affected. The tenderness and the rigidity, though everywhere present, are often more pronounced on the right side, at the upper or lower parts, or throughout the whole extent. So often is this the case that a diagnosis of appendicitis has frequently been made, and, indeed, has been acted upon, the appendix being removed without any suspicion being aroused as to the true place of origin of the peritoneal invasion. I called attention to this fact and to its explanation in my first paper on "Duodenal Ulcer" ("Lancet," 1901, ii, 1656). In that article 49 cases of perforating duodenal ulcer treated by operation were reviewed; in no fewer than 19 had a diagnosis of appendicitis been made. The reason for this mimicry of appendicitis is that fluid escaping from the rent in the duodenum trickles downwards to the upper surface of the transverse mesocolon to the right of the hillock which is formed by the fitting in of the transverse colon to the greater curvature of the stomach. It is then directed downwards to the hepatic flexure, and to the outer side of the ascending colon, to fill the "kidney pouch" described by Rutherford Morison. Thence it flows, still in a downward direction, to the iliac fossa and the pelvis. The tendency of the fluid to drift in this particular direction has been

studied experimentally by Maynard-Smith ("Lancet," 1906, i, 895), who writes:

"With a view to investigate the course taken by fluid from a perforated duodenal ulcer I have carried out a series of experiments on the dead body. The pathological condition was reproduced by passing an œsophageal tube into the stomach from the mouth and attaching to it a glass tube which was passed through the pylorus and brought out of a hole in the duodenum in the usual site of perforation. The end of this tube was then tied in flush with the duodenal surface. It was possible to do this without disturbing the anatomical condition of the parts. The incision in the abdominal wall made for the purpose of these manipulations was then closed. By means of a funnel attached to the œsophageal tube fluid was run down it and made its exit into the peritoneal cavity at the site of a perforated duodenal ulcer. The fluid used was water with zinc oxide suspended in it by means of tragacanth emulsion. In every instance the fluid ran downwards in the direction of the right kidney pouch and collected in a space bounded by: in front, the under surface of the right lobe of the liver and the hepatic flexure of the colon; behind, the anterior peritoneal covered surface of the right kidney and the posterior abdominal wall; outside, the curve of the abdominal wall; and inside, the duodenum itself and the foramen of Winslow. In an upper direction this pouch spreads behind the liver, between the viscus and the diaphragm, but here its process is blocked by the inferior layer of the coronary ligament. Away from the middle line, however, it stretches uninterruptedly to the right of the lateral hepatic ligament to the upper surface of the liver as far as the reflection of the falciform ligament. Downward this space is limited in part by the reflection of peritoneum from the hepatic flexure of the colon on to the surface of the kidney and the second part of the duodenum. When fluid had filled up the right kidney pouch, it always followed certain definite paths. It did not pass through the foramen of Winslow into the lesser sac of peritoneum. It had little tendency to find

its way beneath the diaphragm. It always descended along the outer side of the ascending colon as far as the brim of the pelvis. The level of the fluid rose until it reached the level of the pelvic brim. It then overflowed into the pelvis. It must be remembered that this collecting body of fluid is dammed up on the inner side by the ascending colon. If this has no mesentery, the colon may be so bound down into the loin that the level of the fluid reaches above the summit of the ascending colon "dam" before it rises above the level of the brim of the pelvis. In this case the fluid will first leave the right kidney pouch by crossing the ascending colon—usually a few inches below the hepatic flexure. Even if the fluid takes this course, it still tends to flow to the appendix region, guided thither by the obliquity of the mesentery downwards and to the right and by the slope of the abdominal wall away from the middle line. It does not directly invade the left half of the abdomen, but crosses the termination of the ileum and reaches the right side of the pelvis practically at the same spot as before."

The fluid escaping from the duodenum is from the first prevented from going to the left by the peritoneal reflection of the great omentum from the duodenum and the stomach. If the body be erect, the fluid escapes by the low opening in the cavity, and trickles down the side of the colon. If the body be recumbent, the fluid gravitates to the renal pouch. In both positions the foramen of Winslow lies at a higher level and does not allow of the entrance of fluid into the lesser sac.

DIFFERENTIAL DIAGNOSIS

There are very few cases in which a doubt as to the diagnosis should exist. The early history of the case is of the greatest possible significance. In my own experience a perfectly clear account of the characteristic symp-

toms of duodenal ulcer can usually be obtained. It is true that in some of the recorded cases it is said that there were no previous symptoms or that "only a little indigestion" had been noticed. Such statements require close examination; in the light of the more accurate knowledge we now possess as to the characteristic manifestations of duodenal ulcer they cannot be accepted. We know that in all the cases, other than the acute toxic cases, it is a chronic ulcer of the duodenum which perforates; and no chronic ulcer of the duodenum exists without betraying its presence by symptoms which to those cognisant of them are of the clearest significance. Of all the aids to accuracy in diagnosis there is none that can compare with that given by the anamnesis. The character of the pain affords substantial help also; for it is of so intense a severity as to put all but a few of the abdominal catastrophes out of consideration. The pain is overwhelming; it is referred, as a rule, to the whole abdomen; only rarely is it localised to the right side, or is any mention made of pain in the back, or of pain radiating to the clavicle (Crawford Renton) or breasts. Within two or three hours, however, the pain is almost always of greater severity on the right side, and certainly the sensitiveness and the rigidity are excessive there. The rigidity from the first is absolute. No other condition than a perforation of the stomach or the duodenum ever gives rise to such unalterable and unyielding tension in the muscles. Rigidity is a sign common to many acute intra-abdominal diseases; it is, of course, nothing more than a protective barrier to ward off attack or a muscular splint to ensure rest. But in no other disease, as far as

my observation goes, is the rigidity so complete and absolute, in none does it persist so unchanged, as in cases of gastric or duodenal perforation. Rigidity to this extent implies retraction, which does not vanish till the distension due to peritonitis begins to develop; the rigidity, however, does not lessen until toxæmia is profound, and capillary cyanosis with clammy extremities are the plainest warning that death is imminent.

The differentiation of a duodenal from a gastric perforation is not usually a matter of any difficulty. The early history, of course, differs. The character, time of onset, site, radiation, and relief of the pain are all different in the two cases. After perforation it is possible by careful examination of the abdomen to discover an area, both more resistant and more tender than any other; it is almost as though a local phlegmon were present. Beneath that area lies the ulcer, in all probability. Alexander Miles has also noted this fact. He writes ("Edin. Med. Journ.," 1906, ii, 224): "I have found a remarkable correspondence between the site of the maximum tenderness and the seat of the perforation. When the most tender area was in the left hypochondrium, the perforation has almost invariably been towards the cardiac end of the stomach; when around the umbilicus, in the body of the stomach; and when in the right hypochondrium, near the pyloric end or in the duodenum. So constant is this association that I have come to rely upon it as a guide to the site of incision."

As I have already said, the chief pitfall lies in the close mimicry of the symptoms of appendicitis. In both, the attacks begin abruptly, the pain is sudden in onset,

acute, referred often to the epigastrium or to the whole abdomen, and later it is upon the right side of the abdomen that the chief stress of the disease falls. But the history again is the chief factor upon which to place reliance. The perforation in an appendix case is not preceded by any "indigestion," at least not of the characteristic duodenal type. In appendicitis of the acute perforative variety a history of some slight pain or constipation is usually to be heard, and an aperient has always been taken. Acute perforative appendicitis in almost every case I see is caused, immediately, by an aperient. Moreover, the rigidity in appendicitis is not to be compared in intensity with that in duodenal perforation, nor is the agony so intolerable; the diaphragm is not so tightly held, and therefore the breathing is not of the same short, jerky character. In both there is tenderness in the iliac fossa, and in both there may be tenderness extending up to the liver, if the appendix chances to lie along the ascending colon. But the relative tenderness and rigidity are different. In cases of duodenal ulcer they are never lacking in the right hypochondrium; in cases of appendicitis they are only exceptionally there, and then are of no great severity. It is true, as I pointed out, that the mistake most frequently committed before 1901 was that of considering a large proportion of cases of duodenal perforation as cases of appendicitis. But since attention was then drawn to the matter, the mistakes have been few. Before then the operations for perforating ulcer were infrequent; now they are within the province of very

many surgeons, and ease of diagnosis has come with increase of experience.

There are a few cases, it is well to remember, in which the two conditions, appendicitis and perforated duodenal ulcer, have coexisted. Case 6 in my own series of perforation is a good example, and others are recorded by Bolton Carter ("Lancet," 1901, ii, 1195) and Lediard and Sedgwick ("Lancet," 1904, ii, 761), and there are a large number in which a gastric perforation and appendicitis have occurred almost simultaneously.

Acute pancreatitis may present difficulties of discrimination from perforated ulcer of the duodenum. As a rule, there have been no inaugural symptoms in cases of acute pancreatic inflammation; though the occasional dependence of this condition on the impaction of a stone in the ampulla of Vater is evidence that the characteristic "dyspeptic symptoms" of gall-stones may have been present for months or years before. The pain in acute pancreatitis is always worse in the epigastrium, and it is there that the resistance, tenderness, and subsequent distension are found. Acute pancreatitis indeed is often clinically recognised as epigastric peritonitis, and the enlarged and œdematous gland may even be felt on deep palpation. In the cases of acute involvement of the pancreas the pulse is bad from the first; it is always rapid, thin, of poor quality; its rate, indeed, is at first quite disproportionate to the severity of all the other symptoms or signs. Vomiting, too, is more conspicuous, and there is frequently, as Halsted was the first to note, a deep lividity or cyanosis of the skin, chiefly of the face. Pancreatitis often attacks corpu-

lent people, and it is not seldom met with in women during the early months of pregnancy. A general distension of the abdomen is rare in acute pancreatitis; the right side of the abdomen is not specially involved; and the hurried, jerky respiration, due to the fixed contraction of the diaphragm, is not seen. The differential diagnosis should be made with confidence; though I must confess to the commission of the error in the second case of acute pancreatitis that I saw. The patient, a fat man, inclined to the free use of alcohol, had a lividity of the face, and in less degree of the body, which should have given me the clue to a correct diagnosis. The discovery of fat necrosis in the subperitoneal fat made the diagnosis certain before the peritoneum was incised.

One of the most perplexing difficulties which may confront the surgeon lies in the proper discrimination of acute catastrophes arising in the gall-bladder from those which have their origin in the duodenum. An acute perforation of the gall-bladder may present identical symptoms, both local and general; and nothing but a careful analysis of the previous history can ensure an accurate diagnosis. I have only operated upon one case of a ruptured gall-bladder in which the differential diagnosis needed close consideration and discussion. The anamnesis revealed, however, a definite history of hepatic colic, with jaundice on more than one occasion; the local tenderness was wholly disproportionate to the general sensitiveness of the body, and the illness of the patient, which had extended over nearly forty-eight hours, though it was serious, did not seem so desperate

as would have been the case had the duodenum given way.

Perhaps the most disconcerting of the diagnostic disasters which have occurred are those in which an acute thoracic disease has been mistaken for an acute catastrophe in the abdomen, and an operation performed. I have myself been twice summoned to operate for "perforated ulcer of the stomach or duodenum," and after examination have made what proved to be a correct diagnosis of pleurisy and pneumonia. The mimicry is more commonly of appendicitis, however, than of perforation of a duodenal ulcer.

It is extraordinary with what accuracy an acute intrathoracic disease may clothe itself with the symptoms and the signs of an abdominal disorder. In cases of pleurisy, especially diaphragmatic pleurisy, of pneumonia, or of acute bronchitis the onset may be sudden, the pain may be felt exclusively in the abdomen, the abdominal muscles may be tense, and the surface of the body extremely tender. Indeed, unless the close simulation of acute abdominal lesions by disease above the diaphragm be remembered, the most expert of surgeons may be deceived. Both Dr. Maurice Richardson ("Boston Med. and Surg. Journal," 1902, i, 399) and Mr. Harold Barnard ("Lancet," 1902, ii, 280), who almost simultaneously drew attention to this subject, record cases in which operation was unwisely done, and the former, in an article of characteristic literary felicity and charm, gives a detailed account of one case in which he advised against operation in the belief that the patient was not suffering from any abdominal disease requiring it; a colleague

operated at once, and found a perforated appendix and free pus in the peritoneal cavity. The following case related by Mr. Barnard is perhaps the most perplexing of all:

"A girl, aged seventeen, had been attending the out-patient department of the London Hospital for some months for marked anæmia and gastric ulcer. She had had once before a similar attack to the one which I am about to describe. One morning in 1899 she started for work as usual, and on her way was seized in the street with violent epigastric pain and vomiting. She was brought to the hospital at once in a state of collapse. Her pulse was 120 and very thready and her temperature was 104.5° F. Her abdomen was rigid, motionless, very tender, and distended, and these signs were most marked in the epigastric region. She was admitted to the surgical ward as a case of ruptured gastric ulcer, and within two hours Mr. Eve opened her abdomen. He explored the anterior and posterior surfaces of the stomach, the greater and lesser curvatures, but found no trace of gastric ulcer, nor was there any peritonitis. Unfortunately ether was the anæsthetic given. Misfortunes followed fast. Her cough became so violent that a coil of intestine and some omentum escaped between the stitches and had to be washed and returned and the abdomen again sewn up. On the second day after admission it was clear that she had basal pneumonia, but her temperature had fallen to 101°. On the third day it rose again to 104° and signs of consolidation appeared at the left base, and she died on the fifth day from the commencement of the attack. At the post-mortem examination double basal pneumonia and right diaphragmatic pleurisy were found, and in the stomach was a shallow ulcer of the size of a sixpenny piece which was not even near to perforation. There was no peritonitis."

The fact that a lesion lying above the diaphragm may be the whole explanation of symptoms and signs observed below it, is one that the surgeon can never afford to forget.

The points of chief significance upon which stress should be laid in order to prevent a mistake of this sort being committed are: (a) The temperature. This is the most important of all. It is rare in any case of acute abdominal lesion to find the temperature raised to 102° or more. In the acute thoracic conditions the temperature may range between 103° and 105° . (b) Rapidity of respiration; in several of the recorded cases the rate has been 40 to the minute or more. (c) Disproportion between the rate of the pulse and the rate of respiration. The pulse is not much over 100 in the acute lesions within the chest, while the respiration may be between 35 and 45. A pulse-rate of 120 and a respiratory rate of 25 would be more commonly recorded in an abdominal case. (d) The condition of the abdomen in respect of rigidity and tenderness. There is never the same unchanging resistance of the abdominal wall in any chest condition as there is when the lesion is in the belly, nor is the tenderness more than superficial. The area affected is limited and the amount of its involvement is less. When the hand first touches the abdomen, pain may be felt, but deeper pressure may even give relief, and during the respiratory act a moment at the height of the expiratory phase may find the muscles soft and yielding to the hand. (e) Comparative tranquillity at the lower part of the chest, the respiratory movements in the upper costal zone being exaggerated, in cases where the diaphragmatic pleura is inflamed.

The position is very clearly stated by Dr. Maurice Richardson in these words:

"The diagnosis between acute thoracic and acute abdominal disease is always easy as soon as the characteristic signs of either are apparent. The chief difficulty in making a distinction is to recognise that the necessity for that distinction exists, for the thoracic symptoms are always masked by the more conspicuous and distressing abdominal ones. Once the attention is drawn to the possibility of a thoracic cause, not only for the thoracic but for the abdominal symptoms, an accurate diagnosis is perfectly easy."

TREATMENT

In all cases where an acute abdominal catastrophe has occurred the surgeon is called upon to display the best qualities he possesses if a good result to the patient is to be ensured. Quickness in operating, a sound judgment, and the light hand are all essential. When a duodenal ulcer has perforated, these things combined will do much to save the patient's life; absence of any one of them may lead to disaster.

As soon as a decision to operate has been made I give the patient a hypodermic injection of morphine, gr. $\frac{1}{4}$, with or without scopolamine, gr. $\frac{1}{100}$, unless this has been recently administered by the medical attendant. It eases the intolerable agony of the patient, makes the ordeal of preparation for operation less terrifying, and it permits of the giving of a less quantity of ether (the only anæsthetic I allow for these cases) than would otherwise be necessary. The patient will often have a quiet and most refreshing sleep of two or three hours after operation if scopolamine be given, and the nausea caused by the anæsthetic is sensibly diminished. Every instrument is boiled, every needle threaded, every ligature ready to

hand, before the anæsthetic is administered. While the patient is going to sleep the final preparation of the skin of the whole of the abdomen is made. It is in these cases, when the free rubbing of the abdomen has been impossible, that the application of Harrington's solution as the final part of the cleansing proves so useful; it ensures the sterility of the skin better than anything else. As soon as the patient is ready, and not one moment later, the operation begins. The diagnosis will have been made with such confidence that the incision through the right rectus, as for the operation of gastro-enterostomy, will be made. At the moment the peritoneum is incised there is a rush of gas, and a few bubbles escape. The gas and the fluid which rapidly follows are both inodorous and the fluid is usually sterile. The incision in the peritoneum is rapidly enlarged and the exposure of the ulcer is made. As a rule, there is much thick lymph around and about the ulcer, fixing it perhaps to the under surface of the liver or to the anterior abdominal wall. The omentum, the "abdominal policeman" of Rutherford Morison, is attached by recent, thick, moderately firm adhesions to, or near to, the ulcer; it always plays its part in endeavouring to prevent the perforation or to limit the extravasation when the rupture has actually occurred. When the duodenum is thoroughly exposed by the wiping away of the lymph and the mopping up of much fluid, the perforation is exposed. Happily it is in a very great majority of instances on the anterior surface of the duodenum, and immediately beyond the pylorus. Wherever it lies it is brought as far as possible into the wound, and a few flat gauze swabs are packed into the abdomen around it.

They shut off the operation area for a time and they absorb a large quantity of the fluid which has already escaped into the abdomen. The ulcer is then dealt with; it may be excised, or the aperture in its base may be closed up by suture. I do not myself excise the ulcer, because it needs a little more expenditure of valuable time and because closure of the ulcer has, as A. B. Mitchell, of Belfast, has shewn, the precise effect which the removal of the ulcer produces. I close the perforation therefore by suture, using generally a single catgut stitch to bridge the opening and to prevent leakage during the subsequent application of the thread stitches. These are introduced in two layers, generally continuous, but sometimes interrupted. The continuous suture is perfectly satisfactory, and is applied with greater rapidity and ease. If, however, the ulcer is very large, I usually put in a first layer of interrupted sutures, if it appears likely that these will have to be discharged into the intestine. It is best always to place the stitches in such manner that the resulting line of suture is vertical; for by so doing there is less likelihood of any stenosis of the duodenum being caused, and therefore less urgent need of gastro-enterostomy. After the suture is complete a very thorough cleaning of the parts around is necessary, and while this is being done the stomach, which will usually be found distended, may well be emptied and washed out by the anæsthetist. This step, which I first suggested some years ago, is less often practised than it should be, for although the pylorus probably remains closed for a few hours after operation, the stomach contents, often abundant, must either be vomited or

passed out of the stomach through the duodenum over the newly sutured line, or through a new anastomosis made into the jejunum. Not one of the alternatives is desirable or satisfactory; the better plan is to empty and to cleanse the stomach so that rest for a few hours may be secured.

The toilet of the peritoneum is better done thoroughly; between the liver and the duodenum and in the renal pouch of Rutherford Morison there will probably be a large accumulation of fluid and of massive layers of lymph. The latter should be taken away; the former, in so far as it consists of extravasated materials (currants, pieces of vegetables, and other gross fragments of food), must be removed; but in so far as it consists of the thin serous fluid poured out freely by the peritoneum, in response to the alarm of invasion of its cavity, may be left. This latter fluid is certainly sterile, and probably possesses potent qualities for resisting intrusion by any infective agent. The readiest, and in most cases the only necessary, method of cleansing consists in the wiping of all soiled areas with large, soft swabs sodden with hot normal saline solution. The light hand is at all times necessary; the heavy scrubbing of tender peritoneal surfaces is to be avoided. The question as to the use of lavage is one that can only be decided by the conditions disclosed at the operation. If the perforation has recently occurred, and if no foreign materials are found free in the abdomen, lavage is not necessary; and where not necessary, is possibly harmful. But if the soiling is very extensive and of such a character that the peritoneum cannot deal with it; if, that is to say, there are seeds,

currants, lettuce, peas, nuts, bits of orange (all of which I have seen), then free lavage is certainly needful. I am fully aware of the enormous capacity of the peritoneum for dealing with material left behind after various operations; but I am equally cognisant of the limits of its powers, and of the fact that it is most undesirable to test those powers to the furthest limit. Lavage, then, in my experience, though generally unnecessary, is sometimes imperative. It is best carried out by means of a glass funnel with three or four feet of thick rubber tubing attached to it. I prefer to use no glass tube or nozzle at the end; the rubber tube alone is equally efficacious and is not so likely to do harm. Saline solution at a temperature of 100° to 105° is used, and it is important to see that there are no wide variations in the temperature of the fluid introduced. The most common fault is to have the fluid too cold. Before the flushing begins a tube is placed into the pouch of Douglas through a small suprapubic incision. The peritoneal cavity is then thoroughly irrigated, one region after another, in due order. It is best to cleanse the area around the perforation first, then the parts beneath the diaphragm, and then to descend along the outer side of the ascending colon, to the iliac fossa and to the pelvis, and subsequently to deal similarly with the left side. If a special tube is used for irrigation purposes, that invented by Dr. Joseph Blake, of New York, is certainly the best; one acting upon the same principle is used by Mr. Burgess, of Manchester. Drainage should be adopted, I think, as a rule. In cases of gastric perforation I have seen the abdomen almost full of fluid in less than two hours, and the pelvis may be brimming

over with a thin clear or slightly turbid fluid when all other parts of the abdomen are empty. A drainage-tube passed through the lower part of the linea alba will often give vent to a gush of fluid as soon as it reaches the bottom of the pelvis. I use a rubber tube of large size, split along one side from end to end. Such a tube drains the general peritoneum, as Yates ("Surgery, Gynæcology and Obstetrics," 1905, i, 473) has shewn, only for a very few hours; but it is precisely in those few hours that it is necessary. Doubtless much of the fluid that is found in the abdomen in these cases is poured out by the peritoneum in a hurried response to the irritation of contents escaping from the gut, but it is safer not to presume that this is the case; but even so its office has been fulfilled and it may well be allowed to flow away.

The original abdominal incision may be completely closed by tier sutures in the usual manner; it is very rarely necessary to insert a drain here. It is most necessary always to bear in mind the presence of a second ulcer, which may or may not have perforated. In one of my cases of gastric perforation death occurred on the eleventh day, from the perforation of a second ulcer which had not been observed at the time of operation. The perforation of a duodenal ulcer five days after the closure of a ruptured ulcer of the stomach is recorded by Clarke and Franklin ("Lancet," 1901, ii, 1194).

In all cases of duodenal perforation the question must arise as to the need for gastro-enterostomy. When an ulcer has perforated, the closure of the resulting aperture is accomplished by folding in the wall of the intestine. In a tube of the calibre of the duodenum, this results in

narrowing. Even when the suture is made with the finest accuracy, and the stitches inserted along a vertical line, some amount of stenosis is almost sure to follow at once; and in the subsequent contraction of healing this will very probably become more marked. In the first case of perforated duodenal ulcer upon which I operated, so great a constriction of the duodenum was produced by the sutures that I found it necessary to perform gastro-enterostomy at once. I have since then had to carry out a similar procedure in other cases. It was this experience which first led me to advocate the performance of gastro-enterostomy in all cases where a narrowing of the bowel had been at once produced by the application of the sutures, or where it was likely to be caused in the subsequent contractions which would occur in the process of healing. Other writers have since advocated the routine performance of gastro-enterostomy in all cases of perforation of the stomach, but my experience has shewn that this is quite unnecessary. Gastro-enterostomy is only to be done in those cases where an obstruction is present, or is likely to develop. The advantages of gastro-enterostomy are: that it permits a more assured closing of the ulcer, for the surgeon's mind is not filled with misgivings as to whether his suture may be too widely taken; that it allows of the early unrestricted administration of food; that it avoids the recurrence of the ulcer, or the development of a second ulcer, either of which may perforate. A. B. Mitchell records ("Trans. Ulster Med. Soc.," 1908, i, 68) a case in which perforation occurred on July 21, 1907; the ulcer was closed by suture and the pelvis drained; a second perforation occurred on March 5, 1908,

and a second operation—closure of the ulcer and gastro-enterostomy—was performed with success. I believe it to be the best practice, therefore, to close the ulcer so efficiently as to cut off the pyloric outlet from the stomach, and to perform posterior gastro-enterostomy (or anterior, if thought better) at once. In my own series of 11 cases gastro-enterostomy was done immediately in 4, and became necessary at a later date in 1. One of the patients (Case 8) would certainly have needed a short-circuiting operation had he survived. As soon as the patient is returned to bed, he is propped up in the sitting posture, and continuous rectal infusion (Murphy's method) is at once begun. This I consider a most essential feature of the treatment, and I feel that no small measure of the success attained in recent cases is attributable to this procedure. The sitting position is more comfortable for the patient, and allows drainage to occur to the pelvis, which is tapped by the rubber tube. The mouth is flushed frequently, the teeth brushed, and the tongue kept clean. After the first six or eight hours fluid may be given by the mouth; there is, however, rarely any thirst if the fluid is properly introduced into the rectum. The rubber drainage-tube remains in for about thirty-six hours, more or less, according to the amount of fluid which is discharged through it. An aperient enema is given every twenty-four hours; a hypodermic injection of eserine sulphate, gr. $\frac{1}{100}$, in doses repeated at intervals of two hours until three or four doses have been given, if flatulence is troublesome; and a dose of castor oil or other laxative is given on the evening of the third day.

The treatment of perforating duodenal ulcer has now

attained a remarkable degree of safety. The best record of which I have knowledge is that of Mitchell, of Belfast, who has operated on 16 cases with 16 recoveries—a record of which this accomplished surgeon may well be proud. A record of 10 cases is contained in a paper of the first importance by Alexander Miles (“Edin. Med. Journ.,” 1906, ii, 106).

The first successful case of operation for perforated ulcer of the duodenum is recorded by Dean (“Brit. Med. Journ.,” 1894, i, 1014); the patient died two months later from ileus. The first completely successful case was treated by Dunn (“Brit. Med. Journ.,” 1896, i, 846).

SUBACUTE PERFORATION

The foregoing description applies to cases of acute perforation. I shewed some years ago that in a few cases the perforation was less violent, in its character and in its results, than this, and that, accordingly, a condition of “subacute” perforation should be recognised. I have discussed this condition in full and reported a series of cases illustrating it (“Annals of Surgery,” 1907, xlv, 223). The condition of “subacute” perforation of an ulcer in the stomach or in the duodenum is one which has received less attention than it merits. It is not infrequent, it is of great interest, and its discrimination from “acute” perforation is of no little importance from the therapeutic standpoint.

In subacute perforation of the duodenum there is a sudden rupture of an ulcer, an ulcer which, without exception in my experience, is of the “chronic” type. The chronic ulcer, with its deep excavation, its steep edge,

and its surrounding induration, has eroded the walls of the stomach little by little, until finally and abruptly the thin barrier between it and the peritoneal cavity is broken through. The conditions are, up to this point and in these particulars, in no way different from those existing in "acute" perforation. But whereas in the latter form the rupture is of fair size and at once allows the contents of the gut to spread themselves freely over the general peritoneal cavity, and to cause there a universal infection, in subacute perforation there is, by one agency or another, a definite localization of the fluids escaping from the stomach, and in many instances a narrow circumscription of the peritoneal response to their invasion.

It becomes a matter of interest, therefore, to know the circumstances under which this limitation is affected. I have seen examples of the following:

(1) An empty condition of the stomach. In "acute" perforation the stomach is often full; the rupture of the ulcer, it is frequently remarked, occurs soon after a meal. If the stomach be empty, say five or six hours after a meal, perforation may still occur, but there is, of course, little or no escape of contents. In such circumstances the ulcer may be ruptured by a violent strain, a sudden movement, or a severe shake. It is not long before a most vigorous defence is made by the peritoneum, lymph is thrown out copiously in flakes, and a thin serous fluid begins to fill the peritoneal cavity. The escaping contents of the duodenum, being small in quantity and feeble in bacterial activity, are rapidly circumscribed.

(2) The plugging of the opening in the ulcer with a tag

of omentum. Of this I have seen one perfect example. The ulcer was close to the pylorus; its opening small; into this opening there fitted, as accurately as any cork, the bulbous end of a thin omental tag which came upwards from the greater curvature of the stomach. There was not any adhesion of the stomach to the abdominal wall or to the overhanging liver; nor was there need for any, for a more perfect plugging of an opening could not be conceived. The little omental tag seemed quite to have grown into the opening which it so securely closed.

(3) The opening may be sealed over by layers of plastic lymph. When the abdomen is opened, a clear and slightly turbid fluid is found, but no ulcer is apparent. At some part of the stomach wall a thick adherent mass of plastic lymph will be seen, as thick as wash-leather, and in appearance very similar. On peeling this off a small perforation is found, from which a bubble may be squeezed. This condition may be a later stage of that already referred to (No. 1), but it is equally possible that, as the ulcer deepens, the peritoneum is irritated, and protectively deposits layer after layer of lymph upon the outer side of the base of the ulcer, so that when the final dissolution of the wall occurs there is already a barrier, almost or entirely impenetrable, to check the escape of the stomach contents.

(4) The duodenum becomes adherent at the base of the ulcer. The adhesion may be to the anterior abdominal wall, to the under surface of the liver, or to the pancreas.

Symptoms.—In every particular save one, that is, intensity, the symptoms are the same in subacute as in

acute perforation. There is a sudden onset of pain, severe and almost intolerable, but measurably less than in acute perforation. The pain comes almost without exception in those who have suffered for years or months from the usual symptoms of duodenal ulceration. There are some cases in which there has been a notable exacerbation of pain in the days preceding the rupture; the patients have explained to me that the body or side felt stiff and sore; that laughing or stretching, as in reaching up to a high shelf, caused great discomfort. These inaugural symptoms of perforation are important, and if the practitioner chances to hear of them from a patient whom he knows to have an ulcer in the stomach, he could accept them as undoubted evidence of impending perforation. In my own experience perforation of an ulcer has not occurred without a previous history of duodenal ulcer being given. The pain is sudden in onset, and may be followed rapidly by vomiting and prostration. The abdomen on examination is everywhere tender. A careful examination may reveal an especially tender and resistant area. A patch 2 or 3 inches in diameter may be excessively sensitive, and on palpation it may seem as though a flat, hard disc has been inserted in the abdominal wall.

The symptoms abate slowly. The pulse does not increase, its character improves, vomiting ceases, the abdomen, which was hard and retracted at the first, may become supple except at the one spot, or it may be a little distended, and free fluid may possibly be recognised. The patient's condition may indeed, at this stage, be so satisfactory, as compared with the initial condition, that

the diagnosis may be in doubt. If indeed morphine has been given, as it still very often is, in repeated doses, the aspect of the patient may be little different from the normal. If no operation is practised at this time, there are three directions which affairs may take: either a periduodenal abscess may form, or a secondary rupture into the general peritoneum may occur, or the adhesion of the ulcer to the abdominal wall or liver or pancreas may become firmer, the acute inflammatory conditions subside, and the patients live for many years with a chronic ulcer whose base is formed by one of the structures already mentioned. Of the three, I believe the last to be the most common.

Differential Diagnosis.—The conditions likely to be confused with subacute perforation of the stomach or duodenum are few. The chief difficulty in diagnosis arises in discriminating a subacute perforation near the pylorus from a condition of cholecystitis. In both, there are pain, sudden in onset, severe and possibly colicky; in neither is there any general invasion of the peritoneum; in both a localised peritonitis with a tender resistant area is recognised. The previous history may afford a clue, but is not likely to do so. Lund ("Boston Med. and Surg. Journ.," 1905, i, 516) gives notes of a case in which it was considered possible that a perforation of a malignant growth in the colon had occurred.

Treatment.—If the patient is seen at the time of the onset of perforation, I think there can be no hesitation in advising instant operation. In the first place, accurate and unequivocal discrimination between acute and subacute perforation cannot be made, and by delay

valuable time may be lost. Moreover, though it is true that many of the subacute cases, with rest in bed, abstinence from food, and so forth, may progress to the chronic stage, there are indubitably other possibilities which, when reckoned with, make early operative treatment the safe and prudent course. In all the cases I have seen in the early stage I have operated and have cleared the ulcer of adhesions, infolded it, and occasionally sutured a flap of omentum over the line of stitches. I did this at first because I did not distinguish between the acute and the subacute cases; I did it subsequently because it had seemed to be the right course to have pursued in the early cases. Dr. Lund has, however, suggested ("Boston Med. and Surg. Journ.," 1905, i, 516) that since the perforation is already sealed off, there is no need to expose and then close the rent afresh, and that, accordingly, the proper course is to perform gastro-enterostomy forthwith, leaving, if possible, the ulcer and its secure barriers untouched.

CHRONIC PERFORATION

In chronic perforation of the duodenum the ulcer destroys the coats of the bowel in a very leisurely manner; as the serous coat of the gut is reached a protective barrier of lymph, probably reinforced by the omentum, is raised so as to guard against a rupture into the general peritoneal cavity. By the time the last thin layer of the duodenal wall is destroyed the contents of the bowel are prevented altogether from escaping, or are restricted to a very limited area surrounded by recently formed adhesions. In these circumstances a cavity of gradually

increasing size develops and the contents become purulent. A periduodenal abscess results. There are probably other though less numerous cases in which the conditions are different from this. The perforation may perhaps occur suddenly, and no restrictive barriers are present, but the perforation is of so very minute a size or the duodenum is so empty that the leakage is excessively small. The bastion of lymph is then thrown out and all subsequent leakage is limited to an area to which the bounds have already been firmly set. In this case, too, a periduodenal abscess results. In both, the communication with the duodenum may be shut off completely, or may be closed in such manner as to give way when the abscess has been opened. A duodenal fistula then results.

When an abscess has formed around the perforation in the duodenum, it increases slowly in size and eventually may terminate by rupture in one of several directions. Krauss in his monograph ("Das perforirende Geschwür im Duodenum," Berlin, 1865, August Hirschwald, p. 33) first called attention to this condition and asserted that the abscess always burrowed in a backward direction. He quotes three cases in which this had been observed. The first (Förster: "Würzburg med. Zeitsch.," 1861, ii, 162) occurred in a student nineteen years of age, who had suffered for some time from pain and fullness in the stomach region one to two hours after a meal, and who died rapidly after the sudden onset of acute peritonitis. At the autopsy there were found two perforating ulcers of the duodenum: one on the anterior surface which penetrated into the general peritoneal cavity;

one on the posterior surface which communicated with an abscess which had encroached upon the retroperitoneal space, and had burrowed along the greater vessels, until it reached the neck, where the skin was thin, emphysematous, and reddened. The periduodenal abscess was pointing in the neck. In the second case the abscess pointed between the seventh and eighth ribs posteriorly; and in the third a swelling hard and tender lay at the tip of the right scapula. In the "London Medical Gazette" (1829, iii, 43) Streeton records a case of chronic duodenal perforation occurring in a phthisical woman of thirty-nine. A hard painful tumour formed at the angle of the right scapula and burst; later on a second abscess a little in front of this formed and discharged. After a short time the gastric contents escaped from the sinus within five minutes of ingestion. At the autopsy a perforating ulcer at the junction of the first and second portions of the duodenum was found and from this a fistula led to the opening on the surface of the chest.

Almost any direction may be taken by the pus in its insidious progress. Hoffman ("Virch. Archiv," 1862, xlii, 218) related the case of a woman aged sixty-three who suffered from a chronic perforation of the duodenum. A circumscribed peritonitis resulted and pus formed. The common duct was compressed to closure and jaundice followed. The gall-bladder was penetrated, so that bile escaped into the abscess cavity and thence into the duodenum, through the aperture of perforation. The purulent material in the abscess tracked downwards along the ascending colon to the iliac fossa, and, there collecting, burst at last into the cæcum. A case is re-

corded by Perry and Shaw (Case 211, p. 270) in which a chronic perforation of the duodenum led to an abscess which occupied both iliac fossæ and the pelvis. Four incisions were made, in the loin and iliac fossa of both sides, and pus was drained therefrom for six months, until the patient died.

An interesting case is recorded by Meunier ("Bull. Soc. Anat.," 1893, lxxviii, 487). The patient was a man aged sixty-one, who suffered from indigestion for months before admission to hospital, where he was found to have a dilated and hypertrophied stomach and a tumour (neoplasm?) beneath the right costal margin. He died greatly wasted from gradual inanition and exhaustion. At the postmortem examination an abscess cavity was found on the under surface of the liver; it was circumscribed and its walls were of great thickness. It contained a purulent fluid and was traversed by the duodenum, which was completely severed, as though divided by scissors. The point of division was 3 cm. beyond the pylorus. I can find no report in the literature of so great a destruction of the duodenal wall by ulcer as is described and figured in this case.

The abscess which forms may reach the anterior abdominal wall. Bucquoy ("Arch. Gen. de Méd.," 1887, i, 414 et seq.) records the case of a woman thirty-two years of age who had suffered for a long period from symptoms suggestive of ulcer of the duodenum. Finally after a severe attack of colicky pain a tumidity, at first dull, but later tympanitic, developed on the right side of the abdomen. An abscess opened close to the umbilicus and discharged intestinal contents until the

patient's death. Luneau ("Bull. Soc. Anat.," 1870, xv, 429) gives details of the case of a man of fifty-eight who had suffered from indigestion and hæmatemesis for some weeks. Two or three small abscesses formed in the anterior abdominal wall, burst, and healed. Three months later a large abscess formed and burst "in the gall-bladder region." The half-digested contents of the stomach escaped from the fistula which remained, and continued to do so until the patient's death from inanition eighteen months later. At the postmortem examination a large irregular abscess cavity was found which extended upwards above the liver, and occupied a large space in the abdominal wall in front of the parietal peritoneum.

It is clear from this brief record of cases that an abscess which forms as a result of the languid perforation of the duodenal wall may burrow in any direction and may reach the surface of the body in almost any near region. The fistula which then results, the "external duodenal fistula," as it may be called, gives passage to a greater or smaller quantity of fluid according to its size and position. The escape of this fluid deprives the body of a great part of the material upon which it depends for sustenance, and inanition gradually becomes pronounced. Death comes at last from sheer deprivation of food—starvation. A fatal termination is only to be avoided by the early adoption of surgical treatment on the lines to be presently discussed.

Treatment.—The treatment of a periduodenal abscess is carried out by the same means as hold good for other localised collections of pus in the abdomen. The

matter is evacuated and drainage instituted. In some cases this will suffice; the cavity grows by degrees smaller and smaller and eventually closes altogether. But in other cases, unhappily more numerous, the opening of the abscess, or its spontaneous evacuation, results in the formation of a fistula for which surgical treatment is urgently needed if life is to be saved. The method of treatment which was suggested by Berg ("Cent. f. Chir.," 1903, 556) consists in the performance of gastro-enterostomy together with occlusion of the pylorus. It has been shewn by the work of Kelling ("Arch. f. klin. Chir.," 1906, lxx, 289) that if gastro-enterostomy is done when the pylorus is patent, all the food continues to pass by the duodenum, and that as a rule none, but at the most a very little, of the food escapes through the new opening. That this experimental observation holds good in the case of a man or woman afflicted with an organic lesion of the stomach is now a generally accepted belief. Berg's suggestion was that a new outlet should be effected to the stomach by the performance of gastro-enterostomy, and that the food should be compelled to pass along this new path; this is secured by closing the original outlet by sutures or by a tape tied round the pylorus. Berg ("Annals of Surgery," 1907, xlv, 721), in a further article, mentions that he had lost one patient in three days after the establishment of a duodenal fistula. He then records in detail two cases in which he adopted his own proposal, performing gastro-enterostomy and occlusion of the duodenum. Both patients died, though they lived long enough to demonstrate the sound-

ness of the operative procedure which had been followed. The following is the report of his second case:

"Chas. A. W., a native of England, fifty-two years old, and a mechanic by occupation, was seen by the writer with Dr. Matthews on February 11, 1906. For two years prior to the present illness he had suffered with attacks of vomiting, not associated with the taking of food. On February 1, 1906, the patient was suddenly seized, while at work, with severe abdominal cramps, which subsequently localised themselves to the right iliac fossa. He vomited at the onset, but had no fever or chills. His bowels were constipated. With rest in bed and local applications of ice, he improved, and three days later got up. Twenty-four hours before I saw him, while he was sitting by the stove, he was again suddenly seized, after a severe sneezing spell, with acute abdominal pain and vomiting. The pain was most severe just below the free border of the ribs on the left side. On physical examination, the heart and lungs were normal. The abdominal wall was of board-like rigidity and did not move with respiration. The liver dullness was replaced by dull tympanitic resonance. There was dullness in both flanks, which did not, however, shift with change in the patient's position. There was an area of dullness in the right hypochondrium which corresponded to an ill-defined mass about the size of a teacup saucer. His temperature was 100°, his pulse 108. Diagnosis: Ruptured duodenal ulcer, with encapsulated periduodenal exudate. Immediate laparotomy was proceeded with at Mt. Sinai Hospital. An incision was made over the mass through the right rectus muscle. Immediately on incising the peritoneum fresh adhesions were encountered to the right of the suspensory ligament of the liver and extending downwards to the umbilical region. The adhesions were carefully separated and the peritoneal surfaces thus exposed at once protected by gauze packings. On separating the adhesions towards the liver a large, foul-smelling gaseous abscess containing about a pint of creamy pus was entered into and evacuated. After the pus was removed a perforation was found on the anterior surface

of the first part of the duodenum about the size of a pea, with gangrenous edges; the surrounding peritoneal surfaces of the stomach and duodenum were covered with necrotic fibrin and pus. After this latter was carefully removed the perforation was closed with three layers of Lembert sutures placed in the vertical axis of the duodenum. The abscess cavity was drained and the abdominal wound closed with layer suture down to the emergence of the drains. The patient reacted well from the operation. The highest temperature and pulse for the following week were 100.6° and 104 respectively.

"No drink or food was allowed by mouth for five days, rectal nourishment and saline subcutaneous infusion being used to replace them. On February 18th, *i. e.*, seven days after the operation, there was noticed for the first time an escape of gastric contents and bile from the drainage openings. Recognising at once the fact that we had to deal with a duodenal fistula that, on account of the changed character of its surrounding peritoneal surfaces, could not be closed by suture, and profiting by the sad experience gained in previous cases of duodenal fistula, in which death from inanition and exhaustion followed after forty-eight to seventy-two hours, I at once proceeded to carry out the suggestion I had made in 1903, *viz.*, gastro-jejunostomy with pyloric exclusion. A posterior gastro-jejunostomy without a loop by the suture method was accordingly made, but instead of occluding the pylorus, I sewed up again the opening in the duodenum, hoping thereby to avoid all danger from a possible cutting through of the occluding pyloric suture.

"The patient bore this operation well, and for two days there was no escape of gastric or duodenal contents. Then the suture line in the duodenum again gave way and there was a renewal of the leakage. It was noticed that after the patient took some milk by mouth there would be, within ten minutes, a discharge of milk from the duodenal fistula, and within fifteen to twenty minutes more, approximately all the milk that had been ingested had escaped from the duodenal opening. The wound in which the fistulous opening lay was so infected that I now hesitated, from fear of infecting the

peritoneal cavity, to expose the pylorus sufficiently through it, in order to enable me to pass an occluding ligature around it. I therefore made several further attempts to close the duodenal opening by suture, but each time after twenty-four hours the sutures would cut out and leave the opening as before; and each time the duodenum was open, whatever was taken into the stomach would practically all be discharged through it within fifteen to twenty minutes after it was ingested. On February 28th, *i. e.*, ten days after the gastro-jejunosomy, I was compelled by the progressive deterioration of the patient to brave the danger of a peritonitis, and to mobilise the pylorus and surround it by an occluding ligature, using for the latter a broad piece of tape. This was passed around the pylorus snugly enough to effect approximation of its walls, but with no constriction of the parts, and held in place by a silk suture, the knot of which rested on the tape and not on the pylorus itself, thereby avoiding pressure from it upon the pylorus.

"Immediately after this operation the patient was given 6 ounces of milk and water. There was no leakage, nor was there any further leakage from the fistula during the next twenty-four hours. The patient's strength, however, was so much exhausted by the intermittent but continued discharge of chyme and duodenal contents that he did not rally from this last operation and succumbed the next day.

"Post-mortem examination revealed a gastro-jejunal orifice patent for three fingers, and a ruptured duodenal ulcer."

This procedure would, I think, be improved by merely infolding the pylorus, or the stomach in front of the pylorus, by superimposed sutures applied in the same manner as when an ulcer is infolded and buried.

The following case of duodenal fistula occurred in the practice of my colleague, Mr. Lawford Knaggs, who has very kindly given me details of the history for publication.

Stella R., aged seventeen, was admitted to the Leeds General Infirmary on October 27, 1906. She had previously been an in-patient from September 27 to October 30, 1905, for cystitis, from which she had quite recovered. At the time gonococci were said to be present in the urine.

Three months before her admission under Dr. Barrs she began to have attacks of sickness and diarrhoea, and passed a little blood. The sickness came on after taking food, and she would usually vomit once a day, but occasionally she would go for six or seven days without doing so. She also had pain which came on a quarter of an hour after a meal, lasted about an hour, and went away gradually. This condition persisted until the week before admission, when she became worse. She had lost flesh.

On admission nothing abnormal was found on examination of the abdomen and nothing definitely wrong in the chest, though a slight taint in the family history, nocturnal perspirations, and a rather rapid pulse suggested the possibility of tubercle. The urine was normal.

At first the pain and sickness disappeared, though the patient was put upon ordinary diet, but about November 7th she complained of pain in the right hypochondriac region and the temperature rose and gradually assumed an intermittent type. On December 12th a mass was noticed in the right loin, and the right knee was partially flexed and drawn up. On the 15th there was exquisite tenderness at the bottom of the right side of the chest. On January 9, 1907, under anæsthesia the swelling on the right side of the abdomen was hard and could be felt to disappear under cover of the ribs. It was largest just before it did so. Its boundaries were vague.

On March 14th she was transferred to the surgical side, where the condition was regarded as a subacute suppuration under the psoas sheath, producing flexion of the hip and lordosis.

On January 23d an incision was made in the right loin through muscles that were very firm from inflammatory infiltration. An abscess was opened by manipulation with

the finger through an indurated mass, and alone an ounce of pus escaped and a drainage-tube was inserted.

On March 6th, drainage not being satisfactory, the resulting sinus was opened up, and owing to the disappearance of the induration a considerable cavity could be explored. It was still regarded as situated under the psoas fascia.

On March 25th a portion of orange pulp was noticed on the dressings, and it was then realised that the curious odor of the discharge which had been noticed for several days was due to gastric fluids. There was no trace of bile or of fæces.

Charcoal made its appearance on the dressings four hours after it had been taken. She remained an in-patient till April 16th, when the wound had contracted to the drainage-tube track, but there was still a considerable discharge, having the peculiar odour just referred to, and in which evidence of fluid food was frequently observed. She was now sent home, in the hope that the communication that existed with the stomach or duodenum would gradually close.

She was readmitted on June 13th. No alteration in the amount or character of the discharge from the sinus had taken place, and whenever charcoal was swallowed some of it came away from the sinus in from two to five hours. Occasionally bubbles of gas escaped, and the patient stated that a "rush" of discharge would occur when she was actually masticating her food.

On July 3d the abdomen was opened. Considerable evidence of past inflammation was found in the neighbourhood of the duodenum. The adhesions which existed between the under surface of the liver, the duodenum, the pylorus, and the transverse mesocolon were numerous but not tough. Their separation before the duodenum could be examined caused some trouble. The only trace of ulcer that could be detected was at the posterior surface of the pylorus. The finger pressing upon the anterior wall was felt to impinge upon a depression as big as a threepenny piece. This part of the pylorus was movable to a certain extent. The stomach was quite healthy. A posterior gastro-enterostomy was performed, and then the pylorus was infolded by two rows of Lembert sutures about $1\frac{1}{2}$ inches long, one over the other.

In this way the pyloric end of the stomach was converted into a solid roll a little thicker than the thumb.

After the operation the sour odour at once disappeared from the discharge and no more particles of food were ever seen. The next day bile, which had never escaped before, was mixed with the discharge, and persisted for about a week, gradually diminishing.

The patient left the hospital on August 20, 1907, when the discharge from the lumbar sinus had diminished considerably. The charcoal test was now always negative. A small sinus persisted for a long time, but had finally closed in April, 1908. Her general condition after the abscess cavity was thoroughly drained was always satisfactory, and for the last year or more she has been the picture of health.

The following is a list of my cases of perforating duodenal ulcer.

CASE 1.—April, 1900; male, aged forty-four. Symptoms had been present for eighteen months; the chief of them was pain two, three, or four hours after food. Blood had been observed when the patient vomited; vomiting was frequent but irregular. There was no melæna. On the 25th while in the Infirmary the man became suddenly worse; pain came on acutely in the whole abdomen. Distension and rigidity were soon observed. Collapse was pronounced. The respirations were 28 and the pulse was 128. A diagnosis of perforating ulcer was made and the abdomen was opened. The ulcer was found at the beginning of the second part of the duodenum; its diameter was about three-quarters of an inch. After stitching the ulcer up, the gut was narrowed to at least half its diameter. A gastro-enterostomy with the aid of a Murphy's button was therefore performed. The patient never rallied from his collapse. Time of operation after perforation about twenty-six hours.

CASE 2.—June 18, 1901; male, aged twenty-five. The patient, a sturdy, robust labourer, stated that for about four weeks before admission he had suffered from indigestion and vomiting. On the 18th while climbing a ladder he was sud-

denly seized with intense abdominal pain. He was seen at once by a medical man who happened to be near and was sent to the Infirmary. He was then profoundly collapsed. Breathing was quick and short; his pulse was 128; the abdomen was rigid and unyielding. A diagnosis of perforated ulcer was made. At the operation a perforation equal in diameter to a No. 8 or No. 9 catheter was found in the duodenum one inch from the pylorus. The ulcer was stitched and the abdomen was cleansed and drained. The patient recovered. Time of operation after perforation three hours fifty minutes. The patient was quite well in January, 1908.

CASE 3.—April 20, 1902; female, aged seventeen. For several weeks she had slight indigestion and epigastric pain, but not in sufficient severity to send her to a medical man. On the night of April 19th at 9 P. M. she had a sudden attack of acute epigastric pain. Morphine was given. She was seen at 7 A. M.; the abdomen was very rigid and rather tender, especially over the gall-bladder. She had vomited once. The pulse was 112. Respiration was very shallow. At the operation an ulcer was found to have perforated on the anterior surface of the duodenum, about three-quarters of an inch from the pylorus. There was some fluid above the stomach. The ulcer was closed by suture and the peritoneum was cleansed by wiping with swabs wet with sterile salt solution. There was no lavage and no drainage. The patient recovered. Time of operation after perforation about ten hours. Gastro-enterostomy had subsequently to be performed on account of stenosis. The patient was quite well in 1909.

CASE 4.—March 26, 1903; male, aged twenty-eight. Had suffered from "flatulent indigestion," but was otherwise quite well up to 9 P. M. on March 25, 1903. At that time he was straining heavily at work and suddenly felt a pain in the upper part of the abdomen which caused him to feel faint. The pain lessened considerably in about an hour, but he then felt "as if he had been winded" by a blow on the epigastrium; the abdomen became slightly distended and very rigid; tenderness was especially noticed in the upper part on the right side and downwards towards the appendix. A diagnosis of duodenal

ulcer was made. The abdomen was opened through the right rectus. There was a large quantity of loose flocculent lymph surrounding a perforation in the first part of the duodenum. The ulcer was stitched up by two continuous sutures. The patient recovered. Was sent by Dr. Oldfield. Time after perforation thirty-one hours. Subphrenic abscess followed on twentieth day and was opened; subsequent progress good. Six months later (November, 1903) symptoms ascribed to a cerebral abscess developed and the patient died. No operation was performed and no post-mortem examination was obtained.

CASE 5.—December 27, 1903; female, aged seventeen. She had always been pale and anæmic and for twelve months had complained of indigestion and occasional vomiting. Illness commenced suddenly four days before admission with pain in the right side and across the abdomen. There was vomiting. At the operation perforated duodenal ulcer was found. An incision was made in the right flank; offensive pus was found. Tubes were inserted. The patient recovered and is now in sound health. (A case of subacute perforation.)

CASE 6.—March 24, 1904; female, aged twenty-five. She had had indigestion for twelve years. For many years she had had acid eructations and for the last two years had vomited after food. She had had many severe attacks of pain in the epigastrium. Four days prior to admission, and again one day before, she had attacks, but not any more acute than many she had had previously. During the last three years her weight had dropped from 9 stone to 5 stone 8½ pounds. At the operation there was found to be a perforation of the size of a small pea in the upper part of the first portion of the duodenum. The ulcer was of about the size of a half-crown. There was a little local plastic peritonitis, but no general infection. The perforation was closed by Lembert's sutures and a posterior gastro-enterostomy was performed. The patient recovered.

CASE 7.—May 11, 1904; male, aged twenty-two. He has been quite healthy up to the beginning of April, 1904, when he felt an acute pain in the abdomen. This only lasted a few minutes and then passed off; subsequently he had daily

discomfort one to two hours after food, belching, fullness, and acidity. Three weeks later he was again seized with extremely acute abdominal pain. Within three minutes he was in a state of complete collapse. The pain was most severe in the epigastric region at first, later it was acute in the lower part, and in two or three days it settled in the right iliac region. He vomited at the beginning, not again later. There was slight constipation. He recovered very rapidly and went out for a stroll on the ninth day. On symptoms of a similar kind again coming on, operation was advised. At the operation an incision was made over the appendix. The appendix was found lying along the outer side of the ascending colon and adherent in all its length. It was removed. The hand passed up into the liver region felt numerous adhesions. A second incision was made over the gall-bladder. Numerous adhesions of the gall-bladder to the liver and duodenum were separated, also a very strong one between the duodenum and the under surface of the liver. On examining the surface of the duodenum thus bared, a minute perforation was seen. This was occluded by Lembert's sutures and the abdomen was closed. The patient recovered.

CASE 8.—September 9, 1904 (6 P. M.); male, aged forty. The patient was admitted into the Leeds General Infirmary with a history of having had a large barrel fall on the left side of his abdomen just below the umbilicus two hours previously. The following history was obtained from the wife (subsequent to the operation): He had been in poor health for some time back, having been under the care of a medical man off and on for the past year. For the past two years he had suffered considerably from pain in the upper part of the body coming on soon after taking food. Medical treatment had never done this any permanent good. He vomited occasionally. In the previous week he vomited blood once; the amount was not known. No history was obtainable pointing to melæna. On admission he had a great deal of pain on the left side of the abdomen. There was little evidence of collapse. The pulse was 88 and the respirations were quiet and not shallow. There were great tenderness of the left side of the abdomen and rigidity; there was little movement on this side;

also dullness over the area of the left external oblique and left iliac fossa. Liver dullness was present. During the night he vomited once and next morning he was not so well. The breathing was a little more hurried and shallow: the pulse was 100. The abdomen was a little more distended. There were tenderness and dullness as before. On the 11th his general condition improved; the pulse was 90. The pain and tenderness had wholly disappeared. There was more distension of the abdomen. Movement was fairly good. The dullness on the left side was now limited to the loin; this appeared on rolling him on to his right side. On the 12th his general condition was still remarkably good. The pulse was quiet, under 100. He was entirely free from pain and took a fair quantity of milk by the mouth. Abdominal distension was still considerable. The abdomen was very hard and resistant; there was no tenderness. Liver dullness was present. There was no dullness on either loin. During the afternoon he became markedly worse. He rapidly became extremely collapsed, pale, cold, and sweating. His pulse was weak and intermittent. The abdomen was still more resistant and distended so that it felt almost like a tightly blown football. Vomiting occurred twice during the afternoon. Laparotomy was performed at 6 P. M. (median incision). A large quantity of free, odourless gas was found in the peritoneum. There was general suppurative peritonitis. The pelvis was full of pus and there was flaky lymph over the intestines. In the anterior wall of the first part of the duodenum an aperture of the size of a large quill was found. This was closed by sutures and sequestered by stitching that surface of the duodenum to the stomach wall. Free drainage was made through both loins and from the pelvis. The patient died eleven hours after, despite infusion (twice) and the usual stimulants. Post-mortem, an ulcer on the posterior wall of the duodenum just beyond the pylorus was found. It was an ulcer on the anterior wall which had perforated.

CASE 9.—June 30, 1906; male, aged twenty-nine. Recently has noticed pain two or three hours after a meal, and a "sour fluid" then keeps coming up into his mouth. Has recently been attending the out-patient department of the

Infirmity. At 12.30 P. M., when walking down the street, felt a sudden excruciatingly severe pain in the epigastrium. He fell on the ground and could not rise. About one hour later he vomited "a pint of blood." On admission the abdomen was distended and resistant everywhere. There was more marked resistance and greater tenderness on the right side. A diagnosis of perforated duodenal ulcer was made. A perforation was found on the anterior and upper part of the duodenum about $\frac{1}{2}$ inch beyond the pylorus. The perforation was closed. Posterior gastro-enterostomy was performed. The abdomen was mopped out (there was very little extravasation). No drainage. Patient recovered.

CASE 10.—August 18, 1906; male, aged twenty-eight. For many months has had vomiting after food if he has hurried away after a meal, not otherwise. Fullness and pressure in epigastrium. A sudden attack early on Saturday morning (2 A. M.). A perforation of a small ulcer in duodenum just beyond pylorus; closure. On opening to do posterior gastro-enterostomy it was found that the upper part of jejunum was strangulated in a right duodenal hernia. The obstruction had caused rupture of ulcer. Posterior gastro-enterostomy. Closure (partial) of hernial opening. Drainage and supra-pubic drain. Patient recovered. Was sent by Dr. Oldfield. Operation 6.30 P. M., sixteen and one-half hours after perforation. In this case a very early duodenal ulcer was caused to perforate by reason of the extreme distension of the intestine behind an acute obstruction.

CASE 11.—July 3d, 1907; female, aged forty-two. Has had symptoms of duodenal ulcer for many years. Under treatment continuously for almost twelve months. A sudden acute attack of pain. On examination the patient was gravely ill; the abdomen was hard, tense, and distended. The pulse was 132 and the breathing shallow and panting. A perforated duodenal ulcer just beyond pylorus. Suture; drained. Patient died. Was sent by Dr. Hudson, Leeds. Perforation twenty-six and one-half hours before operation.

CHAPTER X

THE PATHOLOGY OF CHRONIC DUODENAL ULCER

A DUODENAL ulcer which has been the cause of protracted and recurrent symptoms is always visible from the outside of the intestine, is always palpable, and therefore is always demonstrable. To this statement there are no exceptions.

It is remarkable with what constancy the same portion of the duodenum, identically the same, is attacked by the ulcer. In at least 95 per cent. of the total number of cases the ulcer lies within the first portion of the gut, that is, within $1\frac{1}{2}$ inches of the pylorus. In Collin's series of cases, 262 in number, the ulcer was found in the first portion in 242, in the second in 14, in the third in 3, and in the fourth in 3. In Perry and Shaw's series of 149 cases, there were 123 in which the ulcer was in the first part; 16 ulcers were in the second part, and 2 in the third and fourth; in 8 cases the ulcers were scattered. In Oppenheimer's 81 cases the ulcer was in the first part in 69. In my own cases, and probably in the records I have just quoted, cases have been described as lying in the second part when they were certainly in the first portion. It is only within the last three or four years that I have realised the remarkable tendency of some ulcers to be "tucked back," to be adherent to the liver or posterior abdominal wall, and to be there tethered

in such a manner as to make it impossible to present them in an abdominal wound. (In these cases the pain after food usually comes on in three or four hours, instead of in two, as is the rule; and before operation I have frequently predicted with accuracy that this condition would be found.) The ulcer in these circumstances may be said to be in the second part of the duodenum, for

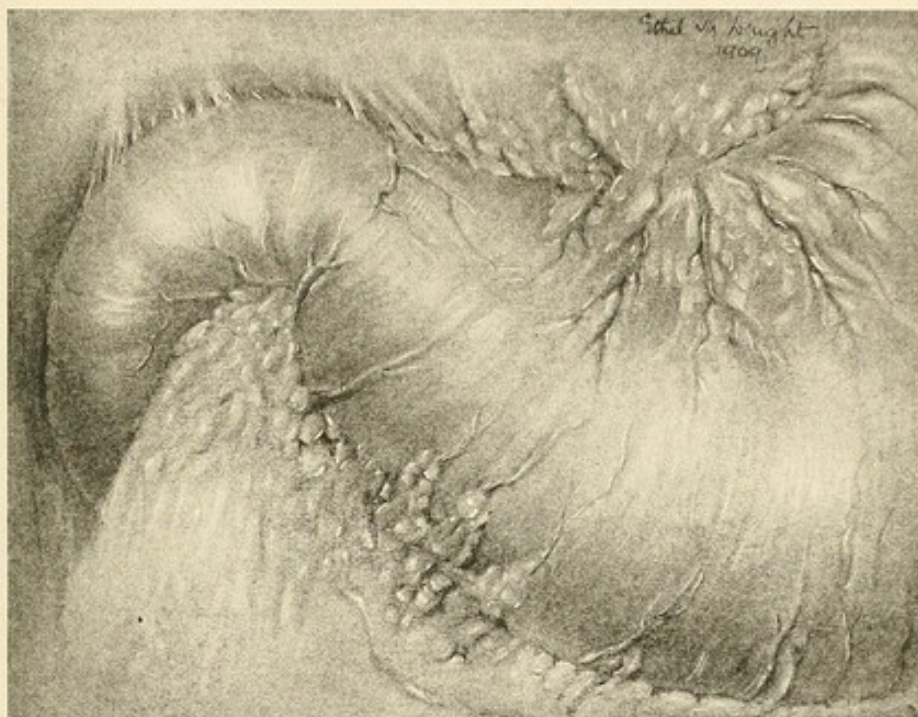


FIG. 50.—THE VEIN WHICH SHEWS THE POSITION OF THE PYLORUS ("PYLORIC VEIN").

the bowel in which it lies seems to be in close contact with the kidneys. But if the position of the pyloric vein be noted, it will at once be seen that the ulcer is within $\frac{1}{2}$ to $\frac{3}{4}$ of an inch of the pylorus. This vein is a most important landmark; it runs generally a little to the gastric side of the pylorus, it is constant, and its recognition during an operation enables one to see at a

glance where the stomach ends and the duodenum begins. The vein runs upwards from the greater curvature and is thick and short. It may oftentimes be met by a smaller vein descending from the lesser curvature; usually the two do not meet in a visible anastomosis.

The most constant position for an ulcer is on the anterior wall of the duodenum, midway between the upper and lower border, and almost exactly half an inch beyond

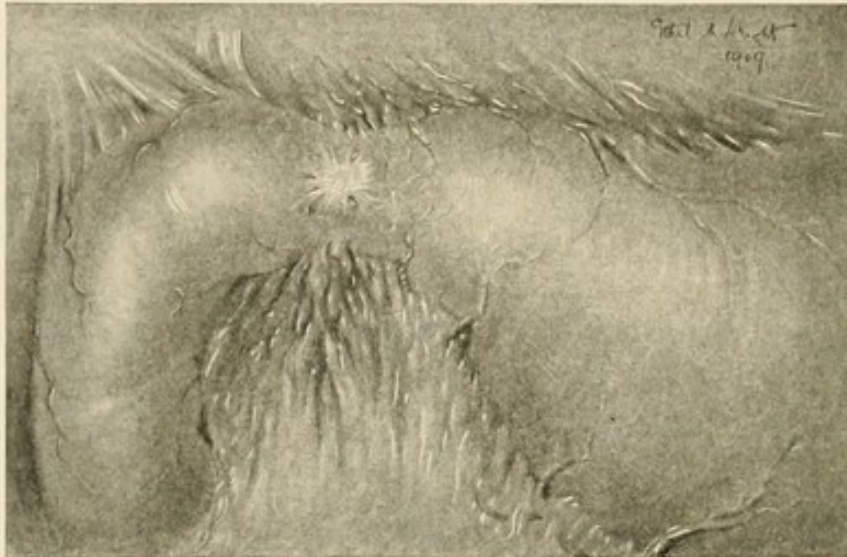


FIG. 51.—DUODENAL ULCER.

The usual position and size of the ulcer are well shown.

the pylorus. It must be that this part of the duodenum is especially prone to attack; it may be that it is against it that the jet of chyme directly impinges as it is expelled through the pylorus. In its early stages the ulcer is circular; the smallest ulcer I have seen was a little less in size than the end of a lead-pencil. The outer surface is white and presents the appearance of a cicatrix. In some cases, however, and especially if the outer surface is wiped over with the finger or with gauze, the ulcer

seems red and vascular, and mottled with bright, blood-stained spots. In older ulcers the base is pearly white, thick, and puckered to the centre, which is depressed and is densely hard. The ulcer then may be picked up in the fingers, and feels as hard and dense as a sixpenny

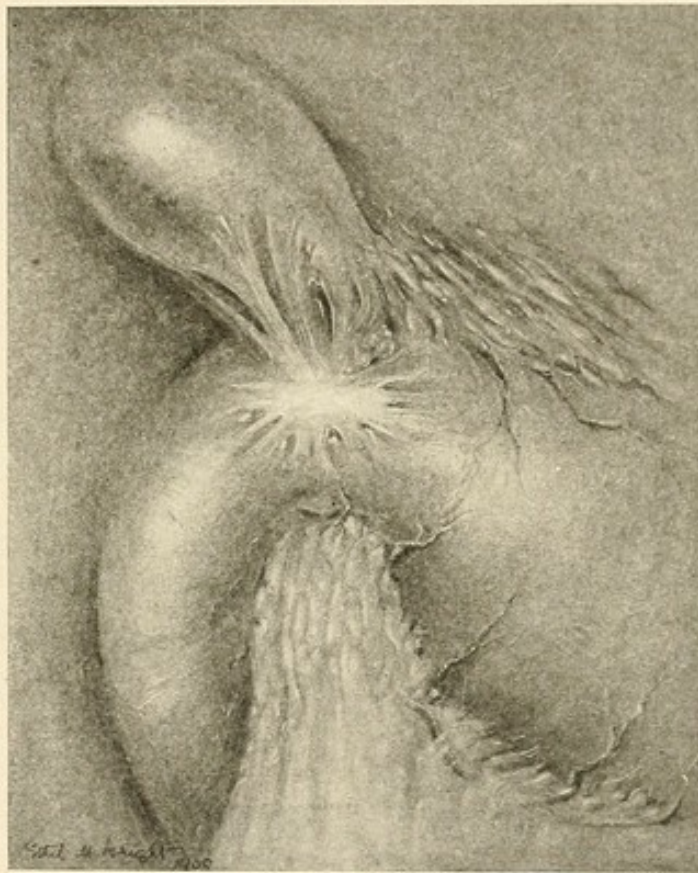


FIG. 52.—DUODENAL ULCER.

Shewing adhesions to the gall-bladder. The radiating scar is not infrequently seen.

piece, with the thickness of three of these coins. If a finger be passed from behind, it will be felt that such an ulcer possesses a crater into which the tip of the fore-finger may fit. The crater seems always to be smaller in size than the white external base; the ulcer, that is,

would look smaller from the mucous than from the serous aspect. When such an ulcer is excised, its inner surface generally shews a clean, punched-out appearance; the crater is deep in proportion to its width and the sides are thick, turgid, and indurated. In some cases there seem to be steps, as it were, leading down the side of the ulcer from the lumen of the gut to the base of the

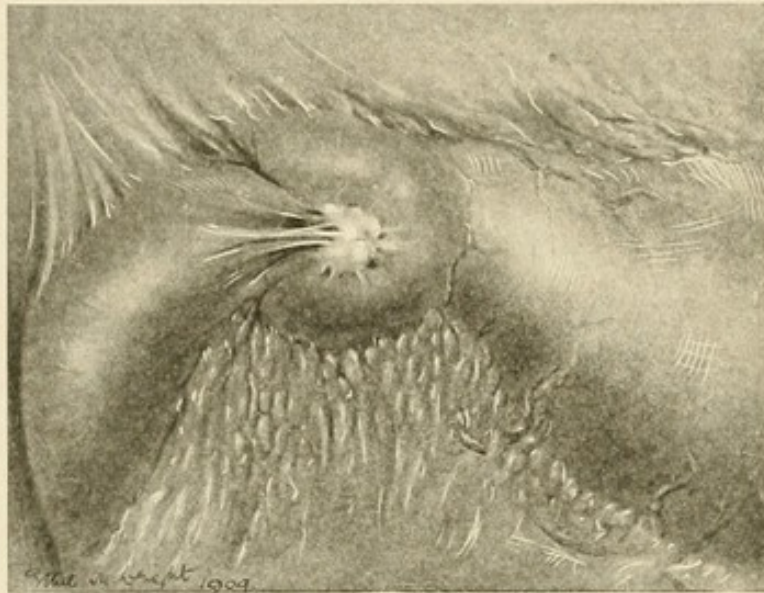


FIG. 53.—DUODENAL ULCER.

Shewing the puckering up of the scar, which leads to "pouching"
(drawn during operation upon the case).

pitted ulcer. In many of the older records the ulcer is said to be "terraced," and in one or two of my own specimens this appearance of ridging is very beautifully seen. In the majority of the cases I have observed the ulcer is free from adhesions, and the bowel in which it lies may be brought well into the abdominal wound, or outside of it, so that any onlooker may easily inspect the parts. Even when the ulcer is quite small, one or more

strings of adhesions, or a thick web of them, may be present. In its simplest form an adhesion may be a thin strand coming from the omentum to be firmly implanted in the centre of the ulcer. It is certain that in

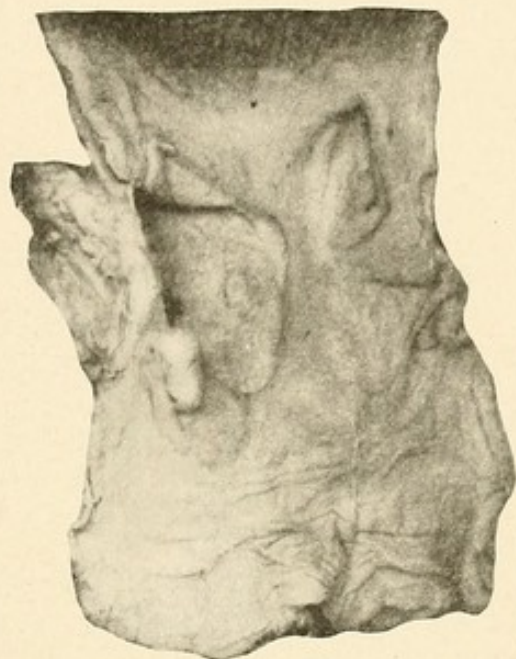

FIG. 54.—CHRONIC ULCERATION OF DUODENUM, WITH FORMATION OF A POUCH.

Portions of the duodenum and stomach from a case of duodenal ulcer fatal by hæmorrhage. The ulcer is immediately contiguous to the pylorus and is about the size of a two-shilling piece; its edges are sharply cut, the mucous membranes being folded over them. To the left of the specimen the ulcer is deeply excavated, the base there being formed by the pancreas. In it is a perforated branch of the pancreatico-duodenal artery, into which a glass rod has been introduced and from which fatal hæmorrhage occurred. Adjacent to the ulcer and immediately contiguous to the pylorus is a pouching of the duodenum. (London Hosp. Museum, No. 1152.)

this way a perforation is prevented and a barrier formed whereby the peritoneal cavity is protected. In no place is the "police" capacity of the omentum better shewn than here.

In the long-standing cases the size and the thickness

of the ulcer are greatly increased. The whole breadth of the anterior wall of the duodenum may be occupied by a dense, white, raised, fibrous mass, which extends even on to the posterior surface. In one patient who had symptoms on and off for over forty years the ulcer was quite cheloid in its thickness, density, and elevation. The puckering which occurs when a mass of tissue contracts almost always seems to radiate towards the centre of the ulcer, which is depressed to a greater or less degree. The ulcer may then appear to be star-shaped, the centre being drawn in and dimpled. The appearances produced by this process of puckering and contraction vary greatly; in some cases a peculiar condition of "pouching" of the gut is produced. A piece of the duodenal wall seems almost separated from the rest, being nipped away from it, as is the bowel in a Richter's hernia. Of this I have seen at least a dozen good examples; the pouch so formed lies always along the lower border of the gut. In some cases the pouching may be very considerable, so that a "diverticulum" is formed. Perry and Shaw give details of several "pouched ulcers" (pp. 277, 278, 279), the sacculus being, in one, of such size as to hold a large walnut. An excellent example is seen in specimen 1152 in the London Hospital Museum.

In the great majority of the cases a healthy margin of the bowel lies between the ulcer and the pylorus, but the lesion may extend up to, or may even transgress, the pylorus. It is interesting to know that when it does so, the gastric margin of this ulcer may be, as Dr. W. J. Mayo has shewn, the starting-point of a carcinomatous growth. The occurrence of a malignant change

in a duodenal ulcer is extremely rare; in only two cases have I seen it. The change from a simple to a malignant form in gastric ulcer is, of course, not very infrequent; it would appear that approximately two cases in three of cancer of the stomach have their origin in an open chronic ulcer or in the scar of a partially or completely healed one. *Ulcus carcinomatosum* in the duodenum must be excessively rare.

The recurrence of the "attacks" in duodenal ulcer may be due to the healing and the breaking down, often repeated, of a solitary ulcer; or to the development of new ulcers. It is certain that the former is of far greater frequency than the latter, for it is not in more than 10 to 20 per cent. of the cases that more ulcers than one can be seen. In this statement there is, however, a source of fallacy; for the large ulcer which is not seldom found may have been due to the merging of one small ulcer with another, and these into a third, and so on. That this is possible seems clear from the close proximity that the small scars of healed ulcers sometimes bear to one another. In this process of healing and of breaking down a great mass of new fibrous tissue may be formed; in one case a tumour, noted at the time to be "of the size of a lemon," was found in the first part of the duodenum around an ulcer whose crater was approximately the size of a florin. The cicatricial tissue in the base, and on all sides surrounding the ulcer, undergoes, as it does everywhere, a process of contraction; and contraction occurring in the wall of a tube of small lumen results in a formidable narrowing of its calibre. A stenosis of the duodenum is formed in this way. The stricture may

be as thin as whipcord, and almost circular, narrowing the bowel precisely as if a string had been tied around it, or the stricture may be long and tortuous and greatly indurated. If the former, a condition of "hour-glass duodenum" may be found. Of this I have seen several examples. Kenneth Mackenzie ("Journ. Amer. Med. Assoc.," 1906, i, 341) gives notes of cases occurring in his own practice in which this condition was well seen.

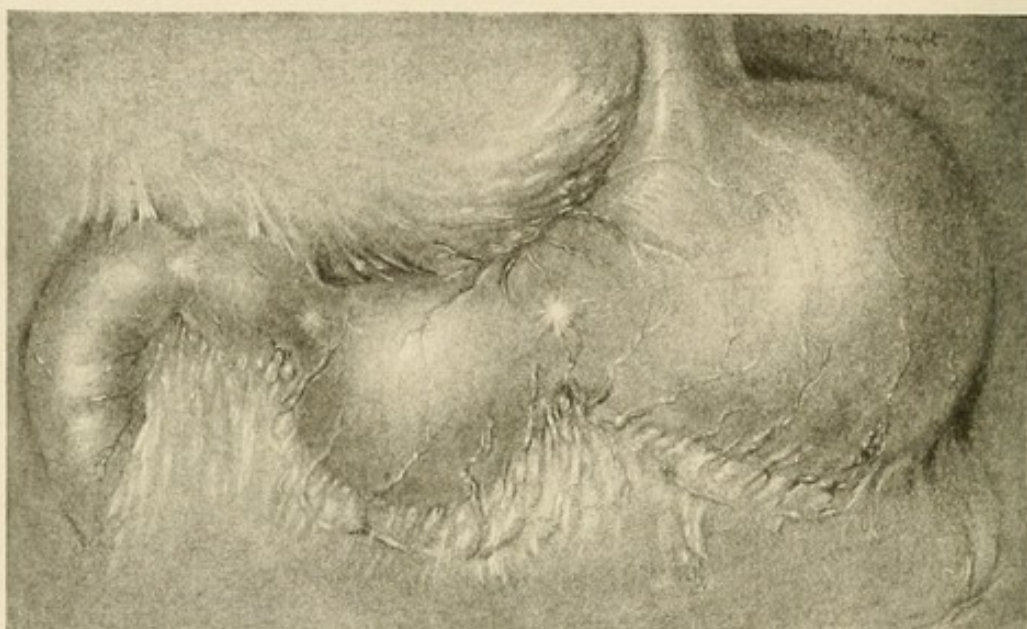


FIG. 55.—HOUR-GLASS STOMACH AND DUODENUM.

Narrowing of the lumen may be caused both by the massive deposit of lymph in and around the ulcer, and by the firm contraction of the scar of an ulcer which has completely healed. In one of my cases of hour-glass stomach, a double stenosis was found; it was due to the tight contractions caused by two ulcers, one immediately beyond the pylorus, and one an inch away. The following are the notes of the case:

Dual stenosis of the duodenum, associated with hour-glass stomach: January 20, 1903; female, aged thirty-one. Nine and a half years ago vomited a "great deal" of blood. Dr. James Mackenzie then diagnosed ulceration of the stomach. Since then has always been ailing, especially after a moderate meal. Five years ago was very ill; acute abdominal pain; severe vomiting and hæmatemesis. Was in Manchester Royal Infirmary with "ulcer of the stomach." One and a half years ago had hæmatemesis. For several years has had no solid food and has never had any ordinary meal. Has lived on milk, custards, porridge. On examination an hour-glass stomach was diagnosed. Woelfler's two signs; paradoxical dilatation; increase in subcostal tympany; gurgling sound at left end of stomach, all well marked. At the operation an hour-glass stomach and an hour-glass duodenum were found. There were two large stomach pouches, united by a narrow isthmus, at the lesser curvature. Tight constriction at the pylorus; the first portion of the duodenum was dilated to form a sac the size of a lemon; beyond this another constriction. The pyloric pouch of the stomach was more densely scarred than any stomach I have seen; its texture was almost wholly fibrous. On its posterior surface also many scars were seen. Gastro-enterostomy and posterior gastro-enterostomy to the pyloric pouch. The patient recovered. The patient was sent by Dr. Mackenzie, Burnley. Within three weeks of the operation she ate solid food heartily, and had taken all the vegetables in season. In June, 1905, quite well, taking ordinary diet. Was well in 1908.

A similar case is also recorded by W. J. Mayo ("Journ. Amer. Med. Assoc.," 1908, ii, 556).

In a certain proportion of cases (between 10 and 20 per cent.) the ulcers are multiple. There are sometimes seen on the anterior surface of the duodenum two, three, four, or more old white scars with an ulcer which is clearly of more recent origin, and in a more active condition. The base of this last ulcer may be thick and

tumid, the peritoneum over it rough, red, and shaggy, and a new adhesion from the omentum may be drawn up to strengthen its base. Old ulcers and new ones are found side by side. When two ulcers are present, they are nearly always close together, almost touching; or the one lies on the posterior wall of the bowel immediately opposite to the anterior ulcer. The two ulcers seem then to have been in exact apposition when the gut was empty; I suggested the term "kissing ulcers," or con-

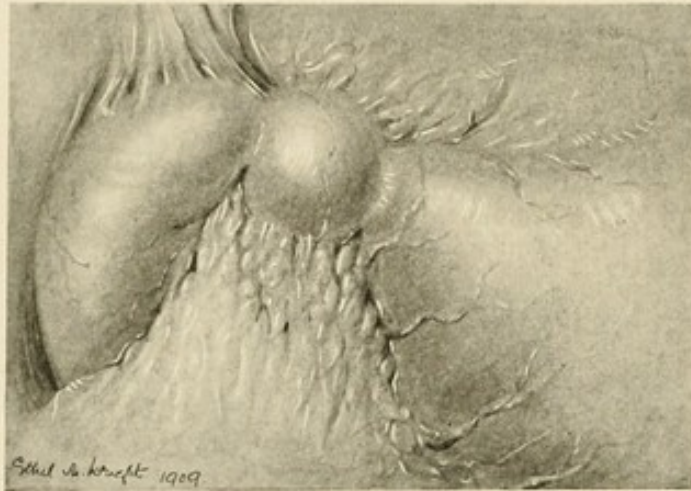


FIG. 56.—DOUBLE STENOSIS IN THE DUODENUM ("Hour-glass Duodenum") (after W. J. Mayo).

tact ulcers, for them. The impression is confidently derived from their inspection that the one is infected from the other. When more ulcers than one are present, they are all usually grouped together in the first part of the duodenum. I have once seen nine definite scars within the space of $1\frac{1}{2}$ inches; and many times I have found three, four, or five ulcers. The upper and the lower borders bear ulcers occasionally; though when a scar is present in either place, other scars are generally

found on the anterior surface. A solitary ulcer on the posterior surface is rare; I have only met with three, in all, when we were quite certain that no other part of the bowel was involved. Inspection of the posterior surface can most easily be carried out through the opening made in the transverse mesocolon for posterior gastro-enteros-

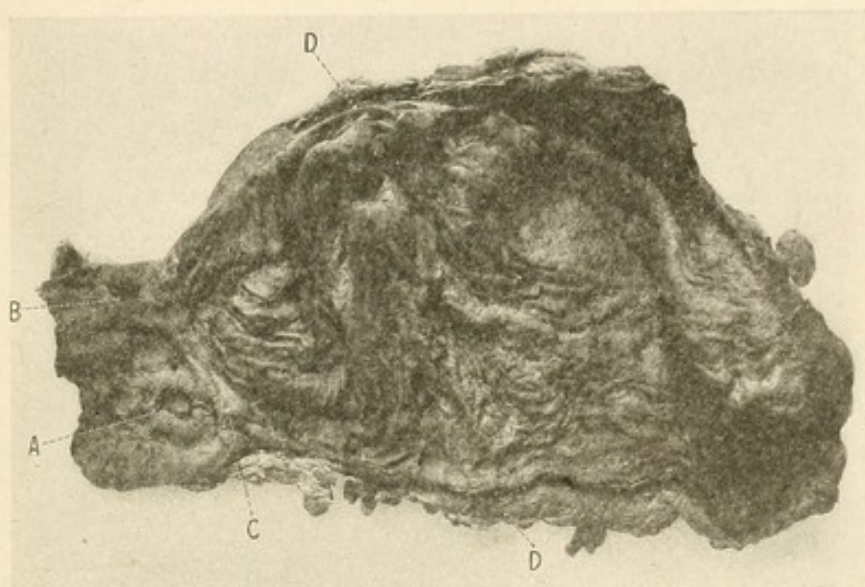


FIG. 57.

A, Perforating ulcer on anterior surface of duodenum; B, "kissing ulcer" on posterior surface; C, pyloric ring; D, cut edge of lesser curvature of stomach. Note the position of the ulcers immediately outside the pylorus.

The specimen was removed from a woman aged thirty, who died about two hours after admission to the Royal Victoria Hospital, Belfast (May, 1909). No operation was undertaken. (From a photograph kindly given to me by Dr. A. B. Mitchell, Belfast.)

tomy. The enormous preponderance of anterior over posterior ulcers in point of frequency cannot possibly be due to caprice. There must be some substantial reason for it, but of such reason we have no present knowledge. When several ulcers are present, there is usually one which seems to have more active processes engaged

in it; but there are times when two or even three ulcers would seem from their appearances to be of equal age and activity. Two such ulcers may perforate at the same moment (Biggs: "New York Med. Journ.," 1890,

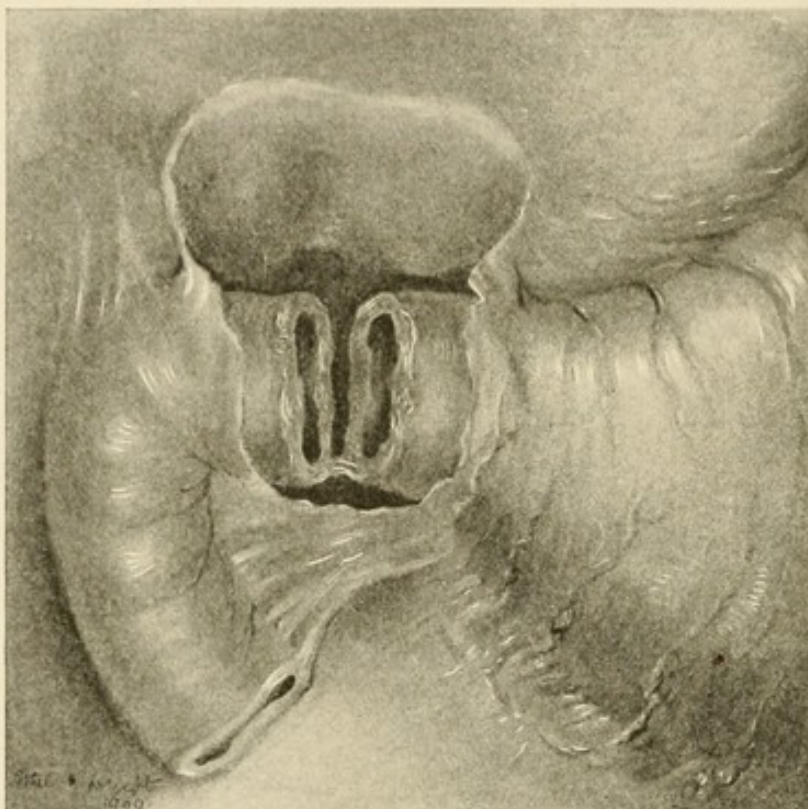


FIG. 58.—CIRCULAR ULCER OF DUODENUM.
Perforation into a localised abscess (Meunier).

i, 77). One case is recorded in which the ulcer was circular and had divided the duodenum completely across:

Annular ulcer of the duodenum (Henri Meunier: "Bull. Soc. Anat.," 1893, i, 488): Henri L., journalist, age sixty-one, admitted under Dr. Millard for severe dyspeptic troubles. Illness commenced three months ago with epigastric pain, loss of appetite, and vomiting. On admission, June 28th, both the general and local conditions were strongly suggestive of cancer. Face cachectic, marked wasting of the body,

abdomen distended by a dilated stomach. In the pyloric region was a resistant swelling, somewhat tender, obstinate constipation, frequent vomiting, the vomit containing food material taken several days previously. Lavage of stomach gave some relief. The cachexia, however, gradually became worse, and death occurred on July 8th.

Post-mortem: Acute general peritonitis. In the pyloric region the following remarkable conditions were present: A cavity was present under the liver, bounded above by the inferior surface of the liver, in front by the gall-bladder, below by the thickened transverse mesocolon, behind by a thickened peritoneal pseudo-membrane. All the walls of the cavity were united together by fibrous adhesions, which completely shut it off from the general peritoneal cavity. The contents of this cavity consisted of a fluid similar to the fluid found in the stomach and containing food particles. On removing this the duodenum was found completely cut across. The division was situated about 3 cm. from the pylorus, and the ends were as clean-cut as if the section had been made with scissors. There was no sign of cancerous induration. The gall-bladder had thickened walls and contained bile, but no stones.

The cicatricial contraction of the ulcer may involve other structures and give rise to various symptoms. It is well known that when the ulcer lies near or around the ampulla of Vater, a stenosis of the diverticulum may result, and so the common bile-ducts and the canal of Wirsung may be involved. Jaundice and grave inanition may consequently ensue and a suspicion of carcinoma of the pancreas may be bred. The following cases may be quoted (see also Krauss: "Das perforierende Geschwür im Duodenum," Berlin, 1865):

1. Old duodenal ulcer affecting region of diverticulum; cicatrization; obstruction of bile-duct; distension of gall-bladder; jaundice; obstruction of pancreatic duct, atrophy

of pancreas (Krauss, Case 13, page 21): Man of thirty-eight, well built, always healthy until March, 1862, when he began to suffer from severe pain in the right costal margin. After eight days jaundice set in, which gradually increased in intensity; admitted to hospital in June; intense jaundice with itching and yellow vision; abdomen somewhat distended; liver extended to the umbilicus; in the anterior border could be felt a large, rounded, fluctuating swelling—the gall-bladder. Death took place in November. On section the bile-passages were all dilated; gall-bladder greatly distended and filled with a light yellowish, watery fluid; liver enlarged; at one part of the gall-bladder the wall was softened and nearly perforated. The hepatic duct and common bile-duct were both dilated, the opening of the latter being extremely narrow, situated in a cicatrised duodenal ulcer. Numerous adhesions were present at this spot between the duodenum, head of the pancreas, and all the surrounding tissues. The scar of the ulcer was situated over the place where the pancreatic duct enters the duodenum. This duct was greatly dilated and was filled with light coloured fluid. Its ostium was closed.

II. Duodenal ulcer in region of diverticulum of Vater; closure of common bile-duct; distension of gall-bladder; jaundice; rupture of gall-bladder; pancreas atrophic (Herzfelder: "Wiener Zeitschrift," 1856, xii, 127 and 146, and "Schmidt's Jahrbucher," 92, p. 50): Man of forty-six, suffered from cramp in the stomach for five years; sour eructations, two years. Appetite good, but severe pain at night in stomach region, relieved by vomiting; stomach dilated; sarcinæ and food-remains in vomit; cessation of symptoms for some time, then fever, jaundice, which rapidly increased in intensity. Liver and gall-bladder increased in size—swelling disappeared before death. On section an ulcer was found on the posterior wall of the duodenum as large as a dollar; opening of common duct closed by cicatrix; stomach dilated and hypertrophied; gall-bladder ruptured.

III. Duodenal ulcer in the neighbourhood of the diverticulum of Vater; stenosis of biliary and pancreatic ducts; suppurative inflammation of both ducts; perforation of gall-bladder (Forster: "Würzburger medizinische Zeitschrift,"

1861, ii, 158): Man, seventy-six years of age, had symptoms of biliary retention for a year. Increased jaundice, frequent complaints of pain in liver region, rapid wasting, and death from peritonitis due to ruptured gall-bladder. On section fibrinous suppurative peritonitis. A scar was found at the entrance of the ductus choledochus and pancreaticus in the duodenum. The two ducts opened near one another; numerous small polypoid growths found in this position. Although each admitted an ordinary sound, there apparently was stenosis of both passages. The pancreatic duct was dilated over nearly its whole extent and contained pus. The common duct was of the diameter of the small intestine and filled with sero-purulent material. The dilation extended back to the small bile-passages.

Four similar cases are recorded by Perry and Shaw (pp. 273, 274); one case by Budd ("Diseases of the Liver," 1857, page 204); one by Zoia ("Gaz. Med. di Torino," 1899, i, 134); one by Mackenzie ("St. Thomas's Hosp. Reports," 1890, xx, 341); and one by Fenwick ("Ulcer of the Stomach and Duodenum," London, 1900, Case 44, page 296).

The common duct may also be involved if the ulcer lies in the first, or at the junction of the first and second portions, on the upper and posterior walls. The common duct just as it passes behind the duodenum may then be gripped firmly by the scar and a complete closure of its lumen result. The following case, which was under my care, is an exemplary instance of this:

Obstruction of common bile-duct by duodenal ulcer; chronic pancreatitis; cholecysto-colostomy: J. D., male, aged fifty. Complains of jaundice of great intensity. Until nearly the end of July was quite well. At that time began to suffer from flatulence and distension after food. Pain never acute or colicky, no vomiting. Occasionally periods of relief

for a few days, but the attacks continued to return until six weeks ago, when he became jaundiced. Since then pain has been absent, but jaundice has gradually deepened. There has been no pyrexia, no rigors, nor does he think the jaundice has lessened in intensity. Has lost 2 stone in weight. On examination of abdomen the liver is felt to be enlarged and is smooth and regular. The gall-bladder can be indistinctly felt. It does not project far beyond the liver border. Just above the umbilicus an indistinct mass was felt on one occasion which suggested an enlarged pancreas.

Pathological report of urine and fæces (by Dr. Helen G. Stewart): A well-marked pancreatic reaction in the urine points to some degree of chronic pancreatitis, which is confirmed by examination of fæces. There is a high percentage of total fats, of which nearly half are combined fatty acids, indicating that although the pancreas is affected, occlusion of the pancreatic duct is not complete, and the obstruction to the common bile-duct must be above its junction with the pancreatic. That obstruction of the common duct is almost complete is shewn by the presence of only a trace of stercobilin in the fæces, but the absence of undigested matter in the fæces also supports the conclusion that the primary site of the disease is in the common bile-duct, and not in the pancreas.

Diagnosis: Obstruction of common bile-duct at a point above the bile-papilla from some other cause than carcinoma of the pancreas.

Operation, October 13, 1908: The liver was enlarged and the gall-bladder much distended, with thickened walls, although it did not project beyond the lesser margin for more than a short distance. Common duct dilated as far as upper margin of duodenum. There was an indurated scar in the duodenal wall which involved the duct and compressed it to complete obstruction. The scar was adherent to and seemed to involve the adjacent part (only) of the head of the pancreas. No tumour of the head of the pancreas. No calculi palpable. Gall-bladder aspirated and found to contain clear mucus only. It was decided to perform a cholecyst-enterostomy. The duodenum could not be brought up to the gall-bladder without dangerous tension, and so the anastomosis was made

between the gall-bladder and transverse colon. Wound closed.

The patient was sent by Dr. Dunderdale, Blackpool, who reports in March, 1909: "He is somewhat sallow, his appetite is good, and he has gained 2 stone since the operation. Between December 28, 1908, and January 5, 1909, had three attacks of colicky pain over the gall-bladder region, followed by elevation of temperature and jaundice lasting three or four days. He now appears to be quite free from all his former inconvenience. The urine contains no bile. The pancreatic reaction has almost disappeared."

In October, 1909, I saw this patient; he was then quite well, and had gained $1\frac{1}{2}$ stone since March. The jaundice had entirely disappeared.

A very few cases similar to this are found in the literature. Case 19 in Trier's work is the following:

Duodenal ulcer compressing the common bile-duct and the portal vein: M., forty-one years. Three years previous to his fatal illness he had an attack of epigastric pain and vomiting, lasting thirteen weeks, on and off. In November he had pain in the back and "hæmorrhoids." On the 17th of the following January vomited 1 pint of dark blood whilst at work; this hæmorrhage recurred twice that day, and he nearly died. Melæna was present. Five days after vomited again 4 or 5 ounces of blood. Blood was passed by the bowels continuously and he died from hæmorrhage on January 26th.

Post-mortem: Stomach contained some pounds of firmly coagulated blood. Varicosities of lower œsophageal veins seen. No ulceration. In duodenum $1\frac{1}{4}$ inches from pylorus was a flat ulcer size of $\frac{1}{2}$ silbergroschen. An opening the size of a pin's head ran from it towards middle line. Around this tract was a mass of inflammatory tissue which pressed up and caused narrowing of the common bile-duct and occlusion of the portal vein, which was filled by a thrombus reaching up to the liver. There was an inflammatory mass, size of a walnut, lying behind the stomach. Intestines contained much blood.

The following case is recorded by Swensson (C. Wallis, "Hygeia," Stockholm, 1888, i, 342):

Case of duodenal ulcer with obliteration of the ductus choledochus, cystic and hepatic ducts, and ducts of Wirsung: A man of forty-three had suffered for ten months from jaundice, wasting, and epistaxis; the gall-bladder was palpable. Operation performed without anæsthesia. First jejunal loop brought out through the wound, gall-bladder emptied by puncture and sutured to the jejunum. Death three days after operation.

Post-mortem: An ulcer was present in the duodenum commencing in its superior portion and extending into the vertical portion. Edges and base of ulcer hard and callous; the induration extended to the porta hepatis. Ductus choledochus could not be found. Both the cystic and hepatic ducts were extremely dilated and each terminated in a cul-de-sac. Canal of Wirsung also dilated and terminated in a cul-de-sac on the indurated connective tissue in and behind the ulceration.

A case of the same type is this:

Duodenal ulcer causing obstruction of common duct (Marchiava, E.: "Bericht über der Verhandl. de Ital. Pathol. Gesellschaft. Rom.," 26-29, April, 1905, "Centralbl. f. allg. Pathol.," 1906, xvii, 325): Case of duodenal ulcer is described which by extension of the inflammatory process produced a periduodenitis as a result of which compression of the ductus choledochus took place. The ulcer later invaded a portion of the duct producing a complete division of the same into a lower portion with two openings (one leading normally into the papilla, the other into the ulcer) and an upper portion passing into the ulcer from which the bile flowed out. Finally infection of the bile-ducts with formation of abscess in the liver took place. Rupture of one of these abscesses and peritonitis ensued.

A similar case is recorded by J. H. Morgan ("Trans.

Path. Soc.," 1876, xxvii, 176), who shewed at the Pathological Society a specimen in which there was an enormous dilatation of the bile-ducts from a stricture of the ductus communis choledochus, due to the contraction in the base of a duodenal ulcer.

"The liver exhibited shewed a condition of extreme distension and dilatation of the gall-bladder, its ducts, and the bile-ducts in the substance of the liver. It was removed from the body of a patient who came to Saint George's Hospital as an in-patient on April 21, 1875, under Dr. Dickinson, to whom I am indebted for the following notes. His age was fifty-two, and he was by occupation a plumber. He came of healthy parents, and had enjoyed good health till four months before admission, when he had suffered from an abscess in the hand following a prick when at work. This was followed by cold, shivering, and diarrhœa, and a day or two after this jaundice had commenced. He appeared to be well nourished when admitted; his skin was a bright yellow colour, the irides and conjunctivæ deeply bile-stained. He complained of constant headache and occasional pain at a spot to the right side of the ensiform cartilage. This pain was increased by pressure and aggravated by coughing. The right rectus abdominis muscle was very tense. The tongue was coated and the bowels loose. The fæces were light and stone-coloured and the urine contained large quantities of bile. No enlargement of the liver could be detected at this time. In spite of all treatment his condition continued much the same for a month, when he began to suffer from intolerable itching, preventing sleep, and causing him to scratch his skin till it bled. No blood was at any time observed in the motions and no gall-stones were passed. On July 2d the liver was found to be much enlarged, both lobes projecting forwards, and giving rise to two tumours, slightly elevated above the surrounding surface of the body. The patient gradually got worse, and died on July 9th.

"At post-mortem examination made by myself fourteen hours after death the skin and all the organs of the body were

found to be deeply stained with bile. There was extensive fatty degeneration of the muscular tissue of the heart. The liver was greatly enlarged and distended; its surface smooth and presenting several slight elevations, whose thin and transparent walls and fluid contents had all the appearance, at first sight, of cysts. These were found especially on the under surface of the left lobe, their sizes varying from an inch and a quarter to a quarter of an inch in circumference. The gall-bladder was much distended. It measured from 5 to 6 inches, and projected some distance below the edge of the liver; it contained dark green inspissated bile mixed with mucus and epithelium. A stricture of the common choledic duct existed just below the point of its formation by the cystic and hepatic ducts. There was but little thickening of the walls of the duct, and below the point of stricture it was patulous and of the normal colour and calibre; above it was dilated to the size of a large finger, and stained green with bile. On the outer side of the duct the duodenum was found to be bound down to it by adherent bands of lymph, and on tearing them apart a perforating ulcer was found to exist at this spot in the walls of the gut, which was only prevented from extravasating its contents by the adhesion. The contraction of this lymph round the duct had caused its constriction. Another ulcer not so far advanced was seen to exist close to this one. The result of this constriction was an obstruction to the onflow of the secretion, and hence a dilatation of all the ducts. This had caused the distension of the gall-bladder and its duct, and also those of the liver, which it had distended to such an extent as to cause their extremities to project on the surface as the cysts above described. The circumference of the duct of the left lobe measured over an inch. These cysts collapsed on pressing out their contents, which consisted of viscid, slightly green mucus, and epithelium."

The cicatrix may also involve the portal vein in its embrace, and so compress it as to cause thrombosis or closure of it. The following case is recorded by Frerichs ("Diseases of the Liver," 1860, i, 272, Case No. 30):

Duodenal ulcer, cicatrisation, partial closure of ductus choledochus, thrombosis and closure of the portal vein, congestion of lower œsophageal and hæmorrhoidal veins, hæmatemesis: A. Petzold, aged forty-one, a workman of robust build, was quite well until three years back, then had "indigestion" for thirteen weeks, accompanied by pain in the epigastrium and vomiting of yellow masses. These symptoms disappeared to a great extent, but a tenderness of the epigastric region remained, which grew worse. Eight weeks ago began to have symptoms of hæmorrhoidal congestion. On January 17th the patient vomited $\frac{1}{2}$ quart of dark blood. Two subsequent attacks of hæmatemesis occurred on the same day; two attacks on the 19th; increasing collapse; death on the 24th. On section stomach contained about 2 lbs. of clotted blood; $1\frac{1}{2}$ inches from the cardia there were varicose veins filled with firm clots. In the duodenum, $\frac{3}{4}$ inch beyond, was a flattened ulcer $\frac{3}{8}$ inch in diameter, in the centre of which was a small opening of about the size of a pin's head, which led into a tubular opening about $\frac{3}{4}$ inch deep, and directed towards the middle line. Surrounding this channel was a quantity of new-formed connective tissue, by the contraction of which the ductus choledochus was narrowed and the portal vein entirely closed. In the anterior wall of the portal vein was a thrombus showing softening in the centre. The thrombosis extended into the right and left branches of the portal vein into the liver.

In a "System of Medicine," by Clifford Allbutt and H. D. Rolleston (second edition, iii, 559), it is written: "Dr. French recorded thrombosis of the portal vein from compression of this vessel as a direct result of deep cicatrisation of a duodenal ulcer." I have not been able, in spite of diligent search, to trace the original reference.

As the ulcer increases in age it invades more deeply the wall of the duodenum. The thickening which is found in the base of the ulcer, the thick white deposit

in and beneath the serosa, and the omental adhesions growing firmly to the outer side of the bowel, are all evidence of the measures taken to prevent the complete penetration of the wall of the gut; they are protective measures. In spite of them, as we know, the ulcer may

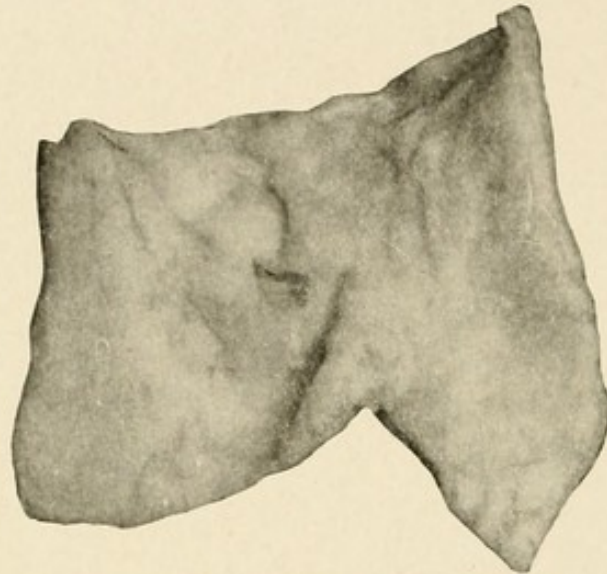


FIG. 59.—PERFORATING ULCER OF THE DUODENUM.

The first part of a duodenum with the adjacent portion of the stomach, shewing just beyond the pyloric ring a small perforating ulcer, the edge of which is abrupt and measures one-third of an inch in thickness. The perforation in the serous coat is considerably smaller than the opening upon the mucous surface. On the reverse of the specimen the peritoneum beneath the ulcer is seen to be thickened.

From a middle-aged man who had long suffered from dyspepsia with pain in the epigastrium. He was suddenly seized with acute symptoms and died twelve hours afterwards. (Guy's Hosp. Museum, No. 743.)

burst through all the coats, and a "perforation" of the intestine results. But if the ulcer should lie in that part of the bowel normally in contact with the pancreas, this gland may be invaded as soon as all the thickness of the duodenum is destroyed. A deep, ragged excavation may be found in the pancreas, which now actually forms

the base of the ulcer. In museum specimens, and occasionally during operations, the deep erosion and excavation of the pancreas is seen or felt, and a cavity large enough to hold a walnut may be formed. If this invasion occupies the head of the gland, the common

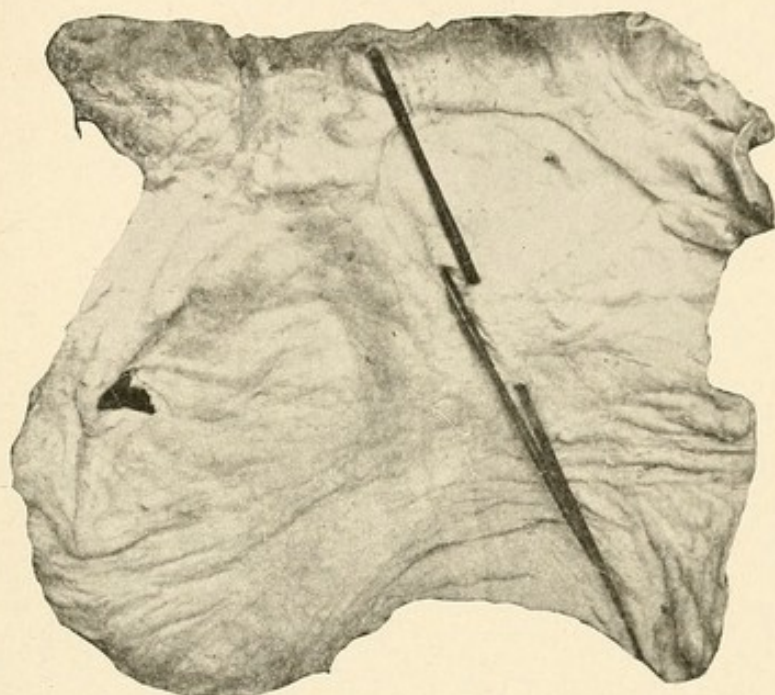


FIG. 60.—LARGE DUODENAL ULCER, ERODING THE PANCREAS AND OPENING THE COMMON BILE-DUCT.

From the body of a man aged forty-one. The base of the ulcer has exposed the pancreas and has ulcerated through the common bile-duct, into the proximal and distal ends of which glass rods are passed. The stomach and duodenum were much dilated. The patient was admitted for abdominal pain and hæmatemesis. (St. George's Hosp. Museum, No. 90 D.)

bile-duct or the canal of Wirsung may be opened. Specimen 90 D, in St. George's Hospital, shows the common bile-duct ulcerated through the upper and lower divided ends, being seen in the base of the ulcer. In like manner the liver may be found in the floor of the ulcer, which has

by degrees become adherent to the under surface of the liver, to the inner side of the gall-bladder. In this steady destruction of the walls of the duodenum the structures lying therein may become involved. Chief among these are the various blood-vessels, which may have their walls eroded. Every vessel, artery, or vein

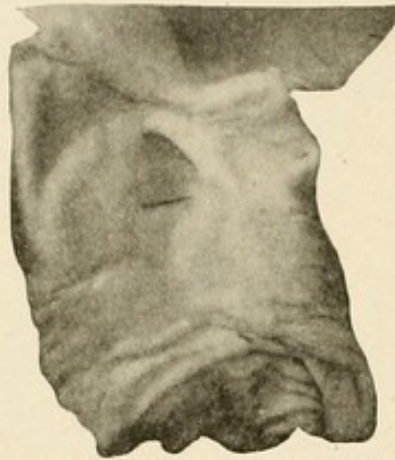


FIG. 61.—ULCERATION WITH EROSION OF ARTERIES.

Part of the duodenum with the pyloric end of the stomach laid open. Close to the pylorus is seen an old ulcer the size of a shilling with round edges and incurved mucous membranes. The pancreas is exposed in the base of the ulcer and a branch of the pancreaticoduodenal artery has been opened. The ulcer is quadratical in form. At its lower end there has been a more recent superficial extension of the ulceration to the apparent right. At the upper end there has been a separation of the adhesion between the pancreas and pylorus, making an opening in the floor of the ulcer at this spot (? p. m.). (London Hospital Museum, Spec. No. 1151.)

lying near the duodenum may be implicated; death may instantly result from the profuse hæmorrhage which occurs upon the destruction of the vessel wall. The gastro-duodenal artery, or a branch of it, is that most often opened; the pancreaticoduodenal is given as the source of the hæmorrhage in more than half the recorded cases. In all the fatal cases I have examined the same

conditions have been disclosed. The artery has thick, rigid walls, and as it lies in the hard, fibrous base of the ulcer, an opening has been eaten through the side. Nothing would appear to be more hopeless than the closure of such an opening, for the vessel is so rigid and the ulcer so unyielding that neither contraction nor retraction are possible. The artery stands up stiffly, its lumen wide open to the blood-stream. A clot which formed in the erosion could hardly withstand the strong current of the blood. The gastro-duodenal, the right gastro-epiploica, and the pancreatico-duodenal have all been opened in so many instances that specific quotation of any case is unnecessary. Perry and Shaw (page 203) write: "In one case hæmorrhage was preceded by the formation of a small aneurysm of the eroded artery, resembling the aneurysms on the pulmonary artery so often found in cases of fatal hæmoptysis from phthisis." In a few records it is noted that there was "aneurysmal dilatation" of the vessel at the point of rupture. In one case the hepatic artery was eroded. The record is given by Broussais ("Sur la duodénite chronique," Thèses de Paris, 1825, p. 65):

Count R., aged sixty-two, strong constitution, had habitually taken emetics and purgatives for his rheumatism. Now experienced digestive disturbances and eructations. Continued for two years. Arm was then amputated owing to a cancerous growth. The wound healed well, but he began to have pain in the gastric region. On the tenth day after the operation he was seized with faintness, general rigor, convulsions, pallor, cold extremities, and death occurred. On section, intestinal tract filled with clumps of blood; ulcer in the first part of the duodenum, which had commenced to

cicatrise. At the base of the ulcer was the hepatic artery opened up. The pyloric end of the stomach was somewhat red, the gut healthy, liver granular and almost bloodless.

In two cases the aorta has been opened; one case is recorded by Stich, and one by Grünfeld.

I. Duodenal ulcer with perforation into the abdominal aorta. (Stich, E.: "Archiv. f. klin. Med.," 1874, xiii, 191): Female, very old, suffering from severe bronchial catarrh, suddenly vomited blood (February 6th). The vomiting ceased for a short time after injections of ergotin, but there were repeated attacks until death from exhaustion occurred on February 24th.

On post-mortem examination a "terraced" ulcer about the size of a "groschen" was found on the duodenum. At the base of the ulcer was seen a perforation which admitted a medium sized sound. This led directly into the aorta about 5 cm. above its bifurcation; the internal surface of the aorta shewed extensive atheromatous degeneration, and a round, atheromatous ulcer not quite the size of a Kreutzer was situated at the site of the perforation. The perforated process had originated in the duodenum; its outer wall, corresponding to the whole extent of the ulcerative process, was firmly adherent to the aorta. Perforation of the aorta had undoubtedly occurred by February 6th. The fact that death was not instantaneous as a result of the hæmorrhage was due to the presence of a clot, which probably had formed rapidly, owing to weakening of the heart's action, and partially occluded the opening.

II. Case of perforated ulcer situated at the duodeno-jejunal angle, opening into the aorta (Grünfeld, F.: Case quoted in "Schmidt's Jahrbucher," 1883, cxcviii, 143): Man, aged fifty-six, had been laid up for nineteen weeks with a fractured femur. Had suffered from cough ever since he could remember, with frequent blood-streaked sputum. During the last year had become very emaciated. Had pain and tenderness in stomach region. On February 26th he had a sudden attack of hæmatemesis and subsequent melæna.

This did not return until March 5th, when he had a second attack of profuse hæmatemesis. Died in twenty minutes.

Post-mortem examination: The stomach was completely filled by black blood-clot. The mucosa was somewhat swollen, but showed no ulceration. The duodenum also contained dark blood, partly clotted, partly fluid. In the duodeno-jejunal flexure was seen a large area of ulceration with circular indurated margins, which penetrated through the mucosa and was adherent to the neighbouring tissues and the aorta at the level of the first lumbar vertebra. Between the perforation and the aorta a large cavity was found in the connective tissue, the walls of which were formed by partially organised, fibrin-coagulated blood. From this cavity a fine opening, easily admitting a sound, led directly into the aorta. At the part of the aorta thus affected there was no trace of aneurysm. In the large intestine were two irregular, superficial ulcers with everted edges. The lungs showed old caseated infiltration and marginal emphysema. The coronary arteries were atheromatous.

Two cases of perforation of the portal vein are recorded by Habershon and Rayer:

I. Ulceration of the duodenum, perforation into portal vein, hæmorrhage (S. O. Habershon, M.D.: "Trans. Path. Soc. Lond.," 1876, xxvii, 155): Celina T., aged thirty, admitted into Guy's Hospital September, 1875. Had a miscarriage in July, and from that time had suffered from pains in her side. Three weeks before admission she had severe rigors which lasted six hours. A fortnight later she vomited about 3 pints of blood. On admission patient was emaciated and anæmic, there was much abdominal pain and distension. Hæmorrhage from the stomach recurred on September 19th and again on October 16th. She shortly afterwards sank.

On post-mortem examination there was a large ulcer with a depressed circular margin in the duodenum about one inch from the pylorus. On the side towards the fissure of the liver there was a large sloughing excavation. The ulceration and sloughing had entirely destroyed the common bile-duct and

the hepatic duct. The portal vein was laid bare and an irregular ulcerative opening was present in it just above the pancreas, from which fatal hæmorrhage had occurred. The adjoining part of the liver contained an irregular abscess and there were several smaller ones in the organ. There was some general peritonitis and a collection of pus in the pelvis.

II. Gall-stones, hepatic ulceration, destruction of gall-bladder, perforation of portal vein, perforation in duodenum and hepatic flexures of colon (Rayer, P.: "Archives générale de Médecine," 1825, vii, 161): Madame P., aged fifty-six, had always suffered from constipation. This occasionally lasted as long as fifteen days. For the last six years has been troubled with digestive disturbances. Abdomen sometimes distended; indiscretions in diet produced exacerbations of pain round the umbilicus. On one occasion after taking a hip bath she had a sudden severe attack of colic. She fainted and had at the same time large evacuations consisting of black clots floating in blood-stained fluid; signs of collapse ensued and death occurred in twenty-four hours.

On post-mortem examination the stomach was large and distended. Its pyloric extremity was adherent to the liver. The hepatic flexure of the colon was likewise adherent to the liver. The gall-bladder had been destroyed. In the position corresponding to it was an ulcerated cavity which contained a gall-stone about 8 lines in diameter. It was granulated outside and lying free in the cavity. This cavity communicated with the duodenum through a perforation, and there was also a perforation into the colon. There were also two perforations in the portal vein.

In one case the superior mesenteric vein was opened.

Case of pylephlebitis suppurativa (Warfvinge: "Schmidt's Jahrb.," 1882, cxcv, 130): Woman, aged forty-five, admitted October 15, 1881, suffering from abdominal pain, chills, and sweats. Temperature varied between 37° and 41° C. No vomiting of blood or melæna. Gradually became jaundiced; bile-pigments appeared in the urine. Urine contained albumen

and pus. Patient gradually became comatose and died November 1st.

On post-mortem examination, faint icteric tinge of skin, œdema and hypostasis of lungs; enlargement and softening of spleen; liver enlarged and parenchyma soft and greenish-yellow in colour. Several of the smaller branches of the portal vein obliterated by thrombi; in the porta hepatica there were masses of thrombi of firm consistence adhering to the walls. The main trunk of the portal vein was thickened and filled with reddish-grey masses of clot resembling thick pus in consistence. The splenic vein was normal, but the superior mesenteric vein was filled with numerous thrombi adherent to the intima. In the interior of the superior mesenteric vein there were two perforations. One perforation led into a small abscess cavity with irregular walls lying between the portal vein and the inferior horizontal portion of the duodenum. This cavity was filled with a reddish-grey fluid and did not communicate with any other organ. The second perforation was situated at the junction of a large mesenteric branch with the superior mesenteric vein. This led into the duodenum and opened at the base of a duodenal ulcer in the anterior and upper surface of the inferior horizontal. The ulcer was roughly circular and 1.5 cm. in its widest diameter; the edges were irregular; the loss of substance affected principally the mucous coat; the muscularis was less affected.

Remarks: The absence of ascites was, in Warfvinge's opinion, due to the fact that the portal vein was not entirely obliterated. The case is also noteworthy because of the unusual position of the duodenal ulcer below the opening of the bile and pancreatic ducts in the horizontal portion.

When the base of the ulcer is completely destroyed, a fistula may be formed between the duodenum and any viscus to which it has become adherent. The most frequent form met with involves the gall-bladder and the duodenum (cholecysto-duodenal fistula); but it is probable that in the great majority of the cases the perforation

is the result of cholelithiasis and has started from the gall-bladder. In the various London museums are several specimens illustrating this, and in two the fistula

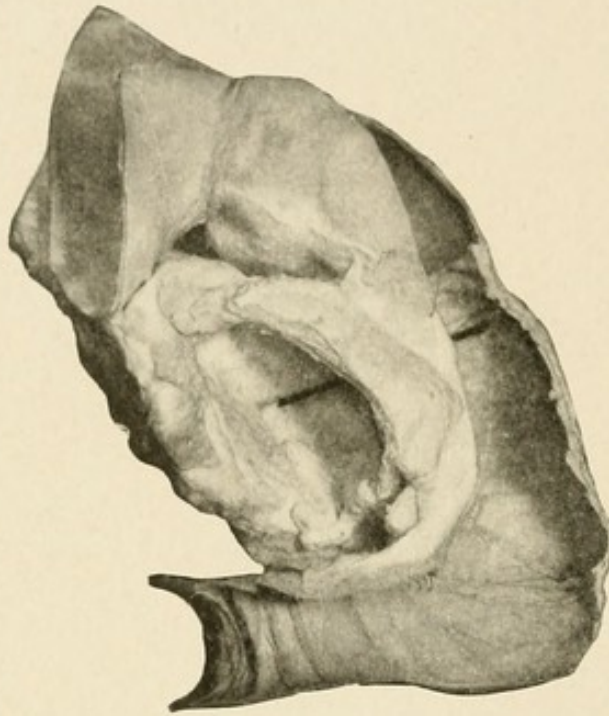


FIG. 62.—PANCREATICO-DUODENAL FISTULA.

A duodenum with the pancreas and a part of the stomach mounted to shew a communication between the duodenum and a cavity in the head of the pancreas, which in the recent state contained blood-clot. The perforation is situated on the concave border of the duodenum two inches below the pyloric ring and an inch and a half above the biliary papilla. Histological examination of the walls of the cavity in the pancreas shews an excess of fibrous tissue between the acini of the gland, but no evidence of malignant growth.

Lizzie C., æt. twenty-nine, was admitted under Dr. Hale White for severe hæmatemesis and melæna, which began eight days before admission. Five days later an exploratory laparotomy was performed, but the source of hæmorrhage was not discovered. She died on the following day. (Guy's Hosp. Museum, No. 757.)

had allowed the passage of a gall-stone, which later became impacted in the ileum and caused death. It must, I think, be assumed that the gall-bladder has been the

starting-point in all cases in which a clear history of duodenal ulcer is not to be obtained. In the very great majority of recorded cases of cholecysto-duodenal fistula the gall-bladder has been small, sclerosed, and gall-

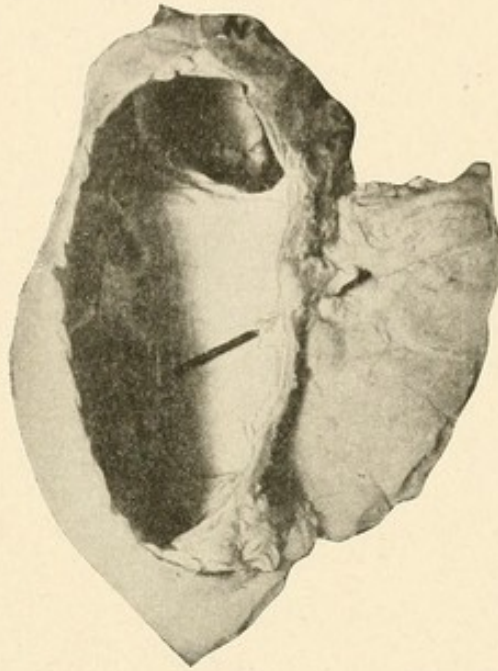


FIG. 63.—CHRONIC ULCER OF THE DUODENUM ERODING THE PANCREAS.

The first four inches of a duodenum, seen from behind, with a portion of the pancreas to which it is adherent. There is a large oval ulcer with thin, clean-cut edges, the greater diameter of which corresponds to the long axis of the intestine and measures about two inches. The floor of the ulcer is formed by the head of the pancreas, and in it is exposed the divided end of the superior pancreatico-duodenal artery, indicated by a red rod.

Thomas L., *æt.* sixty, was admitted under Mr. Golding-Bird for a severe injury to the leg, for which amputation was performed. He died eleven days after the operation with symptoms of severe internal hæmorrhage. At the autopsy much blood was found in the intestines. (Guy's Hosp. Museum, No. 737.)

stones have been present within its lessened cavity, or a stone has been fixed in the cystic duct. In all the cases but one related by Perry and Shaw there can be no doubt that the perforation occurred into the duodenum

from the gall-bladder. The one case in which a duodenal ulcer was probably the origin of the fistula is the following:

Cholecysto-duodenal fistula; ulcers of duodenum: C. W. F., a female, aged twenty-five, died from hæmatemesis, from recurrent attacks of which she suffered during the last six weeks of her life. She was also jaundiced. At the autopsy the gall-bladder was seen to be adherent to the duodenum, and communicated with it by a sinus half an inch long and a quarter of an inch in diameter. Around the opening of the sinus into the duodenum the mucous membrane was ulcerated, and there were several other ulcers adjacent to it. There was a primary malignant growth in the common duct and secondary deposits in the liver. ("Path. Soc. Trans.," 1857, ix, 220.)

The earliest case recorded is given by Long, of Liverpool, in the paper in which for the first time he recorded the occurrence of duodenal ulcer in cases of burns. The following is a brief abstract of the case, which is given more fully elsewhere (Long: "London Med. Gazette," 1840, vol. xxv (new series, vol. i), 741):

Duodenal ulcer due to burns; fistula between the duodenum and the gall-bladder: Anna Jones, aged twenty-eight, previously healthy, was extensively burned. Then had tenderness in epigastrium and frequent vomiting; intense thirst and constipation. Death eight days afterwards. On section stomach shewed in the upper corner of the duodenum an ulcer as big as a shilling, whose edges were loosely adherent to the gall-bladder. At this spot the gall-bladder was soft and eroded. Two smaller ulcers were found in the duodenum.

Hoffman ("Schmidt's Jahrbuch.," cxxxix, 293) relates briefly the following case:

Woman, sixty-three years of age, who had an ulcer in the

first portion of the duodenum. Plastic peritonitis was found round the base of the ulcer, and the common bile-duct was occluded thereby; the biliary channels behind the obstruction were all greatly dilated, and a fistula was found between the distended gall-bladder and the base of the ulcer.

Another interesting example is the following:

Perforated duodenal ulcer; adhesion with gall-bladder; fistula between duodenum and gall-bladder ("Lancet," 1850, i, 776): Woman, aged twenty-five; suffered latterly from hæmatemesis and melæna; very anæmic; jaundiced; liver enlarged and tender. On post-mortem examination the stomach presented a healthy appearance, but on opening the duodenum several ulcers were discovered at a distance of between one and two inches from the pylorus. One of these, situated on the upper wall, had perforated the intestine by a round opening, about a quarter of an inch in diameter, with smooth, rounded edges, this aperture corresponded to a similar opening in the gall-bladder, the two organs having been united by adhesions at this point. Two or three small and superficial ulcerations existed in the neighbourhood of this abnormal connexion, and immediately opposite, on the lower wall of the bowel, there was an irregular, oval ulceration, of similar character, having an area of about half an inch, and close below this spot the free edge of one of the valvulæ conniventes was ulcerated for the length of half an inch.

A case is recorded by Reinhold ("Münc. med. Woch.," 1887, i, 678) in which hepatic abscess had formed as a result of a duodenal ulcer. A fistula between the gall-bladder and the duodenum was present, which was due, it would seem to me, to the blocking of the cystic duct and to the distension of the gall-bladder, both of which are mentioned in the report.

In one case in my own series a fistula readily admitting the tip of the finger was found. There was a long history

of duodenal ulcer, and the gall-bladder was otherwise healthy; there were no stones (No. 81 in case list). In many other cases of mine the gall-bladder has been very closely adherent to the duodenum.

Two cases of duodeno-colic fistula are recorded; one by Sanderson ("Path. Soc. Trans.," 1862, xiv, 173):

J. S., a male, aged thirty, was admitted into the Middlesex Hospital under Dr. Stewart for epigastric pain and vomiting of fifteen years' duration. He had suffered from four similar attacks, the first of which had occurred four years before his admission. On the present occasion the symptoms continued for fourteen days, when he died, and at the autopsy the stomach and first part of the duodenum were much distended. Three-quarters of an inch from the pylorus and on the posterior wall there was a pouch as large as a pigeon's egg projecting from the duodenum, the lining of which was smooth and formed of fibrous tissue. The hinder wall of the pouch was firmly adherent to the head of the pancreas, and its anterior and lower part attached to the transverse colon, with which it communicated by a valvular aperture large enough to admit a swanquill. There was no evidence of growth, and no other disease was found in the body except a small tuberculous cavity at the apex of the right lung.

A second case is related by Perry and Shaw (Case 258, p. 284):

George N., aged twenty-five, was admitted under Mr. Cooper Foster with a lumbar and psoas abscess, from the effects of which he died. He had been in the hospital two years previously under Dr. Wilks with an irregular lump in the epigastric region which was thought by some to be caseous omentum. At the autopsy several vertebræ were found to be carious, and the lumbar and mesenteric glands were caseous. The stomach was slightly lardaceous and adherent to the transverse colon. Immediately beyond the pyloric ring was a small opening in the duodenum which led into a

fistula, and this opened straight into the colon. The transverse colon was at the part irregular on the surface, and showed a large, old, healed ulcer going round the circumference of the bowel, and a little lower down was a similar but larger patch 4 or 5 inches long. There was no other ulceration in the intestine and no tubercle. The intestine was extremely lardaceous all through. The liver, spleen, and kidneys were lardaceous. The gall-bladder was normal.

A few cases are found recorded in the literature in which a fistula between the duodenum and the stomach was found; but in all the explanation given by the recorders, that the ulcer had its origin in the stomach, is very probably correct. I can find no reference to a case in which the fistula seemed to begin from the duodenal side. Cases of external fistulæ also occur. Instances are quoted in the chapter dealing with perforating ulcers.

Ulcus carcinomatosum.—We are now well informed of the fact that chronic ulcer of the stomach in a certain proportion of cases leads to the development of malignant disease. Cancer of the stomach would appear to begin in connexion with a chronic ulcer in something over 60 per cent. of cases. This is the estimate given by W. J. Mayo as a result of the examination of a large number of specimens removed during the operation of partial gastrectomy, and it coincides with that which has been made by other observers, on both clinical and pathological grounds. It is a curious and at present inexplicable thing that a change from a simple to a malignant condition in the duodenum is of extreme rarity. Chronic duodenal ulcer, so far as concerns the cases coming to the surgeon for relief, is a more frequent disorder than ulcer of the stomach. Cancer of the duodenum is very rarely

seen; cancer of the stomach is, unhappily, very common. W. J. Mayo writes ("Journ. Amer. Med. Assoc.," 1908, ii, 558): "We have seen but four apparently primary carcinomas of the duodenum. In two of these the origin was uncertain, and in but one did it seem probable that the cancer had developed in an ulcer. In five cases, however, we have known gastric cancer to develop on the edge of a duodenal ulcer which involved the stomach at the pyloric ring." I have met with only two cases of carcinoma limited to the duodenum; in one there was no history of chronic ulceration; in the second the recurrence of perfectly characteristic "attacks" over a long period made the diagnosis of duodenal ulcer extremely probable; at the operation a malignant growth, strictly limited to the first and a part of the second portion of the duodenum, was found.

CASE 1.—September, 1901. S. F., female, aged fifty-three. (Was sent by Dr. Lockwood, Halifax.) Was in fair health up to two months ago, when she began to lose flesh, and to have persistent vomiting and great discomfort after meals. No blood was vomited and there was no melæna. At the operation a scar of an old ulcer was found in the duodenum. In the hinder wall of the first and second parts of the duodenum a hard, craggy mass was felt involving also the head of the pancreas. Several glands were felt above the pancreas. Gastro-enterostomy was performed with temporary benefit. A post-mortem examination subsequently disclosed an old scar in the first part of the duodenum on the anterior wall. Opposite to this and extending into the second part of the duodenum was a large ulcerating growth which had eaten into the pancreas. It was thought to have started in an ulcer immediately opposite the healed scar in the first part.

CASE 2.—S. S., male, aged fifty-four. (Sent by Dr. Ellis, Halifax.) For ten years has had persistent gastric troubles,

pain after food, vomiting, blood-stained at times, and melæna. Has lost weight steadily in last few months and is now extremely thin and pinched. The stomach is largely dilated. At the operation a large mass was felt involving the pylorus, the duodenum, and the head of the pancreas. The patient died in three weeks. At the autopsy a chronic ulcer of the duodenum was found. Most of the circumference was occupied by large nodular masses of carcinoma which invaded the pancreas also. The portion of the ulcer nearest the pylorus was thick and stiff, but no malignancy was discovered in it.

A very few cases are recorded in the literature. Perry and Shaw (pp. 274, 275, 276) give notes of five cases of "simple ulcers becoming malignant." There are only two of them in which there would seem to be any positive connexion between a chronic ulcer and the growth which was found at autopsy. The following are the cases:

I. Charles L., aged forty-five, was admitted under Dr. Habershon and died eleven days later. No clinical account is preserved. At the autopsy the stomach was enlarged and the omentum was adherent to the pylorus. A puckering of the tissues was seen at this part. On handling the pylorus a hard lump was felt which was composed of the diseased pylorus with some enlarged lymphatic glands and the head of the pancreas. The latter had in it a caseous mass about the size of a walnut. This and the small cancerous lymphatic glands could be dissected away from the intestine, leaving the duodenum and stomach very little affected, "although here was no doubt the primary disease." At the pylorus was an ulcer about the size of a shilling, partly in the duodenum and partly in the stomach. It had raised edges composed of a cancerous material, but these were soft and of cheesy consistence, showing the cancer breaking up and degenerating. The whole thickness of the wall of the duodenum and stomach was not affected, although the glands and omentum were extremely adherent, and there was much puckering of the tissues. There were secondary deposits in the liver.

II. A woman, aged about sixty, was admitted under Dr. Pavy with emaciation and jaundice. The clinical account is not preserved. The stomach was normal, but on passing the finger through the pylorus considerable constriction was felt beyond it, and the duodenum appeared to be puckered. On slitting it open the first part of the duodenum was seen to be surrounded by a tough, firm, fibrous growth, which appeared for the most part outside the wall of the intestine. On the posterior wall of the duodenum beyond the pylorus was an ulcer an inch in diameter with thickened edges and floor, the latter consisting of tough material in the portal fissure, apparently new-growth, though the edge more resembled that of a simple chronic ulcer. However, the ulcer with the thick material at its base had involved the gall-bladder and strangled it so completely that nothing now remained of it save a small cavity of the size of a pea containing greenish mucus. The ductus communis choledochus was followed to its termination, and it was now quite patent, a probe passing easily along it, but about an inch from the papilla its walls were infiltrated for half an inch, and at this part the tube became rather contracted. Beyond this part the duct was dilated so as to admit the little finger easily. "I think," says Dr. Goodhart, "there could be no doubt that before the parts were disturbed there had been complete obstruction behind the growth. The pancreatic duct was not dilated and the portal vein was free. It seemed to be a case of a new growth originating in the floor of a chronic ulcer, and spreading thence to the surrounding parts."

At a meeting of the Royal Academy of Medicine in Ireland Dr. Boxwell exhibited a specimen of carcinoma following on ulcer of the duodenum ("Lancet," 1907, ii, 1687):

The organs were obtained from a man of sixty who had been suffering for some years from attacks of jaundice, sometimes with slight vomiting, but he never had much pain. At the necropsy it was found that there was something like

an ulcer occupying the ampulla of Vater just at the entry of the common duct; carcinomatous nodules were scattered through the lungs, but there were no deposits on the liver.

The following case is recorded by Ewald ("Berl. klin. Woch.," 1886, No. 32, p. 527):

Woman, sixty-seven years of age, had been in hospital for some time with an old fracture of the thigh. Began to have gastric symptoms in the spring of 1885, to which at first very little attention was paid. As the condition did not improve under the ordinary remedies, a test breakfast was given and the stomach contents were examined. Lactic acid was present but no hydrochloric acid. A mixture containing dilute HCl was given with apparently good results. After a time patient began to have severe pain in the epigastrium and round the umbilicus. Anorexia and rapid wasting led to the suspicion of carcinoma. A second examination of the stomach contents still showed the absence of free HCl. Patient gradually became weaker, and died in March, 1886.

Post-mortem: Instead of a gastric carcinoma, which was suspected, there was found a duodenal ulcer which had undergone carcinomatous degeneration. The ulcer was situated 2 cm. from the pylorus over the head of the pancreas. The margins were heaped up and wall-like; the ulcer was circular, smooth, 1.8 cm. in diameter, and projected through the serosa as a nodular growth scarcely as big as a cherry, which was firmly adherent to the margin of the liver. The head of the pancreas, though in close relation to the growth, was not invaded. In the liver, however, the tumour tissue had penetrated a good way. No secondary growths elsewhere. Microscopic examination showed firm connective tissue, and here and there strands of epithelial cells and accumulations of round cells. The condition evidently was a healed round duodenal ulcer, in the scar of which a carcinoma had commenced to develop. Microscopic examination of the stomach wall showed a partly fibrous and partly colloid degeneration of the mucous membrane and atrophy of the glands.

A case is also given by Eichhorst ("Ztschr. f. klin. Med.," 1888, xiv, 519; abstracts in "Schmidt's Jahrbucher," ccxx, 213, 1888):

Man-servant, forty-six years of age. Had swelling in neck for two months, night-sweats, frequent pains in the joints. Legs gradually became weak; girdle pains; complete paraplegia with stoppage of urine set in six days before admission. Present condition: Cachectic man; nodular glandular enlargement in neck. Complete paralysis and anæsthesia of the lower part of the body, with disappearance of the reflexes. Posteriorly, anæsthesia reaches up to the ninth dorsal vertebra. Death after six days.

Post-mortem: Round duodenal ulcer present, with carcinomatous degeneration of the margins. Secondary growths in the liver, lymphatic glands, vertebræ, dura mater, and also extending into the spinal cord itself.

APPENDIX

CONTAINING A DETAILED STATEMENT OF ALL CASES
OPERATED UPON TO THE END OF 1908; WITH
AN ANALYSIS AND SUMMARY

BY HAROLD COLLINSON, M.S., F. R. C. S.

ASSISTANT SURGEON, LEEDS GENERAL INFIRMARY; CLINICAL LECTURER IN SURGERY,
UNIVERSITY OF LEEDS, ETC.

THE patients whose case histories are appended number 186 and the period covered is nine years (1900-1908).

Sex.—Males, 137, or 73.6 per cent.; females, 49, or 26.4 per cent.

Variety of Ulcer.—Amongst the 137 male patients there were 107 cases in which duodenal ulcer alone was found, and 30 cases in which both gastric and duodenal ulcers were present. Of the 49 female patients, 32 had duodenal ulcer alone, 17 both gastric and duodenal ulcers. The proportion of males to females amongst the cases presenting duodenal ulcer only was therefore more than three to one. In the first 40 cases operated upon, evidence of both gastric and duodenal ulceration was found in 24.

Age.—The distribution of the patients in the various decennial periods is as follows:

YEARS		
1 to 10	None
11 " 20	3
21 " 30	37
31 " 40	56
41 " 50	45
51 " 60	27
61 " 70	11
Age not stated	7

The youngest was aged seventeen and the oldest sixty-seven; it must be borne in mind, however, that the age given is that of the patient at the time of operation, and not at the onset of symptoms, and that many of the patients who were over the age of forty had had symptoms for a considerable number of years. The longest duration of illness before operation was forty years (Case 163) and the shortest seven weeks (Case 45); in this case melæna was severe, and practically the only symptom.

Symptoms.—In examining the case histories one is impressed by two facts: First, that in the earlier cases the clinical picture which we are now accustomed to associate with the presence of duodenal ulcer is only imperfectly indicated in the account of the patient's symptoms, whilst in the majority of the later cases the patient's account of his symptoms given after careful enquiry is typical. The second point of interest is that in the early cases operation was in a large proportion of the cases undertaken for the more serious complications of duodenal ulceration rather than for the relief of symptoms due to the ulcer itself. When one divides the cases into those occurring during the first half of the period, *i. e.*, to the end of June, 1904, and those between that date and the end of 1908, it is seen that during the

first period there are 39 patients (Cases 3 and 40 referring to the same patients as Cases 2 and 24), and in the second there are 147 (Cases 54 and 172 referring to one patient).

Amongst the 39 patients operated upon up to the middle of 1904 are 9 (23 per cent.) in whom gastric dilatation is described as being great, and in some instances enormous, and 7 patients (18 per cent.) in whom hæmorrhage was very severe. Amongst the 147 patients operated upon during the second period 15 only (10.2 per cent.) presented dilatation which was described as severe and 11 (7.5 per cent.) hæmorrhage which was alarming.

The details of the cases mark the gradual increase of our knowledge of duodenal ulcer; in the earlier period symptoms were little understood, accurate information as to the time of onset of pain was not sought, and it was only the grosser and more serious results of ulceration which brought the patient into the hands of the surgeon; as our knowledge of, and familiarity with, the condition have increased, so the cases have been seen earlier, their symptoms more carefully investigated, and operation advised and performed in most cases before the onset of dangerous complications.

Hæmorrhage.—Seventy patients (37.6 per cent.) gave a history of bleeding at one time or another; of these 17 had hæmatemesis alone, 23 had melæna alone, 30 had both hæmatemesis and melæna.

Amongst the 139 cases in which duodenal ulcer alone was found, hæmorrhage was noted in 49 cases (35.2 per cent.): 9 had hæmatemesis alone (6.4 per cent.); 18 had melæna alone (13 per cent.); 22 had hæmatemesis and melæna (15.8 per cent.).

In the 47 cases in which there was evidence of both gastric and duodenal ulcers hæmorrhage was apparently mainly due to the duodenal ulceration in 7 cases (Cases 5, 15, 16, 19, 20, 97, 182); 4 of these had melæna only, and 3 both hæmatemesis and melæna.

In 18 cases hæmorrhage was severe, and in most of these was the chief symptom for which the patient sought operative treatment (Cases 7, 14, 19, 20, 27, 28, 41, 43, 45, 46, 72, 86, 95, 114, 138, 152, 153, 181). In 12 of these duodenal ulcer alone was present, and in Case 19, although there was evidence of gastric ulceration, it was the duodenal ulcer which was bleeding. If we add this case to the 139 cases in which duodenal ulcer alone was found, the percentage of cases in which hæmorrhage was really severe amounts to 9.2 per cent.

Stenosis.—Although in a large number of the cases gastric dilatation is described as being present, this was not always accompanied by definite stenosis of the duodenum; in 43 instances, however, the lumen of the duodenum was noticed to be narrowed by the contraction of an ulcer.

Perforation of Ulcer.—Amongst the 139 cases in which duodenal ulcer was found alone, there were evidences of old perforation in 5 (3.6 per cent.). Case 17: Operated upon eight months previously for perforation. Cases 38 and 177: In these a subacute perforation occurred a short time before. Cases 169 and 178: An ulcer had probably perforated a considerable time previous to the operation.

In addition to the above cases, a perforation had probably occurred some time before in Case 98, but it is un-

certain whether it was of a gastric or duodenal ulcer. Case 147 shewed an old perforation of a gastric ulcer.

Tetany.—Three cases (Cases 6, 10, 58) gave a history of tetany. In all of these both gastric and duodenal ulcers were present and the stomach was much dilated.

Cardiospasm.—In three cases (Cases 161, 168, 194) spasm of the cardiac opening of the stomach was present, and in Case 161 this was apparently the chief trouble.

Operative Treatment.—Upon the 186 patients 194 operations were performed.

Eight patients were operated upon twice, viz.:

Cases 2 (see Case 3), 24 (see Case 40), 54 (see Case 172), 80, 83, 99, 100, 173.

The 194 operations may be classified as follows:

Posterior gastro-enterostomy by simple suture.....	78
Posterior gastro-enterostomy by simple suture with infolding of ulcer.....	84
Posterior gastro-enterostomy (with Laplace's forceps), Cases 1 and 2.....	2
Posterior gastro-enterostomy (with Murphy's button), Case 3.....	1
Posterior gastro-enterostomy (Mayo's method), Cases 74, 84, 106, 152.....	4
Posterior gastro-enterostomy and Gastroplasty (Case 108).....	1
Anterior gastro-enterostomy with lateral anastomosis (Case 159).....	1
Modified Roux's operation (Cases 17, 169).....	2
Division of loop and lateral implantation (Case 100).....	1
Lateral anastomosis between limbs of loop (Case 40).....	1
Posterior gastro-enterostomy with cholecystotomy (Cases 12, 78, 83, 130).....	4
Posterior gastro-enterostomy with cholecystectomy (Cases 161, 163).....	2
Posterior gastro-enterostomy with appendicectomy (Cases 75, 176, 189).....	3
Posterior gastro-enterostomy with radical cure of hernia (Case 46).....	1
Posterior gastro-enterostomy with excision of duodenal ulcer (Cases 114, 182).....	2
Excision of duodenal ulcer alone (Case 183).....	1
Excision of gastric ulcer (Case 173).....	1

Closure of pylorus (Case 172)	1
Cholecystenterostomy (Case 180).....	1
Cholecystectomy (Case 80).....	1
Exploratory laparotomy (Case 83).....	1
Excision of perforated jejunal ulcer with fresh anastomosis.....	1
Total.....	194

In Cases 1 and 2 gastro-enterostomy was performed with the aid of Laplace's forceps, with strikingly different results. The former of the two patients is now well and free from trouble. The second returned two months later with a recurrence of symptoms; when the abdomen was opened (Case 3), the stoma was found to be almost closed, and a fresh anastomosis was performed with Murphy's button; the patient is now quite well. These three operations are the only ones in which any appliance was used in the performance of the anastomosis.

In four cases posterior gastro-enterostomy was performed by the antiperistaltic method; the number is too small to allow one to draw any conclusions as to the relative advantages of this method; one of the four patients has been troubled with regurgitant vomiting since the operation.

The other cases which were twice operated upon are of considerable interest.

Case 24 (see also Case 40): A posterior gastro-enterostomy was performed by simple suture; one week later severe vomiting commenced, and lasted with short intermissions for a year, when the abdomen was reopened. It was then found that the whole of the small intestine, with the exception of the last 18 inches, had passed into the lesser peritoneal sac through the opening made in the transverse mesocolon. The herniated bowel was re-

duced and a rather long loop was found to have been left between the flexure and the stoma; a lateral anastomosis was performed between the limbs of the loop and the margins of the opening in the mesocolon were sutured to the line of the gastro-enterostomy opening. A similar accident produced a fatal result in Case 16.

Case 54: In this case there was no stenosis and the duodenum was not infolded at the time of the gastro-enterostomy; for a time the operation conferred some benefit, but the patient returned three years later (see Case 172) with a recurrence of all symptoms, pain two to three hours after food, relieved by food or bicarbonate of soda, and frequent vomiting. The abdomen was reopened and the following condition found: The anastomosis shewed a slightly longer loop than would be left at the present time and the stoma would admit three fingers easily. The pylorus was patent, and at the site of the ulcer found at the previous operation, of which a drawing had been kept in the old notes, a large scar was present; close to this were two other well-marked ulcers, evidently of recent date. The explanation seems to be that pylorospasm was formerly present along with the duodenal ulcer; the gastro-enterostomy acted at first, but as the spasm relaxed the opening ceased to be functional and ulceration recurred. The pylorus was closed by sutures infolding the ulcerated area, and although it is not long since the second operation was performed, the patient is quite free from trouble.

Case 80: At the time of the first operation, which was a gastro-enterostomy for duodenal ulcer, a calculus was felt in the pelvis of the gall-bladder; but owing to the

feeble condition of the patient, it was thought wiser not to prolong the operation. During convalescence an acute attack of epigastric pain occurred, and similar attacks recurred at intervals for the next two years. These attacks came on soon after food, and were more acute than the pain before the first operation, which usually came three hours after a meal. Their character was such that a second operation was decided upon, and the gall-bladder was explored; it was found to be hour-glass in shape and to contain several calculi. It was removed. The scar of the old duodenal ulcer was seen and infolded; there was no evidence of fresh ulceration. The patient has done well.

Case 100: In this case a recurrence of pain and flatulence, with occasional vomiting and some loss of weight, raised a suspicion of a possible malignant change in the ulcerated area, and the abdomen was reopened sixteen months after the first operation. There was no evidence of carcinoma and the pylorus was freely patent. A slight "loop" was present, and so the afferent limb was divided and anastomosed with the efferent by an end-to-side implantation; the pylorus was narrowed by suture. There has been slight improvement in the symptoms as a result.

Case 173: Gave a long history of indigestion, with one attack of hæmatemesis at least. Pain varied in time of onset, sometimes immediately, but generally two hours after food. Liquids caused more discomfort than solids, a drink of water producing almost immediate pain. A diagnosis of duodenal ulcer was made, but at operation no lesion could be detected in the duodenum on either

inspection or palpation. On the lesser curvature of the stomach, however, slightly nearer the cardia than the pylorus, was a large ulcer with induration extending into both anterior and posterior walls. This was excised and the incision sutured. No gastro-enterostomy was performed. Relief followed the operation for four months, and then pain recurred, coming two to three hours after food and always relieved by the next meal. There was no vomiting. The weight which had been regained was rapidly lost. Fourteen months after the first operation the abdomen was reopened; the scar of the previous excision was found to be perfect; there was no narrowing and only a few thin adhesions. The first part of the duodenum was surrounded by adhesions and a large indurated ulcer was found on its anterior aspect. Posterior gastro-enterostomy was performed and the ulcer infolded. The patient has been perfectly well since. There is no doubt that the chief symptoms before the first operation were caused by the gastric ulcer, but the variable time of onset of pain for a few months before operation makes it probable that the duodenum was the site of early ulceration even at that time, although no lesion could be detected on examination of the exterior of the gut.

In three cases anterior gastro-enterostomy had to be performed in place of the posterior operation on account of technical difficulties; in two of these (Cases 17 and 169) the loop was divided and the afferent limb implanted into the efferent, and in the third (Case 159) a lateral anastomosis was performed between the limbs.

In six cases gall-stones were removed simultaneously with the performance of gastro-enterostomy. In case

12 the patient had suffered from repeated attacks of severe colicky pain in the right hypochondrium, accompanied by vomiting and always followed by profuse, tarry stools, but no jaundice. In cases 78, 130, and 161 gall-stones were not suspected before operation. Case 83 was operated upon for the relief of attacks of typical biliary colic and the gall-bladder drained after the removal of a number of calculi; it is a pity that the gall-bladder was not extirpated, for the patient died less than three years after from carcinoma beginning in the gall-bladder and spreading to the liver. In Case 163 gall-stones were apparently the chief trouble and a cholecysto-duodenal fistula existed. Case 180 is of the greatest clinical interest; the history of the case and the physical examination strongly suggested obstructive jaundice due to carcinoma of the head of the pancreas, and it was not until the pathologist's report on the chemical examination of the urine and fæces demonstrated that the obstruction involved the common duct above the level of its junction with the pancreatic that operation was suggested; an indurated scar in the duodenal wall was found to be compressing the common bile-duct and a cholecyst-enterostomy was performed. Unfortunately the junction had to be made with the colon on account of mechanical difficulties, and no doubt the three short attacks of pain and pyrexia with jaundice which the patient has experienced since operation have been due to cholecystitis with an ascending infection. With this exception the operation appears to have brought complete relief.

Cholecysto-duodenal fistulæ were found in two cases

(Nos. 81 and 163); in the former due to duodenal ulceration, in the latter probably due to gall-stones.

In Case 108 an hour-glass contraction of the stomach was present, necessitating the performance of gastroplasty at the same time as gastro-enterostomy.

Excision of a duodenal ulcer without gastro-enterostomy was the operation in Case 183; scarcely a year has elapsed since the operation, but a quite recent report states that the patient is very well.

Operative Results.—Four patients out of the 186 died as the result of the operation (2.15 per cent.): Case 16—acute intestinal obstruction, on the tenth day; Case 33—uræmia, on the third day; Case 99—perforation of jejunal ulcer, on thirteenth day; Case 112—acute tuberculosis, on fourteenth day.

The details of the cases are as follows:

Case 16: Death occurred on the tenth day with symptoms pointing to intestinal obstruction. At the autopsy it was found that almost the whole of the small intestine had passed into the lesser sac through the opening made in the transverse mesocolon for the performance of the anastomosis. A similar hernia occurred in Case 24; this was more gradual in onset, but necessitated operation at a later date. Since that time it has been a routine procedure to suture the margins of the opening in the mesocolon to the line of the anastomosis in order to prevent such an accident.

Case 33: This patient was admitted with a ten-years history of pain after food and vomiting; albumin was noted in the urine before operation, but there is no note as to whether casts were found. At the operation there

were no external evidences of ulceration in the duodenum, but gastro-enterostomy was performed. The patient died three days after with symptoms of uræmia. At autopsy the kidneys were found to be small and granular with much narrowing of the cortex. In the duodenum there was ulceration without induration, probably uræmic in origin.

Case 99: In this case posterior gastro-enterostomy was performed for a duodenal ulcer which was infolded. Until the thirteenth day the patient did very well, and was then allowed to get up. Almost immediately after getting out of bed he complained of acute abdominal pain and vomited. Next day he seemed rather better, but vomited in the evening, and the following day—the fifth after operation—was very ill and the abdomen was reopened. No free fluid was found in the peritoneal cavity, but the coils of small intestine were slightly injected. It was difficult to expose the anastomosis on account of adhesions, and as these were separated a perforation of the jejunum just distal to the anastomosis was found. In order to close this, the anastomosis had to be disconnected. This was done, the ulcer excised, the opening in the stomach closed, and a fresh anastomosis performed away from the first position. The patient died shortly afterwards.

Case 112: This patient had a duodenal ulcer, and in addition several tuberculous deposits at the ileocæcal junction and in the large intestine. He died fourteen days later with symptoms of acute tuberculosis.

Four other patients are since dead at varying periods after the operation.

Case 30: Four years later, from cardiac disease; apparently no recurrence of stomach symptoms.

Case 38: At operation a subacute perforation of a large duodenal ulcer was found. For the first ten months after operation was entirely free from trouble and gained weight; then pain began to recur, at first at long intervals, but gradually becoming more frequent and severe, with occasional vomiting. Two and one-half years after operation she began to lose weight rapidly, and ascites and marked anæmia developed, with inability to retain food. Death ensued from asthenia and exhaustion three years and four months after operation. The cause of death was probably carcinoma, but whether of duodenum or stomach it is impossible to say, as no autopsy was obtained.

Case 55: In this case a suspicion of carcinoma was raised before operation, as the stomach contents were only faintly acid, contained no free HCl, and lactic acid was present. At the operation, however, no evidence of carcinoma could be detected, and the scar of an ulcer was present in the duodenum. The patient's doctor reports that he died two years later from "pernicious anæmia," the symptoms of which had appeared only four months before. There were apparently no symptoms pointing to gastric carcinoma.

Case 83: Operation in this case was undertaken for the relief of symptoms of cholelithiasis, and the gall-bladder, which contained many small calculi, was evacuated and drained. The contracted scar of a duodenal ulcer was present, so gastro-enterostomy was performed. Two years and nine months later he was readmitted to

the Nursing Home with a large tumour in the region of the gall-bladder. An exploratory operation revealed extensive carcinoma involving the gall-bladder and infiltrating the liver. The abdomen was closed and he died some weeks later.

In the remaining 178 cases an attempt has been made to obtain a report of the present condition of the patient by writing to the doctor who sent the case, and in some instances to the patients themselves. In a few cases the patients have been seen personally within the last few months. Reports are attached to the case histories, and wherever possible are given in the words of the patient or medical man.

In 11 cases (Cases 4, 15, 32, 52, 73, 81, 98, 129, 140, 165, 188) attempts to trace the patients have been unsuccessful, and no report is available at a longer period after the operation than a few months.

In 4 cases (Cases 7, 14, 42, 43) a report was obtained in 1905, but none has been available since that time. In cases 7 and 14 this report was three and one-half and two and three-quarters years after operation respectively, and they may be classed as cures; Case 42 was improved, and Case 43, although the report was only twelve months after operation, appeared to be cured. Of the 163 patients concerning whom recent reports have been obtained, 144 may be classed as cured. The remaining 19 cases are not yet entirely free from trouble, and details of them are appended.

Case 17: A case of gastro-enterostomy nine months after operation for perforation of a duodenal ulcer. An anterior operation by Roux's method had to be per-

Detailed Statement of Cases Operated Upon 265

formed owing to the almost universal adhesions. Patient has now occasional epigastric pain, probably due to adhesions, but is otherwise in excellent health. Very much improved.

Case 18: A very good report in 1905 (three and one-half years after operation). Last report not quite so favourable; has occasional bilious vomiting, but is evidently much improved.

Case 23: The patient still suffers from distention and flatulence, but is distinctly better for the operation.

Case 24 (see also Case 40): This patient suffered from severe vomiting which began one week after posterior gastro-enterostomy and lasted with short intermissions until one year later, when the abdomen was reopened. It was then found that almost all the small intestine had herniated through the opening in the transverse mesocolon. This was reduced and a lateral anastomosis between limbs of loop performed. Patient is much better, but still has occasional pain and vomiting. The diagnosis of a medical man who saw him was "ergophobia."

Case 36: Eighteen months after operation reported to be little better. Recent report not very reliable, but appears to be better than he was.

Case 49: Suffers from attacks of regurgitant vomiting, but says she is much better.

Case 70: Occasionally vomits, but is otherwise very well.

Case 74: Still has attacks of regurgitant vomiting every three or four weeks, which he relieves by lavage, but is at work and otherwise well.

Case 75: Occasional pain and vomiting, but is much improved. A "neurotic."

Case 76: Still suffers from flatulence and anæmia, but is much improved.

Case 88: Occasional pain and "water brash," but much better.

Case 91: Regurgitant vomiting of bile about once a week, causing no pain. Otherwise quite well.

Case 100: Much relieved for one year, then recurrence of pain and distension with occasional vomiting. Fifteen months after gastro-enterostomy abdomen opened, as carcinoma was suspected; none found. As a "loop" existed, lateral anastomosis was performed. Recent report (one year after second operation) states that a ventral hernia has developed; he is better but not well.

Case 104: Much improved; practically cured.

Case 113: Says he is no better, although doctor thinks he is. Is a hypochondriac.

Case 125: Still some pain, but has gained 11 lbs. in weight, and is, on the whole, better.

Case 161: Patient suffers from cardiospasm and is still under treatment.

Case 176: Not much improvement six months after operation. Patient is a busy practitioner and is apt to overwork, but when seen recently was very much better.

Case 179: Slow improvement taking place six months after operation; one year after operation much better and back at work.

Of Case 113 one is bound to say that the patient appears to be no better, and in Case 161 improvement is

Detailed Statement of Cases Operated Upon 267

doubtful; the other 17 cases are distinctly benefited, if not cured.

Summarising, therefore, the results of my enquiries, we have the following result:

163 recent reports:

Cured.....	144
Improved.....	17
Doubtful improvement.....	1
No better.....	1

4 reports in 1905:

Cured.....	3
Improved.....	1
Cases not traced.....	11

The operative results work out as follows:

Died as result of operation.....	4 = 2.15%
Died at varying periods of other causes than operation .	4 = 2.15%
Cured.....	147 = 79.0%
Improved.....	18 = 9.6%
Doubtful improvement.....	1 = 0.5%
No better.....	1 = 0.5%
Not traced.....	11 = 5.9%

Cases in Which Post-operative Vomiting Occurred.—

In the following 12 cases vomiting occurred for a variable length of time after operation or is still present.

Case 6: Now cured.

Case 18: Occasional bilious vomiting still present.

Case 24: (See also Case 40.) Severe vomiting due to hernia into lesser sac, much relieved.

Case 27: Temporary regurgitation. Now cured.

Case 34: Temporary regurgitation. Now cured.

Case 42: Occasional vomiting one year after operation.

No later report.

Case 49: Regurgitant vomiting, still persists.

Case 70: Still vomits occasionally.

Case 74: A typical attack of regurgitant vomiting every three or four weeks.

Case 91: Regurgitant vomiting, still persists.

Case 100: Occasional vomiting. Reoperated with some relief.

Case 104: Occasional bilious vomiting.

Of these cases of post-operative vomiting, only six (Cases 24, 27, 34, 49, 74, 91) can be classed as true regurgitant vomiting. In Case 24 the vomiting was severe and the cause removed at a second operation. In Cases 27 and 34 the vomiting was temporary and the cause is not known, unless it be that a loop was left between the anastomosis and the flexure. In Cases 49 and 91 the stomach was found to be very much dilated, and there may be some mechanical difficulty which still causes the vomiting to persist. In Case 74 the operation was performed by the antiperistaltic method, which is now not used.

In arranging the case histories the original description of the operation has been retained with the exception of occasional slight alterations in the wording, and although in some of the earlier cases the evidence of gastric ulceration apparently was based on slighter grounds than would now be accepted, it was thought inadvisable to alter the nomenclature in any way at this date. The reports on the patients' present condition have been entered in the form received.

COMPLETE LIST OF CASES OF CHRONIC DUODENAL ULCER
TREATED BY OPERATION

D. indicates Duodenal Ulcer; G & D. indicate Gastric and Duodenal.

CASE 1.—G & D. January, 1900. Female, aged thirty-one. At the age of sixteen an illness, attended with hæmatemesis on one occasion in large quantity. Pain after food ever since, varying in severity. Diet has been carefully regulated. June, 1899, pain became more acute, and vomiting, which before had been inconstant, now became frequent. Large quantities (4 pints) were vomited. On examination a large contracting stomach was seen; no tumour palpable.

Operation: Much thickening at pylorus and along first portion of duodenum, with stenosis and many adhesions. The adhesions were carefully separated and posterior gastro-enterostomy performed with the aid of Laplace's forceps. Recovery.

Seen July 29, 1902. "Quite well, in first-rate health." March, 1905, was perfectly well, could eat all foods, and had gained 11 lbs. in weight. Seen again March, 1907. Condition still quite satisfactory.

CASE 2.—G & D. January, 1900. Male, aged fifty-five. Dyspepsia for ten or twelve years, culminating five years ago in a severe attack which lasted two weeks, and was remarkable for the severity and continuance of epigastric pain and the persistence of vomiting. Since that time has had periodic seizures of copious vomiting at intervals of twenty-four hours to three weeks. Pain occurring three to six hours after food, varying greatly in severity, but generally not amounting to more than discomfort. On one occasion in hospital, the vomitus measured $5\frac{1}{2}$ pints. Stomach huge and flabby, greater curvature descending behind the symphysis pubis. Visible peristalsis. HCl present.

Operation: An enormous stomach; an ulcer extending from pylorus into first part of duodenum. Marked cicatricial stenosis, adhesion to liver. Posterior gastro-enterostomy with Laplace's forceps; separation of old adhesions. Recovery. Patient was sent by Dr. Bailey, Horsforth. (For further details see Case 3.)

CASE 3.—March, 1900. Male, aged fifty-five. (See Case 2.) After operation in January, 1900, there was considerable relief for about one month. Then after a heavy meal consisting largely of boiled peas there was an attack of pain and vomiting, and from that date his previous symptoms (dyspepsia, pain, and vomiting) gradually returned. On admission his condition was practically the same as before operation.

Operation: The anastomosis made at the first operation, between the stomach and intestine, was practically closed. A second gastro-enterostomy with the aid of Murphy's button was performed. Recovery.

Seen September, 1900. Said he was never better in his life; had gained over two stones in weight and had no gastric discomfort. Dr. Bailey writes, April 3, 1908: "Patient very well indeed; has gained weight; no recurrence of pain nor vomiting. Has not required any medical assistance since operation."

CASE 4.—G & D. February 16, 1901. Female, aged fifty-one. For some years has had pain after food and diarrhœa. For last five or six months pain has been much more severe and has followed every meal. It occurs half an hour after food, and lasts for three hours or more. Vomiting infrequent, unless self-induced to obtain ease. On two occasions has noticed blood, but only in small quantities. Has lost weight and strength. Continuous medical treatment for five months has proved unavailing. Stomach a little dilated; tenderness on pressure over pyloric region; excess of HCl.

Operation: Three ulcers were found, two in stomach near lesser curvature, 1 inch and 2½ inches respectively from the pylorus; a third in the first part of the duodenum, with considerable induration. Posterior gastro-enterostomy by simple suture. Recovery. Patient was sent by Dr. Lockwood, Halifax. When seen three months after the operation, had gained 10 lbs. in weight. Cannot be traced since.

CASE 5. G & D. March 19, 1901. Mr. P., aged thirty. Symptoms for five or six years. Pain in epigastrium after meals, most severe during the night. Slight pain between shoulders. Vomiting of sour, watery phlegm almost every

other day for twelve months. On one occasion blood. Lost nearly a stone in weight; attacks of faintness, prostration, and melæna.

Operation: An ulcer in the first part of the duodenum with many adhesions. Small scar of ulcer on posterior surface of stomach. Posterior gastro-enterostomy. Recovery. Patient was seen with Drs. Millhouse and Anning.

Dr. Anning writes, February, 1908: "Is perfectly well; has gained 6 lbs. in weight. There has been no recurrence of pain, vomiting, nor melæna. Is of good complexion, whereas previously he was always anæmic."

CASE 6. G & D. November 2, 1901. T. T., male, aged forty. Symptoms began in June, 1900. Burning pain and vomiting after food, generally half an hour after the meal. Two months ago a severe attack of vomiting, lasting two days. Extreme irritability of stomach. No hæmatemesis, no melæna. Has had severe muscular cramps in neck and extremities (tetany). On examination a huge, contracting stomach, loud gurglings in pyloric region, free HCl.

Operation: An enormous stomach showing five well-marked ulcers; another ulcer in duodenum just beyond pylorus. Posterior gastro-enterostomy. Recovery. Seen with Dr. Millhouse and Dr. G. P. Anning, Kirkstall.

In April, 1902, had gained 11 lbs. Dr. Anning writes, February 7, 1908: "Patient in very good health; feels better than he has been for the last eight years; gain in weight 6 lbs. No vomiting for two years; until two years ago he had attacks of bilious vomiting at long intervals, accompanied by flatulence lasting a day or two."

CASE 7.—G & D. January, 1902. N. G., female, aged twenty-six. For the last few months pain coming on immediately after food and lasting for three or four hours. Has therefore limited her diet and has lost weight. Four weeks ago had hæmatemesis and melæna. The melæna has continued ever since and is now threatening to end disastrously. Has fainted in bed several times. Very anæmic; pulse 96. Has become much thinner during the last four weeks.

Operation: An elongated and thickened ulcer in the duo-

denum feeling like a date; a second ulcer on the posterior wall of the stomach. Many adhesions. Posterior gastro-enterostomy. Patient was sent by Dr. Ellis, Halifax.

In September, 1902, reported to be in perfect health; had regained her lost weight and 7 lbs. over. Report received from Dr. Ellis, June 26, 1905: "Never better; gained weight; no trouble in any way." This case has not been traced since.

CASE 8.—G & D. February 3, 1902. R., male, aged forty-three. Twenty years ago began to suffer from pain after food, and vomiting. Ever since has been subject to a recurrence of trouble and has carefully limited his diet. Vomiting from time to time in large quantities; motions occasionally tarry. Last October a sharp attack of hæmatemesis and melæna. Stomach now very dilated, reaching 2 inches below umbilicus. Lost one stone in weight in last four months.

Operation: A very large flaccid stomach; at the pylorus and a little beyond much thickening, forming a tumour equal in size to a walnut. On anterior surface of stomach a distinct scar about 3 inches from pylorus. On posterior surface a similar scar with adhesions to transverse mesocolon. Posterior gastro-enterostomy. Recovery. Patient sent by Dr. Ellis, Halifax.

In August, 1902, reported to be in good health; quite free from stomach troubles; gained one stone. Dr. Ellis reports, February 26, 1908: "Gained considerably in weight, no recurrence of pain nor vomiting. Has been perfectly well since operation."

CASE 9.—G & D. June 12, 1902. Miss A., aged thirty-seven. About ten years ago began to suffer from pain after food and vomiting. Was confined to bed on several occasions. The vomiting was "dreadful," but no blood was ever observed. Continual indigestion for seven years; at the end of that period an alarming hæmorrhage. Was in hospital for five weeks. Vomiting and pain continued intermittently since, and for several months has noticed occasionally that stools were "black as ink." Operation advised a year ago.

Operation: A very large stomach, numerous adhesions around pylorus and duodenum, especially on the posterior surface. Some marked local thickening of the head of the

pancreas (an example of chronic interstitial pancreatitis due to gastric and duodenal ulceration). Posterior gastro-enterostomy. Recovery. Patient sent by Dr. Ellis, Halifax.

By August she had gained 12½ lbs.; by September, 4 additional lbs. On October 15th, two stones heavier than at time of operation. February, 1903, gained 6 lbs. more. Dr. Ellis reports, February 26, 1908: "Patient quite well; gained in weight; no recurrence of pain nor vomiting."

CASE 10.—G & D. July 2, 1902. G., male, aged forty-seven. Indigestion for four or five years, gradually increasing in severity up till the present time, when he is disabled from work. Pain coming on about one and one-half hours after meals, increasing in severity for an hour unless eased by vomiting, which always afforded relief. There has never been hæmorrhage. Has had cramps in his arms and hands, rarely in the legs, especially during the last two months (tetany). On examination, a very large stomach, descending 1½ inches below the umbilicus before inflation. A few contractions seen on inflation.

Operation: A very large stomach; a large scar on the posterior surface near the lesser curvature about 2 inches from pylorus. A second scar beginning at the second portion of the duodenum. Many adhesions around pylorus. Posterior gastro-enterostomy. Recovery. Patient was sent by Dr. McNab, Armley. Made a rapid recovery, and within three weeks was eating ordinary meals with great relish. Report received from Dr. McNab June 21, 1905: "The results have completely justified the operation and have given great relief to this man." "Quite well" in December, 1907.

CASE 11.—D. August 7, 1902. J. H. O., male, aged thirty-one. Pain after food and gradual loss of weight for ten months. All solid food has been abandoned little by little, and now fluid diet causes pain. Occasional vomiting in large quantities and distension. Has twice had hæmatemesis. The pain is frequently felt about one and one-half hours after food. Has lost exactly 4 stones in the last nineteen weeks. A very dilated stomach reaching a hand's breadth below the umbilicus; free HCl present.

Operation: The stomach and first portion of the duode-

num were very markedly dilated; a thickening of the duodenum just above the bile-papilla was felt. Posterior gastro-enterostomy. Recovery. Sent by Dr. Norman Porritt, Huddersfield.

In June, 1905, said he could eat anything except a lot of cheese. Had gained from 8 stone 2 lbs. to 9 stone 12 lbs.; was therefore still below his former weight. Complained of soon feeling tired, but had no pain nor sickness. Writes January 13, 1908: "I was operated upon by you in August, 1902, but if you remember I was a long while after the operation and did not receive much benefit. I have improved more in health during this last nine months, than all the other four years. My weight was 8 stone 2 lbs. after the operation and I now weigh 11 stones. I can now eat nearly anything and at any time without feeling any discomfort. When in Leeds I will call and let you have a look at me; you will hardly know I am the same man."

CASE 12.—D. September 24, 1902. T. B., male, aged thirty-two. On April 9th patient was suddenly seized with an acute attack of pain in the right hypochondrium. He vomited frequently and some blood was noticed. The attack lasted two hours, and subsequently the motions were seen to be tarry. Since then he has suffered almost constantly from flatulent distension, especially after food. On several occasions he has had very severe attacks of pain in the right hypochondrium lasting one to two hours and doubling him up. Each attack has been followed by profuse tarry stools, and on two occasions has been accompanied by hæmatemesis. There has never been jaundice. He has lost $3\frac{1}{2}$ stones in weight since February. The stomach is a little dilated; free HCl is in excess. Pain is chiefly situated above and to the right of the umbilicus, and the painful spot can be covered by a finger-tip.

Operation: A duodenal ulcer occupying the first and second portions of the duodenum. It was about the size of a walnut, very thick and adherent to the pancreas. The gall-bladder was full of stones. These were removed and a few stones from the hepatic duct were easily squeezed along the cystic duct into the gall-bladder; the latter was drained (the stones

numbered 1885). Posterior gastro-enterostomy. Recovery. Patient was sent by Dr. McKenzie, Burnley. He was operated on at the Infirmary for Mr. Mayo Robson.

Dr. Crump, Burnley, writes February, 1908: "In April, 1903, had an attack of pain followed by jaundice, but there has not been any illness at all since then. Has been able to do full duty ever since, and considers himself in the pink of health."

CASE 13.—G & D. September 25, 1902. B., female, aged sixty. Failing in health for nine to twelve months. At the outset a sudden seizure of vomiting, very acute, and lasting over twenty-four hours. There has been a series of similar attacks of vomiting. Pain is noticed about an hour before a meal is due and lasts from a few minutes to two to three hours; is never very severe. She has lost flesh and has got weaker, occasionally having to spend part of the day in bed. No melæna, no hæmatemesis. A small hard tumour, slightly movable, felt above and to the right of the umbilicus. On distension with CO₂ an enormous stomach reaching a full hand's breadth below the umbilicus.

Operation: A very large stomach; on the posterior surface one large ulcer with several thick adhesions around it. The tumour was found in the second portion of the duodenum; it was a mass about the size of a large walnut, adherent to the pancreas, with which it seemed inseparately connected. The duodenum above this point was distended. Probably chronic duodenal ulcer with interstitial pancreatitis. Posterior gastro-enterostomy. Recovery. Sent by Dr. Welch, Stanningley.

Dr. Welch reports, June 21, 1905: "I saw Mrs. B. to-day; she tells me she has enjoyed excellent health since the operation and has had no stomach trouble of any sort. She certainly looks very well, and she does all the housework at her own home."

Report February 2, 1908: "Present condition satisfactory; slight gain in weight; practically no recurrence of pain; no vomiting except occasional 'bilious attacks.' Case with undoubtedly good results of apparently permanent character."

CASE 14.—D. October 4, 1902. Male, aged twenty-nine.

Has suffered for several years from a "weak stomach," having pain two or three hours after food and occasional vomiting. On Saturday, August 31st, last, had a long bicycle ride which left him very tired. On Sunday ate heavily and had much discomfort. At night he got out of bed owing to the feeling of fullness in the stomach and great uneasiness. He induced vomiting and the bowels were then moved. He felt faint and cold. On Monday was feeling very tired so did not get up. Still ill and weakly on Wednesday. The stools on both days were quite black. On Wednesday he fainted once when in bed and felt very chilly. On Tuesday he had been noticed to be very pale, and his pallor increased decidedly on Wednesday. On Thursday morning felt very ill and dead tired. Pulse 122; very blanched. The bowels were moved four times, and large tarry stools passed. When seen, he looked desperately ill, the face and buccal mucous membrane being blanched to the last degree. Chronic duodenal ulcer with acute deepening, and the opening of some large vessel was diagnosed. Operation was advised as a last resource.

Operation: Stomach was found very dilated and full of gas. It contained no blood. The first portion of the duodenum was also dilated, and about 1 inch from the pylorus a dense, hard mass, equal in size to a walnut, was felt adherent to the pancreas. Excision of the ulcer was impossible, and therefore gastro-enterostomy was performed. The jejunum at the point opened contained brownish, altered blood, and the transverse colon was a most vivid dark blue in color and full of blood. Recovery.

The patient was sent by Dr. Fearnley, Harrogate. (When lifted on to the operating table the patient complained of being tired and cold and then fainted.) Dr. Fearnley reports June 26, 1905: "Went back to work during the first week in December; has not broken any time from illness since, but has to be most careful in his diet; more so than before the operation." No further report.

CASE 15.—G & D. October 6, 1902. J. H. H., male, aged thirty. Symptoms for five years. Pain occurring one to two hours after every ordinary meal, and occasional vomiting. Eructations, melæna. During the last six months

the pain has been about three hours after food, and has always been easier if a little fluid food or a biscuit has been taken. He is quite unable to take ordinary food, and treatment, although carefully followed out, has not helped him. He is losing weight and is becoming progressively anæmic. Melæna has not been noticed for two months. Has a large, splashy stomach.

Operation: Stomach moderately dilated. Scar of a duodenal ulcer just beyond the pylorus, with some induration and puckering. On the posterior surface of the stomach near the pylorus a white scar the size of a French bean. Some adhesions to the upper part of the transverse mesocolon. Posterior gastro-enterostomy. Recovery. Sent by Dr. H. Woodcock, Leeds. No further report.

CASE 16.—G & D. October 13, 1902. J. H. B., male, aged twenty-eight. Fourteen months ago an acute attack of indigestion lasting five days, with occasional vomiting; no hæmatemesis. He fainted several times and had tarry motions. During the last three months has become progressively worse, has lost over one stone in weight, and has constant pain after food, with occasional vomiting; can now take only fluids and is "wearing down fast." A moderately dilated stomach; free HCl. Old blood noticed almost daily in the stools whilst in the Infirmary.

Operation: An ulcer about the size of a threepenny piece, very hard and slightly adherent, was found in the first portion of the duodenum. A scar on the posterior surface of the stomach near the pylorus. Posterior gastro-enterostomy. Death occurred on the tenth day with symptoms of intestinal obstruction, which at post-mortem was found to be due to hernia of almost the whole of the small intestine through the opening in the transverse mesocolon. Patient was sent by Dr. Stamp Taylor, Leeds.

CASE 17.—D. December 9, 1902. I. S., female, aged seventeen. In April was operated upon for perforation of a duodenal ulcer. For the first two months all went well, but she was never able to take full diet freely. During the last two months the stomach has been very irritable. Pain and discomfort after food have gradually increased until now only

fluids are taken. Stomach dilated especially toward the cardiac end.

Operation: Innumerable adhesions were found. The posterior surface of the stomach could not be traced on account of adhesions of omentum, transverse colon, etc.; nor could the duodeno-jejunal flexure be reached. The cæcum was therefore found and the ileum traced upward from it to the highest point of the jejunum free from adhesions. A Roux's operation was then performed to the anterior surface of the stomach. The cæcum and colon were contained in a mesentery common to them and to the small intestine. Recovery. Patient was sent by Dr. Wainman, Leeds.

By March, 1903, she had gained 11 lbs. in weight. Report received June 20, 1905: "Is now in excellent health, walking three miles to her work daily and back again. In my opinion, she may be considered cured. She has received no medical attention nor medicine for many months." Dr. Wainman reports February 13, 1908: "Patient at regular work in Leeds in moderate health. Weight 8 stone 1 lb., a gain of 4 or 5 lbs. She does not go more than a week without some epigastric pain, which is increased if she is not attentive to diet. Some pain and tightness in breathing after eating is still felt, but general health moderate and operation a great success."

CASE 18.—G & D. January 17, 1903. A. S., female, aged twenty-eight. In May, 1898, a sudden attack of hæmatemesis and fainting; was in bed six weeks. For the next eighteen months very poor health, indigestion, vomiting, and constipation; then six months of good health. In April, 1900, indigestion began again; medicinal treatment for six months with much benefit. January, 1902, hæmatemesis, and again treatment in bed for four weeks. Four months ago another attack of hæmatemesis. Saw Dr. Rowling then for first time and was in bed for seven weeks. During the last few weeks pain has occurred about an hour after food, occasionally immediately after. She vomits three or four times a day. On examination epigastric tenderness, pressure causing a pain through to the back. No dilatation of stomach, excessive free HCl.

Operation: An ulcer 3 or 4 inches from the pylorus and close to the lesser curvature. It was as large as a shilling, very dense, and adherent to the pancreas behind. A second ulcer about $\frac{1}{4}$ inch in diameter in the duodenum just beyond the pylorus. Posterior gastro-enterostomy. Recovery. Sent by Dr. Rowling, Leeds.

By March she had gained 5 lbs. in weight, eating well. Report received from Dr. Rowling, June 26, 1905, says: "I can eat almost anything without it hurting me. I don't have the pain nor yet the vomiting I used to have. Did not want to live before; quite the opposite now. Would willingly undergo the same operation again. Gained three stones since operation."

Report, 1908: Stout, looks fairly well, but somewhat anæmic. Gained 2 stone in weight. Has vomited more or less ever since the operation; nearly every morning directly she gets out of bed. Vomit is described as bitter and bright yellow, and at times very dark, like coffee. Cannot take food in the morning, but enjoys the mid-day meal. Complains of a burning pain in the chest with palpitation and a hot froth rising into the mouth. Is very costive and the stomach symptoms are relieved by suitable aperient. The patient says she is better by far since the operation; it made the difference between being unable to work before, and able to work after. The result is good, but all the stomach symptoms have not been entirely removed.

CASE 19.—G & D. January 22, 1903. J. E., male, aged forty-seven. In January, 1902, when returning from Las Palmas, had a severe attack of melæna. Several years before this had been subject to indigestion and inability to eat heartily, but for a few months before the attack of bleeding had been in better health than usual. Since this attack has had many others of melæna and hæmatemesis. Has been in a Nursing Home in London for thirteen weeks under treatment for duodenal ulcer. While there had occasional severe bleedings and his hæmoglobin count was only 18 per cent. On examination he was very thin and anæmic. A dilated, obviously contracting stomach was seen, from which he shortly afterwards vomited a quart of fluid containing blood. He

looked extremely worn and ill, and it was necessary to infuse saline solution during and after the operation. He had copious melæna during the day and night before operation.

Operation: An enormous stomach, slightly hypertrophied. The first portion of the duodenum was embedded in a mass equal in size to a lemon (inflammatory thickening round an ulcer). On the greater curvature near the pylorus an ulcer the size of a shilling. Posterior gastro-enterostomy. Recovery. The patient was sent by Dr. Bampton, Ilkley, and seen in consultation with Dr. Barrs. Was soon able to take ordinary diet. In the fifth week a severe attack of diarrhœa lasting four days. By March, 1903, had gained 7 lbs. By July, 1903, had gained four stones and could eat heartily. Quite well in July, 1904, and maintaining his weight.

June, 1905, Dr. Bampton reviews the whole progress in this way: "Recovery was uninterrupted, but during convalescence patient's appetite was so voracious that he thought he could eat anything and everything in any quantity; in consequence Mr. E. had two or three vomiting attacks of considerable quantities of bile. Since learning wisdom has had no gastric disturbance of any kind and is able to eat ordinary meals with more comfort than he has experienced for fifteen years. Plays golf, rows, bicycles, takes long walks, and maintains his weight. In every respect the operation has been a complete success, and shows that nutrition improves in spite of the short-circuiting. From this and other experience I think that in recurring hæmorrhage from gastric or duodenal ulcer operation should be the rule just as much as it is in recurring appendicitis."

Report February 22, 1908: "In very good health; maintains weight, feels well, and can enjoy a ten-mile walk, and says: 'I shall be very pleased and grateful if I am allowed to end my days in the comfort I now enjoy, and I am doing my best to negotiate a long term of years.' "

CASE 20.—G & D. February, 1903. Mrs. S., aged fifty-six. In February, 1892, was in the Infirmary for the removal of an ovarian cyst. In the notes it is said that the patient then suffered much from indigestion, and on one occasion had melæna. Since then Dr. Woods has attended

her for chronic indigestion. On several occasions there has been severe melæna. In 1887 a medical man diagnosed an acute illness as "ulcerated stomach." An attack of hæmatemesis in December, 1901. In September, 1902, a prolonged attack of melæna. Now has pain two or three hours after a meal all over upper part of abdomen, and frequently "heaving and vomiting"; can take nothing solid except biscuits. During the last twelve months has lost over three stones in weight and has persistent anæmia.

Operation: A mass the size of a Tangerine orange was found in the first portion of the duodenum. Milky opacity of the overlying peritoneum. In the stomach near the greater curvature about 4 inches from the pylorus an ulcer the size of a sixpence. The omentum was crumpled up and adherent to it. Posterior gastro-enterostomy. Recovery. Sent by Dr. Woods, Batley.

Report received from Dr. Woods, June 26, 1905: "Better now than she has been for years; perfectly well." Report January, 1908: "In excellent health; able to do her housework, wash, bake, clean, etc.; slight gain in weight. No recurrence of pain nor vomiting." Remarks: "Source of income to general practitioner cut off."

CASE 21.—G & D. February 19, 1903. G. B., male, aged sixty-two. Has suffered from indigestion and vomiting for several years. Says he does not remember when he was able to take an ordinary meal in comfort. Three years ago was seen by a physician, who diagnosed pyloric stenosis and gastric dilatation and advised operation. Since then the vomiting and pain have increased to such a degree that the patient says he cannot go on any longer. On examination an enormous stomach, actively contracting.

Operation: A large, hypertrophied stomach shewing several scars. The pyloric region on both gastric and duodenal side was scarred and stenosed. Posterior gastro-enterostomy. Recovery. Sent by Dr. Adam, Sowerby Bridge.

Report received from Dr. Adam, June 26, 1905: "B. is in apparently perfect health. Works overtime as a dyer's labourer without special fatigue. Eats well and sleeps well, and has kept a regular weight of 11 stone for twelve months.

Weight before operation, $8\frac{1}{2}$ stone. No return of stomach trouble, and he told me yesterday he never felt better in his life. The result of operation has been particularly happy. The man had been going his rounds for some years trying all sorts of treatment by medical men, and latterly had used a stomach-pump almost daily. He was most despondent and threatened to commit suicide, and I have reason to believe he would have carried out this threat if he had not been relieved by operation. In my opinion the operation would almost have been justified for the relief of mental symptoms apart from the relief of pain, sickness and distress, etc., and increase of strength and ability to work hard and support himself and family.

Report January 27, 1908: Never better in his life; present weight 11 stone 12 lbs. No recurrence of pain; has vomited about half a dozen times since operation, and on each occasion this was due to overeating or to something wrong with what he had taken. The vomit consisted simply of the food taken. (The man is fond of good living.) This is certainly a remarkable result considering the condition of the man for some years previous to operation. He is at present working long hours as a dyer's labourer, has averaged sixty-eight to seventy hours per week for some time; by no means a bad record for a man of sixty-seven years.

CASE 22.—G & D. April 11, 1903. E. L., female, aged nineteen. Her first symptoms were observed in 1901. Quite at the beginning an attack of hæmatemesis. Was then under careful treatment for over six weeks. On beginning to take solid food pain was noticed generally half an hour after a meal. Pain and vomiting are now constant after all solid food, so that for several months she has lived entirely on fluids. For over three months now pain has become increasingly severe and she has given up her work. Recently a slight attack of hæmatemesis. Stomach slightly dilated.

Operation: An ulcer about 1 inch below the lesser curvature near the cardia; some adhesions around pylorus and duodenum. Posterior gastro-enterostomy. Recovery. Patient was sent by Dr. Goode, Doncaster.

Report received from Dr. Goode, June 21, 1905: "I saw

E. L. not long ago, when she was wonderfully well. She never complains of indigestion now, and on the last occasion she consulted me it was merely for a severe cold." Report, February 26, 1908: "Patient is in good health, gained in weight, no recurrence of pain nor vomiting. Married and has two children."

CASE 23.—G & D. April 19, 1903. H. J., male, aged twenty-seven. Symptoms of indigestion for five or six years. A feeling of weight and oppression in the epigastrium after food. "Rifling," sour eructations. Often feels the food "working about in the stomach." Has very little appetite. Has occasionally had periods during which an intense burning pain has been felt about two or three hours after a meal. Has lost $1\frac{1}{2}$ stone in the last five years. During the last six months the symptoms have been more severe, almost preventing him from doing his work. The stomach is dilated, but no peristalsis is visible.

Operation: Stomach dilated. A few scars of gastric ulcers on the posterior surface of the stomach near the pylorus. A duodenal ulcer the size of a sixpence. Posterior gastro-enterostomy. Recovery. He had a severe attack of bronchitis after the operation with high temperature and rapid pulse. By October, 1904, had gained 9 lbs. The patient was sent by Dr. Rowden, Roundhay.

Dr. Rowden reports, June 20, 1905: "Was relieved by operation, but remained very unwell until six months ago; since then he has been very much better." Report, February 3, 1908: "Present condition very fair, but anæmic; weight about the same. Some recurrence of pain. He still has to be careful in his diet or he has considerable discomfort from distension and flatulence. I do not think there has been any vomiting. The operation has certainly improved the patient's condition, but not to the extent one would have hoped. Stomach is still very considerably dilated."

CASE 24.—D. June 9, 1903. J. R., male, aged thirty. About fifteen months ago first noticed a sharp, burning pain in the epigastrium, a little to the left of the middle line. This was worse after food at first, but latterly he has had most pain when fasting. Now feels easy when a moderate meal is

taken, but in about an hour has "very bitter belching and water brash," and then pain becomes steadily more acute. Has vomited rarely until recently. Is now losing weight—one stone in the last five weeks. The stomach is slightly dilated.

Operation: An ulcer in the first portion of the duodenum about 1 inch beyond the pylorus; a hard pellet of scar tissue in posterior wall of stomach 2 or 3 inches from the pylorus. Posterior gastro-enterostomy. Recovery. Patient was sent by Dr. Crump, Burnley. Weight before operation, 8 stone 3 lbs.; September 9, 1903, 8 stone 8 lbs.; September 3, 1904, 9 stone 1 lb.

Report received from Dr. Crump, June 28, 1905: "He will not admit that he is any better since the operation, but you know he is neurasthenic, and the fact that he is able to work regularly proves to my mind that he is better." (For further progress of case and report, see Case 40.)

CASE 25.—D. June 23, 1903. C. B., male, aged thirty-one. Has been suffering from "indigestion" for two or three years. About three hours after a meal begins to feel a sinking sensation, with pain and burning in the epigastrium, which is eased by gentle pressure of the hand. Pain and tenderness to the right of the middle line. Stomach slightly dilated.

Operation: A duodenal ulcer, about $\frac{1}{2}$ of an inch in diameter, with opaque surface and hard, puckered base, just beyond the pylorus. Posterior gastro-enterostomy. Recovery. Patient sent by Dr. Baxter Tyrie, Keighley. Dr. Kammerer and Dr. Brewer, of New York, present.

Seen by me in November, 1904. After the operation suffered for three months from "acidity," for which a bismuth and morphia mixture and carbonate of soda were given. For twelve months has been quite well. Appetite very good. Eats hearty meals and has gained 15 lbs. in weight. Seen by me January, 1908: "Never a bit of trouble since the operation."

CASE 26.—D. July 14, 1903. H. L. R., male, aged forty-two. Many years indigestion. Pain, burning, and fullness after meals. Pain comes on about two hours after a meal, and lasts till next meal, when he is easy for a time. Pain goes round the right side of the abdomen and through to the

back. Recently has become much worse; suffers from a heavy, burning feeling in the pit of the stomach, and cannot eat with comfort. No vomiting. Very tender to the right of the epigastrium.

Operation: A duodenal ulcer, reddened, indurated, and slightly puckered, was found just beyond the pylorus; a few adhesions upon the posterior surface of the stomach. Posterior gastro-enterostomy. Recovery. Patient sent by Dr. Griesbach, Garforth.

Report, June 13, 1905: "Gained steadily in weight since the operation. Eats well, has no sickness, and is in good general health." Report September 1, 1908: "Stronger, but still has a hot feeling in the stomach every now and again. Has gained 7 or 8 lbs. in weight. Occasionally feels sickly, perhaps every four or five months, for a few hours. No vomiting. Takes ordinary food and has a good appetite. Sums up the improvement since the operation by saying he 'is a great credit to me.' "

CASE 27.—G & D. July 25, 1903. R., male, aged thirty. For several years has suffered on and off from indigestion and had to be careful and sparing in his diet. Two months ago whilst in Sheffield had profuse hæmatemesis and for several days melæna. He fainted. Since then has been kept in bed upon very small quantities of liquid food, but these give him pain, and any attempt at increase causes vomiting.

Operation: A duodenal ulcer was found immediately beyond the pylorus; a dense white, very hard scar of a gastric ulcer near the greater curvature about 3 inches from the pylorus. Posterior gastro-enterostomy. Recovery. Patient was sent by Dr. Hawkyard, Leeds.

Report, June 20, 1905: "R. is in good health and following the occupation of tram conductor." Report, March 6, 1908: "R. is much better; in fact, is quite well, and he eats anything; no vomiting no pain. In the first twelve months after operation he had several attacks of vomiting, some lasting two or three days. Evidently food got into the duodenum, and not being able to pass onward, was with great difficulty ejected. For eighteen months after the operation he was not strong, and did not go back to his old job. Since then

he has worked at his own trade, and I am told he is as well as ever, and has no inconvenience of any kind. Have not seen him for some time as he is living in Sheffield." (A case of temporary regurgitation.)

CASE 28.—D. August 17, 1903. L., male, aged thirty-nine. Some years ago patient had five or six attacks of severe abdominal pain with fainting. The last of these was four years ago. On July 27, 1903, he had another similar attack of pain, and nearly fainted. The pain passed off after about half an hour. On August 1, 1903, whilst cycling home from business, he felt faint and got off his bicycle. He vomited a large quantity of blood. On reaching home he collapsed. Next day he again vomited blood and had several black stools. He is very anæmic; pulse 120.

Operation: An ulcer adherent to the pancreas was found on the posterior wall of the second part of the duodenum. Posterior gastro-enterostomy. Recovery. Patient was severely collapsed after the operation. Sent by Dr. Oldfield, Leeds.

Dr. Oldfield writes, March 26, 1905: "Am pleased to say that Mr. L. is very well indeed. As far as I know he has not been off work a single day since he resumed after the operation. He takes ordinary food, his supper usually consisting of cheese, bread, salad, and beer. There have been one or two rather sharp attacks of diarrhœa, but no vomiting, and no blood has been lost."

Report, February, 1908: "In perfectly good health; slight loss of weight. For three years after the operation he had occasional attacks of severe, colicky pain in the abdomen, lasting half an hour, and followed by a sharp attack of diarrhœa. These have become more infrequent lately. There has been no vomiting. Has never had a day off work for reasons of abdominal trouble since he commenced work after the operation, with the exception of once last summer, when he had an attack of diarrhœa."

CASE 29.—G & D. September 17, 1903. Mrs. H., aged forty-nine. Seventeen years ago had severe "indigestion" with occasional vomiting; never jaundiced. Then remained fairly well up to two years ago; then occasional "spasms." During the last twelve months a return of pain, which has

been steadily getting worse. She has had a severe attack of pain and vomiting every week recently. Pain was in the epigastrium and tended to pass to the left. She has been on liquid food since May, 1903, and has lost one stone in weight.

Operation: Many adhesions fixing the under surface of liver and gall-bladder to duodenum; small scar on front of pylorus. A hard mass size of a small walnut was felt about 2 inches along the duodenum. It could not be exposed because of the universal adhesions, but was thought to be a chronic ulcer. Posterior gastro-enterostomy. Recovery. Patient was sent by Dr. Rolf, Huddersfield.

Report from Dr. Rolf, June 26, 1905: "The operation has been most successful. Mrs. H. has had no gastric symptoms of importance since the operation. At present she is in good health. She is able to travel and to attend to all the duties of her life. She has increased considerably in weight." Seen in November, 1907: "Perfectly well." Dr. Rolf reports, January 25, 1908: "In good health; gain of about 1½ stones in weight. No recurrence of pain nor vomiting. Mrs. H. has been greatly improved by the operation, and has had no marked gastric symptoms since it was done, although she has to be very careful of her diet. Her case may be looked upon as a marked success."

CASE 30.—D. November 23, 1903. R. B., male, aged thirty. Quite well up till eighteen months ago, when he had an attack of pain below and to the right of the umbilicus, accompanied by vomiting. These symptoms have continued at intervals up until now. Latterly he has vomited only at night. Dieting did not improve the condition. No hæmatemesis nor melæna has been noticed, although looked for recently.

Operation: Thickening and puckering of an old ulcer in the first part of the duodenum. Posterior gastro-enterostomy. Recovery. Sent by Dr. Ellis, Halifax.

Dr. Ellis, reports June 26, 1905: "Very well indeed." Dr. Ellis reports February 26, 1908: "This man, so far as his stomach is concerned, did remarkably well. He died last year from cardiac disease."

CASE 31.—G & D. December 2, 1903. P. W., male, aged

thirty-five. For two or three years had slight pain and discomfort after food, with foul and sour eructation. He began to vomit about one year ago, the act being sometimes induced in order to relieve his pain. No hæmatemesis nor melæna noticed. The stomach reaches one inch below the umbilicus.

Operation: Scar of an old ulcer on the posterior surface of the stomach near the lesser curvature. An ulcer about the size of a sixpence also present in the concavity of the first part of the duodenum. Posterior gastro-enterostomy. Recovery. Sent by Dr. Exley, Leeds.

Report, June 26, 1905: "Perfectly well; no symptoms at all; gain in weight; quite fat." Report, February 13, 1908: "Present condition very good; gain in weight. No recurrence of pain nor vomiting. I saw this patient a week or so ago, and he told me he had never been better in his life."

CASE 32.—D. December 2, 1903. E. B., female, aged forty-five. Pain after food and occasional vomiting for ten years. Much worse during the last three months. Has lost one stone in weight during the last eight months. Examination of stomach contents after test-meal showed absence of free HCl and presence of lactic acid.

Operation: A thickened band was found passing across the front of the first part of the duodenum. Many omental adhesions to anterior abdominal wall. Posterior gastro-enterostomy. Recovery. She was sent by Dr. McNab, Armley. This patient has not been traced recently. She was last seen about five or six months after the operation, and was then in good health.

CASE 33.—D. December 3, 1903. A. P., female, aged thirty-eight. Has had symptoms on and off for ten years, becoming worse lately. Symptoms consist of vomiting, pain in the left side, and nausea. Pain is always present, but worse after food. Vomiting makes the pain worse, and the patient says she has sometimes vomited a little blood. The bowels are constipated and she has lost weight (present weight, 5 stone 4½ lbs.). Present condition: frequent vomiting, tenderness in left hypochondrium, free HCl in stomach contents after test-meal. Urine, acid; sp. gr., 1018; albumen; no sugar.

Detailed Statement of Cases Operated Upon 289

Operation: Nothing abnormal found. No scars visible in stomach or duodenum. Posterior gastro-enterostomy. The patient developed hæmaturia and uræmic symptoms, and died on December 8th. She was sent by Dr. Woodcock, Leeds.

Post-mortem report: No peritonitis; anastomosis quite sound. "Kidneys are small and present cysts on their surface. The capsules did not strip readily, being adherent in some places. On passing the finger over the kidney surface, a distinctly granular impression is imparted to it. The cortex is extremely narrow, almost all the kidney surface being made up of the pyramids. The pelves appear normal." There was ulceration without induration in the duodenum, probably uræmic in origin.

CASE 34.—G & D. December 23, 1903. P. H., male, aged twenty-eight. Six years indigestion; pain in epigastrium and between shoulders after food. Much troubled by a feeling of distension; no vomiting.

Operation: A large scar, with thickening on the posterior surface of the stomach; also considerable induration in the duodenum. Posterior gastro-enterostomy. Recovery. Sent by Dr. Mackenzie, Leeds.

Came with another patient March, 1906, and said he had been quite well since the operation, except that he vomited "a lot of bile" for about six months. (A case of temporary regurgitation.)

CASE 35.—D. January 15, 1904. J. H., male, aged thirty-two. Symptoms for three or four years. Pain at first whilst eating; latterly it has occurred an hour or so after food. Vomiting for eighteen months. Loss of weight $1\frac{1}{2}$ stone. No hæmatemesis.

Operation: Adhesions of pylorus and duodenum to the gall-bladder; duodenum dilated. Posterior gastro-enterostomy. Recovery.

Was seen at the Infirmary in January, 1905, when he came to show himself as a good result. He writes January 26, 1908: "I am very pleased to say that I am enjoying very excellent health. I have no trouble whatever with my stomach. I am eating rough food, but keep off pastry and sweet stuff. I have worked as a labourer in the foundry for the last twelve months,

and I have not lost a day from illness. The work is heavy and laborious, so I consider it is a successful cure, for which I am very grateful."

CASE 36.—D. January 20, 1904. J. S., male, aged forty. Has suffered from pain in the epigastrium for eighteen years. During the last three years this has got worse and he has had occasional attacks of vomiting. For six months the pain has been very severe and he has lost one stone in weight. No free HCl present in stomach contents.

Operation: A duodenal ulcer the size of a threepenny piece was found just beyond the pylorus. Posterior gastro-enterostomy. Recovery. He was sent by Dr. Beegling, Huddersfield.

On September 16, 1904, seen by Dr. Douglas Turner: "Little or no improvement." In June, 1905, seen by Dr. Hogarth, Morecambe: "Still troubled a good deal with flatulence and only slightly better for the operation." Dr. Hogarth writes, March 13, 1908: "This patient only consulted me once casually, but on enquiring I heard that he continued in an unsatisfactory state for some time, then went to Canada. When last heard of, he was considerably better, that is, a few months ago."

CASE 37.—G & D. January 27, 1904. M. S., female, aged sixty-one. For the last three months pain and fullness after food, but no vomiting. Pain comes about half an hour after food. Stomach is dilated and a tumour can be felt beneath the upper part of the right rectus.

Operation: A large hypertrophied stomach with considerable inflammatory deposit around the pylorus and duodenum. No gall-stones. Posterior gastro-enterostomy. Recovery. Patient was sent by Dr. Clarke, Doncaster.

Report received June 20, 1905: She is doing her duties and is practically well. Dr. Clarke reports, February 3, 1908: "Patient is very well; has gained a stone or more in weight. There was recurrence of pain for about one year and a half. Pain appeared to be caused by the bowels, for every time they acted she had pain. She had to be very careful of her food for two years and was troubled greatly with wind. No vomiting

Detailed Statement of Cases Operated Upon 291

except an occasional bilious attack. Feels better than she has for several years. She looks very well."

CASE 38.—D. March 24, 1904. C. E. M., female, aged twenty-five. Indigestion for twelve years. For many years has had acid eructations, and for the last two years has vomited after food. Has had many severe attacks of epigastric pain. Four days before admission, and again one day before, she had attacks of pain, but not more acute than many she had before. During the last three years her weight has dropped from 9 stone to 5 stone 8 $\frac{3}{4}$ lbs.

Operation: An ulcer the size of half a crown on the upper aspect of the first portion of the duodenum, with a perforation the size of a small pea. There was a little local plastic peritonitis, but no general infection. The perforation was closed by Lembert's sutures and a posterior gastro-enterostomy performed. Recovery. She was sent by Dr. Rowling.

Report from Dr. Rowling, June 26, 1905: Gained 2 $\frac{1}{2}$ stone in weight during the three months succeeding the operation. Expresses herself as being "a great deal different from what I was eighteen months ago." Says of the operation that it certainly was a success and saved her life.

Dr. Rowling reports, February 15, 1908: "Patient died July 22, 1907. Gained weight during the ten months succeeding operation—about 1 $\frac{1}{2}$ stones; then began to lose weight until she died. For the first ten months after the operation there was no pain, but it then recurred. At first the pain was felt at comparatively long intervals and lasted only a short time. It is described by the husband as a dragging pain across the pit of the stomach; later the pain became more severe and more frequent. In the first ten months no vomiting. For the next eight months water brash at times; then occasionally vomited until nine months before death, when it ceased. Vomit bright yellow colour. On standing, a layer of fat rose to the top. Sometimes contained coffee-ground material, never any bright blood. Suffered from constipation especially during the last twelve months of life."

Report by Dr. Wainman, of Leeds: "There was gradual wasting during the last year of life, with marked anæmia and

a gradually developing ascites, and inability to retain or digest food. Death occurred from asthenia and exhaustion. Cause of death was probably carcinoma of the stomach." (Ulcus carcinomatosum?) Three and one-third years interval.

CASE 39.—G & D. March 24, 1904. T. B., male, aged fifty-eight. Stomach symptoms for thirty years. Pain and vomiting after food. No hæmatemesis. Free HCl in stomach contents after test-meal.

Operation: A large cicatrix on the anterior surface of the stomach near the pylorus. A similar scar on the posterior surface directly opposite. There was also a duodenal scar. Posterior gastro-enterostomy. Recovery. Sent by Dr. Normington, Nelson.

Dr. Normington reports June 22, 1905: "I was in conversation with the patient on Sunday last. The result of the operation is eminently satisfactory. He eats well and digests his food. Is never sick, and walks with an alertness at one time foreign to him. He has largely lost his cachectic look. He told me that just after the operation he felt so well that he overdid eating, but that so long as he exercises ordinary care he has nothing to fear. He thinks, and I agree with him, that the operation saved his life. Splashing in stomach does not exist." Dr. Normington writes, July 2, 1908: "Present condition good. Has gained weight; now stationary. No recurrence of pain nor vomiting. Informs me that he is better than for the last forty years."

CASE 40.—(See Case 24.) D. April 7, 1904. T. R., male, aged thirty-one. Patient has suffered from stomach symptoms since January 19, 1902. He then began to have attacks of pain under the left costal margin. These became gradually more frequent, but were never accompanied by vomiting. Posterior gastro-enterostomy was performed, June, 1903, for duodenal ulcer. A week after reaching home he began to vomit, and has vomited ever since, with the exception of a few intervals of about a week.

Operation: On opening the abdomen the transverse colon was found to lie very low. The greater part of the small intestine, all but the last 18 inches, had herniated through the aperture in the mesocolon into the lesser sac. Adhesions were

separated and the hernia was reduced. The gastro-enterostomy opening admitted three fingers, but a loop had been left between the flexure and the stomach. A lateral anastomosis was effected between the two limbs of the loop; the gut was then stitched to the sides of the opening in the mesocolon to prevent a recurrence of the hernia. Recovery. He was sent by Dr. Crump, Burnley.

Seen by me in March, 1905. Complained of great weakness, but could eat food well. I advised his return to work. Patient does not think that he has received much benefit from the operation, but he is now able to work. Suffers from ergophobia and neurasthenia.

Dr. Crump writes, February 3, 1908: "Has indigestion at times. Present weight 8 stones; stationary. Has pain in attacks; is well some days, and on other days has pain. Lately the pain has been under the left ribs, and is relieved by bicarbonate of soda. Has had attacks of vomiting the last four months. After the first operation, vomiting on his return home was almost daily; brown or green in color and of bitter taste. Says he feels weak and has sour eructations. The condition of the patient, who is a neurotic, has improved considerably since the last operation, but he has always been very loath to admit that he is better. He has been able to follow his employment almost continually since June, 1904."

CASE 41.—D. June 17, 1904. Mr. H., aged forty. Has suffered from indigestion for twenty years. Flatulence and pain coming on one to one and one-half hours after food. Twelve months ago he had a sudden attack of faintness, followed by anæmia and great general feebleness. He noticed that the motions were black for some days after the attack. No hæmatemesis. Six months ago a recurrence of these symptoms; commencing dilatation of the stomach was noticed by Dr. Trotter. Two similar attacks have since been noticed; in the last there was "profuse hæmorrhage." There was copious melæna after admission to the hospital, and patient felt very faint. Great tenderness along costal margin on right side down to umbilicus. Some dilatation of stomach.

Operation: A large duodenal ulcer, about $\frac{3}{4}$ inch beyond

the pylorus, with much thickening and opacity around it. Posterior gastro-enterostomy. Recovery. Sent by Dr. R. H. Trotter, Holmfirth.

Seen by me June, 1905. Gained 2 stones in weight. Eats ordinary diet; absolutely no pain nor discomfort of any kind. Says he is quite cured. March, 1906: His brother tells me he is quite well. Better than ever and weighs more than he has ever done.

Dr. Trotter reports, January 29, 1908: "In good health. Gain after operation to normal weight, which is 12 stones. Now weight varies little. No recurrence of pain nor vomiting. Is perfectly well and eats anything."

CASE 42.—D. July 16, 1904. M. R., female, aged twenty-six. For three years has suffered from pain in the epigastrium and between the shoulders. This comes on immediately after taking food, and is very often followed by vomiting, which relieves the pain. There has been slight hæmatemesis on three or four occasions.

Operation: Stomach slightly dilated, cicatrix on the anterior wall of the first part of the duodenum about $\frac{1}{4}$ inch beyond the pylorus. Posterior gastro-enterostomy. Recovery. Was sent by Dr. Robb, Accrington.

Dr. Robb writes in June, 1905: "She has been 'an improved' since the operation. She has put on flesh, and is physically in better condition, but she has vomiting at times, and occasionally complains of pain also." No further report can be obtained.

CASE 43.—D. August 4, 1904. J. C., male, aged fifty-five. Has been subjected to occasional attacks of pain for several years. Pain is very definitely localised over the upper part of the right rectus. It comes on at night and lasts two or three hours. He rarely vomits. Has occasionally been slightly jaundiced. While in hospital he passed a considerable quantity of altered blood per rectum. Is very thin, anæmic, and prematurely aged.

Operation: A mass of indurated tissue about the size of a hen's egg was found involving the first part of the duodenum. It was considered to be an ulcer with surrounding inflammatory thickening. The colon was quite blue in colour from

contained blood. Posterior gastro-enterostomy. Recovery. Sent by Dr. Woods, Killinghall.

In June, 1905, he was reported quite well, eating ordinary food, and had gained 2 stone in weight. No recent report.

CASE 44.—D. August 17, 1904. A. G., male, aged fifty-two. Has been ailing for about twelve months severely, but slightly for nearly three years. First noticed a pain in the stomach on waking at 2 or 3 o'clock in the morning. Would then vomit "nasty, sour stuff." Pain has recently increased very much, and is now situated to the right of the middle line, where there is tenderness. It occurs one to three hours after food and is accompanied by retching and foul eructations. Has had several attacks of severe vomiting, but never hæmatemesis. The stomach is large, but there is no visible peristalsis.

Operation: Duodenal ulcer. Many adhesions of stomach, duodenum, and omentum to anterior abdominal wall high up. Posterior gastro-enterostomy. Adhesions not separated. Recovery. He was sent by Dr. Norman Porritt and Sir Wm. Broadbent.

Report received from Dr. Porritt, June 21, 1905: "Says he thinks the operation has resulted in a permanent cure. Has gained flesh, enjoys food, works very hard, and stomach symptoms have gone. A very good result." Report, January 29, 1908: "Present condition, fairly good health; gain in weight about 16 lbs. Has had no pain since the latter part of September, 1904, and only when on the sea. The operation has been successful."

CASE 45.—D. September 3, 1904. Mrs. M., aged forty. Patient was confined eleven weeks ago. Three weeks after labour began to feel very weak and languid, and one day she noticed that her motions were quite black; they continued to be so for eight or ten days. She has only vomited once. The vomit, according to her doctor, contained about one ounce of blood. She has never had any pain in the abdomen, but has been unable to take solid food on account of its bringing on palpitation. There was constant melæna from the time of admission until the operation.

Operation: Stomach a little dilated; an ulcer in the first

part of the duodenum. Posterior gastro-enterostomy. Recovery. She was sent by Dr. Lambert, Farsley.

Dr. Lambert reports, June 13, 1905: "Although somewhat anæmic, has had no recurrence whatever of her stomach symptoms. Has never vomited since the operation and has no discomfort after food. She is now quite well and doing her work." Dr. Lambert reports, November 8, 1908: "Saw patient three months ago; she was extremely well, and has no symptoms referable to her stomach."

CASE 46.—D. September 13, 1904. Mr. L., aged twenty-eight. Was operated upon by me four years ago for acute suppurative appendicitis. About two years ago began to have pain about two or three hours after food. Vomiting, no hæmatemesis, frequent melæna. Is profoundly anæmic; has a right inguinal hernia.

Operation: A large duodenal ulcer about $\frac{1}{2}$ inch beyond the pylorus. It was about the size of a hazelnut, very dense, and puckered at the centre, where it seemed on the verge of perforation. Posterior gastro-enterostomy. Radical cure of hernia. Recovery. Sent by Dr. Hinings, Leeds.

Report: In January, 1905, was making rapid progress. Dr. Hinings reports, February, 1908: "Health good; no symptoms connected with digestive organs; colour now normal. Gain of about 8 or 9 lbs. in weight. No recurrence of pain nor vomiting. Patient states that on one occasion a few months after operation he noticed that the stools were tarry, but never since."

CASE 47.—D. October 21, 1904. Dr. F., aged thirty-three.

Operation: Large ulcer about 1 inch in diameter and as big as a shelled walnut about $\frac{1}{2}$ inch beyond the pylorus. Posterior gastro-enterostomy. Recovery. He was seen by Dr. Eve, Dr. Crawford Watson, and Sir Lauder Brunton. Weight at operation, 9 stone 10 lbs.; March 6, 1905, 11 stone 10 $\frac{1}{2}$ lbs. In June, 1905, suffered from some pain and acidity, attributed to overwork and injudicious diet. With care in diet, pain disappeared. Weight 11 stone 9 lbs. Patient reports, February 22, 1908: "Perfectly well. Since operation. I have gained, and am at present about 5 lbs. heavier than I

have ever been. Overworked myself and had a recurrence of pain a few months after operation. No vomiting. Have never felt better in my life as regards my stomach. In fact, can hardly believe I have ever been operated upon. Eat and drink anything without any bad effect."

CASE 48.—D. November 11, 1904. J. B., male, aged fifty-one. Symptoms for eighteen months. At first "hunger pain" late in the afternoon, eased by food. Latterly pain always three hours after food, no matter whether solid or liquid; much flatulence and distension. Recently loss of weight.

Operation: Small ulcer just at the commencement of the duodenum. Gastro-enterostomy. Recovery. Sent by Dr. Alderton, Barnoldswick.

Report from Dr. Alderton, June 21, 1905: "I am very pleased to tell you that B. is in the best of health. He has never felt the least stomach trouble since he came home. He has gained considerably in weight, but has not got his full strength yet. One may say he is completely cured." Report, January 21, 1908: "Perfectly well; has gained in weight."

CASE 49.—D. November 19, 1904. M. B., female, aged forty-nine. Has suffered severely from stomach trouble for six years. Less severely for two years before that. Began with pain an hour or two after food. Belching, flatulence, and distension. Did not vomit often and then only acid mucus. Latterly has lived on milk; has lost two stones in weight during the last few months. Stomach is dilated and visibly contracting.

Operation: Stomach dilated and hypertrophied. A large ulcer just beyond the pylorus; no adhesions, but decided stenosis. Posterior gastro-enterostomy. Recovery. Sent by Dr. Pritchard, Dewsbury.

In March, 1905, was very well. Taking food as well as ever and lost weight had been regained. Dr. Pritchard reports, February 17, 1908: "Frequently has attacks of vomiting and pains in the abdomen. Has gained weight since the operation. The vomited matter is green, bilious, and plenti-

ful. Patient considers she is much better since the operation, but says she is not cured." (A case of regurgitation.)

CASE 50.—D. March 3, 1905. J. L., male, aged fifty. Eighteen months' history of pain after food, to a degree which has entirely incapacitated him for weeks together. During last four months pain, vomiting, and great loss of weight.

Operation: A duodenal ulcer the size of lead-pencil just beyond pylorus. Posterior gastro-enterostomy. Closure of pylorus. Recovery. Sent by Dr. W. H. Thompson, Bradford.

Seen in December, 1905. Quite well; had suffered a good deal from constipation and flatulence. Dr. Thompson reports, January 29, 1908: "On May 26, 1905, an attack of acute abdominal pain with fæcal vomiting and great distension of the abdomen. August 17, 1905, a violent attack of pain with vomiting. In 1906 and 1907 he had recurrent attacks of pain, but less severe in character. The fæcal vomiting on May 26, 1905, has not recurred. He twice had definite signs of intestinal obstruction, which, however, cleared up. No other symptoms beyond constipation. These attacks of pain were very severe, beginning in region of wound and spreading across whole abdomen. He says he is a much better man than he was before his operation and feels quite young again, and can do his work better than ever he could." Weight on March 25, 1905, 8 stone 11 lbs.; January 29, 1908, 9 stone 7½ lbs. Seen by us on March 14, 1908. The attacks of pain and vomiting were apparently due to appendix trouble.

CASE 51.—D. March 3, 1905. Mr. H., aged thirty-eight. A year ago began to suffer from vomiting; before then for a few months had had pain beginning a little more than an hour after food. For the last few months has had pain in the early hours of the morning, generally about 3 A. M., and also in afternoon. Food relieved pain for an hour or more. Has had both hæmatemesis and melæna recently. Stomach is dilated, with faint waves of peristalsis.

Operation: An enormous ulcer in the duodenum with the surrounding thickening making a lump as large as one's fist. Posterior gastro-enterostomy. Pylorus closed on prox-

imal side. Recovery. Sent by Dr. Preston, Morecambe. He gained $1\frac{1}{2}$ stones in four weeks.

Report received from Dr. Preston, June 22, 1905: "The operation has been eminently successful. He has gained over two stones in weight, now being close on 13 stone, as compared with $10\frac{1}{2}$ stone on admission. His appetite is good; no class of food comes amiss to him. His bowels, which were much constipated, and necessitated constant use of enemata, now act regularly and without any stimulation, medicinal or otherwise. In a word he says it is a treat to live and that he never felt better." Seen September, 1907: Absolutely perfect result. Report March 3, 1908: "In splendid health ever since operation."

CASE 52.—D. March 3, 1905. J. McC., male, aged forty-three. A chronic dyspeptic, much worse since November, 1904; almost constant pain and vomiting. Dilated contracting stomach.

Operation: Duodenal ulcer. Posterior gastro-enterostomy. Closure of pylorus. Recovery. Sent by Dr. Lee Potter, Dewsbury.

Report received from Dr. Potter, June, 1905: "His condition on June 2d was very much improved, as he was able to eat and digest an ordinary meal of meat, potatoes, and Yorkshire pudding. Before operation his condition was one of almost continuous pain and vomiting. He could not retain even peptonised food, and had to have rectal feeding as the only means of comfortable nourishment." In 1908 had been lost sight of.

CASE 53.—D. May 17, 1905. Miss C., aged thirty-one. An attack of pain in the stomach and vomiting eight years ago. Since then she has been subject to pain coming on an hour after meals, and a feeling of nausea. Has lived almost entirely on fluids for the last year. Beginning of this year the pain became more acute with occasional vomiting. No hæmatemesis. Tenderness and hyperæsthesia in epigastrium.

Operation: Stomach and first part of the duodenum dilated. A few adhesions to duodenum. Posterior gastro-enterostomy. Infolding of pylorus. Recovery. Sent by Dr. Christie-Wilson, Doncaster.

Report, January 13, 1908: "General health good. Patient says she does not know if she has gained weight, but I am sure she has. She has to be careful in her diet, and has no pain when she sticks to fish, chicken, milk puddings, etc. Cannot take beef or mutton with comfort. Has only vomited twice since operation. Vomit consisted of food which she should not have taken. I think the result is highly satisfactory."

CASE 54.—D. June 17, 1905. A. W., male, aged thirty-four. Six years stomach trouble. Pain two or three hours after food, relieved by food. Tenderness and soreness in epigastrium and back.

Operation: Duodenal ulcer. Posterior gastro-enterostomy. Recovery. Was sent by Dr. Alderton, Barnoldswick.

Report from Dr. Alderton, January 27, 1908: "Strength not what it should be; can do about six hours' work comfortably; after that gets jaded. Weight stationary. Has had recurrence of pain. Pain comes on in pit of stomach and in back when he gets run down; at other times perfectly clear. Vomits frequently, very acid, very little food mixed. Suffers from constipation with a tendency to increase. Feels and is much better than prior to his operation." (See Case 172.)

CASE 55.—D. July 10, 1905. Mr. S., aged fifty. Has had stomach symptoms for rather over two years, which he describes as a sense of weight and discomfort referred to the epigastrium, coming on after meals. He also complains of a pain in the left side above the crest of the ilium. Has a feeling of nausea after meals, but no vomiting. Considerable loss of weight. No definite tenderness nor hyperæsthesia. No tumour felt. Test-meal, faintly acid; no free HCl; lactic acid present; very numerous long bacilli seen.

Operation, July 14th: No evidence of carcinoma. Scar of an ulcer on the anterior surface of the duodenum $\frac{1}{2}$ inch beyond pylorus. Few adhesions to posterior surface of stomach near pylorus. Posterior gastro-enterostomy. Recovery. Was sent by Dr. Clements. Died in autumn, 1907, of "pernicious anæmia," symptoms of which first appeared four months before.

CASE 56.—D. August 18, 1905. J. B., male, aged fifty-

five. First began to suffer epigastric pain about twelve months ago. Pain comes on immediately after taking food. There is frequent nausea, but no vomiting. Several times he has noticed slime and blood in his motions. They are often of a dark colour and sometimes contain "worms." He has limited his diet, although he finds that it makes very little difference to the pain. Stomach dilated. No tumour felt; no local tenderness.

Operation: A small, indurated ulcer on under surface of duodenum just beyond pylorus. An enlarged gland on greater curvature. Posterior gastro-enterostomy; infolding of ulcer. Recovery.

On August 26th: "He was taking a full diet, and had no discomfort after food." Sent by Dr. Mathews, Kirby Lonsdale. Seen recently: "A perfect case, not a trace of any trouble now."

CASE 57.—D. September 22, 1905. Mr. R., aged thirty-nine. Has suffered for about twelve years from pain in the epigastrium, which comes on about three hours after food, and continues until the next meal, which temporarily relieves it. Frequent watery eructations, but vomiting of food in any quantity uncommon. Hæmatemesis on one occasion. Has lately been relieved by bismuth, and except when taking this drug has never noticed his stools to be black. Certain articles of food, such as beef and potatoes, are especially liable to excite pain. Constipation. Stomach dilated; tenderness in upper part of epigastrium on left side. Test-meal contains free HCl.

Operation: Stomach dilated. Scarring and kinking of duodenum just beyond pylorus; first part of duodenum dilated; another kink in its second part. Posterior gastro-enterostomy. Recovery. Sent by Dr. Ross, Scarborough. There was a slight attack of pleurisy during the first week after operation. Report, December, 1907: "Perfectly successful."

CASE 58.—G & D. September 26, 1905. A. B., female, aged thirty-nine. Began to suffer from indigestion eight years ago. Three years ago pain was constantly noticed about three to four hours after food, relieved by next meal. Vomit-

ing at first was infrequent, but latterly has been noticed at least two or three times a week in large quantities. She has cold, livid extremities, and quite characteristic tetany. Stomach enormous; waves of contraction seen at all times.

Operation: Stomach much enlarged and greatly hypertrophied. A hard, puckered lump was found, beginning on the stomach side of the pylorus, and extending about $\frac{3}{4}$ inch into the duodenum. Posterior gastro-enterostomy. Recovery. Was sent by Dr. Charles Richardson, Leeds.

Report, January, 1908: "2½ stone gained. Quite comfortable and delighted with the result."

CASE 59.—G & D. August 27, 1905. Mr. E. Has suffered from stomach troubles for a long time, but was fairly well until five months ago. Then began to suffer from pain about three hours after food. Sour eructations, distension, and every two or three days copious vomiting. The motions are at times black, but he has had no fainting attacks. The vomit was blood-streaked on one occasion. Stomach greatly dilated and contracting; epigastric tenderness.

Operation: Stomach greatly dilated and hypertrophied. A thickening was felt on the anterior surface near the lesser curvature, covered with injected roughened peritoneum and some recent adhesions. First part of duodenum dilated. Induration felt at the junction of first and second parts of duodenum, which was drawn firmly back to posterior abdominal wall. Posterior gastro-enterostomy. Recovery. Sent by Dr. Ellis, Halifax.

Report from Dr. Ellis, January, 1908: "Perfectly well. Has asthma at times and would like gastro-enterostomy done on his lungs!"

CASE 60.—D. November 14, 1905. W. K., male, aged thirty-one. For the last two years has suffered occasionally from pain along the right costal arch as far as the middle line, coming on three to six hours after meals. Latterly this has been more severe and he has lived entirely on fluids. After taking a meal he feels comfortable for about a couple of hours; is then distended and flatulent, and belches sour fluid. About four hours after food pain comes on and increases in severity.

Detailed Statement of Cases Operated Upon 303

It is relieved for a time, however, by taking more food. Has lost half a stone in weight. No dilatation nor stasis.

Operation: A circular ulcer, hard and with puckered centre, the size of a threepenny piece, just beyond the pylorus. Posterior gastro-enterostomy. Infolding of ulcer. Recovery.

Report, January, 1906: "Quite well." Report, January, 1908: "Quite well."

CASE 61.—D. December 8, 1905. Mr. S. Nine years ago suffered from pain one hour after food; this lasted for about two years. Since then he has been well until eight months ago. Since then the pain has returned. It is more or less continuous and at times severe. Occasional slight sickness; no hæmatemesis. Loss of weight $3\frac{1}{2}$ stones. Stomach not much dilated, peristalsis seen on inflation. Tenderness and rigidity in right hypochondrium; no tumour palpable.

Operation: Stomach large; adhesions between duodenum and under surface of liver and gall-bladder; these were so dense as to suggest the possibility of a cysto-duodenal fistula. No stones felt in gall-bladder nor ducts. Posterior gastro-enterostomy. Recovery. Sent by Dr. Shine.

Report, January, 1908: "As good a result as I could wish."

CASE 62.—D. December 8, 1905. Mr. E. Symptoms were those of "hunger pain," etc.

Operation: A chronic ulcer beyond the pylorus, with induration and stenosis. Some swollen glands on lesser curvature. Not much gastric dilatation. Posterior gastro-enterostomy. Recovery. Sent by Dr. Arnley, Stainland.

Report, January, 1908: "Going on well."

CASE 63.—D. December 11, 1905. Miss C., aged twenty-seven. An attack of vomiting five years ago. Since then she has suffered from occasional indigestion. One month ago another attack of vomiting and pain. The vomiting occurred directly after taking food; on a restricted diet it has been better, but the pain continues on the right side of epigastrium and is uninfluenced by meals. No hæmatemesis. Loss of weight. Stomach on inflation reaches to umbilicus; great tenderness and hyperæsthesia to right of navel. After twelve hours' fast, no HCl and no evidence of stasis.

Operation: Stomach and first part of duodenum slightly

dilated. Delicate scar and induration on anterior surface of duodenum just beyond pylorus. Adhesions stretching across duodenum to right lobe of liver. Posterior gastro-enterostomy. Infolding of pylorus. Recovery. Sent by Dr. Hinde.

In January, 1908, was reported "quite well."

CASE 64.—G & D. December 15, 1905. Mr. W., aged sixty-four. Has had a sense of weight and heaviness in the epigastrium after meals for many years, but no severe pain. Has been worse during the last twelve months and occasionally vomits a small quantity of watery fluid. No hæmatemesis. Marked loss of weight and appetite. Stomach on inflation reaches to within one inch of umbilicus. Peristalsis visible. Stomach empty after fourteen hours' fast.

Operation: Stomach not dilated; thickening of ulcer in anterior wall of duodenum just beyond pylorus, which did not appear narrowed. Tough adhesion to posterior stomach wall. Posterior gastro-enterostomy and infolding of pylorus. Recovery. Sent by Dr. McCully. Improved slowly at first, but came in November, 1907, to express his delight.

CASE 65.—D. December 20, 1905. Miss S., aged thirty-seven. Stomach troubles for at least ten years. Pain across the upper abdomen some time after food. Often relieved by food. No vomiting. Lives chiefly on fluids. Loss of weight. An enormous stomach on inflation; faint visible peristalsis.

Operation: An ulcer in the first part of the duodenum with induration. Posterior gastro-enterostomy; infolding of pylorus. Recovery. Sent by Dr. Hebblethwaite, Keighley.

Report, January, 1908: "In splendid health."

CASE 66.—D. January 13, 1906. Mrs. F. Indigestion for the last ten months. Pain in the lower sternal region immediately after food, gradually diminishing in intensity, but leaving a dull ache which is almost continuous. Occasional vomiting; no hæmatemesis. For some months she has confined herself to a liquid diet and vomiting has been less. On two previous occasions she has had somewhat similar symptoms for periods of about three months. Loss of weight. Abdomen lax; stomach hangs low, but is little, if at all,

Detailed Statement of Cases Operated Upon 305

dilated. Marked tenderness and hyperæsthesia in epigastrium; no evidence of stasis.

Operation: Recent adhesions between duodenum and gall-bladder; no ulcer palpable. Stomach hangs low and is slightly dilated. Posterior gastro-enterostomy. Recovery. Sent by Dr. Goode, Doncaster.

Report, November, 1908: "Patient looks much better and stronger. Has gained a stone and a half. Very occasionally has pain and vomiting after a too hearty meal. I consider this case a remarkably good result."

CASE 67.—D. February 8, 1906. Mr. K., aged forty. First taken ill about five years ago with pain across upper abdomen and black stools. This lasted about fourteen days. Somewhat similar attacks have since occurred at intervals of one to two years, though latterly they have become more frequent. During these attacks he has pain across the epigastrium passing round to the back and occurring some time before a meal is due. The stools become black; there is vomiting at intervals of a few days, but never in large quantities. Thinks he has vomited blood. The attacks are generally relieved by liquid diet and rest. Stomach dilated; no visible peristalsis.

Operation: Stomach large; a firm, cartilaginous induration at the junction of the first and second parts of the duodenum, which was bound down to the posterior abdominal wall. Posterior gastro-enterostomy; infolding of pylorus. Recovery. Sent by Drs. Muir and Haigh.

Report, March, 1909: Is perfectly well; has gained 28 lbs. Could never take solid food without pain before operation and always looked anæmic. Now can take any kind of food and looks rosy and in perfect health. Has required no medical attendance since operation.

CASE 68.—G & D. January 24, 1906. Mr. F., aged fifty-five. Suffered from flatulent distension for years. During the last nine months has had heartburn and pain two to four hours after food. Food generally relieves. Pain in the abdomen radiates to the left breast and side. Lately, it has always come "when he wants something to eat again." Has

lost two stones in three months. Stomach before inflation an inch above umbilicus; after inflation, $2\frac{1}{2}$ inches below.

Operation: Stomach large and a little hypertrophied. A large ulcer the size of a walnut in first part of duodenum. Ulceration on the lesser curvature with adhesions to under surface of liver and diaphragm. Posterior gastro-enterostomy. Closure of pylorus. Recovery. Sent by Dr. Veale, Drighlington.

On July 10th: Gained 2 stones 8 lbs. Eats anything; better than for years. Report, March, 1909: Is fat, robust, and healthy; no pain; has gained weight. Says he feels better to-day than for thirteen or fourteen years.

CASE 69.—D. February 2, 1906. Mr. H., aged thirty-eight. Has had stomach trouble more or less all his life. Now complains chiefly of pain and fullness coming on about one or two hours after food. Vomits frequently and copiously. Can take all foods, but solids cause great distension, discomfort, and irritation. Has lost $1\frac{3}{4}$ stones. A large, wavy stomach.

Operation: A large chronic ulcer beyond the pylorus, with many adhesions to surrounding parts. Posterior gastro-enterostomy. Infolding of ulcer. Recovery. Sent by Dr. Mathews, Holmfirth.

Report, July 28th: "Could eat all right; no pain or discomfort." Dr. Mathews reports, November, 1908: "No recurrence of pain nor vomiting. This patient has left the district, but when I saw him last, about six months ago, he was in distinctly high spirits about himself."

CASE 70.—G & D. March 4, 1906. Mr. S., aged twenty-one. Has suffered from indigestion for about three years, chief symptoms being pain after food, usually four or five hours after a meal, though latterly has also had a pain half an hour after. Vomiting commenced five months ago; it often occurs several times a day, and then there may be a few days' interval. Vomit small in amount and has never contained blood. No melæna. Stomach dilated; reaches below umbilicus; no visible peristalsis. Some tenderness to the left of umbilicus.

Operation: Well-marked ulcer in the first part of the duodenum. Some enlarged glands along both curvatures. A

second ulcer, surrounded by considerable induration, on lesser curvature towards cardia. Posterior gastro-enterostomy. Infolding of gastric ulcer and pylorus. Recovery. Sent by Dr. Mitchell, Houten-Pagnell.

Report, November, 1908: In good health. Weighed 7 stone 9 lbs. after operation; 11 stone about one year afterwards; now weighs 9 stone 10 lbs. Has occasional slight pain after a hearty meal. There is some vomiting; it occurs about once a fortnight, and occasionally lasts two or three days. Vomit sour and contains little food. Vomiting is not nearly so bad as it was soon after the operation. He feels much better than he did before, and he never feels the same pain as he had suffered from for years.

CASE 71.—D. May 16, 1906. Mr. D., aged forty-four. Epigastric pain for many months, felt most acutely during the night. He wakes up at 12 to 1 o'clock with severe, cramp-like pains. If pain occurs in the daytime, as it has done recently, it comes two or three hours after a meal. Has occasionally felt great relief from taking food. Has had melæna and several acute attacks of vomiting. Stomach not dilated. A very tender point just above umbilicus.

Operation: A very large ulcer at junction of first and second portion of duodenum. Posterior gastro-enterostomy. Infolding of the ulcer, causing closure of the duodenum. Recovery. Sent by Dr. Cowan Hamilton, Lancaster.

Report, November, 1908: Health very good; gained about 20 lbs.; no pain nor vomiting; not the slightest symptoms of trouble. Dr. Cowan Hamilton says: "He has regained his massive weight. He is the picture of health, and he and I are deeply grateful."

CASE 72.—D. May 16, 1906. Mr. P., aged fifty-three. Began to suffer from dyspepsia eighteen months ago. Pain one hour after food, relieved by food for about an hour. Vomiting, hæmatemesis, and melæna. Ten months ago severe attack in which he fainted.

Operation: A very large duodenal scar on anterior surface just beyond the pylorus. It formed a hard, indurated lump as big as a walnut. Posterior gastro-enterostomy. Recovery. Sent by Dr. Holliday, Gildersome.

Report from Dr. Holliday, November, 1908: "In very good health; is back to his normal weight; says that he has not felt anything since the operation."

CASE 73.—G & D. June 29, 1906. Mr. H., aged thirty-five. Had trouble with his stomach twelve years ago. At the onset a sudden attack of pain, collapse, and vomiting. Now has pain constantly one to two hours after a meal, eased by taking food. Vomits occasionally and is always relieved thereby. A dilated stomach with faint waves.

Operation: Much thickening over the first part of the duodenum; stomach dilated with scars on its anterior surface. Jejunum bound by adhesions to posterior abdominal wall. These were divided and posterior gastro-enterostomy was performed. Recovery. Sent by Dr. Pritchard, Dewsbury. This patient cannot be traced.

CASE 74.—D. June 29, 1906. Mr. M., aged sixty. Has been vomiting more or less for twenty years. At first it occurred only occasionally, two or three hours after food. Gradually became more severe, until it occurred within about an hour after every meal. Some epigastric pain, which is relieved by vomiting. Occasional hæmatemesis and "dark stools." Stomach dilated.

Operation: First part of the duodenum found dilated and thickened. Posterior gastro-enterostomy by Mayo's method. Infolding of pylorus. Sent by Dr. Dimmock, Harrogate.

Report, July 13, 1906: "Has been vomiting about once a day since operation." In October reported to be much better. Report, September, 1909: "I find M. has gained a certain amount of strength. He still has vomiting attacks at intervals of three or four weeks, when he uses the stomach-tube for lavage, but at no other time. Sleeps well and is following his occupation as a painter, only having to desist from work during the attack, about every month, and that only for a day or two."

CASE 75.—D. June 29, 1906. B. B., female, aged twenty-seven. Suffers greatly from abdominal pain, especially after food, but occurring at no regular interval after the meal. Vomits frequently and induces vomiting to relieve pain.

Rest in bed for eight weeks has led to no improvement; no free HCl. Lactic acid present.

Operation: Adhesions between under surface of liver and pylorus and duodenum. Many adhesions around appendix. Posterior gastro-enterostomy. Appendicectomy. Recovery. Sent by Dr. Adams, Sowerby Bridge.

Report from Dr. Adams, November, 1908: "On the whole, better. Able to walk about more and does not spend so much time in bed. No difference in weight. There is occasional pain and vomiting, but much less frequent than before operation. I consider the case is better than she has been for years. There is no doubt a considerable neurotic element present."

CASE 76.—D. July 25, 1906. Mr. W., aged thirty-eight. Indigestion for years. Two years ago this became much worse and hæmatemesis and melæna occurred. A second attack, chiefly melæna, in April of this year. Pain usually three hours after a meal, "when he gets hungry." Pain is always eased by food, so that he always carries a biscuit in his pocket. Since May he has been perfectly well, but fears recurrence.

Operation: A circular, hard ulcer found about $\frac{3}{4}$ inch beyond pylorus on anterior surface of duodenum; few omental adhesions. Posterior gastro-enterostomy. Infolding of ulcer. Recovery. Sent by Dr. Galloway, Otley.

Report, July, 1909: "Much better than before operation, but says he is never quite free from discomfort. This discomfort is mainly attributable to flatulence. Takes ordinary food. Is not so pale as he used to be and looks very much better."

CASE 77.—G & D. August 7, 1906. E. H., female, aged forty. Stomach trouble commenced three years ago. Pain soon after food at first; later occurred some time after food, and was relieved by a meal; finally began to occur irrespective of food and was almost continuous. Quite recently has taken solid food fairly well, but has fullness and heaviness after it. Occasional vomiting, which relieves the distress. A visibly contracting stomach.

Operation: A tight stenosis with evidence of old ulceration

and adhesions in first part of duodenum and along adjacent parts of lesser curvature. Posterior gastro-enterostomy. Recovery.

Report, November, 1908: "The old pain which I suffered from so long is quite a thing of the past. For years I was never so well, and all my life shall feel grateful."

CASE 78.—D. August 21, 1906. Miss T., aged forty-nine. Indigestion and vomiting about fifteen years ago. Ever since then she has been liable to attacks of epigastric discomfort. Hæmatemesis and fainting two years ago. A second attack with melæna four months ago. She rarely vomits, but regurgitates a little fluid into the mouth. The abdominal discomfort is felt about a quarter of an hour after a meal. A stout woman with a prominent epigastrium. Stomach not dilated. Tender above umbilicus, especially towards right costal margin.

Operation: Puckering of ulcer on anterior wall of duodenum immediately beyond pylorus. Gall-bladder distended and containing a stone in its pelvis. Posterior gastro-enterostomy. Infolding of ulcer. Cholecystostomy. Recovery. Sent by Dr. Jalland, York.

Report from Dr. Jalland, November, 1908: "Present condition very good; gain in weight; slight flatulent discomfort after meals. Has vomited occasionally, but this has been generally due to having taken lemon in some form. Looks the picture of good health, and goes about doing everything as usual."

CASE 79.—D. September 19, 1906. J. A. I., female, aged thirty-nine. Two and one-half years ago she began to suffer a dull aching pain in the epigastrium, not severe, and generally with no apparent relation to food. Food and hot drinks, however, usually relieved it. No vomiting. These attacks came on about every three days. For the past six months pain more severe and more frequent. Vomited for the first and only time a month ago. No blood. Loss of weight. Stomach not much enlarged; slight visible peristalsis.

Operation: An ulcer in duodenum close to pylorus. Posterior gastro-enterostomy. Recovery. Sent by Dr. Cass, Ravenglass.

Detailed Statement of Cases Operated Upon 311

Dr. Cass reports, November, 1908: "Present condition very satisfactory. Has occasional pain if overworked; diets herself carefully. On the whole, has very good health; the only symptom that troubles her is the above-mentioned pain, which is usually due to errors of diet or overwork."

CASE 80.—D. September 20, 1906. Mr. P., aged sixty-one. Suffered from indigestion for the last two years. Pain usually occurs about three hours after food. It is felt as a girdle extending across the epigastrium and round to the back. When the pain is at its greatest, the skin enclosed in this girdle is extremely sensitive, even contact with the bed-clothes being unendurable. Pain is immediately relieved by vomiting. Formerly this was self-induced, but for the last three months it has occurred spontaneously about once a week. Vomit is small in quantity and does not contain blood. Melæna has never been noticed. Appetite good, but he has lost 2 stones in weight in the last three months. Stomach dilated; some tenderness just above umbilicus.

Operation: Stomach dilated; no adhesions. Well-marked scar of an ulcer on anterior wall of duodenum half an inch beyond the pylorus. A calculus was felt in the pelvis of the gall-bladder. Posterior gastro-enterostomy. Infolding of ulcer. Owing to the condition of the patient it was not thought wise to prolong the operation in order to remove the gall-stone. Recovery. Sent by Dr. J. J. Anning, Beeston.

During convalescence from operation an acute attack of pain in epigastrium, with much flatulence, which was relieved by vomiting. During the next two years suffered from frequent attacks of severe epigastric pain, which always occurred soon after a meal, and were accompanied by distressing flatulence. Pain usually lasted a few hours, and was relieved by the induction of vomiting and occasionally by morphia. On October 28, 1908, the abdomen was again opened. Gall-bladder was found to be hour-glass in shape and to contain several stones in both compartments. Cholecystectomy. The scar of the old duodenal ulcer was seen and infolded. No evidence of any persisting ulceration.

Report, June, 1909: "Patient is free from pain and has gained in weight, and is, on the whole, in very good health.

A biliary fistula persisted for a considerable time, but has now closed."

CASE 81.—D. September 25, 1906. Mr. D., aged thirty-eight. Suffered from his stomach for the last three years. Attacks of pain and vomiting lasting from two to three weeks to over a month. Between these attacks he can take ordinary food, but during them he confines himself to milk diet. Pain has no very definite relation to taking food. It is felt most severely about the ensiform cartilage, thence passing downwards along each costal margin. Vomiting gives immediate relief to pain. Has lost weight considerably. Abdomen was explored two years ago by another surgeon, but nothing further was done. Epigastrium very tender; on inflation the stomach bulges to the left.

Operation: Omental adhesions to the old scar; stomach not dilated; the duodenum entered a mass of adhesions near the cystic duct. These were separated and a fistula between duodenum and gall-bladder demonstrated. The ascending part of the duodenum was found to lie on the middle line, overlapping the aorta. Posterior gastro-enterostomy, with vertical stoma. Sent by Dr. Johnston, Ilkley.

Report from patient, November, 1908: "My health is very good." No further report can be obtained.

CASE 82.—D. September 26, 1908. Mr. R., aged twenty-three. Subject to indigestion for the last six or seven years. For the first two years of this period used to suffer epigastric pain fairly regularly about 11 A. M. and 4 P. M. Now the pain is less regular in onset, but more constant. The pain is felt about the centre of the epigastrium and passes through to the back. Careful dieting relieves these symptoms for a time; then another attack will be brought on by a return to ordinary food. Six weeks ago had an attack of vomiting—the only one. Stomach rather dilated; no tenderness.

Operation: About $\frac{3}{4}$ inch beyond the pylorus the duodenum was narrowed by the puckered scar of an ulcer on its anterior wall. Posterior gastro-enterostomy. Infolding of ulcer. Recovery. Sent by Dr. Bertram Watson, Harrogate.

Report, November, 1908: "Am sound in every way. No symptoms which have given me the least anxiety. A gain

of about $1\frac{1}{2}$ stones in weight, characterised by a remarkably steady progress. I do not particularise in regard to diet, although on principle I refrain from such things as are commonly known as indigestible. A year ago I was accepted by a leading insurance office as a first-class life on the lowest terms, the history of my illness and operation having been fully considered by the medical officers."

CASE 83.—G & D. October 7, 1906. Mr. S. Many attacks of gall-stone colic since 1897. Pain varies much in severity and is sometimes followed by jaundice.

Operation: Gall-bladder contains many small calculi; contracted scar of ulcer on anterior duodenal wall. One or two dense white scars on posterior wall of stomach. Posterior gastro-enterostomy. Cholecystostomy. Recovery. Sent by Dr. Harbinson.

In June, 1909, was readmitted to the Nursing Home with the following history: Since the operation has never been quite well, and has had discomfort in the upper abdomen, coming on at varying times after meals, but no vomiting. On one or two occasions has had attacks of severe pain in the gall-bladder region. There has been no jaundice. On examination a large, hard tumour can be felt beneath the scar of the previous operation, and evidently connected with the right lobe of the liver. It reaches nearly to the umbilicus and passes just beyond the middle line. A diagnosis of carcinoma beginning in the gall-bladder was made.

Operation, June 19, 1909: Incision through old scar. The peritoneum was opened and a finger passed in. A large malignant mass was felt in the region of the gall-bladder, and on the upper surface of the liver were numerous secondary nodules. Abdomen closed. Patient died several weeks later.

CASE 84.—D. October 26, 1906. E. W., female, aged nineteen. For four years had indigestion at intervals. Worse during the last five months. Pain comes on about one hour after food, making her "sweat." Is sharp and stabbing in character, situated in epigastrium, and radiating towards the left side. Vomits two or three times a week. Recently was eight weeks in bed with rectal feeding, but relapsed immediately on getting up.

Operation: The duodenum for $1\frac{1}{2}$ inches was covered with scars and its serous surface was shaggy and reddened. There were some enlarged glands along the lesser curvature, but no ulcer was apparent. Posterior gastro-enterostomy by Mayo's method. Infolding of ulcers. Recovery. Sent by Dr. Alderton, Barnoldswick.

Report, November 19, 1908: "Quite well, but tires rather easily. Has gained considerably in weight; has had one or two slight bilious attacks, but otherwise no recurrence of pain nor vomiting."

CASE 85.—G & D. November 1, 1906. Mrs. M., aged forty-nine. For three years has been liable to bouts of illness in which she suffers from loss of appetite, vomiting, and a feeling of discomfort after food. During the last four months she has been worse, and although the vomiting has been less, owing to rigid dieting, her appetite has almost completely failed and she has lost weight rapidly. Two days ago she had a severe attack of vomiting. Probably an attack of hæmatemesis at the commencement of her illness. The stomach is dilated, with active peristalsis; a firm, movable tumour palpable beneath umbilicus.

Operation: Stomach much dilated; a large inflammatory mass the size of a golf ball extending from pylorus into duodenum. Posterior gastro-enterostomy. Infolding. Recovery. Sent by Dr. Mackenzie, Manchester.

Report, November, 1908: "Am quite and entirely well; can eat anything; have no troubles of any kind. You made an entire cure of me."

CASE 86.—G & D. November 8, 1906. Mrs. T., aged thirty-three. Five years ago a sudden attack of hæmatemesis. Two years ago a second attack. Between these two suffered almost all the time from dyspepsia. Two years ago in Nursing Home in Dublin under medical treatment for two months, and was better for several months after. Recently a renewal of pain, distress, vomiting. A week ago a severe hæmorrhage. Hæmatemesis, about 10 ounces, and melæna. Several repetitions of this. Now marked anæmia, weakness, feeble pulse. All signs of continued bleeding.

Operation: An ulcer on the lesser curvature near the cardia,

large and hard; peritoneum over it red and shaggy. A second ulcer on the lower border of the duodenum just beyond the pylorus. Posterior gastro-enterostomy. Infolding of duodenal ulcer. Recovery. Sent by Drs. Ryan, Parsons, and Townsend.

Report from Dr. Ryan, November, 1908: "In better health than she has been for years. Has gained considerably in weight. No symptoms of any kind. After the operation became quite healthy and strong and could eat any kind of food without the least inconvenience, despite the fact that she had been a chronic dyspeptic for years. Before the operation she had been fifteen years married and was childless. In September last was confined of a healthy child, and both are at present in the best of health."

CASE 87.—D. November 9, 1906. G. W., male, aged forty. Ten years ago an attack of pain in the stomach, followed by vomiting. Since then repeated attacks. Now has pain one and one-half hours after food, never earlier, often later. Belching, flatulence, acid eructations. Appetite sometimes very keen. Vomiting recently; on some occasions more than a quart. Never hæmatemesis nor mæna. Has lost 1 stone 4 lbs. in three months. Stomach is very much dilated, with obvious waves.

Operation: A large, chronic ulcer on the anterior surface of duodenum. Posterior gastro-enterostomy. Infolding of ulcer. Recovery. Sent by Dr. Hebblethwaite, Keighley.

Report, November, 1908: "In excellent health; has gained 2 stones 6 lbs.; no pain nor vomiting since operation; can eat anything; never any discomfort after food, and bowels have been quite regular."

CASE 88.—D. November 23, 1906. E. B., female, aged forty-eight. Quite well until twelve months ago, when she began to suffer from pain about two hours after food, chiefly after the mid-day meal. The pain came on in attacks lasting about a week; after each one she was easier for a week or longer. The pain has become much more severe recently. It is always easier after a little food. During the last six months she has vomited occasionally, a "sour, bitter stuff." Lost

2 stones in weight this year. A dilated, waving stomach. Tumour palpable in pyloric region. Free HCl present.

Operation: Stomach dilated and thickened; a hard cicatricial ulcer just beyond the pylorus. Posterior gastro-enterostomy. Ulcer infolded. Recovery. Sent by Dr. Goode, Doncaster.

Report, November, 1908: "Patient is much improved; has gained 7 lbs.; complains of a little pain after food at times and occasional 'water brash.' No vomiting. Has been much benefited by operation."

CASE 89.—D. November 24, 1906. Mr. Y., aged thirty-six. Digestive troubles for six years. Pain three hours after food, "hunger-pain." Appetite good; no vomiting. Has employed lavage for five years. Stomach dilated.

Operation: Stomach dilated. Scar of ulcer on anterior surface of duodenum $1\frac{1}{2}$ inches beyond the pylorus. Posterior gastro-enterostomy. Ulcer infolded. Recovery. Sent by Dr. Briggs, Blackburn.

Report, November, 1908: "Patient in better general health than he ever remembers to have experienced. Has gained a few pounds in weight. No pain, no vomiting. The change in the man's condition is really wonderful, and his absolute freedom from every complaint quite different from his experience before operation."

CASE 90.—D. November 25, 1906. T., male, aged fifty. Indigestion for twenty years. Pain occurs directly after food, and comes on in attacks. Hæmatemesis and melæna three weeks ago. Is anæmic. Stomach not dilated.

Operation: Scars of ulcers in first part of duodenum. Posterior gastro-enterostomy. Ulcer-bearing area infolded. Recovery. Sent by Dr. McLeod.

Report, November, 1908: "Patient is in very good health; better than he has been for the last twenty years. Has gained considerably in weight. No recurrence of pain nor vomiting."

CASE 91.—D. December 8, 1906. Miss L., aged forty-six. Ten years ago had an illness attended by enlargement of the spleen and jaundice. Ever since then has had a large lump on left side of abdomen, with slight jaundice. During all this time she has suffered from indigestion. On examination

the spleen is found to descend well below the umbilicus; the stomach is very much enlarged and frequent peristaltic waves are seen.

Operation: A large ulcer was found in the first part of the duodenum adherent in the neighbourhood of the gall-bladder. Stomach much hypertrophied. Posterior gastro-enterostomy. Recovery. Sent by Dr. Denning, Elland.

Report, December, 1908: "Present condition good; has gained one stone in weight. Vomits bile about once a week. It comes up without effort and does not make her feel ill. Has no other trouble. Is working regularly in a factory and takes her food well."

CASE 92.—D. December 13, 1906. Miss L., aged twenty-two. Indigestion for six years. Pain half an hour after food, marked anorexia, weakness, no vomiting. Tenderness and hyperæsthesia in centre of epigastrium.

Operation: Duodenal ulcer. Posterior gastro-enterostomy. Recovery. Sent by Dr. Kennedy, Shepley.

Report from Dr. Kennedy, December, 1908: "Has made an excellent recovery; her general tone is excellent and she now enjoys life. She eats ordinary food and is really cured. Great gain in weight, should say 2 stones."

CASE 93.—D. December 17, 1906. Mr. S., aged thirty-one. Indigestion for three years. Severe epigastric pain at 5 P. M. and at midnight. Last meal in the day is at 6 P. M. Midnight pain often eased by glass of soda and water. Occasional vomiting. Melæna but no hæmatemesis. Stomach not dilated.

Operation: A scar of ulcer just beyond the pylorus. Posterior gastro-enterostomy. Infolding of ulcer. Recovery. Sent by Dr. Haigh, Milnsbridge.

Report, March 6, 1907: "Has gained 17 lbs. and is eating anything." May 27th: Had gained three stones. Report, December, 1908: "Is perfectly well. Has gained 42 lbs. He has required no medical attendance since the operation, and he states that he never felt so well. He can take his food well, and never feels the least discomfort or pain of any kind."

CASE 94.—G & D. December 19, 1906. Mr. H. D., male, aged fifty-one. Indigestion for many years. For the last

six months pain fairly regularly three hours after a meal. No vomiting nor melæna. Stomach dilated. No visible peristalsis.

Operation: Scar of ulcer just beyond pylorus. One or two white scars on posterior surface of stomach. Posterior gastro-enterostomy. Infolding of ulcer. Recovery. Sent by Dr. Johnstone.

This patient has been seen frequently since the operation and is extremely well.

CASE 95.—D. January 10, 1907. J. R., male, aged twenty-nine. Has had pain in the epigastrium for four years. This usually comes on about four hours after food. This has been much worse during last twelve months, and has been accompanied by much distension and flatulence. Has lost 16 lbs. in weight. A month ago, whilst sitting in a chair, suddenly felt faint, sick, and vomited a large quantity of blood. Had melæna afterwards for ten days. On admission to the Infirmary was pale and ill.

Operation: Duodenal ulcer the size of a halfpenny about $\frac{1}{2}$ inch beyond the pylorus. Posterior gastro-enterostomy. Ulcer infolded. Recovery. Sent by Drs. Hawkyard and Mathieson, Leeds.

Report, November, 1908: "Is well nourished and feels well. Has gained 3 stones in weight. No recurrence of pain nor vomiting. Is following his work as a labourer."

CASE 96.—D. January 11, 1907. Mrs. H., aged thirty-seven. Had symptoms for five years. Pain one and one-half to two hours after food. Vomiting. Tenderness along right costal margin.

Operation: Stomach much dilated. Scar of ulcer in first part of duodenum. Posterior gastro-enterostomy and infolding of ulcer. Recovery. Sent by Dr. Falkner, Hull.

Report, November, 1908: "Feels better than she has done for years. She seems to be perfectly well, and eats and drinks anything."

CASE 97.—G & D. February 1, 1907. Mrs. G., aged forty-six. Indigestion for six years. Pain about two hours after food. Occasional melæna. Six weeks ago she had

several attacks of faintness and vomited blood twice. This was followed by melæna.

Operation: Indurated ulcer felt in posterior wall of first part of duodenum. A slight scarring on posterior wall of stomach. Posterior gastro-enterostomy. Duodenum infolded. Recovery. Sent by Dr. Knowles, Barnsley.

Report, November, 1908: "Is very well. Has gained nearly 2 stones. No trouble at all."

CASE 98.—G & D. February 1, 1907. J. W. H., male, aged sixty-five. Has had serious stomach trouble on and off for more than twenty years, and has been in the Infirmary on the medical side several times. On examination a much emaciated, haggard man; weighs 6 stones. Has lost one stone in the last fortnight. Stomach dilated; visible peristalsis.

Operation: Innumerable adhesions, making exploration of stomach very difficult. (Old perforation?) Pylorus and duodenum thick and cicatricial. First part of jejunum very adherent to under surface of transverse mesocolon. Posterior gastro-enterostomy. Recovery. Transferred from Dr. Churton's care.

This patient cannot be traced.

CASE 99.—D. February 8, 1907. W. H. H., male, aged thirty-eight. Attacks of indigestion for several years. The present attack, which is just subsiding, began in November last. He has pain at varying intervals after meals. This is worse between 3.30 and 4 P. M. and lasts until the next meal, which relieves it. As a rule, the pain comes two and one-half hours after meals, and is almost always relieved by lying down. Appetite good. Has lost 7 lbs. in the last five weeks, but is well nourished and plump.

Operation: A duodenal ulcer about the size of a sixpence on the anterior surface of the duodenum just beyond pylorus. Posterior gastro-enterostomy. Infolding of ulcer. The patient did well until the 21st; was eating well and said he was very hungry. On the 21st he was allowed to get up. He had not been up more than two minutes before he complained of acute abdominal pain, vomited, and went back to bed. That night he vomited twice, but on the morning of the 22d seemed

better. In the evening he vomited three times and had a temperature of 103° . Next morning he was very ill, and the abdomen was reopened. No free fluid was found in the peritoneal cavity; the coils of small intestine were slightly injected. The anastomosis was inspected, and in order to expose it some adhesions between the distal loop of the jejunum and under surface of the mesocolon had to be separated. Just distal to the anastomosis a perforation in the jejunum was exposed, evidently a jejunal ulcer which had perforated subacutely. It was impossible to close this perforation without disconnecting the anastomosis. This was done, the ulcer excised, the opening in the stomach closed, and a second anastomosis performed away from the first position. The patient died. Sent by Mr. J. P. Roughton, Kettering.

CASE 100.—G & D. March 1, 1907. Mr. C., aged fifty. Digestive troubles for a very long time. Milk diet for some months. Pain and flatulence after meals. Now the pain is more or less continuous, being relieved by a drink of milk, only to recur in half an hour's time. Occasional vomiting; loss of weight. Tenderness in centre of epigastrium spreading downwards to right. Stomach slightly dilated.

Operation: An ulcer on the anterior wall of the duodenum just beyond pylorus. Thickening of ulcer also felt on greater curvature near pylorus. Adhesions in lesser sac and an ulcer felt on posterior wall close to lesser curvature. Posterior gastro-enterostomy. Recovery.

This patient was much relieved for one year, but then began to suffer from pain and distension two hours after food, with occasional vomiting of yellow, bilious material. By August, 1908, his pain was rather worse; had no appetite and was losing weight. A malignant change in the ulcerated area was suspected.

Operation, August 21, 1908: The scars of previously existing ulcers were apparent, but there was no induration and no evidence of malignancy; pylorus freely patent. Some adhesions about the anastomosis, but apparently of no importance. The afferent limb of the jejunum showed a slight "loop." Division of afferent limb close to anastomosis and

end-to-side implantation into efferent; pylorus narrowed by suture. Recovery. Sent by Dr. Marsden, Lightcliffe.

Report, September, 1909: Patient states that he has suffered from frequent attacks of flatulence since his last operation, but no vomiting. A ventral hernia has developed at the site of the second operation, but a belt has been ordered and is being worn. On the whole, he is better, but considers himself far from well.

CASE 101.—D. March 13, 1907. Mrs. T., aged thirty-nine. Stomach trouble for ten years. Epigastric pain two hours after food, with occasional vomiting. No hæmatemesis; loss of weight. Tenderness in middle of epigastrium; stomach dilated, with visible peristalsis.

Operation: Stomach dilated and much proptosed, the lowest point of the lesser curvature being at the level of the umbilicus. Above this the pancreas was clearly visible. A well-marked ulcer on the upper border of the duodenum just beyond pylorus. Posterior gastro-enterostomy. Infolding of ulcer. Recovery. Sharp attack of bronchitis after operation. Sent by Dr. A. Court.

Report, November, 1908: "Has gained about 2 stones. There has been no recurrence of pain. Appetite is excellent and she eats practically anything."

CASE 102.—D. March 28, 1907. H. C., male, aged thirty-seven. In November last began to suffer from sharp, colicky pain in the abdomen in attacks lasting five or six days. Before and after the attacks suffers from great flatulence and belching. No vomiting. Stomach large.

Operation: A duodenal ulcer just beyond pylorus. Posterior gastro-enterostomy. Recovery. Sent by Dr. La Touche, Ossett.

Report, November, 1908: "Is in good health. Has gained 2 stones since the operation. No return of pain nor vomiting. Has not been off work since he resumed six months after the operation."

CASE 103.—D. April 12, 1907. T. C., male, aged thirty-nine. Has suffered from indigestion for the last five years. Pain in epigastrium about one hour after food, with a feeling of fullness and depression. Last October vomiting began and

pain after food was later in onset. Now has a great distaste for food. The stomach is dilated.

Operation: A duodenal ulcer making a mass the size of a walnut just beyond the pylorus. The omentum was very adherent over it. (Subacute perforation?) Posterior gastro-enterostomy. Recovery. Sent by Dr. McGibbon, Bramley.

Report, November, 1908: "Is robust and perfectly healthy. Has gained $3\frac{1}{2}$ stones. Has had no recurrence of symptoms at all. Appetite is extremely good and can eat anything."

CASE 104.—D. May 24, 1907. A. O., female, aged fifty-four. Was quite well until six months ago, when she began to suffer from pain after food and vomiting. Pain usually came two hours after food and was relieved by vomiting or by taking more food. Has lost 3 stones in weight. Visible peristalsis.

Operation: A duodenal ulcer about as large as a sixpence about $\frac{1}{4}$ inch beyond pylorus. Posterior gastro-enterostomy. Infolding of ulcer. Recovery. Sent by Dr. Carter Mitchell, Topcliffe.

Report, November, 1908: "Is much improved; has gained 18 lbs. in weight. Has occasional attacks of pain in left hypochondrium, striking through to the back, accompanied by bilious vomiting. Has also some heartburn. However, says she is quite a different person since operation. Before that she never had an hour free from pain or vomiting, but is now able to work, although she has occasional pain."

CASE 105.—D. May 26, 1907. L. W., female, aged twenty-six. Indigestion for eight or nine years. Pain occurring one and one-half to three hours after food, with much flatulence. Food always relieves pain. Three attacks of hæmatemesis during the last six years.

Operation: Small duodenal ulcer. Posterior gastro-enterostomy. Sent by Dr. Foley, Scarborough.

Report, November, 1908: "Has gained nearly a stone in weight. Still has to be careful of her diet, and has occasional neuralgic abdominal pains, but no pain similar to before operation. No vomiting. Is decidedly better, but cannot do much hard work."

Detailed Statement of Cases Operated Upon 323

CASE 106.—D. May 27, 1907. Mr. T., aged forty-six. Has suffered from gastric symptoms for twenty years. Pain two or three hours after food, which was relieved by a meal. Intervals of complete freedom between the attacks. No history of hæmatemesis nor melæna. Recently there has been no severe pain, but much flatulence, relieved by vomiting. Has lost 20 lbs. in the last three months. Stomach is dilated; visible peristalsis.

Operation: Stomach much dilated; ulcer in the first part of the duodenum, producing stenosis. Posterior gastro-enterostomy by Mayo's method. Recovery. Sent by Dr. Davidson, Hipperholme.

Report, October, 1908: "In splendid health; gained two stones; has been very well ever since operation, and can now eat and drink anything."

CASE 107.—D. May 29, 1907. Mrs. D., aged forty-two. For fifteen years has suffered from attacks of indigestion and flatulence. Five years ago severe attack with vomiting of coffee-ground material. Recently has suffered from attacks of pain immediately after food, often lasting all day. During these attacks vomiting is frequent. Has lost 12 lbs. in weight. The greater curvature of the stomach reaches below the umbilicus; feeble peristalsis.

Operation: Stomach dilated. Scar of an ulcer about the size of a florin in first part of duodenum. Posterior gastro-enterostomy. Infolding of ulcer. Recovery. Sent by Dr. Bruce Low, Sunderland.

Report, November, 1908: "Fairly healthy, but there is no substantial increase in weight. No recurrence of pain nor vomiting and can take ordinary diet."

CASE 108.—G & D. June 7, 1907. E. H., female, aged forty-one. An attack of pain and vomiting after food when sixteen years old. Similar illness when she was twenty-one, and another when she was thirty-three. In the last she was very seriously ill; great pain soon after food, vomiting, and hæmatemesis. Four years ago she again began to have pain after food, having been quite well since the former attack. The pain then came two hours after food, was always relieved

by vomiting, and sometimes by food. A similar attack two years ago, and a third in February of this year.

Operation: A large, indurated ulcer on lesser curvature near the cardia had narrowed the stomach and produced an hour-glass contraction. A large, indurated, duodenal ulcer. Gastroplasty. Gastro-enterostomy. Recovery. Sent by Dr. Dowsing, Hull.

Report, November, 1908: "Has gained 14 lbs. Has had no pain and no vomiting since operation, and is in better health than she has been for twenty years."

CASE 109.—D. June 7, 1907. W. H. D., male, aged forty-nine. Two years ago began to have pain a long time after food, "consisting chiefly of wind and sour eructations." The pain, he says, "was not due to food, because it was much better for an hour or two, and then it began to come on gradually and got severe." It was always quickly relieved by food. Food used to repeat "very hot" about an hour after meals. Has lost one stone in weight. Never any hæmorrhage. A dilated, waving stomach.

Operation: A large ulcer or ulcers extending over $1\frac{1}{2}$ inches of the duodenum, with warping and puckering of the surface. Many recent adhesions. Posterior gastro-enterostomy. Recovery. Sent by Dr. Haigh, Milnsbridge.

Report, November, 1908: "Is perfectly well; has gained 20 lbs. Has not required any medical attendance since the operation; states that he has not felt so well for five or six years, and he can take any kind of food without the least discomfort.

CASE 110.—D. June 8, 1907. R. T., male, aged fifty-five. For twenty years has had attacks of indigestion, all moderately severe during the few weeks they lasted, but he has been well in the intervals. Three months ago began to suffer similarly, but this attack has been much more severe and he has lost weight rapidly. Pain comes one or two hours after food, and he has severe flatulence and sour eructations.

Operation: An ulcer in the anterior wall of the duodenum immediately beyond pylorus. There were evidences of old tubercular disease, adhesions of intestines, and old calcareous

glands in the mesentery. Posterior gastro-enterostomy. Recovery. Sent by Dr. Lambert, Farsley.

Report, November, 1908: Now in fairly good health; one attack of pain in April, lasting about three weeks. Has worked every day except during attack mentioned.

CASE 111.—D. June 12, 1907. Mr. M., aged sixty-seven. Has suffered as long as he can remember from "delicate stomach." Great flatulence after eating, especially vegetables. For the last thirty-one and one-half years has held the same living, and all through this period has had occasional attacks of indigestion, acidity, flatulence, and disinclination for food. Three and one-half years ago severe hæmatemesis and melæna. The vomit was then so acid that it burnt the throat and lips on ejection. Since then several attacks of acid vomiting. The stomach was not dilated. It was thought that peristalsis was visible.

Operation: An old and very hard duodenal ulcer, causing a faint amount of stenosis. Many adhesions of duodenum to gall-bladder. The upper part of the jejunum was buried in adhesions, which had to be divided before gastro-enterostomy could be performed. Posterior gastro-enterostomy. Recovery.

Report, letter, February, 1909: "The operation has proved a complete success. I have had no pain whatever, no flatulence such as I suffered from for years before, and my digestion is quite regular."

CASE 112.—D. June 13, 1907. Mr. S., aged forty-five. Up to November, 1906, suffered from attacks of acute epigastric pain, coming on some hours after food, and usually followed and relieved by vomiting. Occasionally food seemed to relieve the pain. No hæmatemesis nor melæna. Since November last pain almost continuous during the day, but not present at night. He describes it as a dull aching pain near the umbilicus and down to lower part of abdomen. No vomiting since November. Bowels constipated. Has lost weight rapidly lately (60 lbs.). A large, gaunt man. Stomach reaches to umbilicus.

Operation: The stomach is dilated and coats thickened. On the anterior surface of the first part of the duodenum an

indurated ulcer. A circular deposit of tuberculous disease about the centre of the transverse colon. The ileo-cæcal junction, cæcum, and appendix were more extensively involved. The deposits were not of the hyperplastic form, but the peritoneum was red, granular, and covered by small tubercles; no stenosis. One or two large glands in the mesentery. Posterior gastro-enterostomy. Infolding of ulcer, which was probably tuberculous. The patient died fourteen days after the operation with signs of acute phthisis (generalising tuberculosis). No post-mortem examination.

CASE 113.—D. June 23, 1907. Mr. S. R., aged sixty-five. Periodic attacks of severe pain one and one-half hours after food for fourteen years. The pain is heavy and aching, accompanied by much flatulence, and is relieved by food. There has been no vomiting. The present attack has lasted eight or nine months. He has lost 4 stone 4 lbs. The stomach reaches to the level of the umbilicus. A tender spot above and to the right of the umbilicus.

Operation: Ulcer in first part of duodenum. Posterior gastro-enterostomy. Infolding of ulcer. Recovery. Sent by Dr. Watterson, Morecambe.

Report from Dr. Watterson, September, 1909: "I am sorry, but I really cannot obtain any satisfactory information from him as to result of operation. He persists in saying that he is no better than when under my care before the operation. He goes about regularly, and I believe, as I have stated to him, that he is better for the operation. I will tell you more when next I see you. He is 'perverse' in nature."

CASE 114.—D. July 7, 1907. H. S., male, aged twenty-seven. Twelve months ago for four or five days an attack of "indigestion," with great flatulent distension, eructations, and a feeling of nausea. He attributed all this to smoking a new pipe. On March 21st, after feeling run down and low for a few days, he suddenly fainted, and had to be taken home. For several days there was profuse melæna, and this has been almost constant since then. Has been rigidly restricted to fluids, and during this time has had no indigestion.

Operation: A small, round ulcer on the anterior wall of the duodenum. This was excised. On the posterior wall exactly

Detailed Statement of Cases Operated Upon 327

opposite was a precisely similar ulcer, which was sutured. Duodenum closed. Posterior gastro-enterostomy. Recovery. Sent by Dr. Malim, Rochdale.

Report, December, 1908: "Patient is in good health. There has been no recurrence of pain nor vomiting."

CASE 115.—D. July 8, 1907. W. J., male, aged forty-seven. Quite well up to six months ago; then began to suffer from pain beneath the right costal margin. This was worse two hours after a meal, and continued until the next meal. Recently pain has been very acute, with much epigastric distension and eructation of sour fluids. Frequently the pain wakes him at night. Food relieves pain better than anything else.

Operation: A fairly large ulcer 1 inch beyond pylorus. Posterior gastro-enterostomy. Recovery.

Report from patient, November, 1908: "I have derived a great deal of benefit from the operation, and have not felt as well as I do now for many years past."

CASE 116.—D. July 11, 1907. F., medical man, aged fifty-eight. Five years' history. Severe epigastric pain, occurring about two hours after food. These attacks would last two or three months, and then disappear perhaps for four or five months. Attacks coincident with winter and overwork. During the last three years attacks have increased in number and severity and he has suffered much from pain about 2 A. M. The pain is always relieved by taking food; has never vomited. Blood has been detected in the stools by microscopic examination. A fairly well nourished man. No gastric dilatation.

Operation: Duodenum showed severe scarring by two, or possibly three, ulcers in its first portion. The duodenum was tucked back by adhesions to the under surface of the liver. Posterior gastro-enterostomy. Infolding of ulcer. Recovery. Sent by Dr. Craven Moore, Manchester.

Report: This patient has been seen quite recently, and is extremely well and entirely free from his old trouble.

CASE 117.—D. July 19, 1907. Miss St. G., aged twenty-five. Six years ago an attack of catarrhal jaundice. For four years has suffered from indigestion, severe gnawing pain

coming on two hours after food, which was occasionally relieved by food. There has been no vomiting and no melæna; there is no gastric dilatation.

Operation: An ulcer in the first part of the duodenum. Posterior gastro-enterostomy. Infolding of ulcer. Recovery. Sent by Major Porter, D.S.O., R.A.M.C., Colchester.

Report: A letter from patient, January 25, 1909, states that she had attacks of indigestion and nausea for about six months. Since then these have gradually become more infrequent and she has gained weight. At the present time is very well, and is enjoying winter sports in Switzerland.

CASE 118.—D. July 22, 1907. W., male, aged forty. Since the age of fifteen attacks of pain occurring two and one-half hours after food, with frequent vomiting of very acid fluid. Pain is usually relieved by food. Between the attacks he has had varying intervals of relief. No hæmatemesis, no melæna. Has lost 3 stones in weight. Slight gastric dilatation.

Operation: Several ulcers in first and second parts of the duodenum, which had produced much scarring and deformity. Posterior gastro-enterostomy. Infolding of ulcerated area. Recovery. Sent by Dr. Dowsing, of Hull.

Report, December, 1908: "Is in very good health; has gained 4 stone in weight since the operation. Has not been so well as he is now for ten years, and his only regret is that he did not have the operation done sooner."

CASE 119.—D. July 22, 1907. B., male, aged fifty-one. Trouble for three years. Pain two or three hours after food, frequently accompanied by vomiting. Food relieves. At first there were intervals of relief, but latterly pain has been almost constant.

Operation: Duodenum tucked back beneath liver; ulcer in first portion. Posterior gastro-enterostomy. Infolding of ulcer. Recovery. Sent by Dr. Burnett, Saltburn.

Report, December, 1908: "Patient was much improved several months after the operation and was free from pain, and at that time returned to America. No report received since."

CASE 120.—D. August 6, 1907. O. F., male, aged thirty-

Detailed Statement of Cases Operated Upon 329

two. The last three years has had pain occurring two and one-half hours after food. At the onset of his illness an attack of hæmatemesis, which has not recurred. No melæna. Has lost 1½ stones in the last six months.

Operation: A duodenal ulcer just beyond pylorus. Posterior gastro-enterostomy. Recovery. Sent by Dr. Dearden, Wyke.

Report, May, 1909: "Patient has ailed nothing since the operation. Is now extremely well and has no trouble of any sort."

CASE 121.—D. August 9, 1907. H. J. H., female, aged forty-six. For the last nine years has suffered from pain, fullness, and discomfort at varying periods between one and three hours after food. Immediately after food she is quite comfortable, and she can manage to keep so by "nibbling" all day, but at night the pain nearly always wakes her up. No dilatation.

Operation: A large, indurated ulcer just beyond the pylorus. Posterior gastro-enterostomy. Infolding of ulcer. Recovery. Sent by Dr. Oldfield.

Report, December, 1908: "Very much improved. Her general condition was poor for six months after the operation. Due in part to chronic pleurisy (probably tuberculous), and in part to her not taking sufficient meat food, which she thought was unsuitable. She has now gained considerably in weight, and is better than she has been for twenty years."

CASE 122.—G & D. August 14, 1907. W. B., male, aged twenty-six. For five years has suffered from pain two to three hours after food, which is always relieved by the next meal. A few days before admission had copious melæna and some hæmatemesis, which continued for fourteen days after admission.

Operation: An ulcer on the lesser curvature of the stomach near pylorus; a second large ulcer in the first part of the duodenum. Posterior gastro-enterostomy. Infolding of ulcer. Recovery. Sent by Dr. Isaac Taylor, Leeds.

Report, July 1909: "The operation has been a wonderful success; has gained 11 lbs. and has never vomited since the operation."

CASE 123.—D. August 16, 1907. R. T., male, aged thirty. Has had "stomach trouble" since he was fourteen or fifteen. Pain at first was so bad as to double him up. Pain in the last few years has sometimes come one hour after food, but more commonly two or three hours after. Frequent vomiting of yeasty material. A large, waving stomach.

Operation: A well-marked ulcer just beyond pylorus with a good deal of induration. Posterior gastro-enterostomy. Recovery. Sent by Dr. Andrews, Burmantofts.

Report, October 4, 1907: "Gained in weight and can eat anything." Report, November, 1908: "Is in perfect health; has gained 2 stones. Has had absolutely no recurrence of symptoms, and there are now no signs of gastric dilatation."

CASE 124.—D. August 20, 1907. W. A., male, aged fifty-eight. For several years has had discomfort of varying degrees of severity after food. Twenty months ago a severe blow in the epigastrium, and since then he has been much worse. Eighteen months ago began to lose weight, and in all has lost over 3 stones. Has pain usually three to three and one-half hours after food, and latterly much flatulence, eructation, and acidity. Four months ago a severe attack of melæna, and two days later hæmatemesis. Stomach dilated; no visible peristalsis.

Operation: A large mass, smooth and hard, involving the duodenum in its first and second parts. Posterior gastro-enterostomy and closure of pylorus. Recovery. Sent by Dr. Wilkinson, Starbeck.

Report, December, 1908: "Patient enjoys excellent health; has gained 10 to 12 lbs. in weight, and is now able to follow his former occupation of postmaster, which he was compelled to relinquish some months previous to his operation."

CASE 125.—D. September 2, 1907. N., male, aged thirty-seven. For four or five years has been troubled with a feeling of weight soon after food, followed in two or three hours by an acute, cutting pain. Frequent acid eructations. Food usually relieves.

Operation: The duodenum was firmly tucked back beneath liver; a small ulcer just beyond pylorus. Posterior

gastro-enterostomy. Infolding of ulcer. Recovery. Sent by Dr. J. Nicholson, Roundhay.

Report, January, 1909: "Patient's condition is, speaking generally, good. There has been a gain of about 11 lbs. in weight. He still complains of pain coming on about an hour after food, and slight regurgitation of acid mucus into the mouth."

CASE 126.—D. September 3, 1907. G., male. Indigestion for many years. Pain two or three hours after food, relieved by vomiting of frothy mucus. The pain is frequently worse at night. No hæmatemesis. History of melæna. Between the attacks there have been intervals of complete freedom. Has lost 3 stones in weight, and lately has become markedly anæmic. The stomach contents contain no free HCl and lactic acid is present. There is no obvious dilatation of stomach and no tumour can be palpated.

Operation: No ulcer or growth in stomach; a duodenal ulcer just beyond pylorus. Posterior gastro-enterostomy. Infolding of ulcer. Recovery. Sent by Dr. Sadler, Barnsley.

Report, December, 1908: "I have enjoyed better health this last year than in any year since 1878. I can eat with impunity things I have not ventured to touch for many years. I have gained over 2 stones in weight. The operation has made a new man of me, and whereas life was for many years a miserable burden, it is now a pleasure."

CASE 127.—D. September 7, 1907. McG., male, aged twenty-five. Five years ago received a kick in the abdomen while playing football, and has never been quite fit since then. For the last two years attacks of pain in lower part of chest and epigastrium, coming on at first half an hour, and latterly two hours, after food. Much flatulence, and regurgitation of sour fluid into mouth. Food often relieves pain. Has had intervals of complete freedom between the attacks. At least one attack of melæna; has lost a stone in weight.

Operation: Duodenum fixed tightly back beneath liver; a star-shaped scar and ulcer in first portion. Posterior gastro-enterostomy. Infolding of pylorus. Recovery. Sent by Dr. Leatham, Belfast.

Report, January, 1909: For a time improvement in this

case was very slow; burning in the epigastrium recurred on any indiscretion in diet, and there was no great gain of weight, but during the last two months of 1908 the burning disappeared, and improvement became so marked that the patient considers himself completely cured. A report received during July, 1909, stated that this patient had recently developed signs of phthisis and been sent to a sanatorium, where he was progressing favourably.

CASE 128.—D. September 14, 1907. C. S., female, aged twenty-seven. Eleven years ago had a severe attack of indigestion which lasted three months. Pain and vomiting after all foods. For weeks lived on nothing but milk and water. Was well after that until five years ago, when he began to suffer with pain of a colicky nature before meals, which was relieved by food; no vomiting. Has lost $1\frac{1}{2}$ stones this year.

Operation: Just beyond the pylorus a well-marked ulcer on the anterior surface of the duodenum. The gut was puckered to a hard, œdematous spot. Posterior gastro-enterostomy. Recovery. Sent by Dr. Haigh, Milnsbridge.

Report, December, 1908: Is perfectly well; has gained 10 lbs. Gave birth to twins in June last, and had no vomiting during the whole of the pregnancy. Says she has not felt so well for eight years.

CASE 129.—D. September 17, 1907. T. W. A., male, aged forty-one. Quite well up to three months ago. No pain before then, but occasionally a lot of flatulence. Since then has had several attacks of pain lasting two or three weeks, occurring three or four hours after food, and always accompanied by vomiting.

Operation: Duodenum tightly tucked backwards; an ulcer on its anterior surface surrounded by many adhesions. Posterior gastro-enterostomy. Recovery. Sent by Dr. Corry, Scarborough.

No report can be obtained about this patient.

CASE 130.—Duodenal ulcer and gall-stones. September 27, 1907. J. W. Q., male, aged fifty. Has had pain after food and occasional vomiting for ten years. During the last three years pain in the epigastrium, which used to come at

first during the early hours of the night; subsequently after all meals, at an interval of one to three hours. Food usually relieves, but sometimes flatulence and pain are very severe until belching or vomiting relieves him. Pain always begins exactly in the middle line, which is tender. Melæna on one occasion three weeks ago.

Operation: A long, streaky ulcer, transverse to the axis of the duodenum, with induration and some contraction. Gall-stones. Posterior gastro-enterostomy. Cholecystotomy—about thirty stones removed. Recovery. Sent by Dr. Haigh, Milnsbridge.

Report, December, 1908: "Patient is perfectly well. Has gained 16 lbs. Has required no medical attention since the operation, and can take any kind of food without the least discomfort."

CASE 131.—D. September 27, 1907. J. A., male, aged thirty-four. Quite well up to Christmas, 1906; then began to suffer first from vomiting, and then from pain, which used to come one to two hours after food, lasted several hours, and was relieved by vomiting. For last four months has vomited every few days large quantities of food, never blood. A dilated, waving stomach.

Operation: A large duodenal ulcer. Stomach dilated with thickened walls. Posterior gastro-enterostomy. Recovery. Sent by Dr. Swindale, Clitheroe.

Report, December, 1908: Patient's health is excellent; has gained 21 lbs.; not the slightest recurrence of symptoms.

CASE 132.—D. September 29, 1907. H., male, aged forty-one. Has suffered from attacks of pain some hours after food since childhood; even at that time he found that food frequently relieved the pain. Can remember, even at the age of seven or eight, having pain in the stomach, and more particularly during the night-time, and being taken into his mother's bed. Can also remember when quite young requiring something to eat between regular meals, and taking food to his bedroom to eat in the night, as he found that it relieved the pain. He has had intervals of perfect freedom of varying length. Formerly these used to be six or nine months, but for some time past he has not been free from

trouble for more than a few weeks at a time. During the present year he has kept a record, and this shews that out of two hundred and sixty-seven days he has only been well about ninety days, and these were during the summer. Speaking generally, he is always better in the summer than in the winter. Pain comes on about three hours after a meal. At one time he had a good deal of vomiting, but this has been less recently, with careful dieting. No hæmatemesis and no melæna.

Operation: A large ulcer just beyond the pylorus with much scarring. Many adhesions in lesser sac. Posterior gastro-enterostomy. Infolding of ulcer. Recovery. Sent by Dr. Martland, Oldham.

Report, November, 1908: "Is enjoying good health and has done so ever since operation. Is taking food of all kinds without the slightest ill effect—a thing he never remembers to have done before the operation."

CASE 133.—D. October 25, 1907. H. B., male, aged thirty-six. Stomach symptoms began nine weeks ago. Pain and flatulence two hours after food, followed by vomiting. Every few days his doctor noticed that he became pallid, and on examination melæna was found.

Operation: A large ulcer on anterior surface of duodenum just beyond pylorus. Adhesions to under surface of liver. Posterior gastro-enterostomy. Recovery. Sent by Dr. Normington, Nelson.

Report, December, 1908: "Patient is very well. Has gained at least 30 lbs. No recurrence of pain nor melæna."

CASE 134.—D. October 26, 1907. Mr. W., aged twenty-nine. For the last five or six years has suffered pain two hours after food, with much flatulence. There have been scarcely any intervals of relief; no vomiting and no history of melæna.

Operation: The duodenum was tightly tethered back; two adhesions to the under surface of the liver were divided and an indurated ulcer was found to lie between them. The transverse colon was pulled down by adhesions to the mesentery of the small intestine. Posterior gastro-enterostomy. Infolding of ulcer. Recovery.

Report: "This patient has been seen at intervals up to the

present time. He has no pain, and the result is very satisfactory."

CASE 135.—D. October 30, 1907. Mrs. W., aged thirty-six. Has had indigestion for eighteen months, gradually getting much worse. Pain occurs about two hours after food and lasts till next meal. Melæna has been detected on several occasions since March. Has lost about one stone in weight.

Operation: An ulcer in the first part of the duodenum. No induration. About $1\frac{1}{2}$ inches beyond the pyloric sphincter and distal to the ulcer a circular narrowing of the duodenum appeared every now and then, as though there were a localised hypertrophy or spasm of the muscular fibres. Posterior gastro-enterostomy. Infolding of ulcer. Recovery. Sent by Dr. Ellis, Halifax.

Report, February, 1909: "At first progress was slow, but during the last three months has gained weight rapidly, and is now very well indeed."

CASE 136.—D. November 1, 1907. A. B., male, aged thirty-seven. Stomach symptoms for years and occasional vomiting. Pain comes two hours after food, and is relieved by vomiting. The last four months vomiting has been persistent. A dilated, waving stomach.

Operation: A large mass of induration in duodenum; stomach dilated and thickened. Posterior gastro-enterostomy. Sent by Dr. Friend, Leeds. Transferred from Dr. Churton.

Report, December, 1908: "Eats any food; is troubled with slight flatulence and some constipation; no vomiting. Has gained over a stone in weight."

CASE 137.—G & D. November 15, 1907. Mr. H., aged fifty-five. Pain after food for several years. The pain is situated in left hypochondriac region and occurs one and one-half hours after food. There has been no vomiting and no melæna. A drink of water frequently relieves pain. Has lost one stone during the last three months.

Operation: A large, indurated ulcer on the lesser curvature near cardia. In the first part of the duodenum an ulcer adherent to enlarged glands in gastro-hepatic omentum.

Infolding of duodenal ulcer. Posterior gastro-enterostomy. Recovery. Sent by Dr. Molloy, Blackpool.

Report, November, 1908: "The operation has been an unqualified success. Mr. H. has now a healthy color and complexion. He can take all kinds of food, but has to be careful not to take too much at a time. Is now about normal weight."

CASE 138.—D. December 12, 1907. Mr. L., aged thirty-one. Three years ago began to suffer from pain in the epigastrium, occurring one and one-half to two hours after food, and lasting until the next meal, when it became easier. His meals have been extremely irregular. He had his breakfast very early and went straight away to work, often giving himself only a few minutes' interval for lunch, and occasionally taking very little food until the evening, when he had a very large meal and went to bed. There have been some short intervals of relief from pain up to eighteen months ago, when he became much worse, pain occurring after every meal, although food still relieved it to some extent. There has been no vomiting. Three days before admission a severe attack of melæna, which lasted for two days. On admission the patient was blanched and weak, although the melæna had ceased.

Operation: Stomach not dilated. A hard ulcer about the size of a pea on posterior surface of the duodenum just beyond the pylorus. Posterior gastro-enterostomy. Ulcer infolded by suture from posterior aspect through opening in lesser sac. Pylorus closed by interrupted sutures. Recovery. Sent by Dr. Beaman, Normanton.

Seen July, 1909: "Has gained considerably in weight; has no indigestion; health good."

CASE 139.—D. January 8, 1908. Mr. M., aged fifty-one. Pain occurring after food for the last six months. Sometimes immediately after, usually two to three hours after a meal. Much flatulence. No vomiting, no melæna. Has lost nearly 1½ stones. Stomach large; no food stasis.

Operation: A large stomach, pylorus narrow. An ulcer on the anterior surface of duodenum just beyond pylorus. Posterior gastro-enterostomy. Infolding of ulcer. Recovery. Sent by Dr. Wood, Wakefield.

Detailed Statement of Cases Operated Upon 337

Report, January, 1909: "Present condition very satisfactory. Has gained weight. No recurrence of pain nor vomiting; has been operated on for double empyema since his gastro-enterostomy, but is now quite well."

CASE 140.—D. January 10, 1908. J. C., male, aged fifty. Pain two to three hours after food for the last seventeen or eighteen years; relieved by food. No hæmorrhage.

Operation: A large ulcer just beyond pylorus. Posterior gastro-enterostomy. Infolding of ulcer. Recovery. Sent by Dr. Woodcock, Leeds.

No report can be obtained.

CASE 141.—G & D. January 10, 1908. M. G., female, aged fifty-four. Has had symptoms for twenty years. Pain coming an hour after food, with much vomiting; now has an enormously dilated, waving stomach; daily vomiting of large quantities. Great emaciation.

Operation: Hard, cicatricial mass at the pylorus. At the upper border of the first part of the duodenum a hard scar. At the inferior border a curious pouching of the duodenal wall. Posterior gastro-enterostomy. Recovery. Sent by Dr. Harvey, Swinton.

Report, January, 1909: "Enjoys excellent health; has gained 3 stone 6 lbs. Has had no recurrence of pain. Says she can eat anything. Mrs. G.'s return to health is the talk of the countryside."

CASE 142.—D. January 17, 1908. Mr. M., aged sixty-two. Pain occurring two to three hours after food for a number of years, with intervals of relief. During the last twelve months symptoms have been more acute; much flatulence. Pain frequently severe at night and is relieved by food. Occasional vomiting. No hæmatemesis nor melæna.

Operation: An ulcer in the first part of the duodenum. Posterior gastro-enterostomy. Infolding of ulcer. Recovery. Patient sent by Dr. Rheinhart Anderson, Southport.

Report, January, 1909: "Present condition good. Has gained 24 lbs. Sleeps well; eats anything. This is a case in which the benefit of the operation has been very great. He looks and feels another man."

CASE 143.—D. January 17, 1908. C. W., male, aged

twenty-six. Eight years ago began to have pain in upper abdomen after going to bed. This was usually accompanied by a feeling of great distension; later pain began to come in the daytime, one and one-half hours after food. Since last August has had both hæmatemesis and melæna.

Operation: Two large scars in first portion of duodenum. Posterior gastro-enterostomy. Recovery. Sent by Dr. Fryer, Barnsley.

Report, January, 1909: Feels well in himself and is able to work without any trouble. Has a good appetite; "eats nearly anything." "Is a vegetarian." No pain nor vomiting.

CASE 144.—D. January 19, 1908. Dr. W., male, aged thirty-eight. Since the age of twenty has suffered from attacks of indigestion. Pain occurring two hours after food and lasting until next meal. In February, 1906, a very severe attack; great pain, which was worse at night. December, 1906, melæna lasting for four days. Since then has had very little relief from pain, which is always worse in cold weather. There has been no vomiting.

Operation: Stomach not dilated. In the first part of the duodenum puckered scars of five separate ulcers. Strong adhesion to the neck of gall-bladder. The first part of the duodenum was enveloped by thin adhesions which were separated by gauze stripping. Posterior gastro-enterostomy. Infolding of ulcer. Recovery. Sent by Dr. Crowley, Bradford.

Report, letter from patient, February 15, 1909: "Am glad to be able to tell you that at least I am beginning to feel the benefits of operation. Feeling really well again and getting my spring back. I have to exercise a little care about dieting, but can take most reasonable things now, and hardly ever feel the least pain."

CASE 145.—D. January 19, 1908: Mr. B., aged fifty. Attacks of severe epigastric pain for several years, coming on two to four hours after food, and situated midway between umbilicus and ensiform; almost always relieved by food. Intervals of complete relief from pain; longest about five

months; recently intervals shorter. No vomiting, no melæna. Has lost weight recently.

Operation: Stomach slightly dilated. Duodenum tightly tethered back beneath liver. An indurated ulcer just beyond pylorus. Posterior gastro-enterostomy. Infolding of ulcer. Recovery. Sent by Dr. Buckley, Nottingham.

Report, January, 1909: "Condition very satisfactory; gained about 13 lbs. I have not had occasion to attend Mr. B. since the operation. Have only seen him once, and I consider the result most satisfactory."

CASE 146.—G & D. January 22, 1908. Mr. F., aged forty-four. Symptoms for eight years. At first pain occurred soon after food. Recently has occurred mainly at night, and three to four hours after food. During the last eighteen months has had frequent vomiting, often of large quantities. Has never had hæmatemesis. Recently food has often relieved pain; has lost 2 stones in weight. A large, actively contracting stomach, much food stasis.

Operation: Stomach much dilated. In the prepyloric region scar of old ulceration. In the first part of the duodenum a hard, indurated area size of a Barcelona nut, evidently long-standing ulceration, to which the omentum was adherent. Posterior gastro-enterostomy; first part of the duodenum infolded. Recovery. Sent by Dr. Johnson, Altofts.

Report, January, 1909: "Condition very good. Has gained weight; doing his work and attending public dinners, etc. Result everything that could be desired."

CASE 147.—G & D. January 25, 1908. J. R., male, aged fifty-eight. For twenty-two years pain after food and occasional vomiting. At first pain used to come about one-half hour after food, but latterly has been noticed before food, and food has relieved it. Lately there has been melæna on several occasions.

Operation: The abdominal cavity was opened with difficulty on account of the enormous number of adhesions. The omentum covered the stomach completely, having been entirely turned over. Separation of adhesions very tedious and difficult. There were scars of old ulcers on the lesser curvature, one of which had no doubt perforated on a previous occasion.

In the duodenum a recent ulcer. Posterior gastro-enterostomy. Recovery. Sent by Dr. Marsh, Long Preston.

Report, January, 1909: "Present condition very good. Is perfectly well; has gained about 2 stones."

CASE 148.—D. January 31, 1908. H. G., male, aged forty-two. For seventeen years has suffered on and off from indigestion. Has always been worse in the winter and better in the summer. Five or six years ago began to be much worse. Pain comes two or three hours after food. Sometimes, especially after a heavy meal, pain comes four hours after food; is always relieved by food. For the last two years has had vomiting. Has now a dilated, waving stomach.

Operation: A large, indurated ulcer just beyond pylorus. Posterior gastro-enterostomy. Recovery. Sent by Dr. Richardson, Leeds.

Report, January, 1909: "Is in good health. Weight about the same. He has no pain. Can eat anything and suffers no indigestion. Feels quite well and strong."

CASE 149.—D. February 7, 1908. Mr. C. Fourteen years' history of attacks of epigastric pain, coming on two to three hours after food. Frequently relieved by food. Vomiting occurs soon after the onset of pain. There have been intervals of complete relief, but latterly these have become shorter and less frequent. There has been neither hæmatemesis nor melæna.

Operation: A large, indurated ulcer on the anterior surface of the duodenum $\frac{1}{4}$ inch beyond the pylorus; omental adhesions. Posterior gastro-enterostomy. Infolding of ulcer. Recovery. Sent by Dr. Fawsitt, Oldham.

Report, January, 1909: "Present condition very good. Had gained 10½ lbs. by November. Is very well and can take any kind of food in moderation. Since the operation he has had to take aperients nearly every day, which was not the case previously."

CASE 150.—D. February 8, 1908. J. S., male, aged sixty-three. Two and one-quarter years ago began to have pain after food, generally about three hours after. It lasted one to two hours and was relieved by next meal. Summer

following onset he had no pain at all. It returned, however, in October, and has lasted almost ever since. Lost $1\frac{1}{2}$ stone.

Operation: A large duodenal ulcer, equal in size to a shilling, with adhesions to the liver. Posterior gastro-enterostomy. Recovery. Sent by Dr. Kirke-White.

Report, January, 1909: "Can eat all kinds of food without any pain; appetite good; feels better than he has done for years; has gained about 16 lbs."

CASE 151.—D. February 8, 1908. T. D., male, aged forty-three. Eight years ago began to have pain about one and one-half hours after food, relieved by more food or by vomiting. During the last five years has had signs of pyloric obstruction with frequent vomiting; has now a dilated, waving stomach.

Operation: A large duodenal ulcer adherent to liver. Posterior gastro-enterostomy. Recovery. Sent by Dr. Stephenson.

Report, January, 1909: "Has had no trouble since operation. Has gained 3 stone 10 lbs. in weight, and is one stone heavier than he ever was before."

CASE 152.—G & D. February 10, 1908. Mr. M., aged thirty-eight. Pain one and one-half to two hours after food for several years. Food often temporarily relieves the pain. Has frequent vomiting. There were intervals of relief from pain until two years ago. Since that time pain has been much worse, and almost constant. Has lost weight considerably. Eight weeks ago severe hæmatemesis. Is now very anæmic.

Operation: A large ulcer extending along the lesser curvature of the stomach for one inch into the duodenum. Firmly adherent to the liver above and to the upper border of the pancreas behind. Numerous adhesions to the anterior abdominal wall, probably the result of an old perforation. Posterior gastro-enterostomy by Mayo's method. Recovery. Sent by Dr. Horsfall, Bedale.

Report, January, 1909: "Is in fairly good health, although he is still rather anæmic. Has gained $1\frac{1}{2}$ stones in weight. Has really better health than he has known for twenty years, and is intensely grateful."

CASE 153.—D. February 13, 1908. Mr. C., aged forty-

five. Twenty-years' history of indigestion and heart-burn. Never very severe, but frequently recurring. Seventeen years ago melæna. A second attack noticed in October, 1906, but probably there were several in the interval. In the summer of 1907 an extremely severe attack of hæmatemesis and melæna. Another on January 1, 1908, and another ten days later. A thin, very anæmic man.

Operation: A puckered ulcer the size of a threepenny piece on the anterior surface of the first part of the duodenum, with broad adhesions to gall-bladder. The ulcer was infolded and posterior gastro-enterostomy performed. Recovery. Sent by Dr. Martland, Oldham.

Report, January, 1909: "Condition quite satisfactory. Since the operation there has been no hæmorrhage and he has regained his normal weight and colour, and is quite well and strong."

CASE 154.—D. February 24, 1908. G. R. W., male, aged twenty-four. Five years ago began to suffer from pain in epigastrium, coming on two hours after food. He did not vomit at this time; food sometimes relieved pain, which was not severe enough to make him seek medical treatment. Was free from symptoms for a time, but at Christmas, 1906, pain recurred about two hours after food, and he began to vomit. Gastric lavage and milk diet relieved him, but a fortnight ago the pain returned, and he has had frequent vomiting of large quantities of sour material.

Operation: A large ulcer in the duodenum immediately beyond pylorus. Some induration had extended slightly to the stomach side of the pylorus. Posterior gastro-enterostomy. Infolding of ulcer. Recovery. Convalescence slightly retarded by left pleural effusion. Sent by Dr. J. Lambert, Farsley.

Report, January, 1909: "Looks well, eats well, has worked regularly for the last eight months. Has steadily regained his old weight."

CASE 155.—D. February 12, 1908. C. R., male, aged forty-two. For ten years epigastric pain, coming on about one hour after food. At first did not vomit. Intervals of relief, particularly during the summer. Five or six years ago

Detailed Statement of Cases Operated Upon 343

pain became more severe and vomiting occurred, mainly of mucus, with a little food. Vomiting usually relieved pain. Has lost 6 lbs. during the last two years. No history of hæmatemesis nor melæna.

Operation: Well-marked ulcer just beyond pylorus. Posterior gastro-enterostomy. Infolding of ulcer. Recovery. Sent by Dr. Cowan, Malvern.

Report, January, 1909: "After return home was laid up for some time with phlebitis in veins of left leg. Has gained in weight. No vomiting. Occasional flatulence." Was seen by ourselves at end of 1908, and at that time was extremely well as regards his gastric trouble, but was complaining of symptoms suggestive of renal calculus.

CASE 156.—D. March 6, 1908. H. L., male, aged thirty-six. Nine or ten years ago suffered from attacks of colic, followed by vomiting, which relieved his pain. Was operated upon by another surgeon and the appendix removed. Five months later was seen by myself and a diagnosis of duodenal ulcer made. Operation advised and refused. From that time to this has had frequent attacks of pain, occurring some hours after food and during the night, frequently followed by vomiting, which relieves the pain. Has employed gastric lavage with benefit.

Operation: A large, puckered ulcer $\frac{1}{2}$ inch beyond pylorus. At one point it looked as though perforation was imminent. Posterior gastro-enterostomy. Infolding of ulcer. Recovery. Sent by Dr. Cameron, Dewsbury.

Report, January, 1909: Is in perfect health; never felt better in his life; has gained 1 stone 12 lbs. since his operation.

CASE 157.—D. March 7, 1908. A. F., male, aged thirty-one. Five years ago began to have pain, coming on two hours after food. Pain usually lasted for two or three hours unless relieved by vomiting. Attacks of pain recurred, with varying intervals of relief, up to the present. Three months ago an attack of hæmatemesis and melæna. Since that time pain has been particularly severe.

Operation: A large, star-shaped scar just beyond the pylorus. Posterior gastro-enterostomy. Infolding of ulcer. Recovery. Sent by Dr. Ward, Ferrybridge.

Report, January, 1909: Is very well; has gained 10 lbs. in weight. No recurrence of pain nor vomiting; follows his employment regularly.

CASE 158.—D. March 9, 1908. Mr. H., aged twenty-eight. Pain two to three hours after food for twelve years. Always relieved by food. Attacks have gradually increased in frequency and severity. During the last three years has never been free for more than six weeks. During the last twelve months has had nausea, but no actual vomiting. No melæna. In the last three months has lost 2 stones in weight.

Operation: A large ulcer on the anterior surface of the duodenum just beyond the pylorus, hard and puckered in the centre. Posterior gastro-enterostomy. Infolding of ulcer. Recovery. Sent by Dr. Mason, Boston.

Report, January, 1909: Has occasional pain in epigastrium and under right costal margin, chiefly in the early hours of the morning. His chief complaint is that he cannot eat a good meal without discomfort, sometimes amounting to pain afterwards. Pain is all over the abdomen and in the loins. Is slightly constipated; tongue rather furred and sticky. Motions rather light coloured.

Report from patient, September, 1909: "In response to your enquiry I am pleased to be able to say without any reservation whatever that I am quite well. I have had no trouble at all since March and I can now eat anything."

CASE 159.—G & D. March 10, 1908. Rev. A., aged fifty-five. For rather more than two years has suffered a good deal from abdominal pain. As far as he can remember at first, the pain was in the epigastric and umbilical regions, but latterly has been more localised to the right hypochondrium. There were periods when the pain recurred with great regularity, both by day and night, and he could never go longer than about two to two and one-half hours without having something to eat or drink. Most frequently hot water has given him relief, and at meal-times he has thought that a glass of sherry or hot whisky and water has relieved him. All through last winter, for many weeks together, had to get up in the night and boil water and make a cup of cocoa. There have been occasional periods of a day or

two when he has been quite free from pain. Has often relieved himself by eating mouthfuls of Cheddar cheese. Extra mental strain or anxiety has always aggravated the pain and holidays have always relieved. The urine contained some albumin 5 per cent. (Esbach), and operation was postponed for a few months. In the interval pain was extremely severe, and he was re-admitted in March, 1908.

Operation: Large quantities of omental and subperitoneal fat. Adhesions between anterior surface of first part of the duodenum and neck of gall-bladder. An indurated ulcer on the posterior surface. Extensive adhesions between the posterior surface of the stomach and pancreas, making posterior gastro-enterostomy impracticable. Anterior gastro-enterostomy was performed, with lateral anastomosis between afferent and efferent limbs. Recovery. Sent by Dr. Basil Housman, Stockport.

Report, January, 1909: "Is steadily improving; has lost much superficial fat and looks much better. Has occasional pain after extra exertion or worry, but this is not so severe as formerly and occurs at longer intervals. He is convinced of his steady improvement."

CASE 160.—D. March 19, 1908. Mr. S., aged sixty-one. From the age of twenty to forty suffered from repeated attacks of pain in the pit of the stomach, striking through to the back, coming on about two hours after meals and always relieved by taking food. This pain occurred both day and night, with occasional intervals of freedom, perhaps lasting several months. Was diagnosed as nervous dyspepsia. Between forty and fifty the attacks of pain were most marked at night, and were relieved by large doses of carbonate of soda. After fifty years of age an interval of relief for two or three years, and he gained nearly 2 stones in weight; then the pain returned, and has been accompanied by vomiting, which has usually relieved the pain and preceded a period of comparative comfort. During the last six weeks has been washing out stomach, with considerable relief. Slight gastric dilatation.

Operation: A large, indurated ulcer on anterior surface of first part of duodenum, producing slight stenosis. The

central part was hard, white, and raised above the surrounding part like a keloid. Posterior gastro-enterostomy. Infolding of ulcer. Recovery. Sent by Dr. H. Edgecumbe, Harrogate.

Report, January, 1909: Is quite another man. Feels better than he has done for years. Can eat anything and everything without discomfort. Bowels quite regular. Has gained 11 lbs. in weight.

CASE 161.—D. March 20, 1908. Mrs. H., aged sixty. For years has had pain after food and flatulence. Since November last has suffered from frequent vomiting, occurring almost immediately after taking food. The vomit has always been small in quantity, and just the food which has been taken, with some mucus. Has lost weight rapidly. There has been no hæmatemesis. Attempts at gastric lavage were not satisfactory, and it was doubtful whether the tube was really passed beyond the cardiac orifice.

Operation: Stomach was small; in the first part of the duodenum was the stellate scar of an ulcer. Gall-bladder very small and shrivelled, and tightly embracing two calculi. Posterior gastro-enterostomy. Infolding of ulcer. Cholecystectomy. Recovery. Sent by Dr. Bramley Taylor, Hemsworth.

This patient returned to the Nursing Home July, 1908. Since going home had been better and gained weight, but continued to regurgitate a small quantity of food each evening. X-ray examination after a bismuth meal shewed that the whole of the bismuth was retained in the œsophagus, and caused a shadow considerably broader at the lower than the upper end, and abruptly rounded off at the cardiac orifice. Every few seconds a ring-like contraction travelled down the œsophagus. At the end of half an hour these peristaltic waves were clearly visible, and little, if any, of the bismuth had passed into the stomach. A diagnosis of cardiospasm was made. The cardiac orifice of the œsophagus was dilated by bougies passed along a silk guide, and this treatment is still being carried out, with some improvement.

CASE 162.—D. March 27, 1908. R. B., male, aged fifty-five.

Operation: A large, thickened ulcer on anterior wall of the

duodenum just beyond pylorus. The duodenum was distinctly stenosed for about $\frac{3}{4}$ inch. Posterior gastro-enterostomy. Ulcer infolded. Recovery. Sent by Dr. Swindale, Clitheroe.

Report, January, 1909: Says he has felt better since his operation than he has for the last ten years. Has gained six pounds in weight and is in excellent health.

CASE 163.—D. April 4, 1908. Mr. N., aged forty-nine. For forty years has been subject to attacks of epigastric pain occurring two to three hours after food, with intervals of complete relief. Recently attacks have been more frequent and severe and accompanied by vomiting. Three years ago a very severe attack, diagnosed as appendicitis. There has been no hæmatemesis nor melæna, nor has jaundice been noted at any time.

Operation: Stomach a little dilated. The duodenum and neck of gall-bladder were intimately adherent, and by careful dissection a distinct tube-like fistula $\frac{1}{2}$ inch in length was defined between them. The gall-bladder was full of calculi, some of which were impacted in the cystic duct. The fistula was divided and the duodenum closed. Posterior gastro-enterostomy. Cholecystectomy performed with considerable difficulty. Recovery. Sent by Dr. Nesbitt, Sutton in Ashfield.

Report, January, 1909: "Present condition very satisfactory; with the exception of an attack of pain and vomiting on the 1st of June, has had no pain since operation. Has gained considerably in weight." Was seen by myself in March and had no trouble.

CASE 164.—D. April 8, 1908. Mr. B., aged twenty-one. For four years has had pain and discomfort two hours after food, with flatulence and acid eructations. The pain is occasionally, but not always, relieved by food. Occasional vomiting during last three or four months. During this time he has never really been free from pain. No hæmatemesis and no melæna.

Operation: Duodenum tightly tethered back beneath liver. A large, excavated ulcer on the upper aspect of the first part of the duodenum 1 inch beyond pylorus. Posterior gastro-

enterostomy. Infolding of ulcer. Recovery. Sent by Dr. Tawse, Whitehaven.

Report, January, 1909: Condition has been excellent ever since operation and there have been no symptoms of any sort, and he has obviously gained in weight.

CASE 165.—D. April 10, 1908. E. M. A., female, aged twenty-nine. At the age of eighteen suffered from pain in the stomach directly after food. No vomiting. Four years ago pain began to come three hours after food and she had two attacks of hæmatemesis. Since that time has not worked. Now has pain about two hours after food, frequently severe at night. Relieved by food or milk. Six weeks ago a severe attack of hæmatemesis.

Operation: A well-defined star-shaped scar just beyond the pylorus. Posterior gastro-enterostomy. Infolding of ulcer. Recovery.

Patient cannot be traced.

CASE 166.—D. April 18, 1908. M. A. B., female, aged thirty-eight. For many years has suffered from indigestion. No severe pain until four or five years ago, when she began to have attacks of severe pain in epigastric region, spreading all over the abdomen and accompanied by severe vomiting. The attacks have occurred every two to three months and are rather more frequent in the winter. Has never had jaundice. Has lost about $1\frac{1}{2}$ stones in three years.

Operation: A large scar just beyond pylorus. A firm adhesion passed diagonally across the first part of the duodenum, constricting it. Posterior gastro-enterostomy. Ulcer infolded. Recovery. Sent by Dr. R. H. Trotter, Holmfirth.

Report, January, 1909: "Patient is in good health; has gained weight; no recurrence of symptoms; appears to have been cured by the operation."

CASE 167.—D. June 11, 1908. T. C., male, aged forty-one. Pain on and off for twenty years; occurs some hours after food and is relieved by taking food. Has frequently vomited, but has never noticed blood. Eight years ago an attack of melæna. Recently pain has been almost continuous and he has lost one stone in weight.

Operation: Duodenum shewed two scars: one small, immediately beyond the pylorus; a second, larger one, one inch from pylorus, with much puckering and induration. Posterior gastro-enterostomy. Infolding of ulcer. Recovery.

Report from patient, January, 1909: "I have not had any pain nor sickness since the operation, and have always been ready for my food. I began work in September and think I am going on all right."

CASE 168.—D. June 13, 1908. J. D., male, aged fifty. Patient complained of abdominal pain and vomiting. He had had this pain for ten years; it was heavy and dull, situated in the epigastrium, coming on some time after meals and relieved by vomiting.

Operation: A well-marked ulcer on the anterior surface of the duodenum with much puckering and many adhesions. The mesocolon was adherent to the posterior surface of the stomach. Posterior gastro-enterostomy. Infolding of ulcer.

Report, December, 1908: "Has gained 1 stone 2 lbs. Has a good appetite; feels a different man altogether. When he eats certain food, *e. g.*, badly cooked meat, it seems to stop in the gullet, and has to be brought back. Has tried oysters, and finds that these come back, and for two or three days make all swallowing difficult. All food seems then to have to stop in the gullet." (When in the Infirmary, a skiagraph shewed some dilatation of the œsophagus and cardio-spasm.)

CASE 169.—D. June 17, 1908. G. E. F., male, aged thirty-eight. For thirteen years has suffered from attacks of aching, griping pain on the right side of the abdomen. There have been intervals of relief of varying length. At first the pain was relieved by food, but gradually that ceased to give relief. Care in diet has had no effect. No vomiting, except on one occasion four or five years ago. Has never had melæna.

Operation: The whole surface of the stomach, especially the pyloric end and first part of duodenum, shewed numerous adhesions suggesting perforation. The right lobe of the liver was adherent to the pylorus. Transverse mesocolon was intimately adherent to the mesentery. These adhesions were divided; the lesser sac was opened, and an attempt made to

bring the posterior wall of the stomach to the surface. This was found to be impossible, owing to the adhesions around the pylorus. The opening in the mesocolon was therefore closed and an anterior gastro-enterostomy performed about 9 inches below duodeno-jejunal flexure. The proximal loop was divided and the end implanted into the distal. (Modified Roux's operation.) Recovery. Sent by Dr. Fisher Ward, Bawtry.

Report, December, 1908: Is fit and well; has kept to work continuously since he started after the operation, and has never had to consult me. He is a signal-man on the railway, and has recently applied for, and been appointed to, a more important post. Before his operation he had to give up several better posts and take a gradually reduced wage.

CASE 170.—D. July 27, 1908. A. W. J., male, aged fifty-seven. For twenty years has had pain coming on after food and relieved by vomiting. Always worse in winter. An attack of hæmatemesis twelve years ago, with tarry stools and fainting. Last summer he became worse than ever, with much pain during the night. The pain is dull, heavy, and aching, situated in the epigastrium, and accompanied by much flatulence. It occurs two to three hours after food and is relieved by a meal. For the last two years has been unable to work.

Operation: A large ulcer just beyond the pylorus with considerable induration. Posterior gastro-enterostomy. In-folding of ulcer. Recovery. Sent by Dr. Waugh, Skipton.

Report, December, 1908: Has gained 7 lbs. Is feeling well, and says he is better than he has been for years and can eat practically anything.

CASE 171.—D. August 7, 1908. A. W. P., male, aged twenty-two. Complains of severe pain, coming on about two hours after food, commencing over the cardiac area of the stomach, radiating over the whole of the abdomen, and spreading round to the back. For five years this pain has occurred in attacks which have gradually become more frequent and severe. The pain is usually relieved by vomiting.

Operation: A large, well-marked ulcer on the anterior wall of the duodenum immediately beyond pylorus. Posterior

gastro-enterostomy. Infolding of ulcer. Recovery. Sent by Dr. Wright, Boston.

Report, June, 1909: "Am keeping well. I am able to eat anything without feeling discomfort except for a little flatulence. I can indulge in most exercises without feeling any ill effects. There is no sign of recurrence of my former trouble."

CASE 172.—D. August 7, 1908. A. W., male, aged thirty-seven. In June, 1905, posterior gastro-enterostomy was performed for duodenal ulcer. (See Case 54.) This relieved symptoms for eighteen months, with the exception of occasional vomiting. Since then pain has gradually returned and vomiting has become more frequent. Pain comes two or three hours after food, and is relieved by food, medicine, or by lying down. He frequently vomits in the morning about fifteen minutes after breakfast.

Operation: Some adhesions between the omentum and the anterior abdominal wall. The anastomosis shewed a slightly longer "loop" than would be left at the present time, and there was slight kinking proximal to the anastomosis. The kink was straightened and one or two adhesions separated. Three fingers could be easily passed through the anastomosis. The pylorus was found to be patent, and at the site of the ulcer found at first operation, of which a drawing had been made, a large scar was found. Close to this were two well-marked ulcers, evidently of recent date. The pylorus was closed by sutures which infolded the ulcerated area. In this case pylorospasm was probably present with the duodenal ulcer. The gastro-enterostomy acted at first, then ceased to do so, owing to the pylorus becoming patent, and this was followed by recurrence of ulceration. Recovery. Sent by Dr. Alderton, Barnoldswick.

Report, December, 1908: Appears to be quite well; is gaining in weight; no recurrence of symptoms.

CASE 173.—D. September 1, 1908. Mrs. A., aged forty-seven. In July, 1907, was admitted to Nursing Home with the following history: Has suffered from indigestion for ten or eleven years. Nine years ago a severe attack of pain with hæmorrhage; has had trouble more or less ever since,

especially during the last two years. Now has pain after food, varying in time of onset; sometimes almost immediately, but generally about two hours afterwards. Usually lasts until another meal is taken. It rarely occurs at night. No hæmatemesis recently. Solid food appears to cause her less discomfort than liquids, and she says that the latter, particularly water, almost invariably cause immediate pain. She has lost over a stone in weight. A diagnosis of duodenal ulcer was made.

Operation: July 18, 1907. There was no evidence of a lesion in the duodenum on palpation or inspection; on the lesser curvature of the stomach, at a point slightly to the cardiac side of its centre, was a large ulcer with considerable surrounding induration extending on to both the anterior and posterior walls. The ulcer was excised and the incision sutured. No gastro-enterostomy was performed. For four months relief followed the operation, and then pain began to recur. It came two to three hours after food and was always relieved by the next meal. There was no vomiting. Weight which had been gained was rapidly lost.

Operation: September, 1908. The scar of the former excision was found to be perfect. There were a few thin adhesions, but no narrowing of the lumen. The first part of the duodenum was surrounded by adhesions and a large indurated ulcer was present on its anterior surface. Posterior gastro-enterostomy was performed, the ulcer infolded, and the pylorus closed. Recovery. Sent by Dr. Tweedy, Northallerton.

Report, December, 1908: "Mrs. A. has done well. Can eat anything without pain or sickness, and has regained her normal weight and strength."

CASE 174.—D. September 4, 1908. A. N., female, aged thirty-five. Has had indigestion for the last twenty years. Ten years ago an attack of hæmatemesis; since then has had a recurrence of hæmorrhage on four or five occasions. The last occasion was in June, when there was considerable mæna. Suffers from pain two to three hours after food, with much flatulence and vomiting of large quantities of frothy and yeasty material. A large, waving stomach.

Operation: A large, puckered ulcer was seen on the anterior

wall of the duodenum immediately beyond the pylorus, producing considerable stenosis. Stomach was dilated. Posterior gastro-enterostomy. Infolding of ulcer. Recovery. Sent by Dr. Normington, Nelson.

Report, December, 1908: "Can digest any ordinary plain food. Has gained in weight, but is still rather anæmic. No recurrence of pain nor vomiting."

CASE 175.—D. September 26, 1908. J. L. W. (medical man), aged fifty. Has had stomach trouble for twenty years. Periodic attacks of burning pain coming two to three hours after food, relieved by the vomiting of a small quantity of intensely acid mucus. Always relieved by food or lavage. Twelve years ago a slight attack of hæmatemesis. In 1901 an attack of acute appendicitis with subsequent appendectomy. The present attack of pain began in March. He washes the stomach out usually twice in the twenty-four hours; often has to do so in the early morning (2 A. M.).

Operation: A scarred ulcer with central depression the size of a sixpence on the anterior surface of the first part of the duodenum. Stomach and gall-bladder normal. Posterior gastro-enterostomy. Infolding of ulcer. Recovery.

Report from patient, March 24, 1909: "Very well, but am still rather easily tired. I have gained weight. The result of the operation has been to make a new man of me. I have lost the 'duodenal ulcer aspect.' Am able to eat anything that is put before me, but never make a large meal. My stomach is quite comfortable, better than it has been for twenty years, and I should not know that anatomically all was not quite natural."

CASE 176.—G & D. September 28, 1908. A. F. (medical man), aged forty. For the last seven years has suffered from frequent attacks of pain of a burning, gnawing character two hours after food; much worse during the last two years. During the last year has had one or two very severe attacks of pain suggesting perforation. Food and carbonate of soda have relieved the pain; during the last few months pain has occurred earlier, coming on very soon after food, and lasting for about an hour. There has been no vomiting, and no melæna so far as he is aware.

Operation: Stomach large and hypertrophied. First part of duodenum much scarred and slightly contracted. On the posterior surface of the stomach, just to the proximal side of the pylorus, a crateriform ulcer the size of a shilling. Some adhesions in the lesser sac. Posterior gastro-enterostomy. Infolding of duodenum. The appendix was found to be chronically inflamed and distended with faecal material in its distal half. Appendicectomy. Recovery. Sent by Dr. John Campbell, Belfast.

Report, March, 1909: Weight remains the same; recently there has been some improvement, but since the operation there has been some pain after every meal. This pain is situated in the right side of the abdomen and in the back and chest, and is similar to that felt before the operation.

This patient was seen in August and is much better.

CASE 177.—D. September 29, 1908. Mr. D., aged forty-five. For twenty years has had periodical attacks of pain three to four hours after food, relieved by food. These were always worse in cold weather. Seldom vomited and has never been jaundiced. During the last two years attacks have been longer and more severe. The present attack began during the first week in September and is much the worst he has ever had. He has been confined to bed and has suffered from almost constant acute pain in the epigastrium, with much flatulence and frequent vomiting of considerable quantities of bile-stained fluid. On examination, the abdomen is slightly distended and there is great tenderness and rigidity in the right epigastric and hypochondriac regions.

Operation: A large, indurated ulcer on the anterior surface of the first part of the duodenum with many surrounding adhesions and much recent lymph. Evidently a subacute perforation of the ulcer. Stomach was much dilated. Posterior gastro-enterostomy. Infolding of ulcer. During convalescence a severe attack of bronchitis. Sent by Dr. Veale, Drighlington.

This patient was seen January, 1909. He was rapidly gaining weight, doing his ordinary work, and suffered no discomfort whatever. Report, May, 1909: Absolutely well; better than he has been for twenty years. Has gained 2 stone 5 lbs.

Detailed Statement of Cases Operated Upon 355

CASE 178.—D. September 30, 1908. B., male, aged sixty-one. Six years ago a choledochotomy performed for stone in the common duct. Was fairly well until September, 1907. Then had an acute and sudden attack of epigastric pain, which caused him to roll on the floor in agony. Was very ill for a few days; slowly recovered, but was never quite well. In March, 1908, a similar but less severe attack, accompanied by the vomiting of a considerable amount of blood on two occasions. Since then scarcely ever free from pain, which is aching in character and passes through from the epigastrium to between the shoulders. Vomits about four times a week large quantities of frothy fluid. Has lost $2\frac{1}{2}$ stones in weight. On examination, stomach is dilated, with visible peristalsis. A hard, tender tumour is situated in the right hypochondrium involving the abdominal wall in the situation of the old incision.

Operation: The anterior surfaces of the stomach and duodenum were buried in a mass of adhesions which bound them to the anterior abdominal wall. A hard mass was palpable in the first part of the duodenum, evidently an ulcer which had previously perforated. Posterior gastro-enterostomy performed with considerable difficulty. Recovery. Sent by Dr. Carnes, Leeds.

Report, March, 1909: States that he is in better health now than he has been for four or five years. Has gained about $1\frac{1}{2}$ stones in weight. No recurrence of pain or vomiting; takes ordinary food. Does not diet himself and suffers no discomfort after meals.

CASE 179.—D. October 5, 1908. F. S., male, aged twenty-three. During the last twelve months has suffered from pain occurring one and one-half to two hours after food. At first this was relieved by medicinal treatment, but during the last seven months he has had pain almost constantly, and on one occasion has had hæmatemesis. Much flatulence and feeling of fullness in the epigastrium.

Operation: A large, well-marked ulcer on the anterior surface of the duodenum just beyond pylorus. Posterior gastro-enterostomy. Ulcer infolded. Recovery. Sent by Dr. Carse, Rochdale.

Report, March, 1909: "He is certainly improved in appearance; is losing his anæmia and slowly regaining his strength. His appetite is poor, and he is still troubled with acid eructations occurring about one hour after food. He will not admit that he is improved, but I think that he is." Report, September, 1909: "He has gone to work last week for first time since operation. Much improved in strength and increasing in weight; he does not now show any signs of anæmia. Still troubled with acid eructations one-half to one hour after food (his teeth are very defective). No pain and no vomiting. Rather troubled by flatulence and borborygmi."

CASE 180.—D. October 13, 1908. Mr. D., aged fifty. Was admitted complaining of jaundice of great intensity. Says that he was quite well until nearly the end of July last; then began to suffer from distressing flatulence and distension after food. The pain was never acute nor colicky, nor did he vomit. There were occasional periods of relief for a few days. Six weeks ago the discomfort became more intense and he began to be jaundiced. Since that time pain has been absent, but the jaundice has gradually deepened. He does not think that it has become less in intensity at any time. There has been no pyrexia and no shivering. He has lost 2 stones in weight. On examination, patient is intensely jaundiced; of a greenish-brown tint. Stools are grey, copious, and formed. Urine is bile-stained. The liver is palpable; its border is smooth and regular. The gall-bladder can be indistinctly defined, but is not tender.

Report on examination of urine and fæces: The presence of a well-marked pancreatic reaction (Cammidge) in the urine points to some degree of chronic pancreatitis, and the result of the examination of the fæces confirms this. There is a high percentage of total fats, of which nearly half are combined fatty acids, indicating that although the pancreas is affected, occlusion of the pancreatic duct is not complete and the obstruction of the common bile-duct must be above its junction with the pancreatic; that the obstruction of the common duct is almost complete is shewn by the presence of only a trace of stercobilin in the fæces, but the absence of undigested matter

in the microscopic examination of the fæces also supports the conclusion that the primary site of the disease is in the common bile-duct and not in the pancreas. The percentage of ash shews that there is no colitis, and the absence of blood is in favour of there being no lesion in the alimentary tract.

Operation: The liver was much enlarged and the gall-bladder dilated, with thick, white walls. The cystic and common ducts were dilated as far as the upper margin of the duodenum, where there was an indurated scar which appeared to be involving and compressing the common duct. There was no tumour of the head of the pancreas nor were any calculi palpable in the biliary passages. The gall-bladder was aspirated and found to contain clear mucus only. The duodenal ulcer was deemed to be the cause of the obstruction, and an anastomosis was performed between the gall-bladder and the transverse colon, as it was found impossible to unite the duodenum to the gall-bladder without dangerous tension. Recovery. On November 1st the urine was much less bile-stained and the fæces were approaching the normal in colour. Jaundice rapidly diminishing. Patient sent by Dr. Dunderdale, of Blackpool.

Report, March, 1909: Somewhat sallow; free from pain; bowels regular; appetite good; gaining weight slowly and regularly ("he has gained 2 stones since the operation"). Between December 28, 1908, and January 5, 1909, had three attacks of colicky pain over gall-bladder region, followed by elevation of temperature and jaundice lasting three or four days. He now appears to be quite free from all his former inconvenience.

CASE 181.—D. October 19, 1908: Mr. C., aged forty. For eighteen or nineteen years periodic attacks of pain, of an aching, boring character, in umbilical and lower dorsal region, coming on about three hours after food, and lasting until next meal. Occasional vomiting of small quantities of acid mucus. April, 1903, a severe attack of hæmatemesis and melæna. February, 1905, another attack; in February, 1907, and June, 1908, similar attacks. Since April, 1903, the characteristic attacks of pain have been almost entirely absent.

Operation: The anterior surface of the first part of the

duodenum was found to be a mass of scar tissue, evidently due to multiple ulcers. Posterior gastro-enterostomy. In-folding of ulcerated area. Recovery. Sent by Dr. Aitcheson, Blackburn.

Report, February, 1909: Is very well; the only discomfort he has had has been a little constipation after the operation. The bowels are now regular and he has no discomfort of any sort. Is gaining weight.

CASE 182.—G & D. October 23, 1908. Mr. C., aged twenty-six. For four or five years has suffered from fullness and distension in epigastric region, with regurgitation of acid fluid into the throat occurring about two hours after food. No vomiting until eighteen months ago, when he had an attack of hæmatemesis and melæna lasting two or three days. After the necessary confinement to bed and fluid diet he was free from pain for some months, but symptoms began to return and pain was often severe at night. In June, 1908, melæna but no hæmatemesis. On getting up from bed distension and acidity returned, and he reverted to a diet of peptonised milk, which he has continued to the present time.

Operation: No gastric dilatation; a large, indurated ulcer on anterior surface of first part of the duodenum, and the scar of a gastric ulcer just to the proximal side of the pylorus. The two were almost continuous, and the pyloric vein was obscured by the scarring. The first part of the duodenum shewed marked pouching. Posterior gastro-enterostomy performed. The central portion of the duodenal ulcer was excised, the defect closed by interrupted catgut sutures, and the whole ulcer-bearing area infolded. Recovery. Sent by Dr. Grant, Colne.

Report, March, 1909: Has gained more than one stone in weight. No recurrence of pain nor vomiting.

CASE 183.—D. November 2, 1908. Colonel H., aged forty-three (medical man). For six years has been liable to recurring attacks of epigastric pain, often of a cramp-like nature, coming on two to four hours after food. A number of these attacks appeared to be precipitated by getting wet whilst fishing. On one or two occasions has been kept in

bed and fed per rectum, with only temporary relief. No vomiting at any time; no melæna.

Operation: A small, puckered ulcer was present on the anterior surface of the duodenum. This was excised and the incision closed by interrupted sutures. No gastro-enterostomy performed. Recovery.

December 4, 1908: Patient reported that he was feeling very well. Was eating without discomfort and gaining weight.

CASE 184.—D. November 10, 1908. Mr. C., male, aged forty-six. Since the age of seventeen has been liable to attacks of epigastric pain, occurring about three and one-half hours after food, relieved by the next meal. There have been intervals of complete relief of varying duration. During the last four years pain has been more frequent and severe. It often wakes him at night, when a glass of milk relieves the pain for a time. Lately has had some vomiting, at first small in quantity and induced voluntarily, but during the last week it has been larger in quantity and coffee-ground in character. The motions have been loose and dark coloured. Has occasionally experienced slight difficulty in swallowing at the commencement of the meal, as though there was some obstruction, but this has got less as the meal progressed (slight cardiospasm?).

Operation: Stomach rather small; duodenum tightly tethered back beneath liver and could not be pulled forward. A hard, indurated ulcer the size of a shilling at junction of first and second parts of the duodenum, adherent near neck of gall-bladder. Posterior gastro-enterostomy performed with much difficulty owing to the inability to bring posterior surface of the stomach forward. No attempt was made to infold the ulcer. Recovery. Sent by Dr. Salter, Manchester.

Report, June, 1909: "I am delighted to say I am in splendid health, and have been ever since my operation. I can eat almost anything. Nothing seems to disagree with me. I sometimes wonder whether I am the same man or not."

CASE 185.—D. December 5, 1908. Colonel C., aged fifty-five. Very healthy until fifteen years ago; then began to suffer from pain in epigastrium, coming shortly before a meal, relieved by food or by a bismuth mixture. Attacks

of this character recurred with intervals of a few months' relief until 1897, when he was laid up with a very severe attack accompanied by vomiting. From that time to the present attacks have occurred at shortening intervals, and almost always accompanied by vomiting. In 1898 and 1899 underwent treatment in bed, with rectal feeding, which only gave temporary benefit. The pain is now usually worst in the late afternoon and at night, and interferes considerably with the discharge of his duties. No hæmorrhage noted at any time.

Operation: A large, indurated ulcer the size of a walnut in first part of duodenum, tightly adherent far back beneath liver. Posterior gastro-enterostomy. Pylorus narrowed by sutures. Recovery. Sent by Dr. Turner, York.

Report March 16, 1909: Has not been so well for fifteen years. At present is in excellent health, has gained at least one stone since his operation, and now feels equal to all his military duties.

CASE 186.—D. December 14, 1908. Mr. W., aged forty-five. Since the age of fifteen has been liable to attacks of epigastric pain at varying intervals. Pain is aching and gnawing in character and comes on about three to four hours after food. During the day the pain is not very troublesome, because he takes his meals at short intervals. At night it is particularly bad and occurs in the early morning. Food always relieves and he has occasionally obtained relief by inducing vomiting. He is a well-nourished, healthy looking man. There has been no hæmatemesis and no melæna.

Operation: A hard, indurated ulcer, involving the anterior wall of the duodenum $\frac{1}{2}$ inch beyond the pylorus. There were some omental adhesions and the duodenum was tightly tethered back beneath the liver. Posterior gastro-enterostomy. Ulcer partially infolded with much difficulty and the pylorus narrowed by suture. Recovery. Sent by Dr. Molloy, Blackpool.

Report, March 3, 1909: Is perfectly comfortable; has had no symptoms since his return home; has gained 14 lbs. He is now back at business, looks years younger than before the operation, and is in perfect health.

Detailed Statement of Cases Operated Upon 361

CASE 187.—D. December 18, 1908. Mr. M., aged thirty-five. For twelve years has suffered from abdominal pain occurring some hours after food and particularly bad at night. Stomach considerably dilated.

Operation: A large, indurated ulcer in the first part of the duodenum. Considerable gastric dilatation with hypertrophy. Posterior gastro-enterostomy. Infolding of ulcer. Recovery. Sent by Dr. O'Connell, Leeds.

Report, June, 1909: The patient is doing very well. Has had no trouble since he left the Infirmary. Takes food well; appears to be gaining weight; says he has not felt so fit for many years.

CASE 188.—D. December 18, 1908. A. W., male, aged twenty-nine. For the last six years has had pain, coming on about two hours after food, lasting until the next meal, which relieves it. Frequent vomiting, which also gives relief. On a number of occasions has had hæmatemesis and melæna.

Operation: An ulcer on the anterior surface of the first part of the duodenum. No gastric dilatation. Posterior gastro-enterostomy. Infolding of ulcer. Recovery. Sent by Dr. Dawson, Bradford.

This patient cannot be traced.

CASE 189.—D. December 31, 1909. Mr. M., aged forty. At the age of twelve an attack of acute abdominal pain of a colicky nature necessitating the application of poultices, etc. For the last two years has suffered from periodical attacks of aching pain across the upper part of the abdomen, with much flatulence, coming on without warning and lasting for two or three weeks at a time. Not colicky in nature, but more of the character of an aching discomfort. The pain was not continuous nor did it trouble him at night, but whilst an attack was on he had the pain at some time or another every day. The intervals between the attacks varied in duration and he not infrequently suffered from sharp twinges of pain in the right iliac fossa. Food appeared to have no relation to the pain and he has had no vomiting and no jaundice. Three months ago the bowels were rather loose and mucus was frequently present in the stools; recently they have been

slightly constipated. On no occasion has he had an attack of pain which could be described as colicky. The attacks recently have been more frequent and discomfort has been most marked beneath the right costal margin. He has never had typhoid. Abdominal examination negative. Sent by Dr. Bentley, Stockport.

Operation: Battle's incision. Appendix long and narrow and showing evidence of inflammation; it was lying to outer side of the cæcum with its tip pointing upwards. Appendicectomy. Gall-bladder palpated and inspected; although no calculi could be felt, its walls looked suspiciously white, so a second incision was made over it. The gall-bladder was found to contain no calculi, but the duodenum was tightly tucked beneath the liver and a sharp-edged band-like adhesion passed across its anterior surface and up towards the under surface of the liver. A hard, indurated scar just beyond pylorus, evidently a duodenal ulcer. Posterior gastro-enterotomy. Infolding of ulcer.

Report, June, 1909: "Have gained about 2 stone since the operation. No recurrence of pain. Am again on regular diet and have a very good appetite. Occasionally slightly troubled with flatulence, but am very much healthier in every way."

INDEX OF AUTHORS

- ABERCROMBIE, 19, 20
Adam, 281
Adams, 30
Adriance, 96
Aitcheson, 358
Alderton, 297, 300, 314, 351
Allbutt, 231
Anderson, 337
Andrews, 330
Anning, 120, 271, 311
Attley, 303
- BABINGTON, 56
Bailey, 269, 270
Baillard, 85
Bampton, 280
Barclay, 80
Barié, 44, 45, 48, 52, 66
Barnard, 177, 178
Barrs, 202, 280
Beaman, 336
Beegling, 290
Bentley, 362
Berg, 198
Biggs, 222
Blair, 74
Blake, 184
Bolton, 175
Borland, 95
Bowman, 36
Boxwell, 248
Brewer, 284
Briggs, 316
Bright, 56, 73, 75
Broadbent, 295
Broussais, 235
Brown-Séguard, 36
Brunton, 296
- Bryant, 60
Buckley, 339
Bucquoy, 20, 196
Budd, 225
Burgess, 184
Burnett, 328
- CAMERON, 343
Campbell, 354
Cannon, 111
Carans, 85
Carnes, 355
Carse, 355
Carter, 175
Cass, 310
Cholmeley, 77
Christie-Wilson, 299
Churton, 319, 335
Chvostes, 20
Clark, 75, 78, 79, 185, 296
Claude, 44, 82
Clements, 300
Cock, 55
Codivilla, 22
Collin, 21, 210
Collinson, 251
Corry, 332
Court, 321
Cowan, 343
Crowley, 338
Crump, 275, 284, 293
Cunningham, 122
Curling, 24, 25, 26, 27, 28, 35, 36
- DALCHÉ, 44
Davidson, 323
Dawson, 361
Dean, 21, 188

- Dearden, 329
 Delaunay, 45, 48, 66
 Denning, 317
 de Noble, 93
 Dickinson, 45, 51, 229
 Dimmock, 308
 Donkin, 93
 Dowsing, 324, 328
 Dunderdale, 227, 357
 Dunn, 21, 188
 Dupuytren, 25, 28
 Durham, 32, 34, 53
- EDGECUMBE, 346
 Eichhorst, 250
 Ellis, 246, 272, 273, 287, 302, 335
 Elsasser, 81
 Erichsen, 35
 Eve, 132, 178, 296
 Ewald, 249
 Ewart, 49, 64
 Exley, 288
- FALKENBACH, 19
 Falkner, 318
 Fawsitt, 340
 Fearnley, 276
 Fenwick, 37, 113, 225
 Finney, 160
 Finny, 88, 97, 162
 Fletcher, 61
 Foley, 322
 Förster, 194, 224
 Forsyth, 153
 Foster, 55, 244
 Francine, 83
 Franklin, 185
 French, 231
 Frerichs, 230
 Friend, 335
 Fryer, 338
- GALLOWAY, 309
 Gandy, 37
- Genrich, 85, 91
 Golding-Bird, 241
 Goodhart, 248, 282, 305, 316
 Grant, 358
 Griesbach, 285
 Griffith, 129
 Grünfeld, 236
- HABERSHON, 77, 237, 247
 Haigh, 305, 317, 324, 332, 333
 Haldane, 63
 Halsted, 175
 Hamilton, 307
 Handfield-Jones, 36
 Harbinson, 313
 Harvey, 337
 Hawkins, 42
 Hawkyard, 285, 318
 Hebb, 63, 81
 Hebblethwaite, 304, 315
 Hecker, 85, 89
 Helmholtz, 86, 87, 89, 97
 Henoeh, 85, 94
 Hergott, 85
 Hertz, 108
 Herzfelder, 224
 Hills, 42
 Hinde, 304
 Hinings, 296
 Hirtz, 44
 Hoffman, 195, 242
 Hogarth, 290
 Holliday, 307, 308
 Holmes, 35, 40
 Horsfall, 341
 Housman, 345
 Hudson, 209
 Hughes, 76, 77
 Hunter, 36, 37
- IRVINE, 19
- JALLAND, 310
 Johnston, 312, 339
 Johnstone, 318

- KAMMERER, 284
 Keate, 43
 Kelling, 198
 Kendal, 94
 Kennedy, 317
 Kerr, 157, 158
 Kirke-White, 341
 Kling, 85, 91
 Knaggs, 201
 Knowles, 319
 Kocher, 132, 160
 Krauss, 20, 22, 81, 113, 194, 223,
 224
 Kundrat, 92
 Kuttner, 94, 96
- LAMBERT, 296, 325, 342
 Landau, 87, 91
 La Touche, 321
 Laure, 40
 Leatham, 331
 Lecointe, 45
 Lederer, 85
 Lediard, 175
 Lesser, 37
 Lister, 92
 Liston, 30
 Lockwood, 246, 270
 Long, 28, 30, 31, 242
 Low, 323
 Lund, 192, 193
 Luneau, 197
- MACKENZIE, 218, 219, 225, 289,
 314
 Malim, 119, 327
 Marchiava, 228
 Marsden, 321
 Marsh, 340
 Martland, 334, 342
 Mason, 344
 Mathews, 301, 306
 Mathieson, 318
 Mathieu, 44
 Matthews, 199
- Maynard-Smith, 170
 Mayo, 22, 152, 216, 219, 220, 245,
 246
 McCully, 304
 McGibbon, 322
 McKenzie, 275
 McLeod, 316
 McNab, 273, 288
 Meunier, 196, 222
 Miles, 164, 173, 188
 Millard, 222
 Millhouse, 271
 Mitchell (A. B.), 133, 164, 182,
 186, 188, 221, 307
 Mitchell (Carter), 322
 Molloy, 336, 360
 Moore, 72
 Moore (Craven), 327
 Morgan, 228
 Morison, 169, 181, 183
 Moxon, 45, 58, 59
 Muir, 305
 Munchmeyer, 92
 Murchison, 69, 75, 79, 80
 Murphy, 111, 125
- NESBITT, 347
 Nicholson, 331
 Noble, 93
 Normington, 292, 334, 353
 Nothnagel, 113
- O'CONNELL, 361
 Oldfield, 206, 209, 286, 329
 Oppenheimer, 20, 113, 211
- PAGENSTECHER, 22
 Parker, 157, 158
 Pavy, 76, 248
 Pawlow, 134, 161
 Penrose, 46, 64
 Perry, 21, 35, 36, 40, 42, 43, 45, 46,
 48, 51, 54, 55, 56, 57, 58, 59, 60,
 61, 62, 63, 75, 76, 77, 78, 79, 80,
 81, 113, 196, 210, 216, 225, 235,
 241, 244, 247

- Pitt, 54
 Ponfick, 35, 37, 40
 Porritt, 274, 295
 Porter, 328
 Potter, 299
 Preston, 299
 Pritchard, 297, 308
 Pye-Smith, 60
- QUÈNU, 132
- RAYER, 237, 238
 Rees, 54, 57
 Reinhold, 243
 Renon, 44
 Renton, 172
 Rheiner, 93
 Richardson, 340
 Richardson (Charles), 302
 Richardson (Maurice), 177, 179
 Rilliet, 85
 Robb, 294
 Roberts, 65
 Robson, 275
 Rolf, 287
 Rolleston, 231
 Ross, 301
 Roughton, 65, 320
 Roupell, 78
 Roux, 44
 Rowden, 283
 Rowling, 278, 279, 291
 Ryan, 315
- SADLER, 331
 Saintsbury, 65
 Salter, 359
 Sanderson, 244
 Satterthwaithe, 83
 Saxer, 94
 Sedgwick, 175
 Shaw, 21, 35, 36, 40, 42, 43, 45, 46,
 48, 51, 54, 55, 56, 57, 58, 59, 60,
 61, 62, 63, 75, 76, 77, 78, 79, 80,
 81, 113, 196, 210, 216, 225, 235,
 241, 244, 247
- Shine, 303
 Shukowsky, 85
 Silbermann, 85
 Spiegelberg, 85, 90
 Stassano, 54
 Stephenson, 340
 Stewart, 244
 Stewart (Helen G.), 226
 Stich, 236
 Stokes, 35
 Streeton, 195
 Sturges, 62, 81, 83
 Swensson, 228
 Swindale, 333, 347
- TAWSE, 348
 Taylor (Bramley), 346
 Taylor (Isaac), 329
 Taylor (Stamp), 277
 Thompson, 298
 Torday, 94
 Travers, 17
 Treitz, 45, 51
 Trier, 20, 81, 227
 Trotter, 293, 294, 348
 Turner, 360
 Turner (Douglas), 290
 Tweedy, 352
 Tyrie, 284
- VEALE, 306, 354
 Veit, 97
 von Zerschwitz, 92
- WADHAM, 62
 Wainman, 278, 291
 Waldeyer, 90
 Ward, 343
 Ward (Fisher), 350
 Warfvinge, 238, 239
 Watson (Bertram), 312
 Watson (Crawford), 296
 Watterson, 326
 Waugh, 350
 Weir, 22

Index of Authors

367

- | | |
|------------------------------------|----------------------|
| Welch, 275 | Woods, 280, 281, 295 |
| West, 83 | Wright, 351 |
| Whipham, 62, 80 | Wunderlich, 22 |
| White, 240 | |
| Wilkinson, 330 | YATES, 185 |
| Wilks, 35, 45, 58, 59, 76, 78, 244 | ZERSCHWITZ, 92 |
| Wood, 336 | Zoia, 225 |
| Woodcock, 67, 277, 289, 337 | |

INDEX

- ABDOMEN, examination of, in chronic duodenal ulcer, 109
lavage of, after operation for perforation, 183
- Abdominal suture, 185
- Abscess between pancreas and duodenum in ulcer, 23
periduodenal, 194
burrowing of, 195
extension of, 195, 196
treatment, 197
- Acid dyspepsia, chronic duodenal ulcer and, 108, 112, 117, 118
gastritis, chronic duodenal ulcer and, 107, 108, 112, 117, 118
- Acidity only symptom of chronic duodenal ulcer, 120, 121
- Age, chronic duodenal ulcer and, 101, 251
ulcer from burns and, 40
- Albuminuric ulcers of intestines, 44
- Alimentary tract of newborn, hæmorrhage from, 85. See also *Melæna neonatorum*.
- Allis's forceps in gastro-enterostomy, 146
- Anæmia, splenic, chronic duodenal ulcer and, differentiation, 127
- Anastomosis, antiperistaltic, in duodenal ulcer, 152
end-to-side, in chronic duodenal ulcer, 131
part needed for, 140
- Annular duodenal ulcer, 222
- Anthrax of duodenum, 53, 54
- Antiperistaltic anastomosis in duodenal ulcer, 152
- Aorta, erosion of, 236
- Appendicitis, perforation of duodenal ulcer and, 169
differentiation, 173
with perforated duodenal ulcer, 175
- Appetite in chronic duodenal ulcer, 105
- Arteries, erosion of, 234
- BANTI'S disease, chronic duodenal ulcer and, differentiation, 127
- Basting stitch in gastro-enterostomy, 146
- Berg's treatment of duodenal fistula, 198
- Bile, ulcers from burns and, 36
- Bile-ducts, involvement of, in cicatricial contraction, 223
- Bleeder's disease, chronic duodenal ulcer and, differentiation, 128
- Blood changes in ulcer from burns, 37
- Blood-vessels, erosion of, in chronic duodenal ulcer, 116
- Blown-out feeling in chronic duodenal ulcer, 102
- Boring pain in chronic duodenal ulcer, 104
- Bright's disease, uræmic ulcers in, 44. See also *Uræmic duodenal ulcer*.
- Bronchitis, duodenal perforation and, differentiation, 177
- Burning pain in chronic duodenal ulcer, 104

- Burns, duodenal ulcer from, 24,
242
age and, 40
bile and, 36
blood changes in, 37
cases, 29
causes, 36
character, 38
emboli and, 38
frequency, 32
hæmorrhage in, 42
history, 24
multiple, 39
nature of relationship, 36
perforation, 42
cases, 29-31
position, 38
sex and, 41
shape of, 40
solitary, 39
symptoms, 41
toluylenediamine injections
and, 36
gastric ulcer from, 39
- CANCER, duodenal ulcer and, 245
cases, 216, 245
stomach, from ulcer, 245
- Cardiospasm in duodenal ulcer,
255
- Cholecyst-enterostomy, case, 260
- Cholecystitis, subacute perfora-
tion and, differentiation, 192
- Cholecysto-duodenal fistula, 239
case, 260
- Cholelithiasis, chronic duodenal
ulcer and, differentiation, 122,
124
with duodenal ulcer, case, 257,
259, 263
- Chyme, regurgitation of, in
chronic duodenal ulcer, 118
- Circular duodenal ulcer, 222
- Cirrhosis of liver, chronic duo-
denal ulcer and, differentiation,
128
- Cold, chronic duodenal ulcer and,
106
- Colic in chronic duodenal ulcer,
104, 105
- Colon, fistula into, 244
- Common duct, erosion of, from
duodenal ulcer, 233
involvement in cicatricial
contraction, 225
- Contact ulcers, 220
- Cramp-like pain in chronic duo-
denal ulcer, 104
- Crater of chronic duodenal ulcer,
213
- Curling's ulcer, 25. See also
Burns, duodenal ulcer from.
- DIAGNOSIS of chronic duodenal
ulcer, 101, 106
differential, 122
- Diet after gastro-enterostomy, 154
- Differential diagnosis of chronic
duodenal ulcer, 122
of perforation, 171
of subacute perforation, 192
- Dilatation of stomach in chronic
duodenal ulcer, 110
- Diverticulum from pouching of
ulcer, 216
of Vater, duodenal ulcer in
region of, 223, 224
- Drainage after operation for per-
foration, 184
- Duodenal anthrax, 53, 54
excretion of urinary toxines, 54
fistula, Berg's treatment, 198
cases, 199
external, 197
from ulcer, 194
gastro-enterostomy for, with
pyloric occlusion, 198
into gall-bladder, 239
treatment, 198
ulcer, acute, 24
perforation of, 162
treatment, 180

- Duodenal ulcer, age and, 251
 annular, 222
 calculi with, case, 257, 259, 263
 cancer and, cases, 263
 cardiospasm in, 255
 cases operated upon to end of 1908, 251
 chronic, 101
 abdominal examination in, 109
 acid dyspepsia and, 108, 112, 117, 118
 gastritis and, 107, 108, 112, 117, 118
 adhesions of, 213, 214, 215
 age and, 101
 anæmia and, splenic, differentiation, 127
 anamnesis in, 101, 109
 anastomosis for, end-to-side, 131
 annular, 222
 anterior and posterior, relative frequency, 221
 appearance of, 212
 appetite in, 105
 attacks in, 106
 causes, 106
 onset, 106, 107
 periodicity, 106
 recurrence, 217
 termination, 107
 Banti's disease and, differentiation, 127
 bleeder's disease and, differentiation, 128
 blood-vessels eroded in, 116
 blown-out feeling in, 102
 breaking down and healing of, 217
 carcinoma from, 216, 245
 cases, 273-276, 277, 283-313, 315-319, 321-338, 340-362
 operated upon, 269
- Duodenal ulcer, chronic, cholelithiasis and, differentiation, 122, 124
 cicatricial involvement of other structures, 223
 circular, 222
 cirrhosis of liver and, differentiation, 128
 cold and, 106
 colic in, 104, 105
 crater of, 213
 diagnosis, 101, 106
 differential, 122
 dilatation of stomach in, 110
 diverticulum from pouching of, 216
 duodenum adherent to base of, 190
 dyspepsia and, acid, 108, 112, 117, 118
 early beginning of, 101
 end-to-side anastomosis for, 131
 excision of, 133, 135
 gall-bladder adhesions in, 213
 gastric dilatation in, 110
 ulcer and, differentiation, 122
 gastritis and, acid, 107, 108, 112, 117, 118
 gastro-enterostomy for, 132, 138. See also *Gastro-enterostomy*.
 getting cold and, 106
 hæmorrhage in, 112. See also *Hæmorrhage in chronic duodenal ulcer*.
 hæmorrhagic diathesis and, differentiation, 128
 healing and breaking down of, 217
 heartburn in, 121
 history of patient, 101, 109
 hunger pain in, 103
 cause, 108

- Duodenal ulcer, chronic, hyperacidity and, 107, 108, 112, 117, 118
 hyperchlorhydria and, 107, 108, 112, 117, 118
 in region of diverticulum of Vater, 223, 224
 infolding of, 133, 152, 153
 involvement of aorta, 236
 of arteries, 234
 of bile-ducts in scar, 223
 of colon, 244
 of common-duct, 233
 in scar, 225
 of diverticulum of Vater in scar, 223
 of liver, 233
 of mesenteric vein, 238
 of other structures by cicatrix, 223
 of pancreas, 232, 241
 of portal vein, 237
 in scar, 230
 of stomach, 245
 of veins, 234
 latent symptoms, 120
 liver abscess from, 243
 melæna in, 113
 motor incompetence in, 110, 111
 multiple, 219
 onset of attacks, 106, 107
 operation for, cases, 269
 pain in, 102. See also *Pain in chronic duodenal ulcer.*
 pathology, 210
 perforation of, 163. See also *Perforation.*
 periodicity of attacks, 106
 position of, 210
 posterior and anterior, relative frequency, 221
 pouching of, 214, 215, 216
 pyloric spasm in, 111
 rectus rigidity in, 110
 recurrence of pain of, 123
- Duodenal ulcer, chronic, regurgitation of chyme in, 118
 resection in, including part of stomach, 160
 leaving pylorus intact, 160
 rigidity of rectus muscle in, 110
 Roux's operation in, 152, 155, 156
 Moynihan's modification, 157, 158, 159
 saliva in, 104
 season and, 106
 second ulcer, 185
 sex and, 101, 251
 size of, 215
 solitary, frequency of, 217
 spasm of pylorus in, 104, 105, 111
 splenic anæmia and, differentiation, 127
 stasis of stomach in, 110, 111
 stenosis in, formation, 217
 frequency, 254
 from closure of perforation, 185, 186
 symptomatic effects of meals, 102
 symptoms, 101. See also *Symptoms of chronic duodenal ulcer.*
 tenderness in, 109, 110
 termination of attack, 107
 terraced, 214
 test meal in, 111
 thickness of, 215
 treatment, 129. See also *Treatment of chronic duodenal ulcer.*
 tucked back, 102, 210
 vomiting in, 106
 waterbrash in, 121
 wetting and, 106
 circular, 222

- Duodenal ulcer, contact, 220
 Curling's, 25. See also *Burns, duodenal ulcer from*.
 excision of, case, 261
 fistula from, 194. See also *Duodenal fistula*.
 from burns, 24, 242. See also *Burns, duodenal ulcer from*.
 from scalds, 24, 242. See also *Burns, duodenal ulcer from*.
 gastric ulcer with, cases, 269-273, 275-283, 285-287, 289, 290, 292, 301, 302, 304-306, 308, 309, 313, 314, 317-320, 323, 329, 335, 337, 339, 341, 344, 353, 358
 history, 17
 in newborn, 85
 after eczema, 95
 appearance, 88
 cases, 89-100
 cause, 87
 death from, 89
 in one week, cases, 94
 diagnosis, 89
 frequency, 86
 large, 87
 mortality, 89, 94
 multiple, 86
 perforation, 88
 position, 88
 post-mortem appearances, 89
 prognosis, 89
 symptoms, 89
 thrombosis and, 87, 88
 treatment, 89
 wasting in, 86
 in pemphigus, 54
 kissing, 220
 melena neonatorum and, 85
 mortality of operations, 261
 operation for, cases, 251
 classification, 255
 mortality, 261
- Duodenal ulcer, operation for,
 partial relief from, cases, 264
 results, cases, 261
 perforation of, 162. See also *Perforation*.
 pyloric spasm in, case, 257
 scar of, signs of, 120, 121
 second, 185
 sex and, 101, 251
 spasm of pylorus in case, 257
 stenosis in, from closure of perforation, 185, 186
 formation, 217
 frequency, 254
 surgical history, 22
 treatment, classification of operations, 255
 mortality, 261
 partial relief from, cases, 264
 results, cases, 261
 symptoms, 101, 252
 tetany in, 255
 thrombosis and, 87, 88
 treatment, 129. See also *Treatment of chronic duodenal ulcer*.
 tuberculous, 68. See also *Tuberculous duodenal ulcer*.
 typhoid, 52, 54
 uræmic, 44. See also *Uræmic duodenal ulcer*.
 varieties, 251
- Duodeno-colic fistula, 244
- Duodenum adherent to base of ulcer, 190
 hour-glass, 218
 dual, 218, 219, 220
 posterior surface, inspection of, 221
 resection of, 160
 alone, 160
- Dyspepsia, acid, chronic duodenal ulcer and, 108, 112, 117, 118

- ECZEMA, duodenal ulcer following, 95
- Emboli, ulcers from burns and, 38
- End-to-side anastomosis in chronic duodenal ulcer, 131
- Enema, simple, after gastro-enterostomy, 159
- Excision of chronic duodenal ulcer, 133, 135
- External duodenal fistula, 197
- FISTULA, cholecysto-duodenal, 239
 case, 260
 duodenal, Berg's treatment, 198
 cases, 199
 external, 197
 gastro-enterostomy for, with pyloric occlusion, 198
 treatment, 198
 duodeno-colic, 244
 from ulcer, 194
 gastro-duodenal, 245
 pancreatico-duodenal, 240
- Food, effects on pain in chronic duodenal ulcer, 102, 103
- Forsyth's device for keeping patient in sitting position, 153
- GALL-BLADDER adhesions in duodenal ulcer, 213
 duodenal fistula into, 239
 perforation of, duodenal perforation and, differentiation, 176
- Gall-stone disease. See *Cholelithiasis*.
- Gastrectomy, partial, with resection of duodenum, 160
- Gastric. See *Stomach*.
- Gastritis, acid, chronic duodenal ulcer and, 107, 108, 112, 117, 118
- Gastro-duodenal artery, erosion of, 234, 235
 fistula, 245
- Gastro-enterostomy, 132, 138
 after-treatment, 153
 Allis's forceps in, 146
 anterior, 152, 154
 cases, 259
 antiperistaltic method, results, 256
 basting stitch in, 146
 bowels after, 159, 160
 closing lesser sac in, 151
 diet after, 154
 enema after, 159
 Forsyth's device for keeping patient in sitting position after, 153
 gastroplasty with, case, 261
 in perforation, 185
 infolding of ulcer, 133, 152, 153
 loop-on-mucosa stitch in, 148, 149
 morphine after, 157, 158
 Moynihan's modification of Roux's operation, 157, 158, 159
 Murphy's rectal infusion in, 187
 no-loop method, 138
 part for anastomosis in, 140
 position of patient after, 153
 Roux's operation, 152, 155, 156
 Moynihan's modification, 157, 158, 159
 solid food after, 156
 sutures in, 141, 142, 144
 inner, 146
 needle for, 143
 outer, 143, 144, 151
 technic, 138
 thirst after, 154, 156
 results, 256
 visceral incision in, 142, 145
 von Hacker's method, 138
 with pyloric occlusion for fistula, 198
- Gastro-epiploica artery, right, erosion of, 235

- Gastroplasty with gastro-enterostomy, case, 261
- Gnawing pain in chronic duodenal ulcer, 104
- HÆMATEMESIS. See *Hæmorrhage*.
- Hæmorrhage from alimentary tract of newborn, 85. See also *Melæna neonatorum*.
- in chronic duodenal ulcer, 112
- diagnosis and, 127
- fatal, 116
- frequency, 113, 253
- manner of onset, 115
- occult, 116
- only symptom, 119
- predominance over other symptoms, 119, 120
- profuse, 116
- results, 114
- significance, 114
- sudden, 116
- vessels eroded, 116
- in ulcer due to burns, 42
- in uræmic duodenal ulcer, 44
- Hæmorrhagic diathesis, chronic duodenal ulcer and, differentiation, 128
- Harrington's solution in preparing for operation, 181
- Heartburn in chronic duodenal ulcer, 121
- Hepatic artery, erosion of, 235
- History, 17
- Hour-glass duodenum, 218
- dual, 218, 219, 220
- stomach and duodenum, 218
- case, 261
- Hunger pain, 103
- cause, 108
- Hyperacidity, chronic duodenal ulcer and, 107, 108, 112, 117, 118
- Hyperchlorhydria, chronic duodenal ulcer and, 107, 108, 112, 117, 118
- INFOLDING of chronic duodenal ulcer, 133, 152, 153
- Inspection in earliest case, 18
- KISSING ulcers, 220
- LAVAGE of abdomen after operation for perforation, 183
- of stomach during operation for duodenal perforation, 182
- tube, 184
- Lesser sac, closing of, after gastro-enterostomy, 151
- Liver abscess from duodenal ulcer, 243
- cirrhosis of, chronic duodenal ulcer and, differentiation, 128
- involvement in duodenal ulcer, 233
- Loop-on-mucosa stitch in gastro-enterostomy, 148, 149
- Lymph sealing perforation, 190
- MELÆNA in chronic duodenal ulcer, 113
- neonatorum and duodenal ulcer, 85
- cases, 89
- cause, 88
- frequency, 85
- onset, 85, 86
- Mesenteric vein, superior, erosion of, 238
- Mesocolic band, 139
- Miliary tuberculosis of duodenum, 68
- Morphine after gastro-enterostomy, 157, 158
- before operation for perforation, 180
- in perforation, 168
- Motor incompetence in chronic duodenal ulcer, 110, 111
- Mouth, uræmic ulcer of, 44

- Moynihan's modification of Roux's gastro-enterostomy, 157, 158, 159
- Murphy's rectal infusion after gastro-enterostomy, 187
- NEPHRITIS, ulcers in, 44
- Newborn, duodenal ulcers in, 85.
See also *Duodenal ulcer in newborn.*
- No-loop gastro-enterostomy, 138
- OMENTUM, "police" capacity of, 215
- PACKING in excision of ulcer, 136, 137
- Pain, hunger, 103, 108
in chronic duodenal ulcer, 102
boring, 104
burning, 104
cramp-like, 104
diagnostic value, 102, 124
effect of food on, 102, 103
gnawing, 104
hunger, 103, 108
meals and, 102, 103
recurrence, 122
relief of, 104
severity of, 124
in perforation, 166, 172
in subacute perforation, 190, 191
- Pancreas, abscess of, in duodenal ulcer, case, 23
duodenal fistula into, 240
erosion of, 241
involvement of, at perforation, 232
- Pancreatico-duodenal artery, erosion of, 234, 235
fistula, 240
- Pancreatitis, acute, perforated ulcer and, differentiation, 175
- Pathology of chronic duodenal ulcer, 210
- Pemphigus, duodenal ulcer in, 54
- Perforation, 162
acute, 163
age and, 162
cases, 204
chronic, 193
cases, 204
course of pus, 195
treatment, 197
frequency, 254
of acute ulcer, 162
treatment, 180
of chronic ulcer, 163
absence of antecedent symptoms, 164
acute, 163
pancreatitis and, differentiation, 175
after-treatment, 182, 183
appendicitis and, 169
differentiation, 173
appendicitis with, 175
bronchitis and, differentiation, 177
chronic, 163
closure of, 182
course of fluid from, 169, 170
death from, 166
diagnosis, 171
differential diagnosis, 171
drainage after operation, 184
etiology, 165
fluid from, course of, 169, 170
gall-bladder perforation and, differentiation, 176
gastric perforation and, differentiation, 173
gastro-enterostomy in, 185
lavage of abdomen after, 183

- Perforation of chronic ulcer, lavage of stomach during operation for, 182
 morphine in, 168
 after gastro-enterostomy, 157, 158
 before operation, 180
 mortality of treatment, 187, 188
 operation for, 180
 first case, 21
 pain in, 166, 172
 pancreas and, 232
 pleurisy and, differentiation, 177
 pneumonia and, differentiation, 177
 pulse-rate after, 167
 removal of, 182
 seat of tenderness and, 173
 stenosis from closure of, 185, 186
 suturing abdominal incision, 185
 symptoms, 165
 of complications, 167
 tenderness in, 167, 169
 thoracic disease and, differentiation, 177
 toilet of peritoneum after operation, 183
 treatment, 180
 preparations for, 180, 181
 two at same time, 222
 with abscess between pancreas and duodenum, case, 23
 of gall-bladder, duodenal perforation and, differentiation, 176
 of ulcer due to burns, 42
 cases, 29-31
 of uræmic duodenal ulcer, 48
 seat of, tenderness and, 173
 subacute, 188
- Perforation, subacute, adhesions to duodenum in, 190
 cases, 206
 cholecystitis and, differentiation, 192
 differential diagnosis, 192
 empty stomach and, 189
 localization of fluids, 189
 pain in, 190, 191
 plastic lymph sealing, 190
 plugging of opening, 189, 190
 symptoms, 190
 treatment, 192
 treatment, 180
- Periduodenal abscess, 194
 burrowing of, 195
 treatment, 197
- Peritoneum, toilet of, after operation for perforation, 183
- Plastic lymph sealing perforation, 190
- Pleurisy, duodenal perforation and, differentiation, 177
- Plugging of subacute perforation, 189, 190
- Pneumonia, duodenal perforation and, differentiation, 177
- Portal vein, erosion of, 237
 involvement in cicatricial contraction, 230
- Posterior no-loop gastro-enterostomy, 138
- Post-operative vomiting, cases, 267
- Pouching of chronic duodenal ulcer, 214, 215, 216
- Pus, course of, in chronic perforation, 195
- Pyloric vein, 211
- Pylorus, leaving intact, in resection of duodenum, 160
 occlusion of, with gastro-enterostomy for fistula, 198
 spasm of, in duodenal ulcer, 104
 105, 111
 case, 257
 vein showing position of, 211

- RECTAL infusion, Murphy's, after gastro-enterostomy, 187
- Rectus muscle, rigidity of, in chronic duodenal ulcer, 110
- Resection and end-to-side anastomosis in chronic duodenal ulcer, 131
- Rigidity of rectus muscle in chronic duodenal ulcer, 110
- Roux's operation for duodenal ulcer, 152, 155, 156
Moynihan's modification, 157, 158, 159
- SALIVA, copious secretion of, 104
- Scalds, duodenal ulcer from, 24, 242. See also *Burns, duodenal ulcer from*.
- Scar of duodenal ulcer, symptoms, 120, 121
- Sex, duodenal ulcer and, 101, 251
ulcers from burns and, 41
- Spasm of pylorus in duodenal ulcer, 104, 105, 111
case, 257
- Splenic anæmia, chronic duodenal ulcer and, differentiation, 127
- Stasis, gastric, in chronic duodenal ulcer, 110, 111
- Stenosis, formation, 217
frequency, 254
from closure of perforation, 185, 186
- Stomach, cancer of, from ulcer, 245
dilatation of, in chronic duodenal ulcer, 110
hour-glass, 261
with hour-glass duodenum, 218
lavage of, during operation for duodenal perforation, 182
motor incompetence of, in chronic duodenal ulcer, 110, 111
- Stomach, resection of part of, with duodenal resection, 160
stasis of, in chronic duodenal ulcer, 110, 111
ulcer of, case, 258
chronic duodenal ulcer and, differentiation, 122
from burns, 39
perforation, duodenal perforation and, differentiation, 173
with duodenal ulcer, cases, 269-273, 275-283, 285-287, 289, 290, 292, 301, 302, 304-306, 308, 309, 313, 314, 317-320, 323, 329, 335, 337, 339, 341, 344, 353, 358
- Sudden death, perforation and, 166
- Superior mesenteric vein, erosion of, 238
- Symptoms, 101, 252
absence of, before perforation, 164
except acidity and pain, 120, 121
except hæmorrhage, 119
cases, 252
cicatrical, 120, 121
due to burns, 41
early, 102
latent, 120
mimicry of, 126
of scar, 120, 121
- TENDERNESS in chronic duodenal ulcer, 109, 110
in perforation, 167, 169
seat of perforation and, 173
- Terraced duodenal ulcer, 214
- Test meal in chronic duodenal ulcer, 111
- Tetany in duodenal ulcer, 255
- Thirst after gastro-enterostomy, 154, 156

- Thoracic disease, acute, duodenal perforation and, differentiation, 177
- Thrombosis, duodenal ulcer and, 87, 88
of portal vein from cicatricial contraction in ulcer, 230
- Toluylenediamine injections, ulcer from burns and, 36, 37
- Treatment of chronic duodenal ulcer, 129
by anastomosis after resection, 131
by excision, 133, 135
by gastro-enterostomy, 132, 138. See also *Gastro-enterostomy*.
by infolding, 133, 152, 153
by resection and anastomosis, 131
indications for operation, 129, 130
medical, 129, 130, 131
surgical, 129, 131
cases, 251, 269
choice of operation, 131
indications, 129, 130
when to operate, 129
- of perforation, 180
chronic, 197
of subacute perforation, 192
surgical, 129, 131
cases, 251, 269
choice of operation, 131
indications, 129, 130
results, 261
when to operate, 129
- Tuberculous duodenal ulcer, 68
cases, 74, 75-84
causes, 75
- Tuberculous duodenal ulcer, position, 75
symptoms, 70
types, 69
- Tucked back ulcers, 102, 210
- Typhoid duodenal ulcer, 52, 54
- ULCUS carcinomatosum, 245
- Uræmia, excretory activity of, intestinal tract in, 52
- Uræmic duodenal ulcer, 44
cases, 54-67
causes, 45, 51
death from, 51
hæmorrhage in, 44
multiple, 51
perforation of, 48
position, 44, 50, 51
solitary, 50
ulcer of mouth, 44
- Urinary toxines, duodenal excretion of, 54
- VEINS, erosions of, 234
- Viscera, opening of, in gastro-enterostomy, 142, 145
- Vomiting in chronic duodenal ulcer, 106
post-operative, cases, 267
- von Hacker's method of gastro-enterostomy, 138
- WASTING in infancy, duodenal ulcers and, 86
- Waterbrash in chronic duodenal ulcer, 121
- Wet, chronic duodenal ulcer and, 106

SAUNDERS' BOOKS

— on —

**Practice, Pharmacy,
Materia Medica, Thera-
peutics, Pharmacology,
and the Allied Sciences**

W. B. SAUNDERS COMPANY

925 WALNUT STREET

PHILADELPHIA

9, HENRIETTA STREET, COVENT GARDEN, LONDON

SAUNDERS' SUCCESSFUL PUBLISHING

AS is well-known, the lists of most publishers contain a number of books that have never paid, and for which the publisher will never get back the money invested. Messrs. W. B. Saunders Company would call attention to the fact that they have no such works on their list. In all the years of their business experience they have never published a book at a loss. This they confidently consider a most remarkable record, and submit the fact to the attention of the profession as an example of what might justly be called "Successful Publishing."

A Complete Catalogue of our Publications will be Sent upon Request

Musser and Kelly on Treatment

A Handbook of Treatment. By 76 eminent specialists. Edited by JOHN H. MUSSER, M. D., Professor of Clinical Medicine, University of Pennsylvania; and A. O. J. KELLY, M. D., Assistant Professor of Clinical Medicine, University of Pennsylvania. Three octavo volumes of about 650 pages each, illustrated.

**READY VERY SOON—IN THREE VOLUMES
A PRACTICE FOR QUICK REFERENCE AND DAILY USE**

Every chapter in this work was written by a specialist of unquestioned authority. Not only is drug therapy given but also dietotherapy, serumtherapy, organotherapy, rest-cure, exercise and massage, hydrotherapy, climatology, electrotherapy, *x*-ray, and radial activity are fully, clearly, and definitely discussed. Those measures partaking of a *surgical nature* have been presented by *surgeons*.

THE EMINENT CONTRIBUTORS

Isaac A. Abt, M.D.	M. Howard Fussell, M.D.	B. G. A. Moynihan, Esq.
Sir Clifford Allbutt, M.D.	Thomas B. Fitcher, M.D.	George P. Muller, M.D.
James M. Anders, M.D.	John H. Gibbon, M.D.	John H. Musser, M.D.
John F. Anderson, M.D.	Joel E. Goldthwait, M.D.	Edward O. Otis, M.D.
Lewellys F. Barker, M.D.	Samuel McC. Hamill, M.D.	Henry K. Pancoast, M.D.
Joseph C. Bloodgood, M.D.	Hobart A. Hare, M.D.	Roswell Park, M.D.
George Blumer, M.D.	Charles Harrington, M.D.	Richard M. Pearce, M.D.
Sir Lauder Brunton, M.D.	Ludvig Hektoen, M.D.	Charles W. Richardson, M.D.
Charles W. Burr, M.D.	Albion Walter Hewlett, M.D.	David Riesman, M.D.
Richard C. Cabot, M.D.	Guy Hinsdale, M.D.	Milton J. Rosenau, M.D.
James F. Carroll, M.D.	Guy L. Hunner, M.D.	Joseph Sailer, M.D.
John G. Clark, M.D.	Chevalier Jackson, M.D.	J. F. Schamberg, M.D.
Rufus I. Cole, M.D.	Henry Jackson, M.D.	Henry Sewall, M.D.
Warren Coleman, M.D.	Theodore C. Janeway, M.D.	Bertram W. Sippy, M.D.
Matthew H. Cryer, M.D.	A. O. J. Kelly, M.D.	William G. Spiller, M.D.
Clinton T. Dent, M.D.	Maynard Ladd, M.D.	J. Dutton Steele, M.D.
Francis X. Dercum, M.D.	Egbert Lefevre, M.D.	Alfred Stengel, M.D.
George E. deSchweinitz, M.D.	James Henry Lloyd, M.D.	Charles G. Stockton, M.D.
George Dock, M.D.	G. Hudson Makuen, M.D.	James E. Talley, M.D.
Isidor Dyer, M.D.	Charles F. Martin, M. C.	E. W. Taylor, M.D.
David L. Edsall, M.D.	Edward Martin, M.D.	James Tyson, M.D.
William A. Edwards, M.D.	Charles W. Mayo, M.D.	George H. Weaver, M.D.
Arthur W. Elting, M.D.	William J. Mayo, M.D.	J. William White, M.D.
John M. T. Finney, M.D.	R. Tait McKenzie, M.D.	Alfred C. Wood, M.D.
Charles H. Frazier, M.D.	Herbert C. Moffitt, M.D.	Horatio C. Wood, Jr., M.D.
	Jesse M. Mosher, M.D.	

Kemp on Stomach and Intestines

Diseases of the Stomach and Intestines. By ROBERT COLEMAN KEMP, M. D., Professor of Gastro-intestinal Diseases at the New York School of Clinical Medicine. Octavo of 750 pages, with 300 illustrations.

JUST READY—MEDICAL AND SURGICAL

Of the many works on gastro-intestinal diseases, this is perhaps the only one in which the needs of the general practitioner are given pre-eminent emphasis. It is the practitioner who first meets with these cases, and it is he upon whom the burden of diagnosis rests. After the diagnosis is established, the practitioner, if properly equipped, could frequently treat the case himself instead of transferring it to a specialist. This work is intended to equip the practitioner with this end in view. As visceral displacements have assumed such an important position, their symptoms, diagnosis, and treatment, notably by mechanical methods, are specially described. *Auto-intoxication* has been given unusual attention. Typhoid fever is also included because of its local manifestations.

Deaderick on Malaria

Practical Study of Malaria. By WILLIAM H. DEADERICK, M. D., Member American Society of Tropical Medicine; Fellow London Society of Tropical Medicine and Hygiene. Octavo of 402 pages, illustrated. Cloth, \$4.50 net; Half Morocco, \$6.00 net.

JUST READY—A WORK LONG NEEDED

This is a practical work, one laying special stress on diagnosis and treatment, and one, therefore, that will prove of the greatest service. It is the only book in any language describing the third cycle of the malarial parasite—the parthenogenetic cycle—and the account given of hemoglobinuric fever is full and clear. The chapters on diagnosis and treatment are conspicuous for the clearness of expression, the exactness of statement, and the intuitive way in which the author has grasped the needs of the physician and supplied them. It is a *necessary* book—one that you will want.

Frank A. Jones, M. D.

Professor of Clinical Medicine and Physical Diagnosis, Memphis Hospital Medical College.

"Dr. Deaderick's book is up to date and the subject matter is well arranged. We have been waiting for many years for such a work written by a man who sees malaria in all its forms in a highly malarious climate."

Bonney on Tuberculosis

Tuberculosis. By SHERMAN G. BONNEY, M. D., Professor of Medicine, Denver and Gross College of Medicine, Denver. Octavo of 800 pages, with 200 original illustrations. Cloth, \$7.00 net.

Dr. Bonney's work embodies the results of wide personal experience in observing and treating tuberculous patients, especially those suffering from the pulmonary form. His book is a thorough and complete treatise of the entire subject of tuberculosis, taking up every region of the body and every secondary involvement that can occur. The section on Physical Signs of Pulmonary Tuberculosis is really a complete monograph on the physical diagnosis of diseases of the chest. As is to be expected, treatment is particularly full and practical. There are chapters on prophylaxis; open-air treatment, fully illustrated; diet; sanitarium and climatic treatments; therapeutic measures to alleviate distressing symptoms; and drug and vaccine therapeutics. There are nearly two hundred original pictures, including twenty in colors and sixty *x*-ray photographs.

Maryland Medical Journal

"Dr. Bonney's book is one of the best and most exact works on tuberculosis, in all its aspects, that has yet been published."

Anders and Boston's Diagnosis

A Text-Book of Diagnosis. By JAMES M. ANDERS, M. D., PH.D., LL. D., Professor of the Theory and Practice of Medicine and of Clinical Medicine, Medico-Chirurgical College, Philadelphia; and L. NAPOLEON BOSTON, M. D., Adjunct Professor of Medicine, Medico-Chirurgical College, Philadelphia. Octavo of 950 pages, with 500 original illustrations.

READY IN MARCH—FOR THE PRACTITIONER

This new work is designed expressly for the general practitioner. The methods given are practical and especially adapted for quick reference. The diagnostic methods are presented in a forceful, definite way by men who have had wide experience at the bedside and in the clinical laboratory. The text is profusely illustrated with original pictures, each one representing some point in technic or some diagnostic sign. It is a work for every practitioner.

Anders'

Practice of Medicine

A Text-Book of the Practice of Medicine. By JAMES M. ANDERS, M. D., PH. D., LL. D., Professor of the Practice of Medicine and of Clinical Medicine, Medico-Chirurgical College, Philadelphia. Handsome octavo, 1326 pages, fully illustrated. Cloth, \$5.50 net; Half Morocco, \$7.00 net.

JUST READY—THE NEW (9th) EDITION

The success of this work is no doubt due to the extensive consideration given to Diagnosis and Treatment, under Differential Diagnosis the points of distinction of simulating diseases being presented in tabular form. In this new edition Dr. Anders has included all the most important advances in medicine, keeping the book within bounds by a judicious elimination of obsolete matter. A great many articles have also been rewritten.

Wm. E. Quine, M. D.,

Professor of Medicine and Clinical Medicine, College of Physicians and Surgeons, Chicago.

"I consider Anders' Practice one of the best single-volume works before the profession at this time, and one of the best text-books for medical students."

DaCosta's Physical Diagnosis

Physical Diagnosis. By JOHN C. DACOSTA, JR., M. D., Associate in Clinical Medicine, Jefferson Medical College, Philadelphia. Octavo of 557 pages, with 212 original illustrations. Cloth, \$3.50 net.

ORIGINAL ILLUSTRATIONS

Dr. DaCosta's work is a thoroughly new and original one. Every method given has been carefully tested and proved of value by the author himself. Normal physical signs are explained in detail in order to aid the diagnostician in determining the abnormal. Both direct and differential diagnosis are emphasized. The cardinal methods of examination are supplemented by full descriptions of technic and the clinical utility of certain instrumental means of research.

Dr. Henry L. Elsner, *Professor of Medicine at Syracuse University.*

"I have reviewed this book, and am thoroughly convinced that it is one of the best ever written on this subject. In every way I find it a superior production."

Tousey's Medical Electricity and X-Rays

Medical Electricity and the X-Rays. By SINCLAIR TOUSEY, M. D., Consulting Surgeon to St. Bartholomew's Hospital, New York. Octavo of 1075 pages, with 800 practical illustrations, 16 in colors.

READY IN MARCH—FOR THE PRACTITIONER

This new work by such an eminent authority is destined to take a leading place among books on this subject. Written primarily for the general practitioner, it gives him just the information he wishes to have regarding the use of medical electricity, the therapeutic results obtained, etc. At the same time it tells the specialist how the most eminent electrotherapeutists are securing results, the latest authorities in every country having been consulted for details of practical value. The work gives explicit directions for the care and regulation of static machines, *x-ray* tubes, and all apparatus. Recognizing that the production of a good radiograph every time, without risk to patient or apparatus, is of the utmost importance, the author *tells how to make x-ray pictures* by a practical technic easily followed, even though the operator be inexperienced in this field. The book includes a full detailed description of the author's valuable improvement on the cylinder-diaphragm universally used in radiography. *Dental radiography* the author has made his own. X-ray dosage is fully considered.

McKenzie on Exercise in Education and Medicine

Exercise in Education and Medicine. By R. TAIT MCKENZIE, B. A., M. D., Professor of Physical Education and Director of the Department, University of Pennsylvania. Octavo of 393 pages, with 346 original illustrations. Cloth, \$3.50 net.

RECENTLY ISSUED

This work is a full and detailed treatise on the application of systematized exercise in the development of the normal body and in the correction of certain diseased conditions in which gymnastics have proved of value.

D. A. Sargeant, M. D., *Director of Hemenway Gymnasium, Harvard University.*

"It cannot fail to be helpful to practitioners in medicine. The classification of athletic games and exercises in tabular form for different ages, sexes, and occupations is the work of an expert. It should be in the hands of every physical educator and medical practitioner."

GET
THE BEST

American Illustrated Dictionary

THE NEW
STANDARD

Just Issued—The New (5th) Edition

The American Illustrated Medical Dictionary. A new and complete dictionary of the terms used in Medicine, Surgery, Dentistry, Pharmacy, Chemistry, and kindred branches; with over 100 new and elaborate tables and many handsome illustrations. By W. A. NEWMAN DORLAND, M. D., Editor of "The American Pocket Medical Dictionary." Large octavo of 876 pages, bound in full flexible leather. Price, \$4.50 net; with thumb index, \$5.00 net.

A KEY TO MEDICAL LITERATURE—WITH 2000 NEW TERMS

We really believe that Dorland's Dictionary is the most useful single book that the medical practitioner can own. We are confident you will get more real use out of it than from any one book you ever bought. Nearly every medical paper to-day contains special words which are new to most readers. If you want to get the best out of your journals and text-books, Dorland's Dictionary should be on your desk for ready reference. The new edition contains hundreds of words that cannot be found in any other dictionary.

Howard A. Kelly, M.D., *Professor of Gynecologic Surgery, Johns Hopkins University, Baltimore.*

"Dr. Dorland's dictionary is admirable. It is so well gotten up and of such convenient size. No errors have been found in my use of it."

Goepp's State Board Questions

State Board Questions and Answers. By R. MAX GOEPP, M. D., Professor of Clinical Medicine, Philadelphia Polyclinic. Octavo of 684 pages. Cloth, \$4.00 net; Half Morocco, \$5.50 net.

FOR PRACTITIONERS AND STUDENTS

Dr. Goepp has taken great pains to collect the many questions asked in the past by Boards of the various States, and has arranged and classified them under subjects in such a manner that the prospective applicant can acquire the knowledge on any branch with the least difficulty.

Pennsylvania Medical Journal

"Nothing has been printed which is so admirably adapted as a guide and self-quiz for those intending to take State Board Examinations."

Sahli's Diagnostic Methods

Editors: Francis P. Kinnicutt, M.D., and Nath'l Bowditch Potter, M.D.

A Treatise on Diagnostic Methods of Examination. By PROF. DR. H. SAHLI, of Bern. Edited, with additions, by FRANCIS P. KINNICUTT, M. D., Professor of Clinical Medicine, Columbia University, N. Y.; and NATH'L BOWDITCH POTTER, M. D., Associate in Clinical Medicine, Columbia University. Octavo of 1008 pages, profusely illustrated. Cloth, \$6.50 net; Half Morocco, \$8.00 net.

ILLUSTRATED

Dr. Sahli's great work, upon its publication in German, was immediately recognized as the most important work in its field. Not only are all methods of examination for the purpose of diagnosis exhaustively considered, but the explanation of clinical phenomena is given and discussed from physiologic as well as pathologic points of view. In the chemical examination methods are described so exactly that it is possible for the clinician to work according to these directions.

Lewellys F. Barker, M. D.

Professor of the Principles and Practice of Medicine, Johns Hopkins University

"I am delighted with it, and it will be a pleasure to recommend it to our students in the Johns Hopkins Medical School."

Friedenwald and Ruhräh on Diet

Diet in Health and Disease. By JULIUS FRIEDENWALD, M. D., Professor of Diseases of the Stomach, and JOHN RUHRÄH, M. D., Professor of Diseases of Children, College of Physicians and Surgeons, Baltimore. Octavo of 764 pages. Cloth, \$4.00 net.

RECENTLY ISSUED—THE NEW (3d) EDITION

This new edition has been carefully revised, making it still more useful than the two editions previously exhausted. The articles on milk and alcohol have been rewritten, additions made to those on tuberculosis, the salt-free diet, and rectal feeding, and several tables added, including Winton's, showing the composition of diabetic foods.

George Dock, M. D.

Professor of Theory and Practice and of Clinical Medicine, Tulane University.

"It seems to me that you have prepared the most valuable work of the kind now available. I am especially glad to see the long list of analyses of different kinds of foods."

Hinsdale's Hydrotherapy

Hydrotherapy: A Treatise on Hydrotherapy in General; Its Application to Special Affections; the Technic or Processes Employed, and a Brief Chapter on the Use of Waters Internally. By GUY HINSDALE, M.D., Lecturer on Climatology at the Medico-Chirurgical College of Philadelphia. Octavo of 500 pages, illustrated.

READY IN APRIL

The treatment of disease by hydrotherapeutic measures has assumed such an important place in medical practice that a good, practical work on the subject is an essential in every practitioner's armamentarium. This new work supplies all needs. It describes fully the various kinds of baths, douches, sprays; the application of heat and cold; the internal use of mineral waters and all other procedures included under hydrotherapeutic measures. Then the use of hydrotherapy in the various diseases is detailed concisely, yet explicitly and adequately. Illustrations have been freely used throughout the text. As a practical work on this important subject, Dr. Hinsdale's book will be found to take first place.

Swan's Prescription-writing and Formulary

JUST READY

Prescription-writing and Formulary. By JOHN M. SWAN, M. D., Associate Professor of Clinical Medicine in the Medico-Chirurgical College of Philadelphia. 12mo of 185 pages. Flexible leather, \$1.25 net.

This work contains nearly 1050 prescriptions, selected because of their proved value. There is also other information often needed by the practitioner, such as prescription Latin, a chapter on the United States Pharmacopeia and its official preparations, tables of weights and measures, doses, incompatibility and number of ingredients, abbreviations, and miscellaneous considerations.

Stewart's Pocket Therapeutics and Dose-book

JUST READY
NEW (4th) EDITION

Pocket Therapeutics and Dose-book. By MORSE STEWART, JR., M. D. 32mo of 263 pages.

This little book is a complete therapeutics as well as a dose-book, and it is so arranged that the information sought can be obtained at a glance. The work for this edition has been practically rewritten and entirely reset. It fits the pocket.

AMERICAN EDITION

NOTHNAGEL'S PRACTICE

UNDER THE EDITORIAL SUPERVISION OF

ALFRED STENGEL, M.D.

Professor of Clinical Medicine in the University of Pennsylvania

Typhoid and Typhus Fevers

By DR. H. CURSCHMANN, of Leipsic. Edited, with additions, by WILLIAM OSLER, M. D., F. R. C. P., Regius Professor of Medicine, Oxford University, Oxford, England. Octavo of 646 pages, illustrated.

Smallpox (including Vaccination), Varicella, Cholera Asiatica, Cholera Nostras, Erysipelas, Erysipeloid, Pertussis, and Hay Fever

By DR. H. IMMERMANN, of Basle; DR. TH. VON JÜRGENSEN, of Tübingen; DR. C. LIEBERMEISTER, of Tübingen; DR. H. LENHARTZ, of Hamburg; and DR. G. STICKER, of Giessen. The entire volume edited, with additions, by SIR J. W. MOORE, M. D., F. R. C. P. I., Professor of Practice, Royal College of Surgeons, Ireland. Octavo of 682 pages, illustrated.

Diphtheria, Measles, Scarlet Fever, and Rötheln

By WILLIAM P. NORTHRUP, M. D., of New York, and DR. TH. VON JÜRGENSEN, of Tübingen. The entire volume edited, with additions, by WILLIAM P. NORTHRUP, M. D., Professor of Pediatrics, University and Bellevue Hospital Medical College, New York. Octavo of 672 pages, illustrated, including 24 full-page plates, 3 in colors.

Diseases of the Bronchi, Diseases of the Pleura, and Inflammations of the Lungs

By DR. F. A. HOFFMANN, of Leipsic; DR. O. ROSENBACH, of Berlin; and DR. F. AUFRECHT, of Magdeburg. The entire volume edited, with additions, by JOHN H. MUSSER, M. D., Professor of Clinical Medicine, University of Pennsylvania. Octavo of 1029 pages, illustrated, including 7 full-page colored lithographic plates.

Diseases of the Pancreas, Suprarenals, and Liver

By DR. L. OSER, of Vienna; DR. E. NEUSSER, of Vienna; and DRs. H. QUINCKE and G. HOPPE-SEYLER, of Kiel. The entire volume edited, with additions, by REGINALD H. FRITZ, A. M., M. D., Hersey Professor of the Theory and Practice of Physic, Harvard University; and FREDERICK A. PACKARD, M. D., Late Physician to the Pennsylvania and Children's Hospitals, Philadelphia. Octavo of 918 pages, illustrated.

SOLD SEPARATELY—PER VOLUME: CLOTH, \$5.00 NET; HALF MOROCCO, \$6.00 NET

AMERICAN EDITION

NOTHNAGEL'S PRACTICE**Diseases of the Stomach**

By DR. F. RIEGEL, of Giessen. Edited, with additions, by CHARLES G. STOCKTON, M. D., Professor of Medicine, University of Buffalo. Octavo of 835 pages, with 29 text-cuts and 6 full-page plates.

Diseases of the Intestines and Peritoneum **Second Edition**

By DR. HERMANN NOTHNAGEL, of Vienna. Edited, with additions, by H. D. ROLLESTON, M. D., F. R. C. P., Physician to St. George's Hospital, London. Octavo of 1100 pages, illustrated.

Tuberculosis and Acute General Miliary Tuberculosis

By DR. G. CORNET, of Berlin. Edited, with additions, by WALTER B. JAMES, M. D., Professor of the Practice of Medicine, Columbia University, New York. Octavo of 806 pages.

Diseases of the Blood (*Anemia, Chlorosis, Leukemia, and Pseudoleukemia*)

By DR. P. EHRLICH, of Frankfort-on-the-Main; DR. A. LAZARUS, of Charlottenburg; DR. K. VON NOORDEN, of Frankfort-on-the-Main; and DR. FELIX PINKUS, of Berlin. The entire volume edited, with additions, by ALFRED STENGEL, M. D., Professor of Clinical Medicine, University of Pennsylvania. Octavo of 714 pages, with text-cuts and 13 full-page plates, 5 in colors.

Malarial Diseases, Influenza, and Dengue

By DR. J. MANNABERG, of Vienna, and DR. O. LEICHTENSTERN, of Cologne. The entire volume edited, with additions, by RONALD ROSS, F. R. C. S. (ENG.), F. R. S., Professor of Tropical Medicine, University of Liverpool; J. W. W. STEPHENS, M. D., D. P. H., Walter Myers Lecturer on Tropical Medicine, University of Liverpool; and ALBERT S. GRÜNBAUM, F. R. C. P., Professor of Experimental Medicine, University of Liverpool. Octavo of 769 pages, illustrated.

Diseases of Kidneys and Spleen, and Hemorrhagic Diatheses

By DR. H. SENATOR, of Berlin, and DR. M. LITTEN, of Berlin. The entire volume edited, with additions, by JAMES B. HERRICK, M. D., Professor of the Practice of Medicine, Rush Medical College. Octavo of 815 pages, illust.

Diseases of the Heart

By PROF. DR. TH. VON JURGENSEN, of Tübingen; PROF. DR. L. KREHL, of Greifswald; and PROF. DR. L. VON SCHRÖTTER, of Vienna. The entire volume edited, with additions, by GEORGE DOCK, M. D., Professor of Theory and Practice of Medicine and Clinical Medicine, Tulane University of Louisiana. Octavo of 848 pages, fully illustrated.

PRESS OPINIONS**Boston Medical and Surgical Journal**

"The system as a whole stands pre-eminently as *the best* encyclopedic treatise on medicine now extant."

London Lancet

"We welcome the translation into English of this excellent practice of medicine."

SOLD SEPARATELY—PER VOLUME: CLOTH, \$5.00 NET; HALF MOROCCO, \$6.00 NET

Arny's Principles of Pharmacy

Principles of Pharmacy. By HENRY V. ARNY, PH. G., PH. D., Professor of Pharmacy at the Cleveland School of Pharmacy. Octavo of 1175 pages, with 246 illustrations. Cloth, \$5.00 net.

RECENTLY ISSUED

Professor Arny divides his subject into seven parts: The first part deals with pharmaceutic processes, a striking feature being the clear discussion of the arithmetic of pharmacy; the second part deals with galenic preparations of the Pharmacopeia and those unofficial preparations of proved value; the third part deals with the inorganic chemicals; the fourth part discusses the organic chemicals; the fifth part is devoted to chemical testing, presenting a systematic grouping of all the tests of the Pharmacopeia—a feature not found in any other book; the sixth part discusses the prescription; the seventh part is devoted to laboratory work.

George Reimann, Ph. G., *Secretary of the New York State Board of Pharmacy.*

"I would say that the book is certainly a great help to the student, and I think it ought to be in the hands of every person who is contemplating the study of pharmacy."

Stevens' Therapeutics and Materia Medica

A Text-Book of Modern Materia Medica and Therapeutics. By A. A. STEVENS, A. M., M. D., Lecturer on Physical Diagnosis in the University of Pennsylvania. Octavo of 675 pages. Cloth, \$3.50 net.

JUST READY—THE NEW (5th) EDITION

Dr. Stevens' Therapeutics is one of the most successful works on the subject ever published. In this new edition the work has undergone a very thorough revision, and now represents the very latest advances in therapeutics and materia medica.

The Medical Record, New York

"Among the numerous treatises on this most important branch of medical practice, this by Dr. Stevens has ranked with the best, and the new edition preserves its reputation as one of the most authoritative works on therapeutics and materia medica."

Sollmann's Pharmacology

Including Therapeutics, Materia Medica, Pharmacy,
Prescription-writing, Toxicology, etc.

A Text-Book of Pharmacology. By TORALD SOLLMANN, M. D., Professor of Pharmacology and Materia Medica, Medical Department of Western Reserve University, Cleveland, Ohio. Handsome octavo volume of 1070 pages, fully illustrated. Cloth, \$4.00 net.

THE NEW (2d) EDITION

Because of the radical alterations which have been made in the new (1905) Pharmacopeia, it was found necessary to reset this book entirely. The author bases the study of therapeutics on a systematic knowledge of the nature and properties of drugs, and thus brings out forcibly the intimate relation between pharmacology and practical medicine.

J. F. Fotheringham, M. D.

Prof. of Therapeutics and Theory and Practice of Prescribing Trinity Med. College, Toronto.

"The work certainly occupies ground not covered in so concise, useful, and scientific a manner by any other text I have read on the subjects embraced."

Butler's Materia Medica Therapeutics, and Pharmacology

A Text-Book of Materia Medica, Therapeutics, and Pharmacology. By GEORGE F. BUTLER, PH. G., M. D., Professor and Head of the Department of Therapeutics and Professor of Preventive and Clinical Medicine, Chicago College of Medicine and Surgery, Medical Department Valparaiso University. Octavo of 702 pages, illustrated. Cloth, \$4.00 net; Half Morocco, \$5.50 net.

THE NEW (6th) EDITION

For this sixth edition Dr. Butler has entirely remodeled his work, a great part having been rewritten. All obsolete matter has been eliminated, and special attention has been given to the toxicologic and therapeutic effects of the newer compounds. The classification adopted is a practical one, aiding the student in grasping the subject, and the practitioner in finding the information sought.

Medical Record, New York

"Nothing has been omitted by the author which, in his judgment, would add to the completeness of the text, and the student or general reader is given the benefit of latest advices bearing upon the value of drugs and remedies considered."

Thornton's Dose-Book

Dose-Book and Manual of Prescription-Writing. By E. O. THORNTON, M. D., Assistant Professor of Materia Medica, Jefferson Medical College, Phila. Post-octavo, 410 pages, illustrated. Flexible leather, \$2.00 net.

JUST READY—THE NEW (4th) EDITION

In the revision additions have been made to the chapters on "Prescription-writing" and "Incompatibilities," and references have been introduced in the text to the newer curative sera, organic extracts, synthetic compounds, and vegetable drugs. To the Appendix chapters upon Synonyms and Poisons and their antidotes have been added.

C. H. Miller, M. D., *Professor of Pharmacology, Northwestern University Medical School.*

"I will be able to make considerable use of that part of its contents relating to the correct terminology as used in prescription-writing, and it will afford me much pleasure to recommend the book to my classes, who often fail to find this information in their other text-books."

Lusk on Nutrition

**Just Ready
New (2d) Edition**

ELEMENTS OF THE SCIENCE OF NUTRITION. By GRAHAM LUSK, PH. D., Professor of Physiology in Cornell University Medical School. Octavo of 402 pages. Cloth, \$3.00 net.

"I shall recommend it highly. It is a comfort to have such a discussion of the subject."
—LEWELLYS F. BARKER, M. D., *Johns Hopkins University.*

Camac's "Epoch-making Contributions"

EPOCH-MAKING CONTRIBUTIONS IN MEDICINE AND SURGERY. Collected and arranged by C. N. B. CAMAC, M. D., of New York City. Octavo of 450 pages, illustrated. Artistically bound, \$4.00 net.

"Dr. Camac has provided us with a most interesting aggregation of classical essays. We hope that members of the profession will show their appreciation of his endeavors."
—THERAPEUTIC GAZETTE.

Todd's Clinical Diagnosis

A MANUAL OF CLINICAL DIAGNOSIS. By JAMES CAMPBELL TODD, M. D., Associate Professor of Pathology, Denver and Gross College of Medicine. 12mo of 319 pages, with 131 text-illustrations and 10 colored plates. Flexible leather, \$2.00 net.

Rolleston on the Liver

DISEASES OF THE LIVER, GALL-BLADDER, AND BILE-DUCTS. By H. D. ROLLESTON, M. D. (CANTAB), F. R. C. P., Physician to St. George's Hospital, London, England. Octavo of 794 pages, illustrated. Cloth, \$6.00 net.

"The most extensive treatise on diseases of the liver yet published in English. . . . It reflects an unusual degree of experience in a difficult but highly important branch of study."
—MEDICAL RECORD, NEW YORK.

The American Pocket Medical DictionaryRecently Issued
New (6th) Edition

THE AMERICAN POCKET MEDICAL DICTIONARY. Edited by W. A. NEWMAN DORLAND, M. D., Assistant Obstetrician to the Hospital of the University of Pennsylvania. 598 pages. Flexible leather, with gold edges, \$1.00 net; with thumb index, \$1.25 net.

Pusey and Caldwell on X-Rays

Second Edition

THE PRACTICAL APPLICATION OF THE RÖNTGEN RAYS IN THERAPEUTICS AND DIAGNOSIS. By WILLIAM ALLEN PUSEY, A. M., M. D., Professor of Dermatology in the University of Illinois; and EUGENE W. CALDWELL, B. S., Director of the Edward N. Gibbs X-Ray Memorial Laboratory of the University and Bellevue Hospital Medical College, New York. Octavo of 625 pages, with 200 illustrations. Cloth, \$5.00 net; Half Morocco, \$6.50 net.

Cohen and Eshner's Diagnosis. Second Revised Edition

ESSENTIALS OF DIAGNOSIS. By S. SOLIS-COHEN, M. D., Senior Assistant Professor in Clinical Medicine, Jefferson Medical College, Phila.; and A. A. ESHNER, M. D., Professor of Clinical Medicine, Philadelphia Polyclinic. Post-octavo, 382 pages; 55 illustrations. Cloth, \$1.00 net. *In Saunders' Question-Compend Series.*

Morris' Materia Medica and Therapeutics.

New (7th) Edition

ESSENTIALS OF MATERIA MEDICA, THERAPEUTICS, AND PRESCRIPTION-WRITING. By HENRY MORRIS, M. D., late Demonstrator of Therapeutics, Jefferson Medical College, Phila. Revised by W. A. BASTEDO, M. D., Instructor in Materia Medica and Pharmacology at Columbia University. 12mo, 300 pages. Cloth, \$1.00 net. *In Saunders' Question-Compend Series.*

Williams' Practice of Medicine

ESSENTIALS OF THE PRACTICE OF MEDICINE. By W. R. WILLIAMS, M. D., formerly Instructor in Medicine and Lecturer on Hygiene, Cornell University; and Tutor in Therapeutics, Columbia University, N. Y. 12mo of 456 pages, illustrated. *In Saunders' Question-Compend Series.* Double number, \$1.75 net.

Stoney's Materia Medica for Nurses

New (3rd) Edition

MATERIA MEDICA FOR NURSES. By EMILY A. M. STONEY, Superintendent of the Training School for Nurses at the Carney Hospital, South Boston, Mass. Handsome 12mo volume of 300 pages. Cloth, \$1.50 net.

Bridge on Tuberculosis

TUBERCULOSIS. By NORMAN BRIDGE, A. M., M. D., Emeritus Professor of Medicine in Rush Medical College. 12mo of 302 pages, illustrated. Cloth, \$1.50 net.

Boston's Clinical Diagnosis

Second Edition

CLINICAL DIAGNOSIS. By L. NAPOLEON BOSTON, M. D., Adjunct Professor of Medicine and Director of the Clinical Laboratories, Medico-Chirurgical College, Philadelphia. Octavo of 563 pages, with 330 illustrations, many in colors. Cloth, \$4.00 net.

Arnold's Medical Diet Charts

MEDICAL DIET CHARTS. Prepared by H. D. ARNOLD, M. D., Professor of Clinical Medicine, Tuft's Medical College, Boston. Single charts, 5 cents; 50 charts, \$2.00 net; 500 charts, \$18.00 net; 1000 charts, \$30.00 net.

Mathews' How to Succeed in Practice

HOW TO SUCCEED IN THE PRACTICE OF MEDICINE. By JOSEPH M. MATHEWS, M. D., LL.D., President American Medical Association, 1898-99. 12mo of 215 pages, illustrated. Cloth, \$1.50 net.

Jakob and Eshner's Internal Medicine and Diagnosis

ATLAS AND EPITOME OF INTERNAL MEDICINE AND CLINICAL DIAGNOSIS. By DR. CHR. JAKOB, of Erlangen. Edited, with additions, by A. A. ESHNER, M. D., Professor of Clinical Medicine, Philadelphia Polyclinic. With 182 colored figures on 68 plates, 64 text-illustrations, 259 pages of text. Cloth, \$3.00 net. *In Saunders' Hand-Atlas Series.*

Lockwood's Practice of Medicine.

Second Edition,
Revised and Enlarged

A MANUAL OF THE PRACTICE OF MEDICINE. By GEO. ROE LOCKWOOD, M. D., Attending Physician to the Bellevue Hospital, New York City. Octavo, 847 pages, with 79 illustrations in the text and 22 full-page plates. Cloth, \$4.00 net.

Barton and Wells' Medical Thesaurus

A THESAURUS OF MEDICAL WORDS AND PHRASES. By W. M. BARTON, M. D., and W. A. WELLS, M. D., of Georgetown University, Washington, D. C. 12mo of 535 pages. Flexible leather, \$2.50 net; thumb indexed, \$3.00 net.

Jelliffe's Pharmacognosy

AN INTRODUCTION TO PHARMACOGNOSY. By SMITH ELY JELLIFFE, PH. D., M. D., of Columbia University. Octavo, illustrated. Cloth, \$2.50 net.

Stevens' Practice of Medicine

New (8th) Edition

A MANUAL OF THE PRACTICE OF MEDICINE. By A. A. STEVENS, A. M., M. D., Professor of Pathology, Woman's Medical College, Phila. Specially intended for students preparing for graduation and hospital examinations. Post-octavo, 556 pages, illustrated. Flexible leather, \$2.50 net.

Paul's Materia Medica for Nurses

MATERIA MEDICA FOR NURSES. By GEORGE P. PAUL, M. D., Assistant Visiting Physician and Adjunct Radiographer to the Samaritan Hospital, Troy, N. Y. 12mo of 240 pages. Cloth, \$1.50 net.

Saunders' Pocket Formulary

New (9th) Edition

SAUNDERS' POCKET MEDICAL FORMULARY. By WILLIAM M. POWELL, M. D. Containing 1831 formulas from the best-known authorities. With an Appendix containing Posologic Table, Formulas and Doses for Hypodermic Medication, Poisons and their Antidotes, Diameters of the Female Pelvis and Fetal Head, Obstetrical Table, Diet-list, Materials and Drugs used in Antiseptic Surgery, Treatment of Asphyxia from Drowning, Surgical Remembrancer, Tables of Incompatibles, Eruptive Fevers, etc., etc. In flexible leather, with side index, wallet, and flap, \$1.75 net.

Gould and Pyle's Curiosities of Medicine


ANOMALIES AND CURIOSITIES OF MEDICINE. By GEORGE M. GOULD, M. D., and WALTER L. PYLE, M. D. Octavo of 968 pages, 295 engravings, and 12 full-page plates. Cloth, \$3.00 net; Half Morocco, \$4.50 net.


Hatcher and Sollmann's Materia Medica

A TEXT-BOOK OF MATERIA MEDICA: including Laboratory Exercises in the Histologic and Chemic Examination of Drugs. By ROBERT A. HATCHER, PH. G., M. D., and TORALD SOLLMANN, M. D. 12mo of 411 pages. Flexible leather, \$2.00 net.

Eichhorst's Practice of Medicine

A TEXT-BOOK OF THE PRACTICE OF MEDICINE. By DR. H. EICHHORST, University of Zurich. Edited by A. A. ESHNER, M. D. Two octavos of 600 pages each, illustrated. Per set: Cloth, \$6.00 net.





RC862

M87

Movrihan

Copy 2

Dec 6

