

A resume of surgical operations from April 1, 1892, to April 1, 1893 in the practice of Dudley P. Allen / by William H. Nevison.

Contributors

Nevison, William H.
Allen, Dudley Peter, 1852-1915.
Augustus Long Health Sciences Library

Publication/Creation

Cleveland, 1893.

Persistent URL

<https://wellcomecollection.org/works/gfprpp4z>

License and attribution

This material has been provided by This material has been provided by the Augustus C. Long Health Sciences Library at Columbia University and Columbia University Libraries/Information Services, through the Medical Heritage Library. The original may be consulted at the the Augustus C. Long Health Sciences Library at Columbia University and Columbia University. where the originals may be consulted.

This work has been identified as being free of known restrictions under copyright law, including all related and neighbouring rights and is being made available under the Creative Commons, Public Domain Mark.

You can copy, modify, distribute and perform the work, even for commercial purposes, without asking permission.



Wellcome Collection
183 Euston Road
London NW1 2BE UK
T +44 (0)20 7611 8722
E library@wellcomecollection.org
<https://wellcomecollection.org>

COLUMBIA LIBRARIES OFFSITE
HEALTH SCIENCES STANDARD



HX64062252

RD34 N41

A resume of surgical

RECAP

William H. Nevison

A resume of surgial operations from Apr.
1, 1892 to April 1, 1893 in the practice of
Dudley P. Allen.


RD 34


N41

Columbia University
in the City of New York

COLLEGE OF
PHYSICIANS AND SURGEONS
LIBRARY







Digitized by the Internet Archive
in 2010 with funding from
Open Knowledge Commons

A RESUME
OF
SURGICAL OPERATIONS

FROM APRIL 1, 1892, TO APRIL 1, 1893,

IN THE PRACTICE OF

DUDLEY P. ALLEN, M. D.,

VISITING SURGEON TO

LAKESIDE AND CHARITY HOSPITALS, CLEVELAND, OHIO.

PRESIDENT OF THE OHIO STATE MEDICAL SOCIETY.

By WILLIAM H. NEVISON, M. D.,

ASSISTANT TO DR. ALLEN.

LIBRARY
UNIVERSITY
COLUMBIA

RD34
N 41

A RESUME OF THE SURGICAL OPERATIONS IN THE
PRACTICE OF DUDLEY P. ALLEN, M. D.,
VISITING SURGEON TO LAKESIDE AND CHARITY HOSPITALS,
CLEVELAND, OHIO.
PRESIDENT OF THE OHIO STATE MEDICAL SOCIETY.

From April 1, 1892, to April 1, 1893.

BY WILLIAM H. NEVISON, M. D.,

Assistant to Dr. Allen.

Having been assistant to Dr. Allen during the past year and having witnessed in his practice a number of operations of more than usual interest, it occurred to me to publish a resume which would include the surgical operations performed by him during the above period.

To accomplish this, it has seemed best to tabulate certain portions of the work, giving as briefly as possible the interesting points in connection with each case, and in addition, to give somewhat in detail a few of the more important cases.

The method of classification, with the exception of "Tumors not Abdominal," has been carried out according to the anatomical field of operation; the sub-divisions for the most part according to the pathological conditions found.

The following is a summary of the operations in the order in which they have been considered:

Operations upon the abdomen.....	62
Operations for tumors (not abdominal)	51
Operations upon the genito-urinary organs	46
Operations upon the rectum and anus	17
Operations upon the chest.....	8
Operations upon the head and neck	22
Operations upon the upper extremities	26
Operations upon the lower extremities	32
Miscellaneous operations	10
	—
Total number of operations.....	274

OPERATIONS UPON THE ABDOMEN.

62 operations. Of this number, 49 were laparotomies and 13 were operations, including hernica and kidney cases, and cannot, strictly speaking, be called laparotomies. This number includes but one incomplete, the remaining being all completed operations.

The laparotomies include the following:

15 operations for appendicitis; 12 for cystic diseases of the ovaries; 8 oöphorectomies and salpingectomies; 5 for fibroids of the uterus; 2 for extra-uterine pregnancy; 3 for pelvic abscess; 1 for pancreatic cyst; 1 for volvulus of the ileum; 1 for foreign body and 1 incomplected operation for impacted gall stone.

PREPARATION OF THE PATIENT AND DETAILS OF OPERATION.

When opportunity afforded the patient's bowels were moved with ol. ricini the day before the operation, and an injection and movement the morning of operation. A thorough bath was given the evening before and a moist bi-chloride dressing applied over the field of operation. After the patient was under the anaesthetic, the parts were shaved and again thoroughly scrubbed and cleansed with ether and lastly bi-chloride solution.

Ether was used as anaesthetic in all cases unless contra-indicated by lung or kidney complications.

The instruments, towels, operating gowns and dressings were sterilized, just before using, by raising to a high temperature for half an hour. Sponges were put through solutions of permanganate of potash and sulphurous acid and kept until used in carbolic solution.

During the operation, sponges and instruments were kept in distilled water and no antiseptic solutions were used.

Cat-gut ligatures were prepared by placing for a few hours in bi-chloride solution and preserving in alcohol and juniper oil.

Silk was boiled in carbolic solution and kept in a solution of the same.

Silkworm-gut sutures were washed in bi-chloride solution just before the operation.

Distilled water was used for irrigation.

The hands of operator and assistants were well scrubbed and put through solutions of permanganate of potash, sulphurous acid and bi-chloride of mercury.

The temperature of the room operating was kept at about 75°, and the limbs of the patient wrapped in flannel with hot water bottles at the sides if needed.

In many operations the Trendelenburg position was used to great advantage when difficult pelvic dissections were to be made.

Cat-gut was used for adhesions and heavy silk for the ligation of pedicles. The abdominal incisions were closed with silkworm-gut sutures, taking care to include all the layers of the abdominal wall.

After the operation, patient received nothing by stomach until all feelings of nausea were passed and were then allowed small quantities of water, and later, milk and lime water.

The intense thirst was often much relieved by rectal injections of warm water and stimulants.

Morphine was allowed only when patients suffered severe pain. Bromide and chloral was given by rectum for sleeplessness.

The bowels were first moved by small and repeated doses of hydrarg chlor. mit., followed by Rochelle and injections. In several cases when symptoms of obstruction were present and patients could not retain medicines given by stomach, very satisfactory results were obtained by rectal injections of ol. ricini and aloes.

OPERATIONS FOR APPENDICITIS.—ACUTE CASES WITH CIRCUMSCRIBED ABCESES.

No.	Nat., Age, Sex.	In Consultation with	Date and Place of Operation.	Stage in which Operated.	History of previous Attacks.	Incision.	Subjective Symptoms.	Objective Symptoms.	Operation.	Appendix and Concretions.	Result	Remarks.
IV A. H.	Am. 21 Male.	Dr. J. H. Boyd of Akron, Ohio.	May 10, 1892. Residence.	Acute. 7 days.	Has had similar slight attacks lasting only 4 or 5 days.	Over cæcum.	Commenced with general abdominal pain becoming localized on 3d day.	Tympanitic with slight dullness and extreme tenderness over cæcum. Highest temperature 102° in evening of the 6th day.	Abscess contained in tea cup full of pus. Iodoform gauze tampon.	Appendix perforated near base; ligated and removed. Concretion size of bean in abscess cavity.	R. Uninterrupted recovery. Entirely healed in about 4 weeks.	
V M. S.	Ger. 30½ Fem.	Dr. B. B. Loughhead of Akron, Ohio.	July 5, 1892. Residence.	Acute. 5 days.	Has had numerous attacks commencing in similar manner but subsiding in 3 or 4 days.	Over cæcum.	Pain commenced over transverse colon, then became general, and on 4th day localized to cæcal region.	Tympanites; dullness and resistance over cæcum. Highest temperature 100° on 2d and 4th days.	Abscess contained in six ounces of thin watery pus. Iodoform gauze tampon.	Appendix perforated at base; ligated and removed. Concretion size of hazel nut in abscess cavity.	Death in 2½ days. Given in detail below.	
VI H. B.	Am. 8 Male.	Dr. C. D. Noble of Oberlin, Ohio.	July 11, 1892. Residence.	Acute. 5 days.	None.	Over cæcum.	General abdominal pain: greatest tenderness over McBurney point.	Very tympanitic; slight dullness over cæcum. Highest temperature 102° on 2d day.	Abscess contained about 6 oz. watery pus; had burrowed along rectum into pelvis; irrigated and introduced rubber drainage tube in a Mikulicz tampon.	Appendix perforated near base; ligated and removed. No concretion.	R. Given in detail below.	

VII	Am. 22	Dr. C. D. Noble of Oberlin, Ohio.	Oct. 10, 1892.	Acute. 5 days.	None.	Over caecum.	General abdom- inal pain, local- ized on 4th day.	Well marked dull- ness and indur- ation around cæ- cum. Temperat're 102½. Considerable tym- panites.	Abscess cavity containing quart of pus; appendix constricted some- what in the mid- dle as though from a scar re- maining after former inflamma- tion. Iodoform gauze tampon.	Appendix perforated near base; ligated and removed. No concretion.	R.	Entirely healed in about six weeks; has had no sub- sequent trouble.
VIII	Am. 22	Dr. C. D. Noble of Oberlin, Ohio.	Feb. 8, 1893.	Acute. 2½ days.	None.	Over caecum.	General abdom- inal pain, local- ized on 2d day.— Pain was extreme requiring fre- quent hypoder- mics of morphia.	Very tympanitic; dullness over cæ- cum. Highest temp. 102. Vomited and bad chills during evening before operation.	Abscess cavity con- taining about 3 oz. pus, had dis- sected into pelvis along side of rec- tum. Iodoform gauze tampon.	Appendix; perforated near base ligated and removed. Concretion size of a split pea.	Death in 4 days.	General peri- tonitis devel- oped; autop- sy showed no pus in abdom- inal cavity; everything pertaining to operation in perfect order.
IX	Am. 35	Dr. T. M. Sabin of Warren, Ohio.	Feb. 19, 1893.	Acute. 2½ days.	None.	Over caecum.	General abdom- inal pain; more tenderness in 2d day over caecum.	Excessive tym- panites. No dullness over caecum. Could make out nothing by palp- ation. Temp. 101.	Small abscess; gangrenous plac- ed on anterior surface of caecum size of a dollar. Iodoform gauze tampon.	Appendix not found. No concretion.	Death in 3½ days.	Autopsy show- ed general peritonitis with collec- tion of pus in front of bladder. Appendix was appentatad and in a mass of adhesions.

OPERATIONS FOR APPENDICITIS.—CHRONIC CASES.

No.	Nat., Age, Sex.	In Consultation with	Date and Place of Operation.	Stage in which Operated.	History of previous Attacks.	Incision.	Subjective Symptoms.	Objective Symptoms.	Operation.	Appendix and Concretion.	Result.	Remarks.
X O. C. L.	Am. 19 Male.	Dr. F. W. Upson, Conneaut, Ohio.	May 12, 1892. Charity Hospital.	Chronic.	Repeated attacks during last five months.	Right linea semilunaris.	Pain over cæcum during attacks. Always slight tenderness on deep pressure.	Under an anæsthetic dullness and resistance in cæcum region.	Numerous small abscesses and sinuses dissecting toward liver; cæcum in a mass of adhesions. Tamponed with iodoform gauze.	Appendix could not be found. Concretion size of Hickory nut.	R.	Given in detail below.
XI F. H.	Am. 20 Fem.	Dr. H. J. Lee.	July 2, 1892. Charity Hospital.	Chronic.	3 severe attacks during last five months.	Right linea semilunaries.	Constant pain in region of cæcum, greatly increased during attacks. 1st attack, Aug. '91 2 " Feb. '92 3 " Apr. '92 From this time confined to bed until operation.	Dullness and resistance over cæcum; could not make out a clearly defined tumor.	Numerous sinuses leading to the appendix which was located behind the cæcum. Iodoform gauze tampon.	Appendix perforated near base and filled with a granulation tissue; ligatured and removed. No concretion.	R.	Entirely healed in about seven weeks.
XII C. S.	Ger. 26 Male.	Dr. M. Borts.	Sept. 19, 1892. Lakeside Hospital.	Chronic.	Severe attack several weeks before and since then severe pain at intervals.	Over cæcum.	During 1st week severe pain over cæcum. Tenderness remaining and aggravated by slightest effort to get around.	Dullness and induration over cæcum.	Small abscesses connected by sinuses; cæcum in a mass of adhesions; patient too weak to endure prolonged operation. Gauze tampon.	Appendix not found. No concretion.	R.	Given in detail below.

XIII	Am.	18	Male.	Dr. G. A. Ashmun and Dr. F. J. Bauer of Mogadore.	Dec. 3, 1892.	Charity Hospital.	Chronic.	3 attacks in last six months.	Over caecum.	Pain over caecum during attacks. Tenderness on pressure at all times.	Under anaesthetic; no dullness; no tumor; slight resistance on deep pressure.	No abscess; appendix posterior to caecum and closely adherent; dissected off and sewed with fine silk, inverting the stump; gauze tampon.	Appendix perforated in middle and filled with granulation tissue. No concretion.	R.	Entirely healed in 4 weeks.
XIV	Am.	38	Male.	A. S.	Jan. 17, 1893.	Charity Hospital.	Chronic.	Repeated attacks during last three years.	Over caecum.	Pain over caecum during attacks.	Dullness and fistulous opening from previous operation.	Sinuses leading to appendix. Gauze tampon.	Stump of appendix found with concretion in open end. Amputated and sewed opening with cat-gut. Gauze tampon.	R.	Left hospital Feb. 14th, wound entirely healed, with exception of a few of granulation.
XV	Am.	32	Fem.	Dr. E. F. Cushing.	Jan. 30, 1893.	Lakeside Hospital.	Chronic.	About 2 attacks yearly during last 10 or 12 years.	Over caecum.	Pain over caecum during attacks. No tenderness after acute symptoms had passed.	No dullness; no induration.	No sign of previous peritoneal inflammation; amputated appendix; sewed with fine cat-gut; closed abdominal wound entirely.	Appendix free. Constricted at base; contained 3 concretions; mucous membrane ulcerated.	R.	Healing by first intention. Left Hospital Feb. 25th.

The above cases have, as a matter of convenience, been grouped in three sub-divisions.

FIRST SUB-DIVISION.

The first includes three acute cases in which perforation took place into the abdominal cavity before the operation, causing general suppurative peritonitis. All three cases died

Case I and II had no local symptoms pointing to the appendix, and although appendicitis was suspected, still it was deemed best to make the median incision in order to reach all possible causes of obstruction.

Case III is worthy of mention in detail, as follows:

Patient a strong muscular man, always had good health. Was perfectly well until the morning of Sept. 15th, when he ate a light breakfast and complained of a tired feeling. Had a good movement after breakfast and went to his office. At 2 p. m. felt badly; went home; vomited and went to bed complaining of general abdominal pain. Dr. Ashmun was called about 5 p. m., found no rise of temperature; pulse 72; gave powders of morphia.

Sept. 16th Morning temperature $100\frac{1}{2}$, pulse 84, no vomiting, no pain, gave powders of hydrarg. chlor. mit. ipecac and soda. Early in morning had slight chills. Passed a very comfortable day, and at 10 p. m. was suddenly taken with severe general abdominal pain. Anodynes were given and hot fomentations applied to the abdomen.

Sept. 17th Morning temperature $100\frac{1}{2}$, pulse 84. Drs. Allen and H. K. Cushing were called in consultation and it was decided to operate. At 2 p. m., temperature $102\frac{1}{2}$, pulse 98. Patient suffering most extreme pain, controlled only by large hypodermics of morphia. Operation at 5 p. m. Incision over caecum; abdominal cavity full of pus. The appendix was located to the outer and lower border of the caecum, and no adhesions were formed. Appendix had perforated near its base and contained three concretions; was removed and the stump sewed with fine silk. The

abdominal cavity was flushed with several gallons of boiled water. A rubber drainage tube and Mikulicz tampon were introduced through the abdominal incision into the pelvis and a second drainage tube carried through a counter opening at the edge of the quadratus lumborum in the right flank. Pulse after operation, 124. Patient passed a comfortable night.

Sept. 18th. Morning temperature $101\frac{3}{8}$, pulse 99; external dressings changed without disturbing tubes and tampon. During afternoon gave small doses of hydrarg. chlor. mit. until one grain was taken, and followed by teaspoonful doses of Rochelle salts. At 10 p. m. gave an enema and obtained a passage containing lumps of faecal material. Passed a restless night.

Sept. 19th. Morning temperature $100\frac{1}{2}$, pulse 99. Portion of gauze tampon was removed. Evening temperature $101\frac{2}{8}$, pulse 104. Gave Rochelle, but obtained no movement.

Sept. 20th. Morning temperature 100, pulse 110. Patient very tympanitic. Tampon was removed and Rochelle repeated during the day. At 5 p. m. patient was in a bad condition. The abdomen being greatly distended, an opening was made in a loop of the intestine presenting at the bottom of the wound and three pints of thin faecal material were withdrawn, together with the passage of considerable flatus. The patient was greatly relieved and passed a comfortable night. Was given milk and lime water by stomach, and injections of whiskey and water by rectum.

Sept. 21st. Morning temperature $101\frac{1}{2}$, pulse 98. The wound was irrigated every two hours and the discharge of faecal material continued.

Sept. 22d. About noon had a sinking spell, but revived under hypodermics of strychnia and enemata of digilalis, whiskey and water. At 2 p. m. had another spell; the extremities became cold and the patient gradually failed and died at midnight.

Autopsy 16 hours after death; there was faecal material throughout the lower part of the abdominal cavity with pus along

the under surface of the liver. The puncture in the gut had been made in the ileum about 12 inches from the ileo-caecal valve and five inches above this spontaneous perforation had occurred into the peritoneal cavity. Adhesions had formed around the point of puncture and no infection of the abdominal cavity had taken place from this source. The sutures in the stump of the appendix were in place and the opening was occluded. The ileum near its entrance into the caecum was tightly compressed by the tympanitic intestines against the brim of the pelvis which had caused obstruction.

Great tympanites and pain had resulted from this obstruction. Death was caused by sepsis.

SECOND SUB-DIVISION.

The Second subdivision includes six acute cases with circumscribed abscesses, with three deaths and three recoveries, the cause of death in all three cases being due to the extension of inflammation, resulting in general peritonitis. The following cases are worthy of particular mention:

CASE V.—M. S. Was a delicate woman, lately having been confined. After the operation the patient did not react well, and vomited almost incessantly. On second day attempted to obtain movement of the bowels by small and repeated doses of Rochelle salts. The gauze tampon was removed and large injections of water given by rectum, but no movement could be obtained. The patient gradually failed, and died sixty hours after the operation. Autopsy on the following day showed peritonitis with an accumulation of purulent fluid in the peritoneal cavity.

CASE VI.—H. B. A delicate boy 8 years of age. At the operation the abscess was found to have burrowed into the pelvis along the side of the rectum. After the operation the patient reacted well and went along nicely for the first two days. On the third day developed a severe cystitis. Urine contained albumen and considerable pus. Patient complained of great pain in pelvis, accompanied by some rise of temperature and pulse. The tampon

was removed and cavity thoroughly irrigated. This was followed by a fall of temperature to 99, and patient went on to recovery. The wound was entirely healed in about eight weeks.

THIRD SUB-DIVISION.

The Third subdivision includes six chronic cases, with no deaths. In all of these cases there had been histories of repeated attacks of pain in the caecal region. They were all operated during the quiescent stage. The following cases are worthy of mention.

CASE X.—O. C. L. Always been healthy; was first taken sick about the middle of December 1891. Had fever and pain over the caecum. Was sick seven weeks, most of the time in bed. Was commencing to get around when he had a relapse and from that time on he had frequent attacks of pain, lasting several days. Between these acute attacks there has always remained some tenderness on pressure, over the caecum. Patient walks drawn over to the right side. Examination under an anaesthetic revealed a dullness and resistance in the caecal region.

Operation—Incision through right linea semi-lunaris. The caecum was in a mass of adhesions with small sinuses dissecting upward toward the liver; the appendix could not be found. In the lower part of the abscess cavity was an intestinal concretion about the size of a hazel-nut. The wound was packed with iodoform-gauze and the ends of the incision brought together with silk sutures. Dressings were made every day, and the wound washed out with boracic acid solution. During the first two weeks there was an abundant discharge of pus. Patient sat up during the third week, and left Hospital June 6th. During the summer gained considerably in flesh, but the sinus continued to discharge, and occasionally a few seeds worked their way out. In November had an attack of pleurisy, and made a slow recovery. Patient has since returned for a second operation, in which the appendix was found and removed, and the hole in the intestine sewed with cat-gut.

The patient is still in the Hospital ; being up and about, the wound being closed with exception of few points of granulation.

CASE XII —C. S. Always had good health. In August, 1892, had an attack of appendicitis. Was in bed two weeks. Since then has had some tenderness remaining over the caecum, and on the slightest exertion the pain returned so that he has not been able to attend to any duties. At the operation, numerous small abscesses were found around the caecum, which was in a mass of adhesions. The patient was too weak to stand a prolonged operation, and the appendix was not found. The wound was tamponed with iodoform gauze, and patient improved rapidly after the operation, leaving the Hospital October 29th. During the winter, patient has been able to attend to his duties as a barber, and his general condition is much improved. The sinus closes from time to time, and again breaks open, with a discharge of pus. Patient has since undergone a second operation in which the appendix was found and removed. Wound has now entirely closed.

CASE XIV.—A. S. Had his first attack of appendicitis in February, 1890. Was confined to the house about two months. In June, 1890, noticed an enlargement in the caecal region, which steadily increased in size, and was opened and drained by Dr. Allen in August, 1890. Several concretions were removed, but the appendix was not found. No exhaustive search was made, however, since it was hoped the removal of the concretion would end the trouble. A slight discharge of pus continued until May 1891, when the sinus closed. Since then there has been a discharge of pus about every two or three months. A second operation was performed in January, 1893. The stump of the appendix was found, with a concretion in the open end. Appendix was removed and opening in caecum closed with cat-gut sutures. Patient made an uninterrupted recovery. Left Hospital February 14th, and a week later wound was entirely healed.

CASE XV.—T. S. T. Always been healthy. During the last

10 or 12 years has had attacks of pain in the caecal region about every six months, and of late years the attacks seem to be growing more frequent. Pain had always been localized, and was accompanied by slight rise in temperature, the patient being confined to her bed about a week. In November, 1892, had her last attack, and was treated by Dr. E. F. Cushing. There was no dullness, no induration, but the symptoms pointed to appendicitis, and an operation was advised. At the operation, no signs of peritoneal inflammation were present around the caecum. The appendix hung free in the abdominal cavity. There was, however, slight constriction at the base, and two small concretions could be felt in its interior. The appendix was removed, and opening in the caecum sewed with cat-gut. Abdominal incision was closed with silkworm-gut sutures, no drainage being used. The wound healed by first intention and patient made an uninterrupted recovery.

OPERATIONS FOR CYSTIC DISEASES OF THE OVARIES.

No.	Nat. Age, Social Condition.	Patient sent by	Date and Place of Operation.	History of Patient.	Examination.	Operation.	After Treatment.	Irrigation and Drainage.	Result.	Remarks.
I M. M.	Ger. 59. Mar.	Dr. B. Krause.	May 17, 1892. Charity Hospital.	Always healthy; menstruated at 18; menopause at 48; married at 27; had 6 children—1st child at 28, last child at 41. Never had any trouble until March, 1892, when noticed that abdomen was enlarged.	Percussion varied at different examinations. At one time precussing for ascites, at another for tumor. Fluctuation distinct; firm resistance in pelvis.	6 quarts clear ascitic fluid. Right ovary size of two fists. Adherent and cysts ruptured during removal. Intestines and peritoneum thickly studded with small growths size of millet seeds.	Excessive tympanites during recovery. Went home June 13th, feeling very well.	Irrigation; No drainage.	R.	Given in detail below.
	Am. 24 Mar.	Dr. N. M. Jones.	May 28, 1892. Charity Hospital.	Previous good health; menstruated at 14—regular; married at 22—never pregnant; 5 months ago noticed abdomen was larger, and has lost flesh. During last six weeks has had severe pain on left side.	Physical signs ovarian tumor, reaching nearly to umbilicus; not very movable; fluctuation distinct.	Removed multilocular suppurating cyst of left ovary, with firm adhesions to omentum, abdominal wall, sigmoid flexure and pelvic wall. Right ovary also cystic degenerated, and was removed. Meckel's diverticulum extended from ileum to junction of right tube with uterus, ligated and cut through diverticulum.	Patient very weak after operation; well stimulated; symptoms of peritonitis came on during second day. Could obtain no movement of bowels; patient gradually failed.	Irrigation; Glass drainage tube.	Death in 3½ days.	No autopsy could be obtained.
III M. E. C.	Am. 31 Mar.	Dr. L. G. Moore of Kinsman.	May 30, 1892. Charity Hospital.	Good health; menstruated at 14; never regular; married at 20; pregnant for 1st time at 27; miscarried at 6th month. Had living child at 28; easy labor; good recovery. In Spring '91, noticed heavy feeling in pelvis, and could feel a growth in median line. Has steadily increased in size. Menstruates regularly.	Tumor extends halfway to umbilicus. Fluctuating.	Removed multilocular cyst of right ovary containing two q'ts of a chocolate colored fluid. Left ovary cystic and was removed.	Patient made an uninterrupted recovery and left Hospital June 28th. In July an abscess opened at lower end of incision and discharged until September, when silk ligature from pedicle came away.	Irrigation; No drainage.	R.	Sinus entirely closed in October and no trouble since.

Am. IV A.E.D.	June 1, 1892. Dr. P. E. Beach of Seville.	Medium health; men- struated at 13; mar- ried at 21; no chil- dren; no miscar- riages. History of previous operation given below.	Adherent mass on left side of uterus; could feel nothing distinctly because of cicatrix from former operation.	Removed right ovary; cystic degenerated. Left ovary was pos- terior to uterus and in a mass of adhe- sions; was cystic de- generated and in re- moving the muscular coat of sigmoid was torn.	Very weak after op- eration. Steadily improved; gauze removed 2d day; tube on 3d day. Wound granulated slowly. Went home, July 18.	Irrigation. Glass drainage tube and tampon of iodoform gauze.	R. Case given in detail below.
Am. V K. Y.	Sept. 16, 1892. Dr. A. H. Hise of New Wash'g't'n.	Always delicate; men- struated at 14; mar- ried at 24; 4 children —youngest 16 months old. In October '91 noticed abdomen was enlarged. In Nov. '91 had some pain in left side. Tumor steadily increased and pati- ent lost flesh. Men- struated regularly since Apr. '92.	Tumor extending to umbilicus; fluctu- ating; hard nodu- lar masses to be felt through ab- dominal wall.	Removed multilocu- lar cyst of left ovary containing 2 gal. of chocolate fluid; ad- herent to omentum, intestines and ab- dominal walls. Por- tions of the tumor were suppurating.— Right ovary also cys- tic and was removed.	Patient very weak and required free stimulation. Sept. 26th—had an attack of pleurisy lasting ten days. Oct. 8th—developed phlebitis of left leg. Went home Nov. 25.	Irrigation. No drainage.	R. Reports this winter that she is perfectly well.
Am. VI M.M.J.	Sept. 21, 1892. Dr. L. G. Moore of Kinsman, "	Healthy until 1st child born; menstruated at 14; married at 20; first child at 22—for- ceps case. Always had pelvic pain since. Had twins at 24—easy labor. Since then ab- domen has been somewhat fuller and periods have been irregular. Had more pain during last two months.	Physical signs of ovarian cyst with only partially filled sac.	Removed parovarian cyst of left side, con- taining 2 quarts of clear fluid. Right ovary indurat- ed and enlarged, and was also removed.	Patient made an ex- cellent recovery and was about ready to leave hos- pital when on Oct. 20th developed a pleurisy. Went home Nov. 1st.	No irrigation. No drainage.	R. Saw patient in April '93 entirely recovered.

OPERATIONS FOR CYSTIC DISEASES FOR THE OVARIES.—CONTINUED.

No.	Nat. Age, Social Condition.	Patient sent by	Date and Place of Operation.	History of Patient.	Examination.	Operation.	After Treatment.	Irrigation and Drainage.	Result.	Remarks.
VII O. W.	Am. 47 Mar.	Patient from Youngstown.	Sept. 30, 1892. Charity Hospital.	Healthy until birth of child; menstruated at 17; married at 20; child at 21; hard labor, and has ever since had pelvic pain. Family physician discovered presence of tumor 3 years ago. Patient suffers greatly after any exertion.	Under an anaesthetic; found uterus retroverted, and a fluctuating mass to the right; slightly movable and crowded down in pelvis; was very painful.	Removed interligamentous cyst of right side—containing 3 pints of fluid; was firmly adherent to surrounding parts and could not be shelled out; stitched and cut away entire right broad ligament; small piece of sac left behind. Left ovary cystic and removed.	Omentum caught in drainage tube. Treatment in detail below.	Irrigation. Glass drainage tube.	Death in 5½ days.	No autopsy obtained.
VIII M. M.	Am. 21 Single.	In consultation with Dr. H. J. Lee.	Oct. 8, 1892. Charity Hospital.	Excellent health; menstruated at 15; regular. In May '91 noticed abdomen was somewhat fuller. Steadily increased in size. Courses have been irregular of late; has not lost flesh; very healthy looking.	Tumor was very tense and fluctuation indistinct. Cervix was soft and case had been diagnosed as pregnancy by two surgeons.	Removed multilocular cyst of right ovary containing 6 quarts of thick colloid fluid. Left ovary cystic, degenerated and was removed.	Developed a bad cystitis in 2d week. In 4th week developed pyelitis of right kidney. Had severe attacks which greatly delayed recovery.	Irrigation. No drainage.	R.	Left Hospital Dec. 26; could have gone sooner, but for want of suitable home for convalescence. Has entirely recovered.
IX J. A. A.	Am. 51 Mar.	Dr. D. S. Perkins.	Nov. 21, 1892. Charity Hospital.	Good health; menstruated at 15; married at 18; 5 children—youngest 20 yrs. old. Never had any trouble; ceased menstruating at 48. About this time noticed abdomen enlarged, but could not feel distinct tumor until spring of '92. Had some slight pain on left side. General health remained good.	Tumor fluctuating and extending above umbilicus.	Removed left ovarian cyst, weighing 20 lbs., containing light chocolate fluid. Right ovary normal and not removed.	Not a bad symptom of any kind. Left Hospital Dec. 10th.	No Irrigation. No drainage.	R.	Returned to her home in Michigan in Jan. entirely well.

X	Am.	Dr. G. R. Sherwood of Elyria.	Feb. 16, 1893.	Always healthy; menstruated at 15; menopause at 57; 1 child at 26; no miscarriages; had pleuritic effusion; aspirated 3 times. Cyst aspirated twice. History given in detail below.	Right chest full of fluid. Tumor extended 2 inches above umbilicus.	Removed cyst of right ovary, weighing sixteen lbs. Consisted of large cyst and deep in pelvis was a more solid portion containing papillary cysts. Adherent to omentum and anterior abdominal wall. Left ovary atrophic, not removed.	Uninterrupted recovery. Sat up in 3d week. Went home March 9th.	Irrigation. No drainage.	R.	Entirely Recovered.
XI	Ger.	Dr. A. Brintuall of Liverpool.	March 1, 1893.	Healthy; menstruated at 16—regular; first child at 27; 2nd at 29, no trouble. Three yrs ago noticed tumor on right side, grew slowly at first, but rapidly during last six months. Monthlies regular—no pain.	Tumor very movable and reaching above umbilicus—Very tense; indistinct fluctuation.	Removed simple cyst of right ovary, weighing 5½ lbs. Contents of very thick, chocolate colored fluid. Long pedicle; no adhesions. Left ovary normal; not removed.	March 14th developed slight phlebitis of left leg. Left Hospital, April 5th.	No Irrigation. No drainage.	R.	Patient writes she is doing well.
XII	Col.		March 20, 1893.	Always been delicate; menstruated at 16; married at 25; never pregnant. During last two years had pain in back and pelvis. During last year not able to do any work; had an escape of pus several times from vagina; periods regular.	Enlarged ovary on right side; indurated mass on left.	Removed cystic degenerated ovary—right side—size of an egg. Left tube enlarged and contained pus. Was in a mass of adhesions, and was removed with left ovary.	Uninterrupted recovery.	Irrigation.	R.	Steadily gaining strength.
L. W.	Mar.	Charity Hospital.					Left Hospital, Apr. 24.	No drainage.		

The above tables contain 12 cases with two deaths; the cause of death in both cases being peritonitis. The usual antiseptic precautions were observed during the operations. The abdominal cavity was irrigated in all cases in which there was much hemorrhage or escape of the contents of the cysts. Drainage was employed only in cases where oozing of blood continued after the ligation of adhesions. In those cases in which drainage was used, the tube was cleared by a syringe repeatedly during the first 24 hours and was revolved at each dressing. As soon as the oozing ceased, the drainage tube was removed and a small piece of gauze was placed in the external opening. Silk worm gut was used for sutures, taking care to include all the layers of the abdominal wall, the sutures being removed usually about the tenth day. The wounds as a rule healed by first intention, with now and then an occasional stitch abscess. The bowels, excepting when tympanites developed earlier, were moved on the fourth day by small and repeated doses of calomel and salts. The patients, in order to avoid the dangers of hernia, were not allowed to sit up until the third week. The following cases are given somewhat in detail.

CASE I.—M. M. Had always been healthy. In March, 1892, noticed that abdomen was enlarged, and called Dr. Kraus. Was seen in consultation, with Dr. Allen, in March, and again in April. The physical signs varied at the different examinations; at one time percussing for ascites, and at another for tumor. Ascites was diagnosed and an exploratory laparotomy was advised and performed May 17th. The abdominal cavity contained about six quarts of clear fluid. The right ovary was cystic degenerated, containing several cysts as large as eggs. The cysts easily ruptured during removal. Microscopic examination showed the tumor to be a Papillary Cystoma. The intestines and peritoneum were thickly studded with small growths. The patient made an uninterrupted recovery, and left the Hospital June 13th. The ascites, however, returned in the latter part of August. During the fall the patient was twice

aspirated and several quarts of fluid drawn away. Health gradually failed and patient died March 1893. No post mortem could be obtained; It is presumable that the small tumors on the peritoneum and intestines were small papillae which had escaped by rupture of a cyst and had attached themselves throughout the peritoneal cavity.

CASE IV.—A. E. D. In the fall of 1889, noticed a small lump in the left side which gradually increased in size and caused pain. In May, 1891, laparotomy was performed by a surgeon in Nashville, Tenn. The tumor was adherent and could not be removed. The cyst was opened and stitched to the abdominal wall, with drainage. Patient was entirely healed in about three months, but pains continued, about the same as before operation. In August, 1891, tumor again commenced growing and pain became more severe, so that patient was confined to the house most of the time. A physical examination revealed a hard mass on the left side of the uterus, but owing to the cicatrix and adhesions from former operations nothing could be distinctly felt. Operation was advised and performed June 1st. The old cicatrix was dissected out; right ovary cystic degenerated and removed. Left ovary was in a mass of adhesions and removed with much difficulty. Considerable oozing continued after irrigation and wound was tamponed with iodoform gauze. The operation was much prolonged, and patient left table in a very weak condition. Was freely stimulated, and reacted well. Patient made a good recovery and left the Hospital July 18th. Wound entirely closed, with the exception of a few granulating points. Patient was of a very melancholy disposition, and after leaving the hospital, became much worse. During the fall and winter, had several attacks in which she was violent, but at other times was perfectly rational.

CASE VII.—O. W. Interligamentous Cyst. Was very adherent, and small piece of the sack was left behind. Glass drainage tube was carried down to this point. The patient reacted well after

operation and had a good pulse. There was considerable oozing of blood. Tube was cleared every two hours and rotated at each dressing. Patient went along nicely for four days. Pulse about 100 and temperature under 100. The third day gave calomel and salts, and obtained a good movement of the bowels. Upon fourth day drainage tube was removed, and in spite of the great care that had been taken at each of the dressings, a piece of the omentum had grown through one of the holes in the tube. This was cut away, but in so doing, adhesions were broken, opening channels of infection into the general peritoneal cavity. That evening temperature went to 101; pulse to 120. Complained of intense abdominal pain. The following morning inserted finger deep into the wound and syringed out a purulent material. Tympanites rapidly developed and abdominal pain became more severe. Patient gradually failed and died on the fifth day after operation. No autopsy could be obtained.

CASE X.—A. D. T. Was perfectly well until May, 1891, when she had influenza, but not severe enough to call a physician. Did not fully recover, and was left with a cough. Lost considerable flesh. In September, 1891, called a physician to treat the cough. Had no pain in side. About April, 1892, noticed that the abdomen was enlarged. Had previously had a fullness in the left side, low down in the plevis. Dr. Allen saw the patient in consultation with Dr. Sherwood in July, 1892. Diagnosticated ovarian cyst. Patient also had at that time an effusion in the right plural cavity. Was aspirated on July 26th and removed three quarts of serum. Advised her to return home and wait until fall before considering operation. November 1st, 1892, patient again returned. Was again aspirated with removal of three quarts of fluid. Refused to operate the tumor until the general symptoms should improve. December 22nd, 1892, abdomen was enormously distended. Dr. Sherwood aspirated the tumor, removing 12 quarts of fluid. January 25th the abdomen was again filled and aspirated, removing nine quarts of fluid. These aspirations were advised since the pressure of the fluid was telling

seriously on patient. Patient now begged to be operated at any risk, so it was decided that the chest should again be aspirated, and the patient brought for operation in a few days afterwards. February 7th, 1893, Dr. Sherwood drew off three quarts serum from the right chest. The patient entered Charity Hospital February 14th. Operated February 16th. Dr. J. H. Lee administered the chloroform. Removed tumor of right ovary weighing 16 lbs. Was adherent to the omentum and abdominal wall. Abdomen was closed with silk worm gut sutures. Patient came out of operation with a pulse of 76. Reacted nicely. No vomiting; bowels moved without cathartic on second day. Stitches removed on seventh day. Wound absolutely healed. Patient sat up the third week and went home March 9th. Has been no return of effusion in the right side, and patient is perfectly well.

OOPHORECTOMIES AND SALPINGECTOMIES.

No.	Nat. Age, Social Condi- tion.	Patient sent by	Date and Place of Operation.	History of Patient.	Examination.	Operation.	After Treatment.	Irrigation and Drainage.	Result.	Remarks.
I	Am. 55 Mar.	Dr. H. W. Mowen, Deerfield, Ohio.	April 1, 1892. Charity Hospital.	Always delicate; men- struated at 14, 3 chil- dren—last child at 32; menopause at 48. In June, 1891, noticed white discharge; no odor at first but later very bad odor. Dis- charge comes sud- denly several times a day. Severe pain in pelvis. Can do no work; lost flesh of late.	In consultation with Dr. H. K. Cushing. Could not discover any enlargement of uterus or append- ages.	Removed tubes and ovaries.	Curetted uterus lat- er and treated with intra uterine injec- tions. Details below.	No irrigation; No drainage.	R.	Patient left hospital May 31st. Has had no return of trouble and is entirely well.
II	Am. 43 Mar.	Dr. Wm. Graefe, Sandusky, Ohio.	April 4, 1892. Charity Hospital.	Previous good health; menstruated at 13; married at 21; never pregnant; 12 yrs. ago while lifting was tak- en with pain in pel- vis; since then has had severe pain at intervals. Not able to walk much or at- tend to any duties. Periods come on earlier of late.	Resistant masses on both sides of uter- us. Very tender on pressure.	Tubes enlarged and thickened by inflam- mation; removed with ovaries 2 sub- peritoneal fibroids size of walnuts on anterior surface of uterus; dissected off and sewed incisions with cat gut.	Given in detail be- low.	Irrigation; No drainage.	Death on 17th day.	Volvulus of ileum with complete ob- struction.
III	Am. 31 Mar.	Dr. A. Brintnall, Liverpool, Ohio.	June 24, 1892. Charity Hospital.	Never healthy after periods commenced at age of 11; married at 23; 1st child at 27; always had pelvic pain on slightest ex- ertion; 2d child at 29; hard labor. Since then had several at- tacks of pain and fever and confined to bed several days; not able to do house work. Very melan- choly.	Enlarged tubes and ovaries to be felt. Very tender.	Tubes enlarged to size of lead pencil; contained pus; ova- ries enlarged and hardened; slight ad- hesions to pelvic wall. Removed tubes and ovaries.	In 2d week had se- vere attack of diar- rhea; could retain nothing by stom- ach; pulse weak; some fever; grad- ually improved but patient was very despondent during entire convales- cence.	Irrigation; No drainage.	R.	Patient left hospital July 31st. Health much improv- ed and feeling better than for several years.
S. N.	Mar.		Hospital.							

IV	A. C. K.	Am. 39 Mar.	Dr. F. B. William-son, Massillon, Ohio.	July 13, 1892, Charity Hospital.	Medium health; married at 30. Never pregnant; during past few years had painful menstruation and also continued pain between periods. Can not attend to any duties and slightest exertion brings on severe pelvic pain.	Enlargement of tubes and ovaries. Extreme tenderness on slightest pressure.	Ovaries much enlarged and hardened. Tubes also thickened and adherent; uterus somewhat enlarged and contained several small fibroids. Tubes and ovaries were removed.	Patient did well for 24 hours, then pulse and temperature commenced going up. Tympanites developed and no movement could be obtained; symptoms of peritonitis rapidly developed.	Irrigation: No drainage.	Death on 3d day.	Postmortem showed peritonitis as cause of death. Ligatures were in place.
V	C.M.H.	Am. 30 Mar.	Dr. G. S. Lanterman, Bellevue, Ohio.	October 27, 1892, Charity Hospital.	Healthy; menstruated at 12; married at 18; at 20 miscarried at 6 months. Never so well afterwards. At 23 had full term child; miscarried again at 26 and since then has never been well—confined to bed a good share of time; Periods irregular and accompanied by severe pain.	Tubes enlarged; left ovary much enlarged; could not be moved, very tender on pressure.	Right ovary hardened and enlarged; left ovary cystic. Tubes mass of adhesions. Ovaries and tubes removed with great difficulty; considerable hemorrhage, necessitating drainage.	Given below in detail.	Irrigation. Glass drainage tube.	R.	Went home Dec. 7th. Has at times some pain but is steadily improving and is able to attend to household duties.
VI	A. H. Zipp	Ger. 21 from Congregational Church, Akron, Ohio. Mar.	Patient	Nov. 30, 1892, Charity Hospital.	Healthy until courses commenced at 18; always had great pain; married at 20; since then has more severe pains; during past half year has had frequent and sudden discharges of pus; has never been pregnant.	Under ether could feel greatly enlarged tubes and ovaries; uterus normal size.	Right tube size of a lead pencil and filled with pus; left tube smaller and contained pus; ovaries much enlarged and cystic degenerated; many loose adhesions; removed tubes and ovaries.	Uninterrupted recovery; had no bad symptoms of any kind.	Irrigation. No drainage.	R.	Went home in about 4 weeks after operation. Perfectly well.

OÖPHORECTOMIES AND SALPINGECTOMIES.—CONCLUDED

No.	Nat. Age, Social Condition.	Patient sent by	Date and Place of Operation.	History of Patient.	Examination.	Operation.	After Treatment.	Irrigation and Drainage.	Result.	Remarks.
VII	Ger.			Menstruated at 15; never had any trouble until at 18 fell down stairs and brought on months 2 weeks ahead of time; never been well since; has severe pain 2 days before flow commences and is in bed about 10 days each month. Patient has for several years had cystitis; has an irritable stomach; extremely nervous.	Patient very tender and could only make out enlargements on both sides of uterus. Uterus normal size.	Tubes inflamed; ovaries hardened and cystic; in right broad ligament was cystic size of walnut. Removed tubes and ovaries; stitched uterus in abdominal incision.	Very irritable stomach for 2 weeks after operation. Very nervous during entire recovery. Uterine stitches removed on 21st day and a tampon of wool inserted as a support.	No		Went home March 29th. Health much improved.
	34	Patient from Wooster.	Feb. 1, 1893. Lakeside Hospital.						R.	
VIII	Am.			Always delicate; menstruated at 12; at 16 strained herself while lifting, causing prolapse of uterus to vulva; has severe pain at monthlies lasting 10 days; has tried all kinds of pessaries with no relief.	Uterus prolapsed. Ovaries enlarged and very sensitive.	Tubes and ovaries enlarged and were removed; on anterior wall of uterus was a small fibroid; this was dissected off and the uterus at this point sutured in abdominal incision.	Uninterrupted recovery; uterine stitches removed on 15th day and uterus supported for several weeks by tampons of wool.	No		Went home. Entirely relieved from former troubles.
	38	Dr. H. C. Eyman.	Feb. 9, 1893. Lakeside Hospital.						R.	
S. M.	Sing.							No drainage.		

The above tables include eight cases with two deaths, one death occurring on the 17th day, from intestinal obstruction; the other due to peritonitis. The details of operation were about the same as those carried out in the ovariectomy cases.

CASE I.—C. A. S. Had a discharge of bad smelling pus for about 10 months before operation. Case was seen in consultation with Dr. H. K. Cushing. Symptoms pointed to either a salpingitis or a cancer of the body of the uterus. Laparotomy was performed April 1st. The tubes were somewhat inflamed, and were removed with the ovaries. Abdominal incision healed by first intention. The discharge ceased for a few days after operation and again became profuse and very offensive. The interior of the uterus was washed out daily and treated with applications of iodine, but discharge still continued. May 12th dilated and curetted uterus, packing uterine cavity with iodoform gauze. May 14th gauze was removed and uterus was daily washed with bichloride solution, and interior treated with tincture of iodine. Patient rapidly improved. Discharge diminished and finally ceased. Left hospital May 31st. Has since had no treatment, with no return of the discharge. Patient writes that she is feeling very well, and able to attend to her household duties.

CASE II.—M. S. At the operation the enlarged tubes containing pus were removed with the ovaries. Patient reacted well after the operation. On third day calomel and salts were given, causing two good movements. Patient did nicely until the ninth day, temperature ranging about 99; pulse 90. Abdominal stitches were removed on the seventh day; wound entirely healed with exception of two small points of superficial suppuration. On 9th day patient was taken with sudden pain in the abdomen just after having a movement of the bowels, and on the following day commenced vomiting a stercoraceous material. Stopped all nourishment by stomach, and gave enemata of beef juice and stimulants. Salts were given in repeated doses but no movement could be obtained.

Patient gradually failed and died on the 17th day. Post mortem on the following day. The superficial part of the abdominal incision had opened, evidently as a result of the low condition preceeding death. The peritoneum was closed and the cavity was free from infection. Small intestine was distended down to 19 inches above the caecum. Here the intestine had formed adhesions to the pedicle and was twisted upon itself completely occluding the caliber of the gut. There was no peritonitis or free fluid in the abdominal cavity.

CASE V.—C. M. H. Tubes and ovaries were in a mass of adhesions and were removed with great difficulty. Considerable hemorrhage followed, requiring abdominal drainage. Patient reacted well, but suffered intense pain. The day after operation patient developed excessive tympanites. Small and repeated doses of calomel were given, followed by Rochelle salts, but no movement was obtained and patient commenced vomiting. In the evening patient took a very serious turn for the worse. Vomited incessantly and was in great pain; pulse about 140, temperature $99\frac{1}{2}$. Commenced giving rectal injections of aloes and oil. Injections came away with some lumps of faecal material, but tympanites continued. On second day commenced giving drachm doses of Rochelle salts, followed by rectal injections; passage of small amount of faecal material. The third day patient was slightly better, but could retain nothing on the stomach. On fourth day gave rectal injections containing two ounces of Rochelle salts, but could get no satisfactory movement. On fifth day patient's condition was very serious; excessive tympanites and extreme tenderness over entire abdomen. Hot fomentations were applied and injections of salts and water again given without bringing away any faecal material. Patient's condition was almost hopeless; pulse about 140, temperature 102. Drainage tube had been previously removed and gauze drainage substituted. On sixth day again gave injections of aloes and oil and at same time drachm doses of Rochelle by stomach, resulting in two good movements of the bowels and passage of much flatus.

This was the first satisfactory movement of the bowels after the operation. Patient from this time on steadily improved, but had continued pain in pelvis, aggravated by each movement of the bowels. The abdominal wound healed by granulation. The patient went home December 7th. For some weeks after the operation severe pain came on with each movement of the bowels, but this gradually subsided, and patient is now entirely well.

OPERATIONS FOR FIBROIDS OF THE UTERUS

No.	Nat. Age, Social Condition.	Patient sent by	Date and Place of Operation.	History of Patient.	Examination.	Operation.	After Treatment.	Irrigation and Drainage.	Result.	Remarks.
I L. B.	Am. 36 Single.	Patient from Cuyahoga Falls.	Sept. 22d, 1892. Charity Hospital.	Always healthy; menstruated at 15; regular as to time and quantity. At 22 commenced having severe pain at periods. In Feb. '90 noticed abdominal enlargement, and flowed excessively at periods.	Tumor extended $\frac{2}{3}$ distance to umbilicus; hard, symmetrical and movable.	Incision extended to within one inch of umbilicus. myo-fibroma, weighing 3 lbs. Extra peritoneal treatment of stump.	Serre-neud tightened at intervals during first 48 hours; stump cut away on 18th day. Left Hospital, Nov. 5th.	No irrigation. No drainage.	R.	Healed in seven weeks after operation. No trouble since.
				Healthy; menstruated at 14—regular. In 1888 discovered tumor in pelvis, in median line, '92 commenced flowing excessively. Periods each month and flow continuing 3 weeks.	Tumor extended half way to umbilicus; hard and nodular.	Removed adherent tubes and ovaries.—Fibroid in omentum size of an egg. Enucleated fibroid in anterior wall of uterus, and sewed incision with cat gut. Uterus adherent to pelvic wall, and was not removed.	Patient did not react well after operation. Heart was weak and rapid, and did not respond to stimulants.	Irrigation. Gauze drainage.	Death in 54 hours.	Given in detail below.
III A. M.	Ger. 44 Mar.	Patient from Berea, Ohio.	Dec. 10th, 1892. Charity Hospital.	Healthy; menstruated at 14—regular. Married at 32; child at 34; never pregnant since; noticed tumor in Feb. '88; had seven operations for removal of portions of sloughing fibroid. Given in detail below.	Uterus extended to umbilicus Sloughing mass presenting through os uteri. Discharge very offensive.	Removed sloughing myo-fibroma, weighing $4\frac{1}{2}$ lbs. Uterus amputated, and stump treated extra-peritoneally.		Irrigation. Glass drainage tube.	R.	Case given in detail below.

IV	Am. 32	Patient from Cuyahoga Falls,	Feb. 9th, 1893.	Delicate health; menstruated at 11; never regular. Married at 21; never pregnant; 7 years ago noticed tumor, has steadily grown. In Dec. '92 lost a large amount of watery discharge, and was very weak. Periods of late have been prolonged, and patient was losing strength; unwell last time on Jan. 22, '93; lost large amount of blood.	Tumor extended $2\frac{1}{4}$ inch above umbilicus; hard, symmetrical and very movable.	Incision extended one inch above umbilicus. Ligated broad ligaments with silk. Amputated uterus weighing 6 lbs. Sutured stump extra; peritoneally; applied serre-neud and elastic ligature.	Patient had been a morphine eater, and required large doses to keep her quiet. Serre-neud removed on 11th day. Patient made an uninterrupted recovery and went home April 4th. Wound entirely healed by middle of April.	No irrigation.	R.	Now has excellent health.
V	Irish. 34	Dr. W. A. Knowlton,	March 7th, 1893.	Healthy; menstruated at 13—regular. During last 6 years had fullness and pain in pelvis; bowels constipated; was treated with electricity from Sept. 1891 to June 1892. Improved at first under treatment, then grew worse. No increase in menstrual flow. Had continued pain in pelvis and bearing down sensation.	Porterior to uterus was a mass size of an orange. Very painful on pressure.	Patient in Trendelenburg position. Removed subperitoneal fibroid, weighing $1\frac{3}{4}$ lbs., and attached to posterior wall of uterus; sewed incision in uterus with cat gut. Right ovary was cystic degenerated and was removed. Abdominal incision closed with silkworm gut sutures.	Patient made an uninterrupted recovery and left Hospital April 4th.	No irrigation.	R.	No pain since operation.
M. M.	Single.		Lakeside Hospital,					No drainage.		

The above table includes five cases of operations for uterine fibroids; in three cases abdominal hysterectomy was performed and the stump treated extra-peritoneally. In one case the fibroid was enucleated without removal of the uterus. In the other case both ovaries and an intramural fibroid were removed.

CASE I.—L.B. When about twenty-two years of age began having severe pain at monthly periods. In February, 1890, noticed a tumor low down in the median line, which steadily increased in size. Patient consulted Dr. Allen in June, 1892. Periods lasted five or six days and were attended with such severe pain that patient administered chloroform to herself. A large amount of blood was lost at each period and the general condition of the patient was extremely poor. Advised postponement of operation until fall and sent patient up the lakes. During the summer gained seven pounds and in September returned. Dr. H. J. Lee gave the anaesthetic, ether. The uterus extended two-thirds the distance to umbilicus; there were no adhesions. Applied elastic ligature around uterus; and incised and removed an intramural fibroid before amputating the uterus; the mass weighed three pounds. Applied serre-neud to the stump and sutured extra-peritoneally; heavy ligatures of silk were applied to the broad ligaments. Patient reacted well from the operation. Had suppression of urine until the following morning, when a normal quantity was drawn by catheter. The serre-neud was removed on the eighteenth day. Wound was entirely healed in about seven weeks.

CASE II.—A. D. First noticed enlargement of the abdomen in 1888, but had no trouble at monthly periods until spring of 1892, then commenced losing large quantities of blood. Periods would last three weeks with usually only an interval of one week. Patient did not suffer much pain, but could not work on account of weakness from excessive loss of blood. Dr. Allen saw patient first in June, 1892. Advised a course of tonics, and a postponement of operation until fall. Was operated September 28th, 1892. Dr.

Lee gave anaesthetic—ether. On opening the abdominal cavity, found a fibroid in the omentum about the size of a duck's egg, which had become completely detached from the uterus, and was receiving its blood supply from the omentum. Removed fibroid and piece of omentum. Right ovary was adherent to the omentum and intestine; left ovary adherent to the pelvic wall. Both ovaries and tubes removed. In anterior uterine wall was a fibroid about the size of an orange; this was enucleated. There were also numerous smaller intramural fibroids. The uterus could not be removed owing to dense adhesions posteriorly to the rectum and pelvic wall, so that it could not be raised out of the pelvis. Sewed up the incision in the uterus with heavy cat-gut.

Abdominal cavity was irrigated and incision was about to be closed, when suddenly a considerable venous hemorrhage occurred from the adhesions at the left side of the uterus. The whole surface oozed and could not be controlled by ligatures. A Mikulicz tampon was carried down into this cavity to control the hemorrhage. On account of this hemorrhage, the operation was much prolonged and the patient left the table with a weak pulse of about 140. Previous to the hemorrhage it had not exceeded 90. Stimulants were freely given but patient did not react. Dressings were changed on the day after the operation, but tampon was not disturbed. The hemorrhage ceased, but patient did not rally and died on the second day after operation. Post mortem examination showed that the hemorrhage had been controlled by the tampon; no clots of blood were found in the abdominal cavity, and everything in the way of sutures and ligatures was in place. Death resulted from loss of blood, and patient being short and fat, had the weak heart not uncommon in such persons.

CASE III.—A. M. Was perfectly healthy until the fall of 1886, when she noticed the abdomen was enlarged, and had some pains at monthly periods. Tumor steadily increased and in February, 1888, commenced treatment by electricity. Continued to grow larger and

in October 1888, the fibroid commenced sloughing. Patient had a high fever from septic absorption, and odor from the discharge was very offensive. In November, 1888, consulted a surgeon of this city, and during the winter had three operations in which pieces of the sloughing fibroid were removed with the ecraseur. Patient showed marked signs of septic absorption after each operation. Was treated with hypodermics of ergotine between the operations. Left the hospital in April considerably improved in general condition, but discharge soon commenced as bad as ever. In November, 1889, had the fourth operation; October, 1890, fifth operation; September, 1891, sixth operation; November, 1892, seventh operation. At each time a piece of the tumor presenting through the cervix was removed, but the discharge would reappear in a few weeks and another mass would present itself in the cervical canal. The odor from the discharge was so offensive that patient suffered the greatest annoyance. At times the tumor has extended down in the vagina and presented at the vulva. Dr. Allen first saw the patient November, 1892, but refused to operate. Patient returned repeatedly and begged to be operated at any risk. Has never lost large amount of blood. Patient entered Charity Hospital, December 5th, 1892. Was thoroughly cleansed with bi-chloride douches daily preparatory to operation and vagina tamponed with iodoform gauze. Uterus was very movable; extended to umbilicus. A sloughing mass about the size of an orange presented at the cervix. Operated December 10, 1892. Abdominal incision carried two inches above umbilicus. Broad ligaments were first ligated with silk, and enucleation performed without the use of the elastic ligature. The intestines were carefully protected with sheets of iodoform gauze; the uterus was incised and the sloughing mass pulled upward through the cervix. A serre-neud was then applied and the uterus amputated. When just ready to flush the abdomen, a ligature on the right broad ligament gave way and severe hemorrhage occurred. Patient up to this time had had an excellent pulse, not exceeding

85, but after hemorrhage, was much weakened and pulse went to 125. Patient at this moment came out partially from the anaesthetic and the intestines escaped from the abdominal cavity and were replaced with difficulty. The hemorrhage was controlled; abdominal cavity irrigated and a glass drainage tube carried into the pelvis. Stump was sutured extra-peritoneally; incision closed with silk sutures. Patient was in very weak condition at close of operation. Was freely stimulated. Drainage tube was thoroughly cleansed with a syringe every hour. On second day had symptoms of intestinal obstruction. Injections of aloes and oil were given with no effect. On third day symptoms of obstruction increased, and injections were repeated, causing a good movement. Drainage tube was removed on the third day, and patient went on to an interrupted recovery. The serre-neud was removed on the 20th day. Patient left the hospital, January 31st, and was entirely healed about the middle of February.

CASE I—S. B. Always healthy. Menstruated every three weeks, never much in quantity. First confinement at 25. Had a long tedious labor. Was badly lacerated but made a good recovery and has since been perfectly well. Was unwell for the last time in March, 1892. In April had no courses and thought she was pregnant. About April 27, attempted an abortion by injecting a solution of carbolic acid into the uterus. On May 1st commenced flowing and had considerable pain in the lower part of the abdomen. Thick clots were discharged, and shreds of tissue, which the patient took to be membranes. On May 3rd Dr. J. N. Sipher was called. Bleeding still continued. Patient was put to bed and antiseptic douches given twice daily for five weeks. During this time there had been a slight amount of blood passed each day. Patient was then allowed to get up, and went to doctor's office for treatment during following two weeks. On June 19, was suddenly taken with severe pains in the pelvis and commenced to bleed profusely. On June 23, at 5 p. m., Dr. Allen was first called in consultation. Found patient in great pain, and satisfactory examination was difficult. Could make out enlargement in lower part of abdomen with indistinct fluctuation. Advised operation, and ordered patient to be taken to the hospital. Operated June 24th. Patient had fainted during the night; pulse was about 130, and very weak. Under the anaesthetic, could feel a mass in the abdomen extending to the umbilicus. Fluctuation was distinct. Haematocele was diagnosed and it was decided to open and drain through the vagina. On opening Douglas' sac, about two quarts of clotted blood were removed. It soon became evident that this method would not successfully clear the abdomen, consequently the abdomen was opened by a median incision. Both ovaries were oedematous and enlarged three or four times normal size, and were shelled out; no vessels needing ligation. Again inserting the hand a mass was found and removed. This proved to be the left Fallopian tube which had been ruptured by the ectopic gestation. Abdominal cavity was

irrigated and two rubber drainage tubes introduced, extending through abdominal incision and out through the vagina. Mikulicz tampon was introduced into the pelvis and ends brought out through abdominal opening. Vagina was tamponed from below. The operation was made as quickly as possible, owing to the weak and failing condition of the patient. Pulse after operation, 160; very weak. Patient was freely stimulated, but did not react fully until the following morning. Second day bowels were moved with calomel and salts. On third day gauze tampon and one drainage tube were removed. On sixth day the second drainage tube was removed and gauze drainage introduced through abdominal incision. Patient went along nicely until July 15th, when temperature went to 102. On July 16th there was a discharge of several ounces of pus through the abdominal incision. Patient rapidly improved and left the hospital August 4th. Wound was entirely closed about eight weeks after operation, and patient has since had no trouble of any kind. She still continues to menstruate, notwithstanding both ovaries were entirely removed.

CASE II — H. S. Healthy woman. Menstruates every three and one-half weeks; normal quantity. January 8th, 1893, flow was delayed three days. Had considerable pain and flowed freely, a slight discharge continuing until operation on February 20th. Temperature had ranged from 99 to 101; pulse 100 to 110. About February 10th, noticed an enlargement of the abdomen, which has steadily increased. Dr. Allen was called to Warren, February 19th. Physical examination showed the os-uteri to be patulous, and could insert finger one and one-half inches. An oval mass extended upward and to the left, to the level of the umbilicus. Fluctuation at upper portion of the tumor. Uterus could be felt enlarged three times normal size and connected with this mass. On the right side was a smaller and more dense tumor. Operated February 20th. Dr. Ward gave the anaesthetic—ether. Median incision; left broad ligament greatly distended with blood. Incised and removed

about two quarts of thick clots. Left tube was tied with cat-gut, and removed. Right ovary cystic degenerated, and in a mass of adhesions. Sac of the haematocele was adherent and could not be removed; was stitched to abdominal wall and packed with iodoform gauze. Mikulicz tampon was carried down to the site of the right ovary. Closed the peritoneal cavity above with silkworm-gut sutures. Patient reacted nicely after the operation. On the fourth day the tampon was removed. Patient went on to an interrupted recovery. Was entirely healed in about five weeks.

OPERATIONS FOR PELVIC ABSCESS.

No.	Nat., Age, Social Condition.	In Consultation with	Date and Place of Operation.	History of Patient.	Examination.	Operation.	After Treatment.	Irrigation and Drainage.	Result.	Remarks.
I H. T.	Am. 22	Dr. Wm. Belt, of Kenton, Ohio.	Oct. 12th, 1892. Charity Hospital.	Very healthy; menstruated at 12; married at 18; never pregnant. Had uterus curetted in Feb. '92, and peritonitis followed; did not recover after operation; lost flesh; had some fever and severe pain in pelvis. Temperature before operation ranged 104.	Tumor extended nearly to umbilicus; indistinct fluctuation.	Abdominal incision in median line. Opened several small cysts; emptied abscess cavity, containing 1½ pints of pus and a lumbricoid worm, 8½ in. long. Drained through vagina.	Health of the patient has somewhat improved, but discharge continues. Drainage is now maintained by a few strands of wicking.	Irrigation; Rubber drainage tubes.	R.	Given below in detail.
	Irish. 44	Dr. E. L. Morse, of Ashtabula, Ohio.	Nov. 23d, 1892. At Residence.	Healthy; menstruated at 13; 1st child at 24; 2d at 28; had some pelvic trouble after last confinement; suddenly taken sick August 31st, '92; pain in right side of pelvis lasting a few days; Sept. 5th noticed a tumor, size of an orange, in right pelvis; had some fever, ranging from 101 to 103 during following month. In Sept. examination showed tumor size of a coconut; about middle of Nov. had an attack of pain, followed by chills and fever.	Tumor extended on right side to level of umbilicus. Indistinct fluctuation. Abdomen tympanitic and very tender.	Median abdominal incision. Opened peritoneal cavity; Abscess was opened between retaining sutures, the peritoneal cavity being packed off with iodoform gauze. Stitched abscess wall in abdominal incision; introduced two rubber drainage tubes and gauze tampon. Abscess contained a quart of offensive pus.	Temperature came down after operation. Gauze removed on 2d day, and cavity washed daily with boracic acid solution. In February '93, a slight discharge still continued.	Irrigation; Rubber drainage tubes.	R.	Patient able to be around and assist in household duties.
III. M. T.	Am. 36	Dr. W. G. Smith, of Ravenna, Ohio.	Jan. 31st, 1892. Charity Hospital.	Healthy until birth of child at 25; menstruated at 15; married at 24; never been pregnant but once; has had some pelvic pain since confinement. Feb. '92 had several attacks of abdominal pain lasting a few hours. In July '92 commenced having fever and pain in left ovarian region. Has not been able to do any work; steadily lost flesh and presented appearance of a person with malignant trouble; has not had courses since Oct. '92. Evening temperature about 101; pulse 110 to 120.	Vaginal examination showed uterus pushed downward and to the right; Right pelvis filled with a dense mass; not movable; no fluctuation. Uterus not enlarged. Tumor extended 2½ distance to umbilicus. Albumin in urine.	Dr. Lee gave chloroform.—Median abdominal incision. Opened several small cysts; came upon tumor in a mass of adhesions; aspirated and found pus. Introduced fixation ligatures into wall of tumor; tamponed off the peritoneal cavity and opened abscess containing two quarts of thick pus. Irrigated; made counter opening in vagina and introduced two rubber drainage tubes; sewed abscess wall to abdominal incision; tampon of gauze.	Pulse at close of operation 134. Evening temperature normal. Tampon removed 3d day, and cavity washed daily with boracic acid solution. On March 1st one tube was removed. March 28th 2d tube removed, and a few strands of silk introduced to maintain drainage.	Irrigation; Rubber drainage tubes.	R.	Patient went home March 29. Discharge diminished and all drainage discontinued in about 10 days. Patient entirely healed in latter part of April.

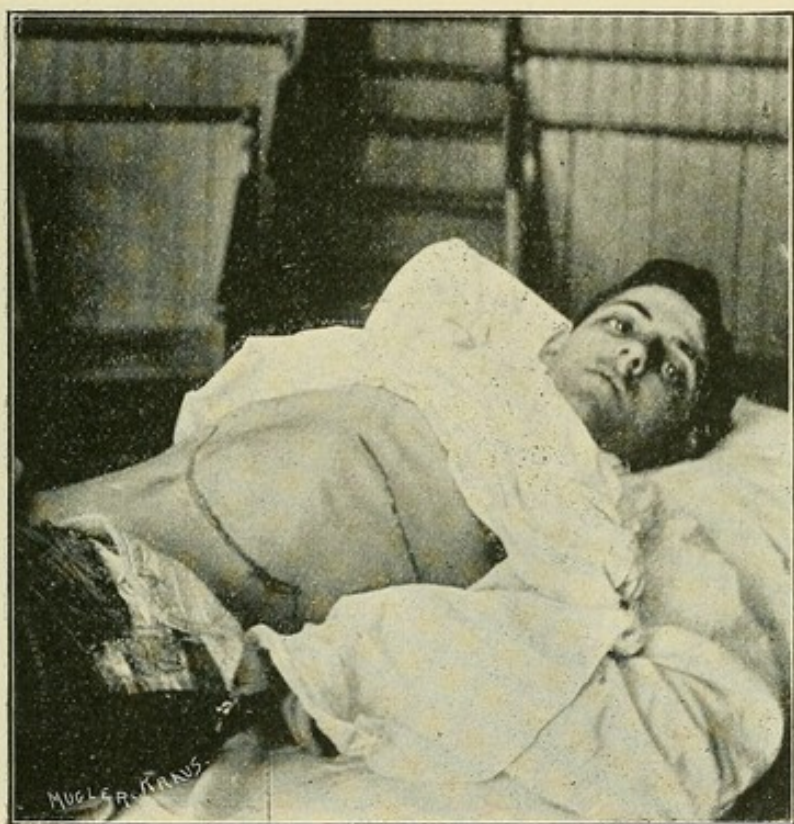
The above table includes three cases with no deaths.

The following case is especially worthy of mention.


CASE I—H. T. Was entirely well until early spring of 1890, then commenced having pain in pelvis, and was treated for retroflexion. In February, 1892, was curetted, the operation being followed by a severe attack of peritonitis. Was confined to bed several weeks. Has since steadily lost in weight. Had almost constant pain in abdomen, accompanied by high temperature every evening. Dr. Allen first saw patient, October 7th, 1892. Abdomen was very tender, and examination difficult. Could make out a mass extending nearly to umbilicus. Fluctuation was indistinct. Laparotomy was performed October 12th. Median incision; the bladder extended to within two inches of umbilicus. Dissected to the side, and came upon several small cysts containing clear straw colored fluid. Below and to the left, opened an abscess cavity containing about one and one-half pints of thick yellow pus. In this cavity was found a lumbricoid worm eight and one-half inches long. Vagina was washed with bi-chloride, and a counter opening made through Douglas' sac. Introduced two drainage tubes extending through abdominal incision and into the vagina. Abscess cavity tamponed with iodoform gauze. Patient reacted well from the operation, and in the evening, temperature came down to normal, having been $102\frac{1}{2}$ on the two evenings preceding the operation. On the following day gauze tampon was removed and abscess cavity washed out daily. November 6th, one of the drainage tubes removed. Patient left hospital, November 19th. Patient's condition continued improving for some time. In latter part of January, commenced having fever at night and abscess did not drain well. February 11th, the sinus was dilated and rubber drainage tubes again introduced. Patient has since had less fever, but is troubled greatly with tympanites. In March, a faecal fistula developed, which is still discharging.

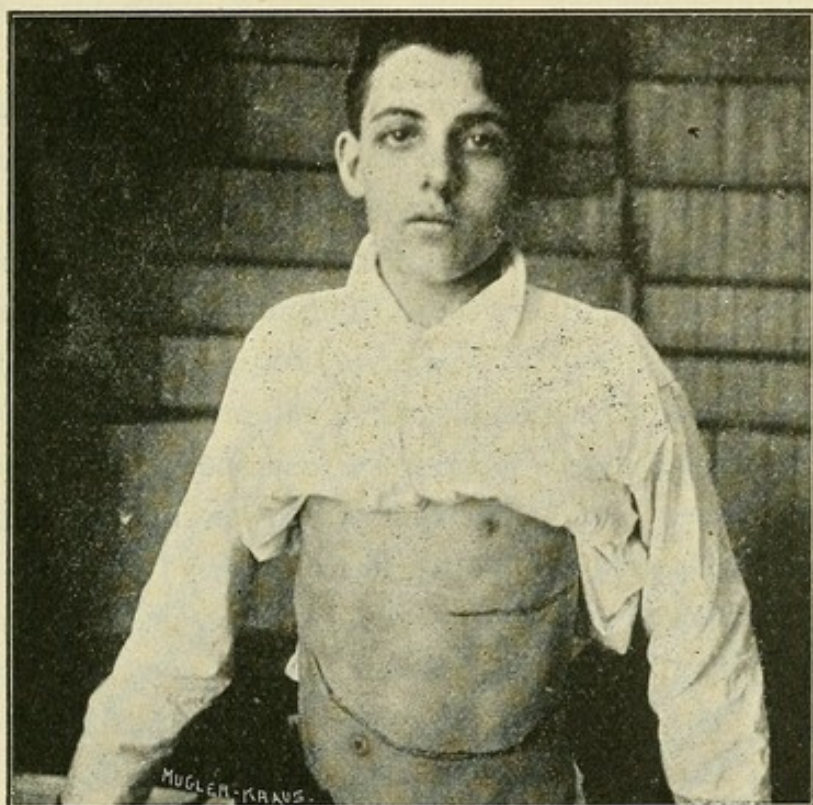
MISCELLANEOUS CASES.

C. H —*Pancreatic Cyst*.—American, 19 years of age, single. Has always been a healthy boy. Nine years ago while running along a railroad track, stumbled and fell on the end of a stick, striking in the region of the stomach. Since that time patient thinks there has been some slight fullness in that region. In December, 1891, commenced having pain in back and noticed a tumor in region of stomach; has lost flesh rapidly and is very anaemic. Patient was seen in consultation with Dr. O. B. Campbell. Entered Lakeside hospital January 28th. Physical examination showed fullness in left hypochondriac region, being most prominent about four inches above umbilicus and three and three-fourths inches to left of median line. Lower seven ribs on left side are somewhat bulging. Dulness extends from sixth rib in the mammary line to level of umbilicus. Dullness crosses median line three-fourths of an inch above umbilicus, extending upward obliquely to the right and is lost in the dullness of the liver in the right mammary line. Rest of the abdomen is clear. Area of dullness is not affected by change of position. There was fluctuation over the prominent portion of the tumor. Operation February 2nd. Incision in median line from ensiform cartilage to umbilicus; opened peritoneal cavity. Liver in normal position; stomach to left of median line, extending downward and to the right, on a line from the seventh rib to a point midway between umbilicus and floating ribs of right side. Stomach was empty. Above was a thick walled cyst between stomach and left lobe of liver. Tumor was incised between retaining sutures, and circumference of opening stitched with silk to the abdominal walls. Previous to this a quart of fluid had been removed by an aspirator. Fluid was thin and of a greenish brown color and had a distinct glistening appearance. After fluid had been removed there remained on inner surface of cyst shreds of brown friable tissue. Outer surface of cyst was slightly redish in color, and uneven. Cyst wall was about 2 m. m.




H. C.—PANCREATIC CYST—SHOWING PROMINENCE OVER REGION OF TUMOR.





H. C.—PANCREATIC CYST—SHOWING LINE OF DULLNESS.



in thickness, and in places seemed almost cartilaginous. Was fairly firm, and did not tear under ligatures. Cyst was irrigated and cavity packed with iodoform gauze. Patient reacted nicely after operation. The tampon was removed on the fifth day. The walls of the cyst gradually collapsed, portions of the sack coming away in shreds. Patient left the hospital March 13th. A small sinus still remains. Fluid removed was very rich in cholesterol.

F. S.—*Intestinal obstruction due to Volvulus*.—Bohemian, 27, married. A strong and robust fellow; always had good health. On September 26th, 1892, had movement of bowels at 3 a. m., and was immediately taken with severe abdominal pain. Dr. A. J. Cook was called during the forenoon; gave salts and injections of water, but could obtain no movement. Patient suffered considerable abdominal pain throughout the day. September 27th, repeated salts and injections, but no movement. Patient was sent to Lakeside Hospital in the evening. Dr. Allen was called in consultation September 28th. Abdomen was greatly distended, and patient suffered intense abdominal pain. Gave small and repeated doses of calomel, followed by salts and injections. Patient vomited several times during the day and no movement of the bowels was obtained. September 29th tympanites increased. Extreme general abdominal pain, not localized. Temperature 100 1-5; pulse 88. Operation at 8 a. m. Dr. Cook present. Median incision. First examined appendix and found in normal condition. On opening abdomen a quantity of fluid escaped, presenting intestine deeply congested. Commencing at the caecum the ileum which was greatly distended, was followed upward, and suddenly came upon collapsed gut about three feet from the ileo-caecal valve. The collapsed gut was followed along for about three feet and suddenly came upon distended gut, which was traced to the stomach. No adhesions were found. Abdomen was irrigated, and incision closed with silkworm gut sutures. Patient was in considerable collapse at close of operation; pulse 148, weak and irregular. Was stimulated freely. At 2 p. m.

vomited. Was in great pain. Gave rectal injection of oleum ricini aloes and small doses of calomel, followed by dram doses of Rochelle salts. Bowels moved at midnight, and again at 3 a. m. the following morning. Next day patient was much better. Tympanites and abdominal pain were diminished. October 5th sutures were removed. Wound suppurated superficially, and healed by granulations. Patient made an uninterrupted recovery; left the Hospital October 21st. Has since been perfectly well.

A. M. H.—*Laparotomy for Foreign Body.* German, aged 5 years. Patient was a pale looking boy, but had never had any serious illness. January 7th, 1893, swallowed a toy sleigh bell. The mother of the boy put her fingers into the throat to remove the bell, but only pushed it further down. During the day patient had considerable pain in the throat and could not swallow liquids, all attempts being followed by immediate expulsion of the fluid mixed with blood. Dr. A. Brintnall, of Liverpool, saw the patient in the evening. On the following day could swallow liquids and on second day took soft diet. After a few days could eat vegetables but has never been able to swallow meat. Stools have been closely watched but bell has not come away. Has had considerable cough, but has been up and around the house and did not complain seriously until about February 1st. Was then taken with severe cramps in the abdomen, not localized. February 2nd temperature was 101. February 3rd, 102 in the axilla. Passed some mucus by bowel. Dr. Allen was called to Liverpool February 4th. The mucus membrane of the mouth and nose was congested and covered with ulcers. Percussion and auscultation of the chest revealed nothing abnormal. Abdomen somewhat tympanitic; no localized dullness. Complained of general abdominal pain. Rectal examination revealed nothing. It was thought probable that the bell had lodged in the oesophagus and had worked its way into the surrounding tissues but owing to the long time which had elapsed, it was considered dangerous to attempt removal with instruments

introduced through the mouth. It was decided to explore the abdomen, making incision over the stomach in order to be able to reach from this point the pylorus, the ileocaecal valve and the oesophagus. On opening the abdominal cavity, pylorus and ileocaecal valve were examined, and afterwards the intestines, but the bell could not be found. The stomach was then opened near the cardiac end and finger introduced into the oesophagus. Long forceps were extended up the oesophagus, but nothing found. Oesophagotomy was then performed; the operation being rendered very difficult by clusters of enlarged cervical glands overlying the vessels and the oesophagus. The oesophagus was opened, but being too small to permit the introduction of the finger, forceps were introduced at the same time from above and below, but nothing could be felt of the foreign body. The patient was in a very weak condition, and it was thought best to do nothing further. The opening in the stomach was closed with cat-gut, and abdominal incision with silk-worm-gut sutures. The oesophageal incision was packed with iodoform gauze. Child was very weak at the close of the operation. Rallied somewhat about 4 p. m., then gradually failed and died at 7 p. m. No autopsy could be obtained. The most probable explanation of the case was, that the bell had ulcerated through the wall of the oesophagus.

P. F.—*Incompleted laparotomy for impacted gall stones.*—American; 60 years of age; married. Had previously been strong and healthy. Fifteen years ago, while in Georgia, had a severe attack of malarial fever and passed a gall stone. Three years later passed the second gall stone and from that time until two years ago has passed gall stones at intervals varying from a few months to a year. In August 1891, commenced losing flesh. Had chills every few weeks, followed by fever. In March, 1892, Dr. Maynard of Elyria, took charge of the case. Since that time the stools have been of a grayish white color. Patient shows marked icterus. The attacks have grown more frequent and have been accompanied by severe

pain. The attacks usually commence with a chill, with an increase of temperature during the attack and sub-normal temperature following. Urine contained bile during the attacks. Dr. Allen was called in consultation October 14th. It was decided to make an exploratory laparotomy. Operation was performed October 17th, Dr. H. A. Tobey of Toledo present. Dr. Maynard gave ether. Incision was made over the region of the gall bladder parallel to the right costal cartilages. On opening the abdominal cavity the omentum was adherent to the abdominal walls and to the liver. The intestines were firmly adherent to the under surface of the liver and all attempts at dissection were followed by considerable hemorrhage. A small movable mass, presumably a gall stone could be felt, but it was thought unsafe to proceed further with the operation owing to the firm adhesions and hemorrhage. The peritoneum was sutured with fine and the abdominal muscles with heavier cat-gut. The skin was united with silk worm gut sutures. The patient reacted well after the operation and went on to an uninterrupted recovery. A few stitch abscesses formed but closed by granulation. Since the operation the health of the patient has been much improved. The attacks have been less frequent and patient has gained much in flesh. Notwithstanding this improvement the further history of the case is looked upon as uncertain. The degree of improvement which has been secured has doubtless been due to the breaking up of adhesions.

ABDOMINAL OPERATIONS. (NOT LAPAROTOMIES.)

ABDOMINAL OPERATIONS NOT LAPAROTOMIES.

Thirteen operations, including two operations for hernia, two nephrectomies and two nephrotomies, one perinephritic abscess, one fistula, and five operations upon the abdominal walls, including tumors, and minor operations.

Operations for hernia; two cases; one recovery, one death, following strangulated hernia.

Case I.—C. K. German; 21 years of age; single. Had always been healthy. Has had a right inguinal hernia since birth, but never caused much trouble until March, 1892, when it came down and was reduced with difficulty. Has tried various kinds of trusses, but without success. Patient also had a hydrocele on the right side. Patient sent by Dr. F. Fliedner. Was operated at Charity Hospital, May 11th. Incision over external abdominal ring. Intestines were easily reduced. Omentum which was adherent to the sac was ligated with silk and stump returned to abdominal cavity; sac also ligated and cut away. Sutures of silver wire were introduced through the pillars of the ring, the ends being carried up through spirals of silver wire and fastened by clamping with a split shot. These sutures are easily removed by cutting away the shot and pulling out the spiral, which leaves the ends of the silver wire free to be seized and withdrawn.

Dissected out the sack of the hydrocele and also removed two small hydroceles of the chord. Sewed the incision with silk; gauze drainage. Patient made an uninterrupted recovery; Wire sutures were removed May 22d. There was some superficial suppuration and wound healed by granulation. Patient went home June 11th. Has a strong scar and no return of the trouble.

Case II.—Mrs. W. German; age 48; always been healthy. Has had a right inguinal hernia for several years, but was able to control with a truss. On March 20th, hernia came down, and could not be reduced. Dr. C. Sihler was called and advised immediate operation, but patient refused. Several attempts were made at

reduction, but failed. Patient was in extreme pain, and commenced vomiting a stercoraceous material. Was taken to Lakeside Hospital March 22nd. Hernia had then been down about 60 hours and patient finally consented to operation. On opening the sac considerable fluid escaped. The gut was much darkened, but regained its color somewhat after the stricture was cut. Patient was in a very weak condition and it was thought best not to attempt a resection, there being a fair chance that the intestine would not become gangrenous. Intestine was returned to abdominal cavity and the sac tied and cut away. The ring was sewed with kangaroo tendon. On following day passed flatus. Temperature ranged between $100\frac{1}{2}$ and $101\frac{1}{2}$; pulse 112 to 116. On third day obtained movement of the bowels. On fifth day patient suffered intense abdominal pain and symptoms of perforation appeared. Rapidly failed and died on fifth day after operation. A post mortem examination revealed a perforation, with escape of faecal fluid into the abdominal cavity, causing general peritonitis.

KIDNEY CASES.

No.	Nat. Age.	Sex, Social Condition.	In Consul- tation with	Date and Place of Operation.	History of Patient.	Examination.	Operation.	After Treatment.	Result.	Remarks.
I E. J. J.	Ger. 41	Widow.	Dr. G. W. Ryal, of Wooster, Ohio.	Oct. 27th, 1892. Charity Hospital.	Good health; married at 17; has 4 children. Had a fall in Oct. '91, and in following Dec. noticed tumor in right side; has had several attacks of pain commencing in region of right kid- ney. Patient has lost flesh rapidly of late.	Hard movable lum- bar tumor in right lum- bar region. Urine full of pus.	Right lumbar neph- rectomy. Removed kidney, which was somewhat enlarged, and pelvis filled out by two calculi; large calculus in ureter. Tampon iodoform gauze.	Tampon removed on 4th day. Patient in bad con- dition for several weeks after oper- ation. Left Hospital, Dec. 18th.	R.	Patient now in excellent health. Case given in detail below.
II L. K.	Am. 26	Female. Married.	Dr. W. H. Humiston.	Jan. 18th, 1893. Dr. Hum- iston's Hospital.	Delicate child — but healthy after periods commenced; had one child and soon after- wards a severe cysti- tis developed. Received injury over left kidney in July '92. Fluctuating tumor developed and Dr. Humiston per- formed nephrotomy in Sept. '92.	Sinus remained open from previous operation, and still discharging pus.	Left lumbar nephrec- tomy. Sinus dissect- ed out; made crucial incision; removed suppurating kidney. 3 times normal size; sutured abdominal incision with silk, leaving a tampon of gauze in cavity.	Had considerable tympa- nites Dressing remov'd on 4th day. Left Hospital Mar. 4th.	R.	Patient has en- tirely recover- ed.
III G. H. W.	Am. 44	Male. Married.	Dr. C. D. Noble, of Oberlin, Ohio.	Sept. 7th, 1892. Residence of Patient.	Had renal colic eight years ago; albumin in urine three years ago. Health gradu- ally failed since Spring of '92. Had fever of late with pain in left lumbar region, and tumor developed.	Fluctuating mass in region of left kid- ney. Urine contained pus.	Left lumbar nephro- tomy. Kidney en- tirely destroyed; ab- scess contained two quarts of pus. Iodoform gauze tam- pon.	Tampon removed on 3d day. Patient improved for 2 months after operation. In Nov. began fail- ing, and was very restless. Iodoform discontin- ued, and patient has improved slowly up to pres- ent time.	R.	Patient much improved in health, but still has some discharge of pus.

IV	Ger	Male.	Dr. B. B. Loughhead of Akron, Ohio.	July 18th, 1892.	In 1888 developed cystitis; had pus in urine; Apr. '92 suddenly became worse; had fever and confined to his bed eight weeks. (Dr. Loughhead performed nephrotomy in June, and opened an abscess which discharged profusely for a time.	Patient in a septic condition. Sinus from former operation discharging slightly.	Left lumbar nephrotomy. Opened abscess of kidney containing several ounces of pus. Tamponed with iodiform gauze.	Patient was better for a time after operation, then gradually failed, and died Oct. 30th, 1892.	Died of exhaustion 3½ mths after operation.	Autopsy showed tubercular disease of kidney and lung.
W. F. B.	35	Married.		Residence of Patient.						
V	Am.	Male.	Dr. H. N. Fenton of Welshfield Ohio.	Dec. 22d, 1892.	Always healthy; June '92 received injury over right lumbar region. Taken sick in September and in December developed an abscess in right side.	Fluctuating tumor filling up right lumbar region. Microscopical examination of urine showed nothing abnormal.	Opened perinephritic abscess of right side containing 2 quarts of pus. Counter opening through the back with rubber drainage tubes.	Made a rapid and uninterrupted recovery.	R.	Saw patient in April. Wound healed and has had no further trouble.
P. R.	40	Married.		Residence of Patient.						

The above table gives five cases all of which are worthy of mention in detail.

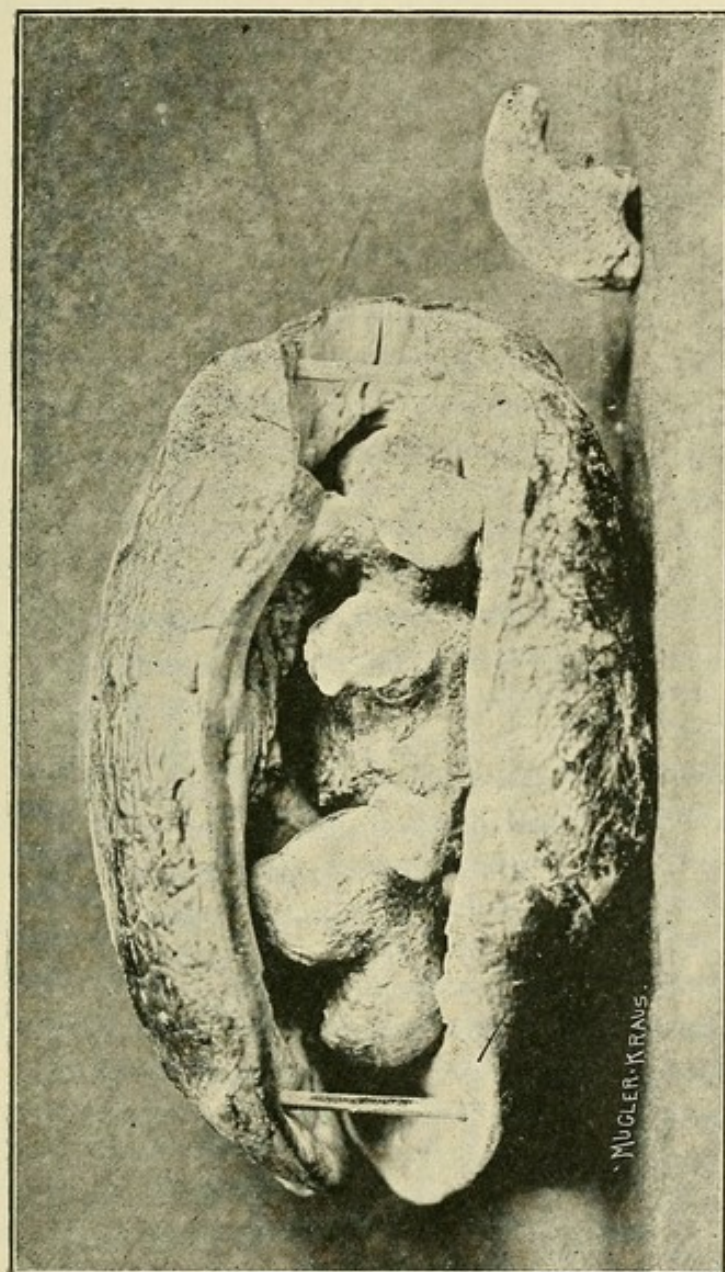
CASE I.—E. J. J.—*Renal Calculi; Nephrectomy; Recovery.*—Healthy until three years ago, when she strained herself while lifting. Felt sudden giving away in the right lumbar region, and was taken with severe pain. Two years later, in October, 1891, while getting out of a carriage, fell and struck on the right side in the lumbar region. In December, 1891, had a sudden illness, commencing with vomiting, followed by a chill and fever. During this illness, had sharp shooting pains in region of right kidney and discovered a tumor. Dr. Ryal of Wooster, diagnosed floating kidney, and found albumen in the urine. Patient was sick about four weeks. In January, 1892, had another attack, which came on gradually, and seemed to radiate from the right kidney over the entire abdomen. Severe pain lasted two or three hours, and left patient greatly prostrated. During this attack, urine was observed to contain pus. Since this time she has had several similar attacks, but not so severe. Patient has been able to be around, but could not attend to any duties. Has had a poor appetite, and lost flesh rapidly. Right leg flexed during the attacks, and causes much pain in straightening. Dr. Allen first saw patient September 27th. Confirmed the diagnosis of floating kidney, and ordered urine saved for examination. September 29th, passed 41 oz. of urine; September 30th, 33 oz; October 1st, 21 oz; October 2nd, 41 oz; October 3rd, 31 oz. Urine was loaded with pus; no sugar, and after filtration through charcoal contained no albumen. October 24th patient entered Charity Hospital. Could feel a movable tumor in the right side somewhat larger than a normal kidney. Operated October 27th. Dr. Lee administered chloroform. Made lumbar incision, extending vertically from the end of the 12th rib to the crest of ilium; colon presented itself in the incision. The kidney found and brought out through the incision. Could feel concretions in its interior, of such a size that it was unwise to attempt to remove them and save kidney. Was re-

moved entire and the pedicle ligated with silk. The ureter was disinfected with bi-chloride and the cut end sutured with cat-gut. Wound was tamponed with iodoform gauze, the ends of the incision being sewed with silkworm-gut. The kidney was somewhat larger than normal, and on incising was found to contain two calculi, making a perfect mold of the pelvis. The ureter was completely occluded by a calculus. The kidney contained considerable pus, and in on place suppuration had extended nearly to the surface. Patient reacted well after operation. The first dressing was made on the fourth day; gauze tampon removed. On November 6th and 7th the temperature rose to 102. November 8th dilated sinus; syringed out considerable pus and introduced rubber drainage tube. November 20th drainage tube was removed. November 21st had a slight attack of pleurisy lasting a few days. The patient was subject to frequent headaches, which were always associated with a diminution in amount of urine secreted. Left hospital Dec. 18th. Patient is now in excellent health. Urine contains no pus. The following table gives the results of daily urinary analyses made by Dr. P. Max Foshay.


WEEKLY AVERAGES.

WEEK.	URINE.	SOLIDS.	UREA.	RATIO OF UREA TO SOLIDS.
NOV	C. C.	GRM.	GRM	
7—13	949		15.14	
14—20	1268	37.78	17.25	1:2.7
21—27	793	47.70	13.35	1:3.
28—Dec. 4	983	45.33	14.00	1:2.8
5—11	684	27.30	10.10	1:2.4
12—16	919	29.63	12.41	1:2.4

THE
JOURNAL
OF
THE
AMERICAN
MEDICAL
ASSOCIATION
PUBLISHED WEEKLY
CHICAGO, ILL., U.S.A.
Vol. 10, No. 1, January 1, 1917
Price, Five Cents
Subscription Price, \$5.00 per Annum in Advance
Single Copies, 15 Cents
Entered as Second-Class Matter, October 3, 1911
Postpaid
Acceptance for mailing at special rate of postage provided for in Act of October 3, 1917
Authorized by Act of October 3, 1917
Copyright, 1917, by American Medical Association
Printed at the American Medical Association, 535 North Dearborn Street, Chicago, Ill.
Published by the American Medical Association, 535 North Dearborn Street, Chicago, Ill.
The Journal of the American Medical Association is published weekly, except on Sundays and public holidays, and is sent free of charge to members of the Association. It is also sent free of charge to libraries and to other institutions that may desire it. The subscription price is \$5.00 per annum in advance. Single copies are 15 cents. The Journal is published by the American Medical Association, 535 North Dearborn Street, Chicago, Ill.



E. J. J.—KIDNEY—SHOWING CALCULI IN POSITION. CALCULUS AT SIDE WAS REMOVED FROM URETER.



CASE II.—L. K. *Pyelonephrosis; Nephrectomy; Recovery.*—American, 26, married. Was a weak, delicate girl until eighteen years old. Menses first appeared at 15, irregular and scanty. After three years became regular. Married at 20. Confined at 21. Had normal labor. When child was three months old, patient began to be troubled with frequent micturition, and smarting in the urethra and bladder, which increased in severity, and urine became full of pus and mucus. Examination revealed an inflamed urethra, uterus retroflexed, cervix lacerated and endometritis. Uterus was curetted and cervix repaired. Patient improved in general health, but pain in the urethra and bladder continued. Bladder was washed with boracic acid solution, with some improvement. Became pregnant about November 1st, 1891; miscarried December 20th. Had fever and considerable hemorrhage. Uterus was curetted and washed out, followed by speedy recovery. July 5th, 1892, patient received a blow on the left side below the border of the ribs. Severe pain followed in left lumbar region. From this time on until September 9th, patient had fever, accompanied by severe pain in left side. A fluctuating tumor developed. Patient was in a very weak condition. Pulse about 140; temperature 104. Daily chills, diarrhoea and vomiting. Urine scanty and full of pus. On September 9th, 1892, the kidney was incised by Dr. W. H. Humiston, with a discharge of about eight ounces of pus. Drainage tube was inserted. The discharge continued free for a few days and gradually subsided. Temperature returned to normal and patient improved rapidly. Urine still contained pus, however, and there was a discharge of urine through the incision. On this account Dr. Allen was called in consultation and operated January 18th, 1893, at Dr. Humiston's Hospital. It having been first determined that sufficient urea was being excreted by the right kidney. Dr. Foshay administered the chloroform. The incision was made from the 12th rib downward to the crest of the ilium. The sinus remaining from the former operation was dissected out. The kid-

ney presented itself in the wound, but owing to its great size and dense adhesions, could not be removed through so small an opening.

A transverse incision was then made, and kidney dissected out with great difficulty. The peritoneal cavity was twice opened, but was immediately closed with fine cat-gut. Pedicle was ligated with silk and kidney removed. The wound was tamponed with iodoform gauze; the ends of the incision being sewed with silk. The kidney was about three times normal size, and interior was full of abscesses. Patient reacted nicely after the operation. The iodoform gauze was removed on the fourth day. Had considerable tympanites on the third day. On fourth day, temperature went to 102. Gave Rochelle salts and enema, causing good movement. From this time on, the patient improved and left the hospital March 4th. The wound was entirely healed about eight weeks after the operation. Patient is now in excellent condition and has no further trouble.

The following table gives the results of daily urinary analyses by Dr. P. Max Foshay:

WEEKLY AVERAGES.

WEEK.	URINE.	SOLIDS.	UREA.	RATIO OF UREA TO SOLIDS.
JAN.	C. C.	GRM.	GRM.	
19—25	690	36.99	16.03	1:2.3
26—Feb. 1	1271	43.72	19.98	1:2.2
2—8	1385	50.77	18.05	1:3.1
9—15	1071	38.41	14.76	1:2.6
16—22	1275	38.91	14.44	1:2.7
23—28	1283	53.20	18.29	1:2.9

CASE III.—G. H. W. *Abscess of the Kidney; Nephrotomy; Recovery.*—Was quite healthy as a child; always been very nervous. Eight years ago had a serious attack of renal colic, and urine contained albumen and casts. Three years ago, went to Carlsbad and took a course of treatment. Remained abroad one year, and returned much improved. In the spring of 1892, patient commenced to run down and lost considerable flesh. September 2, 1892, Dr. Noble, of Oberlin, was called to attend the patient. Physical examination showed a tumor in the left lumbar region. Patient complained of severe pain referred to the region of the left kidney and bladder. The urine was loaded with pus. During the following five days the morning temperature was normal; evening temperature about 103. The patient was very weak. Could take no nourishment, and was kept up on stimulants. Dr. Allen was called to Oberlin, September 6th. Operated September 7th. The entire left lumbar region was dull, with distinct fluctuation over tumor. Dr. Noble administered the chloroform. A vertical incision was made from the ends of the floating ribs to the crest of the ilium. Opened an abscess containing about two quarts of thick bad smelling pus, together with shreds of kidney tissue. Walls of the abscess cavity were rough and bled easily. Irrigated thoroughly with water and tamponed with iodoform gauze. Patient was very weak after the operation but reacted well. The tampon was removed on the third day, and abscess cavity was daily irrigated with boracic acid solution. The temperature ranged from normal in the morning to 99 in the evening. During the following month the general condition of the patient was much improved. In November, 1890, the patient took a bad turn; became extremely restless. Had some fever at night, and commenced losing flesh again. The urine had smelled strongly of iodoform, and owing to the daily packing of the wound with iodoform gauze it was thought that perhaps the condition might be due to iodoform poisoning. Then commenced washing the cavity with peroxide of hydrogen, and used plain gauze as a

tampon. About Christmas the patient commenced improving. The discharge has gradually diminished. Some pus still present in the urine, but in very small quantities. Patient has slowly but steadily improved up to the present time.

CASE IV —Dr. W. F. B. *Tubercular Pylonephrosis; Nephrotomy; Death in 3½ months.*—The father of the patient died of pulmonary tuberculosis in 1889, the mother, of the same disease, in February, 1891. The patient was perfectly well until the fall of 1888, when he commenced having pain in the region of the bladder, accompanied by painful micturition. The urine contained considerable mucus and pus. The patient was treated for inflammation of the bladder, and at times was much better, but the symptoms finally became so severe that he could not attend to his duties and abandoned his practice in the spring of 1890. At this time he came under the care of Dr. B. B. Laughead, of Akron. Microscopic examination of the urine showed an abundance of pus, but no casts. In April, 1892, the patient was suddenly taken with a severe chill, followed by fever, and was confined to his bed about eight weeks, having continual fever with occasional chills. During this time pus was constantly present in his urine. In June, 1891, a fluctuating tumor was discovered in the left lumbar region. This was opened and drained, the discharge at times being very profuse. The patient's general condition steadily grew worse, and Dr. Allen was called in consultation July 18th. The patient had been having a rise in temperature every evening, and it was thought best to establish better drainage. Nephrotomy was performed. A large abscess was found in the left kidney, and was tamponed with iodoform gauze. The patient improved somewhat for a time after the operation, then chills and fever returned. The patient failed and died of exhaustion, October 30, 1893. Post mortem the following day showed the left kidney entirely broken down and in a suppurating mass. Tubercular deposits were found upon the mesentery of the descending colon, along the ureter, and on the base of

the left lung. The right kidney was congested; the bladder was contracted and walls very much thickened. The other organs were normal.

CASE V.—P. R. *Perinephritic Abscess; Recovery*.—The patient was a stout man; never had any severe illness. Received a blow on the right lumbar region in June of 1892; the injury causing him no particular trouble at the time. About September 22nd, commenced feeling badly, but was not confined to his bed until October 13th. Patient complained of pain in the right lumbar region, and walked bent over to the right side. At this time no enlargement was discovered. November 3, 1892, Dr. H. N. Fenton, of Welshfield, took charge of the case. The bowels were regular, stools of somewhat clayish color. Urine was dark, but at no time contained albumen or pus. The evening temperature at this time ranged from 101 to 102½. The patient steadily grew worse until about the first week in December, when a fullness was discovered in the right lumbar region. The pain at this time was not so severe. Temperature at night about 102; pulse 96. Dr. Allen was called in consultation December 18th. Could distinguish an enlargement in the right lumbar region, extending upward toward the liver, and downward into the right iliac region. Fluctuation was distinct. Operation was advised and performed December 22nd. Dr. Fenton administered the chloroform. Incision was made perpendicular from the floating ribs to the crest of the ilium. Opened an abscess containing two quarts of pus. At the bottom of this abscess the kidney could be felt. Made a counter-opening at the outer border of the quadratus lumborum muscle, and introduced two rubber drainage tubes extending through both incisions. Irrigated thoroughly, and packed the cavity with iodoform gauze. Patient reacted well after the operation. The gauze was removed on the second day and cavity daily washed with boracic acid solution. Discharge rapidly diminished, and temperature returned to normal soon after the operation. Early in January, one of the drainage

tubes was removed and two weeks later the second, and gauze drainage substituted. The patient made a rapid recovery, and was entirely healed the latter part of February.

OPERATIONS FOR TUMORS NOT ABDOMINAL.

Operations upon the breast.....	15
Sarcoma of parotid	2
Tumor of thyroid.....	1
Lympho sarcoma of cervical glands.....,	3
Tubercular lymphoma of cervical glands.....	7
Melanotic sarcoma (sub inqual gland and neck).....	1
Carcinoma cervical glands.....	1
Carcinoma of face and nose.....	1
Epithelioma of the lip.....	1
Fibroid tumor of tongue.....	1
Epulis.....	1
Multiple atheroma of scalp (cases).....	2
Atheroma of face.....	1
Naevi.....	3
Carcinoma of rectum.....	1
Carcinoma of cervix.....	1
Sarcoma of testicle.....	1
Lymphomata of groin.....	3
Tumor of thigh (sarcoma).....	1
Lipoma.....	1
Tumors (upper extremity)	4

TUMORS OF THE BREAST

Fifteen operations. One case of a tumor occurring in a man. Eight operations were performed for carcinoma, three for sarcoma, four for cysto-adenoma. The axilla was involved in ten cases, and the contents removed, together with the entire breast. In two cases the breast alone was removed. In four cases the pectoralis major muscle was removed with the growth. In four cases Thiersch's transplantation was made upon the fresh wound. In two cases the skin was so tightly drawn that the stitches cut through,

allowing the flaps to retract and the wound healed by granulation. After two operations there was local return, and after one operation, secondary deposits in the liver occurred. Ether was used as anaesthetic in all cases. The usual antiseptic precautions were observed during the operation, distilled water being used for irrigation. In four cases suppuration of the skin had occurred before operation. In these cases, after disinfecting the skin the suppurating mass was covered with iodoform gauze during the operation. The breast was first removed, all bleeding stopped, and the surface covered with an aseptic towel. The axillary incision was then extended and axillary vein exposed. A careful dissection of the axilla was then made, extending to the clavicle and under the pectoralis minor muscle. A continuous cat-gut suture was employed in three cases, continuous sutures of silk being used in the other cases. In seven cases no drainage whatever was employed and the wounds healed by first intention. In three cases where suppuration had occurred before the operation a rubber drainage tube was inserted in the axilla. During the suturing of the incision the flaps were closely compressed to the chest wall to prevent any oozing of blood. An antiseptic dressing was then applied and the arm firmly fixed to the chest walls by gauze and starch bandages. The first dressing was usually made on the seventh day, and the stitches removed. When Thiersch's transplanation was made, the grafts, which at the operation had been covered with rubber protective, were found in every case to be firmly adherent, and were dressed with gauze moistened in a solution of tincture of myrrh.

TUMORS OF THE BREAST.

TUMORS OF THE BREAST.

No.	Nat. and Age.	Sex and Social Condition.	Heredity and Injury.	History of Patient.	Examination.	Operation.	Wound Healing.	Result.	Microscopic Examination and Remarks.
I	Am. 32	F., Mar.	None.	3 children; youngest 15 mo. old; December, 1891, noticed enlargement in left breast; grew rapidly; no pain.	Tumor size of an egg; tissues indurated.	Apr. 14th, '92, removed breast and axillary glands. Tumor contained pus and numerous small cysts.	Patient healed in seven days.	R. No return.	Cysto-adenoma; interior of tumor had undergone suppuration.
II	Ger. 50	F., Mar.	None.	Six children; 4 years ago noticed tumor in right breast; grown slowly of late; some pain.	Nipple retracted; tumor size of an egg.	Apr. 18th, removed breast and axillary glands. Drew flaps very tense.	Flaps retracted in middle and healed by granulation.	R. No return.	Scirrhous.
III	Am. 45	F., Mar.	None.	No children; noticed tumor of right breast one month before operation; grew rapidly.	Tumor size of an egg.	Removed breast and enlarged axillary glands.	Union by first intention.	R. No return.	Cysto-adenoma; axillary glands enlarged and hardened.
IV	Am. 42	F., Mar.	Grand-mother died of cancer.	No children; noticed tumor 3 years ago in right breast; no pain; grown more rapidly of late.	Tumor size of an orange; nipple retracted.	Removed breast and axillary glands. Flaps short and drawn very tense.	Flaps retracted in middle and healed by granulation.	R. No return.	Carcinoma.
V	Am. 45	F., Mar.	None.	No children; noticed small tumor of left breast about 3 weeks before operation.	Tumor size of a walnut.	Removed tumor only.	Wound suppurated; healed by granulation.	R. No return.	Adenoma.
VI	Am. 49	F., Mar.	None.	No children; 9 months before operation noticed tumor of right breast; nipple retracted.	Tumor size of goose egg.	Removed tumor and axillary glands.	Primary union.	R. No return.	Carcinoma.
VII	Am. 43	M., Mar.	None.	Small tumor since a child; grew rapidly of late.	Tumor size of 4 fists; ulcerated.	Removed tumor and pectoral muscle—axilla not invaded. Thiersch's transplantation.	Healed by granulation.	R. Return locally.	Sarcoma. Given in detail below.

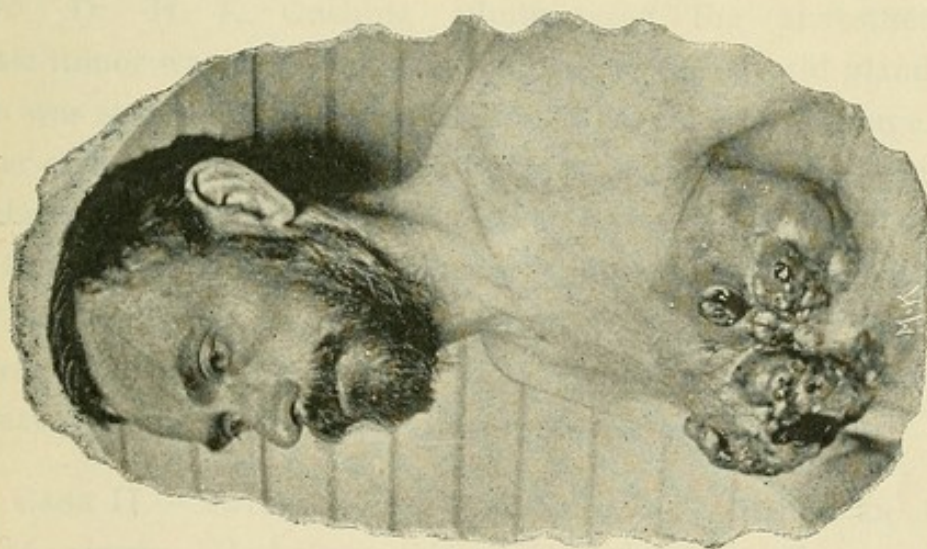
VIII	Am. 43	M., Mar.	None.	Several nodules reappeared and grew rapidly 3 months after operation.	Ulcerating mass size of an egg; smaller nodules size of walnuts.	Curetted and cauterized.	Did not entirely heal.	R. Return locally.	Sarcoma.
IX	Am. 22	F., Sing.	None.	Two years ago noticed small tumor of left breast; grew slowly; skin over tumor inflamed.	Tumor size of hickory nut.	Removed tumor.	Primary union.	R. No return.	Adenoma.
X	Am. 68	F., Mar.	Sister died of cancer of breast.	Fourteen months before operation noticed tumor in left breast; grew steadily; had plasters applied causing ulceration.	Fungus mass size of two fists.	Removed breast and pectoral muscle; axilla not invaded.	Entirely healed by granulation about Jan. 1st.	R. No return.	Sarcoma.
XI	Am. 45	F., Mar.	Grand-mother had cancer.	Four years ago noticed small lump in right breast; grown during last year; nipple retracted.	Tumor size of goose egg. Eczema of nipple.	Removed breast, pectoral muscle and axillary glands. Performed Thiersch's transplantation.	Healed by granulation between grafts.	R. No return.	Carcinoma.
XII	Am. 47	F., Mar.	None.	Two children; noticed tumor in right breast 9 months ago; no pain; grown steadily.	Irregular tumor about two inches in diameter; nipple retracted.	Removed breast and axillary glands.	Primary union.	R. No return.	Carcinoma.
XIII	Irish. 58	F., Mar.	None.	Eight children; 4 months ago noticed tumor in right breast; grew steadily; no pain.	Tumor size of goose egg; nipple retracted.	Removed breast and axillary glands.	Suppuration along middle portion of incision.	R. No return.	Carcinoma.
XIV	Am. 35	F., Mar.	None.	Two children; tumor developed 2 months ago just after confinement.	Tumor not clearly defined owing to enlarged breast.	Removed breast, pectoral muscle and axillary glands. Thiersch's transplantation.	Healed by granulation.	R. Recurrence in liver.	Carcinoma.
XV	Am. 44	F., Mar.	Sister had cancer.	One child; 4 months ago noticed tumor in left breast.	Tumor size of an egg; nipple retracted.	Removed breast and axillary glands.	Primary union.	R. No return.	Carcinoma.

CASE VII.—C. S. A healthy farmer, weighing about 200 lbs. No family history of cancer. Since patient can remember, there has always been a small lump in the left breast, about the size of a pea. Never caused him any trouble until about four years ago, when the tumor became somewhat inflamed from carrying heavy boxes in his arms. Increased in size a little, and then seemed to return to its former size. Shortly afterwards it commenced growing again, and in June, 1889, was about the size of a walnut. The tumor was removed about this time, but commenced growing again in about three months after the operation. Was operated the second time in October, 1890. Tumor was about the size of a fist. In both operations the skin over the tumor was not removed. The growth reappeared in about two weeks, and steadily increased in size. About Christmas, 1891, had reached the size of two fists. The skin ulcerated, and an extremely offensive discharge continued until the operation. About this time the patient came under the care of Dr. G. C. Lathrop, of Dover, and had a severe attack of influenza, which delayed the operation. Pyoktanin was injected into the growth, but caused severe pain, and the treatment was discontinued. The patient did not fully recover from the influenza until the following summer. Was first seen by Dr. Allen July 5th, 1892. The growth was about the size of three or four fists, firmly fixed on the thoracic wall, and ulcerated in numerous places. Patient had of late lost considerable flesh, and was greatly annoyed by the extremely offensive discharge. The patient begged for an operation at any risk. Operated July 8th, 1892. Removed the entire mass, together with the pectoralis major muscle, down to the ribs. The axillary glands were not involved. The tumor had extended into the intercostal spaces between the fourth, fifth and sixth ribs, and these portions of the growth could not be removed without a prolonged operation, which the patient was too weak to endure. Made Thiersch's transplantation of skin from the anterior surface of the thigh, and covered the entire wound with the exception of the

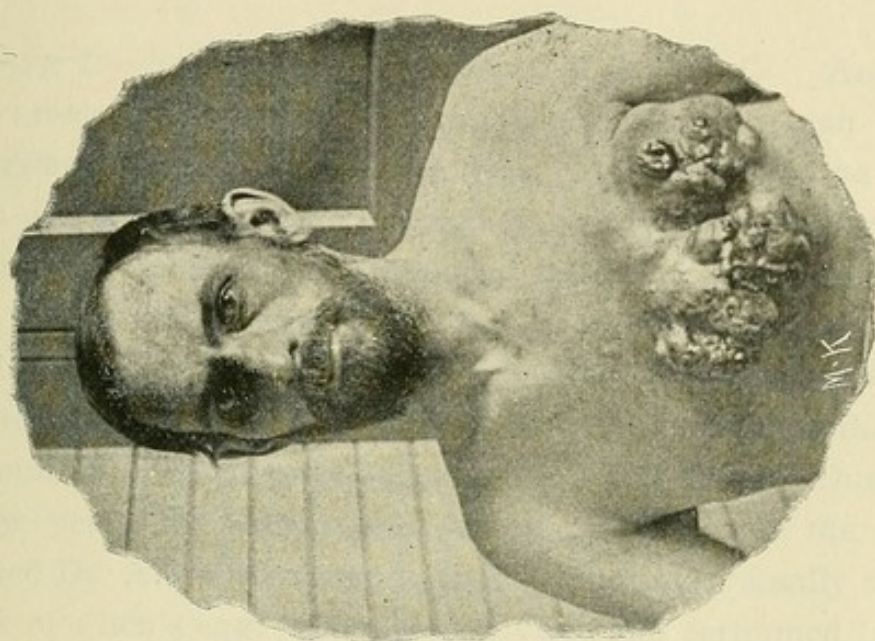
diseased portions. At the end of the operation the patient was in severe shock. Was stimulated freely by hypodermic and rectal injections, and in the evening his condition was considerably improved. On the following day the patient became delirious, and was very restless. During the night he became violent, and tore off the dressings down to the silk protective covering the skin grafts. The dressings were replaced, but on the following morning were soaked with a bloody, serous discharge, so profuse as to wet all the bedding. The patient remained in this condition about a week. Dressings were changed every day, and were completely saturated with a thin, bloody discharge. Stimulation and nourishment were given by the rectum. July 18th the patient commenced to improve. All the grafts adhered, and on July 28th the patient went home, the wound entirely healed, with the exception of a few points of granulation, and the portions from which the tumor could not be entirely removed. The patient gained flesh rapidly during the summer; was able to oversee his farm work, and assisted in some of the lighter work. The movements of the arm were perfect, with the exception of the raising of the arm above the horizontal. In the latter part of August, the nodules again commenced growing, and were treated by Dr. Lathrop with pyoktanin, but without much success. Patient returned to the hospital September 25th, and on the following day the nodules were curetted, and the bases burned with the Pacquelin cautery. The patient remained in the hospital about a week. During the following winter the nodules increased somewhat in size. The patient still enjoys good health, and is at present considering an operation for the removal of the ribs involved by the growth. Microscopic examination showed the tumor to be a sarcoma.

CASE XIV.—L. G. S. Patient has always been healthy. No history of cancer in the family. Was confined 13 years ago and had no trouble with the breast at that time. Was confined the second time in October, 1892. Previous to confinement the

patient observed that the left breast was hard, and that the nipple was retracted. Had some pain of a neuralgic character. Dr. Allen first saw the patient about January 1st, 1893. Both breasts were large and secreted an abundance of milk. A diagnosis at that time could not positively be made and advised the use of an elastic bandage to dry up the secretion of milk. The patient returned January 26th. Operated February 1st. First incised the tumor, which was of a hard consistence, and had the macroscopic appearances of a carcinoma. The entire breast was removed together with the pectoralis major muscle, to which it was firmly adherent. The axillary glands were involved, and removed. Thiersch's transplantation was made from the anterior surface of the thigh. The outer extremities of the incision were brought together with silk sutures. The patient reacted well after the operation. On the sixth day the first dressing was made; all the grafts were in place. Patient did nicely for about 10 days after the operation, then commenced having severe pain in the sides. The pains were so severe that hypodermics of morphia were required. The patient was finally able to sit up a few hours each day. Physical examination showed no trouble in the thoracic cavity. The patient was treated for rheumatism but steadily grew worse and was confined to her bed. About this time it was noticed that the liver was becoming enlarged. Patient has returned home, but is gradually failing. Undoubtedly has secondary deposits in the liver. Microscopic examination showed the tumor to be a carcinoma with large alveoli and little connective tissue, presenting the characteristic appearance of the most malignant of tumors.





CASE VII.—C. S.—SARCOMA OF THE BREAST.
(SIDE VIEW.)



CASE VII.—C. S.—SARCOMA OF THE BREAST.
(FRONT VIEW.)

1870
The first of the year was a very dry one
and the crops were much injured. In May
the weather was very warm and the crops
were much injured. In June the weather
was very warm and the crops were much injured.



MISCELLANEOUS CASES.

Among the miscellaneous cases, the following are worthy of mention :

CASE I.—*Sarcoma of the Parotid.* J. G. W. C. American ; age 56 ; male. The patient has always been a healthy man. About 25 years ago had perioritis of the lower jaw and while the inflammation was still present, he received an injury in the region of the left parotid. A tumor soon developed and grew slowly until it was about the size of a walnut and then remained stationary during several years. Consulted surgeons in New York and in this city about 10 years ago, and was advised against removal of the tumor on account of the danger of injuring the facial nerve. During the last few years the tumor has steadily grown, and the patient consulted Dr. Allen from time to time. The tumor finally attained the size of a hen's egg. Operation advised and performed July 5th, 1892. Dr. H. K. Cushing administered the anaesthetic. A cystic tumor was removed with a portion of the parotid gland. The skin was sutured with silkworm-gut, with cat gut drainage at the lower end. The wound healed by first intention. A slight serous discharge continued through the sinus for about 10 days. None of the branches of the facial nerve were injured by the operation, and the patient has since had no return of the trouble. Microscopic examination made by Prof. W. H. Welsh, of Johns Hopkins University, showed the tumor to be a cysto-chondro-sarcoma.

CASE II.—*Sarcoma of the Parotid.* L. B. American, female, age 36 ; single. Had always been rather delicate. Four years ago fell down stairs and bruised the left side of her face. About a year later noticed a small tumor in region of the left parotid ; this grew very slowly for a time but during the last year increased rapidly and became the size of two walnuts. Within the last five or six months has had some slight pains. Operated November 16, 1892, at Charity Hospital. Removed tumor together with a portion of the parotid

gland. Sewed incision with silkworm-gut sutures and introduced cat-gut drainage in lower end. Sutures removed on fifth day. Healing had taken place by first intention. Some fluid had accumulated in the cavity left by removal of tumor and was discharged. Wound continued to run a considerable fluid for two weeks. This was examined and found to be saliva. Discharge gradually diminished and was entirely healed in about three weeks. There has been no return of the trouble. Microscopical examination showed the tumor to be a sarcoma.

CASE III.—*Melanotic sarcoma of neck developing in a birth mark—Recovery; local recurrence in seven months.* E. T. American 61 Has always been healthy; since birth had a small mark on left side of neck, about the size of a thumb nail. This gave him no trouble until about three years ago when it commenced spreading, and in two years had reached the size of a dollar. During the last year has spread somewhat more irregularly. In June, 1892, a lump—size of a hickory nut—developed, and soon afterwards numerous smaller dots in the region of the discoloration. About August 1st the skin ulcerated and frequently bled. Consulted Dr. Allen Sept. 13th. The discoloration had then spread downward nearly to the clavicle and anteriorly to the median line under the chin. The color was of a very dark blue, with numerous small black points. Below the angle of the jaw was an ulcerating mass, projecting about an inch. Operation was performed Sept. 15th. The discolored portion of the skin was cut away. Numerous small black bodies about the size of millet seeds extended deeper in the subcutaneous tissues of the neck; new points constantly appearing as the dissection proceeded. The sub-lingual gland was enlarged and full of black points, and was removed. The cervical glands were also found to be involved, and were dissected out, and what appeared in the beginning to be a simple operation, developed into a most difficult one. The ends of the incisions were brought together with silk sutures; the central portion left to heal by granulation. The patient made a good re-

covery, and was entirely well in about six weeks. Microscopic examination was made by Dr. I. N. Himes, and by Dr. G. C. Freeborn, of the College of Physicians and Surgeons, of New York city, and tumor pronounced to be a melanotic sarcoma. The tumor returned locally in the cicatrix in April, 1892, and has since been operated a second time. No tumors have developed in any other portion of the body.

CASE IV.—*Tumor of the Thyroid.* K. G. German, age 28, single. Patient has always enjoyed good health. About two years ago noticed small lump in region of the thyroid gland. This steadily increased until about the size of a hickory-nut, and has since remained stationary. The tumor was very hard, and gave the patient no annoyance beyond a pressure and inconvenience when singing, causing her to sing flat in her upper register. Operation was performed July 24th, and a hard, calcareous tumor was removed from the substance of the thyroid gland. The incision was closed with silkworm-gut sutures, with gauze drainage. Some slight discharge continued for about two weeks after the operation. Sinus then closed and patient had no further trouble.

CASE V.—*Secondary deposit in Cervical Glands following an operation for Carcinoma of the Tongue. Recovery, recurrence in three months.* J. S., American, age 57. No history of cancer in family. About two years ago had portion of his tongue removed for a malignant growth. Soon after the operation, patient noticed an enlargement in the neck. This has steadily increased in size, and of late has caused him much pain. Dr. Allen first saw the patient July 6th. The left half of the tongue had been removed, and clusters of hard undurated glands were to be felt on the left side of the neck. The tumor was but slightly movable and extended deep into the neck. The patient was very anxious that an operation should be performed at any risk. Pain had been very severe of late, and the patient had lost considerable flesh. An operation was performed July 9th. The tumor was firmly adherent to

the sheaths of the vessels posteriorly, and during the dissection the internal jugular was twice opened, necessitating its ligation above and below. The wound was closed with silk sutures with gauze drainage at the lower angle. The patient made a good recovery and his general health improved. In August patient received a blow on the neck, followed by suppuration and discharge of pus through the lower end of the incision. The induration following the abscess did not subside. The tumor again developed, and in November ulceration of the skin occurred. The patient is still alive.

CASE VI.—*Carcinoma of the Rectum. Removal, recovery, no recurrence* Mrs. S., age 58. No history of cancer in the family. For a number of years has been greatly troubled by hemorrhoids. During the last year has noticed that with every movement of the bowels, a pedunculated mass was pressed through the sphincter and returned into the bowel with difficulty. Of late this mass has increased considerably in size. The surface became ulcerated and the pain more severe. Operation was performed May 13th. The sphincter was dilated and the pedunculated mass, about the size of an English walnut prolapsed from the bowel. The pedicle was about the size of a lead pencil and about half an inch long. Was ligated and the growth removed. Allingham's operation was then performed upon the hemorrhoids. The patient made a good recovery, and has since had no return of her trouble. Microscopic examination showed the tumor to be a carcinoma. The case is quite remarkable, since the projecting mass which had the appearance of a portion of prolapsed bowel, showed under the microscope typical alveoli filled with epithelial cells.

CASE VII.—*Carcinoma of the Cervix. G. B. Curetting.* No history of malignant disease in the family. The patient considered herself perfectly well until about four months before the operation, when she noticed a bad smelling discharge. Was treated locally, but the discharge steadily increased. First consulted Dr.

Allen May 11th. The entire surface was ulcerated and the vault of the vagina indurated with the growth. Vaginal hysterectomy was out of the question, but the patient desired some relief from the extremely offensive discharge. May 13th the mass was thoroughly curetted and burned with a Pacquelin cautery. The patient had no pain after the operation and left the hospital in about ten days. In August the discharge again commenced and the patient rapidly failed and died in October, 1892.

CASE VIII.—*Sarcoma of the Testicle. Removal. No recurrence.* H. C., age 20. Had always been in delicate health. About December, 1892, noticed that the right testicle was somewhat enlarged. This steadily increased, and of late had some pain. Operation March 4th, 1893. The testicle was about the size of an orange. The chord was dissected out and ligated at the external abdominal ring. The wound healed by first intention and the patient left the hospital in 10 days. The growth was cystic degenerated and microscopic examination showed it to be a sarcoma. Saw the patient three months later. There was no return of the trouble.

CASE IX.—*Multiple Sarcoma.*—W. S. German; age 14, previously healthy. In 1888 had left thigh amputated at junction of upper and middle third, for tumor just above the knee. Stump healed and the boy seemed to be in good health. In August, 1891, broke his left arm and bone did not firmly unite. In October, 1891, complained of pain in right hip, and a swelling appeared in right pelvis. Was aspirated and a bloody serum withdrawn. In December, 1892, the left arm at point of fracture commenced growing and increased rapidly in size. The patient lost flesh rapidly and suffered extreme pain requiring large hypodermics of morphine. Both tumors rapidly developed and skin on the under surface of arm became ulcerated. July 24, while changing bandage on the arm a sudden venous hemorrhage occurred. The blood ran in streams from the openings in the skin and was controled only by a tourniquet. The following morning arm was tightly bandaged and trouerniquet

removed. Patient was very weak and although no further hemorrhage occurred, patient suddenly died about noon. Post mortem on following day showed the humerus entirely absorbed and replaced by a soft, cystic growth. Arm measured 13 inches in circumference. A soft gelatinous tumor had developed in right ilium and extended to umbilicus. Microscopic examination showed the tumor to be a myxo sarcoma.

Among the operations for tumors are included three cases of naevus. In one case the tumor, about the size of a walnut was dissected out, the hemorrhage stopped and the wound closed without drainage. Primary union took place and there has been no return. In the other two cases the discoloration was diffused over the entire cheek. In one case the Pacquelin cautery was used, the superficial skin being slightly cauterized, followed by a sloughing of the epidermis; in another case the electro-cautery was used in a similar manner. In both cases there was considerable improvement.

There were seven operations for tubercular glands of the neck. In three cases the glands were dissected out and primary union followed. In four cases the glands were suppurating and were curetted, the wounds healing by granulation.

Three operations were for removal of the inguinal glands, one case being a secondary deposit following carcinoma of the vagina. The other two cases were for suppuration, following inflammatory conditions.

OPERATIONS UPON THE GENITO-URINARY ORGANS.

Forty-six operations; 20 males, 26 females.

CASE I. F. M. *Suprapubic Lithotomy; Recovery.* German, age 65. Always been a stout, healthy man. In August, 1891, complained of pain in region of the bladder, but required no treatment until Oct. 25th, 1892. The pain had then become very severe and the patient consulted Dr. S. E. Kaestlen. The symptoms pointed to a vesical calculus, and the patient was referred to a surgeon of this city. An operation was performed about the middle of December, 1892, and a

calculus about the size of a walnut removed by lateral lithotomy. The patient suffered the most intense pain after the operation and left the hospital in January. The pain continuing, Dr. Allen was called in consultation by Dr. Kaestlen March 12th, 1893. The bladder was sounded and another calculus discovered. The urine was still discharging slightly through the sinus remaining from the former operation. Operation was advised and performed at Lakeside Hospital, March 18th. It was decided to make the supra-pubic incision. A rectal bag was introduced and filled with 6 oz. of water; and the bladder injected with four ounces of water, pressure being kept upon the fistulous opening. The incision was then made, the peritoneum pushed upward and fixation ligatures introduced into the bladder before opening. The bladder was then incised and a uric acid calculus removed, weighing 64 grains and about the size of a thick lima bean. The bladder was thoroughly irrigated and two large catheters introduced through the abdominal opening. The bladder wall was tightly sewed around the catheters and the ends of the abdominal incision brought together with silk sutures. Antiseptic dressing was applied and the catheters brought through the bandage into bottles at the side of the patient. The patient stood the operation nicely. Had a pulse of 84 at the close. The bladder was washed every two hours with boracic acid solution. The catheters were removed on the fifth day and a rubber drainage tube introduced. Up to this time there had not been a discharge of urine through the abdominal wound sufficient to moisten the dressing. The patient had almost no pain after the operation. Left the hospital March 29th. The wound was entirely healed in about six weeks after the operation and the patient has had no further trouble and is now in excellent health.

CASE II.—*Enucleation of the Testicle* J. F. Am. 64. During the last two years had had considerable pain in the left testicle. Had worn a suspensory bandage but obtained no relief. The patient was

very much worried, and feared the developement of a malignant tumor. At his urgent request, and that of his son, who was a physician, an operation was performed. The testicle was slightly enlarged and somewhat softer than normal. A number of small cysts extended along the chord. The testicle was removed and the wound healed by first intention. Patient has had no trouble since the operation.

CASE III.—*Enucleation of the Testicle*.—Was a patient 32 years of age. About two years ago contracted syphilis. This was followed by deposits in the testicle, which soon ulcerated and discharged through a sinus. The patient was operated November 14th. The testicle was removed and wound packed with iodoform gauze. Healing took place by granulation. The testicle contained several small abscesses.

Hydrocele.—Three operations; three recoveries. In two cases injections had been tried, but failed. In all three cases the sac of the hydrocele was dissected away and the incision closed with sutures of cat-gut, with cat-gut drainage. Primary union took place, and the patients had no further trouble.

Varicocele.—Two cases. Incision and ligation were performed in both cases, with excision of a portion of the veins. Both cases healed by first intention.

Internal Urethrotomy for Stricture.—Two cases. Internal urethrotomy performed, so as to allow the passage of No. 30 French sound. The bladder was washed out with boracic acid solution, and a soft rubber catheter left in urethra for three days. This was then removed, and sounds were passed every other day, until the patients left the hospital. The passage of sounds was continued for several months.

External Urethrotomy.—Two cases. The stricture in both cases was in the membranous portion of the urethra. Urinary infiltration had occurred in one case. A soft catheter was left in

the bladder about four days and the passage of sounds carried out as in cases of internal urethrotomy.

Rupture of the Urethra. One case. The boy was a patient 16 years of age. Fell and struck on the perineum. The following day could not pass urine and symptoms of urinary infiltration developed. Though the skin was not broken, perineal section was performed, and the urethra found to have been ruptured entirely through. A soft catheter was introduced, and allowed to remain for five days. The passage of sounds was then undertaken but without success, and it has since been necessary to anaesthetize the patient in order to pass sounds into the posterior opening.

Phimosis.—Seven cases. The circular method was employed in six cases, the mucous membrane and skin being sewed with cat-gut sutures. In one case a boy 18 years of age, in whom the prepuce was firmly adherent to the glans, the dorsal incision was made, and the adhesions, as far as possible, broken up.

Laceration of the Cervix Uteri.—Five cases. In four cases, uninterrupted cat gut sutures were employed with satisfactory results. In one case sutures of silver wire were used, with only partial healing. This case was operated in a private house where the antiseptics could not be thoroughly carried out.

Laceration of the Perinacum. Seven cases. Three for recent and four for old lacerations. In one recent case, the laceration extended through the sphincter and an inch up the rectum. The operation was performed about three hours after delivery. The bowel was closed with fine cat-gut. Deep sutures of silver wire were introduced, and etage sutures of fine cat-gut continued to the skin. In all three recent cases union by first intention took place. Among the operations for old lacerations, three were ruptured into the rectum. One case had been previously twice operated without success. The cicatrix was dissected away and the rent in the bowel closed with fine cat-gut. Deep sutures of silver wire were introduced. Superficial sloughing took place, but the sphincter united,

and the result is excellent. In another case a laceration, extending into the rectum, had occurred 10 years previously. The patient had no control over her bowels. An operation similar to that in the preceding case was performed at a private residence, where the necessary antiseptic precautions could not be carried out and only partial union occurred. The other two cases were not ruptured into the bowel. They were brought together with silver wire sutures and union occurred by first intention.

Amputation of the Cervix: One case. The cervix was elongated and lacerated. The patient had been troubled with considerable discharge. The uterus was curetted and a wedge shaped amputation of the cervix performed, and the wound closed with cat-gut sutures. Union took place by first intention.

Dilatation and Curetting of the Uterus: Nine cases. The uterus was well washed with distilled water and injections of liq. ferri perchloride used. In five cases the uterine cavity was tamponed with iodoform gauze which was removed about the fifth day.

Suppurating Gland of Bartholene: One case. No history of a specific infection. The gland was about the size of a walnut and had given considerable trouble during the last two years, occasionally becoming inflamed and very painful. Incision was made through the labia, and the suppurating gland together with its duct removed, and the opening into the vagina sewed with fine cat-gut. The incision in the skin was partially closed with silk sutures and the cavity packed with iodoform gauze. The patient was entirely healed in about ten days.

The following case is worthy of special mention. C. D., American, 25 years, married five years. Menstruated first at 14 years. Was regular but always had severe pain. Patient consulted Dr. Allen in March, 1892. The vagina seemed to terminate in a blind pouch about an inch in depth. The cervix could not be seen, but could be indistinctly felt among the deeper tissues. An attempt was made to find an opening through this membrane but without

success. The patient was sent home and instructed to present herself for examination at the commencing of her next menstrual flow. Patient returned April 18th. A small opening could be seen from which an occasional drop of bloody discharge flowed. The following day the patient was anaesthetized and a probe introduced through the opening and the membrane incised and dilated. This membrane was found to be the hymen with a small opening and behind was normal vagina and cervix. Vagina tamponed with gauze. The patient left the hospital in about two weeks, and returned to her home. Patient returned to Dr. Allen July 9th. Had not been unwell since the operation. Examination showed the uterus somewhat enlarged. Pregnancy was suspected. The patient was delivered of an eight pound boy December 28th, 1892.

OPERATIONS UPON THE RECTUM.

Seventeen cases, 17 recoveries.

Operations for Fistula: Seven cases. The fistulous tracks were laid open, curetted and packed with iodoform gauze. Healing took place by granulation. The bowels were moved on the fourth day. All the cases made excellent recoveries.

Operations for Hemorrhoids: Five cases. Allingham's operation of ligation was performed in all five cases with complete cures.

Peri-rectal Abscesses: Two cases. Incision and curetting of the abscess cavity and the wound packed with iodoform gauze.

Fissure of the Anus: Two cases. In one case the patient had had such severe attacks of pain that hypodermic injections of two grains of morphia were required to relieve his suffering. In both cases, the fissure was dissected out and the wound closed with fine cat-gut. Healing took place by first intention and the patients have had no return of the trouble.

Imperforate Rectum: One case. The patient, a baby a few

days old. had no movement of the bowels for several days after birth. Dr. A. J. Cook, the attending physician, made an examination, and found that the rectum ended in a blind pouch. Dr. Allen was called in consultation. The sphincter was dilated and the occluded end of the rectum opened. Beyond this could be felt a mass coming down from above. This was also incised, followed by an escape of faecal material. The bowel was washed out and packed with iodoform gauze. Daily dressings were made, and iodoform gauze introduced. From time to time the rectum became impacted with faecal material and required dilatation. The child is now about a year old and perfectly healthy. The child has also a congenital absence of three ribs on one side.

OPERATIONS UPON THE CHEST.

Seven cases. All the operations were for effusions in the pleural cavity. The following cases are given in detail.

I. M. American, 20, female, single. Had always been very healthy. Was taken sick in April, 1892. Had pain in the right side and was confined to the bed about three weeks. The patient then commenced to get around, but did not improve much and was unable to attend to her duties as teacher. Had a persistent cough and at times, some fever. During summer, chest was aspirated and considerable pus withdrawn. In September the patient grew much worse and commenced expectorating a purulent material. Dr. Allen first saw the patient November 17th, 1892. Patient was very much emaciated. Had a rapid pulse, and a temperature of 103. The physical examination pointed distinctly to a pyo-pneumo-thorax. Operation was performed November 19th at Charity Hospital. Resected about three inches of the 7th and 8th ribs on the right side in the axillary line. The right lung was tightly retracted against the vertebral column. The cavity was washed and drainage tubes

inserted. After the operation the patient slowly improved. The cavity was washed out daily with boracic acid solution. Patient left the hospital December 22nd. The sinus still remains open and at times the patient has a fever. The cavity holds about a pint of water. Patient is now considering a second operation. In this case the radical operation had been too long postponed.

B. S. American ; physician ; 31 years ; male ; single. Always had excellent health, and weighed about 165 lbs. In November, 1886, took a severe cold ; had an attack of acute pleurisy which subsided in about six days ; the following month the patient began to cough and expectorate a purulent material ; lost flesh, and at times had considerable fever. In February, 1887, patient was compelled to discontinue his profession, being confined to his bed with a temperature of 103 ; respiration 30 ; dullness over the entire left side. In March, 1887, had a sudden expectoration of pus in large quantity. The chest was aspirated and five pints of an odorless fluid with flocculi of pus were withdrawn. On the following day an incision was made in the ninth intercostal space, about one inch in front of the axillary line, and a large quantity of pus was discharged. In May, 1887, patient was able to be out of bed, but still had some fever. The amount of discharge daily diminished, and about October 8th, the wound closed. In November, 1887, symptoms of septicaemia again appeared and thora-centesis was again performed, and 8 oz. of pus withdrawn. At this operation a portion of the 8th rib was resected. The fever subsided, appetite returned, and in about two weeks the patient was able to be around. The improvement continued as long as free drainage was maintained, but in January, 1888, the sinus closed, when the patient again commenced to decline. During the following summer he had a hemorrhage, and in September, 1888, patient was again confined to his bed. In December an incision was made through the old cicatrix and drainage re-established. In February, 1889, the incision was enlarged and again the following May. After the last

operation the patient did not improve sufficiently to get ground. Suffered greatly from dyspepsia and was exceedingly nervous. In September, 1889, portions of three ribs were resected, but his condition did not improve. In January, 1890, a portion of the 5th rib anterior to the shoulder-blade was removed, and sinues were found leading upward to a large cavity beneath the scapula. The patient by this time was extremely emaciated. Was taken South, but the change was followed only by slight improvement. In August, 1891, patient first consulted Dr. Allen. Portions of the 6th, 7th, 8th and 9th ribs were resected and the following November the patient was able to get around for the first time in $2\frac{1}{2}$ years. A year later, in November, 1892, the patient again returned. A sinus remained, which could be traced upward toward the apex of the lung. His general condition was improved, but from time to time the sinus would close, followed by symptoms of septic absorption. Operation was performed at Charity Hospital, November 29th, 1892. An incision 8 inches in length was made vertically and midway between the spinous processes of the vertebra and the border of the scapula. The incision was carried through the muscles, and portions of the 3rd, 4th, 5th, 6th and 7th ribs were resected from the vertebra to the border of the scapula. A sinus was found leading upward to a cavity just below the left clavicle. The sinus was enlarged and the cavity packed with iodoform gauze. The patient reacted well after the operation. The tampon was removed on the fifth day and the wound daily irrigated with boracic acid solution and packed with iodoform gauze. The patient improved slowly, had a good appetite and left the hospital about the middle of February, 1893. The patient went South, and unfortunately had an attack of influenza and was confined to his bed six weeks. The patient has again improved but some slight discharge continues. The opening still remains to the cavity below the clavicle.

OPERATIONS UPON THE HEAD AND NECK.
(NOT INCLUDING TUMORS.)

Twenty-two cases with three deaths ; death in two cases being caused by compound fracture of the skull ; in one case by abscess of the parotid following pyemia.

OPERATIONS UPON THE SKULL.—Six cases.

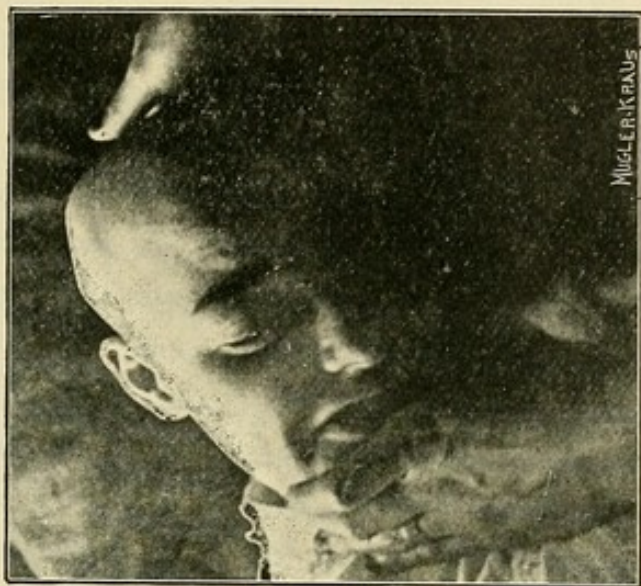
CASE I.—The patient was a Frenchman ; had been a heavy drinker. Received a blow on the head and was brought to the hospital two days later. Was violently delirious and had a temperature ranging about 103 in the axilla. Incision was made over the seat of the injury and a triangular portion of the right parietal bone was found to be depressed, and infection of the wound already to have taken place. The wound was packed open with iodoform gauze, with an antiseptic dressing and ice bag on the head. Patient steadily failed and died two days after the operation.

CASE II.—A boy about 16. Had his head caught between an elevator and floor, his head stopping the elevator. Was brought to the hospital in an unconscious condition. The nasal eminence was fractured and nose flattened. Over the occiput there was considerable swelling and contusion of the scalp. The head was shaved, and incision was made over the occiput and the clots of blood turned out. No fracture was discovered in this locality. The nose was remoulded, and the loose pieces of bone removed. The patient made a rapid recovery and left the hospital in about two weeks.

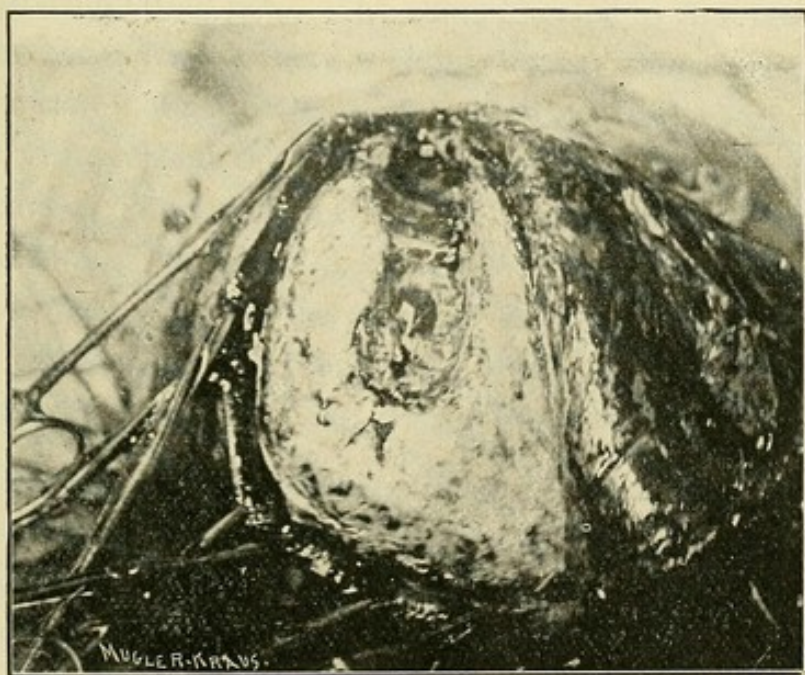
CASE III.—Was an extensive compound comminuted fracture of the skull with severe lacerations of the brain tissue. The patient never regained consciousness, and died on the second day.

CASE IV.—Was struck by a motor and received a fracture over the right ear. Portions of the temporal bone were depressed, these were removed and the edges of the bone cut away with the rongeur. The wound healed by first intention and the patient left the hospital in about three weeks.



CASE V.—*Acquired Porencephalus*. — V. T., American, 20, female, single. Patient sent by Dr. W. N. Boerstler of Peninsula. When six months of age received a blow upon the right parietal bone and has since had a depression of the skull in that region. When two years of age commenced having attacks of an epileptoid nature. These continued about five years, gradually became less in severity and finally ceasing to reappear again when the patient was 14 years old. Dr. Allen first saw the patient in March, 1893, and called Dr. H. S. Upson in consultation. Patient was a small delicate looking girl, not over intelligent. In the right parietal region, half way between the meatus auditorus and vertex were two horizontal ridges projecting above the surrounding skull about $\frac{1}{4}$ of an inch. These ridges were $1\frac{1}{2}$ inches apart and between them was a slight depression. The ridges were four inches in length; the depression was $4\frac{1}{2}$ inches in length and its direction was slightly from below forward to above backwards. The central portion distinctly pulsated and was very tender on pressure. The extremities of the depression had no pulsation and presented a bony resistance. There was marked loss of power in the muscles of the left arm and leg, with contractures, so that the hand was flexed at right angles, and could not be fully extended. The pupils were clear, and reacted to light and were not dilated during the attacks. There was no deviation of the tongue or face. The tactile sensibility was unimpaired over the entire body. The reflex on the right was exaggerated. Fundus oculi normal. The attacks varied in frequency, some days occurring every hour or two. Patient was perfectly conscious during the attacks and would cry out from the severe pain. Operation was performed February 2nd, 1893. The day previous to the operation the scalp was shaved and an antiseptic dressing applied. Ether was used for anaesthesia. Scalp was again disinfected, incised and reflected from the depression. An opening was found in the skull 3 inches in length and $1\frac{1}{2}$ inches in width. This opening was covered with a very dense connective tissue membrane, on cutting



CASE V.—ACQUIRED PORENCEPHALUS.—SHOWING
RIDGES AND DEPRESSION.



CASE V.—ACQUIRED PORENCEPHALUS. SCALP AND PERIOSTEUM REFLECTED
SHOWING OPENING IN SKULL COVERED WITH A DENSE MEMBRANE.



through which there was an abundant discharge of serum. Beneath the parietal eminence there was a cavity extending antero-posteriorly two inches, and transversely $1\frac{1}{2}$ inches. Could see anteriorly to the third ventricle, and at the bottom of the cavity the choroid plexus, optic thalamus and corpus striatum could be plainly seen. The pulse before the operation was 126. Immediately on the escape of the serum it dropped to 74, gradually coming up to 90, and then fell again to 78; was of fair strength until the latter part of the operation, when it became very weak necessitating the raising of the foot of the table. Fifteen minutes after the operation the pulse was 128. The scalp was sutured with silkworm-gut, with cat-gut drainage at the extremities. An antiseptic dressing was applied and held in place by a starch bandage. On the following day the dressings were soaked with serum and were changed. The patient could retain nothing on her stomach for several days. The temperature ranged from 99 to 102 and on the 17th day went to 104. The pulse ranged from 110 to 128. The wound healed by first intention. During the second week there was bulging of the scalp caused by an accumulation of serum beneath. This was relieved by introducing a pair of forceps at the angle of the incision and allowing the serum to escape. The attacks ceased after the operation, and the pain in the head was lessened except when the cavity was fully distended with serum. The patient regained strength very slowly and went home the early part of April. Later she failed and finally died apparently from asthena. No post mortem obtained.

CASE VI.—*Craniectomy*.—H. D., American, eight years and ten months; male. The father of the patient was a peculiar nervous man, but well developed mentally; the mother a healthy woman. The patient has a brother 11 years of age, a very bright boy. None of the family on either side have been idiotic. The birth of the patient was normal, no instruments were used. The anterior fontainell was small at birth and closed early. He commenced teething when four months old and had violent spasms, which were not

limited to any particular part of the body. After a convulsion he would lie several hours in a stupor. The spasms continued until the child was two years old. At this time had talipes varus of the right foot, but gradually outgrew it. When two years of age he knew many words and could form short sentences, also knew his letters, but when about two and one-half years old he seemed to forget, and finally ceased speaking. Patient never took any nourishment but milk until he was 16 months old, but since that time has been a hearty eater, feeds himself, and makes known his likes and dislikes as to what he eats. At the time he had spasms, he vomited a great deal, but has not since. Has control of his bowels and bladder and makes known his wants. Has been in the asylum at Columbus for several years. The parents have no control over him; he continually runs away, but does not seem to have any particular end in view—keeps on going until he is caught and brought back. Will usually mind when commanded to do things, and spoken to in a stern manner. Is in continual motion, twisting his fingers and making a clucking noise with his mouth. Cries when not allowed to have his own way. Seems to know his mother, and will go to her in preference to strangers. Is very restless at night. Dr. Allen first saw the patient, May 19th, 1892. The head of the patient did not look much under size, but the mother stated the family had, as a rule, large heads.

On May 20th, took the following measurements:

Height of patient.....	51 inches.
Circumference of skull over the occipital protuberance and just above the eyebrows.....	21 inches.
Antero-posterior diameter, (from occipital protuberance to nasal eminence).....	7 5-16 in.
Bi-parietal diameter.....	5 5-8 in.
Bi-frontal diameter.....	4 1-16 in.
Bi-auricular diameter.....	5 inches.

The extremities were the same length; body well developed;

eyes light blue, but rather dull and expressionless. Skull seemed considerably flattened posteriorly. The family were extremely anxious to have an operation at any risk, and since the child had at one time been able to speak, it was thought that the present condition might possibly be relieved, although the outlook was not promising. Operation was performed May 29th, 1892, at Lakeside Hospital. The incision commenced at the hair line over the left eye, following toward median line $\frac{3}{4}$ of an inch, and then turned backward and followed the general direction of the sagittal suture $9\frac{1}{4}$ inches, curving laterally at the posterior end. The scalp and the periosteum were reflected. A button of bone $\frac{1}{2}$ of an inch in diameter was removed with the trephine, then with Keen's rongeur a strip of bone $\frac{1}{4}$ of an inch wide was removed the entire length of the incision, with short lateral cuts at each end. The rongeur broke just as a posterior lateral cut was being made, and the operation was finished with a hammer and chisel. The dura mater was not opened. Sewed the scalp with silkworm-gut sutures and introduced cat-gut drainage at each end of the incision. The operation occupied 29 minutes* from the incision to the completion of the sewing up; 34 minutes to the end of the dressing. The pulse after the operation was 124. The patient reacted well, and was no more restless than usual. On the following day the bandage was stained with a bloody discharge, and was changed. On the seventh day stitches were removed and wound entirely healed by first intention. The patient made an uninterrupted recovery. The family thought for some time after the operation that he was much more easily controlled. The journey home was made on a very hot day, and two days later the boy had a spasm. The patient has again been sent to the asylum, and at last report, there was little change in his condition.

OPERATIONS FOR HARE LIP.

Three cases. Two operations were for double hare lip, with cleft of the palate. In one case there was protrusion of the inter-

maxillary bone. Silkworm-gut was used for sutures, and the three cases healed by first intention.

The remaining operations include the following :

One for abscess of the antrum of Highmore.

Two for necrosis of the lower jaw.

One for periostitis.

One for abscess of the parotid.

One for injury following an attempted suicide.

Seven operations for removal of enlarged tonsils.

OPERATIONS UPON THE UPPER EXTREMITY.

Twenty-four cases with no deaths. Operations for palmar abscess, 10 cases. In each case incision was made as early as possible, and free drainage established. The wounds were cleansed with bi-chloride solution; tamponed with iodoform gauze and a moist dressing applied. In three cases, in spite of the free drainage, the inflammation extended to the fore arm and secondary operations were performed.

Phlegmon of the arm; five cases.

CASE I.—*W. P.* The patient had been a heavy drinker, and his general condition was very poor. Received a wound on the extensor surface of the fore arm. In a few days the parts commenced to swell, and when brought to the hospital he had a temperature of 104, and the entire arm was greatly swollen. Free incisions were made, and pus was found everywhere throughout the subcutaneous tissues. The arm was poulticed, and two days after the operation the extensor muscles of the fore arm commenced to turn black and slough away, leaving the bones exposed. Amputation was made at the junction of the upper and middle third of the humerus, and at the same time the shoulder joint was found to be full of pus, and was drained. The fever continued for several days,

when the patient commenced to improve, and recovery soon followed.

CASE II.—*E. S. C.* The patient was a farmer and had good health. December 11th cut his thumb. Dr. Allen first saw the patient the evening of December 15th. The entire arm and hand were much swollen, and the patient had a temperature of 103. Was delirious and in a most critical condition, demanding immediate interference. Ether was given by the rapid method and numerous incisions made, a more radical and complete operation being left until the next morning. The thumb was found to be gangrenous, and was amputated through the metacarpal bone. Pus was found throughout the hand, dissecting along both flexor and extensor tendons of the fingers. Pus was also found throughout the subcutaneous tissue of the arm, extending to the shoulder. Incisions were made, and drainage tubes introduced. The arm was poulticed, and for a time, improved. The latter part of December the temperature again commenced to go up, necessitating another operation with opening of some of the deeper tissues of the hand. At this operation a bullet was found which had been shot into the palm of the hand 16 years previously, and had never given rise to any trouble. The patient went on to recovery, though the hand was seriously damaged.

E. S.—*Osteoclasty for malunion of the Radius.* Patient was a delicate boy 13 years of age. On July 7th sustained a Colles fracture of right radius. This was followed by considerable swelling and the fracture was not discovered. Dr. Allen first saw the patient July 26th. The swelling had subsided and the deformity was plainly visible. Operation was performed July 28th. An anaesthetic was given and the bone refractured. The arm was kept in splints for about three weeks, and then dressed with adhesive plaster. A perfect result was obtained.

The remaining operations include one operation for gun shot wound of the hand, with extraction of the ball; one operation for

abscess of the elbow joint following injury ; and six amputations of the fore arm and hand.

OPERATIONS UPON THE LOWER EXTREMITY.

Thirty-two cases with two deaths, the causes of death being:

One following double amputation for injury, in an old lady 81 years old.

One a secondary amputation of the leg, on account of septicaemia, resulting from compound fracture.

Amputations : Fourteen cases, three being double amputations following injury. The amputations include the following:

Five amputations of the leg.

Three amputations of the thigh.

Two Pirogoff amputations.

Four amputations through the metatarsus.

Operations for Club Foot : Three cases. In one case of talipes varus occurring in a little girl three years of age, a wedge shaped piece of bone was removed at the articulation of the cuboid and astragalus. At the same time the plantar fascia was divided. At a subsequent operation, tenotomy was performed upon the tendo-Achilles. The patient made a good recovery and has but a slight deformity of the foot. In another case, contracture of the tendo-Achilles followed a fracture of the lower end of the tibia and fibula, with slight displacement of the bone backward. Relieved by tenotomy.

Cares of the Tibia : Two cases. In one case the head of the tibia was involved ; the diseased bone was removed with curett and the bone packed with iodoform gauze. A discharge continued for about four months when the sinus closed. In the other case the entire epiphysis of the lower extremity of the bone was involved. The diseased bone was curetted, and the patient made a perfect recovery.

Necrosis of the Femur : Two cases. In both cases the shaft of the bone was opened and the dead portions removed. In one case a small sinus still remains.

Operations for Abscess : Three cases. In one case the patient was an old man 59 years of age. A large tubercular abscess involved the inner and flexor surface of the thigh; was incised and drained and the patient made a complete recovery. Another case was an abscess of the hip joint, following pyemia. About two quarts of pus were taken from the tissues around the hip joint. The patient died of septicaemia six days after the operation. This is the same case reported as having died with abscess of the parotid. The third case was one of abscesses of the leg and knee. At the first operation the parts were thoroughly drained, but the patient gradually grew worse, and two weeks later an amputation was performed at the middle of the thigh. The ankle and knee joints were found to be full of pus and the articular ends of the bone completely destroyed. Patient made good recovery.

F. B — *Osteotomy for Malunion of the Femur*. The patient was a healthy boy 13 years of age. In November, 1890, broke his femur about three inches above the knee joint. Dr. Allen first saw the patient June 28th, 1892. There was considerable deformity at the point of fracture. Operated July 1st. Incision was made along the outer side of the thigh, over the fracture. The bone was divided with a chisel; the incision in the skin sewed with cat-gut and an antiseptic dressing and splints applied. The patient remained in bed five weeks, and was then allowed to go around on crutches. An excellent result was obtained, with only a half inch shortening.

The remaining operations were as follows :

One excision for Hygroma of the knee.

One aspiration for effusion in the knee joint.

One operation for removal of a needle in the thigh.

One operation for periostitis of the tibia.

One operation for an extensive phlegmon of the foot following injury.

One operation for horny growths of the nails.

MISCELLANEOUS OPERATIONS.

Ten operations.

Thierschs, Transplantation: Seven cases. Two of these operations were for extensive burns of the thigh, involving the entire extensor service. All the operations were successful.

Tetanus. Two cases. One death, one recovery.

CASE I.—H. F., American, 27, a healthy man. June 14th, while working in the field, punctured his foot with a harrow. The wound healed, but some tenderness remained. Eight days after the injury, commenced to have severe pain in the scar. The wound opened, and discharged a thin bloody serum. On the ninth day, had symptoms of trismus, and on the tenth day the symptoms were much aggravated and the patient had violent spasms with opisthotonus. Heavy doses of bromide and chloral were given, but with no benefit. Dr. Allen first saw the patient on the 11th day. The wound was curetted and an antiseptic dressing applied. The patient died on the 12th day. Cultures made from the wound showed the bacilli of tetanus to be present.

CASE II.—H. N. August 1st punctured the flexor surface of the wrist with an ice pick. The wound gave him no trouble at the time. On the third day noticed that the scar was tender. On the morning of the fourth day, on rising, found that he could open his jaws only about one-fourth of an inch. The wound had opened, and was discharging a thin bloody serum. The surrounding skin was rednoded, and the inflamed lymphatics could be traced up the arm. The wound was curetted, and an antiseptic dressing applied. The patient was put to bed and given heavy doses of bromide and

chloral. The following day the inflammation around the wound had somewhat subsided. The muscles of the jaw gradually relaxed, and in four days all symptoms of lockjaw disappeared.

philosophy of the following day the indignation against the wound
had somewhat subsided. The muscles of the knee gradually relaxed,
and in four days all symptoms of the knee disappeared.

...

...

...

...

...

...

...

...

...

...

...

...

...


...


...


...

...

...





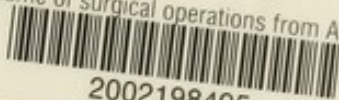

COLUMBIA UNIVERSITY LIBRARIES

This book is due on the date indicated below, or at the expiration of a definite period after the date of borrowing, as provided by the rules of the Library or by special arrangement with the Librarian in charge.

[illegible]

COLUMBIA UNIVERSITY LIBRARIES (hsl, stx)
RD 34 N41 C.1
A resume of surgical operations from Apr



2002198495

RD34

Nevison

N41

A resume of surgical operations..
in the practice of Dudley P.
Allen.

