

Disease of the pancreas : its cause and nature / by Eugene L. Opie.

Contributors

Opie, Eugene L. 1873-1971.
Augustus Long Health Sciences Library

Publication/Creation

Philadelphia, London : J. B. Lippincott Company, 1903.

Persistent URL

<https://wellcomecollection.org/works/n4n2cpu9>

License and attribution

This material has been provided by This material has been provided by the Augustus C. Long Health Sciences Library at Columbia University and Columbia University Libraries/Information Services, through the Medical Heritage Library. The original may be consulted at the the Augustus C. Long Health Sciences Library at Columbia University and Columbia University. where the originals may be consulted.

This work has been identified as being free of known restrictions under copyright law, including all related and neighbouring rights and is being made available under the Creative Commons, Public Domain Mark.

You can copy, modify, distribute and perform the work, even for commercial purposes, without asking permission.



Wellcome Collection
183 Euston Road
London NW1 2BE UK
T +44 (0)20 7611 8722
E library@wellcomecollection.org
<https://wellcomecollection.org>

COLUMBIA LIBRARIES OFFSITE
HEALTH SCIENCES STANDARD



HX64137643

RC857 .Op3

Disease of the pancr


RECAP

**Columbia University
in the City of New York**


College of Physicians and Surgeons



Department of Physiology



Digitized by the Internet Archive
in 2010 with funding from
Open Knowledge Commons



DEPARTMENT OF PHYSIOLOGY
COLUMBIA UNIVERSITY

DISEASE
OF
THE PANCREAS

ITS CAUSE AND NATURE

BY
EUGENE L. OPIE, M.D.

ASSOCIATE IN PATHOLOGY IN THE JOHNS HOPKINS UNIVERSITY;
FELLOW OF THE ROCKEFELLER INSTITUTE
OF MEDICAL RESEARCH



PHILADELPHIA AND LONDON
J. B. LIPPINCOTT COMPANY
1903

YEDJOI2YH5X0TEETEA5E0
YTIEEEVIEU /1E0UJ05

RC857.

Op3

COPYRIGHT, 1903

BY

J. B. LIPPINCOTT COMPANY

PRINTED BY J. B. LIPPINCOTT COMPANY, PHILADELPHIA, U.S.A.

Dedicated
with
Gratitude and Affection
to
William H. Welch

PREFACE.



SELDOM does the preface to a treatise upon diseases of the pancreas fail to emphasize the obscurity of present knowledge concerning its subject. The exaggerated statements regarding the infrequency of pathological changes affecting the organ may in part explain this deficiency. Doubtless the gland is less commonly the seat of generalized conditions, such as amyloid degeneration, syphilis, and tuberculosis, than are the liver and the kidneys, while acute and chronic inflammation less frequently attack it. Pathological conditions readily recognized in other organs may here, owing to the color and consistence of the tissue, be overlooked; hence parenchymatous and fatty degeneration are observable only when far advanced, miliary tubercles are seen with difficulty and acute or chronic inflammation may produce only slight macroscopic changes. Moreover, rapid self-digestion and putrefaction, to which the gland is subject, not infrequently obscure the histological as well as the gross characteristics of otherwise conspicuous alterations. In view of such facts and the slight clinical significance usually attributed to lesions of the organ, scant space is de-

voted to diseases of the pancreas in text-books both of medicine and of pathology.

To uncertainty concerning the structure and functions of the normal gland is due in great part ignorance of its pathology. The importance of the pancreatic juice to intestinal digestion has long been recognized, and facts concerning this external secretion have received adequate elucidation. Heidenhain's studies have shown what changes occur in the glandular cells during the elaboration of the pancreatic ferments and have, indeed, paved the way for an understanding of the processes of secretion in general. But in addition to the secreting cells there occur in the pancreas peculiar morphological elements which find little analogy in other glands. In 1869 Langerhans pointed out certain features which serve to distinguish the so-called salivary gland of the abdomen from all other glandular organs. Within the lumen of the acini he found cells differing in character from those which secrete the pancreatic juice, while even more remarkable is the presence throughout the parenchyma of isolated bodies composed of cells having no relation to the ducts of the gland but in intimate contact with a rich vascular supply. The very nature of the cells which compose these bodies has been disputed, some maintaining that they have a common epithelial origin with the secreting cells, others claiming that they bear a close relationship to cells of connective tissue or of lymph follicles. The function

of bodies of which the structure is so little understood has, as might be expected, remained dubious.

Our appreciation of the physiological and consequent pathological importance of the pancreas has been greatly augmented by observations which have demonstrated its relationship to carbohydrate metabolism. Clinical observations pointed the way to the epoch-making experiments of von Mering and Minkowski, who showed that, in the absence of the pancreas, sugar no longer undergoes normal assimilation, and that in animals a condition closely resembling diabetes mellitus results. The influence which the gland exerts upon assimilation of sugar is independent of the elaboration of the pancreatic juice, and since it is believed to act through the medium of the circulation, a hypothetical internal secretion has been distinguished from the external secretion, the pancreatic juice. The relation of the disease of carbohydrate metabolism, diabetes mellitus, to the lesions of the pancreas which frequently accompany it has been the subject of much study, and since all lesions of the pancreas are not accompanied by diabetes, it has remained to determine the peculiarities of those lesions which are associated with the condition.

Another pathological change which may accompany lesions of the pancreas is the condition known as fat necrosis, first adequately described by Balser. Fat necrosis is an index of pancreatic disease, and, occurring when the pancreatic juice finds its way into neighboring

tissue, bears much the same relation to lesions of the pancreas as does jaundice to hepatic disease. Recognition of the lesion and its significance is of import to the surgeon as well as of purely pathological interest.

The etiology of pancreatic diseases presents problems which have long remained unexplained. Lesions of the organ seldom occur as primary or isolated conditions, but are usually consequent upon changes in the adjacent duodenum, in the liver, or in the bile passages. Abundant proof will be brought that either acute hemorrhagic pancreatitis or chronic interstitial inflammation may be produced by biliary calculi. An intimate relation exists between chronic inflammatory lesions of the liver and those of the pancreas, both being produced by the action of similar etiological factors; acute or chronic lesions may result from infection of the pancreatic duct having its origin in the duodenum.

In the following chapters an attempt has been made to approach the unsolved questions which concern this organ. Access to a considerable material available in the Pathological Laboratory of the Johns Hopkins Hospital has given abundant opportunity for the study of various lesions of the gland and the associated conditions. To the encouraging interest of Dr. William H. Welch I am indebted for many helpful suggestions. Additional material has been obtained through the kindness of Dr. Simon Flexner, of the University of Pennsylvania. Experiments have been undertaken and the


literature of each subject has been reviewed. The Rockefeller Institute of Medical Research has aided the completion of the work.

Conditions peculiar to the organ have received most attention, and it has not been considered desirable to make an exhaustive study of those lesions which present no characteristic features and bear no special relation to the peculiar physiology of the organ. Hence the incidence of tuberculosis has not been discussed, because the lesion in the pancreas presents no distinctive features. For the same reason acute suppurative inflammation does not deserve the attention devoted to acute hemorrhagic pancreatitis, since the latter, long unexplained, is a condition dependent upon characteristic anatomical and physiological peculiarities of the gland. The etiology of chronic inflammation is characteristic; the consequent lesions bear varying relations to different histological structures of the organ, and at times produce such functional alterations that the gland is no longer capable of exerting its normal influence upon metabolism. The rare condition known as hæmochromatosis has been studied in detail, because it illustrates the relation of diabetes mellitus to a form of pancreatitis of which the pathogenesis is explicable. Since the material at my disposal, as might be expected, does not add new facts to the much-studied etiology and pathology of new growths and cysts, these subjects have not been treated in detail.

Pathological changes in the gland have emphasized the importance of certain gross anatomical and histological features, and for this reason the first chapters of the present work have been devoted to the normal structure of the organ. The attempt has been made to give a systematic account of the anatomy of the gland, emphasizing those peculiarities which have a bearing upon subsequent studies, and treating cursorily the details of structure which are described in all text-books of anatomy. The dependence of acute and chronic inflammation upon changes in the biliary passages has given importance to structural details which had been previously regarded as little worthy of consideration; hence the form and size of the ducts and their outlets have been studied with a minuteness which may seem at first sight unnecessary. In the chapter upon histology special attention has been directed to the islands of Langerhans, for few facts concerning their development, structure, and function are not mooted. The physiology of the pancreas has not been treated in a separate chapter, since on the one hand facts relating to the so-called external secretion are well understood, while on the other hand the data upon which is based our knowledge of its internal function belong as much to the domain of pathological as of normal physiology, and have been reviewed in the chapter on diabetes. Here, as else-


where, observation of diseased conditions has indicated the function of normal structures.

Throughout the following pages are numerous references to the symptomatology of pancreatic disease. Since lesions of the pancreas are seldom primary, their clinical manifestations are, as Friedreich pointed out, obscured by accompanying disease of adjacent organs. The recognition of pancreatic lesions, their causes and their consequences, is of great importance, not only to the physician, but notably to the surgeon who opens the abdomen. For illustration, disseminated fat necrosis indicates grave disease of the gland; acute pancreatitis is a not infrequent consequence of cholelithiasis; while chronic pancreatitis, which accompanies the same condition, is frequently mistaken for malignant growth. To the student of internal medicine few conditions present greater difficulties of diagnosis than do the various forms of pancreatic disease; but with increasing knowledge of their etiology, their nature, and their relation to other diseases, means for their recognition are closer to hand.



CONTENTS.

CHAPTER	PAGE
I. THE ANATOMY OF THE PANCREAS AND ITS VARIATIONS	17
II. ANOMALIES OF THE PANCREAS	46
III. HISTOLOGY OF THE PANCREAS—THE ISLANDS OF LANGERHANS	67
IV. VARIETIES OF ACUTE PANCREATITIS	89
V. THE ETIOLOGICAL RELATION OF GALL-STONES TO ACUTE HEMORRHAGIC PANCREATITIS. HEMORRHAGIC AND GANGRENOUS PANCREATITIS	113
VI. FAT NECROSIS	135
VII. THE VARIETIES OF CHRONIC INTERSTITIAL PANCREATITIS	163
VIII. THE ETIOLOGY OF CHRONIC INTERSTITIAL PANCREATITIS	184
IX. HYALINE DEGENERATION OF THE PANCREAS	214
X. THE PATHOLOGY OF DIABETES MELLITUS	236
XI. THE RELATION OF DIABETES MELLITUS TO LESIONS OF THE PANCREAS	261
XII. HÆMOCHROMATOSIS AND BRONZED DIABETES	281
XIII. THE SYMPTOMS AND TREATMENT OF PANCREATIC DISEASE	304
BIBLIOGRAPHY	339
INDEX	355



List of Illustrations.

FIGURE	PAGE
1. Original drawing of Wirsung, showing the pancreatic duct .	18
2. Reproduction of the original drawing of Santorini, showing both ducts of the pancreas	19
3. Development of the pancreas in the sheep, after Stoss, slightly modified	23
4. Reproduction of a drawing of Santorini, published in 1775, by Girardi	26
5. Varying relations of the duct of Santorini to the duct of Wirsung	31
6. Varying relations of the duct of Santorini to the duct of Wirsung	32
7. Diagrammatic drawing of the pancreas, showing the two lobes which form the head	36
8. Diagram showing diverticulum of Vater containing a calculus	40
9. Supporting connective-tissue framework of a pancreatic lobule after digestion of the parenchyma by pancreatin	70
10. Chronic interstitial pancreatitis in the cat, following ligation of the pancreatic ducts.	71
11. Camera lucida tracing of the lobule boundaries in one of a series of sections from the splenic end of a cat's pancreas	72

FIGURE	PAGE
12. Gall-stones from Case I. (actual size)	102
13. Experimental fat necrosis	150
14. Congenital syphilitic pancreatitis	166
15. Chronic interstitial pancreatitis following duct-obstruction .	176
16. Chronic interstitial pancreatitis of interacinar type . . .	182
17. Biliary calculus (actual size)	189
18. Hyaline degeneration of the pancreas	216
19. Drawing made with low magnification (colored plate) . . .	220
20. Drawing made with a higher magnification (colored plate)	220
21. Calculi which in Case XXXIII. were at operation removed from the gall-bladder	330

DISEASE OF THE PANCREAS.

CHAPTER I.

THE ANATOMY OF THE PANCREAS AND ITS VARIATIONS.

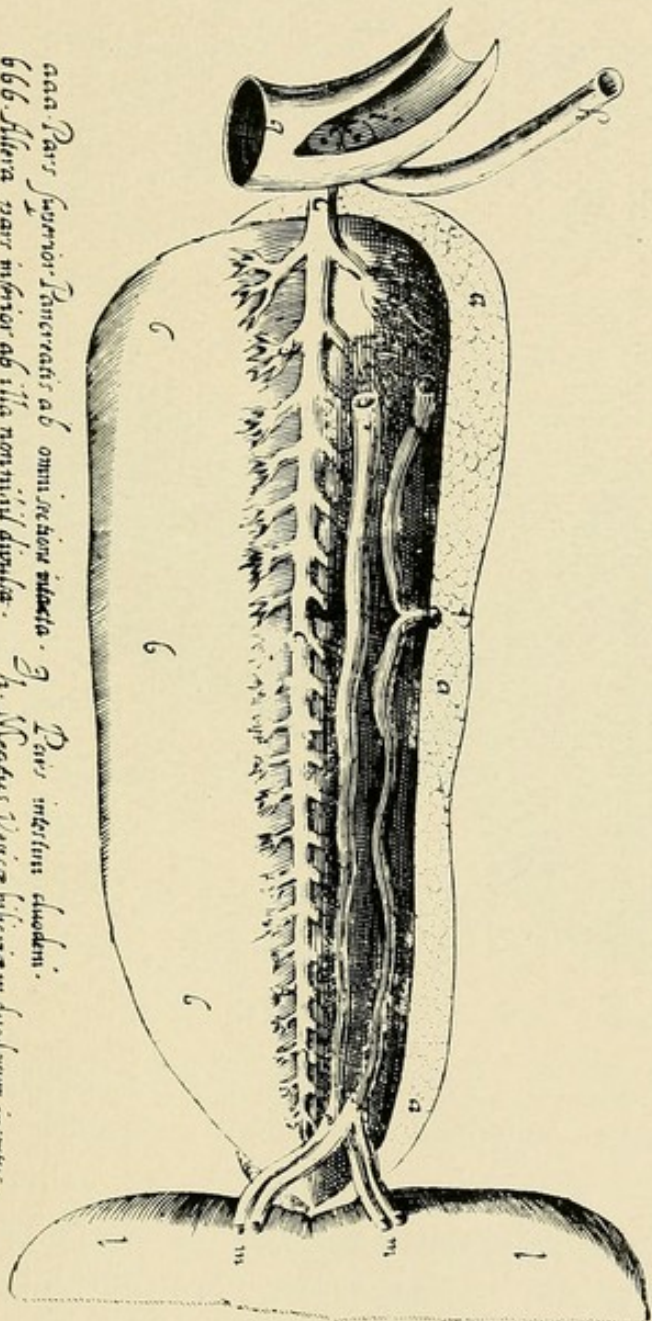
THE pancreas is subject to greater variation in size and shape than other important glandular organs. The ducts of the glands vary widely in their conformation and in their relation to one another and to the common bile duct. In a limited number of instances an accessory duct is capable of assuming the function of the larger outlet; the larger duct usually unites with the common bile duct before it enters the intestine, but in a considerable number of cases the two ducts are wholly separated. Only by a study of many specimens is it possible to determine the relative frequency of anatomical peculiarities which have a physiological significance and constitute an important factor in the production of certain pathological alterations.

The descriptions of the pancreas given by text-books of anatomy vary little, but I believe may be so modified as to give a clearer conception of the topography of the gland. A few well-known facts may be recalled in order to make clear the subsequent description.

The right extremity of the pancreas lying in the concavity of the duodenum being wider and thicker than the remainder of the gland, is termed the head, and forms an enlarged, somewhat bulbous mass, of which the long axis makes an angle with the remainder of the gland. A constricted part, or neck, connected with the upper and anterior aspect of the head, at first directed slightly upward and forward, is continued to the right as the body of the gland. In contact with this neck, in the groove which causes its constriction, lie the superior mesenteric vessels which pass from behind below the organ, while a short process of the head projects behind these vessels, thus deepening the groove in which they lie. The body terminates near the spleen in a slightly tapering extremity called the tail, but no line of demarcation exists between these two parts. The larger duct of the gland, the duct of Wirsung, traverses the organ from left to right, bends downward and backward in the neck, and, approaching the posterior surface of the head, finally reaches the wall of the duodenum, which it penetrates after uniting with the common bile duct.

According to Shirmer, who has collected many his-

*Figura ductus exiensis cum multiplicitate sue ramuli noster in Pancreat a Jo: Georg: Wirsung
 Phil: Med: D: in duobus corporibus humanis observata*



*aaa Pars superior Pancreatis ab omni sectione intacta. g. Pars inferior eadem.
 bbb Alveola pars inferior ab illa nonnulla distincta. h. Vena cava bilis in duodenum inserta.
 ccc Ductus II per longitudinem Pancreatis exiens. Orificium eiusdem tractus.
 dddd Ramuli ductus exiens per lobos omnes pancreatis dispersi. k. Orificium ductus noviter inventi
 ee. Vena splenica. ll. Pars flexa.
 ff. Arteria splenica. m. Angustus Vasorum in flectu. s. Pars j 642*

FIG. 1.—The original drawing of Wirsung, showing the pancreatic duct. Reproduced from the dissertation of Shimer.

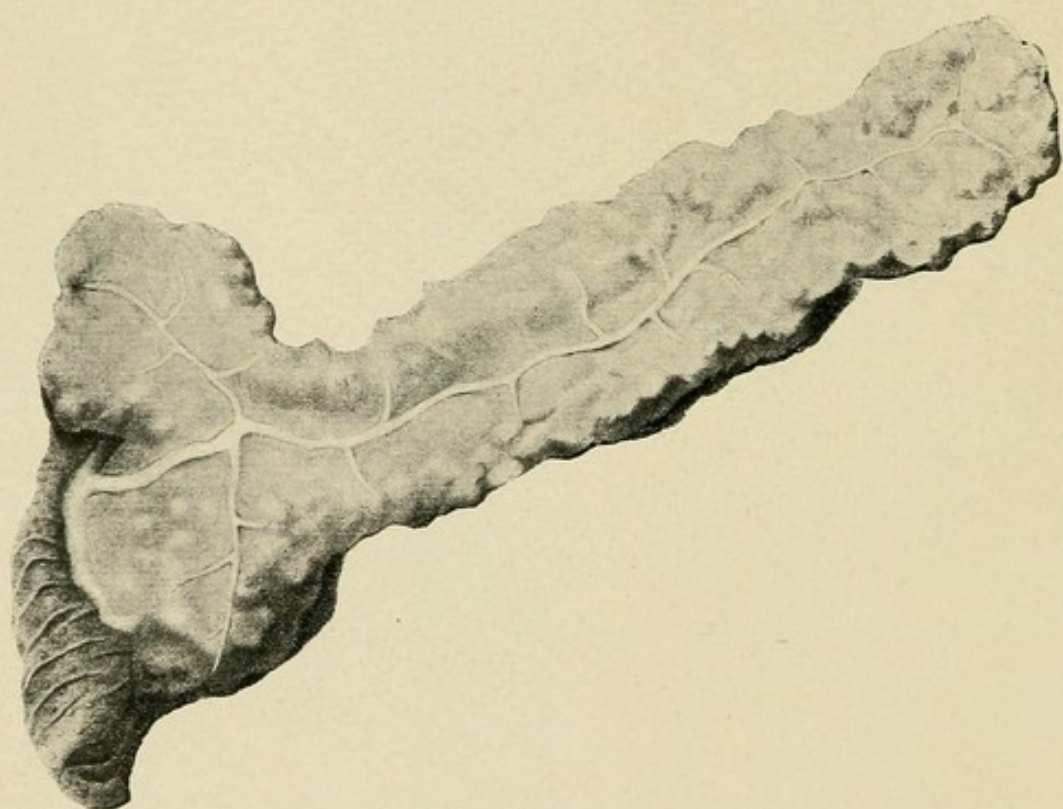


FIG. 2.—Reproduction of the original drawing of Santorini, showing both ducts of the pancreas.

torical data concerning the pancreas, the older writers, including Galen, Vesalius, and Fallopius, believed that the organ existed to support and protect more important structures in contact with it. The recognition of its physiological significance was possible only after the discovery of Wirsung, in 1643, that it is traversed by a duct which, receiving branches from every side, increases in size, and finally opens into the duodenum (see Fig. 1). Shirmer states that Moritz Hoffmann had previously seen a duct within the pancreas of the turkey. Wirsung, studying the duct in man and in lower animals, observed that it was sometimes double; and Albrecht von Haller found that it was often provided with a branch which, diminishing in size, penetrated the intestine at a point removed from the orifice of the main duct.

Santorini, however, first recognized that two ducts are normally present; he described and accurately pictured¹ the smaller duct, to which his name has been given. According to his description, it terminates in a small papilla situated upon the mucous membrane

¹ Figs. 2 and 4 are reproduced from the excellent plates of Santorini, published in 1775, thirty-eight years after his death, by Michael Girardi, under the title, "*Jo. Dominici Santorini anatomici summi septemdecim tabulæ quas nunc primum edit atque explicat usque alias addit de structura mammarum et de tunica testis vaginali.*" For the opportunity to reproduce these plates I am indebted to the kindness of Dr. Howard A. Kelly, from whose library this volume was obtained.

of the duodenum, about two fingers' breadths nearer the stomach than the larger papilla in which terminates the larger pancreatic duct and the common bile duct.

Subsequent anatomists, including Meckel and Cruveilhier, failed to recognize the existence of two ducts and thought that the occurrence of an accessory duct was exceptional until Claude Bernard, in his memoir upon the pancreas, described the second smaller outlet as constantly present. According to Claude Bernard, it appears to be formed by bifurcation of the larger duct, but, unlike the latter, diminishes in calibre as it approaches the intestine; he found that the duct which opens nearer the stomach is occasionally larger than that which terminates with the common bile duct in the ampulla of Vater, while in certain instances, on the contrary, the smaller duct is partially obliterated in the neighborhood of its intestinal extremity.

The number of ducts varies in different animals, and more than one are usually present. In birds from one to three ducts are present, the latter number being found by De Graaf in hens, pigeons, and magpies as early as 1751. Among most mammals the adult, as is well known, possesses two ducts, one of which joins the common bile duct. The pancreas of the cat and of the dog consist of two parts, an upper horizontal arm extending from the duodenum to the spleen and a descending arm lying in contact with the duodenum and projecting into the duodenal mesentery. In the

cat a large duct, sending out branches into both arms of the gland, enters the intestine by a common orifice with the bile duct, while a short distance below a much smaller duct, anastomosing with the larger in the substance of the gland, enters the duodenum. In the dog the larger pancreatic duct enters the intestine several centimetres below the smaller, which joins the common bile duct. In the rabbit, of which the pancreas consists of lobules scattered in the mesentery, a large duct enters the intestine below the bile duct, while the smaller duct is so atrophied that it is almost impermeable.

Development of the Pancreas.—With an increased knowledge of the development of the gland peculiarities of the ducts have been better understood. Earlier investigations seemed to show that the development of the organ varied greatly among different classes of vertebrates, but more careful observations have shown considerable uniformity. In all vertebrates the organ begins its development as an outgrowth or diverticulum from the wall of the intestinal tube, and by multiplication of cells and repeated branching this tubular structure gives rise to the complicated tissue of the adult organ.

The development of the liver begins before that of the pancreas, at a period when the gastro-intestinal tract is an almost straight tube; the liver makes its appearance as a projection upon the ventral wall of what will subsequently become the duodenum. At

a slightly later period proliferation of cells in the dorsal wall of the intestine forms a projecting outgrowth which represents the earliest rudiment of the pancreas. Upon the ventral aspect of the intestine on either side of the hepatic diverticulum appear, according to most recent observers, two additional epithelial buds, which increase in size and by fusion or by partial atrophy give rise to a single mass. By subsequent growth this ventral mass unites with the larger mass which has arisen from the dorsal outgrowth.

Numerous investigations have demonstrated that a dorsal outgrowth and two ventral buds in close proximity to the hepatic outlet represent the primitive rudiment or "anlage" of the pancreas in a variety of diverse vertebrate species. The occurrence of a single dorsal and two ventral outgrowths has been described in various species of fish by Laguesse, von Kupffer, Hammar, Stohr, and Goppert (quoted by Oppel). In the sturgeon, however, von Kupffer claims to have found four rudimentary buds, the dorsal outgrowth, like the ventral, being at first double. In amphibia three original outgrowths have been found by Götte, Goppert, and Felix; while in reptiles similar observations have been made by Brachet and others, though Völker has recently claimed that in the lizard—*Lacerta agilis*—the organ develops from a single dorsal outgrowth.

In mammals three rudimentary buds, one dorsal and two ventral, have been described by Stoss for the

sheep and by Felix for the cat, while analogous observations have been made upon human embryos. Völker, however, differing from other recent embryologists, has found only two rudimentary outgrowths, one dorsal and one ventral.

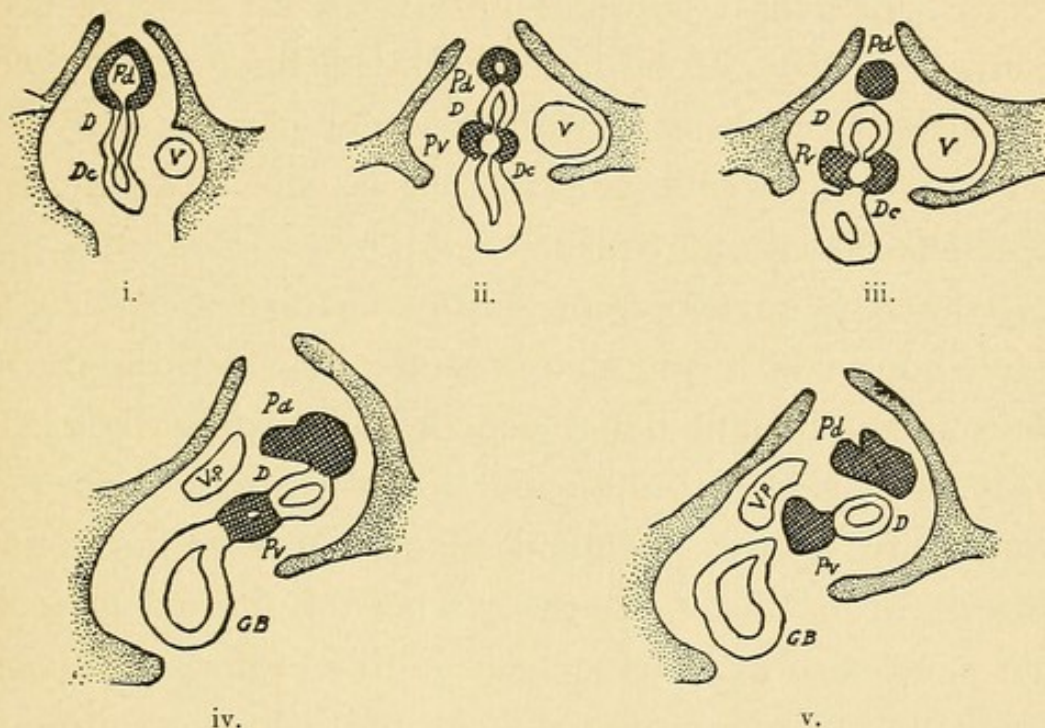


FIG. 3.—Development of the pancreas in the sheep, after Stoss, slightly modified. *D*, duodenum; *Pd*, dorsal "anlage" of the pancreas; *Pv*, ventral "anlage" of the pancreas; *Dc*, ductus choledochus; *GB*, gall-bladder; *V*, umbilical vein; *Vp*, portal vein.

Stoss has carefully described the development of the pancreas in the sheep. The bud-like outgrowth from which the liver develops is formed at a time when the gastro-intestinal tract is a straight tube attached by its mesentery to the posterior abdominal wall. The pancreas makes its appearance as a projection (Fig. 3, i., *Pd*) upon the dorsal surface of the intestine between the liver and the stomach, which is now represented by

a spindle-shaped dilatation of the intestinal tube. Upon the ventral surface of the intestine, at either side of the hepatic duct, appear two diverticula (Fig. 3, ii., Pv) which later fuse to form the ventral rudiment of the pancreas and subsequently grow to meet the dorsal part.

The stomach at first lies in the median plane of the body, and that part which is to become the greater curvature is now the posterior or dorsal border of the organ. The alteration of position by which the stomach becomes transversely placed, the posterior wall becoming the inferior border or greater curvature, is accompanied by a corresponding change in the position of the duodenum and pancreas. The dorsal part of the pancreas, which has pushed its way into the dorsal mesentery of the intestinal tube, comes to lie transversely with its left extremity near the spleen, and at the same time, as Stoss has shown, that part of the duodenum to which the pancreas and liver are attached twists upon its longitudinal axis in such a way that the ventral wall, and with it the openings of the bile duct and ventral pancreatic outgrowth, passes to the right and backward (Fig. 3, v.), becoming the posterior wall of the duodenum. With further growth the part of the pancreas which was originally ventral comes into contact with the larger dorsal part of the organ. The two parts unite to form a conglomerate organ and the two ducts, which were at first separate, anastomose. At an early stage the duct of the dorsal part atrophies, and

finally disappears, so that the single opening which remains in the adult sheep is that of the ventral outgrowth.

Stoss in the sheep and Wlassow in the pig found the dorsal outgrowth bilobed at an early period of development, and think that like the ventral part of the organ it may be originally double. Choronschizky, who has in great part confirmed the observations of Stoss, has found the dorsal outgrowth always single, and believes that the bilobed appearance observed by Stoss and Wlassow is the result of its early branching. Helly has reached the same conclusion.

The development of the human pancreas, according to most recent observations, does not differ from that of other vertebrates. Earlier observers, Phisalix, Zimmermann, and Hamburger, and recently, as before mentioned, Völker, have described two primitive outgrowths. Felix has, however, found three "anlage," a dorsal and a right and rudimentary left ventral, the two latter subsequently fusing. The dorsal rudiment, arising between the bile duct and stomach, forms the ductus Santorini, the ventral the ductus pancreaticus (Wirsungianus). Jankilowitz has found in a human embryo forty-seven millimetres in length a dorsal outgrowth projecting into the mesentery, and on either side of the ductus choledochus an additional projection. The occurrence of such a triple origin has been further confirmed by von Brunn. In an embryo six weeks old

Hamburger has found the dorsal and ventral parts of the gland united, and concludes that anastomosis occurs during the second half of the second month of embryonic life.

Variation of the Pancreatic Ducts.—Embryological study has shown that the greater part of the pancreas, the body and part of the head, develops from the primitive dorsal outgrowth represented in the adult by the duct of Santorini, which enters the duodenum between the bile papilla and the stomach (Fig. 4). The duct of Wirsung enters the duodenum in common with the ductus choledochus below the duct of Santorini,—that is, at a point farther from the stomach,—and in the head of the gland represents the primitive ventral outgrowth. The two ducts usually anastomose at an early period. That part of the upper or originally dorsal duct which lies between the duodenal orifice and its anastomosis with the lower duct undergoes partial atrophy, and the lower channel increasing in size appears to be a continuation of the large duct which, derived from the dorsal outgrowth, follows the axis of the gland. Hence the duct of Wirsung, which affords an outlet for almost the entire pancreatic secretion, is derived in the head of the gland from the ventral pancreas and in the body from the dorsal.

In a certain number of cases the upper duct, or duct of Santorini, remains larger than the lower ; in other instances there is no anastomosis between the two ducts.

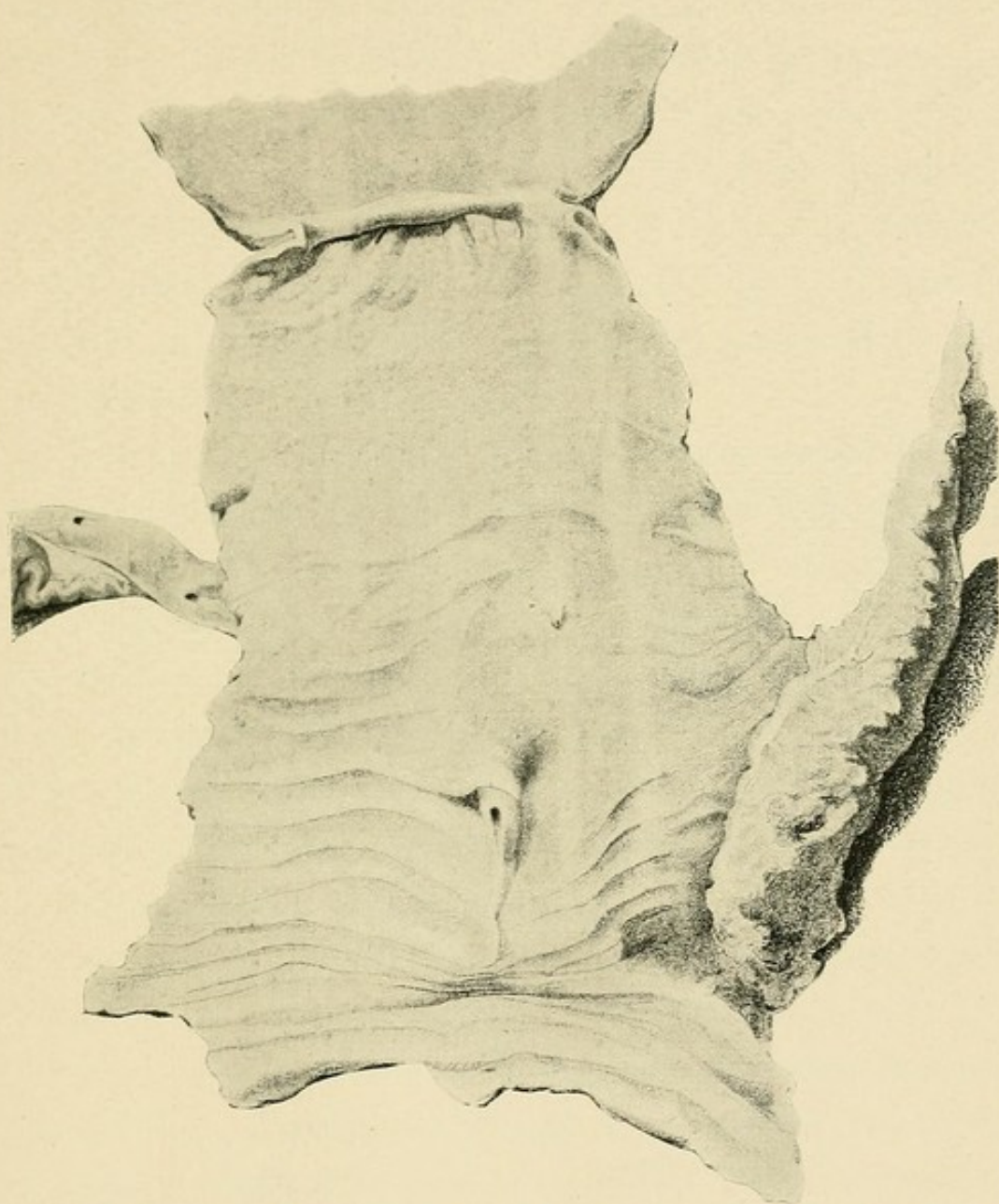



FIG. 4.—Reproduction of a drawing of Santorini, published in 1775, by Girardi. The duodenum has been opened, and both the bile papilla and the papilla of the smaller pancreatic duct are exposed.



Claude Bernard, Henle, Sappey, and other anatomists have described various modifications to which the ducts are subject, while more recently statistical data have been furnished by study of a considerable number of specimens. Increased importance has been given to the relationship of the pancreatic ducts to one another and to the common bile ducts by the study of pathological lesions dependent upon these anatomical peculiarities.

Shirmer has examined the pancreatic ducts in one hundred and four bodies. In order to test their patency he exposed the larger duct in the body of the gland and, inserting a cannula, forced air in the direction of the duodenum, which had been previously opened. By keeping the specimens under water, the escape of air from one or both ducts was determined. The ducts were later carefully dissected. Shirmer described numerous varieties dependent upon the relative size of the two ducts, their anastomosis within the gland, their patency, and their relation to the bile duct. He attempted no classification of the diverse forms, but for the sake of clearness they may be collected into three groups, as follows :

(1) In sixty-six of the one hundred and four specimens two patent ducts anastomosed within the gland. Of these fifty-seven represented what Shirmer regarded as the usual or normal condition ; upon the mucosa of the duodenum were two papilla, a smaller nearer the

stomach and a larger situated below the smaller and containing the common termination of the bile duct and the duct of Wirsung ; the duct of Santorini, which terminated in the smaller papilla, joined the duct of Wirsung several centimetres from the duodenum. In three cases the upper duct, or duct of Santorini, was larger than the duct of Wirsung, though otherwise their relations were those usually present. In six cases, Shirmer states, the bile duct entered the intestine with the upper duct, which in three of these cases was larger than the lower.

(2) In twenty-nine instances one or other of the two ducts was wholly or partially obliterated. In twenty-two of these specimens the upper papilla was not patent ; and in two instances there was no upper papilla. In four examples the upper duct alone existed while the ductus choledochus entered the intestine unaccompanied by a pancreatic duct. In one instance the duct of Santorini and the bile duct entered the intestine together ; a second papilla was found in the duodenum farther from the stomach, but was not patent.

(3) In nine specimens both ducts were present, though they failed to anastomose within the gland. In four of these cases the upper duct was larger than the lower and joined the common bile duct. In the five remaining specimens the larger duct terminated in the lower papilla with the bile duct.

I have dissected the pancreatic ducts in one hundred

specimens. In order to determine their patency and, if possible, the existence of an anastomosis between them a solution of Berlin blue was injected into the duct of Wirsung exposed by transverse section of the body of the gland. To avoid extravasation the injection was made at a low pressure, little more than that of a column of water two feet in height. By compressing that orifice, from which the fluid readily escaped, the attempt was made to divert the flow to a second orifice. Such specimens were hardened in formalin and subsequently preserved in alcohol; the dissection of the ducts was facilitated by the presence of the injected material. In those instances in which the lesser papilla appeared to be closed, serial sections were made in order to more accurately determine its patency.

My observations differ in several respects from those of Shirmer. Though the ducts vary much in their relative size and one has at times undergone partial obliteration, two are constantly present. In twelve instances Shirmer found that the common bile duct joined the upper pancreatic duct while farther from the stomach was a second smaller papilla. His observation is difficult to explain, for in my specimens the relationship of the duct of Wirsung to the common bile duct is constant, as might be expected from the well-established embryological facts already cited.

In ninety specimens the two ducts are united, but in

ten two wholly independent ducts enter the intestine. In eighty-nine cases the duct of Wirsung is larger than the duct of Santorini. In twenty-one instances the duct of Santorini is apparently obliterated near its termination. The varieties found are indicated in the following classification :

I. Ducts in anastomosis.

(1) Duct of Wirsung larger.

(a) Duct of Santorini patent . . . 63

(b) Duct of Santorini not patent . . . 21

(2) Duct of Santorini larger or equal in size to the duct of Wirsung.

(a) Duct of Wirsung patent . . . 6

(b) Duct of Wirsung not patent . . . 0

II. Ducts not in anastomosis.

(1) Duct of Wirsung larger . . . 5

(2) Duct of Santorini larger . . . 5

In considerably more than one-half the specimens both ducts are patent, and the duct of Wirsung, which unites with the duct of Santorini, is larger than the latter (Fig. 5, i.) ; the duct of Santorini diminishes in size as it approaches the duodenum, and opens upon the lesser papilla by a narrow orifice. Receiving numerous branches from the head of the gland, and gradually increasing in size as the duct of Wirsung is approached, the duct of Santorini appears to be a branch of the larger duct into which, in the majority of instances, it doubtless pours its secretion. In only forty-eight in-

stances was it possible to inject fluid at a low pressure through the smaller papilla. In some of these cases, however, the injected fluid escaped readily, and hence it is

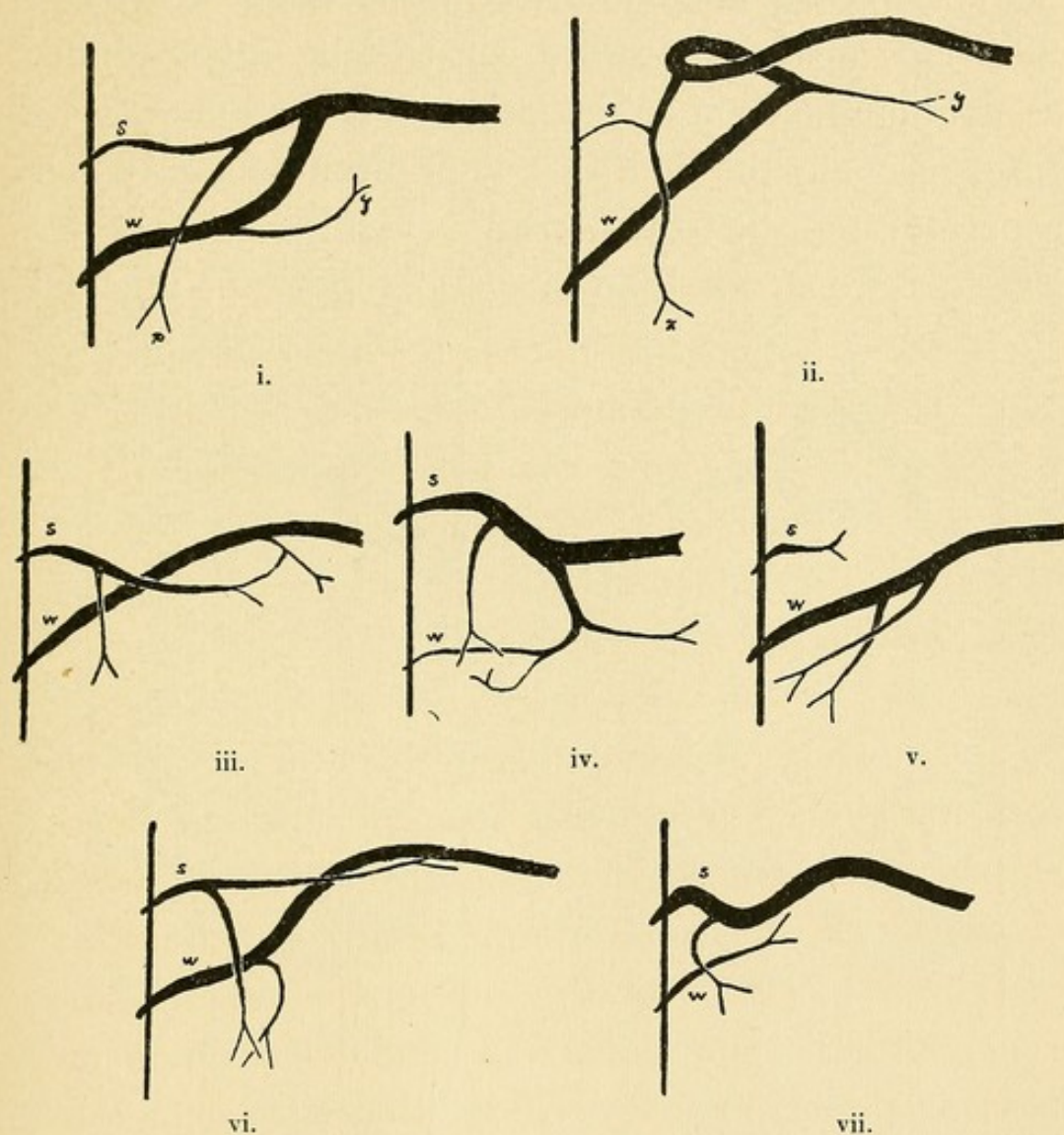


FIG. 5.—Varying relations of the duct of Santorini (*s*) to the duct of Wirsung (*w*). Drawn from dissected specimens.

probable that the duct may occasionally act as a functional outlet. In fifteen specimens the patency of the duct was demonstrated only by microscopic examina-

tion of serial sections through the lesser papilla, while in a very large group of cases it was not possible even by that means to demonstrate its patency. Hence in more than half of all individuals the lesser duct is at its orifice obliterated or so constricted that it cannot assume the function of the larger when occluded.

Occasionally the duct of Santorini enters the upper aspect of the duct of Wirsung (Fig. 5, i.) ; at times it arises from the lower aspect (Fig. 6, i., ii.), and

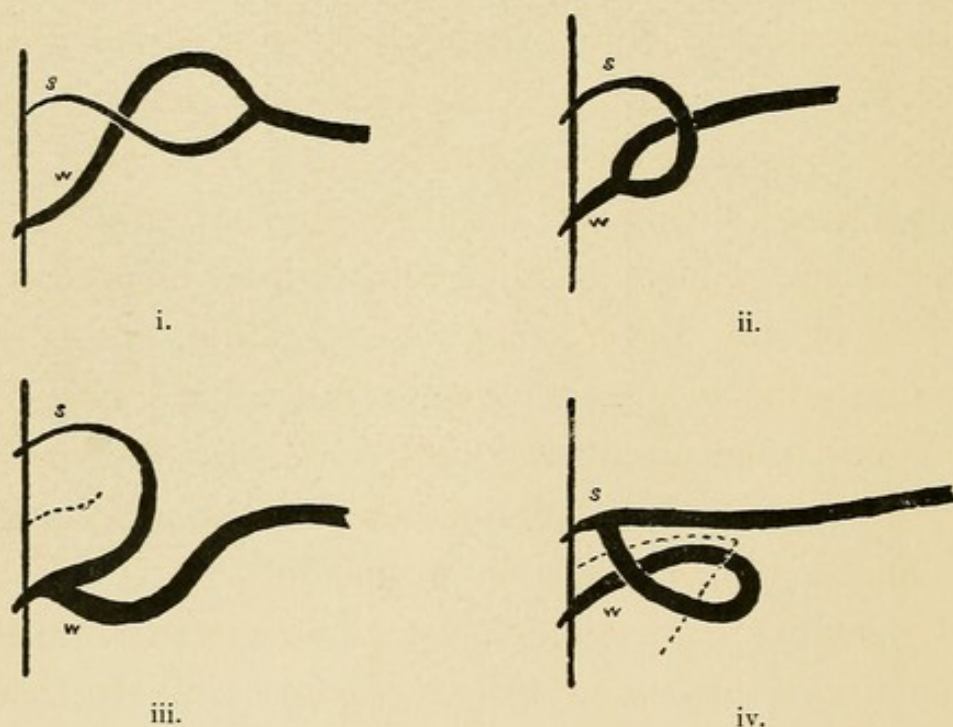


FIG. 6.—Varying relations of the duct of Santorini (*s*) to the duct of Wirsung (*w*). Broken lines are in the plane of the interlobular fissure. Drawn from dissected specimens.

by a somewhat tortuous course reaches the upper papilla. The point at which the anastomosis occurs varies considerably, and though usually several centimetres from the termination of both ducts, may be less

than a centimetre from the duodenal orifice of one, the other duct then following a tortuous course to reach its termination (Fig. 6, iii., iv.). Occasionally the duct of Santorini appears to be a direct continuation of the main channel within the body of the gland (Fig. 6, iv.), thus suggesting the original embryonic condition.

In ten cases (as in Fig. 5, v., vi., vii.) no anastomosis is found between the two ducts. In four additional cases, included in group I. of the table (see Fig. 5, iii.), the duct of Santorini is almost wholly independent of the duct of Wirsung, with which it is united only by a narrow twig. Receiving branches from all sides and gradually increasing in size as it approaches the duodenum, the duct of Santorini in such a case represents the outlet for a part of gland substance and is functionally independent of the lower duct, even though this small communicating twig unites them. Indeed, it is conceivable that when the two ducts appear to be wholly independent a very minute communication, though present, has not been demonstrated.

The relative diameter of the two ducts varies much. When they anastomose, in only seven of ninety cases is the duct of Santorini equal or larger (Fig. 5, iv.), but of ten cases in which there is no anastomosis, in half the specimens the duct of Santorini equals or exceeds the duct of Wirsung (Fig. 5, vii.).

Relation of Parenchyma to the Ducts.—The pancreas consists, it is well known, of lobules held together by

connective tissue, and upon the surface of the gland polygonal areas, varying greatly in size and shape, are mapped out by clefts filled with very loose areolar tissue. By carefully dissecting the loose tissue which these clefts contain the gland may be divided into well-defined masses of parenchyma. Such lobules, the shape of which is dependent upon mutual pressure, are usually a centimetre or more across, and in the body and tail are frequently oblong, with a long diameter at right angles to the axis of the gland; in the head they are irregular in shape. These relatively large glandular masses, separated by loose connective tissue, are found to be further divided by more inconspicuous and less well-defined septa into smaller lobules of varying size and shape, usually several millimetres across. Microscopic examination demonstrates that these are again divisible into even smaller ill-defined areas, which may be regarded as the ultimate units of the gland structure. These smallest units may be designated primary lobules; the larger masses secondary lobules; while the largest bodies, separated by loose areolar tissue, may be conveniently termed tertiary lobules.

The large pancreatic duct, as it passes through the body of the gland, is closely beset with lateral branches, which are most numerous upon its superior and inferior aspects and usually make an oblique angle with the main channel. These branches frequently divide, and from a branch and its subdivisions are given off lateral

twigs which penetrate the tertiary lobules. In some instances the duct of the tertiary lobule may enter directly the duct of Wirsung. In attempting to separate the lobules by breaking through the loose tissue which unites them it is usually found that the interlobular clefts or septa do not reach the ducts upon which the tertiary lobules are situated, but the boundaries of the latter are partially obscured by secondary lobules in intimate contact with the wall of the duct and directly tributary to it.

In the head of the gland tertiary lobules preserve a similar relationship to the two ducts there present and are tributary to branches or sub-branches of the duct of Wirsung or of the duct of Santorini. A large branch (Fig. 5, i. and ii., *x*) of the duct of Santorini usually passes downward and drains a large part of the head, while a similar branch (Fig. 5, i. and ii., *y*) from the duct of Wirsung near its junction with the duct of Santorini, passing downward and to the left, usually enters the projection (Fig. 7, *y*) which lies behind the superior mesenteric vessels. From that part of the duct of Wirsung which lies in the head of the pancreas branches are usually small and enter without subdivision the tertiary lobules.

From the arrangement just described it results that the head of the gland consists of two distinct sets of lobules grouped about the two ducts, and by careful dissection, more readily in hardened specimens, this

condition may be demonstrated. These two groups of lobules are separated near the duodenum by loose areolar tissue, while at the point where the two ducts anastomose they are united. The head of the pancreas (Fig. 7) is in fact composed of two distinct lobes, which

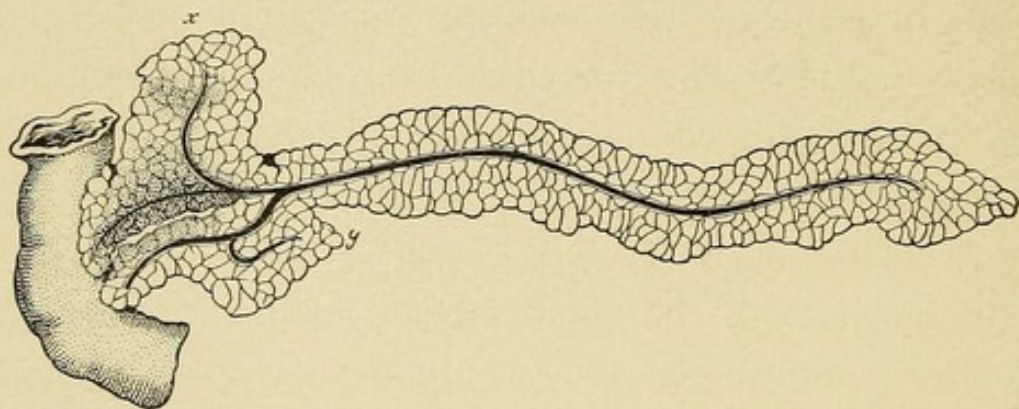


FIG. 7.—Diagrammatic drawing of the pancreas, showing the two lobes which form the head. The interlobular fissure has been opened by dissection, and the lower part (*x*) of the lobe corresponding to the duct of Santorini has been drawn upward in order to expose the lobe corresponding to the duct of Wirsung.

for the sake of convenience may be designated, in correspondence to the two ducts, the lobe of Wirsung and the lobe of Santorini. They are separated by an interlobular fissure or cleft lying midway between the two ducts. The lobe of Santorini, drawn upward in the figure, is larger than the lobe of Wirsung, which lies behind it, and being much wider from above down, forms the lower or descending part of the head (Fig. 7, *x*). The lobe of Wirsung is a relatively narrow compressed mass of parenchyma, flattened anteroposteriorly and surrounding on all sides the duct of Wirsung; a projection (Fig. 7, *y*), before mentioned, usually passes from its upper and left aspect behind the superior mesenteric vessels.

The two lobes are firmly attached to the duodenum in the neighborhood of their respective ducts, but between the ducts each lobe is readily separable from the intestine. The interlobular fissure where it is in contact with the duodenum lies midway between the two ducts in a direction from above downward and slightly forward, and extends into the substance of the head a variable distance, often four to five centimetres, its depth being dependent upon the distance from the duodenum at which the two ducts anastomose. Where anastomosis has occurred near the orifice of one duct (Fig. 6, iii. and iv.), the other duct lengthening during the course of subsequent development becomes much bowed, and with it the corresponding lobe, so that the interlobular fissure can be followed between adjacent surfaces of the lobe, which is, as it were, folded upon itself.

After breaking through the loose tissue filling the fissure, adjacent surfaces of the two lobes are found to be relatively smooth and to resemble the external surface of the organ. Within the fissure are contained branches of the pancreatico-duodenal artery and vein. The common bile duct usually lies along the upper border of the lobe of Wirsung, and the interlobular cleft meets the upper surface of the gland along a line in front and to the left of this duct. In order to expose the fissure, the bile duct may be used as a landmark.

Relation of the Common Bile Duct to the Pancreas and its Ducts.—Study of the diseases of the liver and

of the pancreas has given considerable importance to the anatomical relationship of the bile duct to the pancreas and its ducts. The common bile duct descends towards the duodenum alongside the head of the pancreas occasionally embedded in its substance, and comes in contact with the duct of Wirsung, beside which it lies for a short but variable distance before entering the wall of the intestine.

Helly has carefully studied the relation of the bile duct to the head of the pancreas in forty cases. The lower part of the duct for a distance varying from two to seven centimetres is in contact with the head of the pancreas, or, as I have shown, with the lobe of Wirsung. In fifteen cases (37.5 per cent.) the duct lay in a groove upon the surface of the gland often converted into a canal by the adjacent duodenum. In the remaining twenty-five cases (62.5 per cent.) the duct was completely surrounded for a varying distance by pancreatic tissue.

Embryological study has shown that the ventral pancreatic outgrowth of the intestine arises in contact with the hepatic duct, while the dorsal bud arising at an earlier period is situated between the ductus hepaticus and what will subsequently become the stomach. In accordance with this arrangement the lower pancreatic duct, the duct of Wirsung, in all the specimens which I have examined, approaches the intestine beside the bile duct, while the duct of Santorini enters the intestine above it. Shirmer, however, states,

as before mentioned, that in twelve of one hundred and four cases the bile duct entered the intestine in company with the upper pancreatic duct. It appears not improbable that Shirmer fell into error in the examination of his specimens.

The ductus choledochus and the duct of Wirsung penetrate side by side the coats of the duodenum, through which they pass obliquely a distance of about two centimetres and cause a papilla-like elevation of the mucous membrane. Within the papilla they unite to form a short common cavity,—the diverticulum of Vater. At the point where the common duct enters the wall of the intestine it is constricted, or at least but little distensible, so that gall-stones often lodge in this situation.

The description of the diverticulum, or ampulla of Vater, given by different anatomists does not vary materially. It may be described as a conical cavity into the base of which open the two ducts; the apex, situated at the summit of the diverticulum, is their common duodenal orifice. According to Testut, its length varies from six to seven millimetres; according to Sappey, from seven to eight millimetres. Occasionally the two ducts have no common channel, but open by separate orifices upon the summit of the bile papilla. Claude Bernard describes a mode of termination which has since been observed by others. The bile duct is prolonged as far as the mucosa of the duodenum, upon which it opens by a circular orifice. The terminal part

of the pancreatic duct, like a gutter, embraces the bile duct, and its orifice has the outline of a crescent.

The orifice of the diverticulum of Vater constitutes the narrowest part of the bile channel, and here small calculi not infrequently become impacted. A small stone lodged in the diverticulum may occlude its duodenal orifice, and, too small to completely fill the diverticulum and occlude the two ducts that enter it, may convert the latter into a single closed channel along which bile may be forced by the gall-bladder (Fig. 8, i.). Bile thus




FIG. 8.—Diagram showing, i., diverticulum of Vater containing a calculus; ii., common bile duct (*dc.*) and duct of Wirsung (*dw*) entering intestine separately.

injected into the pancreatic duct causes, as will be subsequently shown, the condition known as acute hemorrhagic pancreatitis. This lesion does not commonly follow the expulsion of a gall-stone from the common duct. For its production it is necessary that the diverticulum of Vater be capacious, with a length at least greater than the diameter of its duodenal orifice.

With these facts in view, the length of the diverticulum has been measured in one hundred specimens ; vary-

ing from zero to eleven millimetres, it averages only 3.9 millimetres. In eleven cases the two ducts open separately at the summit of the bile papilla and no diverticulum exists (Fig. 8, ii.). In only thirty instances does the length of the diverticulum reach five millimetres.

In seventy-five of these specimens the diameter of the duodenal orifice has been measured after the insertion of probes of varying size. The average diameter of the orifice is 2.5 millimetres. In twenty-one cases the diameter of the orifice is equal to or greater than the length of the diverticulum; and it is obviously impossible that a calculus, assuming it to be approximately spherical and lodged in the orifice, could only partially occlude the cavity.

Termination of the Duct of Santorini.—The termination of the duct of Santorini is represented upon the mucosa of the duodenum by an elevated papilla situated at a variable distance above the common orifice of the duct of Wirsung and the bile duct (see Fig. 4). Though often small and inconspicuous, it is recognized in all the specimens which I have examined; in one case it is so small that it has been found only after examination of serial sections through the mucosa opposite the point at which the duct of Santorini reached the intestinal wall. The papilla varies considerably in size and shape, being at times a small, nipple-like projection, at times a low, broad elevation. Within the papilla the duct of Santorini usually becomes very nar-

row and is not infrequently wholly obliterated. In serial sections it is found irregular in outline, provided with many lateral diverticula, and often very tortuous.

Much difficulty has been encountered in determining the frequency with which the smaller papilla is patent. On the one hand a small quantity of mucus within the minute lumen may readily prevent the penetration of injected material, and on the other hand, Henle states, material injected under considerable pressure may produce a false passage. By injecting air into the duct Shirmer was unable to demonstrate its patency in twenty-one of one hundred and four specimens. Helly has more recently made a careful microscopical study of the duct of Santorini as it penetrates the intestine, and in ten of fifty specimens found it obliterated.

In a considerable number of the specimens which I have examined it was not possible to force from the lesser papilla fluid injected under low pressure into the duct which had been exposed by cutting across the body of the gland. Where by such gross examination the patency of the duct of Santorini was not demonstrated, serial sections were made through the papilla, and in twenty-one instances the lumen of the duct was not found demonstrably continuous with that of the intestine. Penetrating the muscularis of the intestine and passing by a tortuous course a variable distance into the papilla, the duct, beset with many lateral diverticula, ends a short distance below the mucosa ; the duct or one

or more of its diverticula approach the mucosa, below which there is occasionally a minute dilatation.

Helly has directed attention to certain microscopic peculiarities of the lesser papilla. In addition to the duct the papilla contains mucous glands, often in considerable number ; but of greater interest is the fact that in a large proportion of cases (twenty-four of fifty instances) the papilla contains pancreatic tissue which is either wholly separated from the body of the gland by the muscular coat of the intestine or is distributed along the duct as it penetrates the muscularis, here lying between separated muscle bundles. A nodule of considerable size, formed by numerous lobules, may be situated near the orifice of the duct immediately below the mucosa. The duct of this pancreatic tissue does not always enter the duct of Santorini, but may open independently upon the overlying mucosa ; the nodule then constitutes a true accessory pancreas.

I have been able to abundantly confirm the observations of Helly, and in thirty-five specimens in which the lesser papilla was examined to determine the patency of the duct of Santorini, pancreatic tissue was absent in only six instances. A compact mass of normal pancreatic tissue, often 0.5 centimetre across, may lie above the duct of Santorini as it passes obliquely through the submucosa of the duodenum. Occasionally individual lobules are separated by coarse bands of connective tissue, while not infrequently the isolated

glandular tissue has undergone advanced chronic interstitial inflammation, and individual acini, having an atrophied appearance and separated by dense connective tissue, are recognizable only by comparison with adjacent less changed parenchyma.

The duct which drains this tissue within the papilla usually enters the duct of Santorini, but in one case it was demonstrated by serial sections to open independently into the duodenum. In one instance the duct of Santorini did not penetrate the duodenal mucosa, but had its origin in small branches draining pancreatic lobules within the papilla.

To explain the occurrence of an accessory pancreas within the papilla Helly suggests two possibilities. The isolated bit of gland tissue may arise as a bud nipped off from the dorsal embryonic outgrowth which subsequently forms the greater part of the pancreas; wholly separated from the main mass, its ducts later form an independent communication with the duodenum. Again, it is possible that the dorsal outgrowth is double, as Stoss and Wlassow, previously cited, have claimed; the accessory tissue might in that case constitute a persistent rudimentary structure.

In a later publication Helly has described the development of the lesser pancreatic papilla. The outgrowth of duodenal epithelium which represents the dorsal rudiment of the pancreas penetrates the mesoblastic part of the intestinal wall, and at a very early

period one or more lateral projections or buds are formed from that part which lies in the intestinal wall between the mucosa and the muscularis. From this lateral projection, after repeated branching, are formed lobules of pancreatic acini lying below the mucosa.

Helly has never found pancreatic tissue surrounding the duct of Wirsung as it penetrates the duodenum, and offers an explanation of its absence. The duct of Wirsung, he says, in most cases does not penetrate the duodenum, but joins the ductus choledochus at a variable distance from its termination. At the period when budding from the duct of Santorini first occurs only a very small part of the duct of Wirsung lies within the intestinal wall, and lateral outgrowths cannot penetrate into its layers. Occasionally, as already shown, the duct of Wirsung may penetrate the entire thickness of the duodenum; and since its development then resembles that of the duct of Santorini, it is not impossible that bits of pancreatic tissue be included in the surrounding intestinal wall. In one of my specimens, in which the bile papilla was very large, microscopic examination demonstrated the presence of pancreatic lobules surrounding the duct of Wirsung as it approached the bile duct (see accessory pancreas, Specimen IX. p. 54). Helly states that Pilliet has made a similar observation. From the description of Pilliet it appears, however, that he observed mucous glands, but no pancreatic tissue, about the ducts.

CHAPTER II.

ANOMALIES OF THE PANCREAS.

SINCE the ducts of the pancreas are subject to such great variation, it is not surprising that the gland presents anomalies dependent upon alterations of the usual process of development. Malformations have been described, particularly by earlier writers. The tail of the gland has been occasionally found to be bifid, or the absence of lobules of parenchyma about the duct for a short distance has caused a division of the body into two parts. Rarely the head of the pancreas completely surrounds the duodenum and may cause a partial constriction of its lumen. Shirmer cites from the older literature instances described by Tiedemann, Becourt, Moyse, Ecker, and more recently such a case is described by Symington. Tieken has reported an additional example.

That part of the gland which projects behind the superior mesenteric artery has been designated, pancreas parvum of Winslow. Though at times well defined by a deep cleft, it is not isolated from the remainder of the gland, and its duct joins the duct of Wirsung.

Accessory Pancreas.—Of greater interest is the occurrence of an accessory pancreas,—a mass of pan-

creatic tissue situated in the wall of the intestine, wholly separated from the pancreas, and provided with a duct of its own. Klob first demonstrated the existence of such isolated masses of pancreatic tissue and described two examples of this anomaly. In one instance a small flattened glandular mass was embedded in the wall of the stomach, near the mid-part of its greater curvature; in the second case a similar tumor-like body occupied the wall of the jejunum four inches from the duodenum.

Zenker subsequently collected six examples of the anomaly, and in every case demonstrated the existence of a duct entering the intestine through the overlying mucosa. These accessory glands were situated in various parts of the small intestine. One occurred between the pyloric orifice of the stomach and the pancreas, while three were found in the upper part of the jejunum near the duodenum. In one case two accessory bodies were present in the jejunum, one sixteen centimetres, the other forty-eight centimetres below the duodenum. Of especial interest is the sixth case, in which at the summit of a finger-shaped diverticulum of the ileum, 5.5 centimetres in length, situated fifty-four centimetres from the ileo-cæcal valve, was a small accessory pancreas, of which the duct opened into the diverticulum. The relation of these bodies to the coats of the intestine varied. In three instances, including two present in the same individual, the accessory gland

lay in the submucosa ; in three cases the chief mass was within the macularis ; while in the sixth case the pancreatic tissue occupied both submucous and muscular layers. Microscopic examination showed that the component tissue resembled that of the pancreas, save that the interlobular connective tissue was frequently more abundant than usual. Zenker thinks that these bodies represent a congenital anomaly of development referable to the existence of an accessory embryonic rudiment which, though at first in immediate proximity to the pancreas, is by the subsequent lengthening of the gastro-intestinal tract carried to a varying distance either above or below the gland.

A few additional examples of aberrant pancreas have been recorded. Wagner has described two such bodies, one in the intestine, the other in the submucosa of the anterior wall of the stomach near the lesser curvature and midway between cardiac and pyloric orifices. Gegenbaur found an accessory pancreas in the submucosa of the stomach near the pylorus. Upon the intestine of a child ten months old Neumann observed, sixty centimetres above the ileo-cæcal valve, a diverticulum three centimetres in length, upon the summit of which was situated a pea-sized body having the structure of pancreatic tissue and provided with a duct entering the diverticulum.

Attached to the ileum of an adult man, Nauwerk found a slender appendage nine centimetres in length,

2.3 metres above the ileo-cæcal valve. It consisted of a small mass of pancreatic tissue attached to the summit of a funnel-shaped diverticulum; a small duct entered the diverticulum. Hansemann has added another example, and Shirmer has described a similar diverticulum surmounted by an accessory pancreas and situated one hundred and fifteen centimetres above the ileo-cæcal valve. In a second case of Shirmer an accessory pancreas occupied the submucosa and muscularis of the stomach a short distance from the pylorus. Glinski has described an accessory gland of large size, 4.5 by 3.5 centimetres across and one centimetre in thickness, situated in the muscularis of the posterior wall of the stomach near the pylorus. In two hundred autopsies Letulle found in as many as five cases aberrant glands, and describes a sixth case in which a partially isolated mass of pancreatic tissue formed part of the head of the pancreas.

Wright has described an unique example of the anomaly. A child twelve years of age had suffered with a congenital umbilical fistula. The fistulous tract was removed, and within the tissue was embedded a nodule 3.5 millimetres in diameter, composed of glandular acini identical with those of the pancreas and containing readily recognizable islands of Langerhans.

Altogether twenty-two instances of this anomaly have been described. The following ten examples collected from eighteen hundred autopsies present features which

I believe explain their process of development, and for this reason are described with some detail. For the sake of convenience they may be divided into two groups,—those situated above the pancreas in the stomach and duodenum and those below the gland in the duodenum and jejunum.

Accessory Gland above the Pancreas.

SPECIMEN I.—*Accessory pancreas of the stomach* in a white man, aged forty years. Near the lesser curvature of the stomach, eight centimetres from the pylorus, is a firm flattened nodule, 1.2 centimetres across, lying below the mucosa and projecting slightly upon the peritoneal surface, which has over it an irregular nodular appearance. Microscopic examination shows a compact mass of tissue identical in structure with that of the pancreas, situated in the submucosa and extending into the muscularis, of which the muscle bundles are separated and much distorted by the presence of numerous scattered lobules of glandular tissue. Between the lobules, and at times within them, particularly in the submucosa, connective tissue is more abundant than in the normal pancreas. Ducts of considerable size are present but are not dilated.

SPECIMEN II.—*Accessory pancreas of the stomach* in a colored boy, aged eleven years. Below the mucous membrane of the stomach, two centimetres from the pylorus, is a firm nodule five millimetres in diameter. Microscopic examination shows a small mass of pancreatic tissue situated in the submucosa. Fibrous stroma is somewhat more abundant between the lobules than in the normal gland. Slightly dilated ducts lined by high columnar epithelium are most numerous and largest near the surface of the nodule next to the muscular coat of the stomach.

SPECIMEN III.—*Aberrant pancreas of the pylorus* in a woman,

aged sixty-five years. At the site of the pyloric valve of the stomach, projecting into the lumen, is an elevation of the mucosa, caused, as microscopic examination shows, by a nodule of pancreatic tissue situated in the submucosa; in the sections examined are found two islands of Langerhans, structures peculiar to the pancreatic parenchyma. Numerous dilated ducts are present, and are most numerous near the muscularis. In the underlying muscle of the pylorus is found a group of small ducts, while immediately below the serosa are on section two widely-dilated, duct-like channels lined by high columnal cells.

31 SPECIMEN IV.—*Accessory pancreas of the stomach and nodule of the pylorus containing dilated ducts* in a white man, aged seventy years. In the wall of the stomach, eight centimetres from the pylorus, is a nodule composed of a gland-like tissue, two centimetres across, projecting upon both the mucous and serous surfaces. At the pylorus is a second nodule-like projection of the mucosa, about seven millimetres across; but here on section no gland-like tissue is found. Examination of the pancreas demonstrates the existence of two ducts, of which the duct of Santorini is smaller and terminates in a small papilla. At the site of the bile papilla is a short diverticulum of the mucous membrane. Microscopic examination of the gastric nodule shows partly in the submucosa but chiefly in the muscularis, separating its muscle bundles, pancreatic lobules and groups of lobules which often contain much interstitial tissue, as though the seat of chronic interstitial inflammation. Islands of Langerhans are fairly abundant, and ducts, often with wide lumina, occur throughout the section. The papillary projection at the pylorus is produced by an increase in the thickness of the submucosa, where, surrounded by a quantity of connective tissue, is found cut transversely a duct-like structure lined by columnar epithelium and identical in appearance with the ducts of the pancreatic nodule. In the underlying muscle of the pylorus several ducts of larger size are cut across, while imme-

diately below the serosa the section cuts twice what appears to be a dilated tortuous duct.

SPECIMEN V.—*Aberrant pancreas* (1) *of the stomach and* (2) *of the duodenum, together with pancreatic tissue in the lesser papilla* in a white boy, aged four years. Immediately below the mucous membrane of the stomach, only two millimetres from the pyloric orifice, is a nodule of gland-like tissue three millimetres across. Below the mucosa of the duodenum, 9.5 centimetres below the pylorus, is a second nodule of similar character, about seven millimetres across. The papilla of the duct of Santorini is represented by a hemispherical elevation, seven millimetres across, which on section appears to contain a third isolated nodule of glandular tissue. Microscopic examination shows that the nodule of pancreatic tissue situated in the submucosa of the stomach has been the seat of moderate chronic interstitial inflammation, and its ducts, which converge towards its under surface, are dilated and contain polynuclear leucocytes; islands of Langerhans occur. The duodenal nodule immediately below the pylorus consists of pancreatic tissue situated in the submucosa and muscularis, of which the bundles are split apart and distorted. It projects beyond the muscle upon the outer surface of the intestine. Ducts and islands of Langerhans occur. In the submucosa, immediately above the duct of Santorini, after it has penetrated the muscularis of the duodenum, is situated a third nodule of pancreatic substance, adding considerably to the size of the papilla.

SPECIMEN VI.—*Aberrant pancreas of the duodenum together with pancreatic tissue in the lesser papilla.* The mucous membrane of the duodenum, four centimetres above the papilla of the duct of Santorini, presents a low elevation seven millimetres across. The papilla of the duct is represented by a low, broad elevation five millimetres across; the duct of Santorini, smaller than the duct of Wirsung, joins the latter and is patent throughout. The nodular elevation of

the duodenum is by microscopic examination shown to be caused by the presence of numerous pancreatic lobules and groups of lobules situated between separated bundles of the muscularis. A few lobules which are the seat of chronic interstitial inflammation are situated in the submucosa, through which a tortuous duct surrounded by numerous diverticula and abundant connective tissue can be traced to the surface of the mucosa. The lesser papilla of the pancreas is on microscopical examination found to contain a few lobules of pancreatic tissue which has undergone chronic interstitial inflammation.

SPECIMEN VII.—*Aberrant pancreas of the duodenum* in a woman, aged fifty-six years. Projecting upon the external surface of the duodenum, between the stomach and the pancreas, is a hemispherical nodule eight millimetres across, which on opening the duodenum is found to cause a slight elevation of the mucosa. On microscopic examination the main mass of the nodule is found to project outside the muscle coats, which are split apart and over a considerable area broken through, so that the nodule is continuous with a smaller collection of pancreatic lobules which have undergone chronic interstitial inflammation and are situated in the submucosa. Ducts are present and islands of Langerhans occur.

Accessory Gland below the Pancreas.

SPECIMEN VIII.—*Accessory pancreas of the duodenum* in a white woman, aged forty years. A small nodule of grayish-yellow tissue situated in the wall of the duodenum below the pancreas causes an elevation of both the mucous and serous surfaces. Microscopic examination shows that a mass of pancreatic tissue is situated in the submucosa, and extending through the circular muscle coat, separates the latter from the longitudinal layer. Dense stroma surrounds and often invades the gland lobules. Ducts lined by columnar epithelium occur.

SPECIMEN IX.—*Accessory pancreas of the jejunum showing advanced chronic interstitial inflammation together with pancreatic tissue in the bile papilla* in a colored woman, aged fifty-nine years. In the jejunum, one hundred and eleven centimetres below the duodenum, is an oval elevation of the mucosa 1.5 centimetres in length, situated opposite the mesentery and caused by an underlying nodule of firm grayish tissue containing minute cysts. Microscopically the tissue resembles at first sight a small adenoma, since embedded in dense fibrous stroma are groups of gland-like structures formed by high columnar cells surrounding a wide lumen. In the centre of each group are one or more larger, irregularly tubular structures resembling ducts, while embedded in the dense stroma occur glandular acini, which are readily identified with those of the pancreas, since they contain centro-acinar cells. The main mass of the nodule, which has undergone advanced chronic intestinal inflammation, is situated in the submucosa, but bundles of the underlying circular muscle are separated and distorted by the presence of dilated ducts. The duct of Wirsung of the pancreas is much smaller than the duct of Santorini, and does not anastomose with it. The bile papilla is of very large size, and examined microscopically is found to contain lobules of pancreatic tissue, adding considerably to its bulk. They surround the duct before it enters the diverticulum of Vater, which is only 2.5 millimetres in length.

SPECIMEN X.—*Accessory pancreas of the jejunum showing advanced chronic interstitial inflammation and resembling a small adenoma* in a white man, aged thirty-eight years. In the jejunum, four metres from the stomach, is an elevation of the mucosa caused by an underlying nodule of tissue about one centimetre across. Microscopic examination shows numerous ducts, isolated or surrounded by mucous glands and identical in appearance with those of the pancreas. They are embedded in abundant dense fibrous stroma, and the appearance agrees with that of Specimen IX., save that lobules

of pancreatic acini are no longer preserved. The nodule is situated wholly in the submucosa.

In the cases just described small masses of pancreatic tissue, usually not more than a centimetre across, have been found in the stomach, in the duodenum, in the jejunum, and even in the ileum. Rarely are two accessory glands found in the same individual. In a case described by Zenker two nodules were found in the jejunum. In Specimen IV. of the present series a second nodule situated at the pylorus, though containing only dilated ducts, doubtless represents a second isolated remnant of pancreatic tissue; in Specimen V. two bodies occur, one in the stomach, the other in the duodenum.

In twenty-six cases, including those just described, and excluding one of Wright, which was without autopsy, one of Wagner, and five of Letulle, in which the location is not definitely stated, the distribution of twenty-nine accessory bodies was as follows:

Above the pancreas:

Stomach, 11.

Duodenum, 4.

Below the pancreas:

Duodenum, 1.

Jejunum, 9.

Ileum, 4.

The situation of the accessory pancreatic tissue with relation to the coats of the intestine varies slightly. It is usually situated in the muscularis of which the muscle bundles are separated and distorted by the presence of pancreatic lobules and groups of lobules, and, it will be shown later, the muscular coat may be much weakened by the presence of the glandular tissue. In three of the cases which I have observed the aberrant gland, was situated wholly in the sub-mucosa, while in four additional instances, though no glandular lobules were present in the underlying muscle layer, ducts were here found. In the remaining instances the body occupied the muscular layer.

The tissue of the aberrant gland does not differ in its histological features from that of the pancreas. Numerous ducts occur, and doubtless open on the intestinal mucosa, though this fact was demonstrated by serial sections in one instance only. Within the acini are found centro-acinar cells. Letulle states that the peculiar bodies known as islands of Langerhans do not occur in the accessory gland. Wright has, however, demonstrated their presence in a pancreatic nodule removed from the neighborhood of the umbilicus, and in five of my cases they have been found.

The isolated nodule of pancreatic tissue tends to undergo chronic interstitial inflammation, and interstitial tissue is almost constantly present in greater quantity than in the normal gland. Inflammatory

changes are probably dependent upon occlusion of the minute, often tortuous, ducts, and are doubtless intensified by the invasion of bacteria from the intestine or stomach. The ducts are frequently dilated, and in one instance (Specimen IV.) some of them contain polynuclear leucocytes. In two nodules, situated in the jejunum, chronic inflammation has reached an advanced stage, and one nodule consists in great part of fibrous tissue and dilated ducts, surrounded by hypertrophied mucous glands, while in the other the pancreatic acini have undergone complete destruction. In such cases the nodules resemble small adenomata.

Origin of the Accessory Pancreas.—The origin of the accessory bodies under consideration is of much interest. Zenker thought that they are referable to the occurrence of an abnormal pancreatic rudiment or "anlage" which, formed in close proximity to the primitive pancreatic outgrowth of the intestinal tract, is subsequently separated from it by the longitudinal growth of the intestinal wall. Arising before the stomach is distinct from the duodenum, the accessory body, carried upward, may finally occupy the gastric wall, while if situated below the pancreas it would be transported in the direction of the ileo-cæcal valve.

To explain the occurrence of these bodies, Glinski directs attention to the development of the pancreas from more than one rudimentary outgrowth of the intestine. Most recent observers, as before mentioned,

have described one dorsal and two ventral diverticula. Since the pancreas of individuals possessing an accessory gland has not been found to be abnormal, Glinski assumes that its development proceeds normally from two primitive intestinal diverticula. The additional rudimentary outgrowth persisting may, Glinski believes, give rise to an accessory nodule subsequently carried above or below the main glandular mass by growth of the intestine. In order to explain the existence of two accessory glands, as in the case of Zenker, it is necessary to assume the existence of four original "anlage," the dorsal embryonic outgrowths in such case being double.

The orifice of the duct of Santorini, which represents the dorsal embryonic outgrowth, has been found in one hundred subjects which I have examined to be constantly situated above (nearer the stomach) the duct of Wirsung, which represents the ventral outgrowth, and is always in contact with the common bile duct. Should an accessory pancreas arise by persistence of one of the two ventral outgrowths, subsequent lengthening of the intestine should carry it in only one direction,—namely, towards the jejunum; while should it arise from part of a double dorsal outgrowth, as Glinski suggests, it would be transported upward in the direction of the stomach. The occurrence of two aberrant glands above the pancreas, as in Specimens V. and VI., would then be explicable only by assuming the occasional occurrence

of a triple primitive dorsal rudiment, since, at least in the cases which I have described, both pancreatic ducts had developed normally. Such a condition has not been found in any vertebrate species.

Helly has shown that a small mass of pancreatic tissue may occur in the papilla of the duct of Santorini wholly separated from the remainder of the gland. Its duct may enter the duct of Santorini, or the isolated tissue constituting a true accessory gland may be provided with a duct opening independently into the duodenum. In the latter case Helly suggests two possibilities: the embryonic dorsal "anlage" is double, or a part of the primitive outgrowth is separated from the remainder and later acquires an independent duct. Helly's subsequent study of the embryonic development of the papilla (cited on page 44) supports the latter hypothesis. At an early period of development lateral branches of the dorsal pancreatic outgrowth penetrate the submucosa or muscularis of the intestine, ultimately forming the lobules which surround the duct as it passes obliquely through the intestinal wall. Should the duct draining these lobules be occluded by the development of adjacent muscle bundles or fibrous tissue, it is by no means inconceivable that a new duct might be established,—for it has long been known that the pancreatic duct after section or ligation regenerates and re-establishes its lumen. This fact was known to Claude Bernard. Pawlow and Smirnow have described

in detail an experiment upon a rabbit in which two months after ligating the pancreatic duct a new channel entering the duodenum was found beside the ligature. Ssobolew, among others, has noted similar regeneration of the duct.

Should one or more embryonic buds of glandular tissue make their way into the wall of the intestine at an early period, they might be carried from the remainder of the gland by the longitudinal growth of the intestine; arising from the dorsal pancreatic outgrowth which is situated above the ventral, the aberrant tissue would be carried towards the stomach; if from the ventral outgrowth, towards the jejunum. The existence of more than one accessory body above or below the pancreas is then explicable without assuming the occurrence of an embryonic condition unknown among the vertebrates.

In accordance with this conception, accessory bodies are formed by a process similar to that which so frequently isolates a bit of pancreatic substance in the papilla of the duct of Santorini; and in the cases where an examination was made, pancreatic tissue was found in the lesser or greater papilla when an accessory nodule occurred above or below the pancreas. In Specimens V. and VI. the papilla of the duct of Santorini was examined microscopically and found to contain lobules of pancreatic tissue. In Specimen V., in which an aberrant pancreas occurred in the stomach and another in the duodenum immediately below the pylorus, the

papilla of the duct of Santorini contained a third isolated nodule of pancreatic tissue. Of greater import is Specimen IX., in which an accessory body occurred in the jejunum; here the bile papilla contained lobules of pancreatic acini—a condition never observed by Helly. If an accessory body arises from the ventral embryonic outgrowth at a time when the distance between the hepatic duct and the umbilical stalk is slight, subsequent growth of the intestine will locate it at some point between these structures. Wright has reported an unique case in which a nodule of pancreatic tissue was removed from the neighborhood of the umbilicus during life.

The results of the preceding study may be summarized as follows: The duct of Santorini, as it penetrates the duodenal wall, is in almost all individuals partially surrounded by lobules of pancreatic tissue lying between separated muscle bundles or forming a more or less compact mass within the lesser papilla. The duct which drains this tissue usually enters the duct of Santorini, but occasionally opens independently into the duodenum. This pancreatic tissue within the intestinal wall frequently undergoes chronic interstitial inflammation and may partially disappear. The duct of Wirsung within the bile papilla is more rarely accompanied by lobules of pancreatic tissue.

Accessory nodules of pancreatic tissue are not infre-

quently found embedded within the wall of the gastrointestinal tract from the pyloric region of the stomach to the ileum. In most instances they are in part or wholly situated in the muscular layer. The glandular tissue of which they are composed does not differ in histological structure from that which forms the pancreas and contains characteristic islands of Langerhans. It tends to undergo chronic interstitial inflammation.

The aberrant pancreas and the isolated tissue within the duodenal papilla owe their origin to the same process. At a very early period of embryonic development lateral branches bud from the rudimentary pancreatic ducts as they penetrate the mesoblastic layers of the intestinal canal; from these branches is formed the pancreatic tissue of the papilla. A small mass of glandular parenchyma entangled in the fibrous or muscular tissue of the embryonic wall may be carried by subsequent longitudinal growth of the intestine a variable distance above or below the pancreas, thus forming an accessory gland.

Diverticula of the Intestine Resulting from Anomalies of the Pancreas.—Among recorded instances of accessory pancreas are several associated with diverticula of the intestine. In one case of Zenker a nodule of pancreatic tissue was situated at the summit of a diverticulum of the ileum 5.5 centimetres in length and fifty-four centimetres from the ileo-cæcal valve. Neumann found in a child ten months of age a diverticulum

situated sixty centimetres from the valve and capped by an accessory pancreas the size of a pea. In a case of Nauwerk a small mass of pancreatic tissue was located at the apex of a funnel-shaped intestinal diverticulum 2.3 metres from the valve. Hansemann states that he has seen an accessory pancreas attached to the summit of a diverticulum of the jejunum.

Zenker thought that the diverticulum which he described was the remains of the vitelline duct and represented the so-called Meckel's diverticulum. Since the pancreas begins its development at a period when the vitelline duct is already formed, Neumann did not think the accessory pancreatic nodule could occupy the summit of a diverticulum formed from that structure. Nauwerk has confirmed this view, for in his case a true Meckel's diverticulum occupied the wall of the ileum between the ileo-cæcal valve and diverticulum upon which was situated an aberrant pancreas. The formation of a diverticulum accompanying the accessory gland is thought by Neumann, Nauwerk, and Hansemann to be the result of traction exerted by the aberrant nodule.

Accessory pancreatic tissue, it has been shown above, is usually situated in the muscular layer of the intestine, separating and distorting the muscular bundles and at times (Specimen VII.) causing a defect in the muscle coat. Pressure within the intestine during peristalsis doubtless causes a hernial protrusion of the

mucosa and submucosa through the weakened muscularis. It appears improbable that the small nodule of tissue exerts appreciable attraction upon the intestinal wall.

Diverticula of the duodenum in contact with the head of the pancreas not infrequently occur, and doubtless owe their origin to a condition resembling that just described. Several older writers quoted by Roth have observed such diverticula, and Roth has described five cases in which the mucosa of the duodenum, passing through the muscular coat, formed a hernial protrusion into the head of the pancreas. In two of these cases two diverticula were present; one opened beside the bile papilla and the other nearer the stomach; in one case the opening of the last-named pouch was in contact with the papilla of the duct of Santorini, while in the other its relation to the duct was not noted. In a third case a single diverticulum was situated beside the smaller papilla, and in a fourth was located three centimetres above the bile duct, but its relation to the smaller papilla was not observed. In a fifth case the location of the diverticulum is not definitely stated.

The following case illustrates the relationship of diverticula of the duodenum to the pancreatic and common bile ducts:

SPECIMEN XI.—*Diverticula of the duodenum beside the bile papilla and the papilla of the duct of Santorini.* In the mucous membrane of the duodenum, immediately above the bile papilla, is

the oval orifice of a diverticulum, which is 1.5 centimetres in length. After partial dissection of the pancreas from the duodenum, the mucosa is found to form a hernial protrusion through the muscularis. This diverticulum penetrates the muscle coat beside the common bile duct as the latter passes obliquely through the wall of the intestine and is continued upward and backward in the direction of the duct. Immediately above the papilla of the duct of Santorini is a second somewhat smaller diverticulum, 1.3 centimetres in length, provided with an oval orifice. It passes into the substance of the pancreas above the duct, and consists of mucosa and submucosa, in contact with which are lobules of pancreatic tissue.

One of the diverticula described lies beside the common bile duct as it penetrates obliquely the duodenal wall, while the second is in contact with the duct of Santorini. Klebs, Hansemann, Fischer, and others have shown that those diverticula of the mucosa, which are not uncommon near the mesenteric attachment of the small intestine, occur at points where blood-vessels penetrate, and consequently weaken the muscular coats. Roth, reviewing the cases which he has described, directs attention to the relative frequency with which diverticula of the duodenum occur in contact with the pancreas, and quotes the conclusions of Fleischmann that the entrance of the biliary and pancreatic ducts are points of predilection, because here the muscle bundles separate to allow the passage of the ducts. Pressure within the intestine produces a protrusion of the mucosa through the muscu-

laris. Such a diverticulum is analogous to that which accompanies an accessory pancreas, and doubtless an additional factor in their production is the previously described occurrence of lobules of pancreatic tissue separating and distorting the muscle bundles about the ducts.

CHAPTER III.

HISTOLOGY OF THE PANCREAS—THE ISLANDS OF LANGERHANS.

BEFORE considering the pathological histology of chronic interstitial pancreatitis and the alterations of the gland associated with diabetes, it is desirable to discuss in detail certain histological peculiarities of the gland. The pancreas is much more complex in structure than the other glandular organs which it closely resembles. Langerhans, in an inaugural dissertation published in 1869, gave the first careful description of its histology, and showed that the organ has not the relatively simple structure of the salivary glands.

Langerhans studied the pancreas of rabbits, which in its essential features does not differ from that of other mammals. The larger ducts are lined by epithelium, composed of a single layer of high columnar cells. As the branches of the ducts become smaller the epithelial cells become lower, cubical, and finally flat, or, as seen in section, spindle-shaped, the nucleus occupying the thicker central part. The smallest ducts end in the acini, composed of high columnar characteristically glandular cells, containing next the lumen numerous zymogen granules. Within almost every acinus, in contact with the secreting cells, Langerhans

found one, two, or more cells of a different nature, and to these he gave the name centro-acinar cells. They closely resemble the flat, spindle-shaped cells lining the very small ducts, and he thinks that the epithelium of the duct is continued over the secreting cells into the lumen of the acinus, but he admits that he is unable to determine with exactness the method by which the duct ends.

Distributed at intervals in the parenchyma are groups of cells differing markedly from those of the ordinary glandular type. Such groups are usually round, and in tissue treated for two or three days with Müller's fluid appear with low magnification as intensely yellow specks. With high magnification they are found to be composed of small, irregularly polygonal cells, with a round nucleus and refractive homogeneous cell-body. Of the nature of these cell-groups Langerhans declares himself entirely ignorant.

Numerous observers have described these structures, which are usually designated islands of Langerhans. Renaut, regarding them as analogous to lymph follicles, speaks of them as "points folliculaires." Podwyssotski calls them pseudo-follicles. They have been designated secondary cell-groups, interalveolar cell-islets, and interacinar islands.

In injected specimens Kühne and Lea found scattered throughout the organ glomerular structures composed of dilated and tortuous capillaries, and showed that

they correspond to the cell-groups which Langerhans described. The interacinar islands are penetrated by numerous wide, tortuous capillaries forming irregular anastomosing columns. Material injected into the duct of the gland does not enter the island of Langerhans, and Dogeil was able to demonstrate by Golgi's stain the absence of ducts within them.

Numerous investigations have demonstrated the occurrence of similar structures in a great variety of vertebrate species, including numerous mammals, birds, amphibia, reptiles, and fish. Harris and Gow studied these bodies in a large number of mammals, and noted minor differences of structure in different species. Studies of the Italian observers, Giannelli and Giacomini, Massari, and Diamare, have dealt with the related bodies of lower vertebrates. Giannelli and Giacomini state that in certain reptiles the columns of cells forming the islands of Langerhans have a tubular structure, being composed of moderately high cylindrical cells which, though they differ in appearance from the ordinary secreting cells of the acini, are arranged about a narrow lumen. At the periphery of the island these tubular columns are continuous with the secreting acini. In certain fish Diamare found near the spleen the hepatic artery, and in other situations isolated structures having the characters of islands of Langerhans. Since islands of Langerhans have been found in a constantly increasing number of diverse species,

there can be little doubt that they are present in all vertebrates.

The Lobule of the Pancreas.—In order to determine the relation of the interacinar islands to the other elements of the gland I have studied the human pancreas under a great variety of conditions. The organ has been studied in lower animals, particularly in cats and dogs, and numerous injections of the blood-vessels and of the ducts have been made.

In the human pancreas groups of acini about terminal ducts are not sharply defined by connective tissue, so that individual lobules, as in the human liver, are indistinctly marked off and in places apparently fuse with one another. In the pancreas of the cat the lobules, like those in the liver of the pig, are much more sharply outlined by interstitial tissue. The parenchyma is divided by septa of fibrous tissue into small polygonal areas varying in size and shape. When injected with Berlin blue a small ramification of the duct is found to penetrate the isolated group of acini. These smallest subdivisions of the parenchyma, which may be designated primary lobules, often appear completely isolated by fibrous tissue from those near by ; but when one of them is traced through a series of sections, its demarcation being incomplete, one may find the parenchyma of adjacent lobules continuous in places. That such polygonal subdivisions are actually independent of one another and represent units of structure is readily de-

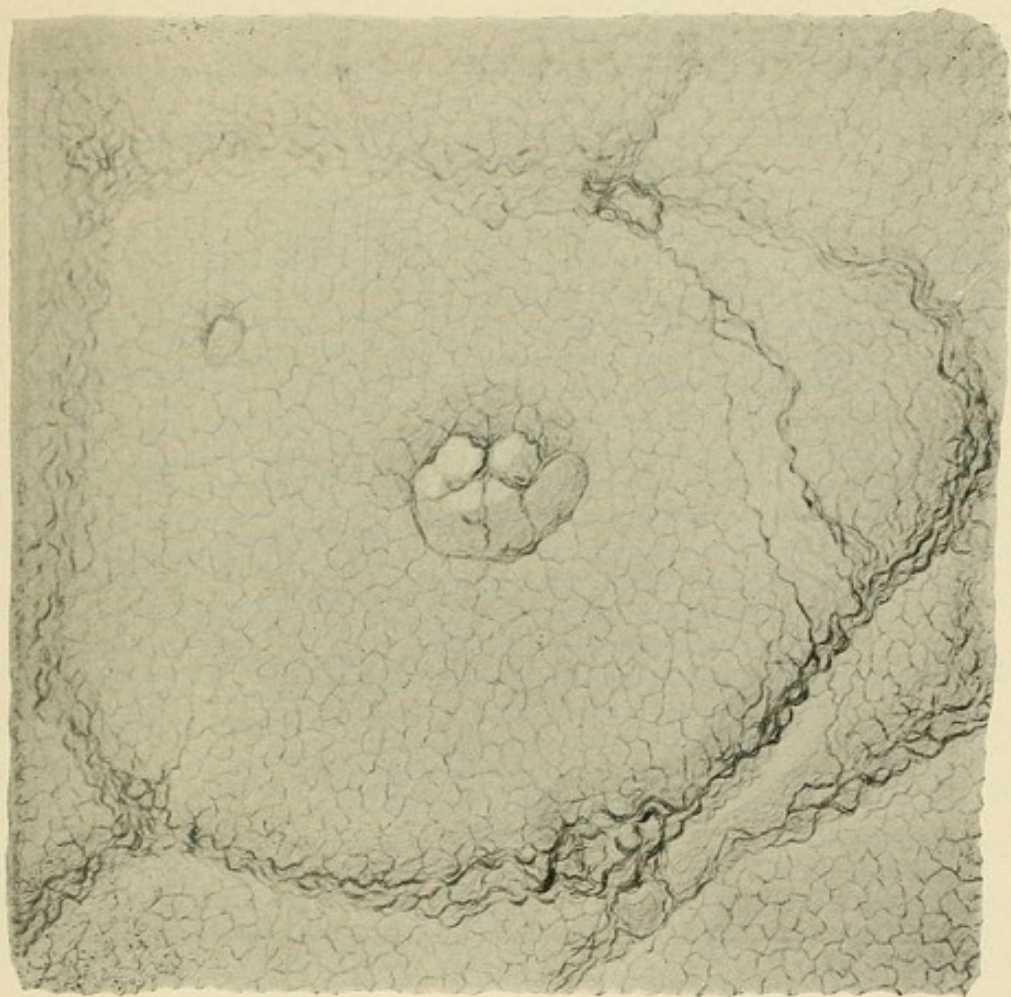


FIG. 9.—Supporting connective-tissue framework of a pancreatic lobule after digestion of the parenchyma by pancreatin. From a specimen prepared by the method of Professor J. M. Flint.

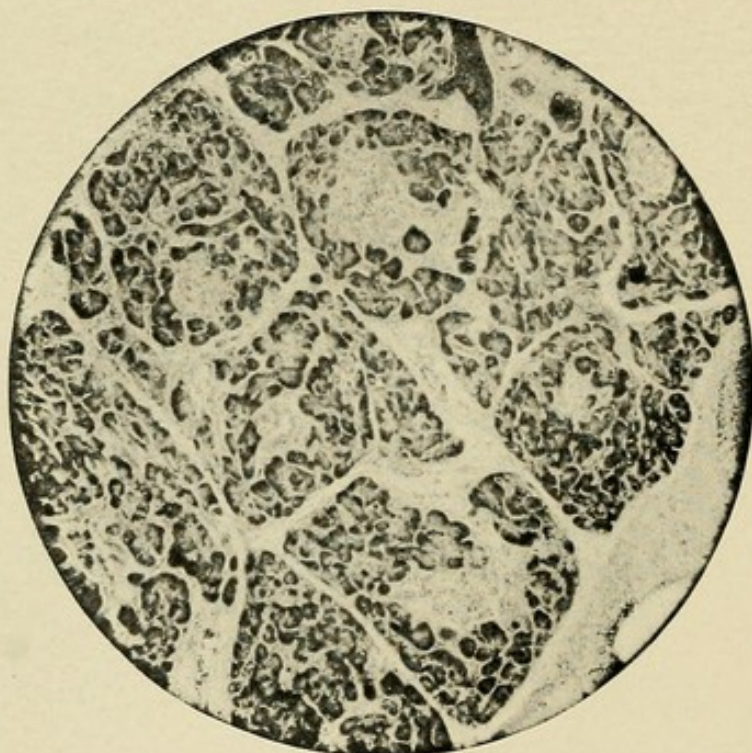


FIG. 10.—Chronic interstitial pancreatitis in the cat, following ligation of the pancreatic ducts. The lobules are defined by septa of connective tissue; in the centre of almost every lobule is an island of Langerhans. From a photograph, for the preparation of which thanks are due to Dr. Charles Potter.

monstrated by causing an inflammatory increase of the interstitial tissue. If the pancreatic ducts of a cat are ligated and the animal killed at the end of two or three weeks, the gland is found to be the seat of chronic interstitial inflammation, characterized by an increase of the interlobular tissue (see Fig. 10). The lobules are completely separated from one another by narrow bands of firm fibrous tissue and appear in sections at rounded, triangular, or polygonal areas of parenchyma.

The islands of Langerhans in the normal pancreas of the cat occupy a position near the centre of the lobule, and in the splenic end of the gland each lobule contains an island. In a given section many lobules, of which the limits are more or less distinctly outlined, are seen to contain islands situated near their centre, while in neighboring lobules such structures may not be discoverable. If, however, serial sections (see Fig. 11) are studied, every lobule is found to contain an island. Its presence within the lobule is not constant in other parts of the organ, and at the extremity of the descending arm of the gland islands of Langerhans are very few in number.

The framework of a typical pancreatic lobule is well seen in the accompanying reproduction of a photograph (see Fig. 9) kindly given me by Professor Flint, of the University of California. The preparation was made by digestion according to the method which he has described. An island of Langerhans marked out

by coarser strands of stroma is situated near the centre of a lobule. A somewhat finer net-work contains in its meshes the secreting acini.

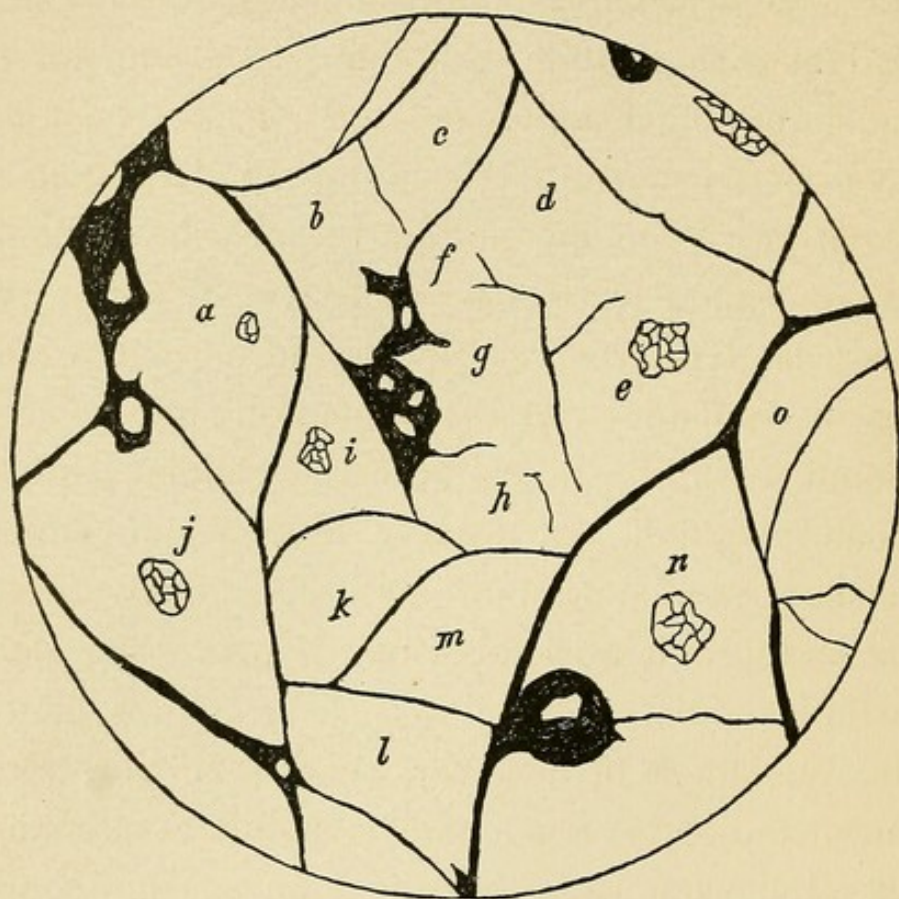


FIG. 11.—Camera lucida tracing of the lobule boundaries in one of a series of sections from the splenic end of a cat's pancreas. The majority of the lobules are well defined. Those marked *d*, *e*, *f*, *g*, and *h* are poorly outlined, but are found to be more readily distinguishable when traced through the series of sections. The lobules, which are lettered (*a* to *o*), were traced through the series, and each was found to contain an island of Langerhans situated near its centre. The section passes through the island in lobules *a*, *e*, *i*, *j* and *n*.

Primary lobules of the cat's pancreas are grouped about the medium-sized ducts. The main ducts give off branches approximately at right angles to their course. Branching one or more times, such a duct forms the centre of a group of lobules, which is usually elongated

in form and tapers to a point at or near the surface of the gland. These lobule-groups, or secondary lobules, as they may be conveniently called, are separated from one another by relatively wide bands of areolar tissue, much looser in texture than that separating the individual lobules. The lobule-groups in the fresh state or in tissue macerated a few days in Müller's fluid may be separated from one another by careful teasing. In the loose tissue lie the larger ducts, arteries, veins, and nerves. An artery and vein penetrate each lobule-group in company with the duct and ramify between its lobules. The smallest arteries occasionally penetrate the lobules, but usually interlobular branches diminishing in size give off capillaries which enter the lobule and form a close net-work between the glandular acini.

The capillaries of the island of Langerhans form a glomerulus of tortuous, freely anastomosing vessels, much wider than those between the acini. A single afferent vessel like that of the glomerulus of the kidney does not enter this group of dilated capillaries, but numerous anastomoses make it continuous with the interacinar capillaries. When Berlin blue is injected through the aorta into the arteries of the pancreas it not infrequently happens that in parts of the gland which are poorly injected the vessels of the island are filled with the injected mass, while the surrounding capillaries are for the most part empty. If, instead of

soluble Berlin blue, a granular injection mass, for example, cinnabar or ultramarine blue, is used, the island may be injected while the interacinar capillaries contain little of the injected material. The glomerular net-work is in very free communication with the smallest arteries and apparently has a richer blood supply than other parts of the lobule.

In the human pancreas primary lobules and lobule-groups are not so regularly arranged as in the cat, but both structures are definable. The lobules vary much in size and are usually not clearly separated from one another. Though an island of Langerhans is often situated in the centre of a more or less clearly defined lobule, no constancy of position is discoverable. The lobule-groups, or secondary lobules, are separated by relatively wide bands of loose areolar tissue in which are contained the medium-sized ducts, the blood-vessels, and the nerves. Within the secondary lobule the arteries and veins, which are side by side, do not, as in the cat, accompany the ducts. As pointed out in a previous chapter, several secondary lobules are usually grouped together to form tertiary lobules, and these represent the largest subdivisions seen upon the surface of the organ.

Morphology of the Islands of Langerhans.—Various opinions have been held concerning the nature of the interacinar cell-groups, and a number of observers, denying the epithelial character of the cells which com-

pose them, have emphasized a supposed resemblance to lymphoid tissue. By certain methods of preparation, notably after hardening in alcohol, the cell protoplasm is inconspicuous, and the nucleus deeply stained may resemble that of a lymphocyte; the arrangement of cells in groups within the meshes of a capillary net-work gives superficially the appearance of a lymphoid follicle.

Renaut has described the pancreas as a lympho-glandular organ composed, he has conceived, of glandular structures and lymphoid tissue in intimate relation. He has described the cell-groups as "points folliculaires" in which cells of a glandular type are situated in the meshes of a reticular tissue. Mouret has supported Renaut's somewhat ill-defined conception of a lympho-glandular organ, but has regarded the cell-groups as small masses of lymphoid tissue. Kühne and Lea and Dieckhoff think it probable that they are small lymph follicles. Schlesinger regards them as a variety of lymph follicle of which the cells differ from those of ordinary lymphoid tissue. Podwyssotski calls them pseudo-follicles, and states that though they resemble lymph follicles their cells have nothing in common with lymphoid cells; while Renaut in his recent treatise on histology, abandoning his former view, describes the common origin of the interacinar cell-groups and the secreting acini.

It has been suggested by several observers, Laguesse and others, that the islands of Langerhans represent a

stage in the embryological development of the glandular acini, those found in the adult organ being persistent rudimentary structures. Subsequent observations upon the histogenesis of the pancreas have caused Laguesse to abandon this view.

When throughout the pancreas are found structures composed of cells differing from those of the acini, having a different arrangement and bearing a peculiar relation to the blood-vessels, it seems probable that, formed in embryological life, they possess an anatomical identity as definite as that of the glomeruli of the kidneys or of the Malpighian bodies of the spleen, and like them subserve some special function. Schäffer directs attention to their similarity to the small ductless structures, the carotid and coccygeal glands and the parathyroid bodies, which are also composed of anastomosing columns of epithelial cells.

The epithelial nature of the cells composing the islands of Langerhans has been clearly demonstrated by embryological investigation. Laguesse has studied the development of these bodies in the embryo sheep. He finds that at an early period of growth the pancreas is composed of tortuous anastomosing tubules formed by a single layer of epithelial cells. Here and there occur cells which stain more deeply than those about them and, like the border cells of the stomach, are situated near the outer surface of the tubule. These cells proliferate to form solid outgrowths upon the tubule and

constitute what he calls primary islands of Langerhans. At a later stage the secreting acini are formed as buds, from the wall of the original tubules, and within them can be recognized two kinds of cells, the ordinary glandular cell containing zymogen granules and the centro-acinar cells which form a second more or less continuous row superimposed upon the secreting cells. At a still later stage islands of Langerhans continue to be formed, but their development differs from that of those which are first formed, for, accepting the observations of Lewaschew to be mentioned later, Laguesse thinks that groups of acini undergo alterations by which they are transformed into interacinar islands, designated by him secondary islands of Langerhans. This mode of formation has not been confirmed, and, as will be shown later, does not occur.

Renaut has described the histogenesis of the pancreatic lobule. His description of the early stages of development agrees with that given by Laguesse. The primitive dorsal and ventral outgrowths from the wall of the duodenum form numerous branches which ramify in the dorsal mesentery of the intestine. At first these branches are solid, but soon they acquire a lumen about which the cells are arranged in a single row, and, anastomosing between themselves, they resemble the tubular columns which form the liver of certain lower vertebrates. At intervals along their walls are formed short outgrowths terminating in a rosette-like

group of blind pouches. At the base or within such a group of primitive acini at least one island of Langerhans is formed by differentiation and multiplication of the peculiar cells already described by Laguesse. The rosette-like group of acini and at least one island of Langerhans represent the primary gland lobule in its undeveloped form, and by subsequent growth give rise to the primary lobule of the adult gland.

The cells which compose the interacinar islands in the adult human pancreas resemble in type the epithelial cells of the acini. They have a large, round, occasionally oval vesicular nucleus and well-defined cell-body. The basal zone of the secreting cell, as is well known, stains deeply with nuclear dyes, for example, hæmatoxylin or methylene blue, while the central part, which contains zymogen granules, remains unstained. The cells of the island, on the contrary, are by nuclear dyes entirely unstained, while with eosin their protoplasm takes a homogeneous bright pink color. The nuclei differ but little from those of neighboring acini; they vary considerably in size, and not infrequently one finds very large, round vesicular nuclei the diameter of which is two or more times that of the adjacent cells. Occasionally the cells, forming columns between which lie anastomosing capillaries, are very closely packed together, and nuclei are situated almost side by side; more frequently the cells of the island are less numerous and nuclei are less closely crowded.

Dogiel and later Stangl have shown that fat is normally present in the protoplasm of the cells. Numerous very fine droplets of almost uniform size are abundant in the islands of Langerhans, while fat droplets within the secreting acini, often much larger, vary greatly in size and are more sparsely scattered.

The outline of the island is usually round or oval, and is not infrequently accentuated by a delicate circle of fibrous tissue. In other instances the outline is less sharp and the body accommodates its shape to that of the neighboring acini. Occasionally one sees, apparently within the island, cells arranged, as in the acini, about a central lumen, and indeed in many instances it is difficult to convince one's self that they do not form part of it. An impression is produced that the columns of the island are in continuity with cells having an acinar arrangement. Since the islands and the secreting acini have a common origin, it is not inconceivable that they may occasionally remain continuous in the adult organ. When the foetal pancreas is affected by congenital syphilis, the islands of Langerhans, I have found, retain their continuity with the secreting structures (see chapter vii.).

In the human pancreas islands of Langerhans were found to be more numerous in the splenic end or tail than elsewhere. To obtain a numerical statement of their relative abundance, their number was determined in a sectional area of 0.5 square centimetre. Sections

about ten micromillimetres thick were made (*a*) from the enlarged duodenal part of the pancreas,—that is, from the head,—(*b*) from the mid-part of the body, and (*c*) from the splenic end or tail. The following table gives the number in 0.5 square centimetre of sections taken from the head, body, and tail of ten normal organs :

TABLE.

Number.	Head.	Body.	Tail.
1.	11	13	30
2.	30	25	42
3.	4	4	19
4.	4	10	13
5.	27	18	59
6.	25	27	26
7.	18	18	29
8.	6	10	29
9.	44	32	61
10.	14	23	32
Mean	18.3	18.0	34.0

The table shows that islands of Langerhans are more abundant in the tail or splenic end than in the head or in the body, where they are present in approximately equal number. They are almost twice as numerous in sections from the tail as in those from other parts ; but since the number in only one plane is recorded, in order to obtain their actual relative abundance it is necessary to square these figures. They are then found to be slightly less than three and a half times as numerous in the tail as elsewhere.

The islands of Langerhans are more numerous, as pointed out by Kasahara, in the pancreatic tissue of

the foetus and of very young children than in the adult. Should we assume that they are formed during embryological development and persist thereafter, this fact is readily explicable. The organ being much smaller in the foetus and in a young child, the same number of islands, though themselves smaller, are more closely together, and therefore appear to be more numerous in sections.

Physiology of the Islands of Langerhans.—An attempt to investigate experimentally the nature of the islands of Langerhans has been made by Lewaschew, working in Heidenhain's laboratory. He studied the pancreas of dogs and cats killed after having been subjected to conditions which cause the gland to secrete actively. After prolonged overfeeding, or after the administration of pilocarpin, which stimulates the pancreas as it does the salivary glands, he claims to have found structures representing transitions between the glandular acini and the interacinar cell-groups. He has observed acini containing one or more cells of which the protoplasm is non-granular and stains lightly. A whole acinus or a number of acini may be composed of these cells. In such areas some of the cells may assume a polygonal shape and are no longer grouped about a central lumen. Other cell-groups consist entirely of polygonal cells without acinar arrangement, and these represent, he thinks, the fully formed islands of Langerhans.

In order to obtain a large increase in the number of altered acini one even maximal stimulation of the gland is not sufficient; but by the repeated administration of pilocarpin this result is accomplished, and the longer and more intense the action of the drug the greater their number. To cause their increase by overfeeding, a very large quantity of food is necessary. Lewaschew believes that the cells composing the inter-acinar groups may reassume their character of secreting cells and again form acini. He mentions that he has found an unusual number of islands under conditions other than those of increased functional activity. They were very numerous in a dog which several days before its death had suffered with fever.

The observations of Lewaschew have not been confirmed. Statkewitsch has, however, described similar alterations in the pancreas of dogs, cats, and rabbits subjected to conditions having no resemblance to those which Lewaschew produced. In animals which have been starved, the secreting cells, he claims, lose their granular inner zone and by a series of transitions similar to those described by Lewaschew assume the character and arrangement of the interacinar cell-groups. He thinks that his researches, as well as those of Lewaschew, show that these structures are merely the result of an intense alteration of the gland cells. Jarotzky has made a careful study of the secreting pancreatic cells in mice under various conditions of

inanution ; from some of his animals food was withheld, others were given only sugar, others only fat, but in none did he find changes similar to those described by Statkewitsch ; and he reaches the conclusion that the islands of Langerhans are independent structures embedded in the glandular parenchyma.

In the normal human pancreas one occasionally finds groups of acini composed of cells differing from the typical glandular type and suggesting a transition from the secreting cell to that of the island of Langerhans. The cell-protoplasm does not take the nuclear dye as does the basal part of the ordinary glandular cell, and when stained with eosin has a bright pink color and homogeneous refractive appearance. The nucleus, which shows no evidence of degenerative change, is situated near the centre of the cell. Occasionally one or more cells of the character described form part of an acinus which otherwise resembles those about it. Usually, however, a group of acini are changed, and such an area often corresponds in size to an island of Langerhans.

The presence of such groups of altered acini the cells of which resemble those of the island of Langerhans confirms at first sight the view of Lewaschew,—namely, that groups of acini may assume the character of the interacinar structures. It is probable that these foci, in part at least, represent what Laguesse and Pischinger have described as stages of transition. The

arrangement of more or less columnar cells about a central lumen is, however, still preserved, and one does not find similar areas in which this arrangement is lost. The lumen, indeed, is usually very conspicuous and is often considerably dilated, filled with products of secretion which stains deeply with eosin. It seems probable that these groups of acini are altered as the result of peculiar functional activity, it may be, of hyperstimulation of the gland. There is at least no evidence that they represent transitional stages between glandular acini and islands of Langerhans.

Such altered acini are observed in a small proportion of normal glands. They were found in three of twenty-seven glands examined carefully for their presence. They were, moreover, present in three of seven relatively normal organs from diabetic patients. The occurrence of voracious appetite and increased food ingestion in individuals so affected may explain the occurrence of these areas which represent possibly foci of peculiar secretory activity. They were particularly abundant in one instance of chronic interstitial pancreatitis not associated with diabetes.

I have attempted to confirm the observations of Lewaschew by injecting subcutaneously pilocarpin muriate into dogs. Since the number of islands varies in different parts of the gland, it was considered desirable to study sections from corresponding parts of the organ. Specimens were prepared (*a*) from the splenic

extremity, (*b*) from the part which is in contact with the duodenum, and (*c*) from the descending arm which lies in the mesentery of the duodenum. In order to determine with accuracy the relative abundance of the islands, their number was counted in a measured sectional area and compared with that found in the pancreas of an animal to which pilocarpin had not been given.

Following is a summary of the experiments performed :

DOG No. 1.—The animal was given daily for nine successive days 0.02 to 0.03 gramme of pilocarpin muriate. Profuse salivation was produced, often accompanied by vomiting and diarrhoea.

DOG No. 2.—During twenty-eight hours pilocarpin muriate 0.005 to 0.01 gramme was injected subcutaneously six times. The drug produced repeatedly profuse flow of saliva.

DOG No. 3.—During twenty-four hours pilocarpin muriate 0.01 gramme was injected subcutaneously seven times. Profuse salivation followed each injection.

In the table the figures represent the number of islands in 0.5 square centimetre of sectional area. The letters refer to the parts of the gland indicated above.

Injected Animal.	<i>a</i>	<i>b</i>	<i>c</i>	Control Animal.	<i>a</i>	<i>b</i>	<i>c</i>
Dog No. 1	61	21	1	Dog No. I.	59	61	14
Dog No. 2	55	20	11	Dog No. II.	39	53	3
Dog No. 3	54	72	8	Dog No. III.	67	89	12
Average	56.6	37.6	6.6	Average	55	67.6	9.6

The figures show that no increase of the number of islands was obtained in the three experiments. Transitional stages between glandular acini and interacinar islets were not observed. The number of islands in that part of the descending arm of the pancreas which lies in the mesentery of the duodenum (*c*) is constantly much less than elsewhere; the number in different glands and in different parts of the same gland varies considerably. In the experiments of Lewaschew these sources of error have apparently not been given sufficient weight.

The diversity of the opinions concerning the structures under consideration has justified, I believe, the preceding detailed discussion of their nature. Certain facts may be considered to be established. The islands of Langerhans are composed of cells of epithelial type having the same origin as those which form the acini. Ramifications of the pancreatic duct do not penetrate the interacinar islands, while on the other hand these bodies have an intimate relation to the vascular system. They occupy a definite position within the pancreatic lobule (of the cat) and are more numerous in certain parts of the gland than in others. It is not possible to transform secreting acini into islands of Langerhans.

The function of these structures has been the subject of some speculation. Harris and Gow, and more recently Jarotzky, have suggested that they are concerned in the elaboration of the pancreatic secretion furnishing

possibly one or other ferment which it contains. Giannelli and Giacomini, who found that in certain reptiles the cells of the interacinar islands are arranged about a central lumen, hold a similar view. In higher animals, however, numerous observations have shown that the ducts do not penetrate the interacinar islands, and the staining method of Golgi employed by Dogiel has failed to demonstrate the presence of ducts, though their finest ramifications become apparent in the adjacent acini.

The intimate relation of columns, of epithelial cells to a rich capillary net-work has suggested that the islands of Langerhans furnish some substance to the blood, the hypothetical internal secretion of the pancreas. Abundant experimental research inaugurated by von Mering and Minkowski having shown that the pancreas exerts an important influence on carbohydrate metabolism, several writers, Laguesse, Schäfer, Diamare, and others, have suggested that the islands of Langerhans perform this function. Ssobolew claims to have obtained experimental evidence that assimilation of sugar causes changes in the cells of these bodies comparable to those which occur, as Heidenhain has shown, in the secreting cells as the result of increased functional activity. The cells of the interacinar islands are, he states, most granular after hunger which has lasted two or three days, but after feeding with carbohydrates in considerable quantity, or after intravenous injection of sugar, the granules within the cells diminish in num-

ber. Schmidt, however, was unable to produce similar phenomena in mice and in guinea pigs after intraperitoneal and intravenous injection of solutions of sugar.

The study of pathological changes associated with the disease of carbohydrate metabolism, diabetes mellitus, has afforded convincing evidence that the islands of Langerhans control the assimilation of sugar. It will be the purpose of a subsequent chapter to define the relationship of diabetes mellitus to diseases of the pancreas and to alterations of the islands of Langerhans.

CHAPTER IV.

VARIETIES OF ACUTE PANCREATITIS.

ACUTE inflammation of the pancreas has attracted much attention, yet the nature and the cause of the lesions which accompany it have been involved in obscurity. While diffuse suppurative inflammation or more localized abscess formation resembles similar processes frequently observed in other organs, so-called hemorrhagic and gangrenous pancreatitis finds little analogy in the liver, spleen, kidneys, or indeed in the salivary glands, which resemble in many respects the pancreas. The difficulty of deciding what shall be regarded an inflammatory process is here encountered; distinctions between hemorrhagic pancreatitis and hemorrhage into the organ, though usually emphasized in writings upon diseases of the gland, are not clearly drawn.

A well-defined classification of acute lesions of the gland was introduced by Fitz, and was based upon an analysis of cases studied by himself, as well as of those recorded in the literature. Inflammatory changes associated with hemorrhage into the organ, so-called hemorrhagic pancreatitis, had already been observed by Rokitsansky and by Klebs.

Both Friedreich and Fitz recognized as an indepen-

dent condition, pancreatic hemorrhage, a lesion unaccompanied by inflammatory changes. The existence of acute inflammation, according to Fitz, is established from an anatomical stand-point by the occurrence of degenerative changes in the parenchymatous cells and by exudation into the interstitial tissue ; but even when anatomical evidence is lacking, clinical symptoms may demonstrate the presence of an inflammatory process ; the uncertain evidence of fever and other symptoms of inflammation may suggest hemorrhagic pancreatitis rather than simple hemorrhage. Fitz found that acute inflammatory alterations of the pancreas fell into three groups which, to emphasize their conspicuous feature, he designated hemorrhagic, suppurative, and gangrenous pancreatitis.

Hemorrhagic pancreatitis, described by Fitz, occurs most frequently in those who have had previous attacks of "gastric or gastro-duodenal dyspepsia." It begins with intense pain in the upper abdomen, followed by vomiting and not infrequently by slight swelling of the epigastrium, associated with tenderness and accompanied by obstinate constipation. The temperature is normal or subnormal, and symptoms of collapse precede death, which usually occurs between the second and fourth days. The pancreas is found to be enlarged, and its interstitial tissue, as well as the tissues in its neighborhood, is infiltrated with blood. Microscopic examination shows the presence of cellular and fibrin-

ous exudates together with necrosis of the parenchyma. In the fat of the omentum and of the subperitoneal tissue are the disseminated foci of necrosis to which Balser has directed attention.

Suppurative pancreatitis resembles suppurative inflammation of other organs ; the gland may contain abscess cavities of varying size, the organ being enlarged and the peri-pancreatic tissue indurated. Suppurative inflammation rarely pursues an acute course, but persists for weeks or months, and abscess cavities may discharge into the stomach or duodenum, or, rupturing into the lesser peritoneal cavity, may here produce an abscess cavity of great size. Pylephlebitis and abscess of the liver may accompany this condition.

Gangrenous pancreatitis, according to Fitz, though it may follow other conditions, is usually the result of hemorrhagic pancreatitis, and in at least half of the recorded cases evidence of previous hemorrhage has been present in the altered gland. The clinical symptoms of the two conditions resemble one another closely, but where the pancreas is found to be gangrenous the illness has been of longer duration, proving fatal at the end of several weeks. The organ is enlarged, often soft and friable, and of a color which varies from mottled red and gray to dark brown or black ; by extension of the gangrenous process to the tissues about the organ almost complete sequestration may result. Since the gangrenous pancreas lies in the posterior wall of

the lesser peritoneal cavity, peritonitis ensues, and this cavity is converted into an abscess containing pus and necrotic material. In some cases the completely sequestered pancreas, attached by only a few shreds of tissue, is surrounded by purulent fluid. Communication may be formed with the intestine, and in two cases described by Chiari a large mass of necrotic material discharged by the rectum was recognized to be gangrenous pancreatic tissue. Disseminated fat necrosis, to be described later, accompanies the lesion.

Suppurative inflammation of the pancreas does not differ essentially from that of other organs, and presents no noteworthy peculiarities. Fitz has pointed out that disseminated fat necrosis is uncommon with this condition, though almost constantly found in association with hemorrhagic and gangrenous inflammation.

Pancreatic Hemorrhage—Of especial interest is the occurrence of hemorrhage, often fatal, into and about the pancreas, the so-called pancreatic apoplexy, comparable, it has been thought, to cerebral apoplexy. Hemorrhage occurring into the substance of the gland may be caused by a variety of factors which present nothing peculiar to the organ, and are familiar in other tissues of the body. Vessels may be ruptured by traumatism, and here, as elsewhere, hemorrhage may accompany the presence of tumors; the contents of pancreatic cysts are not infrequently bloody. Hemor-

rhage of such character, as well as the minute hemorrhages observed in association with purpura, eclampsia, and acute infectious diseases are dependent upon factors which determine their occurrence in other organs and have little in common with the peculiar hemorrhagic lesion to which the pancreas is subject.

Hemorrhage into the pancreas occurring in an individual previously supposed to be in good health may be the only lesion found to explain the fatal termination of an illness lasting only a few hours. The literature of pancreatic affections contains numerous examples of so-called pancreatic apoplexy of which the sudden onset and rapidly fatal end suggest an analogy with the more frequent cerebral hemorrhage. The quantity of blood escaping from the vessels does not bear a direct relation to the severity of the lesion. Such a condition was described by Spiers, in 1866, and since other writers, notably Zenker, Prince, Draper, and Seitz, have recorded additional instances.

In some cases cited as examples of pancreatic hemorrhage it is improbable, as Seitz points out, that the pancreatic lesion was in reality the cause of death, and in the cases described by Reubold and Rehm, after death from poisoning with morphia, after strangling, or after hemorrhage from the femoral vein, the interstitial tissue of the gland and its immediate vicinity has been the seat of such moderate hemorrhagic infiltration that extravasation of blood may have been the result of post-

mortem self-digestion. There remains, however, a large number of cases where, following sudden death, a careful autopsy has disclosed no noteworthy disease other than an extensive hemorrhagic lesion of the pancreas.

Klebs thought that hemorrhage occurring in the absence of inflammatory changes might be due to corrosive action of the pancreatic juice upon the blood-vessels. Fitz recalls the fact that fluids injected into the arteries of a dead body are prone to escape in the neighborhood of the pancreas, and suggests that where arterial sclerosis exists hemorrhage occurs because the arteries of the pancreas are peculiarly susceptible to rupture; he adds, however, that in the great majority of cases there is no evidence of arterial disease. It has been maintained by Seitz that in a limited number of cases arterial sclerosis explains the occurrence of hemorrhage, but the only evidence in support of this supposition is the occasional association of the two conditions. Extensive fat necrosis in and about the pancreas, destroying wide areas of adipose tissue, may cause injury to the walls of adjacent vessels and consequent rupture, but rarely is the necrosis of sufficient extent to afford such an explanation. The relation of fat necrosis to lesions of the pancreas will be discussed later, when it will be shown that the former is secondary to the latter.

The explanation of hemorrhage secondary to inflammatory changes in the gland has been much discussed.

Acute inflammation is accompanied by escape of blood into the interstitial tissue, and the condition has been supposed to resemble hemorrhagic inflammation in other organs. Inflammation is regarded as primary and the hemorrhage its consequence. When both inflammation and hemorrhage co-exist, the difficulty of deciding which preceded the other is obviously great,—for should extensive hemorrhage occur, proximity to the intestine exposes the hemorrhagic tissue to infection and consequent suppuration. Both hemorrhage and acute inflammation being present, it is not possible to determine which antedated the other. From reports of cases of pancreatic hemorrhage, moreover, it is not possible to decide whether hemorrhage alone had occurred or both inflammation and hemorrhage were present; for on the one hand in few cases of simple hemorrhage have inflammatory changes been excluded by a microscopical examination, while on the other hand the diagnosis of inflammation in many instances, as in a few of the cases of Fitz, has been based upon symptoms observed before death.

Seitz, reviewing the cases of Loschner, Oppolzer, Amidon, Osler and Hughes, Hirschberg and Birch-Hirschfeld, finds no evidence of pancreatic inflammation, and concludes that inflammation is not a demonstrable cause of bulky hemorrhage into the organ.

Under certain conditions, which the foregoing review leaves ill-defined, extensive hemorrhage occurs into the

substance of the pancreas. Atheroma of arteries and fatty degeneration of parenchyma are present in only a limited number of cases. Since in some instances there is no evidence of inflammation, while in others inflammation may be a secondary change in tissue infiltrated with blood, it is obvious that no sharp line can be drawn between reported cases of simple hemorrhage and those of hemorrhagic inflammation.

Experimental Hemorrhagic Pancreatitis.—Hemorrhagic pancreatitis has been produced experimentally by the injection of a variety of irritating substances into the pancreas. Thioloix injected several drops of deliquescent chloride of zinc into the duct of Wirsung in a dog. Death occurred suddenly after a short interval, and the pancreas was represented by what appeared to be a blackish clot. Hlava injected artificial gastric juice into the pancreatic duct. This fluid, containing hydrochloric acid in the proportion of one to one thousand, caused death in three days; the pancreas was hyperæmic and in the fat of the omentum and of the mesentery were numerous foci of necroses. Death on the tenth day followed the injection of five cubic centimetres of artificial gastric juice with hydrochloric acid, four to one thousand; the pancreas was the seat of hemorrhagic infiltration and the omentum and mesentery contained foci of fat necrosis. He suggests that in human cases hyperacid gastric juice may be forced by antiperistaltic action of the intestine into the pan-

creatic duct, thus causing the condition. Hlava has produced a hemorrhagic lesion of the gland by injecting cultures of the *bacillus coli communis*, *bacillus lactis aërogenes*, and *bacillus capsulatus* of Friedländer, but thinks that the change is caused by the acid products of these organisms.

By the injection of the ferment, papaine (0.2 gramme in thirty cubic centimetres of water), into the pancreatic duct of a dog, Carnot caused the death of the animal in twenty-five hours; the pancreas was everywhere infiltrated with blood, but there was no necrosis of fat. Smaller doses did not produce hemorrhagic lesions. The same writer produced hemorrhagic pancreatitis by the injection of the diphtheria toxine into the pancreatic duct of a rabbit. A suspension of the *bacillus coli communis* (twelve cubic centimetres) caused a similar lesion fatal in twenty-four hours. Subsequent injections of the same organism caused inflammatory changes without hemorrhage.

More varied and successful experiments have been performed by Flexner. In ten experiments performed upon dogs hydrochloric acid varying in strength in different instances from one-half of one to two per cent., and in amount from three to eight cubic centimetres, was injected into the pancreatic duct. In six instances there resulted hemorrhagic inflammation of the gland, accompanied in five by focal fat necrosis. The lesion was characterized by hemorrhage, necrosis of the parenchyma, and accumulation of inflammatory products. In

three of these cases death followed the operation within twenty-four hours ; in two the animals were killed. In the remaining experiments purulent or chronic interstitial inflammation resulted. Hemorrhagic lesions were produced in two dogs by the use of nitric acid (four cubic centimetres of a two per cent. solution and five cubic centimetres of a one per cent. solution) ; in one by the use of chromic acid (eight cubic centimetres of a one per cent. solution). In a second series of experiments sodium hydroxide solution (two and a half to five cubic centimetres of solutions varying in strength from one to two per cent.) was employed. Hemorrhagic lesions resulted in three cases and were accompanied by fat necrosis in at least two. Suspensions of bacteria were used in a third series. Hemorrhagic inflammation was caused by the bacillus pyocyaneus and in three experiments by the bacillus diphtheriæ, but was unaccompanied by definite fat necrosis. In two experiments the lesion followed the injection of five cubic centimetres of a two per cent. solution of formalin into the duct and was associated with fat necrosis. Flexner and Pearce have subsequently shown that degeneration, hemorrhage, and emigration of leucocytes develop with great rapidity, occurring within one to two hours after the introduction of such an irritant as artificial gastric juice.

Etiology of Acute Hemorrhagic Pancreatitis.—The experiments cited show that a variety of substances

injected into the duct of the pancreas cause hemorrhagic inflammation. How far they can be used to explain the pathogenesis of human cases is doubtful. The suggestion of Hlava that gastric juice may be driven by antiperistaltic action of the intestine into the ducts is not supported by any evidence. No relation between hemorrhagic pancreatitis and bacterial invasion from the intestine has been demonstrated, and in the cases that have been studied no organism has been constantly found.

Dr. Welch cultivated the bacillus coli from foci of fat necrosis accompanying acute hemorrhagic pancreatitis, but reached the conclusion that the organism penetrated the dead tissue after the lesion had been produced. In cases of hemorrhagic pancreatitis Hlava found the bacillus coli associated with the pneumococcus and other diplococci; Cutler and Reynolds and Moore have also isolated the colon bacillus. Leonhard in one case found staphylococci, streptococci, and two unidentified bacilli, while Jackson and Ernst, in a case of Fitz's, isolated four species of bacteria. Ponfick and Marx each cultivated a bacillus closely related to the colon bacillus, but not identical with it nor with one another. The variable and inconstant result of bacteriological examination indicates, as almost all the writers cited agree, that these various organisms are not the etiological factor in producing the lesion, but are merely secondary invaders of injured tissue.

The etiology of hemorrhagic inflammation of the pancreas has remained obscure until a series of cases recently studied has demonstrated a relationship between the lesion and cholelithiasis. Since the common bile duct and the duct of Wirsung unite to form the diverticulum of Vater before they reach the duodenum, changes in the one may be transmitted to the other, thus producing secondary lesions of the liver or pancreas. The association of pancreatic disease with alterations of the bile passages has been noted by a number of writers. Körte, in his monograph upon the surgery of the pancreas, mentions the fact that diseases of the bile passages, especially cholelithiasis, are frequently associated with lesions of the pancreas, and thinks it probable that inflammation can extend from the bile duct to the gland. Oser makes a similar observation, and Lancereaux cites the possibility that a gall-stone lodged in the common duct at the level of the diverticulum may occlude the pancreatic duct and produce conditions favorable to the penetration of micro-organisms into the pancreas.

The Association of Acute Pancreatitis and Cholelithiasis.—My attention was directed to the relationship between acute pancreatitis and the impaction of a calculus in the common bile duct by the following case studied at autopsy :

CASE I.—L. F., male, aged forty-seven years, was admitted to the Johns Hopkins Hospital, in the service of Dr. Osler, complaining of

abdominal pain and fever. He had suffered with somewhat frequent attacks of indigestion, characterized by pain after eating, distention, and rarely nausea and vomiting, but otherwise had enjoyed good health. Six months before his present illness he had had an attack of jaundice, lasting about three weeks, and accompanied by abdominal pain and some fever.

The present illness began eighteen days before admission to the hospital, when the patient was suddenly seized with violent nausea and vomiting, accompanied by intense cramp-like pain in the abdomen. The vomiting continued during the first night, and had since only occasionally recurred. The abdominal pain, which was not localized, remained severe during four or five days, and at times there were symptoms of collapse. The abdomen was distended and the bowels were constipated until the fifth day, when, with the aid of a purgative, movement occurred. The stool was normal in color. On the third day elevation of temperature to 101.5° F. was noted. About the seventh day tenderness and slight swelling were noticed in the right hypochondriac region. Since this time the patient had an irregular temperature (100° to 103° F.), with several chills. After the first few days abdominal pain and tenderness were not severe, but distention of the abdomen gradually increased. Jaundice was not noted.

Physical Examination (note by Dr. Fletcher).—The conjunctivæ have a slightly yellow cast. On inspection of the abdomen a distinct prominence is found to occupy the right hypochondriac and right half of the epigastric region, extending into the upper half of the umbilical region. Its lower margin, which descends on inspiration, is felt in the median line at the level of the umbilicus. Its right border cannot be sharply defined, but in the median line the fingers can be pressed in above it. Over the resistant mass there is dull tympany. The leucocytes number eighteen thousand. The urine is clear, its reaction acid, and specific gravity 1017.

There is no reduction of Fehling's solution. A trace of albumin is present.

On the second day after admission a stool passed was of golden yellow color. On the third day the leucocytes numbered nineteen thousand five hundred, and the temperature varied from 99.2° to 101.8° F. During the night the patient was irrational at times. The temperature rose gradually, reaching a maximum of 104° F. A liquid stool of ochre-yellow color was passed. The urine had a specific gravity of 1020, and no reaction for sugar was obtained.

The diagnosis of suppurative pancreatitis was made by Dr. Bloodgood, and an operation for its relief was performed under cocaine anæsthesia. A linear longitudinal incision was made below the costal margin within the right mammillary line. After incising the great omentum between the stomach and transverse colon an abscess cavity was entered. Grumous, purulent fluid containing necrotic particles was evacuated. A rubber drainage-tube, packed about with gauze, was inserted into the wound. After operation the pulse remained weak, and death followed at the end of about four hours. The duration of the fatal illness was twenty-one days.

Autopsy.—Performed three hours after death. The body is that of a large-framed, muscular man with abundant subcutaneous fat. The omentum, which contains a large quantity of fat, is thickly studded with conspicuous opaque, white areas, usually round, and about three millimetres in diameter. Similar opaque, white areas are present in the fat of the mesentery, in the subperitoneal fat of the anterior abdominal wall, over the bladder, over the kidneys, and about the colon.

The drainage-tube inserted into the abdominal wound passes through a small incised opening in the great omentum and enters an immense abscess cavity, which occupies approximately the site of the lesser peritoneal cavity; the foramen of Winslow is closed. The walls of the cavity are very irregular and ragged, and have a





FIG. 12.—Gall-stones from Case I. (actual size). The calculus removed from the common bile duct near its duodenal orifice is placed in the centre, while those from the gall-bladder surround it.



necrotic appearance, in general opaque and gray, occasionally black. This blackish-gray appearance extends only a short distance below the surface, and where the wall is formed by fat gives place to numerous foci of opaque, white color. The retroperitoneal fat in front of the left kidney and psoas muscle has been eroded, and an extension of the cavity passes behind the jejunum near its junction with the duodenum. To the left of the descending part of the duodenum, occupying the position of the pancreas and projecting forward into the abscess cavity, is a great mass of black material, necrotic in appearance, extending to the left as far as the spleen. This material is reddish-black on section, somewhat spongy in texture, soft, dry, and friable. The cavity contains at least five hundred cubic centimetres of fluid reddish-gray material, in which are fat droplets and black necrotic particles.

The liver is flaccid in consistence. The bile ducts are slightly dilated, and contain thin, yellow bile. The gall-bladder is bound by numerous adhesions to the duodenum and stomach. Its walls are thickened and it is much distended, containing viscid, yellow bile and more than one hundred brown, faceted calculi, varying in diameter from a half to one centimetre (see Fig. 12). The hepatic, cystic, and common ducts are much dilated. On opening the duodenum a stone is felt below the mucous membrane, situated in the common bile duct near its termination. It is seven millimetres in diameter, and resembles those present in the gall-bladder. The pancreatic duct unites with the common bile duct at a point seven millimetres from the duodenal orifice. The pancreatic duct is not distended. The pancreas occupies the posterior wall of the abscess cavity of the lesser peritoneum, and is covered by the mass of reddish-black, friable material, changed coagulated blood, above described. The organ is of large size, and the glandular tissue is in great part firm, yellowish-white, and well preserved. The interstitial tissue has a dull reddish, in places hemorrhagic,

appearance, and contains conspicuous opaque, yellow areas of irregular shape. Where the anterior surface of the head and body is in contact with the overlying material there is a superficial zone of soft, grayish, necrotic appearance.

The other organs—heart, lungs, spleen, stomach, intestines, and kidneys—present no noteworthy alteration.

Histological Examination.—The interstitial tissue of the pancreas is much increased and wide bands of fibrous tissue separate groups of lobules. Numerous irregularly shaped cells filled with brownish-yellow pigment granules, which give the Prussian-blue reaction for iron, afford evidence of former hemorrhage. In a few places well-preserved red corpuscles are diffusely scattered in the tissue. Foci of necrotic fat are present. Many acini are widely dilated; their cells are flat and the lumen is much distended, containing products of secretion and occasionally one or more polynuclear leucocytes. In an area corresponding to the superficial zone of necrotic appearance before mentioned, nuclei no longer stain, and the architecture of the glandular tissue is only obscurely distinguishable. A thick band of newly-formed fibrous tissue, containing an occasional acinus or duct, separates the necrotic parenchyma from that which is still intact. The mass covering the pancreas is found to consist of altered blood; upon and immediately below its surface are numerous polynuclear leucocytes.

Bacteriological Examination.—Cultures from the blood contained in the heart, from the lung, and from the liver, studied by Mr. V. H. Bassett, were found to contain the bacillus coli communis. A plate culture from the material covering the pancreas, and forming part of the abscess wall, contained the bacillus coli communis, the bacillus lactis aërogenes, and the bacillus proteus vulgaris.

Anatomical Diagnosis.—Cholelithiasis; calculus lodged in the common bile duct near its orifice; slight jaundice. Old hemorrhage within and about the pancreas, with localized necrosis and chronic

inflammation ; necrosis of fat of the pancreas, greater and lesser omentum, mesentery, and subperitoneal tissue of the abdominal wall ; peripancreatic abscess limited by the lesser peritoneal cavity. Laparotomy wound.

Symptoms occurring six months before the fatal illness indicated the passage of a calculus along the common duct, and this diagnosis was confirmed at autopsy by the presence of numerous calculi in the gall-bladder. The second attack began suddenly, three weeks before death, with severe nausea and vomiting, accompanied by intense, cramp-like pain in the abdomen. Tenderness was present in the right hypochondriac region, and on admission to the hospital the patient was slightly jaundiced.

Autopsy disclosed a small gall-stone lodged in the common bile duct, a short distance from its orifice. The lesser peritoneal cavity was the site of an abscess, the walls of which were formed in large part by necrotic fat ; the subperitoneal tissue was studded with conspicuous opaque, white foci of fat necrosis. The pancreas was in general well preserved, but its interstitial tissue was increased and gave evidence of having been the seat of hemorrhage. The anterior surface of the pancreas was covered by a considerable quantity of old, clotted blood, having the dark appearance of gangrenous tissue and forming the tumor mass, which was palpable during life. A superficial zone of glandular parenchyma in contact with this material was

necrotic. Since jaundice was slight, and the pancreatic duct was not dilated, it is probable that the calculus produced only temporary obstruction of the two ducts.

I have been able to collect from the literature a number of cases in which, associated with hemorrhagic lesions of the pancreas, a gall-stone was found lodged in the common duct near its orifice, or, perhaps, free in the duodenum, the common duct being dilated (Case A). In the latter case there could be little doubt that it had shortly before occupied the first-named position.

CASE A. (Thayer.)—During sixteen months the individual, male, aged sixty years, had suffered attacks of pain, followed by jaundice. He was suddenly attacked with severe pain in the left hypochondriac and epigastric regions. Collapse preceded death, which followed within twenty-four hours after the onset of symptoms. The thickened gall-bladder contained over a hundred calculi. The common bile duct was dilated to the size of the little finger, and in the duodenum was a calculus the size of a hazel-nut. The pancreas was large, grayish-pink, mottled with reddish-brown. The surrounding fat was moderately infiltrated with blood, and contained foci of necrosis.

CASE B. (Day.)—For several months the patient, male, aged forty-nine years, had suffered with pain in the epigastrium, at times in the right hypochondrium, and once he was jaundiced. About sixteen hours before death he was suddenly attacked with vomiting and severe epigastric pain, followed by collapse. "The gall-bladder contained one small concretion of inspissated bile; two others were lodged in the duodenal extremity of the common duct." The body and tail of the pancreas were enlarged and infiltrated with blood. In the neighborhood of the gland were foci of fat necrosis.

CASE C. (Dieckhoff.)—No clinical history is given. In the common duct, close to its orifice, was a gall-stone; others were present in the duct behind it and in the gall-bladder. The body and tail of the pancreas were beset with green and yellow points, the tail being almost completely necrotic. Old and recent hemorrhages occurred. Microscopical examination demonstrated the presence of suppurative inflammation, apparently having its origin in the ducts.

CASE D. (Cutler.)—For fifteen years the patient, a woman, aged fifty-eight years, had suffered with severe attacks of indigestion on one occasion followed by jaundice; pain in the right hypochondriac region occurred during later attacks. Four days before death she was seized with pain in the right hypochondrium, accompanied by vomiting, chill, and fever, and followed by jaundice. A small gall-stone was found at the outlet of the common duct; others were present in the gall-bladder. The pancreas was enlarged, surrounded and infiltrated with blood. Numerous foci of fat necrosis were seen in its neighborhood.

CASE E. (Kennan.)—The individual, a woman, aged thirty-eight years, was suddenly seized forty-two hours before death with vomiting and pain in the upper part of the abdomen, followed by symptoms of collapse. A gall-stone, about the size of a pea, was found projecting from the orifice of the common duct into the duodenum. Other calculi were found in the gall-bladder and common bile duct. The pancreas was enlarged, and its appearance of intense injection was evidently due to inflammatory change. Slight peritonitis was present.

CASE F. (Simpson.)—The patient, male, aged forty-one years, was suddenly attacked with vomiting and severe abdominal pain. Collapse preceded death, which occurred at the end of forty-four hours. A small cubical gall-stone projected from the end of the common duct into the duodenum; similar concretions were found in the gall-

bladder. The pancreas was greatly enlarged, weighing five hundred and twenty-five grammes, and was mottled with areas of reddish-brown color, due to hemorrhagic infiltration of its interstitial tissue. The organ was surrounded by semifluid, clotted blood, of dark-brown color. The intima of the splenic artery was of a dirty-blue color, and was apparently necrotic about two centimetres from the aorta; the writer regards this vessel as the source of the hemorrhage, although it is not stated that rupture had occurred.

In the preceding seven cases, Case I included, a calculus had lodged in the common bile duct near its orifice, or, having been expelled from this position shortly before death, lay in the duodenum, leaving the common duct dilated. Necrosis of the fat in or about the pancreas occurred in six of these seven cases; in the report of the remaining case (F), briefly described several years after its occurrence, no reference is made to this change.

In five instances recent hemorrhages had occurred into the organ, but, microscopical examination being omitted, it is difficult to determine whether these cases should be classified as examples of simple hemorrhage or of hemorrhagic pancreatitis. In the case which I have recorded there was evidence of past hemorrhage into and about the pancreas, accompanied by necrosis of a small part of the organ. The remainder of the gland was the seat of chronic interstitial change, and, apparently as the result of invasion of micro-organisms into the hemorrhagic and necrotic tissue, an abscess, limited by the lesser peritoneal cavity, had formed about

the organ. In Case C there were old and recent hemorrhages into the pancreas, which had undergone suppurative inflammation and necrosis.

Of special interest are the cases (A, B, E, and F) in which death occurred within thirty-three, sixteen, forty-two, and forty-four hours after the onset of sudden vomiting, pain in the upper abdomen, and collapse. The brief duration of symptoms indicates that the calculus found at autopsy had been lodged only a short time in the common duct. Nevertheless, extensive lesion of the pancreas, hemorrhagic in character, had resulted. With these cases it is impossible, from the data recorded, to distinguish between hemorrhage into the pancreas and hemorrhagic pancreatitis.

The preceding cases include only those in which there is positive evidence that a stone passing along the common bile duct had become impacted in such a position that occlusion of the pancreatic duct might ensue. A calculus might be temporarily so located and cause severe injury to the gland, but finally, being expelled, give no evidence of its former impaction. I have collected from the literature (see accompanying table) a number of cases in which pancreatic lesions were associated with cholelithiasis. Gall-stones were found in the gall-bladder or gall-ducts, but except in Cases 1 to 8 there was at autopsy no convincing evidence that a stone in the common bile duct had occluded the pancreatic duct.

CASES OF ACUTE PANCREATITIS WITH CHOLELITHIASIS.

No.	Author.	Duration.	Pancreatitis.	Remarks.
1	Thayer (A) .	34 hours.	Hemorrhagic.	Calculus in duodenum.
2	Day (B) . .	16 hours.	Hemorrhagic.	Calculi in common duct.
3	Dieckhoff (C)		Hemorrhagic, gangrenous, and purulent.	Calculus in common duct.
4	Cutler (D) .	4 days.	Hemorrhagic.	Calculus in common duct.
5	Kennan (E) .	42 hours.	Hemorrhagic.	Calculus in common duct.
6	Simpson (F) .	44 hours.	Hemorrhagic.	Calculus in common duct.
7	Opie (I) . .	21 days.	Hemorrhagic and gangrenous.	Calculus in common duct.
8	Opie (II) . .	9 days.	Hemorrhagic.	Calculus in common duct.
9	Rolleston . .	2 days.	Hemorrhagic.	
10	Paul	30 hours.	Hemorrhagic.	
11	J. A. Smith .	24 hours.	Hemorrhagic.	
12	Kötschau . .	48 hours.	Hemorrhagic.	
13	Chiari	7 days.	Gangrenous.	Jaundice.
14	Chiari	3 weeks.	Gangrenous.	Jaundice.
15	Mader	13 days.	Gangrenous.	Jaundice.
16	Fitz	10 days.	Gangrenous.	Jaundice.
17	Morian	27 days.	Hemorrhagic and gangrenous.	Jaundice.
18	Bryant	4 days.	Hemorrhagic.	Jaundice.
19	Lund	52 days.	Hemorrhagic.	Jaundice.
20	Lund	7 days.	Hemorrhagic.	Jaundice.
21	Stockton and Williams.	7 days.	Hemorrhagic and gangrenous.	Jaundice.
22	Struppler . .	11 days.	Gangrenous.	Jaundice.
23	Habersohn . .	4 months.	Gangrenous.	
24	Chiari	2 months.	Gangrenous.	
25	König	32 days.	Gangrenous.	
26	Körte	4 months.	Gangrenous.	
27	Körte	1 month.	Hemorrhagic and gangrenous.	
28	Fraenkel . . .		Gangrenous.	
29	Fraenkel . . .	5 days.	Hemorrhagic and gangrenous.	
30	Ehrich	1 month.	Gangrenous.	
31	Scott	15 days.	Gangrenous.	
32	Grawitz . . .	32 days.	Gangrenous.	
33	Bryant	5 days.	Hemorrhagic.	
34	Lund	16 days.	Hemorrhagic and gangrenous.	
35	Hahn	4 days.	Hemorrhagic and gangrenous.	
36	Marx	4 days.	Hemorrhagic.	
37	Marx	4 days.	Hemorrhagic.	
38	Dieckhoff . .	2 days.	Purulent	
39	Simon and Stanley . .	3 days.	Purulent	
40	Rolleston . .	75 days.	Purulent	
41	Fuchs	3 months.	Purulent	Calculus in common duct.

The first eight cases of the table, excluding No. 8, to be described later, are those already cited. A hemorrhagic lesion of the pancreas, hemorrhage or hemorrhagic pancreatitis, was present in cases of the table Nos. 9, 10, 11, and 12. Here gall-stones were found in the gall-bladder or in the bile passages, but there is no record that a calculus was located near the orifice of the common duct. Jaundice was absent, and the autopsy gave no positive evidence that a stone had recently passed into the duodenum. Death followed within forty-eight hours the onset of symptoms, abdominal pain, vomiting, and collapse. The clinical and pathological picture agrees with that of the preceding cases of rapidly fatal hemorrhagic lesion (Nos. 1, 2, 5, and 6). One factor alone is absent the offending calculus has apparently been passed into the intestine and lost.

The table includes additional cases (Nos. 13 to 37), in which cholelithiasis has accompanied hemorrhagic or hemorrhagic and gangrenous pancreatitis. In some it is not improbable that the co-existence of the two conditions may have been accidental, but since cases of hemorrhagic pancreatitis recorded in the literature are not numerous, the relative frequency with which gall-stones have been noted, even though especial attention has not been given them, indicates an intimate relation between the two processes.

In four cases the pancreas was the seat of suppurative inflammation, apparently unassociated with hemor-

rhage or necrosis. In one of them (No. 38) a gallstone had found its way into the pancreatic duct, which was dilated to accommodate it. Of especial interest is Case 41, recently reported by Fuchs. A man aged thirty-two years, who had had recurring abdominal pain and vomiting, suffered for about three months with repeated attacks of great severity, on one occasion accompanied by jaundice. Operation disclosed the presence of a calculus the size of a bean situated within the diverticulum of Vater. In the head of the pancreas was a small abscess. Evacuation of the abscess and removal of the calculus were followed by recovery. Hemorrhagic or hemorrhagic and gangrenous pancreatitis, as in the somewhat similar Cases 1 to 8, may have preceded the formation of an abscess.

CHAPTER V.

THE ETIOLOGICAL RELATION OF GALL-STONES TO ACUTE HEMORRHAGIC PANCREATITIS. HEMORRHAGIC AND GAN- GRENOUS PANCREATITIS.

THE case previously described, together with those found in the literature, suggest no process nor mechanism by which a lesion of the pancreas results from the presence of a calculus in the common bile duct near its duodenal orifice. The autopsy upon a second case of acute hemorrhagic pancreatitis studied in the partial light of that previously cited has demonstrated a mechanism by which a small biliary calculus produces a destructive lesion of the pancreas and at the same time has brought our knowledge of the lesion into correlation with facts demonstrable by experimental means.

CASE II.¹—Mr. T., a corpulent man of robust appearance, aged forty-eight years, had been for several years subject to attacks of "indigestion" accompanied by pain in the epigastrium. After luncheon, nine days before the fatal termination of his illness, he was suddenly seized with severe pain in the abdomen, accompanied by nausea. The pain disappeared, but returned at the end of twenty-four hours. After drinking large quantities of water, the patient

¹ The clinical history of this case has been reported by Dr. Halsted. In the "Bulletin of the Johns Hopkins Hospital," 1901, xii. 182, I described the mechanism by which a biliary calculus causes acute hemorrhagic pancreatitis.

with difficulty forced himself to vomit. The pain persisted, but during the week following he took his meals regularly and slept as usual. About noon of the day preceding his admission to the hospital the pain became so severe that the repeated administration of morphia gave little relief. When seen at nine o'clock in the evening he was able to walk, though in great pain; his pulse was full and regular. The epigastrium was tender on pressure; the skin was markedly cyanosed. The following morning he was taken to the Johns Hopkins Hospital, and at eleven A.M. an operation was performed by Dr. Halsted.

On opening the abdomen in the middle line blood-stained fluid escaped. Numerous foci of fat necrosis were seen upon the omentum, in the mesentery, and along the lesser curvature of the stomach. The pancreas was examined through an opening made in the gastrocolic omentum, and the tissue over it was found infiltrated with blood-stained fluid. Slight distention of the common bile duct was noted. Fluid in the abdominal cavity was removed, and gauze, packed through the wound, was brought into contact with the head of the pancreas. Death occurred twenty-three hours later.

Autopsy.—The body, still warm, is that of a large man with very abundant subcutaneous fat. The peritoneal cavity contains a moderate excess of blood-stained serous fluid. Fat is present in large amount in the omentum, mesentery, and subperitoneal tissue, and is thickly studded with small, usually round, opaque, white areas of necrosis, often surrounded by a narrow zone of injection. They are most abundant in the omentum and in the retroperitoneal fat adjacent to the pancreas.

The pancreas is represented by a blackish swollen mass extending from the descending part of the duodenum to the spleen. The fat in contact with its splenic end has a similar blackish color, and is soft and friable. The pancreas is greatly increased in size and is irregularly cylindrical in shape. The anterior surface is smooth, and has an almost uniform black or reddish-black color. On section the gland-

ular substance is found to be in great part transformed into material of similar color. The head of the organ for a distance of two and a half centimetres from the duodenum is normal in appearance, but tissue which is in immediate contact with this well-preserved gland substance is soft and black in color, mottled here and there with small areas of dull red. The distal half of the organ shows a similar mottling of black and reddish areas, among which are islands of yellowish, relatively well-preserved tissue. On opening the splenic vein where it lies in contact with the pancreas, the intima is found to have a mottled yellow, blackish, and red appearance, due to changes in the underlying tissue. Occupying the lumen is a mixed red and yellow thrombus mass, firm in consistence and adherent to the intima.

The duodenum was opened and the common orifice of the bile and pancreatic ducts examined. The papilla is prominent, but its orifice is of small size, measuring one millimetre in diameter. The common bile duct, which near its termination is completely embedded in the substance of the pancreas, is slightly distended. The gall-bladder when opened is found to contain a moderate amount of viscid, blackish bile; no concretions are present. The termination of the pancreatic duct, which is surrounded by the well-preserved pancreatic substance in contact with the duodenum, was exposed by dissection, and found to unite with the common bile duct ten millimetres from the summit of the bile papilla. A probe passed into the common duct is stopped four millimetres from the duodenal orifice, and cannot be touched with a second probe in contact with the narrow orifice. Examination discloses a small gray-white, very firm concretion, three millimetres in diameter, tightly impacted in the diverticulum of Vater, from which it cannot escape through the narrow duodenal opening. The pancreatic duct and its larger branches, where they traverse the intact tissue of the head, are stained bright green with bile.

In the liver are found portal veins distended and plugged with

red thrombi which probably have had their origin in emboli from the thrombosed splenic vein. The heart, lungs, spleen, kidneys, and adrenal glands present no noteworthy abnormality. The urine contained in the bladder does not reduce Fehling's solution.

Microscopic Examination of the Pancreas.—A section passing through the line of demarcation between intact parenchyma in the head of the gland and the adjacent necrotic tissue shows a very abrupt transition from the one to the other. On the one side the pancreatic acini are well preserved, the secreting cells are normal in appearance and their basal zone stains deeply with hæmatoxylin, while islands of Langerhans are fairly abundant and appear to be normal. The loose interlobular areolar tissue is everywhere infiltrated with red blood-corpuscles; polynuclear leucocytes are present in large numbers and often form collections of considerable extent. Within the margin of the intact tissue are several small areas where the parenchyma presents an early stage of necrosis. Here the secreting cells no longer stain with hæmatoxylin, but assume a homogeneous clear pink color with eosin; the nuclei which are still preserved are much smaller than those of the normal cells, and unlike the latter are irregular and distorted, and stain homogeneously. Small hemorrhages have taken place into the interacinar tissue of such an area, and polynuclear leucocytes are present in moderate number. Nearby, in similarly localized areas, the process is more advanced, and the parenchymatous cells are replaced by formless material which, staining faintly, is mingled with a few nuclear fragments and is densely infiltrated with polynuclear leucocytes and red blood-corpuscles.

The transition from relatively normal parenchyma containing a few islands of necrosis to wholly necrotic tissue is very abrupt and is marked by a zone composed of nuclear fragments, polynuclear leucocytes, red blood-corpuscles, and fibrin. That part of the section which corresponds to the black and reddish-black material seen mi-

microscopically is necrotic, nuclei are no longer present, and though the architecture of the gland is still obscurely definable, both parenchyma and connective tissue have a dark-brown discoloration due to the presence of brown pigmented material which appears to be changed blood.

In sections stained by Weigert's method for the demonstration of fibrin was noted a histological detail inconspicuous by other methods. Capillary vessels in the living tissue near the margin of necrosis, as well as in the immediately adjacent necrotic part, have undergone hyaline thrombosis and form conspicuous deep-blue, often branched lines, as though injected. Examination with high magnification demonstrates at times a close mesh-work of fibrin in these vessels. In sections stained with hæmatoxylin and eosin their contents take a homogeneous bright pinkish-red stain, and red blood-corpuscles are no longer seen, as in adjacent capillaries.

In sections stained for bacteria with methylene-blue, with gentian violet, and by Weigert's method, none were discovered.

Bacteriological Examination.—Plate cultures in agar-agar were made at autopsy from the heart's blood, peritoneal cavity, pancreas (aërobic and anaërobic on hydrocele agar-agar), gall-bladder, liver, spleen, and kidney. They have been studied by Mr. V. H. Bassett, to whom I am indebted for the following report. Cultures from the heart's blood, spleen, and gall-bladder give negative results. The anaërobic culture from the pancreas shows no growth after an incubation of seventy-two hours. The aërobic agar-agar plate from the pancreas contains at the end of twenty-four hours a single superficial colony of a pigment forming coccus of which the cultural characters indicate that it is a contamination from the air. Streptococcus pyogenes and staphylococcus epidermis albus were isolated from the peritoneal cavity. The colon bacillus was present in cultures from the liver and kidney.

Anatomical Diagnosis.—Cholelithiasis; calculus impacted in the

diverticulum of Vater, partially filling it, and occluding its duodenal orifice. Acute hemorrhagic pancreatitis; disseminated abdominal fat necrosis. Partial thrombosis of the splenic vein; embolism and thrombosis of branches of the portal vein.

The preceding autopsy has disclosed a condition which explains, I believe, the pathogenesis of those cases of acute hemorrhagic and gangrenous pancreatitis which are associated with gall-stones. The diverticulum of Vater was ten millimetres in length. Lodged at its apex, blocking the duodenal orifice, was a small calculus only three millimetres in diameter, but too small to pass the narrow opening. Though it occluded the duodenal orifice of the diverticulum, it was so small that the orifices of the common bile duct and the pancreatic duct were unobstructed. The two ducts were, therefore, converted into a continuous closed channel from which it was not possible for either bile or pancreatic juice to escape (see Fig. 8, i., page 40).

On dissecting the pancreatic duct where it passed through the unchanged parenchyma in contact with the duodenum it was found, like the bile duct, to be stained bright green with bile. Where, as in this case, the two ducts become a closed channel, the entrance of bile into the pancreas or of pancreatic juice into the bile passages would depend upon the relative pressure in the two ducts. The pressure at which bile and pancreatic juice are secreted being small, any slight difference that might exist would be overcome by the gall-

bladder, a muscular organ which at intervals forces bile in considerable quantity along the common duct.

A small calculus only partially filling the ampulla of Vater can convert the two ducts into a continuous channel, while a larger stone might simultaneously obstruct the duodenal orifice of the diverticulum and the orifices of the two ducts which enter it, thus damming back bile and pancreatic juice upon their respective glands. In the present case, as previously mentioned, the diverticulum measured ten millimetres in length, the calculus three millimetres in diameter. In many cases of hemorrhagic and of hemorrhagic and gangrenous pancreatitis gall-stones found in the gall-bladder and bile passages at autopsy have been small and are often described as pea-sized. Such statements are made in the reports of Day, Cutler, Kennan, Simpson, Chiari (two cases), Smith, Ehrich, Fränkel, Körte, Morian, Rolleston, Grawitz, Opie (two cases), Bryant, and Lund (three cases).

Anatomical peculiarities of the diverticulum of Vater favor or prevent conversion of the two ducts into a closed channel. The diverticulum may be regarded as a somewhat conical cavity into the base of which open the bile and pancreatic ducts; the apex of the cone situated at the summit of the bile papilla is the common duodenal orifice of both ducts. It has been previously shown that in a considerable number of individuals, about one in ten, the two ducts open separately

into the intestine and no diverticulum exists (see Fig. 8, ii.). Variations to which the diverticulum is subject have been considered (page 39 *et seq.*); in one hundred instances its length varied from zero to eleven millimetres, and in only thirty of these did the length reach five millimetres. The average diameter of the duodenal orifice, measured in seventy-five instances, was two and a half millimetres. In twenty-one individuals the diameter of the orifice was equal or greater than the length of the diverticulum, and it is obviously impossible that a calculus assumed to be approximately spherical could lodge in the orifice and only partially occlude the cavity. Indeed, if possible distention of the orifice be considered, it is hardly probable that a small calculus could lodge in the opening, yet only partially fill the cavity, unless the length of the diverticulum should exceed the diameter of the orifice by several millimetres. Since in only thirty-two of one hundred instances does the length of the diverticulum exceed five millimetres, the average diameter of the orifice being two and a half millimetres, it is probable that in little more than three of ten individuals are the anatomical conditions such that a small calculus might divert the bile into the pancreatic duct. Moreover, it must be remembered, in one of ten cases the bile duct joins the smaller pancreatic duct, while the larger duct of Santorini enters the duodenum at the site of the lesser papilla. These facts explain in part the rarity of

acute hemorrhagic pancreatitis when compared with the relative frequency of cholelithiasis.

Effect of Bile Injected into the Pancreatic Duct.—Experiments previously described in detail have shown that a variety of irritating substances, various acids and alkalies, artificial gastric juice, suspensions of bacteria, etc., injected into the pancreatic duct cause hemorrhagic inflammation of the gland. Cases just described have demonstrated in association with acute hemorrhagic pancreatitis a mechanism by which a small biliary calculus diverts bile into the pancreatic duct. A series of experiments was undertaken in order to determine the effect of bile thus brought into contact with the pancreatic parenchyma. The duodenum of dogs was opened for a distance of several centimetres opposite the larger pancreatic duct. The blunt-pointed nozzle of a syringe was inserted into the orifice of the duct, and bile obtained from the same or from a second dog was injected into the organ. The operations were performed with the usual antiseptic precautions, and the duodenal wound was closed by submucous mattress sutures. The results were almost uniform. Several experiments¹ exhibiting features repeated in the others will be described in detail.

¹ These experiments have been described in the "Bulletin of the Johns Hopkins Hospital," 1901, xii. 182. The experiments here quoted are designated by the numbers used in that article.

EXPERIMENT 2.—Bile (five cubic centimetres) from a dog was injected into the larger pancreatic duct of a second dog. The animal was killed at the end of five days. In the omental fat are several opaque white areas of fat necrosis, while near the splenic extremity of the pancreas are several inconspicuous foci of a similar nature. In the duodenal part of the gland, in the neighborhood of the orifice of the larger duct, for a distance of three and a half centimetres, there is extensive hemorrhagic infiltration separating islands of parenchyma. In places the gland substance is soft and of gray necrotic appearance. The splenic part is firm in consistence, and at several points are areas of hemorrhagic infiltration. Microscopic examination of sections from the hemorrhagic duodenal part shows wide areas of necrosis implicating both lobular and interstitial tissue. The parenchymatous cells are hyaline and without nuclei. Copious hemorrhage has taken place into these areas, and at the margin of intact tissue polynuclear leucocytes are numerous. Fibrin is abundant in the necrotic interlobular tissue. Where wide-spread destruction has not occurred there has been active proliferation of interstitial tissue, replacing in part destroyed parenchyma and containing numerous red blood-corpuscles and polynuclear leucocytes. The remaining acini are often separated by newly-formed interstitial tissue, and there is the appearance of advanced chronic inflammation.

EXPERIMENT 3.—After opening the duodenum of a dog, five cubic centimetres of bile obtained from a second animal were injected into the pancreatic duct. Death followed within twenty hours. The peritoneal cavity contains several cubic centimetres of bloody fluid and the peritoneal surface has an irregularly distributed, deep red injection. The entire omentum is studded with conspicuous opaque white areas of fat necrosis. In the mesentery of the duodenum, near the pancreas, they are numerous, and are also present in the retroperitoneal fat and in the properitoneal fat below the diaphragm. The splenic arm and the upper half of the attached duodenal part of the pan-

creas are swollen and œdematous in appearance, and the lobules are separated by tissue infiltrated with blood. The cut surface has a mottled dull red and gray color, the interstitial tissue being hemorrhagic, while minute hemorrhages are in places seen within the lobular substance. Microscopic examination shows that the dull red areas in the pancreas seen macroscopically represent foci of necrosis where parenchymatous cells stain only with eosin and no longer contain nuclei. The blood-vessels here are widely dilated, and abundant hemorrhage has frequently taken place. Polynuclear leucocytes are present, but are not very numerous. Such an area of necrosis and hemorrhage is at times limited to the central part of a lobule group, while the acini farther from the central duct are intact. The interstitial tissue, particularly in the duodenal part of the gland, has an œdematous appearance, and contains red blood-corpuscles, polynuclear leucocytes, and fibrin.

Should bile enter the pancreas after occlusion of the distal end of the diverticulum of Vater, its only opportunity for escape would be by way of the lesser pancreatic duct. In order to reproduce this condition, in two experiments the duodenum was not opened, but the duct was exposed where it approaches the intestine, ligated close to the duodenum, and partially cut across. By means of a syringe with a blunt nozzle bile was injected into the distal end of the duct, which was then ligated.

EXPERIMENT 6.—Into the larger duct was injected five cubic centimetres of bile obtained by puncture from the dog's gall-bladder. The animal died twenty-four hours later. Opaque, white areas of fat necrosis are numerous upon the surface of the duodenal part of

the pancreas and in the immediately adjacent fat of the duodenal mesentery, and are present in both layers of the omentum. The parenchyma throughout the gland is mottled, small dull-red areas alternating with more normal gray-yellow glandular substance, this hemorrhagic appearance of the parenchyma being most marked in the duodenal part of the gland. Microscopic examination of all parts of the pancreas shows the presence of numerous foci of necrosis. The gland cells have assumed a hyaline appearance and have lost their nuclei. The blood-vessels in these areas are widely distended, and at times there is abundant extravasation of red blood-corpuscles. Polynuclear leucocytes in moderate number are seen between the necrotic cells. The interlobular tissue is in many places much distended, containing red blood-corpuscles, polynuclear leucocytes, and fibrin.

The injection of five cubic centimetres of bile into the pancreatic duct caused hemorrhagic inflammation of the gland in four dogs, two of which died within twenty-four hours after the operation. In these experiments death did not follow the use of smaller amounts, and the changes produced in the organ were less wide-spread and severe. In every case necrosis of the adjacent fat accompanied the lesion of the pancreas, and in two instances in which death occurred spontaneously foci of the necrosis were abundant and disseminated.

These experiments have demonstrated the possibility of reproducing in animals by means of bile the hemorrhagic lesion which occurs in human cases. They afford additional evidence that bile diverted into the pancreatic

duct by a biliary calculus is capable of producing the lesion of acute hemorrhagic pancreatitis.

Frequency with which Acute Hemorrhagic Pancreatitis is Produced by Biliary Calculi.—While the etiology of many cases of hemorrhagic pancreatitis is thus established, it cannot be demonstrated that all are dependent upon the passage of a gall-stone along the common bile duct. In the following case neither the clinical history nor the autopsy affords any evidence of cholelithiasis. A complete autopsy was not permitted, and the possibility cannot be excluded that a single small calculus producing the lesion escaped into the intestine.

CASE III.—The patient, a man, twenty-eight years of age, had, before his fatal illness, been in good health. There was no history of any previous digestive disturbance, and he had never been jaundiced. His illness began four days before death with an attack of nausea and vomiting, coming on shortly after a meal. About an hour later he was attacked with agonizing pain in the epigastric region, and the vomiting continued during the night, but in the morning became less severe. The following day he suffered with violent hiccough, which continued until the time of operation. When admitted to the hospital he seemed ill and vomited almost continuously. Examination of the abdomen showed nothing except distention in the neighborhood of the umbilicus. An exploratory laparotomy was performed by Dr. J. F. Mitchell, and innumerable foci of fat necrosis were found studding the omentum. The lesser peritoneal cavity contained bloody fluid, and the pancreas was covered by a coagulum of blood. The abdomen was closed, a gauze drain being inserted into the wound. The patient died twenty-four hours later.

Autopsy.—An examination of the abdominal contents through the wound was permitted, and it was possible to remove only the pancreas with the gall-bladder and a part of the duodenum. The pancreas was of great size, weighing one hundred and ninety grammes; the head and tail were firm and normal in appearance, but the greater part of the body was soft, mottled red and reddish-black, and was the seat of a hemorrhagic lesion. No gall-stones were found in the gall-bladder or in the gall-duct. The parenchyma had undergone necrosis and the neighboring interstitial tissue had become infiltrated with red blood-corpuscles, polynuclear leucocytes, and fibrin. The capillary vessels at the margin of the necrotic area showed the condition of hyaline thrombosis observed in Case II.

In reports of many such cases gall-stones are not mentioned. In some instances the lesion has been diagnosed upon the operating-table and, no autopsy being obtained, the condition of the bile passages has not been determined. In a large proportion of cases the autopsy report is so meagre that the presence or absence of gall-stones is not evident. The relative frequency with which acute pancreatitis is accompanied by cholelithiasis is difficult to estimate.

In two of three cases which I have examined gall-stones were present. A considerable number of cases recently described by writers who have reported more than one instance, allow a fairer estimate than do reports of isolated cases. Lund, of Boston, has reported five cases, three of which were examined after death, and in all of these gall-stones were found.

Bryant has reported two cases with gall-stones. Hahn reports five, upon three of which autopsy was performed; gall-stones were found in one. Marx has described two cases with gall-stones. Of such recently reported cases in which autopsies were performed, in thirteen, including my three, gall-stones were present in ten.

Pathogenesis of Pancreatic Hemorrhage and of Hemorrhagic Pancreatitis.—Histological peculiarities of acute hemorrhagic pancreatitis explain its relationship to hemorrhage on the one hand and to gangrene on the other. Sufficient importance has not been given to the occurrence of extensive necrosis of the parenchyma and interstitial tissue as an essential feature of the process. Thus Körte, after studying forty-one reported cases of hemorrhagic pancreatitis, of which, indeed, few include an adequate microscopic description, gives the following account of its histology. In the interstitial tissue infiltration with round cells accompanies the escape of blood, and in some cases the interstitial tissue proliferates so that the lobules of the gland are separated from one another. The fat frequently present in considerable quantities between the lobules of the glandular tissue contains foci of necrosis. The acini show fatty degeneration, and in many cases partial or complete absence of nuclear stain indicates the death of the cells. Over a considerable area glandular tissue may have undergone such change that epithelial cells are no longer recognizable.

In two cases (II. and III.) which I have described the lesion has been of short duration and the essential features of the lesion are well illustrated. Widespread necrosis of the parenchyma is associated with abundant hemorrhage and with the accumulation of inflammatory products, notably fibrin and polynuclear leucocytes. A very conspicuous feature of the process is total death of the tissue, implicating at once epithelial cells, interstitial connective tissue, and walls of blood-vessels. For a time the architecture of the tissue is preserved and the outlines of the acini are readily discernible, though the nuclei of the cells are wholly lost. Later the tissue undergoes such complete alteration that the structures composing it are no longer recognizable. Transition from such necrotic material to living tissue is abrupt, marked by a narrow zone containing fragments of nuclei, polynuclear leucocytes, red blood-corpuscles, and fibrin. A character of the lesion not previously noted is the occurrence of hyaline capillary thrombosis within the relatively intact tissue which lies in contact with the necrotic zone. The presence of numerous polynuclear leucocytes and of fibrin leave no doubt as to the inflammatory nature of the change, although bacteriological examination has demonstrated the absence of bacterial invasion.

I have had the opportunity of examining tissue from two additional cases of acute hemorrhagic pancreatitis obtained from the Pathological Laboratory of Col-

umbia University of New York, through the courtesy of Dr. Hodenpyl. In both cases necrosis of parenchyma and interstitial tissue implicating the blood-vessels was associated with profuse hemorrhage into the necrotic tissue. Though a few polynuclear leucocytes were present near the margin of relatively intact tissue inflammatory changes did not form a conspicuous feature of the process. Where, as in Case I., the process is of longer duration, connective tissue in contact with areas of necrosis undergoes proliferation and newly formed fibrous tissue tends to replace parenchyma which has undergone destruction.

By experimental means it is possible to produce a lesion of which the essential features are those observed in human cases, but here, the conditions being under control, various stages in the process can be more readily studied. In the two instances (Experiments 3 and 6) in which death followed within twenty-four hours the injection of five cubic centimetres of bile into the pancreatic duct, foci of necrosis contained widely-distended blood-vessels, while injury to their walls was indicated by the escape of numerous red blood-corpuscles into the tissues adjacent to them. The presence of polynuclear leucocytes in moderate number gave evidence of beginning inflammation. Proliferation of the fixed tissue occurs with rapidity, invading and replacing the injured parenchyma.

In both human and experimental lesions, bile coming

into contact with cells causes their death, and necrosis of the parenchyma is associated with such injury to the adjacent vessel walls that red blood-corpuscles escape in great abundance. Inflammatory and reparatory changes are secondary to death of tissue and occur at the margin of the necrotic area. Hemorrhage may be the result of necrosis before inflammatory changes are well marked. When, as in the case described by Simpson, extensive hemorrhage has followed the lodgement of a calculus at the orifice of the common bile duct, it is doubtless due to necrosis implicating the wall of some vessel of considerable size. Pancreatic hemorrhage and hemorrhagic pancreatitis represent a single pathological process, and cannot be sharply defined the one from the other.

Numerous experiments have shown that a variety of substances, including bile, injected into the pancreas readily cause wide-spread necrosis, which finds little analogy in other organs. The pancreas, a gland secreting substances which effect the digestion of proteids within the intestine, is after death capable, like the stomach, of causing partial digestion of its own substance. It is not improbable that the ferments of the pancreatic juice, notably trypsin, acting upon cells injured by contact with the various irritant substances which can produce hemorrhagic pancreatitis, have a part in the production of the wide-spread disintegration of the parenchyma which results.

Pathogenesis of Gangrenous Pancreatitis.—Though the older literature contains cases in which the pancreas had undergone sequestration, an adequate picture of the condition was first drawn by Fitz, who has shown that acute pancreatitis may terminate in gangrene. From a study of fifteen cases Fitz found that the appearance of the pancreas varies with the duration of the disease. The gland, he says, is at first swollen, dark red, and soft, while on section the tissue is red or mottled red and gray, or may be wholly transformed into a dark slate-colored, foul-smelling mass. At the end of about ten days the pancreas is often dark-brown, dry and firm, and covered by changed blood; hemorrhagic infiltration may extend beyond its limits. Throughout the substance areas of hemorrhage alternate with yellow spots of softening. At the end of the second week the organ may form a soft, black, friable mass, while the lesser omental cavity contains a large quantity of chocolate-colored fluid containing large, bluish-black clots. The gland may be finally transformed into a soft mass attached by a few shreds to the posterior abdominal wall or, indeed, may lie free in the omental cavity, which is distended with bloody or blackish, often ill-smelling, fluid containing necrotic particles of tissue. A striking feature is the occurrence of disseminated fat necrosis.

In reports of at least half the cases studied by Fitz, hemorrhages into the pancreas were mentioned, or the

discoloration described was such as to suggest hemorrhage. He therefore reached the conclusion that gangrenous pancreatitis and peripancreatitis are in a considerable number of cases associated with hemorrhagic inflammation, although they may be the result of perforating inflammation of the gastro-intestinal or biliary tracts. Körte thinks that necrosis may follow extensive purulent inflammation, and mentions certain other possible causes,—for example, traumatism and arterial sclerosis,—but is of the opinion that hemorrhagic infiltration usually precedes the condition.

Histological examination of human cases and study of hemorrhagic pancreatitis produced experimentally has shown that extensive necrosis of tissue is associated with injury to the blood-vessels and consequent hemorrhage. Sufficient importance has not been attached to the occurrence of necrosis; wide-spread death of tissue is an essential feature of hemorrhagic pancreatitis. Subsequent alterations, due to changes occurring in the extravasated blood and to invasion of bacteria, cause such discoloration and disintegration of the affected tissue that it is recognized by the naked eye to be gangrenous. Suppuration with or without perforation of the gastro-intestinal tract is a secondary change and is not the cause of the gangrenous condition. No sharp distinction, therefore, can be drawn between hemorrhagic and so-called gangrenous pancreatitis. The lesion begins with necrosis of tissue, and hemor-

rhage takes place into the necrotic area ; inflammatory changes soon occur, and should sufficient time elapse, those alterations which give to the organ the macroscopic appearance of gangrene ensue.

Gangrenous pancreatitis being a late stage of the hemorrhagic inflammation, from the foregoing one would expect to find gall-stones frequently associated with the lesion. The table (see page 110) includes such cases of acute pancreatitis associated with cholelithiasis ; in eight instances the organ is described as hemorrhagic and gangrenous, while in thirteen gangrene alone is mentioned.

Symptoms of Acute Hemorrhagic Pancreatitis.—The foregoing study has shown that no sharp distinction can be drawn between pancreatic hemorrhage, hemorrhagic pancreatitis, and gangrenous pancreatitis. These processes are essentially wide-spread necrosis of the parenchyma, associated with injury to the blood-vessel walls and hemorrhage ; inflammatory changes rapidly follow, and so-called gangrenous pancreatitis is a late stage of the hemorrhagic lesion : the gland primarily undergoes necrosis. While at present it cannot be denied that other causes may produce the condition, only one etiological factor has been demonstrated,—namely, the impaction of a gall-stone in the diverticulum of Vater, diverting bile into the pancreatic duct.

An individual, usually in fairly good health, with perhaps a history of previous gall-stone colic, is suddenly attacked with pain in the epigastric region, accom-

panied by vomiting and followed by collapse. Death follows often within forty-eight hours, and at autopsy gall-stones are found in the bile passages, while that one which caused the fatal attack may be still lodged in the common duct near its orifice. The pancreas is enlarged, infiltrated with blood, and hemorrhage may have occurred into the surrounding tissue. Foci of fat necrosis are usually present.

A fatal termination may not follow rapidly the symptoms mentioned. Pain in the epigastrium persists, jaundice may be present, and a tumor-mass above the umbilicus may indicate a probable lesion of the pancreas. At the end of one or more weeks or months death occurs, often with symptoms indicating the presence of suppurative inflammation, presumably in the neighborhood of the gland. At autopsy the diagnosis of cholelithiasis is confirmed by the presence of gall-stones in the gall-bladder or in the bile ducts, and occasionally the offending calculus is still lodged in the diverticulum of Vater. The pancreas is dry, black, and necrotic, and evidence of previous hemorrhage may be present. Secondary infection has occurred, and the pancreas lies in an abscess cavity formed by the bursa omentalis. In the wall, and often widely disseminated in the abdominal fat, are foci of necrosis. Since the individual has survived the primary lesion, opportunity has been given for the development of secondary changes in the injured pancreas and neighboring fat.

CHAPTER VI.

FAT NECROSIS.

REPEATED reference has been made to the occurrence of necrosis of fat in association with acute hemorrhagic pancreatitis and other lesions of the gland. The relationship of this peculiar lesion to alterations of the pancreas is now well established, but though disseminated focal fat necrosis has been the subject of much anatomical and experimental research since Balser directed attention to it in 1882, some of the problems it has suggested have not received an adequate solution.

Balser observed in fat immediately about the pancreas small, opaque, white areas, which were shown by microscopic examination to be composed in great part of necrotic fat-cells. This lesion was present in five of twenty-five bodies which he examined. In two cases a similar process not only implicated the fat about the pancreas, but was present in scattered foci at a considerable distance from the organ, and was, he believed, the cause of death.

When widely scattered the condition has been designated disseminated or multiple fat necrosis. The more minute foci, limited to fat within or upon the organ, when carefully sought for, are often found at autopsy, but their frequency is somewhat less than Balser sup-

posed. Larger foci of fat necrosis occupying the fat of the omentum, the subperitoneal and retroperitoneal tissue are, unlike the latter, conspicuous lesions.

Recognition of this condition, difficult only on account of the relative infrequency with which it is encountered, is of considerable importance to the surgeon, since it indicates, as will be shown, the existence of some grave alteration of the pancreas. On opening the abdomen the omentum, and possibly other fat, is found studded with round or oval areas, several millimetres in diameter and very conspicuous on account of their opaque white, or yellow color, which is in sharp contrast with the translucent golden yellow of the normal fat. A narrow hemorrhagic zone frequently surrounds such areas.

This lesion, most extensive in the neighborhood of the pancreas, is usually limited to the fat of the abdominal cavity. Areas of necrosis may be confluent near the gland and thickly scattered elsewhere in the fat abutting upon the peritoneal cavity. In two cases Hanseemann observed foci of fat necrosis in the subcutaneous tissue; they corresponded in location to reddish areas visible during life upon the overlying skin. Chiari has recorded a very remarkable case: areas of fat necrosis, often as large as a pea, were present in the fatty tissue about the bursa omentalis within which lay the necrotic pancreas, in the mesentery, in the subperitoneal fat of the abdominal wall, in the subpericardial and subpleural fat,

and in the subcutaneous tissue. Balser has also seen the pericardial fat implicated in the process.

Spontaneous fat necrosis has been found in domestic animals by several observers,—Balser, Williams, Olt, and others. In pigs very wide-spread dissemination of the lesion has been found by Olt, who records its presence in the subperitoneal fat, in the intermuscular septa, and in the subcutaneous tissue of the abdominal and thoracic walls.

Fitz first has offered the suggestion that fat necrosis is consequent upon a lesion of the pancreas, and has supported this conclusion by numerous instances in which the two conditions have been associated. In the majority of cases hemorrhagic pancreatitis is present, and not infrequently the organ is found to be gangrenous in appearance. Occasionally the gland lies in the cavity of the bursa omentalis dissected almost free from the surrounding tissue; such sequestration, Langerhans thinks, may be the result of extensive necrosis of the fat surrounding it. More rarely other pathological conditions are present; chronic suppurative pancreatitis is rarely accompanied by fat necrosis, and in a few instances chronic interstitial inflammation has co-existed with it.

The chemical and histological studies of Langerhans have explained the essential nature of the process. He has shown that the changes demonstrable within the fat-cells are associated with the splitting of the fat-

molecule into its fatty acid and the soluble constituent glycerin. Fatty acids are deposited as needle-like crystals within the cell which has lost its nucleus and is evidently necrotic, while the soluble glycerin is absorbed. Very soon the fatty acids unite with calcium to form calcium salts, and within the cell outline which is still preserved are irregular, often globular masses, in which the presence of lime salts may be demonstrated by microchemical reactions. A proliferation of fixed tissue-cells occurs at the periphery of the necrotic area, and is most conspicuous in the neighborhood of strands of connective tissue, but often the zone of reaction is not complete, and necrotic cells are in contact with those which are still unchanged.

A few polynuclear leucocytes find their way to the periphery of the necrotic tissue, but when numerous their presence is the result of secondary infection of the dead tissue. In the peripheral zone of cell proliferation, in addition to cells of lymphoid type, are much larger round or oval cells with vesicular nuclei and abundant cytoplasm studded with minute fat-globules, doubtless fat-cells in process of multiplication. Similar cells are occasionally multinucleated and of such size that they may be called giant cells.

Etiology.—Attempts have been made to refer the occurrence of fat necrosis to the action of micro-organisms, and in many cases bacteria have been isolated from the lesion. The explanation of their presence is doubt-

less that proposed by Dr. Welch, who identified the bacillus coli in a case of hemorrhagic pancreatitis with fat necrosis. Diphtheritic and ulcerative colitis was present, and the colon bacillus was found not only in foci of fat necrosis, but in the mesenteric glands, the liver, the bile, the lungs, the spleen, and the kidneys. The lesion of the colon had apparently facilitated the invasion of the bacillus coli, and its presence in foci of fat necrosis was thought to be a secondary event having no relation to their production. Similar conclusions have been reached by a number of observers, Hlava, Fitz, Leonhard, and others, who, cited in a preceding chapter, have isolated a considerable variety of bacteria from cases of fat necrosis accompanying hemorrhagic pancreatitis. The discordant results of bacteriological examinations give little support to the opinion of a few observers who have suggested that the lesion is caused by micro-organisms.

The proximity of foci of fat necrosis to the pancreas and their association with various pancreatic lesions has suggested the possibility that products of the organ are active in their causation. To test this hypothesis, Langerhans injected into the fat-tissue of rabbits and dogs an infusion prepared with antiseptic precautions from the pancreas of rabbits, and in one of thirteen experiments succeeded in producing in the perirenal fat of a dog a small opaque focus which had the histological characteristics of fat necrosis, but was accompanied

by an acute inflammatory reaction. He reached the conclusion that pancreatic juice acting on living fat-tissue causes necrosis. Jung attempted to reproduce the condition experimentally by introducing pieces of the fresh pancreatic tissue of one animal into the abdominal cavity of another, and in one of four experiments succeeded in producing well-marked areas of necrosis. In the remaining instances peritonitis resulted and his success was doubtful.

The experiments of Hildebrand and Dettmer are interesting and important. By placing a ligature about the pancreas they obtained necroses in the fat about that part of the gland distal to the ligature. In other experiments they tied the veins of the ligatured part to prevent, as Hildebrand suggests, the possible absorption of the obstructed secretion. The gland-tissue became congested and infiltrated with blood, and in its neighborhood foci of fat necrosis were somewhat more abundant than in the former instances. They were able, moreover, to produce similar lesions in the immediate neighborhood of the gland by merely cutting the organ transversely, thus allowing the pancreatic juice free access to the abdominal cavity. Hildebrand comes to the conclusion that obstruction to the outflow of the secretion, alone or combined with occlusion of the veins, or the escape of pancreatic juice into the peritoneal cavity results in the production of typical fat necrosis about the pancreas and even in the omentum

and in the mesentery. Both Flexner and Williams have confirmed the observations of Hildebrand and Dettmer. By placing a ligature about the gland, tying the veins of the part of the organ distal to the ligature, and at times tearing the parenchyma with a sharp hook, they obtained fat necrosis in a considerable number of their experiments.

Milisch attempted to reproduce the lesion in cats by allowing the pancreatic juice to escape into the peritoneal cavity. A section, several centimetres in length, was excised from the splenic arm of the gland near the duodenum, thus isolating the remainder of the splenic part and giving its secretion free access to the abdominal cavity. A ligature was applied about the duodenal part of the cut organ to prevent the penetration of infectious material along the severed duct from the duodenum. In two animals so operated upon no fat necrosis resulted at the end of fifteen and of six days; in one of these experiments a small concretion was found near the orifice of the severed duct, while in the other, Milisch states, the duct was found to have been included in a ligature placed about a bleeding vessel, thus preventing the escape of the secretion into the cavity. In three experiments, in which the excised piece of pancreas was left free in the peritoneal cavity, necroses were found in the immediate neighborhood of the organ and about the transplanted tissue. He concludes from his experiments, which are not convincing,

that fat necrosis may be caused by pancreatic juice which has escaped into the abdominal cavity.

Oser produced foci of necrosis about the pancreas and in the omentum by ligating all the blood-vessels of the organ and separating it from the duodenum, thus depriving it of its blood supply. By completely obstructing the circulation of part of the pancreas for twenty minutes, Blume produced hemorrhagic infiltration of the tissue and fat necrosis in the neighborhood of the injured parenchyma. In a large number of experiments Katz and Winkler succeeded in producing fat necrosis by placing a variable number of ligatures, at times as many as ten, about the gland. They came to the conclusion that though the efficient factor in the production of necrosis is the fat-splitting ferment of the pancreas, its activity is developed in those situations where resistance is lowered by infiltration with blood or by obstruction to the circulation, conditions produced by their method of experimentation.

A number of experimenters—Hlava, Körte, Oser, and recently, as already mentioned, Flexner—have obtained necrosis of fat by injecting into the parenchyma of the gland, or into the duct after opening the duodenum, various substances,—artificial gastric juice, dilute acids and alkalies, turpentine, and suspensions of a variety of bacteria,—causing thereby an injury to the gland-substance and in most instances hemorrhagic inflammation.

In the experiments cited above conditions have been present which afford an opportunity for the escape of the pancreatic secretion into the tissue surrounding the gland; it may be forced backward into the tissue as a result of duct-obstruction, or, when the parenchyma is injured, gradual diffusion may take place. Ever since Langerhans explained the process which takes place within the fat-cell, it has been assumed that the fat-splitting ferment of the pancreas is the active factor in producing the lesion. Demonstration of a fat-splitting ferment in the necrotic foci was made by Flexner. Bits of altered tissue from human and from experimental cases, when brought into contact with neutral butter-fat, were found to contain a ferment which has the power of splitting the fat and setting free acids readily recognized by their odor and reaction.

Fat necrosis produced by experimental methods has been limited to the abdominal fat, and usually to the immediate neighborhood of the pancreas. The wide distribution occasionally observed in human cases, where almost the entire abdominal fat may be studded with necrotic foci, is not reproduced.

It is difficult to believe that alterations so widely disseminated and at so great a distance from the pancreas are caused by contact with its secretion, and it has been suggested that the process is not in all cases the same. Oser, in his work upon diseases of the pancreas, summarizes the result of experimental

observations: though the experiments of Hildebrand, Dettmer, Jung, and others indicate that alterations in the pancreas and in the surrounding fat are due to contact with the pancreatic secretion, this hypothesis will not explain the widely disseminated focal necroses observed not only in distant parts of the abdominal cavity but even in the subcutaneous and subpericardial fat.

Experimental Fat Necrosis.—In experiments which I have undertaken¹ it has been found possible to produce focal necrosis of the fat-tissue as wide-spread as that observed in human cases and in lower animals. They show that complete obstruction to the outflow of the pancreatic secretion may cause, after the lapse of several weeks, necrosis of the fat in parts far distant from the pancreas.

Both pancreatic ducts were ligated in two places and cut between the ligatures. In the cat, which was used for these experiments, the main duct enters the duodenum with the common bile duct and is readily found. By carefully separating the pancreas from the duodenum the smaller duct may be exposed, penetrating the intestine about one centimetre below and somewhat to the left of the larger. The operation ne-

¹ Contributions to the Science of Medicine, dedicated to William H. Welch, Johns Hopkins Hospital Reports, 1900, ix. 859. The experiments to be quoted are designated by the numbers used in this article.

cessitates little or no injury to the substance of the gland. In several instances, in order to facilitate the penetration of the secretion into the fat-tissue, the right border of the omentum near its gastric attachment was drawn through the opening made by separating the pancreas from the duodenum. The more successful experiments will be described in detail.

EXPERIMENT I.—A full-grown cat, of which the pancreatic ducts were ligated, died at the end of twenty-five days. The subcutaneous fat over the lower half of the abdomen and in front of the symphysis pubis is profusely studded with conspicuous opaque, white foci of irregular shape, often two millimetres in diameter. On opening the abdominal cavity, which contains a small quantity of turbid, yellowish-white fluid, the omentum presents itself as an almost homogeneous mass of opaque, white, slightly friable material. Its right border is adherent over that part of the pancreas which was separated from the duodenum at the time of operation, and therefore covers the distal ends of the ligated ducts. The fat of the mesentery of both the small and large intestines is converted into the same opaque, white material and the perirenal fat, the retroperitoneal fat, and masses in the pelvis on either side of the bladder show in large part the same transformation. Below the peritoneum of the diaphragm and of the lateral abdominal walls are numerous slightly raised areas of similar appearance. The pericardial cavity contains no excess of fluid. The greater part of the fat in the parietal layer of the pericardium is of normal translucent appearance, but on the right side are several conspicuous areas of opaque, white color, irregular in shape and about two millimetres across. Along the carotid and left subclavian arteries are several similar foci. The pancreas, of which the duodenal part is embedded in a homogeneous mass of

transformed fat, is fairly soft in consistence, though apparently much smaller than usual. A culture on agar-agar from the peritoneal exudate remained sterile. Microscopic examination of stained sections made from the opaque, white fat of the omentum, subcutaneous tissue, and pericardium demonstrates the histological characteristics of fat necrosis. The omentum is not wholly transformed, as it appears to be upon macroscopic examination, but about its blood-vessels is intact tissue. Between the necrotic material and the unchanged fat is usually seen a well-marked zone of cell-proliferation. The pancreas shows a moderate increase of its interstitial tissue.

EXPERIMENT II.—The pancreatic ducts of a full-grown cat were ligated in two places and cut between the ligatures. In exposing the ducts the pancreas was separated from the duodenum for a distance of about four centimetres. The right margin of the omentum was drawn through the opening thus made and fixed by several silk sutures over the distal ends of the severed ducts. The animal died twenty days after the operation. On dissecting back the skin from the abdomen and flanks the subcutaneous tissue is found to contain conspicuous opaque, white areas, the largest of which are about two millimetres in diameter. The fat in front of the symphysis pubis is studded with minute areas of similar appearance. The peritoneal cavity contains turbid fluid. The omentum is transformed into an almost homogeneous mass of opaque, white material, which is somewhat friable in consistence. The mesenteric fat of the small and large intestines is very thickly studded with large, conspicuous, opaque, white areas. The retroperitoneal fat is in large part opaque and white, and upon the surface of the diaphragm are numerous foci of similar character. In the parietal layer of the pericardium are several very conspicuous areas of fat necrosis. The pancreas is of small size and firmer than usual.

Stained coverslip preparations made from the peritoneal exudate

contain numerous desquamated endothelial cells, but leucocytes are almost completely absent, and bacteria are not discoverable. A small piece of omentum and a bit of subcutaneous fat containing opaque foci were tested for the presence of a fat-splitting ferment, and well-marked reactions were obtained.

In these experiments necrosis involving almost the entire omental fat, the greater part of that of the mesentery, and to less extent the fat-tissue below the parietal peritoneum of the perirenal region, the lateral abdominal walls, and the diaphragm, the fat of the subcutaneous tissue and of the pericardium has followed the ligation of both pancreatic ducts. Obstruction to the outflow of the pancreatic secretion causes its diffusion into the surrounding tissue. Although no colored constituent, like the pigment of the bile, makes the pancreatic secretion evident to the eye, its presence is shown by the injurious effects which it has upon the tissues. Jaundice is the index of hepatic obstruction, while fat necrosis indicates obstruction of the pancreatic ducts. In accordance with this relationship to the pancreas, we find that changes in the fat-tissue are most marked in the neighborhood of the organ, while in more distant parts, which may be reached by gradual diffusion through continuous layers of connective tissue, the process is much less extensive.

A fat-splitting ferment, presumably that of the pancreatic juice, has been shown by the method practised by Flexner to be present in the distant foci of the

subcutaneous tissue, as well as in the necrotic fat adjacent to the pancreas.

In the first experiment the animal died at the end of twenty-five days ; in the second, in which the lesion was somewhat less extensive, in twenty days. In four subsequent experiments the animal survived a shorter time, and presumably less opportunity was afforded for the diffusion of the secretion. The distribution of necrosis was much less extensive and was confined to the fat in close proximity to the pancreas.

Disseminated necrosis does not constantly follow ligation of the pancreatic ducts, and in three experiments foci of necrosis were not demonstrable after death. One of these animals survived the operation only twenty-four hours, and the minute yellowish-white areas which were seen about the site of operation and in the omentum near by, proved on microscopical examination to be small collections of leucocytes, which elsewhere were diffusely scattered through the tissue. In another experiment, in which the ducts were ligated and cut and the mesentery fixed over their distal ends, no necroses were found at the end of two days. A third cat, of which the ducts were ligated but not covered by the omentum, survived twenty-five days, and no foci of fat necrosis were found at autopsy ; the pancreas was diminished in size and firm in consistence and the main duct was markedly dilated. Microscopic examination demonstrated the presence of advanced

chronic interstitial inflammation. It is possible that induration of the interstitial tissue consequent upon chronic inflammation may retard the diffusion of the obstructed secretion.

In the experiments, in which widely disseminated necrosis followed ligation of the ducts, the animal survived, one, twenty, the other, twenty-five days; while in several instances, in which the animal lived a shorter time, less extensive necrosis resulted. These facts may be explained by assuming a gradual diffusion of the pancreatic secretion. If such be the case, stimulation of the secreting activity of the gland after ligation of its ducts will hasten the diffusion and more rapidly cause necrosis in parts distant from the organ. In order to test this hypothesis, pilocarpin, which has been shown by Heidenhain, Gottlieb, and others to stimulate pancreatic secretion, was administered to an animal of which the ducts had been ligated.

EXPERIMENT X.—The pancreatic ducts of a full-grown cat were isolated, and each was bound by a single silk ligature; the ducts were not cut. Pilocarpin muriate (0.005 gramme) was injected subcutaneously on the following day at 12 M., and again at 2 P.M.; two days later the same dose was repeated at 2 P.M. On the following day, at 11 A.M., the animal was found dead. The omentum is studded throughout with conspicuous opaque, white areas; along the right border near the stomach they are confluent, and involve almost the whole surface (see Fig. 13). Similar areas are thickly scattered in the duodenal mesentery near the pancreas, and in the mesentery of the small and large intestine. The retroperitoneal tissue, par-

ticularly on the right side, presents large superficial areas of the same character, while in the subperitoneal tissue upon the surface of the diaphragm and in the intermuscular septa of the abdominal wall opaque areas are conspicuous. In the anterior and right wall of the parietal pericardium are scattered opaque, white foci about two millimetres in diameter. The pancreas is firm in consistence.

Control.—The operation performed upon the preceding animal was repeated on a well-grown cat, which was killed at the end of four days; pilocarpin was not administered. Minute opaque, white areas are present in the neighborhood of the ligated ducts, in the omentum near the pyloric end of the stomach, and in the mesentery, but are confined to the immediate neighborhood of the pancreas.

When the ducts of the pancreas are ligated and cut, two possible methods by which its secretion may penetrate into the surrounding adipose tissue suggest themselves: (*a*) dammed back upon the gland, when the pressure within the duct has reached a certain height, the secretion may be forced through the substance of the organ into the tissues about; and (*b*) should the duct rupture at the point where the ligature is applied, it may be poured directly into the neighboring tissue. In several of the experiments cited above, the ligatures applied to the distal cut ends were found surrounded by necrotic fat, lying in softened material, from which they were readily removed. The distribution of the lesion, which is most intense in the peripancreatic tissue and in the neighboring omentum and mesentery, indicates that fat necrosis is not caused by pancreatic secretion

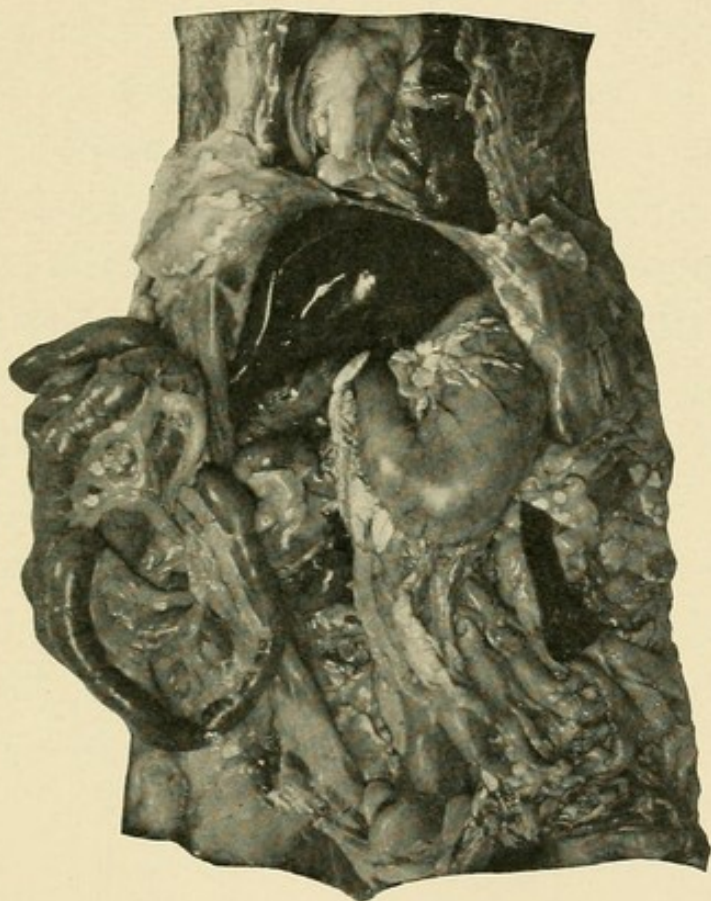



FIG. 13.—Experimental fat necrosis; administration of pilocarpin after ligation of the pancreatic ducts. Foci of necrosis in the omental and mesenteric fat, in fat below the parietal peritoneum and in fat of the parietal pericardium (Experiment X.).



poured directly into the peritoneal cavity. If such were the case, we would expect a more generalized dissemination of the foci. Similar objections are applicable to the conclusions of Milisch, previously referred to.

In order to test the ability of the fully-formed pancreatic juice to produce fat necrosis when injected into fat-tissue, an attempt was made to cause the secretion to escape directly from the gland into the subcutaneous fat. To accomplish this object the following operation was performed: An incision was made through the abdominal wall in the median line below the sternum. Over a small area to the left of the incision the skin and subcutaneous fat were dissected from the underlying rectus muscle; through the muscle was made a short opening parallel to the median line and about one and a half centimetres from it. The pancreatic ducts were ligated in two places and cut between the ligatures, and the pancreas was dissected free from the duodenum. It was now possible to bring the duodenal part of the pancreas bearing the distal ends of the severed ducts through the opening in the rectus muscle. A few silk sutures between the muscle and gland retained the latter in such position that the subcutaneous fat covered the ends of the ducts. The abdominal wound in the median line was closed and the ligatured ends of the ducts now lay in contact with the subcutaneous fat. The previous experiments have shown that in many instances the ligature in time ceases to bind

the duct, and is found loose in the tissue ; but before this had taken place opportunity was afforded for the partial healing of the abdominal wound, so that the secretion, finally escaping, was poured into the subcutaneous fat.

The operation was performed upon three animals. In two instances suppuration of the abdominal wound ensued and no necrosis of fat resulted.

EXPERIMENT XIII.—The operation previously described was performed upon a full-grown cat. The animal, which became much emaciated, died twenty-seven days later. Opposite the transplanted pancreas is a cavity in the subcutaneous tissue undermining the skin for a considerable distance to the left of the median line and containing thick, viscid material, which microscopically shows fat-globules in abundance, but no leucocytes. The cavity has broken through the skin at a point opposite the pancreas. The tissue forming its wall is very thickly studded with irregular, opaque, white areas, which in many places are confluent, forming masses of homogeneously necrotic fat. Foci of fat necrosis are widely scattered in the subcutaneous tissue on the left side over the thorax and over the abdominal wall, where they are most abundant opposite the above-mentioned cavity. The pancreas is diminished in size and firm in consistence.

A section for microscopic examination was made through the wall of the cavity in the subcutaneous tissue. Here and there are groups of necrotic fat-cells, representing usually an entire lobule. The outlines of the cells are for the most part well preserved, and about the foci of necrosis is a zone of newly-formed cells closely packed together. Sections of the subcutaneous tissue, at a considerable distance from the cavity, contain similar areas of fat necrosis.

The foregoing experiments show that, by causing the entire pancreatic secretion of the cat to penetrate into the tissue about the pancreas, wide-spread necrosis of the fat, not only of the abdomen, but of the subcutaneous tissue and of the pericardium as well, may result, thus reproducing the wide-spread dissemination observed in man. The extent of the process is dependent upon the gradual diffusion of the fat-splitting ferment, and corresponds in some degree with the length of time which the animal has survived the operation; stimulation of the secreting activity of the gland hastens this diffusion.

By the methods of experimentation employed, but little injury is done to the substance of the gland and no disturbance of its circulation results. Hildebrand has suggested that obstruction to the venous circulation, preventing the absorption by the blood of pancreatic secretion which has found its way into the tissues, may favor the production of fat necrosis. The wide-spread necrosis produced by mere ligation of the ducts indicates that disturbances of the circulation play but little part in the process. It is, however, by no means improbable that pancreatic ferments free in the tissue are in part absorbed and, it may be, destroyed. Katz and Winkler, as already mentioned, conclude from their experiments that hemorrhagic infiltration or local ischæmia, by lowering the resistance of the tissue, are factors in the production of focal necroses. The ab-

sence of these conditions in the preceding experiments shows that they are at least not essential.

It is well known that chronic interstitial pancreatitis is produced by occlusion of the pancreatic duct ; and in those instances in which the animal survived the operation four or five days this change was evident. That it is not a factor essential to the production of fat necrosis is shown by its absence in one experiment in which, though the animal lived but twenty-four hours after ligation of the ducts, numerous small foci of necrosis were present. It was not observed, moreover, at the end of four days after ligating the ducts and injecting pilocarpin, though, as already described, very widely disseminated focal necrosis resulted. In one before mentioned experiment the animal died twenty-five days after ligation of the ducts, and, though advanced chronic interstitial inflammation resulted, fat necrosis was absent. Indeed, it is not improbable that chronic inflammatory changes following duct-obstruction tend to limit dissemination of fat necrosis by retarding diffusion of the pancreatic ferments.

Application of Experimental Observations.—Conditions resembling in greater or less degree those of the foregoing experiments are at times associated with focal fat necrosis in human subjects. Obstruction of the duct of Wirsung has in a number of cases been accompanied by necrosis of fat, though, as a rule, lesions of the parenchyma secondary to duct ob-

struction have also been present. Dieckhoff records such a case in which the widened duct was filled with concretions and the gland was the seat of purulent inflammation. In an autopsy performed by Dr. Welch in the pathological laboratory of the Johns Hopkins Hospital small foci of peripancreatic fat necrosis were associated with occlusion of the pancreatic duct by numerous calculi; the gland was the seat of chronic inflammation. Williams records a similar case. Carcinoma of the head of the pancreas occluding the common bile duct—and presumably the duct of Wirsung as well—was in a case of Katz and Winkler accompanied by focal fat necrosis.

Dieckhoff describes a case of cholelithiasis in which a gall-stone was found lodged in the duct of Wirsung; and about the pancreas, which microscopic examination showed to be the seat of purulent inflammation, were foci of fat necrosis. In several instances gall-stones have been found lodged in the ampulla of Vater, partially or completely closing the main pancreatic duct; and though the size of the stone or anatomical peculiarities of the diverticulum have prevented the occurrence of hemorrhagic pancreatitis, foci of fat necrosis have been produced. Of especial interest are the cases reported by Flexner and by Fraenkel, in which, though disseminated fat necrosis was present, no lesion of the pancreas was recorded. In the case of Fraenkel a gall-stone was lodged in the ampulla of Vater, while in

that of Flexner gall-stones were present in the common bile duct near its termination. In these cases there can be little doubt that a gall-stone compressed the pancreatic duct. Temporary presence of a large calculus in the same position would have a similar effect; and in the following case fat necrosis was found near the pancreas, though the stone which had produced the lesion had made its way into the intestine and was lost.

CASE IV.—Woman, aged fifty years. *Anatomical Diagnosis.*—Cholelithiasis, calculi in the gall-bladder, cystic, hepatic, and common ducts. Adenocarcinoma of the gall-bladder. Jaundice. Chronic interstitial pancreatitis. Peripancreatic fat necrosis.

The much-contracted gall-bladder and the hepatic and cystic ducts are filled with faceted calculi. The common bile duct contains two stones, each about one centimetre in diameter, but none are present near its termination, where the wall is somewhat thickened and fibrous. The pancreas is the seat of chronic interstitial inflammation, and foci of fat necrosis occur in the neighborhood of the gland.

Both inflammation of the pancreas and necrosis of fat were doubtless due to the passage of one or more calculi through the diverticulum of Vater, and were the result of duct-obstruction.

The not infrequent association of fat necrosis and chronic interstitial pancreatitis admits a similar explanation. In two cases to be cited in discussing chronic interstitial pancreatitis both conditions occur, but are

unaccompanied by any obstruction of the large ducts. The presence of newly-formed contracting fibrous tissue affords abundant opportunity for constriction of the smaller ducts. In one of these cases many such ducts were on microscopic examination found widely dilated and filled with stagnant secretion. Local obstruction to the outflow of the pancreatic secretion doubtless causes its diffusion into the adjacent fat, thus producing foci of necrosis; but, as I have mentioned before, induration of the interstitial tissue probably tends to inhibit dissemination of the lesion.

In some of the foregoing experiments, as I have pointed out, it is probable that the pancreatic secretion passes directly from the duct into the surrounding tissue, this being notably true in the experiment in which the duct-ends were transplanted into the subcutaneous fat. Somewhat similar conditions have occasionally been observed in human cases. Necrosis of the pancreatic tissue has in certain instances, as in those described by Chiari, Fraenkel, and Körte, caused such disintegration of the organ that the ruptured duct communicated directly with the cavity of the bursa omentalis, in which the pancreas lay. Fat necrosis was present in the wall of the cavity, and was widely distributed in the abdominal fat. The remarkable case of Chiari, in which the pericardial and subpleural fat contained foci of necrosis, belongs to this group.

In the majority of cases fat necrosis is associated with hemorrhagic pancreatitis or with its sequel, so-called gangrenous pancreatitis. Experimental hemorrhagic inflammation produced by injecting into the organ a variety of substances, of which the common characteristic is an ability to injure the parenchyma of the gland, is accompanied by disseminated fat necrosis. Here fat necrosis is the result of a lesion which permits diffusion of pancreatic secretion from the injured parenchyma into the surrounding tissue. A similar explanation is applicable to the human cases. Where hemorrhagic pancreatitis is caused by a small calculus lodged in the diverticulum of Vater, an additional factor is involved. Since the calculus occludes the duodenal orifice of the duct, secretion from uninjured parts of the gland is dammed back, and its diffusion into the surrounding fat is facilitated by partial necrosis of the parenchyma.

Parapancreatic Fat Necrosis.—The not infrequent occurrence of minute foci of fat necrosis in and upon the pancreas was first noted by Balser; the condition, which may be designated parapancreatic fat necrosis, was found in five of twenty bodies which he examined. On account of their small size, seldom more than a millimetre in diameter, and their limited distribution, they are frequently overlooked, but otherwise agree in character with the lesion which, owing to its greater extent and distribution, has been designated dissemi-

nated fat necrosis. Langerhans found these minute foci of necrosis in four of twenty-eight autopsies, Kasa-hara once in eighty-three cases, Chiari twenty-three times in seventy-five autopsies, Williams eight times in one hundred. The change has been thought to occur unassociated with lesions of the pancreas. Langerhans believed that it might result from post-mortem action of the pancreatic juice; and in support of this suggestion Williams states that the pancreatic cells near the areas of fat necrosis show evidence of self-digestion.

From a study of seventy-five cases, Chiari reached the conclusion that in about one-half of all subjects the pancreas at the time of death has the capability of causing digestion of its own substance. This condition of self-digestion may be observed in autopsies performed only a few hours after death, and has no relationship to putrefaction, from which it can be readily distinguished. The conditions upon which it depends are not known. Advanced self-digestion affects the entire substance of the organ, which becomes flaccid in consistence; and in sections prepared for microscopic examination nuclei are unstained, so that the tissue has a homogeneous appearance. The change affects the interstitial tissue as well as the secreting parenchyma. In many cases self-digestion is limited to small areas. When the organ undergoes putrefaction, nuclear substance, on the contrary, is not dissolved, but, being

fragmented, appears as fine particles scattered throughout the tissue ; bacteria can be readily found.

The frequent occurrence of advanced self-digestion of the pancreas, unaccompanied by any evidence of fat necrosis, shows that post-mortem contact with the pancreatic ferments is insufficient to produce the change. When, moreover, fat removed from the body is exposed to the action of pancreatic tissue, alterations comparable to those associated with this form of necrosis do not occur.

Chiari believes that self-digestion of the pancreas so frequently observed at autopsy may set in shortly before death, occurring as an ante-mortem or agonal change. Extravasation of blood into the partially digested tissue can occur, he thinks, only before death, and when present gives evidence that self-digestion has begun ante-mortem. Partial destruction of the parenchyma would thus afford opportunity for diffusion of fat-splitting ferment into the surrounding fat. Under such conditions it appears probable that fat necrosis might occur, and in the following instance the lesion accompanied self-digestion associated with multiple hemorrhages.

CASE V.—Man, aged fifty-three years. *Anatomical Diagnosis.*—Emphysema of the lungs ; hypertrophy of the right side of the heart ; chronic passive congestion of the viscera ; self-digestion of the pancreas, with multiple ecchymoses ; parapancreatic fat necrosis.

The pancreas is very soft, and in the interstitial tissue are scat-

tered ecchymoses. Upon the surface of the organ occur very small, opaque, yellow foci of fat necrosis. Microscopic examination shows the existence of advanced self-digestion, with hemorrhage here and there into the interstitial tissue.

Where parapancreatic fat necrosis occurs, microscopic examination of the pancreas may demonstrate the presence of a well-marked lesion previously unobserved by the naked eye. It has been mentioned that foci of fat necrosis more or less disseminated may accompany chronic interstitial pancreatitis, and are doubtless the result of local duct-obstruction. Similar foci limited to the pancreas may be so minute that they deserve the designation parapancreatic. Cases XI. and XIII., to be described later, are examples of this condition.

In other instances it is not improbable that minute foci of necrosis follow duct-obstruction, which presumably has occurred only a few hours before death. In several cases which I have examined the pancreatic duct has been filled with a very viscid secretion containing numerous desquamated cells. It appears that the pancreatic secretion shortly before death has undergone a change, in consequence of which it flows with much difficulty. Stagnation and slight diffusion of the products of secretion are probably responsible for the insignificant fat necrosis which occurs. The following case illustrates this condition :

CASE VI.—Woman, aged fifty years. *Anatomical Diagnosis.*—Chronic nephritis; large red kidneys. Hypertrophy and dilatation of the heart; general anasarca. Parapancreatic fat necrosis.

The pancreas is firm and apparently normal. In the fat, upon its surface, and in the interstitial tissue are small, conspicuous, opaque, white areas of necrosis. The duct of Wirsung is filled with very viscid, pearly-white, semifluid material, which, examined microscopically, contains columnar epithelial cells in great quantity.

The parapancreatic foci of fat necrosis so frequently observed at autopsy are referable to a variety of conditions,—for example, to chronic inflammation of the pancreas, to partial duct-occlusion, and with much probability to other causes, among which agonal self-digestion of the pancreas has a place. Nevertheless, in its essential features the lesion resembles more widely distributed necrosis, and is doubtless produced by the penetration of the fat-splitting ferment of the pancreatic juice into living adipose tissue.

CHAPTER VII.

THE VARIETIES OF CHRONIC INTERSTITIAL PANCREATITIS.

THE causes and varieties of chronic interstitial pancreatitis have been little studied, and slight attention has been given to the classification of various types. The lesion is seldom associated with such definite symptoms that it is recognizable during life, and even at autopsy the condition is frequently overlooked. Though chronic inflammation of the pancreas has not the importance of similar changes in the liver and kidneys, its relation to diabetes mellitus makes it worthy of detailed consideration. Indeed, study of the lesion has contributed important facts to the knowledge of this disease.

The etiology of interstitial inflammation is often obscure. Chronic pancreatitis is not infrequently secondary to changes in the intestine, the bile passages, and the liver. As with other glands, there is more than one path by which inflammatory irritants may reach the organ: by way of the duct, from the blood-vessels, and possibly from the lymphatic vessels. Obstruction to the outflow of the gland secretion, here as elsewhere, is followed by chronic inflammatory changes. The pancreatic duct opening with the common bile duct upon the mucous membrane of the duodenum is subject to ascending infection both from the intestine and from

the biliary passages when inflamed. Bacteria, their toxic products, and injurious substances taken as food, reaching the gland by way of the blood, may cause chronic inflammation; alcohol, syphilis, and tuberculosis are believed to produce the lesion. Alterations of the vessel walls, notably arterial sclerosis, causing grave disturbances of nutrition, are thought to have the same result.

Acute, rapidly destructive lesions of the pancreas—for example, hemorrhagic pancreatitis—affect the various elements of the gland almost simultaneously, and disintegration of greater or less extent results. When the organ is attacked by the less active irritants which produce chronic inflammation, the different histological constituents of the gland are given greater opportunity to exhibit differences in their ability to withstand the destructive process. The islands of Langerhans do not always show alterations corresponding to those which occur in the tissue about them, often persisting though the adjacent parenchyma is destroyed. Moreover, while in one variety of chronic inflammation they are but little implicated in the sclerotic process, in another they may be markedly affected. It becomes of interest, therefore, to study the relation of these bodies to the various forms of chronic pancreatitis that are distinguishable.

That form of chronic inflammation which occurs during fetal life, and is associated with other manifes-

tations of congenital syphilis, presents histological features which distinguish it from the chronic pancreatitis of adult life. It is a disease of the developing organ, and may appropriately be first considered.

Congenital Syphilitic Pancreatitis.

Birch-Hirschfeld first drew attention to the frequency with which the pancreas is affected by congenital syphilis, and described the lesion so accurately that nothing had been added to our knowledge of it until the appearance of the article of Schlesinger, who made a systematic study of the condition.

Birch-Hirschfeld found the pancreas affected in thirteen of twenty-three cases of congenital lues, but subsequent observers have found the lesion much less frequently, and, indeed, Birch-Hirschfeld, studying a second group of cases, found changes in the organ only twenty-nine times in one hundred and twenty-four syphilitic new-born. Schlesinger in six instances found the enlarged firm organ the seat of a diffuse interstitial pancreatitis characterized by proliferation of interlobular and interacinar tissue penetrating at times between the cells of the acini. This inflammatory new growth is followed, he thinks, by destruction of the parenchymatous elements, which, though they do not exhibit appearances of degeneration, atrophy and disappear. The growth of interstitial tissue, he finds, has its origin about the blood-vessels, and the arteries are the seat of

a syphilitic periarteritis, the adventitia being infiltrated with lymphoid cells. As the lesion progresses the capillary net-work about the acini disappears. Schlesinger has observed that the islands of Langerhans are neither invaded by the new growth of interstitial tissue nor implicated in the atrophy which affects the cells of the acini.

Histological details observed in two instances of congenital syphilis of the pancreas are here recorded; the relation of the islands of Langerhans to the inflammatory process is of interest.

CASE VII.—Infant, lived three hours; length of body forty centimetres. *Anatomical Diagnosis*.—Congenital syphilis; interstitial pneumonia; interstitial pancreatitis: splenic tumor; chronic perisplenitis.

Microscopic Examination of the Pancreas.—The interstitial tissue is greatly increased at the expense of the parenchyma, and the lobules, composed of a few acini, are irregularly scattered in dense cellular stroma. The smallest ducts, beset with acini along their course, terminate in a group of acini which, though much less numerous than those ordinarily forming a lobule, are of normal size, and are composed of cells showing no evidence of degeneration. The interstitial tissue between groups of lobules is very rich in cells of lymphoid and epithelioid types. Particularly numerous about the blood-vessels are cells having the characteristics of the plasma cells of Unna. Cells with eosinophilic granules are also abundant. A conspicuous feature of the histological picture is the presence of compact round masses of cells embedded in the interstitial tissue. By the character of the cells and by their arrangement in columns these structures are identified as islands of Langerhans. Though they are

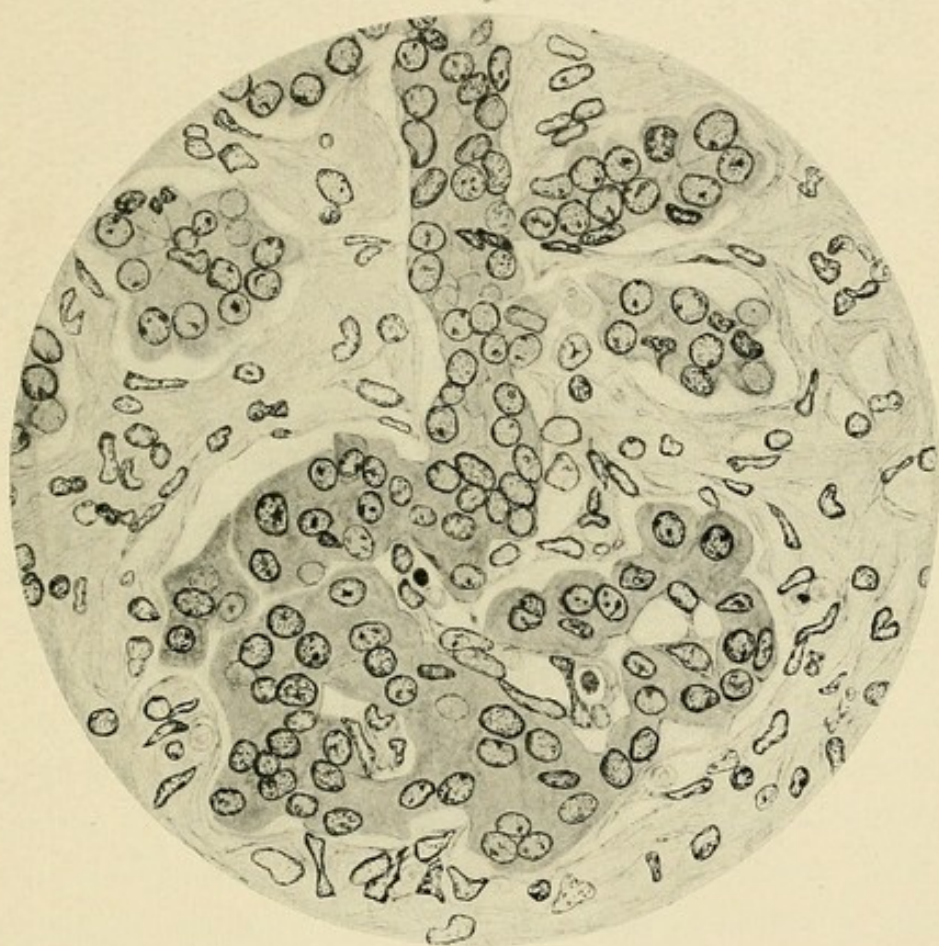



FIG. 14.—Congenital syphilitic pancreatitis (Case VII.). Showing a cell-column of an island of Langerhans in continuity with a small duct.



embedded in the stroma, which separates widely the neighboring acini, they are not invaded by the inflammatory change. At times it is demonstrable, most conveniently in serial sections, that these islands are in continuity with the ducts and acini of the gland (see Fig. 14). At the periphery of the island one of the columns projects beyond the general circular outline and is continuous with epithelial cells which, staining less brightly with eosin, are arranged about a lumen and are in turn continuous with adjacent acini. In many instances, however, an island traced through a series of sections is found completely isolated in the fibrous tissue.

CASE VIII.—Infant, lived four hours ; length of body fifty centimetres. *Anatomical Diagnosis*.—Congenital syphilis ; pemphigus neonatorum ; interstitial pneumonia ; interstitial hepatitis and pancreatitis ; splenic tumor.

Microscopic Examination of the Pancreas.—The interstitial tissue is greatly increased and the parenchyma is in great part replaced by it. The new tissue is very cellular, but the cells are for the most part of the epithelioid type, and accumulations of round cells are not found. Plasma cells and cells with eosinophilic granulations are rarely seen. The acini form small groups which may be regarded as primary lobules, though the acini composing them are much less numerous than those of a normal lobule. Islands of Langerhans are conspicuous as compact round masses of epithelial cells and are scattered abundantly throughout the organ. The fibrous tissue is often concentrically arranged about these interacinar islands, and at times they are completely isolated. Not infrequently, however, as in Case VII., they are in continuity with the neighboring acinar tissue ; a double row of cells is found to be continuous on the one hand with a cell column of the island, on the other with a small duct.

The preceding cases apparently represent different stages of the syphilitic lesion. In Case VII. prolif-

erating fixed tissue cells are very abundant, while cells, in part at least, of vascular origin—namely, plasma cells and eosinophiles—are numerous, and the condition may be interpreted as the active stage of a chronic inflammatory process. In Case VIII., though interstitial tissue is more abundant and the persistent parenchymatous elements are more scattered, cells of the lymphoid type are few in number, while plasma cells and eosinophiles are almost absent. The process here is more advanced and is no longer active.

A conspicuous feature in both cases is the presence of numerous islands of Langerhans surrounded by newly-formed stroma, but uninvaded by it. In many instances the islands are found to be in continuity with the secreting structures of the gland (Fig. 14). A cell column of the island is continuous with a small duct, which is in turn beset with acini; the lumen of the duct does not penetrate into the island, but disappears at the periphery.

Birch-Hirschfeld, finding the pancreas of the syphilitic fetus rarely affected unless it had survived the full period of uterine development, came to the conclusion that the condition has its onset during the last months of fetal life. Schlesinger, however, cites the cases of Müller and Mraczek, in which, at the fifth month of development, advanced lesion of the organ occurred, and from his own experience concludes that the pancreas may be affected as early or as late as other organs.

Since the pancreas arises as an outgrowth from the intestinal canal, development of its parenchyma takes place in a mass of mesoblastic stroma which is replaced as the growth of the gland proceeds. At an early period of development—for example, during the fifth month of fetal life—acini form small groups widely separated by embryonic connective tissue. In my two cases of syphilitic pancreatitis the parenchyma presents the appearance observed about the fifth month of development, save that the islands of Langerhans, which are inconspicuous in the undeveloped organ, are marked features in the syphilitic pancreas. In neither of the syphilitic cases was it possible to observe degenerative changes in the cells. The acini form irregular groups containing much fewer members than ordinarily compose a fetal lobule, or, as in the developing organ, form dilatations upon the sides of the small ducts.

It is probable, therefore, that the disease, like many other syphilitic lesions, is one of the interstitial tissue, and changes in the parenchyma result not so much from destruction of the parenchyma as from interference with its growth. The similarity between the syphilitic and the undeveloped organ may be thus explained. The development of the individual cell is not retarded, and islands of Langerhans are the result of an early cell-differentiation; but in many instances islands remain in continuity with the tubular

structures from which they had their origin. Often, however, the connecting strand of cells is no longer discoverable, and the interacinar islands resemble those ordinarily observed in the organ at the end of fetal development.

Chronic Pancreatitis of the Developed Organ.

Several types of chronic pancreatitis affecting the fully-developed organ have been described, and with the experimental demonstration of a relation between the pancreas and carbohydrate metabolism numerous attempts have been made to distinguish a variety of the lesion constantly associated with diabetes mellitus. A classification of these various forms of chronic inflammation based upon etiological data, though desirable, would be, with our present knowledge, as unsatisfactory as a similar classification of the varieties of hepatic cirrhosis. From an experimental study Carnot reaches the conclusion that pancreatitis may result (*a*) from mechanical cause,—for example, obstruction of the pancreatic ducts,—from the action (*b*) of toxic material, or (*c*) of micro-organisms carried to the gland by the blood, or by the lymph, or by way of the duct. Such a classification does not aid in the interpretation of lesions observed at autopsy, the etiological factors concerned being in many instances obscure.

In some examples of chronic pancreatitis fibrous tissue between the lobules is increased; in others the

interacinar tissue shows marked proliferation; occasionally individual cells are apparently separated by strands of fibrous tissue. Corresponding types of inflammation have been described as interlobular, periacinous, and monocellular.

It has been thought that the increase of interstitial tissue may have at times a constant relation to the blood-vessels or to the ducts, being due, in part at least, to proliferation of the connective tissue about these structures. Lemoine and Lannois have described perivascular interstitial pancreatitis. From a study of four cases of chronic inflammation associated with diabetes they have thought that the new growth of fibrous tissue has its origin in the walls of the blood-vessels. They find about the vessels masses of sclerotic tissue sending processes between the acini and even separating the individual cells (*sclerose unicellulaire*). G. Hoppe-Seyler has described chronic interstitial changes which he thinks are the result of arterial sclerosis. The parenchyma, he believes, undergoes degeneration as a consequence of disturbed nutrition, but no anatomical relation exists between the vessels and the newly-formed tissue. Chronic pancreatitis in a case described by Rosenthal was accompanied by what he regards as alterations of the lymph-vessels (*lymphangitis proliferans*), indicative, he thinks, of a probable syphilitic origin.

In the instances of chronic inflammation of the pancreas which have been available for my study no

constant relation has been discoverable between the newly-formed tissue and the veins, arteries, lymph-vessels, or ducts, and there is no evidence that the process had its origin about these structures.

Two types of interstitial inflammation are, however, distinguishable. On the one hand, though the sclerosis is never accurately confined to one locality, it may be conspicuous between the lobules, the intralobular or interacinar tissue being little, if at all, increased. On the other hand, the interlobular tissue may be only slightly altered, while fibrous tissue which replaces the parenchyma separates individual acini. In the first case the lobulation of the gland, which is normally obscure, becomes more conspicuous, and wide bands of sclerotic tissue separate groups of lobules. The lobules are invaded in greater or less degree by the newly-formed stroma, and often entire lobules are in process of disintegration and replacement, but the progress of the lesion has been apparently inward from the periphery of the lobule. With the second type of chronic inflammation the lobulation of the gland is not accentuated; new fibrous tissue, primarily within the lobule, has a diffuse character and a net-work of irregular fibrous strands, which vary much in thickness, contains the glandular acini in its meshes.

If chronic pancreatitis is well advanced, the organ may present gross appearances characteristic of one or other variety of interstitial inflammation. When the

interlobular tissue is the seat of predominant change, the gland is hard and dense and has a nodular or granular surface. On section the tissue has a compact, homogeneous appearance, loose areolar tissue between secondary and tertiary lobules having been replaced by scar-like sclerotic bands. When, on the other hand, there is a diffuse increase of the interacinar stroma, the organ tends to become tough rather than hard. Not infrequently, however, the pancreas affected with either variety of inflammation may be so little altered that the lesion is recognized only upon microscopic examination. Abundant fat infiltrating the newly-formed tissue between lobules or acini may obscure the gross characteristics of both types. Such fat often contains small foci of necrosis.

The two types of chronic interstitial inflammation—(a) interlobular and (b) interacinar—characterized by the primary localization of the lesion present other histological peculiarities. Of much interest is the different relation which they bear to the islands of Langerhans, and it is desirable to study separately the changes affecting these bodies in the two conditions. The cases which have been studied exhibit individual differences, and in a few instances the histological details will be briefly described.

Chronic Interlobular Pancreatitis.—Sclerosis of the pancreas, produced by obstruction of the duct, belongs to the interlobular type of chronic inflammation. Its

definite causation as well as certain histological features serve to distinguish it from inflammatory changes of which the etiology is more obscure. The pathogenesis of the lesion is not, however, clearly understood. Carnot has summarized the possible factors which have a part in its production. Retained secretion, he believes, has a toxic action upon the parenchymatous cells. Obstruction to the outflow of fluid from the ducts favors the entrance of bacteria from the duodenum. Carnot suggests, moreover, that reflex nervous stimuli, which normally reach the secreting cells, are no longer capable of exciting normal functional activity, and deprived of this influence, the cells atrophy, as do muscle fibres after section of their motor nerve.

Since the cells forming the islands of Langerhans have no communication with the ducts and take no part in producing the pancreatic juice, the possible factors mentioned would, if active, affect primarily the acini and only secondarily, if at all, the interacinar islands.

In the cases which I have studied varying degrees of atrophy and sclerosis have followed partial or complete occlusion of the pancreatic ducts. The occurrence of an active chronic inflammatory process is shown by the presence of numerous lymphoid cells, plasma cells, and eosinophiles in the interstitial tissue. The most marked increase of fibrous tissue is between the lobules, but acini with atrophied nuclei and dilated lumina are not

infrequently separated by new tissues. Islands of Langerhans, however, are completely unaltered.

The following case illustrates an advanced stage of interlobular inflammation, the consequence of duct-obstruction.

CASE IX.—The patient, a woman, aged sixty years, began about one year before her death to suffer with symptoms of obstruction in the common bile duct. At operation performed by Dr. Halsted¹ a carcinoma of the bile papilla and diverticulum of Vater was found and removed. The biliary and pancreatic ducts were transplanted into the duodenum. Subsequently an anastomosis was made between the gall-bladder and duodenum.

Anatomical Diagnosis.—Recurrent carcinoma of the duodenum; metastases in the liver; occlusion of the pancreatic duct; chronic interstitial pancreatitis; biliary fistula.

Pancreas.—On the left lateral wall of the duodenum is a crater-like ulcer with raised edges abutting upon the head of the pancreas. The pancreatic duct is included in the carcinomatous tissue at the base of the ulcer. The duct is greatly dilated and the pancreas is small and sclerotic.

Microscopic Examination.—The parenchyma of the head and body has been almost completely replaced by dense fibrous tissue which contains fat in considerable quantity. Small isolated masses of glandular tissue still persist and are subdivided into lobules by penetrating strands of fibrous tissue. The stroma is in great part very dense and poor in cells. The small ducts are dilated. The persistent glandular tissue is in part normal in appearance, but in other situations is undergoing disintegration, so that the connective

¹The history of this case is described by Dr. Halsted in the "Bulletin of the Johns Hopkins Hospital," 1900, xi. 4.

tissue not infrequently marks out areas which correspond apparently to lobules, but contain only a few atrophied acini composed of flattened cells about a dilated lumen. Here the inflammatory process is active; the connective tissue separating the atrophic acini is very cellular and contains many lymphoid cells, plasma cells, and eosinophiles.

Islands of Langerhans, more abundant in the tail and body than in the head, are almost unaltered, and are not invaded by the newly-formed fibrous tissue which surrounds them and isolates the much changed acini (see Fig. 15). About an unaltered island may be found only a few acini to indicate that it was formerly embedded in the parenchyma, while elsewhere in the dense fibrous bands are seen isolated structures of which the cells do not differ in character or arrangement from those of the interacinar islets. Such islands, though surrounded by sclerotic tissue, are not invaded by it, and their cells, which are normal in appearance, form columns separated by delicate capillary vessels.

These isolated islands, however, finally undergo degenerative changes. They may be diminished in size and distorted. The cells, particularly at the periphery, crowded together, become smaller, and their nuclei, also smaller than usual, are often irregular in shape and stain deeply. Further changes are followed with difficulty, since the much altered groups of cells are hardly recognizable as islands of Langerhans. Small groups of epithelial cells, separated by strands of connective tissue, probably represent a late stage of atrophy and precede their final disappearance and replacement by fibrous tissue.

When advanced chronic pancreatitis has followed obstruction of the ducts, the organ is densely sclerotic, glandular tissue having been replaced in very large part by fibrous stroma. Small masses of relatively well-

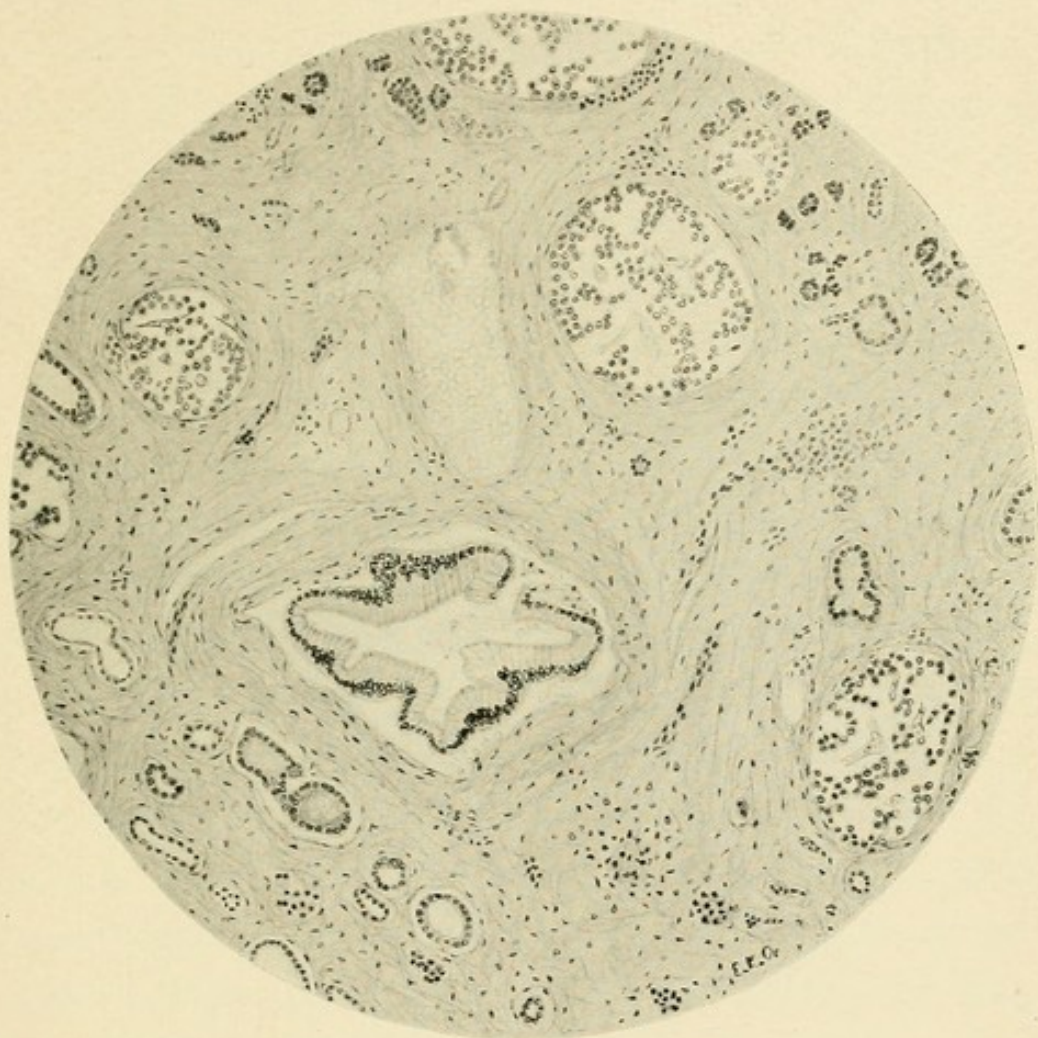



FIG. 15.—Chronic interstitial pancreatitis following duct-obstruction (Case IX.), showing islands of Langerhans unchanged though embedded in sclerotic tissue.



preserved parenchyma, little if at all invaded, are embedded in fibrous tissue which contains almost no epithelial elements.

Areas are seen where disintegration of the glandular substance is in active progress, and here lymphoid cells are present in large numbers. A striking feature of the process is the abundance of plasma cells of Unna, with which are many cells containing eosinophilic granulations. The scattered acini show the atrophic changes previously described. The islands of Langerhans which occur in this altered glandular tissue are unchanged, and, even though the neighboring acini are widely separated by inflammatory new-growth, are uninvaded (see Fig. 15). The secreting tissue about them finally disappears, and they remain completely isolated in the stroma, not infrequently the only vestiges of parenchymatous tissue in wide sclerotic bands. In a section from such an area these isolated islands of Langerhans may be very numerous; and since the sclerotic tissue occupies less space than the acini which it has replaced, they appear to be much more abundant than in the normal glandular parenchyma.

In animals, after experimental ligation of the ducts, the islands of Langerhans show the same resistance observed in human cases. Schulze tied a ligature tightly about the pancreas in guinea-pigs, and found that, though the secreting parenchyma distal to the ligature underwent inflammatory atrophy, islands of Langer-

hans persisted unaltered in the newly-formed stroma. Ssobolew, in a large number of experiments performed on rabbits, dogs, and cats, obtained similar results. In the pancreas of a rabbit which lived four hundred days after operation, fibrous stroma about the pancreatic duct contained, he states, only islands of Langerhans.

As it is improbable that the vessels supplying the islands with blood remain unchanged in the indurated stroma, it can hardly be doubted that the nutrition of their cells suffers. The new tissue, growing older, apparently contracts and compresses them; their cells become smaller, the nuclei are small, irregular, and stain deeply. Such interacinar islands finally disappear, being replaced by fibrous tissue, which may contain an occasional isolated group of much atrophied cells, or may be completely devoid of these structures.

The islands of Langerhans resist the sclerotic process which follows the damming back of secretion upon the gland, and finally suffer only when the acini are almost entirely destroyed and replaced by dense scar-like tissue. Not concerned in the production of the pancreatic juice, they are not exposed to its injurious action when its outflow is obstructed. The changes which completely isolated islands finally undergo are, it appears, due to compression by the contracting scar-like tissue in which they are embedded and to alterations of their blood-vessels. Doubtless the rich vascular system of the parenchyma is in large part obliterated

when the acini are replaced by interstitial tissue, and consequently the net-work of vessels within the island, which freely anastomose with the adjacent capillaries, is, as the process advances, less freely supplied with blood.

Chronic interlobular pancreatitis may be the result of some condition other than duct-obstruction. Ascending infection along the pancreatic duct is associated with alterations similar to those just described, but the lesion is usually less severe; and though wide interlobular bands separate relatively well-preserved lobules and groups of lobules, the parenchyma is subject to less wide-spread destruction. Nevertheless, secreting acini in places atrophy and disappear, but the islands of Langerhans maintain to the process the same relation which is observable when the lesion follows occlusion of the duct. Though the neighboring acini have undergone marked degenerative changes, the islands of Langerhans are unaltered. Here, also, anatomical peculiarities serve to explain their greater resistance to the inflammatory process: (1) Their vascular supply is richer than that of the adjacent acini. (2) Since the ducts do not penetrate them, they are less exposed to the action of irritants which reach the gland by way of the duct. (3) Since the islands of Langerhans are situated within the lobules and frequently near their centre, they are protected from a lesion which progresses from the periphery inward.

Chronic Interacinar Pancreatitis.—The type of pancreatitis which may be conveniently designated “interacinar” is characterized by the presence of newly-formed tissue within the lobules. The lesion is diffuse but somewhat irregular in distribution; at one point there may be thickening of the connective-tissue network supporting the acini, while elsewhere occur compact bands or small masses of stroma. Though the interlobular tissue is not unaffected by the inflammatory change, its proliferation is not a constant feature of the histological picture. The lobulation of the gland is not accentuated, as with the interlobular type, but, on the contrary, is obscured, since masses and strands of new tissue within the lobules make inconspicuous the interlobular boundaries. This type is much less common than the perilobular form, and has occurred in only nine of my thirty cases. One of these was associated with the condition of general pigmentation to which von Recklinghausen gave the name hæmochromatosis, and, differing slightly from the other cases, it will be considered subsequently. The following cases exemplify the lesion :

CASE X.—*Clinical History.*—The patient, a man aged forty-nine years, gave no history of alcoholic excess. The present illness began twenty months before death with polyuria. Much weight had been lost. A year and a half before death the spleen was palpable, and hæmatemesis occurred at intervals. At this time the urine contained 3.5 to 3.8 per cent. of sugar. The patient was

readmitted to the hospital four days before his death with ascites and dilated superficial abdominal veins. The urine contained 2.5 per cent. of sugar.

Anatomical Diagnosis.—Chronic interstitial pancreatitis; cirrhosis of the liver. Thrombosis of the portal, splenic, and mesenteric veins; hemorrhagic infarction of the intestine. Acute serofibrinous and purulent peritonitis; acute splenic tumor.

Pancreas.—The organ is small and firm in consistence.

Microscopic Examination.—The interstitial tissue is greatly increased and is richly infiltrated with fat. Almost every acinus is in greater or less degree surrounded by fibrous tissue, but the lobulation of the parenchyma is not more distinct than usual. In many places the glandular tissue of a limited area is almost completely replaced, being represented only by widely separated atrophic acini. The new growth of tissue, which is often conspicuous about the ducts and blood-vessels, bears no constant relation to these structures.

Islands of Langerhans are very abundant, and are sharply outlined by fibrous tissue, concentrically arranged, which forms coarse capsules, separating them from adjacent acini. There is, moreover, proliferation of the connective tissue within them; along the capillaries irregularly spindle-shaped nuclei are more numerous than usual, and there is an increased amount of fibrillated material. The cells of the islands are often very small, and their nuclei, diminished in size, stain deeply; they are closely packed together to form wide, irregular columns. Not infrequently the interacinar fibrous tissue is much more abundant in the immediate neighborhood of the islands than elsewhere, and here forms a close net-work of coarse strands with small meshes containing atrophied acini.

CASE XI.—*Clinical History.*—The patient, a man, aged forty-seven years, has used alcohol in excess. His health has been good until six months before death. For three months symptoms of diabetes mellitus have been present. The body weight has been fairly

well retained. The patient was in the hospital five days preceding his death, during which time the urine contained from 0.6 to 2.5 per cent. of sugar; acetone was present. He was dull, drowsy, and at times delirious.

Anatomical Diagnosis.—Chronic interstitial pancreatitis; cirrhosis of the liver; chronic passive congestion of the spleen; ascites. Parapancreatic fat necrosis. Arterial sclerosis; gangrene of the leg.

Pancreas.—The organ, weighing one hundred and eight grammes, is firm, particularly at its splenic end. Here lobulation is obscured and the texture of the glandular tissue is compact. In the fat within and about the organ are small, opaque, yellowish-white areas.

Microscopic Examination.—Throughout the organ there is an abundant diffuse new growth of interstitial tissue between the individual acini. The new tissue is poor in cells, and consists in great part of white fibres loosely packed together. In the meshes of the irregular net-work which it forms lie acini, or small groups of acini, which are often atrophic in appearance. Acini of large size, containing many centro-acinar cells, are seen.

Islands of Langerhans are abundant in the tail, and are of large size. They are frequently surrounded by a thick capsule of fibrous tissue, and are invaded by the new tissue, which often forms coarse ingrowths along their capillaries (see Fig. 16). Though all the islands are surrounded by dense sclerotic tissue, some are only slightly invaded. Where marked thickening occurs about their capillary vessels, the epithelial cells are diminished in size and are closely packed together; the nuclei are small and stain deeply.

While with the interlobular type of chronic interstitial inflammation the islands of Langerhans are unaffected by the sclerosis and show changes only when the lesion has reached a very advanced stage, in the cases just recorded a new growth of tissue within the lobules and

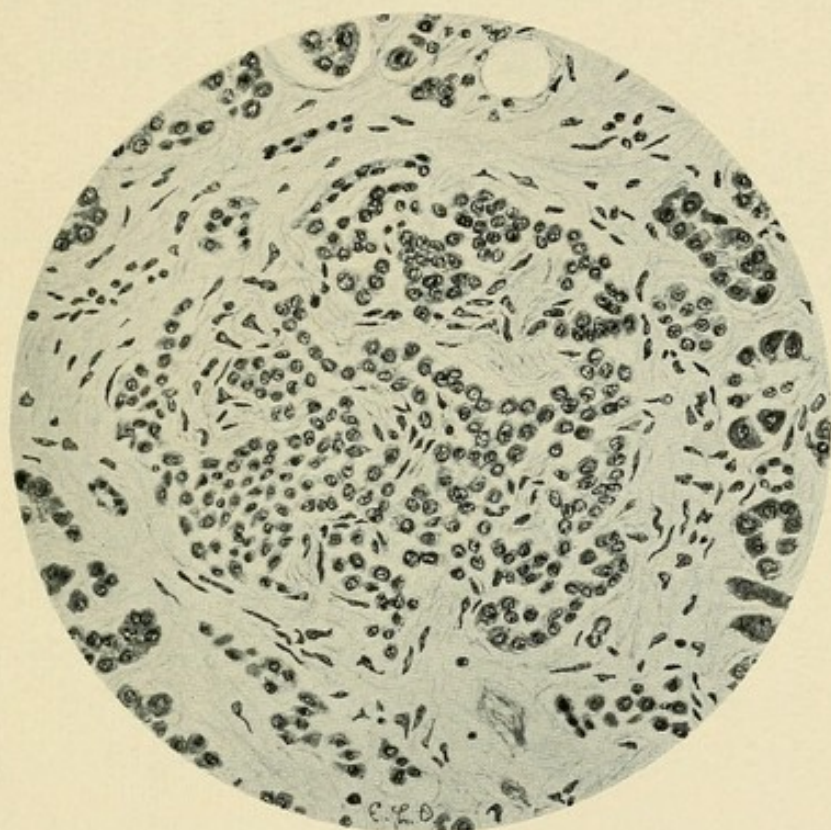


FIG. 16.—Chronic interstitial pancreatitis of interacinar type (Case XI.), showing the invasion of an island of Langerhans by the inflammatory process.

between the acini invades the interacinar islands. The latter are almost constantly surrounded by fibrous tissue, which forms, as it were, a capsule separating them from adjacent acini, which are themselves abnormally separated from one another. About the capillaries of the island there is a proliferation of interstitial tissue forming coarse strands between the columns of cells.

With chronic pancreatitis of the interlobular type proliferation of interstitial tissue occasionally occurs between the acini, but is usually confined to the periphery of the lobule. The islands of Langerhans, situated in the midst of the secreting tissue, often near the centre of more or less clearly defined lobules, are surrounded by the least changed acini. With the interacinar type of sclerosis the condition is different; in the immediate neighborhood of the island may be found the greatest proliferation of stroma, and the acini, separated from it and from one another by coarse strands of white fibrous tissue, are then more atrophic than those at a greater distance. When the inflammatory process affects primarily the periphery of the lobule and progresses towards the centre, the islands are affected only when the lesion is very advanced; but when the change occurs diffusely within the lobule, all parts are equally affected, and the islands suffer in common with the acini. Indeed, it often appears that the favorite seat of the lesion is the immediate neighborhood of these bodies.

CHAPTER VIII.

THE ETIOLOGY OF CHRONIC INTERSTITIAL PANCREATITIS.

ELSEWHERE I have classified cases of chronic interstitial pancreatitis studied in the pathological laboratory of the Johns Hopkins Hospital.¹ Clinical records were obtainable, and in every instance material was preserved for microscopic examination. Of thirty cases, including one not previously considered, seventeen occurred in males and thirteen in females. The age of the affected individuals was as follows :

10 to 20 years	1 case.
20 to 30 years	2 cases.
30 to 40 years	2 cases.
40 to 50 years	9 cases.
50 to 60 years	11 cases.
60 to 70 years	3 cases.
70 to 80 years	2 cases.

Twenty cases, more than two-thirds the total number, occurred between the ages of forty and sixty years.

¹ "The Causes and Varieties of Chronic Interstitial Inflammation," American Journal of the Medical Sciences, June, 1902. Twenty-nine cases of chronic pancreatitis are described; an additional case has been added to the series. In the present chapter occur numerous quotations from this article.

Obstruction of the Pancreatic Ducts.—In ten cases chronic interlobular pancreatitis was the result of duct-obstruction. Ligation of the duct in animals is followed by chronic inflammation; in human cases partial or complete occlusion may be caused by pancreatic calculi within the duct of Wirsung, by biliary calculi within the adjacent terminal part of the common bile duct, or by new growths, usually carcinomata, compressing or invading the gland. The irritant action of retained secretion, and in many cases, at least, associated infection of the obstructed duct, are doubtless concerned in producing the resultant sclerosis, but in individual cases the relative importance of these two factors is difficult to determine.

In human cases conditions which produce obstruction of the pancreatic duct are usually such as favor infection. The pancreas, it has been shown, is provided with two ducts which, in nine of ten instances, anastomose within the gland. The duct of Santorini is occasionally of large size, in about one of ten cases even larger than the duct of Wirsung, and its duodenal orifice is freely patent. In most subjects, however, the duct of Santorini is in part rudimentary, and its orifice is too minute to act as an outlet for the entire pancreatic secretion should the duct of Wirsung be occluded.

Pancreatic Calculi.—The two cases to follow are described in order to illustrate the extreme degree of sclerosis which may follow the presence of calculi

within the pancreatic ducts. The lesion derives its importance, in part, from the fact that diabetes mellitus occasionally accompanies chronic inflammatory changes due to the presence of calculi. This relationship will be discussed subsequently.

CASE XII.—*Summary of Clinical History.*—W. H., male, aged forty-three years, had used beer in large quantity. Ten months before his death he had had an attack of jaundice. Diagnosis: Pulmonary tuberculosis. No symptoms of diabetes were noted.

Anatomical Diagnosis.—Chronic pulmonary tuberculosis; tuberculous pleurisy. Cirrhosis of the liver with fatty degeneration. Splenic tumor. Pancreatic calculi; interstitial pancreatitis; peri-pancreatic fat necrosis.

Pancreas.—The duct of Wirsung and its branches are much distended by numerous calculi. The gland-tissue has in large part disappeared, and is replaced by interstitial tissue containing abundant fat, in which are opaque, white areas of necrosis. The concretions give the reactions of calcium carbonate.

Microscopic Examination.—The parenchyma has been in very great part replaced by dense fibrous tissue, in which are scattered foci of round cells. In the head of the organ are small areas of glandular tissue, subdivided by interlobular fibrous strands. Occasionally gland lobules are found in process of disintegration, atrophied acini with dilated lumina being separated by newly-formed interstitial tissue. Numerous islands of Langerhans, most abundant in a section from the splenic end of the organ, are surrounded and isolated by newly-formed stroma, and though the tissue about is densely fibrous, one sees within the islands delicate capillaries, often distended with red blood-corpuscles. Occasionally an island has the appearance of being compressed and distorted.

CASE XIII.—*Summary of Clinical History.*—The patient, male, aged fifty years, gives a history of alcoholic excess. His illness began five months before its fatal termination with symptoms of pulmonary tuberculosis which gradually increased in severity. On admission to the hospital, two months after the onset of his illness, the urine contained 5.2 per cent. of sugar. When given a diet very poor in carbohydrates (v. Noorden's standard diabetic diet), sugar disappeared from the urine, and reappeared only when carbohydrates were added,—ninety grammes of white bread to the daily diet.

Anatomical Diagnosis.—Pancreatic calculi; chronic interstitial pancreatitis; parapancreatic fat necrosis. Chronic pulmonary tuberculosis. Chronic diffuse nephritis; large white kidneys.

Pancreas.—The organ is much diminished in size and is tough and fibrous. Atrophy is so marked that the body is merely a narrow isthmus connecting the head and tail. The duct, slightly enlarged, contains a number of gritty, yellow calculi, the largest being the size of a split pea. On section the tissue has a grayish-yellow color, and small masses of parenchyma project between thick bands of connective tissue. Minute opaque points suggest fat necroses.

Microscopic Examination.—Sclerosis is far advanced and is most marked in the tail of the organ, where glandular acini are almost entirely absent. The glandular tissue which still persists occurs as small, compact masses embedded in dense stroma. At the periphery of this relatively normal parenchyma are found lobules or parts of lobules in process of disintegration and replacement by the interstitial tissue. Completely isolated in the dense stroma of the body and tail are numerous masses of polygonal cells occupying conspicuous, sharply outlined, round or oval spaces in the sclerotic tissue. These islands of Langerhans are so thickly scattered that in places ten or twelve may be seen in the field of the low power. In the surrounding tissue lymphoid and plasma cells are numerous, and it may be assumed the inflammatory process is still active.

Such persistent islands may be finally implicated in the general sclerosis. An increase of fibrous tissue occurs along their capillaries, which become coarse strands subdividing the body into small masses of atrophied cells. One finds elsewhere broad bands of dense fibrous tissue containing no epithelial elements or only an occasional compressed group of cells similar to those which form the islands.

Biliary Calculi.—Riedel has directed attention to the fact that induration of the head of the pancreas, at times observed during operations undertaken for the removal of gall-stones, may readily be mistaken for malignant growth. Carcinoma of the pancreas was suspected in three of one hundred and twenty-two such operations, but the subsequent history of his patients disproved this supposition, and chronic pancreatitis was found in one patient who died. Mayo Robson has described two similar cases, in one of which chronic inflammation was demonstrated at autopsy, while in the second malignant growth was excluded by recovery of the patient.

The following case illustrates the relation of chronic interlobular pancreatitis to cholelithiasis and demonstrates a mechanism by which the change is produced.

CASE XIV.—The patient, a man, aged sixty-three years, after repeated attacks of jaundice underwent operation, but on account of dense adhesions it was not possible to explore the bile passages. Symptoms of cirrhosis subsequently developed, and the abdomen was tapped several times. The urine did not contain sugar. The patient had used alcohol in excess.

Anatomical Diagnosis.—Cholelithiasis; contraction of the gall-bladder; calculus in the common bile duct; dilatation of bile ducts; cirrhosis of the liver; chronic interlobular pancreatitis; serofibrinous peritonitis; chronic nephritis; arterial sclerosis.

Near the termination of the common bile duct, but just above its junction with the duct of Wirsung, is a large, oval gall-stone, firmly wedged into the common duct in such a position as to compress the terminal part of the pancreatic duct, which, as it enters the diverticulum of Vater, passes immediately below the stone (see



FIG. 17.—Biliary calculus (actual size) which, in Case XIV., completely filled the diverticulum of Vater and occluded the duct of Wirsung; chronic interstitial pancreatitis resulted. Compare with the much smaller calculus which in Case I. (see Fig. 12) caused acute hemorrhagic pancreatitis.

Fig. 17). The pancreas is firm in consistence and compact in texture. The papilla of the duct of Santorini is not demonstrably patent.

A small calculus, as I have shown in a previous chapter, may lodge at the orifice of the diverticulum of Vater, and, occluding it, may convert the common bile duct and the duct of Wirsung into a continuous channel, thus causing the penetration of bile into the pancreas and consequent hemorrhagic pancreatitis. A larger calculus present in the diverticulum of Vater or in the common bile duct, slightly above its junction with the pancreatic duct, may temporarily or permanently compress the latter and produce chronic inflammatory

changes resembling those which follow ligation of the duct in animals.

Doubtless bacterial infection often plays a part in the production of the lesion, and in two additional cases of chronic interlobular pancreatitis the bile passages containing gall-stones were the seat of acute suppurative inflammation; opportunity was thus afforded for ascending infection of the duct of Wirsung. In neither case was a calculus found compressing the pancreatic duct, but at some previous time during the expulsion of a stone into the intestine partial occlusion may have occurred. Since, however, the pancreatic ducts were the seat of acute inflammatory changes it is not improbable that chronic inflammation may have been the result of infection originating in the acutely inflamed bile passages.

Malignant Growth.—In five of my cases chronic interstitial pancreatitis was caused by a malignant growth compressing or invading the organ. In the following case, which may serve as an illustration of this condition, a primary carcinoma of the pancreas arising in the head of the gland compressed the duct of Wirsung and produced chronic interstitial inflammation accompanied by the formation of cysts.

CASE XV.—The patient, female, aged forty-one years, became jaundiced nine months before her death. A tumor mass was palpable in the umbilical region. Autopsy was performed by Dr. Flexner.

Anatomical Diagnosis.—Adenocarcinoma of the pancreas, com-

pressing the bile and pancreatic ducts ; jaundice ; chronic interlobular pancreatitis ; retention cysts of the pancreas ; metastatic carcinoma of the retroperitoneal lymph glands.

The tumor, which arises from the pancreas, consists of two masses, between which the remains of the head and part of the body lie compressed. A fibrous capsule separates the tumor from the glandular parenchyma. Numerous cysts about the size of a walnut occupy the body and tail, and are present but less numerous in the duodenal end. A probe can be passed along the compressed duct.

In a second case, previously described (Case IX.), advanced chronic interstitial inflammation followed the development of a carcinoma of the bile papilla and diverticulum of Vater. Marked dilatation of the pancreatic duct gave evidence of its partial obstruction. Infection from the ulcerated surface upon which the duct opened was with great probability an important factor in producing the advanced chronic interstitial inflammation which resulted.

In three cases chronic inflammatory changes were associated with the invasion of the gland by a carcinomatous new growth of the stomach. When the head of the gland is invaded there is a diffuse interstitial change, but where, as in two cases, the body is invaded while the head is not in contact with the tumor, inflammatory alterations occur only in that part of the gland distal to the point at which the duct is compressed. The carcinomatous tissue, moreover, acts as a local inflammatory irritant and in its immediate neighborhood

there is proliferation of the stroma replacing the parenchymatous elements.

Ascending Infection from the Duodenum ; Association of Chronic Interlobular Pancreatitis and Persistent Vomiting.—Under normal conditions the pancreas, like other glands of the gastro-intestinal tract, is protected against the entrance of micro-organisms. The valve-like folds within the diverticulum of Vater prevent the regurgitation of material from the duodenum into the duct, and if after death fluid is forced under considerable pressure into the duodenum, tied above and below the gland, none enters the duct. The flow of secretion, washing away foreign material, doubtless has a part in the protection of the gland.

Körte has produced chronic inflammation of the pancreas by injecting bacillus coli into the pancreatic duct, and has obtained a similar result by injecting faecal material. By an ingenious method Carnot produced conditions by which an ascending infection from the duodenum results. A thread, inserted into the pancreatic duct, and through its orifice into the duodenum, was left fixed in this position. Advanced sclerosis of the gland resulted, and the walls of the ducts were thickened and infiltrated with leucocytes, while the interstitial tissue of the gland was much increased. In another experiment Carnot produced suppurative inflammation by injecting colon bacilli into the pancreatic duct.

In four of the thirty cases which I have observed, advanced chronic interstitial inflammation has been found in individuals who during life have suffered with persistent vomiting. Since this disease of the pancreas is notably one of advanced life, twenty-five of thirty cases occurring after the age of forty years, two such cases in young women suggest the presence of some unusual etiological factor. In a third case chronic pancreatitis followed persistent vomiting in a man forty-nine years of age, who though once addicted to alcohol, had for ten years led a temperate life; chronic gastritis was found at autopsy. In the fourth case vomiting accompanied carcinomatous constriction of the terminal part of the duodenum. In all of these cases the clinical history affords evidence of continued gastric or gastro-intestinal disease,—namely, epigastric pain, nausea, and vomiting. Since the associated conditions appear to favor infection of the duct, the cases have been described under the present heading.

CASE XVI.—The patient, a deaf mute, female, aged thirty-one years, entered the service of Dr. Osler complaining of “heart-burn” and dyspepsia. She states that at the age of twenty-four years she had “inflammation of the stomach” and was sick for eight weeks. She has since suffered with dyspepsia. She has had one living child and three miscarriages, and is at present pregnant. Four days before her admission she began to vomit; the vomiting has persistently continued and has recurred irrespective of the taking of food. Physical examination disclosed nothing of importance.

After her admission vomiting was almost continuous, but examination of the vomitus gave no noteworthy information. In the afternoon of the following day, the patient becoming much weaker and semi-unconscious, vomiting ceased. Owing to the severity of the symptoms an exploratory laparotomy was performed. The condition after operation was improved and there was no return of vomiting until twelve days later, when it recurred with its previous persistence.

The patient was transferred to the obstetrical ward, and it was decided to empty the uterus; an ovum, two and a half months old, was removed. The patient died on the twenty-second day after her admission. Sugar was not found in the urine.

Anatomical Diagnosis.—Endometritis of the puerperal uterus. Anomalous artery, a branch of the aorta penetrating the substance of the right lung; rupture, with formation of cavity containing blood-clots. Chronic interlobular pancreatitis.

The condition of the uterus and of the right lung will not be described. The stomach is normal, save for the presence of a few submucous ecchymoses; the duodenum is normal in appearance. The pancreas is almost board-like in consistence, and on microscopic examination the interlobular tissue is found to be dense and fibrous, containing many spindle-shaped, lymphoid, eosinophile, and plasma cells. Entire lobules are at times partially destroyed, a few scattered acini remaining in the proliferated stroma, but in general the sharply defined lobules are not invaded by the process.

CASE XVII.—H. B., female, aged twenty-eight years, was admitted to the service of Dr. Kelly complaining of bleeding from the vagina. Her present illness began ten months before her admission with sudden profuse hemorrhage from the vagina. An operation, the nature of which she did not know, was performed five months later, and was followed by much nausea and vomiting. Previous to her admission she had been much nauseated, and states that even a small quantity of water might cause her to vomit, so that, though

often hungry, she was afraid to eat. She has had colicky pains in the epigastrium. Vaginal examination demonstrated the presence of an inoperable fungating carcinoma of the cervix. The urine contained no sugar.

Anatomical Diagnosis.—Carcinoma of the uterus, with metastases in the broad ligaments, pelvic and lumbar lymphatic glands, liver, and rectum; double pyelonephrosis. Chronic interlobular pancreatitis.

The pancreas is firm in consistence and on section very compact in texture. There are no noteworthy changes in the stomach, intestine, or bile passages. Microscopic examination of the pancreas shows an abundant proliferation of the interlobular tissue, which is dense and fibrous, but often contains lymphoid and plasma cells in considerable number.

CASE XVIII.—The patient, male, aged forty-nine years, was admitted to the service of Dr. Osler complaining of rheumatism, cough, shortness of breath, and indigestion. He formerly used alcohol in excess, but for the last ten years had only taken an occasional drink. For a year he had had attacks of vomiting without any apparent cause and with no relation to the taking of food, occurring sometimes in the morning before breakfast. He describes the vomitus as consisting in great part of phlegm. On admission the patient was a well-nourished man slightly cyanosed. The heart was hypertrophied, and a systolic murmur was present at the apex. He died on the fourth day after admission. The urine contained no sugar.

Anatomical Diagnosis.—Chronic endocarditis of the mitral valve; dilatation and hypertrophy of the heart; cardiac thrombi; chronic passive congestion of the viscera; infarcts of the lungs; acute and chronic gastritis; ulceration of the ileum and colon; chronic interlobular pancreatitis with lipomatosis.

The mucosa of the stomach, covered by a thick layer of tenacious

mucus, has a puffy appearance and is red in color, studded with small submucous ecchymoses. The pancreas weighs one hundred and fifty-two grammes. The glandular tissue is in great part replaced by fat. Microscopic examination shows that groups of lobules are widely separated by adipose tissue, while within these groups individual lobules are separated by thickened strands of dense stroma containing many lymphoid cells; in places are seen lobules undergoing disintegration.

The cases just described illustrate the occurrence of chronic interlobular pancreatitis in individuals who during life have suffered with persistent vomiting. They indicate the existence of some relationship between gastro-intestinal disturbance and chronic lesion of the pancreas. It is improbable that persistent vomiting was caused by pancreatic disease, since in many cases the latter has existed unaccompanied by this symptom. Persistent vomiting, even though dependent upon disturbances of the reflex nervous mechanism, or upon the evacuation of toxic products into the stomach, is indicative of some profound change in the organ, and has probably been associated with conditions favoring ascending infection of the pancreatic duct. The mechanical effect of vomiting upon the ducts and their contents is difficult to determine.

The type of the accompanying pancreatic lesion favors the probability of infection by way of the duct, for here pancreatitis is typically interlobular and resembles that observed in those cases where infection of

the pancreas has followed lesions of the gall-ducts with or without duct-obstruction. This explanation is further confirmed by the following case, in which persistent vomiting was the result of partial occlusion of the terminal part of the duodenum.

CASE XIX.—Mrs. F. G., aged fifty-one years, entered the service of Dr. Osler seven weeks before her death, complaining of nausea, vomiting, and loss of weight. Her uterus had been removed seven years before by Dr. Kelly for carcinoma of the cervix; she had since enjoyed good health. Two months before re-entering the hospital she was attacked with very severe vomiting, occurring often five or six times a day and unaccompanied by nausea, but preceded by slight pains in the chest. Food caused no pain. While in the hospital there were frequently repeated attacks of vomiting, usually at intervals of from twelve to eighteen hours, the vomitus consisting of greenish-yellow fluid varying in amount from a few cubic centimetres to a litre; it contained no blood. No sugar was found in the urine.

Anatomical Diagnosis.—Recurrent adenocarcinoma of the retro-peritoneal lymphatic glands and of the peritoneum; indurated carcinomatous tissue constricting the duodenum and left ureter; multiple abscesses of kidney; cystitis; broncho-pneumonia; fatty degeneration of the liver; fibrous myocarditis.

In front of the sacrum, near the promontory, are a few enlarged, firm, lymphatic glands, which on microscopic examination are found to contain adenocarcinoma. Indurated tissue formed by carcinomatous cells embedded in dense stroma is found on either side of the aorta, at the base of the mesentery where the jejunum emerges, and upon the neighboring peritoneal surface. Similar sclerotic tissue invading the wall of the duodenum at its termination has contracted

the lumen to a diameter of twelve millimetres. The constricted area is not more than one centimetre in length, and above and below the intestinal wall is soft. The pancreas is very firm, and upon the surface individual lobules are sharply defined. The ducts are not dilated. Microscopic examination shows an interlobular inflammation of moderate intensity, the lobulation being accentuated by thickened fibrous bands containing lymphoid, plasma, and eosinophile cells in fair abundance.

Alterations of the Blood-Vessels.—In the cases already considered chronic pancreatitis has been secondary to alterations occurring in the ducts; in another group of cases the ducts are unchanged and the lesion is referable to the blood-vessels or to toxic substances brought to the gland by the blood. In the pancreas, as in other organs, general arterial sclerosis has been thought to be the cause of fibroid induration, and G. Hoppe-Seyler and Fleiner have described cases of chronic interstitial pancreatitis, attributed by them to obliterating endarteritis. Both writers think that changes in the vessels are followed by nutritive disturbances which cause degeneration of the parenchyma and its replacement by fibrous tissue. The condition, Fleiner suggests, is analogous to the contracted kidney which is at times associated with general arterial sclerosis and to changes in the liver, heart, and brain following arterial disease. In three cases of arterial sclerosis Kasahara found a moderate increase of the interstitial tissue of the pancreas, but in other cases of

the same disease found nothing more than thickening of the blood-vessels.

In only four cases of the present series is arterial sclerosis sufficiently marked to receive mention in the anatomical diagnosis made at autopsy. In the following case of diabetes advanced arterial sclerosis is accompanied by chronic interacinar pancreatitis. Here both gangrene of the foot and pancreatic lesion are referable, in part at least, to arterial sclerosis.

CASE XX.—The patient, a woman, aged sixty-three years, entered the Johns Hopkins Hospital suffering with gangrene of the right foot, which had begun five weeks before. Sugar was discovered in the urine. Death occurred with coma twelve days after admission. The urine, of which the specific gravity was 1024 to 1027, contained sugar, the largest amount found being 2.2 per cent. ; preceding death acetone was abundant.

Anatomical Diagnosis.—General arterial sclerosis ; calcification of the coronary arteries and of the right posterior tibial and dorsalis pedis arteries. Gangrene of the right foot. Chronic interacinar pancreatitis.

The pancreas, weighing eighty-two grammes, is firm in consistence and is surrounded and infiltrated by abundant fat. The splenic artery in contact with the gland is tortuous and partially calcified. Microscopic examination shows the presence of a diffuse increase of the interacinar stroma, more marked in the tail than elsewhere. The newly-formed tissue is poor in cells. The islands of Langerhans are often surrounded by thickened, capsule-like strands of fibrous tissue, and similar proliferation of connective tissue has occurred along the course of their capillary vessels. Small arteries throughout the parenchyma not infrequently show obliterating endarteritis and hyaline changes in the middle coat.

Doubtless arterial sclerosis has a part in the production of chronic pancreatitis, and in the preceding case it is one of the etiological factors concerned. Nevertheless, the proportion of cases in which arterial sclerosis has been present, five of thirty cases, cannot be regarded as significant when one considers that chronic pancreatitis, with few exceptions, occurs after the age of forty years. Advanced arterial sclerosis, moreover, may be unaccompanied by pancreatitis, and in two cases not included in the present series the arteries of the pancreas were greatly thickened, while only in their immediate neighborhood was there proliferation of the interstitial tissue.

A second alteration of the blood-vessels assigned as a cause of chronic pancreatitis is chronic passive congestion. Friedreich states that pancreatitis is not infrequently the result of long-continued venous gorging, occurring in chronic diseases of the heart, lungs, and liver. The changes, he says, are usually slight and do not cause destruction of the glandular elements, but between the acini are formed small tracts of thickened connective tissue, giving the gland an increased toughness. Small interstitial hemorrhages occur and are changed later into collections of rust-colored pigment.

In the following case the pancreas was the seat of an extreme grade of chronic passive congestion, following complete occlusion of the portal vein by a primary carcinoma of the liver.

CASE XXI.—*Anatomical Diagnosis*.—Primary carcinoma of the liver invading and occluding the portal vein; chronic passive congestion of the spleen, pancreas, stomach, and intestines; ascites. Chronic interstitial pancreatitis with pigmentation.

The pancreas is compressed by the distended splenic vein, and is firm and compact in texture and of a uniform dull brownish-red color. The veins are widely dilated, and are occasionally plugged by carcinomatous tissue. There is a slight increase of the interlobular tissue, and among the acini occur irregular patches of interstitial tissue, poor in cells. Small hemorrhages have in places occurred into the interlobular tissue, and both here and within the secreting cells is found brown pigment which contains iron.

In the preceding case the pancreas is the seat of a slight generalized increase of the interstitial tissue between the acini as well as between the lobules, but it serves to illustrate how small is the influence of extreme chronic passive congestion in causing proliferation of the pancreatic connective tissue. In two additional cases of the present series chronic passive congestion dependent upon a valvular lesion of the heart accompanied chronic inflammation of the pancreas. One of these cases, Case XVIII., in which gastro-intestinal inflammation coexisted, has already been described. In the second case, not cited in detail, inflammatory change cannot be attributed to chronic congestion, since at least one other possible factor existed,—namely, chronic lead poisoning.

The frequency of chronic congestion of the abdominal viscera, and the relative infrequency of chronic inter-

stitial inflammation of the pancreas, is evidence that the former condition is not commonly a cause of the latter. Chronic passive congestion may doubtless produce slight proliferation of the interstitial tissue, but is an unimportant factor in the production of chronic pancreatitis.

In many of the remaining cases belonging to the present series of thirty it is probable that the lesion, like corresponding changes in the liver and kidney, namely, cirrhosis of the liver and chronic interstitial nephritis, is caused by the action of toxic substances present in the blood. Various conditions presumably capable of producing such substances have been assigned as the cause of chronic pancreatitis; those notably worthy of consideration are tuberculosis, syphilis, and alcohol, named in the probable order of their increasing importance.

Tuberculosis.—Carnot has recently directed attention to the occurrence of chronic pancreatitis accompanying tuberculosis. The specific lesion of tuberculosis is, he thinks, relatively uncommon in the gland, and in only one case has he observed acute miliary tuberculosis. Diffuse chronic interstitial inflammation of the pancreas associated with tuberculous lesions of other organs is, he states, much more common, and a number of the older writers, Ancelet, Vulpian, Arnozan, and Morache, have cited such cases. Carnot examined the pancreas in patients dying with tuberculosis, and while in the

majority no lesion was demonstrable, in seven cases he found a variable, usually moderate grade of chronic inflammation causing, in most cases, an increase of the connective tissue normally present about the vessels and ducts and between the lobules.

Carnot was able to produce chronic inflammatory changes in the pancreas of dogs, somewhat varied in extent and character, by injecting suspensions of the bacillus tuberculosis into the duct or into the parenchyma of the organ, but it was necessary to inject a very great quantity of the culture. A caseous abscess resulted in one case, but in the other experiments the lesion presented none of the specific characters of tuberculosis, and tubercle bacilli were not demonstrable in the tissues. In a single case localized sclerosis was produced by injecting into the parenchyma tuberculin extracted from the bodies of the dead bacilli.

In the two cases included in the present series chronic interstitial pancreatitis was found at the autopsy upon individuals dead with advanced tuberculous lesions. In one of these cases miliary tubercles were found in the pancreas, but in the second none were found in the sections examined. In three additional autopsies performed in the pathological laboratory of the Johns Hopkins Hospital tuberculous lesions were present in the pancreas, but there was no generalized proliferation of the interstitial tissue. The two cases of chronic inflammation mentioned give some support to the

conclusion of Carnot that in a few instances generalized tuberculosis is accompanied by chronic pancreatitis, but they afford no explanation of its occurrence. The condition may be dependent upon proximity to a tuberculous lesion, as in one of Carnot's cases, where only the splenic extremity of the gland in contact with a tuberculous kidney was affected, and a similar explanation may be applicable to the cases of Arnozan, in which chronic pancreatitis accompanied tuberculous peritonitis.

Since tuberculosis is, as is well known, a frequent complication of diabetes, its relationship to alterations of the pancreas are of much interest. In the cases just cited diabetes did not occur and the lesion of moderate severity is interlobular, a type of inflammation accompanied by diabetes only when very far advanced. There is, it appears, no reason to suppose that diabetes may be caused by pancreatitis resulting from tuberculosis.

Syphilis.—The autopsy records of the pathological laboratory of the Johns Hopkins Hospital furnish no instance in which chronic pancreatitis has been associated with visceral syphilis; and though the literature demonstrates that the two conditions occur in conjunction, acquired syphilis is certainly not the most common cause of the lesion, as Hansemann, Kasahara, and other writers believe. In only one of the present series of cases was a history of syphilis obtained; and in this case chronic pancreatitis with formation of cysts was

caused by primary carcinoma of the pancreas compressing the duct.

In a case described by Drozda the pancreas was represented by a mass of indurated tissue, in which glandular structures were recognizable only in the head, while here and there occurred caseous gummata embedded in the fibrous stroma. The liver was the seat of syphilitic cirrhosis and the stomach contained an indurated scar. In a case of visceral syphilis described by Chvostek the tail of the pancreas was penetrated by several sclerotic bands of tissue, giving it a lobed appearance.

In these cases the alterations are analogous to syphilitic lesions of the liver and are characterized by the occurrence of gummata or irregular scar-like bands of tissue penetrating the parenchyma; they differ from the more common lesion, in which there is a diffusely distributed increase of the interlobular or interacinar tissue. To the latter type belongs apparently the case of Dieckhoff, in which, though there was a history of syphilis, coexisting carcinoma of the stomach was a possible etiological factor. In two cases of chronic interstitial pancreatitis associated with diabetes Hanseemann obtained evidence of syphilis. Kasahara examined the pancreas in six cases of acquired syphilis, and in two found a moderate increase of the interstitial tissue, in two merely thickening of the blood-vessels, and in two no alterations.

Syphilis is no doubt a cause of chronic inflammation of the gland, and the cases of Droza and Chvostek indicate the existence of a syphilitic pancreatitis characterized by the occurrence of scar-like bands of tissue which may contain gummata. The etiological relationship of syphilis to a diffusely distributed interacinar or interlobular inflammation is doubtful.

Alcohol.—The common cause of cirrhosis of the liver is excessive use of alcoholic drinks. Cirrhosis is relatively infrequent when compared with the prevalence of alcoholic indulgence; but here, as with many diseases, other conditions are necessary in order that the lesion may result. Alcoholic excess is likewise regarded as a frequent cause of chronic interstitial pancreatitis, and in many instances a history of alcoholic indulgence can be obtained. Friedreich found at autopsy upon a drunkard chronic pancreatitis, cirrhosis of the liver, and granular kidneys. Chvostek, Dieckhoff, and Oser have described cases in which cirrhosis of the liver and chronic pancreatitis were associated in alcoholics. In eight of the present thirty cases a history of alcoholic excess was obtained, but in three of these cases (Cases XII., XIII., XIV.) chronic inflammation of the organ had followed obstruction of its duct by biliary or pancreatic calculi, and was indirectly, if at all, referable to the use of alcohol.

In the following case chronic interlobular pancreatitis unaccompanied by cirrhosis of the liver was found

at autopsy in an individual dying with delirium tremens.

CASE XXII.—J. M., male, aged fifty-three years, was admitted to the service of Dr. Osler with delirium. His wife, from whom a satisfactory history was not obtained, stated that he had been drinking very heavily for a month, and on the morning before his admission became delirious and feverish. The patient was completely unconscious, the temperature rose to 105.4° F., and he died on the second day after admission.

Anatomical Diagnosis.—Bronchitis and beginning aspiration pneumonia; acute diphtheritic and hemorrhagic colitis; fatty degeneration of the liver; chronic interlobular pancreatitis; fat necrosis.

The pancreas, of normal size, is very firm in consistence, and the interstitial tissue appears to be indurated. The ducts are normal. Numerous small foci of fat necrosis occur about the pancreas and in the transverse mesocolon. Microscopic examination shows a typical chronic interlobular pancreatitis, and the interstitial tissue contains numerous lymphoid cells.

Few reported cases of chronic inflammation of the pancreas not dependent upon lesions of the duct are described with sufficient detail to determine the presence or absence of an alcoholic history, and a review of them would afford statistics of little value. Alcohol being the common cause of cirrhosis of the liver, the association of chronic pancreatitis with this lesion is significant.

Association of Chronic Pancreatitis with Cirrhosis of the Liver.—In the present thirty cases of chronic pancreatitis cirrhosis of the liver occurs in eight. In

three of these cases pancreatitis is indirectly, if at all, related to the lesion of the liver and has followed readily demonstrable changes in the duct of Wirsung. The relationship of the blood-supply of the liver to that of the pancreas suggests the possibility that venous obstruction may play a part in the production of pancreatic sclerosis, but the small influence which it exerts has already been pointed out.

Chronic inflammation of the liver and pancreas have been found associated by Friedreich, Chvostek, Hanse-mann, Dieckhoff, Kasahara, Oser, and Lefas. In six cases of chronic interstitial hepatitis Kasahara found a marked increase of connective tissue in the pancreas, in two a slight increase, and in two none at all.

Of considerable interest are the observations of Lefas, who studied alterations of the pancreas accompanying different varieties of hepatic cirrhosis. With the so-called atrophic or Laennec's cirrhosis he finds that the weight of the pancreas is often increased to one hundred and twenty or one hundred and thirty grammes, and the newly-formed tissue, which is poor in cells, is uniformly intralobular, penetrating the parenchyma and isolating groups of acini. The point of origin, he says, seems to be the capillaries, but at an advanced stage there is a moderate grade of proliferation about the small veins and arteries. With the so-called hypertrophic biliary cirrhosis of Hanot the pancreas is not enlarged, but the interlobular tissue

is increased in amount and in density, and containing numerous cells, appears most altered about the ducts. The cases of interstitial pancreatitis which I have observed in part confirm the observations of Lefas, though a relationship of the newly-formed tissue to the blood-vessels and ducts is not evident.

In two cases previously described (Cases X. and XI.) chronic interacinar pancreatitis accompanied by diabetes was associated with cirrhosis of the liver of the so-called atrophic type of Laennec. In only one was there a history of excessive alcoholic indulgence.

An excellent illustration of the dependence of chronic lesions of the liver and of the pancreas upon the same etiological factor is furnished by the disease of pigment metabolism, first described by von Recklinghausen, hæmochromatosis. In this condition, to be described subsequently, an iron-containing pigment is deposited in the cells of the liver, pancreas, and various other organs, and its presence is associated with death of parenchymatous cells and consequent proliferation of the stroma. In a case of hæmochromatosis (see Case XXXII.) included in the present series cirrhosis of the liver is accompanied by chronic interacinar pancreatitis, resembling, though less advanced, that observed in the two cases just mentioned (Cases X. and XI.).

In the following case hypertrophic cirrhosis of the type of Hanot was accompanied by interlobular pancreatitis, as in the cases described by Lefas.

CASE XXIII.—The patient, male, aged fifty-six years, admitted to the service of Dr. Osler, gives a history of having used whiskey in excess, usually taking from fifteen to twenty-five drinks a day. He denies having had syphilis. For the last year, until a short time ago, he has had attacks of vomiting, and during the last six months has become weak and short of breath. The liver is enlarged, and there are ascites and other evidences of portal congestion. Sugar was not found in the urine.

Anatomical Diagnosis.—Hypertrophic cirrhosis (of Hanot); ascites; chronic passive congestion of spleen; chronic interlobular pancreatitis; cholelithiasis.

The liver, weighing two thousand eight hundred and eighty grammes, exhibits the gross and microscopic appearance of hypertrophic cirrhosis of Hanot. The gall-bladder contains many small facettted calculi. The pancreas, weighing sixty grammes, is very firm in consistence and evidently sclerotic. The duct of Wirsung in the body and tail of the gland is dilated, and contains solid wax-like material. Microscopic examination shows that the lobules, particularly in the body and tail, are separated by dense sclerotic tissue showing little tendency to penetrate between the acini.

In the case just described the so-called hypertrophic cirrhosis of Hanot was accompanied by interlobular pancreatitis; the condition, however, was complicated by the presence of gall-stones. In an additional case included in my series interlobular pancreatitis of moderate grade accompanied beginning cirrhosis in a woman twenty-two years of age, and though the hepatic lesion corresponded to the so-called atrophic or Laennec's cirrhosis, the alteration of the pancreas differed from that observed by Lefas and found in Cases X. and XI.

It is noteworthy, however, that the lesion was associated with tuberculous peritonitis, while a variety of chronic lesions coexisted in other organs.

Interacinar Pancreatitis of Obscure Etiology.—Of the present series of thirty cases there are five instances of interacinar pancreatitis of which the etiology is wholly obscure; in all of them the lesion is of very slight intensity. In four cases the islands of Langerhans were the seat of a remarkable hyaline change, and diabetes mellitus had resulted. I have described elsewhere one of these cases in which, though the islands of Langerhans were almost uniformly affected by the degenerative change, increase of the interacinar stroma was very inconspicuous. Hyaline degeneration of the islands of Langerhans in association with diabetes has since proved to be of much more frequent occurrence than was at first suspected, and in addition to the subsequent examples which have come to my notice cases have been recently observed by Wright and Joslin and by Hertzog. In one of two cases of Wright and Joslin and in both cases of Hertzog hyaline degeneration of the islands of Langerhans was associated with proliferation of the interstitial tissue of the gland.

In the following case of chronic interacinar pancreatitis the islands of Langerhans were almost wholly unchanged, but the pancreas was the seat of a slight interacinar pancreatitis. The case is of interest because diabetes was absent. The clinical and anatomical diagnoses in this case were as follows:

CASE XXIV.—Male, aged fifty-eight years. *Diagnosis.*—Inoperable carcinoma of rectum; œsophageal diverticulum. Inguinal colostomy was performed, and later the œsophageal diverticulum, which compressed the trachea, was removed. Death followed the latter operation.

Anatomical Diagnosis.—Carcinoma of rectum; metastases in the retroperitoneal lymphatic glands, liver, and lungs; broncho-pneumonia; colon; chronic interacinar pancreatitis (slight).

Macroscopically the pancreas appeared unchanged, but microscopic examination showed the occurrence of thickened strands of connective tissue between the acini. The increase of interstitial tissue is, however, slight, and in many places is entirely absent. Only rarely are the islands of Langerhans implicated in the chronic inflammatory process.

Of nine cases of chronic interacinar pancreatitis, seven were accompanied by diabetes mellitus. In those in which diabetes was absent—namely, in the case with hæmochromatosis and in Case XXIV., just described—the lesion was little advanced and the islands of Langerhans were only slightly affected. The significance of these facts will be considered in the pages to follow.

The data contained in the present chapter may be briefly summarized in the following conclusions:

Chronic interstitial pancreatitis is slightly more frequent in males than in females. The disease is rare in early life, and two-thirds of the total number of cases occur between the ages of forty and sixty years.

The most frequent cause of chronic pancreatitis is obstruction of the duct of Wirsung, due to pancreatic calculi, to biliary calculi in the terminal part of the common bile duct, or to carcinoma invading the head or body of the gland. Obstruction of the duct may be followed by the invasion of bacteria, and these take part in the production of the resulting lesion.

Ascending infection of the unobstructed duct of Wirsung may follow an acute lesion of the duodenum or of the bile passages, and may cause chronic inflammation. In cases which have given a history of long-persistent vomiting, chronic profuse pancreatitis may be found at autopsy, and is probably the result of an ascending infection of the gland.

Following obstruction of the ducts and ascending infection, the lesion of chronic interlobular pancreatitis affects principally the interlobular tissue, only secondarily invades the lobules, and spares the islands of Langerhans.

Accompanying the so-called atrophic or Laennec's cirrhosis of the liver, the pancreas is at times the seat of a diffuse chronic inflammation, chronic interacinar pancreatitis, characterized by proliferation of the interacinar tissue which invades the islands of Langerhans. A similar lesion accompanies arterial sclerosis, hyaline degeneration of the islands of Langerhans, and the condition known as hæmochromatosis.

CHAPTER IX.

HYALINE DEGENERATION OF THE PANCREAS.

THE lesions of the pancreas previously described do not exhibit a tendency to attack and destroy the islands of Langerhans, leaving uninjured the secreting parenchyma. The cells of the interacinar islands often contain fat in much larger quantity than those of the secreting acini, but accumulation of fat occurs with such frequency that it may be regarded as a physiological process. With the interacinar type of chronic interstitial pancreatitis the islands of Langerhans are invaded, but the remaining glandular parenchyma is almost equally affected. One form of degeneration, however, exhibits a specific tendency to select and destroy the interacinar islands, though in most cases it leaves the secreting parenchyma almost unaffected.

In a considerable number of cases recently observed the pancreas has been found to be the seat of a peculiar hyaline change which destroys the islands of Langerhans. The association of diabetes mellitus with the lesion has given much interest to its study. This peculiar transformation affecting the islands of Langerhans belongs to the varied and ill-defined group of degenerative processes of which the common characteristic is the formation of a homogeneous or hyaline

material. This substance stains with acid dyes, such as eosin and picric acid, but does not give the reactions of amyloid, though it resists the action of a variety of solvents, for example, strong acids and alkalies. These characteristics have been used by von Recklinghausen to group together products of cell degeneration occurring in widely different tissues and doubtless representing a variety of essentially different processes, which even yet have received no satisfactory classification.

Several years ago I had the opportunity of studying the pancreas from a girl who for two years before her death had suffered with diabetes mellitus. The organ was the seat of a lesion which obliterated the vascular supply of a considerable proportion of the parenchyma. The process which has the character of hyaline degeneration, though not confined to the islands of Langerhans, has so completely altered them that they are not recognizable. The lesion is so remarkable and its association with diabetes of such interest that the following details are given :

CASE XXV.—The patient, a girl, aged seventeen years, was in the care of Dr. James Carey Thomas. The onset of symptoms of the fatal illness occurred two years before death with extreme thirst and polyuria ; sugar was found in the urine and was constantly present in large amount until death. Upon diabetic diet the sugar diminished in amount but did not disappear. Marked loss of body-weight was not noted. Death occurred with coma, which appeared suddenly and lasted hardly more than twenty-four hours. At autopsy the only lesion noted was that affecting the pancreas ; the entire organ was

preserved for microscopic study and kindly given to me by Dr. Flexner, who performed the autopsy.

Microscopic Examination of the Pancreas.—The organ is in large part self-digested. In the tail, however, several areas where the tissue is well preserved give a clear histological picture of the lesions which are present. The interstitial tissue is increased only in several small areas. Throughout the organ, readily distinguishable even in the most digested parts of the gland, are very conspicuous, sharply defined, round or oval, hyaline areas embedded in the parenchyma; they vary considerably in size. Though the parenchymatous cells stain with hæmatoxylin, these areas stand out conspicuously as almost completely unstained foci. Their structure is as follows (see Fig. 18): Coarse, tortuous, hyaline columns separate strands of tissue, which contain nuclei and represent, in part at least, capillary endothelium, from compressed rows of epithelial cells,—evidently atrophied parenchymatous cells. The hyaline material lies immediately outside the capillary wall, between capillary and adjacent epithelial cells. Occasionally the lumen of the capillary is visible and may contain shadows of red corpuscles.

Epithelial cells between the tortuous hyaline columns form compressed rows varying in width. The cells which are diminished in size are usually arranged in columns. Rarely within the area of hyaline change, most frequently in its periphery, are cells grouped about a well-marked lumen. Islands of Langerhans are not recognizable. The hyaline material does not stain by Weigert's method for the staining of fibrin. Reactions for amyloid are not obtained with specimens hardened in alcohol.

Microscopic Examination of other Organs.—The liver is normal in appearance; there is no increase of interstitial tissue and the blood-vessels are normal. In a section from the kidney a small collection of lymphoid cells is present at one point. Otherwise no change is noted.

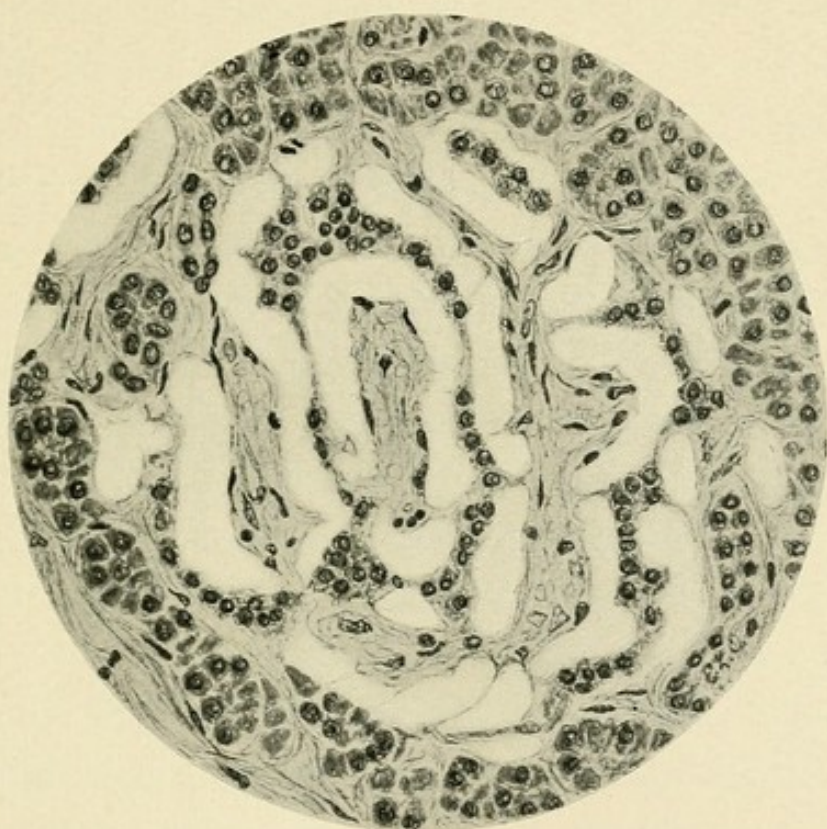



FIG. 18.—Hyaline degeneration of the pancreas. (Case XXV.)



The very remarkable lesion just described has apparently obstructed the vascular supply of a large proportion of the pancreatic parenchyma. Newly-formed hyaline material is deposited between the capillaries and the parenchymatous cells (see Fig. 18). The tissue studied having been hardened in ninety-five per cent. alcohol, the absence of reactions for amyloid is not conclusive. That the lesion is not this form of degeneration is shown by the absence of similar change in other organs which much more frequently than the pancreas are the seat of amyloid degeneration.

In the tail of the pancreas areas of hyaline transformation are larger and more numerous than elsewhere, involving at least two-thirds of the sectional area. Though the remainder of the parenchyma is in a fair state of preservation, islands of Langerhans are not found. The absence of recognizable islands of Langerhans in the tail is especially remarkable when we remember that they are normally most abundant in this part of the organ. It is evident, therefore, that the lesion has implicated these structures ; but that it is not confined to them is shown by the extent and abundance of the affected areas. Often the latter correspond in size and shape to the islands, but they may be several times as large. Moreover, the occurrence of epithelial cells arranged about a lumen, particularly at the periphery of the altered tissue, shows that acini as well as interacinar islets are affected. In the head and body of

the gland, areas of hyaline transformation are less abundant and smaller, usually corresponding in size to islands of Langerhans. Unfortunately, self-digestion of these parts of the organ prevents the recognition of very early stages of the lesion and of their relation to the various histological elements.

Rokitansky states that the pancreas is not infrequently the seat of amyloid degeneration, caused by the usual etiological factors and associated with the presence of the lesion in other organs. Sometimes degenerative changes, he thinks, are limited to the gland. The possibility suggests itself that he observed a lesion similar to the one described; this lesion has many of the characters of amyloid degeneration though the specific reactions are not obtainable. Saunby has described a condition of hyaline degeneration affecting the secreting parenchyma of the pancreas and associated with diabetes. The altered tissue is converted into swollen convoluted masses of transparent material containing a few pale nuclei. He thinks that the secreting cells undergo a process resembling the glycogenic degeneration of the kidneys and at the same time the fibrous interstitial tissue increases in amount.

Hyaline Degeneration of the Islands of Langerhans.—In a second case of diabetes the localization of hyaline changes in the islands of Langerhans has been clearly demonstrated; these bodies are the seat of a degenerative change which has left almost unaltered the secret-

ing parenchyma of the gland. I have made a report of this case in the *Journal of Experimental Medicine*. It is here quoted in considerable detail, because the lesion, previously undescribed, demonstrates very clearly, as will be shown later, the relationship of diabetes mellitus to the islands of Langerhans.

CASE XXVI.—The patient, a negro woman, aged fifty-four years, was admitted to the Johns Hopkins Hospital, in the service of Dr. Osler, complaining of cough. Her present illness began about eleven months before her admission, when, she stated, she had a severe cold which became steadily worse. She had lost much weight. Several months after the onset of cough her urine increased greatly in quantity, so that for a time she was compelled to get up almost every hour during the night to void it. At this time she experienced great hunger and thirst, and ate and drank enormously. These symptoms lasted during part of the spring and summer, and disappeared some months before her admission to the hospital. She had recently voided the usual amount of urine, and there was no excessive hunger or thirst.

When admitted the patient was thin but moderately well nourished. Signs of consolidation were found at the apices of both lungs, and tubercle bacilli were demonstrated in the sputum. The stools were of normal color and contained no fat. The patient gradually became weaker. The temperature was irregular. Death occurred on the seventh day after admission, and was not preceded by a period of coma.

The specific gravity of the urine varied between 1025 and 1035. It contained sugar in abundance; neither albumen nor casts were found. On the fourth day after admission eight hundred and eighty cubic centimetres were collected; the specific gravity was 1028, and four per cent. of sugar was present. On the following day the

amount was twelve hundred cubic centimetres, the specific gravity 1.035, and the quantity of sugar 5.4 per cent.

Autopsy.—The body is that of a sparely nourished woman. Subcutaneous fat is present in small amount. The heart is normal in appearance; within the coronary arteries near their orifices are a few slightly raised, yellow patches. Occupying the upper part of the upper lobe of the left lung is a large, irregular cavity, the walls of which are covered by yellowish necrotic material. The remainder of the lobe is consolidated, and riddled with small cavities. The upper part of the lower lobe is very thickly studded with groups of confluent, partly caseous tubercles. At the apex of the right lung, below the pleura, is a cavity, which in size and appearance resembles that of the left lung.

The liver is pale, and upon the cut surface are seen rather conspicuous yellowish tubercles of minute size. The spleen is not enlarged. The kidneys are of large size, and weigh together four hundred grammes. The surface, after removal of the capsule, is smooth and pale. In the lower part of the ileum are a few scattered superficial ulcers, with irregular, slightly raised edges. A few similar ulcers are present in the large intestine.

The pancreas, which weighs eighty grammes, can be readily dissected from the surrounding tissues. It is soft in consistence, on section has a grayish-yellow color, and appears to be normal.

The intima of the aorta, though fairly smooth, is studded with irregular, slightly-raised plaques. The arteries at the base of the brain are normal in appearance. No lesion of the brain is found; the floor of the fourth ventricle presents nothing unusual.

Histological Characters of the Hyaline Islands of Langerhans.—In sections prepared for histological study from the pancreas of the case just described, is found no generalized increase of the interstitial tissue,

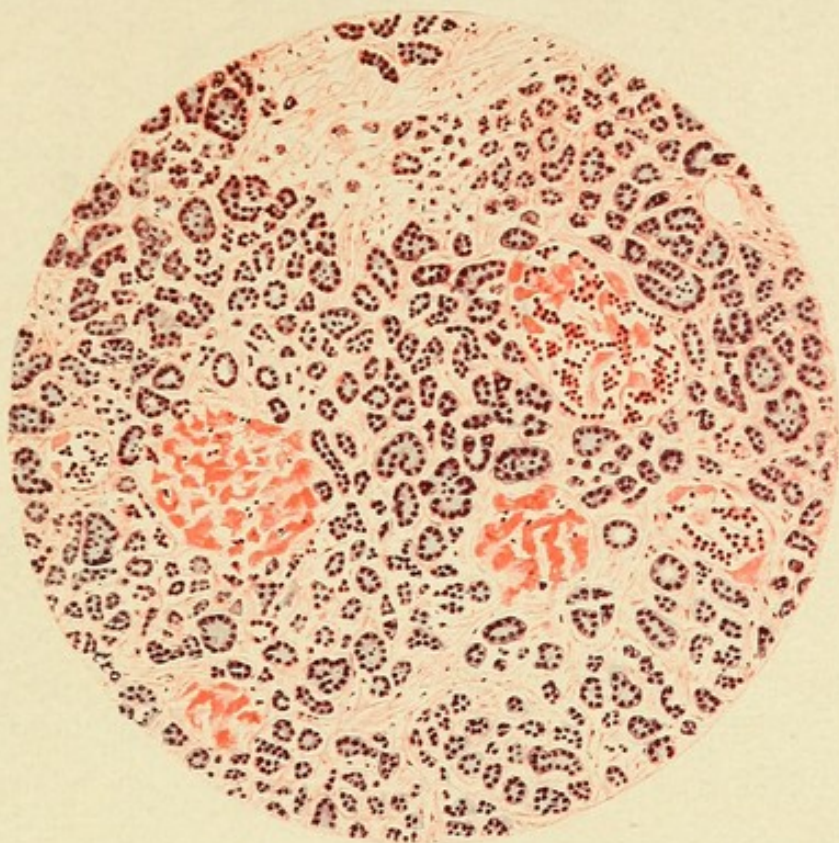


FIG. 19.—Drawing made with low magnification, showing hyaline transformation of the islands of Langerhans.

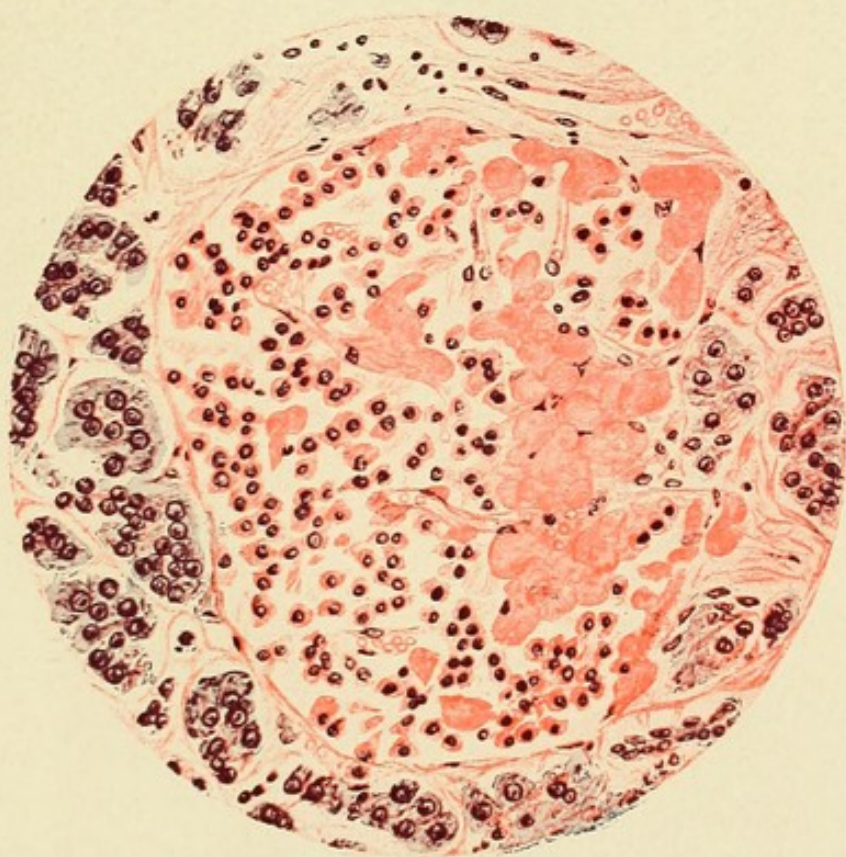



FIG. 20.—Drawing made with a higher magnification, showing an island, cells of which are partly transformed into hyaline material.



but here and there, particularly in the tail of the organ, the fibrous stroma shows some proliferation, and there are irregularly distributed strands of tissue between the acini. This scanty newly-formed interstitial tissue, where it occurs, is poor in cells, but about some of the medium-sized interlobular blood-vessels are small accumulations of scattered lymphoid cells, together with an occasional plasma cell. The ducts are not dilated and appear to be normal. There are no alterations of the veins or arteries.

The islands of Langerhans are the seat of a very remarkable change (see Fig. 19). In varying amount within almost every island is a homogeneous material which stains with eosin. Only rarely is found an unaltered island. Those which are least changed contain a few scattered masses of hyaline material, of which the smallest are irregularly polygonal in shape and correspond in size to the cells of the island; the larger particles are rounded. This hyaline substance lies at times in the midst of groups of cells, but is usually in contact with the capillaries of the island, or next the peripheral fibrous tissue, and is therefore between the remaining cells and the capillary walls. Increasing in amount, it replaces the cells and, where it is abundant, the cells which still persist are small and contain small nuclei, staining deeply with hæmatoxylin; but they do not appear compressed or distorted.

In islands of Langerhans, where the lesion is more

advanced, hyaline material occurs as conspicuous masses in contact with capillaries, the endothelium of which is well preserved. It does not form a uniform zone about them, but occurs as scattered groups of irregular, rounded, often globular masses (see Fig. 19). The cells of the island have been in large part replaced, and between the hyaline particles is seen only an occasional compressed, fusiform, or irregular nucleus.

The hyaline substance may occupy almost the entire area of the island, and besides a few endothelial cells are found only small scattered groups or rows of atrophic epithelial cells. The island is represented by a sharply circumscribed hyaline structure, composed of particles of homogeneous material, giving the impression of broken, twisted columns, between which are capillary walls. The nuclei of the capillary endothelium persist after destruction of the epithelial cells, but finally disappear. The lumen of the capillary remains patent, and red blood-corpuscles are seen between the hyaline masses, although the endothelium no longer contains nuclei. Hyaline metamorphosis is limited strictly to the islands of Langerhans, the glandular acini remaining intact.

Lesions similar to those of the pancreas are not present in other organs. The blood-vessels of the liver, spleen, and kidney are apparently unaltered, and there is no formation of hyaline material in these organs.

Additional Cases of Hyaline Degeneration Affecting the Islands of Langerhans.—The peculiarly localized lesion observed in the preceding cases of diabetes demonstrates, I believe, a casual relationship between alterations of the islands of Langerhans and the disease diabetes mellitus. This relationship will be discussed in a later chapter. Confirmation was afforded by the occurrence of the same lesion in two cases of diabetes which subsequently came to autopsy in the pathological laboratory of the Johns Hopkins Hospital. Since this characteristic lesion had not been described, its occurrence was at first thought to be rare. In addition to these cases, however, other observers studying the pathology of diabetes have recently noted similar changes, so that the association of the two conditions cannot be regarded as uncommon.

In the two cases to follow the islands of Langerhans were the seat of destructive changes comparable to those present in Case XXVI.

CASE XXVII.—The patient, male, colored, aged forty-eight years, was admitted to the Johns Hopkins Hospital in order that an operation for cataract might be performed. For six or seven years he had been troubled with dimness of vision. No evidence of syphilis nor of alcoholic excess was obtainable. The patient had suffered for several months with nausea and vomiting in the early morning. Shortly after the operation the patient became comatose. Sugar was present in the urine, constituting four per cent. ; acetone and diacetic acid were found. The patient died at the end of two days.

Anatomical Diagnosis.—Hyaline degeneration of the pancreas affecting the islands of Langerhans. Hypertrophy of the kidneys with slight chronic diffuse nephritis. Chronic catarrhal gastritis. Oedema of lungs.

The pancreas weighs 61.5 grammes. The substance is flaccid and appears to be normal, being nowhere indurated and not abnormally adherent to the adjacent structures.

Microscopic examination of the pancreas shows a slight increase of the interacinar connective tissue, though in many places, particularly in the head of the gland, the interstitial tissue is normal. Throughout the organ islands of Langerhans exhibit almost universally, but in varying degree, the hyaline change already described. Islands of Langerhans are very numerous in the tail, and here hyaline degeneration is very conspicuous. Where epithelial cells are almost wholly replaced, the hyaline substance has acquired a very homogeneous appearance and forms globular masses, which are pressed together to form tortuous columns lying beside the capillary vessels or in contact with the connective-tissue capsule of the island.

CASE XXVIII.—The patient, male, seventy-three years of age, was admitted to the service of Dr. Osler complaining of weakness and stiffness of the legs. There was no history of syphilis nor of alcoholic excess. None of the usual symptoms of diabetes had been noted. About ten months before his death, when first admitted to the hospital, sugar was found in the urine varying from 1.9 to 4.5 per cent., the total amount excreted in twenty-four hours being 29 to 49.3 grammes. When given a diet free from carbohydrates sugar disappeared from the urine. The patient was again admitted to the hospital about nineteen days before death. Signs of pulmonary tuberculosis were present, and in the sputum tubercle bacilli were found. The urine contained 3.6 per cent. sugar, but shortly before death glycosuria disappeared.

Anatomical Diagnosis.—Hyaline degeneration of the islands of

Langerhans with chronic interacinar pancreatitis. Pulmonary tuberculosis with cavity formation. Chronic diffuse nephritis; large red kidneys. Thrombosis of the left femoral and common iliac veins; thrombosis of the left pulmonary artery. General arterial sclerosis; mural thrombi within aorta. Aberrant pancreas in the wall of the stomach.

The pancreas, weighing one hundred and twenty grammes, is firm in consistence, and fat is abundant between the lobules. Near the pyloric orifice of the stomach is a small nodule of pancreatic tissue situated in the submucosa and muscularis (described in Chapter II.).

Microscopic examination shows that fat is abundant in the interstitial tissue of the pancreas, penetrating in many places between the acini. Throughout the organ there is a moderate irregularly distributed increase of the interstitial tissue between the acini. Islands of Langerhans are abundant in all parts of the gland, and are the seat of hyaline degeneration similar to that already described. In the head and body of the organ occur islands that appear to be normal, but in the tail, where these structures are most numerous, they are almost universally altered. The change in many instances is so far advanced that the epithelial cells are almost completely replaced by hyaline substance.

In the following case diabetes was of mild type, and glycosuria disappeared when the patient was given a diet poor in carbohydrates. Changes in the pancreas, though present, were less extensive than in the preceding cases, and only a few islands of Langerhans were the seat of advanced hyaline changes.

CASE XXIX.—The patient, male, white, aged fifty-one years, denies venereal disease; he has been in the habit of drinking daily several pints of beer and sour wine. The present illness began

with a cough about a year and a half before its fatal termination ; expectoration was abundant and tubercle bacilli were found in the sputum. When first admitted to the service of Dr. Osler the urine contained from seven to eight per cent. of sugar, but with rest in bed and a diet free from carbohydrates glycosuria disappeared. On two subsequent occasions the patient returned to the hospital, and upon similar treatment sugar, present to the amount of from three to six per cent. on admission, disappeared from the urine.

Anatomical Diagnosis.—Hyaline degeneration of the islands of Langerhans with chronic interacinar pancreatitis. Chronic pulmonary tuberculosis with cavity formation. General arterial sclerosis ; fatty degeneration of the heart. Chronic diffuse nephritis. Focal necrosis of the liver.

The pancreas, which weighs sixty-five grammes, is fairly firm in consistence. The splenic artery is thickened and tortuous and its intima shows raised sclerotic plaques.

In sections for microscopic examination from all parts of the pancreas, but most marked in the tail, there is a diffuse, irregularly distributed increase of the interacinar stroma. Islands of Langerhans are fairly abundant, and in the majority of instances show no alteration. Occasionally they are surrounded and penetrated by thickened strands of connective tissue. In the tail are found interacinar islands which contain hyaline material, while in several instances almost complete hyaline transformation has occurred.

In the following case only a small bit of pancreatic tissue was preserved. As in the preceding case hyaline degeneration of slight extent was associated with chronic interacinar inflammation. It is not improbable that had a thorough examination been possible more marked changes would have been found, for in the

cases just cited interacinar islands in the tail of the gland showed most marked alterations. The severity of the diabetes present could not be determined.

CASE XXX.—The patient, male, white, aged forty-seven years, was admitted to the service of Dr. Osler four days before death, complaining of weakness and loss of flesh. Symptoms of diabetes had been present six months, and the body-weight had diminished from one hundred and sixty-five to one hundred and twenty-five pounds. While in the hospital the urine contained 3.5 to 3.75 per cent. of sugar. Death occurred with coma.

Anatomical Diagnosis.—Chronic interacinar pancreatitis with hyaline degeneration of the islands of Langerhans. Emphysema of lungs. Fatty degeneration of heart, liver, and kidneys.

The pancreas weighs ninety grammes, and on gross examination shows no abnormality. On microscopic examination is found moderate, irregularly distributed increase of the interacinar tissue. Islands of Langerhans are numerous, and the greater number appear to be unaltered, but a few are surrounded by thickened fibrous tissue, while others contain in moderate amount the hyaline material observed in previous cases.

Since the publication of Case XXVI., hyaline degeneration of the islands of Langerhans accompanying diabetes has been observed by several writers. Wright and Joslin have described the lesion which was present in two cases. The first patient, aged fifty years, had suffered with diabetes two and a half years. He died in coma with general pyogenic infection. The pancreas was the seat of hyaline degeneration affecting the islands of Langerhans, while the secreting paren-

chyma showed no noteworthy change. The second case was in a woman, aged fifty-eight years, who was treated for diabetes and died with coma. In the islands of Langerhans were hyaline changes; the interstitial connective tissue was increased and contained much fat.

In one of five cases of diabetes Herzog found hyaline degeneration of the islands of Langerhans accompanied by a moderate increase of the interstitial tissue. Schmidt found a similar lesion accompanying diabetes in a woman sixty-two years of age. The change was unassociated with other histological alterations of the pancreas. Weichselbaum and Stangl have doubtless observed the same lesion, though they do not describe it in sufficient detail to identify it with certainty.

The cases already cited throw little light upon the etiology of the lesion. It appears to be equally common in males and in females, and of nine cases described with sex and age (six herewith described, two of Wright and Joslin and one of Schmidt), five were male and four female. One case (Case XXV.) was a girl seventeen years of age, but the remainder occurred after middle life: forty to fifty years, two cases; fifty to sixty years, four cases; sixty to seventy years, one case; and seventy to eighty years, one case. In two of my cases the condition was associated with marked arterial sclerosis, but in other instances the blood-vessels showed no noteworthy changes.

In most cases chronic interstitial pancreatitis of the

interacinar type has accompanied the lesion. In Cases XXVI. and XXVII. inflammatory changes are so insignificant that they are recognizable only in certain parts of the gland. In one case of Wright and Joslin and in the case cited by Schmidt none were observed. The relationship of hyaline degeneration of the interacinar islands to interstitial changes occurring in the secreting parenchyma is doubtful. Since large readily injected capillaries enter the islands of Langerhans, and subsequently anastomose freely with capillary vessels of the surrounding acini, it is possible, though not demonstrable, that interference with the circulation in the interacinar islands may disturb the nutrition of the surrounding parenchyma. On the other hand, it is not improbable that both processes are the result of an irritant carried to the pancreas by the blood. In Case XXV., though the lesion has destroyed the islands of Langerhans, it has overstepped their limits and implicates in wide-spread destruction the secreting parenchyma as well. In the remaining cases, however, the hyaline change exhibits a remarkable tendency to sharply limit itself to the interacinar islands.

Nature of the Degenerative Process.—Under the heading of colloid transformation, von Recklinghausen has included amyloid, hyaline, and mucous degeneration,—processes of which the common character is a formation of substances insoluble in the tissue juices. He recognized that the chemical and physical peculi-

arities ascribed to hyaline material do not serve to identify it as a true chemical compound.

Klebs has attempted to classify more precisely these heterogeneous processes, and to define more clearly certain long-accepted terms which have been applied to them. He reserves the name "colloid" for those albuminous substances which resemble the colloid of the thyroid gland and, like it, are elaborated by secreting cells, though not necessarily preformed within them. As "hyaline" he designated the firm, refractive, and homogeneous albuminous material which does not give the reactions of amyloid, and is formed in connective tissue and in other derivatives of the mesoderm.

By means of staining reactions, P. Ernst has attempted to demonstrate that the various substances grouped together as hyaline are not chemically identical. Hyaline material from different sources, when treated with Van Gieson's mixture, exhibits in its affinity for acid fuchsin and picric acid differences which he attributes to peculiarities of chemical composition. That which is derived from epithelial cells stains orange-yellow with the mixture of the two dyes, being colored by the picric acid, and only tinted by fuchsin, while that which is formed in connective tissue is stained deep red by fuchsin.

Lubarsch regards the staining reactions of Ernst as an uncertain means for the identification of different

hyaline substances, and points out discrepancies between the criteria proposed by Klebs and by Ernst. Although Lubarsch discards the classification of Ernst, he admits that the method employed indicates in many cases the origin of hyaline material. Its advantage, he believes, lies in the fact that by it we can determine if the particular hyaline substance to be examined contains a constituent derived from connective tissue. Normal fibrous tissue is stained intensely red by acid fuchsin, and the substances upon which depend its affinity for the dye are present in the degenerate tissue. Pure hyaline, whatever its origin, Lubarsch suggests, always stains in the same way, while differences in staining reaction are dependent upon the admixture of other substances. Following Lubarsch, we may distinguish hyaline of epithelial origin and that derived from connective tissue, and, again, we may recognize that which, like the colloid of the thyroid gland, is formed outside of cells, presumably by a process of secretion, and that which is formed by transformation of the cell protoplasm.

The material which in the cases herewith described partly or completely replaces the islands of Langerhans was tested with a variety of agents which have been used in the study of hyaline substances. It stains deeply with acid dyes, like eosin and picric acid, but shows little affinity for nuclear stains, as, for example, hæmatoxylin and methylene blue.

The reactions of amyloid were not obtained with iodine, nor with gentian violet, methyl violet, nor iodine green. The material did not stain by Weigert's method for the demonstration of fibrin.

Of much interest, in view of the study of Ernst, is the behavior of the substance towards picric acid and acid fuchsin. It stains with picric acid, but shows no marked affinity for acid fuchsin. The material, therefore, conducts itself towards Van Gieson's stain as does, according to Ernst, hyaline of epithelial origin.

Finding hyaline substance in irregular masses in contact with the cells, I was at first inclined to believe that it was formed by a process resembling secretion. It was pointed out to me by Dr. Welch, who examined my specimens, that transitions occurred between the cells and the hyaline masses. In slightly altered islands one finds small masses of material which resemble the hyaline substance, but, like the cell protoplasm, have a granular aspect. They correspond in size to the adjacent cells of the island, but contain no nuclei.

By the use of certain stains, phosphomolybdic acid hæmatoxylin by the method of Ribbert for white fibrous tissue or aniline blue as employed by Mallory for the demonstration of white fibres and reticulum, the hyaline material acquires a deep-blue color and becomes very conspicuous. In the islands of Langerhans are not infrequently found slightly enlarged cells, which, though still containing nuclei, exhibit a reaction similar to that

of the hyaline material ; the cell protoplasm, which is still granular, has assumed a diffuse blue color.

The degenerative process first manifests itself by an increase in the size of the cell and an alteration of its protoplasm. With the death of the cell its nucleus disappears, and the protoplasm which stains with acid dyes remains for a time granular, but subsequently becomes homogeneous. Such small particles of hyaline fuse with one another and form larger masses which lie in contact with the fibrous septa of the island. After complete transformation of its cells the island is represented by a hyaline mass penetrated by the remains of altered capillaries.

Focal Necrosis of the Pancreas.—An additional case of diabetes has been associated with a lesion which differs from that present in the cases already cited. A destructive lesion of the pancreas affects not only the interacinar islands, causing death of their cells, but has attacked the secreting parenchyma as well. The process does not present the characters of hyaline degeneration already described, but occurring in foci closely resembles the coagulative necrosis so frequently observed in the liver in association with typhoid fever and other infections. Cells of the islands of Langerhans and of the acini have undergone necrosis, but there is no formation of compact hyaline material, the presence of which is characteristic of the lesions previously observed. The process is apparently acute, yet through-

out the gland the presence of beginning chronic inflammatory changes suggests that the interstitial tissue may proliferate in order to replace defects caused by destruction of the parenchymatous cells.

CASE XXXI.—W. M., male, colored, aged forty-eight years, was admitted to the service of Dr. Osler complaining of frequent micturition, great thirst, and hunger, with which he had suffered for three months. Two months previously sugar had been found in the urine. He had a cough, and his weight had diminished from one hundred and sixty-six to one hundred and ten pounds. Shortly before admission to the hospital he suddenly became unconscious, and hemiplegia affecting the left side appeared. Death occurred on the second day after admission. The urine, examined twice, contained from three and a half to seven per cent. of sugar.

Anatomical Diagnosis.—Pulmonary tuberculosis with cavity formation; acute endocarditis of the aortic and mitral valves; infarcts in the spleen and kidney; chronic diffuse nephritis.

The pancreas presents no notable abnormality; a few ecchymoses are seen upon its surface. Microscopic examination shows a slight increase of the interstitial tissue at the expense of the parenchyma. Newly-formed connective tissue, which occurs in irregular isolated patches within the lobules, contains few cells, and is distended as though by oedema. Foci of necrosis are found in the parenchyma, and involve small areas consisting of a considerable number of acini. The secreting cells have here lost their nuclei, and the cell protoplasm takes a bright stain with eosin; the appearance is that of coagulative necrosis in the liver. Within such an area is found in many instances an island of Langerhans which has undergone an analogous change; the cells have lost their nuclei. Rarely the cells of an island have undergone necrosis while the surrounding acini are entirely normal. Delicate interstitial tissue is in process of

formation within one focus of necrosis, and it is not improbable that the irregularly distributed increase of stroma is the result of previous degenerative changes. A few normal islands of Langerhans are found, but throughout the gland these structures are very sparsely scattered. In sections from the head of the gland foci of necrosis are not found, but otherwise the tissue resembles that of the body ; tissue from the splenic extremity was not preserved.

The process occurring in the preceding case presents features which differ from those of the hyaline change previously described. The pancreas appears to be the seat of focal coagulative necrosis similar to that which attacks the liver and other organs. The parenchymatous cells are not converted into homogeneous masses of hyaline material, but preserving their identity for a time, lose their nuclei and stain deeply with eosin. The possibility suggests itself that patches of delicate sclerosis represent previous foci of similar character. Islands of Langerhans are implicated in the process, and their number is much less than that usually found. In the following chapters will be considered the relationship of this and the other lesions of the islands of Langerhans to diabetes mellitus with which they have been found associated.

CHAPTER X.

THE PATHOLOGY OF DIABETES MELLITUS.

BEFORE considering the relationship of the disease diabetes mellitus to lesions of the pancreas, exemplified by many of the cases previously described, it is desirable to review hastily the important facts which concern this important disturbance of nutrition. The literature of diabetes mellitus is very voluminous. To the great clinical importance of the disease is added the interest which attaches to its bearing upon the physiology of carbohydrate metabolism. Nevertheless, facts which have been fully established are few, and though the condition is subject to varied experimentation, the results obtained have been often contradictory. The physiology of carbohydrate assimilation is not as yet explained, and the disturbances which it undergoes are equally obscure.

The normal blood, it is well known, contains a small quantity of sugar, which occurs as glucose or grape sugar, and is almost constant in amount (0.1 per cent. to 0.2 per cent.). A very minute quantity excreted by the kidneys can be demonstrated in the urine, but is not detected by the tests for sugar ordinarily employed. Excretion of an increased quantity of glucose is the

most conspicuous feature of diabetes mellitus, but such glycosuria is dependent upon underlying metabolic disturbances which manifest themselves by a variety of other symptoms. Increased excretion of sugar by the urine can, however, occur without diabetes, and a variety of causes produce glycosuria in the absence of the grave alterations of nutrition which characterize this disease.

Carbohydrates which are ingested with the food, and in very great part absorbed as glucose, are carried to the liver by the portal circulation, and von Mering has shown by direct observation that the quantity of sugar in the portal blood is increased after a meal. The liver has the power to store up sugar carried to it by the blood; Claude Bernard, and later Schöppfer, found that sugar injected into the mesenteric vein disappears, while an equal quantity injected into a systemic vein is not removed from the blood and causes glycosuria.

Claude Bernard made the important discovery that sugar carried to the liver is stored in the form of glycogen, which, when needed, is returned as glucose to the blood. After ingestion of carbohydrates the amount of glycogen in the liver increases, but disappears almost completely after prolonged abstinence from food. The liver, however, is not the only organ that stores glycogen; it is present in considerable quantity in the muscles, being increased by the ingestion of carbohydrates in large amount and diminished by hunger or by pro-

longed muscular exertion. The muscle cells consume carbohydrates during activity.

The ability of the liver to transform glucose into glycogen is limited, and if in a healthy man or animal a very large amount of sugar is rapidly absorbed from the gastro-intestinal tract, the quantity of sugar in the blood is increased, and is consequently excreted by the urine. The liver, therefore, acting as a storehouse prevents the quantity of sugar in the blood from rising above a relatively fixed amount (0.1 to 0.2 per cent.) ; but if within a given time the capacity of the liver is exceeded, sugar accumulates in the blood and is thrown off by the kidneys ; alimentary glycosuria preceded by alimentary hyperglycæmia follows, both being the result of the limited capacity of the liver and certain other organs to store sugar absorbed from the food. This limit varies in different individuals and is diminished under certain pathological conditions.

A normal individual is able to assimilate from one hundred and fifty to two hundred and fifty grammes of glucose taken after fasting, and no sugar appears in the urine. Under certain conditions, notably in many cases of exophthalmic goitre and with certain neuroses, glycosuria follows the ingestion of much smaller quantities. Diseased conditions of the liver might be expected to favor the occurrence of this form of glycosuria, and in some cases of cirrhosis alimentary glycosuria is readily produced, but the result of such investigations have

been by no means constant. Minkowski has shown that alimentary glycosuria may occur in dogs after partial extirpation of the pancreas, and Wille has demonstrated its association with certain lesions of the human gland.

Temporary glycosuria follows a variety of injuries to the nervous system ; the so-called diabetic puncture of Claude Bernard is the best known illustration. Destruction of the gray matter in the floor of the fourth ventricle, a few millimetres above the point of the calamus scriptorius, in rabbits, dogs, birds, and frogs, is followed by glycosuria. In rabbits, within one to three hours after this operation, sugar appears in the urine, and may constitute as much as six per cent. ; excretion of sugar continues only five or six hours. The condition is associated with an increase of the sugar in the blood, and a variety of experiments indicate that the puncture causes a discharge of glycogen from the liver and probably from the muscles and other organs into the blood, but the evidence upon this point is in part conflicting. In animals deprived of glycogen by prolonged hunger the puncture is ineffectual, while after section of all nerves to the liver glycosuria is of very slight intensity.

A variety of other operations upon the nervous system have been followed by temporary glycosuria presumably analogous with that of Claude Bernard's puncture ; glycosuria, for example, has been observed

after extirpation of the superior cervical ganglion after section and stimulation of the spinal cord at the level of the brachial plexus, after stimulation of the central stump of the vagus when cut, and after section of the sciatic nerve and stimulation of its central end.

One form of glycosuria which has been the subject of varied experimentation is unaccompanied by an increase of sugar in the blood. Following the administration by feeding or injection of the glucocide phloridzin glycosuria occurs in man and in lower animals and persists often twenty-four hours or longer, the amount of sugar excreted greatly exceeding that contained in the glucocide. The quantity of sugar in the blood does not increase, even though the kidneys be extirpated or the ureters ligated in order to prevent excretion of sugar. Hence it is believed that the poison produces some change, as the result of which the kidneys are no longer able to hold back the sugar normally present in the blood. Minkowski has suggested that the glucocide phloridzin is split by the kidney into a substance, phloretin, and a sugar closely resembling glucose; the latter is excreted, but the phloretin is retained and unites with more glucose, which is in turn separated by the kidneys.

Asphyxiation and poisoning with carbon monoxide, morphine, curare, and a variety of substances cause glycosuria, the pathogenesis of which is not understood. In all such instances the condition is temporary, and thus distinguishable from the permanent glycosuria which in

man is associated with the constitutional disease diabetes mellitus.

Permanent glycosuria accompanied by symptoms comparable to those occurring in diabetes can be produced by but one experimental means. The epoch-making investigations of von Mering and Minkowski on the pancreas stand in importance next to those of Claude Bernard. They have demonstrated that the organ is essential to normal carbohydrate metabolism, and its extirpation is followed by a condition which reproduces in animals diabetes mellitus.

Extirpation of the Pancreas.—Observations of von Mering and Minkowski, later amplified by Minkowski, have shown that complete removal of the pancreas in dogs is followed within twenty-four hours by the appearance of sugar in the urine. The quantity of sugar gradually increases, and usually reaches a maximum on the third day, when it may form from eight to ten per cent., even though no carbohydrates have been taken into the gastro-intestinal tract. Glycosuria continues and is associated with a corresponding hyperglycæmia. Glycogen disappears almost completely from the liver and other organs. Symptoms analogous to those of human diabetes occur, and there is greatly increased appetite and excessive thirst, accompanied by increase in the amount of urine; gradual emaciation and progressive weakness precede death, which occurs several weeks after the operation. Acetone and diacetic and oxy-

butyric acid have been found in the urine. Minkowski observed that grape sugar taken with the food is completely excreted by the urine. Since glycosuria continues even when the diet is entirely free from carbohydrates, sugar must be formed within the body; the amount bears a constant ratio (2.8:1) to the quantity of nitrogen eliminated. This constant ratio is best explained by supposing that the total quantity of sugar formed in the body from albumin is, after removal of the pancreas, excreted by the kidneys. Immediately before the fatal termination of the disease, when emaciation and weakness are extreme, and particularly with the onset of complications,—for example, suppurative peritonitis as a consequence of the operation,—sugar may disappear from the urine. A similar phenomenon is observed in human diabetes, and is doubtless due to some interference with the absorption of sugar or with its production within the body from proteids.

Partial removal of the pancreas—if a considerable portion, a fourth or a fifth, remains—is not followed by diabetes, but a smaller part—for example, an eighth or a twelfth—does not suffice to prevent its onset. In such case the severity of the disease is very variable, and may be indicated by an intolerance of the organism for sugar, a very small quantity taken as food causing alimentary glycosuria. Alimentary glycosuria may therefore indicate partial insufficiency of the pancreas.

Experiments, always with negative results, have been

undertaken to show that injury to the organs surrounding the pancreas, particularly to the nerves and ganglia, is responsible for the resulting disturbances of metabolism. Slight injury to the pancreas not infrequently causes transient glycosuria, but never diabetes. That the disease is not caused by inhibition of the pancreatic secretion or by its removal from the intestine is shown by the absence of glycosuria after ligation of the pancreatic ducts or after the formation of a pancreatic fistula; though the pancreatic juice fails to reach the intestine diabetes does not result.

The observations of von Mering and Minkowski on dogs have been confirmed by a very large number of experiments, and extended observations indicate that they are applicable to all classes of vertebrates. In rare instances discordant results have been obtained, but have doubtless been due to the mechanical difficulty of completely removing the gland. Diabetes has been produced in cats and in pigs by Minkowski. Both Weintraud and Kausch have removed the gland from various birds,—namely, ducks, geese, falcons, buzzards, and ravens,—and have observed glycosuria persisting until death. Of considerable interest, however, is the fact demonstrated by Kausch that in geese and ducks the lesion is not constantly followed by glycosuria, although the quantity of sugar in the blood is increased as in other species. It appears that sugar is not readily excreted by the kidneys of these animals. Glycosuria

with fatal termination has been shown to follow the operation in frogs and in turtles (Aldehoff), and in eels (Capparelli).

The pancreas of vertebrates is therefore essential to carbohydrate metabolism, and removal or destruction is followed by the accumulation of sugar in the blood and its excretion by the kidneys. How does the pancreas influence metabolism? Abundant observation has demonstrated that injury to the nerves of the pancreas is not responsible; failure of the pancreatic juice to reach the intestine is not its cause, since ligation of the pancreatic ducts is not followed by diabetes. Furthermore, after partial removal of the gland its splenic extremity, alone remaining, may be transplanted into the subcutaneous tissue without complete destruction of its vascular connections. The nerves of the resected part are severed and the pancreatic juice is wholly lost, yet glycosuria does not follow; if now the transplanted part be removed, diabetes ensues.

The pancreas may influence carbohydrate metabolism in two ways: the organ may furnish something essential to normal nutrition, an internal secretion (to be distinguished from the pancreatic juice, the external secretion), or the gland may destroy some product which accumulates in the body and hinders normal assimilation of sugar. The experimental evidence available is insufficient to decide the relative importance of these possibilities. Lepine has believed that he was

able to demonstrate in the blood a glycolytic ferment capable of transforming sugar. He claims that it is present in normal blood, but absent in that of lower animals or human beings suffering with diabetes. This ferment, he thinks, is formed in the pancreas, from which it is carried by the lymph or blood to the tissues and there furthers carbohydrate assimilation. The basis of Lepine's theory is the observation of Claude Bernard that sugar disappears from drawn blood; Lepine believes that this glycolysis is diminished in diabetic patients and in dogs from which the pancreas is removed. Almost all observers who have repeated his experiments have obtained negative results. The success of thyroid therapy in the treatment of diseases presumably due to the absence of an internal secretion produced by the thyroid gland has pointed the way to numerous analogous experiments upon animals suffering with diabetes, but glycosuria has not been prevented nor diminished by the administration of products obtained from the pancreas.

Since sugar is excreted in the urine after removal of the pancreas, even though carbohydrates are not taken with the food, it is evident that glucose can be formed within the body. Since the amount of sugar in the urine bears a constant ratio to the nitrogen excreted, there can be little doubt that sugar is formed from proteids, and that the entire amount of sugar thus formed is unassimilated and excreted. An additional fact of

considerable interest is the disappearance of glycogen from the liver and muscles after extirpation of the pancreas. Hence it appears that removal of the gland renders the tissues unable to take up and assimilate sugar. The inability of the liver to transform sugar into glycogen applies to glucose, but not to the isometric levorotatory sugar levulose,—for after ingestion of the latter glycogen is found in the liver. Schmiedeberg has suggested that in diabetes glucose in the blood is combined with some substance which prevents its assimilation by the tissues. The tissues are nevertheless able to take up the molecule of levulose. A somewhat analogous explanation of phloridzin diabetes advanced by Minkowski has already been mentioned.

Pancreatic Diabetes.—The experimental studies just described have demonstrated the dependence of carbohydrate assimilation upon the pancreas and have shown that its removal is followed by a condition identical with diabetes mellitus. They suggest a probable relationship between this disease and lesions of the gland in man.

A century before the discoveries of von Mering and Minkowski the association of diabetes with grave lesions of the organ had been observed, and since both conditions are relatively uncommon, a casual relationship had suggested itself. Careful study has failed to demonstrate the constant presence of pancreatic dis-

ease, even when special attention has been directed to the organ, and by many writers it has been claimed that in only an insignificant number of cases is diabetes referable to a lesion of the pancreas.

As early as 1788 Thomas Cawley described a case of diabetes associated with pancreatic calculi and consequent atrophy of the gland. Bright in 1833 recorded a case in which the pancreas was the seat of carcinoma compressing the duct and causing atrophy. Bouchardat in 1875 directed attention to the association of diabetes with lesions of the pancreas, and Lancereaux several years later claimed that diabetes accompanied by wasting is the result of disease of the gland, while diabetes without wasting is dependent upon other factors ; but numerous subsequent observations have failed to confirm this clinical distinction between pancreatic and non-pancreatic diabetes. The experimental observations of von Mering and Minkowski having established in dogs a relationship between the pancreas and diabetes, a renewed interest was given the study of the gland in this disease. Such investigation has shown that though lesions occur in a considerable proportion of cases, on the one hand all cases of diabetes are not accompanied by demonstrable lesions of the pancreas, and on the other hand all lesions of the pancreas are not associated with diabetes.

Hansemann in 1894 collected from the literature cases in which diabetes was accompanied by pancreatic

lesions. In seventy-two cases the following alterations of the gland occurred :

Pancreatic calculi	14 cases.
Carcinoma with obstruction of the duct	5 “
Simple atrophy and interstitial inflammation	38 “
Other lesions	15 “

Such a summary of isolated cases reported by different observers, in many instances without microscopic examination of the gland, gives no accurate conception of the relative frequency of various lesions. Uncommon conditions—for example, calculi and carcinoma—are more likely to be reported. Among the unclassified lesions noted by Hansemann is necrosis of the gland. There are also included a number of insignificant lesions,—for example, hyperæmia and fatty degeneration of the parenchyma, conditions which are in a great majority of instances unassociated with diabetes and are doubtless not responsible for its occurrence.

Dieckhoff studied seven cases of diabetes, in all of which the pancreas was diseased, and from the literature collected others in which the condition was, he believed, referable to the gland. In forty-nine cases the lesion was as follows :

Acute pancreatitis	5 cases.
Chronic pancreatitis	15 “
Carcinoma	4 “
Atrophy, lipomatosis	21 “
Cysts	4 “

Statistics of the older writers not based upon careful macroscopic and microscopic examination of the gland are of little value, and those of Windle (pancreatic lesions present in seventy-four of one hundred and thirty-nine cases of diabetes), of Seegen (seventeen of ninety-two), and of others, admit no trustworthy conclusions.

Much more accurate statistics are obtainable, as Hansemann recognized from a series of consecutive cases. In the Pathological Institute in Berlin he studied fifty-four cases, of which in forty occurred lesions of the pancreas; in six no note was made upon the gland; while in eight, though it was examined, no lesion was found.

The lesions observed were as follows :

Atrophy (granular)	36
Fibrous induration (with hypertrophy)	3
Complicated case	1

Williamson studied twenty-three cases of diabetes, of which in twenty-two the pancreas was examined microscopically. In twelve cases the gland was normal (eight cases) or atrophied (four cases) to a degree not out of proportion to the wasting of other organs. In four cases chronic interstitial pancreatitis was present, in one lipomatosis, in two atrophy with fatty degeneration, in three atrophy without other lesion, and in one carcinoma.

I have examined the pancreas from nineteen cases of

No.	No. in Text.	Age, years.	Condition of Pancreas.			Remarks.
			Weight, grammes.	Secreting Parenchyma.	Islands of Langerhans.	
1	33
2	XXX., p. 227	47	90	Interacinar inflammation.	Hyaline.
3	11	25
4	X., p. 180	49	Interacinar inflammation.	Fibroid.
5	47	60	Cirrhosis of the liver.
6	47	58	Pancreas is small.
7	XII., p. 186	43	50	Interlobular inflammation.	Fibroid.	Pancreas is small.
8	14	Scant in number.	Pancreatic calculi.
9	XI., p. 181	47	108	Interacinar inflammation.	Fibroid.
10	10	45	Cirrhosis of the liver.
11	30	51	Scant in number.
12	XXIX., p. 225	51	65	Interacinar inflammation.	Hyaline.	Pancreas is small.
13	XXVI., p. 219	54	80	[Interacinar inflammation.]	Hyaline.
14	XXVIII., p. 224	73	120	Interacinar inflammation.	Hyaline.	Changes slight, except in islands.
15	XXV., p. 215	17	Hyaline degeneration.	Hyaline.
16	54.5
17	XX., p. 199	63	82	Interacinar inflammation.	Fibroid.	Pancreas is small.
18	XXXI., p. 234	48	Focal necrosis.	Necrosis.	Advanced arterial sclerosis.
19	XXVII., p. 223	48	61.5	[Interacinar inflammation.]	Hyaline.	Changes slight, except in islands.

diabetes, and in all the condition of the various histological elements of the gland has been noted. These data are collected in the accompanying table (see p. 250). Many of these cases have been previously cited in describing some of the peculiar lesions to which the organ is subject. The condition of the pancreas noted in the table is as follows :

Chronic interlobular pancreatitis with calculi	1
Chronic interacinar pancreatitis	3
Hyaline degeneration of the islands of Langerhans (Case XXXI. included) with, in some instances, chronic interacinar pancreatitis	7
Atrophic pancreas	4
Normal pancreas	4

The following grave lesions of the pancreas have been found associated with diabetes by the various writers cited : carcinoma destroying the gland ; acute pancreatitis, usually with hemorrhagic necrosis of the organ ; chronic interstitial pancreatitis following obstruction of the ducts by calculi, cysts, or carcinomata ; chronic interstitial pancreatitis due to other causes ; simple atrophy of the pancreas. Certain features associated with each of these conditions demand consideration, but it is unnecessary to discuss the relationship to diabetes of less important alterations,—for example, hyperæmia, parenchymatous and fatty degeneration, which so commonly occur without any disturbance of carbohydrate metabolism.

Destructive Lesions of the Pancreas with Diabetes.—Though complete removal of the pancreas in lower animals is followed by diabetes, numerous writers have claimed that in man complete destruction of the organ, which may be the result of necrosis following hemorrhagic inflammation or of carcinoma invading and destroying the gland, is not invariably followed by diabetes. Hansemann has considered at length the evidence in favor of this objection to a pancreatic origin of the disease.

Acute inflammation of the pancreas associated with suppuration or necrosis may cause extensive destruction of the gland, yet in only two of about one hundred cases cited by Fitz and by Seitz was diabetes present. Total destruction of the pancreas caused by acute inflammation is quickly followed by death, with symptoms of great severity; in less rapidly fatal cases the whole organ is not implicated. After extirpation of the pancreas, moreover, a variable time elapses before sugar appears in the urine; and in most cases, shortly before the fatal termination or with the onset of severe complications, glycosuria disappears.

Destruction of the pancreas may be caused by diffuse carcinomatous new growth invading the organ and replacing the parenchyma. In another category belong those more frequent instances in which a new growth compressing the duct has produced secondary chronic inflammation of the gland. Hansemann describes two cases in which a diffuse primary carcinoma of the pan-

creas had caused such complete destruction of the organ that no glandular tissue was recognizable in the sections which he examined; diabetes, however, was absent. He suggests that though the gland can no longer produce an external secretion,—the pancreatic juice—the tumor cells derived from the parenchyma of the gland are still capable of exerting that influence upon carbohydrate metabolism which favors the assimilation of sugar: the internal function is not lost. He cites the observation not infrequently made that primary carcinoma of the adrenal is usually unaccompanied by Addison's disease.

The difficulty of identifying within a carcinomatous mass small indurated, but yet well preserved, areas of pancreatic parenchyma should be recognized; and even though the secreting acini have been destroyed, it is possible that islands of Langerhans, which superficially resemble alveoli of carcinomatous cells, may still persist. On the other hand, as Ssobolow has pointed out, should we believe that the internal function of the pancreas is performed by the islands of Langerhans, carcinomata arising from these structures could alone supply this deficiency.

Atrophy of the Pancreas with Diabetes.—Accompanying diabetes diminution in the size of the pancreas has been more frequently noted than any other abnormality of the gland. The normal organ is subject to much variation, and its weight is differently estimated by

anatomists. Vierordt has given the normal weight as from eighty-eight to one hundred and two grammes, and Hansemann thinks that it more frequently approaches the larger than the smaller figure; Kraus gives from sixty-seven to one hundred and five grammes. Doubtless a weight below sixty-five grammes should be regarded as abnormal. So-called atrophy has been frequently associated with severe alterations of the parenchyma, notably with chronic interstitial inflammation, in some instances following occlusion of the pancreatic duct, and such cases are to be separated from those in which the tissue presents a normal histological character.

Hansemann discusses the relationship of atrophy to diabetes. Is it a consequence of the general emaciation associated with diabetes, and is it therefore secondary to this disease? The pancreas doubtless shares the atrophy which all organs undergo as the result of cachexia from any cause; but since the pancreas is little affected, although the other organs of an emaciated individual are much diminished in weight, Hansemann concludes that only a slight diminution in size can be secondary to diabetes. Moreover, atrophy of the pancreas is not limited, as Lancereaux supposed, to those cases of diabetes accompanied by emaciation, for Hansemann found that of thirty-six cases in which the pancreas was atrophied, in six instances the affected individual was corpulent.

Hansemann, however, attempts to make an anatomical distinction between the so-called atrophy of diabetes and the less marked atrophy of general cachexia. The distinction which he draws removes the former from the domain of simple atrophy and characterizes it as a variety of chronic interstitial inflammation. Nevertheless, in a carefully studied series of cases Williamson has demonstrated the co-existence of diabetes and extreme diminution in the size of the pancreas unassociated with any demonstrable alteration of the parenchyma. In five of twenty-three cases the pancreas was atrophied to an extent bearing no relationship to the general wasting of the other organs. In two of these cases the glandular cells showed fatty degeneration, but in three cases the parenchyma appeared to be normal. In one instance the organ in a man weighed only a quarter of an ounce (eight grammes).

In four of my cases the pancreas was diminished in size (three glands weighing 60, 58, and 51 grammes in individuals respectively forty-six, fifty-six, and thirty years of age, the fourth, 54.5 in an old woman whose age was not known), but no other alterations were observable. Since the gland shows no structural change, it is conceivable that the condition is congenital, and the pancreas being unusually small, at some period of life fails to meet the demand made upon it, so that diabetes results. The data at hand, however, are insufficient to establish this hypothesis.

Chronic Interstitial Pancreatitis with Diabetes.—The association of chronic interstitial inflammation with diabetes has been very frequently observed. In some instances chronic inflammation has followed obstruction of the pancreatic duct by calculi, carcinoma of the head of the gland or cysts causing compression of the ducts, and such cases are cited in the statistics of Windle, Hansemann, and Dieckhoff. Though a considerable number of cases has been reported, the condition is relatively uncommon; and where consecutive cases of diabetes have been studied by one observer, duct-obstruction is found to be relatively infrequent. In none of forty cases did Hansemann find sclerosis consequent upon the presence of calculi, but in two examples of advanced sclerosis with calculi diabetes was absent. Williamson found among his twenty-three cases of diabetes one with sclerosis following stone-formation.

In only one of the cases which I have described did diabetes accompany pancreatic calculi; here the consequent induration of the gland and destruction of its parenchyma were far advanced. Of considerable importance is the fact that the associated diabetes was of mild character, glycosuria disappearing when carbohydrates were withdrawn from the diet. On the other hand, in two of my cases with advanced sclerosis following obstruction of the pancreatic duct—in one case caused by calculi (Case XII.), in another by carcinoma (Case IX.)—diabetes was absent. Ligation of the pan-

creatic ducts in animals is rarely, if ever, followed by diabetes. The severe inflammatory changes which in human beings follow duct-obstruction, associated in most instances with conditions favoring ascending infection with bacteria, are followed by diabetes only when they have reached such an advanced stage that the parenchyma is almost wholly replaced and compressed by dense fibrous tissue. The relationship of the lesion to the histological elements of the gland will be discussed later.

Chronic pancreatitis due to causes other than duct-obstruction is not infrequently associated with diabetes, but chronic pancreatitis is not always, or indeed in the majority of instances, accompanied by diabetes. Since experimental investigations have shown that in order to produce glycosuria it is necessary to remove a large part of the pancreas, we need not expect the condition with chronic inflammation unless a great part of the parenchyma has been destroyed or functionally impaired.

Various observers have attempted to define a type of pancreatitis peculiar to diabetes. G. Hoppe-Seyler and Fleiner have described cases of the disease in which chronic interstitial inflammation of the organ accompanied general arterial sclerosis. Lemoine and Lannois, as already noted, have studied pancreatitis in four cases of diabetes, and have thought that the new growth of interstitial tissue has its seat of origin in the perivascular

tissue, whence fibrous processes extend between the parenchymatous structures. An important feature of the inflammatory change described by them is the penetration of fibrous strands into the acini, separating the cells and producing what they designate unicellular sclerosis.

Hansemann has claimed that one variety of pancreatitis is always accompanied by diabetes. He designates the condition atrophy, but the character of the lesion and, what he particularly emphasizes, the features which distinguish it from atrophy consequent upon emaciation identify it as chronic inflammation. The organ is diminished in size and is flattened from before back. Its increased interstitial tissue is in continuity with that of the adjacent structures, and consequently removal of the organ is more difficult than usual. The microscope demonstrates an atrophy of the parenchymatous elements which are in part replaced by new fibrous tissue. With cachectic atrophy, on the contrary, glandular cells and interstitial tissue have undergone equal atrophy. Hansemann thinks that this pancreatic lesion characteristic of diabetes is similar to certain forms of granular atrophy of the kidneys. Since the new growth of interstitial tissue is always accompanied by diminution in the size of the organ, he distinguishes granular atrophy from fibrous induration with hypertrophy, which in three instances he found associated with diabetes. This fibrous induration characterized by coarse bands

of newly-formed stroma is usually unaccompanied by diabetes.

In a preceding chapter I have shown that two forms of chronic inflammation of the gland are distinguishable: (1) interlobular pancreatitis, characterized by proliferation of fibrous tissue between the lobules which are invaded from the periphery, and (2) interacinar pancreatitis, where the newly-formed fibrous tissue is more diffusely distributed within the lobules and between individual acini. With the first type the islands of Langerhans are implicated only when the sclerotic process has reached a very advanced grade. To this variety belongs the chronic inflammation which follows occlusion of the pancreatic duct. Though the secreting tissue of the gland is in very great part destroyed and replaced by dense fibrous tissue, the interacinar islands are not affected and persist for a long time as isolated cellular structures almost completely unchanged, though surrounded by scar-like tissue; they suffer only when the process is far advanced. With the interacinar type of inflammation, on the other hand, the islands are affected as are the other elements of the gland, and coarse strands of fibrous stroma following the capillary vessels separate columns of atrophied cells.

Should there be a type of pancreatitis peculiar to diabetes,—that is, a form of inflammation impairing the internal function of the gland,—glycosuria would not ensue until the lesion had reached a certain grade of

intensity, and in its earliest stage the lesion would not be accompanied by diabetes. On the other hand, when chronic interstitial pancreatitis, whatever the type may be, has destroyed a very large part of the parenchyma, diabetes may be expected; the specific type, should such exist, would be associated with the disease at an earlier stage.

Of twenty-one instances of chronic pancreatitis of the interlobular type in only one was diabetes present. Here, as mentioned above, the inflammation which followed obstruction of the pancreatic duct had reached a very advanced grade, and the islands of Langerhans, isolated in the dense stroma, had undergone alterations; the accompanying glycosuria had been of slight severity and had disappeared when the patient was upon a diet poor in carbohydrates. In seven of nine instances of interacinar pancreatitis, diabetes mellitus was present. In one case without diabetes the lesion was but little advanced, and the organ was of large size, weighing one hundred and seventy grammes; while in the other case the lesion was of such slight intensity as to be unrecognizable in many parts of the tissue.

CHAPTER XI.

THE RELATION OF DIABETES MELLITUS TO LESIONS OF THE PANCREAS.

Relation of Diabetes to Lesions of the Islands of Langerhans.—For the purpose of the present study it is pertinent to inquire what histological changes in the pancreas are associated with the occurrence of diabetes. When a lesion of the pancreas is the cause of the disease, is the condition dependent upon changes in the acini or in the islands of Langerhans or in both? Total destruction of the acini is often accompanied by destruction or alteration of the interacinar structures, and rarely are the islands of Langerhans the seat of marked lesion while the acini remain unchanged.

The islands of Langerhans are composed of columns of cells having no communication with the ducts of the gland, but in intimate relation with a rich capillary network, and an analogous condition is found in the thyroid gland and in the adrenal. The pancreas, as do these organs, exerts through the medium of the blood an important influence on metabolism. Whether the gland furnishes some substance which aids carbohydrate assimilation or destroys some noxious product hindering it is immaterial to the present study. Where

diabetes is the result of pancreatic disease, do the islands of Langerhans exhibit lesions?

With the interacinar type of chronic pancreatitis, which, except in its earliest stage, is accompanied by diabetes, the islands of Langerhans are invaded by the inflammatory process. With the interlobular type, which may follow obstruction of the pancreatic ducts or ascending infection of the gland, diabetes ensues only in those relatively uncommon instances in which the lesion has reached a very advanced grade; the sclerotic process, which in many cases at least has its origin in the ducts of the gland, spares the islands of Langerhans and causes their destruction only when the gland is almost wholly transformed into dense sclerotic stroma. These facts, however, do not demonstrate with certainty the dependence of diabetes upon alterations of the islands of Langerhans, for on the one hand with interacinar pancreatitis the secreting parenchyma is equally affected, while on the other hand, in instances of interlobular inflammation, the secreting alveoli are preserved, even when the lesion is far advanced.

In a preceding chapter I have shown the susceptibility of the pancreas to hyaline degeneration. The first example of the lesion which came to my observation was accompanied by a severe type of diabetes, and though the islands were so altered as to be completely unrecognizable, the secreting parenchyma was in great part destroyed. The succeeding instances of this re-

markable lesion clearly demonstrated the relationship of diabetes to a destructive lesion of the islands, for though these structures had undergone very grave alterations and were often converted into almost homogeneous hyaline masses, the secreting parenchyma, notably in Cases XXVI. and XXVII., showed only a very insignificant increase of the stroma, which in many parts of the gland was wholly unaltered.

Subsequent observations have demonstrated the surprising frequency with which this selective lesion accompanies diabetes, and in six of the nineteen cases of diabetes which I have studied it has been found. In three of these cases, XXVI., XXVII., and XXVIII., described in detail, the lesion of the islands had doubtless been of such a character as to render them almost completely functionless, though the remaining parenchyma was relatively well preserved. The other cases, including Case XXXI., in which the lesion resembled coagulative necrosis of the liver, could not be studied so completely, and lesions of the islands appeared to be less widespread.

Since the publication of the observations recorded above, several writers have described lesions of the islands of Langerhans accompanying diabetes. Gentes has described a case of diabetes with chronic interstitial pancreatitis invading the islands of Langerhans. Weichselbaum and Stangl studied the pancreas from eighteen cases of diabetes, and in a considerable number, not

definitely stated, found the islands of Langerhans diminished in size and irregular in shape; the fibrous stroma within them was thickened, and their cells were atrophied and contained small nuclei which stained homogeneously. These writers state that in some instances the stroma was greatly thickened and almost homogeneous, so that the islands resembled degenerate renal glomeruli; hence it is probable that they observed the hyaline condition previously described. Herzog has studied three cases of diabetes in which the islands of Langerhans were the seat of marked sclerotic changes. In one case with a severe type of diabetes interacinar islands were no longer recognizable, but throughout the pancreas, which was the seat of a moderate interstitial inflammation, occurred small round or irregular masses of connective tissue corresponding in size and distribution to these structures, of which they doubtless represented the former site.

In a child ten years of age suffering with diabetes Schmidt observed a lesion of the islands of Langerhans characterized by both acute and chronic changes and affecting only very slightly the secreting parenchyma. Schmidt recognized the interacinar and interlobular type of chronic pancreatitis which I had described, and in two instances found accompanied by diabetes the interacinar lesion which implicated the islands of Langerhans. In another case in which carcinoma occupied the tail of the pancreas, while the remainder of the gland was

the seat of advanced chronic inflammation in consequence of calculi in the duct, the islands, imbedded in dense stroma were the seat of sclerotic changes; diabetes had been present. In a fifth case of chronic pancreatitis islands of Langerhans, though often isolated in dense stroma, were numerous and not invaded by the inflammatory process.

Additional cases of hyaline degeneration of the islands of Langerhans with diabetes have been described by Wright and Joslin, who report two cases with only very slight alterations of the glandular acini. Herzog has described an instance in which the lesion was associated with slight chronic interstitial inflammation, and Schmidt has described a similar case in which there was no lesion of the parenchyma.

Hansemann alone among those who in the last few years have systematically studied the islands of Langerhans in diabetes reaches the conclusion that they have no relationship to the disease. Hansemann, it may be mentioned, discards the now generally accepted view that these bodies are composed of epithelial cells having a common origin with those of the secreting acini, but thinks that they are mesoblastic structures formed about dilated capillaries. He never failed to find interacinar islands in the pancreas from thirty-four cases of diabetes referable to severe lesions of the gland; where almost the whole parenchyma was destroyed they were usually scant in number, though

some persisted without recognizable alterations. In six cases he found the islands of Langerhans invaded by what he regards as hyaline connective tissue, giving an appearance similar, he states, to that which I had described, but they were not more changed than the secreting parenchyma.

Hansemann admits, however, that he has not been able to find similar alterations in cases of interstitial pancreatitis unaccompanied by diabetes. Little significance can be attached to the fact that in no case were all of the islands completely destroyed. It is, moreover, not possible to determine from Hansemann's statement in how many cases of pancreatic diabetes the islands were altered, since he dismisses with little comment those in which the islands were implicated in a wide-spread destruction of the parenchyma.

Relation of Diabetes to a Diminution in the Number of Islands of Langerhans.—Several recent writers have claimed that diabetes may be associated with diminution or even entire absence of the islands of Langerhans. Ssobolew in a preliminary communication published in 1900 cited two cases of diabetes in which he claimed that these structures were wholly absent, and in four of fifteen cases described several years later he failed to find them. Since the secreting parenchyma was entirely normal, he assumed that the islands might disappear without leaving any trace. In nine cases he found the number of islands diminished. Schmidt has

never failed to find interacinar islands and is sceptical of Ssobolew's observations. Ssobolew did not examine sections from the various parts of the pancreas and failed to recognize the fact that islands may be very numerous in the tail of the gland while they may be almost absent in other parts. In single sections I have failed to discover these structures, but in all cases of diabetes which I have examined islands have been found in fair abundance, particularly in the tail of the organ.

Weichselbaum and Stangl carefully studied the islands of Langerhans in the pancreas of diabetics. They compared sections with control specimens made from corresponding parts of the pancreas obtained from individuals of the same age, and reached the conclusion that with diabetes the number of islands may be diminished; and since the pancreas is almost always atrophic, the total number of islands is still further curtailed. They did not, however, separate cases in which the islands showed lesions from those in which they were apparently normal.

In order to definitely determine the number of the islands, it is essential to count them in sections from corresponding parts of the gland. When the interacinar bodies are the seat of destructive lesions, it is obvious that the number capable of functional activity is diminished, but considerable interest attaches to those cases in which no lesion can be demonstrated. In the following cases

of this character sections from three parts of the gland were examined (exceptions are noted) and the number of islands in 0.5 square centimetre determined.

No. of Case. Table, p. 250.	Age of Patient, years.	Weight of Pancreas, grammes.	Relative Number of Islands of Langerhans in		
			Head.	Body.	Tail.
1	33	—	— (9)	— (5)	—
3	11	25	— (7)	—	—
5	47	60	— (23)	— (21)	—
6	47	58	17	16	32
8	14	—	12	5	10
10	10	45	50	19	42
11	30	51	6	5	8
16	—	54.5	32	31	42

NOTE.—In Cases Nos. 1, 3, and 5 tissue was not preserved from different parts of the gland, and the figures in parenthesis represent the number of interacinar islands in sections taken at random.

Comparison with the table on page 80 shows that the above figures present no constant departure from the normal. In the head and body of the pancreas about eighteen islands occur in 0.5 square centimetre; in the tail, approximately thirty-two. A striking diminution is seen in Cases No. 8, and No. 11, and is particularly noteworthy in Case No. 8, a child of fourteen years, in whose pancreas we would expect the number of islands to be greater than in that of the adult. In this case the existence of hereditary diabetes¹ suggests the occur-

¹ The case is described by Dr. Pleasants in a paper on "Hereditary Diabetes Mellitus, with a Report of Six Cases Occurring in a Family." Bulletin of the Johns Hopkins Hospital, 1900, xi., 325.

rence of a congenital defect of the gland. In no instance, therefore, does the appearance of the gland suggest a condition of atrophy, as most writers assume. Since the organ is normal in structure, it is rather more probable that a congenital deficiency of pancreatic tissue has occurred.

Since diabetes does not follow partial removal of the pancreas in dogs when a fourth or a fifth of the organ remains, it seems probable that a gland weighing from fifty to sixty grammes, even should the relative number of islands be small, would be sufficient to prevent diabetes. We are, however, unable to estimate the effect of prolonged exertion on the part of the defective gland to carry on functions necessary to normal metabolism. Moreover, slight, hardly recognizable changes—for example, arterial sclerosis—may at some period of life be sufficient to overtopple the equilibrium heretofore preserved by the overworked gland.

In the series of cases included in the foregoing table, the pancreas, though small, showed no noteworthy deviation from the normal gross or histological structure. While diminution in the size of the gland, together with absolute and relative diminution in the number of interacinar islands, may occasionally explain the occurrence of diabetes, with our present knowledge it is unjustifiable to assume the existence of such functional deficiency when no lesion can be demonstrated by the methods at our disposal.

Relationship of Diabetes to Organs other than the Pancreas.—Most writers agree that cases of diabetes occur in which no abnormality of the pancreas is demonstrable. Case No. 10, in which the normal pancreas of a child ten years old weighed forty-five grammes, may serve as an example. The existence of such cases, however, does not weaken the evidence in favor of the pancreatic origin of the disease in other instances, for abundant experimentation has demonstrated the complexity of carbohydrate metabolism and has shown that the central nervous system and the liver exert an important influence in regulating the amount of sugar in the blood, while removal of an excess present in the blood is effected by the kidneys.

The experimental observations upon temporary glycosuria caused by changes in the central nervous system, the liver, and the kidneys have been followed by the study of human cases in which glycosuria or not infrequently permanent diabetes has been associated with lesions of these organs; but while the relationship of the pancreas to diabetes has been very thoroughly established both by experimentation and observation, the relationship of lesions affecting other organs is much more obscure. Moreover, diabetes has been found to accompany certain relatively uncommon diseases—for example, exophthalmic goitre and acromegaly—with such frequency that the association cannot be regarded as accidental. In some instances where

diabetes has been supposed to be the obscure result of a condition recognizable during life, it is in reality secondary to a lesion of the pancreas the existence of which is not recognizable unless an autopsy is performed.

Arterial sclerosis, as is well known, is present in a large proportion of diabetics, and diabetic gangrene is referable, in many cases at least, to implication of the arteries supplying the extremities. Grube found arterial sclerosis in sixty-six of one hundred and seventy-seven cases of diabetes. G. Hoppe-Seyler and Fleiner have described cases of diabetes in which chronic interstitial inflammation of the organ accompanied general arterial sclerosis. Case XX. of my series illustrates this condition; here both chronic interacinar pancreatitis and gangrene of the leg appear to be the result of advanced arterial sclerosis. In two of my cases, including that just mentioned, arterial sclerosis has been recognizable in sections from the pancreas, the small arteries of the organ showing thickening of the intima or degenerative changes in the media. It is not improbable that arterial sclerosis produces diabetes, or at least favors its occurrence by altering the nutrition of the pancreas.

There is, I believe, sufficient evidence to demonstrate that diabetes accompanying cirrhosis of the liver is, in the majority of cases at least, the result of chronic interstitial pancreatitis; chronic inflammation of the liver and pancreas coexist as the result of the same primary

etiological factor,—for example, alcohol. Diabetes with cirrhosis is a well-recognized condition, and numerous cases are recorded; among one hundred and twenty-eight cases of diabetes observed in hospital clinics by Naunyn, seven were accompanied by cirrhosis, but in his private practice, among one hundred and fifty-eight cases, twenty-two were with cirrhosis. I have studied three cases in which the two conditions were associated, and in all the pancreas was the seat of chronic interacinar inflammation invading the islands of Langerhans. In cases of diabetes accompanying cirrhosis described with autopsy report by Dieckhoff and by Pusinelli, the pancreas showed chronic inflammatory changes.

The relationship of cirrhosis of the liver to chronic interstitial pancreatitis has already been discussed. The condition known as hæmochromatosis, to be described later, offers an excellent illustration of the dependence of cirrhosis of the liver and chronic pancreatitis upon the same etiological factors; in this condition diabetes occurs as a terminal event, when the pancreatic inflammation which is of the interacinar type has reached a moderate grade of severity.

The possibility suggests itself that the alimentary glycosuria inconstantly observed with cirrhosis of the liver by Colrat and Couturier, Krause and Ludwig, and others, may be the result of slight coexisting alterations of the pancreas, for Wille has shown that lesions of the gland accompanying, for example, primary carcinoma

or carcinoma of the stomach invading the pancreas, may be associated with alimentary glycosuria.

Added interest is attached to the remarkable association of acromegaly and diabetes by the fact that the former disease is not infrequently accompanied by induration of the interstitial tissue of the pancreas. Hansemann found diabetes present in twelve of ninety-seven reported cases of acromegaly, a case of his own included. More recently Schlesinger has described three cases of acromegaly, one associated with diabetes, a second accompanied by transient glycosuria, and a third with alimentary glycosuria. Fränkel, Stadelmann, and Benda among four cases of acromegaly observed one with temporary glycosuria and a second with diabetes.

A review of cases described with autopsy reports shows that chronic pancreatitis has been repeatedly observed in association with acromegaly ; the probability is, therefore, strong that diabetes is referable to this lesion, even though cases with diabetes have been described in which it is claimed there was no lesion of the gland. Dallemange found chronic interstitial inflammation of the gland in two cases of acromegaly, one of which was associated with diabetes. In the case of acromegaly with diabetes described by Hansemann chronic pancreatitis was present. In a case with glycosuria, recorded by Fränkel, Stadelmann, and Benda, the pancreas showed a condition described as nodular hyper-

trophy, while in a second with diabetes no lesion was noted, but here no microscopic examination was made. In one case of acromegaly without diabetes, described by the writers just named, and in a similar case described by Mitchell and Le Count, chronic inflammation of the pancreas was demonstrable. Pineles found at autopsy upon a case of acromegaly with persistent diabetes purulent pancreatitis with fat necrosis, but the presence of pre-existing chronic inflammation can only be suspected. The cases cited indicate that induration presumably analogous to that which acromegaly causes elsewhere occurs also in the pancreas and where sufficiently advanced produces glycosuria or even permanent diabetes.

The relationship of diabetes to the central nervous system has been much discussed. The influence of the nervous system upon the excretion of sugar is shown by Claude Bernard's puncture of the floor of the fourth ventricle and by other experimental injuries to the central nervous system. That glycosuria frequently follows injuries to the brain is shown by the statistics of Higgins and Ogden, who found glycosuria in 9.3 per cent. of two hundred and twelve cases of traumatism affecting the head, while of forty-five cases in which the skull was fractured glycosuria followed in 21.9 per cent. Instances of permanent diabetes following cerebral lesions are recorded, but the relationship of the disease to the injury is doubtful. Diabetes is occasionally

associated with tabes dorsalis or with multiple sclerosis, and has been regarded as secondary to the nervous lesions.

Of greater interest, in view of the experiments of Claude Bernard, is the recorded association of lesions of the medulla with diabetes. In cases of multiple sclerosis described by Weichselbaum and by Richardiere plaques occupied the floor of the fourth ventricle. Remarkable instances in which small tumors have encroached upon the floor of the fourth ventricle are recorded by Levrat-Perroton, von Recklinghausen, and Verron. In a case recorded by Michael a cysticercus occupied the fourth ventricle. Even though the great rarity of such conditions be considered, it is not impossible that they may act as exciting causes in the production of diabetes.

Glycosuria following the administration of phloridzin has been mentioned. Since most observers are agreed that with this form of glycosuria the amount of sugar in the blood is not increased, the possibility has suggested itself that the kidneys are so altered that they admit the passage of the sugar normally present in the blood. The occurrence of an analogous renal diabetes in human beings has been suspected. Klemperer has described a case of diabetes associated with nephritis. The amount of sugar in the blood was not greater than normal, and after the administration of one hundred and fifty grammes of glucose the amount of sugar in the urine and in the

blood was not increased. Cases in which pre-existing nephritis has been associated with diabetes are cited by Naunyn and by Eger, but since they may be referable to the more or less accidental co-existence of these two conditions, they do not furnish strong evidence that glycosuria is dependent upon the renal lesion.

Richter has studied experimentally the relationship of glycosuria to lesions of the kidney. Small doses of corrosive sublimate injected into the venous circulation of rabbits cause not only albuminuria, but glycosuria as well. Very small doses, however, may cause glycosuria, but no albuminuria; and since the amount of sugar in the blood is found to be increased, Richter does not think that the glycosuria should be attributed to alterations of the kidneys. Glycosuria produced by phloridzin is, moreover, diminished or prevented if a lesion of the kidney is produced by the administration of aloin or potassium chromate. Elbinger and Selig rendered dogs diabetic and then administered cantharadin in order to injure the kidneys. They found that glycosuria diminished with the onset of renal changes. Lesions of the kidney in animals appear to retard rather than favor the excretion of sugar, while it has been observed that in cases of diabetes glycosuria not infrequently diminishes with the appearance of albuminuria. True renal diabetes may occur as the result perhaps of some peculiar injury to the kidney, but its existence has not as yet been demonstrated.

The association of diabetes with diseases of certain ductless glands is of considerable interest. Exophthalmic goitre has been not infrequently accompanied by diabetes; and Hannemann, who has made a careful survey of the literature, has been able to collect fifteen cases in which the two diseases were associated. At least a dozen writers have observed temporary glycosuria with exophthalmic goitre. Alimentary glycosuria with exophthalmic goitre was first observed by Kraus and Ludwig; later, Chvostek reached the conclusion that it occurs in sixty-nine per cent. of all cases, but Strauss observed glycosuria after the administration of one hundred grammes of grape sugar in only three of nineteen cases. Glycosuria following the therapeutic use of thyroid extract has been observed. In none of the cases of diabetes associated with exophthalmic goitre has the condition of the pancreas been studied.

The claim has been recently advanced that the adrenal gland exerts an influence upon carbohydrate metabolism. Blum has produced temporary glycosuria by injecting extracts made from the adrenal into the subcutaneous tissue or veins of a variety of animals. The extract produces very grave toxic symptoms and not infrequently death, so that it is by no means improbable that the substance acts upon organs which control carbohydrate metabolism. Herter and Richards have found that if the extract known as adrenalin be injected into the peritoneal cavity glycosuria is of greater in-

tensity than after subcutaneous injection. By merely painting the surface of the pancreas with the extract a similar effect is produced.

Summary and Conclusion.—The occurrence of glycosuria and diabetes in association with lesions of the nervous system, with disease of certain ductless glands, and after the administration of certain toxic substances, indicates the complexity of carbohydrate metabolism. Normal assimilation of sugar doubtless depends upon a variety of factors, among which integrity of the pancreas, though very important, does not stand alone, and disturbances of carbohydrate metabolism may be the result of conditions affecting other organs. Hence the occurrence of diabetes unaccompanied by alterations of the pancreas is not surprising and furnishes no evidence to disprove the relationship of the disease to grave lesions of the gland. Nevertheless the occurrence of pancreatic diabetes is much more frequent than has been supposed. The foregoing, moreover, has shown that in many instances, at least, diabetes, associated with a variety of conditions, arterial sclerosis, cirrhosis of the liver, hæmochromatosis, and acromegaly, is secondary to a lesion of the pancreas accompanying these diseases. Arterial sclerosis, hæmochromatosis, and acromegaly produce chronic interstitial inflammation of the pancreas, while cirrhosis of the liver accompanies chronic pancreatitis, because both are the result of the same etiological factor. The relationship,

of the nervous system, of the kidneys, and of the thyroid and adrenal glands to diabetes is more obscure.

In order to accurately determine the frequency of pancreatic diabetes, the relative frequency of accompanying lesions of the pancreas, and the relationship of the gland to alterations in other organs it is essential that a considerable number of cases be studied with such care that it is possible to determine not only the existence of acquired lesions but the occurrence of congenital anomalies, causing, it may be, functional insufficiency. In every case of diabetes the weight of the gland should be determined; sections should be examined from the head, mid-part of the body, and splenic extremity of the gland, and the character and extent of existing lesions determined. In the absence of pathological changes the number of the islands in various parts of the gland should be determined by actual count, and a possible diminution of their relative and absolute number estimated.

The following important facts are, I believe, established: (1) In considerably more than half of all cases diabetes is the result of a destructive lesion of the pancreas. (2) Where diabetes is the result of pancreatic disease, injury to the islands of Langerhans is responsible for the disturbance of carbohydrate metabolism, since that influence which the normal pancreas exerts upon the assimilation of sugar is a function of these structures. (3) The most common lesions which injure the islands of

Langerhans are chronic interstitial inflammation of the interacinar type and hyaline degeneration. Chronic interstitial inflammation may be the result of general arterial sclerosis or of toxic substances,—for example, alcohol causing chronic inflammation of both the liver and pancreas. The islands of Langerhans show a special tendency to undergo hyaline degeneration, but the cause of this lesion is obscure. (4) Other lesions of the pancreas do not exhibit a tendency to select the islands of Langerhans, but produce diabetes because they destroy the interacinar islands along with the secreting parenchyma. Such is true of very advanced interlobular pancreatitis which follows duct-obstruction, the invasion of malignant tumors, and the necrosis of acute inflammatory lesions.

CHAPTER XII.

HÆMOCHROMATOSIS AND BRONZED DIABETES.

THE relationship between diabetes and lesions of the pancreas is well illustrated by the disease known as hæmochromatosis, a disturbance of iron metabolism, which, though rare, has excited much interest on account of its remarkable character and obscure pathogenesis. Its identity with "*diabète bronzé*"—or the diabetes with pigmentation and cirrhosis of French writers—is now recognizable.

Under the designation "*hæmochromatosis*," von Recklinghausen in 1889 described a condition of pigmentation affecting various organs. Brown pigment, which he thought was derived from the hæmoglobin of the blood, is deposited within certain tissues and gives to them macroscopic pigmentation.

The anatomical picture of generalized pigmentation drawn by von Recklinghausen is very clearly defined. Most of the glands of the body assume a deep brown color, and within their secreting cells are found reddish-yellow or ochre-colored granules. Microchemical reactions prove that this pigment contains iron. In the liver pigment is present in the parenchymatous cells and in Küpffer's cells. A second kind of pigment, distinguishable from the first by its finer granules of pure

yellow color, is found in the smooth muscle-cells of the stomach and intestines, of the blood- and lymph-vessels, rarely in the muscle of the urinary bladder, ureters, and vas deferens. It also exists in the connective-tissue cells of certain localities,—for example, Glisson's capsule, the splenic trabeculæ, and the sheaths of blood-vessels. This second pigment does not give the reactions characteristic of iron. Von Recklinghausen called the iron-containing pigment "hæmosiderin," the iron-free pigment "hæmofuscin." The use of these names does not necessarily imply that we have means of identifying the substances as definite chemical compounds or that we can recognize them when they occur in other situations. Von Recklinghausen thought that hæmofuscin, as well as the iron-containing hæmosiderin, was derived from hæmoglobin. In his cases of generalized pigmentation there was an associated cirrhosis of the liver.

Von Recklinghausen studied twelve cases which he regarded as examples of local and general hæmochromatosis. He defined hæmochromatosis as a condition of pathological pigmentation due to the deposition of pigment derived from the blood.

There is, however, a local condition which has been identified with hæmochromatosis by several observers ; pigmentation of the intestine caused by deposition of fine yellow granules in the smooth muscle-cells has been carefully studied by Goebel and others. In adults mod-

erate pigmentation is almost constant, and the amount of pigment present bears a relationship to the age of the individual, so that with increasing age there is an increased pigment deposition. With wasting diseases—for example, tuberculosis and carcinomatosis—there may be an accumulation equal to that present in advanced age. In sixteen of one hundred bodies studied by Goebel the pigment deposit was of sufficient magnitude to cause macroscopic discoloration, characterized by him as rust brown. This accumulation of pigment within the smooth muscle-cells of the intestine is apparently an accentuation of a physiological process much more closely related to brown atrophy of the heart than to general hæmochromatosis.

Von Recklinghausen's description defines a condition presenting no close similarity to any form of local pigmentation with which we are familiar. The important features of this description are: (1) The presence in the epithelial cells of various glands, notably the liver and pancreas, of an iron-containing pigment. (2) The presence of an iron-free pigment in smooth muscle-cells of the gastro-intestinal tract, and of the blood- and lymph-vessels, and in certain connective-tissue cells. (3) The association of cirrhosis of the liver with pigmentation. To this condition, apparently a distinct pathological entity, the term hæmochromatosis should be limited.

Prior to von Recklinghausen's publication several ob-

servers had studied cases of wide-spread pigmentation. Quincke in 1877 observed with anæmia a deposition of iron in various organs, notably in the liver and spleen, and in one instance found macroscopic pigmentation of the liver and pancreas as a result. Tillmanns described brown pigmentation of the liver, of the abdominal lymphatic glands, and in less degree of the spleen and pancreas, in a man who two months before death had sustained a fracture of the pelvis, and, the observer thought, a contusion of the liver. Hindenlang observed in association with morbus maculosus Werlhofii pigmentation of the glands of the body, particularly the liver, which was slightly cirrhotic, and the pancreas, and in these organs found a pigment corresponding to that which von Recklinghausen subsequently described as hæmosiderin.

Hintze has described six cases which he regards as examples of hæmochromatosis, but only three agree in detail with the description which von Recklinghausen has given. Buss has described a typical case of hæmochromatosis associated with cirrhosis of the liver and diabetes mellitus. Letulle records two cases and Richardiere one in which with hypertrophic cirrhosis there was pigmentation of the liver, of the pancreas, and of other organs. In these cases pigmentation of the skin was apparently absent.

The following case which occurred in the practice of Dr. Thomas Opie is an example of the disease. Of

present importance are the alterations of the pancreas which, though unassociated with diabetes, are such as might cause the condition were they more advanced.

CASE XXXII.—The patient, male, white, aged fifty-five years, though never very robust, had enjoyed fairly good health. There was no history of alcoholic excess. For several months he had resided in Porto Rico, and until six or seven weeks before his death was able to continue his work of surveying. The onset of his fatal illness occurred with symptoms indicative of typhoid fever. When first seen, two weeks later, he was evidently very ill. There was elevation of temperature and rose-spots were present upon the abdomen. Deep pigmentation of the skin attracted immediate attention and marked universal bronzing suggested Addison's disease. Jaundice was not present. The urine at no time during the period of observation contained sugar; the first examination was made four weeks before death. Three days before death the urine was clear, of deep amber color, and contained neither sugar nor albumin. The blood-serum caused the agglutination of the typhoid bacillus. Death occurred with increasing weakness.

Autopsy.—The body is that of a very thin, sparely built man. The skin over the entire body shows deep pigmentation of a bronzed metallic hue, most marked upon the back of the hands, about the nipples, and upon the penis, where just above the corona the skin has a dark brown color. The parietal peritoneum, as well as that of the intestines, shows a varying degree of bluish discoloration.

The muscle of the heart has a yellowish-brown color, and is soft and flabby. Upon the surface of the right lung are several prominent areas over which the pleura is dulled; the tissue below is firmly consolidated. The bronchi are intensely injected.

The liver weighs 2270 grammes. The surface has a deep reddish-

brown color of peculiar character, resembling that of iron-rust. The surface of the left lobe, more markedly than that of the right, is superficially nodular and puckered, presenting in moderate degree the appearance of a hob-nail liver. On section islands of lighter brown parenchyma, representing one or several lobules, are surrounded by fibrous stroma of a deeper brown color. Sparsely scattered are opaque, yellowish-white areas, often 1.5 millimetres across.

The spleen, weighing 700 grammes, is soft, and on section the almost diffuent pulp has a deep red color. The mucous membrane of the stomach shows everywhere a deep greenish-black discoloration, evidently not due to post-mortem change. Along the lesser curvature there are a few areas of relatively normal yellowish-white appearance, but elsewhere the pigmentation is uniform. The duodenum has a greenish-black discoloration almost equal in intensity to that of the stomach. The jejunum is less markedly pigmented than the duodenum, while the ileum is of even lighter color, though still preserving a greenish-gray tint. Throughout the lower part of the ileum, usually upon the Peyer's patches, are small round or slightly irregular ulcers with sharp edges and clean base, in which are occasionally seen exposed fibres of the circular muscle-coat. The colon exhibits moderate greenish-gray discoloration.

The pancreas weighs 170 grammes. The organ is of large size, measuring sixteen centimetres in length, and is very firm in consistence. On section the cut surface has a uniform deep chocolate-brown color. The capsule contains much fat, and extending inward from it are septa of adipose and fibrous tissue.

The cortex of the kidneys, of an average thickness of seven millimetres, has a red, cloudy appearance. On section the testicles have a light brown tint. In the retroperitoneal tissue near the hepatic vein, behind the stomach, above and below the pancreas, and on either side of the aorta as low down as its bifurcation, are enlarged, moderately firm lymphatic glands. On section they have a uniform,

brilliant orange-yellow surface. In the gastro-hepatic omentum are enlarged glands of a similar nature.

Anatomical Diagnosis.—Typhoid fever; ulcers in the ileum; acute splenic tumor; cloudy degeneration of the kidneys; broncho-pneumonia. Hæmochromatosis; pigmentation of the liver, pancreas, heart, stomach, intestine, peritoneum, lymphatic glands, skin, and testicles; cirrhosis of the liver; chronic interstitial pancreatitis.

Histological Examination.—The organs which show the most marked pigmentation are the liver, pancreas, heart, and gastrointestinal canal.

Advanced cirrhosis of the liver is indicated by the presence of wide bands of fibrous tissue occupying from one-half to one-third of the area of the cut surface and separating the parenchyma into islands which represent one or several lobules. These septa, which are densely fibrous and in general poor in cells, surround both the portal spaces and the sublobular veins. A very conspicuous feature of the histological picture is the immense amount of yellowish-brown pigment present in the parenchymatous cells. It is deposited in the form of refractive, relatively coarse granules, of variable size. The endothelial cells of the capillaries and Küpffer's cells contain granules of similar character. Pigment is even more abundant in the newly-formed fibrous tissue. Here it exists in part as fine granules within spindle-shaped cells, but the greater quantity is not contained in cells. While this extracellular pigment is of the same yellowish-brown color as that within the cells, the individual particles vary

greatly in size, globules being often found two or three times as large as a red corpuscle. This yellowish-brown pigment gives the microchemical reactions characteristic of iron.

There is present a second less conspicuous variety of pigment, differing from that already described both in situation and in morphology. In certain smooth muscle and connective-tissue cells situated in the media and adventitia of both veins and arteries are deposited fine, pale yellow granules of almost uniform size. This pigment does not give the microchemical reactions of iron, being unchanged by potassium ferrocyanide and hydrochloric acid. In sections stained with methylene blue these granules take a blue, often bluish-black, color and become very conspicuous. This fact has been observed by Buss.

Interstitial tissue of the pancreas is much increased; in many places it defines the lobules, but, as a rule, it is diffusely distributed, occurring as irregular masses and strands separating small groups of acini or individual acini. Yellowish-brown pigment, giving the microchemical reactions of iron, is abundant both in the glandular cells and in the interstitial tissue. The cells of the acini contain this pigment in varying amount; here and there are seen acini the cells of which are distended with pigment granules, their protoplasm being almost entirely replaced. Such cells often show evidence of degeneration; at times the nucleus has an irregular

outline, and stains very palely, while in many instances no nucleus is demonstrable. The fibrous tissue replacing the disintegrated cells contains free granules of pigment, which are larger and more globular than those within the cells.

Islands of Langerhans are fairly abundant throughout the organ, but are most numerous in sections from the tail. They are constantly surrounded by a small area of fibrous tissue containing pigment in considerable quantity. Embedded in stroma, they no longer possess a regular round or oval outline, but are irregular in shape and are penetrated by thickened fibrous strands which follow the capillary vessels. The cells, forming compact columns, contain numerous granules of pigment, which, when least abundant, are situated in the part of the cell most distant from the capillaries, and hence tend to occupy the mid-line of the cell-columns. The cells of the interacinar islands usually contain much more pigment than those of the adjacent acini. In preparations hardened in Fleming's solution fat can be found in many of the secreting cells, but is constantly present in the cells of the interacinar islets.

Pigment deposition and the associated histological lesions in the skin, gastro-intestinal tract, heart, spleen, kidneys, adrenals, and lymphatic glands, though of considerable interest, are not pertinent to the present study, and their description will be omitted.

Bronzed Diabetes.—A condition closely related to the

hæmochromatosis of von Recklinghausen has been studied particularly by French writers. In 1882 Hanot and Chauffard described two cases of diabetes mellitus associated clinically with hypertrophic cirrhosis of the liver and bronze-like pigmentation of the skin. At autopsy upon the first of these cases was found cirrhosis of the liver, characterized by wide bands of connective tissue, and in the hepatic cells, as well as in the interlobular bands, were brown pigment granules in great quantity. In the second case, more carefully studied, the liver and pancreas presented a brown pigmentation and were the seat of advanced chronic interstitial inflammation, both parenchymatous cells and interstitial tissue containing masses of pigment granules. The stomach and duodenum were of a bluish-black color, and pigment in small granules was found below the serosa. Letulle several years later reported two cases of a similar nature. In a second communication, Hanot, in conjunction with Schachmann, recorded a fifth case and reviewed those previously published. He believed that the observations which had been made established the existence of a new form of cirrhosis—*cirrhose pigmentaire diabétique*—and of a new clinical condition—*diabète bronzé*.

The designation “diabète bronzé” has been in general accepted, but not without protest. Bronzing of the skin is not a constant phenomenon, and has been found absent in one case of Letulle, in the case of Hanot and

Schachmann, and in a case recorded by Brault and Galliard.

In the recorded cases of so-called bronzed diabetes the symptoms and pathological findings have been very constant. Clinically, the picture is one of a rapidly fatal diabetes mellitus, associated with cirrhosis of the liver, usually of the hypertrophic variety. Bronzing of the skin is, as stated, not constant, but has been present in a majority of the cases. At autopsy has been found deep pigmentation of the liver and pancreas, associated with cirrhosis, and in cases carefully examined macroscopically and histologically interstitial pancreatitis. An ochre-colored pigment giving the microchemical reactions of iron is present in the parenchymatous cells of the liver, pancreas, and other glands, in the muscle-fibres of the heart, in the interstitial tissue of these organs, and in the lymphatic glands.

Facts relating to the incidence of the disease are of interest. Only one recorded instance of hæmochromatosis (the case of Abbott), or of bronzed diabetes, has occurred in the female. The age of the individuals affected with bronzed diabetes has varied between thirty-three and sixty-two years, the greatest number occurring in the fourth and fifth decades. The cases of simple hæmochromatosis fall within these limits. It has been believed that the disease is more common in France than elsewhere, and this is, to a certain extent, indicated by the fact that of twenty-four cases seven-

teen have been observed in that country. Simple hæmochromatosis, however, has been described more frequently by German writers.

The pathogenesis of the condition has been the subject of varied speculation. Hanot and Chauffard, and subsequently Hanot and Schachmann, have maintained that the primary etiological factor is diabetes mellitus, that the diabetic alteration of the blood, in conjunction with endarteritis, which they have found constant in their cases, causes a disturbance of the nutrition of the liver cells, an alteration of pigment metabolism, and a deposition of pigment within the hepatic cells. The excess of pigment so formed is reabsorbed by the capillaries and diffused possibly in the form of emboli over the entire organism.

Letulle, finding the same process of pigment deposition in other organs—for example, in the heart—that takes place in the liver, comes to the conclusion that the pigment is formed in the cells in which it is found from the hæmoglobin of the blood. He regards diabetes as primary, and thinks that disintegration of hæmoglobin occurs under the influence of hyperglycæmia. Brault and Galliard, Hernandez, Mossé, Rendu, De Massary, and Potier also give prominence to diabetes as the important factor in producing pigmentation.

A second smaller group of writers thinks that the pigmentation is produced by a primary disease of the

blood, that as a result of some fundamental cause there is an alteration of the blood and subsequent formation of pigment from altered hæmoglobin. The relation of the concomitant diabetes and cirrhosis then remain to be explained. Buss, in accordance with an obsolete theory of diabetic metabolism, suggests that glycæmia may be the result of incomplete oxidation of oxidizable carbon, resulting in turn from a diminished oxygen-carrying power of the altered hæmoglobin.

P. Marie thinks that there follows the action of some primitive cause a dissolution of the hæmoglobin, which is transformed by various cells of the body into pigment and is deposited in these cells. The pigment in turn causes degeneration and destruction of the cells in which it accumulates, and consequently chronic interstitial inflammation of various organs, notably the liver. Bronzed diabetes is neither clinically nor pathologically classic diabetes, but is a distinct morbid entity, as is, according to his belief, pancreatic diabetes; and if, he says, it should be necessary to compare the condition with any other, he would turn his attention to pancreatic diabetes. Acard, Dutourier, and Jeanselme reiterate the conception of Marie, and suggest that diabetes perhaps is only an accessory phenomenon which appears with a certain degree of chronic interstitial pancreatitis. Anschütz has convinced himself that the associated diabetes finds its cause in chronic interstitial pancreatitis, which like the accom-

panying cirrhosis of the liver is, he believes, a manifestation of some underlying condition.

French writers who have described cases of "diabète bronzé" do not identify the disease with the hæmochromatosis of von Recklinghausen. In the very early cases no examination of the chemical nature of the pigment was made. Hernandez demonstrated that the brownish-yellow granules found by him in the epithelial cells of the liver, pancreas, and kidney, in the muscle-cells of the heart, in the connective tissue of these organs, and in the lymphatic glands gave the microchemical reactions known to be characteristic of iron. In the case of Hernandez and in subsequent cases this yellowish-brown pigment agrees in morphology and in location with the hæmosiderin of von Recklinghausen.

Buss reported a case of diabetes associated with cirrhosis of the liver and chronic pancreatitis with general hæmochromatosis. He finds not only the iron-containing but the iron-free pigment in locations corresponding to those mentioned by von Recklinghausen. On the one hand there is no reason to doubt that the pigmentation in this case is identical with that of hæmochromatosis, and on the other hand the case presents the clinical and pathological picture to which Hanot has given the name "diabète bronzé."

The case described in the present chapter holds a position intermediate between simple hæmochromatosis and the bronzed diabetes. Associated with hæmo-

chromatosis there is bronzing of the skin, cirrhosis of advanced grade, and chronic interstitial pancreatitis. Diabetes was, however, not present. It is evident that the generalized pigmentation of bronzed diabetes is the hæmochromatosis of von Recklinghausen.

Etiology of Hæmochromatosis. — When considering what etiological factors are concerned in the deposition of great quantities of pigment in the liver and other organs, we direct our attention to the blood, since it cannot be doubted that this iron-containing material is derived more or less directly from the hæmoglobin. It is well known that in pernicious anæmia with active blood destruction there is a deposition of iron within the liver and other organs, but pigmentation of the character under consideration is, at least in the great majority of cases, not found. A considerable proportion of the cases, both of simple hæmochromatosis and of hæmochromatosis associated with diabetes, have been accompanied by conditions which involve active destruction of the red blood-corpuscles. Hindenlang's case of general pigmentation, almost certainly one of hæmochromatosis, was associated with morbus maculosus Werlhofii. In four other cases purpuric eruptions have been observed. In several there have been local hemorrhagic conditions; in the case of Buss, for example, there was found at autopsy hemorrhagic pleurisy and peritonitis and hemorrhagic pachymeningitis. Other forms of local hemorrhage have been noted.

The hæmorrhagic lesions cited present considerable variety, and in many cases have been late manifestations of the disease. Moreover, local hemorrhages have not always been demonstrable. It is, then, unnecessary to assume that the hæmoglobin from which is formed the pigment arises from the destruction of red corpuscles of extravasated blood. It seems probable that with some primitive alteration of the blood there is a tendency to local hemorrhage; the hemorrhage is merely a manifestation of the, as yet obscure, disease of the blood which, associated with intravascular destruction of red corpuscles, causes pigment deposition.

In a case of Jeanselme examination of the blood demonstrated the presence of a moderate grade of anæmia, but otherwise no marked change was noted. Coagulation was not retarded.

Attempts have been made to reproduce experimentally the pigmentation found in human beings. Two methods have been employed: (1) Conditions resembling those of local hemorrhage are reproduced, for example, by injecting blood into the peritoneum. (2) Hæmoglobin is set free within the circulating blood by the use of toxic substances which cause destruction of the red blood-corpuscles. Auscher and Lopicque and Meunier have attempted by these means to produce the general pigmentation of the organs found in bronzed diabetes. Auscher and Lopicque, by injecting

blood into the peritoneum, caused accumulation of an iron-containing pigment in considerable quantity in the spleen, but in very small quantity in the liver. In cases of hæmochromatosis, however, the liver is the prominent seat of pigment accumulation.

It has long been known that toluylendiamin causes a destruction of the red blood-corpuscles, large doses producing in dogs hæmoglobinuria. By the use of this substance numerous experimenters have caused the deposition of an iron-containing pigment in the liver and other organs. Meunier, attempting to reproduce in dogs the pigmentation of bronzed diabetes, succeeded by the repeated injection of small doses in obtaining an iron-containing pigment in moderate amount in the liver, lymphatic glands, spleen, and bone-marrow. The immense iron accumulation of hæmochromatosis, however, has not been reproduced, so that experiments have thrown but little light upon the pathogenesis of the condition.

As already indicated, many of those who have studied cases of bronzed diabetes regard diabetes as the essential etiological factor. Upon an insufficient basis active blood destruction has been assumed to be a result of the diabetic condition. In the ordinary form of diabetes, however, no accumulation of iron takes place in the liver or other organs, as has been shown in cases studied by Zaleski and by Kretz. There is, on the

contrary, reason to believe that diabetes is secondary to hæmochromatosis.

Relation of Hæmochromatosis to Chronic Interstitial Inflammation.—In cases of bronzed diabetes two prominent features in addition to generalized pigmentation are diabetes and cirrhosis of the liver, and it is to the second factor that a number of writers have directed their attention in attempting to explain the pigmentation. It is to be recalled, moreover, that cirrhosis of the liver has been present in cases of simple hæmochromatosis. In all instances of hæmochromatosis, both with and without diabetes, the greatest pigment accumulation has been in the liver, and consequently a disturbed chromogenic function of that organ has suggested itself. Is the altered metabolism accompanying cirrhosis of the liver to be regarded as the essential etiological factor?

A study of the process of pigment accumulation in widely separated organs throws light upon the seat of its formation. The glands I have studied most carefully are the liver, the pancreas, and the adrenal glands. When pigment is in moderate quantity, it is present as relatively fine round granules occupying that part of the cell most distant from the capillaries,—that is, in acinous glands, the part next the lumen. With greater accumulation the whole cell-body contains pigment granules, and finally almost the entire protoplasm is replaced by them. Changes at the same time may be observed in the nucleus of the cell. It becomes

smaller, its outline often becomes irregular, and it assumes a shrivelled appearance. In cells which at first sight appear to be mere masses of granules and globules of pigment, with careful focusing a very faintly-staining vesicular nucleus is occasionally seen, while more frequently are found pigment masses without any trace of nucleus, but still maintaining the cell outline. Finally, the cell outline is lost and a clump of pigment particles of very variable size lies free in the tissue.

The same process observed in the liver takes place in the pancreas and adrenal gland, in the muscle-cells of the heart, and in many other tissues. It is therefore improbable that the pigment is transported as emboli or in phagocytic cells from the liver. Much more probable is it that the same process is taking place simultaneously in all the organs concerned, that the pigment is elaborated by the cells in which it is found from iron-containing material derived from hæmoglobin and dissolved in the surrounding lymph.

Doubtless for the production of hæmochromatosis some factor is necessary besides the mere disintegration of red corpuscles and the setting free of hæmoglobin. Its absence in many conditions associated with blood destruction sufficiently proves this point. Of a series of cases of cirrhosis of the liver studied by Kretz, in about one-half was found an accumulation of an iron-containing pigment resembling hæmosiderin. He comes to the conclusion that some toxic matter

circulating in the blood causes degeneration of the liver-cells, and at the same time acts injuriously upon the red corpuscles. It is the association of the two conditions which simultaneously produces cirrhosis and pigmentation. In hæmochromatosis the toxic material causing blood destruction may be of such a nature that it acts injuriously upon the cells of the liver and other organs, so that they transform into insoluble hæmosiderin the soluble blood pigment which reaches them. Alcohol may possibly under certain conditions have this action. Such speculations merely indicate the complexity of the conditions which underlie this generalized pigmentation.

Degenerate parenchymatous cells overloaded with pigment are, in the case which I have studied, very abundant, and can be readily demonstrated without prolonged search. We have thus an efficient factor for the production of chronic interstitial inflammation; fibrous stroma replaces the cells which are destroyed. In the liver newly-formed fibrous tissue invades the lobule along the central vein, and in places sends out fine radiating bands along the capillaries between the columns of the liver-cells. The fibrous tissue about the central vein and between the lobules contains large quantities of pigment, which is for the most part extracellular, since the cells in which it was formed have undergone degeneration. When it is massed in large quantity, there is usually evidence of active cell

proliferation. In general the interlobular tissue is poor in cells, but in such areas proliferation is indicated by the presence of small round cells. Two factors are, I believe, active in producing the sclerosis : (1) Pigmentary degeneration of the parenchymatous cells ; (2) irritation produced by the presence of the pigment in the interstitial tissue.

Relation of Hæmochromatosis to Diabetes.—In the case I have described the pancreas next to the liver is the organ most conspicuously pigmented. Extreme pigmentation and consequent degeneration of parenchymatous cells has occurred, and the organ is the seat of chronic interstitial inflammation of the interacinar type.

The pancreas has been superficially examined in many of the reported cases of bronzed diabetes, but in those accompanied by a record of its microscopic appearance chronic interstitial pancreatitis has been described. The absence of atrophy has doubtless in some instances prevented the recognition of interstitial inflammation. In but two cases has the gland been found smaller than normal, while it is frequently described as voluminous, enlarged, or normal in size. In seven cases the weight is recorded. The mean of the figures given, varying between ninety-five and one hundred and ninety-five grammes, is 125.7 grammes,—about one-half greater than the normal weight of the organ. The average weight of the liver recorded in

thirteen cases of bronzed diabetes is two thousand four hundred and ninety-seven grammes. Both cirrhosis and chronic pancreatitis are associated with hypertrophy.

As far as one is able to determine from recorded cases, chronic interstitial pancreatitis is constantly associated with bronzed diabetes. In the present case of hæmochromatosis without diabetes the pancreas weighs one hundred and seventy grammes, almost twice the normal weight, and is the seat of interstitial inflammation of moderate intensity. The lesion affects primarily the parenchymatous cells, and the newly-formed fibrous tissue, diffusely distributed, bears no constant relation to the lobules. The alterations of the islands of Langerhans are as follows: Pigment is abundant in the cells, and tends to accumulate in that part which is most distant from the capillaries. The island is usually embedded in a capsule-like mass of fibrous tissue containing pigment granules, and strands of similar tissue often penetrate the island, following its capillaries.

Pancreatitis present is of the interacinar type, and, tending to invade the islands of Langerhans, is that which is most frequently accompanied by diabetes. In the present instance the lesion is little advanced, and has caused such incomplete destruction of the islands of Langerhans that diabetes has not ensued. The individual had been in good health until at-

tacked by typhoid fever. When, as in this case, hæmochromatosis without diabetes has been observed at autopsy, death has been due to some intercurrent affection having no apparent relation to the antecedent disease. The fatal illness in most instances begins with symptoms of diabetes. In the present instance typhoid fever caused death of the individual before chronic interstitial pancreatitis had reached a sufficient grade of intensity to produce glycosuria. Thus hæmochromatosis was prevented from reaching its usual termination—diabetes.

Hæmochromatosis, a distinct morbid entity, is characterized by wide-spread deposition of pigment in various tissues of the body. It is associated with chronic interstitial inflammation, notably of the liver and pancreas. Parenchymatous cells undergo pigmentation and degeneration, and fibrous stroma fills the defect thus produced. In the pancreas chronic inflammation is of the interacinar type, and the islands of Langerhans are implicated in the lesion. When interacinar pancreatitis has reached a certain grade of intensity, diabetes mellitus ensues, and is usually the terminal event in cases of hæmochromatosis.

CHAPTER XIII.

THE SYMPTOMS AND TREATMENT OF PANCREATIC DISEASE.

IN the present chapter the attempt will be made to review the facts previously considered and to point out their relation to diagnosis and treatment. Disease of the pancreas is rarely recognized during life, since the symptoms, though not infrequently of great severity, present little that is characteristic upon superficial examination. The physiology of the organ being well understood, it may seem at first sight surprising that disturbances of function are not more evident, but a variety of causes tends to obscure the manifestations of pancreatic disease.

Situated behind the stomach, almost in contact with the vertebral column, the organ is not palpable in health, and alterations of size comparable to those readily recognized in the liver are not discernible.

Destructive lesions, such as suppuration, hemorrhagic necrosis, and chronic inflammation, or the presence of cysts or new growth, may so impair the functional activity of the gland that on the one hand it no longer furnishes the normal supply of digestive ferments, while on the other hand it may become incapable of exerting its normal influence upon carbohydrate metabolism. Alteration of the so-called ex-

ternal secretion is indicated by disturbance of digestion, while alteration of the internal function finds its expression in glycosuria.

The independence of the two important functions of the gland has received sufficient demonstration in the preceding pages. The secreting alevoli elaborate the pancreatic ferments, while the islands of Langerhans, having no communication with the pancreatic ducts, control the assimilation of sugars. Obstruction of the ducts preventing the entrance of the pancreatic juice into the duodenum causes partial destruction of the parenchyma. The chronic interstitial inflammation which results is of the interlobular type, and the islands of Langerhans are implicated only when the lesion is far advanced. In such case, although characteristic disturbances of digestion may suggest the presence of a pancreatic lesion, carbohydrate metabolism is undisturbed and glycosuria is absent. The islands of Langerhans, on the contrary, may be so altered by the hyaline change previously described in detail that diabetes results, though the secreting parenchyma is little, if at all, affected.

The recognition of pancreatic disease is further obscured by the fact that lesions affecting only a part of the gland may be unaccompanied by symptoms. Experimental extirpation of the pancreas is followed not only by glycosuria, but by characteristic changes in the digestion and absorption of proteids and fats.

Partial extirpation of the gland is followed by diabetes only when the part remaining is a very small fraction of the whole, and experiments have shown, moreover, that a relatively small part of the gland is capable of effecting intestinal digestion. Even complete occlusion of the larger duct is not wholly uncompensated, since the smaller duct of Santorini anastomosing with the larger may in a considerable proportion of all individuals afford an outlet for the pancreatic secretion.

The difficulty of diagnosis is increased by the fact that disease of the organ is seldom uncomplicated, but is usually consequent upon changes in the duodenum, liver, or bile passages. Gall-stones lodged in the common bile duct, for example, are a frequent cause of both acute and chronic inflammation of the gland. A recognition of such relationship indeed may be an important aid to the diagnosis of obscure pancreatic affections.

Symptoms of Pancreatic Disease.—Certain symptoms, notably pain and tumor, by their localization may indicate that the organ is the seat of disease. Pain in the epigastrium is an inconstant symptom of pancreatic affections, and may be absent even when the gland is occupied by an abscess or by carcinoma. Intermittent pain resembling that of biliary colic has been observed in association with obstruction of the pancreatic duct due to calculi or other cause.

Under normal conditions the pancreas is not palpa-

ble, but in individuals with thin abdominal walls, according to Osler, particularly in women with enteroptosis, the organ can be felt. Acute or chronic inflammation rarely, if ever, causes a recognizable enlargement of the gland. A deep-seated epigastric tumor in association with acute suppurative or gangrenous pancreatitis is referable to a peripancreatic abscess limited to the lesser peritoneal cavity. Such a mass overlying the pancreas is situated behind the stomach and colon, is movable, and does not descend with respiration. A cyst or new growth occupying the gland may form a palpable mass in the same region.

It is desirable to consider : first, the symptoms which result from impairment of the internal function of the pancreas ; second, symptoms which follow alterations of the external secretion.

Diabetes and Alimentary Glycosuria.—Experimental studies conducted upon a large variety of animal species have conclusively shown that complete extirpation of the pancreas is followed by a condition identical with diabetes mellitus of man. The numerous clinical observations previously cited have shown that diabetes is associated with destructive lesions of the gland in considerably more than one-half of all cases. Since the islands of Langerhans are the effective agents in the regulation of carbohydrate metabolism, only those lesions which affect these structures cause the disease. When, for example, the interacinar islands

alone are destroyed by hyaline degeneration, glycosuria and other manifestations of diabetes mellitus are secondary to the lesion. Hence, permanent glycosuria may follow a lesion which, leaving unaffected the secreting parenchyma, is unaccompanied by any disturbance of pancreatic digestion.

Diabetes, however, may exist in the absence of any demonstrable lesion of the pancreas; doubtless the influence of the islands of Langerhans is only one of the factors which regulate the assimilation of sugars, and diabetes may be the result of changes other than those which affect the pancreas. Hence, permanent glycosuria does not give conclusive proof that a lesion of the interacinar islands exists; but in considerably more than fifty per cent. of cases such a lesion is present. On the other hand, where a lesion of the pancreas does not implicate the islands of Langerhans, diabetes is absent, and hence it results that by far the greater number of pancreatic lesions are unaccompanied by the disease.

The attempt has been unsuccessfully made to define certain clinical symptoms characteristic of diabetes, when due to lesions of the pancreas. Lancereaux, notably, has described a special type of diabetes referable to pancreatic disease and characterized by extreme emaciation, in company with intense thirst, voracious appetite, and abundant polyuria. He designates the condition "*diabète maigre*," and distinguishes it from diabetes with obesity, "*diabète gras*," unaccompanied by pancreatic

disease. His views have received some acceptance, but few clinicians maintain that it is possible to recognize the sharp distinction claimed by him. Many writers, Lepine, Hansemann, Williamson, among others, have on the one hand cited cases in which emaciation was absent, though diabetes accompanied pancreatic disease; while on the other hand in patients suffering with diabetes and emaciation they have discovered no alteration of the pancreas. Removal of the gland in animals is followed by diabetes with rapid emaciation, absence of pancreatic secretion being followed by grave disturbances of digestion and absorption. In human cases, however, diabetes may be caused by lesions of the gland which destroy the islands of Langerhans, yet leave almost intact the secreting parenchyma.

Wide-spread lesions of the organ, destroying both secreting acini and interacinar islands are accompanied by diabetes only when very little of the gland remains. After partial extirpation in dogs, diabetes does not result if more than an eighth to a twelfth be spared. For a similar reason glycosuria is rarely a symptom of acute hemorrhagic and gangrenous pancreatitis, which usually leaves relatively unimpaired a considerable part of the organ. Diffuse carcinoma attacking the pancreas may also destroy both islands of Langerhans and secreting parenchyma. Here, too, only when the lesion has almost wholly replaced the gland may glycosuria and other symptoms of diabetes be expected.

Minkowski has shown that *alimentary glycosuria* not infrequently follows partial removal of the pancreas when a considerable part still remains. Diabetes does not result, but the ability of the organ to exert its normal influence on carbohydrate metabolism is impaired, and if sugar is given to the animal in large amount temporary glycosuria results. Wille has recently observed alimentary glycosuria in association with lesions of the pancreas, and thinks that this symptom may be regarded as an index to the presence of pancreatic disease. The ability to assimilate sugar was tested in eight hundred patients suffering with a great variety of diseases. In the morning, before other food had been taken, were administered from seventy to one hundred grammes of grape sugar dissolved in a half-litre of tea or coffee. The urine was voided just before the sugar was taken and was then tested at intervals of two hours; when the test was positive, sugar usually appeared at the end of two hours.

Of eight hundred individuals upon whom this test was made, seventy-seven subsequently died and autopsies were performed. Alimentary glycosuria had been found in fifteen of those who came to autopsy, and in ten of these were present grave lesions of the pancreas, chronic interstitial inflammation, or carcinoma of the gland, either primary or secondary to tumors in the stomach, liver, or gall-bladder. Although alimentary glycosuria may occur in the absence of pancreatic

disease and is doubtless frequently associated with a variety of conditions, notably hysteria and other neuroses, chronic alcoholism, exophthalmic goitre, etc., its presence, according to Wille, suggests the existence of a lesion of the pancreas and has considerable value for diagnosis.

Disturbances of Digestion.—Symptoms which follow impairment of the digestive or external function of the pancreas have not been very clearly defined, and, though certain facts have been established, clinical observations are often divergent. The pancreatic juice, it is well known, contains ferments which aid in the digestion of proteids, fats, and carbohydrates, yet it is not the only secretion concerned in the digestion of any one of these substances. Impaired assimilation of proteids and fats is more readily recognized than alterations affecting the digestion of carbohydrates, and hence has been assigned greater diagnostic significance.

Claude Bernard destroyed the pancreas of dogs by injecting oil or other bland substance into the larger duct, and observed that the fæces contained in abundance food material which had undergone little change,—for example, undigested muscle-fibres or even large pieces of meat, together with fat, at times in such quantity that when cold it congealed as a layer covering the surface of the fæcal mass. Subsequent observers have studied by somewhat more accurate methods the dis-

turbances which Claude Bernard described. Abelman found after removing the pancreas in dogs that all fat taken with the food reappeared in the fæces ; an exception was the emulsified fat of milk, of which about fifty-three per cent. disappeared. Under normal conditions little more than five per cent. of fat escapes absorption. Hédon and Ville claim that the statement of Abelman is somewhat exaggerated ; they found that eighteen per cent. of fat which was not emulsified might undergo absorption when the gland was completely removed. After partial extirpation, even when so performed that the pancreatic juice no longer reaches the intestine, at least half the fat ingested is, they claim, absorbed. After complete removal of the organ, according to Abelman, fat is still split, and about four-fifths of that which is unused is represented in the fæces by fatty acids.

In the experiments of Abelman after total excision of the pancreas only about forty-four per cent. of the proteids ingested was absorbed, while after partial removal fifty-four per cent. was retained. Under normal conditions not more than one or two per cent. of nitrogenous material is unabsorbed. Loss of the pancreas also alters the normal digestion of carbohydrates, and, according to Abelman, twenty to forty per cent. of starch may reappear in the fæces, having undergone no transformation into sugar. Subsequent experimenters have confirmed the observations of Abelman.

Disturbances of digestion similar to those which follow experimental extirpation of the gland have been noted in human cases where the pancreas has been partially destroyed by chronic inflammation, by cysts, or by new growths; occlusion of the duct by calculi or by tumor may have the same effect. Even where the gland is injured or its larger duct obstructed pancreatic juice in considerable amount may still reach the intestine, and in many cases digestion proceeds with no manifest impairment.

In human cases *disturbance of proteid digestion* may be recognizable by the presence of unaltered muscle-fibres in the fæces. In the discharges of a patient suffering with diabetes, Fles, forty years ago, found well-preserved striated muscle-fibres, and the administration of an extract made from the pancreas of a calf caused their disappearance. Advanced chronic interstitial pancreatitis with atrophy was found at autopsy. Similar impairment of proteid digestion has been not infrequently noted in cases of pancreatic disease, and in a few instances this disturbance has been tested by quantitative methods. In cases of diabetes possibly due to lesions of the pancreas Hirschfeld recovered in the fæces as much as thirty-two per cent. of the nitrogenous material ingested with the food. In a case of Weintraud, where autopsy demonstrated the presence of advanced chronic interstitial pancreatitis, forty-five and two-tenths per cent. of proteids ingested re-

appeared in the *fæces*. A similar case has been reported by Zoja.

Sahli has devised a means by which he is able, he believes, to test the efficiency of proteid digestion in the intestine. Gelatin capsules hardened in formalin are almost unaffected by gastric digestion, but are dissolved by pancreatic juice. If such a capsule is filled with iodoform, the urine or saliva gives a reaction for iodine at the end of from four to eight hours. Absence of reaction, or its delayed appearance, indicates, according to Sahli, an impairment of pancreatic digestion, provided the mobility of the stomach is normal.

As early as 1820 Kunzmann observed the presence of *fat in the fæces* of a man who subsequently died with obstruction of the duct of Wirsung and induration of the pancreas, together with chronic jaundice. Fles, nearly fifty years later, described the case of a diabetic whose *fæces* contained abundant fat; when an emulsion made from the pancreas of a calf was administered, fat disappeared from the stools. In this case no jaundice was present. A considerable number of similar cases have been described, but in many other instances of grave pancreatic disease no decrease in the absorption of fat has been observed. Finding jaundice associated with pancreatic disease in many cases where fatty evacuations have indicated impaired assimilation of fat, Müller has attributed the symptom to coexisting obstruction of the common bile duct. Nevertheless, experimental as

well as clinical observations leave little doubt that steatorrhœa may follow loss of the pancreatic secretion.

In some cases of pancreatic disease, according to Oser, fat is discharged with the fæces as an oily, yellow fluid, and the condition may be designated a true steatorrhœa. In other cases the fæces are clay-colored or grayish-white, and the increased quantity of fat is demonstrable only by microscopic or chemical examination; such stools contain neutral fats, fatty acids, and soaps.

An abnormally large amount of fat in the intestinal discharges is, however, by no means characteristic of pancreatic disease, and may even appear in healthy individuals after the ingestion of very great quantities of fat. The bile, it is well known, is essential to normal digestion of fats, and occlusion of the bile duct is a frequent cause of fatty stools. Moreover, the absorption of fat is prevented by certain diseases of the intestine,—for example, by tuberculosis, by tuberculosis of the mesenteric glands, and even, according to Nothnagel, by extensive catarrhal inflammation and other alterations accompanied by active peristalsis. It is only in the absence of such conditions that the presence of fat is an aid to the diagnosis of pancreatic disease.

As a consequence of the impaired digestion which results when pancreatic juice is lost or greatly diminished in amount, much of the food material taken into the digestive tract passes through almost unchanged.

Oser has noted the voluminous character of the fæcal discharges in cases of pancreatic disease, and has emphasized the diagnostic importance of this symptom.

Treatment of Pancreatic Disease.—In treatises on disease of the pancreas, such as those of Friedreich, Oser, and Lancereaux, are mentioned a variety of *drugs* which have been claimed to exert an influence upon the diseased gland, but the writers have no faith in the efficacy of these agents. Alkaline carbonates, pilocarpine, preparations of iron, of bismuth, and of mercury, particularly calomel, have been believed to produce beneficial effects where disease of the pancreas was supposed to exist. The difficulty with which pancreatic disease is recognized presents an obstacle to the establishment of an empirical therapy, and the evidence in favor of these remedies has little weight.

Experimental demonstration that diabetes results when the pancreas is removed raised hope that the disease might be successfully treated by administration of pancreatic tissue obtained from lower animals or by the use of extracts prepared from it. The remarkable results which have followed the use of thyroid extracts in myxodema—a disease dependent upon destruction of the thyroid gland—have suggested such a possibility. A number of observers, Minkowski, Thiroloix, and others, soon found that fresh pancreas or extracts administered to animals deprived of their pancreas failed to influence the assimilation of sugar, whether given by

mouth or injected below the skin, into the veins, or into the peritoneal cavity. No better success has been obtained in the *treatment of diabetes mellitus* in man, though in a considerable number of cases similar methods have been employed. A few writers have claimed that some improvement follows the administration of the fresh gland by mouth or the subcutaneous injection of extracts, but the influence upon glycosuria which they note has been temporary and inconstant, and may be referred to other causes. Hector Mackenzie, Fürbringer, P. W. Williams, Hugounencq and Doyon, Oser, and others, have found glycosuria uninfluenced by the same methods. Attempts to graft pancreatic tissue obtained from animals below the skin of patients suffering with diabetes have been unsuccessful.

Better results have in a few instances attended *efforts to supply by artificial means a deficiency of digestive ferments* consequent upon disease of the pancreas. In animals it has been found possible by the administration of fresh pancreas to increase the assimilation of proteids and fats impaired by extirpation of the pancreas. Abelman found that the pancreas of the pig fed to dogs from which the gland had been removed aids the absorption of fat, and so favors the digestion of proteids that now seventy-eight per cent. are absorbed instead of forty-four per cent. These observations have been confirmed by Sandmeyer, Rosenberg, and others.

The remarkable case of Fles quoted by Friedreich has already been mentioned; disturbed digestion of proteids and fat was associated with diabetes mellitus. The fresh pancreas of a calf was rubbed in a mortar with six ounces of water and the mixture strained. A part of the milky fluid obtained was taken after each meal, so that one pancreas was consumed daily. Though the patient continued upon his previous diet of bacon and fat meat, at the end of two days all fat had disappeared from the fæces and the number of undigested muscle-fibres was greatly diminished. Whenever the administration of the infusion was discontinued fat and muscle-fibres reappeared. Although glycosuria persisted unchanged, the general condition of the patient improved for a time, but death finally occurred as the result of phthisis. The pancreas was the seat of advanced sclerosis.

In a case recorded by Langdon-Downs fatty diarrhoea was controlled by the use of pancreatic extract; the urine contained a trace of sugar, but the condition of the pancreas could not be learned with certainty. Oser describes a case in which a tumor mass felt in the epigastrium was accompanied by jaundice; in the fæces were found undigested muscle-fibres and fat. A diagnosis of carcinoma of the pancreas was made. The administration of pancreatin (Merck), one gramme every day, taken in divided doses, was fol-

lowed by well-marked improvement in the digestion of fat and the patient felt stronger.

The few cases cited suggest that pancreatic extracts may be successfully used when there is evidence that digestion suffers from deficiency of the pancreatic secretion. When the lesion is caused by malignant growth or is associated with diabetes, though permanent benefit cannot result, it may be possible to strengthen the patient and retard emaciation.

Clinical Significance of Fat Necrosis.—The lesion known as focal fat necrosis has been previously shown to be caused by penetration of the secretion of the pancreas into the tissues about the organ, and results when the fat-splitting ferment of the pancreatic juice comes into contact with the living fat tissue. Occlusion of the pancreatic duct favors the dissemination of ferments elaborated by the gland, and wide-spread necrosis implicating subcutaneous and pericardial fat as well as that of the abdomen follows ligation of the pancreatic ducts in the cat. In human cases widely-disseminated fat necrosis seldom results from occlusion of the pancreatic ducts. Obstruction occurs gradually, and is associated with chronic interstitial inflammation which apparently retards the diffusion of the pancreatic secretion, so that minute foci occur only in the immediate neighborhood of the gland.

Disseminated necrosis of fat in most instances

accompanies acute hemorrhagic pancreatitis, or its later stage, so-called gangrenous inflammation. In discussing the etiology of acute hemorrhagic pancreatitis it has been shown that the lesion is in many, if not in all, cases caused by a gall-stone lodged at the duodenal orifice of the diverticulum of Vater. Not only is the outflow of pancreatic juice prevented, but bile is injected into the pancreatic duct by the gall-bladder. As a result necrosis of the pancreatic parenchyma ensues, and whatever pancreatic secretion may be present, forced backward into the tissues about the organ, causes necrosis of the surrounding fat. The lesion more rarely accompanies suppurative inflammation of the gland.

By some writers fat necrosis has been described as a disease entity associated with certain more or less ill-defined symptoms. The condition, on the contrary, is always a consequence of pancreatic disease and, as previously pointed out, bears much the same relation to lesion of the pancreas as does jaundice to hepatic disease. Its presence gives evidence that the pancreatic secretion has been diverted from its normal channels into the interstitial tissue of the organ and into the neighboring fatty tissue.

In a case cited by Hanseemann, foci of necrosis occurred in the subcutaneous tissue, and their presence was marked by circumscribed injection of the overlying skin. Rarely, however, does the lesion affect adipose

tissue outside of the abdomen, and during life is recognizable only when the peritoneal cavity is opened. Since in every instance disseminated fat necrosis indicates the existence of grave disease of the pancreas, its recognition is of importance to the surgeon who opens the abdominal cavity. Particularly is this true when pancreatic disease has been unsuspected and operation has been undertaken, perhaps with the purpose of relieving intestinal obstruction suggested by the symptoms. With few exceptions disseminated fat necrosis encountered at operation gives evidence that the pancreas is the seat of acute hemorrhagic inflammation or of secondary gangrenous change.

Foci of necrotic fat are very conspicuous by reason of their homogeneous, opaque, yellowish-white color, in marked contrast to the surrounding translucent yellow fat, and when the omentum is exposed it is unlikely that they will be overlooked if present. To one who has seen the lesion it is unmistakable, but to the inexperienced miliary tubercles or carcinomatous nodules may be suggested by the shape and color of the sharply-defined areas. The lesion, however, is not elevated and nodule-like, but on examination is found to represent a transformation of the pre-existing fat.

When the outflow of bile is hindered and jaundice occurs, biliary pigments make their appearance in the urine. Abundant evidence collected in Chapter V. has shown that fat necrosis is due to the action of the fat-

splitting ferment secreted by the pancreas, and this ferment has been found by Flexner in the areas of necrosis. The possibility suggests itself that the ferment which is free in the tissue may be excreted by the kidneys, though it is not improbable that the acidity of the urine may partially or completely destroy its activity.

I have examined the urine in one instance of acute hemorrhagic pancreatitis (Case IV.), and the result, though not conclusive, is cited in order that its accuracy may be further tested. The method employed is that described by Castle and Loevenhart; ethyl butyrate carefully purified, when acted upon by a fat-splitting ferment, is decomposed with the formation of butyric acid, which gives an acid reaction to the solution.

Following the operation which was performed in Case IV. the patient voided no urine, and in the bladder at autopsy was found only a small quantity. After adding a few drops of litmus solution, this was neutralized with potassium hydroxide (one-tenth normal solution) and divided into two parts. To one part was added a few drops of ethyl butyrate. The second part, used as a control, was boiled in order to destroy the ferment, if present, and ethyl butyrate was added. Both specimens were kept at 37° C., and at the end of twenty-four hours the unboiled specimen had acquired a well-marked acid reaction, while the control specimen was unchanged. Owing to the small quantity of urine obtained it was not possible to repeat the test.

Recognition in the urine of a ferment derived from the pancreas would afford a certain means for the diag-

nosis of obscure pancreatic affections accompanied by fat necrosis, notably acute hemorrhagic pancreatitis. Hence it is desirable to apply in suspected cases the test just described in order if possible to establish its value.

Symptoms of Acute Hemorrhagic Pancreatitis.—The difficulty of diagnosis characteristic of disease of the pancreas is well illustrated by acute hemorrhagic pancreatitis, yet the clinical picture which it presents is often distinctive, and in many instances recognition of the condition is possible.

This lesion, in a large proportion of cases at least, is a consequence of cholelithiasis and is caused by the action of bile diverted into the pancreatic duct by a small calculus lodged at the duodenal orifice of the diverticulum of Vater. Wide-spread necrosis of the parenchyma ensues and is associated with abundant hemorrhage into and about the organ. Inflammatory changes rapidly follow, and death frequently occurs within forty-eight hours after the onset of the symptoms. In a considerable number of cases the individual survives, and the necrotic pancreas, becoming black and softened, assumes the appearance described as gangrenous, so-called gangrenous pancreatitis representing a like stage of the hemorrhagic lesion. Bacteria invade the dead tissue, and inflammation of the adjacent peritoneum not infrequently results in the formation of an abscess cavity limited to the lesser peritoneum.

Fitz describes as follows the symptoms of acute hemorrhagic pancreatitis: "It begins with intense pain, especially in the upper abdomen; soon followed by vomiting, which is likely to be more or less obstinate, and not infrequently by slight epigastric swelling and tenderness, with obstinate constipation. A normal or subnormal temperature may be present, and symptoms of collapse precede, by a few hours, death, which is most likely to occur between the second and fourth days."

Since the lesion is caused by the lodgement of a gall-stone at the duodenal orifice of the bile duct, symptoms of biliary colic may precede those of the pancreatic lesion and may be confounded with them. The intensity of the pain, its diffuse epigastric character, with occasional localization on the left side, and the profound collapse usually present, according to Thayer, give sufficient evidence that the pancreas is implicated. Acute hemorrhagic pancreatitis is frequently mistaken for intestinal obstruction, but the intensity and localization of the pain, the severity of the collapse, and the absence of stercoraceous vomiting in most instances serve to characterize the condition.

The profound collapse and rapidly fatal termination of many cases of acute hemorrhagic pancreatitis suggest the presence of an acute intoxication. A similar condition follows the lesion produced experimentally in dogs, and death within twenty-four hours may be caused by the injection of five cubic centimetres of bile

into the pancreatic duct. Bile, doubtless in association with the pancreatic secretion acting upon the substance of the gland, produces, both in the human and in the experimental cases, substances which, when absorbed, exert a profoundly poisonous action. Such an explanation of the fatal result appears more probable than that which seeks to refer the symptoms of collapse or shock to an obscure lesion of the sympathetic ganglia near the pancreas.

In many instances the symptoms of onset are much less severe than those just described, and perhaps, associated with an attack of gall-stone colic, may be so slight as to be unrecognizable. The patient survives and the disease pursues a more or less chronic course. The symptoms are essentially those previously mentioned, but they occur with less intensity. Pain is localized in the epigastrium, and vomiting may recur at intervals. Symptoms indicative of suppuration finally give evidence that the necrotic tissue of the pancreas has become infected; there is an irregular temperature, and leucocytosis suggests the presence of an abscess. An ill-defined tumor felt above the umbilicus gives more positive proof that fluid has accumulated about the pancreas in the lesser peritoneal cavity. The appearance of such a mass in the epigastric region is due, not to the enlarged pancreas, which is rarely if ever palpable, but to the presence of hemorrhagic or purulent fluid about the organ.

Those disturbances of digestion which have been noted in describing the general symptomatology of pancreatic disease may occur, but rarely is there such complete destruction of the pancreas that its functional activity is wholly destroyed. In Case I. and in Case XXXIII., to be described, the patient passed clay-colored stools.

In only two of forty-one cases of hemorrhagic pancreatitis, and in but three of forty cases of gangrenous inflammation collected by Körte, was sugar present in the urine. The following interesting case of diabetes consequent upon acute hemorrhagic pancreatitis has been recently described by Franke. The patient, a man aged forty-two years, who had previously enjoyed good health, was attacked twelve days before his death with severe abdominal pain, accompanied by vomiting. The pain, which was localized in the region of the umbilicus, continued, and the patient complained much of thirst. When seen, eight days after the onset of symptoms, sugar was found in the urine, and to the amount of 3.5 per cent. was present until death. The fat below the parietal peritoneum, the fat of the omentum, of the mesentery, and of the mediastinum as well, contained numerous foci of necrosis. The pancreas was represented by a large blackish-red mass, which consisted in great part of altered blood, but in a few places still preserved a lobular structure. The gall-bladder was distended and contained a calculus about the size of a plum.

Acute hemorrhagic and gangrenous pancreatitis being caused by the lodgement of a gall-stone in the diverticulum of Vater, patients suffering with this disease not infrequently give a history of preceding gall-stone colic. In Case I. the patient underwent an attack of jaundice six months before his fatal illness. In other instances there has been a history of repeated paroxysms of severe abdominal pain, doubtless due to the passage of calculi which have failed to lodge at the orifice of the bile duct. Preceding attacks of so-called gastric or gastro-duodenal dyspepsia, noted by Fitz, in some cases at least admit of a similar explanation.

In some reported cases recurrent pancreatitis has been described, but attacks of severe pain and vomiting preceding the fatal illness are doubtless often referable to cholelithiasis. Nevertheless, it cannot be denied that acute pancreatitis may recur, for should the patient survive a primary attack, the structure of the diverticulum of Vater being favorable, a second might follow the expulsion of another stone of appropriate size.

Treatment of Acute Hemorrhagic and Gangrenous Pancreatitis.—What has been said concerning the etiology and pathology of acute inflammation of the pancreas demonstrates the futility of medical treatment directed to the palliation of the lesion. At the onset of symptoms the attention of the physician will be directed to the profound collapse, and efforts will be made to strengthen the enfeebled circulation. The in-

tense abdominal pain is often uncontrollable by the use of morphia. For the continued vomiting Körte recommends that the stomach be washed out, food by mouth discontinued, and nutrient and stimulating enemata resorted to.

It is only by surgical means that the seat of the disease can be reached. When it is possible to make a diagnosis of acute hemorrhagic pancreatitis from the symptoms which in a certain number of cases are sufficiently characteristic, the advisability of operation presents itself for consideration. During the primary collapse little is to be gained by interference which would further impair the resistance of the patient; hemorrhage is rarely profuse and bears little relation to the severity of the condition. Should the individual survive the early symptoms of shock, infection of the gangrenous tissue and abscess formation limited to the lesser peritoneal cavity soon demand exploration and drainage. Septic fever, leucocytosis, and the presence of a palpable mass in the epigastrium indicate the necessity for operative interference.

In some cases symptoms are so indefinite that acute hemorrhagic pancreatitis is not suspected, while in other instances, though such a lesion suggests itself, the evidence is insufficient to exclude the presence of other conditions. Experience has shown that the disease is often first recognized by the presence of fat necrosis noted at operation undertaken for the relief of a sup-

posed intestinal obstruction or perhaps performed for the purpose of exploration demanded by continued symptoms of grave abdominal disorder.

Should disseminated fat necrosis indicate the presence of a pancreatic lesion, exploration of the lesser peritoneal cavity through the gastrocolic omentum may disclose the presence of a pancreatic or peripancreatic abscess and permit its evacuation. Thick abdominal walls and omental fat in large quantity, together with an accumulation of necrotic tissue and partially clotted blood within the lesser peritoneal cavity, at times make access to the pancreas itself difficult or impossible, at least undesirable.

During whatever stage of the disease operation is performed the condition of the bile passages is important and may offer an imperative indication for interference. The common bile duct should be examined so far as it is possible, and bearing in mind the mechanism by which a small calculus may produce the lesion, the operator should, if feasible, exclude the possibility that a stone is still lodged in the diverticulum of Vater. If such impaction should be found, removal of the calculus is essential in order to prevent further destruction of the pancreas. The temporary lodgement of a calculus within the diverticulum may produce an extensive pancreatic lesion, yet, finally expelled into the duodenum, the stone may be no longer demonstrable either at operation or at autopsy. Hence in a considerable

number of cases the gall-bladder will be found to be filled with gall-stones, even though the bile ducts are free. These stones may be of such size that any one of them lodged at the orifice of the common duct might divert bile into the pancreatic duct. In Case I. the gall-bladder was distended with small tetragonal calculi, each about the size of a pea (see Fig. 12, p. 102).

In a patient with acute pancreatitis and fat necrosis, operated upon by Dr. Howard A. Kelly, recovery followed the removal of a large number of small gall-stones from the gall-bladder. Dr. Kelly has kindly permitted me to add the following notes of this case, which will be published in detail by Dr. Louis Lehr.

CASE XXXIII.—Mrs. W., aged forty-one years, was admitted to the care of Dr. Kelly, May 17, 1902. For several years preceding, at intervals of almost every two months, she had suffered with attacks of pain in the epigastrium. Her present illness began one week before with severe pain in the left side and back, lasting about three days, and subsequently recurring in paroxysms, which necessitated the use of morphia. There was slight nausea, but no vomiting. The stools were clay colored and of very foul odor; the temperature varied from 98° to 100° F. An operation was undertaken on the tenth day of her illness. After an incision had been made through the thick abdominal wall, the omentum was found to contain opaque, white foci of fat necrosis. An oblong mass about nine centimetres in length and six centimetres broad lying behind the greater curvature of the stomach occupied the position of the pancreas. Further examination was not possible on account of the great quantity of fat. The gall-bladder was found partially collapsed about a large number of small

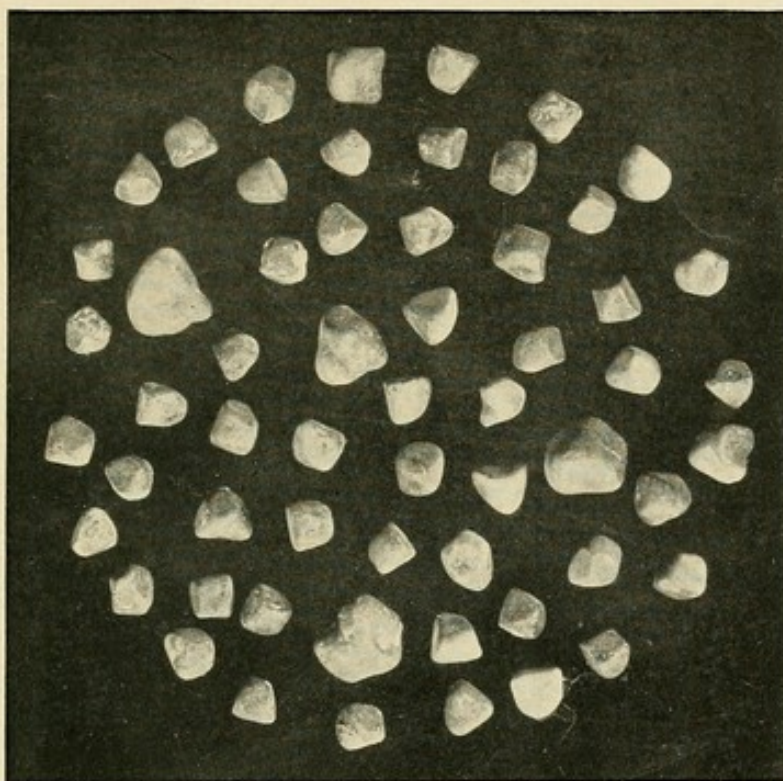



FIG. 21.—Calculi which in Case XXXIII. were at operation removed from the gall-bladder; compare with Fig. 12, p. 102.



gall-stones. An incision was made through the skin and abdominal wall opposite the gall-bladder; the organ was stitched to the edges of the wound and opened. About fifty small calculi of almost uniform size were removed (see Fig. 21). The wound opposite the gall-bladder healed slowly, and the patient made an uneventful recovery.

In the preceding case acute hemorrhagic pancreatitis and consequent fat necrosis was doubtless caused by the passage of a small calculus similar to those so numerous in the gall-bladder. These stones differed but little from those which filled the gall-bladder in Case I., and were of the same uniform size. The clinical history makes it probable that similar calculi had been repeatedly expelled previous to the attack for which operation was performed, but impaction in the diverticulum of Vater had failed to occur. Removal of those still present in the gall-bladder offered the best assurance of immunity from subsequent attacks.

Symptoms of Chronic Pancreatitis.—Chronic pancreatitis is rarely accompanied by such definite symptoms that its recognition is possible during life. In most instances a considerable part of the parenchyma is undestroyed, and is capable of performing, in part at least, the functions of the gland. Hence chronic pancreatitis may be unaccompanied by glycosuria or by any disturbance of digestion. Since chronic pancreatitis usually accompanies grave disturbances of the stomach, duodenum, or bile passages, symptoms of the primary disorder are predominant and hinder recognition of the

pancreatic lesion. On the other hand, disease of neighboring organs may suggest the presence of chronic pancreatitis.

From the clinical stand-point it is desirable to distinguish between an interlobular and an interacinar type of chronic interstitial pancreatitis. The first is rarely accompanied by diabetes mellitus; the latter, affecting both secreting parenchyma and interacinar islands, except in its earliest stage, is associated with diabetes.

The etiology of chronic interstitial pancreatitis has been previously discussed in detail. The disease is uncommon in early life, and two-thirds of the cases occur between the ages of forty and sixty years. Chronic pancreatitis follows a variety of readily recognizable conditions affecting other organs, and hence its existence may be not infrequently suspected.

Chronic pancreatitis of the interlobular type in the greatest number of cases is caused by obstruction of the duct produced by pancreatic calculi, by biliary calculi, or by tumors and cysts compressing the duct as it passes through the head of the gland. In many such cases disturbances of digestion consequent upon loss of the pancreatic secretion have been noted. Acute and chronic inflammation of the stomach and duodenum on the one hand, and of the bile passages on the other, may, as in cases previously described, be accompanied by interlobular pancreatitis, the result of an ascending infection. I have described four cases in

which chronic interlobular inflammation was found at autopsy in individuals who had suffered with persistent vomiting, caused doubtless in three cases, presumably in all, by lesions of the stomach or of the duodenum.

Interlobular pancreatitis is accompanied by diabetes only when the lesion is so far advanced that dense sclerotic tissue, which replaces the secreting parenchyma, surrounds and compresses the islands of Langerhans. Glycosuria was noted in only one of my twenty-two cases. In this case chronic interstitial pancreatitis was caused by calculi obstructing the pancreatic ducts; glycosuria was of mild type, and disappeared when the patient was given a diet poor in carbohydrates.

In at least five of fifteen cases in which Wille found alimentary glycosuria, chronic inflammation—from his description presumably of the interlobular type—was found at autopsy. It is not improbable that, even though the lesion does not implicate the islands of Langerhans, chronic inflammatory changes in their neighborhood may slightly impair their functional activity, perhaps by interfering with their blood supply. Where chronic pancreatitis is suspected, the presence of alimentary glycosuria, tested by the administration of sugar, would give additional evidence.

Distinctive of the *interacinar form of chronic pancreatitis* are glycosuria and other symptoms of diabetes mellitus. Diabetes mellitus, however, is caused by other lesions of the pancreas, and indeed may occur

in the absence of pancreatic disease. In nine of nineteen cases of diabetes which I examined at autopsy interacinar pancreatitis occurred; in six of these cases hyaline changes were also present. Although no group of symptoms, as Lancereaux has claimed, is characteristic of diabetes caused by pancreatic lesion, conditions associated with the disease may give evidence that it accompanies interacinar inflammation of the gland.

In a considerable number of cases previously cited from the literature arterial sclerosis has been associated with chronic interstitial inflammation of the pancreas. In one of the cases included in my series advanced arterial sclerosis in a diabetic was followed by gangrene of the legs, and at autopsy chronic interacinar pancreatitis was found. Where advanced arterial sclerosis accompanies diabetes mellitus, the latter disease is with much probability referable to interacinar inflammation of the pancreas.

The association of diabetes mellitus and cirrhosis of the liver has been very frequently observed, and in some of these cases examined at autopsy the pancreas has been found to be the seat of chronic inflammatory changes. Chronic inflammation of the pancreas and of the liver is doubtless in such cases dependent upon the same etiological factors. In Cases X. and XI. (pages 180 and 181) diabetes and atrophic cirrhosis coexisted, while at autopsy chronic pancreatitis of the

interacinar type was demonstrable. I am indebted to Dr. Libman, of New York, for notes upon a similar case. These observations agree with those of Lefas, who found diffuse chronic inflammation of the pancreas in association with atrophic cirrhosis of the liver. Diabetes with cirrhosis of the liver is with much probability indicative of interacinar pancreatitis.

One form of chronic interacinar pancreatitis with diabetes and cirrhosis may be readily recognized. Diabetes with hæmochromatosis, the so-called bronzed diabetes, is doubtless in all cases the result of chronic interacinar inflammation affecting the pancreas and implicating the islands of Langerhans. The combination of symptoms in such cases is characteristic. Diabetes mellitus is associated with hypertrophic cirrhosis of the liver, and there is often intense pigmentation of the skin. When doubt exists as to the character of this pigmentation, iron may be demonstrated by appropriate methods in sections made from a bit of skin, if such is obtainable from the patient. In a case described by Anschütz, fatty stools gave evidence that the secretion of the pancreas was diminished in amount; but even in the absence of such symptoms, diabetes accompanying hypertrophic cirrhosis with pigmentation may be attributed to chronic pancreatitis of the interacinar type.

Pancreatitis as a Complication of other Diseases.—It has been repeatedly stated that in most instances both

acute and chronic inflammation of the pancreas are secondary to disease of other organs. Acute or chronic inflammation may be the result of an ascending infection of the pancreatic ducts having its origin in the inflamed stomach, duodenum, or bile passages. The occurrence of chronic inflammation in association with persistent vomiting has been emphasized. The close relationship between disease of the liver and of the pancreas is especially noteworthy, chronic inflammation of the liver and pancreas, doubtless due to the same etiological factor, not infrequently occurring in conjunction. Much more common, however, is the association of cholelithiasis and disease of the pancreas; and it is perhaps desirable to consider briefly the conditions under which cholelithiasis is accompanied by pancreatic disease, even though facts previously mentioned be repeated.

Whenever a gall-stone is expelled from the common bile duct, temporary occlusion of the pancreatic duct results. The mechanism by which a small gall-stone lodged at the orifice of the diverticulum of Vater diverts bile into the pancreatic duct and causes hemorrhagic pancreatitis has been described in detail; a variety of conditions must be fulfilled in order that acute pancreatitis follow the passage of a calculus, and in only a small proportion of cases is gall-stone colic accompanied by acute disease of the pancreas. In not more than one-third of all individuals are the anatomical peculiarities of the diverticulum of Vater such that a calculus

can occlude its duodenal orifice yet fail to obstruct the bile or pancreatic ducts as they enter the diverticulum. Even should the diverticulum be of considerable length and provided with a narrow duodenal orifice a calculus can transform the two ducts into a continuous channel only if it be of very small size. In many instances the offending calculi have not been larger, roughly speaking, than a pea. Such facts help to explain the infrequency of acute hemorrhagic pancreatitis when compared with the frequency of cholelithiasis. The symptoms which characterize acute hemorrhagic pancreatitis and distinguish it from uncomplicated biliary colic have already been mentioned.

A large gall-stone lodged in the terminal part of the common bile duct, or indeed within the diverticulum of Vater, prevents the escape of pancreatic secretion, unless the duct of Santorini affords a free outlet, and chronic interlobular inflammation of the gland results. The clinical importance of this condition lies in the fact that the indurated gland felt during an operation undertaken for the removal of gall-stones in the common duct has been frequently mistaken for malignant growth. Recognition of the relation between cholelithiasis and chronic pancreatitis will have an important influence upon the prognosis in such cases, and removal of the occluding calculus will prevent further development of the pancreatic lesion.

THE [illegible] OF [illegible]

[illegible] [illegible] [illegible]

[illegible] [illegible] [illegible]

[illegible] [illegible] [illegible]

[illegible] [illegible] [illegible]

[illegible] [illegible] [illegible]

[illegible] [illegible] [illegible]

[illegible] [illegible] [illegible]

[illegible] [illegible] [illegible]

[illegible] [illegible] [illegible]

[illegible] [illegible] [illegible]

[illegible] [illegible] [illegible]

[illegible] [illegible] [illegible]

[illegible] [illegible] [illegible]

[illegible] [illegible] [illegible]

[illegible] [illegible] [illegible]

[illegible] [illegible] [illegible]

[illegible] [illegible] [illegible]

[illegible] [illegible] [illegible]

[illegible] [illegible] [illegible]

[illegible] [illegible] [illegible]

[illegible] [illegible] [illegible]

[illegible] [illegible] [illegible]

BIBLIOGRAPHY.

- ABBOTT.—A Case of Hæmochromatosis. Trans. of the Path. Soc. of London, 1900, li. 66.
- ABELMANN.—Inaugural Dissertation, Dorpat, 1890.
- ACARD.—Contribution à l'étude des cirrhoses pigmentaires. Thesis, Paris, 1895.
- ALDEHOFF.—Tritt bei Kaltblütern nach Pankreasexstirpation Diabetes mellitus auf? Zeit. f. Biol., 1891, xxviii. 293.
- ANSCHÜTZ.—Ueber den Diabetes mit Bronzfärbung der Haut. Deutsches Arch. f. klin. Med., 1899, lxii. 411.
- AUSCHER AND LAPICQUE.—Quelques recherches chimiques sur un cas de diabète pigmentaire. Compt. rend. Soc. de biol., 1895, xlvii. 402, 510.
- BALSER.—Ueber Fettnekrose. Virchow's Arch., 1882, xc. 520.
- BALSER.—Verhandl. d. xi. Cong. f. innere Med., Wiesbaden, 1892, 450.
- BERNARD, CLAUDE.—Mémoire sur le pancréas. Suppl. Compt. rend. de l'Acad. de sciences, 1856.
- BIRCH-HIRSCHFELD.—Beiträge zur pathologischen Anatomie der hereditären Syphilis Neugeborner. Arch. d. Heilkunde, 1875, xvi. 166.
- BIRCH-HIRSCHFELD.—Gerhardt's Handbuch d. Kinderkrankheiten, iv., Abth. ii. 753, Tübingen, 1880.
- BLUM.—Ueber Nebennierendiabetes. Deutsches Arch. f. klin. Med., 1901, lxxi. 146.
- BLUME.—Beiträge zur wissenschaftlichen Medicin, Festschrift zur Naturforscherversammlung in Braunschweig, 1897, 139.
- BOUCHARDAT.—De la glycosurie ou diabète sucré. Paris, 1875.

- BRACHET.—Le développement du pancréas. *Jour. de l'anat. et de la phys.*, 1896, xxxii. 620.
- BRAULT AND GALLIARD.—Sur un cas de cirrhose hypertrophique pigmentaire dans le diabète sucré. *Arch. gén. de méd.*, 1888, i. 38.
- BRIGHT.—Disease of the Pancreas and Duodenum. *Med.-Chir. Trans.*, 1833, xviii. 1.
- BRUNN, VON.—Pankreas und dessen Entwicklung. *Anat. Hefte, Merkel-Bonnet Ergebnisse*, 1894, Abt. ii., iv. 87.
- BRYANT.—Acute Hemorrhagic Pancreatitis. *Lancet*, 1900, ii. 1341.
- BUSS.—Ein Fall von Diabetes mellitus mit allgemeiner Hämochromatose. *Inaug. Diss.*, Göttingen, 1894.
- CAPPARELLI.—Sur le diabète pancréatique expérimental. *Arch. ital. de Biol.*, 1894, xxi. 398.
- CARNOT.—Recherches sur les pancréatites. *Thesis*, Paris, 1898.
- CASTLE AND LOEVENHART.—*American Chemical Jour.*, 1900, xxiv., No. 6.
- CAWLEY.—*London Med. Jour.*, 1788, 286.
- CHIARI.—Ueber Sequestration des Pankreas. *Wiener med. Woch.*, 1880, xxx. 139, 164.
- CHIARI.—Ueber Fettnekrose. *Prager med. Woch.*, 1883, viii. 285, 297.
- CHIARI.—Ueber Selbstverdauung des menschlichen Pankreas. *Zeit. f. Heilkunde*, 1896, xvii. 69.
- CHORONSHIZKY.—Die Entstehung der Bauchspeicheldrüse. *Diss. Moskow*, 1898. *Ref.*, *Anat. Hefte, Merkel-Bonnet Ergebnisse*, 1899, Abt. ii., ix. 669.
- CHVOSTEK.—Klinische Beiträge zu den Krankheiten des Pankreas. *Wiener med. Blätter*, 1879, ii. 791.
- CHVOSTEK.—Ueber alimentäre Glykosurie. *Wiener klin. Woch.*, 1892, v. 251, 267, 325.

- COLRAT.—De la glycosurie. Lyons méd., 1875, xviii. 553.
- COUTURIER.—Glycosurie dans le cas d'obstruction de la veine porte. Thesis, Paris, 1875.
- CUTLER.—Hemorrhagic Pancreatitis. Boston Med. and Surg. Jour., 1895, cxxxii. 354.
- DAY.—A Case of Pancreatitis. Boston Med. and Surg. Jour., 1892, cxxvii. 569.
- DETTMER.—Die Fettgewebsnekrosen. Inaug. Diss., Göttingen, 1895.
- DIAMARE.—Studii comparativi sulle isole di Langerhans del pancreas. Internat. Monatsschr. f. Anat. u. Phys., 1899, xvi. 155.
- DIECKHOFF.—Beiträge zur pathologischen Anatomie des Pankreas. Festschrift f. Thierfelder, Leipzig, 1895.
- DOGIEL.—Zur Frage über die Ausführungsgänge des Pankreas des Menschen. Arch. f. Anat. u. Phys., Anat. Abt., 1893, 117.
- DRAPER.—Pancreatic Hemorrhage. Boston Med. and Surg. Jour., 1886, cxv. 393.
- DROZDA.—Klinische Beiträge zur Kasuistik der Pankreaserkrankungen. Wiener med. Presse, 1880, xxi. 993.
- DUTOURIER.—Diabète bronzé. Thesis, Paris, 1895.
- EGER.—Zur Frage des Nierendiabetes. Deutsche med. Woch., 1899, xxv. 844.
- EHRICH.—Beitrag zur Kenntniss der Pankreasnekrose. Beiträge z. klin. Chir., 1898, xx. 315.
- ELBINGER AND SELIG.—Ueber den Einfluss von Nierenschädigungen auf den Ablauf des Pankreas-Diabetes. Verhandl. d. 19. Congres. f. innere Med., 1901, 416.
- ERNST, P.—Ueber Hyalin. Virchow's Arch., 1892, cxxx. 377.
- FELIX.—Zur Pankreasentwicklung. Arch. f. Anat. u. Phys., 1892, Anat. Abt., 281.

- FISCHER.—False Diverticula of the Intestine. *Jour. of Exper. Med.*, 1901, v. 333.
- FITZ.—Acute Pancreatitis. *Med. Record*, 1889, xxxv. 197, 225, 253.
- FLEINER.—Zur Pathologie der Pankreascirrhose. *Berliner klin. Woch.*, 1894, xxxi. 5, 38.
- FLES.—Arch. für holländische Beiträge zur Natur- und Heilkunde, 1864, iii. 187. Quoted by Friedreich.
- FLEXNER.—On the Occurrence of the Fat-splitting Ferment in Peritoneal Fat Necroses. *Jour. of Exper. Med.*, 1897, ii. 413.
- FLEXNER. — Experimental Pancreatitis. Contributions to the Science of Medicine. Dedicated to William H. Welch. Johns Hopkins Hospital Reports, 1900, ix. 743.
- FLEXNER AND PEARCE.—Experimental Pancreatitis. *Univ. of Pennsylvania Med. Bull.*, 1901, xiv. 193.
- FRAENKEL.—Die Lehre von der Fettgewebsnekrose. *Münchener med. Woch.*, 1896, xliii. 813, 844.
- FRAENKEL, STADELMANN, AND BENDA. — Ueber Akromegalie. *Deutsche med. Woch.*, 1901, xxvii. 513, 564.
- FRANKE.—Ueber einen Fall von Diabetes mellitus. *Inaug. Diss.*, Berlin, 1902.
- FRIEDREICH.—Diseases of the Pancreas. Von Ziemssen's Practice of Medicine (translation). New York, 1878, vol. viii. 551.
- FUCHS.—Cholelithiasis und Pankreaserkrankungen. *Deutsche med. Woch.*, 1902, xxviii. 829.
- FÜRBRINGER.—*Deutsche med. Woch.*, 1894, xx. 320.
- GEGENBAUER.—Ein Fall von Nebenpankreas. *Arch. f. Anat., Phys., und wissensch. Med.*, 1863, 163.
- GENTES.—Morphologie des islots de Langerhans. Thesis, Bordeaux, 1901.

- GIANNELLI AND GIACOMINI.—R. Accad. d. Fisiocrit. in Siena, 1896. Quoted by Oppel.
- GLINSKI.—Zur Kenntniss des Nebenpankreas. Virchow's Arch., 1901, clxiv. 132.
- GOEBEL.—Ueber Pigmentablagerung in der Darmmuskulatur. Virchow's Arch., 1894, cxxxvi. 482.
- GÖPPERT.—Die Entwicklung des Pankreas der Amphibien. Morphol. Jahrb., 1891, xvii. 100.
- GÖTTE.—Die Entwicklungsgeschichte der Unke, Leipzig, 1875.
- GRUBE.—Zur Aetiologie des Diabetes mellitus. Zeit. f. klin. Med., 1895, xxvii. 465.
- HABERSHON.—Diseases of the Abdomen, Third Ed., 1878, 338.
- HAMBURGER.—Zur Entwicklung der Bauchspeicheldrüse. Anat. Anzeiger, 1892, vii. 707.
- HAMMAR.—Arch. f. Anat. u. Phys., Anat. Abt., 1893, 123.
- HAHN.—Ueber die operative Behandlung bei Pancreatitis hämorrhagica acuta. Deutsche Zeit. f. Chir., 1900, lviii. 1.
- HALSTED.—Bull. of the Johns Hopkins Hospital, 1901, xii. 179.
- HANNEMANN.—Ueber Glycosurie und Diabetes mellitus bei Basedowschen Krankheit. Inaug. Diss., Berlin, 1895.
- HANOT AND CHAUFFARD.—Cirrhose hypertrophique pigmentaire dans le diabète sucré. Rev. de méd., 1882, ii. 385.
- HANOT AND SCHACHMANN.—Sur la cirrhose pigmentaire dans le diabète sucré. Arch. d. phys., 1886, 3 s., vii. 50.
- HANSEMANN.—Berliner med. Gesellschaft, Sitzung, vom 4. December, 1889, and Berliner klin. Woch., 1889, xxvi. 1115.
- HANSEMANN.—Die Beziehungen des Pankreas zum Diabetes. Zeit. f. klin. Med., 1894, xxvi. 191.
- HANSEMANN.—Ueber die Entstehung falscher Darmdivertikel. Virchow's Arch., 1896, cxliv. 400.
- HANSEMANN.—Ueber Akromegalie. Berliner klin. Woch., 1897, xxxiv. 417.

- HANSEMAN.—Ueber die Structur und das Wesen der Gefäßinseln des Pankreas. Verhandl. der Deutschen path. Gesellschaft., 1902, iv. 187.
- HARRIS AND GOW.—The Comparative Histology of the Pancreas. Jour. of Phys., 1894, xv. 349.
- HÉDON.—Physiologie du pancreas. Paris.
- HÉDON AND VILLE.—Compt. rend. Soc. de biol., 1892, xlv., iv. 308.
- HELLY.—Beitrag zur Anatomie des Pankreas und seiner Ausführungsgänge. Arch. f. mik. Anat., 1898, lii. 773.
- HELLY.—Zur Entwicklungsgeschichte der Pankreasanlagen und Duodenalpapillen des Menschen. Arch. f. mik. Anat., 1900, lvi. 291.
- HELLY.—Zur Pankreasentwicklung der Säugethiere. Arch. f. mik. Anat., 1901, lvii. 271.
- HENLE.—Handbuch der systematischen Anatomie des Menschen. Braunschweig, ii. 1873.
- HERNANDEZ.—La cachexie bronzée dans le diabète. Thesis, Montpellier, 1892.
- HERTER AND RICHARDS.—Glycosuria following Experimental Injection of Adrenalin. Med. News, 1902, lxxx. 201.
- HERTZOG.—Zur Histo-Pathologie des Pankreas beim Diabetes mellitus. Virchow's Arch., 1902, clxviii, 83.
- HIGGINS AND OGDEN.—Traumatic Glycosuria. Boston Med. and Surg. Jour., 1895, cxxxii. 197.
- HILDEBRAND.—Ueber Experimente am Pankreas zur Erzeugung von Fettnekrosen. Centralbl. f. Chir., 1895, xxii. 297.
- HINDENLANG.—Pigmentinfiltration in einen Fall von Morbus maculosus Werlhofii. Virchow's Arch., 1880, lxxix. 492.
- HINTZE.—Ueber Hämochromatose. Virchow's Arch., 1895, cxxxix. 459.
- HIRSCHFELD.—Zeit. f. klin. Med., 1891, xix. 294.

- HLAVA.—Bull. internat. de l'acad. des sciences de Bohême, 1898, and Arch. Bohém, 1890, iv. 139. (Cited by Katz and Winkler.)
- HOPPE-SEYLER, G.—Die Beziehungen der Erkrankung des Pankreas zum Diabetes mellitus. Deutsches Arch. f. klin. Med., 1893, lii. 171.
- HUGOUENCQ AND DOYON.—Lyon méd., 1897, No. 45, and Arch. de phys. norm. et path., 1897, ix. 832.
- JANKLOWITZ.—Zur Entwicklung der Bauchspeicheldrüse. Inaug. Diss., Berlin, 1895.
- JAROTSKY.—Ueber die Veränderungen der Pankreaszellen bei einigen Arten der Inanition. Virchow's Arch., 1899, clvi. 409.
- JEANSELME.—Diabète bronzé. Bull. et mém. Soc. méd. d. hôp. de Paris, 1897, 3 s., xiv. 179.
- JUNG.—Beitrag zur Pathogenese der akuten Pankreatitis. Inaug. Diss., Göttingen, 1895.
- KASAHARA.—Ueber das Bindegewebe des Pankreas bei verschiedenen Krankheiten. Virchow's Arch., 1896, cxliii. 111.
- KATZ AND WINKLER.—Die multiple Fettgewebnekrose, Berlin, 1899, and Arch. f. Verdauungskrankheiten, 1898, iv. 289.
- KAUSCH.—Ueber den Diabetes mellitus der Vögel nach Pankreasexstirpation. Arch. f. exper. Path. und Pharm., 1896, xxxvii. 274.
- KENNAN.—A Case of Acute Pancreatitis. British Medical Journal, 1896, ii. 1442.
- KLEBS.—Handbuch d. path. Anat., Berlin, 1869, i. 271.
- KLEBS.—Die allgemeine Pathologie, Theil ii., 100. Jena, 1889.
- KLEMPERER.—Ueber renalen Diabetes. Berliner klin. Woch., 1896, xxxiii. 571.
- KLOB.—Pankreas-Anomalien. Zeit. d. Gesellschaft d. Aerzte zu Wien, 1859, No. 46, p. 732.

- KÖNIG.—Ein Fall von Pankreas-Nekrose. Inaug. Diss., Kiel, 1889.
- KÖRTE.—Chirurgische Behandlung der Pankreaseiterung und Nekrose. Arch. f. klin. Chir., 1894, xlviii. 721.
- KÖRTE.—Pankreasentzündungen und Fettnekrose. Berliner Klinik, 1896, No. 102.
- KÖRTE.—Chirurgischen Krankheiten des Pankreas. Deutsche Chirurgie, Stuttgart, 1898.
- KOTSCHAU.—Zur Casuistik der primären Pankreasblutungen. Cent. f. allg. Path. u. path. Anat., 1893, No. 12.
- KRAUS AND LUDWIG.—Wiener klin. Woch., 1891, iv. 855, 897.
- KRETZ.—Beiträge z. klin. Med. u. Chir., Heft 15, Wien, 1896, and Centralbl. f. allg. Path. u. path. Anat., 1897, viii. 620.
- KÜHNE AND LEA.—Beobachtungen über die Absonderung des Pankreas. Untersuch. a. d. phys. Instit. d. Univ. Heidelberg, 1882, ii. 488.
- LAGUESSE.—Sur la formation des ilots de Langerhans dans le pancréas. Compt. rend. Soc. de biol., 1893, xlv. 819.
- LAGUESSE.—Développement du pancréas chez les Sélaciens. Bibliogr. anat., 1894, ii. 101.
- LAGUESSE.—Sur quelques détails de structure des pancréas humain. Compt. rend. Soc. de biol., 1894, xlvi. 667.
- LAGUESSE.—Sur les principaux stades du développement histogénique du pancréas. Verhandl. der anat. Gesellsch., 1897, 43.
- LANCEREAUX.—Deux cas de diabète sucré avec altération du pancréas. Bull. Acad. de méd., 1877, 2 s., vi. 1215.
- LANCEREAUX.—Traité des maladies du foie et du pancréas. Paris, 1899.
- LANGDON-DOWNS.—Trans. of the Clin. Soc. of London, 1869, ii. 119.

- LANGERHANS, P.—Beiträge zur mikroskopischen Anatomie der Bauchspeicheldrüse. Inaug. Diss., Berlin, 1869.
- LANGERHANS, R.—Berliner med. Gesell., Sitzung von 4. Dec., 1889, and Berliner klin. Woch., 1889, xxvi. 1115.
- LANGERHANS, R.—Ueber multiple Fettgewebsnekrose. Virchow's Arch., 1890, cxxii. 252.
- LANGERHANS, R.—Festschr. Rudolf Virchow, Berlin, 1891.
- LE COUNT.—A Case of Acromegaly. New York Med. Jour., 1899, lxi. 517, 566, 595.
- LEFAS.—Le pancréas dans les cirrhoses. Arch. Gén. de méd., 1900, n. s. iii. 539.
- LEMOINE AND LANNOIS.—Contribution à l'étude des lésions de pancréas dans le diabète. Arch. de méd. exp., 1891, iii. 33.
- LEONHARDT.—Virchow's Arch., 1900, clxii. 299.
- LEPINE.—Etiologie et pathogénie du diabète sucré. Rev. de méd., 1894, xiv. 10 oct.
- LETULLE.—Cirrhose hypertrophique pigmentaire. Bull. et mém. Soc. méd. d'hôp. de Paris, 1897, 3 s., xiv. 205.
- LETULLE.—Pancréas surnuméraires. Compt. rend. Soc. de biol., 1900, lii. 233.
- LEVRAT-PERROTON.—Sur un cas de glycosurie. Thesis, Paris, 1859.
- LEWASCHEW.—Ueber eine eigenthümliche Veränderung der Pankreaszellen bei starker Absonderungsthätigkeit der Drüse. Arch. f. mik. Anat., 1886, xxvi. 452.
- LUBARSCH.—Ueber Hämochromatose. Sitzungsberichte der naturforschenden Gesellsch. zu Rostock, 1894.
- LUBARSCH.—Die hyaline und amyloide Degeneration. Ergebnisse der allgemeinen Path. u. path. Anat., herausgegeben von Lubarsch u. Ostertag, 1895, i., Abt. ii. 200.
- LUND.—Hemorrhagic Pancreatitis. Boston Med. and Surg. Jour., 1900, cxliii. 543.

- MACKENZIE, H.—Brit. Med. Jour., 1893, i. 63.
- MADER.—Gangren des Pankreas. Bericht d. k. k. Krankenanstalt, Rudolfs-Stiftung, 1884; 1885, 371, 435.
- MALLORY.—A Contribution to Staining Methods. Jour. of Exper. Med., 1900, v. 15.
- MARIE, P.—Diabète bronzé. Semaine méd., 1895, xv. 229.
- MARX. — Ueber Fettgewebs-Nekrose. Virchow's Arch., 1901, clxv. 290.
- MASSARI.—Sul pancreas di pesci. Rend. R. Accad. dei Lincei, 1898, vii. 134. Quoted by Oppel.
- MASSARY, DE, AND POTIER.—Diabète bronzé. Bull. Soc. anat. de Paris, 1895, lxx. 354.
- MERING, VON, AND MINKOWSKI.—Diabetes mellitus nach Pankreasexstirpation. Arch. für exper. Path. u. Phar., 1890, xxvi. 371; and Semaine méd., 22 mai, 1889.
- MERING, VON.—Arch. f. Anat. u. Phys., 1877, Phys. Abt., 379.
- MEUNIER.—La cirrhose pigmentaire. Thesis, Paris, 1898.
- MICHAEL.—Deutsches Arch. f. klin. Med., 1899, xlv. 597.
- MILISCH.—Pankreaserkrankungen mit Nekrosen des Fettgewebes. Inaug. Diss., Berlin, 1897.
- MINKOWSKI.—Untersuchungen über den Diabetes mellitus nach Exstirpation des Pankreas. Arch. f. exper. Path. u. Phar., 1893, xxxi. 85.
- MORIAN.—Ein Fall von Pankreasnekrose. Münchener. med. Woch., 1899, xlv. 348.
- MOSSÉ.—Diabète maigre et mélanodermie. Congrès français de méd., 1894, Paris, 1895, i. 776.
- MOURET. — Tissu lymphoïde du pancréas. Compt. rend. Soc. de biol., 1894, xlv. 731.
- MÜLLER, FR.—Ueber Icterus. Zeit. f. klin. Med., 1887, xii. 45.
- NAUNYN.—Der Diabetes mellitus, Nothnagel's spec. Path. u. Ther., vii. Bd., vi. Th., Wien, 1898.

- NAUWERCK. — Ein Nebenpankreas. Ziegler's Beiträge, 1893, xii. 29.
- NEUMAN.—Nebenpankreas und Darmdivertikel. Arch. d. Heilkunde, 1870. xi. 200.
- OLT. — Die Fettgewebsnekrose bei unseren Hausthieren. Deutsche Thierärztl. Woch., 1898, vi. 117.
- OPIE.—Hæmochromatosis. Jour. of Exper. Med., 1899, iv. 279.
- OPIE.—The Histology of the Islands of Langerhans. Johns Hopkins Bull., 1900, xi. 205.
- OPIE.—Experimental Fat Necrosis. Contributions to the Science of Medicine. Dedicated to William H. Welch. Johns Hopkins Hospital Reports, 1900, ix. 859.
- OPIE.—Cholelithiasis and Disease of the Pancreas. American Jour. of the Med. Sciences, 1901, cxxi. 27.
- OPIE.—The Relation of Chronic Interstitial Pancreatitis to Diabetes Mellitus. Jour. of Exper. Med., 1901, v. 397.
- OPIE.—Hyaline Degeneration of the Islands of Langerhans. Jour. of Exper. Med., 1901, v. 527.
- OPIE.—The Etiology of Acute Hemorrhagic Pancreatitis. Bull. of the Johns Hopkins Hospital, 1901, xii. 182.
- OPIE.—The Causes and Varieties of Chronic Interstitial Pancreatitis. Amer. Jour. of the Med. Sc. 1902, cxxiii. 845.
- OPPEL.—Lehrbuch der vergleichenden mikroskopischen Anatomie der Wirbelteire, vol. iii., Jena, 1900.
- OSER.—Die Erkrankungen des Pankreas. Nothnagel's spec. Path. u. Ther., vol. xvii., Vienna, 1898.
- OSER.—Die pathognostischen Symptome der Pankreaserkrankungen. Die deutsche Klinik, 1901, v. 151.
- OSLER.—The Diagnosis of Abdominal Tumors. New York, 1894, p. 118.
- OSLER AND HUGHES.—Trans. of the Philadelphia Path. Soc., 1887, xiii. 24.

- PAUL.—A Case of Acute Hemorrhagic Pancreatitis. Boston Med. and Surg. Jour., 1894, cxxx. 8.
- PAWLOW AND SMIRNOW.—Die Regeneration des Pankreas beim Kaninchen. Arzt, 1889, No. 12; Ref. Jahresbericht ü. d. Fortschritte d. Anat. u. Phys., 1890, xix. Phys. Abt., 439.
- PHISALIX.—Compt. rend. de l'Acad. des sciences, 1887, civ. 799, and Arch. zool. exper., 1888, s. 2, vi. 279.
- PILLIET.—Sur la structure de l'ampoule de Vater. Compt. rend. Soc. de biol., 1894, xlvi. 549.
- PINELES.—Ueber die Beziehungen der Akromegalie zum Diabetes mellitus. Jahrb. d. Wiener k. k. Krankenanst., Jahrgang, 1895, Wien, 1897.
- PISCHINGER.—Beiträge zur Kenntniss des Pankreas. Inaug. Diss., München, 1895.
- PODWYSSOTSKI.—Beiträge zur Kenntniss des feineren Baues der Bauchspeicheldrüse. Arch. f. mik. Anat., 1882, xxi. 765.
- PONFICK.—Zur Pathogenese der abdominalen Fettnekrose. Berliner klin. Woch., 1896, xxxiii. 365.
- PRINCE.—Pancreatic Apoplexy. Boston Med. and Surg. Jour., 1882, cvii. 28, 55.
- PUSINELLI.—Ueber die Beziehungen zwischen Diabetes und Lebercirrhose. Berliner klin. Woch., 1896, xxxiii. 739.
- QUINCKE.—Ueber Siderosis. Festschrift dem Andenken Albrechts von Haller gewidmet. Bern, 1877, 37.
- RECKLINGHAUSEN, VON.—Drei Fälle von Diabetes mellitus. Virchow's Arch., 1864, xxx. 360.
- RECKLINGHAUSEN, VON.—Ueber Hämochromatose. Tageblatt der 62. Versamml. deutsch. Naturforscher und Aerzte in Heidelberg, 1889, 324.
- RECKLINGHAUSEN, VON.—Handbuch der allgemeinen Pathologie des Kreislaufs und der Ernährung. Deutsche Chirurgie, Stuttgart, 1883.

- RENAUT.—Sur les organes lympho-glandulaires et la pancréas.
Compt. rend. d. l'Acad. d. sciences, 1879, lxxxix. 247.
- RENAUT.—Traité de histologie pratique, Paris, 1899, ii. 1506.
- RENDU AND DE MASSARY.—Cirrhose et diabète bronzé. Bull. et
mém. Soc. d. hôp. de Paris, 1897, s. 3, xiv. 163.
- REYNOLDS AND MOORE.—Acute Hemorrhagic Pancreatitis.
British Med. Jour., 1898, i. 1335.
- RICHARDIERE.—De la glycosurie et du diabète dans la sclérose
en plaques. Rev. de méd., 1886.
- RICHTER.—Die Beziehungen zwischen Nieren und Glykosurie.
Zeit. f. klin. Med., 1900, xli. 160.
- RIEDEL.—Ueber entzündliche Vergrößerungen des Pankreas-
kopfes. Berliner klin. Woch., 1896, xxxiii. 1, 32.
- ROBSON, MAYO.—Pancreatitis. Lancet, 1900, ii. 235.
- ROKITANSKY.—Lehrbuch der path. Anat. Vienna, 1863, iii. 313.
- ROLLESTON.—Fat Necrosis. Trans. of the Path. Soc. of London,
1893, xlv. 71.
- ROSENBERG.—Arch. f. Anat. u. Phys., 1896, Phys. Abt., 535.
- ROSENTHAL.—Ueber einen Fall von chronische intersitieller
Pankreasentzündung. Zeit. f. klin. Med., 1892, xxi. 401.
- ROTH.—Ueber Divertikelbildung am Duodenum. Virchow's
Arch., 1872, lvi. 197.
- SAHLI.—Ueber Glutoidkapseln. Deutsche med. Woch., 1897,
xxiii. 6, and Lehrbuch der klinischen Untersuchungs-
methoden, Leipzig, 1902.
- SANDMEYER.—Zeitschr. für Biol., 1895, xxxi. 12.
- SAPPEY.—Traité d'anatomie descriptive, vol. iv., Paris, 1889.
- SAUNDBY.—Lectures on Diabetes. London, 1891.
- SCHÄFER.—Quain's Anatomy. London, 1896, vol. iii., Pt. iv.,
p. 138.
- SCHIRMER.—Beitrag zur Geschichte und Anatomie des Pan-
kreas. Inaug. Diss., Basel, 1893.

- SCHLESINGER.—Die Erkrankung des Pankreas bei hereditärer Lues. *Virchow's Arch.*, 1898, cliv. 501.
- SCHLESINGER.—Ueber die Beziehungen der Akromegalie zum Diabetes mellitus. *Wiener klin. Rundschau*, 1900, xiv. 15.
- SCHMIDT.—Ueber die Beziehung der Langerhans'schen Inseln des Pankreas zum Diabetes mellitus. *Münchener med. Woch.*, 1902, xlix. 51.
- SCHÖPFFER.—Beiträge zur Kenntniss der Glykogenbildung in der Leber. *Arch. f. exper. Path. u. Phar.*, 1873, i. 73.
- SCHULZE.—Die Bedeutung der Langerhans'schen Inseln im Pankreas. *Arch. f. mik. Anat.*, 1900, lvi. 491.
- SCOTT.—Acute Gangrenous Pancreatitis. *American Jour. of the Medical Sciences*, 1899, cxviii. 414.
- SEEGEN.—Diabetes mellitus. Berlin, 1893.
- SEITZ.—Blutung und Entzündung der Bauchspeicheldrüse. *Zeit. f. klin. Med.*, 1892, xx. 1, 203, 311.
- SIMPSON.—On Pancreatic Hemorrhage. *Edinburgh Med. Jour.*, 1897, ii. 245.
- SMITH, J. A.—Impacted Gall-Stones: Acute Hemorrhagic Pancreatitis. *British Med. Jour.*, 1897, ii. 468.
- SSOBOW.—Ueber die Structur der Bauchspeicheldrüse unter gewissen pathologischen Bedingungen. *Centralbl. f. allg. Path. u. path. Anat.*, 1900, xi. 202.
- SSOBOW.—Zur normalen und pathologischen Morphologie der inneren Secretion der Bauchspeicheldrüse. *Virchow's Arch.*, 1902, clxviii. 91.
- STANGL.—Zur Histologie des Pankreas. *Wiener klin. Woch.*, 1901, xiv. 964.
- STATKEWITSCH.—*Arch. f. exp. Path. u. Phar.*, 1894, xxxiii. 415.
- STOCKTON AND WILLIAMS.—Hemorrhagic Pancreatitis. *Philadelphia Med. Jour.*, 1900, vi. 649.

- STÖHR.—Die Entwicklung von Leber und Pankreas der Forelle. Anat. Anzeiger, 1893, viii. 205.
- STOSS.—Zur Entwicklungsgeschichte des Pankreas. Inaug. Diss., Leipzig, 1892, and Anat. Anzeiger, 1891, vi. 666.
- STRAUSS.—Zur Lehre der neurogenen und der thyrogenen Glykoseurie. Deutsche med. Woch., 1897, xxiii. 275.
- STRUPPLER.—Ueber septische Processe bei Pankreasnekrose. Deutsches Arch. f. klin. Med., 1900, lxix. 206.
- SYMINGTON.—A Rare Anomaly of the Pancreas. Jour. of Anat. and Phys., 1885, xix. 292.
- TESTUT.—Traité d'anatomie humaine, vol. iii., Paris, 1894.
- THAYER.—A Case of Hemorrhagic Pancreatitis. Boston Med. and Surg. Jour., 1889, cxxi. 506.
- THAYER.—The Diagnosis of Pancreatic Disease. American Medicine, 1902, iii. 341.
- THIROLOIX.—Le diabète pancréatique. Thesis, Paris, 1892.
- TIEKEN.—Annular Pancreas. American Medicine, 1901, ii. 826.
- TILLMANN.—Veränderungen der Leber und der abdominalen Lymphdrüsen nach Traumen. Arch. d. Heilkunde, 1878, xix. 119.
- VERRON.—Tumeurs du quatrième ventricule. Thesis, Paris, 1878.
- VÖLKER.—Beiträge zur Entwicklung des Pankreas bei der Amnionen. Arch. für mik. Anat., 1902, lix. 62.
- WAGNER.—Accessorisches Pankreas. Arch. d. Heilkunde, 1862, iii. 283.
- WEICHSELBAUM.—Wiener med. Woch., 1881, xxxi. 913.
- WEICHSELBAUM AND STANGL.—Zur Kenntniss der feineren Veränderung des Pankreas bei Diabetes mellitus. Wiener klin. Woch., 1901, xiv. 968.

- WEINTRAUD.—Ueber den Pankreas-Diabetes der Vögel. Arch. f. exper. Path. u. Phar., 1894, xxxiv. 303.
- WEINTRAUD.—Untersuchungen über den Stoffwechsel im Diabetes mellitus. 1893.
- WELCH.—The Bacillus Coli Communis: the Conditions of its Invasion of the Human Body. Med. News, 1891, lix. 669.
- WILLE.—Die alimentäre Glykosurie und ihre Beziehungen zu Pankreasaffektionen. Deutsches Arch. f. klin. Med., 1899, lxiii. 546.
- WILLIAMS, H. U.—Experimental Fat Necrosis. Boston Med. and Surg. Jour., 1897, cxxxvi. 345.
- WILLIAMS, H. U.—Fat Necrosis. Report of the Pathological Lab. of the Univ. of Buffalo, 1900, No. i.
- WILLIAMS, P. W.—Brit. Med. Jour., 1894, ii. 1303.
- WILLIAMSON.—Diabetes Mellitus.—Edinburgh and London, 1898.
- WINDLE.—Morbid Anatomy of Diabetes Mellitus. Dublin Jour. of Med. Science, 1883, lxxvi. 112.
- WLASSOW.—Zur Entwicklung des Pankreas beim Schwein. Morpholog. Arbeiten herausgeg. von Schwalbe, 1895, iv. 67.
- WRIGHT.—Aberrant Pancreas in the Region of the Umbilicus. Jour. of the Boston Soc. of Med. Sciences, 1901, v. 497.
- WRIGHT AND JOSLIN.—Islands of Langerhans of the Pancreas in Diabetes Mellitus. Jour. of Med. Research, 1901, i. 360.
- ZALESKI.—Zur Pathologie der Zuckerharnruhr und zur Eisenfrage. Virchow's Arch., 1886, civ. 91.
- ZENKER.—Nebenpankreas in der Darmwand. Virchow's Arch., 1861, xxi. 369.
- ZENKER.—Hämorrhagien des Pankreas. Berliner klin. Woch., 1874, xi. 611, and Deutsche Zeit. f. prakt. Med., 1874, 351.
- ZIMMERMANN.—Rekonstruktion eines menschlichen Embryos. Anat. Anzeiger, 1889, Suppl. to vol. iv. 139.

INDEX.

- Accessory pancreas, 46
 diverticulum of intestine
 with, 47
 in papilla of duct of San-
 torini, 43
 origin of, 57
 within umbilicus, 49
 Acute pancreatitis, varieties of, 89
 with diabetes, 252
 Adrenal gland, 277
 Alcohol, causing chronic pancrea-
 titis, 206
 Alimentary glycosuria, 238
 as symptom of pancreatic
 disease, 310
 with acromegaly, 273
 with cirrhosis, 272
 with exophthalmic goitre,
 277
 with pancreatic disease, 272
 with partial extirpation of
 the pancreas, 242
 Amyloid degeneration, 218
 Annular pancreas, 46
 Anomalies of the pancreas, 46
 Arterial sclerosis, with chronic
 pancreatitis, 198
 with diabetes, 271, 334
 with pancreatic hemor-
 rhage, 94
 Ascending infection of the pan-
 creatic ducts, 179, 192
 Asphyxiation, glycosuria with, 240
 Atrophy of the pancreas, cachectic,
 258
 with diabetes, 253
 Bernard's puncture, 239
 Bibliography, 339
 Bile, hemorrhagic pancreatitis
 caused by, 121
 Bronzed diabetes, 289, 335
 Calculi, pancreatic, causing chronic
 pancreatitis, 185
 with diabetes, 256
 Carbon monoxide poisoning, glyco-
 suria with, 240
 Carcinoma of the pancreas, causing
 chronic pancreatitis, 190
 with diabetes, 252, 256, 309
 Centro-acinar cells, 69
 Cholelithiasis, with chronic pan-
 creatitis, 188, 337
 with fat necrosis, 155
 with gangrenous pancreatitis,
 III
 with hemorrhagic pancreatitis,
 40, 100, 329, 336
 with suppurative pancreatitis,
 III
 Chronic interacinar pancreatitis,
 180
 interlobular pancreatitis, 173
 interstitial pancreatitis, caused
 by alcohol, 206
 etiology of, 184
 fat necrosis with, 137,
 149, 154, 156
 islands of Langerhans
 with, 164
 of accessory pancreas,
 56


- Chronic interstitial pancreatitis, parapancreatic fat necrosis with, 161
 symptoms of, 331
 varieties of, 163, 170
 with acromegaly, 273
 with bronzed diabetes, 293
 with carcinoma, 190
 with chronic passive congestion, 200
 with cirrhosis, 207
 with diabetes, 252, 263
 with duodenal stricture, 197
 with gastritis, 193
 with hæmochromatosis, 288, 298, 301
 with infection of the pancreatic ducts, 179
 with obstruction of the pancreatic ducts, 173
 with pancreatic calculi, 185
 with syphilis, 204
 with tuberculosis, 202
 with vomiting, 193
 passive congestion, causing chronic pancreatitis, 200
 Cirrhosis of the liver, with chronic pancreatitis, 207
 with diabetes, 271, 334
 with hæmochromatosis, 287
 Coagulative necrosis of the pancreas, 233
 Common bile duct, relation of, to duct of Wirsung, 29, 38
 relation of, to pancreas, 37
 Cysts of the pancreas, 191, 251, 313
 Development of the pancreas, 21
 in lower animals, 22
 Development of the pancreas, in man, 25
 retarded with congenital syphilis, 169
 Diabetes mellitus, as symptom of pancreatic disease, 307
 cases of, 250
 experimental, 241
 metabolism of iron with, 297
 pathology of, 237, 278
 relation of islands of Langerhans to, 261
 treatment of, 317
 with acromegaly, 273
 with acute pancreatitis, 252
 with arterial sclerosis, 271
 with atrophy of the pancreas, 253
 with carcinoma, 252, 256
 with chronic pancreatitis, 256
 with cirrhosis, 271
 with exophthalmic goitre, 277
 with functional insufficiency of the pancreas, 269
 with gangrenous pancreatitis, 252
 with hæmochromatosis, 301
 with interacinar pancreatitis, 259
 with interlobular pancreatitis, 259
 with lesions of the central nervous system, 274
 with nephritis, 275
 without pancreatic lesion, 270
 with pancreatic calculi, 256
 with tuberculosis, 204
 Digestive disturbances, after removal of pancreas, 311
 with pancreatic disease, 313


- Diverticula of the intestine, beside pancreatic ducts, 64
with accessory pancreas, 47, 62
- Diverticulum of Vater, 39
- Duct of Santorini, 19
papilla of, 41
patency of, 42
of Wirsung, 19
within bile papilla, 45
- Ducts of the pancreas, in lower animals, 20
regeneration of, 59
relation of parenchyma to, 33
variations of, 26
- Duodenal stricture, with chronic pancreatitis, 197
- Embryology. See Development.
- Exophthalmic goitre, with diabetes, 277
- Fat necrosis, clinical significance of, 319
disseminated, 135
etiology of, 138, 147, 153
experimental, 139, 144
histology of, 137
in lower animals, 137
parapancreatic, 135, 158
with cholelithiasis, 155
with chronic pancreatitis, 137, 149, 154, 156
with duct-obstruction, 147, 154
with hemorrhagic pancreatitis, 158
with pancreatic hemorrhage, 94
- Fat-splitting ferment, 143, 147
in urine, 322
- Gall-stones. See Cholelithiasis.
- Gangrenous pancreatitis, pathogenesis of, 131
symptoms of, 134, 325
treatment of, 328
with diabetes, 252, 309, 326
- Gastritis, with chronic pancreatitis, 193
- Glucose in blood, 236
- Glycogen, 237
- Glycolytic, ferment, 245
- Glycosuria, alimentary, 338
with acromegaly, 273
with adrenalin injections, 277
with asphyxiation, 240
with exophthalmic goitre, 277
with lesions of kidney, 276
with lesions of the nervous system, 239, 274
with partial extirpation of the pancreas, 242
with phloridzin poisoning, 240
- Hæmochromatosis, 280
chronic interacinar pancreatitis with, 180
pancreatitis with, 288, 298
cirrhosis with, 287
etiology of, 295
with diabetes, 301
- Hæmofuscin, 282
- Hæmosiderin, 282
- Hemorrhage in the pancreas, 92, 130
relation of, to hemorrhagic pancreatitis, 130
with self-digestion of the pancreas, 160
- Hemorrhagic pancreatitis, 90
etiology of, 98, 113
experimental, 96, 121
histology of, 127
pathogenesis of, 127
relation of gangrenous pancreatitis to, 131

- Hemorrhagic pancreatitis, relation of pancreatic hemorrhage to, 94, 130
 symptoms of, 133, 323
 treatment of, 327
 with cholelithiasis, 100, 125
 with diabetes, 309, 326
- Histology of the pancreas, 67
- Hyaline capillary thrombosis, 128
 degeneration of the pancreas, 214
 affecting islands of Langerhans, 219
 etiology of, 228
 with diabetes, 262, 265
 with interacinar pancreatitis, 211, 229
- Interacinar islands, 68
 pancreatitis, 180
 etiology of, 211, 213
 symptoms of, 333
 with diabetes, 259, 262
- Interalveolar cell-islets, 68
- Interlobular fissure, 36
 pancreatitis, 173
 etiology of, 213
 symptoms of, 332
 with diabetes, 259, 262
- Islands of Langerhans, 68
 comparative histology of, 69
 development of, 76
 diminution in number of, 266
 distribution of, 79
 fat in cells of, 79, 214
 hyaline degeneration of, 218
 in accessory pancreas, 56
 physiology of, 81
 relation of, to acini, 79, 81
 relation of, to carbohydrate metabolism, 87
- Islands of Langerhans, relation of, to diabetes mellitus, 262
 relation of, to lobule, 71
 structure of, 74
 with chronic interstitial pancreatitis, 164
 with congenital syphilitic pancreatitis, 168
 with hæmochromatosis, 289, 302
 with interacinar pancreatitis, 179
 with interlobular pancreatitis, 174, 177
- Levulose, 246
- Lobes of the pancreas, 36
- Lobule of the pancreas, 33, 70
- Meckel's diverticulum, with accessory pancreas, 63
- Medulla, lesions of, with diabetes, 275
- Morbus maculosus Werlhofii, 284
- Nephritis with diabetes, 275
- Obstruction of the pancreatic ducts, causing interlobular pancreatitis, 173, 185
 disturbances of digestion with, 313
 fat necrosis with, 147, 154
 parapancreatic fat necrosis with, 161
- Pancreas, historical data concerning, 18
 extirpation of, 241, 312
 parvum of Winslow, 46
- Pancreatic diabetes, experimental, 241
 in man, 246

- | | |
|---|---|
| <p>Pancreatic diabetes, statistics of, 248
 symptoms of, 308
 juice, production of fat necrosis by, 151
 Peri-pancreatic abscess, 91
 symptoms of, 325
 treatment of, 329
 Pernicious anæmia, 284
 Phloridzin, 240
 Pilocarpin, 81, 84, 149
 Primary lobule of the pancreas, 34, 70
 Pseudo-follicles, 68
 Renal diabetes, 275
 Secondary cell-groups, 68
 lobule of the pancreas, 34
 Self-digestion of the pancreas, 159
 relation to pancreatic hemorrhage, 94
 Steatorrhœa, 314
 with hemorrhagic pancreatitis, 326
 Suppurative pancreatitis, 91</p> | <p>Suppurative pancreatitis, fat necrosis with, 137
 relation of, to gangrenous pancreatitis, 132
 symptoms of, 325
 Symptoms of pancreatic disease, 306
 obscurity of, 304
 Syphilis, with chronic pancreatitis, 204
 Syphilitic pancreatitis, 204
 congenital, 164
 Tertiary lobule of the pancreas, 34
 Thyroid gland, 277
 Toluylendiamin, 297
 Traumatic diabetes, 275
 Treatment of pancreatic disease, 316
 with pancreatic extracts, 317
 Tuberculosis, with chronic pancreatitis, 202
 with diabetes, 204
 Vomiting, causing chronic pancreatitis, 193</p> |
|---|---|

THE END.





This book is due on the date indicated below, or at the expiration of a definite period after the date of borrowing, as provided by the library rules or by special arrangement with the Librarian in charge.

This book is due on the date indicated below, or at the expiration of a definite period after the date of borrowing, as provided by the library rules or by special arrangement with the Librarian in charge.

[illegible]

RC 857

Op 3

Opie

Disease of the Pancreas

ON PERSONAL RESERVE SHEET

NOV 5 1911

