

## **Disease of the pancreas : its cause and nature / by Eugene L. Opie.**

### **Contributors**

Opie, Eugene L. 1873-1971.  
Augustus Long Health Sciences Library

### **Publication/Creation**

Philadelphia ; London : J. B. Lippincott, 1910.

### **Persistent URL**

<https://wellcomecollection.org/works/yajctvxs>

### **License and attribution**

This material has been provided by This material has been provided by the Augustus C. Long Health Sciences Library at Columbia University and Columbia University Libraries/Information Services, through the Medical Heritage Library. The original may be consulted at the the Augustus C. Long Health Sciences Library at Columbia University and Columbia University. where the originals may be consulted.

This work has been identified as being free of known restrictions under copyright law, including all related and neighbouring rights and is being made available under the Creative Commons, Public Domain Mark.

You can copy, modify, distribute and perform the work, even for commercial purposes, without asking permission.

**wellcome  
collection**

Wellcome Collection  
183 Euston Road  
London NW1 2BE UK  
T +44 (0)20 7611 8722  
E [library@wellcomecollection.org](mailto:library@wellcomecollection.org)  
<https://wellcomecollection.org>

COLUMBIA LIBRARIES OFFSITE  
HEALTH SCIENCES STANDARD



HX00034088

RC 857

Op 3

Columbia University  
in the City of New York

1910


College of Physicians and Surgeons




Reference Library

Given by

Dr. Evan M. Evans.





# DISEASE OF THE PANCREAS

ITS CAUSE AND NATURE

By

EUGENE L. OPIE

PROFESSOR OF PATHOLOGY, WASHINGTON UNIVERSITY, ST. LOUIS, MO.  
FORMERLY MEMBER OF THE ROCKEFELLER INSTITUTE FOR MEDICAL RESEARCH  
AND PATHOLOGIST TO THE PRESBYTERIAN HOSPITAL  
OF NEW YORK CITY

SECOND EDITION REWRITTEN

*ILLUSTRATED*



PHILADELPHIA & LONDON  
J. B. LIPPINCOTT COMPANY

1910

---

COPYRIGHT 1903, BY J. B. LIPPINCOTT COMPANY


---

COPYRIGHT 1910, BY J. B. LIPPINCOTT COMPANY

---

*Printed by J. B. Lippincott Company  
The Washington Square Press, Philadelphia, U. S. A.*

DEDICATED  
WITH  
GRATITUDE AND AFFECTION  
TO  
WILLIAM H. WELCH



Digitized by the Internet Archive  
in 2010 with funding from  
Open Knowledge Commons

# PREFACE

---

## HISTORY

THE monograph of Friedreich,<sup>1</sup> which contains the meagre clinical data published before 1875, is the first systematic description of pancreatic disease. Available to Friedreich were the monographs of Claessen<sup>2</sup> (1842) and of Ancelet<sup>3</sup> (1866), together with a considerable mass of carefully described cases and pathological records collected by Cruveilhier, Rokitansky, Virchow, Klebs, and others. The part of pancreatic secretion in the digestion of proteins, fats, and carbohydrates had been recognized by Claude Bernard.<sup>4</sup> Nevertheless, symptoms produced by lesions of the gland were so ill-defined that diagnosis of pancreatic disease was impossible; advance of clinical knowledge has been dependent upon a clearer understanding of the peculiar pathology of the organ.

Studies of Heidenhain<sup>5</sup> have shown what changes occur in the gland during the elaboration of the pancreatic enzymes, and have prepared the way for an understanding of the process of secretion in general.

---

<sup>1</sup> Friedreich: Disease of the Pancreas. Von Ziemssen's Practice of Medicine [Trans.], New York, 1878, viii, 551.

<sup>2</sup> Claessen: Krankheiten der Bauchspeicheldrüse, Köln, 1842.

<sup>3</sup> Ancelet: Étude sur les maladies du pancréas, Paris, 1866.

<sup>4</sup> Claude Bernard: Mémoire sur le pancréas. Compt. rend. de l'Acad. de scien., 1856, Suppl., 379.

<sup>5</sup> Heidenhain: Beiträge zur Kenntniss des Pankreas. Pflüger's Arch., 1875, x, 557.

Langerhans<sup>6</sup> (1869) has shown that the pancreas contains, in addition to the secreting cells, morphological elements which find little analogy in other glands; throughout the parenchyma are isolated bodies composed of cells having no relation to the ducts of the gland, but in intimate contact with a rich vascular supply. Recent progress of the physiology of the pancreas is marked by the discovery of enterokinase by Schepowalnikow, a pupil of Pawlow,<sup>7</sup> and of secretin by Bayliss and Starling.<sup>8</sup> In Chapters IV and V the physiology of the gland will be briefly reviewed.

Friedreich described acute primary pancreatitis, acute secondary pancreatitis (parenchymatous degeneration), and chronic pancreatitis, and recognized, following Klebs, the hemorrhagic character not infrequently exhibited by the acute lesions. A classification of acute pancreatic disease, proposed by Fitz<sup>9</sup> in 1889, has been almost universally accepted; he has distinguished three types of inflammation, characterized as hemorrhagic, gangrenous, and suppurative pancreatitis, and has carefully described the symptoms which accompany these lesions. So-called gangrenous inflammation of the pancreas represents in most instances, at least, a late stage of the hemorrhagic lesion, and both are peculiar to the

---

<sup>6</sup> Langerhans: Beiträge zur mikroskopischen Anatomie der Bauchspeicheldrüse. Inaug. Diss., 1869.

<sup>7</sup> Pawlow: The Work of the Digestive Glands [Trans.], London, 1902.

<sup>8</sup> Bayliss and Starling: The Mechanism of Pancreatic Secretion. Jour. of Physiol., 1902, xxviii, 325; Starling, Physiology of Digestion, Chicago, 1906.

<sup>9</sup> Fitz: Acute Pancreatitis. Med. Record, 1889, xxxv, 197, 225, 253.

pancreas, for they have characters not produced by changes in other organs. Recent observations and experiments have shown that these heretofore obscure changes are dependent upon anatomical and physiological peculiarities of the gland. They have shown that the condition is essentially necrosis and not inflammation.

The lesion known as fat necrosis was first adequately described by Balsler<sup>10</sup> in 1882. Studies of Fitz, Chiari, R. Langerhans, Hildebrand and Dettmer, and others, have demonstrated the relation of fat necrosis to lesions of the pancreas and have shown that the condition is not a disease *sui generis*, as many writers have described it, but a sequence of a considerable variety of pancreatic lesions.

Clinical observations inaugurated by Thomas Cawley as early as 1788 have shown that diabetes mellitus is frequently associated with grave disease of the pancreas, but the relationship of the pancreas to carbohydrate metabolism had not been clearly recognized until Von Mering and Minkowski<sup>11</sup> succeeded in completely extirpating the organ in dogs. Their experiments demonstrate, it is well known, that glycosuria and other symptoms characteristic of diabetes follow this operation. Numerous observations made both before and after the publication of these studies have shown that diabetes mellitus, in a large proportion of cases, is associated with disease of the pancreas. Many lesions of the organ are unaccompanied by glycosuria, and numerous attempts have been made to define what pancreatic lesions are

---

<sup>10</sup> Balsler: Ueber Fettnekrose. Virchow's Arch., 1882, xc, 520.

<sup>11</sup> V. Mering and Minkowski: Diabetes mellitus nach Pankreasextirpation. Arch. f. exper. Path. u. Pharm., 1890, xxvi, 371.

peculiar to diabetes. Accumulating evidence obtained by histological studies of the diseased organ has shown that diabetes mellitus accompanies those lesions which attack the ductless structures discovered by Langerhans and known as the islands of Langerhans. That form of diabetes which is referable to a lesion of the pancreas may be regarded as a symptom of destructive changes affecting these structures.

The development of knowledge of pancreatic disease can be followed in the monographs of Fitz, Körte,<sup>12</sup> Oser,<sup>13</sup> Lancereaux,<sup>14</sup> Mayo Robson and Moynihan,<sup>15</sup> Mayo Robson and Cammidge,<sup>16</sup> Truhart,<sup>17</sup> and Lazarus,<sup>18</sup> and in the first edition of this book.

Increased knowledge of pancreatic disease has aided diagnosis, and has materially enlarged the opportunity for successful surgical interference. Since Bozeman<sup>19</sup> and Gussenbauer<sup>20</sup> first described operations for cyst

---

<sup>12</sup> Körte: *Chirurgische Krankheiten des Pankreas*. Deutsche Chirurgie, Stuttgart, 1898.

<sup>13</sup> Oser: *Die Erkrankungen des Pankreas*. Nothnagel's Spec. Path. und Ther., xvii, Vienna, 1898.

<sup>14</sup> Lancereaux: *Traité des maladies du foie et du pancréas*, Paris, 1899.

<sup>15</sup> Mayo Robson and Moynihan: *Diseases of the Pancreas*, Philadelphia and London, 1903.

<sup>16</sup> Mayo Robson and Cammidge: *The Pancreas*, Philadelphia and London, 1907.

<sup>17</sup> Truhart: *Pankreas-Pathologie, I. Th., Multiple Abdominale Fettgewebsnekrose*, Wiesbaden, 1902.

<sup>18</sup> Lazarus: *Beitrag zur Pathologie und Therapie des Pankreas mit besonderer Berücksichtigung der Cysten und Steine*, Berlin, 1904.

<sup>19</sup> Bozeman: *Cyst of the Pancreas*, New York Med. Record, 1882, xxi, 46.

<sup>20</sup> Gussenbauer: *Zur operat. Behandlung der Pankreascysten*. Arch. f. Chir., 1883, xxix, 355.

of the pancreas, surgical treatment has been extended not only to cysts, and in a few instances to tumors, but to the various acute disorders of the organ. Von Mikulicz-Radecki (1903) thus described the status of surgical diagnosis and the usual practice of surgeons: "At the present time most cases are operated upon when the diagnosis is only probable, and only after the abdominal cavity has been opened can a differential diagnosis be made. As is well known, in the beginning of the era of pancreatic surgery most operations were undertaken on a rule, when the pancreas is intact we find other injuries pancreas is deemed probable it is considered wise to submit the patient to an exploratory laparotomy. This practice fortunately is of no great consequence, because, as a rule, when the pancreas is intact we find other injuries or diseases present which justify laparotomy." Study of the pathology of the pancreas, I believe, has removed much of this obscurity concerning its diseases. In the succeeding chapters knowledge of the gland has been systematically reviewed and the attempt has been made to elucidate the clinical aspect of its disease by the aid of experimental and anatomical data.

In the first edition of this book diseases dependent upon the peculiar physiology of the pancreas, namely, hemorrhagic necrosis (acute hemorrhagic pancreatitis), fat necrosis, and diabetes mellitus, received special attention, whereas little space was given to those lesions which resemble similar changes of other organs. During the past seven years abundant data have been collected by many observers with the purpose of testing various hypotheses proposed to explain the normal or diseased activity of the gland. This wealth of material has neces-

sitated a systematic review of the entire subject, but in the present edition, as in the first, detailed discussion has been devoted to those conditions which are as yet obscure. For this reason hemorrhagic necrosis, chronic pancreatitis, and the pancreatic pathology of diabetes mellitus have been described with much detail. The attempt has been made to collect and classify those observations which may serve as a basis for further advance in the knowledge of pancreatic disease.

The present work was begun in 1895 in the pathological laboratory of the Johns Hopkins Hospital under the direction of Dr. William H. Welch. A large part of the data described in the following chapters has been obtained in the pathological laboratories of the Johns Hopkins Hospital and of the Presbyterian Hospital of New York. I am indebted for additional material to the kindness of Dr. G. J. Adami, Dr. C. W. Duval, Dr. E. Eliot, Dr. Simon Flexner, Dr. E. Hodenpyl, Dr. Walter James, Dr. O. Klotz, Dr. F. Kinnicutt, Dr. E. Libman, Dr. Warfield Longcope, Dr. W. G. MacCallum, Dr. F. B. Mallory, Dr. David Marine, Dr. Charles Norris, Dr. H. Oertel, Dr. J. G. Thacher, Dr. F. C. Wood, Dr. J. Homer Wright, and others. I have incorporated in the text the results of a study of hemorrhagic necrosis of the pancreas made in collaboration with Dr. J. C. Meakins. In the chapter on the pathology of the pancreas with diabetes mellitus the observations of Dr. R. L. Cecil have been freely used.

# CONTENTS

CHAPTER	PAGE
PREFACE.....	v
History.....	v
I.—THE ANATOMY OF THE PANCREAS.....	1
Development of the Pancreas.....	4
The Pancreatic Ducts.....	7
Topography of the Pancreas.....	17
Medical and Surgical Anatomy of the Pancreas.....	22
Injury of the Pancreas.....	25
II.—ANOMALIES OF THE PANCREAS.....	29
Accessory Pancreas.....	30
Diverticula Caused by Anomalies of the Pancreas.....	44
III.—HISTOLOGY OF THE PANCREAS.....	50
Pancreatic Lobule.....	51
Ducts and Acini.....	55
Islands of Langerhans.....	59
Histogenesis of the Secreting Acini and of the Islands of Langerhans.....	66
Function of the Islands of Langerhans.....	69
IV.—THE PANCREAS AND DIGESTION.....	77
Pancreatic Juice and its Enzymes.....	78
Disturbances of Digestion Caused by Absence of Pancreatic Juice in the Intestine.....	87
Changes in the Urine Referable to Pancreatic Disease.....	98
V.—THE PANCREAS AND CARBOHYDRATE METABOLISM.....	102
VI.—HEMORRHAGIC NECROSIS OF THE PANCREAS (ACUTE HEMORRHAGIC PANCREATITIS).....	118
Etiology.....	127
Pathology.....	158
Symptoms.....	164
Treatment.....	171
VII.—FAT NECROSIS.....	176

VIII.—ACUTE PANCREATITIS.....	200
IX.—CHRONIC INTERSTITIAL PANCREATITIS.....	209
Varieties of Chronic Pancreatitis .....	210
Etiology.....	224
Symptoms.....	243
X.—TUBERCULOSIS OF THE PANCREAS—SYPHILIS.....	249
Syphilis .....	250
XI.—PANCREATIC CALCULI.....	257
XII.—CYSTS.....	266
Pathology .....	266
Symptoms .....	281
Treatment .....	284
XIII.—CARCINOMA.....	288
XIV.—DEGENERATIVE CHANGES AFFECTING THE ISLANDS OF LANGER- HANS.....	299
XV.—PATHOLOGY OF THE PANCREAS WITH DIABETES MELLITUS.....	317
XVI.—HÆMOCHROMATOSIS AND BRONZED DIABETES .....	365

# DISEASE OF THE PANCREAS

## CHAPTER I.

### THE ANATOMY OF THE PANCREAS.

THE pancreas is subject to greater variation in size and shape than other glandular organ. The ducts of the gland vary widely in their conformation and in their relation to one another and to the common bile duct. Only by a study of many specimens is it possible to determine the relative frequency of anatomical peculiarities which have a physiological significance and constitute an important factor in the production of certain pathological alterations.

The descriptions of the pancreas given by text-books of anatomy vary little, but I believe may be so modified as to give a clearer conception of the topography of the gland. A few well-known facts may be recalled in order to make clear the subsequent description.

The right extremity of the pancreas, lying in the concavity of the duodenum and being wider and thicker than the remainder of the gland, is termed the head, and forms an enlarged, somewhat bulbous, mass, the long axis of which makes an angle with the remainder of the gland. A constricted part, or neck, connected with the upper and anterior aspect of the head, at first directed slightly upward and forward, is continued to the right as the body of the gland. In contact with this neck, in the groove which causes its constriction, lie the superior mesenteric vessels, which pass from behind below the

organ, while a short process of the head projects behind these vessels, thus deepening the groove in which they lie. The body terminates near the spleen in a slightly tapering extremity called the tail, but no line of demarcation exists between these two parts. The larger duct of the gland, the duct of Wirsung, traverses the organ from left to right, bends downward and backward in the neck, and, approaching the posterior surface of the head, finally reaches the wall of the duodenum, which it penetrates after uniting with the common bile duct.

The older writers, including Galen, Vesalius, and Fallopius, believed that the organ existed to support and protect more important structures in contact with it. The recognition of its physiological significance was possible only after the discovery of Wirsung (1643) that it is traversed by a duct which, receiving branches from every side, increases in size and finally opens into the duodenum (Fig. 1).

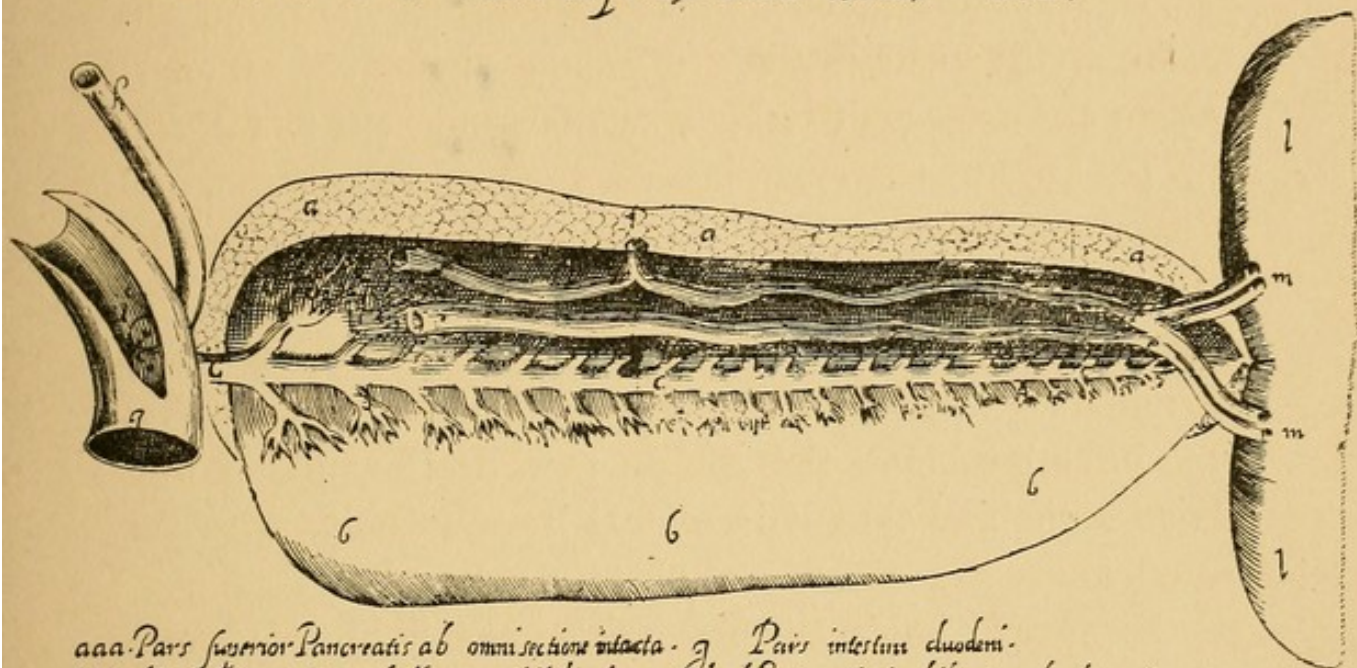
Santorini, however, first recognized that two ducts are normally present; he described and accurately pictured<sup>1</sup> the smaller duct, to which his name has been given. According to his description, it terminates in a small papilla situated upon the mucous membrane of the duodenum about two finger-breadths nearer the stomach than the large papilla in which terminates the larger pancreatic duct and the common bile duct. Subsequent

---

<sup>1</sup> Figs. 2 and 6 are reproduced from the excellent plates of Santorini, published in 1775, thirty-eight years after his death, by Michael Girardi, under the title, "*Jo. Dominici Santorini anatomici summi septem decim tabulæ quas nunc primum edit atque explicat usque alias addit de structura mammarum et de tunica testis vaginali.*" For the opportunity to reproduce these plates I am indebted to the kindness of Dr. Howard A. Kelly, from whose library this volume was obtained.

anatomists, including Meckel and Cruveilhier, thought that the occurrence of an accessory duct was exceptional, but Claude Bernard,<sup>2</sup> in his memoir upon the pancreas, described the second smaller outlet as constantly present.

*Figura ductus cuiusdam cum multiplicibus suis ramulis noviter in Pancreate a Jo: Georg: Wirsung  
Phil. et Med. D. in diversis corporibus humanis observata*



aaa. Pars superior Pancreatis ab omni sectione intacta. g. Pars intestini duodeni.  
 bbb. Altera pars inferior ab illa non nihil divulsa. h. Meatus Vesicæ biliaris in duodenum insertus.  
 ccc. Ductus in per longitudinem Pancreatis extensus. Orificium eiusdem meatus.  
 dddd. Ramuli eiusdem ductus per iduodenum pancreas digerit. k. Orificium ductus noviter inventi.  
 e. Vena splenica. ll. Pars hepatis.  
 ff. Arteria splenica s. mm. Ingressus Vasorum in hepem. s. *Tabula 1642*

FIG. 1.—The original drawing of Wirsung, showing the pancreatic duct. Reproduced from the dissertation of Schirmer

Among most mammals the adult, it is well known, possesses two ducts, one of which joins the common bile duct. The pancreas of the cat and of the dog consists of two parts, an upper horizontal arm extending from the duodenum to the spleen and a descending arm lying

<sup>2</sup> Claude Bernard: Mémoire sur le pancréas. Suppl. Compt. rend. de l'Acad. des sciences, 1856.

in contact with the duodenum and projecting into the duodenal mesentery. In the cat a large duct, sending out branches into both arms of the gland, enters the intestine by a common orifice with the bile duct, while a short distance below this orifice a much smaller duct, anastomosing with the larger in the substance of the gland, enters the duodenum. In the dog the larger pancreatic duct enters the intestine several centimetres below the smaller, which joins the common bile duct. Revell<sup>3</sup> found considerable variation in the size of the two ducts; in twenty-nine out of thirty dogs they anastomosed within the gland and in three animals the condition was exceptional, the two ducts having approximately the same size. In the rabbit, of which the pancreas consists of lobules scattered in the mesentery, a large duct enters the intestine below the bile duct, while the smaller duct is so atrophied that it is almost impermeable.

#### DEVELOPMENT OF THE PANCREAS.

With an increased knowledge of the development of the gland, peculiarities of the ducts have been better understood. Earlier investigations have seemed to show that the development of the organ varies greatly among different classes of vertebrates, but more careful observations have disclosed considerable uniformity.

The occurrence of a single dorsal and two ventral outgrowths has been described in various species of fish (Laguesse,<sup>4</sup> Hammar,<sup>5</sup> Stöhr,<sup>6</sup> and Göppert<sup>7</sup>), in am-

---

<sup>3</sup> Revell: *American Jour. of Anat.*, 1902, i, 443.

<sup>4</sup> Laguesse: *Bibliogr. Anat.*, 1894, ii, 101.

<sup>5</sup> Hammar: *Arch. f. Anat. u. Phys., Anat. Abt.*, 1893, 123.

<sup>6</sup> Stöhr: *Anat. Anz.*, 1893, viii, 205.

<sup>7</sup> Göppert: *Morph. Jahrb.*, 1891, xvii, 100.

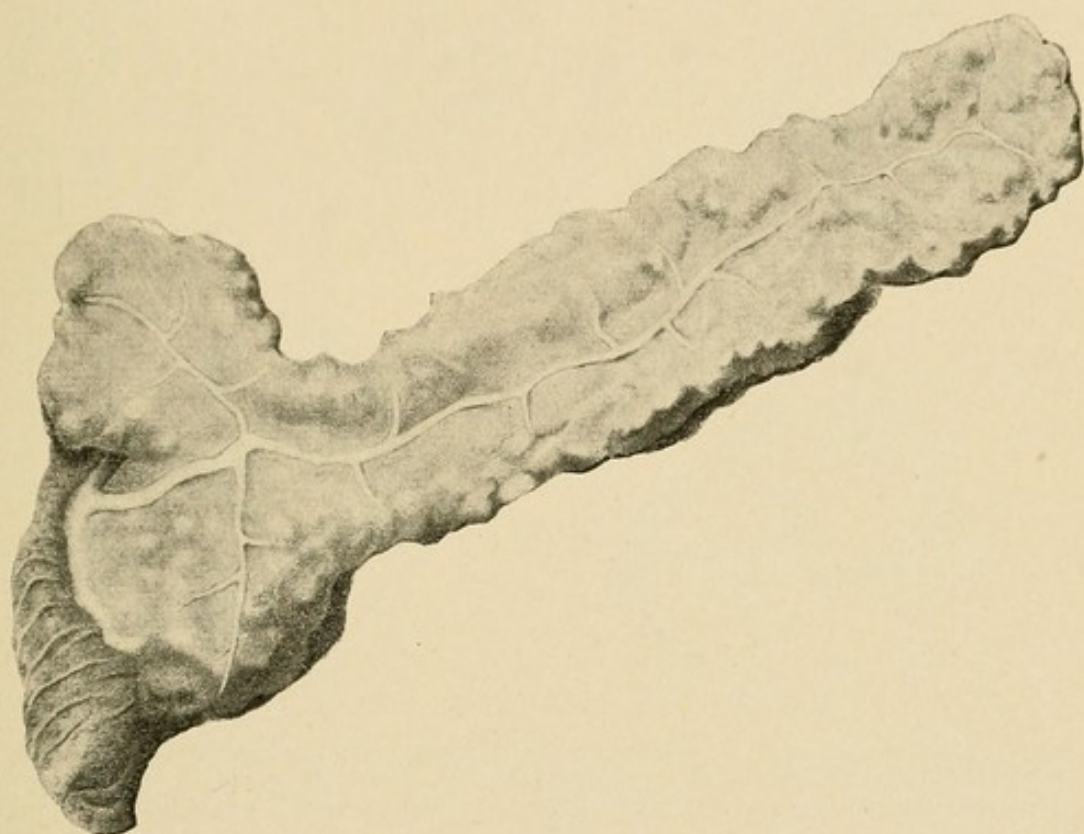



FIG. 2.—Reproduction of the original drawing of Santorini, showing both ducts of the pancreas.



phibia (Götte,<sup>8</sup> Göppert, and Felix<sup>9</sup>), and in reptiles (Brachet<sup>10</sup>), though an occasional observer has found only one ventral outgrowth.

Stoss<sup>11</sup> has carefully described the development of the pancreas in a mammal (the sheep). The bud-like outgrowth from which the liver develops is formed at a

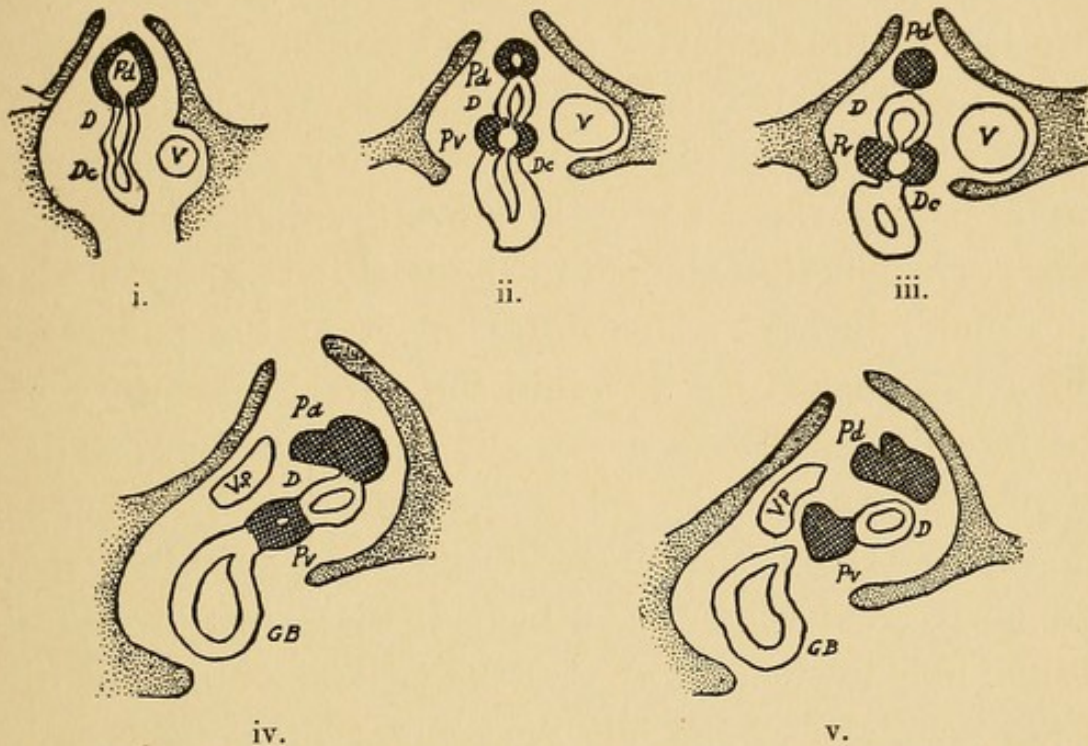


FIG 3.—Development of the pancreas in the sheep. *D*, duodenum; *Pd*, dorsal "anlage" of the pancreas; *Pv*, ventral "anlage" of the pancreas; *Dc*, ductus choledochus; *GB* gall-bladder; *V*, umbilical vein; *Vp*, portal vein. (After Stoss, slightly modified.)

time when the gastro-intestinal tract is a straight tube attached by its mesentery to the posterior abdominal wall. The pancreas makes its appearance as a projection (Fig. 3, i., *Pd*) upon the dorsal surface of the intestine between the liver and the stomach, which is now represented by a spindle-shaped dilatation of the intestinal

<sup>8</sup> Götte: Die Entwicklungsgeschichte der Unke, Leipzig, 1875.

<sup>9</sup> Felix: Arch. f. Anat. u. Phys., 1892. Anat. Abt., 281.

<sup>10</sup> Brachet: Jour. de l'anat. et de la phys., 1896, xxxii, 620.

<sup>11</sup> Stoss: Inaug. Diss., Leipzig, 1892; and Anat. Anz., 1891, vi, 666.

tube. Upon the ventral surface of the intestine, at either side of the hepatic duct, appear two diverticula (Fig. 3, ii., *Pv*), which later fuse to form the ventral rudiment of the pancreas and subsequently grow to meet the dorsal part (Fig. 4).

The stomach at first lies in the median plane of the body, and that part which is to become the greater curvature is now the posterior or dorsal border of the organ (Fig. 5). The alteration of position by which the stomach is transversely placed, the posterior wall becoming the inferior border or greater curvature, is accompanied by a corresponding change in the position of the duodenum and pancreas. The dorsal part of the pancreas, which has pushed its way into the dorsal mesentery of the intestinal tube, comes to lie transversely with its left extremity near the spleen, and at the same time, as Stoss has shown, that part of the duodenum to which the pancreas and liver are attached twists upon its longitudinal axis in such a way that the ventral wall, and with it the openings of the bile duct and ventral pancreatic outgrowth, passes to the right and backward (Fig. 3, v.), becoming the posterior wall of the duodenum. With further growth the part of the pancreas which was originally ventral comes into contact with the larger dorsal part of the organ. The two parts unite to form a conglomerate organ and the two ducts, which were at first separate, anastomose. At an early stage the duct of the dorsal part atrophies, and finally disappears, so that the single opening which remains in the adult sheep is that of the ventral outgrowth.

The development of the human pancreas, according to most recent observations, does not differ from that

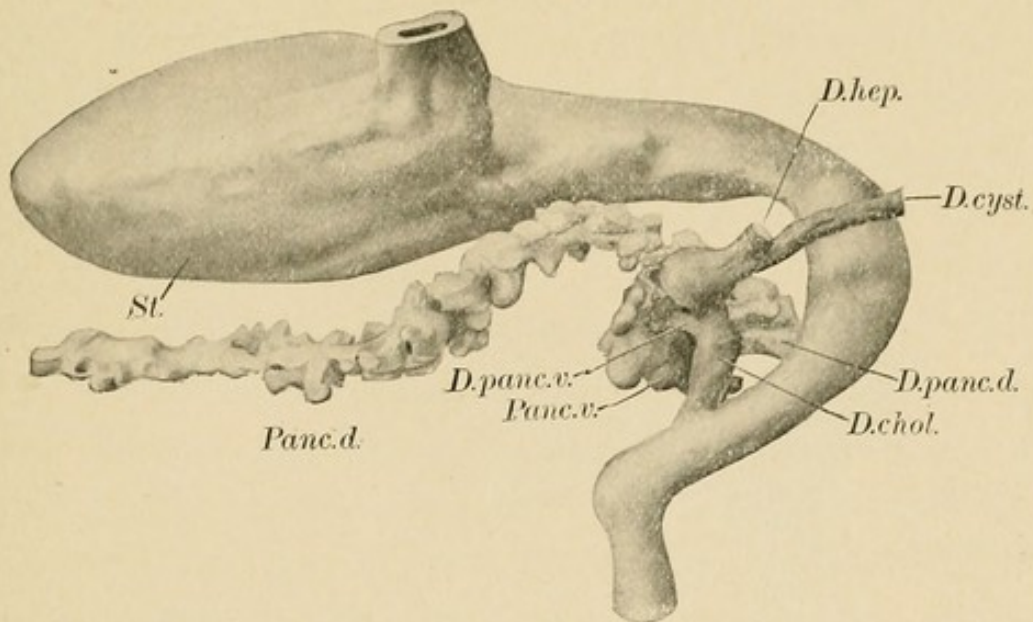


FIG. 4.—Fusion of the dorsal and ventral pancreas in a human embryo 13.6 mm. in length. (After Thyng, *American Jour. of Anat.*, 1908, vii, 499.)

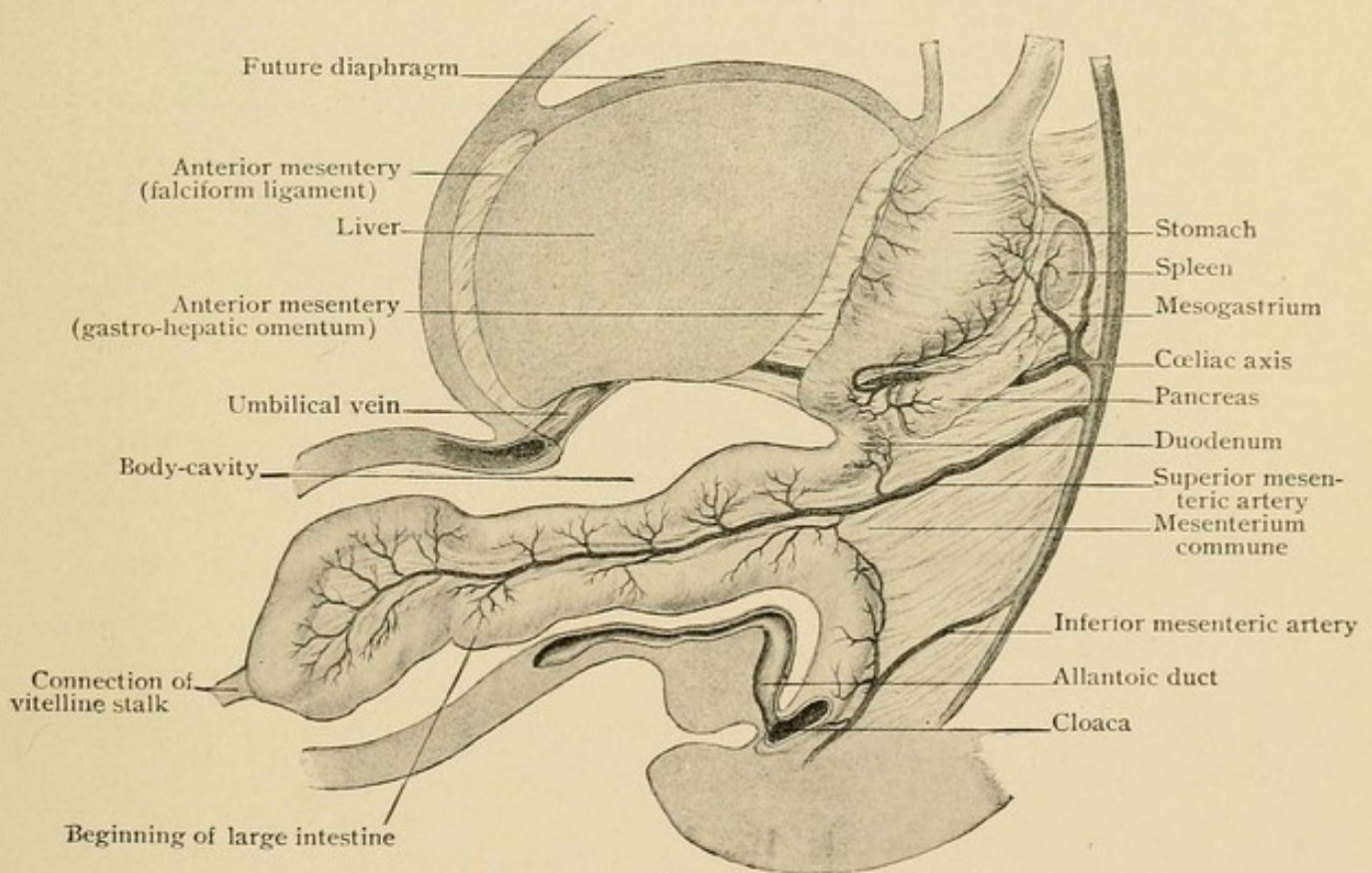


FIG. 5.—Diagram showing intestinal canal and mesentery in the sixth week of fetal life. (Piersol.) (After Mall and Toldt.)

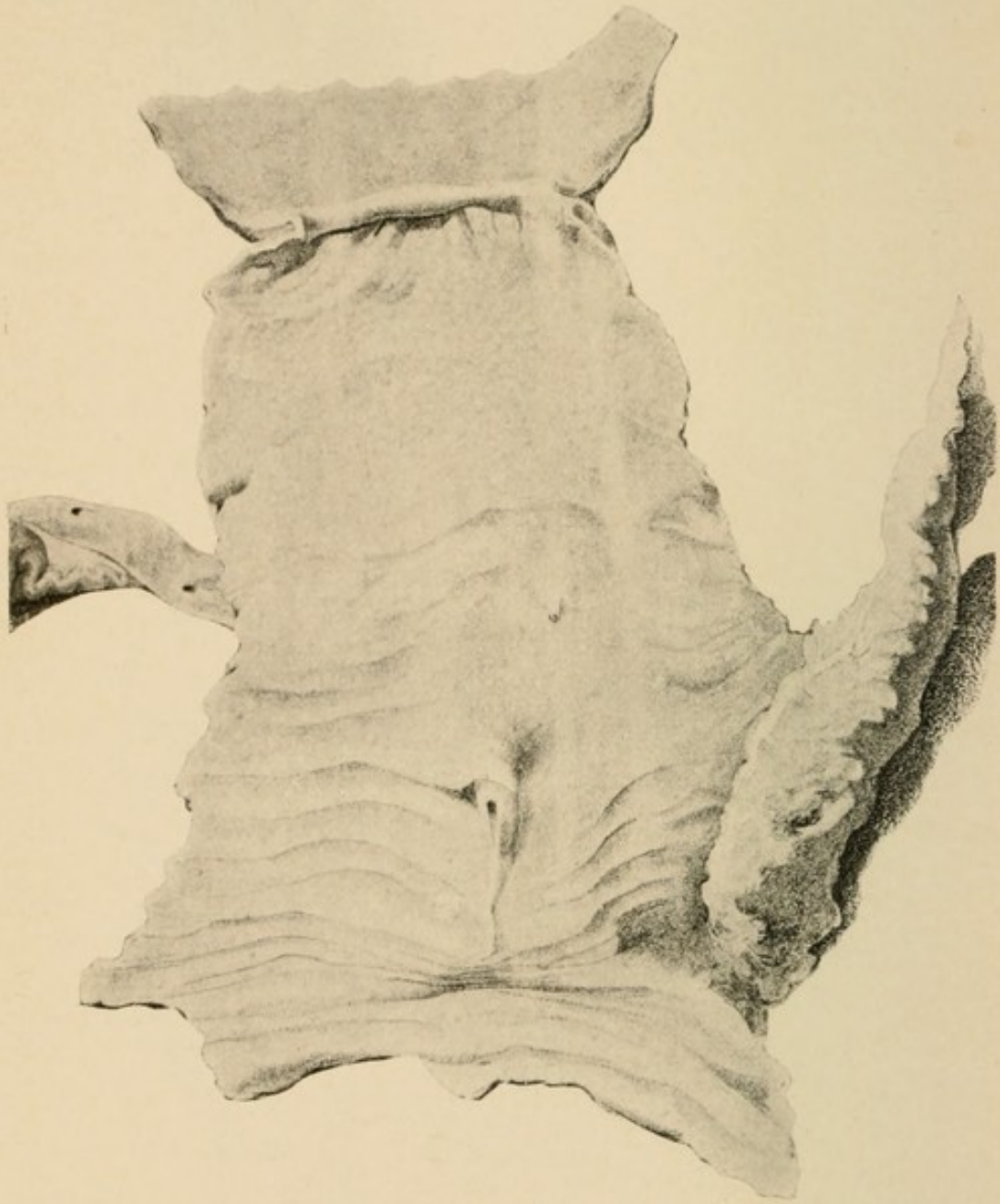


FIG. 6.—Reproduction of a drawing by Santorini, published by Girardi in 1775. The duodenum has been opened, and both the bile papilla and papilla of the smaller pancreatic duct are exposed.

of other vertebrates. Earlier observers, Phisalix,<sup>12</sup> Zimmermann,<sup>13</sup> and Hamburger,<sup>14</sup> and more recently, Völker,<sup>15</sup> and Thyng,<sup>16</sup> have described two primitive outgrowths. Felix, Jankilowitz<sup>17</sup> (in an embryo of 47 mm.) and Von Brunn<sup>18</sup> have, however, found three "anlage," a dorsal and a right and a rudimentary left ventral, the two latter subsequently fusing. The dorsal rudiment, arising between the bile duct and the stomach, forms the ductus Santorini, the ventral the ductus pancreaticus (Wirsungi). In an embryo six weeks old Hamburger has found the dorsal and ventral parts of the gland united, and concludes that anastomosis occurs during the second half of the second month of embryonic life.

#### THE PANCREATIC DUCTS.

*Variation of the Pancreatic Ducts.*—Such embryological study has shown that the greater part of the pancreas,—namely, the body and tail and part of the head,—develops from the primitive dorsal outgrowth, represented in the adult by the ductus pancreaticus accessorius (Santorini), which enters the duodenum in between the bile papilla and the stomach (Fig. 6). The ductus pancreaticus (Wirsungi) enters the duodenum in common with the ductus choledochus below the duct of Santorini—that is, at a point further from the stomach—and in the

---

<sup>12</sup> Phisalix: Compt. rend. de l'Acad. des sciences, 1887, civ, 799; Arch. zool. Exper., 1888, s. 2, vi, 279.

<sup>13</sup> Zimmermann: Anat. Anz., 1889, iv, Suppl., 139.

<sup>14</sup> Hamburger: Anat. Anz., 1892, vii, 707.

<sup>15</sup> Völker: Arch. f. mik. Anat., 1902, lix, 62.

<sup>16</sup> Thyng: American Jour. of Anat., 1908, vii, 489.

<sup>17</sup> Jankilowitz: Inaug. Diss., Berlin, 1895.

<sup>18</sup> Von Brunn: Anat. Hefte, 1894, Abt. ii, iv, 87.

head of the gland represents the primitive ventral outgrowth. The two ducts usually anastomose at an early period. The part of the upper or originally dorsal duct which lies between the duodenal orifice and its anastomosis with the lower duct undergoes partial atrophy, and the lower channel increasing in size appears to be a continuation of the large duct, which, derived from the dorsal outgrowth, follows the axis of the gland. Hence the duct of Wirsung, which affords an outlet for almost the entire pancreatic secretion, is derived, in the head of the gland, from the ventral pancreas and in the body, from the dorsal.

In a few individuals the upper duct or duct of Santorini remains larger than the lower; in other instances there is no anastomosis between the two ducts. Claude Bernard, Henle,<sup>19</sup> Sappey,<sup>20</sup> and other anatomists have described various modifications to which the ducts are subject. Increased importance has been given to the relationship of the pancreatic ducts to one another and to the common bile ducts by the study of pathological lesions dependent upon anatomical peculiarities of these ducts.

Schirmer<sup>21</sup> examined the pancreatic ducts in one hundred and four bodies and tested their patency. He exposed the larger duct in the body of the gland and, inserting a cannula, forced air in the direction of the duodenum, which had been previously opened. By keeping the specimens under water, the escape of air from

---

<sup>19</sup> Henle: *Handbuch der Anatomie des Menschen*, Braunschweig, 1873, ii.

<sup>20</sup> Sappey: *Traité d'anatomie*, Paris, 1889, iv.

<sup>21</sup> Schirmer, *Inaug. Diss.*, Basel, 1893.

one or both ducts was determined. The ducts were later carefully dissected. Schirmer described numerous varieties dependent upon the relative size of the two ducts, their anastomosis within the gland, their patency, and their relation to the bile duct. He attempted no classification of the diverse forms, but for the sake of clearness they may be collected into three groups, as follows:

DUCTS IN ANASTOMOSIS AND PATENT:

Duct of Wirsung larger.....	60
Duct of Santorini larger.....	6

DUCTS IN ANASTOMOSIS; ONE WHOLLY OR PARTIALLY OBLITERATED:

Papilla of duct of Santorini not patent.....	24
Duct of Wirsung absent.....	5

DUCTS NOT IN ANASTOMOSIS:

Duct of Wirsung larger.....	5
Duct of Santorini larger .....	4

I have dissected the pancreatic ducts in one hundred specimens. In order to determine their patency and, if possible, the existence of an anastomosis between them, a solution of Berlin blue was injected into the duct of Wirsung, exposed by transverse section of the body of the gland. To avoid extravasation the injection was made at a pressure little greater than that of a column of water two feet in height. By compressing that orifice, from which the fluid readily escaped, the attempt was made to divert the flow to a second orifice. Such specimens were hardened in formalin and subsequently preserved in alcohol; the dissection of the ducts was facilitated by the presence of the injected material. In those instances in which the lesser papilla appeared to be

closed, serial sections were made in order to more accurately determine its patency.

My observations differ in several respects from those of Schirmer. Though the ducts vary much in their relative size and one has at times undergone partial obliteration, two are constantly present. In twelve instances Schirmer found that the common bile duct joined the upper pancreatic duct, while further from the stomach was a second smaller papilla. His observation is difficult to explain, for in my specimens the relationship of the lower duct,—the duct of Wirsung,—to the common bile duct is constant and agrees with the well-established embryological development of the two ducts.

The varieties of the pancreatic ducts and their relative frequency among one hundred specimens which I have examined are indicated in the following classification:

I. DUCTS IN ANASTOMOSIS:

(1) Duct of Wirsung larger.	
(a) Duct of Santorini patent.....	63
(b) Duct of Santorini not patent.....	21
(2) Duct of Santorini larger or equal in size to the duct of Wirsung.	
(a) Duct of Wirsung patent.....	6
(b) Duct of Wirsung not patent.....	0

II. DUCTS NOT IN ANASTOMOSIS:

(1) Duct of Wirsung larger.....	5
(2) Duct of Santorini larger.....	5

In considerably more than one-half the specimens both ducts are patent, and the duct of Wirsung, which unites with the duct of Santorini, is larger than the latter (Fig. 6, i.); the duct of Santorini diminishes in size as

it approaches the duodenum, and opens upon the lesser papilla by a narrow orifice. Receiving numerous branches from the head of the gland, and gradually increasing in size as the duct of Wirsung is approached, the duct of Santorini appears to be a branch of the larger duct, into which, in the majority of instances, it doubtless pours its secretion. In only forty-eight instances has it been possible to inject fluid at a low pressure through the smaller papilla. In some of these specimens the injected fluid has escaped readily, and hence it is probable that the duct may occasionally act as a functional outlet. In fifteen specimens the patency of the duct has been demonstrated only by microscopic examination of serial sections through the lesser papilla, while in a very large group of cases it has not been possible even by that means to demonstrate its patency. Hence in more than half of all individuals the lesser duct is at its orifice obliterated or so constricted that it cannot assume the function of the larger duct when occluded.

Occasionally the duct of Santorini enters the upper aspect of the duct of Wirsung (Fig. 7, i.); at times it arises from the lower aspect (Fig. 8, i., ii.), and by a somewhat tortuous course reaches the upper papilla. The point at which the anastomosis occurs varies considerably, and though usually several centimetres from the termination of both ducts, may be less than a centimetre from the duodenal orifice of one, the other duct then following a tortuous course to reach its termination (Fig. 8, iii., iv.). Occasionally the duct of Santorini appears to be a direct continuation of the main channel within the body of the gland (Fig. 8, iv.), thus suggesting the original embryonic condition.

In ten cases (as in Fig. 7, v., vi., vii.) no anastomosis has been found between the two ducts. In four additional cases, included in Group I, of the table (see Fig. 7, iii.), the duct of Santorini is almost wholly indepen-

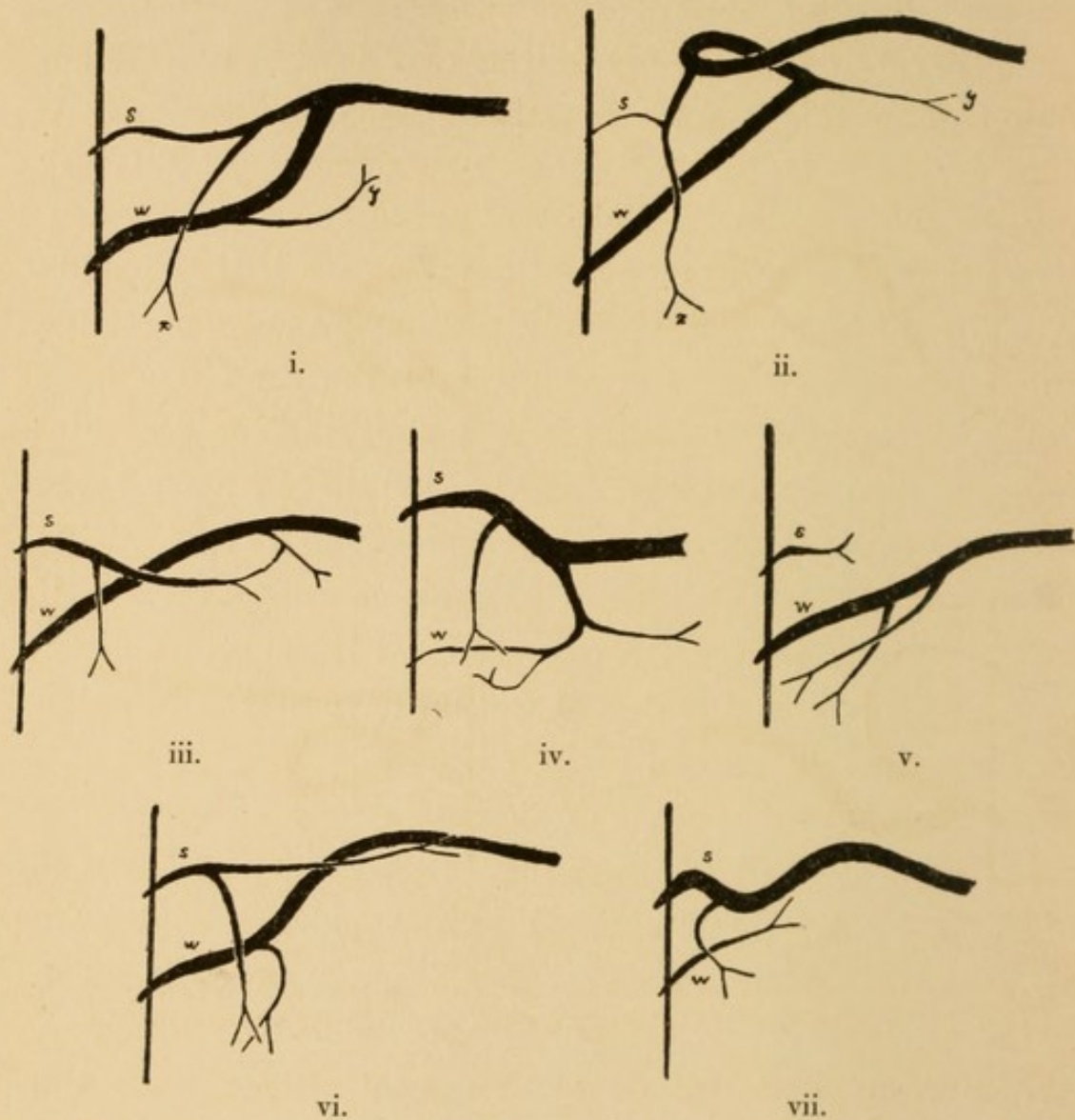


FIG. 7.—Varying relations of the duct of Santorini (*s*) to the duct of Wirsung (*w*). Drawn from dissected specimens.

dent of the duct of Wirsung, with which it is united only by a narrow twig. Receiving branches from all sides and gradually increasing in size as it approaches the duodenum, the duct of Santorini in such case represents the outlet for a part of gland substance and is

functionally independent of the lower duct, even though this small communicating twig unites them. Indeed, it is conceivable that when the two ducts appear to be wholly independent a very minute communication, though present, has not been demonstrated.

The relative diameter of the two ducts varies much. When they anastomose, in only seven of ninety cases is

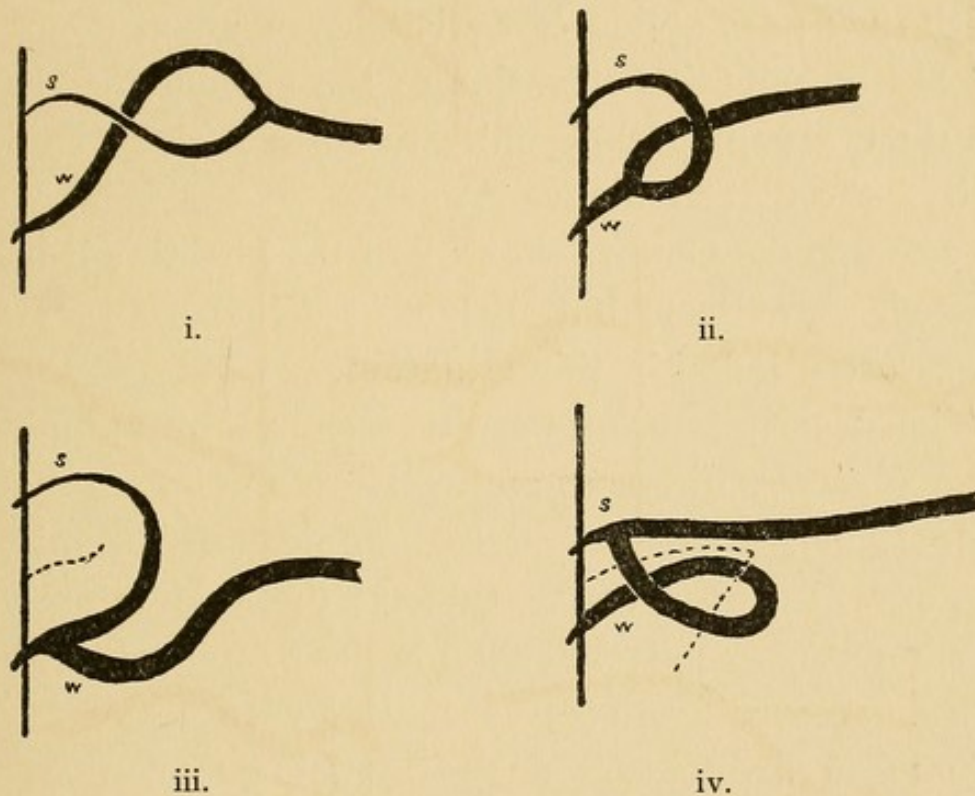


FIG. 8.—Varying relations of the duct of Santorini (*s*) to the duct of Wirsung (*w*). Broken lines are in the plane of the interlobular fissure. Drawn from dissected specimens.

the duct of Santorini equal or larger (Fig. 7, iv.), but of ten cases in which there is no anastomosis, in half the specimens the duct of Santorini equals or exceeds the duct of Wirsung (Fig. 7, vii.).

*The Diverticulum of Vater.*—Embryological study has shown that the ventral pancreatic outgrowth of the intestine arises in contact with the hepatic duct, while the dorsal bud, arising at an earlier period, is situated be-

tween the hepatic duct and what will subsequently become the stomach. In accordance with this arrangement the lower pancreatic duct—the duct of Wirsung—in all the specimens which I have examined, approaches the intestine beside the bile duct, while the duct of Santorini enters the intestine above it.

The ductus choledochus and the duct of Wirsung penetrate side by side the coats of the duodenum through which they pass obliquely a distance of about 2 cm. and end in a papilla-like elevation of the mucous membrane. Within the papilla they unite to form a short common cavity—the diverticulum of Vater. At the point where the common duct enters the wall of the intestine it is constricted, or at least but little distensible, so that gallstones often lodge in this situation.

The descriptions of the diverticulum or ampulla of Vater given by different anatomists do not vary materially. It may be described as a conical cavity into the base of which open the two ducts; the apex situated at the summit of the diverticulum is their common duodenal orifice. According to Testut<sup>22</sup> its length varies from 6 to 7 mm., according to Sappey from 7 to 8 mm. Occasionally the two ducts have no common channel but open by separate orifices upon the summit of the bile papilla. Claude Bernard described a mode of termination which has since been observed by others. The bile duct is prolonged as far as the mucosa of the duodenum, upon which it opens by a circular orifice. The terminal part of the pancreatic duct, like a gutter, embraces the bile duct, and its orifice has the outline of a crescent.

---

<sup>22</sup> Testut: *Traité d'anatomie humaine*, Paris, 1894, iii.

The orifice of the diverticulum of Vater constitutes the narrowest part of the biliary channel, and here small calculi not infrequently become impacted. A small stone lodged in the diverticulum may occlude its duodenal orifice, and, too small to completely fill the diverticulum and occlude the two ducts that enter it, may convert the latter into a single closed channel along which bile may be forced by the gall-bladder (Fig. 9, i.). Bile thus injected into the pancreatic duct causes, as will be subsequently shown, the condition known as acute hemorrhagic pancreatitis. This lesion does not commonly follow the




FIG. 9.—Diagram showing, i., diverticulum of Vater containing a calculus; ii., common bile duct (*dc.*) and duct of Wirsung (*dw.*) entering intestine separately.

expulsion of a gall-stone from the common duct. For its production it is necessary that the diverticulum of Vater be capacious, with a length at least greater than the diameter of its duodenal orifice.

With these facts in view, the length of the diverticulum has been measured in one hundred specimens; varying from zero to 11 mm., it averages only 3.9 mm. In eleven instances the two ducts open separately at the summit of the bile papilla and no diverticulum exists (Fig. 9, ii.). In only thirty instances does the length of the diverticulum reach 5 mm.

In seventy-five of these specimens the diameter of the duodenal orifice has been measured after the insertion of probes of varying size. The average diameter of the orifice is 2.5 mm. In twenty-one instances the diameter of the orifice is equal to or greater than the length of the diverticulum; and it is obviously impossible that a calculus, assuming it to be approximately spherical and lodged in the orifice, could only partially occlude the cavity.

*Termination of the Duct of Santorini.*—The termination of the duct of Santorini is represented upon the mucosa of the duodenum by an elevated papilla situated at a variable distance above the common orifice of the duct of Wirsung and the bile duct (see Fig. 6). Though often small and inconspicuous, it is recognized in all the specimens which I have examined; in one case it is so small that it has been found only after examination of serial sections through the mucosa opposite the point at which the duct of Santorini reached the intestinal wall. The papilla varies considerably in size and shape, being at times a small, nipple-like projection, at times a low, broad elevation. Within the papilla the duct of Santorini usually becomes very narrow and is not infrequently wholly obliterated. In serial sections it is found irregular in outline, provided with many lateral diverticula, and often very tortuous.

Much difficulty has been encountered in determining the frequency with which the smaller papilla is patent. On the one hand a small quantity of mucus within the minute lumen may readily prevent the penetration of injected material, and, on the other hand, Henle states, material injected under considerable pressure may

produce a false passage. By injecting air into the duct Schirmer was unable to demonstrate its patency in twenty-one of one hundred and four specimens. Helly<sup>23</sup> has more recently made a careful microscopical study of the duct of Santorini as it penetrates the intestine, and in ten of fifty specimens found it obliterated.

In a considerable number of the specimens which I have examined it has not been possible to force from the lesser papilla fluid injected under low pressure into the duct exposed by cutting across the body of the gland. Where by such gross examination the patency of the duct of Santorini has not been demonstrated, serial sections have been made through the papilla, and in twenty-one instances the lumen of the duct has not been demonstrably continuous with that of the intestine. Penetrating the muscularis of the intestine and passing by a tortuous course a variable distance into the papilla, the duct, beset with many lateral diverticula, ends a short distance below the mucosa; the lumen of the duct or one or more of its diverticula approach the mucosa, below which there is occasionally a minute dilatation.

#### TOPOGRAPHY OF THE PANCREAS.

*Relation of the Parenchyma to the Ducts.*—The pancreas consists, it is well known, of lobules held together by connective tissue. Upon the surface of the gland polygonal areas varying greatly in size and shape are mapped out by clefts filled with very loose areolar tissue. By carefully dissecting the loose tissue which these clefts contain the gland may be divided into well-defined masses

---

<sup>23</sup> Helly: Arch. f. mik. Anat., 1898, lii, 773.

of parenchyma, the shape of which is dependent upon mutual pressure. Such lobules are usually a centimetre or more across, and in the body and tail are frequently oblong with a long diameter at right angles to the axis of the gland; in the head they are more irregular in shape. These relatively large glandular masses, separated by loose connective tissue, are found to be further divided by more inconspicuous and less well-defined septa into smaller lobules of varying size and shape, usually several millimetres across. Microscopic examination demonstrates that these are again divisible into even smaller ill-defined areas, which may be designated primary lobules; the larger masses may be named secondary lobules; whereas the largest bodies, separated by loose areolar tissue, may be conveniently termed tertiary lobules.

The large pancreatic duct, as it passes through the body of the gland, is closely beset with lateral branches, which are most numerous upon its superior and inferior aspects and usually make an oblique angle with the main channel. These branches frequently divide, and from a branch and its subdivisions are given off lateral twigs which penetrate the tertiary lobules. In some instances the duct of the tertiary lobule may enter directly the duct of Wirsung. In attempting to separate the lobules by breaking through the loose tissue which unites them it is usually found that the interlobular clefts or septa do not reach the ducts upon which the tertiary lobules are situated, but the boundaries of the latter are partially obscured by secondary lobules in intimate contact with the wall of the duct and directly tributary to it.

In the head of the gland tertiary lobules preserve a

similar relationship to the two ducts present in this part of the gland and are tributary to branches or sub-branches of the duct of Wirsung or of the duct of Santorini. A large branch (Fig. 7, i. and ii., *x*) of the duct of Santorini usually passes downward and drains a large part of the head, while a similar branch (Fig. 7, i. and ii. *y*) from the duct of Wirsung near its junction with the duct of Santorini, passing downward and to the left, usually enters the projection (Fig. 10, *y*) which lies

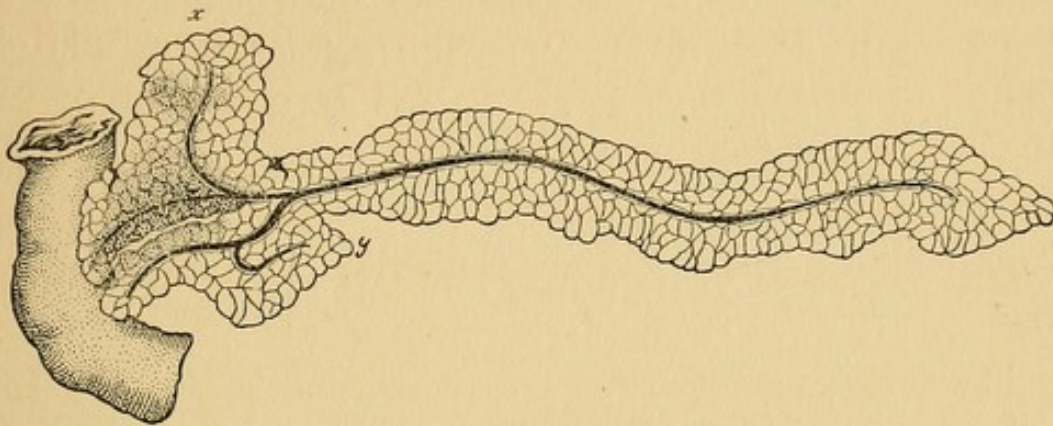


FIG. 10.—Diagrammatic drawing of the pancreas, showing the two lobes which form the head. The interlobular fissure has been opened by dissection, and the lower part (*x*) of the lobe corresponding to the duct of Santorini has been drawn upward in order to expose the lobe corresponding to the duct of Wirsung.

behind the superior mesenteric vessels. From that part of the duct of Wirsung which lies in the head of the pancreas branches are usually small and enter without subdivision the tertiary lobules.

As the result of the arrangement just described the head of the gland consists of two distinct sets of lobules grouped about the two ducts, and by careful dissection, more readily in hardened specimens, the relation of the parenchyma to the two ducts may be demonstrated. The two groups of lobules belonging to the two ducts are separated near the duodenum by loose areolar tissue, while at the point where these ducts anastomose they are

united. The head of the pancreas (Fig. 10) is in fact composed of two distinct lobes, which for the sake of convenience may be designated the anterior lobe of the head (about the duct of Santorini) and the posterior lobe of the head (about the duct of Wirsung). These lobes are separated by an interlobular fissure or cleft lying midway between the two ducts. The anterior lobe, represented as drawn upward in the figure, is larger than the posterior lobe, which lies behind it, and, being much wider from above down, forms the lower or descending part of the head (Fig. 10, *x*). The posterior lobe is a relatively narrow compressed mass of parenchyma, flattened anteroposteriorly and surrounding on all sides the duct of Wirsung; a projection (Fig. 10, *y*), before mentioned, usually passes from its upper and left aspect behind the superior mesenteric vessels.

The two lobes are firmly attached to the duodenum in the neighborhood of their respective ducts, but between the ducts each lobe is readily separable from the intestine. The interlobular fissure where it is in contact with the duodenum lies midway between the two ducts in a direction from above downward and slightly forward, and extends into the substance of the head a variable distance, often four to five cm., its depth being dependent upon the distance from the duodenum at which the two ducts anastomose. Where anastomosis has occurred near the orifice of one duct (Fig. 8, iii. and iv.), the other duct lengthening during the course of subsequent development becomes much bowed, and with it the corresponding lobe, so that the interlobular fissure can be followed between adjacent surfaces of the lobe, which is, as it were, folded upon itself.

After breaking through the loose tissue filling the fissure, adjacent surfaces of the two lobes are found to be relatively smooth and to resemble the external surface of the organ. Within the fissure are contained branches of the pancreaticoduodenal artery and vein. The common bile duct usually lies along the upper border of the posterior lobe of the head of the pancreas, and the interlobular cleft meets the upper surface of the gland along a line in front and to the left of this duct. In order to expose the fissure, the bile duct may be used as a landmark.

*Relation of the Common Bile Duct to the Head of the Pancreas.*—Study of the diseases of the liver and of the pancreas has given considerable importance to the anatomical relationship of the bile duct to the pancreas and its ducts. The common bile duct descends toward the duodenum alongside the head of the pancreas, occasionally embedded in its substance, and comes in contact with the duct of Wirsung, beside which it lies for a short but variable distance before entering the wall of the intestine.

Helly has carefully studied the relation of the bile duct to the head of the pancreas in forty subjects. The lower part of the duct for a distance varying from two to seven centimetres is in contact with the head of the pancreas, or, as I have shown, with its posterior lobe. In fifteen instances (37.5 per cent.) the duct lies in a groove upon the surface of the gland often converted into a canal by the adjacent duodenum. In the remaining twenty-five instances (62.5 per cent.) the duct is completely surrounded for a varying distance by pancreatic tissue.

## MEDICAL AND SURGICAL ANATOMY OF THE PANCREAS.

*Blood-Vessels.*—Blood is supplied to the splenic part of the pancreas by the celiac axis through its branch the splenic artery, which is in contact with the upper edge of the gland; to the head of the pancreas by the celiac axis through the superior pancreaticoduodenal, a branch of the hepatic artery, and by the superior mesenteric artery through the inferior pancreaticoduodenal artery. The posterior and inferior pancreaticoduodenal arteries anastomose, and lying in contact with pancreas and duodenum supply both organs with blood.

Occlusion of the arteries supplying both pancreas and duodenum causes gangrene of the latter. Krönlein<sup>24</sup> has described a case in which gangrene of the colon has followed removal of carcinoma of the pancreas, and has shown that gangrene may be the result of ligation of the median colic artery when, as in a small proportion of individuals, it arises from the superior mesenteric near the pancreas.

Venous blood from the pancreas enters the portal system in great part through numerous branches of the splenic vein and in less quantity through branches of the superior mesenteric vein. The splenic vein is in intimate contact with the posterior surface of the pancreas, and not infrequently undergoes injury with subsequent thrombosis as a result of lesions of the pancreas, especially hemorrhagic necrosis; with suppuration in the pancreas multiple abscesses in the liver may be caused by infected emboli.

*Anatomical Relation of the Pancreas to Adjacent*

---

<sup>24</sup> Krönlein: Beit. z. klin. Chir., 1895, xiv, 663.

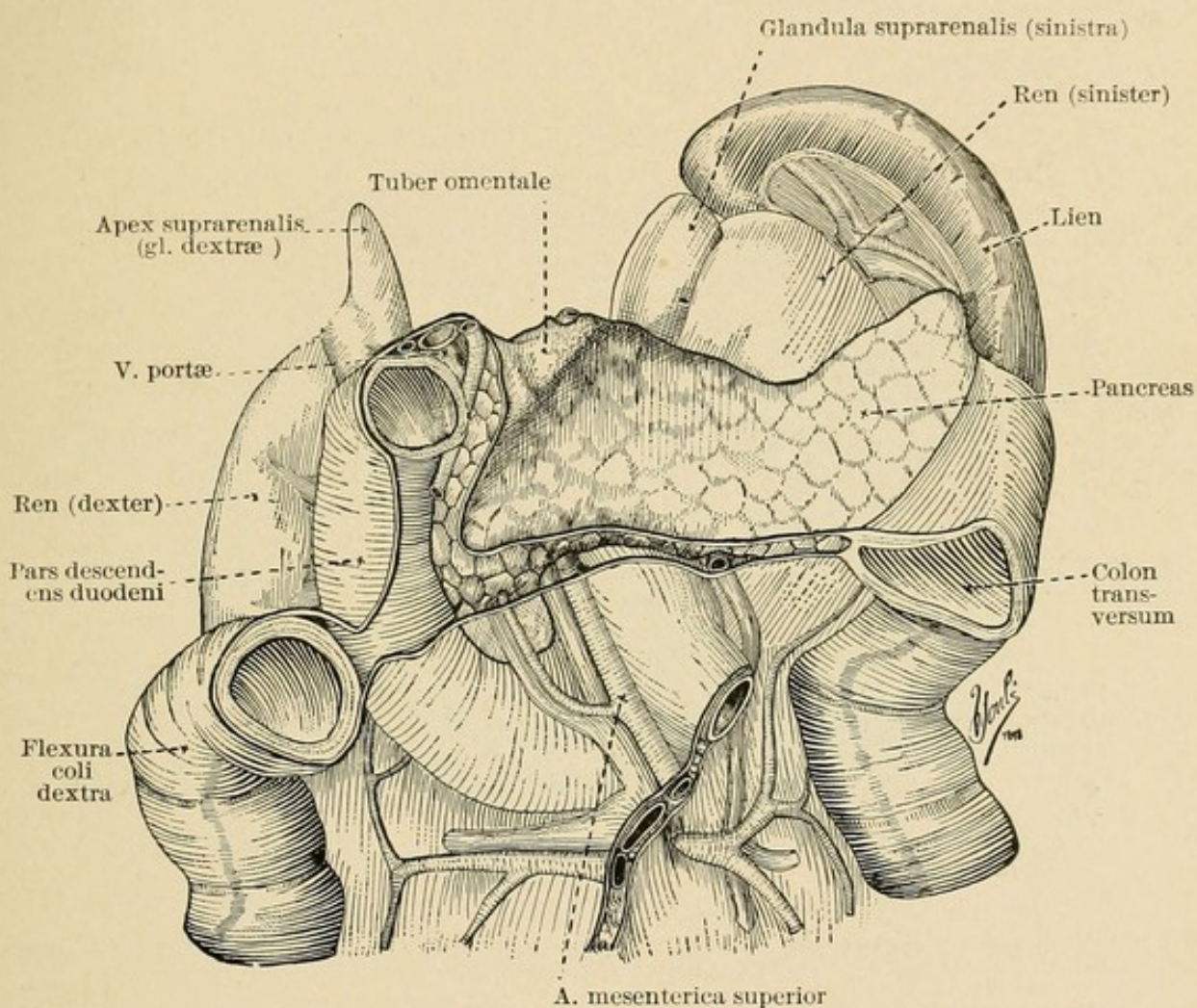


FIG. 11.—Relations of the pancreas. (After His.) (Barker's Laboratory Manual of Anatomy.)

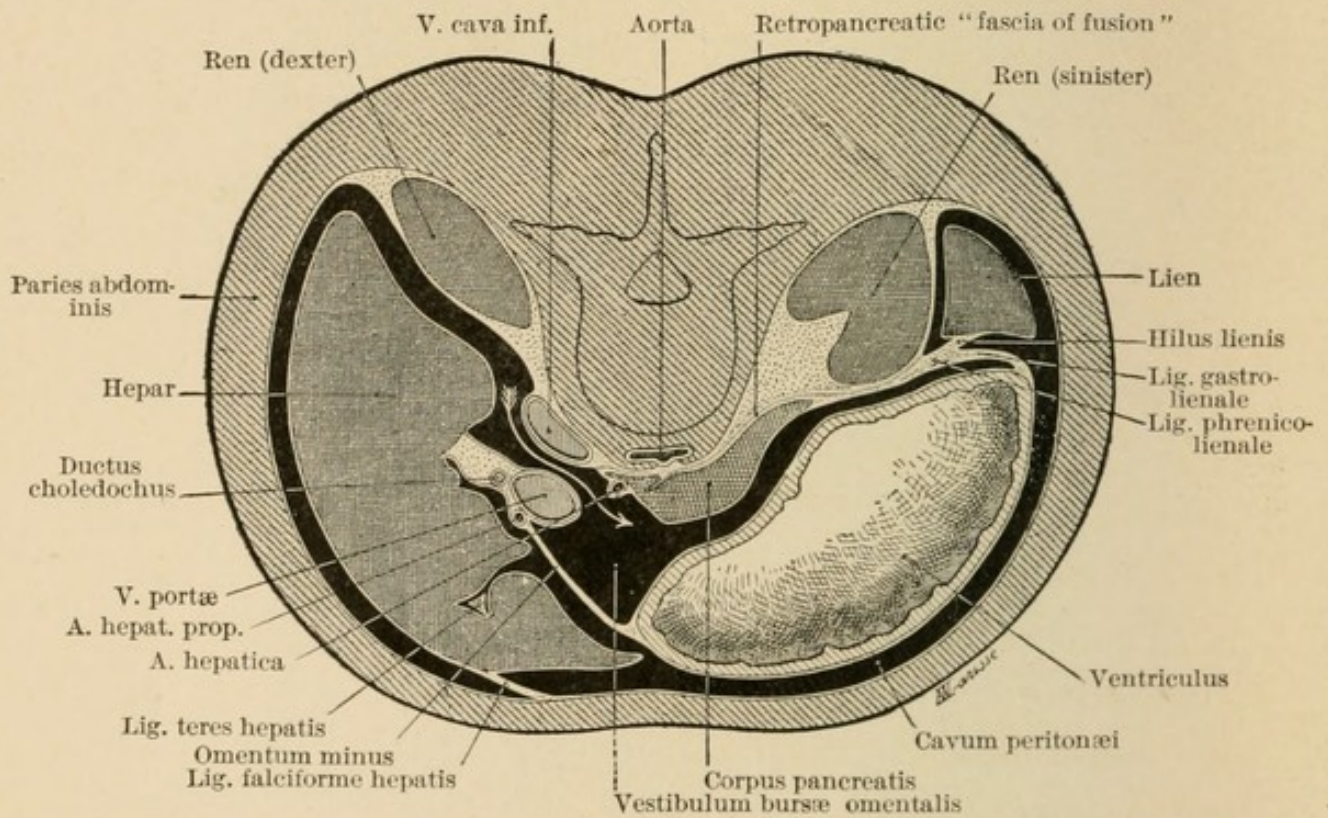


FIG. 12.—Transverse section passing through the bursa omentalis at the level of the foramen epiploicum Winslowi. (After Poirier and Charpy.) (Barker's Laboratory Manual of Anatomy.)

*Organs.*—The head of the pancreas lying within the duodenal loop (Fig. 11) overlies the aorta and inferior vena cava and is firmly attached to the tissues in front of the vertebral column. The tail of the pancreas is less immovably attached and occasionally lies within the transverse mesocolon, so that tumors arising from this part of the gland may have a limited mobility. The anterior surface of the organ is covered by peritoneum, which forms the posterior wall of the lesser peritoneal cavity (Fig. 12). Acute inflammation of the pancreas is frequently transmitted to the overlying peritoneum and peritonitis, usually limited to the lesser peritoneal cavity, follows. Closure of the foramen of Winslow by inflammatory adhesions allows the accumulation of exudate within the cavity of the lesser peritoneum. Blood or exudate within this cavity and overlying the pancreas may cause physical signs not distinguishable from those of tumors (*e.g.*, cyst) situated within the substance of the gland.

The pancreas is covered by liver, stomach, and transverse colon. Körte<sup>25</sup> examined thirty cadavers in order to determine the relation of the pancreas to the adjacent organs after the abdomen had been opened. In twenty bodies the gland was completely covered by these organs, but in ten subjects some part of the gland was covered only by omentum. In six instances the head of the pancreas was exposed between the edge of the liver and the colon, which was found depressed. The pancreas was twice exposed by a cleft between the right and left lobes

---

<sup>25</sup> Körte: Die chirurgischen Krankheiten des Pankreas. Deutsche Chirurgie, Stuttgart, 1898.

of the liver; once it was exposed below the level of the pylorus and once above the lesser curvature of the stomach. In the two remaining bodies the pancreas, lying behind the gastrohepatic omentum, could be seen and felt through a space between the edge of the liver and the lesser curvature of the stomach; this relationship, which occurs with gastropptosis, explains why cysts arising from the head of the gland occasionally present above the lesser curvature of the stomach. In a case recently observed at autopsy in the Presbyterian Hospital, New York, dilatation of the stomach accompanying ulceration and constriction of the pylorus was accompanied by such advanced gastropptosis that the entire head and half of the body of the pancreas lay exposed above the lesser curvature of the stomach.

*Anatomical Facts of Surgical Import.*—Cysts and solid tumors of the tail are more readily extirpated than those situated in other parts of the gland, for they are in less intimate contact with vital structures, and the tail of the gland serves as a pedicle. Section and closure of the pancreatic duct is followed by chronic inflammation of the parenchyma tributary to the occluded duct; consequently the resulting injury to the gland is greatest when section is nearest to the duodenum.

Access to the pancreas at operation is obtained by several routes:

(a) The gland is usually exposed through the gastrocolic ligament, the lesser peritoneal cavity being entered between the stomach and transverse colon.

(b) When the stomach has sunk downward and the pancreatic lesion, usually a cyst or an abscess, is situated near the upper border of the head of the gland, access

may be possible between liver and stomach through the gastrohepatic omentum.

(*c*) When cysts which arise from the tail of the pancreas occupy the transverse mesocolon the lesion may be reached through the lower layer of the mesocolon after the colon has been pushed upward, blood-vessels being carefully avoided.

(*d*) The pancreas may be reached through the lumbar region without opening of the peritoneal cavity. (1) Abscesses have been opened through the left lumbar region, and since they tend to sink in this direction efficient drainage may be thus secured in some instances. (2) A cyst projecting from the head of the pancreas to the right side has been opened through the right lumbar region.

#### INJURY OF THE PANCREAS.

Since the pancreas is almost completely covered by the liver, stomach, and colon, and is in contact with other important structures, injury to the gland uncomplicated by more serious injury to other organs is infrequent. In most instances laceration of the pancreas is associated with grave injury to the liver, stomach, spleen, kidney, or intestine. The observations of Körte previously cited suggest the occasional possibility of injury almost wholly limited to the gland, and in a few instances the gland has been crushed against the vertebral column by force applied over the epigastrium. The passage of a wheel across the abdomen or compression between the buffers of two cars has ruptured the gland. In children the ribs are soft and may yield to pressure, but in adults they are usually broken before the pancreas is crushed.

Injury to the pancreas has been observed with relative frequency in boys.

A sharply localized blow,—for example, the kick of a horse or a blow from the fist,—has been the most frequent cause of localized pancreatic injury. Uncomplicated injury to the pancreas in a case described by Jaun<sup>26</sup> was caused by an unusual form of assault. A Hindoo was severely beaten and kicked after his hands had been tied together and his knees pinned in front of the abdomen by a lath between bended knees and elbows. In a case of Wagstaff,<sup>27</sup> a fall from a cart upon the left side, was followed after two days by vomiting; on the fourth day death occurred, and although there was no other abdominal injury the pancreas was torn across. In the case of Wilks and Moxon,<sup>28</sup> uncomplicated injury to the pancreas was caused by the wheel of a wagon.

Injury of sufficient severity to affect the pancreas is in most instances immediately followed by shock and collapse, but appearance of such symptoms may be delayed. Complete absence of external evidence of injury has been observed with severe contusion of the pancreas.

Accumulation of blood in the lesser peritoneal cavity may be recognizable after injury. A workman was injured by a heavy chest which fell upon his left side and forced him against a post; immediately after the injury Kraske found dulness in the lower part of the abdomen on the right side. On the sixth day there were symptoms

---

<sup>26</sup> Jaun: *Indian Ann. of Med. Sci.*, 1855, iii, 721. Quoted by Leith, *Lancet*, 1895, ii, 770.

<sup>27</sup> Wagstaff: *Lancet*, 1895, i, 404.

<sup>28</sup> Wilks and Moxon: *Pathological Anatomy*, 3d ed., p. 491. Quoted by Leith.

of renewed hemorrhage and dulness appeared below the stomach. Death occurred on the next day; autopsy showed blood in the lesser peritoneal cavity and complete rupture of the pancreas opposite the vertebral column. Immediately after the injury blood doubtless passed through the foramen of Winslow, but subsequent closure by adhesions caused accumulation in the lesser peritoneal cavity.

The following case reported by Randall<sup>29</sup> illustrates the possibility of recovery after operation performed for the relief of pancreatic injury:

A man, 42 years of age, one hour after a meal, while walking backward leading his horses was hit in the epigastrium by the pole of his van and was forced against a second stationary wagon. Violent pain, collapse, and vomiting followed almost immediately, and an hour later his pulse was small and weak and temperature 95° F. There was a painful bruise midway between the ensiform cartilage and umbilicus and well-marked dulness in the right flank. At operation six hours after injury much fluid and clotted blood was found in the peritoneal cavity; the hepatogastric ligament was torn, and an oblique tear through the body of the pancreas exposed a tongue of glandular tissue, at its base half the width of the organ. This rent was closed by four silk stitches and the opening in the hepatogastric ligament was closed by a continuous suture of catgut, space being left for drainage with gauze. Blood was removed from the peritoneal cavity. During three days following operation there was much vomiting and on one occasion collapse. Abundant turbid viscid fluid was discharged from the wound and there was excoriation of the surrounding skin. Ointment was applied. The fluid which escaped became whitish and was so abundant that it spurted from the wound when the patient coughed. The discharge became watery and diminished in amount and seven weeks after injury ceased completely. The sinus closed almost

---

<sup>29</sup> Randall: *Lancet*, 1905, i, 291.

immediately and the patient left the hospital a month later. Sugar was found on only one occasion four weeks after injury. There was emaciation but after the fistula had healed weight was rapidly regained.

The case illustrates the healing of a pancreatic wound, the occurrence of pancreatic fistula with excoriation of the skin, and spontaneous closure of the fistulous tract. The treatment of pancreatic fistula is described in Chapter XII.

The relation of hemorrhagic necrosis of the pancreas (hemorrhagic and gangrenous pancreatitis) to fat necrosis, and of pancreatic cyst to injury of the pancreas, will be discussed in subsequent chapters.

## CHAPTER II.

### ANOMALIES OF THE PANCREAS.

SINCE the ducts of the pancreas are subject to great variation, it is not surprising that the gland presents anomalies dependent upon alterations of the usual process of development. Malformations have been described, particularly by earlier writers. The tail of the gland has occasionally been bifid. The absence of lobules of parenchyma about the duct of Wirsung or its branches for a short distance has caused a division of the gland into two parts; this anomaly, due to impaired development, according to Hyrtl, at points where large blood-vessels,—namely, the superior mesenteric or the left gastro-epiploic arteries,—are in contact with the gland, has been designated *pancreas divisum* and should not be identified with true accessory pancreas.

*Annular Pancreas.*—Of greater importance is the anomaly known as annular pancreas, of which several instances were described years ago by Tiedemann, Becourt, Moyse, and Ecker (cited by Schirmer), while more recently similar cases have been recorded by Symington,<sup>1</sup> Generisch,<sup>2</sup> and Tieken.<sup>3</sup> The head of the pancreas completely surrounds the duodenum and may cause a partial constriction of the lumen. In a case described by Generisch the lumen of the duodenum was so constricted that the tip of the thumb could with difficulty be introduced

---

<sup>1</sup> Symington: Jour. of Anat. and Phys., 1885, xix, 292.

<sup>2</sup> Generisch: Verhandl. d. internat. med. Cong., 1890, ii, 140.

<sup>3</sup> Tieken: American Med., 1901, ii, 826.

at the site of the constricting glandular tissue, whereas the duodenum above the constriction was dilated to the size of the large intestine; the stomach was dilated, and its wall was hypertrophied. Generisch had seen three specimens in which the head of the pancreas almost completely surrounded the duodenum, leaving uncovered only a finger-breath of the duodenal circumference; the duodenum was somewhat constricted and the stomach dilated. In the case described by Tieken the descending part of the duodenum was constricted by a ring of pancreatic tissue and its lumen admitted only the tip of the index finger. The duodenum above the stricture was dilated to nearly half the size of the stomach, but though the muscular coat of the stomach was hypertrophied the viscus was not dilated. The patient, who died with acute endocarditis, had exhibited no symptoms of gastrointestinal disease.

#### ACCESSORY PANCREAS.

A true accessory pancreas is a mass of pancreatic tissue wholly separated from the pancreas and provided with a duct of its own. Such isolated masses of glandular tissue derive some importance from the possibility that they may perhaps vicariously assume the function of the main organ when it is diseased and that they may cause diverticula or herniæ of the intestinal wall. Klob<sup>4</sup> first demonstrated the existence of such isolated masses of pancreatic tissue and described two examples of this anomaly. In one instance a small flattened glandular mass was embedded in the wall of the stomach, near the mid-part of its greater curvature; in

---

<sup>4</sup> Klob: Zeit. d. Gesellschaft d. Aerzte zu Wien, 1859, No. 46, p. 732.

the second case a similar tumor-like body occupied the wall of the jejunum four inches from the duodenum. Zenker<sup>5</sup> subsequently collected six examples of the anomaly, and in every instance demonstrated the existence of a duct entering the intestine through the overlying mucosa.

In ten among eighteen hundred autopsies performed in the Johns Hopkins Hospital one or more accessory pancreatic glands have been found. They present features which I believe explain their development, and for this reason are described with some detail. For the sake of convenience they may be divided into two groups,—those situated above the pancreas in the stomach and duodenum and those below the gland in the duodenum and jejunum.

#### ACCESSORY GLAND ABOVE THE PANCREAS.

SPECIMEN I.—*Accessory pancreas of the stomach* in a white man, aged forty years. Near the lesser curvature of the stomach, 8 cm. from the pylorus, is a firm flattened nodule, 1.2 cm. across, lying below the mucosa. Microscopic examination shows a compact mass of pancreatic tissue situated in the submucosa, extending into the muscularis, and distorting the muscle bundles. Between the lobules, and at times within them, connective tissue is abundant.

SPECIMEN II.—*Accessory pancreas of the stomach* in a colored boy, aged eleven years. Below the mucous membrane of the stomach, 2 cm. from the pylorus, is a firm nodule 5 mm. in diameter. Microscopic examination shows a small mass of pancreatic tissue situated in the submucosa. Fibrous stroma is more abundant between the lobules than in the normal gland.

SPECIMEN III.—*Aberrant pancreas of the pylorus* in a woman, aged sixty-five years. At the site of the pyloric valve of the stomach, projecting into the lumen, is an elevation of the mucosa, caused, as microscopic examination shows, by a nodule of pancreatic tissue situ-

---

<sup>5</sup> Zenker: Virchow's Arch., 1861, xxi, 369.

ated in the submucosa; in the sections examined are found two islands of Langerhans. Dilated ducts are present, and are most numerous near the muscularis. In the underlying muscle of the pylorus is found a group of small ducts, while immediately below the serosa are on section two widely dilated, duct-like channels lined by high columnal cells.

SPECIMEN IV.—*Accessory pancreas of the stomach and nodule of the pylorus containing dilated ducts* in a white man, aged seventy-three years. In the wall of the stomach, 8 cm. from the pylorus, is a nodule, 2 cm. across. At the pylorus is a second nodule-like projection of the mucosa, about 7 mm. across; but here on section no gland-like tissue is found. Examination of the pancreas demonstrates the existence of two ducts, of which the duct of Santorini is smaller and terminates in a small papilla. At the site of the bile papilla is a short diverticulum of the mucous membrane. Microscopic examination of the gastric nodules shows, partly in the submucosa but chiefly in the muscularis, pancreatic lobules, often separated by much interstitial tissue. Islands of Langerhans are fairly abundant, and ducts, often with wide lumina, occur throughout the section. The papillary projection at the pylorus is produced by an increase in the thickness of the submucosa, where, surrounded by a quantity of connective tissue, is found a duct-like structure identical in appearance with the ducts of the pancreatic nodule. In the underlying muscle of the pylorus several ducts of larger size are cut across, while immediately below the serosa the section cuts twice what appears to be a dilated tortuous duct.

SPECIMEN V.—*Aberrant pancreas (1) of the stomach and (2) of the duodenum, together with pancreatic tissue in the lesser papilla* in a white boy, aged four years. Immediately below the mucous membrane of the stomach, only 2 mm. from the pyloric orifice, is a nodule of gland-like tissue 3 mm. across. Below the mucosa of the duodenum, 9.5 cm. below the pylorus, is a second nodule of similar character, about 7 mm. across. The papilla of the duct of Santorini is represented by a hemispherical elevation, 7 mm. across, which on section appears to contain a third isolated nodule of glandular tissue. Microscopic examination shows that the nodule of pancreatic tissue situated in the submucosa of the stomach has been the seat of moderate chronic interstitial inflammation, and its ducts, which converge towards its under surface, are dilated and contain polynuclear leucocytes; islands of

Langerhans occur. The duodenal nodule immediately below the pylorus consists of pancreatic tissue situated in the submucosa and muscularis, of which the bundles are split apart and distorted. It projects beyond the muscle upon the outer surface of the intestine. Ducts and islands of Langerhans occur. In the submucosa, immediately above the duct of Santorini, after it has penetrated the muscularis of the duodenum, is situated a third nodule of pancreatic substance.

SPECIMEN VI.—*Aberrant pancreas in the wall of the duodenum together with pancreatic tissue in the lesser papilla.* The mucous membrane of the duodenum, 4 cm. above the papilla of the duct of Santorini, presents a low elevation 7 mm. across. The papilla of the duct is represented by a low, broad elevation 5 mm. across; the duct of Santorini, smaller than the duct of Wirsung, joins the latter and is patent throughout. The nodular elevation of the duodenum is by microscopic examination shown to be caused by numerous pancreatic lobules situated between separated bundles of the muscularis. A few nodules which are the seat of chronic interstitial inflammation are situated in the submucosa, and a tortuous duct can be traced to the surface of the mucosa. The lesser papilla of the pancreas is found to contain a few nodules of pancreatic tissue which has undergone chronic interstitial inflammation.

SPECIMEN VII.—*Aberrant pancreas of the duodenum* in a woman, aged fifty-six years. Projecting upon the external surface of the duodenum, between the stomach and the pancreas, is a hemispherical nodule 8 mm. across. On microscopic examination the main mass of the nodule is found to project outside the muscular coats, which are split apart and over a considerable area broken through, so that the nodule is continuous with a smaller collection of pancreatic lobules which have undergone chronic interstitial inflammation and are situated in the submucosa. Ducts are present and islands of Langerhans occur.

#### ACCESSORY GLAND BELOW THE PANCREAS.

SPECIMEN VIII.—*Accessory pancreas of the duodenum* in a white woman, aged forty years. A small nodule of grayish-yellow tissue is situated in the wall of the duodenum below the pancreas. Microscopic examination shows that a mass of pancreatic tissue is situated in the

submucosa, and extending through the circular muscle coat, separates the latter from the longitudinal layer. Dense stroma surrounds and often invades the gland lobules. Ducts lined by columnar epithelium occur.

SPECIMEN IX.—*Accessory pancreas of the jejunum showing advanced chronic interstitial inflammation and pancreatic tissue in the bile papilla* in a colored woman, aged fifty-nine years. In the jejunum, 111 cm. below the duodenum and opposite the mesenteric attachment, is an oval nodule 1.5 cm. across. It is composed of firm grayish tissue and contains minute cysts. Microscopically the tissue resembles at first sight a small adenoma. Embedded in dense fibrous stroma are groups of gland-like structures formed by high columnar cells surrounding a wide lumen. In the centre of each group are one or more larger ducts and embedded in the dense stroma occur glandular acini, which contain centro-acinar cells. The main mass of the nodule, which has undergone advanced chronic intestinal inflammation, is situated in the submucosa, but bundles of the underlying circular muscle are separated and distorted by the presence of dilated ducts. The duct of Wirsung of the pancreas is much smaller than the duct of Santorini, and does not anastomose with it. The bile papilla is of very large size, and examined microscopically is found to contain lobules of pancreatic tissue. They surround the duct before it enters the diverticulum of Vater, which is only 2.5 mm. in length.

SPECIMEN X.—*Accessory pancreas of the jejunum showing advanced chronic interstitial inflammation and resembling a small adenoma* in a white man, aged thirty-eight years. In the jejunum, four metres from the stomach, is a nodule 1 cm. across. Microscopic examination shows numerous ducts, isolated or surrounded by mucous glands and identical in appearance with those of the pancreas; they are embedded in abundant dense fibrous stroma. The microscopic appearance agrees with that of Specimen IX, save that lobules of pancreatic acini are no longer preserved. The nodule is situated wholly in the submucosa.

Small masses of aberrant pancreatic tissue are usually about one centimetre in diameter. Glinski<sup>6</sup> has de-

---

<sup>6</sup> Glinski: Virchow's Arch, 1901, clxiv, 132.

scribed an accessory gland of larger size; a nodule 4.5 by 3.5 centimetres across and one centimetre in thickness was situated in the muscular coat of the stomach near the pylorus. More than one accessory gland may occur in the same individual. Zenker found two accessory bodies in the jejunum, one sixteen, the other forty-eight centimetres below the duodenum. In Specimen IV of the present series there is an accessory pancreas in the gastric wall, and a second nodule situated at the pylorus contains only dilated ducts but doubtless represents a second isolated remnant of pancreatic tissue; in Specimen V two bodies occur, one in the stomach, the other in the duodenum, and the papilla of the duct of Santorini contains a third nodule of pancreatic tissue.

Accessory pancreas is not uncommon; no available statistics indicate the frequency with which the anomaly occurs. In five of two hundred autopsies Letulle found aberrant glands and described a sixth case in which a partially isolated mass of pancreatic tissue formed part of the head of the pancreas. The ten specimens which I have described have been collected, as I have stated, from eighteen hundred autopsies.

Accessory pancreas may occur above the pancreas in the wall of the stomach, and of the duodenum or with about the same frequency below the pancreas in the wall of the duodenum, of the jejunum and even of the ileum. Zenker found an accessory pancreas 54 cm. from the ileocæcal valve. Approximately one-third of the aberrant glands which have been described have been situated in the wall of the stomach, usually near the pylorus; the remaining two-thirds have occurred in the intestinal wall.

Wright<sup>7</sup> has described an unique example of the anomaly. A child twelve years of age had suffered with a congenital umbilical fistula which caused discomfort by discharge of moisture. After unsuccessful attempt to close the fistula the fistulous tract was removed and within the tissue was embedded a nodule 3.5 millimetres in diameter, composed of glandular acini identical with those of the pancreas and containing readily recognizable islands of Langerhans. The peritoneal cavity was opened and explored with the finger but no connection between fistula and intestine was found. The operation was entirely successful.

The situation of the accessory pancreatic tissue with relation to the coats of the intestine varies. The nodule is usually situated in the muscularis of which the muscle bundles are separated and distorted by the presence of pancreatic lobules and groups of lobules, and, it will be shown later, the muscular coat may be much weakened by the presence of the glandular tissue. Three of the aberrant glands which I have observed have been situated wholly in the submucosa, and in four additional instances, though no glandular lobules have been present in the underlying muscle layer, ducts have been found here. The five remaining accessory glands have occupied the muscular layer.

Thorel<sup>8</sup> has found in the mesentery of the upper third of the duodenum an accessory pancreatic nodule 1 cm. in thickness; three finger-breadths distant in the wall of the jejunum was a second accessory pancreas.

---

<sup>7</sup> Wright: Jour. of the Boston Soc. of Med. Sciences, 1901, v, 497.

<sup>8</sup> Thorel: Virchow's Arch., 1903, clxxiii, 281.

In the fat of the great omentum about a hand-breadth below the greater curvature of the stomach Warthin<sup>9</sup> found an accessory pancreatic nodule 8 mm. in diameter, and a duct was traced in serial sections to a small cavity about which were foci of fat necrosis; he suggests that a second duct found in the adjacent omental fat has perhaps joined the nodule with the stomach.

The tissue of the aberrant gland does not differ in its histological features from that of the pancreas. Numerous ducts occur, and unite to open upon the intestinal mucosa. Within the acini are found centro-acinar cells. Letulle<sup>10</sup> states that the peculiar bodies known as islands of Langerhans do not occur in the accessory gland. Wright has, however, demonstrated their presence in a pancreatic nodule removed from the neighborhood of the umbilicus, and in five of my cases they have been found.

*Pathological Changes Affecting Accessory Pancreatic Tissue.*—In a case described by Warthin fat necrosis had occurred about an aberrant pancreatic nodule and its duct, which was situated in the omentum near the greater curvature of the stomach.

The isolated nodule of pancreatic tissue tends to undergo chronic interstitial inflammation and interstitial tissue is almost constantly present in greater quantity than in the normal gland. Inflammatory changes are probably dependent upon occlusion of the minute, often tortuous, ducts, and are doubtless intensified by invasion of bacteria from the intestine or stomach. The ducts are frequently dilated and in one instance (Specimen IV)

---

<sup>9</sup> Warthin: *Phys. and Surg.*, 1904, xxvi, 337.

<sup>10</sup> Letulle: *Compt. rend. Soc. de biol.*, 1900, lii, 233.

some of them contain polynuclear leucocytes. In two nodules situated in the jejunum, chronic inflammation had reached an advanced stage and one nodule (Specimen IX) consisted in great part of fibrous tissue and dilated ducts surrounded by hypertrophied mucous glands, while in the other nodule (Specimen X) the pancreatic acini had undergone complete destruction. In these cases the nodules resembled small adenomata, and similar nodules in gastric or intestinal wall have been erroneously described as new growths.

Eloesser<sup>11</sup> and Branham<sup>12</sup> suggest that malignant growth may have its origin in misplaced pancreatic tissue. The tumor described by Eloesser as scirrhus carcinoma of the papilla of Vater was believed to have had its origin in aberrant pancreatic tissue; description of the growth furnishes no evidence of such origin and fails to establish any relationship to an aberrant pancreatic nodule which was found in the wall of the stomach. In the case of Branham a mass two inches long and one inch across occupied the anterior and inferior wall of the pylorus. Microscopical examination made by Prof. Welch showed the presence of pancreatic acini; from these acini had arisen branching alveoli which varied in size and shape and invaded both the muscular and mucous coats of the stomach. The tumor had the characters of a malignant adenoma.

*Aberrant Pancreatic Tissue in the Duodenal Papilla (Santorini) and in the Biliary Papilla.*—Helly<sup>13</sup> has directed attention to certain microscopic peculiarities of

---

<sup>11</sup> Eloesser: Mitt. a. d. Grenz. d. Med. u. Chir., 1907, xviii, 195.

<sup>12</sup> Branham: Maryland Med. Jour., 1908, 144.

<sup>13</sup> Helly: Arch. f. mik. Anat., 1900, lvi, 291.

the lesser duodenal papilla. In addition to the duct the papilla contains mucous glands, but of greater interest is the occurrence (in 24 of 50 instances) of pancreatic tissue which is either wholly separated from the body of the gland by the muscular coat of the intestine or is distributed along the duct as it penetrates the muscularis. A nodule of considerable size, formed by numerous lobules, may be situated near the orifice of the duct immediately below the mucosa. The duct of this pancreatic tissue does not always enter the duct of Santorini, but may open independently upon the overlying mucosa; the nodule then constitutes a true accessory pancreas.

I have been able to confirm the observations of Helly; in thirty-five specimens in which the lesser papilla has been examined to determine the patency of the duct of Santorini, pancreatic tissue is absent in only six instances. A compact mass of normal pancreatic tissue, often 0.5 centimetre across, may lie above the duct of Santorini as it passes obliquely through the submucosa of the duodenum. Occasionally individual lobules are separated by coarse bands of connective tissue, and not infrequently the isolated glandular tissue has undergone such advanced chronic interstitial inflammation that atrophied acini are recognizable only by comparison with adjacent less changed parenchyma. The duct which drains this tissue within the papilla usually enters the duct of Santorini, but in one of my cases serial sections have shown that it opens independently into the duodenum. In one instance the duct of Santorini does not penetrate the duodenal mucosa, but joins the duct of Wirsung; one of its twigs has its origin in small branches draining pancreatic lobules within the papilla.

To explain the occurrence of an accessory pancreas within the papilla Helly suggests that the isolated bit of glandular tissue may arise as a bud nipped off from the dorsal embryonic rudiment of the pancreas; its ducts later form an independent communication with the duodenum. In a later publication Helly<sup>14</sup> has described the development of the lesser pancreatic papilla. The outgrowth of duodenal epithelium which represents the dorsal rudiment of the pancreas penetrates the mesoblastic part of the intestinal wall, and at a very early period one or more lateral buds sprout into the intestinal wall between the mucosa and the muscularis. From such a lateral projection are formed lobules of pancreatic acini lying below the mucosa.

Helly has never found pancreatic tissue surrounding the duct of Wirsung as it penetrates the duodenum. Pilliet<sup>15</sup> has described glandular tissue in the bile papilla but his description indicates that he observed mucous glands, but no pancreatic tissue, about the ducts. Nevertheless, in one of my specimens, in which the bile papilla was very large, microscopic examination demonstrated the presence of pancreatic lobules surrounding the duct of Wirsung as it approached the bile duct (see accessory pancreas, Specimen IX, p. 34).

*Origin of the Accessory Pancreas.*—The origin of the accessory bodies under consideration has excited much interest. Zenker has thought that they are referable to an abnormal pancreatic rudiment or "anlage" which is formed in close proximity to the primitive pancreatic

---

<sup>14</sup> Helly: Arch. f. mik. Anat., 1901, lvii, 271.

<sup>15</sup> Pilliet: Compt. rend. Soc. de biol., 1894, xlvi, 549.

outgrowth of the intestinal tract and is subsequently separated from it by the longitudinal growth of the intestinal wall. Arising before the stomach is distinct from the duodenum, the accessory body, carried upward, would finally occupy the gastric wall, while if situated below the pancreas it would be transported in the direction of the ileocæcal valve.

To explain the occurrence of these bodies, Glinski directs attention to the development of the pancreas from more than one rudimentary outgrowth of the intestine. Most recent observers, mentioned before, have described one dorsal and two ventral diverticula, but in order to explain the existence of two accessory glands, as in the case described by Zenker, it would be necessary to assume the existence of four original "anlage."

The orifice of the duct of Santorini, which represents the dorsal embryonic outgrowth, has been found in one hundred subjects which I have examined to be constantly situated above (nearer the stomach) the duct of Wirsung, which represents the ventral outgrowth, and is always in contact with the common bile duct. Should an accessory pancreas arise by persistence of one of the two ventral outgrowths, subsequent lengthening of the intestine would carry it in only one direction,—namely, toward the jejunum; while should it arise from part of a double dorsal outgrowth, as Glinski suggests, it would be transported upward in the direction of the stomach. The occurrence of two aberrant glands above the pancreas, as in Specimens V and VI, would then be explicable only by assuming the occasional occurrence of a triple primitive dorsal rudiment, since, at least in the cases which I have described, both pancreatic ducts have de-

veloped normally. Such multiple anlage have not been found in any vertebrate species.

Helly has shown that a small mass of pancreatic lobules may occur in the papilla of the duct of Santorini wholly separated from the remainder of the gland. At an early period of development lateral branches of the dorsal pancreatic outgrowth penetrate the submucosa or muscularis of the intestine, ultimately forming lobules which surround the duct as it passes obliquely through the intestinal wall. Should the duct draining such aberrant lobules be occluded by the development of adjacent muscular bundles or fibrous tissue, it is not improbable that a new duct might be established,—for it has long been known that the pancreatic duct after section or ligation regenerates and re-establishes its lumen. This fact was known to Claude Bernard; Pawlow and Smirnow<sup>16</sup> described in detail an experiment upon a rabbit in which two months after ligating the pancreatic duct a new channel entering the duodenum was found beside the ligature and Ssobolew,<sup>17</sup> among others, noted similar regeneration of the duct.

Should one or more embryonic buds of glandular tissue make their way into the wall of the intestine at an early period, they might be carried from the remainder of the gland by the longitudinal growth of the intestine; arising from the dorsal pancreatic outgrowth which is situated above the ventral, the aberrant tissue would be carried toward the stomach; if it arose from the ventral outgrowth, toward the jejunum. The existence of more

---

<sup>16</sup> Pawlow and Smirnow: *Arzt*, 1889, No. 12. Ref. *Jahresb. ü. d. Fortschr. d. Anat. u. Phys.*, 1890, xix, Phys. Abt., 439.

<sup>17</sup> Ssobolew: *Virchow's Arch.*, 1902, clxviii, 91.

than one accessory body above or below the pancreas is then explicable without assuming the occurrence of an embryonic condition unknown among the vertebrates.

In accordance with this conception, accessory bodies are formed by a process similar to that which so frequently isolates a bit of pancreatic substance in the papilla of the duct of Santorini. In the specimens in which an examination was made, pancreatic tissue was found in the lesser or greater papilla when an accessory nodule occurred above or below the pancreas. In Specimens V and VI the papilla of the duct of Santorini was examined microscopically and found to contain lobules of pancreatic tissue. In Specimen V, in which an aberrant pancreas occurred in the stomach and another in the duodenum immediately below the pylorus, the papilla of the duct of Santorini contained a third isolated nodule of pancreatic tissue. Of greater import is Specimen IX, in which an accessory body occurred in the jejunum; here the bile papilla contained lobules of pancreatic acini—a condition never observed by Helly. If an accessory body arises from the ventral embryonic outgrowth at a time when the distance between the hepatic duct and the umbilical stalk is slight, subsequent growth of the intestine will locate it at some point between these structures. Wright has reported an unique case in which a nodule of pancreatic tissue was removed from the neighborhood of the umbilicus during life.

The case of Thorel in which an aberrant nodule has occurred in the mesentery whereas a similar body has been situated in the jejunum near by, and the case of Warthin in which aberrant pancreatic tissue has been found in the omentum near the greater curvature of the

stomach, are explained by longitudinal transportation in the gastro-intestinal wall and subsequent growth into the adjacent fatty tissue. To explain such anomalies it is unnecessary with Endres<sup>18</sup> to assume that rudimentary pancreatic tissue is ensnared and transported in the wall of a developing blood-vessel.

#### DIVERTICULA CAUSED BY ANOMALIES OF THE PANCREAS.

*Diverticula of the Stomach and Intestine with Accessory Pancreas.*—Among recorded instances of accessory pancreas are several associated with diverticula of the intestine occurring in the jejunum or ileum and one with diverticulum of the stomach. In a case of Zenker a nodule of pancreatic tissue was situated at the summit of a diverticulum of the ileum 5.5 centimetres in length and 54 centimetres from the ileocæcal valve. Neumann<sup>19</sup> found in a child ten months of age a diverticulum situated 60 cm. from the valve and capped by an accessory pancreas the size of a pea. In a case of Nauwerk<sup>20</sup> a small mass of pancreatic tissue was located at the apex of a funnel-shaped intestinal diverticulum 2.3 metres from the valve. Bize<sup>21</sup> cites from the literature of the subject cases of Schmauser (two), Heller (two), Schirmer and Brunner,<sup>22</sup> and describes two cases which he has observed. Such diverticula have usually been found in children from less than one (Neumann) to fourteen (Hansemann<sup>23</sup>) years old.

---

<sup>18</sup> Endres: Arch. f. mik. Anat., 1892, xl, 435.

<sup>19</sup> Neumann: Arch. d. Heilkunde, 1870, xi, 200.

<sup>20</sup> Nauwerk: Ziegler's Beiträge, 1893, xii, 29.

<sup>21</sup> Bize: Rev. d'orthop., 1904, v, 149.

<sup>22</sup> Brunner: Beit. z. klin. Chir., 1899, xxv, 344.

<sup>23</sup> Hansemann: Virchow's Arch., 1896, cxliv, 400.

Weichselbaum<sup>24</sup> found an aberrant pancreas at the tip of a diverticulum in the wall of the stomach.

Zenker and Albrecht<sup>25</sup> thought that the diverticula which they described were the remains of the vitelline duct and represented so-called Meckel's diverticula. Since the pancreas begins its development at a period when the vitelline duct is already formed, Neumann did not think the accessory pancreatic nodule could occupy the summit of a diverticulum formed from that structure. Nauwerk confirmed this view, for in his case a true Meckel's diverticulum occupied the wall of the ileum between the ileocaecal valve and a diverticulum upon which was situated an aberrant pancreas.

The formation of a diverticulum accompanying the accessory gland is thought by Neumann, Nauwerk, and Hansemann to be the result of traction exerted by the aberrant nodule. Accessory pancreatic tissue, it has been shown above, is usually situated in the muscular layer of the intestine, separating and distorting the muscular bundles and at times (Specimen VI) causing a defect in the muscular coat. Pressure within the intestine during peristalsis doubtless causes a hernial protrusion of the mucosa and submucosa through the weakened muscularis. It is improbable that the small nodule of tissue exerts appreciable traction upon the intestinal wall.

Diverticula of the intestine caused by aberrant pancreatic nodules have some clinical significance. In cases of Brunner and of Bize there were symptoms of intes-

---

<sup>24</sup> Weichselbaum. Quoted by Warthin.

<sup>25</sup> Albrecht: Sitzungsber. d. Gesellsch. f. Morph. u. Physiol. in München, 1907, Hft. i.

tinal obstruction,—namely, abdominal pain and distention, constipation and fecal vomiting,—occurring in children four and a half and six years of age respectively. Operation in each case disclosed invagination of the small intestine through the ileocæcal valve into the large intestine, and at the extremity of the invaginated intestine was found a diverticulum inverted into the lumen of the intestine and bearing at its end a small mass of pancreatic tissue. In the case of Bize the invagination was reduced and a loop of intestine carrying a diverticulum 4 cm. in length was resected, but death occurred two days later. The diverticulum was the seat of acute inflammation.

In a boy twelve years of age operation was performed by Clogg<sup>26</sup> for the relief of symptoms of intestinal obstruction; there was a rounded resonant swelling in the right iliac and hypogastric regions of the abdomen. About one foot of small intestine was snared under a band and, twisted upon its mesenteric axis, appeared gangrenous. Resection of the intestine together with excision of the constricting band was followed by recovery. The band proved to be an intestinal diverticulum with a flattened mass of pancreatic tissue at the apex. Thomson<sup>27</sup> found at operation, undertaken after sudden onset of abdominal pain and fever (103° F.) in a man thirty years old, a diverticulum surmounted by an aberrant pancreas situated eighteen inches from the ileocæcal valve. Recovery followed removal of the diverticulum.

*Diverticula of the Duodenum in Contact with the Pan-*

---

<sup>26</sup> Clogg: *Lancet*, 1908, i, 639.

<sup>27</sup> Thomson: *Lancet*, 1908, i, 860.

*creas.*—Diverticula of the duodenum in contact with the head of the pancreas not infrequently occur and doubtless like those just described owe their origin to weakening of the intestinal wall by presence of pancreatic tissue. Several older writers quoted by Roth<sup>28</sup> have observed such diverticula, and Roth has described five instances in which the mucosa of the duodenum passing through the muscular coat formed a hernial protrusion into the head of the pancreas. In two instances two such diverticula were present, one opening beside the bile papilla and the other nearer the stomach; in one instance the opening of the pouch which was nearer the stomach was in contact with the papilla of the duct of Santorini while in the other instance its relation to the duct was not noted. In a third specimen a single diverticulum was situated beside the smaller duodenal papilla and in a fourth a diverticulum was located three centimetres above the bile duct, but its relation to the smaller papilla was not observed. For a fifth example the location of the diverticulum was not definitely recorded.

The following case illustrates the relationship of diverticula of the duodenum to the pancreatic and common bile ducts:

SPECIMEN XI.—*Diverticula of the duodenum beside the bile papilla and the papilla of the duct of Santorini.* In the mucous membrane of the duodenum, immediately above the bile papilla, is the oval orifice of a diverticulum, which is 1.5 cm. in length. After partial dissection of the pancreas from the duodenum, the mucosa is found to form a hernial protrusion through the muscularis. This diverticulum penetrates the muscular coat beside the common bile duct as the latter passes

---

<sup>28</sup> Roth: Virchow's Arch., 1872, lvi, 197.

obliquely through the wall of the intestine and is continued upward and backward in the direction of the duct. Immediately above the papilla of the duct of Santorini is a second somewhat smaller diverticulum, 1.3 cm. in length, provided with an oval orifice. It passes into the substance of the pancreas above the duct, and consists of mucosa and submucosa, in contact with which are lobules of pancreatic tissue.

One of these diverticula lies beside the common bile duct as it penetrates obliquely the duodenal wall, while the second is in contact with the duct of Santorini. Klebs,<sup>29</sup> Hansemann,<sup>30</sup> Fischer,<sup>31</sup> and others have shown that those diverticula of the mucosa, which are not uncommon near the mesenteric attachment of the small intestine, occur at points where blood-vessels penetrate, and consequently weaken the muscular coats. Roth, reviewing the cases which he has described, directs attention to the relative frequency with which diverticula of the duodenum occur in contact with the pancreas, and quotes the opinion of Fleischmann that the entrance of the biliary and pancreatic ducts are points of predilection, because here the muscular bundles separate to allow the passage of the ducts. Pressure within the intestine produces a protrusion of the mucosa through the muscularis. Such diverticula are analogous to those which accompany accessory pancreas, for doubtless an additional factor in their production is the previously described occurrence of lobules of pancreatic tissue separating and distorting the muscular bundles about the ducts. Bassett<sup>32</sup> found a duodenal diverticulum beside

---

<sup>29</sup> Klebs: *Die allgemeine Pathologie*, Theil ii, p. 100, Jena, 1889.

<sup>30</sup> Hansemann: *Loc. cit.* (p. 44.)

<sup>31</sup> Fischer: *Jour. of Exper. Med.*, 1901, v, 333.

<sup>32</sup> Bassett: *Trans. of the Chicago Path. Soc.*, 1907, vii, 83.

the termination of the common bile duct, and isolated pancreatic tissue was embedded in the muscular coats of the duodenum above the pouch.

The occurrence of inflammatory changes in a duodenal diverticulum is illustrated by a second case described by Bassett. The mucosa of a diverticulum projecting from the duodenum into the head of the pancreas was injected and inflamed and the pouch contained bloody mucus. What appeared to be the duct of Santorini ended at the margin of the diverticulum and passed through a focus of hemorrhagic necrosis with fat necrosis in the head of the pancreas.

## CHAPTER III.

### HISTOLOGY OF THE PANCREAS.

BEFORE considering the pathological histology of chronic interstitial pancreatitis and the alterations of the gland associated with diabetes, certain histological peculiarities of the gland will be described. The pancreas is much more complex in structure than the other glandular organs which it closely resembles. Langerhans,<sup>1</sup> in an inaugural dissertation published in 1869, has given the first careful description of its histology, and has shown that the organ has not the relatively simple structure of the salivary glands.

Langerhans has studied the pancreas of rabbits, which in its essential features does not differ from that of other mammals. The smallest ducts end in the acini, composed of high columnar characteristically glandular cells, containing next the lumen numerous zymogen granules. Within almost every acinus, in contact with the secreting cells, Langerhans has found one, two, or more cells of a different nature and to these he has given the name centro-acinar cells. They closely resemble the flat spindle-shaped cells lining the very small ducts and he has thought that the epithelium of the duct is continued over the secreting cells into the lumen of the acinus, but he admits that he is unable to determine with exactness the method by which the duct ends.

---

<sup>1</sup> Langerhans: Beiträge zur mikroskopischen Anatomie der Bauchspeicheldrüse. Inaug. Diss., Berlin, 1869.

Distributed at intervals in the parenchyma are groups of cells differing markedly from those of the ordinary glandular type. Such groups are usually round and in tissue treated two or three days with Müller's fluid appear with low magnification as intensely yellow specks. With high magnification it is found that they are composed of small irregularly polygonal cells with a round nucleus and refractive homogeneous cell body. Of the nature of these cell groups Langerhans has declared himself entirely ignorant.

In injected specimens Kühne and Lea<sup>2</sup> have found scattered throughout the organ glomerular structures composed of dilated and tortuous capillaries and have shown that they represent the vascular supply for the cell groups which Langerhans has described. The interacinar islands are penetrated by numerous wide tortuous capillaries forming irregular anastomosing channels between the columns of cells which form these structures. Material injected into the duct of the gland does not penetrate the islands of Langerhans, and Dogiel<sup>3</sup> was able to demonstrate by Golgi's stain the absence of ducts within them.

#### PANCREATIC LOBULE.

In the human pancreas groups of acini about terminal ducts are not sharply defined by connective tissue, so that individual lobules, as in the human liver, are indistinctly marked off and in places apparently fuse with one another. In the pancreas of the cat the lobules, like those in the liver of the pig, are much more sharply

---

<sup>2</sup> Kühne and Lea: *Untersuch. a. d. phys. Instit. d. Univ. Heidelberg*, 1882, ii, 488.

<sup>3</sup> Dogiel: *Arch. f. Anat. u. Physiol., Anat. Abt.*, 1893, 117.

outlined by interstitial tissue. The parenchyma is divided by septa of fibrous tissue into small polygonal areas varying in size and shape. When injected with Berlin blue a small ramification of the duct is found to penetrate the isolated group of acini. These smallest subdivisions of the parenchyma, which may be designated primary lobules, often appear completely isolated by fibrous tissue from those near by; but when one of them is traced through a series of sections, demarcation being incomplete, its parenchyma may be found continuous in places with that of adjacent lobules. That such polygonal subdivisions are actually independent of one another and represent units of structure is readily demonstrated by causing an inflammatory increase of the interstitial tissue. If the pancreas of a cat is examined two or three weeks after the ducts have been ligated, the gland is the seat of a chronic interstitial inflammation, characterized by an increase of the interlobular tissue. The lobules are completely separated from one another by narrow bands of firm fibrous tissue and occur in sections as rounded, triangular, or polygonal areas of parenchyma.

The islands of Langerhans in the normal pancreas of the cat occupy a position near the centre of the lobule and in the splenic end of the gland each lobule contains an island. In a given section many lobules, of which the limits are more or less distinctly outlined, contain islands situated near their centre, while in neighboring lobules such structures may not be discoverable. If, however, serial sections (Fig. 13) are studied every lobule is found to contain an island. Their presence within the lobule is not constant in other parts of the

organ, and at the extremity of the descending arm of the gland islands of Langerhans are few in number.

The framework of a typical pancreatic lobule is well seen in Fig. 14, from a photograph kindly given me by Prof. Flint,<sup>4</sup> of Yale University. The preparation has

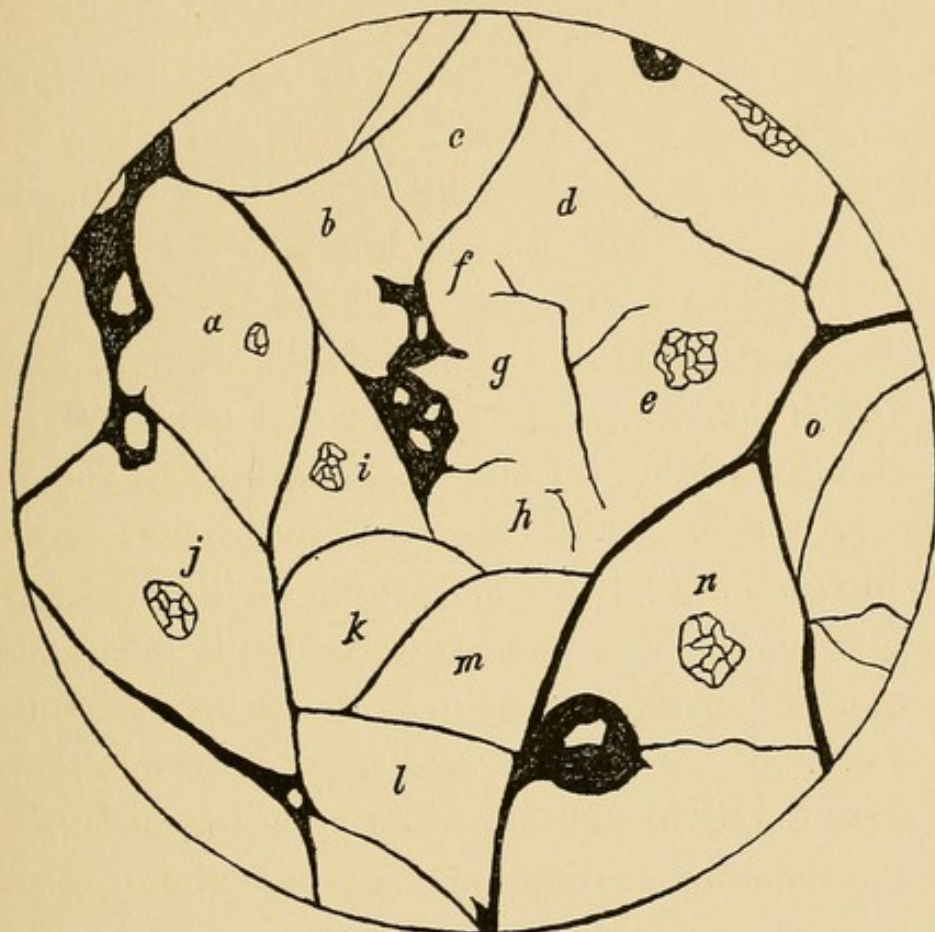


FIG. 13.—Camera lucida tracing of the lobule boundaries in one of a series of sections from the splenic end of a cat's pancreas. The majority of the lobules are well defined. Those marked *d*, *e*, *f*, *g*, and *h* are poorly outlined, but are found to be more readily distinguishable when traced through the series of sections. The lobules, which are lettered (*a* to *o*), were traced through the series, and each was found to contain an island of Langerhans situated near its centre. The section passes through the island in lobules *a*, *e*, *j*, *i*, and *n*.

been made by digestion according to the method which he has described. An island of Langerhans, outlined by a framework, of coarser strands of stroma, is situated near the centre of a lobule. A somewhat finer network contains in its meshes the secreting acini.

<sup>4</sup> Flint: Arch. f. Anat. u. Physiol., Anat. Abt., 1903, 61.

Primary lobules of the cat's pancreas are grouped about the medium-sized ducts. The main ducts give off branches approximately at right angles to their course. Branching one or more times, such a duct forms the centre of a group of lobules, which is usually elongated in form and tapers to a point at or near the surface of the gland. Such lobule-groups, or secondary lobules, as they may be conveniently called, are separated from one another by relatively wide bands of areolar tissue, much looser in texture than that separating the individual lobules. The lobule-groups in the fresh state or in tissue macerated a few days in Müller's fluid may be separated from one another by careful teasing. In the loose tissue lie the larger ducts, arteries, veins and nerves. An artery and a vein penetrate each lobule-group in company with the duct and ramify between its lobules. The smallest arteries occasionally penetrate the lobules, but usually interlobular branches diminishing in size give off capillaries which enter the lobule and form a close network between the glandular acini.

In the human pancreas primary lobules<sup>5</sup> and groups of lobules are not so regularly arranged as in the cat, but both structures are definable (Fig. 15). The lobules vary much in size (from 1 to 2.5 mm. across) and are usually not clearly separated from one another. Though an island of Langerhans is often situated in the centre of a more or less clearly defined lobule, no constancy of

---

<sup>5</sup> Laguesse (*Le pancréas*, *Rev. gén. d'histol.*, 1905, i, 552), designates this subdivision "lobulin" and following Renaut (*Traité d'histologie*, Paris, 1899, ii, 1506) regards the group of smallest subdivisions as a lobule. The dimensions given in the text are from the monograph of Laguesse.

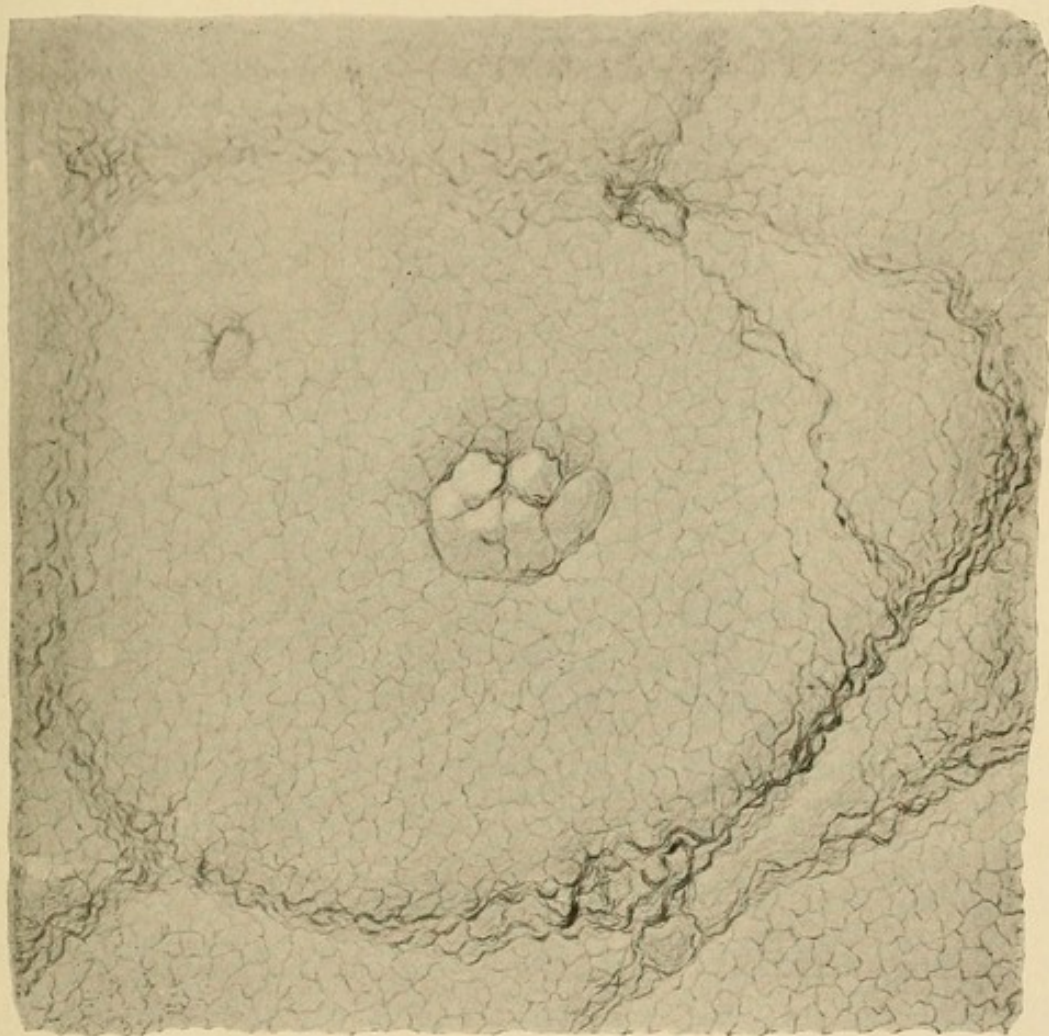



FIG. 14.—Supporting connective-tissue framework of a pancreatic lobule after digestion of the parenchyma by pancreatin. From a specimen prepared by Professor J. M. Flint.



position is discoverable. Groups of from six to twenty lobules, secondary lobules, are separated by relatively wide bands of loose areolar tissue in which are contained the larger ducts, the blood-vessels, and the nerves; the secondary lobules give to the surface of the gland its characteristic lobulated appearance and vary in width

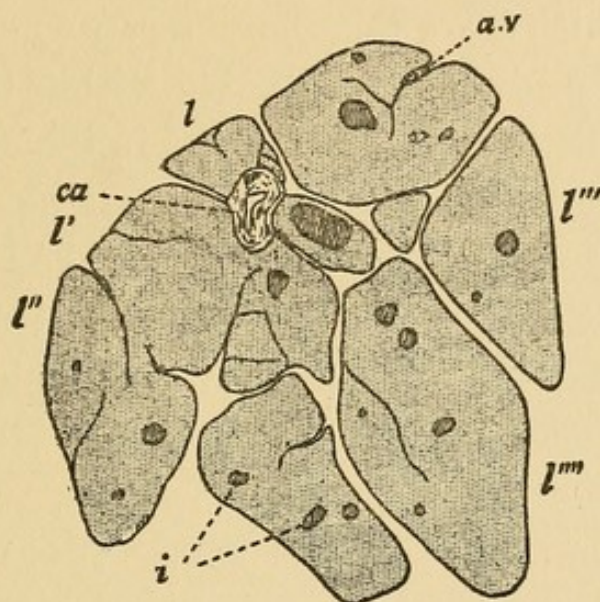


FIG. 15.—Lobules of the human pancreas grouped to form a secondary lobule. (After Laguesse, *Rev. gén. d'histol.*, 1904-5, i, 552) l, l', l'', l''', l''''', lobules; i, island of Langerhans; ca, duct; a.v, artery and vein.

from two to six millimetres. Within the secondary lobule the arteries and veins, which are side by side, do not, as in the cat, accompany the ducts. It has been mentioned in a previous chapter that several secondary lobules are usually grouped together to form tertiary lobules, and these represent the largest subdivisions seen upon the surface of the organ.

#### DUCTS AND ACINI.

*Ducts.*—The large ducts of the pancreas, including the duct of Wirsung and the duct of Santorini and their largest branches, have a wall of connective tissue in

which are both white and elastic fibres and are lined by a single layer of columnar cells. Since granules occur in the inner zone of these cells, and reactions to stains indicate the presence of mucin, many observers believe that they have a secretion which they discharge to mix with the secretion of the alveoli. In the wall of the duct of Wirsung occur small crypts and ramified gland-like structures which have the characters of mucous glands. The ducts of medium size situated within the secondary lobules have little connective tissue in their wall and are lined by low cylindrical or cubical cells. The smallest ducts (intercalary ducts) about which the acini are grouped are formed by flat cells with a large oval nucleus. When the duct is cut longitudinally these cells, of which the central part is distended by the nucleus, are spindle-shaped in outline.

*Acini.*—The shape of the acini differs in different animals and has caused confusion in classification of the gland. With the rabbit the acini are tubular and branched; in the hen, especially at the surface of the lobules, the tubular acini anastomose. Maziariski<sup>6</sup> has shown by the method of reconstruction that the acini of the human pancreas are round or oval, and occasionally have a lobed surface but do not branch.

The pancreatic cells which form the acini have the shape of a truncated pyramid with the apex directed toward the lumen of the acinus. Two zones are distinguishable, namely, an apical zone containing refractive zymogen granules (described by Claude Bernard in 1856) and a basal zone which is homogeneous save for

---

<sup>6</sup> Maziariski: Anat. Hefte, 1901, Hft. lviii, 171.

the presence of striations parallel with the long axis of the cell. In hardened specimens the zymogen granules of the apical zone stain with certain acid dyes, whereas the protoplasm of the basal zone stains deeply with hæmatoxylin. The nucleus situated near the base of the cell is spherical or occasionally oval; its well-defined nuclear membrane gives it a vesicular appearance, and in the nuclear network there is usually a large nucleolus.

Within the acini in contact with the apices of the secreting cells are the centro-acinar cells described by Langerhans; they are fusiform, often flat, and may be provided with short projections which penetrate between the secreting cells. The protoplasm is almost homogeneous and the nucleus is distinguishable from that of the secreting cells by its small size, oval shape, and greater richness in chromatin. These cells closely resemble the cells of the terminal ducts with which they appear to be continuous, as though the duct projects into the lumen of the acinus. Concerning the significance of these cells little is known.

When colored fluid is injected into the acinus through ducts of the gland, the injected fluid penetrates between the secreting cells and marks out short channels which often have a terminal enlargement. The claim that these intercellular canals, first demonstrated by Langerhans, are artificially produced by the injection has been disproven by Ramon y Cajal and Sala,<sup>7</sup> who have employed the Golgi method to stain the secretion contained in the terminal ramifications of the duct.

*Changes in the Acini with Secretion.*—When the gland

---

<sup>7</sup>Ramon y Cajal and Sala: *Terminación de los nervios y tubos glandulares del pancreas*. Barcelona, 1891. Quoted by Laguesse.

is engaged in producing its secretion changes occur in the cells of the acini (Fig. 16). Heidenhain<sup>8</sup> has described the changes observable in sections prepared from the pancreas of a dog kept twenty-four hours without

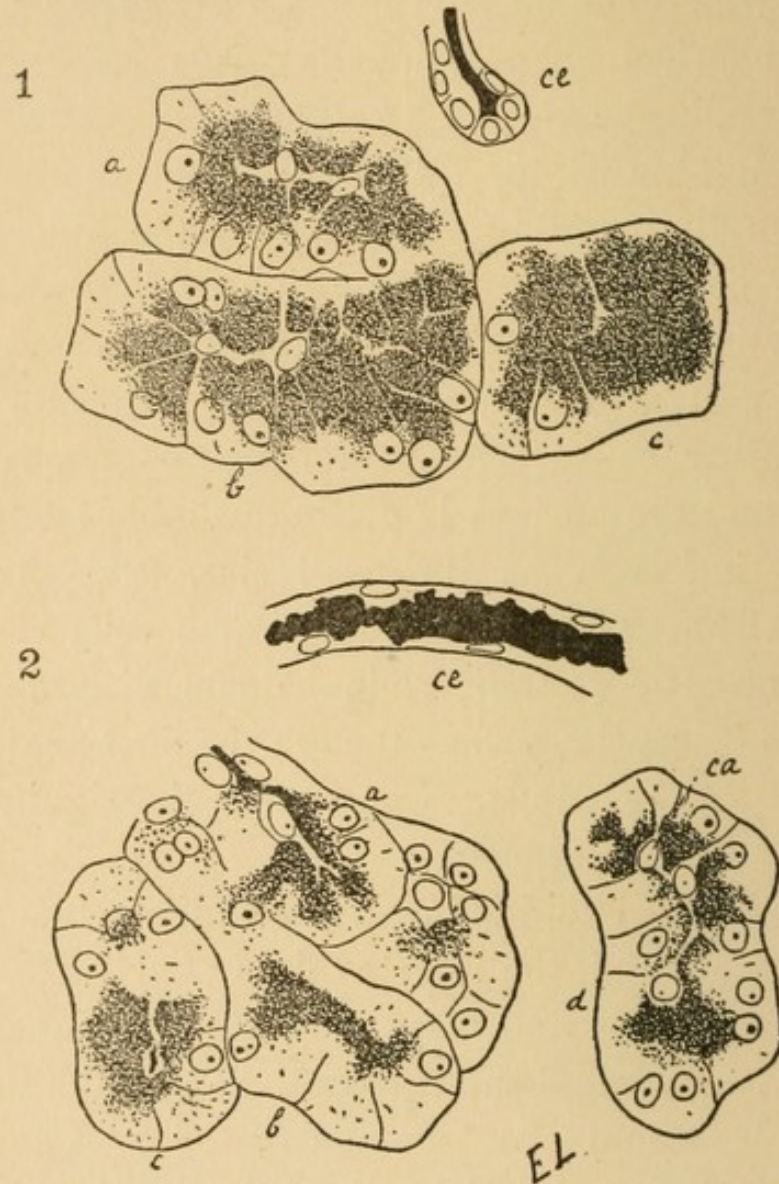


FIG. 16.—Pancreatic acini showing variation during secretion. 1. Pancreatic acini of dog; *a, b, c*, acini containing zymogen granules; *ce*, duct. 2. Acini *a, b, c, d*, after stimulation of the gland by pilocarpin; *ca*, centro-acinar cell; *ce*, duct.

food. During the first six or ten hours after a full meal the inner zone, containing granules, decreases until in many cells it occupies only the tip of the cell. The outer

<sup>8</sup> Heidenhain: Arch. f. d. ges. Physiol., 1875, x, 557.

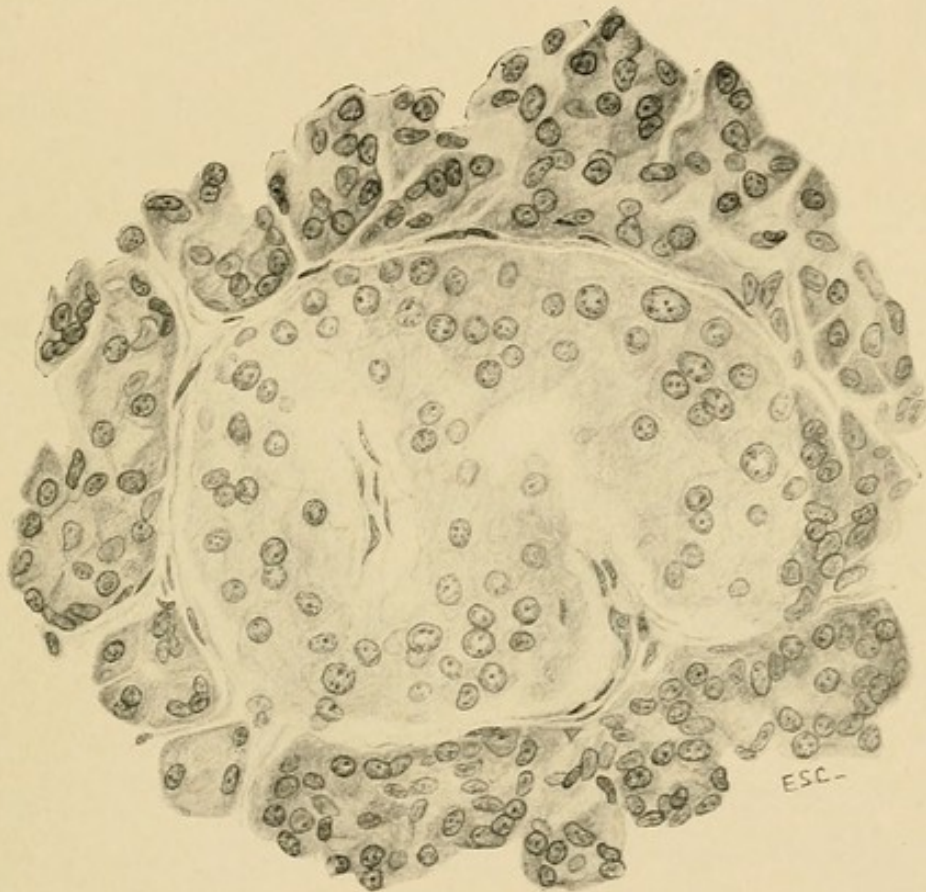



FIG. 17.—Island of Langerhans of the human pancreas. (Figs. 17, 18, 24 26 28, 30, 32, and 49 are from drawings made by Miss E. S. Carrington.)



zone, which stains deeply with hæmatoxylin, increases in height but its increase does not keep pace with decrease of the apical zone, and the cell diminishes in size. During a second stage, lasting from the tenth to the twentieth hour after taking of food, the cell increases in volume; accumulation of granules increases the apical zone and diminishes the basal zone. When animals are fed at short intervals part of the gland will be in one stage of secretion whereas groups of acini will be in the other stage. Kühne and Lea have followed the course of the foregoing changes in the pancreas of the living rabbit, exposed with proper precautions under the microscope.

Experiments of Heidenhain have shown that the abundance of granules in the apical zone of the secreting cells bears a relation to the quantity of zymogen which can be extracted from the gland. The fresh gland does not contain active trypsin but its precursor is abundant in the fasting animal, and gradually diminishes during the first six or ten hours after a meal; subsequently there is gradual increase of tryptic zymogen. The fat-splitting and amylolytic enzymes obtainable from the fresh gland undergo similar changes after a meal, but the relation of these enzymes to the granules of the secreting cells has been questioned.

#### ISLANDS OF LANGERHANS.

The structures which are usually designated islands of Langerhans (Fig. 17) have been described under a variety of names. Renault,<sup>9</sup> regarding them as analogous to lymph follicles, has named them "points folliculaires."

---

<sup>9</sup> Renault: Compt. rend. d. l'Acad. d. sciences, 1879, lxxxix, 247.

Podwyssotski<sup>10</sup> has called them pseudo-follicles. They have been designated secondary cell-groups, interalveolar cell islets and interacinar islands.

Numerous investigations have demonstrated their occurrence in a great variety of vertebrate species, including numerous mammals, birds, amphibia, reptiles, and fish. Giannelli and Giacomini<sup>11</sup> state that in certain reptiles the columns of cells forming the islands of Langerhans have a tubular structure, being composed of moderately high cylindrical cells which, though they differ in appearance from the ordinary secreting cells of the acini, are arranged about a narrow lumen. At the periphery of the island, these tubular columns are continuous with the secreting acini. In certain fish, Diamare<sup>12</sup> found near the spleen, the hepatic artery, and in other situations, isolated structures resembling islands of Langerhans. Since structures having the characters of islands of Langerhans have been found in a constantly increasing number of diverse species, there can be little doubt that they are present in all vertebrates.

Various opinions have been held concerning the nature of the interacinar cell-groups, and a number of observers, denying the epithelial character of the cells which compose them, have emphasized a supposed resemblance to lymphoid tissue. Renaut has described the

---

<sup>10</sup> Podwyssotski: Arch. f. mik. Anat., 1882, xxi, 765.

<sup>11</sup> Giannelli and Giacomini: Accad. di Fisioerit., Siena, 1896. Quoted by Oppel, Lehrbuch der vergleichenden mikroskopischen Anatomie der Wirbeltiere, iii, Jena, 1900.

<sup>12</sup> Diamare: Internat. Monatschr. f. Anat. u. Physiol., 1899, xvi, 155.

pancreas as a lymphoglandular organ composed, he has thought, of glandular structures and lymphoid tissue in intimate relation. He has described the cell-groups as "points folliculaires" in which cells of a glandular type are situated in the meshes of a reticular tissue. Kühne and Lea and Dieckhoff<sup>13</sup> have thought that they are probably small lymph follicles. Schlesinger<sup>14</sup> (1898) has regarded them as a variety of lymph follicle of which the cells differ from those of ordinary lymphoid tissue. Podwyssodski has called them pseudo-follicles, because they resemble lymph follicles though their cells have nothing in common with lymphoid cells. The conception of Von Hansemann<sup>15</sup> is unique; the islands of Langerhans are formed, he believes, by cells of the stroma. At a late period of embryonic life capillary blood-vessels, he thinks, assume a glomerular form and cells of the adjacent stroma increase in size and arrange themselves about the glomerular vessels.

Renaut<sup>16</sup> in a treatise on histology abandoning his former view describes the common origin of the inter-acinar cell-groups and the secreting acini. The greater number of observers have held the same opinion, and studies of the histogenesis of the gland have conclusively demonstrated its accuracy.

*Size.*—The outline of the island of Langerhans in the human pancreas is usually round or oval and is not infre-

---

<sup>13</sup> Dieckhoff: Beiträge zur pathologischen Anatomie des Pankreas. Festschrift f. Thierfelder, Leipzig, 1895.

<sup>14</sup> Schlesinger: Virchow's Arch., 1898, cliv, 501.

<sup>15</sup> Von Hansemann: Verhandl. der Deutschen path. Gesellsch., 1902, iv, 187.

<sup>16</sup> Renaut: Traité de histologie pratique, Paris, 1899, ii, 1506.

quently accentuated by a delicate circle of connective tissue. In other instances the outline is less sharply defined and the body accommodates its shape to that of the neighboring acini. These interacinar structures vary greatly in size, the greater number measuring from 75 to 175 microns in diameter (Heiberg<sup>17</sup>); very large islands more than 0.5 millimetre in diameter have been found. Dewitt<sup>18</sup> has estimated that the amount of tissue forming islands of Langerhans in three normal human glands has been respectively 1/25, 1/50 and 4/500 of the volume of the organ. Heiberg estimated the weight of islands of Langerhans in a human pancreas which he examined as 2.6 grammes.

*Number.*—In the human pancreas I have found islands of Langerhans more numerous in the splenic end or tail than elsewhere.<sup>19</sup> The following table gives the number found in 0.5 square centimetre of section about ten microns thick taken from the head, body and tail of ten normal organs:

Number.	Head.	Body.	Tail.
1.....	11	13	30
2.....	30	25	42
3.....	4	4	19
4.....	4	10	13
5.....	27	18	59
6.....	25	27	26
7.....	18	18	29
8.....	6	10	29
9.....	44	32	61
10.....	14	23	32
Mean.....	18.3	18.0	34.0

<sup>17</sup> Heiberg: *Anat. Anz.*, 1906, xxix, 49.

<sup>18</sup> Dewitt: *Jour. of Exper. Med.*, 1906, viii, 193.

<sup>19</sup> Opie: *Johns Hopkins Bulletin*, 1900, xi, 205.

The table shows that islands of Langerhans are more abundant in the tail or splenic end than in the head or in the body, where they are present in approximately equal number. They are almost twice as numerous in sections from the tail as in those from other parts; but since the number in only one plane is recorded, in order to obtain their actual relative abundance it is necessary to square these figures. They are then found to be slightly less than three and a half times as numerous in the tail as elsewhere.

Tables published by Sauerbeck<sup>20</sup> (six individuals) and by Heiberg (seventeen individuals) show that islands of Langerhans, save in a small proportion of individuals, are much more abundant in the tail than in the head or in the body of the gland. Averages calculated from the number of islands of Langerhans found by Heiberg in 0.5 square centimetre of tissue are as follows: Head, 69.5; body, 94.3; tail, 143.8. These figures differ but little from those of Laguesse<sup>21</sup> and Sauerbeck; they confirm the observation that islands of Langerhans are most numerous in the splenic end of the gland.

The islands of Langerhans were found more numerous, as Kasahara<sup>22</sup> pointed out, in the pancreatic tissue of the fœtus and of very young children than in that of the adult. Should we assume that they are formed during embryonic development and persist thereafter, this fact is readily explicable. The organ being much smaller in the fœtus and in a young child, the same number of islands, though themselves smaller, are more

---

<sup>20</sup> Sauerbeck: *Virchow's Arch.*, 1904, clxxvii, Suppl., 1.

<sup>21</sup> Laguesse: *Compt. rend. Soc. de biol.*, 1905, i, 504.

<sup>22</sup> Kasahara: *Virchow's Arch.*, 1896, cxliii, 111.

closely together and therefore appear to be more numerous in sections.

*Cells.*—The cells which compose the interacinar islands in the adult human pancreas are polygonal in shape and smaller than the cells of the acini. They have a large, round, occasionally oval, vesicular nucleus with several small nucleoli and usually a well-defined cell-body. The basal zone of the secreting cell, it is well known, stains deeply with nuclear dyes, for example, hæmatoxylin or methylene blue, while the apical part which contains zymogen granules remains unstained. The cells of the island, on the contrary, are entirely unstained by nuclear dyes, whereas, with eosin their protoplasm takes a homogeneous bright pink color. The nuclei vary considerably in size, and not infrequently one finds very large round vesicular nuclei the diameter of which is two or more times that of the adjacent cells. The cells form columns between which lie anastomosing capillaries. Occasionally they are very closely packed together and nuclei are situated almost side by side; more frequently, the cells of the island are less numerous and nuclei are less closely crowded.

Dogiel<sup>23</sup> and later Stangl<sup>24</sup> have shown that fat is normally present in the protoplasm of the cells which form the islands of Langerhans. Numerous very fine droplets of almost uniform size are abundant in the islands of Langerhans, whereas fat droplets within the secreting acini, often much larger, vary greatly in size, and are more sparsely scattered.

---

<sup>23</sup> *Loc. cit.*, p. 51.

<sup>24</sup> Stangl: Wiener klin. Woch., 1901, xiv, 964.

The protoplasm of the insular cells is not entirely homogeneous but, as Laguesse<sup>25</sup> and others have shown, contains minute granules which stain with safranin, eosin, gentian violet or fuchsin. Diamare<sup>26</sup> has found in the island of Langerhans of the rabbit in sections stained by methyl green, picric acid and acid fuchsin (Galeotti's stain) large cells brightly colored red, scattered among the more numerous smaller cells which are stained green.

By careful study of the microchemistry of the granules contained in the cells of the islands of Langerhans Lane<sup>27</sup> has demonstrated the existence of two types of cell: (*a*) Cells of large size occur in groups near the centre of the island of Langerhans and contain fine granules which stain with neutral gentian violet after fixation with alcohol (50 to 70 per cent.) but are soluble in Müller's fluid containing bichloride of mercury; while (*b*) smaller cells are more numerous and contain granules which are soluble in alcohol but are fixed by Müller's fluid with bichloride. Each type of granule differs in solubility and in microchemical reactions from the zymogen granules of the secreting cells.

*Blood-Vessels.*—The capillaries of the island of Langerhans form a glomerulus of tortuous, freely anastomosing vessels, much wider than those between the acini. A single afferent vessel like that of the glomerulus of the kidney does not enter this group of dilated capillaries, but numerous anastomoses make the network within the

---

<sup>25</sup> Laguesse: Jour. de l'anat. et physiol., 1895, xxi, 475; Arch. d'anat. mic., 1901, iv, 157.

<sup>26</sup> *Loc. cit.*, p. 60.

<sup>27</sup> Lane: American Jour. of Anat., 1907, vii, 409.

island of Langerhans continuous with the interacinar capillaries (Fig. 18). When Berlin blue is injected through the aorta into the arteries of the pancreas, it not infrequently happens that in parts of the gland which are poorly injected the vessels of the interacinar island are filled with the injected mass, whereas the surrounding capillaries are for the most part empty. If, instead of soluble Berlin blue, a granular injection mass—for example, cinnabar or ultramarine blue—is used, the islands of Langerhans may be injected while the interacinar capillaries contain little of the injected material. Such observations show that the glomerular network is in very free communication with the smallest arteries and apparently has a richer blood supply than other parts of the lobule.

#### HISTOGENESIS OF THE SECRETING ACINI AND OF THE ISLANDS OF LANGERHANS.

The epithelial nature of the cells composing the islands of Langerhans has been clearly demonstrated by embryological investigation. In the embryo sheep Laguesse<sup>28</sup> has traced the histogenesis of the gland (Fig. 19) from the stage in which the organ is represented by a simple diverticulum from the intestinal wall (embryo 4 millimetres). Solid cords of cells arise from this diverticulum (embryos 4 to 18 millimetres) and at the end of the second month give place to tortuous anastomosing tubules formed by a single layer of epithelial cells (embryos 18 to 50 millimetres). Here and there occur cells which stain more deeply than those about them, and

---

<sup>28</sup> Laguesse: *Verhandl. d. anat. Gesellsch.*, 1897, 45.

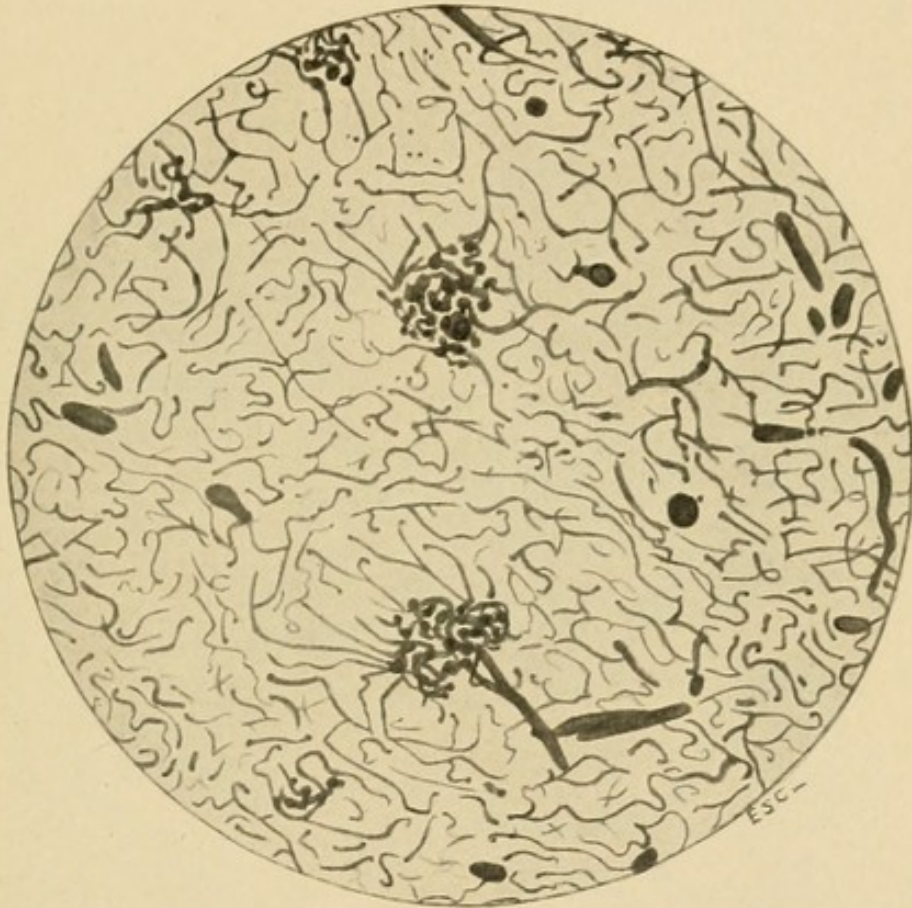



FIG. 18.—Blood-vessels of the pancreas injected in order to show the glomerular arrangement of capillaries in the islands of Langerhans.



like the border cells of the stomach are situated near the outer surface of the tubule. These cells proliferate to form solid outgrowths or loops upon the tubule and

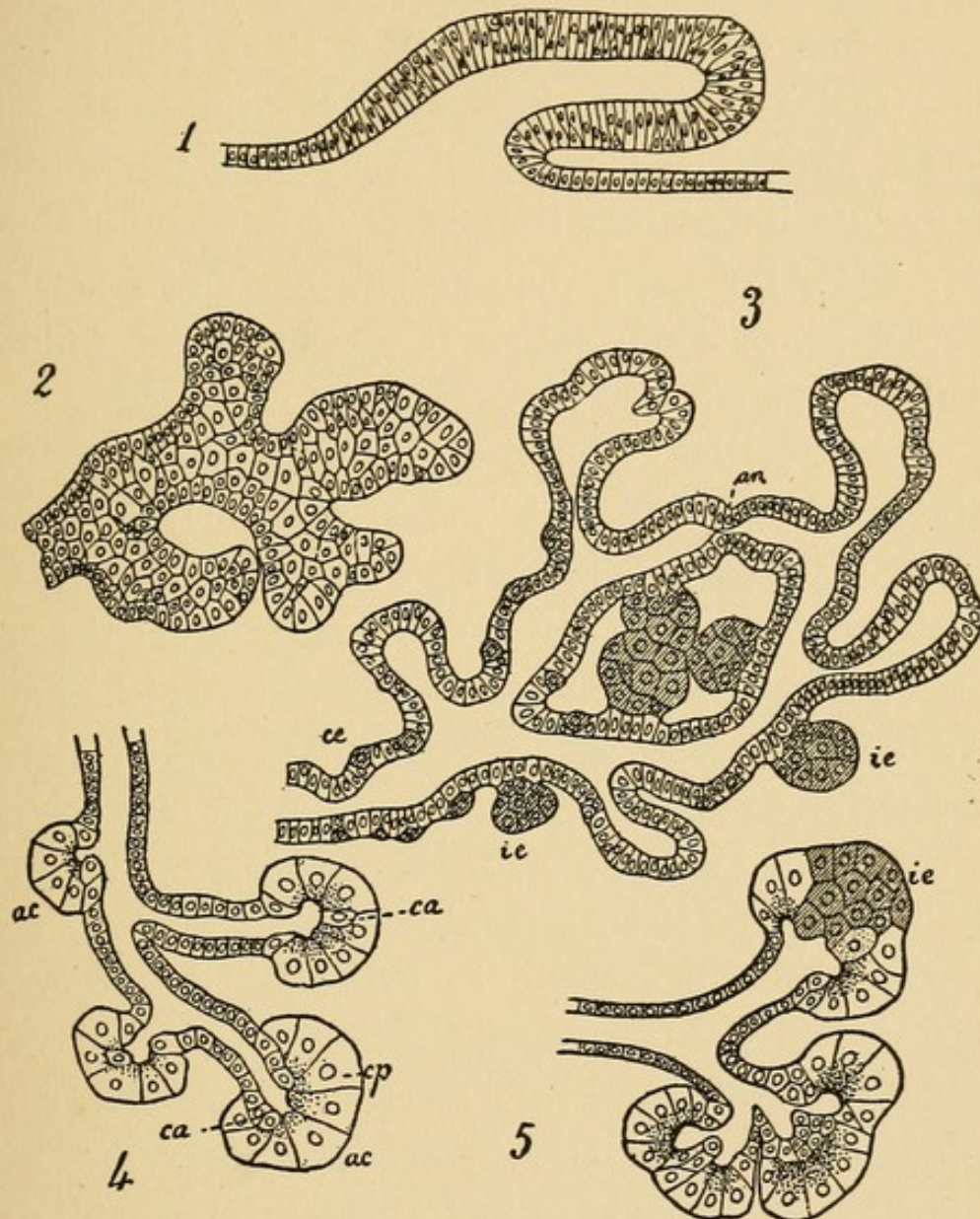


FIG. 19.—Diagrams showing histogenesis of the pancreas. 1. Diverticulum from the intestinal epithelium. 2. Solid branching cords of cells. 3. Tubules which branch and anastomose (*an*); they are enlarged at the extremities and have formed islands of Langerhans (*ie*). 4. Formation of acini (*ac*); *ca*, centroacinar cells. 5. Formation of a lobed acinus. (After Laguesse, *Rev. gén. d'histol.* 1906, ii, 18.)

constitute what Laguesse calls primary islands of Langerhans. At a later stage (embryos 60 to 65 millimetres) the secreting acini are formed as buds, from the wall of

the original tubules, and within them can be recognized two kinds of cells, the ordinary glandular cell containing zymogen granules and the centro-acinar cells which form a second more or less continuous row superimposed upon the secreting cells. At a still later stage (embryos 90 millimetres), Laguesse thinks that groups of acini undergo alterations by which they are transformed directly into interacinar islands, designated by him secondary islands of Langerhans. This mode of formation has received no confirmation from subsequent embryological studies.

Renaut has described the histogenesis of the pancreatic lobule. His description of the early stages of development agrees with that given by Laguesse. The primitive dorsal and ventral outgrowths from the wall of the duodenum form numerous branches which ramify in the dorsal mesentery of the intestine. At first these branches are solid, but soon they acquire a lumen about which the cells are arranged in a single row, and, anastomosing between themselves, they resemble the tubular columns which form the liver of certain lower vertebrates. At intervals along their wall are formed short outgrowths terminating in a rosette-like group of blind pouches. Within such a group of primitive acini at least one island of Langerhans is formed by differentiation and multiplication of the peculiar cells, already described by Laguesse. The rosette-like group of acini and at least one island of Langerhans represent the primary glandular lobule in its undeveloped form and by subsequent growth give rise to the primary lobule of the adult gland.

Studies of Pearce,<sup>29</sup> made upon the human embryo, have clearly established the common origin of the islands of Langerhans and the secreting acini and the final independence of these structures. Islands of Langerhans originate from cells of the primitive secreting tubules. At the end of the third month the solid stalk-like strand of cells connecting the island of Langerhans with the acini becomes constricted and lengthened and complete separation occurs. The rich vascular network of the interacinar island is formed about the same time. Almost identical observations have been subsequently made by Küster.<sup>30</sup>

#### FUNCTION OF THE ISLANDS OF LANGERHANS.

*Relation between Secreting Acini and Islands of Langerhans in the Adult Pancreas.*—An attempt to investigate experimentally the nature of the islands of Langerhans has been made by Lewaschew,<sup>31</sup> working in Heidenhain's laboratory. He studied the pancreas of dogs and cats killed after having been subjected to conditions which cause the gland to secrete actively. After prolonged overfeeding, or after the frequently repeated administration of pilocarpin, which stimulates the pancreas as it does the salivary glands, he claims to have found structures representing transitions between the glandular acini and the interacinar cell-groups. He has observed acini containing one or more cells of which the protoplasm is non-granular and stains lightly, a whole acinus or a number of acini composed of such

---

<sup>29</sup> Pearce: American Jour. of Anat., 1903, ii, 445.

<sup>30</sup> Küster: Arch. f. mik. Anat., 1904, lxiv, 158.

<sup>31</sup> Lewaschew: Arch. f. mik. Anat., 1886, xxvi, 452.

cells; areas in which cells have assumed a polygonal shape and are no longer grouped about a central lumen, and finally cell-groups formed by polygonal cells without acinar arrangement, representing, he thinks, newly formed islands of Langerhans. Lewaschew mentions that he has found an unusual number of islands under conditions other than those of increased functional activity. They were very numerous in a dog which several days before its death had suffered with fever.

The observations of Lewaschew have not been confirmed. I have attempted to repeat his observations by injecting pilocarpin muriate into dogs.<sup>32</sup> The islands of Langerhans were counted in 0.5 square centimetre of sectional area in specimens (*a*) from the splenic extremity of the pancreas, (*b*) from the part in contact with the duodenum, and (*c*) from the descending arm which lies in the mesentery of the duodenum. The number in the pancreas of a dog which had received repeated injections of pilocarpin was compared with that found in corresponding parts of the pancreas of animals to which pilocarpin had not been given. The results are shown in the following table:

Injected animal.	<i>a</i>	<i>b</i>	<i>c</i>	Control Animal.	<i>a</i>	<i>b</i>	<i>c</i>
Dog No. 1.....	61	21	1	Dog No. I.....	59	61	14
Dog No. 2.....	55	20	11	Dog No. II.....	39	53	3
Dog No. 3.....	54	72	8	Dog No. III....	67	89	12
Average.....	56.6	37.6	6.6	Average.....	55	67.6	9.6

The figures show that no increase of the number of

<sup>32</sup> *Loc. cit.*, p. 62.

islands of Langerhans was obtained in the three experiments. Transitional stages between glandular acini and interacinar islets have not been observed. The number of islands in that part of the descending arm of the pancreas which lies in the mesentery of the duodenum (*c*) is constantly much less than elsewhere; the number in different glands and in different parts of the same gland varies considerably. In the experiments of Lewaschew these sources of error apparently have not been given sufficient weight. The effect of pilocarpin upon the islands of Langerhans has been tested with negative results by Hansemann and by Ssobolew.

The discovery of secretin by Starling has suggested a means by which the secreting cells of the acini may be stimulated to exhaustion. Dale,<sup>33</sup> a pupil of Starling, has, he believes, transformed secreting acini into islands of Langerhans by injection of secretin into the circulation repeated during from six to twelve hours; the injections have been accompanied by bleeding toward the end of the experiment. After continued injection of secretin the greater part of lobules in the dog and the greater part of the pancreas in the toad are converted, he claims, into tissue resembling cell-islets, and only traces of alveolar arrangement suggest its former condition. Such widespread changes have little resemblance to the circumscribed islands of Langerhans observed in normal and pathological pancreas, and suggest the possibility that Dale has produced, by profound injury to the gland, degenerative changes in the parenchyma—perhaps the

---

<sup>33</sup> Dale: *Philosoph. Trans.*, 1904, cxcvii, B. 25.

well-known self-digestion which, as Chiari<sup>34</sup> has shown, may have its onset during the death agony.

*Inanition.*—Several observers have claimed that secreting acini are transformed into islands of Langerhans under conditions which have little resemblance to those previously mentioned. In dogs, cats, and rabbits which have been starved, the secreting cells, Statkewitsch<sup>35</sup> claims, lose their granular inner zone and by a series of transitions assume the character and arrangement of the interacinar cell-groups. Vincent and Thompson<sup>36</sup> claim to have observed after starvation increase of islands of Langerhans in the dog, pigeon, and frog. The number and character of their experiments are not described in detail and in only one instance have islands of Langerhans been compared numerically with those of a normal control animal. They state that changes following inanition are more marked than those following the injection of secretin which produces, they think, some increase of interacinar islands.

Jarotzky<sup>37</sup> has made a careful study of the secreting pancreatic cells in mice under various conditions of inanition; from some of his animals food was withheld, others were given only sugar, others only fat, but in none did he find changes similar to those described by Statkewitsch. Ssobolew found no transformation of acini into interacinar islands with inanition. Dewitt made measurements of the size and number of interacinar islands in guinea-pigs after withdrawal of food, and after continued diet of meat or of carbohydrates, but found no departure from the normal.

*Appearances Believed to Represent Transition from Acini to Islands of Langerhans.*—A considerable variety of appearances have been believed to represent transitional stages between secreting acini and islands of Langerhans. The island of Langerhans is usually outlined by a delicate circle of connective tissue, but frequently the outline is less sharp and the shape of the body is modified by encroachment of

---

<sup>34</sup> Chiari: Zeit. f. Heilk., 1896, xvii, 69.

<sup>35</sup> Statkewitsch: Arch. f. exper. Path. u. Phar., 1894, xxxiii, 415.

<sup>36</sup> Vincent and Thompson: Internat. Monatsschr. f. Anat. u. Physiol., 1907, xxiv, 61.

<sup>37</sup> Jarotzky: Virchow's Arch., 1899, clvi, 409.

neighboring acini; an acinus is occasionally found within the area of an interacinar island. Continuity between the cellular columns of the island of Langerhans on the one hand and secreting acini on the other has been described by a number of histologists, but others have maintained that close contact explains the apparent continuity.

In reptiles and in birds, columns of the islands of Langerhans are frequently found continuous with the wall of secreting acini; in the rabbit Dewitt has traced the continuity in a reconstructed model. Since the islands of Langerhans and the secreting acini have a common origin, it is not improbable that they remain continuous in the adult organ. Both Pearce and Köster have shown that the islands of Langerhans in human embryos are connected with the tubules of the gland by a stalk of cells; atrophy of this stalk and complete independence of islands is demonstrable in embryos three months old.

There is little doubt that some authors have described as islands of Langerhans acini within which centro-acinar cells are unusually numerous. Dale differs from all histologists who have studied structure and histogenesis of the pancreas in asserting that centro-acinar cells may represent a transitional stage between secreting cells and cells of interacinar islands.

In the normal human pancreas one occasionally finds groups of acini composed of cells suggesting a transition<sup>38</sup> from the secreting acini to island of Langerhans. The cell-protoplasm does not take the nuclear dye as does the basal part of the ordinary glandular cell, and when stained with eosin has a bright pink color and homogeneous refractive appearance. The nucleus, which shows no evidence of degenerative change, is situated near the centre of the cell. Occasionally one or more cells of the character described form part of an acinus which otherwise resembles those about it. Usually, however, a group of acini are changed, and such an area may roughly correspond in size to an island of Langerhans.

It is probable that these foci, in part at least, represent what Laguesse and Pischinger<sup>39</sup> and perhaps Lewaschew have described as stages of transition. The arrangement of more or less columnar cells

---

<sup>38</sup> Opie: *Loc. cit.*, p. 62.

<sup>39</sup> Pischinger: *Inaug. Diss.*, Munich, 1895.

about a central lumen is, however, still preserved, and similar areas in which this arrangement is lost are not found. The lumen, indeed, is usually very conspicuous and is often considerably dilated, filled with products of secretion which stain deeply with eosin. It seems probable that these groups of acini are altered as the result of peculiar functional activity, it may be of hyperstimulation of the gland. There is at least no evidence that they represent transitional stages between glandular acini and islands of Langerhans.

Such altered acini are observed in a small proportion of normal glands. They have been found in three of twenty-seven glands examined carefully for their presence. They have been present, moreover, in three of seven relatively normal organs from diabetic patients. The occurrence of voracious appetite and increased food ingestion in individuals so affected may explain the occurrence of these areas which represent possibly foci of peculiar secretory activity.

The diversity of the opinions concerning the structures under consideration has justified, I believe, the preceding detailed discussion of their nature. Certain facts may be considered established. The islands of Langerhans are composed of cells of epithelial type having the same origin as those which form the acini; disappearance of the connection between the two structures may be observed during embryonic life. Ramifications of the pancreatic duct on the one hand do not penetrate the interacinar islands, while on the other hand these bodies have an intimate relation to the vascular system. They occupy a definite position within the pancreatic lobule (of the cat), and are more numerous in certain parts of the gland than in others. They have a framework of connective tissue and a vascular supply which differs from that of the secreting acini. Conflicting experimental evidence furnishes no proof that secreting acini may be transferred into islands of Langerhans and

the various so-called transitions between the two structures retain the characters of secreting acini. The cells of the islands of Langerhans contain fine granules which differ in physical and chemical properties from the zymogen granules of the secreting acini.

The function of the islands of Langerhans has been the subject of much speculation; that which has been based upon false interpretation of their anatomy has no present interest, and their supposed relation to the lymphatic system will not be discussed.

The intimate relation of columns of epithelial cells to a rich capillary network has suggested that the islands of Langerhans furnish some substance to the blood, the hypothetical internal secretion of the pancreas. Abundant experimental research inaugurated by Von Mering and Minkowski having shown that the pancreas exerts an important influence on carbohydrate metabolism, several writers, Laguesse,<sup>40</sup> Schäfer,<sup>41</sup> Diamare, and others, have suggested that the islands of Langerhans perform this function. Ssobolew claims to have obtained experimental evidence that assimilation of sugar causes changes in the cells of these bodies comparable to those which occur, as Heidenhain has shown, in the secreting cells as the result of increased functional activity. The cells of the interacinar islands are, he states, more granular after hunger which has lasted two or three days, but after feeding with carbohydrates in considerable quantity, or after intravenous injection of sugar, the granules within the cells diminish in num-

---

<sup>40</sup> Laguesse: *Compt. rend. Soc. de biol.*, 1893, xlv, 819.

<sup>41</sup> Schäfer: *British Med. Jour.*, 1895, ii, 341.

ber. Schmidt,<sup>42</sup> however, has been unable to produce similar phenomena in mice and in guinea-pigs after intraperitoneal and intravenous injection of solutions of sugar.

The study of pathological changes associated with the disease of carbohydrate metabolism, diabetes mellitus, has shown that the islands of Langerhans control the assimilation of sugar. It will be the purpose of a subsequent chapter to define the relationship of diabetes mellitus to diseases of the pancreas and to alterations of the islands of Langerhans.

---

<sup>42</sup> Schmidt: Münchener med. Woch., 1902, xlix, 51.

## CHAPTER IV.

### THE PANCREAS AND DIGESTION.

To study the pancreatic juice unmixed with intestinal contents, and to determine the conditions which influence its flow, it is necessary to collect the secretion as it escapes from the duct of the gland. Shortly after the discovery of the pancreatic duct by Wirsung, Regius de Graaf produced a pancreatic fistula in the dog and collected pancreatic juice through a tube fixed in the duct. In his work, "De natura et usu succi pancreatici," published in 1664, he pictures an animal with both pancreatic and salivary fistulæ.

*Pancreatic Fistula.*—It has long been known that the operation necessary for the insertion of a cannula into the pancreatic duct causes such profound disturbance of the gland that flow of pancreatic juice ceases for a time. When a cannula is fixed in the duct secretion begins after one or two days, but irritation of the gland causes a continuous flow of thin fluid, and pathological changes soon occur in the gland. Pawlow<sup>1</sup> in 1879 first showed that these difficulties might be overcome by transplanting into the abdominal wall the duodenal end of the pancreatic duct, together with the mucosa of the duodenum immediately about it. The gland remains normal; pancreatic juice may be collected by suitable means, and conditions which influence its amount and character may be studied. The success of the experiment is dependent

---

<sup>1</sup> Pawlow: The Work of the Digestive Glands [Trans.], London, 1902.

upon certain precautions. Contact with escaping pancreatic juice causes maceration and erosion of the skin in contact with the wound, so that the animal must lie upon some absorbent material, such as sawdust or sand. Loss of pancreatic juice, it is believed, may have an unfavorable influence upon the animal, so that conditions which diminish the activity of secretion are desirable. Upon a diet of milk and bread with addition of sodium carbonate, which perhaps replaces the alkali lost in the pancreatic juice, an animal may be kept in good health according to Starling<sup>2</sup> during months or even years.

#### PANCREATIC JUICE AND ITS ENZYMES.

Pancreatic juice is a clear watery fluid. The composition of pancreatic juice obtained from fistulæ remaining after operations upon the pancreas in man differs little from that obtained from the dog by the method just described. The specific gravity is only slightly greater than that of water (1.0075–1.0098); water forms approximately 98.5 and solids 1.5 per cent., from a third to two-thirds of solids being ash. Pancreatic juice contains a small quantity of coagulable protein and certain enzymes which it is well known have an important part in the digestion of protein, fat, and carbohydrates.

Experiments upon the secretion of pancreatic juice have been performed in large part upon the dog. In this animal the gland is inactive when food is withheld, but immediately after a meal secretion begins, reaching a maximum during the following three hours. Walther<sup>3</sup>

---

<sup>2</sup> Starling: *Physiology of Digestion*, Chicago, 1906.

<sup>3</sup> Walther: *Arch. de scienc. biol.*, 1899, vii, 1.

has shown that the quantity and the character of the pancreatic juice varies with the character of the food. The following table shows the effect of different diet—namely, 600 c.c. of milk, 250 Gm. of bread, or 100 Gm. of meat—upon the secretion of pancreatic juice:

Food ingested.	Quantity of pancreatic juice.	Duration of secretion.	Per cent. of organic substance.	Per cent. of ash.	Alkalinity of ash as per cent. of sod. carb. in 100 c.c. of juice.
	<i>c.c.</i>	<i>hrs. min.</i>			
600 c.c milk . . . . .	45.7	4 30	4.399	0.869	0.348
250 grammes bread . . . . .	162.4	7 35	2.298	0.925	0.564
100 grammes meat . . . . .	131.6	4 12	1.558	0.907	0.588

Meat has caused rapid secretion of juice relatively poor in solids whereas bread has caused slower secretion of a somewhat greater quantity of juice. Milk has excited the flow of a small quantity of more concentrated juice of which the alkalinity is relatively low.

*Secretion of Pancreatic Juice; Secretin.*—The maximum activity of pancreatic secretion occurs at a time when the stomach is discharging its contents into the duodenum, and there is abundant evidence that the gland is excited to activity during digestion by passage of the acid chyme over the mucous membrane of the duodenum. Experiments of Pawlow have shown that weak hydrochloric acid causes an almost immediate flow of juice; other acids—*e.g.*, water saturated with carbonic acid gas—have the same effect, but alkalies inhibit secretion, perhaps, only because they neutralize the acid of the stomach. Neutralization of the gastric contents during digestion prevents the flow of pancreatic juice which follows ingestion of food.

Much effort has been made to determine the means by which stimulation of the duodenal mucosa excites the pancreas to activity, and the investigations of Bayliss and Starling<sup>4</sup> have recently furnished an adequate explanation. Analogy with the salivary glands has suggested that secretion occurs as the result of a nervous reflex, and Pawlow<sup>5</sup> has succeeded in producing a flow of pancreatic juice by stimulation of both the vagus and splanchnic nerves. Nevertheless, Wertheimer and Lepage<sup>6</sup> have shown that the flow of pancreatic juice excited by the presence of acid in the duodenum occurs after division of the vagus and after excision of the sympathetic nerves.

The experiments of Bayliss and Starling have conclusively demonstrated that acid applied to the intestinal mucosa may cause pancreatic secretion in the absence of any nervous connection between intestine and pancreas. Wertheimer and Lepage<sup>7</sup> had found that acid caused a maximum flow when introduced into the duodenum, whereas the response diminished when acid was introduced into the lower parts of the intestine and disappeared when the lowermost part of the ileum was reached. Bayliss and Starling ligated the two ends of a loop of the upper part of the jejunum, and destroyed its nervous connection with other organs by dividing

---

<sup>4</sup> Bayliss and Starling: *Jour. of Physiol.*, 1902, xxviii, 325; 1903, xxix, 174.

<sup>5</sup> Pawlow: *Arch. f. Anat. u. Physiol.*, 1893, Suppl., *Physiol. Abt.*, 176.

<sup>6</sup> Wertheimer and Lepage: *Compt. rend. Soc. de biol.*, 1899, li, 951.

<sup>7</sup> Wertheimer and Lepage: *Jour. de physiol. et de path. gén.*, 1901, iii, 335.

splanchnics and vagi, extirpating the abdominal sympathetic ganglia and dissecting away all nervous filaments which follow the blood-vessels. Although the loop was connected with the rest of the body only by its blood-vessels, introduction of hydrochloric acid caused an abundant flow of pancreatic juice. Some chemical substance transported by the blood from the intestinal loop to the pancreas had caused the gland to secrete.

Since acid introduced into the blood did not excite pancreatic secretion, Bayliss and Starling suspected that acid introduced into the intestine might cause the intestinal mucosa to elaborate some substance capable of exciting the pancreas to activity, when absorbed by the blood. This hypothesis was confirmed when they found that the epithelial cells of the intestinal mucosa treated with acid yielded an extract which, when introduced into the circulation, caused active flow of pancreatic juice. The substance named by Bayliss and Starling secretin, is not present in the cells of the mucosa, and an extract prepared from them is incapable of stimulating the pancreas; these cells contain a substance, prosecretin, which is converted by acid into secretin.

Pawlow\* has been unwilling to admit that nervous reflex has no part in the mechanism of pancreatic secretion. He does not think that the secretion caused by stimulation of the vagus is wholly referable to movements of the stomach forcing acid contents into the duodenum. As evidence of direct influence of the vagus upon the gland, he points out that pancreatic juice obtained by

---

\* Pawlow: Nagel's Handb. der Physiol. des Menschen., Braunschweig, 1907, ii, p. 666.

stimulation of the vagus is much more concentrated than that obtained by action of acid upon the duodenum; atropine, moreover, paralyzes this action of the vagus, whereas it has no effect upon secretion caused by acid.

It is noteworthy that substances other than acid applied to the duodenal mucosa may excite pancreatic secretion. Fats and soap stimulate secretion, but their action is much less intense than that of acid (Fleig \*).

*Trypsin, Trypsinogen, and Enterokinase.*—Pepsin forms albumoses and peptones from protein, but simpler products such as amino-acids are formed only by prolonged action of the enzyme; with the proteolytic enzyme of the pancreatic juice—namely, trypsin—hydrolysis of protein is more complete and peptones are transformed into amido-acids. The action of trypsin is most powerful in the presence of a weakly alkaline solution; sodium carbonate in 0.2 to 0.3 per cent. solution is favorable to its action. Heidenhain<sup>8</sup> found that the greater the concentration of trypsin the greater was the concentration of alkali necessary for its optimum activity. Trypsin is readily destroyed by heat, and purified solutions lose their activity at a temperature of from 45° to 50° after a few minutes, but the presence of protein, peptones and various salts serve to protect the enzyme so that it withstands much higher temperatures.

The serum of the blood has the power to inhibit the action of trypsin (M. Hahn<sup>9</sup>); this anti-enzyme is precipi-

---

\* Fleig: Jour. de physiol. et de path. gén., 1904, vi, 32, 50.

<sup>8</sup> Heidenhain: Beiträge zur Kenntniss des Pankreas, Pflüger's Arch., 1875, x, 557.

<sup>9</sup> Hahn, M.: Berliner klin. Woch., 1897, xxxiv, 499.

tated with the albumin fraction of the serum and is absent in the globulin fraction. It is destroyed by heat.

Trypsin does not exist within the secreting cells of the pancreas, and extracts made from the fresh gland do not act upon protein. Heidenhain has found that the gland treated with acid yields an active extract, for trypsinogen, the precursor of the enzyme, is transformed into trypsin. Pawlow has shown that juice obtained from a pancreatic fistula contains trypsinogen and his pupil, Chepowalnikow,<sup>10</sup> has made the important discovery that intestinal juice has the power to increase enormously the proteolytic activity of pancreatic juice.

Succus entericus contains a substance, enterokinase, which transforms inactive trypsinogen of the pancreatic juice into active trypsin. A small quantity of enterokinase is capable of converting a large quantity of trypsinogen into trypsin. This substance, which is readily destroyed by heat (67 to 70° C.), is, according to Pawlow, an enzyme—an enzyme which acts upon another enzyme. It is produced only by the intestinal mucous membrane and, Pawlow thinks, in response to a definite stimulus. A tube inserted into an isolated intestinal loop excites a flow of fluid which, with repeated withdrawal, contains less and less enterokinase until finally none is present; the introduction of a small quantity of pancreatic juice causes the secretion of a fluid containing much kinase but boiled pancreatic juice has no such effect. The presence of trypsinogen causes the mucous membrane to produce the activating substance.

---

<sup>10</sup> Chepowalnikow: *The Physiology of Succus Entericus*. Inaug. Diss., St. Petersburg, 1899. Quoted by Pawlow.

According to Starling the pancreas contains only trypsinogen, and the spontaneous occurrence of trypsin is due to accidental contamination with intestinal contents; the juice which is obtained from the pancreatic duct by the use of secretin contains only trypsinogen. Pawlow, on the contrary, has claimed that the juice obtained from a permanent fistula in a dog which has been fed on an exclusive diet of meat contains active trypsin.

The pancreatic juice or extracts from the pancreas exhibit certain properties which are referred by some observers to the action of trypsin, whereas others believe that they are due to separate enzymes. Nucleic acid is in great part precipitated in the stomach but it is dissolved in the intestine. Solution of nucleic acid which is doubtless caused by pancreatic juice has been attributed to an enzyme, nuclease, present in the pancreatic juice (Umber<sup>11</sup>). The power of the pancreas to coagulate casein observed by Kühne, and believed to indicate the presence of a lab-ferment, has been regarded by some observers as a property of trypsin.

*Steapsin.*—The fat-splitting enzyme of the pancreas, steapsin, acts well in the presence of an alkaline, neutral, or acid reaction. It is not only capable of splitting neutral fats into glycerin and fatty acids, with formation of soaps when alkali is present, but can decompose a considerable number of esters of lower fatty acids such as ethyl-butyrate. When this substance is used as a test for the presence of fat-splitting enzyme the amount of acid formed measures the activity of the enzyme. Kastle

---

<sup>11</sup> Umber: Zeit. f. klin. Med., 1901, xliii, 282.

and Loevenhart<sup>12</sup> have shown that the action of the enzyme is reversible; the addition of a glycerin extract of pancreas to a solution of butyric acid and ethyl-alcohol causes the formation of ethyl-butyrate.

Steapsin occurs in the pancreas as zymogen; the pancreatic juice contains some active steapsin. Bile increases the activity of the fat-splitting enzyme two- or three-fold (Nencki,<sup>13</sup> Bruno<sup>14</sup>) but its mode of action is not understood, for the bile contains no substance analogous to enterokinase.

*Amylopsin.*—The amylolytic enzyme of the pancreas forms from starch dextrin and, finally, maltose; invertin is not produced by the pancreas and little if any dextrose is formed from starch by the action of pancreatic juice. As a measure of the activity of amylopsin, Pawlow has used small tubes filled with starch paste; the length of the column dissolved at each end varies with the quantity of enzyme which is present. The enzyme acts in the presence of weak acid and is slightly inhibited by weak alkali. According to Zweifel<sup>15</sup> there is no amylopsin in the pancreas of the new-born infant, and it is not found until more than a month after birth.

*Self-Digestion of the Pancreas.*—The pancreas at autopsy is frequently found to have undergone changes which do not occur in other organs and are doubtless referable to the proteolytic enzyme which it contains. From a study of seventy-five cases, Chiari<sup>16</sup> has reached

---

<sup>12</sup> Kastle and Loevenhart: American Chem. Jour., 1900, xxiv, 491.

<sup>13</sup> Nencki: Arch. f. exper. Path. u. Pharm., 1886, xx, 367.

<sup>14</sup> Bruno: Arch. des scien. biol., 1899, vii, 87.

<sup>15</sup> Zweifel: Verdauungsapparat Neugeborener, Strassburg, 1874.

<sup>16</sup> Chiari: Zeit. f. Heilk., 1896, xvii, 69.

the conclusion that in about one-half of all subjects the pancreas at the time of death has the capability of causing digestion of its own substance. This condition of self-digestion may be observed in autopsies performed only a few hours after death, and has no relationship to putrefaction, from which it can be readily distinguished. The conditions upon which it depends are not known.

Advanced self-digestion affects the entire substance of the organ, which becomes flaccid in consistence; and in sections prepared for microscopic examination nuclei are unstained, so that the tissue has a homogeneous appearance. The change affects the interstitial tissue as well as the secreting parenchyma. In many instances self-digestion is limited to small areas. When the organ undergoes putrefaction, nuclear substance, on the contrary, is not dissolved, but, being fragmented, appears as fine particles scattered throughout the tissue and bacteria can be readily found.

Disappearance of nuclei with self-digestion of the gland is probably referable to trypsin, which quickly attacks nucleic acid. The minute foci of fat necrosis which are found in association with self-digestion are perhaps caused by post-mortem action of the fat-splitting enzyme of the gland (Wells<sup>17</sup>).

The occurrence of extravasated blood in areas of self-digestion in seven of seventy-five cases of Chiari has suggested that pancreatic autolysis may occasionally occur during the death agony. Such extravasation, which sometimes extends into the tissue immediately

---

<sup>17</sup> Wells: *Jour. of Med. Research*, 1903, ix, 70.

about the gland, may give the organ a hemorrhagic appearance and in some instances has doubtless caused an erroneous diagnosis of acute hemorrhagic pancreatitis. The flaccid gland with scattered foci of hemorrhage has little resemblance to the lesion of hemorrhagic necrosis (acute hemorrhagic pancreatitis).

#### DISTURBANCES OF DIGESTION CAUSED BY ABSENCE OF PANCREATIC JUICE IN THE INTESTINE.

Symptoms which follow impairment of the digestive or external function of the pancreas have not been very clearly defined, and though certain facts have been established, clinical observations have had divergent results. The pancreatic juice contains enzymes which aid in the digestion of proteins, fats, and carbohydrates, yet it is not the only secretion concerned in the digestion of any one of these substances. Impaired assimilation of proteins and fats is more readily recognized than alterations affecting the digestion of carbohydrates, and hence have been assigned greater diagnostic significance.

*Experimental Studies.*—Claude Bernard<sup>18</sup> destroyed the pancreas of dogs by injecting oil of other bland substance into the larger duct, and observed that the fæces contained in abundance food material which had undergone little change—for example, undigested muscle-fibres or even large pieces of meat, together with fat, at times in such quantity that when cold it congealed as a layer covering the surface of the fecal mass. Subsequent observers have studied by somewhat more accurate methods the disturbances which Claude Bernard de-

---

<sup>18</sup> Bernard, Claude: Mémoire sur le pancréas, Compt. rend. de l'Acad. des sciences, Suppl., 1856.

scribes. Abelman<sup>19</sup> found after removing the pancreas in dogs that all fat taken with the food reappeared in the fæces; an exception was the emulsified fat of milk, of which only about 47 per cent. reappeared. Under normal conditions little more than 5 per cent. of fat escapes absorption. Hédon and Ville<sup>20</sup> claim that the statement of Abelman is somewhat exaggerated; they have found that some fat which is not emulsified may undergo absorption even when the gland is completely removed, only about 82 per cent. reappearing in the fæces. After partial extirpation only half the fat ingested is unabsorbed. After complete removal of the organ, according to Abelman, fat is still split, and about four-fifths of that which is unused is represented in the fæces by fatty acids.

In the experiments of Abelman after total excision of the pancreas about 56 per cent. of the proteins ingested has escaped absorption, while after partial removal 46 per cent. has escaped. Under normal conditions not more than one or two per cent. of nitrogenous material is unabsorbed. Loss of the pancreas also alters the normal digestion of carbohydrates, and, according to Abelman, 20 to 40 per cent. of starch may reappear in the fæces, having undergone no transformation into sugar. Subsequent experimenters have confirmed the observations of Abelman.

After partial extirpation of the pancreas so performed that the pancreatic juice no longer reaches the intestine, Abelman found absorption of fat much more active than after complete extirpation.

---

<sup>19</sup> Abelman: Inaug. Diss., Dorpat, 1890.

<sup>20</sup> Hédon and Ville: Physiologie du pancréas, Paris.

In a long series of experiments Ugo Lombroso<sup>21</sup> has compared the effect of extirpation with that of operations which prevent access of pancreatic juice to the intestine. He has found in the fæces after removal of the gland an increased percentage of the ingested protein, fat, and carbohydrates, whereas after ligation of the pancreatic ducts or after permanent removal of pancreatic juice by way of a Pawlow's fistula, with an occasional exception there has been unimpaired digestion of these substances. With partial removal of the gland so performed that the secretion of the part remaining no longer reaches the intestine, the result has been variable; and especially when degenerative changes have occurred in the remaining pancreatic tissue, an abnormal quantity of undigested protein fat and carbohydrate may appear in the fæces. Kleckseder<sup>22</sup> has partially removed the pancreas and diverted from the intestine the secretion of the glandular tissue which remains; there is absorption of fat from the intestine. The pancreas, he thinks, furnishes an internal secretion which makes possible the absorption of fat from the intestine.

In performing experiments just mentioned certain errors are possible. It is necessary to occlude both ducts of the pancreas. With an external fistula pancreatic juice may return to the intestinal tract when the animal licks its wound.

Regeneration of a pancreatic duct after section and ligation of both ducts may explain some of the discordant observations which have been described. Visentini<sup>23</sup> found such regeneration with complete absence of functional disturbance, whereas when the ducts were permanently occluded absorption of fat was impaired so that from 50 to 75 per cent. of ingested fat reappeared in the fæces.

Disturbances of digestion similar to those which follow experimental extirpation of the gland have been noted in human cases where the pancreas has been partially destroyed by chronic inflammation, by cysts, or by

---

<sup>21</sup> Lombroso: Pflüger's Arch., 1906, cxii, 531; Arch. f. exper. Path. u. Pharm., 1907, lvi, 357.

<sup>22</sup> Kleckseder: Arch. f. exper. Path., 1908, lix, 407.

<sup>23</sup> Visentini: Virchow's Arch., 1909, cxcv, 555.

new growths; occlusion of the duct caused by calculi or by tumor and followed by degenerative changes in the gland may have the same effect. Even when the larger duct is obstructed pancreatic juice may still reach the intestine through the duct of Santorini in at least three-fourths of all individuals (see p. 17), and in many cases digestion proceeds with no manifest impairment.

*Azotorrhœa.*—In human cases *disturbance of protein digestion* may be recognizable by the presence of unaltered muscle-fibres in the fœces. In the discharges of a patient suffering with diabetes, Fles,<sup>24</sup> forty years ago, found well-preserved striated muscle-fibres, and the administration of an extract made from the pancreas of a calf caused their disappearance. Advanced chronic interstitial inflammation with atrophy was found at autopsy. Fitz<sup>25</sup> has found in the literature of the subject only eight cases in which undigested muscle-fibres in the fœces have been associated with clearly demonstrated pancreatic disease.

In a few instances disturbance of protein digestion has been tested by quantitative methods. In cases of diabetes possibly due to lesions of the pancreas Hirschfeld<sup>26</sup> recovered in the fœces 32 per cent. of the nitrogenous material ingested with the food; under normal conditions only 5 or 6 per cent. is lost. In a case of Weintraud,<sup>27</sup> where autopsy demonstrated the presence

---

<sup>24</sup> Fles: Arch. f. holländische Beit. z. Natur- und Heilk., 1864, iii, 187. Quoted by Friedreich.

<sup>25</sup> Fitz: Trans. of the Cong. of American Phys. and Surg., 1903, vi, 36.

<sup>26</sup> Hirschfeld: Zeit. f. klin. Med., 1891, xix, 294.

<sup>27</sup> Weintraud: Untersuchungen über den Stoffwechsel in Diabetes Mellitus, 1893.

of advanced chronic interstitial pancreatitis, 45.2 per cent. of proteins ingested reappeared in the fæces. A similar case is reported by Zoja.<sup>28</sup>

Sahli<sup>29</sup> has devised a means by which he is able, he believes, to test the efficiency of protein digestion in the intestine. Gelatin capsules, sufficiently hardened in formalin, are almost unaffected by gastric digestion but are rapidly dissolved by pancreatic juice. If such a capsule is filled with iodoform, the urine or saliva gives a reaction for iodine at the end of from four to eight hours. Absence of reaction, or its delayed appearance, indicates, according to Sahli, an impairment of pancreatic digestion, provided the mobility of the stomach is normal.

Intestinal disturbances may impair the value of the reaction and with diarrhœa unchanged capsules may be passed with the fæces. Sahli cites cases of pancreatic disease in which the reaction has been obtained, whereas Fromme<sup>30</sup> cites instances in which it has failed.

Adolph Schmidt<sup>31</sup> has suggested that the disappearance of nuclei in muscle-fibres passed with the fæces may be used as a test for the efficiency of pancreatic digestion. Since nuclear material is, he maintains, undigested in the stomach, persistence of nuclei indicates defective pancreatic digestion. Slightly fibrous beef is cut into small cubes 0.5 cm. across, hardened in absolute alcohol, and enclosed in silk gauze. After alcohol has been removed by washing in water during three hours, cubes are administered together with food. If muscle remains in the gauze passed with the fæces it is examined, after teasing, with the aid of acetic acid or methylene blue, or is hardened and stained with nuclear dyes. Schmidt found that muscle so prepared did not lose its nuclei in the intestinal canal of three dogs from which the pancreas had been removed. In one hundred individuals without pancreatic

---

<sup>28</sup> Quoted by Oser, *Deutsche Klinik*, 1901, p. 151.

<sup>29</sup> Sahli: *Deutsche med. Woch.*, 1897, xxiii, 6; *Lehrbuch der klinischen Untersuchungs methoden*, Leipzig, 1902.

<sup>30</sup> Fromme: *Münchener med. Woch.*, 1901, xlvi, 591.

<sup>31</sup> Schmidt, A.: *Die Funktionsprüfung des Darmes mittelst der Probekost*, Weisbaden, 1908.

disease, and in two cases of pancreatic disease with partial destruction of gland, no nuclei were found, but in two cases in which autopsy showed that pancreatic juice failed to reach the intestine nuclei persisted. In two cases of Hemmeter,<sup>32</sup> one with pancreatic cyst, the other with stenosis of the pancreatic duct caused by cholelithiasis, nuclear digestion was absent but appeared after operation had relieved the condition. In one of two cases of pancreatic disease, on the one hand, and in a case with complete achylia, on the other, Dutton Steele<sup>33</sup> found persistence of nuclei with Schmidt's test and has formed the opinion that its presence may indicate little more than diminution of digestive power.

*Steatorrhœa.*—As early as 1820 Kunzmann<sup>34</sup> observed fat in the fæces of a man who subsequently died with obstruction of the duct of Wirsung and induration of the pancreas, together with chronic jaundice. Fles, nearly fifty years later, described the case of a diabetic whose fæces contained abundant fat; when an emulsion made from the pancreas of a calf was administered, fat disappeared from the stools. In this case no jaundice was present. A considerable number of similar cases have been described, but in many other instances of grave pancreatic disease no decreased absorption of fat has been observed. Finding jaundice associated with pancreatic disease in many cases where fatty evacuations have indicated impaired assimilation of fat, Müller<sup>35</sup> has attributed the symptom to coexisting obstruction of the common bile duct. Nevertheless, experimental as well as clinical observations leave little doubt that

---

<sup>32</sup> Hemmeter: *American Med.*, 1905, ix, 393.

<sup>33</sup> Steele: *Univ. of Pennsylvania Med. Bull.*, 1906, xix.

<sup>34</sup> Kunzmann, cited by Friedreich: *Diseases of the Pancreas*, Von Ziemssen's *Practice of Medicine* [Trans.], New York, 1878, viii, 551.

<sup>35</sup> Müller, Fr.: *Zeit. f. klin. Med.*, 1887, xii, 45.

steatorrhœa may follow loss of the pancreatic secretion, and a review of cases in which steatorrhœa has been associated with pancreatic disease, made by Fitz in 1903, demonstrates the diagnostic value of the symptom but shows that it occurs in relatively few cases. He collected twenty-nine instances in which with conclusive evidence of pancreatic disease there were fatty stools; in seventeen cases there was no jaundice, the lesion of the gland being tumor, usually cancer (seven cases), calculi (six cases), cysts with atrophy (two cases), or a lesion designated fatty degeneration (two cases).

The relation of fat in the stools to chronic pancreatitis is shown by observations of Robson and Cammidge:<sup>36</sup>

	Average per ct. of fat in fœces.
Chronic pancreatitis with obstruction of common bile duct:	
18 cases with jaundice.....	43
5 cases with no jaundice.....	49
Chronic pancreatitis with no obstruction of common bile duct:	
6 cases with jaundice.....	60
27 cases with no jaundice.....	34
Normal individuals (16 instances).....	21

In some cases of pancreatic disease free fat is discharged with the fœces as an oily, yellow fluid, and the condition may be designated true steatorrhœa. In other cases the fœces are clay-colored or grayish-white, often with a metallic or asbestos-like appearance, and the increased quantity of fat is demonstrable only by micro-

<sup>36</sup> Robson and Cammidge: *The Pancreas*, Philadelphia and London, 1907.

scopic or chemical examination; such stools contain neutral fats, fatty acids, and soaps.

An abnormally large amount of fat in the intestinal discharges is, however, by no means characteristic of pancreatic disease, and may even appear in healthy individuals after the ingestion of very great quantities of fat. The bile, it is well known, is essential to normal digestion of fats, and occlusion of the bile duct is a frequent cause of fatty stools. Moreover, the absorption of fat is prevented by certain diseases of the intestine,—for example, by tuberculosis, by tuberculosis of the mesenteric glands, and even, according to Nothnagel,<sup>37</sup> by extensive catarrhal inflammation and other alterations accompanied by active peristalsis. It is only in the absence of such conditions that the presence of fat is an aid to the diagnosis of pancreatic disease.

In cases of pancreatic disease, according to Fr. Müller, the fæces may contain a diminished proportion of split-fat although the total fat is not increased. In normal fæces from 20 to 30 per cent. of fat is neutral fat and from 70 to 80 per cent. is split-fat occurring as fatty acids and soaps. In two cases of pancreatic disease studied by Müller split-fat was diminished to 22.4 and 47.2 per cent. respectively. Fitz has collected from the literature of the subject seven cases of undoubted pancreatic disease without jaundice in which analyses of fecal fat were made during life. Though there was no steatorrhœa, the proportion of neutral fat was normal or less than normal in only one case, and averaged 56.84 per cent.

---

<sup>37</sup> Nothnagel: *Erkrankungen des Darms und Peritoneum*, Handb. d. spec. Path., 1895.

A case described by Walker<sup>38</sup> shows that fatty stools may be passed during a long period with little effect upon nutrition. A man passed during twenty years colorless stools containing oily or solid fat but remained in good health, actively engaged in the practice of medicine, and died at the age of ninety years. The pancreatic duct was occluded by a calculus and the gland was almost wholly replaced by fat.

Although extirpation of the pancreas causes disturbance of digestion of carbohydrates so that an increased proportion of starch ingested with the food reappears with the fæces, determination of undigested carbohydrates has been seldom made and has acquired no significance for the diagnosis of pancreatic disease.

As a consequence of the impaired digestion which results when pancreatic juice is lost or greatly diminished in amount, much of the food material taken into the digestive tract doubtless passes through almost unchanged. Oser<sup>39</sup> has noted the voluminous character of the fecal discharges in cases of pancreatic disease, and has emphasized the diagnostic importance of this symptom.

*Pancreatic Enzymes in Treatment of Digestive Disturbances Referable to Absence of Pancreatic Juice in Intestine.*—Beneficial results have in a few instances attended efforts to supply by artificial means a deficiency of digestive enzymes consequent upon disease of the pancreas. In animals it has been found possible by the administration of fresh pancreas to increase the assimi-

---

<sup>38</sup> Walker: *Medico-Chir. Trans.*, 1889, lxxii, 257.

<sup>39</sup> Oser: *Die Erkrankungen des Pankreas*. Nothnagel's *Spec. Path. u. Ther.*, xvii, Vienna, 1898.

lation of protein and fat impaired by extirpation of the pancreas. Abelman has found that pancreas of the pig fed to dogs from which the organ has been removed aids the absorption of fat, and so favors the digestion of protein that now only 22 per cent. instead of 56 per cent. reappear in the fæces. These observations have been confirmed by Sandmeyer,<sup>40</sup> Rosenberg,<sup>41</sup> and others.

The remarkable case of Fles quoted by Friedreich has already been mentioned; disturbed digestion of protein and fat was associated with diabetes mellitus. The fresh pancreas of a calf was rubbed in a mortar with six ounces of water and the mixture strained. A part of the milky fluid obtained was taken after each meal, so that one pancreas was consumed daily. Though the patient continued upon his previous diet of bacon and fat meat, at the end of two days all fat had disappeared from the fæces and the number of undigested muscle-fibres was greatly diminished. Whenever the administration of the infusion was discontinued fat and muscle-fibres reappeared. Although glycosuria persisted unchanged, the general condition of the patient improved for a time, but death finally occurred as the result of phthisis. The pancreas was the seat of advanced sclerosis. Improved assimilation of fat after administration of fresh pancreas has been observed in a somewhat similar case by Masuyama and Schild.<sup>42</sup> In a case recorded by Langdon-Downs<sup>43</sup> fatty diarrhoea was controlled by the use of pancreatic extract; the urine contained a trace of sugar, but the condition of the pancreas could not be learned with certainty. Oser describes a case in which a tumor mass felt in the epigastrium was accompanied by jaundice; in the fæces were found undigested muscle-fibres and fat. A diagnosis of carcinoma of the pancreas was made.

---

<sup>40</sup> Sandmeyer: *Zeit. f. Biol.*, 1895, xxxi, 12.

<sup>41</sup> Rosenberg: *Arch. f. Anat. u. Physiol.*, 1896; *Physiol. Abt.*, 535.

<sup>42</sup> Masuyama and Schild: *Zeit. f. diat. u. physik. Ther.*, 1899, iii, 451.

<sup>43</sup> Langdon-Downs: *Trans. of the Clin. Soc. of London*, 1869, ii, 119.

The administration of pancreatin (Merek), one gramme every day, taken in divided doses, was followed by well-marked improvement in the digestion of fat; the patient felt stronger.

The few cases cited suggest that pancreatic extracts may be successfully used when there is evidence that digestion suffers from deficiency of pancreatic juice. When the lesion is caused by malignant growth or is associated with diabetes, though permanent benefit cannot result, it may be possible to strengthen the patient and retard emaciation.

*Pancreatic Infantilism.*—Bramwell<sup>44</sup> has described a case which he believes affords evidence that retarded development in children may be referable to pancreatic defect. A boy eighteen years old, who had suffered with diarrhœa during nine years, had exhibited arrest of physical development after the eleventh year. Following the administration of glycerin extract of pancreas there was disappearance of diarrhœa and rapid increase in weight. Thompson<sup>45</sup> described two similar cases with diarrhœa; a man of twenty-four had the appearance of a boy of ten and a boy of eighteen resembled a child of nine years. Improvement followed the use of pancreatic extract. Rentoul<sup>46</sup> records a similar condition occurring in a girl with arrested development. Direct evidence of pancreatic disease in these cases is wanting, and there is some resemblance to the condition of infantilism from chronic intestinal infection described by Herter.<sup>47</sup>

---

<sup>44</sup> Bramwell: *Scottish Med. and Surg. Jour.*, 1904, xiv, 321.

<sup>45</sup> Thompson, cited by Mayo Robson and Cammidge.

<sup>46</sup> Rentoul: *British Med. Jour.*, 1904, ii, 1011.

<sup>47</sup> Herter: *Infantilism*, New York, 1908.

Langdon-Brown<sup>48</sup> saw a boy with congenital syphilis sixteen years of age who had the appearance of a child eight or ten years old; there was diarrhœa with fatty stools. Pancreatitis believed to be syphilitic was found at autopsy.

#### CHANGES IN THE URINE REFERABLE TO PANCREATIC DISEASE.

Numerous attempts have been made to find in the urine changes which indicate pancreatic disease. The conditions with which sugar in the urine may be regarded as an index of pancreatic disease will be discussed in a subsequent chapter.

Diminution of indican and of other ethereal sulphates has been believed to give evidence that pancreatic juice fails to reach the intestine. Since products of pancreatic digestion are more readily decomposed by bacteria than unchanged protein it has been suggested that products of decomposition will reach the urine in diminished quantity when the pancreas is diseased. Gerhardi<sup>49</sup> found indican absent in the urine of an individual with acute hemorrhagic pancreatitis accompanied by symptoms of intestinal obstruction. On the contrary, no diminution of indican has been found after removal of the gland, and Northrup and Herter<sup>50</sup> noted an increased ratio of ethereal to preformed or neutral sulphates in the urine of a patient with carcinoma of the pancreas. Edsall<sup>51</sup> thinks that diminution of ethereal sulphates in

---

<sup>48</sup> Langdon-Brown: Practitioner, 1905, xxii, 233.

<sup>49</sup> Gerhardi: Virchow's Arch., 1886, cvi, 303.

<sup>50</sup> Northrup and Herter: American Jour. of the Med. Scien., 1899, cxvii, 131.

<sup>51</sup> Edsall: American Jour. of the Med. Scien., 1901, cxxi, 401.

the urine suggests pancreatic disease when conditions are present which usually cause their increase, but recognizes the fact that they may be diminished with other conditions which do not affect the gland.

Pentose has been obtained by Hammarsten<sup>52</sup> from a nucleoprotein prepared from the pancreas, and although the same substance has subsequently been split from nucleoprotein of other organs it is believed to be more abundant in the pancreas than elsewhere (Neuberg<sup>53</sup>). Pentose was found by Salkowski and Jastrowitz<sup>54</sup> in the urine of a patient with temporary glycosuria following morphine poisoning, and later Salkowski<sup>55</sup> suggested that the substance may be formed from the pancreas and indicate pancreatic disease. There has been little evidence to confirm this suggestion. Külz and Vogel<sup>56</sup> obtained reactions indicating the occurrence of pentosuria in sixty-four of eighty patients with diabetes, but Bial and Blumenthal<sup>57</sup> have failed to find pentosuria with diabetes.

Cambridge<sup>58</sup> has described a reaction to be used for the diagnosis of various forms of pancreatic disease, including acute and chronic inflammation and carcinoma.

Cambridge has used at first two reactions (reaction A and B) and has found that the precipitate obtained with

---

<sup>52</sup> Hammarsten: *Zeit. f. physiol. Chem.*, 1894, xix, 19.

<sup>53</sup> Neuberg: *Rev. d. deutsch. chem. Gesell.*, 1902, lxxxv, 147.

<sup>54</sup> Salkowski and Jastrowitz: *Cent. f. med. Wiss.*, 1892, xxx, 337, 593.

<sup>55</sup> Salkowski: *Berliner klin. Woch.*, 1895, xxxii, 364.

<sup>56</sup> Külz and Vogel: *Zeit. f. Biol.*, 1895, xxxii, 185.

<sup>57</sup> Bial and Blumenthal: *Deutsche med. Woch.*, 1901, xxvii, 349.

<sup>58</sup> Cambridge: *Lancet*, 1904; *British Med. Jour.*, 1906, i, 1150; *Surg., Gynec. and Obstet.*, 1908, vi, 22.

one (A) has been greater than that obtained with the other (B) whenever pancreatic disease has been present. Differences in the character of the precipitate aid, he has claimed, in distinguishing acute, chronic, and malignant disease of the gland. He has found that the second reaction (B) is caused by glycuronic acid and in a later publication has described a method (reaction C) in which glycuronic acid is removed by basic lead acetate. The phenylhydrazine test applied to urine previously boiled with strong hydrochloric acid and then treated with basic lead acetate causes in cases of pancreatic disease the formation of sheaves of yellow crystals which are soluble in dilute hydrochloric acid and have a melting point near  $160^{\circ}$  C. Cammidge thinks it probable that the reaction is dependent upon the presence of a substance which by hydrolysis with strong acid yields a body giving the reactions of pentose.

The reaction just described has been obtained by Cammidge in both of two cases of acute pancreatitis, in all of 65 instances of chronic pancreatitis, in 4 of 16 cases of cancer of the gland; it has been absent in all save 4 cases without pancreatitis and in the urine of 50 normal individuals. He has examined the urine from 48 diabetics and has obtained a positive result in 36 instances (75 per cent.) Eløesser<sup>59</sup> using Reactions A and B has failed to obtain the reaction of Cammidge in normal individuals; it has been present in three cases of carcinoma of the pancreas, and in four instances of chronic pancreatitis, and has been obtained in two instances of cholelithiasis and in one patient with carcinoma of the stomach. Eichler<sup>60</sup> found that the urine of normal dogs failed to give the reaction but obtained it after the experimental production of acute pancreatitis in three animals.

---

<sup>59</sup> *Loc. cit.*, p. 38.

<sup>60</sup> Eichler: *Berliner klin. Woch.*, 1907, xliv, 769.

Among 110 cases which gave no evidence of pancreatic disease Taylor<sup>61</sup> obtained a positive reaction in 9 instances. Watson<sup>62</sup> studied 121 cases; a pronounced reaction occurred in 12, of which 10 exhibited symptoms suggesting pancreatic disease, confirmed by operation or autopsy in 6 cases; a moderate reaction occurred in 16 cases, of which only six had symptoms—*e.g.*, glycosuria, gall-stones—suggesting disease of the pancreas, confirmed by autopsy in only one instance. A slight reaction was obtained in 18 cases and no reaction in 75 cases; among these cases evidence of pancreatic disease was apparently wanting.

The reaction has been obtained in a large proportion of instances in which pancreatic disease has been demonstrated or suspected. Nevertheless, the reaction may occur without pancreatic disease and is occasionally absent in association with lesion of the gland. Peculiarities of the reaction will not serve to distinguish different forms of pancreatic disease.

---

<sup>61</sup> Taylor: *Lancet*, 1906, i, 1818.

<sup>62</sup> Watson: *British Med. Jour.*, 1908, i, 858.

## CHAPTER V.

### THE PANCREAS AND CARBOHYDRATE METABOLISM.

BEFORE considering the relationship of the disease diabetes mellitus to lesions of the pancreas it is desirable to review hastily essential facts which concern this disturbance of nutrition. The literature of diabetes mellitus is voluminous. To the great clinical importance of the disease is added the interest which attaches to its bearing upon the physiology of carbohydrate metabolism. Nevertheless, observations which have been fully established are few, and though the condition is subject to varied experimentation, the results obtained have been often contradictory. The physiology of carbohydrate assimilation is not as yet explained, and the disturbances which it undergoes are equally obscure.

The normal blood, it is well known, contains a small quantity of sugar, which occurs as glucose or grape sugar, and is almost constant in amount (0.1 per cent. to 0.2 per cent.). A very minute quantity which is normally excreted by the kidneys can be demonstrated in the urine by the use of special methods, but is not detected by the tests for sugar ordinarily employed. Excretion of an increased quantity of glucose is the most conspicuous feature of diabetes mellitus, but such glycosuria is dependent upon underlying metabolic disturbances which manifest themselves by a variety of symptoms. Increased excretion of sugar by the urine can, however, occur without diabetes, and a variety of causes produce

glycosuria in the absence of the grave alterations of nutrition which characterize this disease.

Carbohydrates which are ingested with the food, and in very great part absorbed as glucose, are carried to the liver by the portal circulation, and Von Mering<sup>1</sup> has shown by direct observation that the quantity of sugar in the portal blood is increased after a meal. The liver has the power to store up sugar carried to it by the blood; Claude Bernard, and later Schöpffer,<sup>2</sup> found that sugar injected into the mesenteric vein disappears, whereas an equal quantity injected into a systemic vein, is not removed from the blood and causes glycosuria.

Claude Bernard made the important discovery that sugar carried to the liver is stored in the form of glycogen, which, when needed, is returned as glucose to the blood. After ingestion of carbohydrates the amount of glycogen in the liver increases, but disappears almost completely after prolonged abstinence from food. The liver, however, is not the only organ that stores glycogen; it is present in considerable quantity in the muscles, being increased by the ingestion of carbohydrates in large amount and diminished by hunger or by prolonged muscular exertion. The muscle cells consume carbohydrates during activity.

The ability of the liver to transform glucose into glycogen is limited, and if in a healthy man or animal a very large amount of sugar is rapidly absorbed from the gastro-intestinal tract, the quantity of sugar in the blood is increased, and is consequently excreted by the urine.

---

<sup>1</sup> Von Mering: *Arch. f. Anat. u. Physiol.*, 1877. *Physiol. Abt.*, 379.

<sup>2</sup> Schöpffer: *Arch. f. exper. Path. u. Pharm.*, 1873, i, 73.

The liver, therefore, acting as a storehouse prevents the quantity of sugar in the blood from rising above a relatively fixed amount (0.1 to 0.2 per cent.); but if within a given time the capacity of the liver is exceeded, sugar accumulates in the blood and is thrown off by the kidneys; *alimentary glycosuria* preceded by alimentary hyperglycæmia follows, both being the result of the limited capacity of the liver and certain other organs to store sugar absorbed from the food. This limit varies in different individuals and is diminished under certain pathological conditions.

A normal individual is able to assimilate from one hundred and fifty to two hundred and fifty grammes of glucose taken after fasting, and no sugar appears in the urine. Under certain conditions, notably in many cases of exophthalmic goitre and with certain neuroses, glycosuria follows the ingestion of much smaller quantities. Diseased conditions of the liver might be expected to favor the occurrence of this form of glycosuria, and in some cases of cirrhosis alimentary glycosuria is readily produced, but the result of such investigations have been by no means constant. Minkowski<sup>3</sup> has shown that alimentary glycosuria may occur in dogs after partial extirpation of the pancreas, and Wille<sup>4</sup> and G. Hoppe-Seyler<sup>5</sup> have demonstrated its association with certain lesions of the human gland.

Temporary glycosuria follows a variety of injuries to the nervous system; the so-called *diabetic puncture* of Claude Bernard is the best-known illustration. Destruc-

---

<sup>3</sup> Minkowski: Arch. f. exper. Path. u. Pharm., 1893, xxxi, 85.

<sup>4</sup> Wille: Deutsches Arch. f. klin. Med., 1899, lxxiii, 546.

<sup>5</sup> Hoppe-Seyler, G.: *Ibid.*, 1904, lxxxii, 119.

tion of the gray matter in the floor of the fourth ventricle, a few millimetres above the point of the calamus scriptorius, in rabbits, dogs, birds, and frogs, is followed by glycosuria. In rabbits, within one to three hours after this operation, sugar appears in the urine, and may constitute as much as 6 per cent.; excretion of sugar continues only five or six hours. The condition is associated with an increase of the sugar in the blood, and a variety of experiments indicate that the puncture causes a discharge of glycogen from the liver and probably from the muscles and other organs into the blood, but the evidence upon this point is in part conflicting. In animals deprived of glycogen by prolonged hunger the puncture is ineffectual, while after section of all nerves to the liver glycosuria is trivial.

A variety of other operations upon the nervous system have been followed by temporary glycosuria presumably analogous with that of C. Bernard's puncture; glycosuria, for example, has been observed after extirpation of the superior cervical ganglion, after section and stimulation of the spinal cord at the level of the brachial plexus, after stimulation of the central stump of the vagus when cut, and after section of the sciatic nerve and stimulation of its central end.

One form of glycosuria which has been the subject of varied experimentation is unaccompanied by an increase of sugar in the blood. Following the administration by feeding or injection of the glucoside *phlorhizin*, glycosuria occurs in man and in lower animals and persists often twenty-four hours or longer, the amount of sugar excreted greatly exceeding that contained in the glucoside. The quantity of sugar in the blood does not

increase, even though excretion of sugar be prevented by extirpation of the kidneys or ligation of the ureters. Hence it is believed that the poison produces some change as the result of which the kidneys are no longer able to hold back the sugar normally present in the blood. Minkowski has suggested that the glucoside phlorhizin is split by the kidney into a substance, phloretin, and a sugar closely resembling glucose; the latter is excreted, but phloretin is retained and unites with more glucose, which in turn is separated by the kidneys.

Asphyxiation, poisoning with carbon monoxide, morphine, curare, and a variety of substances, cause glycosuria the pathogenesis of which is not understood. Noteworthy in this connection is the experimental glycosuria produced by Herter and Richards with adrenalin chloride, potassium cyanide and a variety of other reducing substances (see p. 116). In all such instances the condition is temporary and thus distinguishable from the permanent glycosuria which in man is associated with the constitutional disease diabetes mellitus.

Permanent glycosuria accompanied by symptoms comparable to those occurring in human diabetes can be produced by but one experimental means. The investigations of Von Mering and Minkowski<sup>6</sup> stand in importance next to those of Claude Bernard. They have demonstrated that the organ is essential to normal carbohydrate metabolism and its extirpation is followed by a condition which reproduces in animals diabetes mellitus.

---

<sup>6</sup> Von Mering and Minkowski: Arch. f. exper. Path. u. Pharm., 1890, xxvi, 371.

*Extirpation of the Pancreas.*—Observations of Von Mering and Minkowski, later amplified by Minkowski, have shown that complete removal of the pancreas in dogs is followed within twenty-four hours by the appearance of sugar in the urine. The quantity of sugar gradually increases, and usually reaches a maximum on the third day, when it may form from 8 to 10 per cent., even though no carbohydrates have been taken into the gastrointestinal tract. Glycosuria continues and is associated with a corresponding hyperglycæmia. Sugar accumulates in the blood where it may constitute as much as 0.5 per cent.; sugar present in excess in the blood is excreted by the kidneys. Glycogen disappears almost completely from the liver and other organs.

Symptoms analogous to those of human diabetes occur, and there is greatly increased appetite and excessive thirst, accompanied by increase in the amount of urine; gradual emaciation and progressive weakness precede death, which occurs several weeks after the operation. Acetone and diacetic and oxybutyric acid have been found in the urine. Minkowski observed that grape sugar taken with the food is completely excreted by the urine. Moreover, since glycosuria continues even when the diet is entirely free from carbohydrates, sugar is doubtless formed within the body; the amount bears a constant ratio (2.8:1) to the quantity of nitrogen eliminated. This constant ratio is best explained by supposing that the total quantity of sugar formed in the body from protein, after removal of the pancreas, is excreted by the kidneys. Immediately before the fatal termination of the disease, when emaciation and weakness are extreme, and particularly with the onset

of complications,—for example, suppurative peritonitis as a consequence of the operation,—sugar may disappear from the urine. A similar phenomenon is observed in human diabetes, and is probably due to some interference with the absorption of sugar or with its production within the body from proteins.

Partial removal of the pancreas—if a considerable part, a fourth or a fifth (in the dog), remains—is not followed by diabetes; but a smaller part—for example, an eighth or a twelfth—does not suffice to prevent its onset. In such case the severity of the disease is variable, and disturbed metabolism may be indicated only by an intolerance of the organism for sugar, a very small quantity taken as food causing glycosuria. This alimentary glycosuria may therefore indicate partial insufficiency of the pancreas.

Experiments, with negative results, have been undertaken to show that injury to the organs surrounding the pancreas, particularly to the nerves and ganglia, is responsible for the resulting disturbances of metabolism. Slight injury to the pancreas not infrequently causes transient glycosuria, but never diabetes. That the disease is not caused by inhibition of the pancreatic secretion or by its removal from the intestine is shown by the absence of glycosuria after ligation of the pancreatic duct or after the formation of a pancreatic fistula; though the pancreatic juice fails to reach the intestine diabetes does not result.

An exception to the foregoing statements is perhaps the observation of E. Pflüger<sup>7</sup> who has claimed that re-

---

<sup>7</sup> Pflüger, E.: Pflüger's Arch., 1907, cxviii, 267; cxix, 227; 297.

moval of the duodenum or destruction of its nervous connection with the pancreas is followed by fatal diabetes. Ehermann<sup>8</sup> has shown that such operations in warm-blooded animals are not followed by diabetes.

The observations of Von Mering and Minkowski on dogs have been confirmed by a very large number of experiments, and extended observations indicate that they are applicable to all classes of vertebrates. In rare instances discordant results have been obtained, but have doubtless been due to the mechanical difficulty of completely removing the gland. Diabetes has been produced in cats and in pigs by Minkowski. Both Weintraud<sup>9</sup> and Kausch<sup>10</sup> have removed the gland from various birds,—namely, ducks, geese, falcons, buzzards, and ravens,—and have noted glycosuria persisting until death. Of considerable interest, however, is the observation of Kausch that in geese and ducks the lesion is not constantly followed by glycosuria, although the quantity of sugar in the blood is increased as in other species; it appears that sugar is not readily excreted by the kidneys of these animals. Glycosuria with fatal termination has been shown to follow the operation in frogs and turtles (Aldehoff<sup>11</sup>), and in eels (Capparelli<sup>12</sup>).

The results of experimental studies just cited are applicable to man. Franke<sup>13</sup> found the head of the pancreas in a woman sixty-six years of age invaded by malignant growth and with much difficulty removed, he be-

---

<sup>8</sup> Ehermann: *Ibid.*, 1907, cxix, 295.

<sup>9</sup> Weintraud: *Arch. f. exper. Path. u. Pharm.*, 1894, xxxiv, 303.

<sup>10</sup> Kausch: *Ibid.*, 1896, xxxvii, 274.

<sup>11</sup> Aldehoff: *Zeit. f. Biol.*, 1891, xxviii, 293.

<sup>12</sup> Capparelli: *Arch. ital. de biol.*, 1894, xxi, 398.

<sup>13</sup> Franke: *Arch. f. klin. Chir.*, 1901, lxiv, 364.

lieved, the entire gland. Sugar appeared in the urine eighteen days later, the amount reaching 3 per cent.; death occurred after six months. Zweifel<sup>14</sup> recorded the removal of a pancreatic cyst together with the splenic part of the gland six centimetres in length; the part remaining was three centimetres in length. On the tenth day after operation sugar appeared in the urine, persisted three days and disappeared although the diet was unchanged; sugar reappeared on the fifteenth day and again on the twenty-first day, but was absent two months after operation. Hahn<sup>15</sup> states that he has found sugar in the urine after removal of a small piece of the pancreas.

The following case for which I am indebted to the kindness of Dr. David Marine, who performed the autopsy, shows that as much as one-third of the pancreas may be insufficient to prevent the onset of glycosuria.

A well-developed, well-nourished woman, forty-seven years of age, had complained of pain referred to the inner side of the thighs and more severe on the left side. The urine had contained red blood-corpuseles and pus cells and catheterization of the ureters showed that these cells were from the left kidney. Examination of the abdomen showed only slight tenderness. An incision into the abdominal cavity was made through the median line and the appendix which was bound by adhesions was removed. The uterus which was retroflexed was suspended from the abdominal wall. On the left side could be felt what was thought to be a sclerotic and atrophic kidney with a stone in its pelvis; the right kidney, the gall-bladder, the stomach and the pancreas were felt, it was thought, and appeared normal. The left kidney was sought through an oblique incision in the back and the peritoneal

---

<sup>14</sup> Zweifel: *Cent. f. Gynæc.*, 1894, xviii, 641.

<sup>15</sup> Hahn: *Cent. f. Chir.*, 1894, xxi, Beilage zu No. 30, 57.

cavity was entered. A part of the pancreas mistaken for an atrophic kidney was removed; there was considerable hemorrhage, and the wound was packed with gauze. Examination showed that the pancreatic tissue removed was normal and constituted two-thirds of the gland. Several hours after operation the pulse became rapid (156 per minute) and there was considerable pain, nausea and vomiting. On the following day there was violent paroxysmal epigastric pain uncontrolled by morphia. Vomiting ceased and pain became less. There was delirium and elevation of temperature (102.8° F.). The temperature rose further (104.4° F.) and death occurred three days after operation.

Urine before operation, sp. gr. 1010, contained no sugar and a trace of albumin. Eight hours after operation there was slight reduction of Fehling's solution and a moderate amount of albumin. One day after operation (sp. gr. 1015 to 1021) there was slight reduction and a trace of albumin; two days after operation there was moderate reduction of Fehling's solution and the polariscope indicated an increase of sugar during the day from 0.3 to 0.7 per cent.; three days after operation (sp. gr. 1020 to 1021) there was moderate reduction, and on two examinations 0.6 and 1.4 per cent. of sugar.

Partial autopsy has been made through the abdominal incision. The peritoneal cavity contains bloody, slightly fetid fluid. The omentum is attached to the wound of the pancreas and in immediate contact with the gland contains minute yellowish-white foci of fat necrosis. The splenic part of the pancreas has been removed and the tissue in the wound is discolored, soft, and cheesy. The duodenal end of the pancreas measures about 5.5 cm. in length and has formed one-third of the whole gland; the ducts are intact.

The left kidney is converted into a thin-walled sac and the immensely distended pelvis contains opaque fluid. Blocking the pelvic end of the ureter is a calculus measuring 0.5 by 1 cm.

*Anatomical Diagnosis.*—Left hydronephrosis with renal calculus blocking the pelvic end of the ureter; wound of pancreas and absence of two-thirds of the gland; beginning peritonitis; acute splenic tumor.

*How Does the Pancreas Influence Carbohydrate Metabolism?*—The pancreas of vertebrates is essential to

carbohydrate metabolism, and removal or destruction is followed by the accumulation of sugar in the blood and its excretion by the kidneys. How does the pancreas influence metabolism? Abundant observation has demonstrated that injury to the nerves of the pancreas is not responsible and failure of the pancreatic juice to reach the intestine is not its cause, for ligation of ducts is not followed by diabetes. Furthermore, after partial removal of the gland its splenic extremity, alone remaining, may be transplanted into the subcutaneous tissue without complete destruction of its vascular connections; the nerves of the resected part are severed and the pancreatic juice is wholly lost, yet glycosuria does not follow. If now the transplanted part be removed, diabetes ensues.

The pancreas may influence carbohydrate metabolism in one of two ways: the organ may furnish something essential to normal nutrition, an internal secretion (to be distinguished from the pancreatic juice, the external secretion), or the gland may destroy some product which accumulates in the body and hinders normal assimilation of sugar.

Lepine<sup>16</sup> has believed that he is able to demonstrate in the blood a glycolytic enzyme capable of transforming sugar and destroyed by a temperature of 54° C. He claims that it is present in normal blood, but absent in that of lower animals deprived of the pancreas or in human beings suffering with diabetes. This enzyme, he thinks, is formed in the pancreas, from which it is carried by the lymph or blood to the tissues and there

---

<sup>16</sup> Lepine: *Rev. de méd.*, 1894, xiv, Oct. 10.

further carbohydrate assimilation. The basis of Lepine's theory is the observation of Claude Bernard that sugar disappears from drawn blood; Lepine believes that this glycolysis is diminished in diabetic patients and in dogs from which the pancreas is removed. Almost all observers who have repeated his experiments have obtained negative results. The success of thyroid therapy in the treatment of diseases presumably due to the absence of an internal secretion produced by the thyroid gland has pointed the way to numerous analogous experiments upon animals with diabetes, but glycosuria has not been prevented nor diminished by the administration of products obtained from the pancreas.

Extracts prepared from the pancreas do not decompose glucose, and evidence that the pancreas furnishes a glycolytic enzyme to the blood is lacking. Nevertheless, the gland may furnish some substance which increases glycolysis in other organs. Rahel Hirsch<sup>17</sup> found that extract of liver caused slight glycolysis whereas addition of pancreas was followed by noteworthy increase of glycolytic action.

Studies of Otto Cohnheim<sup>18</sup> have suggested an hypothesis to explain the relation of the pancreas to the metabolism of sugar. It is well known that the muscles are capable of assimilating and destroying sugar, yet extracts prepared from muscles have slight or no glycolytic activity; but, whereas juice expressed from muscle causes little decomposition of glucose and the juice expressed from pancreas does not cause glycolysis, a mix-

---

<sup>17</sup> Hirsch: Hofmeister's Beit., 1903, iv, 535.

<sup>18</sup> Cohnheim, O.: Zeitsch. f. physiol. Chem., 1903, xxxix, 336; 1904, xlii, 401; 1905, xliii, 547; 1906, xlvii, 253.

ture of juice from the two organs, according to Cohnheim, has the power to break down sugar, so that it is no longer recognizable by its reducing action. Glycolysis is accomplished by neither organ acting by itself, but the two in combination are effective. The muscle, Cohnheim finds, contains a labile enzyme, extraction of which requires considerable care. The activating substance of the pancreas does not possess the properties of an enzyme and is not destroyed by heat. It is soluble in water and in alcohol and may be preserved as an alcoholic extract. Cohnheim suggests that there is an analogy between enzyme of muscle and activator of pancreas on the one hand, and complement and amboceptor on the other; the analogy is strengthened by the observation that increase of pancreatic activator above a certain optimum may diminish glycolysis caused by a given quantity of enzyme.

Claus and Embden<sup>19</sup> have failed to confirm the observations of Cohnheim, and attribute to bacterial contamination the glycolysis which he has found. Cohnheim has maintained that action of bacteria has been excluded. Hall,<sup>20</sup> confirming the work of Cohnheim, found that extracts of pancreas and muscle in combination destroyed glucose, but failed to decompose levulose. The complexity of the subject is increased by the claim of Stocklasa<sup>21</sup> that all organs, including the pancreas, contain glycolytic enzyme; numerous observers have failed to confirm his

---

<sup>19</sup> Claus and Embden: Hofmeister's Beit., 1905, vi, 214, 343.

<sup>20</sup> Hall: American Journal of Physiol., 1907, xviii, 283.

<sup>21</sup> Stocklasa: Chem. Berich., 1903, xxxvi, 622, 4058; 1905, xxxviii, 664.

opinion. De Meyer<sup>22</sup> has found a pancreatic activator, but has maintained that glycolytic enzyme is formed, not in the muscle, but in the leucocytes.

Since sugar is excreted in the urine after removal of the pancreas, even though carbohydrates are not taken with the food, it is evident that glucose can be formed within the body. Since the amount of sugar in the urine bears a constant ratio to the nitrogen excreted, there can be little doubt that sugar is formed from proteins, and that the entire amount of sugar thus formed is unassimilated and excreted. An additional fact of considerable interest is the disappearance of glycogen from the liver and muscles after extirpation of the pancreas. Removal of the gland renders the tissues unable to take up and assimilate sugar.

This inability of the liver to transform sugar into glycogen applies to glucose, but not to the isomeric levorotatory sugar levulose, for after ingestion of the latter glycogen is found in the liver. Schmiedeberg has suggested that in diabetes glucose in the blood is combined with some substance which prevents its assimilation by the tissues. The tissues are nevertheless able to take up the molecule of levulose. A somewhat analogous explanation of phlorhizin diabetes advanced by Minkowski has already been mentioned.

*Effect of Adrenal and Thyroid Gland upon the Metabolic Function of the Pancreas.*—The occurrence of diabetes mellitus in association with exophthalmic goitre has suggested a relationship between the thyroid gland and the pancreas. The production of glycosuria by ad-

---

<sup>22</sup> De Meyer: Ann. de l'Inst. Pasteur, 1908, xxii, 778.

ministration of adrenalin has suggested that the adrenal glands may influence carbohydrate metabolism. Experimental data concerning the relationship of these three organs are difficult to interpret.

By injecting extracts made from the adrenal gland into the subcutaneous tissue or into veins Blum<sup>23</sup> has produced temporary glycosuria. Herter and Richards<sup>24</sup> have found that adrenalin chloride causes more marked glycosuria when injected into the peritoneal cavity than when administered by other methods; 10 per cent. of sugar may be present in the urine, and glycosuria usually continues during twenty-four hours. By merely painting the surface of the pancreas with the extract a similar effect is produced. Adrenalin, according to Zuelzer<sup>25</sup> and Metzger,<sup>26</sup> causes hyperglycemia, and excess of sugar in the blood is followed by glycosuria.

In animals deprived of the thyroid gland Eppinger, Falta and Rudinger<sup>27</sup> have found that adrenalin fails to cause glycosuria, but if such animals are treated with thyroid extract or with idothyroin, adrenalin has the usual effect. Zuelzer<sup>28</sup> on the one hand has failed to obtain glycosuria with adrenalin if pancreatic tissue has been simultaneously administered; on the other hand, Eppinger, Falta and Rudinger claim that the administration of adrenalin to animals derived of the pancreas increases the excretion of sugar.

---

<sup>23</sup> Blum: *Deutsches Arch. f. klin. Med.*, 1901, lxxi, 146.

<sup>24</sup> Herter and Richards: *Med. News*, 1902, lxxx, 201.

<sup>25</sup> Zuelzer: *Berliner klin. Woch.*, 1901, xxxviii, 1209.

<sup>26</sup> Metzger: *München med. Woch.*, 1902, xlix, 478.

<sup>27</sup> Eppinger, Falta and Rudinger: *Zeit. f. klin. Med.*, 1908, lxvi, 1.

<sup>28</sup> Zuelzer: *Verhandl. d. 24 Kong. f. inn. Med.*, 1907, 258.

Although adrenalin has no effect upon the pupil of normal animals it causes mydriasis, Loewi<sup>29</sup> has shown, in animals deprived of the pancreas; this phenomenon is doubtless produced by action upon the sympathetic nervous system. Eppinger, Falta and Rudinger have found similar contraction of the pupil after injection of thyroid extract into normal dogs.

By ingenious speculations Eppinger, Falta and Rudinger have attempted to explain the phenomena which have been mentioned, and to define the relationship of the pancreas, adrenal, and thyroid gland. Internal secretion furnished by the thyroid stimulates, they suggest, the activity of the adrenal, and the secretion of the adrenal stimulates the thyroid; both organs inhibit the action of the pancreas so that with the increased activity of either the pancreas exhibits diminished ability to control the assimilation of sugar. Administration of adrenalin to a normal animal, according to this hypothesis, increases the inhibition of the pancreas and glycosuria results, but if adrenalin is given on the one hand to an animal which has been deprived of its thyroid gland, or on the other hand, to an animal which receives at the same time pancreatic tissue (Zuelzer) there is no glycosuria. Internal secretion of the pancreas inhibits the excitability of the sympathetic nervous system, according to Eppinger, Falta and Rudinger, and secretion of the adrenal and of the thyroid increases its excitability. In consequence of heightened excitability following removal of the pancreas adrenalin causes contraction of the pupil.

---

<sup>29</sup> Loewi: Arch. f. exper. Path. u. Pharm., 1908, lix, 83.

## CHAPTER VI.

### HEMORRHAGIC NECROSIS OF THE PANCREAS (ACUTE HEMORRHAGIC PANCREATITIS).

ACUTE inflammation of the pancreas has attracted much attention, yet the nature and the cause of the lesions which accompany it have been obscure. While suppurative inflammation resembles abscess in other organs, so-called hemorrhagic and gangrenous pancreatitis finds little analogy in the liver, spleen, kidneys, or indeed in the salivary glands, which resemble in many respects the pancreas. The difficulty of deciding what shall be regarded an inflammatory process is here encountered; distinctions between hemorrhagic pancreatitis and hemorrhage into the organ, though usually emphasized in writings upon diseases of the gland, are not clearly drawn.

*Varieties of Acute Pancreatitis.*—A well-defined classification of acute lesions of the gland was introduced by Fitz,<sup>1</sup> and was based upon an analysis of cases studied by himself, as well as of those recorded in the literature. So-called hemorrhagic pancreatitis, had already been observed by Rokitansky<sup>2</sup> and by Klebs.<sup>3</sup> Both Friedreich<sup>4</sup> and Fitz recognized pancreatic hemorrhage as an independent condition,—a lesion unaccompanied by inflammatory changes. Fitz found that acute

---

<sup>1</sup> Fitz: *Acute Pancreatitis*. *Med. Record*, 1889, xxxv, 197, 225, 253.

<sup>2</sup> Rokitansky: *Lehrbuch der path. Anat.*, Vienna, 1863, iii, 313.

<sup>3</sup> Klebs: *Handbuch d. path. Anat.*, Berlin, 1869, i, 271.

<sup>4</sup> *Loc. cit.*, p. v.

inflammatory alterations of the pancreas fell into three groups which, to emphasize their conspicuous feature, he designated hemorrhagic, gangrenous, and suppurative pancreatitis.

Hemorrhagic pancreatitis, described by Fitz, occurs most frequently in those who have had previous attacks of "gastric or gastroduodenal dyspepsia." It begins with intense pain in the upper abdomen, followed by vomiting and not infrequently by slight swelling of the epigastrium, associated with tenderness and accompanied by obstinate constipation. The temperature is normal or subnormal, and symptoms of collapse precede death, which usually occurs between the second and fourth days. The pancreas is found to be enlarged, and its interstitial tissue, as well as the tissues in its neighborhood, is infiltrated with blood. Microscopic examination shows the presence of cellular and fibrinous exudates together with necrosis of the parenchyma. In the fat of the omentum and of the subperitoneal tissue are the disseminated foci of necrosis to which Balser has directed attention.

Gangrenous pancreatitis, according to Fitz, though it may follow other conditions, is usually the result of hemorrhagic pancreatitis, and in at least half of the recorded cases evidence of previous hemorrhage is present in the altered gland. The clinical symptoms of the two conditions resemble one another closely, but where the pancreas is found to be gangrenous the illness has been of longer duration, proving fatal at the end of several weeks. The organ is enlarged, often soft and friable, and of a color which varies from mottled red and gray to dark brown or black; by extension of the gan-

grenous process to the tissues about the organ almost complete sequestration may result. Since the gangrenous pancreas lies in the posterior wall of the lesser peritoneal cavity, peritonitis ensues, and this cavity is converted into an abscess containing pus and necrotic material. In some cases the completely sequestered pancreas, attached by only a few shreds of tissue, is surrounded by purulent fluid. Communication may be formed with the intestine, and in two cases described by Chiari<sup>5</sup> a large mass of necrotic material discharged by the rectum was recognized to be gangrenous pancreatic tissue. Disseminated fat necrosis, to be described later, accompanies the gangrenous lesion.

Suppurative pancreatitis, described by Fitz, resembles suppurative inflammation of other organs; the gland may contain abscess cavities of various sizes, the organ is enlarged and the peripancreatic tissue is indurated. Suppurative inflammation rarely pursues an acute course, but persists for weeks or months, and abscess cavities may discharge into the stomach or duodenum, or, rupturing into the lesser peritoneal cavity, may here produce an abscess cavity of great size. Fitz has pointed out that disseminated fat necrosis is uncommon with suppurative pancreatitis though almost constantly found in association with the hemorrhagic and gangrenous lesions.

The lesion usually described as acute hemorrhagic pancreatitis has not the characters of an inflammatory process. Wide-spread necrosis of pancreatic parenchyma is primary and such inflammatory changes as occur are

---

<sup>5</sup> Chiari: Wiener med. Woch., 1880, xxx, 139, 164.

found only at the margin of the necrotic tissue. A clearer understanding of the nature of the disease would doubtless result if the term *hemorrhagic necrosis of the pancreas* were used in place of acute hemorrhagic pancreatitis.

Similar lesions do not occur in other organs save, perhaps, in the stomach, where impaired vitality of the mucosa is followed by necrosis and subsequent ulceration, often with hemorrhage brought about by action of the gastric juice upon the injured tissue. The analogy is significant for the pancreas, too, contains an active proteolytic enzyme which unrestrained is capable of destroying tissue. The peculiar necrosis which affects the pancreatic parenchyma is doubtless referable to the trypsin which is contained in the pancreatic cells. Numerous studies have clearly demonstrated that the necrosis of fat which accompanies hemorrhagic necrosis of the pancreas is caused by a second enzyme, the fat-splitting enzyme of the pancreatic juice.

Recognition of the truth that necrosis of tissue is the essential feature of the acute hemorrhagic lesion, explains the relation of hemorrhagic to gangrenous pancreatitis. In individuals who die within from one to three or four days after onset of the symptoms, the gland is swollen and hemorrhagic, but when death occurs after a longer period there are changes in the hemorrhagic tissue so that it becomes black and gangrenous in appearance. It has been customary to describe as separate diseases hemorrhagic and gangrenous pancreatitis, whereas in both the underlying change is death of pancreatic parenchyma, and the two conditions represent two stages of the same lesion.

*Pancreatic Hemorrhage.*—Hemorrhage occurring into the substance of the gland may be caused by a variety of factors which present nothing peculiar to the organ. Vessels may be ruptured by traumatism, and here, as elsewhere, hemorrhage may accompany tumors; the contents of pancreatic cysts are not infrequently bloody. Hemorrhage of such character, as well as the minute hemorrhages observed in association with purpura, eclampsia, and acute infectious diseases are dependent upon factors which determine their occurrence in other organs and have little in common with the peculiar hemorrhagic lesion to which the pancreas is subject.

Hemorrhage into the pancreas occurring in an individual previously supposed to be in good health may be the only lesion found to explain the fatal termination of an illness lasting only a few hours. The literature of pancreatic affections contains numerous examples of so-called pancreatic apoplexy of which the sudden onset and rapidly fatal end suggest an analogy with the more frequent cerebral hemorrhage. The quantity of blood escaping from the vessels does not bear a direct relation to the severity of the lesion. Such a condition has been described by Spiers,<sup>6</sup> in 1866, and since, other writers, notably Zenker,<sup>7</sup> Prince,<sup>8</sup> Draper,<sup>9</sup> and Seitz,<sup>10</sup> have recorded additional instances.

In some cases cited as examples of pancreatic hemor-

---

<sup>6</sup> Spiers: Quoted by Seitz.

<sup>7</sup> Zenker: Berliner klin. Woch., 1874, xi, 611; Deutsche Zeit. f. prakt. Med., 1874, 351.

<sup>8</sup> Prince: Boston Med. and Surg. Jour., 1882, cvii, 28, 55.

<sup>9</sup> Draper: Boston Med. and Surg. Jour., 1886, cxv, 393.

<sup>10</sup> Seitz: Zeit. f. klin. Med., 1892, xx, 1, 203, 311.

rhage it is improbable, as Seitz points out, that the pancreatic lesion has been in reality the cause of death, and in the cases described by Reubold and Rehm, after death from poisoning with morphia, after strangling, or after hemorrhage from the femoral vein, the interstitial tissue of the gland and its immediate vicinity has been the seat of such moderate hemorrhagic infiltration that extravasation of blood may have been the result of post-mortem self-digestion; Chiari has described such insignificant hemorrhage occurring perhaps just before death (see p. 86). There remains, however, a considerable number of cases where, following sudden death, a careful autopsy has disclosed no noteworthy disease other than an extensive hemorrhagic lesion of the pancreas.

Klebs thought that hemorrhage occurring in the absence of inflammatory changes might be due to corrosive action of the pancreatic juice upon the blood-vessels. Fitz recalls the observation that fluids injected into the arteries of a dead body are prone to escape in the neighborhood of the pancreas. It has been maintained by Seitz that in a limited number of cases arterial sclerosis explains the occurrence of hemorrhage, but the only evidence in support of this supposition is the occasional association of the two conditions.

The explanation of hemorrhage secondary to inflammatory changes in the gland has been much discussed. What has been designated acute inflammation is accompanied by escape of blood into the interstitial tissue, and the condition has been supposed to resemble hemorrhagic inflammation in other organs. Inflammation is regarded as primary and the hemorrhage its consequence. When both inflammation and hemorrhage coexist, the difficulty

of deciding which preceded the other is obviously great,—for should extensive hemorrhage occur, proximity to the intestine exposes the hemorrhagic tissue to infection and consequent suppuration. Both hemorrhage and acute inflammation being present, it is not possible to determine which antedated the other.

Seitz (1892), reviewing older literature and citing the cases of Loschner, Oppolzer, Amidon, Osler and Hughes, Hirschberg and Birch-Hirschfeld, finds no evidence of pancreatic inflammation, and concludes that inflammation is not a demonstrable cause of bulky hemorrhage into the organ. Nevertheless the occurrence of necrosis of pancreatic parenchyma in these cases cannot be excluded. Recent literature of the subject contains no well-defined instance of simple pancreatic hemorrhage. In a case of Simpson,<sup>11</sup> described as an instance of pancreatic hemorrhage, a gall-stone has been found lodged at the duodenal orifice of the common bile duct. Since a stone in this position, as it will be shown, may cause hemorrhagic necrosis of the pancreas, the case cannot be regarded as an example of simple hemorrhage. Pancreatic apoplexy analogous to cerebral apoplexy and referable perhaps to arterial disease occurs rarely if at all, and described instances are doubtless examples of hemorrhagic necrosis of the gland.

*Experimental Hemorrhagic Necrosis.*—So-called hemorrhagic pancreatitis has been produced experimentally by the injection of a variety of irritating substances into the pancreas. Thiroloix<sup>12</sup> injected several drops of deliquescent chloride of zinc into the duct of

---

<sup>11</sup> Simpson: *Edinburgh Med. Jour.*, 1897, ii, 245.

<sup>12</sup> Thiroloix: *Thesis*, Paris, 1892.

Wirsung in a dog. Death occurred suddenly after a short interval, and the pancreas was represented by what appeared to be a blackish clot. Hlava<sup>13</sup> injected artificial gastric juice into the pancreatic duct. This fluid, containing hydrochloric acid in the proportion of one to one thousand caused death in three days; the pancreas was hyperæmic and in the fat of the omentum and mesentery were numerous foci of necrosis. Death on the tenth day followed the injection of five cubic centimetres of artificial gastric juice with hydrochloric acid, four to one thousand; the pancreas was the seat of hemorrhagic infiltration, and the omentum and mesentery contained foci of fat necrosis. He suggests that in human cases hyperacid gastric juice may be forced by antiperistaltic action of the intestine into the pancreatic duct, thus causing the condition. Hlava has produced a hemorrhagic lesion of the gland by injecting cultures of *Bacillus coli*, *Bacillus lactis aërogenes*, and *Bacillus capsulatus* of Friedländer, but thinks that the change is caused by the acid products of these organisms.

By the injection of the ferment, papaine (0.2 Gm. in 30 c.c. of water), into the pancreatic duct of a dog, Carnot<sup>14</sup> caused the death of the animal in twenty-five hours; the pancreas was everywhere infiltrated with blood, but there was no necrosis of fat. Smaller doses did not produce hemorrhagic lesions. The same writer produced so-called hemorrhagic pancreatitis by the injection of the diphtheria toxin into the pancreatic duct of a rabbit.

---

<sup>13</sup> Hlava: Bull. internat. de l'Acad. des sciences de Bohême, 1898; Arch. Bohém, 1890, iv, 139. (Cited by Katz and Winkler, *loc. cit.*, p. 191.)

<sup>14</sup> Carnot: Thesis, Paris, 1898.

Varied and successful experiments have been performed by Flexner.<sup>15</sup> Hydrochloric acid varying in strength in different instances from one-half of 1 to 2 per cent., and in amount from three to eight cubic centimetres, injected into the pancreatic duct, caused in six of ten experiments hemorrhagic lesions of the gland, accompanied in five instances by focal fat necrosis. Such lesions were characterized by hemorrhage, necrosis of the parenchyma, and accumulation of inflammatory products. In three experiments death followed the operation within twenty-four hours. In four experiments purulent or chronic interstitial inflammation resulted. Hemorrhagic lesions were similarly produced in dogs by nitric acid and chromic acid. In a second series of experiments sodium hydroxide (2.5 to 5 c.c. of solutions varying in strength from 1 to 2 per cent.) was employed. Hemorrhagic lesions resulted in three experiments and were accompanied by fat necrosis in two. Suspensions of bacteria were used in a third series. Hemorrhagic lesions were caused by *Bacillus pyocyaneus* and by *Bacillus diphtheriæ*. In two experiments the lesion followed the injection of 5 c.c. of a 2 per cent. solution of formalin into the duct and was associated with fat necrosis. Flexner and Pearce<sup>16</sup> have subsequently shown that degeneration, hemorrhage, and emigration of leucocytes develop with great rapidity, occurring within one to two hours after the introduction of such an irritant as artificial gastric juice.

---

<sup>15</sup> Flexner: Contributions to the Science of Medicine. Dedicated to William H. Welch. Johns Hopkins Hosp. Rep., 1900, ix, 743.

<sup>16</sup> Flexner and Pearce: Univ. of Pennsylvania Med. Bull., 1901, xiv, 193.

Gulecke,<sup>17</sup> and Sailer and Speese<sup>18</sup> have produced in dogs similar quickly fatal lesions with fat necrosis by injection of sweet oil into the pancreatic duct immediately followed by ligation of the duct; fatty acids and sodium soaps of these acids have been successfully used, but glycerin is ineffective (Hess<sup>19</sup>).

It is difficult to define any common character of these substances, save their power to injure the tissue with which they come into contact. A variety of bland substances have been tested with negative result; these include blood, blood serum (Flexner and Pearce), agar-agar (Flexner<sup>20</sup>), paraffin (Thirolloix, Hess), emulsion of starch (Hess).

Since active trypsin is not found in the normal gland attempts have been made to produce the lesion by activating with enterokinase the trypsinogen which is present, but Pólya<sup>21</sup> and Williams and Busch<sup>22</sup> have failed to produce hemorrhagic necrosis by injection of enterokinase into the pancreatic duct.

#### ETIOLOGY.

Hemorrhagic necrosis of the pancreas occurs more frequently in men than in women. Of 121 cases of so-called hemorrhagic and gangrenous pancreatitis collected

---

<sup>17</sup> Gulecke: *Arbeiten a. d. chir. Klin. d. König. Univ., Berlin*, 1906, xviii, 368.

<sup>18</sup> Sailer and Speese: *Trans. of the Assoc., of American Phys.*, 1908, xxiii, 540.

<sup>19</sup> Hess: *Münchener med. Woch.*, 1903, 1, 1905.

<sup>20</sup> Flexner: *Jour. of Exper. Med.*, 1906, viii, 167.

<sup>21</sup> Pólya: *Berliner klin. Woch.*, 1906, xliii, 1562.

<sup>22</sup> Williams and Busch: *Trans. of the Assoc. of American Phys.*, 1907, xxii, 304.

by Peiser,<sup>23</sup> 79 were in men, whereas only 42 were in women. Of 41 instances of the hemorrhagic lesion collected by Körte,<sup>24</sup> 27 were in males and 4 in females; of 40 examples of gangrenous lesion, 21 were in males and 19 in females. The disease not infrequently attacks individuals who have apparently been in good health; individuals with abundant fat are, it is claimed, particularly susceptible.

The experiments which have been cited show that a variety of substances injected into the duct of the pancreas cause hemorrhagic inflammation. How far they can be used to explain the pathogenesis of human cases is doubtful. The suggestion of Hlava that gastric juice may be driven by antiperistaltic action of the intestine into the ducts is not supported by any evidence.

*Bacteriology.*—No relation between hemorrhagic necrosis of the pancreas and bacterial invasion from the intestine has been demonstrated. Welch<sup>25</sup> cultivated *Bacillus coli* from foci of fat necrosis accompanying acute hemorrhagic pancreatitis, but reached the conclusion that the organism penetrated the dead tissue after the lesion had been produced. In cases of hemorrhagic pancreatitis Hlava found *Bacillus coli* associated with the pneumococcus and other diplococci; Cutler<sup>26</sup> and Reynolds and Moore<sup>27</sup> have also isolated the colon bacillus. Leonhardt<sup>28</sup> in one case found staphylococci, streptococci, and

---

<sup>23</sup> Peiser: *Deutsche Zeit. f. Chir.*, 1902, lxx, 302.

<sup>24</sup> Körte: *Chirurgischen Krankheiten des Pankreas*, *Deutsche Chirurgie*, Stuttgart, 1898.

<sup>25</sup> Welch: *Med. News*, 1891, lix, 669.

<sup>26</sup> Cutler: *Boston Med. and Surg. Jour.*, 1895, cxxxii, 354.

<sup>27</sup> Reynolds and Moore: *British Med. Jour.*, 1898, i, 1335.

<sup>28</sup> Leonhardt: *Virchow's Arch.*, 1900, clxii, 299.

two unidentified bacilli, while Jackson and Ernst, in a case of Fitz's, isolated four species of bacteria. Ponfick<sup>29</sup> and Marx<sup>30</sup> each cultivated a bacillus closely related to the colon bacillus, but not identical with it nor with one another. The variable and inconstant result of bacteriological examination indicates, as almost all the writers cited agree, that these various organisms are not the etiological factor in producing the lesion, but are merely secondary invaders of injured tissue. It is significant that the necrotic parenchyma may contain no micro-organisms even though it is exposed to bacterial invasion from the duodenum.

*The Association of Acute Pancreatitis and Cholelithiasis.*—The etiology of hemorrhagic necrosis of the pancreas has remained obscure until a series of cases recently studied has demonstrated a relationship between the lesion and cholelithiasis. Since the common bile duct and the duct of Wirsung unite to form the diverticulum of Vater before they reach the duodenum, changes in the one duct may be transmitted to the other, thus producing secondary lesions of the liver or pancreas. The association of pancreatic disease with alterations of the bile passages has been noted by Körte, Oser,<sup>31</sup> Lancereaux,<sup>32</sup> and other writers.

My attention was directed to the relationship between pancreatic necrosis and the impaction of a calculus in the

---

<sup>29</sup> Ponfick: Berliner klin. Woch., 1896, xxxiii, 365.

<sup>30</sup> Marx: Virchow's Arch., 1901, clxv, 290.

<sup>31</sup> Oser: Die Erkrankungen des Pankreas. Nothnagel's Spec. Path. u. Ther., Vienna, 1898, xvii.

<sup>32</sup> Lancereaux: Traité des maladies du foie et du paneréas, Paris, 1899.

common bile duct by the following case<sup>33</sup> studied at autopsy:

CASE I.—L. F., male, aged forty-seven years, admitted to the Johns Hopkins Hospital, in the service of Dr. Osler, had suffered somewhat frequently with pain after eating, distention, and rarely with nausea and vomiting. Six months before his present illness he had had an attack of jaundice.

The present illness began eighteen days before admission to the hospital, when the patient was suddenly seized with violent nausea and vomiting, accompanied by intense cramp-like pain in the abdomen. The abdominal pain, which was not localized, remained severe during four or five days, and at times there were symptoms of collapse. The abdomen was distended and the bowels were constipated until the fifth day, when, with the aid of a purgative, movement occurred. The stool was normal in color. On the third day elevation of temperature to 101.5° F. was noted. About the seventh day tenderness and slight swelling were noticed in the right hypochondriac and right half of the epigastric regions. Since this time the patient had an irregular temperature (100° to 103° F.), with several chills. After the first few days abdominal pain and tenderness were not severe, but distention of the abdomen gradually increased. Jaundice not noted.

On admission to the hospital the conjunctivæ have a slightly yellow cast. The lower margin of a mass which can be felt to the right of the median line is at the level of the umbilicus and descends with inspiration. The leucocytes number eighteen thousand. The urine has specific gravity of 1017 and does not reduce Fehling's solution.

On the second day after admission a stool passed was of golden yellow color. On the third day the leucocytes numbered nineteen thousand five hundred. The temperature rose gradually, reaching a maximum of 104° F. A liquid stool of ochre-yellow color was passed.

The diagnosis of suppurative pancreatitis was made by Dr. Bloodgood, and an operation for its relief was performed under cocaine anæsthesia. After incising the great omentum between the stomach and

---

<sup>33</sup> Opie: American Jour. of the Med. Sciences, 1901, cxxi, 27.





FIG. 20.—Gall-stones from Case I (actual size). The calculus removed from the common bile duct near its duodenal orifice is placed in the centre, and those from the gall-bladder surround it.



transverse colon an abscess cavity was entered. Grumous, purulent fluid, containing necrotic particles was evacuated. A rubber drainage-tube, packed about with gauze, was inserted into the wound. After operation the pulse remained weak, and death followed at the end of about four hours. The duration of the fatal illness was twenty-one days.

*Autopsy.*—The body is that of a large-framed, muscular man with abundant subcutaneous fat. The omentum, which contains a large quantity of fat, is thickly studded with conspicuous opaque, white areas, which are present as well in the fat of the mesentery, in the subperitoneal fat of the anterior abdominal wall, over the bladder, over the kidneys, and about the colon.

An immense abscess cavity occupies the site of the lesser peritoneal cavity; the foramen of Winslow is closed. The walls of the cavity are very irregular and ragged, and have a necrotic appearance, in general opaque and gray, occasionally black. This blackish-gray appearance extends only a short distance below the surface, and where the wall is formed by fat gives place to numerous foci of opaque, white color. The retroperitoneal fat in front of the left kidney and psoas muscle has been eroded, and an extension of the cavity passes behind the jejunum near its junction with the duodenum. Overlying the pancreas is a great mass of reddish-black altered blood. The cavity contains at least 500 c.c. of fluid reddish-gray material, in which are fat droplets and black necrotic particles.

The gall-bladder is bound by numerous adhesions to the duodenum and stomach. Its walls are thickened and it is much distended, containing viscid, yellow bile and more than one hundred brown, faceted calculi, varying in diameter from 0.5 to 1 cm. (see Fig. 20). The hepatic, cystic, and common ducts are much dilated. On opening the duodenum a stone is felt below the mucous membrane, situated in the common bile duct near its termination. It is 7 mm. in diameter, and resembles those present in the gall-bladder. The pancreatic duct unites with the common bile duct at a point 7 mm. from the duodenal orifice. The pancreatic duct is not distended.

The pancreas occupies the posterior wall of the abscess cavity of the lesser peritoneum, and is covered by the mass of changed coagulated

blood, above described. The organ is in great part well preserved. The interstitial tissue has a dull reddish, in places hemorrhagic, appearance, and contains conspicuous opaque yellow areas of irregular shape. Where the anterior surface of the head and body is in contact with the overlying material there is a superficial zone of soft, grayish, necrotic appearance.

The other organs—heart, lungs, spleen, stomach, intestines, and kidneys—present no noteworthy alteration.

*Histological Examination.*—The interstitial tissue of the pancreas is much increased and wide bands of fibrous tissue separate groups of lobules. Numerous cells filled with brownish-yellow iron-containing pigment afford evidence of former hemorrhage. In a few places well-preserved red corpuscles are diffusely scattered in the tissue. In a zone below the surface of the gland, nuclei no longer stain, and the architecture of the glandular tissue is only obscurely distinguishable. A thick band of newly formed fibrous tissue, containing an occasional acinus or duct, separates the necrotic parenchyma from that which is still intact. The mass covering the pancreas is found to consist of altered blood; upon and immediately below its surface are numerous polynuclear leucocytes.

*Bacteriological Examination.*—Cultures from the blood contained in the heart, from the lung, and from the liver, studied by Mr. V. H. Bassett, were found to contain *Bacillus coli*. A plate culture from the material covering the pancreas, and forming part of the abscess wall, contained *Bacillus coli*, *Bacillus lactis aërogenes*, and *Bacillus proteus vulgaris*.

*Anatomical Diagnosis.*—Cholelithiasis; calculus lodged in the common bile duct near its orifice; slight jaundice. Old hemorrhage within and about the pancreas, with localized necrosis and increase of fibrous tissue (hemorrhagic necrosis in process of healing); necrosis of fat of the pancreas, greater and lesser omentum, mesentery, and subperitoneal tissue of the abdominal wall; peripancreatic abscess limited by the lesser peritoneal cavity. Laparotomy wound.

The second attack referable to the passage of gallstones began suddenly, three weeks before death, with

severe nausea and vomiting. Tenderness was present in the right hypochondriac region, and on admission to the hospital the patient was slightly jaundiced. Autopsy disclosed a small gall-stone lodged in the common bile duct, a short distance from its orifice. The lesser peritoneal cavity was the site of an abscess, the walls of which were formed in large part by necrotic fat; the subperitoneal tissue was studded with conspicuous opaque, white foci of fat necrosis. The pancreas was in general well preserved, but its interstitial tissue was increased and gave evidence of having been the seat of hemorrhage. The anterior surface of the pancreas was covered by a considerable quantity of old, clotted blood, having the dark appearance of gangrenous tissue and forming the tumor mass, which was palpable during life. A superficial zone of glandular parenchyma in contact with this material was necrotic. Since jaundice was slight and the hepatic duct was not dilated, it is probable that the calculus produced only temporary obstruction of the two ducts.

Similar cases are recorded in the literature of the subject. The following cases in which a gall-stone has passed into the duodenum just before death or has been impacted at the orifice of the diverticulum of Vater are especially noteworthy:

CASE A. (Thayer.<sup>34</sup>)—During sixteen months a man, aged sixty years, had suffered attacks of pain, followed by jaundice. He was suddenly attacked with severe pain in the left hypochondriac and epigastrie regions. Collapse preceded death, which followed within twenty-four hours after the onset of symptoms. The thickened gall-bladder

---

<sup>34</sup> Thayer: Boston Med. and Surg. Jour., 1889, cxxi, 506.

contained over a hundred calculi. The common bile duct was dilated to the size of the little finger, and in the duodenum was a calculus the size of a hazel-nut. The pancreas was large, grayish-pink, mottled with reddish-brown. There were foci of fat necrosis.

CASE B. (Day.<sup>35</sup>)—For several months the patient, male, aged forty-nine years, had suffered with pain in the epigastrium and right hypochondrium, and once he was jaundiced. About sixteen hours before death he was suddenly attacked with vomiting and severe epigastric pain, followed by collapse. "The gall-bladder contained one small concretion of inspissated bile; two others were lodged in the duodenal extremity of the common duct." The body and tail of the pancreas were enlarged and infiltrated with blood. In the neighborhood of the gland were foci of fat necrosis.

CASE C. (Cutler.<sup>36</sup>)—For fifteen years the patient, a woman, aged fifty-eight years, had suffered with severe attacks of indigestion, on one occasion followed by jaundice. Four days before death she was seized with pain in the right hypochondrium, accompanied by vomiting, chill, and fever, and followed by jaundice. A small gall-stone was found at the outlet of the common duct; others were present in the gall-bladder. The pancreas was enlarged, surrounded and infiltrated with blood. Numerous foci of fat necrosis were seen in its neighborhood.

CASE D. (Kennan.<sup>37</sup>)—A woman, aged thirty-eight years, was suddenly seized forty-two hours before death with vomiting and pain in the upper part of the abdomen, followed by symptoms of collapse. A gall-stone, about the size of a pea, was found projecting from the orifice of the common duct into the duodenum. The pancreas was enlarged, and exhibited intense injection suggesting inflammatory change.

CASE E. (Simpson.<sup>38</sup>)—A man, aged forty-one years, was suddenly attacked with vomiting and severe abdominal pain. Collapse preceded death, which occurred at the end of forty-four hours. A

---

<sup>35</sup> Day: Boston Med. and Surg. Jour., 1892, cxxvii, 569.

<sup>36</sup> *Loc. cit.*

<sup>37</sup> Kennan: British Med. Jour., 1896, ii, 1442.

<sup>38</sup> *Loc. cit.*

small cubical gall-stone projected from the end of the common duct into the duodenum; similar concretions were found in the gall-bladder. The pancreas was greatly enlarged, weighing 525 Gm., and was mottled with areas of reddish-brown color, due to hemorrhagic infiltration of its interstitial tissue. The organ was surrounded by semifluid, clotted blood, of dark-brown color. The intima of the splenic artery was of a dirty-blue color, and was apparently necrotic about two centimetres from the aorta; Simpson regards this vessel as the source of the hemorrhage, although he does not state that rupture had occurred.

In 1903 I collected from the literature of the subject thirty-seven cases of so-called hemorrhagic and gangrenous pancreatitis occurring in association with cholelithiasis. Among one hundred and five recorded cases described as acute pancreatitis Egdahl<sup>39</sup> found cholelithiasis in forty-four instances (42 per cent.). The proportion of such cases is probably greater, for the contents of the gall-bladder and bile passages had been doubtless overlooked or unrecorded in many instances.

The cases which have been cited suggest no process nor mechanism by which a lesion of the pancreas results from the presence of a calculus in the common bile duct near its duodenal orifice. The autopsy upon a second case of hemorrhagic necrosis of the pancreas studied in the partial light of that already described (Case I) has demonstrated a mechanism<sup>40</sup> by which a small biliary calculus produces a destructive lesion of the pancreas and at the same time has brought our knowledge of the lesion into correlation with facts demonstrable by experimental means.

---

<sup>39</sup> Egdahl: Bull. of the Johns Hopkins Hosp., 1906, xvii, 265.

<sup>40</sup> Opie: The Etiology of Acute Hemorrhagic Pancreatitis, Bull. of the Johns Hopkins Hosp., 1901, xii, 182.

CASE II.—Mr. T., a corpulent man of robust appearance, aged forty-eight years, had been for several years subject to attacks of pain in the epigastrium. After luncheon, nine days before the fatal termination of his illness, he was suddenly seized with severe pain in the abdomen, accompanied by nausea. The pain persisted, but during the week following he took his meals regularly and slept as usual. About noon of the day preceding his admission to the Johns Hopkins Hospital the pain became so severe that the repeated administration of morphia gave little relief. When seen by Dr. Halsted<sup>a</sup> at nine o'clock in the evening he was in great pain. Though his pulse was full and regular, the skin was markedly cyanosed. The following morning operation was performed by Dr. Halsted. On opening the abdomen numerous foci of fat necrosis were seen upon the omentum and in the mesentery. The pancreas was examined through an opening made in the gastrocolic omentum, and the tissue over it was found infiltrated with blood-stained fluid. Slight distention of the common bile duct was noted. Blood-stained fluid was removed from the abdominal cavity, and gauze, packed through the wound, was brought into contact with the head of the pancreas. Death occurred twenty-three hours later.

*Autopsy.*—The body is that of a large man with abundant subcutaneous fat. Fat is present in large amount in the omentum, mesentery, and subperitoneal tissue, and is thickly studded with small, opaque, white areas of fat necrosis. The pancreas is represented by a swollen mass of almost uniform black or reddish-black color. The head of the organ is partly normal in appearance, but tissue which is in immediate contact with this well-preserved gland substance is soft and black, mottled here and there with small areas of dull red. The distal half of the organ shows a similar mottling of black and reddish areas, among which are islands of yellowish, relatively well-preserved tissue. The intima of the splenic vein is mottled yellow, blackish, and red as the result of changes in the underlying tissue, and in the lumen is a mixed red and yellow thrombus mass.

The duodenum has been opened and the common orifice of the bile and pancreatic ducts examined. The papilla is prominent, but its

---

<sup>a</sup> The clinical history of this case has been recorded by Dr. Halsted: Bull. of the Johns Hopkins Hosp., 1901, xii, 179.

orifice is of small size, measuring one mm. in diameter. The common bile duct, which near its termination is completely embedded in the substance of the pancreas, is slightly distended. The gall-bladder contains viscid, blackish bile; no concretions are present. The termination of the pancreatic duct, which is surrounded by the well-preserved pancreatic substance in contact with the duodenum, has been exposed by dissection, and is found to unite with the common bile duct ten millimetres from the summit of the bile papilla. A small gray-white, very firm concretion, three millimetres in diameter, is tightly impacted in the diverticulum of Vater, from which it cannot escape through the narrow duodenal opening. The pancreatic duct and its larger branches, where they traverse the intact tissue of the head, are stained bright green with bile.

In the liver the portal veins are distended and plugged with red thrombi which probably have had their origin in emboli from the thrombosed splenic vein. The heart, lungs, spleen, kidneys, and adrenal glands present no noteworthy abnormality. The urine contained in the bladder does not reduce Fehling's solution.

*Microscopic Examination of the Pancreas.*—There is an abrupt transition between intact parenchyma in the head of the gland and the adjacent necrotic tissue. The loose interlobular areolar tissue is everywhere infiltrated with red blood-corpuscles; polynuclear leucocytes are present in large numbers and often form collections of considerable extent. Within the margin of the intact tissue are several small areas where the parenchyma presents an early stage of necrosis. Here the secreting cells no longer stain with hematoxylin, but assume a homogeneous clear pink color with eosin. Near by, in similarly localized areas, the process is more advanced, and the parenchymatous cells are replaced by formless material which, staining faintly, is mingled with a few nuclear fragments and is densely infiltrated with polynuclear leucocytes and red blood-corpuscles.

The abrupt transition from relatively normal parenchyma containing a few islands of necrosis to wholly necrotic tissue is marked by a zone composed of nuclear fragments, polynuclear leucocytes, red blood-corpuscles, and fibrin. That part of the tissue which macroscopically is black or reddish-black under the microscope is necrotic; nuclei

are no longer present, though the architecture of the gland is still obscurely definable; both parenchyma and connective tissue have a dark-brown discoloration due to the presence of brown pigmented material which appears to be changed blood.

Capillary vessels in the living tissue near the margin of necrosis, as well as in the immediately adjacent necrotic part, have undergone hyaline thrombosis and with Weigert's stain for fibrin form conspicuous deep-blue, often branched, lines, as though injected. Examination with high magnification demonstrates at times a close mesh-work of fibrin in these vessels.

In sections stained for bacteria with methylene-blue, with gentian violet, and by Weigert's method, none were discovered.

*Bacteriological Examination.*—Cultures from the heart's blood, spleen, and gall-bladder give negative results. An anaërobic culture on hydrocele agar-agar from the pancreas shows no growth after an incubation of seventy-two hours. An anaërobic agar-agar plate from the pancreas contains at the end of twenty-four hours a single superficial colony of a pigment-forming coccus of which the cultural characters indicate that it is a contamination from the air. Streptococcus pyogenes and Staphylococcus epidermis albus are isolated from the peritoneal cavity. The colon bacillus is present in cultures from the liver and kidney.

*Anatomical Diagnosis.*—Cholelithiasis; calculus impacted in the diverticulum of Vater, partially filling it, and occluding its duodenal orifice. Hemorrhagic necrosis of the pancreas; disseminated abdominal fat necrosis. Thrombosis of the splenic vein; embolism and thrombosis of branches of the portal vein.

The preceding autopsy has disclosed a condition which explains, I believe, the pathogenesis of cases of so-called acute hemorrhagic and gangrenous pancreatitis which are associated with gall-stones. The diverticulum of Vater was 10 mm. in length. Lodged at its apex, blocking the duodenal orifice, was a small calculus only 3 mm. in diameter, but too small to pass the narrow

opening. Though it occluded the duodenal orifice of the diverticulum, it was so small that the orifices of the common bile duct and the pancreatic duct were unobstructed. The two ducts were, therefore, converted into a continuous closed channel from which it was not possible for either bile or pancreatic juice to escape (see Fig. 9, i., page 15).

On dissecting the pancreatic duct where it passed through the unchanged parenchyma in contact with the duodenum it was found, like the bile duct, to be stained bright green with bile. Where, as in this case, the two ducts become a closed channel, the entrance of bile into the pancreas or of pancreatic juice into the bile passages would depend upon the relative pressure in the two ducts. The pressure at which bile and pancreatic juice are secreted being small, any slight difference that might exist would be overcome by the gall-bladder, a muscular organ which at intervals forces bile in considerable quantity along the common duct.

The following case described by Bunting is almost identical with Case II; a small gall-stone had lodged at the duodenal orifice of an unusually capacious diverticulum of Vater and the adjacent part of the duct of Wirsung was stained with bile.

*Case Described by Bunting.*<sup>42</sup>—A man aged fifty-one years died about twenty-four hours after the onset of intense epigastric pain and collapse. There was so-called acute hemorrhagic pancreatitis with fat necrosis. The gall-bladder was distended and tense and the bile ducts were dilated. Gentle pressure failed to force bile from the bile papilla, but increased pressure caused a sudden spurt of bile, carrying with it

---

<sup>42</sup> Bunting: Bull. of the Johns Hopkins Hosp., 1906, xvii, 265.

a small yellowish-white mass which was lost and not identified with certainty. A small calculus, 2 mm. in diameter, was found at the apex of the diverticulum of Vater, and in the gall-bladder were about four hundred light-colored calculi from 0.5 to 6 mm. in diameter. The duct of Wirsung joined the common bile duct 11 mm. from the tip of the papilla; it was dilated and stained with bile for a distance 4 cm. from its end.

*Effect of Bile Injected into the Pancreatic Duct.*—Experiments previously described have shown that a variety of irritating substances injected into the pancreatic duct causes hemorrhagic necrosis of the gland. Cases just described have demonstrated in association with this lesion a mechanism by which a small biliary calculus diverts bile into the pancreatic duct. A series of experiments<sup>43</sup> were undertaken in order to determine the effect of bile thus brought into contact with the pancreatic parenchyma. The duodenum of dogs was opened for a distance of several centimetres opposite the larger pancreatic duct. The blunt-pointed nozzle of a syringe was inserted into the orifice of the duct, and bile obtained from the same or from a second dog was injected into the organ. The operations were performed with the usual aseptic precautions, and the duodenal wound was closed by submucous mattress sutures. The results were almost uniform. Experiments exhibiting features repeated in the others will be described in detail.

EXPERIMENT I.—After opening the duodenum of a dog, 5 c.c. of bile obtained from a second animal were injected into the pancreatic duct. Death followed within twenty hours. The peritoneal cavity contains several cubic centimetres of bloody fluid and the peritoneal

---

<sup>43</sup> Opie: Bull. of the Johns Hopkins Hosp., 1901, xii, 182.

surface is deeply injected. The entire omentum and the fat about the pancreas are studded with conspicuous opaque white areas of fat necrosis. The splenic arm and the upper half of the attached duodenal part of the pancreas are swollen, œdematous and infiltrated with blood. The cut surface has a mottled dull red and gray color, the interstitial tissue being hemorrhagic. Microscopical examination shows that the dull red areas in the pancreas seen macroscopically represent foci of necrosis where parenchymatous cells stain only with eosin and no longer contain nuclei. The blood-vessels here are widely dilated, and abundant hemorrhage has frequently taken place. Polynuclear leucocytes are present, but are not very numerous. Such an area of necrosis and hemorrhage is at times limited to the central part of a lobule group, while the acini farther from the central duct are intact. The interstitial tissue, particularly in the duodenal part of the gland, is œdematous and contains red blood-corpuscles, polynuclear leucocytes, and fibrin.

Should bile enter the pancreas after occlusion of the distal end of the diverticulum of Vater, its only opportunity for escape would be by way of the lesser pancreatic duct. In order to reproduce this condition, in two experiments the duodenum was not opened, but the duct was exposed where it approaches the intestine, ligated close to the duodenum, and partially cut across. By means of a syringe with a blunt nozzle bile was injected into the distal end of the duct, which was then ligated.

EXPERIMENT II.—Into the larger duct was injected 5 c.c. of bile obtained by puncture from the dog's gall-bladder. The animal died twenty-four hours later. Opaque, white areas of fat necrosis are numerous upon the surface of the pancreas, in adjacent fat, and in the omentum. The parenchyma throughout the gland is mottled with small dull-red areas. Microscopic examination shows the presence of numerous foci of necrosis. The gland cells have assumed a hyaline appearance and have lost their nuclei. The blood-vessels in these areas are widely distended, and at times there is abundant extravasation of red blood-corpuscles. Polynuclear leucocytes in moderate number are seen

between the necrotic cells. The interlobular tissue contains red blood-corpuscles, polynuclear leucocytes, and fibrin.

The injection of 5 c.c. of bile into the pancreatic duct caused hemorrhagic inflammation of the gland with fat necrosis in four dogs, two of which died within twenty-four hours after the operation. Death did not follow the use of smaller amounts, and the changes produced in the organ were less wide-spread and severe.

Experiments of Flexner and Pearce, of Hewlett<sup>44</sup> and of Gulecke have furnished additional evidence that bile injected into the pancreatic duct of animals reproduces hemorrhagic necrosis of man. Flexner<sup>45</sup> has shown that the power of bile to cause the lesion is attributable to the bile salts; five cubic centimetres of a solution of sodium taurocholate of strength approximately equal to that of bile causes pancreatic necrosis accompanied by wide-spread fat necrosis. The muciginous residue of the bile, insoluble in alcohol, fails to cause the same change and in common with certain bland colloids tends to diminish the power of bile salts to cause destruction of pancreatic parenchyma.

The foregoing experiments show that bile diverted into the pancreatic duct by a biliary calculus is capable of producing hemorrhagic necrosis of the pancreas.<sup>46</sup>

---

<sup>44</sup> Hewlett: *Jour. of Med. Res.*, 1904, xi, 377.

<sup>45</sup> Flexner: *Jour. of Exper. Med.*, 1906, viii, 167.

<sup>46</sup> It is probable that the physiologist, Claude Bernard, produced the lesion, though he failed to recognize it, years before it had been described in man. In his lectures on experimental physiology, published in 1856, he describes the injection of a mixture of bile and sweet oil into the pancreatic duct of the dog; the animal died after eighteen hours; there was intense peritonitis and the pancreas was red and contained numerous ecchymoses. (*Leçons de physiologie expérimentale*, Paris, 1856, ii, 278.)

*Conditions Which Favor the Occurrence of Hemorrhagic Necrosis of the Pancreas.*—A small calculus only partially filling the ampulla of Vater can convert the two ducts into a continuous channel, whereas a larger stone may simultaneously obstruct the duodenal orifice of the diverticulum and the orifices of the two ducts which enter it, thus damming back bile and pancreatic juice upon their respective glands. In Case II, as previously mentioned, the diverticulum measured 10 mm. in length, the calculus 3 mm. in diameter. In many cases of so-called hemorrhagic and of hemorrhagic and gangrenous pancreatitis, gall-stones found in the gall-bladder and bile passages at autopsy have been small and are often described as pea-sized. This statement is made in the reports of Day, Cutler, Kennan, Simpson, Chiari<sup>47</sup> (two cases), Smith,<sup>48</sup> Ehrich,<sup>49</sup> Fraenkel,<sup>50</sup> Körte,<sup>51</sup> Morian,<sup>52</sup> Rolleston,<sup>53</sup> Grawitz, Opie (Cases I, II, III and IV), Bryant,<sup>54</sup> Lund<sup>55</sup> (three cases) and Bunting.

In the two following cases the bile passages were not occluded but the gall-bladder contained a considerable number of uniformly small stones any one of which might have occluded the orifice of the diverticulum of Vater without filling the cavity of the diverticulum.

---

<sup>47</sup> Chiari: Prager med. Woch., 1883, viii, 285, 297.

<sup>48</sup> Smith, J. A.: British Med. Jour., 1897, ii, 468.

<sup>49</sup> Ehrich: Beit. z. klin. Chir., 1898, xx, 315.

<sup>50</sup> Fraenkel: Münchener med. Woch., 1896, xliii, 813, 844.

<sup>51</sup> Körte: Arch. f. klin. Chir., 1894, xlviii, 721.

<sup>52</sup> Morian: Münchener med. Woch., 1899, xlvi, 348.

<sup>53</sup> Rolleston: Trans. of the Path. Soc. of London, 1893, xlv, 71.

<sup>54</sup> Bryant: Lancet, 1900, ii, 1341.

<sup>55</sup> Lund: Boston Med. and Surg. Jour., 1900, exliiii, 543.

CASE III.—A man, aged thirty-seven years, was admitted to the Johns Hopkins Hospital in the care of Dr. Halsted. An attack of epigastric pain with vomiting had occurred seven months before. The present similar attack began fourteen days before admission.

There was swelling in the region of the gall-bladder, but no jaundice; ill-defined mass was felt in the epigastric region. An exploratory laparotomy was performed. Leucocytes found to number 33,700; temperature was 101° to 104° F. Death occurred four days after admission. The lesser peritoneal cavity was transformed into a cavity containing bloody fluid and necrotic material; there were perforations into the transverse colon, stomach and duodenum. The body and tail of the pancreas was necrotic and in places infiltrated with blood. The diverticulum of Vater was 10 mm. in length. The gall-bladder contained nine faceted gall-stones, the largest being 5 mm. in diameter.

CASE IV.<sup>66</sup>—M. K. female, aged thirty-four years, was admitted to the Presbyterian Hospital of New York in the service of Dr. Eliot on November 8, 1908.

*Present Illness.*—In February, 1908, the patient was suddenly attacked with severe pain in the epigastrium. There was slight jaundice. Symptoms continued for about three weeks, and disappeared. About October 1, 1908, she was again attacked with severe, sharp, epigastric pain accompanied by vomiting, but no jaundice. About the middle of October the pain gradually diminished and almost disappeared. October 24, 1908, she had a severe chill followed by sweating.

On entrance to the hospital the patient was well nourished but very pale; there was no jaundice. In the epigastrium to the right of the midline was a fluctuating, slightly tender mass, 8 cm. in diameter.

On November 9, 1908, Dr. Eliot opened the abdomen and evacuated a large abscess apparently connected with the liver. It contained a large quantity of thick, brownish pus, with very little odor. Agar-agar inoculated with this pus remained sterile. After operation the patient did not improve and vomited frequently.

On November 30, 1908, a second operation was performed. A large

---

<sup>66</sup> This case and Cases VI and VII have been described by Opie and Meakins: *Jour. of Exper. Med.*, 1909, xi, 561.

cavity was found extending to the posterior parietes and for some distance both to the right and to the left of the midline. The patient did not improve after the second operation and died December 1, 1908.

Temperature after admission to the hospital ranged from 100 to 104° F. Urine contained no bile or sugar; the pancreatic reaction of Cammidge was negative.

The white blood-corpuscles on entrance to the hospital numbered 14,800, but diminished to 3000 per mm. Progressive diminution of polynuclear leucocytes with increase of transitional forms, large mononuclear leucocytes and lymphocytes is exhibited by the following counts:

	Nov. 8	Nov. 16	Nov. 18	Nov. 25	Nov. 28	Nov. 30
Total leucocytes ...	14,800	10,700	15,700	4,800	2,750	3,000
Poly. leucocytes .....	78.5%	77%		29%	26%	41.5%
Transitional .....	6	6		16	27.5	15
Large mononuclears ....	2	2		21	4	16
Lymphocytes .....	13	14.5		31	42	25.5
Basophilic leucocytes ..	0	0		0	0	0.5
Eosinophile leucocytes ..	0	0		1	1	.15
Stimulation forms .....	0.5	0.5		2	0	0

*Autopsy.*—In the upper right hypochondrium from the wound of operation there is a deep sinus surrounded by firm adhesions.

In the fat of the omentum over the transverse colon and at the base of the mesentery there are numerous small, white areas of fat necrosis. From the opening in the abdominal wall the sinus with necrotic edges passes directly backward to the duodenum. It communicates with a very large cavity lying in front of the pancreas and representing in part the lesser peritoneal cavity. An extension from this cavity passes downward into the retroperitoneal tissues to the left of the root of the mesentery, and in front of the kidney. Erosion in this region has extended into the abdominal wall and has reached to within about 1 cm. of the surface above the crest of the ilium.

Behind the body of the pancreas, extending upward through the retroperitoneal tissue is a second sinus which communicates with an immense cavity above the stomach and immediately below the diaphragm. The diaphragm to the left of the midline in contact with the abscess

cavity is penetrated by an opening 1.5 cm. across. This opening communicates with a localized pleural abscess (7 by 8 cm.) about which the lung is firmly bound to the diaphragm.

In front of the head of the pancreas is the abscess cavity described above; the surface of the gland is here covered by soft, black tissue. This black gangrenous tissue covers the body of the pancreas half way to the splenic extremity, whereas the remainder of the anterior surface of the body and tail is adherent to the stomach and shows neither necrosis nor erosion. The abscess cavity, which has burrowed underneath the gland about its midpart, dissects the greater part of the posterior surface of the splenic half from the underlying retroperitoneal tissue. The pancreas throughout is firm and on section the lobulation is less clearly defined than usual. On the surface and less frequently in the substance of the gland occur opaque, yellow spots of fat necrosis. On section through the abscess wall into the head of the pancreas a narrow zone of fibrous tissue is found between the necrotic abscess wall and the pancreatic parenchyma. The duct of the pancreas is slightly dilated and patulous. The common bile duct is somewhat dilated and, 1 cm. above the orifice, measures 16 mm. in circumference. The duct of Wirsung joins the common bile duct 7 mm. from its duodenal orifice which measures 3 mm. in diameter.

The gall-bladder contains eleven small gall-stones measuring from 6 to 9 mm. in diameter (Fig. 21). The cystic duct is dilated. The stomach and duodenum are apparently normal.

*Culture* from the peritoneum contains many varieties of bacteria, including streptococci and *B. coli*, together with unidentified bacteria.

*Microscopic examination* shows that the capsule of the pancreas is much thickened. Its outer layer is necrotic and the inner layer consists of vascular granulation tissue in which are hemorrhages. Extending in from the capsule are greatly thickened strands and masses of similar tissue in which there are numerous round cells. In large areas parenchyma is almost wholly replaced and lobules are represented by a few acini.

*Anatomical Diagnosis.*—Hemorrhagic necrosis of the pancreas in process of healing; disseminated fat necrosis; peripancreatic abscess with erosion of retroperitoneal tissue; subdiaphragmatic abscess; per-

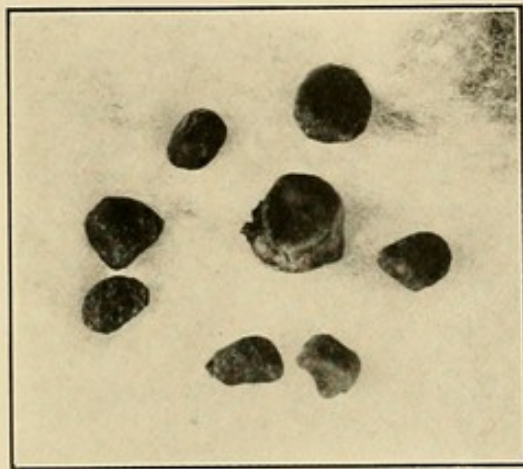


FIG. 21.—Gall-stones from Case IV.



foration of the diaphragm; localized diaphragmatic empyema; pneumothorax. Cholelithiasis; chronic cholangitis; fatty degeneration of the liver. Bronchopneumonia. Fibromyoma of the uterus.

Anatomical peculiarities of the diverticulum of Vater favor or prevent conversion of the two ducts into a closed channel. The diverticulum may be regarded as a somewhat conical cavity into the base of which open the bile and pancreatic ducts; the apex of the cone situated at the summit of the bile papilla is the common duodenal orifice of both ducts. In a considerable number of individuals, about one in ten (see page 15) the two ducts open separately into the intestine and no diverticulum exists (see Fig. 9, ii.). Variations to which the diverticulum is subject have been considered (page 15 *et seq.*); in one hundred instances its length varied from zero to 11 mm., and in only thirty of these did the length reach 5 mm. The average diameter of the duodenal orifice was 2.5 mm. and in about one-third of the subjects examined the diameter of the orifice was equal or greater than the length of the diverticulum. If possible distention of the orifice be considered, it is hardly probable that a small calculus could lodge in the opening, yet only partially fill the cavity, unless the length of the diverticulum should exceed the diameter of the orifice by several millimetres. Since in only thirty-two of one hundred instances does the length of the diverticulum exceed 5 mm., the average diameter of the orifice being 2.5 mm., it is probable that in little more than three of ten individuals are the anatomical conditions such that a small calculus might divert the bile into the pancreatic duct. Moreover, it must be remembered, in one of ten cases the bile duct joins the smaller pancreatic duct, while the larger duct of Santo-

rini enters the duodenum at the site of the lesser papilla. These facts explain in part the rarity of hemorrhagic necrosis of the pancreas when compared with the relative frequency of cholelithiasis.

*Frequency with which Hemorrhagic Necrosis of the Pancreas is Produced by Biliary Calculi.*—While the etiology of many cases of hemorrhagic pancreatitis is thus established, it cannot be demonstrated that all are dependent upon the passage of a gall-stone along the common bile duct. In the following case neither the clinical history nor the autopsy affords any evidence of cholelithiasis. A complete autopsy was not permitted, and the possibility cannot be excluded that a single small calculus producing the lesion escaped into the intestine.

CASE V.—The patient, a man, twenty-eight years of age, had, been in good health before his illness, which began four days before death with nausea and vomiting. About an hour later he was attacked with agonizing pain in the epigastric region. The following day he suffered with violent hiccough, which continued until the time of operation. When admitted to the Johns Hopkins Hospital he vomited almost continuously; there was distention in the neighborhood of the umbilicus. An exploratory laparotomy was performed by Dr. J. F. Mitchell, and innumerable foci of fat necrosis were found studding the omentum. Lesser peritoneal cavity contained bloody fluid, and the pancreas was covered by a coagulum of blood. The abdomen was closed, a gauze drain being inserted into the wound. The patient died twenty-four hours later.

*Autopsy.*—It was possible to remove only the pancreas with the gall-bladder and a part of the duodenum. The pancreas was of great size, weighing 190 Gm.; the head and tail were firm and normal in appearance, but the greater part of the body was soft, mottled red and reddish-black, and was the seat of a hemorrhagic lesion. No gall-stones were found in the gall-bladder or in the gall-duct. Parenchyma

had undergone necrosis and neighboring interstitial tissue was infiltrated with red blood-corpuseles, leucocytes and fibrin. There is hyaline thrombosis of capillary vessels at the margin of necrotic tissue.

A case described by Pearce<sup>57</sup> illustrates the possibility that the bile passages may have contained a single gall-stone which has been lost in the intestinal contents. Hemorrhagic pancreatitis (necrosis) was found in an individual who had been jaundiced two weeks before death; no calculi were found at autopsy but the orifice of the common bile duct was dilated and just above the orifice there was localized dilatation which suggested that a stone had occupied the end of the duct. In an almost identical case described by Thayer (see page 33) a gall-stone was found in the duodenum.

It has been claimed that gall-stones are not more frequently found in association with acute hemorrhagic pancreatitis than in individuals of similar age dying from other diseases. Among eight cases of hemorrhagic necrosis (acute hemorrhagic pancreatitis), which I have had the opportunity of studying, gall-stones have been present in five. Among one hundred and five recorded cases collected by Egdahl, cholelithiasis was present in 42 per cent. This proportion, which may be regarded as an established minimum, is doubtless small, for in many instances data which have been recorded do not exclude the presence of gall-stones. Their presence may have been overlooked or a single calculus causing the lesion has perhaps been lost. According to the statistics collected by Körte, acute hemorrhagic and gangrenous pancreatitis occurs with few exceptions between the ages

---

<sup>57</sup> Pearce: Albany Med. Ann., 1904, xxv, 389.

of twenty and sixty years. According to statistics of Mosher,<sup>58</sup> carefully compiled from German and American sources, the frequency of gall-stones between the ages of twenty-one and sixty years is represented by 8.9 per cent. of all autopsies, less than one-fourth of the proportion found with the acute pancreatic lesion.

The somewhat greater frequency of pancreatic necrosis in men, whereas gall-stones are more common in women, is perhaps referable to the greater ability of the gall-bladder in stout muscular men to drive bile from the gall-bladder into the pancreatic ducts during the passage of a gall-stone from the diverticulum of Vater into the duodenum.

*Hemorrhagic Necrosis Caused by Penetration of Duodenal Contents into the Pancreatic Ducts.*—In many cases of so-called acute pancreatitis there have been symptoms referable to the stomach or intestine, but the etiological relation of gastro-intestinal disturbance (noted in thirty-two of one hundred and five cases collected by Egdahl) is doubtful, for symptoms referred to the stomach may be caused by cholelithiasis and inflammation of the duodenum is frequently secondary to the adjacent pancreatic lesion.

The power of duodenal contents to cause hemorrhagic necrosis of the pancreas has been repeatedly shown by experiments. Hlava, who showed that acid gastric contents injected into the pancreatic duct causes the lesion, has suggested that antiperistaltic movements of the intestine might drive gastric or duodenal contents into the pancreatic ducts; there is no evidence that the lesion is

---

<sup>58</sup> Mosher: Bull. of the Johns Hopkins Hosp., 1901, xii, 253.

produced in this way. The discovery of enterokinase in the intestinal juice has suggested that self-digestion of the pancreas might occur during life should enterokinase find its way into the pancreas. The part played by enterokinase is somewhat doubtful (Pólya, Williams and Busch), but several experimenters (Pólya, Hess<sup>59</sup>) have shown that small quantities of duodenal contents

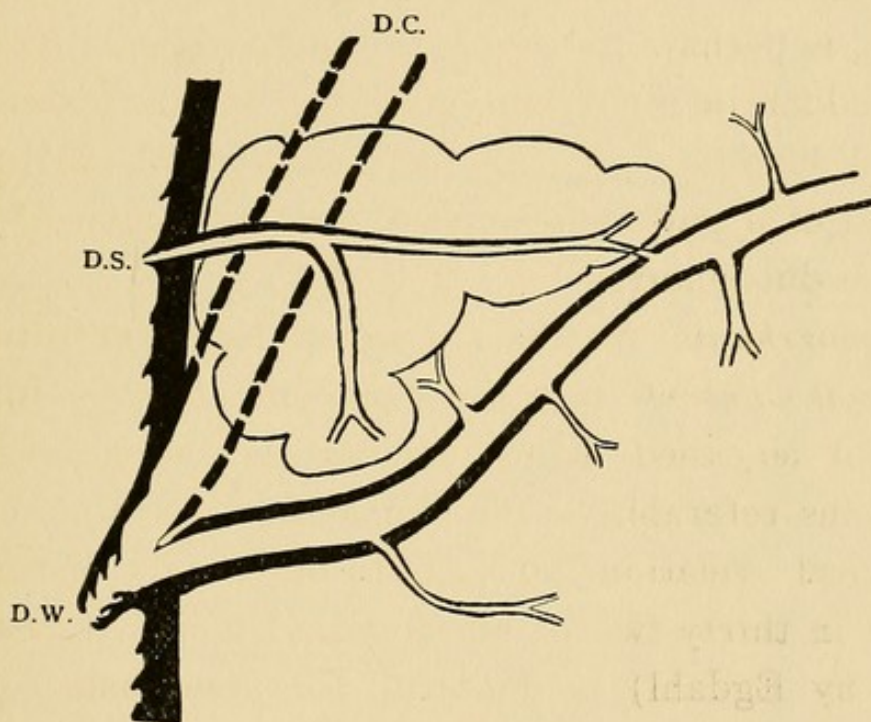


FIG. 22.—Diagram showing the usual relative size of the duct of Wirsung (D.W.) and duct of Santorini (D.S.); the duct of Wirsung joins the common bile duct (D.C.).

injected into the pancreatic duct will produce acute pancreatic necrosis with fat necrosis.

Hess attempted to produce pancreatic necrosis by diverting intestinal contents into the pancreatic ducts; he fixed in the duodenal orifice of the pancreatic duct of the dog a small cannula with a funnel-shaped end projecting into the duodenum and caused stenosis of the duodenum by a ligature below the pancreas. Olive oil injected

<sup>59</sup> Hess: Münchener med. Woch., 1905, lii, 644.

into the duodenum, Hess thought, favored the production of the lesion. In one of three experiments there was hemorrhagic necrosis of the pancreas, with disseminated fat necrosis, and death occurred at the end of two days. Hess cited cases of Gerhardi and of Konig-Werth in which with acute hemorrhagic pancreatitis there was stenosis of the duodenum below the pancreas.

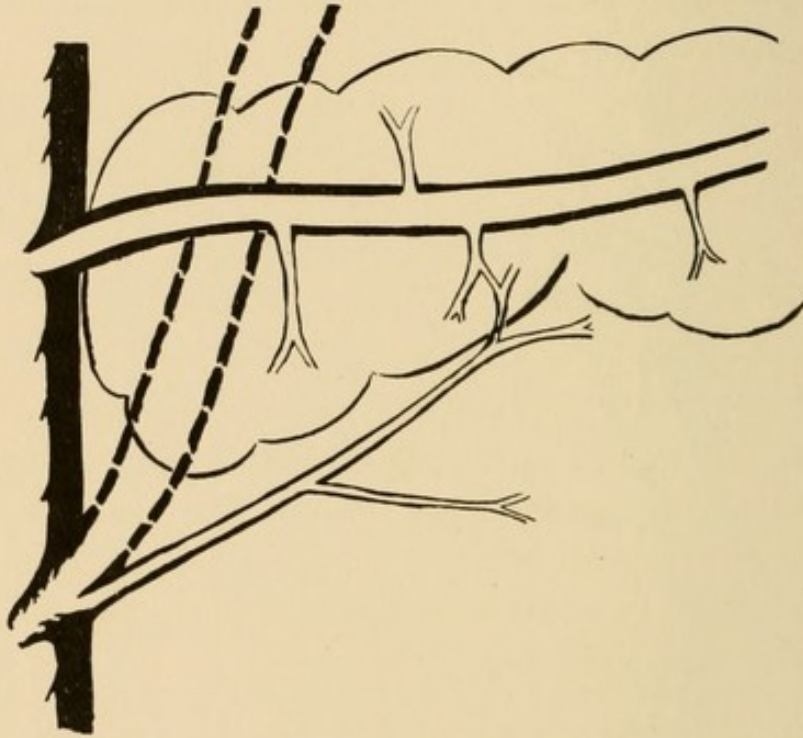


FIG. 23.—Diagram showing the relative size of the two pancreatic ducts in Case VI. The part of the gland drained by the duct of Santorini is indicated in both diagrams by curved lines.

It is well known that increased pressure within the duodenum does not force duodenal contents into the bile duct or into the pancreatic duct after death. The delicate valves found within the diverticulum of Vater prevent regurgitation. In approximately one of ten individuals (see page 10) what is usually the accessory duct of the pancreas—namely, the duct of Santorini, is the chief outlet of the gland and is larger than the duct of Wirsung which joins the common bile duct (Fig. 23).

The orifice of such an anomalous duct is perhaps unable to prevent regurgitation of intestinal contents when pressure within the duodenum is increased by vomiting. In the following case this anomaly exists and perhaps explains the occurrence of the pancreatic lesion.

CASE VI.—J. S. was admitted to the service of Dr. Eliot in the Presbyterian Hospital on October 25, 1908. The patient, male, aged fifty-five years, had used alcohol in excess; in October, 1906, he had acute alcoholic gastritis and suffered with frequent vomiting and severe diarrhœa; there was no jaundice. After this illness symptoms of chronic gastritis continued and there was frequent vomiting and eructation. On October 22, 1908, there was sudden severe epigastric pain followed by vomiting. The pain continued to be severe and extended a little outside the epigastric region. Vomiting was almost continuous; there was constipation.

On entrance to the Hospital the patient was almost moribund; the face and hands were cyanotic; there was no jaundice. Temperature was 99.6° F.; respiration, 40; pulse, 140. The abdomen was symmetrical and distended but not very tense; it moved little with respirations. There was tenderness and rigidity in the right upper quadrant and in less degree in the left upper quadrant. No mass was palpable.

No urine was obtainable for examination.

White blood-corpuscles, Oct. 25, numbered 9900 per mm. Differential count: polymorphonuclear leucocytes, 88 per cent.; transitionals, 5 per cent.; large mononuclear leucocytes, 1 per cent.; lymphocytes, 5 per cent., and eosinophiles 0.5 per cent.

Patient died six hours after entrance to the Hospital.

*Autopsy.*—The mesentery is studded with small areas of fat necrosis, most numerous on the right side, and many large foci are found in the perirenal fat.

The tail and body of the pancreas are soft and in great part dark red, being mottled with lighter, grayish areas. Here and there occur minute white spots of fat necrosis. Upon the surface of the body occur a few black spots extending into the substance of the gland;

they represent the only evidence of hemorrhage. The greater part of the head of the gland shows the same changes and one or two black spots occur; the only part of the gland which has the appearance of normal tissue is situated on the posterior and lower part of the head in contact with the duct of Wirsung.

The gall-bladder, which measures 11 by 5 cm., is distended with rather thick, dark green bile, and contains no stones or sand. The bile ducts are patent. Stomach is large; its mucous membrane is in places injected and covered by blackish mucus. The duodenum is normal.

*Cultures* from spleen and liver contain *Bacillus coli*; aerobic and anaerobic cultures from the pancreas contain only *Bacillus coli*.

*Microscopic Examination of the Pancreas.*—A section from the head near the duct of Santorini shows necrosis and disintegration so that the architecture of the gland is completely lost. In a few small spots parenchyma is well preserved, acini being intact and nuclei well stained. Here interstitial tissue is distended as if by œdema, red blood-corpuscles are fairly numerous and polynuclear leucocytes occur in small number. About the duct of Wirsung there is in places necrosis with loss of nuclei, but except in a few areas the shape of the acini is recognizable, whereas in the greater part of the section tissue is intact and nuclei are stained. A section from the body shows almost complete disintegration similar to that about the duct of Santorini. In an area of intact tissue there is considerable increase of connective tissue in great part about the lobules; this tissue contains numerous lymphoid cells and red blood-corpuscles and a few polynuclear leucocytes. Tissue in the tail of the gland is in part necrotic and disintegrated, in part living. The preserved tissue is in places infiltrated with red blood-corpuscles. Well-preserved islands of Langerhans occur in fair abundance. Small veins contain thrombi.

*Anatomical Diagnosis.*—Hemorrhagic necrosis of the pancreas; chronic interstitial pancreatitis; fat necrosis; chronic pulmonary tuberculosis; chronic interstitial nephritis; fatty degeneration of the liver; arteriosclerosis.

The ducts of the pancreas exhibit an anomalous arrangement. The duct of Wirsung, which joins the com-

mon bile duct, is of small size and drains only a small part of the head of the gland; this area appears to be the least changed part of the organ. The duct of Santorini is the chief outlet of the gland, and, far larger than the duct of Wirsung, traverses the entire length of the pancreas (see Fig. 23). The orifice of this duct readily admits a probe about 2 mm. in diameter. The gall-bladder and bile passages contain no calculi.

Since the duct of Wirsung is relatively small, whereas the main duct of the gland enters the duodenum about 1.5 cm. from the common bile duct, bile could enter only a small part of the pancreas. On the other hand, it is not improbable that an anomalous duct opening by a relatively wide orifice, might have been the portal of entry for material from the duodenum.

Cases recorded in the literature of the subject give some support to this view. Johnstone<sup>60</sup> has described two cases of acute pancreatitis in which the pancreatic duct has opened into the duodenum 1 or 2 cm. from the common bile duct, and although he has described these cases with the purpose of showing that gall-stones have not been an etiological factor in the production of the lesion, he does not suggest that the anomalous condition may explain its occurrence. The description of this author makes it probable that the arrangement of the ducts in these two cases resembles that which I have just described. In an additional case described by the same author the distribution of the ducts is not described, whereas in a fourth case the nature of the pancreatic lesion is doubtful.

Further evidence that the duct of Santorini may be a portal of entry for irritant material from the duodenum is furnished by a case of Bassett.<sup>61</sup> The two ducts of the gland bore the usual relation to

---

<sup>60</sup> Johnstone: *Colorado Med.*, 1907, iv, 93.

<sup>61</sup> Bassett: *Trans. of the Chicago Path. Soc.*, 1907, vii, 83.

one another (Fig. 22); the duct of Santorini was much smaller than the duct of Wirsung and drained only a small part of the gland. This duct terminated at the margin of an anomalous duodenal diverticulum of which the mucosa was inflamed. Limited to the immediate neighborhood of this small duct was hemorrhagic pancreatitis with fat necrosis. The patency of the orifice of the duct of Santorini was not demonstrated. In Case VI, described above, almost the entire gland, of which the chief outlet was the duct of Santorini, was the seat of hemorrhagic inflammation, and the part about the small duct of Wirsung was apparently the least changed part of the organ, whereas in the case of Bassett, with a small duct of Santorini terminating in an anomalous diverticulum, the lesion was limited to the small area drained by this duct. (The domain of the duct of Santorini in the usual and in the anomalous condition is indicated in Figs. 22 and 23.) Although these cases do not afford conclusive proof that duodenal contents cause the lesion, they suggest this possibility with such force that a careful study of the topography of the ducts in cases of hemorrhagic necrosis of the pancreas is desirable.

*Traumatic Necrosis of the Pancreas.*—Typical instances of the lesion usually designated acute hemorrhagic pancreatitis and characterized by necrosis of the pancreatic parenchyma, hemorrhage, and disseminated fat necrosis, have followed abdominal injury in the epigastric region. In such cases there has been a blow or kick over the pancreas, perhaps without injury to the skin, crushing between the buffers of two cars, etc.

A typical case is described by Selberg.<sup>62</sup> A man was kicked over the stomach by a horse and was unconscious for a time. There was pain and gradual distention in the epigastric region, together with vomiting. Death occurred after twenty days. The omentum was studded with foci of fat necrosis; the pancreas was infiltrated

---

<sup>62</sup> Selberg: Berliner klin. Woch., 1901, xxxviii, 923.

with blood and was gangrenous in appearance. In the following case localized hemorrhagic necrosis of the pancreas with localized fat necrosis followed a stab wound of the abdomen.

CASE VII.—J. T., male, aged 20 years, was stabbed on the afternoon of November 4, 1908, in the upper left quadrant of the abdomen with a long stiletto. After about ten minutes there was vomiting and nausea.

On entrance to the Presbyterian Hospital a short time after the injury the temperature was  $100.6^{\circ}$ ; pulse, 96; respirations, 16. Just above the costal margin in the left mammillary line there was a horizontal stab wound one inch long and parallel to the ribs; through the wound projected a mass of omentum, about the size of an egg.

Exploratory operation was performed November 4, 1908. The stab wound in the left costal space perforated the diaphragm, but the pleura was not injured. Upon the anterolateral surface of the stomach was a perforation 1.5 cm. long through which a small amount of fluid had escaped. The posterior wall was apparently normal. The peritoneal cavity contained a large amount of fluid and clotted blood. The intestines and other viscera were apparently uninjured. The perforation in the anterior wall of the stomach was closed by sutures.

During the succeeding days the temperature varied between  $101^{\circ}$  and  $106^{\circ}$ , and the pulse was rapid. There were frequent nausea and vomiting. There was distention of the abdomen, although the bowels moved freely and considerable flatus was expelled. Discharge from the wound was profuse. The patient gradually became weaker and died November 9.

Streptococci in pure cultures were found in the peritoneal exudate removed at operation. A blood culture remained sterile.

White blood-corpuscles numbered from 3000 to 7000 per mm.

Autopsy was performed by Dr. Otto Schultz. Throughout the peritoneal cavity is fibrinopurulent exudate. The wound of the anterolateral wall of the stomach has remained closed and is in process of healing. There is no perforation of the posterior wall of the stomach, but opposite to the wound in the anterior wall

there is upon the mucosa of the posterior wall a circular spot of œdema and injection 2.5 cm. in diameter; a minute central area of necrosis about the size of a pin's head, evidently represents the spot in which the point of the knife has struck. Upon the surface of the pancreas immediately behind this wound is a localized hemorrhagic area about 3.5 cm. in diameter and in the fat of this area are conspicuous foci of fat necrosis. Otherwise the pancreas appears normal.

Microscopic examination of the hemorrhagic area in the pancreas shows hyaline necrosis of the pancreatic parenchyma similar to that frequently observed with so-called acute hemorrhagic pancreatitis; the interstitial tissue is infiltrated with blood and in places contains polynuclear leucocytes. The veins within the hemorrhagic zone are widely dilated and contain thrombi.

It is noteworthy that simple injury to the pancreas of animals fails to produce necrosis, whereas in experiments of Levin<sup>63</sup> crushing of the gland associated with occlusion of blood-vessels has been followed by changes which resemble those of hemorrhagic necrosis. Trivial injury to the pancreas is usually followed by rapid healing but in Case VII injury has been associated with pancreatic necrosis, hemorrhage and focal fat necrosis. It is not improbable that the simultaneous occurrence of localized venous thrombosis and pancreatic injury, both due to a stab wound, explains the occurrence of hemorrhagic necrosis of pancreatic parenchyma.

#### PATHOLOGY.

The appearance of the pancreas varies with the duration of the disease, and in accordance with the aspect of the gland the lesion has been described as hemorrhagic or as gangrenous. When death has occurred within a

---

<sup>63</sup> Levin: Jour. of Med. Res., 1907, xvi, 419.

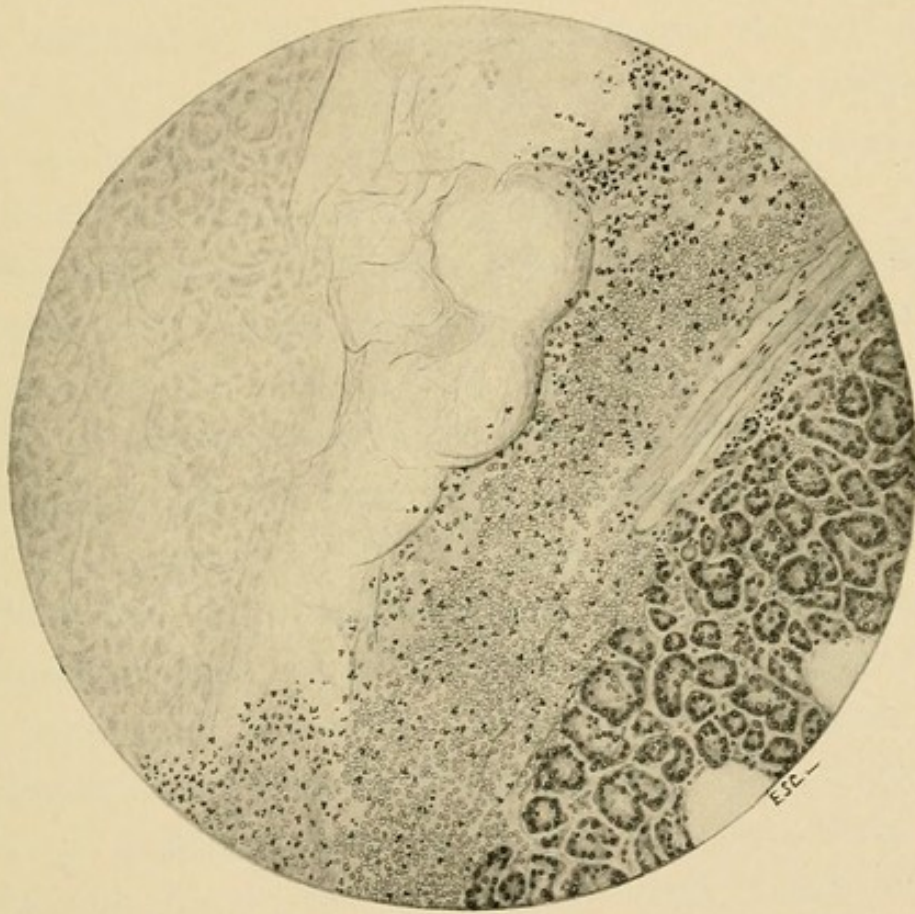



FIG. 24.—Hemorrhagic necrosis of the pancreas showing abrupt transition from normal to necrotic tissue. At the margin of the living tissue are red blood-corpuseles, leucocytes, and fibrin.



few days after onset of symptoms the organ is much enlarged, and very firm, and usually covered by clotted blood which has assumed a blackish-red color. The lesser peritoneal cavity contains blood-stained fluid and the tissues about the pancreas are often infiltrated with blood. Fat necrosis always accompanies hemorrhagic necrosis of the pancreas. The entire substance of the organ is rarely affected by the lesion, and sharply defined areas of relatively normal parenchyma persist and present a sharp contrast to the altered tissue which is dark red, reddish brown or even reddish black in color.

Histological peculiarities of the lesion have explained its relationship to hemorrhage on the one hand and to gangrene on the other. The significance of extensive necrosis of the parenchyma which is an essential feature of the lesion has not been fully recognized.

In five cases (II, V, VI and VII) which I have described the symptoms have been of short duration and the essential features of the lesion are well illustrated. Wide-spread necrosis of the parenchyma (Fig. 24) is associated with hemorrhage and with perhaps trivial accumulation of inflammatory products, notably fibrin and polynuclear leucocytes. There is total death of the tissue, implicating at once epithelial cells, interstitial connective tissue, and walls of blood-vessels. For a time the architecture of the tissue is preserved and the outlines of the acini are readily discernible, though the nuclei of the cells are wholly lost. Later the tissue undergoes such complete alteration that the structures composing it are no longer recognizable. Transition from such necrotic material to living tissue is abrupt, and often marked by a narrow zone containing fragments

of nuclei, polynuclear leucocytes, red blood-corpuscles, and fibrin. Acute inflammation is not constantly present and in some instances (Case VI) there is little or no inflammatory reaction. Even when inflammatory products have accumulated in one part of the tissue, the margin of necrotic areas elsewhere may exhibit no evidence of inflammation. Hyaline thrombosis of capillaries occurs within the relatively intact tissue which is in contact with the necrotic zone. (Cases II and V.)

By experimental means it is possible to produce a lesion of which the essential features are those observed in human cases, but, the conditions being under control, various stages in the process can be more readily studied. In two experiments in which death has followed within twenty-four hours the injection of 5 c.c. of bile into the pancreatic duct, foci of necrosis contain widely distended blood-vessels, while injury to their walls is indicated by the escape of numerous red blood-corpuscles into the tissues adjacent to them. In places polynuclear leucocytes are present in moderate number. Proliferation of the fixed tissue occurs with rapidity and the injured parenchyma is invaded and replaced.

In both human and experimental lesions, bile coming into contact with cells causes their death, and necrosis of the parenchyma is associated with such injury to the adjacent vessel walls that red blood-corpuscles escape in great abundance. Inflammatory and reparatory changes are secondary to death of tissue and occur at the margin of the necrotic area. Hemorrhage may be the result of necrosis before inflammatory changes are well marked. Extensive hemorrhage is doubtless due to necrosis implicating the wall of some vessel of consider-

able size. Hemorrhage on the contrary may be an insignificant feature of an otherwise typical instance of pancreatic necrosis. In Case VI, although the greater part of the gland had undergone necrosis, only a few black spots gave evidence of hemorrhage.

Numerous experiments have shown that a variety of substances, including bile, injected into the pancreas cause wide-spread necrosis, which finds little analogy in other organs. The pancreas, a gland secreting substances which effect the digestion of proteins within the intestine, is after death capable, like the stomach, of causing partial digestion of its own substance. It is not improbable that enzymes of the pancreatic juice, notably trypsin, acting upon cells injured by contact with the various irritant substances which can produce hemorrhagic necrosis, have a part in the production of the wide-spread disintegration of the parenchyma which results.

Both with the human and with the experimental lesion of hemorrhagic necrosis complete recovery may occur. Necrotic parenchyma is absorbed and replaced by fibrous tissue; the presence of iron-containing pigment may give evidence of old hemorrhage. Partial recovery is illustrated by Cases I and IV, in which bands of newly formed fibrous tissue separate and replace lobules of pancreatic parenchyma. In such cases fluid which may have accumulated in the lesser peritoneal cavity is not absorbed after the pancreatic lesion has healed. The cavity contains opaque fluid and necrotic particles and the pancreas is covered by black altered blood; the condition is occasionally though incorrectly described as peripan-

creatitis, the original pancreatic lesion having almost wholly disappeared.

*Stage of Gangrene.*—Though the older literature contains cases in which the pancreas has undergone sequestration, an adequate picture of the condition has been first drawn by Fitz, who has shown that acute pancreatitis may terminate in gangrene. From a study of fifteen cases Fitz found that the appearance of the pancreas varies with the duration of the disease. The gland, he says, is at first swollen, dark red, and soft, while on section the tissue is red or mottled red and gray, or may be wholly transformed into a dark slate-colored, foul-smelling mass. At the end of about ten days the pancreas is often dark brown, dry and firm, and covered by changed blood; hemorrhagic infiltration may extend beyond its limits. Throughout the substance areas of hemorrhage alternate with yellow spots of softening. At the end of the second week the organ may form a soft, black, friable mass, while the lesser omental cavity contains a large quantity of chocolate-colored fluid containing large, bluish-black clots. The gland may be finally transformed into a soft mass attached by a few shreds to the posterior abdominal wall or, indeed, may lie free in the omental cavity, which is distended with bloody or blackish, often ill-smelling, fluid containing necrotic particles of tissue. A conspicuous feature is the occurrence of disseminated fat necrosis.

Histological examination of human cases and study of so-called hemorrhagic pancreatitis produced experimentally has shown that extensive necrosis of tissue is associated with injury to the blood-vessels and consequent hemorrhage. Wide-spread death of tissue is pri-

mary, and subsequent alterations due to changes occurring in the extravasated blood and to invasion of bacteria cause such discoloration and disintegration of the affected tissue that it is recognized by the naked eye to be gangrenous. Suppuration with or without perforation of the gastro-intestinal tract is a secondary change and is not the cause of the gangrenous condition. No sharp distinction, therefore, can be drawn between hemorrhagic and so-called gangrenous pancreatitis. The lesion begins with necrosis of tissue, and hemorrhage takes place into the necrotic area; there is bacterial invasion, and should sufficient time elapse those alterations which give to the organ the macroscopic appearance of gangrene ensue.

Hemorrhagic necrosis of the pancreas appears to be more rapidly fatal in men than in women, for among forty-one instances in which the lesion has been described as hemorrhagic pancreatitis Körte has found only four in women, whereas among forty cases which have reached the stage of gangrene, nineteen have been in women.

*Accumulation of Fluid within the Lesser Peritoneal Cavity.*—With necrosis of pancreatic parenchyma in contact with the overlying peritoneum and with necrosis of fat below the lesser peritoneal membrane there is accumulation of fluid within the bursa omentalis. Adhesions close the foramen of Winslow and separate the lesser from the general peritoneal cavity. The fluid which accumulates contains products of pancreatic secretion; necrosis and erosion of adjacent tissues is doubtless due to action of fat-splitting and proteolytic enzymes. At first the contents of the cavity may be sterile (Case IV), but later bacteria find their way from the gangren-

ous pancreas in contact with the duodenum to the peritoneal surface of the gland. In Case I, in which death occurred after twenty-one days, *Bacillus coli*, *Bacillus lactis aërogenes*, and *Bacillus proteus vulgaris* were obtained, and in Case IV, with death two months after onset of illness, *Bacillus coli* and *Streptococcus pyogenes* were found at autopsy.

The wall of the abscess cavity is formed in large part by soft necrotic fat which is usually blackish or gray. There is abundant brown or gray fluid which contains soft greasy necrotic material. Erosion of the retroperitoneal tissue to the left of the root of the mesentery not infrequently occurs and in some instances (Case IV) a sinus penetrates the abdominal wall and approaches the surface of the body in the left lumbar region. Erosion of tissue behind the pancreas may form a communication with the general peritoneal cavity, and in Case IV an immense sub-diaphragmatic abscess had perforated the diaphragm and caused localized empyema. Erosion from without may cause perforation of stomach, duodenum or transverse colon, and in Case III all of these organs have been perforated by an abscess about a gangrenous pancreas. Discharge of necrotic pancreatic tissue from the bowel is recorded by Chiari.

#### SYMPTOMS.

The foregoing study has shown that no sharp distinction can be drawn between pancreatic hemorrhage, hemorrhagic pancreatitis, and gangrenous pancreatitis. These processes are essentially wide-spread necrosis of the parenchyma, associated with injury to the walls of blood-vessels, and hemorrhage; so-called gangrenous

pancreatitis is a late stage of the hemorrhagic lesion: the gland primarily undergoes necrosis. Whereas other causes, notably traumatism, may produce the condition, the most frequent etiological factor is the impaction of a gall-stone in the diverticulum of Vater, diverting bile into the pancreatic duct.

*Stage of Hemorrhage.*—An individual usually in fairly good health, with perhaps a history of gastric disturbance or of gall-stone colic, is suddenly attacked with pain in the epigastric region, accompanied by vomiting and followed by collapse.

Fitz describes as follows the symptoms of acute hemorrhagic pancreatitis: "It begins with intense pain, especially in the upper abdomen; soon followed by vomiting, which is likely to be more or less obstinate, and not infrequently by slight epigastric swelling and tenderness, with obstinate constipation. A normal or subnormal temperature may be present, and symptoms of collapse precede, by a few hours, death, which is most likely to occur between the second and fourth days."

The pain of onset appears suddenly and is of great intensity; it may be paroxysmal or continuous. It is occasionally localized above the umbilicus and to the left of the median line along the course of the pancreas, but may be most intense in the hypochondriac regions or even below the umbilicus. Nausea and vomiting rapidly follow the appearance of pain and may recur with great frequency.

Symptoms of shock usually accompany the disease and within a few hours may cause death. Profound weakness is accompanied by depression of the circulatory system; the pulse is rapid, and circulation may be

so feeble that cyanosis results. The profound collapse and rapidly fatal termination of many cases of hemorrhagic necrosis suggest the presence of an acute intoxication. A similar condition follows the lesion produced experimentally in dogs, and death within twenty-four hours may be caused by the injection of 5 c.c. of bile into the pancreatic duct. The pancreatic enzymes, perhaps increased in activity by presence of bile, act doubtless upon the substance of the gland and produce, both in the human and experimental lesion products which, when absorbed, exert a profoundly poisonous action. Such an explanation of the fatal result appears more probable than that which seeks to refer the symptoms of collapse or shock to an obscure lesion of the sympathetic ganglia near the pancreas.

To prove that death is due to a toxic substance derived from injured pancreatic tissue, Doberauer<sup>64</sup> has transferred pancreatic tissue rendered necrotic by obstruction of its blood supply into the peritoneal cavity of a normal animal. Death has occurred with symptoms which are similar to those of hemorrhagic necrosis of the pancreas produced by other experimental methods; the possibility of bacterial action has been excluded. Gulecke<sup>65</sup> has claimed that pancreatic tissue of a normal dog introduced into the peritoneum of a second animal causes death within twenty-four hours, whereas pancreatic tissue allowed to undergo autolysis is more rapidly fatal; he attributes symptoms of pancreatic necrosis to absorption of pancreatic secretion and to products formed by disinte-

---

<sup>64</sup> Doberauer: *Beit. z. klin. Chir.*, 1906, *xlvi*, 456.

<sup>65</sup> *Loc. cit.*, p. 127.

gration of pancreatic tissue. Egdahl<sup>66</sup> has shown that pancreatic extracts allowed to undergo autolysis are capable of depressing blood-pressure; their toxic effect is greatest when digestion has gone so far that protein constituents of the extract have been destroyed.

Since hemorrhagic necrosis may be caused by the lodgement of a gall-stone in the diverticulum of Vater, patients suffering with this disease not infrequently give a history of preceding gall-stone colic. In Case I the patient underwent an attack of jaundice six months before his fatal illness. In other instances there is a history of repeated paroxysms of severe abdominal pain, doubtless due to the passage of calculi which have failed to lodge at the orifice of the bile duct. Preceding attacks of so-called gastric or gastroduodenal dyspepsia, noted by Fitz, in some cases at least admit of a similar explanation. Moreover, symptoms of the pancreatic disease may be mistaken for those of biliary colic; jaundice has been present in ten per cent. of the cases collected by Gessner. Intensity of the pain, its diffuse epigastric character, with occasional localization on the left side, and the profound collapse usually present, according to Thayer, give sufficient evidence that the pancreas is implicated.

Symptoms suggesting intestinal obstruction have been present in a large proportion of cases and not infrequently operation has been undertaken with the purpose of relieving such obstruction. Constipation which is present in about half of the cases of pancreatic necrosis is not infrequently relieved, according to Gessner,<sup>67</sup> either

---

<sup>66</sup> Egdahl: Jour. of Exper. Med., 1907, ix, 385.

<sup>67</sup> Gessner: Deutsche Zeit. f. Chir., 1899, xliv, 65.

spontaneously or by means of enemata on the fourth day of the disease. Gessner has found in the literature of the subject six cases in which the enlarged head of the pancreas appeared to compress the duodenum; but in most instances symptoms suggesting intestinal obstruction can not be explained by mechanical occlusion of the intestine. Some writers have thought that irritation of the solar plexus and splanchnic nerve may inhibit peristalsis.

With symptoms of intestinal obstruction diagnosis of pancreatic necrosis may be suggested by the localization of pain and distention in the epigastric region. The stercoraceous vomiting and visible peristalsis of intestinal obstruction are not present.

*Stage of Gangrene.*—The violent symptoms of onset may diminish in intensity; Gessner regards the fourth day as critical. When death does not occur opportunity is afforded for invasion of bacteria and for other changes associated with so-called gangrenous pancreatitis; this transition occurs toward the end of the second week of the disease.

In many instances the symptoms of onset are much less severe than those which have been described, and, perhaps associated with an attack of gall-stone colic, may be so slight as to be unrecognizable. The patient survives and the disease pursues a more or less chronic course. The symptoms are essentially those previously mentioned, but they occur with less intensity. Pain is localized in the epigastrium, and vomiting may recur at intervals. Symptoms indicative of suppuration finally give evidence that the necrotic tissue of the pancreas has become infected; an irregular temperature, perhaps with chills, may suggest the presence of abscess, but occasionally fever is absent. An ill-defined tumor felt above the

umbilicus gives more positive proof that fluid has accumulated about the pancreas in the lesser peritoneal cavity. The appearance of such a mass in the epigastric region is due, not to the enlarged pancreas, which is rarely if ever palpable, but to the presence of hemorrhagic or purulent fluid about the organ.

The tumor mass is usually situated in the epigastric region and extends toward the spleen; it varies much in size and its outline is usually definable with difficulty. Such tumors as large as a child's head have been described. In three cases of Körte a mass first found in the left hypochondrium and flank subsequently became palpable between stomach and colon. Inflation of the stomach and in some instances of the colon may aid in localizing the mass which, occupying the bursa omentalis, is situated between these two organs. The stomach separates the tumor from the liver and when inflated tends to cover it. Not infrequently there is a tendency for the abscess, situated within the lesser peritoneal cavity, to erode the tissue over the left kidney (Cases I and IV). A sinus from the cavity may make its way into the lumbar region and cause swelling below the left costal margin as far as the crest of the ilium.

Both in the hemorrhagic and in the gangrenous stage of the disease, those disturbances of digestion which have been noted in describing the general symptomatology of pancreatic disease may occur, but rarely is there such complete destruction of the pancreas that its functional activity is wholly destroyed. Fatty stools have been found in only one instance (Chantemesse and Griffon<sup>68</sup>). In Case I (see also case of Dr. Kelly, p. 174), the patient

---

<sup>68</sup> Chantemesse and Griffon: Bull. Soc. anat., Paris, 1895, 587.

passed clay-colored stools due perhaps to occlusion of both biliary and pancreatic ducts. In two cases of Chiari necrotic pancreatic tissue identified by careful examination was expelled from the rectum and recovery followed.

In only two of the forty-one cases of so-called hemorrhagic pancreatitis, and in but three of forty cases of gangrenous inflammation collected by Körte, was sugar present in the urine. Transient glycosuria has occasionally been observed shortly after onset of symptoms.

In a case described by Benda and Stadelmann<sup>69</sup> symptoms were those of diabetic coma. Almost immediately after onset of violent abdominal pain the patient became comatose; sugar was found in the urine. The pancreas, save a part of the head, was transformed into a soft bloody mass.

Diabetes consequent upon hemorrhagic necrosis of the pancreas has been described by Franke.<sup>70</sup> A man, aged forty-two years, who had previously enjoyed good health, was attacked twelve days before his death with severe abdominal pain, accompanied by vomiting. The pain, which was localized in the region of the umbilicus, continued, and the patient complained much of thirst. When seen, eight days after the onset of symptoms, sugar was found in the urine, and to the amount of 3.5 per cent. was present until death. The fat of the parietal peritoneum, omentum, mesentery, and mediastinum contained numerous foci of necrosis. The pancreas was represented by a large blackish-red mass, which consisted in great part of altered blood, but in a few places still preserved a lobular structure. The gall-bladder was distended and contained a calculus about the size of a plum.

With hemorrhagic necrosis leucocytosis may be present during the first few days after onset of symptoms; in

---

<sup>69</sup> Benda and Stadelmann: *Deutsche med. Woch.*, 1896, xxii, Vereins-Beilage, 138.

<sup>70</sup> Franke: *Inaug. Diss.*, Berlin, 1902.

a case described by Hunt<sup>71</sup> leucocytes numbered 37,000 per cubic millimetre on the first day of illness. Nevertheless, leucocytosis is not constant. (See Case VI, in which leucocytes numbered 9900 per cubic millimetre on the fourth day of the disease.) With so-called gangrenous pancreatitis leucocytes usually vary between 15,000 and 40,000 per cubic millimetre. Case IV shows that their number may diminish with progress of the disease, becoming subnormal before death.

In some reported cases recurrent pancreatitis has been described, but attacks of severe pain and vomiting preceding the fatal illness are doubtless often referable to cholelithiasis. Nevertheless, it cannot be denied that pancreatic necrosis may recur; for should the patient survive a primary attack, the structure of the diverticulum of Vater being favorable, a second attack might follow the expulsion of another stone of appropriate size.

#### TREATMENT.

What has been said concerning the etiology and pathology of acute inflammation of the pancreas demonstrates the futility of medical treatment directed to palliation of the lesion. At the onset of symptoms the attention of the physician will be directed to the profound collapse, and efforts will be made to strengthen the enfeebled circulation. The intense abdominal pain is often uncontrollable by the use of morphia. For the continued vomiting Körte recommends that the stomach be washed out, food by mouth discontinued, and nutrient and stimulating enemata employed.

---

<sup>71</sup> Hunt: Boston Med. and Surg. Jour., 1905, clii, 13.

Only by surgical means can the seat of the disease be reached. When it is possible to make a diagnosis of hemorrhagic necrosis of the pancreas the advisability of operation during the first stage of the disease must be considered. Both Hahn<sup>72</sup> and Woolsey,<sup>73</sup> who have recorded cases in which operation has been followed by recovery, point out the danger of increasing the shock present in such cases by prolonged operations and by manipulation of the intestines. Statistics of Gessner give evidence that operation during the first two weeks is more frequently fatal (only one of twenty-two patients recovered) than operation undertaken during the stage of gangrene (six recoveries after twenty operations). The larger statistics of Mikulicz-Radecki<sup>74</sup> published in 1903 recorded more favorable results; among forty-six operations performed in the early stage of the disease there were nine recoveries, and among thirty-five operations in the subacute stage, eighteen recoveries. Since the mortality of untreated cases is unknown these figures have little value. Mikulicz-Radecki recommends early operation with evacuation of hemorrhagic exudate which is often present in the lesser peritoneal cavity, and free drainage by gauze.

Hemorrhage is rarely profuse and bears little relation to the severity of the condition. In some cases symptoms are so indefinite that hemorrhagic necrosis of the pancreas is not suspected, whereas in other instances, though such a lesion suggests itself, the evidence is insufficient

---

<sup>72</sup> Hahn: *Deutsche Zeit. f. Chir.*, 1900, lviii, 1.

<sup>73</sup> Woolsey: *Ann. of Surg.*, 1903, xxxviii, 603.

<sup>74</sup> Von Mikulicz-Radecki: *Trans. of the Cong. of Amer. Phys. and Surg.*, 1903, vi, 55.

to exclude the presence of other conditions. Experience has shown that the disease is often first recognized by the presence of fat necrosis noted at operation undertaken for the relief of a supposed intestinal obstruction or perhaps performed for the purpose of exploration demanded by continued symptoms of grave abdominal disorder. Should the individual survive the early symptoms of shock, infection of the gangrenous tissue and abscess formation limited to the lesser peritoneal cavity soon demand exploration and drainage. Septic fever, and the presence of a palpable mass in the epigastrium, indicate the necessity of operative interference.

When disseminated fat necrosis indicates the presence of a pancreatic lesion, exploration of the lesser peritoneal cavity through the gastrocolic omentum may disclose the presence of a pancreatic or peripancreatic abscess and permit its evacuation. Thick abdominal walls and omental fat in large quantity, together with an accumulation of necrotic tissue and partially clotted blood within the lesser peritoneal cavity, at times make access to the pancreas itself difficult or impossible, at least undesirable.

Incision is usually made in the median line or over the most prominent part of the tumor mass and the abscess-like cavity is entered through the gastrocolic ligament. The operation is facilitated by adhesions binding this part of the omentum to the abdominal wall, and Körte recommends that the gastrocolic ligament be stitched to the abdominal wall about the incision when they are absent; the general peritoneal cavity may be protected by gauze. Fluid together with particles of necrotic tissue contained in the peritoneal cavity are evacuated. When the cavity extends far to the left it

may be possible to obtain more effective drainage by a second incision to the left of the first. When erosion has occurred through the retroperitoneal tissue into the left flank, the cavity may be reached through a horizontal or oblique incision similar to that employed for extirpation of the left kidney (Körte). For efficient drainage incisions both in the epigastric and in the left lumbar regions may be necessary.

During whatever stage of the disease operation is performed, the condition of the bile passages is important and may offer an indication for interference. The common bile duct should be examined so far as it is possible, and, bearing in mind the mechanism by which a small calculus may produce the lesion, the operator should, if feasible, exclude the possibility that a stone is still lodged in the diverticulum of Vater. Should such impaction be found, removal of the calculus is essential in order to prevent further destruction of the pancreas. In a considerable number of cases the gall-bladder will be found filled with gall-stones, even though the bile ducts are free. These stones may be of such size that any one of them lodged at the orifice of the common duct might divert bile into the pancreatic duct.

In a patient with acute pancreatic disease and fat necrosis, operated upon by Dr. Howard A. Kelly, recovery followed the removal of a large number of small gall-stones from the gall-bladder.

Mrs. W., aged forty-one years, was admitted to the care of Dr. Kelly, May 17, 1902. For several years preceding, she had suffered with attacks of pain in the epigastrium. Her present illness began with severe pain in the left side and back, lasting about three days, and

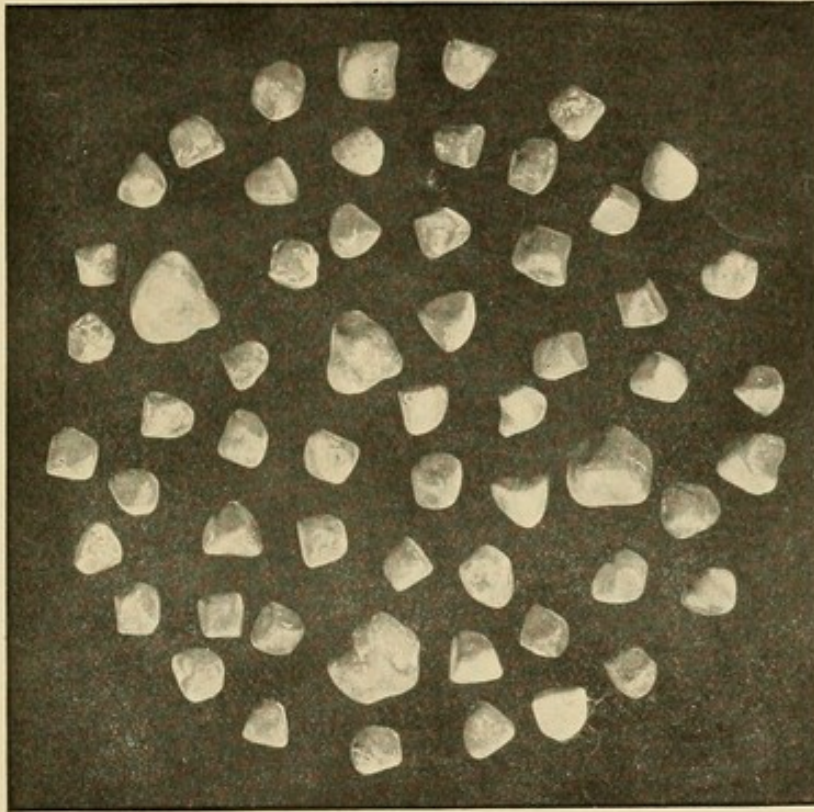



FIG. 25.—Calculi which were removed from the gall-bladder by Dr. Kelly; compare with Fig. 12.



subsequently recurring in paroxysms, necessitating the use of morphia. There was slight nausea, but no vomiting. The stools were clay-colored and of very foul odor; the temperature varied from 98° to 100° F. An operation was undertaken on the tenth day of illness. The omentum was found to contain opaque, white foci of fat necrosis. An oblong mass about 9 cm. in length and 6 cm. broad lying behind the greater curvature of the stomach occupied the position of the pancreas. Further examination was not possible on account of the great quantity of fat. The gall-bladder was found partially collapsed about a large number of small gall-stones. An incision was made through the skin and abdominal wall opposite the gall-bladder; the organ was stitched to the edges of the wound and opened. About fifty small calculi of almost uniform size were removed (see Fig. 25). The wound opposite the gall-bladder healed slowly, and the patient made an uneventful recovery.

In the preceding case necrosis of the pancreas and consequent fat necrosis were doubtless caused by the passage of a small calculus similar to calculi so numerous in the gall-bladder. These stones differed but little from those which filled the gall-bladder in Cases I, III and IV, and were of the same uniform size. Their removal offered the best assurance of immunity from subsequent attacks. Similar instances of recovery following removal of calculi from the gall-bladder of individuals suffering with pancreatic necrosis are described by Mayo,<sup>75</sup> Lilienthal,<sup>76</sup> and Robson and Cammidge.<sup>77</sup>

---

<sup>75</sup> Mayo: *Jour. of the American Med. Assoc.*, 1902, xxxviii, 107.

<sup>76</sup> Lilienthal: *Ann. of Surg.*, 1906, xliii, 143.

<sup>77</sup> Robson and Cammidge: *The Pancreas*, p. 397.

## CHAPTER VII.

### FAT NECROSIS.

REPEATED reference has been made to the occurrence of necrosis of fat in association with hemorrhagic necrosis and other lesions of the pancreas. Disseminated focal fat necrosis has been the subject of much anatomical and experimental research since Balsler directed attention to it in 1882, and the relationship of this peculiar lesion to alterations of the pancreas is now well established.

Balsler<sup>1</sup> observed in fat immediately about the pancreas small, opaque, white areas, which were shown by microscopic examination to be composed in great part of necrotic fat-cells. This lesion was present in five of twenty-five bodies which he examined. In two cases a similar process not only implicated the fat about the pancreas, but was present in scattered foci at a considerable distance from the organ, and was, he believed, the cause of death.

When widely scattered the condition has been designated disseminated or multiple fat necrosis. The more minute foci, limited to fat within or upon the organ, when carefully sought for, are often found at autopsy, but their frequency is somewhat less than Balsler supposed.

Recognition of disseminated fat necrosis, difficult only on account of the relative infrequency with which it is

---

<sup>1</sup> Balsler: Ueber Fettnekrose, Virchow's Arch., 1882, xc, 520.

encountered, is of considerable importance to the surgeon, since it indicates the existence of some grave alteration of the pancreas. On opening the abdomen the omentum, and possibly other fat, is found studded with round or oval areas, several millimetres in diameter and very conspicuous on account of their opaque white or yellow color, which is in sharp contrast with the translucent golden yellow of the normal fat. A narrow hemorrhagic zone frequently surrounds such areas.

This lesion, most extensive in the neighborhood of the pancreas, is usually limited to the fat of the abdominal cavity. Areas of necrosis may be confluent near the gland and thickly scattered elsewhere in the fat abutting upon the peritoneal cavity. In two cases Hansemann<sup>2</sup> observed foci of fat necrosis in the subcutaneous tissue; they corresponded in location to reddish areas visible during life upon the overlying skin. Chiari<sup>3</sup> has recorded a very remarkable case: areas of fat necrosis, often as large as a pea, were present in the fatty tissue about the bursa omentalis within which lay the necrotic pancreas, in the mesentery, in the subperitoneal fat of the abdominal wall, in the subpericardial and subpleural fat, and in the subcutaneous tissue. Balser has also seen the pericardial fat implicated in the process.

Spontaneous fat necrosis has been found in domestic animals by several observers,—Balser, Williams,<sup>4</sup> Olt,<sup>5</sup> and others. In pigs wide-spread dissemination of the

---

<sup>2</sup> Hansemann: Berliner med. Gesellsch., Sitzung vom 4 December, 1889; Berliner klin. Woch., 1889, xxvi, 1115.

<sup>3</sup> Chiari: Prager med. Woch., 1883, viii, 285, 297.

<sup>4</sup> Williams: Report of the Path. Lab. of the Univ. of Buffalo, 1900, No. 1.

<sup>5</sup> Olt: Deutsche Thierärztl. Woch., 1898, vi, 117.

lesion has been found by Olt, who records its presence in the subperitoneal fat, in the intermuscular septa, and in the subcutaneous tissue of the abdominal and thoracic walls.

Chiari found fat necrosis in five of six instances of pancreatic disease. Fitz offered the suggestion that fat necrosis was consequent upon a lesion of the pancreas, and supported this conclusion by numerous instances in which the two conditions had been associated. The lesion which usually accompanies fat necrosis is hemorrhagic necrosis of the pancreas and not infrequently the organ is found to be gangrenous in appearance. Occasionally the gland lies in the cavity of the bursa omentalis dissected almost free from the surrounding tissue; such sequestration, Langerhans has thought, may be the result of extensive necrosis of the fat surrounding it. More rarely other pathological conditions are present; chronic suppurative pancreatitis is rarely accompanied by fat necrosis, and in a few instances chronic interstitial inflammation has coexisted with it.

The occurrence of fat necrosis in association with pancreatic disease has been frequently noted in individuals with abundant fatty tissue. In the statistics of Truhart corpulence has been present in 50 per cent. of cases with fat necrosis; in 90 of 267 cases he designates the condition *obesitas universalis*. In 43 cases infiltration of the pancreas with fat (lipomatosis) was noted.

The microchemical and histological studies of R. Langerhans<sup>6</sup> have explained the essential nature of the

---

<sup>6</sup> Langerhans, R.: Ueber multiple Fettgewebsnekrose, Virchow's Arch., 1890, cxxii, 252.

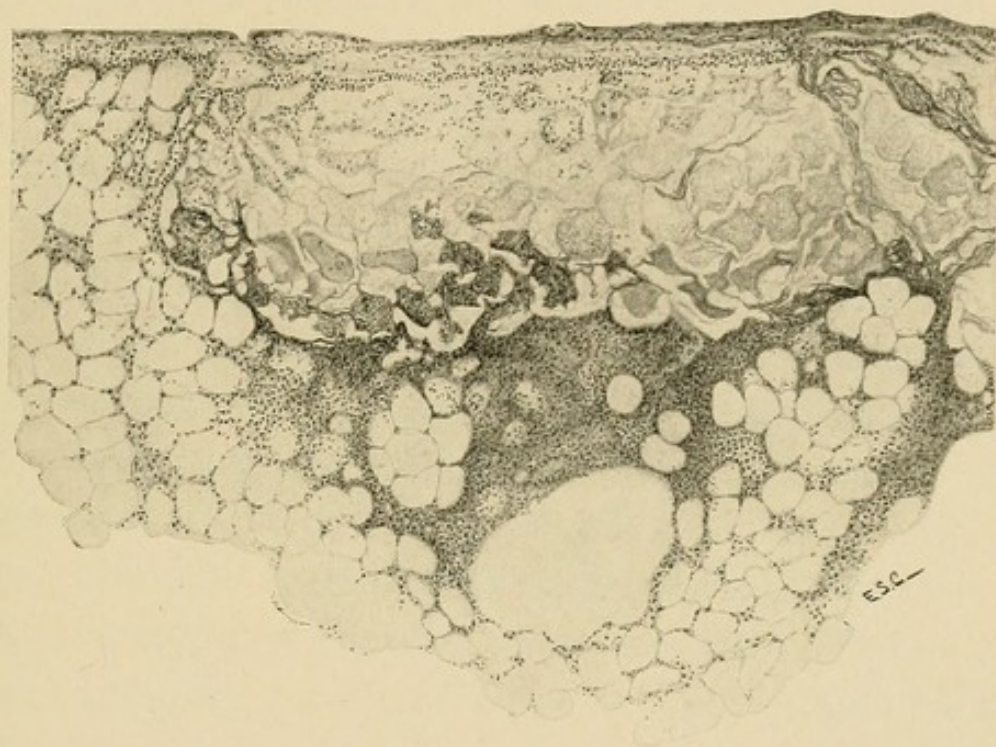



FIG. 26.—Focus of fat necrosis. Fat cells have lost their nuclei but retain their outline; calcium deposited in some of the necrotic cells causes their contents to stain deeply with hæmatoxylin. Nuclear fragments have accumulated at the periphery of the necrotic focus (hæmatoxylin and eosin).



process. He has shown that the changes demonstrable within the fat-cells are associated with the splitting of the fat molecule into its fatty acid and the soluble constituent glycerin. Fatty acids are deposited as needle-like crystals within the cell which has lost its nucleus and is evidently necrotic, while the soluble glycerin is absorbed. Very soon the fatty acids unite with calcium to form calcium salts, and within the cellular outline which is still preserved are irregular, often globular masses, in which the presence of lime salts may be demonstrated by microchemical reactions.

Benda<sup>7</sup> has shown that acetate of copper combines with fatty acid present in necrotic fat and produces a bluish-green compound; calcium salts are less intensely stained, whereas neutral fats of the normal fat-cells are unchanged. By this method it is possible to identify single necrotic cells or groups of such cells so small that they are not recognizable and fat necrosis may be demonstrable in subjects in whom none has been found at autopsy.

Fragments of nuclei which have been destroyed may be abundant at the edge of the focus of necrosis (Fig. 26). A few polynuclear leucocytes find their way to the periphery of the necrotic fatty tissue, but when numerous, their presence is the result of secondary infection of the dead tissue. Proliferation of fixed tissue cells occurs at the periphery of the necrotic area and is most conspicuous in the neighborhood of strands of connective tissue, but often the zone of reaction is not complete, and necrotic cells are in contact with those which are

---

<sup>7</sup> Benda: Virchow's Arch., 1900, clxi, 194.

still unchanged. In this peripheral zone of cellular proliferation, in addition to cells of lymphoid type, are much larger round or oval cells with vesicular nuclei and abundant cytoplasm studded with minute fat-globules—fat-cells in process of multiplication. Similar cells are occasionally multinucleated and of such size that they may be called giant cells.

A case described by Körte shows that foci of fat necrosis may disappear completely. At operation upon a patient with acute cholecystitis typical foci of necrosis were found, but one year later when laparotomy was performed for the removal of gall-stones there was no evidence of fat necrosis. Wells<sup>8</sup> observed complete absence of fat necrosis at the end of eleven days after injection of pancreatin into the peritoneal cavity of a dog, although necrosis of fat had been found when the abdomen was opened on the fourth day after injection.

*Etiology.*—Attempts have been made to refer the occurrence of fat necrosis to the action of micro-organisms, and in many cases bacteria have been isolated from the lesion. The explanation of their presence is doubtless that proposed by Welch,<sup>9</sup> who identified *Bacillus coli* in association with so-called hemorrhagic pancreatitis with fat necrosis. Diphtheritic and ulcerative colitis was present, and the colon bacillus was found not only in foci of fat necrosis, but in the mesenteric glands, the liver, the bile, the lungs, the spleen, and the kidneys. The lesion of the colon had apparently facilitated the invasion of *Bacillus coli*, and its presence in foci of fat

---

<sup>8</sup> Wells: *Jour. of Med. Res.*, 1903, ix, 70.

<sup>9</sup> Welch: *Med. News*, 1891, lix, 669.

necrosis was thought to be a secondary event having no relation to their production. This opinion has been held by Hlava, Fitz, Leonhard, and others. From the literature of the subject Truhart<sup>10</sup> collected 80 records of careful bacteriological examination; no bacteria were found in 43 instances, whereas in 37, bacteria were obtained from the pancreas, from the peritoneal fluid or from foci of necrosis. Various micrococci were found 10 times, bacilli, usually *Bacillus coli*, 22 times, and unidentified micro-organisms in other instances. The discordant results of bacteriological examinations give little support to the opinion that the lesion is caused by micro-organisms and experimental studies oppose it.

The proximity of foci of fat necrosis to the pancreas and their association with various pancreatic lesions have suggested the possibility that products of this organ are active in their causation. To test this hypothesis, Langerhans injected into the fat-tissue of rabbits and dogs an infusion prepared with antiseptic precautions from the pancreas of rabbits, and in one of thirteen experiments succeeded in producing in the perirenal fat of a dog a small opaque focus which had the histological character of fat necrosis, but was accompanied by an acute inflammatory reaction. He reached the conclusion that pancreatic juice acting on living fat-tissue might cause necrosis.

The experiments of Hildebrand<sup>11</sup> and Dettmer<sup>12</sup> are interesting and important. By placing a ligature about

---

<sup>10</sup> Truhart: Multiple abdominale Fettgewebsnekrose, Weisbaden, 1902.

<sup>11</sup> Hildebrand: *Cent. f. Chir.*, 1895, xxii, 297.

<sup>12</sup> Dettmer: *Inaug. Diss.*, Göttingen, 1895.

the pancreas they obtained necroses in the fat near that part of the gland distal to the ligature. In other experiments they tied the veins of the ligatured part to prevent, as Hildebrand suggests, the possible absorption of the obstructed secretion. The gland-tissue became congested and infiltrated with blood, and in its neighborhood foci of fat necrosis were somewhat more abundant than in the former experiments. They were able, moreover, to produce similar lesions in the immediate neighborhood of the gland by merely cutting the organ transversely, thus allowing the pancreatic juice free access to the abdominal cavity. Hildebrand has maintained that obstruction to the outflow of the secretion, alone or combined with occlusion of the veins, or the escape of pancreatic juice into the peritoneal cavity, results in the production of typical fat necrosis about the pancreas and even in the omentum and in the mesentery. Both Flexner<sup>13</sup> and Williams<sup>14</sup> have confirmed the observations of Hildebrand and Dettmer. By placing a ligature about the gland, tying the veins of the part of the organ distal to the ligature, and at times tearing the parenchyma with a sharp hook, they obtained fat necrosis in a considerable number of their experiments.

Milisch<sup>15</sup> attempted to reproduce the lesion in cats by allowing the pancreatic juice to escape into the peritoneal cavity. A section, several centimetres in length, was excised from the splenic arm of the gland near the duodenum, thus isolating the remainder of the splenic

---

<sup>13</sup> Flexner: *Jour. of Exper. Med.*, 1897, ii, 413.

<sup>14</sup> Williams: *Boston Med. and Surg. Jour.*, 1897, cxxxvi, 345.

<sup>15</sup> Milisch: *Inaug. Diss.*, Berlin, 1897.

part and giving its secretion free access to the abdominal cavity. In three of five experiments, the excised piece of pancreas was left free in the peritoneal cavity and necroses were found in the immediate neighborhood of the organ and about the transplanted tissue. He concludes from his experiments that fat necrosis may be caused by pancreatic juice which has escaped into the abdominal cavity.

Oser produced foci of fat necrosis about the pancreas and in the omentum by ligating all the blood-vessels of the organ and separating it from the duodenum, thus depriving it of its blood supply. By completely obstructing the circulation of part of the pancreas for twenty minutes, Blume<sup>16</sup> produced hemorrhagic infiltration of the tissue and fat necrosis in the neighborhood of the injured parenchyma.

A number of experimenters—Hlava, Körte,<sup>17</sup> Oser, Flexner<sup>18</sup> and subsequent observers—have obtained necrosis of fat by injecting into the parenchyma of the gland, or into the duct after opening the duodenum, various substances,—artificial gastric juice, dilute acids and alkalis, oil, and other substances,—causing thereby hemorrhagic necrosis of the pancreas.

In the experiments cited above, conditions have been present which afford an opportunity for the escape of the pancreatic secretion into the tissue surrounding the gland; it may be forced backward into the tissue as a

---

<sup>16</sup> Blume: *Beit. z. wiss. Med., Festsch. z. Naturforscherversam. in Braunschweig*, 1897, 139.

<sup>17</sup> Körte: *Berliner Klinik*, 1896, No. 102.

<sup>18</sup> *Loc. cit.*, p. 126.

result of duct-obstruction, or, when the parenchyma is injured, gradual diffusion may take place. Ever since Langerhans explained the process which takes place within the fat-cells, it has been assumed that the fat-splitting enzyme of the pancreas is the active factor in producing the lesion. Demonstration of a fat-splitting enzyme in the necrotic foci was made by Flexner. Bits of such tissue from human and from experimental lesions, when brought into contact with neutral butter-fat, were found to contain an enzyme with the power of splitting this fat and setting free acids readily recognized by their odor and reaction.

Wells has found that commercial pancreatin injected into the peritoneal cavity of dogs produces fat necrosis but loses this property when exposed during five minutes to a temperature of 71° C.; this temperature destroys both trypsin and steapsin. Extracts of pancreas which have been subjected to autolysis lose their ability to split fat but still cause proteolysis; though they contain trypsin they have lost the power to produce fat necrosis.

Fat necrosis produced by experimental methods has been limited to the abdominal fat, and usually to the immediate neighborhood of the pancreas. The wide distribution occasionally observed in human cases, where almost the entire abdominal fat, fat within the pleural cavity and even subcutaneous fat, may be studded with necrotic foci, is rarely reproduced. It has been claimed (Oser) that alterations so widely disseminated and at so great a distance from the pancreas cannot be explained by contact with its secretion and it has been suggested that the process is not in all cases the same.

*Experimental Fat Necrosis.*—In experiments which I have undertaken <sup>19</sup> it has been found possible to produce focal necrosis of the fat-tissue as wide-spread as that observed in human cases and in lower animals. They show that complete obstruction to the outflow of the pancreatic secretion may cause, after the lapse of several weeks, necrosis of the fat in parts far distant from the pancreas.

Both pancreatic ducts were ligated in two places and cut between the ligatures. In the cat, which was used for these experiments, the main duct enters the duodenum with the common bile duct and is readily found. By carefully separating the pancreas from the duodenum the smaller duct may be exposed, where it penetrates the intestine about 1 cm. below and somewhat to the left of the larger duct. The operation necessitates little or no injury to the substance of the gland. In order to facilitate the penetration of the secretion into the fat-tissue, the right border of the omentum near its gastric attachment in several instances has been drawn through the opening made by separating the pancreas from the duodenum. Several successful experiments will be described in detail.

EXPERIMENT I.—A full-grown cat, of which the pancreatic ducts have been ligated, has died at the end of twenty-five days. The subcutaneous fat over the lower half of the abdomen and in front of the symphysis pubis is profusely studded with conspicuous opaque, white foci of irregular shape, often 2 mm. in diameter. The omentum is an almost homogeneous mass of opaque, white, slightly friable material.

---

<sup>19</sup> Contributions to the Science of Medicine, dedicated to William H. Welch, Johns Hopkins Hospital Reports, 1900, ix, 859. The experiments to be quoted are designated by the numbers used in that article.

The fat of the mesentery of both the small and large intestines is converted into the same opaque, white material and the perirenal fat, the retroperitoneal fat, and masses in the pelvis on either side of the bladder show in large part the same transformation. Below the peritoneum of the diaphragm and of the lateral abdominal walls are numerous slightly raised areas of similar appearance. The greater part of the fat in the parietal layer of the pericardium has a normal translucent appearance, but on the right side are several conspicuous opaque, white areas, and along the carotid and left subclavian arteries are several similar foci. The pancreas, of which the duodenal part is embedded in a homogeneous mass of transformed fat, is much smaller than usual. No growth is obtained on agar-agar from turbid fluid in the peritoneal cavity. Microscopic examination of the opaque, white fat of the omentum, subcutaneous tissue, and pericardium demonstrates the histological character of fat necrosis. The omentum is not wholly transformed, as it appears to be upon macroscopical examination, but about its blood-vessels is intact tissue. Between the necrotic material and the unchanged fat is usually seen a well-marked zone of cell-proliferation. The pancreas shows a moderate increase of its interstitial tissue.

EXPERIMENT II.—The pancreatic ducts of a full-grown cat have been ligated in two places and cut between the ligatures. The animal has died twenty days after the operation. The subcutaneous tissue of the abdomen is found to contain conspicuous opaque, white areas, the largest of which are about 2 mm. in diameter. The omentum is transformed into an almost homogeneous mass of opaque, somewhat friable, material. The mesenteric fat of the small and large intestines, the retroperitoneal fat and the surface of the diaphragm are very thickly studded with large, conspicuous, opaque, white areas. In the parietal layer of the pericardium are several very conspicuous areas of fat necrosis. The pancreas is of small size and firmer than usual.

Stained coverslip preparations made from the peritoneal exudate contain numerous desquamated endotheloid cells, but leucocytes are almost completely absent, and bacteria are not discoverable. A small piece of omentum and a bit of subcutaneous fat containing opaque foci were tested for the presence of a fat-splitting enzyme and well-marked reactions were obtained.

In these experiments necrosis involving almost the entire omental fat, the greater part of the mesenteric fat, and to less extent the fat-tissue below the parietal peritoneum of the perirenal region, the lateral abdominal walls, and the diaphragm, the fat of the subcutaneous tissue and of the pericardium has followed the ligation of both pancreatic ducts. Obstruction to the outflow of the pancreatic secretion causes its diffusion into the surrounding tissue. Although no colored constituent, like the pigment of the bile, makes the pancreatic secretion evident to the eye, its presence is shown by the injurious effects which it exerts upon the tissues. Jaundice is the index of hepatic obstruction, whereas fat necrosis indicates obstruction of the pancreatic ducts. In accordance with this relationship to the pancreas, we find the change most marked in the neighborhood of the organ, whereas in more distant parts, which may be reached by gradual diffusion through continuous layers of connective tissue, the process is much less extensive. In these experiments a fat-splitting enzyme, doubtless that of the pancreatic juice, has been found in the distant subcutaneous foci as well as in the necrotic fat adjacent to the pancreas.

In the first experiment the animal died at the end of twenty-five days; in the second, in which the lesion was somewhat less extensive, in twenty days. In four subsequent experiments of the same series the animal survived a shorter time, and presumably less opportunity was afforded for diffusion of pancreatic secretion. The distribution of necrosis was much less extensive and was confined to the fat in closer proximity to the pancreas.

In two experiments in which death occurred within two days after operation foci of necrosis were not demonstrable. A third cat, with ligated ducts, survived twenty-five days, but no foci of fat necrosis were found at autopsy; the pancreas was diminished in size and firm in consistence and the main duct was markedly dilated. Microscopic examination demonstrated the presence of advanced chronic interstitial inflammation. It is possible that induration of the interstitial tissue consequent upon chronic inflammation may retard the diffusion of the obstructed secretion.

In the experiments, in which widely disseminated necrosis followed ligation of the ducts, the animal survived, one, twenty, the other, twenty-five days; while in several instances, in which the animal lived a shorter time, less extensive necrosis resulted. If this difference may be explained by assuming a gradual diffusion of the pancreatic secretion, stimulation of the secreting activity of the gland after ligation of its ducts will hasten the diffusion and more rapidly cause necrosis in parts distant from the organ. In order to test this hypothesis, pilocarpin, which has been shown by Heidenhain,<sup>20</sup> Gottlieb,<sup>21</sup> and others to stimulate pancreatic secretion, was administered to an animal of which the ducts had been ligated.

EXPERIMENT X.—The pancreatic ducts of a full-grown cat have been ligated. Pilocarpin muriate (0.005 Gm.) has been injected subcutaneously on the following day at 12 M., and again at 2 P.M.; two days later the same dose has been repeated at 2 P.M. On the following


---

<sup>20</sup> Heidenhain: Hermann's Handb. d. Physiol., v, 197.

<sup>21</sup> Gottlieb: Arch. f. exper. Path. u. Pharm., 1894, xxxiii, 261.

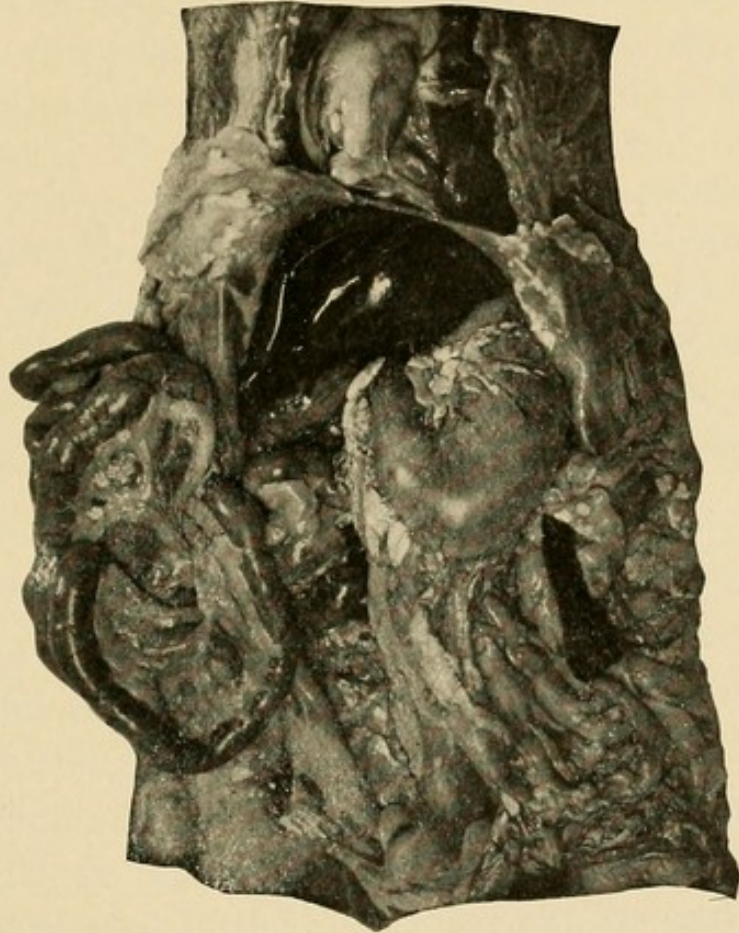

FIG. 27.—Experimental fat necrosis; administration of pilocarpin after ligation of pancreatic ducts. Foci of necrosis in omental and mesenteric fat, in fat below parietal peritoneum, and in fat of parietal pericardium (Experiment x.).



day, at 11 A.M., the animal is found dead. The omentum is studded throughout with conspicuous opaque, white areas; along the right border near the stomach they are confluent, and involve almost the whole surface (see Fig. 27). Similar areas are thickly scattered in the duodenal mesentery near the pancreas, in the mesentery of the small and large intestine, in the retroperitoneal tissue, in the subperitoneal tissue upon the surface of the diaphragm and in the intermuscular septa of the abdominal wall. In the anterior and right wall of the parietal pericardium are scattered opaque, white foci about 2 mm. in diameter. The pancreas is firm in consistence.

*Control.*—The operation performed upon the preceding animal has been repeated on a well-grown cat, which has been killed at the end of four days; pilocarpin has not been administered. Minute opaque, white areas are present in the neighborhood of the ligated ducts, in the omentum near the pyloric end of the stomach, and in the mesentery, but are confined to the immediate neighborhood of the pancreas.

In order to test the ability of the fully formed pancreatic juice to produce fat necrosis when injected into fat-tissue, an attempt was made to cause the secretion to escape directly from the gland into the subcutaneous fat. To accomplish this object the duodenal part of the pancreas with the ligatured ends of the ducts were drawn through an incision in the left rectus muscle and brought in contact with the subcutaneous fat-tissue. Previous experiments had shown that the ligature in many instances ceased after a time to bind the duct, and was found loose in the tissue; but before this rupture occurred opportunity had been afforded for the partial healing of the abdominal wound, so that the secretion, finally escaping, was poured into the subcutaneous fat. The operation was performed upon three animals. In two instances suppuration of the abdominal wound ensued and no necrosis of fat resulted.

EXPERIMENT XIII.—The operation previously described was performed upon a full-grown cat. The animal, which became much emaciated, died twenty-seven days later. Opposite the transplanted pancreas is a cavity in the subcutaneous tissue undermining the skin for a considerable distance to the left of the median line and containing thick, viscid material, which microscopically shows fat globules in abundance, but no leucocytes. The cavity has broken through the skin at a point opposite the pancreas. The tissue forming its wall is very thickly studded with irregular, opaque, white areas, which in many places are confluent, forming masses of homogeneous necrotic fat. Foci of fat necrosis are widely scattered in the subcutaneous tissue over the left side of the thorax and abdominal wall, being most abundant opposite the above-mentioned cavity. The pancreas is diminished in size and firm in consistence. Microscopic examination shows that the opaque white tissue has the histological character of fat necrosis.

The foregoing experiments show that the pancreatic secretion of the cat escaping from the pancreatic duct into the tissue about the pancreas, causes wide-spread necrosis of the fat, not only of the abdomen, but of the subcutaneous tissue and of the pericardium as well, thus reproducing the wide-spread dissemination observed in man. The extent of the process is dependent upon the gradual diffusion of the fat-splitting enzyme and corresponds in some degree with the length of time which the animal has survived the operation; stimulation of the secreting activity of the gland hastens this diffusion. Wells thinks with good reason that diffusion of pancreatic enzymes may occur by way of the lymphatic channels.

*Application of Experimental to Clinical Observations.*—Conditions resembling in greater or less degree those of the foregoing experiments are at times associated with focal fat necrosis in human subjects. Occlusion of the duct of Wirsung may be accompanied by necrosis of fat;

lesions of the parenchyma secondary to duct obstruction are usually present as well. Dieckhoff<sup>22</sup> records such a case in which the widened duct was filled with concretions and the gland was the seat of purulent inflammation. In an autopsy performed by Prof. Welch in the pathological laboratory of the Johns Hopkins Hospital small foci of peripancreatic fat necrosis were associated with occlusion of the pancreatic duct by numerous calculi; the gland was the seat of chronic inflammation. Williams<sup>23</sup> records a similar case. Carcinoma of the head of the pancreas occluding the common bile duct—and presumably the duct of Wirsung as well—was in a case of Katz and Winkler<sup>24</sup> accompanied by focal fat necrosis.

In several instances of disseminated fat necrosis gallstones have lodged in the ampulla of Vater, partially or completely closing the main pancreatic duct; in the absence of hemorrhagic necrosis, foci of fat necrosis have been produced. Of especial interest are the cases reported by Flexner and by Fraenkel,<sup>25</sup> in which, though disseminated fat necrosis has been present, no lesion of the pancreas is recorded. In such cases there can be little doubt that a gall-stone has compressed the pancreatic duct.

In the following case both inflammation of the pancreas and necrosis of fat were doubtless due to the passage of one or more calculi through the diverticulum of Vater, and were the result of duct-obstruction, pancreatic

---

<sup>22</sup> Dieckhoff: Festsch. f. Thierfelder, Leipzig, 1895.

<sup>23</sup> *Loc. cit.*, p. 177.

<sup>24</sup> Katz and Winkler: Die multiple Fettgewebsnekrose, Berlin, 1899; Arch. f. Verdauungskr., 1898, iv, 289.

<sup>25</sup> Fraenkel: Münchener med. Woch., 1896, xliii, 813, 844.

secretion being forced into the tissue in and about the gland.

CASE VIII.—Woman, aged fifty years. *Anatomical Diagnosis.*—Cholelithiasis with calculi in the gall-bladder, cystic, hepatic, and common ducts. Adenocarcinoma of the gall-bladder. Jaundice. Chronic interstitial pancreatitis. Peripancreatic fat necrosis.

The much-contracted gall-bladder and the hepatic and cystic ducts are filled with faceted calculi. The common bile duct contains two stones, each about 1 cm. in diameter, but none are present near its termination, where the wall is somewhat thickened and fibrous. The pancreas is the seat of chronic interstitial inflammation, and foci of fat necrosis occur in the neighborhood of the gland.

The not infrequent association of fat necrosis and chronic interstitial pancreatitis admits a similar explanation. In two cases to be cited in discussing chronic interstitial pancreatitis the two conditions occur, but are unaccompanied by any obstruction of the large ducts. The presence of newly formed contracting fibrous tissue affords abundant opportunity for the constriction of the smaller ducts. In one of these cases many such ducts on microscopic examination were found widely dilated and filled with stagnant secretion. Local obstruction to the outflow of the pancreatic juice doubtless causes its diffusion into the adjacent fat, thus producing foci of necrosis; but, as I have mentioned before, induration of the interstitial tissue probably tends to inhibit dissemination of the lesion.

In some of the experiments which have been described, especially when the pancreatic ducts have been transplanted into the subcutaneous fat, pancreatic juice has passed directly from the duct into the surrounding tissue. Somewhat similar conditions have occasionally been ob-

served in human cases. Necrosis of the pancreatic tissue has in certain instances, as in those described by Chiari, Fraenkel, and Körte, caused such disintegration of the organ that the ruptured duct has communicated directly with the cavity of the bursa omentalis, in which the pancreas has lain. Fat necrosis has been present in the wall of the cavity, and usually widely distributed in the abdominal fat. The remarkable case of Chiari, in which the pericardial and subpleural fat has contained foci of necrosis, belongs to this group.

In the majority of instances widely disseminated fat necrosis is associated with hemorrhagic necrosis of the pancreas or with its sequel, so-called gangrenous pancreatitis. Experimental necrosis produced by injecting into the organ a variety of substances, of which the common character is an ability to injure the parenchyma of the gland, is accompanied by similarly disseminated fat necrosis. Here fat necrosis is the result of a lesion which permits diffusion of pancreatic secretion from the injured parenchyma into the surrounding tissue, and the same explanation is applicable to human cases. Where hemorrhagic necrosis is caused by a small calculus lodged in the diverticulum of Vater, an additional factor is involved. Since the calculus occludes the duodenal orifice of the duct, secretion from uninjured parts of the gland is dammed back, and its diffusion into the surrounding fat is facilitated by necrosis of the parenchyma. Bile enters the pancreatic duct and is mixed with pancreatic juice. The wide distribution of fat necrosis which occurs in such cases and is similarly produced by experimental introduction of bile or bile salts into the pancreatic duct of animals is doubtless due in part to the well-known

power of bile to increase the activity of the fat-splitting enzyme of the pancreas.

It has been claimed that fat necrosis may occur without lesion of the pancreas, but none of the cases which illustrate the independent occurrence of fat necrosis are described so completely that disease of the gland can be excluded. Exceptions perhaps are the unique cases of Wulff<sup>26</sup> and of Fabyan.<sup>27</sup> The following case has been described by Wulff:

A man forty years of age had abdominal pain most severe in the region of the cæcum; incision into what appeared to be an abscess above Poupart's ligament disclosed fat transformed into wax-like material. A pure culture of *Staphylococcus pyogenes aureus* was obtained. Death occurred as the result of hemorrhage on the nineteenth day of the disease. Preperitoneal fat of the abdominal wall had undergone necrosis; there was a retrocæcal abscess containing necrotic fat but the appendix was normal. The omentum and mesentery contained disseminated foci of fat necrosis and similar foci were present in the pericardium. The pancreas was surrounded by fat in which were small foci of necrosis, but the gland was normal. The nature of the retrocæcal abscess was undetermined.

The exceptional character of such cases suggests the possibility that a localized lesion of the pancreas has escaped notice. An aberrant pancreas in the wall of the small intestine might explain a lesion similar to that just described; Warthin<sup>28</sup> has observed fat necrosis about an aberrant gland. The occurrence of fat necrosis produced by intestinal fluid containing fat-splitting enzyme of the pancreas cannot be excluded. In the case of Fabyan fat

---

<sup>26</sup> Wulff: *Berliner klin. Woch.*, 1902, xxxix, 734.

<sup>27</sup> Fabyan: *Bull. of the Johns Hopkins Hosp.*, 1907, xviii, 349.

<sup>28</sup> Warthin: *Phys. and Surg.*, 1904, xxvi, 337.

necrosis limited to the subcutaneous tissue of the face and elsewhere occurred in a child fourteen days old; there was no lesion of the pancreas or intestine.

*Parapancreatic Fat Necrosis.*—The not infrequent occurrence of minute foci of fat necrosis in and upon the pancreas was first noted by Balser; the condition, which may be designated parapancreatic fat necrosis, was found in five of twenty bodies which he examined. On account of their small size, seldom more than a millimetre in diameter, and their limited distribution, they are frequently overlooked, but otherwise agree in character with the lesion which, owing to its greater extent and distribution, has been designated disseminated fat necrosis. Langerhans found these minute foci of necrosis in four of twenty-eight autopsies, Chiari twenty-three times in seventy-five autopsies, Williams eight times in one hundred. The change has been thought to occur unassociated with lesions of the pancreas. Langerhans believed that it might result from post-mortem action of the pancreatic juice; and in support of this suggestion Williams states that the pancreatic cells near the areas of fat necrosis show evidence of self-digestion.

The frequent occurrence of advanced self-digestion of the pancreas, unaccompanied by any evidence of fat necrosis, shows that post-mortem contact with the pancreatic enzymes is insufficient to produce the change. When, moreover, fat removed from the body is exposed to the action of pancreatic tissue, alterations comparable to those associated with this form of necrosis do not occur.

Chiari believes that self-digestion of the pancreas so frequently observed at autopsy may set in shortly before death, occurring as an ante-mortem or agonal change. Extravasation of blood into the partially digested tissue can occur, he thinks, only before death, and when present gives evidence that self-digestion has begun ante mortem. Partial destruction of the parenchyma would thus afford opportunity for diffusion of fat-splitting enzyme into the surrounding fat. Under such conditions it appears probable that fat necrosis may occur, and in the following instance the lesion has accompanied self-digestion associated with multiple hemorrhages.

CASE IX.—Man, aged fifty-three years. *Anatomical Diagnosis.*—Emphysema of the lungs; hypertrophy of the right side of the heart; chronic passive congestion of the viscera; self-digestion of the pancreas, with multiple ecchymoses; parapancreatic fat necrosis.

The pancreas is very soft, and in the interstitial tissue are scattered ecchymoses. Upon the surface of the organ occur very small, opaque, yellow foci of fat necrosis. Microscopic examination shows the existence of advanced self-digestion, with hemorrhage here and there into the interstitial tissue.

Where parapancreatic fat necrosis occurs, microscopic examination of the pancreas may demonstrate the presence of a well-marked lesion previously unobserved by the naked eye. Foci of fat necrosis about the pancreas so minute that they deserve the designation parapancreatic have been found associated with chronic interstitial pancreatitis in Cases XIV and XXVII, to be described later.

In other instances it is not improbable that minute foci of necrosis follow duct-obstruction, which presumably has occurred only a few hours before death. In several cases which I have examined the pancreatic duct has been filled with a very viscid secretion containing numerous desquamated cells. It appears that the pancreatic secretion shortly before death has undergone a change, in consequence of which it flows with much difficulty. This condition has been described as catarrhal pancreatitis. The following case illustrates the association of parapancreatic fat necrosis with this change.

CASE X.—Woman, aged fifty years. *Anatomical Diagnosis.*—Chronic nephritis; large red kidneys. Hypertrophy and dilatation of the heart; general anasarca. Parapancreatic fat necrosis.

The pancreas is firm and apparently normal. In the fat, upon its surface, and in the interstitial tissue are small, conspicuous, opaque, white areas of fat necrosis. The duct of Wirsung is filled with very viscid, pearly-white, semifluid material, which, examined microscopically, contains columnar epithelial cells in great quantity.

Doubtless the parapancreatic foci of fat necrosis so frequently observed at autopsy are referable to a variety of conditions,—for example, to chronic inflammation of the pancreas, to partial duct-

occlusion, and with much probability to other causes, among which agonal self-digestion of the pancreas has a place. Nevertheless, in its essential features the lesion resembles more widely distributed necrosis, and is produced by the penetration of the fat-splitting enzyme of the pancreatic juice into living adipose tissue.

*Clinical Significance of Fat Necrosis.*—By some writers fat necrosis has been described as a disease associated with certain more or less ill-defined symptoms. The condition, on the contrary, is a consequence of pancreatic disease and, it has been previously pointed out, bears much the same relation to lesion of the pancreas as does jaundice to hepatic disease. Its presence gives evidence that the pancreatic secretion has been diverted from its normal channels into the interstitial tissue of the organ and into the neighboring fatty tissue.

In a case cited by Hansemann, foci of necrosis occurred in the subcutaneous tissue, and their presence was marked by circumscribed injection of the overlying skin. Rarely, however, does the lesion affect adipose tissue outside of the abdomen, and during life it is recognizable only when the peritoneal cavity is opened. Since disseminated fat necrosis indicates the existence of grave disease of the pancreas, its recognition is of importance to the surgeon who opens the abdominal cavity. Particularly significant is its recognition when pancreatic disease has been unsuspected and operation has been undertaken, perhaps with the purpose of relieving intestinal obstruction suggested by the symptoms of hemorrhagic necrosis of the pancreas. With few exceptions disseminated focal necrosis of fat encountered at operation gives evidence that the pancreas is the seat of hemorrhagic necrosis or of secondary gangrenous change.

Foci of necrotic fat are conspicuous by reason of their homogeneous, opaque, yellowish-white color, in marked contrast to the surrounding translucent yellow fat, and when the omentum is exposed it is unlikely that they will be overlooked if present. To one who has seen the lesion it is unmistakable, but to the inexperienced partially caseous miliary tubercles or carcinomatous nodules undergoing necrosis may be suggested by the shape and color of the sharply defined areas. The lesion, however, is not elevated and nodule-like, but on examination is found to represent a transformation of the pre-existing fat.

When the outflow of bile is hindered and jaundice occurs, biliary pigments make their appearance in the urine. Abundant evidence has shown that fat necrosis is due to the action of the fat-splitting enzyme secreted by the pancreas, and the possibility suggests itself that the enzyme which is free in the tissue may be excreted by the kidneys, though it is not improbable that the acidity of the urine may partially or completely destroy its activity.

I have examined the urine in one instance of hemorrhagic necrosis of the pancreas.<sup>29</sup> The method employed is that described by Kastle and Loevenhart<sup>30</sup>; ethyl butyrate carefully purified, when acted upon by a fat-splitting enzyme, is decomposed with the formation of butyric acid, which gives an acid reaction to the solution.

Following the operation which was performed in Case V (see page 148) the patient voided no urine, and in the bladder at autopsy was found only a small quantity. After adding a few drops of a

---

<sup>29</sup> Opie: Bull. of the Johns Hopkins Hosp., 1902, xiii, 117.

<sup>30</sup> Kastle and Loevenhart: American Chem. Jour., 1900, xxiv, No. 6.

solution of litmus, this urine was neutralized with potassium hydroxide (one-tenth normal solution) and divided into two parts. To one part was added a few drops of ethyl butyrate. The second part, used as a control, was boiled in order to destroy the enzyme, if present, and ethyl butyrate was added. Both specimens were kept at 37° C., and at the end of twenty-four hours the unboiled specimen had acquired a well-marked acid reaction, whereas the control specimen was unchanged. Owing to the small quantity of urine obtained it was not possible to repeat the test.

Recognition in the urine of an enzyme derived from the pancreas would afford a certain means for the diagnosis of obscure pancreatic affections accompanied by fat necrosis, notably hemorrhagic necrosis.

Experiments of Hewlett<sup>31</sup> have shown that fat-splitting enzyme may appear in the urine as the result of a variety of injuries to the pancreas. The urine of normal dogs contains little if any enzyme capable of splitting ethyl butyrate, but during the first three or even five days after ligation of the pancreatic ducts lipolytic enzyme is demonstrable in the urine. The same enzyme in greater amount is present after hemorrhagic necrosis has been produced by injection of hydrochloric acid or bile into the pancreatic duct.

When fat necrosis is observed at operation the prognosis and treatment are those of the associated pancreatic disease. I have cited instances in which necrosis of fat observed at operation has been found to have disappeared when the abdomen has been subsequently opened. Truhart cites cases in which focal fat necrosis has been observed at operation and recovery has occurred.

---

<sup>31</sup> Hewlett: Jour. of Med. Research, 1904, xi, 377.

## CHAPTER VIII.

### ACUTE PANCREATITIS.

THE use of the term inflammation, to describe the peculiar pancreatic lesion which has been more appropriately described as necrosis, has produced much confusion in the classification of various inflammatory changes to which the gland is subject. Acute inflammation of the pancreas does not differ essentially from acute inflammation of the salivary glands, of the liver, or of other organs. The pancreas, like the salivary gland, may exhibit acute interstitial inflammation characterized by accumulation of inflammatory products in the interstitial tissue of the gland, and likewise this lesion usually has its origin in the ducts of the gland. Analogy with similar inflammation of other organs makes it probable that resolution with recovery may occur, but when there is abundant accumulation of leucocytes solution of tissue ensues and an abscess cavity is formed; acute interstitial pancreatitis is distinguished from suppurative pancreatitis by absence of abscess formation.

In some instances suppuration occurs in consequence of hemorrhagic necrosis of the pancreas, hemorrhagic and necrotic tissue being susceptible to bacterial infection. The occurrence of such abscesses makes a sharp separation of gangrene and suppuration impossible. When hemorrhagic necrosis of the pancreas has occurred, fluid almost invariably accumulates in the lesser peritoneal cavity. With progress of the changes which give to the pancreas the appearance well described as gangrene, changes occur in the mixture of blood, products

of pancreatic secretion and necrotic fat which now fills the cavity. The fluid is usually described as pus, but how much it owes its peculiar properties to inflammatory products—*e.g.*, polynuclear leucocytes,—and how much to products—*e.g.*, enzymes derived from the pancreas,—is doubtful. In many instances at least infection and doubtless true suppuration occurs. In many recorded cases these so-called peripancreatic abscesses have been found at operation, but it has been impossible to decide if hemorrhagic necrosis or suppurative pancreatitis has been responsible for the localized peritonitis; not infrequently the lesion has been described as suppurative pancreatitis although the pancreas itself has not been examined.

There is little evidence that the change which has been designated catarrhal pancreatitis (Curtin<sup>1</sup>) is an inflammatory process. The pancreas is unusually hard; the contents of the larger ducts is viscid, and contains desquamated columnar cells; acini are considerably dilated. There is unusually abundant secretion of mucus or mucus-like substances derived perhaps from the small glands in the wall of the larger ducts, but accumulation of inflammatory products such as leucocytes or fibrin is wanting. Lando<sup>2</sup> thinks that such stagnation of pancreatic secretion within the acini may be followed by chronic interstitial pancreatitis.

*Etiology.*—When suppurative pancreatitis is not secondary to hemorrhagic necrosis it occurs, doubtless with few exceptions, as the result of ascending infection by way of the pancreatic duct. Körte, Carnot and others

---

<sup>1</sup> Curtin: Philadelphia Hosp. Rep., 1902, v.

<sup>2</sup> Lando: Zeit. f. Heilk., 1906, Hft. i.

have produced pancreatic abscess in animals by injection of *Bacillus coli* into the pancreatic duct. The diverticulum of Vater is provided with valve-like folds which prevent entrance of intestinal contents into the pancreatic ducts, and at autopsy it is not possible to force material from the duodenum into the duct of Wirsung. The flow of pancreatic juice aids in preventing entrance of bacteria and occlusion of the ducts affords conditions favorable to their entrance.

Pancreatic abscess occurs in association with cholelithiasis; occlusion of the duct of Wirsung by a biliary calculus lodged in the diverticulum of Vater may allow the entrance of bacteria particularly when the bile passages are the seat of inflammation. In two cases of Mayo Robson, abscess of the pancreas has accompanied cholelithiasis and suppurative cholangitis. With suppurative pancreatitis Dieckhoff found a gall-stone in the duct of Wirsung, which was dilated to accommodate it.

Of special interest is a case reported by Fuchs.<sup>3</sup> A man aged thirty-two years, who had had recurring abdominal pain and vomiting, suffered during three months with repeated attacks of great severity, on one occasion accompanied by jaundice. Operation disclosed the presence of a calculus the size of a bean situated within the diverticulum of Vater. In the head of the pancreas was a small abscess. Evacuation of the abscess and removal of the calculus were followed by recovery. Hemorrhagic necrosis of the pancreas may have preceded the abscess. Chiari<sup>4</sup> has described a similar case.

---

<sup>3</sup> Fuchs: *Deutsche med. Woch.*, 1902, xxviii, 829.

<sup>4</sup> Chiari: *Verhand. d. deutschen path. Gesell.*, 1909, xiii, 301.

Pancreatic calculi are with relative frequency accompanied by pancreatic suppuration.

Suppurative pancreatitis may be caused by carcinoma compressing the pancreatic duct; in a case described by Pearce<sup>5</sup> carcinoma of the diverticulum of Vater has been accompanied by multiple abscesses in the head of the pancreas.

Various micro-organisms have been isolated from pancreatic abscesses; both cocci and bacilli, including *Bacillus coli*, have been found by Maas,<sup>6</sup> and Etienne<sup>7</sup> obtained pyogenic cocci, *Proteus vulgaris* and other bacteria. Dieckhoff has found *Diplococcus lanceolatus* in two instances and *Bacillus coli* in another.

*Pathology.*—The pancreas occasionally exhibits acute interstitial inflammation without suppuration (acute interstitial pancreatitis). In the following case the interstitial tissue of the gland has been œdematous and contains polynuclear leucocytes; in the ducts are leucocytes. It is not improbable that ascending inflammation of the pancreatic ducts has been secondary to acute inflammation of the stomach and duodenum.

CASE XI.—A woman, aged thirty-eight years, admitted to the Johns Hopkins Hospital, had suffered during pregnancy a year before examination with swelling of the feet and frequency of urination. She had had indigestion and had vomited frequently after meals. The urine contained a considerable amount of albumin, hyaline and epithelial casts. Death occurred with uræmic coma eighteen days after admission.

*Anatomical Diagnosis.*—Chronic diffuse nephritis, small granular

---

<sup>5</sup> Pearce: Albany Med. Ann., 1904, xxv, 389.

<sup>6</sup> Maas: Quoted by Étienne.

<sup>7</sup> Étienne: Arch. de méd. exper., 1898, x, 177.

kidneys; hypertrophy of the heart; general arterial sclerosis; chronic passive congestion of the viscera; acute and chronic gastritis and duodenitis; acute interstitial pancreatitis.

The stomach contains clear viscid mucus adherent to the mucosa, which is deep scarlet-red. In the duodenum, particularly upon the summits of the *valvulæ conniventes*, similar injection is seen. The pancreas is very firm.

Microscopical examination shows that the superficial blood-vessels of the *gastric mucosa* are deeply injected; between and within the glands polynuclear leucocytes are present in large number. In the *duodenal mucosa* the same changes are slightly less marked. The interstitial tissue of the *pancreas* is œdematous and infiltrated with polynuclear leucocytes, often forming collections of considerable size. The ducts contain products of secretion and polynuclear leucocytes in abundance.

The foregoing case represents an early stage of the inflammatory process which in some instances is followed by suppuration. The relation between suppurative pancreatitis and infection by way of the ducts has been studied in five cases by Dieckhoff. The ducts of the gland are dilated and have lost in places their epithelial lining; some are filled by clumps of bacteria or by polynuclear leucocytes. From the ducts bacteria enter the acini, or, penetrating the wall of the duct, find their way into the interlobular tissue.

In a case of Musser<sup>8</sup> the head of the pancreas contained an abscess the size of an orange, and the remainder of the gland, which was very hard, contained numerous smaller abscesses. Suppuration may occur diffusely throughout the pancreas; in a case of Etienne the gland was infiltrated with pus, drops escaping from the cut

---

<sup>8</sup> Musser: American Jour. of the Med. Scien., 1886, xci, 449.

ducts. The organ may contain communicating cavities of regular shape, or numerous isolated abscesses may occur. When there is a single abscess cavity it is usually situated in the head of the gland.

Fitz noted the infrequency of fat necrosis with suppurative inflammation of the pancreas, whereas so-called acute hemorrhagic pancreatitis was constantly associated with fat necrosis. The observation is equally applicable to suppurative pancreatitis and hemorrhagic necrosis produced experimentally.

Sequelæ of pancreatic abscess are numerous and dangerous. Peritonitis affecting the lesser peritoneal cavity occurs almost constantly and perforation into the general peritoneal cavity may follow. Rupture into the stomach or intestine has occurred and vomiting or discharge from the bowel of purulent or hemorrhagic material has been described. Thrombosis and infection of the splenic and portal veins may be followed by metastatic abscess of the liver.

*Symptoms.*—In accordance with its diverse etiology the symptoms of suppurative pancreatitis exhibit considerable variation. Occurring as a sequel of hemorrhagic necrosis of the pancreas, cholelithiasis, pancreatic lithiasis or cyst, its symptoms are modified by those of the preceding condition. In about half of the cases according to Körte there is sudden onset with intense epigastric pain, vomiting and collapse, the symptoms being those usually associated with hemorrhagic necrosis of the pancreas. The severity of the symptoms diminishes and the disease pursues a chronic course, though death within two or three days has been observed (Dieckhoff.

Simon and Stanley<sup>9</sup>). In a second group of cases onset is gradual and symptoms less severe; there is abdominal pain which may be little more than discomfort and at the same time gastric disturbance occurs. The tendency of suppurative pancreatitis to take a chronic course is illustrated by cases of Fitz; in six instances death occurred during the first month, in three during the second month, and in five between the fourth and eleventh months.

Without elevation of temperature and with no palpable mass in the upper part of the abdomen, pancreatic suppuration is not recognizable. Nevertheless, in only part of the cases are these symptoms present; in many cases there is fever, temperature reaching perhaps 105° F., with recurring chills, but in another group of cases there is no fever and little to suggest either suppurative inflammation or disease of the pancreas. Leucocytosis has usually been present.

Recognizable tumor has been found in little more than a fourth of the cases (Körte). Since such a tumor is due to accumulation of inflammatory products within the lesser peritoneal cavity, it does not differ from that associated with gangrene of the pancreas.

Disturbance of digestion due to impairment of pancreatic function rarely occurs; fatty stools have been observed by Harley,<sup>10</sup> and Brugsch and König<sup>11</sup> found impaired absorption of fat recognizable only by chemical methods. Glycosuria has rarely been associated with pancreatic suppuration; in cases of Harley and of Atkin-

---

<sup>9</sup> Simon and Stanley: *Lancet*, 1897, i, 1325.

<sup>10</sup> Harley: *Trans. of the London Path. Soc.*, 1862, xiii, 118.

<sup>11</sup> Brugsch and König: *Berliner klin. Woch.*, 1905, xlii, 1605.

son<sup>12</sup> glycosuria followed almost complete destruction of the pancreas. Jaundice may accompany pancreatic abscess which occupies the head of the gland; jaundice may be due to associated cholelithiasis. In a case cited by Thayer<sup>13</sup> an abscess at the junction of the head and body of the pancreas compressed the common bile duct, causing jaundice of such intensity that carcinoma was suspected.

Early occurrence of fever with chills may suggest suppurative pancreatitis, but a differential diagnosis between hemorrhagic necrosis and suppurative pancreatitis is with present knowledge rarely possible, since the symptoms of onset are often the same. When the hemorrhagic lesion has reached the stage of gangrene it is usually indistinguishable from suppurative pancreatitis, for both conditions may be accompanied by abscess limited to the lesser peritoneum. A chronic course suggests the presence of suppuration.

*Treatment.*—Although hemorrhagic necrosis and suppurative inflammation may be indistinguishable before operation, recognition of their peculiarities may have importance for the surgeon who has opened the abdominal cavity. There may be suppurative pancreatitis with no fat necrosis; hemorrhagic necrosis is accompanied by disseminated focal fat necrosis. Recovery may follow uncomplicated necrosis of the pancreas, whereas with suppurative inflammation of the gland operation with evacuation of pus is essential for recovery, and its early performance may prevent the serious complications

---

<sup>12</sup> Atkinson: Jour. of the American Med. Assoc., 1895, xxiv, 999.

<sup>13</sup> Thayer: American Med., 1902, 341.

which have been mentioned. When numerous isolated abscesses are present operation may fail to effect complete drainage, since careful examination of the entire pancreas is rarely possible. In a case of Gallandet<sup>14</sup> evacuation of pus with removal of a pancreatic calculus was followed by recovery; in the case of Fuchs recovery followed evacuation of pus and removal of a gall-stone from the diverticulum of Vater.

---

<sup>14</sup> Gallandet: *Ann. of Surg.*, 1899, xxx, 232.

## CHAPTER IX.

### CHRONIC INTERSTITIAL PANCREATITIS.

THE causes and varieties of chronic interstitial pancreatitis have been little studied, and slight attention has been given to the classification of various types. The lesion is seldom associated with such definite symptoms that it is recognizable during life, and even at autopsy the condition is frequently overlooked. Though chronic inflammation of the pancreas has not the importance of similar changes in the liver and kidneys, its relation to diabetes mellitus makes it worthy of detailed consideration. Indeed, study of the lesion has contributed important facts to the knowledge of this disease.

The etiology of interstitial inflammation is often obscure. Chronic pancreatitis is not infrequently secondary to changes in the intestine, the bile passages, and the liver. As with other glands, there is more than one path by which inflammatory irritants may reach the organ: by way of the duct, from the blood-vessels, and possibly from the lymphatic vessels. Obstruction to the outflow of the secretion of the gland is followed by chronic inflammatory changes. The pancreatic duct opening with the common bile duct upon the mucous membrane of the duodenum is subject to ascending infection both from the intestine and from the biliary passages when inflamed. Bacteria, their toxic products, and injurious substances taken as food, reaching the gland by way of the blood, may cause chronic inflammation; alcohol, syphilis, and tuberculosis are believed to produce the

lesion. Alterations of the vessel walls, notably arterial sclerosis, causing grave disturbances of nutrition, have the same result.

Acute, rapidly destructive lesions of the pancreas—for example, hemorrhagic necrosis—affect the various elements of the gland almost simultaneously, and disintegration of greater or less extent results. When the organ is attacked by the less active irritants which produce chronic inflammation, the different histological constituents of the gland are given greater opportunity to exhibit differences in their ability to withstand the destructive process. The islands of Langerhans do not always show alterations corresponding to those which occur in the tissue about them, often persisting though the adjacent parenchyma is destroyed. Moreover, while with one variety of chronic inflammation they are but little implicated in the sclerotic process, with another they may be markedly affected. It becomes of interest, therefore, to study the relation of these bodies to the various forms of chronic pancreatitis that are distinguishable.

That form of chronic inflammation which occurs during fetal life, and is associated with other manifestations of congenital syphilis, presents histological features which distinguish it from the chronic pancreatitis of adult life. It is a disease of the developing organ, and may appropriately be considered separately.

#### VARIETIES OF CHRONIC PANCREATITIS.

Several types of chronic pancreatitis have been described, and with the experimental demonstration of a relation between the pancreas and carbohydrate metabolism numerous attempts have been made to distinguish a

variety of the lesion constantly associated with diabetes mellitus. A classification of these various forms of chronic inflammation based upon etiological data, though desirable, would be, with our present knowledge, as unsatisfactory as a similar classification of the varieties of hepatic cirrhosis.

In some examples of chronic pancreatitis fibrous tissue between the lobules is increased; in others the interacinar tissue shows marked proliferation; occasionally individual cells are apparently separated by strands of fibrous tissue. Corresponding types of inflammation have been described as interlobular, peri-acinous, and monocellular.

It has been thought that the increase of interstitial tissue may have at times a constant relation to the blood-vessels or to the ducts, being due, in part at least, to proliferation of the connective tissue about these structures. Lemoine and Lannois<sup>1</sup> have described perivascular interstitial pancreatitis. From a study of four cases of chronic inflammation associated with diabetes they have thought that the new growth of fibrous tissue has its origin in the walls of the blood-vessels. They find about the vessels masses of sclerotic tissue sending processes between the acini and even separating the individual cells (*sclerose unicellulaire*). G. Hoppe-Seyler<sup>2</sup> has described chronic interstitial changes which he thinks are the result of arterial sclerosis. The parenchyma, he believes, undergoes degeneration as a consequence of disturbed nutrition, but there is no constant anatomical relation between the vessels and the newly-

---

<sup>1</sup> Lemoine and Lannois: Arch. de méd. exper., 1891, iii, 33.

<sup>2</sup> Hoppe-Seyler, G.: Deutsches Arch. f. klin. Med., 1893, lii, 171.

formed tissue. Chronic pancreatitis in a case described by Rosenthal<sup>3</sup> was accompanied by what he regarded as alterations of the lymph-vessels (*lymphangitis proliferans*), indicative, he thought, of a probable syphilitic origin.

In the instances of chronic inflammation of the pancreas which have been available for my study no constant relation has been discoverable between the newly-formed tissue and the veins, arteries, lymph-vessels, or ducts, and there is no evidence that the process has had its origin about these structures.

Two types of interstitial inflammation are, however, distinguishable.<sup>4</sup> On the one hand, though sclerosis is never accurately confined to one locality, it may be conspicuous between the lobules, the intralobular or inter-acinar tissue being little, if at all, increased. On the other hand, the interlobular tissue may be only slightly altered, while fibrous tissue which replaces the parenchyma separates individual acini. In the first case the lobulation of the gland, which is normally obscure, becomes more conspicuous, and wide bands of sclerotic tissue separate groups of lobules. The lobules are finally invaded in greater or less degree by newly-formed stroma, and often entire lobules are in process of disintegration and replacement. With the second type of chronic inflammation the lobulation of the gland is not accentuated; new fibrous tissue, primarily within the lobule, has a diffuse character, and a network of irregular fibrous strands, which vary much in thickness, contains the glandular acini in its meshes.

---

<sup>3</sup> Rosenthal: *Zeit. f. klin. Med.*, 1892, xxi, 401.

<sup>4</sup> Opie: *Jour. of Exper. Med.*, 1901, v, 397.

If chronic pancreatitis is well advanced, the organ may present gross appearances characteristic of one or other variety of interstitial inflammation. When the interlobular tissue is the seat of predominant change, the gland is hard and dense and has a nodular or granular surface. On section the tissue has a compact, homogeneous appearance, loose areolar tissue between secondary and tertiary lobules having been replaced by scar-like sclerotic bands. When, on the other hand, there is diffuse increase of the interacinar stroma, the organ tends to become tough rather than hard and the surface is smooth. Not infrequently, however, the pancreas affected with either variety of inflammation may be so little altered that the lesion is recognized only upon microscopic examination. Abundant fat infiltrating the newly-formed tissue between lobules or acini may obscure the gross characters of both types. Such fat often contains small foci of necrosis.

The two types of chronic interstitial inflammation—(a) interlobular and (b) interacinar—characterized by the primary localization of the lesion present other histological peculiarities. Of much interest is the different relation which they bear to the islands of Langerhans, and it is desirable to study separately the changes affecting these bodies in the two conditions.

*Chronic Interlobular Pancreatitis.*—Sclerosis of the pancreas, produced by obstruction of the duct, belongs to the interlobular type of chronic inflammation. Its definite causation as well as certain histological features serve to distinguish it from inflammatory changes, of which the etiology is more obscure. The pathogenesis

of the lesion is not, however, clearly understood. Carnot<sup>5</sup> has summarized the possible factors which have a part in its production. Retained secretion, he believes, has a toxic action upon the parenchymatous cells. Obstruction to the outflow of fluid from the ducts favors the entrance of bacteria from the duodenum. Carnot suggests, moreover, that reflex nervous stimuli, which normally reach the secreting cells, are no longer capable of exciting normal functional activity, and, deprived of this influence, the cells atrophy, as do muscle fibres after section of their motor nerve.

Since the cells forming the islands of Langerhans have no communication with the ducts and take no part in producing the pancreatic juice, the possible factors mentioned would, if active, affect primarily the acini and only secondarily, if at all, the interacinar islands.

In the cases which I have studied varying degrees of atrophy and sclerosis have followed partial or complete occlusion of the pancreatic ducts. The occurrence of an active chronic inflammatory process is shown by the presence of numerous lymphoid cells, plasma cells, and eosinophiles in the interstitial tissue. The most marked increase of fibrous tissue is between the lobules, but acini with atrophied nuclei and dilated lumina are not infrequently separated by new tissue. Islands of Langerhans, however, are completely unaltered.

The following case illustrates an advanced stage of interlobular inflammation, the consequence of duct-obstruction.

---

<sup>5</sup> Carnot: Recherches sur les pancréatites, Thesis, Paris, 1898.

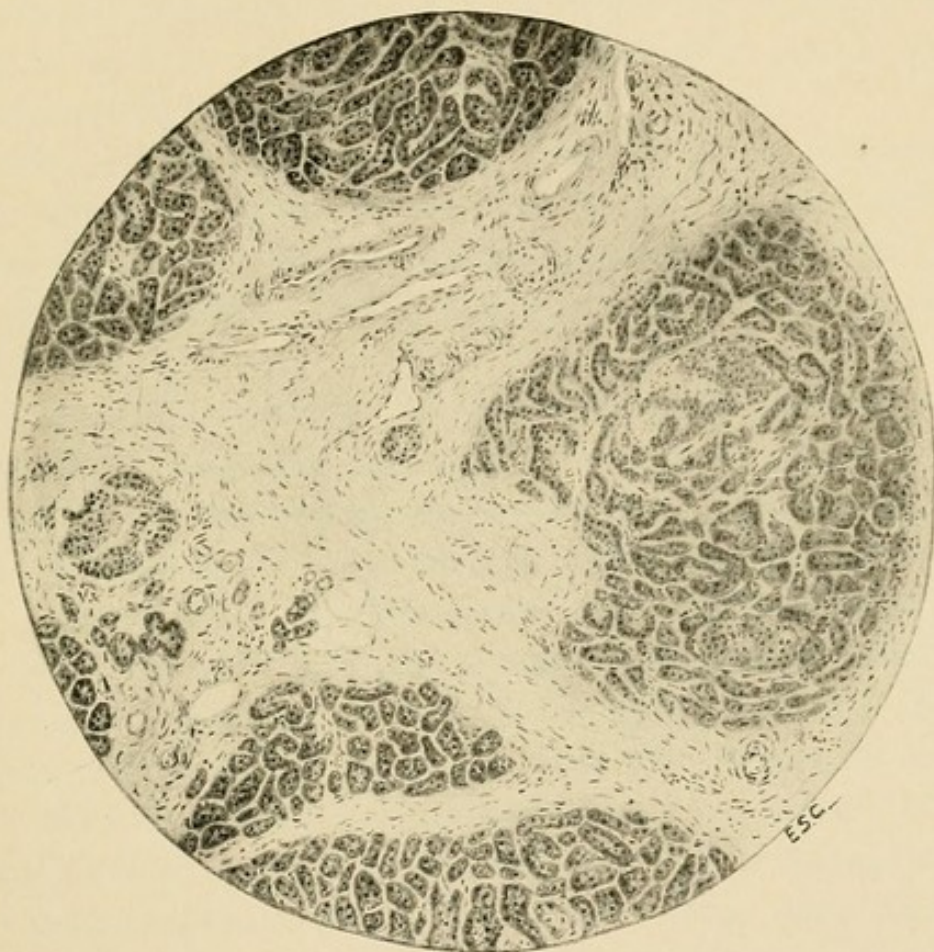



FIG. 28.—Chronic interlobular pancreatitis, showing coarse bands of fibrous tissue separating lobules of parenchyma.



CASE XII.—The patient, a woman, aged sixty years, began about one year before her death to suffer with symptoms of obstruction in the common bile duct. At operation performed by Dr. Halsted<sup>o</sup> a carcinoma of the bile papilla and diverticulum of Vater was found and removed. The biliary and pancreatic ducts were transplanted into the duodenum. Subsequently an anastomosis was made between the gall-bladder and duodenum.

*Anatomical Diagnosis.*—Recurrent carcinoma of the duodenum; metastases in the liver; occlusion of the pancreatic duct; chronic interstitial pancreatitis; biliary fistula.

*Pancreas.*—On the left lateral wall of the duodenum is a crater-like ulcer with raised edges abutting upon the head of the pancreas. The pancreatic duct is included in the carcinomatous tissue at the base of the ulcer. The duct is greatly dilated and the pancreas is small and sclerotic.

*Microscopic Examination.*—The parenchyma of the head and body has been almost completely replaced by dense fibrous tissue which contains fat in considerable quantity. Small isolated masses of glandular tissue still persist and are subdivided into lobules by penetrating strands of fibrous tissue. The stroma is in great part very dense and poor in cells. The small ducts are dilated. The persistent glandular tissue is in part normal in appearance, but in other situations is undergoing disintegration, and the connective tissue not infrequently marks out areas which correspond apparently to lobules, but contain only a few atrophied acini composed of flattened cells about a dilated lumen. Here the inflammatory process is active; the connective tissue separating the atrophic acini is very cellular and contains many lymphoid cells, plasma cells, and eosinophiles.

Islands of Langerhans, more abundant in the tail and body than in the head, are almost unaltered and are not invaded by the newly-formed fibrous tissue which surrounds them and isolates the much changed acini. (Fig. 29.) About an unaltered island may be found only a few acini to indicate that it was formerly embedded in the parenchyma, while elsewhere in the dense fibrous bands are seen isolated

---

<sup>o</sup> The history of this case is described by Dr. Halsted in the Bulletin of the Johns Hopkins Hospital, 1900, xi, 4.

structures of which the cells do not differ in character or arrangement from those of the interacinar islets. Such islands, though surrounded by sclerotic tissue, are not invaded by it, and their cells, which are normal in appearance, form columns separated by delicate capillary vessels.

These isolated islands, however, finally undergo degenerative changes. They are diminished in size and often distorted. The cells, particularly at the periphery, crowded together, become smaller, and their nuclei, also smaller than usual, are often irregular in shape and deeply stained. Further changes are followed with difficulty, since the much altered groups of cells are hardly recognizable as islands of Langerhans. Small groups of epithelial cells, separated by strands of connective tissue, probably represent a late stage of atrophy which precedes their final disappearance and replacement by fibrous tissue.

When advanced chronic pancreatitis has followed obstruction of the ducts, the organ is densely sclerotic, glandular tissue having been replaced in very large part by fibrous stroma. Small masses of relatively well-preserved parenchyma, little if at all invaded, are embedded in fibrous tissue which contains almost no epithelial elements. Areas are seen where disintegration of the glandular substance is in active progress, and here lymphoid cells are present in large numbers. A striking feature of the process is the abundance of plasma cells of Unna, with which are many cells containing eosinophilic granulations.

The scattered acini show atrophic changes similar to those previously described. The islands of Langerhans which occur in this altered glandular tissue are unchanged, and, even though the neighboring acini are widely separated by inflammatory new growth, are uninvaded (Fig. 29). The secreting tissue about them finally disappears, and they remain completely isolated in the

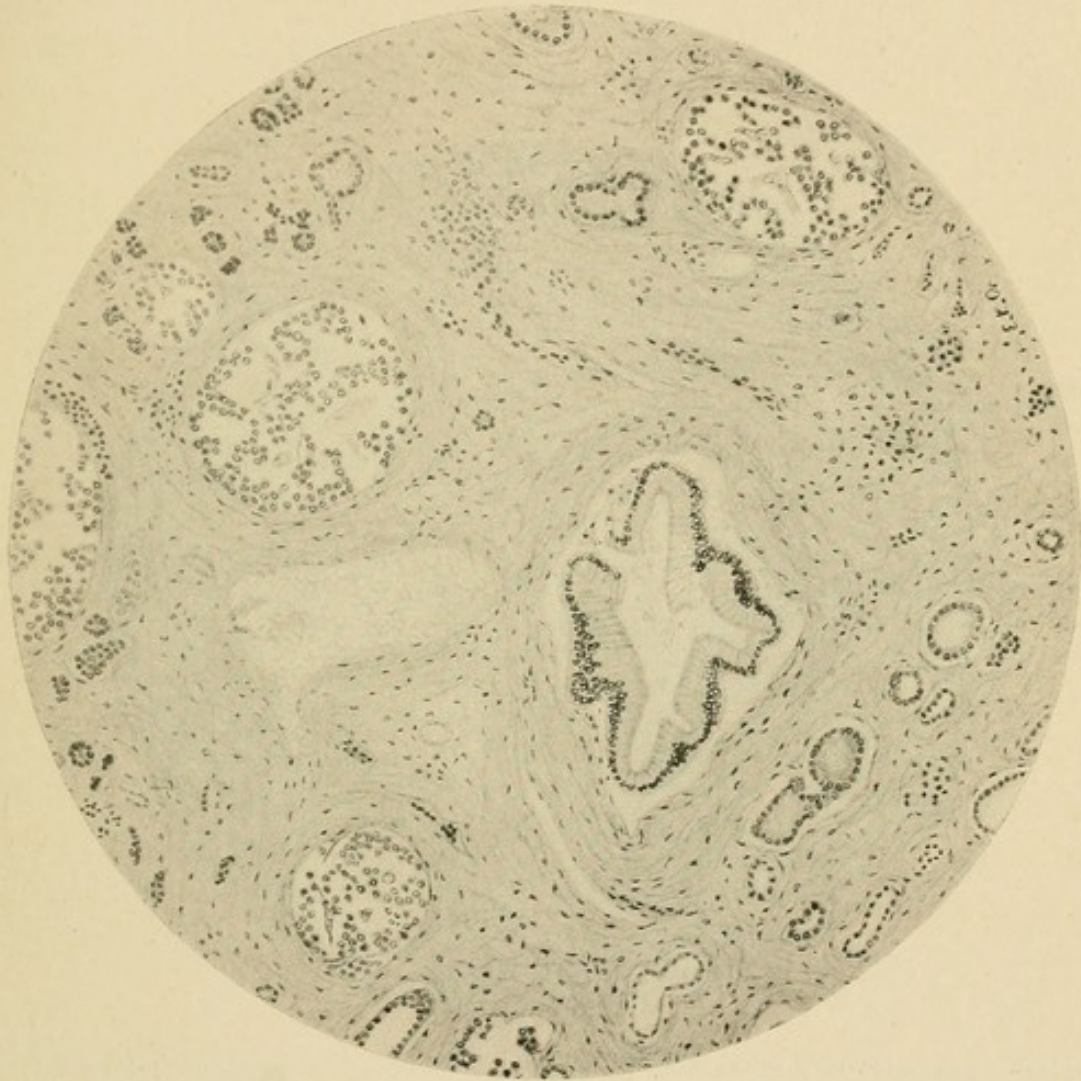

FIG. 29.—Chronic interlobular pancreatitis following duct-obstruction (Case XII), showing islands unchanged though embedded in sclerotic tissue.

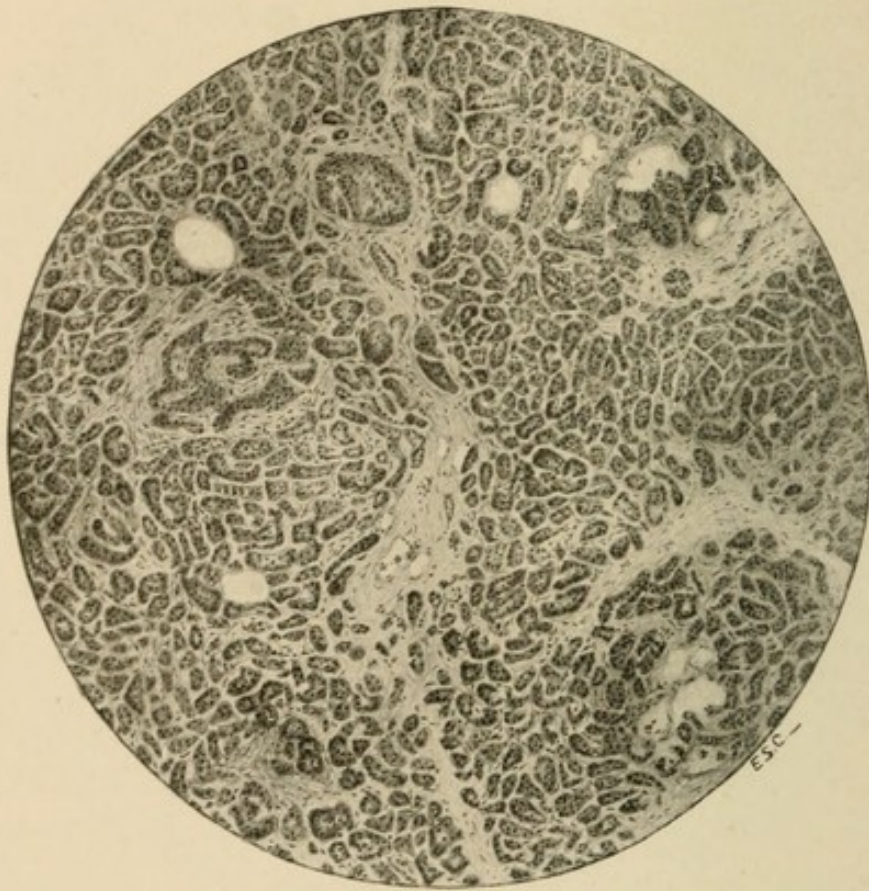


FIG. 30.—Chronic interacinar pancreatitis showing diffuse distribution of newly-formed fibrous tissue and sclerosis of islands of Langerhans (drawn with low power of microscope).

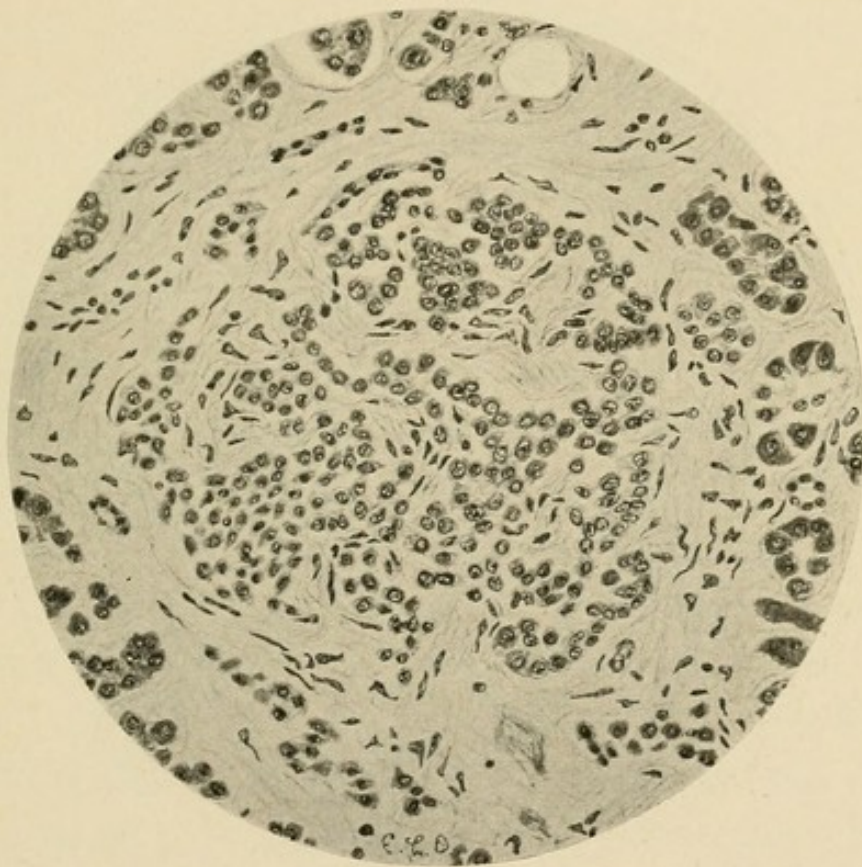


FIG. 31.—Chronic interstitial pancreatitis of interacinar type (Case XIV), showing the invasion of an island of Langerhans by the inflammatory process (drawn with high power of microscope).

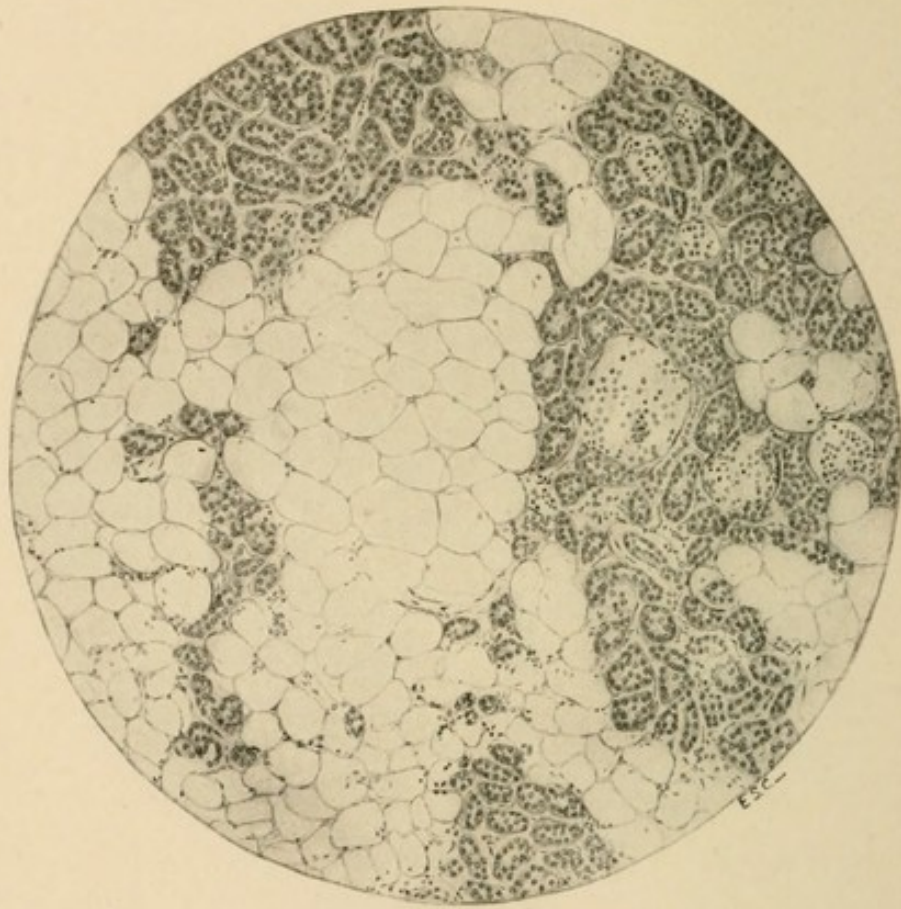


FIG. 32.—Lipomatosis.

stroma, not infrequently the only vestiges of parenchymatous tissue in wide sclerotic bands. In a section from such an area these isolated islands of Langerhans may be very numerous; and since the sclerotic tissue occupies less space than the acini which it has replaced, they appear to be much more abundant than in the normal glandular parenchyma.

In animals, after experimental ligation of the ducts, the islands of Langerhans show the same resistance observed in human cases. Schultze<sup>7</sup> tied a ligature tightly about the pancreas in guinea-pigs, and found that though the secreting parenchyma distal to the ligature underwent inflammatory atrophy, islands of Langerhans persisted unaltered in the newly-formed stroma. Ssobolew,<sup>8</sup> in a large number of experiments performed on rabbits, dogs, and cats, obtained similar results. In the pancreas of a rabbit which lived four hundred days after operation, fibrous stroma about the pancreatic duct contained, he states, only islands of Langerhans; similar observations have been made by Sauerbeck,<sup>9</sup> Zunz<sup>10</sup> and others. Absence of sclerosis noted in the dog by U. Lombroso<sup>11</sup> is explained by failure to occlude both pancreatic ducts or by regeneration of the duct after ligation and even after section (Visentini<sup>12</sup>).

As it is improbable that the vessels supplying the

---

<sup>7</sup> Schultze: *Arch. f. mik. Anat.*, 1900, lvi, 491.

<sup>8</sup> Ssobolew: *Cent. f. allg. Path. u. path. Anat.*, 1900, xi, 202; *Virchow's Arch.*, 1902, clxviii, 91.

<sup>9</sup> Sauerbeck: *Verhandl. d. deutschen path. Gesell.*, 1904, vii, 217.

<sup>10</sup> Zunz and Mayer: *Bull. de l'Acad. roy. de méd. de Belgique*, 1905, xix, 509.

<sup>11</sup> Lombroso, U.: *Jour. de physiol. et de path. gén.*, 1905, xvii, 3.

<sup>12</sup> Visentini: *Virchow's Arch.*, 1909, cxev, 555.

islands with blood remain entirely unchanged in the indurated stroma, it can hardly be doubted that the nutrition of their cells suffers. The new tissue, growing older, apparently contracts and compresses them; their cells become smaller, the nuclei are small, irregular, and stain deeply. Such interacinar islands finally disappear, being replaced by fibrous tissue, which may contain an occasional isolated group of much atrophied cells, or may be completely devoid of such structures.

The islands of Langerhans (Fig. 29) resist the sclerotic process which follows the damming back of secretion upon the gland, and finally suffer only when the acini are almost entirely destroyed and replaced by dense scar-like tissue. Not concerned in the production of the pancreatic juice, they are not exposed to its injurious action when its outflow is obstructed. The changes which completely isolated islands finally undergo are, it appears, due to obliteration of blood-vessels and compression of cells by the contracting scar-like tissue in which they are embedded; when the acini are replaced by interstitial tissue, the network of vessels within the island, which freely anastomoses, with the adjacent capillaries, is, as the process advances, less freely supplied with blood.

Chronic interlobular pancreatitis may be the result of some condition other than duct-obstruction. Ascending infection along the pancreatic duct is associated with alterations similar to those just described. Secreting acini in places atrophy and disappear, but the islands of Langerhans maintain to the process the same relation which is observable when the lesion follows occlusion of the duct, and though neighboring acini have undergone degenerative changes, islands of Langerhans re-

main unaltered. Since the ducts do not penetrate them they are less exposed to the action of irritants which reach the gland by way of the duct.

*Chronic Interacinar Pancreatitis.*—The type of pancreatitis which may be conveniently designated “interacinar” is characterized by the presence of newly-formed tissue within the lobules (Fig. 30). The lesion is diffuse but somewhat irregular in distribution; at one point there may be thickening of the connective-tissue network supporting the acini, while elsewhere occur compact bands or small masses of stroma. Though the interlobular tissue is not wholly unaffected by the inflammatory change, its proliferation is an inconstant and inconspicuous feature of the histological picture. Lobulation of the gland is not accentuated, as with the interlobular type, but, on the contrary, the interlobular boundaries are obscured by masses and strands of new tissue within the lobules. This type is much less common than the perilobular form, and has occurred in only nine of my thirty cases. One of these has been associated with the condition of general pigmentation to which Von Recklinghausen has given the name hæmochromatosis, and, differing slightly from the other cases, it will be considered subsequently. The following cases exemplify the lesion:

CASE XIII.—*Clinical History.*—The patient, a man aged forty-nine years, gave no history of alcoholic excess. The present illness began twenty months before death with polyuria and loss of weight. A year and a half before death the spleen was palpable, and hæmatemesis occurred at intervals. At this time the urine contained 3.5 to 3.8 per cent. of sugar. The patient was readmitted to the hospital four days before his death with ascites and dilated superficial abdominal veins. The urine contained 2.5 per cent. of sugar.

*Anatomical Diagnosis.*—Chronic interstitial pancreatitis; cirrhosis of the liver. Thrombosis of the portal, splenic, and mesenteric veins; hemorrhagic infarction of the intestine. Acute serofibrinous and purulent peritonitis; acute splenic tumor.

*Pancreas.*—The organ is small and firm in consistence.

*Microscopic Examination.*—The interstitial tissue is greatly increased and is richly infiltrated with fat. Almost every acinus is in greater or less degree surrounded by fibrous tissue, but the lobulation of the parenchyma is not more distinct than usual. In many places the glandular tissue of a limited area is almost completely replaced, being represented only by widely separated atrophic acini. The new growth of tissue, which is often conspicuous about the ducts and blood-vessels, bears no constant relation to these structures.

Islands of Langerhans are very abundant, and are sharply outlined by fibrous tissue, which is concentrically arranged, and forms coarse capsules, separating islands of Langerhans from adjacent acini. There is, moreover, proliferation of the connective tissue within these structures; along the capillaries irregular spindle-shaped nuclei are more numerous than usual, and there are thickened fibrous strands. The cells of the islands are often very small, and their nuclei, diminished in size, stain deeply; they are closely packed together to form wide, irregular columns. Not infrequently the interacinar fibrous tissue is much more abundant in the immediate neighborhood of the islands than elsewhere, and here forms a close network of coarse strands with small meshes containing atrophied acini.

CASE XIV.—*Clinical History.*—The patient, a man, aged forty-seven years, has used alcohol in excess. His health has been good until six months before death and he has lost little weight. For three months symptoms of diabetes mellitus have been present. The patient was in the hospital five days preceding his death, during which time the urine contained from 0.6 to 2.46 per cent. of sugar; acetone was present. He was dull, drowsy and at times delirious.

*Anatomical Diagnosis.*—Chronic interstitial pancreatitis; cirrhosis of the liver; chronic passive congestion of the spleen; ascites. Parapancreatic fat necrosis. Arterial sclerosis; gangrene of the leg.

*Pancreas.*—The organ, weighing 108 Gm., is firm, particularly

at its splenic end. Here lobulation is obscured and the texture of the gland-tissue is compact. In the fat within and about the organ are small, opaque, yellowish-white areas.

*Microscopic Examination.*—Throughout the organ there is an abundant diffuse new growth of interstitial tissue between the individual acini. The new tissue is poor in cells, and consists in great part of white fibres loosely packed together. In the meshes of the irregular network which it forms lie acini, or small groups of acini, which are often atrophic in appearance. Acini of large size, containing many centro-acinar cells, are seen.

Islands of Langerhans are abundant in the tail, and are of large size. They are frequently surrounded by a thick capsule of fibrous tissue, and are invaded by the new tissue, which often forms coarse ingrowths along their capillaries (Fig. 31). Though all the islands are surrounded by dense sclerotic tissue, some are only slightly invaded. Where marked thickening occurs about their capillary vessels, the epithelial cells are diminished in size and are closely packed together; the nuclei are small and stain deeply.

While with the interlobular type of chronic interstitial inflammation the islands of Langerhans are unaffected by the sclerosis and show changes only when the lesion has reached a very advanced stage, in the cases just recorded a new growth of tissue within the lobules and between the acini invades the interacinar islands. The latter are almost constantly surrounded by fibrous tissue, which forms, as it were, a capsule separating them from adjacent acini, which are themselves abnormally separated from one another. About the capillaries of the island there is proliferation of interstitial tissue forming coarse strands between the columns of cells.

With chronic pancreatitis of the interlobular type proliferation of interstitial tissue occasionally occurs between the acini, but is usually confined to the periphery

of the lobule. The islands of Langerhans, situated in the midst of the secreting tissue, often near the centre of more or less clearly defined lobules, are surrounded by the least changed acini. With the interacinar type of sclerosis the condition is different; in the immediate neighborhood of the island is found the greatest proliferation of fibrous stroma, and the acini, separated from it and from one another by coarse strands of white fibrous tissue, are more atrophic than those at a greater distance. When the inflammatory process affects primarily the periphery of the lobule and progresses towards the centre, the islands are affected only when the lesion is very advanced; but when the change occurs diffusely within the lobule, all parts are equally affected, and the islands suffer in common with the acini. Indeed, it often appears that the favorite seat of the lesion is the immediate neighborhood of these bodies.

Localization of the lesion especially in the islands of Langerhans is well illustrated by certain cases in which an early stage of the change is represented by accumulation of lymphoid cells in and about these structures. Schmidt<sup>13</sup> described a case of diabetes mellitus in which small round cells were collected almost exclusively about the islands of Langerhans; in some of these bodies there were thickened strands of connective tissue. In five of the cases of diabetes studied by Cecil, islands of Langerhans have exhibited both infiltration with lymphoid cells and sclerosis. The cells are often numerous within the island which is otherwise apparently normal and form a halo about it; in the same gland various stages may

---

<sup>13</sup> Schmidt: *Münchener med. Woch.*, 1902, xlix, 51.

represent a transition from this condition to advanced sclerosis of the interacinar islands, with formation of dense strands of connective tissue poor in cells.

In a few instances an inflammatory process similar to that which with interacinar pancreatitis affects islands of Langerhans and secreting parenchyma has been wholly or almost wholly limited to the islands of Langerhans. Such lesions have been observed in association with diabetes mellitus by Sauerbeck<sup>14</sup> and Cecil.<sup>15</sup> In four cases of Cecil there was sclerosis limited to the islands of Langerhans, and in one instance there was in addition infiltration of the same structures with lymphoid cells.

*Lipomatosis.*—The interstitial tissue of the pancreas contains fat which in corpulent individuals may form conspicuous septa continuous with fat surrounding the gland. In some instances fat is greatly increased and replaces the parenchymatous tissue of the organ; the condition has been designated lipomatosis. A mass of adipose tissue may occupy the position of the pancreas, and glandular tissue is recognizable only when the cut surface of this fat is carefully examined; scattered particles of firm, yellowish-white parenchyma one or two millimetres across are embedded in fat and collected in clusters about the ducts of the gland. Microscopic examination (Fig. 32) shows that fat-cells occur between the acini, and, as the process advances, separate groups of acini or individual acini from their neighbors. Whole lobules are replaced by fat, but islands of Langerhans survive for a time and may persist in masses of fat

---

<sup>14</sup> *Loc. cit.*

<sup>15</sup> Cecil: *Jour. of Exper. Med.*, 1909, xi, 266.

containing no secreting acini. Islands of Langerhans finally disappear.

Such infiltration with adipose tissue occurs in association with chronic interstitial inflammation. Under certain conditions, which are not understood, newly-formed connective tissue is occupied by fat; the lesion is analogous to the fatty infiltration which accompanies atrophy of voluntary muscle. Both interlobular and interacinar types of chronic pancreatitis are accompanied by lipomatosis. With interlobular pancreatitis following obstruction of ducts by calculi there may be advanced lipomatosis. The lipomatosis, which is not infrequently found with diabetes mellitus, usually accompanies interacinar pancreatitis. In three of ninety cases of diabetes described by Cecil advanced lipomatosis occurred in association with interacinar pancreatitis, whereas in many other instances the pancreatitic stroma contained a considerable quantity of fat.

Lipomatosis occurring with obesity has been attributed to excessive use of alcohol. The change is not always associated with obesity, and may occur in emaciated individuals (Dieckhoff, Kasahara, Lépine and Cornil<sup>16</sup>).

#### ETIOLOGY.

Elsewhere I have classified cases of chronic interstitial pancreatitis studied in the pathological laboratory of the Johns Hopkins Hospital.<sup>17</sup> Clinical records were obtainable, and in every instance material was preserved

---

<sup>16</sup> Lépine and Cornil: *Compt. rend. Soc. de biol.*, 1874, 6 ser., i, 372.

<sup>17</sup> Opie: *The Causes and Varieties of Chronic Interstitial Inflammation*, *American Jour. of the Med. Scien.*, 1902, cxxiii, 845.

for microscopic examination. Of thirty cases, seventeen occurred in males and thirteen in females. The age of the affected individuals was as follows:

10 to 20 years.....	1 case
20 to 30 years.....	2 cases
30 to 40 years.....	2 cases
40 to 50 years.....	9 cases
50 to 60 years.....	11 cases
60 to 70 years.....	3 cases
70 to 80 years.....	2 cases

Twenty cases, more than two-thirds the total number, occurred between the ages of forty and sixty years.

*Obstruction of the Pancreatic Ducts.*—In ten cases chronic interlobular pancreatitis was the result of duct-obstruction. Ligation of the duct in animals is followed by chronic inflammation; in human cases partial or complete occlusion may be caused by pancreatic calculi within the duct of Wirsung, by biliary calculi within the adjacent terminal part of the common bile duct, or by new growths, usually carcinomata, compressing or invading the gland.

In human cases conditions which produce obstruction of the pancreatic duct are usually such as favor infection. The pancreas, it has been shown, is provided with two ducts which, in nine of ten instances, anastomose within the gland. The duct of Santorini is occasionally of large size, in about one of ten cases even larger than the duct of Wirsung, and its duodenal orifice is freely patent. In most subjects, however, the duct is in part rudimentary, and its orifice is too minute to act as an outlet for the entire pancreatic secretion should the duct of Wirsung be occluded.

*Pancreatic Calculi.*—Two cases (Cases XXVI and XXVII) illustrate the advanced grade of sclerosis which may follow the presence of calculi within the pancreatic ducts. The lesion derives importance from the fact that diabetes mellitus occasionally accompanies chronic inflammatory changes due to the presence of calculi.

*Biliary Calculi.*—Riedel<sup>18</sup> has directed attention to the fact that induration of the head of the pancreas, at times observed during operations undertaken for the removal of gall-stones, may readily be mistaken for malignant growth. Carcinoma of the pancreas was suspected in three of one hundred and twenty-two such operations, but the subsequent history of these three patients disproved this supposition, and chronic pancreatitis was found in one who died.

Mayo Robson<sup>19</sup> (1900) has described two similar cases, in one of which chronic inflammation was demonstrated at autopsy, while in the second malignant growth was excluded by recovery of the patient. In subsequent publications<sup>20</sup> he has collected many similar instances and believes that there is evidence of chronic pancreatitis in 60 per cent. of patients in whom operation has shown the presence of stone in the common bile duct. The consistency of the pancreas varies considerably and demonstration of chronic inflammation at operation is often uncertain. In 18.6 per cent. of two hundred and eighty-six operations on the common and hepatic ducts cited by W. J. Mayo<sup>21</sup> there was such

---

<sup>18</sup> Riedel: Ueber entzündliche Vergrößerungen des Pankreaskopfes, Berliner klin. Woch., 1896, xxxiii, 1, 32.

<sup>19</sup> Mayo Robson: Lancet, 1900, ii, 235.

<sup>20</sup> See Mayo Robson and Cammidge, *loc. cit.*, p. viii.

<sup>21</sup> Mayo: Jour. of the American Med. Assoc., 1908, 1, 1161.

definite induration and enlargement of the head of the pancreas that no doubt was entertained concerning the diagnosis, whereas the same change occurred in only 4.45 per cent. of instances with disease limited to the gall-bladder.

The following case illustrates the relation of chronic interlobular pancreatitis to cholelithiasis and demonstrates a mechanism by which the change is produced.

CASE XV.—The patient, a man, aged sixty-three years, after repeated attacks of jaundice underwent operation, but on account of dense adhesions it was not possible to explore the bile passages. Symptoms of cirrhosis subsequently developed, and the abdomen was tapped several times. The urine did not contain sugar. The patient had used alcohol in excess.

*Anatomical Diagnosis.*—Cholelithiasis; contraction of the gall-bladder; calculus in the common bile duct; dilatation of bile ducts; cirrhosis of the liver; chronic interlobular pancreatitis; serofibrinous peritonitis; chronic nephritis; arterial sclerosis; diverticula of duodenum.

The common bile duct is greatly dilated and enters the duodenum beside a small diverticulum of the intestinal mucosa. Near its termination, but just above its junction with the duct of Wirsung, is a large, oval gall-stone, firmly wedged into the common duct in such a position as to compress the terminal part of the pancreatic duct, which, as it enters the diverticulum of Vater, passes immediately below the stone. (See Fig. 33.) The pancreas is firm in consistence and compact in texture and microscopic examination shows chronic interlobular pancreatitis. The papilla of the duct of Santorini is not demonstrably patent.

A small calculus, as I have shown in a previous chapter, may lodge at the orifice of the diverticulum of Vater, and, occluding it, may convert the common bile duct and the duct of Wirsung into a continuous channel, thus causing the penetration of bile into the pancreas

and consequent hemorrhagic necrosis of the pancreas. A larger calculus present in the diverticulum of Vater or in the common bile duct, slightly above its junction with the pancreatic duct, may temporarily or permanently compress the latter and produce chronic inflammatory changes resembling those which follow ligation of the duct in animals.

Doubtless bacterial infection often plays a part in the production of the lesion, and in two additional cases of chronic interlobular pancreatitis included in the present series the bile passages containing gall-stones have been the seat of acute suppurative inflammation; opportunity has been thus afforded for ascending infection of the duct



FIG. 33.—Biliary calculus (actual size) which, in Case XV., completely filled the diverticulum of Vater and occluded the duct of Wirsung; chronic interlobular pancreatitis resulted. Compare with the small calculus which in Case I (see Fig. 20) caused acute hemorrhagic necrosis of the pancreas.

of Wirsung. In neither case has a calculus been found compressing the pancreatic duct, but such compression may have occurred at some previous time during the expulsion of a stone. Since, however, the pancreatic ducts are the seat of acute inflammatory changes it is not improbable that chronic inflammation may have been the result of infection originating in the actively-inflamed bile passages.

*Malignant Growth.*—In five of my cases chronic interstitial pancreatitis was caused by a malignant growth compressing or invading the organ. In one instance a primary carcinoma of the pancreas arising in the head of the gland compressed the duct of Wirsung and produced chronic interstitial inflammation with formation

of numerous small cysts closely crowded together in the body and tail of the pancreas.

In a second case, previously described (Case XII), advanced chronic interstitial inflammation followed the development of a carcinoma of the bile papilla and diverticulum of Vater. Infection from the ulcerated surface upon which the duct opened was with great probability an important factor in producing the advanced chronic interstitial inflammation which resulted.

In three cases chronic inflammatory changes followed invasion of the gland by a carcinomatous new growth of the stomach. When the head of the gland is invaded there is a diffuse interstitial change, but where, as in two cases, the body is invaded while the head is not in contact with the tumor, inflammatory alterations occur only in that part of the gland distal to the point at which the duct is compressed. The carcinomatous tissue, moreover, acts as a local inflammatory irritant and in its immediate neighborhood there is proliferation of the stroma replacing the parenchymatous elements.

*Ascending Infection from the Duodenum.*—Under normal conditions the pancreas, like other glands of the gastro-intestinal tract, is protected against the entrance of micro-organisms. The valve-like folds within the diverticulum of Vater prevent the regurgitation of material from the duodenum into the duct, and if after death fluid is forced under considerable pressure into the duodenum, tied above and below the gland, none enters the duct. The flow of secretion, washing away foreign material, doubtless has a part in the protection of the gland.

Körte has produced chronic inflammation of the pancreas by injecting *Bacillus coli* into the pancreatic duct, and has obtained a similar result by injecting fecal ma-

terial. By an ingenious method Carnot has produced conditions by which an ascending infection from the duodenum results. A thread, inserted into the pancreatic duct, and through its orifice into the duodenum, has been left fixed in this position. Advanced sclerosis of the gland has resulted, and the walls of the ducts have been thickened and infiltrated with leucocytes, while the interstitial tissue of the gland has been much increased.

*Association of Chronic Interlobular Pancreatitis and Persistent Vomiting.*—In four of the thirty cases which I have observed, advanced chronic interstitial inflammation has been found in individuals who during life have suffered with persistent vomiting. Since this disease of the pancreas is notably one of advanced life, twenty-five of thirty cases occurring after the age of forty years, two of these cases in young women suggest some unusual etiological factor. In a third case chronic pancreatitis has followed persistent vomiting in a man forty-nine years of age, who though once addicted to alcohol has for ten years led a temperate life; chronic gastritis has been found at autopsy. In the fourth case vomiting has accompanied carcinomatous constriction of the terminal part of the duodenum. In all of these cases the clinical history affords evidence of continued gastric or gastrointestinal disease—namely, epigastric pain, nausea, and vomiting. Since the associated conditions apparently favor infection of the duct, these cases have been described under the present heading.

CASE XVI.—The patient, a deaf mute, female, aged thirty-one years, entered the service of Dr. Osler complaining of "heartburn" and dyspepsia. She has had one living child and three miscarriages,

and is at present pregnant. Four days before her admission she began to vomit; the vomiting has persistently continued and has recurred irrespective of the taking of food. In the afternoon of the day following admission to the Hospital, the patient becoming much weaker and semi-unconscious, vomiting ceased. Owing to the severity of the symptoms an exploratory laparotomy was performed. There was no return of vomiting until twelve days later, when it recurred with its previous persistence. It was decided to empty the uterus, and an ovum, two and a half months old, was removed. The patient died on the twenty-second day after her admission. Sugar was not found in the urine.

*Anatomical Diagnosis.*—Endometritis of the puerperal uterus. Anomalous artery, a branch of the aorta penetrating the substance of the right lung; rupture, with formation of cavity containing blood-clots. Chronic interlobular pancreatitis.

The stomach is normal, save for the presence of a few submucous ecchymoses; the duodenum is normal in appearance. The pancreas is almost board-like in consistence. The interlobular tissue is dense and fibrous, containing many spindle-shaped, lymphoid, eosinophile, and plasma cells. Entire lobules are at times partially destroyed, a few scattered acini remaining in the proliferated stroma, but in general the sharply defined lobules are not invaded by the process.

CASE XVII.—H. B., female, aged twenty-eight years, was admitted to the service of Dr. Kelly complaining of bleeding from the vagina. Her present illness began ten months before her admission. An operation, the nature of which she did not know, was performed five months later, and was followed by much nausea and vomiting. Previous to her admission she had been much nauseated, and states that even a small quantity of water might cause her to vomit. She had colicky pains in the epigastrium. Vaginal examination demonstrated the presence of an inoperable fungating carcinoma of the cervix. The urine contained no sugar.

*Anatomical Diagnosis.*—Carcinoma of the uterus, with metastases in the broad ligaments, pelvic and lumbar lymphatic glands, liver, and rectum; double pyelonephrosis; chronic interlobular pancreatitis.

There are no noteworthy changes in the stomach, intestine, or bile passages. The pancreas is firm in consistence and on section very compact in texture. The interlobular tissue is much thickened, dense

and fibrous, but contains lymphoid and plasma cells in considerable number.

CASE XVIII.—The patient, male, aged forty-nine years, was admitted to the service of Dr. Osler complaining of rheumatism, cough, shortness of breath, and indigestion. Ten years ago he had used alcohol in excess, but for the last ten years had only taken an occasional drink. For a year past he had attacks of vomiting without any apparent cause and with no relation to the taking of food, occurring sometimes in the morning before breakfast. He died on the fourth day after admission with symptoms of mitral insufficiency. The urine contained no sugar.

*Anatomical Diagnosis.*—Chronic endocarditis of the mitral valve; dilatation and hypertrophy of the heart; cardiac thrombi; chronic passive congestion of the viscera; infarcts of the lungs; acute and chronic gastritis; ulceration of the ileum and colon; chronic interlobular pancreatitis with lipomatosis.

The mucosa of the stomach, covered by tenacious mucus, is puffy, red and studded with small submucous ecchymoses. The pancreas weighs 152 Gm. The glandular tissue is in great part replaced by fat, separating groups of lobules; within these groups individual lobules are separated by thickened strands of dense stroma containing many lymphoid cells; in places are lobules undergoing disintegration.

The cases just described illustrate the occurrence of chronic interlobular pancreatitis in individuals who during life have suffered with persistent vomiting. They indicate the existence of some relationship between gastro-intestinal disturbance and chronic lesion of the pancreas. It is improbable that persistent vomiting has been caused by pancreatic disease, since in many cases the latter has existed unaccompanied by this symptom. Such vomiting has doubtless been associated with conditions favoring ascending infection of the pancreatic duct. The mechanical effect of vomiting upon the ducts and their contents is difficult to determine.

The type of the accompanying pancreatic lesion favors the probability of infection by way of the duct, for here pancreatitis is typically interlobular and resembles that observed in those cases where infection of the pancreas has followed lesions of the gall-ducts with or without duct-obstruction. This explanation receives further confirmation by the following case, in which persistent vomiting has been the result of partial occlusion of the terminal part of the duodenum.

CASE XIX.—Mrs. F. G., aged fifty-one years, entered the service of Dr. Osler seven weeks before her death, complaining of nausea, vomiting, and loss of weight. Her uterus had been removed seven years before by Dr. Kelly for carcinoma of the cervix; she had since enjoyed good health. Two months before re-entering the hospital she was attacked with very severe vomiting, occurring often five or six times a day and unaccompanied by nausea. While in the Hospital there were frequently repeated attacks of vomiting, usually at intervals of from twelve to eighteen hours. No sugar was found in the urine.

*Anatomical Diagnosis.*—Recurrent adenocarcinoma of the retroperitoneal lymphatic glands and of the peritoneum; indurated carcinomatous tissue constricting the duodenum and left ureter; multiple abscesses of kidney; cystitis; bronchopneumonia; fatty degeneration of the liver; fibrous myocarditis.

Sclerotic adenocarcinoma invading the wall of the duodenum at its termination has contracted the lumen to a diameter of 12 mm. The pancreas is very firm, and upon the surface individual lobules are sharply defined. Microscopic examination shows interlobular inflammation of moderate intensity, the lobulation being accentuated by thickened fibrous bands containing lymphoid, plasma, and eosinophile cells in fair abundance.

*Alterations of the Blood-Vessels; Arterial Sclerosis.*—In the cases already considered chronic pancreatitis has been secondary to alterations occurring in the ducts;

in another group of cases the ducts are unchanged and the lesion is referable to the blood-vessels or to toxic substances brought to the gland by the blood. In the pancreas, as in other organs, general arterial sclerosis has been thought to be the cause of fibroid induration, and G. Hoppe-Seyler<sup>22</sup> and Fleiner<sup>23</sup> have described cases of chronic interstitial pancreatitis, attributed by them to obliterating endarteritis. Both writers think that changes in the vessels are followed by nutritive disturbances which cause degeneration of the parenchyma and its replacement by fibrous tissue. The condition, Fleiner suggests, is analogous to the contracted kidney which is at times associated with general arterial sclerosis and to changes in the liver, heart, and brain following arterial diseases.

In the following case of diabetes advanced arterial sclerosis is accompanied by chronic interacinar pancreatitis. Here both gangrene of the foot and pancreatic lesion are referable, in part at least, to arterial sclerosis.

CASE XX.—The patient, a woman, aged sixty-three years, entered the Johns Hopkins Hospital suffering with gangrene of the right foot, which had begun five weeks before. Sugar was discovered in the urine. Death occurred with coma twelve days after admission. The urine had contained 2.2 per cent. of sugar; preceding death acetone was abundant.

*Anatomical Diagnosis.*—General arterial sclerosis; calcification of the coronary arteries and of the right posterior tibial and dorsalis pedis arteries. Gangrene of the right foot. Chronic interacinar pancreatitis.

The pancreas, weighing 82 Gm., is firm in consistence and is surrounded and infiltrated by abundant fat. The splenic artery in contact with the gland is tortuous and partially calcified. There is diffuse in-

---

<sup>22</sup> *Loc. cit.*, p. 211.

<sup>23</sup> Fleiner: *Berliner klin. Woch.*, 1894, xxxi, 5, 38.

crease of the interacinar stroma which is poor in cells. The islands of Langerhans are often surrounded by thickened, capsule-like strands of fibrous tissue, and similar proliferation of connective tissue has occurred along the course of their capillary vessels. Small arteries throughout the parenchyma not infrequently show obliterating endarteritis and hyaline changes of the middle coat.

Studies of G. Hoppe-Seyler<sup>24</sup> have furnished additional evidence that pancreatitis in association with arterial sclerosis is interacinar in type. The frequent association of diabetes mellitus with interacinar pancreatitis and arterial sclerosis is well shown by the statistics of Cecil.<sup>25</sup> Among ninety cases of diabetes interacinar pancreatitis occurred in sixty-seven cases (73 per cent.) and arterial sclerosis was present in all save two of these cases; the arteries of the pancreas were thickened and hyaline, and in one-fourth of the cases there was gangrene of the extremities, doubtless referable to the same arterial disease. Nevertheless, general arterial sclerosis, which may be advanced in one group of arteries and absent in another, may be unaccompanied by any change in the pancreas.

*Venous Congestion.*—A second alteration of the blood-vessels assigned as a cause of chronic pancreatitis is chronic passive congestion. Friedreich states that the lesion is not infrequently the result of long-continued venous gorging, occurring in chronic diseases of the heart, lungs, and liver. The changes, he says, are usually slight and do not cause destruction of the glandular elements. The frequency of chronic congestion of the abdominal viscera, and the relative infrequency of

---

<sup>24</sup> Hoppe-Seyler: *Deutsches Arch. f. klin. Med.*, 1904, lxxxi, 119.

<sup>25</sup> *Loc. cit.*

chronic interstitial inflammation of the pancreas, is evidence that the former condition is not commonly a cause of the latter. Chronic passive congestion may doubtless produce slight proliferation of the interstitial tissue, but is an unimportant factor in the production of chronic pancreatitis.

The following case serves to illustrate how small is the influence of advanced chronic passive congestion in causing inflammatory changes in the gland, for the slight increase of interstitial tissue which is present is probably due to local changes in the wall of veins plugged by carcinomatous tissue and to accumulation of pigment both in the secreting cells and in the interstitial tissue of the organ.

CASE XXI.—*Anatomical Diagnosis*.—Primary carcinoma of the liver invading and occluding the portal vein; chronic passive congestion of the spleen, pancreas, stomach, and intestines; ascites. Chronic interstitial pancreatitis with pigmentation.

The pancreas, compressed by the distended splenic vein, is firm and compact in texture and of a uniform brownish-red color. The veins are widely dilated, and are occasionally plugged by carcinomatous tissue. There is a very slight increase of the interlobular tissue, which is denser than usual, and among the acini occur irregular patches of interstitial tissue, poor in cells. Small hemorrhages have in places occurred into the interlobular tissue, and both here and within the secreting cells is found brown iron-containing pigment.

Chronic pancreatitis, like corresponding changes in the liver and kidney—namely, cirrhosis of the liver and chronic interstitial nephritis—is caused by the action of toxic substances present in the blood. Various conditions presumably capable of producing such substances have been assigned as causes of chronic pancreatitis;

those notably worthy of consideration are tuberculosis, syphilis, and alcohol, named in the probable order of their increasing importance.

*Tuberculosis.*—Carnot, citing observations of Ancelet and other writers, has claimed that chronic pancreatitis is not uncommon with tuberculosis. He examined the pancreas in patients dying with tuberculosis, and while in the majority no lesion was demonstrable, in seven cases he found a variable, usually moderate increase of the connective tissue normally present about the vessels and ducts and between the lobules. Finding tubercles in only one case he thinks that the specific lesion of tuberculosis is uncommon in the pancreas. Carnot was able to produce chronic inflammatory changes in the pancreas of dogs, somewhat varied in extent and character, by injecting suspensions of *Bacillus tuberculosis* into the duct or into the parenchyma of the organ, but the lesion presented none of the specific characters of tuberculosis, and tubercle bacilli were not demonstrable in the tissues.

Two of the thirty instances of chronic pancreatitis previously cited occurred in individuals who suffered with advanced tuberculous lesions and in one of these instances miliary tubercles were found in the pancreas. In three additional autopsies performed in the pathological laboratory of the Johns Hopkins Hospital tuberculous lesions were present in the pancreas, but there was no generalized proliferation of the interstitial tissue.

Since tuberculosis, it is well known, is a frequent complication of diabetes, its relationship to alterations of the pancreas are of much interest. In the cases just cited diabetes has not been present and the lesion of moderate severity is interlobular, a type of inflammation

accompanied by diabetes only when very far advanced. There is, it appears, no reason to suppose that diabetes may be caused by pancreatitis resulting from tuberculosis.

*Syphilis.*—The autopsy records of the pathological laboratory of the Johns Hopkins Hospital furnish no instance in which chronic pancreatitis has been associated with visceral syphilis; and though the literature demonstrates that the two conditions occur in conjunction, acquired syphilis is certainly not the most common cause of the lesion, as Hansemann,<sup>26</sup> Kasahara,<sup>27</sup> and other writers believe. In only one of my thirty cases was a history of syphilis obtained; and in this case chronic pancreatitis with formation of cysts was caused by primary carcinoma of the pancreas compressing the duct.

*Alcohol.*—The common cause of cirrhosis of the liver is excessive use of alcoholic drinks. Cirrhosis is relatively infrequent when compared with the prevalence of alcoholic indulgence; but here, as with many diseases, other conditions are necessary in order that the lesion may result. Alcoholic excess is likewise regarded as a frequent cause of chronic interstitial pancreatitis, and in many instances a history of alcoholic indulgence can be obtained. Friedreich found at autopsy upon a drunkard chronic pancreatitis, cirrhosis of the liver, and granular kidneys. Chvostek,<sup>28</sup> Dieckhoff, and Oser have described cases in which cirrhosis of the liver and chronic pancreatitis were associated in alcoholics. In eight of

---

<sup>26</sup> Hansemann: *Zeit. f. klin. Med.*, 1894, xxvi, 191.

<sup>27</sup> Kasahara: *Virchow's Arch.*, 1896, cxliii, 111.

<sup>28</sup> Chvostek: *Wiener med. Blätter*, 1879, ii, 791.

the present thirty cases a history of alcoholic excess has been obtained, but in three of these cases chronic inflammation of the organ has followed obstruction of its duct by biliary or pancreatic calculi, and is indirectly, if at all, referable to the use of alcohol.

In the following case chronic interlobular pancreatitis unaccompanied by cirrhosis of the liver has been found at autopsy in an individual dying with delirium tremens.

CASE XXII.—J. M., male, aged fifty-three years, was admitted to the service of Dr. Osler with delirium. His wife, from whom a satisfactory history was not obtained, stated that he had been drinking very heavily for a month, and on the morning before his admission became delirious and feverish. The patient was completely unconscious, the temperature rose to 105.4° F., and he died on the second day after admission.

*Anatomical Diagnosis.*—Bronchitis and beginning aspiration pneumonia; acute diphtheritic and hemorrhagic colitis; fatty degeneration of the liver; chronic interlobular pancreatitis; fat necrosis.

The pancreas, of normal size, is very firm in consistence, and the interstitial tissue appears to be indurated. The ducts are normal. Numerous small foci of fat necrosis occur about the pancreas and in the transverse mesocolon. Microscopic examination shows typical chronic interlobular pancreatitis, and the interstitial tissue contains numerous lymphoid cells.

Few reported instances of chronic pancreatitis not dependent upon lesions of the duct are described with sufficient detail to determine if there has been alcoholic indulgence, and a review of them would afford statistics of little value. Alcohol being the common cause of cirrhosis of the liver, the association of chronic pancreatitis with this lesion is significant.

*Association of Chronic Pancreatitis with Cirrhosis of*

*the Liver.*—Among my thirty cases of chronic pancreatitis cirrhosis of the liver occurs in eight. In three of these cases pancreatitis is indirectly, if at all, related to the lesion of the liver and has followed readily demonstrable changes in the duct of Wirsung.

Chronic inflammation of the liver and pancreas have been found associated by Friedreich, Chvostek, Hanse-  
mann, Dieckhoff, Kasahara, Oser, and Lefas. In six cases of chronic interstitial hepatitis Kasahara found a marked increase of connective tissue in the pancreas, in two a slight increase, and in two none at all.

Of considerable interest are the observations of Lefas;<sup>29</sup> with the so-called atrophic or Laennec's cirrhosis he finds that the weight of the pancreas is increased and the newly-formed tissue, which is poor in cells, is uniformly intralobular, penetrating the parenchyma and isolating groups of acini. With so-called hypertrophic biliary cirrhosis of Hanot there is no increase in the volume of the pancreas, but the interlobular tissue is increased in amount and in density. Cases which I have observed confirm in part the observations of Lefas.

In two cases previously described (Cases XIII and XIV) chronic interacinar pancreatitis accompanied by diabetes was associated with cirrhosis of the liver of the so-called atrophic type of Laennec. In only one was there a history of excessive alcoholic indulgence.

An excellent illustration of the dependence of chronic lesions of the liver and of the pancreas upon the same etiological factor is furnished by the disease of pig-

---

<sup>29</sup> Lefas: Arch. gén. de méd., 1900, n. s. iii, 539.

ment metabolism, first described by Von Recklinghausen, namely, hæmochromatosis.

In a case of hæmochromatosis (see page 368) included in the present series cirrhosis of the liver was accompanied by chronic interacinar pancreatitis.

In the following case hypertrophic cirrhosis of the type of Hanot is accompanied by interlobular pancreatitis, as in the cases described by Lefas; it is noteworthy that the condition is complicated by gall-stones, which may explain the occurrence of interlobular pancreatitis.

CASE XXIII.—The patient, male, aged fifty-six years, admitted to the service of Dr. Osler in the Johns Hopkins Hospital, gave a history of having used whisky in excess. For the last year, until a short time ago, he has had attacks of vomiting, and during the last six months has become weak and short of breath. The liver is enlarged, and there are ascites and other evidences of portal congestion. Sugar has not been found in the urine.

*Anatomical Diagnosis.*—Hypertrophic cirrhosis (of Hanot); ascites; chronic passive congestion of spleen; chronic interlobular pancreatitis; cholelithiasis.

The liver, weighing 2880 Gm., exhibits the gross microscopic appearance of hypertrophic cirrhosis of Hanot. The gall-bladder contains many small faceted calculi. The pancreas, weighing 60 Gm., is very firm in consistence and evidently sclerotic. The duct of Wirsung in the body and tail of the gland is dilated, and contains solid wax-like material. Microscopic examination shows that the lobules, particularly in the body and tail, are separated by dense sclerotic tissue showing little tendency to penetrate between the acini.

In a second case included in my series previously cited interlobular pancreatitis of moderate grade accompanied beginning cirrhosis in a woman twenty-two years of age, and though the hepatic lesion corresponded to

the so-called atrophic or Laennec's cirrhosis, the alteration of the pancreas differed from that observed in such cases by Lefas and found with atrophic cirrhosis in Cases XIII and XIV. It is noteworthy, however, that the lesion was associated with tuberculous peritonitis, while a variety of chronic lesions co-existed in other organs.

The foregoing data concerning the etiology of chronic pancreatitis may be summarized in the following conclusions:

(a) Occlusion of the pancreatic ducts by gall-stones, pancreatic calculi or other obstruction to outflow of pancreatic juice, is followed by *interlobular pancreatitis*. Acute inflammation of the pancreatic ducts ascending from the duodenum or bile duct may be followed by chronic interlobular pancreatitis.

(b) *Arterial sclerosis* is a frequent cause of *interacinar pancreatitis*. Those conditions which cause cirrhosis of the liver—for example, use of alcohol—not infrequently cause chronic interstitial pancreatitis which in association with atrophic cirrhosis of the type of Laennec is usually interacinar.

The importance of these conclusions will be evident when the relation of diabetes mellitus to chronic pancreatitis is considered. It will be shown that interlobular pancreatitis which spares the islands of Langerhans, and only when far advanced injures them, is rarely accompanied by diabetes, whereas interacinar pancreatitis which attacks these structures is almost constantly accompanied by diabetes mellitus.

## SYMPTOMS.

Chronic pancreatitis is rarely accompanied by such definite symptoms that its recognition is possible during life. In most instances a considerable part of the parenchyma is undestroyed, and is capable of performing, in part at least, the functions of the gland. Hence chronic pancreatitis may be unaccompanied by glycosuria or by any disturbance of digestion. Since chronic pancreatitis in most instances follows grave disturbances of the stomach, duodenum or bile passages, symptoms of the primary disorder are predominant and hinder recognition of the pancreatic lesion. On the other hand, disease of neighboring organs recognizable by clinical methods may suggest the presence of chronic pancreatitis.

Symptoms such as pain in the epigastric region, perhaps in the midscapular region, jaundice, loss of weight and weakness have been frequently found in association with chronic pancreatitis but cannot be referred with certainty to this disease since they may be caused by accompanying changes in the gastro-intestinal tract or in the biliary passages. Vomiting, which frequently occurs with chronic pancreatitis, may be referable to lesions of adjacent organs and there is evidence indeed that it may be a cause of pancreatitis. Mayo Robson and Cammidge, who alone claim that chronic pancreatitis can be recognized with considerable frequency during life, attach special significance for diagnosis to progressive wasting jaundice, disturbances of gastric digestion, the almost invariable presence of the reaction of Cammidge in the urine, and an excess of unabsorbed fecal fat of which the

greater part has not been split to form fatty acids and soaps. (See Chapter IV.)

Enlargement of the pancreas caused by chronic inflammation is not recognizable through the abdominal wall. Under normal conditions the pancreas is not palpable, but in individuals with thin abdominal walls, according to Osler,<sup>30</sup> particularly in women with enteroptosis, the organ can be felt.

It has been claimed that acute or chronic inflammation with swelling of the head of the pancreas may cause jaundice by compression of the common bile duct; chronic inflammation with sclerosis and contraction of newly-formed tissue surrounding the duct as it passes through the gland, it is believed, may constrict and occlude the bile duct. Pourtoy<sup>31</sup> has described a case in which a sharply localized focus of sclerosis of obscure origin had caused constriction of the common bile duct, with jaundice. In none of the other cases collected by this writer has dissection confirmed his claim that jaundice may be caused by diffuse chronic inflammation of the pancreas. Jaundice with acute or chronic inflammation of the pancreas is in most instances adequately explained by cholelithiasis or other hepatic disease preceding or accompanying the pancreatic lesion. Disturbances of digestion such as fatty stools are uncommon. In sixty-three of ninety cases of diabetes Cecil found interacinar pancreatitis. Although no group of symptoms, as Lancereaux<sup>32</sup> has claimed, is characteristic of diabetes caused by pan-

---

<sup>30</sup> Osler: *The Diagnosis of Abdominal Tumors*. New York, 1894, p. 118.

<sup>31</sup> Pourtoy: *Thesis*, Lyon, 1903.

<sup>32</sup> Lancereaux: *Bull. Acad. de méd.*, 1877, 2 s., vi, 1215.

creatic lesion, conditions associated with the disease may give evidence that it accompanies interacinar inflammation of the gland; such lesions are arterial sclerosis and cirrhosis of the liver.

In a considerable number of cases cited in the literature of the subject arterial sclerosis has been associated with chronic interstitial inflammation of the pancreas. Where advanced arterial sclerosis accompanies diabetes mellitus, the latter disease is with much probability referable to interacinar inflammation of the pancreas.

The association of diabetes mellitus and cirrhosis of the liver has been very frequently observed, and in some of these cases the pancreas examined at autopsy has been found to be the seat of chronic inflammatory changes. Chronic inflammation of the pancreas and of the liver is doubtless in such cases dependent upon the same etiological factors. In Cases XIII and XIV diabetes and atrophic cirrhosis have coexisted while at autopsy chronic pancreatitis of the interacinar type has been demonstrable. Seven similar cases are recorded by Cecil. Diabetes with cirrhosis of the liver is with much probability indicative of interacinar pancreatitis.

One form of chronic interacinar pancreatitis with diabetes and cirrhosis may be readily recognized during life. Diabetes with hæmochromatosis, the so-called bronzed diabetes, is doubtless in all cases the result of chronic interacinar inflammation affecting the pancreas and implicating the islands of Langerhans. The combination of symptoms in such cases is characteristic. Diabetes mellitus is associated with hypertrophic cirrhosis of the liver, and there is often intense pigmentation of the skin. In a case described by Anschütz, fatty

stools gave evidence that the secretion of the pancreas was diminished in amount.

*Pancreatitis as a Complication of other Diseases.*—It has been repeatedly stated that in most instances both acute and chronic inflammation of the pancreas are secondary to disease of other organs. Acute or chronic inflammation may be the result of an ascending infection of the pancreatic ducts having its origin in the inflamed stomach, duodenum, or bile passages. The occurrence of chronic inflammation in association with persistent vomiting has been emphasized.

The close relationship between disease of the liver and of the pancreas is especially noteworthy, chronic inflammation of the liver and pancreas, doubtless due to the same etiological factor, not infrequently occurring in conjunction. Much more common, however, is the association of cholelithiasis and chronic pancreatitis. A large gall-stone lodged in the terminal part of the common bile duct, or indeed within the diverticulum of Vater, prevents the escape of pancreatic secretion, unless the duct of Santorini affords a free outlet, and chronic interlobular inflammation of the gland results. The indurated gland felt during an operation undertaken for the removal of gall-stones in the common duct has been frequently mistaken for malignant growth. Ability to distinguish between cancer and chronic pancreatitis will have an important influence upon the prognosis in such cases, and removal of the occluding calculus will prevent further development of the pancreatic lesion.

From a clinical stand-point it is desirable to distinguish between an interlobular and an interacinar type of chronic interstitial pancreatitis.

*Chronic pancreatitis of the interlobular type* in most instances follows obstruction of the duct by pancreatic calculi, by biliary calculi, or by tumors and cysts compressing the duct as it passes through the head of the gland. In some of such cases disturbances of digestion, namely, steatorrhœa or azotorrhœa, consequent upon loss of the pancreatic secretion, have been noted. Acute and chronic inflammation of the stomach and duodenum on the one hand, and of the bile passages on the other, may, as in cases previously described, be accompanied by interlobular pancreatitis, the result of ascending infection. I have described four cases in which chronic interlobular inflammation was found at autopsy in individuals who had suffered with persistent vomiting, caused doubtless in three cases, presumably in all, by lesions of the stomach or of the duodenum.

Interlobular pancreatitis is accompanied by diabetes only when the lesion is so far advanced that dense sclerotic tissue, which replaces the secreting parenchyma, surrounds and compresses the islands of Langerhans. Glycosuria was noted in only one of my twenty-two cases of interlobular pancreatitis and interlobular pancreatitis was present in only four of ninety cases of diabetes studied by Cecil. In my case chronic interlobular pancreatitis was caused by calculi obstructing the pancreatic ducts; glycosuria was of mild type, and disappeared when the patient was given a diet poor in carbohydrates.

In at least five of fifteen cases in which Wille found alimentary glycosuria, chronic inflammation—from his description presumably of the interlobular type—was found at autopsy. Where chronic pancreatitis is suspected, the presence of alimentary glycosuria, tested by

the administration of sugar, would give additional evidence.

Mayo Robson and Cammidge believe that chronic pancreatitis is a dangerous complication of cholelithiasis and may cause death with increasing weakness and emaciation. Removal of gall-stones and drainage of the gall-bladder (they recommend cholecystenterostomy) check these symptoms, they believe, and they have repeatedly observed recovery following the operation although induration of the head of the pancreas at the time of operation has indicated the presence of chronic pancreatitis. It is difficult to determine how much the pancreatic lesion increases the severity of symptoms caused by cholelithiasis. Mayo<sup>33</sup> has not found that the pancreatic lesion has greatly influenced the prognosis of operations performed for the removal of gall-stones.

Chronic interlobular pancreatitis caused by gall-stones rarely if ever causes such advanced destruction of the pancreas that diabetes mellitus ensues. When chronic interlobular pancreatitis follows occlusion of the pancreatic duct caused by carcinoma, by cyst or by pancreatic calculi, diabetes mellitus results only when the pancreatic parenchyma is in great part replaced by fibrous tissue, and islands of Langerhans which tend to remain uninjured are finally attacked. Glycosuria indicates that the lesion is far advanced and suggests grave prognosis.

Distinctive of *the interacinar form of chronic pancreatitis* are glycosuria and other symptoms of diabetes mellitus.

---

<sup>33</sup> *Loc. cit.*, p. 226.

## CHAPTER X.

### TUBERCULOSIS OF THE PANCREAS—SYPHILIS.

VIRCHOW<sup>1</sup> has cited the pancreas to illustrate local immunity from tuberculosis. Whereas large tuberculous lesions are rare and functional disturbance referable to tuberculosis almost unknown, the occurrence of miliary tubercles in association with tuberculosis of other organs is not uncommon. Kudrewetzky<sup>2</sup> found miliary tubercles of the pancreas in 12 of 128 bodies with tuberculosis in other organs; almost half of these secondary tuberculous lesions of the pancreas occurred in children. Among 18 cases of acute miliary tuberculosis in 6 the pancreas contained tubercles. Tubercles were usually situated within the lobules, less frequently in the interlobular tissue and rapidly underwent caseation. With chronic tuberculosis large tubercles replacing groups of acini with newly-formed tissue, were found occasionally.

Tuberculosis may occur in the pancreas by extension from neighboring organs. The disease may begin in lymphatic glands which are in contact with and even within the substance of the gland. Sendler<sup>3</sup> found a small tumor above the umbilicus of a woman who had suffered with pain and vomiting, and a small mass which proved to be a tuberculous lymphatic gland was removed by operation from the head of the pancreas. Carnot<sup>4</sup>

---

<sup>1</sup> Virchow: Die krankhaften Geschwülste, Berlin, 1864-65, ii, 677.

<sup>2</sup> Kudrewetzky: Zeit. f. Heilk., 1892, xiii, 101.

<sup>3</sup> Sendler: Münchener med. Woch., 1896, xliii, 1193; Deutsche Zeit. f. Chir., 1896, xlv, 329.

<sup>4</sup> *Loc. cit.*

found tuberculosis of the splenic end of the pancreas in contact with a tuberculous kidney.

It is noteworthy that fat necrosis in contact with the pancreas has been mistaken for tuberculosis.

Primary tuberculosis of the pancreas has been described. Aran<sup>5</sup> found a tuberculous mass the size of a hen's egg in the tail of the pancreas of a woman aged twenty-five years, who had suffered with pain in the epigastrium, vomiting and discoloration of the skin; there were miliary tubercles about the mass and in the spleen. Mayo<sup>5</sup> has described pancreatic tuberculosis in a woman thirty-eight years old, who had suffered with pain in the right hypogastrium during sixteen weeks; there was jaundice several weeks before death, and a tumor was palpable just above the umbilicus. The head of the pancreas was much enlarged by a tuberculous mass which had compressed the common bile duct and caused considerable distention of the gall-bladder. Tubercles regarded as secondary were found in lymphatic glands, thymus, and kidneys. In a case described by Chvostek<sup>6</sup> the pancreas contained caseous masses the size of a walnut; the enlarged and sclerotic organ compressed both common bile duct and duodenum.

#### SYPHILIS.

*Congenital Syphilitic Pancreatitis.*—Birch-Hirschfeld<sup>7</sup> first drew attention to the frequency with which the pancreas is affected by congenital syphilis. He found the pancreas affected in thirteen of twenty-three cases of

---

<sup>5</sup> Cited by Senn: *Outlines of Human Pathology*.

<sup>6</sup> Chvostek: *Wiener med. Blätter*, 1879, ii, 791.

<sup>7</sup> Birch-Hirschfeld: *Gerhardt's Handbuch d. Kinderkrankheiten*, iv, Abt., ii, 753, Tübingen, 1880.

congenital lues, but studying a second group of cases, found changes in the organ only twenty-nine times in one hundred and twenty-four syphilitic new-born. In six instances Schlesinger<sup>8</sup> found the enlarged firm organ the seat of a diffused interstitial pancreatitis characterized by proliferation of interlobular and interacinar tissue penetrating in places between the cells of the acini. This inflammatory new growth, he thinks, is followed by destruction of the parenchymatous elements, which, though they do not exhibit appearances of degeneration, atrophy and disappear. New growth of interstitial tissue, he finds, has its origin about the blood-vessels; the arteries are the seat of a syphilitic peri-arteritis. As the lesion progresses the capillary network about the acini disappears. Schlesinger has observed that the islands of Langerhans are neither invaded by the new growth of interstitial tissue nor implicated in the atrophy which affects the cells of the acini.

Two instances of congenital syphilis of the pancreas are here recorded; the relation of the islands of Langerhans to the inflammatory process has considerable interest.

CASE XXIV.—An infant, 40 cm. in length, lived three hours.

*Anatomical Diagnosis.*—Congenital syphilis; interstitial pneumonia; splenic tumor; chronic perisplenitis.

*Microscopic Examination of the Pancreas.*—The interstitial tissue is greatly increased at the expense of the parenchyma, and the lobules, composed of a few acini, are irregularly scattered in dense cellular stroma. The smallest ducts, beset with acini along their course, terminate in a group of acini which, though much less numerous than those ordinarily forming a lobule, are of normal size, and are composed

---

<sup>8</sup> Schlesinger: Virchow's Arch., 1898, cliv, 501.

of cells showing no evidence of degeneration. The interlobular tissue contains many fibroblasts and lymphoid cells; plasma cells are particularly numerous about the blood-vessels and cells with eosinophilic granules are abundant. Though islands of Langerhans are embedded in the stroma which separates the neighboring acini, they are not invaded by the inflammatory change. Some of these islands of Langerhans are in continuity with the ducts of the gland (Fig. 34.) At the periphery of the island of Langerhans one of the columns projects beyond the general circular outline and is continuous with epithelial cells which, staining less brightly with eosin, are arranged about a lumen and are in turn continuous with adjacent acini. Nevertheless, many islands of Langerhans, traced through a series of sections, are found completely isolated.

CASE XXV.—An infant, 50 cm. in length, lived four hours.

*Anatomical Diagnosis.*—Congenital syphilis; pemphigus neonatorum; interstitial pneumonia; interstitial hepatitis and pancreatitis; splenic tumor.

*Microscopic Examination of the Pancreas.*—The interstitial tissue is greatly increased and the parenchyma is in great part replaced by it. The new tissue is very cellular, but the cells are in great part fibroblasts, and accumulations of round cells are not found. Plasma cells and cells with eosinophilic granulations are rarely seen. The acini form small groups which may be regarded as primary lobules, though the acini composing them are much less numerous than those of a normal lobule. Islands of Langerhans occur as compact round masses of epithelial cells and are scattered abundantly throughout the organ. The fibrous tissue is often concentrically arranged about these interacinar islands, and at times they are completely isolated. Not infrequently, however, as in the preceding case, they are in continuity with the neighboring ducts; a double row of cells is continuous on the one hand with a cell-column of an island of Langerhans, on the other with a small duct.

The preceding cases represent different stages of the syphilitic lesion. In Case XXIV cells which accumulate with inflammation—namely, lymphoid and plasma cells

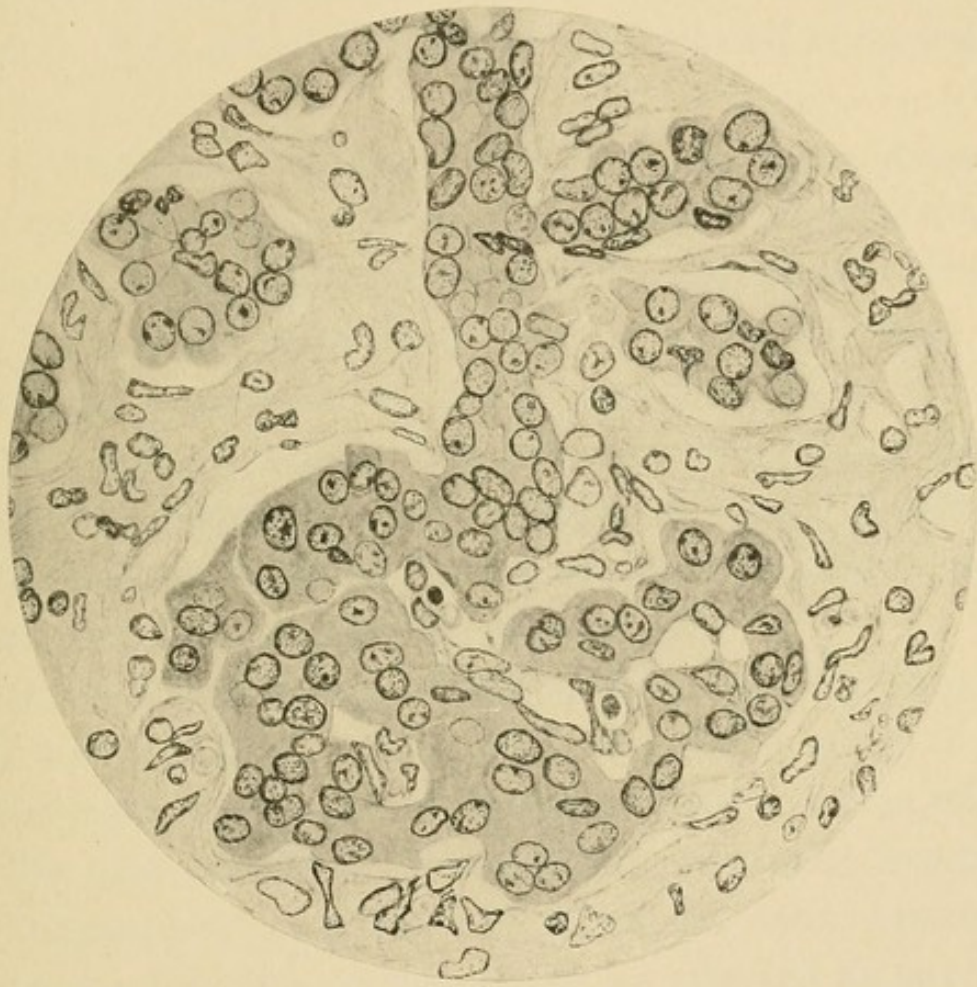



FIG. 34.—Congenital syphilitic pancreatitis (Case XXIV). Showing a cell-column of an island of Langerhans in continuity with a small duct.



and eosinophile leucocytes—are numerous, and the condition represents the active stage of a chronic inflammatory process. In Case XXV, though interstitial tissue is more abundant and the persistent parenchymatous elements are more scattered, cells of lymphoid type are few in number, while plasma cells and eosinophiles are almost absent. The process is more advanced and is no longer active.

A conspicuous feature in both cases is the presence of numerous islands of Langerhans surrounded by newly-formed stroma, but uninvaded by it. In many instances the islands of Langerhans are in continuity with the secreting structures of the gland (Fig. 34). A cell-column of the island of Langerhans is continuous with a small duct, which is in turn beset with acini;<sup>9</sup> the lumen of the duct does not penetrate into the island of Langerhans, but disappears at its periphery.

Birch-Hirschfeld has claimed that syphilitic pancreatitis has its onset during the last months of fetal life. Schlesinger cites cases of Müller and Mraczek, in which, at the fifth month of development, advanced lesion of the organ has occurred, and from his own experience concludes that the pancreas may be affected as early or as late as other organs.

At an early period of development—for example, during the fifth month of fetal life—acini form small groups widely separated by embryonic connective tissue. In the two cases of syphilitic pancreatitis just described the parenchyma has the appearance observed about the fifth month of development. Congenital syphilis of the pan-

---

<sup>9</sup> Opie: Jour. of Exper. Med., 1901, v, 397.

creas, like other syphilitic lesions, affects primarily the interstitial tissue, and changes in the parenchyma result not so much from destruction of the parenchyma as from interference with its growth. Similarity between the syphilitic and the undeveloped organ may be thus explained. Development of individual cells is not retarded, and islands of Langerhans are the result of early cell-differentiation; but in many instances islands of Langerhans remain in continuity with tubular structures from which they have had their origin. Often, however, the connecting strand of cells is no longer discoverable, and the interacinar islands resemble those ordinarily found at the end of fetal development.

Within the newly-formed stroma of the syphilitic pancreas minute foci of necrosis, described as miliary gummata, have been found occasionally. In two of the cases recorded by Birch-Hirschfeld such gummata occurred, and similar lesions have been repeatedly found by other observers.

*Acquired Syphilis.*—With acquired syphilis the pancreas may be the seat of gummata and of syphilitic induration resembling syphilitic cirrhosis of the liver. From the older literature of the subject Friedreich cited a case of Rostan; two gummata were found in the pancreas of a man who had had a chancre fourteen years before death. In a man thirty-four years old Schlagenhauser<sup>10</sup> found scars on the prepuce, syphilitic induration of the testicles with gumma of the epididymis, and syphilitic cirrhosis of the liver; the head of the pancreas was indurated and a broad zone of fibrous tissue sur-

---

<sup>10</sup> Schlagenhauser: Arch. f. Derm. u. Syph., 1895, xxxi, 43.

rounded a yellow nodule with softened centre. There were miliary gummata in the fibrous stroma, endarteritis, and peri-arteritis. In a man sixty-three years of age Thorel<sup>11</sup> found the pancreas hard and irregularly shrunken so that it formed nodular masses; upon the cut surface little glandular tissue was recognizable, and scattered in the sclerotic stroma were small caseous gummata. Truhart<sup>12</sup> found a lobulated pancreas puckered by scar-like fibrous tissue in a man aged thirty-one years who had acquired syphilis four years before death; in the mid-part of the gland was a gummatous nodule.

In a case described by Drozda<sup>13</sup> the pancreas was represented by a mass of indurated tissue, in which glandular structures were recognizable only in the head; here and there occurred caseous gummata embedded in the fibrous stroma. The liver was the seat of syphilitic cirrhosis and the stomach contained an indurated scar. In a case of visceral syphilis described by Chvostek<sup>14</sup> the tail of the pancreas was penetrated by several sclerotic bands of tissue, giving it a lobed appearance.

In the cases which have been cited changes are analogous to syphilitic lesions of the liver and are characterized by the occurrence of gummata or irregular scar-like bands of tissue penetrating the parenchyma; they differ from the more common lesion of chronic interstitial pancreatitis with which there is a diffusely distributed increase of the interlobular or interacinar tissue.

In two cases of chronic interstitial pancreatitis asso-

---

<sup>11</sup> Thorel: Cited by Truhart.

<sup>12</sup> *Loc. cit.*, p. viii.

<sup>13</sup> Drozda: *Weiner med. Presse*, 1880, xxi, 993.

<sup>14</sup> *Loc. cit.*, p. 250.

ciated with diabetes Hansemann obtained evidence of syphilis. Kasahara examined the pancreas in six cases of acquired syphilis, and in two found a moderate increase of the interstitial tissue, in two merely thickening of the blood-vessels, and in two no alterations. These writers have believed that syphilis is a common cause of chronic pancreatitis. There was a history of syphilis in only one of thirty cases of chronic pancreatitis which I examined and in this instance chronic inflammation was caused by carcinoma compressing the duct of Wirsung. Syphilis is doubtless a cause of chronic inflammation of the gland, and the cases of Droza, Chvostek and others indicate the existence of syphilitic pancreatitis characterized by scar-like bands of tissue which may contain gummata. The etiological relationship of syphilis to a diffusely distributed interacinar or interlobular inflammation is doubtful.

## CHAPTER XI.

### PANCREATIC CALCULI.

PANCREATIC lithiasis, unlike cholelithiasis, is rarely found at autopsy and among fifteen hundred autopsies at the Johns Hopkins Hospital occurred only twice. Gall-stones are usually formed within the gall-bladder, whereas pancreatic calculi are formed within the ducts of the gland. The disease is more common in men than in women; of fifty-seven cases collected by Lazarus<sup>1</sup> forty-seven were in men and ten in women, thirty-seven occurring between the ages of thirty and forty years.

*Pathological Anatomy.*—Concretions within the ducts may resemble fine sand, but usually there are one or more small stones, sometimes as many as a hundred. The largest calculus which has been described (Schuppmann<sup>2</sup>) measured one and a half inches across. Concretions are usually hard and white, or grayish white, and consist in great part of calcium carbonate and phosphate, together with other inorganic salts. Two analyses by Johnston<sup>3</sup> are as follows: Case I.—Calcium phosphate, 72.3 per cent.; calcium carbonate, 18.9 per cent.; organic matter, 8.8 per cent. Case II.—Calcium carbonate, 91.65 per cent.; magnesium carbonate, 4.15 per cent.; organic matter, 3 per cent. Calculi containing cholesterin in con-

---

<sup>1</sup> Lazarus: *Beitrag zur Pathologie and Therapie der Pankreas-erkrankungen mit besonderer Berücksichtigung der Cysten und Steine.* Berlin, 1904.

<sup>2</sup> Schuppmann: *Hufeland's Jour.*, 1841, xcii, 41. Quoted by Oser.

<sup>3</sup> Johnston: *American Jour. of the Med. Scien.*, 1883, lxxxvi, 404.

siderable amount have been found and Shattock<sup>4</sup> has removed from a pancreatic cyst a calculus consisting almost wholly of calcium oxalate.

Biliary calculi occasionally make their way into the pancreatic ducts (Dieckhoff) and their presence has been associated with pancreatic suppuration. A pancreatic calculus lodged at the duodenal end of the bile duct may be stained by bile pigments and receive a layer of cholesterolin (Robson and Cammidge).

The duct of Wirsung is narrower than elsewhere at its duodenal termination where it passes through the duodenal wall, and calculi tend to lodge above this point. The outflow of secretion may be completely prevented and the duct may be dilated behind the obstruction. True cysts are rarely formed but Von Recklinghausen<sup>5</sup> has described a cyst the size of a child's head apparently caused by a calculus impacted at the end of the pancreatic duct.

Occlusion of the duct by calculi causes changes similar to those which follow experimental ligation of the duct in animals and, usually associated with bacterial infection, produces the most advanced sclerosis to which the gland is subject. Chronic inflammation is interlobular in type and tends to spare the islands of Langerhans; the following cases illustrate the changes which occur in the pancreas:

CASE XXVI.—*Summary of Clinical History.*—W. H., male, aged forty-three years, was admitted to the Johns Hopkins Hospital suffering with pulmonary tuberculosis. He had used beer in large quantity.

---

<sup>4</sup> Shattock: *British Med. Jour.*, 1896, i, 1034.

<sup>5</sup> Von Recklinghausen: *Virchow's Arch.*, 1864, xxx, 360.

Ten months before his death he had had an attack of jaundice. No symptoms of diabetes were noted.

*Anatomical Diagnosis.*—Chronic pulmonary tuberculosis; tuberculous pleurisy. Cirrhosis of the liver with fatty degeneration; Splenic tumor. Pancreatic calculi; interstitial pancreatitis; peripancreatic fat necrosis.

*Pancreas.*—The duct of Wirsung and its branches are much distended by numerous calculi, which give the reactions of calcium carbonate. Glandular tissue has in large part disappeared, and is replaced by interstitial tissue containing abundant fat, in which are opaque, white areas of necrosis.

*Microscopic Examination.*—The parenchyma has been in very great part replaced by dense fibrous tissue, in which are scattered foci of round cells. In the head of the organ are small areas of glandular tissue, subdivided by interlobular fibrous strands. Occasionally lobules are found in process of disintegration, atrophied acini with dilated lumen being separated by newly-formed interstitial tissue. Numerous islands of Langerhans, most abundant in a section from the splenic end of the organ, are surrounded and isolated by newly-formed stroma, and though the tissue about is densely fibrous, within the islands are delicate capillaries, often distended with red blood-corpuscles. Occasionally an island has the appearance of being compressed and distorted.

*CASE XXVII.—Summary of Clinical History.*—The patient, male, aged fifty years, had used alcohol in excess. His illness began five months before its fatal termination with symptoms of pulmonary tuberculosis gradually increasing in severity. On admission to the Hospital, two months after the onset of his illness, the urine contained 5.2 per cent. of sugar. When given a diet poor in carbohydrates (Von Noorden's standard diabetic diet), sugar disappeared from the urine, and reappeared only when carbohydrates were added,—90 Gm. of white bread to the daily diet.

*Anatomical Diagnosis.*—Pancreatic calculi; chronic interstitial pancreatitis; parapancreatic fat necrosis. Chronic pulmonary tuberculosis. Chronic diffuse nephritis; large white kidneys. Anthracosis of lungs, spleen, and kidneys.

*Pancreas.*—The organ is much diminished in size and is tough and

fibrous. Atrophy is so marked that the body is merely a narrow isthmus connecting the head and tail. The duct, slightly enlarged, contains viscid white fluid and a number of gritty, yellow calculi, the largest being the size of a split pea. On section the tissue has a grayish-yellow color, and small masses of parenchyma project between thick bands of connective tissue. Minute opaque points suggest fat necroses.

*Microscopic Examination.*—Sclerosis is far advanced and is most marked in the tail of the organ, where glandular acini are almost entirely absent. The glandular tissue which still persists occurs as small, compact masses embedded in dense stroma. At the periphery of this relatively normal parenchyma are lobules or parts of lobules undergoing disintegration and replacement by interstitial tissue. Completely isolated in the dense stroma of the body and tail are numerous masses of polygonal cells occupying conspicuous, sharply outlined, round or oval spaces in the sclerotic tissue. These islands of Langerhans are so thickly scattered that in places ten or twelve may be seen in the field of the low power. In the surrounding tissue lymphoid and plasma cells are numerous.

Such persistent islands of Langerhans are finally implicated in the general sclerosis. An increase of fibrous tissue occurs along their capillaries, which become coarse strands subdividing the body into small masses of atrophied cells. Elsewhere broad bands of dense fibrous tissue contain no epithelial elements or only an occasional compressed group of cells similar to those which form the islands of Langerhans.

In Case XXVII the lesion is far advanced, acini are in large part destroyed and islands of Langerhans are in part destroyed, in part hypertrophied; there has been glycosuria, disappearing under appropriate treatment. In a similar case of Lazarus changes affecting the islands of Langerhans have been associated with glycosuria.

Obstruction to the outflow of pancreatic juice may cause its escape into surrounding tissues and fat necrosis may result (Case XXVI). New formation of fibrous tis-

sue doubtless inhibits escape of products of secretion. Passage of calculi through the diverticulum of Vater may occlude the common bile duct and cause jaundice (perhaps in Case XXVI); Gould<sup>6</sup> has observed jaundice caused by lodgement of a pancreatic calculus in the diverticulum of Vater.

With calculi there is usually bacterial infection which is perhaps the cause of lithiasis or, it may be, the result of obstruction to the outflow of pancreatic juice. Pressure of the stone within a duct may cause ulceration of the mucous membrane. Such conditions favor the occurrence of acute inflammation and pancreatic abscess may accompany stone.

The etiology of pancreatic lithiasis is obscure. Associated bacterial infection is probably an etiological factor and Giudiceandrea<sup>7</sup> has found a variety of bacterial forms within pancreatic calculi. Obstruction to the outflow of pancreatic juice may favor the formation of calculi. Pancreatic lithiasis occurs in association with cholelithiasis (Dieckhoff, Lazarus) and may perhaps follow temporary obstruction of the pancreatic ducts by passing calculi. The occurrence of calculi in pancreatic cysts suggests that the retained secretion affords those conditions which are necessary for formation of concretions; Lazarus describes four instances in which cysts contained calculi at times in considerable number.

Little success has attended efforts to produce experimentally pancreatic calculi. Thiroloix<sup>8</sup> and Lazarus

---

<sup>6</sup> Gould: *British Med. Jour.*, 1898, ii, 1816.

<sup>7</sup> Giudiceandrea: *Polielinico*, 1896, iii-M, 33, 126; *Bull. d. Soc. Lancisiana d. osp. di Roma*, 1897-8, xviii, 119.

<sup>8</sup> Thiroloix: *Thesis*, Paris, 1892.

have found small concretions within cysts produced by injury to the pancreas.

*Symptoms.*—Pancreatic calculi may be found at autopsy in individuals who have not suffered with local symptoms referable to pancreatic disease; densely sclerotic pancreas surrounded numerous jagged stones in an individual who, dying with diabetes, had had, according to Lazarus, no epigastric pain. Pain in association with pancreatic lithiasis may be slight and continued, but more characteristic are paroxysms of pain resembling biliary colic and accompanied perhaps by vomiting and collapse, at times with chills and fever. Leichtenstern<sup>9</sup> observed such symptoms unaccompanied by jaundice in a patient who evacuated from the rectum three concretions composed of calcium carbonate and free from bile pigments or cholesterin. In a case described by Lichtheim<sup>10</sup> attacks of severe epigastric pain recurred during eight years; after an interval of six years the patient died with diabetes and pancreatic calculi were found. Colic-like pain in the epigastrium may be more marked on the left side but its localization is not characteristic.

Jaundice with pancreatic calculi may be caused by coexisting gall-stones. A pancreatic calculus passing into the duodenum may occlude the common bile duct and cause jaundice. In a case described by Leichtenstern autopsy demonstrated the occurrence of pancreatic calculi without cholelithiasis; the patient had had attacks of severe abdominal pain, once accompanied by jaundice.

Diabetes mellitus or glycosuria frequently accom-

---

<sup>9</sup>Leichtenstern: Handb. der spec. Ther. von Penzoldt-Stintzing, 1896, iv, 618.

<sup>10</sup>Lichtheim: Berliner klin. Woch., 1894, xxxi, 185.

panies pancreatic lithiasis and has been present in thirty-six of eighty cases collected by Lazarus; nevertheless, only a small proportion of cases of diabetes mellitus is referable to calculi. Disturbance of carbohydrate metabolism is caused not by occlusion of the pancreatic ducts but by the consequent chronic interlobular pancreatitis and occurs only when the lesion is so far advanced that the islands of Langerhans are in part destroyed. In the case of Lichtheim diabetes mellitus had made its appearance thirteen years after the first attack of severe abdominal pain and in the case of Caparelli<sup>11</sup> six years after onset. Alimentary glycosuria present in Case XXVII and in cases of Lichtheim, of Lazarus, and of Keuthe<sup>12</sup> indicates a less advanced stage of the pancreatic lesion. In cases of Polyakoff<sup>13</sup> and of Minnich<sup>14</sup> there has been transient glycosuria following attacks of colic.

Steatorrhœa when present has much significance for diagnosis, but has been recorded in only ten of the eighty cases collected by Lazarus. Chemical analysis in cases of Müller<sup>15</sup> and of Kinnicutt<sup>16</sup> showed a diminished proportion of split fat in the fæces, although the total fat was not notably increased.

Azotorrhœa is less frequently observed than fatty stools; in the case of Lichtheim undigested muscle fibres were found in the fæces.

---

<sup>11</sup> Caparelli: *Il Morgagni*, 1883, Ref. *Virchow-Hirsch Jahresb.*, 1883, ii, 267.

<sup>12</sup> Keuthe: *Berliner klin. Woch.*, 1909, lvi, 47.

<sup>13</sup> Polyakoff: *Berliner klin. Woch.*, 1898, xxxv, 237.

<sup>14</sup> Minnich: *Berliner klin. Woch.*, 1894, xxxi, 187.

<sup>15</sup> Müller: *Loc. cit.*, p. 92.

<sup>16</sup> Kinnicutt: *American Jour. of the Med. Scien.*, 1902, cxxiv, 948.

Diagnosis of pancreatic lithiasis has been made by discovery of pancreatic calculi either in the fæces or in the discharge from a pancreatic fistula. Kinnicutt<sup>17</sup> has collected seven cases which have been recognized during life; in three instances diagnosis has been made by finding in the fæces after attacks of colic calculi composed in great part of calcium phosphate and carbonate without bile salts or other peculiar constituents of bile.

In the case of Lichtheim attacks of colic repeated during many years were unaccompanied by jaundice, and the occurrence of diabetes mellitus suggested that the pancreas was the seat of disease. Robson and Cammidge have found pancreatic calculi more opaque for X-rays than gall-stones, and have proposed the use of X-rays for diagnosis. Suppuration may occur as a complication of pancreatic lithiasis. In a case of Caparelli an abscess in the epigastric region discharged over a hundred pancreatic calculi. In a case described by Nicholas and Mollière<sup>18</sup> hemorrhage from the bowel twice followed rupture into the duodenum of an abscess caused by pancreatic calculi.

*Treatment.*—Conditions which increase the flow of pancreatic juice are believed to aid in overcoming obstruction caused by calculi and to hinder their formation. Secretion may be increased, according to Lazarus, by administration of water in abundance especially when acidified by carbonic gas or by a weak acid. The use of pilocarpin, which has been suggested, is perhaps not without danger, since its administration to cats with

---

<sup>17</sup> Kinnicutt: Trans. Assoc. American Phys., 1902, xvii, 81.

<sup>18</sup> Nicolas and Mollière: Bull. méd., 1897.

ligated pancreatic ducts has rapidly caused death. (See Experiment X, Chap. VII.)

In several cases pancreatic calculi have been successfully removed by operation. Gould<sup>19</sup> opened the abdominal cavity of a patient with symptoms suggesting cholelithiasis and found a lump at the posterior part of the lesser peritoneal cavity, and by incision removed a calculus from the duct of Wirsung; biliary obstruction continued and at a second operation another calculus was removed from the head of the pancreas. Death with suppuration occurred twelve days later. Moynihan<sup>20</sup> removed through the duodenum a calculus projecting from the duct of Wirsung into the diverticulum of Vater; recovery followed. Robson and Cammidge cite a similar successful operation of Dalziel and record a case in which recovery has followed the removal of four pancreatic calculi. One of these calculi has been removed from the duct of Santorini or one of its branches through an incision into the pancreas near the common bile duct; two have been removed from the duct of Wirsung by delicate forceps introduced through an incision into the duodenum opening the bile papilla; and a fourth has been removed from the midpart of the duct of Wirsung after cutting through the gastrohepatic omentum and incising the pancreas over the stone. Staehlin and Roeber<sup>21</sup> cut into the head of the pancreas and removed several calculi from the duct of Wirsung; recovery followed.

---

<sup>19</sup> Gould, P.: *Lancet*, 1898, ii, 1632.

<sup>20</sup> Moynihan: *Lancet*, 1902, ii, 355.

<sup>21</sup> Staehlin and Roeber: *New York Med. Jour.*, 1905, lxxxii, 904.

## CHAPTER XII.

### CYSTS.

TRUE cysts of the pancreas are formed when obstruction to outflow of pancreatic secretion causes retention of fluid and dilatation of ducts or of acini (retention cysts), or when spontaneous proliferation of the epithelial elements of the gland is followed by accumulation of fluid in cavities which are formed (cystic tumors). A large proportion of so-called pancreatic cysts on the contrary have no epithelial lining but are cavities (pseudocysts) containing fluid surrounded by a wall of connective tissue, formed within the pancreas or in contact with its surface. The formation of such pseudocysts, which do not occur in other glands, is doubtless dependent upon the peculiar properties of the pancreatic juice, and their contents are in part at least products of pancreatic secretion.

*Retention Cysts.*—Ligation of pancreatic ducts in animals causes chronic inflammation of the gland with little dilatation of the duct behind the occlusion; obstruction to the outflow of secretion in man is usually followed by similar changes. Nevertheless, under conditions which are not understood, cysts occur as the result of such obstruction; it has been suggested that partial or intermittent occlusion may favor their formation. Such cysts are usually small and do not cause recognizable symptoms. Virchow<sup>1</sup> described as *ranula pancreatica* dilatation of the duct of Wirsung caused by occlusion; numerous sacculations may give the duct a beaded ap-

---

<sup>1</sup> Virchow: Die krankhaften Geschwulste, Berlin, 1863, ii, 276.

pearance or there may be a single cystic dilatation perhaps as large as a man's fist. Klebs<sup>2</sup> gave the name *acne pancreatica* to multiple cysts of small size containing opaque thick fluid; such small cysts are formed from small ducts or even from acini.

Compression of the pancreatic ducts by tumor, by gallstones, or by pancreatic calculi is usually unaccompanied by cyst formation but occasionally multiple cysts result; the following case illustrates cyst formation as a sequel of tumor compressing the duct of Wirsung.

CASE XXVIII.—The patient, female, aged forty-one years, became jaundiced nine months before her death. A tumor mass was palpable in the umbilical region.

*Anatomical Diagnosis.*—Adenocarcinoma of the pancreas compressing the bile and pancreatic ducts; jaundice; chronic interlobular pancreatitis; retention cysts of the pancreas; metastatic carcinoma of the retroperitoneal lymph-glands.

The tumor, which arises from the pancreas, consists of two masses between which the remains of the head and part of the body of the gland lie compressed. A fibrous capsule separates the tumor from the glandular parenchyma. Numerous small cysts of which the largest are about 2.5 cm. in diameter occupy the body and tail and are present but less numerous in the duodenal end of the gland. A probe can be passed along the compressed duct.

*Microscopic examination* shows throughout the gland a moderate increase of the interstitial tissue between the lobules and in slight degree within them. Cysts lined by a single layer of cubical or flat epithelium are abundant in the body and tail. The larger cysts are surrounded by a layer of sclerotic connective tissue in which a few isolated and compressed islands of Langerhans are the only remains of pancreatic parenchyma. Elsewhere these bodies are fairly abundant and normal in structure.

---

<sup>2</sup> Klebs: Handbuch der pathologischen Anatomie, Berlin, 1868, i, 552.

Cysts occasionally of large size have been associated with gall-stones lodged near the orifice of the pancreatic duct (Phulpin,<sup>3</sup> Horrocks and Morton<sup>4</sup>); a pancreatic calculus has been found near the end of the duct of Wirsung (Von Recklinghausen), but its relationship to cyst-formation is not obvious, for it is probable that concretions may be formed within such cysts.

Chronic pancreatitis has been regarded by Tilger<sup>5</sup> as an important factor in the production of pancreatic cyst, for, he has thought, scar-like bands of connective tissue compress and occlude ducts. Chronic pancreatitis on the contrary may be secondary to cyst-formation; by compression of neighboring ducts cysts cause chronic inflammation. Outside of the epithelial lining, which is composed of a single layer of cylindrical cells often flattened by pressure, a wall of dense fibrous tissue is formed. Occlusion of ducts, which may be either the cause or the result of cyst-formation, is always followed by interlobular pancreatitis, and when this lesion implicates the entire gland and is far advanced diabetes mellitus ensues.

*Proliferation Cysts.*—The structure of a small number of pancreatic cysts furnishes evidence that they arise as true tumors. It is doubtful if the presence of small cysts in the wall of a large cyst or the presence of an occasional papillary projection from its inner surface is proof that the cyst is formed by proliferation of epithelial structures, but the occurrence of irregular gland-like growths below the epithelial lining, and the presence of papillary projections from the lining into the cyst, serve to demonstrate spontaneous proliferation. Such cyst-

---

<sup>3</sup> Phulpin: Bull. de la Soc. anat. de Paris, 1892, lxxvii.

<sup>4</sup> Horrocks and Morton: Lancet, 1897, i, 242.

<sup>5</sup> Tilger: Virchow's Arch., 1894, cxxxvii, 348.

adenomata may resemble the similar tumors of the ovary. Körte has collected from the literature of the subject only thirteen instances of cystadenomata and Münzer<sup>6</sup> (1903) has found five additional cases. Of nine proliferation cysts collected by Fitz<sup>7</sup> eight occurred in women. Cystic tumors of the pancreas have rarely been malignant. Hartmann<sup>8</sup> has described *epithelioma cysticum* of the tail of the pancreas accompanied by metastases in the liver and cites a similar case of Hanot and Gilbert. Under the name *adenocystoma papilliferum* Sotti<sup>9</sup> has described a tumor of the pancreas which has formed metastases in the lymphatic glands and in the lungs and by implantation upon the peritoneal surfaces has produced secondary nodules resembling those which occur with similar tumors of the ovary.

*Pseudocysts.*—So-called pseudocysts may be formed within the substance of the pancreas as the result of degenerative changes affecting the interstitial tissue of the gland, and their formation and increase in size is doubtless dependent in large part upon the presence of the irritant and corrosive products of pancreatic secretion. When the surface of the pancreas is implicated similar cysts may be formed in contact with the gland, and a very large proportion of all so-called pancreatic cysts occupy the lesser peritoneal cavity. The wall of such cysts is formed by dense connective tissue of variable thickness. There is no epithelial lining, but the absence of epithelium

---

<sup>6</sup> Münzer: Pankreascysten, Cent. f. d. Grenz. d. Med. u. Chir., 1903, vi, 490, 529, 573, 619, 664.

<sup>7</sup> Fitz: Trans. Assoc. of American Phys., 1900, xv, 254.

<sup>8</sup> Hartmann: Cong. franç. de chir., 1891, v, 618.

<sup>9</sup> Sotti: Arch. per le sc. med., 1906. Ref., Cent. f. allg. Path. u. path. Anat, 1907, xviii, 844.

does not determine the nature of the lesion, for the lining of cysts arising as the result of occlusion of ducts or of epithelial proliferation may be destroyed by the corrosive action of the cystic contents.

Cysts containing blood have been believed to arise as the result of hemorrhage into the pancreas, and apoplectic cysts have been described, but hemorrhage from dilated and injured blood-vessels occurs into cysts of the pancreas as into cysts of other organs. Nevertheless, clinical and experimental evidence proves that cysts may be formed as the result of injuries which cause localized hemorrhage. Lazarus<sup>10</sup> has produced small cysts by crushing the pancreas of the dog. In one instance a hæmatoma has been the immediate result, and at the end of forty days a cyst with fibrous capsule, containing 100 c.c. of watery fluid has been found; products of pancreatic secretion, according to Lazarus, have digested injured tissue and blood.

In thirty-three of one hundred and seventeen instances of pancreatic cyst Körte<sup>11</sup> has found that abdominal injury preceded the appearance of a palpable tumor; eight additional cases have been collected by Lazarus (1904). There has been injury limited to the epigastric region, such as the kick of a horse or compression between the buffers of two cars. To show that indirect force may cause pancreatic cyst, Lazarus cites cases in which cyst has followed a violent fall, and suggests that the weight of the filled transverse colon may tear the movable splenic from the fixed duodenal part of the gland.

---

<sup>10</sup> *Loc. cit.*, p. 257.

<sup>11</sup> *Loc. cit.*, p. viii.

So-called traumatic cysts usually contain blood but evidence of hemorrhage may be entirely absent, the cyst containing clear fluid. In a case described by Richardson<sup>12</sup> the ruptured pancreatic duct opened within the cyst, appearance of which had followed injury in the epigastrium. In the contents of traumatic cysts enzymes similar to those of the pancreatic juice have been found.

The formation of cysts as a sequel of hemorrhagic necrosis of the pancreas is proved by a number of recorded cases.

In a case of Francke<sup>13</sup> sudden appearance of intense epigastric pain with vomiting suggested the onset of hemorrhagic necrosis; two weeks later a tumor was palpable in the left hypochondriac region, and five weeks after onset of symptoms a thin-walled cyst the size of a man's head was found in the lesser peritoneal cavity. The pancreas was the seat of necrosis and old hemorrhage, and the omentum and mesentery contained foci of fat necrosis. Rasumosky<sup>14</sup> has described a similar case in which a tumor mass appeared in the epigastrium five hours after onset of symptoms; a cyst containing necrotic pancreatic tissue was found at operation three weeks later. Adler<sup>15</sup> has described a pseudocyst which probably followed hemorrhagic necrosis of the pancreas. In a case of hemorrhagic necrosis of the pancreas described by Dressel<sup>16</sup> there was a cavity the size of a child's head within the substance of the pancreas; it was filled with

---

<sup>12</sup> Richardson: Boston Med. and Surg. Jour., 1895.

<sup>13</sup> Francke: Deutsche Beit. f. Chir., 1900, liv, 399.

<sup>14</sup> Rasumosky: Langenbeck's Arch., 1899, lix, 565.

<sup>15</sup> Adler: Virchow's Arch., 1904, Suppl. to clxxvii, 154.

<sup>16</sup> Dressel: Inaug. Diss., Giessen, 1897.

clotted blood. Necrotic tissue and blood are doubtless subjected to the solvent action of enzymes contained in the pancreatic secretion and fibrous tissue is formed in the wall of the cavity. The changes which occur in such cases are doubtless identical with those which produce traumatic cysts.

*Contents.*—The character of the fluid within pancreatic cysts furnishes little evidence concerning the origin of the lesion. Blood is usually present and may have undergone changes which render it brownish, coffee-colored, greenish, or even black; after absorption of blood traumatic cysts on the one hand may contain clear fluid, whereas cysts caused by retention on the other hand may contain bloody fluid as the result of erosion or rupture of the dilated blood-vessels in the wall of the cyst. The contents of pancreatic cysts are occasionally viscid and the presence of mucin has been demonstrated. Microscopic examination usually shows the presence of epithelial cells, globules of fat, crystals of fatty acids, red blood-corpuscles, leucocytes, and necrotic tissue.

It is often possible to demonstrate one or more of the three well-known enzymes of the pancreatic juice in the contents of pancreatic cysts, but proteolytic, lipolytic, and diastatic enzymes have been found in fluid removed from abdominal cysts which have not had their origin in the pancreas. Körte has found a weak diastatic enzyme in a mesenteric cyst; the presence of polynuclear leucocytes may give proteolytic activity to any fluid which contains them, whereas the wide distribution of fat-splitting enzymes is well known. Moreover, the contents of true cysts of the pancreas may exhibit no enzymotic activity; the anti-tryptic action of blood-serum may ex-

plain the absence of trypsin in hemorrhagic cysts and Heidenhain<sup>17</sup> has shown that enzymes disappear in the secretion of a chronically inflamed gland. Nevertheless, if an abdominal cyst contains fluid capable of digesting coagulated egg albumen or of splitting starch its origin in the pancreas is probable.

*Relation of Pancreatic Cysts to Adjacent Organs; Physical Signs.*—Cysts of the pancreas are usually spherical and have a smooth surface. In many instances they have been as large as a man's head, but occasionally a pancreatic cyst may distend the abdominal cavity reaching from ensiform cartilage to symphysis pubis. Fluctuation can usually be felt when the tumor is grasped between the hands but occasionally the sac is so tensely distended that it appears to be solid. Körte has collected the recorded cases of pancreatic cyst and has defined the positions which the tumor may occupy. The tumor is usually situated in the midline between ensiform cartilage and umbilicus (forty-eight instances) and may produce a rounded protrusion of the abdominal wall; in forty cases the greater part of the mass has lain to the left of the midline, whereas in only ten cases has the greater part been on the right side. Large or unusually movable cysts have extended into the lower part of the abdominal cavity, and in sixteen cases have projected below the umbilicus.

Cysts of the pancreas usually exhibit little mobility, but when in contact with the diaphragm they move with respiration. Cysts of the tail of the pancreas may be freely movable; in a case of Lazarus a fluctuating tumor

---

<sup>17</sup> Heidenhain: Pflüger's Arch., 1875, x, 557.

the size of a child's head was situated in the left hypochondrium but could be pushed from the margin of the quadratus lumborum on the left to the mamillary line on the right. Cysts in contact with the aorta may transmit its pulsation but cease to pulsate when the patient is in the knee-chest position.

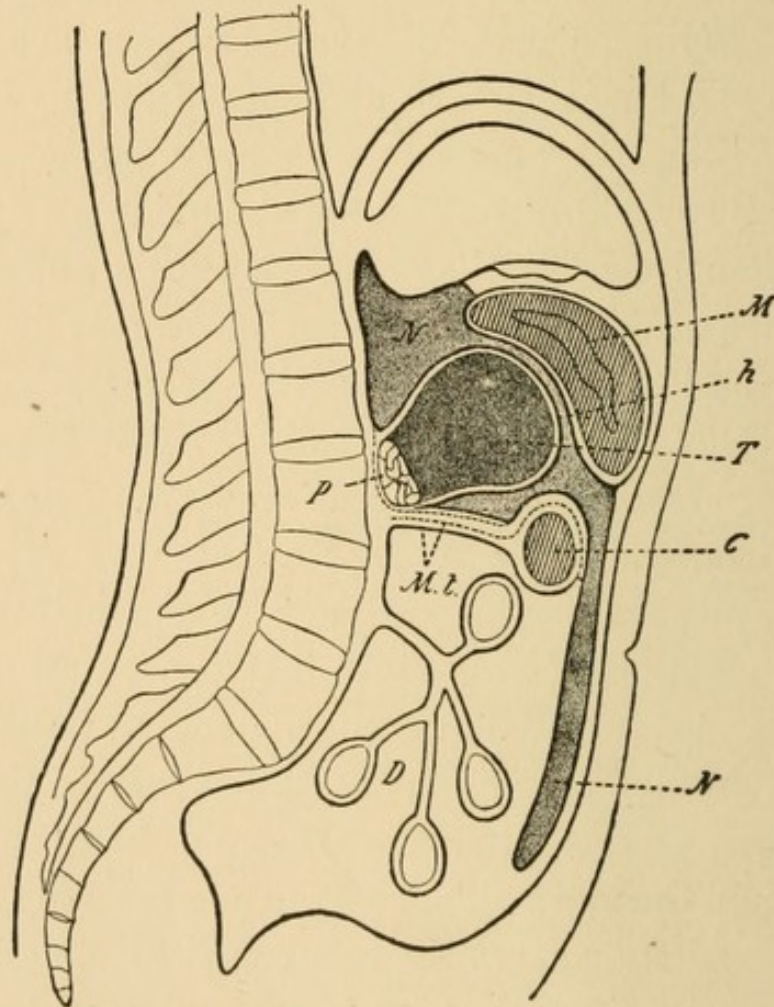


FIG. 35.—A cyst projecting from the ventral surface of the pancreas into the bursa omentalis (from Oser, *Erkrankungen des Pankreas*). The stomach is in front of the cyst and with its growth is pushed upward; the transverse colon is below it. *M*, stomach; *C*, transverse colon; *P*, pancreas; *M.L.*, transverse mesocolon.

The relation of different parts of the pancreas to adjacent organs determines the position of a cyst and the physical signs which it presents. Its relation to the stomach and colon, best defined after artificial distention

of these organs, is important for diagnosis. From a study of one hundred and thirty-three cysts with operation Körte has classified the positions which cysts may occupy as follows:

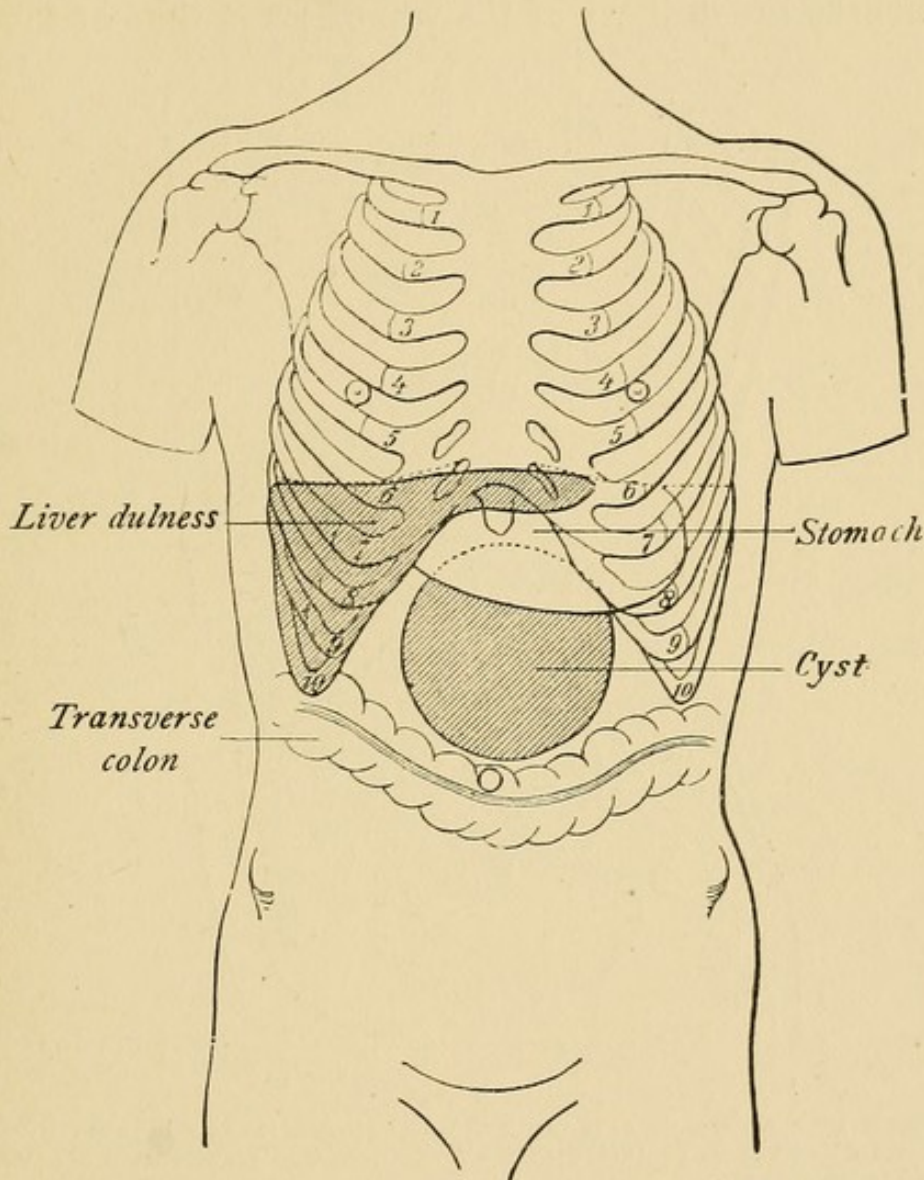


FIG. 36.—The relation of the cyst shown in Fig. 35 to adjacent organs. (From Körte, Die chirurgischen Krankheiten des Pankreas.)

*A* (Figs. 35 and 36).—Cysts of the pancreas usually project from the anterior surface of the pancreas into the lesser peritoneal cavity; pushing the stomach upward they are covered by the gastrocolic omentum. Accumulation of fluid in the lesser peritoneal cavity from what-

ever cause closely resembles pancreatic cyst (Lloyd<sup>18</sup>). Small cysts may lie behind the stomach but as the cyst increases in size the viscus is pushed upward. The stomach when distended lies above the tumor and its tympany separates the dulness of the tumor from that of the liver;

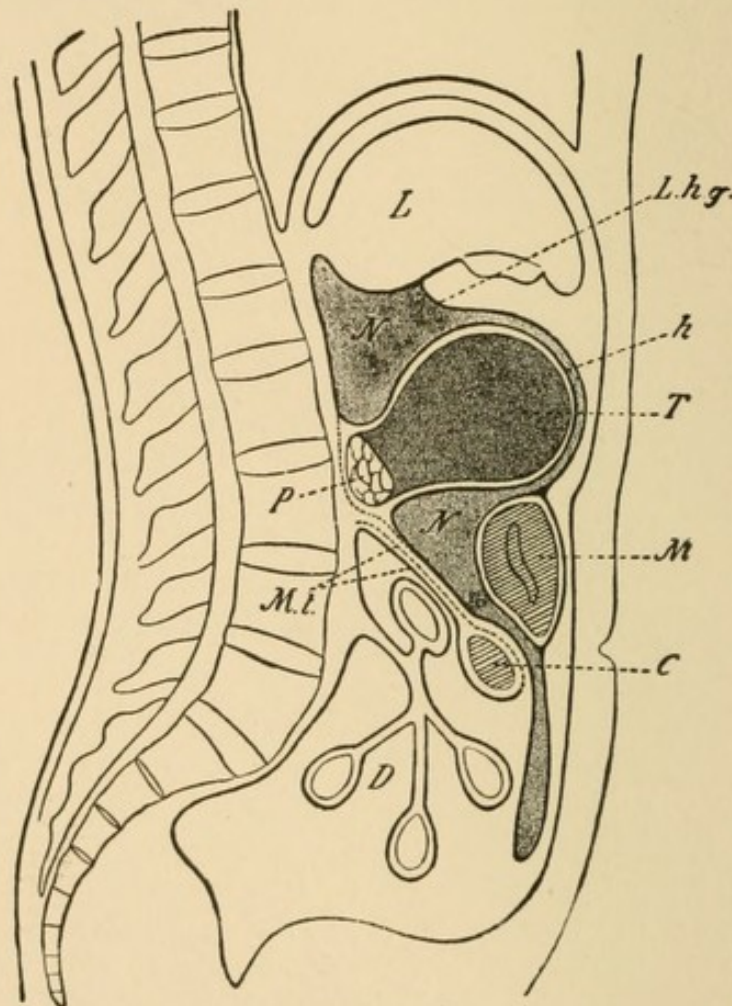


FIG. 37.—A pancreatic cyst (*T*) which has pushed its way between liver (*L*) and stomach (*M*) and is in contact with the lesser omentum (ligamentum hepatogastricum *L. h. g.*) (from Oser).

the colon lies below the tumor and may be pushed downward to the symphysis pubis.

*B* (Figs. 37 and 38).—In a few instances (in nine of the cases collected by Körte) the cyst, arising from the upper border of the body of the pancreas, which is at a

<sup>18</sup> Lloyd, J.: British Med. Jour., 1892, ii, 1051.

higher level than the lesser curvature of the stomach (see Chap. I), makes its way between the stomach and the liver and is covered by the gastrohepatic omentum. Dulness caused by the tumor is in contact with the dulness of

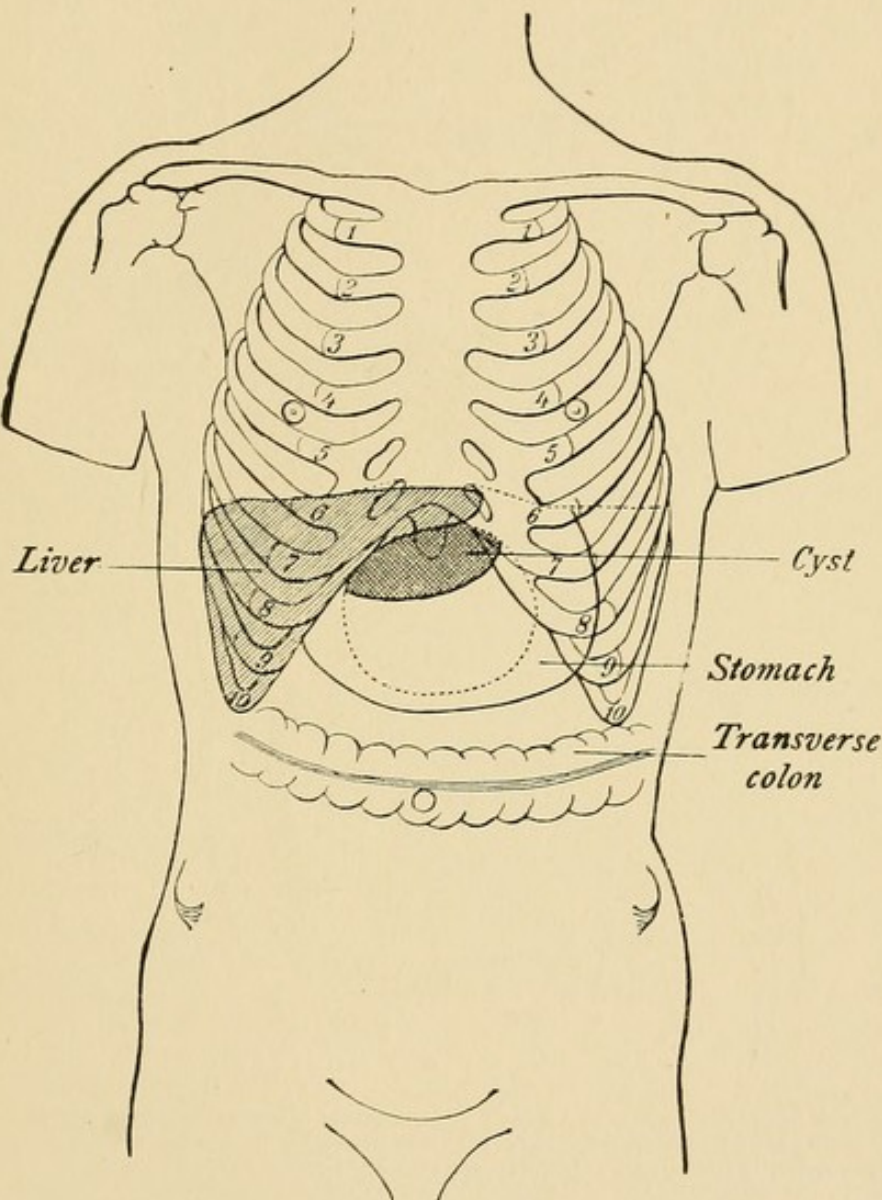


FIG. 38.—A pancreatic cyst (see Fig. 37) between liver and stomach (from Körte).

the liver and the stomach is at the lower border of the cyst, but when distended may cover it completely. Payr<sup>19</sup> has described a case in which the cyst passed

<sup>19</sup> Payr: Wiener klin. Woch., 1898, xii, 629.

through the foramen of Winslow into the general peritoneal cavity.

C.—The cyst may grow between the two layers of the mesocolon. Since the tail of the pancreas lies between the layers of the mesocolon cysts of this part of the gland

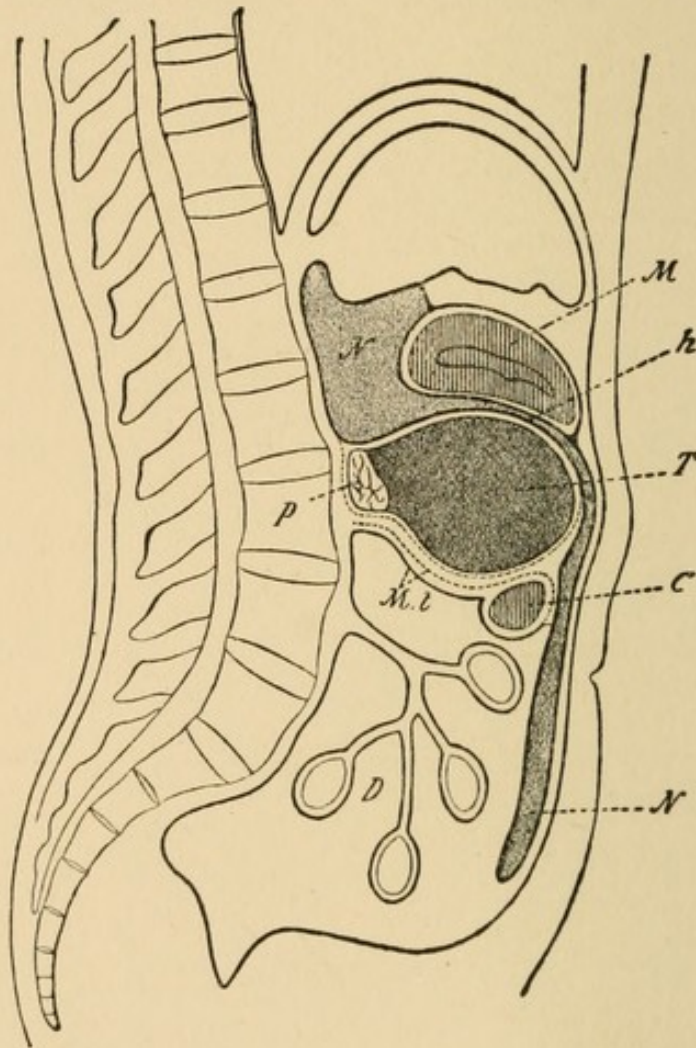


FIG. 39.—A pancreatic cyst (*T*) which has penetrated between the folds of the transverse mesocolon (*M. t.*) and projects upon its upper surface. The stomach is above and the transverse colon is below the tumor (from Oser).

tend to push their way into the membrane. In seven of the cases collected by Körte the cyst projected upon the upper surface of the mesocolon (Fig. 39) and lay between stomach and colon; in three instances the cyst projected upon the under surface of the mesocolon (Figs. 41 and 42) and both stomach and colon lay above it. The colon

may cross the summit of the cyst (Fig. 40) and the layers of the mesocolon are equally distended (Petrykowski<sup>20</sup>).

Dreyzehner<sup>21</sup> has described a case in which the cyst arising from the head of the pancreas grew to the right and lay behind the peritoneum, displacing the right kidney.

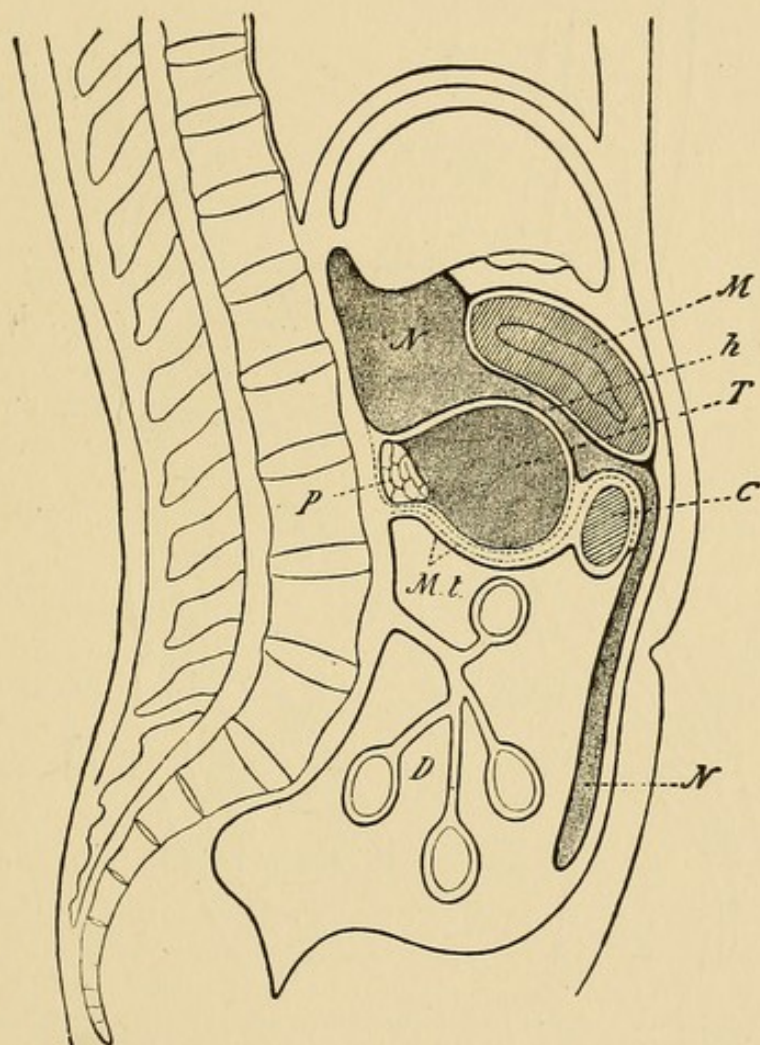


FIG. 40.—A pancreatic cyst (*T*) which has penetrated between the folds of the transverse mesocolon (*M.t.*) and projects equally upon the upper and lower surface. The stomach is above the cyst and the transverse colon crosses it (from Oser).

Cysts of the pancreas may rupture into the peritoneal cavity and in the case of Schwartz<sup>22</sup> rupture has been the result of injury caused by a fall. Spontaneous dis-

<sup>20</sup> Petrykowski: Inaug. Diss., Wurzburg, 1889.

<sup>21</sup> Dreyzehner: Arch. f. klin. Chir., 1895, 1, 261.

<sup>22</sup> Schwartz: Sem. méd., 1893, xiii, 281.

appearance of the tumor without evidence of intraperitoneal rupture has occurred in association with temporary diarrhœa and has suggested that the contents have entered the intestine. In the case of Bull<sup>23</sup> dark masses were passed in the stools, whereas in a case of Parsons<sup>24</sup>

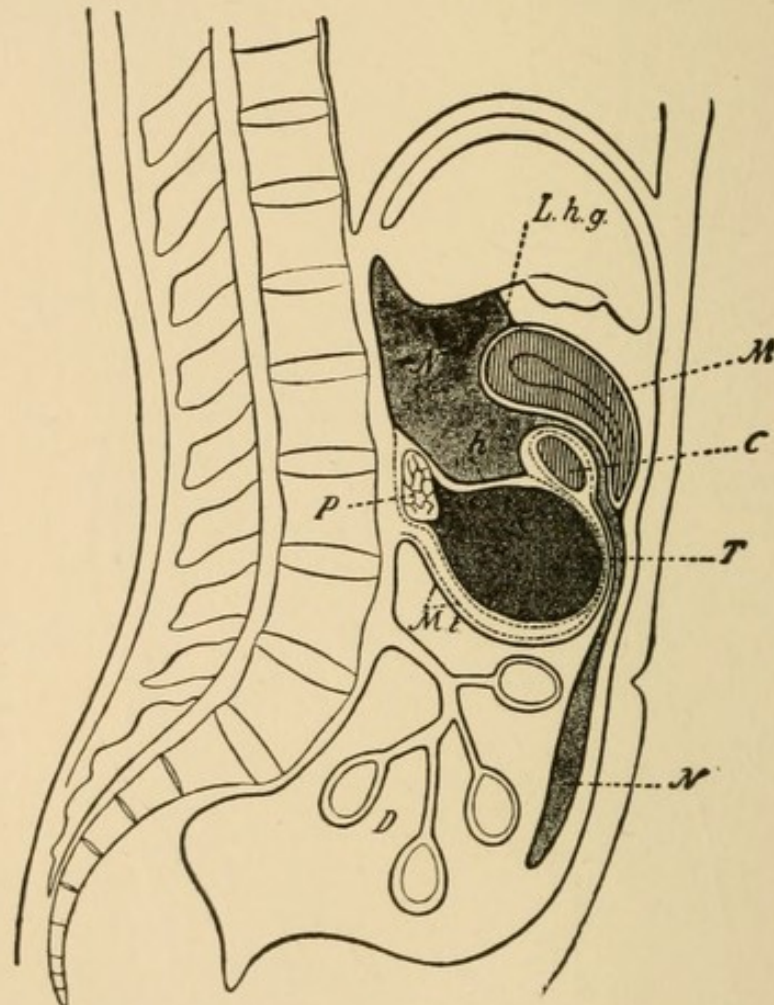


FIG. 41.—A pancreatic cyst (*T*) which has penetrated between the folds of the transverse mesocolon and projects upon its lower surface. Both stomach and transverse colon are above the cyst (from Oser).

there was profuse whitish diarrhœal discharge. Disappearance of an epigastric cyst described by Payr occurred three times during two months and was followed each time by diarrhœa. It is probable that discharge of con-

<sup>23</sup> Bull: New York Med. Jour., 1887, xlvii, 376.

<sup>24</sup> Parsons: British Med. Jour., 1857, i, 475.

tents may occur through pancreatic ducts communicating with the cyst.

*Symptoms.*—Pain is almost always present and may be caused by a cyst which is not palpable. It varies in

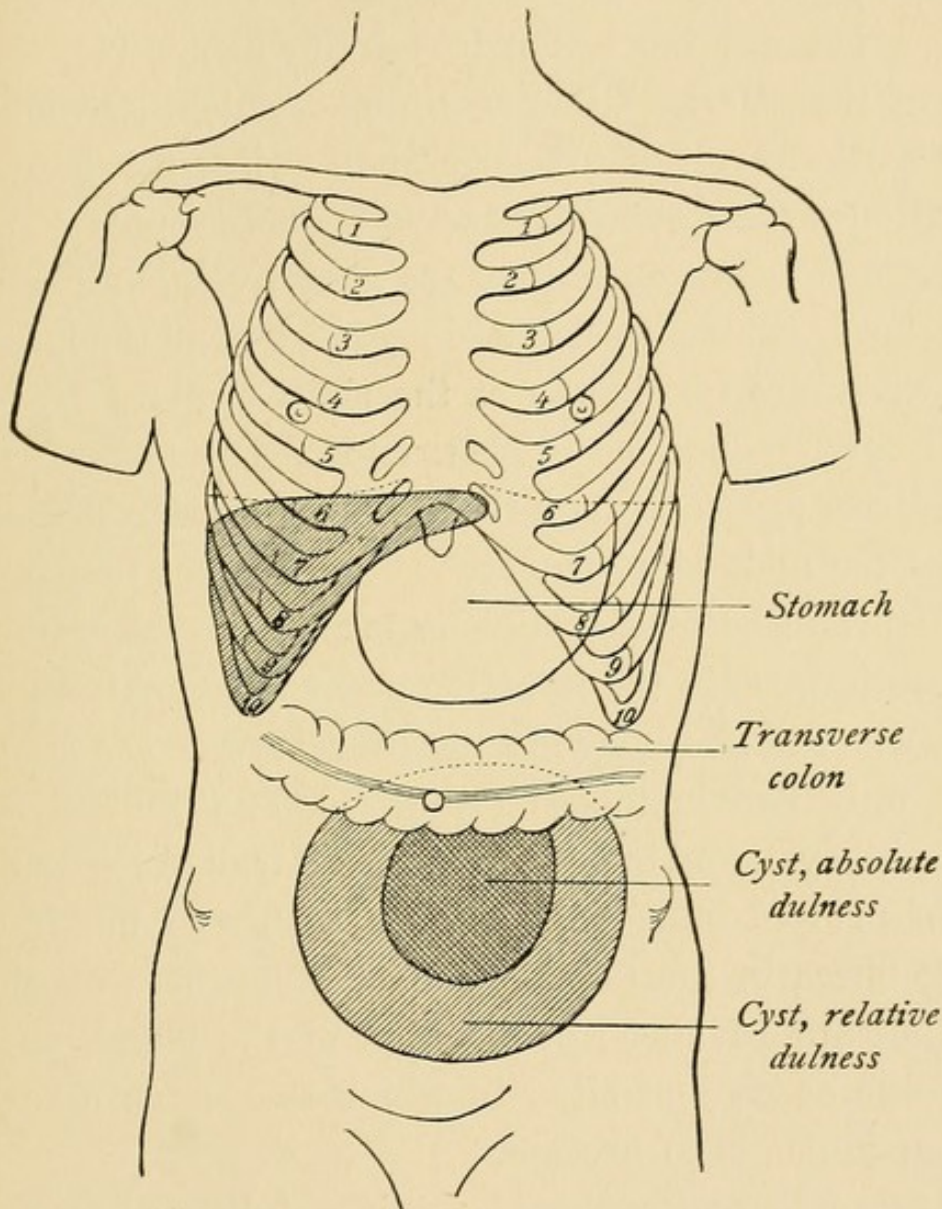


FIG. 42.—A pancreatic cyst which projects from the under surface of the mesocolon (see Fig. 41) (from Körte).

intensity and location and may occur in paroxysms; it has little value for diagnosis. Pressure by the cyst upon the stomach, particularly when the organ is bound to the cyst by adhesions, may cause gastric disturbance asso-

ciated perhaps with vomiting. Colicky pain, constipation, or in rare instances intestinal obstruction, have been caused by pancreatic cysts which compress the intestine and occlude its lumen.

Jaundice is less common with cyst than with carcinoma, because the lesion less frequently occupies the head of the gland. Other symptoms which occasionally occur as the result of pressure upon adjacent organs are dilatation of superficial branches of the portal vein, ascites, due to pressure upon the portal vein, and œdema of the lower extremities, due to pressure upon the inferior vena cava. In two instances the right ureter (Dreyzehner, Reeve<sup>25</sup>) has been obstructed. Dyspnœa results from direct pressure upon the diaphragm or from distention of the abdominal cavity.

Disturbances of digestion referable to diminution of pancreatic juice in the intestine occur in a small number of cases. Fitz,<sup>26</sup> reviewing the literature of the subject, found only two instances (Bull, Goodman) of steatorrhœa with cyst, and in only two cases was disturbed digestion of protein indicated by the presence of undigested muscle-fibres in the fœces. Such disturbances of digestion indicate advanced destruction of the gland, and in all of the cases just cited in which they have occurred glycosuria has been present.

Glycosuria and diabetes mellitus follow chronic inflammation caused by the presence of a cyst which occludes the ducts of the gland. Diabetes occurred in only nine of one hundred and thirty-four cases collected

---

<sup>25</sup> Reeve: *Ann. of Surg.*, 1893, xviii, 227.

<sup>26</sup> Fitz: *Loc. cit.*, p. 90.

by Oser. In a case of Lazarus there was alimentary glycosuria.

Emaciation, which is a frequent symptom of pancreatic cyst, cannot be satisfactorily explained by disturbance of pancreatic digestion. Rapid gain of weight may follow removal of the cystic contents and drainage. Lazarus noted the loss of eighteen kilogrammes of body weight during three months in a young man with pancreatic cyst following abdominal injury. Recovery quickly followed operation and fifteen pounds was regained within six weeks. In another patient of Lazarus twenty-eight kilogrammes of body weight were lost within a year after the appearance of a pancreatic cyst.

A cyst may have been recognizable by the patient years before it is seen by the surgeon and its increase in size is often slow. In a case described by Hulke<sup>27</sup> a cyst in a woman forty-seven years of age had existed since childhood. Cystadenomata develop slowly but sudden increase in size may occur. With pseudocysts rapid enlargement is not infrequent. Traumatic cysts usually appear within a few weeks after injury.

*Diagnosis.*—A fluctuating spherical tumor in the epigastric region, particularly when it is situated in great part to the left of the median line, suggests pancreatic cyst. The cyst usually reaches the abdominal wall between the stomach, which partially covers it, and the transverse colon; the greatest difficulty in diagnosis is with those uncommon cysts which find their way above the stomach and are in contact with the liver.

Percussion while the stomach is undergoing inflation

---

<sup>27</sup> Hulke: *Lancet*, 1892, ii, 1273.

is often useful, for it shows that the lower, or less frequently the upper, border of the tumor mass is gradually covered as the organ increases in size. A cyst of the liver, the distended gall-bladder, or a cyst of the spleen on the contrary remains superficial, for they are not pushed backward and covered by the distended stomach.

Cysts of the mesentery are usually found near the umbilicus and are freely movable in all directions. Cysts of the pancreas situated in the mesocolon as well as cysts of great size may descend as far as the pelvis, and in some instances have been mistaken for ovarian cysts. A history of origin in the epigastric region may indicate pancreatic cyst; location behind the stomach and colon, best shown after distention of these organs, and the absence of any connection with the uterus or ovaries demonstrable by bimanual examination of vagina and rectum, may exclude ovarian cyst. Disappearance of the pancreatic tumor may suggest hydronephrosis; pulsation transmitted from the aorta has suggested the presence of aneurism of the aorta.

*Treatment.*—Cysts of the pancreas have been more successfully treated by surgical methods than other lesions of the gland. The greater number of pancreatic cysts have no epithelial lining and tend to disappear after incision and drainage—a method first used by Gussenbauer<sup>28</sup> in 1883. Of one hundred and two cases with operation collected by Körte one hundred and one have been treated by this method and only four have died as the result of the operation. When the cyst occupies the epigastrium or right hypochondrium it is usually reached with most convenience by incision through the abdominal

---

<sup>28</sup> Gussenbauer: Langenbeck's Arch. f. Chir., 1883, xxix, 355.

wall. In some instances the cyst has been exposed and united to the abdominal wall and several days later opened. Incision through the lumbar region, which may be possible, especially when the cyst occupies the left side of the abdomen, does not open the peritoneal cavity and may afford efficient drainage. The cavity of the cyst is packed with gauze to secure drainage and the wound, frequently complicated by pancreatic fistula, heals slowly.

Attempts have been made to treat pancreatic cysts by aspiration of the contents but the method has proved ineffectual and dangerous. The operation has caused rupture of a cyst. General peritonitis has occurred when the cyst has been the site of pyogenic infection, or hemorrhage has followed puncture of the much enlarged blood-vessels which occupy the wall of many cysts.

After aspiration the contents of the cyst almost constantly reaccumulate. Israel<sup>29</sup> described a case in which recovery followed aspiration. In this instance laparotomy exposed a cyst covered by the stomach which was attached to the tumor by firm adhesions; the cyst was punctured through the stomach and a litre of brown fluid was aspirated; the cyst did not reappear.

Complete extirpation of a pancreatic cyst, first performed by Bozeman<sup>30</sup> in 1882, is rarely possible. The proximity of large blood-vessels and other important structures, the presence of adhesions and the danger of diabetes mellitus after removal of a large part of the pancreas, make the operation in most cases impracticable. Extirpation is performed with least difficulty when the cyst occupies the tail of the gland and has a well-defined

---

<sup>29</sup> Israel: *Deutsche klin. Woch.*, 1900, xxvi, 352.

<sup>30</sup> Bozeman: *New York Med. Rec.*, 1882, xxi, 46.

wall. It offers the greatest chance for permanent recovery when the presence of multilocular cysts or papillary growths suggest cystadenoma; pancreatic fistula, commonly present after incision and drainage, is usually avoided when complete extirpation of the cyst is accomplished. In some cases attempted extirpation has been abandoned because adhesions or other complications have rendered the operation impossible; in such cases the cyst has been partially removed. Mayo Robson<sup>31</sup> found records of one hundred and sixty cases in which cyst had been treated by operation; in twenty instances death followed operation and in eight instances death occurred subsequently as the result of diabetes or other complication. Among one hundred and thirty-eight cases treated by incision and drainage death occurred in sixteen; among fifteen cases with complete excision death occurred in three; among seven cases with partial excision death occurred in one.

Zweifel<sup>32</sup> removed a cyst and all of the pancreas save a part of the head 3 cm. in length; glycosuria, found ten days later, persisted twelve days, but had disappeared at the end of two months.

Pancreatic fistula usually follows incision and drainage or partial removal of pancreatic cysts and occasionally occurs after complete extirpation. Such fistulæ may close after a short time, but in some instances they have persisted a year or more; a fistula described by Körte persisted two and a half years. In a case of Murray<sup>33</sup> fistula had not healed after three years. There may be

---

<sup>31</sup> Mayo Robson: *Lancet*, 1904, i, 773.

<sup>32</sup> Zweifel: *Cent. f. Gynæc.*, 1894, xviii, 641.

<sup>33</sup> Murray and Gies: *American Med.*, 1902, iv, 133.

active secretion of pancreatic juice in which pancreatic enzymes are readily demonstrable; Cushing<sup>34</sup> records the discharge of from 500 to 600 c.c. of fluid daily. Gies<sup>33</sup> studying the secretion from the fistula observed by Murray found from 0.46 to 0.93 per cent. of solids and no evidence of the presence of enzymes derived from the pancreas.

The secretion may irritate and erode the skin about the wound unless the surface is kept clean by careful dressing.

Attempts have been made to hasten the healing of such fistulæ by injection of tincture of iodine, silver nitrate, chloride of zinc, and other substances, and the sinus has been scraped or cauterized. Lazarus describes a case in which injection of silver nitrate was followed by collapse and death, probably caused by hemorrhagic necrosis of the pancreas referable to the irritant. Hemorrhage from the tract may occur and has occasionally followed curetting. In some instances the tract has been excised; in other cases an excision has been made into the sinus from the back and after better drainage has been secured its closure has been hastened. Conditions which diminish the flow of pancreatic juice are believed to favor the disappearance of fistulæ (see page 78). Wohlgemuth<sup>35</sup> has recommended that the patient be put upon a diabetic diet and be given small doses of sodium carbonate; favorable results have been recorded (Heineke,<sup>36</sup> Karewski<sup>37</sup>).

---

<sup>34</sup> Cushing, H. W.: Boston Med. and Surg. Jour., 1898, cxxxviii, 429.

<sup>35</sup> Wohlgemuth: Berliner klin. Woch., 1907, xlv, 47.

<sup>36</sup> Heineke: Cent. f. Chir., 1907, xxxiv, 265.

<sup>37</sup> Karewski: Berliner klin. Woch., 1907, xlv, 187.

## CHAPTER XIII.

### CARCINOMA.

THE incidence of malignant growth of the pancreas is shown by the statistics of Segré,<sup>1</sup> among 11,472 autopsies carcinoma occurred 127 times, and sarcoma twice. Benign tumors, including the so-called proliferation cysts, are even less common. Primary carcinoma occurs more frequently in men than in women; of 106 cases collected by Miraillié,<sup>2</sup> 69 were in men and 37 in women.

The head of the gland is the common site of the tumor; among 57 cases collected by Segré the entire gland was affected in 19 instances, whereas the tumor occupied the head of the gland in 35 instances, the body twice, and the tail once. The head of the pancreas was the seat of primary carcinoma in 82 among 113 cases of Miraillié.

Carcinoma of the pancreas is usually of the scirrhous type and is composed of firm fibrous nodules, but occasionally it is encephaloid, soft and cellular. Colloid carcinoma of the pancreas has been observed. Cystic epithelioma is described by Roux<sup>3</sup> and a malignant papillary adenocystoma described by Sotti<sup>4</sup> formed metastases in lymphatic glands and lungs, and papillary metastases by implantation upon the surface of the peritoneum. Carcinomatous tumors of the pancreas are usually small (5 to 10 cm. across), but occasionally they attain con-

---

<sup>1</sup> Segré: *Annal. univ. di med. e chir.*, 1888. Quoted by Oser.

<sup>2</sup> Miraillié: *Gaz. des hôp.*, 1893, lxvi, 889.

<sup>3</sup> Roux: *Cancer et kystes du pankreas*. Paris, 1891.

<sup>4</sup> *Loc. cit.*

siderable size. When a large tumor invades adjacent organs—namely, the liver, bile passages, stomach and duodenum—its origin may be doubtful. Metastases from pancreatic tumors occur with greatest frequency in the liver.

When the tumor comes into contact with adjacent organs adhesions are formed, and a variety of lesions are the result of pressure. Occlusion of the duodenum or pylorus may cause dilatation of the stomach; the stomach may be compressed against the abdominal wall and compression of the transverse colon may cause intestinal obstruction. Obstruction of the bile duct with jaundice is common. Pressure upon the left ureter may cause hydronephrosis; pressure upon the portal vein may cause ascites; pressure upon the inferior vena cava may be followed by œdema of the lower extremities. Necrosis with ulceration of tumor-tissue invading the stomach or duodenum may cause perforation of these organs.

Metastatic nodules from tumors primary in other organs occur in the pancreas. Secondary invasion of the pancreas by tumors of surrounding organs, particularly of the stomach, is common.

Fähndrich<sup>5</sup> has claimed that tumors apparently primary in the gland are often derived from the mucosa of the stomach. Olivier<sup>6</sup> examined an adenocarcinoma of the head of the pancreas and obtained evidence that it had its origin in Brunner's glands of the duodenum. He thinks that careful microscopic examination is necessary in order to determine the primary site of tumors in this situation.

The origin of carcinoma in various histological elements of the gland has been much discussed. Adenocarcinoma composed of cylin-

---

<sup>5</sup> Fähndrich: Inaug. Diss., 1891.

<sup>6</sup> Olivier: Ziegler's Beiträge, 1894, xv, 351.

dricial cells arranged in irregular alveoli with a central lumen are derived, according to Hulst,<sup>7</sup> from the ducts of the gland, whereas the less common tumors composed of polygonal cells packed together to form solid alveoli are probably derived from the secreting cells of the acini. Olivier, on the contrary, has shown that solid alveoli may be continuous with ducts of the gland. Hulst has found no relation between such tumors and the islands of Langerhans, but Fabozzi<sup>8</sup> from a study of five cases has formed the opinion that carcinoma solidum has its origin in the islands of Langerhans.

Cystic adenomata have been described (p. 268). Solid adenomata of small size have occasionally been discovered at autopsy. Biondi<sup>9</sup> described an encapsulated fibroadenoma of the head of the pancreas which was palpable and caused jaundice; recovery followed removal, and there was no recurrence a year and a half later.

A tawny yellow tumor the size of a large pea has been described by Nichols.<sup>10</sup> It had the histological structure of an island of Langerhans. Helmoltz<sup>11</sup> has described a small tumor of the same kind. A similar body resembling a greatly hypertrophied island of Langerhans has been found by Cecil.<sup>12</sup>

Sarcoma of the pancreas rarely occurs, and Kakels<sup>13</sup> in 1902 was able to collect only twenty-one instances, among which only ten were certainly primary; three of these primary growths were in the tail of the gland. Fibrosarcoma and medullary sarcoma have been found;

---

<sup>7</sup> Hulst: Virchow's Arch., 1905, clxxx, 288.

<sup>8</sup> Fabozzi: Ziegler's Beiträge, 1903, xxxiv, 199.

<sup>9</sup> Biondi: Riforma med., 1896, ii, 97.

<sup>10</sup> Nichols: Jour. of Med. Res., 1902, viii, 385.

<sup>11</sup> Helmoltz: Bull. of the Johns Hopkins Hosp., 1907, xviii, 185.

<sup>12</sup> *Loc. cit.*

<sup>13</sup> Kakels: American Jour. of the Med. Scien., 1902, cxxiii, 471.

lymphosarcoma and angiosarcoma are described. The age of the affected individuals, ranging from four to seventy years, is not significant for diagnosis. Malcolm<sup>14</sup> removed a sarcomatous tumor (not included in the series just mentioned) from the tail of the pancreas of a child four years old; the tumor was five inches across, and had invaded the portal vein.

Chronic inflammation occurs in the immediate neighborhood of carcinoma which is invading and replacing the pancreatic parenchyma. The tumor-mass, which is usually situated in the head of the gland, compresses, when of sufficient size, the pancreatic duct, and causes chronic interlobular pancreatitis of that part of the gland which is distal to the obstruction. In Chapter IX it has been shown that the islands of Langerhans are spared for a time by the inflammatory process which follows occlusion of the ducts, even though the secreting parenchyma is destroyed. Pearce<sup>15</sup> found that the islands of Langerhans persist at the edge of the advancing new growth and, at times hypertrophied, are surrounded by dense stroma which contains no secreting acini. The islands of Langerhans are finally destroyed, and in one of the cases of Pearce carcinoma with diabetes mellitus was associated with advanced sclerosis implicating these islands, whereas in a second case with temporary glycosuria the tumor affected only the head of the pancreas.

*Symptoms.*—Pain is one of the earliest symptoms of pancreatic cancer and is almost constantly present. Its great intensity increasing until death, according to some

---

<sup>14</sup> Malcolm: *Lancet*, 1902, i, 586.

<sup>15</sup> Pearce: *American Jour. of the Med. Scien.*, 1904, cxxviii, 478.

writers, is referable to pressure upon the cœliac ganglion or adjacent nerve-trunks. Pain is usually localized in the epigastric region and may radiate to the back or shoulders. It has been suggested that colicky pain may be caused by occlusion of the pancreatic duct and may resemble the colic of pancreatic lithiasis; in some cases it is doubtless caused by pressure upon the common bile duct and resembles biliary colic.

In only a fourth or a fifth of the cases of primary cancer of the pancreas collected by Miraillié has a tumor-mass been palpable. Abundant fat, muscular abdominal walls or tenderness on pressure may prevent the recognition of a mass. The tumor is usually situated in the epigastric region, but occurs rarely in the right or left hypochondrium. It is deep-seated, in most instances ill-defined, and on palpation appears smaller than it is in reality. It is usually immovable, but occasionally moves with respiration or transmits the pulsation of the aorta.

Metastatic nodules in the liver secondary to cancer of the pancreas, according to Bard and Pic, are small and do not cause the great enlargement of the liver which occurs with metastases from tumors of the stomach and intestine. Nevertheless, Miraillié found the liver enlarged in seventeen of one hundred and thirteen cases of pancreatic cancer. The condition of the liver varies, and in some cases metastatic nodules have been large.

Cachexia occurs with pancreatic cancer, as with malignant growths in other organs, but its progress, it is claimed, is unusually rapid when the gland is the seat of the disease. Disturbances of pancreatic digestion, jaundice, and diabetes may have a part in producing extreme emaciation.

Symptoms of gastric or of gastro-intestinal disturbance often occur before other symptoms; there may be loss of appetite, discomfort after eating, nausea and vomiting. Distaste for meat has been mentioned as a symptom of the disease. Constipation occurs more frequently than diarrhœa, but in some cases neither is present.

Symptoms due to disturbance of pancreatic function are present in a small proportion of instances of primary cancer. Fatty stools occurred in nine of one hundred and thirteen cases of Miraillié; Fitz<sup>16</sup> found in the literature of the subject only eleven cases with steatorrhœa, whereas evidence of disturbed digestion of protein—undigested muscle-fibres in the fœces—has been recorded in two instances. Bulky stools due to disturbed pancreatic digestion, according to Oser, may be a symptom of pancreatic carcinoma.

Diabetes mellitus not infrequently occurs as the result of destruction of the pancreas, caused by cancer; alimentary glycosuria without symptoms of diabetes has been observed. In thirteen of fifty cases cited by Miraillié there was sugar in the urine; eight additional cases with diabetes mellitus and two with alimentary glycosuria cited by Oser. The studies of Pearce, who has described two cases with permanent and one with alimentary glycosuria, show the relationship of cancer to the islands of Langerhans and to disturbance of carbohydrate metabolism. The persistence of islands of Langerhans embedded in carcinomatous tissue explains the absence of glycosuria even though the entire pancreas

---

<sup>16</sup> *Loc. cit.*, p. 90.

has been apparently replaced by new growth. Their ultimate destruction explains its onset. Glycosuria with cancer, as with other conditions which cause cachexia, may disappear before death (Courmont and Bret<sup>17</sup>).

Symptoms referable to pressure of the new growth upon adjacent organs vary with its location; those of greatest frequency are caused by tumors situated in the head of the gland. Jaundice is a common and often early symptom; in eighty-two of one hundred and thirteen cases of carcinoma of the pancreas jaundice has been present. Carcinoma of the pancreas, moreover, is one of the most frequent causes of obstruction of the common bile duct not referable to cholelithiasis, and has occurred in fifty-four of one hundred and thirty-nine cases of obstruction (not due to calculi) collected by Ecklin.<sup>18</sup> Jaundice caused by tumor exhibits no remissions, but usually increases in intensity until death (black jaundice).

Enlargement of the gall-bladder following obstruction of the common bile duct by carcinoma has been described by Battersby,<sup>19</sup> Bard and Pic, and others. Courvoisier<sup>20</sup> has found that the gall-bladder is usually contracted when obstruction of the common bile duct is due to biliary calculi, whereas with occlusion from other cause the gall-bladder is in most instances dilated. The gall-bladder may be so dilated that it is palpable below the ribs on the right side.

---

<sup>17</sup> Courmont and Bret: *Clinique*, 1894, viii, 621.

<sup>18</sup> Ecklin: *Inaug. Diss.*, Basel, 1896.

<sup>19</sup> Battersby: *Dublin Jour. of the Med. Scien.*, 1844, xxv, 219.

<sup>20</sup> Courvoisier: *Die casuistisch-statistischen Beiträge zur Pathologie und Chirurgie der Gallenwege*, Leipzig, 1890.

Ecklin has collected one hundred and seventy-two instances of obstruction caused by gall-stones; the gall-bladder has been contracted, usually by chronic inflammation, one hundred and ten times, normal thirty-four times, and dilated twenty-eight times. Among one hundred and thirty-nine instances in which the duct has been obstructed by other lesions, the gall-bladder has been contracted in nine, normal in nine, and dilated in one hundred and twenty-one instances; in sixty-two of these one hundred and thirty-nine cases obstruction has been caused by carcinoma of the pancreas and among these cases the gall-bladder has been dilated fifty-eight times. Dilatation occurs because inflammatory changes are usually absent.

Pressure upon the pylorus or duodenum may cause dilatation of the stomach. Intestinal obstruction due to compression of the ileum has been observed. Pressure upon the portal vein may cause ascites, swelling of the spleen, and hemorrhoids. Chylous ascites due perhaps to rupture of the thoracic duct has been found.

*Diagnosis.*—For recognition of cancer of the head of the pancreas the most significant symptoms are increasing jaundice attaining great intensity, dilatation of the gall-bladder and epigastric tumor; rapid emaciation and advanced age may suggest malignant disease. The presence of glycosuria, or rarely of steatorrhœa, may give evidence of pancreatic disease. Without jaundice or tumor diagnosis will be doubtful; examination under anæsthesia after the stomach and colon have been emptied increases the opportunity for palpation of a tumor.

With cholélithiasis onset of jaundice is more sudden and remissions often occur; but impacted calculi may cause intense jaundice. A palpable gall-bladder suggests cancer rather than gall-stones, but a thick abdominal wall may prevent the recognition of an enlarged gall-bladder. With cancer there are usually intense pain,

emaciation, and normal or subnormal temperature, whereas cholelithiasis is often accompanied by fever.

According to the well-known observations of Bard and Pic the liver is not enlarged, whereas with hepatic cancer having its primary seat in organs other than the pancreas enlargement is usual; nevertheless, subsequent observations have shown that enlargement of the liver may occur.

The pancreatic tumor is usually less movable than tumors of the pylorus and of the colon and its position does not change with distention of these organs.

Carcinoma of the tail of the pancreas may be mistaken for malignant growth at the cardiac end of the stomach or in the wall of the colon. Takayasu<sup>21</sup> described an immovable tumor felt behind the left rectus muscle; inflation of the stomach, which was above it, caused its partial disappearance, and inflation of the colon at its lower margin caused complete disappearance. Carcinoma of the tail of the pancreas was found at operation.

*Treatment.*—Pain, jaundice, diabetes mellitus, or gastro-intestinal symptoms caused by cancer of the pancreas require appropriate medicinal treatment. Observations upon man (Fles) and experiments upon animals (see Chap. IV) indicate that the disturbances of digestion which are caused by absence of pancreatic juice in the intestine may be favorably influenced by administration of an emulsion prepared from the fresh pancreas of an animal, or by use of pancreatin (Oser), which contains both trypsin and steapsin.

---

<sup>21</sup> Takayasu: Mitt. a. d. Grenzgeb. d. Med. u. Chir., 1898, iii, 89.

Tumors of the pancreas have been removed by operation, and in approximately one-half of such cases the patient has recovered from the immediate effects of the operation; but after removal of a malignant growth death has usually occurred within a few months. Fifteen cases have been collected by Villar<sup>22</sup> (1906); in seven instances the patient recovered from the operation, and in eight death followed immediately. Biondi<sup>23</sup> removed what proved to be a fibro-adenoma occupying two-thirds of the head of the pancreas; the tumor which had caused jaundice was palpable before operation midway between ensiform cartilage and umbilicus, and was apparently the size of a hen's egg. Recovery followed, and the patient was well a year and a half after operation.

Körte collected ten cases in which solid tumors were removed from the pancreas, and in six the mass occupied the tail of the gland. In three instances sarcoma of the pancreas was removed. Extirpation of tumors situated in the head of the pancreas is difficult and dangerous. Only part of the head of the gland can be removed, for obliteration of the ducts is followed by chronic inflammation of the parenchyma distal to the point of obliteration, and advanced sclerosis following occlusion of the pancreatic ducts is accompanied by fatal diabetes. Franke<sup>24</sup> believed that he had removed the entire pancreas containing carcinoma; there was glycosuria from the fifth to the nineteenth day after operation, and death occurred at the end of five months. Complete absence of the gland was not confirmed by autopsy. In the case

---

<sup>22</sup> Villar: *Chirurgie du pancréas*. Paris, 1906.

<sup>23</sup> Biondi: *Clinica chirurgica*, 1896, No. 4. Quoted by Körte.

<sup>24</sup> Franke: *Arch. f. klin. Chir.*, 1901, xliv, 364.

examined by Dr. Marine (see Chap. IV) glycosuria appeared immediately after removal of two-thirds of the pancreas and persisted until death three days later.

Various operations have been undertaken with the purpose of relieving the intense jaundice which accompanies cancer of the head of the pancreas. Cholecystenterostomy allows the bile to escape and at the same time permits its return to the intestine; in some instances the condition of the patient has been improved. Little benefit has followed cholecystotomy, and in most instances death has quickly followed operation. Gastroenterostomy has been performed for the relief of persistent vomiting and other symptoms caused by compression of the pylorus or duodenum; with pancreatic cancer the common bile duct and duct of Wirsung are compressed, and the operation usually fails to improve materially the condition of the patient.

## CHAPTER XIV.

### DEGENERATIVE CHANGES AFFECTING THE ISLANDS OF LANGERHANS.

DEGENERATIVE changes which affect the liver, kidney, and other parenchymatous organs occur in the pancreas as well. The gland may exhibit fatty, hyaline and amyloid degeneration, and may be the site of focal necrosis. All of these changes exhibit a tendency to attack the islands of Langerhans with greater severity than the glandular acini.

*Fatty Degeneration.*—Minute globules of fat, it has been claimed, are constantly found in the cells of the islands of Langerhans. Dogiel,<sup>1</sup> who first noted their presence, thought that they gave evidence that the islands of Langerhans were parts of the gland undergoing degeneration. Stangl,<sup>2</sup> employing osmic acid, found a few particles of fat in the islands of Langerhans of fœtuses and of new-born infants, and at the same time found an occasional globule in the outer zone of the glandular cells. With increase of age the quantity of fat was found to increase, so that in old individuals fat had become abundant in the cells of the acini and of the islands of Langerhans, and was present even in centro-acinar cells and in the epithelial cells of the ducts. Weichselbaum and Stangl<sup>3</sup> found more fat in the islands of Langerhans in individuals who had died with diabetes mellitus than in

---

<sup>1</sup> Dogiel: Arch. f. Anat. u. Physiol., Anat. Abt., 1893, 117.

<sup>2</sup> Stangl: Wiener klin. Woch., 1901, xiv, 964.

<sup>3</sup> Weichselbaum and Stangl: Wiener klin. Woch., 1901, xiv, 968.

other individuals of the same age; but since fat is present in the normal pancreas, they attribute little importance to this observation.

The observations of Symmers<sup>4</sup> who has employed Sudan III as a stain do not wholly agree with those of Stangl, for in forty-nine subjects varying from seven months of fetal life to sixty-eight years of age no fat has been found in the islands of Langerhans, or fat has been present in trivial amount. In twenty-four individuals, on the contrary, fat has occurred as minute granule-like particles or as globules, and has been so abundant that the islands of Langerhans have been conspicuous as red points under the low power of the microscope. Symmers believes that prolonged use of alcohol produces fatty degeneration of the islands of Langerhans, for in twenty-four of thirty-two individuals who had used alcohol in excess the islands of Langerhans have exhibited this change, whereas it has been absent in forty-one individuals who have given no history of alcoholic indulgence.

*Hyaline Degeneration.*—The lesions of the pancreas previously described do not exhibit a tendency to attack and destroy the islands of Langerhans, leaving uninjured the secreting parenchyma. With the interacinar type of chronic interstitial pancreatitis these structures are invaded, but the remaining glandular parenchyma is almost equally affected. One form of degeneration, however, exhibits a specific tendency to select and destroy the interacinar islands, and in most cases leaves the secreting parenchyma almost unaffected.

---

<sup>4</sup> Symmers: Arch. of Inter. Med., 1909, iii, 279.

In a considerable number of cases the pancreas has been found to be the seat of a peculiar hyaline change which destroys the islands of Langerhans. The association of diabetes mellitus with the lesion has given much interest to its study. This peculiar transformation affecting the islands of Langerhans belongs to the varied and ill-defined group of degenerative processes of which the common character is the formation of a homogeneous or hyaline material. This substance stains with acid dyes, such as eosin and picric acid, but does not give the reactions of amyloid, though it resists the action of a variety of solvents, for example, strong acids and alkalis. These characters have been used by Von Recklinghausen to group together products of cell degeneration occurring in widely different tissues, and doubtless representing a variety of essentially different processes, which even yet have received no satisfactory classification.

Several years ago I had the opportunity of studying the pancreas from a girl who for two years before her death had suffered with diabetes mellitus.<sup>5</sup> The organ is the seat of a lesion which has destroyed a considerable proportion of the parenchyma. The process which has the character of hyaline degeneration, though not confined to the islands of Langerhans, has so completely altered them that they are not recognizable. The lesion is so remarkable and its association with diabetes of such interest that the following details are given:

CASE XXIX.—The patient, a girl, aged seventeen years, was in the care of Dr. James Carey Thomas. The onset of symptoms of the fatal illness occurred two years before death with extreme thirst and

---

<sup>5</sup> Opie: *Jour. of Exper. Med.*, 1901, v, 397.

polyuria; sugar was found in the urine and was constantly present in large amount until death. Upon diabetic diet the sugar diminished in amount but did not disappear. Marked loss of body weight was not noted. Death occurred with coma, which appeared suddenly and lasted hardly more than twenty-four hours. At autopsy the only lesion noted was that affecting the pancreas; the entire organ was preserved for microscopic study and kindly given to me by Dr. Flexner, who performed the autopsy.


*Microscopic Examination of the Pancreas.*—The organ is in large part self-digested. In the tail, however, several areas where the tissue is well preserved give a clear histological picture of the lesions which are present. The interstitial tissue is increased only in several small areas. Throughout the organ, readily distinguishable even in the most digested parts of the gland, are very conspicuous, sharply defined, round or oval, hyaline areas embedded in the parenchyma; they vary considerably in size. Where the parenchyma stains deeply with hæmatoxylin these areas stand out conspicuously as almost completely unstained foci. Their structure is as follows (Fig. 43): Coarse, tortuous, hyaline columns separate strands of tissue, containing nuclei and representing, in part at least, capillary endothelium, from compressed rows of epithelial cells, evidently atrophied parenchymatous cells. The hyaline material lies immediately outside the capillary wall, between capillary and adjacent epithelial cells. Occasionally the lumen of the capillary is visible and may contain shadows of red corpuscles.

Epithelial cells between the tortuous hyaline columns form compressed rows varying in width. The cells which are diminished in size are usually arranged in columns. Rarely within the area of hyaline change, most frequently in its periphery, are cells grouped about a well-defined lumen. Islands of Langerhans are not recognizable. The hyaline material does not stain by Weigert's method for the staining of fibrin. Reactions for amyloid have not been obtained with specimens hardened in alcohol.

*Microscopic Examination of other Organs.*—The liver, kidneys and other organs exhibit no noteworthy abnormality; the blood-vessels are normal.

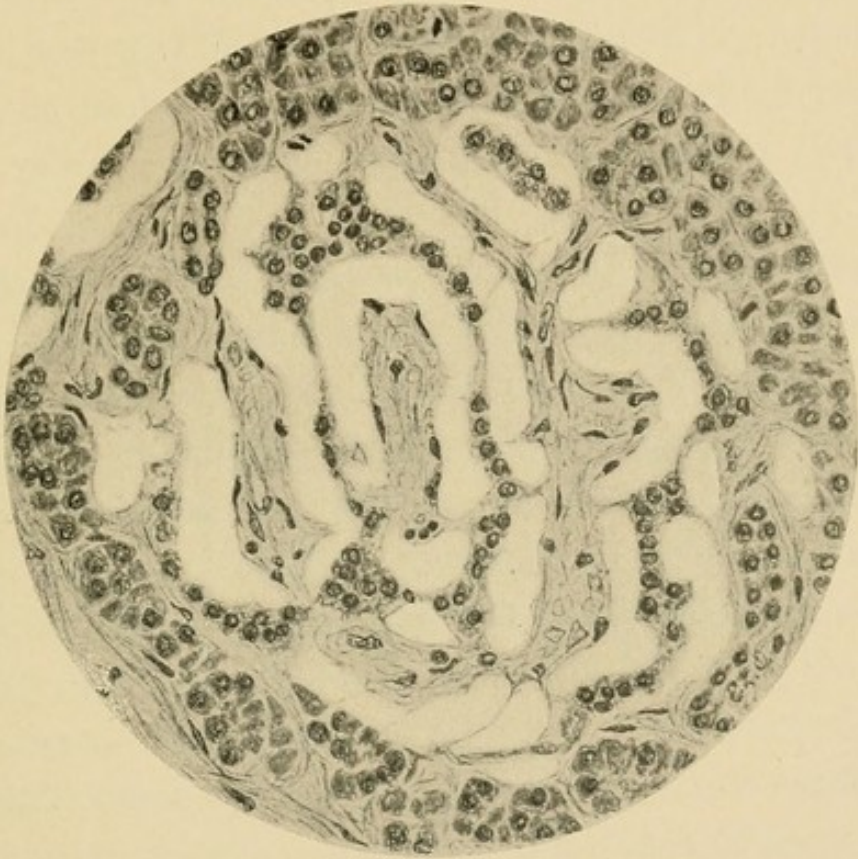

FIG. 43.—Hyaline degeneration of the pancreas. (Case XXIX.)



The remarkable lesion just described has apparently obstructed the vascular supply of a large proportion of the pancreatic parenchyma. Newly-formed hyaline material is deposited between the capillaries and the parenchymatous cells (Fig. 43). Since the tissue examined has been hardened in 95 per cent. alcohol the absence of reactions for amyloid is not conclusive. That the lesion is not this form of degeneration is shown by the absence of similar change in other organs which are subject to more advanced amyloid degeneration than the pancreas.

In the tail of the pancreas areas of hyaline transformation are larger and more numerous than elsewhere, involving at least two-thirds of the sectional area. Though the remainder of the parenchyma is in a fair state of preservation, islands of Langerhans are not found. The absence of recognizable islands of Langerhans in the tail is especially remarkable when we remember that they are normally most abundant in this part of the organ. It is evident, therefore, that the lesion has implicated these structures; but that it is not confined to them is shown by the extent and abundance of the affected areas. Often the latter correspond in size and shape to these islands, but they may be several times as large. The occurrence of epithelial cells arranged about a lumen, particularly at the periphery of the altered tissue, shows that acini as well as interacinar islets are affected. In the head and body of the gland, areas of hyaline transformation are less abundant and smaller, usually corresponding in size to islands of Langerhans. Unfortunately, self-digestion of these parts of the organ prevents recognition of very early stages of the lesion and of their relation to the various histological elements.

In a second case<sup>6</sup> of diabetes the localization of *hyaline degeneration in the islands of Langerhans* has been clearly demonstrated; these bodies are the seat of a degenerative change which has left almost unaltered the secreting parenchyma of the gland. The lesion, previously undescribed, demonstrates very clearly, as will be shown later, the relationship of diabetes mellitus to the islands of Langerhans.

CASE XXX.—The patient, a negro woman, aged fifty-four years, was admitted to the Johns Hopkins Hospital, in the service of Dr. Osler, complaining of cough. Her present illness began about eleven months before her admission, when, she states, she had a severe cold which became steadily worse. She has lost much weight. Several months after the onset of cough her urine increased in quantity, so that for a time she was compelled to void it almost every hour during the night. At the same time she experienced great hunger and thirst, and ate and drank enormously. These symptoms lasted during part of the spring and summer, and disappeared some months before her admission to the hospital. She had recently voided the usual amount of urine, and there was no excessive hunger or thirst.

When admitted the patient was thin but moderately well nourished. Signs of consolidation were found at the apices of both lungs, and tubercle bacilli were demonstrated in the sputum. The stools were of normal color and contained no fat. The patient gradually became weaker and death, which occurred on the seventh day after admission, was not preceded by coma.

The specific gravity of the urine varied between 1025 and 1035. It contained sugar in abundance, but neither albumin nor casts. On the fourth day after admission 880 c.c. were collected; the specific gravity was 1028, and 4 per cent. of sugar was present. On the following day the amount was 1200 c.c., the specific gravity 1035, and the quantity of sugar 5.4 per cent.

*Autopsy.*—The body is that of a sparely nourished woman, and

---

<sup>6</sup> Opie: Jour. of Exper. Med., 1901, v, 527.

subcutaneous fat is present in small amount. The heart is normal in appearance; within the coronary arteries near their orifices are a few slightly raised, yellow patches. Occupying the upper part of the upper lobe of the left lung is a large, irregular cavity; the remainder of the lobe is consolidated, and riddled with small cavities. The upper part of the lower lobe is very thickly studded with groups of confluent, partly caseous tubercles. At the apex of the right lung, below the pleura, is a cavity, which in size and appearance resembles that of the left lung.

The liver is pale, and upon the cut surface are seen yellowish tubercles of minute size. The spleen is not enlarged. The kidneys are large, and weigh together 400 Gm. The surface, after removal of the capsule, is smooth and pale. In the lower part of the ileum and in the large intestine are a few superficial ulcers, with irregular, slightly raised edges.

The pancreas, which weighs 80 Gm., can be readily dissected from the surrounding tissues. It is soft in consistence, on section has a grayish-yellow color, and appears to be normal.

The intima of the aorta, though fairly smooth, is studded with irregular, slightly raised plaques. The arteries at the base of the brain are normal in appearance. No lesion of the brain is found; the floor of the fourth ventricle presents nothing unusual.

In sections prepared for histological study from the pancreas of the case just described, is found no generalized increase of the interstitial tissue, but here and there, particularly in the tail of the organ, the fibrous stroma shows some proliferation, and there are irregularly-distributed strands of tissue between the acini. This scanty newly-formed interstitial tissue, where it occurs, is poor in cells, but about some of the medium-sized interlobular blood-vessels are small accumulations of lymphoid cells, together with an occasional plasma cell. The ducts are not dilated and appear to be normal. There are no alterations of the veins or arteries.

The islands of Langerhans are the seat of a remarkable change (Fig. 44). In varying amount within almost every island of Langerhans is a homogeneous material which stains with eosin. Rarely is an interacinar island found unaltered. Those which are least changed contain a few scattered masses of hyaline material, of which the smallest are irregularly polygonal in shape and correspond in size to the cells of the island; the larger particles are rounded. This hyaline substance at times lies in the midst of groups of cells, but is usually in contact with the capillaries of the island, or next the peripheral fibrous tissue, and is therefore between the remaining cells and the capillary walls. Increasing in amount, it replaces the cells and, where it is abundant, the cells which still persist are small and contain small nuclei, staining deeply with hæmatoxylin; but they do not appear compressed or distorted.

In islands of Langerhans, in which the lesion is more advanced, hyaline material occurs as conspicuous masses in contact with capillaries, the endothelium of which is well preserved. It does not form a uniform zone about them, but occurs as scattered groups of irregular, rounded, often globular masses (Fig. 45). The cells of the island have been in large part replaced, and between the hyaline particles is seen only an occasional compressed, fusiform, or irregular nucleus.

The hyaline substance may occupy almost the entire area of the island, and besides a few endothelial cells are found only small scattered groups or rows of atrophic epithelial cells. The island is represented by a sharply circumscribed hyaline structure, composed of particles of homogeneous material, giving the impres-

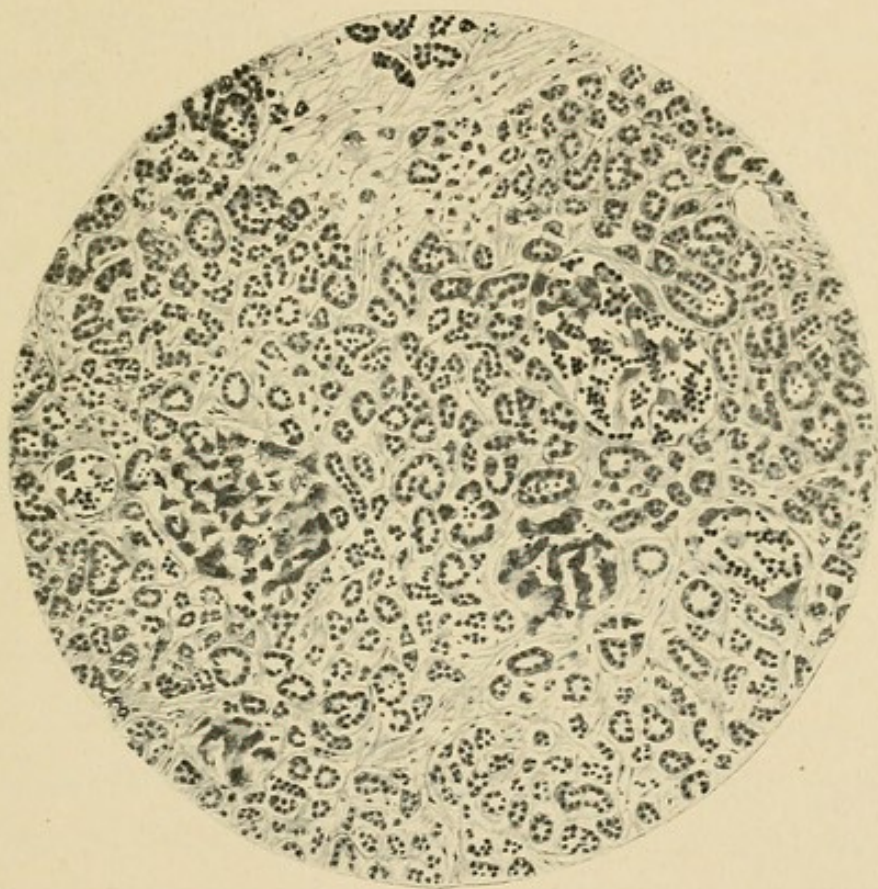


FIG. 44.—Drawing made with low magnification, showing hyaline transformation of the islands of Langerhans.

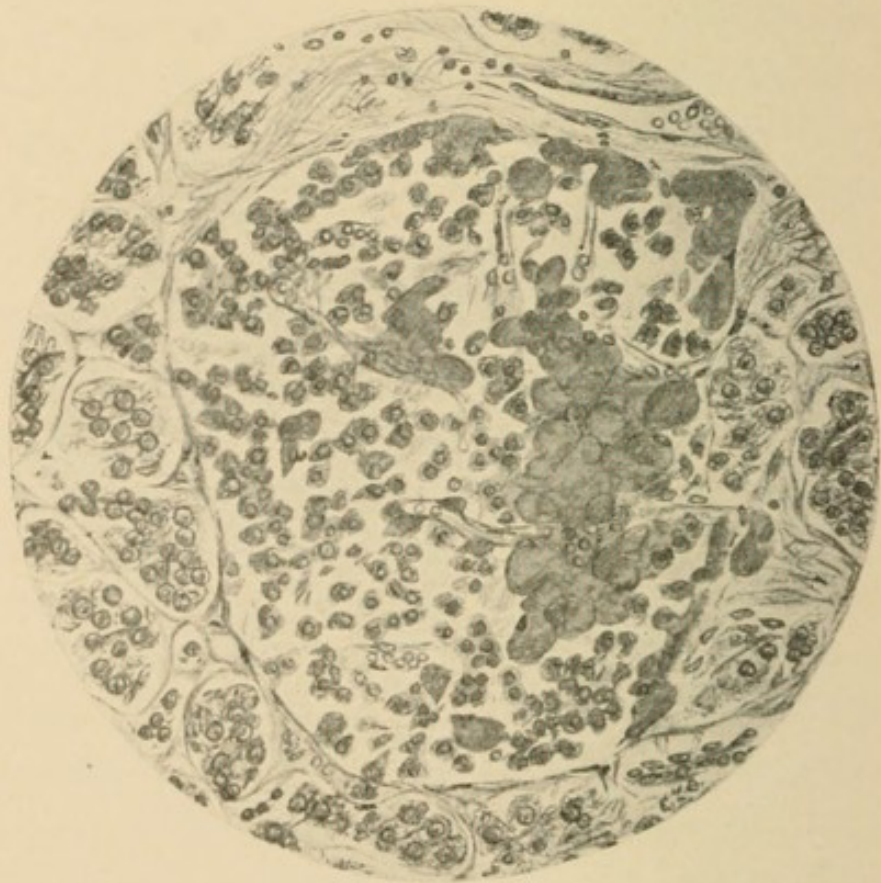

FIG. 45.—Drawing made with a higher magnification, showing an island, cells of which are partly transformed into hyaline material.

sion of broken, twisted columns, between which are capillary walls. The nuclei of the capillary endothelium persist after destruction of the epithelial cells, but finally disappear. The lumen of the capillary remains patent, and red blood-corpuscles are seen between the hyaline masses, although the endothelium no longer contains nuclei. The hyaline metamorphosis is limited strictly to the islands of Langerhans, the glandular acini remaining intact.

Lesions similar to those of the pancreas are not present in other organs. The blood-vessels of the liver, spleen, and kidney are apparently unaltered, and there is no formation of hyaline material in these organs.

The peculiarly localized lesion observed in the preceding cases of diabetes demonstrates, I believe, a causal relationship between alterations of the islands of Langerhans and the disease diabetes mellitus; this relationship will be discussed in a later chapter. Since this characteristic lesion had not been described, its occurrence was at first thought to be rare, but in addition to cases which I have recorded other observers studying the pathology of diabetes have noted similar changes, so that the association of the two conditions cannot be regarded as uncommon.

In the two cases to follow the islands of Langerhans were the seat of destructive changes comparable to those present in Case XXX, but the secreting parenchyma was somewhat more altered, exhibiting in one instance slight in the other advanced interacinar pancreatitis.

CASE XXXI.—The patient, male, colored, aged forty-eight years, was admitted to the Johns Hopkins Hospital in order that an operation for cataract might be performed. For six or seven years he had been

troubled with dimness of vision. No evidence of syphilis nor of alcoholic excess was obtainable. Shortly after the operation the patient became comatose. Sugar (4 per cent.), acetone and diacetic acid were present in the urine. The patient died at the end of two days.

*Anatomical Diagnosis.*—Hyaline degeneration of the islands of Langerhans. Hypertrophy of the kidneys; (slight) chronic diffuse nephritis; chronic catarrhal gastritis; œdema of lungs.

The pancreas, weighing 61.5 Gm., is flaccid and appears to be normal. Microscopical examination shows a slight increase of the interacinar connective tissue, though in many places, particularly in the head of the gland, the interstitial tissue is normal. Throughout the organ islands of Langerhans exhibit almost universally, but in varying degree, the hyaline change already described. Where epithelial cells are almost wholly replaced, the hyaline substance has acquired an unusually homogeneous appearance and forms globular masses, which are compressed into tortuous columns lying beside the capillary vessels of the island.

CASE XXXII.—The patient, male, seventy-three years of age, was admitted to the service of Dr. Osler. There was no history of syphilis nor of alcoholic excess. About ten months before his death, when first admitted to the Hospital, sugar was found in the urine (1.9 to 4.5 per cent.), the total amount excreted in twenty-four hours being from 29 to 49.3 Gm. When given a diet free from carbohydrates sugar disappeared from the urine. The patient was again admitted to the Hospital nineteen days before death. There was pulmonary tuberculosis. The urine contained 3.6 per cent. sugar, but shortly before death glycosuria disappeared.

*Anatomical Diagnosis.*—Hyaline degeneration of the islands of Langerhans with chronic interacinar pancreatitis. Pulmonary tuberculosis; chronic diffuse nephritis; thrombosis of the left femoral and common iliac veins and of the left pulmonary artery; general arterial sclerosis.

The pancreas, weighing 120 Gm., is firm in consistence, and fat is abundant between the lobules. In the wall of the stomach is a nodule of pancreatic tissue (described as Specimen IV in Chap. II).

Microscopic examination shows that fat is abundant in the inter-

stitial tissue of the pancreas, penetrating in many places between the acini. Throughout the organ there is a moderate irregularly distributed increase of the interstitial tissue between the acini. Islands of Langerhans are the seat of hyaline degeneration similar to that already described. In the tail they are almost universally altered. The change in many instances is so far advanced that the epithelial cells are almost completely replaced by hyaline substance.

In the following case diabetes was of mild type, and glycosuria disappeared when the patient was given a diet poor in carbohydrates. Changes in the pancreas, though present, were less extensive than in the preceding cases, and only a few islands of Langerhans were the seat of advanced hyaline changes.

CASE XXXIII.—The patient, male, white, aged fifty-one years, denies venereal disease; he has been in the habit of drinking daily several pints of beer and sour wine. The present illness began with a cough about a year and a half before its fatal termination; tubercle bacilli were found in the sputum. On three occasions the patient was admitted to the service of Dr. Osler and the urine contained from 3 to 8 per cent. of sugar, but with rest in bed and a diet free from carbohydrates glycosuria disappeared.

*Anatomical Diagnosis.*—Hyaline degeneration of the islands of Langerhans with chronic interacinar pancreatitis. Chronic pulmonary tuberculosis; general arterial sclerosis; chronic diffuse nephritis; focal necrosis of the liver.

The pancreas, which weighs 65 Gm., is fairly firm in consistence. The splenic artery is thickened and tortuous and its intima shows raised sclerotic plaques. Microscopic examination of the pancreas shows diffuse increase of the interacinar stroma most advanced in the tail. Islands of Langerhans are fairly abundant, and in most instances show no alteration, but occasionally they are surrounded and penetrated by thickened strands of connective tissue. In the tail are found interacinar islands which contain hyaline material, while in several instances almost complete hyaline transformation has occurred.

By means of staining reactions, P. Ernst<sup>7</sup> has attempted to demonstrate that the various substances grouped together by Von Recklinghausen<sup>8</sup> as hyaline are not chemically identical. Hyaline material which is derived from epithelial cells stains orange-yellow with Van Gieson's stain, being colored by picric acid, and only tinted by fuchsin, while that which is formed in connective tissue is stained deep red by fuchsin.

Lubarsch<sup>9</sup> regards the staining reactions of Ernst as an uncertain means for the identification of different hyaline substances, but admits that the method employed indicates in many cases the origin of hyaline material. Normal fibrous tissue is stained intensely red by acid fuchsin, and the substances upon which depend its affinity for the dye are present in hyaline material derived from fibrous tissue. Pure hyaline, whatever its origin, Lubarsch suggests, always stains in the same way, while differences in staining reaction are dependent upon the admixture of other substances. Following Lubarsch, we may distinguish hyaline of epithelial origin and hyaline derived from connective tissue, and, again, we may recognize hyaline which, like the colloid of the thyroid gland, is formed outside of cells, presumably by a process of secretion, and hyaline which is formed by transformation of the cell protoplasm.

The material which in the cases herewith described partly or completely replaces the islands of Langerhans

---

<sup>7</sup> Ernst: Virchow's Arch., 1892, cxxx, 377.

<sup>8</sup> Von Recklinghausen: Handbuch der allgemeinen Pathologie des Krieslaufs und der Ernährung, Deutsche Chirurgie. Stuttgart, 1883.

<sup>9</sup> Lubarsch: Ergebn. der allg. Path. u. path. Anat., herausgeg. von Lubarsch u. Ostertag., 1895, i, Abt. ii, 200.

was tested with a variety of agents which have been used in the study of hyaline substances. It stains deeply with acid dyes, like eosin and picric acid, but shows little affinity for nuclear stains, as, for example, hæmatoxylin and methylene blue.

The reactions of amyloid are not obtained with iodine, nor with gentian violet, methyl violet, nor iodine green. The material does not stain by Weigert's method for the demonstration of fibrin.

Of much interest, in view of the study of Ernst, is the behavior of the substance toward picric acid and acid fuchsin. It stains with picric acid, but shows no affinity for acid fuchsin. The material, therefore, conducts itself toward Van Gieson's stain as does, according to Ernst, hyaline of epithelial origin, and it is improbable that it is formed, as Weichselbaum and Stangl believe, by transformation of newly-formed fibrous tissue within the islands of Langerhans.

Is the hyaline material formed by a process resembling secretion, or is it formed from the protoplasm of degenerate cells?

By the use of certain stains—namely, phosphomolybdic acid hæmatoxylin by the method of Ribbert for white fibrous tissue or aniline blue as employed by Mallory for the demonstration of white fibres and reticulum—the hyaline material acquires a deep-blue color and becomes very conspicuous. When some islands of Langerhans of a gland exhibit hyaline degeneration there are not infrequently found in other islands slightly enlarged cells, which, though still containing nuclei, exhibit a reaction similar to that of the hyaline material; the cell proto-

plasm, which is still granular, has assumed a diffuse blue color.

The degenerative process first manifests itself by an increase in the size of the cell and an alteration of its protoplasm. With the death of the cell its nucleus disappears, and the protoplasm which stains with acid dyes remains for a time granular, but subsequently becomes homogeneous. These small particles of hyaline fuse with one another and form larger masses which lie in contact with the fibrous septa of the island. After complete transformation of its cells the island is represented by a hyaline mass penetrated by the remains of altered capillaries.

Since the publication of Cases XXIX and XXX hyaline degeneration of the islands of Langerhans accompanying diabetes has been described by many writers. Among two hundred and eighty-eight cases of diabetes collected from the literature of the subject the lesion occurred forty-one times (see Chap. XV); among ninety cases of diabetes studied by Cecil<sup>10</sup> islands of Langerhans were hyaline in twenty-seven. The cases which have been described do not explain its cause; it is almost equally common in men and in women (twenty-nine cases with sex recorded were in men and twenty-five in women). The lesion is uncommon between the ages of ten and forty years, whereas in two-thirds of the cases the age is between forty and seventy years.

Hyaline degeneration is usually accompanied by inter-acinar pancreatitis. Increase of interstitial tissue is often slight, and in some instances hyaline degeneration of the interacinar islands has occurred in an otherwise

---

<sup>10</sup> *Loc. cit.*

normal pancreas. In cases of Wright and Joslin,<sup>11</sup> Schmidt,<sup>12</sup> Herzog,<sup>13</sup> Müller,<sup>14</sup> Norris<sup>15</sup> and Cecil there was no increase of the interstitial tissue of the gland. In Cases XXX and XXXI this increase of interstitial tissue is so insignificant that it is recognizable only in certain parts of the gland. The relationship of hyaline degeneration of the interacinar islands to interstitial changes occurring in the secreting parenchyma is doubtful. Since large readily injected capillaries enter the islands of Langerhans, and subsequently anastomose freely with capillary vessels of the surrounding acini, it is possible, though not demonstrable, that interference with the circulation in the interacinar islands may disturb the nutrition of the surrounding parenchyma. On the other hand, it is not improbable that both processes are the result of an irritant carried to the pancreas by the blood. In Case XXIX, though the lesion has destroyed the islands of Langerhans, it has overstepped their limits and implicates in wide-spread destruction the secreting parenchyma as well. In the other cases the hyaline change exhibits a remarkable tendency to limit itself to the interacinar islands.

Arterial sclerosis has been present in a considerable number of individuals who have exhibited the lesion; in all save two of the cases described by Cecil the arteries of the pancreas have been sclerotic.

*Amyloid Degeneration of the Pancreas.*—With general amyloid disease, amyloid is occasionally recognizable

---

<sup>11</sup> Wright and Joslin: Jour. of Med. Res., 1901, vi, 360.

<sup>12</sup> Schmidt: Münchener med. Woch., 1902, xlix, 51.

<sup>13</sup> Herzog: Virchow's Arch., 1902, clxviii, 83.

<sup>14</sup> Müller: Inaug. Diss., Berlin, 1905.

<sup>15</sup> Norris: Trans. of the New York Path. Soc., 1907, vii, 19.

upon the cut surface of the pancreas after application of solutions containing iodine, and although the lesion does not attain the severity often seen in the liver, spleen, and kidney, microscopic examination usually demonstrates its presence when these organs are affected. Friedreich<sup>16</sup> found the change in the interlobular arteries and in the interacinar capillaries of the gland and Kyber<sup>17</sup> noted similar changes in every instance of amyloid disease in which he examined the pancreas. Birch-Hirschfeld<sup>18</sup> has carefully studied the localization of the lesion and has noted the presence of amyloid in the walls of the capillaries within the islands of Langerhans. In two cases of pulmonary tuberculosis Reitmann<sup>19</sup> found similar localization of amyloid in many islands of Langerhans; the cells were reduced in size and in part destroyed.

With metachromatic stains usually employed for demonstration of amyloid (gentian violet, methyl green, etc.) Butterfield<sup>20</sup> has studied the distribution of the lesion in four cases of amyloid disease; in two of these cases the lesion has been recognized at autopsy by use of iodine. In three instances there has been increase of the interlobular tissue of the gland. Amyloid is deposited in the walls of the small interlobular arteries, in the walls of the capillaries of the islands of Langerhans and occasionally in patches in the walls of small veins.

*Focal Necrosis of the Pancreas.*—In a case of diabetes I have found a lesion of the pancreas which differs from

---

<sup>16</sup> Friedreich: Virchow's Arch., 1857, xi, 387.

<sup>17</sup> Kyber: Virchow's Arch., 1880, lxxxi, 420.

<sup>18</sup> Birch-Hirschfeld: Lehrbuch der path. Anat., Leipzig, 1895, ii, 744.

<sup>19</sup> Reitmann: Zeit. f. Heilk., 1905, xxvi, 1.

<sup>20</sup> Butterfield: Phys. and Surg., 1904, xxvii, 529.

that present in the cases already cited. A destructive lesion affects not only the interacinar islands, causing death of their cells, but has attacked the secreting parenchyma as well. The process does not present the characters of hyaline degeneration already described, but occurring in foci closely resembles the coagulative necrosis so frequently observed in the liver in association with typhoid fever and other infections.

CASE XXXIV.—W. M., male, colored, aged forty-eight years, was admitted to the service of Dr. Osler complaining of frequent micturition, great thirst, and hunger, with which he had suffered during three months. Two months previously sugar had been found in the urine. He had a cough, and his weight had diminished from 166 to 110 pounds. Shortly before admission to the Hospital he suddenly became unconscious, and hemiplegia affecting the left side appeared. Death occurred on the second day after admission. The urine, examined twice, contained 3.5 and 7 per cent. sugar.

*Anatomical Diagnosis.*—Pulmonary tuberculosis with cavity formation; acute endocarditis of the aortic and mitral valve; infarcts in the spleen and kidney; chronic diffuse nephritis.

The pancreas presents no notable abnormality; a few ecchymoses are seen below the surface. Microscopic examination shows a slight increase of the interstitial tissue at the expense of the parenchyma. Newly-formed connective tissue, which occurs in irregular isolated patches within the lobules, contains few cells, and is distended as though by œdema. Foci of necrosis are found in the parenchyma, and involve small areas consisting of a considerable number of acini. The secreting cells have here lost their nuclei, and the cell protoplasm takes a bright stain with eosin; the appearance is that of coagulative necrosis in the liver. Within such an area is found in many instances an island of Langerhans which has undergone an analogous change; the cells have lost their nuclei. Rarely the cells of an island have undergone necrosis while the surrounding acini are entirely normal. Delicate interstitial tissue is in process of formation within one focus of necrosis,

and it is not improbable that the irregularly distributed increase of stroma is the result of similar degenerative changes. A few normal islands of Langerhans are found, but throughout the gland these structures are sparsely scattered. In sections from the head of the gland foci of necrosis are not found, but otherwise the tissue resembles that of the body; tissue from the splenic extremity was not preserved.

Cells of the islands of Langerhans and of the acini have undergone necrosis, but there is no formation of compact hyaline material, the presence of which is characteristic of the lesions previously observed. The parenchymatous cells, preserving their identity for a time, lose their nuclei and stain deeply with eosin. The process is apparently acute, yet throughout the gland the presence of beginning chronic inflammatory changes suggests that the interstitial tissue may proliferate in order to replace defects caused by destruction of the parenchymatous cells. The possibility suggests itself that patches of delicate sclerosis represent previous foci of similar character. Islands of Langerhans are implicated in the process, and their number is much less than that usually found.

Whipple<sup>21</sup> has found focal necroses in the pancreas of forty-one of two hundred and thirty subjects which he examined; the lesion has usually occurred in association with lobar pneumonia or other acute bacterial infection. In small areas acinar cells are granular and have lost their nuclei. Polynuclear leucocytes accumulate within the focus of necrosis. At a later stage lymphoid cells and fibroblasts show that newly-formed fibrous tissue may replace the necrotic parenchyma.

---

<sup>21</sup> Whipple: Bull. of the Johns Hopkins Hosp., 1907, xviii, 391.

## CHAPTER XV.

### PATHOLOGY OF THE PANCREAS WITH DIABETES MELLITUS.

PANCREATIC DIABETES.—The experimental studies which have been described have demonstrated the dependence of carbohydrate assimilation upon the pancreas, and have shown that its removal is followed by a condition identical with diabetes mellitus. A century before the discoveries of Von Mering and Minkowski the association of diabetes with grave lesions of the organ had been observed, and since both conditions are relatively uncommon, a causal relationship had suggested itself.

As early as 1788 Thomas Cawley<sup>1</sup> described a case of diabetes associated with pancreatic calculi and consequent atrophy of the gland. Bright<sup>2</sup> in 1833 recorded a case in which the pancreas was the seat of carcinoma compressing the duct and causing atrophy. Bouchardat<sup>3</sup> in 1875 directed attention to the association of diabetes with lesions of the pancreas, and Lancereaux<sup>4</sup> several years later claimed that diabetes accompanied by wasting (*diabète maigre*) is the result of disease of the gland, while diabetes without wasting (*diabète gras*) is dependent upon other factors; but numerous subsequent observations have failed to confirm this clinical distinction between pancreatic and non-pancreatic diabetes.

The experimental observations of von Mering and

---

<sup>1</sup> Cawley: London Med. Jour., 1788, 286.

<sup>2</sup> Bright: Med.-Chir. Trans., 1833, xviii, 1.

<sup>3</sup> Bouchardat: De la glycosurie un diabète sucré. Paris, 1875.

<sup>4</sup> Lancereaux: Bull. Acad. de méd., 1877, 2 s., vi, 1215.

Minkowski having established in dogs a relationship between the pancreas and diabetes, a renewed interest was given the study of the gland in this disease. Such investigation has shown that lesions occur in a considerable proportion of cases but has failed to demonstrate their constant presence. On the one hand, all cases of diabetes are not accompanied by demonstrable lesions of the pancreas, and on the other hand, all lesions of the pancreas are not associated with diabetes.

Hansemann,<sup>5</sup> who unlike his predecessors supported the modern conception of an internal pancreatic secretion, in 1894 collected from the literature cases in which diabetes was accompanied by pancreatic lesions.

In seventy-two cases of Hansemann the following alterations of the gland occur:

Simple atrophy .....	18
Chronic interstitial inflammation .....	18
Pancreatic calculi .....	15
Necrosis (post-mortem change in part).....	6
Carcinoma .....	5
Lipomatosis .....	3
Fatty degeneration .....	3
Abscess .....	2
Cyst .....	1
Hyperæmia .....	1
	—
Total .....	72

Such a summary of isolated cases reported by different observers, in many instances without microscopic examination of the gland, gives no accurate conception of the relative frequency of various lesions; self-digestion of the pancreas has been frequently described as necrosis. Uncommon conditions—for example, calculi and carcinoma—are more likely to be reported. There are also included a number of insignificant

<sup>5</sup> Hansemann: Zeit. f. klin. Med., 1894, xxvi, 191.

lesions—for example, hyperæmia and fatty degeneration of the parenchyma—conditions which are in a great majority of instances unassociated with diabetes and are doubtless not responsible for its occurrence.

Much more accurate statistics are obtainable, as Hansemann recognized from a series of consecutive cases. In the Pathological Institute in Berlin he studied fifty-four cases:

Atrophy (granular) .....	36
Fibrous induration (with hypertrophy).....	3
Complicated case .....	1
Normal pancreas .....	8
Condition of pancreas not noted .....	6
	—
Total .....	54

In 1898 Oser<sup>o</sup> was able to collect from the literature of the subject one hundred and eighty-eight cases of diabetes in which the pancreas had exhibited lesions. His classification of these lesions is as follows:

Atrophy .....	78
Induration .....	22
Pancreatic calculi .....	24
Carcinoma .....	24
Lipomatosis .....	8
Fatty degeneration .....	2
Cyst .....	9
Abscess .....	6
Hemorrhage .....	3
Necrosis .....	3
Fat necrosis .....	2
Lesions recognizable only by the microscope.....	7
	—
Total .....	188

A clue to the inaccuracy of these statistics which exaggerate the relative frequency of such readily recognizable lesions as calculus and carcinoma, and underestimate the frequency of chronic inflammation of the gland, is found in the last group, including lesions of which the

---

<sup>o</sup> Oser: Nothnagel's Handbuch der Medicin, vol. xviii, Part ii, Vienna, 1898.

common character is recognition by the microscope. Little attention had been given to lesions which were not demonstrable by gross examination.

It has long been known that the pancreas contains structures which differ from the secreting acini and do not communicate with the ducts of the gland. I have shown (1900) that these bodies, the islands of Langerhans, are diseased in diabetes mellitus, and have collected evidence to prove that lesions of the islands of Langerhans are accompanied by that disturbance of carbohydrate metabolism which follows removal or destruction of the entire pancreas. In the first edition of this book I recorded nineteen cases of diabetes mellitus, and in each instance described the condition of the various histological elements of the pancreas.

Discussion of the relation of diabetes mellitus to lesions of the islands of Langerhans has stimulated careful study of the pathology of the pancreas in this disease, and in consequence a large number of cases with records of the histology of the gland are available. In 1904 Sauerbeck<sup>7</sup> was able to collect from the literature of the subject one hundred and seventy-six cases recorded by observers who have given attention to the changes affecting secreting acini and interacinar islands. During several years which have followed the appearance of the article of Sauerbeck one hundred and twelve cases<sup>8</sup>

---

<sup>7</sup> Sauerbeck: Die Langerhansschen Inseln des Pankreas und ihre Beziehung zum Diabetes mellitus. Lubarsch-Ostertag. Ergebnisse der allg. Path. u. path. Anat., 1904, viii, Abt., ii, 538.

<sup>8</sup> Cases of Müller (24 cases); S. Hoppe-Seyler (7); Reitmann (17); Karakascheff (16); Finney, Med. Chron., 1903, v, 137 (8); Curtis, L'Echo méd. du Nord., 1902, vi, 140 (1); Curtis and Gellé (2); Lancereaux (4); Pearce (8); MacCallum (1); Norris (1); Beat-  
tie (1); Lazarus (3); Herxheimer (5); Opie (14).

have been studied with the aid of the knowledge previously acquired. A review of these cases, in which there has been histological examination of the pancreas, furnishes much more accurate information concerning the pathology of pancreatic diabetes than the cases of Oser. There is wide divergence in the statistics from the two sources.

PANCREATIC LESIONS.

Interacinar pancreatitis (fine sclerosis).....	125	(43.4%)
Interlobular pancreatitis (coarse sclerosis).....	13	
Lipomatosis .....	18	
Calculi .....	9	
Cyst .....	1	
Carcinoma .....	5	
Focal necrosis .....	2	
Atrophy .....	65	(22.5%)

Lesions of the islands of Langerhans with normal parenchyma:

Hyaline degeneration .....	6
Sclerosis .....	2
Adenoma-like hypertrophy <sup>p</sup> .....	3

NO LESION OF PANCREAS.

Pancreas normal .....	34	} (13.5%)
Parenchyma normal; number of islands of Langerhans diminished .....	5	
Total.....	288	

Although these figures are based upon a careful histological study of the diabetic pancreas, and are for this reason much more accurate than any previously obtainable, they fail to indicate the relative frequency of certain pancreatic lesions in diabetes. The condition of the gland which certain writers—for example, Reitmann<sup>10</sup>—

<sup>p</sup> Associated with hypertrophy of the secreting acini in parts of the gland.

<sup>10</sup> *Loc. cit.*, p. 314.

describe as simple atrophy does not differ from that which the majority of authors define as chronic inflammation of the interacinar type. Included under the designation atrophy are two wholly different conditions. (a) In one group of cases there is gross and histological evidence that the structural elements of the gland have undergone diminution in size or in number, thus diminishing the size of the gland as a whole; there is with this lesion evidence of degenerative changes in the parenchyma of the gland. (b) In another group of cases the gland is smaller than normal, perhaps as the result of a congenital anomaly, and the histological structure of the organ is unchanged. For the purpose of classification this distinction is important, one condition being an acquired disease, the other doubtless, a congenital abnormality.

Whereas among one hundred and thirty-nine cases of diabetes mellitus collected by Windle<sup>11</sup> in 1883 in 47 per cent. the pancreas has been described as normal, in the present series among two hundred and eighty-eight more carefully studied cases only 13.5 per cent. have been found without noteworthy change of the gland. Even among these cases there have been many in which the records have failed to indicate that the organ was of normal size and possessed the various histological elements in normal proportion.

The lesion which is most common with diabetes has been designated atrophy by one group and chronic inflammation by another. Some of these observers have noted the almost invariable implication of the islands of Lan-

---

<sup>11</sup> Windle: Dublin Jour. of the Med. Scien., 1883, lxxvi, 112.

gerhans when the pancreas is the seat of disease, whereas a smaller number have described little alteration of these structures. The examination of a large number of cases by one observer will furnish data for comparison with the statistics previously obtainable from the literature of the subject. Such a group of cases will determine if, for example, so-called simple atrophy of some writers is identical with the lesion described as chronic inflammation by others. The value of the classification obtained will depend upon the accuracy with which various lesions are designated. With such considerations in view, Dr. R. L. Cecil<sup>12</sup> has studied, in the Pathological Laboratory of the Presbyterian Hospital of New York, the pancreas from ninety cases<sup>13</sup> of diabetes mellitus. The condition of the gland in these cases has been as follows:

Interacinar pancreatitis:

With sclerosis of islands of Langerhans.....	39
With hyaline degeneration of islands of Langerhans.....	19
With sclerosis of the islands of Langerhans and lipomatosis .....	2
With hyaline degeneration of the islands of Langerhans and lipomatosis .....	1
With siderosis of islands of Langerhans (hæmochromatosis) .....	2
	—
Total.....	63

Interlobular pancreatitis:

With sclerosis of islands of Langerhans.....	4
	—
Total.....	4

<sup>12</sup> *Loc. cit.*

<sup>13</sup> Records of cases and tissue from the pancreas was obtained from Dr. J. S. Thacher, Dr. J. Homer Wright, Dr. F. B. Mallory, Dr. Libman, Dr. Longcope, Dr. Oertel, Dr. Charles Norris, Dr. Adami, Dr. Klotz, Dr. C. W. Duval, Dr. White, Dr. W. G. MacCallum, Dr. F. C. Wood, Dr. Walter James, and Dr. Stein.

Parenchyma normal; lesions of islands of Langerhans:	
Sclerosis of islands of Langerhans.....	4
Hyaline degeneration of islands of Langerhans.....	7
Infiltration of leucocytes about islands of Langerhans.....	1
	—
Total.....	12
Pancreas normal in structure:	
Pancreas small and islands of Langerhans few.....	2
Islands of Langerhans few.....	3
No abnormality noted.....	6
	—
Total.....	11

*Relation of Diabetes to Lesions of the Islands of Langerhans.*—For the purpose of the present study it is pertinent to inquire what histological changes are associated with the occurrence of diabetes. When a lesion of the pancreas is the cause of the disease, is the condition dependent upon changes in the acini or in the islands of Langerhans or in both? Total destruction of the acini is often accompanied by destruction or alteration of the interacinar structures, and rarely are the islands of Langerhans the seat of marked lesion while the acini remain unchanged.

The islands of Langerhans are composed of columns of cells having no communication with the ducts of the gland, but in intimate relation with a rich capillary network, and an analogous condition is found in the thyroid gland and in the adrenal. The pancreas, like these organs, exerts through the medium of the blood an important influence on metabolism. Whether the gland furnishes some substance which aids carbohydrate assimilation or destroys some noxious product hindering it is immaterial to the present study. When diabetes is the result of pancreatic disease, do the islands exhibit lesions?

With the interacinar type of chronic pancreatitis, which, except in its earliest stage, is accompanied by diabetes, the islands of Langerhans are invaded by the inflammatory process. With the interlobular type, which may follow obstruction of the pancreatic ducts or ascending infection of the gland, diabetes ensues only in those relatively uncommon instances in which the lesion has reached a very advanced grade; the sclerotic process, which in many cases at least has its origin in the ducts of the gland, spares the islands of Langerhans and causes their destruction only when the gland is almost wholly transformed into dense sclerotic stroma. These facts, however, do not demonstrate with certainty the dependence of diabetes upon alterations of the islands of Langerhans, for on the one hand with interacinar pancreatitis the secreting parenchyma is affected, while on the other hand, with interlobular inflammation, some secreting alveoli are preserved, even when the lesion is far advanced.

In a preceding chapter I have shown the susceptibility of the pancreas to hyaline degeneration. The first example of this lesion which came to my observation was accompanied by a severe type of diabetes, and though the islands were so altered as to be completely unrecognizable the secreting parenchyma was in great part destroyed. The succeeding instances of this remarkable lesion clearly demonstrated the relationship of diabetes to a destructive lesion of the interacinar islands, for though these structures had undergone very grave alterations and were often converted into almost homogeneous hyaline masses, the secreting parenchyma, notably in Cases XXX and XXXI, showed only a very insignificant

increase of the stroma, and in the greater part of the gland was wholly unaltered.

Subsequent observations have demonstrated the surprising frequency with which this selective lesion accompanies diabetes, and it has been found in six of the nineteen cases of diabetes previously mentioned. In three instances, Cases XXX, XXXI, and XXXII, described in detail, the lesion of the islands of Langerhans has doubtless been of such a character as to render them almost completely functionless, though the remaining parenchyma is relatively well preserved. The other cases, including Case XXXIV, in which the lesion resembled coagulative necrosis of the liver, were from necessity studied less completely and the condition of the islands was not so definitely determined.

Cecil has found lesions of the islands of Langerhans in seventy-nine (88 per cent.) of ninety cases of diabetes; in the remaining cases the pancreas has exhibited no lesion, and it is doubtful if diabetes has been referable to this organ. In forty-nine cases there has been sclerosis of these bodies; in twenty-seven instances, hyaline degeneration, often combined with sclerosis; in one instance, acute inflammation alone; and in two cases of hæmochromatosis, deposit of iron-containing pigment with sclerosis. In four instances the islands of Langerhans were sclerotic, and in seven instances they were the seat of hyaline degeneration, although the secreting parenchyma was normal.

Before the histological studies of recent years no common character of the diverse lesions of pancreatic diabetes has been definable. Destruction of parenchyma has not explained the occurrence of glycosuria, for lesions

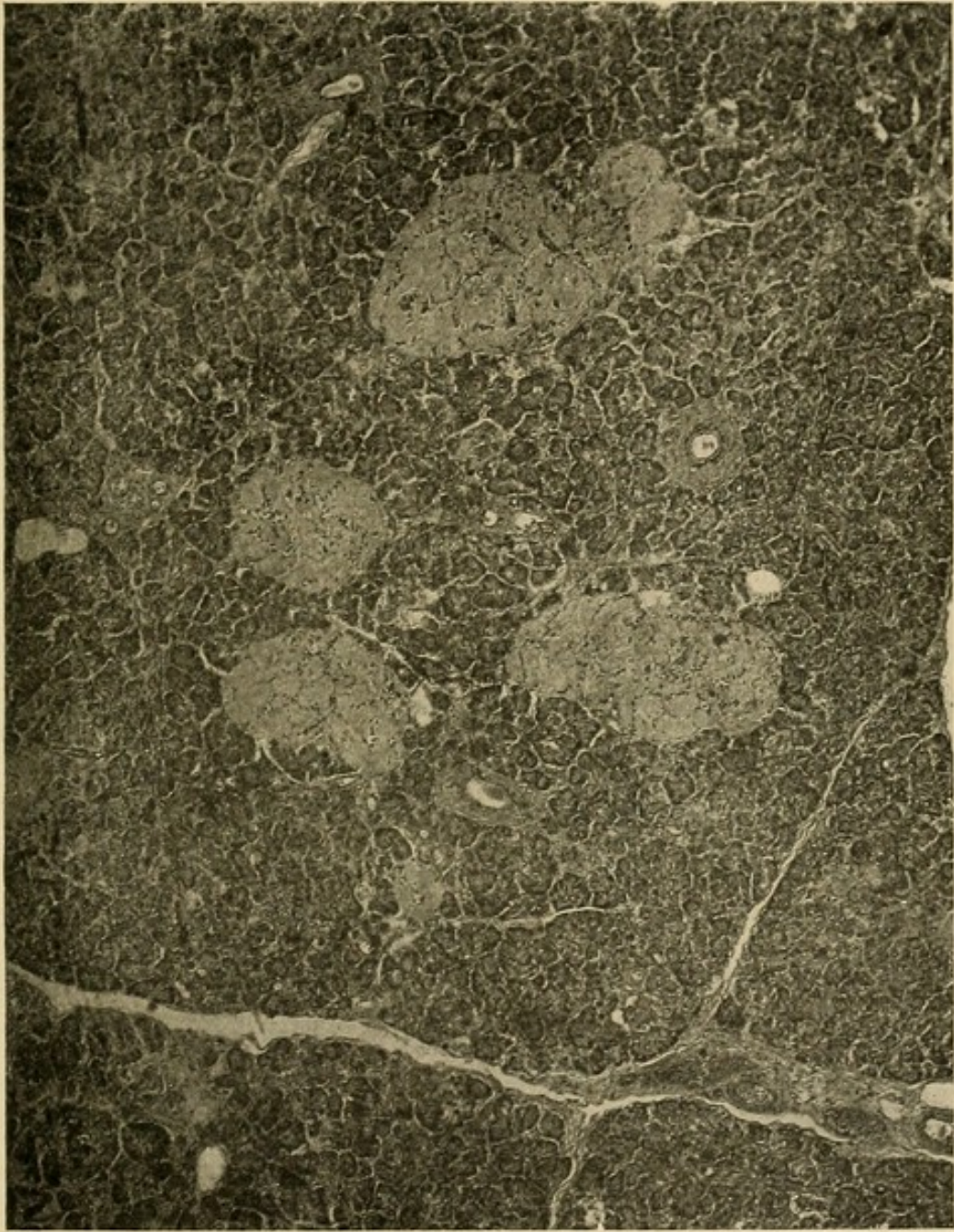

FIG. 46.—Advanced hyaline degeneration of islets of Langerhans; secreting parenchyma normal. Photograph by Dr. Leaming from Case LXXI (diabetes mellitus) of Dr. Cecil.



such as lithiasis or carcinoma, which cause greatest destruction of parenchyma, are in most instances unaccompanied by diabetes mellitus. When the various lesions to which the pancreas is subject are passed in review, it is found that changes which destroy the islands of Langerhans, especially interacinar pancreatitis and hyaline degeneration, are almost constantly accompanied by diabetes, whereas those lesions which destroy the parenchyma and invade the islands of Langerhans only when the change is far advanced—namely, interlobular pancreatitis, lithiasis, carcinoma—are in most instances unaccompanied by diabetes. Sauerbeck has been able to find no cases in which severe lesions of the islands of Langerhans have been unaccompanied by diabetes, whereas there are records of almost innumerable cases in which with no diabetes the islands of Langerhans have been normal, although the secreting parenchyma has undergone very advanced alteration and destruction.

Lesions of the pancreas rarely affect the islands of Langerhans and leave glandular acini unchanged, yet the careful study which has been given to pancreatic disease has revealed instances in which with diabetes islands of Langerhans have been the seat of destructive lesions (hyaline degeneration, sclerosis), whereas the secreting pancreas has been normal (Fig. 46) or has exhibited trivial changes not infrequently found in the absence of diabetes. Wright and Joslin, Schmidt, Herzog, Müller and Norris (see Chap. XIV) have found the islands of Langerhans hyaline, although the secreting parenchyma has been normal; in a similar case of Reitmann, the pancreas has been atrophic in appearance, but there has been no increase of interstitial tissue. Among ninety cases of

diabetes Cecil found hyaline degeneration of the islands of Langerhans unaccompanied by lesions of the parenchyma in seven instances. (The case of Norris mentioned above is included in this series.) Sclerosis limited to the islands of Langerhans and accompanied by diabetes has been described by Schmidt (with foci of acute inflammation), Sauerbeck and Cecil (see Chap. IX).

Such observations have almost the same value as purposely performed experiments, for in the absence of any evidence that these changes are secondary to diabetes they resemble the decisive experiments of Von Mering and Minkowski who, it is well known, have found that extirpation of the entire gland or the greater part of the gland is followed by permanent disturbance of carbohydrate metabolism.

A relation between lesions of the islands of Langerhans and duration of diabetes has been noted by Cecil. With interacinar pancreatitis some of the islands of Langerhans are occasionally surrounded and infiltrated with lymphoid cells; the presence of such cells indicates an early stage in the development of the lesion; when sclerosis is advanced, the interacinar islands are invaded by fibrous tissue poor in cells. In a few instances polynuclear leucocytes within the islands of Langerhans show the existence of acute inflammation. The average duration of diabetes in six cases in which the islands of Langerhans are infiltrated with cells has been eleven months, whereas the average duration in forty-six cases in which the sclerotic tissue of these islands is poor in cells has been three years and eleven months. In sixteen cases in which the islands of Langerhans are the seat of

hyaline degeneration the average duration of diabetes has been three years and six months.

The following grave lesions of the pancreas have been found associated with diabetes by the various writers who have been cited: Carcinoma destroying the gland; acute pancreatitis, usually with hemorrhagic necrosis of the organ; chronic interstitial pancreatitis following obstruction of the ducts by calculi, cysts, or carcinomata; chronic interstitial pancreatitis due to other causes; simple atrophy of the pancreas. Certain features associated with each of these conditions demand consideration, but it is unnecessary to discuss the relationship to diabetes of less important alterations, for example, hyperæmia, parenchymatous and fatty degeneration, which commonly occur without any disturbance of carbohydrate metabolism.

*Destructive Lesions of the Pancreas with Diabetes.*—Though complete removal of the pancreas in lower animals is followed by diabetes, numerous writers have claimed that complete destruction of the organ, by hemorrhagic necrosis, hemorrhagic inflammation, or by carcinoma invading and destroying the gland, is not invariably followed by diabetes.

Acute lesions of the pancreas associated with suppuration or necrosis may cause extensive destruction of the gland, yet in only six of one hundred and five cases collected by Egdahl<sup>14</sup> was sugar present in the urine. Destruction of the pancreas by hemorrhagic necrosis is rarely complete, and in most instances enough parenchyma remains to prevent onset of glycosuria. After

---

<sup>14</sup> *Loc. cit.*, p. 135.

extirpation of the pancreas in animals a variable time elapses before sugar appears in the urine; and in most cases, shortly before the fatal termination or with the onset of severe complications, glycosuria disappears. With rapidly fatal lesions death may occur before onset of glycosuria.

Destruction of the pancreas may be caused by diffuse carcinomatous new growth invading the organ and replacing the parenchyma. In another category belong those more frequent instances in which a new growth compressing the duct has produced secondary chronic inflammation of the gland. Hansemann described two cases in which a diffuse primary carcinoma of the pancreas had apparently caused complete destruction of the organ; nevertheless, diabetes was absent. He has suggested that the tumor cells derived from the parenchyma of the gland are capable of exerting that influence upon carbohydrate metabolism which is attributed to the normal gland.

The difficulty of identifying within a carcinomatous mass small indurated, but yet well preserved, areas of pancreatic parenchyma is considerable; and even though the secreting acini have been destroyed, islands of Langerhans, which superficially resemble alveoli of carcinomatous cells, may still persist. Pearce<sup>15</sup> has demonstrated that islands of Langerhans may survive although the surrounding parenchyma has been destroyed by cancer. At the margin of the advancing tumors islands of Langerhans may persist enclosed within masses of tumor cells. Those islands of Langerhans which are isolated in the stroma may undergo hypertrophy so that they be-

---

<sup>15</sup> *Loc. cit.*

come four or five times their normal size. The resisting islands of Langerhans may be finally destroyed by encroachment of the sclerotic stroma.

*Chronic Interstitial Pancreatitis with Diabetes.*—The association of chronic interstitial inflammation with diabetes is demonstrated by the foregoing tables. Chronic interlobular pancreatitis follows obstruction of the pancreatic duct by calculi, by carcinoma of the head of the gland, or by cysts causing compression of the ducts, and such lesions are cited in the statistics of Hansemann (twenty-one of seventy-two cases) and of Oser (fifty-seven of one hundred and eighty-eight cases). Though a large number of such cases have been recorded they are much less frequent than these figures indicate. When consecutive cases of diabetes have been studied duct-obstruction in association with diabetes is uncommon, lithiasis, cyst, and carcinoma being represented by only fifteen among two hundred and eighty-eight cases collected by Sauerbeck from recent literature of the subject. In none of forty cases observed by Hansemann did he find sclerosis consequent upon the presence of calculi, but in two examples of advanced scleroses with calculi diabetes was absent.

In only one of the cases which I have described did diabetes accompany pancreatic calculi; here the consequent interlobular inflammation of the gland and destruction of its parenchyma was far advanced and the islands of Langerhans were implicated. Of considerable importance is the fact that the associated diabetes was of mild character, glycosuria disappearing when carbohydrates were withdrawn from the diet. On the other hand, in two of my cases with advanced sclerosis following obstruction of the pancreatic duct—in one case caused

by calculi (Case XXVI), in another by carcinoma (Case XII)—diabetes was absent and the islands of Langerhans were intact. In two cases of pancreatic lithiasis accompanied by diabetes, Lazarus<sup>16</sup> found both acini and islands of Langerhans destroyed, but in a similar case without diabetes chronic pancreatitis was less advanced and numerous unaltered islands of Langerhans persisted although surrounding acini had been destroyed. Ligation of the pancreatic ducts in animals is followed by chronic interlobular inflammation, which for a long time spares the islands of Langerhans, and the lesion rarely, if ever, reaches such an advanced stage that diabetes ensues. The inflammatory changes which in human beings follow duct-obstruction are especially severe because they are associated in most instances with conditions favoring ascending infection with bacteria, but they are followed by diabetes only when they have reached such an advanced stage that the parenchyma is almost wholly replaced and compressed by dense fibrous tissue.

Chronic pancreatitis due to causes other than duct-obstruction is not infrequently associated with diabetes, but chronic pancreatitis is not always, or indeed in the majority of instances, accompanied by diabetes. To produce diabetes mellitus in animals it is necessary to remove a considerable part of the pancreas; a case previously cited (page 110) shows that removal of two-thirds of the human pancreas may cause glycosuria. Diabetes mellitus accompanies chronic inflammation of the pancreas only when a considerable part of the parenchyma has been destroyed or functionally impaired.

---

<sup>16</sup> *Loc. cit.*, p. 257.

Various observers have attempted to define a type of pancreatitis peculiar to diabetes. G. Hoppe-Seyler<sup>17</sup> and Fleiner<sup>17</sup> have described instances of the disease in which chronic interstitial inflammation of the pancreas accompanied general arterial sclerosis. Lemoine and Lannois,<sup>17</sup> as already noted, have studied pancreatitis in four cases of diabetes, and have thought that the new growth of interstitial tissue has its seat of origin in the perivascular tissue, whence fibrous processes extend between the parenchymatous structures and even into the acini, separating the cells and producing what they designate unicellular sclerosis.

Hansemann has claimed that one variety of pancreatitis is always accompanied by diabetes. He designates the condition atrophy, but the character of the lesion and, what he particularly emphasizes, the features which distinguish it from atrophy consequent upon emaciation identify it as chronic inflammation. The organ is diminished in size, flattened and unusually adherent to neighboring structures; the microscope demonstrates an atrophy of the parenchymatous elements, which are in part replaced by new fibrous tissue. With cachectic atrophy, on the contrary, glandular cells and interstitial tissue have undergone equal atrophy. Hansemann thinks that this pancreatic lesion characteristic of diabetes is similar to certain forms of granular atrophy of the kidneys. Since the new growth of interstitial tissue never reaches such extent that the organ is increased in size, he distinguishes granular atrophy from fibrous induration with hypertrophy, which in three instances he found

---

<sup>17</sup> *Loc. cit.*, Chap. IX.

associated with diabetes. This fibrous induration characterized by coarse bands of newly-formed stroma is not uncommon, but is usually unaccompanied by diabetes.

Comparison of the series of cases recorded by Hansemann in 1894 with those subsequently studied by histological methods shows that the so-called granular atrophy which he found peculiar to diabetes mellitus corresponds in frequency with the interacinar pancreatitis or fine sclerosis which has been present in a large proportion of more recently recorded cases. With this lesion the islands of Langerhans are implicated; they are invaded by newly-formed fibrous tissue, and are not infrequently the site of hyaline degeneration. Among sixty-three instances of interacinar pancreatitis occurring in ninety diabetics studied by Cecil, the islands of Langerhans have exhibited sclerosis in forty-one, hyaline degeneration in twenty, and deposit of hæmosiderin (hæmochromatosis) in two.

The lesion which Hansemann designated fibrous induration with hypertrophy is doubtless identical with chronic interlobular pancreatitis; it has occurred only three times among thirty-seven cases of Hansemann and only four times among ninety cases of Cecil.

*Simple Atrophy of the Pancreas with Diabetes Mellitus.*—Diminution in the size of the pancreas with or without structural changes has been more frequently noted in association with diabetes than any other abnormality. The normal organ is subject to much variation and its weight is differently estimated by anatomists. Vierordt<sup>18</sup> has found the average normal weight 97.6

---

<sup>18</sup> Vierordt: Anat., physiol. und physikal. Daten und Tabellen, Jena, 1906.

Gm. Krause<sup>19</sup> found the weight from 66 to 102 Gm. Doubtless a weight below 65 Gm. should be regarded as abnormal. So-called atrophy has been frequently associated with severe alterations of the parenchyma, notably with chronic interstitial inflammation, and such cases should be separated from those in which the tissue presents a normal histological character.

Hansemann discusses the relationship of simple atrophy to diabetes. Is it a consequence of the general emaciation associated with diabetes, and is it therefore secondary to this disease? The pancreas doubtless shares the atrophy which all organs undergo as the result of cachexia from any cause; but since he has found the pancreas little affected when the other organs of an emaciated individual are much diminished in weight, Hansemann concludes that only a slight diminution in size can be secondary to diabetes. Moreover, atrophy of the pancreas is not limited to cases of diabetes accompanied by emaciation, for Hansemann found that of thirty-six cases in which the pancreas was atrophied, in six instances the affected individual was corpulent. Moreover, the characters of so-called granular atrophy of diabetes defined by Hansemann remove it from the domain of simple atrophy and characterize it as chronic inflammation.

Ssobolew,<sup>20</sup> Weichselbaum and Stangl,<sup>21</sup> and Reitmann<sup>21</sup> have described groups of cases at variance with those previously cited (page 321), for they contain few, if any, examples of interacinar pancreatitis. In these three series of cases the lesion most frequently observed with

---

<sup>19</sup> Krause: *Handb. der mensh. Anat.*, vol. ii, 1879.

<sup>20</sup> Ssobolew: *Virchow's Arch.*, 1902, clxviii, 91.

<sup>21</sup> *Loc. cit.*

diabetes is designated simple atrophy; Ssobolew found simple atrophy in fourteen of fifteen cases of diabetes, and Weichselbaum and Stangl found so-called simple atrophy in twenty-three of thirty-five cases of diabetes. Ssobolew has found the islands of Langerhans of the atrophic pancreas constantly diminished in number, and Weichselbaum and Stangl have found various degenerative changes—namely, diminution in size of the cells, vacuolization, and pyknosis of nuclei. Since the last-named observers found in some of their cases increase of connective tissue within and about the islands of Langerhans, and in some instances hyaline degeneration, it is probable that so-called simple atrophy described by them is identical in part at least with what the greater number of writers have described as interacinar pancreatitis (or fine sclerosis). The series of cases described by Reitmann is equally anomalous, for among seventeen cases of diabetes he found interacinar pancreatitis in only one case, whereas this lesion has occurred one hundred and twenty-three times among two hundred and eighty-eight cases of diabetes collected from the literature of the subject. Reitmann has found in seven cases simple atrophy characterized by degenerative changes in the secreting parenchyma; in places the glandular cells lose their zymogen granules and become vacuolated, while elsewhere in the parenchyma regenerative changes occur. Such degenerative and regenerative changes are, Reitmann claims, an exaggeration of processes which occur under normal conditions and have been demonstrable in the pancreas of criminals immediately after execution. When degenerative changes are active glandular parenchyma is replaced by fat; there may be increase of connective tissue, so that in certain stages, according to Reitmann, the lesion resembles what Hansemann has described as granular atrophy.

The foregoing considerations show that the change which has been designated simple atrophy by Ssobolew, Weichselbaum and Stangl and Reitman is a chronic inflammatory process which has been described by other writers as interacinar pancreatitis, fine sclerosis, or granular atrophy.

*Abnormally Small Pancreas with Diabetes.*—The pancreas of diabetics is not infrequently described as atrophic merely because it is small. The parenchymatous cells may exhibit no appearance of atrophy, and there may be no evidence that the organ has undergone changes which have reduced its size. The gland in some individuals is far below the average size, and it is possible that such individuals are especially susceptible to diabetes mellitus.

In a carefully studied series of cases Williamson<sup>22</sup> has demonstrated the coexistence of diabetes and extreme diminution in the size of the pancreas unassociated with any demonstrable alteration of the parenchyma. In three of twenty-three cases the pancreas was atrophied to an extent bearing no relationship to the general wasting of the other organs, and the parenchyma appeared to be normal. In one instance the organ in a man forty-six years of age weighed only a quarter of an ounce (8 Gm.).

In three of my cases the pancreas was diminished in size (three glands weighing 60, 58, and 51 Gm. in individuals respectively forty-six, fifty-six, and thirty years of age, but no other alterations were observable. In four of twenty-two cases of diabetes described by W. Müller<sup>23</sup> the pancreas, which was wholly normal in structure, was unusually small. When the gland shows no structural change, it is probable that the condition is congenital, and the pancreas being unusually small, at some period of life fails to meet the demand made upon it, so that

---

<sup>22</sup> Williamson: *Diabetes Mellitus*. Edinburgh and London, 1898.

<sup>23</sup> Müller: *Inaug. Diss.*, Berlin, 1905.

diabetes results. Diminution in the size of the pancreas is presumably accompanied by diminution in the number of islands of Langerhans.

*Relation of Diabetes to a Diminution in the Number of Islands of Langerhans.*—Several writers have claimed that diabetes may be associated with diminution or even entire absence of the islands of Langerhans. Ssobolew<sup>24</sup> in a preliminary communication published in 1900 cited two cases of diabetes in which, he claimed, these structures were wholly absent, and in four of fifteen cases described several years later he failed to find them. Since the secreting parenchyma was entirely normal, he assumed that the interacinar islands might disappear without leaving any trace. In nine cases he found the number of islands of Langerhans diminished. Schmidt has never failed to find interacinar islands and is skeptical of Ssobolew's observations. Ssobolew did not examine sections from the various parts of the pancreas and failed to recognize the truth that islands of Langerhans may be very numerous in the tail of the gland while they may be almost absent from other parts. In single sections I have failed to discover these structures, but in all cases of diabetes which I have examined, and in all of ninety cases examined by Cecil, they have been found in fair abundance, particularly in the tail of the organ.

Weichselbaum and Stangl compared sections from the pancreas of diabetics with control specimens made from corresponding parts of the pancreas obtained from individuals of the same age, and reached the conclusion that the number of islands of Langerhans may be dimin-

---

<sup>24</sup> Ssobolew: Cent. f. allg. Path. u. path. Anat., 1900, xi, 202.

ished with diabetes; and since the pancreas is almost constantly small, the total number of islands is still less than normal. They do not, however, separate cases in which the islands of Langerhans showed lesions from those in which they were apparently normal.

In order to determine definitely the number of the islands of Langerhans it is essential to estimate their number in section from corresponding parts of the gland. When the interacinar bodies are the seat of destructive lesions it is obvious that the number capable of functional activity is diminished, but considerable interest attaches to those cases in which no lesion can be demonstrated.

In the following cases of this character sections from three parts of the gland were examined (exceptions are noted) and the number of islands of Langerhans in 0.5 square centimetre determined.

No. of case.	Age of patient in years.	Weight of pancreas in grammes.	Relative number of islands of Langerhans in		
			Head.	Body.	Tail.
I	33	..	.. (9)	.. (5)	..
II	46	60	.. (23)	.. (21)	..
III	56	58	17	16	32
IV	14	..	12	5	10
V	10	45	50	19	42
VI	30	51	6	5	8
VII	..	54.5	32	31	42

NOTE.—In Cases I and II tissue was not preserved from different parts of the gland and the figures in parenthesis represent the number of interacinar islands in sections taken at random.

Comparison with the table on page 62 shows that the above figures present no constant departure from the normal. In the head and body about eighteen islands occur in 0.5 square centimetres; in the tail, approximately thirty-two. A striking diminution is seen in Cases IV and VI, and is particularly noteworthy in Case IV, a

child of fourteen years, in whose pancreas we would expect the number of islands to be greater than in that of the adult. In this case the existence of hereditary diabetes<sup>25</sup> suggests the occurrence of a congenital defect of the gland. In no instance does the appearance of the gland suggest a condition of atrophy.

The islands of Langerhans were counted by Sauerbeck<sup>26</sup> in the pancreas of thirteen individuals who had suffered with diabetes; in all but one instance the number was less than that found in any one of several normal glands (from  $2\frac{1}{2}$  to  $9\frac{1}{2}$  within an area approximately 4 square millimetres). In three cases of diabetes the pancreas was normal or exhibited "atrophy"; the figures obtained were: (I), 3.4 (aged 84 years); (II), 1.1 (aged 26 years); (III), 0.6 (aged 29 years; "atrophic pancreas"). In one of these instances (I) the number was within the lower limit of the normal, whereas in two instances the number was considerably less than normal.

Müller has counted the islands of Langerhans in a given area of parenchyma, and when the gland has been unusually small has roughly estimated the relation between the mass of the gland and the absolute number of the islands of Langerhans. In three instances in which the gland has shown no lesion he has found that the number of inter-acinar bodies has been unusually small; in a pancreas weighing 46 Gm. from a man aged twenty-one years the islands of Langerhans thus estimated have been one-twelfth as abundant as in the normal pancreas.

Glycosuria may follow the partial removal of the human pancreas, even though one-third of the gland remain (see Chap. V). Nevertheless, a gland weighing from 50 to 60 Gm., even should the relative number of islands be small, might be sufficient to prevent diabetes. We are, however, unable to estimate the effect of prolonged exertion on the part of the defective gland to

---

<sup>25</sup> The case is described by Dr. Pleasants in a paper on "Heredity in Diabetes Mellitus with a Report of Six Cases Occurring in a Family." *Bulletin of the Johns Hopkins Hospital*, 1900, xi, 325.

<sup>26</sup> Sauerbeck: *Virchow's Arch.*, 1904, Suppl. to clxxvii, 1.

carry on functions necessary to normal metabolism. Moreover, slight, hardly recognizable changes—for example, arterial sclerosis—may at some period of life be sufficient to overtopple the equilibrium heretofore preserved by the overworked gland.

*Hypertrophy of the Islands of Langerhans with Diabetes.*—Hypertrophy of the islands of Langerhans has been observed in association with lesions which destroy or injure some of these bodies and presumably force to unusual functional activity those which remain. In the absence of diabetes mellitus, Pearce<sup>27</sup> has found the islands of Langerhans unusually enlarged along the advancing edge of a malignant growth. Though these structures survive the secreting parenchyma, and persist occasionally within a mass of tumor cells, some of them are finally destroyed; a part of those which remain are four or five times the size of normal islands of Langerhans. Ohlmacher<sup>28</sup> has observed cirrhosis of the liver accompanied by hyaline degeneration affecting some of the islands of Langerhans; he attributes absence of glycosuria to the great hypertrophy exhibited by those islands which have been uninjured. To what extent such hypertrophied islands of Langerhans are capable of vicariously assuming the function of those which have been destroyed, it is impossible to decide. Similar hypertrophy has been observed repeatedly in association with diabetes mellitus, and has been found with interacinar pancreatitis when neighboring islands have been the seat of sclerosis and hyaline degeneration (Fig. 47). (Pearce,

---

<sup>27</sup> *Loc. cit.*, p. 291.

<sup>28</sup> Ohlmacher: *American Jour. of the Med. Scien.*, 1904, cxxviii, 287.

Curtis and Gellé,<sup>29</sup> Herxheimer<sup>30</sup> and Müller.) In more than a third of ninety cases of diabetes Cecil found hypertrophy of the islands of Langerhans.

The interacinar islands which have undergone the enlargement just described preserve their usual structure (Fig. 47), but with a second type of hypertrophy which has been observed with diabetes mellitus the cells and their arrangement are altered (Fig. 48). Reitmann<sup>31</sup> described the pancreas of a man sixty-two years of age, whose urine had shown slight reduction when tested for sugar by Nylander's method; there was some increase of the interlobular connective tissue, and the ducts of the gland were acutely inflamed. The greater number of the islands of Langerhans were normal, but limited to the mid-part of the head of the pancreas, and often constituting the chief part of a lobule, were areas in which high cylindrical cells were arranged like those of the islands of Langerhans. The capillaries between these cell-columns were not so wide nor so numerous as those of the normal interacinar islands, and more closely resembled the capillaries about the acini. Ssobolew<sup>32</sup> has designated a similar change, "struma" of the islands of Langerhans. In the pancreas of a diabetic woman, aged fifty-five years, he found a body 1.5 mm. in diameter composed of cylindrical cells with centrally placed nuclei. Some smaller islands of Langerhans had similar character, whereas other interacinar islands were hyaline

---

<sup>29</sup> Curtis and Gellé: *Compt. rend. Soc. de biol.*, 1905, i, 942, 943.

<sup>30</sup> Herxheimer: *Verhandl. d. deutsche path. Gesell.*, 1905, ix, 263.

<sup>31</sup> *Loc. cit.*

<sup>32</sup> Ssobolew: *Virchow's Arch.*, 1904, Suppl. to clxxvii, 123.

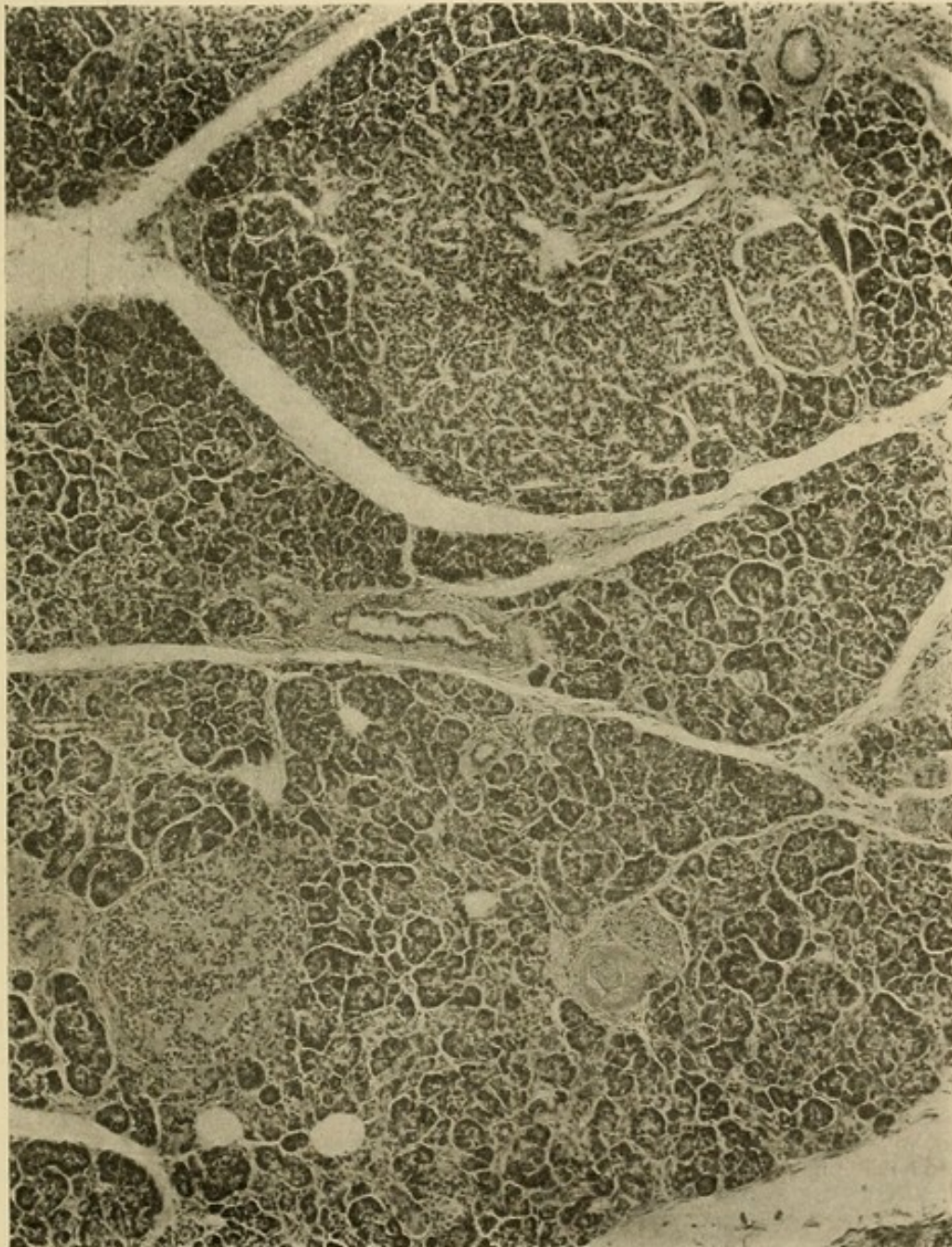


FIG. 47.—Hypertrophy of island of Langerhans (at top of figure) in association with hyaline degeneration of islands of Langerhans. Photograph by Dr. Leaming from Case XXXVII (diabetes mellitus) of Dr. Cecil.

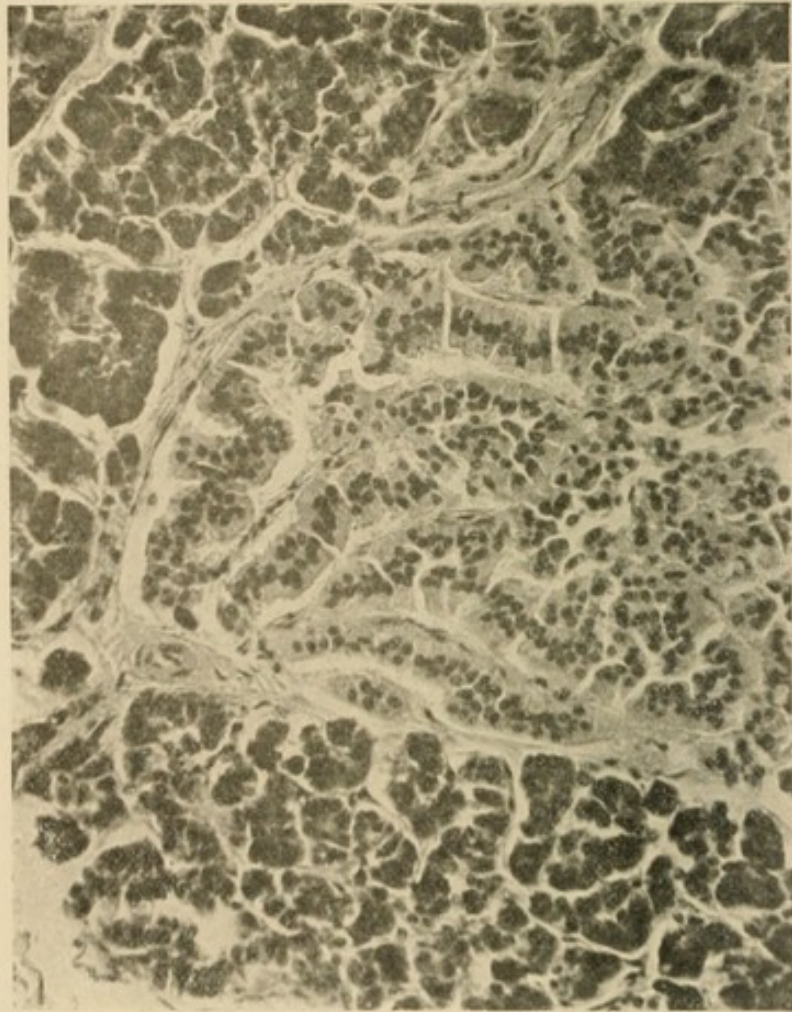


FIG. 48.—Adenoma-like hypertrophy of island of Langerhans showing cells which have assumed a columnar form, and nuclei situated in the mid-part of the cells. Photograph of Dr. Leaming from Case XXIX (diabetes mellitus) of Dr. Cecil.

and sclerotic; the interstitial tissue of the gland was increased.

In two cases of diabetes described by Karakascheff<sup>33</sup> cell-columns of enlarged islands of Langerhans were formed by cylindrical cells; such islands had no well-defined capsule and the cell-columns, it was believed, were continuous with neighboring acini. The condition occurred in individuals aged respectively sixteen and twenty-one years. Herxheimer<sup>34</sup> found the same change in two cases of diabetes, in both instances associated with interacinar pancreatitis, sclerosis, and hyaline degeneration of islands of Langerhans.

In the pancreas, from a diabetic boy ten years of age, MacCallum<sup>35</sup> found enlarged islands of Langerhan's which were not sharply outlined because the strands of cells which composed them were apparently continuous with adjacent acini. Such strands were composed of a single row of elongated cells with square ends; the nuclei, which were large and stained deeply, occupied the centre of the cell and hence formed a line along the middle of each column of cells. About the hypertrophied islands of Langerhans acini and the cells composing them were unusually large. In a second child with diabetes, a boy aged ten years, there were changes identical with those just described.

This peculiar change, which has been designated adenoma-like hypertrophy, has been present in seven of

---

<sup>33</sup> Karakascheff: *Deutsches Arch. f. klin. Med.*, 1905, lxxxii, 60; 1906, lxxxvii, 291.

<sup>34</sup> Herxheimer: *Loc. cit.*

<sup>35</sup> MacCallum: *American Jour. of the Med. Scien.*, 1907, cxxxiii, 432.

ninety diabetics examined by Cecil. In five instances in individuals aged from thirty-one to seventy-five years it has accompanied interacinar pancreatitis, but in two instances in individuals aged respectively twenty and thirty-one years the secreting parenchyma has been normal, though some of the islands of Langerhans have exhibited acute or chronic inflammatory changes. Weichselbaum<sup>36</sup> has repeatedly observed this condition of the islands of Langerhans with diabetes and believes that it represents regeneration of islands of Langerhans. He thinks that such regeneration occurs by development of solid cellular outgrowths from the ducts of the gland, for he has frequently found columns of high cylindrical cells grouped about a small duct, with which they are continuous.

It is not improbable that an adenoma-like type of hypertrophy occurs under conditions which are obscure, in response to an unusual demand upon the islands of Langerhans, and represents an attempt to overcome functional insufficiency of these bodies. This form of hypertrophy occurs in young individuals, and may be unassociated with inflammation of the parenchyma; in older individuals, it accompanies interacinar pancreatitis. The change has been found only in association with glycosuria.

*Experimental Study of the Relation of Islands of Langerhans to Diabetes.*—Experiments on animals have given confirmation to the view that islands of Langerhans control carbohydrate metabolism. It has long been

---

<sup>36</sup> Weichselbaum: Sitz. d. k. Akad. d. Wsch. Math.-nat. Kl., 1908. Ref., Cent. f. allg. Path. u. path. Anat., 1909, xx, 184.

known that ligation of the pancreatic ducts, and consequent chronic interstitial inflammation is not accompanied by diabetes; Schultze<sup>37</sup> has found that inflammatory atrophy of the pancreas, caused by a ligature tied tightly about the gland of guinea-pigs, spares the islands of Langerhans, which persist unaltered in the newly-formed stroma. Ssobolew<sup>37</sup> has studied the changes which follow ligation of the pancreatic ducts in rabbits. Fifteen days after operation secreting acini have disappeared in many lobules, but in a few lobules acini may be present at the end of thirty days. Islands of Langerhans remain almost wholly unaltered though surrounded by the newly-formed connective tissue which has replaced the acini. They persist at the end of four hundred days at a time when smaller ducts have disappeared and the chief pancreatic duct alone represents the secreting apparatus of the gland; nevertheless, there is no diabetes. Ssobolew found that some islands of Langerhans are compressed and destroyed by newly-formed stroma during the period from thirty to one hundred and twenty days after operation. Sauerbeck<sup>38</sup> has confirmed this observation, and in four animals examined within this period has found glycosuria and insular changes. Hypertrophy of islands of Langerhans, noted by Weichselbaum, may explain disappearance of glycosuria at a later period.

Ssobolew has found that islands of Langerhans of the dog persist when a part of the pancreas is transplanted into the abdominal wall; fifty days after operation lobules of the gland are atrophied, but islands of

---

<sup>37</sup> *Loc. cit.*, p. 217.

<sup>38</sup> *Loc. cit.*, p. 217.

Langerhans are well preserved. In an animal killed one hundred and thirty days after operation, the tissue which has remained has contained ducts and a small number of islands of Langerhans. MacCallum<sup>39</sup> has placed two ligatures about the pancreas of a dog and has separated this part from the remainder by a cut between the ligatures. Atrophy of the isolated part has followed and the unchanged part of the organ has been subsequently extirpated. Slight temporary glycosuria has followed this operation, but has quickly disappeared. Removal of the atrophied part has been followed by intense glycosuria persisting until the thyroid gland has been removed for extraneous reasons five days later; death has followed the operation. The atrophied pancreatic tissue has consisted of strands and masses of cells which MacCallum thinks are probably identical with those of the islands of Langerhans.

*Objections to the View that Lesions of the Islands of Langerhans Cause Diabetes Mellitus.*—Several writers have claimed that changes in the pancreas usually associated with diabetes mellitus are secondary to this disease. There is, however, little probability that the numerous lesions which have been found are the result of one cause. All such lesions destroy the islands of Langerhans, but the nature of the destructive change is subject to wide variation.

Hansemann,<sup>40</sup> Herxheimer<sup>41</sup> and Karakascheff<sup>42</sup> have found lesions of the islands of Langerhans with

---

<sup>39</sup> MacCallum: Bull. of the Johns Hopkins Hosp., 1909, xx, 265.

<sup>40</sup> Hansemann: Verhandl. d. deutschen path. Gesell., 1902, iv, 187.

<sup>41</sup> Herxheimer: Festschr. f. Orth., Berlin, 1903, p. 33.

<sup>42</sup> *Loc. cit.*

diabetes, but since they have failed to find such changes in all instances of the disease, maintain the belief that diabetes mellitus is referable to impairment of the entire pancreatic parenchyma. Nevertheless, diabetes mellitus does not occur when duct-obstruction has destroyed almost the entire secreting parenchyma, but has spared the islands of Langerhans, whereas diabetes occurs when the islands of Langerhans are destroyed by hyaline degeneration although the secreting parenchyma is intact.

Both Herxheimer and Karakascheff have modified the view which they first expressed. Herxheimer described fourteen cases of diabetes with interacinar pancreatitis, but in six instances found no changes in the islands of Langerhans. In a second article he cites five cases of interacinar pancreatitis with sclerosis and hyaline degeneration of the islands of Langerhans. Both acini and islands of Langerhans, he thinks, exert control upon carbohydrate metabolism, but interacinar islands which have no part in the production of external secretion have a predominant influence.

Histological findings suggesting transition from acini to islands of Langerhans have led Herxheimer to believe that islands of Langerhans may be formed from the secreting acini; such newly-formed acini, he thinks, may replace those which have been destroyed. The same appearances, on the contrary, have suggested to Karakascheff that islands of Langerhans form secreting acini, replacing acini which have undergone degeneration. Although the acini, he thinks, control carbohydrate metabolism, destruction of islands of Langerhans hastens onset of diabetes, for islands of Langerhans are constantly replacing acini which degenerate and disappear. The view is wholly speculative.

A few observers have claimed that severe lesions of the islands of Langerhans may be unaccompanied by diabetes. Ohlmacher has found advanced hyaline degeneration with no glycosuria, but thinks that vicarious hypertrophy of those islands which have not been de-

stroyed explains the absence of diabetes. Trivial lesions without diabetes have been described by Sauerbeck. Hansemann, who does not believe that islands of Langerhans control carbohydrate metabolism, admits that he has never found in the absence of diabetes mellitus lesions of the islands of Langerhans similar to those which occur in association with the disease.

Reitmann prefaces his description of amyloid degeneration of the islands of Langerhans with the statement that he has searched the literature of the subject in vain for an instance in which advanced lesions of the islands of Langerhans have been unaccompanied by glycosuria. In two cases death occurred as the result of uncomplicated pulmonary tuberculosis; the greater number of the islands of Langerhans were the seat of amyloid degeneration; amyloid substance was deposited about the capillaries and the cells were destroyed or much reduced in size. The secreting parenchyma was entirely normal.

The well-known observation that glycosuria of diabetes may disappear as the result of various intercurrent infections, and of cachexia, may explain its absence in association with amyloid degeneration of the islands of Langerhans. Minkowski found that glycosuria produced by extirpation of the pancreas of dogs may disappear before death when emaciation is advanced, and may cease with the onset of complications such as suppurative peritonitis. Naunyn<sup>43</sup> has given special attention to the complications of diabetes which inhibit glycosuria; one of the most frequent of these complications is tuberculosis.

---

<sup>43</sup> Naunyn: *Der Diabetes mellitus*. Nothnagel's *Spec. Path. u. Ther.*, Vienna, 1898, vii, part vi.

Disappearance of glycosuria occurs when the patient becomes cachectic, and has been observed even when cachexia has been the result of uncomplicated diabetes. In two cases cited by Naunyn diabetes had existed at least five years, yet the onset of cachexia, accompanying tuberculosis in one instance and nephritis in the other, was followed by disappearance of glycosuria, which failed to reappear even when glucose was administered with the food.

In some instances in which pancreatic lesions have been found at autopsy, urinary examination has been limited to the period preceding death. In such cases diabetes may have existed before onset of cachexia, although urinary tests fail to record its presence. With amyloid degeneration islands of Langerhans are injured by a lesion which is always associated with advanced cachexia.

*Relationship of Diabetes Mellitus to Organs other than the Pancreas.*—Most writers agree that cases occur in which no abnormality of the pancreas is demonstrable. Case V (page 339), in which the normal pancreas of a child ten years old weighed 45 Gm., may serve as an example. Careful investigation of the histology of the pancreas has materially diminished the frequency with which normal pancreas has been found in association with diabetes mellitus. The statistics of Windle record the occurrence of a normal pancreas in 47 per cent. of one hundred and thirty-nine cases of diabetes, whereas among cases collected on page 321 only 11.8 per cent. are without lesion or abnormality of the gland, trivial lesions which are usually unaccompanied by diabetes being excluded. Among ninety cases of diabetes examined

by Cecil an even smaller proportion—namely, 6.6 per cent.—exhibited no abnormality of the pancreas. The existence of such cases does not weaken the evidence in favor of the pancreatic origin of the disease in other instances, for abundant experimentation has demonstrated the complexity of carbohydrate metabolism and has shown that the central nervous system and the liver exert an important influence in regulating the amount of sugar in the blood, while removal of an excess present in the blood is effected by the kidneys.

The experimental observations upon temporary glycosuria caused by changes in the central nervous system, the liver, and the kidneys, have been followed by the study of cases in which glycosuria, or not infrequently permanent diabetes, has been associated with lesions of these organs in human cases; but while the relationship of the pancreas to diabetes has been very thoroughly established both by experimentation and observation, the relationship of lesions affecting other organs is much more obscure. Moreover, diabetes has been found to accompany certain relatively uncommon diseases—for example, exophthalmic goitre and acromegaly—with such frequency that the association can not be regarded as accidental. In some instances in which diabetes has been supposed to be the obscure result of a condition recognizable during life, it is in reality secondary to a lesion of the pancreas the existence of which is not recognizable unless an autopsy is performed.

Arterial sclerosis, it is well known, is present in a large proportion of diabetics, and diabetic gangrene is referable, in many cases at least, to implication of the

arteries supplying the extremities. Grube<sup>44</sup> found arterial sclerosis in sixty-six of one hundred and seventy-seven cases of diabetes. G. Hoppe-Seyler<sup>45</sup> and also Fleiner<sup>45</sup> have described cases of diabetes in which chronic interstitial inflammation of the pancreas accompanied general arterial sclerosis. Case XX of my series illustrates this condition; here both chronic interacinar pancreatitis and gangrene of the leg appear to be the result of advanced arterial sclerosis.

Hoppe-Seyler<sup>46</sup> studied a series of cases in which interacinar pancreatitis, occurring in association with advanced arterial sclerosis, caused diabetes mellitus (seven cases) or alimentary glycosuria (two cases). In nine cases chronic inflammation of the pancreas was unaccompanied by glycosuria, and changes in the islands of Langerhans were absent or trivial, whereas among those cases in which glycosuria was present there was a close parallel between the severity of diabetes and the intensity of the changes in the islands of Langerhans. Hoppe-Seyler further studied the ability of individuals with arterial sclerosis to assimilate glucose and found alimentary glycosuria in twenty-six (42 per cent.) of sixty-two cases, the condition being most frequent when arterial sclerosis was associated with acute alcoholism.

Increased attention has recently been given to the condition of the arteries in association with diabetes, for whereas among one hundred and seventy-six cases collected by Sauerbeck arterial sclerosis has been recorded twelve times, among one hundred and twelve cases since recorded general arterial sclerosis together with sclerosis of the pan-

---

<sup>44</sup> Grube: *Zeit. f. klin. Med.*, 1895, xxvii, 465.

<sup>45</sup> *Loc. cit.*, Chap. IX.

<sup>46</sup> Hoppe-Seyler, G.: *Deutsches Arch. f. klin. Med.*, 1904, lxxxi, 119.

creatic arteries has been noted in thirty-two instances; sclerosis of the arteries of the pancreas alone in six.

Cecil has found sclerosis of the pancreatic arteries in 80 per cent. of ninety cases of diabetes; the walls of the small arteries are thickened, and in many instances have undergone hyaline degeneration. The incidence of arterial sclerosis has increased rapidly with age, occurring in 40 per cent. of diabetics between twenty and thirty years of age, in 75 per cent. between thirty and forty, and in all but two instances after the fortieth year. It is noteworthy that arterial sclerosis has been present in all save five of forty-nine instances in which the islands of Langerhans have exhibited sclerosis, and in all save two of twenty-seven instances in which these islands have been hyaline. When arterial sclerosis causes chronic interacinar pancreatitis, the islands of Langerhans are implicated and diabetes mellitus results.

There is abundant evidence that *diabetes accompanying cirrhosis of the liver* is, in the majority of cases at least, the result of chronic interstitial pancreatitis; chronic inflammation of the liver and pancreas coexist as the result of the same primary etiological factor—for example, alcohol. Diabetes with cirrhosis is a well recognized condition, and numerous cases are recorded; among one hundred and twenty-eight cases of diabetes observed in hospital clinics by Naunyn, seven were accompanied by cirrhosis, but in his private practice, among one hundred and fifty-eight cases, twenty-two were with cirrhosis. I have studied three cases in which the two conditions were associated, and in all the pancreas was the seat of chronic interacinar inflammation invading the islands of Langerhans. In cases of diabetes accompanying cirrhosis, described with autopsy report by Dieckhoff and by Pusinelli,<sup>47</sup> the pancreas showed chronic inflammatory

---

<sup>47</sup> Pusinelli: Berliner klin. Woch., 1896, xxxiii, 739.

changes. Seven cases with cirrhosis of the liver and interacinar pancreatitis occurred among ninety cases of diabetes studied by Cecil.

The relationship of cirrhosis of the liver to chronic interstitial pancreatitis has already been discussed. The condition known as hæmochromatosis offers an excellent illustration of the dependence of cirrhosis of the liver and chronic pancreatitis upon the same etiological factors; in this condition diabetes occurs as a terminal event, when the pancreatic inflammation which is of the interacinar type has reached a moderate grade of severity. It is probable that the alimentary glycosuria inconstantly observed with cirrhosis of the liver by Colrat,<sup>48</sup> Couturier,<sup>49</sup> Kraus and Ludwig,<sup>50</sup> and others, may be the result of slight coexisting alterations of the pancreas.

The influence of the nervous system upon the excretion of sugar is shown by Claude Bernard's puncture of the floor of the fourth ventricle and by other experimental injuries to the central nervous system. The statistics of Higgins and Ogden<sup>51</sup> show that glycosuria frequently follows injuries to the brain; they found glycosuria in 9.3 per cent. of two hundred and twelve cases of traumatism affecting the head, while of forty-five cases in which the skull was fractured glycosuria followed in 21.9 per cent. Instances of permanent *diabetes following cerebral lesions* are recorded, but the relationship of the disease to the injury is doubtful. Diabetes is occasionally

---

<sup>48</sup> Colrat: Lyons méd., 1875, xviii, 553.

<sup>49</sup> Couturier: Thesis, Paris, 1875.

<sup>50</sup> Kraus and Ludwig: Wiener klin. Woch., 1891, iv, 855, 897.

<sup>51</sup> Higgins and Ogden: Boston Med. and Surg. Jour., 1895, cxxxii, 197.

associated with tabes dorsalis or with multiple sclerosis and has been regarded as secondary to the nervous lesions.

Of greater interest, in view of the experiments of Claude Bernard, is the recorded association of lesions of the medulla with diabetes. In cases of multiple sclerosis described by Weichselbaum<sup>52</sup> and by Richardiere<sup>53</sup> plaques occupied the floor of the fourth ventricle. Remarkable instances in which small tumors have encroached upon the floor of the fourth ventricle are recorded by Levrat-Perroton,<sup>54</sup> Von Recklinghausen,<sup>55</sup> and Verron.<sup>56</sup> In a case recorded by Michael a cysticercus occupied the fourth ventricle. It is not impossible that such conditions may act as exciting causes in the production of diabetes.

Glycosuria following the administration of phlorhizin has already been mentioned. Since most observers are agreed that with this form of glycosuria the amount of sugar in the blood is not increased, the possibility has suggested itself that the kidneys are so altered that they admit the passage of the sugar normally present in the blood. The occurrence of an analogous *renal diabetes* in human beings has been suspected. Klemperer<sup>57</sup> has described a case of diabetes associated with nephritis. The amount of sugar in the blood was not greater than normal, and after the administration of 150 Gm. of glu-

---

<sup>52</sup> Weichselbaum: Wiener med. Woch., 1881, xxxi, 913.

<sup>53</sup> Richardiere: Rev. de méd., 1886.

<sup>54</sup> Levrat-Perroton: Thesis, Paris, 1859.

<sup>55</sup> Von Recklinghausen: Virchow's Arch., 1864, xxx, 360.

<sup>56</sup> Verron: Thesis, Paris, 1878.

<sup>57</sup> Klemperer: Berliner klin. Woch., 1896, xxxiii, 571.

case the amount of sugar in the urine and in the blood was not increased. Cases in which pre-existing nephritis has been associated with diabetes are cited by Naunyn, and by Eger,<sup>58</sup> but since they may be referable to the more or less accidental coexistence of the two conditions, they do not furnish strong evidence that glycosuria is dependent upon the renal lesion.

Richter<sup>59</sup> has studied experimentally the relationship of glycosuria to lesions of the kidney. Small doses of corrosive sublimate injected into the venous circulation of rabbits cause not only albuminuria, but glycosuria as well. Very small doses may cause glycosuria, but no albuminuria; and since the amount of sugar in the blood is found to be increased, Richter does not think that the glycosuria should be attributed to alterations of the kidneys. Glycosuria produced by phlorhizin is, moreover, diminished or prevented if a lesion of the kidney is produced by the administration of aloin or potassium chromate. Elbinger and Selig<sup>60</sup> rendered dogs diabetic and then administered cantharidin in order to injure the kidneys. They found that glycosuria diminished with the onset of renal changes. Lesions of the kidney in animals appear to retard rather than favor the excretion of sugar, and it has been observed that glycosuria in cases of diabetes not infrequently diminishes with the appearance of albuminuria. True renal diabetes may occur, perhaps as the result of some peculiar injury to the kidney, but its existence has not been demonstrated.

The association of diabetes with diseases of certain ductless glands has considerable interest. *Exophthalmic goitre with diabetes* not infrequently occurs; and Hanne-  
mann,<sup>61</sup> who has made a careful survey of the literature,

---

<sup>58</sup> Eger: Deutsche med. Woch., 1899, xxv, 844.

<sup>59</sup> Richter: Zeit. f. klin. Med., 1900, xli, 160.

<sup>60</sup> Elbinger and Selig: Verhandl. d. 19 Cong. f. innere Med., 1901, 416.

<sup>61</sup> Hanne-  
mann: Inaug. Diss., Berlin, 1895.

has been able to collect fifteen cases in which the two diseases have been associated; at least a dozen writers have observed temporary glycosuria with exophthalmic goitre. Alimentary glycosuria with exophthalmic goitre was first observed by Kraus and Ludwig; later Chvostek<sup>62</sup> reached the conclusion that it occurs in 69 per cent. of all cases, but Strauss<sup>63</sup> observed glycosuria after the administration of 100 Gm. of grape sugar in only three of nineteen cases. Glycosuria following the therapeutic use of thyroid extract has been observed.

Eppinger, Falta and Rudinger<sup>64</sup> have claimed that the thyroid gland inhibits the action of the pancreas; glycosuria, which may occur with exophthalmic goitre is referable, they suggest, to abnormal activity of the thyroid gland. The occurrence of pancreatic lesion in association with combined exophthalmic goitre and diabetes renders this hypothesis unnecessary.

The following case of exophthalmic goitre has been described by Dr. Morris Manges<sup>65</sup> and is included in the series of cases studied by Cecil.

A woman aged forty years has suffered with diabetes during six months. The urine contains as much as 5 per cent. of sugar. There is exophthalmos and tachycardia. The thyroid is enlarged and firm and exhibits glandular hyperplasia. The pancreas is small and weighs 45 Gm.; there is chronic interacinar pancreatitis. The acini are small and in places separated, in places wholly replaced by fibrous tissue, infiltrated with lymphoid and plasma cells. Islands of Langerhans are

---

<sup>62</sup> Chvostek: Wiener klin. Woch., 1892, v, 251, 267, 325.

<sup>63</sup> Strauss: Deutsche med. Woch., 1897, xxiii, 275.

<sup>64</sup> *Loc. cit.*, Chap. V.

<sup>65</sup> Manges, M.: Mt. Sinai Hosp. Rep., 1901, ii, 59.

fairly numerous, but small; where sclerosis is advanced they are surrounded and invaded by fibrous stroma, many being almost wholly destroyed.

The close relation between exophthalmic goitre and myxœdema gives special significance to the following case (recorded by Cecil), in which associated myxœdema and diabetes mellitus accompanied chronic inflammation of the thyroid gland and pancreas.

A woman, seventy-four years of age, was admitted to the Presbyterian Hospital with gradual loss of mental power and thickening of the subcutaneous tissue; the skin was dry and scaly; the hair and nails were brittle, and the tongue was thickened. There was no sugar in the urine. Rapid improvement followed treatment with thyroid extract. A year and a half later the patient was again admitted with thirst, polyuria and glycosuria, the urine containing 4 per cent. of sugar. Myxœdema was much improved. Two years later death occurred with coma. The thyroid gland weighs 8.5 Gm.; alveoli are almost completely destroyed by fibrous tissue. The pancreas is tough and weighs 120 Gm. There is advanced interacinar pancreatitis and lipomatosis. The islands of Langerhans show considerable sclerosis.

It is not improbable that chronic inflammatory changes in thyroid and pancreas are referable to the same cause. Stern<sup>66</sup> cites two cases in which diabetes has preceded exophthalmic goitre, five cases in which the two diseases have appeared simultaneously, and fourteen cases in which diabetes has occurred in individuals who have been suffering with exophthalmic goitre.

Added interest is attached to the remarkable association of *acromegaly with diabetes* by the fact that the former disease is not infrequently accompanied by indu-

---

<sup>66</sup> Stern: Jour. of the American Med. Assn., 1902, xxxix, 972.

ration of the interstitial tissue of the pancreas. Hansemann<sup>67</sup> found diabetes present in twelve of ninety-seven reported cases of acromegaly, a case of his own included. Among one hundred and seventy-six cases of acromegaly collected by Borchardt<sup>68</sup> diabetes occurred in sixty-three (35.5 per cent.); in eight cases there was alimentary glycosuria.

A review of cases described with autopsy reports shows that chronic pancreatitis has been repeatedly observed in association with acromegaly. Dallemange<sup>69</sup> found chronic interstitial inflammation of the gland in two cases of acromegaly, one of which was associated with diabetes. In a case of acromegaly with diabetes described by Hansemann chronic pancreatitis was present. In a case with glycosuria, recorded by Fränkel, Stadelmann, and Benda,<sup>70</sup> the pancreas showed a condition described as nodular hypertrophy, while in a second with diabetes no lesion was noted, but here no microscopic examination was made. In one case of acromegaly without diabetes, described by the writers just named, and in a similar case described by Mitchell and Le Count,<sup>71</sup> chronic inflammation of the pancreas was demonstrable. Pineles<sup>72</sup> found at autopsy upon a case of acromegaly with persistent diabetes purulent pancreatitis with fat

---

<sup>67</sup> Hansemann: *Berliner klin. Woch.*, 1897, xxxiv, 417.

<sup>68</sup> Borchardt: *Zeit. f. klin. Med.*, 1908, lxvi, 332.

<sup>69</sup> Dallemange: *Arch. de méd. exper. et d'anat. path.*, 1895, vii, 589.

<sup>70</sup> Fränkel, Stadelmann and Benda: *Deutsche med. Woch.*, 1901, xxvii, 513, 564.

<sup>71</sup> Mitchell and Le Count: *New York Med. Jour.*, 1899, lxix, 517, 566, 595.

<sup>72</sup> Pineles: *Jahrb. d. Wiener k. k. Krankenanst., Jahrg.*, 1895, Vienna, 1897.

necrosis, but the presence of pre-existing chronic inflammation can only be suspected.

The following case of acromegaly has been described by Dr. Charles Norris:<sup>73</sup>

A man, thirty-three years old, had suffered with headache and vertigo; there was loss of vision, with atrophy of the optic nerves; the jaw, nose, hands and feet had undergone progressive enlargement. Glycosuria had been present during twenty-two months.

The site of the pituitary gland is occupied by a large adenomatous tumor. The pancreas weighs 170 Gm. There is no increase of the interstitial tissue of the pancreas<sup>74</sup> and the glandular acini are normal. Islands of Langerhans are numerous, and many are normal. Some of these bodies are enlarged, one measuring 600 micromillimetres in diameter, and their cells were columnar; they exhibit the adenoma-like hypertrophy previously described. The capillaries of such interacinar islands were thickened by newly-formed fibrous tissue. In a few islands of Langerhans there is advanced hyaline degeneration.

The cases cited indicate that diabetes mellitus accompanying acromegaly is referable to a pancreatic lesion.

Production of glycosuria by injection of extracts of adrenal gland into animals has suggested the *possible association of diabetes mellitus and disease of the adrenal glands*. Lepine<sup>75</sup> has described a case in which with diabetes there has been tumor of the adrenal; this tumor is described as sarcoma, but has perhaps been an hypernephroma.<sup>76</sup> Lepine has collected from the literature

<sup>73</sup> Norris: Trans. of the New York Path. Soc., 1907, vii, 19.

<sup>74</sup> With the permission of Dr. Norris this case has been included in the series of Dr. Cecil.

<sup>75</sup> Lepine: Rev. de méd., 1906, xxvi, 537.

<sup>76</sup> See Meakins: A Malignant Adenoma of the Adrenal with Transformation into Sarcomatous Tissue. Med. and Surg. Rep. of the Presbyterian Hosp. of New York, 1908, viii, 271.

of the subject three instances of diabetes occurring in individuals with lesions of the adrenal, in one instance a tumor. He believes that the evidence which is available is insufficient to establish the occurrence of diabetes mellitus referable to a lesion of the adrenal glands.

*Diagnosis of Pancreatic Diabetes.*—The occurrence of glycosuria and diabetes in association with lesions of the nervous system, and after the administration of many toxic substances, indicates the complexity of carbohydrate metabolism. Normal assimilation of sugar doubtless depends upon a variety of factors, among which integrity of the pancreas, though very important, does not stand alone, and disturbances of carbohydrate metabolism may be the result of conditions affecting other organs. Hence the occurrence of diabetes unaccompanied by alterations of the pancreas does not furnish evidence to disprove the relationship of the disease to lesions of the gland. Nevertheless the occurrence of pancreatic diabetes is much more frequent than has been supposed. Moreover, the foregoing discussion has shown that in many instances, at least, diabetes, associated with such conditions as arterial sclerosis, cirrhosis of the liver, hæmochromatosis, exophthalmic goitre and acromegaly, is secondary to a lesion of the pancreas accompanying these diseases. Arterial sclerosis produces chronic interstitial inflammation of the pancreas, whereas cirrhosis of the liver accompanies chronic pancreatitis, because both are the result of the same etiological factor. The relationship of the nervous system of the kidneys, and of the adrenal glands to diabetes is more obscure.

The attempt has been unsuccessfully made to define certain clinical symptoms characteristic of diabetes when

due to lesions of the pancreas. Lancereaux, notably, has described a special type of diabetes referable to pancreatic disease and characterized by extreme emaciation, in company with intense thirst, voracious appetite, and abundant polyuria. He designates the condition "diabète maigre," and distinguishes it from diabetes with obesity, "diabète gras," unaccompanied by pancreatic disease. His views have received some acceptance, but few clinicians maintain that it is possible to recognize the sharp distinction claimed by him. Many writers, Lepine, Hansemann, Williamson, among others, have on the one hand cited cases in which emaciation was absent, though diabetes accompanied pancreatic disease; while on the other hand, in emaciated patients suffering with diabetes, they have discovered no alteration of the pancreas. Removal of the gland in animals is followed by diabetes with rapid emaciation, absence of pancreatic secretion being followed by grave disturbances of digestion and absorption. In human cases, however, diabetes may be caused by lesions of the gland which destroy the islands of Langerhans, yet leave almost intact the secreting parenchyma.

Study of the pathology of the pancreas has made it possible to define with accuracy the conditions under which glycosuria occurs as a symptom of pancreatic disease. The presence of diabetes mellitus is not conclusive evidence that there is a lesion of the interacinar islands; nevertheless, in only 13 per cent. of cases is diabetes unaccompanied by disease of these bodies. It is noteworthy that diabetes with normal pancreas occurs almost exclusively during the early period of life. Among two hundred and eighty-eight cases of diabetes previously cited

age of the patient has been recorded in one hundred and forty-four, and among ninety cases of Cecil age has been recorded in eighty-eight. The incidence of normal and diseased pancreas in these two hundred and thirty-two cases of diabetes has been as follows:

Age in years	0		10		20		30		40		50		60		70		80	
	to	9	to	19	to	29	to	39	to	49	to	59	to	69	to	79	to	89
With normal pancreas.....	2	10	10	6	2	1	0	1	1									
With lesion of the pancreas...	1	7	24	30	30	48	37	21	1									
Total .....	3	17	34	36	32	49	37	22	2									

During the second decade of life, when diabetes mellitus is relatively uncommon, a majority of cases exhibit no pancreatic lesion; such cases are fairly numerous in the third decade, but at a later period are infrequent. Diabetes occurring during middle life and later is with few exceptions referable to a pancreatic lesion. Lithiasis and carcinoma, like the same changes in other organs, usually occur after the fortieth year, whereas various types of pancreatic inflammation have the age incidence common to cirrhosis of the liver, chronic nephritis, and chronic inflammatory changes in other organs. Interacinar pancreatitis has occurred in one hundred and thirty-one of two hundred and thirty-two cases classified by age in the table; the lesion is uncommon in early life, but after the fortieth year accompanies two-thirds of all cases of diabetes. The frequency of this change in later life is in part dependent upon its association with arterial sclerosis.

Study of the histological changes which occur with diabetes define the relationship of glycosuria to steatorrhœa, azotorrhœa and other evidence of insufficiency of

pancreatic juice in the intestine. Since islands of Langerhans may be destroyed, although the secreting acini are almost wholly unaffected, diabetes may occur without digestive symptoms; most cases of pancreatic diabetes belong to this group. Hemorrhagic necrosis, suppurative pancreatitis, diffuse carcinoma, destroy both elements of the gland and diabetes mellitus follows only in the relatively infrequent instances in which almost the entire organ is destroyed.

Obstruction to the outflow of pancreatic secretion does not cause glycosuria, and the interlobular pancreatitis which follows occlusion of the pancreatic ducts is accompanied by diabetes only when the lesion has reached the advanced stage in which islands of Langerhans are injured. With calculi, cyst, or new growth compressing the duct there may be fatty stools but no glycosuria; among twenty-nine instances of pancreatic disease with steatorrhœa Fitz<sup>77</sup> found diabetes in only eleven.

Application of chemical methods to examination of the fæces, on the one hand, would doubtless demonstrate with greater frequency the existence of disturbed pancreatic digestion in those cases in which with lesions of the secreting apparatus of the glands glycosuria is absent. Determination of the power to assimilate glucose, on the other hand, would not infrequently reveal minor changes in the gland.

Wille<sup>78</sup> has observed alimentary glycosuria in association with lesions of the pancreas, and thinks that this symptom may be regarded as an index to the presence of pancreatic disease. The ability to assimi-

---

<sup>77</sup> *Loc. cit.*, p. 90.

<sup>78</sup> Wille: *Deutsches Arch. f. klin. Med.*, 1899, lxxiii, 546.

late sugar was tested in eight hundred patients suffering with a great variety of diseases. In the morning, before other food had been taken, was administered from 70 to 100 Gm. of grape sugar dissolved in a half litre of tea or coffee. The urine was voided just before the sugar was taken and was then tested at intervals of two hours; when the test was positive, sugar usually appeared at the end of two hours. Of eight hundred individuals upon whom this test was made, seventy-seven subsequently died and autopsies were performed. Alimentary glycosuria had been found in fifteen of those who came to autopsy, and in ten of these were present grave lesions of the pancreas, chronic interstitial inflammation, or carcinoma of the gland, either primary or secondary to tumors in the stomach, liver, or gall-bladder.

Although alimentary glycosuria may occur in the absence of pancreatic disease and is not infrequently associated with a variety of conditions, notably hysteria and other neuroses, its presence suggests (Wille, Hoppe-Seyler<sup>79</sup>) the existence of pancreatic lesion and has considerable value for diagnosis.

---

<sup>79</sup> *Loc. cit.*, p. 235.

## CHAPTER XVI.

### HÆMOCHROMATOSIS AND BRONZED DIABETES.

THE relationship between diabetes and lesions of the pancreas is well illustrated by the disease known as hæmochromatosis, a disturbance of the metabolism of iron, which, though infrequent, has excited much interest on account of its remarkable character and obscure pathogenesis. Its identity with “diabète bronzé”—or the diabetes with pigmentation and cirrhosis, of French writers—is now recognizable.

Under the designation “hæmochromatosis” Von Recklinghausen<sup>1</sup> (1889) has described a condition of pigmentation affecting various organs. Brown pigment, which he has thought is derived from the hæmoglobin of the blood, is deposited within certain tissues and gives to them macroscopic pigmentation.

The anatomical character of this generalized pigmentation is clearly defined by Von Recklinghausen. Most of the glands of the body assume a deep brown color, and within their secreting cells are found reddish-yellow or ochre-colored granules. Microchemical reactions prove that this pigment contains iron. In the liver pigment is present in the parenchymatous cells and in Kùpffer's cells. A second kind of pigment, distinguishable from the first by its finer granules of pure yellow color, is found in the smooth muscle cells of the stomach and

---

<sup>1</sup> Von Recklinghausen: *Tagebl. d. 62 Versamml. deutsch. Naturforscher u. Aerzte in Heidelberg*, 1889, 324.

intestines, of the blood- and lymph-vessels, rarely in the muscle of the urinary bladder, ureters, and vas deferens. It also exists in the connective-tissue cells of certain localities—for example, Glisson's capsule, the splenic trabeculæ, and the sheaths of blood-vessels. This second pigment does not give the reactions characteristic of iron. Von Recklinghausen calls the iron-containing pigment "hæmosiderin," the iron-free pigment "hæmofuscin." The use of these names does not imply that we have means of identifying the substances as definite chemical compounds. Von Recklinghausen thinks that hæmofuscin, as well as the iron-containing hæmosiderin, is derived from hæmoglobin. In his cases of generalized pigmentation there was an associated cirrhosis of the liver.

Von Recklinghausen studied twelve cases which he regarded as examples of local and general hæmochromatosis. He defined hæmochromatosis as a condition of pathological pigmentation due to the deposition of pigment derived from the blood.

There is, however, a local condition which has been identified with hæmochromatosis by several observers; pigmentation of the intestine caused by deposition of fine yellow granules in the smooth muscle cells has been carefully studied by Goebel<sup>2</sup> and others. In adults moderate pigmentation is almost constant, and the amount of pigment increases with age. With wasting diseases—for example, tuberculosis and carcinoma—there may be an accumulation equal to that present in advanced age. In sixteen of one hundred bodies studied by Goebel the

---

<sup>2</sup> Goebel: Virchow's Arch., 1894, cxxxvi, 482.

pigment deposit was of sufficient magnitude to cause macroscopic discoloration, characterized by him as rust brown. This accumulation of pigment within the smooth muscle cells of the intestine is apparently an accentuation of a physiological process much more closely related to brown atrophy of the heart than to hæmochromatosis.

Von Recklinghausen's description defines a condition presenting no close similarity to any form of local pigmentation with which we are familiar. The important features of this description are: (1) The presence in the epithelial cells of various glands, notably the liver and pancreas, of an iron-containing pigment. (2) The presence of an iron-free pigment in smooth muscle cells of the gastro-intestinal tract, and of the blood- and lymph-vessels, and in certain cells of connective tissue. (3) The association of cirrhosis of the liver with pigmentation. To this condition, apparently a distinct pathological entity, the term hæmochromatosis should be limited.

Prior to Von Recklinghausen's publication several observers had studied instances of wide-spread pigmentation. Quincke<sup>3</sup> in 1877 observed with anæmia a deposition of iron in various organs, notably in the liver and spleen, and in one instance found macroscopic pigmentation of the liver and pancreas. Tillmanns<sup>4</sup> described brown pigmentation of the liver, of the abdominal lymphatic glands, and in less degree of the spleen and pancreas, in a man who had sustained a fracture of the pelvis two months before death and, the observer thought, a contusion of the liver. Hindenlang<sup>5</sup> observed in association with morbus maculosus Werlhofii pigmentation of the glands of the

---

<sup>3</sup>Quincke: Festsch. dem Andenken Albrechts von Haller gewidmet. Bern, 1877, 37.

<sup>4</sup>Tillmanns: Arch. d. Heilk., 1878, xix, 119.

<sup>5</sup>Hindenlang: Virchow's Arch., 1880, lxxix, 492.

body, particularly the liver, which was slightly cirrhotic, and the pancreas, and in these organs found a pigment corresponding to that which Von Recklinghausen subsequently described as hæmosiderin.

Hintze<sup>6</sup> has described six cases which he regards as examples of hæmochromatosis, but only three agree in detail with the description which Von Recklinghausen has given. Buss<sup>7</sup> has described a typical case of hæmochromatosis associated with cirrhosis of the liver and diabetes mellitus. Letulle<sup>8</sup> records two cases and Richardiere<sup>9</sup> one in which with hypertrophic cirrhosis there was pigmentation of the liver, pancreas, and other organs. In these cases pigmentation of the skin was apparently absent. Osler<sup>10</sup> has recognized hæmochromatosis during life and has confirmed the diagnosis by demonstration of iron-containing pigment in a bit of the bronzed skin.

The following case, which occurred in the practice of Dr. Thomas Opie, is an example of the disease:

CASE XXXV.—The patient, male, white, aged fifty-five years, though never very robust, had enjoyed fairly good health. There was no history of alcoholic excess. For several months he had resided in Porto Rico, and until six or seven weeks before his death was able to continue his work of surveying. The onset of his fatal illness occurred with symptoms of typhoid fever. When first seen, two weeks later, he was evidently very ill. There was elevation of temperature and rose-spots were present upon the abdomen. Deep pigmentation of the skin attracted immediate attention and marked universal bronzing suggested Addison's disease. Jaundice was not present. The urine at no time during the period of observation contained sugar; the first examination was made four weeks before death. Three days before death the urine was clear, of deep amber color, and contained neither sugar nor albumin.

---

<sup>6</sup> Hintze: Virchow's Arch., 1895, cxxxix, 459.

<sup>7</sup> Buss: Inaug. Diss., Göttingen, 1894.

<sup>8</sup> Letulle: Bull. et mém Soc. méd. d'hôp. de Paris, 1897, 3 s., xiv, 205.

<sup>9</sup> Richardiere: Union méd., 1895, 3 s., lix, 73.

<sup>10</sup> Osler: British Med. Jour., 1899, ii, 1595.

The blood-serum caused the agglutination of the typhoid bacillus. Death occurred with increasing weakness.

*Autopsy.*—The body is that of a very thin, sparely-built man. The skin over the entire body is deeply pigmented and has a bronzed metallic hue, most marked upon the back of the hands, about the nipples, and upon the penis, where just above the corona the skin is dark brown in color. The parietal peritoneum, as well as that of the intestines, shows a varying degree of bluish discoloration.

The muscle of the heart is yellowish brown, soft, and flabby. Below the surface of the right lung are several small areas of firm consolidation; the bronchi are intensely injected.

The liver weighs 2270 Gm. The surface has a peculiar deep reddish-brown color, resembling that of iron-rust. The surface of the left lobe, and in less degree that of the right is superficially nodular and puckered. On section islands of lighter brown parenchyma, representing one or several lobules, are surrounded by fibrous stroma of a deeper brown color. Sparsely scattered are opaque, yellowish-white areas, often 1.5 mm. across.

The spleen, weighing 700 Gm., is soft; the pulp is almost diffuent and has a deep red color. The mucous membrane of the stomach shows a deep greenish-black discoloration; along the lesser curvature there are a few areas of relatively normal yellowish-white appearance, but elsewhere the pigmentation is uniform. The duodenum has a greenish-black color almost equal in intensity to that of the stomach. The jejunum is less markedly pigmented than the duodenum, while the ileum is of even lighter greenish-gray tint. Throughout the lower part of the ileum, usually upon the Peyer's patches, are small round or slightly irregular ulcers with sharp edges and clean base, occasionally exposing the circular muscle-coat. The colon exhibits moderate greenish-gray discoloration.

The pancreas weighs 170 Gm. The organ is large, and very firm in consistence. The cut surface has a uniform deep chocolate-brown color. The capsule contains much fat, and extending inward from it are septa of adipose and fibrous tissue.

The cortex of the kidneys is red and has a cloudy appearance. On section the testicles have a light brown tint. In the retroperitoneal

tissue near the hepatic vein, behind the stomach, above and below the pancreas, and on either side of the aorta, are enlarged, moderately firm lymphatic glands. On section they exhibit a uniform, brilliant orange-yellow color. In the gastrohepatic omentum are enlarged glands of a similar nature.

*Anatomical Diagnosis.*—Typhoid fever; ulcers in the ileum; acute splenic tumor; cloudy degeneration of the kidneys; bronchopneumonia. Hæmochromatosis; pigmentation of the liver, pancreas, heart, stomach, intestine, peritoneum, lymphatic glands, skin, and testicles; cirrhosis of the liver; chronic interstitial pancreatitis.

*Histological Examination.*—The organs which show the most marked pigmentation are the liver, pancreas, heart, and gastro-intestinal canal.

There is advanced cirrhosis of the liver; wide bands of fibrous tissue occupy from one-half to one-third of the area of the cut surface. These septa, which are densely fibrous and in general poor in cells, surround both the portal spaces and the sublobular veins. An immense amount of yellowish-brown pigment, present in the parenchymatous cells, is deposited in the form of brilliant, brownish-yellow, relatively coarse granules, of variable size. The endothelial cells of the capillaries and Kùpffer's cells contain granules of similar character. Pigment is even more abundant in the newly-formed fibrous tissue. Here it exists in part as fine granules within spindle-shaped cells; but the greater quantity is not contained in cells. The extracellular pigment occurs in particles which vary greatly in size and often have a diameter two or three times that of a red corpuscle. This brownish-yellow pigment gives the microchemical reactions characteristic of iron.

There is a second less conspicuous pigment, differing from that already described both in situation and in character. In certain cells of the smooth muscle and connective tissue which form the media and adventitia of both veins and arteries are deposited fine, pale yellow granules of almost uniform size. This pigment does not give the microchemical reactions characteristic of iron, being unchanged by potassium ferrocyanide and hydrochloric acid. In sections stained with methylene blue such granules take a blue, often bluish-black, color and become very conspicuous (Buss).

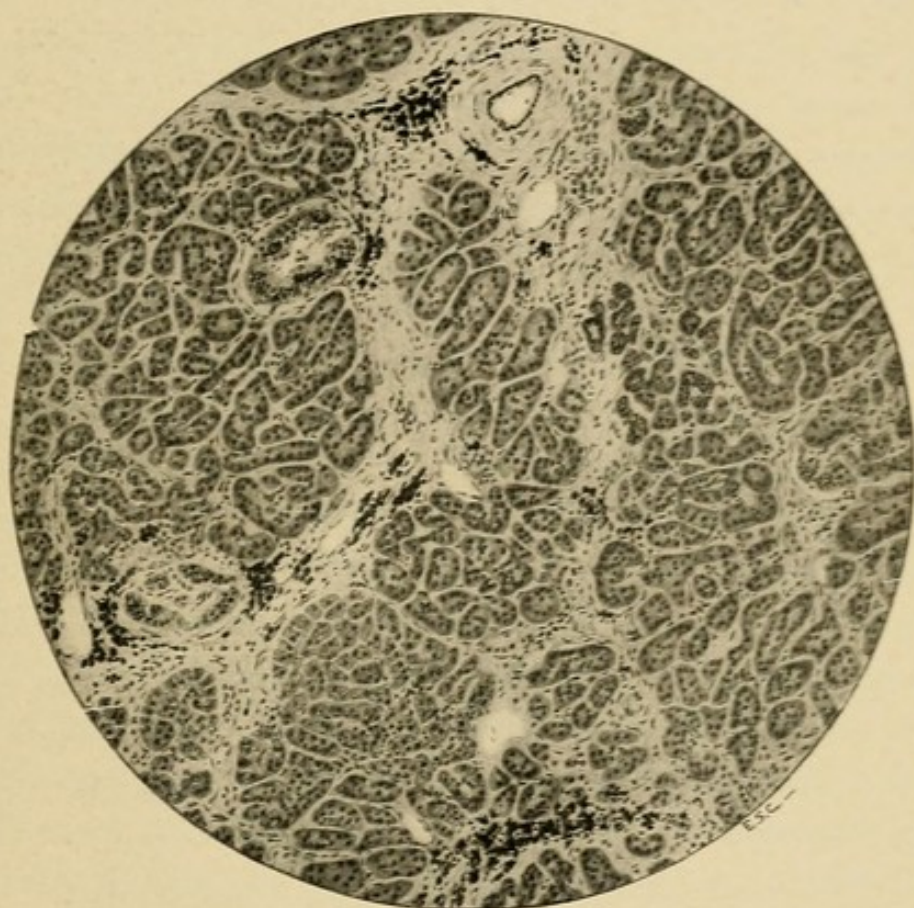



FIG. 49.—Chronic interacinar pancreatitis with hæmochromatosis showing deposition of hæmo-siderin in cells of acini and of islands of Langerhans and in the interstitial tissue.



Interstitial tissue of the *pancreas* is much increased (Fig. 49); in many places it defines the lobules, but, as a rule, it is diffusely distributed, occurring as irregular masses and strands separating small groups of acini or individual acini. Yellowish-brown pigment, giving the microchemical reactions of iron, is abundant both in the glandular-cells and in the interstitial tissue. The cells of the acini contain this pigment in varying amount; here and there are acini of which the cells are distended and almost entirely replaced by pigment-granules. Such cells often show evidence of degeneration; at times the nucleus has an irregular outline, and stains very palely, while in many instances no nucleus is demonstrable. The fibrous tissue replacing the disintegrated cells contains free granules of pigment, which are larger and more globular than those within the cells.

Islands of Langerhans are fairly abundant throughout the organ, but are most numerous in sections from the tail. They are constantly surrounded by a small area of fibrous tissue containing pigment in considerable quantity. Embedded in stroma, they no longer possess a regular round or oval outline, but are irregular in shape and are penetrated by thickened fibrous strands which follow the capillary vessels. The cells, forming compact columns, contain numerous granules of pigment which, when least abundant, are situated in the part of the cell most distant from the capillaries, and hence tend to occupy the mid-line of the cell-columns. The cells of the interacinar islands usually contain much more pigment than those of the adjacent acini. In preparations hardened in Fleming's solution fat can be found in many of the secreting cells, but it is constantly present in the cells of the interacinar islets.

Deposition of pigment and the associated histological lesions in the skin, gastro-intestinal tract, heart, spleen, kidneys, adrenals, and lymphatic glands, though of considerable interest, are not pertinent to the present study, and will be omitted.

*Bronzed Diabetes.*—A condition closely related to hæmochromatosis of Von Recklinghausen has been studied particularly by French writers. In 1882 Hanot and

Chauffard<sup>11</sup> described two cases of diabetes mellitus associated clinically with hypertrophic cirrhosis of the liver and bronze-like pigmentation of the skin. In one case, more carefully studied, the liver and pancreas presented a brown pigmentation and were the seat of advanced chronic interstitial inflammation, both parenchymatous cells and interstitial tissue containing masses of pigment granules. Letulle<sup>12</sup> several years later reported two cases of a similar nature. In a second communication Hanot,<sup>13</sup> in conjunction with Schachmann, recorded a fifth case and reviewed those previously published. He believed that the observations which had been made established the existence of a new form of cirrhosis—*cirrhose pigmentaire diabétique*, and of a new clinical condition—*diabète bronzé*.

The designation “diabète bronzé” has been accepted, but not without protest. Bronzing of the skin is not a constant phenomenon, and has been absent in one case of Letulle, in the case of Hanot and Schachmann, and in a case recorded by Brault and Galliard.<sup>14</sup>

The symptoms and pathological findings in the recorded cases of so-called bronzed diabetes have been very constant. Clinically, there is rapidly fatal diabetes mellitus, associated with cirrhosis of the liver, which is usually hypertrophic. Bronzing of the skin is not constant, but has been present in a majority of the cases. In two cases of Futcher<sup>15</sup> diagnosis was confirmed by

---

<sup>11</sup> Hanot and Chauffard: Rev. de méd., 1882, ii, 385.

<sup>12</sup> *Loc. cit.*

<sup>13</sup> Hanot and Schachmann: Arch. de physiol., 1886, 3 s., vii, 50.

<sup>14</sup> Brault and Galliard: Arch. gén. de méd., 1888, i, 38.

<sup>15</sup> Futcher: American Jour. of the Med. Scien., 1907, cxxxiii, 78.

demonstration of iron-containing pigment in sections prepared from bits of skin. At autopsy there is deep pigmentation of the liver and pancreas, associated with cirrhosis, and in cases carefully examined, interstitial pancreatitis. Ochre-colored pigment giving the micro-chemical reactions of iron is present in the parenchymatous cells of the liver, pancreas, and other glands, in the muscle-fibres of the heart, in the interstitial tissue of these organs, and in the lymphatic glands.

Only one recorded instance of hæmochromatosis (the case of Abbott<sup>16</sup>), or of bronzed diabetes, has occurred in the female. The age of the individuals affected with bronzed diabetes has varied between thirty-three and sixty-two years, the greatest number of cases occurring in the fourth and fifth decades. The cases of simple hæmochromatosis fall within these limits. It has been believed that the disease with diabetes is more common in France than elsewhere, for of twenty-four cases seventeen have been observed in that country. Simple hæmochromatosis, however, has been described more frequently by German writers. Among two hundred and fifty-six cases of diabetes treated in the Johns Hopkins Hospital, Fletcher found two instances of bronzed diabetes.

The pathogenesis of the condition has been the subject of much speculation. Hanot has maintained that the primary etiological factor is diabetes mellitus; diabetes with endarteritis, which he has found constant in his cases, disturbs the nutrition of the liver cells, and, he thinks, alters pigment metabolism so that pigment is deposited. Excess of the pigment, he suggests, is trans-

---

<sup>16</sup> Abbott: Trans. of the Path. Soc. of London, 1900, li, 66.

ported, possibly in the form of emboli, from the liver to the other organs. Letulle thinks that the pigment is formed under the influence of hyperglycæmia within the cells in which it is found. Brault and Galliard, Hernandez,<sup>17</sup> Mossé,<sup>18</sup> Rendu and De Massary,<sup>19</sup> give prominence to diabetes as the important factor in producing pigmentation.

A second smaller group of writers think that pigmentation is produced by some primary disease of the blood. P. Marie<sup>20</sup> thinks that some change causes dissolution of hæmoglobin, which is transformed by various cells of the body into pigment and is deposited in these cells. The pigment in turn causes degeneration and destruction of the cells in which it accumulates, and in consequence chronic interstitial inflammation of various organs, notably the liver; and if, Marie says, it should be necessary to compare the condition with any other, he would turn his attention to pancreatic diabetes. Acard,<sup>21</sup> Dutourier,<sup>22</sup> and Jeanselme<sup>23</sup> reiterate this view, and suggest that diabetes is only an accessory phenomenon which appears with a certain degree of chronic interstitial pancreatitis. Anschütz<sup>24</sup> has convinced himself that the associated diabetes finds its cause in chronic interstitial pancreatitis, which, like the accompanying cirrhosis of

---

<sup>17</sup> Hernandez: Thesis, Montpellier, 1892.

<sup>18</sup> Mossé: Cong. français de méd., 1894. Paris, 1895, i, 776.

<sup>19</sup> Rendu and De Massary: Bull. et mém., Soc. d. hôp. de Paris, 1897, s. 3, xiv, 163.

<sup>20</sup> Marie, P.: Sem. méd., 1895, xv, 229.

<sup>21</sup> Acard: Thesis, Paris, 1895.

<sup>22</sup> Dutourier: Thesis, Paris, 1895.

<sup>23</sup> Jeanselme: Bull. et mém. Soc. méd. d. hôp. de Paris, 1897, 3 s., xiv, 179.

<sup>24</sup> Anschütz: Deutsches Arch. f. klin. Med., 1899, lxii, 411.

the liver, is, he believes, a manifestation of some underlying condition.

French writers who described cases of "diabète bronzé" did not identify the pigmentation with the hæmochromatosis of Von Recklinghausen. Hernandez demonstrated that the brownish-yellow granules found by him in the epithelial cells of the liver, pancreas, and kidney, in the muscle cells of the heart, in the connective tissue of these organs, and in the lymphatic glands, gave the microchemical reactions known to be characteristic of iron. In this case and in subsequent cases the yellowish-brown pigment agrees in morphology and in location with the hæmosiderin of Von Recklinghausen.

Buss reported a case of diabetes associated with cirrhosis of the liver and chronic pancreatitis with general hæmochromatosis. He found not only the iron-containing but the iron-free pigment in locations corresponding to those mentioned by Von Recklinghausen.

The case described in the present chapter holds a position intermediate between hæmochromatosis and so-called bronzed diabetes. Associated with hæmochromatosis there is bronzing of the skin, cirrhosis of the liver of advanced grade, and chronic interstitial pancreatitis. Diabetes, however, has not been present. It is evident that the generalized pigmentation of bronzed diabetes is the hæmochromatosis of Von Recklinghausen.

*Etiology of Hæmochromatosis.*—The iron-containing pigment deposited in the liver and other organs is doubtless derived from the hæmoglobin of the blood. With pernicious anæmia there is destruction of blood, and iron is deposited in the liver and other organs, but pigmentation of the character under consideration is not found.

A considerable proportion of the cases, both of simple hæmochromatosis and of hæmochromatosis associated with diabetes, have been accompanied by conditions which involve active destruction of the red blood-corpuscles. Hindenlang's case of general pigmentation, almost certainly one of hæmochromatosis, was associated with morbus maculosus Werlhoffi. In four other cases purpuric eruptions have been observed. In several instances there have been local hemorrhages; in the case of Buss, for example, there have been hemorrhagic pleurisy, peritonitis, and pachymeningitis. Hæmaturia has occurred in a case of Hernandez and hæmoglobinuria has been observed by Hess and Zurhelle.<sup>25</sup> In a large number of cases local hemorrhages have not been demonstrable.

Discovery of phagocytosis of red blood-corpuscles by parenchymatous cells of various organs, according to Rössle,<sup>26</sup> explains the pathogenesis of hæmochromatosis. A man, thirty-nine years of age, who during three years had repeatedly suffered with slight jaundice, died after an illness of eight days; there was fever, jaundice, cyanosis and œdema of the legs. Rössle found hæmochromatosis; the liver was pigmented, cirrhotic, and atrophic. Microscopic examination showed that cells of the liver had acted as phagocytes and had taken red blood-corpuscles, often from 20 to 25, into their substance. Corpuscles had undergone changes as the result of ingestion, and many had lost their peculiar staining properties; transformation into granules and clumps of pigment had occurred.

---

<sup>25</sup> Hess and Zurhelle: *Zeit. f. klin. Med.*, 1905, lvii, 344.

<sup>26</sup> Rössle: *Ziegler's Beiträge*, 1907, xli, 181.

Rössle believes that such phagocytosis of red blood-corpuses is possible because capillaries in localized areas have undergone disintegration; red blood-corpuses are in contact with liver cells, but it has been uncertain if mere contact is sufficient to explain phagocytosis. At the periphery of foci in which disintegration of the endothelial cells had occurred, regeneration of capillaries with accompanying formation of fibrous tissue was in progress. Phagocytosis of red corpuses by parenchymatous cells was found in the pancreas and in the kidney. Rössle thinks that disintegration of endothelial cells has been caused by the presence of a lanceolate streptococcus found in sections of various organs, but unidentified by culture.

Some of those who have studied cases of bronzed diabetes have regarded diabetes as the essential etiological factor. Upon an insufficient basis active blood destruction has been assumed to be a result of the diabetic condition. In the ordinary form of diabetes, Zaleski<sup>27</sup> and Kretz<sup>28</sup> have found no accumulation of iron in the liver or other organs. There is, on the contrary, reason to believe that diabetes is secondary to hæmochromatosis.

*Relation of Hæmochromatosis to Chronic Interstitial Inflammation.*—Study of the process of pigment accumulation in widely separated organs—for example, the liver, pancreas, and adrenal glands—demonstrates the site of its formation. When pigment is in moderate quantity, it occurs as relatively fine round granules occupying that part of the cell most distant from the capillaries—that is,

---

<sup>27</sup> Zaleski: Virchow's Arch., 1886, civ, 91.

<sup>28</sup> Kretz: Beit. z. klin. Med. u. Chir., Hft. xv, Vienna, 1896; Cent. f. allg. Path. u. path. Anat., 1897, viii, 620.

in acinous glands, the part next the lumen. With greater accumulation the whole cell-body contains pigment granules, and finally almost the entire protoplasm is replaced by them. Changes at the same time may be observed in the nucleus of the cell. It becomes smaller, its outline often becomes irregular, and it assumes a shrivelled appearance. Masses of pigment with no nucleus may retain the cell outline. Finally the shape of a cell is lost and a clump of pigment particles lies free in the tissue.

The process observed in the liver takes place in the pancreas and adrenal gland, in the muscle cells of the heart, and in many other tissues. It is improbable that the pigment found in various organs is transported as emboli or in phagocytic cells from the liver; Margain has found particles of pigment in the circulating blood. The pigment is doubtless elaborated by the cells in which it is found from iron-containing material derived from hæmoglobin; the observation of Rössle suggests that phagocytosis has a part in the process.

Degenerate parenchymatous cells overloaded with pigment are very abundant in the case which I have studied. Such degeneration is an important factor in the production of chronic interstitial inflammation; fibrous stroma replaces the cells which are destroyed. In the liver newly formed fibrous tissue invades the lobule along the central vein, and in places sends out fine radiating bands along the capillaries between the columns of the liver cells. The fibrous tissue about the central vein and between the lobules contains large quantities of pigment, which is for the most part extracellular, because the cells in which it was formed have undergone degeneration. When pigment is massed in large quantity, there is usually accumulation of cells about it. In general the

interlobular tissue is poor in cells, but in such areas proliferation is indicated by the presence of small round cells. Two factors are, I believe, active in producing sclerosis: (1) Pigmentary degeneration of the parenchymatous cells; (2) irritation produced by the presence of the pigment in the interstitial tissue.

*Relation of Hæmochromatosis to Diabetes.*—In the case I have described the pancreas next to the liver is the organ most conspicuously pigmented. Extreme pigmentation and consequent degeneration of parenchymatous cells has occurred, and the organ is the seat of chronic interstitial inflammation of the interacinar type.

In reports of cases of bronzed diabetes, accompanied by a record of the microscopic appearance of the pancreas, chronic interstitial pancreatitis has been described. The gland has been usually described as voluminous, enlarged, or normal in size. In seven cases in which the weight is recorded, the mean of the figures given is 125.7 Gm., about one-half greater than the normal weight of the organ. The average weight of the liver recorded in thirteen cases of bronzed diabetes has been 2497 Gm. Both cirrhosis and chronic pancreatitis are associated with hypertrophy.

In my case of hæmochromatosis without diabetes the pancreas has weighed 170 Gm., almost twice the normal weight, and is the seat of interacinar inflammation of moderate intensity. The lesion affects primarily the parenchymatous cells, and the newly formed fibrous tissue is diffusely distributed and bears no constant relation to the lobules. Alterations of the islands of Langerhans have been as follows: Pigment is abundant in the cells, and tends to accumulate in that part which is most distant from the capillaries. The island is

usually embedded in a capsule-like mass of fibrous tissue containing pigment granules, and strands of similar tissue often penetrate the island, following its capillaries. The lesion is little advanced, and has caused such incomplete destruction of the islands of Langerhans that diabetes has not ensued. The individual had been in good health until attacked by typhoid fever. When, as in this case, hæmochromatosis without diabetes has been observed at autopsy, death has been due to some intercurrent affection having no apparent relation to the antecedent disease. The fatal illness in most instances begins with symptoms of diabetes. In the present instance typhoid fever caused death of the individual before chronic interstitial pancreatitis had reached a grade of intensity sufficient to produce glycosuria, and hæmochromatosis had been prevented from reaching its usual termination—diabetes.

In the pancreas in an individual with hæmochromatosis and diabetes Beattie<sup>29</sup> found few islands of Langerhans. They were surrounded by a capsule of dense fibrous tissue containing pigment; their cells were irregular in shape, and the nuclei stained faintly. Beattie thought that fibrous nodules which he found had perhaps replaced islands of Langerhans. Hess and Zurlhelle described two cases of hæmochromatosis with diabetes; in one instance no islands of Langerhans could be found, and in the other only one of these structures was recognizable.

Cecil has described the pancreas from the two following cases of bronzed diabetes.

---

<sup>29</sup> Beattie: *Jour. of Path. and Bact.*, 1903, ix, 117.

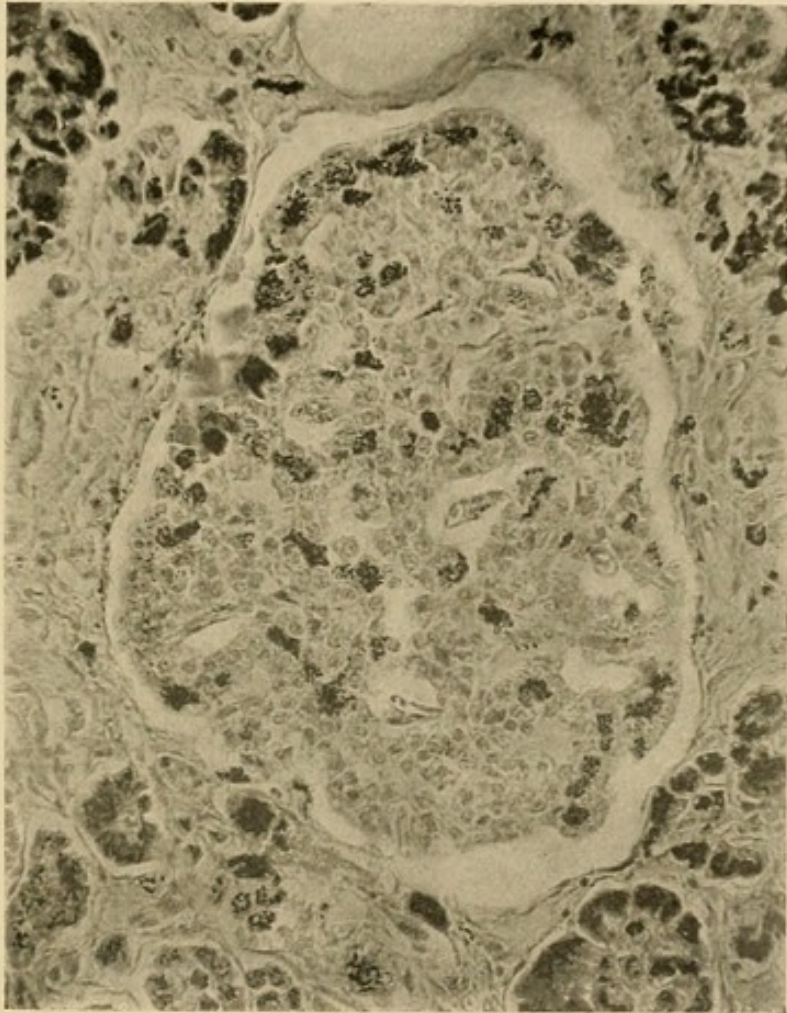




FIG. 50.—Island of Langerhans from case of hæmochromatosis with diabetes mellitus showing deposition of hæmosiderin.



A man, thirty-seven years of age, admitted to the Johns Hopkins Hospital, had suffered with diabetes during nine months; the urine contained 6.5 per cent. of glucose. There was pigmentation of the skin and ascites. Death occurred with coma. The liver was cirrhotic and pigmented; the skin, heart muscle and lymphatic glands were pigmented. The pancreas, which weighed 150 Gm., was firm, brown, and penetrated by fat. A section of the pancreas, obtained through the kindness of Dr. W. G. MacCallum, shows increase of both interlobular and interacinar connective tissue in which there is abundant iron-containing pigment. Many of the acinar cells are loaded with pigment. Few islands of Langerhans can be found; they are very small, and are surrounded by a thickened capsule of fibrous tissue containing pigment. Cells of the interacinar islands contain pigment.

A man, aged forty-three years, was admitted to the Massachusetts General Hospital with diabetes mellitus; there was 3 per cent. of sugar in the urine. Coma preceded death. The liver was cirrhotic and pigmented; the pancreas was dark brown in color. Sections of the pancreas, obtained through the kindness of Dr. James H. Wright, showed the presence of lipomatosis, interacinar pancreatitis, and deposition of pigment in acinar cells and stroma. Islands of Langerhans were fairly numerous, and normal in size; many of them were surrounded by dense fibrous capsules, and about the capillaries was thickened stroma. Many of cells of the islands of Langerhans were distended with pigment (Fig. 50); their nuclei stained poorly. The arteries of the gland were somewhat thickened.

Hæmochromatosis, a disease *sui generis*, is characterized by wide-spread deposition of pigment in various tissues of the body. It is associated with chronic interstitial inflammation, notably of the liver and pancreas. Parenchymatous cells undergo pigmentation and degeneration, and fibrous stroma fills the defect thus produced. In the pancreas chronic inflammation is of the interacinar type, and the islands of Langerhans are implicated in the lesion. When interacinar pancreatitis has reached a certain grade of intensity, diabetes mellitus ensues.



# INDEX

## A

- Aberrant pancreatic tissue in papillæ, 38
- Accessory pancreas, definition of, 30
  - mesentery in, 36, 43
  - omentum, in, 37, 43
  - origin of, 40
  - tumors from, 38
  - umbilicus, of, 36
- Acini, structure of, 56
  - changes with secretion in, 57
- Acne pancreatica, 267
- Acromegaly, 357
- Activator of pancreas, 114
- Acute hemorrhagic pancreatitis (see *Hemorrhagic necrosis of the pancreas*)
  - interstitial pancreatitis, 200
  - pancreatitis, etiology of, 201
  - pathology of, 203
  - varieties of, 118, 200
- Adenocarcinoma, 289
- Adenocystoma papilliferum, 269, 288
- Adenoma, 290
- Adenoma-like hypertrophy of islands of Langerhans, 342
- Adrenal, influence on pancreas of, 115, 359
- Adrenalin, 106
- Alcohol, 238, 351
- Alimentary glycosuria, 104, 108, 263, 283, 293, 353, 363
- Amyloid degeneration, 313, 348
- Amylopsin, 85
- Angio-sarcoma, 291
- Annular pancreas, 29
- Anomalies of pancreas, 29
- Anti-trypsin, 82
- Arterial sclerosis, 233, 245, 313, 333, 350, 362
- Atrophy of the pancreas, granular, 333
  - simple, 334
- Autolytic products of pancreas, toxicity of, 166
- Azotorrhœa, 90, 263

## B

- Bile duct, carcinoma of pancreas and, 294
  - pancreas, and, 21
  - pancreatic ducts, and, 3, 10, 14

- Bile causing hemorrhagic necrosis of pancreas, 140, 193
  - papilla, aberrant pancreatic tissue in, 38
- Blood-vessels of pancreas, 22, 54, 65
- Bronzed diabetes, 137

## C

- Calculi of pancreas, composition of, 257
  - cysts, and, 261
  - diagnosis of, 264
  - formation of, 261
  - interstitial pancreatitis, with, 226
  - incidence of, 257
  - operation for, 265
  - pathology of, 257
  - steatorrhœa, with, 95
  - symptoms of, 262
  - treatment of, 264
- Cambridge's reaction, 99
- Carbohydrates, absorption of, 95
- Carcinoma of pancreas, chronic
  - interstitial pancreatitis, and, 228, 291
  - colloid, 288
  - diagnosis of, 295
  - incidence of, 288
  - metastases from, 289, 292
  - symptoms of, 129
  - treatment of, 296
- Catarrhal pancreatitis, 201
- Centro-acinar cells, 50, 57
- Chronic interacinar pancreatitis, 213, 219
  - arterial sclerosis, and, 235, 351
  - diabetes mellitus, and, 334
  - symptoms of, 248
- interlobular pancreatitis, 213
  - ascending infection, and, 218, 229
  - duct-obstruction, and, 213, 225
  - symptoms of, 247
- interstitial pancreatitis, accessory pancreas, of, 37
  - acromegaly, and, 358
  - alcohol, and, 238
  - arterial sclerosis, and, 233

- Chronic interstitial pancreatitis.—  
*Continued.*  
 azotorrhœa, with, 90,  
 96  
 calculi, and, 226  
 carcinoma, and, 291  
 cat, in, 52  
 causing malignant  
 growth, 228  
 cholelithiasis causing,  
 226  
 chronic passive con-  
 gestion, and, 235  
 cirrhosis, and, 239, 372,  
 377  
 cyst, and, 268  
 etiology of, 224  
 hæmochromatosis, and,  
 377  
 islands of Langerhans,  
 and, 210, 214, 216,  
 221, 380  
 symptoms of, 243  
 syphilis, and, 238  
 tuberculosis, and, 237  
 varieties of, 209, 210  
 vomiting, and, 230  
 Cirrhose pigmentaire diabetique, 372  
 Cirrhosis of the liver, 239, 245, 372,  
 377  
 Colic, pancreatic, 264, 292  
 Cyst of pancreas, apoplectic, 270  
 aspiration of, 285  
 calculi, and, 261  
 contents of, 272  
 diagnosis of, 283  
 hemorrhagic necrosis, and,  
 271  
 operation for, 284  
 position of, 273  
 proliferation, 268  
 retention, 266  
 rupture of, 279  
 symptoms of, 281  
 traumatic, 270, 283  
 Cystadenoma, 268, 283

## D

- Development of the pancreas, 4  
 Diabète bronzé, 365, 372  
 Diabetes mellitus, acromegaly, and,  
 357  
 adrenal lesion, and, 359  
 arterial sclerosis, and, 350,  
 362  
 atrophy of pancreas, with,  
 333, 334

- Diabetes mellitus.—*Continued.*  
 azotorrhœa, with, 90, 96  
 calculi causing, 262, 331  
 carcinoma, and, 291, 293,  
 330  
 chronic interstitial pan-  
 creatitis, and, 331, 361,  
 377  
 cirrhosis of liver, with, 352,  
 372, 377  
 cyst, and, 282  
 diagnosis of pancreatic, 360  
 disease of central nervous  
 system, and, 353  
 exophthalmic goitre, and,  
 355  
 experimental, 107  
 hæmochromatosis, and, 379  
 hemorrhagic necrosis of  
 pancreas, and, 170, 329  
 hypertrophy of islands of  
 Langerhans, with, 341  
 islands of Langerhans, and,  
 307, 322, 324, 341, 344,  
 346, 380  
 lesions of fourth ventricle,  
 with, 354  
 myxœdema, 357  
 normal pancreas, with, 318,  
 322, 349  
 pancreatic, 317  
 renal, 354  
 small pancreas, with, 337  
 suppurative pancreas, and,  
 329  
 Diabetic puncture, 104  
 Diverticula in contact with acces-  
 sory pancreas, 44  
 with pancreas, 46  
 Diverticulum of Vater, 13, 147  
 carcinoma of, 203, 215  
 gall-stone in, 133, 143, 191,  
 202, 208, 227  
 Duct-obstruction, diabetes mellitus,  
 and, 331  
 lesion caused by, 213, 225  
 Duct of Santorini, 2, 16  
 Duct of Wirsung, 2, 55  
 Ducts of pancreas, discovery of, 2  
 histology of, 55  
 ligation of, 89, 92, 108, 185,  
 217, 345  
 in lower animals, 3  
 necrosis of pancreas and  
 anomalies of, 151  
 parenchyma, and, 17  
 regeneration of, 42  
 variation of, 7

Duodenal contents causing hemorrhagic necrosis of pancreas, 150  
 papilla, aberrant pancreatic tissue in, 38

## E

Emaciation, 283, 292  
 Embryology of pancreas (see *Development*)  
 Enterokinase, 83, 151  
 Enzymes, in cysts of pancreas, 272  
   hemorrhagic necrosis of pancreas, and, 121, 147, 161, 166  
   therapeutic use of pancreatic, 95  
 Epithelioma cysticum, 269, 288  
 Etherial sulphates in urine, 98  
 Exophthalmic goitre, 355

## F

Fæces, voluminous, 95, 293  
 Fat, absorption of, 88, 92  
   fæces, in (see *Steatorrhæa*)  
   necrosis, accessory pancreas, and, 37  
     bacteriology of, 180  
     Benda's copper acetate reaction for, 179  
     calculi, and, 206  
     chemistry of, 178  
     chronic pancreatitis, and, 188, 192  
     clinical significance of, 197  
     corpulence, and, 178  
     disappearance of, 180  
     disseminated, 176  
     duct-occlusion, and, 190  
     experimental, 185  
     hemorrhagic necrosis of pancreas, and, 119, 126, 157, 159, 173, 183, 193, 198  
     historical data concerning, 176  
     lower animals, in, 177  
     pancreas, and, 181  
     pancreatin, and, 184  
     parapancreatic, 195  
     pericardial, 177, 186  
     recovery, with, 199  
     self-digestion of pancreas, and, 86  
     subcutaneous, 177, 178, 186, 189, 197  
     suppurative pancreatitis, and, 120, 205  
     without pancreatic lesion, 194

Fat-splitting enzyme, fat necrosis, and, 184, 187, 198  
   urine, in, 198  
 Fatty degeneration, 299  
 Fistula, pancreatic, 286  
   experimental pancreatic, 77, 89

## G

Gall-stones, calculi of pancreas, and, 258  
   cysts, and, 268  
   diverticulum of Vater, in, 133, 143, 191, 202, 208, 227  
 Gangrenous pancreatitis, 119  
 Gastroptosis, 24  
 Glucose in blood, 102, 107  
 Glycosuria, adrenalin, and, 106  
   disappearance of, 106, 348  
   extirpation of duodenum, and, 108  
   hemorrhagic necrosis of pancreas, and, 170  
   injury to nervous system, and, 105  
   suppurative pancreatitis, and, 206  
   toxic substances, and, 106  
 Glycogen, 103  
 Glycolytic enzyme, 112  
 Gumma of pancreas, 254, 255

## H

Hæmochromatosis, case of, 368  
   chronic interstitial pancreatitis, and, 377  
   definition of, 365  
   diabetes mellitus, and, 353  
   etiology of, 375  
   islands of Langerhans, and, 380  
   pathogenesis of, 373  
   symptoms of, 372  
 Hæmofuscin, 366  
 Hæmosiderin, 366  
 Hemorrhage, pancreatic, 122  
 Hemorrhagic necrosis of pancreas, with accumulation of fluid within lesser peritoneal cavity, 163  
   anomalies of ducts and, 151  
   bacteriology of, 128  
   bile producing, 140  
   cholelithiasis, and, 129, 143, 148, 167, 174  
   cyst, and, 271  
   definition of, 118

- Hemorrhagic necrosis of pancreas.—  
*Continued.*  
 duodenal contents,  
 and, 150  
 etiology of, 127  
 experimental, 124, 160  
 histology of, 159  
 injury, and, 156  
 leucocytosis, with, 145,  
 170  
 operation for, 172  
 pathology of, 158  
 perforation of gastro-  
 intestinal tract with,  
 164  
 recurrent, 171  
 relation to inflamma-  
 tion of, 120  
 retroperitoneal erosion,  
 with, 164, 169, 174  
 sex, and, 150, 163  
 stage of gangrene of,  
 162, 168, 173  
 suppuration with, 168  
 symptoms of, 164  
 treatment of, 171
- Histogenesis of pancreas, 66  
 Histology of pancreas, 50  
 Hyaline degeneration, 300, 310  
 thrombosis of capillaries, 160  
 Hypertrophy of pancreas, 334, 358,  
 379

## I

- Inanition and islands of Langerhans,  
 72  
 Indican in urine, 98  
 Infantilism, pancreatic, 97  
 Injury of pancreas, 25, 156, 270, 283  
 Interlobular fissure of pancreas, 20  
 Internal secretion, 75, 112, 117  
 Intestinal obstruction, accessory  
 pancreas, and, 45, 197  
 hemorrhagic necrosis of  
 pancreas, and, 167, 173
- Islands of Langerhans, acini, and, 69,  
 72  
 adenoma of, 290  
 amyloid degeneration, and,  
 313, 348  
 blood-vessels of, 51, 65  
 cells of, 64  
 chronic interstitial pancrea-  
 titis, and, 210, 214, 216,  
 221, 242  
 congenital syphilis, and, 251  
 diabetes mellitus, and, 307,  
 324, 330, 331, 334, 338,  
 361

- Islands of Langerhans.—*Continued.*  
 diminution in number of,  
 338  
 experimental study of, 344  
 fatty degeneration of, 299  
 focal necrosis of, 315  
 function of, 74  
 hæmochromatosis, and, 380  
 histogenesis of, 67  
 historical data concerning,  
 51, 59  
 hyaline degeneration of,  
 300, 304, 327  
 hypertrophy of, 341  
 inanition, and, 72  
 lesions affecting only, 327  
 lymphoid cells in, 222  
 number of, 62  
 pilocarpin, and, 70  
 sclerosis limited to, 327  
 secretin, and, 71  
 size of, 61  
 transplanted pancreas con-  
 taining, 345

## L

- Lab-ferment, 84  
 Lesser peritoneal cavity, fluid in, 163  
 Levulose, 115  
 Lipomatosis, 223  
 Lithiasis (see *Calculi*)  
 Lobes of pancreas, 19  
 Lobules of pancreas, 17, 51  
 Lymphosarcoma, 291

## M

- Medical anatomy of pancreas, 22  
 Myxœdema, 357

## N

- Necrosis, focal pancreatic, 314  
 hemorrhagic (see *Hemorrhagic  
 necrosis of pancreas*)  
 traumatic, 156  
 Nuclear test of Schmidt, 91  
 Nuclease, 84

## P

- Pancreas, experimental extirpation  
 of, 88, 95, 107  
 extirpation of human, 109  
 operation on, 24  
 weight of, 334  
 Pancreas divisum, 29  
 Pancreatic apoplexy, 122  
 Pancreatic juice, composition of, 78  
 digestion in absence of, 87  
 Pancreatin, 184

Pentosuria, 99  
 Peripancreatitis, 161  
 Peritonitis of lesser peritoneal cavity,  
 120, 161, 205  
 Phloretin, 106  
 Phlorhizin glycosuria, 105  
 Pigmentation of intestine, 366  
 Pilocarpin, 70, 188, 264  
 Points folliculaires, 59  
 Prosecretin, 81  
 Protein, absorption of (*see Azotor-*  
*rhæa*)  
 Pseudocysts, 266, 269, 283  
 Pseudofollicles, 60

## R

Ranula pancreatica, 266

## S

Sahli's gelatin capsules, 91  
 Sarcoma of pancreas, 288, 290  
 Schmidt's nuclear test, 91  
 Secondary cell-groups, 60  
 Secretin, action of, 81  
   islands of Langerhans, and, 71  
 Secretion of pancreas, 77, 79  
   acid, and, 79, 80  
   acini, and, 57  
   food, and, 78  
   nerves, and, 80, 81  
 Self-digestion of pancreas, 85, 123  
 Sequestration of pancreas, 120, 162,  
 170, 178  
 Steapsin, 84  
 Steatorrhœa, 92  
   calculi, with, 263  
   carcinoma, with, 293  
   cyst, with, 282  
   experimental pancreatic, 87

Steatorrhœa.—*Continued.*

  hemorrhagic necrosis, with, 169  
   suppurative pancreatitis, with,  
   206  
 Stomach, relation to pancreas, 23  
 Struma of islands of Langerhans, 342  
 Succus entericus, enterokinase of, 83  
 Suppurative pancreatitis, 120, 200  
   cholelithiasis, and, 202, 207  
   symptoms of, 205  
   treatment of, 207  
 Surgical anatomy of pancreas, 24  
 Syphilis, 238, 250  
 Syphilitic pancreatitis, acquired, 254  
   congenital, 250

## T

Thyroid, influence on pancreas of,  
 115, 356  
 Traumatic necrosis of pancreas, 156  
 Trypsin, 82  
 Trypsinogen, 83  
 Tuberculosis, 237, 249  
 Tumor, carcinoma with, 292, 295  
   cyst, with, 273, 283  
   hemorrhagic necrosis of pan-  
   creas, with, 169, 173

## U


Urine with pancreatic disease, 98,  
 198


## V

Vomiting and chronic interstitial  
 pancreatitis, 230

## Z

Zymogen, 59, 85









0043064078

RC857 . SP

Op 3  
1910

Opie.

Disease of the Pancreas

1910

