Clinical surgical diagnosis for students and practitioners / by F. de Quervain ; translated from the 4th ed. by J. Snowman.

Contributors

Quervain, F. de 1868-1940.
Augustus Long Health Sciences Library

Publication/Creation

London : Bale & Danielsson, 1913.

Persistent URL

https://wellcomecollection.org/works/gw67cccd

License and attribution

This material has been provided by This material has been provided by the Augustus C. Long Health Sciences Library at Columbia University and Columbia University Libraries/Information Services, through the Medical Heritage Library. The original may be consulted at the the Augustus C. Long Health Sciences Library at Columbia University and Columbia University. where the originals may be consulted.
This work has been identified as being free of known restrictions under copyright law, including all related and neighbouring rights and is being made available under the Creative Commons, Public Domain Mark.

You can copy, modify, distribute and perform the work, even for commercial purposes, without asking permission.

wellcome collection

Wellcome Collection
183 Euston Road
London NW1 2BE UK
T +44 (0)20 7611 8722
E library@wellcomecollection.org
https://wellcomecollection.org

COLUMBIA LIBRARIES OFFSITE
HEALTH SCIENCES STANDARD
HX64055779
RD35 Qu313 1913 Clinical surgical di
RECAP



J. P. Webster
1915



COLUMBIA UNIVERSITY
THE
LIBRARIES
IN THE CITY OF NEW YORK

CLINICAL SURGICAL DIAGNOSIS

FOR

STUDENTS AND PRACTITIONERS

BY

F. DE QUERVAIN

Professor of Surgery and Director of the Surgical Clinic at the University of Basle

WITH 510 ILLUSTRATIONS AND 4 PLATES

Translated from the Fourth Edition by

J. SNOWMAN, M.D.

NEW YORK

WILLIAM WOOD AND COMPANY

MDCCCCXIII

RD
35
Q4 313
1913

AUTHOR'S PREFACE TO THE ENGLISH EDITION.

THIS book, the English version of which affords me special pleasure, is the outcome of years of association with students, as a teacher, and with medical practitioners at consultations. It is intended to serve as a guide to the former in the vast field of surgical diagnosis which they are required to explore, and to recall to the latter knowledge which has perhaps faded, while drawing their attention to new developments in diagnosis. To this end I have employed the methods of investigation which are available for the general practitioner, or at any rate which can easily be carried out for him. These methods comprise the bacteriological, serological, histological and radiographic researches, without which, nowadays, a reliable diagnosis cannot be obtained.

I adhere throughout to the plan of starting with the symptoms which caused the patient to seek medical advice, and not to the method of deducing symptoms from an already made diagnosis.

If the appropriate questions have been correctly put, the problem will in every case be narrowed down more and more, until, ultimately, the student arrives at a definite diagnosis, either as the result of positive symptoms or by a process of gradual exclusion. After long training in this method, the student may be permitted to diagnose a case as a whole, without first considering each symptom separately. One thing, however, must be borne in mind. Important as it is to have an accurate diagnosis, our endeavours to obtain one dare not entail injury to the patient, nor involve the loss of the most favourable moment for a successful operation, while refinements of diagnosis are being investigated. A diagnosis is not to be made merely for its own sake, but as a means to a cure.

This book represents, above all, the fruit of my own experience, and the illustrations are, with a few exceptions, derived from my own observations. The contents may, in consequence, be necessarily incomplete in certain particulars, but I trust that this is compensated for by vividness of description.

F. DE QUERVAIN.

Basle, February, 1913.

Digitized by the Internet Archive
in 2010 with funding from
Open Knowledge Commons

http://www.archive.org/details/clinicalsurgical00quer

CONTENTS.

PART I.

SURGICAL DISEASES OF THE HEAD.

PAGE

I.—FRACTURES OF THE SKULL 1
1.—Direct Symptoms 2
2.—Indirect Symptoms 4

II.—INJURIES OF THE BRAIN 7
1.—Concussion of the Brain 8
2.—Contusion of the Brain 10
3.—Cerebral Pressure following Hæmorrhage ... 12

III.—ABSCESS OF BRAIN, HÆMORRHAGIC PACHYMENINGITIS, CYST OF BRAIN, TUMOUR OF BRAIN 17
1.—Abscess of Brain 18
2.—Hæmorrhagic Pachymeningitis 20
3.—Traumatic Cysts of the Brain 21
4.—New Growths and Tumours of Granulation Tissue 22

IV.—THE CEREBRAL COMPLICATIONS OF SUPPURATIVE OTITIS MEDIA 25

V.—THE PROBLEM OF EPILEPSY 34

VI.—SOME REMARKS ON CEREBRAL LOCALIZATION AND FOCAL DIAGNOSIS 38

VII.—THE SURGERY OF EXOPHTHALMOS 49

VIII.—ACUTE INFLAMMATORY PROCESSES ON THE SKULL 51

IX.—SWELLINGS OF THE HEAD 51
A.—Congenital Swellings of the Head 51
B.—Acquired Swellings of the Head 55
1.—Innocent acquired Swellings 55
2.—Malignant Tumours of the Head and Chronic Inflammatory Swellings 56

X.—ACUTE INFLAMMATORY DISEASES OF THE FACE 59

XI.—TUMOURS AND ULCERS OF THE FACE 62
A.—Tumours with Overlying Skin unbroken 62
B.—Ulcerative Processes 64

XII.—INJURIES OF THE JAW 73

XIII.—LOCK-JAW 75

PAGE

XXX.—TUMOURS AND ALLIED GROWTHS WITHIN THE THORAX 199
1.—Mediastinal Tumours 199
2.—Tumours of the Lung 207

XXXI.—SWELLINGS AND TUMOURS OF THE THORAX 208
A.—Primary Disease within the Thorax 208
B.—Primary Disease of the Thoracic Wall 210
1.—Acute Diseases 210
2.—Chronic Diseases 211
a.—Chronic Inflammatory Processes 211
b.—Tumours 216

XXXII.—INFLAMMATORY DISEASES OF THE BREAST ... 219
1.—Acute Inflammations 219
2.—Chronic Inflammations 221

XXXIII.—TUMOURS AND ALLIED STRUCTURES IN THE BREAST 223
A.—Multiple Tumours 224
B.—Single Tumours 224
1.—Small and Medium-sized Tumours 224
2.—Large Tumours 232

PART IV.

SURGICAL DISEASES OF THE ABDOMINAL AND PELVIC VISCERA.

XXXIV.—DISPLACEMENTS OF THE ABDOMINAL VISCERA 235

XXXV.—ABDOMINAL INJURIES 244
A.—Injuries without an Open Wound 244
1.—Gastro-intestinal Canal 245
2.—The Spleen 247
3.—Liver and Bile Ducts 247
4.—The Kidneys 248
5.—The Bladder 250
B.—Injuries to the Abdomen with Open Wounds ... 251
1.—Gun-shot Wounds 252
2.—Stabs and Incised Wounds 253

XXXVI.—ACUTE INFLAMMATION WITHIN THE ABDOMINAL CAVITY 254
A.—Abdominal Pain without Perceptible Changes ... 261
B.—Diffuse Peritonitis without Localization ... 263
C.—Localized Peritonitis 265
1.—Epigastrium 265
2.—Right Hypochondrium 265
3.—Left Hypochondrium 266
4.—Lumbar Regions 266
5.—Lower Abdominal Region 266
6.—True Pelvis 275

PAGE

XXXVII.—SUB-PHRENIC ABSCESS 276
1.—Sub-phrenic Abscess without Pleural Effusion ... 277
2.—Sub-phrenic Abscess with Pleural Effusion ... 279

XXXVIII.—TUBERCULAR PERITONITIS 281

XXXIX.—DIAGNOSIS OF ABDOMINAL SWELLINGS IN GENERAL 287

XL.—SURGICAL DISEASES OF THE STOMACH ... 291
A.—Foreign Bodies in the Stomach 292
B.—Displacements of the Stomach 293
C.—Gastric Ulcer 294
1.—Uncomplicated Gastric Ulcer 294
2.—Hæmorrhage 296
3.—Perforation 296
4.—Cicatricial Stenosis 299
D.—Cancer of the Stomach 305
1.—Cancer of the Body of the Stomach 310
2.—Cancer of the Pylorus 311

XLI.—SURGICAL DISEASES OF THE BILIARY PASSAGES 313
1.—Gall-stone Colic 314
2.—Acute Cholecystitis 316
3.—Gangrenous Cholecystitis 318
4.—Obstruction of the Common Bile-duct 321
5.—Hydrops of the Gall-Bladder, Chronic Empyema 323
6.—Acute Cholangitis 324

XLII.—TUMOURS OF THE LIVER 325

XLIII.—SURGERY OF THE PANCREAS 327
1.—Acute Pancreatitis and Pancreatic Hæmorrhage ... 328
2.—Chronic Pancreatitis, Cancer of the Head of the Pancreas, Pancreatic Calculus 329
3.—Pancreatic Tumours and Cysts 329

XLIV.—SURGERY OF THE SPLEEN 330
1.—Abscess of the Spleen 330
2.—Splenic Hypertrophy 330
3.—Tumours of the Spleen 331

XLV.—ACUTE APPENDICITIS 332

XLVI.—COLITIS, SO-CALLED CHRONIC APPENDICITIS AND FUNCTIONAL DISTURBANCES OF THE LARGE INTESTINE 339
A.—Colitis with Definite Anatomical Changes ... 339
B.—Functional Derangements of the Large Intestine without Typical Anatomical Changes 342

XLVII.—INTESTINAL OBSTRUCTION 346
1.—Stenosis of Gradual Development (Chronic Intestinal Obstruction) 347
a.—Symptoms 347
b.—The Position of the Stenosis 350
c.—Form and Cause of the Stenosis 351

PAGE

2.—Acute Intestinal Obstruction 357
a.—Symptoms 357
b.—The Position of the Obstruction 358
c.—The General Varieties of Acute Obstruction ... 360
d.—Causes of Acute Intestinal Obstruction 361
1.—Obstruction due to Bands and Kinks ... 361
2.—Obstruction by Gall-stones 362
3.—Intussusception 363
4.—Volvulus 364
5.—Strangulation of Internal Herniæ 365
6.—Spastic Obstruction 367

XLVIII.—TUMOURS AND SWELLINGS IN THE ABDOMINAL PARIETES 368
1.—The Upper Abdominal Region 368
2.—The Umbilical Region 371
3.—Inguinal Region 374
4.—The Lumbar Region 375
5.—Swellings and Tumours in Atypical Positions ... 376

XLIX.—ABDOMINAL SINUSES 377

L.—EXTERNAL INGUINAL HERNIA 379
1.—Diagnosis in the Absence of Hernial Swelling ... 380
2.—Diagnosis of Inguinal Hernial Swellings ... 382
3.—Diagnosis of Labial and Scrotal Herniæ 387

LI.—INTERNAL OR DIRECT INGUINAL HERNIA ... 390

LII.—FEMORAL HERNIA 392

LIII.—TRAUMATIC HERNIÆ 396

LIV.—STRANGULATED HERNIA 398
1.—Is the Case really one of Hernia? 398
2.—Is the Hernia strangulated? 401
3.—What does the Hernia contain? 402
4.—Where is the Strangulation situated? 403
5.—What is the Condition of the Strangulated Gut? 403
6.—The Questions which may arise during Operation 404
7.—Questions which arise after Reduction by the Open or Bloodless Method 405

LV.—DIFFICULTIES OF DEFÆCATION 407

LVI.—INJURIES OF THE RECTUM 412

LVII.—TUMOURS AND SWELLINGS OF THE SCROTUM 414
1.—Swellings of the Scrotum 414
a.—Acute Swellings 414
b.—Chronic Swellings 415
2.—Swellings of the Scrotal Contents 415
a.—Tumours of the Spermatic Cord 415
b.—Acute Swellings of the Testicle and Epididymis 416
c.—Chronic Swellings of the Testicle and Epididymis 419
1.—Swellings of the Epididymis 419
2.—Swellings between the Testicle and Epididymis 420
3.—Swellings of the Testicle 420

LVIII.—FISTULÆ IN PERINEAL REGION 423
1.—Dermoid Fistulæ 423
2.—Fistulæ in Connection with Bone 424
3.—Fistulæ of the Rectum and Anus 424
4.—Urinary Fistulæ 426

PAGE

LIX.—GENERAL REMARKS ON THE SURGICAL DISEASES OF THE URINARY ORGANS ... 427
A.—DISTURBANCES OF MICTURITION 428
1.—Painful Micturition 428
2.—Difficult Micturition 429
a.—Disturbances of the Mechanism of Micturition 429
b.—Obstruction of the Urethra 430
3.—Deficient Closure of the Bladder 431
4.—Vesical Tenesmus 432
B.—ABNORMAL COMPOSITION OF THE URINE 433
1.—Admixture with Pus 433
2.—Admixture with Blood 435
3.—Admixture with Inorganic Deposits or Concretions (urinary gravel) 436
C.—LOCAL SYMPTOMS 437
LX.—INFLAMMATION IN THE NEIGHBOURHOOD OF THE KIDNEY 442
LXI.—MOVABLE KIDNEY 444
LXII.—HYDRONEPHROSIS AND ITS CONSEQUENCES 447
LXIII.—IDIOPATHIC SUPPURATION IN THE RENAL PELVIS AND KIDNEY 450
LXIV.—STONE IN THE KIDNEY AND URETER 453
A.—PRIMARY STONE IN THE KIDNEY 453
1.—Non-infected Stone 453
2.—Infected Stone 455
B.—SECONDARY STONE IN THE KIDNEY 455
LXV.—TUMOURS OF THE KIDNEY 455
LXVI.—TUBERCULOSIS OF THE URINARY PASSAGES 458
LXVII.—STONE IN THE BLADDER 461
LXVIII.—CYSTITIS 464
LXIX.—TUMOURS OF THE BLADDER 466
1.—TUMOURS OF THE MUCOUS MEMBRANE OF THE BLADDER 466
2.—TUMOURS IN THE MUSCULAR COAT OF THE BLADDER ... 467
LXX.—HYPERTROPHY, TUMOURS, AND ABSCESS OF THE PROSTATE 468
1.—HYPERTROPHY AND TUMOURS 468
2.—INFLAMMATORY PROCESSES 471
LXXI.—INJURIES OF THE URETHRA 472
LXXII.—SURGICAL DISEASES OF THE PENIS 474
1.—SUBCUTANEOUS GROWTHS 475
2.—ULCERATIVE CHANGES 475

PART V.

SURGICAL DISEASES OF THE PELVIS AND SPINAL COLUMN.

PAGE

LXXIII.—TUMOURS OF THE PELVIS 478

LXXIV.—CONGENITAL ABNORMALITIES OF THE SPINAL COLUMN 481

LXXV.—LUMBAGO 486

LXXVI.—INJURIES OF THE SPINAL COLUMN 489

I.—METHOD OF EXAMINATION 489

II.—DIAGNOSIS OF THE NATURE, DEGREE, AND POSITION OF THE INJURY 493

A.—The Degree and the Nature of the Spinal Cord Injury 493

B.—The Position of the Spinal Cord Injury (the Diagnosis of the level of the Lesion) ... 495

C.—Relations between the Injury to the Cord and the Vertebræ 499

D.—The Form of the Spinal Injury 501

1.—Fractures of the Spinous and Transverse Processes 503

2.—Fracture of the Vertebral Arch 504

3.—Compression Fracture 505

4.—Complete Dislocation 506

LXXVII.—THE SURGERY OF NON-TRAUMATIC DISEASES OF THE SPINAL CORD 507

1.—IS A TUMOUR ACTUALLY PRESENT? 508

2.—WHAT IS THE NATURE OF THE TUMOUR? 510

3.—AT WHICH LEVEL IS THE TUMOUR SITUATED? 510

LXXVIII.—INFLAMMATORY DISEASES OF THE SPINAL COLUMN 511

A.—TUBERCULAR CARIES 511

1.—Tubercular Caries without definite Curvature, and without a Burrowing Abscess 511

2.—Spinal Caries with Burrowing Abscess 515

3.—Spinal Caries with Curvature 519

4.—Spinal Caries with Cord Symptoms 519

B.—NON-TUBERCULAR INFLAMMATION OF THE SPINAL COLUMN 520

LXXIX.—SPINAL CURVATURES 522

1.—ANTERO-POSTERIOR CURVATURES 525

2.—LATERAL CURVATURES 526

PART VI.
SURGICAL DISEASES OF THE EXTREMITIES.

PAGE

LXXX.—FRACTURES AND DISLOCATIONS OF THE CLAVICLE 534

LXXXI.—FRACTURES AND DISLOCATIONS ABOUT THE SHOULDER-JOINT 537
A.—Dislocations 539
B.—Fractures 540

LXXXII.—INFLAMMATORY PROCESSES ABOUT THE SHOULDER-JOINT 547
A.—Distinction between Bursal and Joint Disease ... 547
B.—Diagnosis of the Various Forms of Bursitis and Arthritis of the Shoulder 550
1.—Bursitis 550
2.—Arthritis of the Shoulder 550
C.—Primary Diseases of the Bone 553

LXXXIII.—INJURIES ABOUT THE ELBOW-JOINT 553
A.—Inspection 554
B.—Examination of Elbow Movements 554
C.—Palpation 560
D.—Röntgen Ray Examination 567

LXXXIV.—INFLAMMATORY PROCESSES ABOUT THE ELBOW 568
1.—Acute Inflammatory Processes 568
2.—Chronic Inflammatory Processes 571

LXXXV.—TUMOURS AND ALLIED SWELLINGS ON THE UPPER ARM AND FOREARM 572

LXXXVI.—INJURIES OF THE WRIST AND HAND 576
1.—Radius and Ulna 576
2.—Wrist-joint 579
3.—Metacarpus and Fingers 586

LXXXVII.—INFLAMMATORY PROCESSES ABOUT THE WRIST 588
1.—Acute Inflammations 588
2.—Chronic Inflammatory Processes 589

LXXXVIII.—ABNORMAL POSITIONS AND POSTURES OF THE HAND AND FINGERS 592
A.—Results of Injuries to Nerves 592
B.—Abnormal Postures of the Wrist-joint 595
C.—Anomalies in the Posture of the Fingers 598

LXXXIX.—TUMOURS OF THE HAND AND FINGERS ... 599
A.—Innocent Tumours 599
B.—Malignant Tumours 600

XC.—ACUTE INFLAMMATORY PROCESSES OF THE HAND AND FINGERS 601
A.—Inflammatory Processes of the Fingers 601
B.—Acute Inflammatory Processes of the Hand ... 605

XCI.—CHRONIC INFLAMMATION OF THE HAND AND FINGERS 605
1.—The Skin 605
2.—The Tendon-sheaths 607
3.—The Bones 608

XCII.—DISLOCATIONS AND FRACTURES OF THE HIP 610
A.—Method of Examination 611
B.—Diagnosis of the Various Forms of Injury ... 615
1.—Dislocations 615
2.—Contusions, Sprains, Fractures 621

XCIII.—NON-TRAUMATIC DEFORMITIES AT THE HIP-JOINT (CONGENITAL DISLOCATION OF THE HIP AND COXA VARA) 631
A.—Congenital Dislocation of the Hip 631
B.—Coxa Vara 639

XCIV.—ACUTE INFLAMMATORY DISEASES OF THE HIP-JOINT 643

XCV.—CHRONIC INFLAMMATORY DISEASES OF THE HIP 646
A.—Tubercular Hip Disease 646
B.—Non-tubercular Chronic Hip Disease 654

XCVI.—SWELLINGS AND TUMOURS OF THE THIGH ... 656
A.—Swellings of the Soft Tissues 657
B.—Swellings of the Bone 659
1.—Osteoma and Chondroma 659
2.—Sarcomata and Allied Tumours 660
a.—Tumours of the Epiphysis 661
b.—Tumours of the Diaphysis 664

XCVII.—INJURIES IN THE VICINITY OF THE KNEE-JOINT 667

XCVIII.—ACUTE INFLAMMATORY DISEASES OF KNEE-JOINT 677

XCIX.—CHRONIC DISEASES OF THE KNEE 679
1.—Chronic Articular Effusion 679
2.—Fungating Inflammation of the Knee-joint ... 684
3.—Rigidity 686

C.—TUMOURS AND ALLIED STRUCTURES ABOUT KNEE-JOINT 687

CI.—SCIATICA AND OTHER PAINFUL DISEASES OF THE LOWER LIMBS 689

CII.—ULCERS OF THE LEG 693

PAGE

CIII.—SWELLINGS AND TUMOURS OF THE LEG ... 697
A.—Tumours 698
B.—Inflammatory Processes 700
1.—Diffuse Inflammatory Processes 701
2.—Circumscribed Swellings 703

CIV.—INJURIES ABOUT THE ANKLE-JOINT 706
1.—Injuries without Deformity 706
2.—Injuries with Deformity 712

CV.—FRACTURE OF THE OS CALCIS 716

CVI.—INJURIES TO THE FOOT, IN FRONT OF THE ANKLE-JOINT 721

CVII.—INFLAMMATORY DISEASES OF THE FOOT ... 724
A.—Tarsus 724
1.—Acute Diseases 724
2.—Chronic Inflammations 725
B.—Metatarsus and Toes 728

CVIII.—DEFORMITIES OF THE FOOT 729
1.—Flat Foot 729
2.—Talipes, Pes equinus, Pes cavus, Pes calcaneus ... 734
3.—Deformities of the Toes 737

CIX.—TUMOURS AND ULCERS OF THE FOOT 738
1.—Tumours 738
2.—Ulcers 739

Index 741

PART I.

SURGICAL DISEASES OF THE HEAD.

CHAPTER I.

FRACTURES OF THE SKULL.

WHEN Dieffenbach summarized his views on trephining, in his classical work, some sixty years ago, before the question was definitely settled, he wrote as follows :—

"Up to quite recently it was the first urgent duty of the surgeon, immediately after the injury, to make a large crucial incision, and to search for fissures or fractures. Occasionally I found on my arrival that the hairy portion of the head had been ploughed up by incisions, backwards and forwards, crucial and transverse. This was considered to be indispensable in all head injuries. A surgeon who had omitted to make the crucial incision would have incurred the same responsibility as one who failed to open the window in endeavouring to rescue a victim of coal gas suffocation."

At that time there was no "cerebral diagnosis"; but nevertheless the surgeon's need for a diagnosis had to find some expression. To leave an injury to Nature, without knowing whether or not a fissure was present, was considered to be an unworthy and culpable piece of surgical inactivity, because the real danger of a fractured skull had not yet been clearly ascertained. Philosophical speculation took the place of observation, and therefore surgery for a long time was guilty of one of its greatest sins, in breaking the law *primum nil nocere*. We smile at this kind of diagnosis; but posterity will look upon some of our exploratory procedures, involving flaps of half the skull, much in the same way as we regard those meaningless "crucial and transverse incisions." The maxim "nil nocere" must be observed, not only in treatment, but also in examination.

The term "fracture of the skull" has always conveyed to the lay mind a very painful impression; but we have learnt, since the days when trephining was epidemic, that it is not the fracture of the skull, nor even its splintering, which constitutes the danger, but the *injury*

to the brain. It is all-important to recognize this, because this alone can justify or compel interference. The study of *injuries to the skull* is of great assistance in this respect, and we must endeavour to gain a precise conception of them—not by pouring pigment on the exposed skull after the manner of the older surgeons, but by a careful consideration of all clinical symptoms.

(1) DIRECT SYMPTOMS.

The anatomical structure of the skull frequently conceals the usual symptoms of fracture; but the main indications are always present. The symptoms may be summarized as: (1) pain at the seat of fracture; (2) displacement of fragments; (3) unnatural mobility, and (4) hæmorrhage.

(1) The **pain** in fractured skull may be evident in two ways. Pain on *direct* pressure signifies that great care is demanded. A limited area of tenderness on pressure is of no importance, because every bruise is eventually painful. But a definite pain persisting along one line, for several days, should, at any rate, suggest the probability of a complete fissure. Pain may also be elicited at the seat of fracture, by *indirect* pressure, either by compressing the whole skull, or by applying pressure to one of the large fragments. This sign may be important in the case of fissures; but in the case of a comminuted fracture, the unnatural mobility will already have established the diagnosis.

(2) **Displacement** and **unnatural mobility** only occur in comminuted fractures. Displacement manifests itself in the form of a depression—*Depressed fracture*—and unnatural mobility, by resilience on pressure. These two symptoms do not usually occur together; because the fragments become fixed in a depressed fracture, and the depression remains; whereas, if the fragments are movable, the intracranial pressure tends to replace them, and the original depression is spontaneously raised. It is quite easy to recognize these symptoms, and either of them is conclusive proof of a comminuted fracture of the roof of the skull. There is only one possibility of error, which has misled even experienced surgeons; whenever any extensive hæmorrhage occurs under the aponeurosis, or especially under the periosteum, the effused blood feels at the side like a gently sloping, thick mound with a sharp edge, corresponding with the blood-soaked tissues; whereas at the centre, where the blood collects in a larger hollow space, the consistence is softer, and to the examining finger it may appear as a depression. It makes one think first of a depressed fracture. But if gradually increasing pressure causes the disappearance of the mound-like swelling, at any one spot, it is

obviously a large contusion—a cephalhæmatoma—and not a depressed fracture.

The extensive hæmatomata which occur in alcoholics through vascular degeneration easily impart to the finger the sensation of having penetrated within the skull.

A young female, well known as an alcoholic of an advanced type, was once admitted to hospital under my care. Her husband had beaten her about the head with the leg of a chair, so that it resembled a globular mass without the sign of a human feature. The scalp was one crackling area, and I was convinced that a severe fracture was present beneath it. But the withdrawal of a few ounces of blood by means of a puncture rapidly restored things to normal, and I found nothing subsequently to give the least support to a diagnosis of fracture. The only "cerebral symptom" she ever had was the noise with which she came to the Hospital.

It is important not to be deceived by congenital peculiarities in the shape of the skull, such as a deep hollow in the occipital bone, or by the presence of Wormian bones, by syphilitic ulceration, or by depressions due to former injuries.

There are some people to whom accidents are doled out by Fate with exceptional abundance. Thus, I have seen a man who sustained a fractured skull twice within a year, in attempts, as he said, to "preserve the peace" in a public house. He at once explained that a depression found on examination dated back to a similar incident, ten years before.

A case is reported of a patient who fell from a great height, and the surgeon wished to explore over a depression. But the patient recovered consciousness and explained, with just apprehension, that the depression had been present since infancy.

(3) **Hæmorrhage** is a much more constant, and therefore a more significant symptom. It may indeed be the only evidence of a fractured base. After any head injury, immediate inquiry should be made for bleeding from the ear, mouth, or nose.

In *bleeding from the ear*, it is necessary to be sure that the blood does not originate from the auditory canal. If there be but little blood in the canal, it may have been caused merely by a ruptured tympanic membrane, which can occur without a fractured base. More profuse or persistent bleeding, however, points with great probability to a bone injury, which indicates a fractured base, unless the external auditory passage has itself been severely wounded.

The auditory canal has in rare cases been injured by the pressure of an anterior displacement of the lower jaw, consequent upon a blow.

Hæmorrhage from the *nose* and *mouth* is only significant when the injury has not directly involved the face. If such injury can be excluded, it points to a fissure in the ethmoid, sphenoid, or anterior part of the basilar process of the occipital bone. Exceptionally, the blood might come from the Eustachian tube.

Diagnostic importance attaches to *subcutaneous effusions of blood*, as well as to its immediate escape externally. Their situation and their mode of onset are both significant. They usually appear in the region of the orbit and mastoid process. They do not appear directly after the injury, as do effusions from contusion. It requires some few hours for the blood to reach the superficial tissues; occasionally it takes a few days. We must guard against diagnosing every "black eye" as a fractured base. The possibility of the face having been involved in the injury must always be considered; the patient may have fallen on his face in addition to the primary accident. But in the absence of such a cause, we may definitely conclude that there is an orbital fracture, generally on the roof, when close observation reveals a gradual protrusion of the eyeball, a bluish discoloration of the eyelids and hæmorrhagic infiltration of the eyelids—signs all pointing to bleeding within the fatty and cellular tissue of the orbit. If an effusion of blood appears behind the ear a day or two after the injury, we may conclude that the fracture is either in the middle or posterior cranial fossa. If the patient has not come under observation until the second or third day, information as to the onset of the ecchymoses, at any rate the most striking ones in the lid and conjunctivæ, must be obtained from the friends.

A mistake might easily have arisen in the following circumstances. A young man, who had been run over by a cart, was brought into hospital with subconjunctival ecchymoses. A superficial examination suggested a fractured base, but he had numerous punctiform hæmorrhages over his face, neck, and upper portion of the chest. It was evidently a case of *congestive hæmorrhages*, due to compression of the thorax. Some slight cerebral symptoms followed, which indicated that the effects of the congestion had also been felt within the skull. Several cases of this kind have recently been recorded.

(4) After cessation of the hæmorrhage, clear fluid may escape from the nose or ear. If this liquid contain little albumin and much sodium chloride it is cerebrospinal fluid, and this affords an additional aid to diagnosis, which is still further confirmed by the escape of *brain substance*. Fortunately, it is not very often that this latter is mistaken for "pus" by a zealous practitioner.

(2) INDIRECT SYMPTOMS.

The direct symptoms of fracture are frequently complicated by **secondary injuries**, which require careful attention from the point of view of diagnosis and of prognosis. These complications concern the **cranial nerves**, and in the section treating of cerebral localization we shall discuss the differential diagnosis from central palsies (figs. 6, 8, 9, 10).

Facial paralysis is the commonest of these lesions.

The *ocular muscles* are sometimes involved, principally through the *sixth nerve*, but also, occasionally, through the *third nerve*.

The nature of the nerve lesion can be inferred from the time of onset of these paralyses and from their severity. If the paralysis supervenes immediately on the injury and is complete, it is obvious that the nerve must be crushed or torn at its point of exit from the pons or medulla. If its onset is delayed for some hours it suggests compression by hæmorrhage ; if delayed for some days the possibility of infective neuritis may be entertained, in the case of a complicated fracture. In the two latter conditions the paralysis gradually increases, but it will probably remain incomplete.

The following case illustrates the care which must be exercised in the diagnosis of these secondary injuries :—

A workman sustained a severe blow on the top of the head, against a stone floor. A gradually increasing oculomotor paralysis of the left side appeared on the second day. Even if the patient had not been insured against accidents, one would have thought of the connection between the injury and the paralysis. But subsequent detailed examination showed that, not only were all the external muscles of the left eye paralysed, but there was loss of pupil reflexes in both eyes. The site of the lesion must, therefore, have been in the region of the nucleus. Inquiries made of the ophthalmic surgeon, whom the patient had consulted a year previously for a slight accident, elicited the fact that already at that time he had no pupil reflexes. But no evidence of syphilis could then be ascertained. The left-sided ocular paralysis improved under mercurial treatment, which was undertaken by way of experiment, but right-sided paralytic symptoms developed subsequently. The injury, therefore, came at an unpropitious moment, but it evidently was not the sole cause of the trouble. I saw the patient again a few years later, and on this occasion also for a slight injury to the skull. He had constant double vision, and Wassermann's reaction was positive.

Injuries of the optic nerves frequently occur with a fractured base. As a rule, optic atrophy appears after a little time. Sometimes the nerve is only crushed, so that the blindness is not complete : but the prospect of recovery is only small, because the optic nerve does not undergo regeneration like a peripheral nerve.

Deafness results, either from damage to the *auditory nerve*, or from injury or concussion of the *labyrinth*. The symptoms of the latter are noises in the ear, giddiness, and nausea ; but the latter must not be confused with the nausea caused by cerebral pressure. Labyrinthine concussion can occur independently of bone injury, so that a diagnosis of fractured base cannot be made from this condition alone.

After recognizing the presence of a fracture of the skull by means of the previously described symptoms, it is our duty to determine its course and direction.

Assistance is afforded for this purpose by the visible objective signs, and by the position of application of the force, if this is ascertained from the history or by the site of injury on the soft tissues. The skull is *bent* at the point whereon the blow is dealt; if the force is limited in area the bone breaks concentrically and a *perforated fracture* is produced. Thence, cracks radiate towards the opposite pole, *i.e.*, generally towards the base. These constitute the *split fractures*. Sometimes these cracks start at the base of the skull, because this is its weakest section, and run towards the site of the blow; but occasionally they fail to reach it. This explains why so many fissures are limited to the base. *Comminuted fractures* are always surrounded by fissures, produced by bending and splitting. Thoma simplifies this scheme still more, and includes both forms under the term "*deformity fractures*" (*Deformationsbrüche*), due to the abnormal reaction of the bone to traction and pressure.

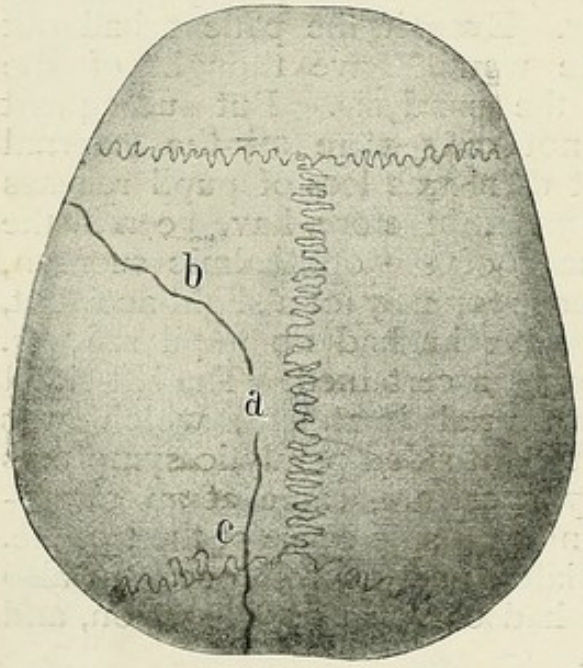

FIG. 1.—(After Kocher.) *a* = Site of application of blow; *b* and *c* = fissures produced.

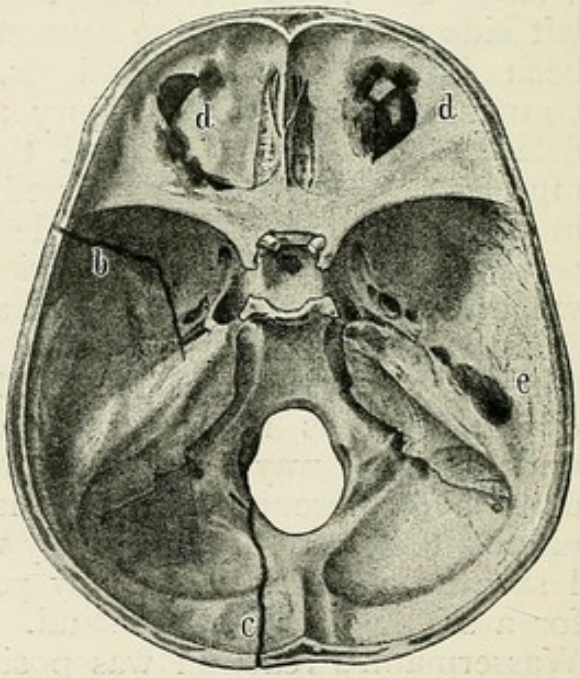

FIG. 2.—(After Kocher.) *b* and *e* = Basal portion of fissures; *dd* = separate contrecoup fractures of orbital roof; *e* = effusion on tegmen tympani.

So-called *contrecoup fractures* are full of interest, and have given rise to much discussion, but they must be clearly distinguished from the split fissures of the base, just described. The existence of these fractures is doubted by some authorities.

As the skull is not a rigid structure, but of an elastic nature and subject to change in shape, a portion of the actual force of every blow which it sustains is received by the brain, and is transmitted through it to the opposite pole. The force is checked at this spot, and the brain sustains a "contrecoup," causing more or less contusion—a contrecoup contusion. If the bone is very thin at this spot (orbital roof, possibly also the tegmen tympani) it may break under the force

of the cranial impulse, or even be completely pressed out of the skull (contrecoup fracture). These fractures at the opposite pole, caused by the continuation of the force within the cerebral substance, are quite independent of the fractures at the base produced by bending and splitting, and which are due to direct damage to the skull cap. The accompanying figures (1 and 2), clearly illustrate these varieties of fracture. They represent a case which I had the opportunity of observing while acting as assistant.

Similarly the force exerted, laterally, by a projectile shot through the skull, from temple to temple, may result in pressing the orbital roofs outwards, *i.e.*, into the orbit.

Attention to these points, and to the observations made on the patient, will facilitate an approximate diagnosis of the direction of the fissures, and particularly the fossa which they traverse. A confident diagnosis of contrecoup fracture can only be made on the exposed skull, because clinically we cannot exclude the possibility of an ordinary split fissure having involved the orbital roof.

CHAPTER II.

INJURIES OF THE BRAIN.

As we have already remarked, the treatment of fractured skull is determined by the injury to the brain, and not to the bone. For this reason our main attention must be devoted to it. Injuries to the brain may be divided into three classes: (1) *Concussion*; (2) *compression by hæmorrhage*; (3) *contusion*. It is useful to ascribe a special clinical picture to each variety; but in practice the differentiation is not very clear, and the different forms tend to coalesce. But individual features of each class can be recognized with more or less certainty, and separated from each other. An example will make this clear :—

A young stoker, who fell off his engine, was picked up somewhat stunned; he remounted, and after the stupefaction had passed off he became very excited. Vomiting, headache, and retardation of the pulse appeared in two hours, and after another couple of hours had passed he was completely unconscious. Examination showed that the left temporal bone was involved. On trephining, it was found that an extradural and an intradural hæmatoma existed under the fractured bone. A second trephining, the next day, revealed a right-sided intradural hæmorrhage. On the day after the injury, the

temperature rose to 104° F., and the pulse became very rapid, so that the prognosis was obviously bad. Death took place on the third day.

This case permitted the formation of an accurate diagnosis step by step during life.

The stunning which came on immediately after the fall indicated *concussion*. The brief interval of freedom which preceded the severe symptoms of pulse retardation and unconsciousness pointed to an increasing *cerebral pressure*, caused by the *hæmorrhage*, which was revealed at the operation. As the trephining which was done immediately, on the site of the injury, did not yield complete relief, it was obvious that there must be either another hæmatoma or a contusion of the brain or both together. The slow pulse becoming so rapid pointed to the probability of an increase in cerebral pressure through a second hæmatoma, which was found when the contrecoup area was trephined. The simultaneous rise of temperature led to the diagnosis of *cerebral contusion*, which was also verified at the *post-mortem*. There was no meningitis present, so that the pyrexia could not be attributed to this cause.

This is not the place to discuss the varying views which are held concerning cerebral pressure, and the numerous explanations which have been offered for so-called cerebral concussion. Fortunately, the careful clinical observation of the injured affords us sufficient indications for treatment, although we may not be able to explain physiologically every individual incident in the case.

Before we ascribe individual symptoms, especially vomiting, to a cerebral origin, we must assure ourselves that there is no other injury in addition to the fractured skull, as for instance an abdominal lesion. A young man, with a fractured skull, began to vomit on the second day, and this was naturally regarded as a cerebral symptom. Examination, however, showed that there was effusion in the abdomen, and laparotomy revealed a rupture in the hilus of the spleen. Finally it must be remembered that cerebral symptoms, such as vomiting and stupor, may supervene after any severe injury, especially fractured limbs. These symptoms are due to fat emboli, and they are associated with abundant fat in the urine, a marked acceleration of the pulse, and probably bloody sputum.

(1) CONCUSSION OF THE BRAIN.

We begin with the mildest degree of brain injury, the so-called **concussion of the brain.** It must be clearly understood that this term as usually applied, is a *general term*, embracing all the milder forms of brain injury. A mild, rapidly evanescent cerebral pressure is also spoken of as concussion of the brain. "Concussion" is also a very comforting diagnosis when an indefinite contusion is sustained, especially on a part of the cortical area, whose function is unknown.

It is very convenient to have such a wholesale term, and the inadequacy of the diagnostic methods available, when an accident has just occurred, compels the practitioner to resort to this term, if he does not wish to acknowledge the impossibility of making an immediate diagnosis. But in truth, the term "concussion of the brain," is of most use to the journalist, who regards it as part of his professional duties to provide his readers with a ready-made diagnosis.

We will, for the present, put aside the cases due to pressure on the brain, or to brain contusion, and consider those which may be attributed to a transient functional disturbance, or, to be more precise, a vascular disturbance. These circulatory disorders have only two absolutely diagnostic signs; one is the fact that they begin immediately after the accident, and the other is their brief duration. The very definition of the term concussion demands that its onset should, as a *sine qua non*, follow forthwith upon the injury. Any interval before its appearance puts pure concussion out of the question. This diagnostic point is available at once; the other, the brief duration of the symptoms, can only be invoked later on, in support of the diagnosis.

The course of a case of concussion varies. The functions of the brain may return to the normal within a few minutes, or at most within a few hours. If the circulatory disturbance has been very severe, death may ensue; or indications of gradually increasing brain-pressure or of brain contusion may supervene on the clinical picture of the concussion.

We have not yet discussed the condition which obtains between the sudden onset of the symptoms and their early decline, *i.e.*, the actual *symptoms of concussion*. There is hardly any single so-called "general symptom" which has been omitted from the descriptions of concussion. These include retardation and acceleration of pulse and respiration, headache, vomiting, loss of consciousness deepening to coma, excitement, pallor, &c. Order can best be introduced into this chaos by adopting Kocher's view that concussion is, in a limited sense, an expression of a sudden rise in cerebral pressure. The pressure curve in concussion would resemble a section from the curve of a slowly rising cerebral pressure, read backwards, descending from the severe to the slight symptoms. It depends, therefore, entirely on the stage in which we find the patient, whether there be signs of paralysis or of irritability, of pulse retardation or acceleration. The symptoms also vary from case to case, in accordance with the severity with which different parts of the brain are affected. If the medulla oblongata suffers most, the pulse and respiratory symptoms will predominate. Disturbance of consciousness will be most in evidence if the main stress has fallen on the cortex.

The following maxim will epitomize the diagnosis :—

Any cerebral symptoms manifested by a patient immediately after an injury to the skull—either of unconsciousness, of disturbance in the medulla, of irritability or paralysis—point to his suffering from "concussion of the brain." We cannot tell whether there be any further mischief, for which we must await subsequent developments. Such a statement will save both ourselves and the relatives from being consoled with a "simple concussion," while the patient shortly succumbs to pressure on the brain. The "further mischief" refers, as already stated, to brain contusion on the one hand, and meningeal hæmorrhage, with gradually increasing pressure, on the other hand.

(2) CONTUSION OF THE BRAIN.

We will now proceed to consider **contusion of the brain**. This consists of mechanical damage to the nerve tissue. This clearly differentiates it from concussion, which is a circulatory disturbance. But nevertheless there are numerous intermediate forms in which it is difficult to decide between the two, even at the autopsy, let alone during life. Experiment and histological research have shown that a severe blow causes, not only circulatory disturbance, but also mechanical damage to the nerve elements and interference with their mutual connections. Although no naked eye changes be produced, the severest functional disorders may follow, and even death. The difference between these changes and foci of contusion visible at an autopsy is only one of degree. There is a whole series of connecting links between an obvious contusion and the microscopic changes which are present in what is clinically a simple concussion.

How can we clinically diagnose a contusion ? As in the case of concussion there is *immediate onset* of the symptoms after the injury. But the principal clinical difference between the two concerns the matter of *duration*. Again, in contusion focal symptoms predominate; there are signs of irritation or paralysis in cortical areas whose functions we know, whereas in pure concussion the "general symptoms" are more evident. But too much importance is generally attached to this distinction. There are many cortical areas whose functions we do not yet know, so that we cannot ascertain clinically whether they have been damaged. When a patient is unconscious it is not possible to test whether all the areas are functional, as for instance the occipital cortex. Some of the slighter and of the moderately severe symptoms must really, as a rule, be referred to the accompanying concussion. A definite contusion of the medulla produces so rapid a death by paralysis of the vital centres, that no time is allowed for diagnostic reflections. But there is always one

symptom which soon leads to an accurate diagnosis, and also permits the formation of a corresponding prognosis. This consists of a *rise in temperature*, no matter whether we regard it as a sign of irritation of the corpus striatum or not. It is quite certain that a persistent and rising pyrexia coming on a day or two after the injury must be attributed to some form of brain contusion. Some fever is frequently present in cases of hæmatoma ; but a temperature of 102° F. and above is very suspicious of contusion, even if a hæmatoma exists at the same time. This temperature does not presuppose an extensive contusion. Indeed the *post-mortem* appearances were almost negative in most of the cases wherein this fever was present; and we must, therefore, assume that microscopic damage of the brain tissue had occurred, death having followed too rapidly for the development of visible foci of degeneration. The diagnosis is easier if limited paralyses, and especially if limited spasms, remain after the symptoms of concussion have passed away. The diagnosis is equally easy if such symptoms come on day by day, while excitement and delirium continue, without presenting the features of brain pressure, to be subsequently described.

A transitory rise of temperature, due to a transitory disturbance of the cerebral circulation, *i.e.*, a pure concussion if possible, has apparently been proved clinically. We are, however, now referring to a *persistent* rise in temperature, which, moreover, *tends to increase* as the case progresses.

The following conclusion may be drawn for the diagnosis of contusion of the brain :—

A patient who, immediately after an injury to the skull, manifests brain symptoms, which persist for a whole day, and which do not fit in with the signs of a gradually increasing cerebral pressure, has sustained a contusion of the brain, in the widest sense of the term. This view is supported by the presence of irritative or localizing symptoms, arising from cortical areas of ascertained function. It is definitely confirmed by a persistent rise in temperature, which cannot be explained by infection from without.

We have hitherto maintained that the symptoms of contusion follow the injury forthwith. As a general rule this is quite true, but their severity often increases gradually, and this might be regarded as due to pressure consequent upon hæmorrhage. Operation or autopsy, however, shows that despite the presence of signs of great pressure (failure of the cerebral pulse and flattening out of the convolutions), there is no corresponding hæmorrhage. We must, therefore, assume that the contusion itself can lead to a persistent disturbance in the circulation with a subsequent rise in pressure. The same thing happens in the brain as in a contused limb—it swells, and becomes too large for the skull, even without any extensive hæmorrhage—acute traumatic cerebral congestion.

(3) CEREBRAL PRESSURE FOLLOWING HÆMORRHAGE.

The third form of damage which the brain suffers as a result of injury is the **rise in pressure consequent upon hæmorrhage.** The source of the hæmorrhage is a torn blood-vessel, either inside or outside the dura. As bleeding to the extent of nearly two ounces can be tolerated without any serious disturbance, it follows that the clinical signs of pressure will not appear at once, but only when the extravasation has reached a certain amount. *An interval* of varied length will intervene between this point of time and the moment of the accident. During this interval we may not recognize anything wrong with the patient, or may regard him merely as suffering from a rapidly recovering concussion. The duration of this "free interval" varies with the rate at which the blood pours out of the torn vessel. It may last from a quarter-of-an-hour to several days—even a week or more. The symptoms consist partly of irritative, and especially of paralytic phenomena, dependent upon the part of the cortex pressed upon—*local cerebral pressure*—and also partly of manifestations of *general cerebral pressure.* The former obviously vary with the situation of the hæmatoma; but the latter usually run a regular course, in which the following stages can be distinguished :—

(*a*) Stage of *commencing cerebral pressure,* marked by signs of irritability, especially headache, psychical excitement and retardation of pulse.

(*b*) Stage of *completed rise of pressure,* marked by a mixture of irritative and paralytic signs, and finally,

(*c*) The *paralytic stage* proper, when irritability has disappeared, and coma, Cheyne-Stokes breathing, and a rapid irregular pulse have supervened.

We may now briefly refer to the diagnostic value of the various so-called classical symptoms of cerebral pressure.

(1) *Headache.*—A continuous headache is the first symptom complained of when the cerebral pressure is beginning to rise. There are many cases of injury to the skull wherein this is, and remains, the only sign of a slight hæmorrhage.

(2) *Vomiting,* as in all forms of cerebral pressure, is an important initial symptom. It is also present in injuries to the labyrinth, and it may be a transitory accompaniment of concussion. It is only of diagnostic value when, after a free interval, it heralds the onset of the other pressure symptoms.

(3) *The state of the consciousness* is of greater significance. The sensorium is not at first affected; and if the hæmorrhage be slight, it may remain unaffected. But as the pressure increases, excitement and even delirium come on; when the pressure has risen high the

signs of irritability abate, and the patient becomes sleepy, lapsing eventually into a persistent stupor, which in severe cases changes with terrible rapidity into complete coma.

(4) *Congestion of the Disc.*—Although this is the rule in pressure due to cerebral tumour, it is rarely met with when the pressure is due to hæmorrhage. It is an early symptom, which has often vanished by the time the patient is examined ophthalmoscopically.

(5) *The pupils* are rather contracted at first, but they react to light. One-sided dilatation, with absence of the light reflex, indicates severe damage—pronounced pressure—of the corresponding side. Dilatation of both pupils is a sign of the paralytic stage.

(6) *The Pressure Pulse.*—This term is used for the full, tense, and slow pulse of the early stage, although the paralytic pulse of the final stage is also a pressure pulse. The presence of this slowing of the pulse is of the greatest diagnostic value. But it may be absent, or at any rate concealed, in cases of quite definite cerebral pressure. There are two possible reasons for this. Slowing of the pulse is, after all, a relative condition; it must be estimated in relation with the other symptoms presented by the patient. For instance, if there is fever, a pulse of 70 or 80 will actually be slow, and represent a pressure pulse. The same consideration holds good, as Kocher remarks, when the breathing, for one reason or another, becomes rapid or deep. Finally, it must not be forgotten that a very high degree of local pressure may exist in an exposed skull fracture, without the development of any general brain pressure.

But, apart from this, the pulse may sometimes remain normal for quite a long time in cases of severe brain pressure, between the initial and the paralytic stages. Probably the presence of contusions may account for this.

Irregularity is not a necessary concomitant of the pressure pulse. It first appears when the patient approaches the paralytic stage. The pulse is first slow but regular, then slow and irregular, and finally rapid and irregular. This last stage is sometimes ushered in by a transition stage, wherein the pulse rapidly changes from slow to fast and *vice versa*. This is a matter of great importance, when the diagnosis rests between pressure and contusion.

(7) *Respiratory Changes.*—The breathing is at first hurried, but, like the pulse in definite cerebral pressure, it then becomes slow; frequently it becomes deep, and, with the further progress of the case irregular. In the paralytic stage, Cheyne-Stokes breathing appears.

(8) *The local pressure symptoms* begin with indications of irritability, viz., convulsions, contractures, increased reflexes, and later on paralysis of the centre exposed to the pressure. There will be mono- and hemispasms, mono- and hemiplegia, according to the situation and extent of the hæmatoma. Conjugate deviation of the eyes towards the healthy side in the stage of irritability, or towards the injured side

in paralysis of the cortical centre, is especially significant. ("In irritation of the centre the patient looks away from this lesion; in paralysis he looks towards it.") If the hæmatoma is in the region of Broca's convolution, a more or less definite cortical motor aphasia will develop. If it is situated over the left temporal lobe, sensory aphasia will be found; if in the occipital region, there will be hemianopia, *i.e.*, blindness of the two halves of the visual field of opposite sides. Further details will be given in Chapter VI.

All the symptoms will vary very considerably according to the situation and extent of the hæmatoma, and according to its rapid or slow formation. As the various centres differ in their irritability, it will often happen that, with the same pressure, one centre will be in a state of irritation, while another is already paralysed. It will, therefore, seldom happen that the symptoms described will be observed in their classical order. Nevertheless we shall not overlook brain pressure from injury, if we adopt the following summary of the foregoing:—

If a patient has sustained an injury to the skull, and then, after a free interval of very variable duration, or after the cessation of initial signs of concussion, brain symptoms of any kind supervene, it is probable that there is pressure from hæmorrhage, whether the brain symptoms be focal or general. If the symptoms increase we must regard the case as one of brain pressure, even if the classical signs of that condition are not present in a fully developed form, viz.: Disturbance of consciousness, slowing of pulse and respiration, and congested disc.

As previously remarked, there are cases of definite brain pressure after an injury, wherein there has been no considerable hæmorrhage at all. In the absence of any striking rise in temperature, pointing to contusion, it is sometimes quite impossible to be sure of the diagnosis.

If we are convinced of the existence of a hæmatoma, our next step is to determine its *situation*. As a rule we are led to a satisfactory conclusion by clinical experience, and by taking into consideration the position of the injury and the existing brain symptoms.

Experience shows that hæmorrhages arising from the middle meningeal artery and situated between the dura and the skull, have a certain typical localization. Most frequently the bleeding indicates a rupture of the root of the artery or its anterior branch, and is situated beneath the squamous portion of the temporal bone. Less frequently, the posterior branch is torn, giving rise to a hæmatoma in the parietal region. More rarely still, a circumscribed hæmorrhage may be found over the frontal lobe, or in the posterior fossa.

A knowledge of the *site of the injury* is important for two reasons, because sometimes the hæmorrhage is immediately underneath, and

because there may occasionally be an intradural effusion from contrecoup, at the opposite pole of the skull.

We have already seen how contrecoup fractures and corresponding brain contusions arise. Fig. 3 represents the same brain as figs. 1 and 2. Whereas contrecoup fractures are practically confined to the orbital roofs, contrecoup contusions with corresponding hæmorrhages may occur at any spot which constitutes the opposite pole of the force of the blow.

In the absence of other symptoms a careful search must be made for wounds or bruises on the skin which will indicate the site of the lesion and the probable situation of contrecoup effects.

The *existing brain symptoms* furnish the most important guides. Aphasia, monoplegia, hemiplegia, perhaps occasionally a hemianopia indicate, at once, the site of the pressure. Localized convulsions or attacks of Jacksonian epilepsy will do the same. Often enough, it is necessary to employ all the three aids to establish an exact diagnosis.

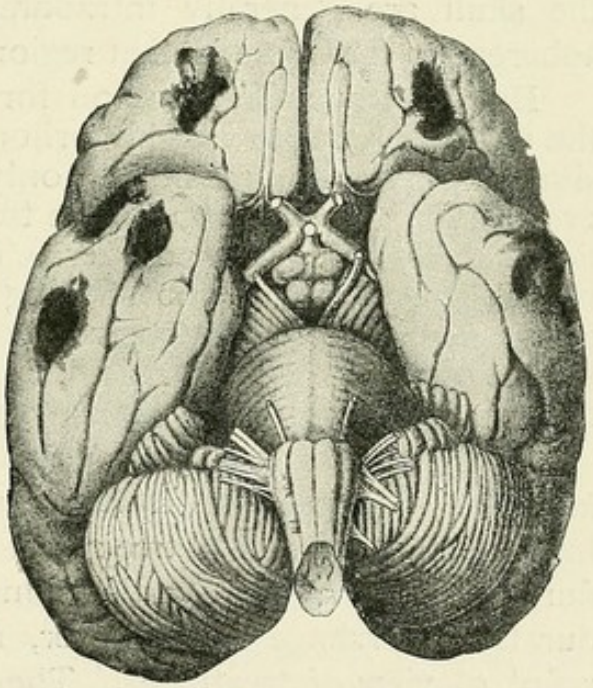

FIG. 3.—(After Kocher.) Contrecoup contusions from force applied on convexity; contrecoup fractures also produced. (See figs. 1 and 2.)

For example: A young man was thrown off a horse, and on the following day he showed symptoms, partly of contusion and partly of brain pressure. As the symptoms increased, it was necessary to interfere. The skin was abraded in the right temporal region, and there was a bruise behind the right mastoid process. There was paresis of the right side of the face and the right arm, and the right thumb was spasmodically contracted into the hand. Conclusion: probably a hæmatoma over the site of injury, but certainly a hæmorrhage by contrecoup over the left hemisphere. Both sides were trephined, and an insignificant hæmatoma was found on the right side under the injured skull, while on the left side a large intradural hæmatoma existed.

Can we distinguish whether the hæmorrhage is *extra- or intradural?* This question has often been raised and has been variously answered. The following anatomical considerations will guide us: An extradural hæmorrhage arises from injury to the middle meningeal artery, a comparatively large vessel; while bleeding under the dura arises from injury of the much smaller vessels of the pia.

Further, the dura is much more adherent to the skull than the soft membranes of the brain. We may, therefore, draw the following conclusion: Owing to the size of the vessel, an extradural hæmorrhage will develop more rapidly than an intradural, but owing to the close adhesion of the dura to the skull the former will remain more limited than the latter. For the same reason the focal symptoms of an extradural hæmorrhage will be more definite than those of the intradural variety. The latter is often characterized by a prolonged free interval, and by the predominance of general pressure symptoms over those indicating disturbance of the motor area. A hæmatoma situated directly over the cerebral cortex is more likely to produce irritation than one with an extradural situation. Intradural hæmatomata are more often accompanied by contusion, and therefore by rise of temperature, than are the extradural. Hæmatomata at the base of the skull are generally intradural, because the dura is so closely adherent to the bone in that region.

But the favourite situation for large intradural hæmatomata is on the convexity, in the neighbourhood of the falx cerebri. Even in this situation aphasia may be the only focal symptom, which comes on eventually. I have seen this in two cases which came under observation shortly after one another. The free interval lasted four to six weeks, and there were no striking symptoms of interference with the limbs, despite a very extensive hæmatoma over the convexity. There were, however, slight aphasic disturbances, which, at any rate, indicated the side upon which the hæmatoma was.

Endeavours have been made to get information from *lumbar puncture*. Blood-stained fluid justifies the diagnosis of intradural hæmorrhage, but a negative result does not necessarily mean an extradural hæmorrhage. The decision as between an extra- and an intradural hæmorrhage is, however, not of much importance from the point of view of treatment. The main question to solve is whether there be a contusion or a hæmorrhage, and lumbar puncture confers no definite assistance in this direction. Blood-stained fluid may be expected both in contusion and in intradural hæmatoma. An *exploration* of the skull is much more valuable in a doubtful case. Sometimes a drill hole opening will suffice, but it is safer to make an opening—a few millimetres in extent—in order to ascertain with certainty the condition of the cerebral membranes and the cortex. Sometimes several such openings will be required before the hæmatoma is discovered. But this is a matter of therapeutics rather than of diagnosis, and should only be undertaken when all preparations have been made for an extensive operation. We do not wish, however, to imply that every case of brain pressure from hæmorrhage requires trephining. Many intracranial hæmorrhages — especially intradural—get absorbed without any interference, and we frequently see the symptoms of an incipient pressure disappear in a few days.

But every patient with signs of pressure ought to be placed in circumstances wherein operation can be performed forthwith if symptoms increase, especially if any disturbance of consciousness occurs. But for this purpose it is necessary to recognize the pressure symptoms early, even without any exploratory trephining.

The sites of traumatic contusions and hæmorrhages are not always on the surface of the brain. Hæmorrhages have been observed in the medullary layer and in the ventricle. These deep-seated injuries are most liable to occur when the concentration of the force, transmitted through the brain, becomes divided, or when the force is diverted from its direct line, as happens in the vicinity of the ventricle, especially the 3rd, and the basal ganglia.

CHAPTER III.

ABSCESS OF BRAIN, HÆMORRHAGIC PACHYMENINGITIS, CYST OF BRAIN, TUMOUR OF BRAIN.

As one of the primary rules for the diagnosis of cerebral abscess or tumour, the proposition must be stated that occasionally both these diseases run a long course without a symptom, and then death may ensue with very few typical symptoms, and with such rapidity as to cause dismay, both to the relatives and to the medical attendant.

A young man, in perfect health, began to complain of pain at the back of the head. The doctor regarded it as an occipital neuralgia of unknown origin ; treated the patient accordingly and, at his last visit, declared that the trouble was insignificant. Two days later, that is, ten days from the onset of the pain, the patient suddenly fell ill and died within a few minutes. The autopsy revealed a glio-sarcoma of the cerebellum, as large as a plum.

With cerebral tumours we must include growths from the meninges, the internal surface of the skull, as well as solitary tubercles and gummata, because all these diseases assert themselves by the same symptoms. These consist of a combination of symptoms due to general brain pressure with signs of local displacement and destruction. These symptoms also apply to cerebral abscesses, but the latter are distinguished from tumour-like formations by their cause, their rapid progress, and occasionaliy by high temperature.

The most important symptom, and the one which the patient notices first, is *headache*. In the early stages it only comes on, in

attacks, and there are long intervals of freedom. But its great intensity should serve to differentiate it from other ordinary headaches. Sometimes there are *attacks of giddiness*, or *epileptiform seizures*, in addition to the headache, before ever any permanent focal symptom can be detected by examination. Occasionally, the brain pressure reveals itself by apparently unprovoked *vomiting*, a symptom recognized as one of the early indications of tubercular meningitis. If the retina is examined, an indispensable proceeding in all cases of severe, persistent, or intermittent headache, a *congested disc* will probably be already found at this stage. This, of course, absolutely excludes the possibility of simple neurasthenia. At first the disc is congested only on one side in tumours of the frontal lobe, but the congestion appears sooner in these tumours than in those of the motor area.

There is usually no *slowing of the pulse* in cases of abscess or tumour; it is only present when symptoms become acute.

It is necessary to utter here a word of warning which may be useful even to experts. Headache, attacks of unprovoked vomiting, and epileptiform seizures may occur during the course of *nephritis*, and an albuminuric retinitis may be confused with a congested disc. An examination of the urine should, therefore, never be neglected when there are brain symptoms of unknown origin!

Although a congested disc or optic neuritis *alone* must at once excite suspicion, it does not clench the diagnosis of cerebral disease, because it may also be present after infectious diseases, in syphilis and lead poisoning. In the latter case the optic neuritis may be associated with other brain symptoms of plumbism which would easily suggest a diagnosis of cerebral tumour if one were not aware of the cause, and the presence of the blue line on the gums. This possibility should always be considered. Error may also be caused by thrombosis of the central veins, which occurs in arteriosclerotic or anæmic persons.

A cerebral tumour of the central convolutions, or their proximity, gives rise usually to an epilepsy of the Jacksonian type, consisting of localized clonic spasms, which eventually merge into generalized attacks as the disease advances. But if the tumour is otherwise situated, the attacks may be indistinguishable from true epilepsy.

Having arrived at the diagnosis of a lesion which is causing pressure on the brain, we must distinguish between comparatively acute conditions, like *abscesses* and hæmorrhages, and those of more gradual progress like *gummata*, *tubercles*, *tumours* and *cysts*.

(1) ABSCESS OF THE BRAIN.

The principal argument in favour of abscess is the comparatively rapid course of all the symptoms. The events in tumour formation,

which are spread over months or years, are often in the case of abscesses crowded into a few weeks. But there are many exceptions. Abscesses which are not very acute may remain unnoticed for months or even a whole year, if they have developed a firm limiting membrane.

Even in these chronic cases the whole course of the disease differs from that in tumour. The development of an abscess is more irregular than that of a tumour, as indicated by periods when the whole condition becomes worse and is complicated by a rise of temperature. We have hardly yet referred to the latter, although, *a priori*, one would expect that the temperature would differentiate an abscess from a tumour. But this is not by any means the rule. In some abscesses there is no rise of temperature at all, or it comes at the very end, when it is too late for professional assistance. On the other hand, there may be an irregular temperature, even as high as 100·5° F., in cases of cerebral tumour, and naturally also in cases of solitary tubercles. A rise in temperature can only be regarded as an aid in the diagnosis of an abscess in the exceptional cases wherein it possesses the definite character of a suppuration pyrexia—*i.e.*, morning remissions with regular evening rises, or if the aggravation of the brain symptoms is accompanied by very high fever. In both these cases we should conclude that the fever points not only to an abscess, but also to its *extension*.

The value of a congested disc for differential diagnosis consists in its pointing to a tumour rather than an abscess.

Pain on *percussing* a limited area on the skull may be a further sign of abscess, but it is also present in tumours and tubercle, so we cannot ascribe to it any differentiating value.

The chief factor in our diagnostic reflections must concern the *etiology*. An abscess of the brain always has a definite cause, in so far as there must be a portal of infection, which can generally be demonstrated clinically. A tumour, on the other hand, has no cause which we can ascertain, at any rate, when it is primary. We must, therefore, primarily search for the source of an infection. If there be an open wound in the skull, this is easy enough, but even here the abscess may supervene long after the wound has healed. Exceptionally, micro-organisms can make their way by metastasis to a contused area of the brain.

On one occasion I saw multiple abscesses following contusion in an old bronchitic patient. These contained pure cultures of Fränkel's pneumococci. But an abscess of the brain is more frequently the sequel of non-traumatic suppuration in the cranial bones, the principal example of which is chronic suppurative inflammation of the middle ear, especially when this has attacked the air spaces in the petrous

portions of the temporal bone and led to its destruction. Every patient who has ear suppuration, even if his brain symptoms are not very striking, must be suspected of abscess of the brain. We shall see in the next chapter how this differs from other complications of otitis.

Suppuration in the frontal sinus must also be taken into consideration, although this is a less frequent cause of cerebral abscess than ear suppuration.

If no focus of suppuration can be found in the skull-cap, we must look elsewhere in the body for a source of infection. Suppuration in the pleura is the most probable source in this connection.

A young man, with a tubercular family history, suffered from an empyema which was at first treated by Bülau's drainage. As the suppuration did not cease, he was transferred to the surgical ward. After resection of several ribs the empyema was cured and there remained only a small fistula in the scar. Then suddenly brain symptoms appeared, signs of pressure without fever and without any focal indication. The tubercular heredity strongly suggested tubercular meningitis. In a week's time right-sided hemiplegia suddenly supervened, followed by death a few hours later. Autopsy revealed a large abscess of the brain in the left precuneus, behind the falx cerebri.

There is no doubt that this abscess formed while the pus in the pleural cavity was under pressure, *i.e.*, before the resection of the ribs, and probably before the drainage. It developed quietly without focal symptoms because it was not situated directly in the motor area.

Suppuration of the gall-bladder can also be the source of infection for an abscess of the brain.

Finally, actinomycosis of the jaw has frequently led to abscess of the brain, either by metastasis or extension.

Directions for the localization of abscesses are given below in connection with tumours, and also in Chapter VI.

(2) HÆMORRHAGIC PACHYMENINGITIS.

Assuming that we have excluded the presence of a chronic abscess of the brain, principally because we cannot fix upon a likely source, we still have other conditions which may explain symptoms with which we are dealing. These are : (1) *Hæmorrhagic pachymeningitis ;* (2) *traumatic softening*, or *traumatic brain cysts.*

Let us take **pachymeningitis** first. This is characterized by persistent headache, or by occasional seizures thereof, by giddiness, and even by hemiparesis in the intervals.

But on the other hand, there is no congestion of the disc, except at the periods of hæmorrhage. The acute exacerbations resemble apoplectic attacks, which is not the rule in the case of tumours. It is, however, distinguished from ordinary apoplexy or from embolism

by the predominance of spastic symptoms and of irritability. If we bear in mind the great tendency of hæmorrhagic pachymeningitis to relapse, and if we remember that most of its victims are chronic alcoholics of an advanced type, the diagnosis will not usually produce any great difficulty.

This subject has acquired surgical significance since good results have followed operative evacuation of hæmatomata. Obviously, such treatment can neither restore the condition of the arteries nor convert the patient into a belated total abstainer.

As the acute exacerbations often come on after a fall, the following medico-legal questions are important :—

(1) Did the patient fall because he had a hæmorrhage, or was the hæmorrhage the result of the fall ?

(2) Assuming that there was an accident, and a hæmorrhage occurred, was the latter due to the accident or to the antecedent alcoholism ?

After considering all the data of the previous history and the special circumstances of the "accident," an expert can often arrive at a definite opinion ; but nevertheless these cases are a fruitful source of litigation.

(3) TRAUMATIC CYSTS OF THE BRAIN.

The diagnosis between tumour and *traumatic softening or cerebral cyst* is difficult. The symptoms may be so much alike that only the history supplies the decisive factor. If the patient is able to report a severe injury to the skull, evidence of which we can find on the scalp, the lines to proceed along are generally clear. It will be necessary, of course, to exclude a chronic cerebral abscess as far as the progress of the case and the temperature chart permit. But in the absence of any injury to the skull, the matter becomes more difficult. A most careful examination of the skin covering, and of the surface of the skull is indispensable. But as *tumours* may follow injury, one should realize a further fact before diagnosing a cyst, *i.e.*, the duration of symptoms—especially epilepsy—for years, without the supervention of new indications, and without any essential change in the patient for the worse.

A man, aged 54, was admitted to hospital for epileptic attacks. The symptoms, principally a right-sided hemianopia, pointed either to a cerebral tumour or a traumatic cyst of the brain. A careful examination of the skull, however, revealed a small scar over the left occipital region. It was not until then that the patient remembered a fall on the head off a hay cart in his youth. The diagnosis was, therefore, a traumatic cyst of the brain, which was confirmed by the operation.

Sometimes we may have to rely on an obstetric injury by forceps. If no history of any kind, pointing to an injury, is available, it is

impossible to diagnose a cyst. But this is of no importance, so far as treatment goes, because a tumour which can be localized ought to be operated upon, if surgically feasible.

Traumatic cephalo-hydrocele, a special variety of cerebral cyst, is referred to later on.

Another special variety of cerebral cyst consists of non-traumatic, separate cystic accumulations in the soft meninges, especially in the vicinity of the cerebellum. Like the corresponding changes in the spinal cord, they possess all the symptoms of tumour, and their diagnosis can only be established at the operation.

(4) NEW GROWTHS AND TUMOURS OF GRANULATION TISSUE.

If there is absolutely nothing pointing to abscess, pachymeningitis or cyst, we have to think of a **growth within the skull**, viz., *neoplasm*, *tubercle* or *gumma*. As already stated, the possibility of a new growth is not excluded by a preceding injury.

This is well illustrated by a case described by Friedrich, wherein an injury suggested the presence of a fibroma in the frontal lobe, but the essential symptoms were of psychical origin.

We now have to discuss the nature of the tumour which may be present. It would be ideal if we could infer it from the clinical symptoms. But as gummata and solitary tubercles are not infrequently extirpated in mistake for new growths, it is evident that we have not yet attained this ideal. The most important consideration for the diagnosis is offered by the general course of the illness. As a rule a *tumour* grows steadily on, whereas a *gumma* presents intermissions in its course, which, therefore, will probably be irregular and capricious.

The previous history and the systematic examination of the patient will afford us more information. Careful attention must be paid to everything which may give a definite lead to the diagnosis, without seizing exclusively on any one point. Severe, rapidly and steadily increasing symptoms will therefore suggest a malignant growth, even if the patient has a tubercular family history. The fact that the patient has had syphilis will not preclude a diagnosis of tumour or tubercle, if there is definite evidence pointing thereto. Again, a patient who has for some time been exhibiting symptoms of tumour, but has just recovered from syphilis, is obviously not the subject of a gumma.

Too much importance is not to be attached to a negative history of syphilis, in view of the fact that patients may be genuinely ignorant of having suffered, especially if they have been victims of "lues insontium." A positive Wassermann reaction is very significant, though it only means that the patient has had syphilis and is not

completely cured, and the tumour may, after all, be a tubercle or a sarcoma.

The final, and often the decisive diagnostic point, is the effect of specific treatment. If energetic treatment, not unduly prolonged, is unsuccessful, or if its effect is doubtful, the patient must be regarded as a "surgical case," provided any focal symptoms are evident, no matter whether our diagnosis be tumour, tubercle, or traumatic cyst. This leads us to the problem of *localization*.

Signs of paralysis are of most value, because these give a more correct indication of the seat of pressure than do symptoms of irritation, which may have their origin in the regions adjacent to the lesion. Localization is easy when the tumour is situated in the *motor area*. When *hemianopia* is the chief symptom, the local diagnosis demands great care, because this may be due either to a lesion in the occipital cortex or in the optic tract. If it is possible to excite the pupillary reflex from the blind half of the visual field—the so-called hemianopic pupillary reaction—the tumour is probably in the visual area. If this reaction is not present, it is an argument against that localization. To test this requires the full consciousness of the patient and also a certain amount of intelligence, which are not always present in cases of cerebral tumour. We must therefore look for assistance from other symptoms, and basal symptoms will almost certainly be in evidence when a tumour is pressing upon the optic tract, as the following case illustrates:—

A young man, free from syphilitic or tubercular antecedents, fell ill with attacks of giddiness and headache. Later on, he also suffered from transitory mental disturbance and aphasic manifestations, for which he was brought to the hospital. A careful examination showed right-sided hemianopia, paralysis of the left oculomotor nerve, very variable speech disturbance, and intermittent mental derangement. It was not possible to obtain the hemianopic pupillary reflex with any certainty, but the discs were severely congested on both sides. The diagnosis appeared to be a tumour of the left frontal lobe, towards the base, pressing on the optic tract. This was the only explanation which would embrace all the chief symptoms—hemianopia, speech disturbance, and paralysis of the ocular muscles. The autopsy revealed a sarcoma as big as a fist occupying the left frontal lobe and growing towards the base. The left optic tract was compressed into a strip as thin as a piece of paper.

It is always necessary to seek for a diagnosis which will elucidate all the symptoms simultaneously. A localization which assumes several foci of disease is either wrong or, if well attested, must also assume a disease wherein the lesions may be multiple, like gumma, tubercle, or secondary growths, and not merely a single new growth.

The details of cerebral localization are given in Chapter VI, but we append here a brief outline of the diagnostic symptoms of tumours,

according to their localization. The same symptoms naturally hold good for abscesses and cysts. (*Compare* figs. 6 to 10.)

Frontal Lobe.—Psychical disturbances, mental disease, sexual perversion, loss of memory, fine tremor of same side, hemiparesis of opposite side, ocular paralysis (extrinsic muscles), compression of optic tract, unilateral congestion of disc, aphasia frequent when tumour is on left side.

Region of Pre-central Sulcus.—Signs of motor irritability or of paralysis on opposite side. Extent of symptoms depends upon extent of tumour.

Parietal Lobe.—Loss of all perceptions comprehended under the term of "muscle sense." When of considerable extent, symptoms arise from adjacent area, such as motor disturbance, signs of acute irritation, hemianopia, and, if the tumour be on the left side, sensory aphasia, word-blindness and agraphia.

Temporal Lobe.—Sensory aphasia (left side).

Occipital Lobe and Cuneus.—Symptoms of optic irritation, homonymous hemianopia, mind-blindness.

Cerebello-pontine Angle.—Trigeminal neuralgia, tinnitus, deafness, labyrinthine giddiness, paralysis of adjacent nerves, especially the sixth and seventh.

Region of Pons.—Spastic paralysis of the opposite limbs. Paralys s of sixth and seventh nerves of same side.

Cerebellum.—Pain back of neck, giddiness, early onset of double optic neuritis, rigidity of posterior cervical muscles, cerebellar ataxia (tendency to fall towards side of tumour), vertigo, nystagmus, forced movements, distant effect on contiguous nerves.

Pituitary Gland.—Pressure signs on optic chiasma, *i.e.*, bitemporal hemianopia, ending in complete blindness. This symptom is almost pathognomonic of a pituitary tumour, in the absence of such a cause as a fractured skull or a gunshot wound. There are often associated symptoms dependent upon the functions of growth, attributed to the pituitary body, *i.e.*, *acromegaly* on the one hand (the result of hypersecretion), and on the other a form of general *obesity* accompanied by defective genital development (typus adiposo genitalis) (the result of deficient function). An example of the latter variety will show how we arrive at the diagnosis of a pituitary tumour :—

A boy, aged 10, had been observed to squint since he was 2 years old, and from the age of 4 there had been defective vision, which culminated in complete blindness of the left eye. On examination, his appearance was very reminiscent of myxœdema, especially his dry scaly skin and defective genital development. But, in contrast to what generally obtains in hypothyroidism, his intelligence was normal. His puffy appearance was more definitely due to deposits of fat than is the case in myxœdema. The thyroid gland was present, but was rather small. The possibility of the presence of pituitary disease was entertained, especially as his mother said that he was particularly sensitive to blows or touches all over his body. Dercum, years ago, looked upon adiposis dolorosa as a pituitary symptom, and this view has again been put forward of late by Froelich and others. If this

assumption were correct in the present case, it would follow that temporal hemianopia would be present in the right eye, which was not yet completely blind. As a matter of fact, it was found that this symptom could be clearly demonstrated, and in addition both optic nerves showed signs of atrophy. Thus the diagnosis of pituitary tumour was established. The slow growth of the tumour indicated that it was not a sarcoma, but probably a very slowly progressive adenoma, comparable to a goitre of the thyroid gland. A skiagram showed, in confirmation of the clinical signs, a great widening of the sella turcica.

I have purposely refrained from mentioning puncture of the brain to determine the nature and situation of a tumour, as recommended by Neisser. The procedure is too dangerous and its results are too doubtful for it to be regarded as of diagnostic assistance to the practitioner. It may, however, be a useful expedient for the surgeon, when everything is ready for an operation.

Röntgen-ray examination is harmless. It will reveal calcified or osseous tumours, and confirm the diagnosis of pituitary tumours by showing a widened sella turcica.

CHAPTER IV.

THE CEREBRAL COMPLICATIONS OF SUPPURATIVE OTITIS MEDIA.

ALTHOUGH all the cerebral complications of otitis media do not originate from *mastoid abscess*, nevertheless it is their principal cause. It reminds us that the otitis is no longer a minor malady, but that it has reached a stage wherein danger to the brain is to be apprehended —a danger which can be prevented by timely treatment. It is the habit of aural surgeons to distinguish between acute and chronic mastoiditis, but as the *clinical* symptoms of both varieties are identical, we shall consider them together.

We must clearly understand that we are not clinically diagnosing a suppurative catarrh of the mucous lining of the mastoid antrum, but its resulting consequence. As long as the pus can freely escape from the antrum we have no means of diagnosing a mastoiditis. Comparative transillumination and percussion may guide us occasionally, but it cannot establish the diagnosis. It is only when the pus is retained, and damage occurs to the bone or periosteum, when caries develops or a sequestrum forms, that definite clinical signs appear

which proclaim the course of the disease. This holds good whether the caries be acute or chronic. Very many apparently trifling cases of otitis are accompanied by suppuration within the adjacent antrum, without our being aware of it. This suppuration is comparatively harmless as long as it does not lead to the results just mentioned. That the recognition of these sequelæ is important is obvious enough from Pitt's voluminous statistics, which show that the cerebral complications of otitis are responsible for $\frac{2}{3}$ per cent. of all deaths.

As most of these cases result from chronic otitis, it is clear that our *first* diagnostic task is to recognize those cases of chronic otitis media which may be rescued by timely surgical treatment from subsequent complications of a severe character. If we only diagnose that our patient has a "chronic otorrhœa," our services will not have been of much value. Neither does a diagnosis of "polypus of the ear" get to the root of the matter. If we say that there is chronic suppurative catarrh behind the polypus, and that something is keeping up this catarrh, we shall be more nearly approaching the truth. If we know that the discharge is frequently fœtid, that the child often complains of headache, and if the region behind the concha is occasionally painful on pressure, we should not be content with diagnosing otorrhœa or polypus, but must inform the relatives that a serious disease is present —a disease with dangerous features, which, however, can be obviated or rendered harmless by operation. If the aural discharge has lasted many years, the term *cholesteatoma* is often applied to the malady. This is not really a tumour, but merely the result of a chronic desquamative inflammation.

It should be said that there are tumours which correspond to the "cholesteatoma" of the older pathologists, but these have little concern with the diseases of the ear.

The following is a typical case of the ordinary aural cholesteatoma :—

A little boy with an old-standing ear discharge was admitted to the hospital on account of an aural polypus. The discharge was offensive, the region behind the ear sensitive, but neither swollen nor inflamed. There were no acute symptoms, temperature was normal, and the general condition was good. Diagnosis : *Cholesteatoma.* The operation revealed a cholesteatoma larger than a pigeon's egg, bathed in fœtid liquid, which had exposed the dura mater to the extent of $1\frac{1}{2}$ sq. cm.

Sometimes such a condition lasts a whole lifetime. I have seen a cholesteatoma excite brain symptoms forty years after the start of the aural suppuration.

There are two further points which support the diagnosis of cholesteatoma. The first is, that most cases follow the very destructive scarlatinal form of otitis media, and the second is, that the perforation of the drum is not central, but in the upper segment. Experience

shows that cases of chronic otitis media with a central perforation are less likely to lead to cerebral complications and recover more easily, after appropriate treatment, than cholesteatomata, which always require surgical measures.

Our *second* diagnostic task, both in acute and chronic otitis media, is to recognize forthwith the onset of severe mastoid complications, in order to prevent, by means of a timely operation, the extension of the infection to the brain. When the infection is severe, especially after scarlet fever, a decision must be made within a few hours; days cannot be afforded for the purpose. It is easy to overlook the beginning of a mastoid inflammation in a child who is already very ill, but this oversight may cost its life.

A sudden *cessation of the discharge*, with a simultaneous *aggravation of the subjective symptoms*, despite the existence of a perforation of a drum, should arouse suspicion. Increase of the pain indicates retention, and the open perforation shows that the retention is deep within the adjacent antrum.

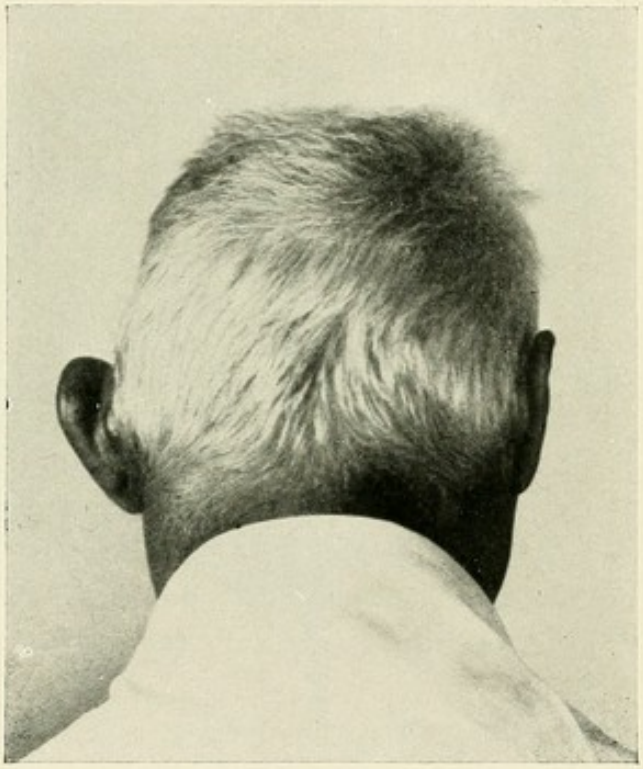

FIG. 4.—Bulging of the ear in mastoid inflammation.

Our view is confirmed if we obtain, on comparing the two sides, definite *tenderness of the mastoid process on pressure*, provided that our examination is properly conducted. We may be deceived by a painful swelling of the glands situated over the mastoid, which may enlarge after a superficial inflammation of the external auditory canal. But careful palpation will avoid any difficulty on the score of these painful glands, because of their limited outline and because the bone beneath is not tender on pressure. If the inflammation of the external auditory passage is intense, the periosteum in relation with it may become tender on pressure, without any suppuration in the air cells being necessarily present. Tenderness limited to the posterior portion of the mastoid process is not, as such, a conclusive proof of a mastoiditis. It is one of the chief symptoms of phlebitis of the emissary vein of the mastoid, and is only an indirect indication of suppuration within the mastoid cells; but, of course, it equally demands operation.

The remarks concerning tenderness on pressure apply also to the *swelling* of the soft tissues which cover the bone. Inflammation of the lymphatic glands and phlebitis may each be a source of error, but if the possibility of these be borne in mind, no mistake is likely to arise.

A definite bulging of the ear away from the head (fig. 4) is an important sign of mastoiditis.

A *reddening of the skin* gives unmistakable support to the diagnosis, as long as it has not been caused by painting iodine or applying a blistering plaster.

Must all these signs be present to justify the diagnosis of mastoiditis? Those who have often operated for mastoid disease know that there may be severe suppuration, and even sequestrum formation, in cases which have presented but little tenderness, and which have had neither swelling nor reddening of the mastoid process. We must therefore take the other symptoms into consideration, principally the temperature and the subjective feelings of the patient. If the original symptoms of an acute otitis have subsided, and then there is another rise of temperature accompanied by pain behind the ear, or if these symptoms appear during the course of a chronic otitis, we may infer the presence of mastoid disease, although the external visible sign may be indefinite. We may explain facial paralysis following aural suppuration in the same way. It should not be forgotten that, exceptionally, mastoid disease can occur without suppuration in the tympanic cavity.

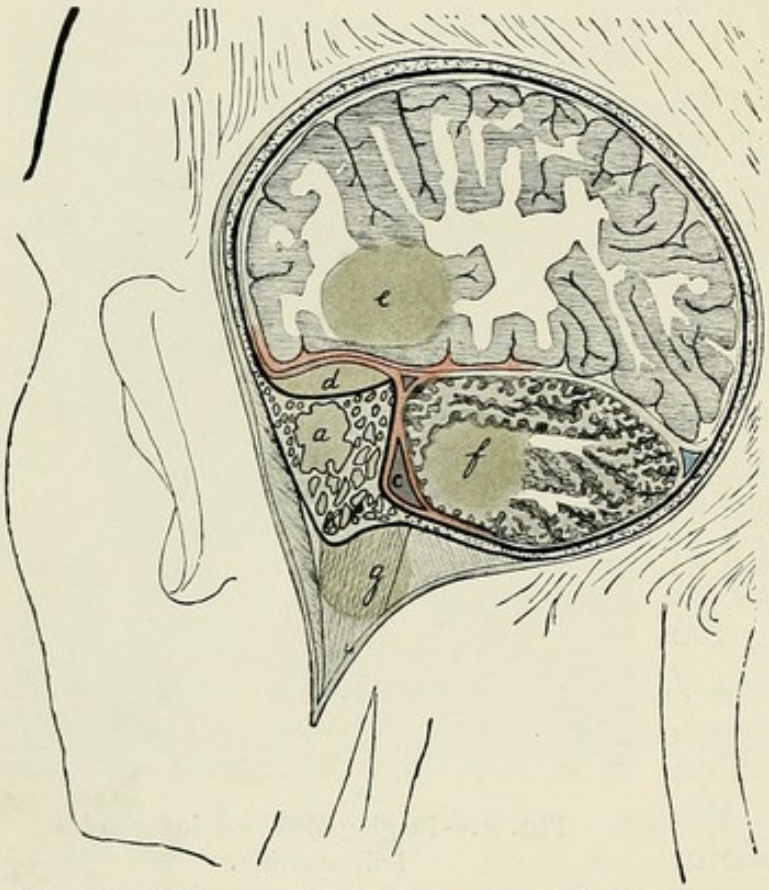

FIG. 5. — Diagram of inflammatory complications in suppuration of the temporal bone area. Green = pus; red = inflamed meninges; blue = venous sinus; violet = thrombosed sinus. *a* = mastoid antrum; *b* = mastoid process cells; *c* = thrombosed transverse sinus; *d* subdural abscess; *e* = abscess in temporal lobe; *f* = cerebellar abscess; *g* = abscess under the sterno-mastoid (Bezold's abscess).

If cerebral complications have supervened, our *third* diagnostic task is to determine their character accurately. Two practical

questions are of urgent importance, viz., are the observed symptoms only sympathetic and reflex, or are they due to anatomical changes within the skull? If the latter, do these represent an epidural abscess, a cerebral abscess, meningitis, or thrombophlebitis of the transverse sinus?

The correct interpretation of these questions is of decisive significance to the life of the patient.

It is obvious that an acute suppurative process in close proximity to the brain has some effect thereon. Every enclosed focus of infection is surrounded by a zone of *circulatory disturbance*, and in the case of a focus in the ear, the neighbouring area of brain and its sheaths may be involved. This explains the existence of a congested disc without any further changes within the skull.

In addition to local circulatory disturbances, there are the pure *reflex processes*, which are especially well marked in children, and the symptoms of a *general intoxication*. Delirium, convulsions, and even rigidity of the neck, when they occur in the first acute onset of an otitis, or in mastoiditis, must not forthwith be put down to meningitis. We should be content with opening the local focus of suppuration in the tympanum or in the mastoid process, and carefully watching the course of events. Actual cerebral complications take a definite time to develop, usually a few days. They *do not accompany* the first aural symptoms, not even in rapidly acute cases; but they *follow them*. But if such symptoms persist after the mastoid process has been properly drained, or if they occur afresh, then not only are we justified in diagnosing an intracranial complication, but we are compelled to do so and to act upon it.

We have hitherto been dealing with the matter from the point of view of an acute onset of otitis or mastoiditis. But this is not an invariable aspect. Discharge from the ear—chronic otitis—may have been present for years. Occasionally there is a temporary cessation of the discharge and the patient feels a dull pain deeply within the ear. The thermometer indicates a slight rise in temperature, but the patient, accustomed as he is to his malady, consults neither a thermometer nor a doctor. He knows that the discharge will soon start again, and he is content. But a fortnight or three weeks after this scarcely noticed incident, there supervene headache and giddiness, without anything remarkable occurring in the ear. Perhaps the patient may forget to tell the doctor that he has been suffering from an aural discharge. Such cases as these are really more serious than those which exhibit convulsions and delirium during an acute otitis.

What is happening within the skull? Are we dealing with an *epidural abscess*, a *meningitis*, a *cerebral abscess*, or a *sinus thrombosis*?

The condition of least gravity is that of **epidural abscess,** *i.e.*, a collection of pus between the roof of the petrous portion of the temporal bone and the dura mater, or more rarely posteriorly, between the petrous and the transverse sinus. These abscesses may be so free from symptoms that they are discovered quite accidentally when opening the antrum for mastoiditis. It is perhaps not correct to term their discovery "accidental," because the experienced surgeon will inspect the roof of the antrum in every case wherein he opens the mastoid process. If he has any suspicion of epidural abscess he will not hesitate to expose a limited area of dura, so as not to miss it. If the abscess is large, it will cause slight pressure symptoms: headache, somnolence, a somewhat slow pulse and a typical pus temperature. Really severe brain symptoms do not usually occur.

It is very exceptional to find any symptoms of local pressure, and then only in children. These concern the adjacent cortical areas and cause aphasia when the lesion is on the left side, and motor disturbances when the accumulation of pus is very extensive.

If the symptoms do not unanimously point to a simple mastoiditis, our first thought should be of an "epidural abscess," although the condition of the patient may not appear to us to be particularly disquieting. We may console ourselves and the relatives with this diagnosis, and yet we must confess that the pus may, after all, be on the other side of the dura. So that anyone who explores for an epidural abscess must be prepared to extend his search, if necessary, beyond the dura into the brain substance.

But are there no symptoms which enable us to diagnose a cerebral abscess forthwith? Let us first consider the fairly common **abscess of the temporal lobe,** which damages the same cortical area as an epidural abscess, when in its usual position on the roof of the petrous bone. We shall discuss cerebral abscess later on. Theoretically, we may anticipate, from a temporal lobe abscess on the *right* side, a diminution of auditory perception in the left ear. But as the right ear is not available for comparison, apart from the fact that both ears are often affected in otitis, we must discard this test. An abscess in the *left* temporal lobe may cause sensory aphasia, but does not always do so. Although it is conceivable, as already stated, that an extensive epidural abscess may cause a certain measure of aphasia, owing to pressure upon the temporal lobe, nevertheless a definite sensory aphasia must be put down to the credit of a cerebral abscess. But in the absence of aphasia, or when the disease is on the right side, we must draw our conclusion from the intensity of the symptoms. If the headache, slow pulse and vomiting are very marked, or if unconsciousness be present, there is much greater probability of cerebral abscess than of a simple epidural abscess. The temperature can be

relied upon as a guide. On the whole, an epidural abscess is more likely to exhibit the regular curve of a pus temperature than a cerebral abscess, wherein the temperature is quite irregular. Days with normal temperature alternate with sudden and steep ascents in the chart. One must not neglect the "impression" conveyed by the patient. A patient with an epidural abscess does not convey the impression of a severe case. The general condition of a case of cerebral abscess does not give rise to great anxiety, except in the last stage. Nevertheless a careful observer will detect "something" in the psychical state which, however, baffles definition. If the patient is a child the parents are quite sure that there is some "change," and a mother's observation is often more acute than that of the medical attendant. In diffuse *purulent meningitis* the clinical picture is quite different. The existence of a severe illness is in striking evidence. As this impression gains in intensity from hour to hour, the diagnosis no longer remains in doubt, for there is a steady progress in meningitis, whereas in cerebral abscess the course is fluctuating.

The following is a typical case of an abscess in the temporal lobe, following otitis :—

A little girl had been suffering from a discharge from the left ear for several years. She began to complain of severe pain behind the left ear three weeks before admission to the hospital. The mother thought that there was a slight swelling, but the pain ceased on the application of domestic remedies, and the child returned to school, apparently in normal health. Then, severe headache and vomiting set in, and the doctor noted, at that time, a slight facial paralysis of the left side. There was a little tenderness behind the ear, but no swelling, though an offensive discharge issued from the meatus. There was neither aphasia nor congestion of the discs; the pulse was not retarded, and there was only a little fever. The facial paralysis indicated a severe inflammatory process within the temporal bone, and the long duration of the disease, together with the offensive discharge, made the diagnosis of cholesteatoma very probable. The headache and vomiting made one think of abscess, but these symptoms may have been remote ones. The operation, which was undertaken immediately, revealed a cholesteatoma bathed in fœtid pus. The facial nerve canal, seen on the floor of the large bony space, was eaten away into an open channel. There was improvement for two days after the operation; then the headache recurred, with striking changes in the psychical condition and signs of aphasia. Congestion of the left disc was beginning, and therefore a diagnosis of abscess in the left temporal lobe was made. A second operation revealed an enormous abscess in this position, filled with fœtid fermenting pus. The aphasia disappeared, the mental condition became normal, and in a few weeks the child left the hospital, completely cured except for a remaining facial paralysis.

The diagnosis of *cerebral abscess* presents greater difficulties. Just

as a temporal lobe abscess is the consequence of the spread of the inflammation *upwards*, so is cerebellar abscess the consequence of its spread *backwards*. The bone is not necessarily destroyed, but the transverse sinus, which runs in the direction of the cerebellum, is frequently involved. If, therefore, signs of a cerebral abscess follow those of a sinus thrombosis, our first thought will be of the cerebellum. The only other symptom which points to this diagnosis is giddiness, of the character of cerebellar ataxia. But it must not be forgotten that any intracranial disease can cause giddiness, and that if the giddiness be very severe it may depend upon the labyrinth being affected. To make the diagnosis of cerebellar abscess probable, the cardinal signs of a cerebral abscess must be present, viz., headache, vomiting, and possibly slow pulse and congested disc, and in addition a giddiness which causes the patient to stagger, or even entirely prevents him from walking. If a sinus thrombosis is also present it supports the diagnosis, because it shows that the inflammatory process has extended backwards, but on the other hand this thrombosis may itself cause symptoms similar to those of a cerebellar abscess. It is therefore prudent to give the first signs of a thrombosis the opportunity of disappearing before proceeding in search of a cerebellar abscess.

The following is a classical case of cerebellar abscess :—

A young man, the subject of an old chronic otitis, suffered from an abscess behind the left ear. His medical attendant opened it by means of Wilde's incision, and rapid healing followed ; but the patient began to complain of headache and giddiness a few weeks later. The pulse became slow and irregular, and definite signs of a cerebral abscess appeared. Giddiness was the only symptom of localizing value, and it was so intense that the patient, whose nervous system was otherwise healthy, could hardly walk. Operation, and unfortunately the subsequent autopsy, confirmed the presence of the expected abscess.

How can we recognize **sinus thrombosis?** Its brain symptoms are of least significance. Of course, the blocking up and the infective inflammation of a large venous channel will produce a disturbance in the cerebral circulation which will manifest itself by certain signs, but these are so indefinite that no diagnosis can be based on them. There will be headache, vomiting and giddiness in cases of meningitis, just as there are in cases of abscess. But there are some special features which permit us to recognize disease of the sinus. These consist of changes in the veins connecting with the sinus. Frequently there is tenderness over the region of the emissary vein in the posterior portion of the mastoid process ; occasionally there may be œdematous swelling due to the spread of the thrombus externally, through the emissary vein.

Special attention must be paid to the condition of the internal jugular vein, which usually shares in the thrombophlebitis, at any rate in its upper section, which presents in its course some œdema, in the form of a cylindrical painful swelling. If these signs follow a previous aural discharge they suffice for a correct diagnosis. But this swelling behind the mastoid process must not be confused with the deep cervical abscesses, which are occasionally noticed after acute and chronic middle-ear suppuration, and which may spread thence over the entire side of the neck. I have seen an abscess of this kind —a fermenting phlegmon—reach down to the gluteal region. This variety of abscess, first described by Bezolt, may follow a purulent sinus thrombosis, but this is not its only cause.

If we suspect a sinus thrombosis in the absence of definite local signs, the diagnosis can be established in severe cases by the general symptoms of an infective thrombophlebitis. Repeated rigors followed by characteristic outburst of perspiration, sudden elevations of the temperature up to 104°—6° F., a pulse-rate of 140 or more, and the subsequent onset of pulmonary embolism—all these form a clinical picture which once seen is never forgotten, and which even the inexperienced cannot fail to recognize.

The only thing which now remains is **meningitis.** If the symptoms do not fit in with any of the previously described conditions, we may diagnose it by a process of exclusion. The disease is ushered in by headache, stiffness of the neck, vomiting and fever. From the very beginning the aspect is grave, and the gravity increases from hour to hour. Sleeplessness alternates with delirium, and as the disease advances unconsciousness becomes more marked. Motor symptoms of irritation and paralysis may come on without any definite order, and in the most variable combinations, but, on the other hand, they may remain entirely absent. The fever persists, the slow pulse becomes rapid, the respiration interrupted, and death ensues in profound coma.

If the diagnosis is doubtful, it may be cleared up by lumbar puncture. A negative result would justify us in searching for a cerebral abscess, but if the fluid is cloudy, operative interference is useless. The few cases of otitic meningitis which have recovered after trephining were of a circumscribed character. We must endeavour to operate in meningitis before the fluid has become cloudy as low down as the lumbar spine.

CHAPTER V.

THE PROBLEM OF EPILEPSY.

THE surgeon occasionally sees all three varieties of epileptics. He is most frequently concerned with those who suffer in consequence of previous *injury*, then with those whose epilepsy depends upon a non-traumatic anatomical lesion of the brain, and finally genuine *epileptics* find their way to him when medical treatment can offer no relief. As the surgeon has to pronounce the final verdict in regard to operation in any given case, he must be able to decide to which class the patient belongs.

The first thing to decide is, whether the patient is really epileptic, and here the difficulty begins. We will assume that no gross diagnostic blunder has been committed, and that neither uræmia nor eclampsia has been mistaken for epilepsy. It is important, however, to recognize accurately the so-called "epileptiform" attacks, and those of "petit-mal," and to distinguish the violent epileptic seizures in hysterical conditions. The differential diagnosis of this last group of cases, which we cannot here discuss, is not always very easy, especially when the tongue is not bitten, when other self-inflicted injuries are absent, and when the moral perversity may be attributed to either one or the other.

As just stated, the surgeon's most frequent opportunities for seeing epileptiform attacks are in post-traumatic cases. The following is an instance :—

The patient was a young man of a low psychopathic type, afraid of work and prone to lying. He sustained a stab in the side with a knife ; the wound healed rapidly, but he developed epileptiform attacks, which kept many observers in doubt for weeks as to their epileptic or hysterical character. He was sent from one hospital to another ; he ran away at times and simulated, consciously or unconsciously, the most varied diseases. He wanted to be trephined, to have his thorax explored, to have a laparotomy performed, and he also indulged in attacks of mild self-injury, &c.

It really matters little whether such an afflicted individual is diagnosed as an epileptic or a hysteric or as a combination of the two. His motor functions, like the rest of his nervous system, are in a state of intense irritability, and a prudent surgeon will leave him severely alone.

But, assuming that the case is one of real epilepsy, we have to consider the *clinical history*, the *course of the attack*, and the *objective condition* during the intervals, before we can classify the patient correctly.

The *clinical history* must be investigated for all those circumstances

which can point to the non-surgical character of the epilepsy, viz., heredity, alcohol, absinthe and lead intoxications, and infections, especially syphilis. But if an alcoholic suffers from epilepsy, it must not be assumed that *only* the alcohol can be credited with it, for it may be due to some accidental injury to the skull. Hereditary predisposition, intoxications, and infections form the basis on which epilepsy develops, when some exciting factor comes into play. This factor may be so trifling that it baffles observation—then the case is, and remains medical. But this factor may be provided by the appreciable results of an injury, and then the case is surgical, in so far as these results can be removed by operation.

If the question of congenital or inherited predisposition is disposed of, we must first ascertain whether the patient has ever sustained an injury to the head, more especially an injury involving both the skull and the brain. Our inquiries must be prosecuted even unto the patient's birth, because epilepsy may be the consequence of a porencephalitis due to injury by forceps.

But, apart from forceps, childhood offers abundant opportunities for cranial injuries. If a child is not dropped by its nurse, sooner or later it will fall on its own account. The skull may be compressed without the attention of the parents being attracted thereto, and the brain may suffer severe damage beneath an apparently uninjured skull cap. This damage may, in its turn, produce softening, with consequent cyst formation or porencephalitis.

If it is clear that the patient has sustained an injury to the skull, we must ascertain whether the epilepsy is a direct or indirect result. This is especially important from the point of view of accident insurance. A patient may have been epileptic before his accident, but may wish to fasten the responsibility for his disease on the period following the injury. But even if it transpires that there has been a long interval between the injury and the first attack of epilepsy—years may have elapsed—we cannot conclude that the epilepsy is not traumatic. To cite one possibility, the injury may have caused a cerebral cyst, and this, many years subsequently may declare itself by means of epilepsy and other symptoms. But as a rule traumatic epilepsy appears within a few months of the accident.

I once had a patient with a traumatic cyst in the frontal lobe. The lad began to masturbate eight years after the injury, and then epilepsy manifested itself in the form of "petit mal" at first. It was quite clear that the individual attacks were a consequence of this habit.

So far we have confined ourselves to injuries of the head, or, rather, of the brain. But there is a form of epilepsy which may follow any peripheral irritation, apart from injury to the brain. This is called *reflex epilepsy*. Any peripheral injury may set up this external irritation

and painful scars over bones, or those involving nerve-trunks have long been credited with this evil. Even foreign bodies in the nose or ear may cause epilepsy. Demme reports a case wherein a rectal polypus acted in this way.

When I was a student I saw a case of Kocher's, in which typical Jacksonian epilepsy appeared to start from a scar in the hand. The excision of the scar proved useless. It was then decided to trephine, but he escaped from this project by dying suddenly. The autopsy revealed a well-circumscribed tumour in the situation selected for the operation.

Although too much has perhaps been attributed to reflex epilepsy, we must not neglect its consideration when examining the patient. Our conjecture will become a certainty if the patient experiences any abnormal sensations in the suspected scar before the attack, or if we are able to directly excite an attack by pressing on the scar.

A boy, aged 3, who had never been epileptic, was brought into hospital with definite attacks, a few days after a fall on his forehead. Examination showed an abrasion of the forehead, from which erysipelas was spreading, and a subjacent abscess. This was opened; there was no fracture of the skull. The fits ceased immediately, and the case, therefore, was either a toxic or reflex epilepsy.

The actual **observation of the fit** is an important part of the clinical history. If it resembles an ordinary attack, beginning with general convulsions, and not regularly affecting any particular region of the body, either by a preceding aura or subsequent effects, we can draw no conclusion regarding its etiology. General convulsions usually signify so-called true epilepsy, *i.e.*, epilepsy with an unknown anatomical basis, but they also occur in other forms of epilepsy, which are caused by certain gross anatomical changes.

It is quite different when the aura, or the post-epileptic paralytic phenomena, either persistent or transitory, indicate a definite area of the cortex as the seat of origin of the attacks. Two varieties may be distinguished in this connection. In one, the convulsions are limited to a circumscribed motor area, and we are therefore confronted with typical Jacksonian cortical epilepsy. In the other, the attack similarly begins in one definite area, but it marches, in anatomical procession, along into other areas, and thus the fit becomes generalized. Temporary paralysis in the area corresponding to the seat of origin, may follow the attack.

The relatives can often furnish useful information on these points, but it is always advisable to personally confirm their statements, or to obtain their confirmation from a hospital trained attendant, because our treatment must frequently be dictated by this information.

Finally, a careful investigation of the **condition of the patient between the attacks** must be undertaken. Scars on the scalp,

irregularities on the surface of the skull, any trace of a previous injury which might be seen or felt, must be searched for to complete the clinical history. At the same time one must look for painful scars anywhere on the body, for the reason already given, and if the patient is a child suffering from recent unexplained epilepsy, the nose and ear must be examined for foreign bodies.

A thorough investigation of the nervous system, with special reference to the motor areas of known function, must follow this external examination. If this reveals such symptoms as paresis of one extremity, unilateral paralysis of a cranial nerve, or hemianopia, the diagnosis of true epilepsy must be discarded, and the cause of the disease must be attributed to some gross anatomical change, viz., infantile cerebral paralysis, old apoplexy, cerebral tumour in its widest sense, or cerebral cyst.

In children, the cause is most likely to be an intra-uterine encephalitis, producing the so-called infantile cerebral paralysis. Tumours, tubercle, gummata, traumatic cerebral cysts may occur at any age, and old apoplectics may suffer from epileptic attacks.

It is only when an epileptic emerges from such an exhaustive investigation without any flaw that he must be regarded as a case of "genuine epilepsy," and as far as our present knowledge goes surgery can offer but little help.

But, on the other hand, not every case of traumatic epilepsy can anticipate benefit from operation. Unfortunately, experience shows that the hopes based on operative measures have fallen far short of anticipation. This is, however, not the place to discuss this circumstance. Nevertheless, interference is advisable in all cases of traumatic epilepsy, unless the long duration of the illness, or the great frequency of the fits, or the mental changes, indicate that the whole central nervous system is too deeply compromised. The prognosis in tubercle and in tumours depends upon the possibility of complete removal of the growth. Post-apoplectic epilepsy we must leave to the physician, and this also marks the limit of the assistance we can give in genuine epilepsy.

CHAPTER VI.

SOME REMARKS ON CEREBRAL LOCALIZATION AND FOCAL DIAGNOSIS.

We have already touched upon the subject of focal diagnosis—*i.e.*, the detection of the situation of a brain lesion, based upon our modern knowledge of localization—but it is necessary to return to it by a more connected method.

Our first work is to distinguish a peripheral from a central lesion of the nervous system; but, as we have seen in the case of a fractured skull or of a cerebral tumour, this is not always easy, because the two lesions may be present at the same time.

Let us begin with (1) **disturbances of vision.**

A glance at the very simplified diagram in fig. 6 suggests the various possibilities which possess surgical interest. *Blindness of one side* indicates an interruption in the path between the retina and the chiasma (*f*), which may be caused by primary or secondary tumours of the orbit, or a fractured base. *Bitemporal hemianopia* is the classical sign of a tumour in the region of the chiasma (*d*), *e.g.*, a pituitary tumour. *Blindness of both sides* depends upon the same cause (*e*), but it indicates a later stage or a more extensive lesion (*e.g.*, gunshot with suicidal intent). It may also occur when there is severe congestion of the disc in cases of chronic cerebral pressure (tumours and cysts in any position, but more especially in the posterior cranial fossa). Finally, it may occur through a simultaneous lesion of both cortical visual areas—but this is rare (tumour of the Falx Cerebri). *Homonymous hemianopia* indicates a lesion in the optic tract (*c*), in the optic radiation (*b*), in the primary visual centres of the optic thalamus, lateral corpus geniculatum and anterior corpus quadrigeminum (b^1), or the cerebral cortex; (*a*), *e.g.*, tumours, cysts, or trauma.

From the surgical standpoint it is most important to distinguish between a lesion in the optic tract and in the cortex (see under Cerebral Tumour). A sign first described by Dufour may be of assistance. He states that if the visual path be interrupted at *c* or *b*, the vision is dimmed; if the lesion be in the cortex the vision is totally absent. The hemiopic pupillary reaction must be tested to determine the mobility of the pupil. If no reaction is obtained, the lesion is at *c*, thus excluding lesions both at *b* and *a*.

The cortical lesion is sometimes incomplete (*e.g.*, in tumours). In such cases the hemianopia is also incomplete, there being merely a homonymous loss of one quarter of the visual field, which, however,

must not be confused with a unilateral scotoma of peripheral origin There still remains another form of visual disturbance, which requires brief consideration, although it rarely possesses surgical interest, as it is bilateral—*i.e.*, **mind blindness.** Whereas the destruction of the cortical area marked (*a*) in the diagram prevents the perception of visual impressions, these impressions still arise if the cortex of the cuneus is unaffected, but they will not be appreciated by the mind, if the fields for visual memory on both sides, or the association fibres leading to them, are destroyed. This latter condition is termed "mind blindness," in contrast to "cortical blindness," due to destruction of the cortex of the cuneus on both sides.

All these examinations demand normal intelligence and retained consciousness, but these patients frequently possess neither the one nor the other. We must then be content with the ability to distinguish unilateral blindness, bitemporal and homonymous hemianopia. The examination can be carried out with approximate accuracy without a perimeter, although a correct visual chart is always desirable.

We may infer from the pupil reflexes that they are served by their own special fibres. Their behaviour may be ascertained from the facts illustrated in fig. 6. Disturbances in the reflexes without simultaneous visual disturbances always suggest an isolated lesion of the oculomotor nerve or its nucleus.

(2) **Derangements of the extrinsic ocular muscles** can only be detected by causing the patient to look in definite directions, otherwise they may be confused with **conjugate deviation.** As soon as the patient is told to move his eyes, it will at once be seen whether he squints. If there is no movement of the eyes when directed to look sideways, there is probably conjugate deviation. Whereas advanced ocular paralysis can easily be detected, its slighter forms can be concealed by patients bringing the non-affected muscles into action. A very careful examination for double vision in all points of the visual field is therefore necessary. It has always been said, and it will subsequently be repeated, that ocular paralyses, except when they are of purely medical significance, indicate trauma, inflammatory diseases, tumours of the orbit or base of the skull, or affections of the base of the brain. Conjugate deviation on the other hand, is always a sign of disease above the nucleus (the patient looks towards the healthy side when there is irritation, and towards the lesion when there is paralysis). In this connection, tumours, cysts, abscesses in the cortex, or in the sub-cortical white substance, and also injuries are especially of surgical interest.

The nucleus of the sixth nerve forms an exception to what has just been said. According to the most recent researches, this nucleus

represents a more deeply situated co-ordination centre. Injury thereof, which hardly possesses any surgical significance, leads to conjugate deviation towards the healthy (opposite) side.

In addition to conjugate deviation, *Nystagmus* must also be

a. Cortical lesion (cuneus, trauma, tumour, cyst, abscess). Homonymous crossed hemianopia (loss of opposite visual fields). Absence of vision complete. Reflexes normal.

b. Lesion of optic radiation, or of primary visual centres(b^1). Causes as above. Symptoms as in *a*, but vision dimmed.

c. Lesion of optic tract (generally tumour). Same symptoms as *b*, and b^1, but pupil reflexes from opposite visual fields lost (hemiopic pupillary reaction).

d. Partial lesion of chiasma (pituitary tumour). Loss of both temporal visual fields (bitemporal hemianopia). Corresponding loss of pupillary reflexes.

e. Complete lesion of chiasma (tumour, traumatism, especially suicidal gunshot wounds). Blindness of both sides, and complete loss of pupillary reflexes.

f. Lesion of optic nerve (trauma, tumour). Unilateral blindness, with loss of reflex on the diseased side, and of consensual contraction on healthy side. If lesion is incomplete, unilateral scotoma, or concentric contraction of visual field.

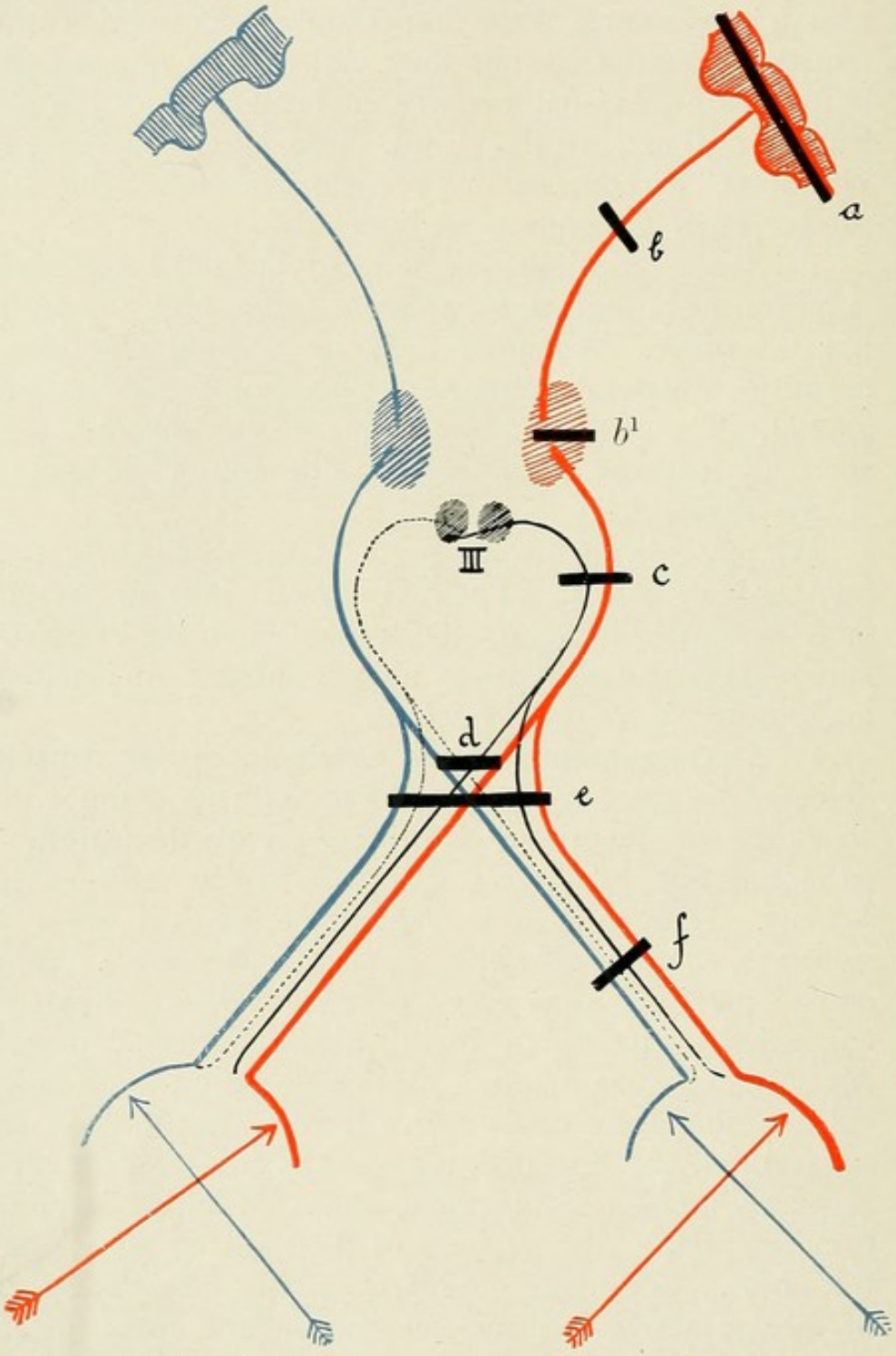

FIG. 6.—Diagram of the principal surgical disturbances of vision. Red and blue = visual fibres. Black = pupillary fibres. III is placed opposite oculomotor nucleus.

mentioned as a symptom of irritation. This may be excited artificially through the vestibular nerve, by injecting cold or hot water into the ear. This symptom is frequently associated with damage to the nerve

itself, and also with tumours in the neighbourhood of the cerebellum. It is obviously also present in diseases in the vicinity of the nuclei of the ocular muscles.

(3) It is most important to understand that in a peripheral injury

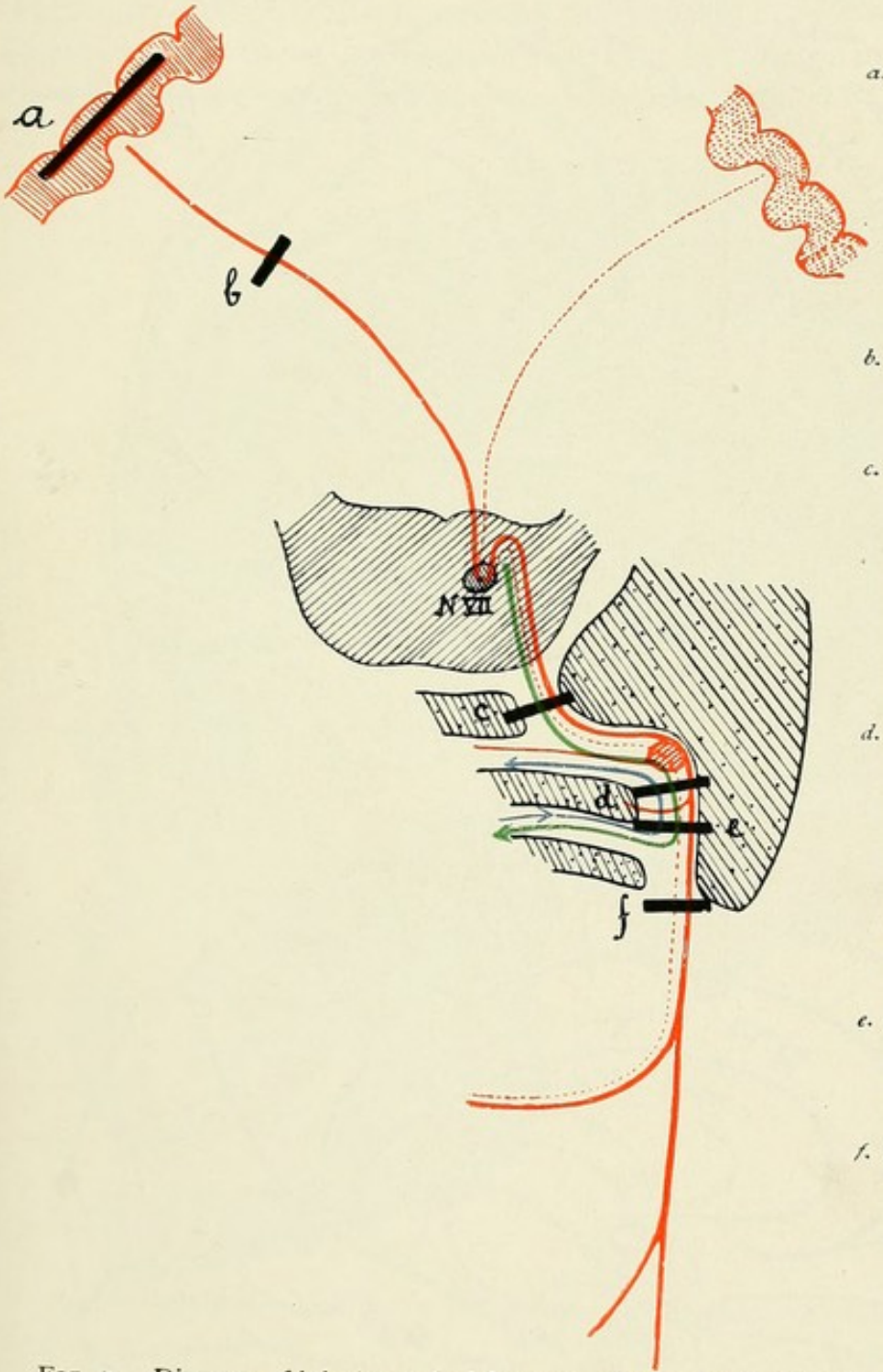

a. Cortical lesion (trauma, tumour, cyst, abscess). Crossed total paralysis of facial distribution to lower region of face; partial paralysis of upper region of face. Taste and salivary fibres normal. Corneal reflex retained. Stapedius not paralysed. No reaction of degeneration.

b. Lesion of internal capsule (causes as above). Same symptoms, but movements of expression retained.

c. Lesion at exit of 7th N. root (fractured skull). Paralysis of all motor, lachrymal and salivary fibres on same side. Stapedius paralysed (hyperacusis). Corneal reflex lost. Taste fibres unaffected. Expression and associated movements paralysed. R.A. more or less pronounced.

d. Lesion in petrous bone, below geniculate ganglion (fractured skull, mastoid osteitis). Complete motor paralysis on same side. Hyperacusis. Salivary and taste fibres paralysed, lachrymation normal. Expression and associated movements paralysed. Corneal reflex lost. R.A. as above.

e. Lesion below offshoot of N. to stapedius (same causes). Same symptoms, except that stapedius is not paralysed.

f. Lesion at stylo-mastoid foramen (trauma, new growths). Same symptoms, but taste and salivary fibres unaffected.

FIG. 7.—Diagram of injuries to facial nerve. Red = motor fibres. Green = salivary fibres. Blue = taste fibres.

of the **facial nerve** (see fig. 7), all the branches to the face are equally involved; but when the lesion is central, the lower facial branches suffer most, because the branch to the forehead is innervated from both sides of the brain. It must also be remembered that peripheral

paralysis is on the same side as the injury, whereas a central lesion produces paralysis on the opposite side. This distinction is valuable when we know the situation of the injury to the skull, but discrimina-

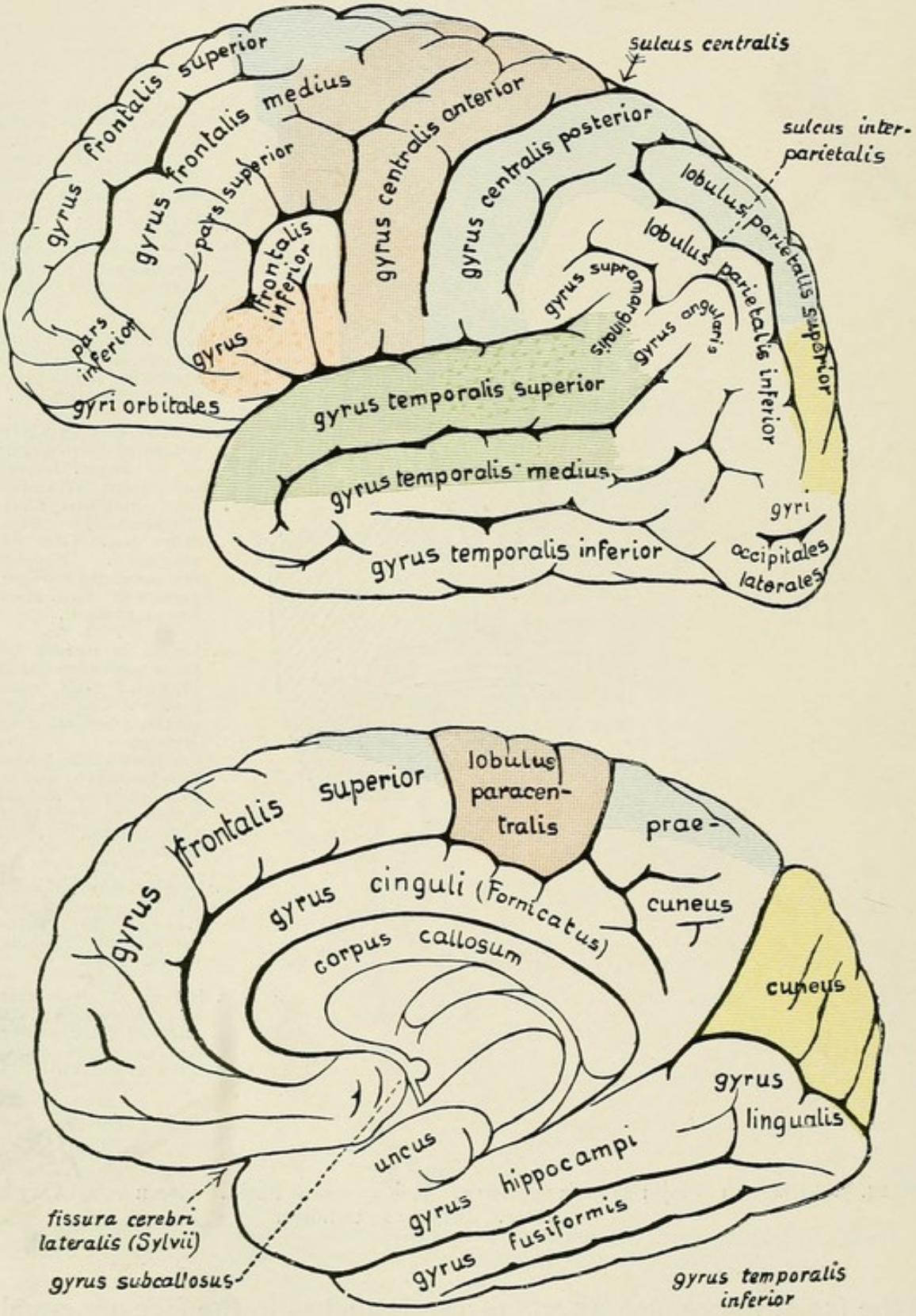

FIG. 8—The most important cortical areas, as at present established. Red = motor area. Dotted red = motor speech centre. Blue = sensory area. Green = auditory area. Dotted green = sensory speech centre. Yellow = visual area.

tion must be exercised, because in cases of injury to the cortex by contrecoup, the paralysis is on the same side as the injury. Signs of irritation, convulsions in the paralysed region, as well as paralysis of the limbs on the same side, denote a central lesion. Definite conclusions may also be drawn from the varying conditions of voluntary movement, associated movements, and those of facial expression. If these last are retained, and at the same time associated, and voluntary movements are completely lost, it is quite certain that

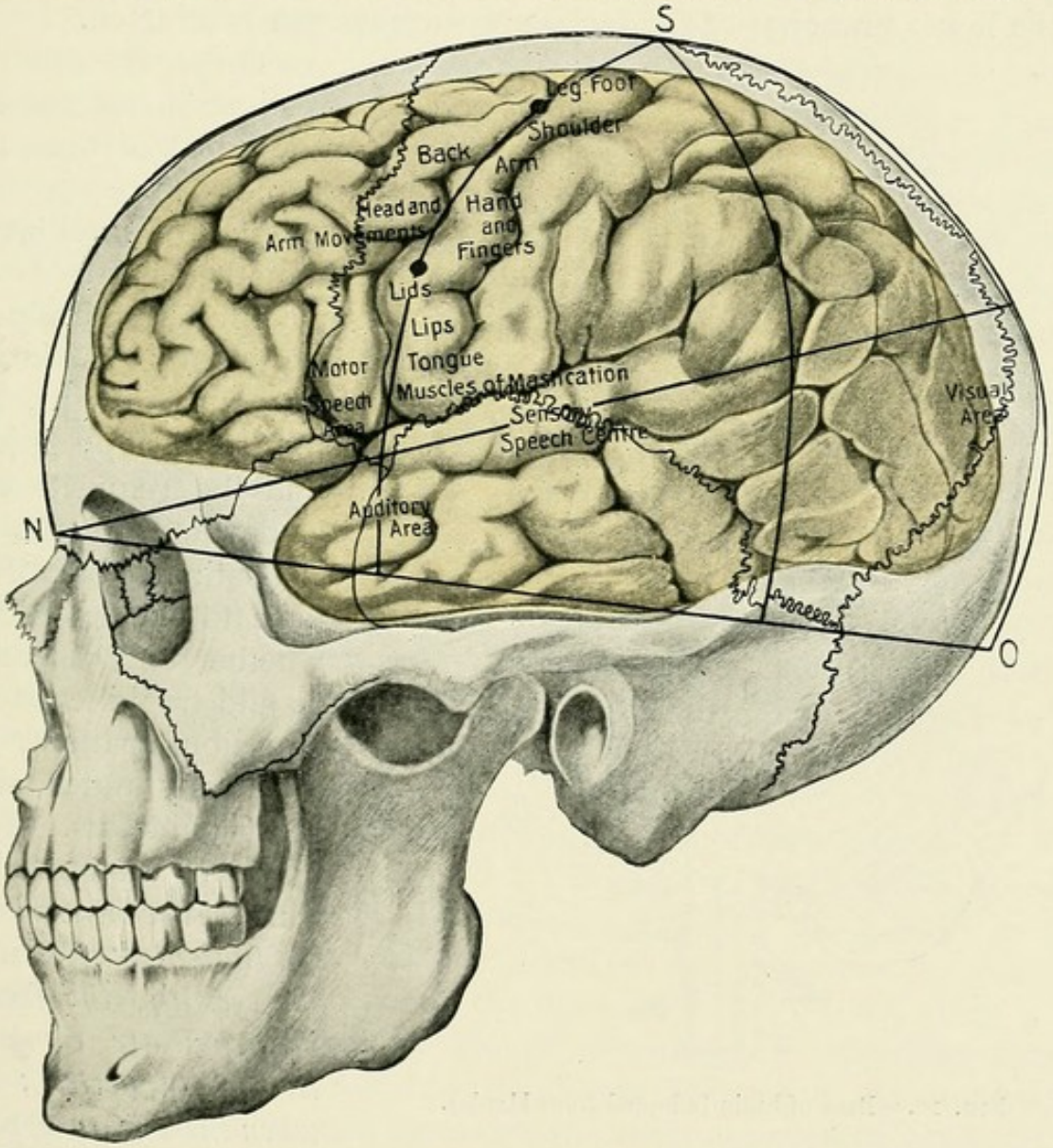

FIG. 9.—Determination of cortical centres after Kocher. Centres filled in partially after Krause.

the lesion is central. But we can infer nothing from the predominance of the voluntary over the associated movements, because this peculiarity may be present in a central as well as in a peripheral paralysis (Sahli). Paralysis of the *secretory and taste fibres* of the facial nerve, shown by a decrease of saliva and by diminution on the corresponding half of the tongue of taste appreciated by the fifth nerve, is only of limited diagnostic value. Motor paralysis due to a

lesion between the nucleus and the geniculate ganglion, really at the base of the brain (fig. 7 *c*), is accompanied by taste disturbance only; but lesions in the petrous bone (fig. 7 *d*, and *c*), below the geniculate ganglion cause taste disturbance and also a diminution of salivary secretion; disturbance of lachrymation is only caused by damage above the geniculate ganglion.

The presence of these defects, therefore, excludes a cortical lesion, but their absence only excludes such a lesion when the upper as well as the lower branches of the facial are simultaneously affected.

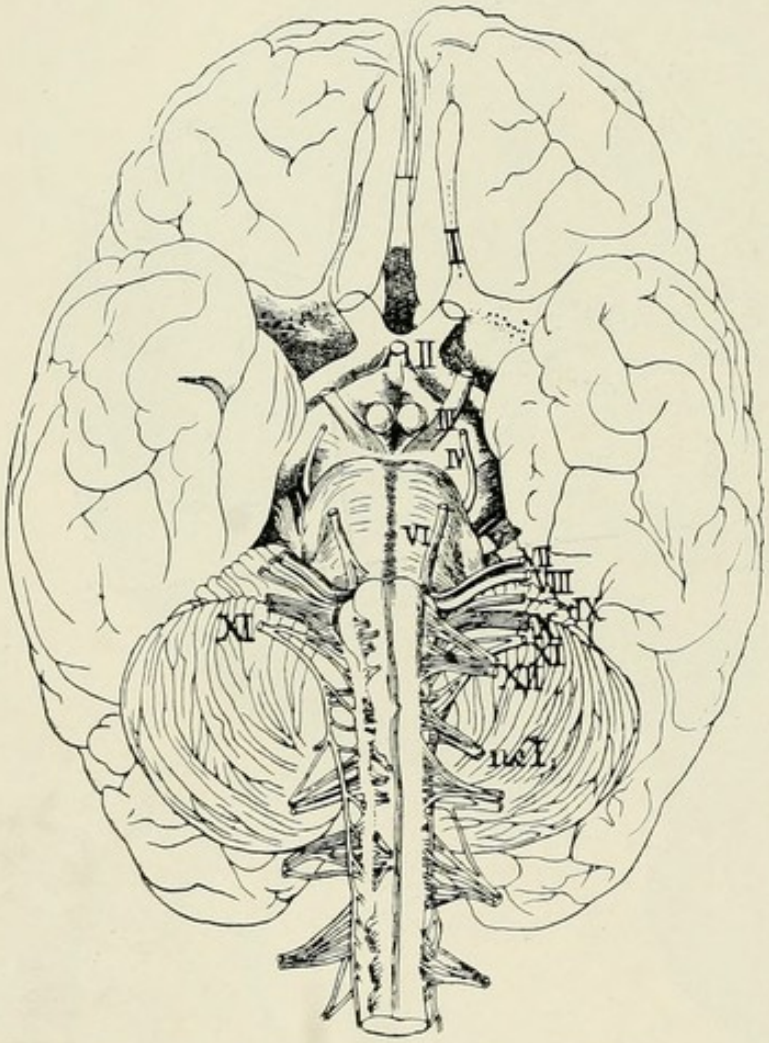

FIG. 10.—Base of brain (adapted from Henle).

These delicate investigations demand a good deal of time, and also require a due amount of intelligence on the part of the patient. It is only exceptionally, as in the case of growths, and the results of injury, that the requisite time is devoted to the examination; but if we have to decide quickly, whether and where we should trephine an unconscious patient, the previously noted signs must guide us. They may be summarized thus: *A central lesion is indicated* (1) *when the eyes and the frontal branches are comparatively unaffected;* (2) *when there is an opposite paralysis after an injury;* or (3) *when the limbs are paralysed on the same side. A peripheral lesion is indicated* (1) *when all the branches are affected on the same side as the injury to the skull;* (2) *when ocular paralyses are also present, pointing to injury of the petrous bone. If there be paralysis of the limbs on the side opposite to the facial palsy, the lesion is at the base, in the neighbourhood of the pons, or there may be two separate foci of disease.*

(4) The **auditory nerve** also possesses many points of surgical interest.

(*a*) Disturbance of the function of the cochlear nerve—which is the essential nerve of hearing—may be due to pathological changes at the base of the skull or at the base of the brain—injury, inflammation or tumour. We are able to decide, by means of Rinne's and of Weber's tests, whether the nerve itself or the sound-conducting apparatus is involved. If Rinne's test is positive, *i.e.*, if air conduction is better than bone conduction, and if Weber's test shows that the note of the tuning fork placed on the vertex appears louder in the injured ear than in the other one, we may assume that the disease is in the nerve structures. We cannot, however, tell whether the nerve itself is affected in its course, or the end organ or the cochlea. Even the loss of high pitched notes (Galton's whistle) only indicates that the damage is in the nerve apparatus, but gives no information regarding its position. There is always some uncertainty as to the significance of auditory disturbances. A definite significance is only possible if the patient's hearing was normal before the onset of the disease from which he is suffering, but in many cases this cannot be ascertained.

(*b*) The *vestibular nerve* is of more importance, surgically, although damage to it cannot be distinguished from damage to the end-organ (semi-circular canals)—or, rather, can only be distinguished from it indirectly. As the vestibular nerve is responsible for maintaining the equilibrium, the characteristic symptom of its injury is loss of equilibrium, appreciated by the patient as giddiness—indeed, as rotatory giddiness. But as the fibres of the vestibular nerve terminate in the cortex of the cerebellum, and especially in the vermiform process, it follows that injuries or diseases of the cerebellum produce the same symptoms of giddiness. According to English authorities, the difference between central and peripheral disturbances of the equilibrium apparatus is to be found in the fact, that when the disturbance is peripheral, external objects appear to the patient to be rotating from the healthy to the diseased side, whereas in central disturbances the rotation is from the diseased to the healthy side.

(5) We will not discuss the special circumstances attending those cranial nerves which are not referred to here, because all the important diagnostic points have been mentioned in their appropriate place.

(6) When there is paralysis of other movements, especially in the *extremities*, the main surgical interest refers to the question whether the lesion is in the cortex or at the base. This must be decided by observing what concomitant symptoms are present, as previously indicated. There is not usually any difficulty in this, because a facial palsy on the same side will point to a cortical lesion, whereas opposite paralysis of the facial, trigeminal, abducens or auditory nerves will point either to a basal lesion or to two separate foci of disease.

Figs. 8 and 9 represent all the points hitherto established.

(7) **Aphasia** can be diagnosed by the well-known general rules. Its surgical significance is, however, small, whether we adopt the usual view of a definite cortical centre, or attribute the so-called cortical motor aphasia to disease of sub-cortical tracts.

v. Monakow has recently endeavoured to explain certain conditions which do not accord with the usual scheme, by assuming that one cortical area may exert an inhibiting effect on another (Diaschisis).

The restoration of the power of speech after destruction of the corresponding cortical convolution on the left side, may, on this theory, not be due to the corresponding area on the right side gradually taking up this duty, but may be explained by the cessation of the diaschisis.

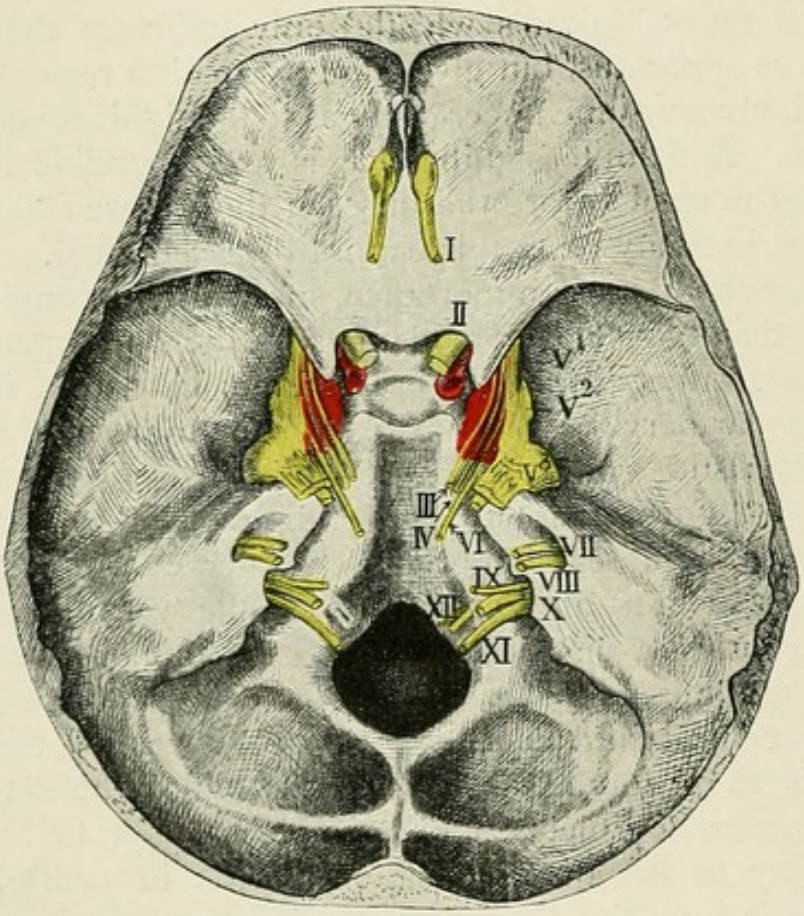

FIG. 11.—Nerves at the base of the skull (adapted from Henle).

It is important to distinguish between anarthria and aphasia. *Anarthria* means "word mutilation," the result of damage to the peripheral speech apparatus (disturbance of function in the vicinity of the nuclei and the emerging roots). *Aphasia*, on the other hand, means a derangement in the power of "word construction" in the region of the cortex and the subcortical association fibres. Anarthria points to tumours in the neighbourhood of the pons and the medulla oblongata, whereas aphasia indicates damage to the cortical centres and the subcortical fibres. It is easy enough to differentiate in the extreme cases, but difficulty arises in the mild cases, because, in slight cortical and subcortical changes, especially when the interruption of the speech fibres is incomplete, disturbances arise which are hardly distinguishable from nuclear and peripheral anarthria. A correct diagnosis can only be made in such cases by taking other symptoms into consideration (those arising from the pons, medulla, or other cortical symptoms). It should be added that the speech centre is usually on the right side in left-handed people.

The study of aphasia has established the following points in regard to the surgical aspect of local diagnosis :—

(1) Definite pure anarthria indicates a lesion in the cerebral peduncle, pons, or medulla oblongata.

(2) If the differentiation between anarthria and aphasia is not quite clear, the remaining physical conditions will enable the diagnosis to be made.

(3) Definite motor aphasia indicates a lesion in Broca's convolution (inferior frontal convolution).

(4) Definite sensory aphasia indicates a lesion in Wernicke's convolution (superior temporal convolution).

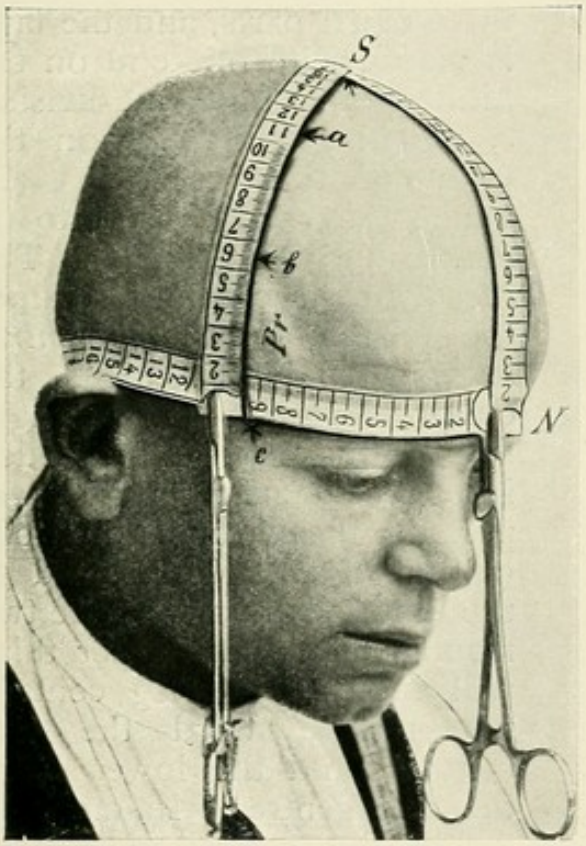

FIG. 12.—Simplified method of defining precentral sulcus.

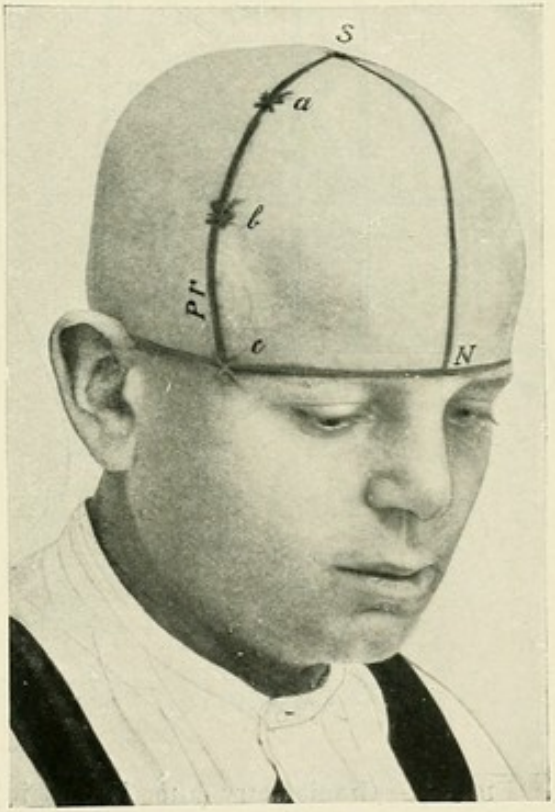

FIG. 13.—Simplified method of defining precentral sulcus.

Numerous methods and instruments have been devised for defining the cortical areas on the surface of the skull. We shall here only refer to the useful and practical methods of Kocher and Kroenlein. The whole procedure is greatly simplified by employing the special craniometer invented for the purpose ; but a tape measure and a blue pencil will do quite well. The most important thing is to define the *anterior central convolution*, wherein the chief motor centres lie. This convolution lies between the central and precentral sulcus. Kocher's method depends upon the simple and certain definition of this latter landmark.

The *base line* is first drawn, by placing the tape measure horizontally just above the concha, and through the glabella and external occipital protuberance. The lower border of the tape measure, fixed in this position, is marked off with the blue pencil (figs. 12 and 13). The *sagittal meridian* is defined in a similar manner, by placing the tape over the vertex, from the glabella to the external occipital protuberance (N. S. O., figs. 8, 12, 13). The length of this line is measured (in adults, about 35 cm.), and its mid-point is marked on the vertex, *i.e.*, 17½ cm. from either end (S. point of vertex). A second meridian must now be defined, with the craniometer, which should meet the saggital meridian at an angle of 60°. This meridian can be ascertained, within 2 or 3 degrees of perfect accuracy, in the following manner. One half of the base line is divided into three equal parts, and the tape is placed with one end on the hinder point of the first division *c*, and the other end on the point of the vertex S. (In adults the point *c* is 9 to 9½ cm. behind the glabella). The meridian so obtained defines the position of the *precentral sulcus* (Pr.) behind which the chief centres are to be sought for.[1] If this meridian be divided into three equal parts, the lower points of the two upper divisions (*a* and *b*) will correspond to the hinder extremity of the two frontal sulci. The upper third will indicate the leg centres, the middle third the arm centres, and the lower third the face centres. In order to define the fissure of Sylvius the tape is applied from the root of the nose to the upper end of the squamous portion of the temporal bone, at the beginning of the lamboid suture. The portion of this line, behind the precentral sulcus, corresponds in its whole extent to the Sylvian fissure.

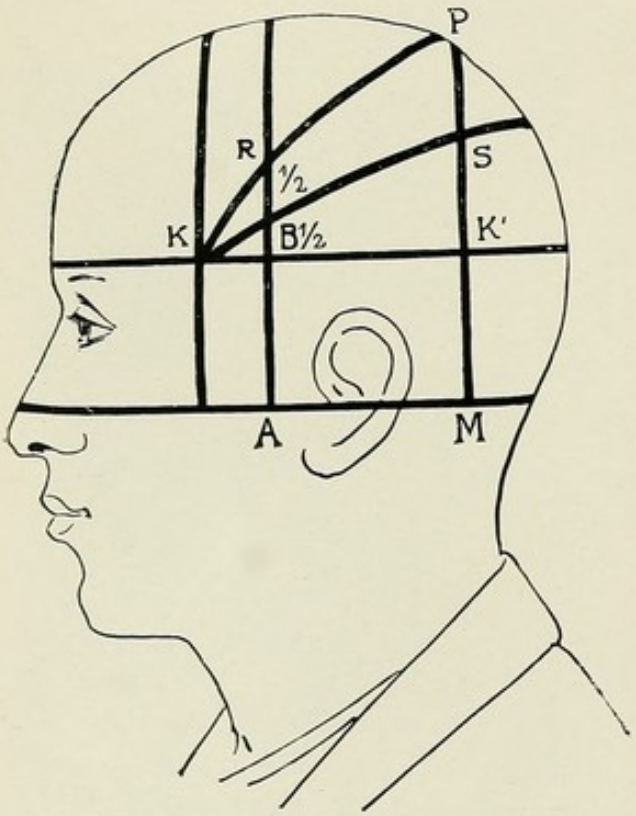

FIG. 14.—Craniometry (after Kroenlein).

Other topographical areas ascertained by means of these fundamental lines are indicated in figs. 8 and 9, which are partially based on the latest work of Krause.

[1] Kocher's precentral line obtained by angle measurement lies further behind. It can be obtained by moving the point *c*, ½ cm. posteriorly. There will then be a difference of 1½ to 2 mm. in the point, making the hinder extremity of the superior frontal sulcus, and a difference of 3 to 4 mm. in the point, making hinder extremity of the inferior frontal sulcus. But I have frequently demonstrated on the cadaver that, as all these methods possess inevitable errors, this difference is of no essential consequence

Kroenlein's method of measurement is particularly useful in the search for a hæmatoma of the middle meningeal artery, or for abscesses of brain, due to ear disease.

The *base line* is determined by means of tape-measure and blue pencil ; the tape being placed at the level of the infra-orbital margin and the external auditory meatus. A *superior horizontal* line is marked off, parallel with this, at the level of the supra-orbital margin. Three perpendicular lines are then drawn in the following positions: (1) *anterior*, through the middle of the zygomatic arch ; (2) *middle*, through the condyle of the lower jaw ; (3) *posterior*, through the hindmost point of the base of the mastoid process. By joining the point where the anterior perpendicular line intersects the superior horizontal, with the point at which the posterior perpendicular intersects the line of the vertex of the head, we then get a line which corresponds to the fissure of Rolands. By bisecting the angle made between this line and the superior horizontal, we obtain the direction of the fissure of Sylvius. The points K and K′ (fig. 14) indicate Kroenlein's landmarks for trephining in cases of hæmatoma of the middle meningeal artery. The square A B K′ M is the area suggested by Bergmann for searching for cerebral abscess of aural origin.

CHAPTER VII.

THE SURGERY OF EXOPHTHALMOS.

A STARING eye always calls for an answer to the question whether it is a real enlargement of the organ, a *buphthalmos*, or a protrusion of the organ—an *exophthalmos*. The former has a certain amount of surgical interest when it is caused by a tumour, a sarcoma of the choroid or glioma of the retina. But as these growths concern the speciality of ophthalmology, which, however, gains very little credit from them, we shall here limit ourselves to the discussion of *exophthalmos*.

If a *bilateral* exophthalmos has come on *gradually* during a course of months or even years, and if it is accompanied by tachycardia and tremors, we may at once diagnose Graves's disease, which will be fully discussed in the section on Swellings of the Neck.

If a *unilateral* exophthalmos has come on in the course of weeks or months, and is accompanied by double vision, the cause is either

a tumour developing within the orbit, or one invading it from without, starting from the base of the skull or the upper jaw—usually a sarcoma. If the symptoms have been slow in manifesting themselves, we should think of an innocent growth, viz., an ivory osteoma of the orbital bones, or a fibroma of the base of the skull penetrating the orbit.

A *unilateral exophthalmos* which has come on *gradually* after an *injury*, and which is accompanied by pulsation of the eyeball, and by a buzzing noise synchronous with the carotid pulse, heard with the stethoscope in the temporal region, represents the clinical picture of what may be briefly called a **pulsating exophthalmos.** This is caused by a rupture of the internal carotid artery into the cavernous sinus, and it is impossible to confuse this condition with any other. But if confirmatory signs are required, these may be found in the dilatation of all the ocular and conjunctival vessels, in the congested disc, in the progressive loss of sight, and in the gradual onset of paralysis of the sixth nerve.

Any injury involving the neighbourhood of the cavernous sinus may produce this condition. A fractured base is the most frequent cause, but stabbing and shooting injuries are occasionally responsible. The same clinical picture sometimes arises quite spontaneously, without any injury, and is then due to *aneurysm of the ophthalmic artery*, or a *cavernous angioma of the orbit*, in which latter the pulsation is not well marked. Finally, exophthalmos pulsans has also been noted as a consequence of venous congestion, due to severe pressure during birth.

In determining the etiology, it is important to realize that the symptoms may not appear for months or even years after the injury.

An *acute* exophthalmos, either *unilateral or bilateral*, generally depends upon a retrobulbar hæmorrhage, usually the result of a fractured base, but not necessarily so. The presence of suffused lids, either immediately, or coming on after a day or two, is a further indication of the cause at work.

If all these causes are absent, there remains only some inflammatory process to be considered, either a retrobulbar *thrombosis or abscess*. The differential diagnosis of these two conditions will be detailed later on.

CHAPTER VIII.

ACUTE INFLAMMATORY PROCESSES ON THE SKULL.

APART from **erysipelas**, which is usually a secondary affection of the scalp, and which is peculiar in the absence of reddening of the skin, the acute inflammations concern the glands or the bones. **Inflamed glands** will be found behind the ear, or in the posterior cervical region. The portal of infection is generally a slight superficial abrasion or a moist eczema, and there is never any difficulty about the diagnosis. Infections of the *bones* are, however, not quite so simple. If the inflammatory process is situated behind the ear, a purulent otitis should be sought for, and it will generally be found. It very rarely happens that the infection misses the middle ear, and settles forthwith in the cells of the mastoid process. In these rare cases, however, it will be possible to trace a previous sore throat or influenza, &c. If the inflammatory process is located elsewhere, we must resort to the diagnosis of **acute periostitis and osteomyelitis** of the skull. This diagnosis is easily made if the infection of the cranial bones represents a metastasis from a distant focus of osteomyelitis elsewhere. But if this is not the case we must recognize in these symptoms a **primary osteomyelitis** of the skull, although this is a rare condition. It is important to make an early diagnosis, because if operation is delayed, there is the danger resulting from the suppuration advancing to the inner table of the skull bone.

CHAPTER IX.

SWELLINGS ON THE HEAD.

OUR first inquiry concerning any swelling on the head should be to ascertain whether it is congenital. If it be so, the diagnosis is either : (1) *Cerebral hernia*, (2) *Hernia of the meninges*, (3) *Angioma*, or (4) *Dermoid*. Other congenital swellings are very rare, and are generally connected with a concealed cephalocele.

A.—CONGENITAL SWELLINGS OF THE HEAD.

(1) Cerebral herniæ are situated in the middle line, mostly above the *nose*, or on the *occiput*.

Cerebral herniæ at the base are very rare and do not possess any surgical interest.

Cerebral herniæ on the forehead form moderately large, flat, semicircular, or sometimes irregular swellings, and they chiefly contain brain substance ; hence their name of *encephaloceles*. Cerebral herniæ at the *back of the neck* are much larger. They contain either a dilated posterior cornu surrounded by a thin layer of brain substance, or a very dilated retiform arachnoideal space with a plug of brain substance at its base (*encephalomeningocele*). A simple protrusion of the meninges, a pure *meningocele*, is a much rarer condition.



FIG. 15.—Superior occipital encephalomeningocele (with a vascular nævus in the region of the cerebral hernia).

Many cases which were previously regarded as pure meningoceles are really encephalomeningoceles of one of the previously mentioned types. Sometimes a microscopic examination is necessary before the real nature of the deformity can be determined.

Superior (fig. 15) and *inferior occipital cerebral hernia* (fig. 16) are distinguished according to their position, *above* or *below* the occipital protuberance.

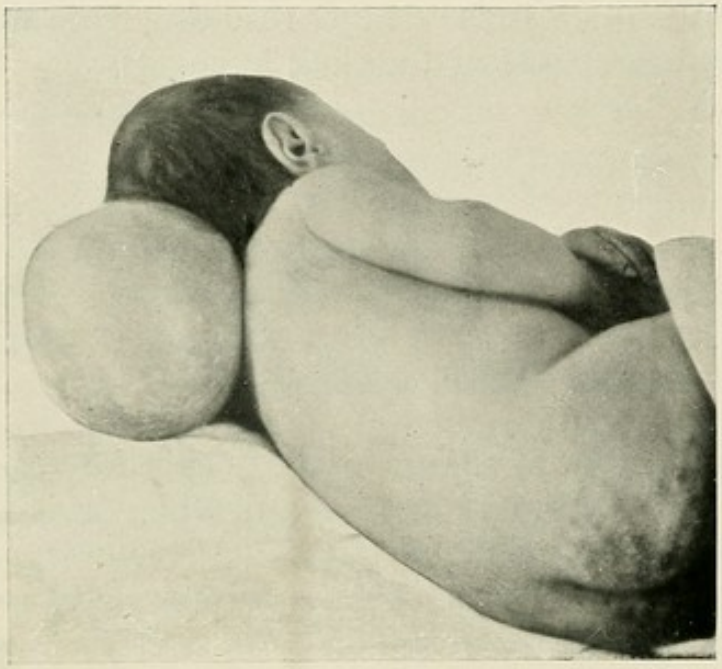

FIG. 16.—Inferior occipital encephalomeningocele.

Whenever these swellings become *more tense on crying*, it signifies a communication with the interior of the skull. The same applies to *pulsation*, which, however, is often absent in the case of cystic hernia of the brain. Displacement on steady pressure occurs with meningoceles

and cystic encephaloceles. This depends upon the extent of the connection with the interior of the skull, and it is obvious that in large swellings the displacement is very imperfect. It is not always possible to detect the hernial aperture, *i.e.*, the gap in the skull, which may be quite small, even when the swelling is large. We sometimes find, especially in large meningoceles, that an incipient *hydrocephalus* is present, which it is most important to recognize, because this complication excludes the possibility of a successful operation.

These congenital swellings must be diagnosed from :—

(*a*) Hæmorrhagic cyst of a sinus, the so-called *Sinus pericranius*. This swelling emanates from within the skull, it is situated in the middle line, generally on the occiput, but it contains blood instead of cerebrospinal fluid. If the swelling is large, and the overlying skin is thin, the dark blue blood will be visible through it ; but if the swelling is small, and the overlying skin has not been thinned out, we shall get no assistance from the colour. But in these cases, the swellings are very easily emptied by pressure, because the cerebral sinuses have many more outlets than the subarachnoid spaces.

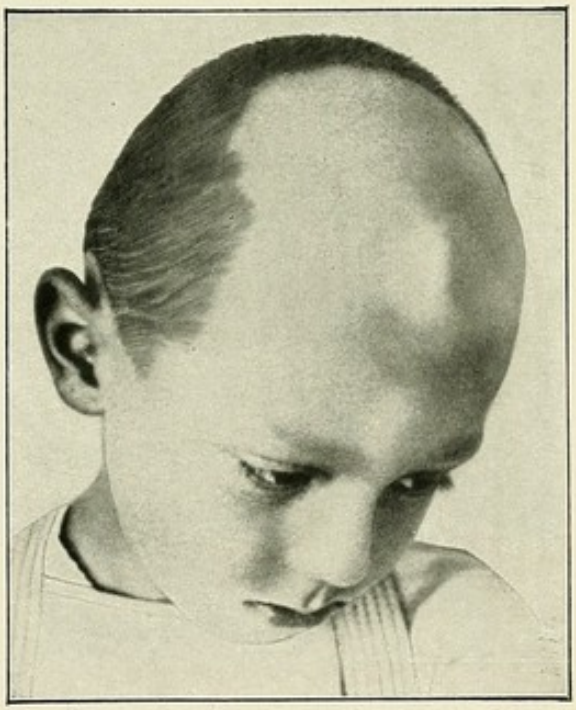

FIG. 17.—Dermoid cyst, situated in a gap of the skull.

(*b*) *Cavernous angioma* which has formed a secondary communication with the longitudinal sinus, as seen particularly at the anterior fontanelle. It is easier to displace the contents of this swelling than a cerebral hernia, and the cavernous structure of the swelling can be recognized through the skin. Furthermore, cephaloceles at the anterior fontanelle are so rare that their existence has been recently denied.

(*c*) *Dermoid*.—In this case there are no signs of communication with the interior of the skull, unless the dermoid is situated in a gap of the skull and presses directly on the dura mater, as in the patient depicted in fig. 17. But even in this last type of case the symptoms noted are very much less definite than in cerebral hernia.

If a child presents a pulsating, displaceable, dome-shaped swelling of the integument of the head, not necessarily in the middle line, accompanied by more or less evident defect of the bone, it must be regarded as a **spurious meningocele** due to some previous injury—

a **traumatic cephalo-hydrocele.** This may be caused when a child has sustained an injury to the skull with contusion of the brain, and a communication has formed between the subcutaneous tissue and one of the cerebral ventricles. The condition is really a traumatic porencephaly, complicated with an effusion of cerebrospinal fluid under the skin. The injury may have been inflicted at birth, with the forceps, when it will be regarded as congenital, or it may have been caused by a blow or a fall; not unfrequently by dropping the child. If the child is rickety the defect in the skull may gradually increase, and therewith also the effusion of the fluid under the skin. In cases of forceps injury we have seen the condition subside completely. The swelling gradually disappears in the course of a year, and is only apparent if the head is in a dependent position, and eventually the aperture is entirely filled in by dense fibrous tissue. Its characteristics are, therefore, quite definite in every stage. If the injury has involved the motor area, an incurable spastic hemiparesis will follow, corresponding completely to the clinical picture of a cerebral infantile paralysis. The examination of the opposite half of the head should, therefore, never be neglected in this variety of paralysis.

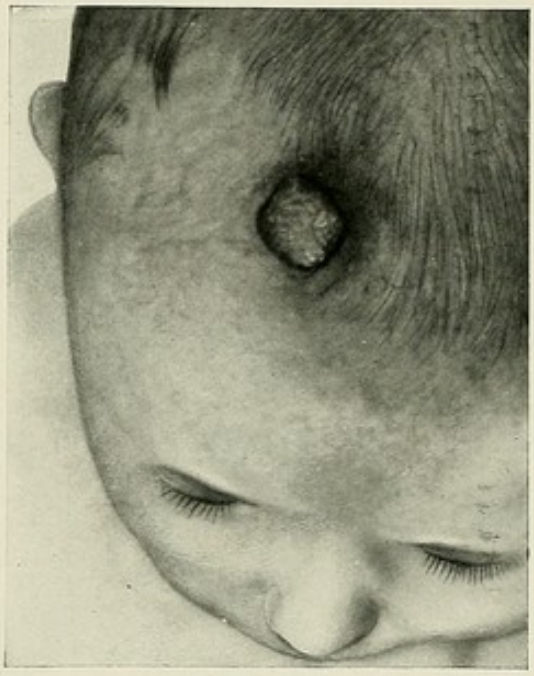

FIG. 18.—Mulberry-shaped angioma in an infant.

Traumatic meningoceles not communicating with the lateral ventricle are very rarely met with. They are small and are only replaceable with difficulty.

(2) We have mentioned **angioma** as the second variety of congenital swelling. All grades of this variety exist, from teleangiectatic stains, which scarcely project above the skin, to large cavernous angiomata. They may occur anywhere on the skull, and the fact that they are freely movable over the bone shows that they are situated in the skin. Their finely nodular surface (fig. 18) and the hue of the blood visible through them as a red or blue colour, permits of the framing of an immediate diagnosis. We have already seen that a cavernous angioma can penetrate deeply and open into a sinus.

(3) **Dermoids** are situated under the skin, generally in the orbital region, more rarely at the back of the neck, but very rarely on the vertex. They are but slightly movable over the bone, and are often situated in a depression thereof, occasionally even infiltrating it.

They can frequently be detected in children, but as a rule, they only develop in later life to a size which is noticeable (figs. 24 and 25).

(4) **Atheromata** (Sebaceous cysts) should also be mentioned in this connection. Although these probably develop from some congenital antecedents they are not usually evident until after the age of 20 or more, appearing anywhere on the skull, sometimes even in crops of dozens. They vary in size from a lentil to a child's head (figs. 20 and 21). Their position and their freedom from the subjacent bone distinguish them from dermoids. The frequently observed family predisposition proves their congenital character.

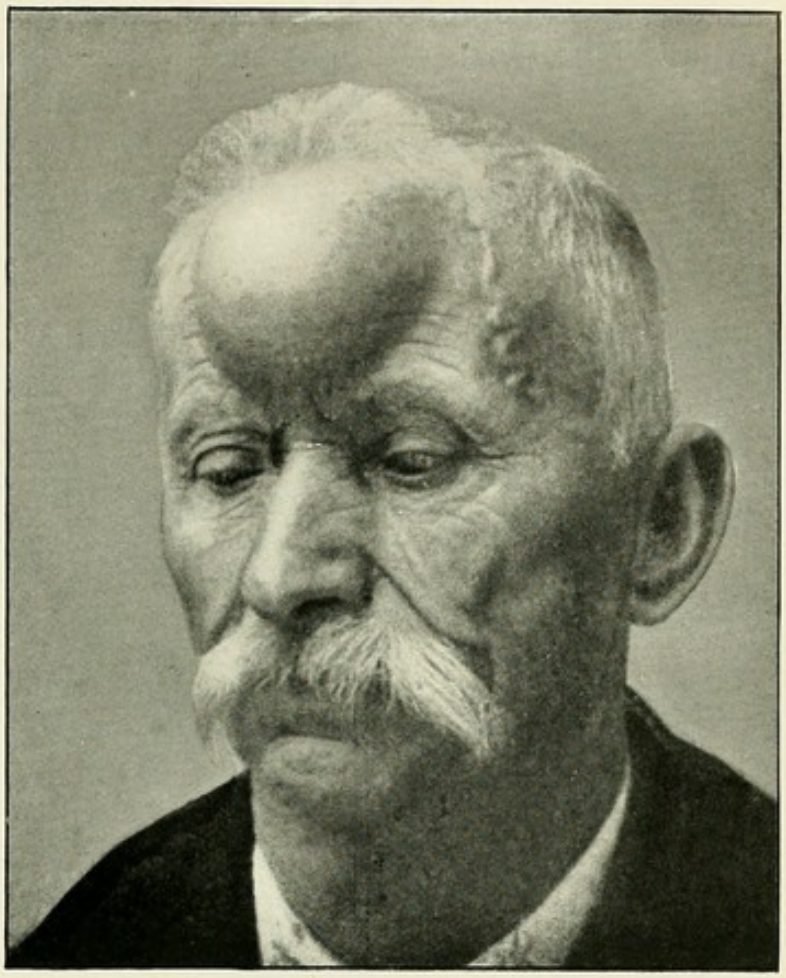

FIG. 19.—Osteoma of frontal bone.

Sometimes these cysts open spontaneously, leaving a sinus from which fatty material discharges itself from time to time. As they usually become infected, suppuration also occurs. Their malignant degeneration is referred to later on.

B.—ACQUIRED SWELLINGS OF THE HEAD.

Sebaceous cysts lead us to swellings of the head and tumour-like formations, which develop in later life. We have here to distinguish between innocent and malignant structures.

(1) *Innocent Acquired Swellings.*

These are soon disposed of, because they include only **osteoma** (fig. 19), often of an ivory consistence, and **soft fibroma** of the skin. The latter is usually but one of several generalized fibromata, and therefore the diagnosis can be made at first sight.

Sometimes a few apparently soft harmless warts may, after existing for years, lead to a fatal result, with the severe symptoms of Recklinghausen's disease.

(2) *Malignant Tumours of the Head and Chronic Inflammatory Swellings.*

(*a*) Swellings which are *closely connected with the bone* may be of the nature of *gumma, tubercle, sarcoma,* or *metastatic tumour* of any kind.

Gummata, which never reach any significant size, are generally multiple, and when recognizable as tumours, are usually soft in the centre. They begin as hard thickenings of the periosteum, which may be distinctly painful on pressure, thus contrasting with the usual painlessness of tertiary syphilitic lesions. When ulcerated, their specific character is attested by the yellowish, fatty base of the ulcer, by the superficial necrosis of the bone, by the irregular ivory-like movable sequestrum, and by the new deposit of bone round about. If no history of syphilis is forthcoming, traces of its attack will probably be found in the form of scars and of irregularities on the bones. In a doubtful case there will always be time to try the effect of potassium iodide and to employ the Wassermann serum test.

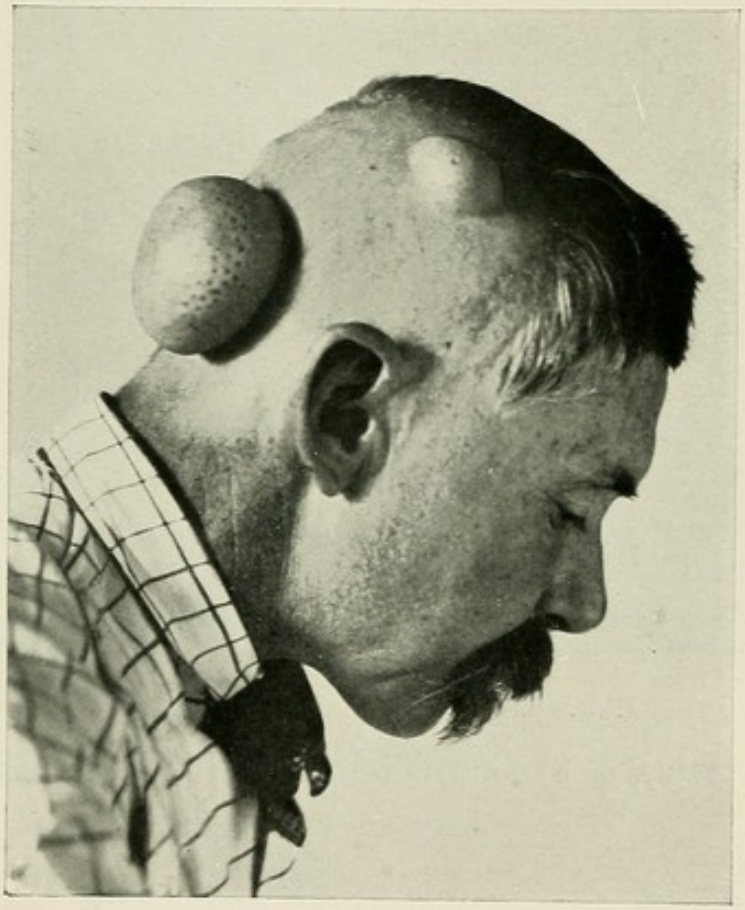

FIG. 20.—Sebaceous cyst on scalp.

Tubercle of the skull, an affection more frequent in children than in adults, is also often multiple in character. A focus of tubercle undergoes softening much earlier than a gumma, and as the disease extends, a cold abscess is formed. These two points are in themselves sufficient to distinguish the two conditions, especially as in tubercle there are probably other foci of disease, if only tubercular glands. But in no circumstance should a non-acute fluctuating swelling of the skull be incised, unless one is prepared to proceed further forthwith. If the abscess be opened or if it burst spontaneously, the ulcer in the bone is seen to have a sharp edge as if punched out, and if there be a sequestrum, it is movable, easily liberated, and there is no new bone formation round about. These characters will clench the diagnosis.

If we are able to exclude both gumma and tubercle, the only condition which remains is a **malignant growth.** As metastases in the skull are not rare, we should first search for a primary focus, especially in the *thyroid gland.* It is well known that even an apparently innocent goitre may give rise to secondary deposits of a malignant character. These may occur anywhere on the skull and may grow deeply into the cranial cavity. In contrast to certain sarcomata, they are remarkably soft to the touch. In the absence, however, of any cause for the growth, it must be regarded as a **primary sarcoma,** which may originate from the periosteum, diploe, or dura mater. The starting point can be distinguished at first fairly accurately, but with the progress of the growth this becomes impossible.



FIG. 21.—Giant sebaceous cyst.

A *periosteal sarcoma* has not any superficial covering of bone, but occasionally its deeper parts are ossified. It is not compressible, but it pulsates, if very vascular. A sarcoma which starts in the diploe is covered superficially by bone, and therefore resembles a simple exostosis. But soft areas soon appear, and it becomes more and more like a periosteal sarcoma. At first it is not compressible towards the interior of the skull, and therefore is clearly distinguishable from a sarcoma of the dura mater. This latter, besides being compressible, is also very pulsatile and follows all the oscillations of the brain pressure. Naturally these symptoms will also appear if a sarcoma of the periosteum or the diploe has eaten through the bone, and involved the dura mater. Bergmann has described a sign which, even at this stage, may indicate the origin of the growth, for in a primary sarcoma of the dura the perforation in the skull has a sharp cut flat edge, where in a sarcoma of the diploe, the external table

of the skull slopes towards the tumour like a roof. The history will also afford material for a decision. If the patient has been suffering, for some time before the growth became visible and palpable, from persistent headaches, and if these have subsided with the external appearance of the growth, then it is a primary sarcoma of the dura mater. If, on the other hand, brain symptoms only occur in the later course of the disease, then we conclude that the growth originates either from the periosteum or bone. But if it is obvious that the skull cap has been perforated and yet none of the previous indications are evident, it is useless to attempt any further diagnostic subtleties, because treatment is identical in either case.

(*b*) In cases of *chronic ulceration* of the skull the problems are somewhat different. If the ulceration has attacked the bone, and the patient states that it was preceded by a tumour-like condition, we must regard it as **gumma of the skull**, especially when the base of the ulcer has a yellowish, fatty appearance. With a similar history, and an ulcer freely movable over the bone, we should consider it to be an open gumma of the skin. But if we are told that the condition was an ulcer from the very beginning, we must think of tertiary syphilis and epithelioma. We recognize the former by its shape, base and border, apart from the history. If grayish plugs can be pressed out of its border, and if at the same time the well-known predisposing changes are present on the skin, viz., seborrhœa and verruca senilis, there is very little difficulty in arriving at the diagnosis of **seborrhœic epithelioma.** In this instance, multiplicity does not contraindicate the diagnosis of primary malignant new growth. Finally, if the patient states that a sebaceous cyst, which he has had for many years, has become hard, ulcerated and painful—probably after an injury to it—there can be no doubt that the diagnosis is cancerous degeneration of the cyst (see fig. 22).

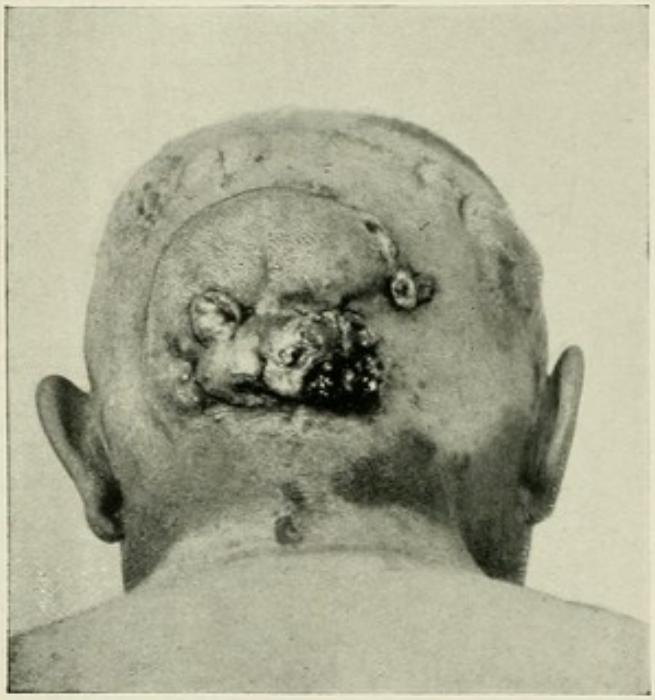

FIG. 22.—Sebaceous cyst of head, undergone cancerous change.

CHAPTER X.

ACUTE INFLAMMATORY DISEASES OF THE FACE.

ALL inflammatory processes about the face rapidly produce severe swelling, because the skin, especially of the lips and cheeks, is richly supplied with blood vessels, and the subcutaneous tissue of the eyelids is very loose. Wherever the origin of the inflammation may have been, there is a considerable resemblance in the appearance of all these cases. The lips are puffed and protuberant, the cheek is bloated, the eyelids are converted into smooth pads, between which the eyes peep with difficulty, if they are visible at all. If we are confronted with such a case, an immediate diagnosis cannot be made without the previous history and more detailed examination. The possibility of **erysipelas** will suggest itself first. This will be confirmed by the symmetry of the swelling, by the deep redness of the skin and the sharp limitation both of the swelling and the redness. We must not look for this limitation in the neighbourhood of the eyelids, because they swell up at once to their full extent, owing to their anatomical characteristics; the margin will be on the cheek or forehead; the patient usually states that the swelling began on the nose. If he has already had previous attacks, which is very likely, he will supply the diagnosis himself and will only want to know whether any improved method of treatment is available. A careful examination of the swelling will show that it is situated in the skin, and that the deeper tissues are free. But if erysipelas is excluded, the diagnosis usually lies between one of the following conditions—*Furuncle of the upper lip, periostitis of the upper jaw, acute inflammation of the maxillary sinus,* or the *frontal sinus, inflammation of the lachrymal sac, inflammation within the orbit,* and finally, accidental infections of various kinds.

In regard to **furuncle of the upper lip**, which, at times, infects the facial veins and leads to pyæmia, the original site of infection must be ascertained from the patient. It is easy to overlook a furuncle, which is not usually large.

Acute **periostitis of the upper jaw**, and an acute exacerbation of **inflammation of the maxillary antrum**, at first sight, appear to have the same symptoms. Besides the swelling, we are struck in both with sensitiveness on pressure over the canine fossa and the vestibule of the mouth, the superficial soft parts not being affected. The difference will usually be evident from the history. In ordinary periostitis there will have been previous toothache, and we shall probably find a carious tooth or one sensitive to pressure. In a recent sinusitis, a history of a preceding cold or influenza will often be elicited. If the condition is

due to an acute exacerbation of an old sinus inflammation, careful inquiry will reveal the typical history of all sinus catarrhs with periods when they become much worse and give rise to profuse discharge of sanious and often foul-smelling pus. Objective examination will frequently afford points of differentiation. In *dental periostitis* the swelling of the soft parts—including the gums—is most prominent, and the sensitiveness to pressure of the upper jaw concerns mainly the alveolar process; but in *acute sinusitis* there is less swelling of the soft parts. In this condition the bone is sensitive to pressure as far as the infra-orbital margin, and in addition there is often a neuralgia affecting the cutaneous branches of the infra-orbital nerve. The nasal mucous membrane on the diseased side is œdematous, and nasal respiration is obstructed. In *chronic sinusitis* there is generally hypertrophy of the mucous membrane over the middle turbinated bone, and polypi are also present. If the patient does not happen to be suffering from retention of the discharge at the time of the examinations, we may be able to detect pus escaping from beneath the middle turbinated bone if the examinations are repeated often enough. Finally, diagnosis may be facilitated by puncturing the sinus from below the nasal duct.

If the inner angle of the eye, which is generally swollen up and very painful, is the centre of the inflammatory disturbance, the condition originates from the lachrymal sac, and a phlegmonous **Dacrocystitis** exists. The tears run over the lid, showing that the lachrymal canal is blocked, and the patients, who usually have had previous attacks and are well posted in the details of their cases, will often relate their experiences of probing the tear duct.

These inflammatory processes have frequently been traced to a streptothrix infection.

Inflammation starting from the **frontal sinus** is recognized by the forehead and upper lid being chiefly involved. Its previous history resembles that of inflammation of the maxillary sinus.

Mild cases of frontal sinusitis are often mistaken for supra-orbital neuralgia. It is quite true that secondary inflammation of the nerve may occur, but it is important to recognize the original and causative factor. Pressure on the wall of the sinus *near* the nerve generally suffices for this.

As we are dealing with the bony margin of the orbit, we may refer to a not uncommon disease in children, which sometimes presents itself as an acute inflammation—*i.e.*, **tubercle of the superior maxilla,** affecting the lower margin of the orbit. This leads to sinus formation, and as there is invariably some secondary infection, extensive swelling of the soft parts occurs if secretion is retained. Tubercle of the lachyrmal sac should be mentioned here, a typical illustration of which is seen in fig. 23.

Inflammatory diseases of the *orbital contents* present a uniformly similar picture, because the swelling is more or less sharply circum-

scribed by the conjunctiva and the lids, and because the globe of the eye is usually protruded. The only exception to this last symptom is in **inflammation of the lachrymal glands,** which is recognized by the situation of the swelling, chiefly on the outer side of the upper lid and the adjoining part of the forehead. If the globe is protruded and both lids are puffed like pillows, the diagnosis can only be between a **retrobulbar abscess** and a **venous thrombosis in the retrobulbar fatty tissue, or in the cavernous sinus.** It is not easy to distinguish between these two processes, because both the symptoms and the etiology are alike, the cause generally being some focus of inflammation on the face or the bony structure. Facial erysipelas, furuncle of the face, ostitis and periostitis of the upper jaw are mainly responsible for these conditions.

If the symptoms are on *both sides*, they must be due to *thrombosis of both sinus cavernosi*. Surgical intervention has, unfortunately, failed hitherto in these cases.



FIG. 23.—Tuberculosis of the lachrymal sac.

A little boy who was suffering from a persistent suppurative periostitis of the jaw had a lower molar extracted by a quack—the same thing may have happened if the operator had been a dentist or a doctor. Immediately afterwards, the lids of both eyes began to swell, the globes protruded, rigors occurred, and the temperature rose to 102°—104° F., the pulse failed, consciousness was lost, and death ensued a few days after the onset of the symptoms, as is usual with septic thrombosis of the sinus cavernosi.

If the disease is *unilateral* we must seek to differentiate as quickly as possible between thrombosis and abscess, in order to institute appropriate treatment. As long as both lids are equally swollen without any circumscribed redness, and in the absence of severe pyrexia, we may regard the condition as retro-orbital thrombosis without purulent softening, and we are justified in waiting. But if one lid, especially the upper, swells up more and becomes redder and painful, it means that there is pus deeply situated and we must interfere.

The following case is very instructive in this connection. A patient who had been bitten by a friend in the left upper lid, was brought into the hospital suffering from erysipelas. The disease spread over the entire head, and caused several subcutaneous abscesses. After these had healed, swelling of the lids suddenly started again on the side which had been bitten, and exophthalmos followed. The swelling was equally distributed over both lids, but there was

no very striking puffiness at any one place. The temperature remained normal. The history suggested an abscess, but the regularity of the swelling and the absence of fever nevertheless made it probable that the condition was thrombosis. We awaited developments, ready for immediate operation. In a few days symptoms began to subside, and finally vanished completely without any complication. The diagnosis of thrombosis was evidently correct, and an untimely operation would only have done damage.

Acute parotitis remains to be mentioned among the acute inflammatory swellings of the face. The malady is immediately recognized by the situation of the swelling in front of the ear and by its extension to the tissues behind the ear lobule. If the temperature is high and both sides are quickly involved, the diagnosis is *epidemic parotitis*, recognized by the stupid frog-like expression which the features acquire when the disease is aggravated in this manner. Orchitis, which is a frequent complication in some epidemics, affords an unwelcome confirmation of the diagnosis. The *unilateral parotitis* which follows infectious diseases—typhoid fever, erysipelas, appendicitis, &c.—is quite different in character, and usually breaks down into an abscess. Finally, there is the acute swelling of the parotid gland due to obstruction of Steno's duct, by *salivary calculi*. This condition is characterized by the frequency of relapses.

CHAPTER XI.

TUMOURS AND ULCERS OF THE FACE.

THE first matter to determine in regard to any swelling of the face is whether it originates in the skin or the deeper tissues. If the skin is movable over the growth, the latter has a deep origin ; but if it is not possible to pick up the skin free from the growth, it is obviously situated within the skin, as long as the growth and the skin are together movable over the subjacent tissue. If the skin, tumour, and underlying tissue are welded together into one immovable mass, it means that either the tumour has penetrated into the skin from the deeper tissues, or has invaded these tissues from the skin. Experience shows that the former contingency is the more frequent.

A.—TUMOURS WITH OVERLYING SKIN UNBROKEN.

We limit ourselves to *tumours of the skin*, because we have already considered new growths arising from deeper structures, when discussing

diseases of the skull and jaw. **Dermoids** and **sebaceous cysts** need not detain us long. Every beginner recognizes that a semi-globular tumour of the skin is a sebaceous cyst, and he is usually correct, if the growth is really situated *in* the skin. But if the skin can be picked up distinctly free from the tumour, then the latter is more deeply placed, and is not a sebaceous cyst, but a subcutaneous **dermoid.** The superior orbital margin is its favourite site. It is important to differentiate between these two, because a dermoid is not so easily shelled out as a sebaceous cyst. A dermoid is frequently



FIG. 24.—Supra-orbital dermoid.



FIG. 25.—Supra-orbital dermoid.

seated in a depression of bone, and requires detaching therefrom (figs. 24 and 25).

It is hardly necessary to warn against confusing a hernia of the brain, either with a dermoid or a sebaceous cyst. Fig. 26 indicates how easily such a mistake might be made, the sebaceous cyst occupying the position of a frontal cephalocele.

Sebaceous cysts are especially prevalent on the cheeks and the temples, but **lipomata** also occur there, and the differential diagnosis is not always easy.

We need not devote much time to **angiomata** of the various kinds (see fig. 28). Their shape and colour proclaim their diagnosis, and

any doubt is dispelled by the fact that they can be dispersed by pressure. A pulsating mass, like earthworms in outline, will be identified, by a beginner even, as a *cirsoid aneurysm*.

Xanthelasma, a flat, pale, yellow growth, often situated symmetrically in the neighbourhood of the lids, is at once recognizable by its colour.

A *calcified epithelioma*, so-called, may be referred to here as a rarity. It appears as a round, flattened, and somewhat nodular tumour, which can be shelled out of the skin quite easily, and is chalky on section. If once seen, it is always recognizable, but the inexperienced cannot be expected to be able to make the diagnosis.



FIG. 26.—Sebaceous cyst at root of nose.

The **cartilaginous pendulous tumours of the skin,** in front of the ear, and the **soft cutaneous warts** so frequent on the face of an old syphilitic subject, are too obvious to detain us. But these soft cutaneous warts acquire something more than cosmetic importance when they become malignant. Rapid growth, an increasing firmness in consistence, and bleeding when lightly touched, are clear proofs of this change.

Angioma and **Lymphangioma** of the ear are not very common, but they are easily recognizable. Lupus in this situation often resembles a tumour (fig. 41), and **hæmatoma of the ear,** which occurs in the insane, is also strikingly similar to a tumour (fig. 27.)

B.—ULCERATIVE PROCESSES.

Diagnostic interest attaches to lesions of the skin of the face, which are ulcerated from the beginning, or have broken down after a brief duration.

(1) We shall adopt a topographical order, starting with the **lips.** A deep **chronic ulcer of the lip** is either a **primary sore** or a **cancer.** The hardness of the base constitutes no distinction, because this character belongs to them both. Their appearance is of more conclusive

import. If we can squeeze out small whitish plugs, consisting microscopically of squamous epithelium, the case is one of cancer. If the base consists of a uniformly reddish, varnished-looking tissue, which yields no plugs, it is probably a primary sore. The condition of the lymphatic glands is unimportant. Although the presence of hard enlarged glands is looked upon as confirmatory of the diagnosis of cancer, their very *absence* in this case may lead us to the same diagnosis. For a primary sore which has existed for a few weeks is invariably accompanied by enlarged glands, whereas they may not appear in cancer of the lip for many months.

We see, therefore, that the diagnosis of cancer of the lip, in the ulcerative stage, is easy. It is quite different, however, in the early stage, when the disease is either overlooked or neglected by the patient—a circumstance pardonable in the patient, but unpardonable in the medical attendant. If a person complains of a somewhat hard sore place, covered by a crust, on his lower lip, which bleeds on removal of the crust, we must not follow the ancient practice of touching the spot with caustic, instead of making a diagnosis. A spot which has been forming crusts for months, and which bleeds slightly, is not something which "may become malignant," as is often said as a matter of precaution, but *is actually* carcinoma, and must be radically removed without regard to the subsequent appearance of the lip, beard, or moustache. We usually see carcinoma of lip affecting the lower lip in males only (fig. 29), but occasionally the upper lip is attacked (fig. 30), and also the female sex, whether or not the habit of smoking a pipe has been indulged in.

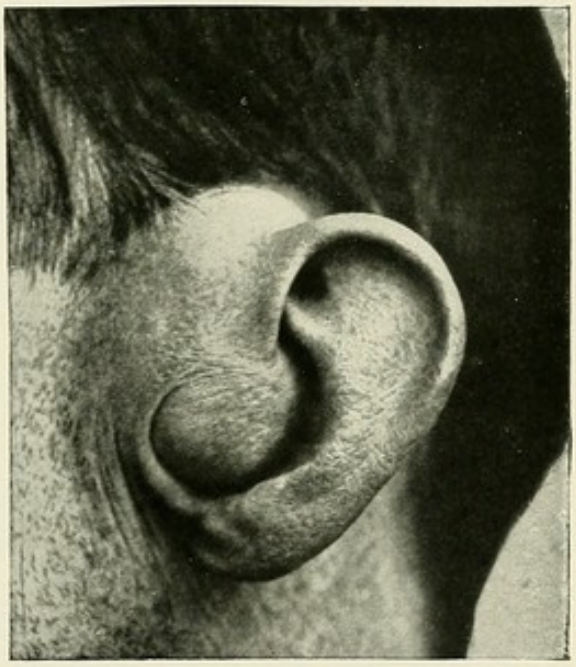

FIG. 27.—Hæmatoma of the ear. (From the Ear Clinic, Basle.)

(2) The *nose* is another favourite situation for ulcers. If the ulcer is in the vicinity of the nostrils, **lupus and tertiary syphilis** must be thought of first. The clinical history is extremely important in these cases, not only from a general aspect, but also in regard to the evolution of the nasal disease. Much diagnostic labour will be saved by exhaustive cross-examination of patients, and by examinations of the brothers, sisters, and children, in doubtful cases.

The course of the disease is of special significance in chronic

inflammatory ulcerative affections of the nose. It enables us sometimes to make an immediate diagnosis, when objective examination leaves us in doubt. It may be postulated as a general rule that the various tuberculides of the skin, grouped together under the name of *lupus*, persist for months and even years, whereas the duration of *tertiary syphilides* is merely weeks, or at most a few months.

In cases of lupus we may learn of occasional improvement, but never of spontaneous and complete cure. In cases of tertiary syphilis the patients will often—not always—tell of some exacerbations, with intervals of complete cure, marked, of course, by scar formation. If the patient is suffering from a first attack, the duration will have been much less than in a case of lupus, with a lesion of the same extent.



FIG. 28.—Angioma of the forehead.

Let us now investigate the nose and its vicinity a little more closely. If, despite a long duration, the whole process is not accompanied by ulceration, we should at once think of tubercle. But, on the other hand, the presence of ulceration is not conclusive, because both lupus and gumma can ulcerate. If the ulcer is serpiginous in outline, and has sharply defined edges with a fatty base, we must regard it as syphilitic. If, however, we find slightly bleeding ulcerated areas situated beneath scabs, with some grey nodules suggestive of tubercle on these areas, then the diagnosis is lupus. The recognition of these points, however, requires much practice. It is easier to draw conclusions from the *area surrounding* the infiltrated or ulcerated site, and, therefore, this requires very careful examination. If the change consists of separate very red nodules, nearer to peas than to lentils in size, which suppurate in the centre, or rather, become necrotic, running together into an irregularly circular ulcer, the case is syphilitic. But if we observe in the vicinity of a superficially eroded, brownish-red, soft, infiltrated area, separate little nodules hardly as big as lentils, situated under a normal or very scaly epidermis, and which change

when pressed upon by a glass side, into little light brown spots, the nodules are certainly those of lupus. Their softness is very significant; a fine probe can easily be thrust within them from the epidermis without any violence. The *hypertrophic forms of lupus* must not be overlooked. These are characterized, besides the small nodules just described, by larger, soft, non-ulcerated nodules, or by thick, light, brownish-red plaques of soft tissue, several centimetres in extent.

These indications will suffice for the local conditions, and they are usually quite adequate for the purposes of diagnosis, having due regard to the clinical history.

We have not yet mentioned **cancer**. This disease does not generally attack the region of the nostrils, like lupus and syphilis, but rather the bridge of the nose, its lateral walls (figs. 31 and 32), and the naso-labial fold. The hardness of its margin and base distinguishes it immediately from lupus and syphilis, even in the chronic flat varieties.

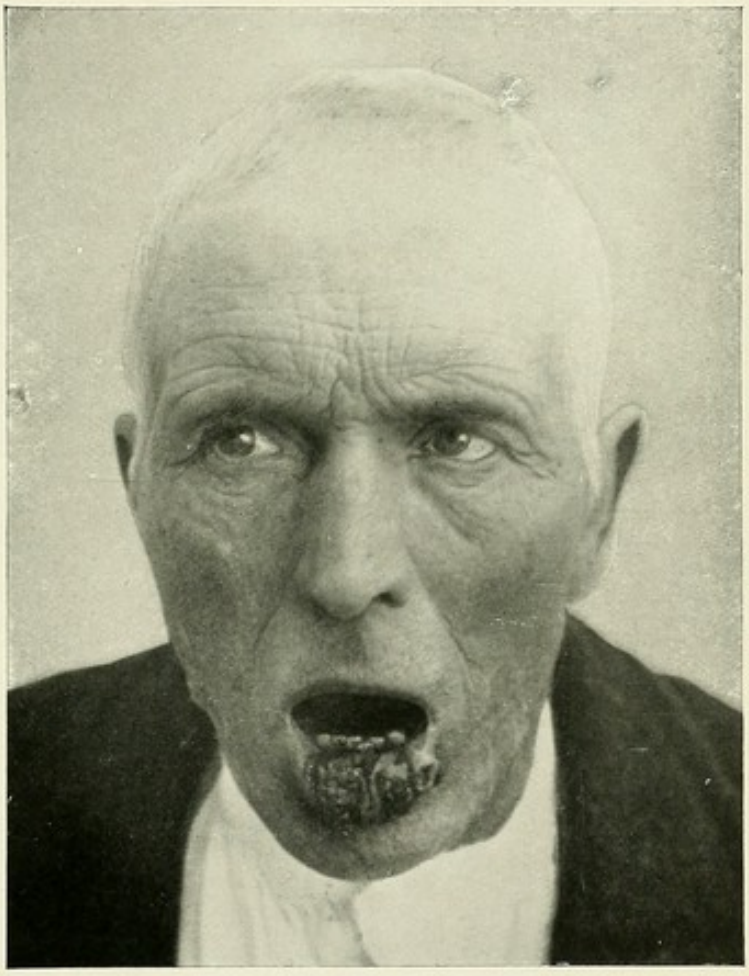

FIG. 29.—Cancer of lower lip.

As far as its *duration* is concerned, it may be said that an ulcer which has persisted for weeks, or for a few months, and which is constantly increasing in size, is always suspicious of cancer. But on the other hand, the fact that an ulcer has persisted for years, and has evinced signs of partial healing, or rather epithelization, is not always a conclusive argument *against* cancer. Indeed, we shall soon see that this course is significant of a definite variety of cancer. Although lupus frequently runs a similar course, the signs already given, and others which will be referred to subsequently, will, as a rule, prevent any confusion. The superficial cancer, known as *rodent ulcer*, often has a few little nodules on its smooth scars, just like lupus. But in contrast to the latter, they are whitish, hard, cannot be penetrated by the probe, and they do not

leave the brownish stains on pressure with a glass slide. These little nodules appear to be isolated, but they are really arranged in a circular manner, and are mainly to be found at the edge of the cicatrized surface (fig. 32).

Although many of these cancers are very benign, it is important to diagnose them before destruction of the deeper tissues occurs, and their *early stages* must be well recognized.

If we are consulted about a somewhat hard patch, scarcely raised above the surrounding part—a patch which is constantly scaling over, or is covered in the centre by a small crust, under which a slightly bleeding surface is evident, we can be confident that we are dealing with the form of skin cancer, designated as *rodent ulcer* (figs. 32 to 34). It is a condition which will gradually begin to invade the subjacent tissue, after lasting for years. Its oldest parts are characterized by central smooth scarring; its margin is of cartilaginous consistence, thick and whitish. There is always some contraction round about, causing the lips to be drawn up, the eyelids to be pulled down, or the cheeks to be drawn in, &c., according to the site of the new growth. The glands are rarely enlarged. If the disease has invaded the deeper structures, the skin becomes adherent to the underlying bone. Once this stage has developed the destruction continues slowly, but inevitably, involving the eyelids, invading the eyeball, eating into the nose and exposing its accessory sinuses, but nowhere causing any definite tumour formation.



FIG. 30.—Cancer of upper lip.

Sometimes we are confronted with a semi-globular wart-like structure, which scales in the centre (fig. 35). Even in this condition, the diagnosis is quite easy. It is differentiated from a fibroma of skin, which is so frequent on the face, by its dense consistence and brief



FIG. 31.—Tumour-like cancer of nose.



FIG. 32.—Cicatrizing flat cancer. (Rodent ulcer.)



FIG. 33.—Cutaneous cancer of angle of eye. (Rodent ulcer.)

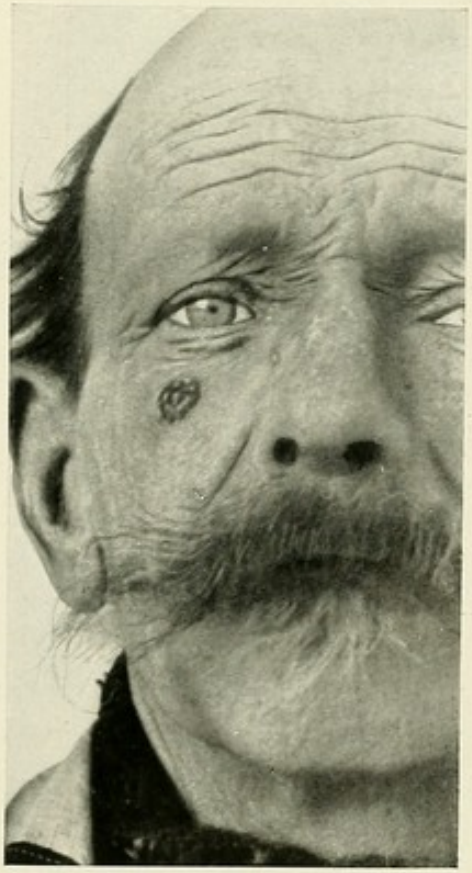

FIG. 34.—Rodent ulcer of cheek in early stage.

life-history. The absence of any inflammation and its sharply definite limits show that it is not of the nature of acne, while the scaling indicates some hyperactivity of the epithelium. If the wart has broken down into an ulcer with tumid proliferating edges (fig. 36), or if it has become a fungating or horny structure projecting from the skin (fig. 31) the diagnosis will be obvious, even to the inexperienced. The progress of this form of cancer is quite different from that of rodent ulcer, because the destruction wrought by it in the course of *months*, requires *years* in the case of the rodent ulcer. Further, the destruction is accompanied by much tumour formation, whereas this is not characteristic of rodent ulcer.



FIG. 35.—Wart-like cancroid of nose.



FIG. 36.—Cancroid of nose with wall-like margin.

Several authors have lately separated cutaneous cancers from epithelial new growths, and classified them with *endotheliomata*. But as this view has been contested from the histological standpoint, and as no clinical differences have hitherto been demonstrated, we may safely adhere to the older conception.

(3) We now come to ulcers, or structures which ulcerate early, in the **neighbourhood of the lids.**

A roundish little growth, varying in size from a hempseed to a pea, and somewhat drawn in at the top, must be looked on as very *suspicious of cancer*. It is distinguished from **molluscum contagiosum,** because the latter is softer and is rarely single, others being usually found close by, or towards the neck. If the contents are expressed, they will be seen to resemble the interior of a sebaceous cyst, and under the microscope, will show the well-known homogeneous molluscum bodies. If we squeeze an incipient cancer, we

we may obtain a few epithelial plugs, but we cannot empty the little tumour as we can a molluscum.

(4) The remarks concerning growths of the nose and eyelids apply equally to the **neighbourhood of the cheeks.** Lupus is the most frequent lesion (figs. 37, 38, 39) and then comes *cancer*, mostly in the form of rodent ulcer (fig. 34). If all the facts are not consistent with a diagnosis of cancer, one must also think of molluscum contagiosum, just mentioned. In this connection the so-called telangiectatic granuloma should be referred to.



FIG. 37.—Lupus of the face.

(5) Ulcers frequently form on the forehead and temple at the **margin of the hair.** These are usually **seborrhœic cancers of the skin.** They occur, as a rule, in old syphilitics, whose skins show very definite signs of seborrhœa and present other changes predisposing to cancerous induration, such as senile warts and even cutaneous horns. Such cancers may be multiple.

In young persons an ulcer at the margin of the hair is very suggestive of an **ulcerated syphilide.**



FIG. 38.—Lupus of the face.

(6) Ulcers of the **auricle** are generally cancroids. If left alone, they lead to complete destruction of the auricle.



FIG. 39.—Lupus of the nose.

Lupus in this position is more rare. In its hypertrophic, non-ulcerating form, it looks very much like a tumour (fig. 41.)

Ulcers which have persisted for some time, not situated on the typical positions already referred to, may be suspected of another origin. For instance, if a patient, who is accustomed to patronize a barber, has recently acquired an ulcer on the chin or cheek, a **primary chancre** must be thought of, at any rate, so long as the asepsis of the barber has not reached the desired standard.

A primary chancre on the conjunctiva may lead to mistakes. A workman allowed his companion to remove a foreign body from his conjunctiva. A little piece of wood had been used for this purpose, which, according to a very dirty custom (to put it mildly) had been previously sucked by several

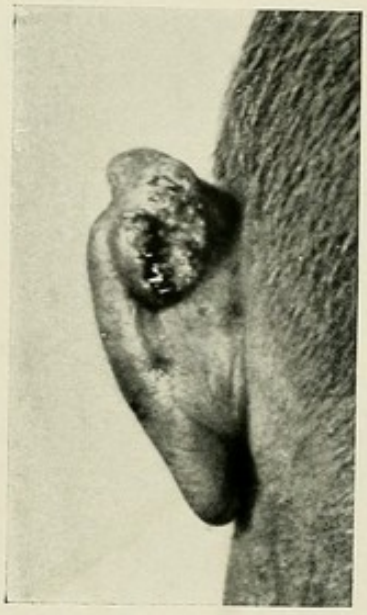

FIG. 40.—Cancroid of the ear.

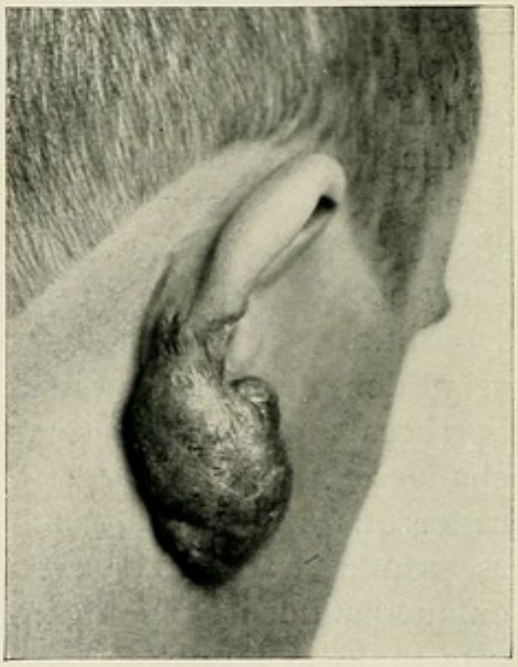

FIG. 41.—Tuberculosis of lobe of ear (Lupus hypertrophicus). (From the Ear Clinic, Basle.)

people. The foreign body was successfully removed, but at the same time the spirochæte was inoculated.

CHAPTER XII.

INJURIES OF THE JAW.

FRACTURES of the lower jaw are so easily recognized that they hardly require any discussion. The most important question to ask is, whether the jaw has been completely fractured transversely, or whether merely the alveolar process has been broken off. The severe disturbance of function, the position of the teeth, and lateral pressure and counter-pressure in the neighbourhood of both angles of the jaw, will answer this question without any difficulty.

A complete fracture may be overlooked when it is situated near the angle of the jaw or on the ascending ramus, that is to say, when it is outside the region of the teeth. But careful examination ought, as a rule, to detect it, because the loss of function and pain on local pressure are both very definite, even when there is no crepitus. The following case, however, gives an example to the contrary :—

A dentist, in extracting a wisdom tooth, unconsciously broke the jaw, which, in that situation, was somewhat atrophic. No conclusion could be drawn from the position of the teeth, because the fracture was at the angle of the jaw, and because there was no displacement. The patient only complained of severe neuralgia in the mandibular nerve, and this diverted attention from the injury to the bone, no suspicion being entertained that the nerve might be nipped between the two fragments. It was not until a phlegmon started at the seat of fracture that attention was directed to the accident.

Fractures of the upper jaw more frequently escape recognition. Not, of course, fractures of the alveolar process due to violent extraction of teeth, or when the jaw is shattered by such an injury as a revolver shot for suicidal purposes. When all the bones of the face are torn asunder, the diagnosis of a fractured upper jaw presents neither difficulty nor interest. But on the other hand, it is important to recognize a fissured fracture when the soft parts are uninjured and the seat of fracture not exposed. This may occur when a force is applied flat to the face, both upper and lower jaw being fractured transversely. The most striking symptom which comes on after the blow is bleeding from the mouth and nose ; but this is not significant of fracture, because this may follow a simple wound of the nose. The presence of a rent in the mucous membrane, or at least a submucous hæmorrhage of the alveolar process of the palate, is more important. Preternatural mobility, or displacement of one of the fragments, would be conclusive evidence. But this is likely to be missed in a superficial examination, because the displacement is much less than in the case of the lower jaw. If, however, the patient complains that some of his

teeth have "become too long" we may assume that we have overlooked some abnormality in position, and that a fracture is present. This very significant statement permits of the diagnosis being made long after the accident. Pain is also an important sign. It is easy to demonstrate by external pressure that there is pain on the anterior surface of the upper jaw, unless a hæmorrhage on the cheek prevents palpation. If such pain is limited to a definite position, we have every right to suppose that there is a fracture. Sometimes the pain can be traced straight across to the opposite jaw. This supposition will be confirmed if pressure on the teeth either in an upward or lateral direction elicits definite pain, whether accompanied by crepitus or not. If sensation is disturbed in the region of the infra-orbital nerve, especially if sensibility is diminished and neuralgia exists, this affords further confirmation of the diagnosis.



FIG. 42.—Dislocation of lower jaw.
(From the surgical clinic at Berne.)

The recognition of such fractures of the upper jaw, or even of less marked ones, has something more than a mere diagnostic interest, because the line of fracture may continue onwards to the base of the skull and involve other nerves, particularly the optic nerve. Such fractures may even lead to meningitis.

A woman was struck on the cheek by a drunken peasant. A few weeks later there still remained pain on pressure over the canine fossa, the feeling of long teeth, and a trigeminal neuralgia. Careful examination showed that the affected eye was blind, and the ophthalmoscope revealed optic atrophy, proving that the fracture had reached the area of the optic nerve.

Partsch has even seen a case of bilateral blindness from this cause.

Dislocation of the lower jaw need not detain us. The patient with his lower jaw pushed forward, with his mouth open, unable to open it any wider or close it, presents such a characteristic aspect that even the layman can diagnose it forthwith (fig. 42).

CHAPTER XIII.

LOCK-JAW.

WHEREAS the inability to *shut* the mouth invariably points to dislocation, inability to *open* it may be due to various causes.

Let us begin with a rare case :—

A young girl was attacked suddenly, from time to time, with inexplicable seizures of lock-jaw, which disappeared when the patient was semi-anæsthetized. This was evidently a functional condition, a spasm, which Kocher compares to spastic torticollis, and which we must assign to the wide domain of neuroses.

The rare cases of trismus, due to an apoplectic lesion in the lower frontal convolution, must also be classified as **lockjaw of nerve origin.** The lockjaw, due to tumours of the pons, is a peripheral irritative symptom.

The following kind of case is much more frequent: The patient had taken a three hours' walk from the country into town to consult a doctor, because he had been unable to open his mouth for the last fortnight, owing to "a bad tooth." Besides his lockjaw, he had facial paralysis of the left side, and a small unirritating scar over his left eyebrow. The latter was due to an injury from an axe, sustained four weeks previously. All the reflexes were increased, the gait was somewhat stiff, and there was a grinning facial expression on the unparalysed side (fig. 43).

This really constitutes the classical picture of **head tetanus.** The beginner, who thinks of the victim of tetanus as absolutely incapacitated, would probably be misled by the history of the three hours' walk. But patients with tetanus often come, walking to the doctor, from a distance. Facial paralysis is not always present, but in its absence the "risus sardonicus" is all the more expressive of the diagnosis, long before the patient has complained of his malady, especially of his bitten teeth.

Fig. 44, a similar case to fig. 43, shows the facial paralysis better, there being complete absence of folds in the skin on the left side.

If these somewhat infrequent causes do not account for the lock-jaw, it is necessary to determine some anatomical causation.

We will proceed with the examination in the natural method. If the patient's cheek has recently become swollen, and if his expression is typical of toothache, we may suspect **periostitis of the jaw.** The mouth is opened as widely as possible, and the offending tooth, which will be near the angle of the jaw, is looked for. There may be nothing wrong to be detected with the tooth, but the fold of mucous membrane between the jaw and the cheek will be more or less obliterated.

Instead of an even and regular swelling of the cheek, there may

be a dense infiltration, with sundry sinuses, foci of granulation and fibrous contractures, reaching down as far as the neck (fig. 46). This will at once suggest **actinomycosis.** The pus expressed from the sinuses frequently contains the well-known yellowish little granules, of the size of millet seeds, which serve to confirm the clinical diagnosis.

We shall see later on that Actinomycosis or its allied Streptomycosis may also begin as a diffuse swelling.

Tuberculosis of the jaw, which somewhat resembles the above, occurs but rarely. The first glance should, however, differentiate it, because the skin is less involved and because the glands are considerably enlarged.

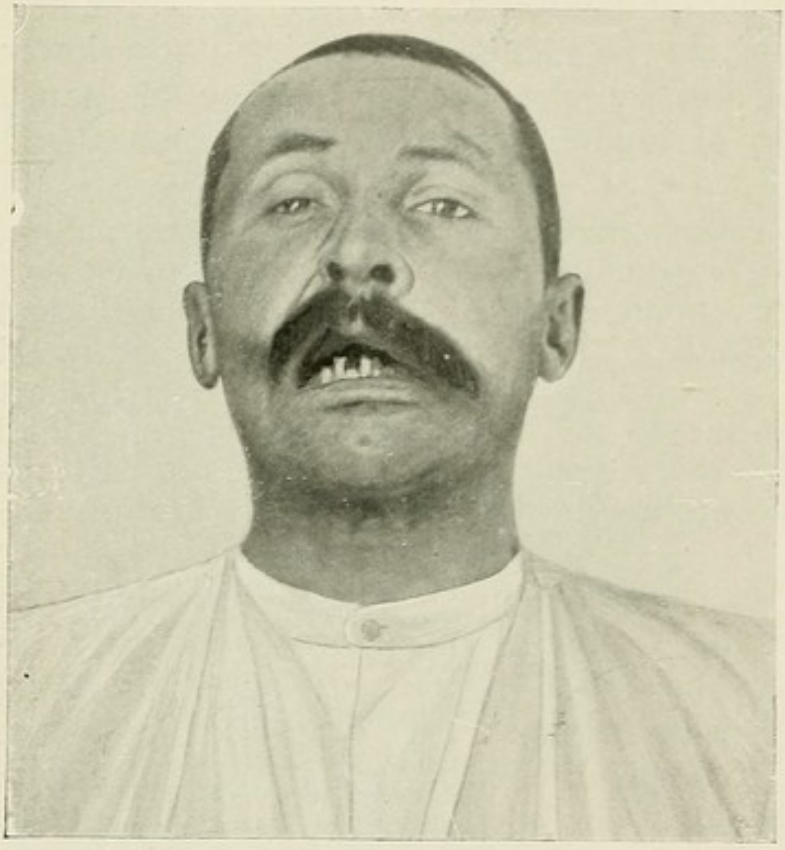

FIG. 43.—Head tetanus. The patient is attempting to open his mouth. Contraction of right side; facial palsy on the left. Scar over left lid.

If the lockjaw has set in acutely, and a diffuse swelling occupies the whole of the lower jaw and the floor of the mouth, we should think of **osteomyelitis of the jaw.**

A swelling more closely confined to the cheeks, with tumid lips and a fœtid, slightly sanious fluid issuing from the mouth, points to one of those rare cases of **gangrenous stomatitis.** *Mercurial stomatitis* may produce a similar clinical picture.

If the aspect of the patient does not suggest any cause for the lockjaw, we must examine the condition of the **articulation of the jaw.** A rapid and painful onset of the trismus will make us think of *acute arthritis*, which occurs in the most varied infective diseases, especially in scarlet fever, acute articular rheumatism and gonorrhœa. The region of the joint appears somewhat swollen, pressure in front of the ear, just under the zygomatic arch, is painful, and the patient complains of radiating pains in the neighbourhood of the joint. Every attempt to open the jaws forcibly produces immediate contraction of the muscles of mastication. If there are no acute inflam-

matory signs and the lockjaw is of old standing, but has followed some acute disease, we must conclude that the articulation of the jaw has become ankylosed through some *antecedent inflammation*. It must not be forgotten that ankylosis of the jaw can develop in the course of a chronic ankylosing polyarthritis.

A very trifling derangement in this region may be mentioned here. It consists of some crepitation in the joint due to a slight looseness of the capsule of the articular condyle (termed discitis, by Lanz). In other cases this crepitation points to arthritis deformans of the jaw, which proceeds, if it is unilateral, to cause obliquity of the part, with corresponding obliquity of the lower teeth.

Among the causes of ankylosis of the jaw are **inflammatory processes in the neighbourhood**, which attack the jaw secondarily. This occurs especially in *suppuration of the tympanic cavity*. **Injuries** also play their part, for they may lead to bony proliferation or to the development of osteomata.

A striking smallness of the lower jaw—a bird face—accompanying the lockjaw, will indicate that the disease dates from infancy. Disuse of bone leads to atrophy, and therefore the ankylosed lower jaw fails to grow adequately.

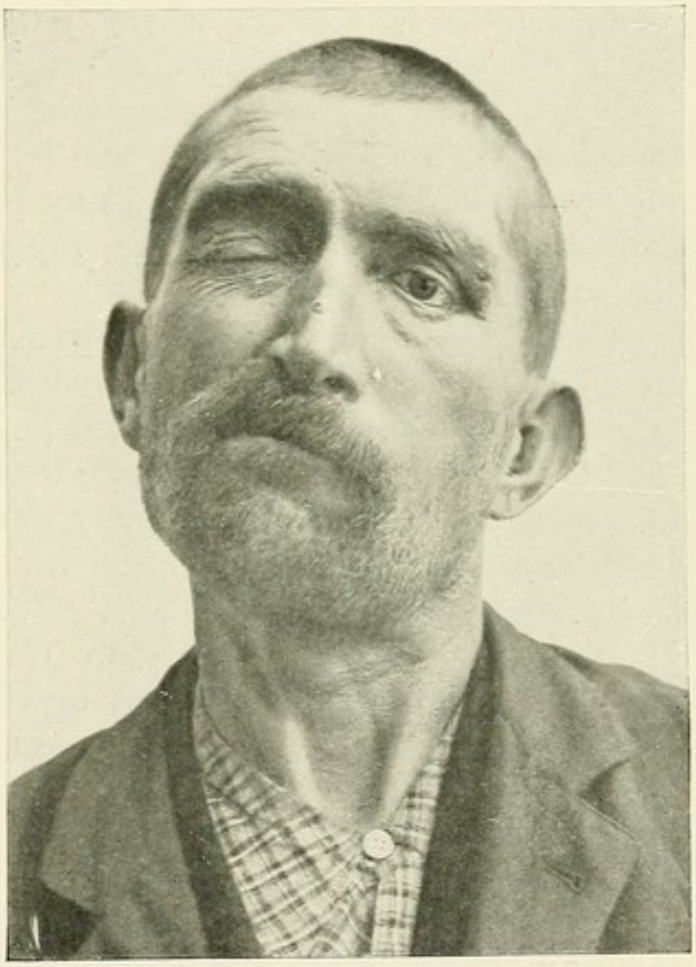

FIG. 44.—Head tetanus, with facial palsy. Small wound on the left eyebrow.

If the exhaustive examination of the joint and its surroundings fails to discover the cause, we must inspect the pharynx. If the disease is recent, it may be due to a *retro-tonsillar abscess*, if chronic, it may be due to *cicatricial bands* in or under the mucous membrane, or to a *malignant neoplasm* near the tonsil.

CHAPTER XIV.

INFLAMMATORY DISEASES OF THE JAW.

In discussing the important symptom of lock-jaw in the preceding chapter, we have already touched upon several inflammatory diseases of the jaw. We must now, however, deal with them again, more systematically.

(1) **Acute periostitis** of the jaw which is always the result of dental disease, presents such a familiar picture that its consideration need not detain us. It can only be necessary to distinguish it from **primary osteomyelitis,** which will be suggested by the great extent of the disease and inability to find any primary lesion in the teeth. The course of this disease resembles, in its severity, acute osteomyelitis of the extremities.

(2) The **chronic inflammations** of the jaw are much more interesting. If we find a limited area of disease, for instance, a sinus in the gum or on the cheek, with more or less swelling on the corresponding section of the jaw, we may be sure that a tooth is responsible and that the condition is one of an ordinary **dental fistula** (fig. 45). The more contracted the neighbourhood of the fistula, the longer will its duration have been. If there is no tooth in the affected situation, a piece of stump will probably be found on opening the alveolus, or in an extensive case, a *sequestrum* may be forthcoming. If the removal of such causes does not cure the inflammation, some more serious disease underlies it, and we shall have to diagnose between *actinomycosis*, *tubercle*, and *phosphorus necrosis*.

The symptoms of *actinomycosis of the jaw* have been briefly described in the previous chapter; it only remains to add that the changes at the site of infection—a tooth or the gum—are so completely overshadowed by the secondary appearances on the cheek and neck, that it frequently becomes impossible to define the spot where the infection entered. But it is interesting to trace *the source of infection*. Usually we can find no clue in the case of the town dweller, and in country districts the bad habit of chewing stalks of grass is so widespread that the patient is most unlikely to remember any such incident. The clue is more definite, if one can ascertain that the patient has been tending cattle with actinomycosis, as once occurred to me in a case of abdominal actinomycosis.

The diagnosis is based on the visible external changes (figs. 46 and 47), on the dense infiltration with brownish-red foci of softening on the somewhat contracted cicatricial areas, on the absence of glandu-

lar enlargement, and finally on the demonstration of the yellowish little granules.

The latter may be confused with the small particles of necrotic tissue which sometimes occur in tubercular abscesses. They may, however, be pretty clearly distinguished, even without the microscope, in the following manner: If a granule of the ray fungus is crushed between two glass slides, and examined, the periphery will be seen to be opaque from pus cells, while the centre will be comparatively transparent, being occupied by the interlacing fibres of the fungus. On the other hand, a pus coagulum, or a particle of necrotic tissue will be uniformly turbid.

When all the described signs of actinomycosis are fully developed, a diagnosis can be made at first sight, even if the characteristic granules are not found. But on the other hand, actinomycosis must not be excluded if there is only a purely diffuse swelling present, without the skin changes (fig. 46). The pus should be examined for the ray fungus (actinomycosis or streptomycosis) in the case of every persistent chronic abscess of the jaw with hard edges. If the immediate examination yields a doubtful result, culture tests should be undertaken.

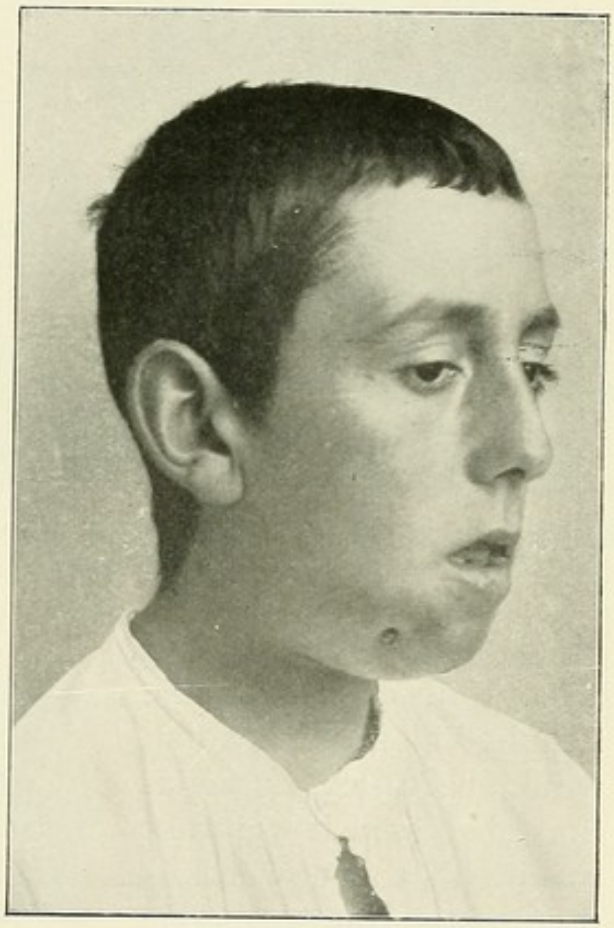

FIG. 45.—Sinus from tooth.

We have already referred to **tuberculosis of the jaw** among the causes of lockjaw. It may appear in the form of *tubercular ulcers of the gum*. These are diagnosed by their sharp margins, chronic course, the presence of enlarged soft glands in the neck, and the failure of antisyphilitic remedies. To expedite the diagnosis, it is necessary to scrape away a piece of the margin of the ulcer with a sharp spoon and it will generally be easy to detect tubercle in the frozen sections. In doubtful cases animal inoculations will yield a decisive result.

The early stages of *tubercular disease of the bone itself* are more difficult to recognize.

The following is a characteristic case:—

A woman, aged 38, gradually became affected with lockjaw. Already at the first examination severe swelling of the cheek and

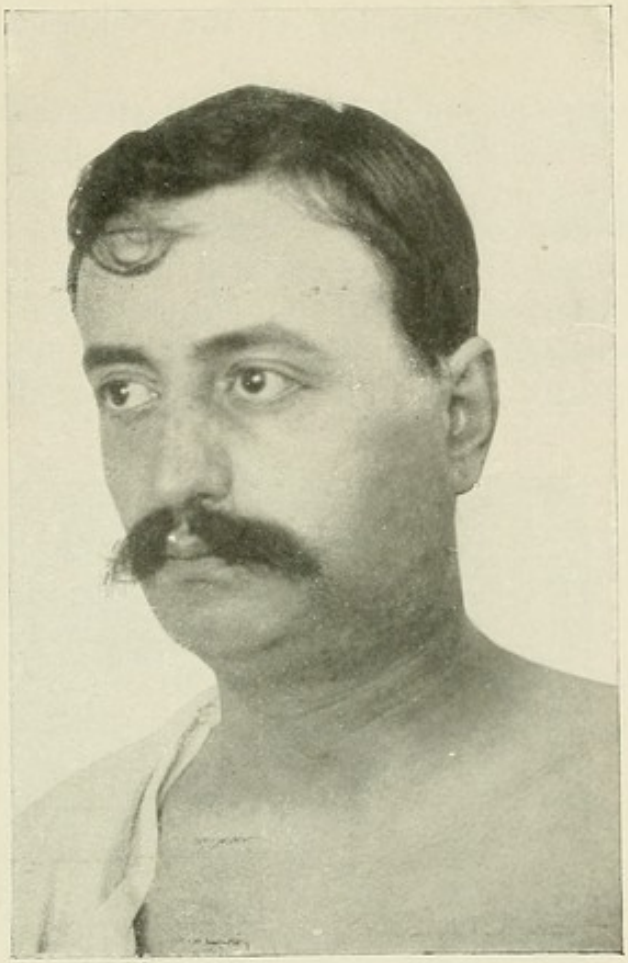

FIG. 46.—Early stage of actinomycosis of jaw (before the bursting of abscess).

temple were present. Some of the molars were absent, and the others did not appear to account for the clinical condition, more especially as the bone was thickened, especially about the angle of the jaw, and the ascending ramus. A little pus exuded from a small sinus behind the last molar, and the probe impinged upon bare bone. A bunch of movable soft and elastic enlarged glands was found in the neck. The swelling over the temple fluctuated.

Four points in this case established the diagnosis forthwith:—

(1) The insidious onset, which distinguished the disease from an ordinary dental periostitis.

(2) The localization on the ascending ramus, which is not usual in dental periostitis.

(3) The obviously tubercular glands in the neck.

(4) The presence of a cold abscess over the temple. This abscess, which would be called a gravitation abscess if it were not making its way upwards, is quite distinctive of tubercle of the lower jaw. Owing to anatomical reasons the pus cannot find its way downwards; it tracks along the line of least resistance, between the pterygoids and the bone, makes its way upwards and gets beneath the temporal muscle. The temporal bone and other bones of the skull may be attacked secondarily as a result of this abscess.

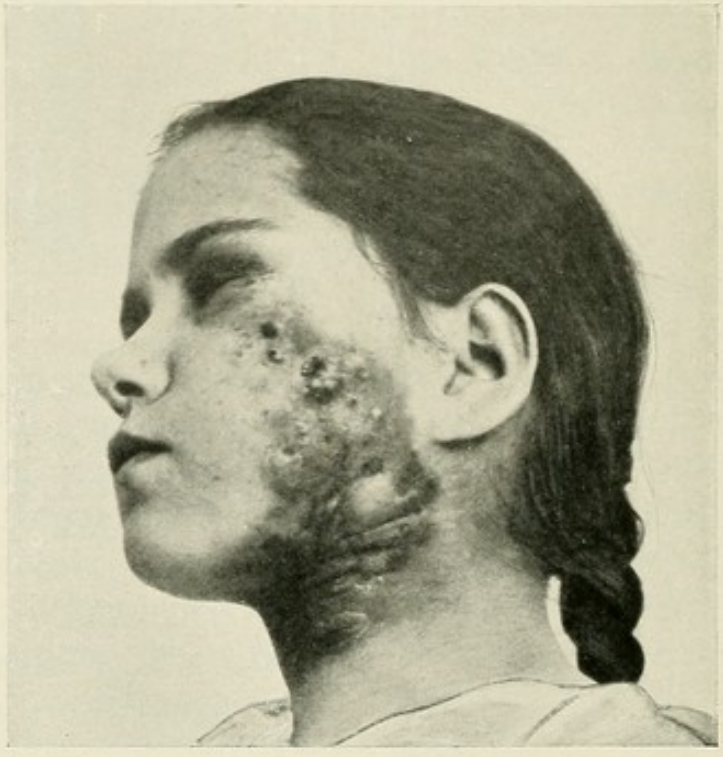

FIG. 47.—Actinomycosis of jaw. (Advanced stage.)

The subsequent progress of the above case was also very distinctive.

The abscess was opened from the mouth, a tubercular sequestrum was removed from the ascending ramus and the bony cavities were scraped out. But this only gave temporary relief. Before the disease was checked it was necessary to resect the whole of the ascending ramus, and subsequently a portion of the horizontal ramus. The tubercle afterwards invaded the upper jaw, and this had to be resected; and two years later the patient had ileo-sacral tuberculosis of both sides.

Most cases of tubercle of the jaw, hitherto described, have run a similar course.

Phosphorus necrosis presents a different picture altogether, the trouble also begins with insignificant symptoms of toothache, but the extraction of the painful teeth does no good. The pain persists, one acute abscess after another appears and they burst, either through the gum or externally, leaving permanent fistulæ. The whole jaw becomes diffusely thickened through the formation of new bone from the periosteum, and finally a piece of the original jaw extrudes itself—the whole lower jaw may indeed become necrosed—and is easily removed by the patient himself or the medical attendant.

In both phosphorus necrosis and osteomyelitis of the jaw extensive sequestra may form; but in phosphorus necrosis this process does not develop from one sudden attack, but is the result of slow stages. Tubercle is similar to phosphorus necrosis in its chronicity, but the latter differs completely in the large extent of sequestrum formation. The only similarity between phosphorus necrosis and actinomycosis is also their chronicity. But the former always remains a bone disease despite abscesses in the soft tissues and despite fistulæ; in actinomycosis the affection of the bone assumes minor importance and the disease of the soft parts predominates. It is obvious that it must be shown that the patient has had long contact with phosphorus in order to confirm the diagnosis of phosphorus necrosis. But it must not be forgotten that the disease may arise many years after the patient has ceased to be under the influence of phosphorus. Phosphorus necrosis might, happily, become merely a matter of history, if new spheres for the employment of yellow phosphorus in industry were not being opened up.

CHAPTER XV.

TUMOURS OF THE UPPER JAW.

Tumours of the upper jaw are imitated by harmless conditions, just as are so many malignant diseases, a circumstance responsible for delayed diagnosis. *Periostitis of the jaw* and *chronic inflammation of the maxillary sinus* are the principal ones. A swelling in the upper jaw, coming on with toothache, sends the patient at first to the dentist, and a few teeth are extracted. If he is disturbed by unusual nasal discharge or by the obstruction of a nostril, he consults a nose specialist to get his antrum washed out. The patient is fortunate if it is recognized that his case does not belong to those specialities, but concerns the surgeon. This summary diagnosis is not difficult if one appreciates the maxim that *any swelling of the upper jaw, however small, accompanied by persistent neuralgic pains, must be suspected of a malignancy.* Other symptoms may be entirely absent, such as displacement of the nose, a sanio-purulent discharge from the antrum, deviation of the eye (squint, double vision), ulceration into the oral cavity or vestibule of the mouth. Nevertheless, there can be no doubt of the diagnosis, if on comparing both sides it is found that the canine fossa is somewhat obliterated, the lower orbital margin spherical or irregular, the floor of the orbit perhaps already raised, and if the neuralgia is of infra-orbital character; especially if one of the other symptoms just mentioned is also present. To confirm the diagnosis, some of the diseased tissue should be removed with a sharp spoon from the antrum, either through the nose, or by making a

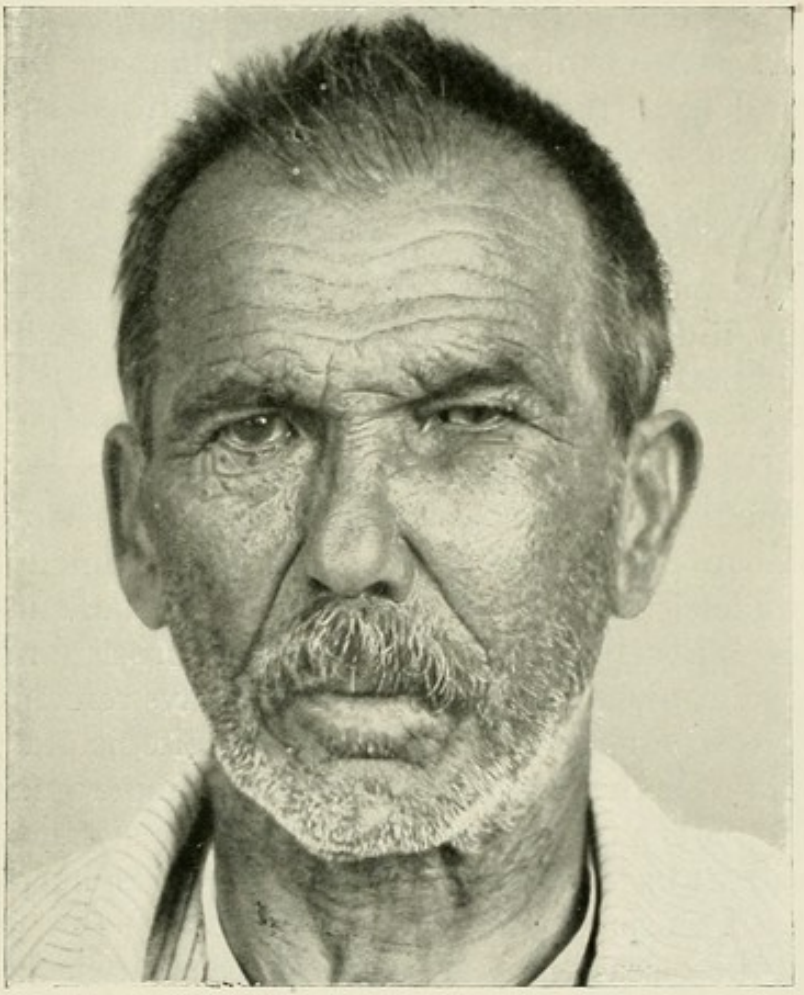

FIG. 48.—Carcinoma of upper jaw.

small incision and opening the antrum from the vestibule of the mouth. The piece removed must be submitted to histological examination, which will at the same time reveal the intimate structure of the growth. Clinical diagnosis cannot go beyond declaring the presence of a *malignant growth*, it cannot define its histological details. Theoretically we should expect that a tumour which at first is confined within the antrum and then gradually breaks through its wall is more likely to be a periosteal sarcoma—a growth which rapidly makes its way externally—than a squamous epithelioma. Experience, however, shows that the very opposite may occur. Sometimes sarcomata are limited to the antrum for months, and squamous epitheliomata may proliferate so rapidly towards the surface that warm poultices are ordered on the assumption that the swelling is due to periostitis. Palpation affords no conclusive evidence. In the case of tumours of the upper jaw it is not possible to rely on the distinction that firm nodular growths are generally cancerous, and that round, elastic growths are usually sarcomatous. Early enlargement of the glands is more important for the diagnosis of cancer, but this sign is often absent.

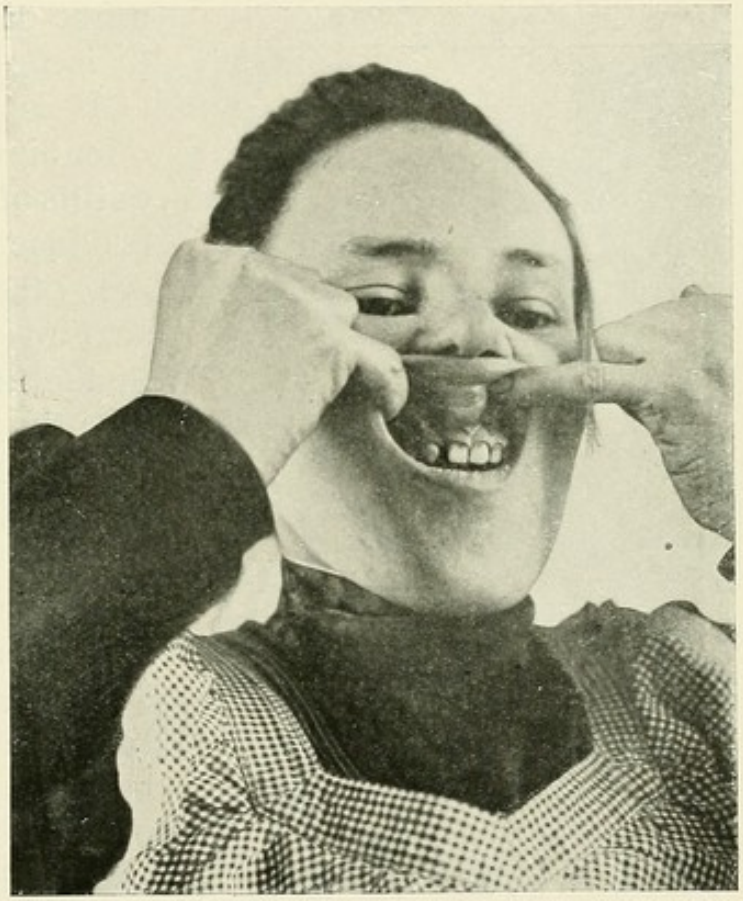

FIG. 49.—Dental cyst on upper jaw. The right lateral incisor is absent below the cyst.

But the practitioner is under no obligation to worry himself over the differential diagnosis. He has done his duty if he has sent the case, in an early stage, to the surgeon as one of malignant growth. From the operative point of view it is immaterial whether it be sarcoma or carcinoma. There is, however, a great difference in the prognosis, as the ultimate results of operations on sarcomata of the upper jaw are much better than those on carcinomata.

As we have already mentioned, difficulties of diagnosis may arise from *empyema of the antrum, periostitis of the jaw, tuberculosis of the jaw,* and *dental cysts*. Each one of these diseases has its characteristic previous history.

In **chronic empyema,** the most striking incident is the periodical discharge of pus. As long as the discharge is free there is absolutely no pain, but when it is retained, there is a neuralgia of racking, beating, and sometimes of a boring character. There is also local pain on pressure in the stage of retention. During the intermediate stage, the pain is dull and quite tolerable. But in the case of malignant growths the pain is severe and tormenting and allows of no respite, even when there is no external sign of irritation or any marked pain on pressure. There is sometimes a purulent discharge in carcinoma, and this may lead to the mistaken diagnosis of ordinary antrum disease. But the fact that there is so much pain in the presence of a free discharge must arouse the suspicion of a malignant neoplasm.

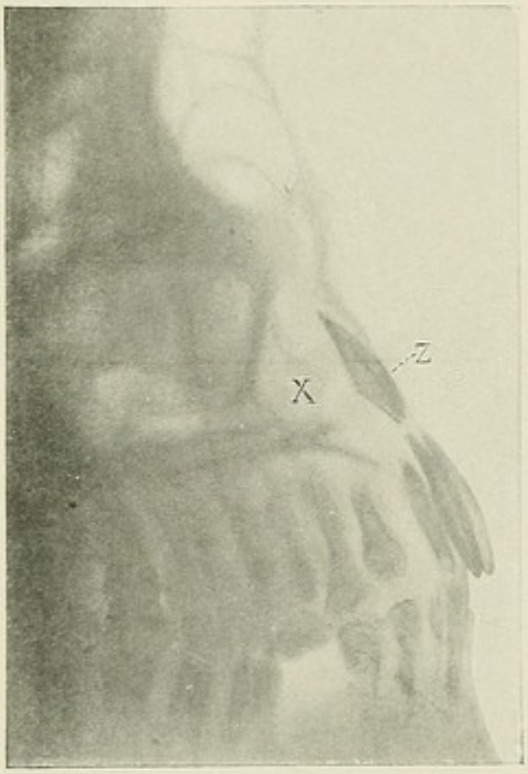

FIG. 50.—Skiagram of fig. 49. *X*, Dental cyst with the missing incisor tooth, *Z*.

It is usually easy to detect the offending tooth in a case of **periostitis of the jaw.** Malignant tumours produce toothache in teeth which are otherwise healthy. The pain also involves the cutaneous branches of the nerves (upper lip) and is frequently accompanied by anæsthesia (anæsthesia dolorosa). In both periostitis of the jaw and in empyema of the jaw, the pain is only present in the acute stage, or in acute exacerbations, and it becomes relieved either spontaneously or after appropriate treatment. One special form of ostitis can give rise to very serious difficulties in diagnosis, namely, **tuberculosis of the jaw.** Its characteristics have been mentioned above.

In cases of **cysts of the jaw,** there is a gradual enlargement of the bone, which eventually crumbles like parchment, but there is usually no pain as long as the contents of the cysts are not infected. In some cases they empty themselves periodically through the nose and then fill up again. They may persist for years, a circumstance which differentiates them from malignant growths, for both in carcinoma and in sarcoma, the diagnosis can generally be firmly established within a few months of the onset of symptoms. If one tooth is missing from the set and is seen, on the skiagram, in the tumour, all doubt is dispelled (*see* figs. 49 and 50).

If we meet with the symptoms of a malignant growth of the upper jaw in an adolescent male, we must also think of a **nasopharyngeal**

fibroma. This growth springs from the base of the skull near the roof of the pharynx and penetrates into all accessible fissures, especially into the nose, the orbit, and circuitously, into the parotid region and the maxillary sinus.

I have seen a case wherein the tumour penetrated thence into the mouth cavity and began to putrefy. This peculiar course at once suggested sarcoma. Histological examination and further progress, showed, however, that it was an ordinary nasopharyngeal fibroma. The patient made a good recovery, although the tumour was not completely extirpated from the base of the skull, it only being possible to burn it away with the thermocautery.

Innocent tumours of the body of the upper jaw, apart from dental cysts, are so rare that they do not enter seriously into the question of differential diagnosis. They behave like the corresponding growths of the lower jaw, the description of which should be referred to.

On the other hand, *innocent tumours*, or *growths only malignant locally*, play the most important part in connection with the *alveolar process*. These will be discussed, together with the growths of the oral cavity.

CHAPTER XVI.

TUMOURS OF THE LOWER JAW.

Apart from neoplasms of the gums and alveolar process, which we shall discuss in connection with tumours of the oral cavity, new growths of the lower jaw present no difficulties of recognition. Care must be taken, however, not to confuse a swelling which appears to be a *tumour*, with what is really an *inflammatory process*. We must abandon the thought of a new growth, and confine ourselves to one of the inflammatory conditions described in Chapter XIV, if the disease has started with toothache, caused by carious teeth which are in evidence; if the thickening of the jaw has been preceded by an acute inflammatory stage; if the patient tells of repeated acute exacerbations and shows the scar of an old dental fistula in testimony thereof; or if we find tubercular glands of the neck in a purely chronic disease. We are, however, justified in diagnosing forthwith a new growth, if the swelling has come on gradually and painlessly; if toothache, when present, is a late symptom, and healthy teeth

become loose without any visible inflammatory changes in the gum. Palpation will sometimes elucidate the condition. An inflammatory swelling gradually merges with the healthy bone, whereas most tumours appear to be sharply separated therefrom. Central tumours form an exception to this rule, because these, at first, expand the bone in a spindle-shaped manner. In these cases, the exclusion of any antecedent dental disorder is decisive from the point of view of diagnosis.

Having concluded that a **growth** is present, the first question concerns its innocence or malignancy. The history supplies the critical factor, because a *slow growth* always means innocence, and a *rapid* growth signifies malignancy. But this criterion must be cautiously applied, because even a sarcoma may last for many years. It is necessary, next, to consider the matter of *painfulness*. Painless tumours, which remain painless for years, are innocent. If toothache comes on, a suspicion of malignancy arises, but only suspicion, for innocent growths may cause neuralgia by pressure on the inferior dental nerve. On the other hand, victims of sarcoma may remain free from pain for a considerable time. It is only in extreme cases, therefore, that the previous history permits of the formation of an immediate diagnosis. In intermediate cases every clinical aid will need to be enlisted, and often enough the microscope will be required to make the final decision. It must not be forgotten that a tumour which has been innocent for years may eventually become malignant. This change can generally be recognized by sudden rapidity of growth.



FIG. 51.—Odontoma of lower jaw.

We have purposely omitted one sign, viz., the absence or presence of metastases in the glands of the neck, because this is not a matter of significance in connection with tumours of the lower jaw. Malignant growths in this situation are *sarcomata*, which usually leave the glands unaffected. Enlarged glands should therefore not be regarded

as a mark of malignancy, but, as previously stated, rather an indication of tubercular disease.

We now proceed to discuss the individual varieties :—

(1) The first group of growths of the lower jaw embraces tumours connected in some manner with the *development of the teeth*, or at any rate with the *epithelial covering of the jaw*. They are not indeed of frequent occurrence, but they are of great theoretical interest. Among these are **dental cysts**, which appear during the period of youth ; they push the jaw *outwards*, and they contain either a tooth which is missing from the series, or a supernumerary tooth. The expansion of the jaw which they cause is very gradual, so that finally the bone gives the crumbling sensation peculiar to parchment. If such a cyst has been incised in ignorance of its true nature, or if it has burst spontaneously, a fistula remains which is very prone to secondary infection, wherewith the whole aspect of the case is obliterated. Another group consists of *odontoma* and *adamantinoma*. These may be soft, or as hard as enamel, or of a mixed character. They arise in young people as an irregular proliferation of the various elements of a tooth, and they gradually, but painlessly, displace the enclosing bone, both *outward and inwards*. Their favourite site is in the neighbourhood of the posterior molars (fig. 51). Another tumour, less associated with tooth development, is the **multilocular cystoma of jaw**, in which the bone becomes gradually expanded by cystic proliferation of its epithelial covering, and finally becomes converted into a vesicular shapeless structure. This change eventually attacks the ascending ramus of the jaw, in contrast to what occurs in simple cysts of the jaw and odontomata.

(2) Turning now to *connective tissue tumours*, we must mention the *innocent growths*, **fibroma, chondroma** and **osteoma**, as of comparatively rare occurrence. If they arise from the surface of the bone, they grow slowly, their structure is nodular, they feel firm or hard, and only become troublesome through secondary changes. But if they exist within the bone, their pressure on the inferior dental nerve may soon produce neuralgia. The bone is expanded, first in a spindle-shaped manner, and having reached the surface it appears as a nodular sharply defined structure.

Sarcomata, *malignant connective tissue tumours*, play the chief *rôle* among the tumours of the lower jaw. The initial symptoms and early discomfort depend upon whether their site is central or peripheral ; but their course is more rapid than that of the tumours previously discussed, even if, exceptionally, the first signs date some years back.

The following observation is very significant :—

A female, aged 50, came to her medical attendant complaining of

a gradual thickening of the right horizontal ramus of the lower jaw. It was regarded as a dental cyst and was opened from the mouth. The knife penetrated into a hollow space, from which a profuse stream of blood flowed. I saw the patient, two years later, with a diffuse expansion of the whole right half of the jaw. The diagnosis pointed to sarcoma, and the operation consisted of removing half of the jaw, which was expanded as far as the articular process into vesicular cavities, just like a multilocular cystoma of the jaw. The small amount of firm tissue present showed the structure of a round celled sarcoma. Two years subsequently I saw the patient again. Locally she was cured, but there were secondary deposits of similar structure in the skull and sternum.

The diagnosis may be difficult in the early stages, as already intimated, but it cannot be missed if the tumour has proliferated into the oral cavity, has caused the teeth to fall out, has become adherent to the skin, or has finally ulcerated to one side or another. It should, however, not be allowed to reach such a degree ; every tumour of the jaw which does not remain quite stationary, ought to be suspected and removed.

A careful examination will generally reveal the starting point of the tumour, notwithstanding many exceptions. The sensation of crinkling like parchment indicates a central site, as also does a bony resistance of the surface, detected by the acupuncture needle. If acupuncture is made in various places and bone is only struck at a great depth, the growth has arisen from the periosteum. But nowadays Röntgen-ray examination should replace acupuncture, because a skiagram gives a clearer conception of the distinction between bony and soft tumours, and also reveals the missing tooth in the case of dental cysts (figs. 49 and 50).

We have said nothing about *cancer of the lower jaw*, but this will be referred to in the next chapter, as it usually grows from the mucous membrane of the gums. Isolated masses of dental epithelium, deeply *displaced*, very rarely undergo cancerous degeneration.

CHAPTER XVII.

ACUTE INFLAMMATORY DISEASES OF THE ORAL CAVITY.

We have already met with some of the acute inflammatory diseases of the interior of the mouth, and we shall come across them again when we discuss some of their main symptoms : lockjaw and difficulties in swallowing and breathing. We shall, therefore, here only collate a few points which have been treated disconnectedly, and supply sundry omissions.

An acute swelling of the *lips* nearly always depends upon the presence of a small **furuncle,** which may have disappeared in the general œdema, assuming, of course, that the swelling is not a part of an extensive inflammation like erysipelas, or the result of a periostitis of the jaw. We have already noted the possible dangers of a furuncle of the lip.

An *acute circumscribed swelling of the gum* indicates either a diseased tooth or a root retained in the alveolus. The precise localization is shown by the position of the most intense redness of the mucous membrane, and the greatest obliteration of the fold between the cheek and jaw. If the offending tooth is still visible, it will readily respond to light percussion.

Acute widespread swelling of the gum is a sign of some form of acute periostitis of the jaw (*see* lower jaw), or of a general stomatitis (*see* below).

Acute swelling of the *floor of the mouth* may be due to many causes. If the swelling is in the middle line, and more definite posteriorly than anteriorly, we should think of a secondarily **suppurating dermoid,** which is common in children, or of an inflamed lymphangioma. In such a case an adult would observe that there had been something abnormal under the tongue before the onset of the acute inflammation.

If the inflammation has proceeded externally towards the submental region, the case is one of **phlegmonous submental lymphadenitis.** A sore on the lip, an acute pustule, a small infected abrasion of the skin, will have afforded the portal of entry of the infection.

If the swelling on the floor of the mouth is rather unilateral, or if the patient can state on which side it began, **acute inflammation of the salivary glands** must be thought of. If the swelling is anterior, the sublingual gland is affected, if lateral, it is the submaxillary gland. In these cases the floor of the mouth, in the vicinity of the gland, may look like a translucent œdema and the swelling feel like a board. The cause of the swelling will be found in a salivary calculus, especially if the patient states that he has suffered from repeated attacks of such inflammation. If these exacerbations are of short duration, and terminate with a discharge of saliva, there is no doubt the swelling indicates salivary retention. If they are of longer duration—a day or more—and increasing infiltration of the tissue takes place, we must conclude that some bacterial inflammation of the salivary glands has become engrafted on the simple retention. If treatment is not undertaken, the swelling will proceed to its natural result—the formation of an abscess.

If the symptoms are distinctly inflammatory from the start and are better developed externally than towards the mouth cavity, the

case is one of **acute submaxillary lymphadenitis.** Its cause will most probably be found on the gum, or the cheek, or nose if the portal of entry still remain demonstrable.

If the infection is very severe, and tends to spread, especially towards the floor of the mouth, it is termed "Ludwig's angina," which is merely a clinical and not an etiological indication. The exciting causes, as usual about the mouth, are staphylococci, streptococci and colon bacilli. The great severity of the infection strongly suggests that the infection arises from some deep focus—directly around the submaxillary gland.

If the swelling involves the *tongue* from the start, and this organ quickly becomes converted into a dense immovable mass, with saliva trickling from the open mouth of the patient, who can neither swallow nor speak, but can just breathe, the case is one of **acute glossitis**, which usually ends with the formation of a lingual abscess. This rare disease is of a metastatic character, and supervenes especially as a sequela of acute infectious diseases. If in the course of glossitis there be dyspnœa with delayed respiration and stridor, it is obvious that the larynx has become œdematous, and that tracheotomy is urgently required. If, on the other hand, the dyspnœa is accompanied by cyanosis and hurried respiration, without stridor, we conclude that aspiration pneumonia has supervened, and our prognosis will be correspondingly doubtful, if not bad.

Sometimes the entire floor of the mouth is involved in a phlegmonous inflammation from the very beginning; and the tongue, which is usually œdematous at the same time, is pressed against the palate. The clinical picture resembles that of Ludwig's angina, but is bilateral from the start. This constitutes a case of **acute phlegmon of the floor of the mouth,** and has three sources of danger—(1) suffocation, (2) aspiration pneumonia, and (3) extension of the inflammation to the connective tissue of the neck and mediastinum.

If the original site of the swelling be the *isthmus of the fauces*, the first glance will suffice to distinguish between *diffuse* and *unilateral* **sore throat.** If it be diffuse, we must think of catarrhal and lacunar sore throat, scarlet fever, diphtheria, and secondary syphilis. As far as these are of surgical importance, they will be discussed later on with the subject of diphtheria.

The inexperienced often miss syphilitic sore throat when it appears in a mild catarrhal form, and is not accompanied by mucous patches on other parts of the mucous membrane. Those affected with "syphilis insontium" are of course unaware of its cause, and the others often enough refuse to know anything about it. But it is just in this stage that diagnosis is so important, both because of early treatment and the protection of the patient's surroundings.

If the sore throat is unilateral, we should entertain the possibility

of a tonsillar or retro-tonsillar **abscess**. If the swelling increases, we should not wait till it bursts spontaneously, but should search for pus in the classical situation before complications supervene.

An acute swelling on the posterior or lateral wall of the pharynx must be regarded as an acute retropharyngeal abscess, which is generally due to a lymphadenitis, but in rare cases may depend upon osteomyelitis of the spine. If the abscess is not accessible externally we must evacuate it from the inside, using a puncture syringe so that the gush of pus should not inundate the larynx.

Further, we must not forget that there are certain acute inflammatory processes which lead to the growth of adenoids on the *roof of the pharynx*. The examination of this region is always important when children suffer from unexplained pyrexia.

If the *lips* and *cheeks* are infiltrated, and a diffuse swelling of the mucous membrane with severe turgidity of the gums is seen when the mouth is opened—as far as the lockjaw permits this—if there are already a few ulcers about, and fœtid froth issues from the mouth, we are contronted by the rare disease **gangrenous stomatitis**, which may be fatal in a few days, but the cause of which is still obscure. This disease exhibits, in the most intense degree, the symptoms present in scurvy and mercurial stomatitis.

If the inflammatory process is so severe that gangrene of the lips and cheeks ensues, it is impossible to miss the clinical picture of **noma**, which occasionally attacks children after debilitating infectious diseases.

CHAPTER XVIII.

TUMOURS AND ULCERS IN THE MOUTH, PHARYNX AND NOSE CAVITIES.

MANY new growths of mucous membrane appear as ulcers; we must therefore discuss them in common, when dealing with the oral and pharyngeal cavities. We have previously stated that *every obstinate ulcer must be suspected of malignancy*, however little aspect of growth it may possess. If this maxim were adequately taken to heart we should not so often see carcinoma treated for weeks with lunar caustic, until the enlargement of the glands of the neck finally takes the confirmed optimist by surprise, but renders the issue of an operation doubtful.

A.—NON-ULCERATING GROWTHS.

We only include here among "ulcerating growths" those wherein ulceration is of the essence of the disease, such as cancer, tubercle or syphilis, but not those which have been exposed to accidental superficial erosion, *e.g.*, an epulis wounded by an adjacent tooth. In cases of cancer it is often necessary to look for the ulcer. A cancer at the base of the tongue may start as a non-ulcerating growth, and only after a careful examination with a mirror or the palpating finger, will a deep, open excavation be discovered posteriorly.

We shall proceed topographically, because the various diseases have their own special sites of preference.

(1) THE MUCOUS MEMBRANE OF THE LIPS AND CHEEKS.

If a patient complains of a little tumour about the size of a hazel nut, situated in the mucous membrane of the lip or cheek—a tumour which disappears and reappears, and examination reveals a bluish translucent, semi-globular structure which is not dispelled by pressure, the diagnosis can only be a **mucous cyst.** But if the tumour in this situation is bluish-red, and is dispelled by pressure of the finger, the case can be nothing but one of **cavernous angioma.** It is noteworthy that the angiomata of the mucous membrane, in contrast to those of the skin, are distinctly encapsuled. A soft pedunculated growth, which cannot be dispelled by pressure, hanging from the mucous membrane of the cheek is a **fibroma,** in which the various components of the mucous membrane, viz., glands, blood-vessels and lymphatics, are more or less extensively proliferated.

(2) THE FLOOR OF THE MOUTH.

The tumours in this region, covered by normal mucous membrane, are usually *cystic* structures, except for the very rare yellowish lobulated **lipomata** which are visible beneath the mucous membrane. The surgeon did not note the yellowish colour of the swelling, depicted in fig. 52, and he incised it, thinking it was a ranula.

A bluish tumour, rather laterally situated, shining through the thinned mucous membrane, soft, elastic, or fluctuating in consistence, and raising the tongue, is a **ranula.** This diagnosis states nothing as to the origin of the structure concerning which embryologists and surgeons are at considerable variance. The view at present prevailing explains most cases on the assumption that they arise as cysts from segments of the sublingual gland, much in the same way as the mucous cysts of the lips or cheeks, varying in size from a pea to a hazel nut, which we have just mentioned.

It has been shown that besides the ordinary ranulæ, cysts may arise in some cases from Bochdalek's ducts, which are lined with ciliated epithelium. Nuhn-Blandin's glands at the tip of the tongue have also produced cystic structures, but these have nothing in common with ranulæ, because they are situated at the tip of the tongue and not *under* it.

If careful attention is given to the various characteristics of ranulæ it is difficult to mistake them. *Lymphangiomata*, which have been observed in this vicinity, are much less sharply defined, and they frequently involve the tongue itself. They are composed of numerous small vesicles and do not constitute a single-spaced structure. *Lipomata* are lobular and appear yellowish, as seen through the

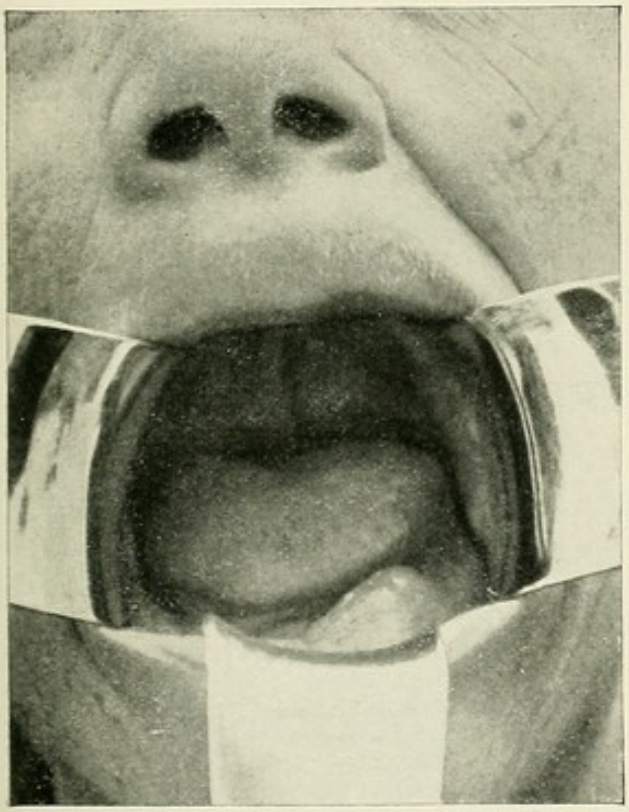

FIG. 52.—Lipoma of floor of mouth.

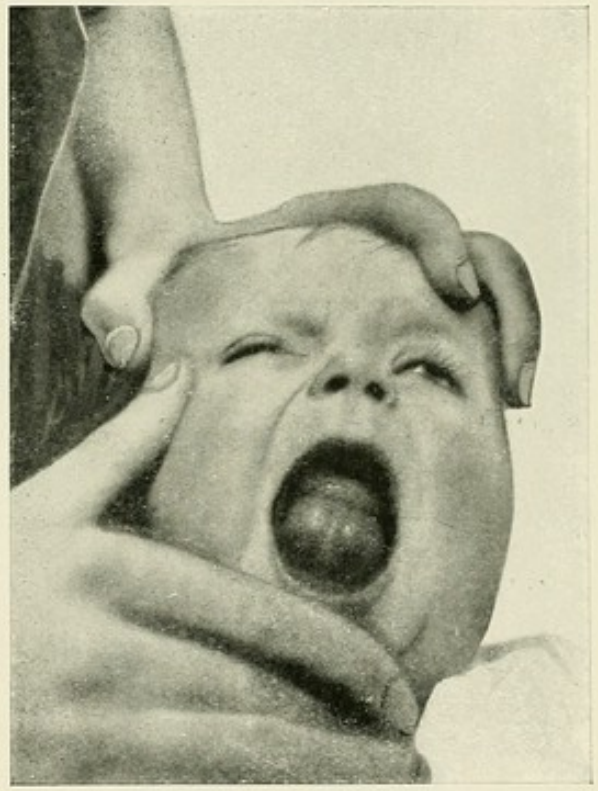

FIG. 53.—Sub-lingual dermoid.

mucous membrane. Only a dermoid could lead to error of diagnosis because it is also a single-spaced structure. Dermoids which occur in this region nearly as frequently as ranulæ, are, however, centrally situated, whereas ranulæ are rather laterally placed (fig. 53). Their walls are thicker than those of ranulæ, and the cysts present rather a whitish-yellow than a bluish appearance from beneath the mucous membrane. Sometimes they are closely adherent to adjacent tissues, or are even attached to the bone, which is never the case with ranulæ. They are also more liable to suppurate than the latter.

If doubt arises, because a tumour apparently in the median line

gleams through the mucous membrane with a bluish tint, *e.g.*, a large ranula which has encroached on the middle line, or because a laterally situated cyst—dermoids are in rare cases lateral—looks like a dermoid, the diagnosis can be cleared up by a puncture, which is quite harmless. The treatment is similar in both conditions, so that an error in diagnosis has no serious consequences.

(3) THE GUMS.

A tumour projecting from the margin of the gum, varying in size from a pea to a walnut, may be summarily diagnosed as an **epulis,** *i.e.*, "a tumour of the gum." This is, of course, no histological



FIG. 54.—Epulis growing from a space between teeth.

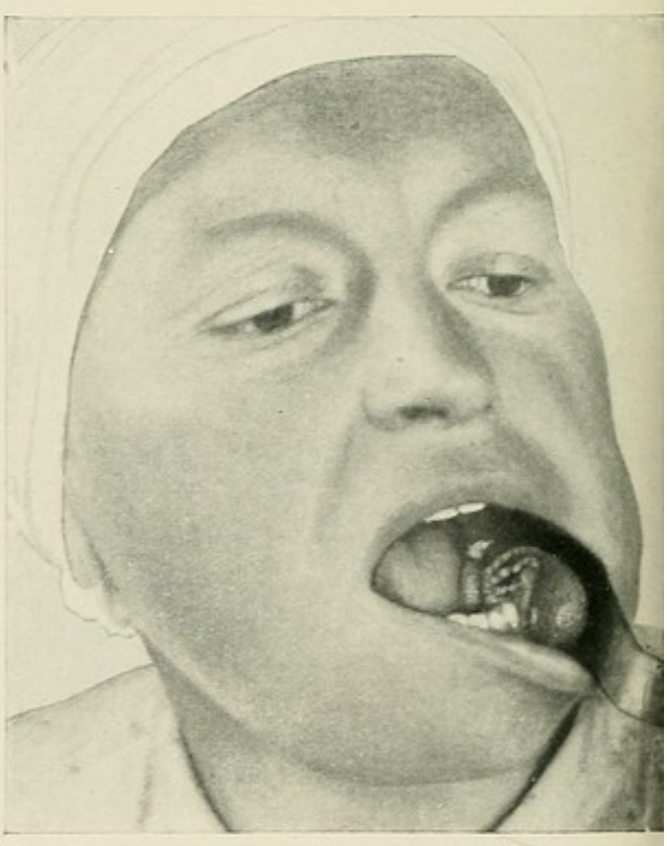

FIG. 55.—Epulis (pure fibroma), with impressions of upper molars.

diagnosis, it is merely a description of what is found. If the tumour is of the same colour as the healthy gum, and is firm, it may be regarded as a *pure fibroma;* if, with the same colour, it is softer, we must conclude that it is richer in cells and blood vessels, and therefore approximates to a *sarcoma*. If the growth is darker, with a faint shade of brown, the case is one of *giant-celled sarcoma*, springing from the alveolar periosteum, the typical form of epulis.

These growths have an abundance of vessels on the surface almost like an angioma, all the rest of the tumour showing the structure of a giant-celled sarcoma. They frequently contain a brown pigment

in addition. Their malignancy is limited to local occurrence; the glands are not affected nor do metastases occur.

It is noteworthy that an epulis will often grow from a site which has been exposed to persistent irritation, *e.g.*, in the spaces between teeth, in the neighbourhood of old stumps (fig. 54). Occasionally the epulis becomes somewhat ulcerated from friction on its surface, and it may even show the impression of the opposite teeth (fig. 55).

They can be promptly distinguished from tumours of the jaw proper by the narrow peduncle which connects them with their site of origin. At first sight they seem to be situated on a broad base, but if they are well elevated it is astonishing to see how slight their attachment really is.

Granulations, which occur so frequently in connection with remains of stumps, and not infrequently in pulp cavities, must be distinguished from epulides which are really genuine tumours. In neglected teeth, the whole row of missing crowns may be occupied by such granulations.

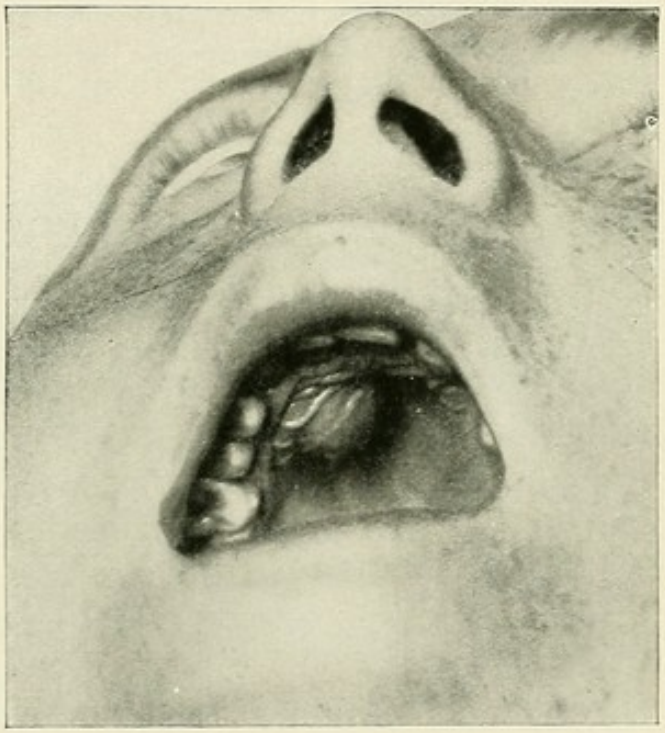

FIG. 56.—Abscess of palate arising from root of tooth.

(4) PALATE, TONSILLAR REGION, BASE OF TONGUE.

A semi-globular swelling which has recently developed in the middle of the hard palate is usually a *gumma;* but if it embraces the margin of the palatal plate, or if it is close to a diseased tooth or an old stump, it is a dental abscess (fig. 56).

If the growth arises from the *soft palate* or the *tonsillar region*, and is definitely capsulated with the mucous membrane movable over it, we must think of one of those **mixed tumours** which more frequently occur in the parotid region. If the tumour has a wide attachment to the tonsillar region, and is only slightly or not at all movable, the case is certainly one of **sarcoma,** and we must not wait for enlarged glands to confirm the malignancy. A striking swelling of the whole of the lymphatic system of the pharynx should suggest the possibility of **leukæmia** or **pseudo-leukæmia.**

The fact that many tonsillar sarcomata have vanished after energetic treatment with arsenic, and also with X-rays, has not only a therapeutic

but also a diagnostic interest. These tumours must be classified with the still somewhat enigmatic group of lymphosarcomata.

Pedunculated polypi are sometimes found on the palatine arch, especially in the form of—purely innocent—papillomata.

A soft, roundish well-defined tumour at the base of the tongue is most likely to be an **aberrant goitre.**

This localization is explained by the circumstance that the central thyroid gland rudiment grows from the position which subsequently forms the base of the tongue. For this reason, accessory goitres may be met with along the whole remaining track of this rudiment, between the foramen cæcum and the processus pyramidalis of the thyroid gland, *i.e.*, the thyro-glossal duct.

Patients with lingual goitre feel as if they have a lump in the throat, which cannot get down. If the growth is extensive the speech becomes nasal, and ultimately respiration is obstructed. Sometimes severe hæmorrhage occurs from the superficial vessels.

(5) PHARYNX.

If a tumour-like structure projects into the pharyngeal cavity, one must endeavour to ascertain its point of origin, by means of the eye, the probe and the finger. If it has a broad attachment to the anterior surface of the vertebral column it might be a **sarcoma,** but it is more likely to be a tubercular **abscess** due to spinal caries. The stiff manner in which the patient holds his head will already have suggested this diagnosis to the careful observer; and the history will show that the tumour in the pharynx was long preceded by difficulty in moving the head. Palpation will also show at once whether we are dealing with an abscess or a solid tumour.

If the tumour projects into the pharynx from above, it may be an ordinary **mucous polypus** arising from the nose. These are remarkably soft to the touch, and they give the impression of receding out of the way of the palpating finger. If they are visible, directly or through the mirror, they are recognized by their well-known bluish colour and their glassy translucent appearance. If the growth is of firmer consistence we may be undecided as between a fibroma springing from the basilar fibrocartilage at the base of the skull in young people, and a sarcoma proper of the base. As the differential diagnosis between these two is of extreme importance for prognosis and treatment, we must dwell upon it for a moment.

A **fibroma of the base of the skull,** usually a **nasopharyngeal fibroma** or a nasopharyngeal polypus, can be excluded if the growth has occurred *after* the termination of adolescence, *i.e.*, after the second decade. Naso-pharyngeal fibromata have the peculiarity of only

developing before the termination of this period. But if the patient has not yet completed adolescence the growth might be of either variety. In doubtful cases, the sex as well as the age is of assistance, because in infancy nasopharyngeal fibromata are of equal incidence in both sexes, whereas at puberty, when they are most frequent, they only attack males. The previous history is also of great importance. If the growth has taken years to develop and has manifested itself by nasal obstruction and occasional severe hæmorrhages, we can definitely exclude sarcoma. On the other hand, if the existence of the growth, the blocking up of the posterior nares, and possibly also hæmorrhages have all taken place within a few months, we must regard the case as one of sarcoma. If the new growth emits processes into all the accessible cavities in the neighbourhood, processes which, if visible, display the same roundish form, and the same sharp definition as the tumour within the pharynx, the case is one of fibroma. On the other hand, a diffuse extension of the tumour, the early onset of neuralgic pains and brain symptoms are in favour of sarcoma.

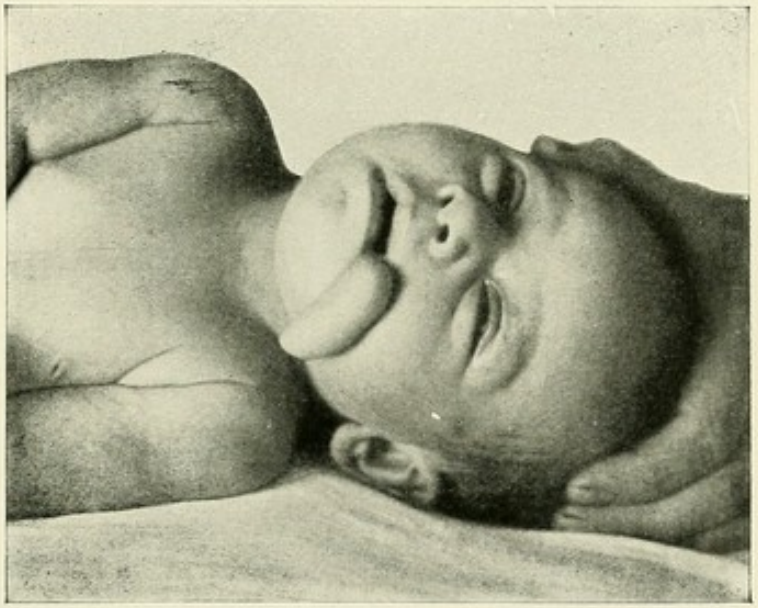

FIG. 57.—Pharyngeal polypus, with a long pedicle arising from the palatopharyngeal arch.

Teratoid growths of various kinds are to be found at the junction of the pharynx and œsophagus as well as in other positions in the pharynx. They may be teratomata proper formed from all the three layers of the embryo, with a tuft of hair on the surface, or they may be simple *lipomata* or soft *fibromata ;* the latter may at times hang out of the mouth like a sausage (see fig. 57). At other times they only appear after some definite cause, such as vomiting, and then are again swallowed by the patient.

(6) THE NASAL CAVITY.

Non-ulcerating new growths in this region, as in the pharynx, may be **mucous polypi, fibrous nasopharyngeal polypi,** or **sarcomata.** We have already discussed the first two, and would only add here there is usually some accessory sinus catarrh behind the mucous polypi. But for the formation of these polypi there is also

required a special, and often a very obstinate predisposition, which tends to the constant development of new polypi. In fact, the shape of the nose may be so greatly deformed in some cases in the course of a few years, that a fibrous polypus or even a sarcoma would be diagnosed, if the previous history were unknown. Sometimes the appearance of a bluish mucous polypus at the nostril leads immediately to a correct diagnosis.

Sarcomata of the nose usually start from the turbinated bones, and in the beginning are merely regarded as hypertrophied membrane. When they take on rapid growth, cause nasal obstruction and hæmorrhage, a small portion excised for histological examination will make the diagnosis positive, or confirm it if already made.



FIG. 58.—Mucous polypus of the nose.

This figure represents a patient who regularly for fifteen years was relieved from time to time of whole bunches of mucous polypi from both nasal passages, before she made up her mind to undergo operative treatment for her bilateral accessory sinus catarrh.

B.—ULCERATION PROCESSES.

Two points must be impressed upon the beginner in regard to the diagnosis of ulcers, viz., to closely examine the characteristics of the margin of the ulcer, and to investigate its base. This rule also applies to ulcers of the oral cavity, but it encounters many difficulties in this region owing to anatomical conditions and the occasional inaccessibility of the tumour. However, a superficial ulcer with a soft border and a soft greyish base is *tubercle;* an ulcer with a fatty, yellowish base is a *gumma;* a hard undermined border with a hard segmented base, often covered with necrotic shreds, points to *cancer;* and an ulcer of firm consistence without undermined edges, but with a smooth, varnished-looking base suggests a **primary chancre.** But one must not conclude from this that a cancer must

always have undermined edges and be segmented, and that a gumma necessarily must have a yellowish, fatty base in all its stages.

Our diagnosis will always be most accurate when we bear in mind the most frequent morbid conditions which occur in the various portions of the oral cavity.

(1) THE MUCOUS MEMBRANE OF THE LIPS AND CHEEKS.

Cancer is the most frequent lesion in this part, although tubercle, gumma, and primary chancre are possibilities. We have already discussed cancer of the lip. Cancer of the mucous membrane of the lip is much rarer, but its prognosis is much worse.

The following case shows how difficult the diagnosis may be, on the assumption that an ulcer of the lip, in an old man, must be cancerous.

A man, over 70, an old sufferer from bronchitis, had an ulcer on his left lower lip, and another one on the mucous membrane of his right cheek. They were both soft, superficial and very painful. There were neither epithelial plugs nor tubercles visible. The history of syphilis was very indefinite, and the pain contra-indicated it. The only point in favour of cancer was the age, everything else was against it, and the pain suggested tubercle. The bronchitis appeared to be ordinary senile bronchitis. The diagnosis of tubercle could only only be made by a process of exclusion, but its accuracy was established by histological examination of a piece of the border excised for the purpose.

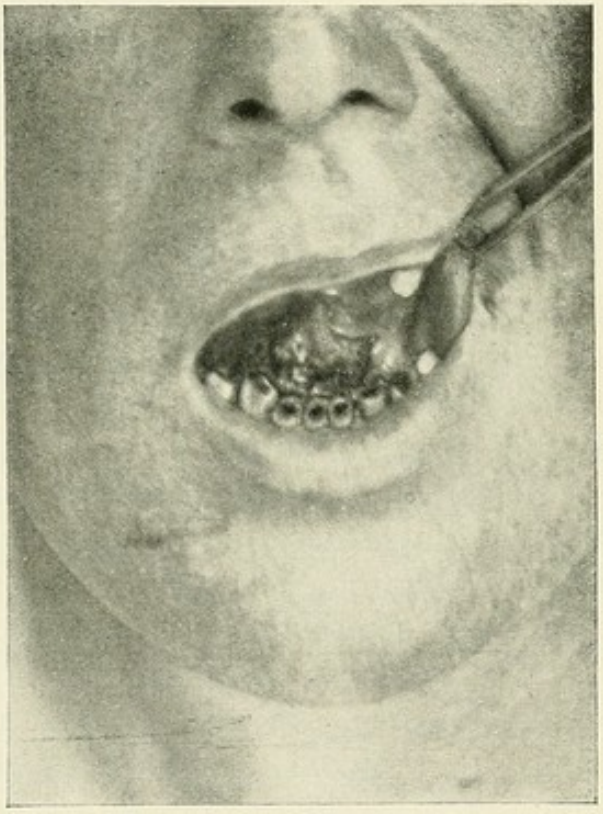

FIG. 59.—Sub-lingual cancer. Tongue drawn aside.

It is hardly necessary to mention the small transitory ulcers on the mucous membrane of the cheek, which are so often produced by *bites*.

(2) THE FLOOR OF THE MOUTH.

Carcinoma is of frequent occurrence on the floor of the mouth ; tubercle and primary chancre are rare. In its early stages the cancer appears as a small, movable, roundish, definitely raised tumour, presenting as its centre a small superficial ulcer surrounded by an

encroaching border. This in itself suffices to justify the diagnosis. The practised observer will involuntarily feel for enlarged hard glands after examining the growth in question, in order to confirm the diagnosis. The presence or absence of glands must, however, not be invested with too great a significance, at any rate their absence is not a conclusive argument *against* cancer. If the tumour has become adherent to the jaw and eventually also to the tongue, so that the latter gets fixed and movements of mastication and speech are interfered with, the diagnosis is easy enough.

(3) THE GUMS.

The careful examination of the gums is not only of importance to the dentist and the physician, but also to the surgeon. For instance, a persistent colic, which might be attributed to organic obstruction of the bowel, will be shown to be toxic in origin, by the discovery of the well-known blue line on the gums.

In a case of obstinate *suppuration* between a tooth and the gum, and general loosening of the teeth, we should not treat the gum, but should examine the urine for sugar. If this examination does not reveal the cause of the *alveolar pyorrhœa*, some other general disease should be searched for.

If called to arrest obstinate hæmorrhage from a tooth, we must not be content with applying a styptic, but must investigate the cause of the bleeding, which may be due to a hitherto overlooked *hæmophilia*, to a *leukæmia*, or to chronic jaundice.

Most *chronic inflammatory diseases* of the gums depend upon dental disease. If they do not recover after extraction of the bad teeth, the removal of stumps or sequestra, we should suspect actinomycosis, tubercle, or phosphorus necrosis. We have already discussed the diagnosis of these conditions.

Ulcers which are surrounded by a definitely inflamed area must be diagnosed in the same way as those on any other part of the oral mucous membrane. It will be necessary to differentiate between *cancer*, *tubercle*, and *gumma*. *Primary chancre* is very rare. The leading points of differential diagnosis have already been adequately stated.

Finally, swellings which bleed easily are due to scurvy, and in little children indicate Barlow's disease.

It is noteworthy that in the latter condition the unmistakable bluish-red swelling of the gum only occurs where teeth have already erupted. The pain in the extremities completes the clinical picture and demands that we should not incise the swelling in the gum, but should adopt immediately the only prompt and effective treatment, *i.e.*, the abandonment of all artificial or artificially sterilized food.

(4) THE TONSILLAR REGION.

Various forms of ulcer, cancer, primary chancre, tubercle and gumma have to be considered here, as well as the somewhat rare non-specific ulcer of the tonsil. The first lead in diagnosis is given by the presence or absence of *glandular enlargement*.

(*a*) If the glands are not enlarged we may exclude chancre, unless it be quite recent; and we should think of cancer and gumma, possibly also of tubercle.

The frequency of **carcinoma** renders its presence more likely than that of any other ulcer. If the patient is an alcoholic, this supports the diagnosis, because, in my experience, tonsillar cancer, and especially cancer of the pharynx, have mainly occurred among heavy drinkers. The fact that only one ulcer is present is also in favour of cancer, apart from its hard base and border. Gummatous and tubercular ulcers are, on the other hand, frequently multiple. Pains radiating towards the ear and robbing the patient of sleep at once dispose of gumma and tubercle. Pain limited to swallowing is strong presumption against a gumma, but not against tubercle. The absence of pain is, however, no evidence against cancer, because pain may not come on until a stage wherein operative measures are useless.

If the consistence and, perhaps, the multiplicity of the ulcers show that it is either **tubercle** or **gumma,** the presence of separate little nodules on a reddened base around the ulcer points to tubercle, whereas the partial aggregation of areas which start as roundish nodules and their subsequent disintegration in the centre, point to gumma. These characteristics are sometimes difficult to detect, and it is therefore all the more important to pay attention to the *history* of the patient and his *general condition*. There is generally some preceding pulmonary or intestinal tuberculosis in cases of pharyngeal tubercle, and although the most carefully taken history will not always reveal syphilis in cases of gummata, it very frequently will do so. In doubtful cases, we must resort to *histological* and *bacteriological* investigation, lest we overlook cancer.

A small piece of the edge of the ulcer should be snipped off with forceps, or scissors, and a part thereof submitted for histological examination and a part used for animal inoculation. The microscope will settle the diagnosis with certainty in a few hours or within a day or two; guinea-pig inoculations take at least four to six weeks to supply definite information. Quite recently some experienced observers have cast doubt on the value of this kind of histological examination. Personally I have employed this method for many years in my own practice, and have had very reliable results when the little pieces are taken from the right place and the sections are cut in a

proper direction. It would be best if the person who has excised the specimen would himself examine it, but as this is usually impracticable, he should inform the pathologist of the exact disposition of the piece submitted, so that sections should be cut perpendicularly to the margin of the ulcer. It would be useful to examine a piece from the *margin* and a piece from the *base* of the ulcer at the same time. If this investigation is negative and clinical signs are suspicious, we must not be content until another and larger piece has been removed, if it is impossible to establish the diagnosis in any other way.

The result of a Wassermann test should always be taken into consideration, but it must not be forgotten that a syphilitic may become affected with tubercle or cancer. Diagnosis "ex juvantibus" still holds the field in syphilis.

(*b*) Diagnosis is facilitated if *enlarged glands are present*. If they have come on soon after the appearance of the ulcer, and have reached a fair size in a short time, and are adherent to the adjacent tissues, we may assume that the glands are in a state of **early fibrosis.** The minutest superficial injuries suffice for infective material derived from dirty drinking vessels to stick to the tonsils.

One illustration, out of many, may be given. A student drank out of a drinking horn directly after an old man, in token of mutual loyalty. The student acquired a tonsillar chancre, and it subsequently transpired that the old man had signs of secondary syphilis in his mouth—an instance, by the way, of the neglect of elementary rules of hygiene, prevalent at the present day.

If the glands have not enlarged until some considerable time has elapsed since the appearance of the ulcer, then the diagnosis lies between carcinoma and tubercle. In the former case they are hard, in the latter rather softer. In both cases they may become adherent, so that no conclusion can be drawn from this condition; but enlarged glands which have existed for many months without contracting adhesions around are more likely to be tubercular than cancerous. The adhesions of cancerous glands are of a very firm kind, so that hard immovable masses are formed. After tubercular glands have contracted adhesions, suppuration generally takes place in the centre, so that it will be found that soft, elastic, and even fluctuating areas exist, surrounded by comparatively hard borders.

No conclusions can be drawn from the condition of the ulcer, or of the glands existing at the time, if the attention of the patient or the medical attendant has first been directed to the presence of an ulcer by the onset of glandular enlargement.

It may be stated finally that Plaut-Vincent's angina (*see infra*) in the ulcerative stage may easily be mistaken for a syphilitic ulcer. The bacteriological findings and the rapid recovery are decisive.

(5) HARD AND SOFT PALATE.

A solitary ulcer spreading from the *tonsillar region* towards the margin of the soft palate is usually a **carcinoma.** Carcinoma rarely begins on the soft palate, but we have seen it entirely eaten away by a primary cancer. A swelling in this region is much more likely to be a **gumma,** especially if it, or the ulcers, are near the *hard palate,* or actually on it, or if they have already perforated it.

Tubercle also occurs on the soft palate. It differs from gumma in its longer duration, in the appearance of the ulcer, and also by causing severe dysphagia, and by rarely failing to produce glandular enlargement.

(6) PHARYNGEAL WALL.

Ulcers on the mucous membrane of the pharynx are of rare occurrence, apart from those at the base of the tongue and the tonsillar region. **Cancers** are usually found at the entrance to the gullet, in the neighbourhood of the roof of the pharynx and in the vicinity of the posterior nares. As they arise in such concealed situations, enlargement of the glands is usually their first indication, and they require a careful rhinoscopic examination. Ulcers on the posterior wall of the pharynx are usually **gummata.** It is also necessary to mention the **bedsore** caused by the cricoid cartilage in very chronic diseases.

(7) NASAL CAVITY.

We leave the round ulcer of the septum to the rhinologist, so that cancer, syphilis and tubercle again come under consideration. A careful examination with a mirror is generally indispensable, but there are certain concomitant conditions of the diseases which are useful for differentiating one from the other.

There are certain tumours and ulcers of the pharynx and nose, which would only be diagnosed if we are aware of the patient's occupation, or of his geographical relationships. These include the **ulcers of glanders** in the nose of people who attend to horses suffering from farcy, **leprosy,** and **rhinoscleroma** of certain districts, the latter usually from the Balkans. The diagnosis of leprosy will be made from the other appearances of the disease, and rhinoscleroma will be recognized by the hardness of the infiltration, the absence of glandular enlargement, and the chronic course of the disease.

A young man returned home from a sanatorium with his pulmonary condition improved, but he had an ulcer in the nose which gradually ate away the septum. In such a case, nothing but *tubercle* would be thought of.

An aged grandmother complained of "a cold in the head," or,

rather, of a persistent and profuse nasal discharge. She produced a few shreds of bone, which, to her amazement, had escaped with the discharge. Her previous history told of one living child after a series of miscarriages. Iodide of potassium worked wonders. We shared her pleasure at this result, but we were careful not to tell her that this was a reminder of her late husband, whose portrait discreetly smiled on us from the wall.

A middle-aged patient came with a bloody, offensive discharge from one nostril, which had lasted for some months. There had been hard glands at the angle of the jaw for the last few weeks. This could be nothing but cancer.

CHAPTER XIX.

CHRONIC DISEASES OF THE TONGUE.

THE custom of the old physicians—who invariably looked at the patient's tongue—was no idle habit, and the younger generation neglect this diagnostic aid too much, in favour of "exact" methods of diagnosis. The surgeon should find interest not only in the colour of, and the deposit on, the tongue, but particularly in its degree of moisture. Nothing affords us a more rapid conception of the patient's condition and of the prognosis in infective diseases, like peritonitis, than a glance at the tongue. A dry tongue of normal colour is worse than a moist tongue, however much coated it may be.

We will not refer to the various superficial changes, such as the map-like tongue, the black, hairy tongue, the wrinkled tongue, &c., because they possess no surgical significance; but **leukoplakia** must be noted, because it forms an excellent soil for the development of cancer. It is now generally recognized that the abuse of tobacco and syphilis are equally responsible for this latter condition.

Fournier has asserted that in Paris cancer of the tongue is, so to say, a sequela of syphilis, with leukoplakia as an intermediate stage. This statement can only be applied to other countries with considerable reserve.

As in the preceding chapter, we must separate here also the ulcerated from the non-ulcerated changes.

(1) NON-ULCERATED TUMOURS AND SWELLINGS.

We must first refer to **macroglossia** among the new growths of the tongue. It is a diffuse enlargement of the whole organ, which does

not concern so much the muscular structure, but consists of an increase of interstitial tissue and lymph spaces, so that it might, with more or less accuracy, be called a *diffuse lymphangioma*. The muscular structures take comparatively little part in macroglossia. When this condition is fully developed it imparts an imbecile expression to the face, but we must not therefore conclude that all who are affected therewith are idiots. Nevertheless, macroglossia does occur most frequently among those whose mental development is defective. One of the signs of hypo- and athyroidism is a certain degree of diffuse enlargement of the tongue, which gradually decreases in size under the influence of specific treatment.

Among the *true tumours of the tongue* **cavernous angioma** is at once recognized by its colour and by easily emptying on pressure. Circumscribed lymphangiomata are not so easily diagnosed. They appear as fairly firm nodules in the soft tissue of the tongue, usually on the dorsum (fig. 60), but sometimes also on its under surface (fig. 61). As with other lymphangiomata their contents cannot be well expressed. Were it not for the long duration of the disease, one might be tempted to think of some chronic inflammatory process, of a tubercular nodule, or of actinomycosis. But if we carefully examine the tongue we shall note that the papillæ around the tumour are prominent and enlarged and that some of them form little vesicles. This is decisive for the diagnosis of lymphangioma.

If we feel soft lobulated growth within the substance of the tongue we may claim it as a **lipoma,** and thus add one more to the dozen cases which have hitherto been recorded.

But much more important than the recognition of such rarities, is the accurate diagnosis of *tubercle, gumma, actinomycosis, sarcoma* and *cancer.*

We mention cancer last, and then only with considerable reserve, because it never occurs in the tongue with an undamaged mucous membrane. Glandular cancer, which alone can come into consideration, is so rare that it is hardly necessary to reckon with it. But, on the other hand, inexperienced observers are liable to declare that a cancer is not ulcerated when they have failed to see it properly. Careful observation will often reveal a deep ulceration below the raised mass of new growth which may be covered by normal mucous membrane, and close inspection will often show that a nodule which can be easily seen and is apparently non-ulcerated, is covered by epithelium which even macroscopically is abnormal.

A *pedunculated nodule,* soft as the tongue itself and situated thereon, must be regarded as a **fibroma**. It is rare, but occurs on the tongue, as it does on other parts of the oral mucous membrane. Its long duration will serve to prevent its confusion with sarcoma. A nodule which has arisen within a few months and is firmer than the tongue

substance must, however, be looked upon as a **sarcoma.** There are also soft sarcomata; but they do not possess the toughness of soft fibromata; they soon break down and form deep ulcers.

If the nodule is *infiltrated* within the tissue of the tongue we must differentiate between *tubercle*, *gumma*, *actinomycosis* and *sarcoma*.

It must be regarded as a *sarcoma* if its size is greater than is compatible with an inflammatory granulation tumour. A lump as large as a hen's egg will be neither a tubercle nor a gumma. In the case of smaller tumours the early onset of radiating pains points to malignancy. But, as a rule, we should only diagnose sarcoma of the tongue when there is no more plausible possibility, because it is a condition of great rarity.

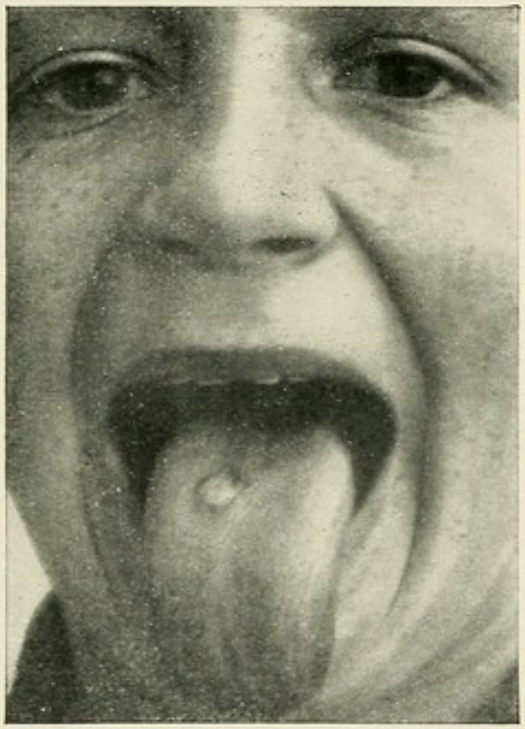

FIG. 60.—Lymphangioma of the tongue.

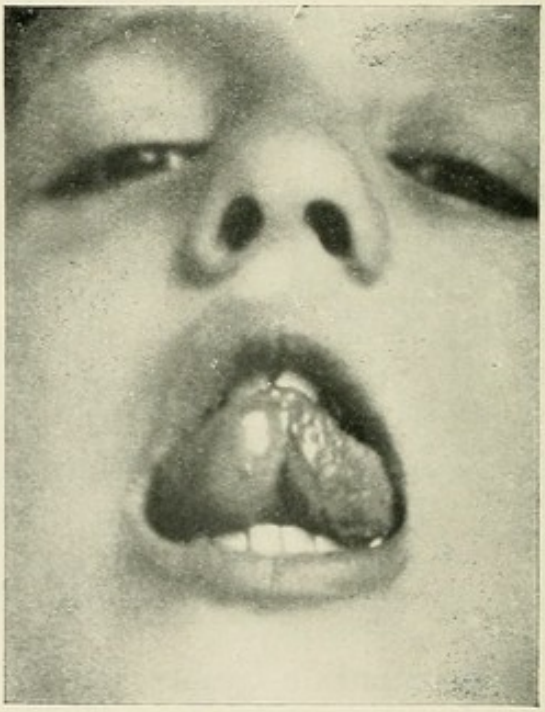

FIG. 61.—Cystic lymphangioma of the tongue.

The local circumstances often suffice to differentiate between **gumma** and **tubercle.** A nodule of a few weeks standing which has not yet broken down, is more likely to be tubercle than gumma. Other things being equal, the fact that a tumour is single, is in favour of tubercle. Tubercular nodules are also more painful than gummata; the latter may be sensitive on pressure but are only very slightly painful in themselves. Soft swelling of the glands of the neck points to tubercle, as already stated in connection with ulcers of the pharynx. Gummata are not associated with glandular enlargement, if they are unbroken and therefore not secondarily infected. The previous history and general condition of the patient are also of importance.

Experience shows that tubercle of the tongue is very rarely a primary manifestation; as a rule, it occurs only in patients who are suffering from pulmonary or abdominal tuberculosis. Similarly, in cases of gumma, the history or the general condition of the patient will provide evidence of old syphilis. Finally, as in all these cases, we have the serum reaction and the therapeutic test as ultimate resources.

A deep-seated *nodule of actinomycosis*, which occasionally occurs in the tongue, is distinguished from gumma by its hardness, and from tubercle by the absence of the characteristic glandular enlargement. If the disease has involved the surface, it consists of a board-like infiltration of the tongue permeated by soft foci of granulation tissue, so distinctive of actinomycosis elsewhere. It is, therefore, only in the early stage that it presents any diagnostic difficulties in the tongue. If it has broken down, it is important to examine the pus repeatedly for the detection of the well-known granules.

(2) ULCERATIVE DISEASES OF THE TONGUE.

In coming to any conclusion about an ulcer, it must not be forgotten that all lesions within the oral cavity tend to ulcerate, especially as a consequence of friction against the teeth. The mucous membrane over a sarcoma may therefore become destroyed from secondary causes. But in such a case the growth itself is usually so prominent that the true state of affairs is perfectly evident. Advanced sarcomata, which have broken down extensively, are easily mistaken for cancer, in the absence of a microscopic examination.

The reader is referred to the discussion on ulcers of the oral cavity, for the differentiation between *tubercle*, *primary sore*, *gumma* and *cancer*; but a few special points may be mentioned here.

When a deep-lying **tubercular** focus breaks down, the lesion in the mucous membrane does not always assume the characters of a fully developed ulcer. A probe only penetrates through a small opening, more like a fistula than an ulcer, into a wide pocket corresponding to the original extent of the diseased focus. But when a **gumma** breaks down there forms immediately an extensive lesion of the connective tissue and mucous membrane. Gummata differ from cancer in being situated in the middle of the dorsum of the tongue or on its tip. Cancer nearly always starts on the edge of the tongue (fig. 62) and gradually invades the centre.

Besides the well-defined gummata of the tongue there occurs occasionally a *diffuse gummatous infiltration* of the organ, but this is differentiated from cancer by its indefinite limitation and the fact that it does not break down.

Finally, it should be noted that deep and often painful *rhagades* on the tongue are to be attributed to tertiary syphilis, although there may be no definite gummatous changes present.

As far as the diagnosis of **cancer** is concerned the warning must again be given that it is negligent to await the development of all possible symptoms and finally glandular enlargement, before informing the patient of the nature and gravity of his disease. It is especially wrong to comfort him with the assumption that he is suffering from an *ulcer caused by a tooth*, until it becomes too late. Often enough it does happen that a sharp tooth or a jagged stump injures the edge of the tongue, causing a small superficial ulcer which fails to heal because it is subject to constant friction. But the removal of the offending tooth or the filing of the sharp points, without doing anything at all to the ulcer, will result in its healing within a few days. If it does not heal, it signifies that the case is somewhat more serious, and careful palpation will no doubt reveal distinct hardness of the base and margin. To wait any longer in such a case, in order not to alarm the patient, is a delicacy of feeling which may cost the patient his life.

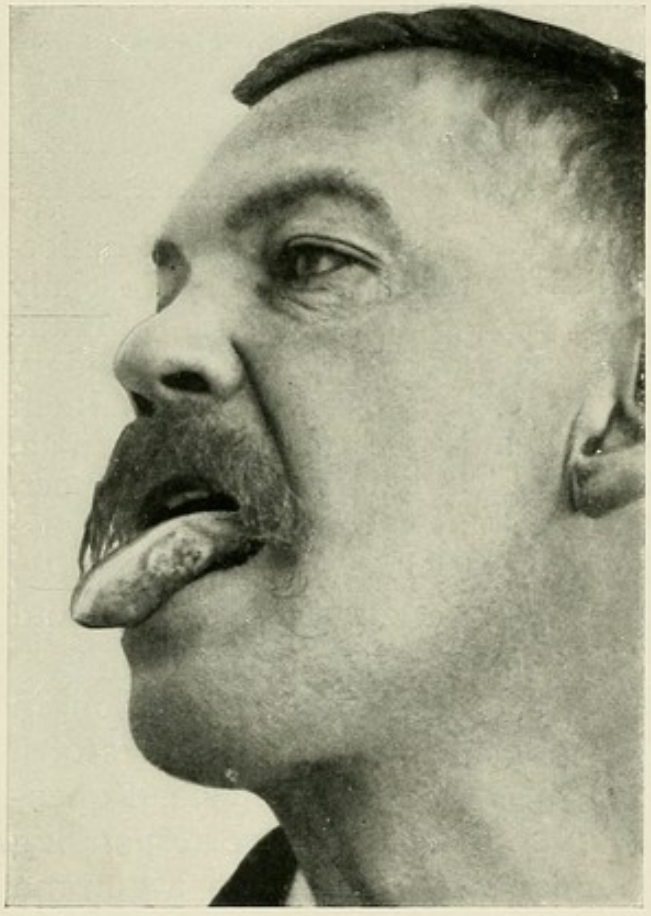

FIG. 62.—Cancer at the edge of the tongue.

But cancer does not always begin in this manner. Sometimes it starts as a small hard nodule, with no loss of surface epithelium visible to the naked eye, but around which slight contractures of the tongue tissue may be seen. Such a condition renders any further observation superfluous; it demands immediate operation. In other cases we have to deal with patients who have been suffering from leukoplakia for years. Having been informed that this disorder predisposes to cancer they bestow the necessary, and more than necessary, notice on their oral mucous membrane, and obtain medical advice as soon as they discover any thickening of a leukoplakia patch. Often enough such a patient is obsessed with the fear of carcinoma, and fancies that there is some hardening present when in reality there is none. The practitioner must not be too ready with his reassurance; the suspected spot must be most carefully palpated and compared with the other spots. If there is any hardening it must be treated as cancer, even

though the unaided eye detects no loss of epithelium. At any rate the patch should be excised and submitted to microscopic examination, with a view to a more extensive operation if the diagnosis is confirmed.

Cancers which so frequently start at the hinder edge of the tongue, opposite the tonsil, escape detection for a considerable time. When they are discovered, they are usually so far advanced that it is impossible to say whether they have started from the tongue and invaded the tonsil or *vice versa*.

It is usually said that cancer of the tongue occurs in middle and in old age, and only in the male sex. But such a generalization should not be allowed to influence us too much in arriving at a decision. This is illustrated by the following case.

A girl aged 22 consulted a doctor about an ulcer on the side of the tongue. The age and sex were such strong contra indications of cancer that the treatment was limited for a long time to gargles and the application of lunar caustic. Eventually, the doctor became uncomfortable at the constant increase of the ulcer. Examination then showed that a large portion of the left border of the tongue was occupied by a shallow ulcer with slightly projecting but somewhat undermined edges. The border and the base were hard, but only to a slight depth. There were a few hard glands in the neck. There were no points in favour of tubercle or syphilis. The clinical diagnosis of cancer was confirmed by a test excision. The operation, which was very extensive, did not succeed in preventing a recurrence.

PART II.

SURGICAL DISEASES OF THE NECK.

CHAPTER XX.

SURGICAL DISEASES OF THE RESPIRATORY TRACT. (LARYNX AND TRACHEA.)

DISEASES of the larynx have become so separate a department of practice that the general practitioner, in the stress of his daily work, does not scruple to declare himself unequal to them, at any rate he consoles himself for not making a careful examination by avowing that he is not a specialist. Although it is true that the diagnosis of these diseases at the present day demands complicated methods which are often out of the reach of the general practitioner, there still remain a number of maladies which he can and must correctly diagnose. It may then be necessary to refer the patient to a laryngologist for confirmation of the opinion or for treatment. It is not to be expected that the general practitioner should be familiar with such new requisitions as the tracheoscope and the bronchoscope, but we may anticipate that he is capable of rendering the larynx accessible by means of the laryngoscope and perhaps also with Kirstein's spatula.

The symptomology of laryngeal diseases is very simple, comprising hoarseness, dyspnœa and difficulty in swallowing. This very simplicity explains the impossibility of making a diagnosis without the laryngoscope, unless the history and extra-laryngeal signs declare the nature of the disease. The examination should invariably be concluded with the laryngoscope, but we should always ascertain as much as we can without it.

We will take the cases as they occur in practice.

A.—ACUTE DISEASES.

(1) INFLAMMATORY PROCESSES IN THE PHARYNX AND LARYNX.

Our first question must be directed to the manner of onset of the laryngeal symptoms. If they have been preceded for a few days or even only for a few hours, by a general feeling of malaise, if they began with difficulty in swallowing and culminated in hoarseness and dyspnœa we shall at once suspect an acute infectious disease—a **pharyngeal and laryngeal diphtheria.** The younger the patient the stronger will our suspicion be. The inexperienced, however, sometimes forget that this disease also occurs among adults. The instances in which medical practitioners contract diphtheria as a sacrifice of their profession are well enough known.

If the *temperature is normal*, we may be relieved as to the severity of the disease, but, despite this, we cannot exclude true diphtheria. Many a slight case, with a trifling rise in temperature, has rapidly developed laryngeal obstruction. Indeed, I would go further and say that mild fever with severe local symptoms distinctly indicate diphtheria, because, other things being equal, Löffler's bacilli do not raise the temperature as much as streptococci do.

It should be noted incidentally that in the very severe cases, the temperature falls to the degree of collapse, after a preceding pyrexia. The gravity of the general condition will lead to a correct conclusion.

It the temperature is raised, it is evident that there is some infection. The *examination of the pharynx* will supply further information. If we find the familiar thick whitish deposit upon the tonsils, fauces and even on the posterior pharyngeal wall—a deposit which can be removed as shreds—we diagnose diphtheria—at least clinically. In the majority of cases we shall be correct, and bacteriological examination will reveal the presence of Löffler's bacilli. In a few cases the bacteriological report will be—streptococci, no diphtheria bacilli. A more careful examination of such cases would show that there was no real membrane present, but merely a greasy deposit breaking up into shreds. But it is not always possible to make a very careful examination of an excited and choking child.

I have nevertheless seen deposits in streptococcal infection which could hardly be distinguished clinically from those of true diphtheria; but these cases are not frequent. They occur mostly in scarlet fever.

If there be merely white specks on swollen red tonsils we must decide whether they are merely plugs of pus situated within the crypts of the tonsils—**follicular tonsillitis,** or whether they are

accumulations *on* the mucous membrane of the tonsils. Only the latter are or can be diphtheritic. I say "can be," because streptococci may mislead us here also. It is not difficult to distinguish between plugs within the follicles and superficial fibrinous infiltrate and deposits, with careful inspection and a little experience. If we do not succeed in making the distinction, there is the prospect of the little specks coalescing into an undoubted membrane, while the bacteriological examination is being made.

If the tonsils merely present a diffuse redness without any white specks at all, the case is most probably one of ordinary catarrhal tonsillitis, but diphtheria is by no means excluded. Every practitioner, relying upon this simple redness, has reassured the parents in many a case, only to find that in the course of a few hours, extreme dyspnœa has peremptorily demanded the performance of tracheotomy. This cannot be absolutely excluded even when nothing has been found in the throat. There is only *one* disease which occasions parents unnecessary alarm—viz., **false croup.** A child who has been running about the whole day in good health, becomes suddenly ill at night with a hacking cough and symptoms of dyspnœa, coming on in paroxysms. On examination, the temperature is normal or only slightly raised, the throat is somewhat reddened, and between the seizures the general condition seems to be good. A moist compress around the throat, the inhalation of steam and a mild sedative suffice to banish all the trouble by the morning. True diphtheria seldom sets in so rapidly, and never departs so quickly.

The foregoing leads to the conclusion that every case of persistent dyspnœa, however mild, associated with general malaise, must be considered as serious. If there are at the same time symptoms of faucial diphtheria, they will confirm our diagnosis of laryngeal diphtheria; but their absence does not exclude this diagnosis.

If the necessary apparatus is at our disposal and if we are sufficiently experienced therein, we should at once remove some of the tonsillar deposit with a small sterile swab and make a cover-glass preparation for the purpose of obtaining confirmation of our clinical diagnosis or justification for the prophylactic dose of serum so often administered when in doubt. In definite cases the bacilli are so abundant that no doubt can remain. But in all cases this immediate examination should be completed by making cultures in a bacteriological institute. This is most important if the diagnosis is not already rendered probable by the prevalence of an epidemic of diphtheria.

We should certainly not await the result of a bacteriological examination as an indication for tracheotomy. If asphyxia threatens, the operation must be performed whether Löffler's bacilli or streptococci are in question.

There are a few *secondary symptoms* which have not yet been mentioned but which deserve consideration. The chief one of these is the *enlargement of the glands* of the neck. The absence of this enlargement is not evidence against diphtheria, but if it is present, the infection is a severe one and we cannot allow ourselves to be consoled with the idea of a false croup. The glands do not indicate the nature of the infection, although they enlarge more frequently in diphtheria than in streptococcal sore throat. The same remarks apply to *splenic enlargement* and to *albuminuria.*

It is obvious from the foregoing that to confuse diphtheria and streptococcal laryngitis is not only pardonable but is often unavoidable. But there are mistakes which should be avoided. More than once has an incomplete history failed to elicit the presence of a foreign body, and a diagnosis of "diphtheria" has been made. In the absence of an epidemic every so-called case of "croup" which has come on suddenly without any prodroma, should remind one of the possibility of a foreign body and the history should be completely investigated from this point of view.

Still more erroneous is its confusion with **pneumonia.**

A little child was brought to the hospital in a state of severe dyspnœa. His temperature was high, and he was evidently very ill. A young assistant, who was much struck by the dyspnœa, forthwith reported the case as one of croup requiring tracheotomy. He did not notice that the child was breathing rapidly without any stridor. A more careful examination showed that the dyspnœa was due to extensive pneumonia.

The beginner should note that obstruction of the upper respiratory tract *slows* the breathing; diminution of the respiratory surface as in pneumonia *accelerates* the breathing. The reason for this is very simple. In order to allow the same amount of air to pass through a diminished transverse area of the respiratory tract, a prolongation and a deepening of the respiratory movements are required, at first at the expense of the respiratory pause. As the difficulty increases, more work is thrown upon the respiratory muscles, and there is more necessity for intervals of rest. The breathing, which at first was only deepened, becomes slowed as it increases in urgency. An accelerated and therewith an unavoidably weakened respiration can only suffice when the respiratory surface is diminished, as in pneumonia, but it would not be able to overcome a mechanical obstruction. When the muscles are fatigued, that is to say, in a state of asphyxia, there may be a relative acceleration of the breathing, even if there is mechanical obstruction, but it does not resemble the hurried respiration of pneumonia.

In addition to the frequency of respiration it is important to note the presence or absence of drawing-in of the soft parts of the thorax, the root of the neck, the supra-clavicular fossæ, the lower thoracic segment, and of the epigastrium. But this must not be confused

with the so-called peri-pneumonic retraction of the lower border of the lung in young children.

It might appear to be quite superfluous to refer to these well-known matters; but I once saw a doctor blamed by parents for having submitted a child who was suffering from pneumonia to tracheotomy. Careful attention must therefore be paid to these signs in every doubtful case, and doubtful cases can occur in diphtheria. For instance, pneumonia may lead to dyspnœa in this disease, just as well as extension to the larynx may. It is therefore necessary to estimate, to which of the two factors the dyspnœa is to be attributed. If it be due to pneumonia, we must await the effect of the serum, if on the other hand, it be due to obstruction, we must operate despite the pneumonia. No sign is more conclusive than the type of the breathing.

The association of ideas by which laryngeal obstruction in children at once suggests diphtheria may lead to mistakes. The cause of the respiratory difficulty need not be either in the larynx or trachea, but the glottis may be blocked by a **retro-pharyngeal abscess.** Such an abscess is often tubercular, and starts either in the vertebral column or retro-pharyngeal tubercular glands. Non-tubercular retro-pharyngeal abscesses are usually the sequelæ of scarlet fever or measles, occasionally of erysipelas. If the pharynx is examined in every case of "croup" before proceeding to tracheotomy, these abscesses will not be overlooked. The experienced observer will already have suspected a vertebral abscess from the stiff posture in which the child holds the head, and from his emaciated miserable appearance, so clearly described by Albert.

Retro-pharyngeal abscesses, especially of the tubercular variety, obstruct the glottis by their own mass, but every acute inflammation in the neighbourhood of the larynx may produce a similar obstruction by exciting an inflammatory œdema of the entrance to the larynx, a so-called **œdema of the glottis,** or to be more correct, **laryngeal œdema.** The loose submucous tissue may swell up so rapidly that the ary-epiglottic folds and the ventricular bands look like cushions, and a fatal result may ensue before assistance is forthcoming. Any infective process in the throat, acute abscesses, phlegmons or erysipelas may be responsible for this condition or it may originate in a small wound caused by a pointed foreign body. Not a year passes without accounts of persons being suffocated before help is available, through swallowing a bee or a wasp with fruit or juice, and being stung by the insect. Œdema of the larynx may also occur after operative procedures in the neighbourhood of the throat; therefore patients who are threatened by this danger should be most carefully watched.

This brings us to the so-called **laryngeal perichondritis,** whose

chief danger is the development of acute laryngeal œdema. This is not a primary disease, it is always the consequence of a *deep laryngeal ulcer* of some kind, or it may be a *metastatic process*. Such ulcers occur in infiltrating injuries, typhoid fever, small pox, tubercle, syphilis, cancer, &c., and suppurating metastases are met with in the course of typhoid, small pox, scarlet fever, and pyæmic diseases from any source.

If hoarseness and dyspnœa occur in any of these diseases, and there are at the same time external swelling and pain on pressure over the whole or part of the larynx, we must think of perichondritis. The laryngoscope will reveal the presence of ulcers, abscesses, and œdematous areas in very varied distribution.

(2) PURE CIRCULATORY DISTURBANCES.

Œdema of the larynx may exist, independently of any inflammatory disease, merely as a consequence of a *pure circulatory disturbance*. It may occur as a part of a general œdema due to circulatory disease, or nephritis, and as a result of new growths in the vicinity of the vessels of the neck, and finally as a variety of **angio-neurotic œdema**. This latter occurs in various parts of the body, either in the form of large urticarial wheals of the skin or mucous membrane, or as œdematous swelling of extensive skin areas. Sometimes the cause is not apparent, but sometimes it follows indulgence in certain food, just as in the case of urticaria. In a patient of mine it always followed the use of white wine. Occasionally a hereditary predisposition exists. Its localization in the larynx is not by any means a very rare event, but its danger is diminished by its usually short duration. In spite of this, however, it is quite conceivable that it would be fatal, if the obstruction of the glottis were complete. Indeed, death has resulted in such a case because medical assistance was not immediately available. But sometimes the œdema disappears as rapidly as it comes, even in the very presence of all the preparations made for tracheotomy. We must probably include in this category those cases of laryngeal œdema which have been observed in persons with an idiosyncrasy towards *iodide of potassium*. Asphyxia has even been observed in such cases.

The diagnosis is not difficult in cases of angio-neurotic œdema, because the patients are usually aware of the nature of their malady and are able to provide their own diagnosis quite accurately. It is quite different in the cases of idiosyncrasy towards iodide of potassium. In every case of unexplained laryngeal œdema, enquiries should be directed towards the administration of some form of iodine, if we have not ourselves prescribed it.

The diagnosis of laryngeal œdema is easy enough. It is quite

possible to feel with the finger the two soft swellings which block up the entrance to the larynx, and a careful examination with the laryngoscope reveals an unmistakable picture.

(3) INJURIES.

Swellings of an inflammatory and circulatory character do not exhaust all the causes of acute dyspnœa. An external blow or stroke may lead to **fracture of a cartilage,** whether it be ossified or not, and the hæmatoma resulting therefrom is liable to obstruct the glottis in a very short time. The presence of unnatural movement on careful external palpation, surgical emphysema and the view of the hæmatoma with the laryngoscope permit us to make the diagnosis. The most varied injuries of the respiratory tract may cause asphyxia by means of *surgical emphysema*.

(4) FOREIGN BODIES IN THE AIR PASSAGES.

The practitioner often sees another cause for sudden dyspnœa, in the inhalation of **foreign bodies.** We can realize the things which have been found in the air passages, if we think of what children put in their mouths and of what adults hold between their lips for convenience. Beans, peas, glass beads, bits of bone are of the most frequent occurrence; nails, needles, and shirt buttons testify to the bad habit of using the lips as prehensile organs. Even pieces of dentures have found their way between the vocal cords, an incident which should always suggest unconscious inhalation in epileptic attacks.

If the circumstances point to the possibility of a foreign body having been inhaled, we must first find out whether it is really in the air passages. If it is acknowledged that it was put into the mouth, and this was followed by a severe attack of coughing and the vomiting of blood-stained phlegm, the probability is that the foreign body *was* in the air-passages, but it may have been expelled by the coughing. The patient may still feel it there for a very long time, varying with his sensitiveness and the amount of injury inflicted on the mucous membrane—at any rate for a few hours. It there is no dyspnœa, there is ample time to use the laryngoscope. A negative finding, the disappearance of the cough without any artificial aid, and the absence of any lung symptoms suffice to reassure us. A foreign body situated more deeply, *i.e.*, in the trachea, manifests itself by attacks of coughing which are incited either on the under surface of the vocal cords or at the bifurcation of the trachea. A foreign body in the bronchus will assert itself by pulmonary symptoms on the corresponding side.

The accuracy of this last statement should be qualified. A foreign body may remain in bronchus for a day or two without causing any symptoms. Thus I saw a youth who confessed to having swallowed a lead-pencil case, but who distinctly denied having any respiratory inconvenience at the moment of swallowing it—this he did in order to put his fault in as favourable a light as possible. It turned out afterwards that, as a matter of fact, he had a severe attack of suffocation. After the foreign body had entered the bronchus, there were no more subjective symptoms, but two days later the pneumonia which supervened, and the skiagram, showed that the metal case was in the left main bronchus. It was successfully removed with the foreign body forceps, through a tracheotomy incision.

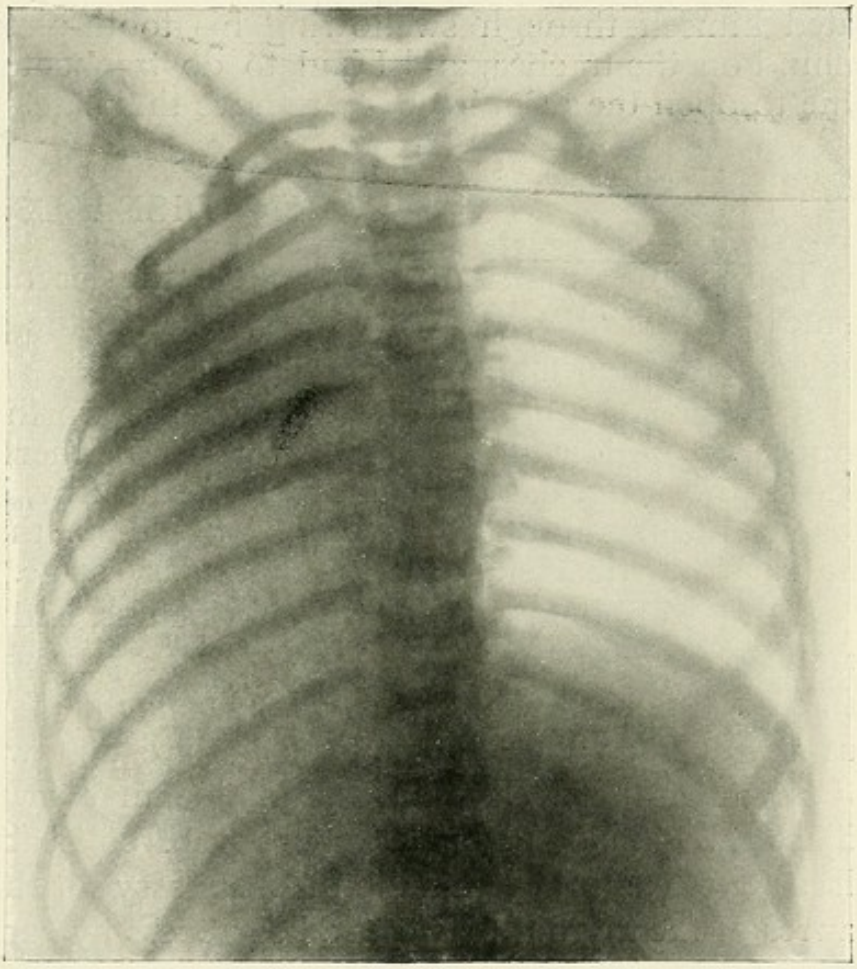

Left. Right.

FIG. 63.—Metal case in end of left main bronchus. Lung tissue extensively thickened (pneumonia).

If there is a persistent or paroxysmal cough, without any sign in the larynx, we must listen for a fluttering sound in the trachea. If this should be heard, it signifies that the foreign body is being wafted between the larynx and the bifurcation, with each breath, and that the cough is being excited from both positions. Such a case will be further elucidated by tracheotomy, when the offending substance may fly out with the first cough. If this does not happen we must look for it with the laryngoscope introduced into the trachea.

If the foreign body cannot be seen in the larynx, but is of such a nature as permits of its demonstration by X-rays, this measure must not be neglected (fig. 63). If this yields no result and the coughing still persists, we must either undertake a tracheotomy, with

some misgiving, or refer the case to an expert in tracheoscopy and bronchoscopy.

The procedure must be quite different, if there is definite *dyspnœa* from the start. All diagnostic speculations must be abandoned and the urgent demand of the moment must be satisfied. When the patient can again breathe and our diagnosis is still unformed, the Röntgen rays and bronchoscopy may be invoked.

We have hitherto assumed that the dyspnœa is caused by the foreign body being situated in the air-passages ; but this is not always the case. I once had an epileptic on the operation table, who suffocated himself through swallowing his tooth-plate. It pressed from behind on the trachea, and I had to do tracheotomy before there was time to open the œsophagus to remove the plate.

B.—CHRONIC DISEASES.

The problems are quite different if the laryngeal symptoms have come on *gradually*, in which circumstance the *previous history* is of the greatest importance.

A remark of a non-surgical character is worth making here. If a young or middle-aged person, who is neither a drinker, a heavy smoker, nor a speaker, and is otherwise healthy, becomes persistently hoarse, the possibility of syphilis should be thought of, especially the catarrhal hoarseness of the secondary stage.

If the trouble has begun with hoarseness, and there has developed, in the course of months, a persistent or paroxysmal dyspnœa, with difficulty in swallowing, *a tumour or ulcer of the larynx* must be suspected. We must, of course, be sure that we are not mistaking a tumour of the neck, such as a malignant growth of the thyroid or adjacent region, or a retropharyngeal tubercular abscess, for a laryngeal disease. A careful examination is necessary for this purpose. A small cancer of the thyroid may cause hoarseness by paralysing the recurrent laryngeal nerve and its pressure may cause both dyspnœa and difficulty in swallowing. This last differs in character from the same symptoms as caused by laryngeal ulcers, because the difficulty of swallowing is due to a *mechanical obstacle*, whereas in laryngeal disease the *pain of the act of swallowing* is the real subject of complaint.

The true nature of the disease can often be suspected before resorting to the laryngoscope. We need not hesitate about diagnosis if a typically tubercular looking patient states that he has been hoarse for years, brings up blood and suffers from night sweats. Of course a consumptive may have syphilis or cancer, but the long duration of the symptoms excludes the latter, and the syphilitic factor can be cleared up by means of Wassermann's test and specific treatment. It takes a *year* or more for a tubercular ulcer to effect the damage

which cancer can do in a few *months*, or a gummatous ulcer in a few *weeks*. The most significant point in the history of *tubercle* is the early onset of pain on swallowing, which is occasionally much more pronounced than difficulty in breathing.

Too much deference must not be paid to the previous history, to the neglect of careful examination. The following case will convey this moral.

A remarkably healthy young woman, hardly 30 years of age, sought advice about difficulty in swallowing, which had persisted for some months, but which had lately become worse. Her main symptoms were pain and a feeling of soreness. The laryngoscope showed an ulcer between the arytenoid cartilages, spreading towards the back of the larynx. Syphilis could be excluded and the case appeared to be clinically tubercle, but the microscopical examination of a small piece of the margin of the ulcer declared it to be carcinoma. Before the patient agreed to an operation she was suddenly attacked by aspiration pneumonia. In this case the position of the ulcer was certainly unusual for tubercle, and its situation in the inter-arytenoid region towards the back of the larynx might have suggested the possibility of carcinoma. Since then, I have seen a similar case, also in a young female patient. It should be added that Sendziak's statistics show that cancer in this particular situation is much more frequent in women than in men.

If a healthy man of middle or advanced age begins to get hoarse, and if this hoarseness, after some months, is accompanied by some slight difficulty in breathing, we should think, instinctively, of **cancer** and examine the neck for hard, enlarged glands. The absence of such glands is no argument *against*, but their presence is a strong evidence *for* it, provided of course that this glandular enlargement is recent. A pronounced fœtor *ex ore* is also in favour of cancer, because this symptom is very rare in other ulcers. Some support to the diagnosis is afforded by the knowledge that the patient is a lover of the bottle. Usually tobacco is blamed quite confidently ; people prefer to be known as inveterate smokers rather than as strong drinkers.

Age plays so important a *rôle* in regard to cancer of the larynx, that *chronic hoarseness coming on in a man over* 50 *must be suspected to be due to cancer*.

But at the same time we must discard all preconceived ideas, as the following case shows.

An old man was sent to the surgeon with the diagnosis of cancer, because he was suffering from hoarseness and difficulty in swallowing. The surgeon refused to operate, and for a good reason, because despite a late appearance, the patient had pronounced pulmonary tuberculosis, and his ulcer was not cancerous but tubercular.

If the patient states at once that he has had syphilis, we must not forthwith conclude that he has a **gummatous ulcer,** but we should,

at any rate, institute specific treatment. The propriety of this course would be confirmed if the patient is neither tubercular, nor at the cancer age, if glandular enlargement is absent and if the subjective complaints are slight, and above all if other traces of tertiary syphilis can be detected.

The history and the general condition having put us on the track, we must next proceed to an *examination with the laryngoscope.*

The *situation* of the lesion is full of suggestion. *Tubercle* prefers the vocal cords, the neighbourhood of the arytenoids, and less frequently the epiglottis. *Syphilis* rather prefers the latter situation, but may occur anywhere in the larynx. *Cancer* is most frequently found on the vocal cords and then in decreasing frequency, on the ventricular bands, the epiglottis, and the posterior wall of the larynx.

The greatest care is required in basing a diagnosis on the *clinical features* of the disease. All the three forms may start as nodules, and all three subsequently ulcerate. If there are a *number of nodules* present, we should think of *tubercle* or *gumma* rather than of *cancer.* A cauliflower-like shaggy appearance indicates cancer. That it is not easy for the inexperienced to decide from the appearance of the ulcer is obvious enough if we consider the difficulty which even the experienced find in diagnosing an ulcer of the oral mucous membrane, quite accessible to the eye. The rules we have already mentioned in connection with the latter ulcers also apply in this instance. Ulcers and growths which extend beyond the boundaries of the larynx, encroaching upon neighbouring organs, are most likely cancerous. In such cases, evidence of a hard margin and base, which can easily be obtained by palpation, is often of decisive significance.

Often enough the laryngoscope does not permit us to get beyond the mere diagnosis of "ulcer." Three other methods may then be resorted to; histological and bacteriological examination and therapeutic experiment.

The piece submitted to *histological examination* should not be too small. It may be removed by the practitioner if he possesses sufficient dexterity, otherwise this procedure should be carried out by the laryngologist. It is most important that the piece should be snipped off the right place. An error in this respect may be disastrous in its consequences, as testified by a famous historical instance which it is unnecessary to recall.

There is no difficulty in recognizing *cancer* under the microscope. The distinction between *tubercle* and *syphilis* may be rather difficult if there is no pronounced general tuberculosis present; but here the gap will be supplied by *bacteriological examination.* It may be possible to detect tubercle bacilli by rubbing the surface of the ulcer with a laryngeal probe covered with cotton wool, and wiping the wool on a cover glass. Animal inoculation with a portion of test specimen

removed is, however, a much more certain method. The experiment of treatment with *iodide of potassium* must be regarded as an ultimate resort, if Wassermann's reaction is positive.

It happens sometimes that although the symptoms have led us to suspect tubercle, syphilis, or cancer, the laryngoscope reveals a sharply circumscribed structure, situated on a vocal cord or on the anterior commissure, with absolutely no morbid change round about. This is in all probability an *innocent growth*, and if it is smooth on its surface like a pea, or somewhat rough, from being an aggregation of separate roundish little nodules, it may be regarded as a **fibroma.** If the growth looks like a cauliflower, or a condyloma with points, it is to be regarded as a **papilloma.** Such papillomata do not always exist in the form of circumscribed tumours, they may extend superficially just like papillomata of the bladder.

Can these innocent tumours not be diagnosed *clinically?* In some cases, certainly they can; in cases wherein the growth is pedunculated and gets caught occasionally between the cords. The history will show that the patient sometimes has a clear voice, and then suddenly gets attacked by hoarseness or even seized by suffocation. If a child suffers from unexplained persistent hoarseness, or from repeated attacks of unexplained suffocation, we should think of a papilloma, because this is not at all a rare condition in children, and is practically the sole laryngeal tumour which occurs among them.

Errors in diagnosis in respect to innocent laryngeal tumours may be made in various directions. A circumscribed tubercular or gummatous nodule may be mistaken for a fibroma, or *vice versa*, but the further course of the case would however clear this up. In other cases we may be doubtful whether a papillary structure which we have discoved is innocent or malignant. Age is of course of great significance here, for a papilloma in an old man is always suspicious of cancer, and if enlarged hard glands are present, the matter is conclusive. One must never wait for enlarged glands to confirm the diagnosis before operating, because in cancer of the larynx the glands are often very late in appearing. When in doubt the only course to pursue is to have an adequate portion excised for examination.

There are some rare laryngeal tumours which cannot usually be diagnosed until after their removal. The practitioner cannot be expected to recognize these accurately. The same applies to tumours of the *trachea*. It may be mentioned as a curiosity that *new growths with the structure of the thyroid gland* have been found in it, obviously arising from a misplaced thyroid rudiment. *Sarcoma* occurs more frequently, and therefore has more practical importance. The diagnosis of a tumour of the trachea is made by a process of exclusion,

if no other explanation for the difficulty in breathing is forthcoming. An expert in the use of the laryngoscope may be able to see the tumour even in this situation. If unsuccessful at first the patient must give several sittings in order to become gradually accustomed to the examination, as is so often necessary when laryngoscopy is not well tolerated.

It must be mentioned that tumours, especially cancer, in the vicinity, may infiltrate the trachea, and grow in a fungiform manner. As a rule, by the time a primary cancer has manifested symptoms pointing to the trachea, it has already declared itself in other ways, so that the diagnosis is attended by no difficulty.

CHAPTER XXI.

DIFFICULTY IN SWALLOWING.

In accordance with an old and useful rule, we must distinguish the difficulty in swallowing caused by some disturbance of the mechanism in the mouth or throat, from the difficulty caused by obstruction in the œsophagus. Obviously this difference implies the existence of very different conditions.

A.—DISTURBANCES OF THE MECHANISM OF SWALLOWING IN THE MOUTH AND THROAT.

Deglutition may be deranged in various ways :

(1) *Paralysis of the muscles of the palate.* In order to swallow efficiently it is necessary that the upper portion of the pharynx should be shut off by the action of the soft palate. If the latter is paralysed it follows that some of the food will gain access to the nose by escaping upwards. This upward flow will not affect the food alone, it will also affect the current of air during speech, and therefore the nasal intonation of the patient will suggest the cause of the difficulty in swallowing, before even we make an examination. *Paralysis of the palate after diphtheria* is a classical example of this condition. The paralytic symptoms in *bulbar palsy* are much more extensive, but in this disease the difficulty in deglutition is preceded by many other paralytic symptoms which will already have established the diagnosis.

(2) Congenital or inherited defects in the development of the soft

palate may interfere with the act of deglutition, just like paralysis The former condition is usually associated with a *cleft of the hard palate*, and the latter is the result of *gummatous* destruction, but a patient with cleft palate is more or less able to compensate for his disability by raising his tongue to close the fissure.

(3) *Scars*, especially after tertiary syphilis, more rarely after burns and corrosions, may interfere with the mobility of the palate and thus prevent the effectual shutting off of the pharynx.

(4) *Pain* is a frequent cause of difficulty in swallowing, for when severe it may completely inhibit deglutition by reflex action. Every layman recognizes the difficulty in swallowing in cases of sore throat; but it is also a special complication of laryngeal tuberculosis, as also of laryngeal and pharyngeal cancer. In tubercle, the difficulty may be so great that feeding becomes almost impossible. The difficulty in swallowing when a foreign body is in the throat, especially in the pyriform fossa, is also due to the inhibition caused by the pain.

(5) Apart from the inhibition caused by pain as just mentioned, *acute inflammatory processes* interfere with the act of deglutition, and may even render it impossible. This is due to inflammatory infiltration of the soft palate, to diffuse swelling of the entire throat, and to extreme bulging of the affected side, if an abscess has formed. The swelling in phlegmonous inflammation of the floor of the mouth and of the tongue causes a similar disturbance.

(6) Swallowing may be mechanically prevented by *pharyngeal tumours* of various kinds, such as *naso-pharyngeal polypi*, *naso-pharyngeal fibromata*, *retro-pharyngeal tumours* and *malignant growths* in any part of the throat. A chronic retro-pharyngeal abscess, generally tubercular, acts in the same way.

(7) The presence of a *foreign body* in the upper part of the pharynx also acts as a mechanical obstacle to deglutition.

The circumstances attendant upon the case will put some limit on the above mentioned possibilities, even before we examine the patient's throat.

A *sudden onset* of difficulty in swallowing, in a healthy person, indicates a **foreign body,** for which search must at once be made, either with the laryngoscope or the finger. If a foreign body is present, it is probably situated in the sinus pyriformis, or behind the larynx above the cricoid cartilage. I have seen a slice of raddish sticking there on one occasion, and on another, two pieces of tough unmasticated tongue.

If the trouble has come on *gradually*, or at any rate has not come on within an hour or two, the *age* must be taken into consideration first of all. Palatal paralysis in a child will suggest a sequela of diphtheria; in an adult it will point to bulbar palsy. If the difficulty

seems to be due to a tumour, a retro-pharyngeal abscess is the most likely cause in a child, in a young person a naso-pharyngeal fibroma is probably responsible, and after 50 the chances are in favour of a malignant neoplasm.

The *voice* is very characteristic. A nasal tone means that the palate does not close up the pharynx satisfactorily, owing either to paralysis or structural defect. If the voice is hoarse, we think instinctively of laryngeal tuberculosis in young people, and of carcinoma in those of a more advanced age. But first impressions must not be permitted to lead us astray, they are only of value as initial guides, as the two cases previously noted will exemplify (p. 119).

Having made a provisional diagnosis from the history and the external circumstances, we next proceed to an *examination of the mouth and throat.* Often enough, one glance into the open mouth suffices for a diagnosis. A lax, dependent soft palate, remaining so even on phonation, indicates paralysis. Sore throat and retro-tonsillar abscess are obvious at once. In retro-pharyngeal abscess the posterior wall of the throat bulges forward. If nothing abnormal is seen, we must palpate the post-nasal space, and finally bring the laryngoscope to our aid. If nothing still appears, we must conclude that the trouble is not in the throat but in the region of the œsophagus.

B.—DISTURBANCES OF THE MECHANISM OF DEGLUTITION IN THE REGION OF THE ŒSOPHAGUS.

We now come to the second and a most important of deglutition troubles, to those which depend upon diseases of the *œsophagus and its vicinity.*

(1) If the *difficulty has occurred suddenly,* we must first think of a **foreign body** in the throat. In a large number of cases it will be found that artificial teeth, pieces of bone or coins, have been swallowed. But clear as the history is in some cases, in others we can elicit nothing of value. An epileptic who misses his artificial plate after an attack will look for it everywhere except in his œsophagus, as long as he feels no discomfort. I have myself seen a case wherein an agricultural labourer swallowed a piece of a goat's skull with his soup, and at first paid no heed to the incident. A child who has swallowed a coin, even if able to speak, will only vouchsafe information about his misdeed when he finds himself in difficulties. So that even if there be no history available, the sudden onset of difficulty in swallowing should always arouse first, the suspicion of a foreign body. But how can the diagnosis be established? If the epileptic just

referred to, consults us a couple of days after he has missed his plate, because he is quite unable to swallow, and some inflammation is already beginning, we are forthwith in a position to tell him the whereabouts of the lost object. But in the absence of such clear indications, we ask the patient to take a little drink carefully, and point out the site of any pain which may be present. But some caution is required in this matter, because the localization of pain is limited to the upper portion of the œsophagus, and even if pain is ascribed to some definite spot in the throat, this only suggests that some injury has occurred there, and not that the foreign body is to be found there. We next proceed to pass a sound, beginning with a soft india-rubber one for the sake of gentleness. If this should be held up in its passage downwards, it will afford approximate information as to the site of the obstruction. A very flexible whale-bone sound gives more reliable information. If it is conjectured that the foreign body has been swallowed a day or two previously, or even before that, the most extreme care will be required, lest inflammatory change has already supervened. In any case we should begin with a sponge sound, after assuring ourselves that the sponge has been carefully cleansed and fits in firmly.

Accidents may happen even to the most expert in the passing of œsophageal bougies. Kocher had a case wherein he had to remove a piece of a whale-bone sound by gastrotomy. It was the first operation of the kind, deliberately carried out on a stomach not secured by adhesions.

If we come to an obstruction on carefully pushing the sponge sound forwards, we must not proceed further, but withdraw it, and see whether there be any blood or pus on it. It will sometimes be necessary to wipe the sponge on a cover glass, and stain with methylene blue, in order to detect the pus. We may next use a firmer sound, which will permit us to estimate the distance of the obstruction from the upper teeth, better than is possible with a soft sound. If we know the nature of the foreign body, *e.g.*, a coin, we may forthwith attempt to extract it with a Gräfe's basket. Otherwise we should employ a whale-bone sound with a metal or ivory top, as a third instrument, in order to determine the nature of the foreign body by the sensation experienced when the sound impinges upon it. But if the sound encounters no obstruction, we cannot exclude a foreign body, for even an artificial plate may be passed by the instrument without detecting it. But if the sound, especially the sponge sound, brings up blood when carefully passed, there is always a suspicion of a foreign body, and if pus is brought up it becomes very probable.

In all cases, but especially in doubtful ones, Röntgen rays should

be employed, or a skiagram taken. Coins appear most distinctly (fig. 64), but in a successful picture, pieces of bone, teeth, and the metal portion of dentures may be visible. As a last resource, the expert may proceed to use the œsophagoscope, which will provide the truest solution. This instrument is naturally not one often used by general practitioners, and therefore must be entrusted to the expert.

Matters are, however, not concluded with the diagnosis of a foreign body. Treatment and prognosis demand some information as to the presence of an injury to the œsophagus, or of a pressure ulcer with an incipient peri-œsophageal phlegmon. In these circumstances the attempts at extraction must be most carefully conducted, the prognosis must be guarded, and the patient must be attentively watched, even after the successful removal of the foreign body. In order that we should not be blamed for symptoms which already exist, we must take the temperature and pulse *before* the extraction; and if the foreign body is in the upper portion of the œsophagus, we must note whether severe pain on pressure, swelling and œdema in the neck, point to the existence of a peri-œsophageal phlegmon.

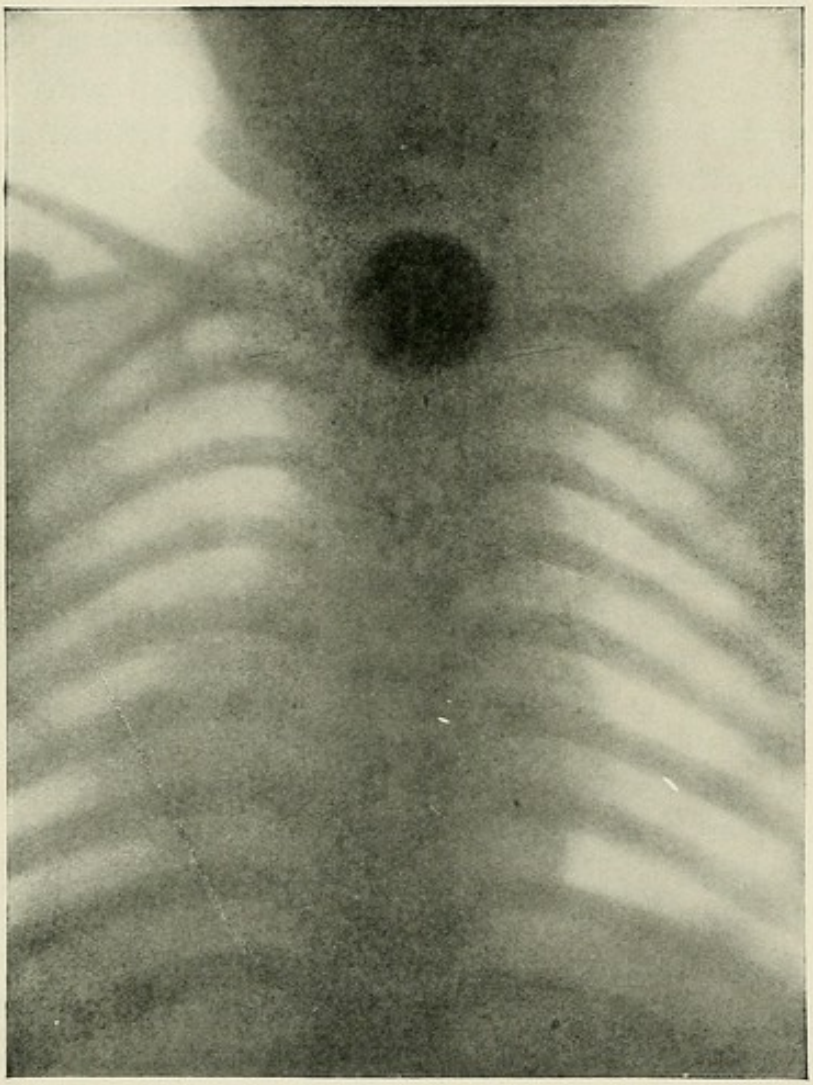

FIG. 64.—Copper coin in the œsophagus (for three weeks).

It seems incredible that a foreign body may lodge in the œsophagus for quite a long time without causing severe symptoms. In the case illustrated in fig. 64, the copper coin had been in the œsophagus for three weeks, and there was such an absence of symptoms that both the doctor and the mother doubted its presence before the skiagram was taken.

Besides foreign bodies, the causes for acute onset of difficulty in deglutition include *corrosion by alkalis or acids, compression by an acute thyroiditis, acute goitrous inflammation,* or a *phlegmon of the neck or mediastinum.*

An accurate history is usually available in cases of **corrosion,** except in children, hysterical individuals, and pronounced mental patients. The very severe initial symptoms generally abate, but in the course of three or four weeks they are replaced by a gradually increasing stricture. In these cases great significance attaches to the persistent regurgitation or vomiting of blood-stained fluid.

Inflammatory processes in the neck are at once recognized by appearance and by palpation, and a **mediastinal phlegmon,** independent of a foreign body or cancerous disease of the gullet or bronchi, is a very great rarity.

If the difficulty in swallowing has come on gradually, the cause may be a **narrowing of the œsophagus,** or **external pressure** thereon, or a **functional disturbance.** The first occurs in cancer and cicatricial stricture after ulcers—mostly due to corrosion or syphilis; and external pressure results from tumours of the neck, changes in the shape of the spinal column, aneurisms, mediastinal tumours of any kind, cold abscesses, and diverticula of the œsophagus.

Before we proceed to use the sound, there are others matters to note, because the instrument is not always safe, and because, not all patients are equally agreeable to its employment. We must, above all, be able to exclude *aneurism.* For this purpose, it is necessary to begin by the percussion and auscultation of the thoracic organs, and by examining for other signs of aneurism. If they are present, we should take care not to pass a sound. If examination reveals some *malignant condition,* the introduction of a sound can yield no fresh information.

It is necessary to note the *precise characteristics of the difficulty in swallowing,* because they point sometimes to the nature and situation of the obstruction. If the patient complains, in the early stage of his disease, of a constant expectoration of saliva, we must conclude that the obstruction is situated high up, so that the gullet cannot dilate above it. We must come to the same conclusion, if a constant desire to swallow is the first symptom. But if the patient states that as soon as he takes a cup of tea or milk he forthwith vomits it, but that the vomit is not sour, that he frequently vomits insipid mucoid material between meals, we may suspect the case is not one of genuine vomiting, but merely of the evacuation of the spindle-shaped œsophageal dilatation which always forms above a deep-seated obstruction. This profuse regurgitation shows that the obstruction is deeply situated and that it is of some considerable duration. These cases

have often been treated for months as gastric disorders. If we ascertain that the act of swallowing has gradually become difficult, that at first, solid food well masticated and mixed with water went down, but that latterly only liquids can be taken ; if there is neither the constant desire to swallow, nor the profuse regurgitation of liquids just drunk, we should think of a gradually developing stenosis in the middle of the œsophagus. A glass of water will afford the opportunity of a test. If the patient begins to cough after the first or second draught, the obstruction is high up. But if he can quickly drink a half or the whole of the glass before it returns, the obstruction must be near the cardiac end ; the more water that can be swallowed the lower it is. The neck of the patient must be inspected during this procedure. If hard glands exist above the clavicle, and the patient complains of pains in the shoulder and back of the neck, there can be no doubt about the diagnosis of *cancer*. If one side of the neck fills up somewhat during the swallowing, we should think of a *diverticulum*.

Having proceeded thus far with our examination we may now resort to the *sound*, provided that we have excluded an aneurism. By means of the sound we can distinguish between a true stricture and a stenosis produced by compression, just as we can distinguish a stricture of the urethra from hypertrophy of the prostrate. If, despite difficulty in swallowing, a medium sized or larger sound immediately passes into the stomach at each attempt, the case is one of a **tumour compressing the gullet from without.** If the sound is at one time arrested at a short distance, whereas at another time it passes easily, there can be no question about the diagnosis of a **diverticulum,** provided that the instrument has not been held up by a fungating projecting carcinoma which has not yet led to stricture. The presence of this last condition would be recognized by slight bleeding. If the neck becomes inflated on swallowing and this swollen part can be emptied on pressure, the diagnosis of diverticulum is confirmed, and it is superfluous to render the stricture visible by filling with bismuth and applying the Röntgen-rays.

The question whether a case is to be grouped under *pressure* or *traction diverticula* is easily settled. The former alone, when full, cause blocking of the upper part of the gullet, and produce clinical symptoms. They are usually situated in the cervical portion of the œsophagus and only exceptionally in the thoracic portion. The latter, when they are large enough, cause the usual symptoms of diverticula, even swelling up to the neck. Absolute accuracy of diagnosis can only be assured by Röntgen-rays. Traction diverticula are usually discovered *post-mortem*, and the sound has no special tendency to catch in them. They hardly enter at all into clinical consideration. Traction diverticula seldom dilate through pressure.

Spindle-shaped dilatation of the œsophagus, previously noted,

and dependent upon some functional disturbance must not be confused with a diverticulum.

It is certain that this condition may sometimes be caused by spasm of the cardiac end of stomach; but the possibility of it being caused in consequence of paralysis of the œsophageal muscle cannot be excluded. Solid food may remain in the œsophagus for days at a time. The sound can be moved about in the œsophagus remarkably easily, and it occasionally catches in its wall, so that a diverticulum would suggest itself, if it were not so deeply situated. The emaciation is often very pronounced, but even after many years' duration, it does not reach the extreme degree which is usually present after one year's suffering from cancer of the œsophagus. As in the case of a diverticulum, the presence of this dilatation can be demonstrated by the Röntgen-rays after a bismuth meal.

If the œsophagus is not permeable to a soft sound of medium thickness (10 mm.), we should endeavour to pass an olivary sound, beginning with one of a somewhat smaller calibre, but not the smallest, because this is much more liable to penetrate a putrefying growth than a thicker one.

Having overcome the first difficulty, the cricoid cartilage at a distance of 15 cm. (6 inches) from the upper incisors, the sound passes along easily until the stenosis is encountered. If delay arises here, the sound is withdrawn somewhat and then pushed on again, in case it may have caught against some projection of the new growth. But if this manœuvre does not succeed in passing the sound further on, without violence, we must try smaller sounds until we hit upon the one which just goes through. The sound is pushed right on into the stomach to see whether there is only *one* obstruction, and in withdrawing the instrument we note the exact spot where it is grasped so as to determine the *lower* limit of the obstruction.

This point is sometimes of practical importance, because carcinomata, whose lower limit is not more than 20 cm. (8 in.) from the incisors, can be removed through the neck.

It is obvious that a physiological obstruction must not be mistaken for a pathological one; the cricoid cartilage, situated 15 cm. from the upper incisors has already been mentioned. A little resilience is also felt at the level of the bifurcation of the trachea (26-27 cm.), and this is a little more pronounced when the sound passes through the œsophageal opening in the diaphragm (38 cm.) We must not be deceived by spastic constriction which occurs now and again in nervous individuals, and which may prevent the passage of the sound, analogous to the case of urethral spasm. We should conclude that this kind of difficulty is present if the condition varies from time to time while genuine signs of diverticula are absent.

If we have found a *stricture*, we must next decide whether it is cancerous or cicatricial. A patient never forgets having drunk a

corrosive acid or alkali, and therefore the evidence for a **stricture from corrosion** is at once available; so that in practice the diagnostic distinction usually concerns **cancerous and syphilitic stricture.** A recently developed hard gland in the supraclavicular region points to cancer.

There is no connection between the size and age of the cancer and the extent of the grandular enlargement. I have seen a bunch of glands as large as a fist, when there was clinically nothing at all definite, the autopsy only revealing a growth of 2 cm., which had not formed a ring, but allowed even the largest sound to pass. On the other hand it is often impossible to feel any enlargement of the supraclavicular glands, although the cancer be of great extent.

Age, addiction to tobacco or alcohol only afford approximate indications. But a history of old syphilis, and especially the presence of other tertiary signs, is of great significance, when enlarged glands are absent.

The course of the disease is conclusive from the clinical standpoint. A syphilitic stricture may develop more quickly than cancer, but once having formed, it does not increase continuously like a cancerous stricture. Neither is syphilitic stricture attended by the spontaneous pain which is seldom absent in advancing cancer.

The diagnosis may be confirmed by œsophagoscopy, by aid of which a piece of the tissue in question can be removed for examination. But cancerous stricture is so much more frequent than syphilitic stricture, that we may well dispense with this method. *A man of advancing years, suffering from a gradually increasing stricture of the œsophagus is in all probability a victim of carcinoma.*

In addition to syphilis and the action of corrosives, certain other rare causes of stricture have been noted, viz., non-traumatic ulcers, peptic ulcers of the lower part of the œsophagus and peri-œsophageal abscesses.

Sarcoma of the œsophagus is very rare, and can only be diagnosed with the microscope.

CHAPTER XXII.

ABSCESSES OF THE NECK.

THE questions involved in acute abscesses and acute phlegmons of the neck are so different from those which present themselves in chronic abscesses, that we separate the two classes, although intermediate forms do occur.

A.—ACUTE INFLAMMATORY PROCESSES.

In cases of phlegmon or abscess of the neck, our first concern is to ascertain the position of the inflammation. If the latter corresponds to the known situation of glands, we shall not be wrong in assuming that there is *suppuration of the glands*. This diagnosis is confirmed by daily experience, but our task is not completed therewith. Glands do not suppurate of themselves; there must be some antecedent infection from without, and the suppuration represents the attempt of the glands to prevent the micro-organisms gaining further access into the system. We must, therefore, search for the *portal of entry*. If the sub-mental or sub-maxillary glands, or those along the large vessels are involved, there may be some easily visible skin infection such as a furuncle, but the origin is more probably in the mouth or pharynx, especially in connection with the gums, teeth, or tonsils. This kind of cervical abscess is most prevalent after scarlet fever and diphtheria. Sometimes the inflammation at the portal of entry is so slight that the most careful examination is required to detect it. If the glands at the back of the neck are suppurating, a condition to which children are prone, the experienced practitioner will at once look for an eczema of the scalp, and he will rarely be disappointed.

We will now discuss the various regions of the neck.

(1) THE SUB-MENTAL REGION.

Sub-mental abscesses are easy to recognize, for they almost always arise from the *lymphatic glands* and not merely from the jaw. The portal of entry for the infection is usually situated on the under lip or chin. A persistent abscess in this neighbourhood, which fails to heal after incision, must be regarded as a *suppurating dermoid* of the floor of the mouth, although these usually grow towards the mouth. The sub-lingual gland very rarely comes into question, and it is so situated that if it does inflame the swelling is inwards.

In acute glossitis and in cellulitis of the floor of the mouth there is also œdematous swelling of the sub-mental region.

(2) THE SUB-MAXILLARY REGION.

Acute inflammatory swellings of the **sub-maxillary region** may be due to one of the following causes :—

(*a*) *Periostitis of the jaw* after caries of the teeth. Examination of the teeth and gums, palpation of the jaw will indicate the existence and situation of the inflammation.

(*b*) *Osteo-myelitis of the jaw.* This differs from periostitis by its

great extent (usually bi-lateral) and the greater severity of the general symptoms.

(*c*) *Acute inflammation of the sub-maxillary gland* (*salivary*), through obstruction of Wharton's duct (salivary calculus), infection from the mouth, or as part of an epidemic parotitis. The gland can be more or less easily felt, both in the mouth and externally. Sometimes pus exudes from Wharton's duct when pressure is made on the tumour. The occurrence of repeated attacks suggests calculus, which can occasionally be felt within the mouth, especially after its exact position has been ascertained by a skiagram. If the parotitis is predominant, there is no difficulty about the diagnosis.

(*d*) Inflammation of the lymphatic gland tissue enclosed in the capsule of the salivary glands, so called *angina ludovici*. Here also, the swelling projects mainly into the mouth, but the general symptoms of infection are much more severe than in inflammation of the salivary glands, and there is in addition a very widespread œdema.

(*e*) Inflammation of the *superficial lymphatic glands* superjacent to the salivary glands. This is the most frequent form of sub-maxillary phlegmon, and chiefly spreads outwards. It causes fluctuation much more quickly than intra-capsular suppuration, and is less dangerous. The infection may start from the nose, eye, cheek, or gums.

A *laryngeal perichondritis* may open externally in this direction, and suppurative *periostitis of the hyoid bone* may be mentioned as a curiosity.

(3) THE SIDE OF THE NECK.

Practically the only condition which presents itself at the **side of the neck,** in the sterno-mastoid region, is *glandular abscess*. If no focus of infection is found on the skin or mucous membrane, we must assume that the original disease, eczema of the head, rhagades on the nose, and inflammation of the gums, &c., had already recovered when the abscess came on. Injury to the mucous membrane of the pharynx or gullet by a fish-bone or similar pointed foreign body is a rarer cause of cervical abscess. Abscesses tracking from the *œsophagus* always appear first in the neighbourhood of the sterno-mastoid, and are recognized by the fact that they cause pain on swallowing from the very beginning. The patient will also, as a rule, be able to recall the severe sudden pain caused by the foreign body responsible for the mischief. Pain on deep pressure can usually be elicited before any inflammatory change appears on the skin ; and the abscess does not reach the surface in the form of a circumscribed swelling but as a diffuse phlegmon.

(4) SUPRA-CLAVICULAR REGION.

Abscesses and phlegmons in the **supra-clavicular fossa** are less frequent. The glands in this position very rarely suppurate, because the infective organisms are usually arrested by glands higher up. The abscesses which do occur in this region are usually due to extension of suppuration from above. If a phlegmon does arise primarily in the supra-clavicular fossa, we must think of *osteo-myelitis of the clavicle*.

(5) ANTERIOR TRIANGLE OF THE NECK.

We now proceed to the somewhat rare abscesses of the **anterior triangle of the neck.** They usually originate in the *thyroid gland*, whether the change therein is only goitrous or not. If the patient is seen in an early stage when the inflammatory process is limited to the thyroid gland or to a goitre, there is no difficulty in the diagnosis. But if the patient is not seen until a state of diffuse phlegmon has supervened, it may be necessary to consider the possibility of *myositis of the sterno-mastoid*. *Osteo-myelitis of the manubrium sterni* with the pus tracking upwards, might also be mistaken for inflammation of the thyroid gland; but the pain on pressure over the sternum should guide us to a correct diagnosis.

Finally, there are *phlegmons of the anterior mediastinum* which appears in the neck. I have seen two cases which ended fatally, despite early incision.

(6) POSTERIOR CERVICAL REGION.

Abscesses in the **posterior cervical** region and its neighbourhood are more frequent. If the abscess is situated *posteriorly, below the mastoid process*, and has been preceded by middle-ear symptoms, we cannot fail to diagnose a *Bezold's abscess, i.e.*, an abscess of the mastoid process which has burst into the neck.

How can this latter variety of abscess be distinguished from one of the ordinary superficial glandular abscesses of this region? An abscess starting from the petrous bone, or mastoid process is at first deeply situated and covered by the insertion of the sterno-mastoid. The patient therefore complains of pain and holds his head stiff, before any swelling or redness of the skin appears. But on the other hand, glandular abscesses are from the first quite close to the skin; the subjective disturbances, therefore, go hand in hand with the visible and palpable development of the abscess.

A **carbuncle at the back of the neck** presents a very distinctive picture. The simple posterior cervical furuncle demands no diagnostic skill; and it is not easy to mistake a carbuncle formed by the

agglomeration of a group of contiguous furuncles—sometimes called anthrax, after its French designation.

Both terms occasionally mislead the beginner into thinking of true anthrax. Before the advent of bacteriology the differential diagnosis was often difficult. As a matter of fact the typical carbuncle at the back of the neck has nothing to do with anthrax. It is a staphylomycosis which finds a favourite soil for growth in the aged or diabetic.

The inflammatory process is not always limited to the diseased hair follicles and their immediate vicinity. The entire integument of the back of the neck, from ear to ear, may become indurated and of a bluish red colour. The persistence of fever after the evacuation of cores of pus shows that some deep inflammation exists. A phlegmon may develop over a muscle, beneath superficial skin which is perforated like a sieve, but the cutaneous infiltration renders the detection of fluctuation very difficult. Nevertheless, it is important to open such a phlegmon as quickly as possible, in order to anticipate the deep extension of the pus.

If there is no furuncle to explain the condition, disease of the bone must be thought of, *i.e.*, *osteo-myelitis of the occipital bone*, which is more likely to be metastatic than primary.

Suppuration of a tumour at the back of the neck is rarer still. While acting as assistant, I saw a girl with a large fistulous abscess at the back of the neck constantly discharging fœtid pus. It was a case of a *dermoid*, containing a large bunch of hair. *Lipomata* may also suppurate, exceptionally.

B.—CHRONIC ABSCESSES.

A slowly developing, painless and circumscribed swelling at the back of the neck should suggest a new growth, and this diagnosis should only be abandoned in favour of a **tubercular or cold abscess** if all the circumstances are not in accord with it. The possibility of cold abscess has occasionally been forgotten, and immediate operation has been undertaken in the expectation of finding a tumour or a cyst. This error is easily avoided if the glands are suppurating, because the multiplicity of the swellings will indicate, even to the beginner, that glandular disease is present. But it is quite otherwise when a deep-lying abscess starts from a *tubercular vertebra*. If it has not yet reached the surface, the presence of fluctuation cannot always be detected, and the original specific disease may not have manifested itself in any striking manner. There is, however, even in this early stage, a symptom very significant of tubercular abscess, and that is, the situation of the swelling *behind* the thyroid and *behind* the carotid, to which further reference will be made in discussing tumours of the neck. A swelling which pushes the carotid artery forward must be a tumour

of the vertebral column, or of the deep cervical muscles, or a cold abscess.

If the pus has tracked to the surface by one route between the muscles, the deep origin of the abscess may be obscured. It is therefore always necessary to examine the inside of the throat, because the origin of the abscess may be easier to detect from there than from the surface of the neck.

A careful examination of the spine will generally reveal signs of tubercular disease before the patient is conscious of any trouble. The experienced eye will also note the stiffness of the neck, and will be struck by the fact that the patient never turns his head without turning his back at the same time.

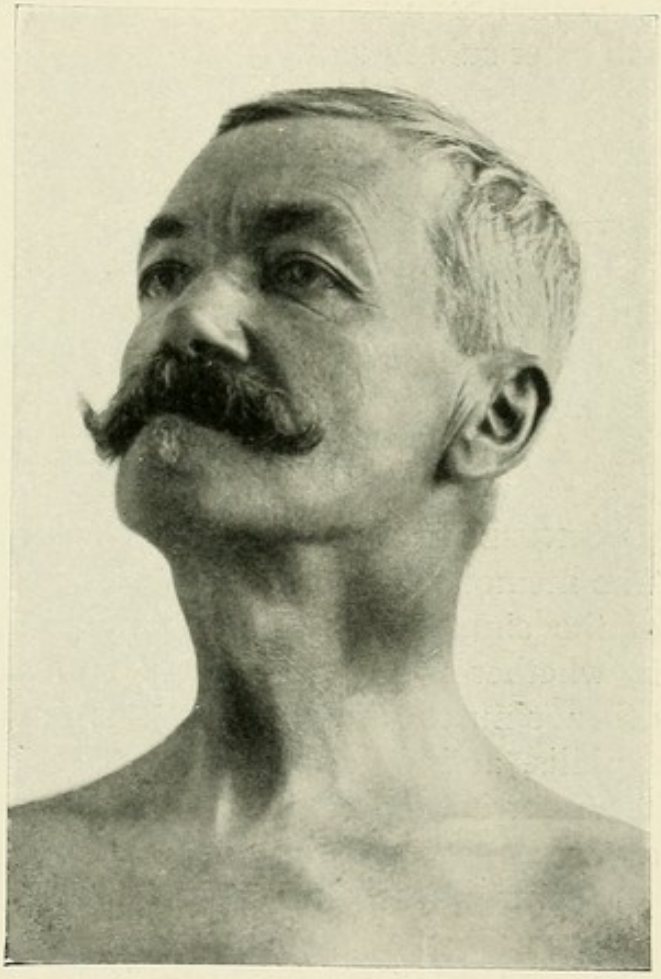

FIG. 65.—Tubercular abscess from spinal disease. Upper half of sterno-mastoid bulged forward.

A full *œsophageal diverticulum* projecting into the side of the neck may feel like a chronic abscess. But its long duration, extending over years, and its objective condition of expressibility render the diagnosis quite easy.

Not all chronic abscesses of the neck are tubercular. These are always distinguished by their softness, but there are some chronic abscesses in the neck which are, on the contrary, remarkably hard. Reclus applied to them the term **"phlegmon ligneux,"** and in German the expression **"holzphlegmone"** (board-like phlegmon) has been adopted. *Actinomycosis*, which we have already discussed, is one example of the cases which must be ascribed to this group. The occurrence of small soft areas in the midst of the board-like induration allows us to recognize actinomycosis before the characteristic granules have been discovered.

Cases of hard chronic inflammation, which are not to be attributed to the ray-fungus, have been found to be due to various schizomycetes. The patients are always in a feeble state of general health and of an advanced age. The board-like nature of a phelgmon does not, therefore, represent any specific disease; it is merely the distinctive reaction

evinced by old cachectic individuals towards the presence of any kind of suppuration. Instead of the abscess breaking, it becomes surrounded by an induration of connective tissue, which renders it all the more difficult either to get absorbed or to burst through. Thus it is that the whole process is so protracted.

Finally, it should be noted that these "board-like phlegmons" must not be confused with Ludwig's angina, a mistake which has occurred, owing to their hardness on palpation. Notwithstanding the term "phlegmons," these cases are of a definitely chronic character, whereas Ludwig's angina is characterized by its acuteness. These cases have also often been mistaken for malignant growths, a matter to which we will refer subsequently.

CHAPTER XXIII.

SINUSES IN THE NECK.

SINUSES which result from *injuries* offer no diagnostic difficulties. The memory of the injury abides with the patient, and the direction of the sinus can be inferred by noting whether air bubbles through it, whether food issues from it or pure saliva flows therefrom. All other sinuses arise either from inflammatory processes (tubercle, syphilis, actinomycosis), or from *congenital anomalies*.

A correct diagnosis can usually be made from the *mode of origin*, *course*, and *external appearance*.

Gummatous inflammation does not lead to sinus formation, unless there be extensive destruction round about, and such a sinus does not persist very long, if no deeply situated organ has been perforated. The sinuses which are present in actinomycosis are situated, as previously mentioned, in hard board-like tissue; they are not drawn in, but are found on the summits of small dark-red projections of soft skin. Their duration is short, unless the disease has affected deeper organs, such as the spinal column and the base of the skull, when the sinuses may last for months, and become contracted while the characteristic changes of actinomycosis round about may become obliterated. In such cases there is always some secondary infection at work. **Tubercular** sinuses arise either from glands or from *tubercular foci in bone*, generally in the vertebral column. In the former case their duration is a matter of weeks, or at most

months, and there will usually be present, among old scars, some remaining tubercular glands in various stages of suppurative softening. But sinuses arising from bone, such as in spinal caries, may persist for years. Here, however, signs of tubercular disease in the spinal column will always be present.

The points already mentioned will usually enable us to distinguish between a sinus due to *inflammation* and one due to *congenital causes*. The history will, as a rule, inform us whether the sinus dates from birth; but we must not exclude its congenital origin, because the sinus first appeared in later years. It frequently happens that a branchial-cleft cyst persists in the deeper parts for years after birth, and then gradually makes its way to the surface, finally penetrating the skin and forming a sinus. Neither must we at once assume that a sinus has an inflammatory origin, because signs of inflammation appear round about, for these branchial-cleft cysts are often the seat of inflammatory processes. Inflammation of a cyst alternates with the breaking out of the sinus, so that the patient complains of an "abscess in the neck," which empties itself from time to time, and which, after a longer or shorter existence, again develops a sinus. The inflammatory changes in cases of congenital sinus are of small extent, and abate as soon as the sinus develops. It appears as a small punctiform opening, surrounded by a somewhat in-drawn area of skin, either normal or slightly irritated by secretion. A sinus of many years' duration, with these characters, is almost certainly of congenital origin.

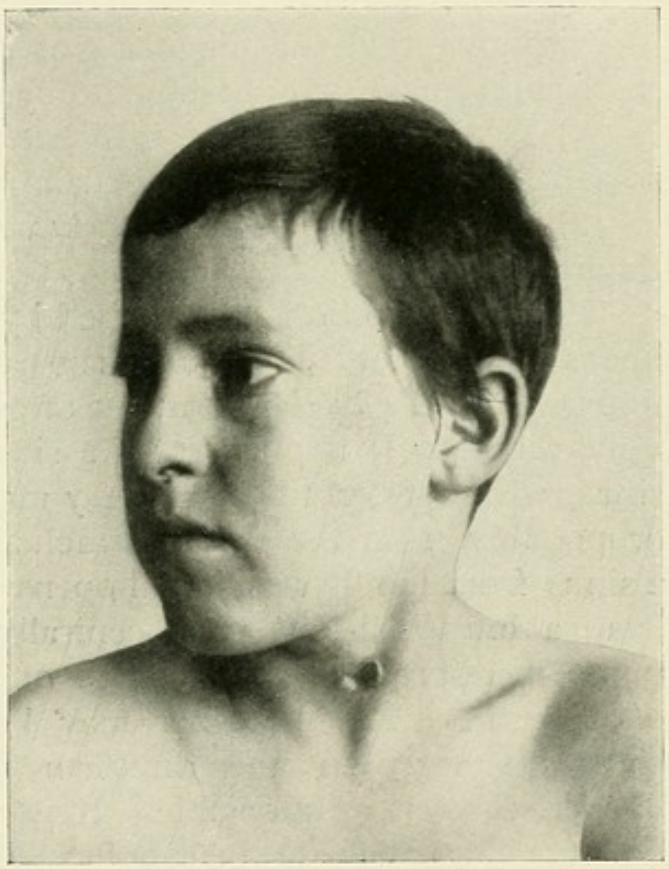

FIG. 66.—Congenital sinus of neck, originating in the middle but opening at the side.

The *secretion* from a sinus affords us an additional diagnostic aid. Pure pus escapes from an inflammatory sinus; but in the case of actinomycosis it is occasionally mixed with the characteristic granules. Congenital sinuses discharge a purely mucoid or muco-purulent fluid, in which epithelial cells can be demonstrated as well as pus cells.

The *position* of the sinus also yields useful indications. Congenital sinuses are situated in the middle line, or in the region of the sterno-mastoid, whereas the sinuses of spinal disease, with which they may easily be confused, are generally located much more posteriorly. But if all this does not suffice, we may test the connection between the sinus and the oral or pharyngeal cavity by injecting some harmless colouring matter or a bitter fluid.

Finally, we may scrape some tissue off the wall of the sinus with a fine, sharp spoon. If, on examination, this is shown to be pure granulation tissue, with probably some tubercles, we are dealing with an inflammatory fistula ; if epithelial cells are found, the case is one of congenital sinus.

Assuming that the diagnosis of **congenital sinus** is established, there still remain two questions to be answered.

(1) Is the case one of a *branchial-cleft sinus*, or is it one of so-called *median sinus*, arising from the thyreo-glossal duct ?

(2) Is the sinus *complete* or *incomplete*, *i.e.*, is it connected with the throat or not ?

The first question is answered by the position of the sinus. If it opens in the middle line, and it runs along the course of the middle line towards the hyoid bone, its origin in the thyreo-glossal duct is quite certain. If it opens at the side, it is usually a branchial-cleft sinus, arising from the first (very rarely the ear region), the second, or possibly from the third, branchial-cleft. Confusion may arise if a sinus from the thyreo-glossal opens duct laterally (fig. 66), and one from a branchial-cleft runs centrally, as sometimes happens. We must, therefore, note the course of the sinus as well as the point of its exit. The beginner may be inclined to use a probe in order to ascertain the direction of the sinus, but this is as dangerous as it is unreliable. It is very easy to penetrate the wall of the sinus with the end of a fine probe, and thus infect the surrounding tissue without ascertaining the direction of the sinus. This must be determined mainly by palpation, for the track of the sinus feel like a firm cord. As the course of the sinus which originates in the thyreo-glossal duct is a comparatively superficial one, we may be able to follow the whole tract as far as the body of the hyoid bone. If a sinus opens in the centre, and it is not possible to follow its course in this way, we must assume that the passage runs deeply, and *to the side*, that is to say, that it is the sinus of a branchial-cleft. If one has the opportunity for an X-ray examination, some bismuth emulsion should be injected into the sinus, and its course followed either on the screen or in the skiagram.

There are some cases wherein the microscope affords the first definite differentiation. Sinuses originating in the thyreo-glossal duct

are generally surrounded by minute lobules of thyroid gland tissue, a feature which is, of course, absent in the cases of sinuses from genuine branchial clefts.

To determine whether the sinus is *complete*, and reaches as far as the throat, we must adopt the method of injection, as already observed. In the case of a sinus of the thyreo-glossal duct the coloured fluid will appear at the foramen cæcum, in front of the epiglottis ; in the case of a branchial-cleft sinus it will appear at the lateral pharyngeal wall.

Finally, there remains one special form of sinus, with its orifice at the front or side of the neck. It is usually situated in the scar of an incision, and thus shows its artificial origin. When the patient swallows, it rises upwards and forwards with the thyroid gland, and if a probe is carefully introduced, it loses itself in a swelling which can be identified as a goitre. The case is therefore one of a *sinus from a goitre*, originating after incision of a goitrous abscess. Such sinuses may persist for years, if the inflammation has developed in a cystic goitre with calcified walls. The sinus can only be radically cured either by removing the whole cyst or by extirpating all the tissue which is incapable of cicatrizing.

Sometimes towards the end, *cancers of the mouth, larynx, or throat* break through to the surface, but this condition can hardly be termed a sinus. The diagnosis is easily made by the appearance of the opening on the skin and by the symptoms connected with the original diseases.

CHAPTER XXIV.

TUMOURS AND ALLIED SWELLINGS OF THE NECK.

As the neck contains a variety of organs, it offers examples of tumours of every kind. In discussing these, we purposely include certain congenital cystic structures as tumours, and at the same time embrace chronic inflammation of the lymphatic glands in this section.

Before we ascertain the nature and point of origin of a new growth, we must be quite sure that we are really dealing with a *tumour*, even in the somewhat extended application of the term as just indicated. There are morbid conditions in the neck, producing **pseudo-tumours** which may mislead even the experienced.

Tubercular abscesses should be especially mentioned in this connection. These start from the vertebral column, gradually track towards the surface, and have, as previously stated, often been mistaken for tumours (p. 134).

If we find a hard, slightly movable tumour in the submaxillary region, or even posteriorly thereto, we must think of the *board-like phlegmon*, of varied origin. The absence of fever and pain on pressure, its sharp limitation and sometimes a certain mobility of the skin over it, appear to point to a new growth. Even if the skin has become extensively adherent, the limitation of the structure is so sharp that it is difficult to discard the idea of a malignant growth. The careful consideration of all possible sources of infection will, however, lead to the recognition of the true nature of the disease. But sometimes an *exploratory* puncture only will give the first clue.

This occurred to me in the case of an aged female who had a phlegmon at the side of the neck which looked like the terminal stage of an inoperable carcinoma. Its explanation was found in a periostitis of the root of a molar, which had run its course almost unnoticed.

On another occasion I had a case which seemed to be a sarcoma of the side of the neck, and which had become adherent to the skin. It had been preceded by symptoms arising from the cranial nerves. A trial puncture showed that the case was probably one of *actinomycosis* starting in the sphenoidal sinus, and this was subsequently confirmed by autopsy.

Tubercular or *gummatous* deposits in *muscles*, especially in the sterno-mastoid, may be mistaken for tumour. The same applies to *œsophageal diverticula*.

We shall refer to the diagnostic difficulties presented by inflammation of the *salivary glands* and the *thyroid gland* in their appropriate place. We shall also subsequently discuss the not infrequent errors of diagnosis to which *aneurysms* and *cervical ribs* give rise.

In order to facilitate the survey we will discuss the conditions topographically.

A.—THE ANTERIOR TRIANGLE.

This triangle and its lateral vicinity consist of the space between the external borders of the sterno-mastoids and a horizontal line drawn through the upper border of the thyroid cartilage. It is so dominated by the *thyroid gland* that our first question in regard to any tumour in this space must be to ask whether it originates in this gland or not. *One* classical sign will seldom fail us, *i.e.*, the ascent of the tumour with the larynx and trachea on swallowing. This sign only becomes indefinite or entirely absent if the diseased

gland is so firmly adherent to the adjacent structures that it actually prevents the ascent of the trachea.

Further evidence is afforded by palpation, because this demonstrates with more or less certainty the connection of the tumour with the thyroid gland. The relation of these tumours to the sterno-mastoids is not at all constant. They may project forwards between them, or glide under them towards the sides of the anterior triangle, or the muscles may be spread out flat over them.

The most common disease of the thyroid gland, a tumour in the wide significance of the term, is **goitre.**

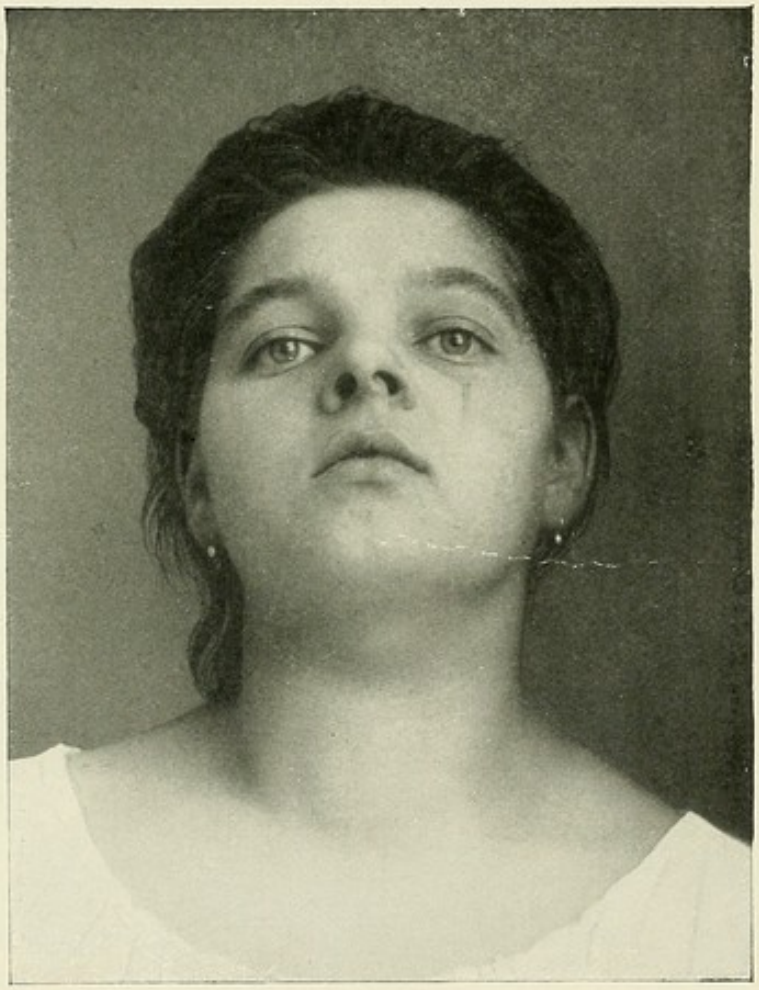

FIG. 67.—Simple hyperplasia of the thyroid gland ("full neck") in a chlorotic girl.

The connection between *goitre* and the *thyroid gland* appears to us to-day to be obvious. But up to the middle of the nineteenth century the terms *bronchocele* and *air-goitre* (Luftkropf) prevailed in German literature, thus showing the predominance of imagination over observation. At the end of the eighteenth century the theory was maintained that a goitre was a hernia of the air-passage, and the term bronchocele still persists in English as a vestige of this error. In the Middle Ages and up to within the last hundred years there was a general confusion between goitre and lymphatic gland enlargement. A vestige of this error still remains in the use of the term "struma" for "tubercle," which was formerly common in France and still is in vogue in England.

I have called a goitre a tumour in the "widest sense of the term," because most goitres are not tumours in the pathological sense, but are processes of hypertrophy, hyperplasia and degeneration, often associated in striking confusion with changes which possess certain characteristics of tumour formation. The external appearances of the goitre afford some indications of all this. However, to ascertain *which* variety of goitre we are dealing with is not a mere whim, but is a matter of therapeutic significance.

(1) THE EXTERNAL APPEARANCES OF GOITRE.

We have in the first place to distinguish between (*a*) the *diffuse*, and (*b*) the *circumscribed* or *nodular* goitre.

(a) Diffuse Goitre.

The **diffuse goitre** (fig. 68) imitates in considerable measure the horse-shoe shape of the normal thyroid gland, and is of fairly uniform consistence throughout. If it feels soft, like a normal thyroid gland, and there are no accompanying vascular symptoms, the case is one of simple *hyperplasia*, without any other histological changes, except, perhaps, a slight enlargement of the vesicles. Such a goitre hardly grows beyond three times the size of the normal thyroid gland. It usually occurs in young, and especially chlorotic, girls in the period of adolescence. If the goitre is rather firm, and feels some what nodular, the case is one of *diffuse colloid goitre*, in which the vesicles are greatly dilated, the colloid material increased, and under pressure. If the tumour is softly elastic, compressible, and has an expansile pulsation, and if on auscultation all kinds of blowing murmurs, appreciated by the hand as thrills, are heard over the large thyroid vessels as well as over the goitre, the case is one of *vascular goitre*.

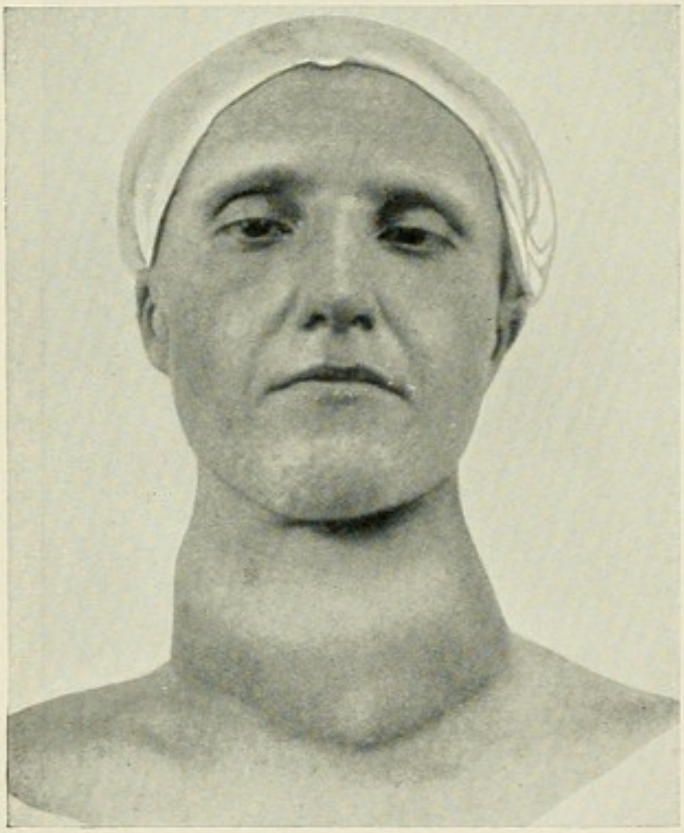

FIG. 68.—Diffuse colloid goitre.

It may be noted here that the superior thyroid artery can easily be felt on the external surface of the thyroid cartilage, whereas the inferior thyroid artery retires from the finger, owing to its deep situation. In examining for pulsation, one must be careful not to mistake the beating of the carotid artery for expansile pulsation, and, of course, care must be taken not to look upon a burrowing abscess beneath a forwardly displaced carotid artery as a pulsating goitre—as has actually occurred.

If we are confronted by a vascular goitre, we should instinctively look for the other symptoms which go to make up "**Graves's disease.**"

If the whole symptom-complex is well pronounced—a pulsating goitre, exophthalmos, tremor, and tachycardia—even the most inexperienced can have no doubt about the diagnosis. The exophthalmos, more than anything else, would indicate the diagnosis to him.

If there be leisure for further diagnostic exercises, a search may be made for the rarer symptoms. As far as the eyes are concerned, some of these are due to mechanical causes, and others to muscular weakness—for instance, the width of the palpebral fissure, the fixity of the lids (Stellwag), deficient movement of the upper lid on looking upwards and downwards (Gräfe), insufficiency of convergence (Möbius). Genuine ocular paralyses, which are occasionally met with, must not be confused with these symptoms.

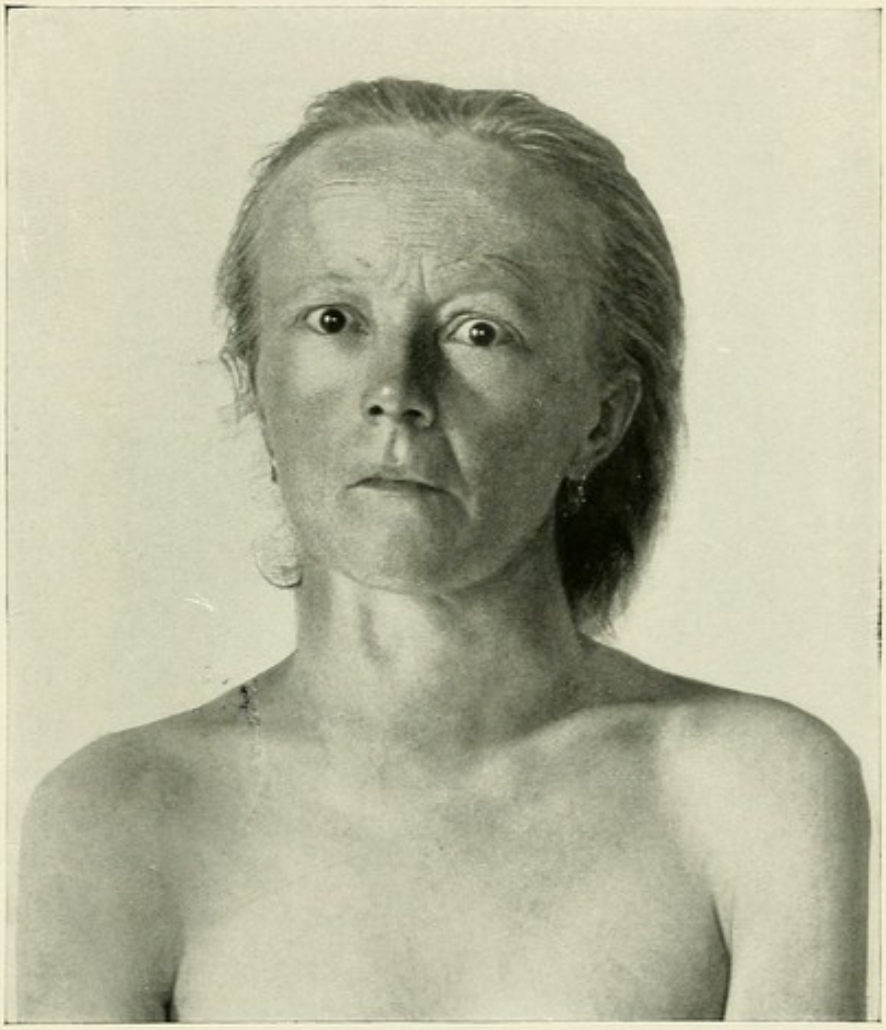

FIG. 69.—Early stage of Graves's disease.

Is there anything in the form of the goitre in favour of, or against, Graves's disease? This evidence is only circumstantial. In Graves's disease the goitre is diffuse and vascular (figs. 69 and 70). Histologically a diminution of colloid substance can be demonstrated, and a proliferation of epithelium. But any variety of goitre may become "Graves's disease" secondarily. We must therefore not conclude that a case is not Graves's disease because the patient has a nodular goitre.

Easy as the diagnosis is, when the classical triad of symptoms is present, it may be extremely difficult when the disease runs an

irregular course. The clinical picture presented by the disease is, however, more frequently atypical than typical, and a large number of subordinate varieties have been described—to the great confusion of students, and even of experts. If we rigidly cling to the view that hyper-thyroidism is the cause of most of the symptoms of Graves's disease, it is not always easy to distinguish between the normal and pathological, because transitory anomalies of function are conceivable in the thyroid, as in other glands. We should therefore limit the designation of Graves's disease to symptoms of hyperthyroidism which remain permanent.

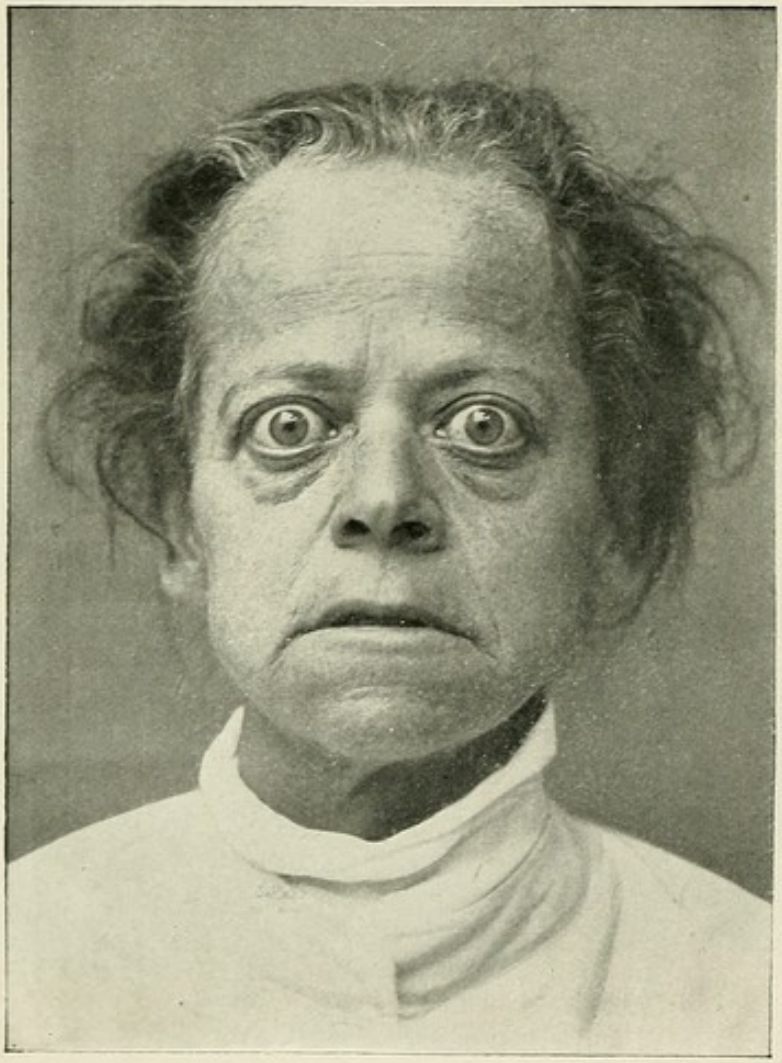

FIG. 70.—Pronounced Graves's disease.

The clinical picture remains incomplete in many cases for months, and even for years. The patient complains of emaciation, increasing muscular debility, tremors, slight perspirations, unexplained diarrhœa, long before any exophthalmos indicates the diagnosis to the practitioner. If such a patient, when completely at repose, presents strong pulsation of the carotids, it is as definite an evidence in favour of Graves's disease as a normal amplitude of the carotid pulse would be against that diagnosis.

The instability of the psychical equilibrium of the patient is frequently so predominant that the case may be treated for years as one of neurasthenia or hysteria, until a careful examination reveals the cause of the nervous disturbances. In other cases, the cardiac symptoms are the most predominant, and the goitre itself attracts little attention, as long as no other symptoms of Graves's disease have appeared. Whether these cases should be regarded as thyro-toxic goitrous hearts, or as examples of the "forme fruste" of Graves's disease is merely a matter of terminology.

It is obvious that we must not confuse circulatory disturbances, which are caused by the mechanical effect of the goitre, with cardiac disturbances, which are of toxic origin. I admit that the distinction is not always easy. Finally, one must not conclude that every case of prominent eyes is one of Graves's disease. Prominence of the eyeballs may be a family peculiarity. In order to establish the diagnosis of Graves's disease, it is necessary to show that the previous position of the eyes was normal, for which purpose we can derive assistance from earlier photographs of the patient.

The examination of the blood is of interest for the diagnosis of Graves's disease, although this is rather a matter for the laboratory than for the consulting room. According to Kocher and others, Graves's disease is characterized by a decrease in polynuclear leucocytes, an increase of lymphocytes, large mononuclears, and eosinophiles, and by a decrease in coagulability.

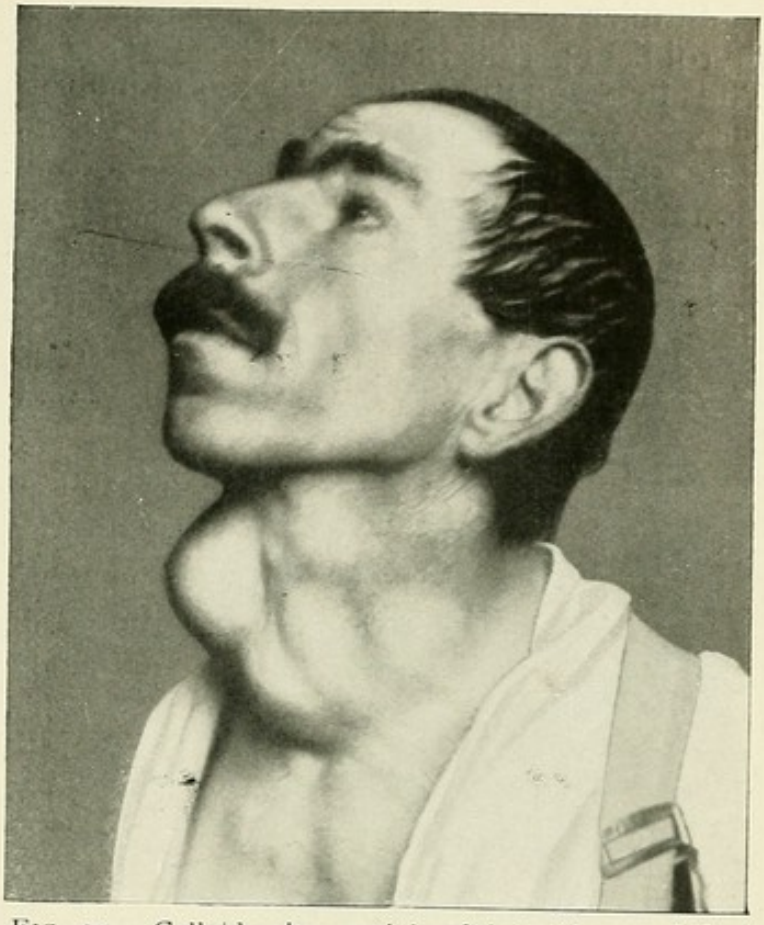

FIG. 71.—Colloid goitre, mainly of right side, consisting of separate lobules.

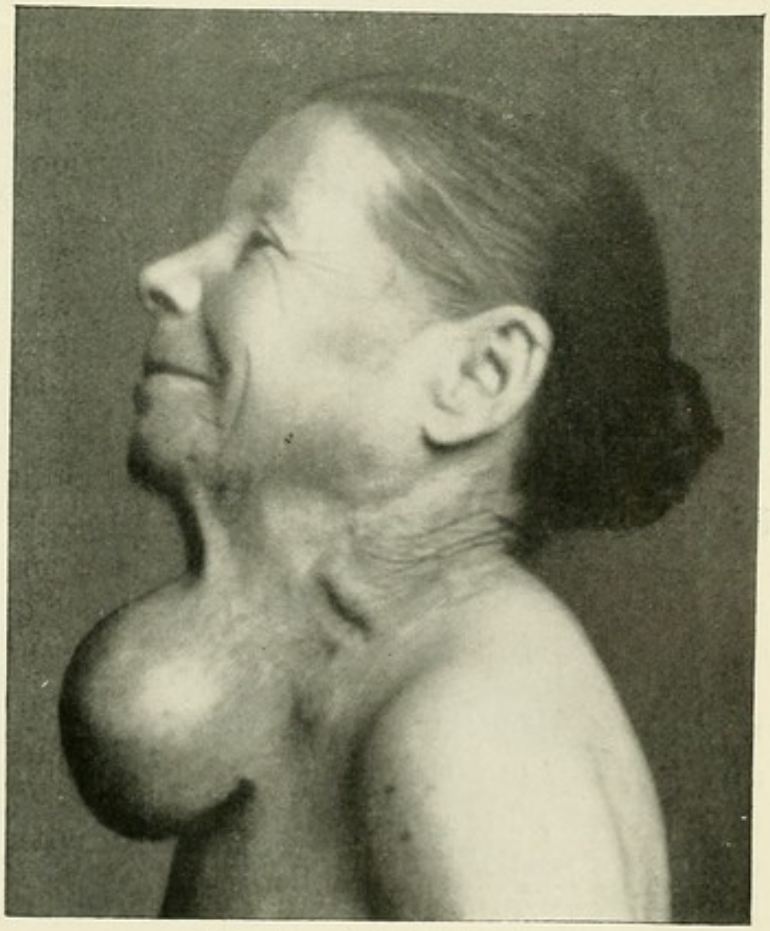

FIG. 72.—Pendulous goitre.

Similar changes occur in ordinary goitre, and even in hyperthyroidism; but in the latter the coagulability is often increased. The interpretation of the blood-picture therefore requires great care. Our own experience seems to show that more importance attaches to a pronounced increase in the antitryptic content of the blood, but the demonstration of this cannot be expected from the general practitioner. Nevertheless, the employment of this test is desirable in doubtful cases, because of the prevailing fashion of diagnosing "Graves's disease" on insufficient evidence. Not every goitrous individual who trembles occasionally is the subject of Graves's disease.



FIG. 73.—Cystic goitre.

Recent researches have shown that certain relations exist between Graves's disease and changes in the thymus; but no useful assistance from the point of view of diagnosis has hitherto followed therefrom. Still less has this followed from the more or less hypothetical relations which have been stated to exist between the thyroid and other glands, with internal and external secretions.

If an elderly person is suffering from symptoms of Graves's disease, we should always inquire whether iodine has been taken. The rapid disappearance of goitrous tissue after iodine treatment leads to a flooding of the system with thyroid gland products, which manifest themselves, especially in old people, by symptoms of Graves's disease, persisting for months.

(b) Circumscribed Goitre.

In the circumscribed goitrous degeneration of the thyroid gland, **nodular goitre**, the entire parenchyma is more or less damaged—at any rate histologically—but the appreciable changes are limited to a few places which grow into nodules. These nodules are at first composed partially of tissue rich in colloid material, and partially of hyperplastic and adenomatous-like proliferation; they may secondarily liquefy and become cysts.

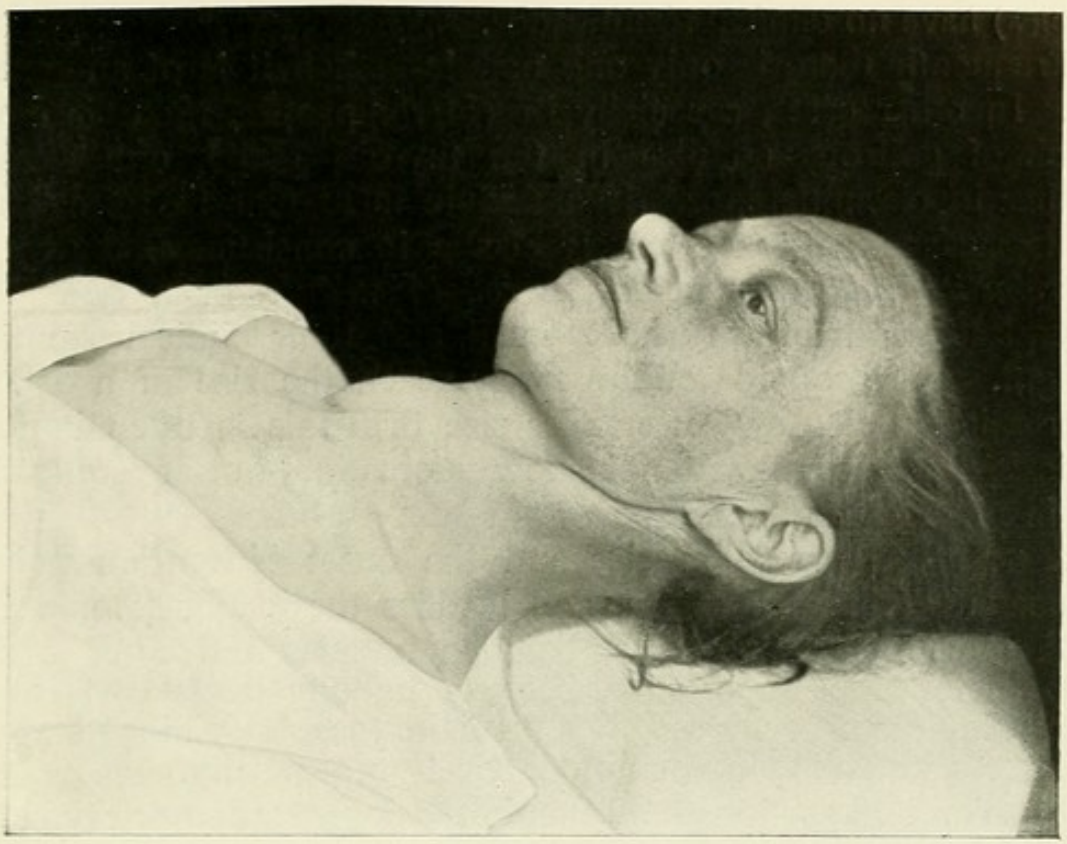

FIG. 74.—Sunken goitre with relaxed sterno-mastoids.

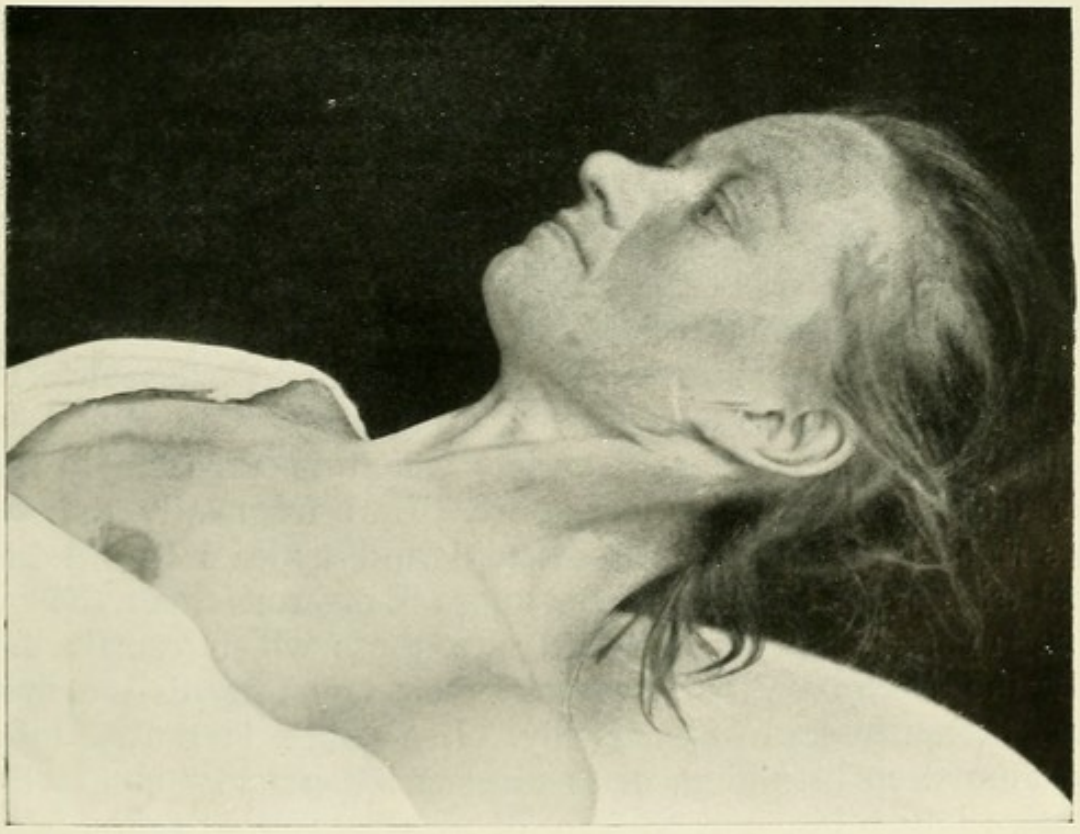

FIG. 75.—Sunken goitre pressed deep down by contraction of sterno-mastoid.

The cysts which arise from dilatation of individual vesicles (giant vesicles) have no clinical significance.

Frequently there is only one nodule—when it is of an extensive size. In other cases, especially in elderly people, there is a whole bunch of goitrous nodules in the thyroid gland, one exceeding another in circumference. If a nodule is regular in form, smooth on its surface, softly or tensely elastic in consistence, it may be a *hyperplastic (follicular) nodule, a colloid nodule*, or a *cyst*. Purely hyperplastic nodules are usually small, and their clinical significance is slight. Pure colloid nodules rarely reach the size of a fist. The differentiation of a cyst of smaller size than this is often impossible clinically, because they do not show fluctuation, but are softly elastic, just like colloid nodules.

A sudden increase in size and the onset of tension points to hæmorrhage within a cavity, and justifies the diagnosis of a cyst.

The distinction, however, between nodules and cysts is not of great therapeutic importance, because nobody treats cysts now by puncturing them or by opening them in the old-fashioned way, like an abscess, and allowing them to shrivel up gradually.

Firm or hard portions indicate fibrous degeneration or calcification, as can be easily demonstrated by Röntgen rays. This change may occur both in colloid nodules and in cysts, especially in old people.

There is an intermediate form between the diffuse and nodular goitre, in which the whole thyroid gland has become converted into a conglomeration of small colloid nodules.

(2) POSITION OF THE GOITRE.

The *point of origin* and the *position of the goitrous nodule* have their significance. It usually arises from one of the lateral lobes, and but seldom from the isthmus, even when it appears to be just in the middle of the throat. The sterno-mastoids cause it to follow this route. If it goes on growing in this position, it will finally become a *pendulous goitre*, a variety which is exceedingly rare in these days of operations for goitre. Less frequently the nodule glides right under the sterno-mastoid and appears in the inferior lateral triangle of the neck. But more dangerous than the goitres which make their way outwards are those which remain hidden under the sterno-mastoid, or make their way towards the aperture of the thorax instead of externally. If a goitre is drawn into the thorax on deep breathing, or is displaced therein by contraction of the sterno-mastoids, it is spoken of as a *wandering goitre*, a *sunken goitre, goitre plongeant* (figs. 74 and 75). It is quite easy to make

such a goitre evident by swallowing, or making the patient droop his head so as to relax the sterno-mastoids. A goitre which is visible and palpable in the neck, but whose lower extremity is so far within the thorax that it cannot be reached except by means of the manœuvre just mentioned, is called a *deep goitre*. A goitre situated mainly or entirely in the thorax is called an *intra-thoracic retro-sternal goitre*. We shall discuss this in connection with mediastinal tumours. The extent of a deep or intra-thoracic goitre within the thorax can be fairly well estimated by *percussion*, and quite accurately determined by a *skiagram* (fig. 111). Diffuse goitres sometimes penetrate behind the trachea (*retro-tracheal goitre*) or behind the œsophagus and pharynx (*retro-visceral goitre*) and cause the posterior pharyngeal wall to bulge like a retro-pharyngeal abscess. We should especially think of these varieties if the difficulties of breathing and swallowing are not clearly explicable by the palpable part of the goitre.

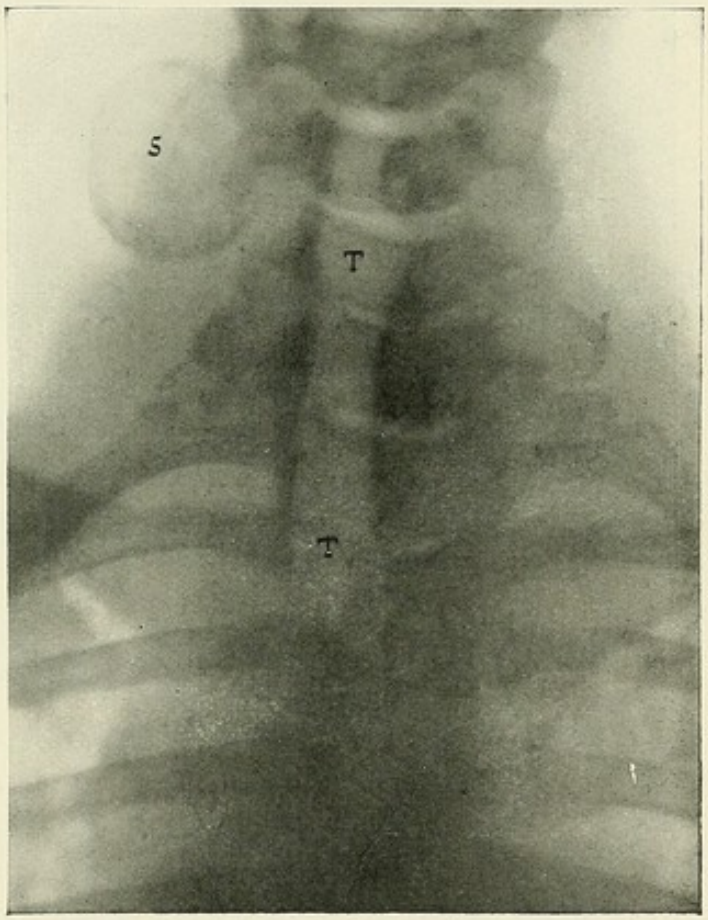

FIG. 76.—Skiagram of goitre (posterior view). S = calcified cyst. T-T, skiagram of trachea. Slight concavity on right.

If both sides are affected, it is important for the purpose of operation to know definitely from which side the trouble mainly arises. As a rule it is not the side which is blamed by the patient, and frequently by the beginner also; in other words, not the side which is the more projecting. Alternate pressure on both sides of the goitre, and especially the raising of the one lobule and the other from the trachea where this is feasible, will very often show whence the difficulty comes. A laryngoscopic examination, of course, yields more definite information. It not only shows the lateral displacement, the twisting and bending of the larynx, but also the convexity of one tracheal wall or the flattening of both walls. A skiagram demonstrates the entire condition of the trachea even more clearly, and one should be taken in every case which is

not quite clear. It may then be possible to tell the patient before the operation that it is not the externally visible goitre which is to be removed, but a much more dangerous one, which is concealed.

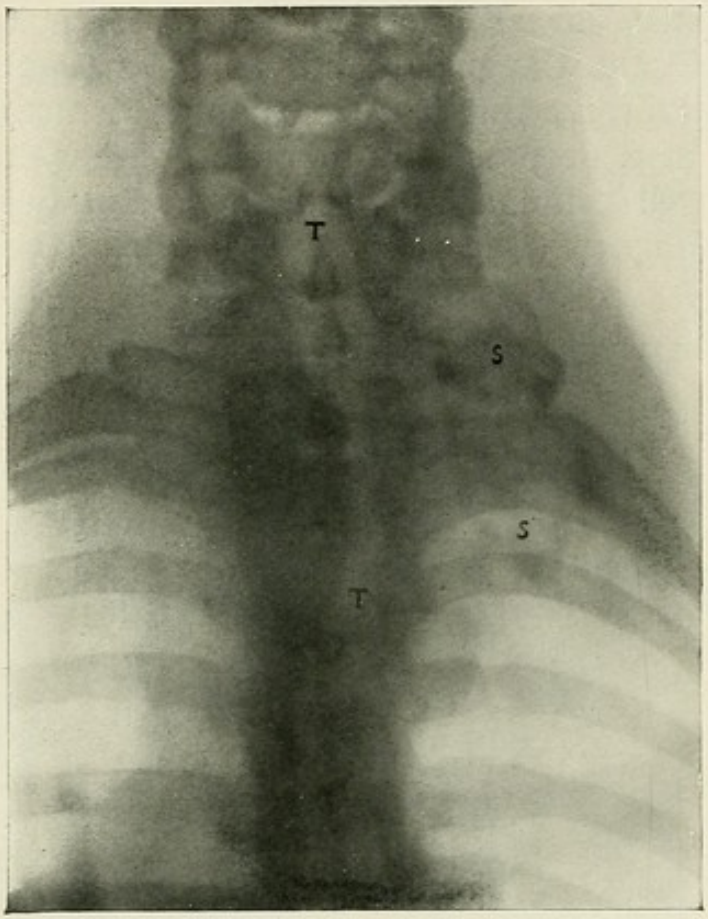

FIG. 77.—Skiagram of goitre. Severe compression of trachea on left. S = calcified colloid nodule on right.

In discussing the anomalous positions which goitres may occupy we have hitherto assumed that the abnormally placed goitre is directly connected with the thyroid. As a matter of fact, this is generally the case ; but the goitre may have developed in an accessory thyroid gland. These are termed *secondary goitres*, as suggested by Wolfler. They are called *genuine* if they have no anatomical connection with the main gland, and *false* if they are connected with it by means of a bridge of tissue. Lingual and tracheal goitres are always secondary goitres, sometimes also the intra-thoracic variety, but the other forms, such as retro-visceral, are rarely so.

(3) COMPLICATIONS OF GOITRE.

HÆMORRHAGE, INFLAMMATION AND MALIGNANT DEGENERATION.

The *complications* of goitre possess diagnostic interest as well as the condition itself. These complications consist of *hæmorrhage*, *inflammation* and *malignant degeneration*.

(a) Hæmorrhage.

A patient suffering from a colloid or cystic goitre may suddenly, or sometimes overnight, be seized with rapidly increasing dyspnœa, combined with a feeling of tension in the goitre and visible enlargement thereof, with moderately severe pains radiating towards the jaw, back of the neck, ear and shoulder. These symptoms may come

without any external cause, or after an injury, or congestion of the circulatory system through coughing or vomiting. They reach their maximum in a short time, then they remain at a standstill, and subsequently decrease gradually. This assemblage of symptoms points to **hæmorrhage**. The goitrous nodule is found to be tensely stretched, even hard, somewhat painful on pressure and, if not of great circumference, quite movable. This mobility enables us to exclude forthwith any inflammatory process or malignant goitre with similar symptoms.

A colleague of mine watched his own goitre in a mirror enlarging until severe dyspnœa set in. He made the diagnosis and drove off at once to the surgeon. Meanwhile the hæmorrhage had attained its maximum and no interference was required.

I once operated on a young girl whose goitre increased during a pleasant evening's walk from unnoticeable dimensions to that of a medium-sized apple. A little morphia calmed the dyspnœa, and the operation which was done immediately showed that the nodule was tensely filled with blood.

On another occasion I was consulted about a young girl with malignant goitre. The diagnosis had been based by an experienced practitioner on its hard consistence, radiating pains and recent increase in growth. The nodule was, however, too movable to attribute the radiating pains to malignant goitre, and further the pains and enlargement had come in attacks within the last two months. The case was therefore one of cystic goitre with hæmorrhage, a diagnosis confirmed by the operation.

(b) Inflammation.

If the swelling and difficulty in breathing and swallowing do not reach their maximum in the course of minutes or hours, but only after a day or two, and if there exist also severe pain on pressure, sharp local and radiating pains, adhesion to the skin and the deeper organs, and more or less high fever from the beginning, the case is not one of hæmorrhage into the goitre, but of inflammation thereof—an **inflamed goitre**. If the skin is œdematous and red, and fluctuation is present, or if pus bursts through eventually—rarely into the trachea or pharynx—the state of affairs is obvious.

Timely intervention by operation nowadays renders it impossible for a suppurating goitre to burst into the trachea; but even without operation this is a rare contingency. But on the other hand the pressure of the goitre on the trachea, or the inflammatory œdema of the laryngeal mucous membrane, may lead to dangerous dyspnœa or even to suffocation.

Peter Frank, who wrote on this subject a century ago, describes the case of a 7-year-old lad who was nearly suffocated by a suppurating

goitre. The village quack said that a nerve in the vicinity of the larynx was torn and that a fatal result was unavoidable. The mother made a more correct diagnosis, and she implored the local barber to open the abscess between the swollen veins. The desired result followed.

A practitioner of the middle of the last century describes how he allowed a young man to die from gradual suffocation of an inflamed goitre, bemoaning his sad fate, but without the energy to venture on the life-saving incision.

An inflamed goitre is always of a metastatic nature, and comes on especially after scarlet fever, typhoid, or puerperal fever, but also after trifling derangements of the trachea and œsophagus—sore throat or intestinal catarrh, &c. This fact may be important in differentiating between this condition and hæmorrhage. The bacteriological examination of the pus has made it possible to establish the diagnosis of a recent attack of typhoid.

If the swelling has arisen in the course of a catarrhal affection of the respiratory tract, there may be some doubt about the diagnosis. The infection would point to an inflamed goitre; the increased pressure through coughing would suggest hæmorrhage. No importance is to be attached to a slight rise in temperature, because this may occur in hæmorrhage, quite apart from the catarrh. The differentiation depends upon the whole course of the symptoms and upon the local findings. If the tumour is immovable and there is considerable local heat and pain on pressure, the case is one of inflamed goitre, notwithstanding that the other symptoms may be in accord with the diagnosis of hæmorrhage.

The *normal* thyroid gland may inflame just as a goitre. This usually occurs after infectious diseases, especially typhoid, malaria, influenza and articular rheumatism, but may occur as a *clinically primary* disease. This is not an inflamed goitre, but a *thyroiditis*—a condition insufficiently recognized. Just as in the case of an inflamed goitre, this does not always lead to suppuration, but may resolve in the course of a few days. This is the form which follows acute rheumatism, malaria and influenza, and is also the clinically primary form. It is best termed, as Mygind suggested, *simple thyroiditis*. It is not always easy to decide whether there is any suppuration, and if spontaneous resolution occur it does not by any means signify that there was no pus.

In a case reported by Breuer as one which ran its course apparently without suppuration, I found at the autopsy, seven months afterwards, a small abscess with inspissated staphylococcal pus.

Suppuration can as a rule be diagnosed by attention to the temperature chart and to the increasing adhesion of the gland to the adjacent organs, which circumstances show the necessity for early surgical intervention.

Sometimes the inflammation travels over the whole gland in the course of a few weeks, and finally attacks the pyramidal lobe, when the inflammation of the lateral lobes has gone down. Recurrences, with intervals of months or years, take place but rarely.

There is one important differential sign, in the initial stage, between an inflamed goitre and thyroiditis, apart from the history of the goitre. This depends upon the fact that the swelling in an inflamed goitre is usually limited to one individual lobule, but nevertheless may attain a considerable circumference, whereas in thyroiditis a whole lobe, if not the whole gland, is affected, and still the swelling does not exceed the size of a goose's egg. The extension of the inflammation over the whole of the thyroid gland indicates thyroiditis.

(c) Malignant Degeneration.

Inflamed goitre and **malignant goitre** are occasionally mistaken for one another, and errors of diagnosis are made in both directions. I have seen cases of indefinitely outlined swellings of the thyroid, with redness of the skin and pyrexia, and with rapid growth, declare themselves as sarcomata at the operation. On the other hand a chronic inflammation in an old hard goitrous lobule may present all the clinical signs of malignant growth, including even metastases and a fatal result. It is quite impossible to distinguish between those rare conditions **syphilis** and **tubercle** of the thyroid on the basis of the clinical symptoms. If the clinical course, the history, and a positive Wassermann reaction suggest syphilis, and if the symptoms are not urgent, a trial of specific treatment is indicated. Otherwise, any suspicion of malignancy demands operation without delay. Hitherto, tubercle has been first discovered at the operation, or more correctly speaking has been recognized on histological examination, there having been no clinical symptoms.

A malignant goitre can usually be confidently diagnosed from the following signs:—

(*a*) An unexplained steady growth of a goitrous nodule in a patient over 30 years of age.

(*b*) The onset of hoarseness not accounted for by the size of the tumour (paralysis of the recurrent laryngeal).

(*c*) Radiating pains towards the jaw, ear, back of neck and shoulder without any acute inflammatory symptoms or signs of hæmorrhage.

(*d*) Diminution of mobility, irregularity and unevenness in form, and hard consistence of the goitre.

As long as the malignant degeneration is limited to the interior of the goitrous lobule, the unexplained growth is its only striking

feature. There is neither hoarseness nor radiating pain. Nothing short of the microscope can yield a positive diagnosis.

I once removed a malignant goitre in such a case, thinking it was an innocent growth. Unfortunately no microscopic examination was made, but a recurrence of the cancer first notified me of the error and enforced the lesson that every goitre removed should be examined for malignancy.

On the other hand, a contracting cancer and even a sarcoma, in consequence of early adhesions with adjacent structures, may cause hoarseness, radiating pains, possibly also narrowing of the pupils and other signs of sympathetic paralysis, while the growth itself has not yet attracted the attention of the patient and may really require looking for.

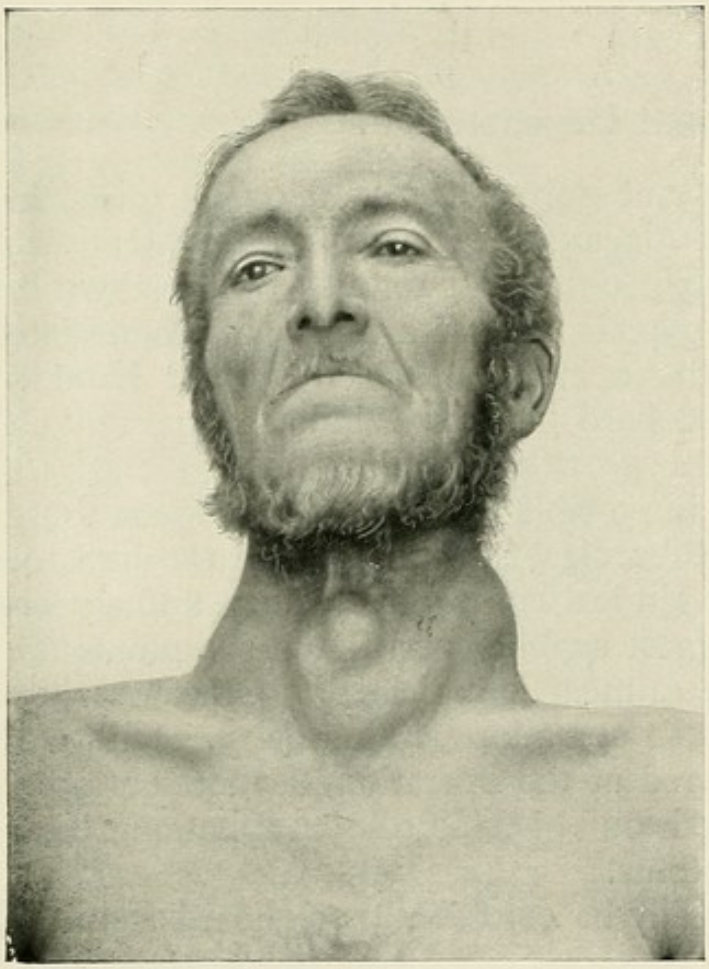

FIG. 78.—Malignant Goitre (from the Surgical Clinique at Berne).

Operation must never be delayed until all the signs of malignancy are present, because the aim is not diagnosis but cure. The prognosis in malignant goitre is only favourable as long as the growth is within the capsule of the goitre, and therefore must be suspected rather than diagnosed.

The distinction between *sarcoma* and *carcinoma* need not detain us, because even the interpretation of the histological appearances is not always easy. The differentiation between the various forms of carcinoma appears to be of even less practical importance so far. But it should be observed that the adenomatous variety (the "proliferating goitre" of Langhans) runs a remarkably slow course, despite the presence of all the signs of malignancy.

On one occasion I declined a further operation on a female patient suffering from paralysis of the recurrent laryngeal, with extensive adhesions and thrombosis of the veins of the neck, and informed the friends that the course of the disease would be rapid. The patient, however, lived for nearly ten years in great suffering.

The *metastatic growths* from thyroid gland tumours have certain special characteristics which are also of diagnostic interest.

Colloid goitres, which are clinically and histologically apparently innocent, sometimes give rise to metastases, especially in the bones, with a structure partly composed of normal thyroid tissue, partly of colloid goitre and partly of cancer.

Sometimes the metastases of definite thyroid gland cancers consist of normal thyroid tissue by way of atavism.

All forms of cancer of the thyroid have a predilection for metastases in the osseous system.

Growths independent of the thyroid gland which occur in the anterior triangle of the neck are rapidly disposed of. They are *branchial cleft cysts*, or, when situated in the median line in front of the thyroid cartilage, they are cysts of the *thyro-glossal duct*. We shall discuss these in connection with the other cysts of the neck.

B.—TUMOURS OF THE SIDE OF THE NECK AND ITS VICINITY.

The **tumours** which are found at the **side of the neck** differ widely in character, and in order to avoid repetition we shall include among them new growths under the sterno-mastoid and those which occur in the submaxillary and parotid regions.

(1) ENLARGEMENT OF THE LYMPHATIC GLANDS.

In the first place we must be quite sure whether we are not dealing with **enlargement of the lymphatic glands.** These always declare themselves by their number and their arrangement in groups. If a tumour, which is apparently single, is really made up of separate lumps or nodules, we must think of a mass of adherent glands. Appreciable swelling of one individual gland may occur, both in tubercle and in secondary malignant degeneration, but is not common in either.

If we recognize the tumour to be of glandular origin, it may be due either to inflammation, or to new growth, or to the intermediate condition of malignant lymphoma.

I am not treating now of acute inflammation of the cervical glands. Their behaviour is similar to that of the abscesses to which they give rise, to the description of which the reader is referred.

If a child suffering from eczema or a chronic mucous membrane catarrh has enlarged glands in the area drained by the corresponding lymphatics, the diagnosis is simple **lymphadenitis**. We must assume that the glands have been affected by the constant introduction of mildly virulent organisms or by their toxins.

Formerly, simple and tubercular lymphadenitis were included

under the one term "*scrofula*." To-day this term has no meaning, unless we reserve it to express that general state of lowered resistance which is due to hereditary causes (alcohol and syphilis), and to unfavourable hygienic surroundings, and which prepares the soil for various micro-organisms. If the tubercle bacillus be among these—a very frequent circumstance—then scrofula becomes tuberculosis. Adolf Czerny and his school apply the term "exudative diathesis" to any condition wherein there is hyper-sensitiveness to infective organisms, and they only speak of "scrofula" if a tubercular infection is super-added to this diathesis.

Even the beginner knows that a chain of nodules which are partly elastic and movable, partly hard and infiltrated or even fluctuating, are tubercular. Scattered scars indicate to him that the disease is not recent, and that there is no reason to entertain the idea of malignancy (fig. 79). If there be but little pain, and the mobility is free, and the consistence is elastic with no sign of involvement of the skin despite their long existence, we know that the glands are of the non-caseating, or of the very slowly caseating variety. If there be definite pain on pressure, with only slight mobility, and the superjacent skin can only be picked up with difficulty, it shows that caseation is proceeding and that peri-adenitis has begun. If the skin has become red, and the glands are fixed and their firmness is replaced by a softly elastic or fluctuating consistence, there can be no further doubt about their suppuration.

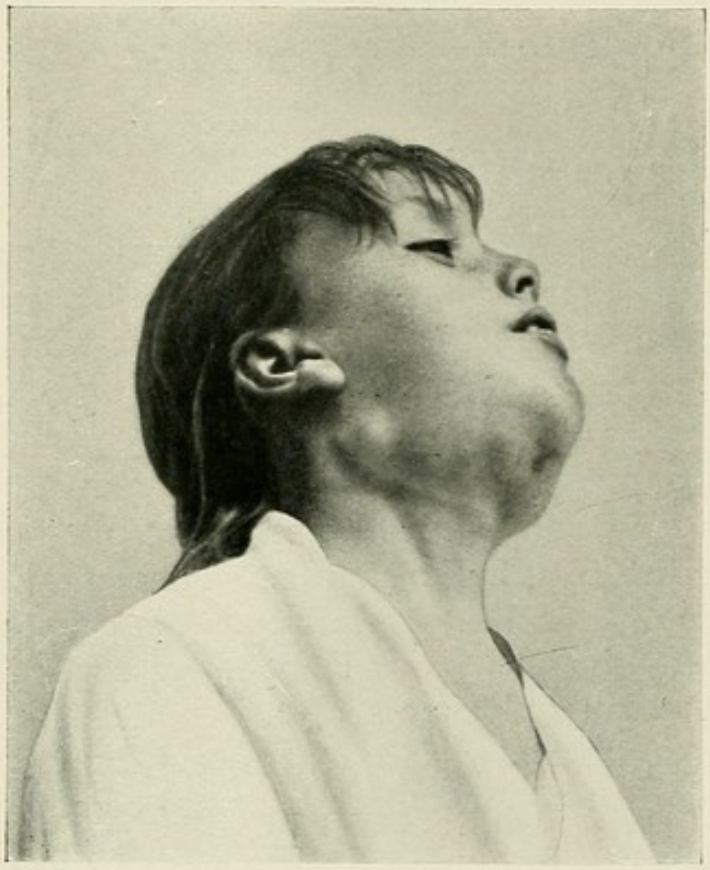

FIG. 79.—Tubercular lymphoma.

If a patient who has hitherto been free from glands, acquires a bunch of them on one side, within a short time, one must think of the possibility of a syphilitic infection, and a primary sore must be looked for in the area drained by the corresponding lymphatics, especially in the mouth or nose.

Sometimes it is difficult to distinguish between tubercular glands and the large glands which occur in the course of such lymphatic

diseases as leukæmia and lymphadenoma. **Leukæmic** changes are very easy to recognize because the glandular enlargement is overshadowed by the signs of leukæmia—pallor, debility and the hæmorrhagic diathesis—and the examination of the blood sets aside any doubt.

Pseudo-leukæmic glandular hyperplasia, i.e., malignant lymphoma (lymphadenoma or Hodgkin's disease) is equally easy to recognize if all the glandular situations are affected, if the liver and spleen are enlarged and the patient has a cachectic appearance, with blood not typical of leukæmia.

We adhere here to the usual view that pseudo-leukæmia is a clinical unity, despite the fact that it has been shown that it graduates into true leukæmia on the one hand, and sarcomatous processes on the other. The histological differentiation of one type wherein the glands are converted into a kind of granulation tissue (Sternberg's variety) and of another type wherein there is hyperplasia of the lymphadenoid tissue (Cohnheim's variety) is, so far, of no diagnostic interest clinically, because it is not possible to distinguish the two, with any certainty, and because their course is the same.



FIG. 80.—Lymphadenoma (pseudo-leukæmia). Early stage.

Finally, there are some rare cases wherein everything points to Hodgkin's disease, but the bacteriological examination declares for tubercle. Further, pseudo-leukæmia may occur in tubercular subjects, and tubercle may become engrafted on pseudo-leukæmia. Observations such as these have given rise to the suggestion that pseudo-leukæmia is fundamentally a tubercular disease. The probability is that it is a chronic infection, *sui generis*, the organism of which (antiformin-fast bacillus of Fraenkel-Much) is morphologically similar to the tubercle bacillus, but is clinically more malignant. The view that Hodgkin's disease, at any rate Sternberg's type, is caused by an attenuated form of the tubercle bacillus is refuted by its clinical course.

Tubercular glands are rarely met with, equally developed in all glandular situations, as is the case in lymphadenoma. They generally show some points of tubercular softening if the trouble is widespread.

In the initial stage when the neck alone is affected, and therefore the extension of the glandular enlargement offers no points of differentiation, the diagnosis may be indeed difficult. Our opinion must be based on the size and condition of the glands and their relation to the surrounding parts. If they are of medium size, soft and immovable, it is, unfortunately, impossible to dogmatize about the diagnosis, because a non-suppurating form of tubercular lymphoma cannot at this stage be distinguished from the soft variety of malignant lymphoma. In such cases the latter is always first recognized by its generalization, or by excising a portion for examination.

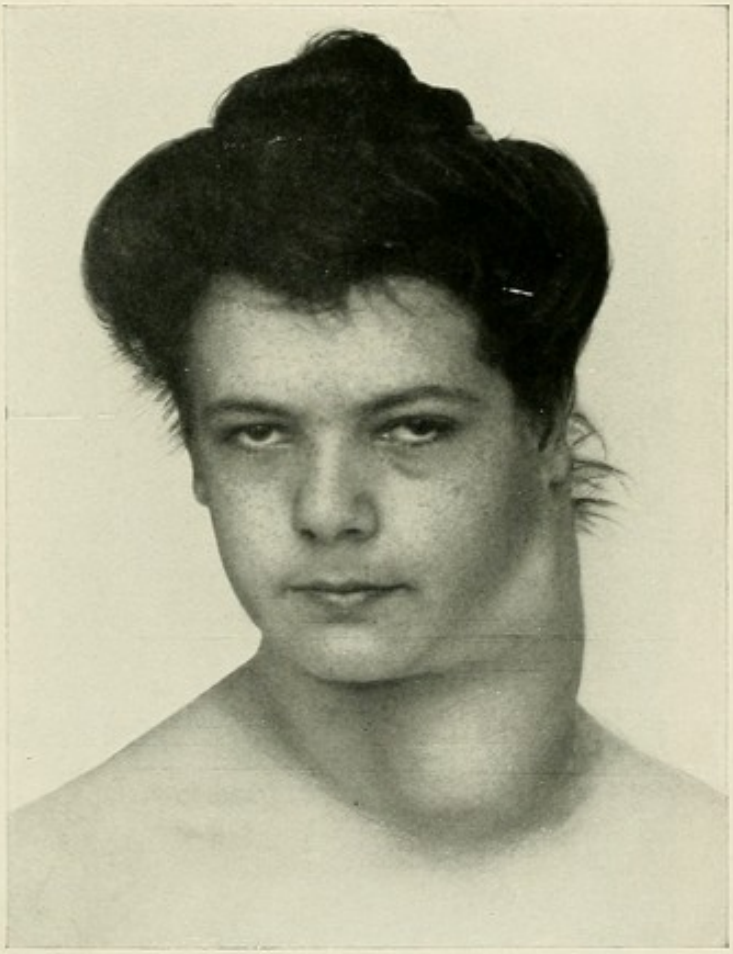

FIG. 81.—More advanced case of lymphadenoma, but still confined to the neck.

It is quite different if numerous movable, but hard, glands are present. Such a condition indicates the hard form, or rather the hard stage of Hodgkin's disease. Tubercular glands only exhibit the pronounced hardness, which the latter disease occasionally manifests, after a recent inflammation. But in such cases signs of peri-adenitis, and especially of adhesions with the surrounding tissues, are present.

It must not be supposed that the glands cannot become pretty fairly adherent in lymphadenoma. Indeed, adhesions do occur, but they are not accompanied by as much peri-adenitic infiltration of the tissues as occurs with caseating tubercular glands. Although the glands may be very hard in lymphadenoma their outlines can be distinctly felt, and this serves to differentiate it from tubercle. The glands are also more prominent, so that the whole aspect resembles a caricature of tubercular adenitis. These considerations suggested a diagnosis of malignant lymphoma in fig. 80, although the upper

glands only were affected. A small portion excised for examination confirmed this diagnosis. I have even seen diffuse necrosis—not caseation—in cases of Cohnheim's type, as in some of the glands depicted in fig. 81, in which case tubercle was excluded by microscopic examination and animal inoculation.

Blood examination affords but little information. It merely reveals the signs of an ordinary moderately severe anæmia, possibly also a relative increase in the lymphocytes. There is one rather rare symptom which is in favour of lymphadenoma (and leukæmia), and against tubercle, as showing that the bone marrow participates in the disease, and that is, severe pain on percussion over the sternum.

The stress laid upon the differential diagnosis from tubercle is justified by the great difference in the prognosis of the two diseases.

Malignant enlargement of glands is especially indicated, when they are hard, contract early adhesions to surrounding parts, and cause radiating pain. It is often very difficult to demonstrate the primary tumour, because it frequently bears no relation in size to the extent of the glandular enlargement and may, therefore, lie in a very concealed situation.

I once found a small carcinoma at the hinder end of the middle turbinate bone (fig. 82), as the primary growth in a case of considerable enlargement of the glands at the side of the neck. In another case the primary growth was at the posterior border of the septum nasi.

A growth in the neck can only be regarded as primary, if a careful search has excluded cancer from the various sites of the internal mucous membrane which are usually attacked.

If the cancerous infiltration has gone beyond the glands, and has penetrated the skin and become secondarily infected, it is very liable to be mistaken for a chronic inflammatory process (fig. 83).

On the other hand, there are certain very rare cases wherein cancerous glands have an elastic consistence and are very late in contracting adhesions. Sometimes it is quite impossible, even at the operation, to distinguish these from hyperplastic tubercular lymphomata.

(2) TUMOURS WITH LIQUID CONTENTS.

If we have excluded disease of the lymphatic glands, and at the same time recognize that the growth is a tumour in the widest sense of the term, further deductions must be based primarily on its *consistence*.

If a tumour at the side of the neck is soft or elastic in consistence, or if it fluctuates, we must conclude that its contents are fluid. We can only be misled by a *lipoma*, which also has a soft or elastic consistence, but subcutaneous lipomata may be recognized by their lobular structure and the deep subfascial lipomata are too rare to merit early consideration.

The *liquid contents of the tumour* may consist of *lymph, blood* or the *product of an epithelial secretion.* The liquid is either in numerous small vesicles or within one large cavity, or both conditions may be combined. This already gives rise to a large number of varieties, which are increased by the circumstance that the blood within these tumours may be either arterial or venous.

The variety is, however, not so great, if we leave a few rarities out of account and limit ourselves to a small number of typical conditions, whose diagnosis is not difficult.

(*a*) If the growth is so near the surface that its contents gleam through, but not with dark blue colour indicative of blood, the case is one of **lymph tumour** (*i.e.*, lymph cyst) if the growth is smooth and round, but is a *cavernous lymphangioma* if it appears to be multilocular or spongy in consistence. These tumours look reddish in transmitted light and light blue in direct light, if the skin-covering is thinned out sufficiently.



FIG. 82.—Cancerous glands, with small primary growth on the middle turbinated bone. (From the Surgical Clinique at Berne).

In addition, lymph-containing tumours react much less to changes in states of pressure (posture of body, squeezing) than do blood-cysts, and their contents are much less displaceable.

If a growth of the neck resembles a blood tumour in colour, but has all the other characters of a lymph cyst, we must first ascertain whether it has been punctured. A puncture may sometimes cause the contents of a lymph cyst to remain permanently bloody.

We have just drawn a distinction between one-chambered lymph cysts and cavernous lymphangiomata, but there is really no sharp differentiation between the two. The most pronounced lymph cysts permeate deeply among muscles by means of cavernous strands, and many cavernous lymphangiomata contain large cystic cavities between spongy portions.

The diagnosis of cystic lymph tumours is facilitated by the circumstance that they occur in two well-defined forms, viz., *cystic*

lymphangioma of infants (congenital cystic hygroma of the neck), and the *lateral lymphatic cyst of adults*. The former is present at birth, and is situated in the upper part of the anterior triangle of the neck, below the parotid region. It spreads thence, rapidly increasing in size, to all sides, and if bilateral it encircles the neck like a collar. As it approaches nearer and nearer to the skin, the latter becomes thinned out in places to a fine membrane, and at the same time the cyst penetrates deeply between the muscles and interferes with the structures in the neck, through its increasing extent. Sometimes it is possible to feel hard fibrous portions situated within the soft elastic cysts, and the whole tumour shakes like jelly on being moved.

The lymphangiomata of adults are mostly situated in the supra-clavicular fossa, and occur generally in women. They consist either of large single cysts or of a conglomeration of smaller cysts.

The growth illustrated in fig. 84 consisted of one large cavity, and of a pedicle made up of dilated lymph spaces, which ran down deeply among the cervical muscles.

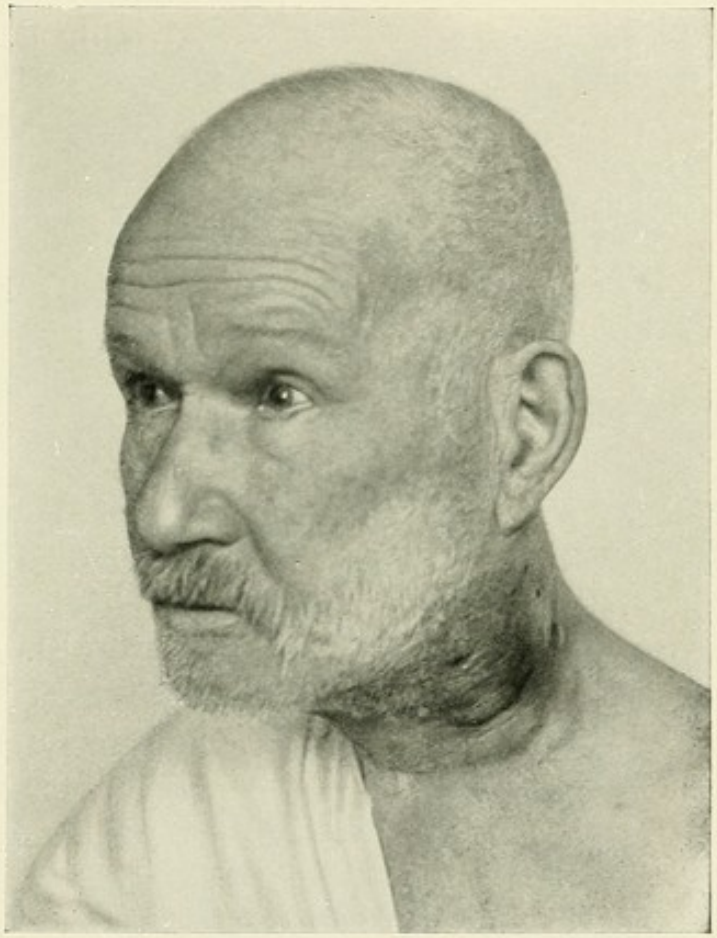

FIG. 83.—Diffuse carcinoma of neck. Primary growth on tonsil. (Resembles actinomycosis, or board-like phlegmon).

The purely cystic forms are liable to be confused with branchial cleft cysts, which will be discussed subsequently. In adults the lymph does not gleam through the skin as clearly as it does in children. Both growths are essentially congenital in origin, but they do not develop till later years. If the cyst is situated very much to the side, this is the only sign really valuable for the diagnosis of lymphatic cyst; positive accuracy can only be obtained by puncturing the cyst and microscopic examination of a portion of its wall.

(*b*) If the contents of the tumour look dark blue through the thin skin, the case is one of a **blood-tumour**. If the surface is

irregular and rough, it is called a *cavernous angioma*, and if it is round and regular it is known as a *blood-cyst*. In both varieties the contents of the cysts are definitely expressible, thus contrasting with lymphangiomata; but as soon as the pressure is relaxed the cyst immediately fills up. A deeply situated venous blood-tumour is not recognizable by its colour, but it becomes inflated when the intra-thoracic pressure is raised by coughing, crying or squeezing, or by keeping the head low. This sign distinguishes it from a deep lipoma of lymphangioma.

As we have mentioned the matter of expressibility, we must again refer to *diverticulum of the œsophagus*. Its contents can also be expressed, but it does not fill up forthwith when the pressure is relaxed. The diagnosis is readily made from the history and the fact that there is difficulty in swallowing when the diverticulum fills up, owing to pressure on the gullet.



FIG. 84.—Lymphatic cyst at the side of the neck.

(*c*) The *tumours containing venous blood* just referred to, proclaim the nature of their contents by their colour and expressibility; but structures filled with *arterial* blood, **aneurisms**, possess another characteristic symptom, viz., pulsation.

This feeling of pulsation may be appreciated under three different circumstances :—

(1) The tumour itself may pulsate—expansile pulsation.

(2) The tumour may be rhythmically raised by the pulsation of the carotid artery—a communicated pulse.

(3) The carotid artery itself may be pushed forward by a tumour lying beneath it.

In order to differentiate between these conditions, one must endeavour to grasp the tumour between two fingers. If these are stretched apart from each other, in all situations and in all directions, the pulse is then an expansile one. If the fingers are lifted with each pulsation, but are not stretched apart, the tumour is merely

raised by the carotid—it belongs to the second variety. If only a pulsating strand is felt *over* the tumour, while the rest shows no pulsation, the tumour lies *under* the carotid.

If an expansile pulse really exists, the beginner is apt to think at once of an aneurism; but *very vascular sarcomata* may also yield an expansile pulse and be accompanied by loud hæmic murmurs.

Although a vascular goitre may have a pronounced expansile pulse, it could only be mistaken for an aneurism after a very indifferent examination. A vascular goitre usually affects the whole thyroid, and is, therefore, bilateral. The fact that it follows the movements of deglutition ought to remove any doubt.

The carotid artery sometimes undergoes dilatation in old syphilitic subjects at the point of bifurcation, and this may lead the beginner to think that an aneurism is developing.

If he overlooks the pulsation and neglects to examine the other side, he may regard the swelling as an enlarged gland, especially if the presence of a cancer of the lip causes him to look for one.

A communicated pulse may be observed in enlarged glands lying on the carotid artery, goitrous nodules and other tumours, especially deep-lying branchial cleft cysts.

The mistakes which occur, owing to the carotid pulsating *in front* of a pathological structure, mainly concern *burrowing abscesses* and deep *sarcomata of the neck*. Similarly a subclavian artery, pushed forward by a *cervical rib*, has often been diagnosed as an aneurism.

The *etiology* is always an important factor in the diagnosis of aneurism. Arterial dilatation is always preceded by some morbid condition of the vessel wall, produced by arteriosclerosis or syphilis, or is the result of some trauma.

If, after considering all these points, we arrive at the diagnosis of **aneurism,** we must determine the artery whence it arises. If the tumour is behind the sterno-mastoid we should think of the carotid, and if it seems to start low down its origin will probably be at the root of this artery. The delay of the pulse in the temporal artery is an important corroborative sign, but its absence is not an unconditional proof against aneurism. If the tumour is situated high up and it displaces the tonsillar region inwards, it can be nothing but an aneurism of the external or internal carotid. If the temporal pulse is weakened and delayed, we must conclude that it is an aneurism of the *external carotid*—the more frequent variety.

If an aneurismal swelling is found in the supra-clavicular fossa, there is no difficulty in diagnosing an aneurism of the *subclavian artery*. Weakening and delay of the pulse in the corresponding radial, pressure signs referable to the brachial plexus, are the classical symptoms.

It is necessary to mention a very rare condition, which, however, the experience of recent wars with modern firearms shows to be getting more frequent. In this condition the region of the common carotid presents a scar resulting from a gunshot wound, stab or cut, beneath which there is a pulsating tumour, varying in size from a walnut to a hen's egg, with hæmic murmurs audible over it. The patient complains of symptoms pointing to disturbance of the cerebral circulation, and the superficial veins of the corresponding side of the head and neck are dilated. This condition is one of **arterio-venous aneurism**, and is caused by a simultaneous injury to the common carotid artery and internal jugular vein. Exceptionally a similar condition may occur in connection with other arteries of the neck, viz., the external carotid and subclavian.

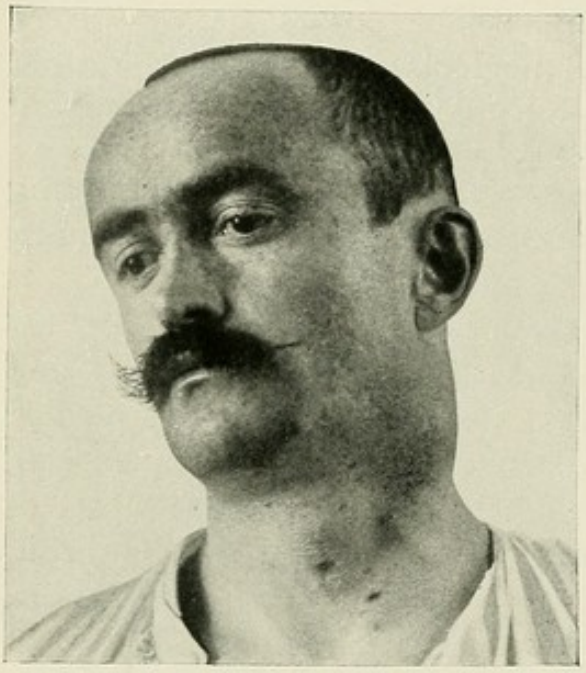

FIG. 85.—Deep cyst of the branchial cleft. (Deep dermoid of neck.)

There is a difference between an *arterio-venous aneurism proper*, wherein the blood exists in a space between the artery and vein, and an *aneurismal varix*, wherein the blood flows directly from the artery into the vein. The former is somewhat irregular in outline, the latter is more circular in shape.

(*d*) A cervical cyst, which does not fit in with any of the groups just described, one which is neither a blood nor a lymph cyst —is probably an **epithelial cyst** arising from some *congenital rudiment*.

If it is situated in the middle line above the thyroid gland it arises from the thyro-glossal duct, which runs from the foramen cæcum at the base of the tongue towards the thyroid gland. A cyst in the course of this duct must be ascribed to its imperfect obliteration, whether it contain mucus or epithelial *débris*.

It might be mistaken for a swelling of the sub-hyoid bursa, a median goitrous cyst, a simple sebaceous cyst of the region, or even for an abscess in connection with the hyoid bone. But these are all rare eventualities, which can only be definitely determined by the microscope. But the history will allow us to distinguish between a cyst on the one hand, and some suppurative process on the other. Exceptionally, such a median cyst may be displaced as far as the root of the neck.

If the cyst is situated laterally, at the inner border of the sterno-

mastoid, or even—in its lower portion—at its outer border, anatomical research shows that it is derived from the second, or even from the third and fourth, branchial cleft. It will contain mucus, muco-serous fluid, or fat and epithelial *débris*, like a dermoid, varying with its lining epithelium. The skin covering it is usually normal; but where it is thinned there is an absence of the translucent appearance seen in a lymphatic cyst. These cysts often stand forth quite distinctly and well defined above the level of the surrounding skin. There is one group of cases in which we can feel an oval structure lying deeply beneath a diffuse indefinite prominence of one side of the neck. If the head is turned towards the opposite side, the sterno-mastoid can be felt to contract over it. These tumours have been described as *deep dermoids of the neck* (fig. 85); but there is no justification for separating them from cysts of the branchial cleft. Their origin from the pharyngeal epithelium is betrayed by the abundant lymphoid tissue which is deposited in their epithelial layer stratum.

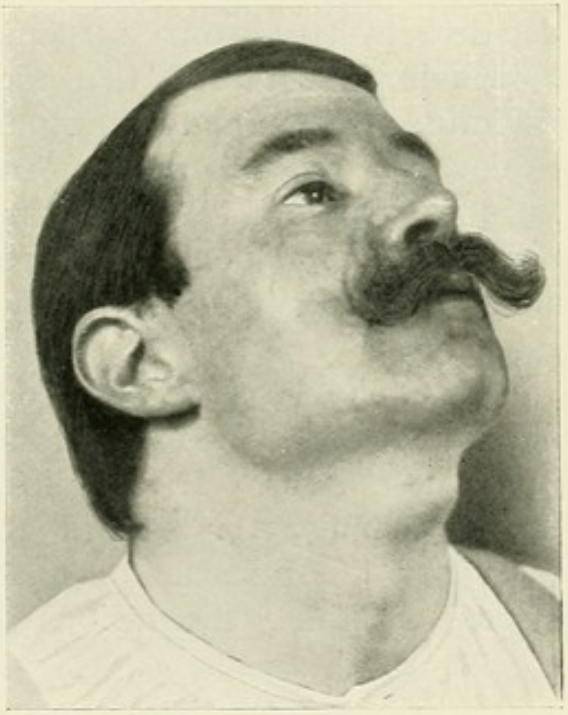

FIG. 86.—Sebaceous cyst, in exact position of median cyst of neck, but more superficial.

The diagnosis of the so-called branchial cleft cysts is not usually difficult, even when the tumour is completely closed in. But in most cases there is a small depression in the skin over the tumour, which renders it impossible to mistake the condition, and facilitates the diagnosis for beginners. The patient probably informs us that a whitish fluid exudes from it occasionally, whereupon the "gland" vanishes, only to reappear again in a short time. Sometimes this evacuation is preceded by an inflammatory attack, and then the exudation is more or less purulent. The picture is complete if we find a small scar in the vicinity of the sinus. We must not be misled into diagnosing tubercular glands, because we find the condition on both sides. Branchial cleft cysts and sinuses may occur on both sides, symmetrically arranged.

Sebaceous cysts situated *in* the skin, in favourite situations of the neck, must not be mistaken for branchial cleft cysts.

(3) SOLID TUMOURS OF THE NECK.

We now proceed to deal with the solid tumours of the neck. As we have already mentioned, a **lipoma** is on the borderland between the fluid and solid tumours, and we should think of it when palpation leaves us in doubt as to which variety is in question. We shall not here refer to the easily recognizable superficial lipoma, which we shall discuss in connection with tumours at the back of the neck—the usual site of this tumour. The *deep sub-fascial* lipoma occurs, but rarely, to add to diagnostic difficulties; and although it is well defined, its processes permeate between the various organs in the neck.

The questions which centre around most solid tumours of the neck are quite of a different character. These tumours are usually distinctly firm in consistence, if not hard, and we have, therefore, to decide between fibroma, sarcoma, and carcinoma.

Having recognized that the tumour is primary, the question of its innocence or malignancy arises. If the growth has taken years to develop, and still remains movable, it must be regarded clinically as innocent, though it should not be forgotten that a **fibroma of the neck** may be on the borderland between innocence and malignancy, and that it may spontaneously become malignant after many years' existence.

It is only in a very few definite situations that any question of differential diagnosis can arise as between a fibroma and some other innocent tumour. It may, however, occur in the neighbourhood of the submaxillary or parotid gland, including the region behind the ear. For the purpose of making a general survey, we propose to discuss separately the various sections of the side of the neck.

(a) Submaxillary Region.

Chronic inflammatory processes are occasionally observed in the *submaxillary gland*, leading to its enlargement through increase of the connective tissue, while the glandular tissue itself diminishes. The diagnosis generally points to new growth, and the comparatively rapid growth usually suggests malignancy. It is quite easy to demonstrate by palpation that the growth is connected with the submaxillary gland.

As it is not always possible to distinguish this condition accurately from a real tumour without the microscope, and as the loss of one submaxillary gland is not a very serious matter, the course will usually be adopted of removing the structure.

This chronic inflammation of a *single* submaxillary gland must not be confused with the symmetrical chronic inflammation of *all*

the salivary and lachrymal glands, known as *Mikulicz's disease*. In some cases this enlargement is merely one manifestation of leukæmia or lymphadenoma. Tuberculosis of the submaxillary gland is so rare, that it can only be recognized by the microscope, unless the diagnosis is suggested by a chronic abscess.

Omitting rarities, the only innocent tumour among those which are genuine growths, which we need consider, is the so-called **mixed tumour.** A movable hard tumour which has slowly grown in the submaxillary region is a fibroma of the neck, if we can feel the salivary gland quite separate from it, on making bi-manual palpation, externally and in the mouth. If the gland cannot be demonstrated as distinct from the tumour, and if it has a smooth surface, it is suspicious of chronic fibroid inflammation of the salivary gland. If the new growth is perfectly movable, but has a strikingly nodulated surface and has existed for years, we should regard it as a so-called mixed tumour. If we learn that the tumour has been noticed for many years, but that the rate of growth has increased rapidly within the last few months, we must assume that it is a mixed tumour which has become secondarily *malignant*, a not infrequent event. In these cases the growth soon loses its mobility, and at the operation it cannot be shelled out as easily as an innocent mixed tumour. Primary malignant tumours of the gland are very rare, and we will discuss them in common with those of the parotid.

On examining these mixed tumours a little more closely, we shall see on section that they are partly fibrous, partly gelatinous and partly like soft cartilage. Histologically they consist of a richly cellular tissue in which there are regularly arranged strands of cells, called by some observers epithelial cells, and by others, with equal confidence, endothelial cells. In addition there are numerous islets of cartilage, and areas which have undergone mucoid degeneration.

(b) Parotid Region.

The considerations referring to the submaxillary region hold good for the parotid region, but here the differential diagnosis is more limited in one respect, although more extensive in another. Fibroma does not occur and chronic inflammatory processes which look like growths have not been observed in the parotid, with the exception of the diffuse swellings, which have been described in syphilis. But, on the other hand, there is the possibility of confusing **tubercular glands** with a new growth. It is easy to avoid this confusion in the submaxillary region, because the tubercular glands are multiple and can be felt separately. In the parotid region, however, there are small lymphatic glands within the capsule of the salivary gland, and when these become tubercular, they gradually lift up the capsule, still being

confined within its limits. It may, therefore, be quite impossible to feel the individual glands as separate structures, because they constitute as it were a common growth within the capsule. The presence of other glands in other situations of the neck might of course lead us to think of tubercle.

A female of healthy antecedents, aged 30, consulted her family doctor because of a swelling, elastic in consistence, which was gradually making its appearance in the parotid region. Lower down in the neck there were a few soft glands, apparently deeply situated, but not adherent to their surroundings. The facial nerve was unaffected and there was no pain. Everything pointed to tubercular glands rather than to a growth. But the shape of the tumour, which corresponded to that of the parotid gland, including even its posterior process, behind the lobule of the ear, looked startling and made one think of a new growth. Nevertheless the operation showed that the case was one of tubercular glands; they were as if moulded within the parotid capsule, and the parotid tissue itself was entirely displaced into the deeper parts.

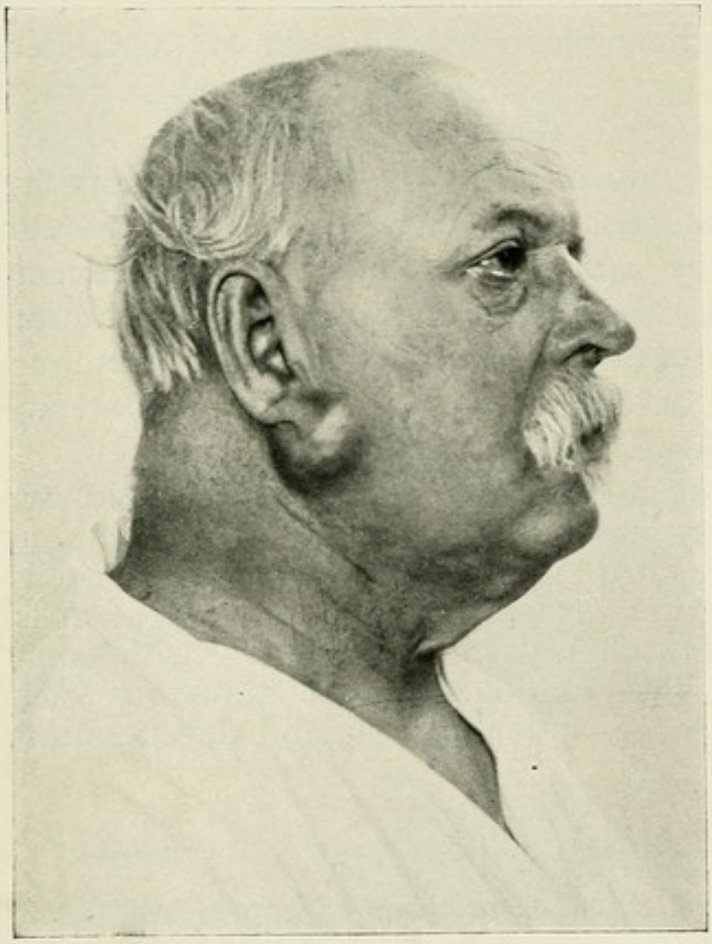

FIG. 87.—Mixed tumour of the parotid.

Tuberculosis of the glandular substance itself, which is a rare condition, must be distinguished from tubercle of the lymphatic glands over the parotid. If the patient is not tubercular and there is no chronic abscess present to give a clue, it is hardly possible to make the diagnosis. At any rate, we are not able to differentiate it clinically from tubercle of the lymphatic glands over the parotid.

If we have excluded tubercular disease, the innocent tumours which remain are the mixed tumour, described in connection with submaxillary gland, and pure enchondromata, which are rare. The **mixed tumours** of the parotid are so typical of new growths, that no mistake can be made in their diagnosis, even if they do not present those grotesque shapes which used formerly to be seen. Every movable irregular nodular tumour of the parotid region must,

at first, be assumed to be a mixed tumour, but the question at once arises, whether it is still innocent. The absence of facial paralysis and of radiating pains in addition to its free mobility should be conclusive in this respect. Pure **enchondromata,** apart from the pre-auricular skin appendages which contain cartilage, are of much rarer occurrence.

We now come to the primary **malignant tumours** of the submaxillary and parotid region, whose chief symptoms—adhesion to the surrounding parts, especially to nerves—we have already noted.

We conclude that a case is one of *primary* sarcoma, or carcinoma of the affected salivary gland, from the absence of any stage of long duration which is characteristic of an innocent tumour, and which could hardly be overlooked by the patient. Can we go beyond this and distinguish between carcinoma and sarcoma? As a rule we cannot, because even the histological picture of salivary gland tumours is variously interpreted. Experience, however, teaches us that cancer is more frequent in the salivary glands than is sarcoma.



FIG. 88.—Cancer of the parotid. The lobule of the ear is pushed forwards by the posterior process of the gland.

It should be added that cancer does not always exist in the form of a "tumour." The parotid is sometimes affected by a *scirrhous cancer*, just as the breast, in which condition the skin is puckered rather than swollen. Such new growths manifest themselves early by means of radiating pains, especially towards the head, and also by paralysis, or paresis of some of the facial twigs, if not of the whole nerve. If such symptoms are present we must not neglect making a thorough examination of the parotid region, although there may be no tumour apparent.

(c) Side of the Neck.

We now come to the side of the neck in the more limited sense. As mentioned above, the *innocent* tumours in this region are mostly *fibromata*, or *neuro-fibromata*; the primary malignant tumours are, with two exceptions, *sarcomata*.

Cancer of the œsophagus and trachea are not included here, because they are fatal before they give rise to any growth externally.

Cancer of the cervical portion of the gullet may at times be palpable from the outside, but the difficulty in swallowing is so prominent a feature that the site of the disease is always perfectly clear.

Fibromata and **neuro-fibromata** occur as slowly growing, firm, movable, spindle-shaped, or oval tumours, over which the skin is freely movable. If their origin is deep—from the sympathetic, from the pre-vertebral connective tissue, or from the vertebral column itself—their position is more or less retro-pharyngeal and they cause correspondingly early symptoms of dysphagia and even of dyspnœa. These tumours are frequently confused with fibromata growing from the base of the skull and with retro-pharyngeal abscess. The same applies to **fibro-sarcomata**, except that these grow more rapidly and are less movable. Even with the microscope their distinction from fibromata on the one hand and sarcomata on the other is very difficult.

Neuro-fibromata have a special tendency to become sarcomatous. Often they are only one indication of a general fibromatosis known as "Recklinghausen's disease." Congenital psychical abnormalities are often associated with this disease, viz., imbecility, infantilism, psycho-neuroses. The fibromatosis may encroach on the central organs and give rise to the most varied nerve symptoms.

Sarcoma of the neck may originate in any of the connective tissue structures of this region, *e.g.*, fascia, periosteum, muscular connective tissue, nerves, &c. Its favourite seat is, however, in the lymphatic glands, even leaving out of consideration their enlargement in malignant lymphoma.

In connection with *lymphatic gland sarcoma* it is necessary to distinguish between "*lympho-sarcomata*" and "*sarcomata of the lymphatic glands.*" The former are sarcomatous proliferations of the lymphatic tissue; the latter are sarcomata of the supporting tissue. The former are, therefore, round small-celled sarcomata, sometimes with an interlacing reticulum; the latter are mainly spindle-celled sarcomata. The difference is interesting from the standpoint of pathological anatomy, but it would be too much to expect that the difference should be detected from clinical signs. If the tumour is definitely soft and the growth is infiltrating, we should suspect "lympho-sarcoma"; if it is definitely hard it should be regarded as a "sarcoma of the lymphatic glands."

"*Malignant lymphoma,*" referred to above, must not be confused with these sarcomata. The former is a constitutional disease, whereas *lympho-sarcoma* and *sarcoma of the lymphatic glands* are tumours of individual glands. Intermediate forms have been described, but these are either very malignant forms of "malignant lymphoma"—with rapid growth and surrounding infiltration—or "sarcomata of the lymphatic glands" with secondary metastases. The whole subject is, however, still in some obscurity, especially in regard to so-called lympho-sarcomata.

Vascular sheath sarcoma formerly constituted a separate variety. It is undoubted that sarcomata may grow from the sheaths of large vessels, but most of the cases thus described were really sarcomata of the lymphatic glands. We must be reconciled to the difficulty of determining clinically their point of origin, especially as it is usually impossible to do so, even at the operation.

In every case of primary malignant growth of the neck the question, whether it is one of the rare primary forms of **carcinoma**, eventually arises.

Tumours have often been found in the upper part of the side of the neck, which have been demonstrated by histological examination to be cancers, with stratified pavement epithelium and for which no primary growth could be found. Their origin must therefore be ascribed, as Volkmann suggests, to congenitally displaced epithelium of a branchial cleft, or to some persistent epithelium of this rudiment. If, in the position indicated, and in a man of middle age, there be a tumour with the signs of a malignant growth, especially if there are severe pains radiating towards the head and back of the neck, the case is in all probability a **branchiogenous carcinoma**. Hitherto these cases have only been noted in males.

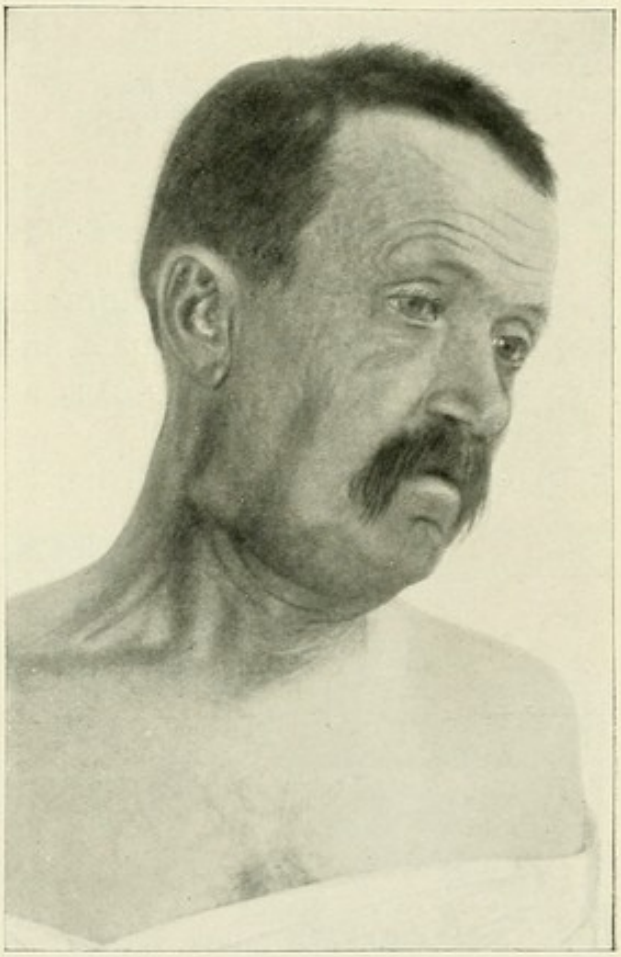

FIG. 89.—Branchiogenous carcinoma.

In some few cases it has been possible actually to demonstrate the transition of a congenital cyst, situated at the side of the neck, into a carcinoma. Malignant growths of the parathyroids may also be regarded as branchiogenous carcinomata in the widest sense of the term, as also the much rarer growths which arise from the post-branchial bodies, the so-called lateral thyroid gland rudiments.

On the other hand, cancer of the accessory thyroids are not related to the branchial apparatus but to the thyreo-glossal duct. An accurate diagnosis of this growth is impossible without the microscope.

There is yet another tumour, worth bearing in mind, which occurs in the same situation as the usual branchiogenous squamous

epithelial cancer. It is neither a carcinoma nor a sarcoma, but a structure, *sui generis*, just like a hypernephroma. It is a new growth arising from the **carotid body**, found in both sexes and at very various ages. It is definitely encapsuled, and its growth extends over many years, thus exhibiting a comparatively innocent character. In this way, it shows a clinical differentiation from a branchial cancer. Vessel walls are constantly observed to grow through, and local recurrence frequently occurs. It is usually soft or elastic in consistence, and its close connection with the carotid artery imparts to it a pulsatile movement.

Microscopically this tumour is similar to a normal carotid body. It is composed of a tissue made up of polygonal epithelioid cells, like the main structure, and is traversed by blood spaces invested by endothelium, after the manner of a sponge.

(d) Supra-clavicular Region.

The genuinely primary tumours of this region are the rare deep lipomata as well as fibromata and sarcomata. **Cervical ribs** often give rise to errors of diagnosis, and we shall therefore now proceed to discuss them.

A cervical rib is a small hard structure which can be felt in the supra-clavicular fossa. Its existence may give rise to no subjective symptoms, but on the other hand it may cause neuralgia or paresis of the nerves of the arm, and exceptionally it may produce circulatory disturbances in the subclavian artery.

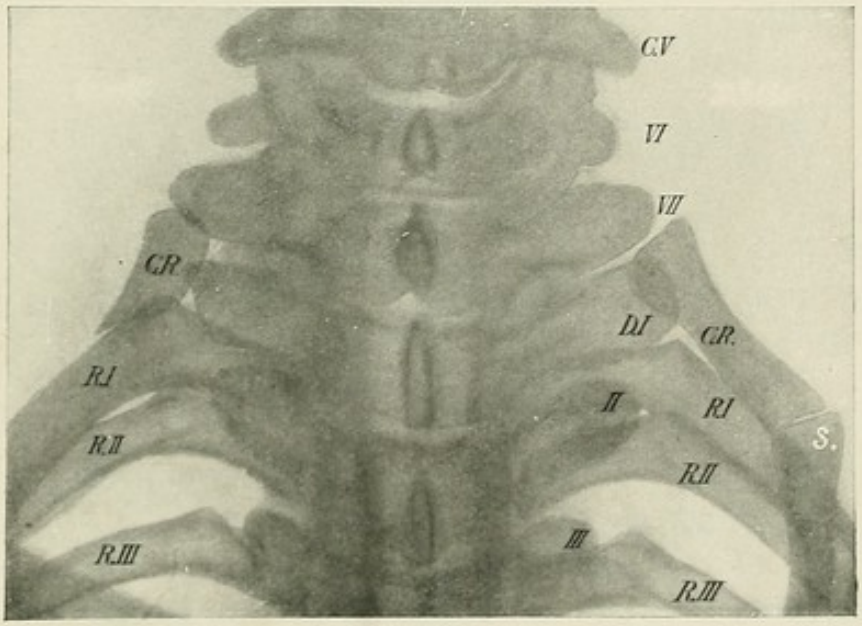

Right. Left.

FIG. 90.—Bilateral cervical ribs. On the right, a small rudiment *C R* attached to the first rib. On the left, a larger rib which is continued to the sternum by means of a clasp *S*. *R I—III* indicate 1st, 2nd, and 3rd ribs. *C V—VII, D I—III* are placed on transverse processes of cervical and dorsal vertebræ.

Sometimes these symptoms of pressure on the nerve plexus or on the artery only supervene after some definite cause. Thus I have seen, in a soldier with a cervical rib, complete obliteration of the radial pulse from the effect of the leather strap of his knapsack.

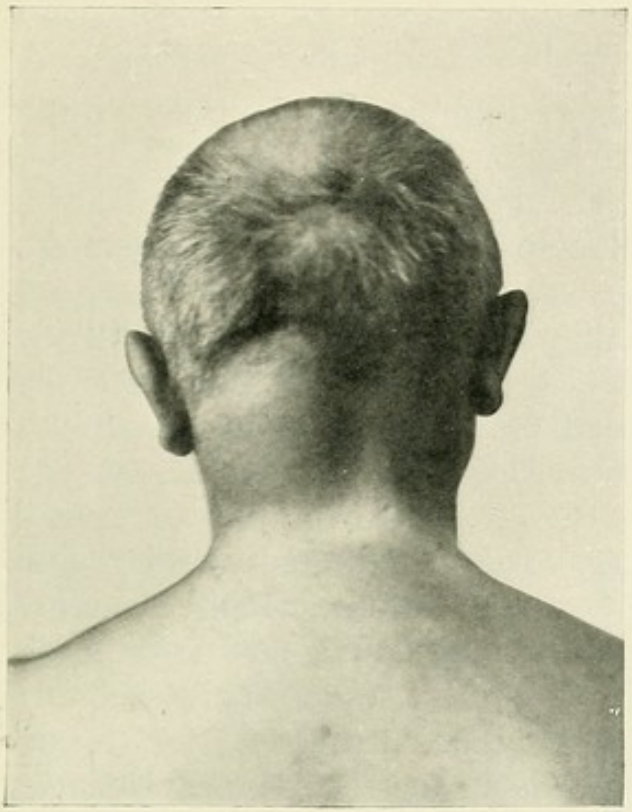

FIG. 91.—Unilateral lipoma of back of neck.

The subclavian artery either runs over the rib, or in front of it. The abnormality is usually bilateral, but more pronounced on one side than on the other. Very rarely two ribs are found on the same side, with the subclavian artery running between them.

If the medical attendant does not bear in mind the possibility of a cervical rib and is misled by the hardness of the structure, he will diagnose a malignant growth; if he is struck by the pulsation of the subclavian artery, which is pushed forwards, he will regard the case as an aneurism, as the following instance illustrates.

A middle-aged male consulted his doctor in reference to throat trouble. The latter found, after a conscientious examination, a small pulsating tumour in one of the supra-clavicular fossæ, and he thought of a subclavian aneurism. But a closer investigation revealed a small hard structure over which the sub-clavian artery ran, but the artery was not enlarged—hence the condition was one of *cervical rib*. The diagnosis was clearly confirmed by a skiagram (fig. 90). The throat trouble was due to chronic pharyngitis.

If the hard resistance were strikingly great, one would think of a *chondroma* or *osteoma* starting from a cervical rib. If the pulsating structure near or over the cervical rib were larger than the circumference of a normal subclavian, one would entertain the possibility of an aneurism caused by a cervical rib.

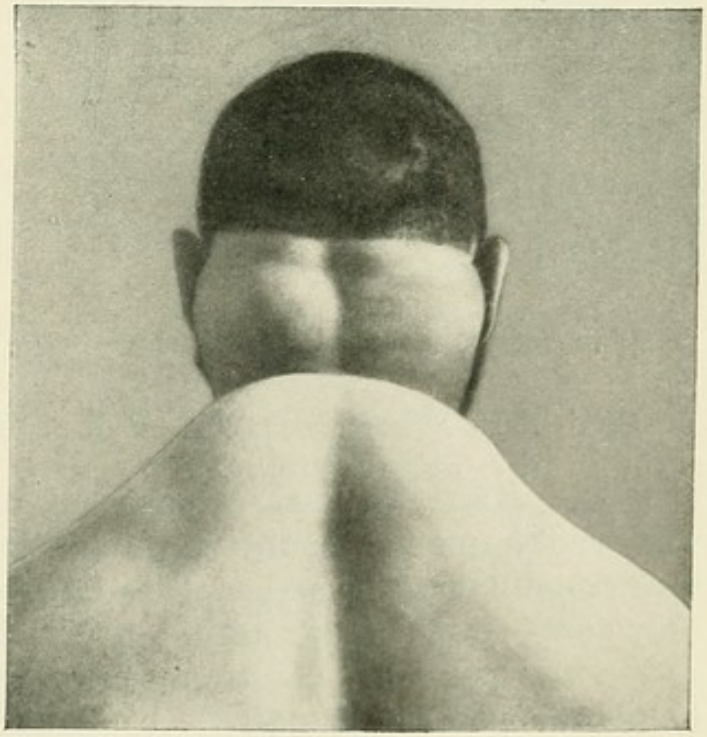

FIG. 92.—Symmetrical lipoma at back of neck. (From the Surgical Clinique at Berne.)

C.—THE BACK OF THE NECK.

We shall conclude the discussion of tumours of the neck with the new growths of the posterior cervical region.

A median, cystic, soft, elastic or fluctuating tumour is usually a **meningocele** or **meningo-encephalocele** (fig. 16); rarely a **dermoid.** The contents of the first two varieties are displaceable on pressure, and vary in tension according to variations in cerebral pressure. They are usually found in children only, because the patients generally succumb unless successfully operated on. But dermoids are found at a later age also, as well as superficial **sebaceous cysts.**

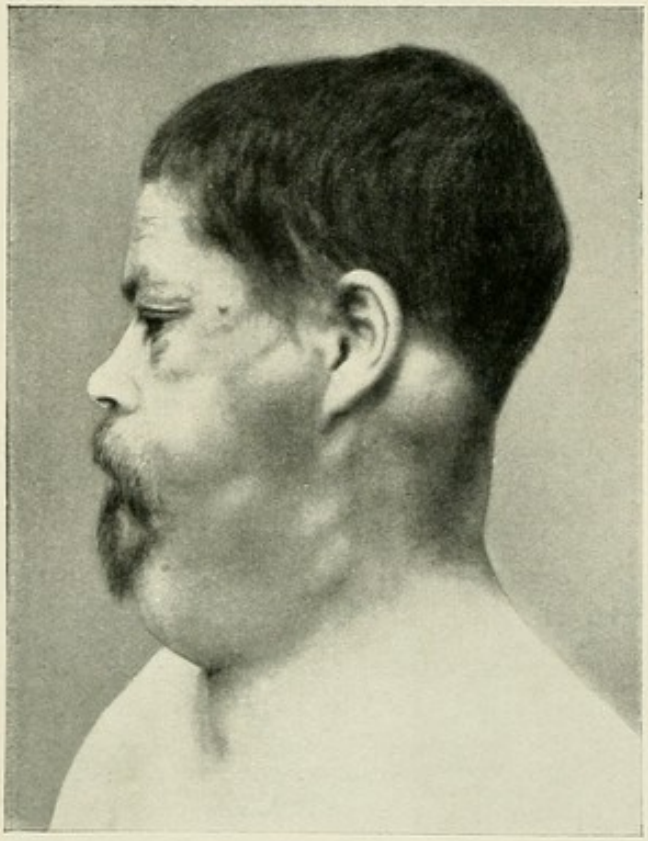

FIG. 93.—Peri-glandular lipoma.
(From the Surgical Clinique of Berne.)

Apart from these, the most frequent tumours in this region are **lipomata.** If the structure is lobulated, soft in consistence, single, and laterally situated (fig. 91), it is an ordinary *encapsuled lipoma*, which can be shelled out with the greatest ease. If, on the other hand, there are two tumours, symmetrically placed near the middle line, which are not definitely lobulated but rather nodular and hard, with no tendency to become pendulous, the diagnosis is *symmetrical posterior cervical lipoma*, a condition which occurs especially among disciples of Bacchus. Frequently these tumours are accompanied by another pair, situated lower down (fig. 92).

Beginners should be warned that the removal of these tumours should not be lightly undertaken. They dip in between the interstices of the muscles, and have extensive adhesions, so that the operation is very troublesome and apt to be attended by severe hæmorrhage.

Peri-glandular lipoma is a third form of lipoma, which occurs not only at the back of the neck, but also in other situations of the neck and body generally, as circumscribed accumulations of fat around lymphatic glands (fig. 93).

Diffuse lipoma of the neck, as described by Madelung, must be distinguished from the ordinary symmetrical lipoma of the back

of the neck. The whole neck is surrounded by a fatty mass, as by a collar, out of which the head appears to emerge.

Probably the two latter forms of lipoma have some connection with *adiposis dolorosa* or *Dercum's disease*. This disease is recognized by the distribution of nodular or diffuse masses of fat in different parts of the body, associated with severe pain on pressure, neuralgia, and other sensory disturbances. Certain clinical and anatomical findings suggest a connection between this disease and functional disturbances of the thyroid or pituitary gland (see p. 24).

Hard tumours, mostly situated at the side of the posterior cervical region, are either **fibromata** or **sarcomata**. They may arise from the aponeurotic connective tissue, more rarely from the vertebral spine, but sometimes even from the skin. The rapidity of its growth, its adhesions, its consistence and the condition of the superjacent skin will indicate whether the growth is more fibromatous or more sarcomatous in nature, or whether it is a pure sarcoma.

A very rare case is recorded by Dower. This was a fibroma of the dura mater with a slender peduncle, which made its way between the second and third cervical vertebræ, and formed an orange-sized tumour at the side of the neck. The main feature of the case was the compression of the spinal cord. A very similar case was successfully operated on by Wilms.

CHAPTER XXV.

ABNORMAL POSTURES OF THE HEAD.

It is said that a politician once felt much encouraged during the delivery of a long speech by the remarkably attentive posture of his immediate neighbour in the audience. He thanked the listener after the speech, but the latter, not quite appreciating the gratitude, said he had a stiff neck. Obviously the speaker was not a medical practitioner. *We* infer from a stiff neck something quite different to special attentiveness.

We must first note whether the patient carefully avoids any movement of the head for fear of pain, or whether, although he holds the head in an abnormal position, he is able to move it partially without pain.

A.—PAINFUL RIGIDITY OF THE NECK.

Every painful condition about the neck has the effect, on the cervical vertebræ, which we call muscular fixation when it occurs

in other joints. A boil at the back of the neck suffices to produce this effect. The nature of the case is evident as soon as we see the patient coming with a compress on his neck or a plaster applied. There is no need for the patient to state his case; but the underlying cause of the condition may be difficult to ascertain. If the muscles on both sides are equally tense and the head is held in the middle line, we may assume that the lesion which excites the pain is centrally situated, whereas if the head is held asymmetrically the lesion is on one side. We shall discuss each variety separately, because the considerations we shall advance proceed from the beginning, in different directions.

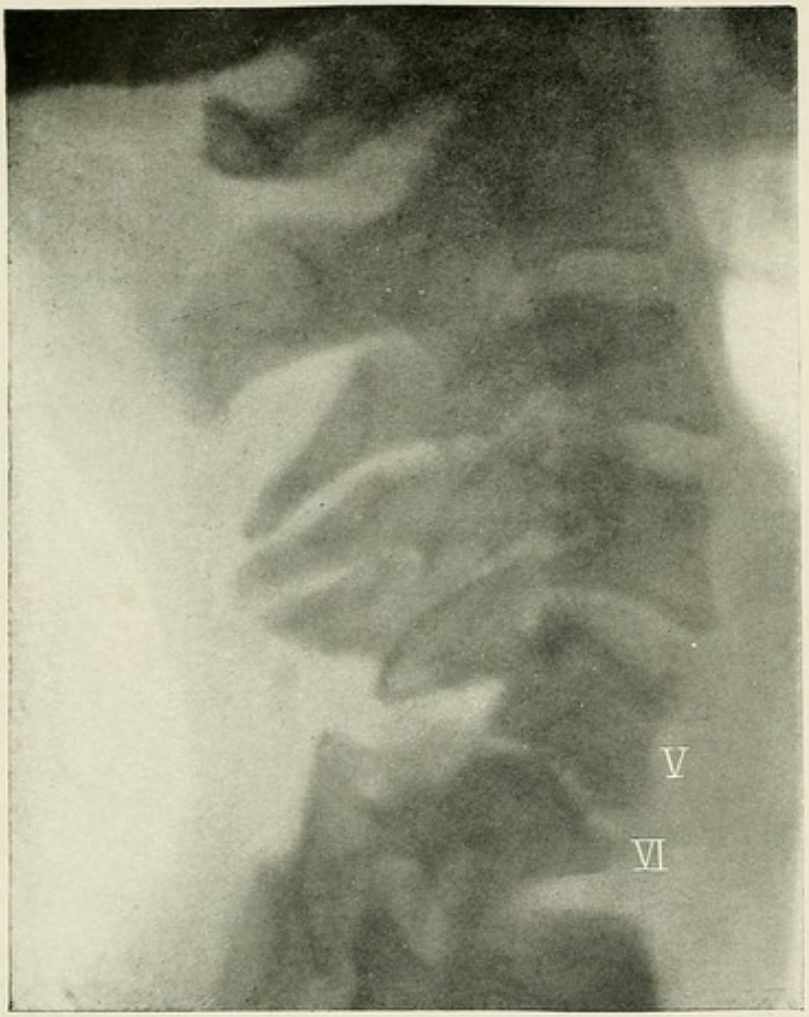

FIG. 94.—Complete forward dislocation of the 5th cervical vertebra on the 6th. Compare fig. 96.

(1) SYMMETRICAL FORMS.

As the muscular causes which may produce rigidity are generally unilateral and therefore result in *wry-neck*, we should at once think of a median structure, *the cervical spine*, when the rigidity of the head is in a *straight* posture. But even then, our conception of the case will vary with the sudden or gradual character of the onset.

(a) Rigidity with Sudden Onset.

If the rigidity has come on suddenly, we first enquire about an **injury.** In cases of severe injury to the cervical vertebræ, the patient supplies his own indications thereof.

In bilateral or **complete dislocation,** or in fracture-dislocation, with the dislocation still persistent, the profile shows significant displacement of the head forwards, usually associated with flexion. The dislocation always occurs in a manner which causes the upper

vertebra to project beyond the lower, and which, with few exceptions, brings about slight flexion at the same time.

We must recall the actions of the various parts of the cervical spine in order to test the functions of the neck. The movement of nodding occurs between the occiput and atlas; the movement of rotation between the atlas and axis, and lower down the chief movement is that of bending the whole neck backwards and forwards. It should be remembered that the various joints of the neck are able, to a great extent, to replace one another.

On palpation an unusual space is to be noted between two spinous processes. The spinous process of the dislocated vertebra is also displaced upwards, touching the spine of the next highest vertebra (fig. 96).

In lean subjects the spinous process of the axis can be distinctly felt, but those of the third and fourth vertebræ are indistinct. The spine of the fifth vertebra is again distinct, and those of the sixth and seventh are very clearly felt.

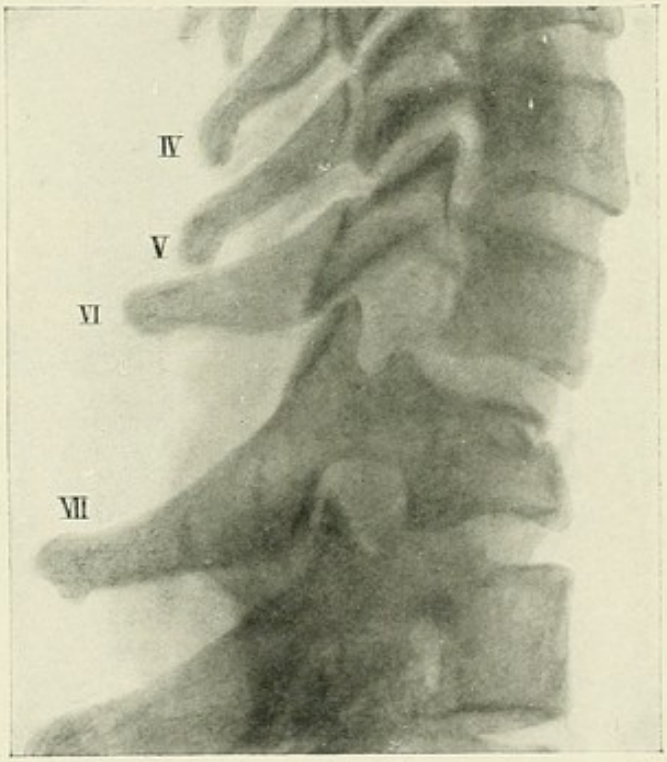

FIG. 95.—Fracture-dislocation between the 5th and 6th vertebræ, fixed in the position of subluxation. (*Post-mortem* preparation.)

The demonstration of displacement of the lateral portion of the vertebra would be of value in diagnosis, but this is very difficult. On the other hand, a widening of the neck as seen in profile, in addition to bending of the head, is very significant. The displacement which is most common concerns the fifth vertebra, in relation to the sixth, wherein the spinal cord sometimes escapes injury, as was especially pointed out by Steinmann. Complete dislocations higher up are nearly always fatal. But should such a case survive, the diagnosis could be established by feeling through the pharynx and by external palpation of the side of the neck. But sometimes the displacement is very slight in compression fractures (fig. 96), and it is quite impossible to decide upon the nature of the injury merely by means of palpation. A diagnosis can only then be made by X-rays. These are the cases which form the intermediate stage towards **contusion** and **sprain**.

There is no change in the shape of the cervical spine in these latter cases. Spine and lateral processes are in correct position.

It is only the active movements which are deranged, and this is quite relative. It is caused, as previously explained, by muscular fixation induced by the pain. Careful and slow manipulation will not only allow of the performance of all passive movements, but will also permit of their active performance. Theoretically there should be no pain in a case of sprain when pressure is made in the long axis, but it is sometimes present because, as a consequence of the normal curvature of the cervical spine, every thrust causes an increase of dorsiflexion and therewith some tearing of the ligaments. If such pressure is very painful it suggests contusion of an intervertebral disc, or even a fracture unaccompanied by dislocation.

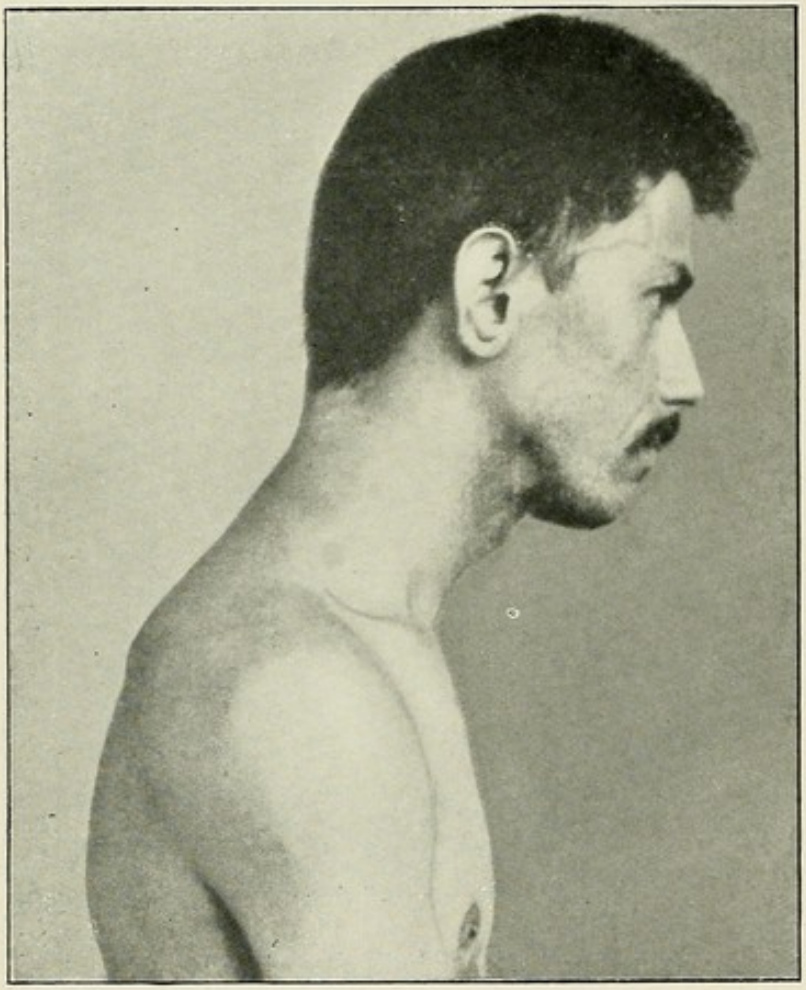

FIG. 96.—Complete forward dislocation of 5th cervical vertebra. Compare with fig. 94.

On the other hand, the pain caused by pressure in the long axis in cases of severe contusion and compression fracture, is sometimes less than might *a priori* be anticipated.

Pressure on the spinous process may also be painful in cases of sprain, because it may produce slight displacement and tearing of the injured ligaments.

The *site* of the sprain may be inferred from the character of the disturbed functions and from the position of the pain. If the nodding movement is affected, but the neck can still be bent, the injury exists at the occipito-atlantal joint. If there is difficulty in turning the head the sprain is probably between the atlas and axis. If the power of bending backwards and forwards is involved the sprain is more deeply situated. Very careful observation is required to distinguish between nodding movements and bending of the neck, but this differentiation can be made out quite accurately. The existence of damage to the spinal roots (neuralgias) is also of value for the diagnosis.

The foregoing remarks require some amplification. There are

some injuries of the first two cervical vertebræ which cause no striking alteration of posture, but produce very severe pain on movement and a corresponding muscular fixation. Fractures of the first two vertebræ are immediately fatal if combined with definite dislocation, but if not so complicated they may recover, unless some unforeseen movement or careless examination causes a dislocation as a supplementary injury. A case of this kind is recorded wherein the patient died suddenly as the nurse was helping to sit him up. These patients are constantly holding their head with their hands, because they feel very uncertain about its stability. The fracture is either in the arch of the atlas or axis, or in the odontoid process of the latter. A fairly accurate diagnosis can only be made in the former condition, if by examination through the mouth of the palpable portion of the atlas it is possible to detect any displacement or abnormal mobility. No other diagnostic manipulation ought to be undertaken if there be any suspicion of such a severe injury. But it is permissible to take an X-ray picture (from the side and from the front with the mouth open) as long as the process can be carried out with the necessary care.

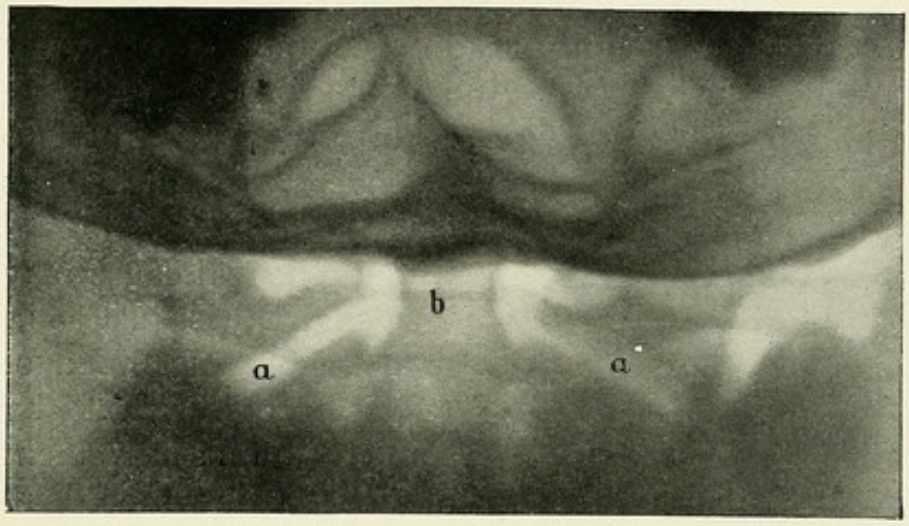

FIG. 97.—Normal vertebra taken with mouth widely open. a, Joint between atlas and axis; b, odontoid process of axis.

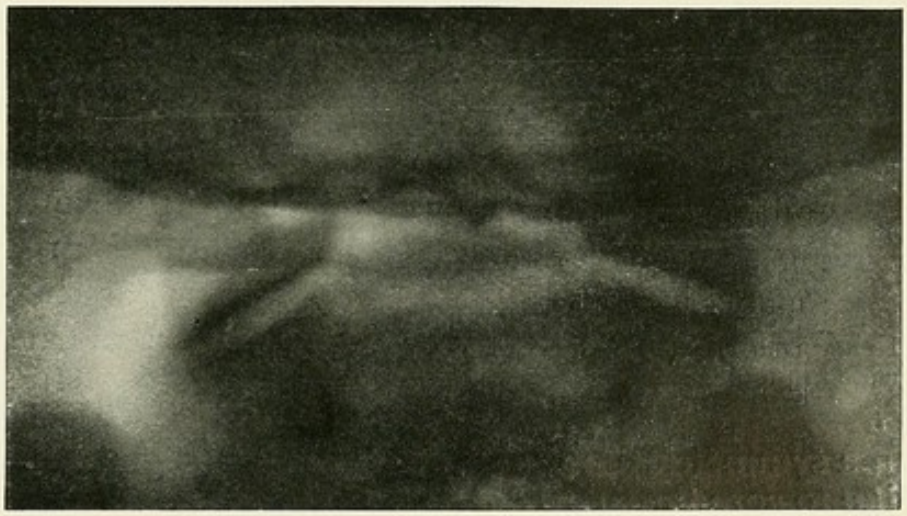

FIG. 98.—Fracture of odontoid process, taken through the mouth. The two articular surfaces between atlas and axis are united by line of fracture.

Fractures of the odontoid process cannot be diagnosed clinically, but they can be shown on a skiagram of the first vertebra, if taken with the mouth widely open (figs. 97 and 98).

It is not very easy to distinguish partial fractures of the lower cervical vertebræ without displacement, from sprains. Detachment from the articular process with incomplete rotation—dislocation, is an example of such an injury. A long continuance of symptoms, assumed to be due to a sprain, is strongly suggestive of this lesion, but a decision can only be arrived at by a skiagram.

A patient in whom sudden rigidity of the neck comes on, is not always aware of an antecedent injury. **"Torticollis"** is looked upon very much like "lumbago," and there is always a tendency to discover a chill as its cause.

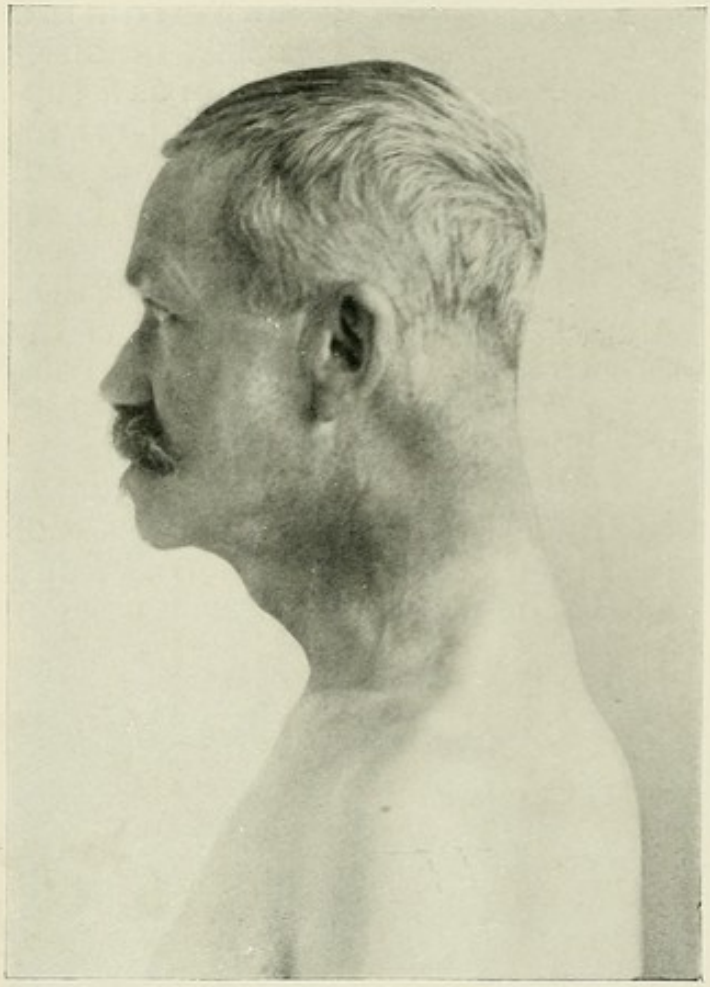

FIG. 99.—Caries of 5th and 6th cervical vertebræ. Head displaced slightly forwards. Neck abnormally wide in profile.

But the real cause may be a slight twist just as in many cases of lumbago. It is brought about by some fortuitous movement of the neck, in which there has been neglect to fix the individual vertebræ in the necessary manner by appropriate muscular action. Sometimes pains radiating towards the shoulders occur, as in the case of the more severe sprains. But none of the spinous processes are definitely painful on pressure, nor is pressure along the axis of the spine painful. Those who have themselves suffered from this kind of sprain are best able to appreciate its true nature.

In some cases wherein the head is held fixed in a symmetrical position the cause is a slightly acute cervical adenitis due to sore throat.

If there has been no injury and the symptoms of rigidity are accompanied by rigors and fever, we must think of the possibility of **osteo-myelitis of the spine.** Active movements in the adjacent vertebral joints are in abeyance, there is pronounced pain on pressure over the spine and lateral portions, and if the disease is situated high up, pressure through the pharynx demonstrates pain on the anterior surface of the vertebra. Pressure along the axis of the

spine is painful, corresponding to the extent of the inflammation. The diagnosis would be confirmed if the history revealed any recent acute inflammatory disease which might serve as the primary focus. Further confirmation is afforded by the course of the disease, in which nerve root and spinal cord symptoms supervene, and, unfortunately, by the almost invariably fatal termination.

I have seen osteo-myelitis of this kind in a man aged 71, which came on as a sequel of a mild pneumonia.

(b) Rigidity with Gradual Onset.

If the rigidity has come on *gradually* the cause is usually tuberculosis of the vertebræ (fig. 99), or more rarely a new growth. The examination must be conducted most carefully, because any excessive diagnostic zeal may be rewarded by the breaking off of the odontoid process of the axis—an accident which has actually occurred. We ascertain the extent of active movements, the amount of pain on pressure over the long axis of the spine, and on the spinous processes, and finally we test sensitiveness to pressure through the pharynx. We diagnose the site of the lesion, just as we do the site of an injury by means of the disturbance of movement, the change in shape of the spine, and by the situation of the severest pain on pressure. Sharply limited neuralgias often facilitate the local diagnosis. We should also look for burrowing abscesses, and test the patellar reflexes in order to not overlook the commencement of some pressure on the spinal cord in the neck.

Further information is given in the chapter on "Inflammatory Diseases of the Spinal Column."

(2) ASYMMETRICAL FORMS.

If the posture of the head is not symmetrical, but is inclined towards one side and turned towards the other, the condition is one of "*wry-neck.*" If this has come on *suddenly*, the question of myositis should immediately arise. This diagnosis would be borne out, if a muscle, especially a sterno-mastoid, were not only tense but also swollen and painful on pressure. If the malady follows an acute infectious disease, or if it is only one manifestation of multiple myositis with high temperature, the condition is really serious, because it may lead to a permanent wry-neck, through subsequent fibrous degeneration of the muscle. But if there are no severe symptoms and the swelling of the sterno-mastoid is the solitary morbid symptom, we may regard the case as one of *rheumatic myositis* and give a favourable prognosis.

Many cases which are called rheumatic myositis are really due to *acute adenitis* of a cervical gland lying beneath the sterno-mastoid, and careful examination will often reveal some dental trouble or sore-throat as the primary cause.

If the muscle is not swollen, but some injury has preceded the rigidity, the case is probably one of a simple *sprain*, which we shall be able to distinguish from a more serious accident by means of the rules previously given. The more serious *one-sided* injuries in this situation are usually **one-sided dislocations.** The head is held in such a distinctive manner in these cases, that the diagnosis presents no difficulty. The head is bent towards the dislocated side and turned towards the uninjured side (fig. 100).

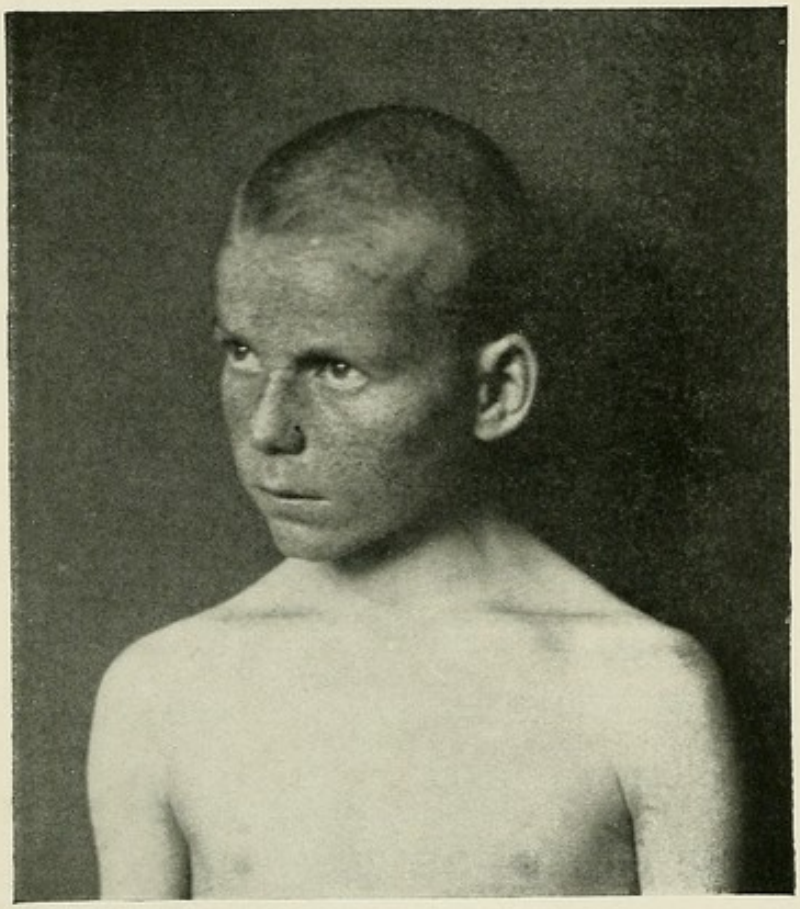

FIG. 100.—Left-sided dislocation between atlas and axis, rotation of head to opposite side.

At any rate this is the posture assumed in cases of one-sided dislocation with interlocking of the articular processes, when the articular process of the upper vertebra has become displaced to the front of the corresponding process of the lower vertebra (figs. 102 and 104). But if the twist has only proceeded halfway, that is to say, that the articular process of the displaced vertebra rests on the edge of the process of the lower vertebra (fig. 103), we should expect, theoretically, that the head would assume a different posture. The head should be inclined towards the uninjured side, so that the injured side would be lengthened and only slightly turned. This variety of dislocation is, however, so unstable, and carries with it so little risk to life, that it has never been demonstrated *post mortem*. Only a skiagram could show whether such a picture, as conceived by most writers, represents the truth. We might suspect this form of dislocation, clinically, in a case wherein the amount of turning was insignificant in comparison to the bending, and where the spinous process and lateral portion were only slightly displaced. The much more frequent cases of complete rotation-dislocation with detachment of an articular process can likewise only be diagnosed by a skiagram.

As in the case of other dislocations, the faulty position in the neck can be increased artificially, whereas considerable resistance is offered to *opposed movement*, especially when there is interlocking. Spon-

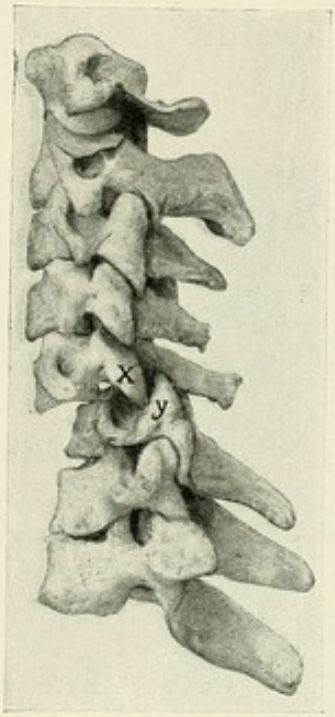

FIG. 101.—Complete dislocation.



FIG. 102.—One-sided dislocation with interlocking.

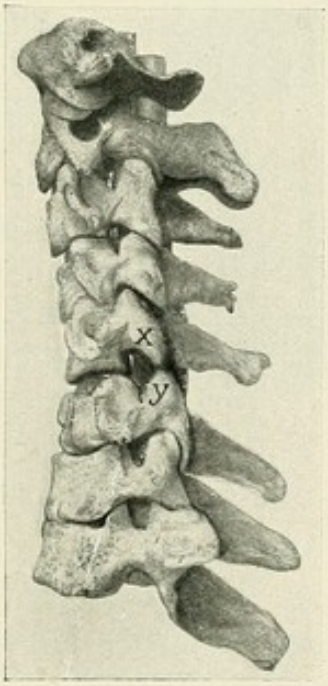

FIG. 103.—One-sided dislocation without interlocking.

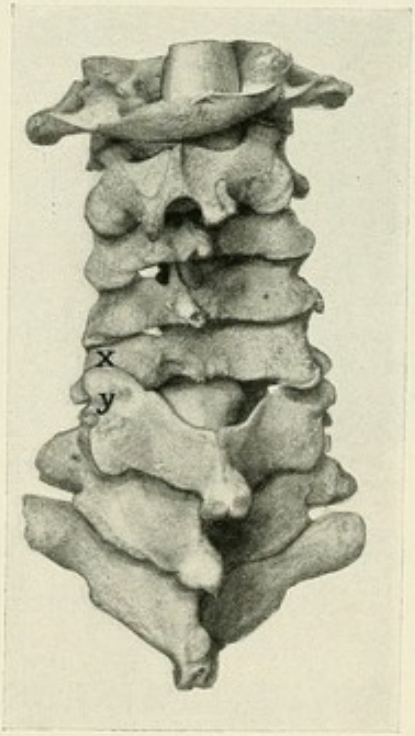

FIG. 104.—One-sided dislocation with interlocking.

taneous pain is often quite trifling, but in recent cases all *movements for the purpose of examination*, as well as pressure on the spine of the dislocated vertebra, are painful, not always because of the dislocation,

but, as Kocher remarks, because of the twisting of the non-dislocated side; palpation affords the most feasible proof of dislocation. The spines of the upper vertebræ cannot always be distinctly felt, so that we must examine through the pharynx and endeavour to make out whether we can detect a lateral portion forwardly displaced. Any kind of asymmetry is abnormal. If we are not quite sure about our results, we must examine with the index-finger of the other hand for the purpose of control. In this way it is quite possible to recognize dislocation of the first two vertebræ, and of the third vertebra also if the examining fingers are long enough and the patient's neck not too long.



FIG. 105.—Congenital torticollis.

An examiner with specially long fingers has been able to reach as far as the sixth vertebra in a patient with a short neck. This may be possible in toothless corpses, but not in living persons.

On the other hand, no reliable results are yielded by the palpation of the spinous processes and the lateral portions in cases of rotation-dislocation.

Spinal caries must be mentioned among the causes of painful wry-neck. If the damage is only on one side, it may imitate the signs of a one-sided dislocation, or rather, it may lead to that condition.

B.—PAINLESS RIGIDITY OF NECK.

It will, of course, be understood that these cases are always chronic. A *symmetrical* rigidity must be due either to some form of painless spinal caries, to an old bilateral dislocation, or to a healed compression-fracture. But if the condition is one of *wry-neck* and an old unilateral dislocation can be excluded by palpation, the case

must be grouped under the extensive class of so-called **caput obstipum** or **muscular torticollis.**

The causation of this common malady is still a subject of controversy. Stromeyer and many others attribute it to injury of a sterno-mastoid during birth, with subsequent fibrous degeneration and contraction of the muscle. Petersen's view is that the condition is of intra-uterine origin, due to the cramped space. He bases his view on the cases which are undoubtedly congenital and even hereditary. This conception is confirmed by recent observations (Voelker), because it has been shown that the shoulder pressing against the neck *in utero* leads to atrophy of the sterno-mastoid. Kader, however, as a result of definite observations, attributes all wrynecks to the result of *infective myositis*, which comes on *after* birth, but very frequently owing to trauma during birth. According to Mikulicz, this explanation would account for *intra-uterine* shortening of the sterno-mastoid.

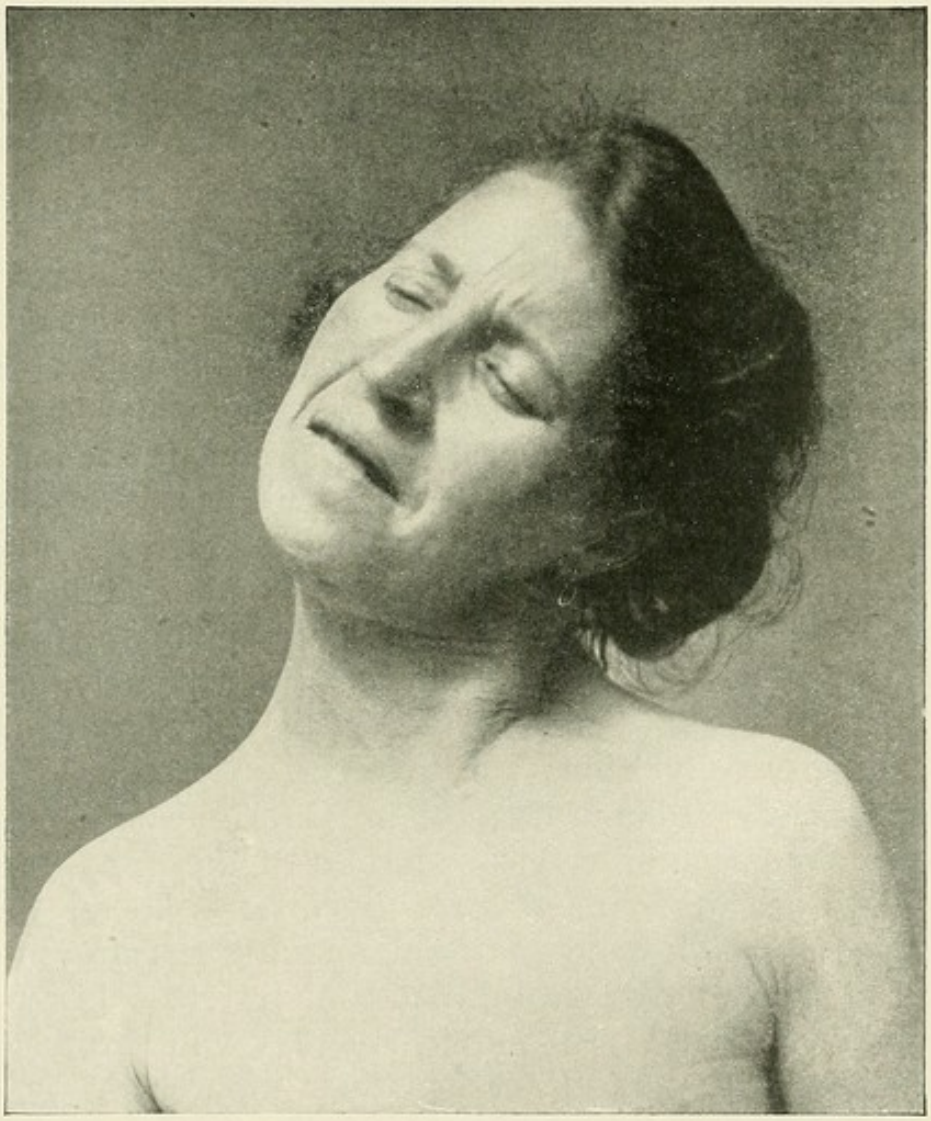

FIG. 106.—Spastic torticollis.

However this may be, the chief factor in diagnosis lies in the circumstance that the malady has appeared during infancy. This explains the fact that the whole skeleton has become adapted to the abnormal posture of the head. The skull is asymmetrical, shortened and widened on the affected side, the spinal column shows cervical scoliosis with a continuation thereof in the dorsal region, the convexity being towards the healthy side. Sometimes there is, in addition to the cervical scoliosis, a dorsal scoliosis towards the opposite side

and lumbar scoliosis towards the same side as the cervical scoliosis. The one sterno-mastoid in the neck is shortened, resembling a narrow, hard, projecting band, whereas the other is often abnormally well developed. The most striking thing about the posture of the head, especially in children, is the inclination of the neck towards the affected side, with comparatively slight rotation towards the healthy side (fig. 105). As the disease progresses this lateral inclination of the head diminishes but the rotation increases, so that the head may deviate entirely towards the healthy side. The complicated vertebral curvatures also belong to this latter category.

There is, finally, another clinical picture, which essentially belongs to the department of medicine, but which often appeals to surgery when therapeutic measures have failed.

As soon as the patient begins to describe his malady—which, however, is quite unnecessary—his head is suddenly and violently jerked to one side and turned towards the other. The more excited he becomes thereby, and the more anxious he is to impress us with his distressing condition, the more frequent become these spasmodic movements. Sometimes the facial muscles, the muscles of the floor of the mouth and even the shoulder muscles co-operate in these convulsive movements. They are sometimes intermittent and clonic, at other times persistent and tonic, involving not merely isolated muscles, but muscles which work co-ordinately, and muscle groups on both sides. For this reason the older designation of "spinal accessory convulsions" is incorrect. The clinical picture represents **spastic torticollis** in its most usual form, wherein one sterno-mastoid and the posterior cervical muscles of the opposite side act together. There are other allied forms such as bi-lateral contractions of the muscles which bend the head, nodding spasms and the contractions of the posterior cervical muscles—the "retrocollis spasm" of English authors. There are some patients who experience the greatest difficulty in putting food in their mouths owing to these spasms. I know a practitioner in whom the disease started in the form of a writer's cramp in the right arm, and as the malady progressed the shoulder muscles participated in the spasmodic movements of the head. No wonder, then, that these patients turn to the surgeon for relief when internal treatment has failed.

It is still uncertain whether the situation of the disease—which must be looked upon as a neurosis—is exclusively in the cerebral cortex or also in the more deeply placed centres of co-ordination. Possibly both are involved. At any rate it is quite certain that the results of operative treatment, division of the muscles which take part in the convulsions, cannot be attributed to pure suggestion. It is more probable that the irritable cortical centre is put out of action for a considerable time owing to the absence of centrifugal impulses from the tense muscle, and thus repose is ensured for it.

PART III.

SURGICAL DISEASES OF THE THORAX.

CHAPTER XXVI.

FRACTURES OF THE BONES OF THE THORAX.

It is obvious that the ribs may be fractured by means of severe violence, directly—at the site whereon the force is applied—or indirectly at the site where the curvature is most pronounced. But it is not quite so easy to appreciate that a rib may break when the violence is very slight, or even as a result of muscular contraction only. Such cases, however, presuppose a debilitated osseous system through one cause or another, mostly senility. I knew an old man who fractured a rib through cutting a loaf. Ribs have been broken during labour through muscular contraction, and even while sneezing. After a severe injury, in which several ribs have been broken, it may be quite possible to hear crepitus with each breath, even in an adjoining room, but in the slight cases just mentioned it is often necessary to search for the injury in order to make an accurate diagnosis.

The outstanding symptom is pain felt as each breath is drawn, pain which effectually prevents any deep inspiration. Gaping, sneezing and laughing are particularly painful, and it was, therefore, a thoughtless joke on the part of a medical student who sent a colleague suffering from fractured ribs an amusing newspaper article to cheer him up, the perusal of which brought into play all the muscles required for a hearty laugh. The interference with respiration is not necessarily the result of a fractured rib ; it may be due to a hæmatoma in the muscle or beneath the pleura. Both these conditions are, however, very frequent in cases of fractured ribs.

If, on palpating the ribs, we feel or hear crepitus anywhere on deep respiration, there can be no doubt about fracture. The stethoscope may be of assistance in this examination. But sometimes we only find a very painful spot without any signs of abnormal mobility. This may indicate nothing but a contusion. The

distinction is made by the possibility or impossibility of eliciting pain indirectly by making pressure and counterpressure on both extremities of the ribs, *i.e.*, by increasing their curvature. Pain produced in this way, remote from the points of pressure, is significant of fracture or, at any rate, of incomplete fracture of a rib.

If this examination elicits pain, both in the back and in the front, it follows that the rib has been broken behind as well as in front, a frequent incident in contusions of the whole thorax. In these cases there is usually concomitant damage to several other ribs.

Fracture of the sternum sometimes runs its course quite unnoticed, because the injury is rather of the nature of a fissure than a complete fracture with abnormal movement and displacement. It is impossible to mistake this latter form owing to the superficial position of the sternum.

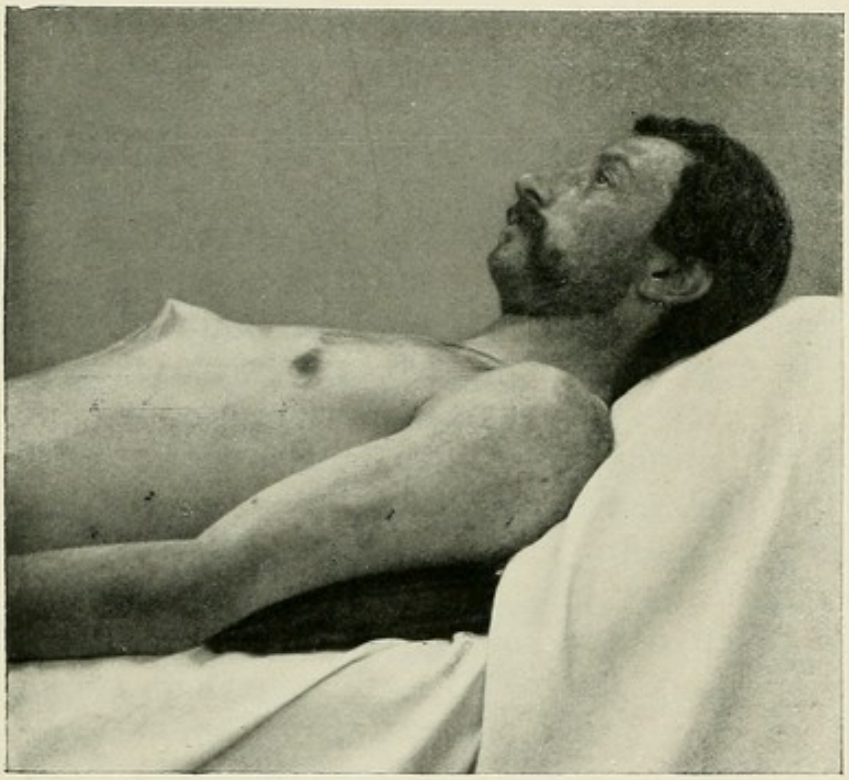

FIG. 107.—Fracture of the sternum with projection of lower fragment externally.

The following case refers to an unusual variety of dislocation :—

A workman fell against a box which he was holding in front of him, in such a way that the ensiform process hit against its edge. When the patient undressed he noticed a remarkable projection in the epigastrium. The sternum had been transversely split at the level of the fifth rib, and was displaced towards the skin. The rib cartilage was bent forwards and held the displaced fragment so firmly in position that reposition by the open method became necessary (fig. 107).

In cases where the accident is nothing more than a simple transverse fissure, notice is first attracted to the injury by the ecchymosis, which comes on in the course of a few days. As stated elsewhere, these fractures are generally indirect, and accompany fracture of a vertebra. It is, therefore, most important to examine the vertebral column in every case of fractured sternum, and *vice versâ*.

CHAPTER XXVII.

INJURIES OF THE LUNG.

If a liquid effusion rapidly makes its appearance within the thorax of a patient suffering from **contusion** thereof, or from fractured ribs, we must diagnose *hæmorrhagic effusion*, which may originate either from a ruptured intercostal artery or from the blood-vessels of the lung. We can only be certain of the latter origin if signs of *pneumothorax* supervene upon those of the effusion, or if the patient *coughs up* blood. The injury to the lung becomes quite obvious if air penetrates into the subcutaneous tissue and gives rise to the well known appearance of *cellular emphysema*, which often extends over a very wide area. Death ensues rapidly if a main bronchus has been completely torn away from the lung and opens into the mediastinal cellular tissue and inflates it. The effusion of blood and the pneumothorax must be carefully watched, because their increase, in association with a worse condition of the pulse and respiration, may demand operative interference. Sometimes, however, the initial symptoms of contusion of the lungs are so slight that the injury is overlooked, and it is only diagnosed after consecutive **pneumonia** has arisen.

Pneumonia, following contusion, usually appears within the first four days, a circumstance which is very important in arriving at a medico-legal opinion in doubtful cases.

Injuries of the pleura open to the skin are of more practical importance because they demand rapid decision as to treatment. The instrument inflicting the injury is usually a bullet, knife or dagger, even in times of peace.

The thorax has been pierced right through, from axilla to axilla, by the domestic broomstick, as recorded by Franke, with subsequent recovery.

Gunshot wounds of the pulmonary tissue are remarkably well tolerated because of its great elasticity. Recent wars have afforded numerous instances of people shot through and through, who kept on marching or riding for hours, and who returned to duty after a brief detention in the field hospital. This applies, at any rate, to injuries inflicted by modern small-calibre bullets with their small surface of attack. More serious results follow, especially severe hæmothorax and rapid hæmorrhage, when shrapnel bullets are used, or when the projectile, on its way through the thoracic wall, has torn up buttons or splinters of rib. The intensely severe conditions which result from shell injuries are usually so obvious that diagnostic reflections are quite superfluous.

Incised and *penetrating wounds* of the thorax cause expectoration of blood, whether the lung is involved or not. A simple hæmatothorax is not conclusive of the precise nature of the injury, because it may originate from a wounded intercostal or mammary artery as well as from a pulmonary vessel. A pneumothorax is only significant of an injured lung if the condition continues to increase when the external wound is hermetically sealed.

We must also be careful in diagnosing emphysema in cases of injury to the thorax. Whereas an extensive surgical emphysema points definitely to an injury of the lung, the slighter forms are due to aspiration of air through the external wound if the latter is situated in the vicinity of the armpit, and the patient is frequently lifting and dropping his arm.

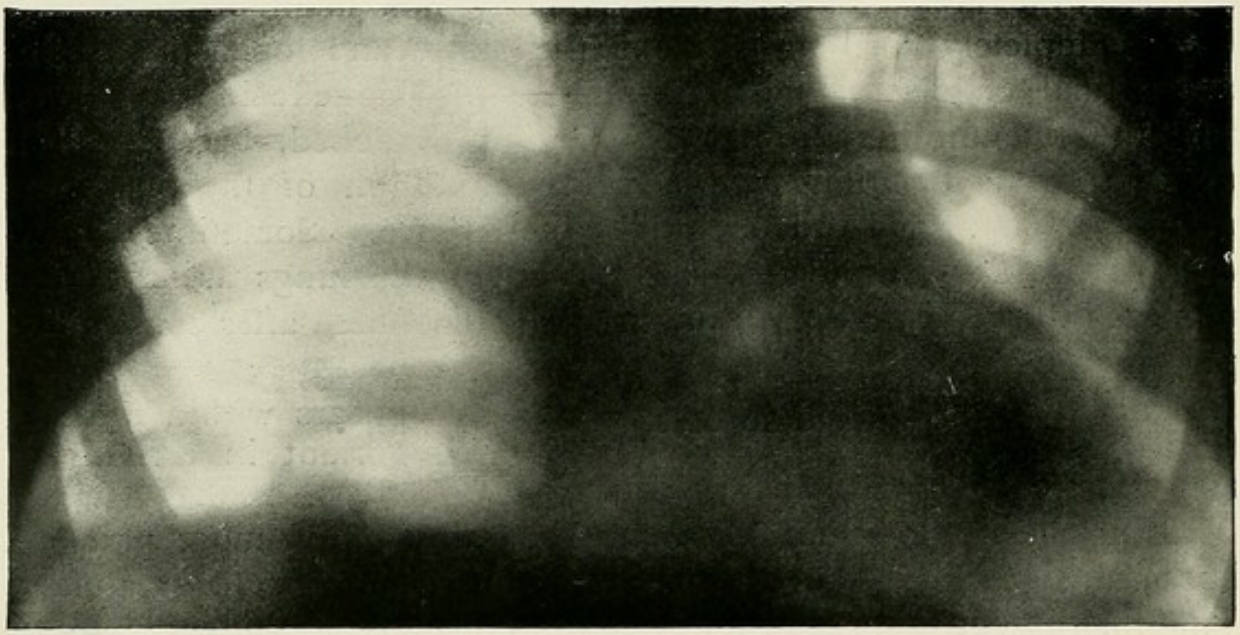

FIG. 108.—Pneumothorax through detachment of right bronchus. Considerable clear area. Contracted lung lying against median shadow.

In conclusion, a very important rule for the examination and treatment of injuries to the lung. *Rest* is of the utmost importance, because every change in position accelerates the respiration and may cause a fresh hæmorrhage. Diagnostic energy must, therefore, not be pushed too far, and we must be satisfied to move the patient as little as possible.

Although we may be clear about the injury to the lung, we must not forget that it is often accompanied by **secondary injuries.** The diaphragm and the viscera in relation therewith are especially endangered. A stab in the right side often involves, not only the lung but also the diaphragm and liver. We must, therefore, never neglect to examine for hæmorrhage within the abdomen, lest a patient may be bleeding from a wound of the liver while we assume he has only

sustained an injury to the lung, not of a dangerous character. The same consideration applies on the left side, to the spleen. The stomach is less frequently involved, because it more easily escapes the knife than the solid viscera. Injuries to the diaphragm on the left side produce immediate or subsequent *diaphragmatic herniæ*. The following case shows that this result is not limited to penetrating injuries like gunshot wounds or stabs.

A workman was brought to hospital in a moribund state after a severe crush of the thorax. The autopsy revealed several broken ribs, with a deep laceration of the left lung caused by the point of one of the rib fragments. The same fragment had pierced the diaphragm, and the wound therein was immediately filled up by a fungiform plug of omentum which projected into the pleural cavity.

Injuries to the lung are sometimes complicated by *wounds of the heart*, which then demand the chief attention, as being of the greatest danger. If the injury involves the *large vessels* in the mediastinum, an autopsy is inevitable. The easily deflected *œsophagus* is least exposed to danger.

CHAPTER XXVIII.

INJURIES OF THE HEART.

TWENTY years ago, death from wounds of the heart seemed quite the obvious thing, and recovery was ascribed to a lucky accident. Suture of the heart has however now been performed some dozens of times and in two-fifths of the cases the result has been successful. But it is necessary that the diagnosis should be made with rapidity and accuracy if surgical interfence is to be afforded adequate opportunity.

The *position* and the *character* of the wound are the principal indications which raise the suspicion of injury to the heart. Any wound situated over the cardiac area or its vicinity should excite suspicion, and in this connection it must not be forgotten that the heart may be wounded, in exceptional cases, by stabs or shots from behind. If the wound is not directly over the heart, the direction and the length of the instrument which inflicted it will show whether it is possible that the heart may have been involved.

The *probe* must *never* be employed in examination. The only reason for determining whether the wound is a penetrating one is

to ascertain the presence of an injury to any underlying organ, but the probe is unable to give information in this type of case. The probe may actually impinge upon the heart and yet we may be unable to tell whether it is injured or not. Beyond this, there is an element of danger in probing an injured heart, for this procedure has re-started a hæmorrhage which had already ceased. The patient is also unnecessarily exposed to the risk of infection because the superficial parts of the wound are not always aseptic.

If the wound is large, examination may be made with the finger, which will, as a matter of fact, enable a conclusion to be arrived at better than a probe, especially if the finger not only explores *over* the heart but also the actual wound itself, as recommended by Longo. But we should only resort to this not entirely harmless examination when everything is ready for operation and our finger is aseptic.

In judging the symptoms, it should always be remembered that not all cardiac injuries present the same clinical picture, and that not all the classical signs appear in every case. The decision as to treatment and the framing of a diagnosis must therefore not be delayed until all the text-book symptoms supervene and the patient is moribund.

The *subjective sensations* experienced at the moment of the injury, often referred to as those of indescribable fear, are of significance. *Reflex signs* such as fainting and vomiting may follow immediately on the injury, but these must be distinguished from its mechanical effects, which will be referred to forthwith.

Apart from those rare cases in which the patient bleeds externally from his wound, there are two distinct forms of cardiac injury: (1) in which the pericardium and heart are alone involved, and (2) in which the pleural cavity is also opened.

In a *purely cardiac injury* the most striking features, in addition to a certain reflex pallor, are the cyanosis and dyspnœa of the patient. The pulse is weak, rapid, and markedly irregular; the heart sounds are feeble and appear to come from afar. The cardiac dulness is more or less increased, but the results of percussion and auscultation of the lungs are normal.

We have just said that the *cardiac dulness* is increased. This is true of most cases of purely cardiac injury, but the extent of the increase varies considerably. It must not be estimated by the standard which obtains in cases of pericardial effusion, as the inexperienced are apt to do. An acute hæmorrhage does not distend a healthy pericardium to the same degree as a gradually developing effusion. We can, therefore, only expect any considerable increase in the area of dulness after cardiac injuries in cases wherein blood is

slowly oozing for days. In the very severe cases, on the other hand, death is too sudden to permit of the recognition of any striking distension of the pericardium.

Observation of the patient over a number of hours will probably show moments of improvement alternate with periods of exacerbation which appear to come on in attacks, signifying that the heart temporarily recovers, only to succumb in the struggle against unfavourable mechanical conditions. The exacerbations get worse and worse and the patient sinks unless hæmorrhage ceases spontaneously or is checked by suture of the heart.

This picture constitutes the condition known as *compression of the heart* by means of the blood enclosed within the pericardium. Whether the usual explanation of auricular compression is correct or not is an open question.

The following case will illustrate the foregoing remarks. A young melancholic stabbed himself three times in the cardiac region with a sharp file, and was brought into hospital three hours later with a miserable rapid pulse. During the examination dyspnœa and cyanosis became severe, the pulse inappreciable and the eyes glassy. A rib was immediately resected and the pericardium, which was full of blood, was opened. At this moment the nurse who was looking after the blood exclaimed, "The pulse has come back again!" No hæmorrhage had occurred into the pleura. The signs were therefore not those of anæmia but of compression of the heart. The patient was taken back to bed with a good appearance and full pulse. The heart was not sutured because the hæmorrhage ceased spontaneously, and the patient recovered.

The picture is quite different when the **cardiac injury is complicated by injury to the pleura.** If the pleuro-pericardial wound is large enough the patient simply bleeds into the thoracic cavity and he presents the appearance of an acute anæmia. The patient looks pale rather than cyanotic, the cardiac dulness is very little enlarged, if at all, but an increasing liquid effusion takes place in the injured pleural cavity. The pulse is rapid, small and irregular, and the patient manifests the same momentary improvements and sudden exacerbations which occur in purely cardiac injuries. On auscultation the cardiac sounds prove to be feeble. Various valvular murmurs are audible, but nothing distinctive. A splashing murmur like the sound of the wheel of a water-mill is of more importance, because this is conclusive of the entry of air into the pericardium.

We must, however, not expect to find a *typical picture* in any individual case. If the pleuro-pericardial wound is small blood may escape from it into the thoracic cavity, so that the patient becomes to a certain extent anæmic; but the opening may be eventually closed by a clot, so that symptoms of heart compression will be present in addition to those of anæmia. In these intermediate cases it is not

so important to diagnose all the details of the injury as to recognize the fact of cardiac injury as soon as possible, and appraise accurately the indications for surgical interference.

The following statement may be taken as a guide in practice :—

If an injury in a situation wherein the heart may be involved is followed by derangement in cardiac action or by acute anæmia, we must assume the probability of an injury to the heart, whether the cardiac dulness be increased or not. If the symptoms gradually increase despite transitory improvement, surgical measures must be adopted unless contra-indicated by external conditions.

"Unless contra-indicated by external conditions." The maintenance of strict asepsis is so important in these operations which usually concern the pleura and pericardium that cardiac suture ought only to be undertaken when all external conditions are favourable, unlike the rule for tracheotomy. If at all possible the patient should be conveyed to the nearest hospital. Experience shows that there is ample time for this if the diagnosis has been made without delay.

Do the foregoing remarks justify us in concluding that there is *no* cardiac injury in the absence of anæmia and circulatory disturbances? Certainly not. Even penetrating wounds may run their course without symptoms and may remain unrecognized despite careful examination.

An old man stabbed himself three times with a kitchen knife in the cardiac area. Although the heart was most carefully examined no sign of injury could be detected. The patient died in eight days from pneumonia, and the autopsy revealed a small stab wound which had gone right through the left ventricle, at the apex, but which had been sealed up by fibrin. The pericardium only contained a little blood-stained fluid.

Such a case is not one for immediate operation, but it requires careful watching, lest subsequent hæmorrhage necessitate an operation eventually.

A word of warning in conclusion. Too much zeal must not be evinced in this newly-acquired surgical province. Many uninjured hearts have been exposed, showing the necessity for most careful examination to avoid confusing an injury of some other thoracic organ with a cardiac injury.

CHAPTER XXIX.

THE SURGERY OF INFLAMMATORY DISEASES OF THE LUNG.

THERE are certain diseases of the lung in which the patient is entitled to the benefit of surgical treatment. Nothing demonstrates this so clearly as the action of a physician who, doubting the efficacy of his prescriptions, recently betook himself to the knife and has now become one of the most experienced of lung surgeons.

The diagnosis of surgical diseases of the lung comes within the province of the physician and general practitioner, because these maladies are purely "medical" at first. The surgical sense of the practitioner should evince itself by recognizing the exact moment when resort to the knife is required.

Empyema, abscess of lung and gangrene of the lung are the diseases which are of main interest in this connection. Bronchiectasis and actino-mycosis of the lung only rarely lead to operative procedures. The surgical treatment of phthisis and of emphysema is in much too early a stage to justify any discussion here.

A.—EMPYEMA, ABSCESS OF THE LUNG, GANGRENE OF THE LUNG.

From an etiological standpoint the following possibilities exist :—

(1) A **pneumonia** fails to resolve in the desired manner, or if pyrexia recurs after the crisis the first thought which enters one's mind is that of empyema. The diagnosis is made from dulness at the base, weakened respiration and loss of vocal fremitus and confirmed by exploratory puncture. An empyema extending to the spine of the scapula, and unrecognized, must be ascribed to a thoughtlessness on the part of the medical attendant. A careful observer will never be taken by surprise by an empyema bursting through into bronchi or thoracic wall. If an empyema is indicated by fever, dyspnœa and emaciation, but physical signs are absent, we need not doubt the accuracy of the diagnosis, but must search for the empyema in the correct situation. It may be interlobular and therefore fail to yield the ordinary signs. A circumscribed area of diminished respiration and of dulness, generally with some adjacent bronchial breathing bounded about and below by normal lung resonance and well-preserved respiratory murmur, usually directs us to its position. A needle correctly aimed will demonstrate pus at once. (See under Sub-phrenic Abscess.)

But in such a case the differentiation from abscess of the lung is difficult. This is also a frequent sequel of pneumonia, and if not situated at the base has an area of more or less normal lung tissue below it. The greater extent of the dulness and the later occurrence or entire absence of perforation into the bronchi are, however, distinctive of empyema.

A skiagram may render some assistance in this differentiation, because a more or less transverse non-transparent area indicates an empyema, whereas a restricted roundish thickening points to abscess (fig. 109).

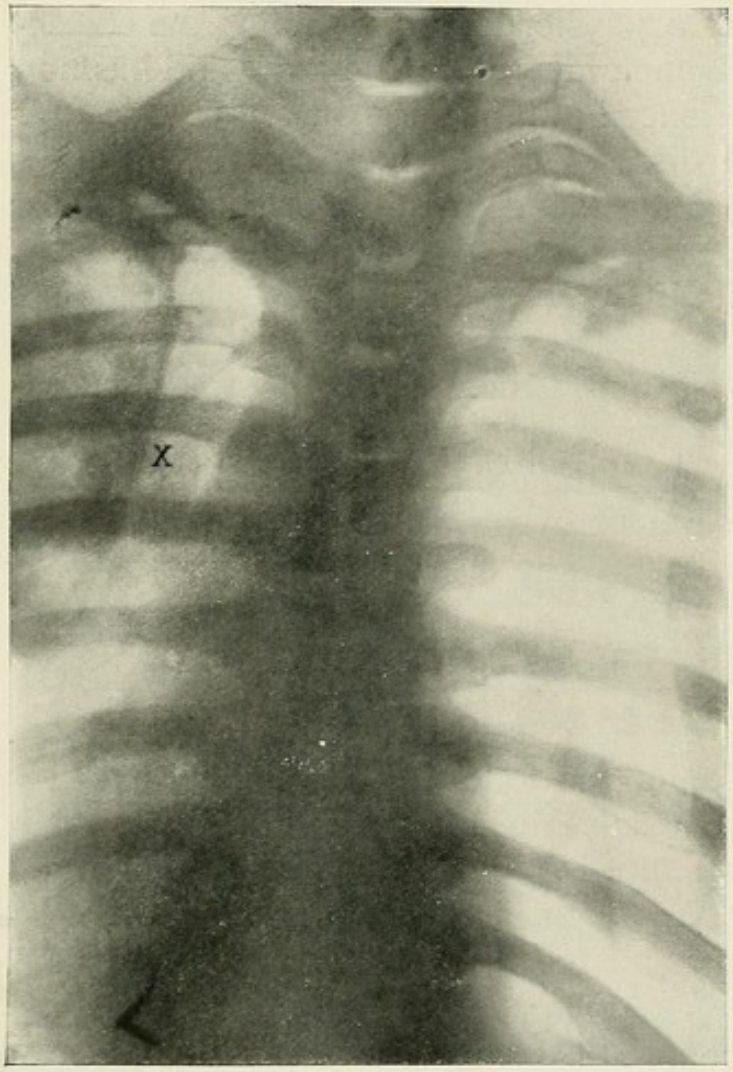

FIG. 109.—Skiagram of abscess of lung (X).

If the expectoration has a peculiar fœtid smell and contains shreds of lung tissue, the case is no longer merely one of abscess; it has become gangrenous.

If *copious pneumonia* has been the antecedent disease, as we have hitherto assumed, experience shows that some form of empyema is most probably in question.

(2) If the pneumonia has been caused by the inhalation of any kind of foreign body, or of fluids, the conditions are different. It is quite true that empyema is not a rare sequel, but *abscess of the lung* is of more frequent occurrence, and *gangrene* often follows it.

As we have previously seen, foreign bodies include everything taken into the mouth foolishly by children and adults and inhaled through carelessness. The consequent abscess may run a very chronic course and persist for years, even ten or more. I have seen a female aged 40 suffering from a chronic pulmonary abscess and bronchiectasis which she rightly attributed to inhaling a bean in her youth.

It is also necessary to note the occurrence of the inhalation of fluids, especially in the vomiting of anæsthesia and in operations on the mouth and throat, for the removal of putrefying carcinomata,

or for the extraction of teeth under general anæsthetics. The extraction of numerous teeth under anæsthesia is no trifling matter; nevertheless the operation is, unfortunately, often undertaken when the patient is quite unfitted for it.

If some lung complication supervenes with these circumstances the diagnosis is generally easy. At first a pneumonia is diagnosed. If an effusion takes place in the pleural cavity puncture with a needle will show whether it is serous or purulent. If the sputum after settling separates out into three layers—the lowest of pure pus, then clear liquid and the highest of mucus—an abscess must be present. If we are met by a repulsive odour on entering the sick room, the case is either fœtid bronchitis or gangrene. The sputum in the latter case is greenish or brownish and putrid, separating into three layers, and contains greyish or dark shreds of necrotic lung tissue, or, at any rate, elastic fibres visible under the microscope. If repeated examinations fail to reveal any of these structures, we must content ourselves with the diagnosis of fœtid bronchitis.

(3) In a third group of cases the lung symptoms are preceded neither by the inhalation of a foreign body nor by pneumonia. The disease follows some inflammatory process which may possibly be situated at some distance from the lung; and the exciting cause of the infection reaches the lung by way of an **embolism.** Any inflammatory process may serve as the cause, *e.g.*—sore throat, a furuncle, suppuration within the abdominal cavity, especially on the region of the female genitalia. If a few organisms only, or very minute particles of infected material are conveyed, the result will be according to their localization either a pleurisy or multiple small abscess formation with the signs of pneumonia. If, on the other hand, a larger infective thrombus reaches the pulmonary artery a more or less extensive focus of gangrene will result.

The history and physical examination, as we have seen, usually suffice for a correct diagnosis. If an empyema is confirmed by puncture the indications are for an immediate evacuation by surgical measures either by simple syphon drainage or by the more reliable method of rib resection. If we suspect an abscess of the lung or a gangrenous area, we must be more careful in regard to puncturing, because the pleural cavity is probably still free. We must therefore rather resort to a skiagram or a screen examination, and only proceed to puncture when everything is ready for an operation. It is even better to abandon the puncture altogether, or, at any rate, until the lung is exposed, The nature of the expectoration also testifies to suppuration, and its position is more correctly estimated by means of physical examination and a skiagram than by puncture.

We have hitherto assumed that the diagnosis of disease within

the pleural cavity can be made with absolute certainty; but this is not always the case. In discussing subphrenic abscess we shall see that it is very easy to mistake this for an empyema, especially on the right side. The diaphragm may be so tightly pressed against the thoracic wall, and the lung pushed up so far that although the needle shows the pus to be situated apparently in the sixth or seventh intercostal space, the abscess is really below the diaphragm. On the other hand, a circumscribed diaphragmatic pleurisy in the depths of the inferior surface of the lung may be mistaken for a subphrenic abscess.

B.—BRONCHIECTASIS.

Bronchiectasis is either of congenital origin or the result of some circumscribed inflammatory process of the lung or pleura, such as pneumonia or abscess.

The diagnosis is based upon the paroxysmal attacks of expectoration, amounting sometimes to a whole mouthful, especially in the morning; to the separation of the sputum into three layers—after standing, and to the presence of the particles of pus known as Dittrich's plugs. On physical examination moist râles are heard in cases of small bronchiectasis, and when large circumscribed cavities are present the signs are those of infiltration and cavitation. A skiagram should always be taken, because we may derive therefrom important conclusions regarding the situation and extent of cavities, if not about the very nature of the disease (fig. 115).

In the diffuse form there is only evidence of thickening of the lung tissue, which is indistinguishable from a severe tubercular infiltration; but in sacular bronchiectasis a cavity which is hardly distinguishable from a tubercular cavity may be visible.

It is well known that clubbed fingers develop after some years in cases of bronchiectasis, but this condition may also be due to quite different causes, and is, therefore, not of much value from a diagnostic standpoint.

In the differential diagnosis of bronchiectasis care must be taken to distinguish it from *pulmonary abscess* and from *tubercular cavities*. If there are no tubercle bacilli in the sputum the latter may probably be excluded. Pulmonary abscess differs from bronchiectasis in that it supervenes directly after the primary disease, *e.g.*, pneumonia or inflammation caused by a foreign body, whereas bronchiectasis takes months or years to develop. If there has been no causative disease, bronchiectasis is the most probable diagnosis.

C.—ACTINOMYCOSIS.

The early stages of actinomycosis of the lung are either entirely overlooked or confused with tubercle. If the patient has a chronic

cough with purulent sputum and elevations of temperature, he will generally be diagnosed as a case of phthisis—and justly so. But there are certain signs which ought to suggest the possibility of actinomycosis even at this stage. These consist of a localization of the disease to the middle and lower lobes, leaving the apices free, and also the incidence of pleuritic attacks with simultaneous drawing-in of the chest. A positive diagnosis may be obtained by examining the expectoration, at any rate if it contains the actinomycosis granules. The diagnosis is easier when the disease reaches the thoracic wall and becomes evident on the surface. We shall return to this in a subsequent section, but would only add here that operative treatment of this disease has affected a complete cure in many cases.

CHAPTER XXX.

TUMOURS AND ALLIED GROWTHS WITHIN THE THORAX.

PATHOLOGICAL growths within the thorax naturally fall under two groups: (1) Those of the mediastinum; (2) those of the lungs. Each group possesses its characteristic symptom-complex, and will therefore be discussed separately.

There are transitional forms here, as elsewhere, which introduce difficulties in diagnosis. Thus a small cancer of the lung with enlarged mediastinal gland will yield the symptoms of a mediastinal tumour, whereas a sacculated aneurism growing towards one lung will suggest the possibility of a pulmonary tumour.

(1) MEDIASTINAL TUMOURS.

No region is so inaccessible to direct examination as the mediastinum, and nowhere do tumours sail so long under false colours as here. The diagnosis is only made under a feeling of great responsibility, because the impotence of therapeutics renders the diagnosis a sentence of death.

Most of the new growths of the mediastinum chiefly involve the lung or the larger bronchi. An *irritating cough*, without expectoration, and *dyspnœa* are, therefore, the symptoms which dominate the clinical picture for a considerable time and suggest some form of pulmonary disease—phthisis in young people, chronic bronchitis and emphysema

in elderly patients. If there is, in addition, *paralysis of the recurrent laryngeal nerve*, the condition is looked upon with more gravity, although this form of paralysis may exist without any serious significance. If careful attention is bestowed on the form of the dyspnœa, it will often be noted that an attack comes on in certain postures of the body and that it ceases in other postures. The consideration of this symptom should suggest the possibility of some mediastinal growth, provided there is nothing in the neck like a goitre or other tumour to account for it. If the *veins of the neck gradually dilate*, and a collateral venous anastomosis develop at the same time, our suspicion will secure new support. At this stage there will generally be somewhere in the thorax, especially over the sternum, an abnormal *dulness on percussion*, and the aid of the *X-rays* should also prove of service. As the tissue of the tumour is less transparent than lung tissue, a mediastinal growth of any appreciable size, of whatever nature it be, will throw a superimposed shadow on one side or other of the sternum. The peculiarities of this shadow often afford further diagnostic assistance and provide definite conclusions as to the nature of the growth. But other clinical methods will furnish information on this head.

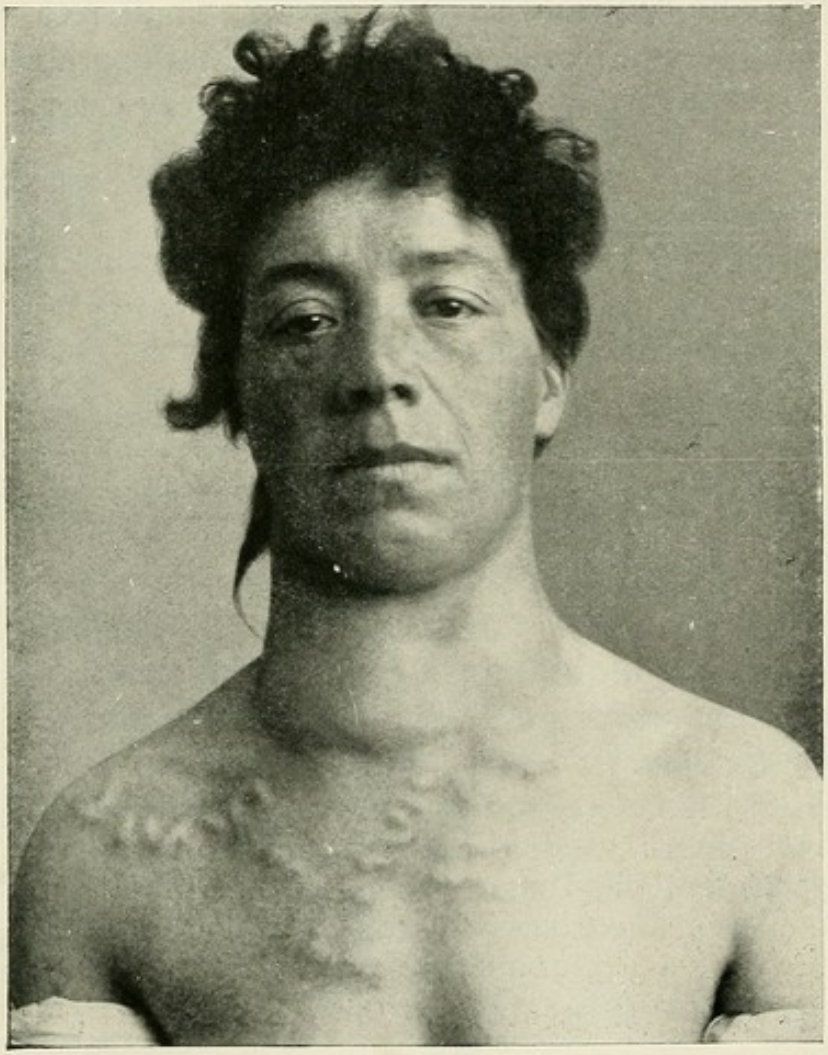

FIG. 110.—Diffuse colloid goitre with a considerable part inside the thorax (see fig. 111). Pronounced caput medusæ. Dyspnœa.

Let us consider the main possibilities: In infancy the most likely condition is *hypertrophy of the thymus gland*, or some unusually great *hyperplasia of the bronchial glands*. In older patients we endeavour to decide between an *aortic aneurism* or a genuine *tumour*.

Innocent tumours mainly consist of intra-thoracic goitres, dermoid and hydatid cysts, and malignant tumours comprise carcinoma and sarcoma, which may arise from the thymus, bronchi, lymphatic glands or connective tissue. Cancer of the œsophagus, which should properly be included here, is generally fatal before reaching dimensions which bring it in the category of mediastinal tumours.

The early recognition of **hypertrophy of the thymus** is particularly important, because many cases have been successfully operated on.

Hypertrophy of the bronchial glands in scrofulous, or rather in tubercular children, is only important surgically as a matter of differential diagnosis. Without a skiagram the diagnosis is usually nothing more than a suspicion, unless opportunely there are such definite signs as glands in the neck, dulness over the sternum, and paralysis of the recurrent laryngeal nerve. The skiagram, however, shows these glands with the clearest distinction, and should, therefore, always be procured whenever this diagnosis is entertained.

In adults the differential diagnosis mainly lies between **tumour** and **aneurism**; but the shape of the area of dulness permits of a definite conclusion being arrived at. In large aneurisms the dulness projects in front to one or both sides of the upper part of the sternum, and it appears posteriorly chiefly in the region of the left and sometimes of the right upper lobe of the lung. Mediastinal tumours may present the same condition in regard to dulness, but they do not adhere to any rule.

If the thoracic wall bulges and pulsates, and the hand feels a definite thrill, and if a souffle is heard with the stethoscope, the diagnosis requires no great skill, especially if the radial pulses are unequal and there is a history of syphilis (fig. 114). But sometimes nothing is heard on auscultation, the radial pulse is equal on both sides, and there is no previous history of syphilis. The actual symptoms, dulness, dyspnœa, paralysis of the recurrent laryngeal, intercostal pain, and possibly also inequality of the pupils due to pressure on the oculo-pupillary fibres of the sympathetic (to be examined in semi-darkness), the emaciation and even the shape of the demonstrable dulness might just as well be due to a mediastinal tumour, or, in exceptional cases, to greatly enlarged tubercular bronchial glands. We must, therefore, be guided by indirect diagnostic considerations. The symptoms of an aneurism usually come on very slowly, taking years to develop, and the patient is quite unconscious of them. Unless a sudden rupture occurs their progress is very gradual. A mediastinal tumour, on the other hand, develops more rapidly, and after having once given rise to symptoms proceeds uninterruptedly to the end.

Sometimes we are led upon the right track by the condition of other organs. Thus we may conclude from the presence of enlarged

glands in the neck, axillæ or groins, that the mediastinal disease also depends upon enlarged glands. The consistence of these glands may perhaps indicate whether they are leukæmic, but more reliance is to be placed upon the appearance of the patient and the blood count. But if the neck alone presents enlargement of the glands of recent date, we may assume the presence of a primary malignant tumour of the mediastinum or of the lung, unless it be a rare case of Hodgkin's disease beginning in the mediastinum. Fruit-juice, blood-stained expectoration would support the diagnosis of primary tumour of the lung. Old-standing pulmonary tuberculosis would

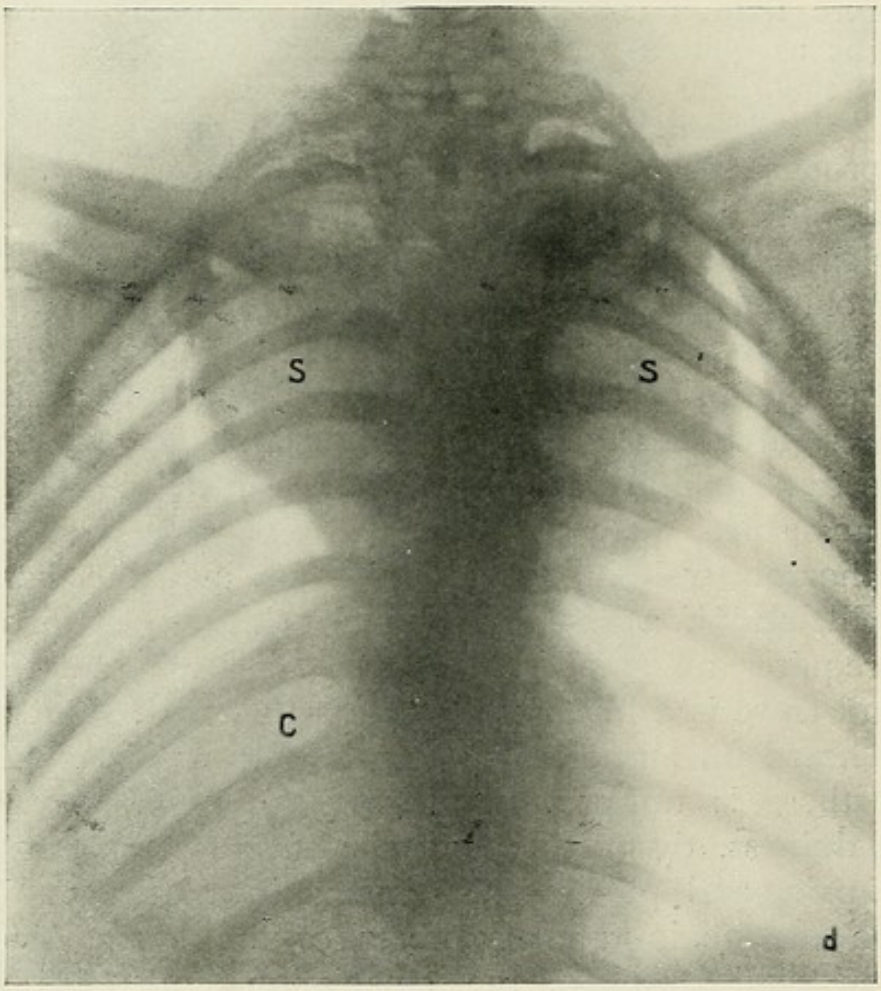

FIG. 111.—Intra-thoracic Goitre. *S—S*, the goitre; consisting of both lower cornua, as shown by the operation. *c* = heart, *d* = diaphragm and liver.

suggest mediastinal glands of a tubercular nature. If the patient has a malignant growth anywhere, we should discard all thoughts of aneurism and assume the presence of a metastasis in the mediastinum. Sometimes the primary tumour presents no symptoms at all, and the secondary growth in the mediastinum is alone in evidence, as in fig. 113.

But, as stated above, the most reliable conclusions are yielded in doubtful cases by *Röntgen rays*, especially by examination with the screen.

In the case of an aneurism a thick, sharply-limited, rounded shadow is seen. If the aneurism arises from the *ascending aorta* or *aortic arch*, the shadow is situated above the heart, fitting over it like a cap, corresponding to the dulness previously described (fig. 114). If it is an aneurism of the *innominate artery* the shadow is situated to the right of and above the aortic arch, and is not distinguishable from a saccular aneurism arising from the arch and growing towards the right. A semi-circular shadow on the left side, situated much lower down, indicates an aneurism of the descending aorta, if the shadow can be distinctly defined separately from the heart shadow.

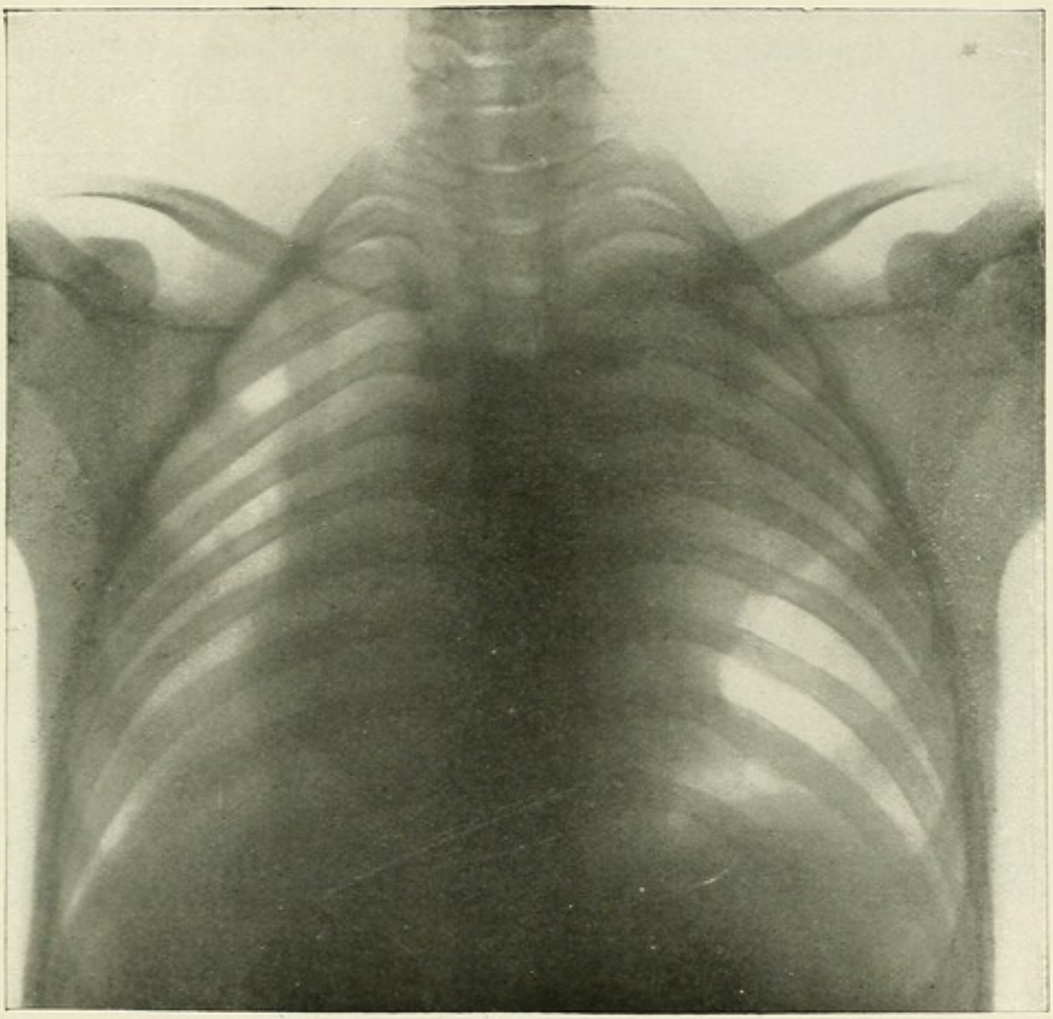

Left. Right.

FIG. 112.—A mass of mediastinal glands encroaching on the right lung in a case of lymphadenoma.

The penetration of an aneurism through the thoracic wall can be recognized clearly. All this is visible in the skiagram, but the screen allows us to see the pulsatile movement of the margins of the shadow. The absence of this pulsation is, however, no proof *against* aneurism, because there are such things as non-pulsating aneurisms; but the presence of an extensive pulsatile dilatation of the margins of the shadow, especially if bilateral, may be regarded as positive proof of aneurism. But if the pulsation is unilateral only, or if it is limited to one place, the case may be one of new growth pushing up the aortic arch.

The shadows cast by mediastinal and pulmonary tumours are quite different to the typical shadow of aneurism. Like the dulness produced by these tumours, their shadows have no typical situation, but they invade irregularly the median shadows cast by the spinal column and sternum, either to the right or left, encroaching into the lung area. Their limits are less sharp than in cases of aneurism (fig. 113), the border line especially being less regularly defined. Sometimes it is possible to see quite clearly that the growth is composed of separate nodules. We shall see later that there are exceptions to this rule.

The following case illustrates the considerations which lead up to the diagnosis of aneurism.

An alcoholic male, aged 42, who had been losing flesh for some time, suffered from indefinite general malaise, which was attributed

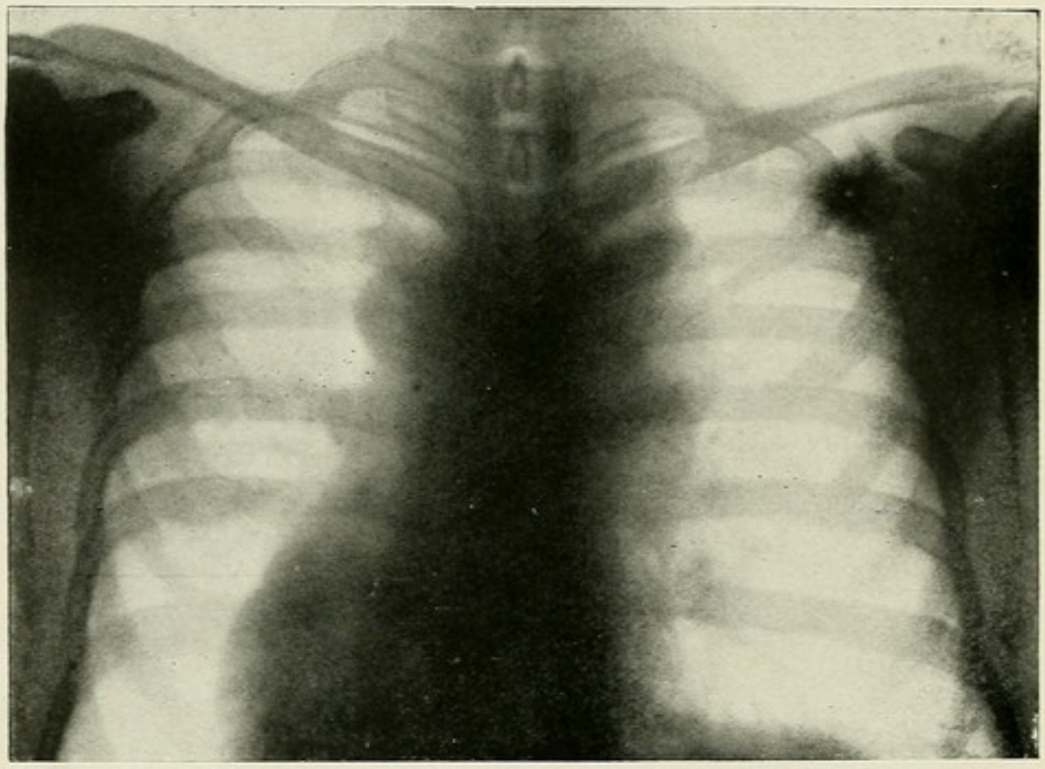

Left. Right.

FIG. 113.—Mediastinal tumour. Metastasis from a hypernephroma which produced no clinical symptoms.

to a cirrhosis of the liver, with which he was afflicted. During the last few weeks striking dyspnœa and hoarseness developed, and the patient came into the consulting room emaciated and short of breath. He might have been taken for a case of advanced phthisis, had he not stated that he had had no cough up to quite recently, and even now there was no expectoration suspicious of tubercle. The breathing was rapid, but auscultation disposed of the idea of pulmonary disease. Cardiac action was rapid, but the heart sounds were pure, there were no bruits or murmurs. The dyspnœa could not be accounted for by pulmonary disease or by valvular defect. The clinical picture did not fit in with disease of the heart muscle. The only explanation was offered by a slight dulness on both sides of the upper half of the sternum, which might be caused by an

aneurism or by a tumour. The radial pulse was equal on both sides. Röntgen-ray examination revealed a shadow, corresponding in form to an aneurismal shadow, above the heart, reaching to the throat. There was, however, no distinct pulsation, and it was proposed that the patient should come into the hospital for further examination of this point and for closer observation. But, instead of coming to the hospital, his doctor reported, in a few days' time, that the patient had died from hæmorrhage within a few minutes.

If an aneurism manifests itself for a considerable time, merely by a single symptom which is not very typical, much difficulty may be encountered before a diagnosis is established. Thus, I saw a patient who had been treated for two years for intercostal neuralgia, the explanation of which was not revealed by physical examination of the thoracic organs. Resection of three intercostal nerves afforded temporary relief. The recurrence of the pain suggested an X-ray examination, and then an aneurism was discovered!

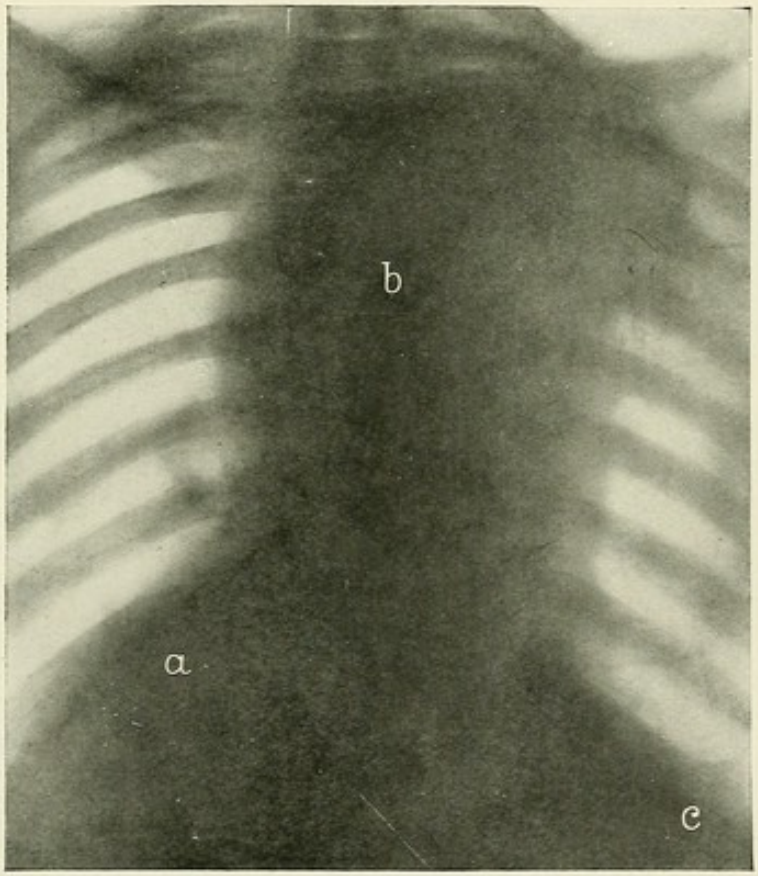

FIG. 114.—Aneurism of the aortic arch. *a* = heart, *b* = aneurism, *c* = diaphragm and liver.

Such cases show how easy it is to overlook an aneurism. We do not, however, mean to suggest to certain journalists that they should diagnose "ruptured aneurism" any more frequently than they do at present in cases of sudden death.

If, after considering all the diagnostic signs of aneurism, we exclude this condition and diagnose a **new growth,** our next step is to determine its nature.

We have already mentioned intra-thoracic goitre, dermoid and hydatid cysts as innocent tumours. A **goitre** is easily recognized if it is merely a continuation of one, visible and palpable in the neck (deep goitre). The diagnosis is, however, more difficult if the whole goitre is concealed within the thorax, and the corresponding lobe of the thyroid gland cannot be felt or is only rudimentary (pure intra-thoracic goitre). In such cases the goitre originally develops

from an inferior cornu of the thyroid gland, extending very low down. The goitre grows into the thorax and becomes so large that it can no longer slip out, and as it grows it drags the rest of the thyroid lobe down with it. It may also originate, as a true or false secondary goitre, from an accessory thyroid gland.

A female, aged 68, who had been suffering from bronchitis for many years, came to the hospital because of extreme dyspnœa. She could only breathe in a sitting and bent-up position. There was dulness on both sides of the sternum, and the skiagram showed a sharply defined shadow, like a cap, above the heart, reaching as

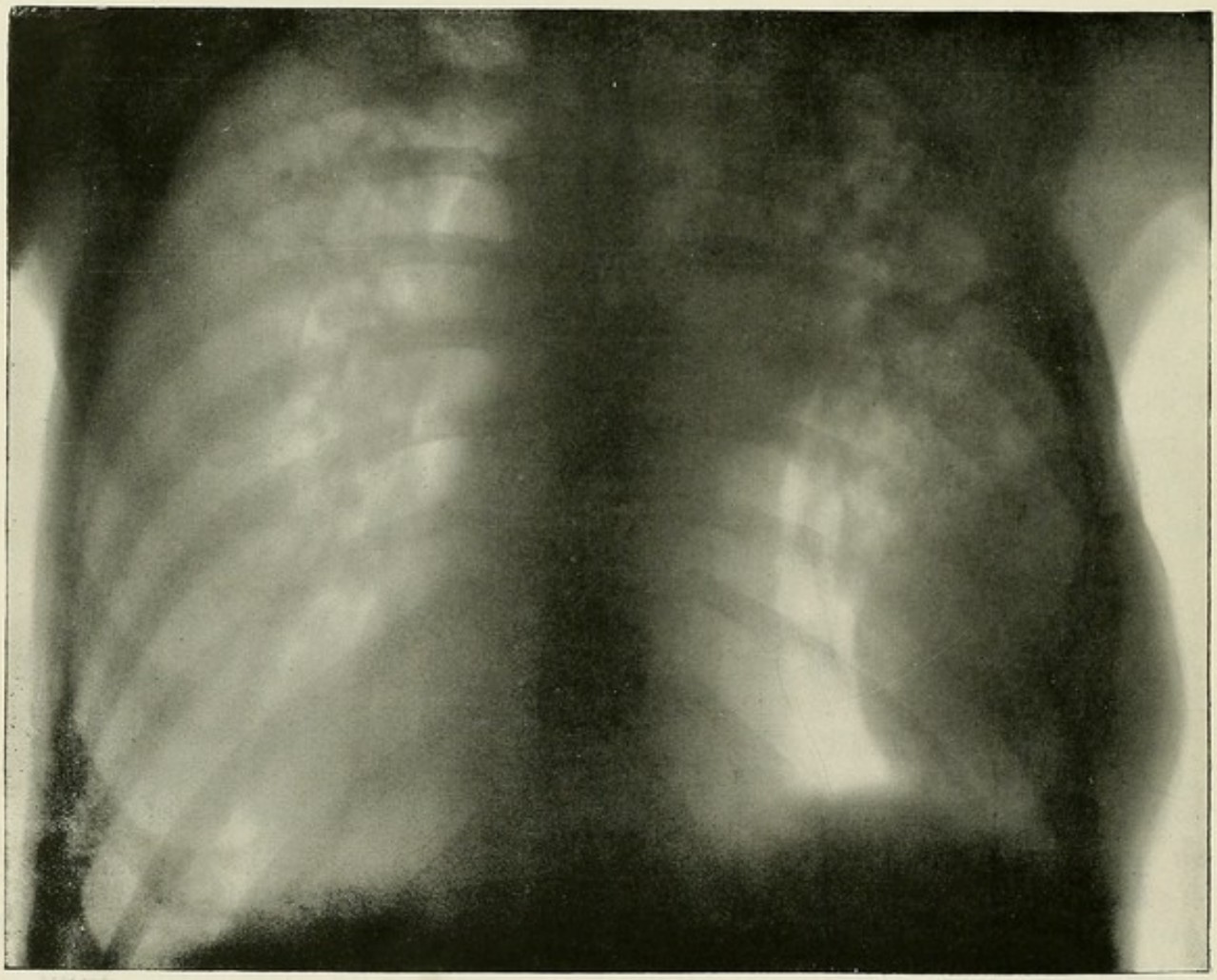

Left. Right.

FIG. 115.—*a* = Cancer of the right lower lobe penetrating through the thoracic wall. *b* = Diffuse bronchiectasis of the right upper lobe. *c* = Old tubercle of the left upper lobe.

far as the throat, which suggested an aneurism by its shape. But its edge did not pulsate, and other evidences of aneurism were also wanting. The right lobe of the thyroid gland contained a few small colloid nodules. Nothing could be felt of the left lobe of the thyroid except some indefinite resistance in the throat. The case, therefore, appeared to be one of intra-thoracic goitre, which would also account for the bronchitis. The operation confirmed this diagnosis, and the removal of the goitre permanently cured the malady. The operation

in the cases depicted in figs. 110 and 112 was followed by the same result.

Dermoids of the mediastinum are mostly situated behind the manubrium, and are accessible to operative treatment. The diagnosis has occasionally been based on the expectoration of hairs, after perforation of the dermoid into a bronchus. Otherwise we cannot get much beyond suspicion.

Hydatid cysts will only be thought of in districts where they are endemic, and then the diagnosis is something of a guess, unless the nature of the disease is betrayed by attacks of urticaria.

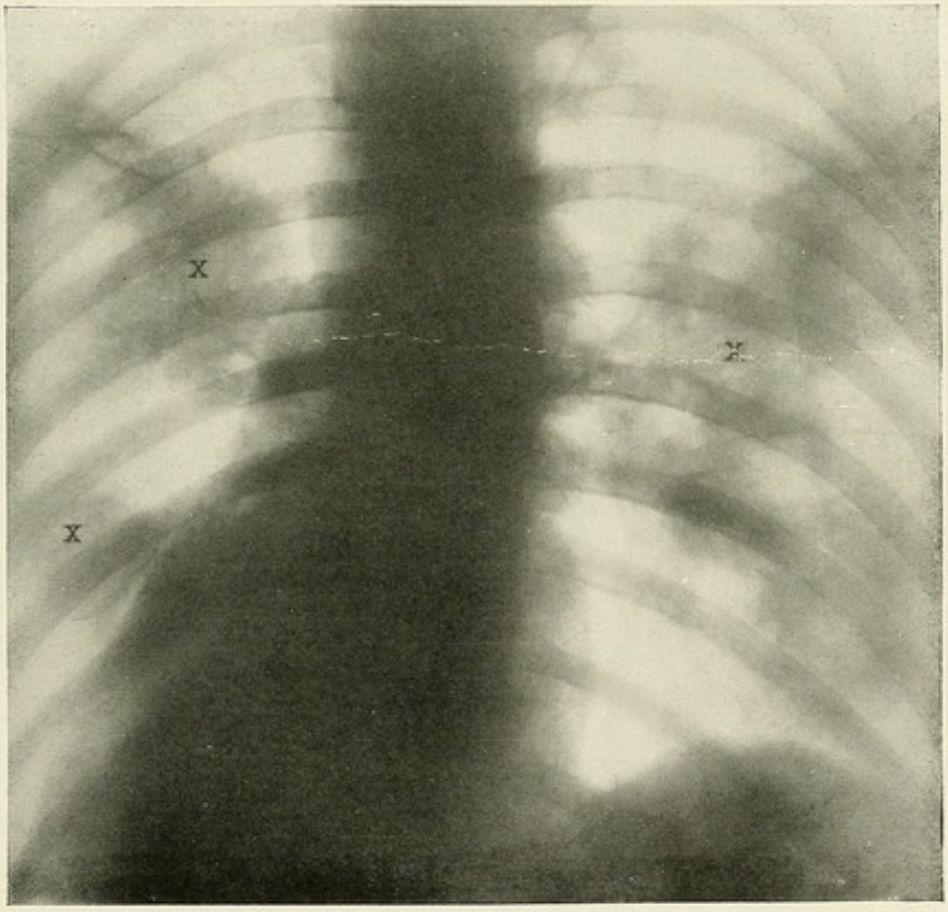

FIG. 116.—Metastatic cancer of lung. x x = foci in both lungs.

Malignant tumours are recognized by their rapid growth and the correspondingly swift increase of all symptoms. They are also indicated by the significant extent and rapid increase of the dulness. We have already referred to their skiagraphic appearances. They are usually **sarcomata,** originating either in lymphatic glands or connective tissue.

(2) TUMOURS OF THE LUNG.

Tumours of the lung, like those of the mediastinum, consist of **dermoids, hydatids, carcinomata, sarcomata,** and of **chondromata,** the last starting in the bronchial cartilage. In their early stages all

these growths, if they give rise to symptoms at all, are mistaken for tuberculosis. A dermoid is only recognized when hairs are coughed up; a hydatid only when it bursts into a bronchus and causes suffocation, or when this occurs under the very eyes of the unsuspecting practitioner as a result of an exploratory puncture. If the patient does not succumb, the microscopic examination of the fluid, and the occurrence of urticaria consequent upon the puncture, will establish the diagnosis. The skiagram, with its sharply defined spherical shadow, is very significant of hydatid cyst. If the symptoms do not accurately fit in with those of tuberculosis, we should think of a malignant growth, especially if the patient is expectorating reddish fruit-juice sputum. Sometimes cancer can be recognized by particles of tissue in the expectoration. Malignant disease of the lung is more likely to be carcinoma than sarcoma, but even carcinoma is quite rare.

According to Schwalbe, the presence of stridor is in favour of sarcoma, and its absence suggests carcinoma. In sarcoma, the bronchial glands undergo more enlargement than in carcinoma.

The accompanying illustrations of secondary cancerous nodules in the lungs show how clearly tumour areas can be marked out by means of X-rays.

It is of interest to note the occurrence of lympho-sarcoma of the lungs in miners, who inhale arsenic-containing dust.

CHAPTER XXXI.

SWELLINGS AND TUMOURS OF THE THORAX.

SWELLINGS and tumours on the surface of the chest originate from one of the thoracic viscera, usually the lung or pleura, or from the chest wall itself. It is important to arrive at some decision on this fundamental point before making a physical examination, and this can be done by obtaining a careful clinical history.

A.—PRIMARY DISEASE WITHIN THE THORAX.

If the appearance of a tumour on the chest wall is the final episode of a long history of illness, which began with an irritating cough without expectoration, dyspnœa and hoarseness, and which was followed by disorders of the circulation, we must think of a lung or mediastinal tumour, an aneurism or of some inflammatory condition.

We must think of the possibility of aneurism because an exploratory puncture, thoughtlessly undertaken, may place us in a very awkward predicament.

We have already dealt with the important points which concern tumours of the mediastinum and of the lung.

A swelling appearing in the thorax after a disease which began with *inflammatory symptoms*—either of an *acute* character like pneumonia, or of a *chronic* character like a slow pleurisy—is suspicious of a pleural empyema which has made its way to the surface, a so-called **"empyema of necessity."** Nowadays we lay more stress on the "necessity" of operative treatment before the pus has become subcutaneous.

We will give three typical cases illustrating the most important forms:—

(1) The empyema which has burst through may be of an **acute infective** variety.

A middle-aged man suffered from a circumscribed pneumonia, with which signs of pleurisy were associated. A diffuse, phlegmonous, rapidly extending swelling at the back indicated the urgency of surgical aid. Examination showed that there was an effusion into the left pleural cavity with a phlegmonous swelling of the soft parts on the corresponding thoracic wall. Diagnosis: ruptured empyema. This was confirmed by operation. The rupture was due to a cause which is in no way unique. Two days beforehand the pleura was punctured for bacteriological diagnosis, and evidently this afforded an opportunity for the introduction of infection from the soft parts along the puncture wound. This is a lesson that in acute cases operation should immediately follow puncture, should pus be discovered.

(2) Another variety is of **tubercular** origin.

A young man, whose previous history pointed to tubercle, complained about the gradual development of a painless swelling, about the size of a goose's egg, immediately to the right of the sternum. The swelling could not be displaced, and it did not undergo any change in volume with respiration, indicating some connection with the interior of the chest. But there were definite evidences of tubercular disease over the right upper lobe of the lung, which led to the conclusion that there was some direct connection between the two conditions. Operation showed that the superficial abscess was in direct connection with an encapsuled collection of pus within the thorax.

If the tumour could have been displaced our diagnosis would have been better founded. This symptom was absent because the intrapleural collection of pus was quite small in circumference, and was bounded by firm and indurated tissue.

If a cavity ruptures externally the swelling will evidently contain gas. There is always some secondary infection in a cavity, and this confers acute inflammatory characters upon the abscess, as happens when a purely tubercular collection of pus breaks through.

We shall subsequently enter into the details of differential diagnosis between a tubercular empyema which has burst through, and tuberculosis of the ribs.

(3) The third possibility is illustrated by the following case :—

A young girl, suffering from symptoms of chronic pleurisy, was admitted to the hospital with a bilateral effusion. The needle met with pus on the left side, but not on the right. Resection of the ribs, on the left side, was performed. The chronic course of the disease and the curious appearance of the pus suggested tubercle at first; but the pus really contained filaments similar to actinomyces, without granules. After a little while a swelling appeared in the anterior axillary line parallel with the ribs. At the periphery it was board-like in consistence, without any reddening of the skin, whereas in the middle it was soft and red. Even without the bacteriological examination of the left side these appearances would have strongly suggested actinomycosis. As a matter of fact, the pus from the right side contained the characteristic granules in large amount.

Here, as in all cases of **pulmonary actinomycosis,** the first thought was of tubercle. This rare disease can only be identified by the discovery of the actinomycotic filaments or the characteristic granules in the sputum or pus, unless the board-like infiltration previously described, which indicates that the process has reached the surface, betrays the correct diagnosis to the experienced eye.

B.—PRIMARY DISEASE OF THE THORACIC WALL.

If nothing in the history or physical examination points to disease of the thoracic viscera, we must assume that the structure under investigation arises from the *bony wall of the chest* or from its *integuments*. We are not here concerned, however, with tumours of the mammary glands, as these are dealt with in a separate chapter.

(1) ACUTE DISEASES.

Acute swellings need not detain us long, as they rarely occur on the chest. The principal one is **acute osteomyelitis** of the scapula or clavicle, which can hardly be mistaken for anything else. The sudden onset with rigors and high temperature indicate the nature of the disease, and the bone affected is shown by the position of the swelling and the pain on pressure. An acute osteomyelitis of a rib, which is very rare, might be mistaken for an empyema which has broken through, but in the latter case the distinctive antecedent symptoms would not have been present.

Phlegmonous processes are not of rare occurrence in the vicinity of the axilla. They generally originate in *lymphatic glands*, the infection being introduced from the periphery. The experienced observer

will at once examine the *fingers*, and look on each one for some lesion, however insignificant.

Sometimes red streaks of lymphangitis lead towards the original wound. Frequently the wound is already healed by the time an abscess has developed in the axilla.

Occasionally very deep axillary abscesses form, as a result of *acute pustules* and *furuncles* which are not infrequent in this region. Purulent inflammation of the *sweat glands* (hydro-adenitis) should also be mentioned.

Finally, a phlegmon may develop under the pectorals, tracking towards the axilla, and it may be quite impossible, despite the most careful examination, to trace the entrance of the infection.

(2) CHRONIC DISEASES.

In a *gradually developing swelling* our first endeavour is to decide whether it is inflammatory or a new growth. As cystic tumours, apart from those of the breast, occur very rarely on the thorax, fluid contents point to pus. The only difficulty is to be sure of the fluid, because it is not always easy to differentiate the fluctuation of fluid in small tumours from the soft elastic consistence of a lipoma, for example. The beginner is apt to confuse fluctuation with this soft elasticity, even in the case of larger tumours. When in doubt as between a lipoma and an abscess, one should remember that a lipoma is characterized by a lobulated structure and numerous slight puckerings of the skin, whereas the skin over an abscess is quite smooth. The doubt can at once be solved by a puncture, but this should be left to the end of the examination if it is indispensable. If suppuration has not yet occurred an inflammatory origin would be indicated by spontaneous pain and tenderness on pressure.

(a) Chronic Inflammatory Processes.

Tuberculosis and *syphilis* are, with few exceptions, the principal causes of chronic inflammatory conditions on the thorax, whether the swelling be non-suppurative or whether it be an abscess. The inflammation may start in one of three tissues, viz., *lymphatic glands*, *muscles*, or *bones*.

Chronic inflammatory processes starting in the *lymphatic glands* are of a tubercular nature. They are situated in the neighbourhood of the axilla—sometimes in front in the infra-clavicular fossa, sometimes below, between the anterior and posterior axillary line, and sometimes behind, under the scapula. The infra-clavicular glands cannot as a rule be felt separately, like the cervical glands, because they are situated under a thick layer of muscle. When they are

diseased they present the appearance of a diffuse swelling of the deeper tissues, firm at first, but eventually declaring itself as an abscess which reaches the surface. But tubercular glands in the axilla feel exactly like those in the neck, and are therefore easily recognizable. The axillary glands are, however, rarely affected alone. The cervical glands are, as a rule, also involved. As in the case of the neck, there is also here the liability of confusing tubercle with malignant lymphoma; but we have already referred to the differential diagnosis in discussing tumours of the neck.

If an inflammatory area is situated within a **muscle**, the condition is usually *tubercular*, and rarely *gummatous*. It manifests itself as a painful hard little tumour, and its intra-muscular situation is easily recognized by the fact that it is freely movable when the muscle is relaxed, and is quite fixed when the muscle is contracted.

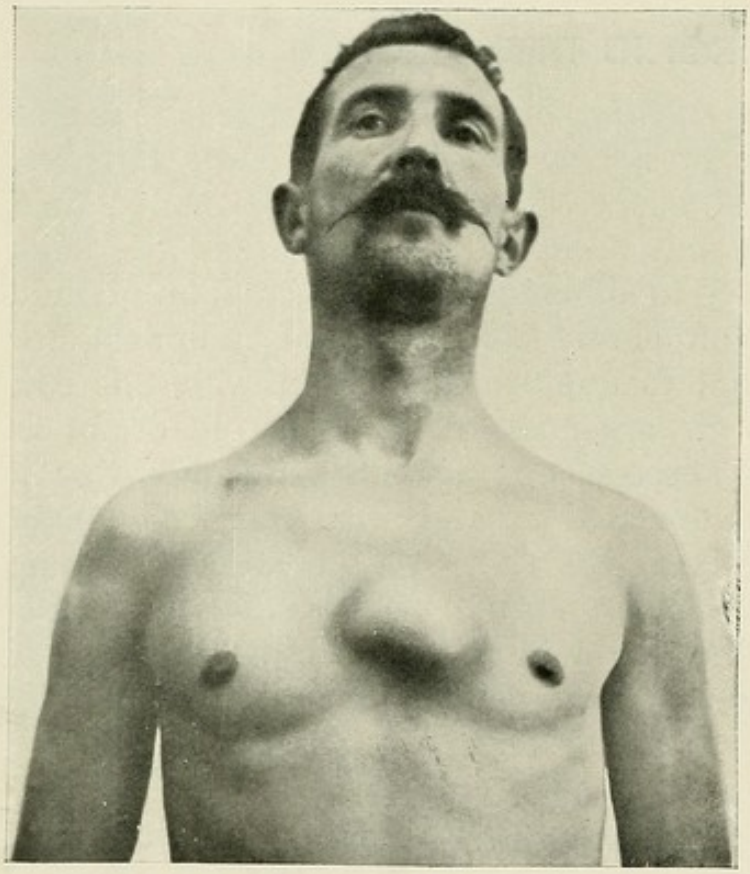

FIG. 117.—Tubercle of the sternum.

But most of these inflammatory processes arise from the **bones**, and all the bones of the thorax and shoulder girdle participate therein; the clavicle is, however, rarely at fault. There is one important distinction in regard to disease of these various bones, for, whereas disease of the superficial bones, like the ribs, sternum, and parts of the shoulder blade, may be recognized in the earliest stage before an abscess develops, spinal caries is only diagnosed after an abscess has formed, unless attention has been directed to the matter by functional disturbances. In these cases the abscess has often tracked a considerable way before reaching the surface.

A swelling of the *clavicle* of gradual origin should at once suggest **malignant new growth**, because tubercle and gumma are of very rare occurrence there. If no other new growth is discoverable we must regard it as a primary **sarcoma**. But microscopic examination will often surprise us, and indicate that a primary **carcinoma** is concealed

somewhere. Cancer of the thyroid, breast, or prostate should suggest themselves, because their secondary deposits preferably affect the bones; but tumours of other glandular organs, such as the gastro-intestinal tract, should also be thought of.

If there gradually form over a *rib* a spindle-shaped swelling, rather painless in itself, but still sensitive on pressure, we should at once think of **tubercle,** but even here an error is possible. Sometimes a **gumma** of the periosteum of the rib may have features very similar to tubercle.

Primary disease of the marrow (as shown by skiagram) points to tubercle; primary periostitis is not decisive.

A young man was admitted to the hospital with a spindle-shaped, somewhat sensitive swelling at the junction of the fourth rib and cartilage. The case had been diagnosed as tubercle, and the patient had been treated with iodoform injections. An affirmative answer was given to the question whether he had suffered from *typhoid fever*, and he added that the swelling started a few weeks after his recovery therefrom.

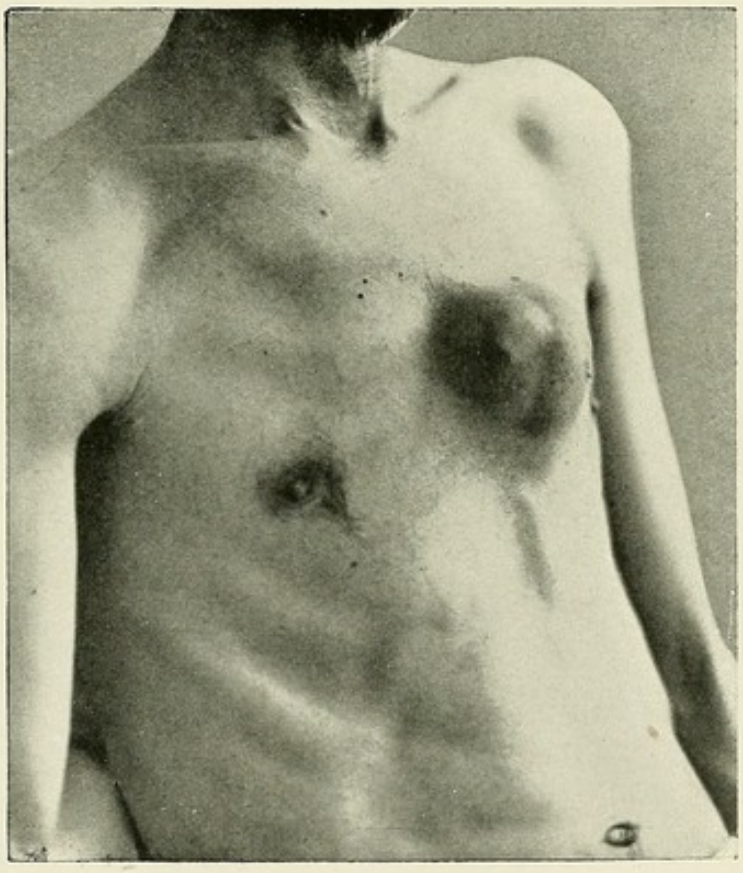

FIG. 118.—Thoracic wall, perforated by aneurism of ascending aorta.

It is quite conceivable that typhoid fever may excite tubercular disease when a predisposition exists towards it—I have seen this in lymphoma of the neck. But such an assumption was out of the question in this case. We know that **post-typhoid osteitis and chondritis of the ribs** represent a special type of disease, with a very chronic course. Sometimes recovery occurs spontaneously, sometimes only after the extrusion or operative removal of a bony or cartilaginous sequestrum.

On the *sternum* the diagnosis lies between **tubercle** (fig. 117) and **gumma,** but we should also think of **malignant new growth** as long as no suppurative softening of the tumour has occurred. The differential diagnosis is, however, difficult, and Küster has removed a large gumma in mistake for a sarcoma. In doubtful cases a Wasser-

mann test ought to be undertaken, and a trial made with specific treatment before operating.

The constitution of the pus brought away by the syringe may afford some information, before the bacteriological examination is made. Flaky, very liquid pus points to tubercle, viscous mucoid pus points to gumma, but this rule is not always maintained.

On one occasion I saw a young man, who had a tubercular family history, with a swelling over the manubrium sterni. There was no evidence of acquired syphilis, and hereditary infection was improbable. The pus obtained by the syringe was brownish, viscous, and mucoid. Nevertheless the guinea-pig which was inoculated became tuberculous and the treatment by potassium iodide which had been started was quite ineffectual.

Swellings of gradual origin on the *shoulder blade* are usually **tubercular** or **sarcomatous.** In the early stages there may be some serious difficulty, because adjoining the hard places are to be found soft portions, which resemble abscesses, a circumstance which also occurs with tumours. But when suppuration takes place in tubercle it becomes evident, in a short time, and often becomes quite extensive; so that in every case where the diagnosis is doubtful we must suspect sarcoma and treat accordingly. Anyhow, an early exploratory incision allows radical measures to be

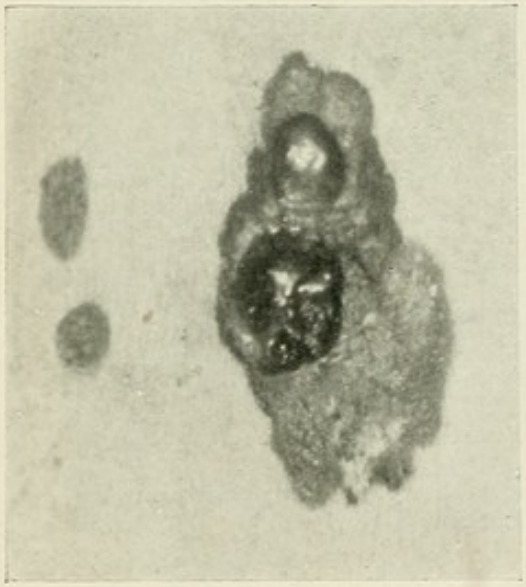

FIG. 119.—Pigmented nævus of the lumbar region, with partial sarcomatous degeneration.

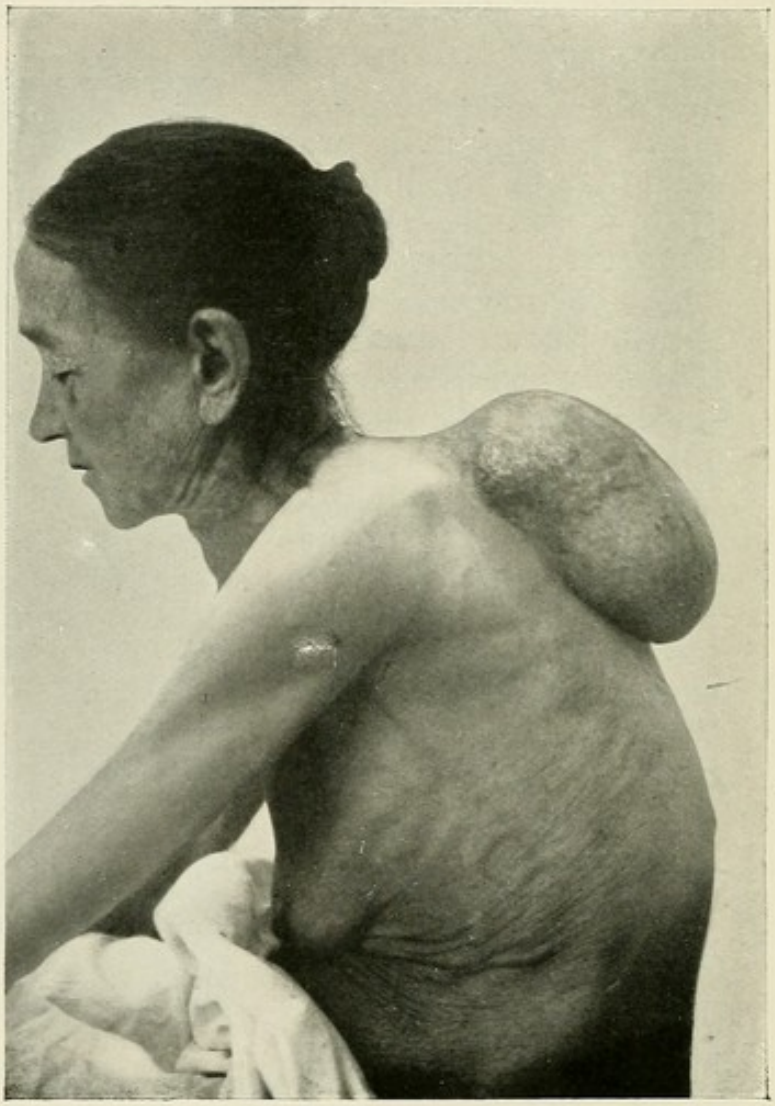

FIG. 120.—Fibro-sarcoma of the skin of the back.

undertaken in a case of tubercle, and offers the only prospect of cure in sarcoma.

A history of *injury* is of no special value either for the one or the other diagnosis, because an injury may excite either tubercle or sarcoma. The following is an example of the former.

A young lad was for a long time engaged in unloading very heavy cement pipes, which he always carried on his right shoulder. After about two months a swelling appeared over the supraspinous fossa, and a number of abscesses developed which clearly contained tuber-

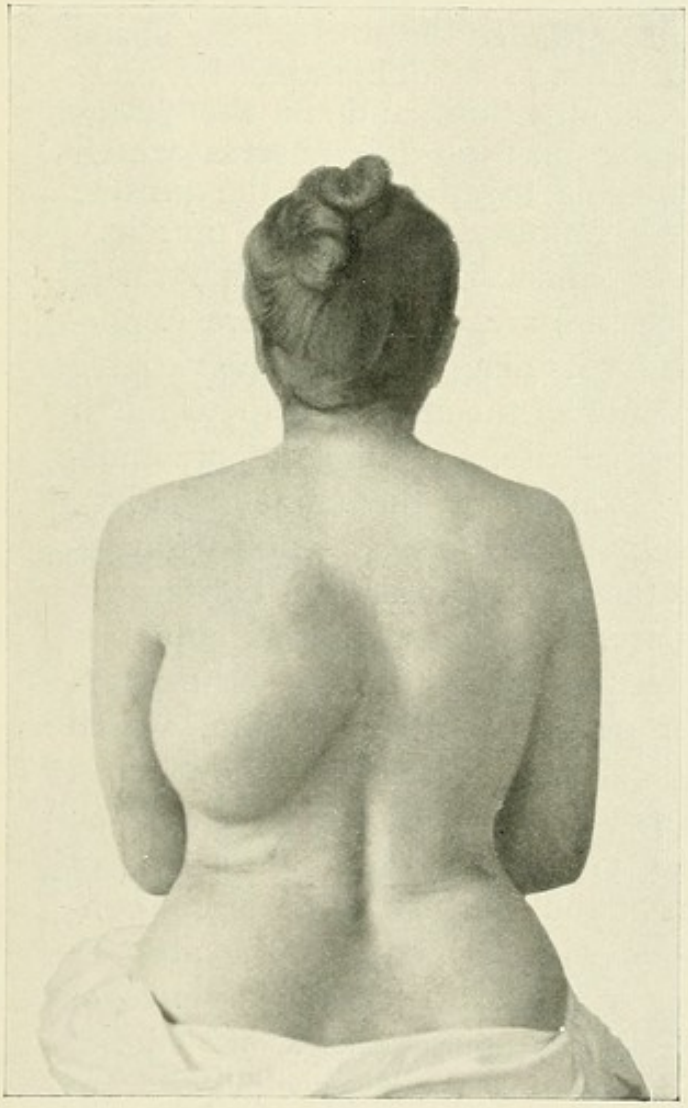

FIG. 121.—Unilateral lipoma of the back.

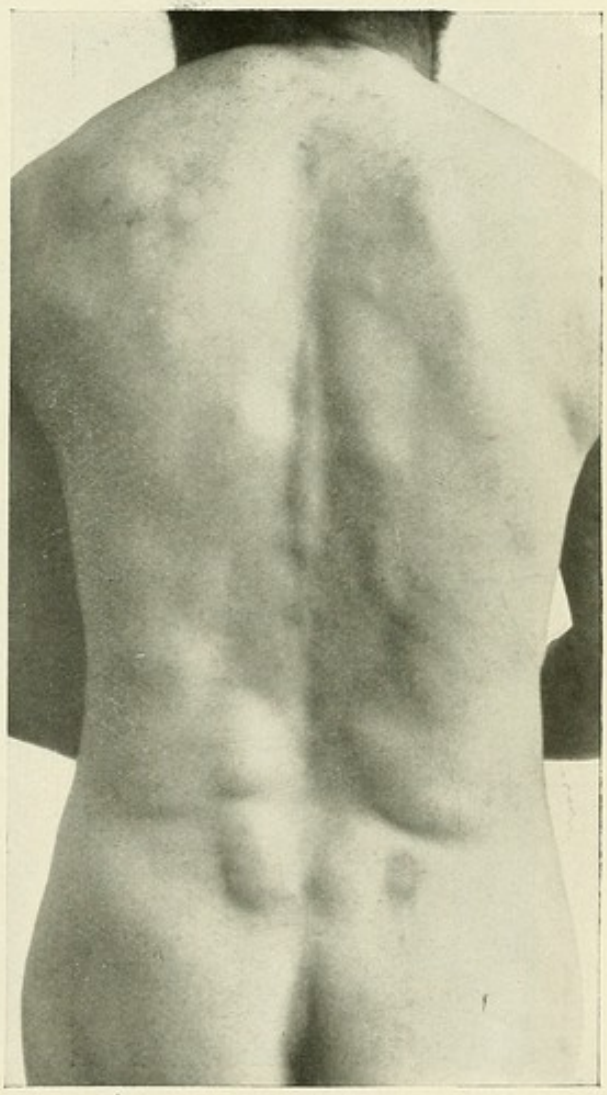

FIG. 122.—Symmetrical lipomata of the shoulders and loins.

cular pus. It is difficult in a case like this to avoid considering the persistent trauma to be the opportune cause of the tubercular attack. But, of course, this does not mean that the tubercle was the "consequence of the injury," in the legal sense.

If a cold abscess on the back appears to have no relation either with a rib or the shoulder blade, it probably arises from a *vertebra* —from the transverse process, vertebral arch or spinous process.

The behaviour of these abscesses gives rise to many interesting

problems of diagnosis, although they may have little connection with the origin of these abscesses. A burrowing abscess, after bursting through layer upon layer, from its deep origin, may spread widely over the surface. The superficial position of an abscess is, therefore, no argument against its origin from bone. But if we are able to demonstrate the deep origin of an abscess, we shall be all the more decided in our search for the diseased bone which gave rise to it.

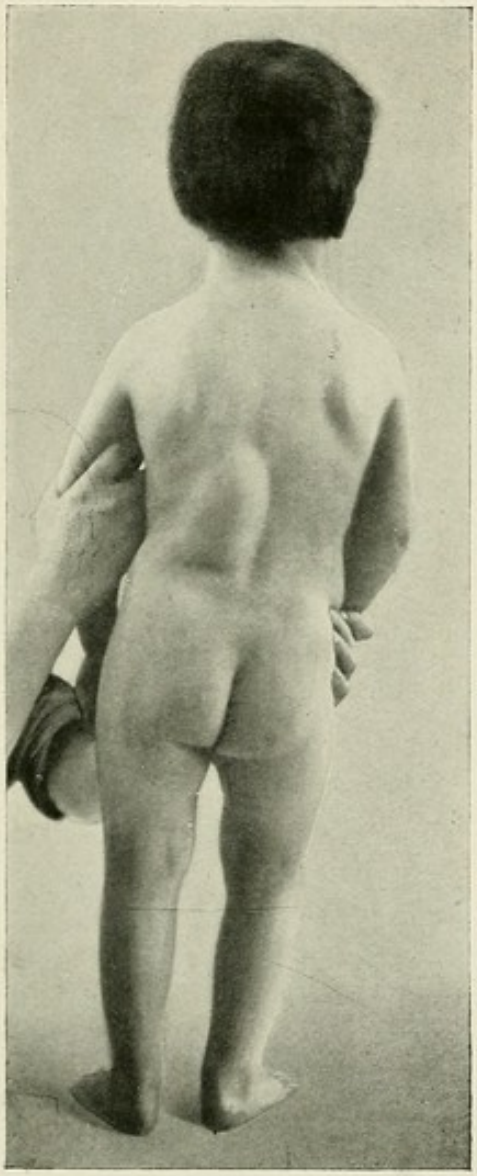

FIG. 123.—Fibro-lipoma of the muscles of the back.

An abscess *above* the fascia is always more prominent because the contraction of the underlying muscle gives it a firm base. If the pus is situated *within* or *under* the muscle, the shape of the abscess is obliterated by muscular contraction, and in the intramuscular position the abscess which is movable together with the muscle is itself immovable over the muscle.

The classical signs of spinal caries (which see) are of much more importance for its diagnosis than the variable behaviour of the abscesses to which it may give rise. These signs are muscular fixation of the spine (rigidity), pain on axial pressure—not always—curvature, and local sensitiveness to pressure. The last symptom is the one chiefly present in tubercle of the posterior portion of the vertebra, which is concerning us just now, the pain on pressure being manifest on the affected spinal process. But this sign is only of value if the sensitive spine is not contiguous with the wall of the abscess, but lies above it. In the absence of any sign of spinal caries, we cannot decide whether the disease arises from the vertebra or from the posterior segment of a rib, unless a skiagram clears the matter up. But if this also leaves us in the lurch we must conclude in favour of the more frequent occurrence, *i.e.*, spinal caries.

(b) Tumours.

We now proceed to those morbid structures which are recognized as **tumours,** without any qualification.

The innocent tumours on the skin are **sebaceous cysts, angiomata** and **fibromata,** the last in the form of soft warts. The ordinary

rules are applicable to their diagnosis (fig. 124). **Sarcomata** of the skin usually start in pigmented or in non-pigmented warts (fig. 119). The chief signs of malignancy are sudden rapidity of growth, hardening of consistence, and bleeding on slight provocation. Every tumour of the skin which has not existed for a long time and which feels hard should be suspected of malignancy.

Rarely, slowly growing sarcomata occur on the skin, and then they may be more or less pendulous (fig. 120), but never so much as lipomata. Their firm consistence, from the beginning, excludes all doubt.

Lipomata, which are so frequent on the back (fig. 121), have their seat of origin in the *subcutaneous fat*. They are at once identified by their lobulated form and by the slight puckering of the overlying skin. There is no difficulty in distinguishing them from cold abscesses.

The back, just like the neck, may present symmetrical lipomata (fig. 122) as well as the more usual unilateral variety. They are generally associated with a development of multiple lipomata over the whole body, and constitute a feature of so-called Dercum's disease (see neck).

Tubercular abscesses of the scapula often imitate perfectly the usual lipomata of the back, and are easily mistaken for them. They may be even more easily confused with the rare *cystic* lymphangiomata of the subcutaneous tissue. The latter, which are always of congenital origin, although they may not appear until later in life, often occur in the vicinity of the axilla. They feel soft like lipomata, but in some parts, where comparatively large cysts are present, there may be genuine fluctuation. But they are distinguished from lipomata by the fact that they are not clearly defined from the surface on which they rest, as they send processes downwards between

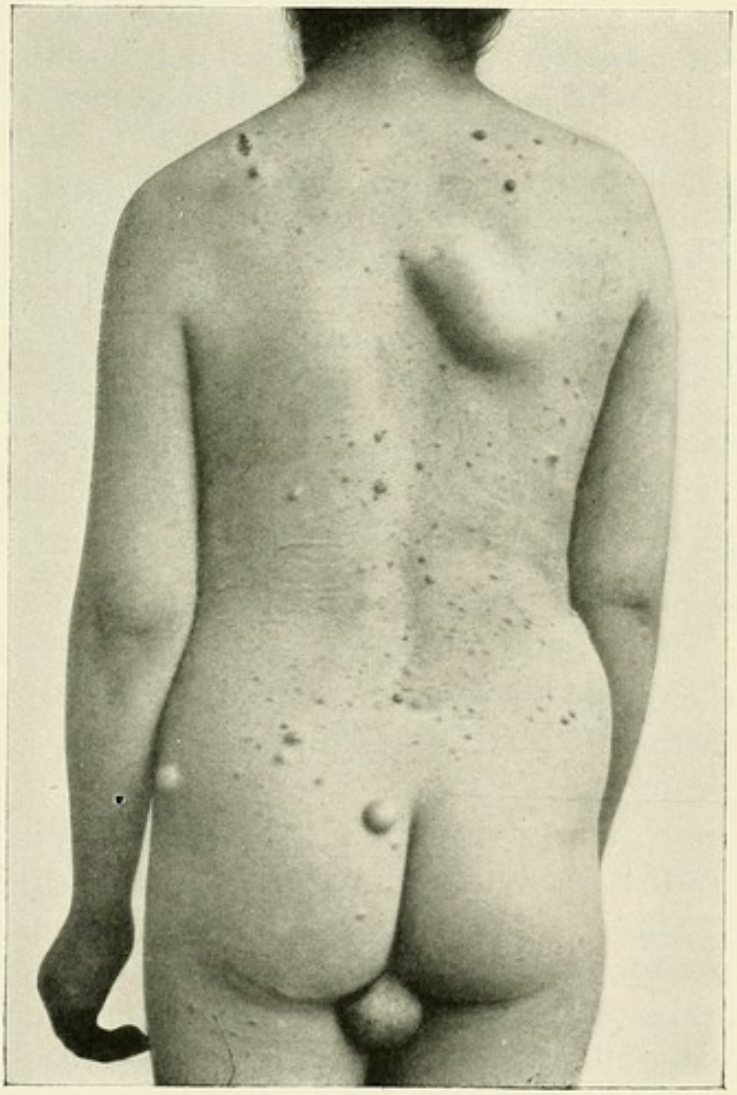

FIG. 124.—Multiple fibromata of the skin in a woman. One situated on the perinæum looks like a scrotum. Under the right scapula there is a deeply-placed neuro-fibroma.

the muscles. Sometimes the overlying skin is so thin that the whole structure is almost transparent, like a hydrocele over which the skin is made tense.

If there is any doubt about the relations of a tumour of the subcutaneous tissue to the deeper parts it is only necessary to make the muscle beneath contract in order to see whether the tumour is held fast by this action or not.

Tumours may also arise from the *muscles* or *fasciæ*. They are mostly **sarcomata,** and more rarely **fibromata** or **lipomata.** One example will suffice.

A little boy had on his back, near the spine, a flat, long, oval tumour (fig. 123) with a lobular outline which suggested a lipoma. But it did not actually lie in the skin, which could be easily picked up over it. On the other hand, it was not connected with the bone, because it was quite movable over it. The tumour was held fast on muscular contraction, showing that it was connected with the muscles. The aponeurosis became very definitely tense over it when the muscles contracted. It was so well circumscribed that no suggestion of an infiltrating malignant growth could be entertained. Its cake-like flatness pointed to an innocent growth, and this view was more consistent with the anatomical conditions, especially the pressure of the fascia, than would be the idea of a sarcoma. The diagnosis, therefore, appeared to be : sub-aponeurotic or intra-muscular lipoma or fibroma. As a matter of fact, it was a lipoma rich in connective tissue, which had been flattened out between the muscle and aponeurosis.

If a tumour is not movable over the *bone*, it has either arisen therefrom or become adherent to it secondarily. We assume the former if this immovability has been noted early or from the very beginning.

Primary tumours of the bone are either **enchondromata** or **sarcomata ;** and much more rarely **osteomata.** Histologically, the former are innocent, but their clinical behaviour manifests all transitions to pronounced malignancy. They appear as round protuberant growths, and are distinguished by the enormous circumference which they may attain. Sarcomata may also reach to a considerable circumference. It is important to know whether the growths extend into the chest, and how far. These tumours often resemble icebergs in the respect that the portion visible is the smallest part of their mass. Auscultation and percussion may yield definite information on this point. But a skiagram is more conclusive, and one ought to be taken before venturing upon any rash removal of such a growth.

Finally, if we find in the middle line of the back a tumour only slightly movable over the spine, we should at once think of **spina bifida** and its sequelæ, which we will refer to later on in detail.

CHAPTER XXXII.

INFLAMMATORY DISEASES OF THE BREAST.

EVERYONE feels capable of diagnosing such a superficial and easily recognizable disease as mastitis. Nevertheless it is sometimes mistaken for cancer—not only tubercular mastitis, but even the ordinary acute infective condition. The following considerations should, however, prevent error :—

(1) Tumours rarely occur before 20, and they are not very frequent between 20 and 30. On the other hand, inflammatory conditions are rare after 50.

I have, however, opened a large retro-mammary abscess, diagnosed as a new growth, in a woman of 60. The breast stood forth in a semi-spherical shape, and the swelling felt hard like a growth, because the abscess was behind the gland. Even intra-mammary subacute abscesses in old women are mistaken for carcinomata, an instance of which is depicted in fig. 126. The patient was 49 years of age, and the swelling in the breast was only slightly tender on pressure ; but the œdematous indurated condition of the skin over it enabled a diagnosis to be made quite easily.

(2) An association with the *puerperal period* is of special importance for the diagnosis, because this always points to inflammation, notwithstanding the slow progress of the swelling and the absence of fever.

A case was referred to me, with an induration in the breast, which came on gradually several months after the patient had recovered from puerperal mastitis. It was considered to be suspicious of carcinoma, but a small incision cleared up the matter, by the appearance of a small amount of staphylococcic pus. In these atypical cases of mastitis sugar is sometimes found in the urine.

(3) On the other hand, it must be remembered that a rapidly growing malignant tumour with extensive destruction of tissue may cause œdema and redness of the skin before ulceration or bacterial invasion occurs, and this may lead to errors of diagnosis. But in these cases the history will usually show that a growth, independent of the skin, was present for some time before the inflammatory symptoms.

(1) ACUTE INFLAMMATIONS.

We will now consider the various forms of **mastitis**, beginning with the **acute** forms.

(*a*) The inflammation of the breast which occurs in **infancy** or at **puberty**, but sometimes also in the intervening period, in both sexes, and which very rarely suppurates, presents no difficulty in diagnosis The gland feels like a hard round plate which is movable over

the underlying muscle. It is very painful at first, and may remain tender for a long time after the subsidence of the acute symptoms.

This persistence of pain caused me to shell out the breast of a young man, at his urgent request, retaining the integument of skin and the nipple—an operation which is not justifiable in a female. An

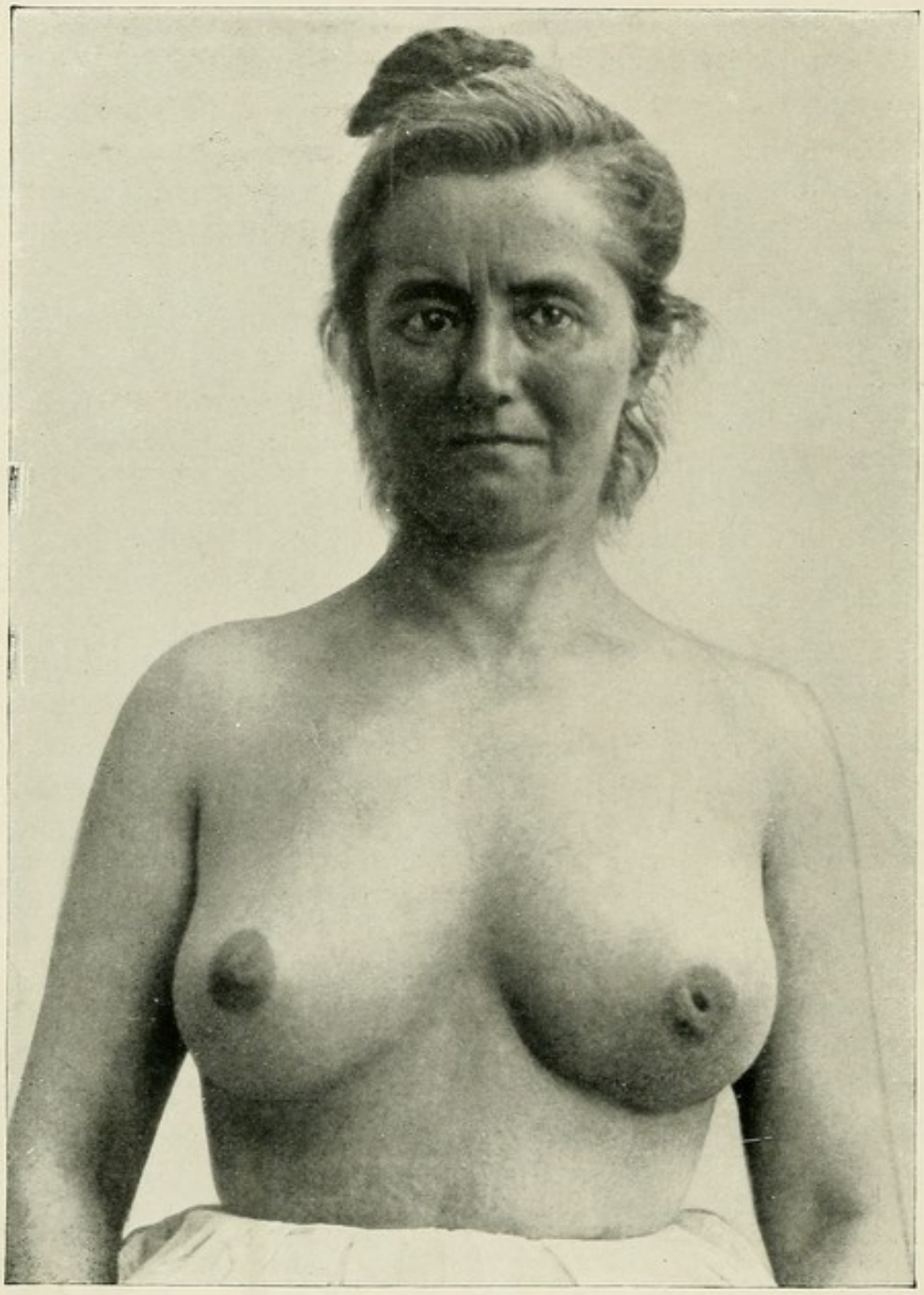

FIG. 125.—Abscess in the outer half of the left breast. Retraction, but no elevation of the nipple.

irritable condition of breast in girls at puberty has been attributed to masturbation—whether with justice remains doubtful—and this must not be confused with a bacterial inflammation.

(*b*) **Puerperal mastitis** is the type of *acute inflammation of the breast*, and in its classical form is incapable of leading to an error in

diagnosis. A mistake can only arise, as previously mentioned, when the onset of the inflammation is delayed until months after the confinement, and does not occur within the first few weeks as is generally the case. But in such a case there will have been slight inflammatory attacks soon after the confinement.

The condition previously termed *stagnation of milk* is now known to be a mild infective process taking place, either in the milk congested within the ducts and their ramifications, or, as is more usual, in the connective tissue.

It is important to recognize the degree of the inflammation and the *site* of the *suppuration* for the purpose of treatment. If the temperature subsides after the initial rigor and the pain ceases after a few days, suppuration is improbable. But if slight fever persists, and if a soft area, however small, appears in the middle of the infiltrated segment of the breast, it is quite certain that pus is present.

As far as the *position* of the pus is concerned, we must distinguish between abscesses *in front* of, *in*, and *behind* the breast. The *superficial*, purely subcutaneous abscesses are usually situated in the vicinity of the areola and arise from a circumscribed superficial lymphangitis. There is no difficulty about their diagnosis.

Abscesses within the *parenchyma* appear at first as more or less well defined firm nodules, over which the skin is still normal. If spontaneous resolution does not occur, the skin becomes immovable, œdematous, and finally reddened, a soft area developing in the middle of the hard portion. If the abscess is not opened at this juncture it spreads further under the skin and pronounced fluctuation can be detected.

Deep, *retro-mammary* abscesses arise from deep intra-mammary foci, which take the nearest course and spread towards the loose connective tissue behind the breast. The whole gland may be diffusely tender, but sometimes there is a complete absence of pain and the diagnosis must be based on apparent enlargement of the breast, due to its abnormal *prominence*.

(*c*) An acute mastitis may occur at any age without the above mentioned causes, through infection of a nipple which has been mechanically irritated, but this is rare.

(2) CHRONIC INFLAMMATIONS.

These are generally due to *tubercle*, rarely to *gumma* or *actinomycosis*. But one may repeat here what was said at the beginning of the chapter, that the sub-acute or chronic *staphylococcic* or *streptomycotic* infections also occur.

(*a*) **Tuberculosis of the breast** may appear as an *isolated nodule*

and thus be mistaken for carcinoma. But the presence of other tubercular stigmata, and enlarged glands in the axilla, which rapidly become adherent to the skin and soften, would be strongly suggestive of tubercle. The diagnosis is easier if several tubercular foci are present in the breast, and especially if some of these foci have softened in places, contracted adhesions to the skin, which has become reddened and broken down (fig. 126). In the latter case the diagnosis can be confirmed by bacteriological examination of the pus and histological investigation of a piece of the granulation tissue.

It does not always follow that a cold abscess behind or near the breast really originates therein. As a matter of fact, it more frequently arises from a rib. If the lesion of the rib is not directly accessible to examination we must depend upon the absence of any change in the breast itself to suggest caries of the rib. The final verdict must, however, rest with a skiagram, which may often reveal the lesion of the rib quite distinctly.

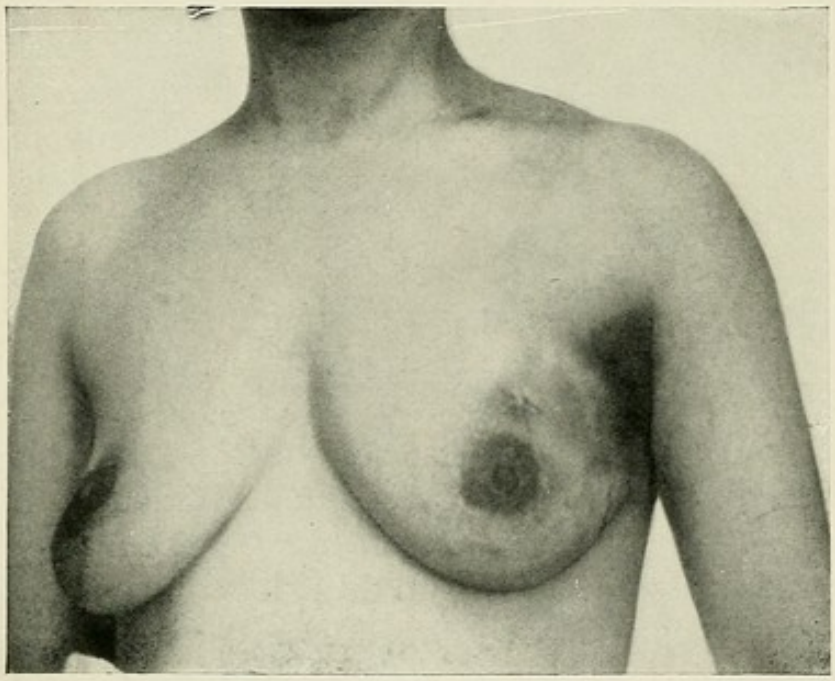

FIG. 126.—Tuberculosis of breast.

(*b*) Tuberculosis of the breast is somewhat similar to **actinomycosis**, a few cases of which have been recorded. In the latter, however, the glands are not enlarged, and the hard infiltration is very distinctive. If an abscess or a sinus be present we must search for the characteristic granules.

The diagnosis of **gumma** of the breast can only be arrived at by exclusion; and is confirmed by the previous history, the serum test, and the result of specific treatment.

Very rarely, chronic inflammatory processes which do not suppurate, and which cannot be referred to any of the causes just mentioned, occur in the breast. *Chronic cystic mastitis*, which we will discuss in connection with tumours, is *not* of inflammatory origin.

CHAPTER XXXIII.

TUMOURS AND ALLIED STRUCTURES IN THE BREAST.

THE breast, like other glandular organs, is often the seat of structures which are not genuine tumours, but which are not sharply differentiated from them. They have nothing to do with bacterial inflammation. As the epithelium and connective tissue are both concerned in these processes they are best designated by the general term of fibro-epithelial degeneration. Examples of this morbid process occur in the *thyroid as goitre*, and in the *prostate as hypertrophy*. In the *breast* the following types may be differentiated :—

(*a*) Preponderating cyst formation, either as a solitary cyst or as a conglomeration of small cysts (Reclus' or König's disease).

(*b*) Preponderating proliferation of the connective tissue ; formation of so-called fibro-adenoma phyllodes.

(*c*) Preponderating proliferation of the epithelium: Fibro-adenomata of purely adenomatous or of papillary character.

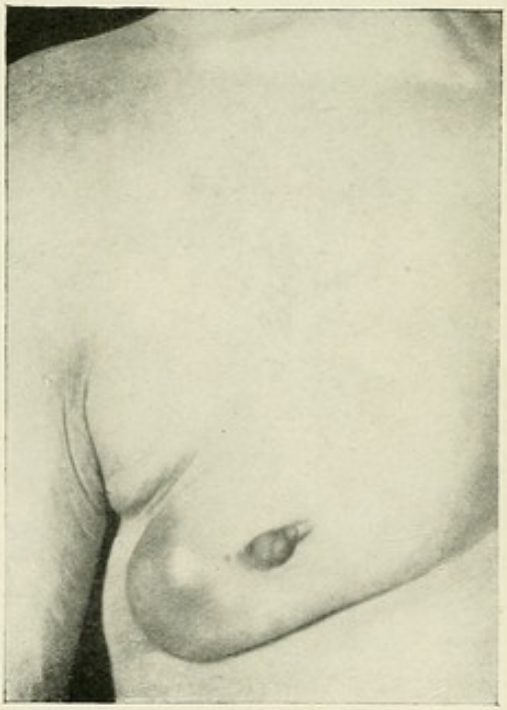

FIG. 127.—Superficial cyst of the breast.

All these changes may occur, either in a diffuse form or as circumscribed encapsuled tumours. They may occur as single or as multiple nodules, and are frequently present in both breasts. Sometimes all the various types are combined in one growth ; at others, nodules which have arisen at the same time in both breasts may manifest quite different characters. Very frequently, as one might expect, *cancerous* or *sarcomatous* degeneration occurs. We have digressed somewhat into these pathological details, but in view of the existing controversy on the matter this was not superfluous. We will now proceed with the diagnosis proper of tumours of the breast.

If we have decided that a swelling of the breast is not of inflammatory or infective origin, and therefore regard it as the result of *fibro-epithelial degeneration*, or as a genuine *new growth*, we are met with the great question of **innocence** or **malignancy**—in other words, is the case one for immediate operation, or is it one wherein the advisability of operation may be discussed with the patient ? The precise histology of the disease is of very secondary importance in comparison with this question of innocence or malignancy. The first point to ascertain is whether the tumour is single or multiple.

A.—MULTIPLE TUMOURS.

If the tumours have arisen in *both* breasts about the same time, or if there are several in the *same* breast, we may conclude with great probability that they represent the innocent process of fibro-epithelial degeneration. But in order to establish the diagnosis they must possess the characteristics to be described in the following section. It is, however, quite possible for one nodule of an originally innocent fibro-adenoma to become cancerous, or cancer may suddenly burst forth in any old harmless fibro-adenoma. Unfortunately, both patients and practitioners are liable to forget this possibility, and many hesitate to make the diagnosis of cancer because some old cysts are present, either on the same or the opposite breast.

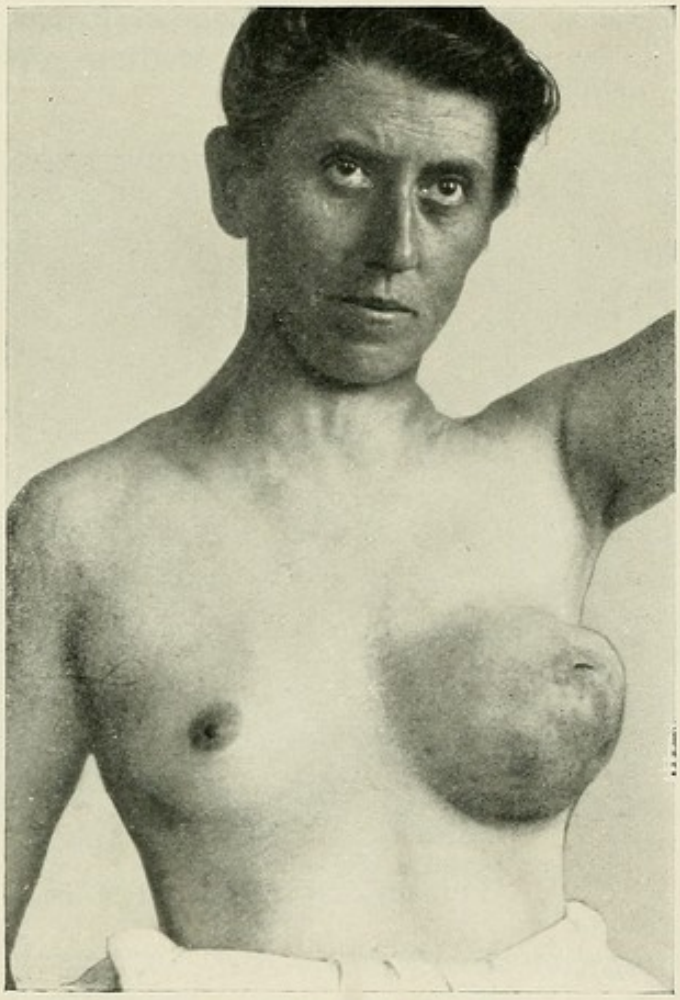

FIG. 128.—Polycystic fibro-adenoma.

B.—SINGLE TUMOURS.

We will divide these according to their size, because the questions which arise in regard to them vary according to their dimensions.

(1) SMALL AND MEDIUM-SIZED TUMOURS.

We begin with *small and medium-sized tumours, i.e.*, those which do not exceed a fist in size.

The fundamental sign which after a little palpation almost always differentiates between innocence and malignancy is the *movability of the tumour in relation to the rest of the breast tissue.* A certain amount of practice is required to estimate this mobility correctly, but it can be acquired by the attentive examination of a few cases. An index finger is placed on each of two points on opposite sides of the tumour, which is jerked backwards and forwards between them, a shaking movement being imparted to it at the same time. If the tumour yields easily to this manœuvre it is innocent If this mobility is absent it is practically conclusive of malignancy, even if the growth is not adherent to the skin or to the pectoral

fascia, and the nipple does not yet show any indication of being drawn in. Only an inflammatory attack can temporarily deprive an innocent tumour (cyst) of its mobility. If pressure is made on the tumour with the hand flat upon the chest it is less distinctly felt if it is a cyst, whereas if it is cancer it is more distinctly felt. Whenever I was in doubt about the degree of mobility, I generally found at the operation that the tumour was malignant.

Our decision must never be influenced by the patient. Every surgeon knows of cases wherein the apprehensive patient considered her harmless cyst to be a cancer, and also of cases wherein a

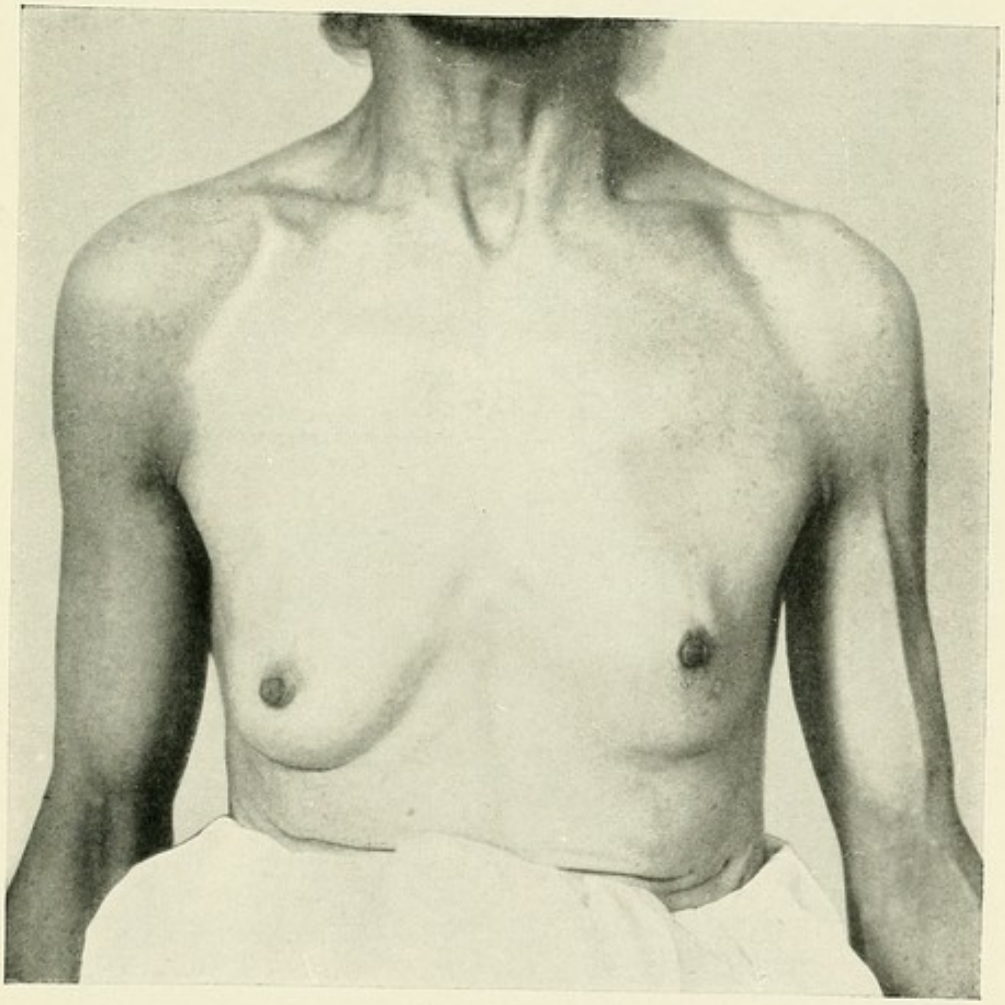

FIG. 129.—Early scirrhus. Nipple drawn up and slightly retracted.

"hardening" of the breast has been shown casually to the medical attendant, when it had already reached the limits of cure by operation.

(*a*) Having decided from the above considerations that the tumour is **innocent**, we may now proceed to determine to which of the foregoing anatomico-pathological groups it should be ascribed. If the breast is diffusely indurated over a large extent, that is to say, if it has become converted into a conglomeration of small hard movable nodules, the case is one of the formation of numerous little *cysts*. Single nodules up to the size of a goose's egg are either *encapsuled*

fibro-adenomata or *solitary cysts*. As the latter do not show any fluctuation owing to their extreme tension, the clinical differentiation is often impossible.

Cysts are usually indicated by variation in volume, by increase in size and by pains during menstruation or at the onset of pregnancy, and by the discharge of milky fluid from the nipple.



FIG. 130.—Advanced scirrhus with retraction and elevation of nipple and diminution in size of its areola.

A brownish or sanious secretion especially signifies a papillary cyst, or an adeno-papilloma developed within a cyst, which stands just on the border line of malignancy (so-called "bleeding breast," see below). Superficial cysts have a bluish transparency and fluctuation is often present (fig. 127).

If the nodule exceeds a goose's egg in size the case is not one of

a solitary cyst, but is some form of encapsuled fibro-adenoma, or the whole breast may have become changed into a mass of multiple cysts (fig. 128).

We have hitherto regarded the fact that a tumour is freely movable over the rest of the breast tissue as a positive sign of innocence.

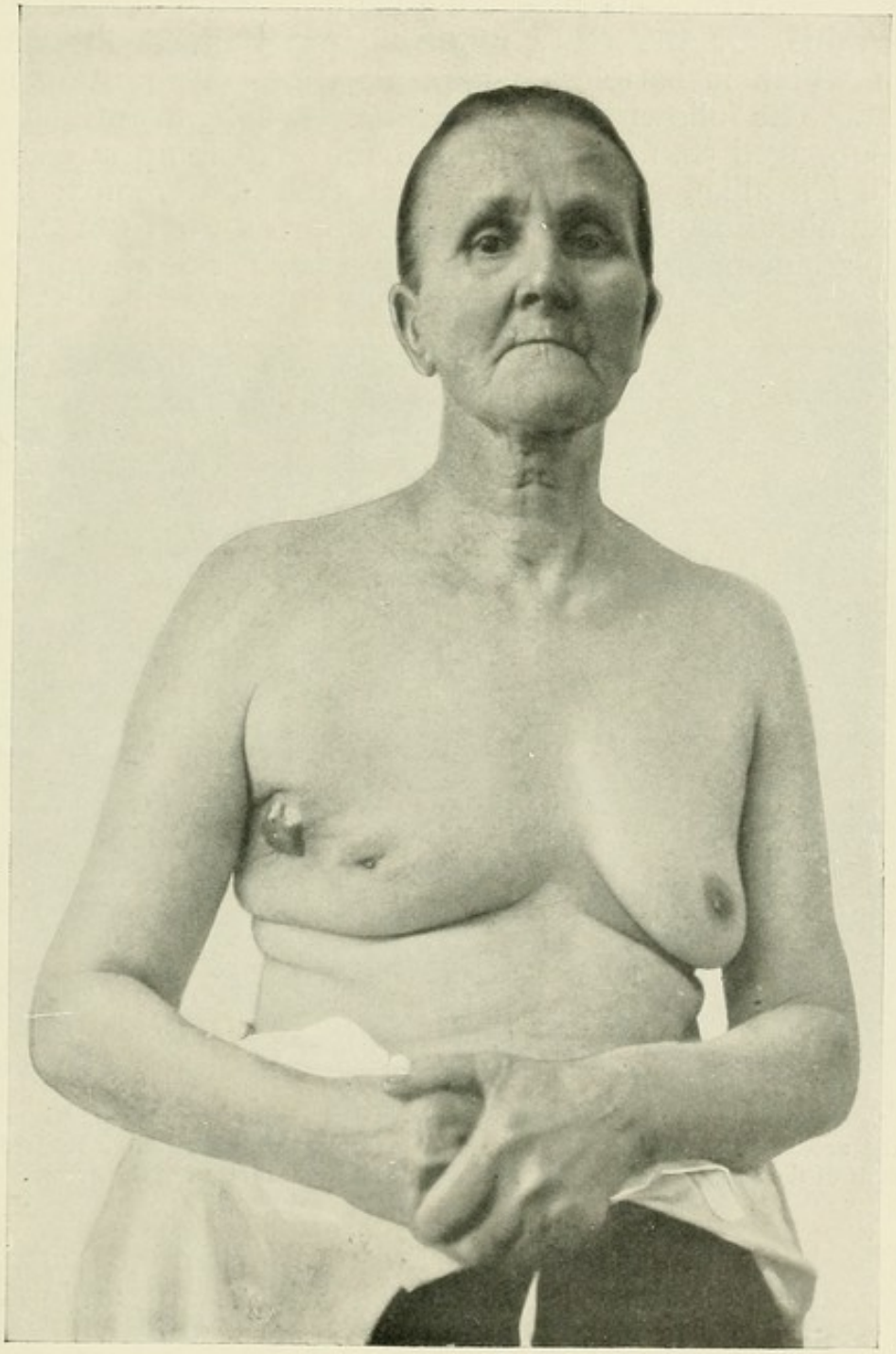

FIG. 131.—Cancer of breast, slightly contracting, situated at the periphery. Elevation and retraction of nipple, diminution of areola.

But, unfortunately, there are exceptions. A primary cancer occasionally remains quite movable for a long time; but the history is distinctive in such a case. If the tumour has only been present a matter of months it is probably cancer; if for a year or more

it is a fibro-adenoma. Further, fibro-adenomata not rarely undergo cancerous change, and this alteration is not signified by any recognizable clinical symptom. For this reason we should propose to the patient the removal of any circumscribed tumour, however innocent it may appear to be. If she agrees, the growth is removed while the conditions are healthy, or better still the whole breast is shelled out.

The excision of a small piece of a mammary tumour for diagnosis is of no value, for the piece removed may happen to come from a portion which is harmless, whereas a cancerous portion may still be present. The following case indicates the difficulty of diagnosis:—

A person, aged 50, noticed a small movable lump in each breast. They both felt alike, were diagnosed as cysts and removed. Histological examination showed that the tumour on the right side was an early fibro-adenoma, and that the one on the left side was an innocent

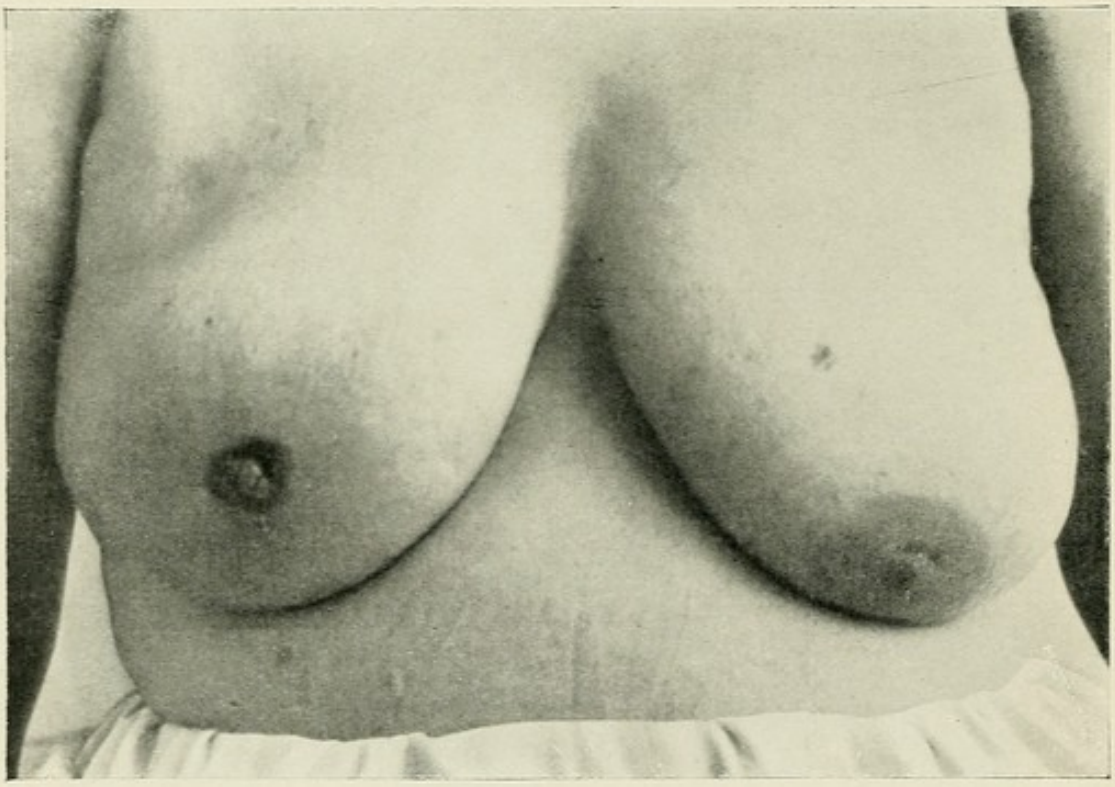

FIG. 132.—Ulcerated cancer of right breast in patient aged 65. Apparently a cutaneous cancer of the areola (with ulceration above and to inner side of nipple), but really a contracting cancer of the breast with elevation of nipple and diminution of the areola.

cyst. The latter preparation was, however, examined again some years later, and a circumscribed, classical infiltrating carcinoma a few millimetres in size was noted close to the cyst. Meanwhile, enlarged glands appeared in both axillæ, and after their removal it was shown that they were—tubercular. The patient came from a tubercular stock.

(*b*) If the tumour is only slightly movable or quite immovable over the rest of the breast tissue, our diagnosis must be a **malignant** growth, especially a **carcinoma**, even if the ordinary criteria of this disease are absent, viz., retraction and elevation of the nipple, enlarged

glands in the axilla, and adhesions to the skin and pectoral muscles. All these signs eventually make their appearance, but the practitioner who awaits them before making a diagnosis is in no enviable position.

Retraction of the nipple is an early sign only in the contracting forms of cancer; but it sometimes occurs in chronic cystic mastitis and even in chronic abscesses. The *diminution of the areola around the nipple* is much more distinctive of cancer (fig. 130), and the elevation of the nipple is of great significance (figs. 128 to 132) because it indicates a process of contraction and points to cancer, even if the nipple itself is scarcely retracted at all (fig. 129).

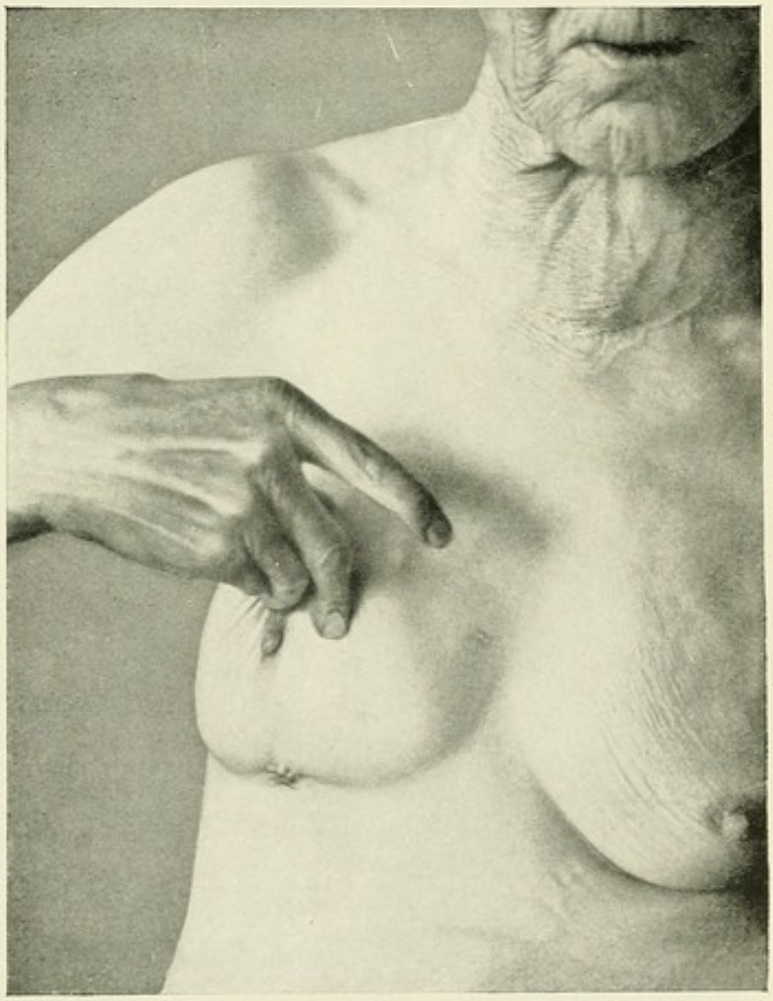

FIG. 133.—Small contracting cancer in the fold under the breast.

Enlargement of the axillary glands occurs in some slight degree even in the case of innocent cysts, and nearly always in tubercular disease. Tubercular glands are usually softer than the malignant variety and break through the skin sooner.

Sarcoma attacks the glands much more rarely than carcinoma. The difficulty of detecting early cancerous enlargement of the glands, in fat women, is frequently realized first at the operation. But the *demonstration of cancerous glands has a prognostic rather than a diagnostic importance; cancer of the breast can and must be recognized without them.*

Exceptionally, the enlargement of the glands dominates the whole clinical picture and the cancer itself is overlooked. Thus, a patient, aged 47, was treated for eighteen months for enlarged movable glands in the left axilla, which, according to the family history, might have been tubercular. This diagnosis was apparently supported by the occurrence of similar glands in the right side of the neck. Careful examination, however, showed that there was on the left side a very slight induration behind the nipple, which had hitherto been

overlooked. Histological examination of the breast and glands confirmed the diagnosis of cancer.

Adhesion to the pectoral muscles is recognized by the fact that the tumour is movable when the muscle is relaxed, and that it appears to be immovable when the muscle is contracted.

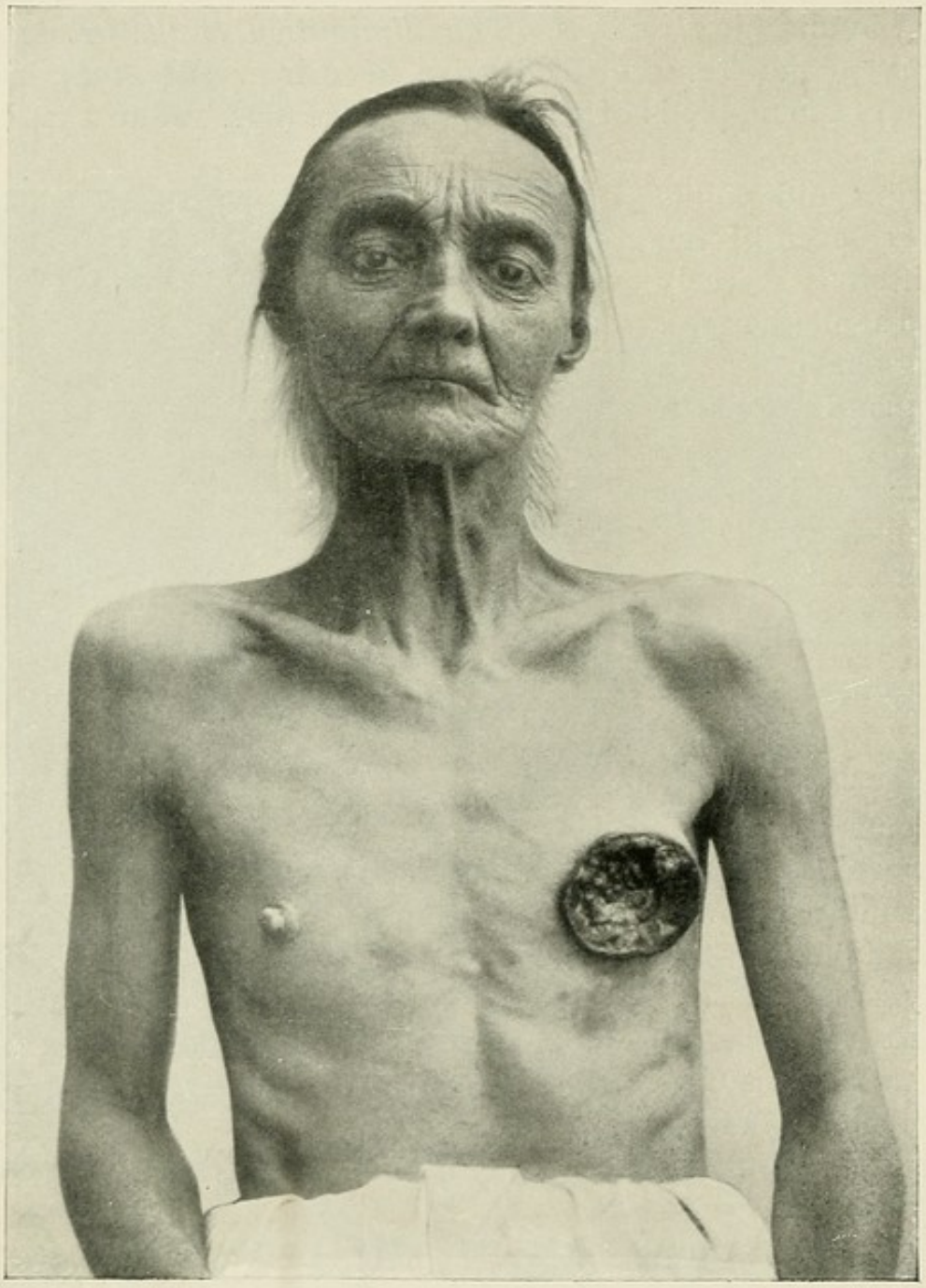

FIG. 134.—A rapidly breaking-down cancer of breast. The whole tumour converted into an ulcer.

We have not yet said anything about *ulceration*, because this does not afford any fresh material for diagnosis. It occurs in those forms which have a tendency to rapid destruction and wherein the whole tumour resembles an ulcer (fig. 134), and also in the scirrhous variety wherein the skin is soon involved, especially when situated

near the nipple (fig. 132) or in the fold of skin at the lower border of the breast (fig. 133). Finally, almost every form of carcinoma will naturally ulcerate, if left long enough.

The small contracting cancers of the nipple (fig. 132) and those which occur in the fold of skin under the breast (fig. 133) represent typical forms. Their early ulceration and their whole appearance lead the beginner to the diagnosis of cancroid. They are really cancers of the breast with portions deeply situated, and on palpation they are recognized to be much larger than their superficial appearance suggests.

If an eczematous condition of the nipple and its vicinity has preceded the development of the tumour we diagnose the well-known form of cancer, termed *Paget's disease*. Every obstinate eczema in this region must be suspected, although there may be no tumour present.

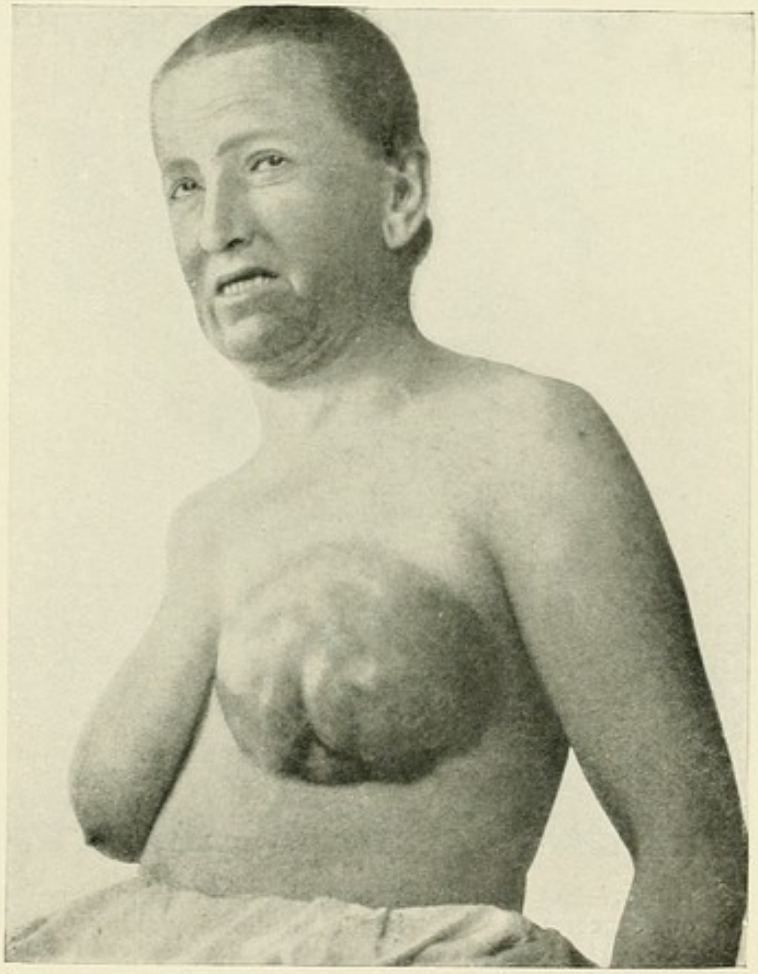

FIG. 135.—Medullary cancer of breast.

The only constant sign of cancer common to all forms is its *slight mobility on the healthy breast*. All the other characteristics are variable, and there are numerous transitions from the soft medullary cancer rich in cells, which frequently attains the size of a fist and more (fig. 135), to the contracting scirrhus, poor in cells, which constitutes a loss of tissue, although it is actually a growth (figs. 129 and 130).

Having decided upon the diagnosis of cancer, the matter of accurate *prognosis* claims our attention. If *secondary* growths are found further discussion is useless. In this connection the *vertebral column* should be thought of, and it is worth while examining the breast in cases of unexplained sciatica or intercostal neuralgia.

A patient was undergoing electrical treatment for several months by a neurologist for lumbar neuralgia. Notwithstanding the sparks, there was no illumination of the breast until the cancer therein became an inoperable scirrhus, which was accidentally discovered by the family practitioner. Paraplegia soon set in.

There are three other signs which exclude the possibility of a complete recovery, and these must be considered before any advice is offered: (1) *adhesion to the ribs;* (2) the presence of *scattered cancerous nodules in the surrounding skin* (fig. 136); and (3) *involvement of the supra-clavicular glands.* If there are any indications for an operation in these circumstances it can only be one for relief of local symptoms.

We have hitherto limited our discussion of malignant growths to cancer, and have said nothing about **sarcomata**. If these are of an *infiltrating* type from the commencement they are indistinguishable clinically from a medullary cancer. All that we have said about the latter applies to this form of sarcoma, with the exception of the involvement of the lymphatic glands. *Encapsuled* sarcomata, as long as they do not exceed a fist in size, are only distinguishable from fibro-adenomata by their more rapid growth. The diagnosis of sarcoma is of more importance in regard to the larger tumours of the breast, to which we will now turn.

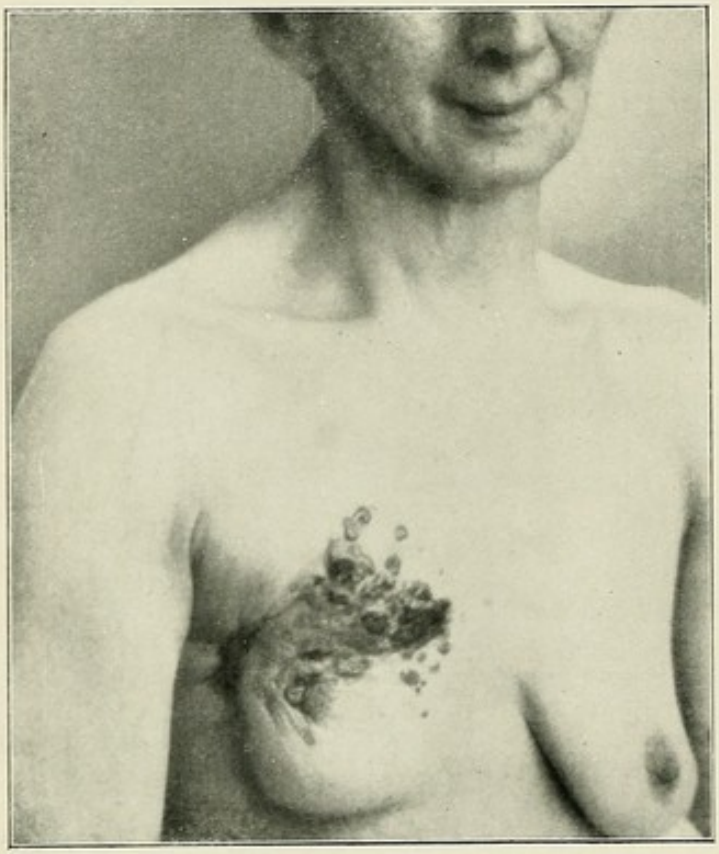

FIG. 136.—Contracting cancer of breast, with numerous cancerous nodules in the surrounding skin.

(2) LARGE TUMOURS.

A *large* new growth of the breast may be merely an example of hypertrophy (*giant growth*), and then it is usually bilateral. Apart from this we have to distinguish those that belong to the class of fibro-adenomata on the one hand—*i.e.*, **fibro-adenoma** or **cysto-adenoma** and **cysto-sarcoma** phyllodes—from **true sarcomata** on the other hand. Notwithstanding the modern zeal for operation both classes are still responsible for *enormous tumours.*

Thus a patient allowed her tumour (fig. 137) to attain the weight of $5\frac{1}{2}$ kilos and to become extensively putrefied in the course of a year during which she was under "nature treatment." That the patient eventually became intensely cachectic was not a matter of surprise considering the amount of putrefaction and the dietetic restrictions which she underwent. Nor was it at all surprising that the

"nature-curer" claimed the credit for the relief which the operation gave. At the operation the growth was still well encapsuled, and histologically it was composed of a typical fibro-adenoma with some partial sarcomatous degeneration of the stroma. Two years afterwards the patient succumbed to multiple metastases, which consisted histologically of pure spindle-celled sarcomata.

Fibro-adenomata or cysto-adenomata phyllodes, as well as the sarcomatous degeneration of the latter, known as cysto-sarcomata phyllodes, are well encapsuled tumours, which only ulcerate if the skin over them becomes tightly stretched. Metastases occur in the sarcomatous form, but more rarely than in the case of *primary sarcoma* of the breast.

The latter are either encapsuled or infiltrating, and occur under the most varied histological forms. Cystic formation also takes place in these cases, but not as the product of epithelial structures as in cysto-sarcoma proper, but as the result of tissue necrosis.



FIG. 137.—Fibro-adenoma phyllodes of breast, broken through and partially undergone sarcomatous degeneration.

If the tumour shows no infiltrating growth the differential diagnosis must be based on the history. If it has been present for a year or more, and has been growing regularly or by fits and starts, the tumour is a fibro-adenoma. The sudden rapid growth of a tumour which has been quiet for years indicates sarcomatous degeneration. A tumour of wide extent, despite short duration, is a primary sarcoma.

A word must here be said about the **"bleeding breast."** The exudation of fluid, varying in colour from brownish-red to pure blood-red, either spontaneously or on pressure, is usually a sign of fibro-epithelial degeneration. It occurs especially when papillomatous proliferations are present in cysts, communicating with the milk ducts. The symptom is, therefore, not so serious as the patient usually imagines; but she should not be reassured too confidently, for I have also seen this bleeding in cancer.

In this case, however, there were some fibro-epithelial changes, innocent cysts, from which the bleeding obviously emanated, in addition to the malignant portion of the growth. But the history indicated that the hæmorrhages occurred with the onset of the

carcinoma, which was still recent. It follows, therefore, that the carcinoma must have indirectly excited the bleeding.

As examples of purely innocent tumours of the breast, there should be mentioned lipoma, which is rare, and chondroma, which is still more rare. The former usually occurs *near* and not *in* the breast, and is recognized by its softness, just as the latter is recognized by its cartilaginous hardness. The whole breast seems to be enlarged in lipoma, but it is in a dependent position, just like the healthy breast. Finally, it should be stated that the male breast may be affected with any of these forms of tumour, but, according to Schuchart, in the proportion of 1 to 100.

PART IV.

SURGICAL DISEASES OF THE ABDOMINAL AND PELVIC VISCERA.

CHAPTER XXXIV.

DISPLACEMENTS OF THE ABDOMINAL VISCERA.

THE accuracy of the topographical diagnosis of abdominal diseases depends upon the assumption that the viscera occupy their normal position. But this is not always the case. All the abdominal viscera are liable, in more or less degree, to displacements, some of which date from birth, while others are acquired in later life.

A.—We may begin with the **congenital displacements.** The only paired viscera in the abdominal cavity—the kidneys—are occasionally subject to peculiar conditions.

The kidneys, for example, may be fused together and lie in front of the spine, in the shape of a horse shoe or a cake. They may also be fused together at their extremities and lie on the same side, one above the other. If one kidney is entirely absent, the other is abnormally large. Congenital displacement of one or both kidneys into the pelvis is of still greater importance diagnostically. Sometimes the displaced kidney lies at the side, sometimes it is in the middle; occasionally it is found in the false pelvis, at other times even in the true pelvis. With the methods accessible to the practitioner, it is impossible to diagnose these anomalies with any certainty; more especially, as such kidneys do not exhibit the mobility of the ordinary movable kidneys, nor are they capable of being replaced into their normal position. Therefore in operating upon a "tumour of the adnexa," the diagnosis of which is not clear, it is always desirable to think of the possibility of this condition. The significance of a mistake in connection with a displaced *solitary kidney* need not be mentioned.

These cases can only be clearly distinguished by skiagraphy combined with catheterism of the ureters, or, better still, by a skiagram taken after the renal pelvis has been filled with collargol.

The fundamental variety of displacement of the *unpaired* abdominal organs is the "typus inversus." This is comparatively easily detected on clinical examination, provided the thoracic viscera are affected in the like manner. But if the displacement only concerns the abdominal organs, it is very likely to be overlooked, although palpation and percussion would probably reveal the rare cases wherein the positions of the **liver** and **spleen** are reversed. A doubtful case is immediately cleared up by a skiagram, because the position of the stomach is also reversed in these circumstances.

Displacement of the *intestine alone* is much more frequent and therefore of greater surgical importance.

The following are the chief varieties which have been distinguished :—

(1) The large intestine lies in its whole extent, *behind the small intestine*, because of the failure of the umbilical loop to revolve (*retroposition*). The mesentery may either be free or may contract adhesions with the posterior abdominal wall.

(2) The entire large intestine lies on the *left side of the abdomen* because, although the umbilical loop has revolved in the right direction, it has failed to do so completely, *i.e.*, to the extent of permitting decussation of the small and large intestine (*sinistro-position*). The mesentery may either be free or may have contracted secondary adhesions. In the former case both small and large intestine are connected with a free, common mesentery, the so-called *mesenterium commune*.

(3) The entire large intestine is in the *right half of the abdomen*, because the umbilical loop has incompletely revolved in the wrong direction (*dextro-position*). The condition of the mesentery is as in No. 2.

(4) There has been complete decussation of the small and large intestine, but in a *reversed position*, because, although the umbilical loop has revolved completely the direction has been wrong (*situs inversus abdominalis partialis inferior*).

These are the extreme varieties, but a much more frequent abnormality is one which we may regard as an intermediate form between the normal position and the left-sided position of the large intestine, with free mesentery. Here the cæcum and ascending colon possess a free mesentery, which merges with that of the lowest coil of the small intestine. At the same time the ascending colon is frequently shortened, so that the cæcum is abnormally high. If there is no ascending colon at all, and the cæcum lies directly against the border of the liver, we are within the border line of a left-sided position. We can tell this at a glance when the cæcum is so far displaced to the left that the large and small intestine no longer decussate. The significance of this abnormality may be gathered from the fact that

it is found in its mildest form—*mesenterium commune ileo-cæcale*—in 10 per cent. of all autopsies. The more pronounced variety has certainly been encountered by all surgeons during the performance of laparotomies.

There are two matters to which practical importance attaches in connection with these displacements : (1) The *position of the appendix*, and (2) the question of the *decussation of small and large intestine*.

Let us begin with the *appendix*.

Whereas this may lie in the true pelvis in cases of enteroptosis or when the cæcum is abnormally long, it may be found *high up* in front of the right kidney, at the edge of the liver, or even under the liver close to the gall bladder in cases of shortening of the ascending colon, which are so often associated with a free mesentery of the ileo-cæcal coil. I have found it in all these situations during laparotomy. The more free the ileo-cæcal coil, the nearer it will be to the middle line. When the large intestine is displaced to the left, it usually lies in the umbilical region or even to the left of it. In complete transposition it is found in the left side of the pelvic cavity. In this condition the entire position of the intestine is that of the normal, as seen in a mirror. It follows, therefore, that the appendix has made a complete circuit of the abdomen, and we must be prepared to meet with it anywhere.

The matter of the *decussation of the small and large intestine* is not so much one of diagnostic interest as of technical importance for operation. In all cases of incomplete revolving of the umbilical coil with a free mesentery this decussation is absent. This demands special notice because it is customary in performing gastro-enterostomy to search for the highest coil of small intestine, where it comes out under the transverse colon. If, on opening the abdomen, the position of the intestine shows that decussation has not taken place, we must follow the duodenum in order to find the highest coil of jejunum. In cases wherein the large intestine is on the left, the duodenum winds towards the region of the right kidney, and thence passes into the jejunum in the vicinity of the right side of the pelvis.

Besides these typical displacements, there are other rarer anomalies which do not admit of classification, and are only accidentally recognized in a skiagram or discovered during an operation. The intestinal displacements caused by diaphragmatic hernia belong to this group.

On one occasion the transverse colon was found, drawn up as far as the ensiform process and held tightly there, by means of the omentum, which was involved in a congenital diaphragmatic hernia into Morgagni's space.

Even the typical displacements previously referred to cannot be diagnosed clinically without the aid of a skiagram. We shall discuss the technique connected therewith later on.

B. **Acquired displacements** of the abdominal organs are grouped

together under the term of enteroptosis. French clinicians have been familiar with this condition for many years, but a due prominence has lately been given to it by Stiller. In regarding it, however, as a symptom of "asthenic constitutional disease," he merely *paraphrases* his observations and does not *explain* the pathology of the condition. We do not really possess any genuine explanation of the clinical picture presented by enteroptosis, and we will therefore not enter here into the discussion of theories. We shall only refer to the symptomology of those forms which are of diagnostic importance, leaving the clinical details to the chapters dealing with the individual organs.

Even the public are aware that the **kidney** may be movable, and **floating kidneys** which, a few decades ago, were unknown to medical men, have now become the common property of the civilized world. Every practitioner recognizes the oval swelling which descends from the hypochondrium with each inspiration, and remains fixed in that position, but is capable of again being displaced under the ribs, by pressure.

Similarly but much more rarely, the **liver** and **spleen** become movable. But whereas, a **movable liver** is due to general relaxation of the suspensory ligaments, a movable spleen depends upon some morbid enlargement of the organ.

The downward displacement of the spleen is thus the only acquired visceral malposition which depends upon some morbid condition of the organ itself rather than upon weakness of its suspensory ligaments.

A **movable spleen** is easily recognized by its sharp anterior border, and by the fact that the splenic dulness is absent from its normal situation.

This sharp border serves as a guide, if the spleen is situated at a distance from its normal position. I had a case of a young lady who was sent to Europe from a malarial country on account of an "ovarian tumour." She had a tumour, occupying the *right half* of the abdomen and the *true pelvis*, which presented on the right side a remarkably sharp border. The normal splenic dulness was absent. This sufficed for the diagnosis of a movable spleen, and the heavy organ, weighing two and a half kilos, was removed. The pedicle of the spleen was drawn out over the transverse colon, and ran downwards to the right.

We must consider ptosis of the stomach and of the intestine, together, not only because of their clinical connection, but also because they are recognized by the same diagnostic methods. We shall begin with **palpation.**

It has long been known that palpation of the kidneys, liver and spleen renders definite indications for the diagnosis of acquired ptosis, but it was not appreciated that indications of ptosis of stomach and intestine might be obtained in the same way. Glénard and his school have indeed been teaching, for the last twenty-five years, how

to palpate the large intestine. They erred, however, in their view that only a diseased, or at any rate a morbidly contracted large intestine is palpable. This error has been exposed by Obrastzow, who has shown that a considerable portion of the course of the large intestine, and also a certain portion of the normal stomach, can be demonstrated by palpation, even in health. This has been confirmed by all who have worked systematically at the subject. The frequency with which one section or other of intestine, or portion of stomach, can be palpated, depends not only upon the experience of the examiner, but also upon the clinical material available. Patients suffering mainly from medical diseases (Hausmann) will yield a higher percentage of positive results than those suffering from surgical affections, because the latter group will include many cases of meteorism and inflammatory diseases. The greatest care must be taken not to perform any systematic palpation of the individual portions of the intestine, if there is the slightest risk of causing any damage, *e.g.*, in all recent acute inflammations of the biliary passages, the appendix or the bowel. It is much better to remain in doubt in regard to the course of the intestine, than to burst an encapsuled abscess, or to rupture an appendix which is threatening to perforate.

What are we able to feel through a relaxed abdominal wall, which is not too fat ?

(*a*) Every portion of the digestive canal which contracts upon its contents, against an obstruction (gastric and intestinal rigidity).

(*b*) The large intestine, even if it contracts in an empty state (*la corde colique*) or when it is filled with fæces.

(*c*) Any section of bowel, even if empty, which can be rolled, in a localized manner, on a firm underlying surface.

This leads us to the following conclusions as far as the various sections of the gastro-intestinal canal are concerned (see also fig. 138).

In the *stomach*, the pyloric region can be felt if it is not overlain by the liver ; and the greater curvature, if it is not too low down, on account of ptosis. If the stomach has dropped considerably, the pancreas, which undergoes less displacement, may often be felt lying transversely in front of the vertebral column.

In regard to the *small intestine*, it is only possible to feel the termination of the last coil where it opens into the cæcum, even in the most favourable circumstances, as Hausmann correctly remarks.

It is very rarely possible, if at all, to feel the *appendix* in normal conditions. The termination of the final portion of the small intestine (Hausmann) or as I would suggest, at any rate its lower border, is often felt and this is assumed to be the appendix. In *pathological conditions*, a mass formed of appendix and adherent omentum, and frequently also of adjoining coils of intestine, is often taken to be the appendix.

In most patients it is possible to feel the cæcum and the ascending colon, almost as far as the hepatic flexure, and in the majority of

patients the descending colon is palpable together with the upper segment of the sigmoid flexure. We are sometimes able to feel the beginning of the transverse colon, to the inner side of the ascending colon, and its end, to the inner side of the descending colon. But the main portion of the transverse colon is only palpable when it is sufficiently high above the symphysis to permit of its being rolled on the vertebral spine, and if the patient is not fat and the small intestine only slightly filled. This combination of circumstances does not, however, often occur. A transverse colon which does not lie too low, and which is in a condition of spastic contraction can always be felt, but the renal flexure of the large intestine can practically never be palpated.

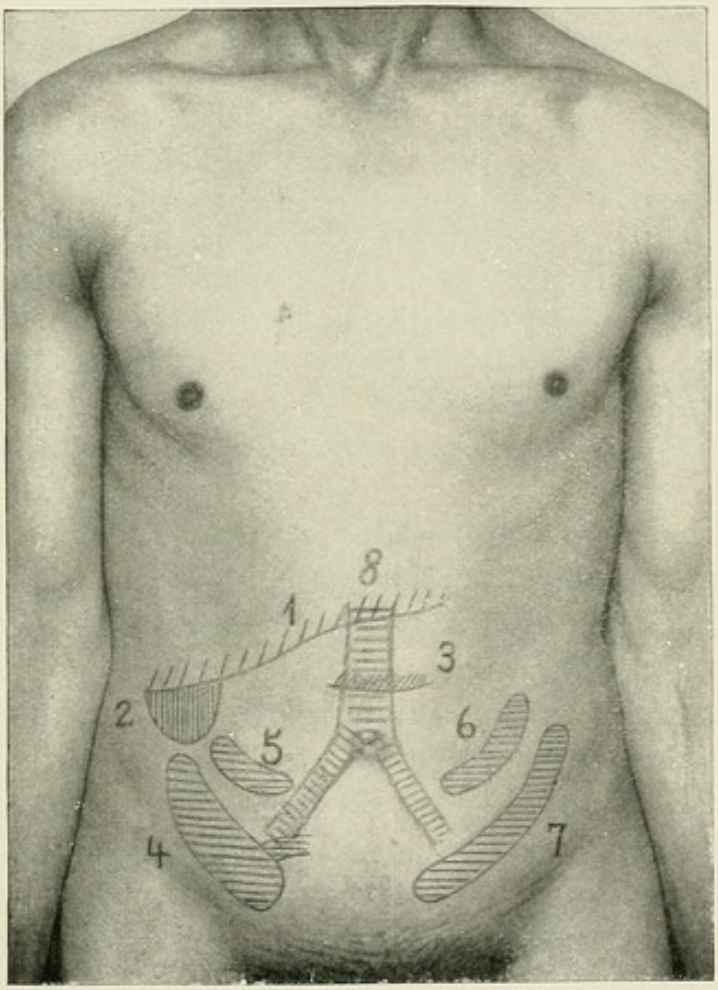

FIG. 138.—Diagrammatic representation of the abdominal organs which can most frequently be felt. (1) Liver; (2) Right kidney; (3) Greater curvature of the stomach; (4) Cæcum and ascending colon; (5) Beginning of transverse colon; (6) End of transverse colon; (7) Descending colon and upper segment of sigmoid flexure.

Although palpation affords many indications as to the position of individual portions of the bowel, the results obtained by this method do not equal in reliability those which are furnished by a skiagram.

A preliminary word in regard to *method*. It is simple enough as far as the stomach is concerned. Changes in position are visible immediately, upon the screen or upon the plate, if the patient is examined directly after taking the appropriate contrast-forming meal (*see* under "Diseases of Stomach").

In regard to the *large intestine*, the most suitable procedure would appear to be that of injecting some contrast-forming, thin fluid emulsion, on the same principle as the old practice of distending the rectum with gas, or filling it with water—and this method has been largely employed. But it is becoming quite clear that the filling of portions of the bowel, which are intended to hold rather solid contents, with large quantities of liquid produces unnatural distortions thereof. However useful this procedure may be for some purposes, it can only present a caricature of the normal shape of the bowel (*see*

figs. 139*a* and 139*b*). A better conception of the position of the large intestine can be obtained by giving the contrast-forming meal by the stomach, and then following its progress through the intestine by means of screen examinations or plate impressions. It is as a rule sufficient to take impressions after six to eight hours, and after twenty-four hours, and again after forty-eight hours if there is any unusual sluggishness of intestinal movements, in order to draw a correct conclusion as to the position of the whole large intestine. The older methods of distension and injection of water are quite unreliable, and they had better be discarded as a means of diagnosing the position of the large intestine.

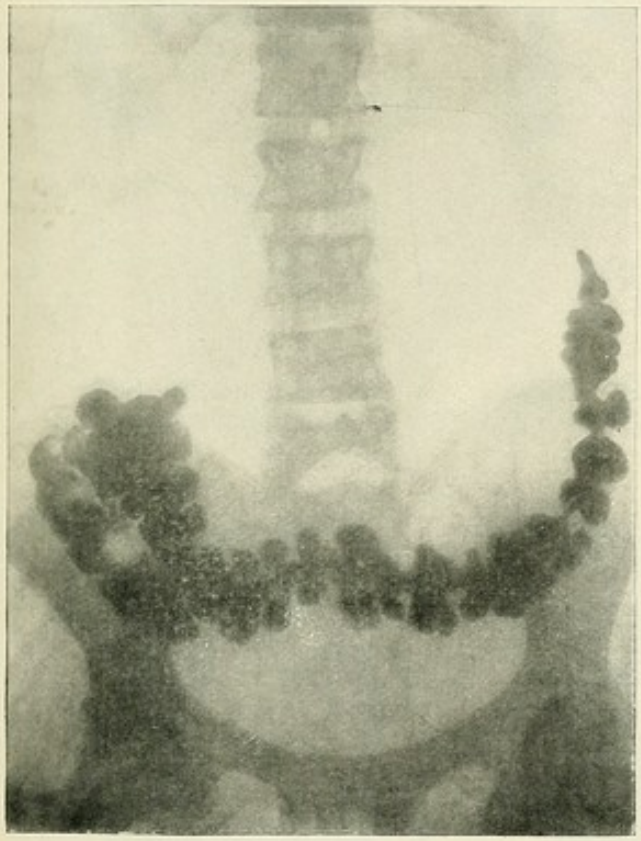

FIG. 139*a*.—Skiagram of large intestine, twenty-four hours after taking the bismuth meal. Normal position and shape.

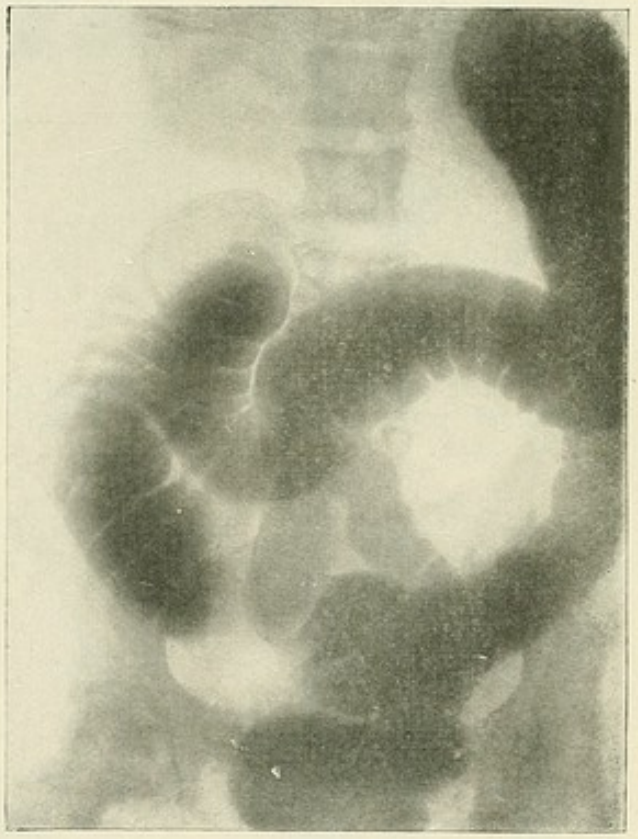

FIG. 139*b*.—Skiagram of same case after bismuth injection, showing distortion in position and shape.

The X-rays examinations have clearly pointed out what the essential feature, is in the diagnosis of visceral displacements. Thus, in the *stomach* neither a low-lying greater curvature, nor the position of the smaller curvature, which usually runs in a vertical direction, is of so much importance as the position of the pylorus. A flabby weak stomach may become temporarily distended to a low level from the pressure of its semi-solid contents, without the pylorus necessarily having been dragged down. A case should only be regarded as one of genuine ptosis, when the skiagram shows that the pyloric orifice has been displaced downwards (*see* fig. 140).

The position of the transverse colon was always looked upon as the criterion, as far as the large intestine was concerned, and this still holds good. Skiagraphy has, however, shown that the transverse colon may reach down as far as the true pelvis in consequence of its great development in length, without there being any visceral ptosis—

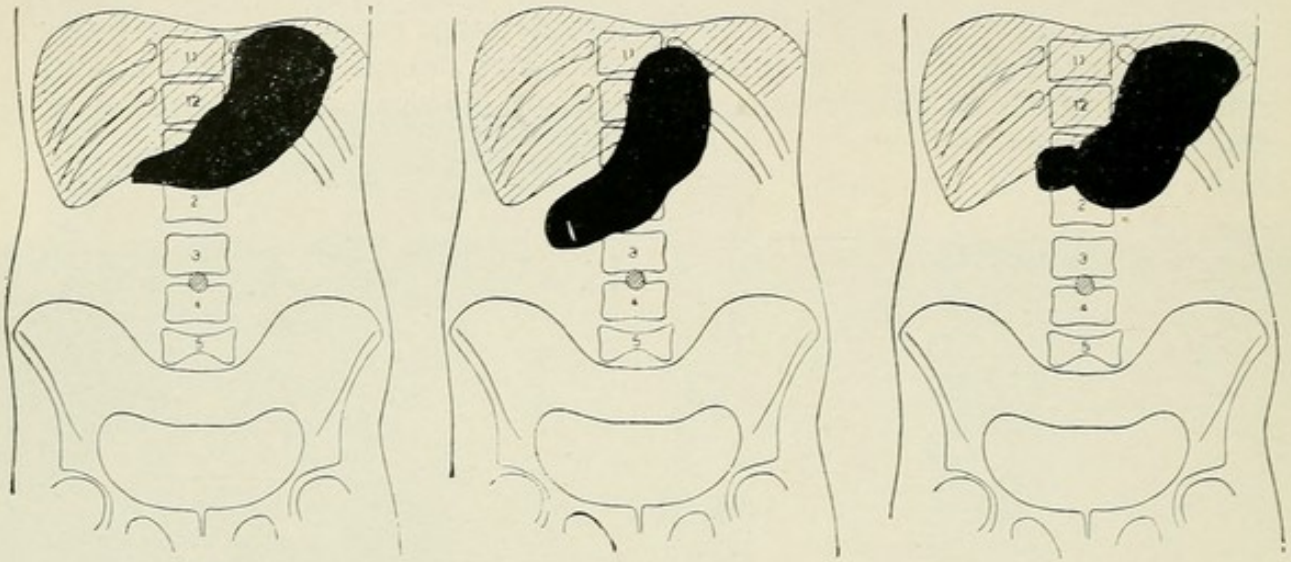

(*a*) Normal stomach. Abdominal position. Bull's horn shape.

(*b*) Normal stomach. Right side position.

(*c*) Normal stomach. Same case. Abdominal position.

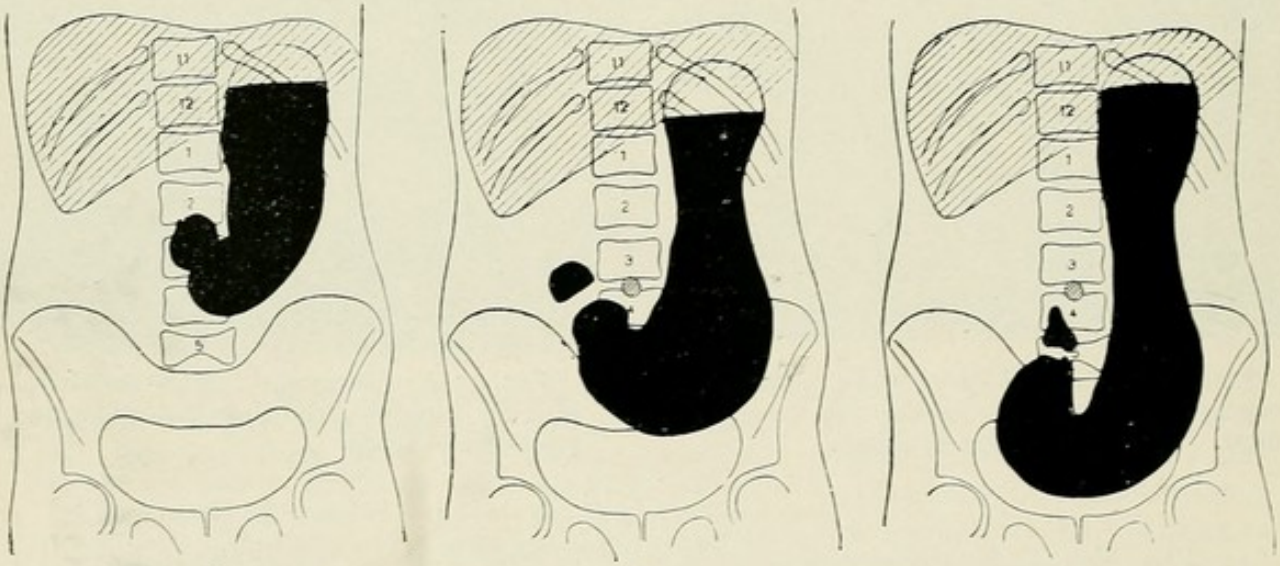

(*d*) Normal stomach. Same case. Standing position.

(*e*) Slight degree of ptosis. Standing position.

(*f*) Extreme degree of ptosis. Standing position.

FIG. 140.—Semi-diagrammatic representation of the more important shapes and positions of the stomach.

a confirmation of a fact previously known, but to which little attention was paid. Displacement of both flexures is of greater importance; it is seen in its most marked form in the hepatic flexure, because of the greater mobility of the right kidney. The left flexure, like the left kidney, does not descend so low, even in pronounced ptosis. These

conditions can only be recognized in a skiagram, with complete certainty. This shows that the position of the transverse colon varies considerably in the same patient, with the different conditions of contraction which it may present—a point which confirms results which can also be obtained from palpation.

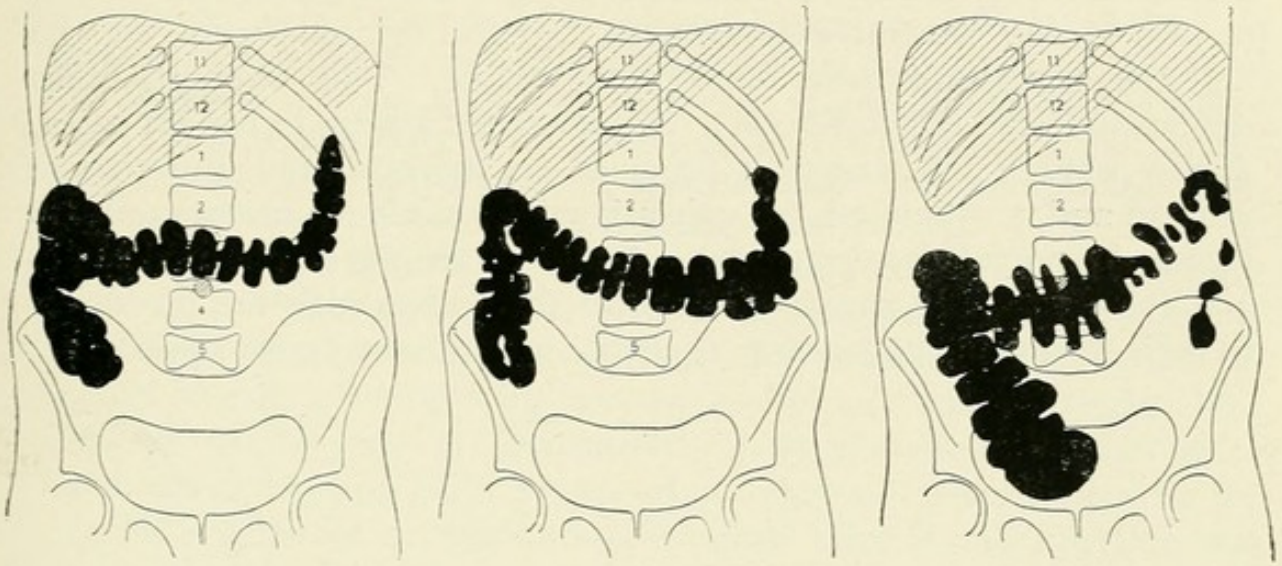

(*a*) Transverse course of transverse colon.

(*b*) Descending course of transverse colon.

(*c*) Ascending course of transverse colon.

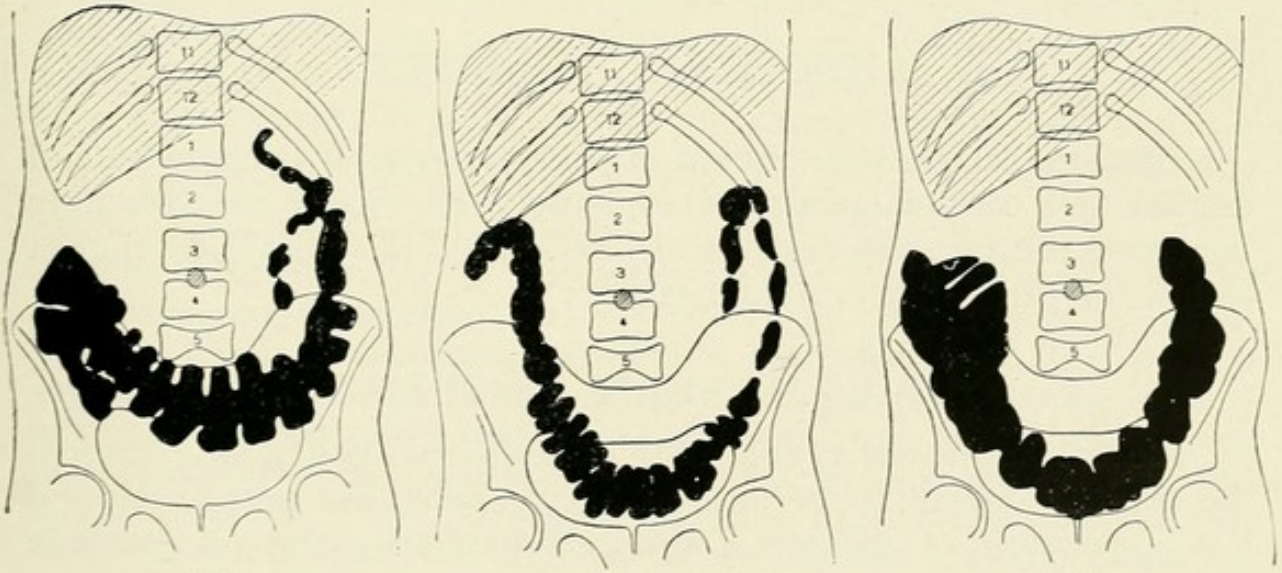

(*d*) Dependent position of transverse colon, rather low.

(*e*) Dependent position of transverse colon, very low. Flexures at normal level.

(*f*) Same case, with low position of flexures.

FIG. 141.—Semi-diagrammatic representation of the more important shapes of large intestine. Taken mostly twenty-four hours after administration of contrast-forming substance per os.

The criteria furnished by skiagraphy in regard to gastro- and enteroptosis may be briefly summarized as follows: Low level of the greater curvature and pylorus, low level of hepatic flexure, and very frequently an encroachment of the cæcum beyond the linea inominata *down into the true pelvis.*

Although these are all matters of no slight diagnostic interest it does not follow that enteroptosis affords a successful field for therapeutic activity. Nearly all the abdominal organs have been stitched up, and the statement has been made that all the viscera can be restored to their normal position. This may be true anatomically, but we cannot ascribe all the numerous discomforts of "*des équilibrés du ventre*, merely to the visceral displacement. Defective innervation of the digestive organs must bear some of the blame. This, of course, does not exclude the possibility of a vicious circle arising in certain cases, due to primary disturbance of function on the one hand, and change in form and position on the other hand—a circle which can only be broken by operative interference. But these are the exceptional cases, and the surgeon is always anxious to participate with the physician in their treatment, however anxious the patient may be for operation.

CHAPTER XXXV.

ABDOMINAL INJURIES.

FROM the surgical standpoint abdominal injuries demand careful examination, early diagnosis, and rapid decision. Lives are constantly sacrificed because diagnosis is delayed until the complete clinical picture of peritonitis is developed.

A.—INJURIES WITHOUT AN OPEN WOUND.

The cases wherein *violence has produced no open wound* present the greatest difficulties, because we rarely know the precise spot of the application of the force, and therefore the range of possible organs involved is much larger than in cases of perforating, incised, or gunshot wounds. It is therefore necessary in every case to examine all the abdominal organs, for nothing is more fatal than to overlook, for instance, a rupture of the bowel in a case wherein a renal injury is the predominant clinical feature. In examining, we must think first of the most urgent danger which is liable to follow these injuries, *i.e.*, *hæmorrhage*. If we can exclude this, we next investigate for *rupture of the gastro-intestinal tract*, and finally for an *effusion* from one of the *hollow viscera*, such as the gall bladder or urinary bladder.

(1) GASTRO-INTESTINAL CANAL.

If the injury has merely been a **contusion,** there may be no severe symptoms at first, except the initial shock. The injury may only be recognized from blood appearing in the stools, or by symptoms of slight intestinal obstruction coming on after two or three days.

Similar symptoms will be caused by injury to the portion of mesentery in contact with the bowel, or by a clean detachment of the mesentery from a coil of intestine, if circulatory disturbances short of gangrene have been produced in the intestinal wall. If the extent of mesenteric detachment has exceeded two centimetres, gangrene will, however, not usually be long in appearing.

In a case of **rupture,** the injury is not as a rule narrowly circumscribed, as with a gunshot or perforating wound. There is usually laceration of a considerable part of the circumference of the intestine, or even a whole loop may be completely torn through. The *entrance of gas into the abdominal cavity* is therefore much more likely when the injury has produced no external wound than in the case of a gunshot or perforating wound. But if the intestine was empty at the time of the injury this symptom cannot always be demonstrated.

One must never assume that there is no free gas in the abdominal cavity, as is often done, because the liver dulness is still present. The amount of free gas may be very small, and in that case it would only show itself in the highest point of the abdomen by its very tympanitic or metallic note, and by its change of situation with the altered position of the patient. These two signs are so reliable, and their method of demonstration so harmless, that we may entirely abandon puncture, as a test for the presence of gas in such cases.

The following case is instructive in this connection: A young man was caught between the buffers of two locomotives, and was brought to the hospital two and a half hours later. The liver dulness was still present. The pulse was quiet—80 per minute—temperature and general appearance normal. But there were spontaneous pains and tenderness on pressure in the epigastrium and in the left hypochondrium. The abdominal muscles were reflexly contracted. On percussion there was dulness in the lumbar regions, extending lower on the left than on the right. Liver dulness was present, but careful percussion elicited a metallic note over a very limited area in the region of the ensiform process. When the patient was turned to the right the metallic note shifted to the left; when he was turned again on to his back it returned once more beneath the ensiform process. The patient vomited once. Diagnosis: injury to intestine when comparatively empty, with exit of an insignificant amount of gas which occupied the highest portion of the abdominal cavity. Immediate operation was undertaken, which revealed a loop of the jejunum torn transversely. This was sutured and recovery followed.

This movable metallic note, which is demonstrable immediately

after the injury, must not be confused with a similar change in note which occurs later on in the vicinity of the injured coil, and which is immovable. This latter is due to local meteorism, consequent upon inflammatory changes. Neither must it be confused with the collections of gas which form in the free abdominal cavity, or in encapsuled abscesses later on in the course of peritonitis. In some cases there is no exit of gas at all, as I have myself seen in a case wherein there were three complete transverse rents. This is especially true of ruptures of the jejunum; and in these cases the diagnosis must be based on the symptoms to be subsequently discussed.

The presence of *dulness* is of uncertain value in diagnosis. When the intestine is empty, a portion of the abdominal cavity is often dull, even under normal conditions, especially the left hypochondrium and the hypogastrium. Even if the dulness is to be attributed to the injury, it might just as well be due to blood as to an effusion of gastric or intestinal contents. Pronounced *defense musculaire* points to the effusion of intestinal contents, but slight muscular contraction is rather in favour of hæmorrhage. Striking pallor points to hæmorrhage, and if cyanosis begins, it is probable that the intestine has been ruptured.

If there is nothing suspicious on the first examination we should wait, watching the patient carefully, examining him again and again at short intervals. If the condition becomes at all worse it must arouse grave suspicion. If a widespread contraction of the abdominal wall persists, associated with tenderness on pressure and pain on deep inspiration, then the more certain can we be of an intestinal injury the more circumscribed were the limits of the contusion. Thus experience shows that ruptures of the intestine are especially frequent after kicks with a hoof. *It must again be emphasized that, in this early stage, one must not expect pinched features, dry tongue, distended abdomen or thread-like pulse, even if the injury has been severe. Vomiting may even be completely absent.*

We may summarize our diagnostic reflections in the following sentence: *If a patient, a few hours after an abdominal contusion, has a somewhat rapid pulse, reflex muscular contraction, tenderness on pressure, pain on deep inspiration, and manifests slight restlessness without simultaneous signs of a severe hæmorrhage, then the case is so suspicious of an injury to the intestine that an exploratory incision is urgently indicated, if the surrounding circumstances are adapted thereto, as in hospital.*

The symptoms just described, apparently slight, but very expressive, may persist for twelve or even twenty-four hours without any striking changes. But then the scene changes, and vomiting meteorism, a rapid small pulse, show us that peritonitis has set in and threatens to defy all therapeutic measures.

No skill is required to recognize a rupture of the intestine in this stage, but it is then of no use, and only gives the medical attendant the satisfaction of not allowing the patient to die without a diagnosis.

The foregoing remarks concerning the *intestine* also apply to the *stomach*, which, however, is much more rarely injured by violence without an external wound.

(2) THE SPLEEN.

If an increasing area of dulness in the left half of the abdomen is accompanied by symptoms of continuous hæmorrhage, without signs of an injury to the intestine, we must think of a **ruptured spleen**, although such an incident as an isolated injury is exceedingly rare when the spleen is *normal*. It is quite different when the *spleen is enlarged*, as in leukæmia, malaria, chronic congestion, and cirrhosis of the liver. In these cases the spleen is no longer protected by the ribs, and is therefore more liable to injury. The following case illustrates this.

An alcoholic female, aged 50, was found one morning dead in bed next to her husband. The autopsy showed all the signs of severe alcoholism, and revealed the cause of death in the rupture of a spleen three times the normal size, with the effusion of three litres of blood into the abdominal cavity. Numerous traces of bruises on the body, and the evidence of a night scene between the deceased and her equally inebriated husband, elucidated the cause of the injury to the spleen.

The danger to which an enlarged spleen is exposed is shown by the circumstance that a malarial spleen has ruptured simply owing to palpation through the abdominal integuments.

(3) LIVER AND BILE-DUCTS.

Injuries to the liver and bile-ducts are much more frequent than ruptures of the spleen, occurring even after falls from a height. The danger is caused both by the risk of *hæmorrhage* and the effusion of *bile* into the abdominal cavity. Hæmorrhage supervenes very quickly, and shows itself by dulness over the right side of the abdomen, in addition to the usual signs of loss of blood. It is stated that this dulness does not usually descend into the hypogastrium, thus contrasting with splenic hæmorrhage. If at the same time the liver region is sensitive to pressure, and there are radiating pains towards the right shoulder, the diagnosis is obvious. But it is not always as easy as this ; sometimes it is difficult to discover whence the blood is issuing, even after the abdomen is opened.

It is even more difficult to recognize a flow of bile into the abdominal cavity. The dulness is of much more gradual onset, and its position will vary according to the direction in which the bile is

poured out. It may flow behind the stomach into the lesser omental sac, or into the lateral and inferior portions of the abdomen, or it may be limited, by rapidly formed adhesions, to the mid-abdominal region. If a diagnosis of injury to the bile ducts is based on an existing and gradually increasing fluid effusion into the abdominal cavity, without signs of acute peritonitis or of anæmia, a careful consideration of all the clinical symptoms will often indicate the approximate position of the injury. An example will save the necessity of any long disquisition.

A nine year old lad was caught under the wheel of a cart. After the subsidence of the first severe symptoms, a complete dulness of the whole upper abdominal region supervened, with subsequent bilious vomiting, partial but not complete absence of colouration from the stools, and slight jaundice. The gradual onset of epigastric dulness without anæmia pointed to an effusion of bile, and the jaundice showed that the bile was absorbed into the circulation. But as there was vomiting of bile and as the fæces retained some biliary colouring matter it was obvious that the bile duct was not torn. But the possibility of an injury to the gall-bladder or to a branch of the hepatic duct remained. The operation showed that the bile had collected in the lesser omental sac, pushing the stomach forward. This, of course, excluded an injury to the gall-bladder, so the lesion could only be a rent of a branch of the hepatic duct, with rapidly forming fibrous adhesions around the foramen of Winslow.

This observation confirms the general experience that the flow of healthy bile into the abdominal cavity is comparatively well tolerated. A fibrinous peritonitis usually develops around the effusion of bile, which shuts it off from the rest of the abdominal cavity, and if not subjected to anything but very slight disturbance, leads to spontaneous recovery. But if the effusion of bile is considerable, and if instead of reaching the intestine it becomes absorbed by the peritoneum, the patient finally succumbs to cholæmia.

It is quite different when an infected ulcerated gall-bladder bursts in the course of cholecystitis or becomes perforated by a stone. A fatal general peritonitis generally supervenes in a very short time.

(4) THE KIDNEYS.

Despite the comparatively protected situation of the *kidneys*, they are often involved in injuries which produce no external wound, especially after a fall from a height or after being run over. *Pain on pressure over the renal region*, and *blood in the urine* confirm the diagnosis, at any rate where it is possible to exclude injury to the lower urinary tract, that is to say, when there is no injury to the pelvis or perineum and micturition presents no difficulty. Sometimes the pain on pressure over the injured kidney is not very great; but,

on the other hand, the *reflex spasm of the lumbar muscles* on the injured side is very striking. Unilateral *renal colic* is very significant (obstruction of the ureter by a clot).

Hæmorrhage is the principal danger in renal injuries. The extent of an *extra-peritoneal injury*, at any rate, can be estimated by feeling a swelling over the renal region by means of palpation from before and behind, noting its increase and also the onset of extending dulness in the front. The most reliable conclusions are however to be drawn from the signs of an increasing anæmia, which we must not confuse with the initial signs of shock. If the swelling and dulness increase in the course of the following day, without corresponding signs of anæmia, we must assume that *urine* as well as blood is being effused, and this must be regarded as an urgent indication for interference. But sometimes anæmia may occur without any corresponding palpable change in the renal region. We must not, in such a case, assume that the blood is retained in the renal pelvis or retro-peritoneal tissue, but rather that it is flowing freely into the abdominal cavity, that is to say that the peritoneal covering of the kidney is torn through. These *intra-peritoneal injuries of the kidney* are especially prevalent among children, because their kidneys are not so closely enveloped in perirenal fat as those of adults.

One may feel inclined to differentiate between extra and intra-peritoneal injury of the kidney on the basis of the presence or absence of the gastric and intestinal symptoms, *i.e.*, vomiting and meteorism. But caution is necessary; because gastric disturbances are sometimes noted in extra-peritoneal injuries of the kidney. This may be due to reflex causes, but it is also known that the effused blood may extend widely in the retro-peritoneal tissue and produce functional disturbance of the large intestine, with all the symptoms of obstruction. On the other hand, vomiting and meteorism, as a sign of peritoneal irritation, are not indispensable accompaniments of an intra-peritoneal rupture of the kidney. Indeed a certain amount of blood and even of urine is well borne by the peritoneum. The formation of fibrinous adhesions, as shown by experiments on animals, acts as a defence against a persistent inflow of urine, a circumstance which justifies waiting, as long as symptoms are not on the increase.

There remain therefore two definite evidences of intra-peritoneal injury of the kidney, viz. (1) the absence of definite swelling in the renal region, with (2) the simultaneous presence of a fluid effusion free in the abdominal cavity, arising from the neighbourhood of the affected loin. But not even this absolutely assures our diagnosis, because we must be able to prove that the fluid effusion does not originate from an injury to some other abdominal organ. For instance, an extra-peritoneal contusion of the kidney may occur together with a rent in the liver or spleen. But in these cases our diagnosis cannot get beyond the range of probability.

Even if the first few critical days after an injury to the kidney

have passed, the onset of local inflammatory signs and an aggravation of the general condition after an initial improvement may, at this later stage, indicate the necessity for immediate laparotomy. Tissues infiltrated by urine are especially liable to infection, and even if sepsis of the urinary tract by catheterism has been avoided, bacteria may gain access from the blood stream or from the neighbouring intestine.

(5) THE BLADDER.

Rupture of the bladder only occurs when the viscus is full, and the accident is especially liable to happen to an intoxicated person, because he tolerates an abnormally full bladder with equanimity, owing to his state of alcoholic anæsthesia, and because after a bout of wine and beer, at any rate, the bladder possesses the fulness necessary to permit of the injury.

The following is an illustrative case : An alcoholic had reached the stage when he began to assault one of his comrades. He was therefore ejected, but not in a very gentle manner. Very shortly afterwards he died, and his friends were charged with causing his death from a ruptured bladder.

The clinical picture varies according to the site of the rupture, viz., within the abdominal cavity—*intra-peritoneal rupture*, or into the peri-vesical cellular tissue—*extra-peritoneal rupture*.

Let us imagine that a patient is brought to us on account of a severe abdominal contusion. He complains of persistent strangury, but cannot micturate. Our first thought is of a urethral injury with obstruction of the passage. But no blood flows from the urethra, and the bladder is not distended above the symphysis pubis. We percuss the abdomen immediately, but elicit nothing therefrom ; but while we are examining the patient, he succeeds in passing a few drops of blood-stained urine. These few symptoms suffice for the diagnosis of a recent *intra-peritoneal rupture of the bladder*. We introduce an ordinary metal catheter, with rigid aseptic precautions. It enters quite easily, but only a few drops of bloody urine escape—although the patient assures us that he has not micturated for several hours. On moving the catheter about, we miss the sensation which we obtain when it is in a full bladder. The differential diagnosis lies between one of two things only—(1) reflex anuria following trauma, or (2) intra-peritoneal rupture of the bladder. The strangury and the presence of blood in the scanty urine are, however, decisive, for the latter. If the patient is seen for the first time, a few hours or a day after the injury, an additional sign is present on percussion—viz., a fluid effusion in the lower abdominal region, which, however, does not present the convex half-moon shape at the superior border, which is found in a free intra-peritoneal effusion. The catheter enters the

empty contracted bladder, but after moving it about therein, we may suddenly find that it becomes quite free, and a large amount of fluid escapes, which, on chemical examination, is shown to be highly albuminous. This means that the catheter has gone through the rent in the bladder into the abdominal cavity, and has drawn off the collection of urine, mixed up with albuminous exudation. The dulness which was present immediately before the catheter was passed has now vanished. If the patient is seen in a still later stage, there will be found some slight peritoneal irritability with increasing effusion of fluid in the abdominal cavity. If attempts have been made to pass a catheter there is every prospect that this peritoneal irritability will rapidly become a definite peritonitis. We should, however, avoid this result by sewing up the bladder before any large collection of urine takes place within the peritoneum, or before uræmic or septic symptoms arise.

Extra-peritoneal rupture is quite different. The patient complains principally of strangury, but he passes much more urine than in cases of intra-peritoneal rupture, and the catheter shows that the bladder is not completely empty. The fact that there is an injury to the bladder is indicated by the presence of strangury, while the urethral canal is quite permeable, and by the presence of blood in the urine without symptoms pointing to the kidneys or urethra. It is just in this circumstance that careful attention will demonstrate a symptom concerning which Dittrich stated : "*If air enters the bladder by means of the catheter, we shall detect a limited area with a metallic note immediately over the symphysis.*"

The symptoms hitherto mentioned are apparently mild, but they are rapidly complicated by the onset of infiltration of urine into the pelvic cellular tissue, which causes dulness over the symphysis. This may be followed by infiltration and phlegmonous swelling of the lower abdominal region, and even by signs of uræmia. Signs of peritoneal irritation may supervene, but these play quite a subordinate part.

Though typical cases of both forms of injury are easily distinguished, the diagnosis may be very difficult between an *intra-peritoneal rupture of slight extent* and an *extra-peritoneal injury of very extensive* character. In the former case errors are caused by the fact that the bladder always contains some urine, and in the latter case because a peritonitis may be associated with the manifestations of extra-peritoneal rupture. The main thing, however, is to recognize the fact there is a rupture of the bladder.

B.—INJURIES TO THE ABDOMEN WITH OPEN WOUNDS.

Open injuries are generally caused by stabs, incisions, or by bullets. Diagnosis is facilitated because the position and direction of the injury to the soft parts give some definite information about the

possibility or probability of injury to one or other abdominal organ. The following case shows that one must take into consideration the course of origin of the injury in order to decide upon its direction.

A young man was hit in the gluteal region by a Flobert bullet, which came from a weapon carelessly placed on the floor behind him. He complained at once of abdominal pain, which his friends attributed to something he had eaten—a quite probable cause, as the accident happened on a public holiday. It was not thought at first that a bullet in the gluteal region could cause abdominal pain. Thirty hours later he was brought to the hospital with symptoms of acute peritonitis. The wound of entry was found above the left gluteal fold, but no wound of exit could be seen. The bullet had struck posteriorly and inferiorly, and must have gone through the left great sciatic foramen to reach the abdominal cavity. As a matter of fact the X-rays revealed the bullet in the right lower abdominal region, and the operation showed that there was a double perforation in the last coil of the small intestine.

(I) GUNSHOT WOUNDS.

Gunshot wounds of the stomach and intestine caused by the ordinary small firearms differ from subcutaneous lacerations by the smallness of their extent. In the case of bullets of very fine calibre, the opening is so small that it is very difficult to discover it even at the operation. This also applies, as recent wars have shown, to the bullets of modern military firearms, especially to the conical bullets, which cause little deformity, except those which strike diagonally. But on the other hand, several loops of intestine are often shot through at the same time.

The symptoms of gastric or intestinal injuries are naturally the same as those caused by violence without an external wound. But the symptoms may be so very slight when the diameter of the intestinal wound is small, and the bowel is empty, that spontaneous healing is much more likely to take place than in the case of subcutaneous lacerations. Advantage is taken in war of this favourable outlook, where the impossibility of opening the abdomen at the right moment compels us to dispense with this procedure. It is quite different in civil practice, when, as a rule, timely surgical assistance is available for the injured. We must not, therefore, wait and see what the man's luck is going to be, but must give him the best opportunity of recovering by means of an immediate laparotomy. *Every abdominal gunshot wound which by its direction may involve the stomach or intestine is so suspicious of having caused injury to the intestinal canal if the projectile cannot be found in the abdominal integuments, that it is absolutely urgent to bring the patient to the hospital at once.*

We have just said "if the projectile cannot be found in the abdominal integuments." This is, however, not an instruction to undertake a search for it, on the spot. Formerly the surgeon used to take a probe out of his pocket-case, insert into the wound, and if it reached any depth would exclaim "The case is hopeless." Of course it is quite clear that the probe can often inform us whether the injury has perforated, but it is equally clear that the procedure may arouse a fresh hæmorrhage, tear through protective adhesions, and infect a wound which has hitherto remained aseptic. It would be a safer plan to lay the gunshot track freely open, after thoroughly cleansing it, in order to see whether the bullet still remains therein or has gone through the peritoneum. But this procedure is only permissible when everything is in readiness to undertake a regular laparotomy and suture the stomach or intestine. Otherwise, we should leave our probe in the pocket-case, with the other instruments, apply a first aid dressing and send the patient to hospital forthwith. I have never seen projectiles discharged at close quarters lodge in the abdominal integuments. This could only occur with a defective charge, or when the bullet has been stopped by pieces of clothing. To enlarge the wound of entry in a hurry simply affords opportunity for infection before laparotomy can be undertaken, and deprives the surgeon of the important indication which the direction of the track gives him in his search for the injured intestine. We should limit our activity to a careful estimate of the state of affairs—the distance and direction of the bullet—and leave the wound alone, despite the urgent demands of the patient and his friends for the "instant removal of the bullet."

Gunshot wounds of the liver, kidneys and bladder are diagnosed on the same principles as injuries of these organs without an external wound.

(2) STABS AND INCISED WOUNDS.

Stabs and incised wounds which penetrate the abdominal wall are so suspicious of intestinal injury that it is our duty to make the same search, as in the case of gunshot wounds. How do we ascertain whether a gunshot wound of the abdominal wall has perforated? The rules laid down in this regard apply equally to *punctured wounds*, *i.e.*, a "search" may only be instituted if it can be immediately followed by a laparotomy. In all other circumstances the indications are—first aid dressing, careful history and removal to hospital.

If there be no protrusion of bowel in *incised wounds*, we should, when circumstances permit, separate the wound with clean hands, and this will often show whether it has penetrated to the abdominal

cavity. In cases of extensive incised wounds, and of the notorious laceration inflicted by the horns of bulls, the intestines are frequently protruding when the patient is brought for treatment. In such circumstances no attempt must be made to replace the bowel; a large first aid dressing must be provided, and the injured at once sent into hospital, after having been given opium as an intestinal sedative.

It is not always easy to discover the perforated coil, even at the operation. For example: A fat man was stabbed in the left lumbar region with a slaughtering knife. No symptoms of internal hæmorrhage, no signs of intestinal injury, and no blood in the urine. The position of the wound accorded with an injury to kidney or spleen; the length of the knife was sufficient to have wounded the bowel. On opening up the wound, an injury to the lower pole of the kidney was discovered, and laparotomy revealed the expected complete rent of two-thirds of the circumference of the descending colon at the renal flexure, although this is a rare event.

Stabs of the large intestine are, as a rule, much rarer than knife wounds of the small intestine.

CHAPTER XXXVI.

ACUTE INFLAMMATION WITHIN THE ABDOMINAL CAVITY.

BEFORE attempting to discover the origin of any inflammatory disease within the abdomen, we first make sure that an inflammatory process really exists. This is, however, not always easy.

Let us consider two typical cases. A patient suddenly begins to complain of abdominal pains and to vomit. The temperature is slightly raised, the pulse is accelerated, the breathing is shallow, and almost exclusively thoracic in type; the abdomen is not distended—it is, however, tender on light percussion, and responds thereto by muscular contraction. Pressure over the lumbar regions is painful either on one or on both sides. Neither flatus nor stools pass; but there is no visible peristalsis. The patient complains of a constant, dull pain, which varies in severity, but does not cease completely. There is no doubt at all that *peritonitis* is beginning in this case. Let us compare this with the other case. The illness also begins with abdominal pains and vomiting; but the pulse is quiet and full, except at the actual time of nausea and vomiting; the temperature is

normal, the breathing is not accelerated, nor particularly shallow. The abdomen is not distended, or only slightly so; during the periods of repose it is not tender either to pressure or percussion, and the abdominal muscles do not markedly contract on palpation. Neither flatus nor stools pass. An attack of pain occurs from time to time, during which peristalsis can be seen if the abdominal wall is thin. The attack hardly lasts a minute; when it is over, the patient feels well until the next attack warns one that some severe disturbance is in progress. Evidently this is a case of *intestinal obstruction*. The differential diagnosis between peritonitis and intestinal obstruction is usually quite easy in the early stage. But this early stage must be most carefully watched, and if we are called too late for this we must obtain its history as accurately as possible, because as the illness advances the differentiation becomes more difficult. In peritonitis the abdomen distends gradually, the temperature is not always raised, but often becomes sub-normal, and symptoms of functional or mechanical obstruction are frequently added to those of simple inflammation. In obstruction, on the other hand, the pulse becomes small and rapid, as the case progresses, the temperature may rise, and the abdomen remains tensely tympanitic even in the intervals which are free from pain. The pain eventually becomes persistent, and the mechanical obstruction is supplemented by intestinal paralysis, or even by peritonitis.

If the initial symptoms lead us to the conclusion that some inflammatory irritation of the peritoneum exists, we must not be content with the vague diagnosis of "peritonitis," but must endeavour to trace its sources as quickly as possible. Careful investigation and observation at the beginning are of the greatest importance for this purpose, for once the peritonitis has become generalized we are no more able to discover its origin than we can detect the origin of a fire when the whole house is ablaze. In this stage it is generally too late to successfully overcome the inflammation.

The method by which inflammation of a limited area spreads over the whole abdomen follows various types :—

(1) In the first group, we are confronted within the first few hours by a diffuse, and generally a simple toxic irritation of the peritoneum, presenting all the symptoms of a mild generalized peritonitis; but there may be no specially sensitive spot to indicate the origin of the mischief. In fact, in these cases, the patient is unable to say where the pain started. On opening the abdomen a serous, or even a somewhat turbid exudation containing leucoytes, but always odourless, is found; but no organisms can be cultivated therefrom. In a few hours, or at any rate after a few days' interval, the general symptoms abate, the spontaneous pain as well as the pain on pressure limit themselves more and more to an area which corresponds to the original seat of the mischief. Indeed an abscess is forming, and cure

may take place either by its absorption or by perforation into the bowel (fig. 143, *a*—*h*).

(2) In the second group the initial symptoms resemble the above, but the reaction of the peritoneum is more acute. The exudation soon contains bacteria—usually from the second day in cases of appendicitis—and often has an offensive odour if the infection has come from the intestine. Subsequently the peritonitis diminishes in some places, in others fibrinous investments form, whereas at the periphery of the abdomen there is a tendency to the development of encapsuled abscesses, entirely independent of the original area of the disease (fig. 143, *k*), the so-called "residual abscesses" (Restabszessen). We agree with Sprengel, &c., in interpreting in this sense, the "progressive fibrino-purulent peritonitis" of Mikulicz and Burckhardt.

(3) In other cases, after the general peritonitis subsides and the inflammation has become localized, a fresh and more severe attack of peritonitis may supervene, which signifies that either the primary or a residual abscess has burst into the peritoneal cavity.

(4) In the severest cases the symptoms are generalized from the beginning, and remain so until death. The sero-purulent peritonitis merges into the diffuse purulent form, and the clinical symptoms depend more upon the virulence of the micro-organisms than upon the anatomical conditions.

Some additional general remarks are required to introduce the discussion of the individual forms of peritonitis.

The *previous history* is often very valuable. Sufferers from appendix trouble and gall stones, who have already experienced attacks, recognize the seat of their malady. In females, a reliable history is indispensable, but is often difficult to obtain. For instance, in criminal abortion, as well as in spontaneous abortion which the patient is reluctant to confess, she often endeavours to make her friends and medical attendant adopt the view that the case is appendicitis.

If some general disease has preceded the peritonitis we should think of typhoid perforation. These perforations are more frequently overlooked than one imagines, because the symptoms are partially masked by the underlying disease. A few years ago a well-known surgeon died from an undiagnosed perforation occurring in the course of an undiagnosed typhoid fever, although he was surrounded by physicians and surgeons—which ought to be very consoling to the general practitioner.

The *age* and *sex* of the patient must be taken into consideration. In the *male sex*, up to the age of 20, the vermiform appendix is so frequently at fault, that this ought to be our first thought, in every case of peritonitis, even if it has not started on the right side. After the age of 20 such comparatively rare causes as perforated gastric or duodenal ulcers may suggest themselves, or exceptionally, perforation of a tubercular ulcer of the small intestine. From the age of 40 or 50, or even earlier, we should also think of the gall-bladder. Indeed,

with the advance of age, the probability of the gall-bladder being responsible, and not the appendix, increases. Intestinal perforation due to cancer falls within the same age period. I have only once seen a case of calculous cholecystitis imitate appendicitis before the age of 20, and this was in a girl aged 18.

In the *female sex*, among girls, we have to think, in addition to perityphilitis, of pneumococcal peritonitis—a rarity among boys. This often develops quite independently of the vermiform appendix, and we shall deal with it again later on. After puberty, once the hymen is ruptured, all the inflammatory processes which may start in the sexual organs must be taken into consideration. An intact hymen, as McRae rightly says, points to appendicitis in doubtful cases.

We begin our *physical examination* with a *general view of the entire patient.*

Nothing is so reassuring as a face in repose. Nothing fills us with so much apprehension as the restlessness which the patient manifests about everything; the haste with which he persuades us that nothing ails him, that he feels well, although his pulse is hardly perceptible. Flushes on the face and ears indicate that he is within the grasp of peritonitis, and cyanosis, first to be detected on the finger nails, signifies that the toxæmia is well advanced. Jaundice, sometimes nothing more than a slight pigmentation of the sclerotics, is not rare in general peritonitis, and it is of bad omen. A moist tongue is a good sign, although it may be coated. A dry tongue, even uncoated, shows that mischief still persists somewhere, that the system has not yet mastered the infection. We conclude from rapid shallow breathing in which the nostrils participate that the peritonitis is on the increase, or when the face is generally flushed that some complication exists in the lung. Quiet, painless breathing shows that the inflammatory area has become limited. A full pulse, slow in relation to the temperature, is a good sign; a small soft pulse, rapid in relation to the temperature, is of bad import; a pulse of normal amplitude, but soft and rather dicrotic, indicates an inflammatory focus in the abdomen, which has not yet been overcome.

The age and sex of the patient must be taken into consideration when estimating the pulse-rate. Sometimes a peritonitis may be fully developed, especially in men, and the pulse does not exceed 90. On the other hand, in children, a pulse-rate of 120 to 140 is not of serious significance. If the pulse persists at 130 and over, in adults, the condition is very grave.

The temperature as taken in the axilla is of but little value. Often enough, it does not exceed the normal, even in fatal peritonitis. But it is important, when compared with the rectal temperature; for the greater the divergence, the worse the outlook.

We now proceed to the *examination of the abdomen.* We must first empty the bladder with a Nelaton catheter: even if the patient has micturated in our presence. Patients with abscesses in the lower abdomen do not completely empty the bladder, and it often happens that the full bladder is mistaken for an effusion "because the patient has only just micturated."

We seize the opportunity of using the catheter, to examine the urine, and if albumen or much indican be present, we conclude that the illness is severe. Bile pigment indicates disease of the bile ducts, and sugar suggests some pancreatic affection.

In estimating meteorism, we must remember that the abdominal circumference in young people and in the male sex is, *ceteris paribus*, smaller than in females. In percussing, very light movements are required in order to detect a superficial thin layer of effusion.

Direct, one-finger percussion, known as *palpation-percussion*, is a valuable method, in patients who are not too stout. The whole abdomen is percussed lightly with the middle finger applied flat, by which device, dulness can be *felt* as well as it can be *heard.* It is best always to employ both methods of percussion and compare the results.

The presence of a metallic note over individual loops of intestine is of special significance. It is an important sign of a strangulation, a kink, or of local peritonitis; the same applies to circumscribed crepitations always heard over the same place, or to the peristaltic metallic note so carefully described by Wilms and Leuenberger. Palpation must be very cautious. It is better to remain uncertain of the precise extent of an abscess, rather than to break down protective adhesions through want of care. The more carefully one proceeds the more reliable will be the result of the examination. If the percussion is carefully conducted reflex muscular contraction will cause much less interference and liability to error, than when a rough method is adopted. We cannot entirely avoid this muscular contraction; its presence is very well known, but is not sufficiently appreciated as an aid to diagnosis.

This contraction, or "defense musculaire" which we have already mentioned in connection with abdominal injuries, occurs in the muscles which cover over the diseased area and it constitutes the first sign of inflammatory irritation of the parietal serous membrane. It diminishes with the course of the disease, or limits itself to those areas which the inflammatory process has involved, in its spread. In cases wherein the whole abdominal cavity is inundated by infective material, particularly after extensive gastric perforation, the entire abdominal wall becomes firmly contracted, or at least contracts as soon as the slightest touch impinges upon it. In perityphlitis, the contraction is usually limited to the right lower abdominal region, and if the process spreads towards the loin then the lumbar muscles of the right side contract. If the lumbar muscles of the left side also contract on pressure, we may be sure that the peritoneal irritation

has spread to that quarter. This is the more pronounced, the more the parietal peritoneum is involved in the inflammation, and it may therefore be entirely absent when the inflamed area is deeply situated, *e.g.*, in meso-cæliac or pelvic appendicitis. The respiratory fixation of the muscles in the vicinity of the diseased area is also due to this reflex contraction, as shown by Küster. It is noteworthy that this reflex contraction is much slighter in puerperal cases than in those infected from the intestine.

In examining for sensitiveness to pressure, we must not be misled by expressions of pain which nervous people will manifest, just like spoilt children, even when pressure is made on healthy organs. If the peritoneum is really inflamed, pain will be elicited when the hand is suddenly removed after gentle pressure.

It is necessary to make a brief observation here, regarding the perception of pain in the abdominal organs. Although Harvey and Haller had already shown that the viscera do not respond to ordinary irritation, by pain, nevertheless the site of morbid pain sensations at any rate, was localized in the viscera themselves, until a few years ago. Lennander opposed this view, as a result of his careful investigations, and he sought to explain all sensations of pain by dragging or friction of the nerves of the anterior or posterior abdominal wall, including the mesenteric attachments. Ross, and subsequently Head, assumed that local pain sensibility may occur in the abdominal viscera themselves, giving rise, reflexly, to sensations of pain in a corresponding area of the abdominal wall. Head went a step further and endeavoured to show by numerous investigations, that disease of a thoracic or abdominal organ produced severe localized hyperæsthesia in a very definite segmentary area of skin integument, corresponding to the abdominal organ. If we adopt this theory, we must not any longer attribute local hyperæsthesia to pure functional disturbance (hysteria), without considering the possibility of some deep-seated disease. James Mackenzie has made numerous observations which have led him to certain conclusions of no small diagnostic interest, and which we will here briefly summarize. Like Lennander, he assumes that stimuli such as pinching, pricking, and burning are inadequate to excite the sensation of pain in the abdominal organs themselves. Even an adequate stimulus like contraction does not suffice to excite a sensation of pain, under normal circumstances. But if these stimuli exceed a certain degree they irritate, in the sense of a viscero-sensory reflex, sensory fibres in the spinal cord, which come from the corresponding area of the abdominal integument, and they also irritate, as a viscero-motor reflex, motor fibres which proceed to corresponding muscle segments. Thus, if we pinch an intestinal segment, we excite no pain. But if the intestine contracts in an unusually marked degree, the irritation reaches the spinal cord and stimulates therein spinal pain fibres, causing the brain to appreciate pain in the corresponding spinal segment. This pain is referred to the corresponding area of abdominal skin and not to the abdominal viscus, from which the irritation arises (referred pain). The muscles of the corresponding

segment may be simultaneously irritated, causing reflex abdominal contraction.

Although this view is to some extent hypothetical, it explains Lennander's observations, which are in themselves very accurate, much better than his own theory.

Finally we should make a rectal or a vaginal examination, which will clear up the condition of the female genital organs, afford information as to the existence of a pelvic abscess, and allow us to decide whether it should be opened from above or below. The more deeply it is situated the more evident it will be, not only by the bulging but also by the œdematous swelling of the mucous membrane—feeling like velvet—and by the profuse discharge of jelly-like mucus. Tenesmus is rarely absent.

In arriving at a decision in cases of peritonitis, we must bear in mind a fact which is often forgotten in practice, that all cases do not present a typical, clinical picture. Sometimes on operating we find the intestines swimming in pus, although the clinical symptoms may not have led us to anticipate any severe disease. The pulse remains good, the reflex muscular contraction is slight. There is neither vomiting nor intestinal paralysis, and the patient recovers despite the gloomy outlook. There are two reasons for these exceptional cases. In the first place the peritonitis is not so generalized as it appears to be. The convolutions of the small intestine, although bathed in pus, are not infected between the individual loops, being protected by the omentum and by fibrous adhesions (Lennander's peripheral peritonitis). The second reason is just as important, if not more so: the slight virulence of the pus organisms. For instance, the pneumococcus is comparatively harmless in children, and a central peritonitis due to it may run an excellent course although the condition found at operation leads us to think that the case must prove fatal. Other micro-organisms may also be equally innocuous, in exceptional instances. We need only think of cases of acute peritoneal sepsis which are fatal before anatomical changes have had time to form in the serous membrane, to realize that the prognosis of peritonitis depends more upon the virulence of the micro-organisms than upon the extent and intensity of the anatomical changes.

In concluding these general observations we must mention that our attention must not be devoted to the abdomen alone. There is often a recurrence of fever in the course of peritonitis, after some improvement has begun. The tongue becomes dry again. Nothing is, however, to be felt in the abdomen; but the remarkably rapid breathing, the diffuse congestion of the face, and the dicrotic pulse will forthwith suggest some lung complication to the experienced observer. Careful examination will reveal either a **pneumonia** or a **pleurisy**, or both together, usually as a metastatic process, but in the case of pleurisy it may be the result of direct extension through the diaphragm.

Attempts have been made for a number of years to base indications for diagnosis and prognosis on the condition of the white corpuscles in cases of inflammatory disease—especially of the abdominal cavity.

As a point of diagnosis it is established that a great leucocytosis, independent of digestion, probably indicates an inflammatory disease. On the other hand, a normal or even a diminished leucocyte count does not by any means exclude an infective disease (typhoid). As far as *prognosis* is concerned a high leucocyte count in the presence of severe general symptoms is a good sign ; a low count is a bad sign.

Endeavours have been made to arrive at more definite indications from a *differential count of the white cells* of the blood and from special changes in the neutrophil polynuclear leucocytes. Schindler takes into consideration the number of myelocytes; Arneth counts the nuclei, or fragments of nuclei, of the neutrophil polynuclear leucocytes, and draws conclusions from their greater or lesser fragmentation. Sondern finds an aid to prognosis in the proportion of the leucocytosis in general, to the percentage of the polymorpho-neutrophil leucocytes. All these various methods give some information concerning the defensive activities of the organism. But it is indispensable, in the case of them all, that the examinations should be made at regular intervals, just like the taking of temperature. This, however, requires adequate laboratory equipment and a certain amount of technical experience, in addition to more time than a practitioner can usually devote to individual patients, and therefore these methods must be practically limited to hospitals and clinics. The practitioner does not possess the necessary leucocyte curve at the moment he is called to the patient to enable him to arrive at a decision, and to wait for the preparation of one may frequently delay surgical intervention until it is too late. As Kocher once said, the main thing in appendicitis is not to demonstrate a hyper-leucocytosis, but to prevent its onset by early operation. On the other hand, a leucocyte curve is of value for the hospital surgeon in deciding, for instance, whether a late case of appendicitis requires operation, or whether a second operation is necessary in the course of a suppurative disease of the abdominal cavity.

We now proceed to construct a diagnosis from the conditions found upon physical examination. The most frequent of these conditions may be classified as follows :—

(*a*) Symptoms of pain without perceptible changes.

(*b*) Symptoms of pain, with signs of general peritoneal irritation without definite localization.

(*c*) Peritoneal irritation, with circumscribed changes.

A.—ABDOMINAL PAIN WITHOUT PERCEPTIBLE CHANGES.

The first group of symptoms, characterized by spontaneous pain and by local pain on pressure, without any obvious change, is responsible for most of the errors of diagnosis. We may hesitate

between hysteria, crises of tabes, a mild attack of appendicitis, an attack of mucous colic, renal or biliary colic, some disease of the female genitalia, acute intestinal obstruction, and even an inflammatory disease of the thoracic organs.

Suspicion of some **hysterical condition** will be aroused by any striking contrast between the complaints made and the actual condition found. Formerly, hyperæsthesia of the skin suggested hysteria, but as we know now that disease of deeply situated organs may be recognized by superficial hyperæsthesia, we must be cautious in the interpretation of this sign. Simultaneous deep and superficial hyperalgesia *may* be due to hysteria, but is *not necessarily* so. But "appendicitis" is *certainly* hysterical if the hyperæsthesia is exclusively confined to the skin.

We must examine for **tabes** in every case, wherein the other conditions are reconcilable with this diagnosis.

A female, aged 50, became ill suddenly one night with severe abdominal pain, which suggested an acute gastric or intestinal perforation. Although physical examination proved negative, the question of laparotomy was contemplated, but the history made one hesitate. Her husband had died twenty years ago from paralysis, she had had one miscarriage, and a swelling on the skull which had been cured by potassium iodide. Further examination showed that the pupil reflex was lost, and that the knee jerks were absent—the only signs of tabes. The abdomen was not opened. Rectal crises occurred later on, in confirmation of the diagnosis.

Attacks of **mucous colitis** are often mistaken for inflammatory diseases. Muco-membranous colitis, with its ileo-cœcal pain, tenderness on pressure over the appendix region, and its transitory pulse of collapse and vomiting may completely resemble an attack of appendicitis.

We merely refer to the matter here, but will discuss it more fully in connection with *chronic appendicitis*. Other symptoms of pain in the large intestine, the significance of which is often difficult to decide, will be dealt with together later on.

The gums should always be examined in unexplained colic, lest a case of *lead colic* be missed.

In **renal colic** either a normal or enlarged kidney, sensitive to pressure, is felt, or, at any rate, pronounced reflex contraction of the lumbar muscles is present. The pain radiates into the genital organs and even to the thigh, and the corresponding testicle may be abnormally sensitive to pressure.

Gall-bladder colic is distinguished from renal colic and appendicular pain by the situation of the sensitive area, which is internal to the outer border of the rectus, and at the level of, or above the umbilicus. They may easily be mistaken for duodenal pain; but gall-stones usually occur in females and duodenal ulcers in males.

Temporary strangulation of a **hernia**, which has been overlooked both by patient and doctor, may be mistaken for a mild attack of appendicitis, quite apart from appendicitis in a hernial sac.

On one occasion I removed the appendix of a middle-aged woman on account of the history of appendicitis, and the diagnosis made by the medical attendant during the attacks. But the attacks returned, and I eventually discovered the cause in a right-sided crural hernia, which could hardly be detected by the most careful examination. The mistake could have been avoided by accurate observation of the temperature during the attacks. There is invariably some rise of temperature in appendicitis, but if it is slight it may have passed away before the arrival of the doctor. If there are no physical signs to account for a high temperature taken by the patient himself, we should then take it ourselves, so as to exclude any artificial pyrexia due to friction against the thermometer. In one hysterical case the thermometer was so manipulated by the patient that the surgeon removed his appendix—in good faith.

One should not forget the possibility of **painful menstruation** in females.

Intra-abdominal menstruation must also be thought of, if this condition is really diagnosable. Such cases have more than once been operated on with the diagnosis of appendicitis.

We have already referred to **intestinal obstruction**, and will discuss it in detail later on.

The attacks of pain induced by adhesions, by anomalies of position and of form, belong to this group. If the history and skiagram do not afford any definite guidance, a positive diagnosis can only be obtained if the transitory kink, twist or band leads to genuine intestinal obstruction with a subsequent operation, or examination *post-mortem*.

Finally it must not be forgotten that little children usually refer the pain of **pneumonia** or **pleurisy** to the abdomen. In adults also, diaphragmatic pleurisy is manifested by pain on one side of the abdomen and muscular contraction.

The pain of **tubercular caries** rarely extends so far into the abdomen as to cause serious diagnostic difficulties.

B.—DIFFUSE PERITONITIS WITHOUT LOCALIZATION.

The *second group* of cases confronts us with different questions altogether. The physical condition—accelerated pulse, pyrexia, general tenderness, a rigidly contracted musculature or a distended abdomen, an effusion, either free or badly localized—shows that the peritoneum is acutely inflamed. The diagnosis of nervous disease or colic is no longer possible.

But it is just here that there is the danger of confusing **obstruction** with peritonitis. We have already stated the main points of the differential diagnosis at the beginning of this chapter. The effusion,

which so often accompanies strangulation by bands, adds to the resemblance, especially as peristalsis is frequently inhibited in strangulation, thus banishing the chief symptom of difference between peritonitis and obstruction.

We may similarly be deceived by strangulation due to a pre-existing, but frequently overlooked **tubercular peritonitis.** The tubercle produces the exudation, and the strangulation evokes the acute symptoms.

A young girl, aged 18, hitherto quite well, except for some vague indigestion, was suddenly attacked by abdominal pain, vomiting and fever. Two days later I found her in the following condition : high fever, rapid hardly perceptible pulse, accelerated respiration, dry tongue, red flushes on face, distended sensitive abdomen with dulness in the dependent part. Everything pointed to a generalized peritonitis subsequent to appendicitis. But there was one sign which caused hesitation. When I arrived the patient was sitting half up, and she resumed this posture without any difficulty during the examination. A patient with severe peritonitis never does this ; and therefore some other diagnosis had to be found. This was suggested by the fact that there were two tubercular uncles, and that the patient had previously suffered from digestive trouble. The inference was that the case was one of an overlooked tubercular peritonitis on which an acute obstruction had supervened—the latter condition having rapidly reached the stage of diffuse distension of the abdomen and rapid small pulse. Hence this picture of peritonitis. This diagnosis was confirmed at the operation.

We may also be deceived by a **"meso-cœliac" appendicular abscess** lying between or behind the coils of the small intestine (fig. 143*d*). These abscesses are situated too high to allow of their being felt per rectum. If the forwardly displaced loops of small intestine are so distended that the abscess cannot be felt through the abdominal wall, one usually thinks of generalized peritonitis, or of obstruction, unless the consideration of the whole course of the illness leads to a correct diagnosis.

There are yet two other conditions which may lead us astray, viz., **acute pancreatitis with acute fat necrosis,** and **blocking of the mesenteric vessels.** The former condition is suggested when the symptoms are mainly confined to the upper abdominal region, and the patient is a stout man of middle age or older. The presence of sugar in the urine is a valuable aid to diagnosis, but the patients usually succumb before the onset of glycosuria.

The blocking of the mesenteric vessels generally concerns an artery, and less often a vein. In the case of arterial blocking, the cause is either embolism, or thrombosis ; when a vein is blocked the cause is always thrombosis. The anatomical result is infarction, or gangrene of a more or less considerable section of the intestine. The early clinical signs partake of the character of peritonitis, with persistent deep, dull pain and effusion, rather than that of obstruction.

Blood in the stools, and the vomiting of lumps of blood, and the retention of flatus, should arouse suspicion. The existence of valvular disease, indicates embolism, especially if the patient has manifested other signs of embolism. Diseased blood-vessels, and general defects of the circulation would point to thrombosis. As a rule, the embolism is first recognized, either at the operation or at the autopsy.

Having established the diagnosis of acute infective peritonitis, we must endeavour to determine its origin. The considerations with which we introduced the discussion of peritonitis will be of great assistance, as also the remarks to be made in the next section on localized inflammatory processes. When in doubt, we must suspect appendicitis, at any rate, in civilized countries. In other regions it may be otherwise, because this disease is not equally prevalent everywhere.

It is stated that only whites suffer from appendicitis in China and South Africa. It is uncertain whether this is a matter of race or of nutrition.

C.—LOCALIZED PERITONITIS.

If there are clear symptoms, pointing to a localized area of inflammation, our task is much easier, whether general symptoms are present or not. We will proceed topographically, starting with the upper portion of the abdominal cavity.

(1) EPIGASTRIUM.

The most frequent origin of inflammation in the epigastrium is in the **stomach**, and the cause is either a gradual or sudden perforation of an ulcer, or more rarely of cancer. Perforation of a duodenal ulcer close to the pylorus causes identical symptoms. **Pancreatic hæmorrhage and pancreatitis**, which we have already referred to, should also be mentioned. Exceptionally, a hepatic abscess may be situated in the middle of the epigastrium.

(2) RIGHT HYPOCHONDRIUM.

In temperate climates the **bile ducts** are mainly responsible for inflammation in this region, with extension into the liver substance in the form of septic cholangitis. In the Tropics, **abscess of the liver** is the most frequent occurrence. This does not exclude the possibility of hepatic abscess in temperate climes, but then the abscess is generally the result of gall-stone disease, which is predominant clinically, or it is metastatic in nature, and recedes into the background in comparison with the other signs of the pyæmia. Rupture of a duodenal ulcer must next be mentioned. If the rupture has been gradual it causes a

localized inflammation, if it has been sudden it causes generalized peritonitis.

We shall see later on that, occasionally, a vermiform appendix may wander into this region.

(3) LEFT HYPOCHONDRIUM.

Inflammatory processes occurring in this vicinity, are nearly always the result of **perforated gastric ulcers.** **Abscess of the spleen** is very rare, but it has been observed especially in typhoid fever. In cases of appendicitis, secondary abscesses often occur in the left hypochondrium, or travel up into this region from below.

(4) LUMBAR REGIONS.

Retro-peritoneal inflammation in the lumbar region is mainly concerned with the **kidney.** If the inflammation has extended so far forward that we must assume that the *peritoneum is involved*, then on the right side, we should first think of **appendicitis** (fig. 143, *g*). This diagnosis is obvious if the ileo-cæcal region is also involved. On the other hand I have seen experienced practitioners in doubt, even where this area has been quite free, and when the whole process has been confined to the lumbar region. The lumbar variety of appendicitis is, however, not always, intra-peritoneal. When the appendix is in this position, it is usually either entirely or partially retro-peritoneal, so that the peritonitic symptoms are not predominant, and the disease process tends toward the back, appearing as a phlegmon of the cellular tissue attended by high fever (fig. 143, *l*).

Very significant of this form of phlegmon, which usually contains gas-forming bacteria, is the change of the reddened skin into a yellowish hue. It cannot be a mere accident that I have seen so many of these cases end in pyæmia.

Appendicitis is often the cause of apparently primary abscesses of the *left* lumbar region. In these cases, the appendix lies in a very dependent position, and the primary abscess, which is not palpable from above, originates in the true pelvis (fig. 143, *e*), and then advances towards the left.

It should finally be mentioned that **parametritis** often extends towards the lumbar region.

(5) LOWER ABDOMINAL REGION.

(*a*) If an inflammatory process occurs in a female, *exactly in the middle line*, our first thought must turn to the **uterus** and its vicinity, and we must not be misled either by the married or single state of the patient. If we do not at once ascertain that the disease has followed a confinement or miscarriage, we enquire about the last

menstruation, and the more hesitating the reply the stronger are our suspicions. Experience shows that nearly all infections which follow miscarriages are due to the use of the sound in procuring abortion. Sometimes it happens that an apparently inflammatory swelling situated directly in the middle line of the lower abdominal region is really due to an *extra-uterine gestation*, concerning which more will be said later on. If the clinical history and vaginal examination exclude disease of the genital organs, we must look elsewhere for the cause of the trouble, and again we fall back upon the **appendix**, which is often responsible for a primary abscess in the middle line.

In rare instances a **perforated Meckel's Diverticulum** causes a median abscess, or one situated rather more to the right beneath the umbilicus. This is also the favourite place for the pointing of an abscess due to **pneumococcal peritonitis** in little girls. If these

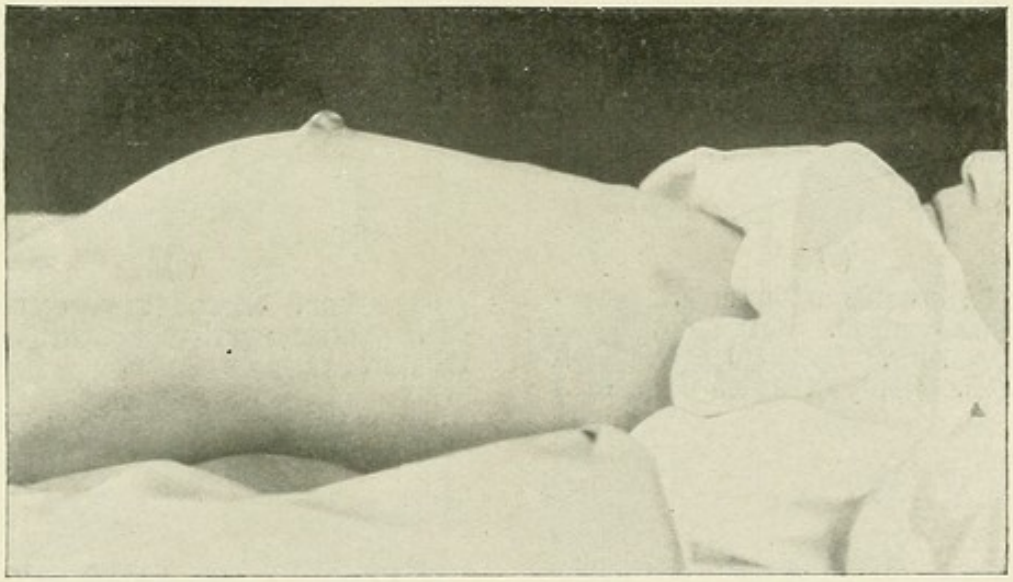

FIG. 142.—Pneumococcal peritonitis on the point of bursting through the umbilicus.

abscesses are not opened in time, they eventually burst through the navel (fig. 142). They are distinguished from other abdominal abscesses by their remarkable softness.

Ovarian cysts with twisted pedicles or which have **suppurated** are usually situated in the middle line. A superficial examination is liable to mistake them for abdominal abscesses, or for appendicitis if they are situated towards the right side. Their sharply defined upper border should usually establish the diagnosis. Twisting of the pedicle is comparatively frequent, while suppuration of an ovarian cyst is rare. The former condition is very sudden in its onset, and to some extent is distinguished from a suppurating ovarian tumour by the course of the temperature. In the latter, the leucocyte count of the blood is high.

FIG. 143.

Diagrammatic Representation of the more Important Phases and Forms of Appendicitis, and of some Considerations in Differential Diagnosis.

Green = abscess contiguous to the anterior abdominal wall.
Shaded green = abscess covered by intestine.
Yellow = serous or sero-purulent exudation, aseptic on first day, infected early exudation on second day.
Yellowish-green = sero-purulent exudation.
Blue = extra peritoneal abscess.
Red = blood effusion.

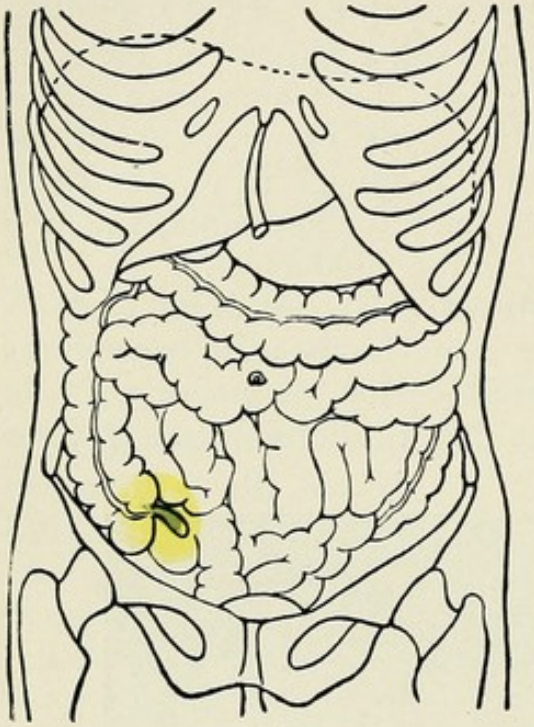

(*a*)

Appendix forwards and inwards. Appendicitis, antero-parietal. First stage. Purulent appendicitis. Localized serous peri-appendicitis. (Early exudation beginning.)

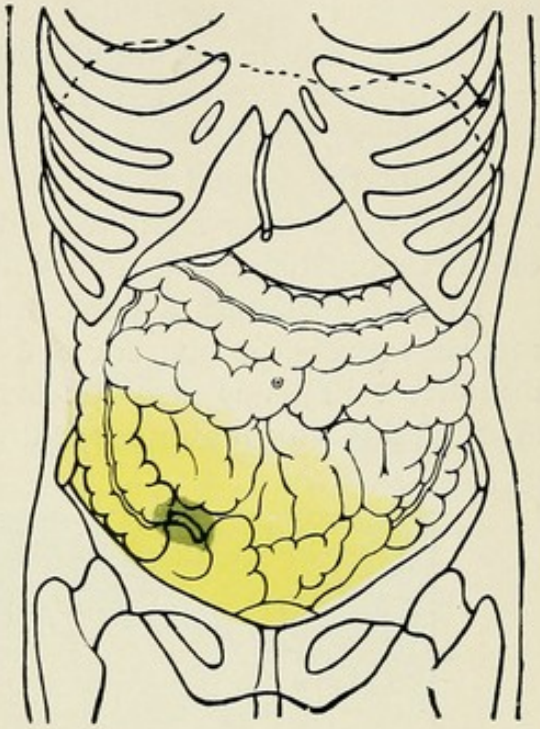

(*b*)

Same form. Second stage, second to third day. Purulent peri-appendicitis beginning. Extensive early exudation.

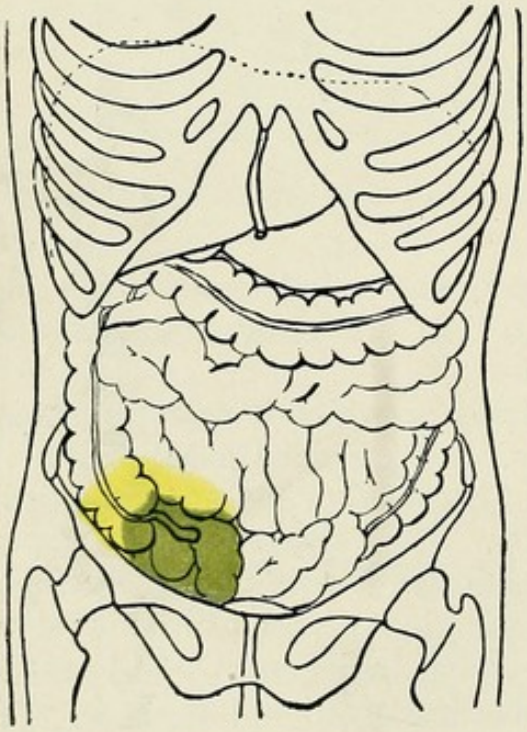

(*c*)

Same form at end of first week. Third stage. Large antero-parietal encapsuled abscess. Early exudation has subsided.

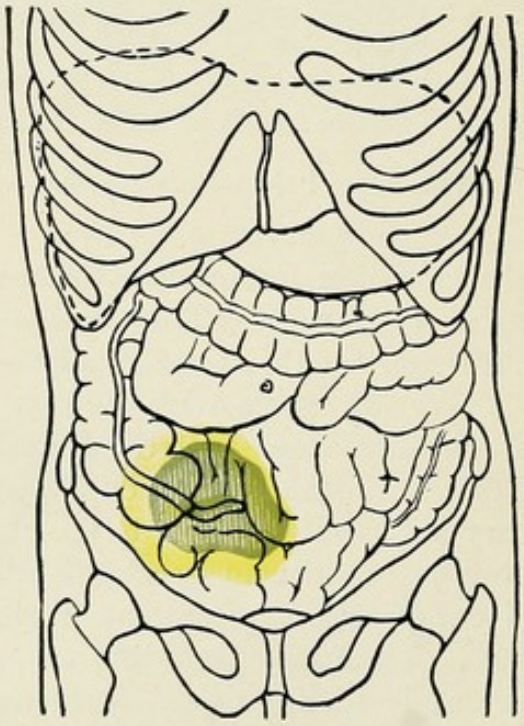

(*d*)

Same stage, but appendix situated in convolution of small intestine. Abscess covered by intestinal loop. Meso-cœliac appendicitis.

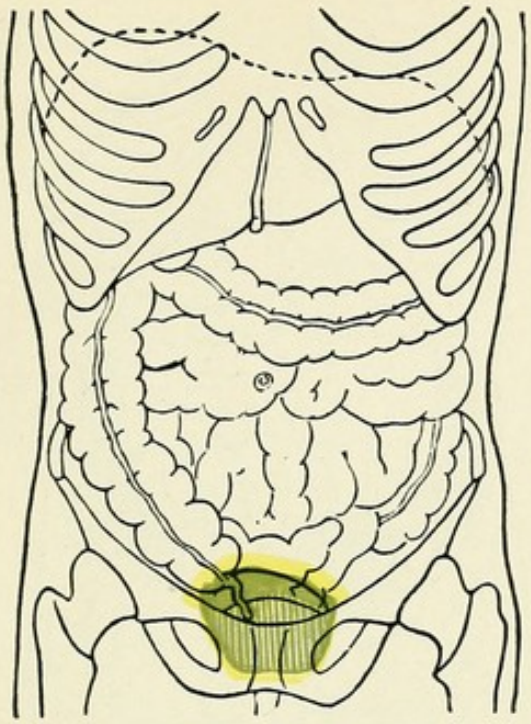

(*e*)

Same stage. Appendix in true pelvis. Pelvic appendicitis.

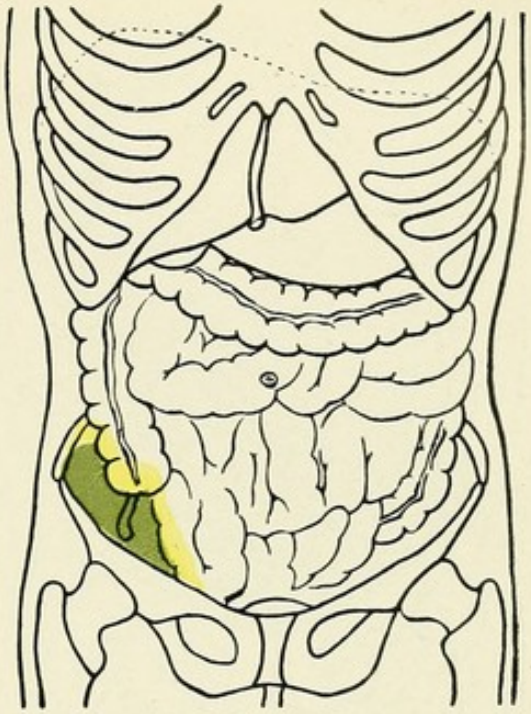

(*f*)

Same stage. Appendix situated outwards and downwards. Ileo-inguinal appendicitis.

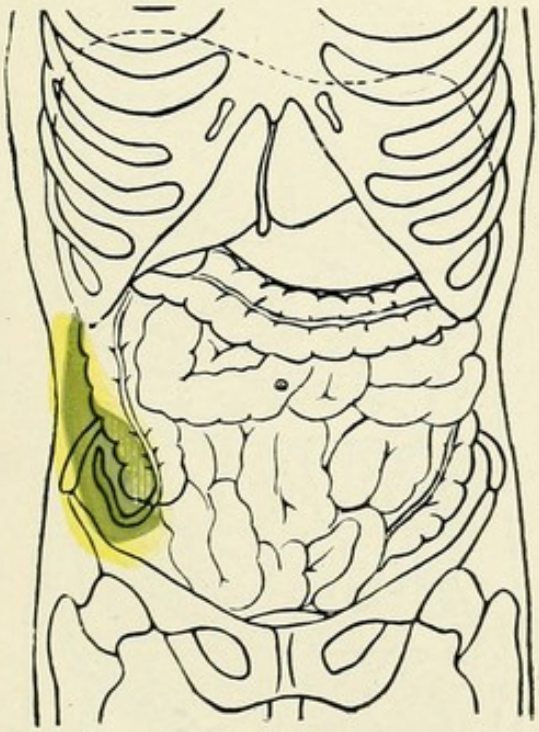

(*g*)

Same stage. Appendix directed upwards and outwards. Abscess partially behind cæcum. Ileo-lumbar intra-peritoneal appendicitis.

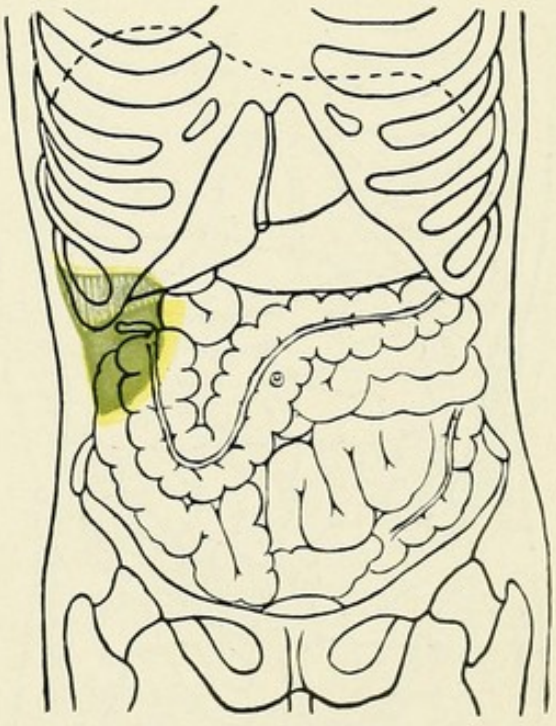

(*h*)

Same stage. Cæcum and appendix drawn upwards. (Beginning of left-sided transposition of colon. Common ileo-cæcal mesentery.) Sub-hepatic appendicitis. (Abscess in same position when cæcum is normal, but when very long appendix is drawn upwards and outwards.)

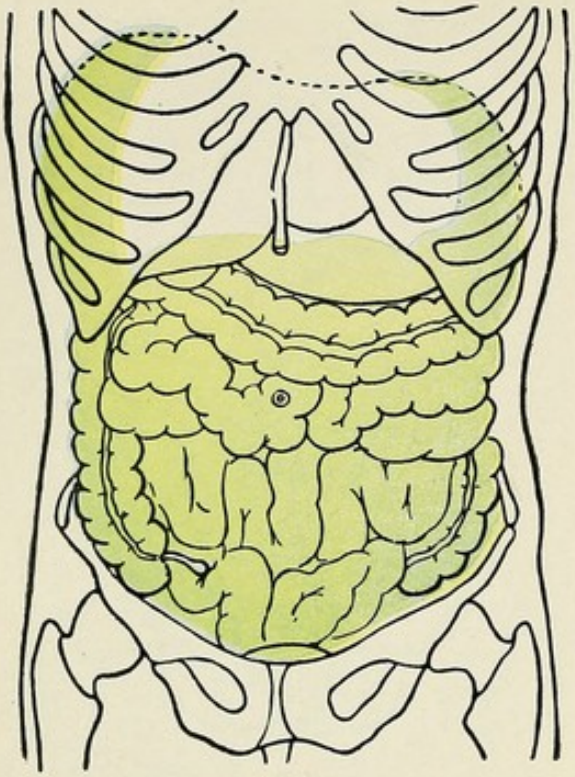

(*i*)

Diffuse sero-purulent peritonitis, in a very virulent infection, large perforation or gangrene of appendix, or secondary rupture of encapsuled abscess. This form of peritonitis is fatal, or recovery only occurs with abscesses remaining.

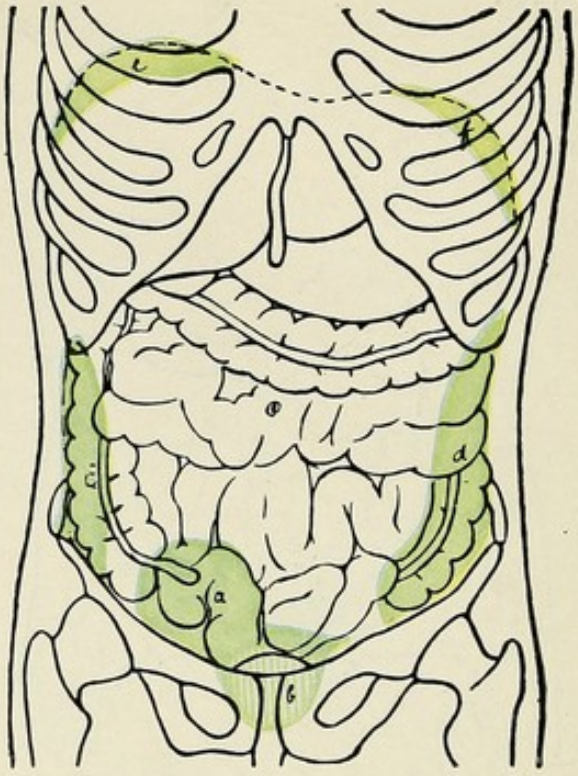

(*k*)

Multiple abscesses (residual) after general sero-purulent or purulent peritonitis. The figure shows the most common positions. These abscesses frequently intercommunicate, thus *a* and *b*, often *a* and *c*, or *a* and *d*, &c. The "progressive fibrinous purulent peritonitis" of Mikulicz and Burckhardt depends upon this process.

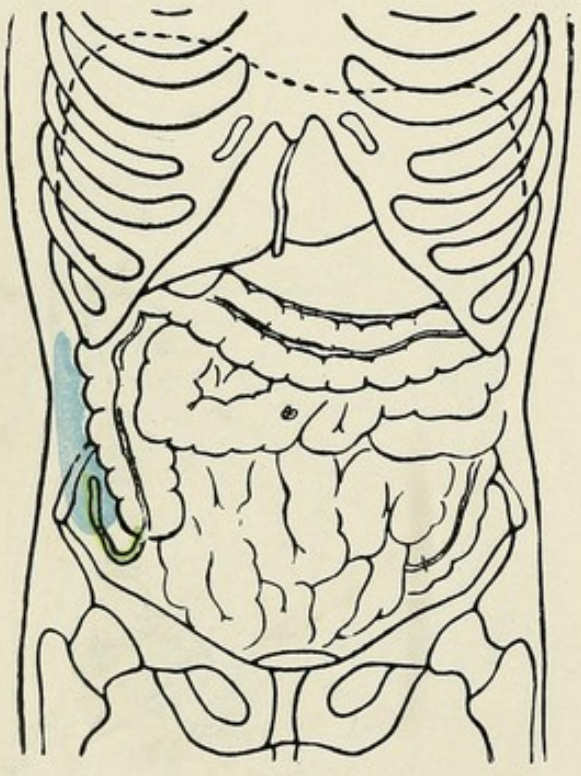

(*l*)

Appendix inclined upwards and outwards. The abscess is extra-peritoneal, sub-serous and finally became superficial in the form of a phlegmon in the lumbar region. Lumbar appendicitis or ileo-lumbar sub-serous appendicitis.

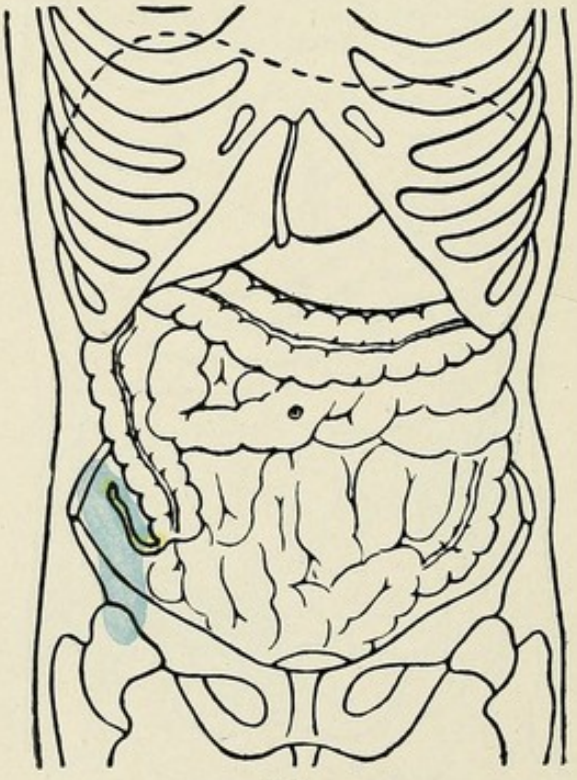

(*m*)

The abscess is under the iliacus fascia. Ileo-inguinal sub-fascial appendicitis. The abscess may reach the thigh by tracking under Poupart's ligament.

FIG. 143.

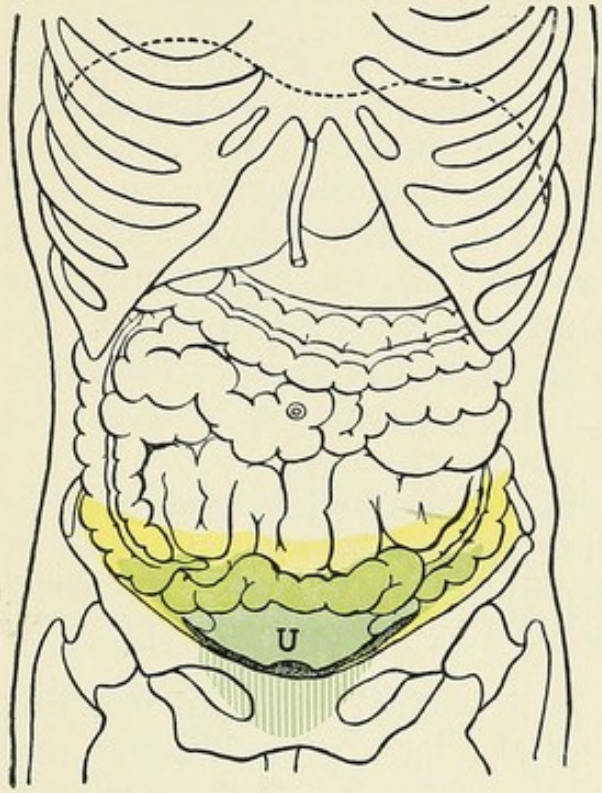

(*n*)

Purulent peritonitis, exciting serous peritonitis in the vicinity. U = uterus.

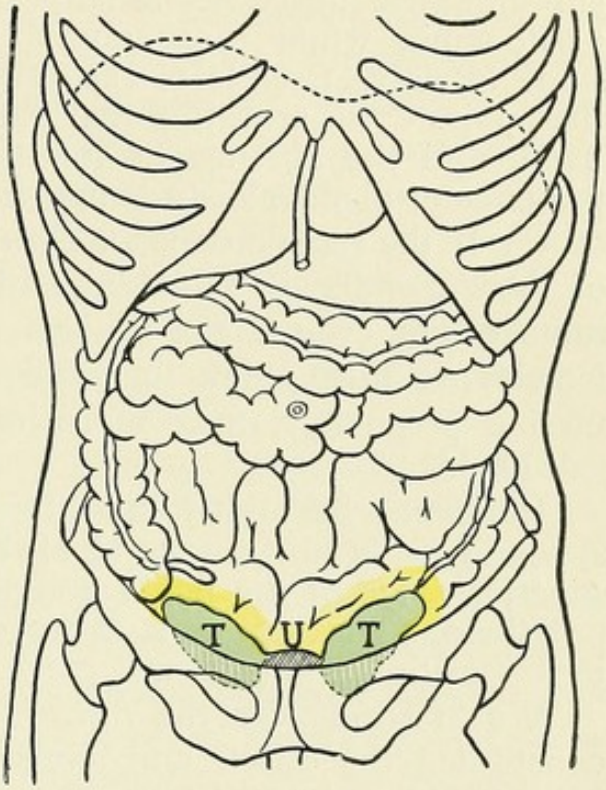

(*o*)

Bilateral pyosalpinx, with some serous perisalpingitis.

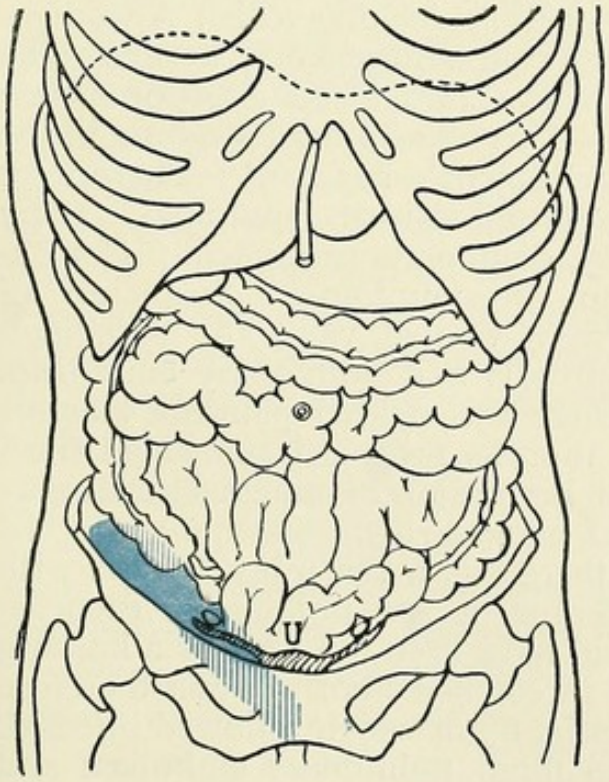

(*p*)

Parametritis extending as far as Poupart's ligament.

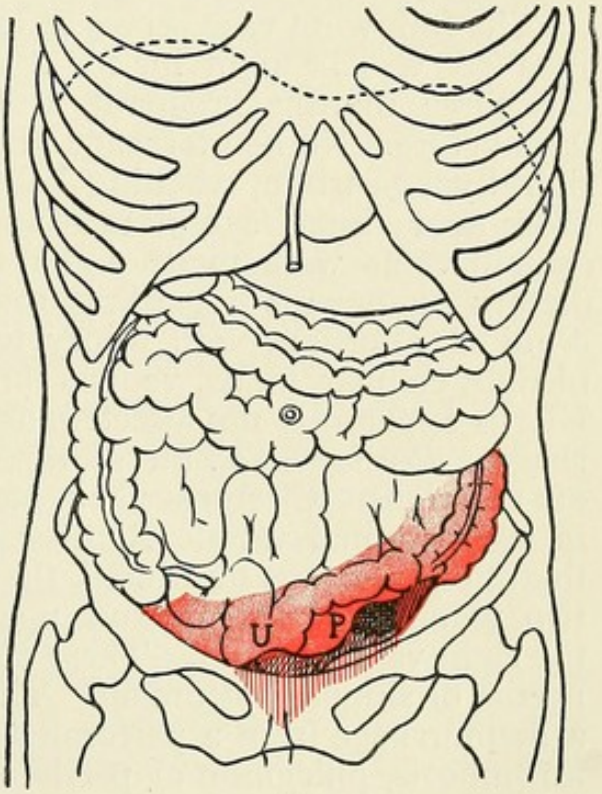

(*q*)

Rupture of a pregnant tube. P = placenta, with a peri-tubal hæmatoma around.

Abscesses in the *abdominal wall*, below the umbilicus and above the symphysis, must not be mistaken for abdominal abscesses. The sub-umbilical abscesses usually arise from infective disease of the peritoneum, while those above the symphysis originate either in some infective trouble of the urinary tract or from osteomyelitis of the pubis. The sensation that the abscess is immediately beneath the hand, and the absence of intestinal symptoms with the occasional presence of bladder disturbance, makes the diagnosis quite easy.

(*b*) If the resistance is *at the side* we are fully justified in thinking of the appendix on the right, and we shall often have to assume the same origin, even if the abscess is on the left side, in males. In females we must think, in addition, of salpingitis, parametritis, extra-uterine pregnancy, and more often than in males, also of the gall-bladder.

It should be added that the position of the diseased area, in appendicitis, is not always at McBurney's spot, between the anterior superior spine of the ileum and the umbilicus ; indeed it is usually not there. The appendix, as we shall see later on, varies very much in its position (fig. 143, *a*, *d*, *g*, *h*).

We first consider the *history*. If abdominal pain and vomiting constituted the onset, and similar attacks have preceded, the case is probably appendicitis or may be cholelithiasis. If the symptoms have come on with the menstruation, or if they have apparently brought it on early, this should not tempt us from the first diagnosis. But if the illness has followed a miscarriage or a confinement and is not accompanied by signs of peritonitis, we can only assume that it is a case of phlegmon of the broad ligament (fig. 143, *f*).

The following case serves as an example for diagnosis : A woman, aged 38, was brought in, for a suspected strangulated hernia. She was three months pregnant, and had a threatened abortion a few days before. No hæmorrhage now. There was a hard swelling in the right hypogastrium, reaching below Poupart's ligament. There were prominent lung symptoms and blood-stained sputum. Many examinations were made and many diagnoses suggested. Contradictory statements regarding origin of symptoms. Suspicion of criminal abortion, with injury to right vaginal vault and phlegmon of right cellular tissue, venous thrombosis and pulmonary embolism. Uterus apparently not affected, as there was neither pain nor hæmorrhage. *Per vaginam*, uterus three months pregnant, somewhat fixed on the right. Circumscribed, hard infiltration of mucous membrane in right vaginal vault. Right-sided parametritis. Speculum showed that the portio was uninjured, that there was a thrombosed varix with two wounds of the mucous membrane, a few millimetres each, in the right vaginal vault. These could have been inflicted by a knitting needle or similar instrument. The threatened abortion was therefore a hæmorrhage from a perforated varix, upon which followed infective thrombosis, phlegmon of pelvis and thigh, pulmonary embolism and multiple abscesses,—and finally the patient recovered.

A cylindrical or irregularly circular sharply-defined swelling at the border of the true pelvis and the iliac fossa, which has taken months or years to form, is a **salpingitis.** In its development, frequent, but not severe inflammatory attacks occur, and careful investigation will generally reveal a history of gonorrhœa or tubercle. The disease may be unilateral or bilateral (fig. 143, *o*). The history of gonorrhœa can only be obtained by confidential questioning of the husband, if there be one. If we are informed that irregular hæmorrhage occurred after one or two periods had been missed, and that the lateral swelling which we detect has been accompanied by severe pain, collapse and perhaps by vomiting, we shall seldom go wrong in diagnosing a **ruptured tubal gestation,** or a tubal abortion (fig. 143, *q*).

We derive most information from *physical examination.* By this method we are able to define morbid conditions above, towards the gall bladder, as well as those below, towards the pelvic organs. If the resistance is more clearly limited below than above, and if the maximum point of pain on pressure is high up we should think of **disease of the bile ducts.** If the gall bladder is greatly enlarged and inflamed, this point of maximum pain may be displaced below the line of the umbilicus, especially if the adjacent loops of intestine are involved in the inflammation. Jaundice naturally points to biliary disease, but not unconditionally, any more than the absence of jaundice is an argument against it. The age of the patient, whether male or female, is of significance; as the probability of cholelithiasis increases with age.

If the morbid process tends downwards, we decide upon **appendicitis** if the pain and the maximum point of tenderness on pressure are found above the true pelvis, while the symptoms are definitely less, lower down. On the other hand, we diagnose **parametritis,** if the swelling and tenderness have started close to the uterus, whence they have spread upwards towards Poupart's ligament, or even to the pelvic fossa or lumbar region. Vaginal or rectal examination may detect a perityphlitic exudation reaching into the true pelvis, *behind* the uterus, or an extra-peritoneal parametritic exudation *at the side* of the uterus, displacing it towards the healthy side, and more or less fixed to the pelvis. In a case of extensive **pyosalpinx,** a more or less sausage-shaped, sharply defined resistance can be felt from above, and its connection with the uterus can be made out by bi-manual examination. But even apart from this, the sharply defined limitation of the structure facilitates its distinction from an acute perityphlitic abscess.

The frequent exacerbations of peri-salpingitis occurring in a pyosalpinx render the diagnosis difficult. But even in these instances the limitation above is quite sharp, which is not often the case with appendicitis.

The diagnosis of a ruptured right-sided pyosalpinx is difficult. The following is a typical case. A girl aged 20 was seized at night, after a festive occasion, with "appendicitis," and was admitted within twenty-four hours with the symptoms of a commencing diffuse peritonitis. Temperature was 104·8 F., face was remarkably flushed. Indefinite resistance was felt on the right side, per rectum. As the flushed face was very unusual for appendicitis, and as the height of the temperature was still more unusual for the first day, we thought of rupture—sub coitu ?—of a right tube, and the operation confirmed the diagnosis. The pus contained a pure culture of *Staphylococcus aureus*.

Cases wherein an acute appendicitis becomes engrafted on an old salpingitis are not very rare, but it is quite impossible to unravel the maze of symptoms and make a diagnosis.

There may not be any less difficulty in differentiating between appendicitis and a **ruptured tubal gestation.** The swelling is situated midway between the position of an appendicular abscess and a parametritis. It is intra-peritoneal like the former, but connected with the uterus like the latter. It often reaches as far as the appendix, so that the roof of the blood cavity is formed by the appendix, cæcum and last loops of the small intestine, all combined.

On one occasion I found a shrivelled fœtus of about ten weeks gestation tucked away with a thrombosed placenta under the cæcum.

It will of course be understood that the oval swelling close to the uterus is only *one* of the symptoms of ruptured tubal gestation, or of tubal abortion, *i.e.*, the *peri-tubal hæmatoma*. If the history is indefinite or unreliable, it may be very difficult to distinguish it from a unilateral pyosalpinx in which peri-salpingitis has occurred—as gynæcologists know very well.

If the hæmorrhage is severe or is repeated, then the hæmatoma is no longer lateral, but becomes *retro-uterine*, and should rarely be confused with an appendix abscess in the pelvis. But if there should be any doubt, extra-uterine gestation is confirmed by softening of the vaginal cervix, enlargement of the breasts, the exit of drops of milky fluid when they are squeezed, anæmia and slight jaundice. The presence of fever is no contra-indication. A glance at the patient's ears is the most rapid indication of the degree of anæmia. Their marked pallor is as significant of a severe internal hæmorrhage as their blueness is of peritonitis, other symptoms being equal. If some abnormal swelling can be felt in Douglas' pouch in the first twenty-four hours, the case is probably a hæmatocele, because appendicitis does not lead to an abscess in Douglas' pouch so soon. If, on the other hand, the history points to extra-uterine pregnancy, and the tumour is strikingly movable, we must think of an unruptured tubal gestation or of an abdominal pregnancy. Too energetic an examination may cause a severe hæmorrhage in such a case.

The condition of the *abdominal muscles* is important in a doubtful case. The degree of their reflex spasm depends upon the nature and

intensity of the irritation, and the extent to which it has involved the anterior abdominal wall. It is most pronounced in appendicitis, less so, or absent in salpingitis and ruptured tubal gestation. In the latter case, it depends upon the extent of contact of the hæmatoma with the abdominal wall, and the sensitiveness of the individual towards an intra-peritoneal effusion of blood. It should also be remarked that individual differences in reflex irritability, and the special characteristics of the micro-organisms concerned, play an important rôle, even in suppurative diseases. The blood examination is of value, in so far as a great decrease in the hæmoglobin and red corpuscles indicates hæmorrhage. But leucocytosis does not necessarily indicate an inflammatory process, because this may occur, even in an extreme degree, in ruptured tubal pregnancy.

If the displacement of gas from the descending colon towards the cæcum, by pressure upwards from the left of the pelvic fossa, causes pain in the appendix, this always means appendicitis, according to Rovsnig, or, at any rate, some inflammatory process involving the cæcum. I agree with Hausmann, that—at any rate in many cases—the pressure is communicated to the inflamed area, not by the column of gas in the large intestine, but through the distended small intestine.

Diseases of the left side of the pelvis require mention, although they only half belong to the surgeon. He shares the diseases of the female genitalia with the gynæcologist, on account of the frequency of errors of diagnosis. The physician occasionally refers to him cases of **sigmoiditis**, *i.e.*, localized subacute, or acute, inflammation of the sigmoid flexure. This condition should be thought of, when a sausage-shaped swelling is felt in the left lower abdominal region, in association with symptoms of colitis : diarrhœa, mucous discharge and blood. It is still a medical disease in this stage, but if signs of peri-sigmoiditis, *i.e.*, irritation of the peritoneum, supervene, the cases become surgical and the question of operative assistance arises. We shall refer to this again in another connection.

(6) TRUE PELVIS.

To discuss inflammations within the true pelvis is apparently an intrusion into the province of gynæcology. We may, however, disarm this criticism by beginning with the *male sex*. It often happens that nothing can be felt in the whole abdomen, and then it is found that Douglas' pouch is occupied by an inflammatory swelling. What may this be ? It is most probably an **appendicular abscess**, originating in an appendix hanging down into the true pelvis. But I have found there an **intussusception of the small intestine**, which I looked upon as an appendicitis until the operation. An inflamed coil of small intestine, obstructed by a **gall-stone** is often found in the true pelvis. **Cancer of the rectum** often gives rise to peri-rectal suppuration. Finally, there occur abscesses arising from the urinary tract,

which are specially to be attributed to **prostatic suppuration**, of **suppurating diverticula**, in prostatic patients.

A rare cause of inflammation may be mentioned here, as arising from the multiple **diverticula of the descending colon**, varying in size from a millet-seed to a cherry-stone, which have been described especially by Graser.

With the exception of prostatic suppuration, all the above conditions also apply to the *female sex*, who also suffer from the special diseases associated with the female genitalia. Some controversy has raged around the proper limitations of the work of the surgeon and gynæcologist. In order to avoid this, I will only mention here the association of **pregnancy or the puerperal state with appendicitis.** When pains occur in the hypogastrium of a pregnant woman we naturally connect them with the pregnancy, but the possibility of appendicitis must not be overlooked. This combination is most unfortunate, as it generally leads to abortion, or miscarriage. If the pregnant uterus forms a portion of the abscess wall, as is usually the case, rupture of the abscess is almost inevitable, and therewith fatal peritonitis also. The midwife or doctor is usually blamed for this, unless an autopsy throws light on the tragedy. I have seen a similar catastrophe at the end of a normal pregnancy.

For this reason, one should not shirk removing, during pregnancy, an appendix threatened with inflammation. If an abscess has formed it is imperative to open it before abortion or labour occurs.

It is sometimes very difficult to distinguish exacerbations of acute (generally of gonorrhœal origin) salpingitis, which occasionally occur in the puerperal period, from attacks of appendicitis, especially when there is a previous history of appendix seizures.

CHAPTER XXXVII.

SUB-PHRENIC ABSCESS.

If a patient has continuous high fever without any obvious suppuration in any of the easily accessible regions of the body, we should bear in mind the various possibilities of sub-phrenic abscess. The existence of such an abscess is highly probable, if the patient has recently had any inflammatory disease within the abdominal cavity. About half the cases of sub-phrenic abscess originate in appendicitis ; the rest are due, in the abundant experience of Körte, to affections of the stomach, liver, spleen, kidneys, pleura, ribs, intestine and pancreas —in descending proportion.

The main aid to the diagnosis of sub-phrenic abscess is to bear it in mind and search for it. We shall describe a typical case before detailing the symptoms.

A young man passed through a severe attack of perityphlitis, which was operated on, in the stage of widespread peripheral peritonitis. All the symptoms gradually abated. The temperature rose again two months after the beginning of the illness, but examination with the view of detecting a sub-phrenic abscess revealed nothing. But as the fever persisted, the patient was re-examined. The lower border of the liver was at first in the normal position, its dulness did not extend upwards above the usual limit ; the condition of the lung was normal and there was a complete absence of subjective symptoms. A small patch of broncho-pneumonia on the left side misled us and prevented us from making an immediate exploratory puncture on the right side. Eventually the liver dulness began to extend upwards and its lower border downwards, and slight pain on breathing supervened. This confirmed our suspicion. Screen examination by X-rays showed normal movements of the right arch of the diaphragm, but its shape was remarkably semi-spherical and it appeared to be very high. Exploratory puncture and immediate operation demonstrated a sharply localized sub-phrenic abscess, which caused considerable upward bulging of the diaphragm.

The diagnosis is rendered very difficult by the fact that percussion over the lung as well as over the abscess may yield very varying results. The lung may give a normal note, or a dull note if there be any associated pleurisy, whereas a sub-phrenic abscess will be tympanitic if it contain gas; otherwise it will be dull. The situation of the abscess is not constant, sometimes it is confined to the upper surface of the liver, sometimes its position is more forwards, at others it is situated backwards and downwards, in which case it resembles a peri-renal abscess. We will treat this subject in two parts, corresponding to the fundamental difference of the presence or absence of pleural effusion.

(1) SUB-PHRENIC ABSCESS WITHOUT PLEURAL EFFUSION.

If the abscess contains little or no gas, as in the previously described case, the only local sign is that the edge of the liver is lower, whereas its upper border of dulness is higher. The lower limit of the healthy respiratory sounds is also pushed upwards, corresponding to the liver dulness. There may be more or less definite signs of compression, but they may be quite absent. How can we distinguish this physical condition from pleural effusion ? The degree of the downward displacement of the liver and the bulging of the lower part of the thorax, in sub-phrenic abscess, are too variable to be of any value as differentiating signs. Very marked signs of pulmonary compression and

infiltration point to empyema; if these signs are absent they are in favour of sub-phrenic abscess. But it is more important to realize that the upper border of the dulness in sub-phrenic abscess is convex, whereas in empyema it is rather horizontal or runs obliquely towards the spine. A screen examination by X-rays is of great value, and its result furnishes even stronger evidence. The shadow cast in empyema is either horizontal, or oblique towards one side or the other, mostly towards the spine, whereas in sub-phrenic abscess it is convex upwards.

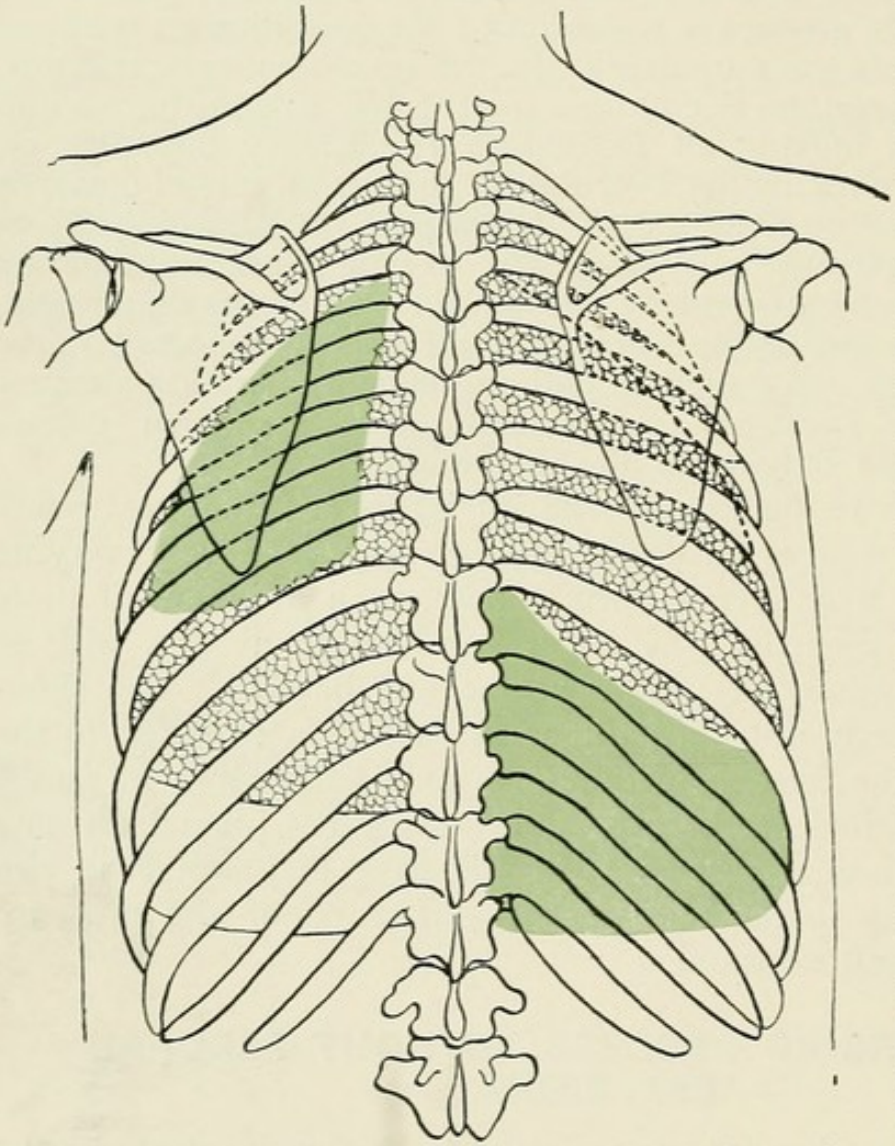

FIG. 144.—Green = pus in contact with the chest wall. Collections of pus in contact with the chest wall. On the right side, the usual basal empyema; on the left, interlobar.

But the history is most conclusive. Empyema usually follows some disease of the lung; a sub-phrenic abscess is the consequence of an infective process within the abdomen. But as a secondary pleurisy is of frequent occurrence in this latter condition, we must take into consideration the manner in which the secondary illness has started. A secondary pleurisy arises after the manner of an embolism, and sets in with more or less sudden and severe respiratory difficulty; but a sub-phrenic abscess develops slowly, and does not as a rule cause pain until it has attained a definite size. The pain is also much duller than the pleuritic pain which makes the breathing so difficult. If a pleurisy should subsequently develop into a sub-phrenic abscess, it will be obvious from the chronological order of the symptoms that the latter was not the original trouble.

In any case we should not be satisfied with the demonstration and

evacuation of a serous pleural effusion, if the symptoms have set in gradually and a high temperature persists. If the effusion is sterile, the presence of a sub-phrenic abscess is at any rate extremely probable.

The diagnosis is easier if the abscess contains much gas, for percussion will yield the well-known zones : below, dulness corresponding to the liver and the fluid contents of the abscess, then a tympanitic note due to the gas, and finally the normal note of the lung (fig. 144). This also applies to the left side, *mutatis mutandis*. An abscess which contains no gas is more easily recognizable on the left than on the right, because of the extensive dulness and the displacement of the spleen downwards; sometimes also by the upward displacement of the heart. If the abscess contains gas the three zones just mentioned can be detected.

The large gas-containing abscesses described of old are seldom seen nowadays, because they are not allowed sufficient time to develop.

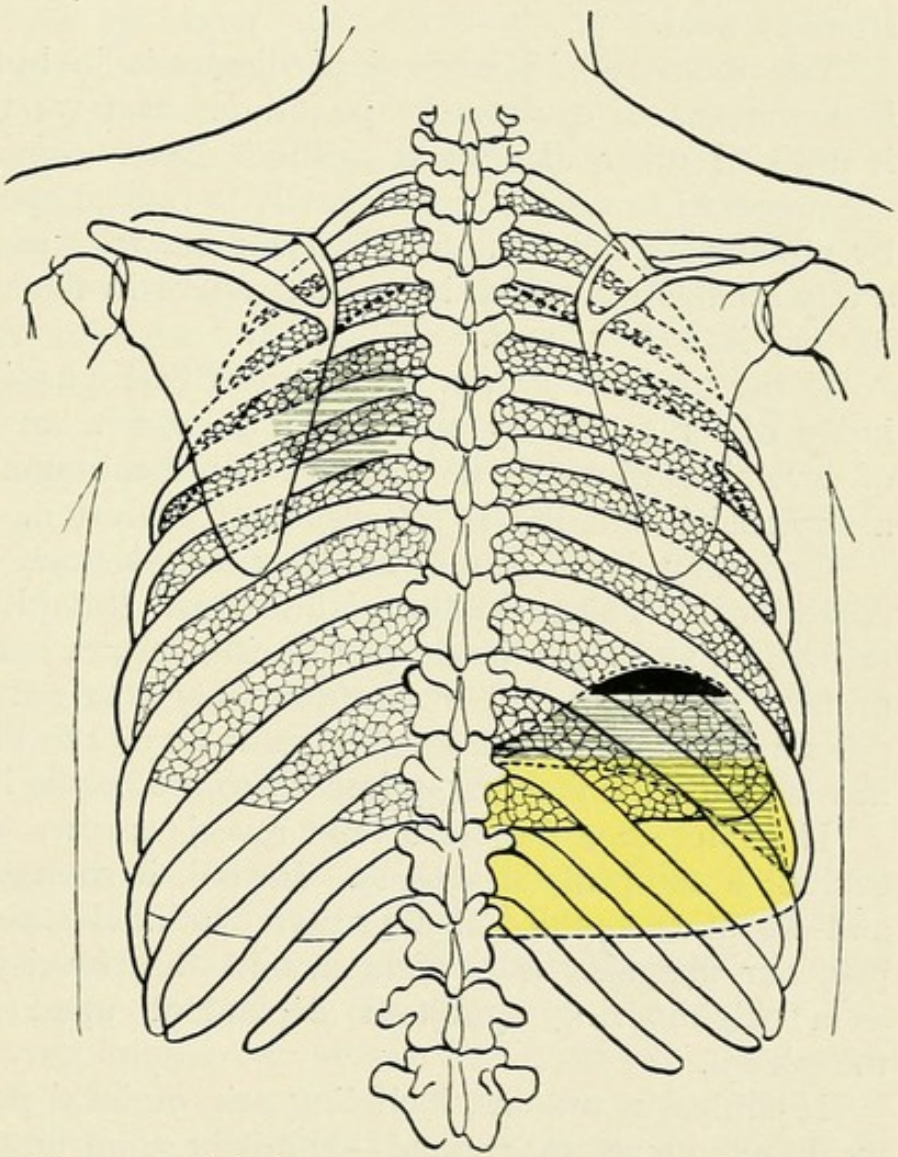

FIG. 145.—Shaded green = pus beneath lung and diaphragm. Yellow = serous effusion. Black = air vesicle. The chest wall in contact with collections of pus. On the right, a sub-phrenic abscess with gas vesicle and serous pleural effusion ; on the left, an abscess of lung.

(2) SUB-PHRENIC ABSCESS WITH PLEURAL EFFUSION.

The conditions are much more complicated if there is a pleural effusion in addition to the sub-phrenic abscess. On the right side it is quite impossible to make a definite diagnosis from physical examination alone, because of the normal presence of the liver dulness. The etiology and course of the illness must be taken into

consideration. A skiagram may yield some information, because the serous effusion will be more transparent than the greatly bulged arch of the diaphragm. It is easier to differentiate on the left side, between a sub-phrenic abscess and a simple pleural effusion, because of the extent of the dulness downwards. If the abscess contain gas, the diagnosis is easier on both sides, but on the left side the stomach note must not be mistaken for an indication of gas. The percussion over the supposed air cavity must always be compared with the true stomach note.

The most certain method of diagnosis in both groups of cases is by means of exploratory puncture. But we must not resort to it until all other diagnostic methods have been exhausted, and we are prepared to proceed immediately to radical operation. Otherwise, by puncturing through the pleural space we run the risk of making a way for the pus, which is under pressure in the sub-phrenic abscess, to open into the pleura.

If the exploratory puncture shows that pus is present, we can judge of its origin by the depth at which we reach it. A depth of several centimetres points to a sub-diaphragmatic collection, but a superficial situation is no argument against it.

One may be inclined to draw conclusions from the pressure conditions. Theoretically, pleural pus should flow out during expiration, and sub-phrenic pus during inspiration. But as a matter of fact, adhesions and indurations may also put pleural pus under pressure during inspiration. The same applies to the respiratory movements which the diaphragm imparts to the needle inserted into it.

If exploratory puncture only reveals serous fluid, this does not exclude a sub-phrenic abscess. Indeed, it strengthens our suspicion, and we must explore at a greater depth. If then we strike gas or pus, our diagnosis is confirmed, and the pleurisy is to be regarded as a neighbouring symptom dependent upon toxic irritation of the pleura.

If clinical symptoms, including pain on local pressure—a symptom we have not yet mentioned—definitely point to sub-phrenic abscess, we must not be content with one exploratory puncture which gives a negative result. We must insert the needle at one or several sittings in different directions, and thus we may at times be able to discover localized abscesses, or those difficult of access.

I have, more than once, seen the gradual disappearance of a sub-phrenic abscess which has been diagnosed from the clinical symptoms, but which the needle has failed to find. There can be no doubt that the peritoneum has the power of absorbing pus from this situation also. But if the puncture has revealed the abscess, we must not content ourselves with this possibility, but it is our duty to open it.

CHAPTER XXXVIII.

TUBERCULAR PERITONITIS.

THE surgeon has a double interest in tubercular peritonitis, which was for so long considered an exclusively medical condition. In the first place, it demands his consideration in the differentiation of the various diseases of the abdomen, and, secondly, he is often called upon to pave the way for its cure, by the performance of laparotomy. Our knowledge of the disease has been derived, to a considerable extent, from its surgery, which has also greatly increased its general interest.

Every student knows from his reading of special pathology that tuberculous peritonitis is of frequent occurrence, that it may exist in a serous, nodular or adhesive form, and that these forms may all be combined in one case. Nevertheless, it is a most common occurrence in practice to overlook these cases in their early stages. This is accounted for, to a considerable extent, by their protean nature. Many cases are diagnosed as "nervous dyspepsia," chronic, gastric, or intestinal catarrh, &c., when a careful examination of the abdomen would already reveal an effusion, or palpable tubercular masses. This oversight is due to the fact that in its early stages the disease has no specially characteristic symptoms to draw attention to its existence, and it is therefore most important to examine carefully and repeatedly patients who complain of indefinite discomfort in the abdomen.

This indefinite discomfort consists of loss of appetite, a sensation of pressure in the stomach and bowels during digestion, irregularity of the stools, occasionally diarrhœa, attacks of colic and a vague feeling of heaviness and soreness in the abdomen; sometimes also dysuria. If these symptoms have persisted for weeks or months, anæmia and emaciation supervene, and both patient and practitioner begin to think of some serious malady. If the patient is young, if he comes from a tubercular stock and has probably some previous tubercular history himself, it requires no complicated association of ideas to think of tubercular peritonitis. But in the absence of such indications, even the most experienced practitioner may grope in the dark, especially in a patient over 50 years of age.

After general examination, directed especially to the lungs and kidneys, in addition to any striking external signs of existing or old tuberculosis—scars of glands, bone disease—we proceed to an investigation of the abdomen. This may be quite flat, and without any abnormal dulness. But we are struck by slight rigidity of the

abdominal muscles; much less than in an early septic peritonitis, but still quite demonstrable. Palpation is not really painful for the patient, but is unpleasant. Such a condition, found at repeated examinations, ought to excite serious suspicion. This represents the stage wherein the parietal peritoneum, which alone is capable of receiving sensations of pain, has become sensitive owing to the implantation of tubercles. Later on, this sensibility becomes diminished by the fluid effusion which lies as a protection between the intestine and abdominal wall, and by adhesions. This stage is common to all varieties, but its subsequent course varies considerably. In most cases, it is possible to detect a movable *effusion* after a few weeks; sometimes, however, not until after a few months. This effusion is not always abundant. If the patient when viewed in profile has an abdomen too prominent for his figure (fig. 146), if he has shifting dulness over the symphysis — N.B., when the bladder is empty — and above Poupart's ligaments, this suffices to establish the presence of effusion. It is not necessary to wait until the whole abdomen fluctuates and the carriage of the patient resembles that of a pregnant woman. In other cases we may look in vain for any sign of effusion. On the contrary, some portions of the abdomen will be felt to be harder than usual, and to develop into flat, firm, cake-like masses or into roundish, and somewhat fixed *nodules*, which are nearly always painful on pressure. In certain other cases the abdomen gradually gets larger, without effusion and without these hard masses, being tympanitic all over, but remarkably incompressible and tender throughout. This is the

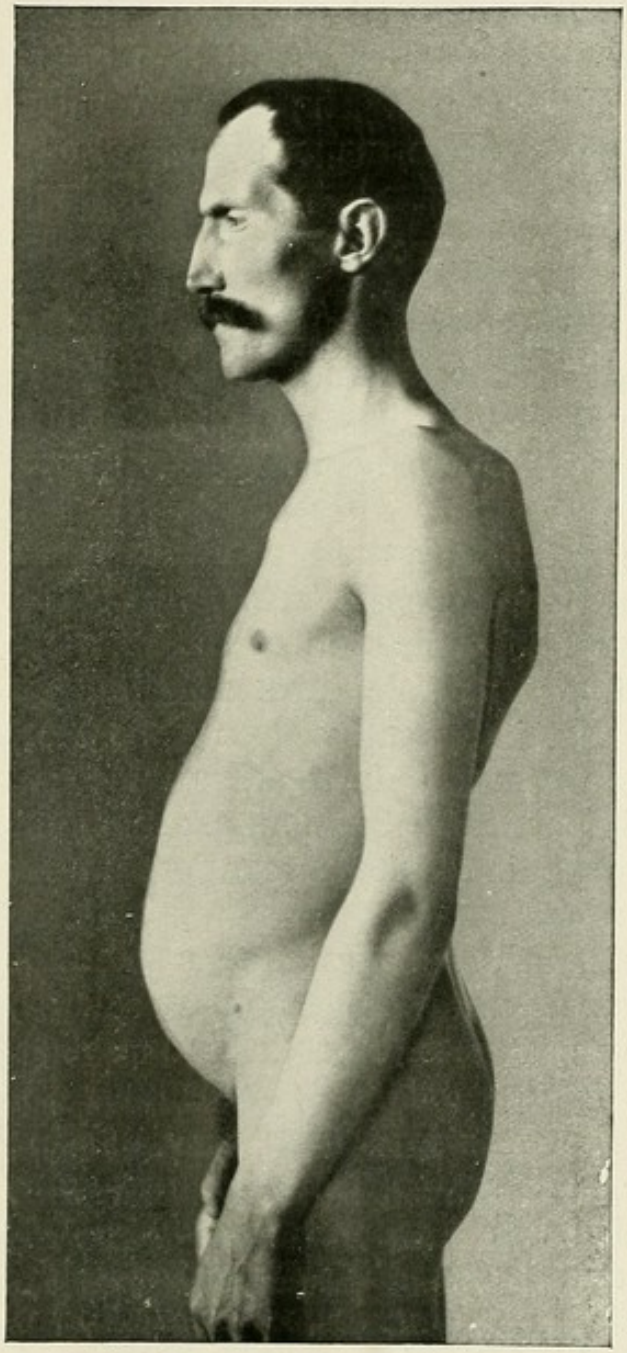

FIG. 146.—Tubercular peritonitis. Moderately extensive effusion. Abnormally prominent abdomen for a man.

adhesive form, wherein the coils of intestine are glued together in layers, by the tubercular process, thus hampering their free movement and peristaltic action.

This explains the slight compressibility of the stomach and the meteorism.

Among the *mixed forms*, it is necessary to particularize those wherein there exist *encysted effusions of fluid*, caused by a combination of adhesive and exudative processes. These effusions are generally situated in the middle or lower abdominal region, and usually contain serous fluid, but sometimes their contents are purulent, or in layers of a sero-fibrinous-purulent fluid. The nodular form of tubercular peritonitis is not as a rule pure in character, but is combined with exudative or adhesive processes.

Each of the above described varieties has its special difficulties of differential diagnosis.

(1) The purely *exudative* variety may be confused with *cirrhosis of the liver*, especially if the patient is elderly and previous addiction to alcohol cannot be excluded. In such a case, an evening rise in temperature points to tubercle; but a normal temperature is no argument against it.

It should be emphasized here, that it is not enough to take the temperature now and again, at the doctor's visits. In all cases wherein tubercle is in question it must be recorded regularly for weeks, at least morning and evening. In tubercular peritonitis, as in other tubercular processes, periods of normal temperature may alternate with periods of a slight rise, or definitely high temperature.

A firm consistence of the liver, if it be palpable, and pronounced enlargement of the spleen, are points in favour of cirrhosis of the liver, whereas tenderness on slight pressure and spontaneous pains are in favour of tubercle.

The difficulty in differential diagnosis is illustrated by the circumstance that tubercular peritonitis may lead to cirrhotic changes in the liver, and that some of the effusion may be due to circulatory disturbances in the region of the portal vein.

Peritoneal tuberculosis may be confused with *chylous ascites*, more especially as the latter comes on as the result of tubercular swelling of the retro-peritoneal glands. It is, however, distinguished by the remarkably rapid onset of debility and the great enlargement of the abdomen, which becomes distended to an extent which is, at any rate, unusual in tubercular peritonitis. A definite diagnosis can only be obtained after exploratory puncture, which we will discuss later on.

Chronic serous peritonitis of the older authors does not enter into the problems of diagnosis. This term really includes tuberculosis,

miliary carcinoma or sarcoma, and endothelioma of the peritoneum. The exceptions are exceedingly rare; they cannot be diagnosed even when the abdomen is opened, and can only be detected by histological or bacteriological examination.

(2) The considerations in regard to the **nodular** form are entirely different. In these cases, the diagnosis lies between tuberculosis and *new growth*. To a certain extent, we should be influenced by the age of the patient; at any rate below 30 the chances are in favour of tubercle, but discretion must be exercised. After 40, the age factor has very little weight in diagnosis.

For instance, a female, aged 60, was referred to me because of numerous abdominal tumours, which at first sight suggested cancer. Careful examination, however, showed that the case was one of nodular tubercular peritonitis, and this was confirmed by operation. On the other hand, cancer of the ovary is no rarity among women of 30 to 35 years of age.

More importance must be attached to any kind of rise in temperature, but here also caution is necessary.

A young woman, after undergoing treatment in a sanatorium for pulmonary disease, came under surgical treatment for a small, movable tumour in the right lower abdominal region. The structure was hardly as big as a walnut, but close to it were some deep, but less movable lumps, and a little free effusion was present. There were no signs of narrowing of the intestine. The elevations of the temperature were very striking: they often exceeded 102°F., and could not be explained by the condition of the lungs, in which there was nothing abnormal. Everything pointed to tubercle, but the striking mobility of the small tumour made one think of the possibility of carcinoma, because tubercular masses soon lose their mobility. Operation revealed a small carcinoma of the small intestine which had produced no constriction, and early infection of the peritoneum with carcinomatous infiltration of the retro-peritoneal glands.

In women the clearest information can be obtained by examining the uterine appendages, which constitute the most frequent starting point both of tubercle and cancer of peritoneum. Bilateral, sausage-shaped, or nodular induration of the tubes points to tubercle or chronic gonorrhœa; the presence of a nodular tumour in the vicinity of one ovary points to cancer. But primary ovarian cancer is sometimes so small that it can hardly be detected.

The demonstration of nodules in Douglas's pouch may signify either tubercle or cancer. The presence of tubercle in the urinary tract is more decisive, because it is a very frequent accompaniment of tubercular peritonitis.

(3) The purely **adhesive** forms, as far as they cause symptoms, are most likely to be mistaken for intestinal obstruction, due to chronic adhesions, which are the result of some previous inflammatory process within the abdomen. But their chronic course, the

diffuse character of their symptoms, and the tenderness on pressure constitute valuable evidence for tubercle.

(4) The differential diagnosis of **encysted tubercular effusions** is of great importance, although not always easy. In these cases the question arises whether we are not dealing with a *cystic tumour—i.e.*, an ovarian, omental, or mesenteric cyst. This question is all the more pressing, because these encysted tubercular effusions often occupy the median line, as we have already seen. The character of the dulness is the same in both—*i.e.*, dulness in the middle of abdomen with a normal intestinal note above and at the sides; whereas in a recent effusion the conditions are just the reverse. The decision depends upon the mobility of the structure as a whole, and it will often be necessary to give an anæsthetic in order to abolish the abdominal rigidity before determining this. A cyst, even if extensively adherent, is usually somewhat movable, and gives the impression of a round tumour, independent of the abdominal wall, if the latter is completely relaxed. An encysted effusion, on the other hand, is hardly movable at all; and even if it appears to be round in shape, is usually connected to the anterior abdominal wall.

The case of a little girl, who was suspected of having an encysted tubercular effusion, occurs to me. Careful examination showed that the structure was movable, though only slightly so, and therefore the diagnosis seemed to be a cyst, whose situation suggested an origin either from the omentum or mesentery. Operation proved that it was a large serous omental cyst, and its histological examination excluded the possibility of its tubercular origin.

Finally, it is necessary to refer to the confusion of a tubercular exudation with a sacculated *pneumococcic peritonitis*. A pneumococcic exudation causes so little surrounding inflammatory reaction that it is very often mistaken for tubercular peritonitis (fig. 142), unless the practitioner has followed the whole course of the case from the beginning. If the patient is a young girl, and there is a history of a sudden illness, starting with high fever, rigors, vomiting and diarrhœa which subsided into a quieter stage after one to two weeks, we may be quite sure that the case is one of tubercular peritonitis.

The "regular" course of tubercular peritonitis, as described above, is often interrupted by intervals which are caused by partial or complete intestinal obstruction, due to kinking of the bowel, by localized adhesions, or omental bands. We will again meet with these conditions, in discussing intestinal obstruction.

Our task is not exhausted with the mere diagnosis of tubercular peritonitis. We must endeavour to determine its **point of origin**, at any rate, as far as it concerns treatment. We have already mentioned tubercle of the *tubes*. A second source of origin is to be found in the

intestine. We do not recognize intestinal tuberculosis so much by palpation as by functional disturbance, because the results of palpation in extensive tubercular peritonitis are very equivocal. Tuberculosis of the small intestine often leads to stenosis; ileo-cæcal tuberculosis nearly always does so. We therefore witness the picture of chronic intestinal obstruction, the description of which will be found in the appropriate chapter.

It must not be assumed that the association of tuberculosis of the mucous membrane of the bowel with extensive tubercular peritonitis is the regular thing. On the contrary we often see intestinal tuberculosis combined with very localized tubercular changes in the peritoneum. The production of a widespread tubercular peritonitis probably requires the simultaneous invasion of a large amount of infective material, such as is most likely to be derived from a tuberculous tube or a softened mesenteric gland. If a tubercular ulcer of the intestine leads to tubercular peritonitis, there is usually an intermediate stage provided by tubercular glands. Tubercular peritonitis often follows a pleurisy of similar origin. As is well known, the diaphragm is not bacteria proof.

Exploratory puncture is not always harmless in cases of tubercular peritonitis, and, therefore, should only be performed when the indications are definite; for instance in the ascitic form, if the differential diagnosis between it, cirrhosis of the liver and chylous ascites cannot otherwise be made.

It only now remains to consider how an accurate diagnosis helps us in framing indications for prognosis and treatment. That tubercular peritonitis, even in the anatomical sense, is susceptible of cure has been proved by surgical experience. Recent statistics show that one-third of the cases recover, even without operation. It has been suggested that the numerous cases which have been treated medically without any benefit, and then have promptly recovered after operation, were really on the point of spontaneous recovery. But this only begs the question and does not explain it. In the early stage, operation should only be undertaken to remove the primary disease, *e.g.*, a tuberculous tube. Otherwise we must continue for weeks, or if the patient's social circumstances permit, for months, with dietetic and climatic treatment, sunshine and X-rays. Sunshine seems to be the most important of these methods. If this is ineffectual, operation is indicated, unless there are other foci of tuberculosis which are threatening the patient's life. The recognition of the variety of tubercular peritonitis is important, therefore, not merely as a general indication, but as an element in the prognosis. This is very much more favourable in the ascitic form than in the other varieties. The prospects are rather unfavourable if the nodules undergo caseation or suppurative softening. But we should not abandon operation in these cases, because every now and again an unexpected and permanent success compensates for many failures. It is only in the purely adhesive form that operation is hopeless.

CHAPTER XXXIX.

DIAGNOSIS OF ABDOMINAL SWELLINGS IN GENERAL.

THE abdomen is the seat of various **false tumours**. Everyone knows how easily the *abdominal aorta* is felt in thin subjects, and its pseudonym "student's aneurism" is fully deserved. More than one practitioner, even, have been deceived by it. On the other hand, a genuine aneurism may be mistaken for a new growth. If the abdominal wall is not very yielding, so that the structure cannot be adequately grasped, it may be impossible to distinguish between a heaving and an expansile impulse. The phantom tumour caused by contraction of the upper part of the *abdominal rectus* is also well known. Error can generally be avoided by palpating the opposite side. If the pylorus is sensitive to pressure, the right rectus contracts when it is palpated, whereas on the left side the muscle remains quite lax. If the patient is directed to sit up without the help of his arms, it can be readily felt that the doubtful swelling is the muscle itself. The *pancreas* may constitute another false tumour. In very emaciated persons its head may be distinctly felt to the right of the spinal column, and it may easily be mistaken for a thickened pylorus. Distension of the stomach, however, causes the pancreas to recede, whereas a pyloric tumour would become more superficial. In persons with relaxed or thin abdominal integuments, it is quite possible under favourable conditions to feel parts of the normal stomach—the pylorus and greater curvature. *Fæcal accumulations* should rarely lead to mistakes, if one remembers the course of the large intestine, and if the patient has been purged before the examination. It can happen but rarely, that a mass of fæces in the cæcum will resist for many days attempts at purgation, although I have had such a case in an old woman.

In "Hirschsprung's disease" the sluggishness of the bowels may permit of the accumulation of fæces to the extent that a sarcoma is diagnosed.

Sometimes intussusception imitates a tumour, apart from the cases wherein a new growth—*e.g.*, a polypus—has caused the intussusception. The typical tumour of intussusception is recognized by its cylindrical shape and its position quite close to the spinal column.

Tumours and swellings of the abdominal wall, described in a separate chapter, must not be confused with abdominal tumours.

Finally, it must be remembered that inflammatory changes may resemble abdominal tumours. This applies to inflammatory swellings of the omentum, which develop as a result of an omental secretion,

that is not quite aseptic, as first shown by Braun. A clue is afforded by the history and the pyrexia.

An ordinary *appendicitis* may sometimes develop into a hard immovable lump, as large as a fist or larger, filling up the pelvic fossa, and requiring weeks or months for its absorption. This phenomenon is due either to some special peculiarity of the organisms causing the inflammation, or to some abnormally sluggish reaction of the system.

In a case of this kind, in an elderly man, even at the operation I made a provisional diagnosis of cancer of the cæcum, and performed an intestinal anastamosis. A few months later the whole resistance had disappeared, and the patient enjoyed good health for seven years after the operation.

Such cases are very similar to the "phlegmon ligneux" of the neck. If we consider the extent and duration of the induration which may be caused by a small perimetritic abscess, it is not at all surprising that a similar result may ensue from appendicitis.

Actinomycosis occasionally causes a movable swelling in the ileo-cæcal region, but, in contrast to cancer, it does not usually lead to symptoms of obstruction.

If a genuine—or false—abdominal tumour is definitely *movable*, its pedicle affords the best indication of its origin. But as this pedicle cannot always be felt, we can draw some conclusion as to its origin from the segment of the circle which can be described by the tumour, as pointed out by Pagenstecher. This task will be facilitated by marking the segment of the circle on the abdominal wall. For instance, if the case is one of movable swelling of the gall-bladder, wherein the tumour can be displaced even as far as the left hypochondrium, the centre of the segment of the circle described by the tumour will always be at the normal site of attachment of the gall-bladder. The curve will be concave upwards in contrast to the curve of a pedunculated ovarian cyst, which is concave downwards, with a centre which is either in the mid-line or more or less to one side. In a similar manner, it is possible to ascertain the origin of a swelling which consists of a floating kidney.

An organ which under normal conditions is only slightly movable, may be susceptible of considerable displacement when it is the seat of a tumour, especially the pylorus. For instance, I found a carcinoma of the lesser curvature, the size of a large fist, situated at the anterior superior spine of the left ilium, in a young girl; the tumour could be dragged about, almost all over the abdomen (see under Cancer of the Stomach).

Tumour formation in an organ which is congenitally displaced may render the diagnosis difficult. This applies particularly to the kidneys, which may be found lying transversely in front of the spine, or more laterally at the inlet of the true pelvis.

It has occasionally been noted that an ovarian cyst may become

free and take up its quarters elsewhere. This of course causes an insoluble problem in diagnosis, before the abdomen is opened. On one occasion, I found a left ovarian dermoid engrafted on the hepatic flexure of the colon. The remains of the tube were still attached to the left side of the uterus.

If a swelling is remarkably movable, but no indication is afforded by its pedicle or by the curve described by its movement, we should think of a tumour of the *small intestine*, *mesentery* or *omentum*, if it is situated in the middle of the abdomen. The first is the most probable if the tumour is hard or uneven; the other two if it is roundish and elastic in consistence.

The determination of the point of origin is easier if the tumour is *less movable* and *not too large*, because the number of organs with which it might be connected are more limited. But even then, the diagnostic problem may be very difficult, as for instance the differential diagnosis between cancer of the duodenum and of the pancreas, enlarged gall-bladder and a commencing hydronephrosis, cancer of the intestine and a displaced kidney which has become fixed, &c. A correct diagnosis can only be formed by taking into consideration at the same time the history, the functional disturbance, the condition found on palpation, and a skiagram.

Tumours which occupy the *whole* or almost the whole of the abdominal cavity are particularly difficult to diagnose. If they are *hard*, they are essentially *fibro-myomata of the uterus*, rarely *fibro-sarcomata* of the ovary; in children they are usually enormous *sarcomata* or *mixed tumours of the kidneys*. Bimanual gynæcological examination, and if necessary the sounding of the uterus, afford a conclusive decision. A sarcoma of the kidney is recognized by its somewhat lateral position, if it has become very extensive, and by the fact that it reaches up into the hypochondrium. Tumours of the fatty capsule of the kidney, just referred to, do not adhere to any rule.

If the tumour is softly elastic, or fluctuating and therefore probably a cyst, it is necessary to distinguish between *ovarian cyst* and *hydronephrosis*. The former should be diagnosed if its consistence is unequal, being uneven and hard in some places, soft or tensely elastic in others. The difficulty in diagnosis really begins when the cystic tumours are uniform.

An ovarian tumour of moderate size can be best defined at its superior border, a hydronephrosis at its lower border. In more advanced stages, external examination may be quite inconclusive. If both ovaries can be felt on bimanual examination, the matter is decided, because parovarian cysts are not in question where large tumours are concerned. But if, as usually happens, the two ovaries cannot be felt, the large intestine should be distended to see whether the bowel lies to the outer side of and above the tumour, or to its

inner side and beneath it. In the latter case it is probably a renal tumour; in the former, probably an ovarian tumour. We say "probably," because we have also seen the large intestine running above and to the outer side of a renal tumour. But if this proceeding leads to no definite conclusion, we are thrown back on a consideration of the previous history. In the case of hydronephrosis there will probably have been attacks of renal colic with sudden and profuse micturition of clear or blood-stained urine. The patient will also have noticed that the tumour which before had been situated high up has now gradually become lower. An ovarian tumour, on the other hand, is practically painless, unless subjected to torsion occasionally, and grows from below upwards. Finally, a decisive conclusion may be arrived at by cystoscopy. If urine escapes from one ureter only, we have every reason for assuming that there is a closed hydronephrosis on the other side. If both ureters are functional we must exclude hydronephrosis.

If the tumour does not fit in any of these categories, we should think of one of the rare *mesenteric* or *omental cysts* (the latter, as experience shows, especially in girls under 10), or an *encapsuled tubercular peritonitis*, if the structure seems to be less movable and less well defined than a genuine cyst.

The rare condition of *cystoma of the uterus* is very apt to cause error. In one such case, the tumour filled up both hypochondria, although the cervix was prolapsed between the labia.

We must also think of the *pregnant uterus* which has sometimes been subjected to the surgeon's knife, to the silent but malicious satisfaction of the accoucheur. It is therefore by no means superfluous to examine the breasts in doubtful cases, and also to employ the stethoscope. It is of course well known that too much reliance cannot be placed on the history, in these circumstances. If in a case of suspected pregnancy the size of the uterus is too large for its estimated duration, and if no fœtal parts are felt, we should think of a *hydatidiform mole*. If, in a case of suspected pregnancy, a slightly movable or a definitely movable tumour is found at the side of a somewhat enlarged and soft uterus, we should diagnose an extra-uterine gestation.

Every tumour raises the question of **innocence** or **malignancy**; a question which we can very often answer, even if the origin of the tumour is not clear. Three signs indicate malignancy: (1) Rapid growth, and early emaciation of the patient; (2), the presence of free fluid in the abdominal cavity; and (3) multiplicity of the new growth.

To demonstrate a *small* amount of *effusion*, it is necessary to percuss as *gently as possible*, with the patient on the back and on the sides.

If the onset of effusion has been preceded by an exacerbation of acute peritoneal symptoms, we should always think of the possibility

of torsion of an innocent ovarian tumour. Multiplicity of the tumours indicates either malignancy or tubercle. We have already discussed their differential diagnosis.

As in the case of other abdominal diseases we have purposely refrained from mentioning *exploratory puncture*. Its value is still always *over-estimated*, its disadvantages *under-estimated*. Puncture of a solid tumour is harmless, unless the bowel is perforated by too powerful a needle, but it is quite useless. If we succeed in puncturing a cyst with an adequately strong needle, we must inevitably permit the escape of some of the contents of the cyst into the abdominal cavity. This may be a matter of indifference if the swelling is innocent, but it is most undesirable in cases of cancer, hydatid or suppurating cyst. Thus I was once consulted in the case of a young girl who developed acute peritonitis as a consequence of exploratory puncture of a cystic abdominal swelling. Operation was performed immediately, and it revealed a suppurating ovarian cyst in which the puncture was still visible as the starting point of the suppurative peritonitis. As every ovarian cyst, and every tumour whose differential diagnosis is doubtful should be operated on, and as exploratory puncture so often leaves us in the lurch, this procedure is limited in practical value to the information which it may give as to the aseptic or purulent condition of the contents of the cyst. But, as just stated, puncture is least permissible if there be any suspicion of suppuration. If, however, we consider puncture to be indispensable, it should not be done until everything is in readiness for operation, or better still until after the abdomen has been opened and the cyst exposed. We can then, at any rate, prevent the unnoticed entrance of pus into the abdominal cavity.

CHAPTER XL.

SURGICAL DISEASES OF THE STOMACH.

If this heading should be understood to include all diseases of the stomach which have been treated surgically, it would be necessary to detail the diagnosis of every chronic gastric disease. There are very few diseases of the stomach upon which the surgeon has not operated, some would say, out of pure pruritus operandi ; others, because of the failure of medical treatment. Although the indications for a few of the diseases are still uncertain, the main lines of most of them are well defined and recognized alike by surgeon and physician. To these mainly we will devote attention, and only touch incidentally upon ground which is still contested.

Gastric diagnosis, as already mentioned, has made great advances within the last few years. Thanks to the labours of Rieder, the skiagram has enabled us to complete our diagnoses directly by the sense of sight, instead of relying upon indirect conclusions, as hitherto. X-ray examination of the stomach has its own sources of error, however, just as every method of diagnosis. A diagnosis should, therefore, not be based exclusively on a skiagram, which should rather be used as a supplement to other methods.

A knowledge of the *technique* is indispensable, in order to understand the subsequent remarks.

The patient is given a contrast-forming meal, on an empty stomach. It consists of 40 grm. of carbonate of bismuth or 80 grm. of sulphate of barium, with 400 grm. of some carbohydrate porridge (in cases of dilatation, 600 grm.). A skiagram is taken immediately in the abdominal and in the erect position. If a well filled pars pylorica is not shown in either of these positions, another picture must be taken with the patient lying on the right side, or with the upper portion of the body lowered. These pictures are indispensable because the surgeon must possess some actual record on which to base his decision. He cannot rely upon the report of a professional radiographer, who may not have had any surgical training, as to what was found on the screen, especially as a screen examination does not bring out adequately certain details, which may sometimes be of great importance. This applies particularly to cases wherein there is a question, not only of displacement of the stomach, but also of ulcer or cancer. A screen examination may be taken afterwards, and this will enable a decision to be made regarding the motor functions of the stomach. It is useful to get a rapid idea of the position of the organ by means of the screen, before plates are taken, but this opportunity must not be employed to study its movements. In order to obtain a useful picture showing a well filled stomach, the skiagram must be taken very soon after the contrast-forming meal. Another skiagram should be taken in six hours, to ascertain whether the stomach is empty or whether there is retention.

Before one decides that the shape of a stomach is pathological, it is necessary to consider carefully the normal range of shape of the organ. The main varieties are illustrated in fig. 140, which shows the varied appearances of the stomach, according to its state of replenishment, the position of the body, its condition of motility, quite apart from the influence exerted upon it, of external tumours and growths of adjoining organs.

The following morbid conditions come within the province of the surgeon, either entirely or partially.

A.—FOREIGN BODIES IN THE STOMACH.

It is well known that a variety of articles may gain access to the stomachs of jugglers and the insane. As a rule, even large objects, such as spoons, forks, thermometers, &c., pass on spontaneously, and find their way through the much narrower

intestinal canal, without injuring it. Surgical intervention is, therefore, but rarely required. Should it, however, be necessary, there is no difficulty about the diagnosis, and if the history is unreliable a skiagram will generally elucidate any obscurity. It is noteworthy that small foreign bodies are more likely to remain in the stomach than larger ones.

In proof of this it is only necessary to refer to the case in which the whole contents of a nail-box were removed from the stomach: over 1,500 nails, hooks, tacks, conglomerated into a mass weighing 1 kilo, certainly a record, even if similar cases have been described more than once.

We may refer here to **concretions** which develop in rare instances, within the stomach itself. If we feel a strikingly movable hard lump through the abdominal wall, and the patient is a man who has much to do with varnish, and is addicted to strong drink, we should think of a *resin stone*. If such a swelling is found in a girl with a long plait, who confesses to biting her hair frequently, the diagnosis is obviously a *hair tumour*.

B.—DISPLACEMENTS OF THE STOMACH.

We have referred to these, briefly, in discussing the abnormalities in position of the abdominal viscera. These displacements possess two distinctive signs: (1) The low level of the greater curvature, sometimes even as low as the symphysis, easily demonstrable by ordinary clinical methods; and (2) the low level of the pylorus, which can often be demonstrated by palpation, but quite easily by a skiagram. This does not, however, convert the case into a surgical one. A displaced stomach so often discharges its functions quite normally, that we must rather attribute the main cause of symptoms to inefficient muscular power, or to inefficient—or more correctly to purposeless—innervation, and not to the mechanical circumstance of the gastric ptosis. Even if it has been proved clinically, and where possible also by a skiagram, that the stomach does not empty itself quickly enough, *i.e.*, in the course of six hours, this is not sufficient to justify operation, if it is the only symptom present. In testing the motor functions of the stomach, it is most important to limit the contrast-forming meal to a carbohydrate porridge, because fats and albumins delay the course of gastric digestion.

It may be mentioned as a curiosity that the stomach has often been found twisted, with the circulatory disturbances corresponding to a volvulus. This condition has not yet been diagnosed, but it should be suggested by fruitless movements of vomiting and by the impossibility of emptying the distended stomach by means of the tube.

C.—GASTRIC ULCER.

Until quite recently, the diagnosis of gastric ulcer was exclusively reserved for the physician. But since surgeons have been operating on certain cases of simple ulcer, quite independently of the complications to be discussed subsequently, and since the X-rays have rendered it possible to establish the diagnosis with certainty, even in many uncomplicated ulcers, the diagnosis of gastric ulcer has been tending to fall within the province of the surgeon.

(1) UNCOMPLICATED GASTRIC ULCER.

A gastric ulcer was "suspected" formerly—although its presence could not be proved—if a patient complained, not of vague indigestion, but of pain coming on at a definite time, mostly immediately after meals, radiating to the back and towards the left side. This symptom was usually associated with a pronounced and well-defined pain on pressure over a sharply localized area, generally in the neighbourhood of the smaller curvature. Confirmation of the diagnosis was derived from the discovery of hyperacidity, and it was further strengthened if the patient happened to be a young chlorotic girl. But as long as no severe symptoms came on, the diagnosis always remained a "suspicion." It became more probable if blood could be detected microscopically in the fæces after a diet which contained no meat. I say the diagnosis only became "more probable," because the case might be one of duodenal ulcer or of some ulcerative condition lower down in the intestine. Confusion with a duodenal ulcer was not a matter of great importance because the treatment—at any rate, the non-operative—was the same in both, and because a duodenal ulcer may often be so close to the pylorus that its site of origin may remain in doubt, even at the operation. The only clinical differences consisted in the facts that the seat of the spontaneous pain and the pain on pressure in the case of a duodenal ulcer was a little more to the right than in gastric ulcer, and that the spontaneous pain in duodenal ulcer did not supervene immediately after food, but was delayed for a few hours, indeed, until the need for another meal was felt, constituting the so-called hunger pain, often coming on in the course of the night. These clinical differences still remain the only ones known. Finally, it should be mentioned that gastric ulcer is most frequent in the female sex, whereas duodenal ulcer is practically limited to males.

There can be no doubt that, in this manner, ulcers were often diagnosed which were *not* present, and were very frequently overlooked when they were present. X-rays have enabled us to make great advances in this respect, although many a case may still remain obscure.

The skiagram is of value in the following way :—

A superficial gastric ulcer is not visible as such, but if it has attained a depth of 2 to 3 mm. it appears, under favourable conditions, as a slight, sharply defined bulging in the shadow, and thus looks like a depression as viewed from the stomach. If it has penetrated the gastric wall and has extended to adjacent tissue (retro-peritoneal connective tissue, liver, pancreas, or spleen), the depression becomes quite like a recess—the so-called Haudek's diverticulum, and there is often a layer of gas over its bismuth shadow when the skiagram is taken in the erect position. But certain consequences of the ulcer are visible before the ulcer itself, the most important of these being persistent spasm of the gastric wall at the level of the ulcer. In the very frequent cases of ulcer of the lesser curvature, this spasm appears as a sharply limited contraction of the greater curvature. Such muscular spasms, always persistent in the same place, also occur in cases of scars of old ulcers and in operation scars, but probably do not occur in normal stomachs. Accidental spastic contractions, which are often met with as momentary pictures of a peristaltic wave, can only be distinguished from persistent spasm by repeated examinations.

Reflex delay in the emptying of the stomach is a second indirect sign of ulcer. Skiagrams have also shown that pyloric spasm may result from an ulcer which is not situated at the pylorus, but anywhere along the lesser curvature.

Cicatricial contraction of the stomach at the level of the ulcer, or the development of hour-glass contraction, may be mentioned as a third indirect sign. This matter will be referred to later on.

How is the so-called "*indolent*" *ulcer* to be diagnosed ? It cannot be detected clinically, but can only be determined at operation or at an autopsy. All ulcers which penetrate the entire thickness of the gastric wall possess indolent, *i.e.*, thickened edges. The thickening varies very much in degree in accordance with the position of the ulcer, its relations to adjacent organs, and probably also with the constitutional reaction of the patient. An indolent ulcer may therefore be diagnosed, if we feel a tumour-like structure, without being able to find any diagnostic signs of cancer. But an indolent condition of the ulcer does not necessarily signify the presence of perigastric changes. An ulcer may cause perigastritis long before the "indolent" changes occur, and on the other hand the perigastric changes associated with such an ulcer may develop so slowly that no clinical manifestations arise.

How does radiography help in distinguishing a gastric from a duodenal ulcer ?

Principally by a *negative* sign. If the clinical suspicion of an ulcer is supported by the presence of blood in the stools, but a careful X-ray examination of the stomach fails to find any abnormality, we are bound to diagnose a duodenal ulcer, by exclusion. Moynihan and Haudek state that this diagnosis is all the more probable the more rapidly the stomach empties itself, because a duodenal ulcer

produces a reflex patency of the pylorus, in contrast to a gastric ulcer. The absence of any downward displacement of the pylorus in a skiagram of the full stomach in the erect position is additional evidence of duodenal ulcer.

Positive changes in the duodenal shadow have not often been obtained in cases of ulcer. They consist, either of cicatricial contraction of the duodenum, or of the formation of recesses in this situation. These changes are, however, very rare.

Does the skiagram offer any indications for surgical treatment, apart from the complications to be discussed below? This is hardly to be expected; the necessity for operation depends upon the subjective symptoms, and the possibility of their relief by medical measures. It is entirely a clinical matter; but skiagraphy has rendered it possible to confirm the diagnosis, in those cases wherein operation is suggested, with unquestionable accuracy.

(2) HÆMORRHAGE.

We learn from general medicine how to recognize the gastric origin of a hæmorrhage, and how to distinguish it from hæmorrhage due to cirrhosis of the liver. But special reference should be made to *hysterical hæmorrhage*, because this is apt to be frequently repeated, and therefore to simulate just that kind of gastric ulcer which should receive surgical treatment.

Josserand points out that in hysterical vomiting of blood there is much admixture with mucus, so that it looks like fruit juice, and as a rule it does not coagulate. Josserand suggests that the blood comes from the œsophagus.

I was once misled, in common with the physician in attendance, by such vomiting of blood, and, after considerable internal treatment, decided upon gastro-enterostomy. The further progress of the case showed that we had been deceived by hysteria. The comparatively trifling degree of anæmia, by which we were indeed struck, should have made us hesitate.

The course to adopt in regard to hæmorrhages is rather difficult to decide. The practitioner calls in the surgeon even when small hæmorrhages threaten life by their frequent repetition, and the decision as to operation is left to him. We should advise non-interference in the case of a single severe hæmorrhage if this seems to him the preferable course.

(3) PERFORATION.

The diagnosis of a *perforated* ulcer, on the other hand, falls quite within the province of the surgeon. Rapid reflection and immediate treatment are indispensable. Cases operated on within the first twelve hours usually recover; after the first twenty-four hours the mortality is 75 per cent.

If a person—remarkably enough it generally happens in a man—suddenly experiences severe pain like the thrust of a dagger in the epigastrium, followed by rigidity of the abdominal muscles, local pain on pressure, acceleration of pulse and occasionally a rise in temperature, we should think of a perforated ulcer, although the patient may not have manifested any signs of gastric ulcer previously. The perforation is often, but not always, associated with collapse, from which the patient may temporarily recover before the classical symptoms of peritonitis set in. In such cases, even the delay of half a day "for the purpose of better observation," means to abandon the patient to almost certain death. If we first see the case at a later stage there is either general peritonitis, the origin of which cannot be traced, or there may be the condition termed by Lennander peripheral peritonitis. After perforation the gastric contents flow towards the anterior surface, preferably under the liver towards the right lumbar region, thence into the true pelvis, and the peritonitis eventually ascends along the left side, without always affecting the convolutions of the small intestine, which are covered by omentum. This peripheral form remains longer accessible to surgical treatment than the central form. If we find the patient, as is usually the case on the second or third day, in a condition of cyanosis with a tympanitic abdomen, cold extremities, and a thread-like pulse, it is always questionable whether operation is worth while. It may only shorten the patient's life by a few hours and redound but little to the credit of our art.

The rare exceptions, when the perforation is minute and a cure ensues without operation because the stomach is empty, constitute, of course, no argument against the above. I have had this experience in a case where operation was refused. We must not risk the patient's life on such an uncertain hazard.

We must now deal briefly with some details. In most cases the *previous history* permits of the diagnosis of gastric ulcer, or at any rate suggests it, but not always. If premonitory symptoms have preceded the perforation, the diagnosis becomes much easier. But as a rule there are none. The very suddenness and great violence of the *pain in the gastric region* are, however, of themselves symptoms of the greatest significance, and the patient is well able to distinguish them from ordinary gastralgia.

In certain cases the perforation is preceded by perigastric symptoms. In one of my cases the patient neglected these warnings, so that they proved of no service to him. If they occur in a case wherein an ulcer has already been diagnosed, they, at any rate, give due notice of the possibility of the threatening danger, and if perforation actually occurs, operation can take place all the more readily.

The initial pain is never absent, but it may be less severe than

usual if the perforation does not exceed a pin point in size, as sometimes happens. The pain often radiates into the back, especially between the scapulæ, or into the left shoulder and left arm, just as the pain of biliary disease radiates into the right shoulder.

The distribution of the pain which occurs later on, is of less value for diagnostic purposes. It depends upon the direction taken by the flow of the gastric contents, and is situated towards the lower abdominal region, either on the right or left. This explains why perforation of the stomach has so often been taken for disease of the female pelvic organs. The same applies to the pain on pressure. I have found this to be most pronounced, twenty hours after perforation, in the left lower abdominal region.

Pulse, *temperature* and *respiration* behave as in any other perforation of a viscus. The pulse is slightly accelerated, but may remain so full, strong, and quiet for the first few hours, probably through vagus stimulation, that the inexperienced may entirely dispose of the idea of perforation. A normal temperature does not exclude perforation, but, on the other hand, a rise in temperature shows that the case is not an ordinary stomach ache. Respiration is hurried, shallow and thoracic. It is an error to suppose that vomiting does not occur; on the contrary it is frequently present.

The most important *local signs* are :—

(1) Extensive reflex rigidity, especially in the upper abdominal region, but generally over the whole abdomen, both sides being equally involved.

The degree and extent of the reflex rigidity distinguish acute perforation of the stomach from all other conditions which enter into the differential diagnosis. Those who devote their attention to this sign will not usually find any difficulty in the diagnosis.

(2) The presence of gas in the free abdominal cavity. The remarks already made in connection with laceration of the intestine apply here also : liver dulness is usually present, and there is no escape of gas in most cases; but if gas is present, it may limit itself to a movable collection at the uppermost region of the abdomen, revealing itself by a localized metallic note.

(3) Friction murmur, and soft friction appreciable by the hand over the gastric area. This sign is rare, but if present is of great value.

(4) Rapidly increasing dulness in the flanks, especially on the right.

Important as it is to diagnose a perforated gastric ulcer early, nevertheless we must not make this diagnosis just because the patient happens to be a girl at an age when gastric ulcer is common. We may easily be misled by *acute intoxications*, especially as a reliable history is not often obtainable in these cases.

Symptoms of a perforated gastric ulcer in a pregnant girl always suggest poisoning—a circumstance not exactly creditable to the "stronger sex."

There is hardly any disease of the abdomen which has not been confused with perforated gastric ulcer, especially *cholecystitis, pancreatitis, rupture of a pregnant tube, torsion of an ovarian tumour*, and *acute obstruction*. Even acute pneumothorax has been taken for a gastric perforation. The same applies to the *crises of tabes*.

It does not take very long to examine the reflexes, and the physician has a just cause for criticism if the abdomen of a tabetic is opened on four occasions for gastric crises, as was recently reported.

The foregoing remarks on rupture of a gastric ulcer hold good also for that of a duodenal ulcer. In both cases an operation is indicated. The diagnosis of duodenal ulcer can be made, at any rate with probability, from a consideration of the antecedent symptoms (see above).

In the present age of necessary and of unnecessary gastro-enterostomies, the presence of an operation scar in the epigastrium indicates a special type of perforated ulcer—perforation of a *peptic ulcer* in the region of the gastro-intestinal anastomosis. This form of ulcer is one of the darkest spots in the whole of gastric surgery.

(4) CICATRICIAL STENOSES.

We get much more time for observation in the late effects of ulcers, *i.e.*, in *cicatricial stenosis* of the pylorus, than we do in a perforated ulcer. We shall begin with a brief review of the clinical symptoms of the various degrees of stenosis.

The severe cases are the easiest to recognize. Increasing emaciation and diminution of the amount of urine are always observed in these. Hysterical or neurasthenic vomiting may reduce the body to the state of a mere skeleton, and greatly diminish the urine, but this form of vomiting usually comes on soon after food, in contrast to the vomiting of retention. The functional examination of the stomach in these hysterical cases will show varying abnormalities in the composition of the gastric juice, and indicate that there is no genuine retention.

Among my most grateful patients, I reckon a young girl who had undergone dietetic treatment for many years, and finally had to be fed *per rectum*, or subcutaneously, on account of persistent vomiting. Both the patient and her parents would gladly have consented to some curative operation. The history showed that the vomiting followed immediately upon a meal, and examination of the stomach showed that its chemical and motor functions were normal. The removal of the patient from her surroundings and the strict injunction not to vomit, worked wonders. The vomiting ceased forthwith, all

food was well tolerated, and the body weight increased by 12 kilos within a few weeks. The cure persisted for years.

Unfortunately similar cases are often subjected to operation, either because the surgeon does not diagnose them, or because he is unacquainted with the significance of psychical therapeutics, *i.e.*, treatment by suggestion. If these measures fail, the benefit of operation is only of brief duration. The neurologist justifiably upbraids the surgeon on account of a number of avoidable gastro-enterostomies, and for displaying too much operative zeal. We may hope that the neurologist will never deserve the retort of treating patients by suggestion, without the previous indispensable exhaustive examination of the stomach, until it was too late for the necessary operation. *No operation without previous careful investigation of the functions of the stomach, neither any psychotherapy without the same precaution.*

The cases wherein there is no vomiting, but wherein the gastric contents are emptied into the duodenum with painful colic, are more difficult to diagnose. If the abdomen is watched for some time, at any rate in thin subjects, the stomach will be seen to rear itself up against the obstruction, so that its entire shape can be discerned through the skin. Sometimes this occurs in a regular rhythm of eighteen seconds. The fear of the pain causes these patients to reduce their food to a minimum, and therefore they become weaker and weaker, even before the outset of the vomiting.

It is possible to estimate precisely, in these cases, the degree of disturbance in the motor functions and the amount of retention, by means of repeated examinations with a test breakfast.

The milder cases are susceptible of improvement under appropriate diet, but the patients are often glad enough, after a time, to obtain surgical relief.

An individual can survive a great deal of inconvenience from a narrowing of the pylorus. I have seen a case of constriction of pylorus by a cicatricial band on its exterior surface, which reduced the pylorus to an *external* diameter of 7 to 8 mm. When the patient came under surgical treatment, he was *in extremis*, with a weight of 37 kg. His weight had doubled a few months after gastro-enterostomy.

The main symptom of stenosis, as is evident from what has been said already, is retention of the gastric contents. This retention varies from a slight interference with the passage of the food to a complete obstruction. The well-known methods for the clinical examination of gastric motility, which enable us to detect even slight disturbances, are employed to demonstrate this stagnation of food. If the disturbance is only slight, the question as to its functional or organic origin arises—whether it is due to muscular weakness or defective innervation of the stomach, *i.e.*, general atony, or whether it is due to spasmodic contraction of the pylorus consequent on an ulcer at that situation, or elsewhere in the body of the stomach. A

comparison of the physical signs with the skiagram is of great value in arriving at a decision.

We must distinguish between the retention of large portions of solid food and that of liquid contents. The former condition without the latter only occurs when there is an organic change, *i.e.*, in cases wherein large fragments of food are detained within excavated ulcers or ulcerated tumours, or wherein an organic stricture permits liquids to pass, but not solid masses of any large size. If, on washing out the stomach in the morning, we find whortleberries, damson skins or pieces of orange, which were eaten the previous evening, we may confidently assume that some organic change exists, whatever be the result of other tests.

Skiagrams furnish the clearest evidence of the retention of liquid or mucilaginous contents, for they enable us to watch quietly the whole process of the emptying of the stomach, without disturbing it, by the introduction of a tube. It is, however, indispensable that the examinations should always be made in the same way, with an indifferent contrast-forming substance, and that the vehicle should always be the same.

If we find that the stomach is *completely empty within six hours*, after a carbohydrate contrast-forming meal, it follows that there is no organic obstruction, or if there be one, that it is compensated for, by increased muscular power. This increased peristalsis can be seen very well, both on the screen and on the plate. But we must be on our guard against error, for increased peristalsis occurs in tabes, and in a slighter degree in hysteria, so that these diseases must be excluded before deciding that an early stenosis exists.

The *delay of a few hours in the emptying of the stomach*, without any subjective symptoms, indicates simple *muscular weakness*, and possesses no surgical importance. Delay, accompanied by colicky pains, strongly suggests *pyloric spasm* or some organic change. It is not always easy to differentiate between these two conditions, more especially as the two are often associated—for instance, when a local spasm supervenes upon an ulcer, which often occurs in cases of hour-glass contraction. The more persistent these derangements are, the more likely are they to be due to *organic narrowing*, and the less effect will atropine have on the physical condition revealed by the X-rays.

If the *bulk of the meal is still within the stomach after six hours*, and if the viscus is not completely empty after twelve hours, *organic stenosis* is, at any rate, very probable.

So far, the symptoms are the same, wherever the situation of the stenosis.

Whereas it was hitherto assumed that a stenosis must be at the pylorus, and that any other situation was quite exceptional, more extensive surgical experience and skiagraphy have shown that ulcerative constriction occurs much more frequently in the body of the

stomach than was formerly realized—hour-glass stomach due to cicatrization of an ulcer. The symptoms of stenosis are common to both situations, but there are also certain clinical differences.

Let us begin with pyloric stenosis, which is the much more common form. This is recognized in the skiagram by the dilatation

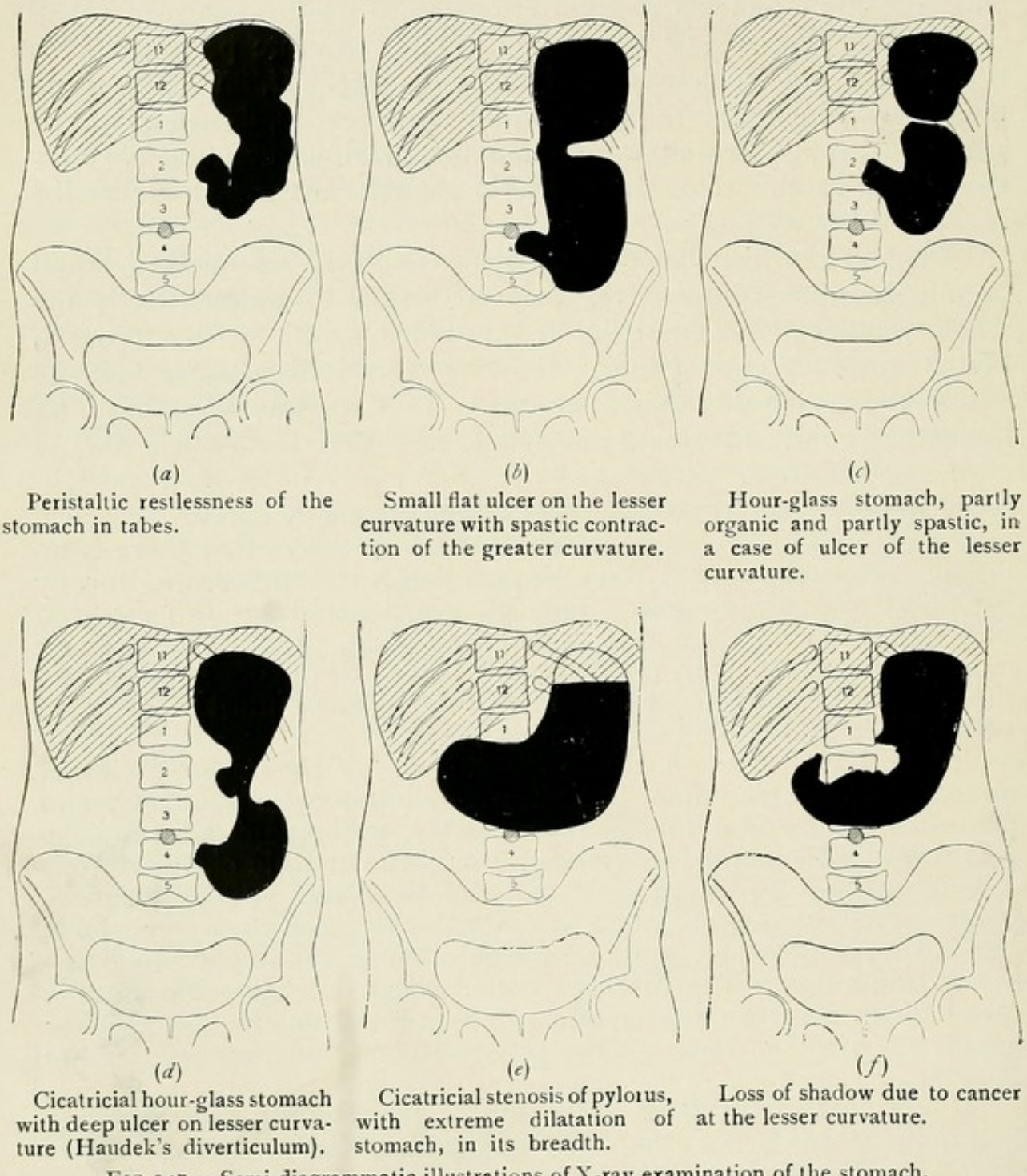

(*a*) Peristaltic restlessness of the stomach in tabes.

(*b*) Small flat ulcer on the lesser curvature with spastic contraction of the greater curvature.

(*c*) Hour-glass stomach, partly organic and partly spastic, in a case of ulcer of the lesser curvature.

(*d*) Cicatricial hour-glass stomach with deep ulcer on lesser curvature (Haudek's diverticulum).

(*e*) Cicatricial stenosis of pylorus, with extreme dilatation of stomach, in its breadth.

(*f*) Loss of shadow due to cancer at the lesser curvature.

FIG 147.—Semi-diagrammatic illustrations of X-ray examination of the stomach.

of the stomach in its breadth, in contrast to the condition in ptosis when the organ hangs down like a loose sack in the left half of the abdomen, reaching as far as the pelvis or even to the symphysis, the pylorus appearing usually just in front of the spinal column, if not to the left of it. (Compare figs. 140 and 147.)

It may exceptionally happen that the entire distension of the stomach is towards the left, even in the case of pyloric stenosis. This will occur when the stomach has originally been displaced, and the pylorus has been fixed in the middle line, or to the left of it, by perigastric adhesions.

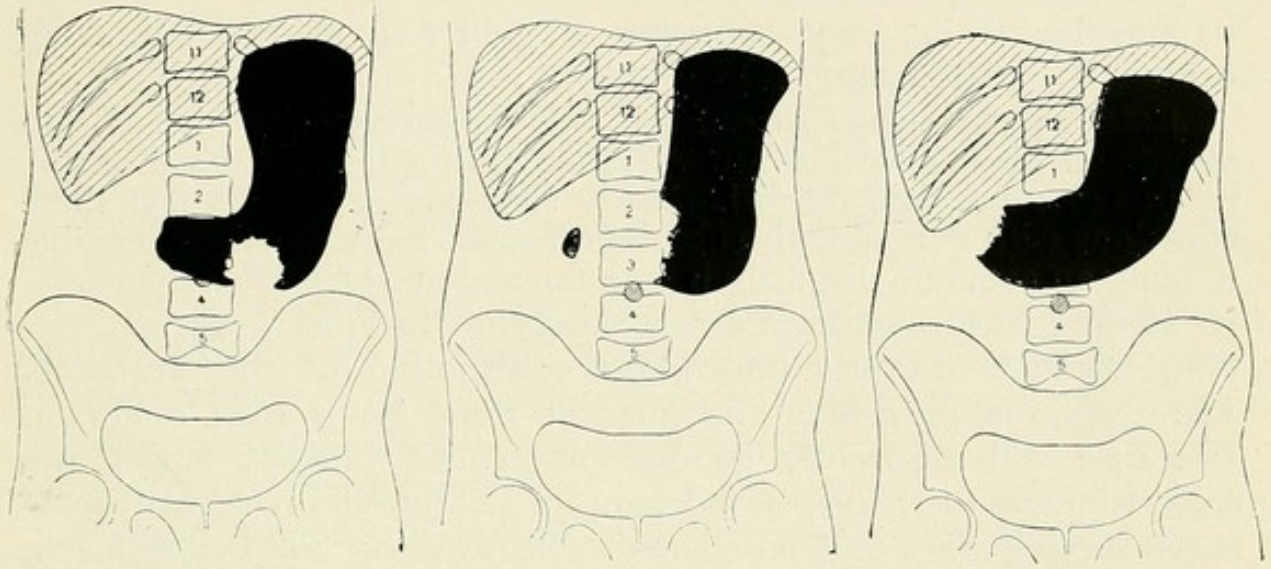

(*g*) Loss of shadow due to cancer of the greater curvature.

(*h*) Cancerous degeneration of antrum pylori, with its complete absence from the shadow.

(*i*) Cancer of pylorus. Its duodenal end badly defined, instead of the normal clear definition.

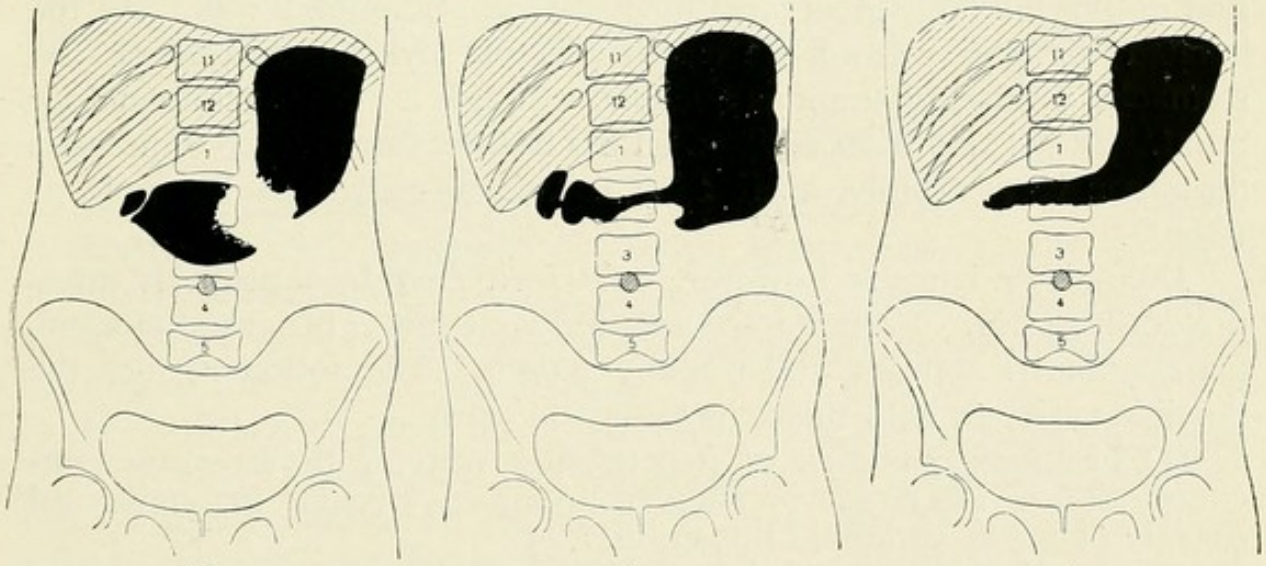

(*k*) Cancerous hour-glass stomach.

(*l*) Loss of shadow, owing to a tumour external to the stomach.

(*m*) Cirrhosis of the stomach, in diffuse scirrhus.

FIG. 147.—Semi-diagrammatic illustrations of X-ray examination of the stomach.

In this connection one may remark that the term *dilatation of the stomach* ought to be discarded from the nomenclature of gastric disease. At any rate, the term is no diagnosis, although it is still employed in this sense occasionally. Dilatation of the stomach is a result of various diseases, but is not a disease of itself. If gastric dilatation is discovered, it is then necessary to determine its cause.

In days gone by, the stomach tube was indiscriminately prescribed for all patients with dilated stomach, without any thought being devoted to the cause of the trouble; but we may hope that this era has finally terminated.

Having established the diagnosis of pyloric stenosis, we are confronted by the question as to its innocence, as hitherto assumed, or its possible malignancy—a matter we will deal with in discussing cancer of the stomach.

Extensive adhesions around the pylorus occasionally give rise to symptoms similar to those of stenosis, although the calibre of the pylorus may be quite normal. Many surgeons have separated these adhesions with permanently successful results, but it is hardly possible to make an accurate diagnosis before the abdomen has been opened.

Medio-gastric stenosis is a rare variety of post-ulcerative constriction, which constitutes **hour-glass contraction of the stomach.** The diagnosis may often be inferred from *the clinical condition.* The case will apparently be one of pyloric stenosis, but if the epigastrium and left hypochondrium are percussed on several occasions, varying notes will be elicited. On washing out the stomach, pure water runs out after the stomach contents are emptied, and then suddenly stomach contents will again run out. From this it is obvious that the stomach must consist of two cavities connected by a narrow channel. This can be proved by distending the stomach and noting the hour-glass form through the abdominal wall. As the inflated air passes from the cardiac to the pyloric section of the stomach, a buzzing sound is audible, which is a further confirmatory point. It has also been observed that liquids introduced sometimes disappear very rapidly, as if they flowed directly into the pylorus (Roux).

Definite evidence is, however, only furnished by a properly interpreted skiagram. Proper interpretation is required because the hour-glass stomach appears under many guises. The following are the possible varieties, with their characteristic signs :—

(1) Momentary picture of a peristaltic wave, with an evanescent contraction of the larger or smaller curvature, circular in shape and sharply defined; variable in position.

(2) Persistent spasm in the vicinity of an organic lesion (ulcer, old scar) on the smaller curvature. Narrow, deep, sharply-defined contraction on the larger curvature always found in the same position (fig. 147, *b*).

(3) Constriction from without by perigastric bands. The constriction is also narrow and sharply defined, the stomach sometimes appearing to be divided into two. Cannot be accurately diagnosed before operation.

(4) Constriction by a round band from the liver, embracing the stomach. The constriction is sharply defined, but not of a very extreme degree. No clinical significance.

(5) Constriction by cicatrized ulcers—true hour-glass stomach. The picture often resembles the condition in No. 2; but there is also an incurving of the lesser curvature. As a rule, however, the stenosed portion is stretched out to some extent, and possesses infundibuliform processes on both sides, forming the correct shape of an hour-glass. Haudek's diverticulum is often seen on the lesser curvature, at its narrowest portion or near it (fig. 147, *d*).

(6) Constriction of the stomach by a ring-shaped carcinoma. The constriction is not well defined, or may be irregularly sinuous.

Nos. 2 and 5 are often associated, so that an organic narrowing, which in itself may be insignificant, will appear on the skiagram as a complete subdivision of the stomach shadow, owing to a simultaneous spastic contraction.

It follows from the foregoing that the interpretation of a skiagram of the stomach is no easy matter; at any rate, it is no easier than the clinical methods of gastric examination, hitherto in vogue. Nevertheless skiagraphy has already become an indispensable adjunct of the examination, in most cases.

Pyloric stenosis of infants still remains an unexplained disease. Some authorities regard it simply as a spasmodic contraction, others as a genuine hypertrophy of the pyloric wall. Probably both conditions occur. It is, however, established that operation ought to be undertaken if the infant vomits all food, without bringing up any bile, and if the rigidity of the stomach can be appreciated. The necessity to save life outweighs all theoretical considerations.

D.—CANCER OF THE STOMACH.

Gastric patients are divisible into two classes: (1) Those who have suffered with their stomachs for years, some patients will say that they have always suffered; and (2) those who declare that they have previously enjoyed the digestive powers of an ostrich, and whose symptoms are of very recent date.

We will first consider the latter class. If there be nothing wrong with the other viscera and indications of biliary disease are absent, if the symptoms cannot be explained by some non-surgical condition such as nephritis, nor by recent or chronic poisoning, such as alcohol and tobacco, and if in addition the patient has begun to lose flesh, we are justified in thinking of cancer, and our whole examination must be directed towards settling this point. The gradual and unexplained onset of gastric symptoms in a patient, hitherto free from indigestion, is a most significant feature of this disease.

Chronic dyspeptics are also divisible into two classes. The one class always adheres to a "diet," which is sometimes prescribed by an authority; at other times is merely the formula of some nature-cure, but at intervals there is considerable indulgence in the pleasures

of the table. These patients often get alarmed after reading some popular article on medicine and consult a surgeon, in fear of cancer, although they are not really any worse than they have always been. Even these patients must be carefully examined, because they are just as susceptible to cancer as others. As a rule, nothing will be found, and unless we can convince them that they ought to feed like other people, we shall have to leave them to resume their own dietetic ways. The other class of patients consists of those who have a history pointing to ulcer ; they may be suffering from severe hæmorrhages or other symptoms previously described, which indicate that they have an old unhealed ulcer, or that they may be subjects of a recent ulcer. But we must not lightly dismiss cancer in these cases, because this disease is apt to develop on the base of an old ulcer, or even on its scar. Cancer must be suspected if the symptoms have lately assumed a new aspect, and if the general condition, which had previously been unaltered for years, has become worse during the last few weeks or months.

We have no accurate information as to the frequency of the change of a chronic ulcer or its scar into cancer. Many of the facts hitherto advanced, do not stand criticism, and my surgical and pathological experience seems to indicate that the frequency of this occurrence has been exaggerated.

Owing to the diversity of the symptoms which they present, it is necessary to distinguish between *growths at the cardia, growths at the pylorus and cancer of the body of the stomach itself, the last usually originating on the lesser curvature.* As the symptoms of cancer of the *cardia* resemble those of œsophageal cancer, we have discussed them in connection with the latter.

Before entering into details of the various forms, we shall point out some general diagnostic signs of cancer of the stomach.

The practitioner usually demands three signs for the diagnosis of cancer of the stomach : viz., a tumour, hæmorrhages, and chemical derangement, sometimes also cancerous cachexia. This kind of diagnosis is, however, a relic of the time when a patient with cancer was inevitably doomed, so that there was no hurry for the diagnosis. But an enormous change has occurred in the position within the last twenty years, and the cure of the patient now turns upon early diagnosis. We must, therefore, study the possibility and method of attaining an early diagnosis.

We must first discuss the significance of the above-mentioned symptoms, because at least one of them is usually present when the patient consults the doctor.

We begin with the question of tumour, and must at once say that if one is found it is not an unconditional evidence for cancer, nor is the absence of a tumour the slightest evidence against cancer.

A gastric ulcer may, in many ways, resemble a tumour. An inflamed and indurated pylorus may feel like a movable tumour, whose size is increased by the functional hypertrophy of the adjoining musculature. The tumour is wider towards the left than towards the right, just as in an early pyloric cancer. In other cases the ulcerated segment of the stomach is adherent to the liver, omentum or intestine, and forms a tumour which is only slightly movable, but which is free from the abdominal wall. On rare occasions, it happens that an ulcer on the anterior surface of the stomach, which is on the point of perforation, contracts adhesions to the abdominal wall and leads to inflammatory infiltration thereof. The superficial situation of this swelling is easily recognized, because it cannot be moved independently of the abdominal wall, nor does it move independently of it during respiration. If the swelling persists for any length of time it may cause phlegmonous inflammation of the abdominal wall, spontaneous perforation and the development of a gastric fistula. On the other hand, a tumour may be absent in cases which are otherwise obviously cancer, from the clinical standpoint. This occurs in :—

(1) Flat cancers, chiefly situated on the posterior wall of the stomach.

(2) Cancers which are covered over by the liver, especially frequent at the lesser curvature.

(3) Small contracting pyloric cancers, even when the pylorus is accessible to palpation.

(4) Soft polypoid cancers, which do not infiltrate the abdominal wall.

It follows, therefore, that we must not delay our diagnosis of cancer until the appearance of a tumour. But there is no justification for the apparent paradox, that all palpable cancers of the stomach are too late for radical operation. As a matter of fact, some of the largest growths, *i.e.*, those of the cauliflower variety, have the best prognosis.

Before concluding that a tumour is absent, it is essential that we should have searched for it properly. If the patient is very fat, or if the reflex rigidity of the recti is very great, an anæsthetic is required. In other cases, repeated examinations without anæsthesia after emptying the stomach and bowels, must be undertaken, before arriving at a positive conclusion.

The patient should lie fully relaxed in a horizontal position. The examiner sits at his side and feels with gentle pressure along both sides of the spinal column, from above downwards. If the abdominal integuments are soft and not too firm we should ordinarily be able to feel the larger curvature, sometimes also the pylorus, and even the lesser curvature, but this depends upon the degree of ptosis of the stomach. An indurated pylorus will usually appear as a transverse movable hard pad, which recedes from the palpating finger with a

sudden jerk, just as the normal structure. In the case of thin patients with ptosis one must avoid being confused by the pancreas, which can sometimes be palpated throughout its whole length. Confusion is more likely to occur when there is chronic pancreatitis or cancer of the head of the pancreas.

We do not always find the growth situated where we usually suppose the stomach to be. In cases of ptosis, the whole stomach, including the pylorus, may be in the left half of the abdomen, so that cancer in a stomach thus displaced will be encountered on the left side, occasionally even as low down as the pelvis. On palpating such a tumour, its connection with the stomach will be suggested by the ease with which it can be pushed over to the right, and by the fact that it can be displaced over an extent which corresponds to the segment of a circle around the normal position of the pylorus. A more striking evidence of its connection with the stomach is afforded by its displacement towards the right, when that viscus is distended with gas.

If we are in doubt whether the tumour is connected with the stomach or with the transverse colon, we must endeavour to trace the latter from the hepatic flexure, by palpation. If we are able to feel the transverse colon, in its entire extent, as separate from the tumour, obviously it cannot be connected with the bowel, and therefore probably arises from the stomach. If the tumour is on the left side, we must palpate both the ascending and descending limb of the splenic flexure, in order to be sure that it is not connected with the bowel.

For the sake of completeness, it should be mentioned that a tumour originating in the kidney or its fatty capsule may simulate a tumour of the stomach. In such a case, the skiagram would show the stomach displaced and compressed.

There is not much to say about hæmorrhage. It merely indicates the existence of some ulceration. Every tyro knows that acute arterial hæmorrhage points to a simple ulcer, and that coffee-grounds vomit points to cancer. But exceptions occur in both directions. Sometimes there is no hæmorrhage visible to the naked eye ; and to wait for coffee-grounds vomit would mean to miss more than half the cases of gastric cancer. Early diagnosis depends in great measure on the repeated microscopical and micro-chemical examination of the syphoned-off stomach contents, for traces of blood which are otherwise invisible. If such traces are regularly present, we may be confident that there is at any rate some ulceration within the stomach. Traces of blood in the stools would lead to the same conclusion, with the reservation that the blood may be coming from some lower site in the digestive canal, especially the duodenum.

The examination of the *chemical conditions* of the stomach often

furnishes further evidence, and the following four statements summarize the information hitherto established on the subject :—

(1) Free hydrochloric acid very soon disappears in most cases of cancer, but on the other hand the absence of the free acid or even a deficiency of the combined acid is in no sense an evidence of cancer. (In those cases wherein it is assumed that cancer has become engrafted upon an ulcer, the free hydrochloric acid may persist for a considerable time).

(2) The presence of a definite and intense lactic acid reaction indicates a stenosis caused by cancer ; but on the other hand the absence of lactic acid is not an argument against cancer.

(3) Even if there be no definite lactic acid reaction, the presence of numerous long bacilli (lactic acid bacilli) strongly suggests cancer.

(4) The increase of hydrochloric acid, or decrease of the hydrochloric acid deficiency when the quantity of the test meal for ulcer is raised, contra-indicates cancer. (Gluzinski and Kocher.)

We now come to the fourth of the above-mentioned signs—the *cancerous cachexia*. Controversy has been raging around this subject for some decades, but it is quite clear now that much of what was attributed to cachexia is really due to the functional disturbance of vital organs, to repeated hæmorrhages, to ulceration of the cancer and septic absorption. All these factors are especially active in cancer of the stomach. Nevertheless, recent hæmatological research has shown that there is something real in the old conception of cancerous cachexia. The peculiar sallow, waxy appearance of many cancerous patients, which strikes the experienced observer forthwith, the early depression of cardiac force, indicated by the rapid soft pulse, correspond to blood changes which are imperfectly understood, but which can be estimated by certain qualities of the serum, such as the increase of its antitryptic index. A definite increase of this index, to about double the normal, is a strong evidence of cancer, in the absence of any other cause (advanced tubercle, parenchymatous goitre, Graves's disease). Unfortunately the determination of this index is much too complicated a process for the use of the general practitioner, and the same applies to all the other serological tests for cancer which have been investigated within the last few years.

There is no one single reliable sign of cancer. The diagnosis must be based on the combination of the various signs. The assistance which may be derived from skiagraphy will be referred to when discussing the special forms of cancer.

There can be no doubt about the nature of the disease, if circumscribed nodules can be felt in the liver, if free fluid is detected within the abdomen, or if hard glands are found in the supra-clavicular fossæ—as first described by Troisier and Virchow.

(1) CANCER OF THE BODY OF THE STOMACH.

The favourite position is at the lesser curvature. Cancer does occur on the anterior and posterior surface, as also on the greater curvature, but very much more rarely. All cancers of the body of the stomach characteristically manifest themselves by a prolonged period of indefinite indigestion, until the increasing anæmia, the size of the tumour, and secondary malignant peritonitis indicate the nature and situation of the disease. Occasionally, the growth perforates into the colon, with the appearance of symptoms, which are obviously due to a fistula between the stomach and large intestine.

These cancers are concealed beneath the liver and they often cannot be felt, but the persistent tension of the abdominal integuments in the epigastrium and its indefinite resistance eventually suggest organic disease and then it is usually too late for operation. They do not, as a rule, give rise to distinct symptoms until they invade the pylorus. Most of the too-late diagnoses—whether due to the neglect of the patient or of the practitioner—fall within this group, and tragically enough this fate fell, a few years ago, to the lot of a surgeon who had distinguished himself by his work on the early operation for gastric cancer.

As we shall soon see, these cancers could be demonstrated by skiagrams before they give rise to clinical symptoms; but in the absence of symptoms there are no indications of illness, and therefore advice is not sought.

The anatomical peculiarities and the clinical details of these cancers permit of their division into the following four varieties :—

(1) *Superficial cancer*, "rodent ulcer of the stomach," can only be felt in the late stages. The skiagrams are characterized by a mere faintness of the shadow in the region of the cancerous infiltration, rather than by circular areas where there is real loss of shadow.

(2) *Protuberant Broken-down Cancer with Deep Ulceration in the Centre.*—This is the most frequent variety of cancer of the body of the stomach, and is situated astride of the lesser curvature, like a saddle. Unless concealed by the liver, it can be felt earlier than the flat cancer. It appears in the skiagram as a well-defined, roundish area, from which the shadow is absent. As such light areas may also be due to remains of food not derived from the bismuth meal, it is necessary to confirm the result by repeated examination. Mistakes may also arise, from tumours outside the stomach pressing thereon (fig. 147, *l*). This shows how important it is to interpret the skiagram, in relation to the existing clinical signs, for the diagnosis of gastric disease based upon X-rays alone is not of great value.

(3) The *polypoid form* of gastric cancer is also recognized by areas of loss of shadow. Its consistence may allow of its easy palpation, or it may be so soft that it cannot be felt through the stomach wall, even when the abdomen is opened. These forms are liable to bleed

freely, and they are clinically characterized by anæmia. These are the cases which are often regarded for months as pernicious anæmia, until a careful examination reveals the diagnosis. Every case of pernicious anæmia ought to be subjected to an exhaustive examination of the stomach, and a skiagram should be taken. In one of our cases, the diagnosis was established by a piece of tissue obtained by washing out the stomach; in another case, a girl, aged 24, a tumour could actually be felt.

(4) The clinical signs of *diffuse cancerous cirrhosis* of the stomach (Brinton's cirrhosis, linite plastique of French authors) depend upon the fact that the organ has become converted into a rigid tube of small capacity (pocket-flask stomach). Vomiting immediately after a meal is, therefore, the chief symptom, which is liable to suggest the regurgitation due to a low œsophageal cancer, or to a carcinoma of the cardia. A tube can be introduced into the stomach quite easily, but the viscus cannot be distended nor can any large amount of fluid be retained. If the growth can be felt distinctly, it appears as a diffuse or cylindrical resistance in the upper part of the epigastrium.

This diffuse contraction of the stomach is recognized on the skiagram as a narrowing of the shadow. As a rule, the change affects the uppermost portion of the stomach last, and then the shadow of the stomach has a funnel-shaped appearance.

(2) CANCER OF THE PYLORUS.

The symptoms of pyloric cancer are much more definite, and it is therefore easier to establish an early diagnosis. The principal symptoms are due to mechanical obstruction, just as in cicatricial stenosis at the pylorus. The same trend of manifestations occurs in both conditions: (1) *Painful gastric peristalsis, often visible through the abdominal wall* (fig. 148); (2) *retention which can be demonstrated by the stomach tube*, and (3) *retention vomiting*.

We must not delay our diagnosis until these signs are fully developed. Epigastric pressure, from which a patient has hitherto been free, coming on after meals, or colicky pains—even if only slight—in the gastric region, occurring periodically during digestion, are symptoms demanding careful examination, which will usually show, after the use of the stomach tube, that the food remains in the stomach too long. As a rule, there is no vomiting at all, in this stage. A skiagram, which is indispensable when these clinical symptoms are present, usually shows the following points:—

The impression taken immediately after the bismuth meal shows a normal outline; at any rate, the dilatation in the transverse diameter, which is so significant of post-ulcerative stenosis, is absent. At most, the region of the antrum pylori may appear somewhat distant. On the other hand, we may be struck by the presence of deep peristaltic waves, in one impression or the other. It is especially noticeable that the stomach shadow is not well marked in the pyloric region.

The stomach looks as if it had been cut off transversely, and its boundary line presents irregularities which remind one of the areas of missing shadow which occur in cancer of the body of the stomach.

We must be on our guard against deception also here. A distended gall-bladder, probably with inflammatory adhesions to the pylorus, may extinguish the shadow in the pyloric region. This is especially likely to happen through remains of food not derived from the bismuth meal. It is, therefore, imperative to confirm any apparently pathological condition by a second examination, in the right lateral posture, if necessary.

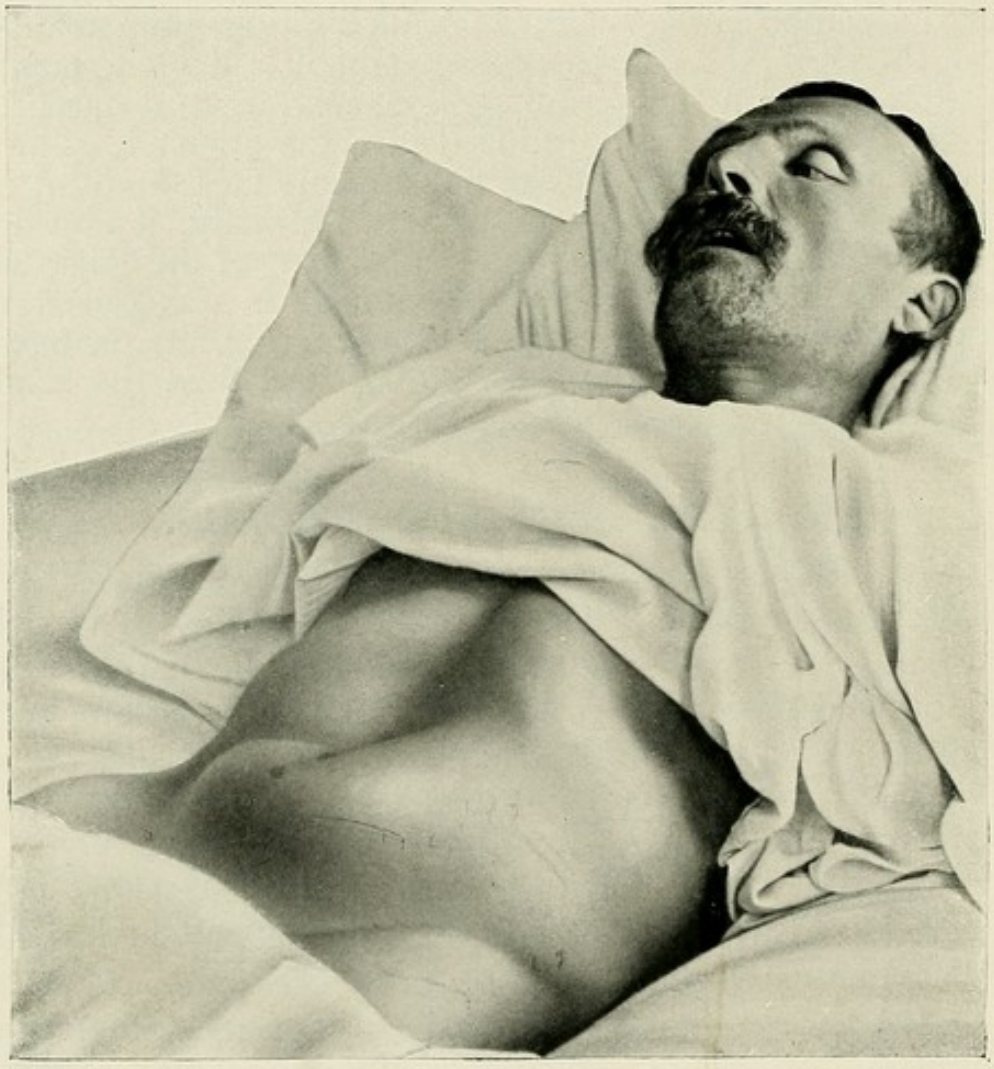

FIG. 148.—Pyloric stenosis due to cancer. Attack of gastric rigidity. (Stomach not artificially distended.)

Sometimes, a tapering or conical process of the stomach shadow indicates the path by which the food makes its way through the cancerous masses.

If examinations are made after six, twelve, or twenty-four hours, the stomach is generally found partially full, thus confirming the clinical evidence of retention. The longer the disease has lasted the greater is the food residue, the wider is the stomach shadow and the nearer does the picture approximate that of post-ulcerative stenosis of the pylorus. But whereas in the latter the boundary line of the

stomach shadow is sharply defined, in cancer we almost always find, in all its stages, that the shadow is cut across towards the pylorus, or at any rate that its border is indefinite and irregularly wavy.

Cancer of the stomach often begins on the lesser curvature, but is not recognizable until it invades the pylorus and constricts it. If we cannot diagnose it from the history and the results of palpation, it can often be detected on the skiagram by the loss of shadow extending considerably towards the left.

CHAPTER XLI.

SURGICAL DISEASES OF THE BILIARY PASSAGES.

NOTWITHSTANDING the better appreciation of the nature of gall-stone disease, which we have gained during the last twenty years, there still remain some practitioners in whose minds the ideas of "jaundice" and "gall-stones" are indissolubly connected. We still hear the assertion "there are no gall-stones because the patient has no jaundice." Jaundice is a symptom which *may* occur in gall-stone disease, but is *not essential* thereto, and is moreover present in many other diseases.

If a patient informs us that his liver is affected, or if we have the impression that he is so suffering, our first thoughts should be of the "medical" diseases—simple *biliary catarrh*, the various forms of *hepatic cirrhosis*, and *acute yellow atrophy of the liver*.

If a patient with indigestion but without pain, becomes yellow but otherwise remains well, we must diagnose *catarrhal jaundice*. But if the general condition is profoundly affected, and the temperature is high, the disease is *infective jaundice*, which may also occur in the epidemic form. This also constitutes the rare malady known as Weil's disease. If a high degree of jaundice is associated with symptoms of severe general illness and rapid loss of strength, we should assume either *acute yellow atrophy of the liver*, as a result of poisoning (phosphorus, arseniuretted hydrogen) or some form of septic infection. A certain amount of jaundice, without any profound anatomical changes in the liver, often exists in acute septic conditions, especially in septic peritonitis, and all experienced observers are acquainted with the terrible dirty greenish look—due to the yellow of the jaundice combined with the blue of the cyanosis—of patients who have succumbed to this disease. A patient who gets about for years, with

more or less jaundice, but without any particular pain, but who complains occasionally of slight feverish symptoms and a general deterioration of his health, must be suspected of suffering from *hypertrophic cirrhosis of the liver*—which is merely a chronic infection of the organ with acute exacerbations.

The jaundice of Banti's disease should be mentioned here, in which condition the enlargement of the liver is associated with great splenic hypertrophy. Secondary and tertiary syphilis may also produce jaundice.

The above comprise all the usual conditions which may suggest forms of gall-stone disease. But if the patient's "liver trouble" does not appear to fit in any of these categories, we are justified in concluding, by exclusion, that the case is probably one for surgical treatment. We should accordingly think of gall-stones, malignant growth, abscess of the liver and hydatid cyst.

We have just included Banti's disease among purely medical diseases, but this is not quite accurate, for good results have followed extirpation of the spleen in this condition. The difficulty consists in the fact that our conception of the disease is not definite, either from the clinical or etiological standpoint. The condition is probably a composite one. Furthur experience is necessary to clear up the matter.

We may now apply our diagnostic reflections to a few concrete cases.

(1) GALL-STONE COLIC.

In one group of cases, pain is the predominant feature. The patient is seized, at rare or frequent intervals, with severe pain in the upper part of the abdomen or more definitely in the gall-bladder region. Nothing but morphia suffices to relieve the pain which, however, does not last more than a few hours, or at most, a day. There is usually no rise in temperature, nor is there, as a rule, any jaundice, so that the patient, and often the doctor, diagnoses "colic." But gastric colic is really very different to gall-stone colic, both in its onset and in its nature. Pains arising in the stomach generally radiate to the left and towards the back; biliary colic radiates towards the right, even as far as the right shoulder. If gastric pain is caused by an ulcer, it is increased on taking solid food. If caused by hyperacidity, food relieves the pain. In both cases the pain comes on almost regularly at definite hours of the day or night. The pain in an acute attack of gall-stones, so-called **biliary colic**, is quite independent of food and it occurs at irregular intervals of months or years. This also differentiates it from the pain of duodenal ulcer, which is situated on the right side and comes on at the completion of gastric digestion. This is termed "hunger pain."

After an attack of gall-stones it sometimes happens that somewhat less severe but more persistent or periodical pains remain. These are apt to cause confusion. They indicate that stones are still present, or that the attacks have led to advanced anatomical changes.

In other cases there are no attacks at all; the disease is only betrayed by certain indefinite digestive troubles, the origin of which may, however, be suspected from the painfulness on deep pressure over the region of the gall-bladder. From this condition, it is only one step to the cases of gall-stones wherein the symptoms are quite latent—constituting 95 per cent. of the whole. This explains the impossibility of making a diagnosis in so many of the cases.

We may now return to the attack of colic itself. This may be mistaken for any acute painful seizure in the upper abdomen, viz., for pain caused by *hernia of the epigastrium* or *umbilicus*, renal colic, and the severe conditions to be described in the following section.

Biliary colic may be distinguished from renal colic, even in the cases where there is no palpable swelling to assist in localization, by the position of the reflex muscular rigidity. If we press simultaneously in front of and behind the painful region, in a case of renal colic, the lumbar muscles will become rigid, whereas in a case of biliary colic, it is the right rectus which becomes rigid. It has been stated that in gall-stone disease there is a particularly characteristic painful spot close to the right side of the spine below the twelfth rib; but one must use this diagnostic point with discrimination.

In order to explain the mild attacks of gall-stone disease, on an *anatomical basis*, we must assume that the stones are incarcerated in the gall-bladder, cystic duct or common bile duct, and that the degree of surrounding inflammation is very slight indeed, passing off very rapidly after having attained its height within a few hours of onset. Unless recurrences are very frequent, surgical aid is unnecessary. We will discuss the *position* of the stone in connection with other forms of cholelithiasis; but it is usually very difficult to localize it in mild attacks. The discovery of the stone in the stools after the attack often shows that the pains are due to the extrusion of the calculus. Some patients are able to exhibit a stone for each attack. There is no jaundice in these slight attacks because the obstruction of the common duct is too brief.

The attacks of pain caused by adjacent adhesions are sometimes indistinguishable from mild biliary colic. These attacks may occur whether the stone has passed naturally or has been removed by the surgeon.

It is often important to be able to decide whether attacks of pain of which a patient has complained were really due to gall-stones. Two practical rules are applicable in this connection. The patient is able to go to his doctor for very many attacks of pain, but the doctor is obliged to come to the patient for biliary colic.

An anodyne prescription suffices for ordinary pain, but a hypodermic injection of morphia is indispensable in the pain of gall-stones. Exceptions are rare.

(2) ACUTE CHOLECYSTITIS.

The following case raises somewhat different problems of differential diagnosis, in regard to acute biliary colic.

A patient is suddenly seized with symptoms of pyrexia and severe pain in the right side of the abdomen. He vomits on one or more occasions, indicating peritoneal irritation. The colour of the skin is normal, the pulse is good, the abdominal muscles, especially on the right side, are tense or become so, as soon as they are touched, and we think of appendicitis, because of its frequency or perhaps because it is in fashion. On careful examination, it will, however, be found that the centre of the painful area and the rigid musculature is not situated in the line joining the anterior superior spine and the umbilicus, or below it, as is the rule in appendicitis, but higher up in the region of the gall-bladder. Percussion probably shows that the liver dulness projects below its normal limits, even extending as far as the level of the umbilicus. If palpation is possible, despite the muscular rigidity, an area of resistance, with its lower border circular in shape, will be felt, connected with the liver. If this be the physical condition found, there can be no doubt that the case is one of *acute cholecystitis*, and if the pyrexia persists for many days it is certainly of a suppurative character. The position of the pain and the pyrexia often suffice for the diagnosis, without it being possible to demonstrate the typical lobular or tongue-shaped area of resistance. In such case we may assume that a contracted gall-bladder, concealed under the liver, has become inflamed, and we will generally obtain an old history of gall-stones, in confirmation of this assumption.

A recent perforation of a *gastric or duodenal ulcer* might suggest acute cholecystitis. But in perforation, the reflex muscular rigidity very quickly affects the whole abdomen, and generalized peritonitis soon sets in if the case is neglected, symptoms which only occur in cholecystitis if an infected gall-bladder perforates into the free abdominal cavity.

Pancreatitis and *pancreatic hæmorrhage* should also be mentioned in this connection.

If the gall-bladder and appendix were invariably in their normal positions, differential diagnosis would be very easy. This is, however, not the case. Sometimes the gall-bladder reaches as far as the ileo-cæcal region, whether the liver be movable or not. But much more frequently, the appendix is high and directed outwards.

At other times its position is in close proximity to the gall-bladder (fig. 143, *h*) especially when there is a "mesenterium commune ileo-cæcale." I once saw it, at an early operation, strung up by a lateral band of connective tissue, close to the gall-bladder behind the liver.

These abnormalities in the position of gall-bladder and appendix have led to many errors in diagnosis. The following is an instance :—

A female, aged 40, was operated on by an experienced surgeon for a "perityphlitic abscess," and she subsequently had a persistent fistula in the ileo-cæcal region. Two years later she was admitted to hospital, suffering from acute hemiplegia. She died in a few days, and the autopsy showed that the fistula, which opened at the upper part of the inguinal region, led into the gall-bladder, which contained a large stone. The cystic duct was closed. The hemiplegia was the result of a cerebral abscess, in which were found diplococci similar to those in the gall-bladder. Neither the surgeon nor the physician was fortunate in the diagnosis of this case, although they were both experienced observers.

When the inflammatory process occurs above the line joining the anterior superior spine to the umbilicus, we should think of appendicitis if the pain or resistance reach far *towards the side*, and if the lumbar muscles respond to pressure, by contraction ; but any inflammatory process internal to the external border of the rectus must be ascribed to the gall-bladder. If jaundice supervenes in addition, the beginner will immediately decide in favour of gall-stones. This is usually a good guess, because the extension of the inflammatory swelling from the gall-bladder to the common duct often leads to a mild temporary jaundice. But, on the other hand, we often find a certain amount of jaundice in appendicitis, not necessarily in the severest cases. If the appendix lies near the gall-bladder, so that the biliary passages are secondarily involved in the inflammation, the jaundice may become very pronounced.

A young man was brought into the hospital with a high temperature, severe jaundice, and abdominal resistance reaching outwards from the lateral border of the rectus, immediately adjoining the liver, and extending as far as the crest of the ilium. Despite the jaundice a diagnosis of appendicitis was made, based upon the lateral position of the resistance. This was confirmed at the operation.

A rule to the following effect often enables a correct diagnosis to be made, when the painful spot is situated just on the border line : if the dulness reaches as far as the flank, the case is appendicitis, but if an intestinal note can be elicited externally to the painful area, cholecystitis is present.

It is important to make a correct diagnosis. Early operation, within the first twenty-four hours, should be proposed in appendicitis ; but in cholecystitis it is better to wait until the severity or the duration of the symptoms demand interference. If the acute stage has

passed over without any interference, the appendix should be removed after two or three months, if the disease was appendicitis; but, on the other hand, operation should be avoided if gall-stones have become completely latent. If we still remain in doubt after taking all physical signs into consideration, we must be guided by the rule that appendicitis is more probable the younger the patient, and gall-stones the older he is. Nevertheless I have twice seen girls, aged 18, sent in for appendicitis, but who were really suffering from cholecystitis.

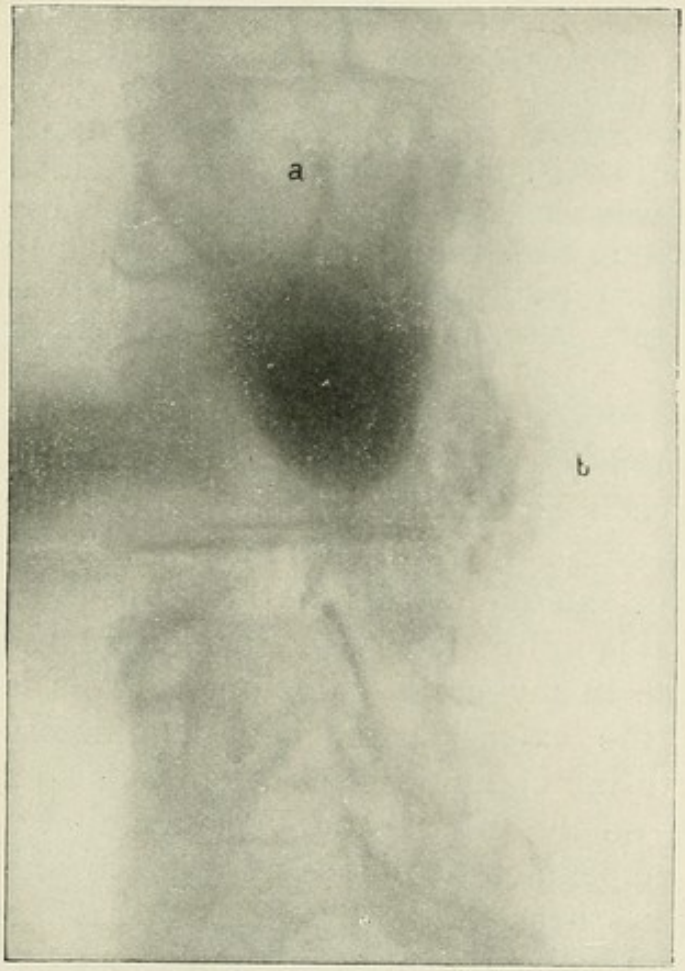

Left. Right.

FIG. 149.—*a*, Bismuth shadow in duodenum. *b*, Calcium carbonate gall-stones. (See also fig. 150, 5.)

A special form in which cholecystitis may manifest itself should be referred to. Just as cases of gall-bladder inflammation come to the surgeon with the diagnosis of appendicitis, so do others present themselves which have been diagnosed as "ileus." Indeed cholecystitis may at its beginning or during its progress, cause adhesions between the intestine and gall-bladder, kinking or inflammatory infiltration of the intestinal wall, extensive, serous or sero-purulent peritonitis, which may either produce mechanical obstruction, or the toxic symptoms of an obstruction. A correct diagnosis can only be made from the previous history of the patient, and the presence of pain and resistance, or at least of a localized area of pain on pressure, in the region of the gall-bladder.

(3) GANGRENOUS CHOLECYSTITIS.

In the forms of gall-bladder inflammation so far described, the disease has been limited to the gall-bladder and its immediate vicinity. But if the clinical aspect is much more severe and septic symptoms develop rapidly, or if an increased resistance follows upon a very acute stage, we should suspect *gangrenous inflammation* of the gall-bladder, with extensive participation of the peritoneum.

A man, aged 65, was suffering from severe inflammatory symptoms

(1) Bilirubin-lime calculi from the intra-hepatic biliary ducts, containing neither calcium carbonate nor calcium phosphate.

(2) Gall-stones mainly consisting of cholesterin, with bilirubin in the centre.

(3) Facetted gall-stones, consisting of cholesterin, pigment and some calcium phosphate.

(4) Mammillated gall-stone with a deposit of Ca. and Mg. carbonates and phosphates.

(5) Gall-bladder with calculi resembling thorn-apples, consisting almost exclusively of calcium carbonate (from case shown in fig. 149).

(6) Ureteral stones, containing organic material, carbonate and phosphate of calcium and magnesium.

(7) Vesical stone, consisting of calcium oxalate.

(8) Urethral stone, containing organic material, calcium and magnesium phosphate.

(9) Salivary stones, containing organic material, calcium phosphate and a little magnesium phosphate.

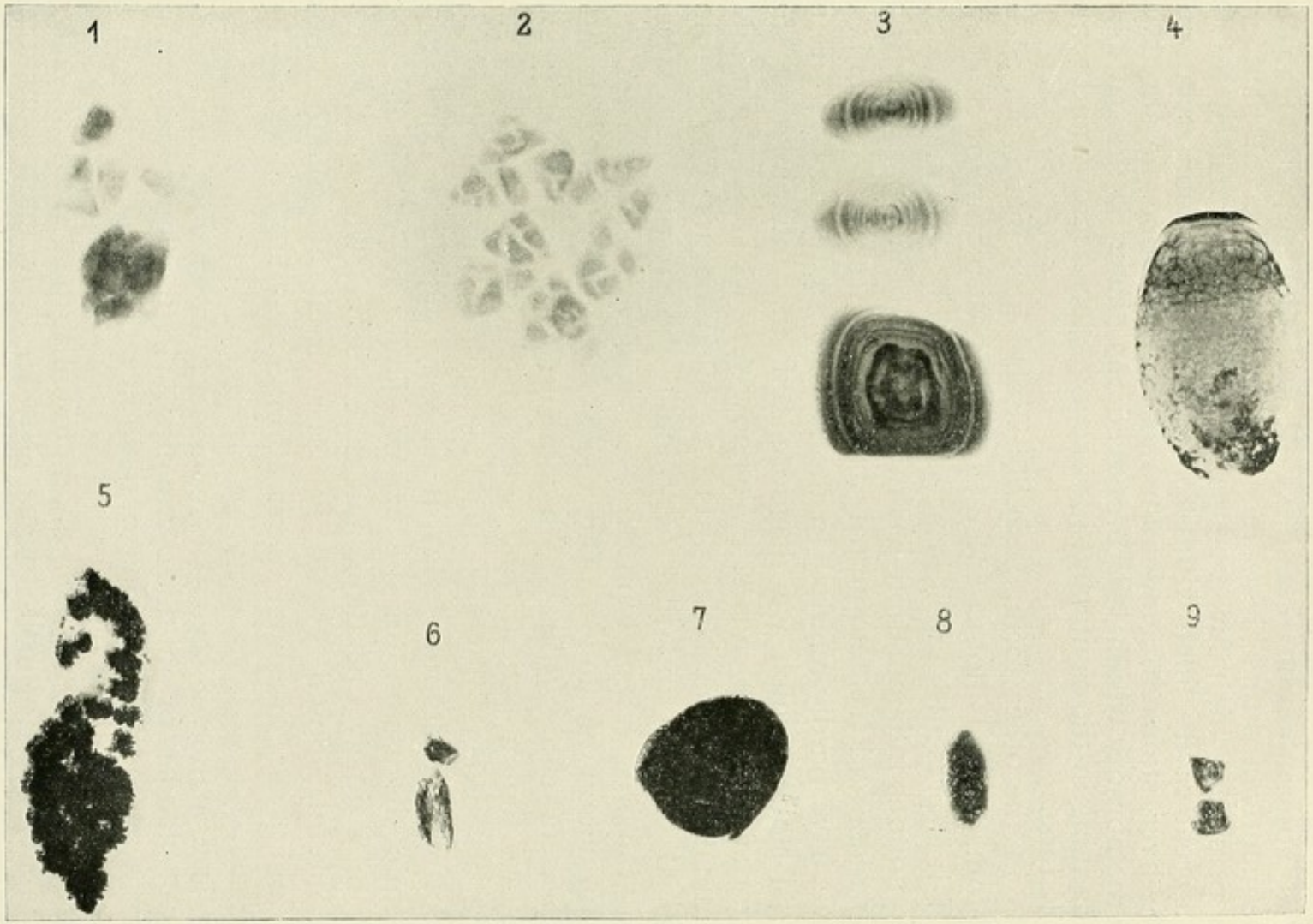

FIG. 150.—Comparative illustrations of skiagrams of a few calculi.

in the upper abdominal region. At first they seemed to abate, but subsequently a diffuse resistance developed in the gall-bladder area, with persistent high fever. Operation was performed at this stage, and a great cavity filled with offensive pus was encountered, bounded by the liver, stomach, duodenum and large intestine. A shreddy dark grey membrane, which still preserved the shape of the gall-bladder, was hanging in the cavity, but it was completely necrotic and contained a gall-stone.

As in the other form, *jaundice* is also here merely an accessory symptom, which is not essential to the clinical picture of cholecystitis. But if it is present—and it is usually transitory—we must infer that a phlegmonous inflammation has invaded the biliary passages from the gall-bladder and has temporarily arrested the free flow of the bile.

We have hardly referred to the gall-stones themselves. It is not the gall-stones which we diagnose, but the inflammatory changes which their presence causes. We know very well that slight catarrhal inflammation of the biliary passages often occurs after gastric and intestinal catarrh, and that very acute cholecystitis may supervene during the progress of typhoid fever, dysentery and cholera, without any formation of stones. But these only account for one-tenth of the cases of cholecystitis which come under observation. It follows, therefore, that a patient who suffers from cholecystitis without any of the antecedent illnesses just mentioned, most probably is the subject of gall-stones. But it is very regrettable that a purely academic discussion on the matter should be responsible for the delay of a timely operation, and that a stone, whose existence may be doubtful, should eventually assert itself by gall-stone obstruction and fatal intestinal perforation, examples of which I have witnessed.

It is a matter of secondary consideration whether the stone is in the gall-bladder or in the cystic duct. In the latter case there will be more acute exacerbations of jaundice than if it is situated in the gall-bladder.

Many attempts have been made to enlist the service of skiagraphy in the diagnosis of gall-stones. But as their main constituent is cholesterin, a substance which is almost equally transparent to the X-rays as the soft tissues of the human body, not much is to be anticipated from this method of examination. Positive results have only been obtained in the very rare cases of pure calcium carbonate stones, and with cholesterin stones which contain a large amount of calcium and magnesium salts (or are encrusted therewith) as a result of secondary infection. Pigmented lime stones, on the other hand, are so loosely built up that they cannot be detected in a skiagram. The accompanying figure (150) shows how a few of the most important calculi are brought out on a skiagram, and fig. 149 represents a calcium carbonate stone revealed by skiagraphy of the living body (found accidentally after a bismuth meal).

(4) OBSTRUCTION OF THE COMMON BILE-DUCT.

This presents a totally different clinical picture. Jaundice is the predominant feature; localized dulness and swelling are hardly ever present. The liver is enlarged, the urine contains much bile pigment and the stools are colourless. These symptoms indicate that some obstruction exists in the common duct, and we have to determine whether this is caused *only* by a **stone** or whether a **malignant new growth** may be present. In cases of stone the obstruction is not merely caused by the foreign body, but also, and to a great extent, by the accompanying inflammatory condition, and therefore the biliary content of the stools and the degree of jaundice are liable to variations. But if the obstruction is caused by carcinoma there is a constantly increasing mechanical pressure exerted by the new growth, and therefore the stools are always free from bile and the jaundice is persistent. If, in addition, we realize that the pain is not due to congestion of the bile, but to the inflammatory process, we will understand that attacks of pain point to gall-stones, whereas painless jaundice suggests a tumour. These are two fundamental differences between the two conditions. These remarks concerning the attacks of pain apply equally well to exacerbations of high temperature, with or without rigors. But we must be on our guard against diagnosing gall-stones merely because there is a previous history of biliary colic. In at least five-sixths of the cases of cancer of the gall-bladder there has been a previous history of gall-stones. How, then, are we to make a correct diagnosis? An example may perhaps indicate this.

A middle-aged female suffered for many years with regular attacks of recurrent gall-stones, in testimony whereof she produced a box full of stones which she had passed spontaneously. The last "attack" was a particularly mild one, but the jaundice, which was more intense than on previous occasions, did not pass off in the usual manner; indeed, it had persisted for several weeks unaltered. The general condition had also suffered much more than in previous attacks. These few indications sufficed to establish the diagnosis of cancer. The slight pain, but the persistent jaundice, were the cardinal symptoms, and the commencing cachexia was corroborative evidence.

The importance of jaundice existing without pain is shown by the following case:—

An aged female suffered from complete obstruction of the common bile-duct, but had no pain. A firm, somewhat nodular, resisting mass could be felt in the region of the gall-bladder. Diagnosis: carcinoma. The operation revealed an inflamed gall-bladder, filled with pus and stones, but no cancer. The history, however, suggested very strongly that there must be something more present, and as a matter of fact, a deeply-seated cancer, which probably originated in the duct, was found.

Physical examination, on the whole, affords little definite information. Palpation is only conclusive if a large irregular nodular tumour is found—but this is exceptional. Nodulated swellings which do not exceed a goose's egg in size, may be the result of gall-stones.

Courvoisier's rule, if carefully applied, is very useful. If we find a tensely filled gall-bladder in a case of chronic obstruction of the common duct, we may conclude that the walls of the gall-bladder are capable of being stretched, and therefore are not chronically inflamed. But as calculous obstruction generally occurs after prolonged suffering from cholelithiasis, that is to say, after the gall-bladder has undergone chronic inflammation and contraction, it follows that a distended gall-bladder contra-indicates calculous obstruction, and suggests the presence of a new growth pressing upon the common duct, but leaving the gall-bladder itself free. On the other hand, if the gall-bladder cannot be felt, it is an argument against a tumour, and is in favour of obstruction by a stone. This latter conclusion is, however, only applicable if the tumour does not originate in the gall-bladder itself. Primary cancer of the gall-bladder is very frequently quite unable to be felt, or only as a small nodular swelling connected with an inflamed contracted gall-bladder, just as in the case of calculous obstruction. On the other hand, calculous obstruction sometimes occurs when the gall-bladder is still healthy, or at least still remains capable of distension, and then it can be felt on palpation just like a congested gall-bladder due to obstruction by a growth.

We must always search for *secondary deposits* (*e.g.*, nodules on the upper surface of the liver, Virchow-Troisier's glands beneath the insertion of the sterno-mastoid), and especially examine the abdomen for a *free effusion*. This symptom may be conclusive, even when nothing else appears to point to cancer.

A strong man, aged about 40, who had no previous history of biliary disease, suffered from such severe pain of the gall-bladder that a large amount of morphia had to be prescribed. A diagnosis of gall-stones was made, and this appeared to be fortified by the presence of jaundice. But the jaundice persisted, and then a slight fluid effusion came on, as the first positive sign that the case was one of cancer. Œdema of the legs soon came on as confirmatory evidence, and the fatal result was not long delayed.

Ascites occasionally comes on in cases of obstruction by stone, as a result of the secondary cirrhosis of the liver, which is due to the biliary congestion.

If the symptoms gradually and spontaneously vanish, after we have diagnosed *calculous obstruction*, it does not signify that our diagnosis was wrong, nor can we be sure that the stone has passed. As soon as the inflammatory swelling has subsided, the bile can flow freely alongside the stone, which may remain latent in the common duct. If it still remains there, after six to eight weeks, it should be removed by choledochotomy. The spontaneous passage of large

stones into the intestine is not usually effected *per vias naturales*, but through a fistulous opening between the gall-bladder and intestine.

If we have arrived at the diagnosis of *obstruction by tumour*, we must determine the situation and origin of the new growth. But this is not often possible. Cancer of the gall-bladder so often runs its course without symptoms until it gains a great depth and obstructs either the common duct or the hepatic duct, causing the same symptoms as the rare primary cancer of the common duct, or cancer of the head of the pancreas. Palpation does not often yield any positive information. Deficient digestion of fats would strongly suggest some change in the head of the pancreas, but it would not differentiate between a new growth and chronic pancreatitis.

(5) HYDROPS OF THE GALL-BLADDER, CHRONIC EMPYEMA.

Cases occur, wherein a single pear-shaped tense swelling which can be felt in the gall-bladder region, indicates disease of the biliary passages. If this swelling is only slightly movable, and is somewhat tender on pressure, and there is also a history of inflammatory attacks, the diagnosis of **chronic empyema** of the gall-bladder may be made. But if the swelling is not tender on pressure, if it is strikingly movable, and the history is negative, the diagnosis can only be **hydrops** of the gall-bladder. The cause is usually a small solitary, oval, finely lobulated stone, incarcerated in the cystic duct.

A young woman was sent to be operated on for an abdominal tumour. A tensely elastic tumour of the size of a small fist was found in the upper part of the abdomen. It was situated on the right of the spine, but it could easily be pushed to the left, and would remain in the left hypochondrium. On marking out on the surface of the abdomen the circuit of the tumour, the segment of a circle was described, whose mid-point was below the liver. This rendered some connection with the gall-bladder very probable. The patient suffered no pain and had no jaundice, and she had complained neither of her liver nor gall-bladder. Apparently, the swelling was functionally distinct from the biliary system. It was ascertained that the swelling varied in size, but the fluctuations were not associated with any pain. All this pointed to hydrops of the gall-bladder. At the operation the contents were found to consist of a slightly mucoid, limpid fluid, and a solitary stone was discovered in the cystic duct, as anticipated.

If a gall-bladder affected with hydrops can be pushed towards the right, more easily than towards the middle line, it is almost always mistaken for a *movable kidney*, even by experienced observers. The difference can only be established by carefully determining the usual position of the swelling, and the ease with which it can also be moved towards the left. On the other hand, a hydronephrosis or a

pyonephrosis may have grown so much towards the middle line and to the front that it can be felt and even seen in the gall-bladder area. Under these circumstances, the cystoscope is required before a diagnosis can be established.

(*a*) Facetted stones, or large single stone in the gall-bladder. *Without inflammation*, no symptoms. *With inflammation*, cholecystitis, severe spontaneous pain and also on pressure, fevers, rigors occasionally, and vomiting. Usually no jaundice, stools coloured, urine clear. More or less rapid subsidence, or transition to chronic empyema.

(*b*) Solitary stone in cystic duct, oval, generally wedged in firmly. *Without pronounced inflammation*, hydrops of gall-bladder, no jaundice, stools coloured, urine clear, no pain. *With inflammation*, empyema of gall-bladder, symptoms of cholecystitis as in *a*, but gall-bladder larger, and jaundice somewhat more frequent.

(*c*) Stone in upper part of common duct. *Without inflammation*, little or no pain. *With inflammation*, obstruction of common duct of varying degree, jaundice, pruritus, urine brown. Stools yellowish or greyish-white. Liver enlarged, gall-bladder unusually small, pancreatic digestion normal. Frequent attacks of pain, high temperature, rigors. Ascites in the later stages.

(*d*) Obstruction in upper part of common duct, due to a tumour (cancer of gall-bladder, cystic duct or common duct). Persistent severe jaundice, pruritus, urine brown, stools constantly grey. Attacks of pain, high temperature and rigors usually absent. Early ascites, pancreatic digestion normal.

(*e*) Obstruction by stone in lower part of common duct. *Without inflammation*, no pain or indefinite. *With inflammation*, as at *c*, but jaundice more persistent. Occasionally disturbance of pancreatic digestion.

(*f*) Obstruction by tumour at lower part of common duct. (Cancer, more rarely chronic inflammation of head of pancreas, cancer of duodenum), as at *d*, but generally disturbance of pancreatic digestion.

(*g*) Amorphous calcium bilirubin concretions in the biliary duct. Not recognizable clinically. Cause, so-called genuine stone diathesis.

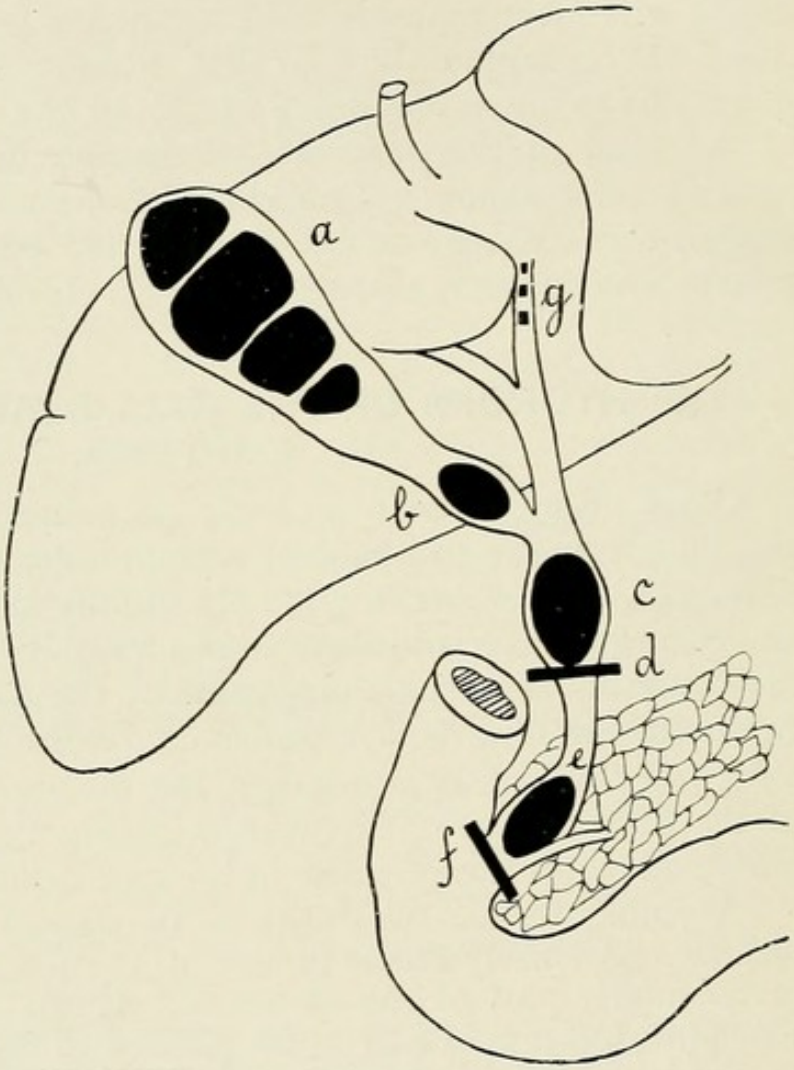

FIG. 151.—General diagrammatic view of the forms of obstruction of the biliary passages.

(6) ACUTE CHOLANGITIS.

Some cases of incarceration of stone in the common duct, or of acute infective disease (typhoid, cholera, pneumococcic infection) are followed by an intensely septic state, and there supervenes a clinical picture of rigors, with high fever and jaundice. This indicates an acute cholangitis, which is caused by an ascending infection in gall-stone disease, and as a blood infection in the disease just mentioned.

We assume that there is passive congestion of the bile when the fæces are colourless and the urine contains bilirubin, and that the jaundice is due to damage to the liver cells, when the fæces remain coloured and the urine contains urobilin in addition, or alone.

CHAPTER XLII.

TUMOURS OF THE LIVER.

It has happened that—on casual examination—a **movable liver** has been mistaken for an abdominal tumour. Careful examination will, of course, show that the liver is absent from its normal position, and that therefore the structure felt in the mid-abdominal region must be this missing organ. It is only necessary to place the patient in a posture wherein the thorax is lowered to observe that the liver resumes its normal situation. It may also happen that a liver, which is not especially movable, is pushed so far downwards by an extensive right pleural effusion that palpation suggests, for the moment, that an abdominal tumour is really present. Such an error is more conceivable in cases of a **constricted lobule** of the liver, especially if, owing to an aberration of the sense of beauty, the patient has undertaken self-treatment of the constriction, and has thus produced various derangements of digestion. The diagnosis is usually easy, and is indicated by the unnatural waist-like constricting furrow, which is visible on the skin, and by the fact that the lobule, which is felt, is connected with the liver. If the lobule is very movable, it is easily mistaken for a movable kidney, especially as it can sometimes be displaced into the renal region.

As a rule, it is quite easy to decide on careful examination whether a tumour-like structure is connected with the liver. If the tumour projects far downwards, the transverse colon may lie over it, and on percussion a zone of intestinal note will appear to separate it from the liver. The condition can, however, be cleared up, by examining the patient in varying states of intestinal fulness, or after artificial emptying of the colon. Tumours of the liver are sometimes simulated by large cancers of the stomach and occasionally by renal tumours which have grown forward.

Let us assume a case in which there is a localized tumour-like structure in a liver, which is not otherwise enlarged. The most probable diagnosis is a **secondary malignant growth**, and this view would be confirmed by a history of general malaise and wasting for some considerable period before the appearance of the tumour, or by the presence of several nodules. We may only assume that the case is one of **primary growth of the liver**, if an exhaustive examination has failed to reveal an original focus.

It is not possible to definitely distinguish between an innocent and malignant growth, before the onset of jaundice and cachexia. If it is possible to feel through the abdominal wall that the tumour is round in form and soft in consistence, it would suggest an innocent growth, cyst or cavernous angioma. But if the tumour is nodular,

or if umbilication is detected, which is quite possible in thin subjects, then it is almost certainly malignant—**cancer**. But a **gumma** of the liver may closely resemble a tumour, and thus lead to errors ; therefore the serum test and specific treatment are indicated in all doubtful tumours of the liver.

If the patient is jaundiced the question of malignancy is settled, and therewith also the uselessness of surgical intervention. If there are multiple growths in the liver we are justified in concluding that they are of a secondary metastatic nature, and therefore that they are malignant. The former conclusion is, however, not always accurate. There are primary **adenomata of the liver**, which are multiple and which permeate the whole organ with large nodules. These are usually accompanied by jaundice, and they behave clinically like malignant growths. **Cysts** which are quite innocent may also be present in some number.

This leads us to **cystic tumours** of the liver. If we find, in immediate connection with the liver, a structure which by its size, roundness of form, and soft elasticity of consistence, declares itself to be a cyst, we should not abandon further investigation and proceed to an exploratory puncture, in order to decide whether it is an **abscess**, a **hydatid** or some other **cyst**. The puncture will probably shed no new light on the diagnosis and may kill the patient. However fine the trocar, the fluid, if under pressure, and if the cyst is suppurating, may infect the peritoneum. Death has also followed rapidly, from the absorption of non-infected hydatid fluid. We must, therefore, endeavour to arrive at a diagnosis by other means. An example will illustrate the method.

A young man came from Bulgaria to our neighbourhood, which is free from hydatid disease. After four years' residence a tumour appeared in the hepatic region. The patient incidentally told the doctor that he had noticed a sudden onset of urticaria after a blow sustained over the tumour. The doctor argued as follows : Dogs play a much greater part in the life of Bulgaria than they do among us ; therefore there is a greater probability of echinococcus infection. The blow over the tumour may have led to the absorption of some of its contents, and experience shows that a fluid whose absorption causes urticaria is hydatid fluid ; therefore the tumour must be a hydatid cyst. The operation confirmed this conclusion.

Urticaria is indeed a very significant sign of absorption of hydatid fluid. But if no such indication is present, and the neighbourhood is free from echinococci, there is no other course to pursue but that of exploratory laparotomy. Sometimes it remains for the pathological anatomist to make a definite diagnosis.

As we are on the subject of hydatids we must mention the rare form of *multilocular hydatid*, which hitherto has only been diagnosed *post mortem*. If a patient is suffering from an unusual enlargement of

the liver, accompanied by more or less pronounced jaundice, which even in the course of years causes no deterioration in the general health, the possibility of this variety of hydatid should, at least, occur to us. There can be very little doubt about it, if the patient's habits have brought him into close contact with dogs, and if the enlargement of the liver no longer resembles in shape and size that of hypertrophic cirrhosis, for which a multilocular hydatid is most likely to be mistaken.

But if there is no indication of hydatids, and, on the other hand, the patient has lived in the Tropics, or has suffered from gall-stones, we should think of **abscess of the liver**. This assumption is confirmed by intermittent or remittent high temperature, by rigors, pain in the right shoulder, pleuritic symptoms and increasing cachexia. The absence of these symptoms, however, need not make us discard the diagnosis of abscess. Liver abscesses may exist for a very considerable time **without fever**, so that the local swelling, the localized pain and the etiology must suffice to indicate the nature of the malady. But if these local signs are also absent, because of the deep situation of the abscess, the diagnosis is quite impossible and the condition may remain undetected for months.

A chronic hepatic abscess, in these latitudes, is very likely to be mistaken for cancer, because this latter is a much more frequent sequel of cholelithiasis than is a solitary abscess. In doubtful cases, an exploratory incision is advisable, because this may lead to the cure of an abscess and can do no harm in the case of cancer.

If a fluctuating swelling is found, in the absence of any history supporting either a hydatid or an abscess, we must assume that it is one of the rare forms of **non-parasitic liver cyst** (dermoid, ciliated cyst, cystic adenoma), the nature of which can only be ascertained by microscopic examination.

CHAPTER XLIII.

SURGERY OF THE PANCREAS.

We have already mentioned that the whole of the pancreas can sometimes be felt in thin people, with enteroptosis. This is a fact of importance, for the inexperienced are liable to mistake such a pancreas for a pathological structure. Diseases of the pancreas are not frequent, but those which can be diagnosed with reasonable probability are among the rarest incidents of surgical practice. We shall, therefore, deal with them briefly.

The symptomatology of these diseases may be classed under three headings :—

(1) ACUTE PANCREATITIS AND PANCREATIC HÆMORRHAGE.

If an individual—generally a male of advancing years—is attacked by symptoms which resemble either acute peritonitis or intestinal obstruction, often after suffering some indefinite prodromal intestinal discomfort, and if these symptoms are mainly localized in the upper abdominal region, we are justified in thinking of the possibility of pancreatic hæmorrhage or acute pancreatitis. This assumption is not negatived by slight jaundice, but it is supported by an early acceleration of the pulse and a lowering of the blood-pressure. If the initial, spontaneous and pressure pain is especially pronounced in the upper abdominal region, and if, after the cessation of the muscular rigidity, a diffuse resistance is appreciable in the epigastrium, the assumption becomes a probability. The rapid loss of strength and enfeeblement of the pulse, the early onset of low delirium and the possibility of evacuating gas by means of enemata, without relieving the patient or causing the vomiting to abate, are points against ileus. The absence of generalized abdominal rigidity and the early onset of meteorism are points against acute perforation of the stomach, although the seizure of pain may be just as sudden as in perforation. It may be some consolation for the practitioner who makes his diagnosis at the autopsy, to know that Germany's greatest surgeon recently succumbed to acute pancreatitis without anyone even suspecting the possibility of this condition. These diseases appear to be more frequent in some districts than in others. The fact that the cases sometimes come on as a result of cholelithiasis is not of much help to diagnosis, because any recurrence of disease in such patients would naturally be ascribed to an acute exacerbation of the old trouble.

Although the diagnosis can, as a rule, only be suspected or regarded as probable, nevertheless, the relationship between this disease and biliary disease does permit a more definite conclusion to be arrived at in certain cases. For example :—

A stout female patient, aged 50, was recovering from mild jaundice, associated with a gall-stone attack, when she was suddenly seized with severe pain in the upper abdomen, accompanied by collapse and followed by vomiting, retention of flatus and slight meteorism. In the course of the next twenty-four hours there was definitely increased dulness in both flanks. The pulse was rapid and soft. The pain was localized to the left of the middle line, thus contrasting with the pain of biliary colic. There were two possibilities ; either perforation of the gall-bladder or acute pancreatitis. The position of the pain favoured pancreatitis, and this diagnosis was confirmed by the operation, which was performed forthwith.

In the rare cases wherein a patient withstands an acute attack of

pancreatitis, and a localized collection of pus follows in the upper abdomen, we may confidently diagnose pancreatic suppuration, provided there is no reason to assume ulcerative perigastritis. The presence of glycosuria is of great diagnostic importance in these cases, but this condition is only found if the entire gland is destroyed.

Cammidge's pancreatic reaction of the urine has hitherto not proved of much practical value in these diseases, because this test is not specific and requires an experienced chemist with a chemical laboratory. Neither is the examination of the stools for trypsin of clinical value. The presence of fat in the stools is only of significance when the bile is normal.

(2) CHRONIC PANCREATITIS: CANCER OF THE HEAD OF THE PANCREAS: PANCREATIC CALCULUS.

In a case of persistent jaundice, with stools which show a deficient absorption of fat and digestion of meat, and wherein there is also a very dilated gall-bladder, we are justified in thinking of some morbid change which is simultaneously obstructing the common bile-duct and the pancreatic duct.

If, in addition, a resistance can be felt in the epigastrium on the right, close to the spine, we may assume that the head of the pancreas is diseased. But we cannot tell from the clinical symptoms whether the disease is *cancer*, chronic *interstitial inflammation*, or a *pancreatic stone*. We cannot tell definitely whether it may not be a cancer of the common duct or of the duodenum, which is resembling disease of the head of the pancreas. It is sometimes very difficult or even impossible to make an accurate diagnosis, even at the operation.

Chronic interstitial inflammation may result from a gall-stone in the papilla of Vater as well as from a pancreatic stone. But it may also be of a specific nature—syphilis more frequently than tubercle. Chronic, sub-acute suppuration, or even gangrene, of the pancreas may occur owing to the presence of stones. If one thinks of this possibility in any given case, the diagnosis might be confirmed by a skiagram, as these stones mainly consist of calcium carbonate, otherwise it will be made, for the first time, at the operation.

(3) PANCREATIC TUMOURS AND CYSTS.

A localized tumour in the mid-line of the epigastrium, between the stomach and transverse colon, but which can be shown to be independent of these organs by distending them with air, and which does not give rise to jaundice or any other striking symptom, suggests a pancreatic tumour which does not involve the head of that viscus. If the structure is not very large, but is firm or nodular, it is probably a malignant growth. But if it is larger and rounder, and more or

less tensely elastic in consistence, it is a *cyst*. One cannot be quite sure that it arises in the pancreas, because there are other retro-peritoneal cysts, such as dermoids and hydatids. A cyst may still be of pancreatic origin, even if it appears above the stomach, or below the colon.

A positive diagnosis can only be made by means of an exploratory puncture, but this is as inadvisable here as in other abdominal cysts.

CHAPTER XLIV.

SURGERY OF THE SPLEEN.

THE spleen exemplifies especially well the present-day border line between medicine and surgery. The surgeon is left in undisputed possession of abscesses, genuine tumours and hydatids; but certain forms of splenic hypertrophy are still the subject of controversy.

(1) ABSCESS OF THE SPLEEN.

The previous remarks concerning abscess of the liver also apply to splenic abscess: its course may be quite free from symptoms, and remain unrecognized until it bursts into a neighbouring organ. If it is attended by symptoms, they consist of enlargement of the organ, pain on pressure, and also spontaneous pain, in the left hypochondrium. But another consideration is necessary before we can make a diagnosis, viz., the etiology, because splenic abscesses are apt to occur after typhoid fever, intermittent fever, or any pyæmic disease. But as the spleen so frequently enlarges in these conditions, we must not assume the presence of an abscess, unless the enlargement is greater than usual, and increases rather than diminishes after the subsidence of the original disease. Inflammatory symptoms in the vicinity, such as left-sided pleurisy and œdema of the anterior or lateral wall of the abdomen, are points in favour of the diagnosis. Puncture is as inadvisable here as in hepatic abscess, unless one is prepared for immediate operative treatment of the abscess.

(2) SPLENIC HYPERTROPHY.

The diagnosis of the various forms of diffuse enlargement of the spleen must be shared with the physician. He justly claims all enlargements due to *circulatory disturbance*, as congested spleen, the

splenic enlargement of hepatic cirrhosis and the various forms due to portal obstruction. There is no surgical treatment for these, unless an attempt is made by means of Talma's operation. The splenic hypertrophy in all these cases is secondary to some other condition. Surgery is equally ineffectual when the hypertrophy is associated with a blood or lymph disease, such as leukæmia, pseudoleukæmia, or polycythæmia. Enormous leukæmic spleens have been removed, but the results have invariably been fatal. *Banti's disease* forms an exception, but we do not know whether this is a disease *sui generis*, and how it should be classified. Extirpation of the spleen has benefited some cases, although the hepatic condition associated with it seems to play an important part. The diagnosis can be made, if the malady has started with splenic enlargement and has been followed by slight jaundice, bile in the urine and cirrhosis of the liver.

Infective and toxic enlargements of the spleen (*congenital syphilis* and *amyloid disease*) cannot be influenced by surgery. The *malarial spleen* forms an exception, for I have myself seen its removal followed by an unexpected recovery from a severe malarial cachexia. The diagnosis of a malarial spleen is not difficult, if we remember its tendency towards downward displacement. It can always be recognized by its sharp edge, even if it has sunk over to the right side. I have, however, seen a malarial spleen sent in for operation as an ovarian tumour, because its lower end was adherent in the true pelvis.

(3) TUMOURS OF THE SPLEEN.

If the splenic region is occupied by an irregular tumour which does not conform to the shape of the spleen at all, or only does so indefinitely, we are justified in thinking of a new growth, usually, as experience shows, a *sarcoma*. The confusion with a renal tumour may be avoided by remembering that the spleen can always be felt more definitely in front, while the kidneys are better felt from behind. This applies to the rare *serous cysts of the spleen* and to *hydatids*, which are also not very frequent.

A pronounced splenic tumour in a tubercular subject should suggest the possibility of a tubercular spleen, a condition in which surgery has effected some useful results.

CHAPTER XLV.

ACUTE APPENDICITIS.

We have already seen in Chapter XXXVI how to recognize appendicitis, and to avoid the numerous diagnostic errors which may attend it. It now remains to determine what physical examination can teach us about the *condition of the appendix and its surroundings*. We shall confine ourselves to those facts which are recognizable with ease, and which are important in treatment. As long as one is quite clear about these, no blame will attach to him if he is in doubt about details of pathological processes in the appendix.

These chief points range themselves around the following four questions :—

(1) *Is the inflammation limited to the appendix and its immediate neighbourhood, or has it already extended beyond ?*

We purposely say "and its immediate neighbourhood" because as long as the inflammation is exclusively confined to the appendix the clinical signs of an "attack" cannot have appeared. These only arise at the moment when the inflammation involves the neighbouring serous surface. This condition represents what is usually termed the early stage. The peritoneum is slightly reddened, and some fibrin is sometimes already found on the appendix. The abdominal cavity contains some early exudation in most cases.

In exceptional cases this early exudation is purely serous, but as a rule it contains a number of polynuclear leucocytes from the start. It differs from the infective exudate of appendicular peritonitis proper, by its homogeneous appearance and its freedom from smell. It is also usually free from bacteria, on the first day, but from the second day it is more or less crowded with micro-organisms. On the other hand, the exudate of a fully developed purulent peritonitis usually has an evil odour, contains a large number of micro-organisms, and —in the worst cases—only a few leucocytes. It is also distinguished from the harmless early exudate by its less homogeneous appearance to the naked eye.

One is tempted to diagnose this early stage from the circumstance that the attack has come on within the last twenty-four hours. This would no doubt be true in most cases, but not in all, for we sometimes find signs of severe infection at the end of the first day, and even pus about the appendix. On the other hand, the disease may remain in the first stage for a considerable time, so that an "early" operation can be done after several days without any danger. The decisive point does not lie with the element of time, but with the result of physical examination. We must consider that the patient

is still within the first stage of his attack *if the upper half of the abdomen and the left side are still soft and not tender, if there is no pain in the lumbar regions, at any rate the left, and if the pain on pressure and localized reflex contraction are limited to the suspected site of the appendix without any extensive dulness or definite resistance* (fig. 143, *a*). It is always wrong, and frequently dangerous to assume that the early stage lasts forty-eight hours.

If we see the patient in what is really the early stage, it is our duty to propose an immediate operation, which then has every prospect of being a radical procedure.

If in spite of this advice the patient decides to accept the risk of a fully-developed attack of appendicitis, we can at least say, "*Disci et salvavi animam meam.*" But we must be absolutely sure of our diagnosis in order to advise operation with a good conscience. The removal of an appendix in hysteria, muco-membranous colitis, typhoid fever, or even in pneumonia, does not redound to the credit of surgery.

(2) *Is an inflammation which has gone beyond the first stage localized or generalized?*

If the disease has extended beyond the first stage of strictly limited appendicular inflammation, and of early aseptic exudation, confined to the immediate vicinity, we have to decide how far the inflammatory process has travelled. *If the abdomen is everywhere sensitive to light percussion, if pressure on the lumbar regions elicits pain, and if palpation produces extensive reflex muscular contraction, it is quite certain that there is considerable involvement of the peritoneum, even if there is no dulness to be detected in the dependent parts. But if we can demonstrate an area of resistance which is sensitive to pressure, dull, or highly tympanitic on percussion, whereas the rest of the abdomen is comparatively soft, not at all or only slightly distended, and not sensitive to pressure, then the process before us is a localized one.* This localized process probably represents a fibrinous or fibrino-purulent inflammation of the neighbouring intestinal coils in those cases wherein the symptoms abate in a few days; and in those wherein the resistance persists for three or four days, or actually increases, it means a definite abscess.

(3) *Upon what does a general involvement of the peritoneum depend?*

In regard to this we must distinguish two conditions which are quite separable clinically, in typical cases. The case may be one of simple "early exudation," which will subside after the inflammatory area has become encapsuled.

This diagnosis should be made if *the attack is at its commencement, with pulse and temperature in correct relation to each other, if the patient does not look very septic, if the muscular rigidity is neither severe nor very extensive, and if the vomiting has ceased on the second day.*

The generalized inflammation may, on the other hand, depend upon an initial *severely septic infection* of the whole peritoneum. This is usually due to acute gangrene of the appendix, or to an extensive perforation which has flooded the peritoneal cavity with septic material. The exudation is very septic from the start, and, indeed, contains more bacteria than leucocytes. We base this diagnosis on the presence of *pallor, cyanosis, rapid thread-like pulse, normal or subnormal temperature in the extremities and in the axilla, but a high rectal temperature, dry tongue, and on semi-consciousness supervening on the second or third day* (fig. 143, *i.*). If these symptoms should appear during the later course of the disease, it means probably that an abscess which had been originally localized has burst into the abdominal cavity. In these cases it is still generally possible to discover the site of the original localized inflammation.

The cases of *sero-purulent peritonitis* are intermediate between those with mild, sterile, or slightly infective early exudation and those of severe septic peritonitis. Their diffuse symptoms of inflammation generally abate during the first week, but they leave infective germs in various portions of the abdominal wall, which are partially absorbed, but which also lead to the formation of localized abscesses—so-called *residual abscesses*—in the course of two or three weeks.

The differentiation of these various forms of general peritonitis is not merely of theoretical interest, but has important therapeutic bearings. If we or the patient have allowed the opportunity of an early operation to slip by, and the case is in the stage of early exudation of mild character, we need not be anxious, but may await its subsidence with a clear conscience, and anticipate the localization of the process. But if a diagnosis of diffuse septic peritonitis has been made, the abdomen must at once be opened in several places—it must be washed out and thoroughly drained as circumstances demand. The younger the patient, the more likely is the issue to be successful. It is more difficult to recognize the intermediate forms, which often enough develop into localized abscesses even without our intervention. But, nevertheless, it is better to open the abdomen in the middle line and in the loins, in order to wash it out and provide free drainage. This small procedure will often succeed in tiding the patient over a critical period—if combined with the application of warm compresses, subcutaneous and rectal infusions and the administration of stimulants.

Immediate operation must be undertaken if a fresh attack of acute general peritonitis starts from a localized area after the subsidence of the original diffuse symptoms.

(4) *What is the position of the localized abscess which we have decided to be present?*

The outlines of this position are at once determined by percussion and palpation. A glance at fig. 143 will show the chief positions which are involved. But there are other points to be elucidated in

the interests of correct treatment, and these demand a careful examination. In the first place, we must decide whether the pus is intraperitoneal, retroperitoneal or even sub-fascial, *i.e.*, beneath the fascia of the iliacus muscle. If the abscess definitely projects into the abdominal cavity, it is intraperitoneal. If it fills the pelvic fossa and its shape is flat, we conclude it is intraperitoneal; if there is pronounced reflex contraction of the anterior abdominal wall we conclude that it is retroperitoneal; if there is contraction of the flexors of the hip joint, and if this contraction is very pronounced, we conclude that the abscess is under the iliacus fascia. If the resistance is more in the lumbar region, we decide for an intraperitoneal position, if the illness started with definite signs of peritoneal irritation; but if not, we decide for retroperitoneal position, as also if a phlegmon appears in the lumbar region after a few days. Abscesses which track under Poupart's ligament are always sub-fascial. In doubtful cases, a temperature between 102° and 104° F., and rigors, point to an extraperitoneal position.

We must endeavour to determine the upper and lower limits of intraperitoneal abscesses, and also whether they are in contact with the anterior abdominal wall. If the lumbar region is painful on pressure, and is dull, and if the muscles are rigid, it signifies that the abscess reaches towards the kidneys, generally along the outer side of the ascending colon. If the patient complains of bladder trouble, the suppuration extends towards the true pelvis. If rectal symptoms are also present, and jelly-like mucus escapes from the rectum, the abscess is situated in Douglas's pouch. If the rigidity of the anterior abdominal wall is so great that the limits of the abscess cannot be clearly determined by palpation, we assume that it is directly in contact therewith. If, on the other hand, its limits are very easily defined, there is probably a free peritoneal space between the abscess and the anterior abdominal wall. If meteorism is present, an abscess deeply situated between the loops of the small intestine (meso-cœliac) may completely elude palpation. Unless we have watched such a case from the beginning, we are liable to diagnose either a generalized peritonitis or an ileus. The latter mistake is all the more pardonable, because such an abscess occasionally causes genuine obstruction by compressing or kinking the bowel.

The correct determination of the position of the abscess is important in order to decide *whether* and *how* to operate.

If we see a patient on the third or fourth day with the inflamed area in process of encapsulation and probably already subsiding, we should do nothing lest we disturb the natural defences of the body, or rather maintain an "armed peace," because the process may burst forth anew, and again become dangerous.

If the general and local symptoms show no sign of subsiding at the end of the first week, or if, indeed, they increase, an operation

must be performed without any further delay, not so much for the purpose of removing the appendix, but in order to evacuate the pus and thus avoid the immediate danger. We should act in the same way if a primary or secondary collection of pus forms anywhere during the second or even the third week. No special scheme of operation should be followed, nor should any particular incision, recommended by one surgeon or another, be adopted, but the abscess should be opened at its most superficial situation and with as little anatomical damage as possible, *i.e.*, in the ileo-cæcal region, lumbar region, linea alba, or finally in the vagina or rectum. Large incisions are not only unnecessary, but they are responsible for the subsequent development of hernia in the scars. It is therefore important to find, by means of a careful local diagnosis, the point where the smallest incision will suffice. If the pus is behind the peritoneum, we must approach it from the side. If it is deeply situated, in the meso-cœliac area, separated from the abdominal wall by the free peritoneal cavity, we should not hurry quite so much with its incision and, if necessary, must carefully protect the free abdominal cavity during the operation.

We have not yet said anything about *exploratory puncture* in the diagnosis of appendicitis. Careful observers, and those who have had opportunities of witnessing the topographical condition during operations for appendicitis, will not feel the want of this method. As Roux says, "It is not always free from risk, is often useless and is always unnecessary." It is only useful in subphrenic or pelvic abscesses which are more or less inaccessible to direct examination, and then it is indispensable.

We have hitherto had in view the pure, typical attack. But if, either through our own fault or that of the patient, he has arrived at a stage when we no longer have full control over the disease, we have to reckon with several complications which will make demands upon our diagnostic skill. We will assume that the initial peritonitis, as such, has been overcome, that the abdomen has become temporarily softer, the respiration quieter, and the temperature normal, or approximately so.

One group of complications is indicated by the fact that the improvement stops short at a certain point, and that the temperature rises again and takes the form of an abscess chart. In such a case it is very probable that germs diffused throughout the abdominal cavity are developing into *residual abscesses*, the favourite positions of which are indicated in fig. 143. Experience teaches us that we should look for them in *Douglas's pouch*, and in the *left flank* during the first and second week. An abscess in Douglas's pouch can at once be recognized by rectal examination. If we have neglected to search for it in time, our attention will be drawn to its presence by a discharge of mucus from the rectum, by tenesmus, and sometimes even by failure of the action of the bowels. Occasionally, we may be taken by surprise, by the spontaneous rupture of the abscess into the rectum or vagina.

An abscess in the *left flank* is easily recognized by local pain on pressure, by muscular rigidity and by dulness. We should also think of the *right flank* if the case has not been operated on, or if the drainage in the right lumbar region is inadequate.

After the third week a *subphrenic abscess* is the most likely complication. It rarely comes on earlier, and is usually situated on the right side. If nothing abnormal is found in any of these positions, and the abdomen still refuses to become soft, it is probable that small residual abscesses exist between the coils of the intestines. It is best, as a rule, to allow these abscesses to become spontaneously absorbed, because the search for them is liable to do more harm than good.

In other cases the complications are indicated by colic, followed by vomiting, either very rapidly, or within a few days. The temperature remains normal, or is only slightly raised, and the patients appear to be quite well between the attacks of colic. These cases certainly depend upon a partial or complete *intestinal obstruction*, due to adhesions and kinking of a coil of intestine. These complications usually occur in the fourth to the sixth week, and sometimes earlier. Experience shows that this obstruction has a greater tendency to disappear spontaneously, the earlier it sets in. This should be borne in mind as a therapeutic indication.

In contrast to this early obstruction, there is another form which may come on, after months or years, and which is due to narrow bands of connective tissue. Immediate operation is required in this variety.

If we unexpectedly find the patient very feverish, with flushed cheeks and rapid shallow breathing, and with a dicrotic pulse, we should at once suspect a respiratory complication, either a metastatic pneumonia or a pleurisy. In the latter case, we may be quite certain that it arises from a concealed focus of inflammation in the lung, or from an undetected subphrenic abscess—the latter especially if the pleurisy is on the right side.

Among other "unforeseen" complications which occasionally occur in appendicitis may be included, phlebitis, parotitis, and other inflammatory processes which can easily be localized.

Much anxiety is often caused, both to the medical attendant and the patient, by the long persistence of sinuses after the opening of abscesses. This is almost always due, either to the tubercular nature of the disease, or to a fæcal concretion which has escaped from the appendix into the abdominal cavity, but which has not yet been discharged in the pus.

The foregoing remarks apply to the cases wherein it is possible to diagnose the *onset of appendicitis* with certainty. In the *intermediate stage*, however, the diagnosis is much more difficult, often indeed

impossible. If a severe case of appendicitis happens in a family, the other members devote considerable attention to their own ileo-cæcal regions, and anxiously consult their medical adviser as to the propriety of removing the appendix; they complain of stabbing, burning or dragging pains in that vicinity, and feel that it is very sensitive to pressure. With the very best of intentions, the doctor can detect nothing; his diagnosis must be that of a hysterical or imaginary appendicitis, and he sends the patient home. He will generally be right, but not always, and therefore should not entirely lose sight of the patient.

I refused to operate, under these circumstances, on a young man upon whose sister I had just operated; but advised him to report himself if he really got a genuine attack of pain. He did so a few weeks later on. I operated at once, and found a highly inflamed appendix, with a commencing fibrinous peri-appendicitis.

What criteria can guide us in these circumstances? *History* is of the first importance. If the patient has previously had an "inflammation of the bowels," which can be designated as an attack, or better still, if a definite antecedent attack has been reliably observed by a doctor—not a mere abdominal pain lasting a few hours—the patient is correct, and we must accede to his wish.

But if the ileo-cæcal, gastric or more diffuse pains are indefinite and do not keep the patient in bed, we must reserve our verdict. It may be a form of appendicitis which has not yet developed a "first attack," called by Ewald "larval appendicitis." But as Gussenhauer has remarked, it is only larval in the sense that the doctor has not been able to diagnose it. But in this connection, the remarks made in Chapter XXXVI should be recalled.

The *physical condition* will often fill in the gap. In the first place we must endeavour to exclude any other abdominal disease, especially in women. Then we should palpate the normal situation of the appendix. Daily experience of operations during the free interval teaches us that this is not at the point where the outer border of the rectus meets the line joining the anterior superior spine with the umbilicus, which, according to McBurney, marks the orifice of the appendix. It is the ileo-cæcal valve, which is usually situated at this spot. The position of the appendix is more simply and more certainly ascertained by marking the spot where the line joining the two spines cuts the outer border of the right rectus (Sonnenburg). If nothing abnormal is found here, or in any of the other situations usually accredited to the appendix, we still remain in doubt; and if the history is indecisive, we must await events. If the history is definite, however, the negative result of our physical examination is of no significance. If there is a complaint of moderate pain upon pressure, but no change can be detected by palpation, we must rely

upon the history, because a certain degree of sensitiveness to pressure may exist in normal circumstances. But if this pain on pressure is very pronounced, and much greater than the pain caused by pressure on the left side, we may assume that some chronic inflammation is probable, bearing in mind the possibility of chronic colitis (see next chapter). If, finally, we discover in a patient with a slightly flexed hip a sensitive structure, which can be distinctly rolled under the fingers, we must regard it either as an appendix or an adherent mass of omentum, bowel, and appendix, and should recommend operation to the patient.

We have already seen that it is quite exceptional to be able to palpate the normal appendix, and even if it has once been inflamed it can only rarely be felt during the free interval.

CHAPTER XLVI.

COLITIS, SO-CALLED CHRONIC APPENDICITIS AND FUNCTIONAL DISTURBANCES OF THE LARGE INTESTINE.

SEVERAL different conditions are grouped together under the terms colitis, chronic appendicitis, pseudo-appendicitis, &c. They are not all really examples of inflammatory processes, but they are classified together because they apparently merge into one another by means of borderland and transitional forms. The study of these cases convinces us that a true appreciation of them can only be obtained by differentiating those due to organic causes from those originating in functional disturbance. We therefore distinguish :—

A.—COLITIS WITH DEFINITE ANATOMICAL CHANGES.

This includes all the cases of inflammation which are recognizable by definite histological changes, and which usually terminate in ulceration of the mucous membrane. As these cases generally come to the surgeon in the stage of ulceration, they may be grouped together under the term of colitis ulcerosa.

How are these to be recognized ? Mainly by the great frequency of the diarrhœa, by the admixture with mucus and occasionally with blood, or at least with traces thereof, and also by tenesmus, if the

disease affects the lower section of the large intestine. The physical signs consist of the rigid contraction of some intestinal segments, or their inflammatory infiltration. The symptoms are much less definite if the first part of the large intestine is alone involved, because the longer course of the intestinal contents may enable them to regain their normal state. There is not always diarrhœa in these cases, and the symptoms are usually limited to vague pains, or to definite attacks in the ileo-cæcal region, which are usually diagnosed as appendicitis.

We must first satisfy ourselves that this colitis is not a manifestation of a more grave disease, such as intestinal cancer, or of polypus of the large intestine, which latter is very rare. It is a serious matter for the patient if he is treated for weeks and months without examination of the large intestine, merely for mucous and bloody evacuations, while he is suffering all the time from a rectal cancer, which could easily be felt. It must also be very annoying to all taking part in the case if it is allowed to go on until the surgeon finds the growth firmly fixed in the true pelvis. Every diagnosis of colitis invariably demands a rectal examination. If nothing abnormal is found, the sigmoidoscope must be used, and the whole of the large bowel must be palpated for a tumour, unless it is quite clear from the history and the onset of the disease that it has some other origin.

Having excluded, as far as possible, a new growth, and naturally also a pelvic abscess irritating the bowel, we must next determine the variety of *the colitis*. We can only tell for certain by means of the sigmoidoscope whether the case is chiefly of an ulcerative character. A skiagram may very probably give some information on this point, and it will also show the position and extent of the disease. As already indicated by the diarrhœa, an ulcerated intestine endeavours to evacuate its contents as quickly as possible, or, to put it scientifically, exhibits increased motility. Stierlin has demonstrated in our clinic that this peculiarity is shown in the skiagrams by the rapidity with which the bismuth meal is hurried along the affected portions of the bowel. Indeed, they are always found empty when a series of impressions is taken. The border line between the bowel which is pathologically empty and that which is normally filled, is so sharply defined that the comparative examination of several impressions usually gives an accurate idea of the extent of the disease.

We must, however, make one reservation. Portions of the bowel, which are rigidly infiltrated by tubercle or cancer, show the same rapid onward movement of their contents, of a passive character. We can tell, by means of a bismuth injection, whether the condition is one of excessive motility, or one of conversion of the bowel into a rigid tube. In the former case the bowel is dilated by the injection, but not in the latter case.

Having recognized the ulcerative character and the extent of the

disease, we have now to determine its nature. Is it due to *syphilis* or *tubercle?* Is it the late stage of an *amœbic enteritis*, a *dysentery caused by the Shiga-Kruse-Flexner-bacillus?* Is it a case of *chronic ulcerative colitis of unknown origin*, affecting a localized portion of the large intestine or its whole extent, of a type to which attention has recently been drawn?

Let us take **syphilis** first. This is usually limited to the lowest portion of the large intestine, and produces the well-known clinical picture of rectal syphilis, which we shall refer to later on. It rarely extends higher up into the bowel. Our diagnosis will be supported by the history, Wassermann's test and by the presence of other signs of old syphilis.

Tubercle is much more important. The diagnosis will be suggested by a tubercular heredity and previous history, the chronic start of the malady, and by other existing foci of tubercle. A positive diagnosis can only be made by a histological, or, if necessary, a bacteriological examination of a piece of the tissue taken from an ulcer with the aid of the rectoscope. The discovery of tubercle bacilli in the stools is of value, but it does not decide the diagnosis, because the patient may be suffering at the same time from pulmonary tuberculosis.

An **amœbic** or **bacillary dysentery**, in their late stages, will be suggested if the patient comes from a district in which these diseases are endemic, chiefly from the Tropics. Physical examination does not elucidate matters in these late stages, as long as we do not possess an effective serum test.

If there is nothing pointing to any of the above-mentioned forms, we may assume that the case is one of **chronic ulcerative colitis**, of unknown origin.

But it may be asked, what has all this to do with surgery?

As far as diagnosis, and especially differential diagnosis, is concerned, the position is clear. But experience has, however, shown that the most reliable, and often the only, remedy for ulcerative colitis is to divert, by means of operation, the intestinal contents into a cæcal opening, in order to put the large intestine at rest. Benefit sometimes follows the partial rest given by a simple appendicostomy or by a narrow cæcal fistula. In tuberculosis we often go beyond this and completely remove the whole of the diseased segment of the large intestine if the other abdominal organs are healthy.

Whereas amœbic or bacillary colitis is extensive in its area, tubercular ulcers usually are more limited in their distribution, the favourite sites being the cæcum, ascending colon and sometimes also the beginning of the transverse colon. The ulcers, associated with ulcerative colitis of unknown origin, are also frequently limited to

definite segments of the large intestine, to the cæcum on the one hand and the sigmoid on the other—sometimes referred to as **ulcerative typhlitis** and **sigmoiditis.** This localization is explained by the fact that the fæces are retained longest in these positions and therefore they become *loci minoris resistentiæ.* The sigmoid is also particularly liable to localized disease in women, owing to its unfortunate proximity to the internal genital organs with their infirmities.

As the disease of the intestinal mucous membrane penetrates into the deeper layers, reaction appears in the serous membrane in the form of fibrin deposit or as a localized hyperæmia—according to the severity of the inflammation. If the disease of the mucous membrane persists for a long time, fibrous deposits eventually occur, and an extensive *peri-colitis* develops, which is also called *peri-typhlitis* (independent of the appendix) or *peri-sigmoiditis*—according to its position. The peri-colitis rarely proceeds to suppuration. It is, however, both superfluous and inappropriate, to invest peri-colitis, which is always secondary, with the dignity of separate disease.

B.—FUNCTIONAL DERANGEMENTS OF THE LARGE INTESTINE, WITHOUT TYPICAL ANATOMICAL CHANGES.

The more names a disease possesses, the less definite is our knowledge of it. **Muco-membranous colitis**, with which we shall mainly deal in this section, has received at least a dozen different names during the last thirty years. This disease embraces all the functional derangements which may affect the large intestine: *motor derangements,* in the form of *constipation* alternating with *diarrhœa; sensory derangements,* in the form of regularly recurring *colic* or severe seizures thereof; *secretory derangements* in the form of persistent or occasional copious *discharge of mucus,* either in a glairy condition, or as coagulated masses of a tape-like or tubular shape. Clinical experience shows that this symptom-complex may come on after some psychical disturbance, may last for months or even for years, and then disappear as a result of mental excitement—without any typical anatomical change. But this symptom-complex may also represent the reaction of the large intestine to various pathological conditions, both within and without itself, ranging from cancerous, tubercular or other ulceration to displacements of the large intestine and inflammatory processes in its vicinity. It may also be due to toxic causes, such as alcohol, tobacco and mercury, and also to bacterial poisons.

The latter circumstance explains the erroneous conception of muco-membranous colitis, as the result of an intestinal infection.

The main surgical interest of this disease concerns its diagnosis. The practitioner must recognize it as a disease in itself, which,

especially in women, is capable of mimicking all possible painful affections of the abdominal cavity, and which makes neurasthenics fearfully apprehensive of cancer, but he must also appreciate the important fact that this disease may be a concomitant manifestation of genuine cancer. It also has surgical interest from the point of view of treatment, because attempts have been, and are still being, made to cure the very severe forms of the disease by procedures, varying from a simple cæcostomy to extensive resections of the bowel, as no prospect of recovery is offered by medical treatment, including baths, diet, electricity or psycho-therapy. It is sometimes quite impossible to restore the intestinal reflex actions to a normal condition, in a neuropathic individual, in whom all reflexes are out of gear.

The prognosis is most favourable in those cases wherein we have been able to cure some causative disease, such as cholelithiasis, a malady of the female genitalia, or appendicitis. In regard to this last, however, our prognosis must be guarded, as we shall see later on. The connection between appendicitis and muco-membranous colitis does not always turn out as we expect, and the colitis may continue despite the removal of a diseased appendix.

The entire large intestine does not invariably exhibit this abnormal reaction, nor are all the three previously mentioned forms of functional disturbance fully pronounced. As a rule, only the motor, and, to some extent, the sensory disturbances are in evidence, while the secretory derangements are either absent or not striking. The condition is then essentially one of **painful constipation**. This leads to the question of the *localization of the functional derangement*, which may be solved by X-ray examination.

If a meal, consisting of 200 grm. of carbohydrate porridge and 80 grm. of barium sulphate, is given to a normal individual, the whole of it will be found in the cæcum, ascending colon and to some extent in the beginning of the transverse colon, after six to eight hours. The ascending colon is empty, or nearly so, after twelve to eighteen hours, and the contents are seen or are visible in the lower section of the large intestine. The whole intestinal canal is empty after twenty-four to thirty hours. If digestion in the large intestine is slow, the delay may be distributed over the whole of the large intestine, or it may occur exclusively in that section wherein the fæces remain longest in order to become inspissated, namely in the first portion as far as the level of the gall-bladder (Stierlin's ascending type of constipation). The delay may also occur in the last section of the large intestine (sigmoido and proctogenic constipation).

In our experience the *ascending type* of constipation gives rise to most subjective symptoms. This is due to the fact that the intestinal contents in this position are still semi-liquid and are more prone to cause fermentation with the development of gases than the more or less dry fæces retained in the sigmoid, or lower down.

All this prepares us for the conception of a clinical picture, which has been described in France for the last fifteen years under the terms of *typhlocolite* or *typhlite ptosique*. It has only generally been recognized in Germany quite recently as *cæcum mobile* (Wilms), *typhliklasie*, *typhlatonie*, &c.

In the year 1897, shortly after the appendicitis rage set in, there was a great tendency to ascribe all ills in the ileo-cæcal region to the appendix, and the old idea of stercoral typhlitis was entirely discarded. At this time, however, Dieulafoy, who was himself an advocate for early operation in real appendicitis, pointed out that there were attacks of pain in the ileo-cæcal region which had nothing to do with the appendix, but which signified the localization of the muco-membranous colitis in the cæcum. Although names and theories have undergone much change since then, or rather have been considerably multiplied, no real advance has been made upon the position defined by Dieulafoy.

The established facts, as far as they possess diagnostic importance, may be summarized as follows :—

There are many persons, mainly females, who complain of their cæcal region, but who never get real attacks of appendicitis, lasting days or weeks, with the development of resistance or peritoneal exudation. The so-called "attack" usually resolves itself into a severe seizure of pain about the cæcum, which only lasts a very few hours and has generally disappeared by the time the doctor arrives. But if the patient can be examined during the attack, it will be found that tenderness exists in the ileo-cæcal region on pressure, but that there is no muscular rigidity. Indeed, a structure like an elastic cushion may be felt, and sometimes this vanishes under the hands of the examiner ; but if it can be carefully palpated it will be recognized as the distended cæcum. Exceptionally, the temperature may be somewhat raised, and patients with active reflexes are liable to vomit. Sometimes the attack terminates in looseness of the bowels, at other times in diarrhœa. Then the tenderness on pressure also disappears ; no localized pain remains over the appendix for a few days, as is the case even after a mild appendicitis. On the other hand, we do find, as Dieulafoy has pointed out, painful, contracted portions of the large intestine, indicating a state of abnormal irritability or chronic colitis, and, occasionally, the onset of mucous discharge confirms the diagnosis.

The cæcum can often be felt to be movable and capable of being displaced hither and thither. A skiagraphic examination of intestinal function will show that the contents are unduly delayed in the cæcum —*i.e.*, constipation of the ascending type.

Many of these cases have been submitted to operation, some

under the mistaken diagnosis of appendicitis; others were diagnosed correctly and were operated on, because the disease was interfering with the nutrition of the patients and their ability to do their work. The anatomical conditions found consist of a large cæcum extending low down, a normal appendix, remains of inflammatory adhesions on the cæcum itself, and the so-called peri-colonic veil (which is merely the stretched mesenteric attachment caused by the tilting of the cæcum) on the ascending colon, reaching as far as the hepatic flexure. These changes do not, however, explain all the symptoms, even if we include the kinking of the small intestine in front of Bauhin's valve, as recently described by Lane. At least every tenth person has an abnormally movable cæcum, and very frequently adhesions and kinks produce no symptoms at all. Delay of the fæces in the cæcum also occurs without symptoms. We must, therefore, revert to our original view that functional causes play the chief *rôle* in all these troubles of the large intestine. A normally innervated large intestine overcomes all possible difficulties, and even resists the effects of abnormal conditions of nutrition and life generally. But if the innervation of the bowel departs from the physiological standard, it reacts towards abnormalities in the mode of life and slight mechanical difficulties, by simple constipation or by more or less definite symptoms of muco-membranous colitis.

We are now in a position to state what we mean by the rather inappropriate expression, **chronic appendicitis.** Logically, the term should only be applied to that form of appendicitis in which the appendix does not recover from its inflamed condition. This is especially the case with tubercular *appendicitis*, but this condition requires no new name. It also occurs in very many ordinary attacks of appendicitis, wherein the complete subsidence of the inflammatory symptoms is prevented by fæcal concretions, stenoses, adhesions, and kinks. In some cases the owner of the appendix is unconscious of this chronic irritation; in other cases he suffers frequent but slight pains, reflex disturbances of the intestinal function, and even from muco-membranous colitis. Other patients only experience an indefinite discomfort in the right side of the abdomen. As most appendices which have suffered from several attacks remain in a state of chronic irritability, there is no object in separating them clinically from those cases in which this irritation becomes more pronounced than usual. This constitutes one class.

The other class has nothing at all to do with the appendix. It embraces those cases which were formerly justifiably termed stercoral typhlitis, and consists of localized ulcerative colitis, localized functional disturbances of the large intestine in their various forms, such as "typhlo-colite," cæcal distension, &c., either of mechanical

or functional origin. It is obvious that these cases ought not to be called chronic appendicitis.

We would not have gone into this matter so much in detail were it not that it possesses great practical importance.

When may the practitioner be satisfied with the assumption that the case is one of mere functional disturbance of the cæcum, and therefore abstain from operation during the first twenty hours? He is justified in this course if the attacks are frequent and of short duration (only a few hours), if there is mucous discharge and a pronounced neuropathic history, and if the actual attack subsides within a few hours. This affords adequate time for observation, so as not to miss the opportunity of early operation if the case is one of genuine appendicitis. In this connection it must be emphasized that pulse and temperature are in no way decisive, because we have seen cases of appendicitis with pus formation wherein the pulse has not exceeded 100 per minute and the temperature has not been above 99·5. A leucocyte count is of some value, because a definite leucocytosis indicates appendicitis, but if the leucocytes are normal in amount it cannot be regarded as an argument against the disease. If the patient has not recovered at the end of the first twenty-four hours it is our duty to propose operation. It is to be hoped that the recently acquired knowledge regarding the cæcum and the ascending colon will not increase the mortality from appendicitis through neglect of operation.

CHAPTER XLVII.

INTESTINAL OBSTRUCTION.

One of the most grateful tasks which can fall to the lot of the surgeon is to relieve a malady which is popularly recognized to be attended with great suffering. Early diagnosis and an accurate appreciation of the moment to interfere, are, however, essential for this purpose. Cases of intestinal obstruction exemplify better than any other condition how dangerous it is to wait for the fully developed clinical picture before arriving at a decision. To pursue this course is to sacrifice the life of the patient to refinement in diagnosis, excellent though the motive be. There is no object in being able to proclaim at the autopsy that we had correctly diagnosed

the situation and nature of the obstruction. Our main object must be to recognize when surgical relief should be afforded, although we may not always know the precise position and character of the obstruction. This is no encouragement, however, to laxity in diagnosis. On the contrary, *careful observation, thorough examination*, and a *consideration of all signs* are indispensable, but this must be done *rapidly*, and we must *decide rapidly*, if our reflections are to be of any use to the patient.

In practice it is necessary to distinguish two great groups of intestinal obstructions: (1) A *complete* form which comes on *suddenly*; and (2) a form which comes on *gradually* and which is *incomplete* while it is developing into *chronic obstruction*. We will deal first with the latter, in which the process can be followed more leisurely in all its details.

I.—STENOSIS OF GRADUAL DEVELOPMENT.

(Chronic Intestinal Obstruction.)

A.—SYMPTOMS.

Colic, *i.e.*, the painful contraction of a portion of the intestine, is the first symptom of narrowing in its lumen. But colic is of such frequent occurrence that it does not signify very much by itself. But if pains of the same type regularly recur in the same area of the intestine they definitely point to a local trouble in the shape of a local obstruction of the intestine. This, however, is not sufficient for a diagnosis. Such pains may be present in **colitis** of any origin.

In order to confirm such a condition it is necessary that there should be abnormal **dilatation** and visible or palpable **contractions** of the bowel above the site of obstruction. The dilatation is recognized by the repeated occurrence of a highly tympanitic or metallic note, occasionally by the metallic sound of the peristalsis at the same site, and by spontaneous crepitant noises. Abnormal contraction is recognized by the periodical *hardening of the bowel*, which is very different to the contraction of the intestine in colitis. In the latter case, the bowel, which contracts when it is empty or contains a little fæces, feels like a firm band ("corde colique" of the French), whereas the hardened intestine—either the large or small—above an obstruction gives one the impression of an elastic tumour. That we are dealing with rigid intestine is quite clear from the tympanitic note on percussion, and from the periodical onset and disappearance of resistance. If we are fortunate enough to detect a **buzzing sound** at this spot as the resistance disappears, there can be no further doubt about the existence of a constriction. This applies not only when

one coil of intestine hardens and relaxes with a heaving movement, but even when a whole segment of bowel shares in this process—when, as sometimes happens, as many as four parallel tumid coils are present (fig. 152). It is often necessary to wait and watch for some considerable time at the patient's bedside in order to witness these phenomena, if they cannot be elicited by palpation of the bowel. As the illness progresses and the compensatory hypertrophy of the intestinal muscle is no longer able to overcome the obstruction, compensatory disturbance occurs, which declares itself by persistent abdominal distension, leading to complete intestinal paralysis. But this distension is by no means a *sine qua non* for the diagnosis of stenosis of the bowel, as beginners often imagine. We have, for instance, seen a case of ileo-cæcal stenosis which was too narrow to admit a cherry-stone, and, nevertheless, the abdomen was quite flat, or even depressed.



FIG. 152.—Rigid contraction of bowel, through obstruction of small intestine by a fibro-sarcoma.

The above-described symptoms are most pronounced in *stenosis of the small intestine.* The hardening in the *large intestine* is often very indefinite, which accounts for so many late diagnoses. This hardening can very frequently still be detected in stenosis of the ascending colon or hepatic flexure, but then it also involves the lowest coils of the small intestine after Bauhin's valve has been thrown out of action.

One sign, which we meet with in acute complete obstruction, is almost completely absent in incomplete cases, *i.e.*, **vomiting.** It occurs first when the obstruction becomes temporarily or persistently complete, and the higher up the obstruction is, the earlier it takes place.

The condition of the **stools** affords important information, but not quite so much as is generally supposed. One often hears the verdict—there is no obstruction because the patient has normal stools; or, on the other hand, that there is obstruction because the fæces are in little masses, looking like sheep's fæces. The one

conclusion is as erroneous as the other. The stools form themselves slowly in the large intestine from the transverse colon onwards. If the obstruction is in its upper part, where the fæcal contents are normally liquid, there is nothing to prevent the normal formation of fæces below the obstruction. The patient, therefore, continues to have regular well-formed stools—often up to the moment when complete obstruction comes on. Even if the stenosis is in the neighbourhood of the splenic flexure the fæces may still be formed normally. But when changes in the stools ensue as a result of more deeply situated stenoses of the large intestine they take the form neither of sheep's fæces nor of, "tape," but of alternate complete retention —still euphemistically called constipation—and the evacuation of pulpy, soft fæces. This means that the intestinal contents above the stricture are not solid, "inspissated," but are pulpy or putty-like ; the narrower the stricture the more liquid they are. If in a case of obstinate constipation we meet with fæces of the shape of balls, even very small balls, there is no occasion for anxiety, for we may safely assume that this is due to mere sluggishness of the bowel, which leads to abnormal inspissation of the intestinal contents, in contrast to what occurs in stenosis.

In a case of mine, the medical attendant justly suspected cancer, on account of persistent diarrhœa, the patient being an old man. The tumour was not palpable from the abdomen, but I discovered it at once on bi-manual recto-abdominal examination. It was situated below the sigmoid.

The so-called "tape-like" fæces occur when they are of clayey consistence, and have squeezed themselves through a constriction near the anus, within reach of the finger—but never higher up. Tenesmus is always present in these cases (see "Difficulties in Defæcation"). In every case of "*constipation*" we must ascertain its duration. If it has existed for years there can be nothing seriously wrong ; but if it has only been present for a few months in a person who had not been constipated previously, it is a serious symptom and requires careful examination.

A man, aged 50, consulted his medical attendant because of recent constipation. He found nothing in the abdomen and prescribed fruit. The patient continued to eat fruit with the greatest diligence for four months, and, eventually, came with cancer of the rectum, situated so high up that it was hardly operable.

The conclusions to be derived from stools *mixed with blood* are only relative. If blood is present in a case already suspected of cancer, the suspicion is thereby strengthened. But we must not forget, that any ulcerative colitis may be accompanied by the passage of blood. Blood may also be present in muco-membranous colitis. In these cases the hæmorrhage is seldom profuse, but the masses of

mucus contain within them specks of blood which lead to a correct diagnosis. The rectal mucous membrane sometimes bleeds when there are neither ulcers nor internal piles, the only change being one of hyperæmia.

An *intermixture with pus* indicates a deep ulcerative process in the lower part of the large intestine, such as may occur with a large excavating cancer or dysenteric ulcers. If the cancer is situated higher up, the pus is so intimately mixed with the stools that it is no longer separately recognizable. Any considerable evacuation of pus per rectum signifies that an abscess has broken into the bowel.

The significance of *intermixture with mucus* is not very great, because this occurs whenever the large intestine is irritated, in idiopathic colitis, as well as in colitis which follows tubercle or cancer.

We must be very careful in drawing any diagnostic conclusions from the **effect on the general condition**, because if the compensation is satisfactory, nutrition does not at first suffer. If the attacks of colic are frequent, the patient instinctively diminishes the amount of his food, and therefore emaciates, even if there is no persistent constipation. The question of emaciation is not decided by the amount of fat which the patient retains, but by the amount which *he has lost*. It is enough to pinch up a fold of skin, especially over the abdomen or thigh, to show us what was there before. If the relative obstruction has persisted for some time, there will always be a certain amount of cachexia.

B.—THE POSITION OF THE STENOSIS.

Palpation very often settles the question of position. We may be quite clear about the site of the stenosis if we feel a tumour in the region of the large intestine, or if we observe above it the previously described symptoms of hardening of the bowel, metallic note, &c. But it is quite another matter if we can feel nothing in the quiet stage, and if the hardening of the bowel and the colicky pains do not enable us to localize the trouble. In such circumstances we must endeavour to decide by means of systematic examination and logical deduction. But we must first realize what will be stated later on when discussing the localization in acute cases, that the symptoms in chronic obstruction are not pronounced from the start, because the obstruction is only incomplete. We shall subsequently refer to the importance of the skiagram in diagnosing the locality of the obstruction.

One important peculiarity, which may give rise to error, should also be mentioned. Wherever the obstruction may be in the large intestine, *e.g.*, in the sigmoid, the maximum dilatation of the bowel

will not be immediately above it, but will always be in the cæcum, as long as Bauhin's valve is in working order. The explanation, which can be inferred both experimentally and mathematically, is due to the double factor that in the ascending colon and cæcum the diameter of the bowel is greater, but the thickness of its wall is less than in the lower parts of the large intestine. This also explains why the most numerous and the deepest ulcers, which follow the dilatation, are to be found in the cæcum and ascending colon, even if the obstruction is at the lower part of the sigmoid.

A veritable ulcerative typhlitis or peri-typhlitis may arise in this way, and lead the practitioner to look for the obstruction at the valve, where it is not situated. But the onset of peri-cæcal inflammation in the course of the illness will actually make the expert think of the possibility of a deeper origin. If acute perforation occurs in a case of intestinal cancer, we must accordingly not look for it just above the obstruction, but in the beginning of the large intestine. I have seen a dilatation ulcer burst in this position in an old woman, in whom a peri-metritis had constricted the rectum.

C.—FORM AND CAUSE OF THE STENOSIS.

Gradual obstruction of the lumen of the bowel is the result of concentric narrowing, through disease of the intestinal wall, or of external pressure.

(1) *Concentric narrowing* occurs especially in cancer, tubercle, syphilis of the bowel, which is much rarer, and finally in non-specific cicatricial stenosis.

The differential diagnosis between **cancer** and **tubercle** is determined by the *age* of the patient and by the *localization* of the stenosis. Tubercle may occur at any age, but the multiple form of intestinal tubercle which so often causes constriction has been especially observed in young people, whereas ileo-cæcal tuberculosis occurs both in the young and old. Tubercular stenosis may also occur in the further course of the large intestine, but not often. The behaviour of carcinoma is different. Cancer of the small intestine certainly occurs among young people, but it is a rare condition. Most intestinal cancers are to be found in the large intestine after the age of 30, the upper portion being affected at the earlier age-period, and the sigmoid usually after 50.

The *condition found on palpation* also has its significance. If a chronic obstruction in the small intestine is distinctly palpable, it is most likely to be carcinoma, because a tubercular stricture very easily escapes the palpating finger. But both carcinoma and tubercle are equally easily palpable over the ileo-cæcal valve. The latter is less sharply circumscribed than the former.

In cases of tubercle, intestinal symptoms will already have been

present for two or more years, periods of aggravation alternating with occasional longer periods of improvement. In cases of cancer, the patient will previously have enjoyed good health, but from the moment symptoms appear they continue to become progressively worse. There may be remissions, and occasional improvement in the general condition, but of very short duration, and despite the brief time during which the malady has existed, the emaciation is very striking. Exceptionally, cancerous stenosis may drag on for years before a definite clinical diagnosis can be made. If X-rays are not decisive, an exploratory laparotomy is preferable to indefinite waiting. It should also be mentioned that in cases of ileo-cæcal tuberculosis, a mixed infection often causes acute attacks of peri-typhlitis, which are at first mistaken for ordinary appendicitis. I have encountered large abscesses with stinking pus in such cases. The same may happen in cancer, but much more rarely than in tubercle.



FIG. 153.—Cancer of the sigmoid in the shape of a constricting ring.

Carcinomata in the rest of the large intestine as far as the splenic flexure, are easily felt, especially as they usually give rise to definite tumours, early in their course. The splenic flexure itself is not easily accessible to palpation, and it is necessary to get the patient gradually accustomed to the deep palpation which is required. The same applies to the hepatic flexure, especially in men. Cancer of the sigmoid cannot often be felt, because this part of the bowel so frequently lies in the true pelvis, and because the growth is usually very small. The bowel looks as if it has been tied round with a piece of string (fig. 153), and not as if it is affected by a growth. Bi-manual examination, under an anæsthetic, per rectum and abdominally, is often indispensable. If the obstruction is not found higher up, recto-sigmoidoscopy must not be neglected, because this is the only method which reveals the condition of the lowest 10 to 12 inches of the large intestine.

Cancer of the rectum, even if situated low down, may cause extreme narrowing of its lumen and produce symptoms resembling ileus. But the history of these cases shows that the chief complaint refers to tenesmus, so that to mistake a rectal cancer for one higher up is hardly conceivable, if a history is at all obtainable, and if a rectal examination has been performed, which ought never to be omitted in any case of obstruction.

Pure cicatricial constrictions are much rarer than the cancerous or tubercular variety. They should only be thought of when the

history definitely suggests the possibility. Although strictures produced by typhoid and dysenteric ulcers do not possess the importance previously ascribed to them, we do know now that *injuries* of various kinds may lead to stenosis. For instance, *contusion of the bowel* may cause an infiltration in its wall, and this may lead to a temporary disturbance in its lumen, but it very rarely results in a permanent or in an increasing stenosis. The *tearing off of a piece of mesentery*, or what amounts to the same thing, *thrombosis of the mesenteric vessels*, is a much more serious matter. The interference with the circulation injures the mucous membrane, and by its destruction, leads to a cicatricial stricture, even if the nutritive conditions are adequate for the other layers of the intestine.

A circular stenosis more often follows the *replacement of a strangulated hernia*, whether performed by the bloodless or open method. We will discuss this incident in connection with strangulated hernia.

For the sake of completeness we must mention *syphilitic* strictures, which, however, are always situated in the rectum and therefore cannot be confused with strictures higher up.

Sarcomata and innocent tumours rarely cause obstruction of gradual onset, but they may cause more or less complete obstruction through volvulus or intussusception.

(2) We now turn to chronic ileus caused by *tumours pressing on the bowel from the outside*. The actual obstruction may depend upon one of three conditions—(1) on direct compression, (2) fixation of the bowel by adhesions, (3) infiltration into the wall of the bowel. The first condition is the rarest. As long as the bowel remains movable it can usually find some position in which its function can be maintained. Therefore it is that chronic ileus so rarely occurs in the most extensive innocent tumours as long as they are not affected by inflammatory irritation. Even in cases where there is not much room for dilatation of the bowel away from the tumour—as in a fibro-myoma fixed in the true pelvis—the tumour and intestine do not usually interfere with one another. A **retroflexed pregnant uterus** is an exception to this rule, because of its unrestrained growth. But in the case of a malignant tumour which fixes itself to the adjacent bowel and prevents its dilatation, chronic obstruction from the pressure is very likely to occur, even if the growth has a comparatively small circumference. This occurs in **carcinoma** of the *kidney* and ovary, in large *cancers of the uterus*, and in sarcomata in various positions of the abdomen.

The symptoms of chronic obstruction in **inflammatory processes** are milder and always more transitory. In these cases the bowel is simultaneously compressed, fixed and infiltrated, the latter con-

dition interfering to some extent with its normal peristalsis. This variety of obstruction is most prevalent in connection with abscesses and band formation after *peri-metritis, appendicitis, peri-nephritis* and *tubercular peritonitis.*

Hitherto we have been assuming that chronic obstruction is, despite brief interruptions, a slowly progressive malady, wherein the leisurely development of symptoms leaves adequate time for examination and reflection, but wherein the symptoms never cease completely. This is true for most cases, at least in a certain stage, but not for all cases, and especially not for the *beginning* of the disease. Chronic ileus may be **intermittent**, although the cause of the disease continues unchanged. Periods of colicky pain and bowel hardening may alternate with times when the patient feels nothing abnormal. This depends upon the compensatory state of the intestinal musculature and possibly upon destructive changes within the stricture.

In such cases, the medical attendant, who is called when the patient feels ill, makes a correct diagnosis and advises operation. But as he improves the patient declines to entertain the idea of operation, and he consults, for the persisting "dyspepsia," a more cheerful physician, who treats the case in the intermediate stage and perceives nothing seriously wrong, and reassures the patient in good faith. But the catastrophe is not long delayed; the patient is brought on to the operating table *in extremis*, too late for him and for the reputation of surgery.

The less significant the symptoms are during a quiet interval, the more weight must be attached to the history. If the unequivocal signs of a stenosis have only once been reliably observed, *i.e.*, localized colic, probably vomiting, circumscribed hardening of the bowel and the characteristic auscultation sounds, the case must be considered serious, even if all symptoms have temporarily disappeared.

Chronic obstruction is not always progressive. If it is caused by a moderate amount of scar tissue, *e.g.*, after a strangulated hernia or an injury, it is quite possible that the symptoms may gradually abate and finally disappear completely. This is even more likely to occur in cases wherein the lumen of the bowel is interfered with by inflammatory processes. These cases constitute a fair proportion of instances of intestinal obstruction which recover without operation, in addition to cases of volvulus and intussusception to be discussed later on.

Much has been expected from *X-ray examination* in the diagnosis of intestinal obstruction, but not all the anticipations have been realized hitherto. The basis of the examination is a bismuth meal, just as in the case of the functional derangements of the large intestine, discussed in the previous chapter.

Narrowing of the *small intestine* is usually the result of tubercular

stenosis. The narrowing is recognized by the stagnation of the bismuth meal in front of the stenosis. The small intestine should normally be quite empty four to six hours after a bismuth meal of

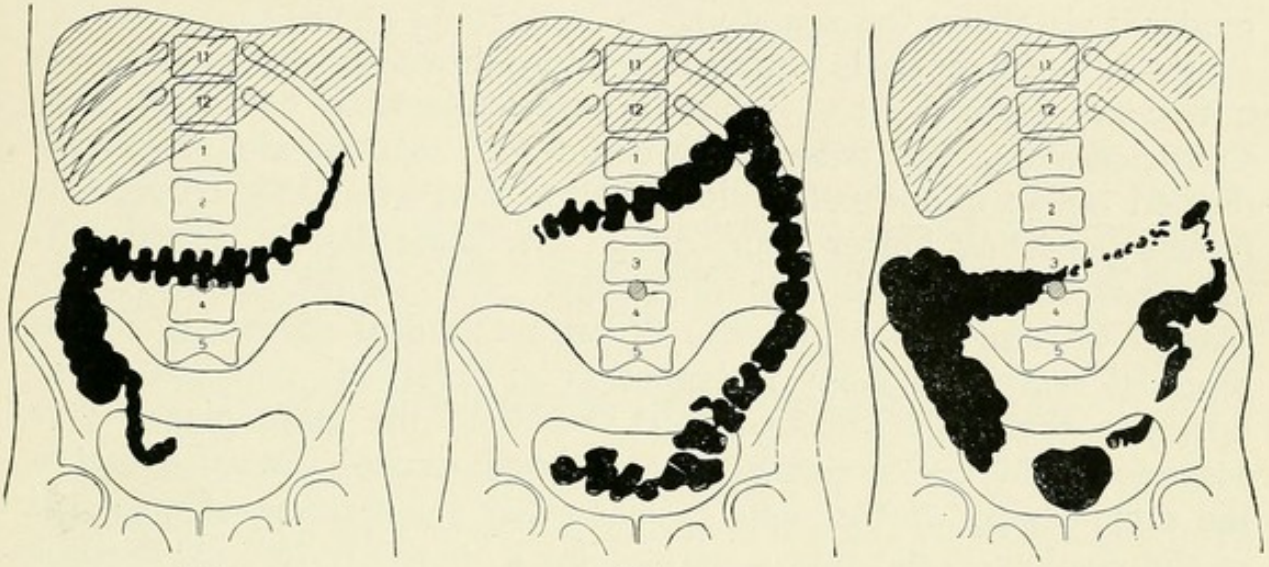

(*a*) Normal large intestine six to ten hours after bismuth meal.

(*b*) Normal large intestine twenty to twenty-four hours after bismuth meal.

(*c*) Large intestine after twenty-four hours in a case of spastic contraction of tranverse colon.

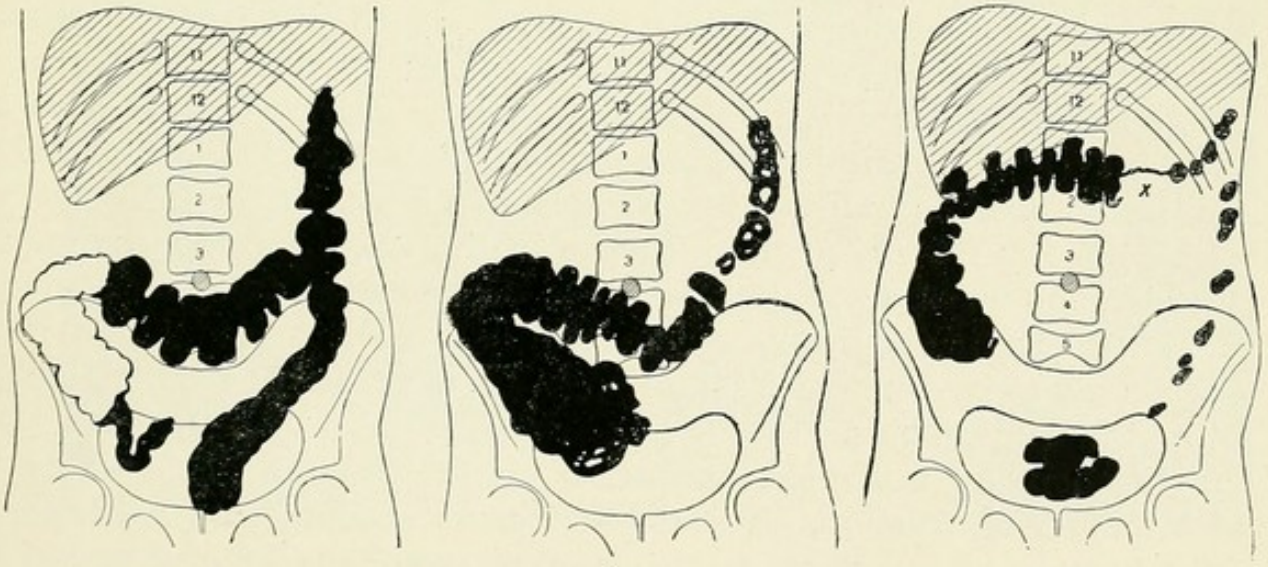

(*d*) Large intestine in case of tubercle of cæcum and ascending colon. (Absence of shadow in diseased areas.)

(*e*) Stagnation of fæces in cæcum and ascending colon in a case of cancer of sigmoid.

(*f*) Loss of shadow in cancer of transverse colon (x). Stagnation of fæces in cæcum. (Taken after twenty-four hours.)

FIG. 154.—Semi-diagrammatic illustrations of skiagraphy of large intestine.

200 grm. of porridge, at least if this is not soon followed by another larger ordinary meal, which would tend to delay the expulsion of the bismuth meal from the stomach.

The following facts must be taken into consideration in regard to the large intestine :—

(*a*) The higher the position of the stenosis, and therefore the more liquid the fæces are, the narrower must be the stenosis in order to render it visible on the skiagram.

(*b*) If the stenosis is situated very low down, the stagnation does not occur just in front of it, but in the cæcum, as we have just seen. Constrictions of the descending colon and sigmoid are mainly indicated by an abnormally filled cæcum and ascending colon, this fulness persisting longer than usual. The same picture is also seen in constipation of the ascending type. We should, therefore, not suspect or assume the presence of an anatomical narrowing unless repeated skiagrams show a stagnation of intestinal contents lower down in the large intestine, and always in the same place. Our suspicion will be confirmed if the fæcal masses always preserve the same shape at this spot. There may be a funnel-shaped gap in the shadow, indicating a narrow track in the bowel, or the loss of shadow may be at the side. Repeated examinations are indispensable, because such pictures may be the result of pure accident. In doubtful cases this test may be controlled by *injecting* 80 to 100 grm. of bismuth carbonate, or double this amount of barium sulphate, in 1½ or even 2 pints of very thin mucilage of starch. But as such a mucilage trickles through most constrictions, they are not always clearly demonstrated by this method. Attempts have therefore been made to follow the injection on the screen, and the results have been better. The temporary stagnation of the material injected has rendered it possible to localize the stenosis in a few cases. (Haenisch.)

Skiagraphy renders great assistance in the diagnosis of intestinal disorder, and may be able to localize the disease when other methods fail, but as we have already said in connection with the stomach, it ought only to be employed for purposes of diagnosis in conjunction with other clinical aids.

Hirschsprung's disease occupies a special position in the study of intestinal obstruction. The disease occurs in children—mostly in little boys—and is characterized by slight symptoms of obstruction combined with extreme distension of the large intestine by fæcal masses. The blocked bowel is quite easily visible through the skin of the emaciated patient. On making a rectal examination masses of clay-like fæces are at once encountered, not only filling the ampulla but dilating it very considerably. The cleaning out of the bowel with the finger, spoons, and similar means, may occupy may hours.

Apart from the exceptional cases wherein the large bowel is unusually long and convoluted, or wherein the valve formation is abnormal, this disease is not due to anatomical changes, but merely

to a purely functional disorder of defæcation. The little patients neglect their bowels either because of some accidental pain—fissure of anus—or because of some reflex disturbance, which would be called "sluggishness" in older patients. The habit of constipation is thus formed, if this may justly be termed a habit. Unless the mother notices this condition, the fæces collect first in the rectum, then fill up the sigmoid and finally extend beyond. After a certain stage has been reached, spontaneous evacuation is impossible, owing to hyper-distension of the bowel and sometimes also to some secondary valve mechanism. If assistance is not rendered, these children finally succumb to marasmus or symptoms similar to obstruction. The widely dilated coils of intestine are easily recognizable in a skiagram, with or without a bismuth meal.

II.—ACUTE INTESTINAL OBSTRUCTION.

A.—SYMPTOMS.

Acute intestinal obstruction differs from the chronic form in the suddenness of its onset and the completeness of the stoppage. It manifests, within the course of a few hours or of a day, the incidents

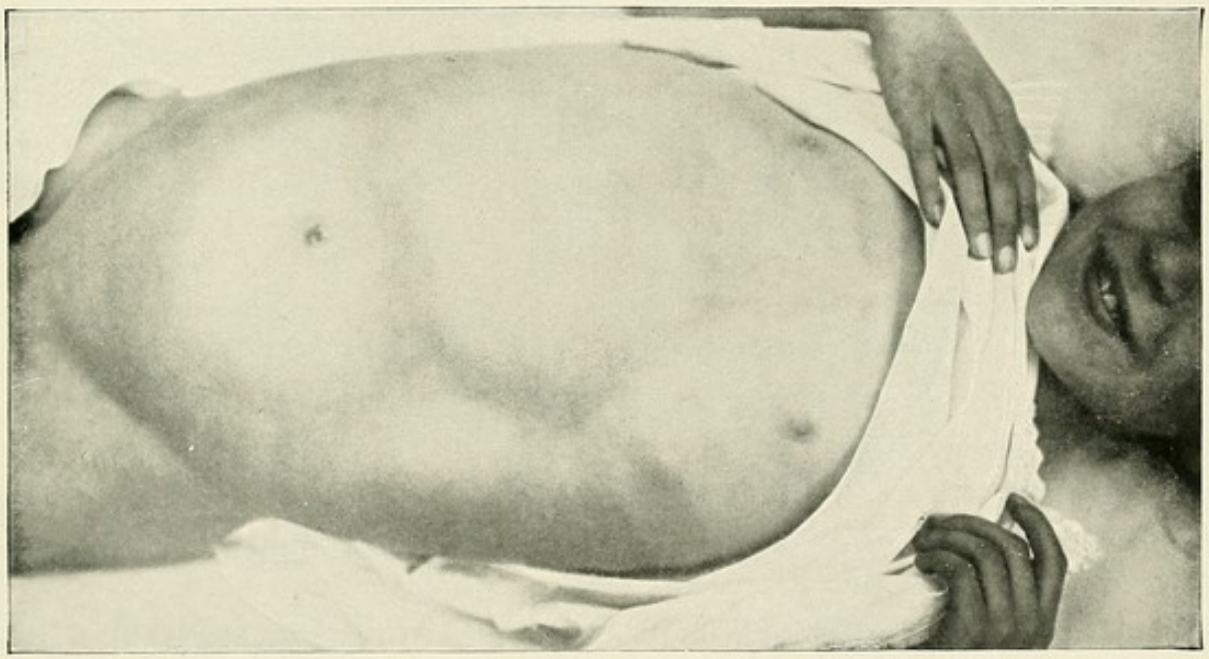

FIG. 155.—Hirschsprung's disease.

which take weeks or months to develop in chronic cases, and shows more besides. In addition to the essential symptoms of intermittent colicky pains and localized hardening of the bowel, there occurs the important and regular sign of *vomiting*, which in chronic cases is only met with during an acute exacerbation. The general condition deteriorates rapidly owing to the lack of fluid intake and to the absorption of toxins. The urine diminishes in amount and contains indican; the pulse, which at first is quiet and full, soon becomes rapid and small;

the breathing, which at first is only hurried during the actual colic, becomes rapid and shallow as meteorism increases, and the patient dies in a few days of hunger and thirst, unless peritonitis has ended the scene more quickly.

The diagnosis is often rendered difficult, because the symptoms of obstruction may be masked by those of the initial shock, which manifests itself by accelerated pulse and collapse. In a very severe case these symptoms merge almost uninterruptedly into the paralytic manifestations of the terminal stage, so that the pure signs of intestinal obstruction are not observed at all. In such a case the diagnosis may rest between acute perforative peritonitis and obstruction.

Perforation of a *gastric or duodenal ulcer*, with its disastrous symptoms, must be thought of in this connection, as also any condition which causes sudden shock and reflex intestinal paralysis, *e.g., pancreatic hæmorrhage and inflammation, torsion of an ovarian or omental tumour, embolism of the mesenteric arteries, tubal abortion, or ruptured tube, and even tabetic crises.* Repeated percussion and auscultation afford the best aid to diagnosis. If we repeatedly hear at any one place a metallic note, splashing or ringing noises, or, exceptionally, a stenotic murmur, and if the abdomen appears to be asymmetrical, with a localized area of the intestine, despite its tympanitic note, more resistant than its surroundings, we ought especially to think of ileus. But, on the other hand, the prevalence of dead silence from the beginning in an equally distended bowel most probably points to peritonitis.

B.—THE POSITION OF THE OBSTRUCTION.

The diagnosis of the seat of obstruction is comparatively easy when it is either high or low; but difficult or impossible when it is in the mid-portions of the intestine. The most important indications are given in the accompanying table, and it is only necessary to add a few general observations.

The peristaltic movements in the small intestine are much more active than in the large intestine. But no conclusion can be drawn from the degree of meteorism, because it may be just as pronounced when the obstruction is low down in the small intestine, as when situated in the large bowel. "Meteorism in the flanks" ("cadre colique"), ostensibly a sign of obstruction in the large intestine, is more of a theoretical condition, because only the upper and middle portions of the bowel distend to any great extent—from the cæcum to the transverse colon—so that the frame is only half formed. If the distension proceeds further onwards, and the sigmoid is well developed, it will involve the mid-portion of the lower abdomen, but will not form a

frame. But we may consider it established that a high tympanitic note in the right lumbar region points with great probability to obstruction of the large bowel.

(*a*) *Obstruction at cardia.*—Abdomen flat, regurgitation of food by cupfuls, mixed with blood and mucus, often alternating with vomiting. Cancer, rarely cardio-spasm.

(*b*) *Pyloric obstruction.*—Epigastrium distended, rest of abdomen flat. Vomiting, by the dishful, of food taken days before, mixed with gastric juice and often with mucus, blood and coffee grounds. No bile. Stenosis after ulcer. Cancer.

(*c*) *Duodeno-jejunal obstruction.*—Abdomen as in *b*. Splashing sounds to the right of umbilicus (lower part of duodenum). Biliary vomiting, not fæcal. Arterio-mesenteric intestinal obstruction, Treitz's hernia, tubercular band.

(*d*) *Obstruction at upper part of small intestine.*—Meteorism, if present, moderate, central or diffuse. Vomiting biliary, rather fæcal, powerful peristalsis. Bands, volvulus, tubercle, tumours, intussusception, internal hernia.

(*e*) *Obstruction at lower part of small intestine.* Meteorism, if present, general. Fæcal vomiting, powerful peristalsis (Causes as in *d*.)

(*f*) *Obstruction at ileo-cæcal valve.* — As in *e*, but condition usually palpable in right pelvic cavity. Intussusception, volvulus, cancer, tubercle.

(*g*) *Obstruction of large intestine at hepatic flexure.* Meteorism if present, general. Cæcum and ascending colon distended. Active peristalsis occasionally. Fæcal vomiting. Possible to inject 1½ to 2 litres of fluid into rectum. If obstruction incomplete, stools are formed. Condition generally palpable. Cancer, tubercle very rarely.

(*h*) *Obstruction of large intestine at splenic flexure.*—Meteorism as above, but transverse colon also somewhat distended. Injections of 1 to 1½ litres possible. If obstruction incomplete, stools generally formed. Palpation more often negative than in *g*. Cancer, tubercle very rarely, or syphilis.

(*i*) *Obstruction at sigmoid.*—Meteorism as above, main distension of colon at cæcum. Slight peristalsis. Injection of ¼ to ½ litre possible, seldom more. If obstruction incomplete, diarrhœa alternates with constipation. Palpation often negative owing to smallness of growth, but sigmoidoscopy and bi-manual examination under chloroform advisable. Volvulus, cancer.

(*k*) *Obstruction in upper part of rectum.*—Meteorism as above. Constipation alternating with diarrhœa, or always thin evacuations. Exceptionally ribbon-shaped. Tenesmus occasionally. Cause detected by rectal or combined examination. Cancer, syphilis, tumours and inflammation within true pelvis.

(*l*) *Obstruction in ampulla.*—Tenesmus, fluid or ribbon-shaped stools. Causes : Cancer, syphilis. Can be felt and sometimes seen.

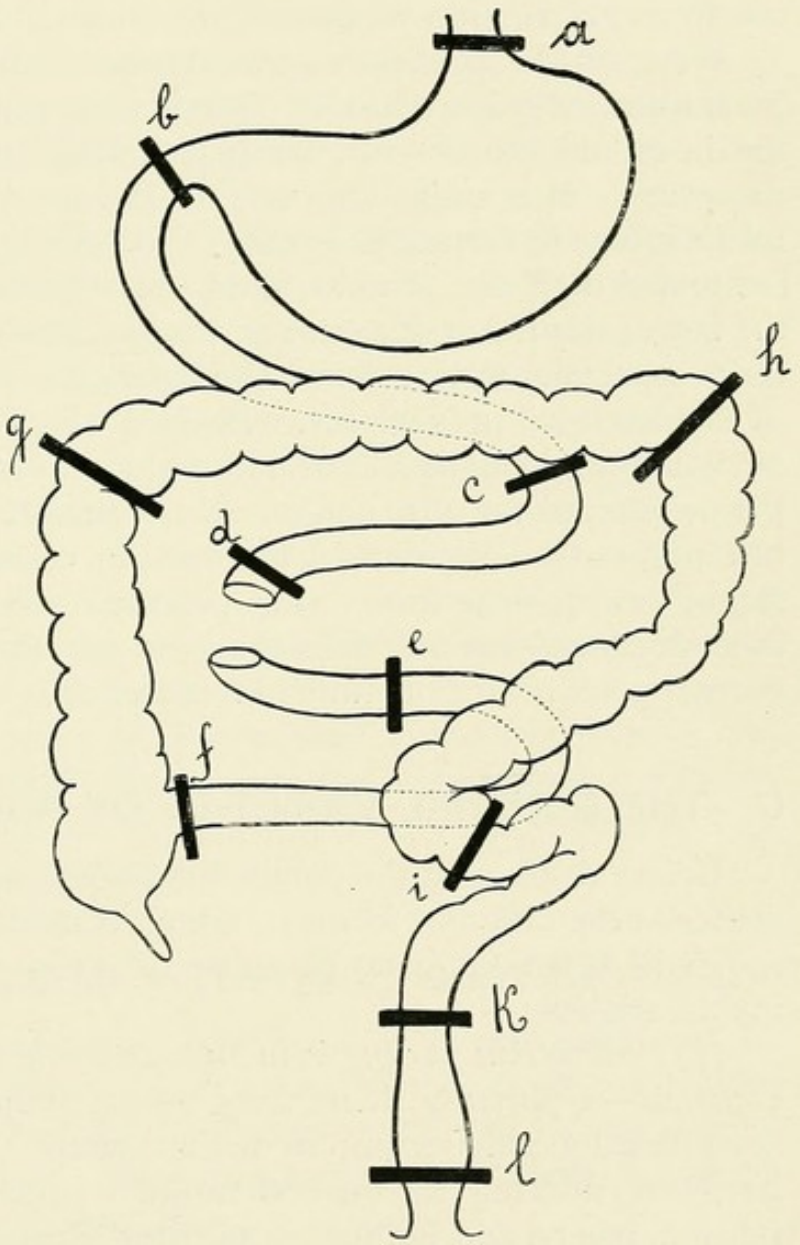

FIG. 156.—Diagram of the typical positions of intestinal obstruction.

Obstruction high up leads to many mistakes in diagnosis, because flatus and stools still pass and the abdomen remains flat, even if the obstruction is long persistent. These cases often suggest cerebral,

uræmic or even hysterical vomiting, gastric crises or the onset of peritonitis. The last, however, can be excluded by the absence of any local irritative symptoms, uræmia by the condition of the urine, cerebral or tabetic vomiting by the absence of any other cerebral or spinal cord symptom. The obstinacy of the vomiting, the rapid decrease of urine and the cessation of the passage of stools and flatus within a few days will finally convince those who cannot conceive of intestinal obstruction without a drum-like abdomen.

We cannot expect much elucidation from X-rays in cases of complete intestinal obstruction. There is no time for an examination of the intestinal movements, because immediate operation is, as a rule, necessary. It is quite conceivable, however, that X-rays may be useful in subacute forms, to localize the obstruction accurately, when it is situated high up. Similarly in cases of obstruction low down, in the large intestine, a skiagram may be valuable after a bismuth injection, more especially as this delays the operation less than an examination of the intestinal movements. Besides this, a bismuth meal is liable to be vomited, and the site of the stagnation of the test material is not the position of the obstruction. But a skiagram taken after an injection has not only a theoretical interest, in complete obstruction of the large intestine—the time is too precious for theoretical examinations in such cases—but possesses the great practical value of indicating the correct position for operative interference.

C.—THE GENERAL VARIETIES OF ACUTE OBSTRUCTION.

Before discussing the detailed causes of acute obstruction, we will glance at the different forms in which it may appear. This consideration will often facilitate accurate diagnosis. The following are the main varieties :—

(1) *Obstruction passing from an Incomplete Chronic into a Temporarily Complete—apparently Acute, Stage.*—Cancerous and tubercular disease constitute the chief examples of this group. If an elderly patient who has been suffering for several months from colic and increasing distension, has passed neither stools nor flatus for two days, but vomits bowls full of brown fœtid material, it is highly probable that he has a constricting carcinoma of the colon, particularly of the sigmoid. If a younger man with tubercular antecedents and a history of months' or years' suffering from colic, shows signs of complete obstruction, he probably has a tubercular stricture in the small intestine or at Bauhin's valve. Many cases of obstruction during the course of tubercle or cancer of the peritoneum should be included in this group. In both, the apparently sudden onset of complete obstruction will always have been preceded by some abdominal discomfort, especially

colic and loss of appetite, which shows that the event has long been in preparation.

(2) *Intermittent Obstruction.*—This term applies to all cases wherein sudden attacks of transitory obstruction alternate with intervals of complete freedom of a variable duration, sometimes even of years. There is no permanent narrowing in these cases, but a temporary obstruction of the lumen of the bowel repeatedly occurs, caused by some existing abnormality, which becomes latent at intervals, or by some anatomical change. This variety is mostly exemplified in torsion of the sigmoid, or more rarely by an abnormally movable ileo-cæcal segment of the bowel, or, still more rarely, of the small intestine. Obstruction by omental or cicatricial bands, by abnormalities connected with Meckel's diverticulum, strangulation of internal hernia, kinking produced by tubercular adhesions, as well as arterio-mesenteric intestinal obstruction, may belong to the same group.

(3) *Sudden and unanticipated Onset of Acute Obstruction.*—This group includes the rare cases of sudden obstruction by cancer in apparently healthy individuals without any pathological antecedents. But the more carefully the history is taken, the more frequently some indication of previous disease will be found, if only some dyspepsia, slight pain, irregularity of the bowels, or unexplained wasting. Obstruction may also occur suddenly in tubercle, before any diagnosis of intestinal disease has been made.

All the enumerated causes of intermittent obstruction come into consideration again if a first attack is under observation. Finally, there are cases in which, as a rule, one attack only occurs, *e.g.*, intestinal obstruction from gall-stones.

D.—CAUSES OF ACUTE INTESTINAL OBSTRUCTION.

We now propose to consider whether any given case can be referred to one of the classical forms on the evidence of history and physical symptoms, and for this purpose we will briefly discuss the most important of these forms, beginning with those to which the history provides the clearest clues.

(1) Obstruction due to Bands and Kinks.

If the patient has had an abdominal operation, however long ago, we shall rarely err if we diagnose obstruction by a band. Bands, which result from operative procedures are more dangerous, because they are usually more circumscribed than those which arise spontaneously after inflammation. Nevertheless, the latter may also produce obstruction by bands, *e.g.*, after appendicitis, cholecystitis, inflammation of the female genital organs, and tubercular peritonitis.

The last may produce adherent omental bands in the true pelvis. The adhesions, which occur after ulceration of the large intestine, pericolic cords and bands, are flatter, and therefore are more liable to give rise to chronic obstruction.

If signs of obstruction in the upper part of the small intestine occur in an emaciated individual, the subject of lateral curvature or Pott's disease, we should think of *arterio-mesenteric intestinal obstruction, i.e.*, kinking of the small intestine at the duodenal boundary by the root of the mesentery. A duodenum with a very low-lying situation is necessary, or at any rate is a favourable condition for the causation of this form of intestinal obstruction. The knee-elbow position removes the obstruction and confirms the diagnosis.

The classical picture of arterio-mesenteric intestinal obstruction was seen in a girl, aged 13, the subject of disease of the cervical spine and compensatory lordosis in the lumbar region. The stomach and the duodenum, which, as the operation showed, reached considerably to the right, were greatly distended, and gave evidence of splashing on auscultation. The stomach was tympanitic and the duodenum yielded a metallic note. The cervical disease prevented the use of the knee-elbow position for the purpose of treatment, and the fact of tuberculosis did not, of course, exclude obstruction by a band. Laparotomy was, therefore, performed, and I found the whole of the small intestine deeply in the true pelvis. The kink was situated at the junction of the duodenum with the jejunum. The latter became filled with gas as soon as it was lifted up.

It is an open question whether one should include here the duodenal obstruction which has been observed after laparotomy, especially in the upper portion of the abdomen. This condition depends upon atony of the gastric musculature, which sometimes occurs after operations on the abdominal cavity, and is analogous to atony of the rectum. It is a condition which certainly occurs in the slight infections which are overcome by the peritoneum in a few days. In other cases the peritoneum possesses an idiosyncrasy towards blood. The greatest degree of rectal atony which I have seen occurred in a case of post-operative hæmorrhage, which was bacteriologically sterile.

(2) Obstruction by Gall-stones.

If pain on pressure over the gall-bladder occurs *simultaneously* with symptoms of acute intestinal obstruction, the case is probably one of acute cholecystitis. This disease frequently produces temporary signs of obstruction, either as a reflex process or by extension of the inflammation to the transverse colon or small intestine.

If an attack of gall-stones *has occurred previously* the obstruction is most likely to be due to a **gall-stone** rather than to the so-called "bride-péricolique." The entrance, even of a large gall-stone into the small intestine, usually takes place by a process of suppuration

without any striking symptoms, and the last attack of gall-stones observed by the patient may have occurred long previously. Some support for the diagnosis of "gall-stone obstruction" is afforded by feeling a firm and somewhat tender swelling in Douglas's pouch on vaginal or rectal examination. Most of these gall-stones remain fixed in the lower portion of the small intestine, and the coil containing the stone is dragged down into the cavity of the true pelvis.

It might be thought that gall-stone obstruction ought to be included in the chronic variety, owing to the length of time the stone remains within the bowel. This is true for some cases, wherein the symptoms are very protracted and remittent, and the stone eventually departs spontaneously. But in most cases the symptoms come on very acutely, and we often find that signs of peritonitis supervene at the same time, or at any rate very soon afterwards. If the stone is in a healthy coil of intestine, it will allow flatus to pass by it. But if it remains for any length of time, the intestinal wall becomes irritated and draws itself lightly over the stone, which then allows nothing to pass by it. At the same time a pressure ulcer develops, so that the intestinal wall becomes inflamed and infiltrated, and instead of grasping it by active contraction, becomes stiff by infiltration, and embraces the stone tightly but passively. At this moment the "attack of gall-stone obstruction" often begins. The inflammation rapidly involves the serous membrane, so that local peritonitis occurs early. If we make the diagnosis of gall-stone obstruction in such a case on the evidence of the clinical history, we must not hesitate to operate *immediately*, on the assumption that most gall-stones pass through the bowel by themselves. The actual symptoms, indeed, show that the stone, in such a case, will not do so.

The following is an illustrative case :—

A man, aged about 50, who had suffered from a severe attack of gall-stones one year previously, was suddenly seized at night, without any warning, with abdominal pain and vomiting. Twelve hours later, the pulse was already rapid, the abdomen tender and slightly distended, and contained some free fluid. The vomiting continued. The diagnosis wavered between obstruction by a band, or by a gall-stone, combined with severe peritoneal irritation and slight effusion. Operation was done at once, and a gall-stone was found in the lower portion of the small intestine, in firm contact with the inflamed and infiltrated bowel. A pressure ulcer had already perforated, and the abdomen contained sero-purulent fluid. The operation, however, was unable to restrain the advance of the peritonitis.

(3) Intussusception.

Exceptionally, a positive indication is supplied by the age of the patient. This is true of **intussusception** in so far as it occurs in infants, who very rarely suffer from any other form of obstruction. The symptoms vary with the degree of disturbance of the circulation in the invaginated portion, and they range from the very severest type,

with rapid death from peritonitis, to chronic intussusception of many months' duration. The beginning of the disease is usually marked by the passage of blood-stained, fruit-juice-like fluid with the stools, and the intussusception can, as a rule, be felt, on careful examination, as a sausage-shaped swelling, close to the spinal column. The intussusception rarely reaches so far as to be felt in the rectum, like the vaginal portion of the cervix, or be mistaken for a prolapse of the rectum.

Intussusceptions which are not of the ileo-cæcal variety are, as a rule, caused by *Meckel's diverticulum* or *innocent tumours of the bowel*. In both cases the upper portion of the intestine with the tumour, or with the inverted diverticulum, is dragged into the lower portion. I once saw the characteristic etiology well exemplified in a little boy; the lower portion of intestine was fixed by tubercular mesenteric glands, the upper, forming the intussusception, was, however, free. This corresponds to the condition at the ileo-cæcal valve, where the more movable portion of the intestine becomes inverted into a less movable portion.

We have mentioned the passage of blood-stained liquid as an important sign of intussusception. The same symptom occurs in *infarction* of the bowel, caused by blocking of a blood-vessel, which is usually accompanied by the symptoms of sudden intestinal obstruction. The simultaneous *vomiting* of blood-stained material points to infarction.

(4) Volvulus.

There is a geographical indication which points to **volvulus** as the diagnosis of the form of intestinal obstruction. In most countries, neither the student nor surgeon sees many instances of this condition, but in Russia, especially in the Baltic Provinces, volvulus is the most frequent variety of obstruction brought into hospital.

Gruber states that this is due to the greater length of the Russian intestine; others attribute it to the abundant dietary of potatoes. I know many places where the potato is a great favourite, but where volvulus is almost unknown. Gruber's view is also stoutly contested. Indeed, volvulus is more likely to be due to congenital or acquired abnormalities in the mesentery, which permit a more extensive movement of some parts of the intestine, than to the length of the bowel in metres. To allow of the twisting of the bowel the mesentery requires a certain amount of independence, which is given it by a long mesentery with a narrow attachment. Such a condition is only normal in the sigmoid, and it can be increased by the greater development of this coil or by the abnormal approximation of its lower extremity. Sometimes the ileo-cæcal portion is provided with so profuse a mesentery that it occasionally twists about on its long axis. Finally, the *whole of the small intestine*, either itself or with the *large intestine*, may possess such a narrowly attached mesentery that the whole bowel is capable of twisting in its entirety. I saw an instance

of this in Kocher's wards, in a young man in whom the torsion occurred after an enormous meal of cherries, including the stones. The occurrence of torsion in a *single coil of small intestine*, presupposes a condition in which it has been subjected to traction for a considerable time, such as long detention in a hernial sac, or the pull of an intestinal tumour.

The diagnosis of volvulus of the sigmoid is very easy. In this condition the whole abdomen is occupied by an enormously distended coil, with its head in the upper part, and with its more or less parallel limbs, which can be distinctly felt, and even seen. Confirmation is afforded by the impermeability of the sigmoid to an injection of water. An *ileo-cæcal volvulus* may be diagnosed if, instead of a long and distended coil, we find that a roundish tympanitic tumour has suddenly formed, with a seizure of vomiting, and that an injection of water can be successfully given. Volvulus of the *whole small intestine* yields the symptoms of duodeno-jejunal obstruction, plus meteorism. The symptoms of volvulus of the *small and large intestine* together are about the same, but it is impossible to inject any large quantity of water into the rectum. It is not possible to differentiate volvulus of a *single coil of small intestine* from obstruction by a band, and from strangulation into a peritoneal pouch.

It is equally impossible to detect clinically the *nodules* which are to be found in the vicinity of a volvulus, and which depend upon the presence of Meckel's diverticulum and the bands of connective tissue arising from it.

The foregoing remarks apply to volvulus which has caused complete obstruction and a torsion of 360°. If the obstruction is incomplete (torsion of 180° to 270°), the symptoms are less severe, and often disappear spontaneously. For instance, I once saw the desired evacuation of flatus occur after a long journey, at the very moment when everything was about to be expedited for an operation. In all these cases, however, the diagnosis is only a matter of pure probability.

(5) Strangulation of Internal Herniæ.

Strangulation into a congenital peritoneal pouch is one of the rare causes of intestinal obstruction; but sometimes this diagnosis is suggested by the demonstration of a localized distension. But before we think of an internal hernia, we must exclude *strangulation of an external hernia*, which is not always so easy to do as it may appear, especially in cases of pro-peritoneal and intermuscular inguinal herniæ—herniæ of the obturator foramen, lumbar, and gluteal herniæ.

I recall a case which occurred when I was an assistant. A young woman was sent into the surgical ward after suffering from obstruc-

tion for several days. She had already been examined for hernia, but none had been detected. Nevertheless a slight resistance at the apex of the internal inguinal ring pointed to strangulation of an interstitial hernia; and at the operation it was found that the contents of the hernia were already gangrenous at the constricting ring.

An error in connection with an obturator hernia is more pardonable. In a typical case, however, the pain or deep pressure below Poupart's ligament, and the neuralgia of the obturator nerve—probably called old rheumatism by the patient—allows the diagnosis to be made with the greatest probability.

But, on the other hand, not every hernia which may accidentally be present, even if irreducible, must be credited with the causation of intestinal obstruction. If the hernia is not tense, and if there is no pain on pressure over its neck, it has nothing to do with the obstruction, even if old adhesions have rendered it irreducible.

If a hernia has been reduced previously to the occurrence of obstruction, the neighbourhood of the ring must be examined. Any in-drawing of the tissues, or indefinite resistance, or pain on deep pressure points to *reduction en masse;* but if the hernial ring is normal, it indicates that the obstruction has some other origin.

There are three particularly important forms of **internal herniæ**: (*a*) *Hernia* at the *Foramen of Winslow.* When strangulated, this causes a tumour behind the stomach. It has often been operated on, but has not previously been diagnosed. (*b*) Diagnosis ought to be more possible in *duodeno-jejunal hernia.*

This begins at Treitz's pouch, where the jejunum passes under the transverse colon. The pouch opens to the left of the first part of the jejunum, and is directed thence obliquely upwards and to the left. It may become large enough to contain the major portion, or, indeed, the whole of the small intestine.

The symptoms of these herniæ are intermittent in character; but this circumstance is common to several other forms of intestinal obstruction. The hernial tumour is situated in the epigastrium, rather towards the left. There have been cases recorded wherein strangulation has occurred in a similar pouch arising from the right of the jejunum.

(*c*) The third typical position for internal herniæ is in the *appendix region.*

Of the various pouches described by anatomists only two possess surgical importance, viz., the *ileo-appendicular,* which is situated between the appendix and the end of the small intestine under the region of Bauhin's valve; and the *retro-cæcal,* which runs laterally from the appendix behind the cæcum.

In both forms a hernial swelling is found in the ileo-cæcal region, and if no other cause for the intestinal obstruction is evident, it is fair to assume that one of these varieties of hernia is responsible.

We shall not mention any of the rarer forms of internal hernia, for it is quite impossible to diagnose them clinically. This applies to strangulation in openings of the mesentery, omentum, or broad ligament.

Diaphragmatic herniæ are seldom suspected before operation, unless a previous injury to the diaphragm has suggested its probability. A tympanitic note or dulness over the left lower lobe and marked dysphagia might arouse suspicion. These herniæ are either on the left side, or in a space in the diaphragmatic attachment to both sides of the sternum (Morgagni's space). An X-ray examination after a bismuth meal furnishes the best means of diagnosis.

(6) Spastic Obstruction.

Spastic contractions of the intestine, without any evident cause, sometimes occur after abdominal operations, and if they persist for any length of time lead to symptoms of intestinal obstruction, *i.e.*, **spastic obstruction.** The following is a typical case :—

A young, healthy man came to the hospital with symptoms of obstruction high up in the small intestine and a temperature of 99·6° F. The family history suggested tubercle. It was remarkab e that his general condition remained comparatively good, despite the continuance of the obstruction. Operation showed that a coil 15 cm. in length, in the upper part of the small intestine, had contracted to a thin band. When the spasm relaxed all symptoms vanished.

It is possible that atropine might have been effective here, and permitted the making of a diagnosis. As a rule, no diagnosis is made until the abdomen is opened ; spastic conditions of the large intestine are more frequent, but less serious.

Persistent vomiting must not be confused with spastic obstruction, because hysteria may imitate intestinal obstruction. But in that condition the physical signs do not correspond with the general severity of the symptoms arranged by the patient. If it is pretended that solid fæces are vomited, this must baffle even those who easily believe what they are told, because lumps of fæces are not vomited by anti-peristalsis. They get into the vomit in a much simpler way. Relapses have been observed in cases wherein the first "exhibition" was successful. A thorough course of psychical treatment is required to prevent these relapses.

CHAPTER XLVIII.

TUMOURS AND SWELLINGS IN THE ABDOMINAL PARIETES.

THE superficial situation of a tumour or swelling indicates that it is in the abdominal wall and not in the abdominal cavity. But in very thin people a genuine intra-abdominal tumour may appear to be quite superficial. It is, therefore, necessary to make the abdominal muscles contract. If the tumour then disappears, it must be situated within the abdominal cavity, or, at any rate, under the abdominal muscles. If however, the tumour can still be felt, and at the same time becomes immovable, it is obviously connected with the muscles or fasciæ. Should the muscular contraction make no difference at all, the tumour is situated either within the skin or subcutaneously.

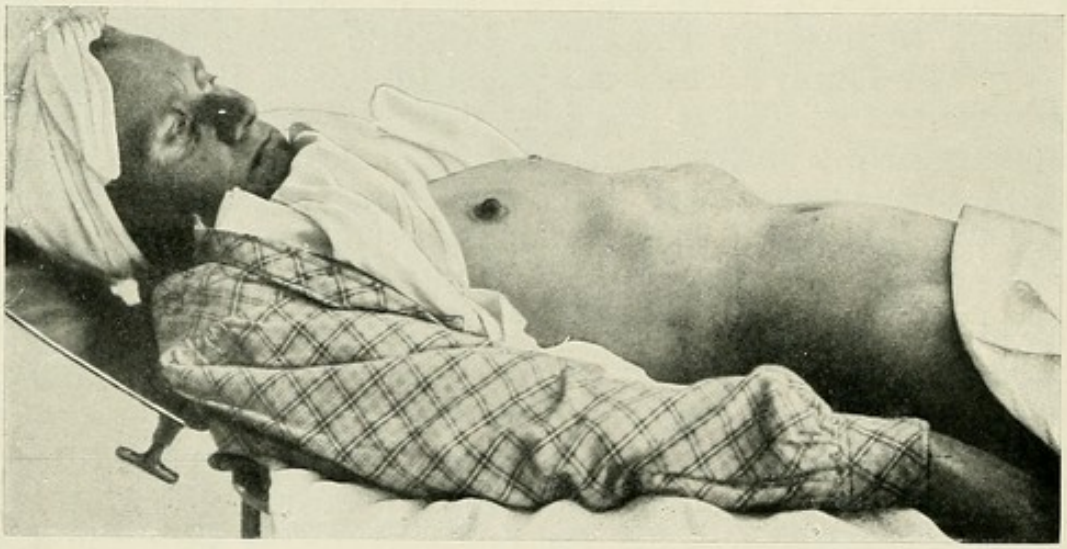

FIG. 157.—Chronic abscess in epigastrium.

In order to obtain a correct idea amid all the various possibilities, it is very important to note whether the tumour is in a position "typical" of these pathological changes, *i.e.*, in the middle line, in the inguinal region, in the lumbar region, or whether it has appeared at some other point.

(1) THE UPPER ABDOMINAL REGION.

A swelling in the epigastric region may, apart from exceptional rarities, be one of three things; viz., (1) an epigastric abscess; (2) subcutaneous lipoma, or (3) an epigastric hernia.

If the swelling is acute, and presents the appearance of a firm infiltration, which, after a little while, begins to soften in the centre

and fluctuate, there is no difficulty in recognizing an **epigastric abscess.** The chronic form, in which the skin remains unchanged for a considerable time, may easily give rise to doubt. But even in these cases the wide base of the swelling (fig. 157), and the fluctuation which is rarely absent, suffice to indicate an abscess. The source of infection is often a gastric ulcer which has become adherent to the abdominal wall, and which has protruded after suppuration.

Theoretically, one would imagine that these abscesses contain gas, and that their incision would lead to the formation of a gastric fistula. But, as a matter of fact, this is not always the case, for the collection of pus may have no connection with the interior of the stomach, and may heal up without delay.

Figure 157 represents such a case. The cause—gastric ulcer—was only suspected; it was not strictly demonstrated.

In other cases, the swelling may be an abscess due to tubercle of the ribs or sternum. Rarely it may be a burrowing abscess making its way through the abdominal muscles.



FIG. 158.—Subcutaneous lipoma of the epigastrium.

Subcutaneous lipomata differ in no respect from lipomata in other situations. The accompanying illustration (fig. 158) shows that they may attain an ordinary size. They are distinguished from epigastric herniæ and from subserous lipomata, by their free mobility over the sheath of the rectus.

Epigastric herniæ and **subserous lipomata** are, however, much more frequent.

In order to appreciate their origin we must realize that a large amount of fat is contained in the upper triangular area of peritoneum which has its apex at the umbilicus. The first stage in the development of a hernia is the protrusion of a lobule of fat through an oval slit, which is always situated transversely in the fibrous tissue of the linea alba. If this lobule continues to grow after it has become free,

it develops into an ordinary *subserous lipoma* (fig. 159*a*). As it grows it usually pulls up some peritoneum into the slit, so that it obtains a pedicle of peritoneum, which, however, contains no abdominal viscus within it (fig. 159*b*). If this peritoneal protrusion in front of the slit in the aponeurosis develops into a hernial sac, into which omentum or bowel finds its way, the case is one of *epigastric fatty hernia* (fig 159, *c*). If, finally, the hernial development is greater than the fatty proliferation, the case is one of ordinary epigastric hernia (fig. 159, *d*).

The differential diagnosis, in these conditions, depends to a great extent on the question of reducibility. If, despite patient and gentle pressure, the swelling cannot be reduced at all, and if we are told that

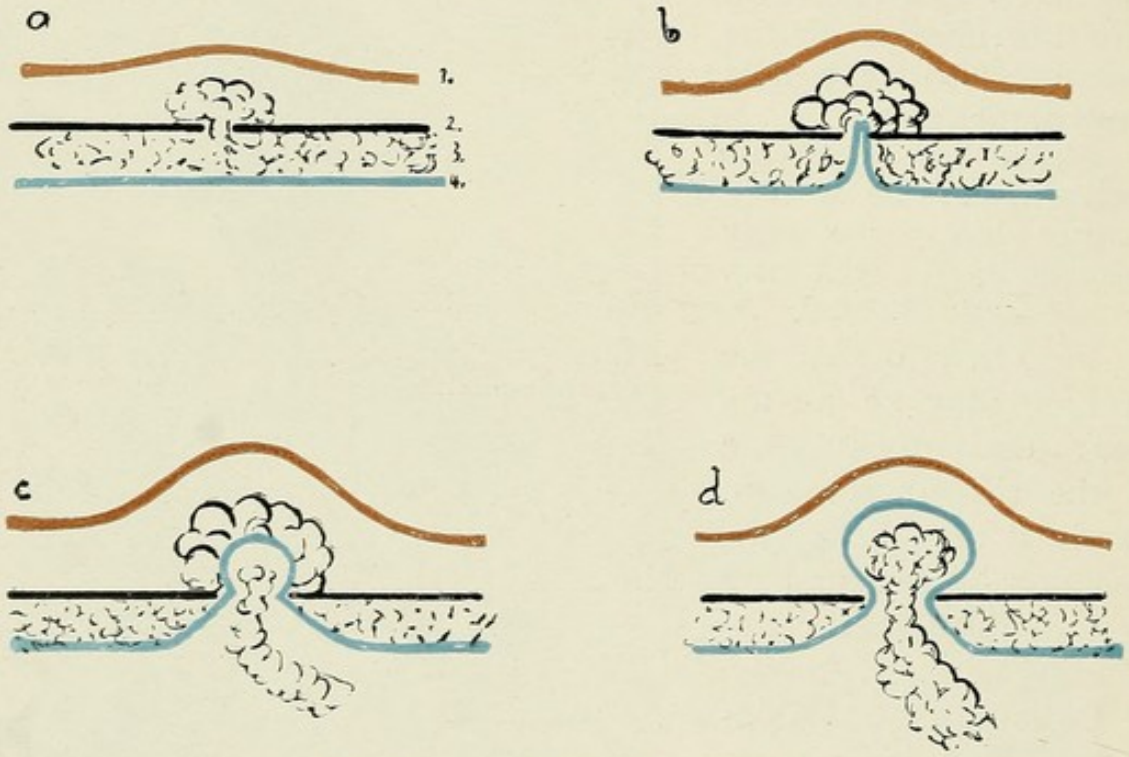

FIG. 159.—Epigastric hernia and subserous lipoma.

(1) Skin. (2) Rectus sheath. (3) Subserous fat. (4) Peritoneum.
(*a*) Subserous lipoma, after breaking through sheath of rectus.
(*b*) ,, ,, with some peritoneum pulled up into fascial slit.
(*c*) ,, ,, with a hernial sac containing some protruded omentum. (Epigastric fatty hernia.)
(*d*) Pure epigastric hernia, without lipoma.

the circumference of the tumour is always the same, the case is one of pure *subserous lipoma*, an illustration of which is given in fig. 160. If the tumour becomes large under the influence of abdominal pressure, but always permits of partial reduction, it is most probably a *hernia*, but the possibility of subserous lipoma cannot be entirely excluded. As far as their external appearance is concerned, they both look like the swelling depicted in fig. 160. The hernia seldom attains the size illustrated in fig. 161.

A mass of omentum adherent to a hernia may resemble a lipoma, as the thickness of the abdominal wall does not usually permit of differentiating between omentum and a lipoma.

If the diagnosis of epigastric hernia were always made in time, it would prevent many so-called "dyspeptics" wasting years on treatment for indigestion, when a simple surgical measure could at once restore them to health. The "dyspepsia" is caused by the pull on the peritoneum, or on the omentum firmly grasped within the hernial sac. But, on the other hand, one must not overlook a cancer of the stomach, because there happens to be an epigastric hernia present. Both the abdominal wall and the stomach must be investigated.

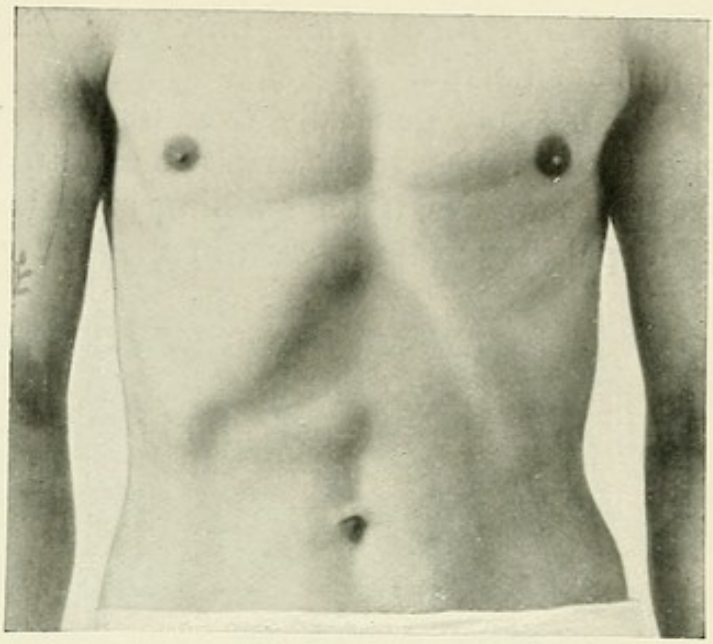

FIG. 160.—Subserous lipoma in epigastrium.

I have, several times, seen the ligamentum teres of the liver in this hernia, a circumstance which, as Graser remarks, is not without its influence on the symptoms complained of.

(2) THE UMBILICAL REGION.

If we find that a newly-born infant has a swelling in the umbilical region, generally with a broad base, and but rarely pedunculated, in which the intestinal contents — usually the liver and bowel—can be seen through a veil-like membrane, the case is clearly one of **hernia of the umbilical cord** (fig. 163). It is quite impossible to mistake this for any other condition, and therefore need not detain us.

If the umbilicus projects in a semi-globular form and eventually in a conical or cylindrical shape, in

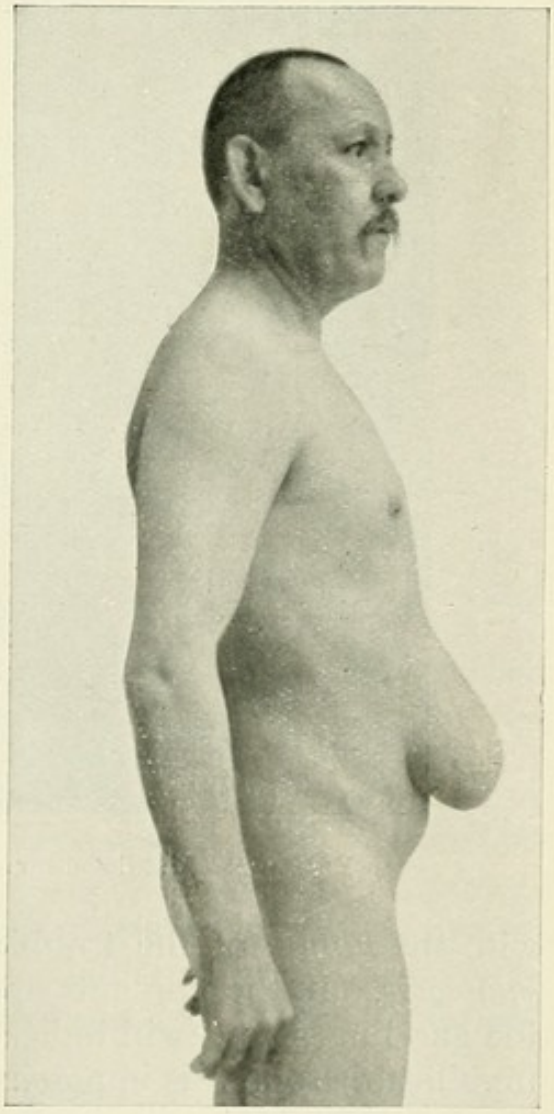

FIG. 161.—Large epigastric hernia.

a shrieking *little child*, only *one* diagnosis is possible, that of **umbilical hernia.**

If an adult, generally over forty, presents a tumour, varying in size from a pea to a man's head, in the same region, the same diagnosis applies, if the swelling is, at least partially, reducible. The principal diagnostic interest in these cases, is not so much concerned

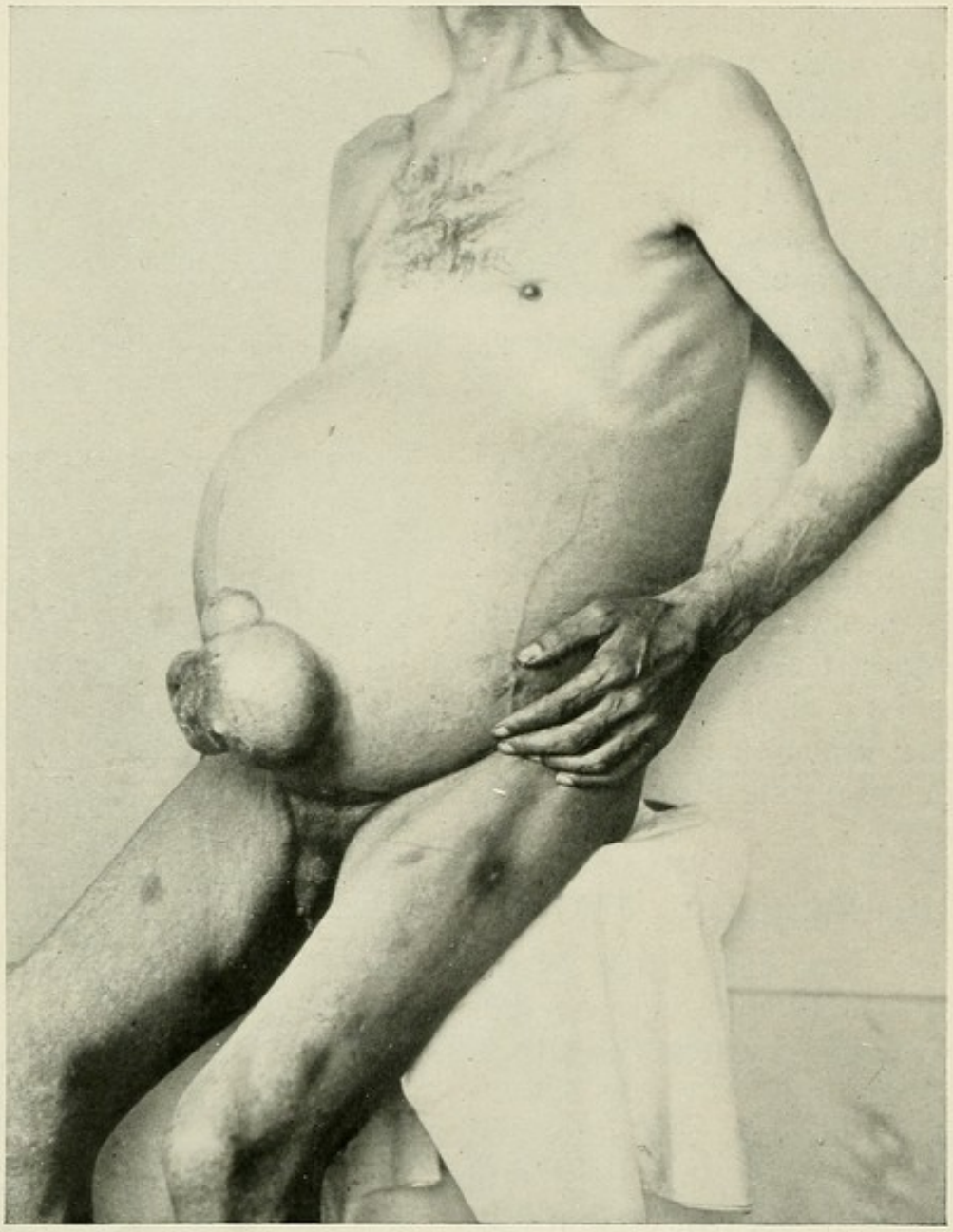

FIG. 162.—Multilocular umbilical hernia in cirrhosis of the liver.

with the *nature* of the trouble, as with certain of its *accompanying symptoms.* If the contents are reducible, either the granular feel or the gurgling sound will indicate omentum or intestine. But in some umbilical herniæ it is impossible to demonstrate the one or the other. The contents are easily displaced by pressure, but neither the reduction nor the refilling is accomplished with a jerk, which suggests

that the contents must be fluid. On careful examination, free fluid will also be found in the abdominal cavity, and the liver may exhibit signs of cirrhosis, or some cause for the ascites may be discovered in the heart or kidneys (fig. 162).

In large old-standing cases of umbilical hernia (fig. 162) it can be seen, even externally, that they consist of separate loculi. Some of these may be reducible while others are not. It sometimes happens that a hard and tender swelling arises in one of these loculi, while the rest of the hernia still remains reducible. The most likely explanation of this occurrence is the strangulation of intestine or omentum in one of the loculi.

But other causes are conceivable. For instance, in the case of an old woman, whom I suspected of such partial strangulation, the localized inflammatory symptoms were really caused by a tubercular

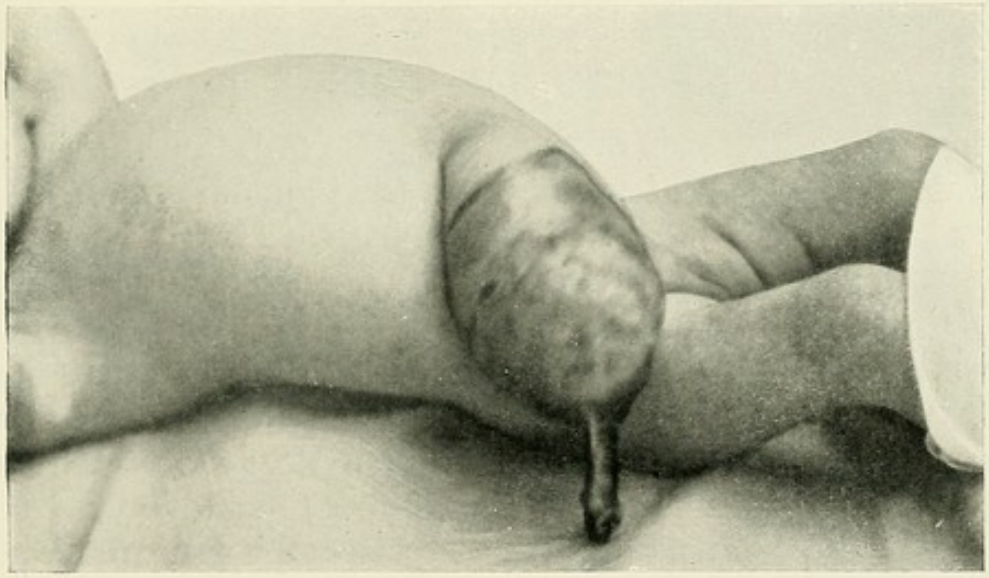

FIG. 163.—Hernia of the umbilical cord in an infant.

peritonitis which had involved the hernial sac. This might very well occur also with cancerous peritonitis. On another occasion I witnessed a peritonitis, which arose from the suppuration of an ovarian cyst, involve a large omental hernia and form a circumscribed abscess. An inflamed gall-bladder, and even the appendix has been found in an umbilical hernia.

If the tumour presenting at the umbilicus is not reducible at any stage we must ascertain whether it fluctuates, or, at any rate, whether it feels elastic, in which circumstances it may be one of the various cysts occurring in this region, especially a **dermoid** or epidermoid. If the cyst is situated in or beneath the abdominal wall, opposite the bladder, it is probably connected with the **urachus**; if directly behind the umbilicus, with the **vitelline duct.**

Solid tumours are usually **secondary** and represent metastases or direct extensions of cancer within the abdominal cavity. If, how-

ever, such a causation can be excluded, they must, apart from rare exceptions, be regarded as **primary cancers** or **sarcomata** if they grow rapidly, and as **fibromata** if their growth is slow.

The primary cancers start from the *skin* and appear as ulcers with hard margin and base, or as cauliflower-like papillomata. Cancer of the umbilicus may also arise from *intestinal epithelium*, which has become displaced into the umbilical scar. Finally, the epithelium of the *urachus* may undergo cancerous degeneration. We should think of this origin, if the cancerous tumour stretches downward from the umbilicus towards the bladder. The *sub-umbilical abscess* may also be mentioned. This occupies a triangular area with its base upwards under the umbilicus and behind the recti. The pus organisms reach this space from the viscera of the lower abdominal cavity, or from the abdominal integuments. The course of this abscess is either chronic or acute, depending upon the nature of the organism—tubercle bacillus, staphylococcus, colon bacillus, &c.

(3) INGUINAL REGION.

Owing to the presence of the spermatic cord, the round ligament, and the vaginal process of peritoneum, the inguinal region is the seat of many kinds of swelling, which we shall meet with later on. For the moment we are only concerned with the leading features of diagnosis in this region.

We must first ascertain whether the swelling can be reduced, or whether its contents can be displaced. If so, the case must be either a **hernia**, a **bilocular** or **communicating hydrocele,** or a **burrowing abscess.** If an intestinal note is found over the swelling, or if it feels granular or lumpylike omentum, there is no doubt about it being a hernia. The same applies, if its reduction is accomplished in a sudden manner. But if it is only displaced gradually and the swelling corresponds accurately to the direction of the inguinal canal, we must think of one of the forms of hydrocele just mentioned. If the swelling is more laterally situated and can only be incompletely displaced, and if, in addition, it is painful on pressure, we should think of a burrowing abscess and search for confirmation in the vertebral column.

Finally, if the swelling is reducible, but feels neither like intestine nor omentum, but like a smooth roundish body, the case is one of an inguinal testicle or a prolapsed ovary.

If, however, the swelling is irreducible, but is soft or tensely elastic in consistence, we must think, according to its position, either of an enclosed hydrocele in the inguinal canal, or of a burrowing abscess which admits of no displacement. In this connection it is worth mentioning that there a so such a condition as a *hydrocele in the female.*

A solid tumour is more probably an *inguinal gland*, especially if it is subcutaneous, of the shape of a bean, and multiple. The examination of the appropriate lymphatic district will show whether its origin is due to cancer, hard or soft chancre, or merely a simple herpes genitalis.

Should no such origin be discoverable, there arises the question of *tubercle* or *lymphadenoma*, for the latter occasionally starts in the inguinal region. We have already discussed the differential diagnosis in the chapter on Tumours of the Neck.

If the swelling consists of a large uniform tumour which has grown rapidly and soon becomes immovable, it must be regarded as a **sarcoma.** If its size increases but slowly, it must be regarded as a **fibroma of the abdominal wall.** A movable, spindle-shaped or cylindrical, hard tumour in the inguinal canal of a woman is most probably a **fibromyoma of the round ligament.**

(4) LUMBAR REGION.

A swelling which appears in the lumbar region during an abdominal strain is a **lumbar hernia,** whether it is spontaneously reducible or only by pressure.

There are two sites for hernial protrusion in the lumbar region. One is at the outer border of the quadratus lumborum, just under the twelfth rib (Grynfeldt), the other is at Petit's triangle, the three sides of which are formed by the iliac crest, the external abdominal oblique, and the latissimus dorsi. Congenital lacunæ in the muscles seem, however, to be of more importance.



FIG. 164.—Pseudo-hernia in the lumbar region, due to localized muscular paralysis.

In certain rare cases of *infantile paralysis* the muscular atrophy may affect the muscles in front of the quadratus lumborum, which become paralysed and atrophic over a definite limited extent. The border of the paralysed area is so sharp that it imparts the same sensation as the boundaries of a genuine hernial ring. Fig. 164 depicts such a case; one of the first in which this paralysis was shown to be the cause of the pseudo-hernia.

A lumbar swelling, which is only partially reducible after steady pressure, is either a **burrowing abscess** or a **tubercular perinephritic abscess,** which has burst through, behind. An examination of the urine will differentiate between these two possibilities. If the tumour

is soft, but quite irreducible, with a perfectly smooth surface, and a more or less distinct fluctuation, it is a cold abscess with the origin just mentioned, or it may have started in one of the lower ribs. If it has a lobulated structure, and its situation is definitely subcutaneous, it must be regarded as a **lipoma.**

(5) SWELLINGS AND TUMOURS IN ATYPICAL POSITIONS.

If a swelling is not in one of the usual typical positions, but still possesses the features of a **hernia,** we are bound to assume a traumatic origin for it. Such trauma is almost always a laparotomy wound, which at once reveals itself by the scar. It is much more rare



FIG. 165.—Tuberculosis of the abdominal wall.

for such localized destruction of the abdominal wall to be due to accidental injuries or inflammatory processes.

The very rare abdominal hernia which appears at the outer border of the rectus muscle, in the vicinity of the linea semicircularis, should be distinguished from other abdominal hernia because of its rather typical occurrence.

Irreducible tumours, connected with the *skin* and *subcutaneous tissue*, are **lipomata,** more rarely soft **fibromata,** occasionally also **nævi which have become sarcomatous.** (See under "Tumours of the Back," Chapter XXXI.) If they are more deeply situated and

are connected with the *muscular layer of the abdominal wall*, they may be either fibromata of the abdominal integument, which have been previously mentioned, or *tubercle* of the muscle, which not infrequently attacks the abdominal *muscles*. The female sex, and a spindle-shaped, sharply defined, uniformly hard tumour are points in favour of a fibroma; but an irregular shape, partial softening, slight mobility and relaxation of the abdominal integuments are points in favour of tubercle (fig. 165).

If a hard fibrous tumour appear in the operation area months, or even years, after an abdominal operation—*e.g.*, the radical operation for hernia—we shall probably find a few threads of silk floating about in a little deeply situated pus, or embedded in granulations, as first shown by Schloffer.

Experience shows that a hard, board-like swelling in the ileo-cæcal region, which gradually reddens the skin and eventually produces sinuses, is most probably **actinomycosis,** originating in the cæcum. Every localized inflammatory swelling of the abdominal wall should be referred to infection breaking through from the intestine, but it is more likely to be tubercle or cancer than actinomycosis, except in the ileo-cæcal region.

CHAPTER XLIX.

ABDOMINAL SINUSES.

A SINUS may arise anywhere in the abdominal wall, as the result of an abscess or a malignant growth breaking through. There is, however, nothing typical about such an occurrence. We will, therefore, confine ourselves here to sinuses whose position and characteristics are of diagnostic significance.

Most sinuses originate at the **umbilicus,** the point at which most abdominal organs meet in their embryological history, and which is the weakest spot in the abdominal wall, as far as later morbid processes are concerned.

(1) **Congenital umbilical sinuses** may be connected through a patent vitelline duct with the small intestine, or through a patent urachus with the bladder. The distinction is quite easy, because in the former cases fæcal matter escapes from the sinus, in the latter, urine. It is somewhat more difficult to account for a third umbilical sinus, which discharges neither fæces nor urine, but a thin mucoid fluid. This variety leads either into a piece of urachus,

which is open at the umbilicus but is closed towards the bladder, or into a piece of vitelline duct, closed towards the intestine. As far as observations have gone hitherto, the latter is the more frequent termination.

These incomplete vitelline sinuses discharge a peculiar acid secretion like the gastric juice, and were formerly regarded as gastric fistulæ. The secretion sometimes causes digestion of the skin, and ulcerates the area surrounding the sinus.

(2) We diagnose an **acquired umbilical sinus** from the nature of the secretion, and thus differentiate pure suppurating fistulæ, biliary fistulæ, fæcal fistulæ, and urinary fistulæ.

(*a*) *Suppurating fistulæ* usually result from an intra-abdominal inflammatory process, which has burst through the abdominal wall at the umbilicus, *i.e.*, its weakest spot. As a rule it occurs in peritonitis which has become chronic (pneumococcus infection, fig. 142). A localized tubercular peritonitis may exceptionally burst through at the umbilicus.

Rupture of a suppurating hydatid or ovarian cyst may be mentioned as a very rare cause of suppurating fistula at the umbilicus. Empyema of the gall-bladder may occasionally open at the umbilicus and cause a suppurating fistula, as long as the cystic duct remains closed. Finally, the sub-umbilical abscess at the back of the abdominal wall, previously referred to, may escape through the umbilicus.

A carefully passed probe will attain a certain depth in all these forms of umbilical sinus. But if, after several attempts, the probe does not reach beyond the umbilicus, the case is probably one of an *umbilical concretion* enclosed in a cutaneous pouch, or a ruptured *sebaceous cyst* or *dermoid* of the umbilicus, or, finally, a very small sub-umbilical abscess. If the microscopic examination of the secretion reveals chiefly detritus and epithelial cells, one of the first three possibilities should be thought of, but its accurate differentiation cannot be made out until the sinus is laid open. If the secretion is entirely purulent we should think of sub-umbilical abscess.

(*b*) *Biliary fistulæ* arise in the manner previously indicated if the cystic duct regains its patency after rupture of the empyema of the gall-bladder.

(*c*) *Gastric and intestinal fistulæ*, which are easily recognizable by the character of their secretion, are caused by rupture of an ulcer. In the case of the stomach, this is either a simple gastric ulcer or cancer; in the case of the intestine, it may be due to cancer or tubercle, but it may also be the consequence of a strangulated gangrenous umbilical hernia. The latter origin would at once be clear from the history.

(*d*) *Urinary fistulæ* may arise through extension of cystitis into

a persistent urachus, with eventual rupture at the umbilicus. In other cases they may be due to the rupture of a phlegmon of the abdominal wall caused by infiltration of urine.

Typical sinuses are also found in the inguinal region arising from a strangulated hernia, or through rupture of a burrowing abscess. The character of the discharge from the sinus (intestinal contents or pus) and the previous history will lead to a correct conclusion. In addition, a sinus situated very much at the side points to a burrowing abscess. But if the sinus is in a more central position, either between both recti or at the outer border of one of them, there may arise a question of tubercle of the pubic bone, or of osteomyelitis with a sequestrum. Finally, urinary fistulæ after strictures may occasionally wander into the lower abdominal region.

We shall not discuss *ectopia vesicæ*, because this malformation cannot be mistaken for anything else.

CHAPTER L.

EXTERNAL INGUINAL HERNIA.

ALTHOUGH abdominal herniæ are matters of daily occurrence, and the more common forms are correctly diagnosed by the public as well as by the profession, nevertheless there are some points worth referring to, even in this region. We begin with some observations on the subject of a "tendency to hernia," an expression which to many people conveys no clear conception.

A tendency to hernia implies certain anatomical conditions, which may lead to the development of hernia when the intra-abdominal pressure is raised, i.e., even to the slightest temporary entrance of any of the abdominal viscera into a process of peritoneum. A tendency to hernia may involve either the peritoneum or the muscular wall of the abdomen, or both.

In the former case the hernial sac is small, very narrow and congenital, being due to the imperfect obliteration of the *processus vaginalis* of the peritoneum. The sac is too narrow to admit any of the abdominal contents (fig. 166, *a*). The development of the muscles and aponeurosis may be quite normal.

In the latter case the primary change consists of a congenital or acquired weakness of muscles and fasciæ, combined with abnormal width of the canal. Every act of coughing presses the peritoneum, which is quite closed in the normal manner, against the unresisting internal inguinal ring, and causes it to bulge therein in a conical form (Kocher) (fig. 166, *b*).

Finally, both conditions, patent *processus vaginalis* and weak abdominal walls, may occur together.

The first variety of "tendency to hernia" cannot be demonstrated clinically as long as it is really only a "tendency." In the second variety of tendency the finger introduced into the inguinal canal meets with the well-known impulse. This also applies to the combined variety, in which the "tendency" rapidly develops into a complete hernia.

There is no doubt that the congenital tendency to hernia, in the form depicted in fig. 166, is of more importance than the acquired form, but this is no justification for throwing any doubt upon the occurrence of the latter.

After these preliminary remarks we now turn to simple inguinal hernia, dealing first with the form which manifests nothing abnormal externally.

(1) DIAGNOSIS IN THE ABSENCE OF A HERNIAL SWELLING.

To examine a patient for hernia, when there is nothing visible externally, we place him in a standing posture, with his legs somewhat separated, and direct him to cough or press, while we see whether any bulging occurs. If the whole region above Poupart's ligament becomes pushed forward in a diffuse manner, without any visceral projection, we term the condition "soft groin," *i.e.*, a congenital or acquired weakness of the abdominal wall. But if, on feeling both groins simultaneously, we appreciate a definitely circumscribed impulse on one side we may conclude that a hernia is beginning. Then we invaginate the scrotal skin into the inguinal canal with the index finger, and press again. In normal conditions this manœuvre causes the posterior superior limit of the inguinal canal to become more tense owing to contraction of the internal oblique; but if there is any tendency to hernia a soft bulging forwards of the posterior wall of the canal will be felt.

If any of the intestinal contents have entered the canal it is no longer a matter of tendency to hernia, but of a hernia actually begun. It is advisable to let the patient lie down before making any further examination into the direction and range of the inguinal canal. If the abdominal contents remain within the canal after the abdominal pressure has been relaxed, but do not emerge from the external ring on subsequent coughing, the case is one of intestinal, or, better, of inter-muscular hernia.

It sometimes happens that we are unable to secure any exit of intestine at the first examination, although a hernia is present. In such cases we may derive some assistance from carefully feeling the

spermatic cord. If it is definitely thickened on one side, and if it is possible to demonstrate the presence of a narrow transverse pad, we may assume the existence of a hernial sac. This narrow pad represents the ring-shaped thickening which is often observed in older hernias, and which had been situated previously at the internal inguinal ring. If this examination is inconclusive, it is necessary

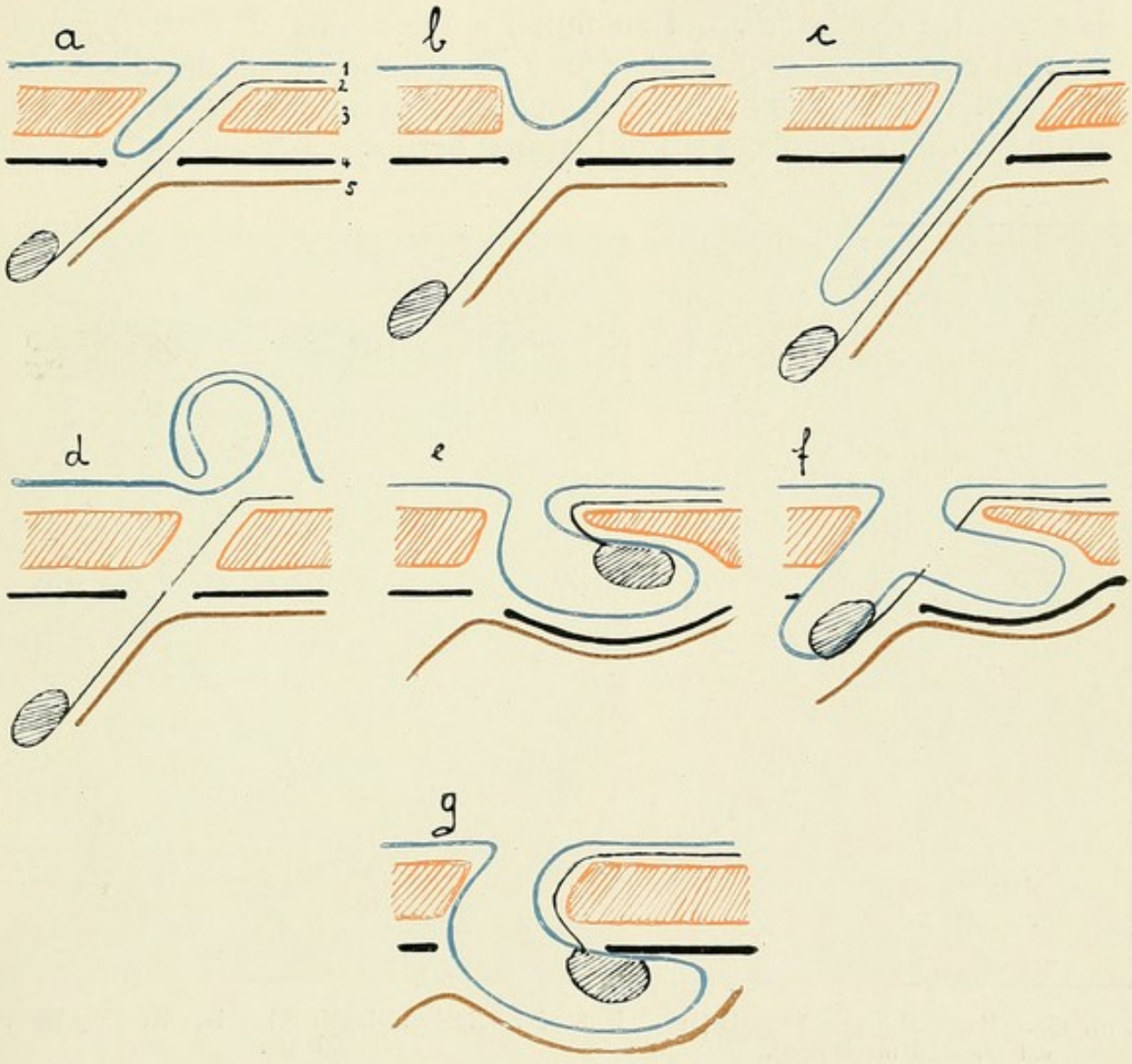

FIG. 166.—Relations between external inguinal hernia and the abdominal wall.

(1) Peritoneum. (2) Spermatic cord. (3) Muscular layer (especially internal oblique). (4) Aponeurosis of external oblique. (5) Skin.

(*a*) Congenital tendency to hernia.
(*b*) Acquired tendency to hernia with weak muscles.
(*c*) Fully developed inguinal scrotal hernia.
(*d*) Pro-peritoneal hernia.
(*e*) Intermuscular hernia (interstitial).
(*f*) Intermuscular bi-locular hernia.
(*g*) Subcutaneous hernia.

to repeat the examination by making a patient lift a heavy weight, with his legs outspread and his body bent backwards.

It is not easy to demonstrate the presence of an inguinal hernia in *females* if it does not happen to be down at the time of examination. The narrowness of the inguinal canal does not allow of the intro-

duction of the finger, as in the case of a male. If no impulse is seen or felt on coughing, we must endeavour to feel the hernial sac, which can be done more easily than in boys or men, because the round ligament in females disturbs us less than the spermatic cord in males. We place the index fingers on each side, median to the external inguinal ring over the pubic bone and move the skin over the latter, upwards and downwards, comparing the two sides. If a hernial sac is present, there is felt, not so much a thickening of tissue as fine friction caused by the gliding of one serous surface on the other. If this sign can be demonstrated at repeated examinations, we may be quite secure in our diagnosis of inguinal hernia.

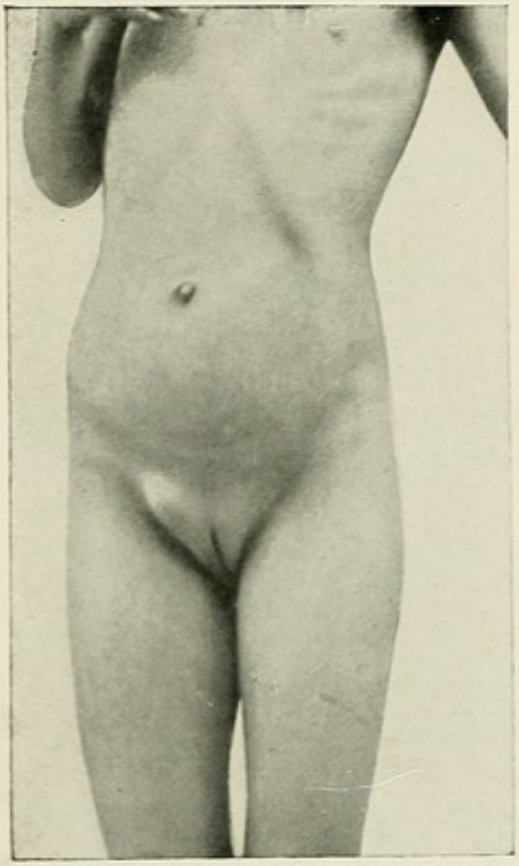

FIG. 167.—External inguinal hernia (at external abdominal ring).

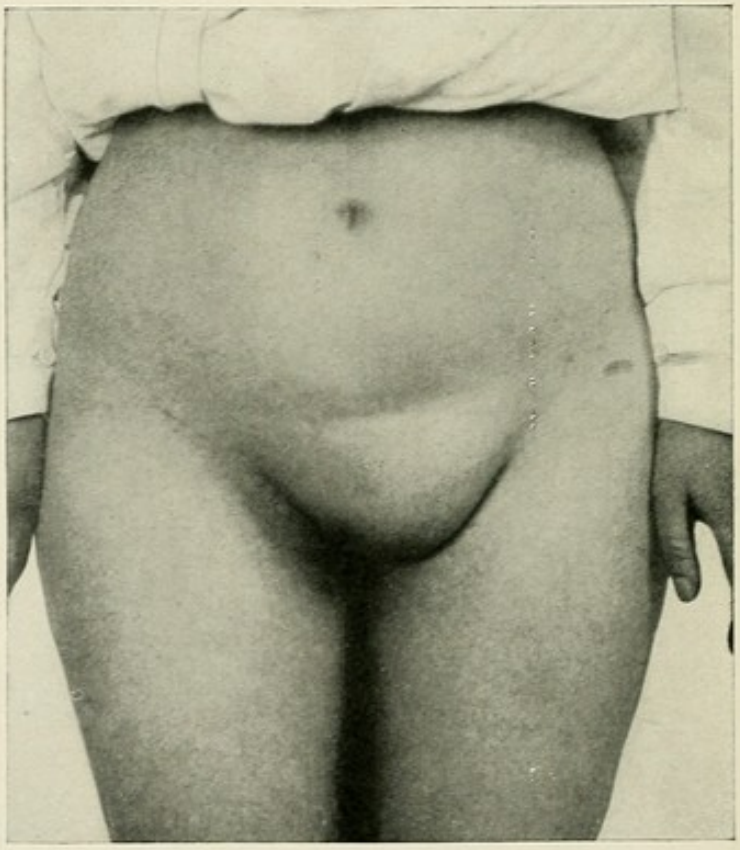

FIG. 168.—External inguinal hernia, extending into the labium.

This simple examination will sometimes explain severe attacks of abdominal pain which have been attributed to appendicitis, movable kidney, and other possibilities before the discovery of the hernia.

(2) DIAGNOSIS OF INGUINAL HERNIAL SWELLINGS.

If an abnormal swelling bulges forward in the inguinal region, the examination is a much simpler matter. If the swelling can be displaced backwards, and probably also yields an intestinal note on percussion, it is an interparietal intestinal hernia. If it is irreducible

but yields a definite intestinal note, the diagnosis is the same. If the swelling, whether reducible or not, feels like a soft granular mass, it is an interparietal omental hernia. But if, on the other hand, we define clearly a smooth, roundish body, it must be an inguinal testicle in a male, an ovarian hernia in a female.

Every now and then, such a swelling is a testicle, although the patient has a plait and bears a girl's name. A *pseudo-hermaphrodite* is proclaimed by a somewhat enlarged clitoris (fig. 169), but possessing both testicles and a vagina, the patient is too much of a male to be a woman, and too much of a female to be a man. It is fortunate if this state of affairs is discovered before marriage is contracted. Some of these pseudo-hermaphrodites celebrate the discovery of their sex by indulgence in tobacco and alcohol; others, despite their testicles, retain the sensitiveness of the female and remain true to their frocks.

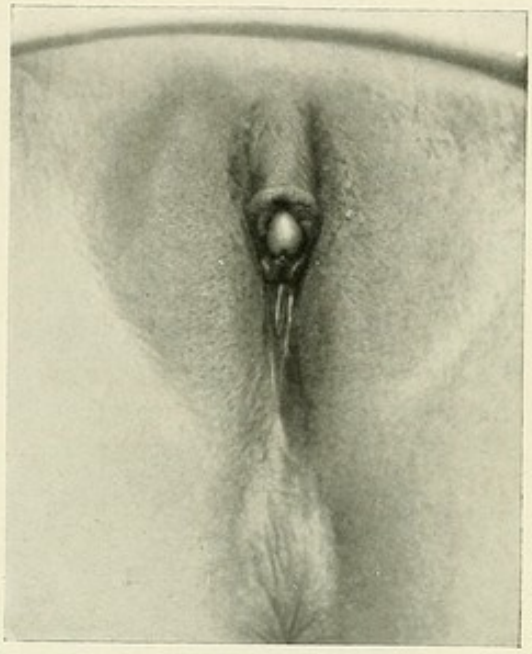

FIG. 169.—Genitalia of a male pseudo-hermaphrodite, with a vagina, and with testicles in a hernial sac.

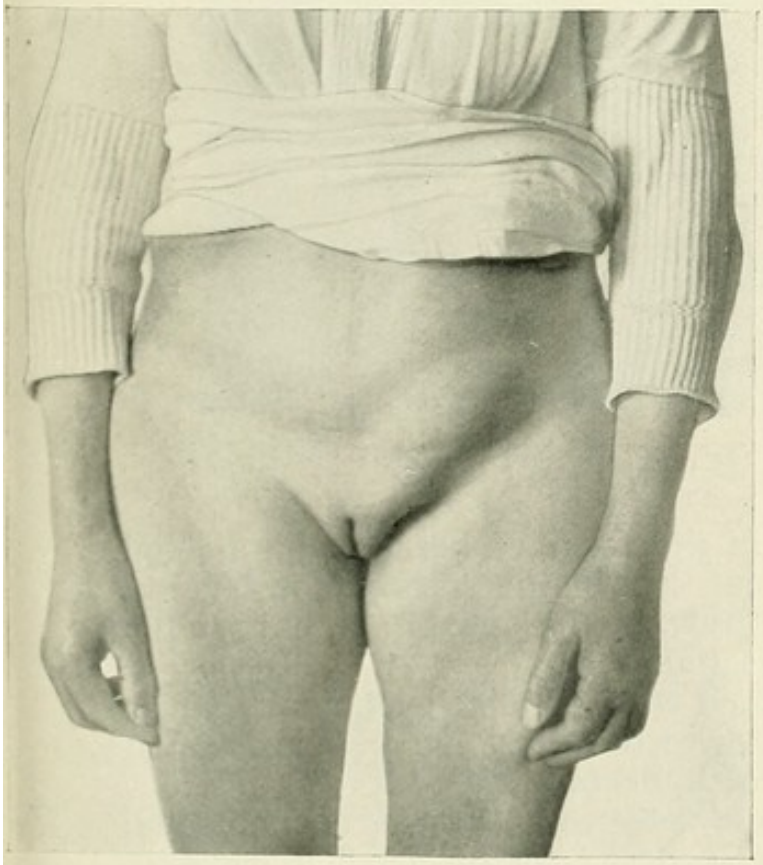

FIG. 170.—External inguinal hernia with a divided sac (one portion being labial, the other intermuscular, filling and emptying separately).

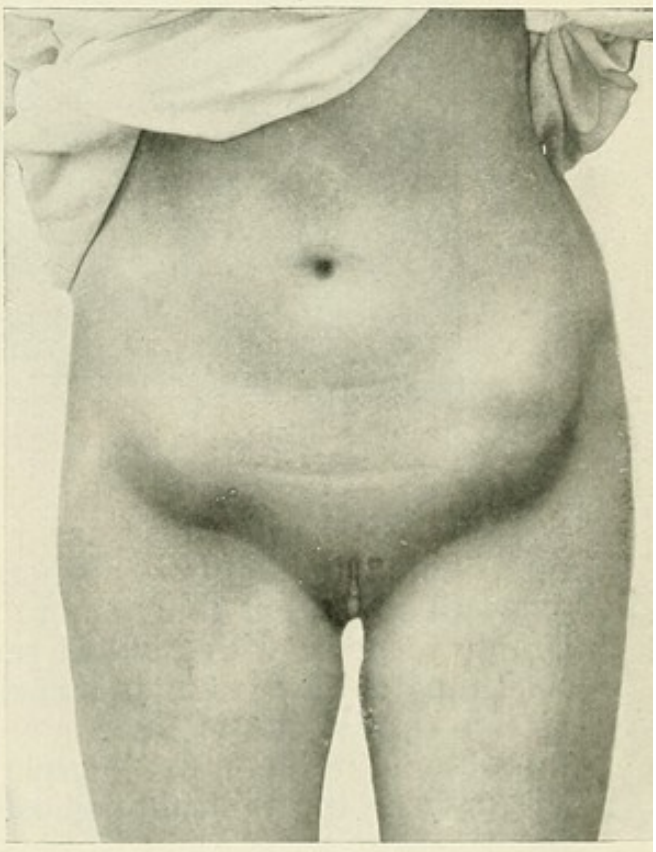

FIG. 171.—Bilateral burrowing abscess due to spi caries.

The detection of an inguinal testicle does not, of course, exclude a hernia ; indeed it renders the presence of a hernia very probable.

These herniæ may be divided into three main forms, according to their position :—

(1) *Pro-peritoneal hernia*, situated immediately under the parietal serous membrane (fig. 166, *d*).

(2) *Inter-muscular hernia*, in the area of the muscular abdominal wall, generally between the internal oblique muscle and the aponeurosis of the external oblique. (Interstitial hernia in a narrow sense ; subaponeurotic hernia.) (Fig. 166, *e* and *f*, and fig. 174.)

(3) *Subcutaneous hernia*, between the aponeurosis of the external oblique and the skin (inguino-superficial hernia, sub-fascial hernia). (Fig. 166, *g*, and fig. 174.)

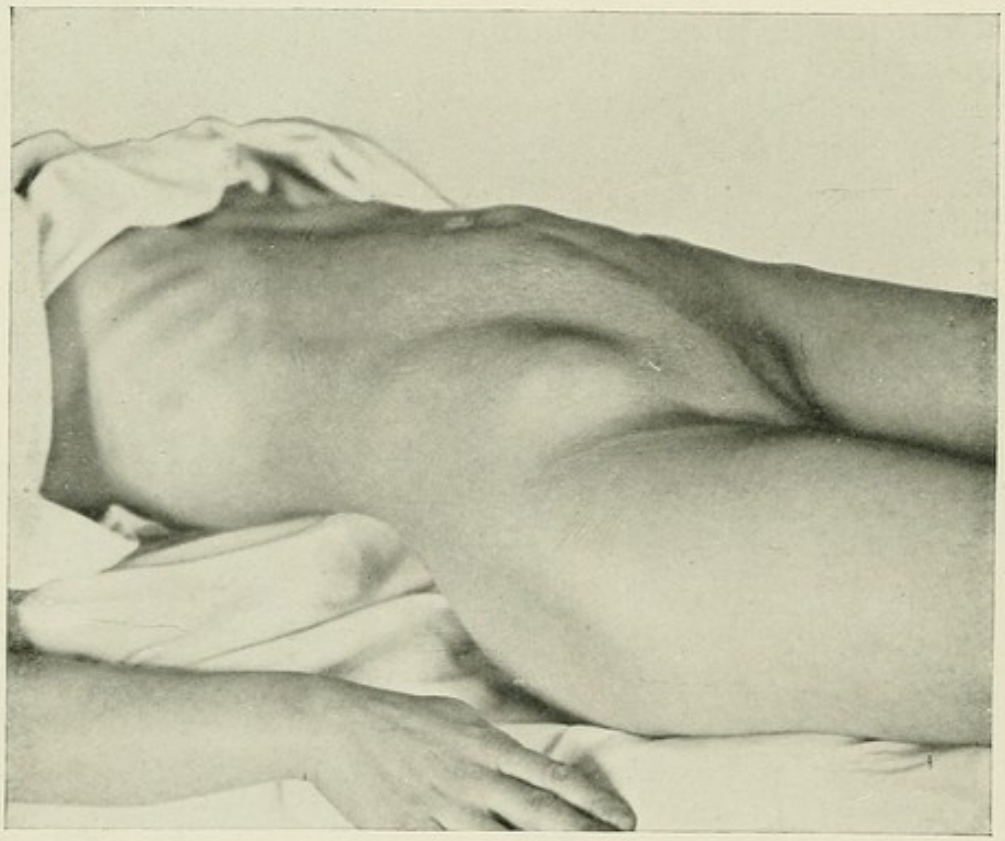

FIG. 172.—Right-sided burrowing abscess, admitted into hospital as "hernia."

All these herniæ may occur in the form of herniæ with divided sacs, which unite into one hernial sac in the scrotum or labium. They all occur, but much more rarely, in the female sex, both in the simple form or with divided sacs (fig. 170).

In males they are often associated with a retained inguinal testicle. If the hernial sac is of the subdivided variety the testicle is often found lying in the upper interparietal portion.

As far as the clinical diagnosis of these various forms is concerned, the *pro-peritoneal* variety is, as a rule, detected first when it becomes strangulated. The symptoms are those of internal strangulation, and a roundish resistance can be felt deep down behind the internal

inguinal ring. The diagnosis of the *intermuscular* and the much rarer *subcutaneous* varieties, has already been referred to in common; but their differentiation is of some interest. For this purpose, the patient is directed to sit up without supporting himself by his arms. If the aponeurosis of the external oblique then becomes tense *over* the hernia, the latter is intermuscular (fig. 174); in other cases it is subcutaneous (fig. 175). In this illustration the laxity of the hernia indicates its subcutaneous position at the first glance.

The following case is typical of a hernia with a divided sac:—

I operated on a man, aged 68, for what was apparently an ordinary scrotal hernia, without opening the inguinal canal, but I excised the sac as high up as possible. All went well until the patient stated, three weeks subsequently, that the hernia had returned. As a matter of fact, protrusion of the intestine could be seen above the internal inguinal ring, when the patient coughed. A second operation revealed

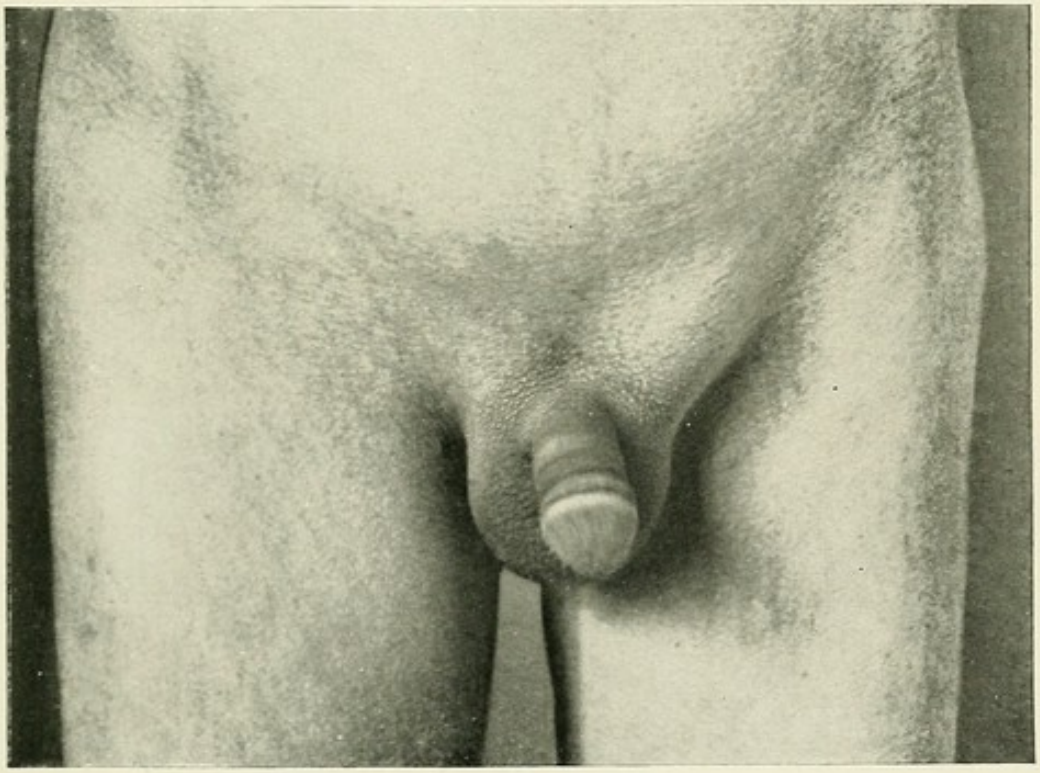

FIG. 173.—Hydrocele of spermatic cord.

an intermuscular hernial sac running laterally under the aponeurosis of the external oblique. It was quite as large as its scrotal offshoot, which had been removed three weeks previously, but was overlooked at the operation, because it had not been felt at the previous examination.

Simple as the diagnosis of interparietal hernia would appear to be from the foregoing remarks, nevertheless mistakes do occur. Femoral herniæ, with processes extending over Poupart's ligament, are especially liable to be mistaken for inguinal herniæ and *vice versa* (figs. 186 and 187). But it is not only with other herniæ that confusion arises, but

also with other diseases. Thus trusses have been ordered for burrowing abscesses, and not by quacks only, for medical practitioners sometimes neglect to make an examination from misplaced motives of delicacy, or conduct it so indifferently that it is quite useless.

Such errors are easily avoided by careful examination. As a rule, a spinal abscess shows fluctuation; a hernia does not. It is true that the pus can sometimes be displaced, but this only occurs gradually after steady pressure, and not suddenly with a gurgle, as in the case of the intestine. When the pressure is relaxed the swelling gradually returns without any straining, whereas a hernia requires some change of

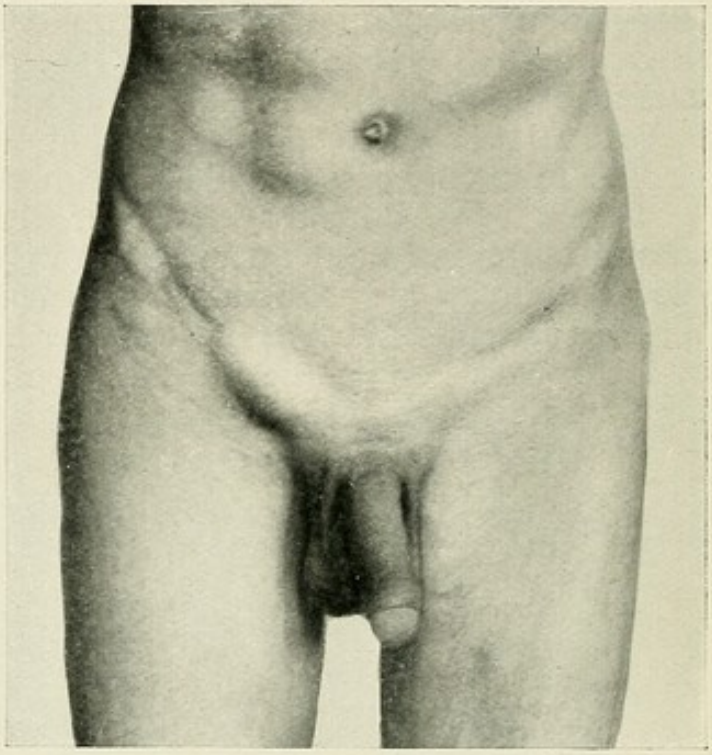

FIG. 174.—Intermuscular inguinal hernia, under the aponeurosis of the external oblique.

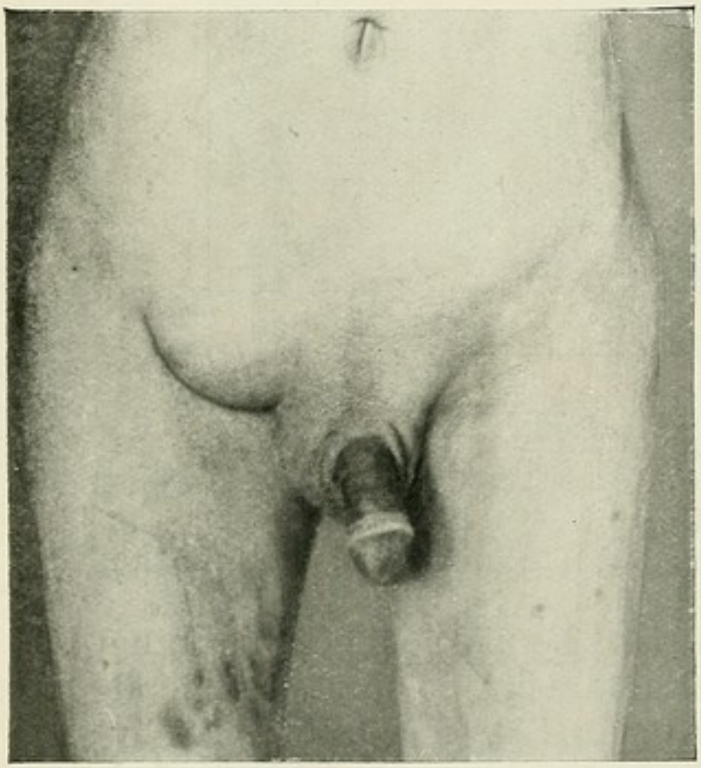

FIG. 175.—Subcutaneous inguinal hernia (H. inguino superficialis) situated under the skin.

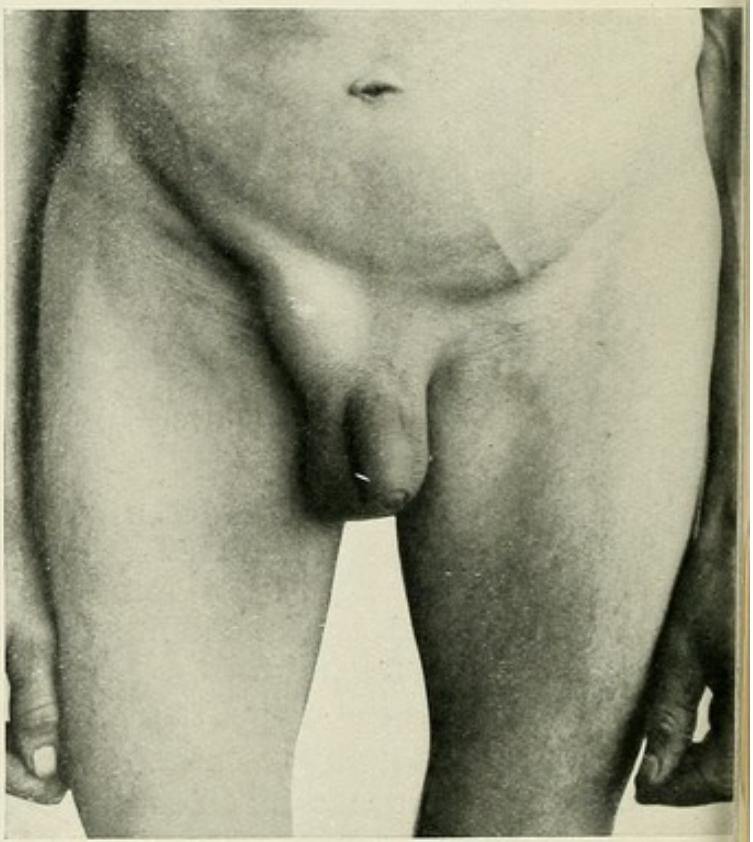

FIG. 176.—External inguinal hernia, just come through the external ring.

posture or the straining of abdominal pressure before it makes its re-appearance. Finally, most burrowing abscesses are situated more laterally than inguinal herniæ usually are (figs. 171 and 172).

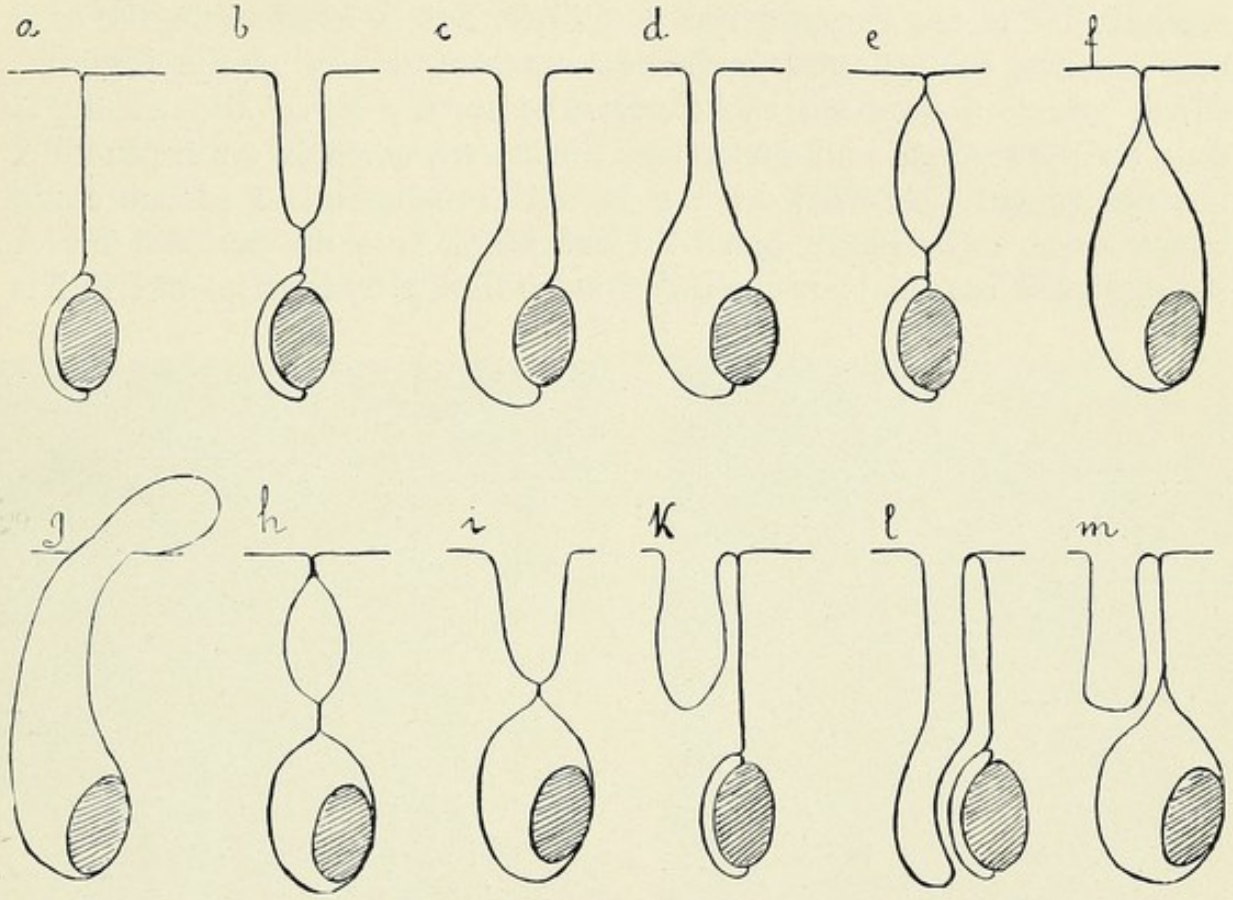

FIG. 177.—Diagrammatic representation of the relations between the vaginal process of peritoneum, in congenital and acquired herniæ and in hydrocele.

(*a*) Normal obliteration of the process.
(*b*) Partial patency of the process. Funicular hernia.
(*c*) Complete patency of the process. Testicular hernia.
(*d*) ,, ,, ,, ,, with narrow neck, communicating hydrocele.
(*e*) Patency in centre of process. Funicular hydrocele.
(*f*) Patency at lower part. Testicular hydrocele.
(*g*) Outgrowth of *f* upwards. Bilocular hydrocele.
(*h*) Combination of *e* and *f*. Funicular and testicular hydrocele.
(*i*) Combination of *b* and *f*. Funicular hernia and testicular hydrocele.
(*k*) Acquired funicular hernia.
(*l*) ,, ,, ,, reaching as far as the testicle, and imitating (*c*) congenital testicular hernia.
(*m*) Combination of *f* and *k*. Acquired funicular hernia, and congenital or acquired testicular hydrocele.

(3) DIAGNOSIS OF LABIAL AND SCROTAL HERNIÆ.

A swelling situated within the scrotum or labium can only be a hernia if it has a pedicle running in the inguinal canal. If this be not the case (fig. 178), there is no hernia. If, however, there be such a pedicle, we must see whether the swelling is reducible (fig. 179). If the swelling can be displaced backwards, possibly with a buzzing or gurgling sound, the case is one of hernia. If the reduction is slow and requires steady pressure, the condition is usually one of communicating hydrocele, and only rarely a bilocular hydrocele with the second sac in the abdomen.

A varicocele is apparently reducible, but the filling up of the swelling like a handful of earthworms, when the patient stands, and its immediate relaxation when he lies down, without, however, any of its contents actually receding, ought to exclude the possibility of any confusion. If the swelling has a pedicle, but is irreducible, the case may be one of testicular hydrocele reaching as far as the inguinal canal. Such a swelling is, however, uniformly tense and elastic, is dull on percussion, and generally translucent, whereas an irreducible, unstrangulated intestinal hernia is not translucent, is of more lax consistence, and usually gives the intestinal note on percussion. A strangulated hernia is indeed also tense like a hydrocele, but it has

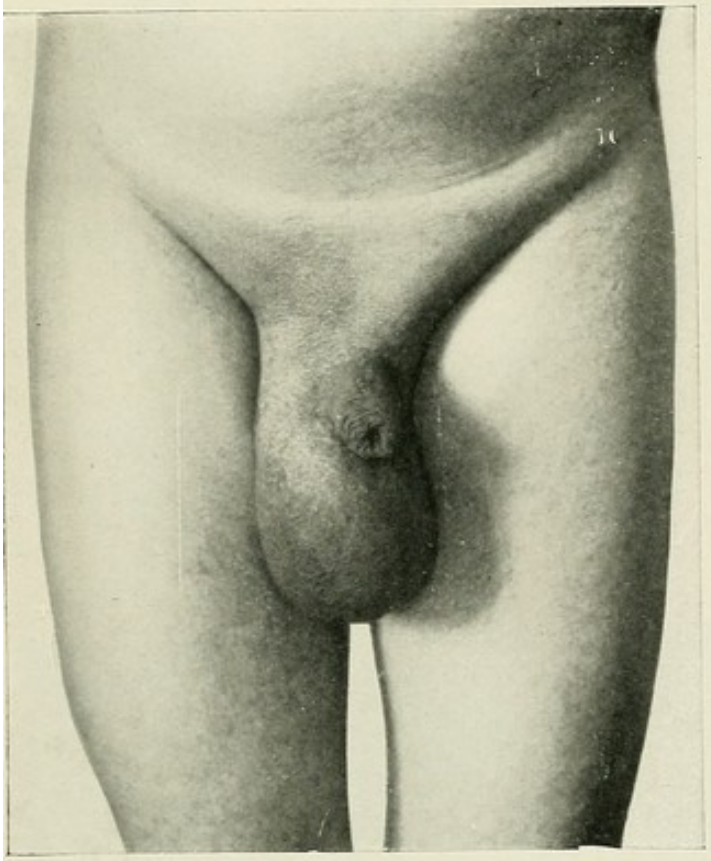

FIG. 178.—Testicular hydrocele.

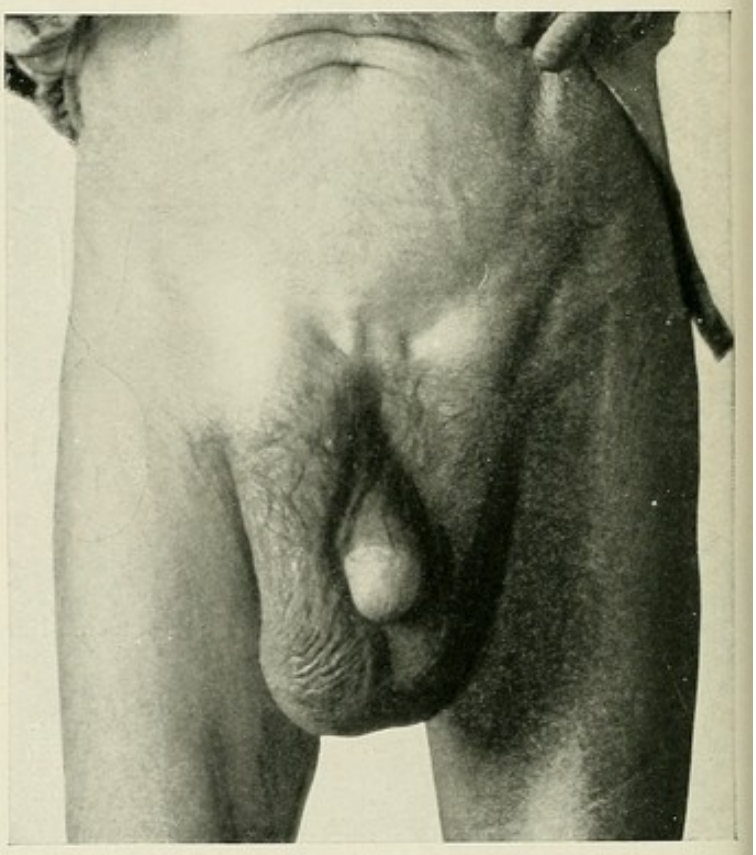

FIG. 179.—Bilateral external scrotal inguinal hernia.

a smaller and very tender pedicle, and, moreover, is always attended by symptoms of intestinal obstruction. But the following case will indicate how error can arise.

A young man sought advice for a classical pear-shaped irreducible testicular hydrocele, with a narrow neck in the inguinal canal. He stated that he had felt, two months ago, just before the appearance of the hydrocele, a sudden pain in the left hypogastrium. We attached no importance to this, and adhered to the diagnosis. At the operation, a hydrocele was indeed discovered, but it had a narrow offshoot in the inguinal canal, containing a small adherent plug of omentum. The patient, therefore, had a small strangulated omental hernia in a congenital sac, and the fluid was really hernial in character. The

pain in the hypochondrium was due to the dragging of the omentum at the moment of strangulation. If we had paid more regard to the history, an accurate diagnosis could have been made.

An irreducible granular or lobulated scrotal swelling which possesses a pedicle may be one of three things : (1) Omental hernia ; (2) hernial sac, with much peri-hernial fat ; or (3) a lipoma of the spermatic cord. Unaltered omentum in a hernial sac feels more finely granular than a lipoma of the spermatic cord. But this distinction is a very delicate one, and can only be appreciated by very experienced fingers. The history is really of more value in this connection. If the patient states that the size of the swelling is very

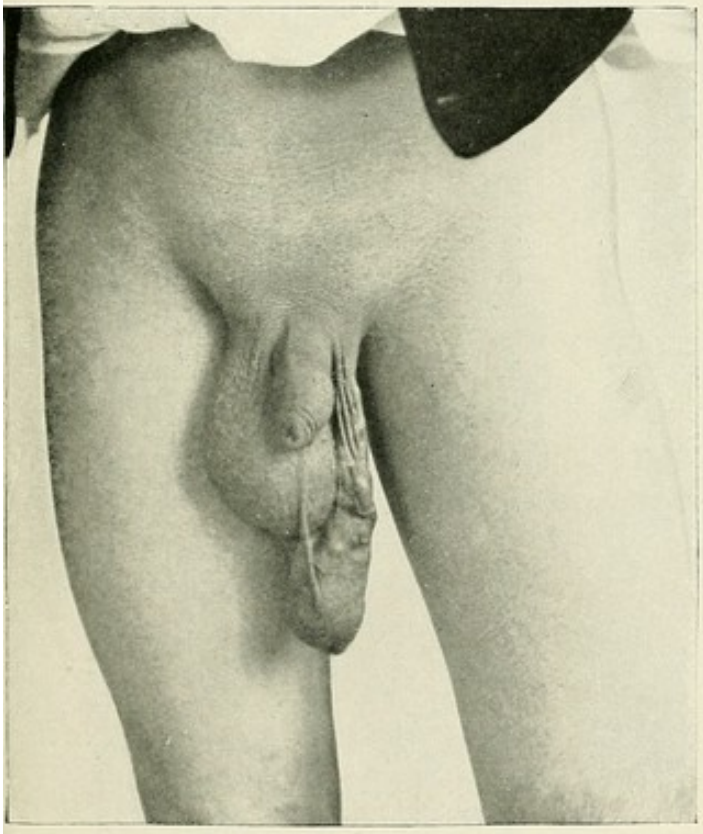

FIG. 180.—Varicocele with atrophy of testicle.

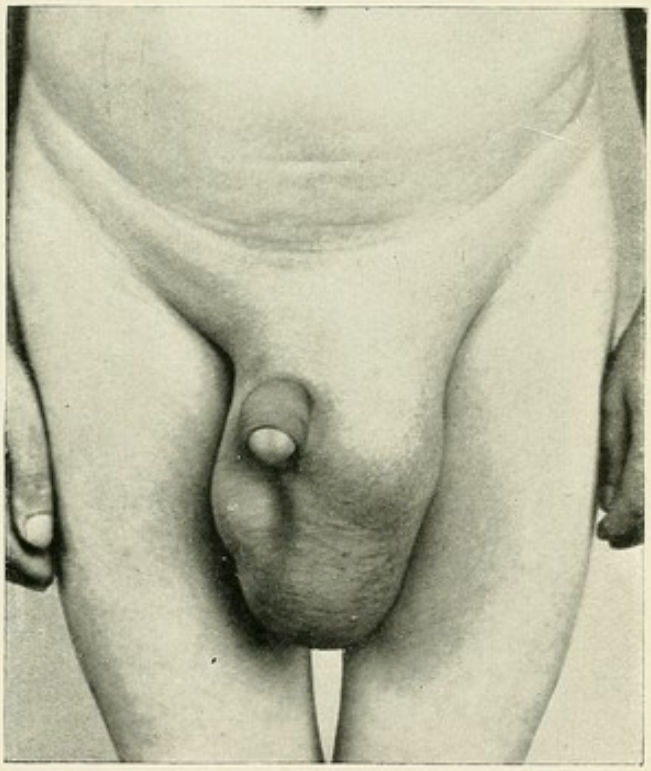

FIG. 181.—Left-sided hydrocele and external inguinal hernia.

variable, we should think of hernia, as also if he frequently complains of pain during digestion. The not infrequent cases wherein a small lipoma of the spermatic cord is present with a hernia are hardly capable of being diagnosed.

It is of diagnostic importance to know that inguinal hernia and lipoma of the spermatic cord are sometimes accompanied by obstinate spermatic cord neuralgia, the cause of which remains obscure until the hernia or the lipoma appears.

Diffuse extension of peri-hernial fat is rarely found in external inguinal herniæ, but it is quite general in internal inguinal herniæ and in femoral herniæ.

CHAPTER LI.

INTERNAL OR DIRECT INGUINAL HERNIA.

THERE is usually no difficulty in distinguishing an internal direct inguinal hernia from an external indirect hernia, if one bears in mind that in the former the hernial ring leads directly into the abdominal cavity, and does not run through the inguinal canal. This form is frequently bilateral, and does not descend into the testicle, but remains above the root of the penis after giving rise to a pronounced transverse fold in this region (fig. 183). In contrast to the external variety, internal hernia usually occurs in the middle-aged and the old, and almost always in males. On coughing a semi-globular swelling appears, which is more sharply defined laterally than in the case of an external inguinal hernia.

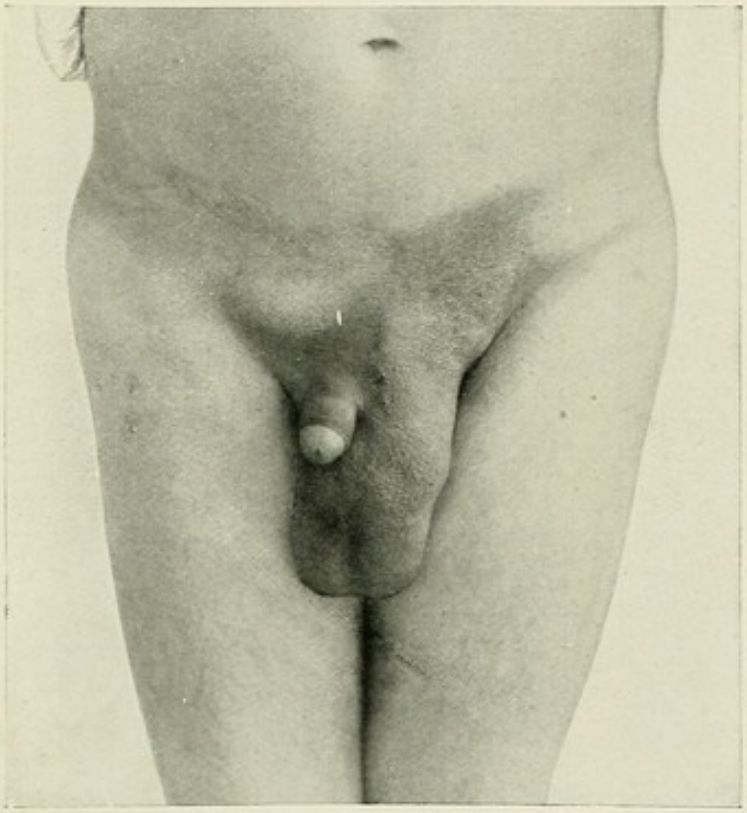

FIG. 182.—Internal inguinal hernia on the right, and external hernia on the left.

No importance should be attached to the clinical demonstration of the position of the deep epigastric artery. It runs upward, along the inner side of an external hernia, and along the outer side of an internal hernia. Valuable as this sign may be at the operation, when a case is doubtful, it is, as a rule, impossible to palpate the artery before operation.

In addition to the cases which fit in the above scheme, there are two varieties of inguinal hernia which may present some difficulties in diagnosis :—

(1) External inguinal herniæ of old standing, wherein the canal has lost its obliquity, and the hernial ring opens directly into the abdominal cavity just as in the case of an internal hernia, but the hernial sac has not descended into the scrotum. The gradual protrusion of the swelling towards the side may, in these circumstances, be the only sign pointing to an external hernia.

(2) Internal inguinal herniæ which descend to a small extent into the scrotum—a condition noted by Berger, and one which we have

occasionally observed—and which are easily mistaken for external herniæ. Difficulty in diagnosis will be encountered if it is not possible, on examining the hernia after reduction, in a recumbent posture, with one finger in the canal and the other introduced directly into the ring, to demonstrate that there is still a bridge of tissue between the two fingers.

The question which arises occasionally in connection with a direct hernia, as to whether it is more of a lipoma or more of a hernia, is unimportant, because it is quite a relative matter. All internal inguinal herniæ have a more or less extensive fatty layer within the sac, and the personal equations come in in deciding where a hernia ceases and a lipoma begins.

A final word concerning **hernia of the bladder.** This may occur either in an external or an internal inguinal hernia, but more frequently in the latter. It will be understood that one cannot speak of hernia of the bladder, when a piece of this organ is dragged up into the ring during the course of a radical operation on the hernia. A portion of the bladder must be part of the regular contents of the hernia—not necessarily of the hernial sac, because the bladder often extrudes itself, extraperitoneally, along the side of the sac, to the ring. Disturbance of micturition would justify the suspicion of a hernia of the bladder, whether it be difficulty in emptying the organ, or frequent tenesmus. The suspicion would be confirmed if it were observed that these disturbances coincided with fulness of the hernia. It is possible to demonstrate in such cases that when the bladder is very full there is fluctuation in the hernia and dulness over it on percussion, signs which disappear after the bladder is emptied. In some circumstances the catheter is required to empty the bladder, because internal inguinal herniæ happen to be most frequent in patients with enlarged prostates.



FIG. 183.—Bilateral internal inguinal hernia.

CHAPTER LII.

FEMORAL HERNIA.

THERE are not many swellings which can be mistaken for femoral hernia. Errors may, however, possibly arise in connection with hernial protrusion of the saphenous vein, enlarged glands, lipomata, burrowing abscesses in the crural ring, and, finally, inguinal herniæ. We will consider these in order. The not infrequent **protrusions of the saphenous vein**, if visible, glimmer with a blue colour through the skin, the slightest pressure suffices to make them vanish, but they return as soon as the pressure is relaxed. They react with mathematical, or rather with physiological, precision to every variation in venous pressure, such as is caused by coughing, vomiting, &c., and even to the normal breathing, in a recumbent position. These signs are so clear that confusion would apparently seem impossible, but as a matter of fact errors have arisen. **Burrowing abscesses** do not, as a rule, break through the spaces transmitting the vessels, but more laterally through a muscular interspace; they are frequently multilocular, and are displaced on gradual pressure, yielding a sensation of elastic resistance. They fill up again as soon as the pressure is relaxed, without any abdominal straining or change in the posture of the patient. But even in the cases wherein these abscesses appear towards the middle line, as in fig. 185, the other signs are so definite, that an error is hardly possible after careful examination.



FIG. 184.—Bulging of the femoral region through varicose swelling of internal saphenous vein.

Enlarged glands may present more difficulties. The entrance of the infection is usually found somewhere on the leg or foot. The chief characteristic of enlarged glands, even when chronic, is their sharp limitation at the femoral ring, whereas a hernia always possesses

a pedicle which runs under Poupart's ligament, and which is compressible against the pubic bone. The rare subserous **lipomata** are also, strictly speaking, pedunculated, but the pedicle cannot be felt like the neck of a hernia. The absence of a palpable process into the abdomen, combined with the absence of any variation in volume and symptoms of hernial protrusion, would suggest a lipoma, behind which there may be a small pouch of peritoneum, although it may never have contained any intestine or omentum. It is very significant of femoral herniæ that a very small hernial sac is often surrounded by a large amount of fatty tissue, which grows into a lipomatoid structure.

Superficial lipomata also occur in this region, either as isolated growths, or as a partial manifestation of a general lipomatosis (fig. 188).

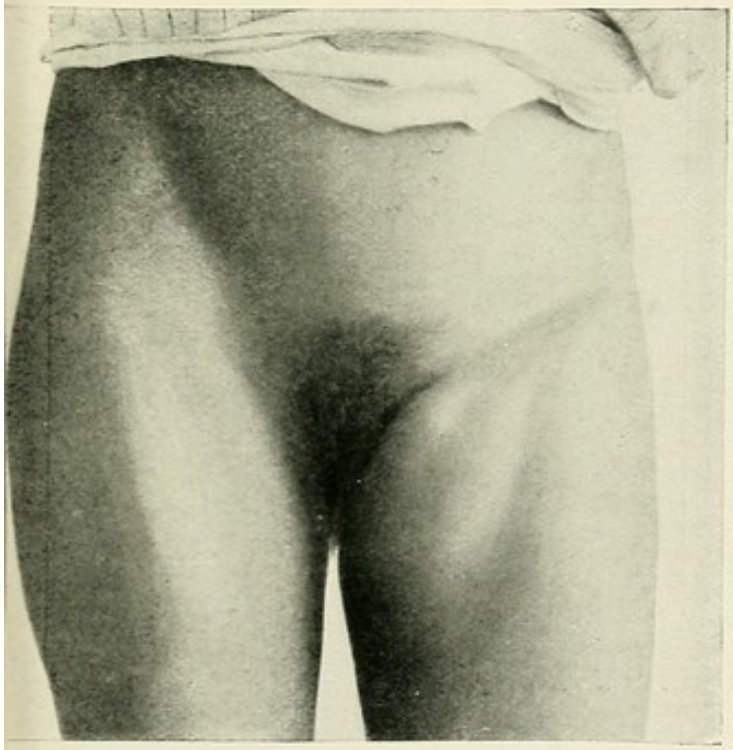

G. 185.—Crural burrowing abscess from spinal caries.

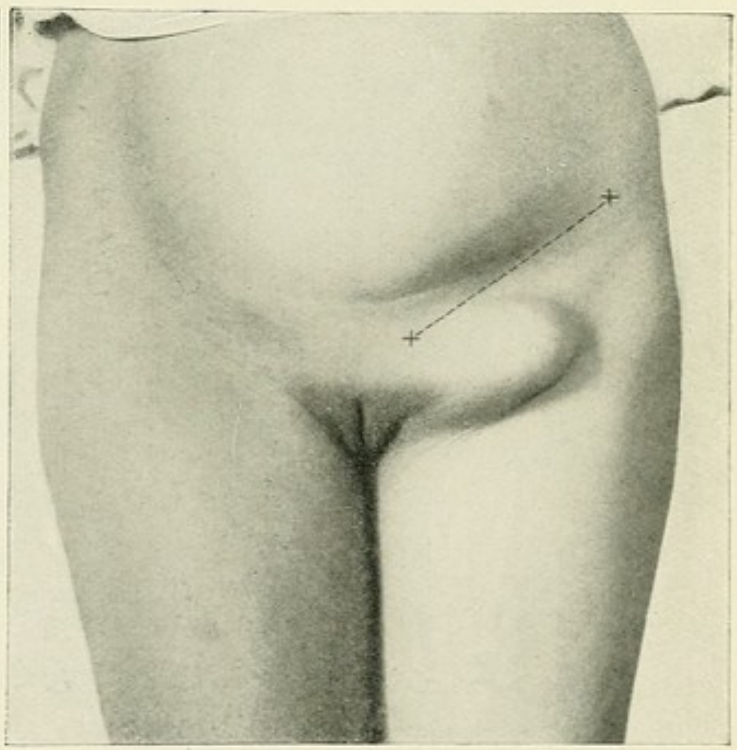

FIG. 186.—Crural hernia in female. Its relation to Poupart's ligament, X—X.

If the swelling has a definite pedicle which becomes lost under Poupart's ligament, the diagnosis of **hernia** can hardly be mistaken. But if there is no intestinal note, the case is either one of peri-hernial lipoma, just mentioned, or an omental hernia.

The differentiation depends less upon the physical condition found on palpation, than upon the presence or absence of symptoms of omental dragging, as already indicated in the case of inguinal herniæ. The question, is, however, one of indifference, because if treatment is called for, operation must be undertaken in either case.

If a pedunculated swelling feels definitely elastic, there must be a collection of fluid in an old obliterated hernial sac. If attacks of sudden

abdominal pain, without intestinal obstruction, have preceded the onset of a tense hernial swelling, it is obvious that a small piece of peritoneum has been strangulated in the ring and has led to the development of hernial fluid.

Having determined that the swelling is a hernia, the question still remains as to whether it is really a **femoral hernia.** If the tumour is clearly below Poupart's ligament, the matter is settled; but if it is riding on the ligament the solution is not so clear. It may be an inguinal hernia which has wandered downward, or it may be a femoral hernia which has grown upwards (figs. 189 and 190). The differentiation is not difficult, if we are able to reduce the hernia. We base our decision on the position in which it recedes, and by feeling the

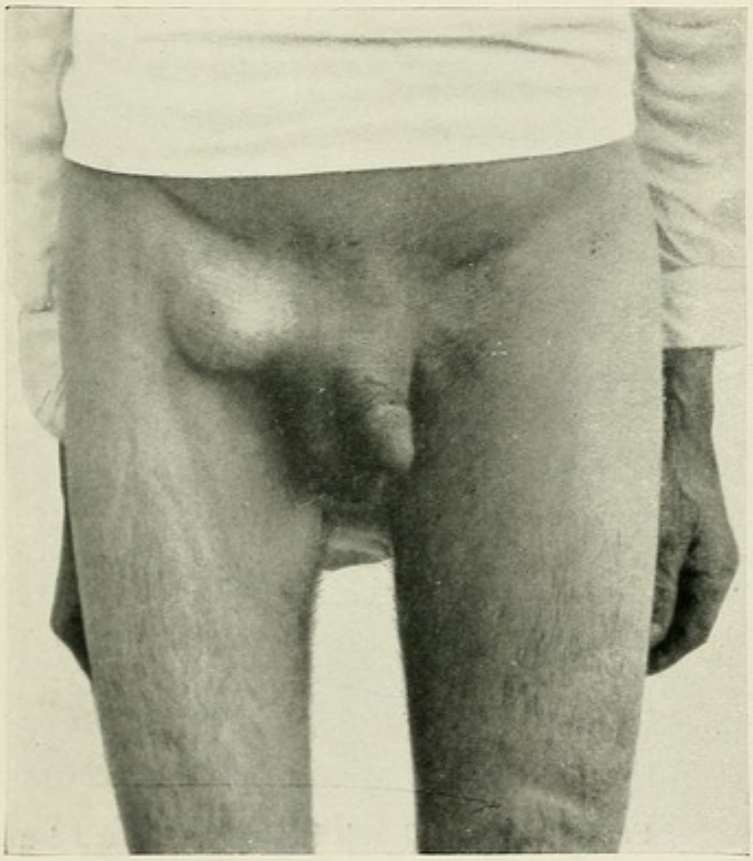

FIG. 187.—Femoral hernia in a male.

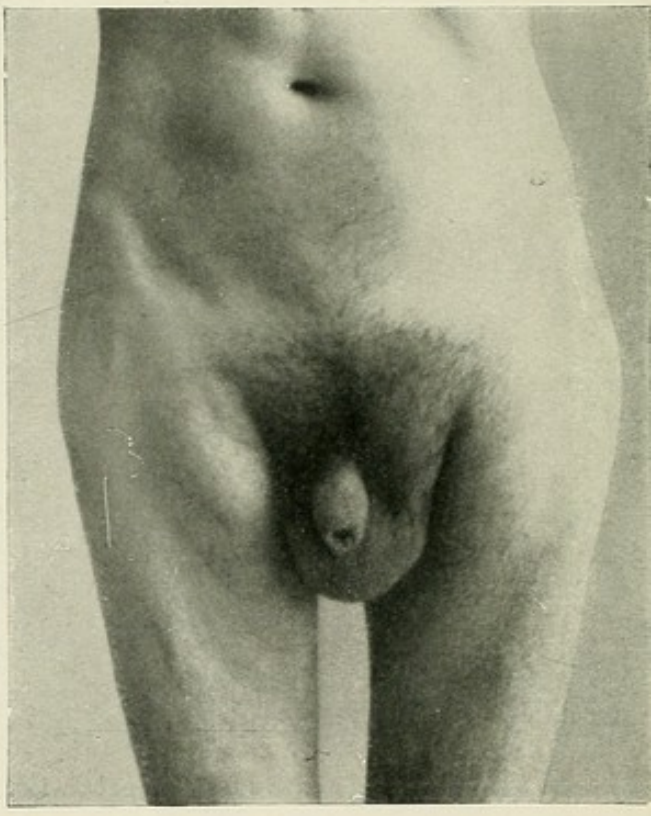

FIG. 188—.Symmetrical lipomata in crural regio

ring. It is, however, otherwise, if the hernia is irreducible, whether it be strangulated or not. Incorrect diagnoses are very frequent in such cases, and as a rule a femoral hernia is taken to be an inguinal hernia. As Poupart's ligament cannot be clearly defined because it is overlain by the hernia, and because it is obscured by fat in elderly women, Malgaigne's line has been adopted to indicate its position, *i.e.*, the line joining the spine of the pubis with the anterior superior spine of the ilium (fig. 186). Everything above this line is to be ascribed to inguinal hernia, and below it, to femoral hernia. But this criterion is not always reliable. More importance is to be attached to the position

and direction of the neck of the hernia, which can generally be felt on careful palpation, and which is recognizable, when strangulated, by its size and tenderness on pressure. If it runs vertically and is capable of being moved from side to side on the crest of the pubes, or if it appears to run deeply down when the hernia is displaced upwards, the case is one of femoral hernia. If it runs outwards and upwards, or directly outwards, the case is one of inguinal hernia. This sign enables a definite diagnosis to be made in such a case as fig. 190, although the major portion of the hernial swelling was above Poupart's ligament.

If there is a history of hernia, but we find nothing at our first examination, we must carefully compare the two sides for slight tissue thickening, or for fine friction, as already mentioned in connection with inguinal hernia. We must especially observe whether the area of the fossa ovalis is fuller on one side than on the other. In this way we may sometimes discover the explanation for inexplicable abdominal pains, even if the patient denies any hernial protrusion. I have already mentioned that I once removed an appendix because of the history and the diagnosis of the family practitioner, and then, later on, recognized that the pains which continued were really due to a small concealed femoral hernia on the right side.

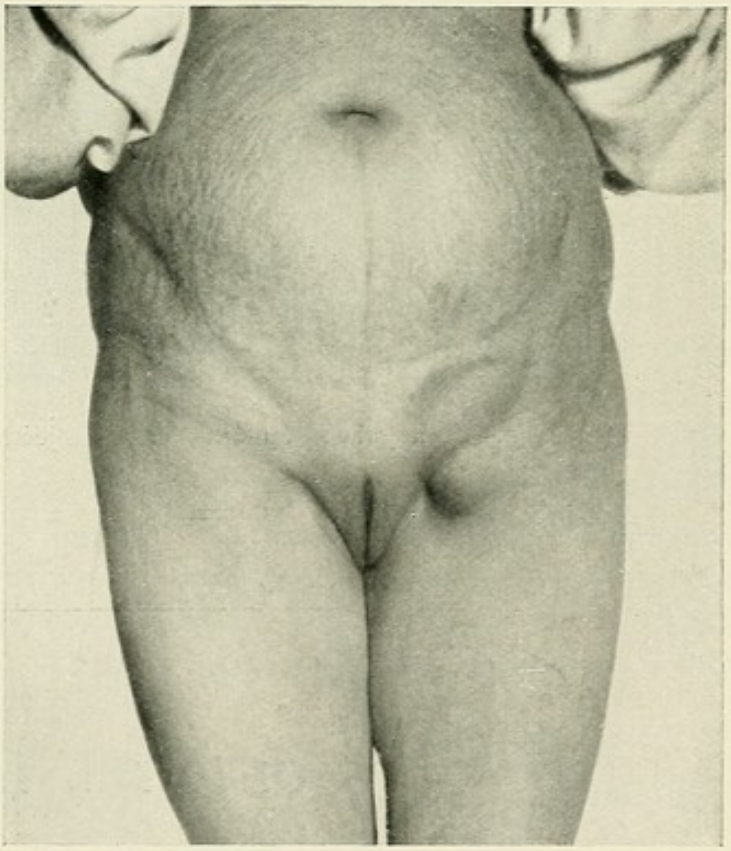

FIG. 189.—Bilocular femoral hernia encroaching above Poupart's ligament.

There are a few *abnormalities* in connection with femoral hernia, which are generally only discovered at the operation, but which might be recognized, or at least suspected, on careful examination.

For instance, the hernial sac may pierce into the muscle under the *fascia of the pectineus*, and thus resemble an obturator hernia—a rare condition only occurring in women and designated after Cloquet. The hernia may descend *under the large vessels*, or it may appear to their *outer side* in the opening through which they run, or it may leave the abdominal cavity through a muscular interspace. This latter

form, the so-called *Hesselbach's hernia*, has been recognized before operation by means of its broad base and its lateral position. Finally, we find here, as in inguinal hernia, a *pro-peritoneal* form, which does not come through the abdominal wall.

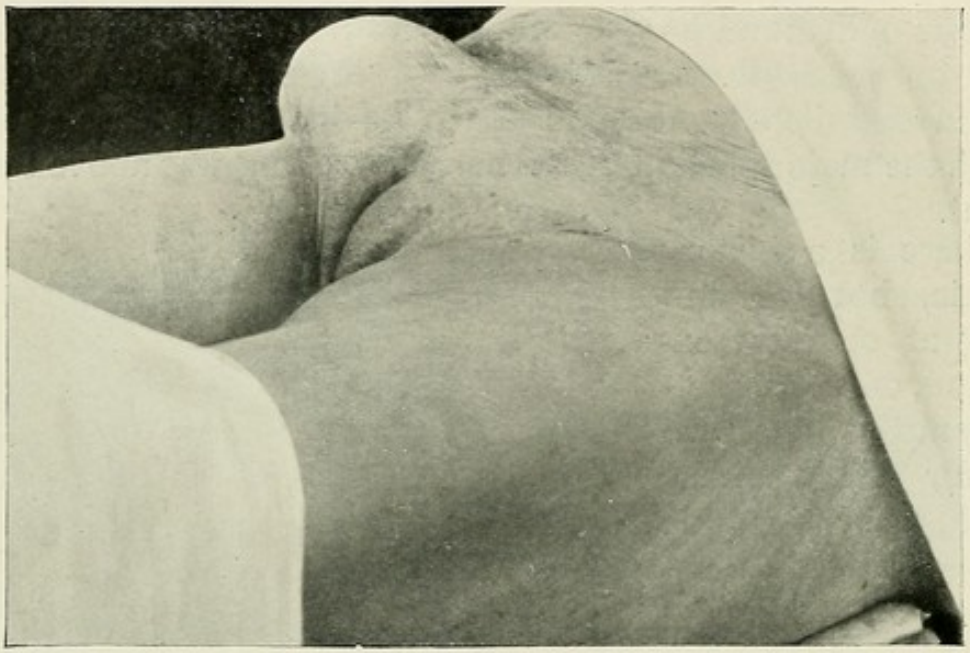

FIG. 190.—Strangulated femoral hernia projecting above Poupart's ligament.

CHAPTER LIII.

TRAUMATIC HERNIÆ.

THE surgeon will occasionally be confronted with the question as to whether the hernia which he has demonstrated has arisen through an "accident." The term is usually meant to include any sudden strain, which does not come within the patient's ordinary occupation, or one within his occupation, if it has overtaxed his strength. Most of these cases are accounted for by the sudden strain of abdominal pressure, with the body in disadvantageous posture.

The story of the Zouave trumpeter is typical of this. As he was blowing for the attack at Malakoff, he fell into a hole, and got up with a hernia.

We have to take into consideration both direct and indirect trauma. Neither form can cause a hernia in persons hitherto perfectly normal. But indirect trauma—rarely direct—may convert a

tendency to hernia into actual hernia, *i.e.*, the stretching of the pre-existing small hernial sac and the consequent dragging of the parietal peritoneum may determine the entrance of some intestine or omentum into the sac. This process is, as a rule, so painful, that it prevents any further bodily exertion, and the patient feels bound to seek medical advice. These two conditions are usually associated in the evidence of a "traumatic hernia," though there are exceptions varying with the occupation and energy of the workman.

A hernia which has arisen in this manner is small—at most the size of a hen's egg—the sac is thin, and not palpable ; the hernial ring is generally small but it may be of medium size. The intestine does not always protrude when the patient assumes the erect posture, but once having protruded it does not always return when he lies down. The hernia is only slightly movable, without, as has been asserted, necessarily being strangulated. There should be no traces of a truss on the skin.

The consideration of these circumstances enables us to decide whether the hernia could possibly be traumatic, *i.e.*, whether it could have arisen from sudden strain. As a rule, nothing more definite can be said, unless the patient happens to have been examined shortly before, specially for hernia. However reasonable the claim of the workman for compensation may be, for the genuine traumatic change of his "tendency to hernia" into an actual hernia—for instance, a radical cure by operation, without any money payment—nevertheless the practitioner should be extremely cautious in countenancing the fashion of making a profit out of these too easily assumed cases of traumatic hernia.

The extent to which these attempts may go is illustrated by the fact that even gonorrhœal epididymitis and inguinal buboes after soft chancres have been represented as "traumatic hernia."

Most so-called traumatic herniæ are of the external variety ; but all forms have been at times ascribed to injury. We may, however, discard the possibility, in internal inguinal herniæ and umbilical herniæ, and should be very sceptical with femoral herniæ. An epigastric hernia is much more likely to be due, in some considerable degree, to trauma.

CHAPTER LIV.

STRANGULATED HERNIA.

It is most important to observe that *strangulation* must not be confused with *irreducibility*, for it is only one special variety of irreducible herniæ. Both intestine and omentum may be *irreducible* without being strangulated; the cause usually is the presence of adhesions. Moreover, the omentum within the sac may develop so much, entirely of its own accord, that it is unable any longer to slip back through the hernial ring, even if no adhesions exist.

A special form of irreducibility is found in connection with certain herniæ of the cæcum and ascending colon, and also of the sigmoid and descending colon. In these cases, not only does the intestine, which is covered by peritoneum, leave the abdominal cavity, but also its extraperitoneal site of attachment, and, in consequence of the slipping down of this surface of attachment into the area of the hernia, the intestine loses all its tendency to return within the abdomen.

It may be mentioned incidentally that it is obvious that the hernia has no sac on this surface.

There are also those enormous herniæ which are met with less frequently than formerly, which, apart from adhesions, are irreducible, because the abdomen no longer contains enough space to receive them. Petit aptly said that these herniæ "have lost their right of domicile."

The subjective symptoms of a non-strangulated but irreducible hernia are not, as a rule, any more severe than those of a free hernia. But dragging pains are often present; though they manifest themselves in the upper part of the abdomen rather than in the hernial region. Local pain usually arises if the patient maltreats the hernia with a truss.

Strangulation is a form of irreducibility which arises suddenly, and is attended by constriction of the pedicle, fixity of the presenting intestine, with disturbance of the circulation in the contents of the sac. A number of questions require answering in this connection.

(1) Is the Case really one of Hernia?

This is no superfluous question. Every surgeon has had infants referred to him with the diagnosis of strangulated hernia, when the case has been one of acutely arising *hydrocele in an infant*. The distinction is really not difficult. The tense hydrocele swelling is, as a rule, definitely limited above, and does not run into the inguinal canal. The infant passes motions and flatus and does not vomit,

at any rate persistently. It takes the breast or bottle, again, after a short interval, an indulgence which an infant with a strangulated hernia never enjoys. It certainly cries, because the rapidly increasing effusion is a source of discomfort, but it does not appear to suffer severely. If one has made certain of the diagnosis, by careful examination, the swelling may be tapped quite safely and the anxious parents be convinced of the accuracy of the diagnosis.

Besides the hydrocele of young children, there are complications connected with an *inguinal testicle* which may resemble strangulated hernia, namely, *twisting of the pedicle* of the testicle and its *strangulation*. This error is all the more accountable because most inguinal testicles are associated with herniæ, and the patient will therefore give a history of hernia. Formerly, inflammation and strangulation of the inguinal testicle were the only recognized morbid conditions thereof, but since the time of Nicoladoni it has been agreed that torsion of the abnormally pediculated testicle is the usual affection, and the possibility of strangulation has been somewhat neglected. But that it exists appears from the following case :—

A patient who had a left-sided hernia, which, however, had not come out of the inguinal canal since his fourteenth year, felt a severe pain in the left inguinal region, on lifting a heavy weight. A tender swelling, which looked like a strangulated hernia at first sight, appeared. But the emptiness of the left half of the scrotum and the patency of the intestine enabled a correct diagnosis to be made, and the operation showed that the inguinal testicle had slipped down to the narrow external inguinal ring and had been conducted externally under the skin. The kinking of the spermatic vessels at the external abdominal ring, and their dragging, owing to the abnormal position of the testicle, had led to the formation of a considerable infarct. In this case the diagnosis could only lie between torsion and strangulation with subcutaneous displacement. The subcutaneous position of the testicle contra-indicated simple torsion. If a testicle within the inguinal canal becomes twisted, it remains within the canal.

The symptoms of the more frequent condition of *torsion* are as follow : sudden severe pain and the appearance of a tumour. In addition, there are often reflex symptoms which suggest strangulated hernia, viz., severe abdominal pains, temporary obstruction to the passage of motions and flatus, and even collapse. In the inguinal region, there will be found a tender swelling, like a strangulated hernia. The empty scrotum and the return of the passage of motions and flatus after the cessation of the original reflex symptoms, usually enable a diagnosis to be made. But as it is impossible, at the beginning, to distinguish, with absolute certainty, between a twisted testicle in the inguinal canal and a strangulated interparietal hernia, and as surgical intervention is urgent in either case, it is bad practice to wait until the diagnosis is established by signs of intestinal gangrene ; but treatment

must at once be undertaken, to save the structure which is in trouble, whether it be intestine or testicle.

A boy, aged 1 year, suddenly developed a tense swelling about the size of an almond in the right inguinal region, and therewith had pain, with signs of general malaise. The right testicle was absent from the scrotum, and the left one had only incompletely descended. There were three possibilities: (1) strangulated hernia; (2) acute hydrocele in the inguinal canal; and (3) torsion of a testicle. All these three circumstances were favoured by the presence of an inguinal testicle. The absence of persistent vomiting, the softness of the abdomen, and especially the passage of motions, were points against a strangulated hernia. Flatus was retained, but nothing definite could be inferred from this. The marked disturbance of the general condition showed that it could not be a mere hydrocele. Torsion of the testicle remained, therefore, as the most probable diagnosis, and this was confirmed by the operation, which was performed forthwith. The little patient repeated the whole procedure, a year later, on the other side.

The same considerations should guide us in the case of torsion of a testicle, which is in the *scrotum*. There is, of course, no emptiness of the scrotum, as a diagnostic sign in such a case.

There are some circumstances in which we may hesitate as to the diagnosis between a strangulated hernia and a mass of swollen glands. If there are any intestinal symptoms there cannot be any possible doubt, and it is incredible that any practitioner should order poultices to what is really a strangulated femoral hernia, in order to "ripen" the swelling. The following case will, however, show that both patient and practitioner may succumb to a series of misleading circumstances.

A female, aged 50, became ill with acute cholecystitis, and suffered from very painful swelling of the gall-bladder. The initial vomiting ceased and the cholecystitis subsided somewhat. But at the same time the doctor accidentally discovered a tender swelling in the left groin. No definite pedicle could be distinguished. As there was neither vomiting nor colic, and as the abdomen was soft, and as there was an erosion on the corresponding lip of the vulva, which suggested a glandular swelling, the patient was watched for a day. The absence of the passage of flatus determined the diagnosis of strangulated hernia after the lapse of this time—but it was too late. The patient died suddenly during the preparations for operation. The autopsy showed not only a severe suppurative cholecystitis but also a strangulated hernia, with gangrene at the constricting ring. The strangulation evidently took place during the cholecystitis as a result of the vomiting, but the patient was not intelligent enough to notice it. There was no vomiting or colic because the patient was under dietetic treatment owing to the cholecystitis, and therefore the intestine was almost empty, The erosion on the vulva also contributed its share towards the error.

(2) Is the Hernia Strangulated?

One of the most important pieces of evidence for strangulation is afforded by the pain on pressure over the site of the constriction, usually at the hernial ring. The obstruction of the bowel, and the symptoms consequent thereon, constitute further evidence. This obstruction also occasionally occurs in Littré's hernia, which involves only the intestinal wall. Strangulation of omentum is distinguished from ordinary irreducibility thereof by the sudden onset of symptoms, the pain on pressure over the site of strangulation, and the tension of the hernia owing to the development of hernial fluid.

We have mentioned an example of such strangulation of omentum in the chapter on Inguinal Herniæ.

There is *one* further possibility in connection with strangulated hernia. Formerly one heard much about *inflammation* of a hernia, and strangulation was regarded as inflammation. There is nothing surprising in the fact that the sac of a strangulated hernia may inflame after a time, in consequence of infection by organisms which wander through from the bowel. The inflammation is, however, secondary in such circumstances. Primary inflammation of a hernia is, on the other hand, not frequent. The following conditions are most important :—

(*a*) *Appendicitis in a Hernial Sac.*—The appendix is not infrequently found in right-sided herniæ; it has even been found on the left side and also in umbilical herniæ. It may become inflamed within the hernial sac and perforate there. Such a case is usually mistaken for a strangulated hernia, until the error is rectified at the operation. But the sequence of symptoms ought to give a correct clue. In a strangulated hernia the first symptoms are those of intestinal obstruction, and then, after they have persisted for some time, comes the inflammation—the hernial phlegmon. But if appendicitis starts in a hernial sac, the inflammatory symptoms come first, and there is pyrexia. Should intestinal obstruction eventually supervene, it is a much later phenomenon. In most cases of strangulated hernia the pain on pressure is especially marked over the hernial ring; in appendicitis, however, it is from the first in the hernia itself.

(*b*) The involvement of the hernial sac in a *General Peritonitis.*—The differential diagnosis depends upon those considerations which were advanced in distinguishing between peritonitis and intestinal obstruction. The same applies to a hernia involved in the sequelæ of an *acute pancreatitis.* In both cases the severity of the abdominal symptoms will be very striking, considering the short duration of the supposed strangulation.

(*c*) *Tubercle of the Hernial Sac.*—This is usually a consequence of general tubercular peritonitis. But it sometimes happens that this latter causes no symptoms, and the practitioner is only consulted about the disease of the hernial sac. Whereas a miliary tuberculosis of the hernial sac with fluid contents is most likely to be taken for a

hydrocele, the nodular form is easily confused with a strangulated, or at least with an irreducible, mass of omentum. If, however, one bears in mind the possibility of tubercle of the hernial sac, suspicion thereof will be aroused by the presence of isolated nodules, by the pain on pressure, and by the great hardness of the swelling. A careful examination of the abdomen may perhaps find support for the diagnosis. Abdominal pains are of less diagnostic significance, because, although they are frequent in tubercular peritonitis, they may also be caused by strangulated omentum.

(*d*) Sutter and others have shown that metastatic inflammation of an empty hernial sac may resemble the clinical symptoms of strangulation.

There are three possible events which may introduce error into the solution of the last two problems, with which we have been dealing; first, the *combination of external hernia with internal intestinal obstruction*. Let us assume the case of a patient with all the signs of intestinal obstruction, in whom we also find an irreducible hernia, and we are inclined to ascribe to it the cause of the obstruction. If the hernial swelling is soft and not painful on pressure, the cause of the obstruction must be elsewhere; either in another hernia, which has been overlooked, or in some disease within the abdomen itself.

On the other hand, there are cases wherein we find no hernia, and are therefore inclined to attribute the intestinal obstruction to some internal cause. On inquiry we may learn that the patient has put back a hernia. Careful examination of the site occupied by the hernia may then show some slight retraction, and we may discover in the abdomen, behind the ring, an indefinite resistance, which is painful on pressure. Our diagnosis must then be that of *reduction en masse*. These cases are, however, becoming rarer, as fortunately violent taxis is giving way to herniotomy.

It occasionally happens that an omental hernia becomes painful on pressure. Symptoms occur, at the same time, suggestive either of peritonitis or of intestinal obstruction. There may be found in the abdomen a tumour-like painful area of resistance with corresponding dulness, or even, under some circumstances, a free fluid effusion. If these symptoms occur on the right side, in a patient who has already suffered from attacks of pain in this region, the diagnosis usually made is that of appendicitis with extension of the inflammation into the sac. This diagnosis seems all the more likely as the process is often accompanied by moderate fever. Operation, however, shows that the case is one of *torsion of a large mass of omentum*, the extremity of which is firmly fixed in the hernial sac—a condition with which all surgeons are familiar, but which has been specially described by Hochenegg.

(3) What does the Hernia Contain?

If signs of intestinal obstruction are present, we must assume that the *hernia is intestinal;* if they are not present the hernia must be *omental*. One must be very cautious in drawing any conclusion from

physical examination. A tympanitic note of course indicates an intestinal hernia. A dull note is of no significance, as small intestinal herniæ are very liable to yield complete dulness on percussion. The feel of the hernia can never be relied on. The granular consistence of omentum may be concealed by hernial fluid, and, on the other hand, a small coil of intestine is often found strangulated in cases wherein an omental mass can be definitely demonstrated. If there is a small movable body in the hernial sac of a female, the case is one of a *strangulated ovary*, a condition which is not rare, even in young girls.

(4) Where is the Strangulation Situated?

The strangulation may be in the neck of the sac, at the hernial ring, or in the sac itself.

The strangulation is especially at the neck of the sac in inguinal herniæ, which usually present a ring-shaped thickening at the level of the internal ring. As this ring may shift as far as the peripheral end of the sac, in consequence of the constant onward movement of the peritoneum, the strangulation may occasionally occur quite close to the head of the sac. We may assume the presence of this condition, if the central portion of the hernial swelling is soft and painless, while the peripheral portion is tense, and tender to pressure. As a rule, a strangulation within the sac is at the level of the internal inguinal ring, and one may assert that most strangulations at this spot are strangulations within the hernial sac, because the internal ring is not itself tight enough to cause a strangulation. If the diagnosis is at all possible, it will depend upon the localization of the greatest amount of pain on pressure. Strangulation at the external ring is recognized in a similar manner, but here the strangulation is not caused so much by sac as by the fibrous elements of the inguinal ring.

In cases of *femoral hernia*, the strangulation usually takes place at the femoral ring; in *umbilical hernia*, it is due to constriction at the umbilical ring, but it may occur in one of the frequent pouches of the hernial sac. In the latter case, only one segment of the hernial swelling will be tense and painful on pressure.

Finally, there are cases wherein the intestine is caught by a noose-like band of connective tissue arising from the hernial sac. Such a condition is first recognized at the operation.

(5) What is the Condition of the Strangulated Gut?

The duration of the strangulation affords important information, because the intestine usually retains its vitality for the first twenty-four hours, though the constricting furrow may become necrotic after

twelve hours. If, however, the constriction is not very tight, the intestine may recover itself, even after several days' strangulation. All depends upon the degree of circulatory disturbance, which is usually greater in small herniæ than in large ones. Gangrene is therefore more probable in a small hernial swelling than when a large mass of intestine and omentum is present. The presence of omentum in the hernia permits us to make a more favourable prognosis in regard to the intestine, because the omentum serves as a protecting pillow to it in the hernial ring. As long as the hernial swelling remains movable and the skin above it can be picked up, and is neither red nor œdematous, so long is the recovery of the intestine not impossible. But if inflammatory symptoms have occurred in any degree, from simple œdema of the integument to a definite hernial phlegmon, we must expect that the intestine has been severely damaged.

Although the indications are for immediate operation in all cases, nevertheless if circumstances prevent it being carried out forthwith, we may venture upon a modest attempt at taxis, if the strangulation is recent and inflammatory symptoms are absent. But if the operation can be done at once—and this is always the case nowadays, except in remote districts—one may quite conscientiously abandon taxis. Infants, however, provide an exception. Strangulated hernia is very rare during the first year of life; at this period herniæ are easily reducible and never cause gangrene. As a rule, the hernia goes back when the child is put in a bath.

(6) The Questions which may Arise during the Operation.

We shall not waste any words over the recognition of the various layers of the hernial coverings—a hobby-horse of the older surgeons. The layers may represent the usual coverings in recent herniæ, but in old herniæ they may be considerably increased in number by the growth of new layers of connective tissue. The careful operator will succeed in entering the hernial sac, *tuto* if not *cito*, even without counting the layers; but he must remember that not every space containing fluid is the hernial sac. Cystic spaces containing serous fluid often occur around the hernial sac, especially in femoral hernia, and if the hernia is strangulated the serous fluid may be mixed with blood.

The decision made from the *appearance of the intestine* is of greater importance; and it is necessary to consider not only the strangulated coil but also the bowel leading towards it. In order to pull it sufficiently forward it is necessary to widen the constriction previously, but care must be taken lest the hernial coil slips back into the abdomen unexpectedly and unperceived. If the intestine is smooth and shiny, and if definite contractibility is present in the whole of

the strangulated coil, including the constricted ring, we may safely reduce it, even though it may have seemed congested at first and felt somewhat thick. The bluish discoloration improves as we wait, and the thickening is preferable to the opposite condition. The intestine may be suspected if the contractions only start after long waiting, and are then very indolent. In such doubtful cases the circulation in the mesentery must be observed, and special attention must be paid to the arteries to note whether they are pulsating, and to the veins, to see whether they are thrombosed. Intestine should not be replaced if it cannot be excited to contract in every part, including even the constricted ring. Even if its consistence remains normal, or only slightly thickened, it should not be replaced. It is quite certain that if necrosis has once started it will become complete, in cases wherein the intestinal wall is disposed in small folds and its consistence is diminished, whether its colour be black, green, or grey. The character of the hernial fluid may prove of value in doubtful cases. A clear, odourless fluid indicates that the intestine is capable of recovery; a turbid offensive fluid shows that necrosis has begun. Obviously, we must not allow an apparently healthy hernial fluid to reassure us, if, for instance, we find clear signs of necrosis at a constricting ring. On the other hand, the fluid may be somewhat offensive or slightly turbid in cases wherein the bowel is capable of recovery.

I was once called to a distant village to see an old woman with a strangulated femoral hernia. When I arrived the practitioner informed me that the symptoms of obstruction had subsided, but that the hernial swelling was increasing. The swelling felt very tense, and when it was opened a little offensive gas escaped. This led into the femoral hernial sac, which contained a very few drops of pus, and which was separated from the abdominal cavity by obviously recent adhesions. Recovery followed in a short time without further intestinal disturbances. The intestine which had been strangulated had returned of its own accord, leaving behind some bacteria, which did nothing more but infect the hernial sac. This case reminds us of the observations which we have already made in regard to inflammation of an empty hernial sac.

(7) Questions which Arise after Reduction by the Open or Bloodless Method.

A coil of intestine which has been strangulated for some hours does not always resume its functional activity forthwith. We must, therefore, not be surprised if some colic still persists for several hours, or for a day or two after the strangulation has been relieved. It may not be easy to obtain the passage of motions and flatus even after copious enemata. If reduction has been effected by taxis we

must not allow this fact to reassure us very easily, but should think of the possibility of a *reduction en masse*. An operation must be resorted to if the symptoms continue for several hours with the same severity. If herniotomy has been performed we may wait longer, but must undertake laparotomy if the symptoms increase instead of abating, especially if the pulse becomes unsatisfactory. There may be some additional intra-abdominal trouble, such as a volvulus, or kinking, owing to adhesions. The acceleration of the pulse should suggest to us that we have probably erred in deciding that the intestinal coil retained its vitality.

I have seen gangrene come on in an entire coil after a skilfully performed herniotomy in a case wherein the strangulation had not existed for twelve hours.

There are some cases in which everything goes well at first, but wherein the patient begins to complain again, after the lapse of several weeks, of attacks of colic, and, finally, of retentions of motions and flatus—in a word, of the symptoms of chronic intestinal obstruction. If we operate we find that a ring-shaped or a channel-shaped narrowing exists in the place of the strangulated coil, or that the whole coil has been caked into an inextricable ball through adhesions. Both these conditions show that we were too optimistic in our opinion of the intestine at the time of operation. They both indicate that the mucous membrane has sloughed more or less extensively, and this may occur even when the serous surface appeared to be capable of living and has, as a matter of fact, retained its vitality. The only early warning of the onset of this *late stenosis* is offered by intestinal hæmorrhage and persistent diarrhœa coming on in the first weeks after the reduction.

A female, aged 60, was operated on for strangulation of an umbilical hernia, which had persisted for eighteen hours. The intestine appeared to be healthy and was replaced. The intestinal functions were normal for the first few days, but classical symptoms of chronic intestinal obstruction occurred after the second or third week. They increased so much that another operation became necessary in the seventh week. The intestine which had been strangulated had developed into an S-shaped mass, with very firm adhesions of one portion of the coil. An entero-anastamosis was performed, with complete and permanent recovery.

CHAPTER LV.

DIFFICULTIES OF DEFÆCATION.

In the popular sense this term includes several conditions of varied significance which the practitioner must separate from one another. They comprise functional derangements of the whole intestine, or, at least, of the large intestine, and also disorders which are due to some local affection of the rectum or its vicinity. We have discussed the former in the section on "intestinal obstruction."

The following are the symptoms by which rectal disease manifests itself :—

(1) *Simple Constipation, i.e., Difficulty in evacuating the Fæces, but no Pain or Tenesmus.*—This form of constipation is rare. It occurs in simple weakness of the rectal muscle (proctogenic constipation), with tumours of the true pelvis, which mechanically compress the rectum from without, and a fair amount of compression is required before defæcation is compromised. **Retroflexion of the gravid or myomatous uterus, exudations within the true pelvis, cysts, and solid tumours** may be mentioned as examples. The notorious "tape-like" fæces are sometimes found in these circumstances.

We have been told by a patient with a dermoid in the pelvis that his motions were as thin as cardboard.

(2) *Constipation associated with Constant Tenesmus.*—The evacuations are soft and pulpy, or even quite liquid, and are frequently expelled in very small quantities at a time. The patient experiences an incessant desire to go to stool. This picture is most frequently encountered in cases of progressive pressure on the rectum from without by one of the swellings just mentioned.

(3) *Tenesmus,* **without** *Constipation, but with the Passage of Blood, Mucus or Sero-sanious Fluid, during the Acts of Defæcation, and in their intervals.*—If a patient complains of these symptoms, and especially if his clean shirt is soiled with red or pinkish stains, we may at once assume that some ulcerative process is present, which does not lead to stenosis. It may be associated with an ulcerative colitis, extending low down, an **innocent polypus, a syphilitic or tubercular** lesion, or it may be due to **cancer** which has not yet reached the stage of stenosis—the most frequent cause.

(4) *Tenesmus* **with** *Constipation, Passage of Liquid, Pulpy or softly formed Fæces in small Quantities, accompanied by Blood or Sero-sanious Fluid.*—This assemblage of symptoms points to an *ulcerative* lesion, which is also *causing stenosis, i.e.,* to **cancerous, syphilitic, or gonorrhœal stricture.**

The history affords certain indications; thus in childhood polypus is the most frequent cause; in females from adolescence to middle age syphilis or gonorrhœa is, under certain conditions, the most probable cause; in elderly people a villous polypus, or cancer, is most likely to be present. Examination of the rectum must never be omitted. The trouble must never be attributed to piles, which may accidentally be present, and they should never serve as an excuse for an incomplete examination. That so many advanced cases of cancer are sent for operation with the mistaken diagnosis of rectal catarrh or hæmorrhoids is due to the shyness of the patients—and often of practitioners—in the matter of rectal examination. It is quite intelligible and praiseworthy that the practitioner who is engaged in surgery or in obstetrics should avoid contaminating his fingers unnecessarily; but nowadays a finger-stall removes the risk of contamination, and a rectal examination in this type of case is never "unnecessary."

If we feel a soft movable structure, with a more or less long stalk, which easily escapes the finger, the case is one of **polypus**—a *mucous polypus* in children, a mucous polypus or a *villous polypus* in adults. If the mucous membrane appears to be softly granular over a diffuse area, or if it be studded with superficial ulcers, which are most distinctly recognizable with a rectal speculum, the condition represents an early stage of chronic **gonorrhœal or syphilitic proctitis.**

Flat, very painful ulcers in the vicinity of the anus suggest **tubercle.** We have already discussed the differential diagnosis between this condition and non-specific ulcerative colitis.

If the finger defines a shell-like elevation of the mucous membrane with an overhanging, more or less firm border, and a friable, easily bleeding surface, the case is one of **cancer,** which has not yet encircled the bowel. If there be any doubt, such as might arise in the presence of a flat non-pedunculated papilloma, a histological examination must be made. Such papillomata often become malignant. The same applies to the **polypoid condition of the rectum,** in which the whole rectum, and often a considerable portion of the large intestine, is invaded by numerous polypi. If the finger enters into a smooth-walled, rigid, cylindrical tube, the case is one of **stricture,** following **gonorrhœal** or **syphilitic proctitis.** If, on the other hand, we feel a circular wall, into whose centre the finger can scarcely impinge, owing to the narrowness of the opening, and if the friable tissue breaks down, there can be no question that we are dealing with a **ring-shaped carcinoma.** If the growth is high up, we must direct the patient to bear down, or we must press the abdomen downwards with our free hand. According to Hochenegg, a remarkably wide ampulla should raise the suspicion of a cancer,

situated high up, and fixing the pelvic colon. If a cancer of the lower segment of the rectum protrudes through the anus, the diagnosis is easy enough (fig. 194). **Sarcoma** is much more rare in this region (fig. 196).

(5) *Painful Defæcation.*—We meet with this symptom in various conditions :—

(*a*) If a patient tells us that he suffers from severe cutting pain in the anus after every action of the bowels, that the pain starts immediately, and lasts for about fifteen minutes or longer, and that he postpones defæcation as long as possible on account of the pain, we may conclude that he is suffering from a **fissure.** On examining the anal aperture, we see one or more radiating cracks which, if carefully separated from each other, look like defects in superficial epidermis, with a reddened base. Sometimes they are situated between small nodules of hæmorrhoids of a perfectly unirritating character.

(*b*) If, on the other hand, the pain is only occasional, and comes on in attacks lasting for a few days, the pain at first being confined to the moment of defæcation, but subsequently becoming more persistent, only to disappear for some time, after the loss of considerable dark blood, we may be certain that the condition is one of inflammatory changes in **hæmorrhoids,** *i.e.*, thrombosis in their venous spaces. One of my patients compared the severity of the pain to toothache. Sometimes the loss of blood only occurs periodically at long intervals ; at other times the loss of blood may be constant at each action of the bowels over a protracted period—the loss being to the extent of a dessertspoonful or more. The condition found on inspection varies with the stage in which the patient happens to be. We may only find a few withered folds of skin or mucous membrane (fig. 191), or a bunch of bluish-red tense nodules, tender on pressure, or even a whole crown of them. If the patient is in the bleeding stage, one of these nodules will be ulcerated, and it may be possible to see a black coagulum projecting from the point whence the hæmorrhage occurred. If internal hæmorrhoids became thrombosed, they prolapse very easily, and may be strangulated by the sphincter ani, with such damage to their circulation that necrosis may follow. They look like bluish-black or brownish-black nodules, surrounded by œdematous anal skin, or by a ring of œdematous and swollen external hæmorrhoids (fig. 193). Further extension of the inflammation may cause retention of the urine, abscesses, and even general septic infection.

If the subjective symptoms and the hæmorrhage indicate the presence of hæmorrhoids, which are invisible on inspection, we must endeavour to get the rectal mucous membrane to prolapse, in order to bring internal hæmorrhoids into view.

We must never assume the presence of *internal* hæmorrhoids, without local examination, merely because there are no *external* hæmorrhoids.

Very rare cases have been recorded wherein the hæmorrhoids have been situated 10 to 20 cm. above the anus. The diagnosis may be suggested by hæmorrhage, but it can really only be established by rectoscopy.

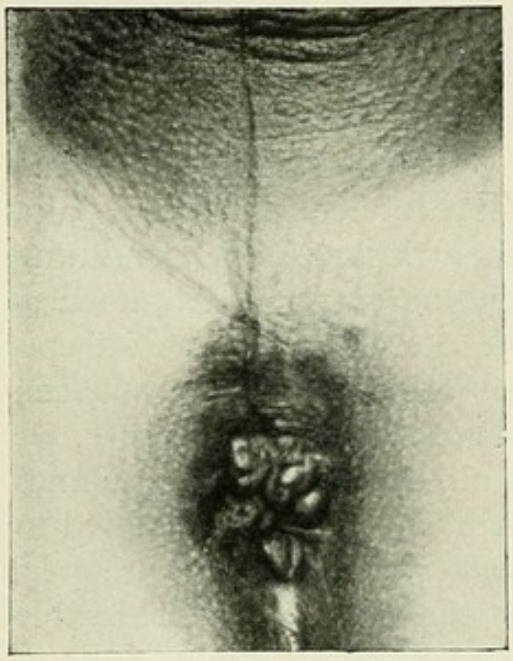

FIG. 191.—Relaxed hæmorrhoids.

(*c*) A patient who complains of occasional attacks of pain in the region of the anus, on sitting down or on defæcation — pains which increase for a few days and then suddenly disappear after the evacuation of a certain amount of pus—is suffering from a **peri-proctitic abscess.** There may be intervals of months or years between these attacks, but the patient will sometimes observe that some pus escapes even during these free intervals, indeed that flatus passes despite the firm contraction of the

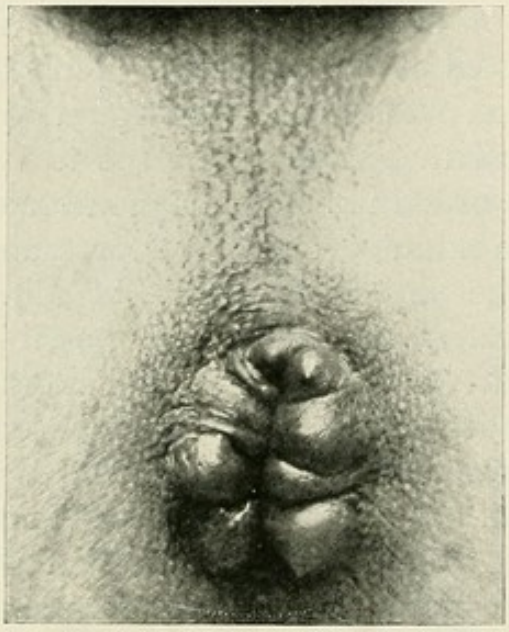

FIG. 192.—Inflamed external hæmorrhoids.

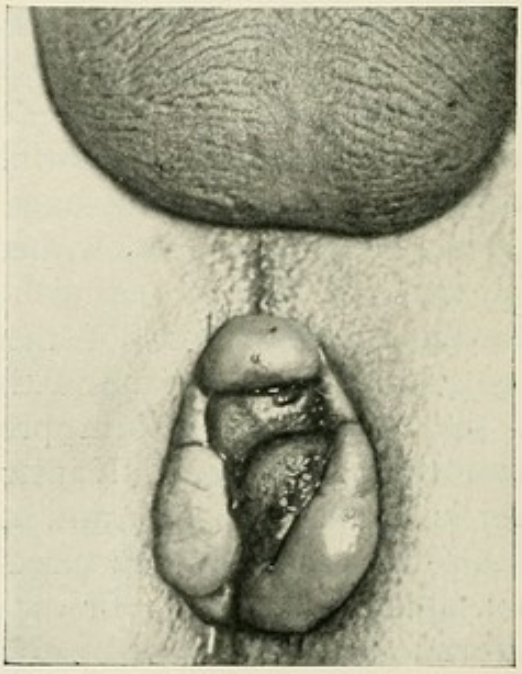

FIG. 193.—Prolapsed internal hæmorrhoids surrounded by external œdematous piles.

sphincter. In such a case we may conclude that the abscess has been followed by an **anal fistula or a rectal fistula.** We shall discuss the details of the examination of these fistulæ in a separate chapter.

(*d*) If the pain occurs *before* defæcation, rather than *during* this

act, and if there be, at the same time, pain on micturition, the case is one of **prostatitis**, probably of **gonorrhœal** origin, but possibly also of a **tubercular** nature.

(*e*) If the symptoms do not fit in with any clinical picture, but consist of tenesmus, blood and possibly pus in the stools, constipation, pains in the pelvis, we should think of a **foreign body**. We shall see in the next chapter, the variety of articles which have been introduced into the rectum.

(6) *Prolapse of the Anus.*— Sometimes the difficulty in defæcation consists of a prolapse of the rectal mucous membrane. The diagnosis can be made by a layman; we have to decide whether the prolapse merely concerns the lowest portion of the mucous membrane — **prolapsus ani** — or whether the mucous membrane higher up is involved — **prolapsus recti** — or whether both conditions are present



FIG. 194.—Cancer of the anal portion of the rectum.

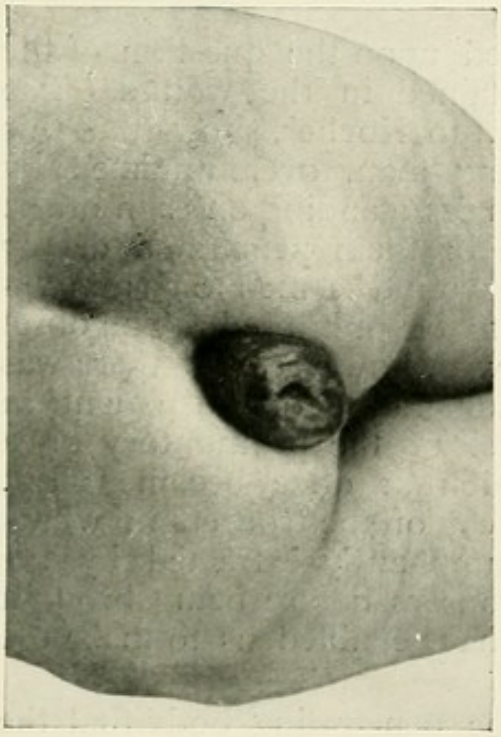

FIG. 195.—Prolapse of the anus and rectum.

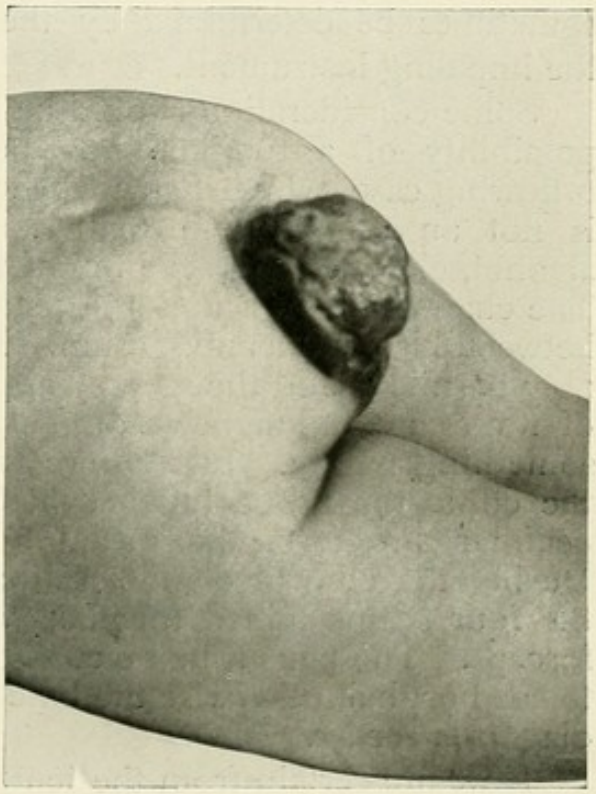

FIG. 196.—Sarcoma of the anus.

(fig. 195). Our decision must be based on the size of the prolapse and upon the level at which the doubling up of the bowel is found—at the anus or higher.

Prolapsus ani is purely a matter of mucous membrane prolapse. In *prolapsus recti*, all the layers of the intestinal wall are turned in and the peritoneum may even be dragged, so that a perineal hernia may be formed—a so-called hedrocele.

CHAPTER LVI.

INJURIES OF THE RECTUM.

Apart from lacerations of the intestine and rectum during labour, the injuries of this region are mostly due to impalement or to foreign bodies introduced for various purposes and in different ways.

Impalement may be caused by falling on a garden fence, the handle of a broom, the barrel of a gun, or the leg of a chair, &c. Agricultural labourers are often impaled by falling off a haystack on to the handle of a fork. The laceration of the rectum by the horns of a bull produces a similar injury to impalement. The external wound is easily recognized in all these accidents; diagnosis is mainly concerned with the question of the extent of the injury above. This may sometimes be determined by the length of the tract of blood on the impaling instrument.

Some consideration should be bestowed upon the question of the possibility of a foreign body being retained in the wound. The following case, which I saw when assistant to Kocher, shows that this is not an unimportant matter. A young man, overstimulated by alcohol, climbed up to the top of three chairs standing on each other. The chairs fell over, and the leg of one of them penetrated deeply between his rectum and sacrum. But the wound seemed to be remarkably harmless, and the rectum appeared to be uninjured. The onset of fever and of offensive discharge showed, however, that there was something wrong. Just before the demonstration of the patient in the clinic the probe touched at the level of the promontory on a peculiar structure, the meaning of which at once became clear. During the clinical demonstration the seat of the trousers in which the four seams joined together was triumphantly extracted by the forceps. The patient had changed his trousers before being brought to the hospital, otherwise the hole would have enabled us to make the diagnosis earlier.

If we are certain from the length of the penetrating body that the

peritoneum has been torn, the abdomen must be opened and searched, so as to avoid a belated diagnosis of intraperitoneal injury to the intestine, when peritonitis supervenes after a few days.

Among the **foreign bodies purposely introduced**, one should mention especially the *nozzles of enema syringes*. Fatal injuries have been inflicted in this way, especially when the enema is administered into the abdominal cavity. These accidents happen, naturally, more frequently when the mucous membrane is diseased, as in cancer, than when it is healthy.

In contrast to an enema syringe employed for constipation, a wood-chopper in the forest put a wedge of wood into his rectum, for diarrhœa. A colleague has informed me of a case wherein a man introduced a liqueur glass, in order that he might be able to witness a festive procession, undisturbed. Sometimes foreign bodies are used for masturbation.

There is no complete account of these cases in literature, and the most unique examples of these occurrences do not exhaust all the possibilities, but in them all, the patient complains of tenesmus and hæmorrhage. We should, therefore, never neglect a rectal examination in any case wherein such symptoms come on, apparently without cause.

As we cannot obtain any reliable information concerning the nature of the foreign body, we must be careful to protect the finger with a stall, to prevent injury to it. Inspection with a speculum, which is sometimes indispensable for the diagnosis, should be left until the extraction is undertaken, as this requires anæsthesia.

The rectum is occasionally injured during attempts to procure abortion. I once made an autopsy on a young girl who died of peritonitis after an attempt at abortion. The posterior vaginal wall and Douglas's pouch were perforated and the rectum was impaled: The midwife who was accused set up the defence that she was much too experienced to have attempted to gain the right orifice in this clumsy manner.

CHAPTER LVII.

TUMOURS AND SWELLINGS OF THE SCROTUM.

When we are consulted for any scrotal swelling, we must first determine whether the swelling originates in the testicles or in the scrotum. This can only be done if it is possible to feel the testicle and its appendages quite distinctly, apart from the investing skin. But if the swelling, the testicle and the skin all form one connected mass, we must depend upon the history to tell us whether the change involved at first the scrotal contents only.

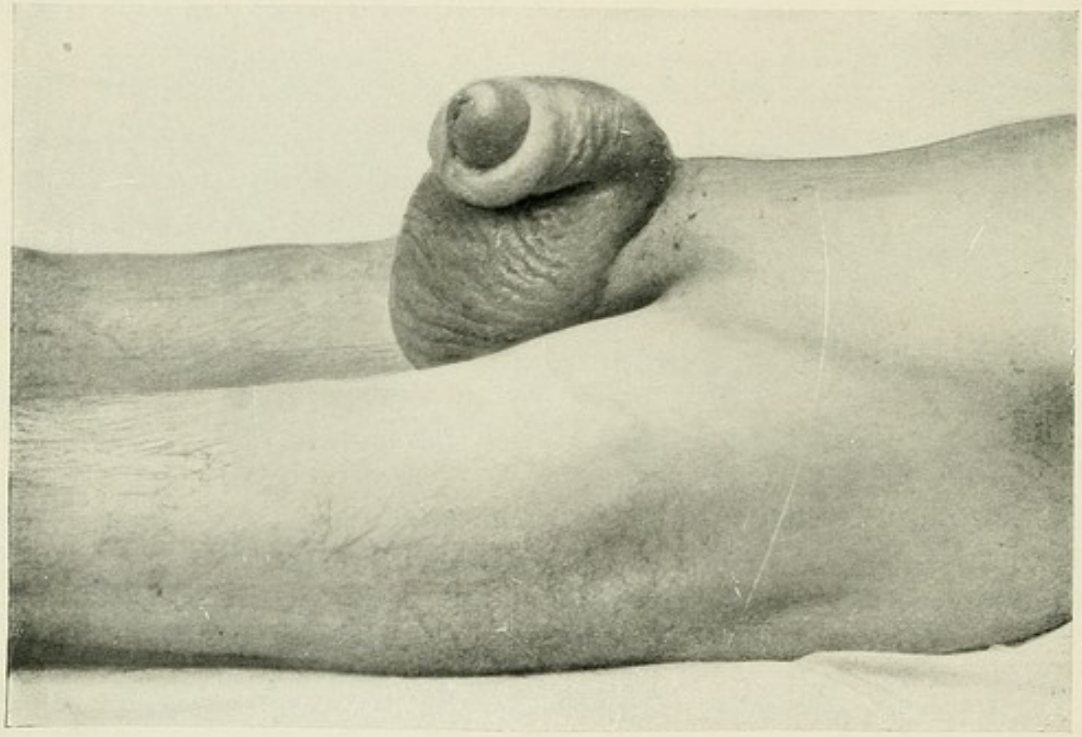

Fig. 197.—Acute extravasation of urine, in a case of neglected urethral stricture.

I.—SWELLINGS OF THE SCROTUM.

A.—ACUTE SWELLINGS.

If the swelling has arisen suddenly, the first point to consider is the question of **contusion,** which may cause a severe degree of blood extravasation. Then there is the possibility of **acute inflammatory diseases,** especially erysipelas, or of **extravasation of urine** consequent upon an injury or a neglected urethral stricture, a matter of the greatest importance, because the treatment depends upon the accuracy of the diagnosis. If one meets with such a clinical picture as is illustrated in fig. 197, he must not be content with the diagnosis

of phlegmon, &c., but must at once provide for the free escape of the urine, in order to prevent his patient dying from uræmia and sepsis.

B.—CHRONIC SWELLINGS.

(1) If a diffuse swelling has arisen gradually, as a result of repeated acute inflammatory attacks, *e.g.*, erysipelas, or as a consequence of chronic multiple urinary fistulæ, the term applied to it is **elephantiasis.** The same name is applied to the enormous hypertrophy, which occurs in the tropics, from filarial disease. In this condition the patient is hardly able to walk, because of the appendage to his scrotum.

(2) *Circumscribed tumours* of the scrotal skin are diagnosed according to their consistence. If they show fluctuation, are soft or tensely elastic, they may be **dermoids, sebaceous cysts** or **cystic lymphangiomata.** The former are unilocular and non-translucent; the last are multilocular and translucent, but are distinguished from hydrocele by their superficial situation.

If the circumscribed tumour is hard, it may be either a **fibroma** or a **sarcoma,** in accordance with its rate of growth.

If the scrotal tumour is of an ulcerating character, we should think instinctively of **chimney-sweep's cancer** or **tar cancer.** We should examine the history from this point of view, and note whether there be any eczema which paves the way for the cancer, or any so-called soot-warts. But if the history does not support this view, we should remember that the scrotum may be a seat of a primary chancre, and that tertiary ulcers may resemble carcinomata.

II.—SWELLINGS OF THE SCROTAL CONTENTS.

If the swelling is in relation with the normal contents of the scrotum, we must first ascertain whether it has a pedicle at its upper part, in other words, whether it runs into the inguinal canal. If this should be the case, the conclusions to be drawn are already discussed in the chapter on Inguinal Herniæ.

In acute inflammation of the testicle and epididymis there is nearly always some infiltration of the spermatic cord, which may then resemble the pedicle of a tumour, a matter which will be referred to later on. The same applies to advanced cancer.

A.—TUMOURS OF THE SPERMATIC CORD.

An elastic or tense swelling in connection with the spermatic cord, quite free of the testicle and epididymis, is a **funicular hydrocele.** The diagnosis is absolutely certain if the swelling is, in addition, translucent.

We have seen in Chapter LIV. that the acute hydrocele of little boys is often mistaken for strangulated hernia.

A soft non-translucent swelling is in all probability a **lipoma of the spermatic cord** (p. 389). A hard tumour, adherent within the spermatic cord, suggests the rare form of **sarcoma,** which grows rapidly towards the abdominal cavity.

We now proceed to deal with diseases of the testicle and epididymis, which, logically, should be considered separately. But as the apparent position of the swelling does not always correspond with its true topography, we propose to group them together in the first instance and then, later on, endeavour to distinguish between the testicle and epididymis.

B.—ACUTE SWELLINGS OF THE TESTICLE AND EPIDIDYMIS.

Let us assume the case of a patient who consults us for an acute painful swelling of the scrotal contents, and who tells us that it has resulted from a blow, a statement which should be taken *cum grano salis* if the patient is insured against accidents. We find the testicle and epididymis fused together into a very tender oval-shaped mass. The skin of the scrotum is slightly œdematous, the spermatic cord is hard and swollen, and resembles a pedicle running into the inguinal canal, and the vas deferens cannot be felt as a separate structure. If we agree that an injury has been the cause, we should think of a **traumatic hæmatocele,** *i.e.*, an effusion of blood into the tunica vaginalis and into the cellular tissue of the scrotum. The diffuse swelling which obscures the division between testicle and epididymis and the infiltration of the spermatic cord may very well be attributed to the œdema which accompanies such an injury. Our assumption will be correct if the swelling exceeds in size the usual dimensions of a recent orchitis or epididymitis, *i.e.*, if it is larger than a goose's egg. Sometimes confirmation may be obtained from a dark blue discoloration of the scrotum, especially on the posterior surface; at any rate this discoloration should appear within a few days. If, however, the swelling be smaller, and there be no discoloration despite the lapse of a few days since the alleged accident, our thoughts should run in another direction, although we should not entirely discard the traumatic theory. Pressure on the urethra may cause a few drops of the anticipated discharge to exude, and then further discussion is unnecessary, especially if the swelling mainly concerns the epididymis. The case is one of **gonorrhœal epididymitis.** If we do not obtain any discharge, which sometimes ceases with the onset of the epididymitis, we should inquire for the date of the last attack of gonorrhœa. If this meets with a negative reply, we should make a rectal examina-

tion, exerting slight pressure on the prostate, and then direct the patient to urinate. Abundant gonorrhœal threads and small flakes of pus suffice for the diagnosis. But if these are not present, and the urine is somewhat turbid and of offensive odour, containing numerous pus-cells, micro-organisms, and probably crystals of triple-phosphate, we must abandon the idea of gonorrhœal epididymitis. The patient has cystitis either as the result of stricture, hypertrophied prostate or tubercle, &c., and the **epididymitis** or **orchitis** has arisen owing to extension from the bladder. As these infections are frequently caused by trifling injuries, we should ascertain whether the patient has passed a catheter on himself or has recently had one passed.

All this does not exclude the possibility that gonorrhœa may have been the original starting point of the disease. The gonorrhœa may have occurred years previously, and the infecting organism at the moment is not necessarily the gonococcus, but an ordinary pus organism such as the staphylococcus or streptococcus.

We may assume inflammation of this kind if the testicle rather than the epididymis is involved. But if no source of infection is discoverable in the uro-genital apparatus there remains the possibility of **metastatic orchitis.** This includes the inflammation of the testicle which sometimes occurs in mumps, and occasionally after other infectious diseases such as typhoid fever. Finally, there are some very rare cases which cannot be explained, even in this manner; the orchitis is apparently spontaneous and has no connection with any other disease. The testicle is, as a rule, alone involved in these cases, so that they are easily distinguished from gonorrhœal inflammation.

If this form of swelling appears to extend beyond the testicle, it usually depends upon a slight attack of secondary hydrocele, in association therewith. In such a case there would be no sharp separation between testicle and epididymis; but, as stated previously, they would merge into one oval-shaped swelling. In a simple orchitis the epididymis is situated above the swollen testicle like a narrow ledge. On the other hand, in a case of simple epididymitis, the uniformly enlarged epididymis lies against the testicle like the crest on a helmet.

If we are in doubt about the nature of an orchitic swelling owing to the absence of any accurate history, we may resort to an exploratory puncture, lest we overlook a purulent inflammation until it is too late to save the testicle.

Before making the puncture we should warn the patient that his testicle may atrophy as the result of the disease, otherwise the incident which happened to us, owing to our neglect of this precaution, might be repeated. A young man had a testicle as large as a plum, which was very painful on pressure; fever and pain persisted so that a puncture was made with a fine needle, but without any

result. The inflammation, however, subsided, and the patient was discharged. He returned in a few days looking very sad, because not only had the inflammation disappeared but the testicle also, and he blamed the exploratory puncture for this. Indeed, there only remained a hard body, not bigger than a bean, instead of the plum-sized swelling. We had then to offer the explanation which we had previously neglected to do by way of prognosis, and the patient finally consoled himself with the reflection that the presence of one testicle was sufficient.

It happens occasionally that, although everything points to a gonorrhœal epididymitis, we learn that the patient has had of late more frequent calls to micturition than usual, the stream still being normal, and that he is obliged to get up one or more times during the night for this purpose. He may have noticed a fine, whitish deposit, or, exceptionally, a little blood in the urine. This usually signifies the beginning of uro-genital tuberculosis. How, then, is the acute onset of the swelling to be explained? This may be due to an acute perforation of a tubercular focus into the tunica vaginalis, with a consequent tubercular hydrocele. Examination would show that the epididymis cannot be separately defined from the testicle, and that the latter appears to be enlarged, and may even present fluctuation. Or it may be that the epididymitis is not purely of a tubercular nature. There may have been a nodule which the patient had not noticed, and it may have become secondarily infected, a circumstance which often happens in uro-genital tuberculosis, even if catheterization has not been practised. Examination of the urinary sediment shows mononuclear and polynuclear leucocytes, possibly a few red cells also, epithelial cells, *Bacillus coli*, staphylococci and streptococci. As the disease progresses an abscess will probably form in the epididymis, and spontaneous rupture finally occurs.

Contusion of the testicle and the various forms of inflammation do not, however, exhaust all the possible causes of acute swelling. If the symptoms have come on very suddenly, and are accompanied by such reflex signs as vomiting, retention of flatus, if the swelling is somewhat high up and we are informed by the patient that his testicle had never completely descended, we should think of **torsion of the testicle,** a condition already referred to in connection with strangulated hernia. The results of this torsion are hæmorrhagic infarction and gangrene of the testicle (p. 399).

The anatomical basis of this event is an abnormally developed mesentery of the testicle, which permits it to hang free in the tunica vaginalis. The only condition with which it could possibly be mistaken is an *embolic* infarction of the testicle occurring in a patient with heart disease.

C.—CHRONIC SWELLINGS OF THE TESTICLE AND EPIDIDYMIS.

Although we are not able to clearly distinguish the testicle from the epididymis when they are acutely swollen, this distinction is somewhat more possible in the early stages of chronic swellings.

(1) Swellings of the Epididymis.

If the epididymis is hard and swollen in an irregularly nodular manner, or if a hard, tender nodule is felt in an otherwise normal organ, we should immediately think of tuberculosis. We seek for confirmation of this diagnosis in the characteristic nodular or cylindrical thickening of the vas deferens, which is early recognized because the vascular elements of the cord usually feel quite normal when the tubercle is not accompanied by secondary infection, in contrast to what we have seen in acute orchitis, gonorrhœal epididymitis, and tubercle with secondary infection. If the vas deferens is not thickened, we must look for traces of tubercle in the prostate, bladder, kidneys, as described in fuller detail in the chapter on urogenital tuberculosis. The kidney is often the organ first affected, and the disease of the epididymis is only detected first because of its accessibility.

There are three conditions with which this early stage of tuberculous epididymitis may be confused :—

(*a*) The *remains of gonorrhœal epididymitis*, hard, somewhat tender, indurations in the epididymis. The distinction is made by the history and other physical findings, especially by a careful examination of the urine.

(*b*) *Syphilitic epididymitis of the secondary stage*, recognized by its almost painless onset and other diagnostic signs of syphilis.

(*c*) A small cyst connected with the head of the epididymis—**spermatocele.** Its striking mobility, the smoothness of its surface, and its painlessness settle the diagnosis.

But if we do not see the patient until a later stage of the disease, when he has an old, retracted, slightly discharging sinus, the problem is quite different. Testis and epididymis are fused together into one shapeless mass and cannot be felt separately. The principal question to decide is whether the case is one of tubercle or *tertiary syphilis.* A gumma attacks the testicle by preference, while tubercle starts in the epididymis. The patient may perhaps be able to inform us of the original site of the disease, but if he cannot do so we should diagnose a gumma when the epididymis is only slightly involved and the testicle considerably affected, especially if spontaneous pain and tenderness are but slight.

If a sinus has already formed it is convenient to remember Reclus'

sign, to the effect that a syphilitic sinus generally lies *in front* and that a tubercular sinus lies *behind*, corresponding to the situation of the two diseases in the testicle and epididymis respectively.

One must not forget, however, that if the testicle is inverted a tubercular sinus may lie forward. It is therefore necessary to observe the position of the vas deferens in the spermatic cord to see whether it is in front or behind, before drawing any conclusion from the situation of the sinus.

(2) Swellings between the Testicle and Epididymis.

Cystic tumours lying between the head of the epididymis and the testicle, and seated on the latter like a cap or helmet, are grouped together under the term **spermatocele.** When such a cyst is present it is either impossible to feel the head of the epididymis as a separate structure, or it lies, as just stated, on the spermatocele, so that the latter is fixed between it and the testicle. In order to render the diagnosis more certain an exploratory puncture may be performed, which, although generally superfluous, never does any harm if asepsis is preserved. The diagnosis is confirmed by the turbid watery appearance of the liquid, and by the presence of seminal threads visible under the microscope.

(3) Swellings of the Testicle.

(*a*) An oval or pear-shaped tumour with a smooth surface and of soft or tensely elastic consistence, indicates an accumulation of fluid in the tunica vaginalis. If it be of small extent, the epididymis can still be appreciated as a separate structure, and we may even be able to feel the testicle if the fluid is not very tense. If, however, the swelling is large and the tension greater, both testicle and epididymis only present somewhat more resistant places in the wall of the swelling. If the effusion has a thick wall, it may be quite impossible to define them. The case is one of **hydrocele or hæmatocele of the testis, a serous or proliferating or hæmorrhagic peri-orchitis,** which may vary in size from a hen's egg to enormous proportions, if the patient waits until it is necessary to draw off the fluid by the pint.

If the swelling is translucent it is a hydrocele, and puncture is then not merely an exploratory procedure, but is a therapeutic measure, at any rate of a palliative nature.

If puncture of a tense translucent swelling is not followed by a flow of fluid, we should not diagnose cancer as a young practitioner once did, but rather a bad syringe.

If, however, the swelling is not translucent, the diagnosis is usually proliferating peri-orchitis, *i.e.*, a hydrocele whose wall has become thickened by connective tissue proliferation, by crest- and cone-like

indurations, and by deposits of gradually organizing fibrin. If, on exploratory puncture, a fresh bloody fluid, or more frequently a chocolate-brown fluid, exudes, the case is one of hæmatocele, which we must look upon as a sub-variety of proliferating peri-orchitis, when it is not of traumatic origin.

Serous peri-orchitis, as well as the proliferating and hæmorrhagic forms, give rise, in different ways, to many points of differential diagnosis.

A *serous peri-orchitis*, associated with appreciable changes in the testicle and epididymis, may be *secondary* or symptomatic. Such effusions within the tunica vaginalis occur in herniæ, tubercular epididymitis, and cancer of the testicle ; but they rarely become so large that the underlying disease is obscured. If we find that the upper end of a hydrocele which extends high up is very painful on pressure, and that there is probably some thickening of the spermatic cord at this spot, it is very likely that a *fragment of omentum has become strangulated* in a communicating sac with a narrow neck, so that the hydrocele is another instance of the secondary form (p. 388). In a case of *proliferating peri-orchitis*, our diagnostic reflections take another direction, at any rate before an exploratory puncture is done. A *malignant growth* will very frequently suggest itself ; unequal consistence usually indicates a tumour, although in simple proliferating peri-orchitis its wall may present soft, thin areas as well as hard ones. A rough nodular surface is clear evidence of new growth. Some tumours, however, have a perfectly smooth surface in their initial stage. As the infallible signs of a malignant growth, *i.e.*, enlargement of the retroperitoneal glands of the same side and other metastases, are absent at the beginning, we must fall back upon the history. A simple proliferating or hæmorrhagic peri-orchitis has usually existed for months, or even years, whereas a malignant tumour can only have been present at most for a few months.

There is nothing absolutely conclusive in these signs, because a hæmatocele may develop very rapidly after an injury, and some malignant tumours grow very slowly. I once saw a malignant tumour which had been under the observation of the family practitioner for many years. These are, however, exceptional cases, and the practical rule remains that the duration of hæmorrhagic peri-orchitis is a matter of years, while that of cancer or sarcoma is a matter of months.

After having taken all these points into consideration, puncture with a sufficiently strong and wide cannula is justifiable.

In proliferating or hæmorrhagic peri-orchitis, a serous or morbid chocolate-coloured liquid or fresh blood is obtained ; from a tumour, however, nothing is forthcoming, or at most a few drops of blood, or a plug of tumour tissue may be found in the needle. The latter is useful for histological examination. If exploratory puncture yields nothing at one spot, whereas some mucous fluid is obtained at another

spot, we should diagnose a *cystic adenoma*. If the fluid is of a light brown colour like *café-au-lait*, and contains epithelial cells, detritus and cholesterin crystals, the case is a *dermoid*, or at any rate an embryoma of similar constitution to the much more frequent ovarian dermoids, both of which may undergo cancerous degeneration

The state of the testicle and epididymis is of no significance in cases of old-standing proliferating and hæmorrhagic peri-orchitis, because both these structures become atrophied and absorbed in the indurated cystic wall.

If the clinical picture of proliferating or hæmorrhagic peri-orchitis is combined with signs of acute local inflammation, with fever, and probably even with rigors, we should remember that these forms of peri-orchitis may easily become infected, and we should inquire whether there has been any therapeutic interference, such as puncture or injection of iodine.

(*b*) The diagnosis is very much easier when there is a solid tumour, definitely connected with the testicle and independent of the epididymis, or when both testicle and epididymis are fused together into one uneven tumour. If neuralgic pains are present in the spermatic cord there is no doubt about its malignancy; but it is not always possible to tell from the clinical signs whether it is **sarcoma** or **carcinoma**, a differentiation which is not always easy, even after histological examination.

A cystic adenoma or cystoma of the testicle is a very rare tumour, but we should bear it in mind if the swelling is irregularly roundish and nodular and contains both hard and soft areas, and if the above mentioned mucous fluid is obtained on exploratory puncture.

It is important to distinguish cancer and sarcoma from the swellings described by Wilms as *embryoid tumours*, which are derived from all the three layers of the embryo and grow in an erratic manner. The dermoids or embryomata just mentioned are innocent tumours, but these embryoid tumours behave clinically like cancer, and can only be distinguished microscopically. A tumour of an inguinal testicle may very probably be of this nature, at any rate, such has been my experience.

Tertiary syphilis of the testicle—either as a single gumma or a diffuse gummatous sclerosis—is the only disease which may lead to error in regard to moderately sized tumours limited to the testicle. If there are no metastases, and if we have no very good reason to definitely exclude tertiary syphilis, iodide of potassium should always be given. But if no result follows, operation must be undertaken, because cancer of the testicle soon gives rise to secondary deposits, and therefore the organ must be removed without hesitation.

A word with reference to **accidents**. How much attention should be paid to the assertions of insured patients that these various diseases have come on after an injury? It is undoubted that even tumours may have a traumatic basis. Such a sequence is, however, very rare,

and it is very necessary to ascertain in every case whether there was not some morbid change present before the accident. This also applies to tubercle. It is also a fact that the onset of gonorrhœal epididymitis is favoured by injury; but this is no justification for claiming workmen's compensation, when the testicle has only been subject to the ordinary impact it may encounter during work, and its possessor has previously provided the necessary gonococci. This would be a defiance to the aims of accident insurance.

CHAPTER LVIII.

FISTULÆ IN THE PERINEAL REGION.

THE perineal region, the seat of various natural apertures, is also the gathering place of various fistulæ, some of which are congenital, while others only appear in later life. The principle of classification which we will adopt depends upon the site of origin of these fistulæ. The period of their appearance is not a satisfactory basis for classification, because even congenital fistulæ may not develop fully for many years. Neither can classification be based upon their position, because similar fistulæ may have very different situations. Sometimes microscopic examination is required to decide the nature of the discharge from the fistula.

We distinguish:—

(1) DERMOID FISTULÆ.

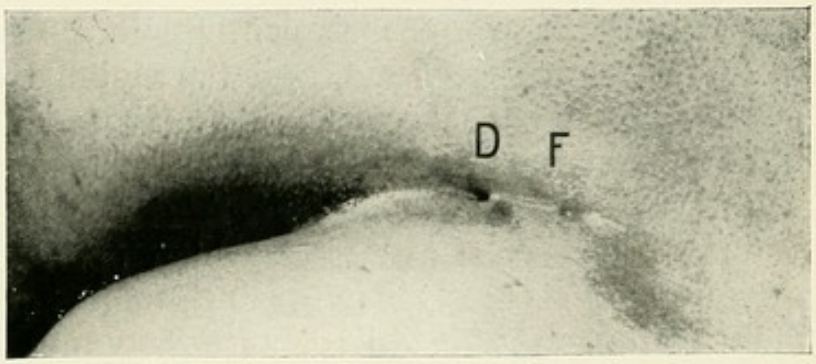

FIG. 198.—D = Dermoid fistula. F = Foveola coccygea.

A fistula in the coccygeal area, discharging a small amount of secretion, which has been present for many years and which admits a probe into a short blind sac, is a dermoid fistula. The diagnosis is confirmed if on miscroscopic examination there be found not only pus, but also pavement epithelium and even hairs.

The patient who had the fistula depicted in fig. 198, drew out many hairs from it, with the aid of a mirror.

Apart from these embryonic invaginations, there is often found in this region a depression, the *foveola coccygea* (fig. 198) which corresponds to the point of attachment of the caudal ligament to the skin.

(2) FISTULÆ IN CONNECTION WITH BONE.

These are almost always tubercular, and usually originate in the sacrum or ileo-sacral joint; more rarely in the coccyx or spinal column. The discharge from these fistulæ is always purulent, and the probe introduced reaches down to bone.

We can draw no conclusion as to the origin of these fistulæ from the histological demonstration of tubercle, because many simple rectal fistulæ are tubercular, and it is just from these that the differential diagnosis has to be made. Neither do negative results justify any definite conclusion, because the fistula may still be coming from bone, affected by osteo-myelitis.

Even if a fistula comes from bone, we are not justified in excluding the possibility of all connection with the rectum. The abscess may have opened secondarily into the rectum before appearing at the perinæum.

An unequivocal proof for its bony origin is only obtained if a skiagram shows the presence of a primary focus in the bone, or if this focus (vertebro-ileo-sacral tuberculosis) begins to manifest clinical symptoms.

(3) FISTULÆ OF THE RECTUM AND ANUS.

(*a*) *Congenital Fistulæ.*—These may be referred to three types, in accordance with the degree of occlusion and the sex of the patient :—

(1) The anal aperture is itself reduced to the size of a narrow fistula, which opens either in the anal cleft, the scrotum or penis.

(2) The anus is closed, and the ampulla is connected by a fistula with the vagina, or more frequently with the vestibulum.

(3) The anus is closed, and the ampulla opens into the urethra. The state of the anal fossa and the position at which the fæces escape permit an accurate diagnosis to be made forthwith.

(*b*) *Acquired Inflammatory Fistulæ.*—These are usually the final results of peri-rectal abscesses, which open externally near the anal aperture, and generally also break through somewhere in the rectum. They cannot be recognized, as a beginner might suppose, by the escape of fæces therefrom, for they are usually much too small for this. Besides, many of them are situated entirely below the sphincter, and others, despite their name, have no opening in the rectum. A fistula which has burrowed through, and opened above the sphincter, may, however, sometimes allow flatus to pass involuntarily. Before a fistula can be designated either rectal or anal, it ought to be shown that the original inflammatory process started in the rectum or anus.

This is not possible, as a rule, and therefore our diagnosis is eventually made by exclusion; that is to say, a fistula in this region is either rectal or anal in the narrow sense, if we can find no other explanation for it.

The portal of entry for the infection is very varied. The infective process may have become engrafted on a fissure, a hæmorrhoid, an accidental wound, a simple eczema, or even on a urethritis. In other cases the infection probably attacks peri-rectal tubercular glands.

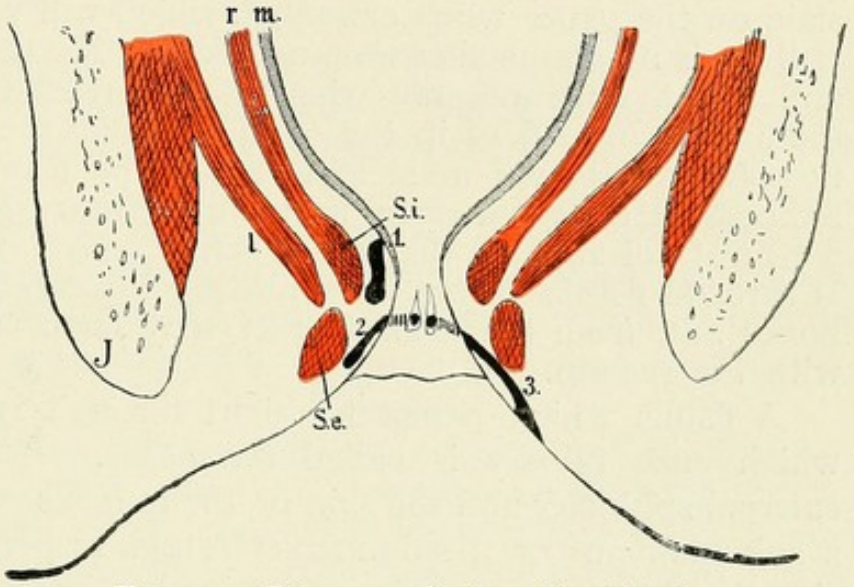

FIG. 199.—Diagrammatic view of anal fistulæ.

m = Mucous membrane of rectum.
r = Muscular layer of rectum.
Si = Internal sphincter.
Se = External sphincter.
l = Levator ani.
J = Ischium.

1 = Incomplete submucous fistula.
2 = Incomplete subcutaneous fistula.
3 = Complete subcutaneous fistula.

At other times the infection may enter through the folds of Morgagni (Chiari), or through Hermann's sinus, in which certain glands described by this observer open—this sinus itself opening into Morgagni's folds (Tavel). These fistulæ are invested with pavement epithelium. In order to determine whither the fistula leads, the bowel must be emptied and the patient placed in the lithotomy position and a moderately thick probe is passed into the fistula with one hand, while the index finger of the other is in the rectum for purposes of control. If we obtain no result the examination must be repeated after the introduction of a rectal speculum. If no connection is even then visible a sausage-shaped

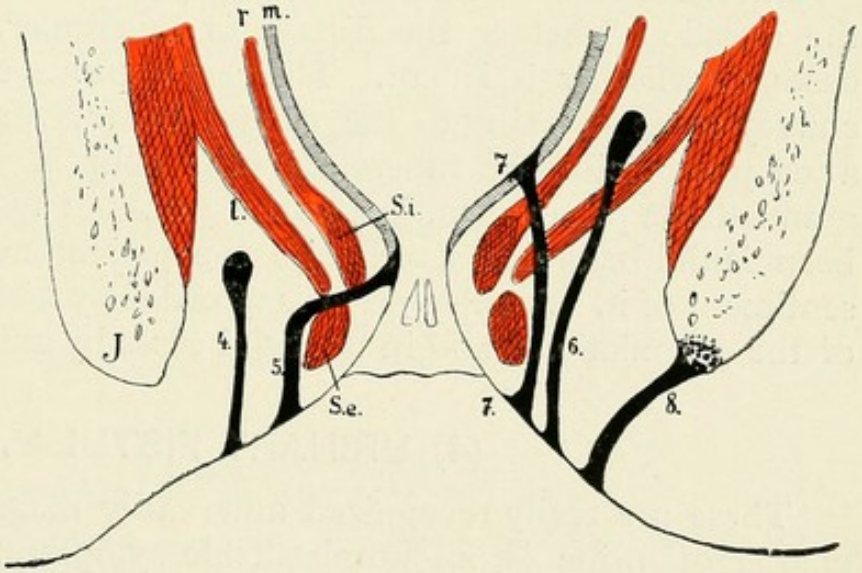

FIG. 200.—Diagrammatic view of anal and rectal fistulæ.

Anatomical details as in fig. 199.

4 = Incomplete ischio-rectal fistula.
5 = Complete ischio-rectal fistula.
6 = Incomplete pelvi-rectal fistula.
7 = Complete pelvi-rectal fistula.
8 = Fistula leading from tuber ischii.

roll of gauze should be gently put into the rectum as high up as possible and the external opening of the fistula injected with a few cubic centimetres of a 1 per cent. solution of methylene blue. If there is any connection between the fistula and the bowel there will be a blue stain on the gauze when extracted, which will also show its position. If there is no connection we must see whether the probe reaches bone, and if not, must observe whether the injected solution appears in the urethra instead of in the rectum. If all these examinations yield negative results we must still regard the fistula as a rectal fistula, although it does not open into the rectum. But, on the contrary, we must not suppose that every fistula which opens into the rectum is a rectal fistula, as we have already indicated. Both fistulæ from bones and from the urinary tract may form secondary connections with the rectum.

A fistula which penetrates right through is called *complete*, one which ends blindly is called *incomplete*. If it runs between the external sphincter and the skin or the mucous membrane we speak of a subcutaneous or a submucous fistula respectively. If it lies outside the external sphincter and under the levator ani we call it *ischio-rectal*. If such a fistula is complete it usually opens just above the external sphincter, between it and the internal sphincter. If a fistula pierces through the levator ani it is called *pelvi-rectal*. If there is an internal opening to it, it will be found above the internal sphincter (fig. 200).

In regard to the treatment and prognosis we are confronted with the question whether the disease is tubercular, as it is in half the cases, or whether it is not. The very appearance of the fistula may convey some meaning to the careful observer, and he will entertain a deep suspicion of tubercle if the skin is undermined and the granulations pale brown, just as he would if apical tuberculosis had been found beforehand, although the patient may have had no presentiment of it. Positive proof is afforded by histological examination of the granulations, and in doubtful cases by animal inoculation.

(4) URINARY FISTULÆ.

These are easily recognized and easily diagnosed, because a discharge of urine is an unmistakable symptom, and one which the patient realizes at a very early stage.

(*a*) We will begin with *congenital urinary fistulæ*. These obviously only occur in males and are caused by the urethra opening in the perinæum—hypospadia, scrotalis and perinealis—or in the rectum. This hypospadias merges into hermaphroditism.

(*b*) Acquired urinary fistulæ are of greater importance. We shall not refer to urogenital fistulæ of females, which belong to the department of gynæcology, but shall limit ourselves to the male sex.

The first question to decide is the source of the fistula. The mode and manner of the urinary flow may be conclusive on this point. If it is constantly dripping the fistula must run into the bladder, or some previous disease must have destroyed the action of the sphincter.

This form of fistula is rare. I have seen it in an old prostatic patient in whom a retroprostatic pouch had led to an extravasation of urine towards the perinæum, and therewith to the formation of a fistula.

On the other hand, if urine only exudes at the time that the patient micturates voluntarily, not, however, through the natural opening, but through more or less numerous fistulæ, it follows that the urethra must be leaking between the sphincter and some obstruction peripheral to it.

The spot at which the urine escapes is a matter of indifference. One finds sometimes, as a result of extensive urinary infiltration, fistulæ on the scrotum, penis, perinæum, lower abdomen, and even on the thigh, so that the patient eventually micturates as from a basin full of holes.

If the distinction between fistulæ from the bladder and from the urethra is once made, the etiology follows naturally. In cases of vesical fistula the obstruction must be at the neck of the bladder, and consists either of a tumour or prostatic hypertrophy. In cases of urethral fistula the obstruction must lie peripherally to the neck of the bladder, and consists of gonorrhœal or traumatic stricture, rarely of tubercle or cancer; but in the Tropics Bilharzia disease is frequent.

The fistulæ which develop after open injuries, and which concern the urethra rather than the bladder, follow no rule. The same applies to the fistulæ which develop in consequence of malignant growths of the urethra or anus.

CHAPTER LIX.

GENERAL REMARKS ON THE SURGICAL DISEASES OF THE URINARY ORGANS.

THE cystoscope, catheterism of the ureters, the intravesical separation of the urine, and cytoscopy, may have improved the accuracy of diagnosis of urinary disease, but it has certainly robbed it of simplicity, and there is a risk that the practitioner will think that urinary disease, with the exception of nephritis, cannot be diagnosed without all these accessories. This would be, however, a grave error, and the

exaggerated significance which was at first attributed to some of these methods is to blame. The general practitioner still sees urinary troubles in their earliest stages, and the responsibility rests upon him of recognizing when surgical assistance is required. Every practitioner has, or should have, a microscope at his disposal, and is conversant with the elementary methods of the chemical and bacteriological examination of the urine. These two aids, in addition to careful clinical observation, permit the diagnosis to be made in most cases sufficiently early for timely surgical treatment—if this is attainable.

We will not proceed to consider ready-made diagnoses like the headings of a text-book, but will take the symptoms which lead the patient to the medical attendant. These consist either of some disturbance in micturition or of some abnormal constitution of the urine. Then there come into consideration local symptoms in the area of the diseased organ.

A.—DISTURBANCES OF MICTURITION.

Micturition may be *painful* (dysuria) or *difficult* (retention), or, on the other hand, it may be *too free* (incontinence), or, finally, there may be a persistent strangury (tenesmus). *Involuntary* micturition, which is otherwise normal, has only rarely a surgical interest.

(1) PAINFUL MICTURITION.

Pain on micturition may originate either in the urethra or in the bladder and its vicinity. We distinguish the following possibilities :—

(1) If the urine scalds when it passes through the *urethra*, there is either some abnormality in its composition (concentrated, or chemically changed), or the urethra is inflamed. The former condition may be caused by indulgence in certain beers, or by taking beer to which one is not accustomed ("biertripper"). In recent urethritis it will not, as a rule, be difficult to fix the blame on the gonococcus.

The observer must convince himself of the condition of the urethra by inspection, lest he treat a gouty urethritis for a gonorrhœa. The differential diagnosis is easy, because there is no discharge in the former, whereas in the latter it is always present in some form.

A pain which originates in the bladder is sometimes referred to the urethra, and the patient complains of a scalding in the glans penis, when, for instance, the bladder is irritated. Pain on micturition may also arise from some localized disease of the urethra, a stone, a foreign body introduced from without, or rarely from the early onset of carcinoma.

(2) Pain in the *neighbourhood of the bladder*, especially at the end of micturition, indicates disease in the bladder itself or in its vicinity.

(*a*) Stone and tuberculosis are the principal *diseases of the bladder* in this connection. Tumours do not cause pain until their later stages, unless cystitis supervenes. In tuberculosis, and more especially in stone, the pain occurs chiefly at the end of micturition, remains a long time after the completion of the act, and may radiate into the urethra.

In cases of stone there is the very significant circumstance that the pain and the accompanying strangury increase with bodily movements, such as riding on an uneven road.

(*b*) When the inflammatory process is in the *area adjacent to the bladder*, as in the case of perimetritis or of appendicitis, &c., wherein the bladder is directly involved in an abscess wall, the pain occurs at the beginning of micturition and remains more limited to the neighbourhood of the bladder; patients with appendicitis often retain their urine for many hours to avoid this pain. The same applies, although in a less degree, to the bladder pain which often occurs in cases of tubercular peritonitis.

(2) DIFFICULT MICTURITION.

This is caused either by some disturbance of the mechanism or by obstruction in the passage.

Whenever there is no urine passed, it is most important to show, by percussion or catheterism, that there is urine in the bladder, and that the failure of micturition is not due to suppression of urine. We have already discussed in connection with abdominal injuries the apparent anuria which occurs in laceration of the bladder.

(a) Disturbances of the Mechanism of Micturition.

Retention, due to disturbance of the mechanism, by an interruption in the reflex arc or by cerebral inhibition, is of medical rather than of surgical interest. The surgeon often sees this form of retention after operations, due to psychical inhibition.

It is not at all necessary that the operation should be on the genitals, urinary tract or their vicinity. Retention may also follow other operations, such as excision of a goitre, or radical cure of hernia. Sometimes it is only the horizontal posture which disturbs the patient; in other cases micturition is impossible in any position. This form of retention may be compared with what is often seen in neurasthenics, who, for instance, are quite unable to micturate in the presence of another person.

The retention observed in semi-comatose patients, especially in the course of meningitis, indicates functional disturbance of the reflex process. The voluntary retention in cases of painful micturition previously noted is quite of a different character. In cases of retention

due to over-distension of the bladder, the cause is partially due to disturbance of the mechanism of micturition, but as the chief cause is some mechanical obstruction, we shall discuss this type of retention in the latter group.

Anatomical destruction of the nerve tracts is found in injuries of the spinal cord, and in compression thereof by tubercular caries or tumours.

(b) Obstruction of the Urethra.

The difficulty caused by mechanical obstruction of the urethra has much greater surgical importance. The following comprises a summary of the causes of such obstruction : foreign bodies and stone, inflammatory and traumatic strictures, compression of the urethra from without by a hæmatoma, tumour or inflammatory material, &c., and laceration of the urethra. Each one of these conditions possesses its own peculiarities, which, as a rule, render the diagnosis quite easy.

(*a*) A sudden onset, accompanied by pain and possibly by the passage of blood, strongly suggests a *foreign body in the urethra*. It may be a stone from the bladder, which has lodged in the urethra, a very probable contingency if there be a history of the passage of stones or of discomfort due to stones. But a foreign body may have been introduced from without, obstructing the urethra either by its size or by the inflammation which it provokes. History is usually silent in these cases, and nothing less than the ocular demonstration of the foreign body suffices to extort a confession. A metal catheter and a urethroscope are required for the diagnosis. The extent to which sexual perversion may go is shown by a case in our clinic, wherein the patient filled his urethra, as far as the sphincter, with plaster of paris.

Stones may remain in the urethra for a considerable time without leading to obstruction. These are stones lying in diverticula and their symptoms are of a chronic nature.

If the urethra is free, the cause of a sudden obstruction must be at the exit from the bladder, and then stone at the vesical neck is most probable. In certain positions such a stone may block up the neck of the bladder like a ball-valve. In most of these cases the patient will already have discovered that he can only micturate easily in a certain posture of his body. Often, the micturition will be suddenly interrupted, or the previously powerful stream becomes suddenly feeble.

If obstruction has apparently come on suddenly at the neck of the bladder, and it remains absolutely unchanged as a complete obstruction for a day or more, we should think of **enlarged prostate** if the patient is an elderly man.

A careful inquiry into the history of these cases will elicit the fact that there have been symptoms of mild obstruction previously, but that the patient has not appreciated their importance. The sudden obstruction is also partially due to over-distension, and therefore to disturbance of the mechanism of micturition.

(*b*) *Subacute obstruction of the urethra* is the term applied to those cases wherein the process develops, without any warning, in the course of a few days. They are usually caused by rapidly growing swellings which press on the urethra from without—in males, by **abscesses of the prostate or vesiculæ seminales,** or **peri-proctal suppuration**; in females, by some **genital tumour** strangulated in the true pelvis and becoming rapidly larger through circulatory disturbances, by a pregnant retroflexed uterus, or by some **effusion** under high pressure.

(*c*) *Gradual obstruction of the urethra* presents quite a different clinical picture.

The patient complains that for weeks or months he has had to strain during micturition, and that the stream does not reach as far as formerly. Attacks of catarrh of the mucous membrane or of over-distension of the bladder may increase the symptoms spasmodically, but the obstruction may become complete quite suddenly, and its degree never varies, as it does in cases of obstruction by stone.

The causes of this gradual obstruction include stricture, new growth, stone in a urethral diverticulum, enlarged prostate, pelvic tumour, or a very chronic abscess. The age and history of the patient will suggest the selection from these causes, and local examination, which we shall describe later on, will allow us to make a more definite diagnosis.

(3) DEFICIENT CLOSURE OF THE BLADDER.

Inability to retain the urine, *incontinence*, may be due to many causes, some of which are concerned with medicine, others with surgery.

Disturbances of innervation are the most important of these causes. They may be of a purely psychical character and transitory in nature (fright or excitement). In other cases there may be organic paralysis of the sphincter, in which condition the incontinence is not primary, but merely the result of retention with overflow, from an over-filled bladder (paradoxical incontinence). The urine dribbles away, yet the bladder may reach as far as the umbilicus. Retention with overflow also occurs when mechanical obstruction has led to over-distension of the bladder, *e.g.*, in enlarged prostate.

Incorrect diagnosis of these various disturbances is quite frequent. Pure incontinence as a result of sphincter paralysis is

confused with overflow from a full bladder due to paralysis of the detrusor. The difference is, however, very obvious, because in the former case the bladder is empty, while in the latter it is full. The constant micturition which occurs when the capacity of the bladder is very small (as in tuberculosis or stone) is sometimes mistaken for genuine incontinence. Finally, pure nervous derangements may be regarded as the result of mechanical obstruction, and a patient with masked tabes diagnosed as a case of enlarged prostate. These mistakes can only be avoided by a complete examination of the patient.

Ulcerative destruction of the sphincter by new growth or tubercle may also lead to constant flow of urine.

(4) VESICAL TENESMUS

must not be confused with incontinence. This term is applied to all cases wherein there is increased frequency of micturition, accompanied by abnormal sensation of irritation. The first thing which usually strikes the patient is that he is bound to get up once or more in the night, although he has not taken more than his average allowance of liquid. Then, he begins to be annoyed by frequency of micturition during the day, and, finally, strangury sets in, which prevents him from attending to his occupation.

The bladder is in a constant state of contraction owing to some persistent irritation. It is unable to fill up, and the urine escapes at short intervals, although the sphincter still retains the full powers of closure. The main cause of this condition is cystitis, especially of tubercular origin, but it is sometimes due to a large stone in the bladder. In persons with extreme reflex irritability, such as is attributed to Rousseau, there is no relation between the physical state and the degree of vesical contraction. Even a small ulcer may suffice to produce the so-called "irritable bladder." The diagnosis is based on the frequency of micturition and the diminution of the capacity of the bladder, which can be demonstrated by the injection of fluid.

Whereas a normal bladder easily holds 200 to 250 c.c., an irritable bladder sometimes rebels against one-tenth of this quantity, and it is often quite impossible to inject the 80 to 100 c.c. which are required for cystoscopy, at any rate, without the aid of morphia or anæsthesia.

As the various conditions which lead to the anomalies of frequent micturition are very liable to confusion, they may be briefly summarized once again :—

Anuria.—Absence of urinary secretion, or its retention in the kidneys (the former in severe nephritis, the latter in stone in both kidneys) ; but the power of emptying the bladder is *not* lost.

Oliguria.—Very small amount of urine secreted, without regard to the frequency of micturition (*e.g.*, in nephritis, ileus and diarrhœa).

Polyuria.—Increased secretion of urine, without reference to the frequency of micturition (*e.g.*, in diabetes).

Pollakiuria.—Abnormal frequency of micturition, without reference to the quantity of urine. This may be the result of :—

(*a*) Abnormal filling of the bladder, with incomplete micturition (*e.g.*, enlarged prostate).

(*b*) A condition of abnormal irritability (vesical tubercle, vesical stone).

(*c*) An abnormally large quantity of urine.

B.—ABNORMAL COMPOSITION OF THE URINE.

The substances which a patient notices as abnormal constituents of his urine are pus, blood, and inorganic deposits in the form of concretions.

(1) ADMIXTURE WITH PUS.

The naked eye should never be relied upon for the diagnosis of pus ; it is always necessary to employ chemical examination and the microscope. This, however, does not mean that the naked eye cannot discover a good deal in a cloudy urine.

The following type of case is not infrequent : A patient consults us for a condition which has been diagnosed, either by himself or by others, as cystitis. He complains of tenesmus, and in evidence of his disease he puts on the table a bottle containing whitish cloudy urine. While describing his symptoms in full detail, a sediment forms in the bottle, which the experienced observer sees at once is not pus, but *carbonates* and *phosphates*. A few drops of acid dissolve this precipitate. A microscopic examination of the deposit will reveal amorphous calcium salts, and probably also the beautiful crystals of di-calcium phosphate ; sometimes also calcium oxalate. A few general directions for the *regimen* of the body and mind suffice to cure the patient of his " cystitis."

If the urine is slightly cloudy, but forms no deposit even after long standing, nor clears up on the addition of acid, it is most probable that the specimen is not fresh, but has become a culture medium for bacteria. A glance with the microscope shows us swarms of bacteria but no pus cells. If the patient assures us that the somewhat cloudy and offensive urine has been passed quite recently, the probability is that the bacterial culture has developed in the urinary passages, and another examination with a catheter specimen would prove this. Pus cells are entirely absent, neither are there any clinical signs of inflammatory disease of the urinary passages. The case is one of "*bacilluria*," generally due to the *Bacillus coli* but sometimes to the typhoid bacillus.

If there really be *pus* in the sediment, the urine must be examined very carefully with the naked eye. If gonorrhœal threads or small

flakes of pus float about in it, the urethra of the patient must be examined, and, according to circumstances, the urine must again be investigated after washing out the urethra, or the three-flask test must be undertaken. If the pus only comes from the anterior urethra, or from the posterior urethra as well, leaving the bladder free, the case is gonorrhœa. If both the urethra and the bladder discharge pus, we shall rarely err if we diagnose cystitis as a complication of gonorrhœa. But if all the pus comes from the bladder, we must inquire whether there is always a sediment in the urine, or whether the cloudiness in the specimen under examination is a first appearance, or whether such cloudy specimens have been passed on previous occasions. If the urine is uniformly purulent, or at any rate if the pus contents are not subject to sudden changes, the lesion may be in the bladder, although the pus may come from the pelvis of the kidney.

A single evacuation of very purulent urine, or of pure pus, indicates, either that a pyonephrosis has suddenly emptied into the bladder, or that a perivesical abscess has broken into it. Such an abscess may originate in the appendix, female sexual organs, prostate, or pelvic bones. This event will always have been preceded by symptoms which permit of the establishment of a diagnosis. The appearance of pus in the urine is only an incident in the course of the underlying disease. The site of the perforation can be seen with the cystoscope.

We now proceed to the *chemical examination of the urine.* The chief information which this affords, apart from the demonstration of carbonates and phosphates previously mentioned, concerns the reaction of the urine. Diminution of acidity, or even the presence of an amphoteric reaction, has no serious significance, as long as the urine is odourless, and if any cloudiness which may be present disappears on the addition of acid. On the other hand, a diminution of acidity in pus-containing urine, and the presence of an alkaline reaction, indicates secondary infection of the urinary passages by organisms like the staphylococci and *Proteus vulgaris,* which decompose urea. The latter causes, in addition to an alkaline reaction ammoniacal fermentation, which betrays itself at once by the smell. If pus-containing urine is acid, but does not smell offensively, the condition is usually tubercular or one of streptococcal infection. If it is acid and offensive in smell, the *Bacillus coli,* and probably other inflammatory organisms, are responsible.

It goes without saying that the chemical examination of the urine must always include tests for albumin and sugar, and for biliary and blood pigment when necessary.

The most important part of the *microscopic investigation of the urine* concerns the various *forms of cells.* If polynuclear leucocytes preponderate, the morbid process is an acute one; if mononuclears

preponderate we should rather think of tuberculosis. Bladder epithelium indicates the presence of ulcers, especially if it is found in shreds, and if specimens of the deeper layers occur (caudate epithelium). Red blood corpuscles point to the same conclusion. Whenever pus cells are present, cylindrical cells should always be sought for.

It is then necessary to note the presence of various kinds of *micro-organisms*. The demonstration of tubercle bacilli possesses a special significance, and to prevent their confusion with smegma bacilli, a catheter specimen must be obtained, a precaution requisite in all bacteriological investigations of urine. If nothing is found, this is naturally no evidence against tuberculosis. But we must not hastily conclude that the suppuration has been adequately explained by the discovery of the *Bacillus coli*, staphylococci or streptococci. These organisms may certainly exist independently, but they often accompany the tubercle bacillus, even in uncatheterized cases, and may indeed completely overshadow it in the urine. We may even go a step further and say that every case, wherein these organisms persistently occur in the urine, is very suspicious of tubercle. The suspicion is even greater, if only pus cells are found and no micro-organisms at all. Such cases are almost always tubercular. This diagnosis is obviously arrived at by a process of exclusion, but it can be confirmed by the inoculation of guinea-pigs—a procedure which should never be neglected if tubercle bacilli are not found in the direct examination of purulent urine, in cases wherein there is no other cause for the suppuration. If this experiment, conducted with an adequate amount of sediment, yields no result, we are then justified in assuming that the case is one of pyelitis due solely to the "ordinary" pus organisms. Experience, however, shows that such cases are really of quite unusual occurrence.

(2) ADMIXTURE WITH BLOOD.

The presence of blood in the urine is always a serious matter, whether there are only a few red cells detected by the microscope, or whether there has been profuse hæmorrhage.

(1) If the blood is quite red and also flows independently of micturition, it comes from the urethra and must be ascribed to injury, possibly by a foreign body.

Smaller periodical hæmorrhages independently of micturition indicate some ulcerative process in the urethra (cancer, or stone in a diverticulum). The appearance of *blood-stained semen* should also be mentioned. Cases occur wherein there is a discharge of blood-stained semen, quite apart from any sexual activity, and even after the period of sexual life has been left behind, although no objective demonstrable disease of the sexual organs be present.

(2) If the blood is mixed with the urine and appears only with micturition, it must come from the *bladder*, *ureter* or *kidneys*. Attempts have been made to decide whether the blood comes from the kidneys or the bladder, on the basis of the more or less pronounced change in the colour of the blood. These are, however, unreliable, because everything depends on the rapidity of the hæmorrhage, the amount of blood and the duration of the contact between the urine and the blood. If the hæmorrhage in the bladder is slight, and the blood remains within it for any considerable time, it undergoes the same changes as occur in hæmorrhage in the pelvis of the kidney. Much more reliable conclusions may be derived from the associated symptoms. If the hæmorrhage is attended by *vesical colic* —due to the expulsion of coagula—and by *no other* symptom, the blood most probably comes from the bladder. If *renal colic* is present, its origin is in the kidneys. If there be no pain, nor any indications of tumour in the bladder or kidney, we may be able to obtain some information by examining the urine after massage of the kidneys. The last stage of the examination consists of cystoscopy.

(3) If there be pus in the bloody urine, or in the urine of the intervals wherein it is free from blood, we should think especially of tubercle, or of some vesical or renal disease with secondary infection, however slight the traces of pus may be.

(4) Microscopic traces of blood, constantly found in the sediment or the centrifugalized portion, indicate either stone or tuberculosis.

(5) Intermittent hæmorrhage and the presence of cylindrical cells and albumin in the intervals when the urine is free from blood, are signs of chronic hæmorrhagic nephritis.

Nephritis may, however, occur without albumin and without cylindrical cells, as shown by Rovsing. But we should only conjecture such a diagnosis in cases wherein the blood comes from both sides and cannot otherwise be explained.

It is also necessary to add, for the sake of completion, that renal hæmorrhage may occur in hæmophilia and in transitory hæmorrhagic diatheses, as in purpura. Whether, apart from the above-mentioned conditions, bleeding may occur from healthy kidneys—idiopathic renal hæmorrhage—as is often assumed, must be left an open question. Such a diagnosis can only be made with certainty *post mortem*, because anatomical changes cannot be excluded unless histological examination of both kidneys has been undertaken.

(3) ADMIXTURE WITH INORGANIC DEPOSITS OR CONCRETIONS. (URINARY GRAVEL.)

Inorganic sediment is the third form of urinary admixture which worries the patient and impels him to seek advice. This sediment varies from a flocculent deposit of microscopic particles and

crystals, to the size of a pea, *e.g.*, to a calibre which can just pass through the urethra. We have already referred to sediment composed of carbonates, phosphates and oxalates. In the case of "gravel" or larger concretions the diagnosis of calculous disease is obvious. But such a diagnosis should not satisfy us. It is much more important to decide whether we are dealing with an "aseptic" or with an "infected" case. In the former, the urine is free from pus and the concretions consist of calcium oxalate, uric acid, urates and occasionally of cystin. In the latter, the urine is purulent and the concretions consist, exclusively or largely, of ammonium-magnesium phosphate and basic calcium phosphate.

Combustible	Murexide test { With ammonia—purple red / With caustic potash—purple violet		Uric Acid Urates
	Murexide test { With ammonia—yellow / With caustic potash—orange		Xanthin
	The powder burns with a slightly luminous blue flame, and smells like burning sulphur and oil of asafœtida		Cystin
Incombustible	The powder effervesces with hydrochloric acid		Calcium Carbonate
	The powder does not effervesce with hydrochloric acid	but does so after heating to redness	Calcium Oxalate
		and does not do so, even after heating to redness	Earthy Phosphate

The diagnosis can often be made from the microscopical examination, because the urine frequently contains, in addition to the peculiar granules of gravel, some crystals of the corresponding salts, illustrations of which are given in any text-book of clinical methods. If these crystals are, however, absent, the diagnosis can be made by the experienced observer without any difficulty, from the above scheme suggested by Ultzmann.

The *origin* of these concretions cannot be determined forthwith, at any rate not of all of them. We may, however, assume that clinically aseptic concretions originate in the renal pelvis, while secondary stones may form either in the renal pelvis or the bladder. Gravel might come from either source, but small facetted burnished stones usually originate in the renal pelvis.

C.—LOCAL SYMPTOMS.

An accurate diagnosis can only be made after the direct examination of the organs concerned. We shall later on discuss the various groups of disease in detail, but for the present, will limit ourselves to a

few remarks on the *method of examination*, and the so-called *functional diagnosis of renal disease.*

The patient must first pass a portion of his urine—if he can—and we put this aside for a careful examination, particularly to ascertain whether there is any admixture with blood. The character of the stream and the naked-eye appearance of the urine will already have furnished important information (gonorrhœal threads, pus, gravel). We then feel the urethra, lest we miss some foreign body, tumour, or scar tissue which may be felt from the outside, and afterwards we palpate over the bladder and kidneys. A wide Nélaton catheter is then introduced, having previously satisfied ourselves as to the condition of the instrument.

It is very unfortunate if the practitioner has to extract a broken piece of catheter himself, or obtain the services of some one else to do it for him.

The following are the usual possibilities :--

(1) If the catheter enters the bladder easily, although the patient cannot himself micturate, the neck of the bladder must be obstructed by a stone, foreign body, or tumour ; or it may be a case of enlarged prostate, or compression of the urethra from without—assuming, of course, that a nervous derangement is not in question. In cases of enlarged prostate or external compression of the urethra, the catheter experiences some little difficulty when it reaches the pars prostatica. We then take a medium-sized metal catheter of the ordinary curve, and introduce it very carefully. If we reach the bladder after impinging on a hard, rough substance, there can be no doubt about the diagnosis of stone or foreign body. If nothing is felt, we must notice whether it is necessary to depress the eye of the catheter very much before the urine flows. In this event the pars prostatica is lengthened, which means that an enlarged prostate is probably present. Sometimes it is necessary to elevate the patient's pelvis in order to depress the catheter sufficiently. The diagnosis obtains further confirmation if we cannot empty the bladder with the ordinary shaped catheter, but succeed in doing so with a semi-circularly curved tin catheter, or with an elastic catheter with Mercier's curve.

Having succeeded in introducing into the bladder a medium-sized or wide catheter, either with or without this special manœuvre, the question arises as to whether we are dealing with a simple prostatic hypertrophy, a prostatic tumour, or with some pathological structure in the vicinity, which is pressing on the urethra. The latter usually signifies a swelling, which is more often malignant than innocent, and includes tumours of the pelvic bones and connective tissue, such as sarcomata, chondromata, osteomata, and cysts, mainly dermoids. The distinction between these conditions and enlarged prostate is made by rectal and combined recto-abdominal examination.

With the finger introduced into the rectum, we first feel the anterior wall of the ampulla, and follow the outlines of the prostate with the finger tip. It is impossible to learn from books what this feels like; it must be studied on the living subject. If the mucous membrane is soft and œdematous, with the prostate enlarged and rather elastic, feeling like a pillow, and at the same time tender to pressure, the case is one of acute prostatitis or of prostatic abscess. If the swelling is higher up, the case is one of inflamed vesiculæ seminales.

If the prostate is enlarged, but not painful on pressure, the case is one of enlarged prostate, cancer, or sarcoma. If there is nothing special found in the prostate, the hypertrophy may be in the direction of the bladder with or without a middle lobe, or the prostate may be in a state of diffuse sclerosis, or there may even be a contracting cancer present. (See further Chapter LXIX.).

Otherwise there must be present one of the previously mentioned tumours, pressing on the neck of the bladder from without. (See Chapter LXXIII.).

In the female sex, in addition to the pressure of the fœtal head during labour, it is necessary to mention uterine tumours incarcerated in the true pelvis, as well as retroflexion of the gravid uterus. Everyone of experience knows those tumours, reaching as high as umbilicus, which beginners look upon as ovarian cysts, but which disappear as soon as a catheter is passed. It is most important to make an accurate estimate of the state of affairs, as a very prolonged over-distension may result in complete sloughing of the mucous membrane of the bladder. A similar result may occur from rapidly growing tumours, strangulated within the true pelvis, as I have seen in a case of sarcoma of the uterus.

(2) If a medium-sized catheter does not enter the bladder, but a narrow one does, a stricture is present. If it is not very definite, it is useful to employ Guyon's olivary bougie, because we are better able to appreciate the obstruction with this instrument than with a cylindrical or a cylindro-conical catheter. But if even the smallest catheter will not enter, we must try a series of elastic bougies of the calibre of catgut, putting in one after the other. A path will sometimes be found in this manner. The cause of the stricture is either gonorrhœa or new growth. If the age and history of the patient, and slight hæmorrhage from the stricture suggest cancer of the urethra, it may be possible to establish this diagnosis by palpating the urethra and the use of the urethroscope.

(3) If no instrument at all passes, the case is a severe example of one of the two above-mentioned classes. If the age, sex, and external circumstances do not give a clue, and if the over-filled bladder prevents a satisfactory examination, we must puncture the bladder as a

matter of urgency, and then provide an exit as rapidly as possible, either above or below, in accordance with the physical condition found.

(*a*) Unilateral inhibition of the renal function (trauma, infarct). Local symptoms. No marked disturbance of urinary excretion (function taken on by other kidney).

($a + a^1$) Bilateral inhibition of the renal functions (nephritis). Anuria. Bladder empty. Death from uræmia.

(*b*) Unilateral obstruction of renal pelvis (kinking owing to abnormal insertion, or floating kidney, blocking by stone). Unilateral renal colic. Hydronephrosis. No uræmia.

($b + b^1$) Bilateral obstruction of renal pelves (most frequently stone). Bilateral renal colic, anuria, uræmia.

($b + a^1$) Obstruction by stone, with reflex anuria. Same symptoms, but colic only unilateral.

(*c*) Blocking of one ureter. (Stone, pressure by tumours). Same symptoms as in *b*.

$c + c^1 = b + b^1$.
$c + a^1 = a + b^1$.

(*d*) Obstruction of neck of bladder by stone. Retention of urine. Bladder distended. Flow of urine variable. Catheterism easy.

(*e*) Neck of bladder obstructed by tumour. (Enlarged prostate, cancer, sarcoma.) Retention of urine, partial (residual urine) or complete. Large catheter usually passes easily.

(*f*) Obstruction by urethral stricture. (Trauma, gonorrhœa). Retention of urine. Only a small catheter can be passed, but this sometimes fails.

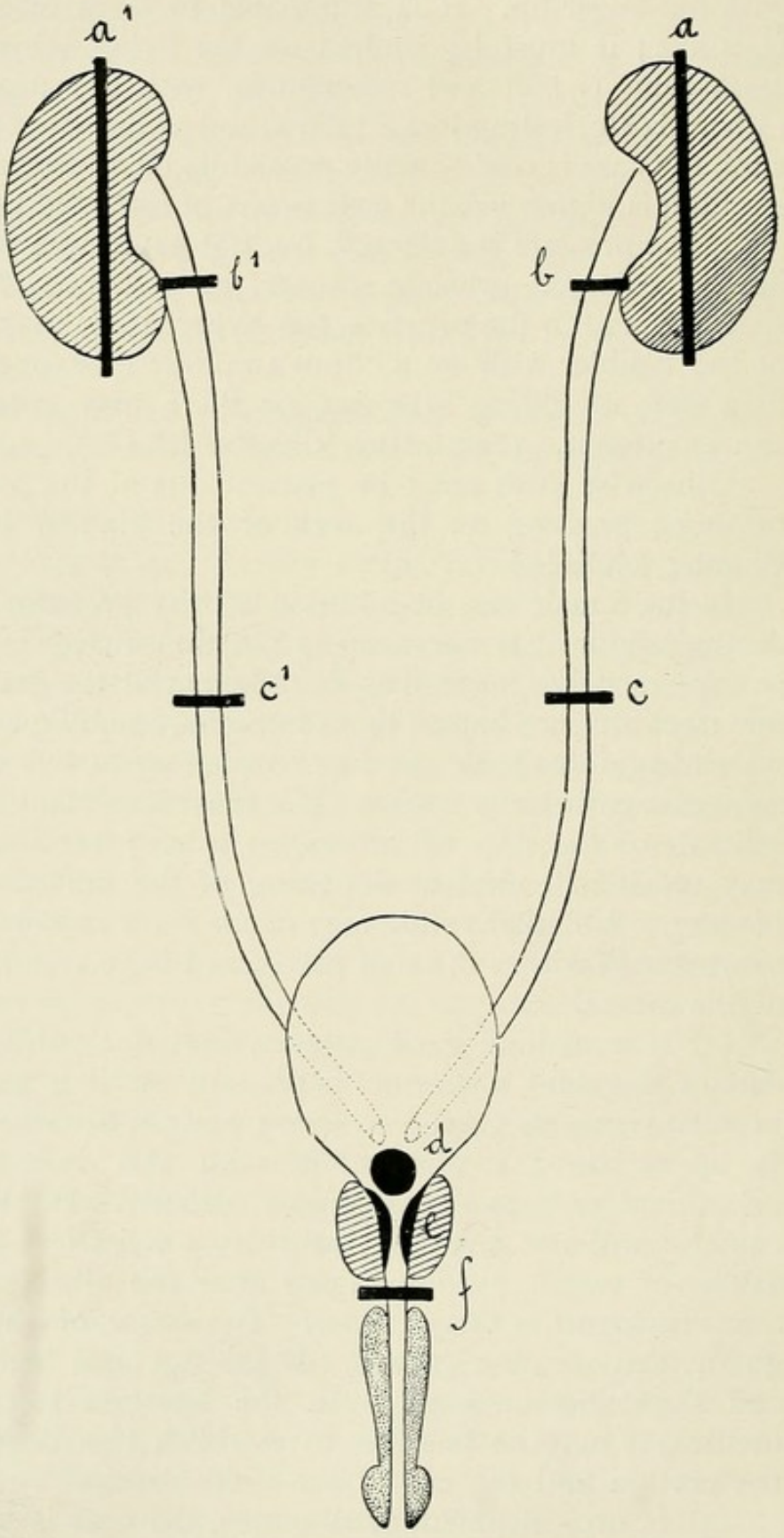

FIG. 201.—Diagram of the various surgical derangements of micturition.

(4) If the bladder is easily accessible, and it is necessary to decide the nature of the vesical disease, or the source of blood or pus, we must employ the aid of the **cystoscope.**

This instrument shows us whether the mucous membrane is healthy, inflamed, covered with fibrin, or ulcerated. It also shows us the position of ulcers which may be present, and if they are arranged around one ureteral orifice, it indicates to us which kidney is diseased. It also shows us the shape of the ureteral orifices, it tells us whether the wall of the ureter is thickened, and enables us to decide the character of the urine, which trickles at intervals from the ureteral orifice, in accordance with its transparency or cloudiness. By its means we are also able to see stones, foreign bodies, tumours, and diverticula. But it is indispensable that the bladder should be able to hold 80 c.c. of water, and that there should not be any severe hæmorrhage.

The technique of the examination is not described here, because the general practitioner cannot be expected to do more than have the examination carried out early enough for the successful issue of any surgical operation which may be necessary.

If, finally, we have to determine the functional capacity of the whole renal apparatus, or of each individual kidney, this is a matter of the so-called **functional diagnosis of renal activity.** This does not come within the province of the general practitioner, because it requires more technical practice, experience, and time than he has at his disposal. He will, however, desire to know how it is carried out, and what results it yields.

The functional activity of the total renal parenchyma is first estimated, and then that of each individual kidney.

The first task demands the *estimation of the freezing point of the blood*, according to Koranyi. The lower this is, the more "urinary" substances there are in the blood, and the functional activity of the total renal apparatus is correspondingly unsatisfactory. The normal freezing point is 0·59, but the lower limit of 0·56 is allowed. There are many sources of error in the method, but in some cases it is useful. Important information may be derived from the estimation of the amount of urea passed in a day on a definite diet, and by testing the permeability of the kidneys to water and to sodium chloride.

The solution of the second problem demands the separation of the products of the two kidneys, by means of an intra-vesical partition or by catheterizing the ureters. The *activity of each kidney* is then tested by determining the freezing point of the urine, by estimating the nitrogen, or by examining the reaction of the kidneys towards certain subcutaneous injections. Thus the time which it takes for a gluteal injection of indigo carmine (4 c.c. of a 4 per cent. sterile solution) to appear in the urine is estimated (normal time ten to fifteen minutes). Or a subcutaneous injection of ·005 grm. of phloridzin is given and the amount of sugar excreted by one kidney in a definite time is measured; or one notes accurately when the excretion begins. None of these methods as hitherto employed are quite free from objection, but the sum total of the conclusions which they yield may be of distinctive significance from the point of view of diagnosis and treatment.

CHAPTER LX.

INFLAMMATION IN THE NEIGHBOURHOOD OF THE KIDNEY.

It is necessary to begin with a word about nomenclature. An attempt has been made to distinguish between paranephritis and perinephritis, which were previously considered synonymous. It has been suggested to limit the term *perinephritis* to inflammation of the connective tissue capsule of the kidney, and *paranephritis* to suppuration within the fatty covering. Further, Israel has designated the inflammation which occurs exclusively between the kidney and retrorenal fascia as *epinephritis*. However logical these distinctions may be, they cannot be applied in actual practice, because these three different anatomico-pathological conditions do not present separate clinical pictures. Perinephritis, defined as above, is never a disease by itself, but is always an accompanying symptom, and has neither diagnostic nor clinical significance. It is almost impossible, clinically, to suspect any distinction between paranephritis and epinephritis. Such a distinction is only possible at the operation or the autopsy, and it really possesses no practical significance. We therefore will adhere to the term *perinephritis* as implying all inflammation between the kidneys, peritoneum and lumbar muscles—a uniformity of nomenclature which should obtain international sanction.

There are three stages of perinephritis, each of which gives rise to a special train of diagnostic considerations.

(1) The indications which should suggest a perirenal abscess are somewhat similar to those which suggest a subphrenic abscess. The patient becomes ill with high fever and obscure symptoms, which he attributes to some malady in the loin, because that region is painful. If the lumbar spine is rigid, and probably also held obliquely, the suspicion of perirenal abscess is confirmed, and the condition of the lumbar muscles must be investigated. If they are contracted on one side, or if they contract on being palpated, we are in all probability within reach of the site of the disease.

In this stage the most frequent error arises from confusion with *pleurisy*. In the latter, however, the pains radiate towards the shoulder, whereas in perinephritis they radiate towards the half of the abdomen on the affected side, towards the external genitals and even as far as the thigh.

I have had a case wherein definite lumbar pain which radiated downward caused me to expose the kidney, whereas the real trouble was a commencing empyema which, however, afforded no clear local symptoms. The difficulty in diagnosis would be much greater if a purulent pleurisy supervened on an early perinephritis. The result obtained by an exploratory puncture is attended by the same difficulty of interpretation as occurs in cases of subphrenic abscess.

(2) In the second stage the diagnosis is much easier, because, in addition to the above symptoms, a resistance can be felt in the lumbar region. If this resistance is sharply defined, and round in contour, the inflammation is usually in the kidney itself. If it is diffuse and indefinite, the perirenal tissue is involved, although, of course, the kidney itself may also be affected. If we are doubtful about the definition of the swelling, because it appears to be too sharply defined for a phlegmon, and insufficiently defined for a kidney, we must note whether the swelling moves on respiration. A kidney always moves downwards on deep respiration, even if it is morbidly enlarged, provided there are no perirenal changes. A perirenal abscess remains immovable.

Sharply defined abscesses are otherwise generally of a tubercular nature, and are recognized by the slight pain which they cause on pressure and by the very moderate effect which they have on the temperature of the body.

(3) In the third stage, the abscess may open into the lumbar region, causing a subcutaneous phlegmon, or it may travel into the pelvic fossa, provoking flexion of the thigh, or, finally, it may reach the pleural cavity, and burst into a bronchus. In all these conditions, the diagnosis of abscess can hardly be mistaken, but its original source in such advanced cases can only be ascertained from the history.

We should not, in any case, be content with the diagnosis of *psoas abscess*, which used to be a very favourite one. Psoas abscess may be a tubercular burrowing abscess, an osteo-myelitic suppuration, inflammation arising from the kidney or intestine invading the muscle, or, finally, a phlegmon which has originated in the broad ligament ; a psoas abscess never constitutes a disease of itself.

So far, our diagnosis has been directed to suppuration in the perirenal fatty tissue. We look for its origin particularly in the kidney, pelvis, or spinal column. But its source may also be in one of the intraperitoneal viscera—appendix, liver, gall-bladder or large intestine.

If the urine contain pus, we must refer the perinephritis to renal tuberculosis, nephrolithiasis or some other kidney disease attended by suppuration. If the history does not point to any previous kidney trouble, we should think of some acute metastatic renal abscess, and search for a primary source of infection, *e.g.*, a furuncle, sore throat or eczema. In other cases the primary disease is some infectious disorder, such as typhoid fever, small-pox, &c. If nothing abnormal is found in the urine, this is not to be regarded as conclusive against a renal origin. If, despite the absence of any abnormality in the urine, there is a history of some old-standing renal disease, we must assume that the ureter on the affected side is blocked up.

If there be no evidence whatsoever pointing to the kidneys, we must examine the adjacent bony parts, not only when the abscess is

chronic and bears tubercular characteristics, but also when the abscess has developed acutely, because this may be due to osteo-myelitis of the pelvis. Should nothing be elicited here, we must next think of the appendix, which, not infrequently, lies in a lumbar or even a pre-renal position. In such cases we cannot attain to anything more than a probable diagnosis, unless the appendix had originally been intra-peritoneal and given rise to typical attacks of appendicitis.

There is no difficulty in diagnosis in the cases wherein a phlegmonous parametritis, following an abortion or confinement, has extended as far as the lumbar region. Liver and gall-bladder abscesses rarely encroach upon the perirenal tissue, but such secondary abscesses are recognizable by their history and the localization of the antecedent inflammatory symptoms.

If no other cause whatsoever can be discovered, we may assume that the case is a primary perinephritis, *i.e.*, an infection of perirenal tissue by micro-organisms of unknown origin, and without any demonstrable involvement of the renal tissue. These abscesses usually arise through the coalescence of small abscesses of the renal cortex, which cause no symptoms in themselves, and do not alter the character of the urine.

CHAPTER LXI.

MOVABLE KIDNEY.

At one time movable kidneys were very fashionable, and to undergo treatment for them was regarded as an evidence of good tone; but this is now a thing of the past. We are now better able to realize the significance of this condition than we were fifteen years ago, and although movable kidneys have been unjustifiably condemned for all kinds of ills, nevertheless they do raise important problems of diagnosis, which should be considered together.

Firstly, as to the *evidence of their existence.*

The term should only be applied to kidneys which have *acquired increased mobility*, and not to those which are the subject of congenital displacement—a matter already discussed. This acquired mobility may, however, often be due to congenital causes. Thus I have seen a movable kidney in a young girl, aged 11, who was otherwise in perfect health—an abnormality which was most probably the result of some congenital predisposition.

The following method should be adopted to demonstrate a movable kidney. The patient—usually a female—must lie flat and as relaxed as possible. The lumbar muscles must be supported with one hand, but they must not be allowed to become tense; the other hand is gently pressed under the costal margin against the spinal column, but care must be taken not to make the muscles contract. The patient is then told to breathe deeply with the diaphragm. In this way it is usually possible to detect the descent of the kidney. In some cases, however, the kidney is first felt at the moment it slips upwards into its bed. The examination is immediately successful if the patient is thin and is able to breathe according to instructions, but if she is fat and cannot carry out the abdominal type of breathing as requested, a little practice is necessary. If examination with the patient on her back yields no result, she must be turned on to her side—on to the left side for the right kidney—or she must be examined in the erect posture.

What is the *normal* degree of mobility?

This varies in the two sexes. In a male, it should hardly be possible to feel the lower pole, even of the right kidney; but in a female there is nothing abnormal in being able to feel the lower third. In slender women it may be possible to feel even a half of the kidney, without the condition being pathological, whereas in a man this should certainly be regarded as an early stage of movable kidney. If the upper pole of the kidney can easily be felt, it is obviously abnormal.

We have been assuming that the structure felt at the side of the abdomen is really the kidney; but this assumption is not always correct. On the left side, we may be deceived by an intestinal tumour, but only if we fail to observe that the structure does not move with respiration. On the right side, error may arise not only from an intestinal tumour, but especially from a constricted lobe of the liver and from a tensely filled gall-bladder. We have, however, discussed these possibilities in connection with the surgery of the liver and biliary passages, to which section the reader is referred.

Exceptionally, it may be quite impossible to arrive at a decision. If the diagnosis is important from the point of view of treatment, some assistance may be derived from a skiagraphic examination, after introducing a ureteral catheter, opaque to X-rays, or a collargol solution as far as the renal pelvis.

If the structure felt is really the kidney, we must next inquire whether it is responsible for the pains of which the patient complains, bearing in mind that most movable kidneys never cause any symptoms at all, even when the degree of mobility is great. On the other hand, we should remember that a movable kidney is not usually an isolated phenomenon, but is part of a general visceroptosis which is, primarily or secondarily, associated with a neurotic state which depresses the patient, both physically and

mentally. Stiller calls this condition "constitutional asthenia," although, of course, this term does not explain it. The psychical and organic reflexes are abnormally irritable in this condition, and the slightest discomfort—sometimes even physiological processes—is felt as a severe pain, or, at any rate, complaint is made. But, nevertheless, a movable kidney may itself give rise to pain by attacks of so-called strangulation—a term which is meaningless and ought to be abandoned. These attacks are really due to intermittent hydronephrosis, which will be described in the next chapter, and which are produced by the sharp kinking or twisting of the ureter, as a result of the displacement of the kidney. But, apparently, paroxysms of pain may also be caused by kinking or twisting of the renal nerves, also a result of the abnormal mobility of the kidney. It is, therefore, better to speak of torsion, rather than of strangulation. The polyuria which usually follows these attacks, does not depend upon the discharge of urine which has been dammed back, but upon some reflex process, as is also the case in many instances of intermittent hydronephrosis. As abnormal mobility of the kidney may produce these severe paroxysms, it is only natural to suppose that milder pains may also be due to the same cause. But this assumption should only be made under certain conditions, a main one being that the pain is limited to the affected side, or, at any rate, is strictly distinguishable from other pains of which the patient may complain. The pain should radiate towards the inguinal region, scrotum and thigh, in contrast to the pain of gall-bladder disease, which radiates towards the right shoulder. The principal point, however, is that the pain is increased by any movement which displaces the kidney considerably downwards (over-flexing the trunk backwards, raising the arms on high) and is relieved by the horizontal posture. The pain is often diminished by wearing an effectual binder on the lower abdomen (especially Glenard's abdominal binder) and also by the support of the gravid uterus.

If the patient describes attacks which appear to be due to torsion, we must wait until another one comes on, and examine the patient during its continuance, in order to determine whether the kidney is tender and swollen. We may then find that the pain has nothing to do with the kidney, but that it indicates an attack of mucous colitis. The same care and repeated examinations of the bowel and stools are especially necessary when the pains vary between the right and left side, although the movable kidney is unilateral. Such pains are nearly always of intestinal origin, and are usually accompanied by alternating diarrhœa and constipation, and by the passage of some mucus. To attempt to stitch up the sunken organ in such individuals, would usually mean to

operate on the kidneys, stomach, colon, liver and uterus. The result would probably be a failure, because the pains due to excessive mobility would merely be replaced by pains due to adhesions. It is this kind of experience which has damped the enthusiasm of those who were staunch advocates of stitching-up displaced viscera, and it is now recognized that a movable kidney does not necessarily require stitching, because its anatomical disposition is not the only matter to be taken into account. These patients principally require a rational diet and a natural mode of life to invigorate their tissues and improve their nervous system. We may, indeed, prescribe these remedies, but we cannot secure them for the patients, because some are too low in the social sphere, while others are too high.

CHAPTER LXII.

HYDRONEPHROSIS AND ITS CONSEQUENCES.

THE retention of urine in the pelvis of the kidney produces a number of clinical pictures, varying with the conditions under which it has arisen, and each one gives rise to its own diagnostic problems. We may distinguish :—

(1) **Closed Hydronephrosis.**—This appears as a tense swelling, situated in the hypochondrium, and its differential diagnosis is discussed in the chapter on Abdominal Tumours. It is only necessary to add that, in rare instances, cystic swellings which do not depend upon retention in the renal pelvis, make their appearance in the kidney region. These are the congenital cystic kidneys (see also under Renal Tumours), which are distinguishable from hydronephrosis by their nodular surface, and which are often associated with a cystic liver. One should also think of hydatid cyst in districts where this is endemic.

As has already been observed in connection with hydatid of the liver, unexplained attacks of urticaria may suggest this diagnosis.

If the sac of a hydronephrosis becomes infected through the blood-stream, it develops into a closed abscess with all the symptoms of pus retention. Unless an exit is made for the pus, the perirenal tissue may become infected, and, finally, also the pleura. The following case is typical :—

A middle-aged female was suffering from a movable tumour, which had been discovered by her medical attendant eight years previously. An operation was proposed, but she refused, because the swelling gave her no pain. But after an attack of influenza the swelling became larger, painful and immovable. High fever and great weakness set in. There was no pus in the urine. Diagnosis: Infected closed hydronephrosis. At the operation, the perirenal tissue was found to be already infiltrated with pus, and pints of streptococcal pus issued forth from the renal sac. The subsequent course of the disease was marked by suppurative pleurisy of the same side.

(2) **Open Hydronephrosis.**—This is distinguished from the closed variety by the fact that, within certain limits, its volume is variable. It may be subject to an ascending infection along the urinary tract, which cannot occur to a closed hydronephrosis, and in this event the urine will contain pus, either temporarily or persistently.

(3) From the point of view of diagnosis, **intermittent hydronephrosis** is the most interesting form. It depends upon congenital anomalies in connection with the renal pelvis or ureter, or upon the results of a movable kidney. This latter cause acts most frequently on the right side and in women.

The patient, who is either in perfect health or has been suffering from a dull ache in the loins, is seized with severe pain in one kidney—pain which radiates to the inguinal region, the genitals and the thigh. Sometimes the picture is completed by vomiting, great pallor, a collapsed pulse and cold sweats. If the hypochondrium is examined at this time it will be found to be occupied by a swelling varying in size from a fist to a man's head. This swelling is sometimes very difficult to feel, because of the reflex rigidity of the muscles. The symptoms persist for a few hours, rarely more than a day, and then subside after the profuse micturition of clear urine, which occasionally also contains blood. Sometimes the emptying of the kidney is delayed, especially if the sac is large; in other cases the kidneys do not return to their normal volume between the attacks—*remittent hydronephrosis.* This may merge into the chronic open variety, and, finally, into the acute variety. On examining a case of pure intermittent hydronephrosis during a free interval nothing abnormal is found, except perhaps a movable kidney. The diagnosis may be made in some cases from the fact that a swelling is to be felt in one side of the abdomen during the attacks and that they end with the abundant evacuation of clear urine, sometimes also containing blood. If, however, these indications are not present, one must wait until the next attack occurs. It is impossible to miss the diagnosis during the attack itself, at any rate, if the hydronephrosis has attained any definite size. But in the early stages before the tumour has reached the size of a fist the muscular

rigidity may render its detection very difficult. The diagnosis will then lie between renal colic, biliary colic and even appendicitis, the last because the pain radiates downwards. But the localization of the pain on pressure and of the muscular rigidity in the lumbar region is decisive against biliary colic or appendicitis. Nevertheless there are cases wherein the question of an attack of gall-stones must be left in suspense.

It may be still more difficult to distinguish pure hydronephrosis from hydronephrosis due to an attack of stone. If red blood-cells can be demonstrated in the centrifugalized urine between the attacks, and if these cells increase in number after active exercise, there is a great probability of stone. But this sign will fail in the case of a small stone in the ureter. A skiagram should be taken as a final means of diagnosis.

If the renal pelvis is filled with a colloidal silver solution by means of a ureteral catheter, it can be rendered visible on the skiagraphic plate.

If the hydronephrosis has become infected more or less pus will be found in the urine during the free intervals, and signs of infection will be present in addition to those due to the retention, viz., fever, rigors, dry tongue. The longer the disease lasts the more serious becomes the condition of the patient. Cystitis follows the hydronephrosis, and the other kidney is involved by an ascending infection. The disease finally terminates in uræmia, with or without the secondary development of stones.

When confronted with such a clinical picture as this, we must always inquire whether tuberculosis is not responsible, for this may for a long time perfectly resemble in symptoms a case of infective, intermittent hydronephrosis.

It may be remarked in conclusion that intermittent hydronephrosis enables the practitioner to come to a decision in regard to the function of the other kidney without the process of separating the urine. For instance, if in a case of aseptic hydronephrosis albumin is always found in the intervals of the attacks—that is to say, when *both* kidneys are acting—but is not present during the attacks, we may draw the conclusion that the albumin comes from the hydronephrotic kidney, and that the other kidney is healthy.

CHAPTER LXIII.

IDIOPATHIC SUPPURATION IN THE RENAL PELVIS AND KIDNEY.

URINE which persistently contains pus, ascertained by the previously explained methods to be coming either entirely or partially from the kidneys, always raises the question whether the suppuration is an independent process, or whether it is a consequence of some antecedent condition, such as hydronephrosis, stone in the kidney, tumour or tuberculosis.

We purposely avoid the terms "primary" and "secondary," because the manner in which they are generally used is liable to cause misunderstanding.

An infection of the kidney is *primary* when the cause is introduced directly from without, and the kidney constitutes the first seat of attack. The same term is applicable if the causal organism has produced no pathological change at the point of entry, but has reached the blood, and thence has become deposited in the kidney.

The suppuration is *secondary* if the kidney is not the first organ to be attacked; for instance, if a cystitis has preceded the pyelitis (*urogenous infection*); or if the kidney infection which has taken place is *metastatic*, by way of the blood-stream, and has arisen from some anatomically demonstrable primary focus.

If, however, the renal suppuration arises and remains within *the kidney itself* without the aid of any other morbid condition, it should be termed *idiopathic*. If it has followed any serious pathological change in the organ, such as tuberculosis, stone or tumour, we apply to it the term *complication* or *sequela*.

After all, it is only a matter of words, and we might, with equal justice, insist on some other nomenclature. The main point is, however, always to use the same expression for the same pathological process. No scheme has the advantage of being strictly maintained throughout, and there are always some processes which might properly be classified in various positions. For instance, pyelitis, which is caused by urinary obstruction in enlarged prostate, may be looked upon either as a sequela or as an independent suppurative process. The point turns upon the amount of predisposing influence we will allow before we abandon the conception of "independent suppuration." There is really no definite border line, and if we have, for example, fixed it on the other side of prostatic hypertrophy it is solely for the purpose of classification.

Tuberculosis is certainly a form of "idiopathic" suppuration, but as we are discussing the causes of *acute* suppuration, and as urogenital tuberculosis is clinically an independent disease, we will not include it here, but will devote a special chapter to it.

When the purulent infection is merely a *sequela* or a *complication* of an existing renal disease, it will usually have been preceded by a

stage wherein the symptoms of the primary disease have been clearly manifested, especially in the case of hydronephrosis, often also in the case of stone, and occasionally, though less definitely, in tumours. If not, we must rely upon the physical examination for the differential diagnosis. An abscess sac as large as an infant's head, or larger, does not indicate idiopathic suppuration, but has probably originated in an old hydronephrosis. A large irregular tumour indicates a new growth. A constant, although slight, admixture of blood with the urine, in a case of renal suppuration suggests stone or tuberculosis; greater hæmorrhage might also be due to stone. But if nothing of this kind can be discovered, we may regard the suppuration as "idiopathic" in the above limited sense, and we must search for the conditions which might account for it. Boils, erysipelas, sore throat and gonorrhœa—in an ascending scale—are the main distributors of infection, and pregnancy, the puerperium with its deficient micturition, are causes of slight urinary obstruction, in addition to others already mentioned frequently. The midwife often provides the infective material in these latter cases.

It is only rarely that *bacteriological examination* will elucidate the matter—for instance, if it demonstrates the presence of *Staphylococcus aureus*, the pneumococcus or the typhoid bacillus. Streptococci and colon bacilli are, however, such frequent denizens of diseased urinary passages that we cannot draw any definite conclusion from their presence.

The gonococcus is hardly ever found. This is, as a rule, only the first link in the chain of infection, and is followed by cystitis and pyelitis due to mixed infection—these are the second and third links. I have seen vesical stone and renal stone after gonorrhœa—constituting fourth and fifth links, and in a similar case also cancer—a sixth link. Of course, a "harmless" gonorrhœa does not always proceed as far as this. More frequently a stricture is interposed in the chain of sequelæ, which may lead, in after years, to an ascending urinary infection.

It is important to ascertain whether such an infection is *unilateral* or *bilateral*. The etiology may help to decide this point, for the pyelitis of pregnancy and post-gonorrhœal pyelitis are usually unilateral —at any rate at first—whereas in prostatic patients it is generally bilateral. If the disease is metastatic in origin, it may be on one side or on both. If the patient states that his pain is sometimes in one loin and sometimes in the other, the pyelitis is very probably bilateral. Valuable diagnostic points are afforded by the demonstration, by palpation, of tenderness on pressure, by reflex muscular rigidity and sometimes by enlargement of the kidney. Frequently, however, the kidney is neither tender nor enlarged when in a condition of pyelitis. It is then advisable to attempt to palpate the ureters, either *per vaginam*

or *per rectum*. If they can both be felt as cords, then both kidneys are diseased (Garrè). A final decision may be arrived at by means of the cystoscope and the separation of the urine.

The *anatomical diagnosis* presents the most difficult problem, and it involves the differentiation of the following conditions—simple catarrh of the renal pelvis, *i.e.*, pyelitis; simultaneous disease of the renal parenchyma, *i.e.*, pyelonephritis; and, finally, disease exclusively confined to the parenchyma, *i.e.*, simple or multiple abscess of the kidney.

Both **pyelitis** and **pyelonephritis** are very frequently due to ascending infection, but they are of a hæmatogenous nature, more often than was previously supposed. Pain on pressure and enlargement of the kidney, as well as acute symptoms, only occur in either condition during the stage of retention (pyonephrosis). The involvement of the renal tissue is recognized by the fact that the albumin is proportionately too high in comparison with the amount of pus, and also occasionally by the presence of cylindrical casts. But even in the absence of these signs, experience tells us that the renal tissue does not remain healthy after a long-continued pyelitis.

Renal abscess, whether single or multiple, is the result of metastasis, and is accordingly a pure infection, in contrast to an ascending infection, which is usually of a mixed character. It is easily overlooked, because there is no pus in the urine at first, and nothing but the fever and lumbar pain indicate its presence. There is no difficulty in distinguishing it from pyelitis, but it is impossible to differentiate it from early perinephritis, and as far as the indications are concerned, it is quite unnecessary. We cannot tell whether multiple abscesses are present, but palpation will detect whether the affection is unilateral or bilateral.

In rare cases a renal abscess sets up so little local reaction that one is tempted at first to think of a new growth.

A man, aged 60, came for advice regarding an indefinite pain in the left loin. Examination showed that there was in this region a moderately tender, somewhat nodular and rather movable swelling. There was no pus in the urine, but a quantity of sugar. There was moderate pyrexia, and the patient died in a few days from pyæmia. At the autopsy it was seen that what appeared to be a renal tumour was really the kidney, infiltrated by a well encapsuled abscess.

The following case will show how one may occasionally be misled:—

A middle-aged man was suffering from an old neglected gonorrhœal stricture, cystitis and intermittent attacks of "urinary fever." He received some casual treatment from a chemist, but suddenly became ill with severe septic symptoms, spontaneous pain and tenderness on pressure over the right kidney, which, however, was not enlarged. The left kidney was slightly tender, but also of normal size. The urine was almost free from pus, which was attributed to retention

within the pelvis of the right kidney. But nephrotomy on the right side showed that there was neither retention nor pus. The septic symptoms increased and the patient soon died. The autopsy revealed recent multiple non-infective *infarcts* in both kidneys, due to vegetative endocarditis.

CHAPTER LXIV.

STONE IN THE KIDNEY AND URETER.

PRIMARY stone in the kidney plays a very small part in the renal pathology of some countries, while in others it is one of the most frequent of maladies. In some countries stone has even become quite a disease of children.

We distinguish primary from secondary stones, and we separate the former into a non-infected and a secondarily infected variety.

A.—PRIMARY STONE IN THE KIDNEY.

(1) NON-INFECTED STONE.

There are four important symptoms which establish the diagnosis of nephrolithiasis, *viz.*: (1) attacks of renal colic; (2) dull aching pain in one loin during the intervals; (3) hæmaturia, which may be very slight, but increases with movement; (4) presence of gravel or larger concretions in the urine.

Renal colic runs a similar course in stone, as in intermittent hydronephrosis, with the one difference, that the swelling due to the retention is not so large, and that, in consequence, the urine which is passed after the attack is over is smaller in quantity and contains less blood. But, nevertheless, a temporary reflex polyuria may occur. The radiation of the pain into the inguinal region may resemble an appendicitis, and the pain on pressure under the liver may lead to confusion with gall-stones. Spontaneous pain at the testicle is very suggestive of renal stone. The testicle is very often tender on pressure.

Dull aching in the loin is a symptom of great significance, but must be employed with discretion, especially if there is any doubt about the diagnosis of renal disease, as against biliary colic, for example.

We have already dwelt in detail on *hæmaturia* and *gravel* in the general section, and we have seen that the former symptom is more constant, but less in amount, than in cases of tumour. Recent

observers have laid great stress on the fact that traces of blood in the sediment of the urine, increasing in amount after movement, may, for a long time be the only sign of stone in the kidney. There may be no renal colic, and the dull pain in the loin may be entirely absent, as occurs with stones which remain latent for years. These cases do not, as a rule, seek any advice. The traces of blood in the urine are discovered quite accidentally; for instance, if the patient consults his doctor for indigestion or some other condition which apparently has no connection with the kidney. The dull pain in the loin is often put down to lumbago or rheumatism. If there be no pain at all in the case of a small stone situated in the ureter and causing no hæmaturia, a diagnosis is absolutely impossible during the quiet interval.

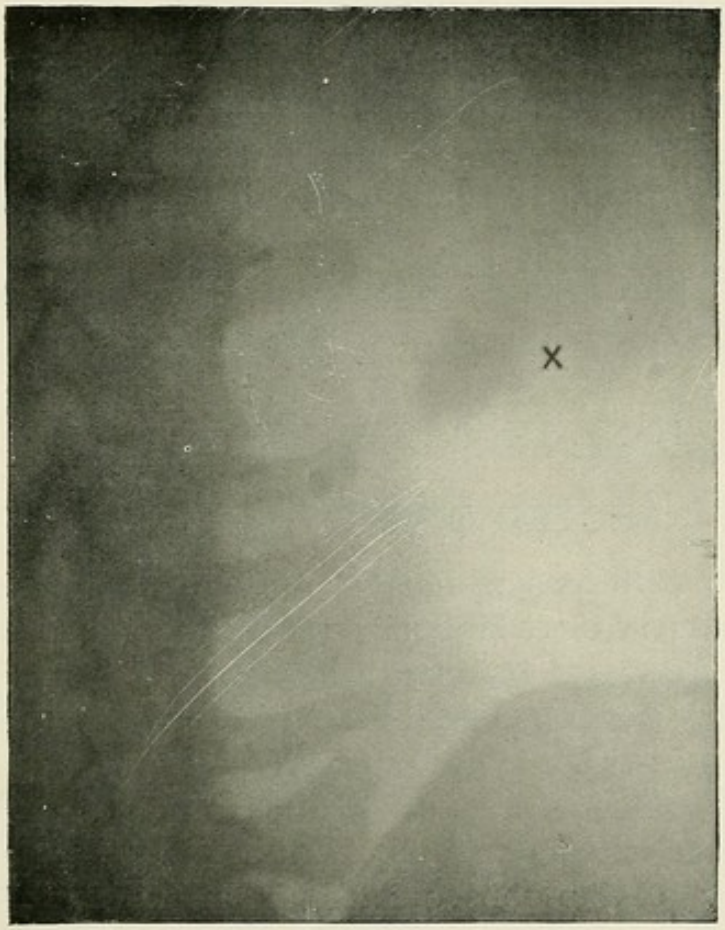

FIG. 202.—Skiagram of stone in kidney. X.

A *skiagram*, taken by an expert and interpreted by an experienced observer, should have the last word in all diagnostic difficulties connected with stone in the kidney.

The diagnosis of stone in the kidney by the X-rays is not easy, because stones composed of uric acid and of urates only cast a faint shadow, which in fat patients is hardly perceptible. But the experience in districts wherein this disease is common has been that even these stones often contain so much lime that they may be rendered visible on the plate, under proper conditions. No decisive conclusion should, however, be made until every doubtful appearance has been examined on several impressions.

The *composition* of the stone is important from a therapeutic aspect.

If the patient is a gouty subject, or if he comes from a gouty stock, the stone probably consists of uric acid or of urates, even in children. If crystals or gravel be found in the urine, we shall obtain some guidance from their microscopic and chemical examination, the details of which have already been referred to (Chapter LIX).

(2) INFECTED STONE.

In addition to the symptoms of aseptic nephrolithiasis, those of infection are present: pus in the urine; fever and rigors where there is retention. The correct diagnosis is very often missed, and the condition appears to be either an independent pyelitis or tubercle. It must be remembered that when the ureter is temporarily obstructed the urine may be quite normal, because it all comes from the healthy kidney, and it is, therefore, always necessary to examine the urine during an interval when the ureter is not blocked.

B.—SECONDARY STONE IN THE KIDNEY.

Most renal concretions which occur in non-calculous districts are secondary in character. Their symptoms consist of those of the underlying suppurative disease, to which are superadded the symptoms of stone. The clinical picture is practically the same as that of an infected primary stone, but the history is different. In the present instance, suppuration precedes the stone; in the other instance the stone precedes the suppuration. This consideration will indicate the difficulties which may arise in differential diagnosis, as well as their solution, and we will therefore not repeat what has already been said. Chemically, all secondary stones consist of earthy phosphates and carbonates. Their formation is recognized in the urine by its ammoniacal smell and the abundance of triple phosphates. Röntgen-rays reveal these stones very clearly, because of their rich calcium content.

CHAPTER LXV.

TUMOURS OF THE KIDNEY.

TUMOURS of the kidney, as long as they are not infected, are recognized by three symptoms: (1) *hæmorrhage;* (2), local, and especially radiating *pain;* and (3) *swelling.* The predominance of the one symptom or of the other depends upon the position or manner of growth of the tumour.

Hæmorrhage is absent in very few cases only. It is much more profuse, but also much more irregular, than in the case of stone. If the hæmorrhage is very pronounced, the clots may obstruct the ureter temporarily, causing genuine renal colic, which must, however,

be distinguished from the persistent radiating neuralgic pain. It is noteworthy that such hæmorrhages may continue for years. The radiating pain does not occur until a late stage, so that the hæmorrhage, with or without renal colic, may be for years the only symptom of a small stationary tumour of the kidney, which cannot be felt. It is only by the cystoscope, showing that the blood comes from one side, that such a case can be distinguished from chronic hæmorrhagic nephritis, which may exist for a long time without albumin or cylindrical casts. If the cystoscope does not yield a decisive result, it can then only be obtained by an exploratory incision.

If the hæmorrhage is very profuse and persistent, one should think of the possibility of a new growth from the *pelvis of the kidney*, especially if no appreciable swelling can be demonstrated, or if the examiner can feel a hæmatoma which is causing extreme distension of the renal pelvis (Israel).

Persistent, local, and radiating neuralgic **pain** merely tells us that the tumour is malignant, and that operation will probably be fruitless. If such pain is unaccompanied by any other symptom, the unfortunate diagnosis of lumbago is often ascribed to it, but this is an error which tumours of the kidney share with all painful diseases of this region.

If the **tumour** is the most striking symptom we must first decide whether it is really connected with the kidney. If hæmaturia is present at the same time the matter is clear. But if the urine is normal, and the cystoscope shows that it comes from both kidneys, then we should think of a liver or gall-bladder tumour on the right side, a splenic tumour on the left side, and a tumour of the large intestine on either side. If the tumour is of unusual size, an ovarian cyst should be thought of. There is, however, one sign which distinguishes a renal tumour from all of these, the fact that, on bi-manual palpation, it can be felt most distinctly from behind, in the angle between the spine and the twelfth rib. A tumour of the intestine would generally cause some intestinal disturbance. A tumour of the gall-bladder has its own special previous history, and a swelling of the spleen betrays itself by the sharp anterior border, which can usually be felt quite easily. It is only in the case of an irregular round tumour of the spleen that serious difficulty can arise. An ovarian tumour is recognized by the circumstance that when the intestine is artificially distended it is seen that the large bowel runs over the new growth. It takes the same course in the case of new growth of an ectopic kidney. Soft tumours of the fatty capsule of the kidney (lipomata, fibromata, myxosarcomata) which may attain a large size, have hitherto only been diagnosed at the operation. They may cause the most extraordinary displacements of the viscera.

A cystoscopic examination may enable a decisive opinion to be

given either for or against a renal tumour (persistent absence of urinary flow from one side).

Having decided that a tumour of the kidney is present, we must determine whether it is a *retention tumour*—hydronephrosis or pyonephrosis—or whether it is a genuine new growth. This point is usually elucidated by the history and the condition of the urine. The consistence of the tumour may be very misleading, because a sarcoma may feel just as elastic as a hydronephrosis. One would only think of a *hydatid* in districts where this disease is rife, but localization in the kidney is always very rare. Exploratory puncture, which is occasionally recommended, is just as inadvisable here as it is in the case of the liver, and the serum test is still unreliable.

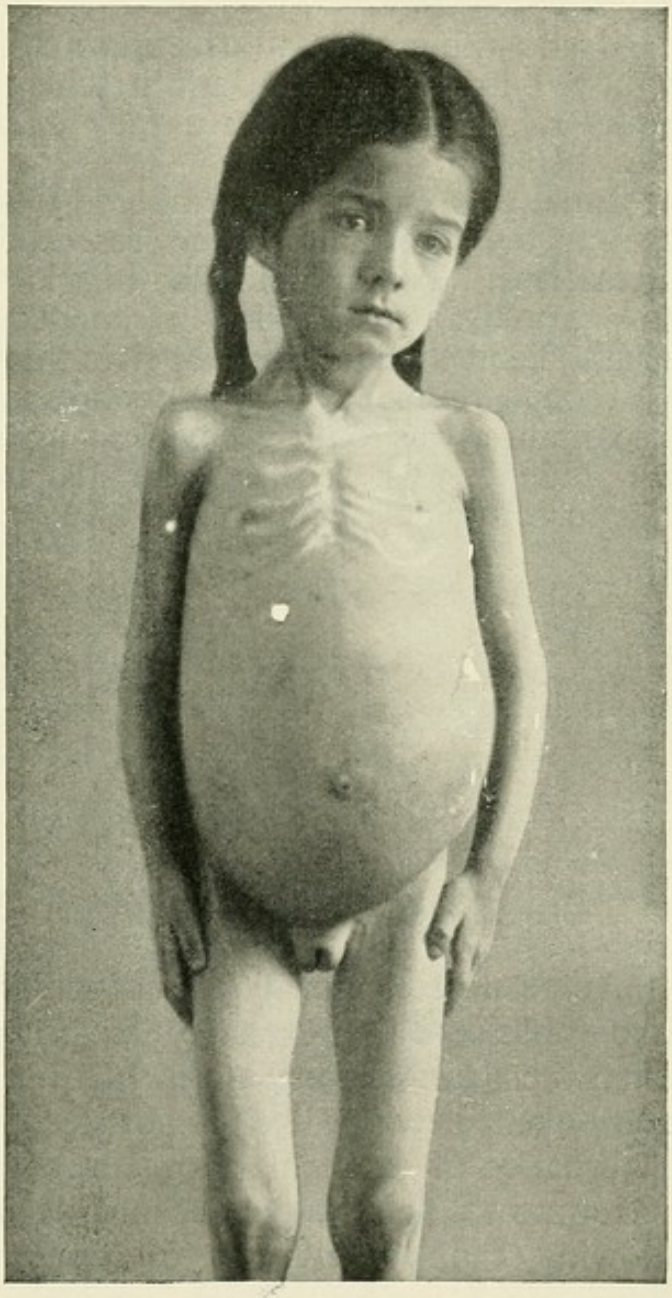

FIG. 203.—Sarcoma of the left kidney.

It is difficult, or quite impossible, to infer anything about the histological characters of a renal tumour diagnosed by its clinical signs. There are of course cases wherein the uneven surface and the slight mobility of the tumour stamps it conclusively as malignant. But we often remain in doubt because, as we have seen, the hæmorrhage from malignant tumours even may persist for years. It is only rarely that external circumstances permit us to make a definite diagnosis on clinical grounds. This, however, applies to the tumours of childhood, which experience shows are either pure sarcomata or mixed sarcomatous tumours. If there is no hæmorrhage one would be obliged to think of hypernephroma, which so often arises in the cortex. If the tumour is bilateral, round and uneven, without

hæmorrhage or suppuration, and if the discomfort is limited to a dull pain with occasional renal colic, the only possible diagnosis is congenital cystic kidney, especially if there is also enlargement of the liver (cystic liver).

From the point of view of treatment the precise nature of a new growth of the kidney is not of much importance, because *as soon as a renal tumour has been demonstrated it must be removed, unless it is too late.*

Cystic kidneys are an exception to this rule; these are only to be removed in the rare instances wherein it is certain that they are unilateral, and then only if they cause sufficient trouble to justify the operation.

Finally, it must be remembered that renal tumours do not always occupy their normal position, resembling in this respect the kidneys themselves. Tumours in floating kidneys are not uncommon, and new growths may develop in congenitally displaced kidneys, which usually lie at the level of the pelvic inlet.

I once removed a hypernephroma of such a pelvic kidney. Its true nature was only recognized at the operation by the fact that the kidney was absent from its normal position. The clinical diagnosis fluctuated between a solid ovarian and a renal tumour.

CHAPTER LXVI.

TUBERCULOSIS OF THE URINARY PASSAGES.

ALTHOUGH the prognosis of tubercle of the urinary passages is favourable in its early stage, the prospect is one of the gloomiest when the disease is advanced. Unfortunately the early stage is often overlooked, because it does not declare itself very definitely. Every disturbance of the urinary organs of gradual onset should therefore make one think of tubercle, and decide for or against it, instead of allowing the patient to go about for months, with the vague diagnosis of vesical catarrh, vesical irritation, or simply "neurasthenia," and with unsystematic or so-called "symptomatic" treatment. The first symptom is usually a certain amount of tenesmus. The patient notices, as the most striking objective sign of this change, that he has even to get out of bed once or twice during the night. This differentiates him from a neurasthenic, who may micturate very frequently during the day, but is not disturbed at night. At this stage, the naked eye can detect nothing wrong with the urine. A

careful examination may, however, reveal traces of albumen and a slight deposit of pus cells, epithelial cells and isolated blood cells, in the centrifugalized sediment. There are usually no bacteria present, nor even tubercle bacilli. This condition of the urine absolutely excludes a simple neurasthenia, in which one finds phosphates, carbonates, calcium oxalate and occasionally one or two seminal threads. Such a urine supports the view of some organic disease, and the patient should be thoroughly examined, when it is most likely that some old scars of glands or an apical catarrh will be met with. At this stage, palpation of the kidneys will not usually yield any result, but a tender spot will often be found in the prostate, especially on its superior surface, and occasionally also a nodule in the epididymis. But if none of these points affords a positive indication of tubercle, it will be necessary to inoculate a guinea-pig with an adequate amount of the scanty sediment. It may then be found that, although the recent examination of the urine revealed no tubercle bacilli, the animal becomes tubercular within four to eight weeks. In this way, an *early diagnosis* of tubercle may be made, and appropriate treatment started.

Having thus detected that the urinary system as a whole is affected with tubercular disease, we must now search for its *point of origin*. Clinical experience is accumulating proof that the disease starts in the *kidneys*, or in one of them. Spontaneous pain, local tenderness on pressure, slight rigidity of the lumbar muscles, perhaps also some demonstrable enlargement of the organ, and, occasionally, thickening of the ureter, felt through the rectum or vagina, will show which kidney is affected. If none of these indications is present, the practitioner will have done his duty by referring the patient to the surgeon as a case of "urinary tuberculosis," and a case may go on for years without definite indications, especially if the tubercular process is developing itself in the renal pelvis rather than in the parenchyma. If however the practitioner is able to avail himself of a cystoscope, the inspection of the two ureteral openings will show which is the diseased side.

On the affected side the margins of the ureteral opening are reddened and swollen, whilst the orifice itself is often strikingly gaping. Around it, there may be a few tubercles or small ulcers. In somewhat more advanced cases the urine which escapes is distinctly turbid.

This examination is completed by separating the urine within the bladder. If this procedure is repeated several times it yields most useful results. Catheterization of the ureters is even more reliable, but demands more skill. The question of operation and its method must then be left to the surgeon. The decision depends upon the presence of a healthy, or at least of an adequately functional and non-tubercular kidney on the other side.

In this connection, it must be emphasized that all these manipulations must be carried out with special care and with asepsis. An instrument should not be introduced into a tubercular bladder, which is not affected by a mixed infection, or only slightly so, unless some definite diagnostic information is anticipated from the procedure, or unless it is done for a definite therapeutic purpose. Whenever an examination is made with a sound, cystoscope, separator or ureteral catheter, it should have been preceded by the administration of a urinary antiseptic such as urotropine, or at any rate be followed by it.

The differential diagnosis of the early stage of urinary tuberculosis varies with the initial symptoms. If *hæmorrhage* is the predominant sign, as occurs in exceptional cases, one thinks of *new growth*. If the early stage is characterized by *renal colic*, there is a possibility of confusion with *stone in the kidney*, *intermittent hydronephrosis*, and even with *appendicitis*.

I once saw a patient whose first symptom of renal tuberculosis was an attack which was regarded by most experienced surgeons and physicians as one of appendicitis. The correct interpretation of the condition was not forthcoming until the urine was examined.

If there are no striking bladder symptoms, but *lumbar pain* is present, the diagnosis of rheumatism or lumbago usually suffices, if the patient thinks it at all necessary to consult a doctor.

But there are some cases in which we must assume an original focus of tubercle in the kidney, but wherein the bladder symptoms are so predominant that they attract all the attention. Generally, it is the *vesical tenesmus* which is so conspicuous and causes the patient most torture.

But this is not always a proof of associated tubercle of the bladder ; because it may arise reflexly from the kidney. If it is very severe, it suggests the secondary formation of stone.

The later stages of urogenital tuberculosis are often mainly characterized by this *formation of stone*, with all the symptoms of secondary infected renal and vesical stones, with renal colic, fever and rigors.

The liability to secondary stone formation starts, as we have seen, at the time when the urine, which was originally acid, becomes alkaline owing to mixed infection. This affords us a reliable means of recognizing whether the renal colic which is present is due to stone or not. Sometimes, however, this diagnosis is facilitated by the passage of small concretions.

It is important to recognize this secondary stone formation early, because the removal of these stones will give great relief even in cases where, owing to the tubercle affecting both sides, there is no prospect of complete cure.

In a case of bilateral renal tuberculosis, where radical operation was impossible, I removed a large number of stones in two sittings from the right pelvis, one stone from the right ureter, and a large stone from the bladder. In this way great relief was afforded to the

patient for about a year, although, of course, it did not prevent the eventual onset of uræmia.

On the other hand, we must not attribute, without careful examination, a genuine case of stone to suspected tubercle, as has actually happened. Even large vesical stones may cause no other symptom but tenesmus.

We must also refer here to **perinephritis**—a not infrequent complication of renal tuberculosis. It occurs in two forms, which are easily distinguishable clinically. One form consists of a sharply-defined abscess which, without any marked symptoms, tracks downwards or bursts through, in the lumbar region. Cultures made from the pus are sterile, but an inoculated guinea-pig becomes tubercular. This form constitutes the purely tubercular stage of the disease, wherein the focus in the kidney bursts externally just as a focus in bone leads to the development of a cold abscess. In the other form the perinephritis manifests itself by acute symptoms, fever, rigors, and severe pain, and instead of a circumscribed abscess we have a phlegmon. This process is really a mixed infection, and its intensity depends upon the virulence of the streptococci or colon bacilli, &c., which take part in it. We must, therefore, not discard the possibility of a tubercular origin for the renal malady because of the acute character of the perinephritis. Tubercle does not usually penetrate lower than the sphincter vesicæ, but may cause changes at that site which may be mistaken for late sequelæ of gonorrhœa, if there be a history of that disorder and a bacteriological examination of the urine is neglected. Tuberculosis of the genital organs is not dealt with here, having already been discussed in a previous chapter.

CHAPTER LXVII.

STONE IN THE BLADDER.

We differentiate between aseptic and infected stones, just as in the case of renal stones.

(1) Three symptoms point, as already seen in Chapter LIX, to **non-infected stones in the bladder**: irregular and varying disturbances of micturition, not affected by changes in posture, vesical tenesmus and hæmorrhages.

Obstruction at the neck of the bladder by a valve action is very significant of stone, but this is frequently absent, especially when the

stone is large or within a diverticulum—in the latter circumstance the stone is no longer aseptic.

Tenesmus is the result of direct mechanical irritation, and is very marked in the case of rough oxalate concretions. The tenesmus is aggravated by any vibration of the body, especially by riding.

A patient of mine with an oxalate calculus always selected the back platform of a last carriage when on a railway journey, so that he could empty his bladder from there, as the need became urgent. The *hæmorrhage* is usually very moderate, just as it is in renal stone, and in contrast to the hæmorrhage of new growths.

Whenever a vesical stone is suspected we should investigate the history in regard to gout, and also search for any indications of renal stone. Most vesical stones originate in the kidney, but become large in the bladder. We then examine the urine, or the sediment obtained from a large quantity thereof, for crystals or small concretions. Then, after the bowel is emptied, a bi-manual examination of the bladder is made with one finger either in the rectum or vagina and the other hand on the abdomen. Large stones may then be felt quite easily. We may next proceed to use the sound. This examination must be conducted with great patience and with the bladder in varying degrees of fullness, if the stone cannot be felt on the first attempt. The sound also gives information as to the smoothness or roughness of the surface of the stone; in some cases we may be able to tell its size, and occasionally also whether there is more than one specimen present. If nothing can be demonstrated, and the suspicion still remains, we must resort to the cystoscope and an X-ray examination (fig. 204).

The patient must be undressed for this examination, otherwise one runs the risk of opening the bladder for stone when in reality the shadow is due to a trousers button—an incident which has actually happened.

An aseptic stone in the bladder may be mistaken for—

(*a*) *Tumour of the bladder*, especially for a *polypus* at the neck of the bladder, causing obstruction by valve action, and tenesmus—a very rare occurrence. Such a condition should be thought of, if the sound and the skiagram yield negative results. Under these circumstances a cystoscopy is decisive.

(*b*) *Stone in the kidney*, if the predominant symptom is reflex vesical tenesmus. If there are no renal symptoms the case can only be fully elucidated by X-ray examination and by the cystoscope. Sometimes stones are present in the kidney and in the bladder at the same time.

(2) If a bladder containing a stone become infected spontaneously or through catheterization, the previous symptoms are supplemented by *suppuration* and by an increase in the tenesmus. The other

symptoms remain *in statu quo*. The case is then very liable to be mistaken for some form of cystitis—especially of a tubercular nature.

Secondary stones in the bladder resemble, in their behaviour, infected primary stones. They are found as a result of suppurative infection of the urinary passages and of alkaline, generally ammoniacal, decomposition of the urine. Their nucleus is often some foreign body, such as a piece of catheter, a hairpin, a nail, &c. The history of these secondary stones differs from that of the infected primary stones, because in the former the infection either with or without a foreign body precedes the stone, whereas in the latter the stone precedes the infection—just as in the case of renal stones.

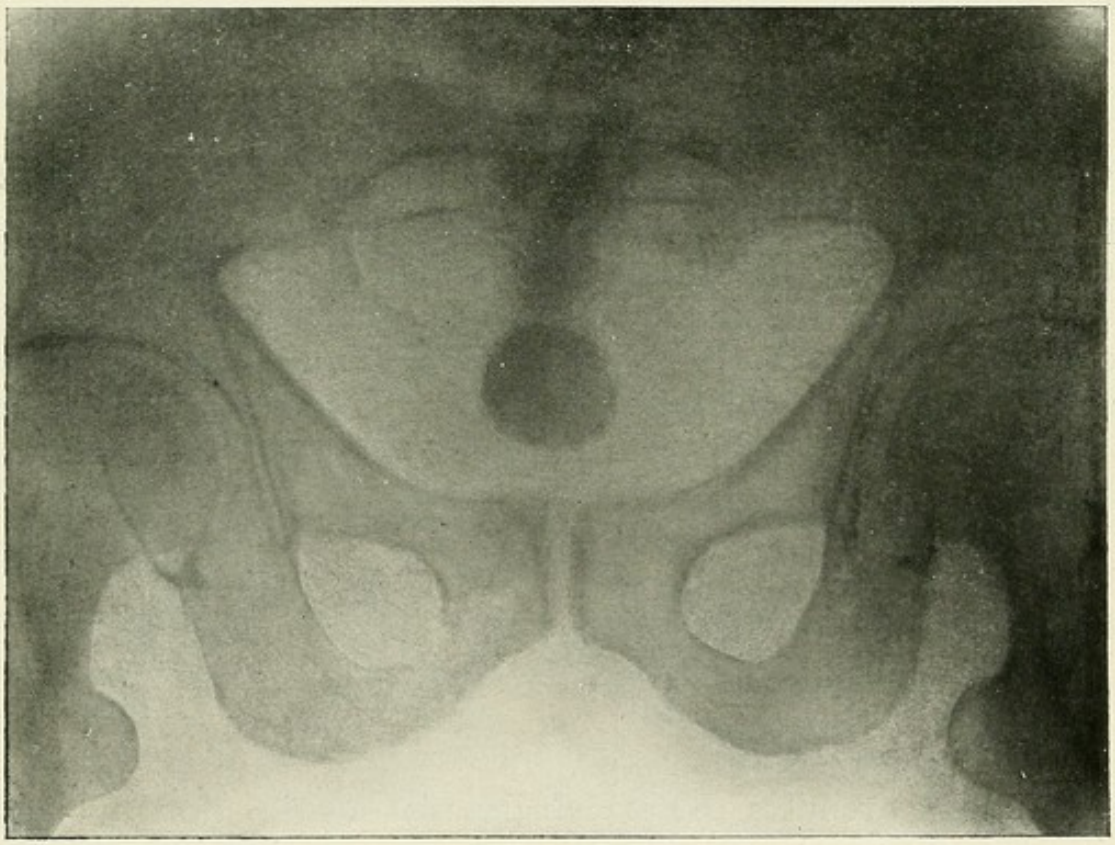

FIG. 204.—Skiagram of stone in bladder.

The *original malady* is often an old gonorrhœal or puerperal cystitis or one due to spinal paralysis. In other cases it may arise from urinary infection after an enlarged prostate; sometimes tubercle is the underlying cause. In rare cases it is a congenital diverticulum which has led to local congestion of urine, to the occurrence of a spontaneous infection, and, eventually, to the formation of stone.

It happens sometimes that there is no interference with micturition, which is due to the circumstance that the stones may be firmly fixed in *diverticula*, or that they may be too large to act as ball valves. These cases manifest themselves by an extremely agonizing

vesical tenesmus, which cannot possibly be relieved, and which eventually resembles incontinence. Stones within diverticula are easily missed by the sound, and this makes their diagnosis all the more difficult. Cystoscopy sometimes fails to yield the desired result in these cases, because of the diminution in the capacity of the bladder, consequent upon the constant strangury; but these stones can always be demonstrated by a skiagram.

CHAPTER LXVIII.

CYSTITIS.

In devoting a few lines, in addition to what has already been said, to the diagnosis of cystitis, the most important consideration to emphasize is, that this diagnosis is made too often. There is a tendency to be content with the assumption that there is a catarrh of the bladder, instead of ascertaining the origin of the trouble. One who always diagnoses cystitis when there is pus in the urine and strangury is present, will miss most cases of prostatic abscess, uro-genital tuberculosis, pyelitis and infected stones. It matters not that there is some catarrh of the bladder present in most of these cases, because it is not the incidental malady, but the fundamental disease which has to be recognized and treated. Even if the cystitis should be the primary and original disease, we must not be content with this diagnosis, but must, if the disease does not rapidly recover, follow up the secondary changes—pyelitis and stone formation—which permit of the trouble becoming chronic.

The etiology renders the principal assistance in the diagnosis of a primary cystitis. Catarrh of the bladder never originates "of itself," through some constantly prevalent infection, like a cold. It is always due to some definitely demonstrable cause—introduction of some infective organisms from the kidney or from without, on the one hand, and such predisposing conditions as *urinary congestion*, *injuries* and the presence of *foreign bodies* on the other hand. The more virulent the organisms, the less individual predisposition is required to evoke an attack, and vice versa.

The puerperal bladder, with its dilatory powers of micturition, affords a well-known example of the influence of even slight congestion.

The following cases illustrate the significance of injuries to the mucous membrane:—

A healthy young woman, in whom gonorrhœa could be excluded, was suddenly seized with severe cystitis, and the passage of offensive urine. The history, which was elicited with difficulty, showed that in using a vaginal injection prescribed by her physician, she had by mistake introduced the tube into the urethra, and this had severely injured the neck of the bladder. The bladder would have soon got rid of the infection if it had not been for the injury.

The same applies to foreign bodies. A practitioner had the misfortune to leave a piece of a Nélaton's catheter in the bladder of an elderly female. Severe cystitis with ammoniacal decomposition rapidly supervened, and I found the foreign body on examination, fourteen days subsequently, completely encrusted with triple phosphates. This cystitis did not signify that the practitioner was not cleanly in his procedure—he was well acquainted with the theory and practice of asepsis—but simply that a slight, and perhaps unavoidable, infection sufficed to provoke a severe catarrh of the bladder in the presence of a foreign body.

I say "perhaps unavoidable," because we know that even a healthy urethra harbours micro-organisms which we may introduce into the bladder, even with the most careful asepsis. The reason that the passage of a catheter does not more frequently lead to an infection than it does, is because the normal bladder is able to dispose of most micro-organisms quite easily. For the same reason, cystitis occurs so rarely when micro-organisms are excreted from the kidneys into the bladder. Indeed, the very fact of bacteria shows that micro-organisms may continue to develop in the urine without injuring the healthy bladder.

If a large amount of pus suddenly appears from the bladder without any severe signs of irritation of this organ, the most probable cause is rupture of a perivesical abscess into it; the symptoms of the original disease—generally appendicitis—easily allow the diagnosis to be made.

Our modern period of operations for hernia has often witnessed infected sunken sutures and ligatures make their way into the bladder instead of externally, and thus cause cystitis, or the secondary formation of stones.

If nothing points to the cause of the infection of the bladder, and if its progress from the start has been very gradual, we shall rarely err in ascribing it to tubercle. Nevertheless we often find, even in children and young people, cases of obstinate cystitis, which soon lead to deposits of lime, whose chronic character can only be explained by some general decrease in resistance, in the sense in which we have used the term scrofula, but which are not definitely tubercular. (Chapter XXIV.)

CHAPTER LXIX.

TUMOURS OF THE BLADDER.

(1) TUMOURS OF THE MUCOUS MEMBRANE OF THE BLADDER.

THE chief symptom of these tumours, like those of the kidney, is irregular hæmorrhage, which, having once started, becomes very severe and may cause profound anæmia, before any other signs appear.

All the other symptoms depend upon the position and form of the tumour, and upon complications. Thus, if the growth is near the neck of the bladder *strangury and retention* may occur; if it is of polypoid shape the symptoms are very *variable;* if it soon begins to invade the surrounding parts, *radiating pains* are felt in the region of the pelvic nerves and the great sciatic; if it compresses a ureteral orifice *renal colic* is experienced, and *difficulty in defæcation* if it grows into the rectum. A growth situated at the vertex of the bladder will betray itself chiefly by increased strangury, in addition to hæmorrhage, but, nevertheless, this form is one which goes longest unrecognized. As soon as cystitis supervenes, and this rarely fails in growths from the mucous membrane, vesical tenesmus occurs in addition to hæmorrhage, and becomes predominant, whatever be the situation of the growth. This tenesmus increases if deposits or concretions of triple phosphates form.

These symptoms having suggested a tumour of the bladder, we must examine the urine for the narrow villous-like shreds, which may at once furnish a diagnosis, or for the greyish-red pieces of tissue which require microscopic examination to determine their nature. We then palpate the bladder in the full and empty state, after the bowels have been emptied. Growths of the base of the bladder can be felt distinctly, either from the rectum or vagina—frequently, however, as a diffuse resistance rather than as a defined growth. New growths of the vertex of the bladder can be more easily reached from the abdomen, but always by bi-manual examination, even in the male sex. A fat patient, or one whose abdominal wall is unyielding, will require an anæsthetic.

If we feel a resistant circumscribed structure, it may even be a stone, which, if enclosed in a diverticulum, will be immovable. Examination with the sound and cystoscope will at once show whether a stone is or is not present. Care must be taken not to mistake the not infrequent incrustation upon a growth for a stone, and in using the cystoscope in a female the uterus projecting into the

bladder must not be regarded as a tumour. If sufficient experience is brought to bear upon the interpretation of the cytoscopic appearance, it should be quite decisive in regard to the diagnosis of tumour. But sometimes the size of the growth and the smallness of the interior of the bladder prevent such an examination. In such circumstances, however, palpation can elucidate the condition, except in the case of a very soft papilloma. If the cystoscope does not exclude the diagnosis of stone, an X-ray examination should be made.

Stones and incrustations are both recognizable upon the skiagram. This aid to diagnosis is especially valuable in the case of stones within diverticula, which, otherwise, may easily be mistaken for growths, on bi-manual palpation.

The question of the innocence or malignancy of the growth is not one of great importance, because the only histologically innocent tumour of the mucous membrane—**a papilloma**—is often clinically very much on the border line. A small villous tumour which has been removed quite early, may be innocent, but an extensive papilloma approximates very much to a malignant growth, owing to its tendency to spread at its edges and to recur. Papillomata which are apparently innocent at first, may eventually become **cancerous**, and definite cancers may originally have possessed all the external characters of papillomata. A growth which bleeds and feels hard must be regarded as cancer, without hesitation.

If nothing, or at most some indefinite resistance in the bladder region, is felt on palpation, we should think of a papilloma as most probably present. This may invest the whole bladder, without forming a large tumour. A cystoscopic examination is indispensable in such a case.

This sometimes reveals the cause of severe hæmorrhages to be a small papilloma, which could not be demonstrated by any other method. It looks like a small shrub on the mucous membrane, or like a piece of red coral, presenting a most striking appearance, because of the shadow which it casts.

(2) TUMOURS IN THE MUSCULAR COAT OF THE BLADDER.

The conditions are quite different when a tumour arises in the muscular layer—**fibroma, myoma, sarcoma.** The tumour breaks down and the hæmorrhage starts, if at all, in a late stage, so that the disease is only recognized when its extension compromises the functions of the bladder by mechanical interference. If the new growth is on the posterior wall of the bladder, it may resemble a myoma of the uterus growing forward ; an operation alone can reveal the correct relations of the tumour.

A myoma of the uterus sometimes grows between this organ and the bladder, connected to the uterus by a narrow stalk only, displacing the muscular layer of the bladder to a very large extent, and may in fact cause its total disappearance. On the other hand, a fibroma or myoma arising in the wall of the bladder may invade the uterus to such an extent that it is only the absence of a pedicle connecting it to that organ which shows that it is independent thereof.

CHAPTER LXX.

HYPERTROPHY, TUMOURS AND ABSCESS OF THE PROSTATE.

ALTHOUGH we have already touched upon diseases of the prostate, we will summarize once more the most important of them and amplify our previous remarks by a few points.

(1) HYPERTROPHY AND TUMOURS.

If an elderly man has constant trouble in emptying his bladder, although a large catheter can be introduced, we should at once think of enlargement of the prostate. Rectal examination will in most cases show that the organ is enlarged. If we can inspect the interior of the bladder, we will usually see two lateral swellings of somewhat unequal size at its entrance; sometimes only one eminence in the centre (clinically known as the middle lobe); occasionally a ringed-shaped pad-like projection is seen at the neck of the bladder.

Enlargement of the prostate does not usually affect the whole organ, nor even any special part of it; but consists generally of a fibro-adenomatous proliferation of the tissue of the gland, which immediately embraces the urethra, and is separated from the rest of the prostate by a layer of smooth muscle. The two lateral lobes are flattened by the proliferating mass and displaced to the sides. This explains why the hypertrophied tissue shells out so easily, and also that it does not form part of the lateral lobes, even when it appears to consist of two lobes. It also explains why the vasa deferentia are not interfered with, and why, fortunately, recurrences are so rare.

The wall of the bladder will already in the early stage present the appearance of a trabeculated bladder. In simple cases it is quite impossible to mistake the diagnosis.

We must take care not to confuse the early stage of tabes with enlargement of the prostate. This is quite possible if the tabetic

patient micturates frequently and has residual urine. The trabeculated condition of the bladder would appear to support this mistaken diagnosis, unless one remembers that it also occurs in tabes. The distinguishing point is the fact that the tabetic has genuine incontinence. He allows his urine to pass long before his bladder is filled to its maximum, and therefore, as it were, runs away. We should at once be very suspicious if the patient is not well within the age when enlargement of the prostate is common.

Having diagnosed hypertrophy of the prostate, it becomes important to ascertain the *stage* in which the patient is, and also the *complications* which have taken place. The examination of the urine will show whether this is infected ; the use of the catheter immediately after spontaneous micturition will indicate whether the patient can empty his bladder completely or has residual urine ; and palpation of the kidneys will sometimes—by no means always—inform us whether any infection has ascended as far as the renal pelvis. The diagnosis of pyelitis can, however, be more securely based on lumbar pains, sometimes on the right and sometimes on the left side, on persistent digestive disturbances, and especially on acute attacks of retention, with fever, rigors, vomiting, diarrhœa, headache and occasionally slight delirium. These symptoms proclaim that the patient has arrived at the condition which Guyon has classically described as "urinaire," composed of signs of uræmia, at first intermittent and subsequently persistent, combined with septic absorption. Infection very often leads to the secondary formation of stones which are not necessarily free in the bladder, but which may be fixed in diverticula like a deposit in a boiler. They are most commonly found in the post-prostatic pouch, which so frequently forms in prostatic patients, and in which further diverticula may develop.

This **classical course** may be attended by several *variations*, which are important from the diagnostic standpoint. Sometimes the *symptoms appear to set in suddenly*. This may occur after indulgence in an abundance of liquor, when the alcohol temporarily paralyses the micturition mechanism, or when there has been more opportunity of filling the bladder than of emptying it ; in these circumstances the patient wakes up to find that he cannot pass his urine. He has carelessly allowed it to become overdistended, and the detrusor is no longer capable of overcoming the obstruction. On close questioning of the patient, one can generally elicit that he has had, of late, to get up frequently at night, and that the urinary stream has long lost the force which it possessed in his youth.

In other cases the first complaint does not concern difficulty in micturition, but *rectal tenesmus*, or some unpleasant sensation in the rectum or perinæum. One patient complained of feeling "as if he sat on a ball."

Examination showed that there was a distinctly enlarged prostate in this case. Although there was no trouble with the urine, in the ordinary sense, the cystoscope showed that the bladder was definitely trabeculated. The patient was still in the stage of perfect compensation, *i.e.*, he had no residual urine.

In some cases, *hæmorrhages* are predominant. They may be very profuse and cause rapid debility.

Hitherto we have been assuming that the prostate is found to be enlarged on rectal examination. But this is not always the case. A middle lobe may—not very often—be responsible for the urinary difficulty; or a hard prostate, although not very much enlarged, may be responsible, so that one may, with justice, speak of "prostatic patients who have no hypertrophy of the prostate." The cystoscope clears up all these points, and may also reveal a cancer which has been masquerading in the form of a slight hypertrophy.

The more often prostates are removed the more frequently does one come across carcinoma, instead of the expected innocent hypertrophy. The whole subject of malignant growths of the prostate is at the present moment under revision, and to all appearances the diagnosis does not promise to be very much facilitated. A malignant neoplasm is at once suggested if we feel an uneven asymmetrical tumour in the prostatic region, growing towards the rectum, or if we feel a hard mass, which is not especially tender to pressure, but is sharply defined at the sides. If the cystoscope reveals an uneven irregular structure, instead of the two smooth swellings, we should make the same diagnosis. If a round circumscribed tumour develops in a completely asymmetrical manner the condition is very suspicious. It depends entirely upon the direction of the growth whether rectal or urinary symptoms predominate, but this has no bearing on the diagnosis. The diagnosis is corroborated if the patient begins to complain of sciatica, or if we find any metastases—especially in the skeleton. It is sometimes possible to tell from its shape whether the tumour is carcinoma or sarcoma. If it is hard and uneven we think of cancer, if it is soft and roundish, of sarcoma. But, as already stated, operation has shown that cancer is often concealed within a hypertrophy which appears to be innocent, both to the examining finger and to the cystoscope. The suspicion of cancer is not confined to the cases of pronounced enlargement, but is shared by the small hard forms. It is not possible to be dogmatic, but we may say that every enlargement of the prostate, whose symptoms are on the increase, is suspicious of cancer.

The presence of cystitis or the formation of secondary stones do not help the diagnosis, because these may occur both with innocent hypertrophy or with cancer. But if persistent hæmorrhages occur the case is very suggestive of cancer.

(2) INFLAMMATORY PROCESSES.

Chronic irritative conditions of the prostate, such as occur in gonorrhœal cases, are of much less interest to the surgeon than **prostatic abscess** proper. If a patient suffers from rectal tenesmus and severe pain on defæcation, upon which symptoms there supervene shortly afterwards strangury and possibly also complete obstruction of the urethra, it is obvious that there must be some acute inflammatory process between the rectum and the exit from the bladder, *i.e.*, in the region of the prostate. If, on passing a finger into the rectum and on feeling over one of the lateral lobes, we detect a soft or elastic swelling over which the mucous membrane is thickened like velvet, we diagnose an abscess. The speculum shows the mucous membrane to be œdematous and sodden, but otherwise it does not give such a realistic picture of the disease as the finger does. The introduction of a Nélaton catheter into the urethra will encounter a more or less definite obstruction.

Metal catheters should not be used in these cases, because they may easily injure the œdematous mucous membrane.

It sometimes happens that the whole clinical picture disappears suddenly by itself, with the discharge of pus into the rectum or into the bladder, or into both, and the patient, thus relieved, begs us to put aside the knife which was held in readiness. But if this simple termination does not occur, we must operate in order to give relief.

The *cause* of the abscess is important from the point of view of prognosis. The principal question to decide concerns its gonorrhœal or tubercular origin, and there is not usually any difficulty in this. Gonorrhœa, even if not confessed to, may usually be recognized at the stage wherein it causes a prostatic abscess, by the remains of urethral discharge. But it is also necessary to be able to demonstrate the presence of the gonococcus. The discharge of the pus from the abscess into the urethra, which does not always pour out, but may only exude drop by drop, may completely resemble an active gonorrhœa, and it is therefore indispensable to examine the pus microscopically, when the history is negative.

A young man had a typical bilateral prostatic or periprostatic abscess. On examination a few drops of thick pus exuded from his urethra, and he appeared to have a recent gonorrhœa. But this suspicion could be put aside, absolutely definitely, for the bacteriological examination showed a pure culture of *Staphylococcus aureus*. The patient had recently suffered from a large boil on his sacrum.

If nothing points to gonorrhœa we should think of tubercle, and if the symptoms have come on suddenly the infection is a mixed one.

A young man with a very tubercular family history became ill suddenly with typical symptoms of prostatic abscess. Gonorrhœa

could be excluded. The abscess opened into the bladder and the pus contained a pure culture of the *Bacillus coli*. A guinea-pig inoculated with the pus became tubercular. Nevertheless the focus in the prostate healed rapidly, so that without the inoculation the diagnosis would have remained doubtful.

If both tubercle and gonorrhœa are excluded we must think of some other source of infection, as in the case previously mentioned.

CHAPTER LXXI.

INJURIES OF THE URETHRA.

THE injuries which concern the posterior portion of the urethra possess the greatest diagnostic interest. They are divisible into three groups: (1) Injuries from within the urethra; (2) injuries produced by external violence without causing a wound; and (3) the consequence of fracture of the pelvis.

False passages play an important part in the causation of **injuries from within the urethra.** A hæmorrhage, which is generally rather severe, warns the practitioner who passes a catheter carelessly, or the patient, that some damage has been done.

These injuries are most easily inflicted by the so-called English catheters, which were formerly in considerable vogue and were given to patients for their own use as being harmless. Unfortunately they have not entirely gone out of fashion. They are not stiff enough for introduction without a stylet, but are quite stiff enough to do some damage.

Injury by such articles as pencils, nails, hairpins, &c., are less general. One should think of this possibility if a patient otherwise healthy—at any rate, physically—bleeds from the urethra and has pain on micturition, apparently without cause. It would appear from English's summary that almost everything which could possibly get in has been found in the urethra.

Contusion of the urethra by violence which causes no external wound is of great practical importance. If one falls astride on the edge of a board, on a pommel, or a bicycle wheel or some similar object, the urethra is crushed between the pubic arch and surface on which it rests. A kick on the perinæum produces a similar result in a different way. The symptoms which are observed after such an injury indicate very distinctly the nature of the anatomical damage, even without passing a catheter. This pro-

ceeding, which is not always free from danger, should be the final step in diagnosis.

The following forms may be distinguished in this variety of injury :—

(1) If the patient has some trouble in micturating, but is able with a certain amount of force to empty his bladder of urine, which is free from blood, he has sustained a *peri-urethral hæmatoma* without any injury of the mucous membrane. The effusion of blood may be felt in the perinæum as a hard exudate. The catheter should not be used as long as the patient can pass his urine.

(2) If some blood comes with the first few drops of urine, although the bladder can be completely emptied, some slight *injury has been inflicted on the mucous membrane;* but the passage of a catheter is not justified unless signs of extravasation of urine appear.

(3) But there is another series of symptoms which occur with such constant uniformity that, once seen, they can never fail to be recognized. The patient lies groaning, because, notwithstanding strong contractions of the bladder, and his own pressure, he can only evacuate pure blood from the urethra, although the bladder is quite full. There is a hard, dark blue swelling which extends symmetrically like a butterfly's wings on either side of the perinæum. The longer one waits the more tense becomes the swelling and the patient's condition more agonizing. In the presence of such a clinical picture the diagnosis is clear enough without passing a catheter. The patient has a complete, or almost complete, rupture of the urethra, and all the urine which the bladder cannot retain is being extravasated into the connective tissue of the perinæum. The urine must inevitably decompose unless relief is given by operation. As a rule the catheter is held up at the site of injury, and it would only be a lucky accident if it entered the bladder by following up the anterior surface of the urethra, which sometimes is not torn through. The fact that such a lucky accident is possible justifies a cautious attempt at passing a catheter, but we must be careful not to draw a false conclusion. Clinical records often relate that the practitioner has withdrawn a certain amount of bloody urine, but the patient experiences no relief therefrom. If we make the attempt we shall arrive at the same result, and at the same time feel that we have not succeeded in entering the bladder. The explanation is probably that the urine, which is escaping from the bladder under pressure, has found a cavity for itself in the perinæum, which holds a certain quanity of blood and urine. In such cases we should not persist with the catheter, but must at once provide for emptying the tissues of urine by a perinæal incision.

Obstruction of the urethra through a **fractured pelvis** is of less frequent occurrence. The considerations mentioned in connection with contusions from without, apply here also. The difficult evacuation of pure urine without blood strongly suggests compression of the urethra by a hæmatoma, such as would occur in the case of fracture of the symphysis. But the cause may be kinking of the urethral canal, due to its being dragged on by the displacement of the two pubic bones one against the other. If the normal function return within a few days, and if a catheter passed subsequently encounters no obstruction, the case is one of a simple hæmatoma. But if we still meet with some obstruction after the lapse of time—obstruction which cannot be overcome at all, or which requires some special form of catheter or some special manœuvre to do so—we must assume that there is a kink in the urethra due to displacement of the bones, although there may be little difficulty in spontaneously emptying the bladder.

In these cases the skiagrams show that one pubic bone overrides the other to the extent of one or more centimetres.

If blood is passed with the urine, the urethra is certainly injured—perforated, crushed, or lacerated by a fragment—but not torn right through. A catheter must not be passed in such a case, as long as the bladder can empty itself and there is no extravasation of urine.

If nothing but blood comes from the urethra, and the bladder fills up, while signs of extravasation of urine appear, we must decide to adopt the same treatment as in the cases which manifest the same symptoms after external contusion.

CHAPTER LXXII.

SURGICAL DISEASES OF THE PENIS.

Injuries or **deformities** of the penis present no diagnostic difficulties. The so-called **fractures** or **dislocations** of the organ are only curiosities, and have little practical importance. **Constriction** is easy to recognize, if effected by means of the neck of a bottle or a female screw, but not so easy if a wire ring or a loop of thread has been employed. The last may cut so deeply into the penis that surgical interference is required to render it visible and to remove it. A similar condition is seen in **paraphimosis** caused by the retraction of a tight prepuce (fig. 205).

In the case of deformities, the first glance shows whether the cleft is above or below, whether **epispadias** or **hypospadias** is present. The degree of the latter is determined by the place at which the urethral orifice is situated. (See reference to Hermaphroditism, Chapter L).

Tumours and **ulcers** are much more important from the diagnostic standpoint. For practical purposes we must differentiate between subcutaneous growths on the one hand and inflammatory ulcers or ulcerated growths on the other hand.

(1) SUBCUTANEOUS GROWTHS.

These very rarely occur on the penis. **Sebaceous cysts** and **dermoids** are the only innocent growths which ever occur, and **sarcoma** the only malignant one. The former are either in the skin or under it; the latter usually arises in the corpora cavernosa. The diagnosis presents no difficulty, but one must not mistake the hard nodular or cord-like induration which indicates **chronic inflammation of a corpus cavernosum** for a commencing sarcoma. **Bony growths in the penis,** which are very rare, are easily recognized by palpation and X-ray examination. **Elephantiasis,** a condition which is very frequent in the Tropics, is not really a growth, but it converts the penis into a club-shaped, and finally into an enormous and shapeless tumour. A similar condition occurs in other countries after repeated attacks of erysipelas.

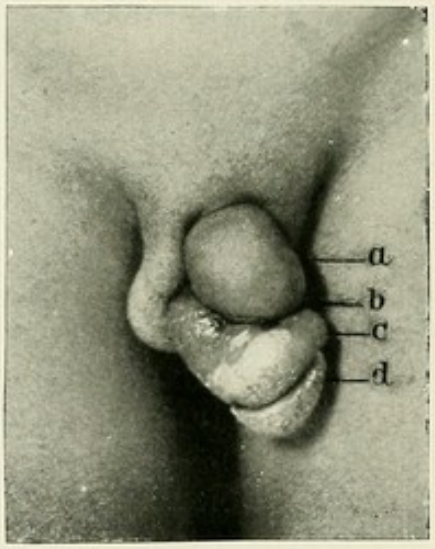

FIG. 205.—Paraphimosis.
a = Penis. b = Constricting furrow.
c = Prepuce. d = Glans penis.

(2) ULCERATIVE CHANGES.

In addition to venereal ulcers there exists a whole series of intermediate clinical forms, ranging from acute inflammatory conditions to an ulcerating cancer, which require complete exposure of the glans —sometimes with the aid of the knife—before they can be diagnosed.

(*a*) If there be pronounced inflammation of the foreskin and glans at an age when venereal infection is more or less infrequent, we should think of simple **balanitis** or **balano-posthitis.** In young lads, the cause is almost always phimosis; in old people it may also be due to retention of smegma or narrowing of the foreskin. If the inflammation is very pronounced or very obstinate, or if it dates from middle age, the urine should be examined for sugar—always assuming the presence of a certain degree of retention of smegma.

Sometimes considerable inflammation of the foreskin or glans occurs in the course of severe acute infective fevers.

It is, of course, obvious that the inguinal glands may enlarge in all these conditions. Extensive lymphangitis and phlegmonous complications may exceptionally occur.

(*b*) If venereal disease is not excluded—there is no age limit in regard to chancre, and even impotence is no guarantee against it—the prepuce and glans must be carefully examined, and a diagnosis of balanitis must not be made unless it is quite certain that no circumscribed ulcer is present. It is, of course, important not to confuse a superficial erosion with a genuine ulcer. Erosions may occur in any, case of balanitis, and are especially common in **herpes genitalis.** But they heal in a very few days with any mild treatment if the part is kept clean, whereas a real ulcer takes a long time to scar over. Sometimes a hard chancre looks like a superficial erosion, but it can be easily distinguished from a harmless erosion by its indurated base.

(*c*) If the disease does not consist of any diffuse change, but merely of a circumscribed ulcer, we have to think of those conditions which we have already studied in connection with the oral mucous membrane, although, of course, they do not occur in the penis with anything like the same frequency. A **tubercular ulcer** has been observed on the foreskin and glans in cases of uro-genital tuberculosis, but it is extremely rare.

Instances have been recorded wherein tubercular lesions have followed suction of the blood by a tubercular operator, after ritual circumcision.

The problems of diagnosis mainly centre around the differentiation between soft and hard chancres, gumma, and cancer. An ulcer which appears a few days after sexual intercourse is usually a **soft chancre,** but it may become a hard chancre within two or three weeks. The former diagnosis is proved by the onset, within a few days, of diffuse infiltrating and painful buboes. The diagnosis of subsequent syphilitic transformation is proved by the obstinacy with which the chancre resists non-specific treatment, by the demonstration of spirochetæ, and by the serum test, but above all by the appearance of constitutional symptoms. If the ulcer has not appeared until after two or three weeks' incubation, the diagnosis of a **hard chancre** is quite certain ; the discovery of spirochetæ and the onset of glandular enlargement after another couple of weeks, only serve to confirm the diagnosis.

The diagnosis is more difficult when a patient, who has just entered within the cancer period, denies all possibility of infection—an old proverb says "Omnis syphiliticus mendax." No denial is of avail in the presence of a soft chancre with rapidly forming buboes, and the

diagnosis of hard chancre only requires a little patience if a search cannot at once be made for the spirochæte. Consequently, there can only be any real doubt as between **gumma** and **cancer**. Experience shows that an error of diagnosis may damage a practitioner both in reputation and in money. If he amputates for a gumma, as has actually happened, he becomes responsible for wanton mutilation. If he treats a cancer for weeks or months as a gumma he runs the danger of converting a curable malady into an incurable one, and the patient will make him responsible for the loss of the organ. But both mistakes are avoidable by a little examination. A *cauliflower-like cancer*, if definite, is immediately recognizable. This form usually follows an old phimosis, and in time ulcerates through the external foreskin. A *flat cancer* bears more resemblance to a syphilitic ulcer, but it lacks the fatty base of the gumma. The *medullary nodule-forming cancer* is quite unmistakable.



FIG. 206.—Cancer of glans penis.

We have already seen that the glands do not enlarge in cases of gumma, and that their enlargement *may* be absent in cases of cancer, or supervene at some later time, whereas the enlarged glands in connection with a hard chancre always appear at the classical moment.

If any doubt still persists, a small piece of the base of ulcer should be taken for microscopical examination. A positive diagnosis can then be obtained within a few days, and until then no suggestion should be made for the removal of the penis; otherwise the patient is perfectly justified in rejecting such a proposal.

Cancer can often be detected in its early stage, when phimosis is present, by the offensive discharge from the prepuce.

Finally, some confusion is conceivable between a commencing papillary cancer and an **acuminate condyloma**. The assertion that the latter is always a consequence of gonorrhœa is incorrect, and is misleading to diagnosis. Acuminate condyloma is an infective condition of its own; but is distinguished from cancer by its invariably soft base.

The significance of phimosis may be inferred from the statement of Barney that Jews very rarely suffer from cancer of the penis. Just as other cancers, this form may also develop in a venereal scar.

PART V.

THE SURGICAL DISEASES OF THE PELVIS AND SPINAL COLUMN.

CHAPTER LXXIII.

TUMOURS OF THE PELVIS.

THE major portion of the pelvis is so extensively covered by soft parts, that it is very easy to overlook tumours in their early stage, even if they do not grow exclusively inwards. It is therefore most important to devote due and timely attention even to their indirect symptoms.

If a pelvic tumour grows inwards, it will sooner or later *press upon and displace the pelvic organs.* Bladder and rectal derangements will usually point to this result. A definite conclusion can only be formed after a careful bi-manual examination, per rectum and the lower abdominal region, an examination which should never be neglected in any obscure case of bladder disturbance.

The derangements which occur during labour are well known, and they may be imitated by tumours within the pelvis, even if they are small. The experienced obstetrician will always think, among other possibilities, of a new growth in the pelvis, when the head of a child refuses to engage normally.

Symptoms of displacement of the pelvic viscera are not always predominant in the clinical picture. If the growth extends mainly outwards, or if it is situated in the false pelvis, it gives rise to two other symptoms—the *appearance of a protuberance* in some part of the pelvis, and the result of *pressure on the nerve-roots.* A new growth of the pubic crest is distinguished by the early stage at which it can be seen and felt. It requires no further diagnostic consideration. But a growth more often announces itself by nerve disturbances long before it can either be seen or felt, and the patient is accordingly provided with various diagnoses and ordered to all possible spas.

A man, aged 52, had consulted many doctors for sciatica. At our

first examination no organic cause for the neuralgia was evident. The rectum was free, the prostate normal, and nothing could be felt in the pelvis. The spinal column was also normal. The treatment for the sciatica had apparently secured temporary improvement. The patient returned in nine months' time, and then it was clear that the pains affected the region supplied by the anterior crural nerve rather than the sciatic nerve region; at the same time there was a striking weakness of the flexors of the thigh. The patient had to lift up his left leg with both hands to put it on the examination stool. In addition there were pains in the lumbar region; the twelfth dorsal vertebra and the centre of the sternum were painful to pressure. The diagnosis of "sciatica" was obviously discredited, and one had to think of organic damage to the great nerve-roots which supply the left leg. Meanwhile a tumour of the left iliac bone had become palpable on deep pressure, and this explained all the symptoms. A loud souffle could be heard with the stethoscope over it, and this confirmed the diagnosis of "sarcoma." The pain over the lumbar spine and the sternum indicated metastases, which therefore contra-indicated any operative interference.

It is not always pressure on nerves which suggests a concealed pelvic tumour; sometimes the pressure is exerted on *blood-vessels*, producing an increasing œdema of one leg. If both symptoms are present simultaneously, the suspicion becomes very great.

How can we tell whether a tumour which is found in the pelvis really originates from the pelvic bones? First, we must be able to exclude any connection between it and the pelvic viscera by considering the previous history and the actually existing symptoms. For instance, if a patient has for months been losing blood with his motions, and has symptoms of rectal stenosis with a growth adherent to the sacrum, he is not the subject of pelvic tumour, but of a rectal cancer which has contracted secondary adhesions to the sacrum. *Physical examination*, however, furnishes the clearest indications. Tumours which grow from the internal surface of the pelvic bones are usually more or less globular or uneven structures, connected with the pelvis itself at a narrowly circumscribed site. Malignant growths of the pelvic viscera, once they have become fixed to the pelvis, give the impression of a diffuse hard mass, which seems to have been poured out by the pelvic cavity. Innocent growths of the pelvic viscera never become so firmly fixed to the pelvis as to cause any mistake.

It might be quite possible to mistake a pelvic enchondroma for a firmly incarcerated fibromyoma; but examination under anæsthesia would clear this up, because some movement could then be obtained, even with a firmly incarcerated myoma.

In exceptional cases a very elastic, tense *burrowing abscess* which occupies the pelvic fossa, or the true pelvis, may be mistaken for a sarcoma, especially if it causes circulatory disturbances in one leg.

But such an error would only be pardonable in the absence of any physical sign of tubercular disease of the spine or pelvic bones.

If a pelvic tumour has become large enough to be grasped by the hand, or to make special demands upon the tailor, there is no longer any difficulty in diagnosis. Tumours of a knotty structure within the pelvic cavity, especially in the vicinity of the ileo-sacral joint, are either **osteomata** or **chondromata.** They may, in the course of years, grow as large as a man's head, or even larger. They are not absolutely innocent, because they do sometimes produce metastases. But, in contrast to sarcomata, they do not cause any nerve disturbances until late. On the other hand, if we are dealing with a tumour which announced itself by pressure on nerves, before it could be demonstrated objectively, and whose symptoms are rapidly increasing, there can be no doubt about the diagnosis of "sarcoma." If auscultation shows that there is vascular engorgement (a systolic murmur), this tends to confirm the diagnosis of sarcoma.

If the clinical diagnosis should still remain in doubt, it can be settled by a *skiagram*, which will also show how much new bone formation there is in the tumour, its extent, or the amount of bone destruction which it has caused.

Sarcoma of the acetabulum presents a special clinical picture. At first it suggests hip disease, but the early onset and persistent neuralgia, combined with the absence of any disturbance in the mobility of the joint, makes the careful observer suspect something worse. Similarly, sarcoma of the ileo-sacral region is at first thought to be ileo-sacral tuberculosis. But it is just in this case that auscultation enables an early diagnosis to be made in some circumstances.

In addition to the pelvic tumours hitherto discussed, one should mention the rare **fibromata** which grow from the iliac bone into the anterior abdominal wall. They usually occur in the female sex and their clinical behaviour approaches malignancy, so that they are very suggestive of the well-known fibromata of the abdominal integuments.

In considering the diagnosis of pelvic tumours one must think of **fibroma** and **sarcoma of the pelvic muscles,** which are most frequently found originating in the gluteal muscles. As long as they are movable while the muscles are relaxed, they present no difficulty in diagnosis, and their recognition either as a sarcoma or fibroma is made by their form and consistence and comparative rapidity of growth.

But this is not always possible, because some growths, which to the naked eye and microscopically appear to be fibromata, are liable to persistent recurrence, and their histological appearances may even change to those of sarcoma in the course of time.

If the tumour has become adherent to bone, even the skiagram may fail to indicate its site of origin.

The subject of pelvic tumours suggests reference to another class

of tumours, which usually escape adequate discussion among abdominal tumours, because they do not originate in a viscus.

These are the **tumours of the connective tissue of the pelvis.** With few exceptions they are **dermoids,** which originate in the pelvic connective tissue, or rather in the peri-rectal tissue, develop above the levator ani, generally on the left side, behind the rectum. If they grow chiefly upwards, they are usually looked upon as ovarian tumours adherent in Douglas's pouch—occurring as they mostly do in the female sex. If they extend in a downward direction, they are especially liable to be taken for burrowing abscesses. But their tense consistence, their well-defined roundish shape, and the extreme displacement of adjoining viscera should show that they are independent growths. Positive evidence is only furnished by exploratory puncture and operation.

The rule not to perform exploratory puncture until everything is ready for operation applies here just as well as on other occasions. Dermoids suppurate very easily and the portion of the body through which the puncture has to be made, does not always permit of thorough cleansing.

These dermoids are very rare in males, but when they do occur, and the patient is at the age of prostatic hypertrophy, they usually suggest this condition.

For eighteen years a patient of mine went about with this diagnosis. But after he had made a false passage for himself and even the village midwife failed to pass a catheter, he came to the hospital with a cyst the size of a man's head.

The same applies to the very rare **cysts of the prostate** or of the **retroprostatic connective tissue.** Sufferers from these tumours do not usually consult the surgeon until they get retention of the urine, and probably have a false passage in addition. The diagnosis is first made at the operation. In a few cases, hydatids have been found in this region.

CHAPTER LXXIV.

CONGENITAL ABNORMALITIES IN THE SPINAL COLUMN.

If a new-born infant presents a median swelling situated on the spinal column, either slightly or not at all movable, we should at once think of a "spina bifida." As it is not possible to distinguish all the finer differences in this malformation by clinical signs, we shall merely detail the main features upon which the diagnosis turns.

In some cases the spinal column, the spinal meninges and spinal

cord are completely cleft, and form a hood over a shallow groove, or cause a protuberance, if a kyphosis is also present—**posterior rachischisis** (fig. 208). Other malformations, incompatible with life, usually exist at the same time, especially on the skull and in the brain.



FIG. 207.—Diagrammatic scheme of the more important forms of spina bifida.

1. (black) Skin. 2. (blue) Dura. 3. (red) Pia. 4. (yellow) Spinal cord. P—P1. Polar depressions. (*a*) Meningocele. (*b*) Myelocystocele. (*c*)—(*e*) Various degrees of myelo-meningocele. (*f*) Myelocysto-meningocele.

In less severe cases the spinal cord is also cleft and gives rise to the reddish medullo-vascular area, but the extent of the fissure is less. The "tumour" is formed by an increased collection of cerebro-spinal fluid in the area of the soft spinal meninges on the ventral side of the hooded cord—**Myelo-meningocele** (fig. 209). This form merges by

intermediate varieties into the form wherein the spinal cord is closed, but projects out of the canal, adherent to the posterior wall of the sac. The collection of fluid in this form is also found ventrally in the soft membranes, but is often found at the same time in the dilated central canal—**Hydromyelo-meningocele.** The tumour has normal

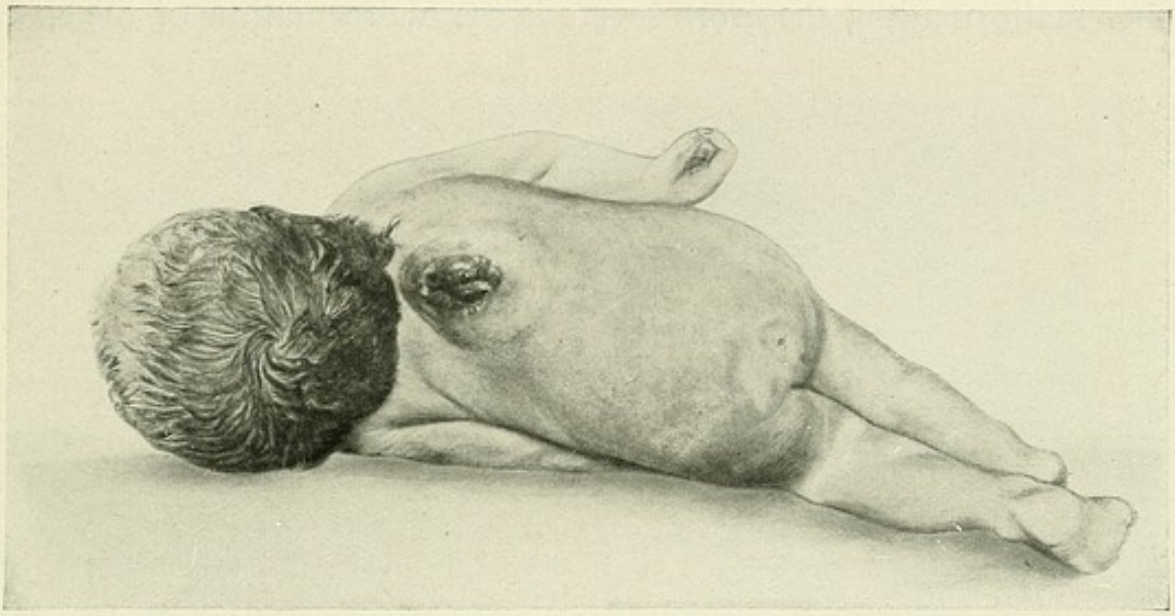

FIG. 208.—Posterior rachischisis. The dark portion corresponds to the medullo-vascular area.

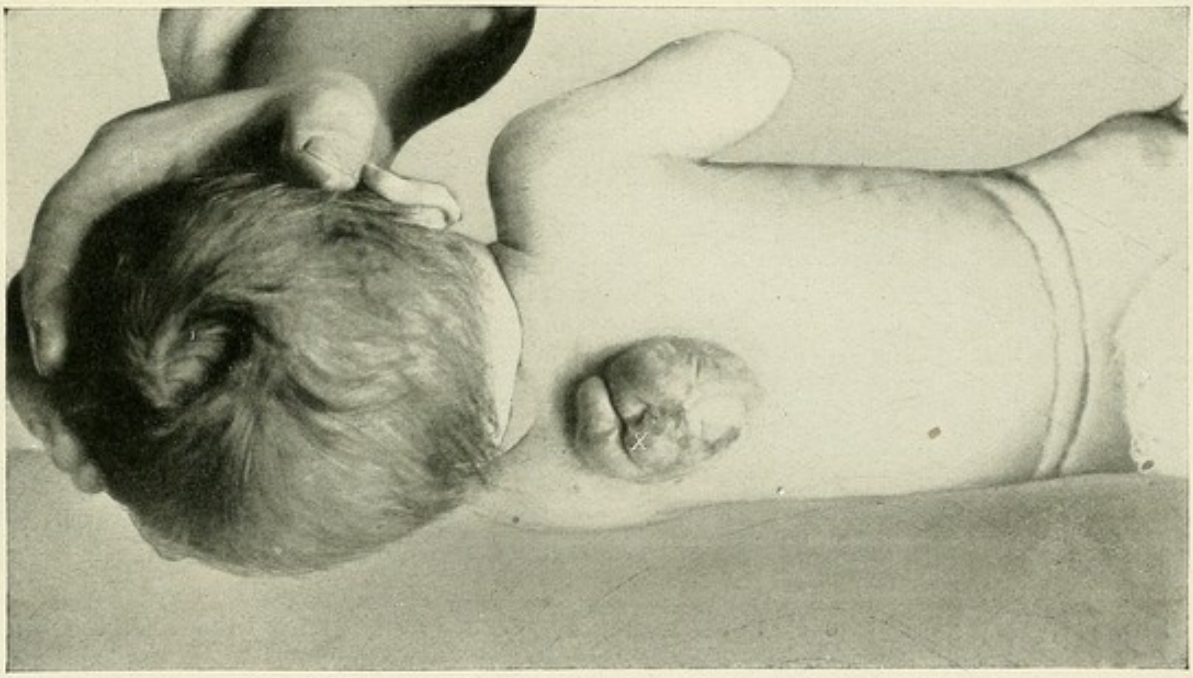

FIG. 209.—Myelo-meningocele with the superior depression clearly seen in the illustration (X).

skin at the periphery, and is covered at its top with fine scar-like epidermis (fig. 210).

If the spinal cord is free in the sac, and entirely covered by arachnoid membrane, and if the central canal is considerably dilated, the case is one of **myelo-cystocele.** If the tumour only consists of

protruded arachnoid, the case is one of **pure meningocele.** The dura takes no part here either in the composition of the wall of the sac, but stops short at the level of the gap in the bone.

How can these various forms be distinguished clinically? In the first place by the rest of the child's condition. The more severe any other malformation, the more severe is the malformation of the spinal

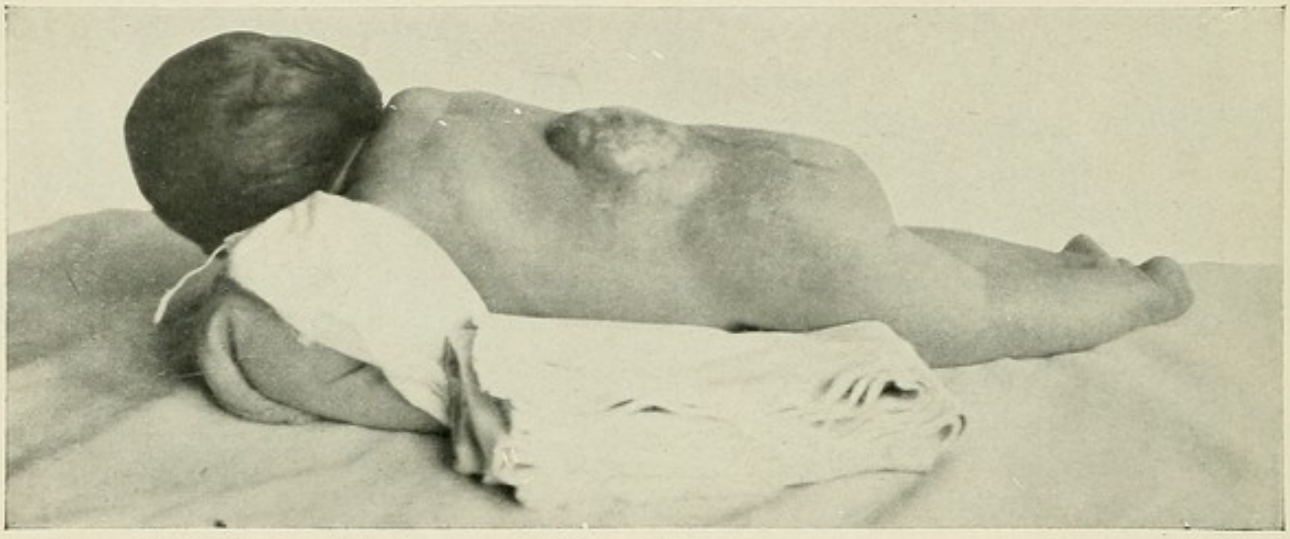

FIG. 210.—Myelo-meningocele.

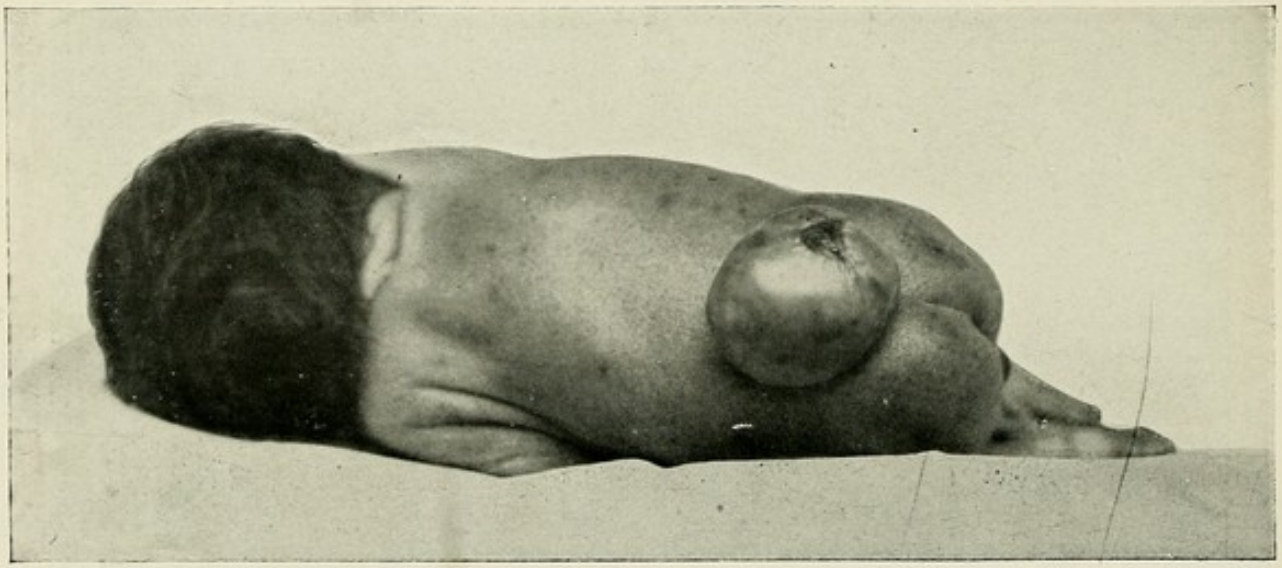

FIG. 211.—Myelo-meningocele in the region of the conus terminalis and the cauda equina.

cord. Then the condition of the tumour itself is significant. If there be a medullo-vascular area present, or if a superior and inferior depression are found on an epidermal surface (fig. 209), one may be certain that the spinal cord is cleft. If tracts are seen through the sac wall, running from a dorsal thickening thereof towards the spinal column, they will be recognized as nerve-roots, and we may assume that the spinal cord, whether cleft or not, is adherent to the dorsal

wall of the sac. If such tracts are absent, the case is either a myelocystocele or a meningocele. But the latter may also contain in its wall coiled-up nerve-roots, running back to the spinal canal, and thus the diagnosis may be rendered difficult. When the sac is very large the diagnosis can be facilitated by examination through transmitted light, and also by the circumstance that a pure meningocele only occurs in the sacral region.

The diagnosis is most difficult when the condition occurs at the lower end of the spinal column, where the conus terminalis and the cauda equina may be more or less extensively prolapsed.

Special diagnostic interest attaches to those somewhat infrequent cases wherein the cleft formation of the spinal column and the change in the spinal cord or in its cavity are so indefinite that they are not observed on a superficial examination. The patient, however, seeks advice about slight sensory or paralytic symptoms, or occasionally about trophic disturbances of the lower extremities. If the symptoms are specially of a motor character, one is inclined to attribute them to poliomyelitis. But, on an inspection of the back, we will at once be struck by the well developed hairiness of an area, usually situated in the lumbar region. The hairs are generally arranged in a semicircle, transversely to the spinal column, with its convexity downwards. They often become quite long. Slight cicatricial changes are frequently seen on the skin. On palpating the spinal column a gap will be noted in the series of vertebral spines, at the level of the hairy patch. In this gap there is an elastic swelling, which usually varies in size from a pea to a cherry. This constitutes the malformation known as **spina bifida occulta.** The swelling, which is felt, may either be a *pure meningocele* or a *myelo-meningocele.* In some cases there is not even any nervous disturbance, and the only indication of the malformation is the abnormal hairiness.

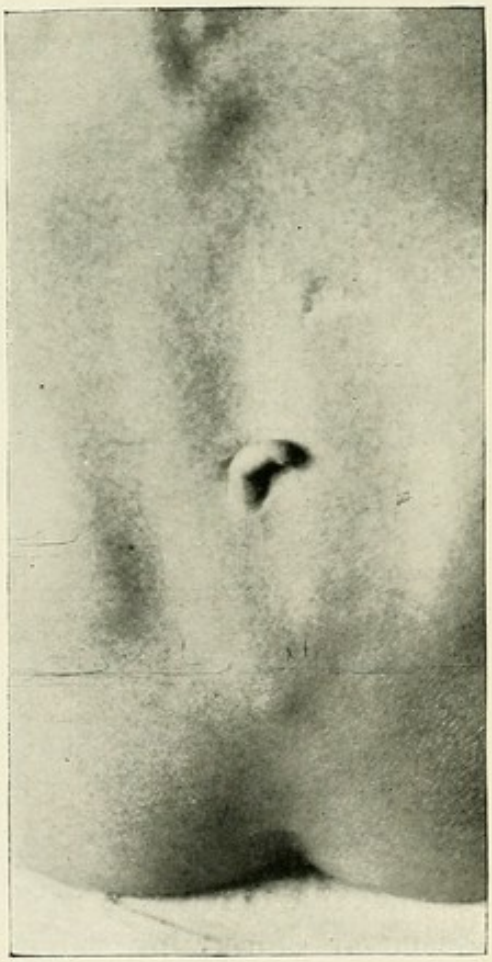

FIG. 212.—Vestigial tail.

When assistant to Kocher, I saw a peasant lad in whom temporary paralytic symptoms of the lower limbs supervened after a blow on the back. The abnormal hairiness of the lumbar region easily led

to the diagnosis of spina bifida occulta, which had been injured by the blow.

Finally, the sacral region is the site of all possible congenital tumours: Fibromata, angiomata, lipomata, sarcomata, teratomata. The last include an unbroken series from simple dermoid cysts to fœtal implantations and double monsters. These tumours are sometimes isolated, at others they are associated with clefts in the spinal column and spinal cord. Sometimes the peculiar character of the tumour allows it to be identified as a fibroma, lipoma, dermoid or lymphangioma; but as a rule one must be content with the diagnosis of **congenital sacro-lumbar tumour,** and further detail must be left to the microscope. If a dermoid ruptures it gives rise to a *dermoid sinus*, already referred to among the perinæal fistulæ.

If the sacrum has an appendage looking like a tail, it can very rapidly be decided by palpation and by a skiagram whether the structure only consists of soft tissue—a *false tail* (lipoma, fibroma) or is a vestigial tail without bone—or whether it contains a prolongation of the spinal column and constitutes a *real tail*.

These vestiges of a "tail" period are never found among an entire people, as has been stated. They occur in individuals (generally males) of all races, and vary from a modest stump to a quite conspicuous structure, even resembling the tail of a pig.

CHAPTER LXXV.

LUMBAGO.

MANY a diagnosis, made with a pretence of learning, is merely the cover of our ignorance by a classical term. This is very often true of "lumbago." A pain in the lumbar region, whose cause we do not know, is usually provided with this name. We cannot apparently dispense with this term, but we should reserve it for a pain which comes on suddenly. It is because of the suddenness of the pain and its unknown causation that it is called in German "Hexenschusz" (witch's shot). This excludes a large number of lumbar pains which have nothing to do with general lumbago. Among these may be mentioned as the more important the lumbar pains of tabes and paralysis; spinal caries, renal stone and tuberculosis; chronic colitis (especially on the left side). The lumbar pains which occur in acute febrile diseases, from influenza to small-pox, are also excluded. Our

discussion of the subject is, therefore, limited to the two conceptions—**rheumatic lumbago** and **traumatic lumbago.** Formerly, the malady was called either rheumatic or traumatic, according to personal taste, and the nomenclature had no further significance.

But since insurance against accidents has become the vogue, there is hardly any condition as fertile as lumbago as a cause of actions for damages. The blame for this is not only to be attributed to the proverbial greed of the insured for compensation, but to some extent to the circumstance that the diagnosis of rheumatic lumbago is based on very insecure foundations. Here, as elsewhere, a condition which we cannot explain is termed rheumatic.

No one who has ever suffered from lumbago, and, therefore, observed its progress with accuracy, can possibly believe that a genuine inflammation, be it of rheumatic or other nature, can set in with such suddenness. It always originates in some slight and unexpected movement which the spinal column is not prepared to meet by the fixation of its joints. The first consequence of this want of fixation is that the lateral articulation gives way, and the final result is twisting of this joint. There can be no doubt that some people suffer from an effect of this kind more than others; but this is no evidence for the inflammatory origin of the pain. This does not, however, dispose of the contingency that pains may also arise owing to rheumatic inflammation of the muscles of the back or the lumbar nerves. But although these pains apparently begin without any direct cause, they are not sufficiently sudden in their onset to merit the designation of lumbago. The confusion between the two conditions is due to the fact that the pains in both are similarly localized, and are of the same subjective character.

Thus we see that there is no sharp line of demarcation between the ordinary and the traumatic form of lumbago; the transition between them is gradual. The actual strain which causes traumatic lumbago may be so slight as to be well within the range of normal movements; the traumatic effect is simply due to the neglect of the individual to fix the spine in anticipation of the movement.

As far as the legal definition of "accident" is concerned, the term "traumatic lumbago" should be limited to injuries which result from abnormal movements of the spine, such as over-bending, over-straining and excessive twisting — movements which are calculated to produce distortion, rupture of muscles, and tearing off of articular and transverse processes, despite any amount of muscular fixation.

In both groups of cases the most striking feature consists of the muscular rigidity of the affected spinal segment, generally, but not always, the lumbar spine. There is, in addition, a certain amount of localized pain on pressure and on movement; but no sign is

absolutely conclusive in the differential diagnosis. A definite diagnosis can be more satisfactorily based upon a correct knowledge of the trauma on the one hand, and the course of the symptoms on the other hand.

Reliable information as to the injury is often unattainable, because the patient's statements are apt to be exaggerated. It is only when there has been some evident cause (lifting an unusually heavy weight, a fall, or external violence) for a severe trauma, that we should regard the symptoms which are present as due to an "accident" in the legal sense.

The course of the symptoms furnishes conclusive evidence of the diagnosis, except in the case of insured patients, who have an interest in the prolonged duration of their malady. Ordinary lumbago disappears in a few days, but the consequences of an extensive rupture of muscle, of a severe twist, or the tearing off of bone, may persist for weeks and months. The diagnosis is easy enough if a good skiagram reveals a torn fragment of bone (fracture of a transverse process). But in the absence of this, or of evidence supplied by a hæmorrhagic discoloration of the skin, a few days after the accident, pointing to a superficial hæmatoma, we are bound to rely on the *bona fides* of the patient, and on careful observation in hospital.

The differential diagnosis receives little aid from inquiries directed to previous rheumatic symptoms, because genuine lumbago has nothing to do with rheumatism.

It is much easier to recognize pain in the back which follows a *direct contusion*. The nature of the trauma is obvious, and we often find its immediate consequences in abrasions and ecchymosis of the back.

Compression fracture of the spinal column can only be mistaken for lumbago if the history has not been taken into account, and the symptoms of compression-fracture are unknown to the practitioner.

It is important to realize that fragments of bone may be broken off by indirect violence — either through muscular contraction, or the dragging of ligaments. Such small fragments may be missed, even on careful X-ray examination, especially in fat patients.

Cases which show no physical symptoms, but wherein the subjective complaints are severe, constitute the most difficult of medico-legal problems. The patients delay their return to work from time to time, extending over a period of years, whereas they would resume their occupation in a few weeks or months if they were not insured.

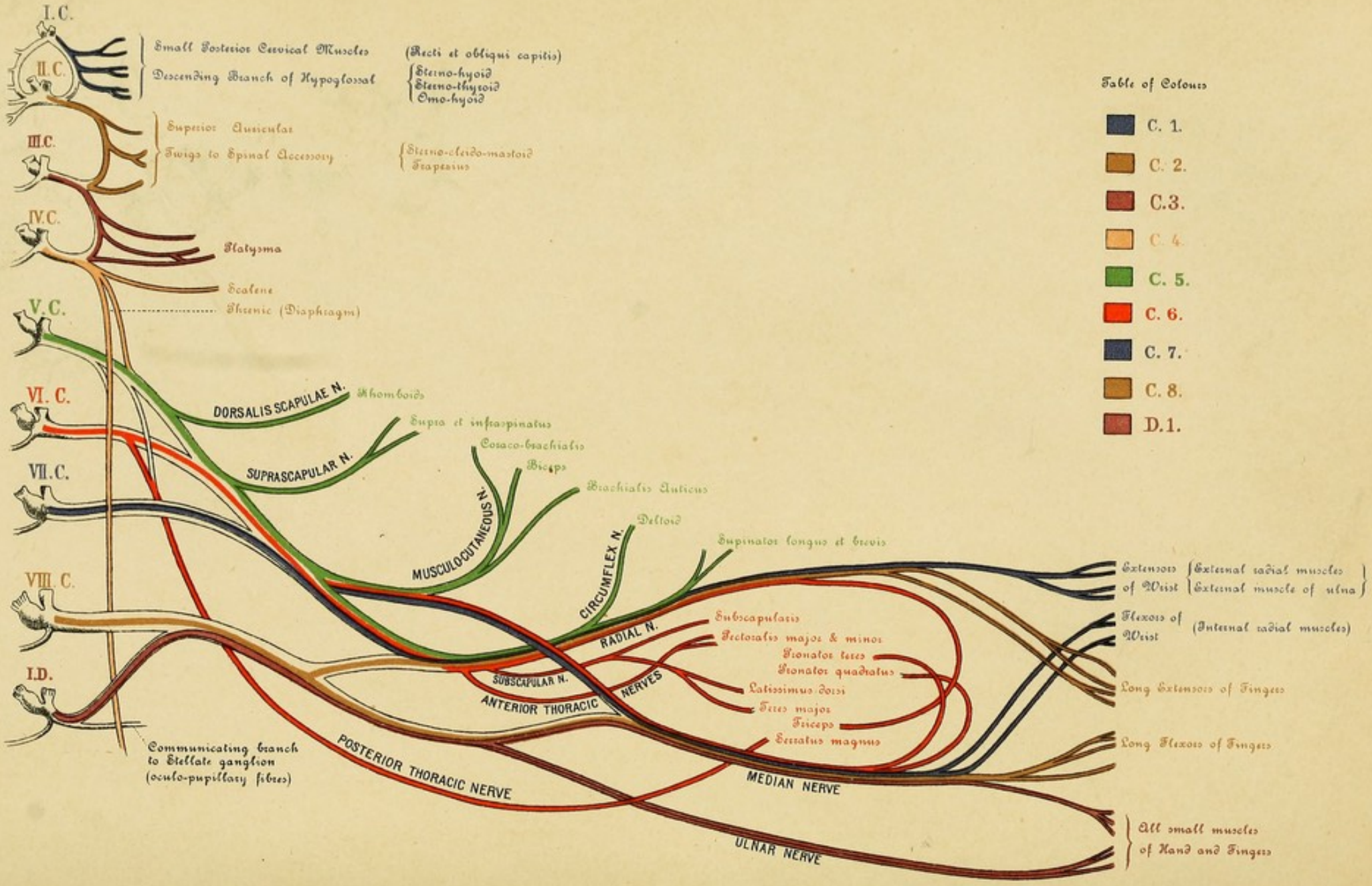

From "Kocher's Injuries of the Spinal Column." (M. a. d. Grenzgeb. d. Medz. u. Chirg. Vol. I.)

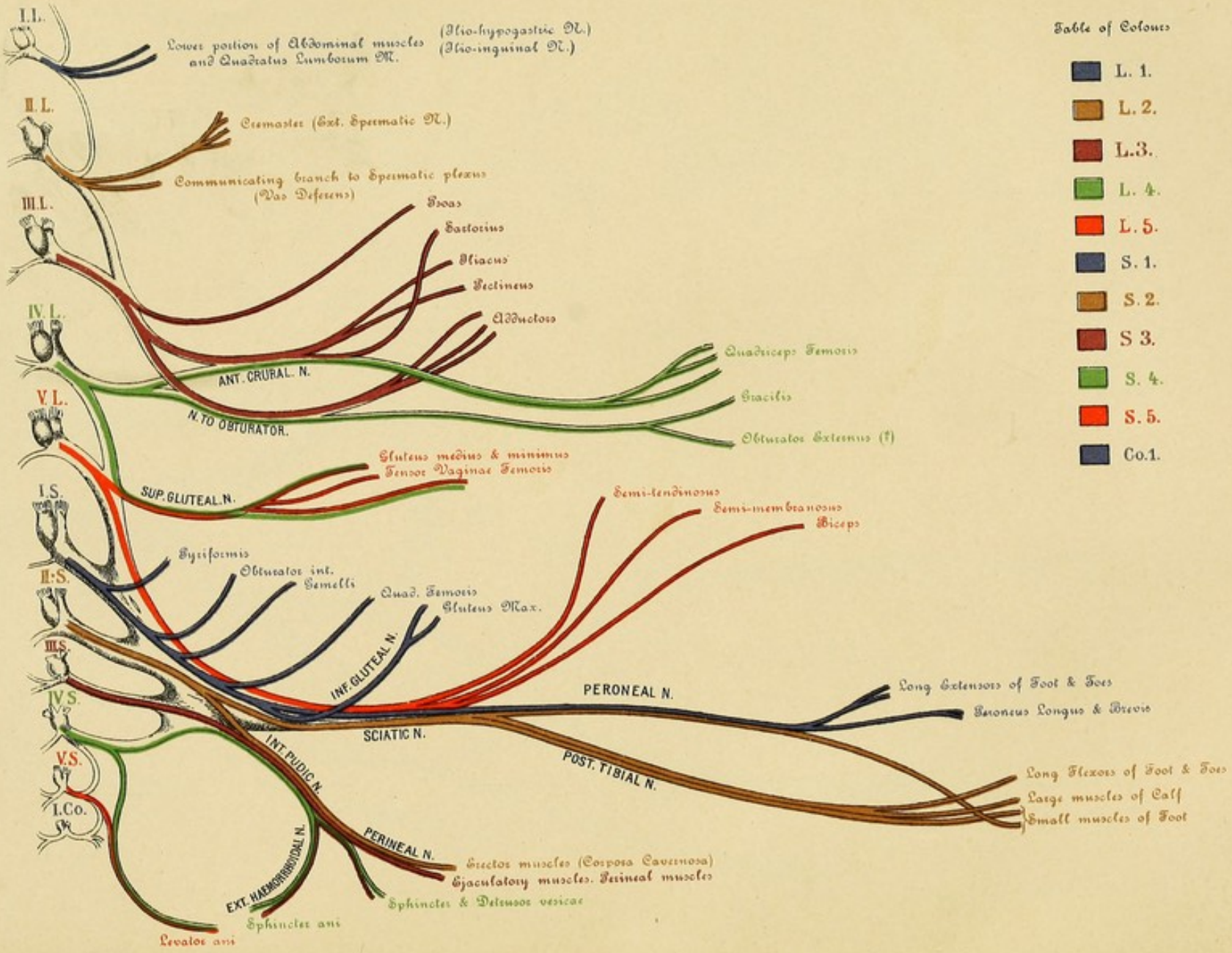

From "Kocher's Injuries of the Spinal Column." (M. a. d. Grenzgeb. d. Medz. u. Chirg. Vol. I.)

CHAPTER LXXVI.

INJURIES OF THE SPINAL COLUMN.

INJURIES of the spinal column resemble those of the skull, in that their study is dominated by the associated injury sustained by its contents. In our examination, chief attention must be devoted to this consideration.

Let us assume the case of a patient who has had an injury to the spine, generally through a fall from a height, or through something having fallen on him, and who then complains of his back. But he comes on foot, and presents no change in the shape of the spine, nor any symptoms connected with the nervous system. He is suffering either from a contusion or distorsion, or possibly from a fracture of a spinal or transverse process, the situation of which is indicated by the spine that is most painful on pressure. The absence of dislocation is shown by the normal position of the spinous processes, by the normal posture of the head or back, and, as far as the upper cervical vertebræ are concerned, by the absence of any displacement which can be felt through the pharynx. For further details, see Chapter XXV.

We only propose to deal here with the more serious injuries of the spinal column in relation to the spinal cord.

I.—METHOD OF EXAMINATION.

Let us start with a concrete case.

A man has fallen off a scaffold, and is brought in, on an ambulance. We place him in bed, being careful to support his entire spine. Our next task is to make a diagnosis, and therewith also a prognosis, with the very minimum of disturbance to the patient.

(1) In order to examine his power of *mobility*, we first ask him to carry out a few ordinary movements. If he lifts one leg after the other, extends and flexes the knees as directed, we may at once be reassured as to the worst ; he has no complete lesion of the spinal cord. But if he does not lift his feet, but contracts his thigh muscles with pain, we may conclude that the nerve-tracts retain their conductivity, but that movement is hindered by the pain. He may have sustained a severe injury to the spinal column, he may even have a fracture of both thighs, but the spinal cord has not been crushed through. If he is able to raise *one* leg, while the other remains helpless, he either has a unilateral injury to the spinal cord, which is very rare in the case of fracture, or a unilateral contusion or compression of the cauda equina, which is also rather rare. The most

probable condition is a fracture of the thigh or pelvis, which may at once be assumed if the patient can move the foot and toes, while he is incapable of moving the thigh.

The mobility of the *trunk* is next examined, for which purpose the method of respiration is of great assistance. If the respiration is purely of the abdominal type, *i.e.*, diaphragmatic breathing, and if thoracic respiration is impossible, it means that the intercostal muscles are paralysed, and that only the phrenic nerve, which arises from the fourth and fifth cervical segment, remains in action. The injury is therefore severe and situated high up.

We come next to the mobility of the *upper extremities.* The very position of the arms is significant. If they are freely movable down to the finger-tips, and can adopt any posture desired, it means that the injury is at any rate lower than the first dorsal segment. If the hands are half closed, the elbows flexed, and the forearms are lying moderately pronated on the chest, we may conclude that the injury is about the level of the seventh cervical segment (fig. 213). If the arms are turned outwards and held upwards, with the fingers semi-flexed, the forearms supine, and the elbows bent, the sixth segment is injured (fig. 214). If they lie immobile, completely paralysed against the trunk, the position of the injury is at the fifth segment. It cannot be any higher, because all severe injuries above this level cause paralysis of the phrenic nerve and sudden death.

In the case illustrated in figs. 213 and 214, the autopsy showed that there was a contusion between the seventh and eighth segments. When the patient came into hospital his posture was as depicted in fig. 213. On the following day, when the circulatory disturbance had increased, he presented the posture shown in fig. 214, and the hyperæsthetic zone was displaced one segment higher up. In a few days there was so much improvement that even the eighth segment resumed its functions ; but death from broncho-pneumonia followed three weeks later. Fig. 216 illustrates the spinal injury which had occurred in this case.

(2) After this summary examination of mobility we proceed to test **sensation.** If this is preserved in the lower extremities, although possibly weakened, or lost to certain stimuli, a complete lesion can be excluded, even if motion is entirely absent. But if it is entirely lost, as is usually the case when there is total motor paralysis of the corresponding section, complete contusion of the spinal cord is very probable. The level of the injury can be ascertained from the limits of normal sensation.

An area of complete anæsthesia is frequently bounded by a zone of partial loss of sensation and a zone of hyperæsthesia.

This zone of hyperæsthesia is not only caused by irritation of the nerve-roots, but also by irritative changes within the cord itself, as is

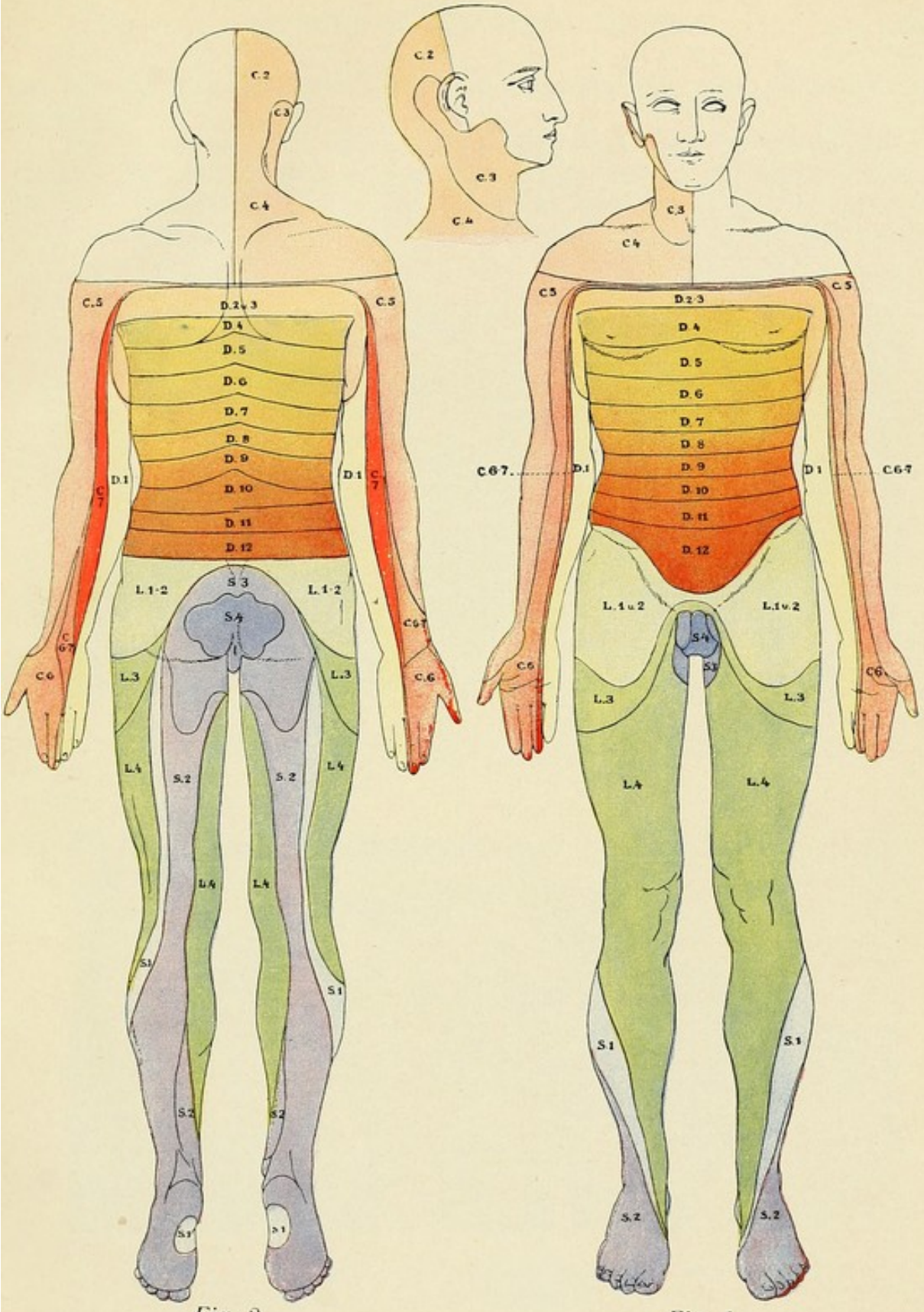

Fig. 2. *Fig. 1.*

Distribution of sensory root-segments on the superficial skin (after Kocher).

Note: L. 1 u. 2, L. 1 u. 2 on groin should appear as L. 1—2.

proved by the fact that this zone ascends in cases of ascending myelitis.

The examination of the sensation should always be completed by testing the sensations to pain and temperature. In cases wherein there is partial disturbance of sensation, various kinds of sensation produce different reactions. Sensibility to pain and temperature is

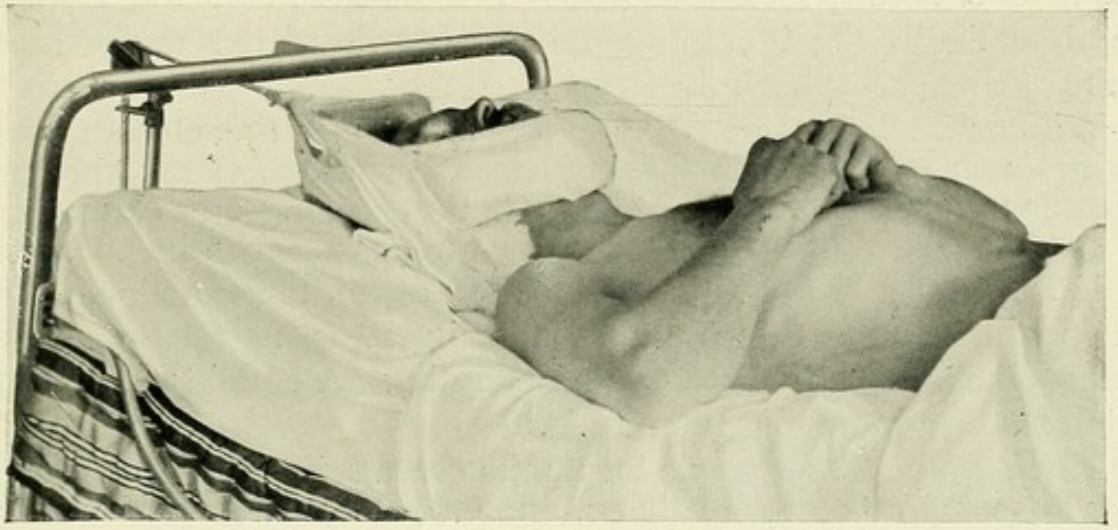

FIG. 213.—Posture of arms in a transverse lesion at the level of the seventh cervical segment.



FIG. 214.—Posture of arms in a transverse lesion at the level of the sixth cervical segment.

more greatly deranged than the sensation of taste, or the pain and temperature sense may be completely lost, while the sense of taste is only slightly disturbed.

(3) We now examine the condition of the **vasomotor nerves.** Their paralysis is indicated by hyperæmia of the paralysed extremities, by a rise in the temperature of the skin, and by congestion of the corpora cavernosa penis. This organ is usually in a state of moderate

congestion, and if touched, for instance to pass a catheter, it may pass into a state of erection, and emission may follow.

(4) The condition of the bladder and rectum are especially important in regard to the **visceral functions.** In a total lesion both these organs are completely paralysed. Paralysis of the bladder is shown by a retention of urine, combined with so-called paradoxical incontinence. The bladder is fully distended and is recognizable at a first glance at the abdominal wall; it empties only by overflow after the resistance of the sphincter has been overcome.

We cannot here argue the question whether the closure of the sphincter is merely an action of elasticity (Kocher) or whether it depends upon some peripheral innervation thereof. Nor can we here go into the details of the diagnosis of paradoxical incontinence.

If the injury is not situated too low down, the function may in time unconsciously return at periodic intervals, as the spinal cord resumes the automatic discharge of its duties. A condition comes on, which Kocher compares to enuresis.

It matters not whether we locate the centres involved in the sacral segments or in the sympathetic, in accordance with the views of most recent authors (L. R. Müller). In either case the fibres run through the conus medullaris. If they are torn through, a permanent loss of voluntary power over the bladder and rectum follows in every case.

The newer researches indicate that automatic action may return after a complete destruction of the conus, a circumstance untenable according to the older views. The onset of enuresis after paradoxical incontinence has once started, is especially found in cases of partial damage to the spinal cord. We know that this may also occur in dogs after a complete lesion, but the subject has not been sufficiently worked out in man.

On examining the rectum, it will be found to be full of fæces, as long as they are solid—retentio alvi. If the rectal contents are liquid, they escape involuntarily—incontinence of fæces.

Extreme meteorism, which is a sign of *intestinal paralysis*, is another symptom of visceral derangement. It is a sign which has often suggested genuine intestinal obstruction, and which has led to the performance of laparotomy.

We must finally refer to disturbances in the *innervation of the pupils.* If reflex fixation of the pupil be present with miosis, it follows that the pupillo-dilator fibres are interrupted somewhere in their course through the spinal cord, and that therefore the lesion must be above the first dorsal segment, in the roots of which these fibres leave the cord.

(5) There now remains the important matter of the examination of the **skin and tendon reflexes.**

In a complete lesion the **superficial or skin reflexes** are usually lost, but they return again. Kocher has, however, pointed out that the genital reflexes are not lost, viz., the erection reflex, and unilateral contraction of the lower abdominal muscles on squeezing the testicle (Kocher's testicular reflex). The **tendon reflexes,** especially the *patellar reflex,* are of greater importance. If it is absent, it signifies a very severe injury, generally a complete lesion. If it remains permanently absent there is no doubt at all about this (Bastian-Brun's law). It may also be absent in partial lesions. It does not then usually take more than a few hours for it to return, though I have seen the absence persist for days, in rare cases. If, on the other hand, the patellar reflex remains after an injury to the spinal cord, or is actually increased, we may safely exclude a complete lesion, even if the other symptoms are severe.

These remarks only apply to human beings and to sudden traumatic complete laceration. In *dogs,* the tendon reflexes may also, in such a case, return after a short delay. In *man,* the reflexes are either retained or even increased, in cases of *gradual* interference with the cord, through tumours or inflammatory processes. On the other hand, there is no record of a case wherein the tendon reflexes had previously been normal, and in which they were either retained or increased after the spinal cord has been suddenly torn through. I will not dispute the possibility of a partial return of the tendon reflexes months after a complete traumatic division of the cord, even in man, but I have never seen such a case; but this does not invalidate the diagnostic importance of Bastian-Brun's law.

II.—DIAGNOSIS OF THE NATURE, DEGREE AND POSITION OF THE INJURY.

Our examination now puts us in a position to answer the two important questions to which every spinal injury gives rise, namely:—

(1) Is the injury complete or partial?

(2) At which level is it situated, and what conclusions may we draw from the injury to the cord, in regard to the injury to the spinal column?

(A) THE DEGREE AND THE NATURE OF THE SPINAL CORD INJURY.

We have first to decide whether the injury has caused *complete* or *partial* division of the cord. We may summarize the indications already referred to in the following way:—

We may assume a complete lesion when there is persistent, symmetrical, total, flaccid motor paralysis, with sensory paralysis in the corresponding area, and when the tendon reflexes are lost for a considerable

time, and when the bladder and rectum are paralysed, in the absence, however, of all motor and sensory irritative symptoms in the paralysed regions.

We must, on the other hand, assume a partial lesion when signs of voluntary innervation and of sensation are present below the site of injury; when, in their absence, the patellar reflex is retained or is soon restored; when motor or sensory symptoms of irritation appear in the paralysed regions, in the first few days after the accident, and when bladder and rectum still act voluntarily, or at any rate when their automatic function sets in early.

A partial lesion can naturally occur in various degrees and forms.

Hemi-section of the cord produces a somewhat typical form of lesion with a symptom-complex to which the name of Brown-Sequard's paralysis has been given. The more complete and the sharper the hemi-section, the more accurately do the symptoms correspond to the following scheme, viz. :—

On the *side of the injury* :—

(*a*) Motor-paralysis, in the form of paralysis of a pyramidal tract, with a localized zone of cornual paralysis at the upper border.

(*b*) Vasomotor paralysis.

(*c*) Hyperæsthesia for all forms of sensation.

(*d*) Loss of the muscle sense, which is no longer generally recognized as a separate function (deep sensibility).

(*e*) Increase of the tendon reflexes in consequence of the break in the conducting path.

(*f*) In the cervical cord; paralysis of the oculo-pupillary fibres.

On the *uninjured side* we find :—

Sensory paralysis either for all or for certain forms of sensation.

It would be of great interest from the point of view of treatment, if we could go further and distinguish between *contusion* and *compression*. The present state of our knowledge, however, does not allow us to do so.

We might very well indirectly conclude that contusion had taken place if we can demonstrate displacement of a vertebra. If we have concluded, from the absence of this sign and from the slightness of the symptoms, that the case is one of mere compression by a *hæmatoma* (always a very uncertain diagnosis), then the presence of much blood in the cerebrospinal fluid, drawn off by lumbar puncture, would suggest that the hæmatoma is situated inside the dura. This intradural hæmorrhage is also distinguished from hæmorrhage inside the the cord (hæmatomyelia) by the predominance of *symptoms of irritation*. (Paræsthesia, increase in the muscle tone and of the reflexes.)

In hæmatomyelia the *paralytic symptoms* predominate; if the hæmorrhage is in the cervical cord, the disturbance is most marked in the lower extremities. The sensations of pain and of temperature

undergo most disturbance, just as in syringomyelia. Very circumscribed hæmorrhages lead to **diplegia**, and as they are most frequent in the cervical cord, the diplegia is of the brachial type. Finally, it should be noted that such hæmorrhages in the cord (especially in the grey substance) may occur without any injury to the spinal column, as they have been observed to follow a temporary *overstrain* of the spine and consequent *dragging on the cord*. These have always been situated in the cervical or in the lumbar cord.

(B) THE POSITION OF THE SPINAL CORD INJURY.

(The Diagnosis of the Level of the Lesion.)

The level of the lesion may be ascertained by co-ordinating the results of the tests for motion and sensation. We need not enter into details because they are clear, from Plates I, II, and III, taken from Kocher's work, which are diagrammatic representations of the distribution of motion and sensation in accordance with the individual segments, and also from the adjoining diagram (fig. 215). It is only necessary here to add a few general remarks.

(1) In injuries of the cervical cord the posture of the arms tells us at once the approximate level of the injury, as previously stated. We must, however, not be content with the demonstration of these postures, but must carefully examine *power of movement*.

In comparing what we find with the plates, we must remember that motor symptoms are not all due to the same cause. They may be caused :—

(*a*) By compression, or the tearing through of the pyramidal tracts.

(*b*) By destruction of the anterior cornua and of the intramedullary roots.

(*c*) By damage to the roots after their exit from the spinal cord or from the dural sheath.

According to the rules of spinal cord pathology, the first form should cause spastic paralysis, without the reaction of degeneration, the other two should cause flaccid paralysis with the reaction of degeneration. But, as a matter of fact, all paralyses are flaccid at first, and even when due to a break in the pyramidal tract, the spasticity does not come on for some considerable time, indeed until the lower spinal segment has regained its automatism. But, on the other hand, the reaction of degeneration enables us to distinguish between paralysis due to a break in the pyramidal tract and paralysis due to a lesion in the cornua or in the roots, at any rate after a few days. The nuclei are, however, not accurately divisible into segments, so that the nerve supply of one muscle may be derived from several segments. The reaction of degeneration, however, only manifests itself when the whole of the nucleus or all the roots are destroyed. If a transverse lesion, for example, hits off the upper end of a

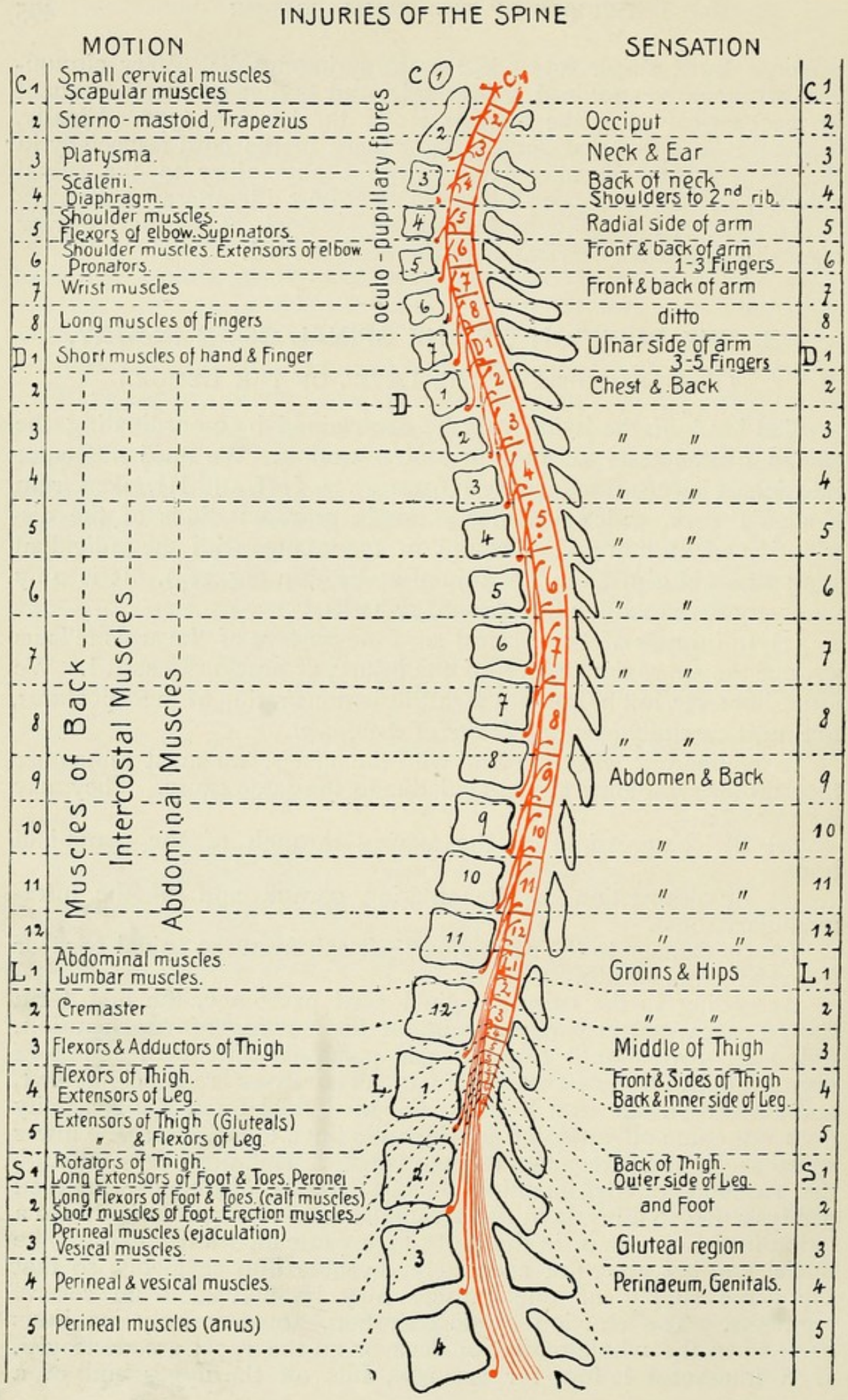
INJURIES OF THE SPINE
MOTION
SENSATION
C 1 Small cervical muscles Scapular muscles
2 Sterno-mastoid, Trapezius
3 Platysma.
4 Scaleni. Diaphragm.
5 Shoulder muscles. Flexors of elbow. Supinators.
6 Shoulder muscles. Extensors of elbow Pronators.
7 Wrist muscles
8 Long muscles of Fingers
D 1 Short muscles of hand & Finger
2
3
4
5
6
7
8
9
10
11
12
L 1 Abdominal muscles Lumbar muscles.
2 Cremaster
3 Flexors & Adductors of Thigh
4 Flexors of Thigh. Extensors of Leg.
5 Extensors of Thigh (Gluteals) & Flexors of Leg
S 1 Rotators of Thigh. Long Extensors of Foot & Toes. Peronei
2 Long Flexors of Foot & Toes. (calf muscles) Short muscles of Foot. Erection muscles.
3 Perineal muscles (ejaculation) Vesical muscles.
4 Perineal & vesical muscles.
5 Perineal muscles (anus)
Muscles of Back
Intercostal Muscles
Abdominal Muscles
oculo-pupillary fibres
C
D
L
S
Occiput
Neck & Ear
Back of neck Shoulders to 2nd rib
Radial side of arm
Front & back of arm 1-3 Fingers
Front & back of arm
ditto
Ulnar side of arm 3-5 Fingers
Chest & Back
" "
Abdomen & Back
Groins & Hips
Middle of Thigh
Front & Sides of Thigh Back & inner side of Leg
Back of Thigh. Outer side of Leg. and Foot
Gluteal region
Perinaeum, Genitals.

FIG. 215.

nucleus, only a small part of the muscle undergoes trophic change. The rest of the muscle is paralysed owing to the break in the pyramidal tract, and we must not expect the reaction of degeneration. Patients with severe damage to the cervical cord have generally succumbed before the reaction of degeneration has had time to develop.

We are apt to diagnose the lesion in too low a segment, owing to the fact that auxiliary innervation may be derived from the segment next highest to the one affected. On the other hand, the upper limit of the symptoms may, in exceptional cases, be due to an ascending *traumatic myelitis*, or to some transitory distant cause, and so we may diagnose the lesion higher up than it really is. It is, therefore, of the greatest importance to make repeated examinations, comparing the one with the other before deciding as to the level of the injury.

In general, we may say that the shoulders and the elbows are supplied from the fifth and sixth segments, the wrist from the seventh, the long muscles of the fingers from the eighth, the small muscles of the hand and fingers from the first dorsal segment, which is functionally connected with the eighth cervical.

We examine *sensation* on the arms, because the neck and shoulder, as well as the thorax as high as the level of the second rib, are supplied by the fourth segment (supraclavicular nerves). The radial side of the arm corresponds to the fifth cervical segment, the ulnar side to the first dorsal segment. The areas corresponding to the other segments lie between them in the form of bands. As the segments also coalesce in regard to sensation, we must only make use of complete loss thereof, for the purpose of focal diagnoses, at any rate in total lesions.

Kocher's Plate III is constructed on this assumption ; for instance, the upper border of the sixth segment does not indicate the limit up to which its fibres themselves reach, but it represents the limit to which the auxiliary fibres of the fifth segment reach ; in other words, it is the upper limit of total anæsthesia caused by destruction of the sixth segment. When the lesion is partial we define its level by the zone in which the disturbance is most pronounced and in which the most forms of sensation are lost, that is to say, we do not take into consideration the sensibility to touch only, but also to pain and temperature.

Symptoms of irritation are of more importance here than in the case of motor disturbances. They do not, in cases of a total lesion, indicate the actual segment which is injured, but the one directly above it, sometimes even one higher. This is the case if auxiliary fibres are irritated in the area corresponding to the next higher segment. In partial lesions of the cord, the irritative symptoms may also correspond to the injured segment itself. We may assume this to be the case, when irritative and paralytic symptoms are combined in the same zone, and when there is no complete paralysis below it.

Ascending myelitis may affect sensation just as it does motion, and therefore give rise to the diagnosis of a segment, which is one too high.

(2) In injury to the *cord in the dorsal region*, the *motor* conditions are not of great value for focal diagnosis, because neither the nerve supply of the muscles of the back, nor that of the intercostals can be applied to the purpose. The nerve supply to the abdominal muscles, derived from the seventh to twelfth dorsal segments, are equally useless for this purpose.

The *sensory* nerve supply is, therefore, of more importance. As previously remarked, the supraclavicular nerves, derived from the fourth cervical segment, supply sensation as far as the second intercostal space. Next to this lies the area of the second dorsal segment, with its border transverse, and not parallel to the ribs, and the other dorsal segments follow. These areas lie lower than the point of exit of the corresponding nerves in the upper part of the chest to the extent of three spinous processes, and lower down to the extent of four or five.

Kocher has suggested a very convenient indication, according to which the upper border of insensibility corresponds to the lowest anterior point of the intercostal space in which the injured nerve runs. From this point the border line runs, not obliquely, but rather horizontally backwards. The areas widen out in the neighbourhood of the linea alba, because the area of the twelfth intercostal nerve reaches as low down as the symphysis.

What has been said of the cervical cord, in regard to the limitation of the areas, applies here also.

The behaviour of the *pupils* will show whether the first or the second dorsal segment has been destroyed, as previously stated.

(3) As the segments of the *lumbo-sacral cord* are very small in extent, we may expect several to be involved in one injury. The cornual lesion predominates over the paralysis of the pyramidal tract, and the return of automatic activity to the cord below the site of injury is compromised by the great extent to which it is injured. The shortest reflex arcs are very liable to be directly interrupted, so that some reflexes do not return, even after prolonged delay. The diagnosis is also rendered difficult owing to the course of the nerve trunks being more oblique than in the other parts of the spinal cord, and therefore more subject to extensive contusion. It may even be difficult, under these circumstances, to decide whether there is a genuine lesion of the cord, or merely a contusion of the cauda equina.

In actual practice, the following may be taken as a guide: if, in a case of complete motor and sensory paralysis, some reflexes are still obtainable, the condition is certainly one of *cord lesion;* a comparison of the physical features found on examination with the

appropriate plates, will show the *precise position* of the lesion. If no reflexes are obtainable, we may be in doubt, especially for the first day or two, whether the cord or the cauda equina has been injured. In such a case the onset of irritative symptoms, "paraplegia dolorosa," would point to *compression of the cauda equina*. If, later on, some reflexes return, despite the persistence of the paralysis, it shows that the cord has, at any rate, participated in the injury. If the reflexes are persistently absent, the onset of the reaction of degeneration in all the paralysed muscles, strongly suggests contusion of the cauda equina, whereas the persistence of electrical irritability in some of the paralysed muscles would indicate that the cord is also injured. Subsidence of the paralysis and a simultaneous return of the reflexes naturally also occurs in contusion of the cauda equina. The *position of the injury in the spinal column* is obviously of significance. If it can be shown that it is situated above the first lumbar vertebra, it is conclusive of injury to the cord; if the injured vertebra is much lower down, it is equally conclusive of injury to the cauda equina. But it is very often impossible to tell which is the injured vertebra, or the indications are too indefinite to be relied upon.

A young man, who was hurt in a motor-car accident, sustained, among other injuries, a contusion in the sacral region. He exhibited for a few weeks nervous disturbances, which, from his description, appeared to be due to a lesion of the cauda equina. Examination, however, showed that the only trace of his accident consisted of great increase of the tendon reflexes, especially on one side. This was conclusive of injury to the cord.

Many *types of paralysis* have been described in connection with the lumbo-sacral cord, as for the cervical cord—almost as many types as segments. It is quite unnecessary to enumerate them, because they can all be inferred by co-relating the motor and sensory nerve areas as depicted in the plates. They are not so striking to the observer as the types of cervical cord injury, recognized by the peculiar postures of the extremities.

(C) RELATIONS BETWEEN THE INJURY TO THE CORD AND THE VERTEBRÆ.

Just as clinical examination and skiagraphy often enable us to diagnose the level of a lesion in the cord, so, on the other hand, are we able, in some cases, to diagnose the segment affected by the displaced vertebra. A few anatomical data are necessary for this.

We begin with the *cervical vertebræ*. The cervical cord has eight segments, and as the first dorsal segment lies behind the last cervical vertebra, if follows that the seven cervical vertebræ correspond to nine segments. The segment in the middle of the cervical cord must be one higher in number than the corresponding vertebra. At the end of the cervical vertebræ, the number of the segment is one and a half to two higher; thus behind the 6th vertebra, we have, not the 6th

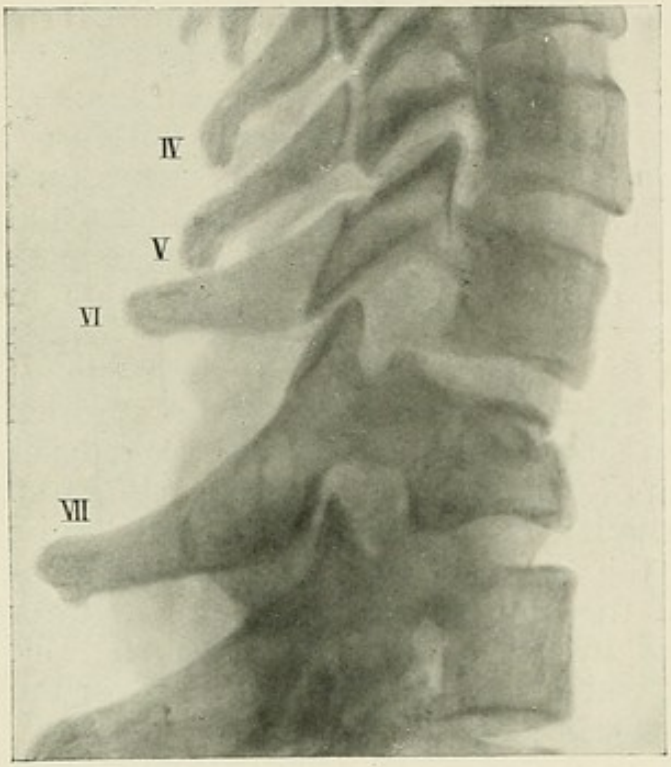

FIG. 216.—Dislocation-compression-fracture in the dislocated position. (From a *post-mortem* preparation). The 7th cervical vertebra is compressed, and the 6th is displaced slightly forwards. The 5th vertebral spine overrides the 6th. The articular processes of the 6th and 7th are not interlocked, but their extremities are in contact with each other.

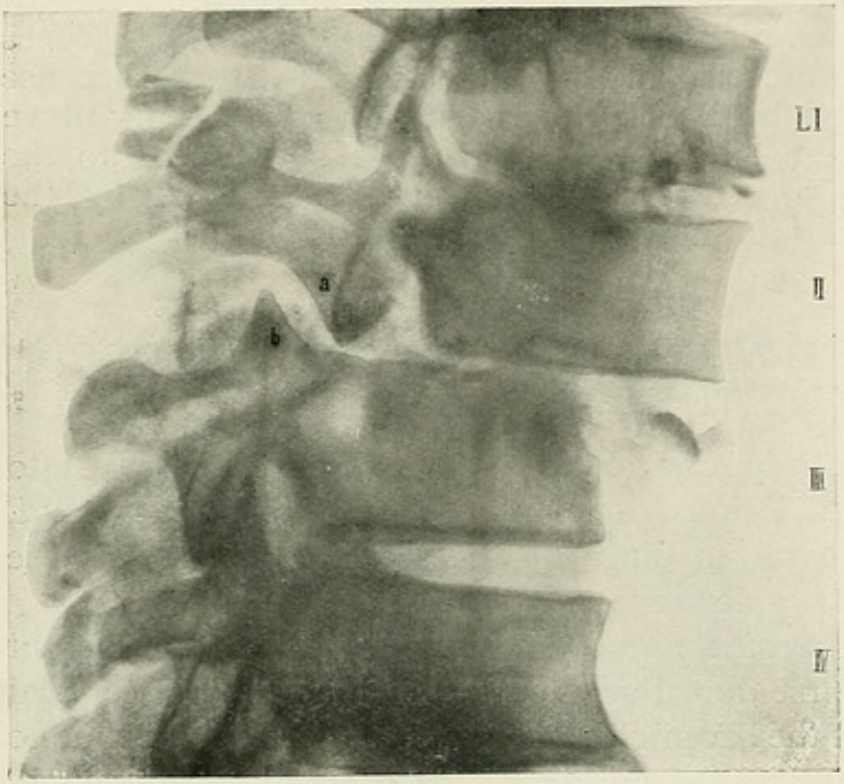

FIG. 217.—Complete bilateral dislocation between the 2nd and 3rd lumbar vertebræ. Interlocking of the articular processes a and b. Indication of an oblique fracture at the anterior border of the 3rd lumbar vertebra. (From a *post-mortem* preparation.)

segment, but the 7th and a portion of the 8th, and behind the 8th vertebra there are the remainder of the 8th and the whole of the 1st dorsal segment.

In the *dorsal vertebræ*, eleven segments (2-12) are divided between the first ten vertebræ. In the upper of these vertebræ the number of the segment is one higher than that of the corresponding vertebra, whereas in the lower vertebræ the difference is two. Thus the 3rd segment lies behind the 2nd dorsal vertebra, while the 12th segment is mainly behind the 10th vertebra.

The whole of the *lumbar and sacral segments* lie behind the 11th and 12th dorsal and the 1st lumbar vertebræ. It is not practicable to separate these segments anatomically. We may, however, say that the upper edge of the 12th dorsal vertebra corresponds to the 2nd lumbar segment, and that the upper edge of the 1st lumbar vertebra corresponds to the 5th lumbar segment.

If we apply on the basis of these

statements and the table in fig. 215, the existing nerve disturbances to the *indirect diagnosis of the injured vertebra*, we must remember that the cord is not contused by the anteriorly displaced vertebra, but by the upper edge of the one immediately below (fig. 217). Sometimes the cord is contused by a small piece of the upper displaced vertebra, resting on the posterior edge of the vertebra below (fig. 220). In cases of compression-fracture the cord may be damaged by a fragment of the vertebral body, forced into the spinal canal.

If we wish to verify the diagnosis based upon the nerve symptoms and obtain a *direct determination* of the displaced or injured vertebra, we must be careful to move the patient with the very greatest caution.

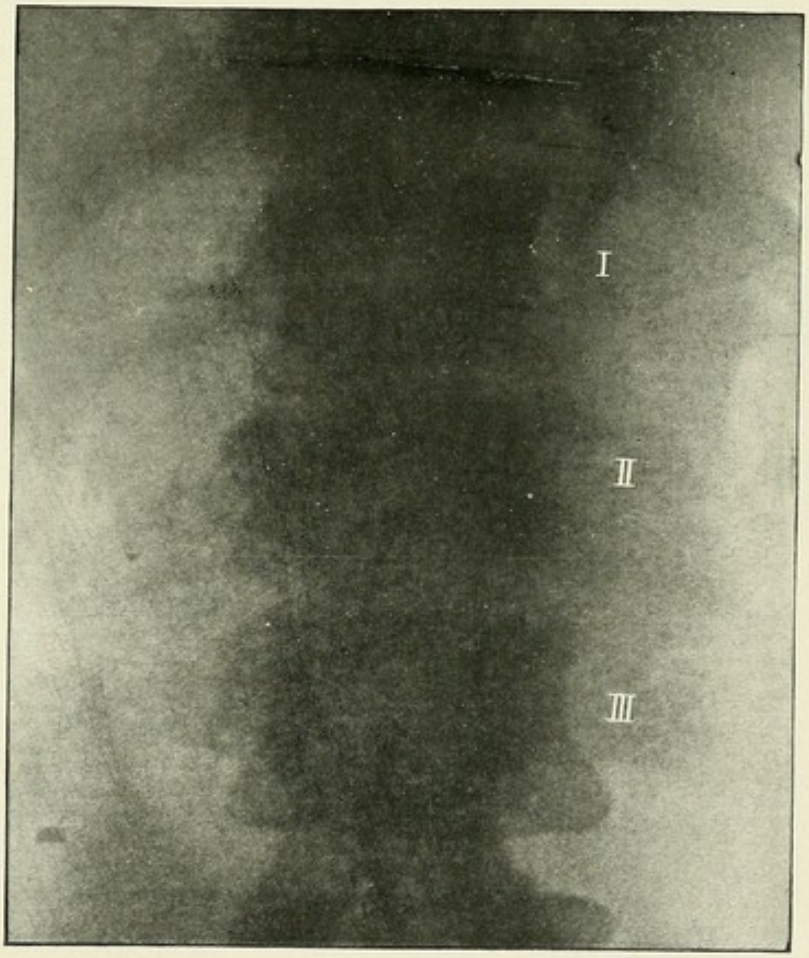

FIG. 218.—Compression-fracture of 2nd lumbar vertebra. The vertebra lower than the adjoining ones. Intervertebral disc narrower than normal.

Anticipating what will be said later, we will observe here only that the spine of a vertebra displaced forwards, either by dislocation or by fracture-dislocation, is depressed, and generally turned somewhat upwards, and that it, therefore, limits anteriorly the gap found in the row of spinous processes. If, on the other hand, one individual vertebra is compressed, its spine projects somewhat backwards as the summit of a more or less pronounced angular kink in the spinal column. If several vertebræ are compressed, their spines will form a round curvature.

(D) THE FORM OF THE SPINAL INJURY.

It is of therapeutic and prognostic importance to recognize the form of the spinal injury. If this is not elucidated by a skiagram, we must depend upon the indirect evidence furnished by the spinal cord injury, or by the signs found in the spinal column.

We may distinguish, in accordance with old custom, between

dislocations and fractures, at any rate on paper. The *dislocations* are either unilateral (rotation-dislocation), or bilateral (total dislocation). They are incomplete when the articular processes override each other (fig. 216) and complete when the particular processes are interlocked (fig. 217). *Fractures* concern either the arch and processes only, or the body itself. The latter, which claim our main interest here, are either compression-fractures (figs. 216, 219, 221), or oblique fractures, *i.e.*, fractures which traverse the body of the vertebra obliquely, from

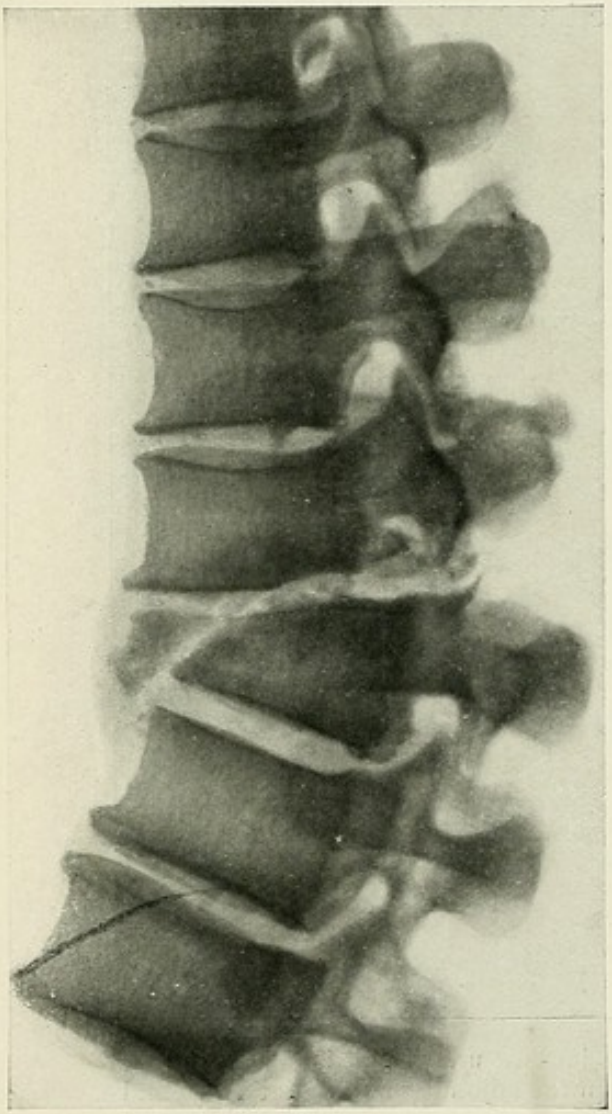

FIG. 219.—Oblique fracture-dislocation. (From a *post-mortem* preparation.)

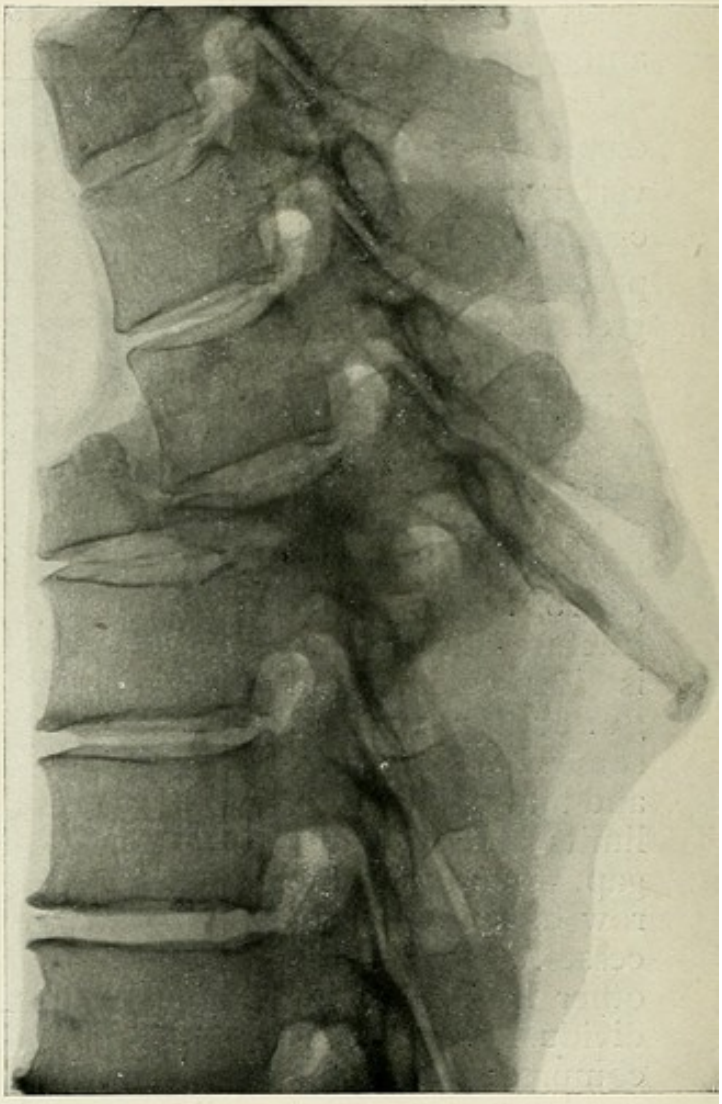

FIG. 220.—Compression-fracture-dislocation, with displacement of upper section, backwards. (*Post-mortem* preparation.)

above and behind to below and forwards. These oblique fractures sometimes involve two neighbouring vertebræ. It is only rarely that the line of an oblique fracture ascends from one side to the other. There are finally some fractures, intermediate between oblique fractures and compression fractures, in that the wedge-shaped fragments exhibit signs of shattering by pressure, in addition to their wedge-like form. The right to distinguish between oblique and compression fractures follows from the different ways in which the two

injuries occur. In compression-fracture the force acts in the axis of the spinal column; in oblique fractures it acts more or less vertically to it. The more these two forces co-operate the more mixed is the type of the fracture. The more the force acts perpendicularly to the spinal column, the more displacement takes place between the two vertebræ, and the final effect of the injury is to resemble a dislocation. If the displacement has produced complete dislocation we describe it as a *total dislocation fracture*, which may be either an *oblique fracture dislocation*, or a *compression-fracture dislocation*, according to the degree and form of the shattering.

How much can we recognize clinically of all this? The main question which concerns the future of the patient is this: Is he suffering from an injury without displacement and therefore generally without severe contusion of the cord, or from an injury with displacement and therefore with more or less severe contusion thereof? Compression-

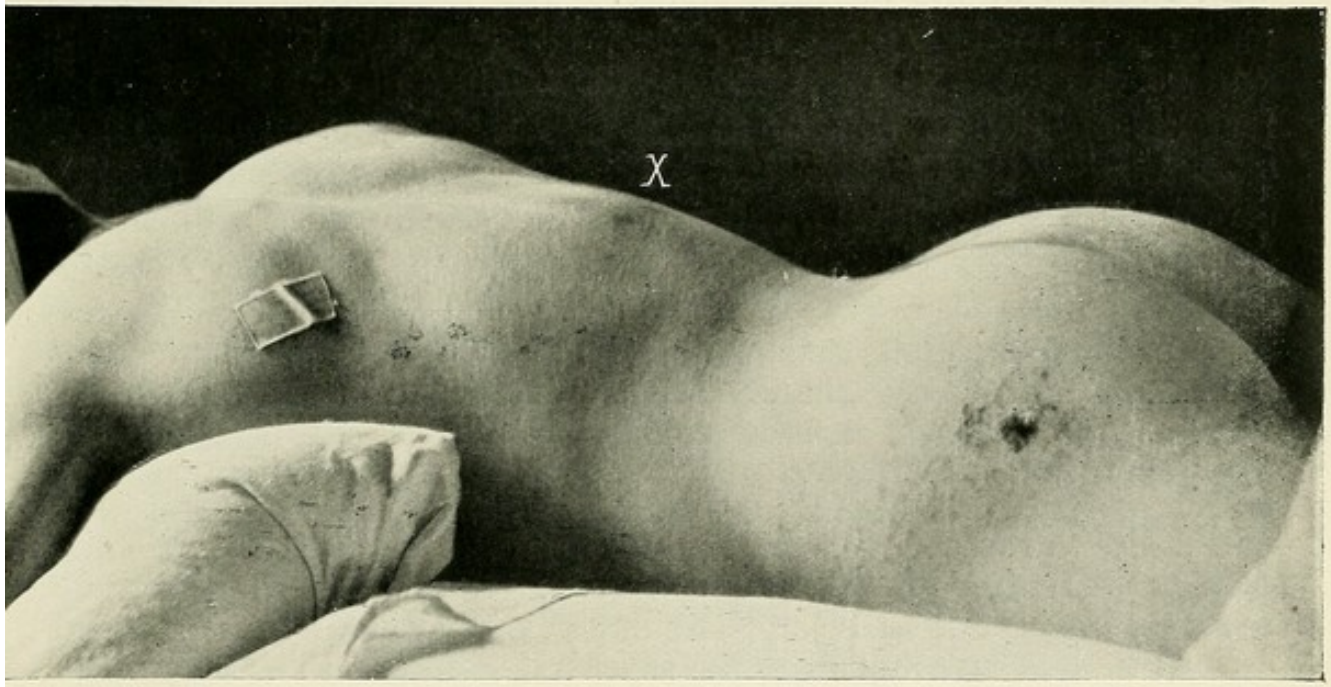

FIG. 221.—Compression-fracture of the lower dorsal vertebræ (X). Very slight cord symptoms. Simultaneous localized compression-fracture of 3rd dorsal vertebra and transverse fracture of the sternum.

fractures and fractures of the arch belong to the first group, total dislocations and total dislocation-fractures in their various forms belong to the second group—injuries which we may class together as *total displacements*.

(1) Fractures of the Spinous and Transverse Processes.

Fracture of a spinous process is caused by a direct localized force, and the objective signs consist of a circumscribed persistent pain on pressure over the spinous process, striking preternatural mobility thereof, and the subsequent onset of ecchymosis. As a rule, however,

a positive diagnosis can only be made from a skiagram, taken from the side.

It is more difficult to recognize fracture of a *transverse process.* This injury may result from direct violence or from muscular action. It may be suspected from the presence of a persistent and pronounced pain on one side, on lateral flexion of the spinal column, and from pain on pressure on one side, while the corresponding spinous process is not painful. A positive diagnosis can only be made after an X-ray examination. This injury is practically confined to the lumbar vertebræ, and often causes prolonged discomfort. The actual pain may not be very great, but it suffices to incapacitate people from employment for many months, especially when there is no ardent zeal for work.

Fracture of a transverse process in the neck is directly combined with fracture of the *articular process.* The mechanism of rotation-dislocation usually comes into play, but the interlocking of the articular processes is prevented by the fracture of one of them, so that the position of rotation is not fully developed. Under these circumstances the diagnosis is very difficult. The symptoms are too severe for a simple sprain, and insufficiently distinct for a unilateral dislocation. The differential diagnosis is only possible by X-ray examination.

We thus see that opportunities for wrong diagnoses are very abundant, unless X-ray examination is employed, especially when the patients are workmen insured against accidents. Formerly, if the symptoms did not coincide with the physical signs, some observers called the patient a malingerer, others of a more kindly disposition called him the subject of a "traumatic neurosis." But it has become evident that pure malingering is rare, and that the term traumatic neurosis ought not to be applied unless the accident has produced serious results, accompanied by psychical damage. The view now taken of the cases where there is no anatomical injury, is that it is neither a matter of malingering nor of traumatic neurosis, but rather of—often unconscious—exaggeration. This is a much more probable view, and, psychologically more intelligible.

The main point, however, is that the patients must be thoroughly examined, and if the skiagram is doubtful, additional pictures must be taken in various positions until the case becomes clear.

(2) Fracture of the Vertebral Arch.

If there are no spinal cord symptoms, there is every probability that the arch only has been fractured, but it does not necessarily exclude fracture of the spinous process. In the presence of cord symptoms we should think of fracture of an arch, if the spinal column has not lost its supporting power, and if axial pressure is only slightly,

or not at all painful, and when these symptoms are combined with a severe pain on pressure over one spinous process, possibly with some anterior displacement thereof, and moreover if there is also a local hæmatoma and the injury has been direct and narrowly circumscribed.

The early diagnosis of fracture of the arch is important from the point of view of treatment. It is the only form of fracture in which, when complicated by damage to the cord, early operation is clearly indicated—the elevation or removal of the depressed arch—and in which very good results are obtained.

(3) Compression-fracture.

This is suggested when the cord symptoms are slight, or quite absent, when the spinal column loses its hold, either incompletely or not at all, but when—in contrast to fracture of the arch—there is very pronounced pain on axial pressure. Caution is required in applying this test. The injury is usually in the nature of a blow in the long axis of the body, being produced by a fall from a height on the head or the feet, or on the buttocks. The bodies of the vertebræ, which are chiefly composed of spongy bone, yield more readily to these blows than the arches and the articular processes, which are mainly composed of compact bone. The crushing of *one* vertebral body causes the spine to bend forwards in an angular manner, but when *several* vertebral bodies are involved, as is usually the case, the bending is more like a kyphosis. When only one vertebra is compressed, the curvature may be limited to a slight prominence of the spinous process of the affected vertebra, and a hardly perceptible angular kink in the spinal column, whereas if several vertebræ are crushed there is always a round curvature (fig. 219). Sometimes one has to search carefully for the symptoms, for the fracture may easily be overlooked in the absence of cord symptoms, especially if our attention is diverted to other injuries besides those of the spine, or if the patient walks about again soon after the accident.

A young man was brought into the hospital with a compound fracture of the skull and a fracture of the leg after falling from a scaffolding on to his head. As there were no suspicious symptoms, the spinal column was not specially examined, but as soon as the patient left his bed and put his weight on his spinal column, he began to complain of pains in his back. As a matter of fact there was a slight kink at the level of the fourth dorsal vertebra, with local pain on pressure, which must have been due to compression-fracture.

These compression-fractures are most frequently found in the dorsal and lumbar vertebræ. When situated in the upper dorsal vertebræ, our attention is often directed thereto by a *transverse fracture in the upper portion of the sternum*.

Slight compression-fracture in the lumbar vertebræ does not

usually cause any visible kink or protuberance. The change of form is just sufficient to straighten out the normal lordosis of the lumbar spine.

It frequently happens that vertebræ which have been damaged by a compression-fracture undergo secondary absorption of bone, and then give way after long delay, so that a protuberance appears months after the accident—possibly also with nervous symptoms. This is known as Kümmel's disease, and is also, inappropriately, termed traumatic spondylitis.

Axial contusion of the spinal column represents the slightest degree of damage by a blow in its long axis, the intervertebral discs being especially damaged. We may diagnose this condition when, after such an injury, there is pain on axial pressure, but neither any change in shape nor cord lesion.

(4) Complete Dislocation.

Complete dislocation may be diagnosed when a severe or complete cord lesion exists, and when the spinal column has completely lost its supporting power. The latter symptom is not always present in complete dislocation in the cervical spine, because the ligaments may retain some supporting power. The cord lesion is much less severe in these cases than in fracture-dislocation.

A very powerful trauma is required to cause a complete displacement, and it must, at any rate partially, be of the character of an overbending. The diagnosis must be based, as in compression-fractures, on the presence of change in shape of the spinal column, apart from the chief symptoms previously mentioned. But the nature of the injury is such that the dislocation may rectify itself spontaneously by appropriate posture, and on examination it may not be possible to discover anything beyond a spinous process which is painful on pressure and is depressed. The absence of any striking change in form does not, therefore, exclude a complete displacement as long as indirect symptoms thereof exist. In the cases wherein the change in shape persists, we find an increased interval between two spinous processes. The spine, which limits the gap above, is depressed forwards, in consequence of the displacement of the vertebral body, with which it is connected. If two vertebræ are broken, this gap is found between the spines of these two vertebræ, and here also the lower spine is the more prominent.

An exception to this condition occurs in the rare cases when the upper vertebra is displaced backwards instead of forwards (fig. 220).

It would be too much to expect any further details in diagnosis, and to decide between the various forms of complete displacement, in the living patient. Besides, it is quite impossible to distinguish oblique fracture-dislocations from dislocation-compression-fractures. Indeed,

the matter has no practical significance. It is more important to be able to distinguish between complete dislocation and dislocation-fracture in the cervical spine, because the former is capable of being correctly reduced, and the reduction should be carried out. Complete dislocation without interlocking of the articular processes, is in no way distinguishable from dislocation-fracture, because in the latter case also, the kinking and displacement may be rectified by appropriate posture (spontaneous reduction). It is quite different, however, if complete dislocation is combined with interlocking. Whether the head is bent forwards or backwards it is always anteriorly displaced in relation to the back, and there is no tendency for it to return to its normal position, either spontaneously or by appropriate posture. This immovability and the freedom of the cord should always suggest a complete dislocation rather than a dislocation-fracture, and we should therefore attempt reduction. A skiagram furnishes conclusive evidence.

Complete dislocations, pure and simple, have been observed in the upper dorsal vertebræ, but they resemble dislocation-fractures in every respect, and it is quite impossible to effect any reduction, as in the case of dislocations in the neck.

CHAPTER LXXVII.

THE SURGERY OF NON-TRAUMATIC DISEASES OF THE SPINAL CORD.

THE recently qualified practitioner, during the first few years of practice, usually endeavours to classify the spinal cord diseases which he sees under one of the schemes he learnt as a student. But as their memory begins to fade and the more he realizes his therapeutic helplessness the simpler become his diagnoses, and he finally limits himself to such groups as tabes, syphilis, paralysis due to spinal caries, infantile paralysis, and "obscure diseases of the spinal cord." The patient suffers no great harm from this process of simplification, unless his case happens to be one which surgery can cure, or, at any rate, relieve. This applies especially to tumours within the spinal canal.

Not all the tumours which damage the spinal cord possess equal interest for us. If an obstinate sciatica or an intercostal neuralgia

comes on a few years after an apparently successful operation of cancer of the breast, it is easy to diagnose a secondary growth in a vertebra; but, unfortunately, the therapeutic interest is *nil*. If a period of unexplained neuralgia is followed by the appearance of a tumour on the surface of the spinal column, and if the spine kinks simultaneously with the sudden onset of a paraplegia, there is no difficulty in diagnosing a primary malignant growth, but the therapeutic significance is no greater than in the case of a secondary growth. But, in addition to these very frequent incidents, tumours which are accessible to operative treatment occasionally occur. Such are the innocent tumours of the *spinal column*, which grow into the spinal canal, especially *osteomata*, *fibromata*, and *chondromata* and hydatid cysts, and also *new growths* and *inflammatory granulation tumours* of the *spinal cord* and its coverings.

Root symptoms, most of a *sensory character*, appear first as a rule; *i.e.*, localized unilateral neuralgias, hyperæsthesia, and, finally, anæsthesia or, at any rate, hypo-æsthesia. *Motor* symptoms very rarely appear first. It is only in cases of tumour of the cauda equina that the root symptoms are from the first symmetrical and both sensory and motor in character.

It is obvious that these root symptoms do not exist, or at least are not pronounced, if the position of the tumour does not encroach upon the roots.

Pressure upon the spinal cord itself begins after a certain time, varying with the growth of the tumour. The result of this pressure is more or less loss of the conducting power of the cord. If the tumour has a *lateral* situation the symptoms are essentially those of *Brown-Sequard's paralysis*.

Otherwise, the only difficulty in determining the exact relation of the tumour to the spinal cord or the extent to which it has penetrated, is due to the fact that not only must one take into consideration the anatomical position of the growth but also the susceptibility of the individual nerve-tracts to pressure.

The following questions present themselves as the suspicion of a spinal cord tumour arises :—

(1) Is a Tumour Actually Present?

(*a*) We may begin with the stage of *root symptoms*. One should think first of tabes in the differential diagnosis from the common spinal cord diseases; but this condition is easily recognized by its characteristic symptoms, especially by the loss of the knee-jerks. In tumour of the cord these are increased. Then it is important to decide whether the symptoms may not be due to an early **spinal caries** or a rare **hypertrophic pachymeningitis**; but the symptoms

are usually bilateral in these conditions, whereas, in cases of tumour, they are always unilateral at first. They are also much less severe in pachymeningitis than in tumour. It is more difficult to exclude a commencing *spinal caries;* indeed, it is quite impossible to make a differentiation as long as the symptoms are unilateral and no change in the spine can be detected either clinically or by X-rays, and the patient himself is not tubercular nor possesses hereditary disposition thereto. The greater frequency of *herpes zoster* in cases of tumour furnishes only a very indefinite indication, and nothing but the continued progress of the case can elucidate it. In spinal caries the root symptoms either become bilateral in the course of a few months or the cord symptoms subside, but in cases of innocent tumour the root symptoms may remain unilateral for years without any other essential changes occurring.

The appearance of spinal column symptoms, viz., pain on pressure, prominence of a spinous process and pain on axial pressure, disposes of the posssibility of spinal cord disease and pachymeningitis, as well as of tumour of the spinal canal. The diagnosis must then lie between **spinal caries** and **sarcoma of the spinal column;** but the differentiation is sometimes impossible. The fact of the much greater frequency of spinal caries, however, justifies the practitioner in diagnosing that condition. If the case is not eventually cleared up by the appearance of a burrowing abscess on one side or the other, or by metastatic growths, then we may follow Bérard in deciding upon the possibility of a tumour if confinement to bed and weight extension produce no improvement. A skiagram should also be taken.

(*b*) If the patient has *paraplegia* without any deformity in the spinal column we should not, even then, entirely exclude spinal caries, although this would be a very rare event. The case is more likely to be **chronic myelitis,** or **multiple sclerosis,** and if the lesion is in the cervical cord, **hypertrophic pachymeningitis.** If a neuralgic stage preceded the paraplegia, or if radiating pains persist, we may exclude myelitis and multiple sclerosis. If the paraplegia was not preceded by pain, the diagnosis may be in doubt, or exploratory operation may be indicated, for cases of spinal cord tumour occur wherein sensory root symptoms are completely absent.

(*c*) If *root and cord symptoms have occurred simultaneously with deformity in the spinal column* the diagnosis lies exclusively between **spinal caries** and **malignant growth.** If a burrowing abscess be present, it decides the matter, but sometimes a **hydatid cyst** which has reached the surface has been mistaken for such an abscess. In the absence of all objective indications, we must rely upon the history, and if the symptoms have existed for years we must attribute

them to spinal caries; if their course has been rapid and does not extend beyond months, they must be attributed to a sarcoma. Very vascular sarcomata are sometimes recognizable by loud murmurs.

(2) What is the Nature of the Tumour?

The remarks already made in connection with tumours of the brain apply also to **solid tuberculomata** and **gummata** of the cord. The history should guide us, but not control us.

Solitary tubercles may exist in the spinal cord, exhibiting all the symptoms of tumour. They may be shelled out like tumours—an operation which has been attended by good results.

In a neighbourhood where the **echinococcus** is endemic, we should think of the possibility of hydatids, and our diagnosis would be confirmed if the patient presented any other localization of this disease. Symptoms which have persisted for years, without causing any appreciable change in the spinal column, suggest a more or less **innocent tumour of the spinal canal,** especially of the **spinal meninges.** Schlesinger holds that a tumour which has persisted for more than three years is generally intradural and solitary, and therefore appropriate for operation. The more localized the symptoms, the more hopeful is the prognosis. This is of course very unfavourable in the case of the more widespread symptoms caused by **sarcoma of the spinal cord itself.**

Operation has often revealed, instead of the expected tumour, *localized encapsuled collections of serous fluid* which might probably have been removed by simple puncture if the diagnosis had been possible (Krause, Oppenheim, Nonne, &c.).

(3) At Which Level is the Tumour Situated?

The accurate diagnosis of the level is an indispensable precedent of operation. Reference should be made to the remarks in connection with spinal cord injuries, and it is only necessary to add here that in practice the level which is diagnosed is usually too low. One should always fix upon the highest possible root which may be involved; but this may often be too low, and it will be necessary to search higher up at the operation.

CHAPTER LXXVIII.

INFLAMMATORY DISEASES OF THE SPINAL COLUMN.

A.—TUBERCULAR CARIES.

TUBERCULAR caries is so much more frequent than any other form of inflammatory disease of the spine that, as far as the practitioner is concerned, it may be considered as the only important one. Difficulty in diagnosis only exists before the appearance of the characteristic symptom—sinking in of the diseased vertebra and the resulting deformity of the spine, the so-called Pott's curvature.

For purposes of diagnosis the disease is divided into several classes :—

(I) TUBERCULAR CARIES WITHOUT DEFINITE CURVATURE, AND WITHOUT A BURROWING ABSCESS.

This occurs more frequently in adults than in children, because the diseased vertebra soon softens in children, and the curvature develops early in a pronounced form. Nevertheless, a careful mother often seeks advice before the disease has reached the stage of deformity. The history and the method of examination varies with the age of the patient.

(*a*) If an *infant* is brought with the complaint that its entire behaviour has changed, that it is in marked distress, that it has become helpless, that it avoids any rapid movement of the body, that it cries even if lifted out of bed, although the mother is sure of not having hurt it, we should at once think of spinal disease. There is probably nothing to be seen on the back. At most, there may be a little rigidity, combined, perhaps, with some scarcely perceptible diffuse kyphosis, or at least with loss of the normal lumbar lordosis. A similar kyphosis is seen in rickets, but the spine remains movable in that disease, and the back at once makes a concave bend, if we swing the child, with its abdomen downwards, by its four extremities, as remarked by Hoffa. In spinal disease the vertebral column remains rigid, even in this posture, owing to the muscular fixation.

We might also be misled by Barlow's disease (scurvy-rickets) due to improper feeding. In this condition the child is also helpless, and cries when moved; but the pain is situated in the legs, and not in the back. Swelling and bluish-red discoloration of the gums in the vicinity of the erupted teeth indicate the nature of the disease.

(*b*) If the *child already walks*, we will be struck by the fact that it no longer plays with other children, and that it has difficulty in going up, and especially down, stairs.

On the other hand, children are sometimes seen with definite curvature, but without any subjective disturbances. This means that the acute process is over, that cicatrization and consolidation, which take place much earlier in children than in adults, have already occurred.

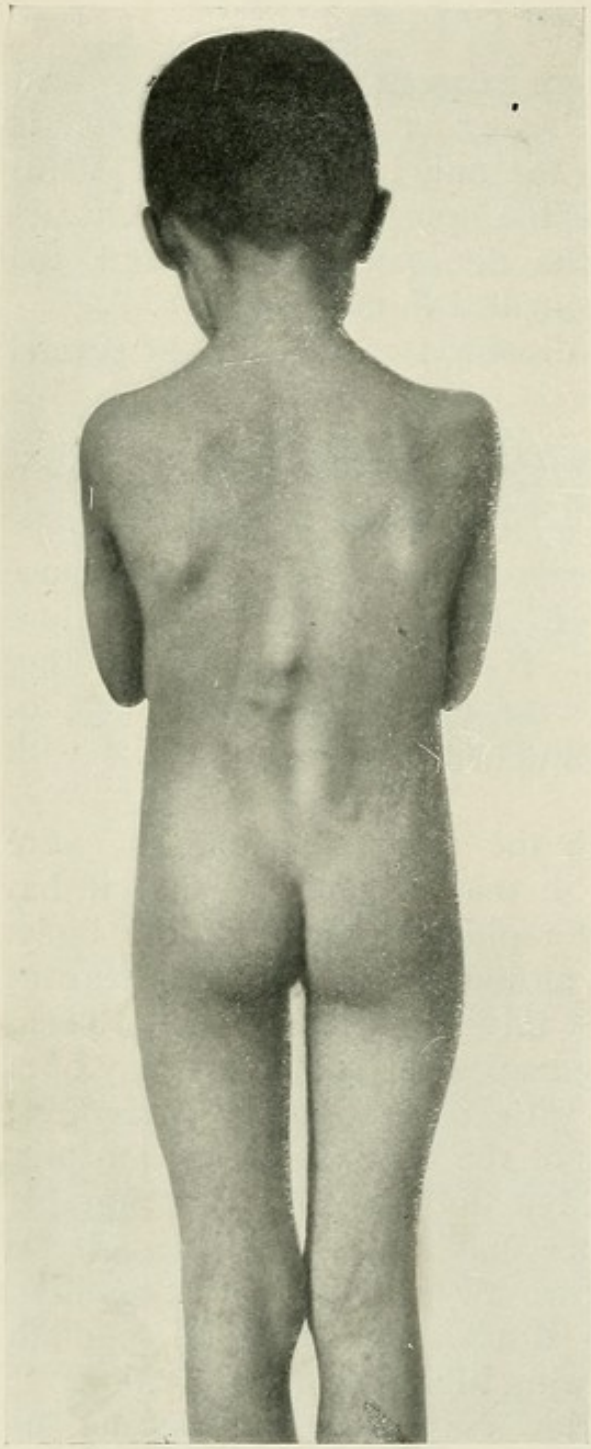

FIG. 222.—Early stage of spinal caries.

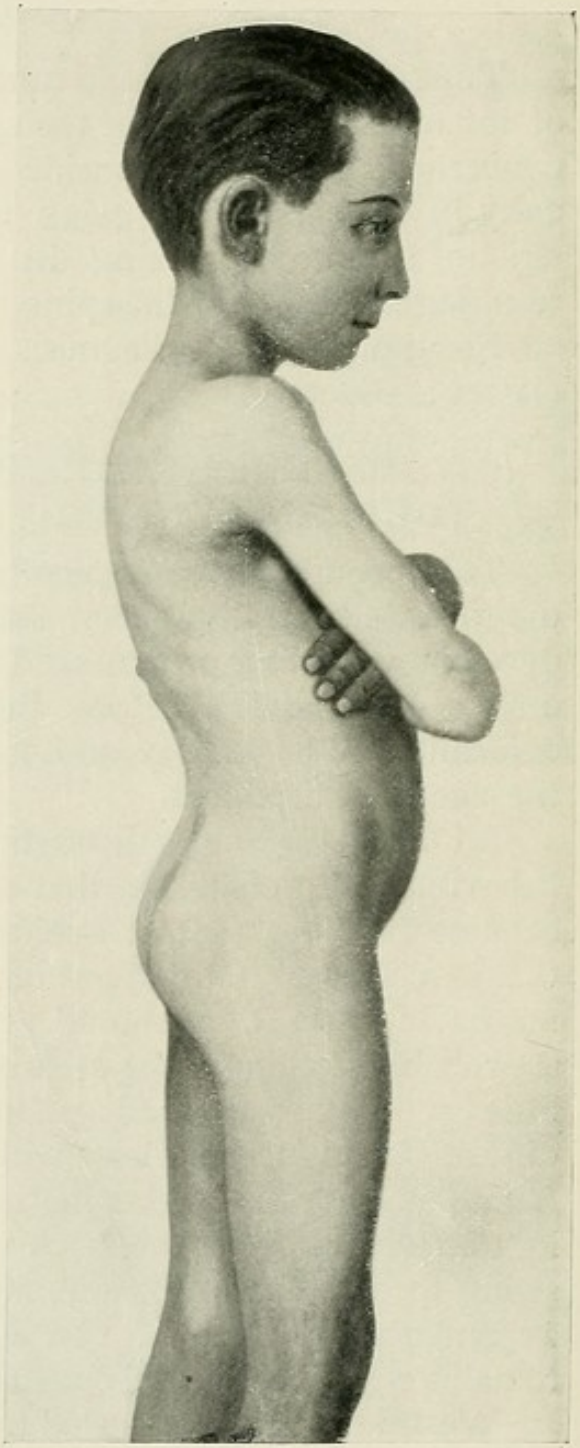

FIG. 223.—Same case, seen in profile.

On examination, we are struck by the rigidity with which the spine is held, and by the way in which the child carefully avoids any movement of bending, over-straining, or rotating the spine. If the child is told to look round, he turns the whole body. If he has to

get up from the floor, he behaves like a child with progressive muscular atrophy, *i.e.*, he supports the hands on the knees. If we palpate the vertebral column, pressing on each spinous process separately, we shall be able to elicit pain at one definite spot. This also occurs if we press upon the spinal column in its long axis, obviously with care. If on repeated examination we are able to elicit this double form of sensitiveness to pressure, we are justified in assuming that caries has started—although it may be difficult to make the parents understand that some bone has already been eaten away, notwithstanding the striking mildness of the symptoms. It is necessary forthwith to explain the significance of the disease, otherwise it is impossible to secure the requisite careful treatment, and the patience which is demanded for it.

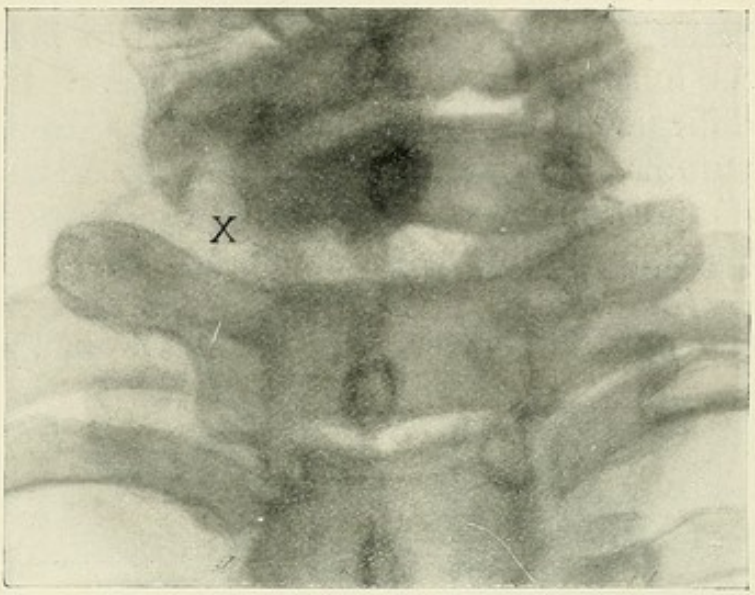

FIG. 224.—Early stage of caries in cervical spine. At X, edge of vertebral body eaten away. (From living subject.)

(*c*) The previous history will be somewhat more ample in the case of *older children and adults*. We are, however, liable to be misled in these cases unless we have the possibility of spinal caries in view. Sometimes the patient localizes his pains to the umbilicus. More frequently we are

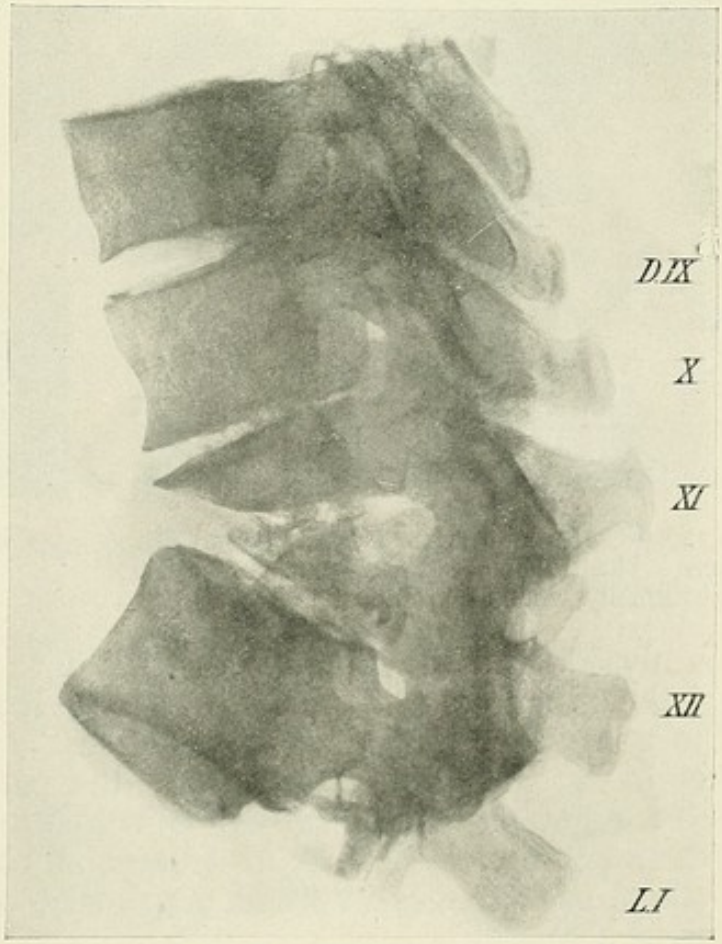

FIG. 225.—Bending of spine due to caries. Greater part of 11th and 12th vertebral bodies destroyed. (*Post-mortem* preparation.)

consulted for sciatica, indefinite, abdominal, or lumbar pains, intercostal neuralgia, "rheumatic" pains in the arms or back of the head. As long as these pains are unilateral, the diagnosis is often very difficult. But they almost always become bilateral after a few months, thus pointing definitely to disease of the spinal column. As previously stated, pain in the back on going down stairs, or knocking up against a stone on a level road, is quite pathognomonic.

An elderly, apparently vigorous, man became paraplegic without any apparent cause. On examination, the legs were found to be

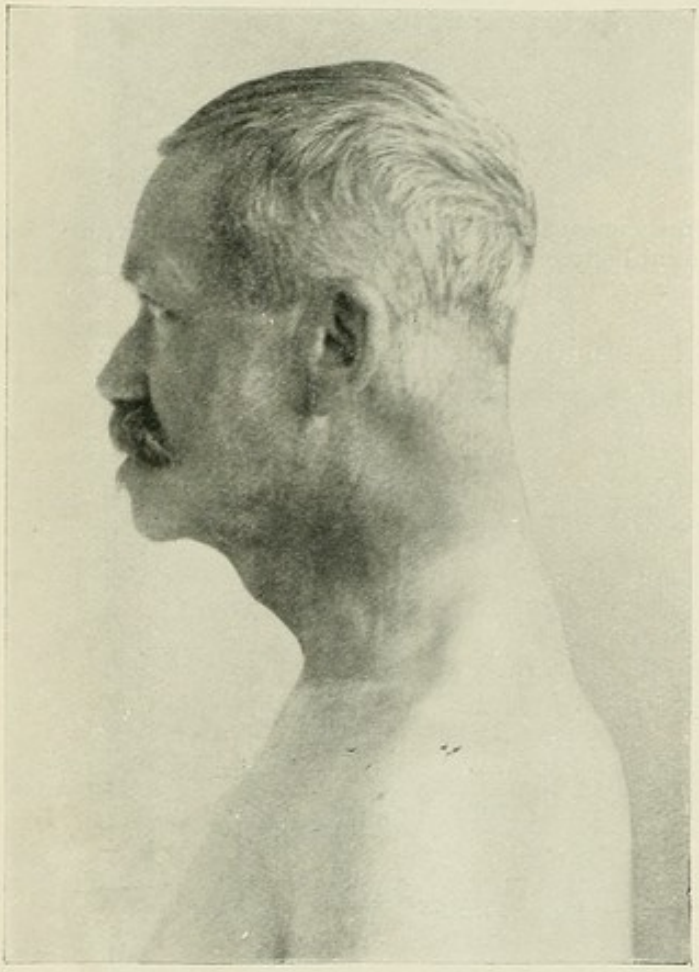

FIG. 226.—Caries of cervical spine (5th and 6th vertebræ). Head displaced somewhat forwards. Neck abnormally wide in profile.

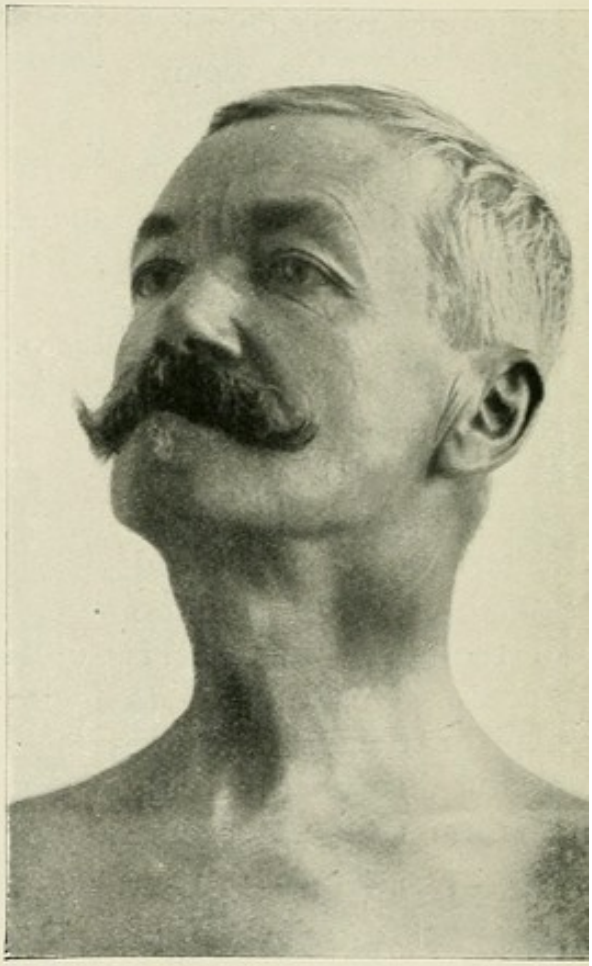

FIG. 227.—Abscess of neck due to caries.

paralysed, and the bladder distended to the umbilicus. The shape of the spinal column showed nothing special, and the excellence of the general condition did not suggest any tubercular disease. The key to the condition was found in the patient's statement that he had felt for some weeks increasing pain in the back when walking about, when bending his spine, and especially when going downstairs. In such a case the question of a primary or a secondary new growth might also arise.

The occurrence of very severe pain in the lower extremities, on any head movement, is very significant of commencing tubercle in the cervical spine.

The patient must be undressed for examination, and must stand with his knees close together, and be directed to bend his back forwards and backwards. If the movement is but slow and imperfect, and limited to the hip and knee joints, it must excite very grave suspicion, especially if the attempt to bend the spine backwards is a failure, and causes the patient to groan. There can be no doubt about the diagnosis if, in addition, pain on axial pressure is present.

This latter test must be done very carefully, especially if the disease is in the cervical spine. We should not take the risk of making a patient paraplegic, or breaking off the odontoid process of the axis, in order to establish the diagnosis.

On pressing upon each separate spinous process, the detection of the diseased vertebra usually becomes very easy. Careful palpation and inspection of the patient in profile may probably reveal, even at this stage, some slight projection beyond the adjoining spinous processes (fig. 223), if this is not already evident from behind (fig. 222). In caries of the cervical spine there will also be some rigidity, and often some slight displacement of the head forwards (widening of the neck in profile) before any definite curvature is evident (fig. 226).

The cases wherein these primary symptoms of pain on axial pressure and local tenderness are absent are more difficult to diagnose.

A vigorous young girl, aged 20, the picture of health, began to complain of lumbar pains, and wandered therewith from one hospital to another. The brother was tubercular. Caries was thought of, but the most careful examination failed to substantiate this view. The diagnosis remained in suspense until a burrowing abscess confirmed the suspicion. Even then there were no appreciable symptoms in the spinal column. The patient died from amyloid disease two years later. Fig. 225 is the skiagram of the preparation, and it shows very clearly the process of the formation of the curvature.

The skiagram does not always, however, show anything conclusive in the early stage of cases of this kind.

(2) SPINAL CARIES WITH BURROWING ABSCESS.

In every case of spinal caries we must look for that common accompaniment of all tubercle of bone—**a cold abscess**—which is termed a **burrowing abscess,** because of its usual course. Its importance for diagnosis and treatment is evident from the fact that it is present in at least one-fourth of the cases—according to other statistics, one half.

There are cases wherein a burrowing abscess is the first, and for a long time the only appreciable sign of spinal caries. Before we discuss its diagnosis, we will briefly refer to its anatomical relations.

In caries of the *upper cervical spine* it is found in the posterior pharyngeal wall, or, more frequently, at the side of the neck, in front of or behind the sterno-mastoid. Exceptionally it may run under

the clavicle towards the axilla. If the caries affects the *lower cervical spine*, and the abscess originates in the transverse process or the vertebral arch, it may also run under the muscles of the back, but as a rule it tracks along the œsophagus, penetrates the thorax, and behaves like abscesses which are derived from the *dorsal vertebræ*. The latter reach the surface between the twelfth rib and the ilium, or they dive down deeply, following the large vessels over the ileo-psoas muscle as far as Poupart's ligament, and eventually burst somewhere through the muscles and reach the surface.

If, in lumbar caries, the diseased focus is in the body of the vertebra, the abscess burrows in front of the spine, in the sheath of the psoas, travelling downwards either over or under Poupart's ligament, to appear in the inguinal region or in the anterior femoral

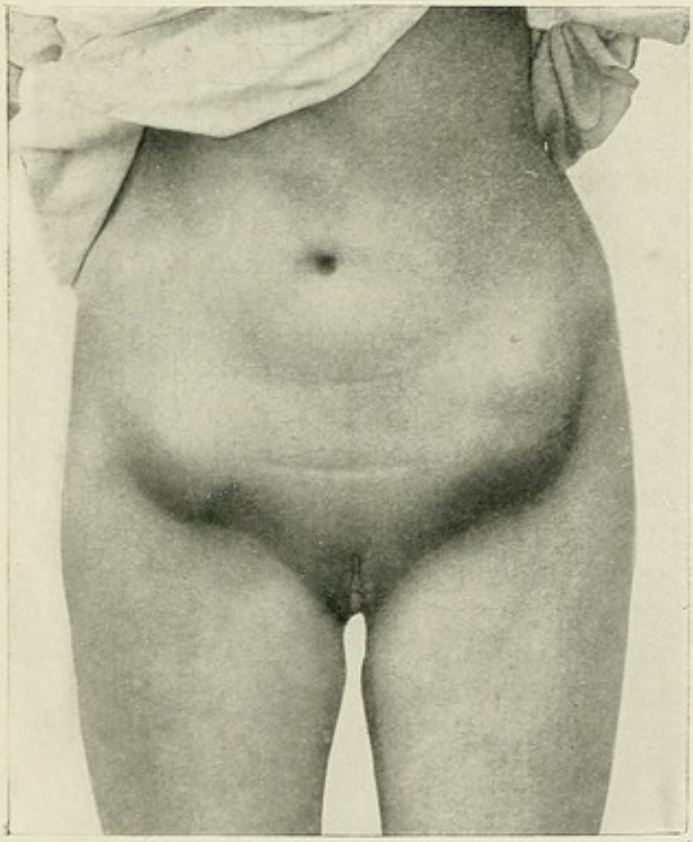

FIG. 228.—Caries of 4th lumbar vertebra, with bilateral inguinal burrowing abscess.

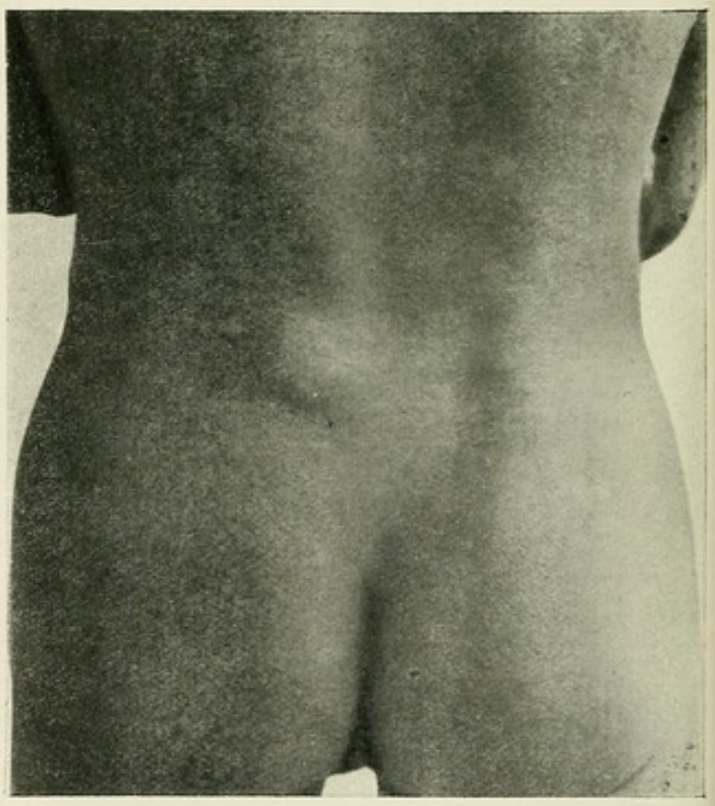

FIG. 229.—Commencing abscess in tubercle of left sacro-iliac joint.

triangle. The abscess appeared in the former position in the case illustrated in fig. 228. Despite the two burrowing abscesses, there was neither curvature nor definite disturbance of function at first; nothing but slight tenderness on pressure over one spinous process. The skiagram showed clearly that the fourth lumbar vertebra was affected.

More rarely the abscesses follow the hypogastric artery and the sciatic nerve, traverse the great sciatic foramen, run under the gluteal muscles, and sometimes from there proceed to the posterior surface of the thigh.

If the focus of disease is situated in the *lateral portions* or in *the vertebral arch*, the abscess appears on the back.

The same applies to foci of disease which are situated posteriorly in cases of *tuberculosis of the sacrum*, or of the *sacro-iliac joint*. But if the disease is situated on the anterior surface of this joint, the pus gains access to the sheath of the iliacus muscle, fills the side of the pelvis, and may burrow thence under Poupart's ligament into the thigh (fig. 230, so-called iliac abscess). It is then situated either at the side of, or beneath the sartorius. If the focus of the disease is more deeply situated, the abscess burrows towards the perinæum and makes its appearance there as a peri-rectal abscess.

If we have already ascertained the correct diagnosis by means of signs in the vertebral column, there is no difficulty in understanding the significance of a burrowing abscess. But if this is the first symptom which the patient notices, and for which he consults the doctor, many errors of diagnosis are possible, as already mentioned in detail, unless a careful examination is made.

We may summarize these once again for the purpose of taking a rapid view of the position.

In the *neck* one might think of a deep lipoma, a deep branchial-cleft cyst, or of an œsophageal diverticulum. Burrowing abscesses have even been mistaken for goitres.

In the *thorax* one should think especially of lipoma, cold abscess originating in the rib, or a pleural effusion which has spontaneously broken through.

In the *lumbar region* one should think of lipoma, lumbar hernia, caries of the ribs or pelvis, and also of the possibility of a tubercular perinephritis, which has burst through posteriorly. The urine must, therefore, be examined in every case of lumbar abscess.

An abscess of the pelvic fossa may, if on the right, be mistaken for an ileo-cæcal tumour; if on both sides, for caries of the pelvis or chronic pelvic osteo-myelitis, or even for pelvic tumours. The correct diagnosis depends upon the accurate observation of the superior connections of the swelling. Very frequently flexion of the hip-joint is produced, and thus spinal caries may be mistaken for hip disease. The pelvic cavity must, therefore, be examined as thoroughly in what is apparently hip disease as in spinal caries.

Abscesses of the pelvic fossa, as we have already seen, consist of iliac and psoas abscesses. When there is extensive suppuration, it is not possible to draw a sharp distinction between the two forms, nor is it important to do so. The occurrence of clinically primary suppuration in the psoas muscle is exceedingly rare, and then it is generally to be attributed to some trauma. This condition might justify the popular old term "psoas abscess" as a separate disease.

Inguinal abscesses have been mistaken for inguinal hernia and hydrocele of the canal, especially in women. But these abscesses are situated more towards the side, and have a wide connection with the pelvic bone by broad processes, so that this mistake should be avoided; the very rare bilocular hydroceles may, however, still give rise to difficulty.

Abscesses of the thigh may be mistaken for femoral herniæ, if situated in the middle line immediately under Poupart's ligament; if towards the side, for an enlargement of the sub-iliac bursa. If the pus can be displaced at all, it goes back *gradually*, a hernia goes back with a jerk. If it is not displaceable—this is the rule—its consistence is generally elastic or fluctuating, which, of course, excludes a

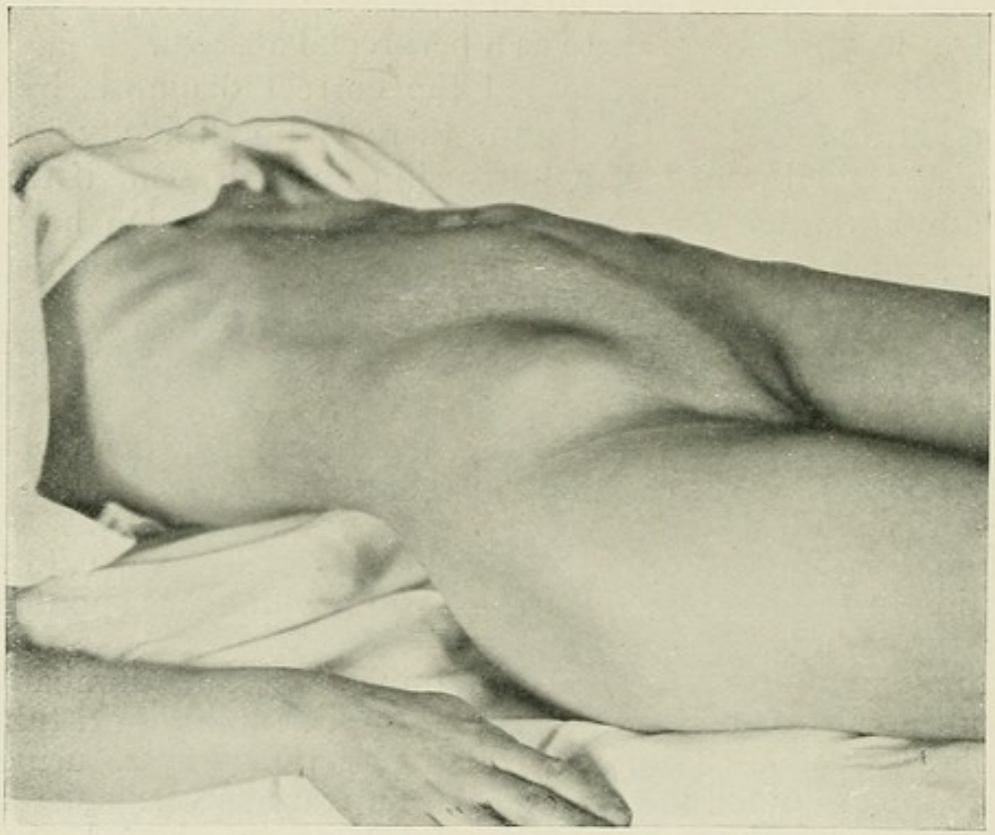

FIG. 230.—Burrowing abscess in the iliac fossa in a case of sacro-iliac tuberculosis.

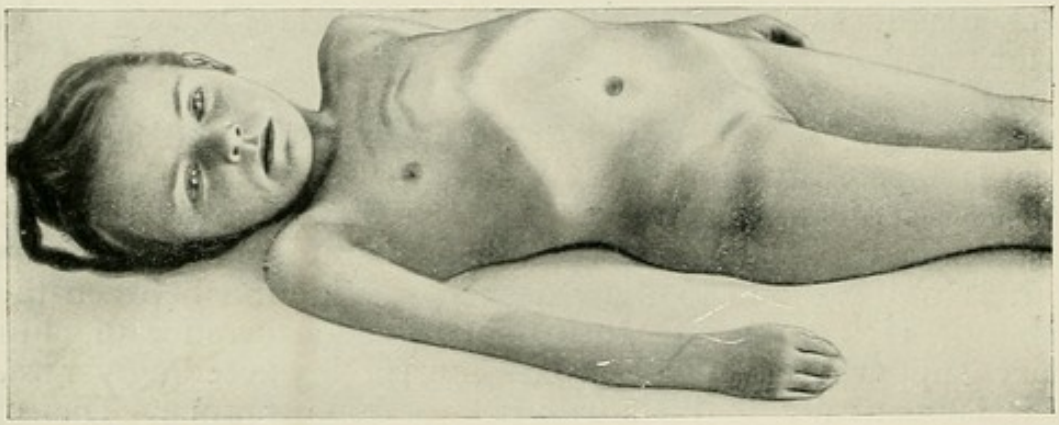

FIG. 231.—Caries of the dorsal spine with a transversely divided burrowing abscess sac.

hernia. An enlarged bursa is recognized by its deep situation under the iliacus, whereas an abscess, even if it descends within the sheath of the muscle, always has a tendency to reach the surface. Many burrowing abscesses are distinguished by possessing a subdivided sac (fig. 231). If the femoral abscess is situated lower down, it may

be mistaken for sarcoma of the femur, or of the adductor muscles. The flexion of the hip-joint may sometimes suggest hip disease.

Unless the hip-joint is itself secondarily affected with tubercle, a burrowing abscess due to spinal caries only prevents extension, whereas in true hip disease abduction and rotation are especially limited.

In *perineal abscesses* the diagnosis has to be made from dermoids and the various forms of peri-proctitis. The most likely diagnosis in the rare cases of *gluteal* burrowing abscesses is hip disease, which can only be excluded by a careful investigation of the spinal column and the hip-joint.

The origin of doubtful cases of suppurating fistulæ is best ascertained by means of a skiagram, after they have been injected. The most useful preparation for this purpose is one composed of vaseline with 20 per cent. of zircon oxide, a modification of Beck's methods, as bismuth salts are not quite free from risk.

(3) SPINAL CARIES WITH CURVATURE.

Once the typical curvature is developed, a glance at the patient's back suffices for the diagnosis. It is usually very easy to avoid any confusion with spinal deformities due to other causes. As the kyphosis in spinal caries depends upon the destruction of one, or at most of two or three, vertebræ, it appears more or less in the form of an *angular kink*, the apex of which is formed by one spinous process. All other changes in the shape of the spinal column, except those which result from accidents, are not merely kinks but *curves*, because they concern several vertebræ. There should never be any confusion with scoliosis and kypho-scoliosis, because lateral curvature is so predominant in these, but is only very exceptionally present in tubercular disease. Even if a vertebra is diseased asymmetrically, as occurs occasionally, and therefore breaks down more on one side than on the other, there is no real scoliosis, but always an essentially anterior kink, a gibbus. In rachitic bending of the spine, the result is more frequently pure or nearly pure kyphosis, and the deformity consists of a definite *curve* and not of *kink*. If a child, suspected of caries, is *carefully* suspended, by all its limbs, with the abdomen downwards, the back will bend in rickets, but not in caries.

(4) SPINAL CARIES WITH CORD SYMPTOMS.

If a patient with spinal caries becomes affected with *spastic paraplegia*, it obviously indicates compression of the cord, but simple loss of power of gait is sometimes ascribed to the vertebral disease, although it is really the result of an early spastic paraparesis. We may even go further; any definite *increase in the tendon reflexes*, in the parts supplied from below the lesion, must be regarded as a sign of commencing

pressure. Sometimes *symptoms of pain* predominate ; occipital neuralgia in "malum sub-occipitale," neuralgic pains in the arms in caries of the lower cervical vertebræ, crural neuralgia and sciatica when the lumbar spine is affected—sometimes also in cervical caries. These symptoms point to compression of the roots and should prepare us for the rapid onset of cord symptoms, or compel us to try to avoid them by means of permanent extension. The absence of dislocation of a vertebra in no way negatives the diagnosis of damage to the cord, which is often involved in an actual extension of the disease to the membranes, and is not compressed by displacement of the vertebra. In such cases there is, of course, but little to be expected from extension treatment.

In a case wherein all four extremities were completely paralysed, I found, at the *post-mortem*, nothing but tubercular pachymeningitis of the cervical cord, and no displacement of vertebræ at all.

B.—NON-TUBERCULAR INFLAMMATION OF THE SPINAL COLUMN.

We have, hitherto, been assuming that the spinal disease is of a tubercular nature, which, as a matter of fact, is true for the majority of cases. But there are various exceptions to the rule.

Certain changes in the spine, for instance, follow injuries, and the significance of these has loomed large since the prevalence of insurance against accidents.

An elderly man rolled down a small incline in his garden. He felt some pain in the lower portion of his cervical spine, but only kept his bed for a short time. Later on, his cervical spine began to bend forwards, and there developed a curvature which was something between an angular kink and a roundish kyphosis. There was no burrowing abscess, no pyrexia, &c., and the vertebra which formed the apex of the curve was not tender on pressure.

Did the patient suffer from tubercular caries of a traumatic nature, brought on by his fall ? It is possible, but experience shows that a similar clinical picture may develop without any tubercular change. The comparatively short period, during which pain was complained of, is very unlike tubercle. It is much more likely that the patient sustained a *compression-fracture* of the spine, and that the damaged vertebral body gradually broke up and sunk in ; and we may be quite reassured as to the further progress of the case, even if a permanent protuberance remains on the back.

The diagnosis may be very difficult in cases wherein the original trauma was slight, and the development of the curvature very slow, as previously mentioned (Chapter LXXVI). The cases in which the symptoms of pain persist for a long time also suggest spinal caries.

We either have to leave the diagnosis in doubt, or base it upon the presence or the absence of other tubercular manifestations, unless a skiagram or a burrowing abscess decides the matter.

A kink or a bend is not always the most prominent result of an injury. In rare cases, *rigidity* of the spinal column is the chief symptom, which may be associated with an extensive but slight kyphosis of the major portion of the spine. Bechterew has described such a case, in which bony union of the vertebral bodies was found. The accompanying symptoms, due to the spinal cord and the nerve roots, should be distinctive of this condition.

Another variety of vertebral disease may occasionally be confused with caries, namely **ankylosis of the spine**, better called *arthritis deformans of the vertebral joints*. It manifests itself by gradual stiffening of the spine, and by curvature. The disease has been especially described by Strümpell, and by Pierre Marie.

This disease is characterized by the simultaneous ankylosing or deforming process in other joints, and is often the consequence of some infective malady. I have seen it in association with chronic ankylosing arthritis of the elbow, wrist, one knee and temporo-maxillary joint.

Confusion with spinal caries is only likely to occur in the first stage of the disease, when the portion of vertebræ originally diseased —most frequently in the lumbar spine—is exceedingly painful. But the subsequent course of the disease, and particularly the involvement of various other joints, makes the diagnosis quite clear.

Gummatous periostitis in **tertiary syphilis**, by destroying the affected vertebræ, may produce a clinical picture very similar to spinal caries. The diagnosis must be based on the history, or on Wassermann's test, and on the result of specific treatment.

Finally, one should mention the rare occurrence of **acute osteomyelitis** of the spine, and that metastatic inflammation of the spine that has been observed after acute infective diseases, such as **pneumonia** and especially **typhoid fever**. The course of these diseases depends upon the virulence of the organisms. It is the duty of the practitioner to detect abscess development as early as possible, but this does not, however, occur in all cases.

CHAPTER LXXIX.

SPINAL CURVATURES.

ORTHOPÆDICS has, of late, become so much of a speciality, that not only the general practitioner but even the surgeon gladly leaves spinal curvature to this department. Expedient as this may be for therapeutics, because only an orthopædic institute can possess all the mechanical apparatus for the treatment of scoliosis, it is not so as far as diagnosis is concerned. To detect the beginnings of scoliosis, nothing is required beyond an observant eye and a plumb line. Nevertheless the strictures applied by Albert years ago, in regard to overlooking scoliosis, are equally applicable to-day. Perhaps lady doctors would have the advantage in the diagnosis of this condition, because females possess a keener eye for deformity than males. It is for this reason that the mother first detects that the "child has one shoulder higher than another," or that "the back or hip sticks out."

In considering the *causes* of spinal curvature, we must recollect, as Schulthesz has especially pointed out, that it is not a *clinical and etiological entity*, but is in most cases only a *symptom*. When the statics of the body are disturbed at any point, the spinal column provides for the restoration of the equilibrium. Shortening of one leg causes obliquity of the pelvis, and a corresponding scoliosis occurs to compensate for this disturbance (figs. 232 and 233). An abnormal inclination of the pelvis, due to flexion of the hip, is compensated for by an increased lumbar lordosis. These are *static curvatures*, and are recognized by their disappearance as soon as the pelvis is restored to its natural posture (figs. 232 and 233). Temporary curvatures are often due to some painful condition, the best example of which is sciatica (fig. 234), a matter to which we shall again refer. In other cases the curvatures are due to disturbances in the supporting power of the *muscles*. Thus we find considerable lumbar lordosis in progressive muscular atrophy (fig. 235); scoliosis in anterior poliomyelitis, in syringomyelia, and in Friedreich's disease (fig. 236). *Diseases of the thoracic organs* sometimes are at fault, as in the case of scoliosis which occurs in consequence of contraction after pleurisy, and especially after empyema. Heart disease with enlargement, by causing asymmetry of the thorax, may also lead to curvature of the spine.

We should only look in the *spinal column itself* for the origin of the trouble, if we have excluded all these causes. *Inflammatory diseases* play their part among these spinal changes. Caries leads mainly to kyphosis, but occasionally produces a slight lateral curvature.

Arthritis deformans of the lumbar spine may also cause lumbar kyphosis. Injuries may be responsible, for sometimes kyphosis is caused by a compression-fracture.

Finally there is a group of cases in which the change in form is due to a *congenital asymmetrical deformity of the spine*, such as a wedge-

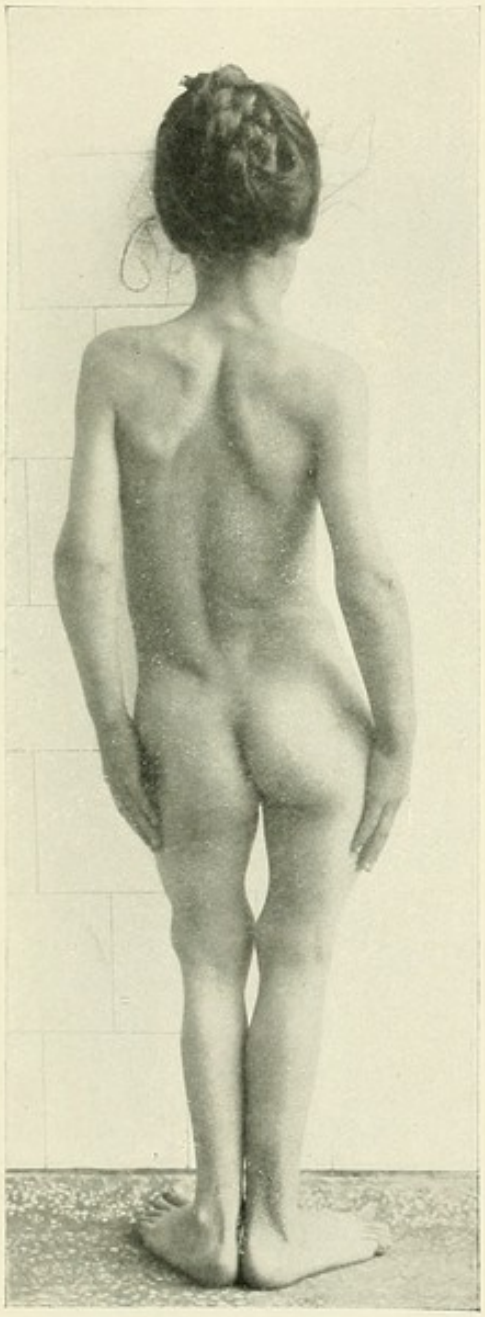

FIG. 232.—Lumbar scoliosis with convexity to the left, due to 4 cm. shortening of left leg.



FIG. 233.—Same case, after compensating for the shortening.

shaped outgrowth of a vertebra, with a supernumerary rib on the broad side, or fusion of two vertebræ on one side, with the absence of a rib on that side. If the cervico-dorsal portion is affected, the deformity manifests itself by one shoulder "*standing out*" (fig. 237). This congenital prominence of a shoulder may also be due to simple

muscular anomaly, or to a clasp-like bony communication between the scapula and the cervical spine. A skiagram is always required to elucidate these conditions. These deformities are mainly responsible for the so-called "numerical variations" of the spinal column, *i.e.*, they interfere with the ordinary subdivision of vertebræ and ribs into the separate segments (Dwight, Böhm). It still remains to indicate those forms of slight asymmetry which are responsible for ordinary scoliosis.

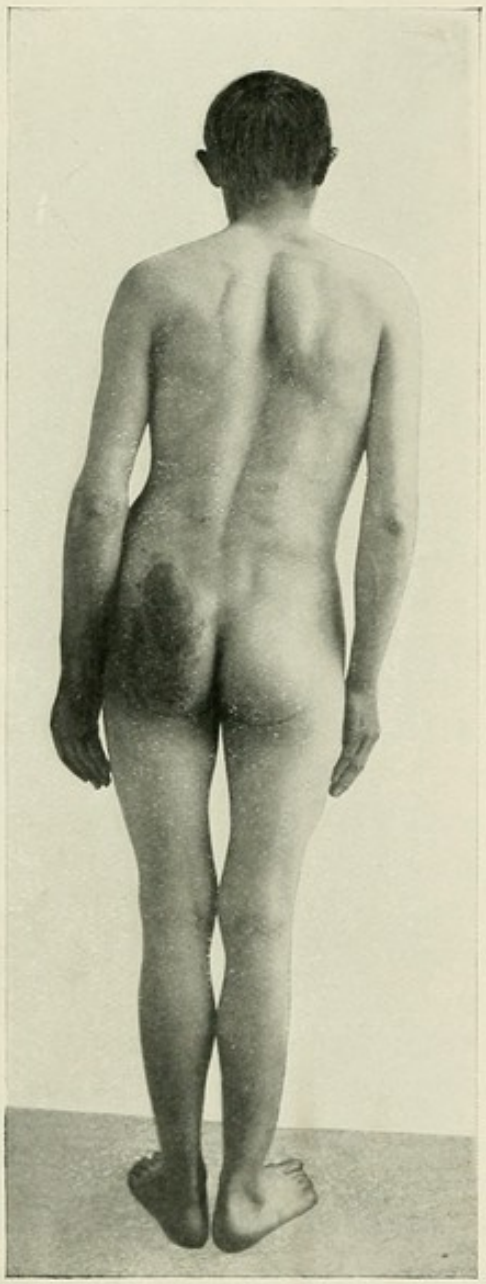

FIG. 234.—Scoliosis due to sciatica.

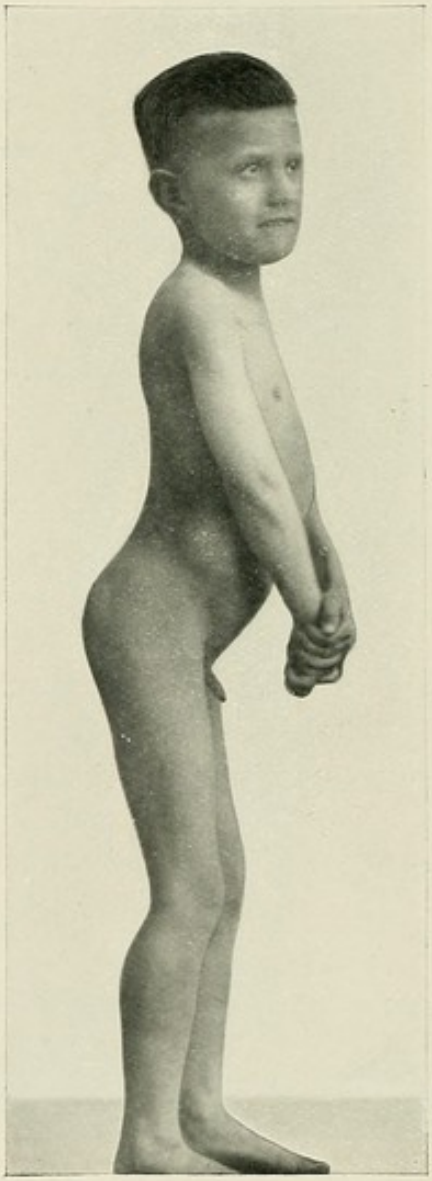

FIG. 235.—Progressive muscular atrophy with lordosis.

The further consideration of this subject comprises that which is usually understood by the term "*curvatures of the spine.*"

These curvatures are (1) symmetrical or antero-posterior, (2) asymmetrical or lateral.

(1) ANTERO-POSTERIOR CURVATURES.

These may either consist of an **abnormal flatness,** the bootmaker's type of spine, or of an increase in the normal curves, or, finally, of really abnormal curvatures. The increase of the normal curve in the lumbar region constitutes **lordosis** and in the back **kyphosis.** The mechanical and the nerve conditions already referred to are the principal causes, but rickets and osteomalacia should also be especially considered. Then there is the so-called "round back" which is



FIG. 236.—Friedreich's ataxia with scoliosis.

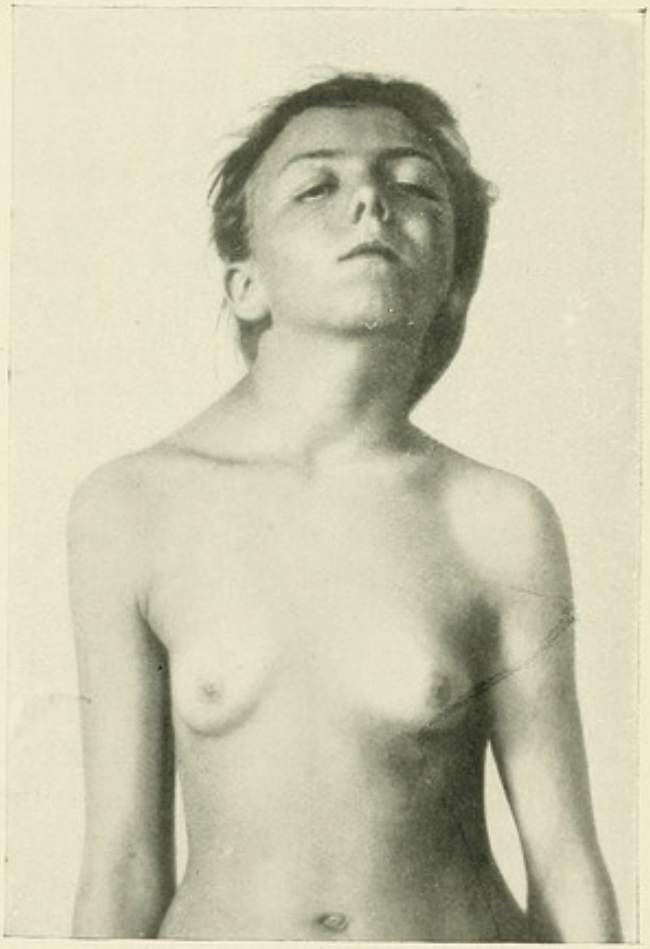

FIG. 237.—Congenital cervico-dorsal scoliosis with convexity to the right, and prominence of the shoulder, due to a symmetrical outgrowth of spine and ribs.

hereditary. Such abnormal curvatures as **lumbar kyphosis** usually depend upon rickets or osteomalacia.

The diagnosis of these antero-posterior curvatures is easy. It only requires some slight appreciation of form, and we will therefore not dwell on it any longer.

It is only necessary to remark that one must examine for lateral curvature in all antero-posterior curvatures. Slight scoliosis with definite torsion is often concealed behind an ordinary round back.

(2) LATERAL CURVATURES.

Lateral curvatures, or **scoliosis**, involve the practitioner in great responsibility, because they generally bring their own revenge for delayed treatment.

The patient should stand for examination, completely nude, or at least undressed as far as below the hips; the two feet must be held in the same posture, the arms must hang down loosely, and otherwise the whole attitude must be as unconstrained as possible. Then we look at him from the back, making an inspection from head to foot. We note whether the head is exactly over the mid-point of the feet, whether it is held obliquely or erect, whether the shoulders are at the same level, whether the scapulæ are at equal distances from the spine and stand out equally from the thorax. Our eyes follow the line of the spinous processes, and we can at once detect, especially in thin subjects, whether the furrow between it and the transverse processes is equally developed on both sides, or whether it is somewhat obliterated on one side and deepened on the other. We compare the distance of the arms from the body, in other words the two triangles of the waist, *i.e.*, the triangle formed by the arm with the outline of the body, and also the shape of the thorax, the position and shape of the hips, the level of the gluteal folds, and, finally, the shape and posture of the legs. Then the patient is directed to walk a few steps, in order to see whether he limps. After he has walked round the room, we tell him to resume his former position. This slight interruption in the examination has the advantage of showing us whether the posture observed at first is really the normal posture of the patient. This is a precaution which should not be omitted even in slight cases of scoliosis which can easily be straightened out, and especially not in cases of complete scoliosis (figs. 241 and 242). We next proceed to a more careful examination of the spinal column. We drop a plumb line (fig. 238) from the seventh cervical spine, and note whether it falls midway between the buttocks, and lower down between the feet. We thus find to which side the thorax is displaced, and the extent of the displacement in relation to the pelvis, and also the distance by which the convexity of the curvature deviates from the plumb line (figs. 238 and 239). We then feel the spine and mark on the skin the position of each spinous process with a pencil. This also gives the opportunity of observing whether there is any tenderness on pressure. We then proceed to test the movement of the spine, and we direct the patient to bend his back forwards, backwards, and to each side, with his knees close together. This examination, in the first place, will reveal any caries which may have been overlooked, for the movements are but slightly restricted and never painful in scoliosis,

whereas caries may always be recognized by painfulness and the limitation of movement by pain which bears no relation to deformity. But the examination of the back, when bending forward, teaches us something more. On inspecting the bent back from the nape of the neck downwards, we may be struck with the fact that one side of the

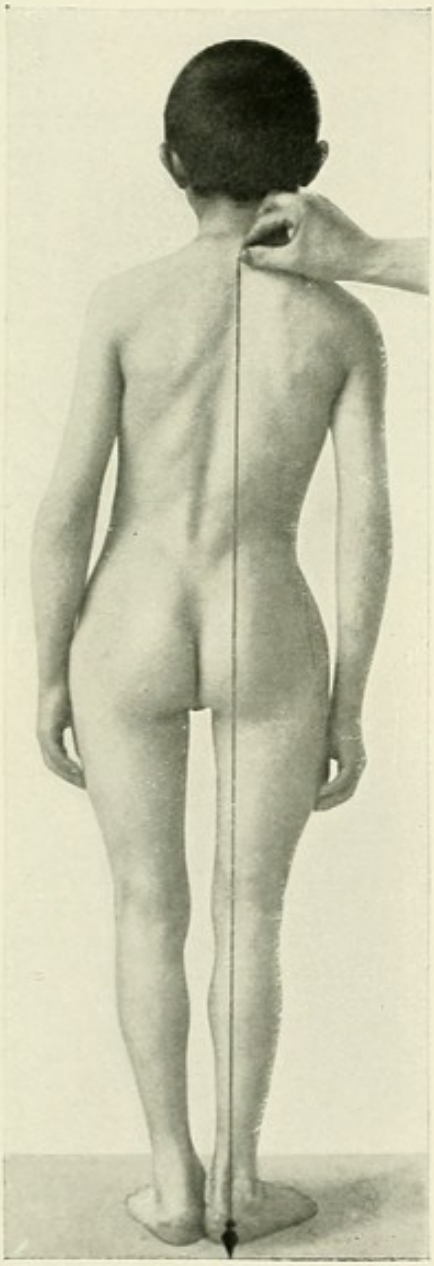

FIG. 238.—Rachitic, lumbar scoliosis with convexity to the left, and displacement of thorax to right, *i.e.*, to the side of the concavity (through over-compensation).

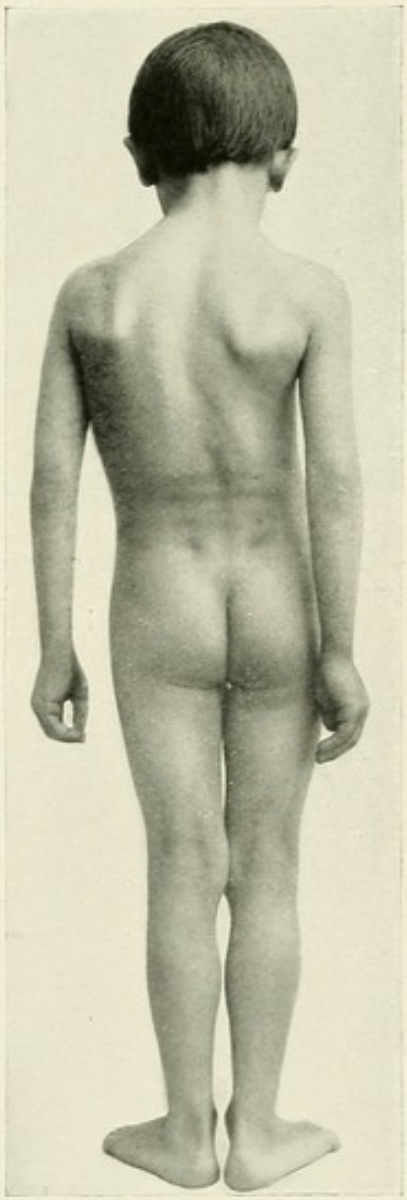

FIG. 239.—Dorsal scoliosis with convexity to left, and displacement of thorax to left, *i.e.*, to the side of the convexity.

thorax is higher than the other, that is to say, that there is protuberance of the ribs (figs. 243 and 245). This permits us to estimate the degree of torsion of the vertebræ, and the amount of the deformity. We can, however, usually detect the protuberance of the ribs when the patient is erect.

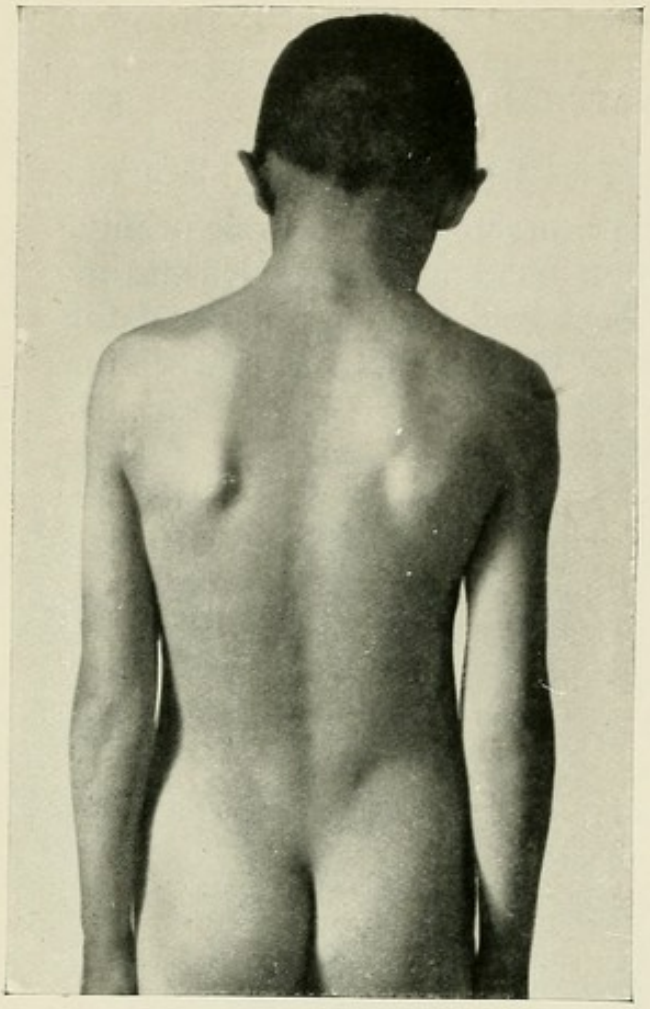

FIG. 240.—Complete scoliosis with convexity to left, displacement of thorax to right. Right waist triangle enlarged. Right axillary fold shortened.

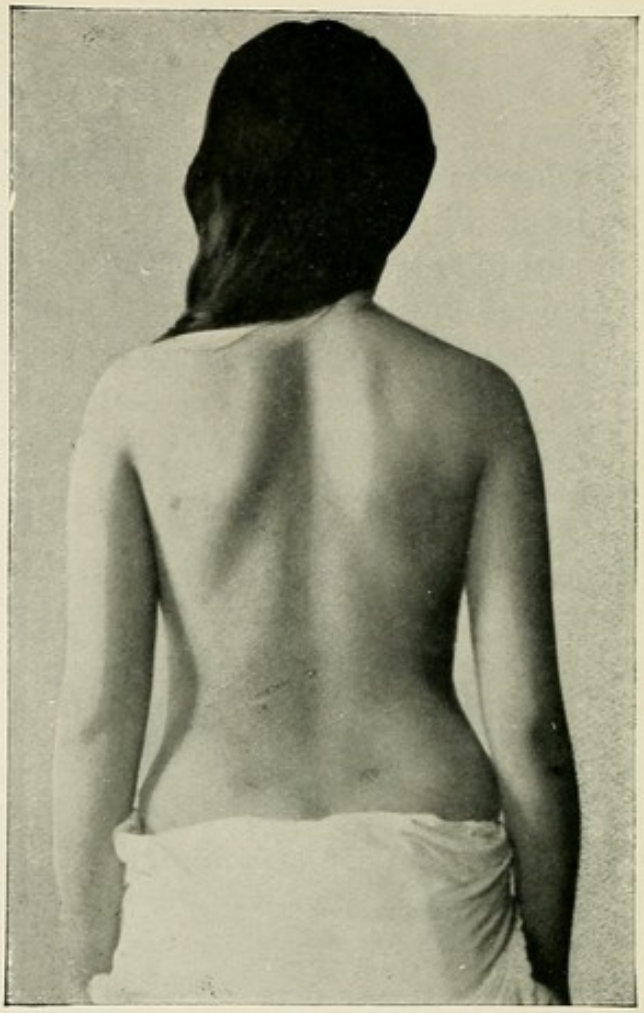

FIG. 241.—Lumbar scoliosis with convexity to left, of very slight degree; only recognizable by shape of waist triangle.

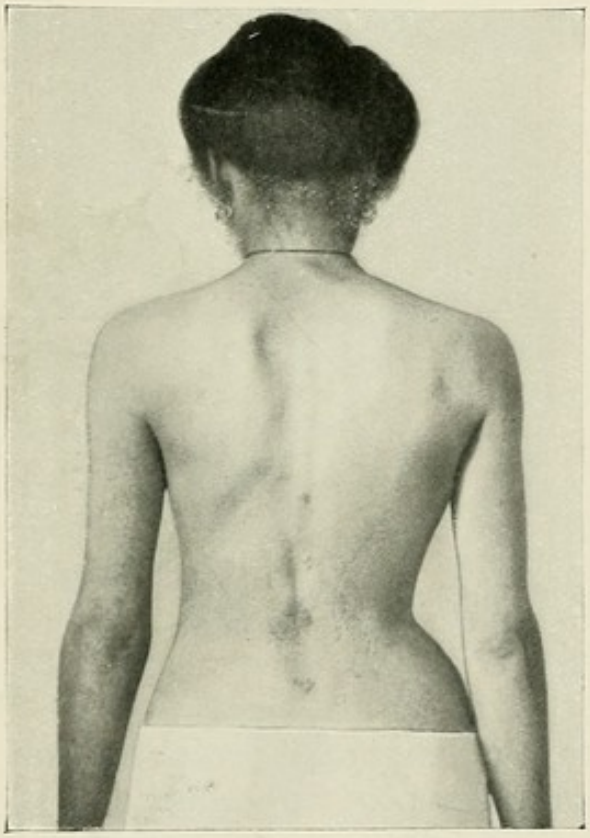

FIG. 242.—Lumbar scoliosis of severe degree with convexity to the left, and dorsal scoliosis with convexity to the right. Despite an apparently slight curvature of the spine, the right waist triangle is deeply indented.

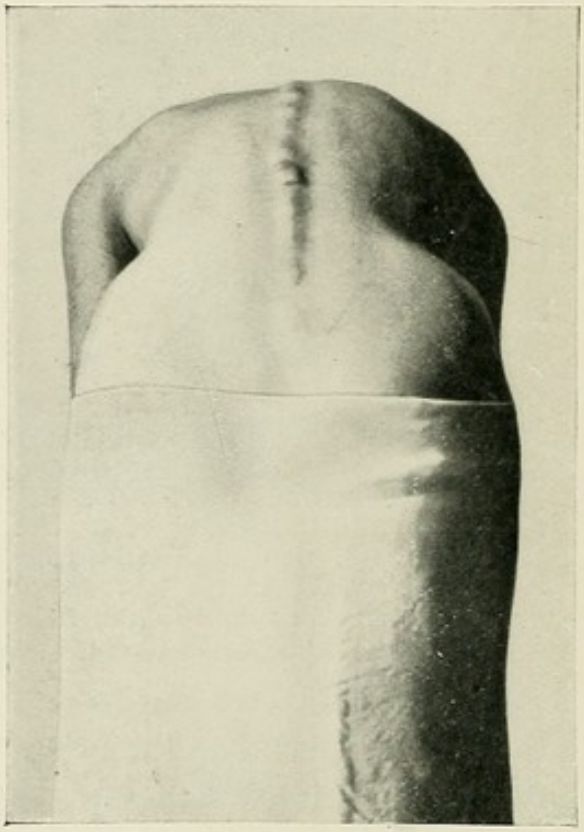

FIG. 243.—Same case as fig. 242. Pronounced protuberance of ribs on right side, despite an apparently slight lateral curvature.

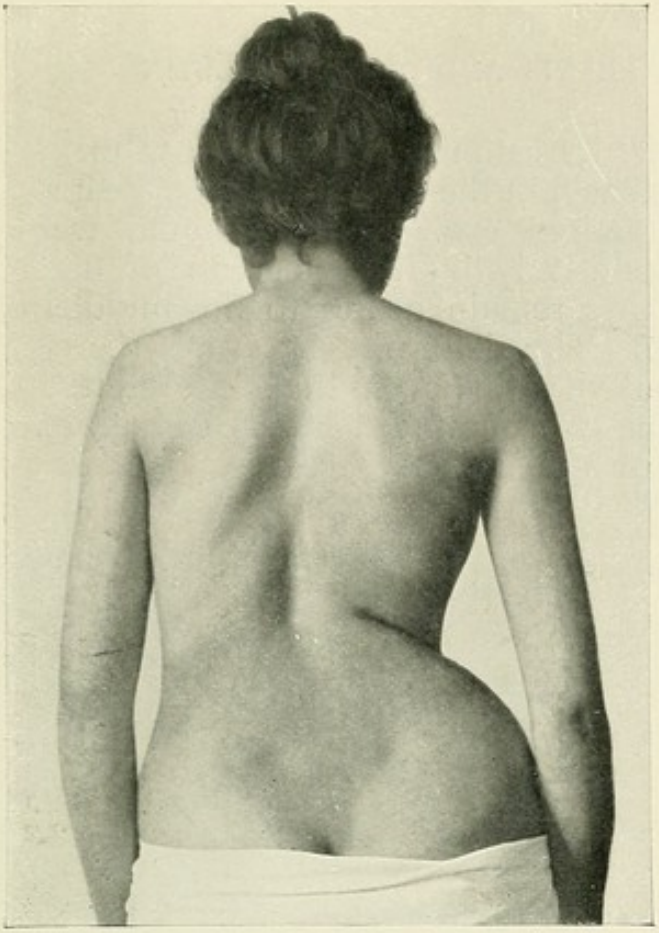

FIG. 244.—Severe lumbo-dorsal scoliosis, with convexity to the left and compensatory dorsal scoliosis with convexity to the right.

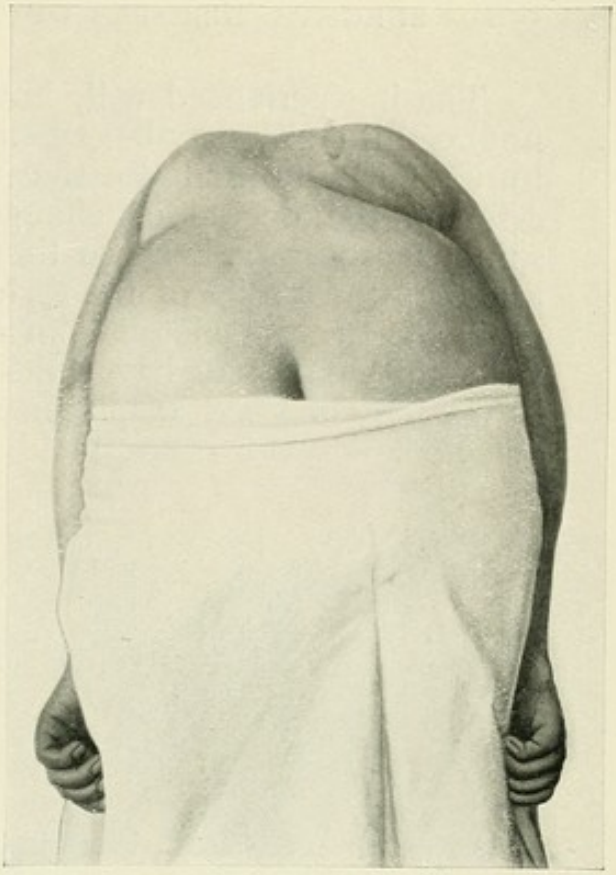

FIG. 245.—Same case as fig. 244. Lower protuberance of ribs to the left, upper protuberance to the right.

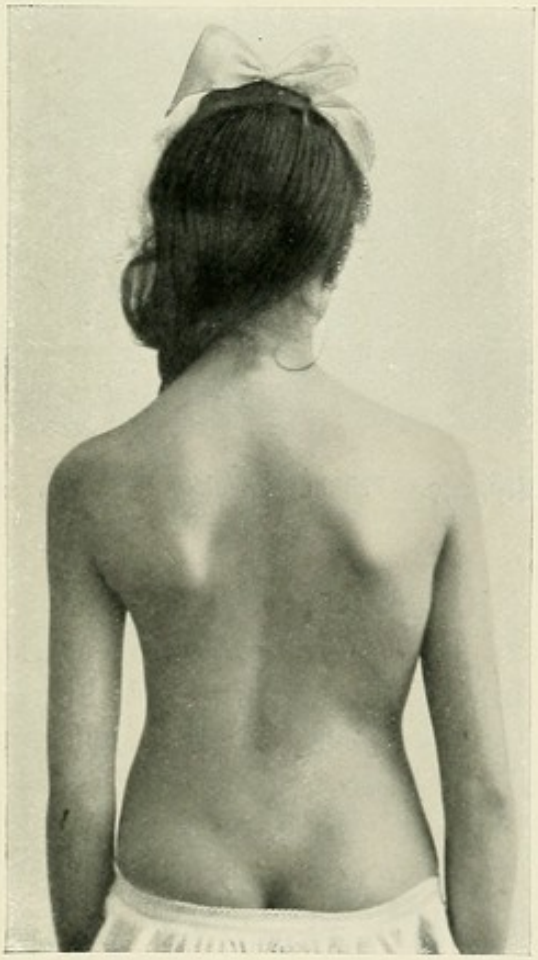

FIG. 246.—Primary dorsal scoliosis with convexity to the right. Mild case.

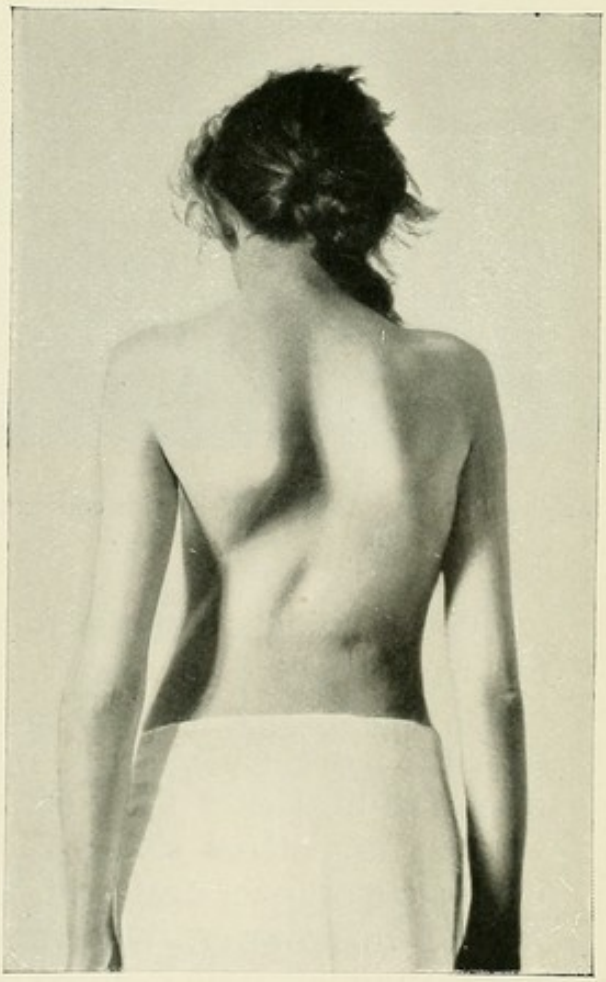

FIG. 247.—Primary dorsal scoliosis, with convexity to right. Severe case.

The inexperienced will, however, be astonished to see how pronounced it really may be, when the back, in the erect posture, appears to be fairly normal to the unpractised eye. Neither should we estimate the degree of change exclusively by the position of the spinous processes, because they always remain nearer to the middle line than the bodies of the vertebræ. The deformity is always more noticable on the skeleton from a front view than from the back, and the vertebral spine may have undergone a pronounced lateral deviation before any marked displacement of the spinous processes can be detected.

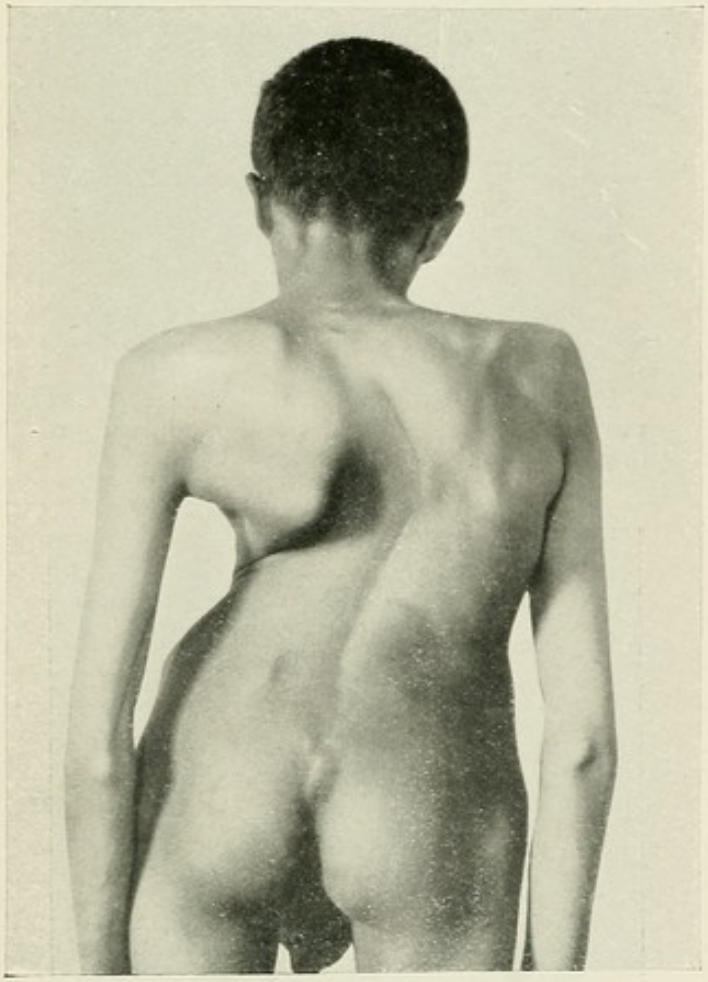

FIG. 248.—Primary dorsal scoliosis with convexity to the right. Very severe case.

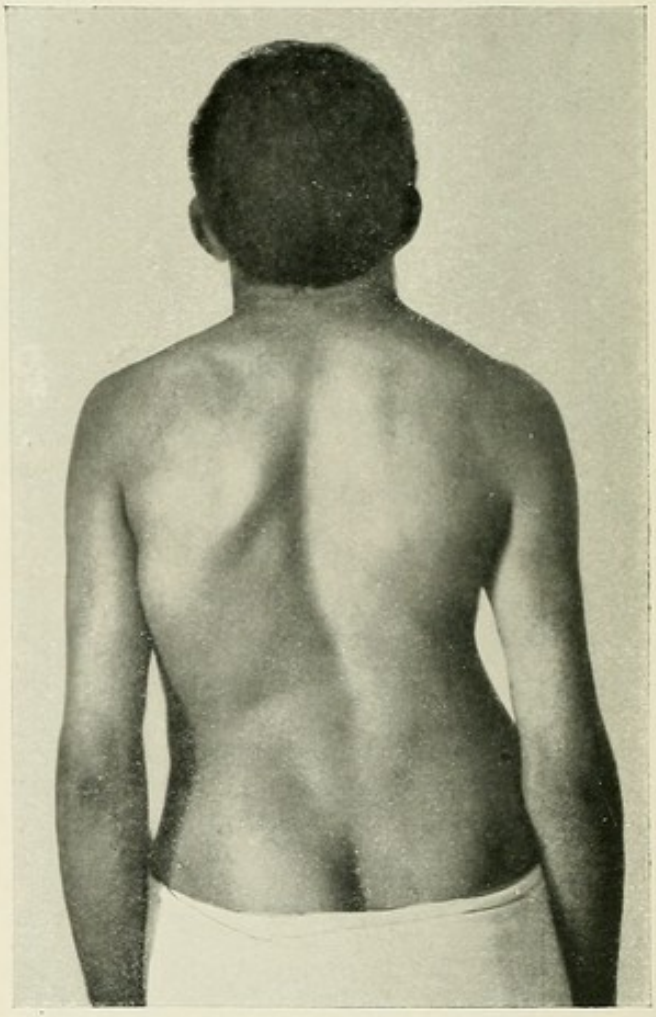

FIG. 249.—Primary dorsal scoliosis with convexity to the left.

The examination of the functions of the spinal column indicates, finally, the *stage* of the deformity. If all the movements are carried out symmetrically to the same extent, and if the deformity vanishes with the movements, or if it is only noticed occasionally, for instance when the muscles of the back are tired, the case is in an *early stage*, wherein no material changes in the spinal column have yet formed. Under appropriate treatment, this condition may be cured in a few weeks. If, however, the deformity is present in the same manner at every examination, but can be completely straightened out, actively by

muscular exertion or passively by suspension, the case is one of *mobile scoliosis* (figs. 250 and 251). Immediate treatment promises good results even here. We must not be content, however, with prescribing a tonic and giving general directions that the patient must not tire himself. We must either take the treatment in hand ourselves, energetically—and complicated apparatus may not be required in this stage—or we must send him to an orthopædic institute. If the deformity can only be partially straightened out, it is in a *position of contracture*; if it cannot be straightened out at all, the case is one of *fixed scoliosis*.



FIG. 250.—Mobile complete scoliosis with convexity to the left. Muscles relaxed.

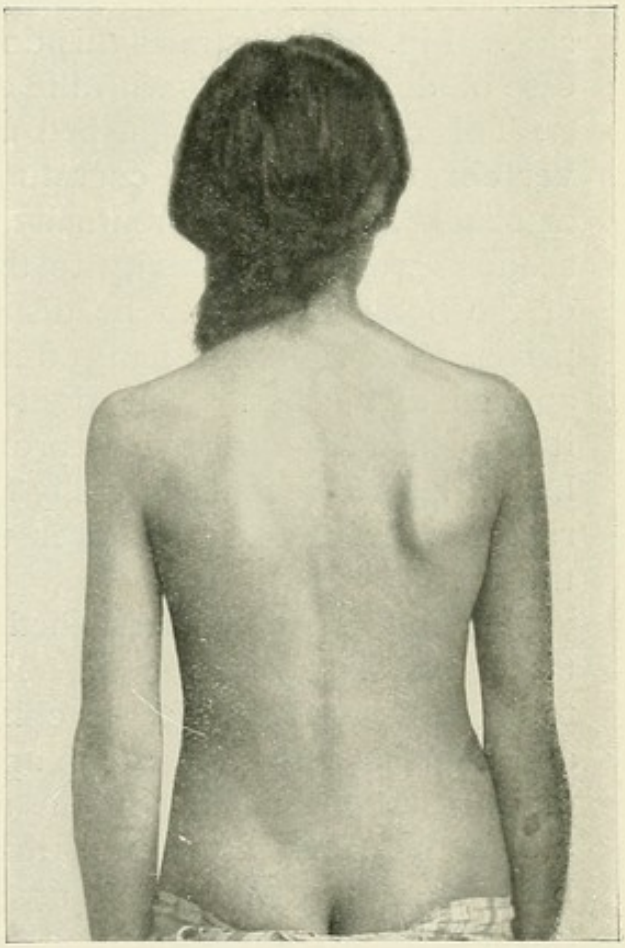

FIG. 251.—Same case, with the muscles tense.

We now have to consider *the form* of the scoliosis. If the whole spine constitutes one curve, we speak of **complete scoliosis**, which is usually *convex to the left*. It is recognized by the fact that the waist triangle on the convex side is diminished with sharp angles above and below, whereas on the concave side the triangle is enlarged and more deeply indented (fig. 240). In early cases the back is usually displaced to the left in relation to the pelvis.

In complete scoliosis the protuberance of the ribs is generally found on the concave side, *i.e.*, towards the right, in contrast to the condition in partial scoliosis.

If the curvature is mainly localized in the lumbar region, we speak of *lumbar* or *lumbo-dorsal scoliosis*. Here also the convexity is usually to the left (figs. 238, 240-245). The displacement of the back in relation to the pelvis is more pronounced than in the previous form, the waist triangle on the convex side is also diminished or filled out, the protuberance of the ribs is on the convex, *i.e.*, the left side. In slight cases the shape of the waist triangle is the only indication of the curvature (fig. 241). This form has a great tendency to be followed, in the course of time, by a compensatory curvature of the dorsal vertebræ in the opposite direction, *i.e.* towards the right, and, of course, a second protuberance of the ribs develops on the right side. Fig. 245 illustrates this double protuberance of ribs in a severe case of dorsal scoliosis with the convexity to the right.

This must be distinguished from **primary scoliosis of the dorsal vertebræ**, wherein the curvature has its *convexity to the right* (figs. 246-248), and which eventually becomes compensated by a lumbar scoliosis with its convexity to the left. The whole of the upper part of the body appears to be displaced to the right in relation to the pelvis. The right arm hangs free in the air, whereas the left is closely applied to the hip. The right scapula appears to project, because it is pushed forward by the protuberance of the ribs. On the other hand, the left scapula is really farther away from the body than the right one, because it lies over the flattened or retracted half of the thorax.

Having correctly ascertained the form of the curvature, our next task is to discover its *cause*. There is no difficulty in this if we are told by the mother that the child was late in walking and in talking, and that the teeth were late in appearing, and if we also find evidences of *rickets* still persisting in the skeleton. We may also obtain some indications from the form of the rib protuberance, for if the ribs are bent close to the spine this points strongly to rickets. Sometimes there are no indications of definite rickets, but other abnormalities of the skeleton, such as flat-foot or knock-knee, show that the cause must be ascribed to *late rickets*. In other cases, the examination of the brothers and sisters, or even a glance at the mother's back, may show that there is a *hereditary tendency*, which cannot be identified with rickets.

Finally, what is our position in regard to *school scoliosis?* There can be no doubt that the most frequent types of lateral curvature are commonest among school children, viz., lumbar or complete scoliosis with the convexity to the left and dorsal scoliosis with convexity to the right. On the other hand, we often see these types develop at an age before it is possible that the posture adopted in writing could have any effect. We must, therefore, assume that the

scoliosis produced in school develops on some pre-existing tendency thereto. Not only do the cramped posture of writing, the position of the copy-book, and the shape of the letters contribute towards the development of the curvature, but also the bad habit of always carrying the school books home under the same arm. Worse than all this, however, is the practice, which was universally prevalent up to a few years ago, of making children sit up straight for hours on forms without adequate supports for the back. No wonder that weak muscles of the back become tired and the spine sinks into a posture to which a pathological predisposition inclines it.

This predisposition probably depends upon an exaggeration of some slight asymmetry of the spine, normally present. But this must not be classed, without further consideration, with the condition previously referred to as "numerical variation," depending upon an essential mal-development, the significance of which is not quite clear.

PART VI.

SURGICAL DISEASES OF THE EXTREMITIES.

CHAPTER LXXX.

FRACTURES AND DISLOCATIONS OF THE CLAVICLE.

(1) If a patient is unable to raise his arm beyond the horizontal, after a fall on the shoulder or a fall on the arm which transmits its force to the shoulder, if he inclines his head towards the injured side (fig. 252), and if the shoulder appears to be drawn forwards and inwards, we involuntarily look to the clavicle, in the anticipation of finding a fracture in its outer half (fig. 252). The patient suffers extreme pain when the fracture is manipulated. But this striking picture is not always in evidence. In children especially, the fracture is frequently sub-periosteal—green-stick fracture. The displacement is limited to a slight angular kink, or may be absent entirely; while the power of movement may suffer no definite interference, and the arm may be raised vertically without any hesitation. The careful observer will, however, notice that the child takes care of his injured side when playing, and that he does not willingly allow himself to be led by the affected arm. But if the child has not been carefully observed, as is so often the case, the doctor is not consulted by the parents until the thickening, due to callus, has made its appearance.

(2) Injuries in the vicinity of the **sterno-clavicular joint** are equally easy to diagnose. These are, with few exceptions, dislocations, and are caused by dragging on the shoulder-girdle or pressure thereon. Inspection and comparison with the opposite side indicate without any difficulty whether the dislocation is forwards, as is most usual, or upwards, or inwards behind the sternum, which is the rarest variety. Dislocation of the sterno-clavicular joint is often

accompanied by other injuries, especially fracture of several ribs, when there has been severe compression of the thorax. The dislocation may easily be overlooked in such cases, because the fractured ribs and the contusion of the lung, which nearly always complicates these severe injuries, concentrate all attention.



FIG. 252.—Fracture of the right clavicle.

(3) **Injuries in the neighbourhood of the acromio-clavicular joint** are more interesting from the diagnostic point of view, because they are more difficult to recognize. The differential diagnosis concerns contusion, sprain, and dislocation of the joint, fracture of the acromion, and of the extremity of the clavicle.

(*a*) If there be no deformity, and pain is the only symptom, we have to distinguish between *contusion* and *sprain*. We may only assume the former when the joint has sustained a *direct* injury. We will probably find some evidence of this in bruising which has supervened, or even in some abrasions. If the injury was *indirect*, the case can only be one of sprain. If the pain is mainly a pressure pain, affecting the whole joint, it strongly suggests contusion, whereas, if it is elicited mainly on

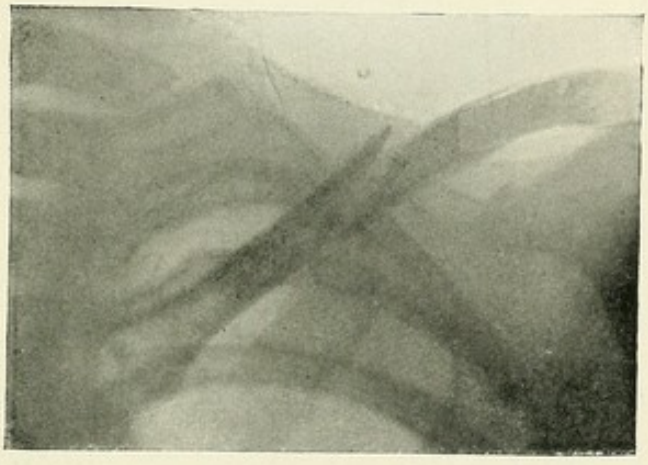

FIG. 253.—Fractured clavicle.

movement—raising the arm beyond the horizontal—and if the pressure pain is limited to the fold of the joint, it suggests sprain.

(*b*) A slight deformity, consisting of a little step-like ascent from the acromion to the clavicle, may be regarded as a *sprain*—although the condition is one of loosening of the ligaments which approximates very closely to a luxation. There is no sharp line of demarcation between a sprain and a subluxation. On the contrary, fractures of the end of the clavicle or acromin may be mistaken for sprains or contusions if they are periosteal, and therefore produce no dislocation. If there is also no crepitus on movement, nothing but a skiagram can demonstrate the presence of the fracture.

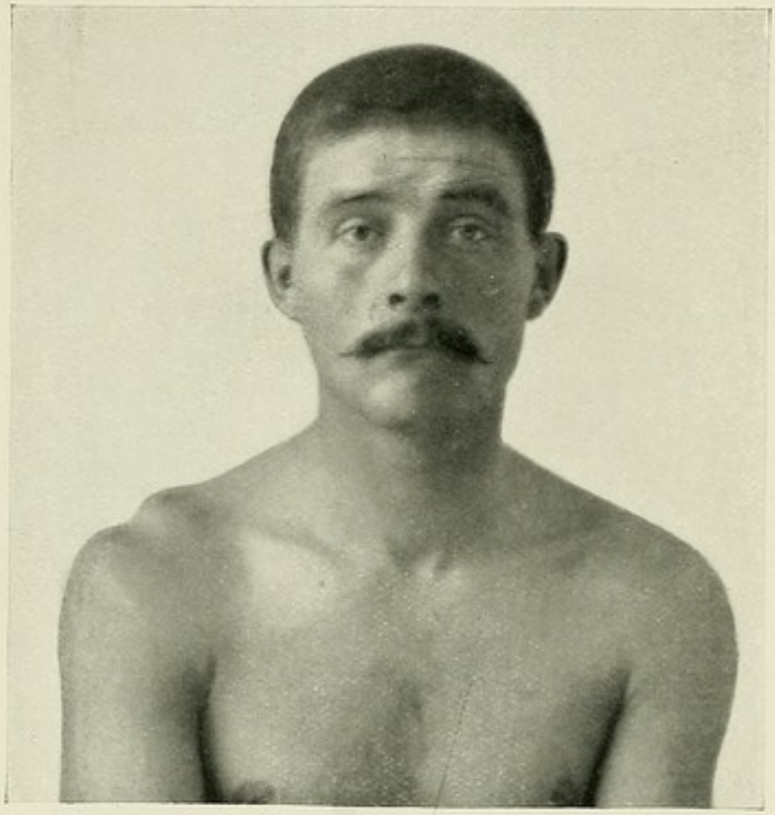

FIG. 254.—Right acromio-clavicular dislocation.

(*c*) If, however, we do find definite deformity—and this usually consists of a step-like drop of the shoulder (fig. 254), we must distinguish between (1) *fracture of the outer end of the clavicle;* (2) *acromio-clavicular dislocation;* and (3) fracture of the *acromion*. Some indication is afforded by the position of the maximum pain

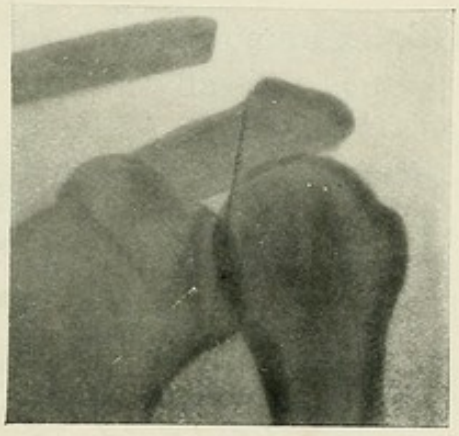

FIG. 255.—Skiagram of fig. 254 (taken from behind, and therefore, apparently reversed).

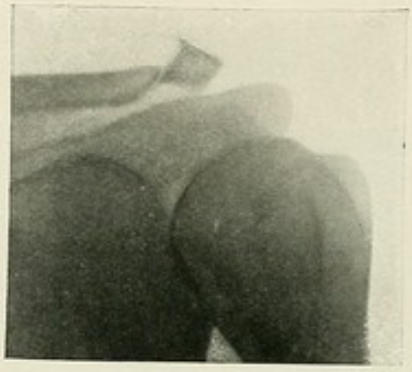

FIG. 256.—Detachment of distal end of clavicle.

on pressure and of the displacement. The palpation of both sides and comparative measurements will usually clear up the condition. In doubtful cases the irregular shape of the prominent edge and the crepitus permit of the distinction between fracture and dislocation. The differential diagnosis has usually to be made between dislocation and fracture at the end of the clavicle. In addition to the results of palpation and measurement, we must also take into consideration the visible external deformity. A very striking step-like formation suggests dislocation rather than fracture. The severity of the pain on pressure is also of some value, because it is more pronounced in fracture than in dislocation. The skiagrams are easy to interpret, and are conclusive (figs. 255 and 256).

There may be some difficulty in interpretation in the case of children, because the lateral cartilaginous portion of the clavicle is transparent. A fracture of the cartilage may therefore be mistaken for a dislocation. This error may be avoided by controlling the skiagram by a comparative measurement of the median fragment.

It may be noted finally that the distal end of the clavicle has occasionally been displaced *under the acromion*, and even *under the coracoid process*. These rare injuries are quite recognizable by those who are skilled in palpation.

CHAPTER LXXXI.

FRACTURES AND DISLOCATIONS ABOUT THE SHOULDER-JOINT.

A MERE glance and an examination of the power of movement usually suffice to make a diagnosis in the case of a patient who has fallen upon his shoulder, or upon his arm, the latter outstretched to avert the fall. If we employ palpation in addition, it is hardly possible to err, unless an unusually large hæmatoma renders an accurate examination impossible. The fact that so many errors of diagnosis are actually made is due to a want of anatomical consideration. A skiagram, which we may adopt as our last resource, ought only to confirm an already made diagnosis and reveal a few details, but should never be a substitute for diagnostic reflection.

We place the patient before us, with the upper part of his body undressed, and direct him to slowly lift both arms from the side. If the injured arm can be raised perpendicularly, the shoulder-joint is

free, and there is certainly no serious injury of the shoulder or shoulder-girdle. In the case of sub-periosteal fracture of the clavicle in children, free movement may still persist, as stated in the previous chapter.

If the arm on the injured side can only be raised above the horizontal line in a hesitating manner, we should let it down again gradually. If the patient lets it drop from the horizontal position with a sudden grimace of pain, we may be almost positive that the collar-bone is broken.

If the arm cannot be raised at all, or only very slightly, or if the

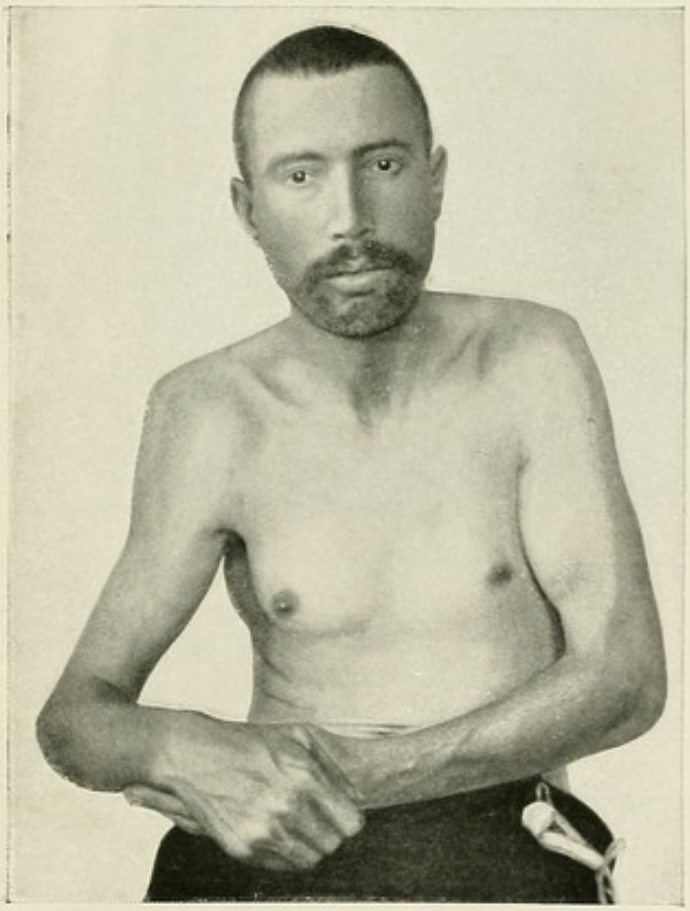

FIG. 257.—Sub-coracoid dislocation of humerus. Arm abducted. Axis deviated inwards. Shoulder flattened.

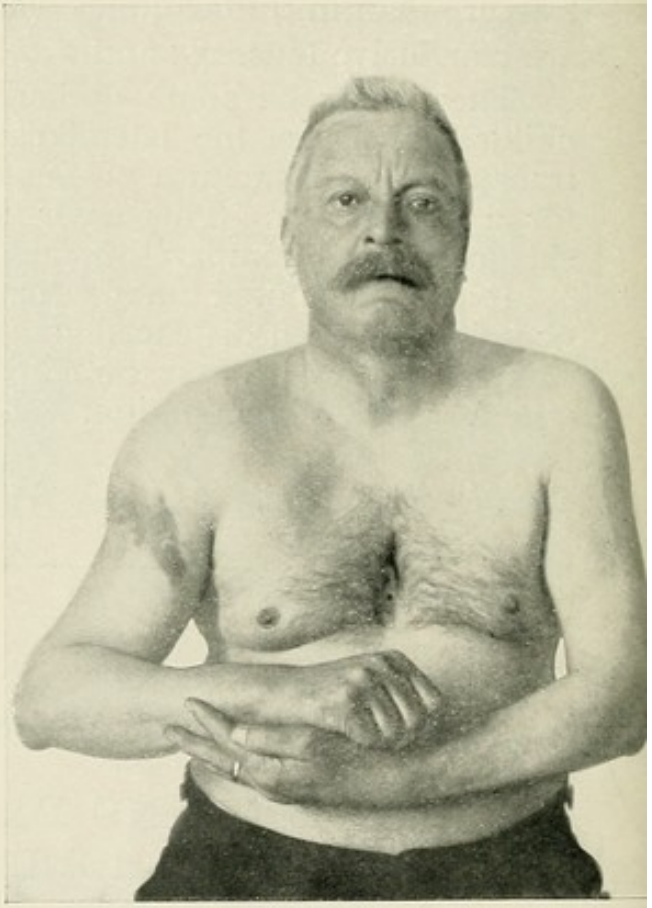

FIG. 258.—Axillary dislocation of humerus. A greatly abducted. Axis deviated inwards more th in adjoining case. Shoulder bulged by a la hæmatoma.

patient supports it with his other hand, it indicates the presence of a severe injury—a dislocation or fracture about the shoulder-joint.

In dislocations it may be possible, in some circumstances, to raise the arm as far as the horizontal already on the second day, with a certain amount of pain. In these cases, however, it will be observed that the movement chiefly takes place at the clavicular joint.

If the axis of the humerus is deviated inwards so that the continuation of its line would intersect the clavicle, and if the elbow is abducted from the side of the body, the case is either one of dislocation or of fracture. If the curve of the shoulder is flattened (fig. 257) it is a

dislocation ; if the curve is retained, it is a fracture (fig. 259). This flattening may, however, be concealed by an extravasation of blood (fig. 258) ; but if dislocation be present in such a case, pressure with the finger below the acromion would show that the glenoid fossa is empty, in comparison with the other side. This sensation of the emptiness of the glenoid fossa is so unequivocal that if it is not present, we may positively exclude dislocation in any doubtful case. Unless a hæmatoma had attained an extraordinary size, it could not prevent the detection of the gap in the normal position of the head of the humerus. Should any doubt still remain, we must try passive movements. If these are limited in certain directions, the case is certainly one of dislocation ; if they are normal or unusually free, especially in the direction of adduction and outward rotation, the case is one of fracture. If the glenoid cavity is empty, but crepitus and preternatural mobility are present, the rare combination of fracture with dislocation exists.

A.—DISLOCATIONS.

Having diagnosed a **dislocation,** we have next to decide whether it is of the axillary (sub-glenoid) or sub-coracoid variety ; other forms are exceedingly rare. If the arm is greatly abducted from the side (fig. 258) and the head of the humerus is distinctly felt in the axilla, the dislocation is axillary. If the arm is less greatly abducted and the head can be felt and seen under the coracoid process (fig. 257), the dislocation is sub-coracoid. The fact that the head of the bone can be seen and felt in Mohrenheim's fossa must obviously dispel any doubt about the presence of a dislocation.

We purposely do not lay too much stress upon the demonstration of the head of the humerus in a misplaced position, because a dislocation can, and should be, recognized without this sign. When there has been much extravasation of blood with infiltration of the soft parts, especially in an axillary dislocation, it is often impossible to make this examination without an anæsthetic, and many a dislocation would be overlooked if the diagnosis depended upon the discovery of the head of the humerus in an abnormal position.

In the absence of any considerable extravasation of blood, an indication for distinguishing between the two forms of dislocation may be obtained from the amount of *increase in the circumference of the shoulder-joint,* as measured through the axilla and over the acromion. If the increase does not exceed 2 cm., the dislocation is sub-coracoid, but if it is as much as 4 cm. the dislocation is axillary. In these cases, however, palpation is quite easy, and if there is much extravasation of blood the sign is of doubtful value.

One who is able to recognize these two important varieties of dislocation of the shoulder will have no difficulty in detecting the rare forms, wherein the head of the humerus is *in front, under the clavicle*

(subclavicular dislocation) or *above the coracoid process* (supra-coracoid dislocation) or *upwards and backwards* (sub-acromial dislocation) or *backwards and downwards* (infra-spinous dislocation). We must always be guided by the three above-mentioned cardinal signs, (1) absence of the head of the humerus from its normal position, (2) diminished range of passive movements, and (3) the presence of the head in an abnormal position, a sign which can, as a rule, be easily demonstrated in the forms last noted.

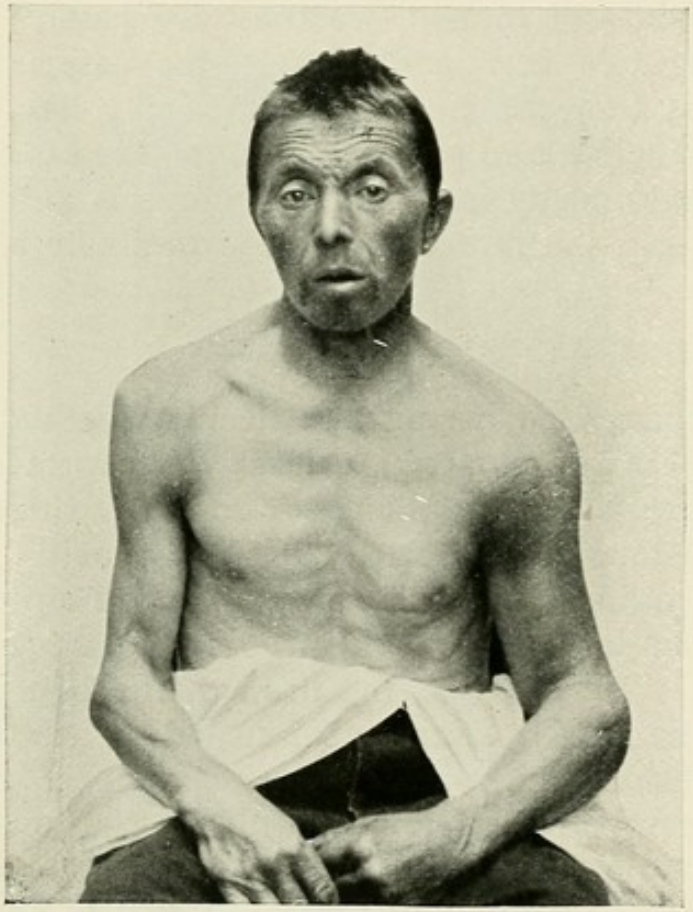

FIG. 259.—Fracture through the tuberosities. Arm abducted, but curve of shoulder maintained (after Kocher).

B.—FRACTURES.

If the head of the humerus is in its normal position, and passive mobility is increased, or remains normal, while active movements are quite impossible, and the power of the shoulder is lost, we diagnose a **fracture**. This may be confirmed by feeling, or even by hearing *crepitus* on manipulation. This symptom is, of course, conclusive when present, but its absence is not in any sense an argument *against* fracture. The lower fragment may be so much displaced that it no longer rubs up against the upper one, or the crepitus may fail owing to impaction of the fragments, or to the sub-periosteal position of the fracture. In cases of separation of the epiphysis in young people, the crepitus is nothing more than a soft grating which may easily be overlooked.

Displacement of the lower fragment often furnishes further confirmation of the diagnosis of fracture. This fragment may be in a position of abduction or of adduction, and may also be completely displaced, either backwards or forwards. We have already studied the *position of abduction*, in which the elbow projects away from the side, and in which the axis of the humerus is directed towards the centre of the clavicle (figs. 259 and 263), because of its similarity with the usual posture of the arm in dislocation. The *position of adduction* is indistinguishable from the normal posture of the arm, and therefore can only be recognized on a skiagram (fig. 265). The *forward*

displacement of the shaft of the humerus is of greater importance. This displacement is recognized by the fact that the axis of the arm, when looked at from the side, does not go through the acromion, but in *front* of it. If there is any doubt about this, we can always feel that the margin of the lower fragment presses, as a sharp edge, against the anterior surface of the shoulder circumference. If the skin itself is impaled by the lower fragment, so that a dimple forms, there can be no possible doubt about the existence of a fracture. The same applies *mutatis mutandis* to the rarer forms, in which the humerus is displaced backwards.

In some cases nothing abnormal beyond a diffuse swelling is visible on inspection, and neither unnatural mobility, nor crepitus, can

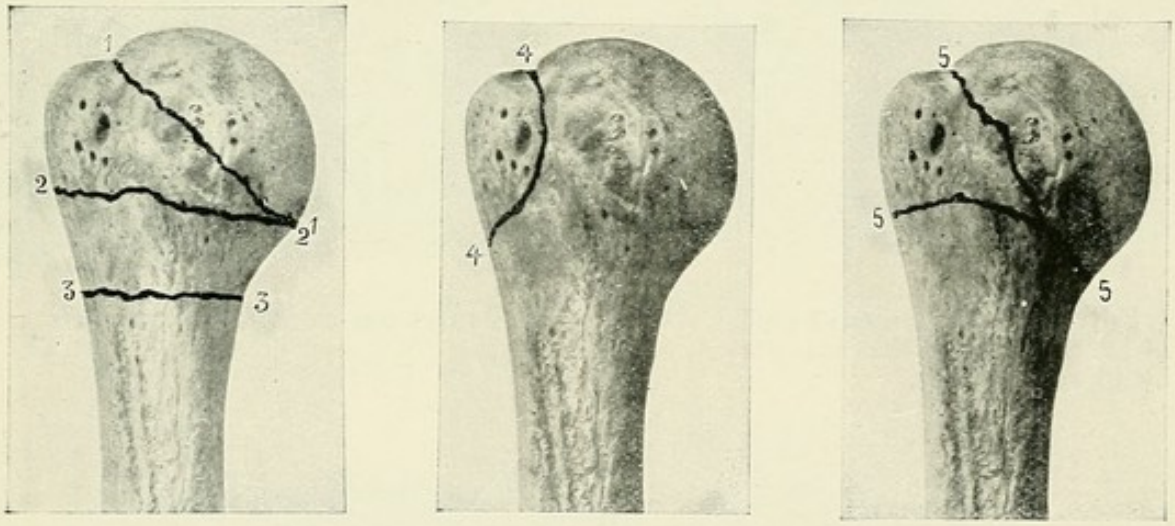

FIG. 260.—The most frequent varieties of fracture at the upper end of the humerus.

1. Fracture of the anatomical neck.
2. Fracture through the tuberosities.
3. Fracture below the tuberosities.
4. Fracture of the great tuberosity.
5. Y-Fracture.

be detected, owing to the impaction of the fragments. Comparative measurements of the length of the humerus from the acromion to the external epicondyle may also fail to give any positive indication. If it were not that the persistent loss of power pointed to some severe injury, one would be inclined to be content with the diagnosis of contusion of the shoulder. In such cases we are assisted by the presence or absence of "fracture-pain." We press, with equal force, the tips of two or three fingers under each acromion. A circumscribed severe pain resulting from this pressure points to fracture. Then we test whether axial pressure elicits pain; this is done by pressing the elbow upwards, with counter-pressure over the shoulder. In recent cases, the presence or absence of pain on axial pressure is decisive, for or against fracture respectively.

If there is no displacement, this pain on axial pressure may be very indefinite, and disappear after twenty-four hours, although pain on local pressure continues.

It is never justifiable to attempt any extensive movements under

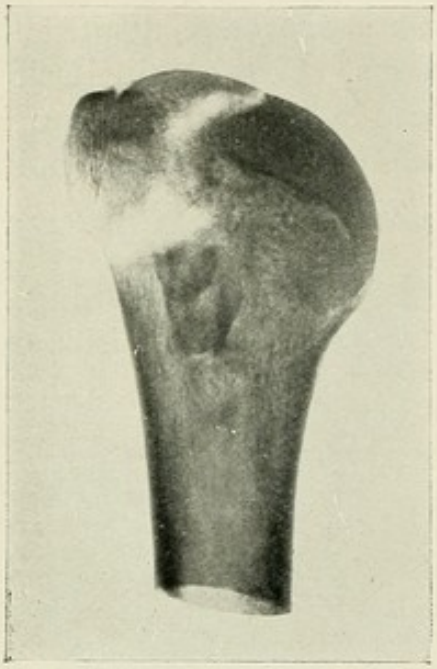

FIG. 261.—Shattering of head of humerus (patient was run over by railway carriage).

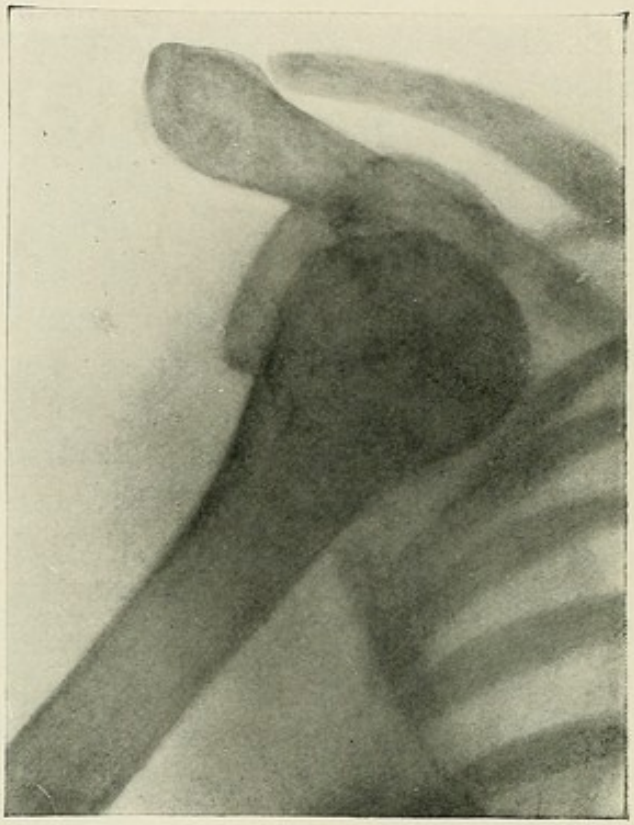

FIG. 262.—Sub-coracoid dislocation.

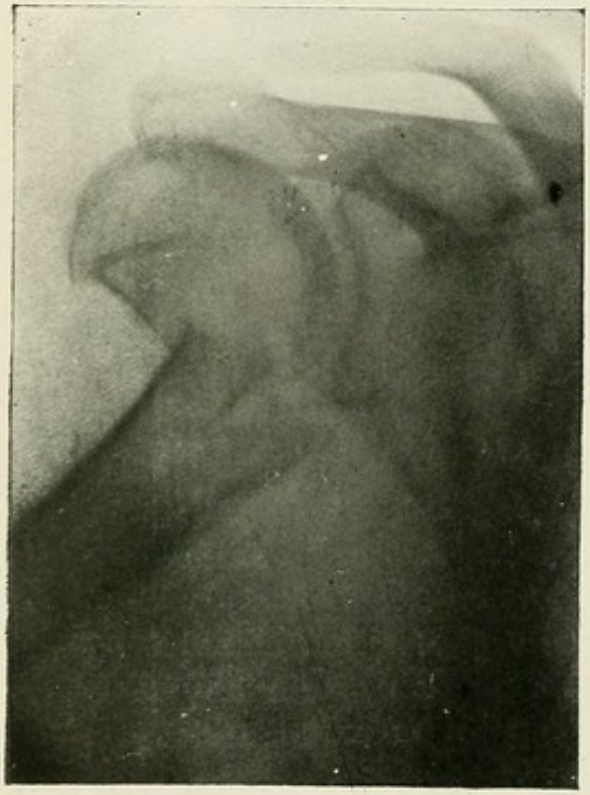

FIG. 263.—Fracture of humerus, through tuberosities, in position of abduction, as in dislocation (*cf.* fig. 262).

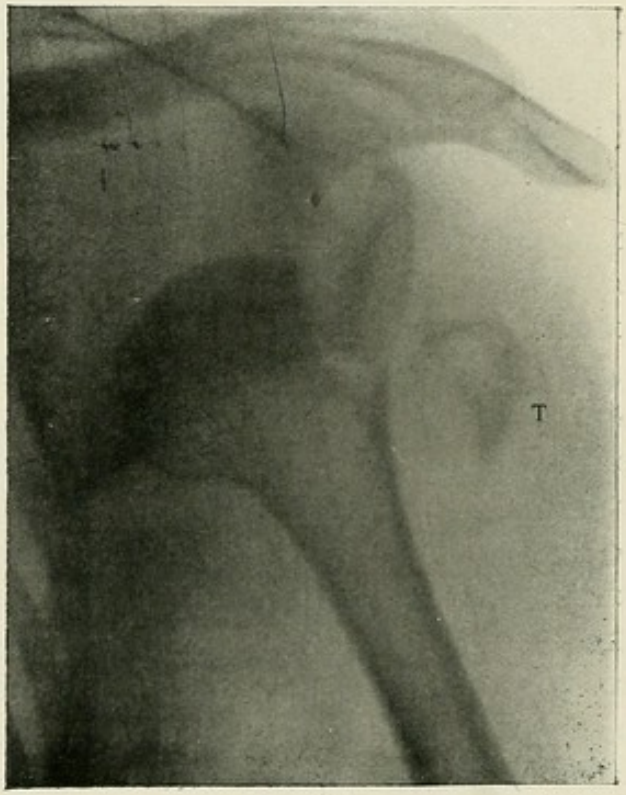

FIG. 264.—Axillary dislocation with detachment of great tuberosity.

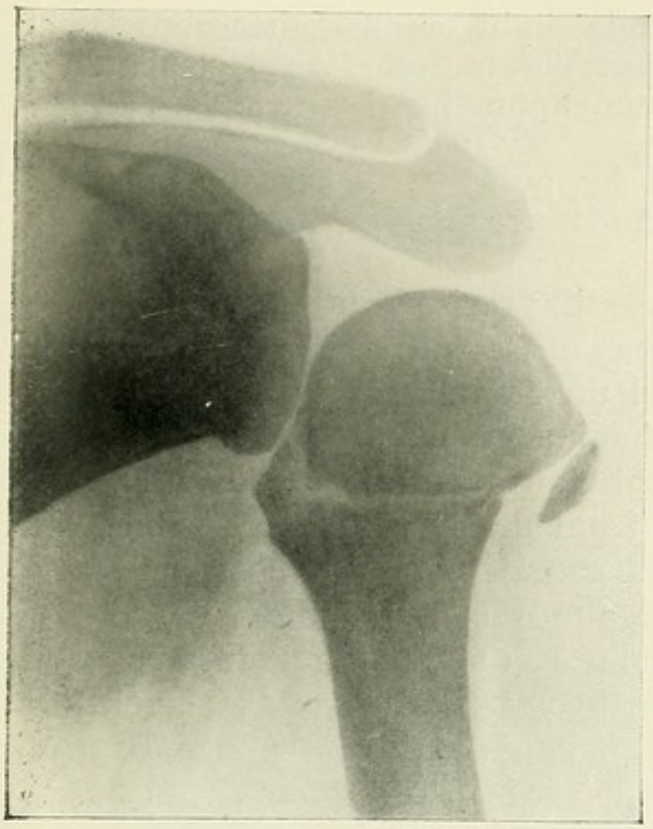

FIG. 265.—Fracture of humerus through tuberosities, in position of slight abduction. Also fracture of great tuberosity, indicating Y-fracture.

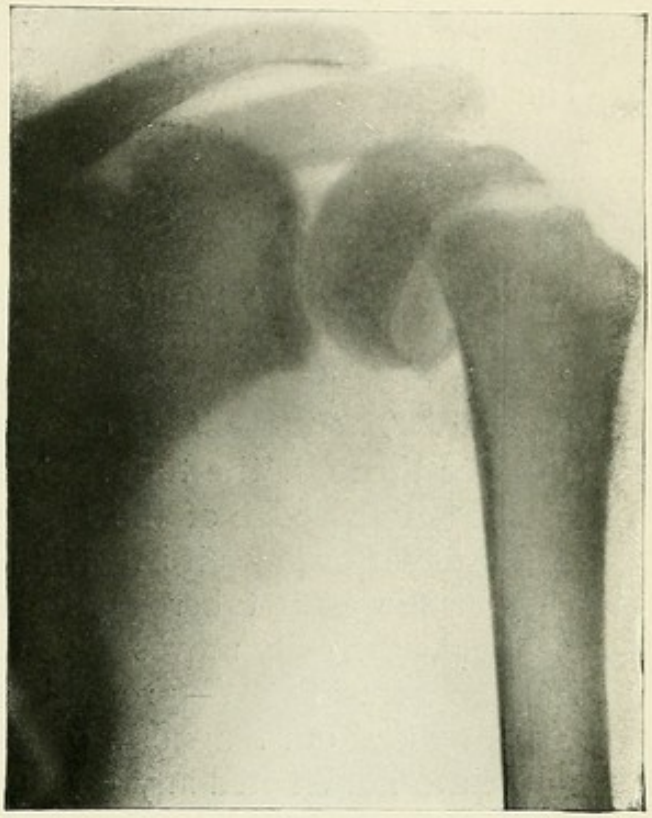

FIG. 266.—Fracture of humerus through tuberosities in position of adduction.

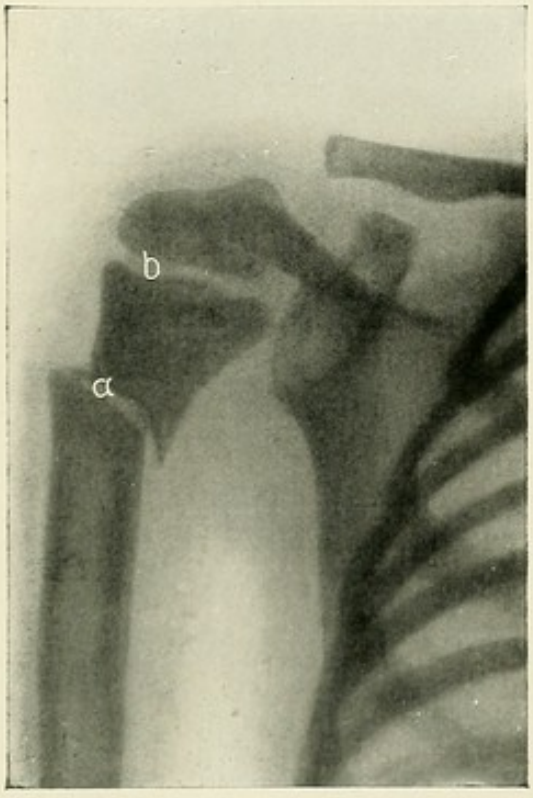

FIG. 267. — Fracture of humerus, below tuberosities: (a) line of fracture; (b) epiphyseal line.



FIG. 268.—Fractured great tuberosity in a reduced sub-coracoid dislocation.

an anæsthetic when the displacement is slight or altogether absent. Such may result in causing a very undesirable amount of displacement. The diagnosis of fracture can be based upon the complete loss of power and the pain on pressure. The variety of the fracture can be ascertained by direct palpation and by noting whether the great tuberosity does or does not follow the movement of the bone on rotating it.

We are now in a position to diagnose the precise form of fracture, if we take into consideration the typical lines of fracture shown in fig. 260.

It is only possible actually to feel the fracture when it is extracapsular. Therefore if the edge of a fragment is felt the fracture must either be **through the tuberosities**, or **below the tuberosities.** The distance of the edge of the fragment from the joint indicates which of these two varieties it is. If the edge cannot be felt, one must test whether the great tuberosity follows the movements of the bone. If the great tuberosity moves with the humerus on rotation, the fracture must be intracapsular—probably a **fracture of the anatomical neck**, assuming that our diagnosis of fracture is confirmed by crepitus. But if we have not elicited any crepitus, and have only based our diagnosis on the presence of pain on axial pressure, there may be an impacted fracture between the tuberosities which is the more frequent event.

But if the great tuberosity does not move when the humerus is rotated, the choice lies between the fracture which goes through the tuberosities, and the fracture which runs below them. Even if we cannot feel the edge of a fragment, the diagnosis can be made with considerable accuracy from the position of the maximum pain on pressure.

Fracture of the metaphysis (between the epiphysis and the diaphysis) caused by sudden pressure, for instance, by a blow in the direction of the axis, produces the least symptoms. We will describe this form of fracture in connection with the radius, but Iselin has shown that this variety also occurs at the upper part of the diaphysis of the humerus. The diagnosis can only be made from the local pain on pressure.

If the **great tuberosity is detached as an isolated fragment**, it naturally does not follow the humerus on rotation, but in such a case there is no pain on pulling or pressing on the axis of the limb. This detachment is usually a complication of a dislocated shoulder (figs. 264 and 268), and the signs of dislocation are therefore predominant. The complicating fracture can only be recognized, apart from a skiagram, if we obtain crepitus or are able to feel the detached great tuberosity through the skin. An isolated fracture of the great tuberosity, without dislocation, can be detected by the circumscribed pain on pressure if the displacement is slight. If the displacement is greater and the patient is thin, it can be seen that the shoulder is flattened out and broadened, as viewed from the front. There will

also be two distinct bulgings—the one behind representing the detached tuberosity, the one in front representing the somewhat anteriorly displaced head of the humerus.

As the external rotators (supra- and infra-spinatus and teres minor) are inserted into the great tuberosity, active external rotation becomes impossible, and the arm can, at most, be raised as high as the horizontal. This fracture sometimes occurs, indirectly, through muscular contraction.

It is only in thin subjects, and when there has been little extravasation of blood, that it is possible to suspect clinically a **Y-shaped fracture**, from the combination of symptoms of the lines of fracture 1 and 2, or 2 and 4 (fig. 260). The symptoms of **separation of the epiphysis** resemble those of fracture through the tuberosities.

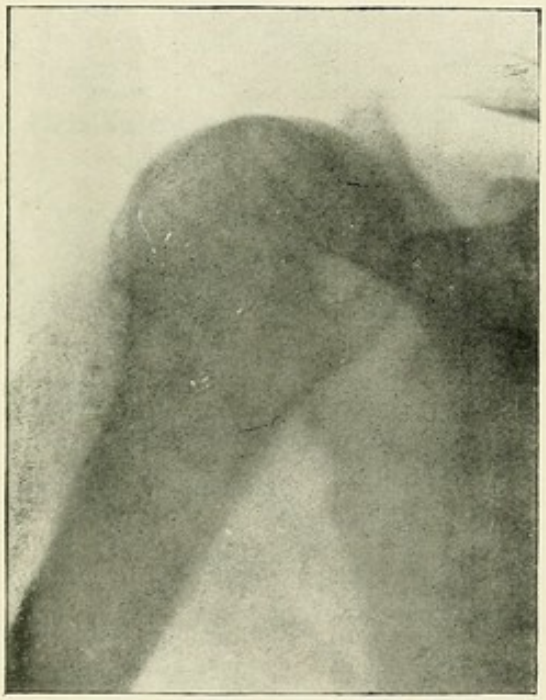

FIG. 269.—Fracture through the tuberosities. Taken from the front. No apparent displacement.

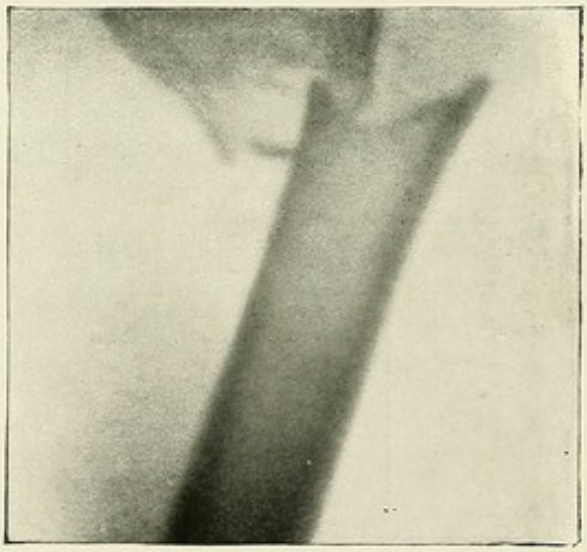

FIG. 270.—Same case. Taken from the side. Displacement evident.

Special mention should be made of *separation of the epiphysis*, in infants during delivery, and *separation of the epiphysis in infants with congenital syphilis*, owing to syphilitic osteo-chondritis. The loss of movement in the arm is the most striking symptom in these children—so-called "pseudo-paralysis."

If the shoulder is flattened and the head of the humerus is approximated to the thorax, just as in the case of dislocation, but if, at the same time, there are increased mobility, crepitus and pain on axial pressure as in a fracture, though nothing can be found wrong in the humerus, we should think of a **fracture of the neck of the scapula**, more especially of detachment of the articular process and coracoid process. Confirmation of this diagnosis is furnished if the deformity is corrected by displacing the humerus to the side and pressing upwards, and by the return of the deformity immediately the pressure is relaxed.

Figs. 261 to 268 indicate the skiagraphic appearances. The importance of taking a lateral view (if possible with the arm abducted) is shown by comparing Figs. 269 and 270.

We should only be content with the diagnosis of **contusion** or **sprain**, if nothing is yielded by an examination, carried out as here directed, whether the injury be direct or indirect. We append to this chapter a summarized table which will facilitate diagnosis in any given case.

Curve of shoulder flattened	Glenoid fossa can be deeply pressed into; head of humerus to be felt in an abnormal position.	Passive movements limited in certain directions (adduction).	(1) **Dislocation of humerus** (usually axillary or sub-coracoid).
		Passive movements free.	(2) **Dislocation with fracture.**
	Glenoid fossa cannot be deeply pressed into; head of humerus not felt in an abnormal position.	Head of humerus shows nowhere circumscribed pain on pressure (not even through the axilla), but the scapula is painful on pressure through the axilla. Coracoid process follows the movements of the arm. The whole shoulder region can be displaced upwards, but immediately sinks downwards again.	(3) **Fracture of neck of scapula.**
		Circumscribed pain in head of humerus on pressure.	(4) **Fracture of humerus with position of abduction.**
Shoulder curve retained	Curve over shoulder can be deeply pressed in; passive movements limited; head of humerus can be felt in abnormal position	.. ..	(5) **Dislocation of humerus with hæmatoma.**
		No pain on axial pressure; loss of power moderate; no local pain in bone on pressure; pain about the capsule.	(6) **Sprain of humerus.**
		No pain on axial pressure. Severe circumscribed pain on pressure over great tuberosity; active outward rotation, *nil*. Rarely tuberosity can be felt to be movable.	(7) **Fracture of great tuberosity.**
		Pain on pulling or pressure in long axis; local pain on pressure, especially through axilla; great tuberosity follows rotation; severe loss of power.	(8) **Fracture of head or anatomical neck.**
	Curve over shoulder cannot be pressed in; passive movements free; head of humerus not felt in abnormal position.	Ditto, but the pain on pressure through axilla is felt in scapula and not in head of humerus (see also above).	(9) **Fracture of neck of scapula.**
		Ditto, but pain on pressure at level of tuberosity, also demonstrable from outer side; loss of power slight or disappears rapidly.	(10) **Impacted fracture through tuberosities.**
		Ditto, but great tuberosity does not follow rotation; lower fragment often displaced anteriorly; anterior margin can be felt through deltoid; loss of power more than in 10, but in children may be slight.	(11) **Free fracture through tuberosities** (separation of epiphysis) either without displacement or in a position of adduction, or displacement anterior.
		Ditto, but local pain on pressure below the tuberosities; site of fracture clearly felt from the axilla; loss of power very great.	(12) **Fracture of humerus below tuberosities** (surgical neck).

CHAPTER LXXXII.

INFLAMMATORY PROCESSES ABOUT THE SHOULDER-JOINT.

INFLAMMATION about the shoulder is situated, apart from rare exceptions, in the *bursæ*, *the joint*, or in *the bones*.

A.—DISTINCTION BETWEEN BURSAL AND JOINT DISEASE.

The *subscapular bursa* and the *bursa between the tuberosities* are only dilatations of the capsule of the joint, and require no special attention, because they are never diseased independently. The *subcoracoid bursa* is too small to be of any importance. The *bursa under the deltoid* is, however, of importance pathologically. It lies between the deltoid muscle, the capsule of the joint and the humerus, and is often subdivided into two parts, an upper, the *sub-acromial bursa*, and a lower, the *sub-deltoid bursa proper*.

How can we distinguish between an effusion into this bursa and an effusion into the joint ?

In the first place, by *inspection*. If the sub-deltoid bursa is filled up, it raises the deltoid muscle from off the joint and the humerus, especially at its external and anterior portions. Küster has pointed out that this bulging is best recognized by looking at the patient from behind and above, and comparing the two shoulders. On the other hand, an intra-articular effusion does not make the curve of the shoulder any more pronounced, because even a tensely filled capsule is unable, for anatomical reasons, to lift up the deltoid to any considerable extent. If the deltoid muscle bulges to a great distance downwards, an intra-articular effusion is at once excluded, and we must assume that the effusion is in the deltoid bursa. If the effusion in the joint is so great that it causes a visible swelling, this swelling will also manifest itself where the joint is least covered by muscles, *i.e.*, in the posterior region, and also in the diverticulum of the capsule along the biceps tendon.

This does not imply that the shoulder-joint which contains an effusion does not appear to project away from the body more than on the healthy side. But this is due to the fact that an extensive effusion presses the humerus and all that covers it somewhat away from the body. This broadening of the shoulder, as seen from the front is, however, quite different from the protuberant bulging just described in connection with effusion into the bursa. The outline of the shoulder is otherwise retained.

If, on palpation, it appears that it is something like a tense cushion under the deltoid and over the bone which causes the enlargement of the shoulder, the case must be one of a bursal effusion. But if we at once come upon the humerus under a muscle of normal thickness, and the shoulder is nevertheless widened, as seen from the front, the humerus must be displaced by an articular effusion.

A *bursitis* is only painful on pressure over the area of the bursa, but an arthritis is painful over the whole extent of the joint, especially if pressure is made directly over the capsule, *i.e.*, at its posterior and inferior regions.

Loss of power is another piece of evidence in favour of disease of the joint.

In disease of the shoulder-joint, as in that of other joints, there is always the reflex attempt to keep the joint at rest, and allow its function, as far as possible, to devolve upon some other joint. In the hip this "muscular fixation" is at once manifest as a limp, because the joints of the lumbar vertebræ only make a poor substitute for it. But in the shoulder, the joints at the two extremities of the clavicle are able to compensate for it, to a considerable extent, and thus conceal the loss of movement. We must, therefore, examine for loss of power, bearing in mind the behaviour of the scapula and clavicle. In the ordinary way, the scapula does not participate in the movement of the shoulder until the arm is raised above the horizontal. But if the scapula participates before the arm reaches this level, it is obvious that there must be some limitation of movement in the shoulder-joint. A steep position of the clavicle and the approximation of the shoulder to the middle line, also signify limitation of movement. Fig. 271 (left-sided muscular fixation of the shoulder-joint) illustrates this latter symptom very clearly. If this stiffness is only occasional, *e.g.*, when the patient is tired, or if it disappears under anæsthesia, it is purely of a muscular nature. If some force is required under the anæsthetic to overcome the stiffness, it indicates that definite changes have already occurred, especially contraction of the capsule and adhesions between the head of the humerus and the glenoid fossa. If the joint remains entirely fixed, even under the anæsthetic, there are either very old-standing fibrous adhesions, or bony ankylosis exists.

The patient chiefly notices this disability, whether it be due to the muscle or fibrous tissue, in the movements wherein the rest of the shoulder girdle cannot act as a substitute—*e.g.*, in adduction of the arm to the middle line behind the back. Interference with this movement is sometimes the first complaint in tubercle of the shoulder-joint.

There are three conditions which we must guard against, in examining the function of the shoulder-joint. The first has been included under the general term of "*joint neurosis*," and usually occurs in the form of *hysteria*.

A "neurosis of a joint" may occur in children, especially in little

girls. If the patient has sustained an accident and looks forward to compensation, it is dignified with the designation of "traumatic neurosis." We cannot investigate here the respective parts played in this condition by deliberate exaggeration and by involuntary auto-suggestion. These, no doubt, vary in different cases. But the fact is that many patients who assert that they can hardly lift their arm to the horizontal are often able, within a few minutes, to raise it quite vertically, provided that the neurotic habit is not too deeply rooted within them. As a rule there is no interference with passive movements, and this, of course, excludes the possibility of any serious injury to the joint. But we must be careful not to fall into the second source of error, viz., a *genuine paralysis*.

A workman dislocates his shoulder. It is promptly reduced by a doctor, but still remains powerless ; the patient cannot raise his arm.

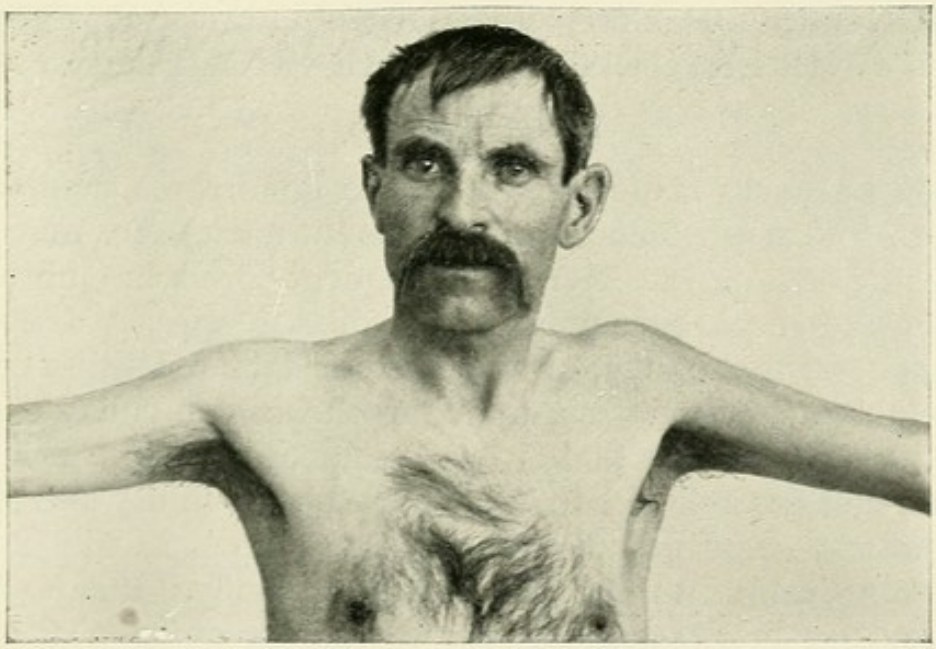

FIG. 271.—Approximation of the level of the shoulder to the middle line, and steep position of the clavicle, when the arms are raised, signs of stiffness of the shoulder (early stage of arthritis of shoulder).

At first the doctor thinks of some damage to the joint through the injury. Then he thinks that the patient may be malingering, because the passive movements are quite free. Examination, however, shows that the deltoid does not contract at all when the movements are being tested, and that the reaction of degeneration is present. The patient has, therefore, sustained a *paralysis of the circumflex nerve*, as a result of his dislocation.

Malingerers and hysterical patients usually contract their muscle somewhat, in order to show their "good intentions"; whereas in paralysis this is impossible. But *paresis* may cause great difficulty, because a certain amount of voluntary contraction occurs, just as in malingering. We can generally escape from this difficulty, however, by examining with the faradic and galvanic currents, and by testing

the sensation in the area supplied by the circumflex nerve—*i.e.*, over the deltoid muscle.

If we base our differential diagnosis between bursitis and arthritis of the shoulder-joint on what has already been said, it will follow that the only movement which is hindered in bursitis is the one wherein the inflamed bursa is compressed between the acromion and the humerus—*i.e.*, raising the arm from the side; the other movements are quite free. But when the joint itself is inflamed and its function is interfered with, all the movements are more or less limited, both active and passive.

Finally, it should be mentioned that *inflammatory changes in the axilla* (lymphadenitis) may also interfere with the movements of the joint.

B.—DIAGNOSIS OF THE VARIOUS FORMS OF BURSITIS AND ARTHRITIS OF THE SHOULDER.

(1) BURSITIS.

In rare instances acute infections, like gonorrhœa, acute articular rheumatism and staphylococcic infections (furuncle), &c., may give rise to bursitis by metastasis. The most frequent forms are, however, the **traumatic** and the **tubercular.** If the disease appears directly after a contusion of the shoulder, or after the constant repetition of a slight trauma—including any unaccustomed work which involves the deltoid muscle—we may assume that it has a traumatic origin. But if there has been a considerable free interval between the injury and the onset of the bursitis, or if the disease has come on gradually and quite spontaneously, we must think of tubercle, especially if this is supported by a hereditary predisposition, and by the previous history of the patient.

Occasionally the bursitis is not primary, but has been caused by the rupture into the bursa of an extra-articular focus in the bone. Positive information can only be furnished by a skiagram.

(2) ARTHRITIS OF THE SHOULDER.

In discussing the etiology of this condition, it is necessary to distinguish the acute from the chronic cases.

(*a*) *Acute inflammation of the shoulder-joint* may be one symptom of **acute articular rheumatism.** Such a case would be left to the physician, but we must remember that there is a complete chain of transitional forms—from the purely serous polyarthritis of rheumatism to the suppurative inflammation of pyæmia—which, under certain circumstances, may require surgical treatment. The most important of these is **scarlatinal arthritis,** which often attacks the shoulder; and

we must be careful lest we compromise the functions of the joint by delaying incision too long. **Gonorrheal arthritis** is another transitional form between rheumatism and pyæmia, and is usually recognized by the fact that only one joint is affected. This variety should be thought of, if the patient has outgrown the stage of children's ailments, but has not yet learnt how to avoid the gonococcus. But one must never forget that this micro-organism may occur in childhood (especially in little girls)—*Gonococcus insontium.* **Pyæmic arthritis of the shoulder** is mostly met with in puerperal infections, but may occur in any pyæmic disease.

(*b*) The diagnosis is much more difficult in *chronic arthritis of the shoulder.* It is most important, from the therapeutic point of view, to decide whether it is **tubercular** or not.

In the first place one has to consider **traumatic arthritis of the shoulder.** The histories of these cases are very similar, with slight variations. A middle-aged or elderly man has sustained a sprain of the shoulder, or some severe injury, such as a dislocation, which has been properly reduced. The patient may, of course, be a female, but the condition rarely happens in this sex. The original pain disappears quite normally, but there is no restoration of the power of the joint. Attempts at movement remain painful, and they are often attended by creaking and grating. Pain frequently radiates towards the back of the neck and the elbow. On examination, it will be found that the joint is more or less stiff, and that the capsule is distinctly painful on pressure; but there is not sufficient effusion to permit of recognition. If untreated, the condition may persist for weeks and months, but in slight cases it rapidly yields to proper treatment, especially if the patient is otherwise well, and has not instituted a claim for damages. In old people, in rheumatic and gouty subjects, this traumatic arthritis of the shoulder may develop into one of the varieties of "chronic rheumatism," which proves refractory to all treatment.

If this disease has not followed the injury, but has come on gradually some time after the subsidence of the immediate effects of the accident, we should think of *post-traumatic tuberculosis.*

The more trifling the injury, and the more pronounced the inflammatory symptoms, the more naturally will this diagnosis suggest itself. Sometimes we can do nothing but give a test injection of tuberculin, or wait and watch the case—which is equally good. A skiagram can only help the diagnosis if changes in the bone have already occurred, but as these changes can never be excluded, this method of examination should never be neglected. In such cases, we may assume with the greatest probability that the injury has merely caused a latent tuberculosis to assert itself.

The diagnosis is easier if there has been no antecedent injury, for

then it is only necessary to decide between **tubercle** and **chronic articular rheumatism.**

The *anatomical* changes which occur in this latter include processes of serous effusion, fibrous adhesions, proliferation, and destruction—indeed, any morbid change which may occur in a joint. Their *etiology* includes injuries, toxic processes (lead), infections (an original acute infective rheumatism), and finally neuropathies (tabes, syringo-myelia) apart from cases which we cannot account for at all. It must be stated, however, that none of the anatomical varieties presupposes any definite etiology; one and the same cause may be responsible for the most differing anatomical forms.

The tendency towards the affection of many joints in a symmetrical manner is an important diagnostic sign, common to all varieties, whatever be their causes—even if traumatic. This circumstance permits the diagnosis to be made at once in a large number of cases. It is true that tubercle often affects many joints, but, as a rule, there is at any rate one focus so much involved that there is no difficulty about the diagnosis. It is more difficult to diagnose the cases of subacute or chronic rheumatic polyarthritis, wherein several joints are attacked at long intervals. If only *one* joint is diseased, we may remain long in doubt. Early muscular atrophy, progressive deterioration—even if slow—depression of the general health, and possibly also a slight rise in temperature, would point to tubercle; but a variable local condition with good general health would indicate a "rheumatic" affection. Some weight in making a diagnosis may also be attached to the success or failure of spa-treatment All these difficulties apply to those frequent forms of shoulder-joint tubercle, wherein there is neither effusion nor any demonstrable swelling of the capsule, wherein the morbid process manifests itself by slow destruction and simultaneous absorption of the articular ends of the bones—a clinical picture which used to be termed "caries sicca." On the other hand, there can be no doubt about the diagnosis of tubercle if a localized swelling gradually forms, even at the posterior region of the joint, with suppurative softening of the tissues, and the formation of sinuses which discharge their pus and pieces of caseous material.

Gummatous disease of the shoulder-joint may occur, but it is so rare that it does not enter into practical consideration.

We may now briefly summarize the foregoing:—

If the signs of inflammation of the shoulder—loss of power, spontaneous pain, tenderness on pressure—come on immediately after an injury, we may assume the presence of a purely traumatic arthritis of the shoulder-joint, even if the malady persists for weeks or months. But if these symptoms come on spontaneously, or supervene a few weeks after a slight injury, we should think of tubercle, especially in young patients. If

in addition to the shoulder, other joints become affected with inflammatory symptoms at longer or shorter intervals, but without, anywhere, presenting the classical signs of a tubercular focus, the case probably represents one of the forms of chronic articular rheumatism, and the older the patient is, the more probable is this diagnosis.

C.—PRIMARY DISEASES OF THE BONE.

We have referred to the bones as the third source of inflammation in the neighbourhood of the shoulder-joint. So far as the bone disease manifests itself in the form of *inflammation of a joint* the foregoing remarks will apply. The involvement of the bone, or the presence of the primary focus within it can only be demonstrated by a skiagram. But the bone may be diseased, *and the joint itself not be involved.* This condition will be suggested, when there are pain and swelling in the neighbourhood of the joint, while its movements remain free. The localization of the changes will, at once, enable us to distinguish whether the disease originates in the scapula or the humerus, and its course generally enables us to determine whether it is acute osteomyelitis, tubercle or gumma. In its early stages, a *sarcoma* may be confused with a chronic inflammatory disease.

CHAPTER LXXXIII.

INJURIES ABOUT THE ELBOW-JOINT.

ALTHOUGH the elbow-joint is superficial in position and easily felt, injuries thereof are a source of great perplexity of diagnosis. There are two reasons for this; firstly, the fact that three bones participate in the construction of the joint, and secondly, the extensive swelling of the soft parts which occurs—much more extensive, for example, than in the case of the wrist. But if we accustom ourselves to draw logical conclusions from what is actually felt, we shall find that the undiagnosable injuries about the elbow will tend to become fewer and fewer.

Having decided from the loss of power and deformity that some severe injury to the elbow has occurred, we must first d termine whether a fracture or a dislocation is present, and then the variety of the one or the other.

Some indications are furnished by the *age* of the patient.

Fractures and separation of the epiphyses, with secondary dislocations, are more apt to occur in early childhood, whereas adults are more subject to pure dislocation, because of the relatively greater firmness of their bones.

We will now proceed to detail the method of examination.

A.—INSPECTION.

Sometimes a mere glance suffices for the diagnosis. If the outlines of the sigmoid fossa are visible through the skin of a thin individual and the head of the radius projects behind, no one can doubt the existence of a dislocation (fig. 272). If the axis of the forearm, as seen from the front, instead of deviating slightly externally is directed internally, we immediately think of certain forms of fracture (fig. 287), &c.

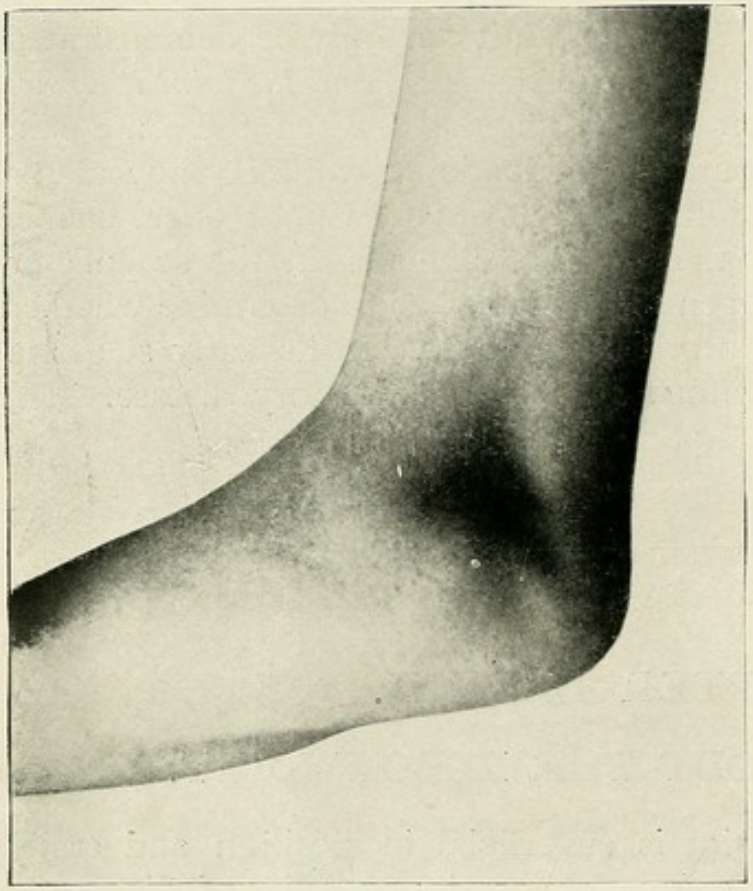

FIG. 272.—Backward dislocation of elbow.

On inspection, we note the following points, which we shall make further use of, in the course of examination.

(1) Position of the elbow (flexion or extension, abduction or adduction, pronation or supination, abnormal position of the axis of arm or forearm). (2) Degree of the swelling. (3) Prominence of the bony parts. (4) Ecchymoses. (5) Impalement of the skin. (6) Posture of the hand (paralysis of the radial nerve).

B.—EXAMINATION OF ELBOW MOVEMENTS.

We first ask the patient to carry out a few movements in various directions. If he complies with our request, and the movements attain the normal range, he has neither a dislocation nor a fracture which interferes with the mechanism of the joint. If *active* movements are restricted, we must endeavour to ascertain the extent

of the *passive* movements, at first, gently without anæsthesia, and then, if necessary, under an anæsthetic. The following possibilities have to be considered :—

(*a*) If there be an excessive amount of movement in one definite direction, while movement in the opposite direction is *restricted* by the tension of the uninjured ligaments, we may conclude that a **sprain** has occurred.

In **posterior or postero-external dislocations,** which constitute the majority of these cases, it is possible to over-extend the elbow, but it is not possible to flex it beyond a right angle. In pure **lateral dislocations** flexion is indeed possible, but the aspect of the joint, as seen from the front, with the lateral displacement of the forearm in relation to the humerus (the bayonet shape of the arm) is so striking, that the dislocation of the joint cannot be missed. We must, however, decide whether it is a complete or incomplete backward dislocation, or a dislocation backwards and outwards, or the rare backward and inward form, or the still more rare backward dislocation of the ulna only. Careful palpation of the projecting bony landmarks will furnish information on all these points.

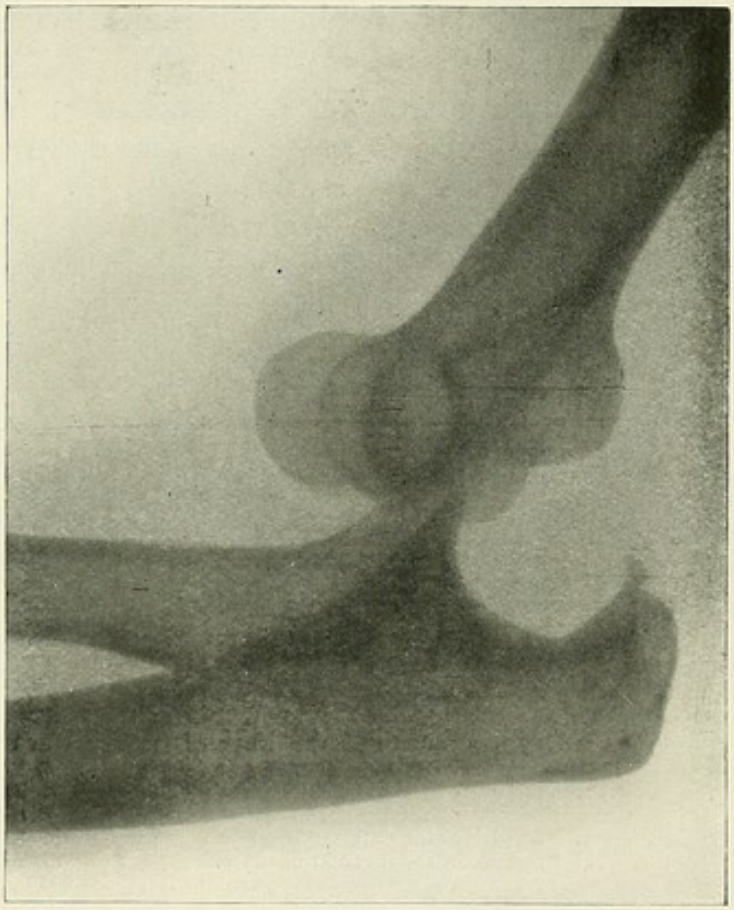

FIG. 273.—Dislocation of elbow backwards. Skiagram of fig. 272.

(*b*) If our examination has shown that there is *no interference with passive extension and flexion*, thus excluding the possibility of any ordinary dislocation, the case is one of **fracture**, or there may be no severe injury at all.

Before coming to any definite conclusion and diagnosing the exact form of fracture, it is desirable to recall the possible varieties by a glance at the accompanying diagrammatic illustration (fig. 274).

The skiagrams which follow illustrate again the most important and typical fractures, mostly of children. Owing to the epiphyseal cartilages, the interpretation of their skiagrams often presents great difficulties.

The examination of the power of the elbow and the testing for false mobility may yield the following possibilities :—

(1) *If all passive movements are free,* and the only derangement consists of the *impossibility of active extension,* it is obvious that some break has occurred in the continuity of the extension apparatus, and experience shows that this usually indicates a **fracture of the olecranon** (fig. 277).

If, anticipating the order of the examination, we palpate its surface, and come upon a gap in the bone, or find thereon a transverse, sensitive groove, the diagnosis is confirmed. If doubt still remains, the attempt should be made to displace the tip of the olecranon from the ulna—a manœuvre which is very painful for the patient.

It is obvious that the examination for active extension must be conducted in such a way that the drop of the forearm by its own

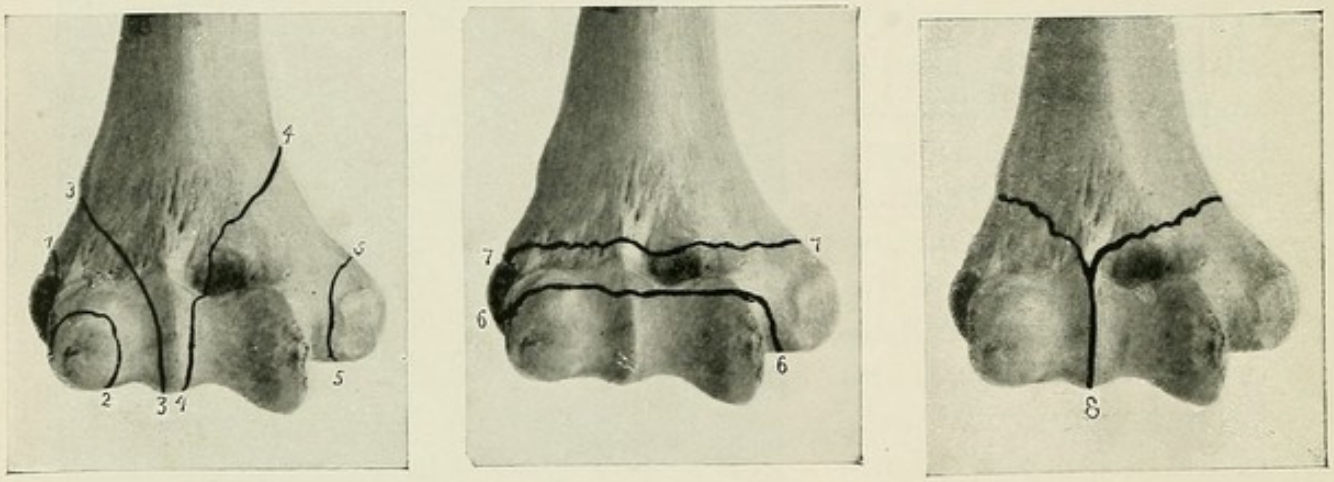

FIG. 274.--Course of the lines of fractures at the lower end of the humerus.

1. Fracture of the external epicondyle.
2. Fracture of the rotula.
3. Fracture of the external condyle.
4. Fracture of the internal condyle.
5. Fracture of the internal epicondyle.
6. Fracture through the condyles.
7. Fracture above the condyles.
8. Y-shaped fracture.

weight should not mislead the observer into thinking that active extension has been performed.

(2) If the olecranon is uninjured, the forearm, which is usually flexed to a right angle, should be moved backwards and forwards in relation to the humerus. If this is possible, and if the epicondyles are felt to move *with* the olecranon, there must be a break in the continuity *above* the joint, *i.e.*, a **supra-condylar fracture.**

If, on displacing the olecranon backwards, it gets into the position of a posterior dislocation, but the epicondyles do not follow it, and if it can easily be replaced into its normal position, we should think of fracture of the **coronoid process of the ulna,** especially if these movements are associated with some crepitus. This fracture was rarely recognized before the advent of X-rays, but the light now

shed thereon renders the diagnosis possible in the future even without the rays. The signs just noted ought always to raise the suspicion of the very rare fracture of the base of the coronoid process. We shall describe a somewhat more frequent form later on.

(3) If we cannot move the forearm backwards and forwards in relation to the humerus, we must examine for another important sign,

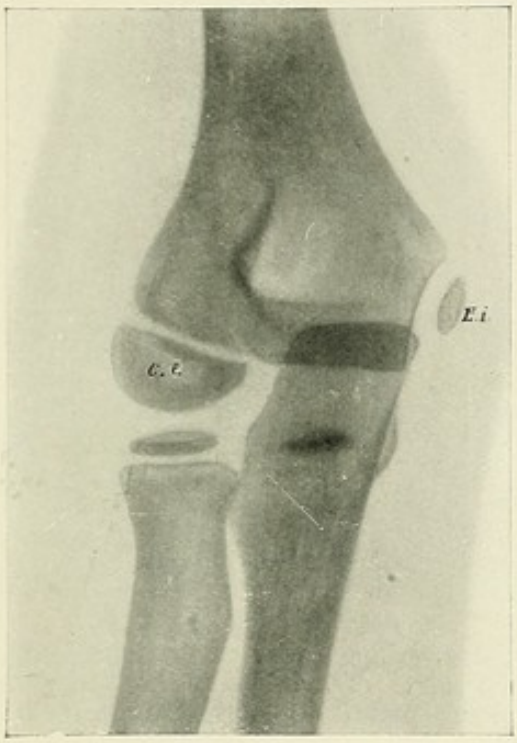

FIG. 275.—Normal elbow taken from behind. Boy aged 11. *E.i.* = centre of ossification of epicondyle. *C.e.* = external condyle. The centre of ossification of internal condyle is not yet present.

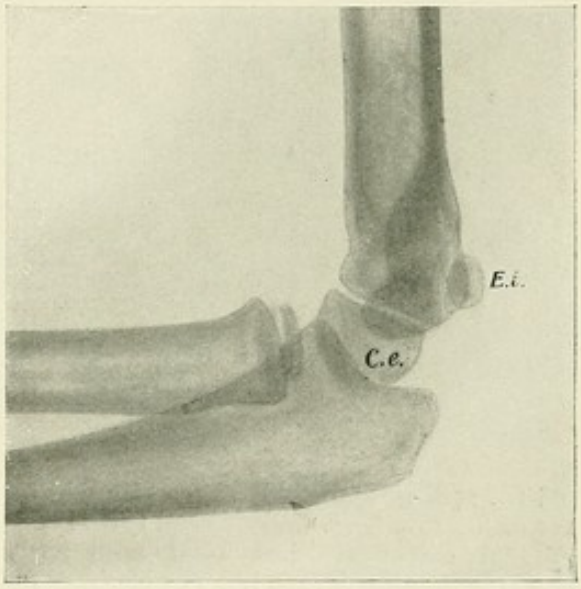

FIG. 276.—Normal elbow taken from the side. Boy aged 11. References as in previous figure.

i.e., for abnormal lateral mobility, in the sense of *adduction or abduction*.

As there is always a certain amount of abduction and adduction normally possible in children, it is necessary to compare the injured side with the uninjured one. The forearm makes an obtuse angle with the arm, the angle being open outwards, thus constituting a slight degree of valgus, as in the knee. This valgus posture is more pronounced in females than in males.

If, on comparing the two sides when both arms are kept in the same attitude, it is seen that the normal abduction is lost on the injured side (fig. 284), or, indeed, replaced by a position of adduction,

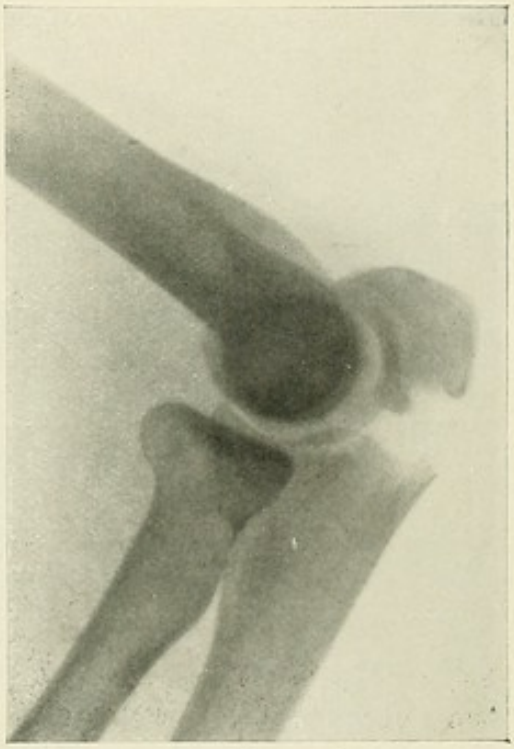

FIG. 277.—Fracture of the olecranon.

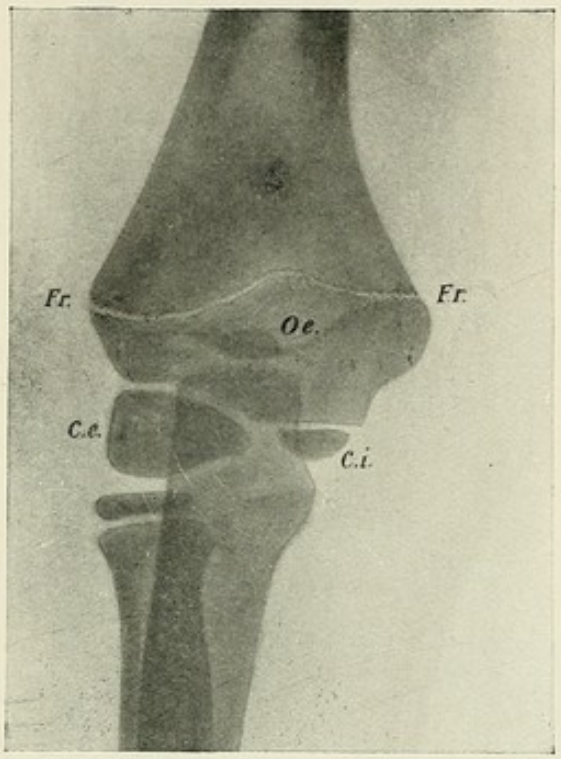

FIG. 278.—Supracondylar fracture without dislocation (*F.r.*). Boy aged 12. The internal epicondyle has fused with the humerus (unusually early). The centres of ossification for the internal condyle (*C.i.*), and the olecranon (*O.l.*), have appeared.

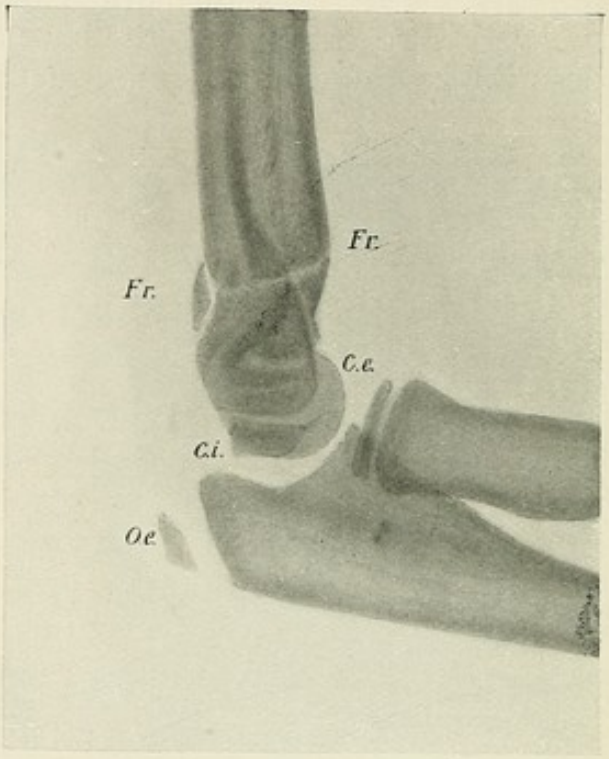

FIG. 279. — Same case as previous figure, from the side. *F.r.* = line of fracture with small piece separately broken off at the back.

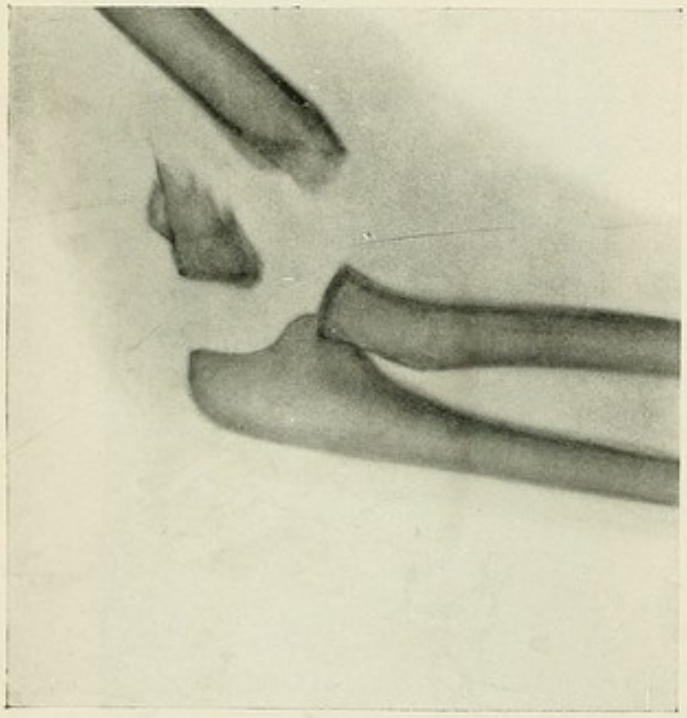

FIG. 280.—Supra-condylar fracture (hyperextension fracture) in a girl aged 3, taken from the side, showing the backward displacement.

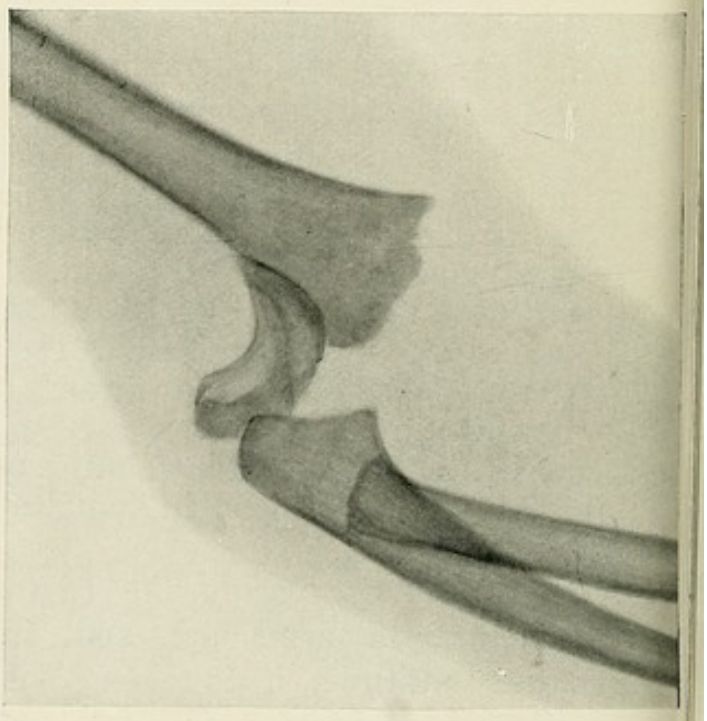

FIG. 281.—Same case, taken from the side, showing lateral displacement (bayonet shape).

we can at once conclude that there is abnormal lateral mobility. Passive movements will show whether this increased mobility is present in both directions, or only in one direction. In the former case the condition must be one of *supra-condylar* fracture, which we have already recognized by the fact that the forearm can be displaced from before backwards. In the latter case the condition must be one of damage to the ligaments of one side, not, as a rule, merely a simple rupture of a ligament, but a *fracture* of the portion of bone into which the ligament is inserted, *i.e.*, the *internal or external condyle or the epicondyle*. If ulnar adduction is increased, the external radial lateral ligament must have given way, or the **external condyle** may have been torn off with it (figs. 289 and 290). On the other hand, increased *abduction* signifies the **tearing off of the internal epicondyle** (figs. 285, 286, 287), or the much rarer fracture of the **internal condyle.**

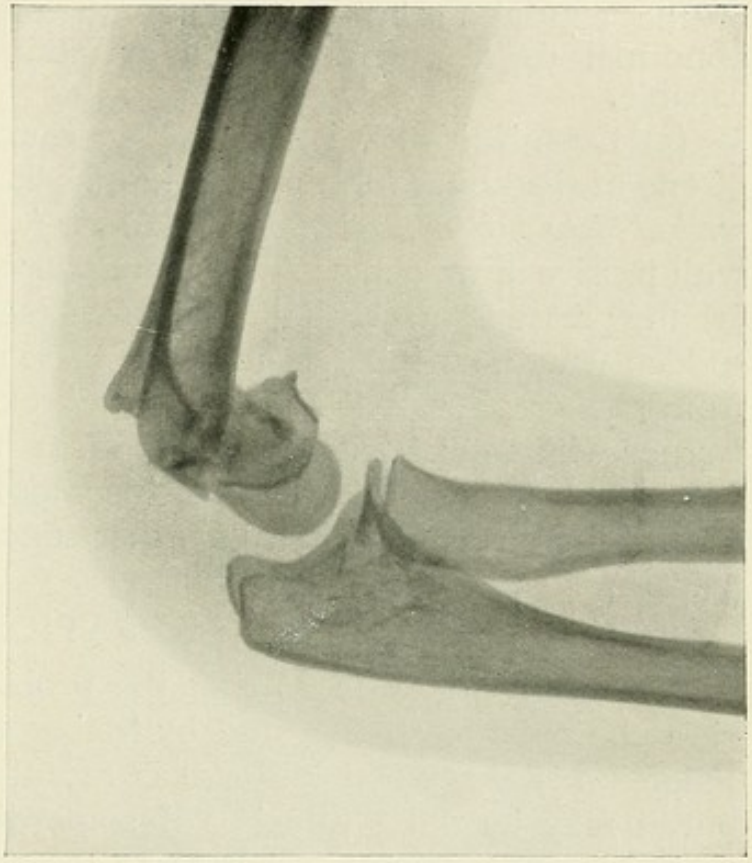

FIG. 282.—Supra-condylar fracture (flexion fracture), in a boy aged 10. Lower fragment displaced to the front.



FIG. 283.—Piece of cartilage bone broken off the rotula (*cf.* fig. 291).

(4) But even this examination may fail to give us an unequivocal result. It may be possible to displace the forearm to some extent, both backwards and forwards, there may be increased mobility in the direction of abduction and adduction, but not one of these signs may be sufficiently pronounced to base a diagnosis thereon. We must therefore make one final test by firmly grasping the humerus at the epicondyles, and attempting to move the bones of the forearm, at the elbow joint, in a *lateral direction*. The object of this manœuvre is not to bring the forearm to an angle with the humerus, but to displace it into a direction parallel therewith. If we can do this, it is very probable that a piece of bone consisting

of the trochlea and rotula has been broken off; in other words, that a **fracture through the condyles** has been sustained.

It is very likely that this movement may be effected in the case of other fractures which extend into the joint, especially in fractures of the condyles; but these have already been recognized by the abnormal degree of adduction or abduction of which they are capable.

(5) Even if this test is negative, we cannot definitely exclude injury of one of the bones forming the joint. There still may be a *circumscribed piece of bone broken off, within the joint*, which does not interfere with passive movements. Two symptoms will lead to this assumption: (1) the presence of crepitus when free movements are made, and (2) sudden temporary interference with these movements. We conclude from the crepitus that something is broken, and the sudden interference with movement, as occurs when a loose body is in a joint, shows that some solid substance becomes incarcerated between the ends of the bones (fig. 283). Further conclusions may be drawn from palpation.

C.—PALPATION.

This will aid us in solving the problems which have not been cleared up by inspection and by testing the movement of the joint. Palpation is easy when the case is recent and the swelling is slight; but it may be quite valueless if some time has elapsed since the accident, and the joint has become tense with effused blood and its whole neighbourhood extensively infiltrated. In these circumstances we must have recourse to anæsthesia, and massage the œdema away as far as possible, before making the examination. It is most important to determine whether the swelling is situated within the joint or outside the capsule. If the latter be the case, it is in favour of a para-articular fracture (supra-condylar).

This happened in the case illustrated in figs. 278 and 279. There was no false mobility and it was only the circumscribed swelling and pain on pressure which made one suspect a "fracture of the bone above the joint."

We have next to feel the three well-known bony landmarks, *viz.*, the tip of the olecranon and the two epicondyles.

We know from anatomy that these three points form an equilateral triangle (fig. 288 (b) and (c)) lying in the same plane as the humerus, when the arm is flexed to a right angle, whereas they are all at the same level, or, mathematically speaking, in a plane vertical to the humerus (fig. 288 (a)), when the arm is extended. It is always advisable to compare the injured with the uninjured side, while making the examination, in order the better to appreciate slight changes in these relations.

The following possibilities must be taken into consideration :—

(1) If the tip of the olecranon is displaced *upwards* when the arm is extended, or displaced *backwards* when the arm is flexed, *i.e.*, has shifted from the plane of the humerus, whereas the epicondyles retain their relation to this bone, the case is either one of backward dislocation or fracture through the condyles. Marked projection of the olecranon, combined with limitation of movement—impossibility of complete flexion—points to **dislocation.**

Slight projection with free passive movement indicates **fracture through the condyles,** which is rare, or **detachment of the coronoid process,** which is equally rare.

If the projecting olecranon, notwithstanding its backward displacement, still remains midway between the external and internal epicondyle, the case is one of **simple posterior dislocation.** If we can distinctly palpate the sigmoid fossa and the head of the radius, the dislocation is **complete**; in other cases it is **incomplete.** If the head of the radius remains, however, in its normal position, or slightly displaced inwards, the case is an example of the rare **posterior dislocation of the ulna alone.**



FIG. 284.—Right supra-condylar fracture, in a boy aged 11. The normal cubitus valgus is straightened out (angle very definite on left side). Shortening.

(2) If the *tip of the olecranon and epicondyles are together* displaced *backwards* in regard to the plane of the shaft of the humerus, so that the relation of the epicondyles to the shaft of the humerus is altered, and so that they are movable against the humerus, the case can only be a **supracondylar fracture**—a **hyperextension fracture,** whose course runs from forward and below to behind and above (fig. 280).

(3) If the olecranon *alone,* without the epicondyles, is displaced *forwards* and movement is limited it must be one of the rare cases of **anterior dislocation**; if passive mobility is free, and the epicondyles are displaced forwards at the same time, the case must be one of

supracondylar fracture, arising through **flexion** (fig. 282). In the latter case it may be possible to feel the pointed end of the upper fragment of the humerus through the soft parts above the olecranon, if there is not too much swelling, and we may also be struck by the unusual rotundity of the elbow in profile.

(4) If the *olecranon appears to be displaced laterally* in relation to the *epicondyles*, we must note whether this displacement is in relation to *both* condyles. If it is so, there must be an incomplete or **complete lateral or postero-lateral dislocation**, according to the degree of ligamentous rupture and displacement.

(5) If the tip of the olecranon only preserves its normal relation in regard to *one* epicondyle, we must assume that the other condyle or epicondyle has been broken off and displaced. The epicondyle is usually broken off by itself on the inner side, whereas on the outer side it is generally a matter of fracture of the condyle. The symptoms, in regard to false mobility, are, in principle, the same in both cases; hyperabduction when the fracture is on the inner side, and hyperadduction when the fracture is on the outer side. If the swelling is not too great, palpation is quite conclusive. On the outer side

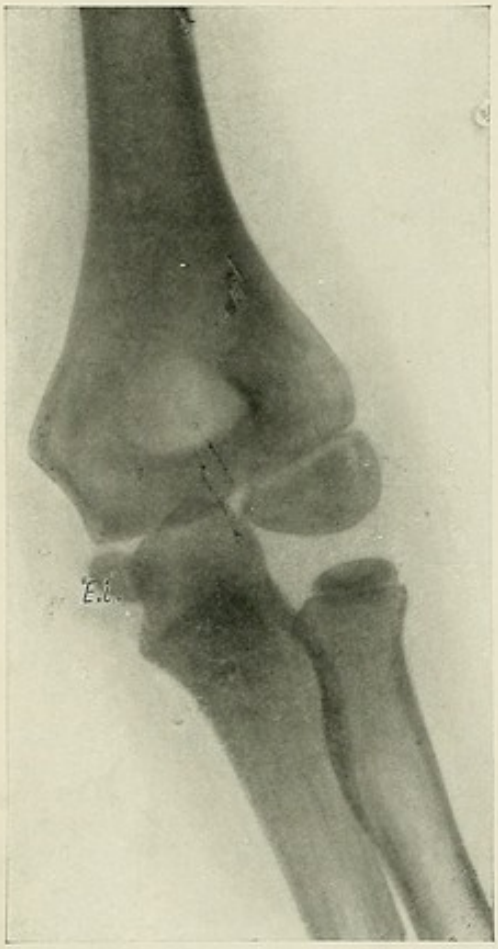

FIG. 285.—Detachment of internal epicondyle and its displacement towards the forearm.

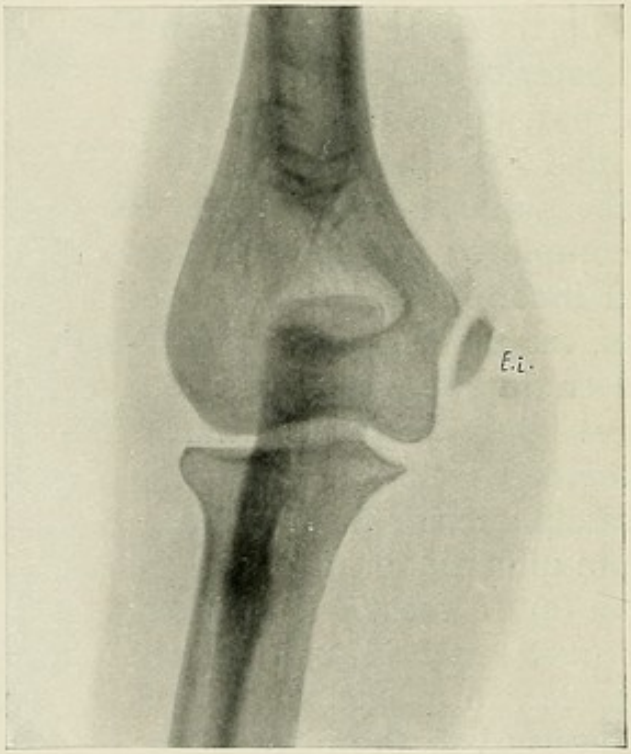

FIG. 286.—Detachment of internal epicondyle without displacement. The slight indication of callus shows, apart from the age of the patient, that it is not merely physiological cartilage.

we often find the **detached condyle** rotated to the extent of 90° or even 180°.

In fracture of the internal epicondyle the detached piece of bone is sometimes found hanging from the lateral ligament in its normal position, but often towards the anterior surface, and displaced even as far as the level of the fold of the joint (fig. 285).

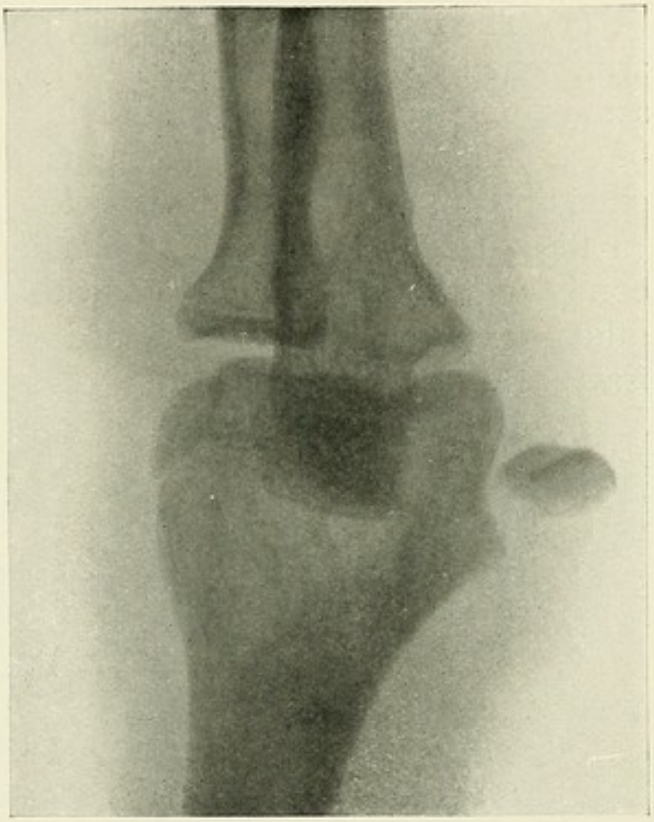

FIG. 287.—Detachment of internal epicondyle, and its rotation to the extent of 90°.

(6) If we feel the three chief points in their proper position, but the head of the radius is displaced, there must be a dislocation of the radius alone. The radius usually deviates forward (fig. 293) or outwards, rarely backwards, and the injury generally occurs in children as a result of extreme pronation combined with abduction. The so-called **subluxation of the radius** forwards, which is also frequent in children, must be distinguished from complete dislocation of the radius. This is at present looked upon as an interposition of the posterior wall of the capsule between the radius and humerus.

This injury often occurs to children, when they are dragged by

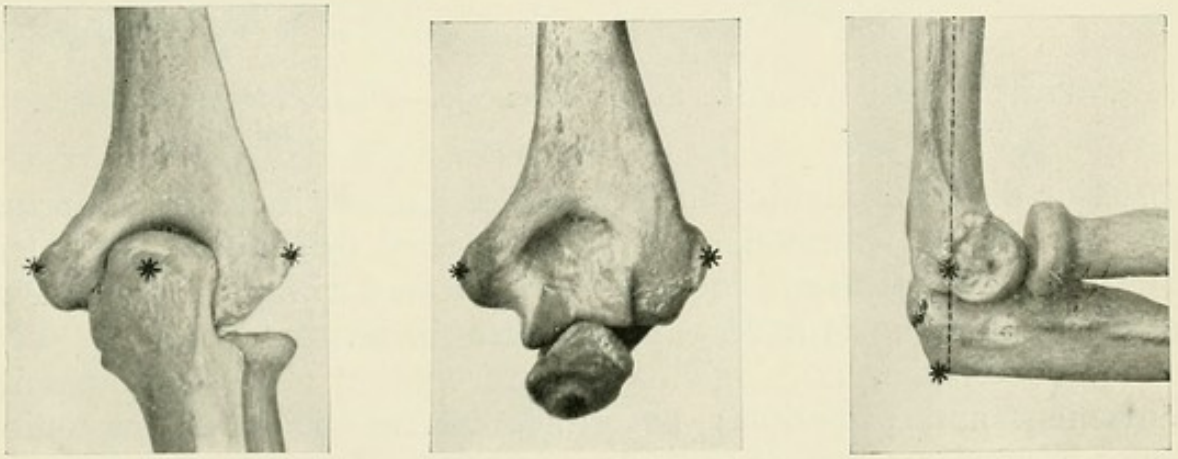

FIG. 288.—Relative positions of three bony projections on elbow, which serve as landmarks.

(a) Extension. (b) Flexion as seen from behind. (c) Flexion as seen from the side.

the arm. On palpation nothing can be found, in striking contrast to the incapability of performing any movement. The accuracy of the diagnosis is proved by the result of treatment; power of movement is at once regained if the normal conditions are restored by supination and flexion.

(7) There may be pronounced posterior displacement of the forearm, when considerable passive movement is applied to it. At the same time each separate condyle can be displaced from the shaft of the humerus. The movements are accompanied by a sound of crackling like a bag of nuts, in the joint, which is filled with blood. In these circumstances there can be no doubt that there is a supracondylar fracture, combined with fracture of both condyles — in other words, a T- or Y-shaped fracture (fig. 292).

(8) If the ordinary signs of a

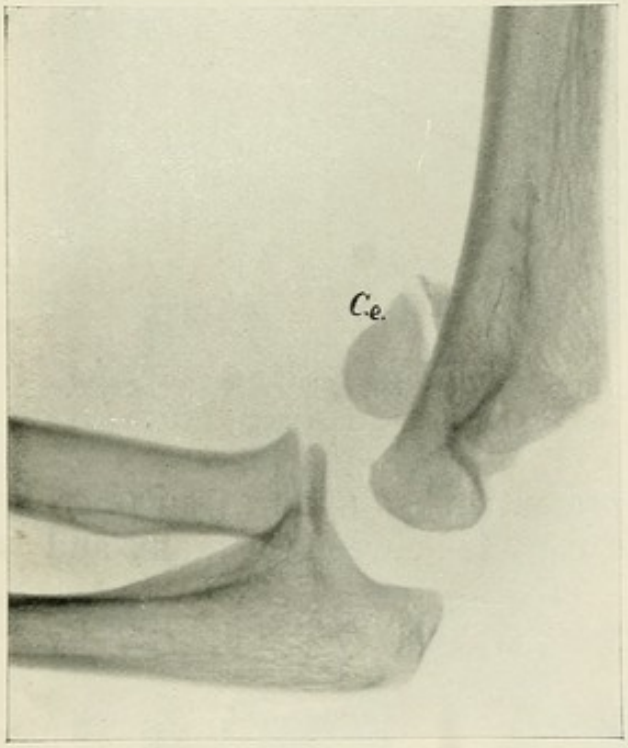

FIG. 289.—Fracture of external condyle. Seen from the side.

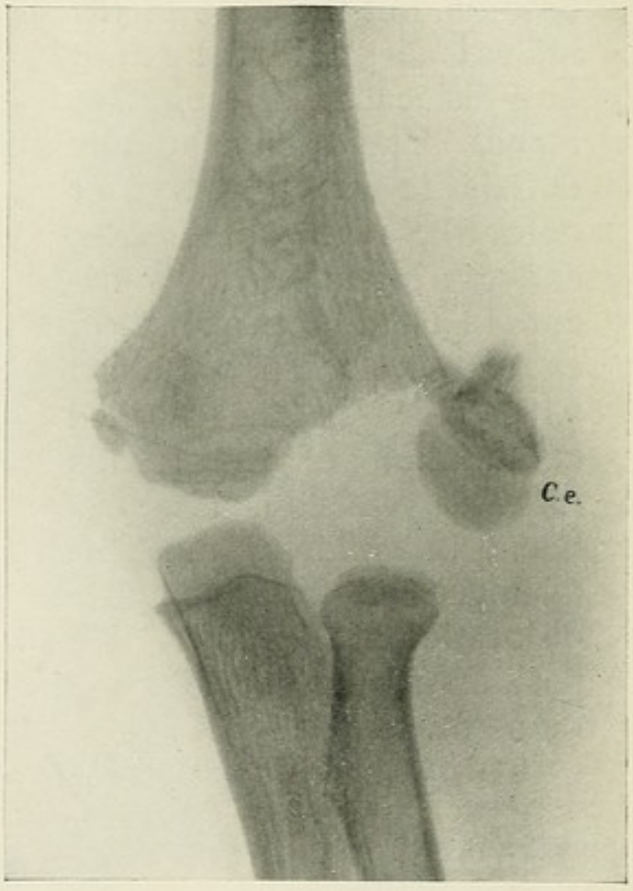

FIG. 290.—Fracture of external condyle. From behind.

posterior dislocation exist, and if in addition crepitus and abnormal mobility of the external condyle or internal epicondyle are noted, it is obvious that the dislocation is associated with a fracture. This latter combination is a very typical occurrence.

(9) Sometimes, nothing may be recognized at first on passive movement and palpation; nevertheless, a suspicion of crepitation being present, we cannot exclude a fracture. In some cases, pronation and supination are deranged, in some flexion is painful, and in

others the derangements vary so much that they suggest a "dérangement interne"—although this is not a diagnosis.

(*a*) If there is localized pain on pressure over the **head of the radius**, if it is thickened and abnormally prominent, with a circumscribed effusion of blood in its vicinity, if pronation and supination are painful and if they are accompanied by rotation of the head of the radius, the case is one of **fracture of the head itself** (chisel fracture, *Bruns;* fig. 294). But if the pain on pressure is mainly limited to the neck, there is probably a **fracture of the neck**, whether the head moves on rotation or not (fig. 295). The detached head is sometimes turned to an angle of 90°, so that its depression can be felt.

(*b*) If the symptoms of a foreign body in a joint are the most prominent combined with some limitation of extension, we should think of an **abrasion fracture of the eminentia capitata humeri**,

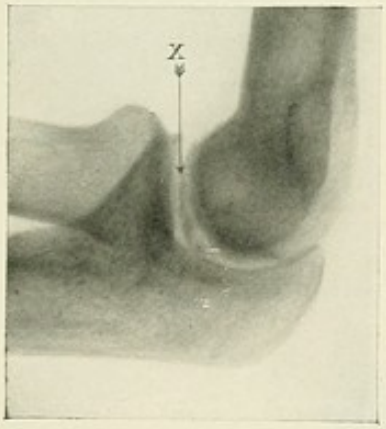

FIG. 291.—Detachment of cartilage and some bone (X) from the eminentia capitata humeri (see corresponding fragment in fig. 283).

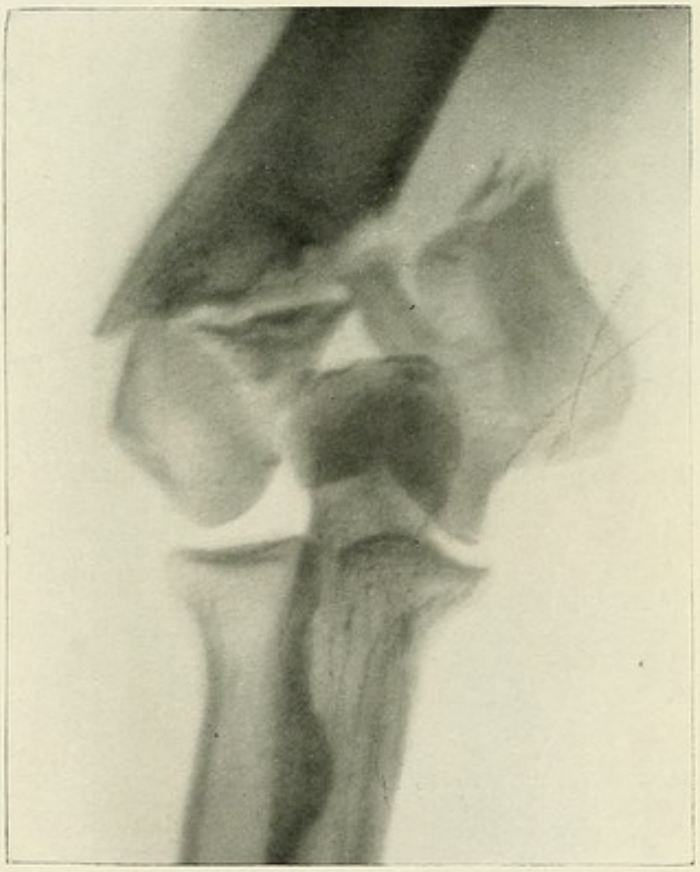

FIG. 292.—T-fracture of lower end of humerus.

which was first carefully described by Kocher. In this fracture, only a localized piece of cartilage with a small fragment of bone are broken off (fig. 283). This piece may sometimes be felt as a loose body, between the external condyle and the head of the radius, as soon as the arm is extended. On flexion, the piece of cartilage disappears within the joint.

If some bone is detached with the cartilage, the diagnosis can also be made by X-rays (fig. 291).

(*c*) But if nothing is found, except that there is localized pain on

pressure and ecchymosis of the elbow, we may assume that there is a **detachment of the coronoid process.** As soon as callus develops, it is very easy to detect this injury by palpation (fig. 296).

The diagnosis of "**sprain**" is only justified if an exhaustive and systematic examination fails to elicit anything definite.

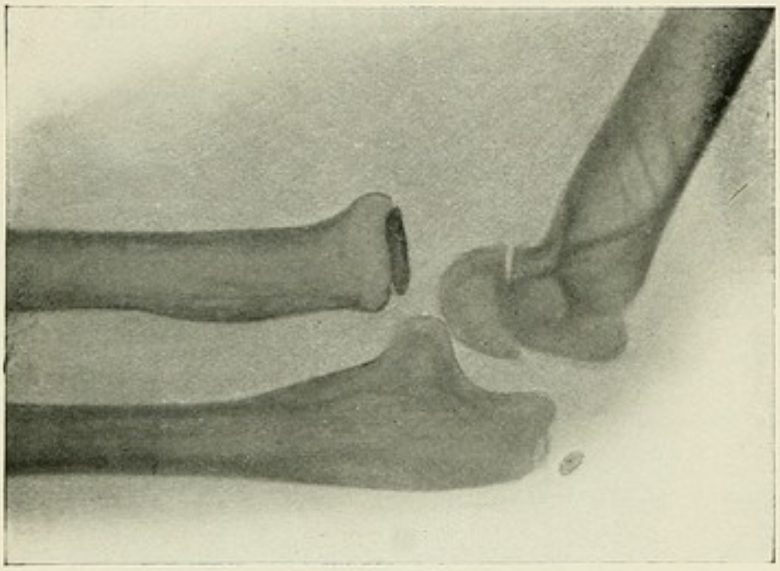

FIG. 293.—Forward dislocation of radius alone.

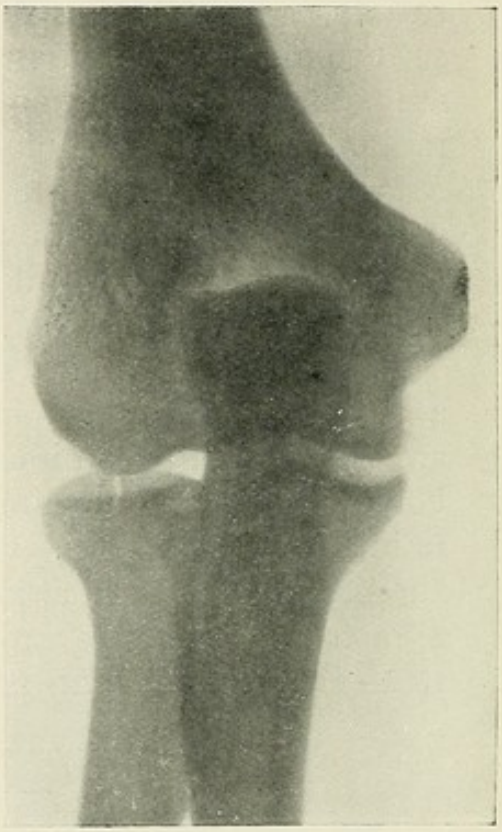

FIG. 294.—Chisel fracture of head of radius.



FIG. 295.—Detachment of head of radius.

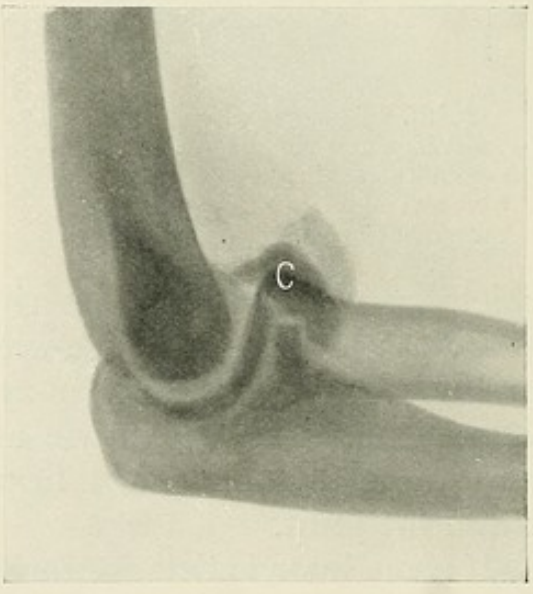

FIG. 296.—Detached fracture of the coronoid process of ulna. (C) Proliferation of callus visible above the fragment.

D.—RÖNTGEN RAY EXAMINATION.

We must never be content merely with a *screen* examination. The clearest picture on a screen fails to exhibit the details which a moderately good skiagram shows. It is impossible to avoid overlooking on a screen, subordinate, though important, injuries which may accompany the chief injury, *e.g.*, a dislocation—an injury which is recognizable even without X-ray examination. Another precaution which must be observed, especially when dealing with growing individuals, is always to take a **control picture** *of the uninjured side*, in the same position as that in which we have examined the injured side. If this is neglected, we are liable to interpret the cartilaginous ends between the various centres of ossification as fractures of the external condyle, the olecranon, &c., and in all probability we will overlook actually existing injuries. It is also indispensable to examine the joint in *two directions perpendicularly to one another*, from the front and from the side. The X-ray examination of an elbow injury is therefore not always an easy task, and the correct interpretation of the skiagram may be just as difficult as the accurate appreciation of what is found on palpation.

We may summarize the above in the following scheme—

	Moderate and transitory loss of power; nothing severe; pain on pressure; usually a little effusion.	(1) **Sprain.**
	Ditto, but severe pain on pressure over the head of the radius or its neck. The head often appears to be somewhat thickened; localized hæmatoma in its neighbourhood.	(2) **Fracture of the capitulum of the radius** (or detachment of the head).
	As in 1, but severe pain on pressure in the flexure of elbow; possibly also swelling and crepitus therein; loss of power of active flexion (brach. internus muscle).	(3) **Fracture of coronoid process of ulna.**
No displacement of the cardinal landmarks (except sometimes in 7, when the olecranon is movable).	Joint free, but pain on pressure transversely above it.	(4) **Supracondylar fracture** without displacement.
	Loss of power variable; symptoms of foreign body in joint; loose body to be felt between rotula and head of radius, on extension.	(5) **Abrasion of eminentia capitata.**
	Severe loss of power and effusion; forearm can be displaced somewhat, forwards and backwards (in position of dislocation). Some lateral displacement also possible.	(6) **Fracture through the condyles.**
	Passive movements free; active movements restrained; olecranon movable, sometimes proximally displaced.	(7) **Fracture of olecranon.**

Olecranon displaced in relation to the axis of the humerus, but not movable in relation to the ulna. The epicondyles not movable in relation to one another.	Displacement backwards.	Epicondyles not displaced; passive flexion restrained.	(8) **Posterior dislocation.**
		Epicondyles share in displacement, and movable in relation to shaft of humerus; passive movements free, or more extensive than normal.	(9) **Supracondylar fracture in hyperextension.**
	Displacement forwards.	Epicondyles not displaced.	(10) **Dislocation forwards** (rare).
		Epicondyles share in displacement forwards; passive movements free.	(11) **Supracondylar fracture in flexion.**
Epicondyles or condyles separately displaceable in relation to the shaft of the humerus.		Internal epicondyle movable; usually displaced distally and dorsally.	(12) **Fracture of internal epicondyle.**
		Internal condyle movable.	(13) **Fracture of internal condyle** (very rare).
		External epicondyle movable.	(14) **Fracture of external epicondyle** (very rare).
		External condyle movable, usually rotated about 90° to 180°.	(15) **Fracture of external condyle.**
		Both condyles separately movable, in relation to one another and to the shaft of the humerus.	(16) **Y and T Fractures.**

CHAPTER LXXXIV.

INFLAMMATORY PROCESSES ABOUT THE ELBOW.

(1) ACUTE INFLAMMATORY PROCESSES.

ACUTE inflammation of the soft tissues about the elbow may resemble an acute arthritis, just as in other joints. One should first think of **phlegmon of the forearm**, originating from a lymphangitis, which is so frequently the result of infected wounds of the hand.

The etiology—*i.e.*, a peripheral injury—at once indicates the correct diagnosis. It is not often that the elbow-joint is involved after these injuries. Apart from other symptoms, their chronological order serves to differentiate a superficial phlegmon from an acute arthritis. In the latter, pain and difficulty in movement appear first, and the superficial changes follow; in the case of a phlegmon, swelling and redness of the skin appear first, and the difficulty of movement later on. If the inflammation is limited to the antero-internal side of the joint, or at least has arisen in this situation, we may conclude with great probability that the phlegmon or the abscess has originated in the *glands of the elbow*. If the phlegmon has started behind, we look to the

olecranon bursa for its origin. This bursa, like the pre-patellar, has a great tendency to inflammation, and the slightest skin abrasion in its vicinity suffices to afford entrance to the cocci and to cause an extensive phlegmon of the whole of the back of the elbow region. The more acute the process, the further it encroaches beyond the immediate limits of the bursa, and extends to the front and to the upper arm.

In contrast to this superficial inflammation, which at any rate at first leaves one side of the joint free, in **acute arthritis** the entire circumference of the joint is painful on pressure. The swelling is most evident where the capsule is most superficial, namely, about the radius and at both sides of the triceps tendon. But the soft parts in front soon swell up, and the whole region of the joint finally becomes

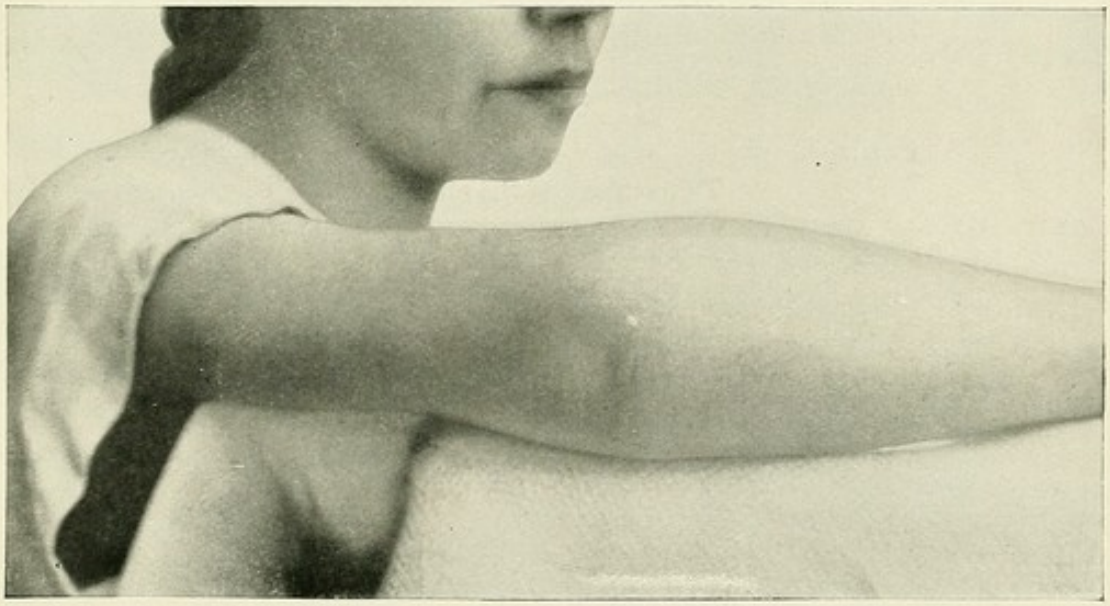

FIG. 297.—Tubercle of the elbow. Spindle-shaped swelling of the joint. Slight depression at the site of the triceps tendon.

red and œdematous. Reference should be made to the remarks on the shoulder-joint for the causes of the inflammation.

Let us begin with the *soft tissues*. There are certain chronic inflammatory processes on the arm, the diagnosis of which is not clear at first sight. Examination shows that there is no primary disease of the underlying bone, and no portal of entry for organisms is evident. The changes consist of swelling and purulent infiltration of the subcutaneous tissue and of the skin, the brunt of the affection falling either on the one or the other. If any tubercular change, *e.g.*, caries, disease of the tendon sheath, or lupus, be found on the hand, we diagnose the condition of the arm as one of *tubercular lymphangitis*, with its sequelæ, tubercular abscess of the soft tissues or tubercular destruction of the skin. Individuals suffering from this form of



FIG. 298.

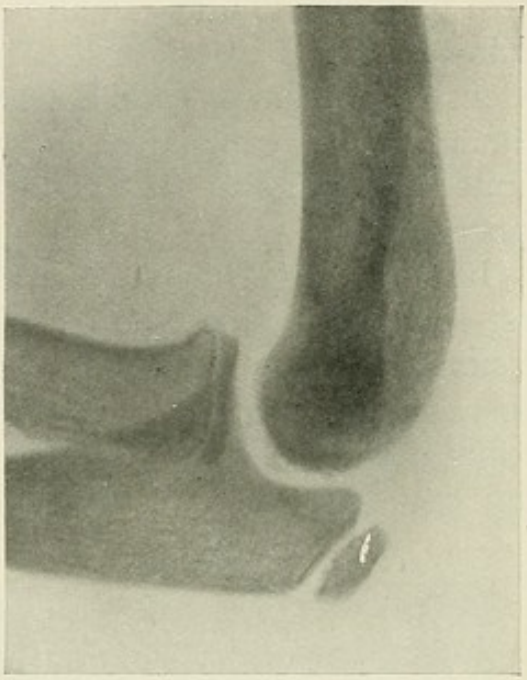

FIG. 299.

Tuberculosis of the elbow.

(a) Diseased side. Cartilage has disappeared; bone eaten away, especially on the ulna.

(b) Healthy side.

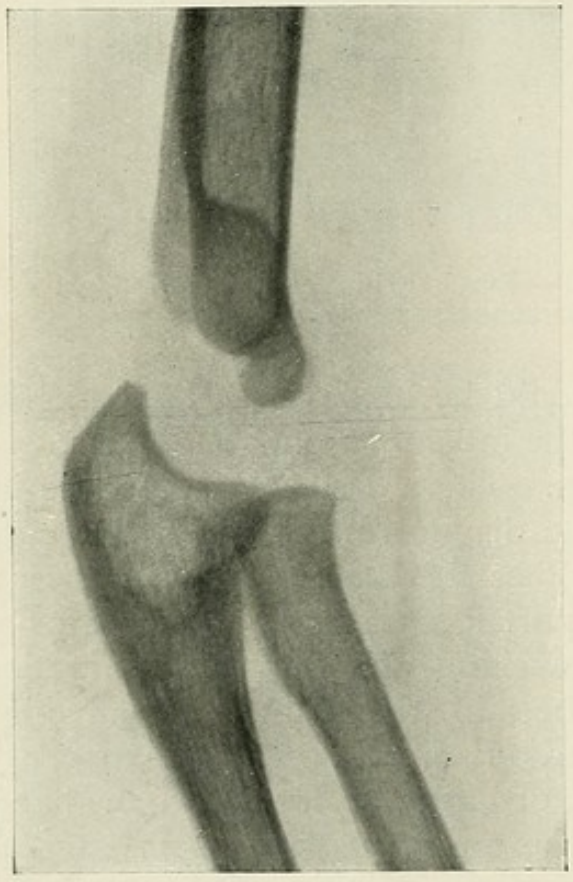

FIG. 300.—Tubercular focus in ulna.

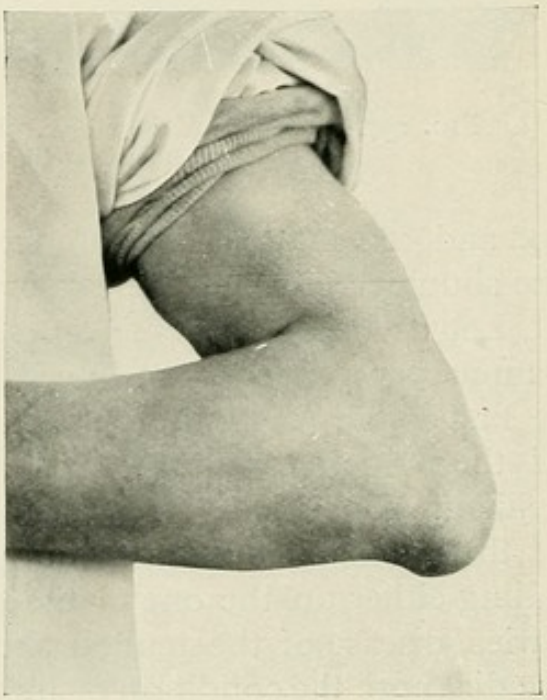

FIG. 301.—Chronic inflammation of olecranon bursa.

tubercle have very little resistance to the bacillus, and we therefore frequently find other foci of the disease present.

If there is no indication of this kind, we should think of the purely metastatic tubercle of the soft tissues, which is a rare form, or of *syphilitic gumma*, which is more likely, or of *actinomycosis*, which is, however, very rare, in the extremities. Until quite recently our diagnosis might have ended here. But within recent years it has been shown that a special variety of mycelial fungus (*Sporotrichum Beurmanni*) may cause persistent changes in the skin, the deeper tissues and even the bones, with signs intermediate between gumma and tubercle. This diagnosis of *sporotrichosis* has been made in many countries in isolated instances ; but it can only be based on bacteriological examination of the pus—another reason for examining pus, the origin of which is not quite clear.

(2) CHRONIC INFLAMMATORY PROCESSES.

Chronic inflammation of the elbow depends upon the same causes which we have encountered in chronic disease of the shoulder-joint. If several other joints are involved, we find in the term **chronic articular rheumatism,** discussed in that connection, a convenient diagnosis rather than a clear conception. If the elbow alone is diseased, it can hardly be anything but **tubercle.**

Careful palpation, comparing both sides, will generally detect the capsule, even if only slightly distended or swollen, in the form of two symmetrical pads (fig. 297) on both sides of the triceps tendon, and as a transverse pad at the level of the head of the radius. If the capsule is definitely thickened, the case must be regarded as one of tubercle, even if there be not much interference with movements. The axilla must always be examined for enlarged glands, although they may be less frequent in tubercular arthritis than in tubercular disease of the skin.

Whereas tubercle usually appears in the shoulder-joint in the form of a dry caries, without swelling of the capsule and without effusion, the fungating and caseous-suppurative forms occur most frequently in the elbow, both being accompanied by a moderate amount of effusion. The joint soon assumes a spindle-form shape, and the tendon of the triceps stretches at a slight depth between the two pads of capsule at the back of the joint.

It is but rarely that the skiagram indicates any osteoporosis (the purely synovial form). Definite foci in the bone (fig. 300) or superficial portions of the joint eroded away, are usually seen (fig. 298). In exceptional cases I have seen a certain amount of peri-articular formation of new bone, especially when fistulæ are present. If the

bone formation is very extensive, it should raise the suspicion of syphilis.

A harmless chronic **inflammation of the olecranon bursa,** corresponding to the same condition of the pre-patellar bursa, must not be confused with a localized tuberculosis of the olecranon (fig. 301).

Occasionally one comes across persons who complain so persistently of pain in the region of the internal epicondyle, that one is inclined to think of tubercle. Sometimes a history of slight injury is given, but more often not. Nothing is to be detected, either by physical examination or by a skiagram. These cases have been termed *epicondylitis* (Francke) and the symptom has been attributed to traumatism of the insertion of the ligament and of the periosteum; and to slight inflammatory changes, *e.g.*, after influenza or rheumatism.

CHAPTER LXXXV.

TUMOURS AND ALLIED SWELLINGS ON THE UPPER ARM AND FOREARM.

We encounter the same tumours and swellings in the upper extremity as we shall come across in discussing the lower limb, especially the thigh; but they are rarer in the arm.

There is nothing characteristic about the tumours of the *skin* and the *subcutaneous tissue* of the upper limb. Only lipoma of the shoulder (fig. 302) and the pendulous lipoma of the axilla (fig. 303) merit special mention.

Spindle-shaped tumours, following the course of a *nerve*, and originating in the *deeper soft tissues*, are usually **neuromata** or **neurofibromata,** but may be **sarcomata.** If the tumour becomes fixed on muscular contraction, we may assume that it has an *intramuscular origin*, in which connection we should think of an angioma of the muscle, of a sarcoma, of a gumma or of tubercle.

If the swelling can be emptied on pressure, or by elevating the arm, and fills up again when the arm is dependent, it is suggestive of an **angioma of the muscle.** These signs, however, only apply if the angioma is definitely of the cavernous type. But most of these tumours contain a large amount of connective tissue and of fat, and smooth muscular fibres proliferate therein, so that they feel firm and even hard. The cavernous type is badly defined and extends in a

diffuse manner ; but the hard variety is definitely circumscribed and could easily be taken for sarcoma or early tubercle, if it were not for two contra-indicating circumstances—the long duration of the disease, and the attacks of acute swelling (thrombosis) which the patients frequently describe.

Tubercle of the muscle appears first as a small oval swelling which is definitely painful on pressure. As long as no suppurative softening and abscess formation bursting through the muscle occur, the diagnosis can only be one of probability, supported by a previous history of tubercle. If an abscess has formed, it is easier to recognize the nature of the disease ; but nevertheless it may be impossible in some circumstances to exclude primary disease of the bone before the operation and without a skiagram.

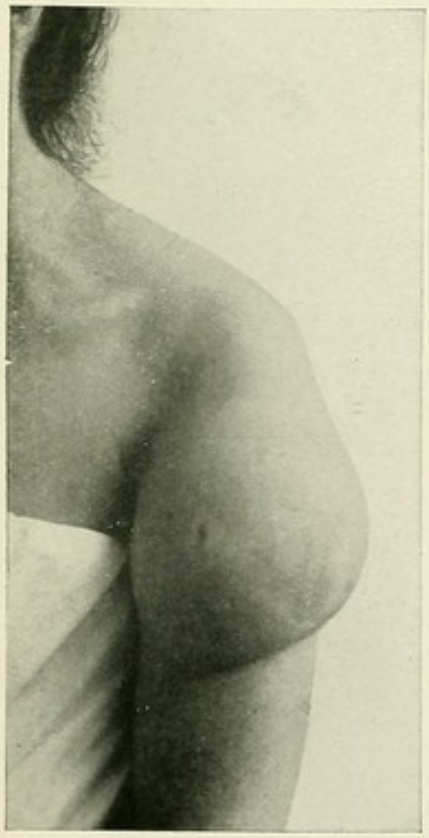

FIG. 302.—Lipoma of the upper arm.

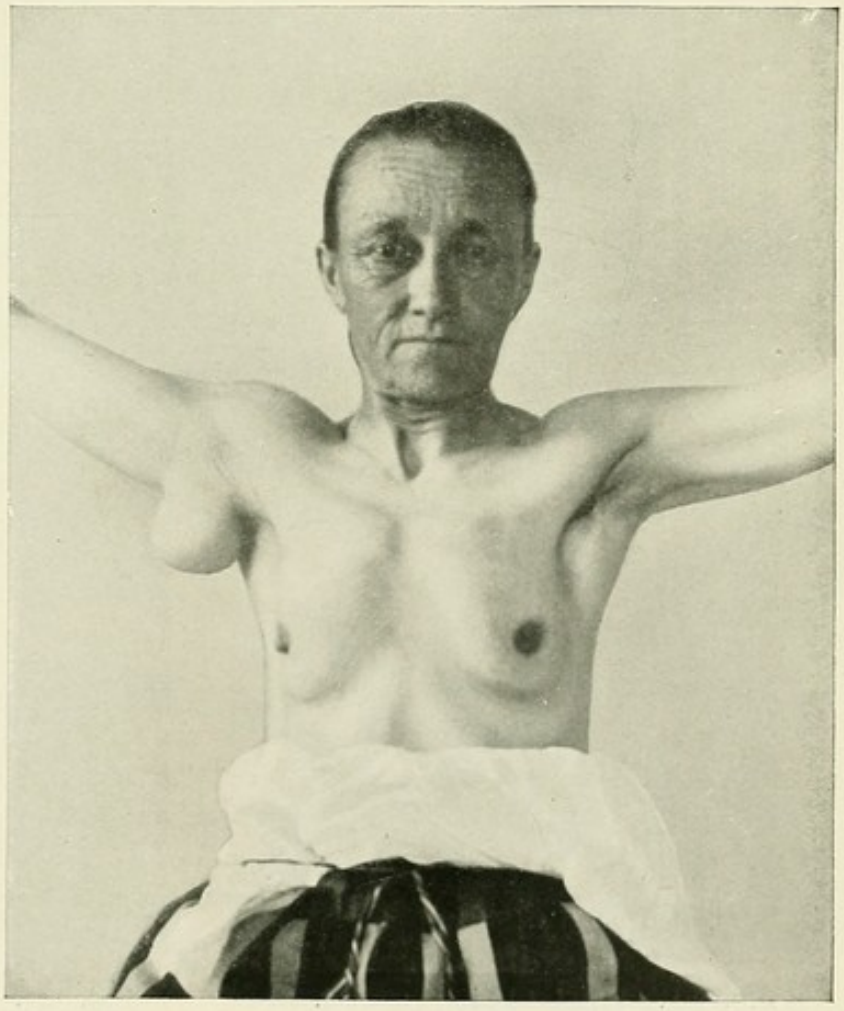

FIG. 303.—Pendulous lipoma of the axilla.

A young man showed me a swelling, which had arisen a few weeks previously, on the anterior surface of the left forearm, in a position where there were no glands. Examination showed that the swelling was either intermuscular or intramuscular ; family history revealed tubercle in a brother. Diagnosis : tubercle of muscle. The operation showed that the major portion of the palmaris longus

had been converted into a tubercular area, which had not yet suppurated.

If the tumour appears to be neither an angioma nor a tubercle, the question of **gumma** and of **sarcoma**, which are rare, will arise.

If we find a tumour over the biceps, resembling a pad transversely to the muscle, appearing when the muscle contracts and vanishing when it relaxes (fig. 304), it can only be a **hernia of muscle**, *i.e.*, a firmly contracted mass of muscle projecting through a space in the aponeurosis.

This defect may be of traumatic origin; but it is occasionally bilateral and is probably then a congenital peculiarity. This was the case in the subject depicted in fig. 304, in whom the change was equally pronounced on both sides.

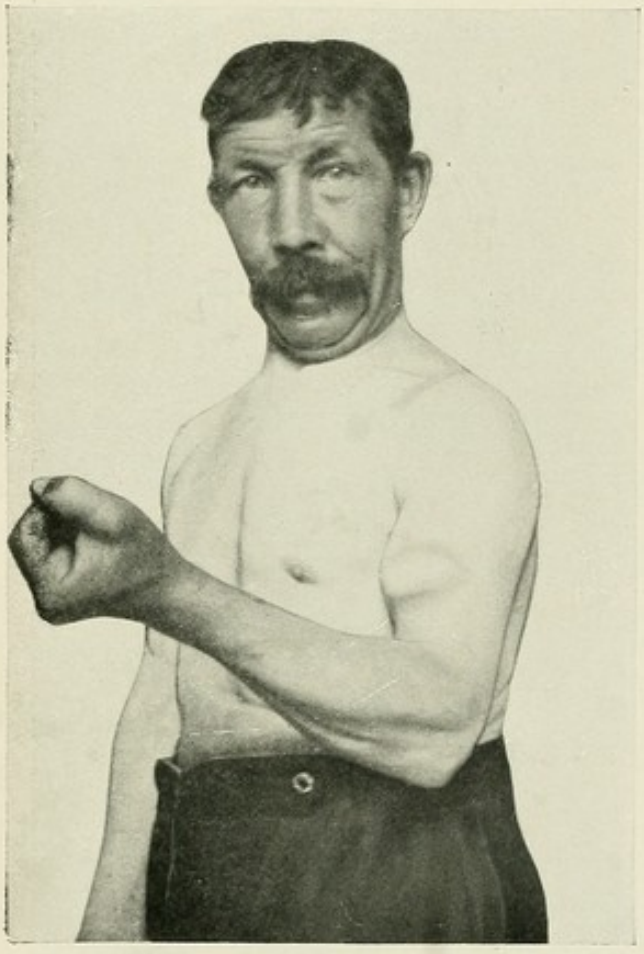

FIG. 304.—Hernia of biceps muscle.

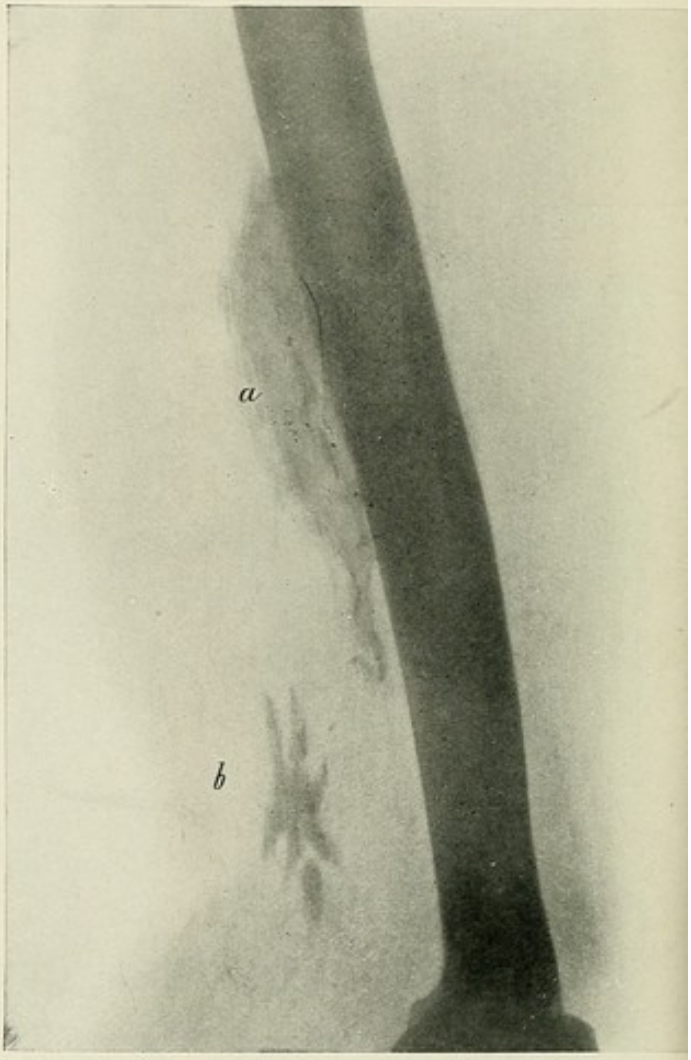

FIG. 305.—Intramuscular osteoma after a contusio
a, Connected with the periosteum. *b*, Lying free i
the muscle.

If a tumour of bony hardness has developed after an injury—contusion of muscle, laceration of muscle after dislocation—we may assume the case to be one of **traumatic osteoma**, a circumscribed ossifying myositis. This is a process intermediate between new growth and inflammation, and occurs mostly in the brachialis internus muscle (fig. 305).



FIG. 306.—Gummatous periostitis and ostitis of the humerus and end of the ulna.

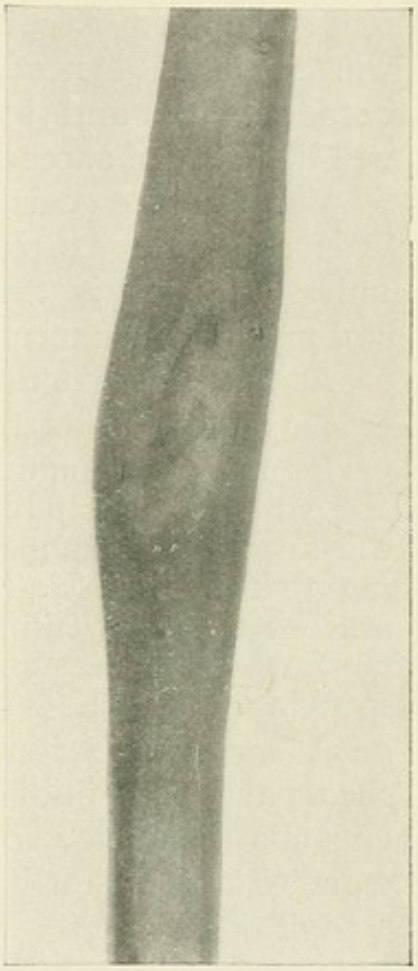

FIG. 307.—Chronic localized osteomyelitis of the humerus (abscess of bone and sequestrum).

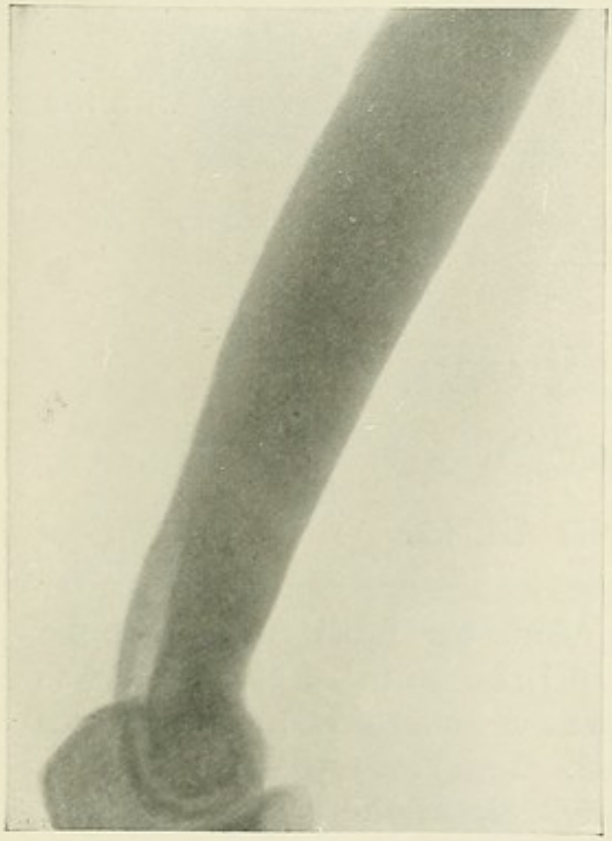

FIG. 308.—Old diffuse osteomyelitis of humerus.

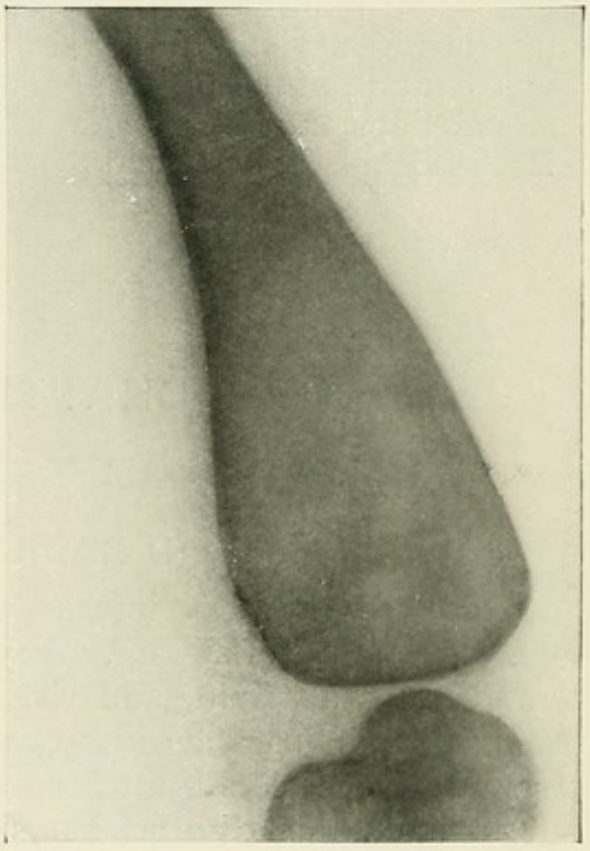

FIG. 309.—Myelogenous tubercle of lower end of the humerus and of the ulna (in a child). Club-shaped deformity of bone.

If a tumour is connected with the bone, and is increasing somewhat rapidly, it is necessary to differentiate between **tubercle, gumma, osteomyelitis and sarcoma**; if the growth is slow, the diagnosis will lie between **sarcoma, fibroma, and chondroma.**

We should especially think of *tubercle of the diaphysis* in children. This condition can easily be mistaken for a chronic osteomyelitis, unless the pus is examined bacteriologically, both in its periosteal and myelogenous forms.

A *gumma* is diagnosed by the history of its comparatively painless course and by a skiagram.

I once saw a gummatous swelling which had existed for two years, and which I definitely looked upon as a sarcoma before ascertaining the history and having a skiagram taken. The patient, however, told me that he had had syphilis fifteen years before, and he himself attributed the swelling to this cause. He was right; the skiagram confirmed his diagnosis (fig. 306), and the swelling vanished after specific treatment.

A *sarcoma* is usually first recognized when its circumference shows that it cannot be either tubercle or gumma. If the patient consults the doctor soon enough, it is quite possible that a skiagram would enable an early diagnosis to be made.

Distension of the bone, if very circumscribed, points to tubercle, but may also indicate sarcoma. Periosteal deposits in children occur in tubercle and in comparatively recent osteomyelitis; in adults almost exclusively in the latter condition and in gummata. Diffuse, smooth induration (fig. 308) or slight spindle-shaped distension points to old osteomyelitis which has run its course. The distension may still be concealing a sequestrum (fig. 307). Irregular proliferation of the periosteum must be ascribed to a gumma (fig. 306). A nebulous transparency of the bone in its entire thickness with the loss of details of its structure suggests a sarcoma.

CHAPTER LXXXVI.

INJURIES OF THE WRIST AND HAND.

(1) RADIUS AND ULNA.

THE diagnosis of injuries of the wrist was a very simple matter before the time of X-rays. Anything which was not a fracture of the radius was a sprain, and vice versa. Dislocation of the wrist was looked upon as a curiosity, and it was asserted that the injury was so rare that it could not be diagnosed. The X-rays have shed some light upon this comfortable simplicity, but at the same time have

raised new problems of diagnosis. In addition to fracture of the radius there are also numerous injuries and displacement of the carpal bones and their combinations. If these could only be recognized by X-rays, the matter would be no more difficult in practice than heretofore. Cases previously diagnosed as sprains would now be sent straightway to the radiographer as "injuries to the wrist," and nobody would take the trouble to attempt to diagnose a fracture of the radius. But fortunately these injuries can be diagnosed without X-rays if they are properly examined.

Fracture of the radius with pronounced fork-like posterior displacement need not detain us. It cannot be mistaken for anything else, if the classical symptoms are present, viz., displacement of the anterior fragment with the hand posteriorly and towards the radial side, freedom of the wrist-joint (fig. 311) and deviation of the styloid process of the radius with the wrist away from the axis of the radius (fig. 312).

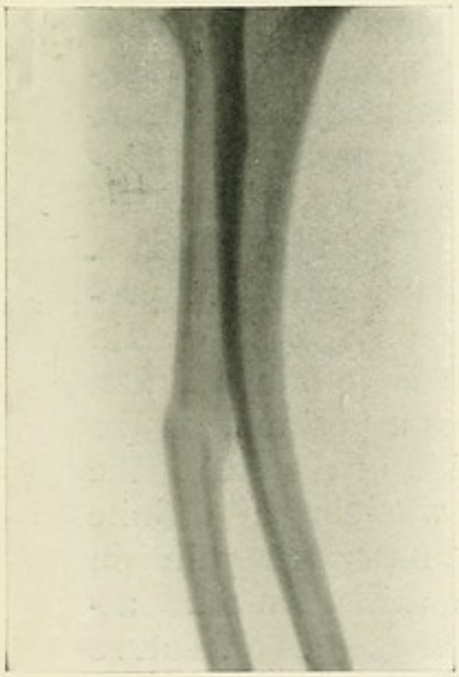

FIG. 310.—Sub-periosteal greenstick fracture.

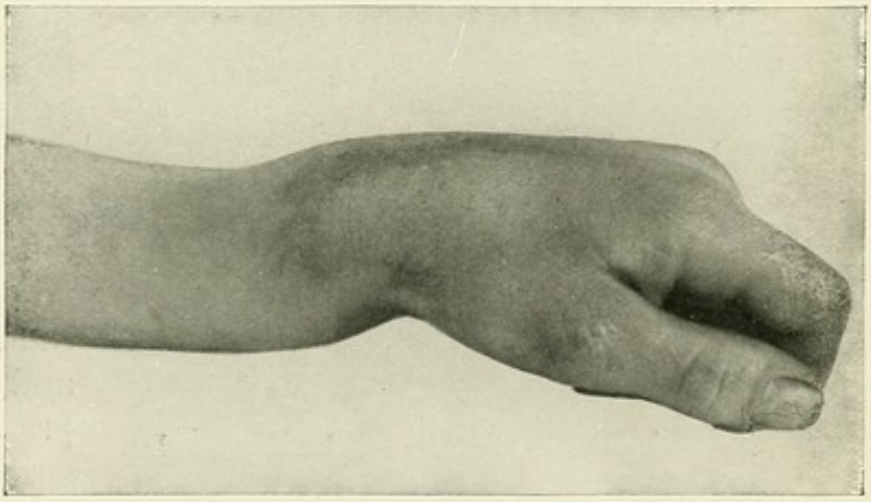

FIG. 311.—Fork-like posterior displacement, with fracture of radius (case of detachment of epiphysis with great displacement).

The styloid process of the ulna is usually broken off in distal fractures (fig. 314, &c.), and the entire lower end of the ulna in more proximal fractures (fig. 319). This latter variety usually occurs in children and in old people with weak bones. Further back, there occurs the greenstick fracture which is so common among children (fig. 310).

If the fracture **involves the joint,** and the displacement is not very pronounced, the diagnosis is more difficult, for we have to take into consideration both sprains and injuries to the carpus.

If the movements of the wrist-joint are free and painless, there can be no damage therein, so that if there be an injury at all it must involve the radius at some distance from the joint. If the movements

are painful or cannot be carried out, it is obvious that the joint is affected. If, after fixing the joint so as to prevent any movement therein, pressure in the axis of the forearm causes no pain, we may exclude a recent transverse fracture of the radius. But, on the other hand, if it does cause pain, we may only attribute it to a fracture if it is distinctly localized on the elbow side of the wrist-joint.

After this preliminary examination, we proceed to a more accurate palpation. If the styloid process of the radius or ulna is very painful on pressure, and if it is also somewhat thickened, we may conclude that there is a fracture, even if it is not possible to feel a movable fragment distinctly.

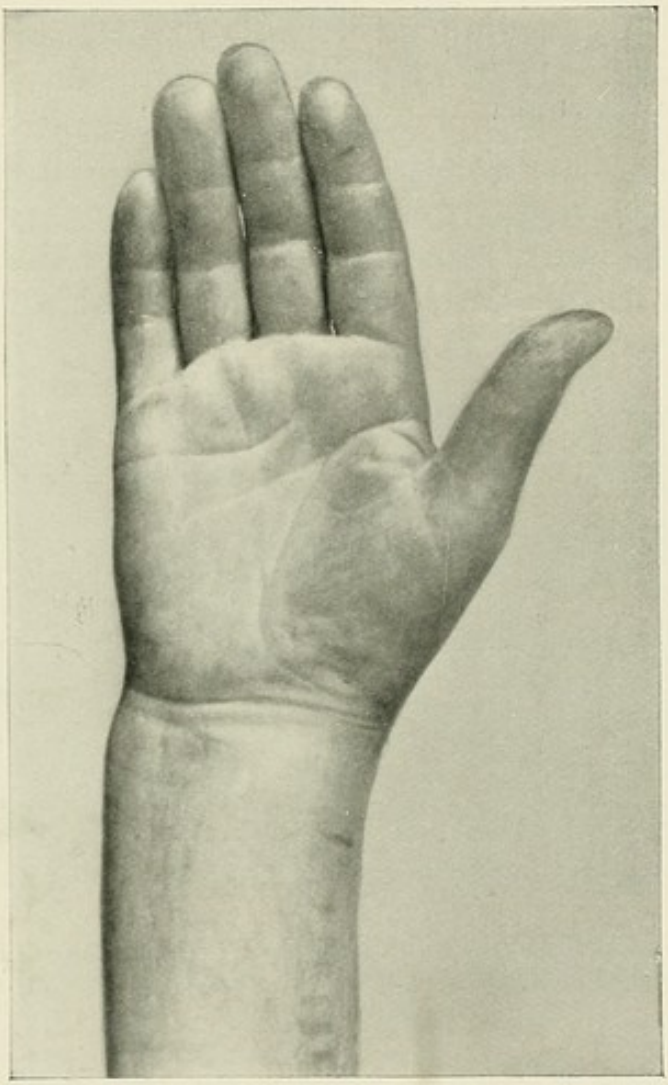

FIG. 312.—Deviation of hand from the radius in a case of fractured radius.

We then feel the radius carefully from before backwards, and as a control from behind forwards, ascertaining, point by point, the amount of pain on pressure. If there is no very pronounced pain, it is certain that there is no fracture. But if there is a position, on the elbow side of the end of the radius, wherein a definite and circumscribed pain on pressure exists, we must assume that there is a **fracture of the radius**, even if there be no visible displacement, which may, of course, be concealed by the general swelling. If this circumscribed pain on pressure can be traced over the whole width of the radius, the case is an ordinary transverse extra-articular fracture (figs. 315 to 318); but if the pain is only pronounced at the outer side and if, at the same time, there is some effusion into the joint, the case is one of an oblique fracture involving the joint (fig. 321). This variety of fracture, described by Barton some seventy years ago, was at that time the subject of considerable controversy. We now know, thanks to the X-rays, that this fracture is not at all rare.

The presence of articular effusion, or at least of hampered activity

of the joint, in association with more or less pain on pressure in a transverse direction, should raise the suspicion of a combined fracture, the ordinary varieties of which are illustrated in figs. 322 and 323. These fractures also occur more frequently than was previously thought.

On the other hand, an isolated fracture of that portion of the end of the radius which is turned towards the ulna is very much rarer. Such a fracture may be suspected when there is a localized pain on pressure between the radius and ulna, and when the movement of rotation is painful.

A separation of the epiphysis must be thought of if the fracture is situated in the vicinity of the epiphyseal line in a young person. These injuries are often accompanied by damage to the bone itself, in that the line of the transverse fracture only corresponds partially to the cartilaginous end, or by the existence of a longitudinal fissure in the bone—which, however, is rare (fig. 313).

We must refer to *another* variety of fracture, which occurs mostly among young people. This is illustrated in figs. 317 and 318, wherein the fracture is caused by sudden axial pressure, for instance, a fall on the palm of the hand. In this case there is neither false mobility nor displacement. The loss of power is often so slight that no fracture is suspected. But careful examination will show that there is a sharply defined transverse area of pain on pressure, above the edge of the radius over the whole extent of the metaphysis. The skiagram reveals on either side a slight roof-like projection of the bone, showing that the radius has been compressed and that the crushed bone has been pushed out laterally because of the insufficient strength of the bone in its long axis.

If it is certain that a fracture of the radius is present, we must examine for the injuries which so often accompany this accident, namely, detachment of the styloid process of the ulna and fracture of the scaphoid (see below).

(2) WRIST-JOINT.

If nothing is found in the radius, we must consider whether the carpal bones have sustained any injury, or whether the case is one of a simple sprain. The typical examples of the former consist of palmar dislocation of the semilunar bone, fracture of the scaphoid, and a combination of the two.

(*a*) If we find, under the flexor tendons, a bony protuberance projecting towards the palm, or even only a marked thickening of the skeleton of the wrist in an antero-posterior plane, in a case wherein the joint is very painful and has lost its power, we must assume that there is probably a palmar **dislocation of the semilunar bone.** This diagnosis would be confirmed by the subsequent onset of neuralgia in the terminal fibres of the median nerve.

These injuries are nearly always recognizable in skiagrams taken



FIG. 313.—Commencing separation of the epiphysis of radius, with a longitudinal fissure.

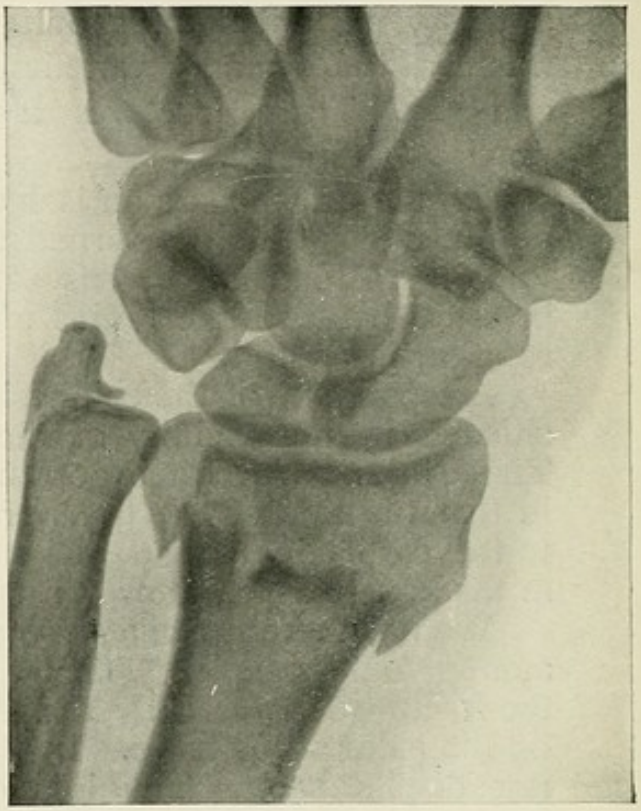

FIG. 314.—Transverse fracture of radius, with detachment of styloid process of ulna.

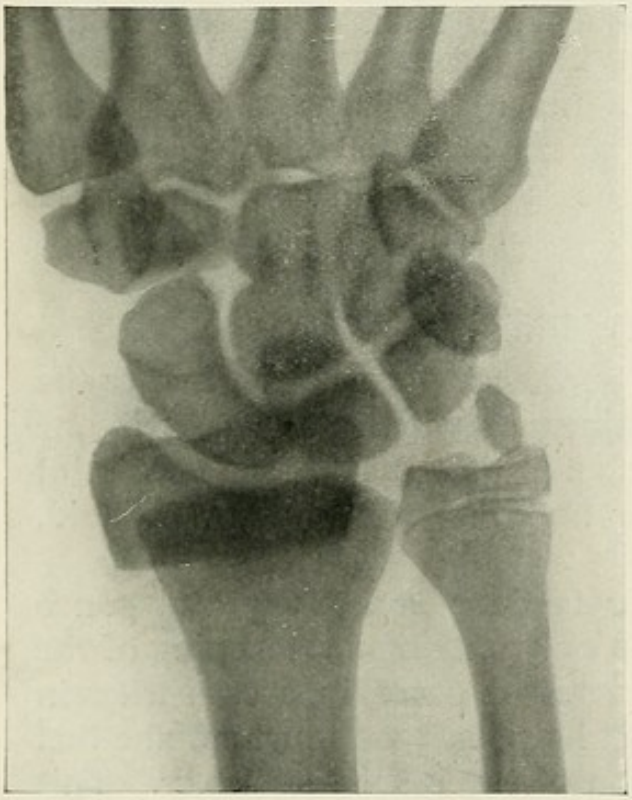

FIG. 315.—Separation of epiphysis of radius, with displacement of radius backwards. Patient aged 19. (Case of fig. 311.)

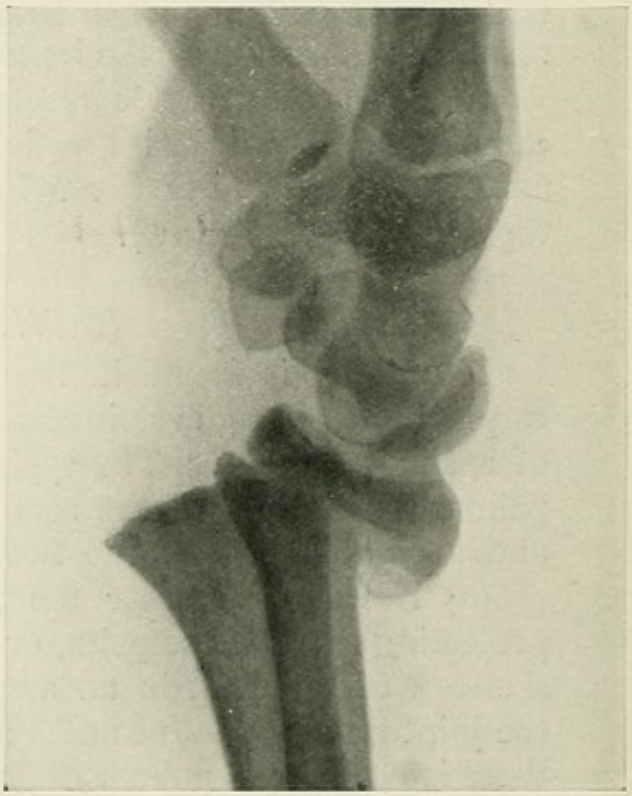

FIG. 316.—Same case, from the side.



FIG. 317.—Fracture of radius, caused by axial pressure, in a boy aged 10.

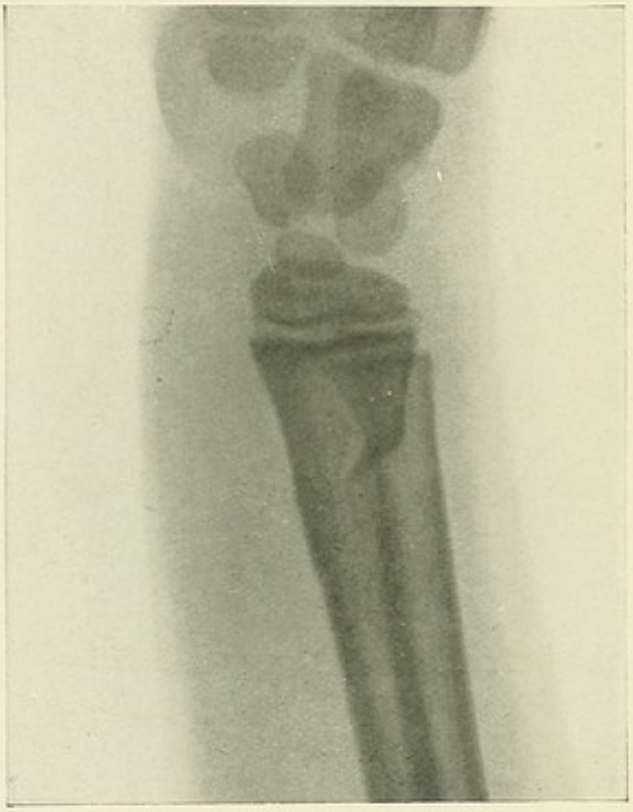

FIG. 318.—Same case, from the side.



FIG. 319.—Fracture of radius far back, with detachment and partial shattering of lower end of ulna.



FIG. 320.—Same case, from the side.

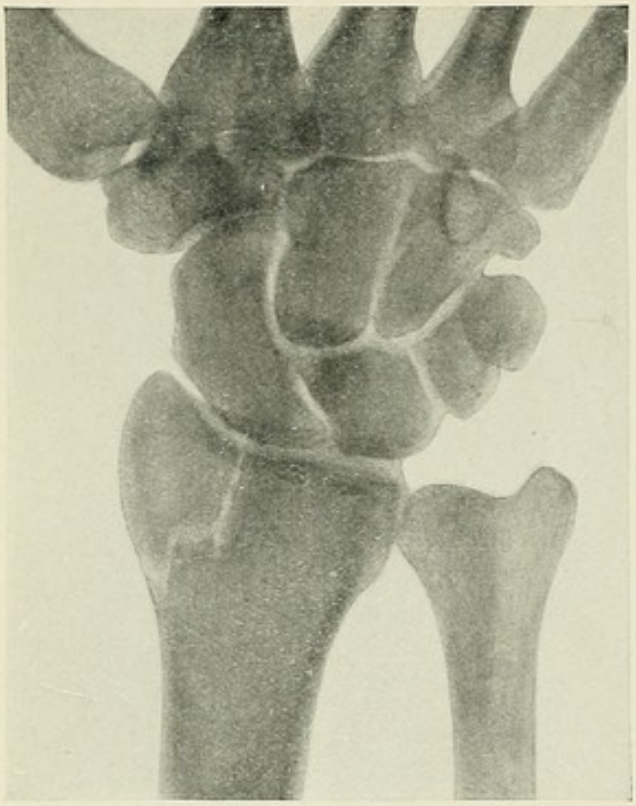

FIG. 321.—Oblique fracture of lower end of radius.

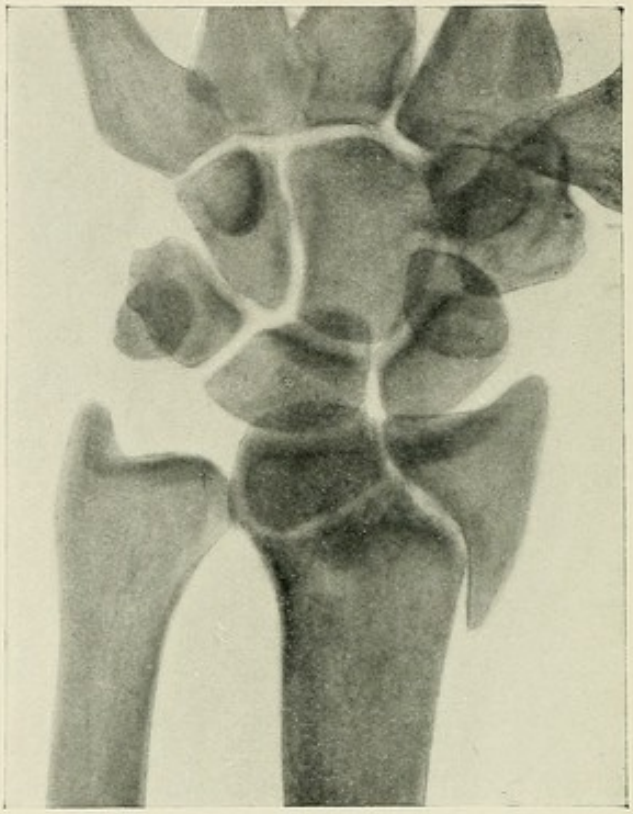

FIG. 322.—Combined fracture of radius. (Oblique fracture on the radial and ulnar side.)

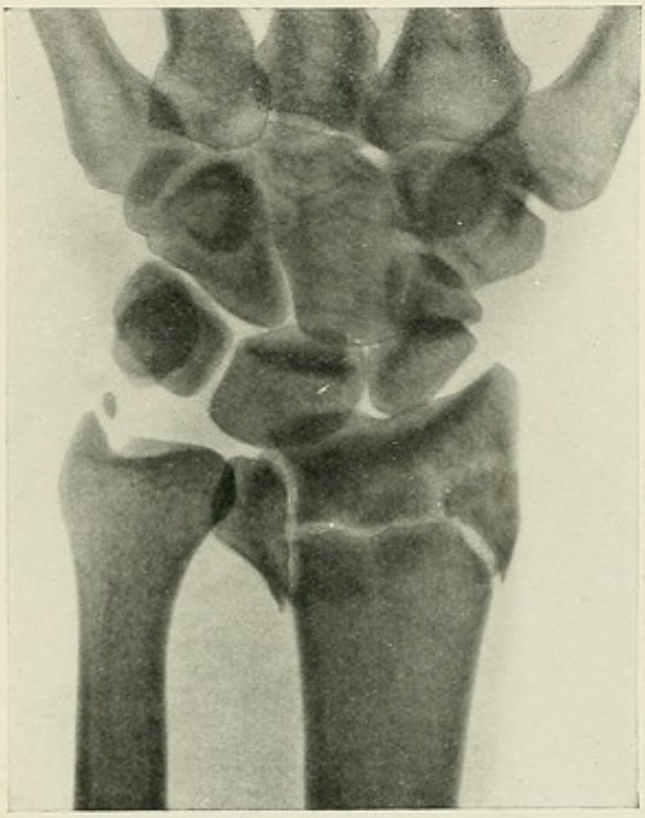

FIG. 323. — Combined fracture of radius. (Transverse fracture, with oblique fracture on the ulnar side.)



FIG. 324.—Dorsal deviation of the distal fragment in a case of fractured radius. (An old case, in which line of fracture is still clearly recognizable.)

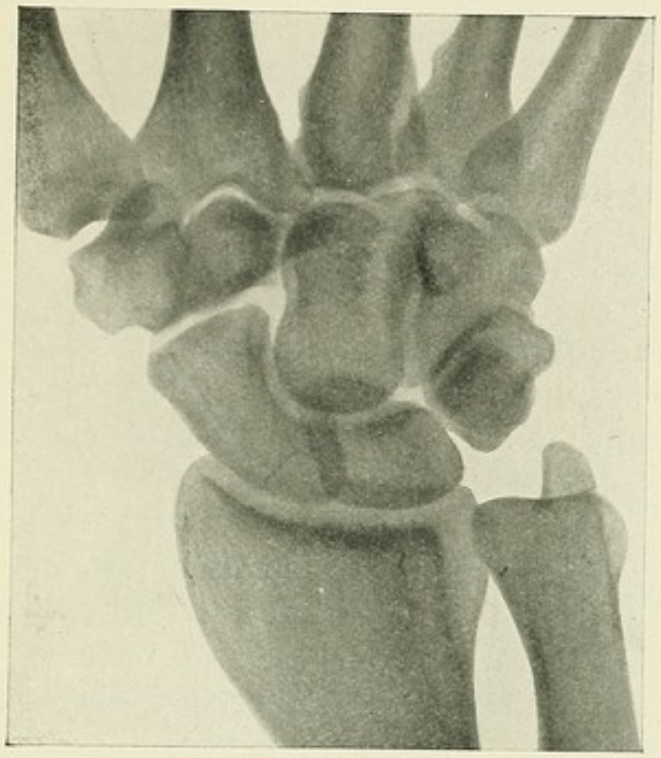

FIG. 325.—Normal wrist-joint.

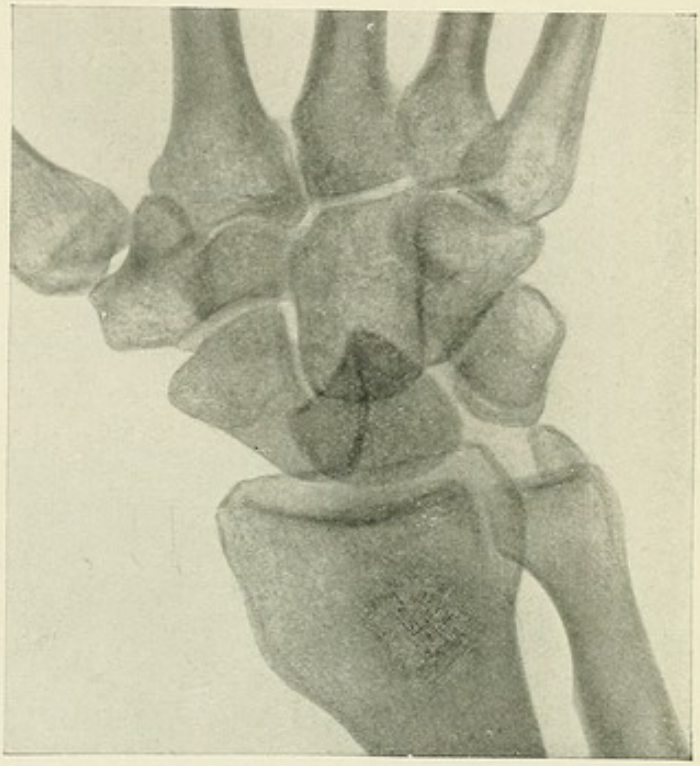

FIG. 326.—Palmar dislocation of the semilunar bone.

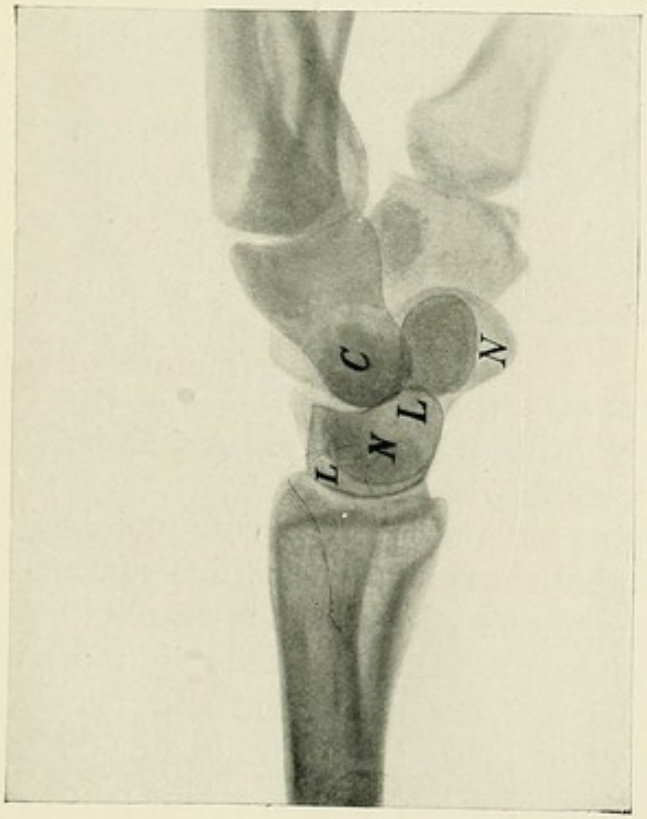

FIG. 327.—Normal wrist. *C* = Os magnum. *N* = Scaphoid. *L* = Semilunar.

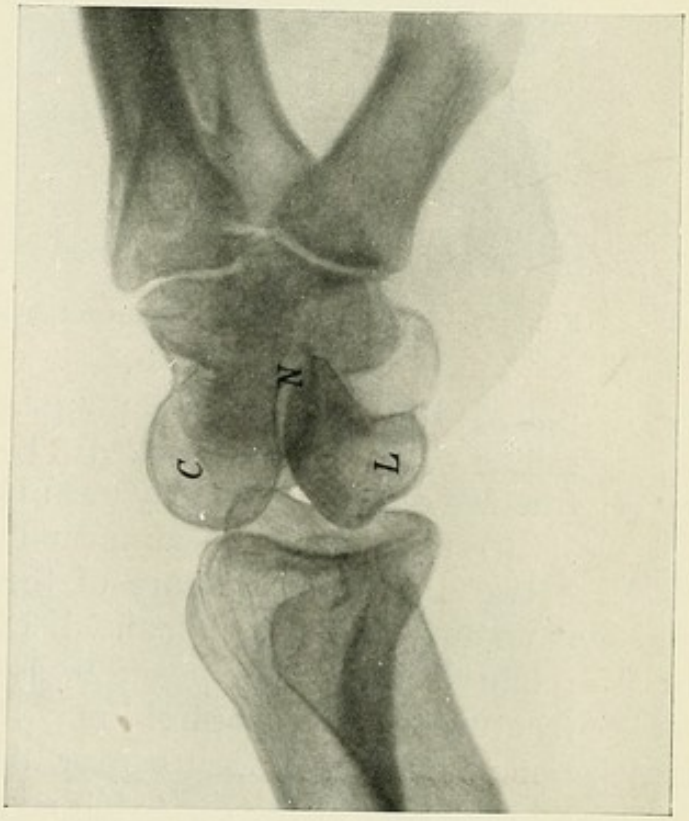

FIG. 328.—Palmar dislocation of the semilunar. References as in previous figure.

in the dorso-palmar position. The semilunar is somewhat obliquely directed towards the scaphoid, and its distal articular surface looking towards the radius is easily detected (*cf.* figs. 325, 326). A skiagram taken in the lateral position always exhibits these injuries very clearly, and this measure should never be neglected in any obscure injury of the carpus. Such a skiagram shows the semilunar bone deviated towards the palm, with the head of the os magnum lying upon its dorsal surface (*cf.* figs. 327 and 328). In these cases the os magnum might be looked upon as dislocated just as well as the semilunar.

(*b*) If in addition to a moderate amount of palmar projection, there is definite pain on pressure over the scaphoid with shortening of the carpal region, and probably also some radial displacement of the hand, we must assume that the wrist has sustained a combined injury. This combined injury usually consists, as I have shown, of fracture of the scaphoid with palmar dislocation of the semilunar and the proximal fragment of the scaphoid attached to it. We term this for convenience the **typical intercarpal dislocation fracture.**

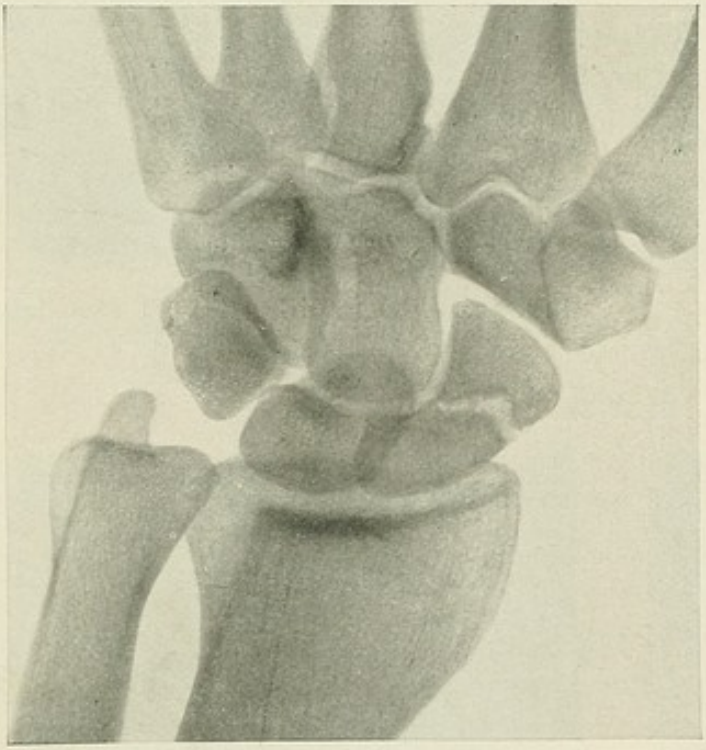

FIG. 329.—Transverse fracture of the scaphoid without displacement.

Fig. 330 is taken from the case, in which both sides were affected, which first suggested to me the typical character of this injury. Sometimes there is a transverse fracture of the os magnum combined with the injury; the styloid process of the radius or of the ulna may also be broken off occasionally. A definite fracture of the radius may even be present.

(*c*) If there be no abnormal bulging we must differentiate mainly between a simple fracture of the scaphoid and a pure sprain—apart from anything exceptional. If both fragments of the broken scaphoid retain their normal position, as is often the case, the only sign of **fracture of the scaphoid** may be a narrowly circumscribed and persistent pain on pressure over the broken bone, *i.e.*, in an area distal and internal to the easily felt styloid process of the radius. This pain on pressure sometimes permits us to suspect this fracture long after the infliction of the injury. The diagnosis is easier when the

proximal fragment is displaced towards the palm, because a careful comparison of the two hands would probably show that there was a projection towards the palm on one radial side.

A skiagram usually demonstrates a fracture of the scaphoid at the first glance (fig. 329). Doubt can only arise if the scaphoid is placed steeply, so that its distal portion overlays its proximal portion. The skiagram is then liable to erroneous interpretation, as occurred so often when X-ray diagnosis was in its infancy. When the scaphoid is in such a position it is not possible to recognize fracture thereof at the first glance (see, *e.g.*, the scaphoid in fig. 323). A control skiagram must therefore be taken with the wrist slightly flexed and adducted towards the ulna.

If there is no local pain on pressure over the scaphoid, we are justified in limiting the clinical diagnosis to that of a **sprain.** But if pain persists after an injury which has been assumed to be a wrench, or if any doubt exists from the first, we must resort to an X-ray examination. This will probably show that we have missed some injury which is not palpable, *e.g.*, a **contused fracture of the semilunar bone** which can hardly be detected without an X-ray examination, and which may lead to atrophy or to the partial formation of a sequestrum. I have seen such an injury occur as a result of an indirect trauma.

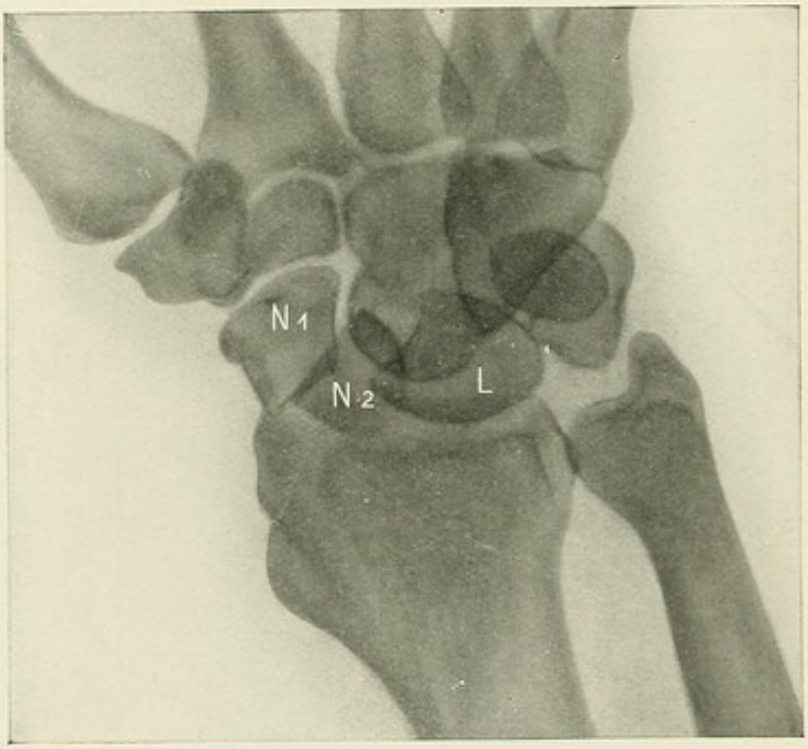

FIG. 330.—Typical intercarpal dislocation-fracture. (Fracture of the scaphoid, with palmar dislocation of the semilunar, L, and of the proximal fragment of the scaphoid, N_2.)

It is most important to make an X-ray examination in all injuries resulting from accidents, which we may be inclined, perhaps unjustifiably, to attribute to malingering and exaggeration. If the skiagram fails to reveal anything, we may then definitely speak of a sprain, and make our prognosis accordingly.

We have hitherto confined ourselves to injuries which frequently occur in practice, and the diagnosis of which is important for the general practitioner. But there are, in addition, rare *dislocations* in the radiocarpal joint, in the intercarpal joints and carpo-metacarpal

joints, some of which can be diagnosed by careful palpation, taking into consideration the position of the styloid processes, but which can all be definitely diagnosed by means of X-rays.

(3) THE METACARPUS AND FINGERS.

Fracture of the metacarpals can easily be distinguished from simple contusions by traction and pressure on the corresponding fingers. Only a longitudinal fracture would remain painless on such manipulation.

Fracture of the base of the first metacarpal may be mentioned as a typical, though not as a frequent injury. It is usually regarded as a sprained thumb, but the persistent pain shows that some more severe injury is present.

The skiagram shows

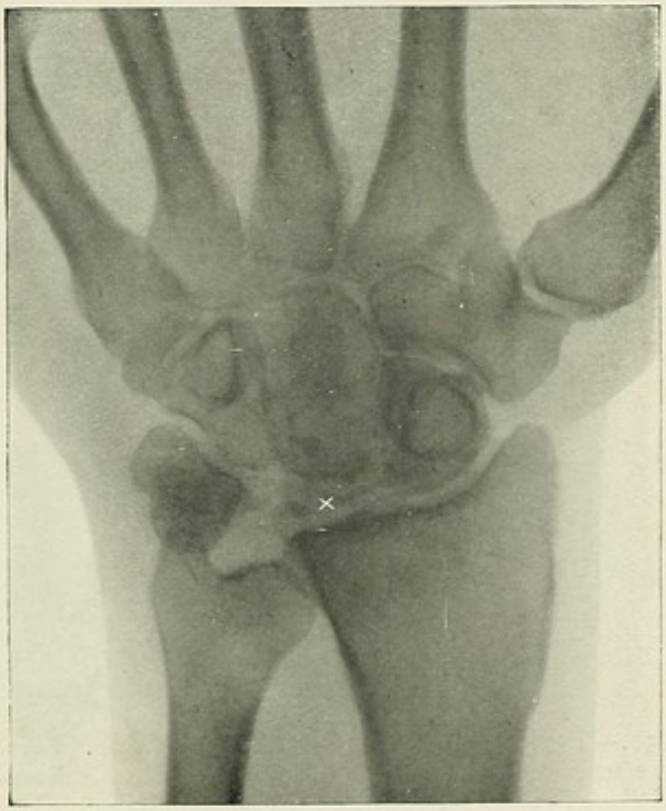

FIG. 331.—Contusion fracture of semilunar X (traumatic softening).

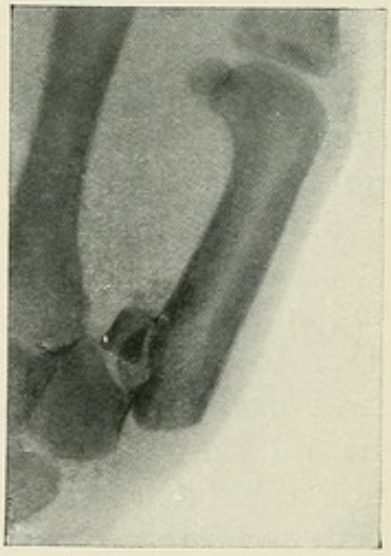

FIG. 332.—Fracture of the base of first metacarpal.

either a transverse fracture of the upper end of the base (fig. 332), or a piece of bone broken off its palmar surface (Bennett's fracture).

The circulatory disturbances which follow injuries of the bones and soft parts are most pronounced on the *back of the hand*, just as in the case of inflammation. They are liable to persist in this position for a considerable time, even if they are not kept up by the manipulation of the patient who is insured against accidents. This condition has been termed "hard traumatic œdema of the back of the hand" (Secretan), but it has also been shown to be the result of percussion, practised by those who shirk work while seeking compensation.

Fractures and dislocations of the fingers are so easy to recognize that they need not detain us. The same applies to dislocation of the thumb, so well known, because of the difficulty of its reduction. It is an injury which cannot be mistaken for anything else.

The following scheme summarizes the foregoing remarks on injuries of the wrist :—

No deformity of bone, evident on inspection or palpation.	Radius nowhere showing any localized pain on pressure; carpus usually somewhat swollen; loss of power always pronounced; Röntgen rays always required.	Pain on pressure diffuse.	(1) **Sprain of hand.**
		Localized pain on pressure in the tabatière.	(2) **Fracture of scaphoid.**
		Localized pain on pressure over the semilunar (middle of the back of carpus).	(3) **Contused fracture of the semilunar.**
	Radius painful on localized pressure, *behind* the line of the wrist-joint.	Wrist free; the pain on pressure runs in a transverse direction.	(4) **Extra-articular transverse fracture of the radius.**
		Wrist swollen; loss of power; pain on pressure close to dorsal edge of radius.	(5) **Fracture of radius extending into joint.**
Definite deformity of wrist.	Shape of wrist like the back of a fork, with the bend more towards the elbow.	.. ..	(6) **Extra-articular** fracture of radius, 3-4 cm. or more behind the joint; usually with detachment of lower end of ulna.
	Shape of wrist like the back of a fork, with the bend near the carpus.	Joint free.	(7) **Extra-articular** fracture of radius near joint; often with fracture of styloid process of ulna (also separation of epiphysis).
		Joint swollen, tender and stiff.	(8) **Intra-articular** fracture of radius (oblique fracture or transverse and oblique fracture).
	Dorso-palmar thickening of the joint without definite fork shape of wrist.	No definite shortening of hand; localized prominence of bone under the flexor tendons.	(9) **Dislocation of the semilunar.**
		Shortening of hand; large mass of bone under the flexor tendons; pain on pressure over tabatière.	(10) **Inter-carpal dislocation-fracture** (fracture of scaphoid and dislocation of semilunar); not rare.

CHAPTER LXXXVII.

INFLAMMATORY PROCESSES ABOUT THE WRIST.

(1) ACUTE INFLAMMATIONS.

We need only briefly refer to the severe inflammatory œdema of the back of the hand, which may follow any infected wound of the skin, either on the palm or on the dorsum. We must, however, deal in more detail with **inflammations of the tendon-sheaths,** wherein there may be some doubt at first as to the primary seat of the inflammation. If the patient states that the swelling has followed a perforated wound of the finger, or a bite, &c., we should at once think of the tendon sheaths, because such insignificant peripheral wounds frequently lead to acute suppuration within them.

The character of the loss of power furnishes an important differentiating sign. Inflammation of the tendon sheath especially interferes with the *movements of the fingers,* whereas disease of the joint affects the *movements of the wrist.* An inflamed wrist is painful all over, whereas in inflammation of the tendon sheaths the affected side only is painful. In acute arthritis, traction and pressure in the axis of the wrist is painful, but this is not the case when the tendon sheaths are inflamed. Finally, teno-synovitis always spreads in a longitudinal direction, whereas arthritis remains limited to the neighbourhood of the joint.

It sometimes happens that the joint becomes secondarily involved after a primary inflammation of the tendon sheaths. We may assume that such an event has occurred if pain, œdema and pyrexia persist, despite the opening of all superficial areas of pus, or if we feel and hear a sound of grating on moving the joint. This latter sign indicates that the articular cartilage has been partially separated or destroyed by the inflammation. On the other hand, the tendon sheaths may become secondarily involved as a result of disease in the joint or in the bones.

If the teno-synovitis has extended to the forearm, and is accompanied by fever, œdema and pain, we must carefully search for suppuration in order to make a timely incision into the abscess. As this is often situated deeply on the interosseous ligament, we must not wait for fluctuation before making a diagnosis.

Having diagnosed an **inflammation of the joint,** we must next determine its *nature* and its *cause.*

If other joints are also affected, and the inflammation subsides after the administration of salicylates, we may assume that the case is one of acute articular rheumatism. If only one joint is affected, and the salicylates are ineffective, gonorrhœa is the most probable

cause, even if an injury is invoked as a pretext, or has actually happened.

An hotel servant sought to claim his accident compensation because of an acute swelling of his wrist, having sprained it in lifting a portmanteau. When asked whether he had had gonorrhœa, he at once gave the desired reply. The lifting of the portmanteau was merely the occasion of the first appearance of symptoms of inflammation; although, of course, the sprain may have favoured the attack of the gonococci on the joint. The patient should produce the most irrefutable evidence of an accident before an injury can be made responsible, even in a limited manner, for such an arthritis.

For the rest we may refer to what has already been said in connection with the shoulder-joint. In a few cases the diagnosis must be made by the course of the disease. Acute articular rheumatism runs a rapid course and does not usually impair the power of the joint; gonorrhœa takes a long time to recover, often lasting for months. In some cases it leaves the joint free, in others stiff. Staphylococci and streptococcic infection lead, as a rule, to suppuration and to partial stiffening.

(2) CHRONIC INFLAMMATORY PROCESSES.

No difficulty usually attends the diagnosis of inflammation of the wrist, which is chronic from the start. If several joints have been affected symmetrically, the case is one of **chronic articular rheumatism,** the varieties and causes of which have already been discussed in connection with inflammations of the shoulder-joint.

If, on the other hand, only one wrist is affected, there is no alternative but to assume that the case is one of **tubercle** (fig. 334). It is most important to recognize this condition in its early stages. If the extent of the movements at the wrist gradually becomes restricted, if those which are executed are painful, if there is also slight pain on pressure, and some muscular atrophy supervenes in the forearm, we should think of tubercle, even though there be no visible swelling. If there is swelling, the question as to its differentiation from **tubercular teno-synovitis** may arise. The clinical pictures of the two diseases are, however, quite different. In tubercle of the joint the whole wrist is thickened in a spindle-shaped manner, in advanced cases the hand is in a position of slight palmar dislocation with complete extension of the fingers (fig. 334). The pain on pressure is equally pronounced on both sides of the joint, and there is also pain on traction or pressure in the axis of the wrist, as well as on any attempt at active or passive movements of the joint. In teno-synovitis, however, the swelling is only on one side, generally



FIG. 333.—Wrist in arthritis deformans.

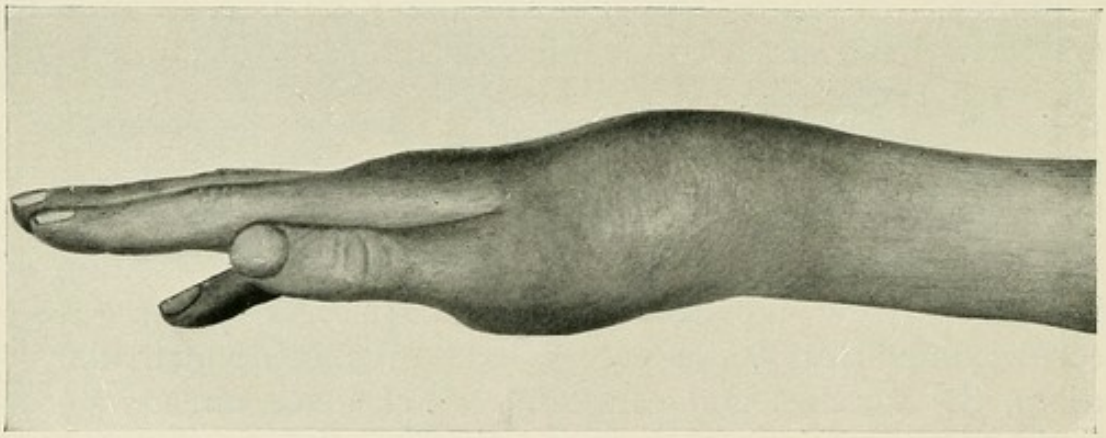

FIG. 334.—Tubercle of the wrist.



FIG. 335.—Tubercular teno-synovitis of the flexor tendons. Fingers slightly contracted in flexion.



FIG. 336.—Arthritis deformans. (Skiagram of fig. 333.)



FIG. 337.—Tubercular arthritis.

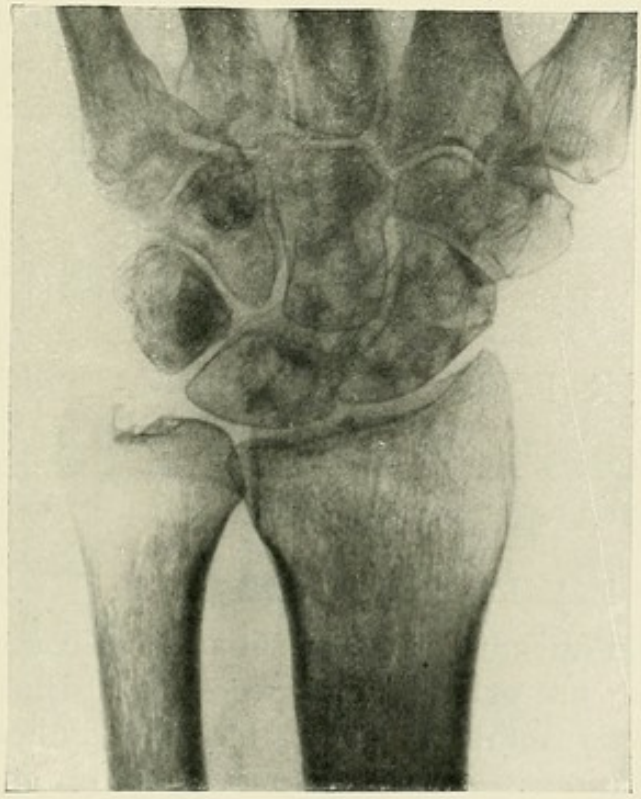

FIG. 338.—Acute maculated osteoporosis in a case of complicated fracture of the elbow.



FIG. 339.—Rickety changes in bone.

on the palmar surface, and its maximum degree is not at the level of the wrist, where the tendon sheath is firmly bound down by the strong anterior carpal ligament, but either proximally or distally thereto (see fig. 335). The fingers are not extended, but are slightly contracted in flexion, and there is no palmar subluxation of the hand. If there be any pain on pressure, it is limited to the affected surface. The movements of the joint are only mechanically hindered by the swelling, but are scarcely painful. Pressure on the joint causes no pain.

If the joint is stiff and the movements of the fingers very restricted, and if fistulæ are present, it is neither necessary to inoculate guinea-pigs nor to take a skiagram in order to establish the diagnosis of tubercular arthritis.

A skiagram gives valuable information in all stages of the disease concerning the site and extent of the affection of the bone, and of the condition of the articular cartilage. In the early stage of synovial disease, X-ray examination only shows a diffuse osteoporosis, which differs by its greater uniformity from the acute maculated osteoporosis which occurs in acute inflammatory processes and in fractures (fig. 338).

If the disease starts in the bone, it can be recognized very early. In both forms the cartilage disappears in the course of the disease, and the individual bones come into direct contact. In the later stages the bones appear merely as shapeless and nebulous structures (fig. 337).

The extreme degree of bony changes which may exist in arthritis deformans is shown in fig. 336. It is interesting to compare with it a skiagram of a case of rickets (fig. 339).

CHAPTER LXXXVIII.

ABNORMAL POSITIONS AND POSTURES OF THE HAND AND FINGERS.

A.—RESULTS OF INJURIES TO NERVES.

We have already referred on various occasions to paralytic conditions of the upper limb, which are of surgical importance. But it may not be superfluous to briefly summarize what has already been said, and to make a few amplifications.

Two questions arise in every case of paralysis :—

(1) Which muscles are paralysed ?

(2) Where is the interruption in the conducting path of the nerve?

The reply to the first question only demands a knowledge of muscular function and a careful examination. Often a mere glance at the patient suffices for an approximate diagnosis, when the limb is held in a characteristic posture. If the hand hangs prone and lax, and the fingers cannot be extended, it is obvious that the case is one of *radial nerve paralysis*. If the thumb is extended against the index finger and cannot be moved away from this position, we should think of *paralysis of the median nerve*, and should test the power of abduction and flexion of the index and middle fingers especially. If this power is lost, and if at the same time the sensibility of the dorsal surface of the terminal phalanges is abolished, there can be no doubt about the diagnosis. If, on the other hand, the thumb cannot be actively approximated to the index finger, if the basal phalanges of the second and fifth fingers are slightly over-extended while the middle and terminal phalanges are slightly flexed, we should at once suspect *paralysis of the ulnar nerve*. It is easier to diagnose this condition at a first glance in the later stages, when the thumb, hypothenar eminence, and interossei are atrophied and the fingers have assumed the well-known posture of "main en griffe," *i.e.*, over-extension of the basal phalanges with severe flexion of the middle and terminal phalanges (fig. 346).

If the patient cannot actively raise his arm at the shoulder, though the movement can be performed passively without difficulty, we should think of paralysis of the circumflex nerve, and should test whether there is any loss of sensation in the area to which the sensory branches of the nerve are distributed (over the deltoid muscle).

The second question, relating to the *site of the damage*, is, however, of greater importance from the point of view of surgical treatment. This is frequently quite clear from the original cause of the disturbance (*e.g.*, aneurism, tumour, &c.), or from the position of an injury, such as a cut, stab, or fracture of bone. Cuts over the wrist, which frequently involve the ulnar or even the median nerve, and fractures of the humerus, which may sacrifice the radial nerve, are mainly responsible. At the level of the shoulder-joint the dislocated head of the humerus may bruise the circumflex nerve, or, more rarely, one of the large cords of the brachial plexus. In the supraclavicular region the plexus may be directly injured, or indirectly, by means of a fragment of a broken clavicle.

In the absence of any such indication, or in cases wherein the injury involves simultaneously several sections of the limb, we should always give the preference to the causation which is able to attribute all the paralysis to one individual lesion. An example will make this clear.

A workman was hit on the head and shoulder by a large block of stone. When we saw him a few weeks subsequently, we were particularly struck by the posture of the left hand, which corresponded to that of radial paralysis. A fracture of the upper third of the humerus, which had healed somewhat at an angle, appeared at first sight to furnish the required explanation. But further examination showed that not only did the paralysis concern the extensors of the fingers and wrist and the supinators, but that it also involved the deltoid muscle, and that there was loss of sensation over the area supplied by the circumflex nerve. All this made it evident that the circumflex nerve was damaged when the fracture of the upper arm occurred. But this did not explain the paralysis and atrophy of the supraspinatus and infraspinatus muscles, which were no less striking than the other paralysis. There must, therefore, have been some injury higher up, and, as a matter of fact, there was a badly united fracture of the clavicle, the peripheral end of whose central fragment exactly corresponded with the position of Erb's point.

We were obviously not dealing with separate paralyses of the radial, circumflex and suprascapular nerves, but with a contusion of the nerve cord composed of the fifth and sixth roots, between the clavicle and the first rib—the so-called Erb's point. The accuracy of this assumption was proved by the fact that the muscles whose nerve supply corresponded exactly with the fifth and sixth roots were completely paralysed, *i.e.*, the supraspinatus, infraspinatus, deltoid, coraco brachialis, brachialis anticus, supinator longus and brevis. The nerve fibres to the long extensors of fingers, which are given off much lower down, were, however, evidently less directly involved, and the corresponding muscles therefore suffered less damage.

Just as damage to the upper roots of the brachial plexus, causing Erb's **paralysis**, produces a fairly uniform clinical picture, notwithstanding certain irregularities, a similar result follows from damage to the lower roots, causing **Klumpke's paralysis**. In this condition, the paralysis of the small muscles of the hand, and the disturbed sensation in the region of the median and ulnar nerve, are combined with oculo-pupillary derangements, such as miosis, narrowing of the palpebral fissure and retraction of the eyeball. The more protected position of the lower roots usually prevents their exposure to injury, and therefore Klumpke's paralysis is more frequently encountered as a result of tumours or inflammatory diseases of bone (*e.g.*, spinal caries).

The patient has not always paralysis when he consults the surgeon. The latter often has more occasion to see paralyses of the upper extremity arise as a result of treatment. These include *anæsthesia paralysis, Esmarch's paralysis* and *crutch palsy*.

The first condition usually represents paralysis of the circumflex or radial nerve, and depends upon compression of the nerve-roots between the humerus and thorax, or between the humerus and the edge of the operating table, when the arm is raised. The mechanism

of the two other forms of paralysis requires no further explanation. In all the three forms the motor fibres are usually alone affected, and spontaneous recovery occurs in a few weeks, or at latest in a few months. The course of ischæmic paralysis which comes on after too tight an application of a firm bandage, is quite different, because in such a case there is direct damage to the muscle in consequence of the deficient blood supply. The final result is not one of recovery but a fibrous degeneration of the muscle with contracture, in other words a permanent damage.

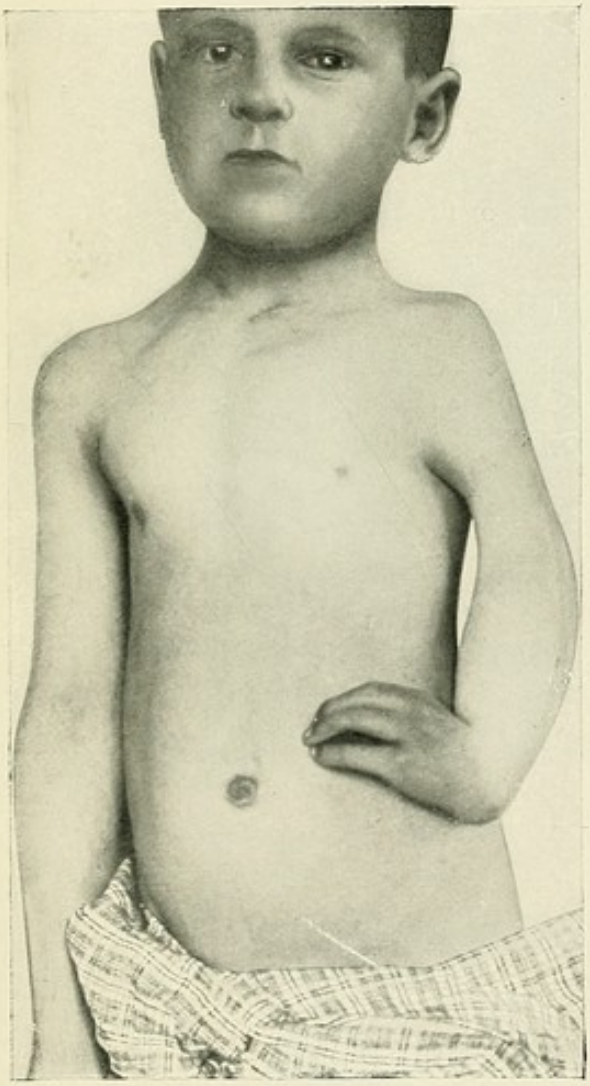

FIG. 340.—Manus vara. Absence of radius and of thumb.

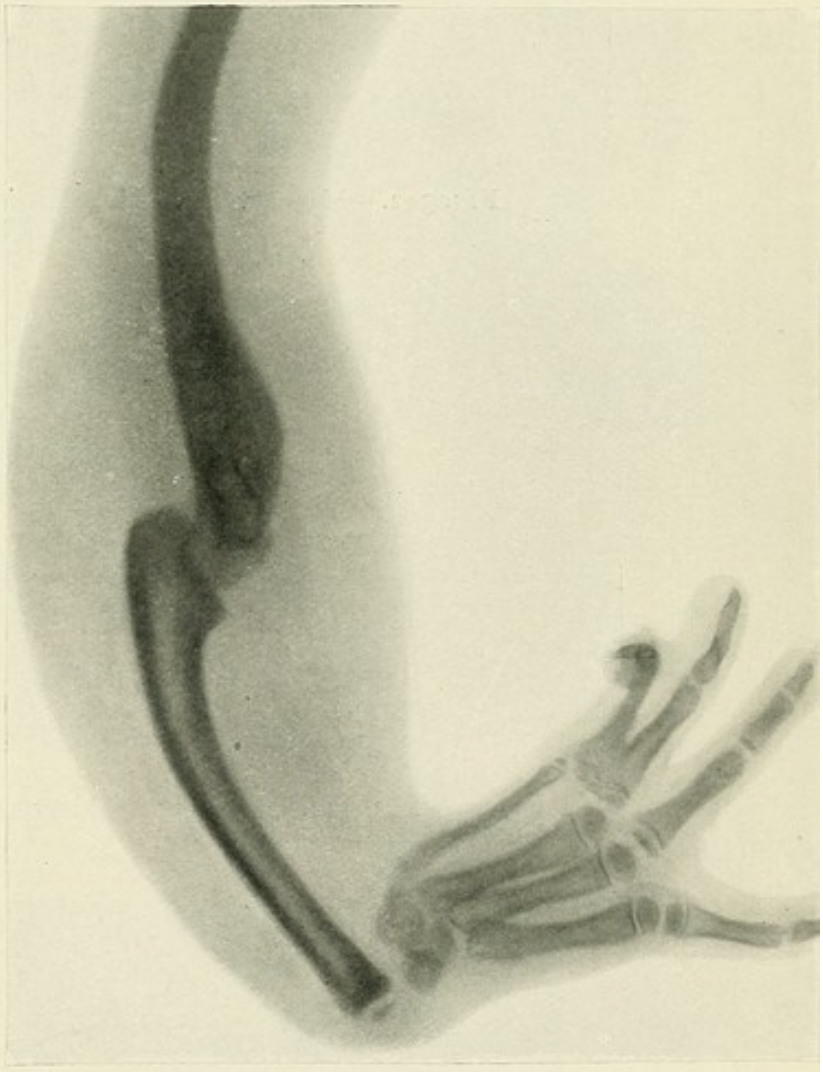

FIG. 341.—Skiagram of same case.

B.—ABNORMAL POSTURES OF THE WRIST-JOINT.

Abnormal postures of the hand are less frequent than those of the foot. Apart from ordinary traumatic deformities we distinguish congenital manus vara and acquired manus valga.

Manus vara, clubbed hand, which is generally seen in infants, always indicates a partial or complete defect in the radius. The thumb is often absent in these cases (figs. 340 and 341).

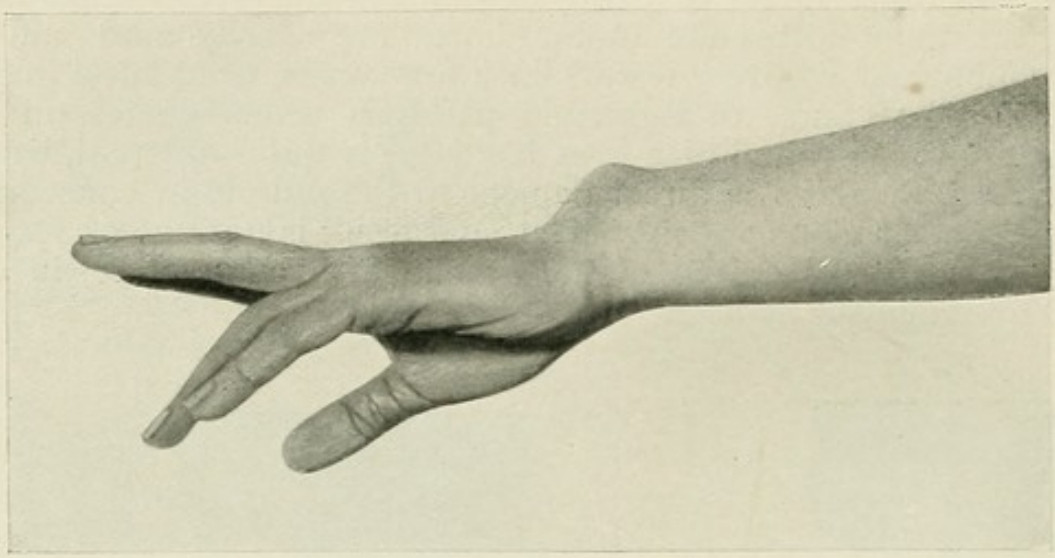

FIG. 342.—Manus valga. Madelung's deformity of the hand.

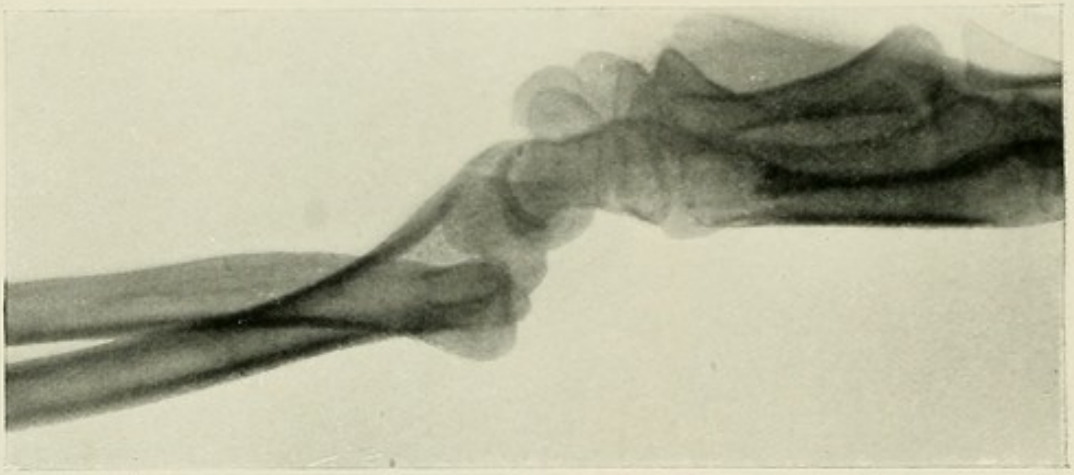

FIG. 343.—Radio-ulnar skiagram of the same case.

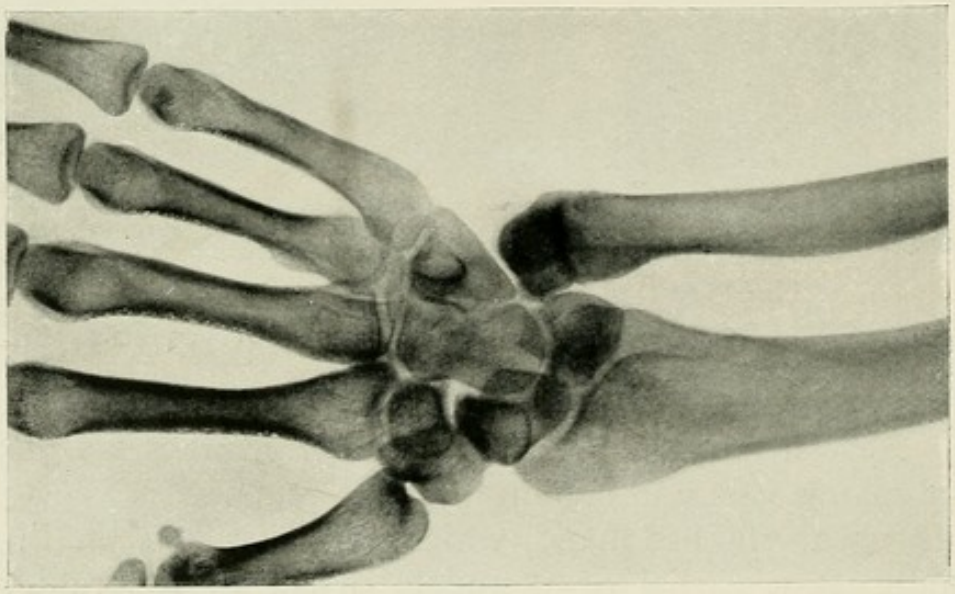

FIG. 344.—Dorso-palmar skiagram of the same case.

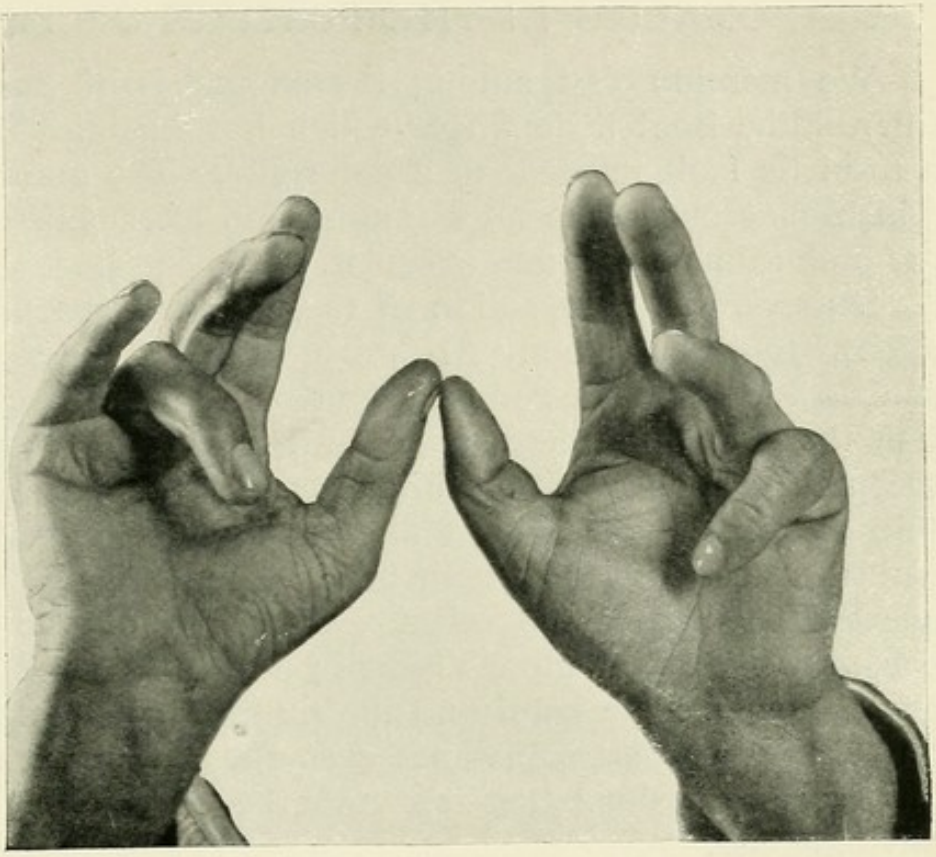

FIG. 345.—Bilateral Dupuytren's contraction.

Manus valga, "Madelung's deformity of the hand," occurs, not very infrequently, in females. The hand looks as if it had sustained a palmar subluxation. The lower end of the ulna is entirely displaced from its normal connections and projects markedly towards the dorsum. There is pain for a certain period of the disease, just as in genu valgum and pes valgus, and then it completely disappears.

The cause of this condition is not so much the result of occupation, as was originally thought, but is due to some change in the bone, depending upon curvature of the whole radius, resulting from late rickets. Its distal articular surface inclines towards the ulna and towards the palm, and thus allows the whole carpus to glide palmwards, causing a subluxation (figs. 343 and 344). The diagnosis is made at first sight.



FIG. 346.—Contracture in ulnar paralysis.

It is but rarely that separation of the epiphysis due to injury gives rise to this kind of deformity. A traumatic origin might be suspected if the manus valga were distinctly unilateral.

C.—ANOMALIES IN THE POSTURE OF THE FINGERS.

We mention first among the anomalies of posture of surgical interest, the **bent little finger** which is sometimes hereditary, but is a cosmetic fault rather than a deformity. The anomalies of posture which may supervene after trauma and after tubercle of the bones are both innumerable and irregular.

Dupuytren's contraction of the **palmar aponeurosis** forms quite a characteristic picture. At first the patient merely notices that he can no longer fully extend his fourth and fifth fingers. On examination there will be found a localized remarkably hard thickening of the palmar aponeurosis running towards the affected fingers. The skin also exhibits swellings alternating with retracted areas. The disease usually involves both hands symmetrically, or one becomes affected soon after the other. Extension of the affected fingers becomes more and more difficult; the thick swelling continues to extend towards the hand and the fingers, the process involving one finger after another, sometimes even the thumb. The posture of the fingers is so striking that it cannot be overlooked or mistaken for anything else.

In rare cases an injury has been suggested as the cause; in other cases, a tendency to gout and nervous influence have been blamed, and I have seen alcohol suspected in more than one instance. In the majority of cases the etiology is quite obscure. It occasionally happens that a contracture, which we must regard as Dupuytren's, is said to have come on after an injury in a case where there is some prospect of compensation. If the other hand also shows the beginning of a contracture we must not then attribute much significance to the unilateral injury.

We may also refer incidentally to the **trigger finger.** This symptom consists of the arrest of the movement of the finger in a certain position and its sudden advance with a jerk as a further effort is made. The symptom may depend upon some joint disease, *e.g.*, on some abnormality in the shape of the articular ends due to injury or inflammation. But the cause is usually to be found in the tendon or tendon-sheath, and consists of a localized thickening, which produces mechanical obstruction in one definite position of the finger.

CHAPTER LXXXIX.

TUMOURS OF THE HAND AND FINGERS.

A.—INNOCENT TUMOURS.

THE most frequent tumour-like swelling is known as a **ganglion.** As we now know that these structures represent areas of gelatinous degeneration in the connective tissue of the joint capsule, and arise independently of the synovial sheath of the tendons and of the joint, we no longer trouble ourselves to differentiate between tendogenous and arthrogenous ganglions. They have nothing to do with tendon sheaths, but are closely related to the joint capsule, because they arise within its tissue. If there is any communication present, it must have arisen secondarily. It follows from the origin of the ganglion that its cavity is only separated from the joint cavity by a thin layer of connective tissue, which lies directly upon the synovial membrane. Unless, therefore, we proceed with the utmost care in extirpating a ganglion, we must be prepared for opening the joint over a limited area. There is, of course, no harm in this, if asepsis is maintained.

Some quacks tell their patients that a "nerve is displaced," in order to impress them with the belief that they are able to replace it. I know of a quack who provided every disease or injury of the limbs with this diagnosis, and nevertheless, or perhaps because of it, had a large clientèle. Voltaire says, quite justly, that quackery started when the first swindler discovered the first fool.

One point is of diagnostic interest. It sometimes happens, in cases of tubercular wrist, that *granulation masses of tubercle* protrude between the tendons as far as the skin, as visible, separate tumours. Ollier has described cases wherein only a localized protrusion of the capsule has become affected with tubercle (tuberculomes juxtasynoviaux).

I had such a case, in which the wrist movements were perfectly free, and I proceeded to operate in the belief that an ordinary ganglion was present. My mistake only appeared during the operation.

Cystic tumours of the hand and fingers are either **sebaceous cysts,** which are usually situated on the dorsum, or **traumatic epithelial cysts,** which are always found in the palm. The latter are generally considered to be due to some trauma which has displaced some epithelial cells into the deeper tissues.

Franke thinks that some of these cysts are of congenital origin.

Lipomata are generally on the palmar surface, but they may grow between the metacarpal bones and appear on the dorsum. Like tuberculosis of the tendon-sheaths, they may spread towards the

fingers, but in contrast thereto they always come to a termination at the carpal ligament.

Fibromata always present their usual characters: they are well encapsuled, are hard, and grow slowly in the tissue of the true skin, the palmar aponeurosis, the tendon-sheaths or the tendons. They frequently cause neuralgic pain.

Angiomata occur in every variety, as telangiectases, cavernous angiomata, and as circinate angiomata. They are situated in the skin, in the subcutaneous connective tissue or in the muscle. Sometimes an injury appears to be the cause of the origin of an angioma.

Chondromata have a very characteristic appearance. They occur as hard nodular growths of the fingers, and are often multiple, just as those which occur in connection with the toes (which see).

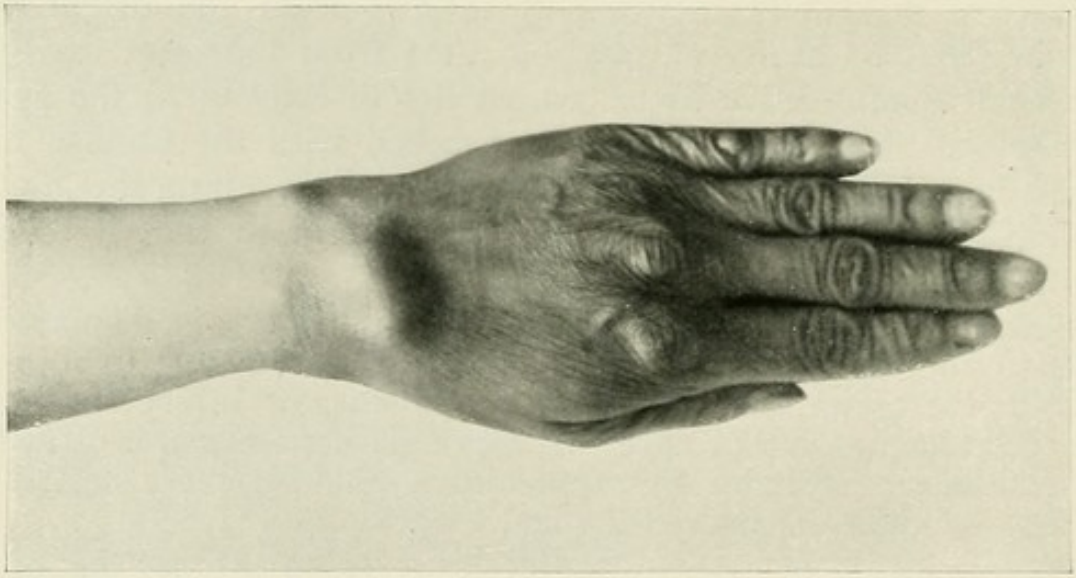

FIG. 347.—Ganglion of wrist.

Finally, one should refer to a small inflammatory tumour, which is occasionally found on the hand or fingers. It is about the size of a pea, or somewhat larger, resembles a raspberry in appearance, has a thin stalk and is surrounded by a collar of epidermis. It is a granuloma, first described by Poncet and Bérard as **botriomycosis**, and is essentially a disease of horses. The one observer attributed it to a definite variety of *Staphylococcus botriomyces;* the other, to the *Staphylococcus aureus.* The appearance of the tumour is so characteristic that it cannot be mistaken if once seen. Histologically, it is a telangiectatic granuloma.

B.—MALIGNANT TUMOURS.

The principal malignant tumours which occur on the hands and fingers are sarcomata and cancer of the skin.

Sarcomata have been seen on all parts of the hand, but most

frequently on the fingers. They may arise in the skin, in the tendons or tendon-sheaths, or in the bones, in which latter case they may be mistaken for chrondromata.

Cutaneous cancer always occurs on the back of the hand. It appears at first as a flat, more or less warty growth, which subse-

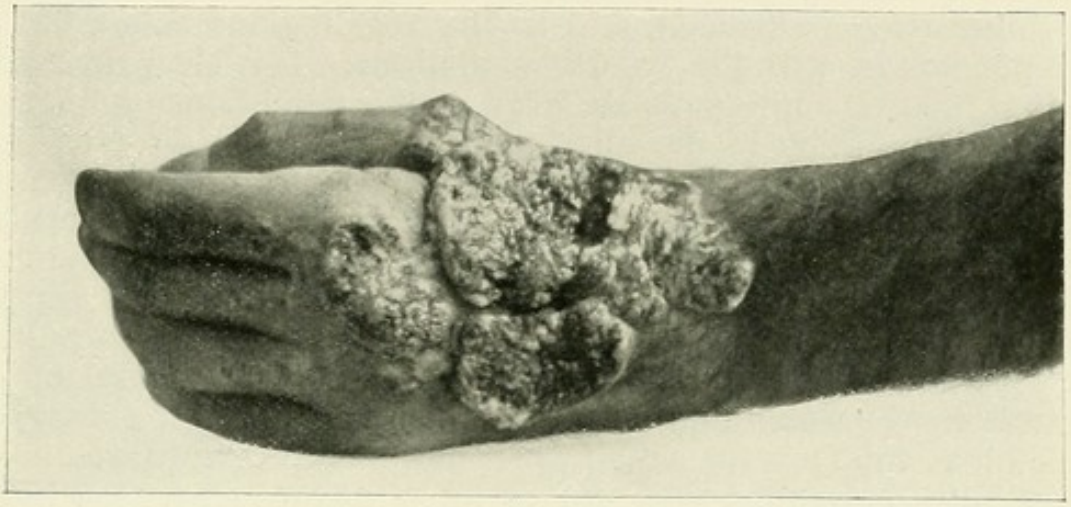

FIG. 348.—Cancer of the back of hand.

quently ulcerates extensively and assumes the usual characters of cancer (see fig. 348). Cutaneous cancer, arising from chronic X-ray dermatitis, or from localized hyperkeratosis independently thereof, deserves special mention, as many well-known radiographers have fallen victims to it.

CHAPTER XC.

ACUTE INFLAMMATORY PROCESSES OF THE HAND AND FINGERS.

A.—INFLAMMATORY PROCESSES OF THE FINGERS.

ALTHOUGH inflammatory processes of the hand and fingers are routine matters of minor surgery, they do occasionally raise interesting problems.

If a patient comes with a swollen and inflamed finger, as a rule we diagnose a whitlow forthwith. But this does not complete our diagnostic task. Several diseases sail under the flag of whitlow, and we shall deal with them briefly.

We must anticipate, by insisting upon a careful examination for lymphangitis of the arm, and enlarged glands of the axilla, in every case

of infective disease of the fingers. A trifling wound of the finger, which may have been healed within a few days, can lead to enlarged glands of the axilla and subsequent suppuration.

(*a*) **Dermatitis.**—A patient consults us for a severely swollen and inflamed middle finger, which looks more like a beetroot than anything else. He states that he had sustained a slight injury to the skin, which he treated by lysol fomentations on the direction of his doctor. The finger became swollen, and as the swelling increased, the more assiduous was he with the lysol fomentations. It is clear on examination that the two contiguous surfaces of the neighbouring fingers are inflamed, in addition to the middle finger. There is no extension of the inflammation to the hand or the arm in the form of lymphangitis; neither are there any general symptoms of infection. There is no sign of disease in the bone or tendon sheath, and the original wound is almost healed. Considering the entire condition, and especially the involvement of the two contiguous surfaces of the adjoining fingers, we are bound to assume that the case is one of **drug dermatitis.** The abandonment of all disinfectants and a dressing of simple ointment soon caused all the symptoms to disappear.

A similar condition may attend other disinfectants, for instance corrosive sublimate, and especially iodoform. **Iodoform dermatitis** was a very common occurrence when the practitioner used to think that he had not discharged his duty adequately unless his patient reeked of iodoform.

Where the infective inflammation is deeply seated, the skin is tense and elastic, the epidermis smooth and shining. In drug dermatitis the superficial epidermis is infiltrated, uneven and rather rough, and is often raised by numerous little definite vesicles, or even by large blebs.

I once saw a slight wound of the finger, treated by sublimate compresses to prevent infection, which resulted in bulbous dermatitis reaching to the shoulder. The whole arm resembled an enormous sausage and was covered all over with blisters. In this case also the patient applied the compresses the more diligently as the dermatitis increased.

If the infection is deeply situated the patient complains of a stabbing, boring, aching pain, which prevents any rest, either by day or night; in dermatitis, however, the complaint is rather of a troublesome irritation and burning. In the former case local pressure causes great pain, in the latter case very little.

(*b*) **Primary inflammations of the bed of the nail.** If the inflammation starts superficially at a circumscribed spot and gradually spreads to the whole phalanx, the case is one of *infection of the nail-bed*, even if the bone necroses subsequently.

If the inflammation does not involve the bone, and nevertheless fails to subside in the ordinary manner, we should remember that a *primary chancre* has often been mistaken for a whitlow, and also that

there is such a condition as *paronychia syphilitica*, in the secondary stage. If the patient exhibits a striking tendency to whitlows, although his occupation does not predispose towards them, we should examine for syringo-myelia (fig. 352), Raynaud's disease, and diabetes. An ordinary whitlow, which runs a particularly severe course, is always suggestive of diabetes.

(*c*) An inflammation situated in the **subcutaneous cellular tissue** is distinguished from one due to primary disease of the bone by the fact that it is of very limited extent at first. If the accumulation of pus is not incised early, the inflammation may attack the tendon-sheaths and then rapidly extend.

(*d*) We must also refer to **erysipelatoid inflammation** of the finger, which was described by Rosenbach and more recently by Tavel, cases of which we have ourselves observed. Redness and hard swelling of the skin develop as a result of some insignificant wound of the skin, and the condition slowly spreads towards the hand, without leading to suppuration or causing general symptoms. In other cases lymphangitis, painful swelling of the axillary glands, and pyrexia occur. The disease is very liable to recurrence, and people who are occupied with meat, or animal offal, are the most frequent sufferers.

(*e*) We now come to **acute inflammations of the tendon sheaths.** These do not usually arise spontaneously, but follow some injury, extending as far as the tendon-sheath. Perforating wounds and bites are especially dangerous in this respect, because if they introduce septic organisms in deep situations, they are not easily dislodged, and have abundant opportunity of developing undisturbed.

If swelling of the finger occurs after such a history, the course of the tendon-sheath should be noted and an immediate opening made, without waiting for definite fluctuation, if there is pain on pressure along the sheath.

Teno-synovitis is distinguished in its early stages from ostitis and periostitis by the fact that the inflammation is not limited to the course of one phalanx, and that the pain on pressure and the swelling are more pronounced on one side of the finger than on the other. The distinctness of the clinical picture often becomes obliterated in the more advanced stages, because a periostitis may develop from a teno-synovitis, and a secondary inflammation of the tendon-sheath may follow primary disease of the bone. If an injury can be excluded, *gonorrhœa* should be thought of. Gonorrhœal teno-synovitis usually begins very acutely, almost like a phlegmon, and then proceeds to a quiet chronic stage. Suppuration occurs especially in mixed infections.

If a manual labourer complains of a slightly painful swelling over the long extensor of the thumb, which has come on after hard work, and we feel distinct crepitation over the tendon and muscle, the

diagnosis is *crepitant teno-synovitis*, a fibrinous inflammation of the tendon-sheath, the tissue around the tendon and the muscle.

(*f*) **Suppurative inflammation of the bone,** whether primary or secondary, can be recognized :—

(1) By the diffuse swelling and tenderness of the entire circumference of the finger, in the extent of one phalanx.

(2) By pain on axial pressure.

(3) By false mobility and crepitus in the adjacent joint, as the disease progresses.

A skiagram is of no assistance in the initial stage, but is very valuable later on, when the course is protracted and there is a develop-



FIG. 349.—Whitlow causing secondary disease of bone. Infection of extensor tendon sheath by prick of a needle.

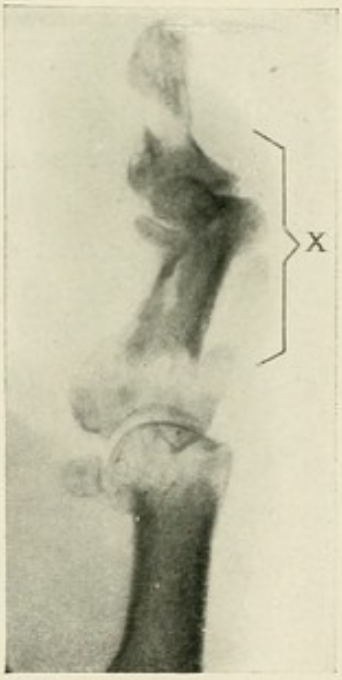

FIG. 350. — Skiagram of same. X = part of bone which has formed a sequestrum.

ment of new periosteal bone, or an involucrum begins to form, or if the case is somewhat more acute and the dead bone becomes divided from the healthy part by a light zone, even without the formation of any new bone (fig. 350).

(*g*) It is important to know something about **acute inflammation of the finger joints.** The first interphalangeal joint is most frequently affected. It acquires a spindle-shaped thickening and looks somewhat like a radish in form. It is usually the consequence of some injury, and I have seen it particularly in butchers. The joint may remain distended with clear fluid for weeks after the subsidence of acute symptoms, even in mild cases. If the disease lasts for a long time, the cartilage finally disappears, as may be demonstrated by X-rays, before the joint yields any crepitus on movement. Gonor-

rhœa should be thought of if only *one* joint is affected, and if the disease has had a sudden and spontaneous onset.

The finger-joints may be involved *secondarily* in cases of suppurative teno-synovitis and ostitis. The clinical picture is, however, dominated in such circumstances by the primary disease, and the arthritis is merely a complication.

B.—ACUTE INFLAMMATORY PROCESSES OF THE HAND.

These arise from three different causes, leaving out of account the rare cases of **primary periostitis and osteomyelitis of the metacarpal bones.** They may originate as an extension **from the fingers,** as a result of **injuries to the hand,** or from suppuration of the **bursa,** which exists so frequently in the case of manual labourers, under the **callosities of the palm.** The diagnosis is usually very easy, but one must remember that even if the site of inflammation be in the *palm*, the œdema is most intense in the *dorsum*, because of the greater laxity of the skin. This peculiarity often leads the beginner to make his incision in the wrong place.

The practitioner often has to decide whether suppurative inflammation of the bursa beneath callosities is the result of an accident or not. If a wound of the skin, however minute, has led to infection, the decision is clear enough. But suppuration occasionally occurs without it being attributable to such a cause, and we are bound to regard it as a malady arising from occupation, and not as the consequence of an accident.

It should be mentioned that an **acute attack of gout** may exceptionally occur in the hand.

I have seen such a case incised as phlegmon—a mistake which may be pardoned owing to the rarity of the incident.

CHAPTER XCI.

CHRONIC INFLAMMATION OF THE HAND AND FINGERS.

THE skin, the tendon sheaths, the bones or the joints may be the seat of chronic inflammation in the hand or fingers.

(1) THE SKIN.

Chronic inflammatory conditions of the skin and subcutaneous tissue include primary chancre, lupus, leprosy, syringo-myelia, the trophic disturbances associated with Raynaud's disease, in addition to

chronic eczema and to gumma, which latter is, however, of rare occurrence.

A **chancre** may be diagnosed by the history, early enlargement of the glands, and possibly by the secondary symptoms. Many a practitioner has fallen a victim to a primary sore of the hand in the course of his profession.

Practitioners who cannot restrain themselves from touching every wound or ulcer with their fingers, may be reminded that, even if they do not fear the organisms of suppurations, they may still be in dread of the spirochætes. A well-known dermatologist says, not unjustly, "Whoever touches every ulcer with his fingers, shows that he does not know what it may be, or that he has already had syphilis." If the ulcer must be touched, an india-rubber finger-stall should be used, for the protection of oneself and other patients.



FIG. 351.—Lupus of back of hand. (Tuberculosis verrucosa cutis.)

Lupus, in its various forms, is mostly situated on the back of the hand or fingers. It is recognized by its usual characteristics, and we would especially refer to what has already been said in connection with lupus of the face, for the points of distinction between it and tertiary syphilitic lesions. Lupus may, in rare cases, ulcerate very deeply and even destroy the tendons, eventually causing severe contractures. If the tubercular process attacks the bones and joints, there may ensue an amount of destruction which is suggestive of leprosy.

Post-mortem tubercle and skin tuberculosis of butchers should also be thought of, if the appropriate causes exist.

Leprosy of the fingers is chiefly recognized by the fact that it leads to their spontaneous amputation. If this condition exists we must at once ascertain whether the patient has lived in a leprosy district. In addition to the well-known regions of leprosy, there are

numerous scattered centres of leprosy in rarely visited districts, which should be taken into consideration. In doubtful cases, we must search for traces of macular leprosy in persistent, atrophic, superficial and cicatricial cutaneous changes in various parts of the body, and in thickening of the large nerves, especially the ulnar.

The mutilation in syringo-myelia and Raynaud's disease compete with that in leprosy. The symmetry and the associated nerve symptoms are always conclusive. The latter must, however, be carefully sought for, because the patient is often quite unaware of them (see fig. 352, which is taken from a patient who had no intimation of his syringo-myelia).

(2) THE TENDON-SHEATHS.

Inflammation of the tendon-sheaths, which is chronic from the start, and which is accompanied by swelling, is, practically without exception, of a tubercular nature. The flexor tendons are most frequently affected.

I once saw a case of extensive tubercular teno-synovitis of the extensor tendons in a butcher, who had wounded himself on the corresponding place fifteen years previously with a splinter of bone of a tubercular cow. An old scar still remained in evidence of the wound.

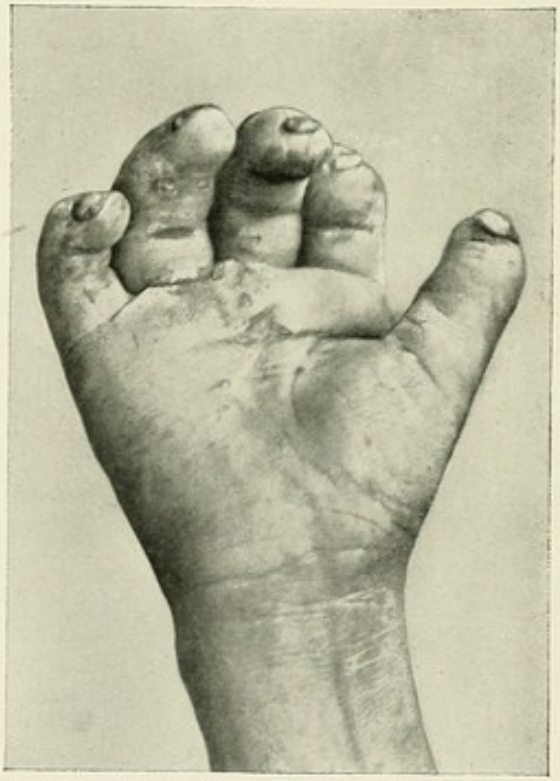

FIG. 352.—Mutilation of hand, due to syringo-myelia.

Tubercular teno-synovitis is easily recognized by the puffy induration in the region of the tendon-sheath and by the stiffness of the corresponding finger on slight flexion (fig. 335). The common tendon-sheath under the anterior annular ligament is occasionally affected, and the disease extends therefrom in four processes to the second, third, fourth and fifth fingers. There is frequently no fluctuation, or it may be more or less clearly recognizable in the palm only. If there is any considerable effusion the sac is subdivided, being constricted by this ligament just mentioned. The fluid can be displaced from the palm to the forearm and vice versa. Crepitation indicates the formation of melon-seed bodies. At first, the tendon sheaths only are affected, but spindle-shaped areas of granulation tissue with separation of the tendon-tissue into brush-like masses, may develop in course of time. Chronic enlargement of the

axillary glands confirms the diagnosis, if confirmation should be necessary.

Tubercle could only be mistaken for the subacute stage of *gonorrhœal teno-synovitis* or for the much more rare *lipoma of the palm*. The former would be indicated by a sudden onset with severe pain; the latter by a painless onset.

We must still refer to another malady, which may cause the patient much agony, although it is trifling, and easy to relieve. This consists of the relative narrowness of the compartment of the tendon-sheath, lying on the styloid process of the radius, which transmits the extensor pollicis brevis and the abductor pollicis longus—a condition which I first described sixteen years ago, at Kocher's suggestion, as **contracting teno-synovitis.** It is not an inflammation in the strict sense of the term. The patients, who are mostly females, complain of pains radiating towards the thumb and forearm on any effort. On physical examination, the only thing to be noted is a striking tenderness on pressure, and sometimes a slight swelling in the vicinity of the above-mentioned compartment of the tendon-sheath.

If the tendon-sheath is exposed under local anæsthesia, the tendons are seen to be constricted within it. The sheath should be split, which may also be done subcutaneously with a tenotome, and the patient is immediately and permanently cured. Histological examination merely shows thickening of the wall of the sheath, without any inflammatory changes.

(3) THE BONES.

A spindle-shaped swelling of a metacarpal bone or a phalanx, which has developed gradually and with little pain, and which eventually suppurates and forms a sinus, is almost always **tubercle.** We say *almost*, because there is a very similar condition of the phalanx, which is due to **syphilitic dactylitis.** But the mere diagnosis of tubercular disease does not exhaust all that is necessary to know. From the point of view of prognosis, it is important to ascertain whether the disease has started in the *medulla* or in the *periosteum*. In adults the origin is usually periosteal, but in children almost exclusively medullary.

My impression is that children who are the subject of congenital syphilis also display the periosteal variety of tuberculosis more frequently. Whether this is actually a fact must, however, remain an open question.

The fate of the finger differs in the various forms of the disease. In tubercle arising from the medulla, ordinary tubercular dactylitis (fig. 354), the bone becomes more and more distended, or, to put it more accurately, becomes destroyed internally and is replaced by new bone from the periosteum. In this condition, the periosteum may remain

at least partially healthy. The spongy tissue becomes absorbed, or forms a sequestrum which is either expressed spontaneously or removed surgically. The phalanx becomes bent to one side, but practically the whole of it remains. In the periosteal form, however, the whole diaphysis gradually becomes deprived of its nutrition (fig. 353), necroses, and is expressed or removed surgically after prolonged suppuration. But as the periosteum itself is tubercular, no healthy involucrum is formed as in the case of staphylococcic osteomyelitis, but the finger becomes shortened by about the length of the

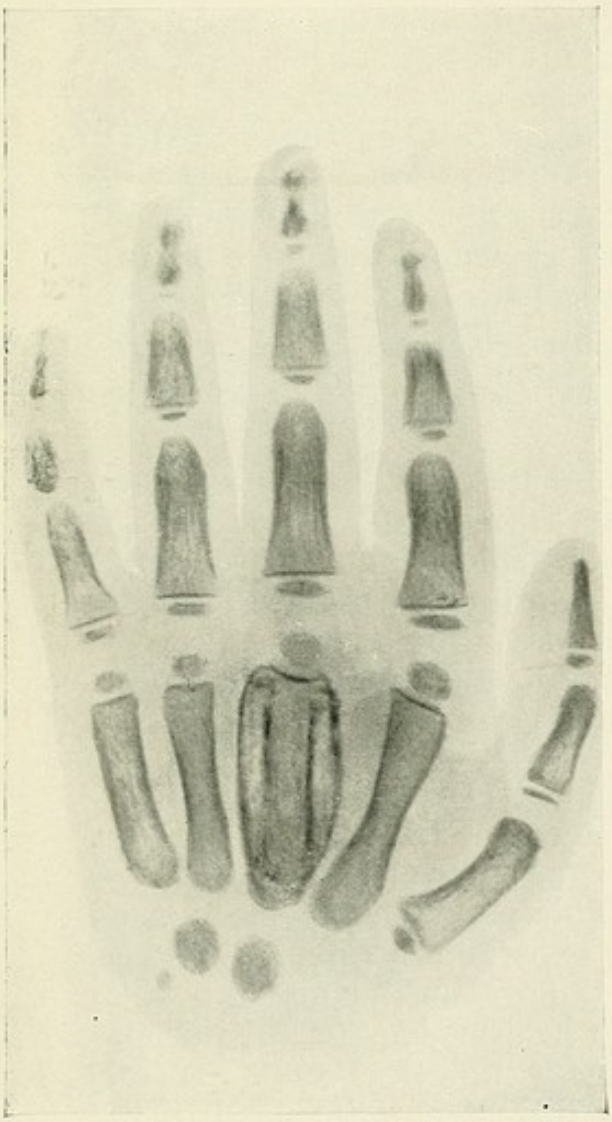

FIG. 353.—Tubercular dactylitis of periosteal origin.



FIG. 354.—Tubercular dactylitis of medullary origin.

diaphysis, after a few splinters of bone, formed from the periosteum, have been removed as sequestra.

The differential diagnosis between these two forms cannot be made clinically, at any rate as long as there is no fistula. It can, however, be made by a skiagram, upon which we must always base our treatment.

If there is a history of congenital syphilis or a positive serum

reaction, the probability of syphilitic dactylitis is indicated. There is, however, no certain clinical symptom, and every case, which is not clearly one of tubercle, but in which there is some suspicion of syphilis, should have specific treatment before any other course is undertaken.

CHAPTER XCII.

DISLOCATIONS AND FRACTURES OF THE HIP.

THERE is no joint which presents so much difficulty to the beginner, and sometimes also to the experienced, as the hip, because of the inaccessibility of the articular ends both to sight and to palpation. All conclusions relating to the joint are, therefore, necessarily based on indirect signs, and the hip thus places a severe tax on the diagnostic powers of the examiner.

The most striking symptom of all hip diseases is **limping**; and we shall therefore briefly consider the most important forms of this symptom. The simplest variety is that which follows *shortening*. In this condition, the body inclines towards the diseased side at every step; not because the limb gives way, but because it is too short. The leg is by no means spared, but still serves as a normal support. If the shortening is slight, the complete sole is planted down, but if it is extreme, only the toes reach the ground. The limp becomes noticeable in adults if the shortening exceeds 1½ cm. (⅝ in.).

The *paralytic limp*, in the widest sense of the term, is very similar. The limb is insufficiently supported, either because of muscular weakness or because of dislocation. The patient supports himself vigorously on the affected leg, evidently experiences no pain therein, but inclines with each step towards the diseased side, and then supports himself the more firmly on the healthy leg for the purpose of throwing the diseased leg forwards for the next step. If this variety of limping is due to congenital dislocation, the head of the thigh bone may be seen to move upwards, under the gluteal muscles, towards the pelvis. If the disease is bilateral, the gait is waddling, like that of a duck.

Painless stiffness of one hip produces quite a different kind of limp. The entire extremity, including the half of the pelvis, is moved forward as a whole, because a normal function of the other joints is not conceivable if *one* joint is stiff. But as there is no pain, the limb is not spared as a means of support, and the weight of the body is equally received by both legs. If the patient walks slowly, he is therefore able to render his disability less noticeable. The gluteal fold is obviously obliterated on the diseased side. A peculiar gait is

produced by *bilateral stiffness of the extremities* as in cases of severe double coxa vara. The patient wearily moves forwards, first one half and then the other half of the pelvis alternately, and therewith the corresponding limb. The pelvis rotates around a vertical axis, and not around a sagittal axis, as in cases of bilateral dislocation.

In cases of *painful limping*, the movement of any joint is painful, and as all the joints of the lower limb are interdependent—for instance, a twisting movement of the foot is impossible without the participation of the knee and hip joints—the patient stiffens all the joints by muscular action, and avoids, as far as possible, putting any weight on the diseased limb, and inclines his body towards the healthy side. This latter circumstance distinguishes painful limping from limping due to painless rigidity, for otherwise most of the symptoms are common to both conditions, including especially the obliteration of the gluteal fold.

There are several types of disturbance in gait. In unilateral congenital dislocation, it depends upon shortening and laxity of the joint; in old hip disease, it depends upon shortening and stiffness.

Doubt should rarely arise as to whether an injury to the hip-joint consists of a dislocation or a fracture. As a rule, such doubt indicates that the examination has not been conducted properly, or that the physical condition has not been correctly understood. In order not to fail in the appreciation of indispensable anatomical points, every practitioner should possess a skeleton, and he should consult it frequently. Expenditure on this is by far more advisable than on instruments which the practitioner purchases on the recommendation of manufacturers, but rarely, if ever, uses.

A.—METHOD OF EXAMINATION.

We begin with *inspection*, and note the position and posture of the injured limb as well as the external visible injuries, extravasations of blood and swellings.

The experienced observer will often be able to make a diagnosis from the posture of the injured extremity, or at least will narrow down the possibilities to a very limited extent. Thus, if the injured person lies helpless and motionless, with his leg in a state of complete external rotation, he will at once think of a fracture below the neck of the femur. A flexed thigh, rotated internally and adducted, will suggest a dislocation. He will also notice whether the region of the hip, on the injured side, is drawn in, or whether it projects unnaturally. A roundish bulging in the inguinal region is not likely to escape him any more than the fact of the one patella being higher than the other —a condition which indicates shortening.

We next proceed to what is for the patient the least painful procedure of examination, the *measurement of the length* of the limb, and

for this purpose, it is necessary to bring both limbs into exactly the same position, to avoid mistakes.

We measure on both sides the distance (1) between the anterior superior spine of the ilium and the tip of the external malleolus (*c* in fig. 355) and (2) the distance between the tip of the trochanter and the malleolus (*b*). (In cases of extreme external rotation the first measurement is also taken to the internal malleolus.) If the measurements are equal on both sides, we may, as a rule, exclude any change in the bone, provided that the limb used as the standard for comparison has not been shortened by a previous accident. If one or other of these measurements, or both of them, be shortened, there is certainly either a dislocation or a fracture, unless the shortening be due to some previous injury or disease. If the distance between the anterior superior spine and malleolus (*c*) is alone shortened (supra-trochanteric shortening) the case is either one of dislocation or fracture of the neck of the femur. If both measurements *b* and *c* are shortened, the separation of continuity must be below the tip of the trochanter (infra-trochanteric shortening), and the case can only be one of fracture below the tip of the trochanter.

We next determine the relation of the trochanter to the pelvis, in order to control the measurements previously obtained. It is generally said that for this purpose the most important thing is to ascertain Roser-Nélaton's line. Unfortunately, it is very difficult to do this when the injury has been severe. It is better to make use of this line in cases of abnormal positions, of *non-traumatic* origin. In *recent injuries* we should adopt other measurements which are equally reliable and easier to carry out, and which do not demand any change of posture in the injured person. These measurements consist of Bryant's triangle and the trochanter—anterior superior spine—umbilicus line, which will be referred to in detail in the next section. The determination of Bryant's triangle is of special significance because the measurement of the horizontal base line of this triangle intimates to us the alteration in the position of the trochanter, and gives its level, and thus enables us, by comparing the two sides, to ascertain how far the trochanter has been displaced upwards.

If the trochanter is abnormally high, there is either a dislocation or a fracture of the neck of the femur. If it is in a normal position the injury is not associated with any displacement, or, if there be any, it must be below the trochanter.

In slight bending of the neck of the femur, or in fractures which are slightly impacted, the shortening may be so small in amount as to come within the ordinary limits of errors of measurement. In anterior dislocations the trochanter is not displaced upwards in any marked degree. But in these cases, its definite approximation to the mid-line of the body shows that some anatomical damage has been sustained. We also find a certain amount of approximation to the middle line in impacted fractures of the neck of the femur. But, as we shall see later on, there are other definite signs which distinguish these fractures from anterior dislocations.

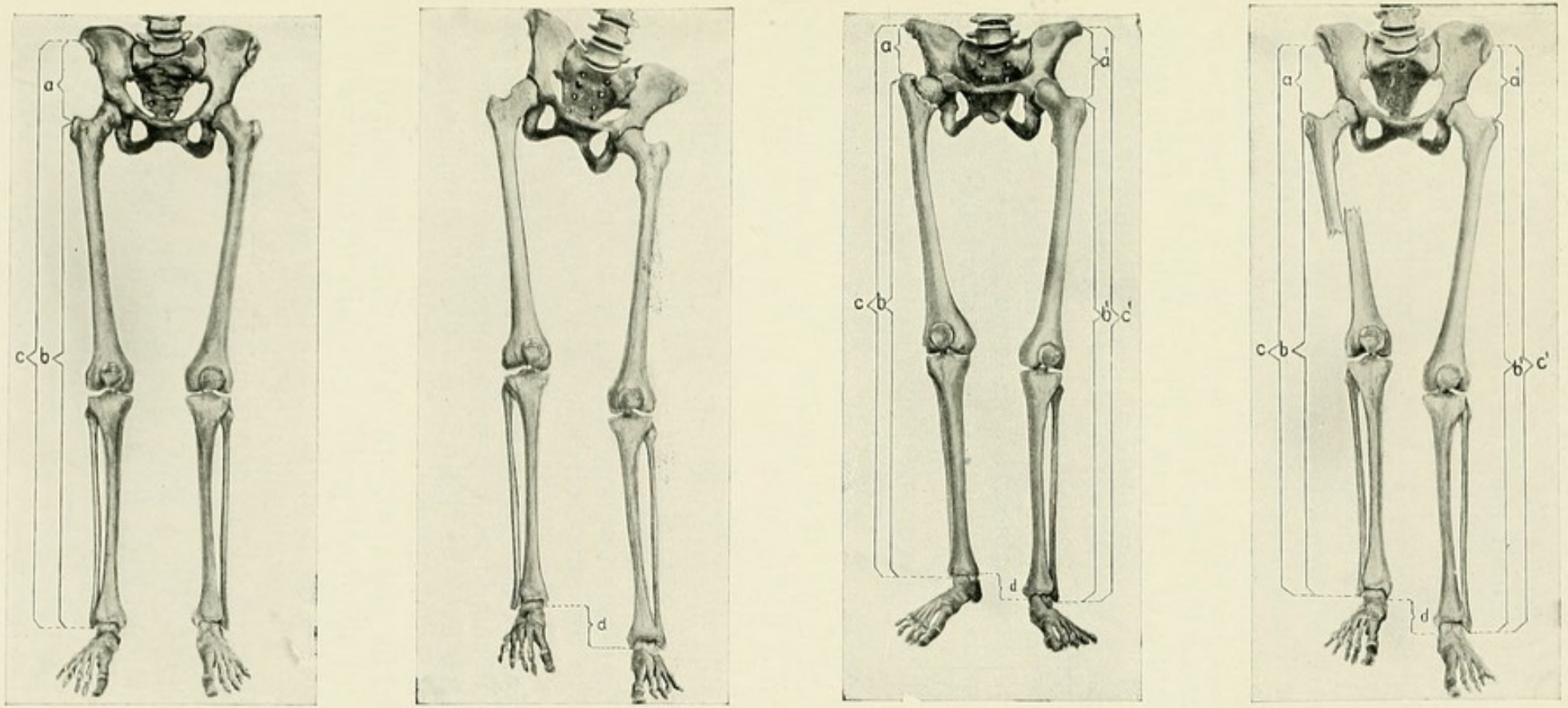

(*a*)

Normal relations. a = Level of trochanter, as judged by length of horizontal line joining the ant. sup. spine to tip of trochanter. b = Distance between trochanter and malleolus. c = Distance between ant. sup. spine and malleolus

(*b*)

Apparent shortening. d, in consequence of adduction of right leg. (In the same posture pathological abduction of the left leg would produce apparent lengthening of the right.)

(*c*)

Actual supra-trochanteric shortening. The difference between the levels of the malleoli, d, is equal to the difference between the distances from the ant. sup. spine to the malleolus on each side, c^1 and c, and is also equal to the difference between the lines joining the ant. sup. spine to the tip of the trochanter on each side, a^1 and a. The distances between trochanter and malleolus on each side are equal. $d = c^1 - c = a^1 - a$; $b = b^1$. This condition is found in fractures of the neck of the femur proper, in coxa vara, and congenital dislocation of hip.

(*d*)

Actual infra-trochanteric shortening. Difference in level of malleoli, d, equal to difference in distances between ant. sup. spine and malleolus, and also equal to difference in distances between trochanter and malleolus. Level of trochanters, same on both sides. $d = c^1 - c = b^1 - b$; $a = a^1$. This condition is found in all fractures through or below the trochanter, and also in all fractures lower down the limb.

FIG. 355.—Length measurements of lower limb.

After ascertaining the measurements of the limb, we must determine the range of *active movements*.

For this purpose, the patient must lie flat in bed, undressed, and endeavour to raise the injured limb in the position of extension. If he can do this without hesitation, although there may be pain, there is certainly neither dislocation nor fracture. A sprain or a contusion is the most likely thing. If he flexes the thigh with difficulty, without, however, raising the heel from the bed, the case may probably be one of impacted fracture. We then ask the patient to perform movements of rotation. If external and internal rotation are perfectly free, there can be no severe injury present. But if there is a definite limitation of active internal rotation, whereas outward rotation appears to be normal, or even exceeds the normal in extent, the case is probably one of impacted fracture of the neck of the femur. If no active movements of rotation are possible and at the same time the limb is turned outwards, there is probably a fracture below the trochanter. But if the external rotation is not complete, and some trace of active power of rotation still persists, the probability is that the case is one of non-impacted fracture of the neck of the femur.

We cannot elicit much information from abduction and adduction movements, because the raising of the whole leg is necessary to perform them. But the same remarks apply to these movements as to rotatory movements.

We now proceed to *passive movements*, which must perhaps be carried out under anæsthesia. It is obvious that the manipulations must be performed with the greatest care, lest a useful impaction becomes separated in the process.

If passive movements are free, or only slightly hampered on internal rotation, the case is certainly one of *fracture*, assuming that a severe injury has been sustained. If the movements exceed the normal range in certain directions, and encounter a spring-like insurmountable resistance in the opposite directions, the case is certainly one of *dislocation*.

This rule is subject to the slight limitation that there is some diminution of internal rotation on passive movement, in cases of impacted fracture of the neck of the femur, and, exceptionally, there is also diminution of external rotation.

Finally, we proceed to *palpation*. In dislocations, the head of the femur can be felt in an abnormal position, and in fractures, we can recognize thickening of the trochanteric mass and strikingly abnormal protuberance of bone. The examination of active and passive movements, and the palpation afford the opportunity of noting the degree and the localization of the *pain*.

We have now arrived at the stage wherein we may apply the results of our examination to the formation of a diagnosis.

B.—DIAGNOSIS OF THE VARIOUS FORMS OF INJURY.

(1) DISLOCATIONS.

Having diagnosed a **dislocation,** it remains to determine its variety :—

(*a*) If the thigh is rotated *inwards,* a simple mechanical consideration will show that the head of the femur must have gone *backwards,* and therefore the case is one of *posterior dislocation.* In ordinary dislocations the Y-shaped ligament is not ruptured, and this structure maintains the thigh in the position of flexion and adduction. If the three characteristic anomalies of posture—internal rotation, adduction and flexion—are not very pronounced, we may conclude that the head of the femur has escaped in an upward direction, towards the iliac fossa (fig. 356) **iliac dislocation.** If, however, the abnormal posture is very pronounced we assume that the head has escaped in a backward and downward direction—**a sciatic dislocation** (fig. 357). In the former case, the rent in the capsule is at the back and above, in the latter case it is at the back, or behind and below. We may summarize the differences into a definite law as follows : *An iliac dislocation exists if the patient, on lying down, is able to conceal the flexion by means of compensating lordosis of the lumbar spine, and bring his two legs into an approximately parallel position, and if, on standing up, he is able to touch the ground with his toes. On the other hand, a sciatic dislocation is present, if the most extreme lumbar lordosis is unable to abolish the flexion, if the patient, on lying down, places the thigh of the dislocated leg on the healthy thigh, and if he is unable to touch the ground with his toes on standing up.*

It sometimes happens that our examination points to an iliac dislocation, but we are told that the abnormality of position was much more striking immediately after the accident, and that the limb has gradually returned to a more normal position, either spontaneously or after unsuccessful attempts at reduction by the friends of the injured person or by a quack. We must not treat such information lightly, but must rather conclude therefrom that the dislocation was originally of the sciatic variety with a rent in the capsule, behind and below, but that as a result of the weight of the limb or of the attempts at reduction, the head of the femur has glided upwards and reached the position of an iliac dislocation. This conclusion is very important from the point of view of effecting complete reduction.

It is absolutely impossible to mistake posterior dislocation for any other injury of the hip. Impacted fractures of the neck of the femur with internal rotation do certainly occur, but very rarely. But in such cases the freedom of abduction and the absence of the head of the bone from an abnormal situation show that no dislocation exists.

The similarity of this unusual form of impacted adduction fracture to posterior dislocation may be very close indeed, and I have seen an example of this in the wards of a colleague. In this case, the idea of dislocation was only dispelled by the absence of the head of the bone from an abnormal position, and by the skiagram.

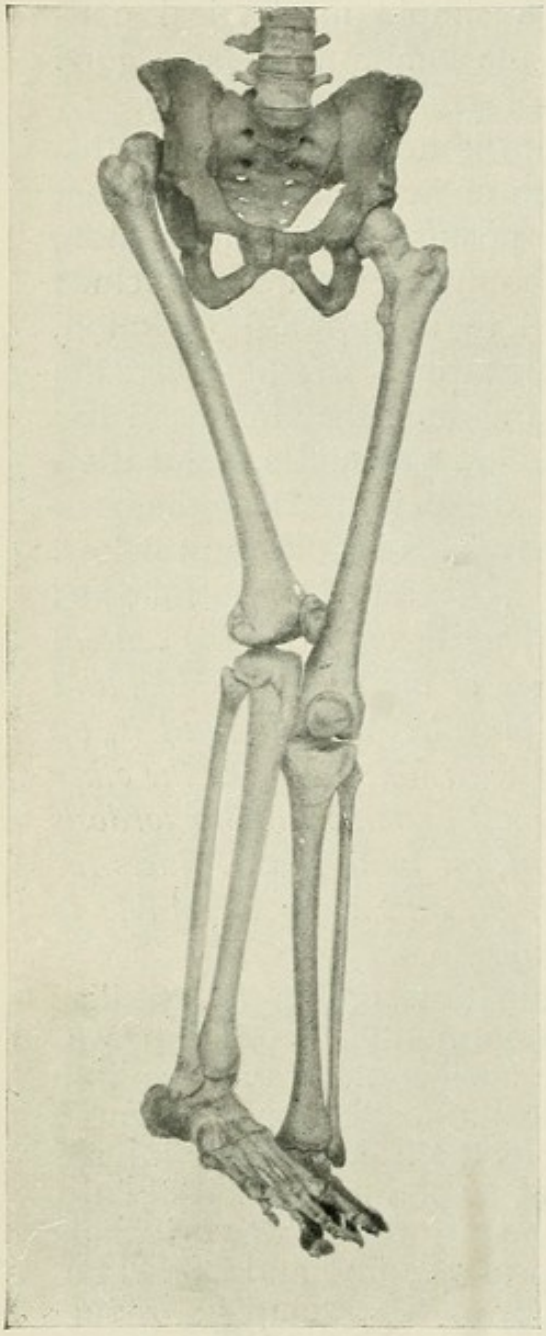

FIG. 356.—Iliac dislocation.

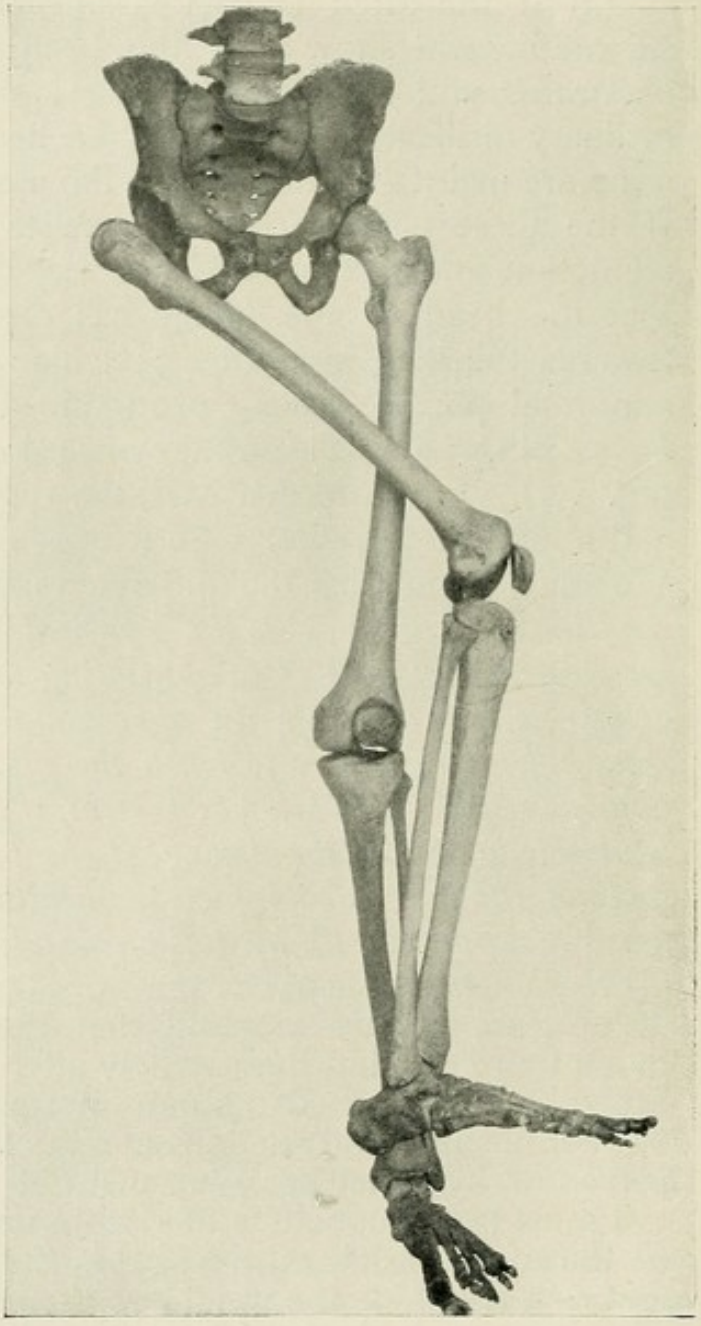

FIG. 357*a*.—Sciatic dislocation.

If a *posterior dislocation is complicated by other injuries*, greater difficulties of diagnosis occur. If the injury has resulted from some great violence, the Y-shaped ligament may occasionally be torn and then a regular dislocation be converted into an irregular one. The limitations of movement which ordinarily indicate a dislocation, would not be present in such a case, but, on the other hand, the head of the femur would be more accessible to palpation and thus afford evidence

of the dislocation. In some typical cases of posterior dislocation, grating and crepitus are heard, which lead to errors in diagnosis and suggest fracture of the neck of the femur. As a matter of fact, a *portion of the margin of the acetabulum* has been torn off in these

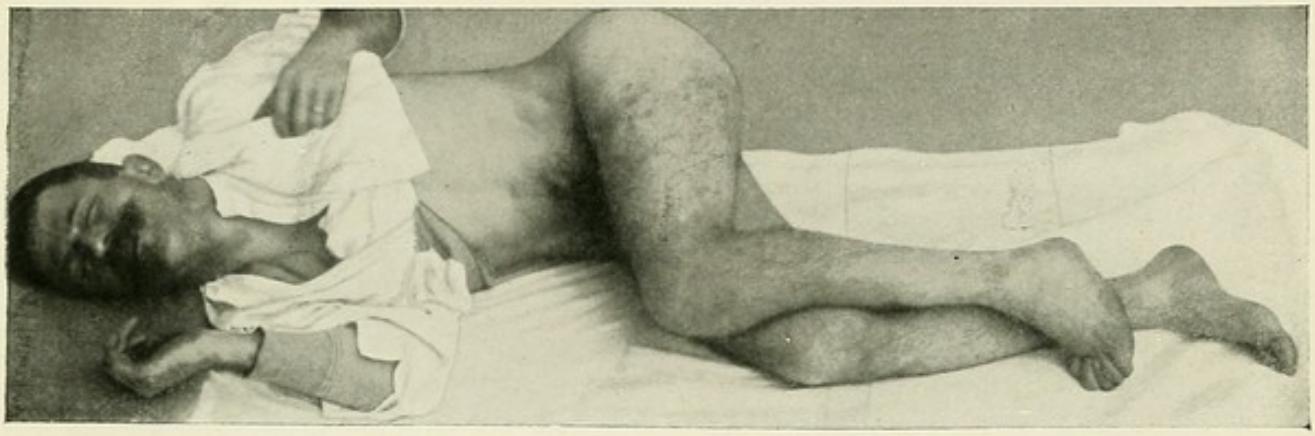

FIG. 357*b*.—Sciatic dislocation.

cases. If the piece of acetabulum broken off is large, the displaced head will not be retained in any of the typical positions of dislocation. In such a case the diagnosis from subcapital fracture can only be made by means of a skiagram. A *combination of dislocation with fracture of the neck of the femur* is very difficult to diagnose, because it presents a very unusual picture. The diagnosis can only be arrived at by demonstrating that the head of the bone does not follow the limb on rotation, and that it is in an abnormal position.



FIG. 358.—Portion of upper margin of acetabulum detached.

(*b*) If there is limitation of movement indicating dislocation, and the limb is turned *outwards*, we must conclude that the head of the bone has escaped *forwards*, and that, therefore, an *anterior dislocation exists*. We have already seen that the approximation of the trochanter to the middle line is another indication of this injury. As the Y-shaped ligament remains intact a more or less considerable abduction results. If this abduction is not very pronounced, and the injured limb can be placed parallel to the sound one, and is also in a position of extension, the dislocation is *forwards and upwards*. It is termed **ilio-pectinal dislocation** or **pubic dislocation** in accordance with the

situation in which the head of the bone is found (fig. 359). The fact that the head of the bone can be felt on the horizontal ramus of the pubis in the inguinal region furnishes a clinching demonstration of the accuracy of the diagnosis. The slight abduction gives the

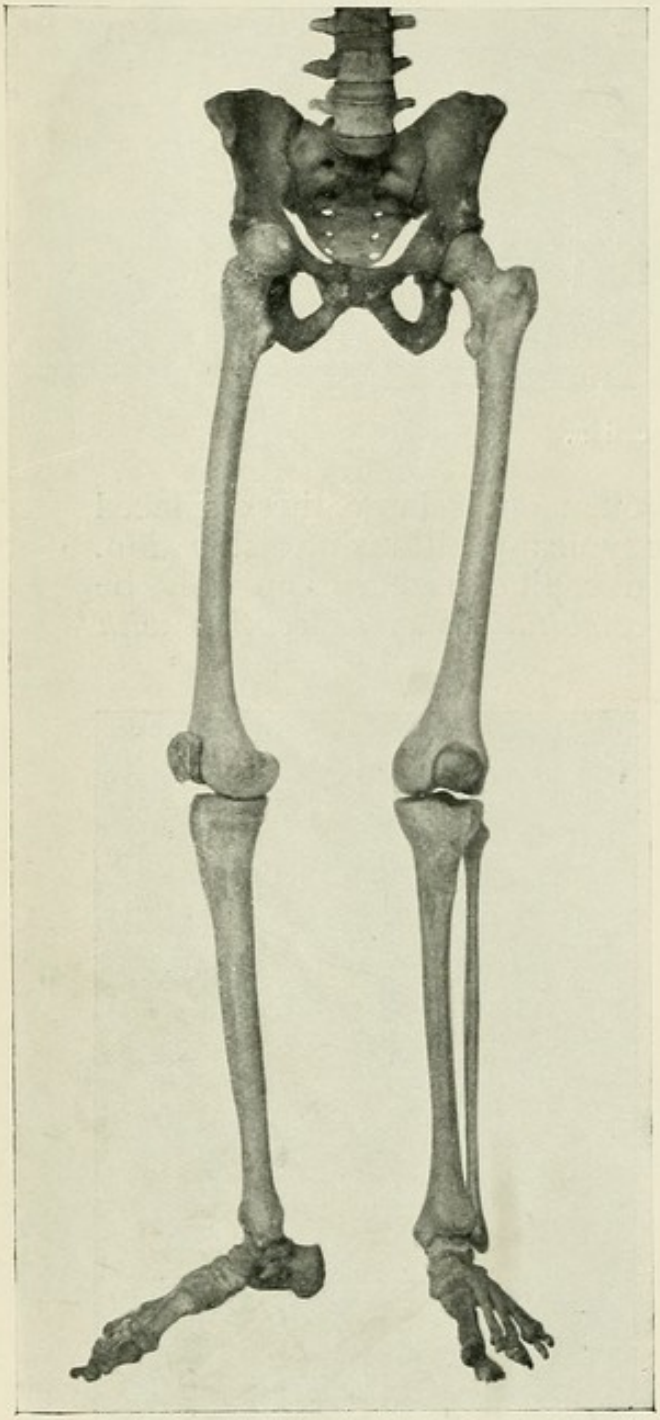

FIG. 359.—Ilio-pectineal dislocation.

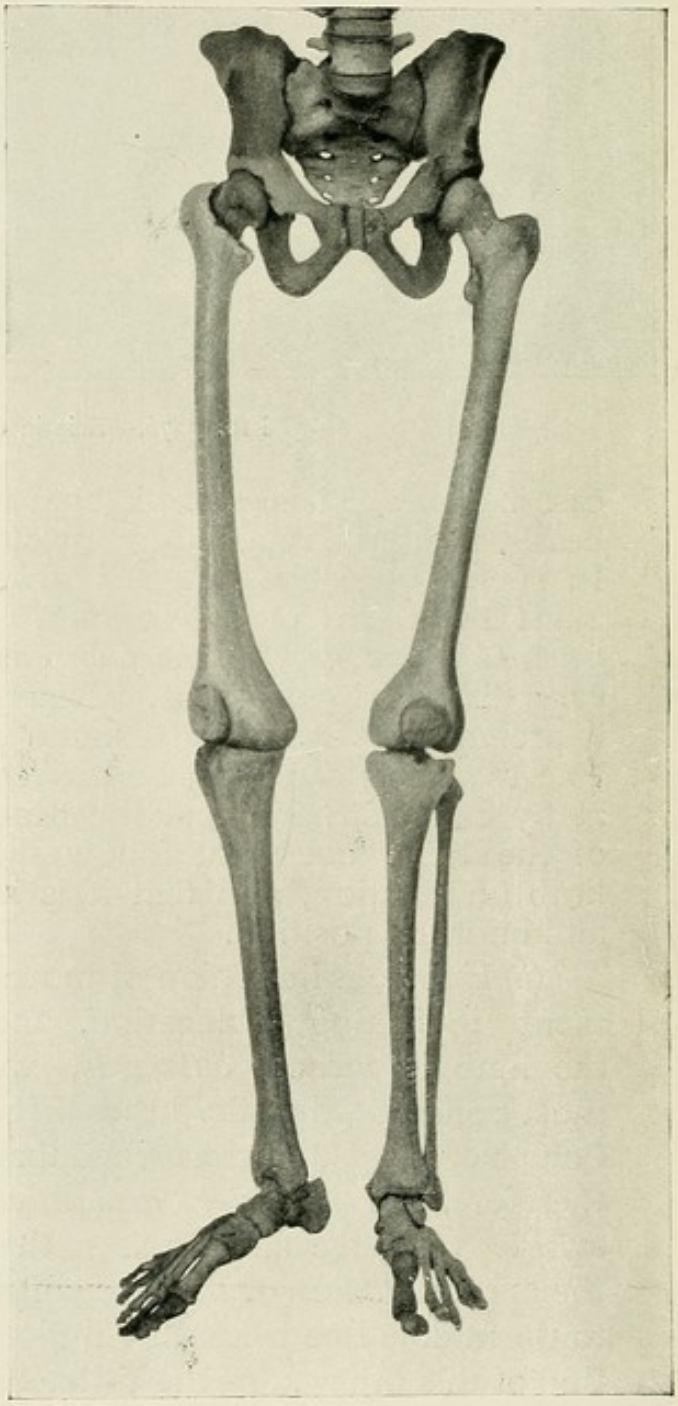

FIG. 360.—Inter-trochanteric fracture.

limb the appearance of some lengthening, and when the sound limb is adducted close to the injured one the sound limb looks shortened and the injured limb lengthened. If both limbs are, however, measured in the same position, some shortening of the distance between the anterior superior spine and the malleolus will always be found.

In this dislocation the femoral artery can be felt internal to the head of the femur, and, indeed, the artery may be lifted up by it. Neuralgic pains and disturbances of sensation in the area of the anterior crural nerve indicate that this nerve has been injured.

If the abduction is much more definitely pronounced, and is associated with flexion, and the head of the bone is not found on the horizontal ramus of the pubis, we make the diagnosis of **obturator dislocation.** In well-developed muscular persons the head of the bone cannot easily be felt. In confirmation thereof the region of the trochanter will not only be flattened out, as in suprapubic dislocation, but will also be drawn in. Finally, we shall infer, from radiating pains and paræsthesia on the inner side of the thigh, that the obturator nerve has been compressed.

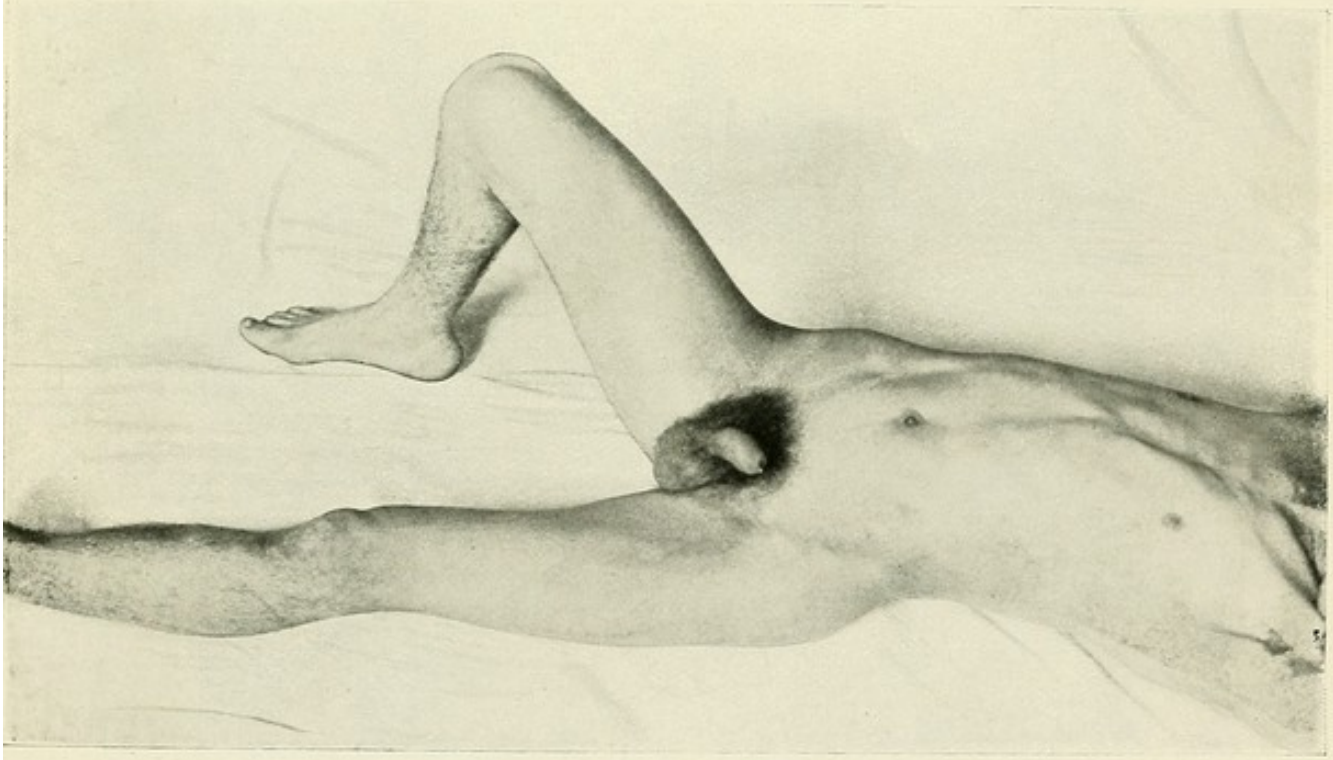

FIG. 361.—Obturator dislocation.

If a case presents, with outward rotation, an increase of the flexion to a right angle, we may diagnose the very rare dislocation towards the perinæum, *i.e.*, *perineal dislocation.*

We may now consider what mistakes may arise in connection with anterior dislocations. Supposing the external rotation in a case of suprapubic dislocation would, for a moment, suggest fracture of the neck of the femur (*cf.* figs. 359 and 360), the presence of the head of the bone in an abnormal position should at once establish the diagnosis of dislocation with so much certainty that no other differential signs would be required. Obturator dislocation is distinguished from fracture of the neck of the femur by abduction of the limb, by considerable flexion, and also by indrawing of the trochanter region (fig. 361). This last sign is only equally

pronounced in fracture of the pelvis when the head of the femur is driven into the pelvic cavity—the so-called *central dislocation.*

Perineal dislocation, with the very unusual posture arising therefrom, cannot be mistaken for any fracture.

(*c*) It is necessary to mention finally the very rare dislocations, *upwards* and *downwards.*

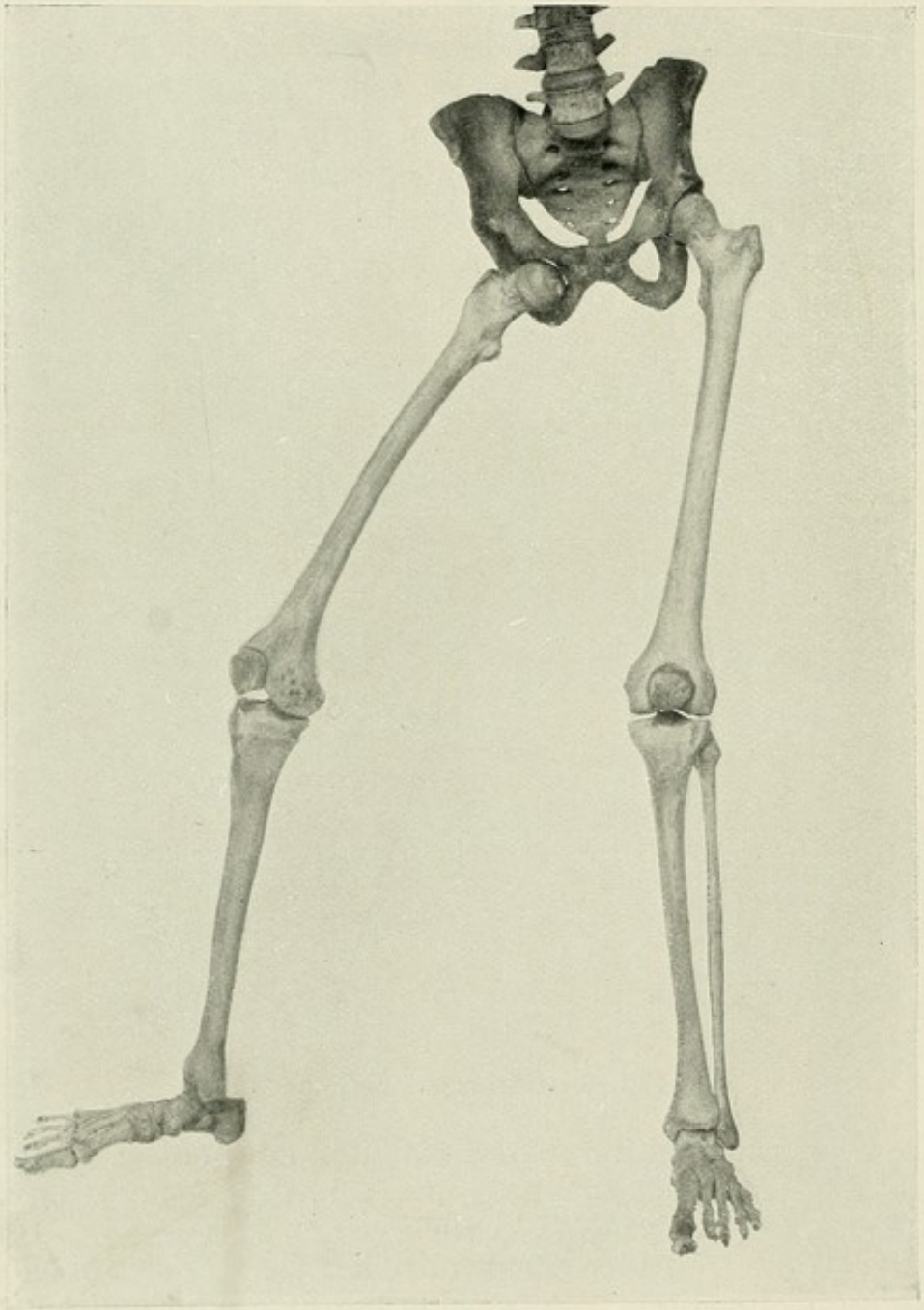

FIG. 362.—Obturator dislocation.

Supracotyloid dislocation resembles a suprapubic dislocation, forwards and upwards, except that the head of the bone is felt immediately below the anterior superior spine. This form is easily recognized. **Infracotyloid dislocation,** *i.e.*, downward dislocation, is recognized by the flexion of the thigh to a right angle, with slight external rotation and abduction. It approximates in signs to an obturator dislocation.

(2) CONTUSIONS, SPRAINS, FRACTURES.

If the passive movements in the foregoing examination have been free, and therefore the possibility of dislocation is excluded, we have to decide between **contusion, sprain** and **fracture.**

Some indications will already have been furnished by the *cause.* A contusion arises from a direct injury to the hip. But, in the absence of such a cause, a sprain is the most likely diagnosis, as, for instance, when an elderly man collapses after an excessive movement of external rotation. This injury would not, however, completely abolish the supporting function of the limb. If the patient makes fruitless attempts to stand and to walk, and finally allows himself to be carried home and put to bed, we may assume the presence of a fracture. But if he walks home on foot, the case is either one of contusion or sprain, in accordance with the form of the injury.

There is, however, one important exception to this rule, which not so much concerns the fact that sometimes contusions and sprains cause very grave disturbances of function, as that certain fractures are attended by very little derangement. It happens, especially in the case of impacted fractures, and even in separation of the epiphyses in young people, that the patient is often able to walk home. If the practitioner relies upon this circumstance to exclude a fracture, and neglects a more careful examination, both he and the patient may be confronted, in the course of a few weeks, with the unpleasant surprise of a healed fracture, with shortening and external rotation, *i.e.*, a *traumatic coxa vara;* unless the fracture has, in the meantime, been diagnosed by another practitioner.

If the patient lies extended on his bed, the position of the limb affords certain indications. A normal position is in favour of a simple contusion, as most fractures of the neck of the femur are associated with external rotation.

We have already mentioned the rare cases of impaction in internal rotation. This possibility must always be thought of, lest a dislocation be wrongly diagnosed.

If it is impossible to raise the extended limb, we must assume the presence of a fracture, as previously stated.

We must also consider the amount of spontaneous pain and the painfulness of the joint, when it is interfered with. As Kocher points out, the spontaneous pain in contusion may be disproportionately great, despite slight loss of power, whereas in fracture it may be very slight, despite complete loss of power. On the other hand, the pain caused by pressure exerted in the axis of the femur is slight or completely absent in contusion, whereas it is always present in cases of recent fracture. Thus we arrive at the following rule :—

If a person suffers a severe loss of power in consequence of a direct or

indirect, seemingly insignificant injury to the hip, a fracture is highly probable. The greater the contrast between spontaneous pain and the extent of functional disturbance, the more likely it is that a fracture has taken place. If the supporting function of the limb is abolished, although the spontaneous pain is only slight, there is certainly a fracture present.

In these circumstances, there is no difficulty in bringing forward direct evidence of the fracture. It is certain that a complete fracture exists if there is *shortening* which cannot be attributed to a previous injury, or if the trochanter is above its normal position, or if there is an approximation of the femur to the pelvis.

Partial fractures of the trochanter, detachments or abrasions of small pieces thereof, can only be distinguished from simple sprains by means of a skiagram, because of the great effusion of blood into the soft parts.

Complete detachment of the great trochanter, which is rare, may be diagnosed by the loss of power of support in the hip, despite the normal condition of the joint, and by the demonstration on palpation of the upwardly displaced fragment.

Detachment of the small trochanter, which is still more rare, may be recognized, according to Ludloff, by the fact that the patient cannot raise his limb when in a sitting posture.

We must not base the diagnosis of a bone lesion merely on the presence of crepitus. There are cases in which, independently of any injury, the anterior margin of the tendon of the gluteus maximus, or the ileo-tibial band of the fascia lata, glides over the trochanter with palpable and audible crepitus, when the muscle contracts powerfully. This has been termed in French, "*hanche à ressort*," but the German expression, "*schnappende Hüfte*," is more expressive.

Having decided that a **complete fracture** exists, we must next determine where it is situated, and whether it is loose or impacted. We cannot rely on skiagraphy, even as much as in elbow or shoulder cases, because the conveyance of a patient with an injured hip to an X-ray institute is mostely quite impracticable. But, nevertheless, a correct diagnosis is most important for prognosis and treatment.

We may here briefly review the various forms of fracture. It was formerly the custom to distinguish between *intracapsular* and *extracapsular fractures*. But as the capsule extends farther towards the trochanteric region on the anterior surface than it does on the posterior surface, and as also the line of fracture is often irregular, it follows that numerous fractures of the neck of the femur are of a mixed variety, partially extra- and partially intra-capsular. We, therefore, adopt Kocher's classification and divide these fractures according to their position, regardless of their relations to the capsule.

One line of fracture (fig 363, 1) lies at the border between the head and the neck. This variety is termed by Kocher, *fractura subcapitalis*, and if pure, is always intracapsular. Another line of fracture lies along the neck itself, where it merges with the trochanter mass, that is to say in the region of the intertrochanteric line

(fig. 363, 2)—*fractura intertrochanterica*. This fracture is partially intra- and partially extra-capsular. The *pertrochanteric fracture*, the line of which traverses the trochanter mass, lies close to the line of the fracture of the neck of the femur. It generally runs obliquely, from outwards and upwards in front, to downwards and inwards behind (fig. 363, 3); this fracture is more common than the pure intertrochanteric variety. The *subtrochanteric fracture*, which traverses the bone below the lesser trochanter, belongs to the fractures of the shaft, but it is more practical to discuss it with the fractures of the neck of the femur (fig. 303, 4 and 5).

Intertrochanteric and pertrochanteric fractures are not usually pure in form. The former is very often associated with a fracture in the trochanter mass—indeed recent autopsies show that this is probably

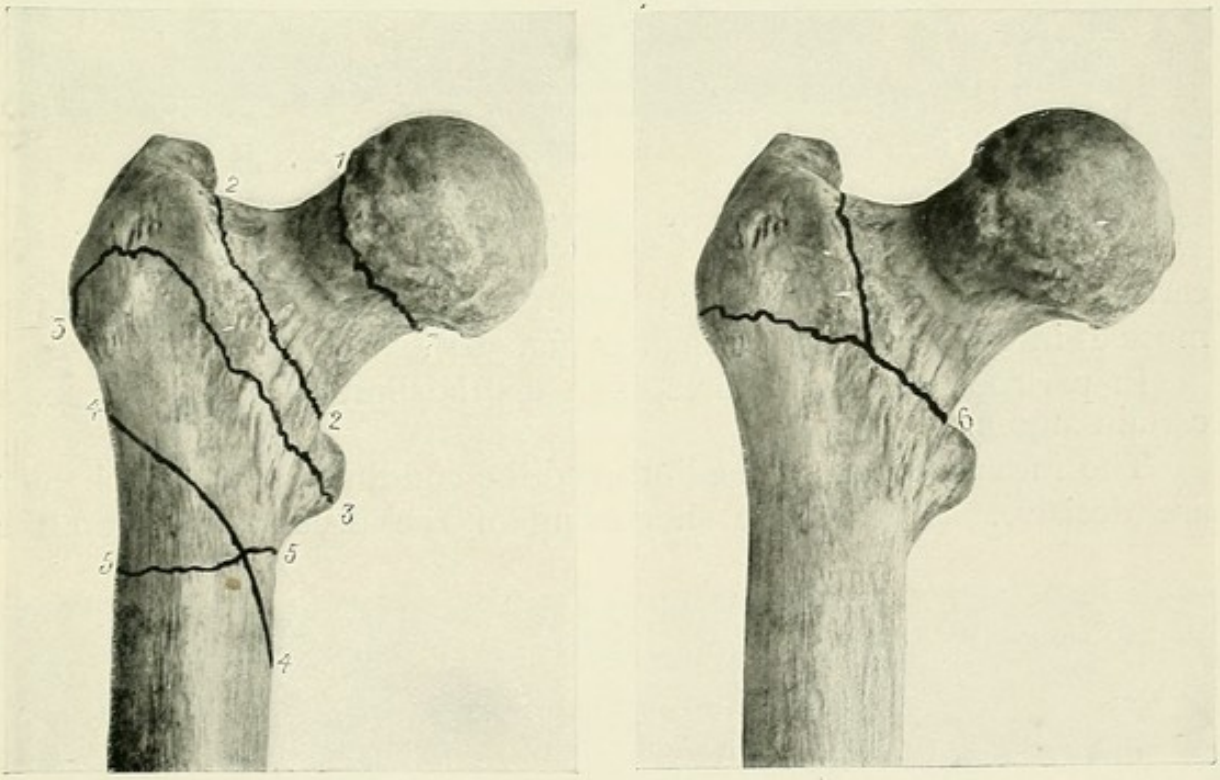

FIG. 363.—*a*–*b*, Typical lines of direction of fractures at the neck of the femur.

a

1. Fractura subcapitalis.
2. ,, intertrochanterica.
3. ,, pertrochanterica.
4. ,, subtrochanterica (oblique variety). Rotation fracture.
5. ,, Ditto (transverse variety).

b

6. Y-shaped fracture.

the rule—so that really a Y-shaped fracture results (fig. 363, 6). Pertrochanteric fractures may also be combined with intertrochanteric, as well as with subtrochanteric fractures.

Impaction may occur in all forms, except in a pure subtrochanteric fracture.

How much of this can be recognized with certainty in the living subject without X-rays?

(*a*) In the first place we must decide whether a **pertrochanteric** or **subtrochanteric fracture** is present or not. As the line of fracture

in both of these varieties is below the insertion of the internal rotators, the limb lies in a position of complete external rotation (fig. 365) because of its own weight. It is quite impossible for the patient to effect the slightest internal rotation. If we turn the leg inwards, it falls limp on to its outer side as soon as we leave go, in contrast to fractures seated higher up, in which the limb retains a

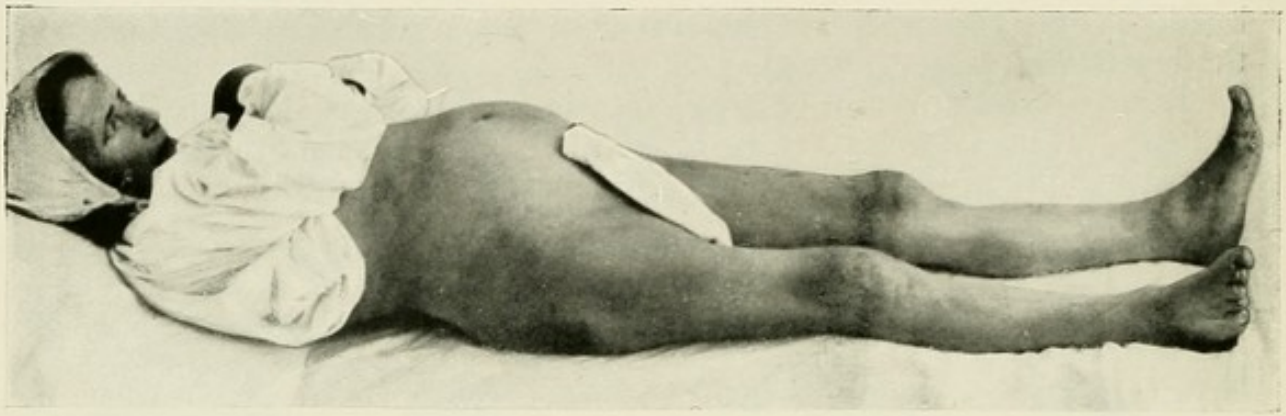

FIG. 364.—Intertrochanteric fracture. Incomplete external rotation. Shortening.

certain amount of power in the absence of impaction, because of the muscles inserted into the trochanter (fig. 364).

In pertrochanteric fractures, high up, the limb always possesses a certain amount of power.

The measurements of the limb and the condition of the trochanter are decisive. If there be shortening of the distance between the

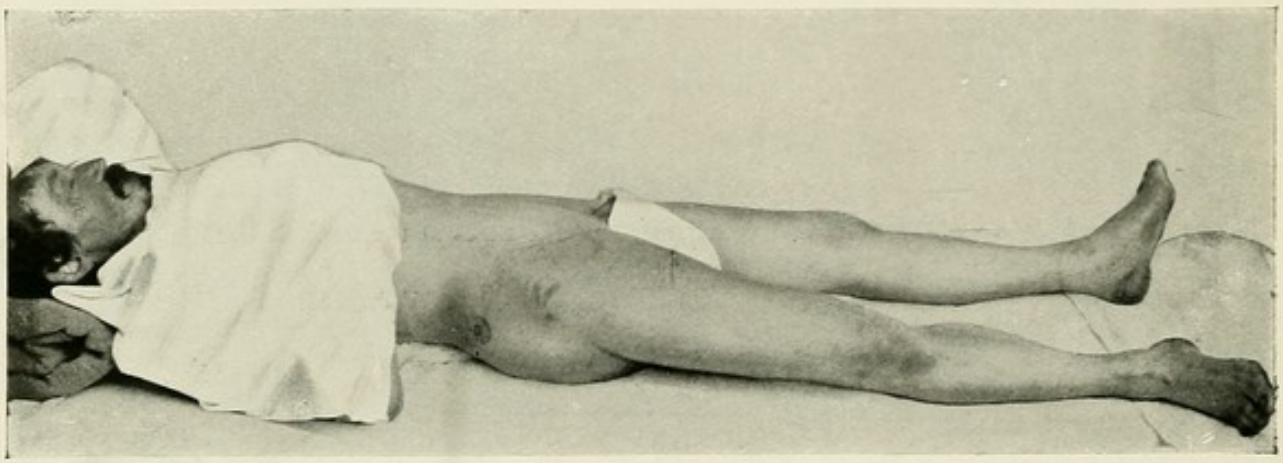

FIG. 365.—Subtrochanteric fracture. Complete external rotation. Shortening.

anterior superior spine and the malleolus, and of the distance between the trochanter and the malleolus, with the trochanter in a normal position, the fracture must be below the trochanter. If, on the other hand, only the distance between the anterior superior spine and malleolus is shortened, and the trochanter is abnormally high in position, the fracture cannot be below the trochanter (see fig. 355). If

the intense swelling of the soft parts or some old shortening render the results of measurement indecisive, the case may be elucidated by the *behaviour of the trochanter on rotation of the thigh*. If the tip of the trochanter revolves with the rotation, the fracture is above it; if it does not revolve, the fracture is below it. An impacted pertrochanteric fracture is often recognizable by the presence of a double prominence instead of the great trochanter, further by the tenderness over the trochanter itself, even when the pressure is made externally, and often by the involvement of the thigh in the swelling.

If the fracture is below the tip of the trochanter it may either be *pertrochanteric or subtrochanteric*. In the latter case the whole trochanter mass remains unmoved on attempting rotation; in the former case, the tip of the trochanter does not follow the movement of rotation, but the trochanter mass, grasped lower down, will be felt to turn with the lower fragment. Fracture through the trochanter is also recognized by definite broadening of this structure, and by very pronounced pain on pressure in its vicinity. In fractures below the trochanter there is no broadening of this structure, and the maximum swelling is below it.

In a typical pertrochanteric fracture, wherein the plane of the fracture runs from the front downwards and backwards, it is very often possible to feel the sharp edge of the *lower* fragment, which is displaced upwards and forwards, as Kocher has pointed out. On the other hand, in a pure subtrochanteric transverse fracture, the lower end of the *upper* fragment, which is kept flexed by the ileo-psoas, can be felt beneath the muscles.

(*b*) If we have excluded both a per- and sub-trochanteric fracture, and therefore limited the diagnosis to **fracture of the neck of the femur**, we still have to distinguish between a *subcapital* and *intertrochanteric fracture*, and also to decide whether it is *impacted* or *non-impacted*.

We first endeavour to localize the seat of maximum *pain on pressure*. If it is beneath the middle of Poupart's ligament in the neighbourhood of the head of the femur, we may conclude that the fracture is subcapital. If the site of maximum pain on pressure is in the proximity of the trochanter mass, we may assume that the fracture is intertrochanteric. At the same time, we notice whether there is any marked *swelling*. If there be any in the neighbourhood of the trochanter mass it is clear that an intertrochanteric fracture must be present. If, on the other hand, the trochanter region can be freely grasped, the fracture must either be subcapital or an intermediate form.

In order to examine the trochanter for pain on pressure and for change in shape, we press with the tips of the second, third and fourth fingers in the groove behind the trochanter and make counter-pressure with the thumb in front of it.

We may also derive important information by *examining the movements*. If crepitus is felt, impaction is excluded. It is also excluded if the thigh can be moved backwards and forwards on the pelvis—obviously without using force (the *va et vient* movement of French authors).

If we find on rotating the limb that the tip of the trochanter turns on its own axis and does not describe any definite curve, a loose intertrochanteric fracture must be present.

If the trochanter describes a definite curve when the limb is rotated —a curve which is always smaller than normal in the case of fractures —there are two possibilities present. If the signs previously mentioned enable us to exclude impaction, the neck of the femur, which represents the radius of the curve described by the trochanter, must still be attached to it. In other words, a non-impacted subcapital fracture is certainly present. If, on the other hand, we must assume that there is impaction, we can only suspect the exact situation of the fracture by localizing the direct pain on pressure and the thickening of the bone.

If there is too much swelling to permit of this, it does not prejudice the question of treatment. Every impacted fracture which is suspicious of a subcapital fracture must be handled with due attention to the impaction, because this offers the safest guarantee for bony union. It is better to do without a definite diagnosis than to disengage the impaction. Only an X-ray examination can define the line of fracture and enable us to disengage the impaction, when the fracture is not directly at the head, and the eversion of the limb renders it desirable to improve its position.

In some cases the *etiology* assists in the forming of a diagnosis, but very often the patient himself does not know the details of the accident, and his statements are quite indefinite and useless. If he has fallen on his feet and the blow has thus been imparted from below, a subcapital fracture is the most likely result. A fall on the region of the trochanter is the most frequent cause of intertrochanteric fracture. Extreme external rotation is just as likely to be due to pertrochanteric or to subtrochanteric fracture as to subcapital fracture, but does not suggest intertrochanteric fracture.

So far we have purposely not laid any stress on the *age* of the patient. Too much importance has hitherto been attached to the statement that fracture of the neck of the femur is the prerogative of old people. There is no doubt that old age predisposes to it, but fracture of the neck of the femur is by no means a rarity in young persons.

The patients, after a slight injury, remain in bed for a few days, sometimes even for two or three weeks, with the diagnosis of contusion of the hip, or with no diagnosis at all, and then begin to resume their occupation. After a few months have elapsed, they consult their doctor because of pains in the hip and slight lameness. Examination then reveals a shortening of 1 to 2 cm., a corresponding elevation of the level of the trochanter, diminution of the power of abduction and

possibly some slight external rotation. This, of course, establishes the diagnosis of *coxa vara*, and a careful investigation of the history may be required in order to detect the traumatic origin of the malady.

It may be quite impossible to distinguish between traumatic and spontaneous coxa vara, and even a skiagram may not always enable us to come to a conclusion, as illustrated in fig. 384 *a*.

I remember one occasion on which two surgeons who had had considerable experience of this condition were unable to agree, even when the head of the bone had been excised. The bending does not usually take place in the middle of the neck of the femur in the coxa vara of young people, but in the neighbourhood of the epiphyseal line, which is also the most frequent site of fractures. The matter is of importance in regard to accident insurance. As far as our present experience goes, it would appear that the accident should always be held responsible, if an injury has really been proved, and if no hip symptoms existed previously. The other hip should always be examined and a skiagram made. If it shows signs of commencing coxa vara the accident can only be credited as an aggravating factor.

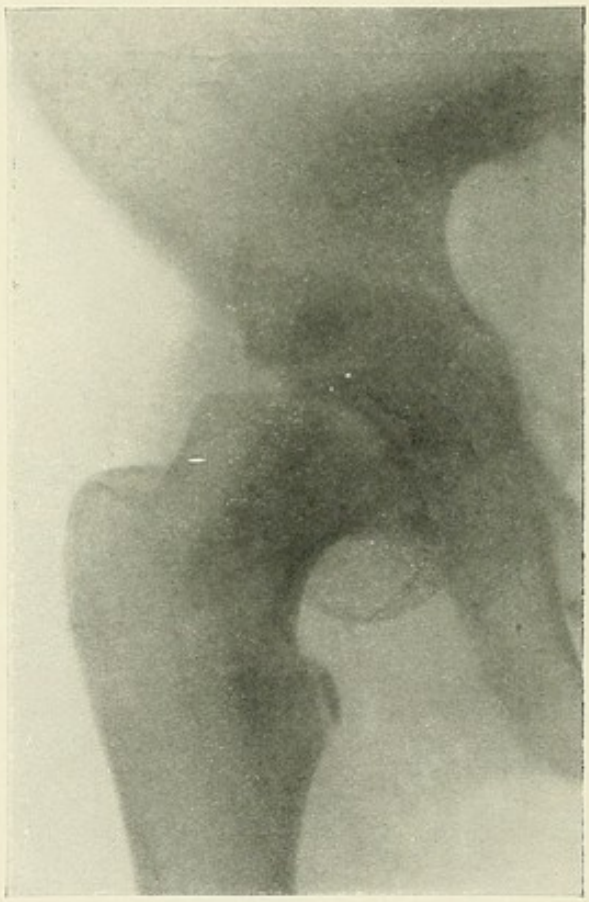

FIG. 366.—Separation of epiphysis in a girl aged 14.

Much controversy has raged as to whether fractures during the period of growth are **separations of the epiphysis** or not. But this is mainly a quibble about words. If the fracture is situated close to the trochanter mass, as actually occurs, the case is simply one of the ordinary intertrochanteric fracture. The question can only concern subcapital fracture, where the epiphyseal line always constitutes a locus minoris resistentiæ. This does not, however, mean that the whole extent of the line of fracture must follow the epiphyseal line. It may deviate from this line either towards the head or towards the neck, just as happens with fractures close to other epiphyseal lines. It is quite immaterial from the point of view of treatment whether these cases are regarded as separations of epiphyses or as fractures. There is only one differentiating sign, but this must be appealed to with caution. If we only feel soft crepitus we may assume that the line

of fracture runs along the cartilage, but the rougher the crepitus is the more the fracture will have involved the bone.

Can a fracture of the neck of the femur be *mistaken for any other injury*, apart from dislocation, contusion, and sprain, which have already been referred to?

Fractures of the shaft of the femur do not come into serious consideration, because the seat of the injury is very clearly evident on palpation and on testing for abnormal mobility. But, on the other hand, in very severe injuries, such as those sustained in the collapse of a building, a fracture of the neck of the femur may be

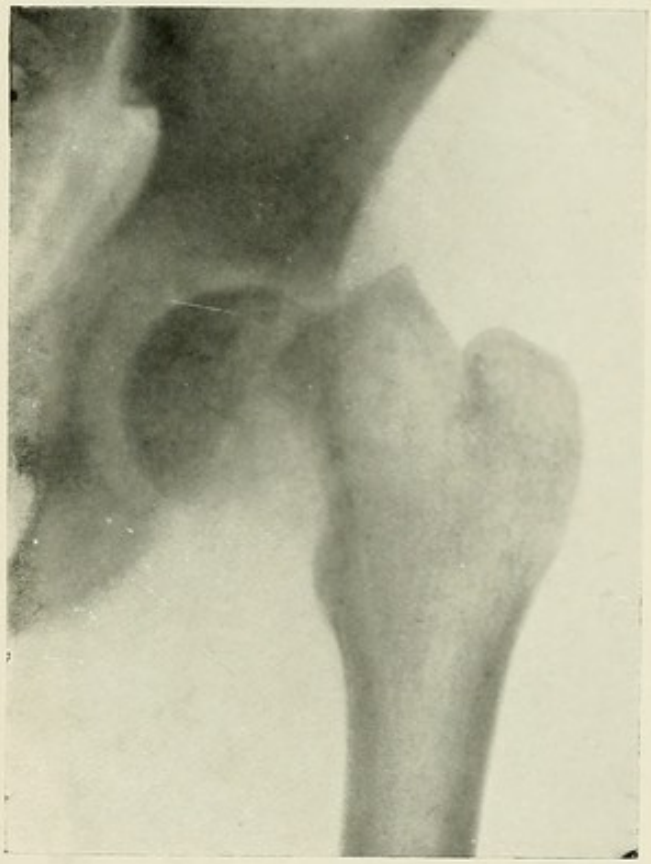

FIG. 367.—Subcapital fracture.

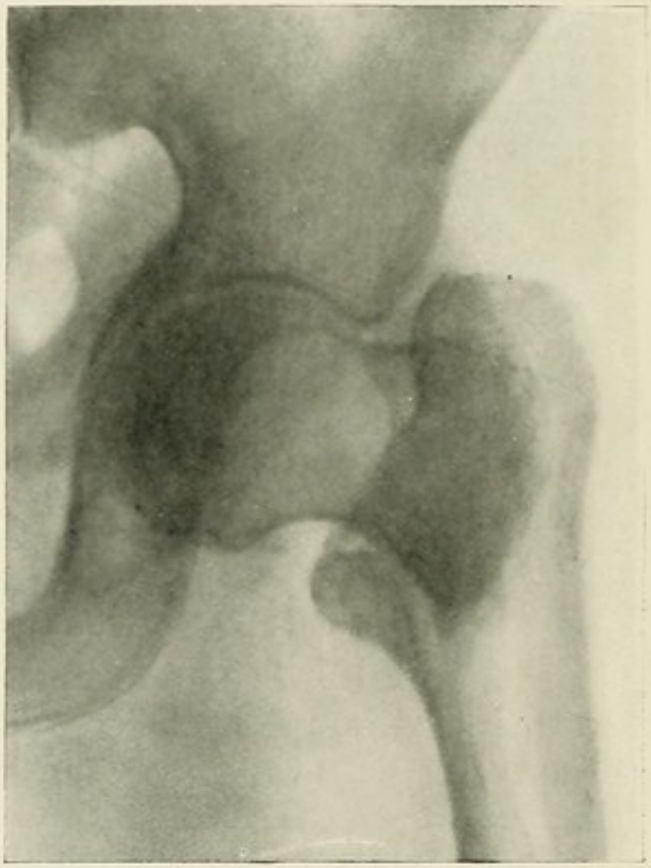

FIG. 368.—Intertrochanteric fracture.

associated with fracture of the shaft, and the diagnosis thus be rendered difficult.

It is, however, quite conceivable that a **fracture of the pelvis** may be mistaken for a fracture of the neck of the femur.

If there is a striking limitation of active movements, especially of flexion, although the measurements and the passive mobility are normal, we should think of a *fracture of the ring of the pelvis, unaccompanied by displacement.* This would be confirmed by pain on pressure on the pelvic fossa, by pressing the two pubic bones away from one another, and by force applied in the axis of the femur. We

should endeavour to determine the exact course of the fracture by palpating the accessible portions of the pelvis, more especially the iliac crest, the pubis (both internally and externally), and the sacrum.

If, in addition to the loss of power just described, there is also shortening, which is evident to the eye, but which cannot be demonstrated by the tape measure, we must conclude that the entire portion of the pelvis, embracing the acetabulum and the anterior superior spine, has been separated from its connections through a *double fracture of the pelvic ring*, and has been at the same time displaced upwards



FIG. 369.—Pertrochanteric fracture.

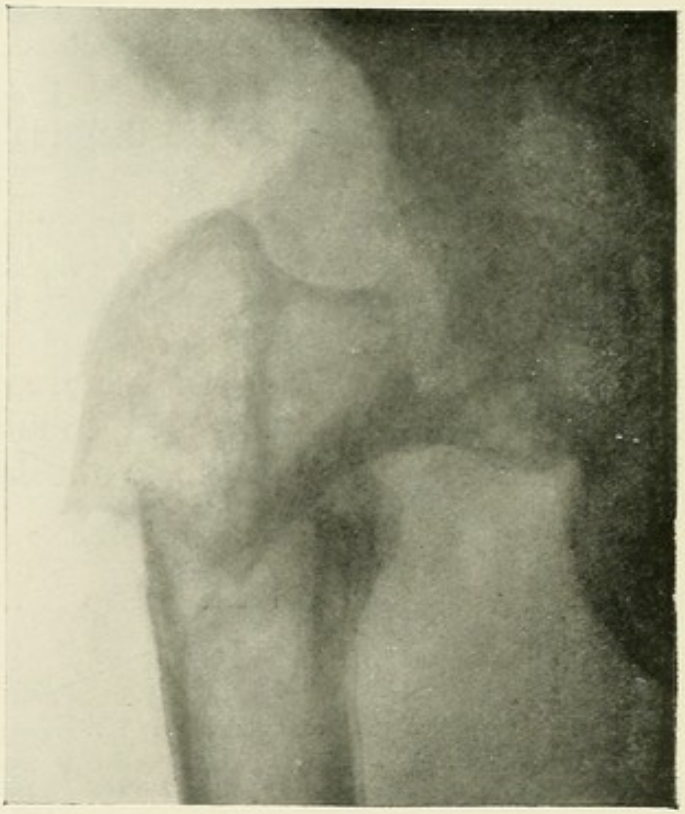

FIG. 370.—Subtrochanteric fracture.

(double vertical fracture of Malgaigne). The limb is usually everted in these cases, just as in a fracture of the femur.

The limb may appear to be lengthened, although the measurements are normal, in cases wherein the one half of the pelvis is displaced downwards in relation to the other half, as a result of a complete fracture of the pubis and a simultaneous loosening of the sacro-iliac articulation.

If the distance between the anterior superior spine and the malleolus is lengthened, without simultaneous lengthening of the distance between the trochanter and the malleolus, and without evident lengthening of the whole limb, and if at the same time passive movements are normal, and the supporting power is retained, the

case can only be one of fracture of that portion of the pelvic fossa which includes the anterior superior spine (Duverney's fracture). Pressure on the pelvic fossa may elicit pronounced pain, and possibly crepitus in confirmation of this assumption. There is no pain on pressure in the axis of the femur.

If the limb is shortened and fixed in a position of eversion, but the head of the bone cannot be felt to be displaced forwards as in an ileo-pubic dislocation, the acetabulum must be shattered, and the head of the bone driven into the pelvis. Rectal examination will confirm this diagnosis of *central dislocation*, which is a very rare injury.

If the hip-joint is quite free, but pain is caused in the *sacro-iliac articulation* by pressure or traction, the cause must either be a *sprain* or a *fissure* in the vicinity of the articulation. If nothing can be detected on palpation, the diagnosis must be made by means of the X-rays.

In all cases of pelvic fracture attention must be paid to the *condition of the urinary tract*, for, as already stated, the urethra may be injured in various ways, and the bladder may be impaled by a splinter of bone. It is sometimes the urinary symptoms which draw attention to an overlooked fracture of the pelvis.

The following table will enable the beginner to appreciate the symptomology of injuries to the hip with greater facility :—

Active and passive movements free in all directions, but partially painful; power of support retained; no shortening	Direct trauma (Ecchymoses)		**Contusion** (rarely an impacted fracture with slight displacement).
	Indirect trauma	Active flexion quite free	**Sprain.**
		Active flexion impossible in the sitting posture	**Detachment of lesser trochanter.**
Active and passive movements abnormally free in certain directions, and restrained in others; power of support almost always lost, at any rate, at first	Limb inverted, adducted and flexed; head to be felt on the pelvis	The foot reaches the ground on standing (with the other limb extended), or at least the heel of the other foot	**Iliac dislocation.**
		The foot does not reach the ground	**Sciatic dislocation.**
	Limb everted and somewhat abducted	Limb extended; abduction slight; head visible and palpable over the pubic crest	**Ileo-pectineal and pubic dislocation.**
		Head not palpable there	**Central dislocation.**
		Limb semi-flexed; pronounced abduction; head not distinctly palpable.	**Obturator dislocation.**
Active movements entirely lost, or almost so; passive movements free in all directions, or somewhat limited on internal rotation; shortening (sometimes very slight)	Level of trochanter normal; distance between ant. sup. spine and distance between trochanter and malleolus shortened (infratrochanteric shortening); tip of trochanter does not follow on rotation; limb completely everted	Trochanter mass painful on pressure up to the top, thickened; upper end of lower fragment often to be felt near tip of trochanter.	**Non-impacted pertrochanteric fracture.**
		Pain on pressure below the trochanter mass; upper fragment often to be felt under the skin in flexion	**Subtrochanteric fracture.**

- Active movements entirely lost, or almost so; passive movements free in all directions, or somewhat limited on internal rotation; shortening (sometimes very slight)
  - Level of trochanter very high; distance between ant. sup. spine and malleolus shortened; distance between trochanter and malleolus normal (supratrochanteric shortening); tip of trochanter follows on rotation; limb usually in semi-eversion
    - Slight active movements present; sometimes even some power of support; no crepitus; femur not movable on pelvis; trochanter mass and tip of trochanter clearly palpable, and not painful on pressure externally — **Impacted intertrochanteric or Subcapital fracture** (distinction often impossible clinically without X-rays).
    - Trochanter mass widened, painful on pressure externally; two protuberances to be felt on tip of trochanter — **Impacted pertrochanteric fracture**, or mixed form with **impacted intertrochanteric fracture.**
    - Active mobility slight; no power of support; femur movable on pelvis with crepitus; pain on pressure, especially under Poupart's ligament, and not in the trochanter region; trochanter describes a curve on rotation — **Free subcapital fracture** or **separation of epiphysis.**
    - Active mobility and power of support *nil;* femur movable on pelvis with crepitus; pain on pressure on inner side of trochanter (as felt from behind); latter revolves on itself (*i.e.*, in its long axis) — **Free intertrochanteric fracture.**
  - Distance between ant. sup. spine and malleolus normal; passive movements free; active movements also free, but some looseness of support on standing — Localized pain on pressure over great trochanter — **Fracture of great trochanter.**
  - Distance between trochanter and malleolus normal; distance between ant. sup. spine and malleolus increased; function of hip normal — Compression of pelvic fossa painful also, but apparent shortening
    - **Fracture of pelvic ring** without displacement.
    - **Double vertical fracture.**
    - **Fracture of pelvic fossa.**

CHAPTER XCIII.

NON-TRAUMATIC DEFORMITIES AT THE HIP-JOINT. (CONGENITAL DISLOCATION OF THE HIP AND COXA VARA.)

COXA VARA and congenital dislocation of the hip appear to be two very different diseases, and yet they are sometimes mistaken for one another. Even experienced observers are in doubt in certain cases. The difficulty is easily solved by a skiagram, but the apparatus for this purpose is not always available. We must, therefore, endeavour to establish the diagnosis without this aid.

A.—CONGENITAL DISLOCATION OF THE HIP.

In congenital dislocation of the hip, the head of the bone is no longer in the acetabulum, but is either above or below it. The first

and inevitable result of this change in position is a *shortening of the distance between the anterior superior spine and the malleolus* and an elevation in the *level of the trochanter*. The shortening amounts to about 2 cm. even in little children.

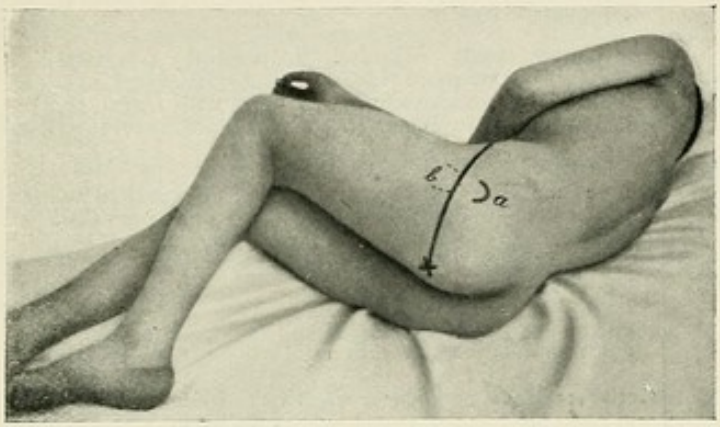

FIG. 371.—Estimation of the level of the trochanter by means of Roser-Nélaton's line in a case of coxa vara. *a* = Actual level of the trochanter (here raised), *b* = normal level of the trochanter.

The level of the trochanter can be estimated rapidly and reliably in three different ways :—

Roser-Nélaton's line, which joins the tuberosity of the ischium with the anterior superior spine of the ilium, is determined with the hip semi-flexed (135°). The trochanter lies normally in this line. If it is above this the level of the trochanter is said to be raised (fig. 371). A displacement of ½ to 1 cm. is not considered pathological, as it comes within the limits of error of measurement.

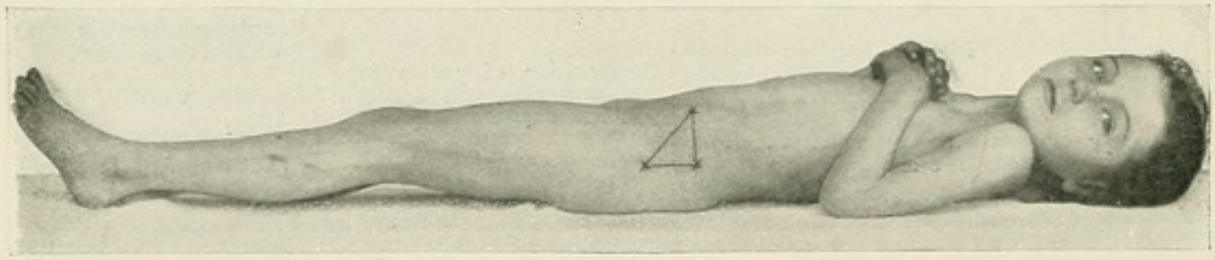

FIG. 372.—Measurement of Bryant's triangle in case of unilateral congenital dislocation of the hip. Normal side. The triangle is isosceles.

Bryant's triangle is also employed, and is constructed in the following manner : The patient lies flat on his back and the axis of the femur is prolonged with a blue pencil line above the trochanter.

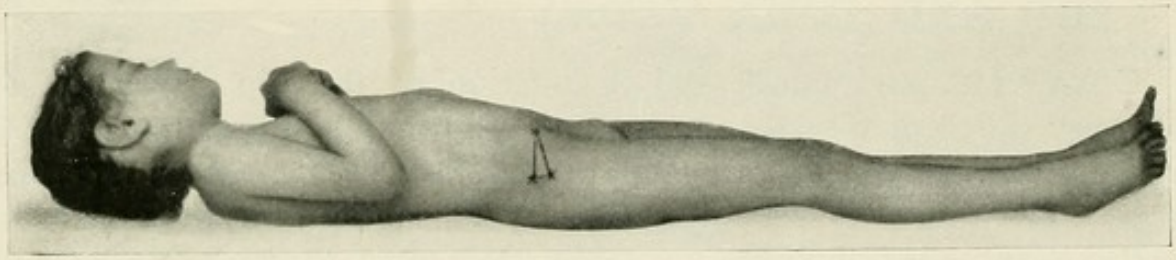

FIG. 373.—Same case. Dislocated side. The triangle is acute angled. The comparative measurement of the horizontal base gives the amount of displacement.

A vertical line is then drawn from the anterior superior spine to this base line, and another line is drawn joining the iliac spine with the tip of the trochanter. The right-angled triangle so obtained

is normally an isosceles triangle, whereas the base line formed by the prolongation of the axis of the femur is shortened, compared to the opposite side, when the level of the trochanter is raised (figs. 372 and 373).

Shoemaker's method is even more simple, and it consists *of prolonging the line joining the trochanter with anterior superior spine, on to the abdomen.* This prolonged line normally meets the median line at the level of the umbilicus or above it; but when the level of the trochanter is raised it intersects this line below the umbilicus (fig. 374).

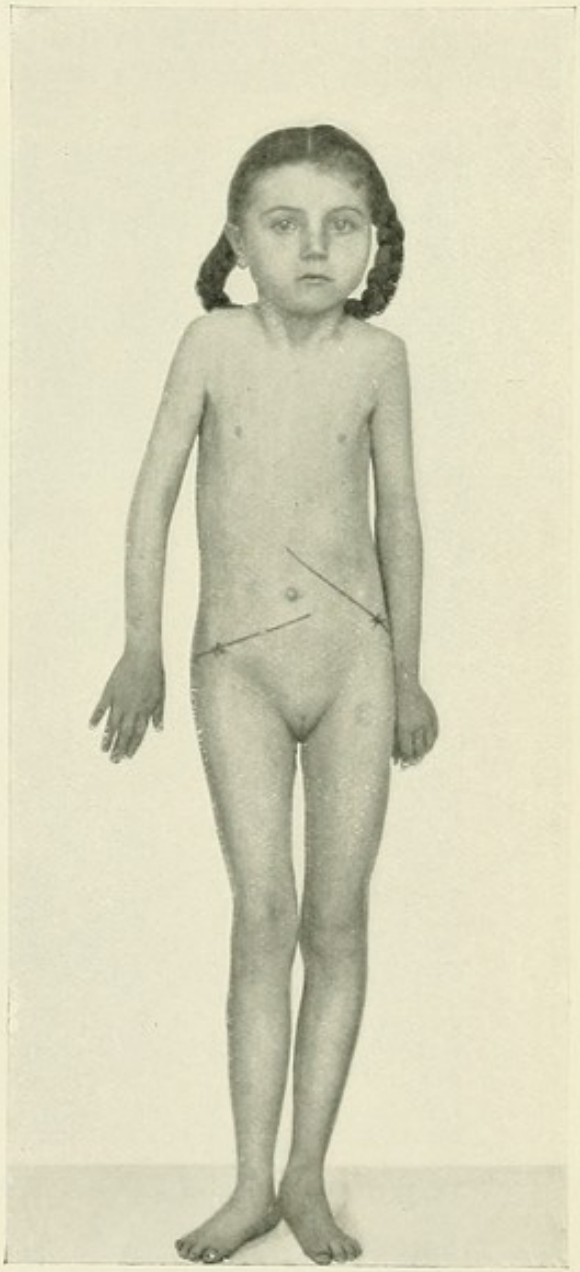

FIG. 374.—Same case. Determination of level of trochanter by prolonging towards the umbilicus the line which joins the trochanter to the anterior superior spine.

The head of the femur does not leave the capsule in cases of congenital dislocation. The capsule becomes dragged out, in the shape of a pocket, and is displaced posteriorly with the head. The thigh does not, therefore, assume the typical, mathematically fixed position in relation to the pelvis which it presents in cases of traumatic dislocation. Indeed the drawn-out capsule permits abnormally free play for the movements of femur. Congenital dislocation of the hip is therefore characterized by remarkably great *acrobatic mobility of the thigh,* and there is no pathognomonic position in cases of congenital dislocation of the hip in young children. Freedom of movement only diminishes after the lapse of years, but even then, abnormality of position is much less pronounced than in cases of traumatic dislocation.

Another important sign, connected with this defective fixation of the head, is the *possibility of moving it backwards and forwards on the pelvis.* This sign is never absent in cases of congenital dislocation of the hip, if they are not too old, but it can only be demonstrated in refractory children when the muscles are relaxed by anæsthesia. Before proceeding to this test, we must endeavour to

show that the *head is in an abnormal position*, and we shall generally find it above or behind the acetabulum.

In the case of thin girls it is quite possible to see the head of the bone moving about, with every step, in the gluteal region. But it is not evident externally in very small fat children, nor can it be readily felt, especially if it is not fully developed. Sometimes anæsthesia is indispensable for the examination, but whether employed or not, we proceed in the following manner, as taught by Malgaigne (fig. 375). The child is laid upon the healthy side; the leg of the deformed side is flexed to a right angle, and, if necessary, is somewhat

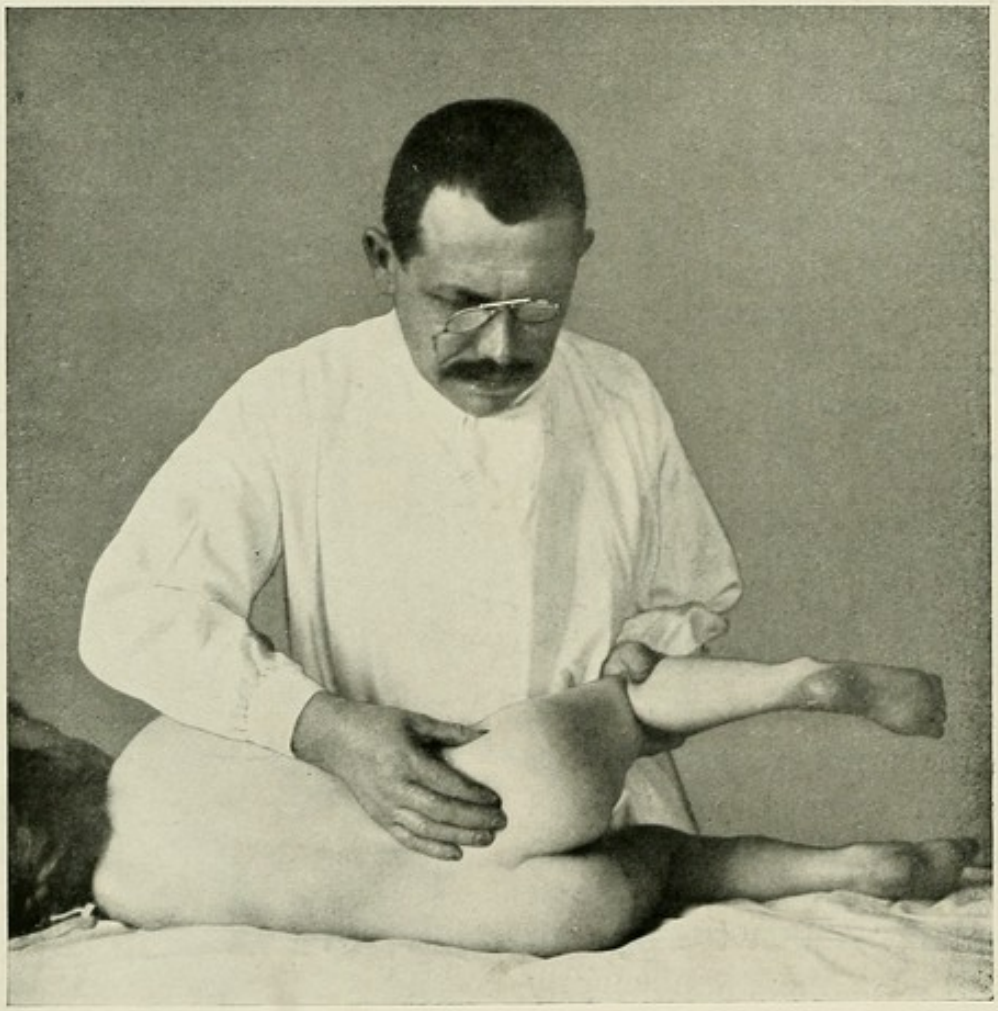

FIG. 375.—Palpation of the head of the bone in congenital dislocation of the hip.

adducted. Attempts are made by pressure on the femur from the knee, with one hand, to press the head of the bone as far as possible away from the pelvis. At the same time movements of rotation are made with the same hand, while the upper end of the femur is being palpated by the other hand. If only *one* protuberance is felt, this is the trochanter, and there is no dislocation present. But if *two* protuberances are felt, one must be trochanter, and the other is the head of the bone, and a dislocation does exist.

Children who have already walked for some time present another important symptom, especially when the dislocation is bilateral, *i.e.*, a

great degree of *lumbar lordosis*, which depends upon the rotation of the pelvis forwards, upon its transverse axis.

The dislocation causes the centre of gravity of the back to fall along a line anterior to the points of body support, and the endeavour to bring it back again over the feet is the cause of the lordosis.

The diagnosis of congenital dislocation of the hip is established if there is shortening, with abnormal mobility of the thigh, elevated level

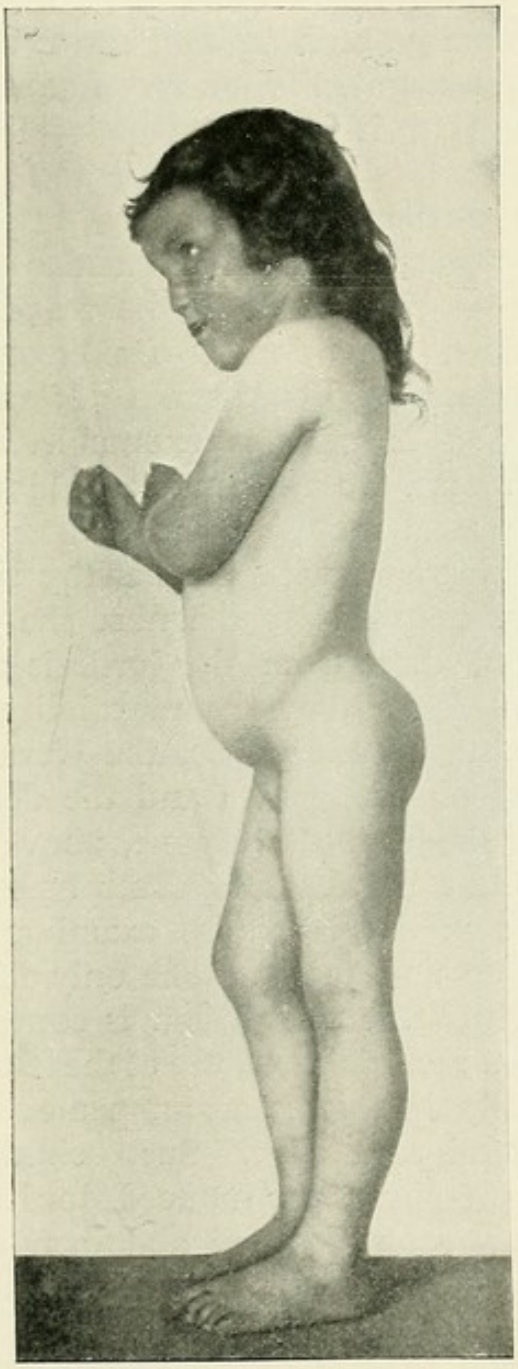

FIG. 376.—Congenital dislocation of the hip. (Lordosis !)

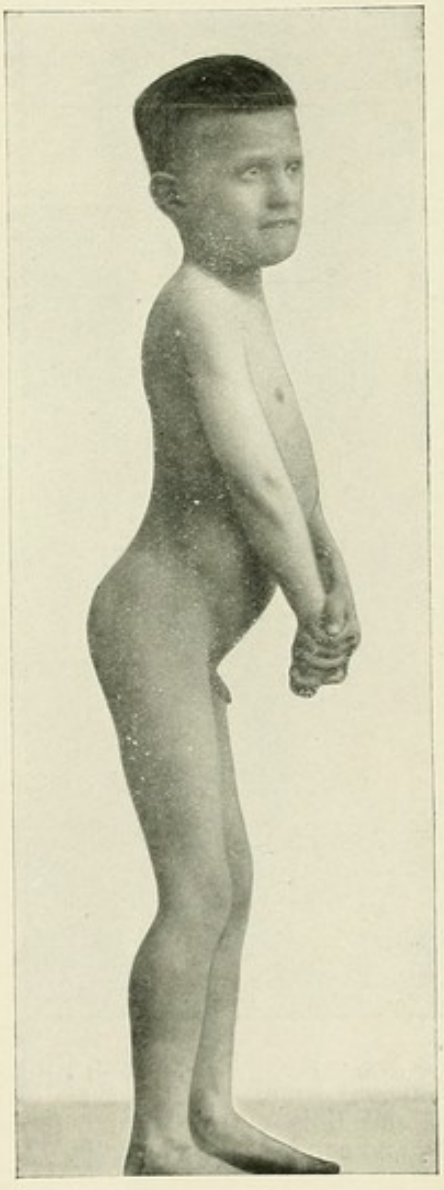

FIG. 377.—Lordosis in progressive muscular atrophy.

of the trochanter and displaceability of the femur on the pelvis, and if a protuberance is felt besides the trochanter, and if, in addition to all this, lumbar lordosis is also present.

A skiagram can only add a few details to the diagnosis, in regard to the shape of the acetabulum and the head of the bone.

We have not yet referred to the *history*, which usually relates that nothing was noticed in the first year, but that a slight lameness was observed as soon as the child attempted to walk. If the dislocation is bilateral, the gait will be described as waddling, and it will have been attributed to weakness; but the disability will be said to be constantly increasing.

As we have already seen, the signs are so striking, and can usually be demonstrated with so much accuracy that it is hardly possible to overlook a definite case, and the favourite diagnosis of a past generation—"weakness of the muscles and bones"—ought never to be made by a modern practitioner. An error in regard to a slight degree of *bilateral dislocation* is perhaps excusable. In such a case, we are unable to judge of abnormal mobility and shortening by comparison with the healthy side. We are only able to diagnose the dislocation, apart from the lordosis and the duck's gait, by the movability of the femur on the pelvis, the elevated level of the trochanter, and the detection of the head of the bone, above or behind the acetabulum. Both types of cases sometimes require examination under an anæsthetic. The only affection with which confusion is conceivable is a rachitic curvature of the femur, especially if this is accompanied by a bilateral *coxa vara*. Such children often present a pronounced lordosis, *i.e.*, they protrude their abdomen forwards, in order to regain the equilibrium, which is disturbed by the curvature of the femur (fig. 378). The gait is often awkward, and resembles the waddling in the case of congenital dislocation of the hip. The similarity of the conditions is enhanced by the fact that the level of the trochanters is raised in coxa vara and because they project abnormally far at the sides (see shape of hips in fig. 379).



FIG. 378.—Rachitic coxa vara, with simultaneous bending of the shaft of femur and tibia outwards and forwards, and compensatory lordosis.

But an important difference is afforded by the abnormal mobility in congenital dislocations, in contrast to the restricted movements in

coxa vara. There are, however, cases of coxa vara wherein the restriction of movements is but slight, namely the coxa vara of little rachitic children, and, on the other hand, there are cases of congenital dislocation—mostly in older children—wherein the abnormal mobility has become diminished. If, finally, the head of the femur is only slightly developed, and is therefore difficult to feel as a separate structure, and if the dislocation is not definitely of the iliac variety, but of the supracotyloid variety, which, exceptionally, may remain in that position until an advanced age, it is quite conceivable that the case may be obscure until an examination is made under an anæsthetic. Trendelenburg has indicated a sign which may be valuable in such a case. He points out that when a normal individual stands on one

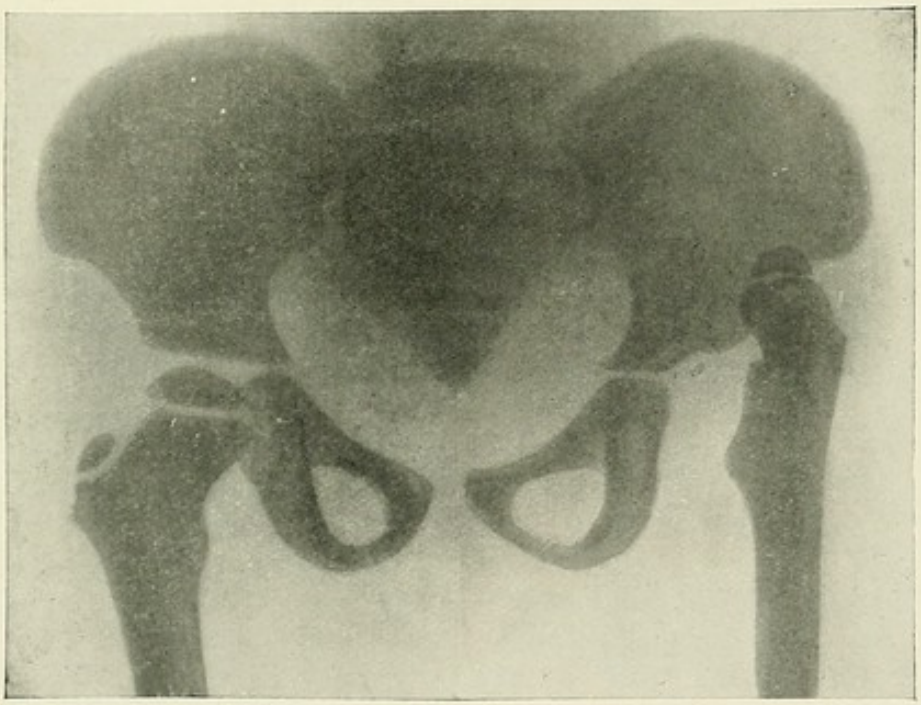

FIG. 379.—Congenital dislocation of right hip (seen from behind).

foot, the opposite half of the pelvis is raised, on account of the muscular fixation of the joint. In an individual with congenital dislocation, this fixation of the joint is absent, and therefore the opposite half of the pelvis sinks. However, if there be a dislocation, anæsthesia will enable the head to be felt, and the oscillating movement to be detected. If doubt still remains, it can be finally cleared up by X-ray examination.

Infantile paralysis, once affecting the gluteal muscles, may involve the beginner into difficulty. The lameness is very similar to that of dislocation (paralytic limp). The trochanter becomes so prominent, owing to the atrophy of the gluteal muscles, that the inexperienced is apt to mistake it for the head of the femur. Owing to the muscular paralysis the passive movements of the limb are very extensive, and in

old cases there may be some shortening. But the history in infantile paralysis is that the little patient previously walked quite well, that he became ill with infective symptoms, and had, at first, widespread paralysis which gradually subsided somewhat. Physical examination at once shows that the femur is not displaced on the pelvis, and that the prominence seen under the glutei is not the head of the femur, but an abnormally evident trochanter. Although the limb may be shortened, the level of the trochanter is not raised, showing that the whole femur is shortened and not merely displaced upwards, as in dislocation.

Sometimes genuine dislocations are associated with paralysis—not congenital, but acquired *paralysis*. In infantile paralysis they are unilateral, and depend upon the traction of the unparalysed, but un-antagonized adductors. In congenital spastic paraplegia—Little's disease—the dislocations may be bilateral, due to spastic contraction of the adductors. The paralysis may predominate the clinical picture so that the dislocation may be entirely overlooked, especially in bed-ridden children, although, owing to the muscular atrophy, this could easily be detected on grasping the hip.

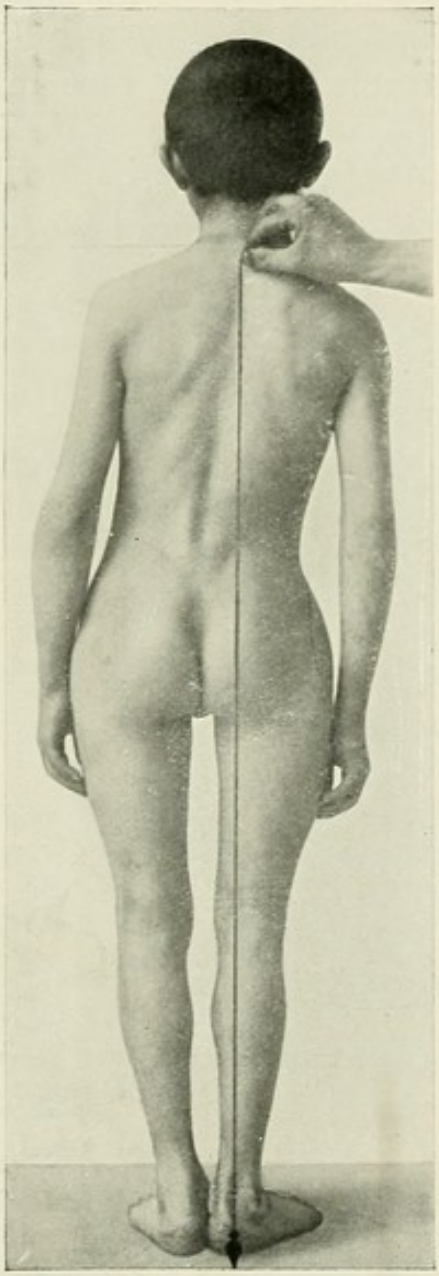

FIG. 380.—Bilateral rachitic coxa vara. Extreme projection of the trochanter region.



FIG. 381.—Rachitic coxa vara. (Skiagram of fig. 380.)

Progressive muscular atrophy (fig. 377) is a disease which at first sight may suggest congenital dislocation of the hip because of the lordosis. A careful examination will, however, quickly expose the error.

Congenitally dislocated hips are frequently affected in the course of time with inflammatory processes of the nature of *arthritis deformans*, causing considerable pain. This may impel the patients to seek advice, rather more than for the deformity—a circumstance which may be of diagnostic significance.

A female patient, aged 24, sought advice for "rheumatic" pains in the right hip. She was of normal girth, but short in stature, and she had a striking stiff, peculiar measured gait. She had suffered with her hips from infancy, and had always been treated for "general weakness." Examination showed a congenital bilateral dislocation of the hip, with arthritic changes on the right side. The skiagram showed that the heads of the femora were displaced to the extent of 9 cm., and that a new joint had developed on either side of the pelvis.

The slow stiff gait was very remarkable in this case. Her æsthetic taste had unconsciously and gradually adapted it to such an extent as to completely conceal the waddling. Some female patients entirely lack this compensatory influence, and the term "duck's gait" hardly does justice to what is seen in some advanced cases.

The following case is equally significant. A female patient, aged 36, in whom some "weakness" of the left leg had already been detected in childhood, began to suffer pain in the left hip and to limp when she was 31. She went from one practitioner to the other, and was considered to be a case of "rheumatism." This diagnosis did not, however, explain the shortening of $1\frac{1}{2}$ cm. Palpation did not reveal anything definite, because of the patient's stoutness. A skiagram had to be made in order to distinguish between the results of an old hip disease, or of an injury, and congenital dislocation. The skiagram was in favour of the latter. It was not the dislocation which caused the patient to seek advice but the secondary arthritis.

B.—COXA VARA.

If the head of the femur is not in an abnormal position, and if the bone cannot be displaced on the pelvis, there cannot be any dislocation. But if, despite these circumstances, the level of the trochanter is raised, it must be caused by the bending of the neck of the femur.

In some cases coxa vara depends upon the diminution of the obtuse angle at the neck of the femur, and, finally, its decrease to a right angle (fig. 381), or even to an acute angle (*coxa adducta* of Kocher). In other cases the head of the bone is bent downwards

and backwards, while both the head and the neck undergo a spiral twist backwards, when the neck is in a normal position. (*Coxa vara in the strict sense of the word* according to Kocher).

The causes of this bending are the same as in the case of other bony deformities—*i.e.*, rickets in infancy, the strain of abnormal weight during the period of growth, and in rare cases osteomalacia in later years. In addition, there are cases of *false coxa vara*, due to osteomyelitis, tubercle and injury, and, finally, very rare examples of congenital coxa vara.

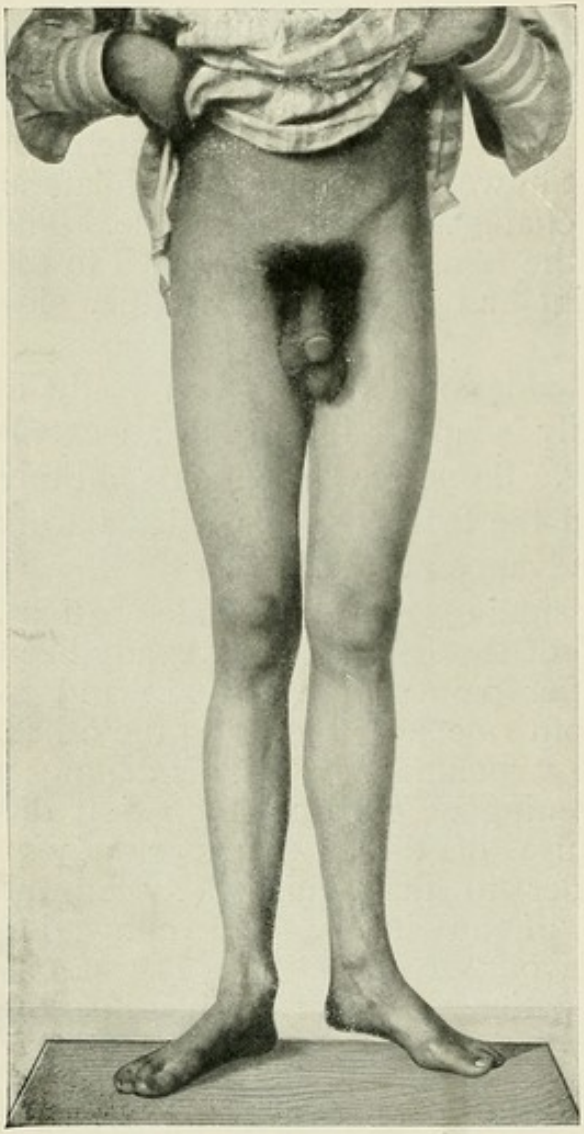

FIG. 382.—Left sided coxa vara in a youth.

If the cause is rickets the disease is usually bilateral, but if the condition has been caused by abnormal weight-bearing (coxa vara of adolescents), it may be either unilateral or bilateral.

But even in this case we must assume some abnormality in the constitution of the bone. It matters very little whether we classify it with late rickets or designate it in some other way, because we are not fully acquainted with the nature of late rickets.

Let us first consider in detail a case of *rachitic coxa vara* in a child. The posture of the leg and foot is as normal as the rachitic curvature permits, but we are struck by the extreme projection and the great elevation of the trochanters. The gait of the little patient is exceedingly clumsy, and may sometimes be characterized as slightly waddling. The movement of the projecting trochanter, which is visible under the skin, resembles somewhat the movement of the head of the femur under the gluteal muscles in congenital dislocation of the hip. But, as already stated, the resemblance is merely superficial, for in coxa vara there is only *one* protuberance, whereas in dislocation there are *two*. On examining the individual movements we find that there is freedom of flexion, that external rotation is normal or only slightly restricted, but that abduction is diminished or almost impossible. The only abnormality shown

by the skiagram (fig. 381) is adduction of the neck of the femur towards the shaft, usually to an angle of about 90°—*coxa adducta*.

If we examine the rest of the skeleton we are almost sure to find other signs of rickets in the bones (fig. 378).

The restriction of abduction varies. In young children it is slight, but later on, between the eighth and tenth year, it may be very pronounced and constitute the most troublesome symptom.

In unilateral coxa vara the distance between the anterior superior spine and the malleolus is shortened in the affected limb, and there is corresponding *unilateral lameness*. This is, however, a condition which is much rarer in rickets than the coxa adducta which occurs after fractures of the neck of the femur, osteomyelitis, or tubercle.

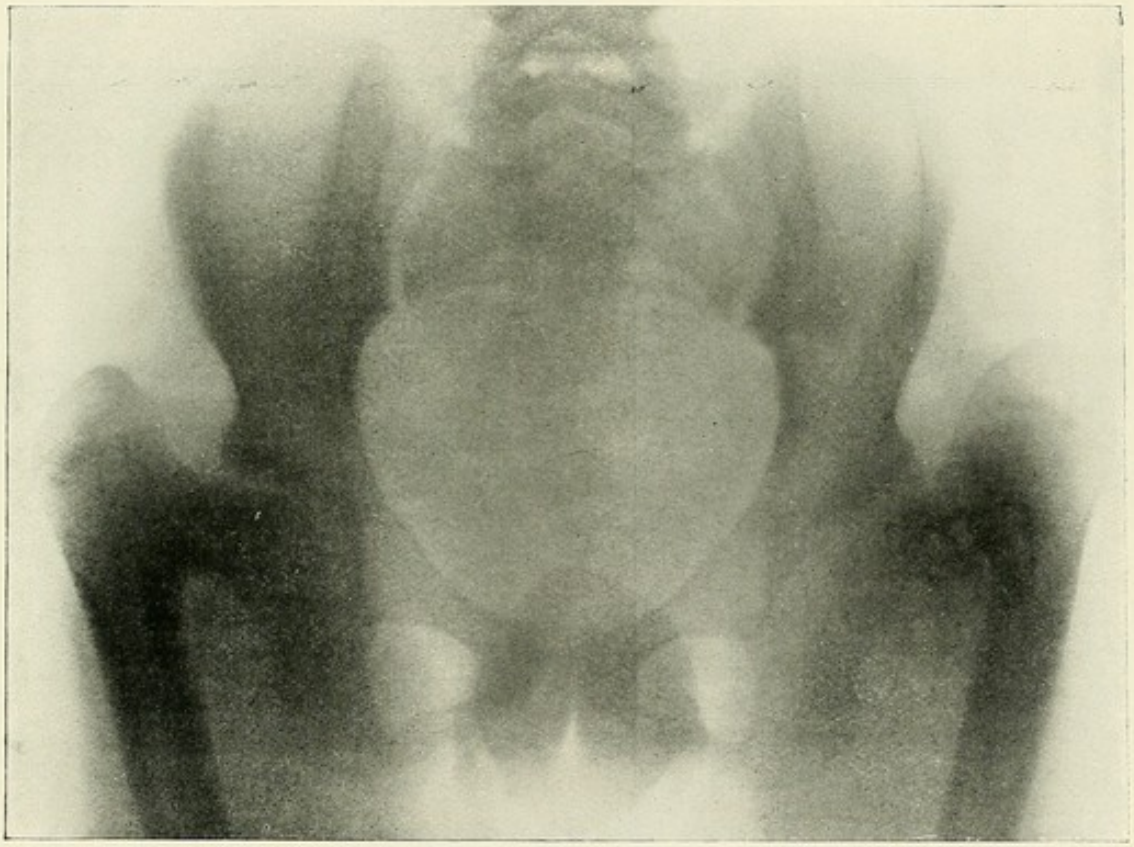

FIG. 383.—Severe bilateral coxa vara, patient, aged 15. Rachitic form.

A more complicated clinical picture presents itself in children, in cases of *coxa vara in the strict sense of the word, i.e.*, bending of the head downwards and backwards, often with simultaneous twisting of the neck.

For the head to retain its normal relation to the acetabulum, the shaft of the bone, and therewith the whole limb, would have to assume a position of adduction, external rotation and hyperextension. In order to improve upon this impossible position, the limb—head and shaft—executes a movement which is composed of abduction, inward rotation and flexion. The more pronounced the deformity, the more is the whole range of the movement in these directions taken up in merely attaining a normal posture, and the less is it possible to abduct,

invert or flex the limb any further. These simple considerations explain the disturbances of function, which we meet in this form of coxa vara.

The gait of a patient with a unilateral affection presents the same lameness as a case of painless stiffening and shortening of the limb. The pelvis is pushed forwards at each step and the limb proceeds as a rigid whole with the pelvis. When the affection is bilateral, there is the peculiar gait wherein the pelvis oscillates around a vertical axis with every step. We will also notice that the affected limb is always held in a position of eversion, an obvious result of the downward inclination of the head, which is no longer fully compensated for. The skiagram shows mainly a downward displacement of the head, in the epiphyseal line, on a normally placed neck (fig. 384).

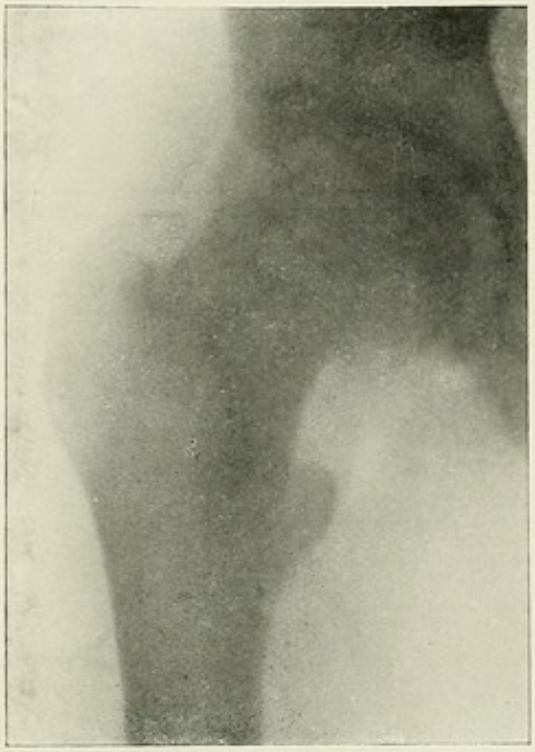

FIG. 384a.—Coxa vara in a youth. Bending in the vicinity of the epiphyseal line.



FIG. 384b.—Healthy side in same patient.

We may summarize what has already been said, in regard to *coxa adducta*, as follows: *Prominence and elevation of the level of the trochanter, restricted abduction, and shortening if the affection is unilateral.* In regard to *coxa vara in the strict sense of the term*, we may summarize thus: *Prominence and elevation of the level of the trochanter with external rotation and restriction of abduction. Internal rotation and flexion, and shortening with lameness of one side if the affection is unilateral.*

These points should facilitate the *differential diagnosis from other diseases of the hip.* We have already discussed the differential diagnosis from *congenital dislocation of the hip.*

Sometimes unilateral coxa vara in a youth is mistaken for *commencing hip disease*. Coxa vara has, like flat foot, a painful stage which may easily be regarded as some inflammatory affection.

A young man (fig. 382) sought advice for commencing "hip disease." He limped slightly towards the left, but two facts were noticeable at first sight: the limp was not painful, as he planted his left foot down quite firmly without any special care. It rather appeared to be due to shortening. In addition, the foot was considerably everted. This, of course, excluded hip disease. The stage wherein eversion exists is accompanied by some abduction and apparent lengthening. This stage is also so painful that it is impossible to bring the foot down to the ground, without special care. Our thoughts, therefore, proceeded in another direction. We measured the leg and found 2 cm. of shortening, which is hardly possible in early hip disease. The level of the trochanter was definitely raised. On testing the movements it was found that abduction, flexion and inward rotation were restricted. This established the diagnosis of coxa vara, and the skiagram could do nothing but confirm it.

Complete rest with the application of an extension apparatus relieve the painful symptoms much more quickly than in the case of hip disease, which affords a further proof of the accuracy of the diagnosis.

If a young man presents the symptoms of a unilateral coxa vara, we must, as we have already seen, investigate his clinical history for an injury, before attributing them to a deformity produced by mechanical conditions. If, however, such an injury cannot be recalled by the patient, we must not endeavour to persuade him of its occurrence.

CHAPTER XCIV.

ACUTE INFLAMMATORY DISEASES OF THE HIP-JOINT.

A PATIENT is suddenly seized with severe pains in the hip, and is unable to move his leg with freedom. We have excluded acute disease of neighbouring structures, such as phlegmonous inflammation of the crural or inguinal glands, or an acute abscess of the pelvic fossa. It therefore only remains to decide whether the case is one of acute arthritis of the hip-joint, or osteomyelitis of the shaft of the femur, or even of the pelvis.

It is true that there is pain with every movement in osteomyelitis, just as there is in hip disease, but nevertheless passive movements

may be carried out within certain limits, if due care is exercised. The local pain on pressure does not correspond to the region of the joint, but has its highest point at some distance from it below the trochanter, at the extreme limit of the osteomyelitis—or, on the other hand, upwards towards the pelvis. If there is secondary involvement of the joint the symptoms of the two diseases coalesce, but we ought to be able to decide the sequence of events by the fact that the pain on pressure extends comparatively far either upwards or downwards, and by the thickening of the bone. In acute hip disease, however, including a circumscribed osteomyelitis of the head and neck of the femur, we are struck from the very beginning with the intense painfulness of any passive movement of the joint, if not by its complete muscular fixation, no matter in which position this fixation has taken place. The maximum pain on pressure is in the vicinity of the head of the bone, *i.e.*, beneath the middle of Poupart's ligament. On inspection and palpation it may be noted that this region is fuller than on the healthy side. The pyrexia proves that some acute inflammatory disease exists.

What is the nature of this inflammation? If several other joints are involved simultaneously, or in rapid succession, we should think of acute articular rheumatism—but one must be sure that only the joints are affected. If the disease is limited to the hip, and the patient is young, the condition is most probably one of acute osteomyelitis of the neck and head of the femur, involving also the joint. This diagnosis becomes quite certain if other areas of bone disease exist, or if some suppurative inflammation is actually present at the time, or has recently subsided.

If the patient is a child convalescent from scarlet fever, we know that the case is one of scarlatinal arthritis, which may recover without incision, and with complete restoration of function, or which may rapidly destroy the joint. Similar forms of inflammation of the hip may more rarely come on, after typhoid fever, small-pox or measles. The hip is sometimes involved in puerperal articular disease. In default of any of these more frequent causes, we must seek other possible portals of entry for organisms of inflammation, and we should not forget gonorrhœa. Subacute inflammation of the hip may occur in secondary syphilis and in the congenital disease, but it is rare. Sometimes it is quite impossible to determine how the infection entered, or to discover any cause.

This is especially true of certain cases of acute hip disease in little children, who recover after simple evacuation of the pus, sometimes without leaving any serious derangement. Bacteriological examination should never be neglected in this type of case, lest one overlooks an acute onset of tubercle.

The organisms of acute suppuration sometimes give rise to a form of inflammation which is mistaken for tubercle, because staphylococcic and streptococcic infections of the neck of the femur do not always produce their familiar clinical picture. On the contrary, the disease may run such a mild course, despite its acute onset, that it easily suggests tubercle, unless a very reliable history is at hand. The records of von Brun's clinic have shown that this mistake is by no means rare.

The following is a typical case :—

We were consulted about a lad aged 12, who presented all the symptoms of early hip disease—moderate pain on axial pressure, and on pressure over the trochanter, fixation of joint in a position of slight flexion, adduction and inversion ; temperature practically normal. This condition had existed unchanged for several weeks. Had we had no reliable history, we might have assumed that the case was tubercular. But as a matter of fact, the patient had been admitted to hospital with the diagnosis of acute osteomyelitis of the upper end of the femur. The disease had started suddenly, with severe, though transitory, fever. We accepted the diagnosis of the family practitioner, and it was confirmed during the course of the next month by the development of osteomyelitis of the shaft of left humerus, with sequestrum formation. The lad had complained of pain in the left arm from the beginning, but he laid no stress on it, as his hip symptoms were much more distressing.

One word in reference to the results of these inflammations. As long as the measurement between the anterior superior spine and malleolus is of normal length, having regard to the position of the leg, and the tip of the trochanter is at the correct level, the case is one of pure *arthritis*. But if there is sudden shortening, or if the trochanter becomes displaced upwards, there must be some *pathological dislocation*, usually backwards, or a *separation of the epiphysis*. The former is more frequent after typhoid or scarlet fever ; the latter, after osteomyelitis, in which condition a fracture near the shaft may occur. The actual state of affairs can be determined by careful examination. If the limb is slightly everted and can be moved hither and thither on the pelvis, and if soft crepitus can be felt, a separation of the epiphysis is present. If the leg is in the position of a posterior dislocation, *i.e.*, flexion, adduction and inversion, and if the head of the femur is felt under the gluteal muscles it is obvious that a dislocation is present.

There is another, a further, possibility, which is, however, rare in acute arthritis, but may lead to an error of diagnosis.

A little girl was suffering from scarlatinal hip disease and her limb was shortened and in a position of eversion. It was possible to move the femur on the pelvis, and soft crepitus was felt. We diagnosed inflammatory separation of the epiphysis. The skiagram, however, showed severe destruction of the upper border of the acetabulum and partial destruction of the head of the femur, which was not detached.

The case was really one of pathological dislocation in which there was no pathognomonic malposition, and in which there was no possibility of successful reduction, in consequence of the destruction of the joint. As soon as the residue of the head was brought into a normal position, it glided backwards again, because of the destruction of the upper border of the acetabulum. An operation was performed subsequently and this confirmed the X-ray diagnosis.

CHAPTER XCV.

CHRONIC INFLAMMATORY DISEASES OF THE HIP.

CHRONIC inflammatory diseases of the hip are mainly comprised within two groups. The one includes tubercular coxitis, the other embraces all that is understood by the term chronic rheumatic arthritis. There are other rare conditions, which will be referred to when discussing differential diagnosis. An approximate distinction is furnished by the circumstance that the tubercular disease affects growing individuals, while the non-tubercular arthritis affects adults; but the borderland cases which lie between the two, cause difficulty in diagnosis.

A.—TUBERCULAR HIP DISEASE.

The diagnosis of tubercle is forced upon us if a child begins to complain of feeling tired and has a painful limp after walking for some distance, if the gluteal fold is obliterated and some muscular atrophy on the affected side is also possibly noticeable. As the limp is not permanent at first, but only comes on when the patient is tired, and as it can be suppressed when an effort is made to do so, it has been called a "voluntary limp"—an expression which constitutes an unjustifiable reproach. The progress of the case is a comment on its "voluntary" nature. Sometimes the child complains more about the knee than about the hip, but a cursory examination will show that the knee-joint is free.

Having examined the gait of the child with his clothes off, we lay him upon a flat table and direct him to extend both legs completely. A hollow is observed to form in the back, so that the hand can be passed flat under the lumbar region. If we make the back fit closely against the table, the knee of the affected side becomes slightly raised. This preliminary examination suffices to show that the hip is held in a

constrained position of slight flexion, although otherwise the limb may either be abducted and everted, or adducted and inverted, both positions being met with in the early stages.

If we cannot get the back to lie close against the table, we may adopt the simple and painless method of Thomas, *i.e.*, we flex the *healthy* hip as much as possible in order to throw the pelvis backwards, and thus the spinal column will certainly be forced close against the table. If there is the slightest degree of flexion on the diseased side, the knee will then be raised, so that, at any rate, the hand can be passed under it (figs. 385 and 386).

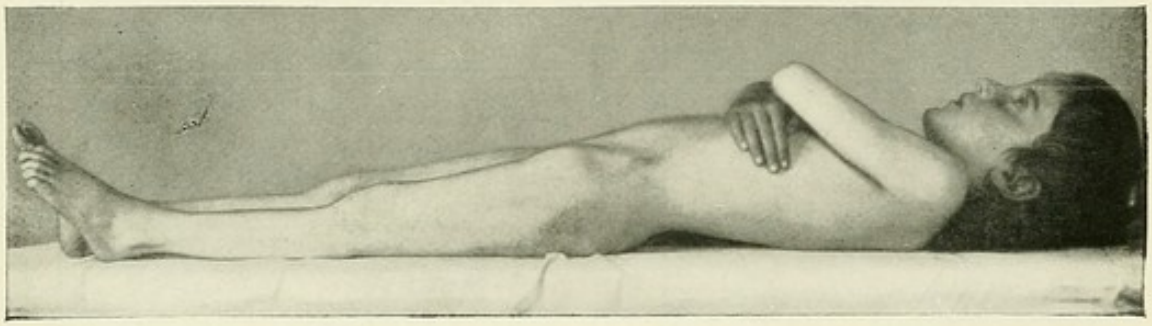

FIG. 385.—Left-sided hip disease. The position of slight flexion compensated for by the lumbar lordosis.

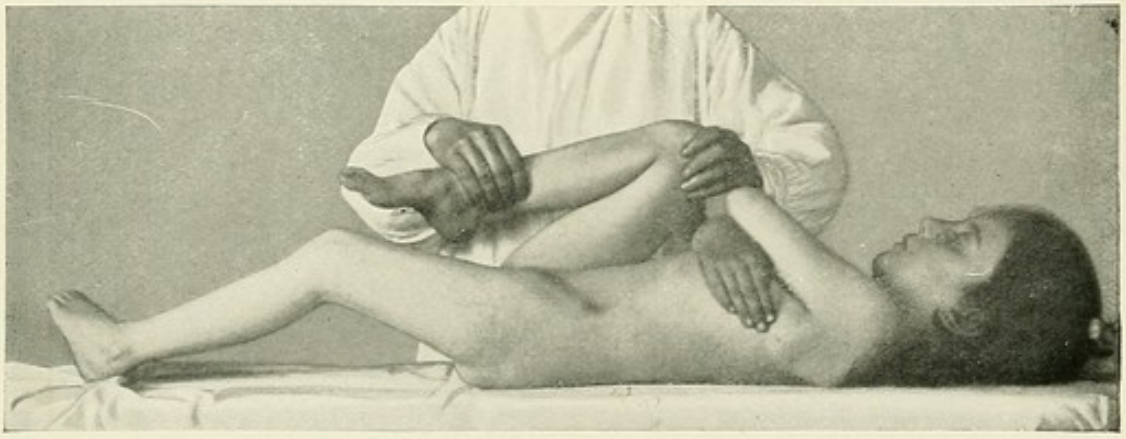

FIG. 386.—Same case. The flexion demonstrated by Thomas's manœuvre.

We then proceed to a careful examination of the separate movements, as compared with the healthy side. The more limited flexion, extension, adduction, abduction, external and internal rotation are, the more does the patient endeavour to transfer these movements to the lumbar spine, and he moves his pelvis and leg as one fixed whole. In other words, the pelvis participates in the movements. We must then inquire whether this fixation depends upon pure muscular spasm, or upon any organic changes in the joint. If the degree of fixation after a long rest differs from the degree present when the patient is very tired, it would indicate a muscular origin, but if there is no difference, the rigidity must depend upon causes within the joint. An absolute

decision can only be arrived at by examination under an anæsthetic, when muscular fixation vanishes forthwith without any forcible manipulation. Abduction and rotation are the movements which are generally first interfered with. If the adductors become tense on attempting to perform abduction rapidly, the hip-joint is certainly involved, even if extension and flexion remain perfectly free.

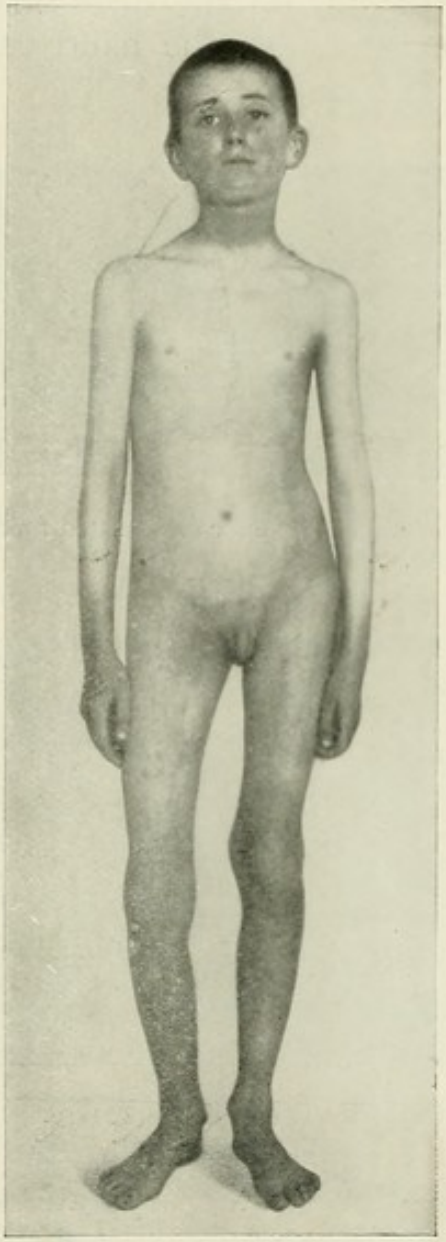

FIG. 387.—Early stage of hip disease on right side, *with external rotation, flexion and abduction.*



FIG. 388. — Early stage of hip disease on right side, *with flexion, adduction and inward rotation.*

It may happen in this stage that all symptoms disappear after a few weeks' rest in bed, so that one thinks an error in diagnosis has been made. But the symptoms return in a few months, or even after a few years, and the classical picture of hip disease develops.

If we are not quite clear about the limitation of abduction we direct the patient, after taking off his clothes, to spread out his legs as much as possible while standing. Any asymmetry which then exists

in the posture of the leg or back is an indication that abduction is interfered with.

A certain amount of importance attaches to the division of hip disease into *stages, in accordance with the posture* of the limb. As König has shown, the patient endeavours to spare his hip-joint as much as possible in all stages of the disease. For this purpose the position of slight abduction and external rotation, with a little flexion, is the most useful, as long as the patient walks without crutches (fig. 387). But if the patient does go about on crutches, he raises his



FIG. 389.—Advanced hip disease of left side with extreme flexion and abduction.



FIG. 390.—Advanced hip disease of left side, with internal rotation, adduction and flexion.

diseased leg, that is to say, he flexes it more, but still holds it in abduction. If the patient takes to his bed in the earlier stage of his disease, he supports his flexed, diseased leg on the healthy one, thus bringing it into the position of adduction and internal rotation (figs. 389 and 390).

There is an *anatomical* cause for this position, if the head of the bone has left its normal situation and has become displaced posteriorly, or backwards and upwards, either through destruction of the capsule or gradual destruction of the posterior border of the acetabulum (so-called displacement of the acetabulum [Pfannenwanderung]

fig. 391). The position then assumed is one of subluxation or even of dislocation.

After testing the power of movement we proceed to *palpation*, which, combined with inspection, will show whether any abnormal swelling exists. The principal swellings to be thought of are enlargement of the inguinal glands and abscesses which have made their way to the surface. These usually appear in front (see fig. 385, where there is an abscess below the anterior superior spine), but also occur on the outer and on the posterior surface of the hip.

We next examine for *pain*.



FIG. 391.—Hip disease with "displacement of acetabulum" and coxalgic pelvis. (Skiagram of fig. 385.) Small sequestrum at x.

We test for pain on direct pressure, where the joint is most accessible, *i.e.*, in the front, just below the middle of Poupart's ligament. This pain is often an early sign of hip disease, although it is not so significant as loss of power of movement. Importance also attaches to indirect pain, elicited by force applied in the long axis of the femur or to the trochanter. We have already seen that any movement, carried out to an extreme degree, is painful.

The differential diagnosis raises the following considerations :—

(*a*) If it is quite evident that there is *actual disease of the hip-joint*

itself, we must first exclude the *subacute forms* of *infective hip disease*. For this purpose it is necessary to give due weight to all the points advanced in the previous chapter, and only diagnose tubercle in the absence of any other cause.

As already remarked in the previous chapter, an acute onset of hip symptoms indicates an acute infective origin, even if the disease develops into a chronic condition. The sudden rupture of a tuberculous periarticular focus into a joint also causes acute symptoms, including fever, but as a rule this event would have been preceded by slight articular symptoms, pointing to tubercle. A rigor, or herpes labialis, accompanying the acute exacerbation, are indications *against* tubercle.

If the onset is very gradual, the possibility of tubercle must be entertained even if the hip symptoms have followed some acute infectious disease. A child who begins to limp in the slightest degree a few weeks after measles is probably the subject of early hip disease, the measles having prepared the soil for the tubercle.

We must next exclude the so-called *chronic rheumatic arthritis*, which we shall deal with at the end of the chapter.

We have already seen that *congenital dislocations of the hip* and that *coxa vara* are subject to irritative stages, wherein some confusion with hip disease is quite conceivable. But such an error can be avoided by careful examination. The same applies to the hip symptoms which eventually arise in fracture of the neck of the femur, and which belong to coxa vara traumatica.

We should think of primary or secondary *malignant growth*, including hydatid cyst, if the features of the case do not completely accord with hip disease, especially if the slight limitation of movement and its relative painlessness present a striking contrast to the severe and spontaneous radiating pains.

(*b*) *Diseases, independent of the joint*, may simulate hip disease, by causing flexion of the hip and pain in its vicinity, leading to a painful limp.

The most frequent cause of spastic flexion of the hip, not due to joint disease, is a *burrowing abscess from a tubercular spine*, or *pelvic tubercle*. This condition may resemble hip disease so closely that examination of the spinal column and palpation of the pelvic fossa are always essential in cases of spastic flexion of the hip.

The diagnosis is easy if a dorsal curvature is evident, or if an abscess is found filling up the iliac fossa. But matters are not always so simple. The curvature may be quite absent in adults, and the connection of the abscess with the spinal column may be limited to a narrow sinuous track. In abscess due to spinal disease, however, abduction and rotation are usually free at the hip, whereas these movements suffer first if the joint itself is affected. A conclusion may also be based on a skiagram.

In rare cases, a *paranephritic* or *appendicular abscess* may cause spastic flexion of the hip, and an inadequate examination may lead to a wrong diagnosis.

Effusion into the iliacus bursa may also lead to a wrong diagnosis because of the spastic flexion and the swelling immediately over the hip-joint. But as abduction, adduction and rotation are quite free, despite the spastic flexion, such an error ought not to be made.

Unless attention is paid to the free mobility of the joint, *sciatica* and *periarticular neuralgia* are liable to be mistaken for early hip disease, more especially in connection with gynæcological conditions. In some cases of *hysteria* there appears to be a real contracture at the joint; but symptoms usually vanish on correct treatment by suggestion.

It is sometimes difficult, in the case of a young girl, to decide at the first examination whether the condition is hysterical or the early stage of hip disease. The family history as well as the previous history must be taken into consideration. I have seen a girl simulate several tubercular joints in the course of a year, but the contractures rapidly disappeared after appropriate psychical treatment. In another case, I was at first inclined to diagnose hysteria, because the symptoms disappeared at times; but the sequel showed that hip disease really existed.

The foregoing considerations having led us to the diagnosis of tubercular hip disease, we must next endeavour to determine the *variety* and *degree* of the disease.

It would be interesting to know whether the case is one of pure synovitis, or whether there has been a primary focus in the pelvic bone or femur. A diagnosis of pure synovitis can only be made, as in other joints, by the exclusion of primary bone disease. But as this usually causes no special clinical signs, and cannot as a rule be directly demonstrated, owing to the inaccessibility of the joint, we must remain uncertain of this point unless a skiagram is taken. If, however, acute exacerbations occur, and subside rapidly on complete rest, we may suspect the presence of diseased bone close to the joint, which has not yet extended into it, but is nevertheless capable of producing slight attacks of serous coxitis.

If a tubercular abscess appears in the neighbourhood of the joint, which, however, remains free, we should think of the possibility of a para-articular focus of disease which has penetrated externally. Such a case is not really one of coxitis, as the joint is free.

If severe pain is felt when force is applied to the joint, one may be tempted to diagnose primary disease of the bone; but such a conclusion is not reliable because the same pain would be elicited if the bone disease were secondary. Pain caused by putting weight on the joint only indicates that the bone is involved in the general condition, but one cannot even be quite certain of this.

An *X-ray examination* is the best method for the early diagnosis of a diseased area in bone.

If the bony outline is normal, and the gap representing the cartilage is of the ordinary size, but the bone itself is abnormally transparent to the rays (osteoporosis), and the shaft of the femur is narrowed, we may conclude that there is atrophy from disuse, as is usual with tuberculosis. It is, however, impossible to decide whether a primary synovitis exists, or whether a small focus of disease is present in the bone.

If the transparent streaks corresponding to the articular cartilage are narrower than on the healthy side, but the picture is otherwise as just described, we must assume that the cartilage has already become partially absorbed.

If the sharp edge of the head of the bone or of the acetabulum is replaced by a rough irregular border, it means that the cartilage has been destroyed and the adjacent bone eaten away; but even this condition does not exclude a primary synovitis. But whatever the aspect of the outline of the bone may be, there can be no doubt about the existence of a primary focus of bone disease if there is a transparent area, in the head (fig. 392), the neck, or in the pelvis. This area may either be sharply defined or confused in outline, and is sometimes surrounded by a thick zone (osteosclerosis) with a more opaque structure in the centre (sequestrum).

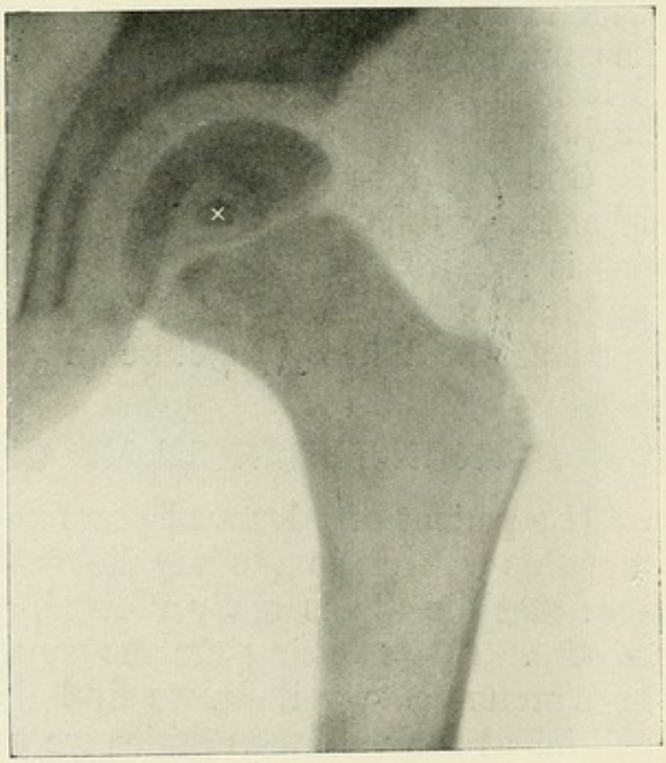

FIG. 392.—Tubercular focus and sequestrum (x) in head of femur.

In the later stages it is necessary to diagnose the *secondary changes*, viz., displacement of the acetabulum, spontaneous dislocation, and separation of the epiphysis. The differentiation of these various processes possesses a certain therapeutic importance.

If the displacement has occurred suddenly, or, at any rate, has been aggravated suddenly, for example, as the result of a slight injury, it indicates either a spontaneous dislocation or a separation of the epiphysis—or even fracture of the neck in the vicinity of a large area of disease. The diagnosis, as between fracture and dislocation, is made on the ordinary principles. It should, however, be noted that when the joint capsule is severely affected, the displacement is less and the mobility is greater than in a traumatic dislocation. If the

displacement occurs gradually, it means that the capsule has worn away by degrees, and the head of the bone has escaped unnoticed, or that the acetabulum has been gradually changing its position, its upper border being displaced upwards, or upwards and backwards by pressure atrophy (fig. 391). The acetabulum thus loses its circular shape, and assumes that of a fish dish. In either case the limb takes up the position of adduction, flexion, and internal rotation. It is quite impossible clinically to distinguish between a severe degree of displacement of the acetabulum and a dislocation of gradual onset. This is, however, of no importance, because such dislocations, unlike those which occur suddenly, are incapable of reduction.

The distinction may, however, be made by means of a skiagram, which will show at the same time the changes which the entire pelvis has undergone (coxalgic pelvis, fig. 391). The diseased side of the pelvis is inclined considerably forwards in relation to the other side, having rotated on a frontal axis (Hofmeister).

One point in conclusion: A tubercular abscess, which is not secondarily infected, should never be opened in hip disease. If the pus is required for examination, it must be obtained by an aseptic exploratory puncture, and if it is desired to empty the abscess this must also be done by puncture and aspiration.

B.—NON-TUBERCULAR CHRONIC HIP DISEASE.

If a patient of advanced years comes complaining of his hip, our thoughts will run in a totally different direction. We must first make sure that the hip is really affected, and that the case is not one of *sciatica*. If, on testing the movements of the limb with the patient in a recumbent position, we find that their extent is restricted and painful at their extreme limits, we should think of one of the various forms of non-tubercular chronic arthritis.

Of course these conditions may occur in young people, but they are as rare as tubercular hip disease is among adults.

We then determine the degree of limitation of movement, just as in a tubercular hip, and endeavour to find the cause. If some movement still exists, we must note whether it is accompanied by grating.

A skiagram will show the presence and degree of osseous changes, and indicate whether the arthritis is merely the result of some other skeletal deformity, such as congenital dislocation, or coxa vara, &c.

We then examine to see whether the hip is the only joint affected, and we must take a careful clinical history with special reference to the various forms of "chronic articular rheumatism" mentioned in Chapter LXXXII. We will only now, however, refer to the conditions which especially affect the hip-joint.

Anatomically, the most important are those processes which pro-

duce *deformity*, partially destructive and partially proliferating in character. The next in frequency are the forms which produce *ankylosis*.

As far as etiology is concerned, the cases wherein the disease remains permanently, or at any rate for a long time localized to one joint, are of more interest to us than those cases wherein the multiplicity of the affected joints facilitate the diagnosis. In the former cases the disease often originates in an injury, sometimes a simple contusion. The younger the patient, the more likely this causation. On the other hand, elderly individuals may suffer from arthritis of the hip with deformity, in the absence of any demonstrable injury, *i.e.*, *senile disease of the hip*. In these cases, however, the disease does not always remain limited to one joint.

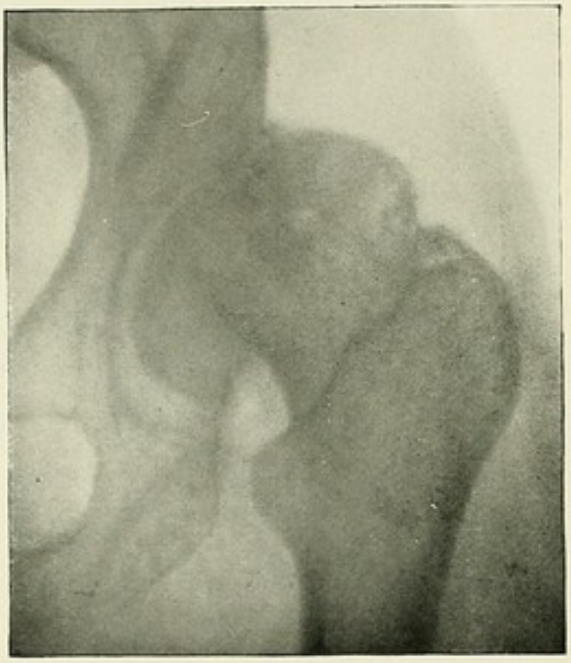

FIG. 393.– Chronic hip disease with deformity.

In the absence of a history of injury, an examination should be made for nervous diseases, especially tabes and syringo-myelia.

Although we have regarded adult age as a contra-indication of tubercle, it may still be necessary to fall back upon this diagnosis in cases which are otherwise insufficiently explicable, especially if the patient has a tubercular heredity, or has already suffered from some tubercular condition, and if the pain is very severe, and the disease progresses somewhat rapidly without any temporary improvement. Tubercular hip disease has exceptionally been met with, even at the age of 80.

The diagnosis is sometimes rendered difficult by the fact that tubercle may occasionally affect several joints, and thus completely resemble a non-tubercular chronic arthritis. Unless some typical sign (osseous focus, sequestrum, abscess) occurs in one joint, the case may remain obscure for years, and even for a lifetime.

CHAPTER XCVI.

SWELLINGS AND TUMOURS OF THE THIGH.

If we see a patient who has suffered a severe injury, lying with his thigh abducted and the knee slightly flexed, and the whole limb in a position of complete eversion, there is only one diagnosis possible, fracture of the shaft of the femur; if, on closer observation, we see that the thigh is thickened and its axis slightly bent (fig. 394), all doubt is dispelled.

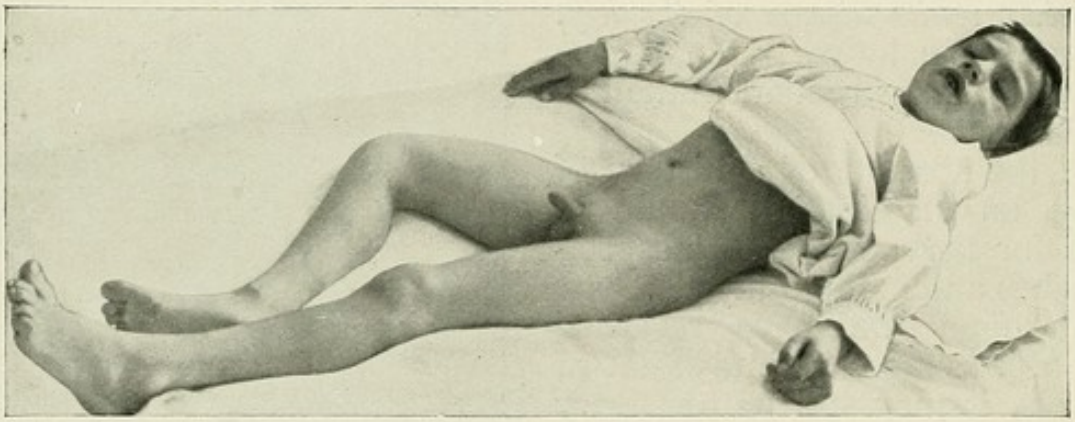

Fig. 394.—Fracture of the shaft of the right femur.

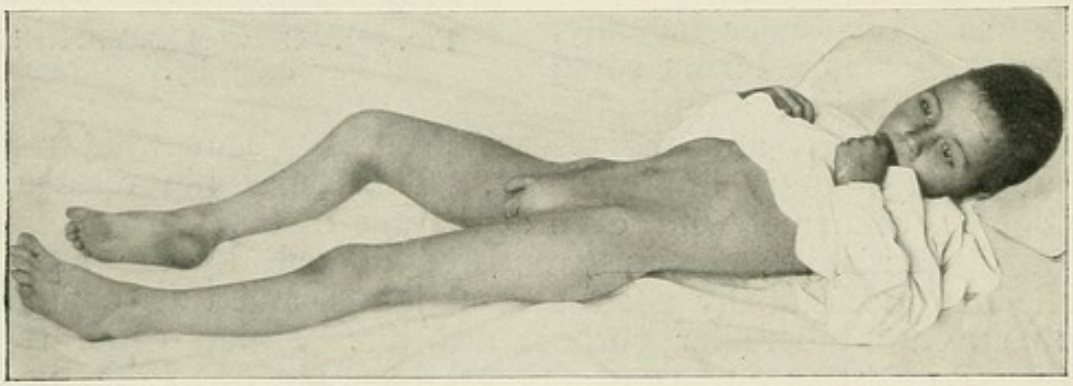

Fig. 395.—Acute osteomyelitis of the right femur.

If a little child, who can give us no history, and whose mother does not know whether it has had a fall, presents a swelling of the thigh and cries when touched, avoiding any movement with the leg, the question of fracture or of the early stage of acute osteomyelitis will at once pass through our mind (fig. 396). But we should be relieved from doubt by finding either false mobility on the one hand, or general and local rise in temperature on the other hand.

If the swelling is only slight, but bilateral, the case is neither fracture nor osteomyelitis, but is probably one of **Barlow's disease,** in which very painful subperiosteal effusions of blood occur over

the femur. This diagnosis is verified by dark bluish swelling of the gums where the teeth have erupted.

If a young person becomes ill with high fever and severe pain in the thigh, and diffuse swelling thereof occurs within a few days, the diagnosis of acute osteomyelitis is clear.

We shall refer to its various stages in connection with osteomyelitis of the tibia. A comparison of fig. 394 with fig. 395 shows how closely the position of the femur in osteomyelitis resembles the position in fracture.

Swellings which come on gradually and without fever are not necessarily cold abscesses or new growths, but may be chronic forms of staphylo- or streptomycosis of the bone. In order to distinguish between the various possibilities, we must decide whether the swelling arises from the soft tissues or from the bone. This can only be determined by its degree of mobility in relation to the bone when the muscles are completely relaxed. As the swellings are not, as a rule, painful, this examination can usually be made without an anæsthetic. If a sarcoma, originating in the soft tissues, has once become adherent to bone, differentiation is no longer possible. The history may, however, indicate that the swelling was movable at first.

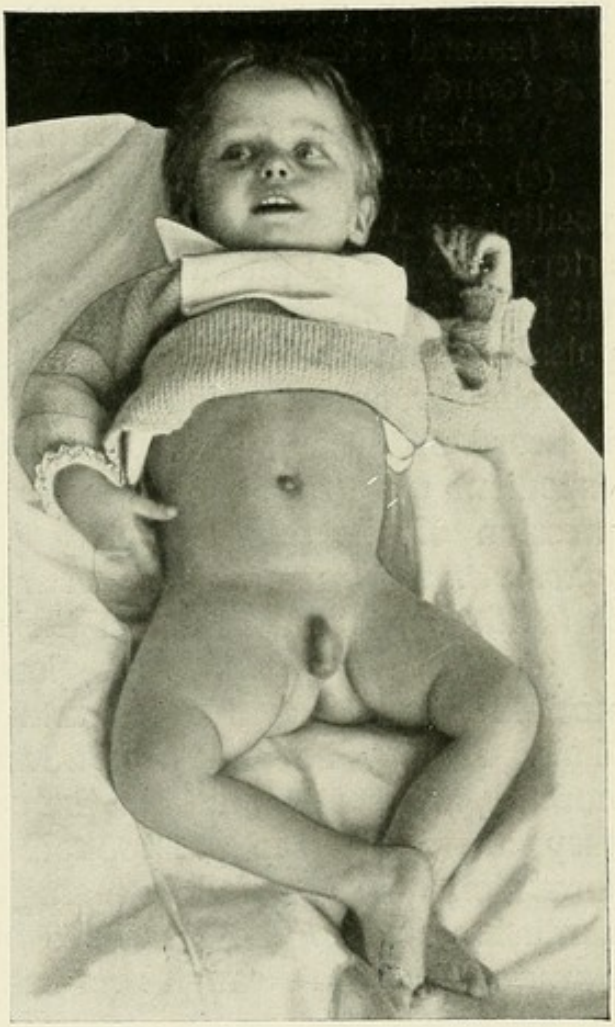

FIG. 396.—Acute osteo-myelitis of the right thigh.

A.—SWELLINGS OF THE SOFT TISSUES.

(1) The *skin and subcutaneous tissue* may be the seat of **soft fibroma**—fibroma molluscum—**lipoma,** especially in the upper part, **lymphangioma,** and occasionally **sarcoma,** originating in a nævus. Their differential diagnosis is too easy to require any consideration here.

(2) *Swellings of the deeper soft tissues* may arise in the lymphatic glands, blood-vessels, muscles, aponeurosis, nerves, and the loose connective tissue.

(*a*) *Swellings of the Lymphatic Glands.*—The **crural glands,** which

alone concern us here, receive lymph from the whole of the lower limb, including the contiguous region of the perinæum. Any swelling in this region demands a search for some portal of entry of infection before we think of anything unusual.

A young man came to the out-patient department with a small swelling in the crural region. The swelling pulsated, or at any rate appeared to do so. The recently qualified assistant, therefore, diagnosed an aneurism. It was, however, an inflamed gland over the femoral artery, and a small septic wound of the skin of a toe was found.

We shall refer to sarcomata of the lymphatic glands later on.

(*b*) *Aneurisms.*—The diagnosis of aneurism is easily made by its position in the course of a large vessel, almost always the femoral artery, and by its pulsation, as also by the vascular conditions below the tumour, and, finally, by its frequent traumatic origin. Not every pulsating tumour is, however, an aneurism, for there are some very vascular sarcomata which pulsate, and over which a distinct murmur is heard on auscultation. It is therefore necessary to employ every expedient to verify the diagnosis of aneurism, especially the compression of the femoral artery just above the swelling. *Arterio-venous aneurisms* may also occur in the thigh, but their diagnosis is facilitated by the fact that their origin is always traumatic.

(*c*) *Muscular Swellings*—**Angiomata, tubercular and gummatous nodules, herniæ and osteomata of muscle** behave as in the upper limb. It may be stated, however, that herniæ, as well as bony nodules, are mostly found in the adductor muscles of riders, because they are subject to great strain ("rider's bone"). Such a bony formation may also follow a single injury, for instance, a muscular contusion due to the kick of a horse. I have also seen it follow rupture of muscle through over-extension.

There has been much controversy as to the possibility of ossification within a muscle, independently of injury to the periosteum and misplacement thereof. In my opinion there is no doubt about this possibility, although it happens that in the thigh the periosteal origin of such traumatic muscular osteomata has been demonstrated in many cases.

We will discuss sarcomata together with tumours of the connective tissue.

(*d*) *Connective Tissue.*—These tumours consist of **fibromata** and **sarcomata.** They may arise from the connective tissue between the muscles and nerves or within them. A firm tumour, which remains movable for years and causes no disturbance beyond its size, is a fibroma. The more rapid the growth of a tumour, the sooner it contracts adhesions and the more pain it excites, the richer it is in nucleated cells, and the more it approximates therefore to the

type of sarcoma. As no sharp limitations can be drawn, even histologically, a positive diagnosis cannot be made clinically. It is better to eradicate the tumour before it becomes malignant than to wait until a positive diagnosis is possible.

There are some fibromata, which at first recur as such, but in course of time their histological type approximates to that of sarcoma. It is therefore necessary to remove even the most innocent tumour while the patient is still in good health.

The relations of the tumour to the muscles may be ascertained by examining it when the muscles are relaxed and when they are tense and comparing the results. A **neurofibroma** is diagnosed by its position along the course of a nerve, by its spindle or cylindrical shape, by the early onset of neuralgia and paræsthesia, and occasionally by its multiplicity or the existence of similar tumours in other portions of the body. The risk of secondary malignant degeneration is always present in these cases.

B.—SWELLINGS OF THE BONE.

(1) OSTEOMA AND CHONDROMA.

If we find close to the lower epiphyseal line a nodular bony tumour which has existed for some time, and which is gradually growing away from the joint, we have before us the classical picture of a **cartilaginous exostosis** (figs. 397 and 398).

These growths are congenital and arise from misplaced fragments of cartilage; they consist of bony tissue covered over by a thin layer of cartilage, and they continue to grow until the bone to which they belong has completed its growth. As they are usually situated on the diaphyseal side of the epiphysis, they become more and more distant from this line as the bone grows in length. Sometimes these exostoses occur in separate attacks, and we may therefore find several on the same bone, at various distances from the joint. Sometimes they drag with them an extremity of the joint capsule with which they have contracted adhesions in their original position; in other cases they are covered by a mucous bursa, quite independent of the joint—*exostosis bursata*. If the diagnosis still remains uncertain despite the consideration of all these points, we should examine the other epiphyses of the body and probably find similar exostoses in other positions. Chiara found as many as a thousand in one person.

Pure cartilaginous tumours, which may also exist at some distance from the epiphyseal line, form the transition between these innocent tumours and malignant growths of the femur. If they are accessible to palpation, they present the well-known nodulated surface and a consistence less hard than osteomata. Central chondromata, are not, as rule, diagnosed, until they lead to spontaneous fracture.

(2) SARCOMATA AND ALLIED TUMOURS.

We must never diagnose a primary malignant growth of the femur, before assuring ourselves that the case is not one of secondary growth. This is more especially necessary in connection with the upper half of the femur, because it is a favourite situation for such metastases. Cancer of the breast is the most likely original source, but the primary disease may be cancer or sarcoma anywhere.

I have seen fracture in the upper third of both femora occur in an aged female after cancer of the breast. The accident was merely a slight slip.

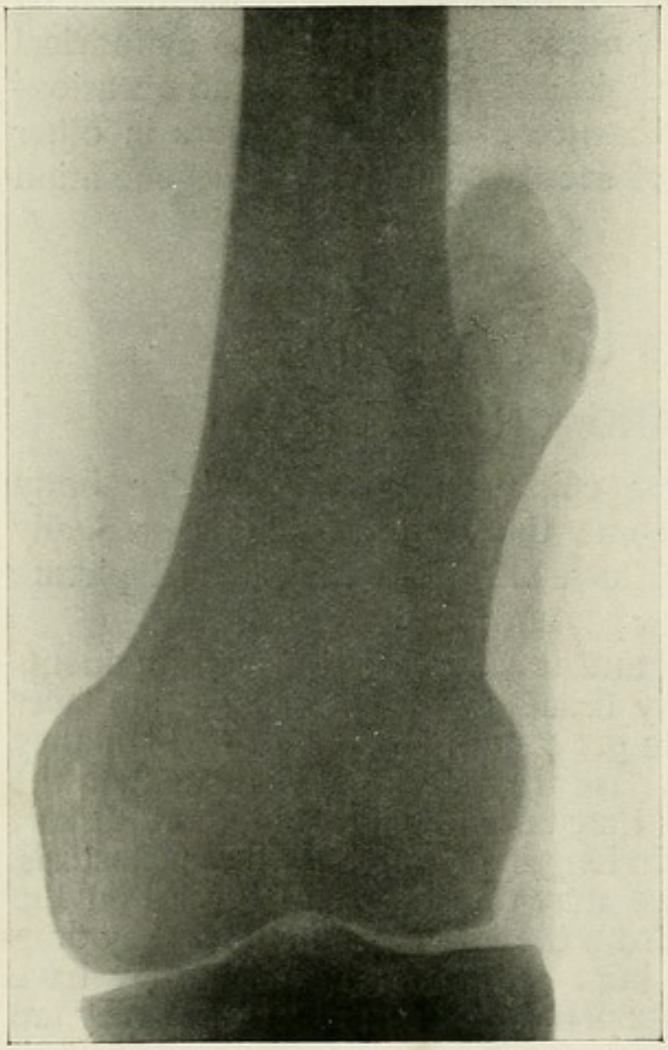

FIG. 397.—Cartilaginous exostosis of femur.

In the absence of such an origin, we may assume that a new growth is present—probably some variety of sarcoma.

The so-called *blood-cysts of the long bones*, some of which were formerly termed *aneurisms of bone*, are of a doubtful nature; at any rate they are not obviously sarcomata. A spindle-shaped distension of the diaphysis, looking like a large beetroot, takes place. The cortical portion of the bone is converted into a thin shell, and its interior is occupied by trabeculæ. The structure contains pure blood. There are no tumour elements visible; but it may be possible to separate from the internal surface a thin layer of tissue, containing elements similar to bone marrow, especially giant cells. But whether the condition is a tumour, an inflammatory process ("ostitis fibrosa"), or the result of an injury (an abnormality of callus) is a subject of controversy (see also under "Leg"). Attention is usually first drawn to this condition in the femur by a spontaneous fracture.

In other cases these growths are rather of *connective tissue* nature, and they cause bending, before spontaneous fracture occurs. Growths of this kind have been described as occurring in the subtrochanteric region.

Putting aside these conditions, which are rarities, sarcoma of the femur presents itself either as a diffuse thickening of the epiphyseal region or as a spindle-shaped distension of the diaphysis, which, later on, becomes nodular in character. For the purpose of discussing the differential diagnosis, we must separate these two forms, and we shall begin with the tumours of the *epiphysis*.

(a) Tumours of the Epiphysis.

Sarcoma of the upper end of the epiphysis is usually treated as a form of hip disease, or as sciatica, or even as osteomyelitis, until the

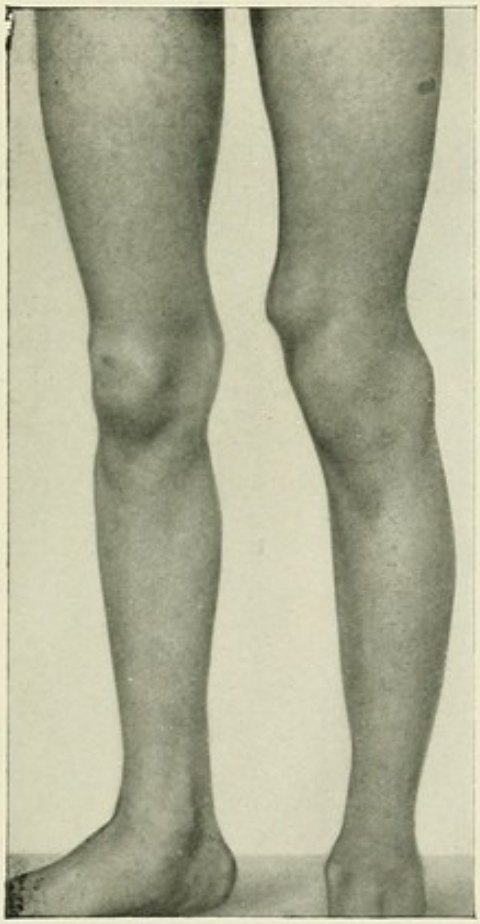

FIG. 398. — Cartilaginous exostosis of the left femur.

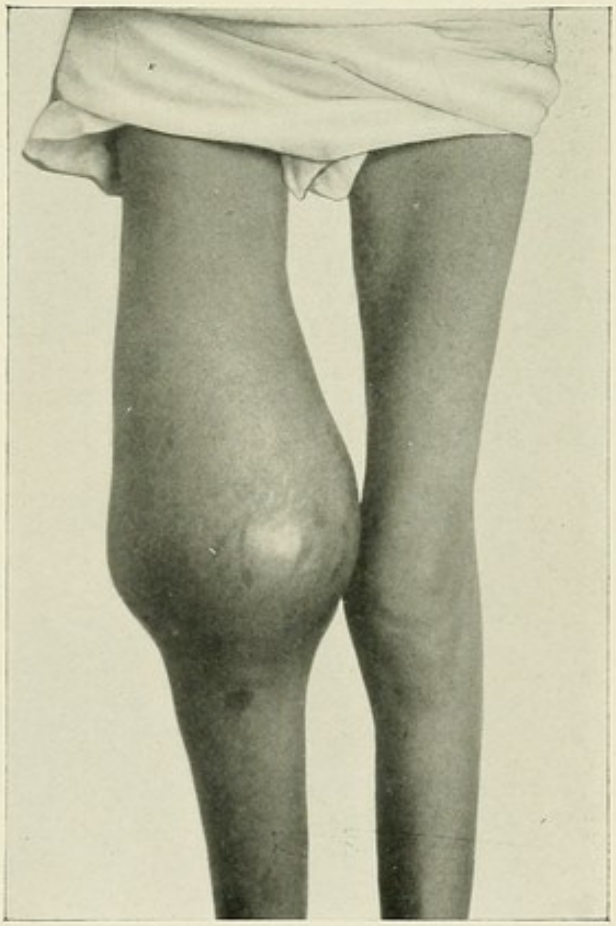

FIG. 399. — Sarcoma of the lower end of the femur.

neck of the femur suddenly breaks, or the skiagram reveals the existence of something which is neither an ordinary inflammation of the hip-joint nor a simple neuralgia.

I once saw a young man who was of an age when osteomyelitis is frequent, with a high temperature and a rapid pulse. There was at the upper end of the thigh a soft elastic swelling which any clinical student would have considered fluctuating. I also thought that the swelling probably contained fluid, and I made an exploratory puncture in order to decide between tubercle and osteomyelitis. The examination of the tissue thus obtained, and the

exploratory incision itself led to the conclusion that there was a small round-celled sarcoma of gelatinous appearance invading the pelvis. This was before the time of Röntgen rays and the young man rapidly succumbed.

A vigorous man had kept his bed for several months because of "sciatica." On measuring, it was found that there was supra-trochanteric shortening, and the skiagram showed distension of the trochanter by a growth, with the neck of the femur wedged into it.

Sarcoma at the lower end of the femur is easily mistaken, at first, for a tubercular joint.

A middle-aged man noticed a slight swelling about the knee, after a blow. A very experienced practitioner made the diagnosis of tubercular knee, and a surgeon who was called into consultation agreed. Five years went by, with iodoform injections and waiting. The knee continued to swell, but the movements of the joint remained free. Finally, the lower end of the femur assumed the appearance of a club-shaped structure, about as big as two fists. It was evidently a case of giant-celled sarcoma, covered by a thin shell of bone, similar to the case illustrated in fig. 399, which was also first diagnosed as tubercle.

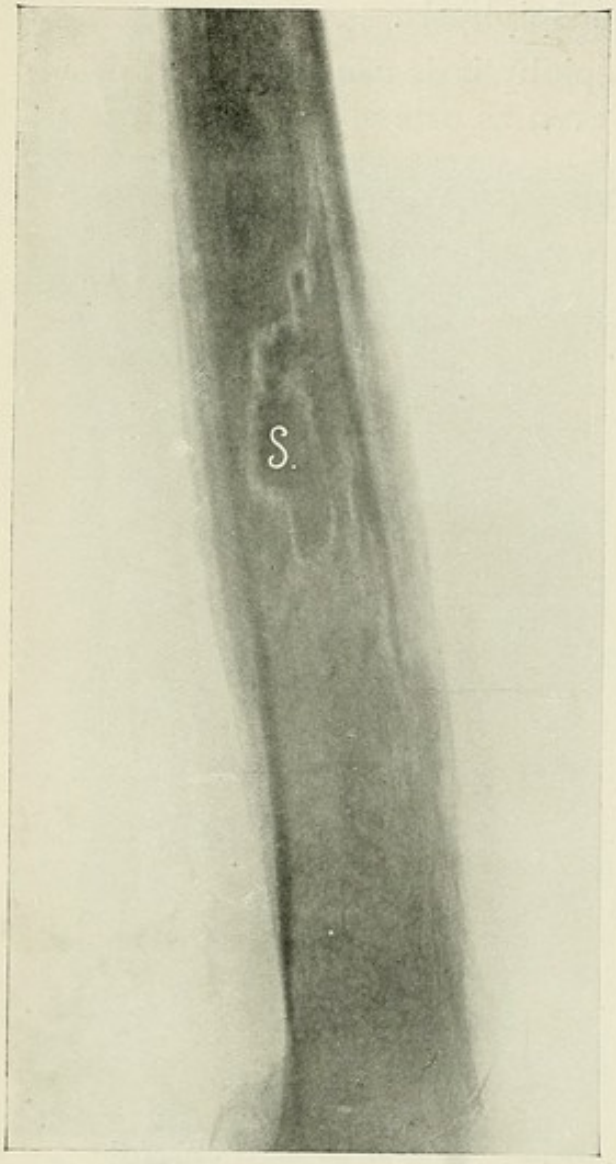

FIG. 400.—Osteomyelitis of the femur, of a few months' duration. Periosteal bone formation beginning. s = sequestrum.

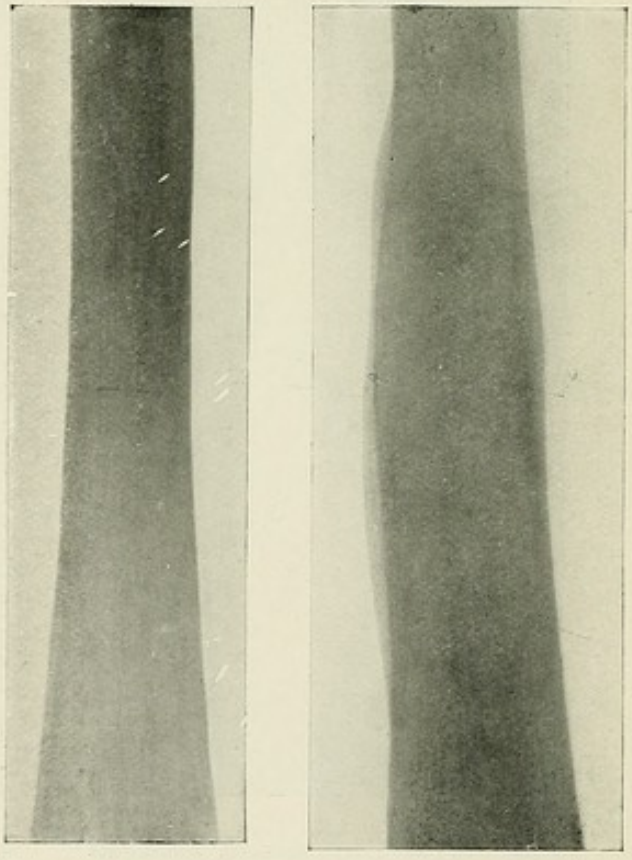

a *b*

FIG. 401.—Localized staphylomycosis of the medulla. *a* = healthy side; *b* = diseased side.

The main point in diagnosing these cases is to localize the swelling accurately. In tubercle the *capsule* is thickened, but the underlying *bone* is of normal dimensions. The thickness of the capsule is easily detected by comparing both knees on palpation, especially at the borders. If the whole region of the knee appears to be swollen,

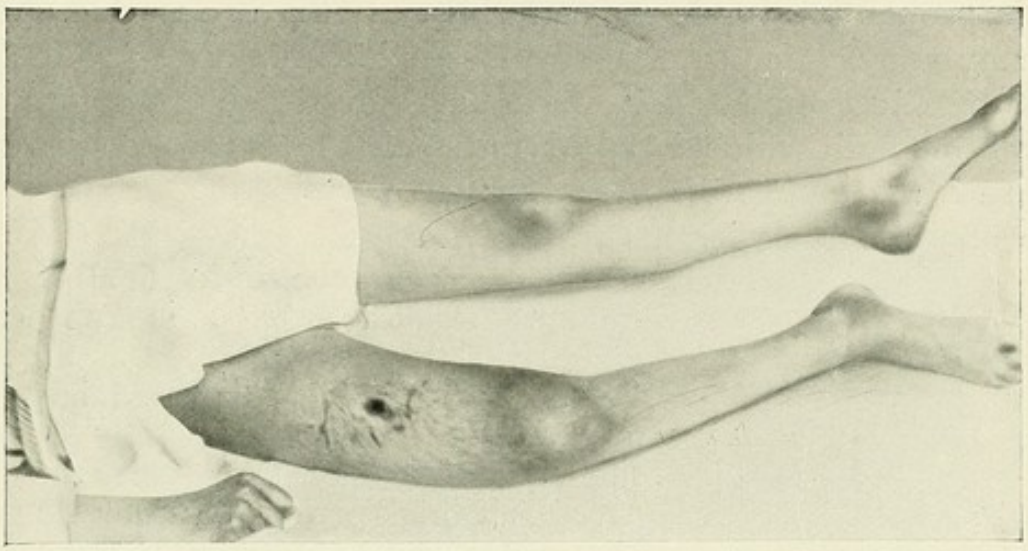

FIG. 402.—Osteomyelitis of femur, with bending of the lower end of the diaphysis.

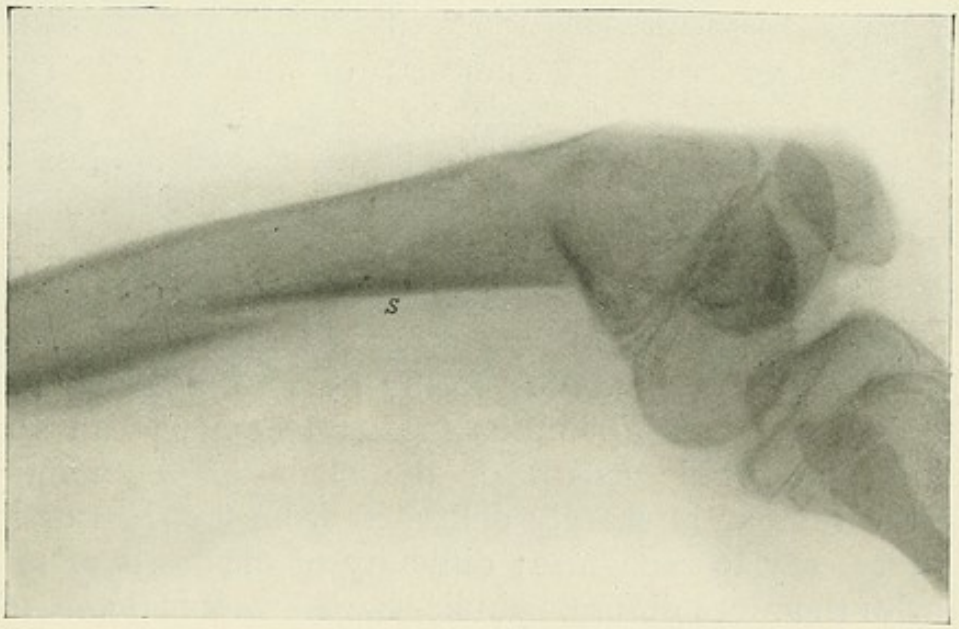

FIG. 403.—Skiagram of fig. 402. *S* = sequestrum.

although the soft tissues and the capsule are free, we must assume the existence of a more deeply situated process—either a tumour of the bone or a chronic osteomyelitis. We may derive much assistance from the mobility of the joint. Movements persist for a long time in cases of tumour, but they are quickly interfered with by tubercle, although some tubercular knees retain their mobility for years.

Thickening of the capsule which decides the diagnosis is, however, always present in these cases.

Chronic osteomyelitis is more likely to be a source of error than tubercle. If the growth is characterized by sudden exacerbations, and especially if there are periods of deep and throbbing pain in the bone, accompanied by acute transitory effusion into the joint, the case is probably chronic osteomyelitis. If the disease has persisted for many years, we must assume that an inflammatory process exists. In the case just quoted there was a duration of five years; but this is the extreme limit which is consistent with the diagnosis of sarcoma. As a rule, the course of these tumours permits the diagnosis to be made very much earlier than this.

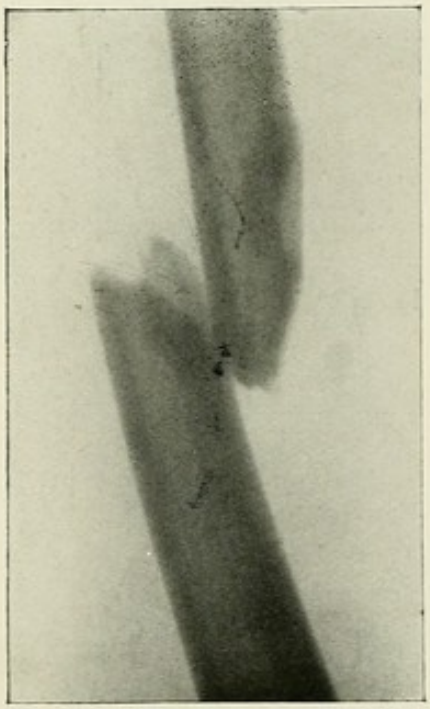

FIG. 404.—Fracture of healthy shaft of femur.

The appearance of a definite subcutaneous *venous network* is another sign which should be mentioned as an indication that the deeply situated large veins are compressed. This rarely occurs in tubercle, but may take place in osteomyelitis if thick periosteal indurations form. It occurs most frequently, however, in connection with malignant growths.

(b) Tumours of the Diaphysis.

Tumours of the *diaphysis* are more difficult to diagnose than those of the epiphysis, because they are less accessible to palpation, and because the characteristic changes in the knee-joint are less in evidence. Otherwise the rules applicable to the epiphysis apply here also. It should be especially noted that osteomyelitis has a much greater tendency than sarcoma to travel along the whole extent of the shaft of the femur. Cases wherein the tumour is sharply delimited from the shaft of the femur are therefore easy to recognize; difficulty of diagnosis arises in connection with the more diffuse, spindle-shaped sarcomata.

Two examples will illustrate how errors of diagnosis may be caused by the unusual behaviour of the staphylococcus.

A man, aged 32, otherwise in good health, had been suffering pain in his right thigh for a few weeks. The pain did not come on suddenly, and the patient was not conscious of any antecedent febrile disease, nor had there been any previous injury. For some time the patient thought he had rheumatism, but eventually consulted a doctor, who found a slight thickening in the middle of the femur, and thought of sarcoma. On palpation, however, the structure was somewhat

more tender than one would expect in the case of a tumour. The X-rays revealed a slight thickening of the cortex, indicated by a sharply defined shadow (fig. 401). This pointed to an inflammatory condition. As tubercle practically never occurs in the shaft of the femur, the diagnosis was evidently a very mild form of "acute osteomyelitis," or rather a chronic staphylomycosis, which better describes the actual condition present. But even this designation was exposed to the risk of error, because an identical clinical picture can be produced by the streptococcus and other pus organisms. The operation, however, showed that staphylomycosis was correct, because the small amount of pus which was found yielded the *Staphylococcus aureus*.



FIG. 405.—Spontaneous fracture in myelogenous sarcoma.

I saw the other case as a student in Kocher's clinic. It was subsequently recorded by Kocher and Tavel in their work on staphylomycoses. The tumour was situated in the lower portion of the femur, and completely simulated a sarcoma. It contained a brownish yellow granulation-like tissue, under a thick indurated sheath. A piece of the tissue was examined by a competent histologist during the operation, and declared to be sarcoma. Amputation would have been resorted to had not a small sequestrum which was found deep down, indicated another diagnosis. Inoculation on a nutrient medium yielded the *Staphylococcus aureus*, and the leg was saved.

Spontaneous bending of the bone sometimes occurs as a result of osteomyelitis, and is due to the traction of the flexors of the knee on

the partially destroyed diaphysis. Figs. 402 and 403 illustrate the consequent typical deformity. If there is a fistula, as there was in this case, the diagnosis cannot be missed.

Sometimes—but not always—the *skiagram* differentiates between osteo-myelitis and sarcoma. The following applies both to the epiphysis and the diaphysis.

The skiagram of osteomyelitis shows either (1) a normal edge to the bone; or (2) sharply defined, often clearly laminated deposits (figs. 400 and 401), gradually shelving away on both sides. The former appearance means that the process is comparatively recent, and that the palpable swelling depends upon periostitis without new bone formation. The latter appearance means that the process is somewhat old, and has led to periosteal bone formation. The limits of the sequestrum (figs. 400 and 403) may often be recognized at this stage. The older the process, the less clear is the lamination, so that finally the appearance is that of a diffuse spindle-shaped or cylindrical thickening of the bone (partially in fig. 402).

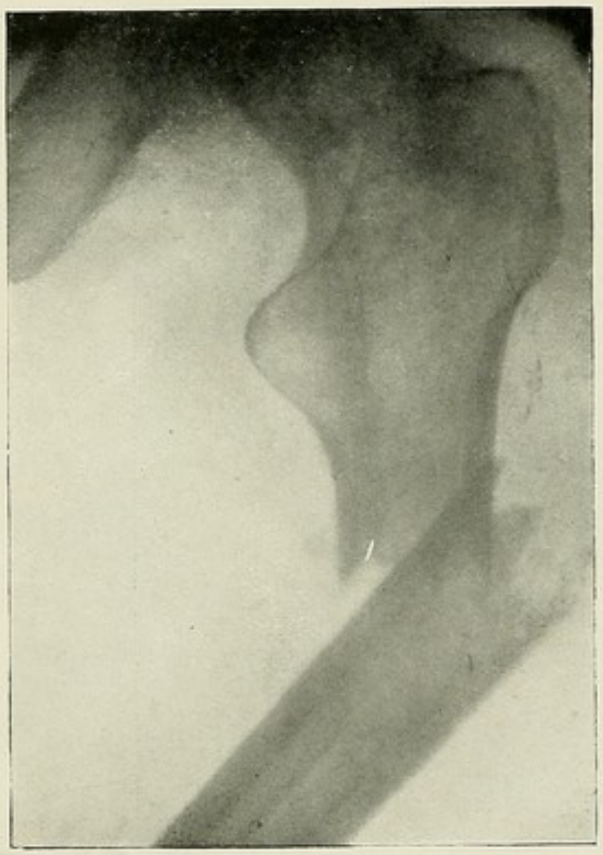

FIG. 406.—Spontaneous fracture in a metastasis of cancer of breast.

In myelogenous sarcoma the borders of the femur are equally enlarged, or on one side only. The cortex of the distended portion of the bone is greatly thinned—it may be as thin as paper. The osseous structure is obliterated, and light patches appear in the bone. Spontaneous fractures caused by malignant growths are remarkable, as seen in the skiagram, by the rounded ends of the fragments or by the peculiar erosion of the cortex (*cf.* figs. 405 and 406). Periosteal sarcoma appears as a deposit, on the normal or more or less deeply eroded bone, and casts a light shadow. Sometimes pronounced deposits of periosteal bone appear, which make the picture very similar to that of osteomyelitis.

CHAPTER XCVII.

INJURIES IN THE VICINITY OF THE KNEE-JOINT.

In falling forward we instinctively bend the upper part of the body backwards, in order to protect it—and especially the face—from damage. The force of the fall is therefore borne by the knee, and by the hands which are extended at the same time. This explains the great frequency of injuries to the knee-joint.

(1) If we find a swelling in front of the knee, after a fall directly upon the joint, and if on palpating the patellar region a cushion-like feeling is obtained, there is an **effusion into the prepatellar bursa.** The more quickly the swelling develops after the fall, the more likely is it to contain blood; the longer its development is delayed, the more likely is it to be a *serous effusion*, i.e., *prepatellar bursitis.*

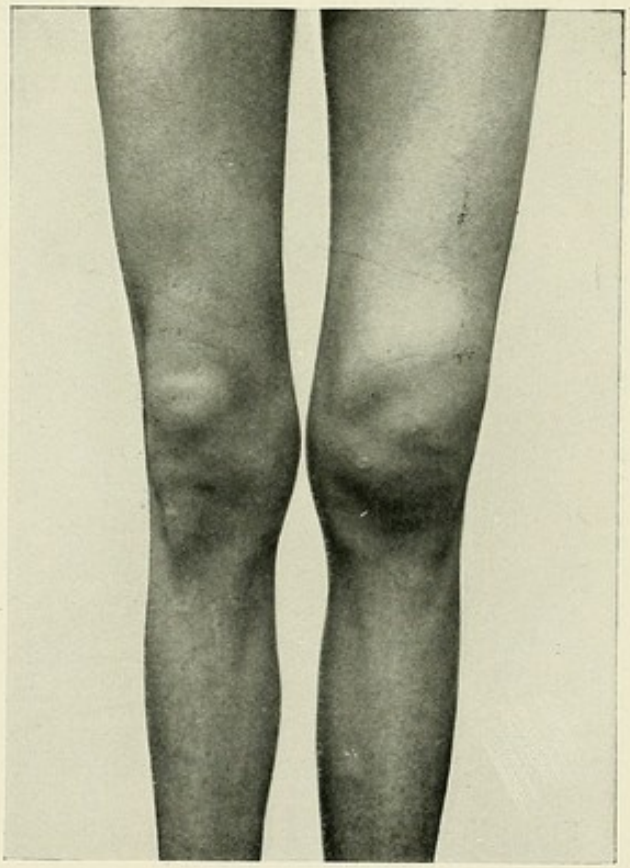

Fig. 407.—Effusion into the joint in sprained knee.

(2) It is more frequent to find some interference with movement — limitation of flexion — and a swelling not localized to the *front* of the patella, but *around* it, the groove on either side of it being obliterated (fig. 407). At the same time a transverse swelling appears above the patella, especially when the quadriceps tendon is relaxed. Sometimes the obliterated lateral grooves become converted into genuine swellings, and the superior transverse swelling increases in size. The patella is raised, and although it may be pressed back against the condyles of the femur, it instantaneously returns to its former level—so-called "riding" of the patella. The French term "ballottement" is, however, more accurate. Such a condition indicates an effusion within the joint; whether it is more of a serous or of a hæmorrhagic character, depends upon the rapidity of its development. If the skin presents abrasions, in evidence of the *direct effect* of the force, and if the parts upon which the force fell—the

patella and tuberosities of the tibia—are tender, while the region of the lateral ligaments is free, the diagnosis is **contusion** of the knee-joint.

If the injury was indirect, taking the form of excessive adduction or abduction or rotatory movement, we must assume the existence of a **sprain,** as long as the symptoms are limited to effusion and interference with movement.

The manner in which the accident happened often makes it impossible for us to distinguish between contusion and sprain. The patient, for example, has fallen down, and lights upon his leg in a constrained attitude—more or less in the "tailor's attitude." He may have sustained a contusion or a sprain. The absence of cutaneous abrasions does not necessarily exclude the latter. We therefore adopt another sign to differentiate between these two injuries: the localization of the tenderness to pressure. We have already seen where this is in cases of contusion. In sprains, however, it is found in the vicinity of the lateral ligaments, because the main force of the injury is situated there. Sometimes the tenderness exists over both lateral ligaments, or over their attachments to the femur and tibia; sometimes only over one ligament—generally the inner.

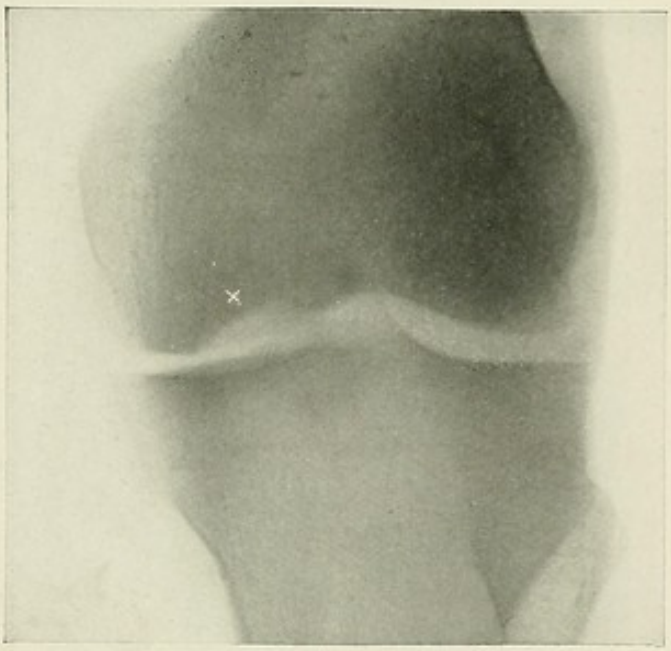

FIG. 408.—Fracture of cartilage over median condyle of femur (X).

It may be objected that these points are unnecessary refinements, seeing that the treatment is identical. It should, however, be remembered that contusions and sprains have their special complications, which will be indistinguishable clinically unless the nature of the original injury is recognized. In both cases, it sometimes happens that the trouble does not subside in the usual way. Creaking sounds, which are often audible at a distance, may occur in the joint; sudden severe pains interfering with movements, or a rapidly developing effusion may arise—conditions which were previously described by the term **"dérangement interne."** This vague diagnosis was rendered necessary by the vague knowledge of the actual conditions within the joint, in pre-antiseptic days, when operation was justifiably avoided. But to-day we possess data which enable a more accurate diagnosis to be made. If the original injury was a contusion, the

internal lesion consists of the **fracture of the cartilage** of one of the condyles of the femur—generally the median. The detached piece has hyaline cartilage on the one side, and more or less altered bone on the other side. The depression, covered by a smooth cartilage-like scar, may be found, years afterwards, on the condyle.

It is obvious that these fractures are more likely to happen if the cartilage or bone be diseased, *i.e.*, in arthritis deformans. As the injury which causes these detachments may be very slight, even in young people, König assumes the existence of an *osteo-chondritis dissecans* as a predisposing cause—an assumption which has, however, met with considerable objection. We cannot enter into the question here. The main thing is to recognize the injury, whatever be its pathological antecedent.

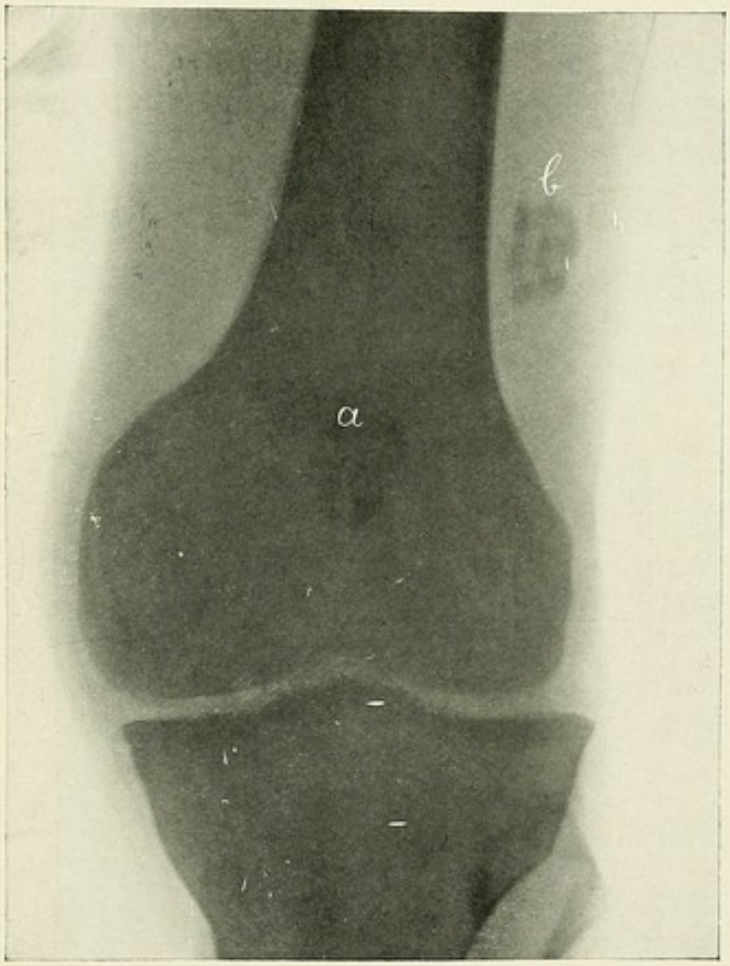

FIG. 409.—Knee joint with two free foreign bodies (*a* and *b*). Patient aged 38.

The principal evidence

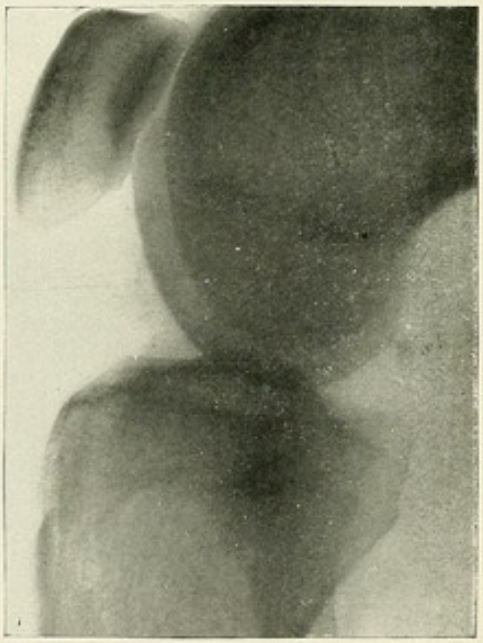

FIG. 410.—Sesamoid (*s*) bone in popliteal space.

of the presence of a foreign body in the joint is derived from actually feeling it, and from an accurate knowledge of the direction of the injury. Repeated examinations may be required in order to palpate the foreign body, and even then one may fail. X-ray examination is conclusive, if some bone is attached to the cartilage, as is usually the case.

A sesamoid bone (fig. 410) in the flexor tendons of the knee must not be mistaken for a foreign body in the joint.

There are some foreign bodies in joints which do not arise from injury. Cartilaginous proliferations in certain forms of arthritis may

be broken off quite unknown to the patient. *Cretinism*, or at any rate *hypothyroidism*, plays a definite *rôle* in this connection.

If the injury was a sprain (generally an eversion of the femur on the fixed tibia), the "dérangement interne" consists of the **detachment** and **displacement** and temporary **"locking" of a semilunar cartilage,** especially the internal. Besides the characteristic pain associated with this lesion, there are two other symptoms which lead to the diagnosis: (1) Pain on pressure over the attachment of the corresponding lateral ligament, or over the attachment of the semilunar cartilage to the tibia; and (2) the extrusion of the cartilage from the joint cavity on extension of the limb—a somewhat rare symptom.

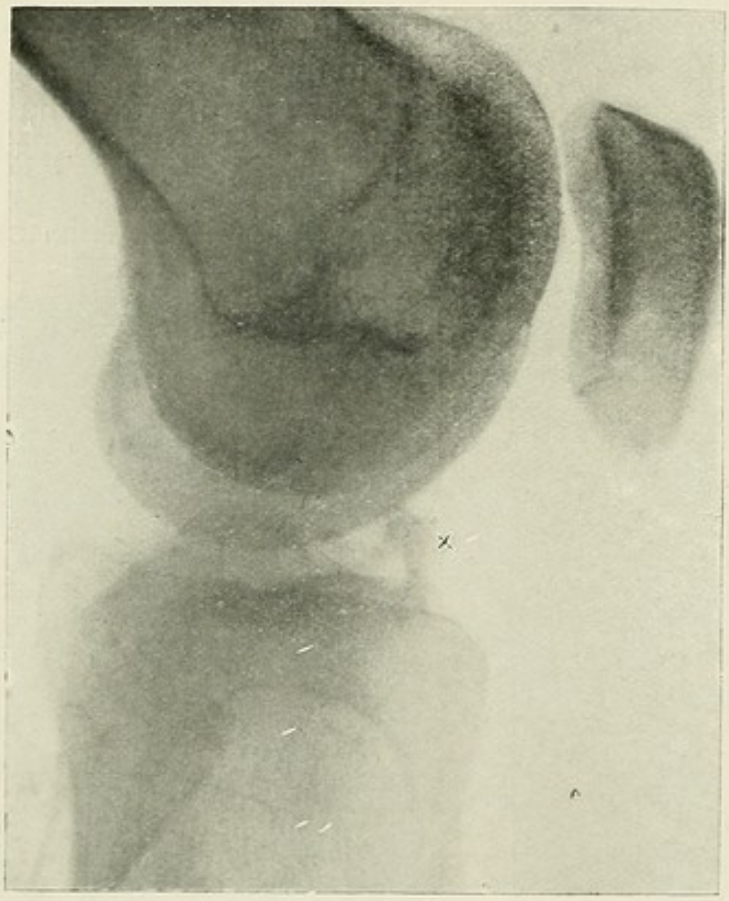

FIG. 411.—Sprained knee with detachment of the insertion of crucial ligament into the tibia (x).

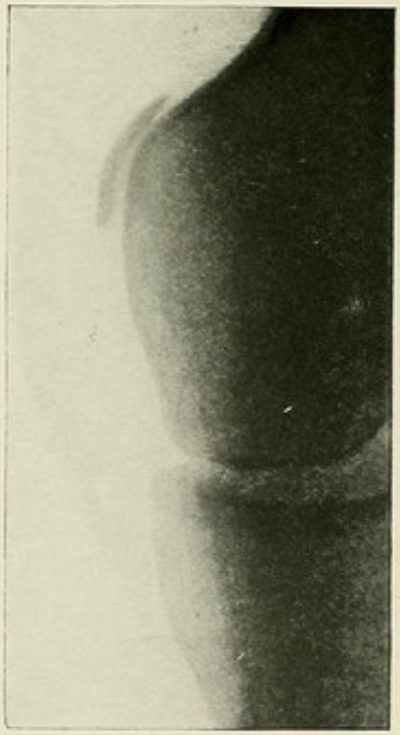

FIG. 412.—Fragment detached from internal condyle of femur.

The former symptom is only found in comparatively recent cases, and the latter is frequently entirely absent, so that we often have to rely exclusively on the history. The differential diagnosis between fracture of the articular cartilage and laceration of the semilunar cartilage may also be suggested by the frequency of the attacks. If these are infrequent, but accompanied by very severe disturbances within the joint, the case is probably one of fracture of the cartilage over one of the condyles. If the attacks are frequently repeated, and if loud grating occurs on any extensive movement, the case is probably a laceration of the semilunar cartilage.

It should be mentioned that in Barth's opinion fractures of the

cartilage over the femoral condyles may also be caused by sprains. He assumes that a piece of cartilage may be torn off by means of one of the crucial ligaments. This, however, would be a rare contingency which does not invalidate what has already been said. Fig. 411 shows that the attachments of the crucial ligaments to the bone may be torn off in cases of severe sprain.

Stieda has described a lamella of bone at the upper end of the internal lateral ligament as a late sequela of sprains.

It is not clear whether this is due to a detachment of periosteum and bone at the moment of the injury, or whether it is due to secondary bone formation in the torn ligament. Both causes may possibly contribute. I have observed the entire disappearance of this lamella within a few months.

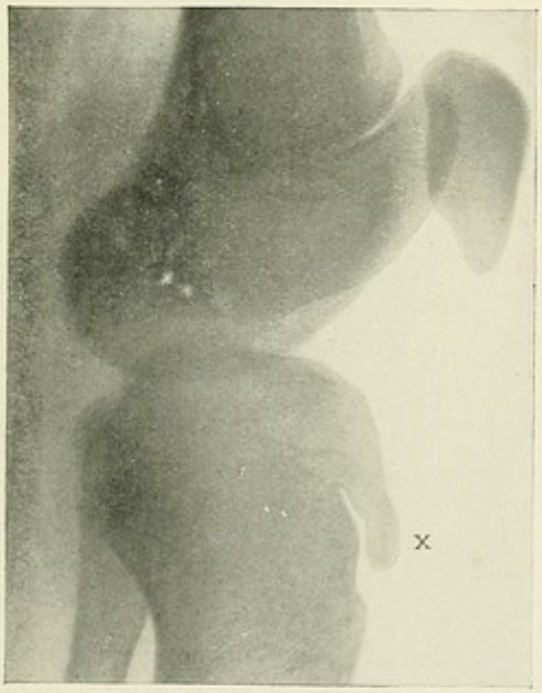

FIG. 413.—Normal spine of tibia in a young person.

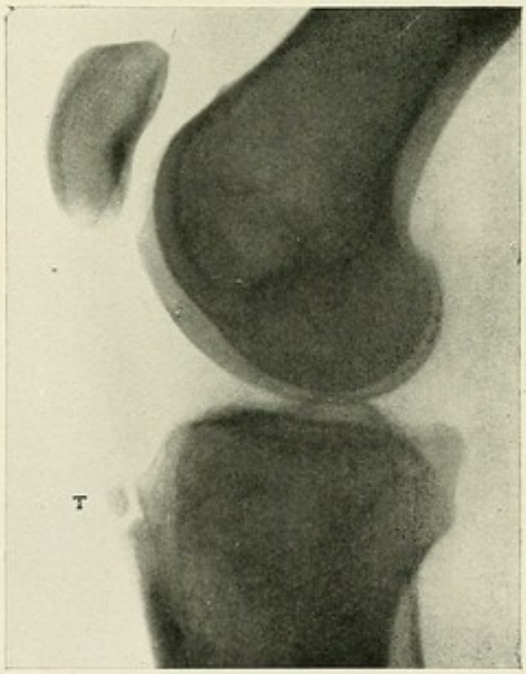

FIG. 414.—Detachment of spine of tibia.

To return to the recently inflicted injury. A patient suffering from a sprain or contusion can lift his leg in a position of extension, although it may cause pain. If this is impossible, we must conclude that there has been some injury either to the extensor apparatus or to the bone itself.

(3) We can tell in a moment whether there is shortening, or pain on pressure on the axis of the limb, and thus decide as to fracture in the continuity of the bone. In the absence of this, the only other possible condition is *laceration of the extensor apparatus*. This may occur in one of three situations: (1) In the quadriceps tendon above the patella; (2) in the patella itself; and (3) below it, *i.e.*, in the ligamentum patellæ. Palpation of the region involved will at once give an approximate idea of the situation of the injury. **Laceration**

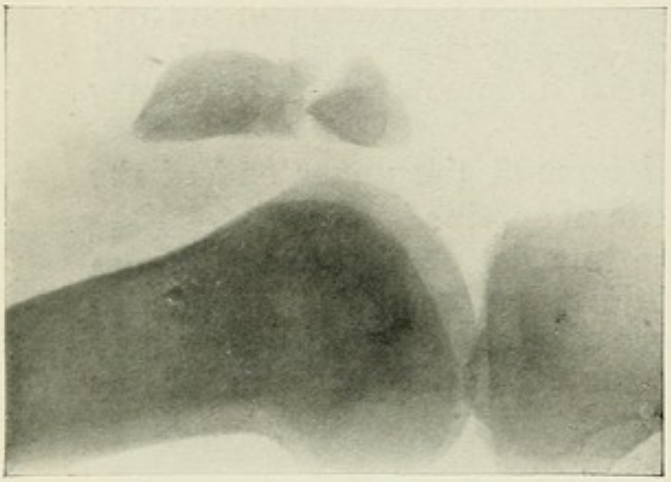

FIG. 415.—Transverse fracture of patella.

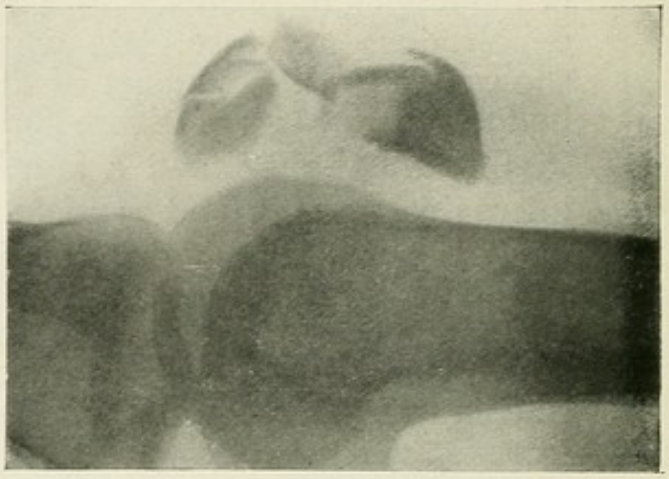

FIG. 416.—Comminuted fracture of patella.

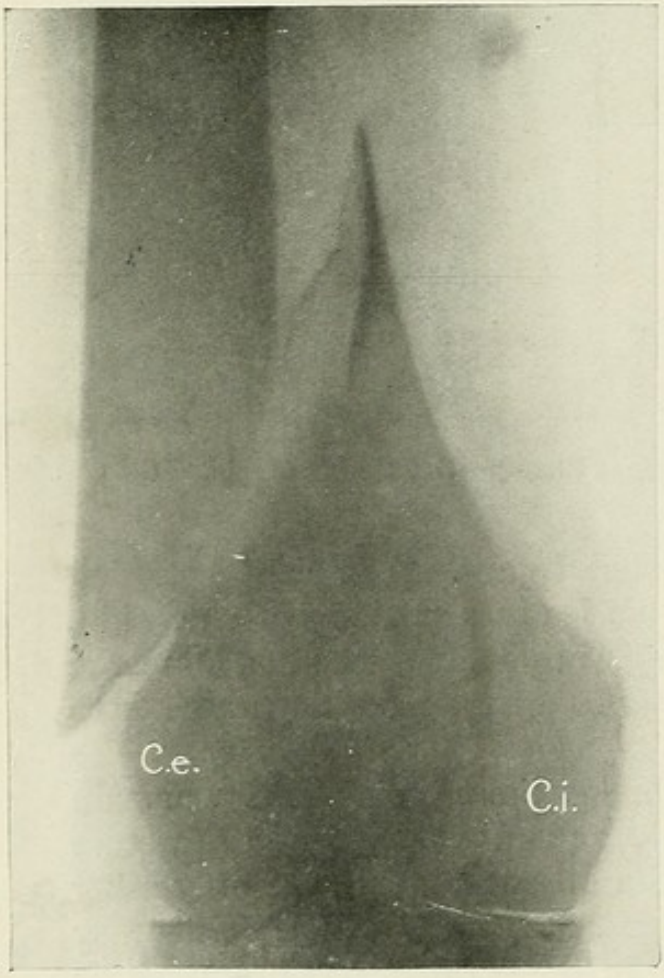

FIG. 417.—Supracondylar fracture, seen from the front, with typical displacement. *C.e.* = external condyle. *C.i.* = internal condyle. Upper fragment displaced forwards and outwards.

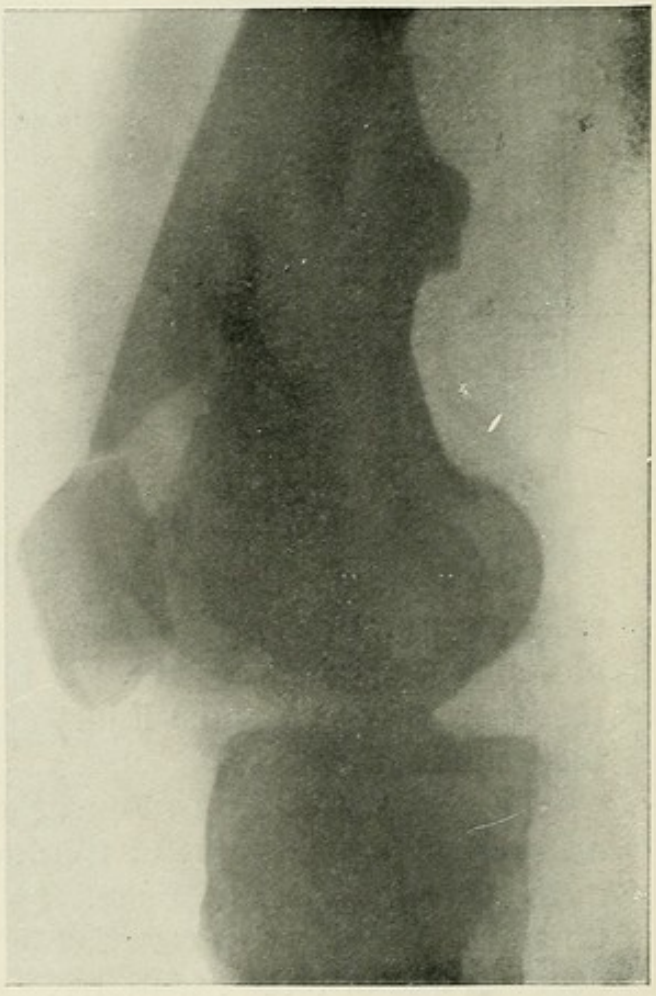

FIG. 418.—Supracondylar fracture, seen from the side. Typical displacement of lower fragment.



FIG. 419. — Supracondylar fracture. (From a case of cretinism.)

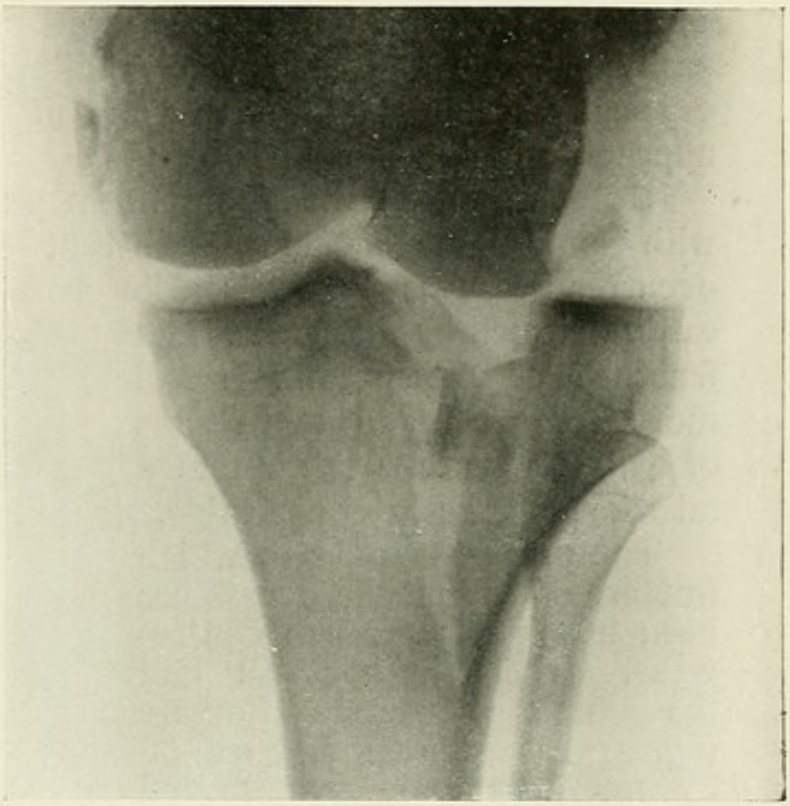

FIG. 420.— Fracture of external tuberosity of the tibia. Fragments torn and broken off the femoral condyles.

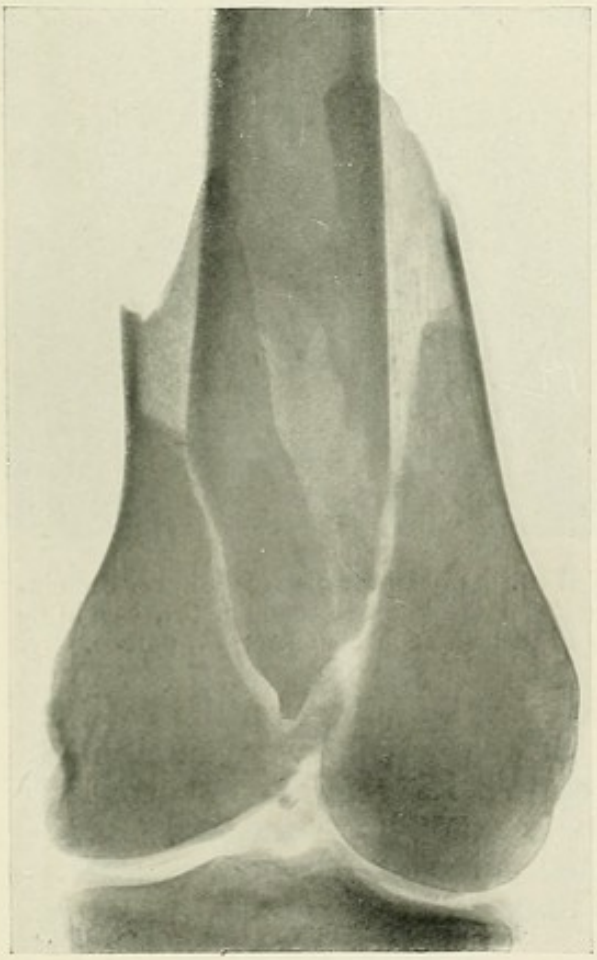

FIG. 421.—Condylar fracture. (*Post-mortem* preparation.) Y-shaped fracture.



FIG. 422.—Fracture of the tibia, below tuberosities.

of the quadriceps tendon, the rarest of these injuries, produces an easily palpable and even visible hollow above the patella. This is especially striking if the upper end of the tendon rolls up, and thus appears to be thickened.

Detachment of the ligamentum patellæ close to the knee-cap, with some bone substance adherent to it, is of more frequent occurrence. This injury is also easily detected by the finger. But **fracture of the patella** is still more frequent, and the results of palpation are so clear that a mistake is scarcely conceivable.

The precise manner in which fracture of the patella occurs has been a subject of much controversy. It has been stated that the simple transverse fracture (fig. 415) is indirect, and caused by muscular contraction, and that the **Y**-shaped or radiate fracture (fig. 416) is caused by direct force, *i.e.*, by falling on the patella. Four-fifths of the cases of fracture of the patella were attributed to muscular action, whereas, as a matter of fact, recent careful observations show that the proportion is exactly the reverse.

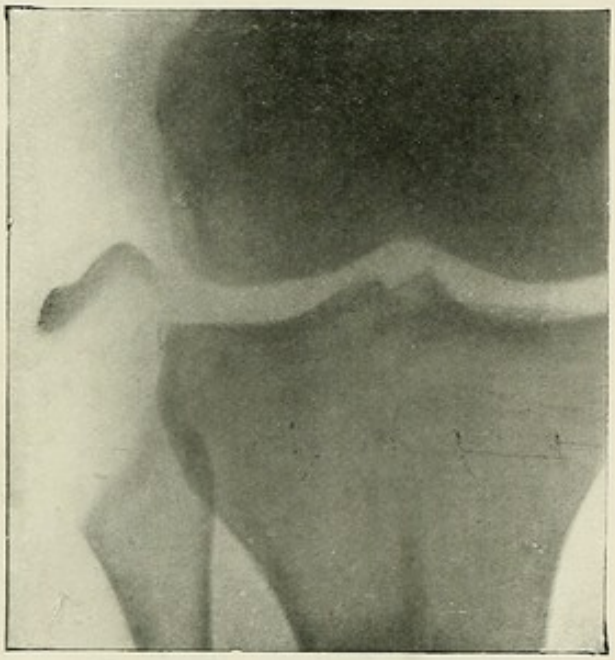

FIG. 423.—Detachment of head of fibula.

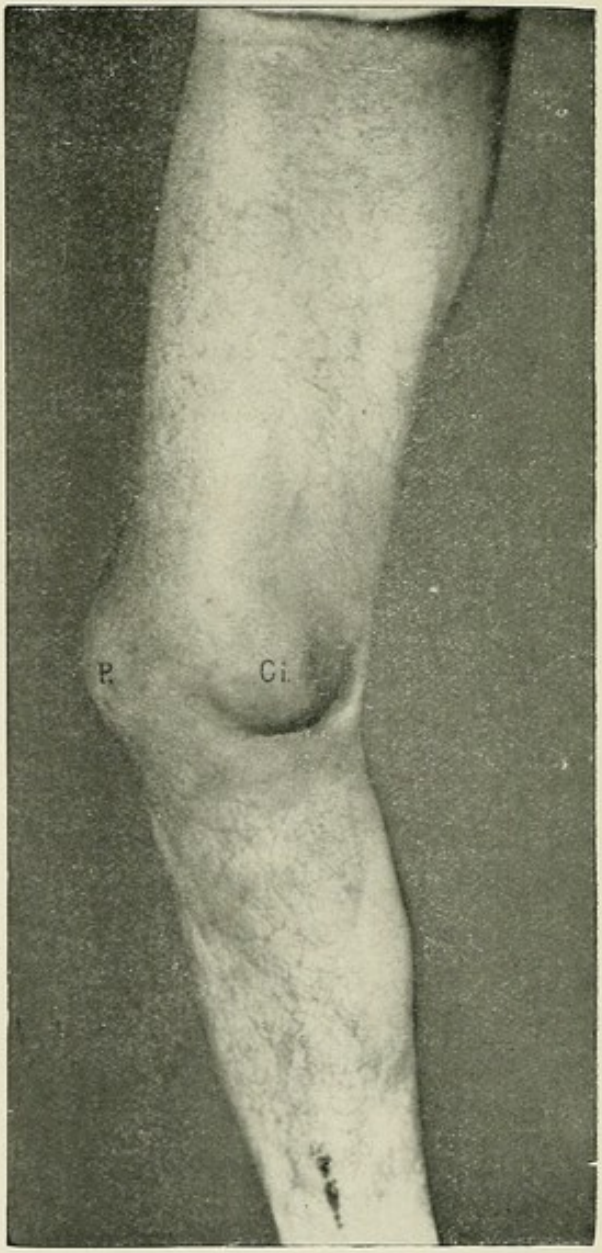

FIG. 424.—Dislocation of the knee. Prominence of the internal condyle. *Ci.*, caught by the buttonhole mechanism; *P.*, patella.

Schlatter describes cases wherein the spine of the tibia has been torn off or broken off at the epiphyseal line in young persons (fig. 414).

One must, however, guard against mistaking the normal line of the epiphysis, however unusual it may look, for the result of some trauma (fig. 413). In most cases the pains are due to tearing and not to gross anatomical changes.

(4) If, on the contrary, there is pain on axial pressure with shortening, however slight, combined with severe hæmorrhagic effusion into the knee-joint, we conclude that the lesion is not in the extensor apparatus, but that it is located in the *continuity of the limb*, *i.e.*, either a fracture of the lower end of the femur or the upper end of the tibia.

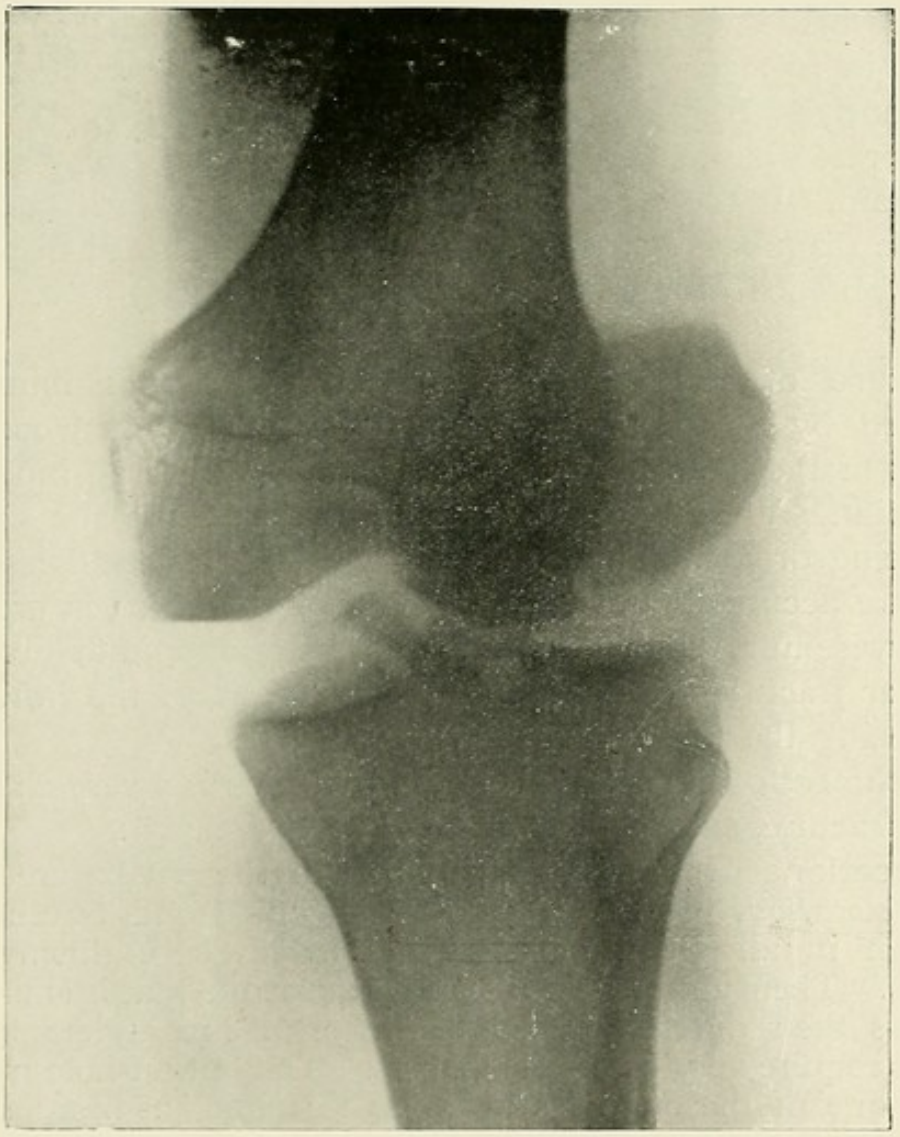

FIG. 425.—Skiagram of same case. Attachments of crucial ligaments to tibia, torn off.

These fractures are classified as supracondylar, diacondylar (in the epiphyseal line of the femur), fractures of the external and internal condyle, combined Y- and T-shaped fractures, and infracondylar (tibia). These various forms, however, are less subject to rule than the corresponding fractures at the elbow.

Supracondylar fracture does not involve the joint directly, but it often happens that the upper fragment, which is usually displaced

forwards and outwards, penetrates the joint between the lower fragment and the patella. The joint cavity is thus opened up and participates in the hæmatoma. The usual course of the lines of fracture is seen figs. 417-419.

Fig. 419 represents the case of a dwarfed cretin, whose femora had, for a whole year, undergone subperiosteal bending at the same situations. Hypothyroidism is one of the chief causes of diminished bone stability. I was once consulted for a patient with thyroid inadequacy who had just sustained his twenty-second fracture.

If the hæmorrhagic effusion is considerable, an accurate diagnosis cannot be made without an X-ray examination, which should always be made in two directions at right angles to each other.

Diacondylar fracture, occurring as a separation of the epiphysis, is a very rare event, and if the displacement is slight may be mistaken for a sprain. If the displacement is considerable, or if false mobility exists, the diagnosis is based upon the facts of lateral displaceability and the absence of any interruption of continuity *above* the joint line.

Fracture of the condyles in their various combinations are recognized by the mobility of one or both detached condyles, on the shaft of the femur, and by the varus or valgus position assumed by the joint. **Y**- and **T**-shaped fractures arise from the shaft of the femur being driven in, like a wedge, between the condyles (fig. 421). Details are accurately obtained by a skiagram, which is preferable to the otherwise unavoidable examination under an anæsthetic.

Similar fractures occur in the **tibia** (fig. 422); the **infracondylar** variety being the most frequent.

Detachment of the head of the fibula, which is a very characteristic but rare fracture, should be mentioned here (fig. 423).

Dislocations of the knee-joint and of the patella are still more rare. *Dislocations of the knee*—both congenital and traumatic—have been seen in all directions, forwards, backwards, downwards and outwards. Their appearances are so remarkable that it is unnecessary to discuss their differential diagnosis. But incomplete lateral dislocations require very careful palpation. The button-hole mechanism, whereby one of the condyles becomes "caught," as first described by Iselin, is worth noting. It is illustrated in fig. 424.

Displacements of the *patella*, which are usually external, are diagnosed by careful palpation. This bone is quite superficial, and there is no difficulty in detecting whether it is displaced outwards or inwards, or perched on its edge. Two cases of vertical torsion through an angle of 180° have been described, but the diagnosis of this condition would be more difficult.

CHAPTER XCVIII.

ACUTE INFLAMMATORY DISEASES OF KNEE-JOINT.

ACUTE inflammation of the knee-joint rarely presents any diagnostic difficulty. The first point to settle is, that the disease is really in the joint. Superficial examination may lead to a diagnosis of suppuration within the knee, when the condition is really one of **prepatellar phlegmonous bursitis**, if, as frequently happens, many ounces of pus are present and the whole knee appears to be swollen in an unshapely manner. But the distinction is easy if the examination is careful. The swelling is in *front of* the patella in bursitis ; in a suppurating knee, however, the prepatellar region is rather flattened out, and the patella itself can be felt just under the skin. In bursitis the popliteal space is free, whereas, in acute arthritis of the knee, it is painful on pressure.

In considering the knee-joint itself, we must be quite clear as to the elements which such an inflammation may comprise, *i.e.*, (1) effusion of fluid, (2) swelling of the capsule, (3) bony and cartilaginous changes. Often only one of these signs is present, but frequently there are two, and sometimes all three.

Effusion into the joint is recognized by the filling out of the fossæ on either side of the patella, and by the distension of the supra-patellar bursa. If the effusion is considerable the phenomenon of "riding of the patella" appears. If the capsule becomes lax after the subsidence of the effusion, the knee-cap can be displaced, to a remarkable extent, in all directions.

In order to detect any slight degree of *swelling of the capsule*, it is necessary to compare its fold of reflection on both knees. Normally this can just be felt if the patient is not too fat.

Involvement of the bone is often difficult to recognize, unless some striking change in shape is present. A tender area, which is sharply limited, and not at the situation where the capsule is reflected, indicates a lesion in the bone.

Views differ as to the significance of the pain on axial pressure. This is usually held to be a sign of bone disease, but this cannot be correct if, as Lennander assumes, the bone itself is insensitive and only the periosteum possesses sensation.

The *etiology* of **acute inflammation of the knee** is the same as that of acute arthritis elsewhere. We have already discussed this in full in connection with the shoulder-joint, and will only refer here to a few characteristic conditions.

If we are consulted about a case of acute effusion in a joint, we

must first inquire whether there has been any recent injury. In the absence of such a cause we must inquire about former injuries, and previous attacks of sudden joint swelling. If we ascertain that such attacks have occurred and that they have been occasionally accompanied by severe pain which prevented any further movement, we should think of a *foreign body in the joint* and *locking of a semilunar cartilage*. If necessary, the differential diagnosis must be made by means of X-rays (fig. 409). If the effusion occurs periodically, without the signs of a foreign body, we should think of the rare cases of *intermittent hydrops* of the knee, probably of nervous origin.

In the absence of any injury or any previous attacks of a similar character, we should conclude that the case is of an *infective nature*, if the effusion has come on within a few days with severe pain, tension and pyrexia. If the patient is a young man and the knee is the only joint affected, we should ask him *sotto voce* when he had *gonorrhœa*. He will rarely deny the impeachment, but may ask that it should be treated as rheumatism, out of regard "for the old-fashioned ideas of his parents."

We should make the same diagnosis if a young woman has "caught cold" on her honeymoon.

Secondary inflammation of the knee has been observed in infants with gonorrhœal ophthalmia, as also in little girls with gonorrhœa.

Insured persons will attribute it to an accident. In some cases this will be pure invention, but it is quite conceivable that a slight sprain may afford the gonococcus the opportunity of attacking a joint, if the organism already exists in the body.

An acute inflammation of the knee-joint after a *confinement* or a *septic abortion*, presents difficulties of a therapeutic rather than of a diagnostic nature.

Acute arthritis occurs more frequently in the knee than in other joints, as a result of *direct injury*, varying from a needleprick—the needle remaining in the capsule—to the cut of a hatchet. This is not always followed by acute suppurative inflammation with great swelling and high fever. The knee more frequently swells up gradually in the course of a few days, the fever is slight and the periarticular changes are trivial. The shape of the distended articular space is very clearly discernible through the soft parts. As the symptoms are so mild, nothing but a purely serous exudation is expected; but exploratory puncture shows that some turbidity already exists owing to fibrin and pus cells. If the case is treated without delay in an appropriate manner the knee will be saved, but if delay is incurred stiffness will result.

In growing children every case of acute inflammation of the knee should suggest the possibility of *acute osteomyelitis* of one of the adjacent bones. An articular effusion, sometimes purely serous,

is often the only symptom of a localized diseased area in an epiphysis.

Diagnostic interest may also attach to the *late sequelæ of acute inflammatory knee-joints.* If, despite extensive incision, the temperature remains high and the neighbourhood of the joint remains swollen, we must assume that *periarticular* abscesses have developed, which are most frequently found under the extensor muscles and the patella. Sometimes the joint continues to suppurate despite multiple incisions, and the temperature persists at 100·5° although no periarticular abscesses can be demonstrated. X-rays will show that the interval between the femur and tibia is abnormally narrow, owing to more or less destruction of the cartilage. On exposing the joint the cartilage will be found to be eroded, the underlying bone more or less destroyed, and in young people the epiphysis may have formed a sequestrum. In other cases the joint itself may have undergone little change, but the adjacent metaphysis may be involved, and a sequestrum may even have formed.

CHAPTER XCIX.

CHRONIC DISEASES OF THE KNEE.

THERE is no joint which varies so much as the knee in appearance as a result of chronic inflammation from one and the same cause. Great caution must be exercised in diagnosing the cause from the anatomical conditions present.

Thus simple hydrops of the knee may exist in chronic traumatic inflammation, in tubercle, or in neuropathic disease of the joint; ankylosis may exist in chronic articular rheumatism, and in tubercle, &c.

A chronically inflamed knee may present three essentially different conditions, each one of which possesses its own problems of differential diagnosis :—

(1) Chronic articular effusion.
(2) Thickening of the capsule, including the synovial membrane.
(3) Rigidity of the joint.

(1) CHRONIC ARTICULAR EFFUSION.

We have already studied, in connection with acute traumatic effusions, how to recognize an articular effusion. Chronic effusions, however, last longer and attain a larger size, though their degree of tension is not so great.

Certain articular effusions were previously termed *idiopathic*. We now know, however, that, apart from very rare intermittent effusions due to nervous disturbances, that there is no such variety. The more careful the history is taken, and the more accurate the examination, the more certain is some cause to be discovered.

(*a*) The diagnosis is usually **chronic articular rheumatism**, if several joints are affected simultaneously or in rapid sequence, and the remarks already made on this malady, when dealing with diseases of the shoulder, should be recalled. In the latter, the most frequent varieties are the adhesive and the destructive caries sicca, whereas in the knee exudative processes predominate. In the neuropathic forms there is a great tendency to proliferative processes. The diagnosis of rheumatism is often merely a refuge of ignorance. It should never be made until all other possibilities have been excluded. An example will illustrate this.

A boy aged 10, suffering from articular effusion of both knees, was sent into the hospital as a suspected case of tubercle. But as the affection was on both sides, and as there were no other indications, we thought the case was one of chronic rheumatism. One morning, however, we noticed some injection of the eye and slight cloudiness of the cornea, which had supervened since the previous evening. This at once suggested "the sins of the fathers," and it was clear that the serous inflammation of the knees was due to congenital syphilis. The result of mercurial treatment confirmed this diagnosis.

If there has been no attack of recent parenchymatous keratitis, **hereditary syphilis** may probably be indicated by old corneal opacities or by the shape of the teeth, in addition to the bilateral effusion. In other cases, we may ascertain that the patient bleeds easily, and that any pressure leaves a blue mark. This suggests that an early stage of so-called **hæmorrhagic effusion** is present—but this is a rare contingency.

We have hitherto been assuming that all the articular diseases are of a serous nature. Although this is true for cases of congenital syphilis, it is not true for hæmorrhagic joints and for genuine chronic rheumatism, in both of which there may be effusion on one side and ankylosis on the other.

(*b*) The problem is quite different if only *one joint* is affected. The most important question is whether *tubercle* is present. In addition, one has to think of (1) chronic or recurrent traumatic effusions, (2) foreign bodies and dislocation of a semilunar cartilage, (3) gonorrhœa with an unusually protracted course, (4) the proximity of a focus of osteomyelitis, (5) tertiary syphilis, (6) rheumatism exceptionally remaining in one joint, (7) a neuropathic joint, and finally, (8) a mono-articular hæmorrhagic effusion. On the other hand, if the effusion is limited to one side, hereditary syphilis may be confidently excluded. We will deal briefly with these possibilities, reserving tubercle till the end.

Traumatic effusions come on in an acute manner. If the trauma is frequently repeated, or if the patient is rheumatic, the effusion may become chronic. There is no evident thickening of the capsule, and this constitutes the distinction from tubercle supervening after an injury. The "locking" of foreign bodies and of the semilunar cartilages, are distinguished by their intermittent character.

A knee, the mechanics of which has been disturbed by a fracture—even extra-articular—may be subject to intermittent and remittent serous effusions, years after the accident.

The diagnosis of **chronic gonorrhœal effusion** is made from the history and usually also from the condition of the urethra.

Synovitis due to osteomyelitis is easy to recognize if the patient has the scars of that disease on the femur or on the tibia. There are, however, cases, which for years are called "rheumatism," when in reality an abscess exists in the bone, close to the epiphysis, and somewhat acute attacks occur from time to time, accompanied by effusion into the joint. We must depend upon the history for the correct diagnosis, but examination will show that the main situation of the swelling and of the pain is not in the joint, but in the adjacent bone.

The diagnosis of **tertiary syphilitic synovitis** is suggested by the history and the slightness of the pain; but one cannot be certain of its accuracy until specific treatment has met with success. We may assume the presence of chronic **mono-articular rheumatic synovitis** if the capsule is not markedly thickened, the temperature over the joint is not definitely raised, and if the trouble has persisted for years without getting much worse.

Mild forms of tubercle may drag on from infancy far into adult age without abscess formation and with a tolerable amount of movement, but with intermittent exacerbations. In these cases, however, the capsule is always definitely thickened.

In the **neuropathic forms** the diagnosis is established by the absence of pain, despite advanced changes in the joint, and by the early onset of deformity, in addition to the pure synovitis.

This variety of arthritis has been appropriately termed a "caricature of ordinary arthritis." If symptoms of tabes or syringomyelia co-exist, the diagnosis is naturally easier; but sometimes it will be necessary to search for these diseases, because the joint trouble may be the first symptom of nervous disease to attract the attention of the patient.

Hæmorrhagic effusion has already been referred to. We have now arrived, by way of exclusion, to **tubercle,** which is by far the most common form of serous inflammation of the knee. The vast majority of these cases occur in infancy, but adults may become affected, and it is not rare even in old age. It is only distinguished from other forms of serous inflammation by the fact that the capsule

is somewhat thickened from the very beginning, and by the persistent elevation of the temperature over the diseased joint. The thickening of the capsule must always be looked for at its *folds*, that is to say, at its superior border, and on both femoral condyles. If the healthy knee is examined at the same time it will be easy to appreciate how far the folds can be palpated in the normal condition.

If the joint is full and tense, this sign cannot be demonstrated. In such a case, the joint should be *punctured*, and a positive diagnosis will be obtained by examining the fluid. Blood, pure or nearly so, indicates hæmorrhage into the joint. Clear, serous, or mucous fluid may be found in every variety of inflamed knee, but if the fluid is purulent, turbid, or contains shreds of fibrin, the case is probably tubercular.

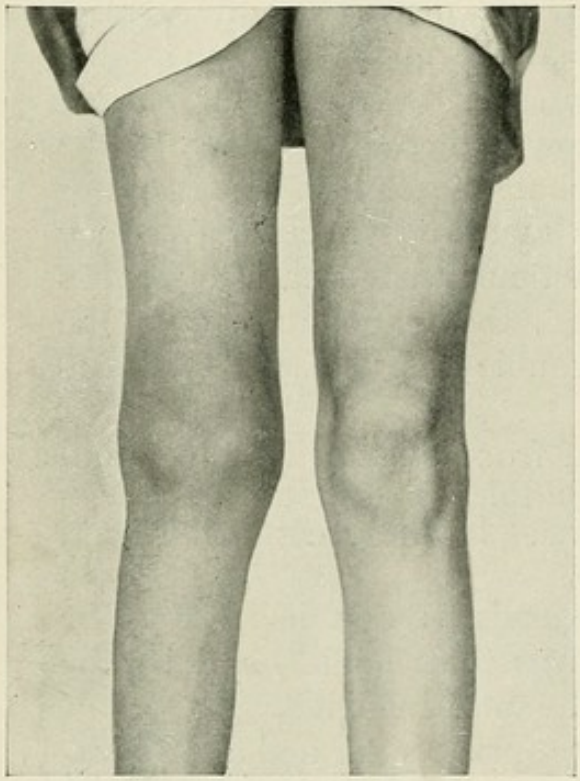

FIG. 426.—Slight tubercular hydrops of the right knee with almost completely free mobility. Very slight muscular atrophy, considering that the disease has lasted nine years.

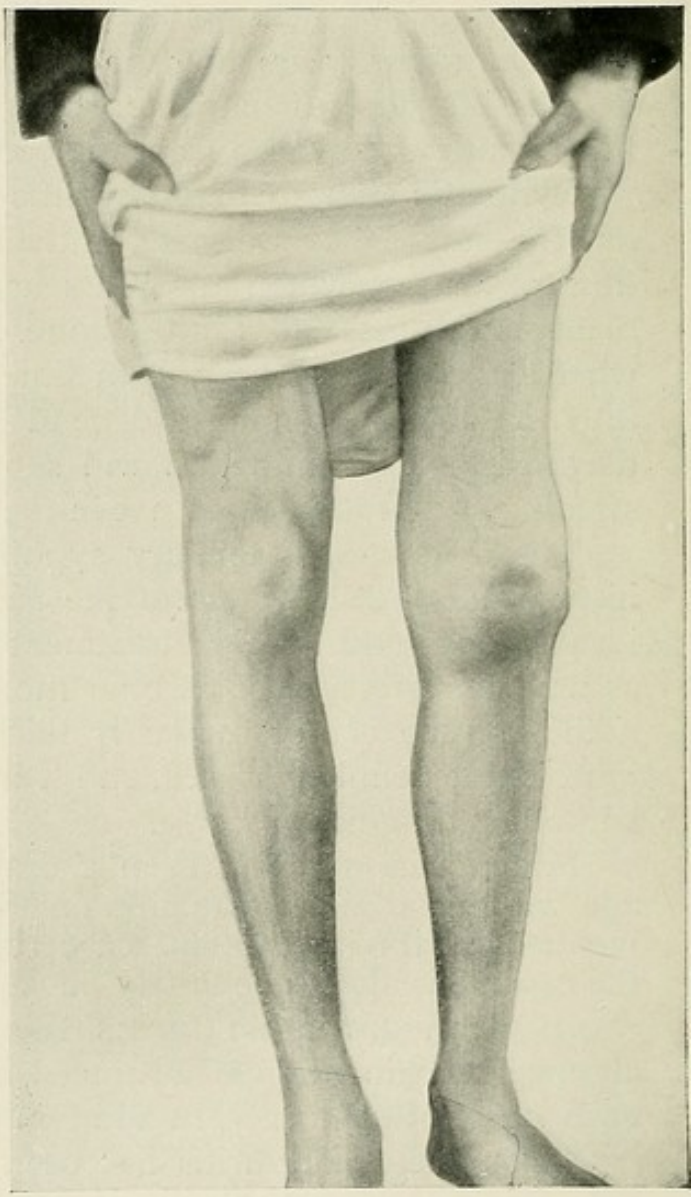

FIG. 427. — Proliferating tubercular disease of knee, with moderate amount of serous effusion. Mobility still partially retained.

In order to test the temperature, it suffices to lay both hands lightly upon the two equally long exposed knees. Effusions due to gonorrhœa, osteomyelitis and recent injury, show some local elevation of temperature, but this vanishes much more rapidly than in tubercle, wherein the same amount of heat can be detected for many months at each examination.

We might expect that tubercular disease of the knee-joint would lead to *early limitation of movements*, as occurs with other joints. But, as a matter of fact, this is very often not the case. The excursions of the knee may remain perfectly free even in tubercular synovitis of many years' standing, as long as the joint is not over distended by the effusion. In such cases the muscular atrophy does not supervene as soon as it does in tubercle with early ankylosis.

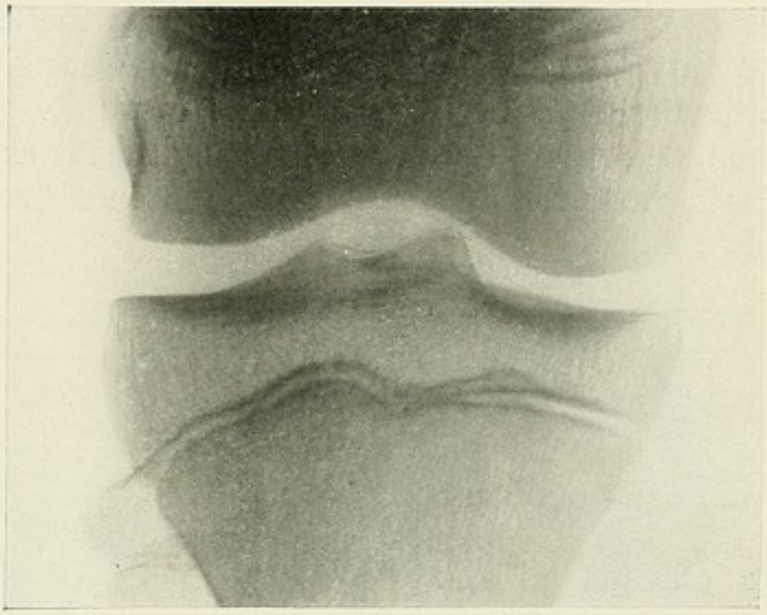

FIG. 428*a*.—Normal knee.

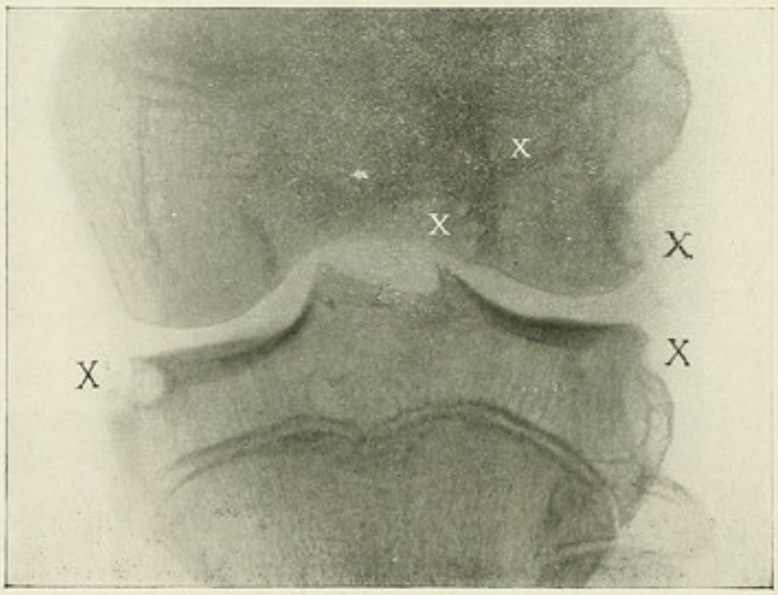

FIG. 428*b*. Tubercular knee. Secondary erosion of bone at X X. Cartilage somewhat narrowed.

We may briefly summarize the above, as follows: Every monoarticular, chronic, serous inflammation of the knee, wherein there is definite thickening of the reflected folds of the capsule, and wherein there is a persistent definite local elevation of temperature, must be regarded as tubercular, even if mobility still remains free and pronounced muscular atrophy is absent. Nothing but very clear evidence to the contrary warrants us in departing from this rule of diagnosis.

In rare cases, one or more movable foreign bodies may be felt in the swollen joint. They are not completely free and can only be moved in a small circle. These are examples of the *polypoid form of tubercular knee* (Plate IV, fig. *b*). The polypi consist of hard connective tissue, more or less abundantly permeated by tubercles.

(2) FUNGATING INFLAMMATION OF THE KNEE-JOINT.

If the capsule is greatly thickened in a *diffuse* manner, the case is either **tubercle,** or the very rare condition of **gummatous arthritis,** whether there be effusion present or not.

Localized fungating degeneration of the capsule might, apart from gumma, be confused with the rare condition of **sarcoma** of the articular capsule, if the joint is movable. But as we have already seen, free mobility does not by any means exclude tubercle. In other cases, however, movement is soon interfered with, and finally complete rigidity supervenes.

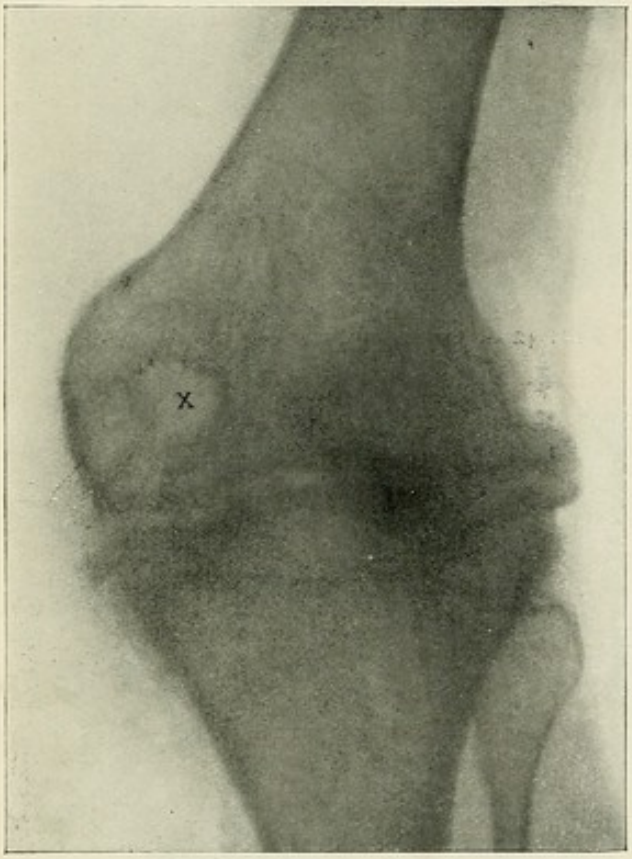

FIG. 429.—Tubercular knee, with complete destruction of articular surfaces, and with an area of disease in the internal condyle of the femur.

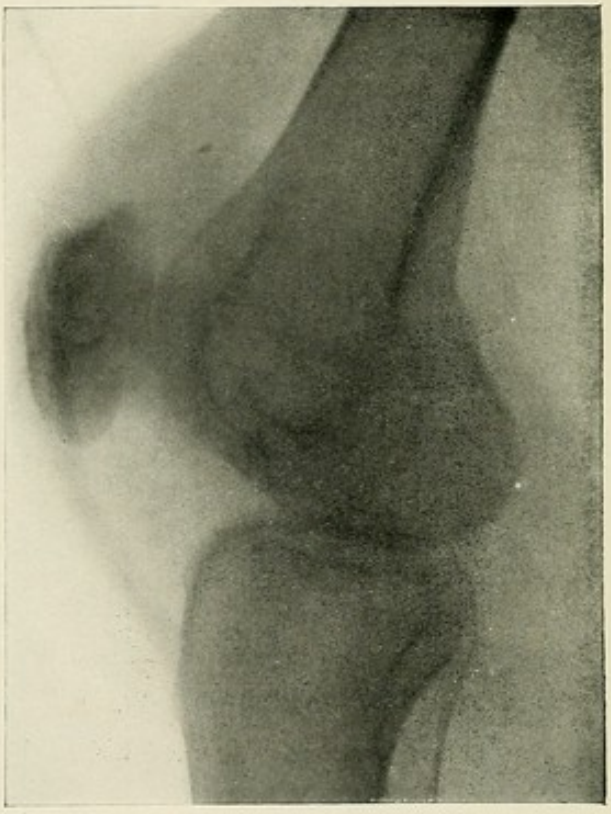

FIG. 430.—Tubercular knee with area of disease, and a sequestrum in the patella (X).

A momentary glance often suffices to distinguish these two forms, before we ask the patient to make any movements. If the *mobility is preserved* the muscles of the thigh and leg are not strikingly atrophied, and the thickened capsule resembles a moderate amount of effusion, more especially as some effusion usually exists. In cases of *early rigidity*, however, the diffusely swollen knee is slightly bent, the muscles of the thigh and knee are wasted, so that a spindle-shaped appearance results.

The principal question from the diagnostic standpoint is whether

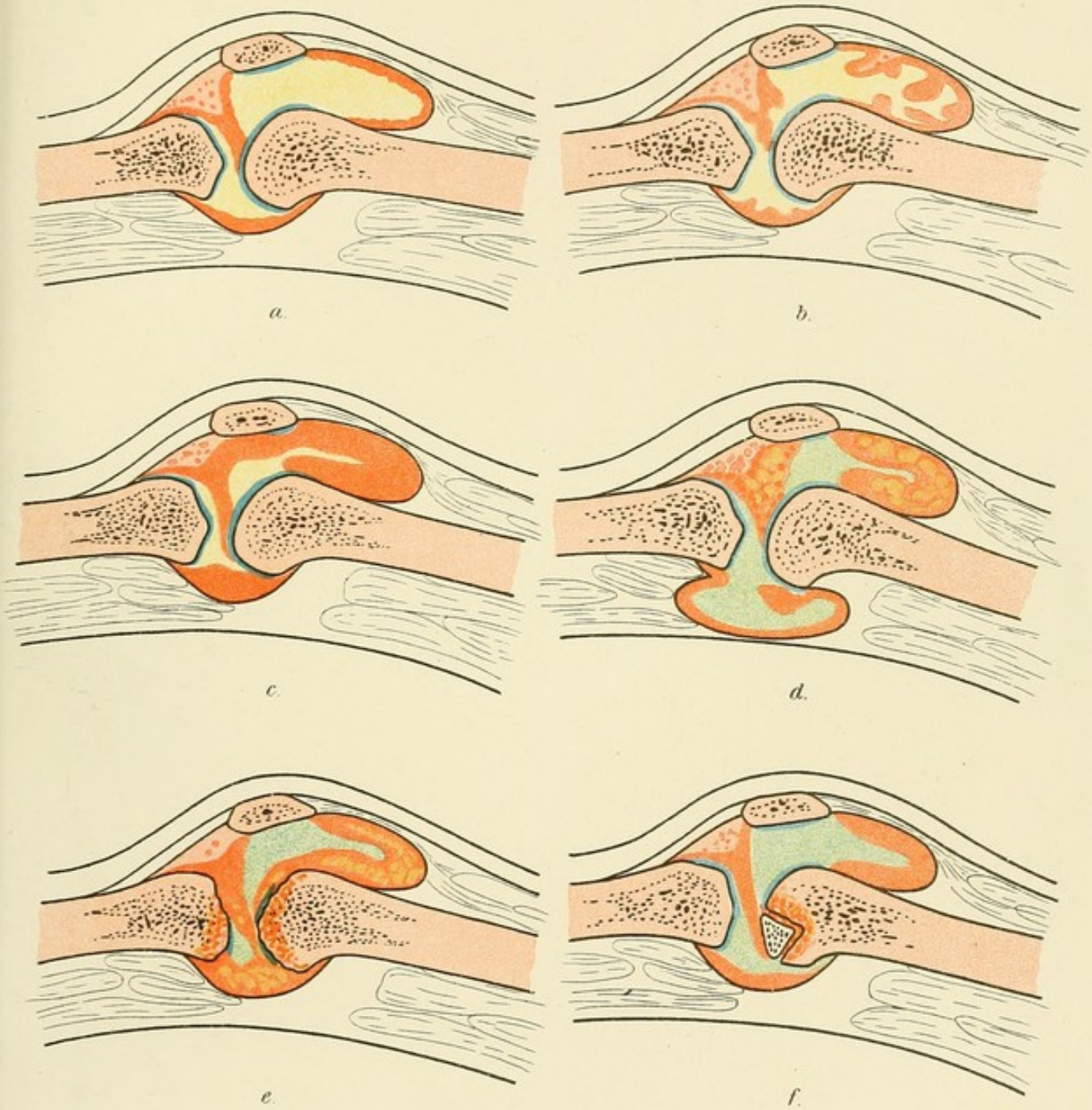

Diagrammatic Representation of various forms of Tubercular disease of the Knee.

Light pink = normal bone
Blue = cartilage
Red = Inflamed Synovial membrane
Light yellow = serous effusion
Green = pus
Orange = Caseous thickening

a. Serous inflammation of Knee. Synovial membrane slightly thickened, invaded by tubercles. Serous effusion.
b. Polypoid inflammation of Knee. On synovial membrane large fibrous polypi with tubercles.
c. Fungating inflammation of Knee. Slight exudation. Much thickening of synovial membrane.
d. Fungating & caseating inflammation of Knee. Caseous thickening of fungating masses. Purulent exudation. Abscess behind bend of Knee.
e. The same, but cartilage of bone removed and destroyed by tubercular proliferation.
f. Primary disease of bone, in the form of a wedge shaped area, with sequestrum.

the condition is of a *purely fungating* character, with or without serous effusion, or whether it has become *purulent*. We may confidently assume that suppuration has occurred if there appear a circumscribed, elastic, or fluctuating bulging, which seems to be just under the skin. This appearance may present anywhere, but it is most frequent at the level of the joint cleft.

It used to be the practice to incise such swellings early, in order to see their contents, or to remain loyal to the old maxim "*ubi pus, ibi evacua.*" As a rule the abscess refused to heal; a fistula developed and secondary infection occurred. In this condition the case was turned over to the surgeon. We now know that such an incision into a tubercular abscess of a bone or a joint, however aseptically performed, almost unavoidably leads to secondary infection by pus organisms and does the patient considerable harm. It is only justifiable to open a tubercular abscess if one is prepared to proceed forthwith to a radical removal of the diseased area in the bone or of the capsule.

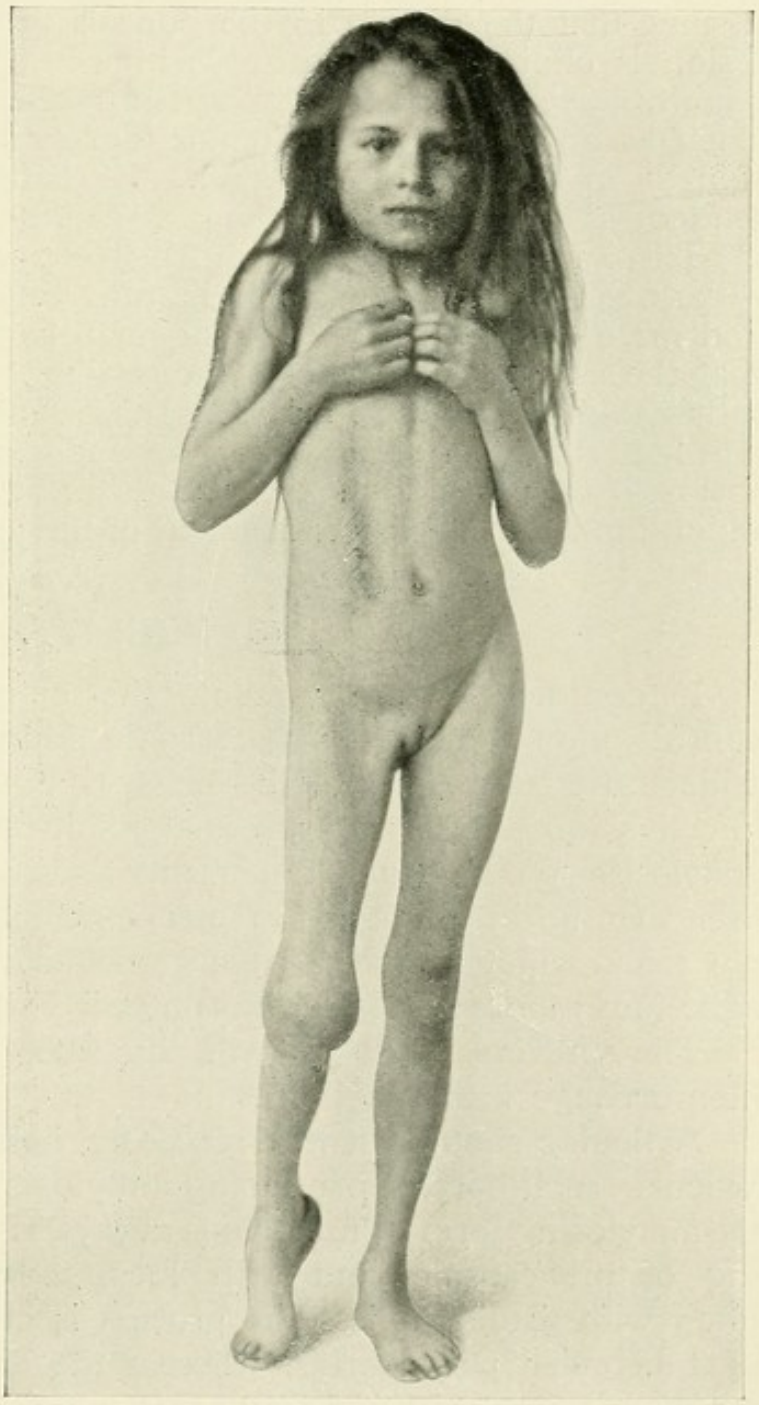

FIG. 431.—Tubercular knee, slightly flexed and contracted, and in valgus position, with subluxation of the tibia backwards and outwards.

Even if the tubercular nature of the malady is doubtful, incision is unjustifiable. An aseptic exploratory puncture suffices to obtain the requisite information, and does no harm to the patient. If staphylococci or streptococci can be cultivated from the unincised joint, the disease is osteomyelitis—or, more rarely, an acute suppurating arthritis. If the cultures remain sterile,

and gonorrhœa can be excluded, the case is certainly tuberculosis. A decisive conclusion would be given by animal inoculation.

We have already made several references to the starting-points of disease. The bone lesion is very often secondary, as shown by the existence of numerous smaller foci on the articular surface of the bone, especially where the capsule is reflected (fig. 428). We should only assume that the disease in the bone is primary, if an extra-articular lesion is clinically demonstrable in a case wherein the joint is but slightly affected, or if the skiagram reveals a large localized lesion. Such lesions may be in the femur (fig. 429) or in the tibia, and exceptionally in the patella (fig. 430). The latter is indicated by striking tenderness on pressure over the knee-cap.

There are some rare cases, in which examination leaves one in doubt as between a serous effusion and a fungating thickening of the capsule, and on operation it is found that neither one nor the other exists, but that the condition is one of a lipoma-like proliferation of the articular tufts—so-called **lipoma arborescens**. As this change may occur in chronic arthritis of different origins, and exceptionally also in tubercle, it is not easy to make an accurate diagnosis. I have found this condition limited to the upper segment of the joint.

(3) RIGIDITY.

If contractures are present, the conditions which come into consideration for diagnosis are again abundant. One must first put aside those cases wherein the history points to some form of acute infective inflammation of the knee-joint, preceding the contracture or ankylosis. We have only to consider rigidity of *gradual* onset, and may even then be in doubt as to the (1) terminal stage of hæmorrhage into the joint, which is rare; (2) chronic articular rheumatism forming adhesions; and (3) tubercle causing early rigidity.

The previous history will indicate whether there has been **hæmorrhage into the joint.**

Articular rheumatism, producing ankylosis, is as rarely monoarticular as **tubercle, producing ankylosis,** is polyarticular. Further, the ankylosing form of tubercle is always associated with some thickening of the capsule, and with local elevation of temperature and often with fistulæ, unless the process is completely at an end. Cases of tubercular polyarthritis, wherein the diagnosis remains uncertain for many years, exist, but they are very rare.

The contracture does not always develop into a simple flexion. We often find, especially in tubercle, that the posture is one of slight valgus, with subluxation of the tibia backwards and outwards, as illustrated in fig. 431.

CHAPTER C.

TUMOURS AND ALLIED STRUCTURES ABOUT THE KNEE-JOINT.

THE knee-joint occasionally presents structures which do not fit in with the previously described bone sarcomata, arising from the femur or tibia, nor with chronic inflammatory processes.

(*a*) Let us begin with the *anterior surface*.

Chronic **prepatellar bursitis** is at once evident, even to the beginner, owing to its superficial position, in front of the patella. The structure may vary in size from an almond to a fist, and accurate anatomical examination shows that it may be just under the skin, under the superficial fascia, or under the deep aponeurosis. Diverticula extending laterally are of importance from the operative standpoint.

If the wall of the structure is strikingly thick and persistently painful on pressure, one should think of **tubercle of the bursa**, which is, however, rare. X-rays will show whether it originates in tubercle of the knee-cap.

Occasionally, a change, corresponding to prepatellar bursitis, is found somewhat lower down, situated in front of the patellar ligament. (*Bursitis prætibialis*). Bursitis of the deep *infra-patellar bursa behind* the patellar ligament is still more rare. The swelling has a sub-divided appearance, and bulges on both sides of the ligament. The larger it is, the more it interferes with the movements of the joints.

Among the rare tumours of the anterior surface of the joint should be noted, **sarcoma of the patella; lipoma, fibroma** and **sarcoma of the synovial membrane** or the sub-synovial connective tissue. **Lipoma arborescens**, *i.e.*, lipomatous proliferation of the articular fringes, has already been mentioned as occurring in various forms of chronic arthritis and in tubercle. It may be regarded as on the border line of tumour formation. Fibrous polypi which may attain the size of almonds and which feel very much like foreign bodies within the joint, are seen in rare cases of tubercle (Plate IV, fig. *b*). The freedom of the joint movements is characteristic of all these tumours.

(*b*) With few exceptions, swellings in the *popliteal space* are either **extensive bursæ** or **aneurisms**. The distinction is at once evident on palpation and inspection, from the absence or presence of *pulsation*. This, however, may occasionally be absent, even in the case of an aneurism, if its contents are coagulated. But no mistake ought to arise, as the consistence of the structure is

comparatively firm, and the patient can always testify to the previous presence of pulsation. Soft or elastic non-pulsatile swellings are, as a rule, enlarged bursæ ; the *bursa under the popliteus*, if situated laterally, and the *semimembranous bursa*, if situated towards the middle line. They may be confused with the very rare lipomata of this region, and also with a cold abscess. Differentiation is easy, if the contents of the swelling can be reduced into the knee-joint, as is often possible in enlarged bursæ. Otherwise, if the swelling is very easily displaced, we should regard it as a lipoma ; if it has an atypical situation, is painful on pressure, and if the movements of the joint are also interfered with, we should regard it as a cold abscess. If the abscess originates in an extra-articular lesion, it may not be possible to diagnose it without a skiagram and an exploratory puncture.

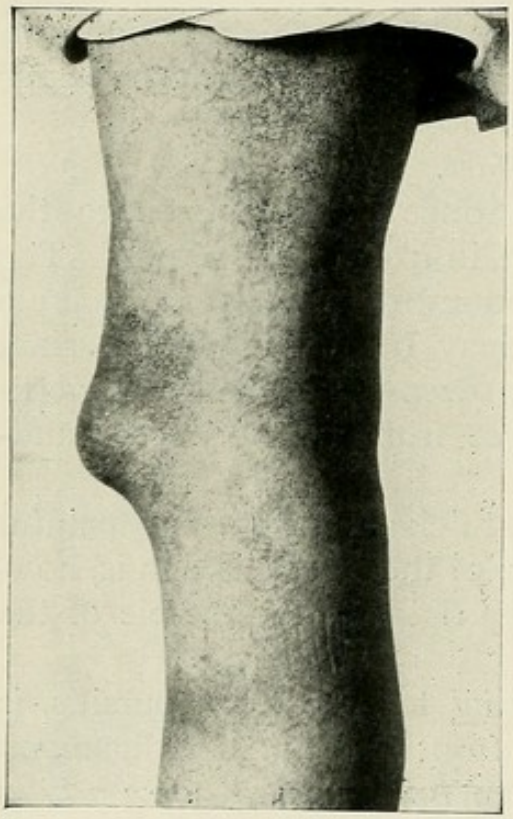

FIG. 432.—Prepatellar bursitis.

Effusion into a bursa may be due to chronic serous (rheumatic) inflammation of the knee-joint. The removal of the bursa is then occasionally followed by an unusually severe effusion into the joint.

We need only add, in reference to the unmistakable diagnosis of aneurism, that this soon causes neuralgic pains and paræsthesia in the leg, and that it may, after reaching a certain size, fix the joint in semi-flexion. It is due to the same causes as other aneurisms, *i.e.*, trauma, arteriosclerosis and syphilis—especially the last, even if there is a history of injury.

CHAPTER CI.

SCIATICA AND OTHER PAINFUL DISEASES OF THE LOWER LIMBS.

MEDICAL nosology contains a number of vague terms which fortunately help to conceal the bitter truth from a patient, without prejudicing the diagnosis, but unfortunately these terms occasionally satisfy the doctor as well as the patient, to the latter's great detriment. Thus a multitude of ills may be embraced under the designations of anæmia, liver trouble, intestinal colic, &c. The same is true of "sciatica." Neuralgic pains of the lower extremity are often summarily diagnosed as sciatica, as if this condition were a clinical entity.

Although references have already been made to this subject, we shall once more describe how a case of "sciatica" should be examined, not only by a surgeon, but by any practitioner.

It is most important to examine the urine and the reflexes—patellar and pupillary—because the condition may be due to diabetes, tabes or paralysis. Then the surgical possibilities must be thought of. The gluteal region must be palpated, because an obstinate sciatica may be the first symptom of **sarcoma**, originating in the bone or muscle. The course of the nerve must be followed, because sciatica may be due to a malignant growth of the thigh or even lower down. A diffuse thickening of the shaft of the femur, indicating chronic osteomyelitis, may possibly be found. If an injury has preceded the sciatica the question of a foreign body may arise.

A young man fell on a heap of wooden palings, while in an inebriated state. He was subsequently treated for many weeks for "sciatica," and a colleague of mine then succeeded in withdrawing a long piece of paling. The original wound had healed completely over the piece of wood.

If palpation elicits nothing, we must direc our examination towards the spine. Spinal caries, sarcoma of the lumbar vertebræ, or caries of the ileo-sacral joint may simulate a simple sciatica.

If the patient is a young man, of an age when idiopathic sciatica is rare, we should inquire about **gonorrhœa**, and, if necessary, examine the urethra.

I was once consulted by a young man for sciatica. My inquiry regarding gonorrhœa was answered by a decided and resentful negative in the presence of his father. But the youth reappeared on the following day, saying: "I have merely come to tell you that you were quite right."

This cause should also be borne in mind, even in the case of patients of advanced age.

A grey-haired grandmother consulted me for sciatica. She was also suffering from a profuse white discharge. Had her husband not consulted me a fortnight previously for gonorrhœa, I would hardly have diagnosed the cause of her sciatica correctly.

We now proceed to rectal examination. This should never be neglected in a case of sciatica, however objectionable it may be to the patient and unpleasant for the practitioner. We examine in both sexes for cancer of the rectum and for new growth in the pelvis ; for malignant disease of the prostate in males and for some disease of the generative organs in the female. In the latter a vaginal examination should also be made. If this systematic examination were invariably practised, we should no longer come across cases wherein women, at the climacteric age, have been treated for weeks or months for sciatica, until at length, an offensive discharge or profuse hæmorrhage has led to a gynæcological examination. The doctor is not always to blame. Female patients often refuse a vaginal or rectal examination because they cannot conceive what bearing it has on their sciatica. The young, inexperienced practitioner may yield to this refusal, but nevertheless he incurs the responsibility for his error of diagnosis. It may be said that such an error is of no consequence to the patient, because a malignant tumour, which has caused sciatica, is already beyond radical removal. Although this may be correct in the majority of instances, it is nevertheless true that an accurate diagnosis is better, not only for the reputation of the practitioner, but also for the interests of the patient and his friends, than futile spa and electric treatment and similar measures. But not all gynæcological diseases which cause sciatica are of malignant nature. Pelvic exudations and incarcerated myomata may irritate the sciatic nerve; indeed rectal constipation may sometimes explain sciatic pains.

Is it possible to distinguish clinically the sciatica which results from malignant growths from idiopathic sciatica ? The pain in the former is, on the whole, persistent, in the latter it is rather of a paroxysmal nature. In sciatica due to cancer the patients soon exhibit a peculiar restlessness. Even if the pain is not severe they are still restless, whatever posture they adopt. They cannot be persuaded to sit down, even in the doctor's consulting room; they often persist in walking up and down restlessly. In simple sciatica the disturbances are limited to sensations of pain, there is not usually any loss of sensibility. If, however, it should be present, it does not usually reach any extreme degree. There are never any disturbances of motion. But both these conditions are as a rule present in advanced cases of sciatica, due to compression. Carcinoma may also produce nerve manifestations, owing to the

wandering and proliferation of cancer cells into the lymphatics of the nerve trunk. We must therefore regard "sciatica," which comes on after removal of rectal or uterine cancer, as a recurrence, although we may not be able to detect any cancerous mass compressing the nerve.

If old people complain of severe "sciatica pains" in the leg extending to the toes—pains which often come on quite suddenly and cause limping, we should think of Charcot's "intermittent limp," and should at once inquire whether attacks of pallor or bluish-red discoloration occur in the painful extremity. The occurrence of such attacks indicates the prospect of **gangrene**, especially if on examination the foot is sometimes found to be pale and cold and at other times in a state of venous congestion. This diagnosis would be confirmed by the obliteration of the pulse in the dorsalis pedis artery and posterior tibial, and certainly by the absence of the popliteal pulse. This cause for pain is especially prevalent among old people, as the expression "senile gangrene" indicates. Younger people are, however, not immune from gangrene, but in their case some special cause is responsible, *e.g.*, diabetes, early syphilitic arteriosclerosis, or acute infectious disease, typhoid fever being the most common. I have seen thrombosis of both femoral arteries and eventually of the abdominal aorta, follow a slightly septic finger in a girl aged 20. In some cases, however, no antecedent disease can be discovered. These cases are included under the comprehensive term of Raynaud's disease, the principal indication of which is its symmetry. This condition is attributed to a primary vasomotor disturbance, for want of a better explanation.

The following case belongs to this category, although the affection is unilateral :—

A healthy man, aged 30, who had not suffered from syphilis, began to complain of severe neuralgia of his left foot. There was no obvious cause for this, except perhaps excessive gymnastics. The foot was sometimes pale and cold, at others, bluish-red. Eventually the cyanotic discoloration persisted and gangrene of the foot developed, requiring amputation. Pains and vasomotor disturbances supervened a few years later in the other foot, but gangrene did not follow.

We should think of arteriosclerosis, in the absence of any other cause, if pain is present, even without severe vasomotor disturbances.

Varicose veins should also be included among the causes of pain and "cramp" in the leg, especially in the calf. *Deep* varicose veins are conveniently blamed, when the diagnosis is obscure, because they cannot be seen, and therefore their presence cannot be denied.

On the other hand, sciatica may be mistaken for some other condition—especially the form of sciatica termed *scoliosis ischiadica* (Chapter LXXIX). Patients with sciatica often walk with an oblique

gait, inclining the trunk, sometimes to the healthy side, at others to the affected side. A beginner, unaware of this habit, may easily devote his chief attention to the scoliosis, and look upon the sciatica as a secondary matter. This view would, however, only be justified in those rare cases wherein the sciatica results from disease of the lumbar spine, such as caries, and the scoliosis is a consequence of the lateral compression of the diseased vertebra. In such cases, all doubt is removed by the tenderness of the affected spinous process and the pain elicited by axial pressure. But in cases of true "scoliosis ischiadica" the condition is one of primary disease of the nerve. The patient endeavours to relax the sciatic nerve by abducting and slightly flexing his leg. Ehret has shown that this posture causes a remarkable approximation of the terminal points of the trunk of the sciatic nerve. The patient involuntarily compensates for the pelvic inclination thus caused by assuming the posture of scoliosis and slight lumbar lordosis.

Recent researches, however, appear to show that scoliosis is more frequently due to involvement of the lumbar nerves in the morbid process.

The foregoing remarks regarding sciatica apply *mutatis mutandis* to **neuralgia affecting the anterior crural nerve, the external cutaneous and the obturator nerves.** But as neuralgia of these nerves rarely occurs as an idiopathic affection, it is more likely than sciatic neuralgia to suggest, even to the beginner, some special cause. Search should be made for pelvic tumours, spinal caries, burrowing abscesses, and also for malignant retroperitoneal and inguinal glands. The primary growth may be situated in any part of the area drained by these glands, so that the whole of it will require investigation.

Obturator hernia may be the cause of an obturator neuralgia, but as advice is not usually sought for this hernia until strangulation takes place, it is necessary to inquire for this neuralgia, in order to ascertain anything about it. If it is present, it enables us to exclude internal intestinal obstruction.

Neuralgia of the external femoral cutaneous nerve has been described as a disease, *sui generis*, and provided with the designation of "meralgia paræsthetica." This term should, however, not induce us to abandon attempts to form a more accurate diagnosis. As the position of this nerve exposes it to external damage, we should always think of some isolated or repeated injury (*e.g.* the friction of an abdominal belt) if there be no other cause of neuritis. It may be mentioned incidentally that this meralgia has been described as a consequence—very indirect—even of flat foot.

Many painful conditions of the foot have received special names, *e.g.*, *talalgia*, *tarsalgia*, Morton's *metatarsalgia*, *pternalgia*, &c. The practitioner is apt to believe that a diagnosis has thus been made, and that there is no further need to search for the cause of the pain. This cause may, however, reside in the most varied conditions of disease. Flat foot is the most frequent of these, but they include the sequelæ of

injury, localized inflammatory changes in the bursæ, tendon sheaths, joints, ligaments, fasciæ, and also gout, neuritis (alcohol), and tabes, apart from various neurasthenic pains and the result of badly-fitting boots.

Finally, it must not be forgotten that women often complain of severe pains and paræsthesia in the legs at the menopause. The correct diagnosis is frequently suggested by the fact that similar sensations, although of a less severe character, are experienced in the arms.

CHAPTER CII.

ULCERS OF THE LEG.

"ULCER of the leg" has become quite a standard type of lesion, so that the beginner is apt to imagine that there is only one variety of ulcer in this region. In addition to the ulcerative processes which occur around the orifices of fistulæ, and which may themselves be of a tubercular nature if the fistulæ are tubercular, there are three other forms of ulcer which affect the leg, *i.e*, (1) varicose ulcer, (2) syphilitic ulcer, and (3) cancer of the skin.

Varicose ulcers are usually already diagnosed by the patient. As they preponderate enormously over the other two forms, we are justified in accepting the patient's diagnosis in most cases—not however, before seeing the ulcer. Varicose ulcers vary so much according to the stage in which we see them that we cannot speak of any characteristic appearance. Sometimes we see a brownish-red, hard infiltration of the skin with a circumscribed, superficial, and remarkably painful erosion in its centre. The beginner looks upon this as too trifling to deserve the name of ulcer, until he learns by experience that this erosion, unless it is treated, may develop into an ulcer lasting for weeks and even for months. Sometimes this will occur, even if the erosion does receive treatment.

An ulcer of the leg may present itself as a deeply penetrating loss of substance from the skin, with a necrotic base, and with edges which are serpiginous, steeply shelving, or even undermined. This may be a simple ulcer of the leg without any other supplementary element. The offensive discharge and the inflamed area around merely indicate neglect, either due to social causes or to laziness. At other times we find a flat ulcer with a granulating base and smooth edges, on which new epithelium is developing. Obviously this must

be an ulcer on the point of healing, and the duty both of the patient and practitioner is to do nothing to interfere with the healing process, by unsuitable treatment or inappropriate conditions.

Are varicose veins really indispensable for the diagnosis of a varicose ulcer? As a rule they are present; but sometimes it is necessary to search for them, and for this purpose the patient must stand up for a little while. If the patient has been confined to bed for any length of time, it may be impossible to see even very pronounced varicose veins. The absence of any abnormally dilated veins, does not, however, justify us in assuming a syphilitic basis for the ulcer. It is more likely to have resulted from some indefinite injury, from an abrasion or contusion of the skin, which has developed into an ulcer owing to the unfavourable healing conditions of the leg, or through neglect. These ulcers heal rapidly if the patient lies in bed, and if the necessary cleanliness is adopted in the treatment of the wound. On the other hand, the presence of varicose veins is not in itself enough to justify the diagnosis of a varicose ulcer. Syphilitic patients may have varicose veins which probably encourage the development of gummatous processes.



FIG. 433.—Varicose ulcers of the leg.

The appearance of the ulcer, as already indicated, shows us the *stage* of the ulcer, but does not of itself tell us anything definitely of its *origin*. Many errors will be made if all ulcers which are somewhat polycircular in shape or have serpiginous edges are put down to syphilis, or if all undermined ulcers are regarded as cancerous. There can, of course, be no doubt about *syphilis*, if the polycircular shape is very pronounced, probably in several ulcers, if there also co-exist round, kidney-shaped or horse-shoe-shaped erosions of the skin, looking as if they had been punched out with a perforating apparatus, and if they have been preceded by well-defined, painless, cutaneous gummata, instead of a diffuse, hard and painful infiltration of the skin. The localization of these morbid changes is very striking in less typical cases. Simple ulcers of the leg are situated in its lower half, extending as far as the malleoli. They may affect any part of this region, the front, back, the external or internal surface, and may even

become ring-shaped. Ulcers situated higher up towards the knee, or lower down on the dorsum of the foot, may indeed be due to injury or to a ruptured varicose vein, but in the absence of such a cause, they are, so to say, always syphilitic. It occasionally happens that such a syphilide is found directly over the knee-joint, a position in which a varicose ulcer never occurs.

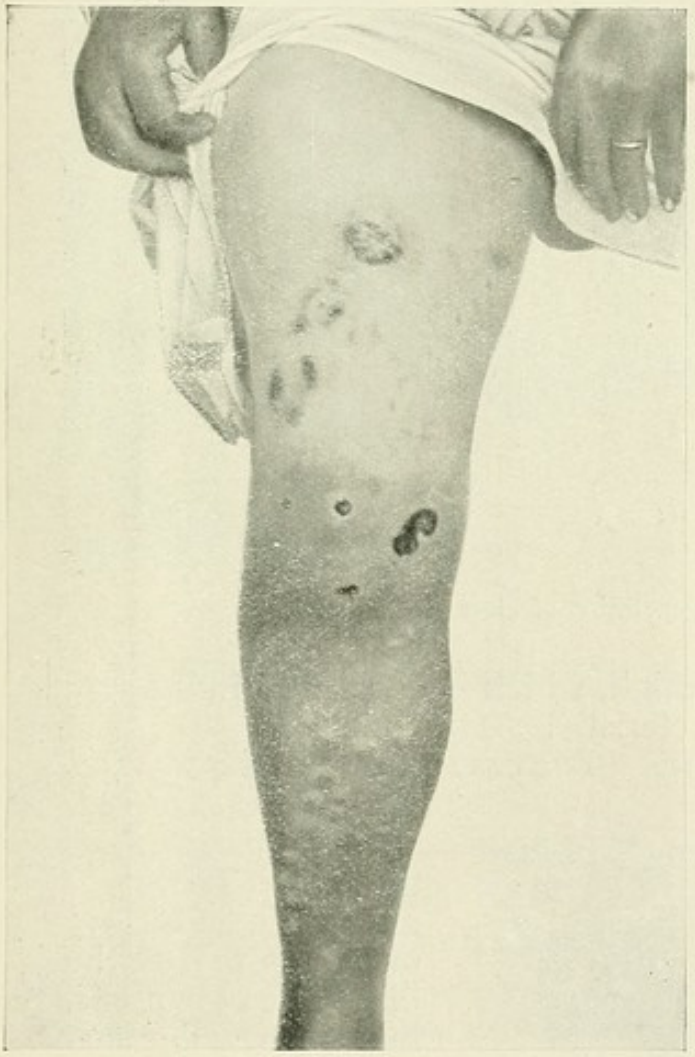

FIG. 434.—Tertiary syphilitic ulcers on the right leg, which is also affected by severe varicose veins.



FIG. 435.—Same case as fig. 434, one year later. Left leg. *a*, congested horse-shoe shaped ulcer; *b*, an old puckered scar; *c*, cicatrizing ulcer.

Fig. 434 illustrates the case of a vigorous peasant woman who came to the hospital for "an ulcer of the leg." The diagnosis seemed obvious, and there appeared to be no question of syphilis. She had numerous varicose veins, and had had thirteen confinements without any miscarriage. But the ulcers were on the upper half of the leg, partially in front of the knee, above which was an area of sharply defined red infiltration on the point of softening. There was a puckered scar on the front of the opposite patella, which the patient said was due to a similar ulcer, cured ten years previously by some domestic remedy. This of course settled the diagnosis, and iodide of

potassium produced the anticipated result. I learnt subsequently that this patient had been treated twenty years previously for recent syphilis, contracted from her first husband. A year later, this patient

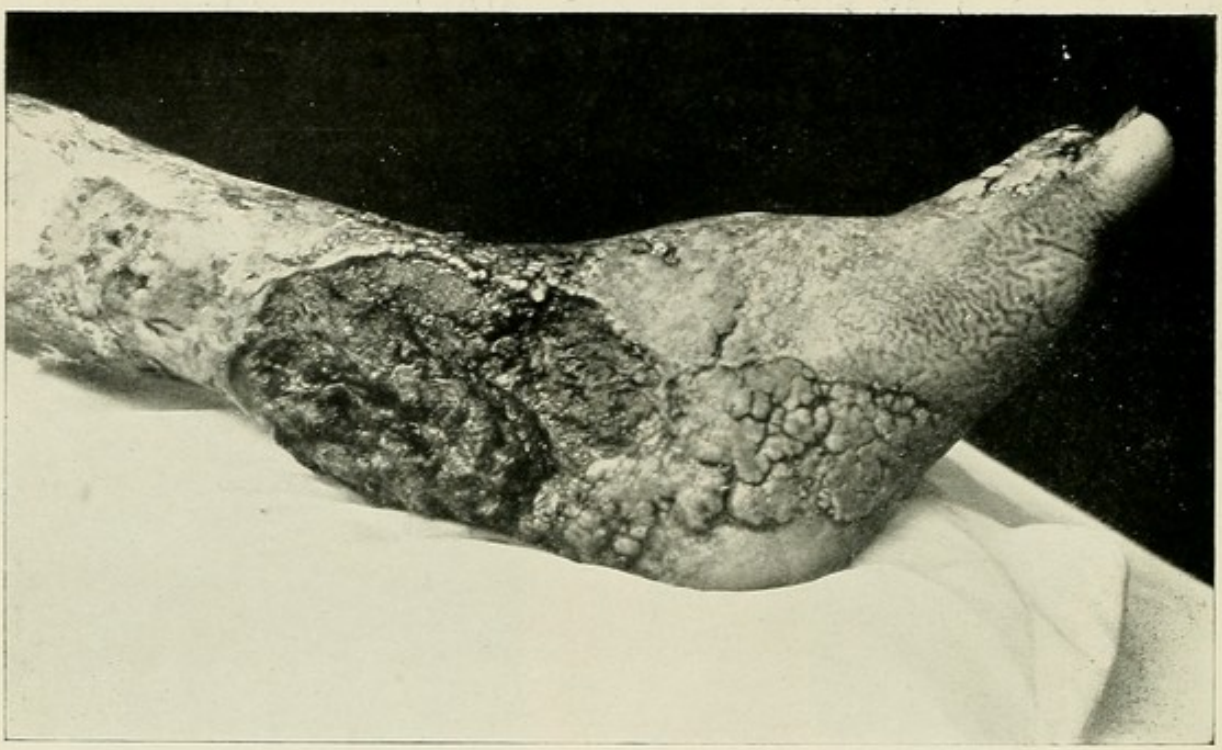

FIG. 436.—Cancerous degeneration of ulcer of the foot.

returned with an ulcer of the left thigh, which is illustrated in fig. 435 and seen to be perfectly characteristic. The puckered scar, just mentioned, is seen at *b* in the figure. The case illustrated in fig. 437, came as one of old-standing "caries" of the foot. There was nothing in the history on which to base the diagnosis of syphilis, but it was suggested partially by the situation and partially by the shape of the ulcer, and also by its yellow fatty-looking base. This diagnosis was confirmed by the result of treatment.

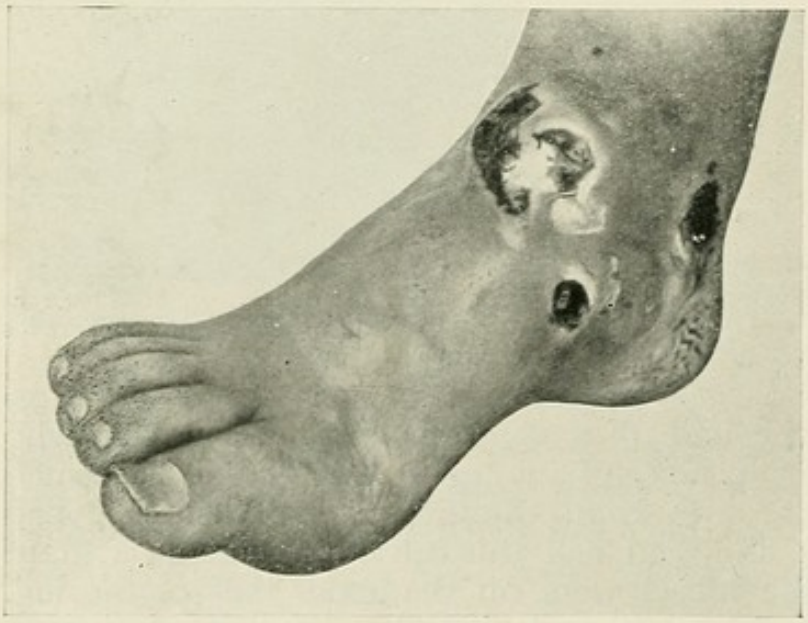

FIG. 437.—Tertiary syphilitic ulcer of the foot.

It has been stated above that undermined edges are not enough to arouse the suspicion of *cancer*. Indeed, an ulcer without undermined edges may be cancerous—although ordinarily this condition is an important sign.

If an old scar breaks down and ulcerates—old scars have a decided tendency to become cancerous—and not only refuses to heal but actually increases in extent, this indicates a tendency to cancer. If the ulcer does not become covered with healthy red granulations, this constitutes a more important sign, and we must entertain some doubt. If the base constantly remains granular in appearance and if the well-known little whitish plugs can be squeezed out of the more recent portions, a histological examination of a piece of the margin is demanded forthwith.

Sometimes the diagnosis of cancer is not made until the onset of enlarged glands in the popliteal space and groin. This occurred in the case of a young man, whom I saw while acting as an assistant. A very obstinate ulcer developed on an old scar due to a burn. The youth of the patient disarmed any suspicion of cancer at first. But the onset of enlarged glands led to a histological examination and a diagnosis of cancer was made.

CHAPTER CIII.

SWELLINGS AND TUMOURS OF THE LEG.

(1) SWELLINGS and tumours of the leg present similar conditions to those which we have considered in detail in connection with the thigh. But the proportion of *affections of the soft tissues* to tumours of the bone is less than obtains in the thigh—if we except ulceration and its associated changes. Otherwise they have no peculiarities specific to the leg. Perhaps the commonest of the tumours of the soft tissues are the small growths no larger than peas (tubercula dolorosa), or the larger *fibromata* or *neuro-fibromata*, which cause local and radiating pains (fig. 441).

Sometimes large bunches of varicose veins look just like tumours. There can, however, be no difficulty in diagnosis if the serpentine course of the veins is visible, and if their lumen is clear, so that slight pressure or a change of posture suffices to empty them. Diagnostic interest centres around the questions whether the veins belong to the large or small saphenous group and whether the valves in the former have become incompetent. Trendelenburg's sign is useful in this connection.

The patient lies down, to empty the veins of the limb. The root of the large saphenous vein is then compressed with the finger and the patient is instructed to stand up. If the veins remain empty but fill

up as soon as the pressure is relaxed, it is obvious that the large saphenous vein is affected (*cf.* figs. 438*a* and *b*).

Even if the veins are thrombosed, the diagnosis is easy, as long as separate serpentine cords are recognizable. The beginner may be uncertain when confronted by an isolated thrombosed convolution of veins, looking like a tumour, but even then the history will give a clue, and the patient will probably have made the diagnosis already.

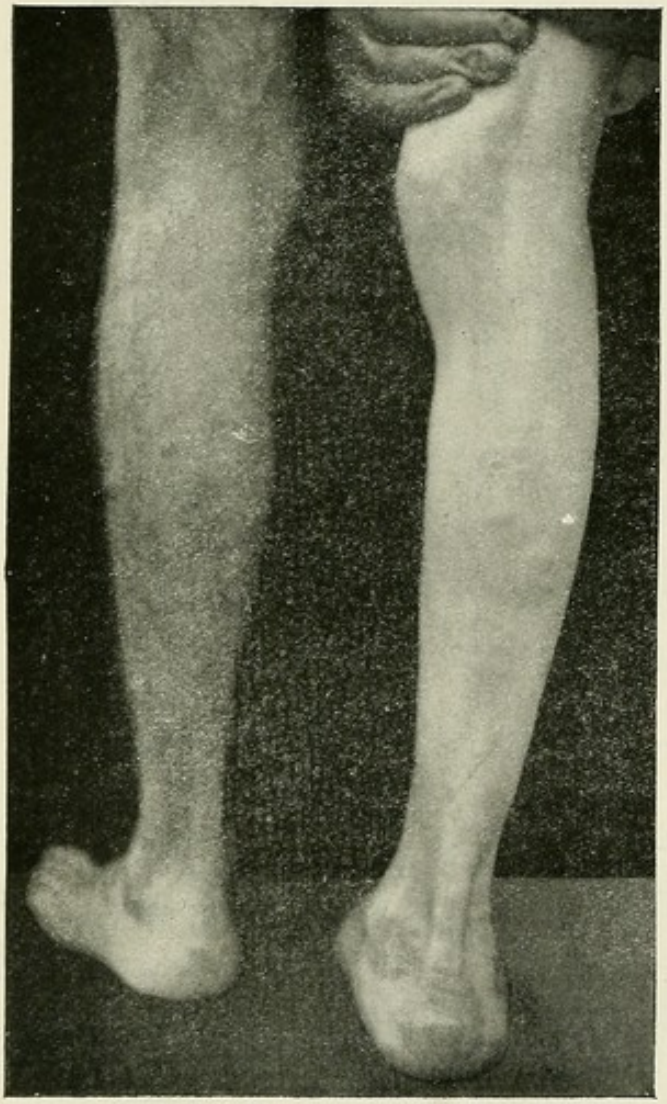

FIG. 438*a*.—Varicose veins, after the limb has been emptied of blood and the root of the large saphenous vein is being compressed.

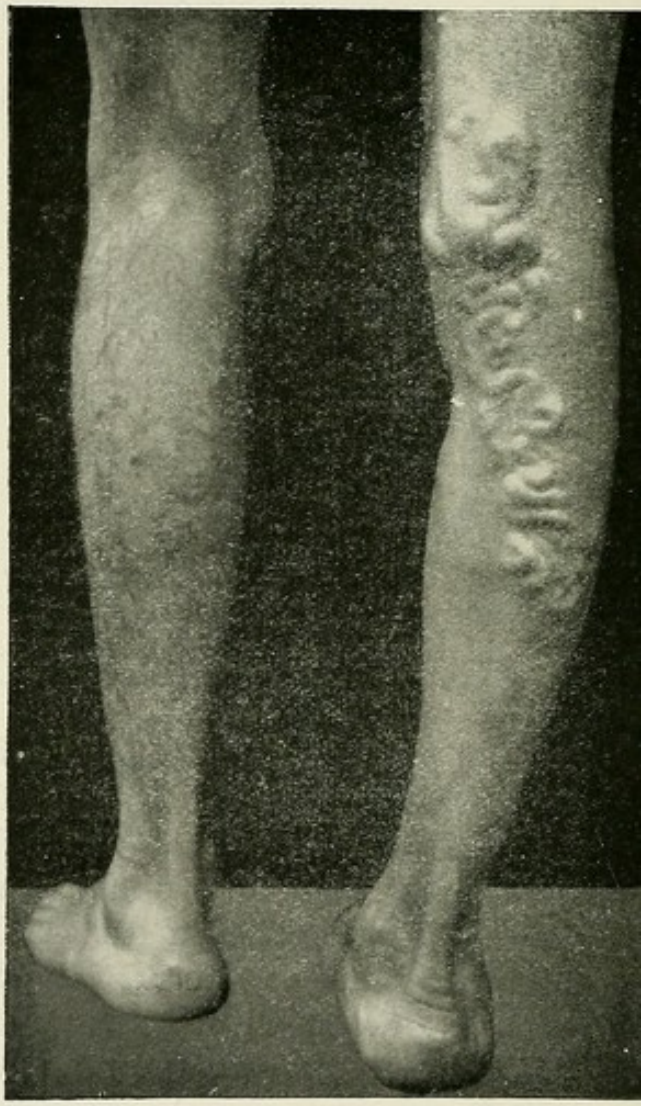

FIG. 438*b*.—Same case, after relaxation of pressur from the vein (Trendelenburg's sign).

(2) *Changes in the bone* are for anatomical reasons more accessible to examination than in the case of the thigh, and their diagnosis is therefore easier. We distinguish between tumours and inflammatory swellings.

A.—TUMOURS.

Having considered the diagnosis of tumours in connection with the arm and thigh, it will be unnecessary to do more than briefly refer to a few forms which possess diagnostic interest. The most important

of these is, **medullary sarcoma of the upper end of the tibia,** which may easily be mistaken for a somewhat chronic osteomyelitis, more especially as it may, like all sarcomas, raise the temperature and may sometimes be very painful on pressure.

A girl, aged 20, had been limping for some weeks, and complained of severe pains below the knee. The inner side of the head of the tibia was slightly swollen and very tender, but the skiagram revealed nothing characteristic. We thought of subacute osteomyelitis, particularly as the temperature rose in the evening to 101·5°. At the

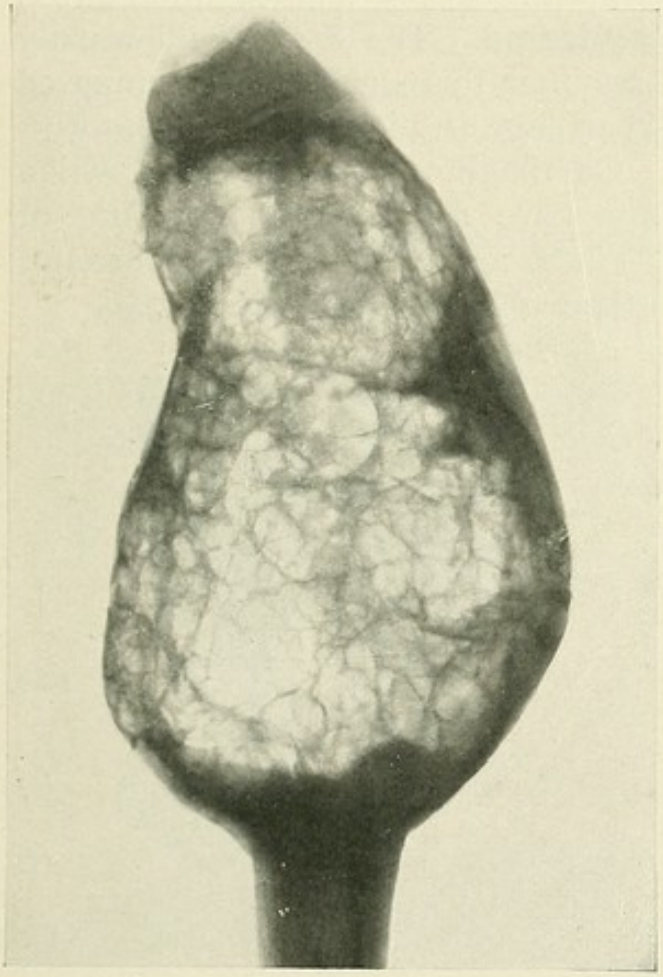

FIG. 439.—So-called aneurism of the fibula. Skiagram of the specimen obtained by operation. (Cystic disease of bone.)

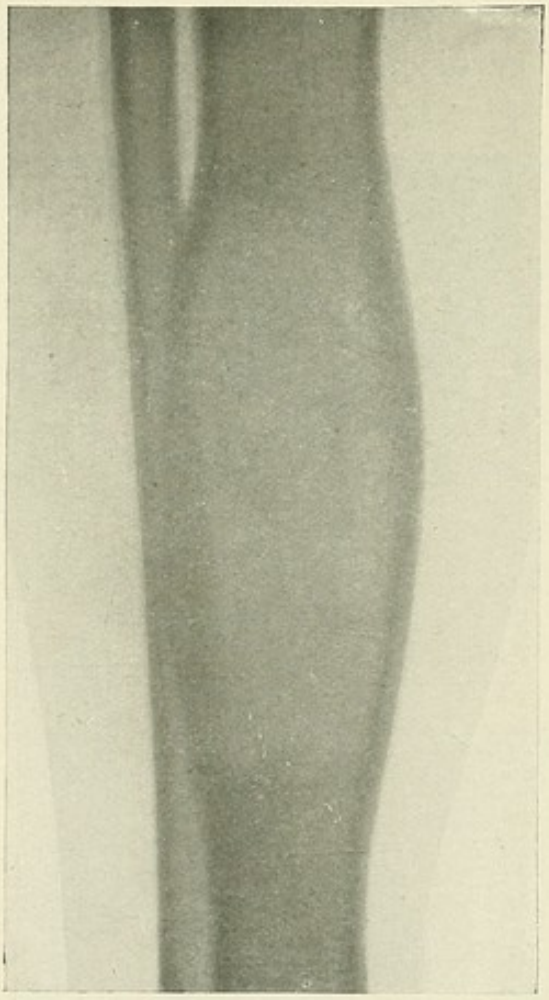

FIG. 440.—Fibro-sarcoma of tibia originating in the medulla.

operation, the bone was found to be surrounded and partially penetrated by a soft granulation-like tissue, such as is sometimes seen in chronic osteomyelitis; but there was neither pus nor sequestrum. The cultures which were prepared remained sterile, and microscopic examination of sections of the tissue showed the presence of sarcoma. This case occurred in the early days of skiagraphy. We should now conclude from the absence of any bony thickening or of an osteosclerotic zone around the diseased area, that the case was not one of chronic osteomyelitis or of tubercle, but rather one of new growth (*cf.* figs. 439 and 440 with figs. 446 and 447).

Cystic disease of bone (aneurism of bone) is indicated by distension of the fibula or tibia to the shape of a beetroot, by the sensation of parchment crackling over the bone, and probably by hearing murmurs over it with a stethoscope (fig. 439). This condition is possibly allied to sarcomata. A medullary growth may in its early stages resemble an abscess of bone, both clinically and in a skiagram (*cf.* fig. 440 with fig. 447). If the spindle-shaped distension reaches a certain size, there can be no question of abscess, and the diagnosis of **sarcoma** becomes clear.

A hard finely lobulated tumour, with sharply defined boundaries, projecting from the bone, is a **chondroma**. The X-rays will usually show that this structure is composed of cartilage and islands of bone.

Cartilaginous exostoses, which only have an external covering of cartilage, are not of rare occurrence in the leg (see Chapter XCVI).

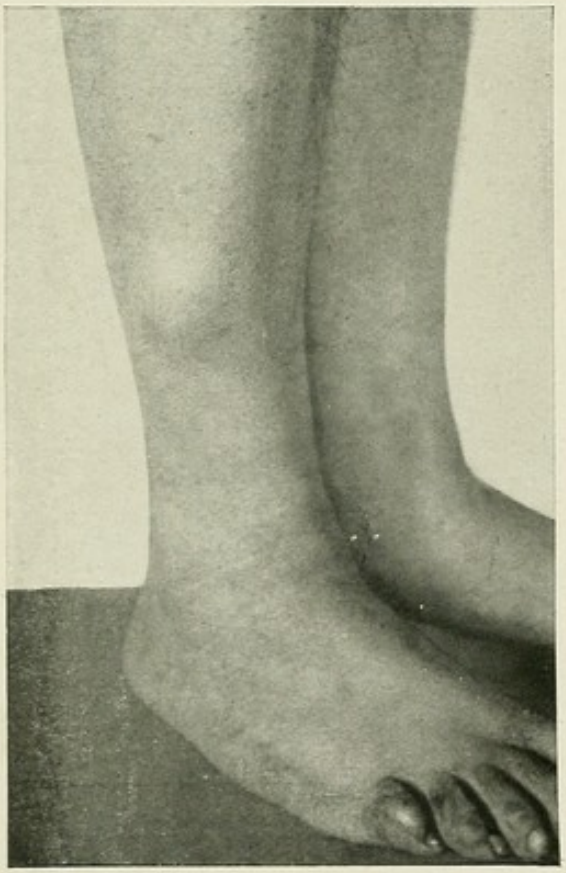

FIG. 441.—Neurofibroma of the superficial peroneal nerve.



FIG. 442.—Chondroma of the tibia.

B.—INFLAMMATORY PROCESSES.

Acute osteomyelitis only requires brief notice because its diagnosis presents no difficulty, as the position of the tibia is so superficial. It could only be missed in those rare cases wherein the patient is intensely septic and semi-conscious, so that he does not complain of the tibia, and a fatal result occurs before the pus has reached the surface. More interest attaches to the diagnosis of the *stage* of the disease, and of the anatomical changes which the operation may show.

Fig. 443, which represents acute osteomyelitis of the long hollow bones, renders it unnecessary to enter into any detailed discussion of these points.

The principal exceptions to the usual course illustrated in this scheme depend upon the size and the number of the sequestra. They may be flat or circular, single or multiple. The medulla of the epiphysis may or may not be involved. If one has a clear conception of the pathological processes which may occur, there is no difficulty in correctly diagnosing the cases which run an irregular course.

The diagnosis of **chronic inflammation of the bone** requires more detailed consideration, because it is frequently missed, or is the source of great difficulty. It is important to distinguish between the diffuse and circumscribed varieties of this inflammation.

(1) DIFFUSE INFLAMMATORY PROCESSES.

Diffuse swellings should suggest a mild form of **osteomyelitis**, which is usually due to **syphilis**, thus contrasting with what we have seen in regard to the femur. If the disease is *acquired*, the diagnosis of gumma is established by the presence of isolated, circumscribed, and scattered inflammatory areas on the anterior surface of the tibia quite apart from the history. In chronic osteomyelitis, the thickening of the bone is usually more diffuse, which is again a contrast to gumma (fig. 444). Localized abscesses, which heal up after the extrusion of a small sequestrum, often occur in this condition. The problem is, however, quite different in the case of children. *Hereditary syphilis* of the tibia is not usually of a gummatous nature, but is recognized by diffuse infiltration of the periosteum, and in its subsequent course by diffuse thickening of the bone (fig. 445). If, therefore, palpation and X-rays demonstrate a circumscribed localization (fig. 446), it is an argument against syphilis and in favour of osteomyelitis. Syphilis often proceeds just like osteomyelitis, by means of exacerbations, but it is differentiated from the latter by the absence of elevations in temperature and by its symmetry. Obviously the history is conclusive. It may be mentioned incidentally that the tibia and the bones of the forearm are the favourite sites for these lesions of congenital syphilis.

A girl, aged 7, suffered from periodical attacks of painful swelling of both tibiæ. A diffuse tender thickening of the bone could be demonstrated (see fig. 445). There was no pyrexia. The previous treatment had been directed against tubercular disease. The only indication of a syphilitic heredity was the mother's statement that the father occasionally suffered from an ulcerative skin lesion. Antisyphilitic treatment caused the symptoms to disappear in a very short time.

Bright red = normal bone marrow. Red = inflammatory exudation. Green = pus formation.



(*a*)

Inflammatory infiltration of the bone marrow. M = Early suppuration therein. Inflammation of the periosteum.

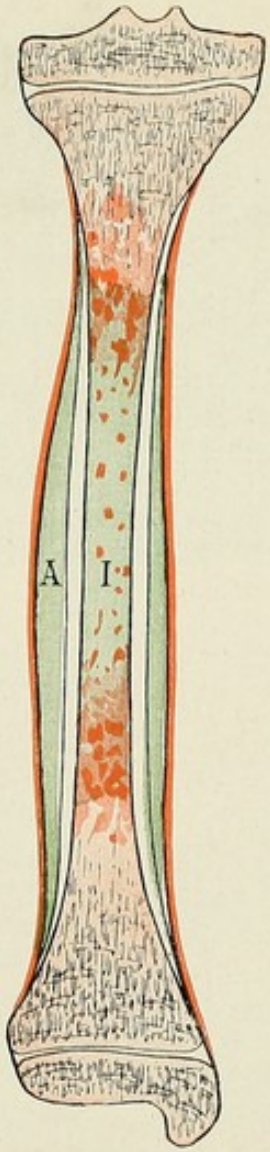

(*b*)

Suppuration within (I) and without (A) the bone. Periosteum stripped up by the pus.

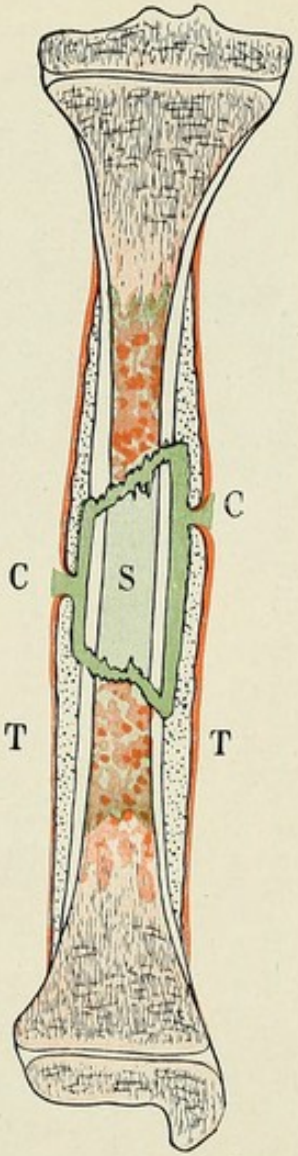

(*c*)

Formation of ring sequestrum (S). Periosteal new bone formation. T = sheath of new bone formed in necrosis, with C cloacæ. Granulation formation in medulla of diaphysis.

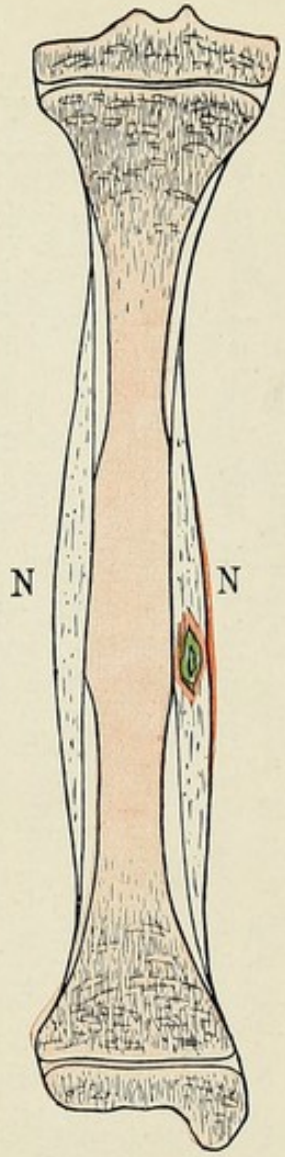

(*d*)

Sequestrum replaced by newly formed bone (N) of compact character. Regeneration of the bone marrow. Secondary formation of a small cortical sequestrum in the newly formed bone.

FIG. 443.—Course of acute osteomyelitis of tibia.

(2) CIRCUMSCRIBED SWELLINGS.

The distinction between diffuse and circumscribed swellings is obviously somewhat arbitrary. We include among the latter only those wherein the swelling and tenderness do not extend beyond one half of tibia, but which definitely originate within a much smaller compass. The principal diseases which enter into consideration are (1) the isolated **gumma**, (2) the circumscribed chronic forms of **osteomyelitis** (usually staphylomycosis) and (3) **tubercle**, this again in contrast with the femur.

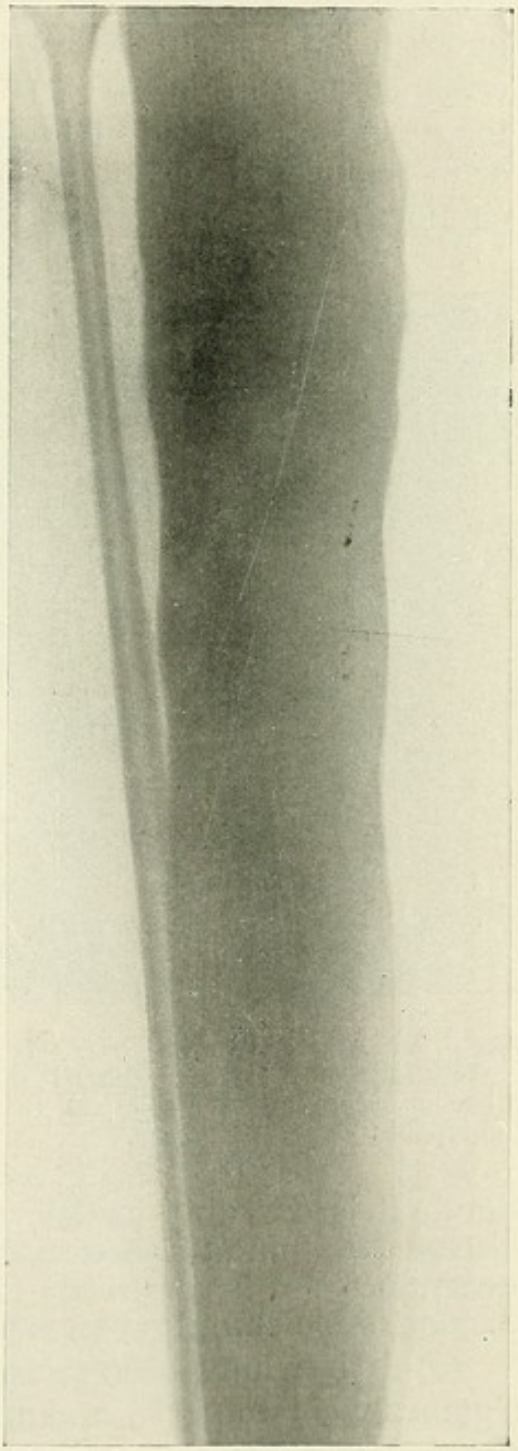

FIG. 444.—Old diffuse osteomyelitis of the tibia.

We have already dealt with syphilis. In regard to the other two diseases, the most prominent objective signs are the swelling and new bone formation in the neighbourhood of the periosteum, so that the inexperienced observer is liable to be content with the diagnosis of *periostitis*. But the more carefully these cases are examined and the more often the assistance of a skiagram is invoked, the more frequently will we find that this periostitis is due to changes in the bone marrow, either of the nature of an abscess or of an area of granulation, with or without sequestrum formation.

Is it, however, possible to tell, by inspection whether the disease is tuberculosis or osteomyelitis? It must be confessed that clinical examination often leaves us completely in the lurch. We will consider separately the diseases of the diaphysis and the epiphysis :—

(*a*) It was previously assumed that disease in the *diaphysis* could only be tubercular if it occurred in children; disease in the diaphysis in adults was always considered to be osteomyelitis. But as bacteriological examination became more frequent, it

was seen that tubercular disease occurs in the medulla of the diaphysis of the tibia. To a considerable extent, we must depend upon the history for the distinction. An acute feverish onset with exacerbations of the same character denote osteomyelitis, but these symptoms are not always present. A gradual onset and a gradual increase of symptoms denote tubercle, but this may also take a sudden turn for the worse. The diagnosis is easier if the disease follows an acute infection such as typhoid fever, scarlet fever, &c. We shall probably be correct in attributing the cause to the organism of the primary disease (*e.g.*, typhoid bacillus), or to secondary infection by one of the ordinary pus organisms. The circumscribed osteomyelitis illustrated in fig. 446 followed a case of whooping-cough.

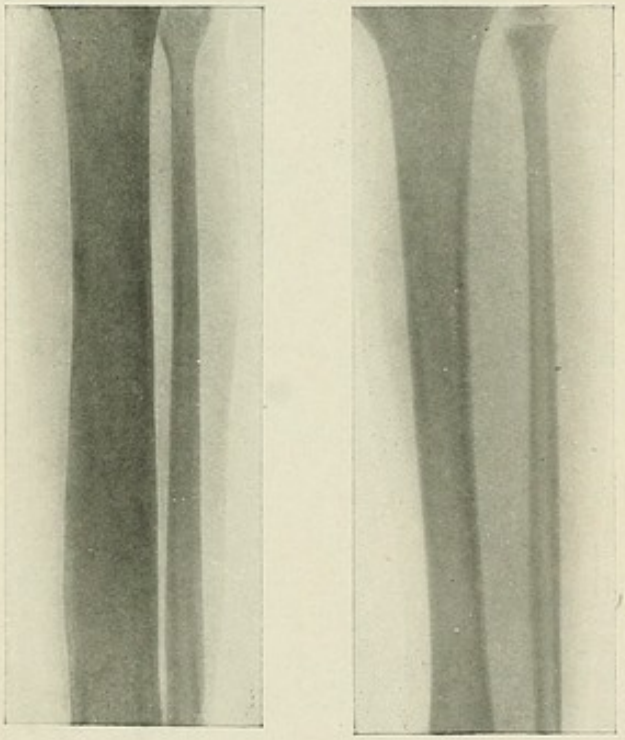

(*a*) Periostitis of the tibia due to congenital syphilis.

FIG. 445.

(*b*) Normal tibia in child of the same age.

If no conclusion can be arrived at, either from the history or from the rest of the physical condition—other tubercular or other osteomyelitic foci—we must be content with the anatomical diagnosis, an abscess of the bone.

If the abscess is situated immediately under the skin, cultures should be made from the pus obtained from an exploratory puncture, and within two days it can be ascertained whether organisms of acute suppuration are present or not. If they are not present the case is probably tubercular. If pus cannot be obtained without operation, the bacteriological examination may be supplemented by animal inoculation, if necessary even after the operation. It is our duty to the patient not only to open the abscess, but also to determine the nature of the disease, especially if tubercle is in question. We have already seen that tumours of the medullary cavity may resemble chronic abscess of bone, both clinically and in a skiagram.

(*b*) It has long been recognized that disease in the *epiphysis* is very significant of tubercle, and there is always the risk of regarding as tubercle what is really osteomyelitis of the epiphysis, in contrast to what we have already said in regard to the diaphysis. If the history and the rest of the physical condition are not conclusive, we may be guided by the extent of the periosteal thickening in the direction of the adjoining diaphysis. If the periosteal thickening is very circumscribed, it suggests tubercle ; if it is extensive it suggests osteomyelitis.

Finally, the existence of a *sarcomatous new growth* is greater in this situation than in the diaphysis.

We have, so far, been assuming that the practitioner has made the diagnosis of some bone disease. But this is not always so. These cases are often treated as rheumatism, and salicylates or ointments are given. Patients may thus wander for years from one doctor to another, and from one quack to another, until someone takes the trouble to carefully compare one tibia with the other, in regard to palpation and tenderness. If such an examination reveals any thickening, however slight, associated with

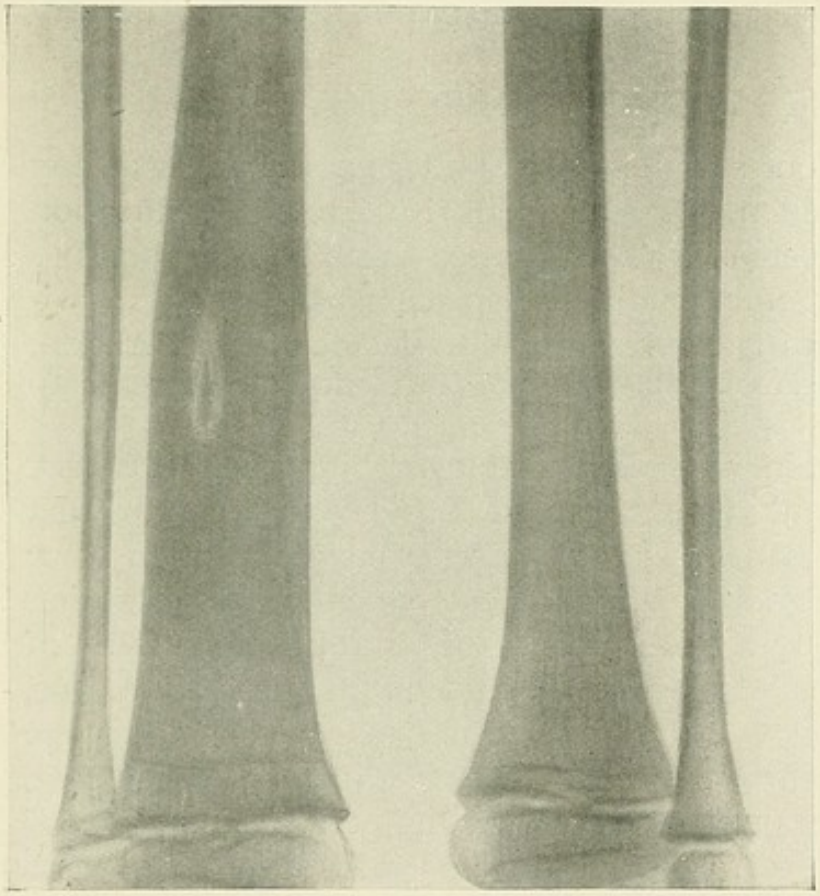

FIG. 446.—Localized subacute ostitis after whooping-cough. A small sequestrum is seen in an abscess surrounded by a sclerosed area.

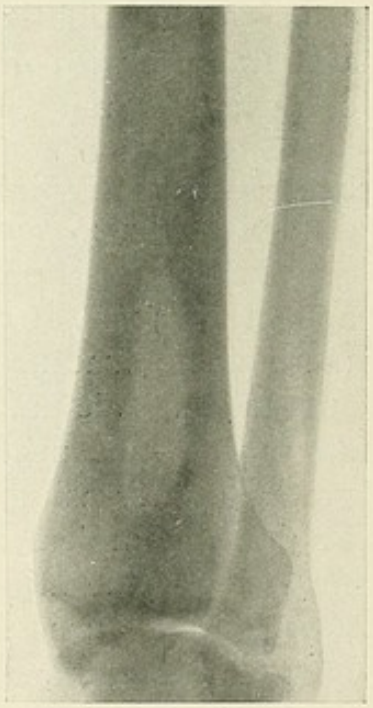

FIG. 447.—Chronic abscess of bone in the lower end of the tibia.

tenderness which has its maximum at this area, and which is the seat of periodical throbbing pains, severe enough to disturb the patient's sleep for weeks at a time, we are justified in diagnosing an abscess of bone, and we should resort to the aid of the X-rays. In the absence of a skiagram, the only condition which may lead to an error of diagnosis is the pain caused by syphilitic disease of bone.

CHAPTER CIV.

INJURIES ABOUT THE ANKLE-JOINT.

In examining an ankle after an injury, the most important practical consideration is to ascertain whether there is any deformity or not. Indeed we shall adopt the absence or presence of deformity as a basis of classification, although at first sight it may not appear to be very scientific.

(1) INJURIES WITHOUT DEFORMITY.

If the shape of the foot remains normal after an injury, or at any rate is only slightly swollen, we may forthwith exclude dislocation and fracture with displacement. This at once limits the diagnosis to contusions, sprains, or fractures without displacement.

The diagnosis of **contusion** requires no detailed consideration, because it is easily inferred from the nature of the injury and presents no difficulty whatsoever.

The diagnosis of **sprain** is made by exclusion, just as in the wrist and elbow; *i.e.*, it can only be entertained if it is quite certain that there is no **fracture** present. The *history* is, however, often very suggestive. We may diagnose a sprain, if the patient, after sustaining an injury—not necessarily a severe one—to his ankle, complains of gradually increasing pain and tension, which do not entirely disappear, even on complete rest. On the other hand, a severe pain at the moment of the injury, which subsides when the limb is kept at rest, and which returns when any movement is attempted, would *a priori* suggest a fracture.

The explanation is quite simple. Pain which is not severe at the moment of the injury, but which gradually increases and does not disappear in spite of rest, indicates an effusion of blood within the joint—a circumstance which occurs in a sprain. A fracture may also lead to intra-articular effusion, but as the fracture opens up a path for the blood in the surrounding tissue, the effusion is under less tension. The general experience of fracture is, that the pain disappears when perfect rest is maintained once the fracture has occurred, and that it only returns as a result of movement. But it must not be assumed that all sprains present the same clinical features, for in some, laceration of the extra-capsular structures is the predominant lesion, and the pain therefore occurs mainly on movement, just as in fractures.

Loss of power of movement is by no means decisive. The beginner is apt to diagnose a sprain if the patient is able to walk, and to diagnose a fracture if he is not able to do so. But, as a matter of fact, the position may be quite reversed. We often see that a patient who has a subperiosteal fracture of the malleolus—especially the fibula—is

able to walk, whereas a patient with a severe articular effusion will anxiously avoid the least step, even if the bone is not injured.

The *localization of the pain on pressure* is of great importance for diagnosis. But before proceeding to palpation, we should test the *pain produced by axial pressure.* If this pain is pronounced, it indicates fracture of the tibia above the malleoli, or fracture of the tarsus. There is usually no pain on axial pressure in simple malleolar fractures without displacement. We now palpate the joint. A diffuse tender swelling over the entire anterior surface indicates an effusion of blood under tension—most probably a sprain. We next examine the ends of the bones of the leg. If the tibia presents a narrowly circumscribed

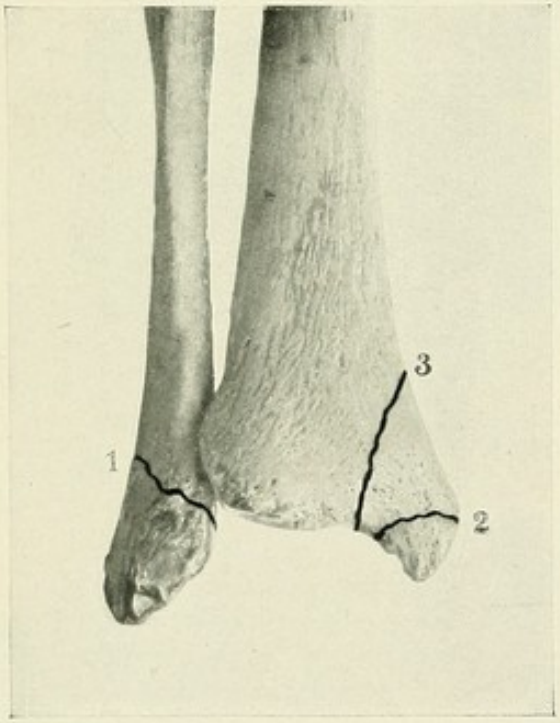

FIG. 448*a*.—Fractures of malleoli through adduction. Fracture lines 2 or 3 may occur alone; fracture line 1 occurs in combination with 2 or 3.

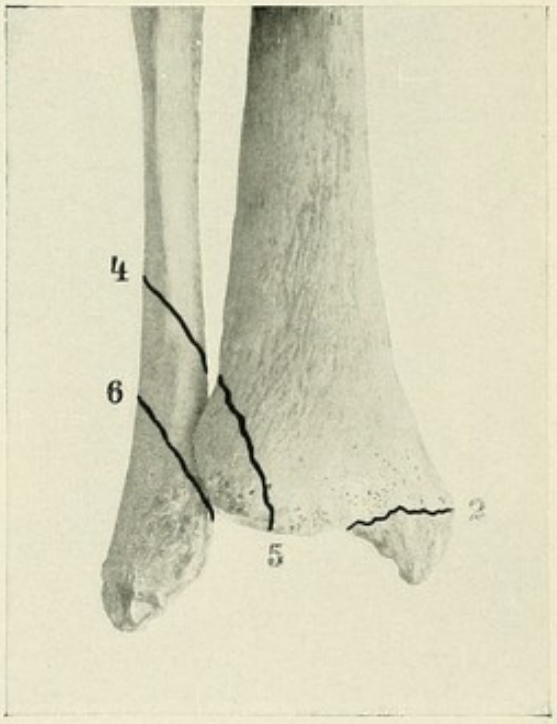

FIG. 448*b*.—Fractures of malleoli through abduction. Fracture lines 2, 4 or 6 may occur alone. Fracture line 2 may occur in combination with 4 or 6; or 2 may occur with 4 and 5.

area of tenderness above the joint line, traversing the entire thickness of the bone, it is quite certain that a supra-malleolar fracture exists, or, in a young person, a separation of the epiphysis (fig. 451). The same condition will usually be found in the fibula, either higher up or lower down. If the continuity of the tibia is unbroken, we should palpate the internal malleolus. Circumscribed tenderness of its extremity indicates that the internal lateral ligament is torn off or lacerated, thus constituting a sprain. If the tenderness runs transversely over the malleolus (fig. 452), or obliquely or even directly upwards (fig. 450), we must assume that a fracture exists, although it may be impossible to feel any fissure, sharp edges or false mobility. We examine the

external malleolus in a similar manner. Tenderness at its extremity indicates laceration of a ligament; tenderness higher up points to a fracture. False mobility can be obtained much more frequently than on the inner side, but cannot always be elicited.

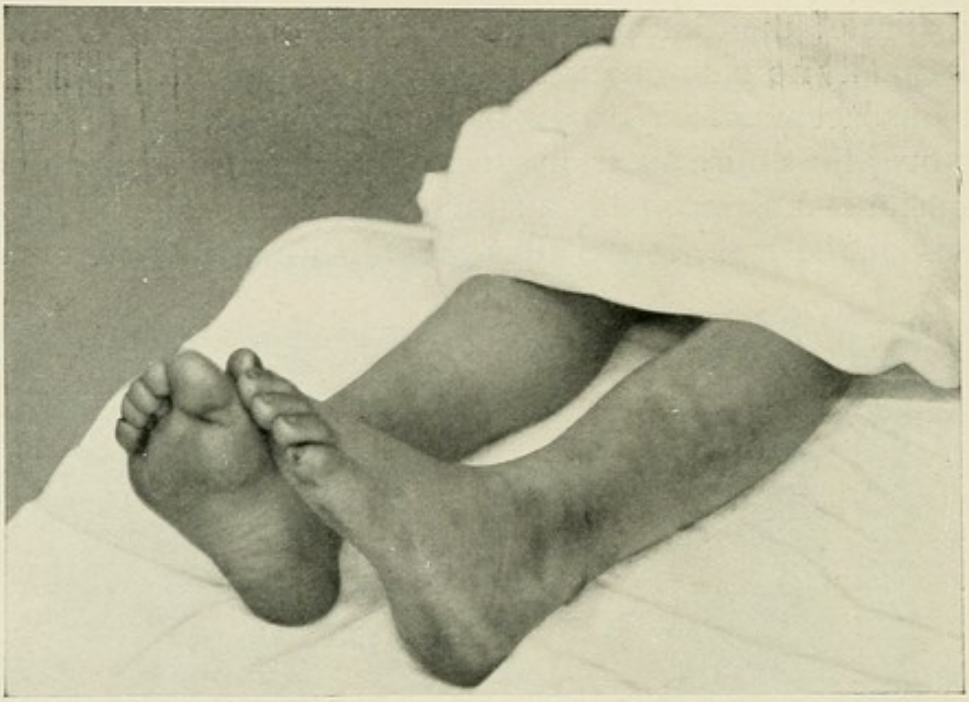

FIG. 449.—Adduction fracture of left internal malleolus. (See fig. 450 for skiagram.)

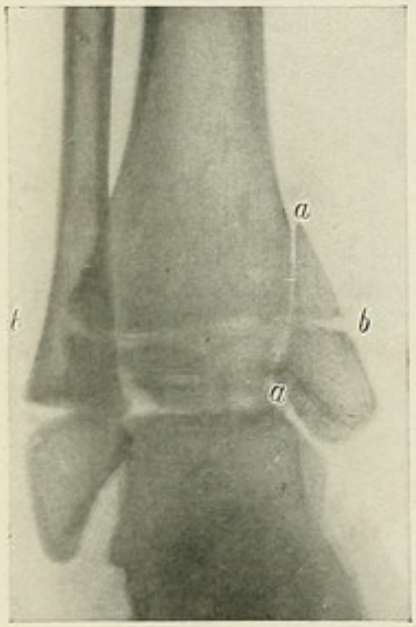

FIG. 450.—Adduction fracture of internal malleolus (see fig. 449). *a*—*a*, line of fracture. *b*—*b*, line of epiphysis.

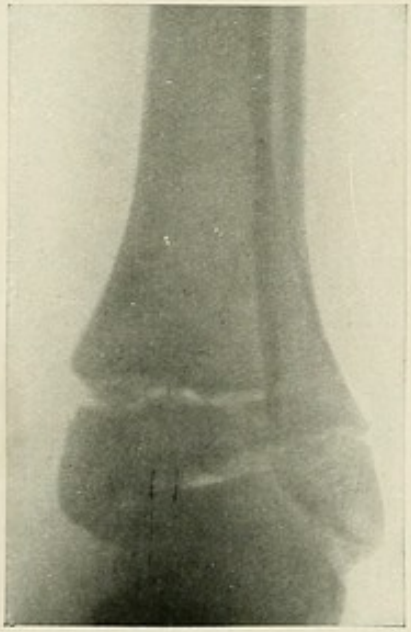

FIG. 451.—Slight cracking of fibula in classical position, with separation of the epiphysis of tibia (reduced).

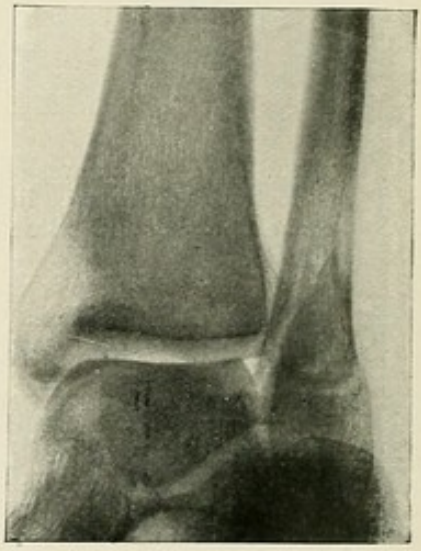

FIG. 452.—Fracture of external malleolus, situated low down.

The easiest method of detecting this mobility is to place one finger on the tip of the malleolus and another on the most tender spot, and then to impart a see-saw movement to the lower end of the fibula.

Indirect pain on pressure is another though less constant sign, which points to fracture of the fibula. This sign is obtained by pressing the fibula against the tibia in the middle of the leg. If the patient then feels a circumscribed pain lower down, there can be no doubt about the presence of a fracture, or at any rate of a fissure.

If we are not in a position to confirm our diagnosis by means of a skiagram, confirmation will be derived from the angular shaped ecchymoses which form below and behind the broken malleolus, in the course of two to three days. Similar ecchymoses may, however, also appear after severe sprains.

It is of some interest, from the points of view of treatment, to recognize the *mode of origin of the fracture* and the *position and*

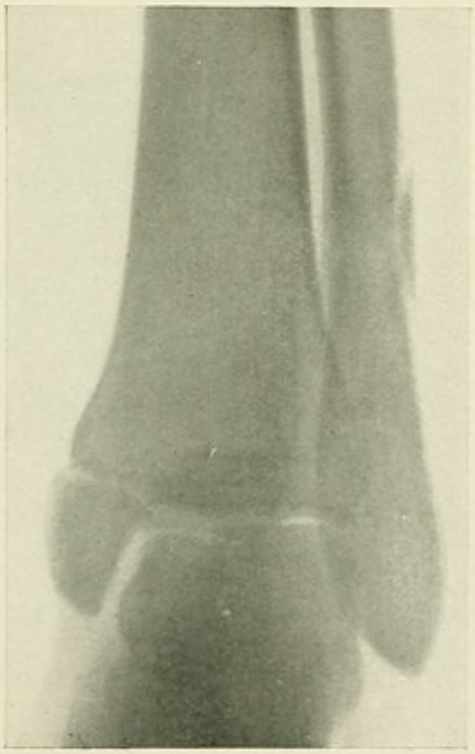

FIG. 453.—Abduction fracture with cracking of fibula, in classical position.

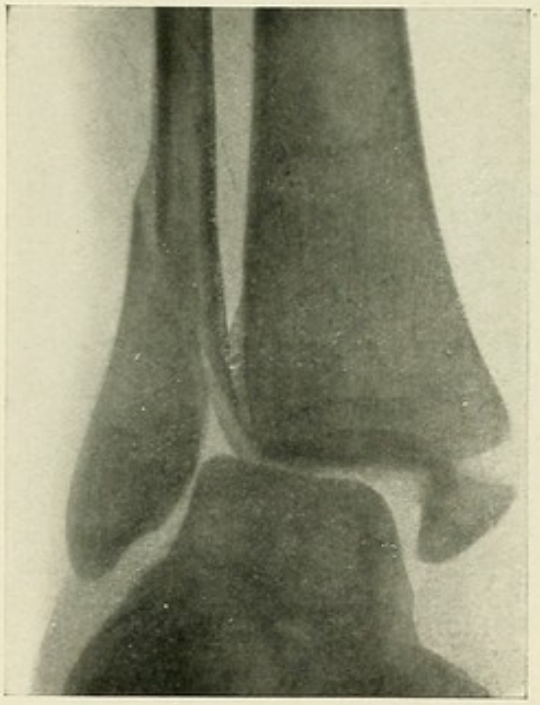

FIG. 454.—Torsion fracture (spiral fracture of fibula, with detachment of internal malleolus).

direction of the line of fracture. Fractures of the malleolus are divided into those produced by violent adduction, by abduction and by eversion of the foot.

In an *adduction fracture* the internal malleolus is always broken off, either in the same plane as the joint line, or in an oblique or vertically ascending direction. A fracture of the external malleolus is often associated with it at about the same level as the joint cleft (figs. 449, and 450). The fracture in the former instance is produced by bending, and in the latter by tearing.

In an *abduction fracture* the internal malleolus is torn off near its base; skiagrams show that the fibula is broken at what is considered

to be its weakest spot, *i.e.*, about 5 or 6 cm. above the tip of the malleolus. It is, however, frequently cracked much lower down. There is often, in addition, a detachment or a fracture of a wedge-shaped fragment of the outer margin of the tibia (fig. 448 and 456). In *fracture produced by torsion* the signs are similar to an abduction fracture, *i.e.*, supramalleolar fracture of the fibula, sometimes a wedge-shaped detachment of the external margin of the tibia and generally a detachment of the internal malleolus. The fracture of the fibula does not, however, present the appearance of a fracture produced by cracking, but it is of a spiral shape (fig. 454).

It is not safe to base the diagnosis exclusively on the position of the foot. The position of adduction (fig. 455) is fairly conclusive of an adduction fracture, but abduction may be the secondary result of

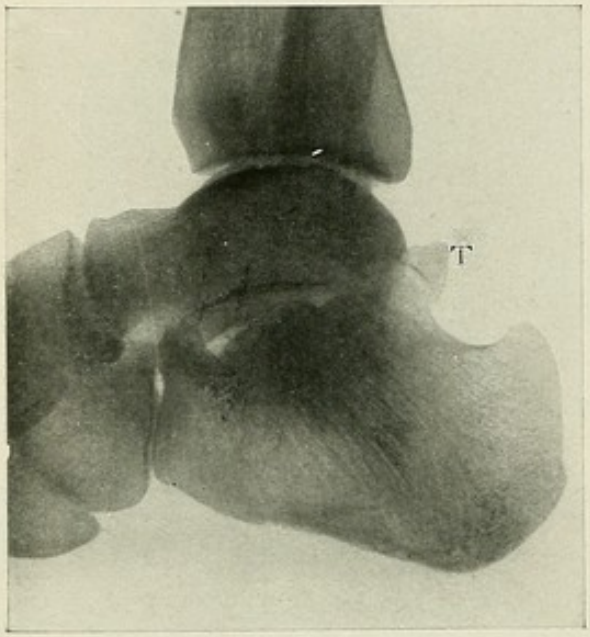

FIG. 455.—Os trigonum (T).

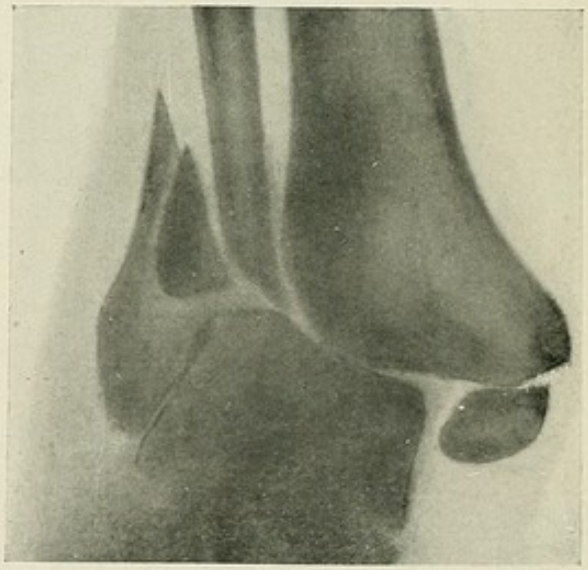

FIG. 456.—Bi-malleolar abduction fracture, with detached fragment from the outer side of the tibia, and with subluxation of the foot backwards and outwards.

attempts at walking, even if the original injury has been an adduction fracture.

Over excessive *dorsal or plantar flexion* are rare causes of fracture; the former leads to the detachment of a piece of the anterior surface of the tibia (Lauenstein); the latter leads to a detachment from the posterior edge of the tibia, or its posterior surface. This latter fracture was termed by French surgeons, long before the Röntgen period, "fracture marginale postérieure du tibia," and it has lately been described, with the aid of skiagrams, by Meissner of Von Brun's clinic. The fragments in both cases are usually triangular in form. The diagnosis is based upon the etiology, the results of palpation and the skiagram (figs. 458 and 460). Corresponding fractures may also be produced by the laceration involved through reversed movements. Leuenberger has proved from the

material in our clinic, that the detachment of a fragment from the posterior surface of the tibia is an injury which occurs at about the same age-period as the separation of the epiphyses, the epiphyseal line still partially persisting, *i.e.*, from the thirteenth to the fifteenth year (fig. 457).

If no lesion can be found in connection with the malleolus, but the patient nevertheless complains of sharp pain as soon as he puts his weight on the foot, so that walking is impossible, we must palpate the tarsal bones, especially the astragalus, as far as this is accessible. An effusion of blood on the anterior surface of the ankle, and great tenderness over the head of the astragalus with severe pain

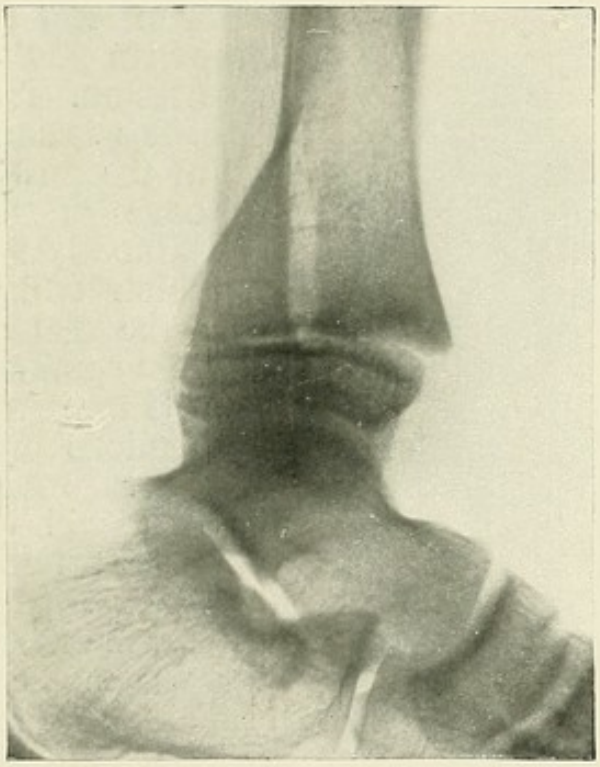

FIG. 457.—Separation of the epiphysis, with detached bone from the posterior surface in a lad aged 15.

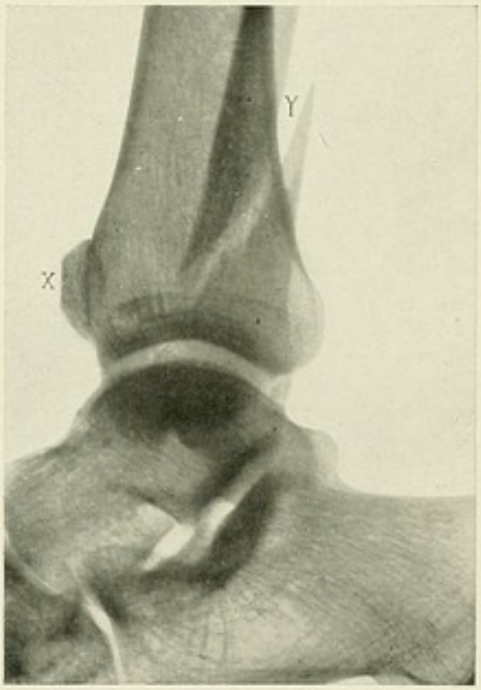

FIG. 458.—X, detachment of bone from anterior margin of tibia. Y-fracture of fibula.

on dorsi-flexion, render it very probable that a **fracture of the astragalus** has occurred.

A positive diagnosis cannot be made without a skiagram. In interpreting it, however, it should be remembered that a small Wormian bone (os trigonum) is occasionally seen at the posterior end of the astragalus (fig. 455). This structure in the early days of X-ray diagnosis was erroneously diagnosed as a fracture (Shepherd's fracture). I once had a case wherein this os trigonum led to a protracted action for damages.

Fractures of the *os calcis* are much more frequent. The symptoms are such as to differentiate this injury clearly from fracture of the malleolus or from a sprain. A special section will be devoted to this subject.

We should not be content with the diagnosis of **sprain** until a careful examination of the bones has yielded a negative result. Many a case of traumatic flat foot and years of persistent pain have been the result of an inaccurate diagnosis and an untimely permission to walk.

Laceration of the anterior tibio-fibular ligament may be mentioned as a special form of sprain. It is recognized by localized pain and probably by an effusion of blood above the ankle-joint, between the tibia and fibula.

Another injury is worthy of attention, despite its rarity. The patient himself probably hears a distinct crack at the moment of the accident and makes his own diagnosis of fracture. But neither palpation nor a skiagram reveal such a lesion. The tenderness is situated at the posterior edge of the external condyle—a position which is not the seat of pain in a sprained foot. If the peroneal tendons are, however, made tense, it will be seen that they move forwards, one after the other, over the malleolus, if indeed they are not already found there at the beginning of the examination.

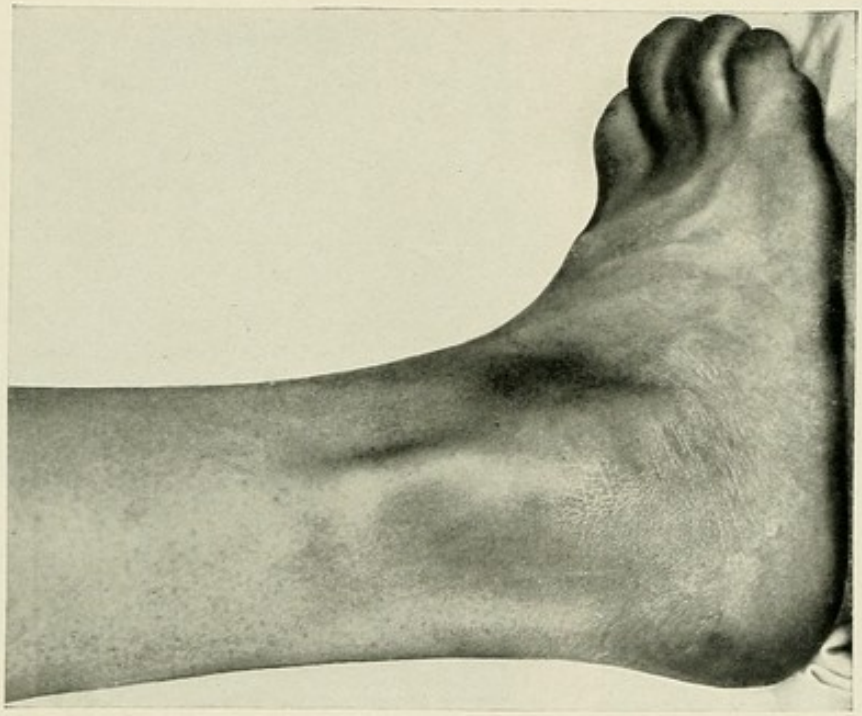

FIG. 459.—Dislocation of peroneal tendons, which project like cords over the external malleolus.

The case is thus a typical **dislocation of the peroneal tendons** (fig. 459), and the crack corresponded to the moment in which the wall of the tendon-sheath compartment yielded to the sudden and sharp contraction of the muscle.

(2) INJURIES WITH DEFORMITY.

The diagnosis of sprain does not enter into consideration if, after an injury, the shape of the foot shows any deviation to one side or the other. The question then arises as to a **fracture** or a **dislocation** being the cause of the displacement, or as to the possibility of both being equally concerned in the injury.

We must first recognize the nature of the deformity. For this

purpose both limbs are brought into the same position with the patella directed forwards. We then compare the direction of the axis of the leg and the instep on either side, as seen from the front, and the relations of the axis of the leg to the sole, as seen from the side. On inspection from the front we must note whether the long axis of the foot forms an abnormal angle with the axis of the leg, or whether it is displaced parallel to its normal position. On inspection from the side, we must test whether the axis of the leg strikes the foot too far forwards or too far backwards. If we are in doubt about any of these deviations, we should see whether we can cautiously rectify any indication thereof, or, on the other hand, whether we can increase it.

The commonest displacement of the foot is *postero-external*, wherein the axis of the foot usually makes with the axis of the leg an obtuse angle, open outwards. The foot thus has slipped backwards and outwards, and at the same time has become tilted somewhat outwards. The foot is usually in a condition of slight plantar flexion (fig. 460).

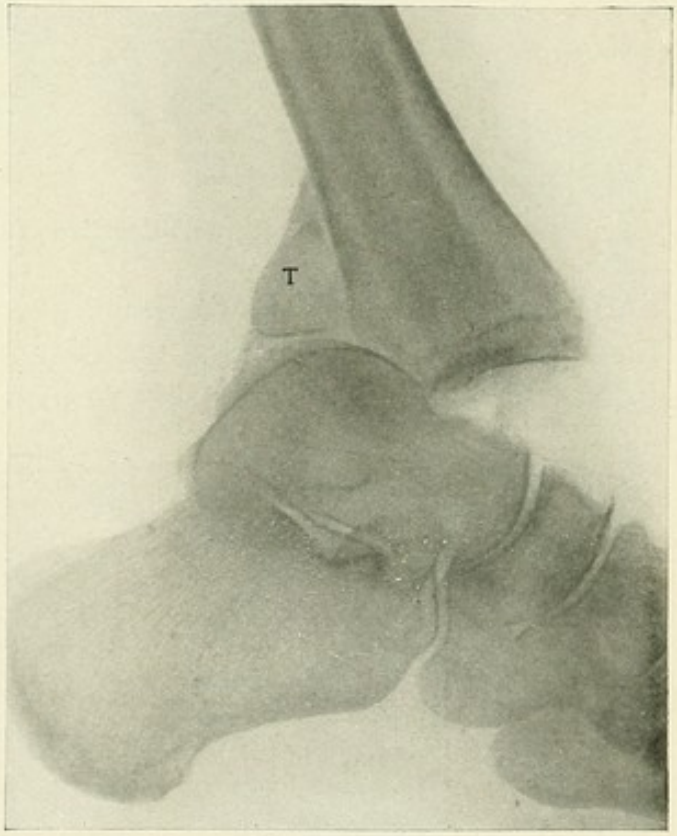

FIG. 460.—Bi-malleolar fracture with detachment from posterior edge of tibia (T), and backward displacement of foot (the tibia forwards).

We start by palpating the lower end of the shaft of the tibia, because the displacement just described is often caused by a **supra-malleolar fracture**. We then proceed to the malleoli. The most frequent condition found consists of an abduction fracture thereof, *i.e.*, a detached fragment from the internal malleolus, and a fracture of the fibula due to excessive bending. The astragalus is displaced outwards, and the upper fragment of the fibula rests directly upon it as shown in the skiagram (fig. 456). At the same time the foot is displaced backwards in relation to the leg, so that on a lateral view the tibia appears to project forwards, beyond the trochlear surface of the astragalus (fig. 460). Thus there is a **bi-malleolar fracture with subluxation of the foot backwards and outwards**, and displacement of the tibia forwards and inwards. The predominance of the one or other aspect of the deformity depends upon the nature of the injury. The more pronounced the displacement, and the less definite

the fracture, the more justifiable is it to speak of a **dislocation**, without, however, being able to draw a hard-and-fast line between the two forms of injury. If we feel both malleoli intact, through the skin,

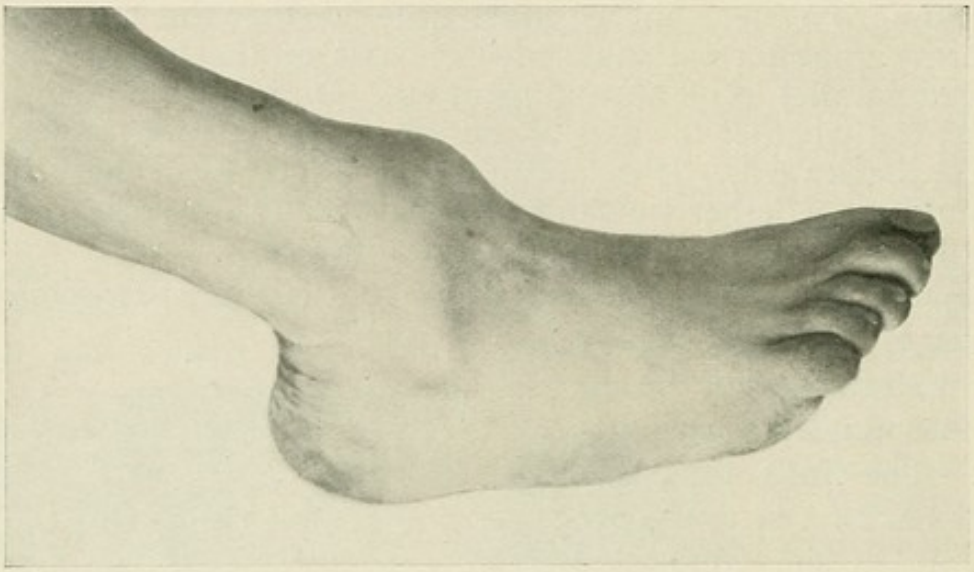

FIG. 461.—Dislocation of the foot backwards.

and also see the outline of the bifurcation of the malleoli projecting forwards (fig. 461), we at once diagnose a *pure dislocation*. We may, however, still be in error, because a fracture of the fibula may exist much higher up.

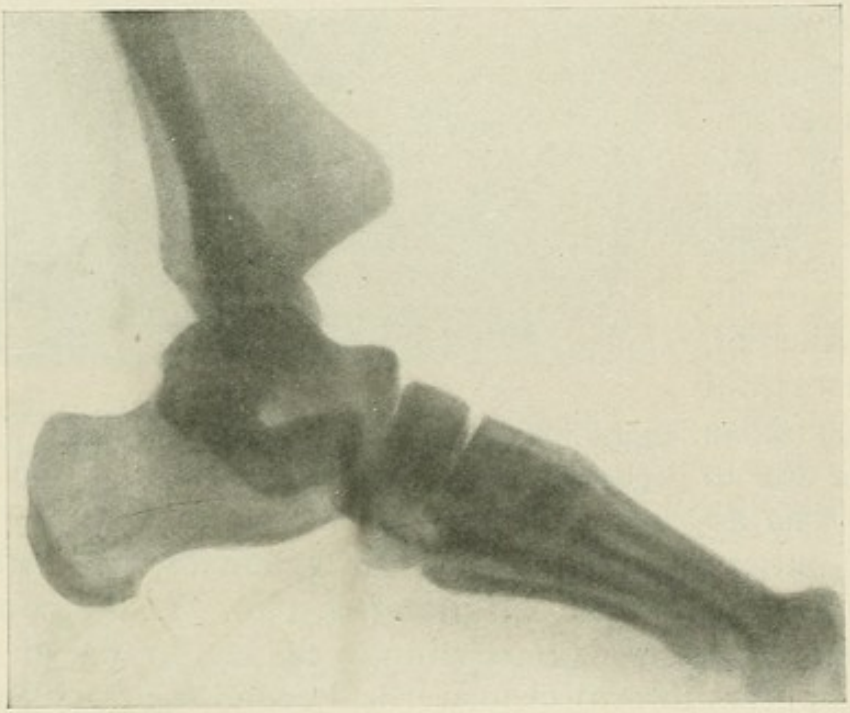

FIG. 462.—Incomplete posterior dislocation of the foot.

This occurred in the case illustrated in fig. 462, in a manner which is by no means uncommon in the present age of athletics. The patient, who was devoted to sleighing, knocked up against an obstacle with his heel, while the vis inertiæ of his tibia continued forwards. Clinically, the case seemed to be one of pure dislocation, but the skiagram showed that there was a fine subperiosteal fissure in the middle of the fibula.

In other cases the skiagram shows (fig. 460) the previously mentioned detachment of a piece of the posterior surface of the tibia,

with or without separation of the epiphysis, according to the age of the patient.

We diagnose, in a similar manner, the very much rarer **dislocations** and **dislocation-fractures with displacement of the foot to the inner side and forwards.**

It is worth mentioning that the foot may be displaced *forwards* with the tibia resting on the posterior portion of the trochlear surface of the astragalus. This gives rise to a subsequent deformity which has been appropriately termed "*Assyrian foot*," owing to its resemblance to Assyrian sculptures (fig. 463).

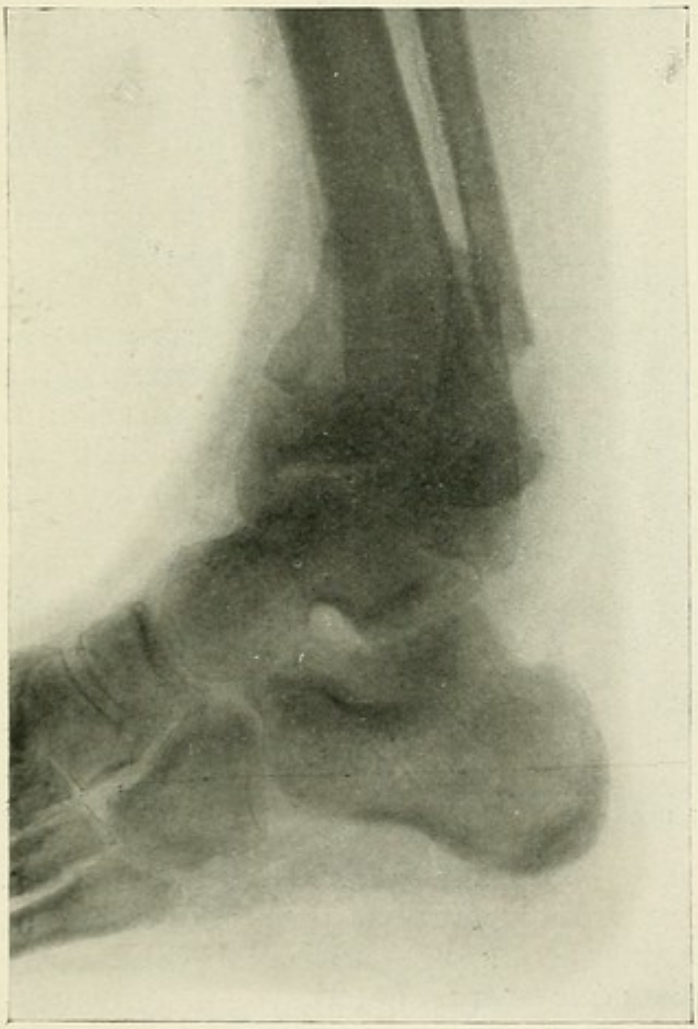

FIG. 463.—Bi-malleolar fracture, with displacement of the foot forwards (old case, so-called "Assyrian foot").

We now come to a very

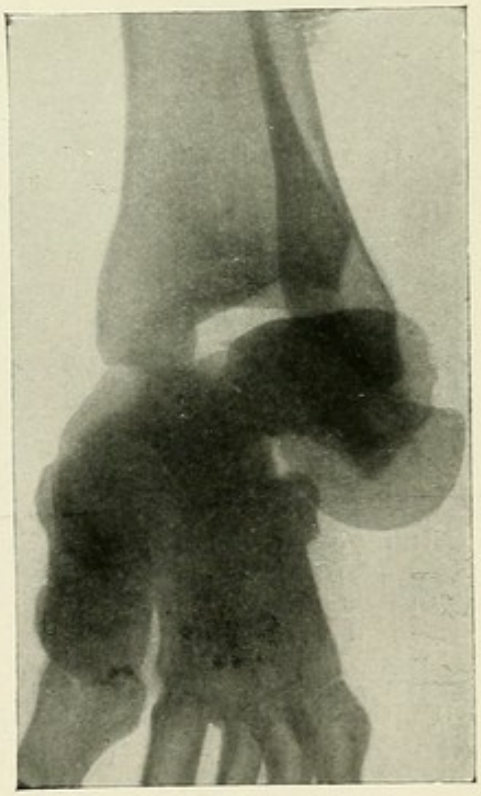

FIG. 464.—Dislocation of the astragalus. (Skiagram of fig. 465.)

different clinical picture of an injury, which may present itself in the same anatomical region. In this condition, which occurs after a severe injury to the foot, we find a round bony projection directly in front of the anterior edge of the tibia, or somewhat to its inner or outer side; the skin is tightly stretched over this projection, according to the position in which the foot is displaced in relation to the tibia, either forwards, inwards or outwards. These signs point to one diagnosis only, viz., **dislocation of the astragalus**, *i.e.*, the disconnection of the astragalus from all its ligaments and its displacement

under the skin. It does not matter, from the point of view of treatment, whether the bone is uninjured or actually broken—as sometimes happens. Fracture could only be detected clinically if crepitus is distinctly heard.

It is very important to make the diagnosis of dislocated astragalus as soon as possible, because the stretched skin over the displaced bone may become gangrenous within a few days, unless early treatment is applied.

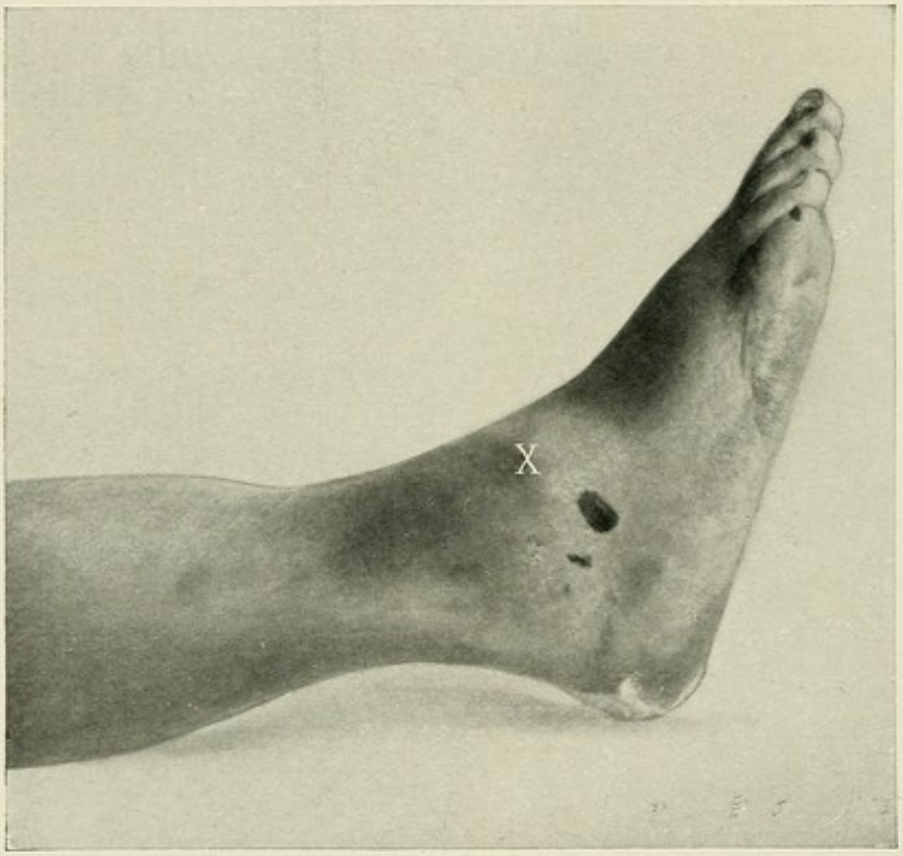

FIG. 465.—Dislocation of the astragalus forwards and outwards. X = projection of head of astragalus; necrosis of skin beginning (formation of vesicles).

If we find a striking displacement of the foot in relation to the leg, although nothing wrong can be detected in the malleoli, whose relations with the astragalus seem to be normal, the cause may still be a **dislocation below the astragalus**. Such dislocations are extremely rare, but they may occur in any direction. An intelligent inspection and palpation will easily decide whether the foot is displaced forwards, backwards or outwards.

CHAPTER CV.

FRACTURE OF THE OS CALCIS.

A TYPICAL fracture of the os calcis cannot be mistaken for anything else, and yet it is an injury which is frequently overlooked. It occurs either through the pull of the tendo Achillis—a laceration fracture—or through its compression between the astragalus and underlying surface—a compression fracture.

The term *laceration fracture* should be limited to the cases wherein the fracture involves the tuberosity of the os calcis, and then only if the line of fracture run parallel to the beam of the bone (fig. 466a); or if its course is more oblique towards the plantar surface, the term should be limited to the cases wherein the fracture does not reach as far as the under surface of the bone. All the other fractures are *compression fractures*, whether they involve the body of the bone or its anterior process.

This does not, however, justify us in concluding that we can tell the form of the fracture from the nature of the injury. Both laceration fractures and compression fractures of the heel are usually due to falls on the sole from a height, and it occasionally happens that both forms of fracture occur in the same bone (fig. 466). Clinical examination and a skiagram render the differentiation of the two varieties very easy.

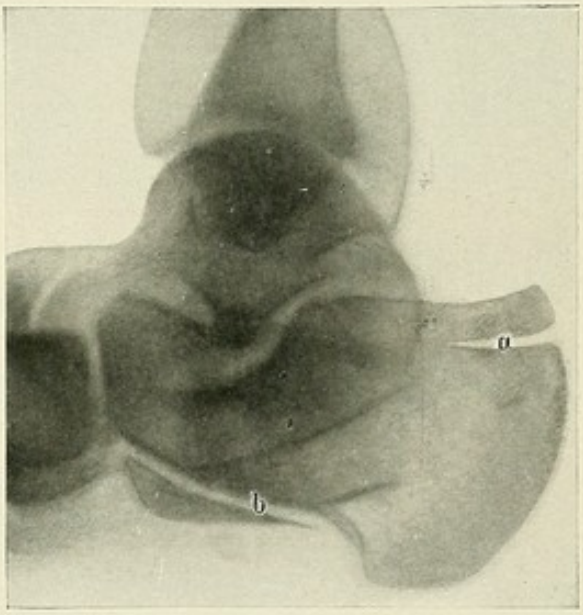

FIG. 466.—Double fracture of the os calcis. *a*, Laceration fracture; *b*, compression fracture.

The clinical signs may be divided into four groups corresponding to four principal varieties of fractures of the os calcis.

(1) In fractures of the first variety, occurring after a fall from a height, we find that the foot is not lower than normal, that is to say, that the extremities of the malleoli maintain their normal distance from the ground. On the other hand, however, we are struck by a localized thickening at the lower end of the tendo Achillis, at the upper part of the tuberosity of the os calcis. On palpation the swollen area is found to be tender, but there is no tenderness on the under surface of the os calcis. We may possibly be able to obtain crepitus. Pressure in the axis of the leg is not painful. The patient is able to stand on his foot, and even to walk with a certain amount of pain. If ecchymosis occurs, it will be found on both sides of the tendo Achillis. In such a case the localized situation of the changes enables us to make the definite diagnosis of *laceration fracture*, which is very easily confirmed by a skiagram.

(2) In other cases there is nothing abnormal to be felt at the tuberosity of the os calcis. The distance of the malleoli from the ground is normal, and the heel, as seen from behind, does not appear to be broadened. Nevertheless the patient avoids putting any weight on the injured foot. On palpation some slight thickening may be found, but there will be a special indication of pronounced tenderness

situated towards the tuberosity of the os calcis, or on the plantar surface, or towards the anterior process. Pressure on the sole of the foot in the axis of the leg is painful. The bruising usually occurs on the sole. In such a case we should think of a *compression fracture without marked displacement of the fragments.*

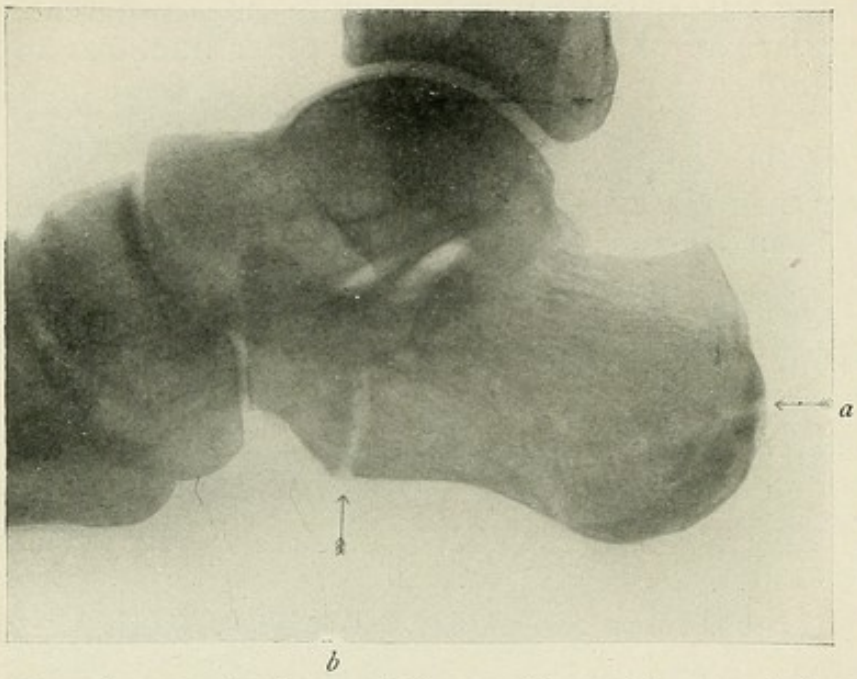

FIG. 467.—Double fracture of the os calcis. *a*, Fracture of the tuberosity of the os calcis; *b*, detachment of the anterior process.

The skiagram shows either a certain amount of obliteration of the bony structure, from which we would conclude that a slight degree of crushing of the inside of the os calcis has occurred, or we may find distinct fissures running along the length of the bone (fig 466*b*) and transversely to it. Detachment of the anterior process is a special feature of this injury (fig. 467).

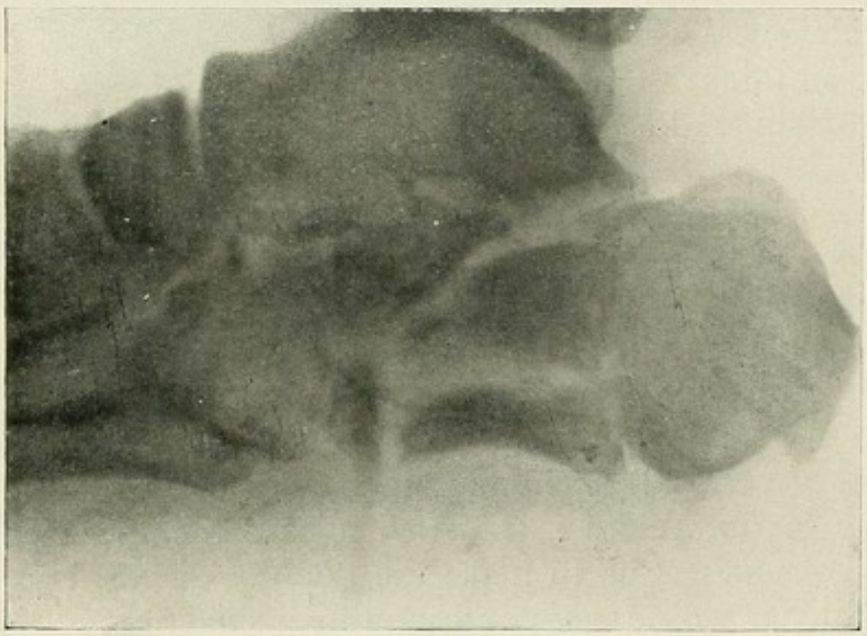

FIG. 468.—Severe crushing of the os calcis.

These cases are usually diagnosed at first as sprains or contusions. It is only when the patient attempts to put his foot to the ground in two or three weeks' time, and the pain still persists, that a more severe form of injury is thought of. Palpation will now reveal a distinct thickening of the os calcis by callus, even in those cases wherein nothing abnormal could be found on the first examination.

(3) The cases in the third group are much more easily recognized. The heel, as seen from behind, is evidently broadened from the

very beginning, and the malleoli are lower than on the uninjured side. The os calcis is felt to be thickened, and is tender both on lateral pressure and on pressure in the axis of the leg. These are cases of *comminution fractures*, which are made up of fissures running lengthwise and also transversely. Obviously the more accurate details can only be made out from a skiagram. A tracing of the foot will show that it is widened about the heel. Patients are sometimes able to walk about even after this injury, although the pain is considerable; pronation and supination are particularly deranged.

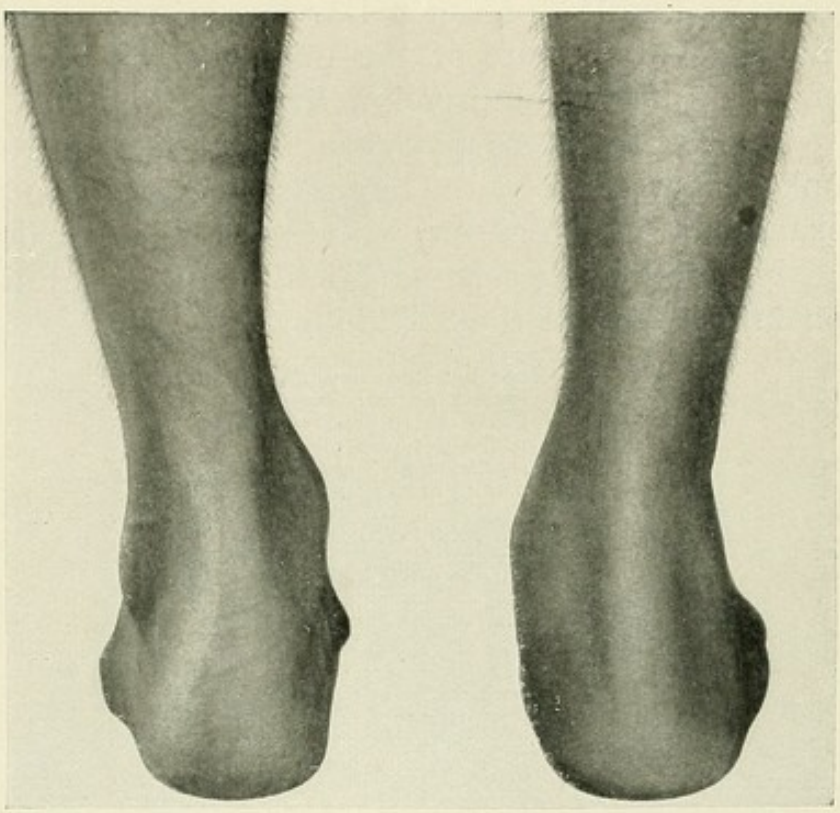

FIG. 469.—Old compression fracture of the right os calcis, treated as a sprain. The heel is broadened, the malleoli are low, and the position is one of slight valgus.

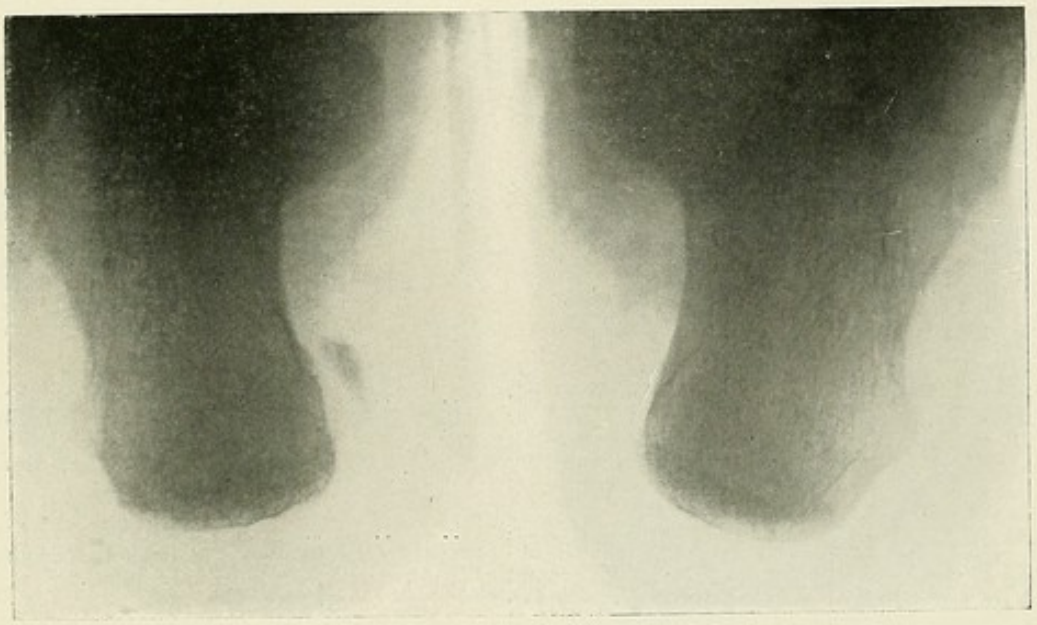

FIG. 470.—Detached fragment from inner side of os calcis.

(4) *Detachment of the sustentaculum tali*—a very rare condition—should be thought of if we find that the foot is definitely in a valgus

position, and the region below the internal malleolus tender, without the signs of fracture of the malleolus or of the astragalus, or those of an ordinary compression fracture.

(5) Finally, there may exist lateral detachments of bone, which are only recognizable by the circumscribed pain on pressure and by X-ray examination from above, with the foot greatly dorsi-flexed (fig. 470).

The following scheme briefly summarizes the foregoing remarks on injuries about the ankle-joint.

No striking deformity, at most a little swelling	Bone nowhere very tender, except at attachment of ligaments to one or other malleolus; pain often persists, even when at rest. No pain on axial pressure.	.. ..	**Sprain of ankle.**
	Tenderness of bone transversely above joint (generally on tibia and fibula); pronounced pain on axial pressure	.. ..	**Supra-malleolar fracture without displacement.**
	Great tenderness of one or both malleoli at a more or less considerable distance above their extremities; false mobility not always demonstrable, but most likely in the fibula; no pain on axial pressure.	.. ..	**Malleolar fracture without displacement.**
	Tibia and fibula not tender on pressure; pain on axial pressure (by pressing os calcis on underlying surface) usually present; pain on lateral compression of the os calcis	Malleoli at normal level; pain over tuber calcanei	**Fracture of tuberosity of os calcis.**
		Ditto, but pain in body of os calcis	**Fracture of body of os calcis without displacement.**
		Malleoli abnormally low; pain in body of os calcis	**Fracture of body of os calcis; bones compressed.**
	Ditto, but pain on pressure in the astragalus and not in os calcis; dorsi-flexion particularly painful	.. ..	**Fracture of astragalus.**
Foot displaced in relation to axis of leg	Bone not tender; bifurcation between malleoli can be felt under skin	.. ..	**Simple dislocation** (foot usually displaced backwards and outwards).
	Both bones tender transversely above the malleoli	.. ..	**Supra-malleolar fracture with displacement**, before the age of 14 usually a **separation of epiphysis** (foot generally displaced backwards and outwards as in dislocation).
	Bone tender above tip of malleolus (tibia or fibula) or above the malleolus (fibula); sometimes accompanied by an actual dislocation	.. ..	**Fracture of malleolus with displacement** (foot generally displaced as above, rarely forwards).
	Malleoli not tender; bifurcation between malleoli abnormally easily felt; a round body projects, usually forwards, under the stretched skin	.. ..	**Dislocation of astragalus** (often combined with fracture).
	Malleoli normal on palpation; the bifurcation between them not very easily felt; considerable displacement of foot below astragalus; head of latter to be felt	.. ..	**Dislocation below astragalus** (occurring in various directions).

CHAPTER CVI.

INJURIES TO THE FOOT, IN FRONT OF THE ANKLE-JOINT.

We need not occupy any time over such rare injuries as *dislocations of Chopart's or Lisfranc's joints*. The displacement is so striking that the diagnosis can be made from anatomical considerations, unless the swelling is very great, in which circumstance a skiagram will be necessary.

More interest attaches to certain trivial, but not infrequent, injuries, which are quite characteristic, and which were previously overlooked or incorrectly diagnosed. Owing to recently acquired knowledge, these injuries may now be recognized by their clinical signs.

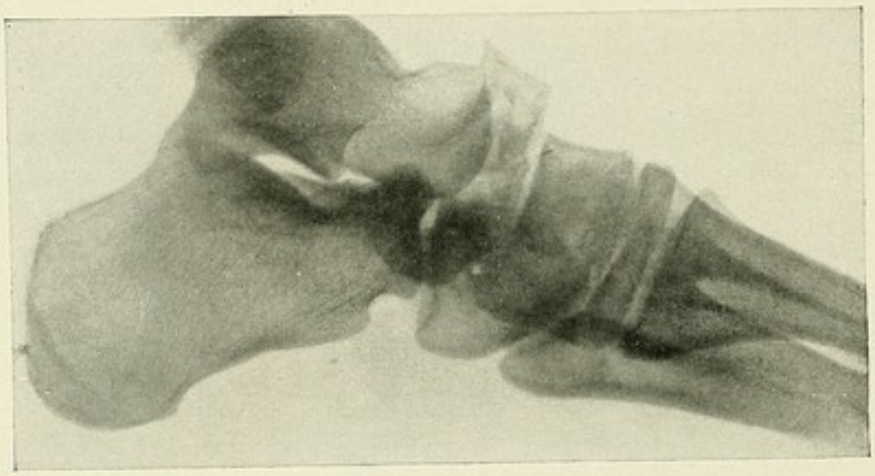

Fig. 471.—Compression fracture of scaphoid.

(1) **Compression Fracture of Scaphoid.**—If a person falls from a height on to his toes, the force is to a great extent gathered up by the scaphoid and transmitted to the astragalus. If the scaphoid is not sufficiently resistant, it becomes compressed, and, so to speak, is squeezed out of the skeleton of the foot. It then gains the dorsal surface, and can be distinctly felt through the soft parts (fig. 471).

In the female sex a Wormian bone, described by Gruber as the os tibiale externum, is often found on the tubercle of the scaphoid (fig. 472). Ignorance of this abnormality has led to the erroneous diagnosis of detached fracture,

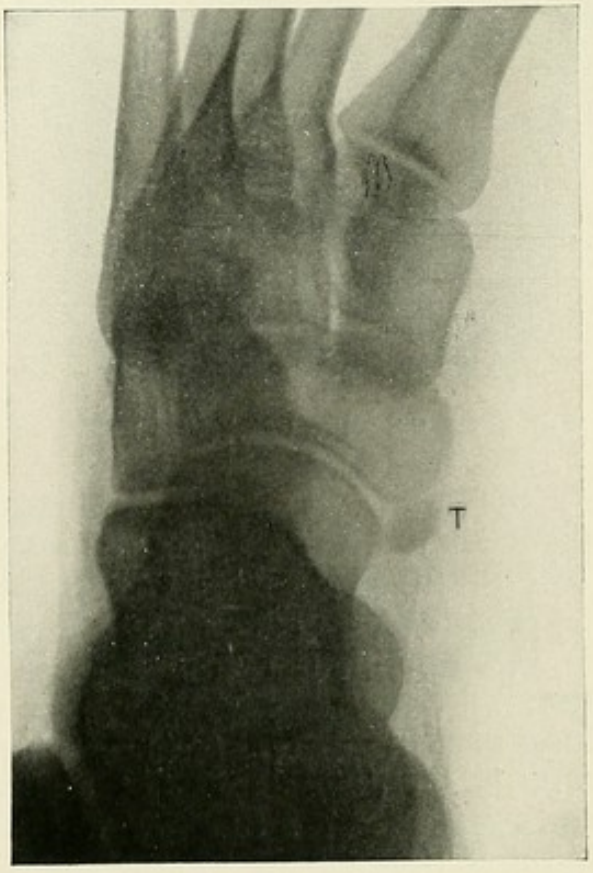

Fig. 472.—Os tibiale externum (T).

when in reality the pain complained of has been due to stretching of ligaments, which occurs in this situation through dancing.

(2) **Fracture of a metatarsal bone** is much more frequent. If a heavily laden soldier, wearied by many hours' marching, begins to relax, and fails to impart the necessary elasticity to his steps by the proper use of the muscles of his foot, it is very easy for the metatarsus to become overweighted, and for one of the bones—usually the second—to crack. The symptoms thus caused: spontaneous pain, tenderness on pressure, and swelling, were previously attributed to inflammatory changes in the soft tissues, until it was shown that they were really caused by a subperiosteal **metatarsal fracture,** usually without any dislocation.



FIG. 473.—"Swollen foot." Old callus.



FIG. 474.—"Swollen foot." Recent callus.

Sometimes the skiagram which is taken forthwith reveals no change at all, because the fissure in the bone is purely subperiosteal. But in a few weeks' time slight callus is visible in the skiagram.

The following is an illustrative case :—

A slimly-built recruit showed the well-known signs of "swollen foot" in the neighbourhood of the second right metatarsal after a long march. The skiagram, which was taken immediately, revealed nothing; but a diagnosis of fissure was nevertheless made. A subsequent examination in a few weeks revealed definite callus. In a few months' time the young man had to resume his military duties, and the symptoms returned in his left foot after a long march with full

equipment. On this occasion also the skiagram was negative, but examination a few weeks later showed the condition illustrated in figs. 473 and 474. The second metatarsal bone of the right foot,

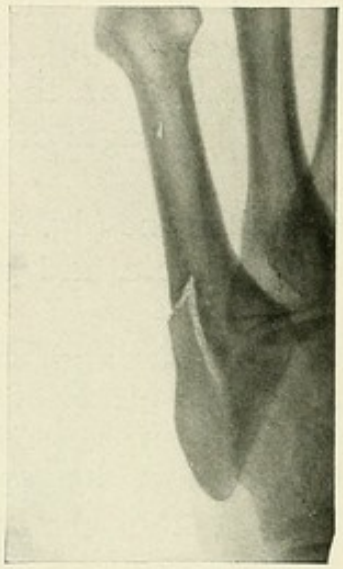

FIG. 475.—Fracture of tuberosity of fifth metatarsal.

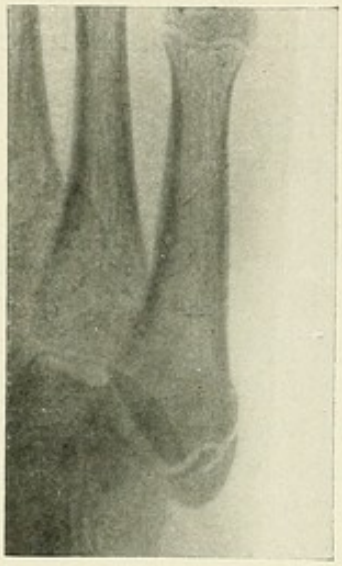

FIG. 476.—Epiphyseal line at base of fifth metatarsal (from lad aged 14).

which was injured first, presented a spindle-shaped thickening which represented the remains of callus. The second metatarsal of the left foot presented well-developed recent callus. Before entering military service the patient had done much mountaineering without any result-

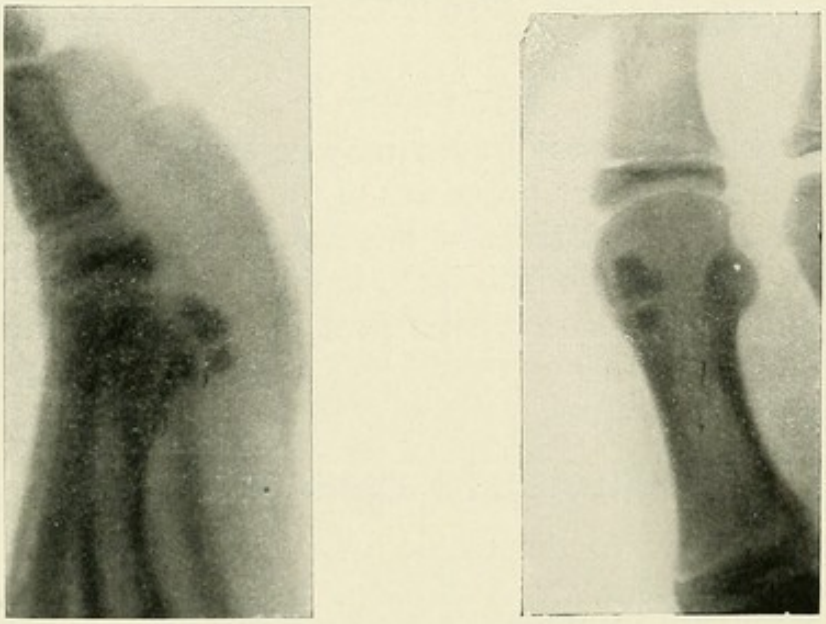

(*a*) (*b*)

FIG. 477.—Fracture of sesamoid bone, seen from below and from the side.

ing injury to the bones of his foot, thus showing that the military conditions are really responsible, *i.e.*, the heavy equipment and the forced marching of the weary soldier when his muscles are exhausted.

(3) **Fracture of the tuberosity of the fifth metatarsal bone** is also a characteristic injury of the metatarsus. It can be diagnosed clinically, but is easily overlooked. It may be caused by direct violence, and probably also by the contraction of the peroneus brevis; it has the appearance of a detached fracture (fig. 475). This fracture must not be confused with the separation of the epiphysis (fig. 476), which occurs in this situation between the ages of 12 and 14, as described by Kirchner and Iselin.

(4) The possibility of fracture of a sesamoid bone (fig. 477) will be suggested by localized pain on pressure over the sole, and by painfulness of the movements of the toes.

We need not enter into details of the numerous and varied fractures and dislocations which may occur about the heads of the metatarsal bones and the toes. Pressure and traction on the separate toes will always show which of them is involved; but a skiagram will be required for further details.

CHAPTER CVII.

INFLAMMATORY DISEASES OF THE FOOT.

A.—TARSUS.

INFLAMMATORY diseases of foot may be termed *podarthritis* on the principle that inflammatory processes of the wrist are sometimes called *cheir-arthritis*. A general term of this nature may be justifiable in the case of the wrist, because of the small amount of bony structure which is involved, but in the case of the foot the diagnosis must be more definite.

We differentiate :—

(1) ACUTE DISEASES.

It is usually easy to determine whether an acute inflammation involves the ankle-joint, or is situated more forwards in Chopart's or Lisfranc's joint. In the vast majority of cases the ankle-joint is alone involved, or at least is the principal seat of the affection.

The nature of these acute inflammations is similar to those which occur in the shoulder and knee, and as also happens in these joints, the original site of the disease is frequently in the adjoining bone, and not in the joint itself.

(2) CHRONIC INFLAMMATIONS.

Tubercle is, as always, the most important of the chronic inflammations. Adults are more frequently affected with tuberculosis of the ankle than any other joint. The patients usually complain of pain, of a few weeks' or months' duration, about the ankle. There is consequently some lameness. There is frequently no evident change at this stage; the only sign of disease may be a certain amount of tenderness in the region of the capsule of the upper part of the ankle-joint. A skiagram may reveal nothing but a striking transparency of the bone (fig. 478)—osteoporosis—due to the disappearance of lime salts. If the disease is somewhat more advanced, there may be swelling of those portions of the capsule accessible to palpation, or there may possibly be a para-articular abscess. The grooves on either side of the tendo Achillis are very frequently obliterated at this stage, and the tendon itself may appear to lie in a depression (fig. 480). The skiagram will show that the articular surfaces are partially eaten away. The mutual approximation of the bones indicates that the cartilage has already to some extent disappeared. It may be possible to detect individual areas of disease in the bone.

We have seen, in connection with the knee-joint, how to distinguish between primary and secondary lesions.

When the capsule is swollen the condition may be mistaken for **gummatous disease** or chronic **gonorrhœal** effusion.

I was inclined to diagnose syphilis in the case of a young healthy man, because the swelling was so remarkably painless. The history was definitely against this view, and I, therefore, decided to operate. I immediately alighted on gummatous tissue, and, therefore, desisted from further interference. The patient made a rapid recovery under iodide of potassium.

If the disease process has broken through externally, it supports the diagnosis of tubercle, as against rheumatism or gonorrhœal arthritis. It is not, however, any contra-indication of syphilis; on the contrary, it suggests tertiary disease if the appearance on the skin is not that of a fistulous orifice, but that of a sharply marginated ulcer.

In the Tropics we may be confronted with "madura foot," a disease allied to *actinomycosis* which may give rise to a clinical picture similar to tubercle or syphilis.

In the cases hitherto discussed the principal feature has been involvement of the ankle or its neighbouring joints. But we frequently find that lameness and pain in the foot may arise, although the *movements of the joints are perfectly free.* Accurate examination will show that the tenderness is not in the capsule of the ankle-joint, or of Chopart's joint, but that it is in the lower end of the tibia, or the os calcis, or in rarer cases in the scaphoid or cuboid.

Tubercle of the lower end of the tibia may occur in one of three forms: (1) A simple central abscess of the bone, with diffuse thickening of the cortex; (2) a lesion with a spongy sequestrum situated quite close to the joint; (3) small areas of granulation. The last applies to **tubercle of the os calcis,** which is rather frequent, and which is usually situated in its posterior half. We generally find one or more abscesses surrounded by sclerosed bone, which often contains large spongy sequestra. The disease sometimes remains within the os calcis for years, and only becomes manifest from time to time by fresh inflammatory exacerbations. This intermittent course and the

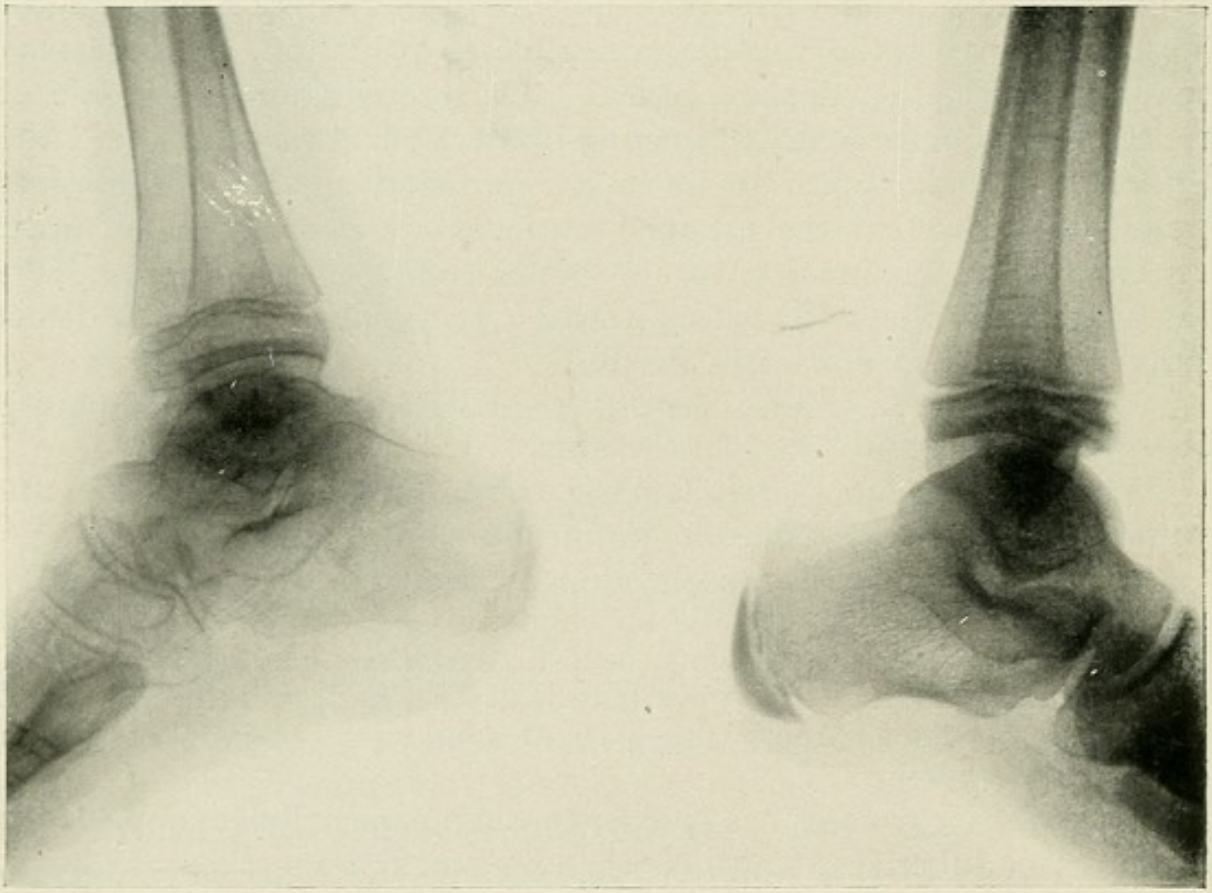

Left (diseased) side. Right side.

FIG. 478.—Early stage of tubercular synovitis of the left ankle-joint. The skiagram only shows great osteoporosis.

skiagram render it easy to differentiate tubercle from **sarcoma,** which has occasionally been observed in the os calcis.

It is very important not to confuse early tubercle with the so-called **Achillodynia.** This term indicates a painful inflammation of the mucous bursa between the tendo Achillis and the os calcis—due either to rheumatism, gout, or gonorrhœa. It may also come on, after fatiguing marches, and is thus particularly liable to occur in soldiers, or in mountaineers, who have no kind of predisposition thereto.

Affections of the *bursa subcalcanea*, and of the *bursa Achillea posterior*, which lies on the tendo Achillis, may occur under similar

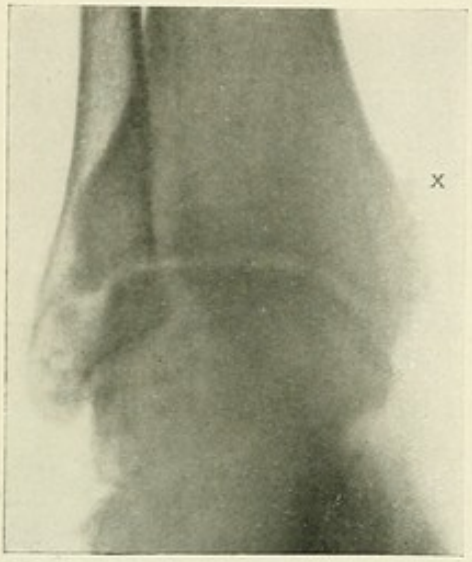

FIG. 479. — Tubercle of ankle. Narrowing of cartilage. Bone eaten away. Lesion in external malleolus. New bone formation at X.

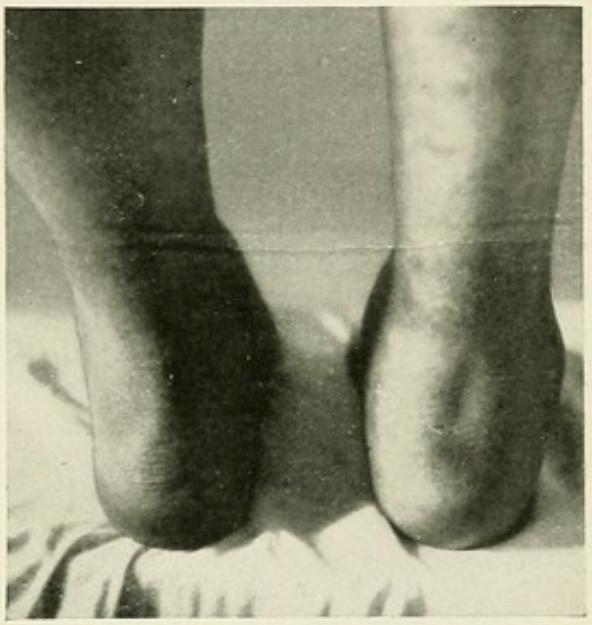

FIG. 480.—Tubercle of right ankle. Tendo Achillis looks like a furrow between the two lateral swellings of capsule.

circumstances. Traumatic or painful inflammatory swellings are sometimes found in the *tendo Achillis itself*, after long marches.

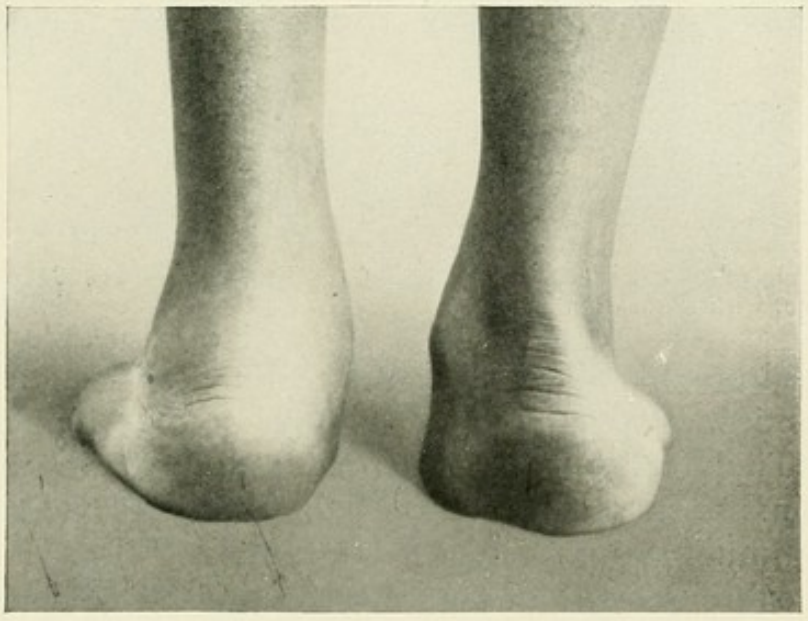

FIG. 481.—Tubercle of left ankle (both feet are flat). The grooves on either side of tendo Achillis are obliterated on the left.

The pain produced by the sub-calcaneal bursa has been incorrectly termed "talalgia." "Calcanalgia" is a more correct designation, but "pternalgia" is quite superfluous.

B.—METATARSUS AND TOES.

If the metatarso-phalangeal joint of the great toe becomes tender on pressure, inflamed and spontaneously painful, a typical **attack of gout** is obvious.

It is of some diagnostic interest to recognize that a typical attack may occasionally be followed by signs of visceral gout. In rare cases the attack starts with visceral manifestations, to be followed by a typical seizure in the great toe. I have, for instance, seen a gouty subject, who had been free from attacks for ten years, suffer successively from angina, trigeminal neuralgia, gouty seizure in the foot, non-purulent urethritis, proctitis, sciatica, pneumonia and nephritis.

Acute phlegmonous processes in the neighbourbood of a **hallux valgus** are generally due to suppuration in the bursa over the head of

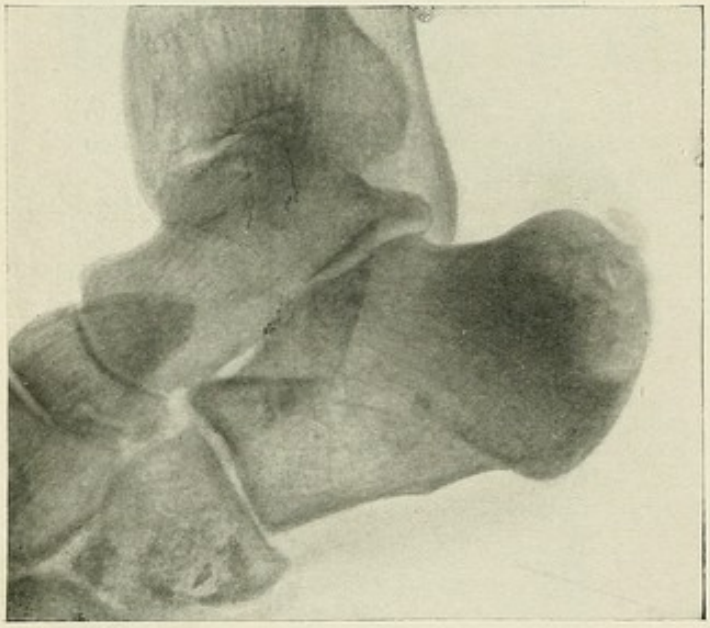

FIG. 482.—Tubercle of os calcis (superficial lesion in bone, with sequestrum).



FIG. 483.—Tubercle of os calcis (deep abscess in bone).

the metatarsal bone. These abscesses in the foot, which are situated under callosities, often assume the shape of a stud, just as they do in the hand. They really consist of two abscess cavities, the one being under the *epidermis*, the other more deeply situated under the *skin*, the two intercommunicating by a narrow opening.

If a toe exhibits signs of intermittent bluish-red congestion, with pains not limited to the discoloured area, but which may even extend to the leg, we should think of **commencing grangrene** in elderly or diabetic patients.

The considerations which apply to **dactylitis** of the hand and fingers are also applicable to **chronic inflammatory processes of the metatarsus and toes**. The first metatarsal bone suffers most frequently.

CHAPTER CVIII.

DEFORMITIES OF THE FOOT.

Most deformities of the foot are so easily recognized that difficulties in diagnosis hardly ever arise. We shall therefore only refer to a few points which occasionally perplex beginners.

(1) FLAT FOOT.

The frequency with which a valgus foot and a flat foot are combined has given rise to the impression that both deformities are of the same significance—an error which has led to much bad treatment.

I once saw a patient who had a pes valgus calcaneus (figs. 492 and 493) provided by the bootmaker with a flat foot pad, although an abnormally well-developed arch was present, because the practitioner had not given any accurate instructions.

Pes valgus, or everted foot, is characterized by the inclination of the os calcis outwards, *i.e.*, it is not directly in the line of the axis of the leg, but forms an obtuse angle with it, as seen from the outer side. This angle disappears as soon as the foot is placed upon a correspondingly inclined plane (fig. 484). The foot becomes *flat—pes planus*—when the arch sinks, and the anterior part of the foot at Chopart's joint becomes abducted, so that its axis deviates externally from the perpendicular to the line connecting the malleoli (fig. 485).

A flat foot in the valgus position, with these signs, is obvious even to a lay observer. In such cases, the impressions made by the sole of the foot will be of the character illustrated in figs. 490 and 491. These severe cases do not, however, possess as much diagnostic interest as those wherein the patient complains of pain in various places on his foot, without the presence of any definite flattening of the arch. But careful inspection will often show that the heel is turned somewhat outwards and that the anterior part of the foot has undergone some lateral deviation. The impression of the sole may nevertheless be almost normal, or at most show a somewhat wide connection between the heel and the balls of the toes (fig. 489).

The pain is sometimes localized to definite spots, *i.e.*, astragaloscaphoid joint, the head of the astragalus, the internal side of the scaphoid and the area in front of and below the external malleolus. In other cases the pain is more diffuse, extending over the whole tarsus, or radiating forwards between the metatarsal bones. The pain is very sharp on standing, it is less severe on walking, and it disappears rapidly on resting. Well-fitting boots relieve it; low soft shoes

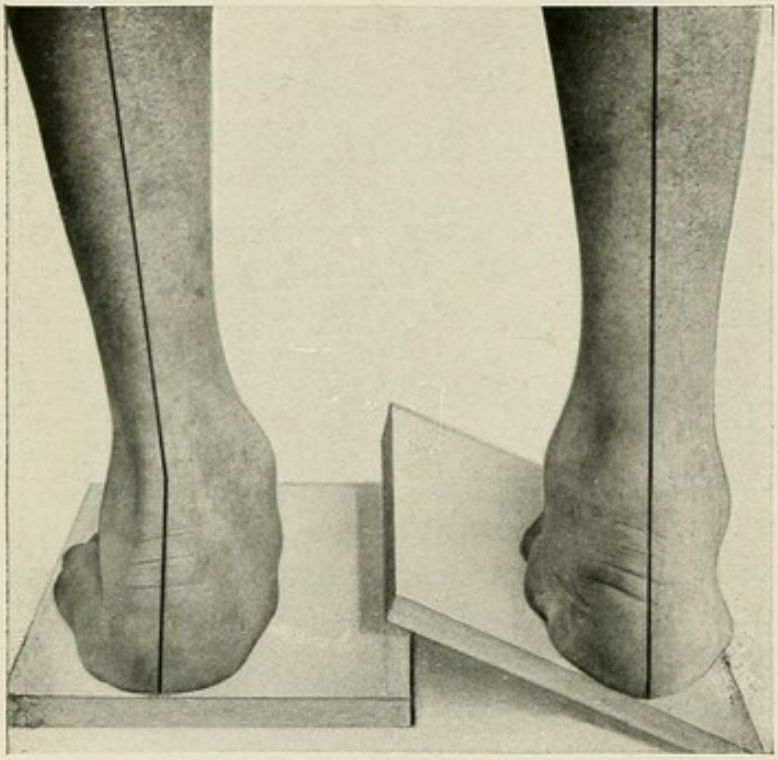

FIG. 484.—Bilateral pes valgo-planus. On the right side the valgus position has disappeared, because foot is resting on an inclined plane.

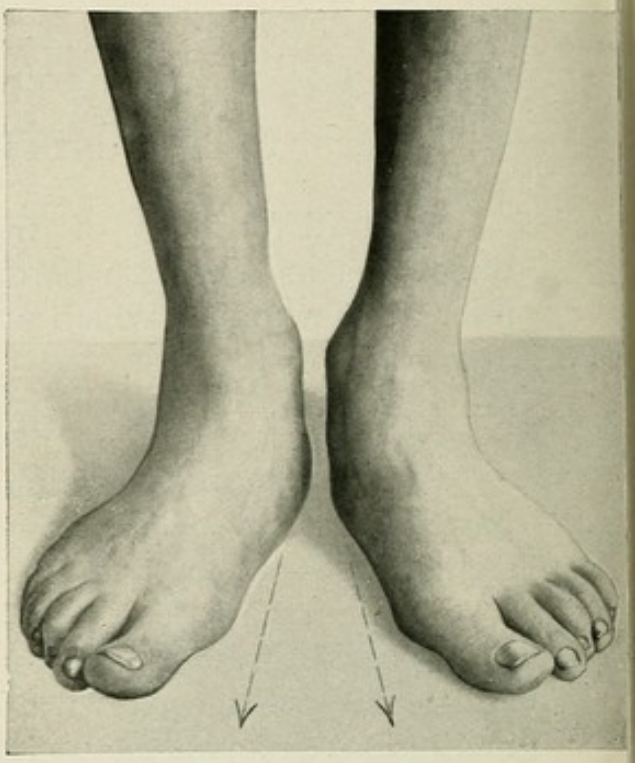

FIG. 485.—Same case from the front. External deviation of the anterior part of foot; the arrows indicate the normal positions of the inner margins of foot.

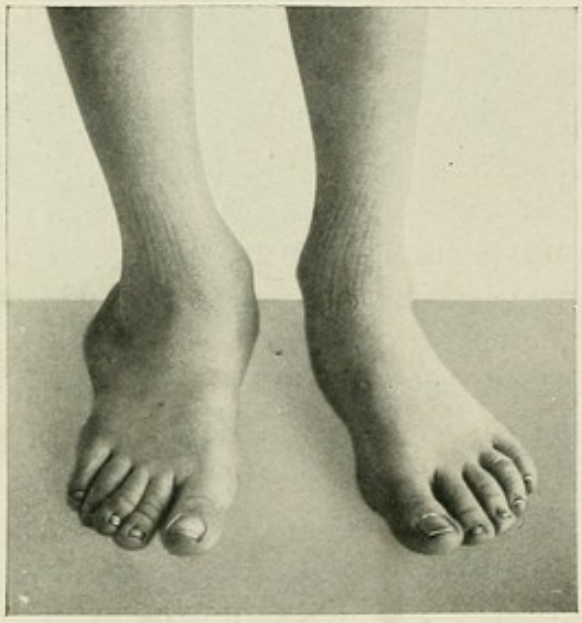

FIG. 486.—Pes valgo-planus on right side after traumatic division of the tibialis posticus tendon.



FIG. 487.—Same case from behind.

increase it. Occasionally the pains are felt as much in the calf as in the foot, or even more so. They may even be felt in the thigh.

If one neglects to make an examination in this stage, or does so only cursorily, such an unsatisfactory diagnosis as talalgia or metatarsalgia, &c., is apt to be given.



FIG. 488.—Normal foot.



FIG. 489. — Commencing flat foot.

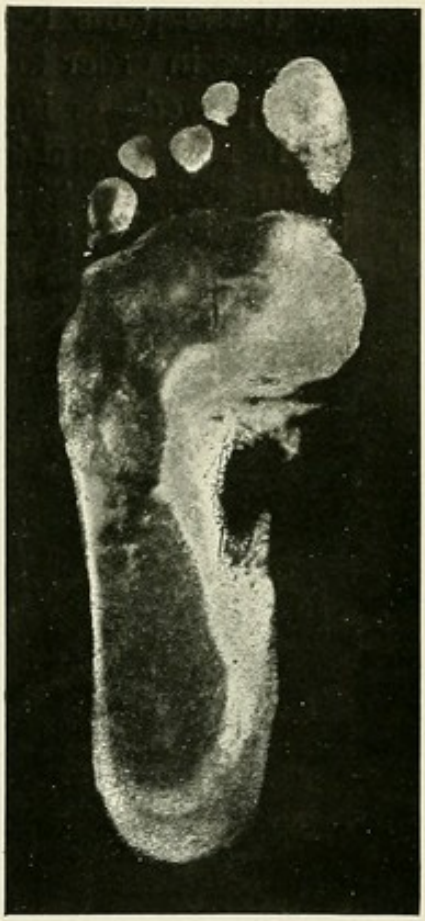

FIG. 490.—Moderate flat foot.



FIG. 491.—Severe flat foot.

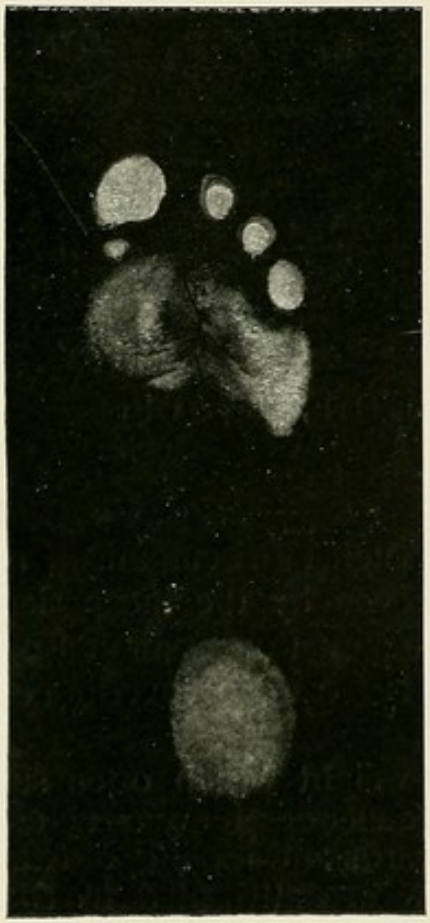

FIG. 492.—Pes calcaneus.

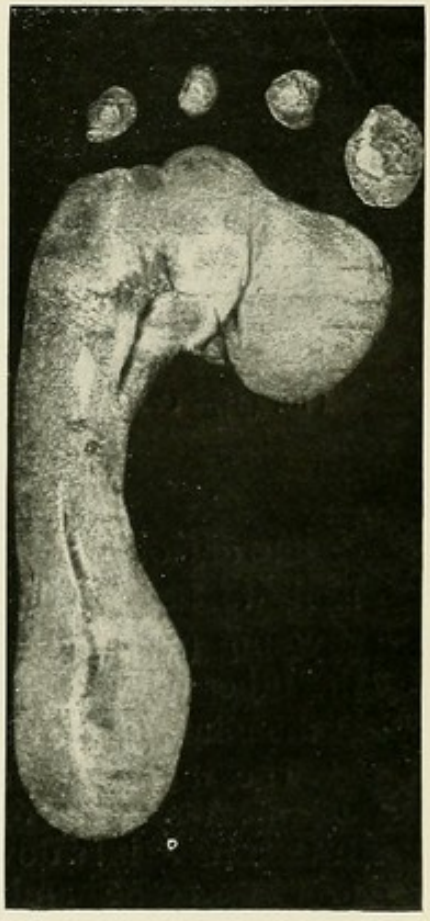

FIG. 493.—Pes excavatus.

If the pains become so severe that the patient contracts all the muscles in order to fix the joints of the foot, the term *spastic flat foot* is employed—or incorrectly, *inflammatory* flat foot.

It may resemble a commencing tuberculosis in this stage. Flat foot may accidentally coincide with tubercle. If the first examination is not decisive, the patient must be instructed to rest for two or three weeks. The pain of flat foot will then disappear, but that of tubercle will either persist or only abate in a slight degree.

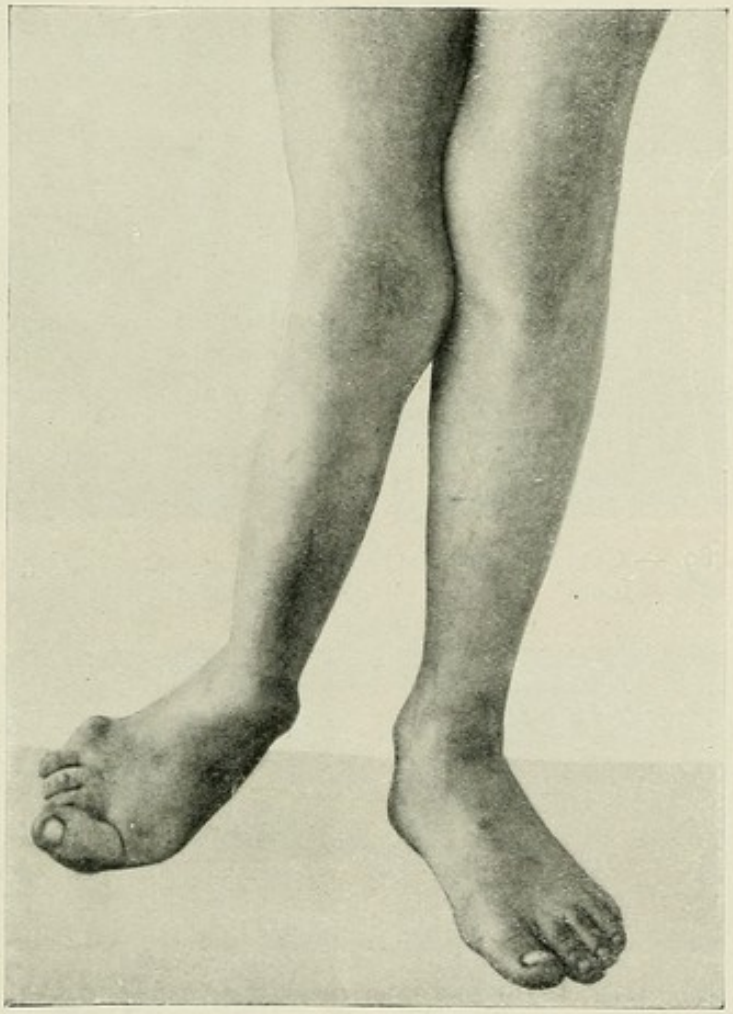

FIG. 494.—Congenital absence of fibula, with pes valgus, in girl aged 8 years.

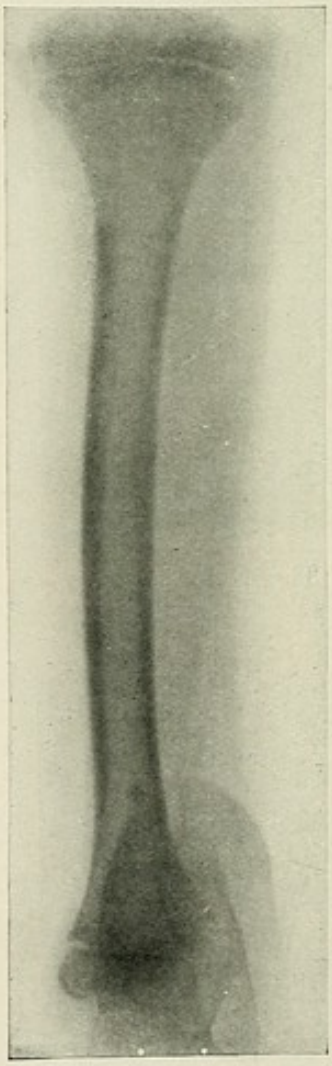

FIG. 495.—Congenital absence of fibula; skiagram of fig. 494.

Errors of diagnosis, such as rheumatism, neuralgia, &c., are not likely to be committed even by the inexperienced, if the patient is a young person whose occupation demands constant standing. On the other hand flat foot is frequently overlooked in corpulent women at the climacteric period.

The increased body weight which often sets in at this age puts too great a strain on the slender bony structure of a woman's foot. It therefore sinks downwards and inclines outwards. The pains of flat foot supervene, and they are attributed to rheumatism, neuritis, to

varicose veins, which are usually evident, and if they are not, to "deep varicose veins" which are usually discovered *ad hoc*. The fact that the pain is felt in the calf muscles is the basis of this last assumption.

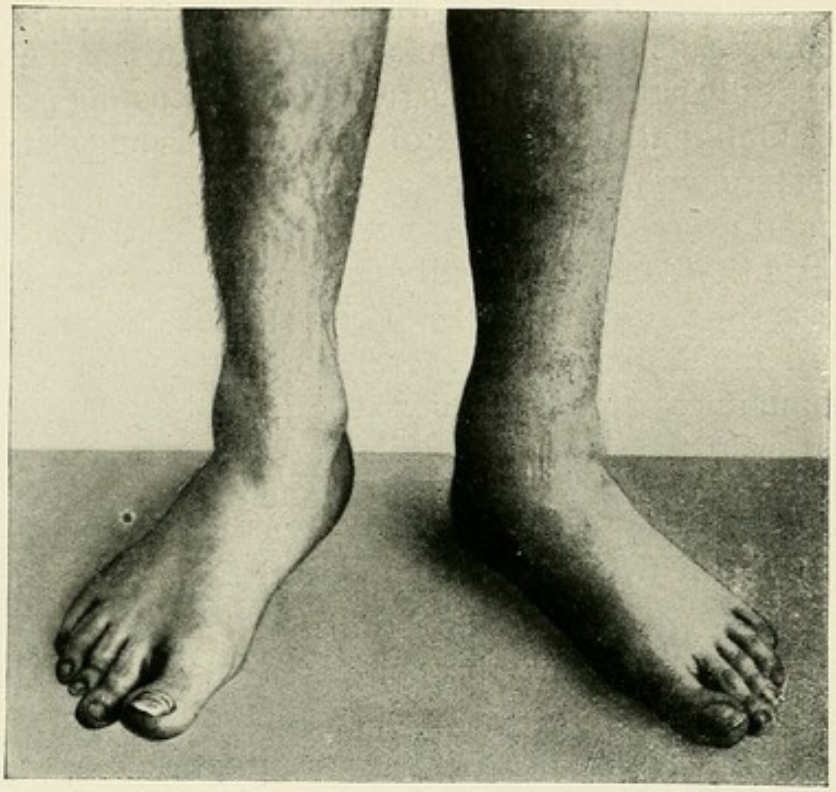

FIG. 496.—Habitual contracture of left foot in valgus position, after a healed fracture of fibula without dislocation.

A valgus foot or a flat foot, resulting from an *injury* (fracture of the malleolus, os calcis, or a metatarsal bone) often remains misunderstood for a considerable time, because the foot does not assume the classical picture of flat foot from the beginning. On the other hand, pes valgus may arise as "habitual contracture" after an injury, without any deformity of bone (fig. 496).

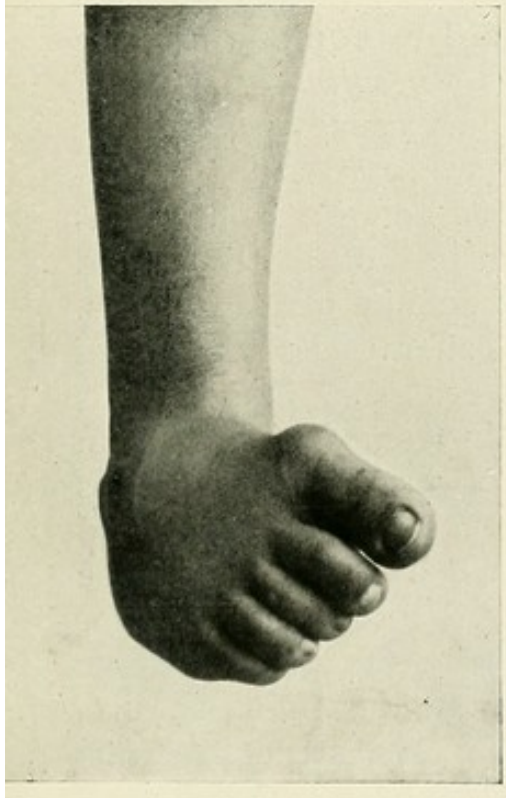

FIG. 497.—Congenital club foot (simple form).



FIG. 498.—Habitual contracture of left foot, assuming a club foot posture, after a sprain and completely healed fracture of posterior process of astragalus.

Paralytic flat foot as a symptom of paralysis, especially of infantile paralysis, is easily recognized. It resembles the flat foot which results from division of tendons (tibialis posticus, figs. 486 and 487).

Congenital absence of the fibula is suggested by a striking valgus posture with shortening of the limb and curving of the tibia forwards and inwards. Palpation will show that the external malleolus is absent. The tibia usually presents a scar-like stripe, running lengthwise (figs. 494 and 495). This mal-development is frequently bilateral and the fibula is absent, either completely or partially. The toes are sometimes quite perfect, at others they are imperfectly developed towards the little toe. The so-called *Volkmann's subluxation of the foot outwards* constitutes a slight degree of this deformity.

(2) TALIPES, PES EQUINUS, PES CAVUS, PES CALCANEUS.

These deformities are so distinctive where their characters are once known, that we may be content with a few typical illustrations. The *cause* of these deformities is, however, of importance, from the therapeutic standpoint. Whereas in flat foot the mechanical and rachitic changes predominate over those of paralytic or congenital origin, the deformities at the head of this section are mainly due to congenital or paralytic causes, rarely to injuries and never to rickets. The first question in regard to **equinus** must be in regard to its *congenital* or *acquired* origin. The history usually supplies the answer. If not, we may assume a paralytic or acquired origin if there is coldness or blueness of the foot, and obviously also if definite paralysis exists. Atrophy of the calf muscles is of itself not conclusive evidence, because this may also arise in course of time from want of activity of certain muscle groups as a result of congenital club foot, and may indeed reach a very considerable degree. Neither does the unilateral or bilateral existence of the deformity give any information on this point, because the congenital and the acquired forms may both affect either one or two sides. But if it once be ascertained that the talipes is of the paralytic variety, certain important conclusions as to the *cause of the paralysis* follow therefrom.

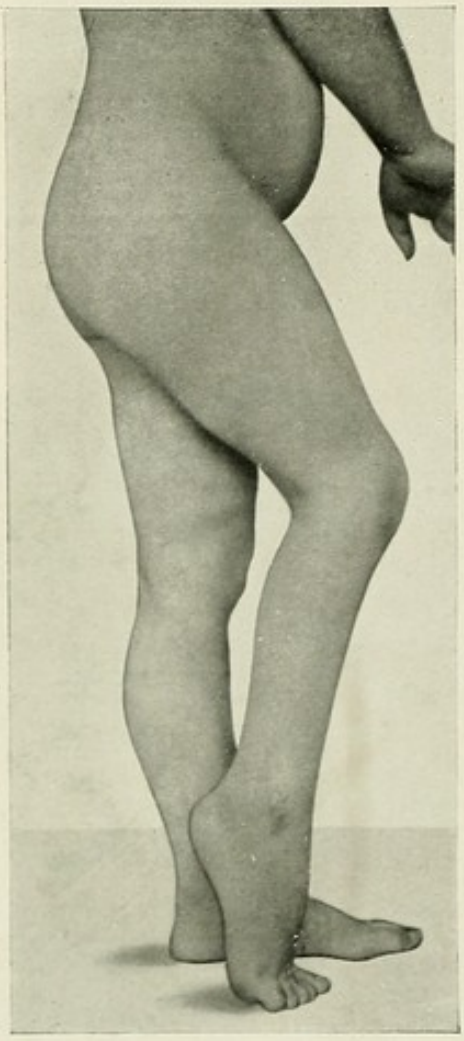

FIG. 499.—Paralytic pes equinus.

Unilateral talipes with flaccid paralysis is usually due to acute anterior poliomyelitis, but may exceptionally be the result of spina bifida. The latter cause is suggested by the simultaneous existence of

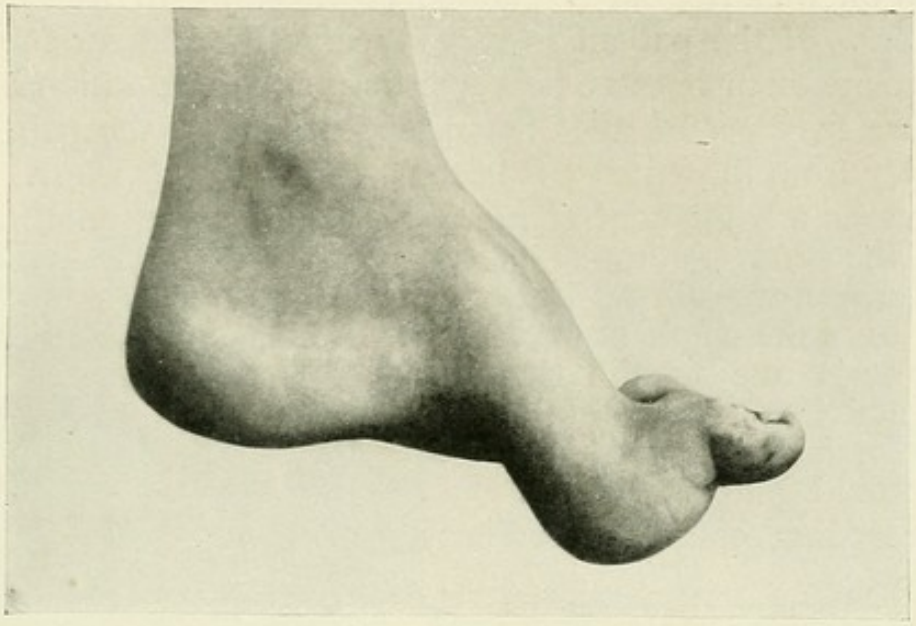

FIG. 500.—Paralytic pes cavus in a case of spina bifida.

disturbances of sensation and incontinence of urine. If no swelling is evident on the back, a spina bifida occulta should be looked for. Similarly, bilateral talipes with flaccid paralysis should suggest some congenital defect in the lumbar cord.

Unilateral talipes combined with spastic paralysis is due to infantile cerebral paralysis, but is in exceptional cases the result of an injury to the brain (see false meningocele). If both feet are affected with talipes and spastic paralysis, we may assume that the cause is Little's disease, the pathology of which we cannot here discuss.

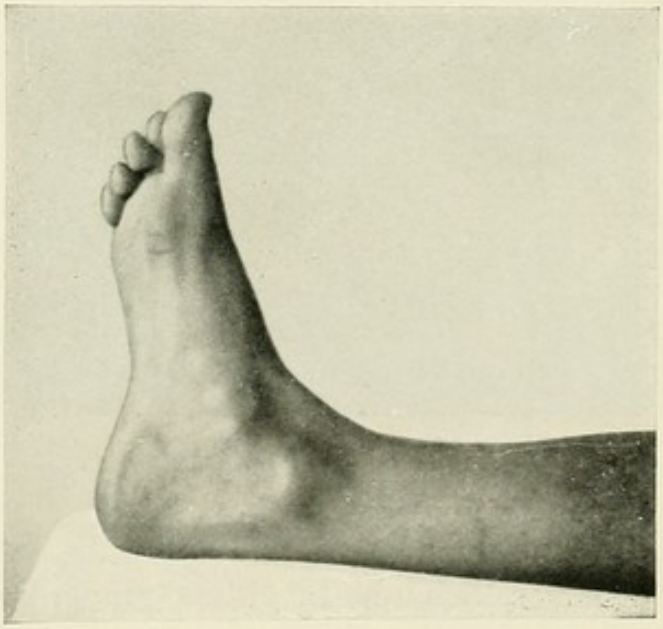

FIG. 501.—Pes calcaneus of slight degree, congenital origin.

The spastic forms of club foot are classified as acquired, although their ultimate cause is congenital. The development of the deformity does not, however, occur until post-fœtal life.

One form of talipes deserves special mention because it plays an important part in the consideration of accidents, *i.e.*, the so-called

habit contracture. If for some reason or other, generally an injury, the movements of the ankle and Chopart's joint become painful, these joints are held rigid by muscular fixation so that the foot does not yield at all on walking, but is planted down stiffly on its outer edge, as in talipes. If the patient is very sensitive to pain, or has neuropathic tendencies, or if there be a question of compensation involved, this posture may persist after the disappearance of the pain or after the recovery from the injury ; it becomes a *habit contracture.*

I have seen a habit contracture of this kind come on after a contusion of the foot. Although there was not the slightest anatomical change, the foot was always held in the talipes position on walking. The muscles of the whole limb were somewhat atrophic, and there was some cyanosis due to the deficient muscular activity. The condition had been present for three years owing to the protracted legal proceedings.

The preceding remarks on ordinary talipes apply also to **pes equinus, pes calcaneus** and **pes cavus.** These varieties may be either congenital or acquired, and in the latter case are usually of paralytic origin. Bilateral pes cavus and sometimes also pes calcaneus may gradually develop in advanced infancy or at puberty, without any definite ascertainable cause.

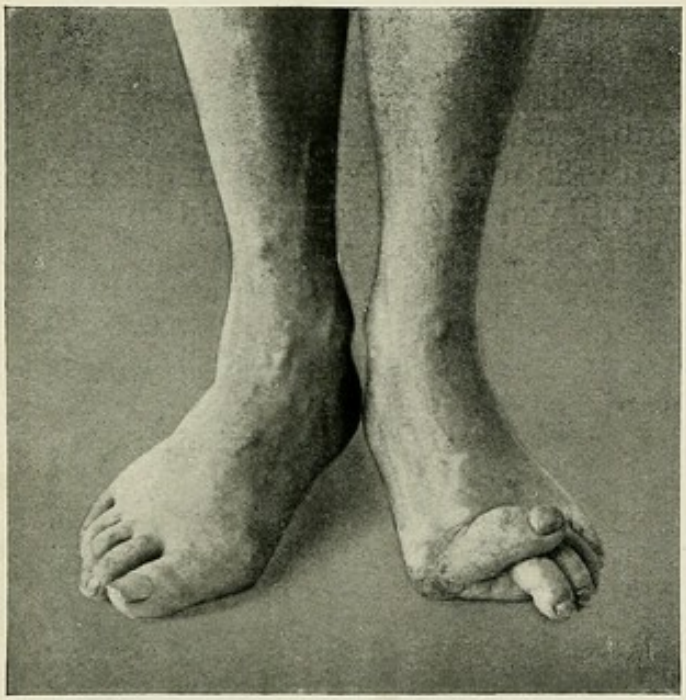

FIG. 502.—Hallux valgus of various degrees.

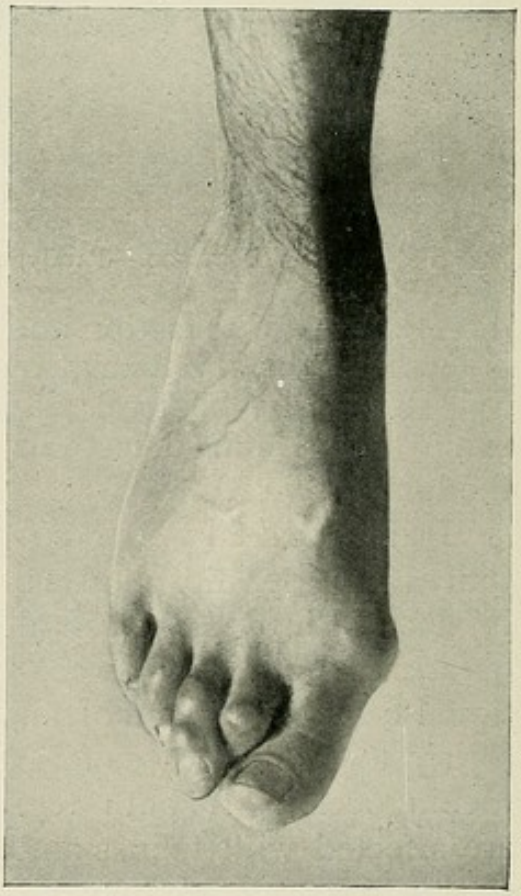

FIG. 503.—Hammer-toe (second).

It is probably due to some congenital disturbance of the co-ordinating power of the various muscle groups, and may be a very slight sign of some hereditary mal-development of the spinal cord, such as defective development of certain anterior horn cells.

Fig. 499 shows that pes equinus may be mistaken at first sight for hip disease.

(3) DEFORMITIES OF THE TOES.

Many an elegant shoe conceals deformities which not only offend the æsthetic taste, but which also make the life of the wearer a torture, until the patient decides to part with the toe or to permit a resection of the deformed joint.



FIG. 504.—Hallux valgus. Skiagram of fig. 502.



FIG. 505.—Hallux valgus. Skiagram of fig. 502.

This is especially true of the deformity, which is a product of civilization, known as **hallux valgus.** A glance at the two degrees of the deformity, as depicted in figs. 502, 504 and 505, suffices for the purposes of diagnosis. We have already referred to the secondary inflammation of the bursa which may ensue.

Hammer toe (fig. 503) is another frequent deformity. It may be due to hereditary disposition, as well as to badly fitting boots. When this condition gives rise to pain, it is mainly the result of inflammation of the bursa.

CHAPTER CIX.

TUMOURS AND ULCERS OF THE FOOT.

MANY different forms of tumours and of ulcers have been observed on the foot, as on the hand, but there are very few characteristic enough to deserve mention.



FIG. 506.—Multiple chondromata of the toes (from the surgical clinic, Berne).

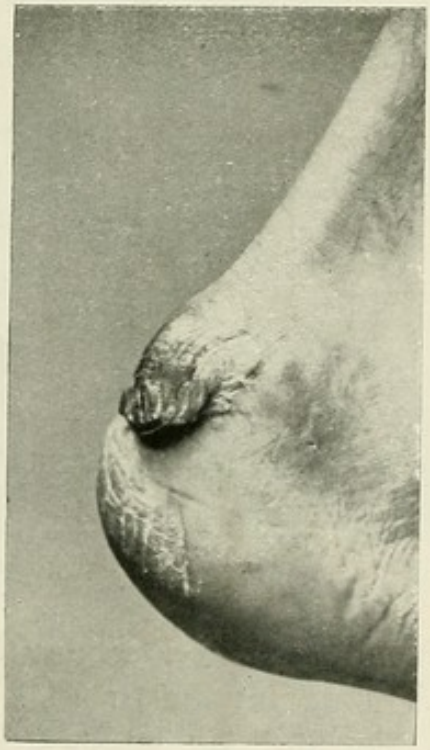

FIG. 507.—Cutaneous horn on heel.

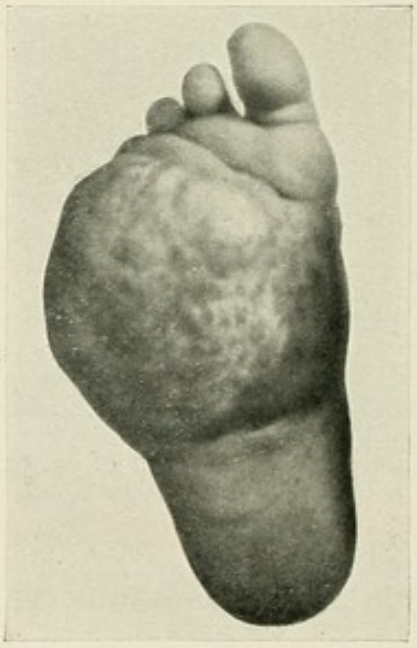

FIG. 508.—Cavernous angioma of foot.

(1) TUMOURS.

Chondroma of the toes is the most important of the *innocent new growths*, and its character is similar to that of chondroma of the fingers (fig. 506).

If a toe-nail is gradually raised by a tumour-like structure beneath it, a **sub-ungual exostosis** is suggested, as already described by Dupuytren. **Fibromata** originating in the nail-bed, and growing under or close to the nail, are rare. Cutaneous horns (fig. 507) are also unusual.

Lipomata have been seen on the metatarsus and they are liable to spread between the bones and plantar aponeurosis. **Cavernous angiomata** of congenital origin also occur on the foot.

Although these are histologically innocent, they invade various tissues such as skin, muscle and tendons, and they may lead to profound disturbances therein. Their granular surface, and their translucent bluish-red colour, and their emptying on pressure are signs which render them immediately recognizable. Fig. 508 is a typical illustration of the appearance of a cavernous angioma in general.

Sarcoma of the os calcis is the only *malignant tumour* which is at all characteristic in this region. Its diagnosis from tubercle has already been discussed.

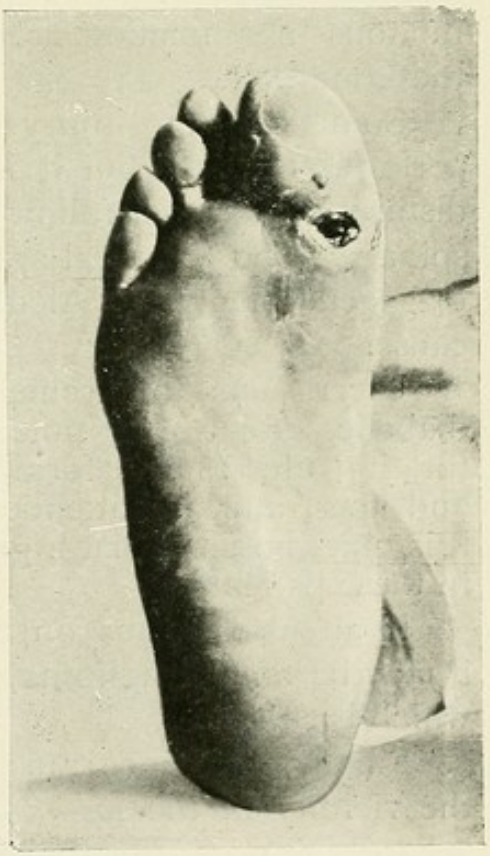

FIG. 509.—Perforating ulcer due to alcoholic neuritis.

(2) ULCERS.

In addition to the well-known triad of ulcers—tubercular, syphilitic and malignant—the foot presents frequent examples of "perforating ulcer" and of circumscribed gangrene of the skin. The nature of the ulcer can generally be diagnosed from its situation. In the *dorsum* they are usually tubercular or syphilitic (fig. 437), rarely malignant. The recognition of syphilis and of tubercle has been dealt with in Chapter CII. A malignant ulcer is differentiated from both of these by its papillomatous appearance, or by its hard edge and base. If we find a discoloration of the skin, either circular or map-like in shape, towards the toes, associated with loss of sensation in the affected area and with neuralgic pains, we must diagnose commencing gangrene and should examine for arterio-sclerosis, diabetes, or nephritis. Alcohol and syphilis may be indirect causes, if the patient is young. The gangrene becomes quite definite in the course of two or three weeks, the area involved becomes black and sloughs away from the healthy skin. The condition of the arteries and of the general

circulation determines whether the process ceases with this circumscribed destruction, or whether it is merely the prelude to an ascending gangrene.

An ulcer on the sole is either malignant or of a neuro-paralytic nature. The latter (**perforating ulcer**) is diagnosed from its situation on parts especially subjected to pressure, such as the heel, the ball of the great or little toe, by its slight local painfulness and its associated disturbed sensation and anæsthesia, often combined with radiating pains. These pains are not accidental accompaniments, but are indicative of the cause of the malady, *i.e.*, of a neuritis. The margin of the ulcer is formed of thickened epithelium, and the central necrosis may extend to the tendons and bones. Attacks of phlegmonous inflammation around the ulcer are very characteristic of the condition.

Sometimes an injury to a peripheral nerve accounts for the perforating ulcer, but it is more frequently the result of the nerve disturbances which follow on spina bifida, or of some disease of the spinal cord or cerebral system, such as syringo-myelia, tabes dorsalis or general paralysis. Alcoholic neuritis is, however, the most frequent cause.

Ulcers due to circumscribed gangrene in arterio-sclerotic and diabetic subjects, as noted above, must not be confused with perforating ulcer. The former occur usually on the dorsum of the foot and toes, and are attended by severe neuralgic pains. Of course, it is quite possible that a genuine perforating ulcer may also develop in these patients.

If an ulcer forms on a part of the sole not subject to pressure it may be an **epithelioma**, which is rare, or a **sarcoma of the skin**, which is still rarer.

Finally, reference must be made to the ulcerative processes in the vicinity of the *toe-nails*. **Ingrowing toe-nail** is so familiar that it hardly requires mention from the diagnostic aspect, were it not that **syphilitic** and **tubercular** ulcers also occur at the same spot. The latter is sometimes termed **onychia maligna.** Syphilis is diagnosed from the history, Wassermann reaction, and the results of specific treatment. Tubercle is diagnosed if the treatment for ingrowing toe-nail and for syphilis fail to cure the ulcer; but it is a better plan to remove a small piece of the margin for the purpose of histological examination.

INDEX.

A

ABDOMEN, surgical diseases of, 235
—, injuries of, 244
— —, with external wound. 251
— —, without external wound, 244
Abdominal cavity, acute inflammation in, 254-276
— —, effusion of bile into, in injuries of liver, 247
— —, entrance of gas into, in ruptured intestine, 245
— — — — — — — —, in perforation of stomach, 298
— —, tumours in, demonstration of, 287-290
— — — —, by exploratory puncture, 291
— hernia, epigastric, 369, 370
— injuries, gunshot, 252
— integument, abscess of, 272, 369
— —, actinomycosis of, 377
— —, fibroma of, 374, 375, 376, 377
— —, tenderness of, in peritonitis, 258, 259
— —, tumours of, 287, 368-376
— — —, atypical positions, 376
— — — in inguinal region, 374
— — — lumbar region, 375
— — — umbilical region, 371
— — — upper abdomen, 368
— lipoma, subcutaneous, 369, 376
— muscle, tuberculosis of, 376, 377
— nævi, sarcomatosis, 214, 376
— rigidity, reflex after intestinal injuries, 246
— — — — —, in peritonitis, 258, 275
— sinuses, 377
— — in groin, 379
— — at umbilicus, 377
— tumours caused by inflammatory changes, 287
— — causing intestinal obstruction, 287
Abdominal tumours, consistence of, 289
— —, determination of origin of those which fill up entire abdomen, 289
— —, innocence and malignancy of, 290
— —, movable, 288
— —, phantom, 287
— —, slightly movable and not very extensive, 289
— —, type of displacement of unpaired organs, 236
— viscera, diagram of parts felt on palpation, 240
— — displacements, 235; congenital, 235; acquired, 237
— wounds, perforating and incised, 253
Abducens nerve (6th), focal symptoms in lesion of, 40
— —, paralysis of, in fractures of base of skull, 5
Abrasion fracture of eminentia capitata humeri, 565, 567
Abscess, appendicular, 335, 336; position of, 334
— —, diagnosis from hip disease, 652
— — — —, peritonitis, 262, 272, 273
—, Bezold's, 33, 133
—, cerebellar, 32
—, epidural, 30
—, epigastric, 368, 369
—, gluteal, 519
—, inguinal, 517, 518
—, meso-cœliac, diagnosis from peritonitis, 264
— of abdominal wall, 274
— axilla, 211
— brain, 18
— —, diagnosis, 17, 18
— —, etiology, 19, 20
— —, symptoms, 17, 18, 19
— breast, 220, 221

Abscess, breast, superficial, 221
— kidney, 447, 452
— liver, 265, 326, 327
— lumbar region, 375, 517
— lung, 195, 196
— —, diagnosis from bronchiectasis, 198
— neck, 134, 135, 517
— —, chronic, 134, 135
— —, due to caries, 518
— —, tubercular (cold), 134, 135, 138
— palate, 95
— pelvic bones, 517
— seminal vesicles, 431
— spleen, 266, 330
— supra-clavicular fossa, 133
— supra-symphysis pubis, 272
— temporal lobe, 30, 31
— tibia, lower end, 705
—, peri-articular, of foot, 725
— — knee, 679
—, perineal, 519
—, peri-nephritic, tubercular, 375, 442
—, peri-proctal, 410
—, pharyngeal, 96
—, posterior cervical, 133
—, prostatic, 431, 471
—, residual, in peritonitis, 256, 268, 336
—, retrobulbar, 50, 61
—, retromammary, 219
—, retroperitoneal, 266, 335
—, retropharyngeal, 91, 114
—, retrotonsillar, 91
—, submental, 131
—, subphrenic, 195, 276
— —, in appendicitis, 337
— —, with pleural exudation, 279
— —, without pleural exudation, 277
—, sub-umbilical, 272, 378
—, tubercular (cold), of skull, 56
— — — of spine, 135, 215, 515, 516
Accessory goitre, 96
— —, true and false, 150
— thyroids, malignant growths of, 171
Acetablum, fractures of, 617
—, displacement of, in hip disease, 649, 650, 653
Achillodynia, 726
Acne pustules of axilla, 211
Acromegaly in tumours of pituitary body, 24
Acromio-clavicular joint, injuries of, 535, 536
Actinomycosis of ileo-cæcal region, 288, 377
— jaw, 78, 79
— limbs, 571
— lungs, 198, 210
— mamma, 222
— neck, 135, 140
— —, with sinus formation, 136
— tongue, 107
Adamantinoma, 87
Adenoids of roof of pharynx, 91
Adenoma of liver, 326
—, testicle, 422
Adiposis dolorosa, 24, 175
Air-goitre, nature of, 141
Air passages, diseases of, chronic, 118
— — —, surgical, 110
— —, foreign bodies in, 116, 117
— —, injuries of, 116, 189
Albuminuria in diphtheria, 113
Alveolar process, hæmorrhage in fracture of upper jaw, 73
— tumours, 85
Anæsthesia dolorosa in tumours of jaw, 84
— paralysis, of upper limb, 594
Anal region, fistulæ, 410, 424, 425
— — —, complete and incomplete, 426
— — —, nature of, 426
— —, injuries of, 412, 413
— —, prolapse of, 411, 412
— —, tumours of, 409-412
Anarthria, diagnosis and surgical significance of, 46
Aneurism, cirsoidal, of face, 64
— of aorta, 201, 205
— —, penetrating through thoracic wall, 213
— carotid, 163
— fibula, 699
— innominate artery, 203
— neck, 127, 162
— —, arterio-venous, 164
— —, diagnosis from other tumours of neck, 140, 163
— thigh, 658
—, femoral, 658
—, ophthalmic, 50
—, popliteal, 687
—, subclavian, 163
Angina, diffuse and unilateral, 90, 91

Angina, dysphagia in, 123
—, Ludovici, 132
—, Ludwig's, 90
Angioma of arm, 572
— face, 63, 64, 66
— foot, 738, 739
— hand, 600
— longitudinal sinus, 53
— mouth cavity, 94
—, mulberry-like, of infant, 54
— orbit, 56
— sacral region, 485
— scalp, 51, 52, 53, 54
— thigh, 657, 658
— thoracic wall, 216
— tongue, 105
Ankle, contusions of, 706
—, dislocations of, 714, 715
—, fractures of, 706, 709, 710
—, gonorrhœal effusion of, 725
—, injuries of, with deformity, 712
— —, without deformity, 706
— —, summary of, 720
—, sprain of, 706, 710
—, tuberculosis of, 726, 727, 728
Ankylosis of hip-joint, 655
— jaw, causes, 76, 77
— knee-joint, 686
— vertebral joints, 521
Anuria, 427, 443
Aorta, aneurism of, 201, 202, 203, 205
— —, skiagraphy in, 203
— —, diagnosis from tumour, 201, 287
Aphasia, focal diagnosis of, 46, 47
— in cerebral abscess, 30
— — cerebral pressure, 14
Appendicitis, 266, 272, 332
—, chronic, 262, 339, 345, 346
—, complications, 336, 337
—, condition of vermiform appendix and its surroundings in early stages of, 332
—, diagnosis of, 332
— — in the intervals, 338
— —, from abdominal tumour, 288
— — cholecystitis, 317
— — hip disease, 652
— — peritonitis, 267
— — ruptured tubal pregnancy, 273
— — urinary tuberculosis, 460
—, diagram of its most important forms, and some diseases concerned in differential diagnosis, 268-271
Appendicitis, exploratory puncture in, 336
—, history of, 272, 338
—, ileus in, 337, 354
— in hernial sac, 401
—, pregnancy and puerperal period, 276
—, larval (Ewald), 338
—, physical signs, 338, 339
—, position and extent of appendix abscess, 334, 335
—, residual abscesses and their significance, 334, 336
—, symptoms in localized peritonitis, 333
— — in early stage, 332
— — when accompanied by general peritonitis, 333, 334
— with peritoneal symptoms, 264, 333
Appendix vermiformis, abscess of, 272, 333
— —, displacement of, 237, 317, 318
— —, its condition and surroundings in early stage of appendicitis, 332
— —, palpation of, 239
— —, position of, 334
Arm, chondroma of, 576
—, fibroma of, 576
—, gumma of, 574, 575, 576
—, mobility in injuries of spinal column, 490
—, muscular angioma of, 572
—, muscular tuberculosis of, 573
—, myositis ossificans of, 574
—, neuroma of, 572
—, osteoma, traumatic, of, 574
—, osteomyelitis of, 575, 576
—, posture of, in transverse lesion of spinal cord, 491
—, sarcoma of, 576
—, tuberculosis of, 573, 575, 576
Artery, femoral, aneurism of, 658
—, mesenteric, embolism of, 264
—, ophthalmic, aneurism of, 50
Arthritis, acute, of elbow, 569
—, deformans 589, 590, 591
— of foot, 724
— hip, 643, 644, 646
— jaw, 76
— —, ankylosing, 77
— shoulder, 550
— vertebral joints, causing chronic deformity, 521
— wrist, 588
— —, tubercular, 589, 590, 591

Articulation, sacro-iliac, sprain of, 630
— — —, fissure in neighbourhood of, 630
Ascites, chylous, in old umbilical herniæ, 373
— — — — —, diagnosis from exudative tubercular peritonitis, 283
Assyrian foot, 715
Astragalus, dislocation of, 715
—, fracture of, 711
—, injuries of, 715
Auditory nerve injuries through fractured base, 5
— — — — —, focal symptoms in, 44, 45
Axial rotation of intestine, 364, 365
Axilla, abscess of, due to acne pustules or furuncles, 211
—, enlargement of glands, 210, 211
— — —, in cancer of breast, 229, 230
—, hydro-adenitis of, 211
—, lymphadenitis of, 550
—, pendulous lipoma of, 572, 573
—, phlegmon of, 210, 211

B

BACILLURIA, 434
— in cystitis, 465
Back, flat, 525
—, mobility of, after vertebral injuries, 490
—, muscles of, fibro-lipoma of, 216
— —, fibroma, lipoma, and sarcoma of, 218
—, round, 525
—, skin of, tumours of, and their differentiation, 214, 215, 216, 217
Balanitis, 475
Balanoposthitis, 475
Banti's disease, 314, 331
Barlow's disease, signs of diagnostic importance, 100, 511, 656
Base of skull, fractured, symptoms of, 3, 5, 6
Bayonet fracture, supra-condylar, in elbow-joint, 558
Bennet's fracture, 586
Biceps muscle, hernia of, 574
Biliary passages, catarrh of, 313
— —, injuries of, 247, 248
— —, obstruction of, 321-323, 324
Biliary passages, surgical diseases of, 313
— — — —, with peritoneal symptoms, 265, 273
Bites of mucous membrane of cheeks, ulcers due to, 99
Bladder, calculi, 461
— —, aseptic, 461
— —, cystoscopy in, 462
— —, diagnosis from tumours of, 462
— — —, from stone in kidney, 462
— —, in diverticula, 463
— —, infected, 463
— —, in skiagram, 463
— —, obstructing urethra, 430
— —, primary and secondary, 463
— —, symptoms of, 461
—, catarrh of, 464, 465
—, colic of, 436
— disturbances in spinal injuries, 492
—, ectopia of (vesical), 379
—, examination of, 438
— —, with cystoscope, 440
—, fibroma of, 467
—, fistulæ of, 427
—, foreign bodies in, 465
—, gunshot wound of, 252
—, hæmorrhage from, 436, 467
—, hernia of, 391
—, inflammation of, 429, 464
—, injuries of, 250, 465
—, papilloma of, 467
—, rupture, extra-peritoneal, 250
— —, intra-peritoneal, 251
— —, difference between extra-peritoneal and intra-peritoneal, 251
—, sarcoma of, 467
—, tenesmus of, 432, 458, 462
—, tuberculosis of, 459, 460, 465
—, tumours in muscle of, 467
— —, mucous membrane of, 466
Blindness, unilateral and bilateral, focal diagnosis, 38, 39
Blood, condition of, in Graves's disease, 145
— cysts, in long bones, 660
—, effusion of, diagnostic importance in fractured ribs, 189
— — — — — skull, 3, 4
—, freezing point in kidney disease, 441

Blood in joints, 680, 681, 686
— tumours at side of neck, 162
—, vomiting of, hysterical, 296
— —, in cancer of stomach, 310
Bone, abscess of, chronic, at lower end of tibia, 704, 705
— —, with sequestrum, in humerus, 575
—, aneurism of, in femur, 660
—, cysts of, in leg, 699, 700
—, perineal fistulæ, in connection with, 424
—, tumours of, in ileo-sacral region, 480
— —, in thorax, 218
Botriomycosis of hand, 600
Brain, abscess of, 17, 18, 19
— —, diagnosis, 17, 18
— —, etiology, 19, 20
— — in temporal lobe after aural suppuration, 30, 31
— —, symptoms, 19, 20
—, angioma of, 50
—, base of, nerves of, 44
—, concussion of, 8, 9
— —, course, 9
— —, diagnosis, 8, 9
— —, symptoms, 9, 10
— — —, local, 14
—, contusion of, 7, 10, 11
— —, diagnosis, 10, 11
— —, symptoms, 10, 11
—, cortical areas of, 42, 43
—, cysts of, 19, 21, 22
—, focal diagnosis, 38
— — —, in tumours, 23, 24
—, gumma of, 18, 22
—, hernia of, 51, 52
— —, differential diagnosis, 53
— —, position of, 51, 52
— —, symptoms of, 52
—, injuries of, 17
—, tubercle of, 18, 22
—, tumours of, 17
— —, diagnosis, 18
— —, localization, 23, 24
— —, new growths and granulation tumours, 22
— —, diagnosis from abscess of brain, 17, 18
— pressure, 7, 8, 12
— —, general and local, 12
— —, commencing and complete, 13
Brain pressure, commencing, diagnosis, 14
— —, symptoms, classical, 13, 14
— — —, local, 14
Branchial cleft cancer, 171
— — fistulæ, 138, 139
— — cysts, 155, 164
— — —, diagnosis of, 165
Breast, *see also* Mamma
—, bleeding, 233
—, cancer of, diagnosis, 228
— —, adhesions to pectoral muscles in, 229
— —, contracting, 227, 229, 232
— —, diminution of the areola in 229
— —, elevation of nipple in, 229
— —, enlargement of axillary glands in, 229
— —, medullary, 231
— —, prognosis, 231, 232
— —, retraction of nipples in, 229
— —, scirrhus, 225, 226
— —, secondary growths, 231
— —, ulcerating, 228, 230
Bronchial glands, enlargement of, 200, 201
Bronchiectasis, diagnosis, 198
— —, from abscess of lung and tubercular cavity, 196
— diffuse, of right upper lobe of lung, 206
Bronchocele, 141
Bronchoscopy, diagnostic importance of, 110, 118
Brown-Sequard's lesion, 494, 508
Bryant's triangle, determination of, in injuries of hip, 612, 632
Bulbar palsy, dysphagia in, 122
Buphthalmos diagnosis from exophthalmos, 49
Burrowing abscess, due to spinal caries, 383, 386, 393, 515, 518, 519, 651
— —, gluteal, 519
— —, inguinal, 374, 384, 386, 392, 516, 517
— —, perineal, 519
— — in iliac fossa, 518
— — — loin, 375, 517
— — — neck, diagnosis from aneurism, 163
— — — true pelvis, 479
Bursa, iliac, effusion into, 652

Bursa, mucous, of hand, inflammation of, 605
— — foot, inflammation of, 727
— — knee, inflammation of, 677, 687, 688
— — shoulder, inflammation of, 550
— pre-patellar, tuberculosis of, 687
Bursitis, infra-patellar, 687
— over olecranon, 570, 572
— — tendo Achillis, 726
—, pre-patellar, 687, 688
— —, phlegmonous, 677
—, pre-tibial, 687
—, sub-calcaneal, 727
—, traumatic and tubercular of shoulder-joint, 547, 550
— under callosities of palm, 605

C

Cadre colique, 358
Cæcal region, herniæ in, as causes of intestinal obstruction, 366
Cæcum, movable, 344, 345
Calcanalgia, 727
Calcaneus, compression fractures, 718, 719
—, crush fractures, 719
—, fractures, 716, 717, 718, 719, 720
—, laceration fractures, 717
—, sarcoma of, 726, 739
—, tubercle of, 726, 728
Cancerous cachexia, diagnostic significance of, 306
Cancroid of back of hand, 601
— concha of ear, 72
— lips, 65
— nose, 70
Caput obstipum, 185
— —, congenital, 184
Carbuncle of back of neck, 133
Carcinoma, branchiogenous, 171
— of bladder, 467
— breast, 225, 227, 228
— —, contracting, 227, 229
— — —, ulcerating, 228, 230
cervical glands, secondary, 159
— cheek, 67, 68, 69
— clavicle, 212
— concha of ear, 72
— floor of mouth, 99
— — —, perforation of, 139
— hand, 601
Carcinomâ of intestine, 351, 352
— kidneys, causing intestinal obstruction, 353
— larynx, 119
— —, histology, 120
— —, perforation, 139
— —, position, 120
— lips, 64, 67, 68
— liver, 325, 326
— —, secondary, 207
— lung, 207
— nose, 67, 69, 70
— œsophagus, 127, 130
— ovary, 353
— pancreas, 329
— parotid gland, 169
— penis, 477
— pharyngeal wall, 103
— — —, perforation of, 139
— prostate, 470
— puncta of eye, 69
— pylorus, 311
— rectum, 275, 352, 407, 408, 411
— scalp, seborrhœic, 58
— scrotum, 415
— sigmoid flexure, 352
— soft palate, 103
— stomach, 305
— —, cardiac end of, 306
— —, body of, 310
— submaxillary gland, 169
— testicle, 422
— thyroid gland, 153
— — —, secondary deposits, 155
— tongue, 108, 109
— tonsillar region, 101, 161
— umbilicus, 374
— upper jaw, 82, 83, 84
— uterus, 353
Caries of spine. *See* Spinal caries
Carotid gland, new growth of, 172
Carpo-metacarpo-phalangeal joint, dislocation, 585
Cartilage, detachment of, in knee-joint, 670
Cartilaginous tumours in pelvic joints, 480
Catheterization of urinary passages, 438, 439
— — — in ruptured bladder, symptoms, 250
— — —, injuries through, 472

Cauda equina, compression of, irritative symptoms, 508
Cavernitis, chronic, of penis, 475
Cellular tissue, subcutaneous, of finger, inflammation of, 603
Cephalhæmatoma, 3
Cephalo-hydrocele, traumatic, 22
Cerebellar abscess after chronic otitis, diagnosis of, 32
— tumours, 24
Cerebello-pontine angle, tumours of, 24
Cerebral injuries, 1, 7
— —, pressure symptoms, 12, 13
— —, symptoms, 8, 9
— localization, 38
— —, auditory nerve disturbances, 45, 46
— —, disturbances of peripheral ocular muscles, 39
— —, facial nerve lesions, 41, 42, 43
— —, methods of marking most important motor centres on surface of skull, 43, 47, 48
—, new growths in brain, 22, 23
—, paralysis of limbs, 44
—, speech disturbances, 46, 47
—, visual disturbances, 38
— pressure, 9
— puncture, diagnostic value in brain tumours, 25
— swelling, traumatic, 14
Cerebro-spinal fluid, discharge of, from ear and nose in fractures of base of skull, 4
Cervical cord, injuries of, diagnosis of segment, 497
— fistulæ, 136
— —, arising from a goitre, 139
— — —, cancer, 139
— —, branchial-cleft sinuses, 138
— —, complete and incomplete, 138, 139
— —, congenital, 138
— —, median, 138
— —, mouth, larynx, and pharynx, 139
— —, origin, course, and external appearance, 136
— —, position, 138
— —, secretion, 137
— ribs, 140, 163, 172
— —, symptoms of, 172, 173
Cervical spine, injuries of, disturbances of motion in, 495
— — — —, sensation, 497
— — —, irritative symptoms, 497
— veins, dilatation in mediastinal tumours, 200
— vertebræ, caries of, 184, 514, 515, 516
— —, contusions, 177
— —, dislocation fracture (complete dislocation), 176, 177, 178, 183
— —, unilateral (rotation-dislocation), 180, 182, 183
— —, fracture of axis, 179
— —, injuries, 176
— —, normal position of atlas and axis, 179
— —, osteo-myelitis of, 180
— —, sprains, 177
— —, tubercle of, 134, 136, 515, 516
— —, tumours of, 181
Cervico-dorsal scoliosis, with elevation of shoulder, 525
Chancre, hard and soft, 476
—, on the fingers, 606
—, primary, on face, 72
— —, fingers, 606
— —, gums, 100
— —, lip, 64, 98
— —, tongue, 107
— — tonsillar region, 102
Cheeks, bites of, 99
—, gangrene of, 91
—, lupus of, 71, 72
—, molluscum contagiosum of, 71
—, rodent ulcer of, 68, 69, 70
—, tumours of, 71
— —, mucous membrane of, 92, 99
Cheyne-Stokes's respiration, in brain-pressure, 12, 13
Chimney sweep's cancer of scrotum, 415
Cholangitis, acute, 324
Cholecystitis, acute, 316
— —, differential diagnosis, 299, 316, 317
—, gangrenous, 318
Cholesteatoma of temporal bone, diagnosis, 26, 31
Chondritis of ribs, 213
Chondroma of arm, 576
— cervical rib, 173
— hand, 600

Chondroma of lower jaw, 87
— mamma, 234
— parotid gland, 169
— spine, 517
— thigh, 659
— thorax, 207, 218
— tibia, 700
— toes, 738
Chopart's joint, dislocation of, 721
— —, inflammation of, 724
Cicatricial stenosis of bowel, 352
— — pharynx, 123
— — stomach, 299
Circumflex nerve, paralysis of, raising of arm in, 594
— — —, through dislocation of shoulder, 549
Cirrhosis of liver, hypertrophic, 314
— stomach, 311
Clavicle, carcinoma of, 212
—, dislocation of, 534, 535, 537
—, fracture of, 534, 535, 536
—, osteo-myelitis of, 210
—, sarcoma of, 212
Club foot, 734, 735
— —, bilateral, with flaccid paralysis, 735
— — —, spastic, 735
— hand, 595, 597
Cochlear nerve, focal symptoms in injury of, 45
Colic, intestinal, 347
— —, in obstruction, 360
Colitis, 339
—, chronic ulcerative, 341
—, muco-membranous (symptoms and diagnosis), 342, 343
Colloid goitre, diffuse, 142, 148
— —, unilateral, 145
Colon, *see* Large intestine
Comminution fracture of head of humerus, 542
— — lower end of ulna, 581
— — os calcis, 719
— — patella, 672
Common bile-duct, closure of, 321, 324
— — — by stones, 321, 322
— — — tumour, 321, 322
— — metastases in, 322
Compression fractures, cause of curvature, 523
— —, diagnosis from lumbago, 488
Compression fractures of os calcis, 717, 719
— — scaphoid, 721
— — spinal column, 502, 503, 505
— brain, 9
Concretions in stomach, 293
— umbilicus, 378
— urine, 436
Concussion of brain, 7, 8, 9
Condyles of femur, fractures of, 673, 676
— humerus, fractures of, 559, 560, 561, 562, 563, 556-565
Condylomata, tip of penis, 477
Conglomerate goitre, 145
Conjunctiva, chancre of, 72
Constipation, causes of, 343, 345
—, ascending type, 343
—, painful, 343, 409
Contracture, Dupuytren's, 597, 598
— —, of foot, 733
— in ulnar paralysis, 598
—, posture of spinal column, 531
Contrecoup contusion of brain, 15
— fractures of skull, 6, 15
Contusion, axial, of spinal column, 506
—, fracture of semilunar bone, 585, 586
—, intramuscular osteoma after, 574
— of ankle, 706
— brain, 7, 10, 11
— —, diagnosis, 11
— cervical vertebræ, 177, 178
— gastro-intestinal canal, 245
— — — —, symptoms, 246
— hip-joint, 621
— knee-joint, 668
— scrotum, 414
— shoulder-joint, 535, 546
— thorax, 189, 190
— urethra, without external wound, 472
Coronoid process of ulna, fracture of, 556, 561, 566, 567
Coxa vara, 631, 639-643
— —, diagnosis between spontaneous and traumatic forms, 627
— —, diagnosis from hip disease, 642
— —, from congenital dislocation of hip, 631, 642
— —, due to rickets, 636, 638, 640, 641

Coxa vara, due to injury, 621, 627
— —, false, 640
— —, important diagnostic signs, 642
— — of adolescence, 640, 642, 643
— —, unilateral, limping in, 641
Cranial nerves, injury of, 4, 5
— — —, focal symptoms, 38-47
Craniometry, after Kocher and Krönlein, 47, 48, 49
— — — —, diagrams of, 47, 48
Cretinism, fractures in, 670, 673
Crutch-palsy, 594
Cubitus valgus, 561
Curvature of spine, 522-533
Cyroscopy, 441
Cystadenoma phyllodes of the breast, 232
Cystic goitre, 146, 148
Cystitis, 433, 465
—, causes of, 464
—, composition of urine in, 434, 465
—, primary, diagnosis of, 464
—, tubercular, 465
Cystoma of jaw, multilocular, 87
— testicle, 422
Cysto-sarcoma phyllodes of the breast, 232
Cystoscopy, 427, 440, 441, 456, 459, 462, 464
Cysts between testicle and epididymis, 420
—, blood, 162
— in true pelvis, 407
—, lymph, 161
— of abdominal cavity, diagnosis from sacculated tubercular effusions, 285, 290
— bones of leg, 699, 700
— brain, traumatic, 17, 20
— branchial clefts, 155
— breast, 223, 224, 225
— hand, traumatic, 599
— jaw, 84, 87
— kidneys, congenital, 458
— liver, 326
— —, parasitic, 327
— mouth cavity, 92, 93
— neck, congenital, 155, 164
— pancreas, 329
— prostate and retro-prostatic tissue, 481
— spleen, 331
Cysts of thyreo-glossal duct, 155
— thyroid, 148
— umbilicus, 373
— urachus, 373
— vitelline duct, 373

D

DACROCYSTITIS, phlegmonous, 61
Dactylitis, syphilitic, 608, 609
Défense musculaire in abdominal injuries, 246, 258
Degeneration, fibro-epithelial, of mamma, 223
Dental cysts, 83, 84, 87
— periostitis, 60
— sinus, inflammation of jaw in, 78
Derangement, internal, of knee-joint, 670
Dercum's disease, 175
Dermatitis of hand, 602
— —, through drugs, 602
Dermoid fistulæ around coccyx, 423, 486
— of back of neck, 174
— face, 63
— floor of mouth, 89, 93
— lung, 207
— mediastinum, 207
— neck, 165
— pelvic cellular tissue, 481
— penis, 475
— sacral region, 486
— scrotum, 415
— skull, 51, 53
— testicle, 422
— umbilicus, 378
—, sublingual, 93
—, suppurating, 89, 131
—, supra-orbital, 63
Detached fracture of coronoid process of ulna, 561, 566
— — head of fibula, 674, 676
— — internal condyle of femur, 670
— — — epicondyle of humerus, 563
— — os calcis, 718, 719
— — rim of acetabulum, 617
— — spine of tibia, 671, 674
— — styloid process of ulna, 518, 577, 580
— — trochanter of femur, 622
— — tuberosity of humerus, 542, 544

Dextroposition of stomach, 236
Diaphragmatic hernia, after injuries to lung, 191
— —, diagnosis of, 367
Diaphyseal tuberculosis of humerus, 576
— — tibia, 703
— tumours of femur, 664
Diphtheria, bacteriology of, 112
— of larynx, 112, 113
— throat, 112
—, paralysis of palate in, 122
—, secondary symptoms, 113, 114
Diplegia, from spinal cord hæmorrhage, 495
Diploe, sarcoma of, 57
Dislocation, acromio-clavicular, 539, 540
—, axillary, 542
—, central, of femur, 620, 630
—, compression-fracture of spine, 505, 507
— — of cervical vertebræ, 176, 505
—, congenital, of hip, 631, 634, 635
— fracture, complete, 503
— — in ankle, 715
— — of cervical vertebræ, 177
— — spinal column, 503
— —, typical, inter-carpal, 585, 587
—, iliac, 615, 616
—, ileo-pectineal of pubic, 617, 618
—, infra-cotyloid, 620
—, obturator, 619, 620
— of ankle, 712, 714, 716
— astralagus, 715, 716
— carpo-metacarpo-phalangeal joint, 585
— Chopart's and Lisfranc's joint, 721
— clavicle, 534, 536
— elbow, 555
— —, backwards, 554, 561-568
— —, forwards, 568
— —, lateral, 562
— —, outwards, 561
— femur, 615
— —, central, 620
— hip, 610, 615, 616, 617, 618, 619, 620
— —, backwards, 615, 616
— —, complicated, 616, 617
— —, congenital, 631, 634, 635, 637
— —, forwards, 617
Dislocation of hip, inflammatory, 645
— humerus, 538, 539, 540
— inter-carpal phalangeal joints, 584
— knee-joint, 676
— lower jaw, 74
— lumbar vertebræ, 500
— neck, unilateral, 182, 183
— —, complete, 176, 178, 182
— patella, 676
— peroneal tendons, 712
— shoulder-joint, 538, 539
— tibia, 676
— ulna, 561
— vertebral column, 502, 503
— — —, complete, 506
— wrist, 578, 579, 583, 584, 585
—, perineal, 619
—, radius, 563, 566
—, sciatic, 615, 616, 617
—, semilunar bone, 579, 583
—, sub-astragaloid, 716
—, sub-coracoid, 539, 542
—, supra-cotyloid, 620
— —, congenital, 637
Diverticula in lower portion of large intestine, inflammation, 276
—, Meckel's, invagination of intestine, caused by, 364
— of bladder, stones therein, 467
— œsophagus, 128, 135, 140, 162
—, perforation of, 267
Dorsal scoliosis, 527, 528, 529, 530, 531
— spinal cord, local diagnosis, 500, 501
— vertebræ, compression fracture, 503
— —, primary scoliosis of, 532
— —, segmental diagnosis of, 500
— —, suppuration, 516
— — —, with burrowing abscess, 517
Duodenal ulcer, diagnosis from cholecystitis, 316
— — — gastric ulcer, 297
— — — intestinal obstruction, 358
— —, perforated, 299
— —, peritonitis in, 265
Dupuytren's contraction, 597, 598
Dura mater, hæmatoma of (local pressure symptoms), 12, 13, 14
— —, pedunculated fibroma of, 175

Dysentery, diagnosis from intestinal obstruction, 347
— —, ulcerative colitis in its later stages, 341
Dyspnœa in cerebral pressure, 13
— diphtheria, 113, 114
— mediastinal tumour, 199
— perforated gastric ulcer, 298
Dysuria, 429

E

Ear, cancroid of, 72
—, concha of, prominence of, in mastoid otitis, 27, 28
—, hæmorrhage from, diagnostic significance in fractured base, 3
—, lupus of, 72
Echinococcus of kidney, 465
— liver, 326
— —, multilocular, 326
— lung, 207
— mediastinum, 207
— spleen, 331
— vertebral column, 509, 510
Elbow glands, inflammation of, 568
— joint, dislocation, 554, 555
— — —, backwards, 554, 555, 556, 557
— — —, complete and incomplete, 561
— — —, forwards, 556, 557, 567
— — —, lateral, 555, 562
— — —, outwards, 555
— — fractures, at lower end of humerus, 555, 556, 557, 558, 559, 560, 561, 562-565
— — —, coronoid process, 566
— — — head of radius, 565, 566, 567
— — — olecranon, 556, 557
— — — ulna, 556, 561
— —, inflammation, 569, 571
— —, injuries of, 553
— — —, examination for, 554
— — — — by inspection, 554
— — — — palpation, 560
— — — — testing movements, 555
— — — — X-ray examination, 567
— —, normal, 557
— —, position of three lines of fracture of, 563
— —, sprain of, 566, 567
Elbow joint, syphilis of, 571
— —, tuberculosis of, 569, 571, 572
Elephantiasis of penis, 475
— scrotum, 415
Embolism of mesenteric artery, 264
— lung, 197
Embryoma of testicle, 422
— —, diagnosis from embryoid tumour, 422
Eminentia capitata humeri, abrasion fracture, 565
Emissary mastoid vein, thrombophlebitis of, 33
Emphysema in injuries of thorax, 190
Empyema necessitatis, 209
— of antrum of jaw, 83
— gall-bladder, 323
— lung, 195, 196
— —, scoliosis after, 522
Encephalocele, 52
Encephalomeningocele, 52
Enchondroma, *see* Chondroma
Endothelioma, relation to cutaneous cancer, 70
Enteroptosis, 235, 236, 242, 243
—, confirmation by palpation, 240
— — by skiagram, 241
Epicondyle of humerus, internal, fracture of, 558, 559
Epicondylitis of humerus, 572
Epididymitis, gonorrhœal, 415, 416, 417, 419
—, syphilitic, 419
—, traumatic, 416
— —, sinuses in, 420
—, tubercular, 420
Epigastrium, acute inflammation, 265
—, chronic abscess of, 368, 369
—, hernia of, 369, 371
—, subcutaneous lipoma of, 369
Epilepsy, diagnosis from hysteria, 34, 35
—, diagnostic significance of course of attacks, 36
— — —, the history, 35, 36
— — —, physical condition in intervals, 36, 37
—, epileptiform attacks in brain tumours, 18
—, Jacksonian, attacks of, in cerebral pressure, 17
— — — cerebral tumours, 18, 37
— —, typical form of, 36

Epilepsy, surgical significance of the various forms, 34
Epinephritis, 442
Epiphyseal swellings of femur, 661
Epiphysis of tibia, tuberculosis of, 704
—, separation of, at head of femur, 627, 645
— — in the new-born, and in infants with hereditary syphilis, 545
— — radius, 579, 580
Epispadias, 475
Epithelial cysts of neck, congenital, 164
— — —, traumatic, of hand, 599
Epithelioma of face, calcified, 64
Epulis, 94
Erb's paralysis, posture of hand and fingers in, 594
Erysipelas of face, 59
— scalp, 51
Erysipeloid of finger, 603
Esmarch's paralysis in the upper extremity, 594
Eye muscles, nerves of, injuries to, 5
— —, peripheral derangements of, focal diagnosis, 39-41
— — — —, in Graves's disease, 143
Eyelids, cancer of, at puncta, 69
—, ulcers on, 70
—, xanthelasma of, 64
Eyes, conjugate deviation of, in cerebral pressure, 13, 14
— — — — —, diagnosis from peripheral derangements of ocular muscles, 39
Exophthalmos, diagnostic significance of unilateral and bilateral, 49, 50
— in Graves's disease, 49, 143
— pulsating exophthalmos, 50
—, surgical, 49
— —, mode of origin, 50
Exostosis of femur, cartilaginous, 659, 660, 661
—, subungual, of foot, 739
— tibia, 700
Expansile pulsation in aneurism, 163
Extension apparatus of knee-joint, laceration of, 671
— fracture of lower end of humerus, 558, 561
Extra-uterine pregnancy, peritoneal symptoms, 273
Extremities, measurement of the lower, after injuries, 612, 613, 626
Extremities, mobility of, after cerebral injuries, 44
— — — vertebral injuries, 489, 490
—, rigidity of the lower, causing limp, 611
—, sciatica and other painful diseases of the lower, 689-693
—, surgical diseases of, 536

F

Face, angioma of, 64, 66
—, cirsoid aneurism, 64
—, cutaneous warts of, 64
—, dermoid of, 63
— —, supra-orbital, 63
—, epithelioma of, 64
—, erysipelas of, 59
—, inflammatory processes of, 59
—, lipoma of, 64
—, lupus of, 66, 68, 71
—, primary chancre of, 72
—, sebaceous cyst of, 63, 64
—, syphilide of, 71
—, tumours of, 62
— —, closed, 63, 64
—, ulcerative processes of, 62, 64
—, xanthelasma of, 64
Facial nerve injuries, focal diagnosis of, 41-43
— — —, diagram of, 41
— paralysis in fracture of skull, 5, 41, 42
— —, tetanus, 75, 77
False croup, symptoms of, 112
— tail in sacral region, 486
Fat necrosis in pancreatitis, 264
Fatty neck, Madelung's, 174
— tissue, retrobulbar, venous thrombosis of, 61
Femoral hernia, 392, 393-394
— —, abnormalities in, 395
— —, diagnosis of, 394, 395
— — —, from burrowing abscess, 392
— — — distension of saphenous vein, 392
— — —, glandular enlargement, 392
— — — pedunculated subserous lipoma, 393
— —, external, 395
— — in women, 393
— — —, with divided sac, 395
— —, pro-peritoneal, 396
— —, strangulated, 396, 403

Femur, Barlow's disease, 657
—, chondroma of, 659
— dislocation, 615
— —, anterior, 617, 618, 619
— —, central, 620, 630
— —, complicated, 617
— —, congenital, 631
— —, posterior, 616, 617
—, exostosis, 659, 660, 661
—, fracture of cartilage of, 668, 669
— —, diaphysis, 628
— — — at upper end, 622-630
— — — at lower end, 672, 673, 675, 676
— — —, spontaneous, 665, 666
—, osteomyelitis of, 643, 656, 657, 659, 662, 663, 664, 665
—, sarcoma of, 657, 658, 661
—, tuberculosis of, 658, 661, 663
Fibro-adenoma of mamma, 224, 226, 232, 233
— —, phyllodes, 223, 233
Fibro-lipoma of muscles of back, 216
Fibroma of abdominal wall, 374, 375
— arm, 572
— back of neck, 175
— bladder, 467
— hand, 600
— knee-joint, 687
— larynx, 121
— leg, 87
— lower jaw, 697
— mouth cavity, 92, 94
— nail-bed of toes, 739
— naso-pharynx, 84, 85, 96, 121
— neck, 166, 169, 170
— pelvis, 480
— sacral region, 486
— scalp, 55
— scrotum, 415
— thigh, 657, 658
— thorax, 216, 217, 218
— tongue, 105
— umbilicus, 374
Fibro-myoma of ligamentum teres, 375
— of the uterus, 289
Fibro-sarcoma of neck, 170
— skin of back, 214
— small intestine, 348
— tibia, 699
Fibula, aneurism of, 699
—, bending of, 708, 709
Fibula, congenital defect of, 732, 734
—, fracture of, 707, 708, 709, 710
head of, detachment, 674
Finger, anomalies of posture in nerve lesions, 593, 594, 595
—, bent little, 597
—, derangement of movement in tendon-sheath inflammation, 588
—, dermatitis of, 602
—, destruction of, by leprosy, Raynaud's disease and syringomyelia, 607
—, Dupuytren's contraction, 597, 598
—, erysipeloid, 603
—, inflammation of, 601
— —, chronic, 605
— —, subcutaneous cellular tissue of, 603
—, injuries of, 586, 587
— joint, inflammation of, 604
— — —, gonorrhœal, 603
— —, purulent inflammation of bone, 605
—, syphilis of, 603, 608, 610
—, teno-synovitis of, 588, 590, 603
— — —, crepitating, 604
— — —, gonorrhœal, 603
—, trigger, 598
—, tuberculosis of, 599, 606
—, tumours of, 599
— —, innocent, 599
— —, malignant, 600, 601
Fissures of fibula, 714
— pelvic bones, 630
— rectum, 409
— skull, 6, 7
— —, course of, 6, 7
— upper jaw, 73, 74
Fistula in ano, 424, 425
— —, acquired, inflammatory, 424
— —, congenital, 424
— in connection with goitre, 139
Flat-foot, 729, 730, 731
—, contracture in, 733
—, paralytic, 734
Flexion fracture of lower end of humerus, 562
Flexor tendons of fingers, teno-synovitis of, 590
Focal diagnosis in cerebral diseases, 38
Foot, angioma of, 738, 739

Foot, bursa of, inflammation, 726
—, carcinoma of, 739
—, chondroma of, 738
—, deformities of, 729
—, dislocation of, 712, 713, 714, 715
— —, at Chopart's and Lisfranc's joint, 721
— —, Volkmann's, 734
—, fibroma of, 739
—, gout of great toe, 728
—, gumma of, 725
—, habit contracture of, 732, 733, 736
—, inflammation of, 724
— — metatarsus and toes, 728
— — tarsus, 724
—, injuries of, 721-724
—, lipoma of, 739
—, normal, 731
—, perforating ulcer of, 739
—, peri-articular abscess of, 724
—, sarcoma of, 726, 739, 740
—, syphilis of, 725, 740
—, tuberculosis of, 725, 726, 740
—, tumour of, 722
—, ulcers of, 738, 739
Foreign bodies in bladder, 438
— — knee-joint, 669, 678
— — larynx, 114, 116, 117, 118
— — —, dyspnœa in, 118
— — œsophagus, 123, 126
— — pharynx, 123, 124
— — rectum, 411, 412
— — stomach, 293
— — trachea and lungs, 116, 117, 196
— — urethra, 430
Fork-like posture of hand in fracture of radius, 577
Foveola coccygea, 423
Fracture at ankle-joint, 706, 710
— knee-joint, 672-676
—, Bennet's, 586
—, bi-malleolar, 710, 713, 715
—, diacondylar at knee-joint, 675
—, greenstick, 534, 577
— of anatomical neck of humerus, 541, 544
— astragalus, 711
— axis, 179
— capitulum radii, 565, 567
— clavicle, 534, 535
— condyles of femur, 673, 676
Fracture at coronoid process of ulna, 556, 561, 566, 567
— epi-condyles of humerus, 556, 559, 562, 563, 568
— femur, at lower end, 672, 673, 675, 676
— femur, at upper end, 610, 614, 618, 621, 623, 624, 627, 628, 631
— —, shaft of, 628
— —, spontaneous, 665, 666
— fibula, 674, 708, 709, 711
— humerus at lower end, 562-568
— — at upper end, 540, 541, 543, 545, 546
— — below tuberosities, 541, 543, 544
— —, condyles of, 556, 559, 560, 561, 562, 563, 564
— —, diacondylar, 556, 560, 561, 567, 569
— — through tuberosities, 540, 541, 542, 543, 544, 545
— laryngeal cartilage, 116
— leg, 672, 673, 676, 707
— lower jaw, 73
— malleoli, 706, 707, 708, 709, 710, 713, 715
— metacarpal bones, 586
— metatarsal bones, 722, 723
— neck of femur, 625
— — —, inter-trochanteric, 623, 624, 625, 628, 631
— — —, per-trochanteric, 623, 625, 629, 631
— — —, subcapital, 622, 623, 625, 628
— — —, subtrochanteric, 623, 624, 625, 629, 630
— neck of scapula, 545, 546
— olecranon, 556, 557
— os calcis, 716, 717, 718, 719
— patella, 672, 674
— pelvic fossa, 628, 629
— pelvic ring, 628, 629
— pelvis, 474, 629
— radius, 565, 566, 577, 578, 579, 580, 581, 582
— ribs, 187
— rotula, 556, 559
— scaphoid of wrist, 584, 587
— — of foot, 721
— scapula, 545, 546
— semilunar bone, 585, 586

Fracture of sesamoid bone of foot, 723, 724
— skull, 1
— —, course of, 6
— —, secondary injuries, 5
— sternum, 188
— sustentaculum tali, 719
— tibia, 673, 676
— —, at lower end, 706, 707, 708, 709, 710, 711, 714
— —, infracondylar, 673, 676
— tuberosity of fifth metatarsal, 723, 724
— upper jaw, 73, 74
— vertebral column, 176, 177, 488, 502, 503, 504, 505
—, Shepherd's, 711
—, supracondylar, at lower end of humerus, 556, 557, 558, 559, 561, 568
— —, knee-joint, 672, 673, 676
—, supramalleolar, 713
Furuncle in axilla, 211
— of back of neck, 133
— lips, 59, 89

G

GALL-BLADDER, abnormalities of position, 316, 317
— —, empyema of, 323
— — —, source of infection for cerebral abscess, 20
— — fistulæ, 378
— —, gangrene of, 318
— —, hydrops of, 323
— — —, diagnosis from floating kidney, 323
— —, rupture of, 248
Gall-stone colic, 314
— — —, anatomical basis of, 315
— — —, diagnosis from epigastric hernia, 315
— — — — from peritonitis, 262
— — — — renal colic, 315
— stones causing intestinal obstruction, 321, 362
— —, diagnosis of, 314, 318, 319
— —, in small intestine, 275
Ganglion of wrist, 600
Gangrene of foot, diagnosis from sciatica, 691
— lung, 195, 196
—, senile, 691
Gangrene of toes, 728
Gastro-intestinal canal, contusion of. 245
— — — —, diagnosis, 246
— — —, gunshot wounds of, 252, 253
— — —, rupture and its symptoms, 245, 246
Gastroptosis, 238, 241, 242
Genitalia, diseases of, in women, examination for, 439
— of hermaphrodite with vagina and testicles in hernial sac, 383
Glanders, ulcers of nose in, 103
Glandular abscesses in neck, 132, 134, 135
— — —, chronic, 135
— swelling in cancer of breast, 229
— — inguinal region, 657
— — — —, diagnosis from hernia, 392
— — in leukæmia and pseudo-leukæmia, 157
— — supra-clavicular fossa in cancer of stomach, 309
— — syphilis, 156
— — tonsillar ulceration, 101, 102
— — tuberculosis, 156, 157
— — of neck, 155, 156
— — —, malignant, 159
Glossitis, symptoms of, 90
Glottis, œdema of, 114
Goitre, aberrant, 96
—, abnormalities in position of, 149
—, circumscribed nodular, 146, 148
—, complication of, 150
—, cystic, 146, 147, 148
—, deep, 149
— —, diagnosis from mediastinal tumour, 201
—, diagnosis from aneurism, 163
—, diffuse colloid, 142
—, external appearances of, 142
—, hæmorrhage in, 148, 150
—, heart, thyreotoxic, 144
—, inflamed, 151, 152
— —, œsophageal stenosis in, 127
— in Graves's disease, 143, 144
—, intra-thoracic, 149, 200, 202, 205
—, malignant, 153, 154
— —, diagnostic signs of, 153
—, pendulous, 145, 148
—, plongeant, 147, 148
—, proliferating (Langhans'), 154

Goitre, retro-sternal, 149
—, retro-tracheal, 149, 150
—, retro-visceral, 149
—, secondary growths, 57, 155
—, skiagram of, 148, 149
—, vascular, 142
Gonorrhœa, diagnosis from sciatica, 689
—, examination of urine in, 433
— of ankle, 725
— epididymis, 416
— finger-joints, 605, 606
— hip-joint, 644
— knee-joint, 678
— pelvis of kidney, 451
— penis, 477
— prostate, 471
— rectum, 408, 411
— shoulder-joint, 551
— tendon sheaths of hand, 603
— urinary passages, 433, 434
— wrist, 589
Gout, 728
— of foot, 728
— hand, 605
Granulation of dorsal spinal cord, 508
—, tubercular, of hand, 599
Granulomata, inflammatory of brain, diagnosis, 22
— — —, local, 23, 24
Graves's disease, blood condition in, 145, 146
— —, changes of thymus in, 146
— —, commencing, 143
— —, diagnostic signs of, 49, 143-146
— —, forme fruste, 144
— —, pronounced, 144
Groin, bilocular or communicating hydrocele in, 374, 387
—, burrowing abscess, 374, 375
—, glandular enlargement in, 382
—, lymphadenoma, 375
—, sarcoma of, 375
—, sinuses in, 378
—, strangulation of testicles in, 399
—, testicles in, 374, 383
—, tubercular, 375
—, tumours of, 373, 375
Gumma of arm, 571, 574, 575
— brain, 18, 22
— foot, 725
— knee-joint, 691
— larynx, 120
Gumma of leg, 701
— liver, 326
— mamma, 222
— mouth cavity, 100, 101, 102
— neck, 136, 140
— palate, 95, 103, 105
— penis, 477
— pharyngeal wall, 103
— — — causing paralysis, 123
— ribs, 213
— shoulder, 553
— skull, 56, 58
— spinal cord, 510
— sternum, 213
— testicle, 419
— thigh, 658
— thoracic wall, 211
— tongue, 106, 107
— tonsillar region, 101
— vertebræ, 521
Gums, acute circumscribed, and widespread swelling of, 89
—, growths of, 94
—, hæmorrhage from, 100
—, lead line on, 100, 262
—, pus from, 100
—, tubercular, 79
—, ulcers of, 100, 108

H

Habit contracture of foot, 733, 736
Hæmatocele of testis, 416, 420
—, retro-uterine, 274
Hæmatoma, extradural, 12, 16
—, intradural, 12, 16
— in vicinity of Broca's convolution, 14
— of ear, 64, 65
— spinal cord, 494
—, peri-tubal, 271, 274
—, peri-urethral, 474
Hæmatomyelia, symptoms of paralysis in, 494
Hæmaturia in renal calculi, 454
— — tumours, 456
— urinary tuberculosis, 460
Hæmophilia, effusion in knee-joint in, 682, 686
—, hæmorrhages of gums in, 100
—, renal hæmorrhages in, 436
Hæmorrhoids, 409, 410
Hair tumour in stomach, 293

Hairy margin of head and face, tumours of, 71
Hallux valgus, 728, 736, 737
Hammer-toe, 736, 737
Hand, abnormal postures of, 592
— — — in fracture of radius, 577, 578
— — — nerve paralysis, 592-595
— — —, position of damage, 593
—, angioma, 600
—, botriomycosis of, 600
—, carcinoma of, 601
—, chondroma of, 600
—, deformity of Madelung's, 596, 597
—, dermatitis of, 601
—, epithelial cysts of, traumatic, 599
—, fibroma of, 600
—, ganglion of, 599
—, gout of, 605
—, inflammation of, acute, 601, 605
— — bursæ under callosities, 605
— — bone, 608
— —, chronic, 605
— — skin, 605
— — tendon sheaths, 607
—, injuries of, 576, 605
—, leprosy of, 606
—, lipoma of, 599, 608
—, lupus of, 606
—, œdema of dorsum of, 586, 588, 605
—, osteomyelitis of, 605
—, *post-mortem* tubercle of, 606
—, sarcoma of, 600
—, sebaceous cyst of, 599
—, syphilis of, 608
—, tendon sheath, inflammation of, 588, 602
— — — —, gonorrhœal, 608
— — — —, tubercular, 589, 607
—, tubercle of, 599
— — bone, 608
—, tumours of, 599
— —, innocent, 599
— —, malignant, 600
Head, abnormal posture of, 175
— — —, asymmetrical, 181
— — —, symmetrical, 176, 184
—, rigidity of, painful, 175
— — of gradual onset, 181
— — of sudden onset, 176
—, surgical diseases of, 1
— tetanus, 75
Head, tetanus, with facial paralysis, 75, 76, 77
— tumours acquired, 55
— — —, innocent, 55
— — —, malignant, 56-58
— —, congenital, 51
Heart, compression of, by effused blood, 193
—, injuries of, 191
— —, avoidance of probing in, 191
— —, cardiac dulness in, 192
— —, diagnosis, 194
— —, pure, 192
— —, subjective sensations in, 192
— —, with injury to pleura, 193
— — — —, position and nature of, 191
— — — —, reflex symptoms in, 192
Hemianopia, diagnostic significance of, in cortical tumours, 23
Hemianopsia, diagnostic significance in brain pressure, 14
—, focal diagnosis of, 38, 39, 40
Hernia, abdominal, 376
—, crural, 392, 393, 394, 395
—, duodeno-jejunal, 366
—, epigastric, 370, 371
— —, diagnosis from biliary colic, 314
—, Hesselbach's, 396
— in cæcal region, 366
—, incarcerated, 365, 398, 400
—, inguinal, 374
— —, external, 379, 386
— —, internal (direct), 390
— in linea semicircularis Spigelii, 376
—, intermuscular, 380, 381, 385, 386
—, internal, in cæcal region, 366
— in Winslow's foramen, 366
—, irreducible, 398
—, labial, 382, 387, 388
—, Littré's, 401
—, lumbar, 375
—, multilocular, 372
—, obturator, 365
— of diaphragm, 191, 367
— umbilical cord, 373
—, pro-peritoneal, 381, 384, 396
—, scrotal, 387, 388
—, strangulated, irreducibility of, 398

Hernia, strangulated, condition found at operation, 403, 404
—, strangulated, 398-406
— —, after reduction, 353, 366, 405, 406
— — — —, diagnosis from a strangulated inguinal testicle, 400
— — — — — hydrocele, 398
— — — — — peritonitis, 263
— — — — diagnosis of, 310, 398, 399
— —, fistulæ subsequent to, 379
— —, its position in femoral herniæ, 396, 403
— — — — in inguinal herniæ, 403
— — — — in umbilical herniæ, 403
— —, intestinal obstruction with, 366, 402
— —, reduction en masse, 402, 406
— —, stages of, 404
—, subcutaneous, 381, 384, 386
—, tendency to, 379, 381
—, traumatic, 396, 397
—, umbilical, 371, 372
Hernial sac, appendicitis in, 401
— —, contents of, 402
— — — in male hermaphrodite, 383
— —, peritonitis of, 401
— —, sub-divided, 384
— —, tuberculosis of, 401
— — with peri-hernial fat, 389
Hip, adducted (coxa adducta), 639, 640
— — — —, important diagnostic symptoms, 641
— disease, 643
— —, acute infective, 643, 644, 646
— — — —, consequences of, 645
— —, chronic, non-tubercular, 654, 655
— —, diagnosis of, differential, 650, 651
— — — by gait, 646
— — — painfulness, 650
— — — palpation of joint, 650
— — — posture of leg, 649
— — — skiagram, 653
— — — testing movements of joint, 647, 648
— —, secondary changes in, 653
— —, tubercular, 646, 647, 648, 649, 650, 653
— —, variety and degree of, 652
— joint, acute inflammation of, 643
Hip-joint, acute inflammation of, results, 645
— —, arthritis deformans of, 639, 645, 655
— —, chronic inflammation of, 646
— —, contusion of, 621
— — —, diagnosis, 614
— —, deformities of, congenital, 631-639
— — —, non-traumatic, 631
— —, dislocation of, 615-620
— — —, anterior, 617, 618, 619
— — —, complications, 616, 617
— — —, congenital, 631, 634, 635, 637, 639, 651
— — —, inflammatory, 649
— — —, irregular, 616
— — —, posterior, 615, 616, 617
— —, examination of, 611
— — — by inspection, 611
— — — palpation, 614
— — — testing mobility, 614
— —, fracture of, 610, 621-627
— —, gonorrhœa of, 644
— —, injuries, table of, 630, 631
— —, osteomyelitis, 643
— —, rheumatism of, 651
— —, sarcoma in vicinity of, 480
— —, senile disease of, 655
— —, skiagraphy of, 653
— —, sprain of, 621
— —, tuberculosis of, 646
Hirschsprung's disease, 356, 357
— —, diagnosis from abdominal tumour, 287
Hodgkin's disease, *see also* Pseudo-leukæmia
— —, signs of, 157, 158
Horns, cutaneous, 71
— —, on heel, 739
Hour-glass stomach, 302, 303, 304
— — —, causes of, 305
Humerus, dislocations of 539, 540
— —, varieties, 538, 539, 542, 546
—, fractures at lower end of, 555-568
— — upper end of, 540-546
—, muscular hernia over, 574
—, myositis ossificans over, 574
—, osteomyelitis of, 576
—, sprain of, 546
—, tumours of, 572
— —, bone, 576
— —, muscles and nerves, 572

Humerus, tumours of, skin and subcutaneous tissue, 572
Hydatids, *see* Echinococcus
Hydro-adenitis of axilla, 211
Hydrocele, bilocular in inguinal canal, 374, 387, 388
—, communicating, 374, 387
—, diagnosis from strangulated hernia, 398
— of spermatic cord, 385, 387, 415
— women, 374
— testis, 387, 388
—, relation of vaginal process of peritoneum, 387
Hydrocephalus in meningocele, 53
Hydro-myelomeningocele, 483
Hydronephrosis, closed, 454
— —, diagnosis from ovarian tumour, 289
—, intermittent, 448, 460
—, open, 448
—, remittent, 448
Hydrops of bursa iliaca, 652
— gall-bladder, 323
— —, diagnosis from movable kidney, 323
— knee-joint, 679
— —, intermittent, 678
— —, traumatic, 681
— —, tubercular, 680
— prepatellar bursa, 667
— subdeltoid, diagnosis from effusion into shoulder-joint, 547, 548
Hygroma of neck, congenital, 161
Hyperextension fracture, 558, 561
Hyperkeratosis of hand, 601
Hypernephroma, 458
—, secondary, 204
Hyperthyroidism in Graves's disease, 143, 144
Hypochondrium, inflammatory foci in, 265
Hypospadias, 426, 475
Hypothyroidism, predisposition to fracture of cartilage of femoral condyles in, 670
Hypertrophy of bronchial glands diagnosis from mediastinal tumours, 200, 201
— of prostate, 468, 469, 470
— spleen, 330, 331
— thymus, 200
— —, diagnosis, 201
— thyroid, 142
Hysteria, abdominal pain in, 259
—, diagnosis, from epilepsy, 34
— — hip disease, 652
— — intestinal obstruction, 367
— — paralysis, 548, 549

I

Ileo-cæcal region, tumours of, 377
Ileo-sacral tuberculosis, 517
— — —, burrowing abscess, 516, 518
Incised wounds of abdomen, 253
— — thorax, 189
Incontinence of fæces, 493
— urine, 431
—, paradoxical, 431, 492
Infantile paralysis, club-foot following on, 735
— —, spinal, diagnosis from congenital dislocation of hip, 637
— —, unusual localization of, 375
Infarct of bowel, 364
— kidneys, 453
— testicle, 418
Infiltration, diffuse gummatous of tongue, 107
Inguinal abscesses, 516, 517
— herniæ, 379-391
— —, bladder in, 391
— —, diagnosis of external, in absence of swelling, 380
— — —, in the presence of a swelling, 382
— — —, labial and scrotal herniæ, 387, 388
— —, differential diagnosis from femoral hernia, 385-394
— — — — burrowing abscess, 386
— — — — varicocele, 388
— — — — of external and internal, 390, 391
— —, external, 379, 381, 382, 383, 386, 387, 388, 389
— — in women 381
— —, intermuscular, 383, 384, 385
— —, internal, 390, 391
— —, properitoneal, 381, 384
— —, relations of, to abdominal wall, 381
— — —, to vaginal process and hydroceles, 387, 388
— —, scrotal, 387, 388
— —, site of strangulated, 403
— —, subcutaneous, 381, 385, 386
Intercarpal joints, dislocation of, 584

Intestinal crises, tabetic, diagnosis from obstruction, 358
— distension, abnormal, with visible and palpable contractions of bowel above, 347
— —, murmurs, at seat of, 347
— murmur in stenosis, 347
— obstruction, 346
— —, acute, 357
— — —, causes, 361
— — — — (axial rotation), 364
— — — — (bands and kinks), 361, 362
— — — — (gall-stones), 362, 363
— — — — (intussusception), 363
— — — —, position of obstruction, 358, 359
— — — — (strangulation of an internal hernia), 365, 366
— — — — symptoms, 357, 358
— — — —, varieties, 360, 361
— —, arterio-mesenteric, 362
— —, chronic, 347
— — —, appearance of bowel in, 347, 348
— — —, condition of stools in, 348, 349
— — —, through external compression, 353
— — —, position of stenosis in, 350
— — —, variety and cause of stenosis in, 351
— —, combined with external hernia, 409
— —, diagnosis from cholecystitis, 318
— — — perforative peritonitis, 358
— — — peritonitis, 255, 262
— —, effect on general condition, 350
— —, hysterical, 367
— — in appendicitis, 337
— —, intermittent, 354, 361
— — in tubercular peritonitis, 285
— — of sudden onset, 361
— —, spastic, 367
— —, transition of incomplete to complete, 360
— rigidity, 348
— stenosis, cicatricial, 352
— —, concentric, in cancer and tubercle of bowel, after reduction of a strangulated hernia, 353, 406
— —, condition found on palpation, 351
Intestinal stenosis, condition of stools in, 348, 349
— —, general condition in, 350
— — of gradual development, 347
— — large intestine, 345, 406
— — small intestine, 348
— —, skiagraphy in, 354, 355, 356
— — through tumours in bowel, 353
Intestine, abnormalities of position, 236
— — —, decussation of large and small intestine in, 237
— — —, position of appendix in, 237
— — —, principal varieties, 236, 237
—, appearance of, in strangulated herniæ, 403, 404
—, axial rotation of, 364, 365
—, carcinoma of, 351, 352
—, fibroma of, 353
—, fistulæ of, 378
—, hæmorrhage of, 244
—, herniæ of intestinal wall, 401
—, infarction of, 364
— injuries, 245, 246, 247, 353
— —, clinical picture of, 245
—, intussusception of, 275, 364
—, lipoma of, 353
—, myoma of, 353
—, obstruction of, 358
— paralysis in injuries to spinal column, 492
—, sarcoma of, 353
—, syphilitic stricture of, 353
—, tuberculosis of, 286
— —, diagnosis from cancer, 351, 352
—, ulcers of, 351, 358
Intussusception of bowel, 363, 364
— —, diagnosis from tumour, 287
Iodoform dermatitis, 602
Isthmus faucium, inflammation of, 90

J

JACKSONIAN epilepsy, 15, 36, 37
Jaundice, catarrhal, 313
— — in cholecystitis, 316
— —, infective, 317
— — through obstruction of common bile duct, 321
Jaw, actinomycosis, 76, 78, 80
—, ankylosing, 77
—, antrum of, empyema of, 83
— —, inflammation, 59
—, arthritis, 76

Jaw, cancer of, 82, 83, 85
—, cysts of, 83, 84
—, dislocation of, 74
—, fractures of, 73, 74
—, inflammation, acute, 78
— —, chronic, 78, 79
—, lower, chondroma of, 87
— —, dislocation of, 74
— —, fibroma of, 87
— —, fractures of, 73
— —, multilocular cyst, 87
— —, osteoma of, 87
— —, sarcoma of, 87, 88
— —, tumours of, diagnostic signs, 85-88
—, multilocular cystoma of, 87
—, osteoma of, 87
—, osteomyelitis, 76, 78, 131
—, periostitis, 59, 60, 75, 78, 83, 84, 131
—, phosphorus necrosis of, 81
—, sarcoma of, 86, 87
—, tuberculosis of, 60, 76, 79, 80, 81, 83
—, upper, carcinoma of, 83
— —, empyema of, 83
— —, fractures of, 73, 74
— —, periostitis of, 59, 83, 84
— —, sarcoma of, 82, 83
— —, tuberculosis of, 83, 84
— —, tumours of, 82
— — —, innocent, 85
— — —, malignant, 83

K

KIDNEY, abnormal mobility of, 444
— abscess, 452
— calculi, 453, 454
— —, composition, 451
— — in renal tuberculosis, 460
— —, primary, 453
— —, secondary, 455
— —, X-ray diagnosis, 454
—, carcinomata, 456
—, colic of, 436, 453, 460
— —, diagnosis from biliary colic, 315
— — — peritonitis, 262
—, cysts of, 458
—, displacements of, 238
— —, acquired, 444
— —, congenital, 235
Kidney, displacements of, diagnosis from distended gall-bladder, 323
—, examination of functions of, 441
— hæmorrhage, 249, 436
— — in hæmophilia, 436
— — tuberculosis of, 460
— — tumours, 455, 456
—, hydatid of, 457
— infarcts, 453
—, inflammation around, 249, 266, 442
—, injuries of, 248
— —, extra-peritoneal, 249
— —, intra-peritoneal, 249
—, pelvis of, inflammation of, 452
— —, new growths of, 456
— —, suppuration of, 450
—, sarcoma of, 456, 457
—, spontaneous suppuration of, 450
— — —, bacteriology of, 451
— — —, diagnosis, 452
—, tuberculosis of, 443, 450, 458
— tumours mixed, 289
— — of, 455
— —, diagnosis, 456, 457
— —, displaced, 458
Klumpke's paralysis, posture of hand and fingers in, 594
Knee-joint, abscess, peri-articular, 679
— —, aneurism, 687
— —, bursal inflammation, 667, 687, 688
— —, chronic rheumatism of, 679, 680, 688
— —, contracture of, 686
— —, contusion of, 668
— —, detachment of internal semi-lunar cartilage, 670
— — — — — —, its incarceration, 670, 678
— — — cartilage of femur in, 669
— —, dislocation of, 674, 676
— —, effusion, acute, 667, 679
— — —, chronic, 679
— — —, idiopathic, 680
— — —, traumatic, 681
— —, fibroma of synovial membrane, 687
— —, foreign body in, 669, 678
— —, fractures of, 670, 672, 673, 676
— —, fungating, 685
— —, gonorrhœa of, 678, 681

Knee-joint, gumma of, 684
— — in hæmophilia, 680, 681, 686
— —, injuries of, 667, 676
— —, intermittent hydrops of, 678
— — — —, tubercular, 679, 682
— —, lipoma arborescens of, 686, 687
— —, normal, 683
— —, osteomyelitis of, 678, 681
— —, rigidity of, 684, 686
— —, sarcoma of, 684, 687
— —, sesamoid bone, 669
— —, sprain, 668, 669, 670
— — —, results of, 671
— —, syphilis of, 680, 681
— —, tuberculosis of, 680, 681, 682, 683, 684, 685
— — —, ankylosing, 686
— —, tumours and allied structures in neighbourhood of, 687, 688

L

LABYRINTH, injuries of, 5
Large intestine, displacements, chief varieties, 236
— — — in skiagram, 240, 241, 242, 243
— —, disturbances of function, with anatomical changes, 339
— — — —, without typical anatomical changes, 342
— —, diverticula of (inflammation), 276
— —, stenosis of, 350, 351, 352, 355
— — —, diagnosis from stenosis of small intestine, 358
— —, syphilis of, 341
— —, tubercle of, 341
Laryngoscopy in laryngeal diseases, 110
Larynx, carcinoma of, 119, 139
—, circulatory disturbances of, 115
—, diphtheria of, 111
— —, diagnosis from lacunar tonsillitis, 111, 112
— — — pneumonia, 113
— —, secondary symptoms, 113
—, false croup, 112
—, fibroma of, 121
—, foreign bodies in, 116, 117
—, fracture of cartilage of, 116
—, inflammation of, 111
Larynx, injuries of, 116
—, œdema of, 114, 115
— —, angioneurotic, 115
—, papilloma of, 121
—, stenosis of, 115
—, surgical diseases of, 110
— — —, acute, 111
— — —, chronic, 118
—, syphilis of, 118, 119, 120
—, tubercle of, 119, 120
—, tumours of, 121
—, ulcers of, 115
— —, differential diagnosis, 120
— —, position, 120
Leg, abscess of bone of, 704
—, bony cysts of, 699, 700
—, carcinoma of, 696
—, chondroma of, 700
—, diffuse inflammation, 701
—, dislocations of, 712-716
—, exostosis of, 700
—, fibroma and fibro-neuroma of, 697, 700
—, fractures of, 706-712
—, gumma of, 703
—, localized inflammation, 703
—, osteomyelitis of, 700, 701, 702, 703
—, sarcoma of, 699, 705
—, swellings and tumours of, 697, 698, 703
—, syphilis of, 695, 696, 701
—, tuberculosis of, 703, 704
—, ulcers of, 693
— —, malignant, 696
— —, syphilitic, 695, 696
— —, varicose, 693, 694, 695
—, varicose veins of, 691
Length measurements of lower limbs after injuries, 612, 613
Leprosy of hand, 606
— of nose, 103
Leukæmia, glandular swelling in, 157
—, hæmorrhage from gums in, 100
—, pharyngeal swelling in, 95
—, splenic enlargement in, 331
Leukoplakia of tongue, 104
Ligamentum patellæ, detachment of, 674
— teres, fibromyoma of, 375
— tibio-fibulare anticum, laceration of, 712
Limping, 610
—, intermittent, 691

Limping, painful, 611
—, paralytic, 610, 637
— through rigidity of limbs, 611
— — shortening, 610
—, unilateral, 640, 642
—, voluntary, 646
Lipoma in femoral canal, 394
— — —, diagnosis from hernia, 393
— of abdominal wall, 369
— axilla, 572, 573
— back, 216, 217
— neck, 134, 173, 174
— —, periglandular, 174
— breast, 211, 234
— epigastrium, 369, 370
— —, subserous, 370, 371
— face, 63
— floor of mouth, 92, 93
— foot, 739
— hand, 509, 608
— knee-joint, 686, 687
— lumbar region, 376
— neck, 166
— pharynx, 97
— sacral region, 486
— shoulder, 572
— spermatic cord, 389, 391, 416
— thigh, 657
— tongue, 105
— upper arm, 573
—, perihernial, 393
Lips, cancer of, 64, 67, 68, 99
—, furuncle of, 59, 89
—, gangrene of, 91
—, primary chancre of, 64
—, tumours of mucous membrane of, 92, 93, 99
Lisfranc's joint, dislocation of, 721
— —, inflammation of, 724
Little's disease, spastic club-foot after, 735
Littré's hernia, intestinal obstruction in, 401
Liver, abscess of, 265, 326, 327
—, acute yellow atrophy, 313
—, adenoma of, 326
—, carcinoma of, 326
—, cirrhosis of, 314
—, constricted lobe of, 325
—, cysts of, 326
— —, parasitic, 326
—, diagnosis from tubercular peritonitis with effusion, 283
Liver, displacements of, 236, 238
—, floating, 238, 325
—, gumma of, 326
—, hydatid cyst of, 326
— — —, multilocular, 326
—, injuries of, 247, 253
—, tumours of, 325
— —, primary, 325
— —, secondary malignant, 325
Lordosis of spine, 524, 525
Lumbago, 486
—, course of symptoms, 487
—, diagnosis from renal tumour, 456
—, rheumatic and traumatic, 487, 488
Lumbar kyphosis, 525
— lordosis, 525
— — in congenital dislocation of hip, 634, 635
— pains in renal disease, 456, 460
— puncture in cerebral pressure, 16
— — meningitis, 33
— region, abscess, perinephritic, 375
— —, areas of inflammation in, retroperitoneal, 266
— —, burrowing abscess of, 375
— —, false hernia, 375
— —, hernia of, 375
— —, lipoma of, 376
— —, pigmented nævus of, 214
— —, reflex muscular rigidity in unilateral renal injury, 249
— scoliosis, 523, 527, 528, 532
— vertebra, caries of, 516, 517
— —, compression fracture of, 501
— —, determination of injured, 500
— —, dislocation of, 500
Lumbo-dorsal scoliosis, 529, 532
Lumbo-sacral cord, segmental diagnosis of lesions, 495
— — —, symptoms of injury of, 498
— — —, types of paralysis, 499
Lung, abscess of, 195
— — in skiagram, 196
—, actinomycosis of, 198, 210
—, bronchiectasis of, 198
—, cancer of, 207
— —, metastatic, 207
—, chondroma of, 207
—, dermoid of, 207
—, embolism of, 197
—, empyema, 195
—, foreign bodies in, 117, 196
—, gangrene of, 196, 197

Lung, hydatid of, 207
—, injuries of, 189
— —, diagnostic signs of, 190
— —, secondary injuries, 190
—, sarcoma of, 207
—, surgical diseases of, 195
—, tubercular cavities in, 198, 209
—, tumours of, 199, 207
— —, differential diagnosis, 208
Lupus of cheek, 71
— of face, hypertrophic, 67, 72
— hand, 606
— nose, 65, 72
Lymphadenitis, acute submaxillary, 90, 132
— in neck, 155, 182
— —, malignant, 159
— of axilla, 550
—, phlegmonous submental, 89, 131
Lymphangioma of ear, 64
— floor of mouth, 89, 93
— neck, 160
— sacral region, 486
— scrotum, 415
— thigh, 657
— thorax, cystic, 217
— tongue, 105, 106
Lymphangitis of arm, tubercular, 569
Lymphatic cysts of neck, 161, 162
— gland, enlargement in axilla, 211, 212
— — — cancer of breast, 229
— — — inguinal region, 375, 392
— — — neck, diagnostic significance, 155
— — —, sarcoma in neck, 170
— — — thigh, 657
— — — ulcers of tonsil, 101, 102
— — — — —, causes of, 155, 156
Lymphoma, malignant, 158, 159, 160
— —, diagnosis from lymphosarcoma, 170
— of neck, tubercular, 156
Lymphosarcoma of neck, 170
— lung, 207

M

MACROGLOSSIA, 104
Madura foot, 725
Malarial spleen, 331
— —, rupture of, 247
Malleoli, fractures, 706, 707, 708, 709, 710, 711
Malleoli, fractures, position and direction of lines of fracture, 710
Mamma, abscess of, 211, 219
— —, retro-mammary, 221
—, actinomycosis of, 222
—, carcinoma of, 226, 227, 228, 232
— —, important diagnostic signs, 229-232
— —, scirrhus, 229, 231
— —, secondary, 231
— —, ulcerating, 230
—, chondroma of, 234
—, cysto-adenoma phyllodes of, 232
—, cysto-sarcoma phyllodes of, 232
—, cysts of, 223, 224, 225
— —, solitary, 226
—, fibro-adenoma of, 223, 224, 226, 232, 233
—, giant growth of, 232
—, gumma of, 222
—, inflammation of, 219
— —, acute, 219
— —, chronic, 221
—, lipoma of, 211, 234
—, sarcoma of, 232
— —, secondary, 233
—, tuberculosis of, 221, 222
—, tumours of, 223
— —, isolated, 224
— — of the male breast, 234
— —, multiple, 224
— —, types of, 223
Manubrium sterni, osteomyelitis of, 133
— —, *see also* Sternum
Manus valga, 596, 597
— vara, 595
Mastitis, acute, 221
—, chronic cystic, 223
— neonatorum, 219
—, puerperal, 220
Mastoiditis, brain symptoms of, 25, 29, 30
Mastoid process, inflammation of, 28
Median nerve paralysis, posture of hand in, 593
Mediastinum, dermoid of, 207
—, hydatid of, 207
—, injuries of, 191
—, phlegmon of, 127, 133
—, sarcoma of, 207
—, tumours of, 199, 204
— —, malignant, 207, 208

Mediastinum, tumours of, malignant, diagnosis from deep and intra-thoracic goitre, 205
— — — — enlargement of bronchial glands, 201
— — — — — of thymus, 201, 202
— — — — innominate and aortic aneurisms, 201, 202
Medullary cancer of breast, 231
— — penis, 477
— sarcoma of upper end of tibia, 699
Meningitis, diagnosis of, 33
—, purulent, resulting from otitis media, 29, 30, 31
—, serosa circumscripta spinalis, 510
Meningocele, 52, 174, 482, 484, 485
—, spurious, 53
Meningoencephalocele, 174
Menstruation, intra-abdominal, 263
—, painful, diagnosis from peritonitis, 263
Meralgia paræsthetica, 692
Mercurial stomatitis, 76, 91
Mesenteric cysts, 285, 287
— vessels, thrombosis of, 353
— — —, diagnosis from ileus, 358
— — — — peritonitis, 264
Mesentery, common, 236
—, detachment of, 353
—, ileo-cæcal, 237
Metacarpus, fracture of, 586
—, osteomyelitis and periostitis of, 605
Metatarsus, fracture of, 722, 723, 724
—, inflammatory processes of, 728
—, tumours of, 738
Middle ear, inflammation, purulent, brain complications of, 20, 21, 25, 26, 27
Mikulicz's disease, 167
Mind blindness, 30
Mixed tumours of kidneys, 289, 457
— — palate, 95
— — parotid, 168
— — submaxiliary region, 167
Molluscum contagiosum of face, diagnosis from cutaneous cancer, 70, 71
Motion, power of, after cerebral injuries, 44, 45
— — — vertebral injuries, 493, 495
Mouth cavity, acute swelling in floor of, 89, 90
Mouth cavity, angina of, 90, 91
— —, angioma of, 93
— —, cancer of, 99
— — —, perforating, 139
— —, cysts of, 92, 93
— —, dermoid of, 89
— — —, sublingual, 93
— —, examination of, in dysphagia, 124
— —, fibroma of, 92, 94
— —, gangrenous stomatitis of, 91
— —, gumma of, 95, 98, 100
— —, hæmorrhage from, due to fractured base of skull, 3
— —, inflammatory processes in, 88-91
— —, lipoma of, 92, 93
— —, lymphadenitis of, 89, 90
— —, lymphangioma of, 89, 93
— —, noma, 91
— —, primary chancre of, 100, 101
— —, salivary glands inflammation, 89
— —, tubercle of, 98, 100
— —, ulcers of, 98, 99
Mucous colic, diagnosis from peritonitis, 262
— cysts of mouth cavity, 92
— polypus of nose, 98
— — pharynx, 97
— — rectum, 407
Muscle of thigh, osteoma of, 658
Muscles of neck, gumma in, 140
— thigh, gumma in, 658
— thorax, gumma in, 212
Muscular angioma of arm, 572
— — thigh, 658
— atrophy, progressive, with lordosis, 522, 524, 635, 639
— hernia of thigh, 658
— — upper arm, 574
— paralysis of abdomen, localized, 375
— tuberculosis of abdominal wall, 375
— — arm, 573
— — neck, 140
— — thigh, 658
— — thorax, 212
Myelitis, chronic, 509
—, traumatic, 497
Myelo-cystocele, 483
Myelo-meningocele, 483, 484, 485

Myoma of bladder, 467
— intestine, 353
— uterus, 289, 468
— —, constipation in, 407
Myositis in wry neck, 181, 185
— of sterno-mastoid, 133
— ossificans of arm, 574

N

NÆVUS of abdominal wall, becoming sarcomatous, 376
—, pigmented, 214
—, vascular, 54
Nail-bed, inflammation of, 602
— —, syphilitic, 603
—, tumours of, 139
—, ulcers of, 740
Naso-pharyngeal fibroma, 84, 97, 123
— — polypi, 96, 97, 123
Neck, abscesses of, 130, 133, 516
— — after aural suppuration, 33
— —, chronic, 134, 135
— — due to spinal caries, 514
— —, tubercular, 134, 140
—, actinomycosis of, 80, 135
— — with sinus formation, 137
—, aneurism of, 140, 162, 163
—, back of, abscesses in, 133, 134
— —, carbuncle of, 136
— —, cerebral hernia in, 52, 174
— —, dermoids in, 134, 174
— —, fibroma of, 175
— —, lipoma of, 134, 173, 174
— — , rigidity of, with gradual onset, 181
— — —, with sudden onset, 176
— —, sarcoma of, 175
— —, sebaceous cysts in, 174
—, blood cysts of, 161
—, branchiogenous carcinoma of, 171
—, cavernous angioma of, 162
—, congenital hygroma of, 161
—, cysts of, 155, 160, 161, 163, 164, 165
—, dermoid of, 165
—, diffuse carcinomatosis of the lymphatic glands, 160
—, enlarged glands of, 113, 131, 132
—, fibroma of, 166, 169, 170
—, fibroma-sarcoma of, 170
—, gumma of, 136, 140
— — in muscle of, 140
Neck, gumma of, inflammatory processes of, 127, 131, 135, 166
—, lipoma of, 166
—, lymphangioma of, 161
—, lymphatic cysts of, 161, 162
— — glands of, swelling, 102, 155, 156, 157, 158
— — —, malignant, 159
—, lymphosarcoma of, 170
—, neuro-fibroma of, 169, 170
—, phlegmon of, 127, 130, 133
—, pseudo-tumours of, 139
—, sarcoma of, 169, 170
— —, deep, 163
— —, vascular, 163
—, sebaceous cyst of, 165
—, surgical diseases of, 110
—, syphilis of, 136, 156
—, tubercle in muscle of, 140
— — of, 136, 141, 156
—, tumours of, 139
— — back of, 174
— — side of, 155, 169
— — —, in anterior triangle, 140, 155
— —, solid, 166
— —, with liquid contents, 159
Nephritis, chronic hæmorrhagic, 436
Nerves of base of skull, 46
Neuralgia of anterior crural nerve, 692
— external femoral cutaneous, 692
— inferior dental nerve, 73, 86
— infra-orbital nerve in malignant growths of upper jaw, 82
— obturator nerve, 692
— sciatic nerve, 689
—, peri-articular of hip, diagnosis from dip disease, 652
Neuro-fibroma of arm, 572
— back, 217
— leg, 697, 700
— neck, 169
— thigh, 659
Neuroma of arm, 572
Nipple, retraction of, 229
Noma of lips and cheeks, 91
Nose, cancer of, 67, 68, 69, 70, 160
—, glanders of, 103
—, hæmorrhage from, in fractured base of skull, diagnostic significance of, 3
—, leprosy of, 103
—, lupus of, 65, 72

Nose, lupus of, hypertrophic forms, 67
—, mucous polypi of, 97, 98
—, rhino-scleroma of, 103
—, sarcoma of, 97, 98
—, sebaceous cyst at root, 64
—, syphilis of, 65, 66
—, tubercle of, 103
Nystagmus, local diagnostic significance of, in brain lesions, 40, 41

O

OCCIPITAL bone, cerebral hernia at, 52
— —, osteo-myelitis of, 134
— lobe, tumours of, 24
Oculo-motor nerve, injuries of, 5
Odontomata, 86, 87
Œdema of back of hand, 586, 605
— glottis, 114
— larynx, angioneurotic, 115
Œsophagus, carcinoma, 129, 130
—, compression, 128, 129
—, difficulties in swallowing in neighbourhood of, 124-130
—, diverticula of, 128, 135, 140, 162
—, foreign bodies in, 124, 126
— — —, diagnosis of, 124, 125
— — —, removal of, 127
—, injuries of, 191
—, spindle-shaped dilatation of, 128
—, stenosis of, 127
—, stricture of, syphilitic, 130
— —, corrosive, 127, 130
Olecranon, fracture of, 556, 557
—, tubercle of, 572
Oliguria, 432
Omental cysts, 287
— hernia, 389
— —, strangulated, 402, 403, 421
— tumours, 287
— —, torsion of, and its symptoms, 358, 402
Onychia maligna, 740
Optic nerve, injuries of, 5
— — —, localization, 38, 39
— neuritis, diagnostic significance in cerebral abscess, 18
— — — — — tumours, 18, 19
Orbit, angioma of, 50
—, injuries of, 4
—, osteoma of, 50
Orchitis, 417
—, metastatic, 417
Os calcis, *see* Calcaneus
Osteo-chondritis dissecans of knee-joint, 669
Osteoma of arm, traumatic, 574
— cervical rib, 173
— lower jaw, 87
— orbit, 50
— skull, 55
— thigh, 658, 659
— thorax, 218
— vertebra, 511
Osteomyelitis of arm, 576
— clavicle, 133, 210
— femur, 656, 657
— finger, 604, 605, 609
— hand, 605
— hip-joint, 643, 644
— humerus, 553, 575, 576
— jaw, 78, 131
— knee-joint, 665, 666, 680
— occipital bone, 134
— ribs, 210
— scapula, 210
— shoulder-joint, 553
— skull, 51
— spine, 180, 521
— sternum, 133
— thigh, 643, 644
— —, chronic, 662, 663, 664
— tibia, 700, 701, 702, 703
Osteoporosis in fracture of elbow, 591
— of bones of foot, 725, 726
— carpus, 592
Ostitis fibrosa of femur, 660
— — finger, purulent, 604
— — humerus, 575
— of mastoid, prominence of concha in, 27, 28
— ribs, chronic, 213
Os trigonum, 710, 711
Othæmatoma, 64, 65
Otitis media, chronic, cerebral complications of, 19, 25, 26-33
— — —, symptoms of, 27, 28, 29
Ovarian cysts, 289
— —, diagnosis from hydronephrosis, 289
— —, torsion of, 267, 299, 358
— hernia, diagnosis of, 383
Ovary, cancer of, causing intestinal obstruction, 353

Ovary, fibro-sarcoma of, 289
—, strangulated, 403

P

PACHYMENINGITIS, hæmorrhagic, diagnostic signs of, 17, 20, 21
—, hypertrophic, 508, 509
Palate, abscess of, originating in root of tooth, 95
—, acute inflammation of, 123
—, carcinoma of, 103
—, defects in, 123
—, paralysis of, 122
—, polypi of, 96
—, scar development in, 123
—, syphilis of, 103
—, tubercle of, 103
—, tumours of and their diagnosis, 95, 96
Palati, velum, ulcerative processes on, 103
Palm, callosities of, with dilatation of mucous bursæ beneath, 605
—, lipoma of, 608
Palmar aponeurosis, Dupuytren's contraction of, 597
Panaritium (Whitlow), 602, 603, 604
Pancreas, cancer of head of, 329
—, cysts of, 329
—, diagnosis from cholecystitis, 316
—, hæmorrhage of, 264, 265, 328
— —, intestinal paralysis in, 358
—, stones in, 329
—, surgical diseases of, 327
—, tumours of, 329
Pancreatitis, acute, 328
—, chronic, 329
— —, fat necrosis in, 264
—, diagnosis from cholecystitis, 316
— — ileus, 358
— — perforated gastric ulcer, 299
— — peritonitis, 264
—, urinary reaction in, 329
Papilloma of bladder, 467
— larynx, 121
— palate, 96
Para-goitres, 171
Paralysis in cerebral pressure, 12, 14, 15
— congenital dislocation of hip, 637, 638
—, complete injuries of spine, 493
Paralysis, ischæmic, 595
—, partial injuries of spinal cord, 494
— of arm, diagnosis from traumatic neurosis, 549
— hand and fingers after nerve lesion, 592-595
— palate, 122
—, types of, 499
Parametritis, 267, 271, 273
Paranephritis, 442
Paraphimosis, 474, 475
Paraplegia dolorosa in compression of cauda, 499
—, spastic, occurrence of, 509
— — — in spinal caries, 519
Paresis of shoulder muscles, diagnosis of, 549
Paronychia syphilitica, 603
Parotid, abscess of, 62
—, cancer of, 169
—, chondroma of, 169
—, mixed tumours of, 168
—, sarcoma of, 169
—, tubercle of, 167, 168
Parotitis, 62, 132
—, epidemic, 62
Patella, dislocation of, 676
—, fracture of, 672, 674
—, laceration of ligamentum patellæ, 674
—, riding of, in articular effusion, 667
—, sarcoma of, 687
Patellar reflexes in vertebral injuries, 493
Pelvic cellular tissue, tumours of, 481
— — —, dermoids of, 481
— cellulitis, 271, 273, 275
— viscera, surgical diseases of, 235, 273, 274, 275, 276
Pelvis, abscesses of, 517
—, burrowing abscesses in, 479
—, crushing of acetabulum of, 637
—, exudation in, 407, 431
—, fibroma of, 480
—, fractures of, 628
— — pelvic fossa, 630, 631
— — — ring, 629, 631
—, inflammatory process in, true, 275, 276
—, injuries of urethra in fractures, 474, 630

Pelvis, sarcoma of bones of, 480
— — muscles, 480
—, sinuses of, 424
—, true, cysts of, 407
—, tumours of, 480, 481
— —, examination of, 479, 480
— — in true, symptoms caused by compression and displacement, 407, 431, 478
Penis, constriction of, 474
—, deformities of, 475
—, injuries of, 474
—, osseous nodules in, 475
—, subcutaneous tumours of, 475
—, surgical diseases of, 474
—, ulcers of, 476
— —, cancerous, 476, 477
— —, tubercular, 476
Perichondritis, laryngeal, 114, 132
Pericolitis, 344, 345
Perimetritis, intestinal obstruction in, 354
— with peritonitis, 271
Perinephritis, 442
—, diagnosis from pleurisy, 442
— —, tubercular hip, 652
—, ileus in, 354
—, in renal tuberculosis, 461
—, origin of, 443
Periorchitis, 420
—, secondary, 421
—, serous and proliferating, 421
Periostitis of bones of skull, 51
— humerus, 575
— hyoid, 132
—, *see also* Osteomyelitis
— jaw, 59, 60, 78, 79, 83, 85, 86, 131
— metacarpals, 605, 609
— tibia, 703, 704
Periproctitis, 275, 431
Perisalpingitis, 271
Peritoneum, congenital pouches of, strangulation of bowel in, 366
—, inflammation of, 254-265
— —, spreading from one area over whole abdomen (types), 255
—, tuberculosis of, 264, 281
Peritonitis, 254-261
—, adhesive, 284, 285
—, commencing, 255
—, determination of leucocyte blood count in, 261
—, physical condition in, 257-261
Peritonitis, diagnosis from dysmenorrhœa, 263
— — gall-bladder pain, 262
— — hysteria, 262
— — ileus, 286
— — intestinal obstruction, 255, 263
— — mucous colic, 262
— — pneumonia and pleurisy, 263
— — renal colic, 262
— — spinal caries, 263
— — tabes, 262
— — of cases of abdominal pain without evident changes from strangulated hernia, 263
—, diffuse, 254, 255
— —, without localization, 263, 264
—, examination in, 282
—, exudative, 283
— in a hernial sac, 401
—, indications for exploratory puncture in, 286
— in intestinal injuries, 246
—, localized, 265
— —, in epigastrium, 265
— —, hypochondrium, 265
— —, hypogastric region, 266
— —, lumbar region, 266
— —, true pelvis, 275
—, nodular, 284
—, origin of tubercular, 285
—, perforative, 254, 258
—, peripheral (Lennander's), 259, 297
—, prognosis of, 261
—, residual abscesses after, 256, 270, 334
—, sero-purulent, 255
—, serous, 255, 268
— —, in appendicitis, 270, 334
—, significance of age and sex in diagnosis of, 256
— — history in diagnosis of, 255, 256
—, tubercular, 264, 281, 282
— —, with saccular exudation, 283, 285, 290
Phantom hernia of lumbar region, 374
— tumours of abdomen, 287
— of neck, 139
Pharynx, abscess of, 91, 96
—, adenoids in, 91
—, cancer of, 142
—, diphtheria in, 111
—, examination of, 111
— —, in dysphagia, 125

Pharynx, foreign bodies in, 123, 124
—, inflamed, diffuse and unilateral, 90
—, inflammatory processes in, 111
—, polypus of, 96, 97
—, pressure sore in, 103
—, sarcoma of, 95, 96
—, syphilis of, 90, 98, 101, 103
—, teratoid tumours of, 97
—, ulcers in, and their diagnosis, 98, 99, 101, 102, 103
Phlegmon in axilla, 210
— ligneux, 135, 288
— of floor of mouth, 90
— front of arm, 568
— frontal sinus, 60
— mediastinum, 127, 133
— scalp, 51
— supraclavicular region, 133
Phosphorus necrosis of jaw, 81, 100
Pituitary gland and its relation to obesity, 175
— —, injuries of, 38
— —, tumours of, 24
Pleura, inflammation of, after peritonitis, 260, 263
— —, purulent, 209
—, injuries of, 189
— —, with cardiac wounds, 193
Pleural exudation in subphrenic abscess, 279
Pneumococcal peritonitis, 267, 285
Pneumonia, croupous, 196
—, diagnosis from diphtheria, 113
— — peritonitis in children, 263
—, metastatic, 260
—, purulent, 195
—, resulting in spinal caries, 521
—, traumatic, 117, 189
Pneumothorax, traumatic, 189
Pollakiuria, 433
Polyposis of rectum, 408
Polypus at neck of bladder, 462
— in nasopharynx, 96, 97, 98, 123
— of ear, 26
Polyuria, 433
Pons, injuries of, focal symptoms, 44
—, tumours of, diagnostic signs, 24
Porencephaly, traumatic, 35, 54
Pott's deformity, 511
Pouches, ileo-appendicular and right retrocæcal hernia in, 366
Precentral sulcus, determination of, on skull, 47
Pressure diverticulum of œsophagus, 128
Processus vaginalis of peritoneum and herniæ, 387
Proctitis, gonorrhœal and syphilitic, 408
Prolapse of anus and rectum, 411
Prostate, abscess of, 431, 471
— —, diagnosis, 276, 439
—, carcinoma of, 470
—, cysts of, 481
—, examination of, 438, 439
—, gonorrhœa of, 471
—, hæmorrhage from, 470
—, hypertrophy of, 430, 431, 438, 439
— —, symptoms and course, 469, 470
—, sarcoma of, 470
—, tuberculosis of, 471
Prostatitis, 411
—, diagnosis of, 439
Pseudo-hermaphroditism, 383
Pseudo-leukæmia, glandular enlargement in, 157, 158, 203
—, pharyngeal swelling in, 95
—, splenic enlargement in, 331
Psoas abscess, 443, 517
Pupils in cerebral pressure, 13
—, reaction of in vertebral injuries, 502
— — in visual disturbances in, 39, 40
Pyelitis, 451, 452
—, anatomical diagnosis of, 452
—, gonorrhœal, 451
— in prostatic hypertrophy, 450
— of pregnancy, 451
Pyelonephritis, 452
Pyloric cancer, 311
— —, signs of retention in, 311
— —, skiagrams of, 302, 303, 312
— spasm, 301
— stenosis, cancerous, 303, 311, 312
— —, innocent, 304
— — of infants, 305
Pyonephrosis, 449, 450
Pyorrhœa alveolaris, 100
Pyosalpinx, 271

Q

QUADRICEPS tendon, laceration of, 671

R

RACHISCHISIS, posterior, 482, 483
Radial paralysis, posture of hand in, 593
Radio-carpal joint, dislocation of, 585
Radius, absence of, 595
— fracture, 577, 578, 580, 581, 582
— —, combined, 579
— — —, caused by wrench, 579
— — —, with fork-like posture, 577
— — —, into joint, 577
—, head of, chisel fracture, 565, 566
—, individual dislocation of, 563, 576
—, separation of epiphysis, 577, 579, 580
Ranula, 92
—, differential diagnosis, 92, 93, 94
Raynaud's disease, 603, 606, 607
Recklinghausen's disease, 55, 170
Reclus's disease, 223
Rectal fistulæ, 410, 424, 425
— —, acquired, inflamed, 424
— —, complete and incomplete, 426
— —, congenital, 424
— —, ischio-rectal and pelvi-rectal, 426
Rectum, carcinoma of, 408, 409, 411
— —, causing perirectal suppuration, 275
— — — stenosis, 352
—, condition of, in spinal injuries, 492
—, fissure of, 409
—, fistulæ of, 410
—, foreign bodies in, 412
— — —, introduced into, 413
—, gonorrhœal stricture of, 407
—, injuries of, 412, 413
—, polyposis of, 408
—, prolapse of, 411
—, sarcoma of, 409, 411
—, syphilis of, 341, 353, 407, 408
—, tenesmus of, 407
—, tuberculosis of, 341, 407
Recurrent nerve paralysis, 200
— — —, symptoms of, 118
Reflex epilepsy, 35
— symptoms after wounds of heart, 192
— — of chronic purulent otitis, 29
Retention swellings of kidney, 457
Retrobulbar fatty tissue, venous thrombosis of, 50, 61
Retroflexion of gravid uterus causing constipation, 407
— — — causing ileus, 353
Retropharyngeal abscess, 91, 114
— —, important diagnostic signs of, 123, 124
Retroperitoneal inflammation, 266
Retrotonsillar abscess, 91
Rhagades on tongue, nature of, 107
Rheumatism of ankle, 725, 726
— elbow, 571
— hip, 639, 651, 654
— knee, 679, 681
— —, ankylosing, 686
— shoulder, 550, 552
— wrist, 589
— —, chronic, 589, 590
Rhinoscleroma, 103
Ribs, chondritis of, after typhoid, 213
—, fractures of, 187
—, gumma of, 213
—, ostitis of, 213
—, protuberance of, 528, 529, 531, 532
—, tuberculosis of, 213, 222
Rickets, bone changes in, 591, 636
—, protuberance on ribs, due to, 532
Rider's bone, 658
Risus sardonicus in tetanus, 75
Rodent ulcer of face, 68, 69, 70
Röntgen dermatitis of hand, 601
Roser-Nelaton's line, determination of, 612
— — — in congenital dislocation of hip, 632
Rotation dislocation of cervical vertebra, 182, 183
— fracture of thigh, 623, 624, 625

S

SACRAL tuberculosis, 517
Sacro-lumbar tumours, congenital, 486
Salivary glands, swelling of, 89
— — —, diagnosis from tumours of neck, 140
— stones in Steno's duct, causing acute swelling of parotid, 62
— — Wharton's duct, causing inflammatory swelling of submaxillary, 132
Salpingitis, 273
—, diagnosis from appendicitis, 276
Sarcoma of abdominal wall, 376

Sarcoma of arm, 572, 574
— back of neck, 175
— bladder, 467
— cervical glands, 170
— clavicle, 212
— diploe, 57
— femur, 657, 661, 665
— gluteal region, 689
— gum, 94
— hand, 600
— kidneys, 457
— knee-joint, 684, 687
— lower jaw, 87, 88
— lung, 207, 208
— mamma, 232, 233
— mediastinum, 207
— neck, 170
— —, pulsating, 163
— nose, 97
— os calcis, 726, 739
— parotid gland, 169
— patella, 687
— pelvis, 480
— penis, 475
— pharynx, 96
— prostate, 470
— rectum, 409, 411
— sacral region, 486
— scapula, 214
— scrotum, 415
— shoulder, 553
— skull, 57
— spermatic cord, 416
— spinal cord, 509
— spleen, 331
— submaxillary gland, 170
— testicle, 422
— thigh, 657, 658, 659
— thorax, 217, 218
— thyroid, 154
— tibia, 699, 700, 705
— tongue, 106
— tonsillar region, 95
— trachea, 121
— umbilicus, 374
— upper jaw, 83, 84
— vascular sheaths of neck, 171
— vertebral column, 509
Scalp, fibroma of, 55
—, gumma of, 56, 58
—, sebaceous cysts of, 55, 56, 57, 58
Scaphoid of foot, fracture of, 721
— hand, fracture of, 584, 587
Scapula, fracture of, 545, 546
—, osteo-myelitis of, 210
—, sarcoma of, 214
—, tuberculosis of, 214
Scarlatinal arthritis of hip, 644
— — shoulder, 550
School scoliosis, 532
Sciatica, 689-693
—, diagnosis from hip disease, 652, 654
—, scoliotic, 522, 524, 691
Scirrhus of breast, 225, 226
Sclerosis, multiple, paraplegia in, 509
Scoliosis, 523, 524, 525, 527, 528, 529, 530, 531
—, causes of, 532
—, complete, 531
—, fixed, 531
— ischiodica, 522, 524, 691
—, mobile, 531
— of dorsal vertebræ, primary, 532
Scrofula, tubercular lymphoma, 156
Scrotum, acute inflammation of, 414
—, carcinoma of, 415
—, contents, 415
—, dermoid of, 415
—, elephantiasis of, 415
—, fibroma of, 415
—, lymphangioma of, 415
—, sarcoma of, 415
—, sebaceous cyst of, 415
—, swellings of, 414
—, tumours of, 414
—, urinary infiltration of, 414
Scurvy, gangrene in, 91
—, hæmorrhage from gums in, 100
Sebaceous cyst of face, 63, 64
— — hand, 599
— — neck, 165, 174
— — penis, 475
— — root of nose, 64
— — scalp, 55, 56, 57
— — —, malignant degeneration of, 58
— — scrotum, 415
— — skin of back, 216
— — skull, 55
— — — with sinus formation, 55
— — umbilicus, 378
Segmental diagnosis of spinal cord, 495, 496, 499, 510
Semilunar bone, dislocation of, 579, 583

Semilunar bone, fracture of, 585, 586
— cartilage, incarceration of, 670, 678
— —, laceration and displacement of, 670
Seminal vesicles, abscess of, 431
Sensation in vertebral injuries, 490
— — —, partial, 493, 494
Sesamoid in knee-joint, 669
— of tarsal bones, fracture of, 723, 724
Shoulder, rigidity of, 549
Shoulder-joint, contusion of, 546
—, dislocation of, 538, 539, 540
—, elevated level of, congenital, 523, 525
—, fractures of, 537, 538, 539, 540
—, gonorrhœa of, 551
—, injuries of (examination for), 537, 538, 539
—, inflammatory processes, 547
— — —, diagnosis from diseases of bursa and of joint, 547, 548
—, primary disease of bones of, 553
—, sprain of, 546
—, testing movements of, 548, 549
—, tubercle of, 551, 552
Sigmoid, cancer of, 352
—, stenosis of, 356
—, volvulus of, 365
Sigmoiditis, 275
—, ulcerating, 342
Sinus at umbilicus, 378
—, cavernous, thrombosis of, 61
— from biliary tract, 378
— intestine, 378
— rectum, 424, 425
— stomach, 378
— thyroid gland, 139
— urachus, 377
— vitelline duct, 377
— frontal phlegmon, arising therefrom, 60
— in perinæum, 424, 425
—, longitudinal, angioma of, 54
—, maxillary, chronic inflammation of, 82
— of abdomen, 377, 378
— branchial cleft, 138
— inguinal region, 379
— urinary tract, 378, 426
— on neck, 136
— —, actinomycotic, 136
Sinus on neck (complete and incomplete), 139
— —, congenital, 137, 138
— —, gummatous, 136
— —, traumatic, 136
— —, tubercular, 136
—, pericranial, blood cyst of, 53
—, secretions of, 378
— thrombosis, after aural suppuration, 29, 32, 33
Sinusitis, acute, 60
—, chronic, 60
—, frontal, 60
Situs inversus of unpaired abdominal viscera, 236
— —, partial inferior, 236
Skin appendages in front of ear and on face, 64
— cancer of, on foot, 740
— —, on face, 69, 70, 71
— —, on hand, 601
— —, on umbilical region, 374
— reflexes in spinal injuries, 493
—, seborrhœa of, 58
— —, on forehead and temples, 71
Skull, acute inflammatory processes on, 51
—, base of, fibroma of, 96, 97
— —, fractures of, 3, 6
— —, nerves at, 46
— —, sarcoma of, 96
—, chronic inflammatory swellings of, 56
— —, ulcerating growths of, 58
—, demarcation of cortical centres on the surface of, 47, 48, 49
—, dermoid of, 53, 54
—, erysipelas of, 51
—, exploration of, 16
—, fissures of, 6
—, fractures of, 1
— —, direct symptoms, 2
— —, indirect symptoms, 4
— —, position and course of, 5, 6
—, gummata of, 56, 58
—, injuries of, causing epilepsy, 34, 35
—, new growths of internal layer, 22
—, osteoma of, 55
—, osteomyelitis of, 51
—, periostitis of, 51
—, phlegmon of glands of, 51
—, sarcoma of, 56, 57

Skull, sarcoma of, periosteal, 57
—, sebaceous cyst of, 55
—, secondary growths of, 57
—, tubercle of, 56
Small intestine, gall stones in, 275
— —, intussusception of, confusion with appendicitis, 275
— —, palpation of, 239
— —, stenosis of, 349, 355, 359
— — — through fibro-sarcoma, 348
— —, torsion of, 364
— —, tumours of, 289
Solitary kidney, displacement of, 235
Spermatic cord, hydrocele of, 385, 415
— — —, diagnosis from inguinal hernia, 388
— —, tumours of, 415
Spermatocele, 419, 420
Sphincter of bladder, ulceration of, as a cause of incontinence, 432
Spina bifida, 218, 481
— —, forms of, 482
— — occulta, 485
— — —, club foot in, 735
— — —, pes cavus in, 735
Spinal caries, 509, 511
— —, ankylosing, 521
— — causing bending of spine, 522
— —, cervical, 515, 516, 517
— — —, commencing, 513, 514
— — commencing, 512, 513
— —, diagnosis from peritonitis, 263
— — — spinal cord tumour, 509
— — — sarcoma of vertebra, 510
— —, non-tubercular, 520
— — —, ankylosing, 521
— — —, secondary after pneumonia and typhoid, 521
— — of dorsal vertebræ, 513, 516, 517
— — lumbar vertebræ, 516, 517
— —, osteo-myelitic, 521
— —, posture of head in, 180, 514
— —, syphilitic, 521
— —, traumatic, 520
— —, tubercular, 181, 215, 511, 515
— — —, in adults, 513
— — —, in children, 511
— — with burrowing abscess, 515
— — cord symptoms, 519
— — without protuberance and without burrowing abscess, 511
— cord, Brown-Sequard's syndrome, 494, 508
Spinal cord, compression of, 494, 520
— —, congenital clefts in, 485
— —, contusion of, 494
— —, gumma of, 510
— —, hæmorrhage in, 495
— —, injuries of, 489
— — —, complete, 493
— — —, partial, 494
— —, non-traumatic diseases of, 507
— —, sarcoma of, 510
— —, segmental diagnosis, 495, 496, 499
— —, solitary tubercle of, 510
— —, tumours of, 508, 509
— meninges, innocent growths of, 510
Spine of tibia, detachment of, 671
— — —, normal picture of, 671
Spleen, abscess of, 266, 330
—, amyloid disease of, 331
—, congenital syphilis of, 331
—, displacement of, 236, 238
—, hypertrophy of, 331, 332
—, injuries of, 247
—, swelling of, in diphtheria, 113
—, tumours of, 331
Sporotrichosis of elbow region, 571
Staphylomycosis of breast, 221
— medulla of femur, 662, 665
— tibia, 703
Sterno-clavicular joint, injuries of, 534
Sterno-mastoid, gumma of, 140
— —, myositis of, 133
— —, tuberculosis of, 140
Sternum, abscess of, 211
—, fracture of, 188
— —, transverse, in upper portion, 505
—, gumma of, 213
—, malignant growth of, 213
—, osteo-myelitis of, 133
—, tubercle of, 212, 213
Stomach, abnormalities in position of, 236, 242, 293
—, cancer of, 302, 303, 305
— — at cardia, 306
— — fundus, 310
— — pylorus, 311
— —, chemistry in, 309
— —, varieties of, 310, 311
—, cicatricial stenosis of, 299, 300, 301, 303
—, contusion of, 245, 247
—, dilatation of, 302, 303

Stomach, foreign bodies in, 292, 293
—, gunshot wounds of, 252, 253
—, hæmorrhage from, 296, 308
— hour-glass, 302, 303, 304
—, perforation of, 296
— —, differential diagnosis, 299
— —, local symptoms, 298
—, shape and position of, abnormal, 292, 302, 303
— — —, normal, 240
—, sinuses from, 378
—, skiagram of, 302, 303
— — in retention of contents, 301
— —, technique and diagnostic significance, 292
—, surgical diseases of, 291
— — —, with peritoneal signs, 265, 266
—, ulcer of, 294, 302
— —, diagnosis from cholecystitis, 316
— — — ileus, 358
— — indolent, 295
— —, perforating, 266, 296, 297
— —, uncomplicated, 294
Stomatitis, gangrenous, 76, 91
—, mercurial, 76
Stones of kidney, infected, 455
— —, non-infected, 453
Stools, blood in, 245, 349, 407
—, diagnostic significance of their consistence, 407, 408
—, incontinence of, 492
—, pus in, 350
—, retention of, 349
—, shape of, 348, 349, 407
Streptococcal laryngitis, diagnosis from diphtheria, 111
Streptomycosis of breast, 221
Stricture of rectum, gonorrhœal and syphilitic, 407
—, urethral, examination of, 439
Styloid process of radius, fracture of, 577, 578
— — ulna, fracture of, 577, 578
Subluxation of foot, 713, 715
— radius, 563
—, Volkmann's, 734
Submaxillary gland, inflammation, 132
— — —, chronic, 166
— —, mixed tumours of, 167
— —, sarcoma of, 169
— —, tubercle of, 167
Surgical emphysema after injuries to air passages, 116
Surgical emphysema, lung injuries, 189
Swallowing, difficulty in, 122
— —, position and nature of obstruction, 127
— —, through affections of mouth and throat, 122, 123, 124
— — — foreign bodies, 123
— — — laryngeal diseases, 118
— — — œsophageal disease, 124
Sweat glands of axilla, inflammation, 211
Synovitis of ankle, tubercular, 725, 726
— knee, osteo-myelitic, 681
— —, rheumatic, 681
— —, syphilitic, 681
Syphilis insontium, 22, 90
— of brain, 22
— elbow, 571
— epididymis, 419, 426
— face, 65, 71
— finger, 603, 608
— foot, 696, 725, 740
— hand, 605, 608
— intestine, 353
— knee, 681
— large intestine, 341
— larynx, 120, 121
— leg, 695, 696, 700
— lips, 64, 99
— mouth, 90, 99, 100
— neck, 136, 156
— nose, 65, 66
— œsophagus, 130
— palate, 95
— penis, 476, 478
— rectum, 341, 408
— testicle, 422
— thoracic wall, 211
— thyroid, 153
— tibia, 701, 704
— vertebræ, 521
Syringo-myelia, hand deformity in, 607

T

Tabes, diagnosis from perforation of stomach, 299
— — peritonitis, 262
— — tumour of spinal cord, 508
Talipes, 729, 730, 731, 733, 734, 735, 737
Tar cancer, 415
Tear ducts, inflammation of, 60, 61, 167

Tegmen tympani, suffusion of, 6
Temporal lobe, abscess of, after otorrhœa, 30
— —, tumours of, 24
Tendon reflexes, condition of, in spinal caries, 519
— — — vertebral injuries, 493
Tenesmus of bladder, 432
— — in stone, 462
— — urinary tubercle, 458
— rectum, 407
— — with constipation, 407
Teno-synovitis of hand, 588, 603
— —, gonorrhœal, 603, 608
—, tubercular, 589, 590, 599, 607
Teratoma of pharynx, 97
— sacral region, 486
Testicle, gumma of, 419
—, hæmatocele of, 416, 420
—, hydrocele of, 387, 388, 420
—, infarction of, 418
—, inflammation of, 416, 417
— —, metastatic, 417
—, injuries of, 416
—, spermatocele of, 419, 420
—, strangulation of, 399
—, syphilis of, 422
—, torsion of, 399, 418
—, tumours of, 422
Tetanus of head, with facial palsy, 75, 77
Thigh, abscess of, 518
—, aneurism of, 658
—, blood cysts of, 660
—, dislocations of, 615-620
— —, congenital, 631
—, fractures of, 621, 631
—, muscular swelling of, 658
—, osteo-myelitis of, 656
—, tumours of, 656, 657, 659
— —, in epiphysis, 661
— — diaphysis, 664
Thorax, angioma of, 216
—, bones of, fracture, 186, 187
—, burrowing abscess of, 517
—, empyema, breaking through, 209
—, enchondroma of, 218
—, fibroma of, 216
—, inflammatory processes of, 210-216
—, injuries of, 187-188
—, lipoma of, 211, 215, 217, 517
—, lymphangioma of, 217
Thorax, malignant tumours of, 212, 213
— muscle, gumma of, 212
—, osteoma of, 218
—, osteo-myelitis of, 210
—, sarcoma of, 216, 217, 218
—, sebaceous cyst of, 216
—, surgical diseases of, 186
— — —, external, 208
— — —, internal, 199
—, tuberculosis of, 209, 212
—, tumours within, 199
— — without, 208, 216
Thrombo-phlebitis of transverse sinus in aural suppuration, 29, 32, 33
Thymic death, 201
Thymus, condition of, in Graves's disease, 146
—, hypertrophy of: diagnosis, 200, 201
Thyroid, cancer: secondary deposits, 57, 155
— — — —, symptoms, 121, 155
— fistulæ, 139
— gland in obesity, 175
— —, inflammation of, 133, 151
— —, simple hyperplasia of, 141, 142
— —, tumours of, 154
Tibia, chronic abscess of, 703, 704
—, dislocation of, 676, 712
— —, posterior, 685
— —, at lower end, 706, 707, 711, 713
—, fractures of, 675, 676
—, laceration of crucial ligaments, 675
—, normal, 704
—, osteo-myelitis of, 699, 700, 701, 702, 703
—, periostitis of, 703
— —, syphilitic, 704
—, syphilis of, 701, 703
—, tuberculosis of, 703, 704, 726
—, tumours of, 697, 699, 700
Tic, rotatory, 186
Toe-nail, ingrowing, 740
Toes, chondroma of, 738
—, deformities of, 737
—, gangrene of, 728
Tongue, actinomycosis of, 105, 106, 107
—, angioma of, 105
—, cancer of, 99, 108, 109
—, dry (significance of), 104

Tongue, fibroma of, 105
—, gumma of, 105, 106, 107
—, leucoplakia of, 104
—, lipoma of, 105
—, lymphangioma of, 105, 106
—, primary chancre of, 107
—, sarcoma of, 106
—, swelling of, 90, 104
—, tuberculosis of, 105, 106, 107
Tonsil, cancer of 101, 103
— —, metastasis in neck, 161
—, gumma of, 101
—, mixed tumours of, 95
—, primary chancre of, 102
—, sarcoma of, 95
—, tuberculosis of, 101
Tonsillitis, 111, 112
Torticollis, 180, 184, 185, 186
Trachea, surgical diseases of, acute, 111
— — —, chronic, 118
Trismus, 75
Trochanter, fractures of, 622, 623, 624
—, level of, 612, 632
— —, in congenital dislocation, 632, 636
— —, coxa adducta, 639, 640
Tubal pregnancy, ruptured, 271, 273, 274
— — —, diagnosis from gastric ulcer, 299
— — — — ileus, 358
Tubercle of abdominal wall, 376, 377
— arm, 573, 576
— bladder, 463, 465
— brain, 17, 22
— cervical vertebræ, 134, 136, 511
— elbow, 509, 570, 571, 572
— epididymis, 419, 420
— femur, 653, 658, 662
— finger, 608
— floor of mouth, 99, 100
— foot, 725, 726, 727, 728, 740
— gum, 79, 100
— hand, 607, 609
— hernial sac, 402
— hip, 645
— humerus, 551, 573, 575, 576
— inguinal glands, 375
— intestine, 351
— jaw, 60, 76, 79, 80, 81, 83, 84
— kidney, 450, 451
Tubercle of knee, 680, 681, 682, 684
— lachrymal sac, 61
— larynx, 119, 120, 121
— leg, 703
— lobule of ear, 72
— lungs, suppurative, 198, 209
— mamma, 221, 222
— neck, 134, 138, 152
— nose, 103
— os calcis, 726, 728
— palate, 103
— parotid, 167, 168
— pelvic bones, 651
— peritoneum, 264, 281
— pre-patellar bursa, 687
— prostate, 471
— rectum, 341, 408
— ribs, 213
— scapula, 214, 552
— shoulder, 550, 551
— skull, 56
— sternum, 212, 213
— subdeltoid, 550
— submaxillary gland, 167
— tendon sheaths of hand, 599
— thorax, 209, 211
— thyroid, 153
— tibia, 703, 704
— —, at lower end, 725, 726
— tongue, 105, 107
— tonsillar region, diagnosis from gumma, 101, 102
— urinary passages, 458, 461
— vertebræ, 181, 215, 511, 515
— wrist, 589, 590, 591, 599
Typhoid fever, arthritis of hip, after, 644
— — — vertebral joints, after, 521
— —, ostitis and chondritis of ribs, after, 213
Typhlitis, ulcerative, 342

U

Ulcers of concha of ear, 72
— face, 62, 64
— foot, 696, 739
— gum, 100
— intestine, 353, 358
— larynx, 115, 119, 120
— leg, 693, 694, 695, 696
— oral cavity, 98
— penis, 475, 476

Ulcers of scalp, 58
— scrotum, 415
— stomach, 294
— tongue, 106
— tubercular, 79
Ulnar paralysis, posture of hand and fingers in, 593, 598
Umbilical cord, hernia of, 371, 373
— hernia, 372
— —, in cirrhosis of liver, 372
— —, strangulation of, 403
Umbilicus, abscess of, 378
—, concretions in, 378
—, fistulæ of, congenital and acquired, 378
—, tumours of, 374, 378
Urachus, cysts of, 373
—, fistulæ of, 377
Ureter, catheterism of, 427, 441
—, in urinary tuberculosis, 459
Ureteral stones, 453
Urethra, fistulæ in, 426
—, foreign bodies in, 430
—, hæmorrhage from, 435
—, injuries of, 472, 473
— —, in fractured pelvis, 474, 630
—, obstruction of, 430
—, stricture of, 439, 440
— —, of gradual onset, 431
Urethritis, differential diagnosis in, 428
Urethroscopy, 439
Urinary disturbances, 429, 440
— —, difficult and painful micturition, 429, 432
— —, involuntary micturition, 431
—, fever, 452, 455
—, fistulæ, 378, 379, 426, 427
—, gravel, 436, 453
—, tract, surgical diseases of, 427
— — — —, local symptoms, 445
— —, tuberculosis of, 434, 435, 458
Urine, albumin in, 452, 459
—, blood in, 249, 251, 435, 454, 470
—, examination of, 434, 435, 436
—, extravasation of, 414
— —, in injury of kidneys, 249
— —, rupture of bladder, 250, 251
— —, urethral injuries, 473
—, pus in, 433, 434, 449
—, retention of, 430
— —, results, 447, 464
—, sugar in, 329
Urticaria, in hydatid disease, 326
—, hydronephrosis, 436
Uterus, cancer of, causing intestinal obstruction, 353
—, cystoma of, 290
—, fibrous myoma of, 289
—, inflammation in and around, 266
—, pregnant, diagnosis from abdominal tumour, 290

V

Varicocele, 388
—, with atrophy of testicle, 389
Varicose veins of leg, 693, 694, 697, 698
— — thigh, 657
Varix, aneurismal, diagnosis from arterio-venous aneurism, 164
Vein, internal jugular, thrombo-phlebitis of, 33
—, saphenous, dilatations of, 392
Verruca senilis, 58
Vertebral column, arthritis deformans of, 521
— —, congenital deformities of, 481, 523
— —, curvatures of, 519, 522, 525, 526
— —, dislocations of, 176, 500, 502, 503
— —, fractures of, 176, 488, 501, 502, 503
— —, injuries of, 489, 493, 494, 495, 499, 501, 505, 506
— —, osteo-myelitis of, 180, 576
— —, partial injuries of, 493, 494
— —, rigidity of, 521
— —, sarcoma of, 509
— —, sprains of, 487, 488
— —, syphilis, tertiary, of, 521
— —, tubercular abscess of, 134, 140, 215, 515, 519
— —, tumours of, 508, 510
— — —, diagnosis from spinal caries, 509
—, injuries, examination of, 489
— — — for movements, 490
— — — reflexes, 492, 493
— — — sensation, 490, 491
— — — vasomotor state, 491
— — — visceral functions, 492
Vestibular nerve, disturbances of, 45

Volvulus, 364
—, ileo-cæcal, 365
— of sigmoid flexure, 365

W

Warts, soft, of face, 64
Whitlow, 602, 603, 604
Wrist, abnormal postures of, 595
—, arthritis of, 588, 590
—, bones of, fracture of, 584, 585
—, dislocation, fracture of, 584, 585
— — of, 579, 583
—, gonorrhœa of, 589
—, injuries of, 577
— —, scheme, 587
—, normal, 583
—, rheumatism of, 589
Wrist, rheumatism of, chronic, 589
—, sprain of, 576, 577, 586
—, tuberculosis of, 589, 590, 592, 599
Wry-neck, 180, 184, 185, 186

X

Xanthelasma of face, 64

Y

Y-shaped fracture of femoral condyles, 673, 675, 676
— — fibula, 711
— — head of humerus, 545
— — lower end of humerus, 556, 564, 568
— — neck of femur, 623

COLUMBIA UNIVERSITY LIBRARIES (hsl,stx)
RD 35 Qu313 1913 C.1
Clinical surgical diagnosis for students
2002120780